

## **The student's guide to diseases of the eye / by Edward Nettleship.**

### **Contributors**

Nettleship, Edward, 1845-1913.  
Harvey Cushing/John Hay Whitney Medical Library

### **Publication/Creation**

London : J. & A. Churchill, 1884.

### **Persistent URL**

<https://wellcomecollection.org/works/y9uwc26h>

### **License and attribution**

This material has been provided by This material has been provided by the Harvey Cushing/John Hay Whitney Medical Library at Yale University, through the Medical Heritage Library. The original may be consulted at the Harvey Cushing/John Hay Whitney Medical Library at Yale University. where the originals may be consulted.

This work has been identified as being free of known restrictions under copyright law, including all related and neighbouring rights and is being made available under the Creative Commons, Public Domain Mark.

You can copy, modify, distribute and perform the work, even for commercial purposes, without asking permission.



Wellcome Collection  
183 Euston Road  
London NW1 2BE UK  
T +44 (0)20 7611 8722  
E [library@wellcomecollection.org](mailto:library@wellcomecollection.org)  
<https://wellcomecollection.org>





*J.B. Mackay.*  
*Glenelg.*

*Helensburgh*

YALE  
MEDICAL LIBRARY



HISTORICAL  
LIBRARY

THE GIFT OF  
MEDICAL LIBRARY ASSOCIATION  
EXCHANGE

THE  
STUDENT'S GUIDE  
TO  
DISEASES OF THE EYE






THE  
STUDENT'S GUIDE  
TO  
DISEASES OF THE EYE

BY  
EDWARD NETTLESHIP, F.R.C.S.

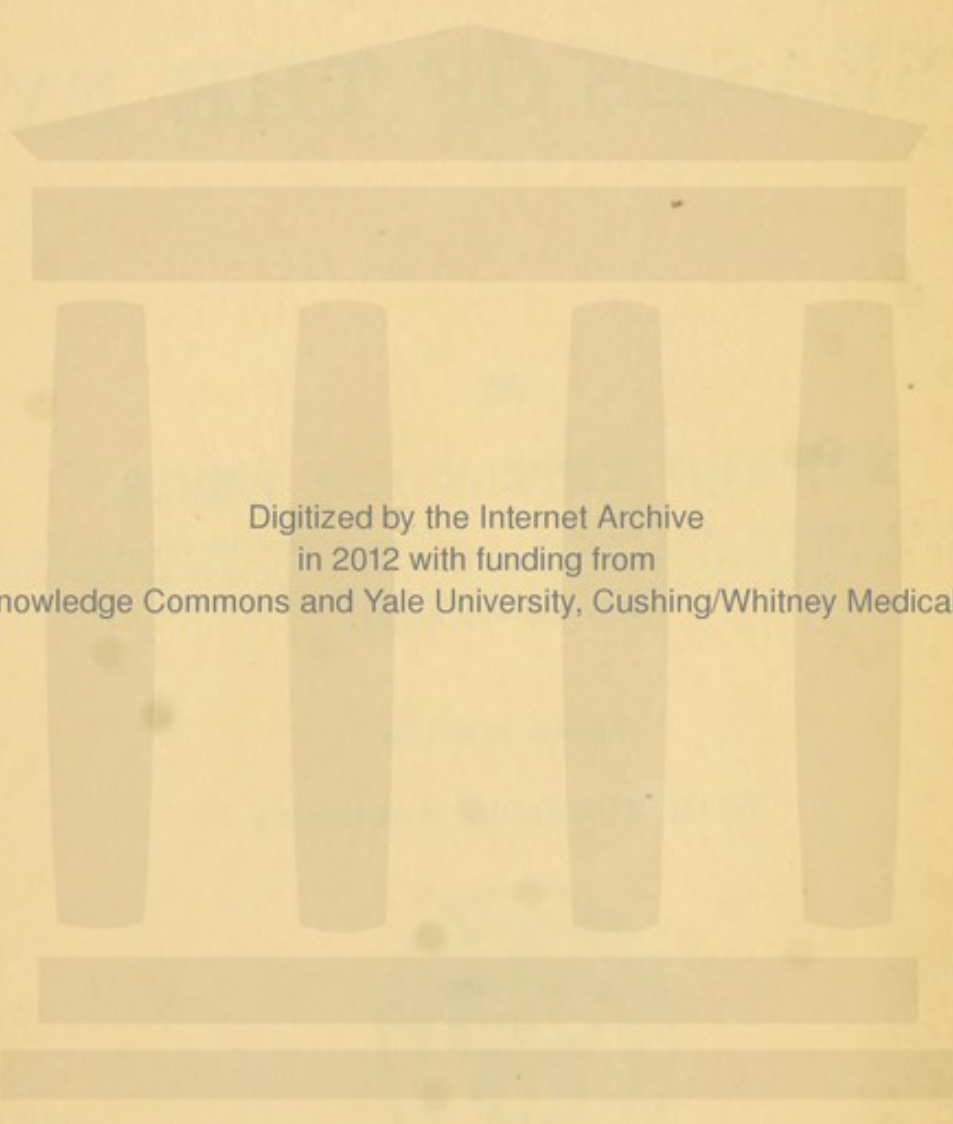
OPHTHALMIC SURGEON TO ST THOMAS'S HOSPITAL, ASSISTANT SURGEON TO THE  
ROYAL LONDON (MOORFIELDS) OPHTHALMIC HOSPITAL; LATE OPHTHALMIC  
SURGEON TO THE HOSPITAL FOR SICK CHILDREN,  
GREAT ORMOND STREET

THIRD EDITION  
WITH NUMEROUS ADDITIONS



LONDON  
J. & A. CHURCHILL  
11, NEW BURLINGTON STREET  
1884





Digitized by the Internet Archive  
in 2012 with funding from  
Open Knowledge Commons and Yale University, Cushing/Whitney Medical Library

To

JONATHAN HUTCHINSON, F.R.S.,

CONSULTING SURGEON TO THE MOORFIELDS OPHTHALMIC

HOSPITAL, AND TO THE LONDON

HOSPITAL, &c.,

THIS

BOOK IS DEDICATED

IN GRATEFUL ADMIRATION OF HIS EMINENT QUALITIES

AS A

CLINICAL TEACHER AND INVESTIGATOR



JOYATIAN DISTRICTS, ETC.

JOYATIAN DISTRICTS, ETC.

JOYATIAN DISTRICTS, ETC.

JOYATIAN DISTRICTS, ETC.

JOYATIAN DISTRICTS, ETC.

JOYATIAN DISTRICTS, ETC.

JOYATIAN DISTRICTS, ETC.

JOYATIAN DISTRICTS, ETC.

JOYATIAN DISTRICTS, ETC.

# PREFACE

## TO THE

### THIRD EDITION

---

THE whole book has been carefully revised and a considerable amount of new matter added, the number of pages being sixteen more than in the Second Edition.

The new features of most importance are the fuller account now given of Retinoscopy, the description of Diseases of the Orbit in a separate Chapter (Chapter XIX), and the introduction of woodcuts illustrating Retinoscopy, alterations in the Visual Field in various diseases, and the changes in the permanent incisor teeth characteristic of hereditary syphilis.

I am indebted to Mr. F. W. MARLOW for much assistance in seeing the book through the press.

*January, 1884.*



RE 46  
884 N

# PREFACE

## TO THE

### FIRST EDITION

---

THE aim of this little book is to supply students with the information they most need on diseases of the eye during their hospital course. It was apparent from the beginning that the task would be a difficult one, all the more as several excellent manuals, covering nearly the same ground, are already before the public. That not one of them singly appeared exactly to cover the ground most important for the first beginner in clinical ophthalmology encouraged me to attempt the present work.

The scope of the work has precluded frequent reference to authors, those named being chiefly such as have made recent additions to our knowledge in this country. I am greatly indebted to Dr Gowers, Dr Barlow, and other friends for much information, and for many valuable suggestions. My best thanks are due to Mr A. D. Davidson for his kind assistance in reading the sheets for the press.

WIMPOLE STREET;  
*October, 1879.*



# THE

OF

## THE

OF

The first of these is the fact that the book is a very valuable one. It contains a great deal of information which is not to be found elsewhere. The second is that the book is written in a very clear and concise manner. The third is that the book is written in a very interesting and readable manner. The fourth is that the book is written in a very accurate and reliable manner. The fifth is that the book is written in a very complete and thorough manner. The sixth is that the book is written in a very up-to-date and current manner. The seventh is that the book is written in a very well-organized and systematic manner. The eighth is that the book is written in a very well-illustrated and well-figured manner. The ninth is that the book is written in a very well-referenced and well-cited manner. The tenth is that the book is written in a very well-indexed and well-annotated manner. The eleventh is that the book is written in a very well-compiled and well-bound manner. The twelfth is that the book is written in a very well-preserved and well-maintained manner. The thirteenth is that the book is written in a very well-protected and well-secured manner. The fourteenth is that the book is written in a very well-kept and well-looked-after manner. The fifteenth is that the book is written in a very well-used and well-loved manner. The sixteenth is that the book is written in a very well-known and well-recognized manner. The seventeenth is that the book is written in a very well-liked and well-liked manner. The eighteenth is that the book is written in a very well-remembered and well-remembered manner. The nineteenth is that the book is written in a very well-remembered and well-remembered manner. The twentieth is that the book is written in a very well-remembered and well-remembered manner.

OF

OF

# CONTENTS

---

## PART I.—MEANS OF DIAGNOSIS

	PAGE
LIST OF ABBREVIATIONS . . . . .	1

### CHAPTER I

OPTICAL OUTLINES . . . . .	1—17
----------------------------	------

Lenses and prisms; Refraction of the eye, and conditions of clear vision (p. 12); Numeration of spectacle lenses (p. 14); Table showing the equivalent numbers of lenses made by the inch scale and metrical scale respectively.

### CHAPTER II

EXTERNAL EXAMINATION OF THE EYE . . . . .	19—36
---	-------

Examination of:—(1) Surface of cornea; (2) Tension of eye; (3) Mobility of eye; (4) Squint or strabismus, apparent strabismus; (5) Diplopia; (6) Protrusion and enlargement of eye; (7) External blood-vessels of eye; (8) Colour of iris; (9) Pupils; (10) Field of vision; (11) Acuteness of sight; (12) Accommodation; (13) Apparent size of objects; (14) Colour perception.

### CHAPTER III

EXAMINATION OF THE EYE BY ARTIFICIAL LIGHT . . . . .	37—60
--	-------

- (1) Focal or "oblique" illumination (p. 37).
  - (2) Ophthalmoscopic examination:—Experiments showing indirect and direct methods (p. 39); Use of the ophthalmoscope (p. 42).
- Indirect method (p. 43):—Appearances of Optic Disc; scleral ring, physiological pit, *lamina cribrosa*:—of Choroid:—of Retina:—vessels, yellow spot, *fovea centralis*.
- Direct method (p. 49):—Examination of vitreous; Determination of refraction; Table of relation between refraction and length of eye; Examination of fine details by direct method.
- Retinoscopy (Keratotomy) (p. 55).



## PART II.—CLINICAL DIVISION

## CHAPTER IV

PAGE

## DISEASES OF THE EYELIDS . . . 61—68

Blepharitis; Styne; Meibomian cyst; Horns and warty formations; Molluscum contagiosum; Xanthelasma; Pediculus pubis. Ulcers (p. 66):—Rodent cancer; Tertiary syphilis; Lupus; Chancre. Congenital ptosis (p. 68); Epicanthus.

## CHAPTER V

## DISEASES OF THE LACRIMAL APPARATUS 69—73

Epiphora, stillicidium lacrimarum, and lacrimation.

Epiphora from alterations of punctum and canaliculus (p. 69); Dacryo-liths.

Diseases of lacrimal sac and nasal duct (p. 70):—Mucocoele and lacrimal abscess; Stricture of nasal duct.

## CHAPTER VI

## DISEASES OF THE CONJUNCTIVA . . . 74—89

General diseases (p. 74):—Purulent and gonorrhœal ophthalmia; Muco-purulent ophthalmia; Catarrhal, and other forms of muco-purulent ophthalmia; Membranous and diphtheritic ophthalmia;—Atropine and eserine irritation; Partial diseases (p. 83):—Granular Ophthalmia, Follicular conjunctivitis;—Results of granular ophthalmia (p. 86); Pannus, Distichiasis and trichiasis, Organic entropion;—Chronic conjunctivitis;—Amyloid disease.

## CHAPTER VII

## DISEASES OF THE CORNEA . . . 90—113

## A. Ulcers and non-specific inflammation (p. 90).

Appearances of the cornea in disease:—"Steamy" and "ground-glass" cornea; Infiltration; Swelling Ulceration; Nebula and leucoma (p. 91).

Symptoms in ulceration:—Photophobia; Congestion; Pain (p. 92).

Clinical types of ulcer (p. 92):—Central ulcer of children; Facetting ulcer;—Phlyctenular affections (p. 93); Phlyctenular, or recurrent vascular, ulcer, Marginal keratitis (Spring-catarrh);—Serpiginous



ulcer (p. 96); Abscess and suppurating ulcer; Hypopyon; Onyx.

Treatment of ulcers of cornea (p. 98).

Conical cornea (p. 104).

#### B. Diffuse keratitis (p. 105).

Syphilitic keratitis (p. 105). Other forms of keratitis (p. 109):—Keratitis punctata; Corneal changes in glaucoma; Buphthalmos (Hydrophthalmos); Calcareous film; Arcus senilis; Inflammatory arcus; Opacity from use of lead lotion; Staining of conjunctiva or cornea from use of nitrate of silver.

### CHAPTER VIII

#### DISEASES OF THE IRIS . 114—124

Iritis, Symptoms (p. 114):—Muddiness and discoloration of iris; Synechiæ; Corneal haze; Ciliary congestion; Pain; Lymph nodules; Hypopyon.

Results of iritis (p. 118).

Causes (p. 120):—Syphilis; Rheumatism; Gout; Sympathetic disease; Injuries.—Chronic iritis.

Treatment of iritis (p. 121).

Congenital irideremia; Coloboma; Persistent pupillary membrane (p. 124).

### CHAPTER IX

#### DISEASES OF THE CILIARY REGION . 125—137

Episcleritis (or Scleritis), Sclero-keratitis and allied diseases (p. 125):—Cyclitis (irido-choroiditis) (p. 129); Chronic "serous" form; "Idiopathic phthisis bulbi;" Traumatic cyclitis (or Panophthalmitis).

Sympathetic affections (p. 131):—Sympathetic irritation (p. 133); Sympathetic inflammation (p. 133); Treatment (p. 135).

### CHAPTER X

#### INJURIES OF THE EYEBALL . 138—147

Contusion and concussion injuries (p. 138):—Rupture of eyeball; Intraocular hæmorrhage; Detachment of iris; Dislocation of lens; Detachment of retina; Rupture of choroid; Paralysis of iris and ciliary muscle; Iritis; Commotio retinæ; Traumatic myopia.—Treatment of blows on eye (p. 140).



- Surface wounds of Eyeball (p. 141):—Abrasion and foreign body on cornea; Foreign body on conjunctiva.  
 Burns and scalds (p. 142); Prognosis uncertain for some days:—Lime-burn; Serious results of severe burns.  
 Penetrating wounds of eyeball (p. 143):—Slight cases. Severe cases (p. 144):—Traumatic cataract; Cyclitis; Foreign body in eye. Treatment (p. 144):—Rules as to the excision of wounded eyes. Electro-magnet for removing bits of iron (p. 145).

## CHAPTER XI

### CATARACT . . . 148—165

- Senile changes in lens (p. 148).  
 Definition of cataract:—General cataract (p. 149):—Nuclear and cortical, each may be hard (senile) or soft (juvenile); Congenital. Partial cataract (p. 150):—Lamellar; Pyramidal; Anterior and posterior polar. Traumatic and concussion cataract (p. 157).  
 Primary and secondary cataract (p. 152).  
 Symptoms and diagnosis of cataract (p. 152).—Prognosis before and after operation (p. 158).  
 Treatment (p. 159):—Palliative; Atropine. Radical:—Extraction, Discission or solution, Suction.  
 Rules as to operating for cataract (p. 160); Causes of failure after extraction (p. 162); Hæmorrhage; Suppuration of cornea; Iritis; Prolapse of iris.  
 Sight after removal of cataract (p. 163).  
 Treatment of lamellar cataract (p. 164).  
 Dislocation of the lens (p. 165).

## CHAPTER XII

### DISEASES OF THE CHOROID . . 166—180

- Participation by the retina and the vitreous.  
 Appearances in health (p. 167); appearances in disease (p. 168):—Atrophy; Pigment in choroid and retina; Exudations, syphilitic, tubercular; Rupture; "Colloid" change; hæmorrhages.  
 Clinical forms of disease (p. 174):—Syphilitic choroiditis disseminata; Myopic changes; Central senile choroiditis; Other forms.  
 Coloboma (p. 179); Albinism (p. 180).



## CHAPTER XIII

PAGE

## DISEASES OF THE RETINA . . 181—201

Appearances in health (p. 181):—Blood-vessels, yellow-spot, and "halo" around it; "Opaque nerve-fibres" (p. 183).

Appearances in disease (p. 183):—Congestion; Retinitis, (1) Diffuse, (2) and (3) Localised, with white spots and hæmorrhages.

Hæmorrhage (p. 187); Pigmentation; Atrophy; Disc in atrophy of retina; Detachment (p. 188). Single patch of retinitis caused by choroiditis.

Clinical forms of disease (p. 191):—Syphilitic retinitis; Albuminuric; Hæmorrhagic; Retinitis apoplectica and large single hæmorrhages; Embolism and thrombosis; Retinitis pigmentosa; Retinitis from direct sunlight.

## CHAPTER XIV

## DISEASES OF THE OPTIC NERVE . 202—216

Relation between changes at the Disc, disease of the Optic Nerve, and affection of Sight (p. 202).

Pathological changes in optic nerve (p. 202).

Appearances of optic disc in disease (p. 204):—Inflammation, optic neuritis, papillitis, or choked disc; Atrophy after papillitis (p. 207); Papillo-retinitis.

Etiology of papillitis (p. 209). Retrobulbar neuritis; Syphilis causing papillitis. The pupils in neuritis (p. 210).

Atrophy of disc (p. 210):—Appearances and causes; Clinical aspects (p. 213); State of sight, field of vision, and colour-perception; A. Double atrophy (p. 214); B. Single atrophy (p. 215).

## CHAPTER XV

AMBLYOPIA AND FUNCTIONAL DISORDERS OF SIGHT  
217—230

"Amblyopia" and "Amaurosis" (p. 217):—Single Amblyopia (p. 217):—From suppression; from defective images; from retrobulbar neuritis. Double Amblyopia (p. 219):—Central Amblyopia (Tobacco amblyopia).

Hemianopia (p. 222); Hysterical amblyopia and Hyperæsthesia oculi (p. 223); Asthenopia (p. 224).



	PAGE
Functional disorders of vision (p. 226); Endemic nyctalopia; Snow-blindness; Electric light. Hemeralopia; Micropsia; Muscæ volitantes; Diplopia; Malingering; Colour-blindness (p. 228).	

## CHAPTER XVI

### DISEASES OF THE VITREOUS HUMOUR. 231—235

Usually secondary to other disease of Eye.

Examination for opacities (p. 232):—Cholesterine; Blood; Blood-vessels in vitreous; Cysticercus.

Conditions causing disease of vitreous (p. 234):—Myopia; Blows and wounds; Spontaneous hæmorrhage; Cyclitis, choroiditis, and retinitis; Glaucoma.

## CHAPTER XVII

### GLAUCOMA . . . 236—254

Primary and secondary.

Primary glaucoma (p. 237):—Premonitory stage; Chronic or Simple; Subacute; Acute; Absolute.

Ophthalmoscopic changes; Cupping of disc (p. 238). Symptoms explained (p. 240); Mechanism (p. 245); General and diathetic causes (p. 247); Treatment (p. 248); Prognosis (p. 251).

Secondary glaucoma (p. 253); Conditions causing it.

## CHAPTER XVIII

### TUMOURS AND NEW GROWTHS. . 255—262

A. Of the conjunctiva and front of the eyeball (p. 255).—Cauliflower wart; Lupus; Syphilitic tarsitis; Pinguecula; Pterygium; Lymphatic cysts; Dermoid tumour; Episcleritis simulating tumour; Fibro-fatty growth; Cystic tumours; Epithelioma; Sarcoma.

B. Intraocular tumours (p. 258).—Glioma of retina; Pseudo-glioma. Sarcoma of choroid; Tubercular tumour of choroid. Tumours of iris (p. 261):—Sarcoma; Sebaceous tumour; Cysts; Granuloma.

## CHAPTER XIX

### INJURIES, DISEASES, AND TUMOURS OF THE ORBIT 263—271

Contusion and concussion injuries (p. 263):—Emphysema of orbit; Traumatic ptosis.

Abscess and cellulitis of Orbit (p. 264); Inflammation and abscess of lacrimal gland (p. 265).



- Wounds (p. 266) :—Of eyelids; of orbit; large foreign bodies in orbit.
- Tumours of orbit; General symptoms (p. 267).—Distension of frontal sinus; Ivory exostosis; tumours growing from parts around the orbit; Pulsating exophthalmos (p. 267); Cystic tumours; Solid intra-orbital tumours p. 269). Nævus. Dermoid tumour in eyebrow.

## CHAPTER XX

## ERRORS OF REFRACTION AND ACCOMMODATION. 272—306

- Emmetropia; Ametropia; Accommodation (p. 272).
- Myopia (p. 273—285).—Symptoms (p. 275):—Insufficiency of internal recti. Posterior staphyloma and crescent; Other complications. Tests for; Causes (p. 281). Measurement of degree (p. 283); Treatment (p. 282); Spectacles; Tenotomy.
- Hypermetropia (p. 285—295).—Symptoms (p. 287): Accommodative asthenopia, Convergent strabismus. Tests for Hypermetropia (p. 293); Treatment (p. 291): Spectacles; Treatment of the strabismus (p. 294).
- Astigmatism (p. 295—303).—Regular and irregular; Seat; Focal interval; Cylindrical lenses; Forms of regular astigmatism; Detection and measurement (p. 299); Spectacles.
- Unequal refraction in the two eyes (Anisometropia) (p. 303).
- Presbyopia (p. 303—306):—Rate of progress; Treatment (p. 305).

## CHAPTER XXI

## STRABISMUS AND PARALYSIS . 307—320

- Definition of strabismus (p. 307); Diplopia; True and false image; Homonymous and crossed diplopia; Suppression of false image.
- Causes (p. 310):—Strabismus from Over-action; from Weakness; from Disuse; from Weakness following tenotomy; from Paralysis.
- Paralysis of Sixth nerve (external rectus) (p. 312); of Fourth nerve (superior oblique) (p. 313); of Third nerve (p. 314).—Primary and secondary strabismus; Giddiness in paralytic strabismus (p. 315).



	PAGE
Paralysis of Internal muscles of eye (p. 316):—Iris alone ; Ciliary muscle alone ; Both Iris and Ciliary muscle. Causes and treatment of external ocular paralyses (p. 317):—Syphilitic growths ; Meningitis ; Tumours ; Rheumatism. Causes of internal ocular paralyses.	
Nystagmus (p. 319).	

## CHAPTER XXII

	OPERATIONS	321—358
A. On the eyelids (p. 321). Epilation ; Eversion of lid ; Meibomian cyst ; In- spection of cornea ; Spasmodic entropion ; Organic entropion and trichiasis ; Ectropion ; Canthoplasty ; Peritomy ; Ptosis.		
B. On the lacrimal apparatus (p. 329). Lacrimal abscess ; Slitting canaliculus ; Stricture of nasal duct, (1) Probing, (2) Incision.		
C. For strabismus (p. 331). Tenotomy :—Critchett's ; Liebreich's. Readjust- ment.		
D. Excision and Abscission of the Eye. Optico-ciliary neurotomy (p. 336).		
E. On the cornea (p. 338). Foreign body ; Paracentesis ; Corneal section (Sae- misch's operation) ; Conical cornea.		
F. On the iris (p. 342). Iridectomy :—For artificial pupil ; for glaucoma ; Iridodesis ; Iridotomy (iritomy). Sclerotomy.		
G. For cataract (p. 349). Extraction :—Linear ; Graefe's " modified linear ; " Corneal section (Liebreich, Lebrun) ; Short flap (Wecker) ; Old flap. Treatment after extraction. Secondary operations. Discission or Solution ; Suc- tion. Treatment after solution and suction.		



# PART III.—DISEASES OF THE EYE IN RELATION TO GENERAL DISEASES

PAGE

## CHAPTER XXIII . . . 359—383

### A. GENERAL DISEASES (p. 359)

Eye diseases caused by:—Syphilis, acquired and inherited, diseases of optic nerve in relation to syphilis; Small-pox; Scarlet fever, typhus, &c.; Diphtheria; Measles; Chicken-pox and Whooping-cough; Malarial fevers; Relapsing fever; Epidemic cerebro-spinal Meningitis; Purpura and Scurvy; Pyæmia and Septicæmia; Lead poisoning; Alcohol; Tobacco; Quinine; Kidney disease; Diabetes; Leucocythæmia; Pernicious anæmia; Heart disease; Tuberculosis; Rheumatism and gonorrhœal rheumatism; Gout, personal and inherited; Struma; Entozoa.

### B. LOCAL DISEASE AT A DISTANCE FROM THE EYE (p. 374).

Eye symptoms caused by:—Megrin; Neuralgia; Diseases of brain;—Cerebral tumour; Syphilitic disease; Meningitis; Cerebritis; Hydrocephalus; Convulsions. Diseases of spinal cord:—Myelitis; Locomotor ataxy. General paralysis of insane.—Motor disorders of eyes and affections of the pupils in cerebral and spinal disease.

### C. THE EYE SHARING IN A LOCAL DISEASE OF THE NEIGHBOURING PARTS . . . (p. 381)

Eye symptoms caused by:—Herpes zoster of fifth nerve; Paralysis of fifth, of facial, and of cervical sympathetic nerves; Exophthalmic goitre; Erysipelas and orbital cellulitis.

The teeth in inherited syphilis (with woodcut, p. 383).

## APPENDIX . . . 385—396

Formulæ (p. 385).

Shades. Protective glasses (p. 392).

Test types, &c. (p. 392).

Ophthalmoscopes (p. 393).

Tests for colour blindness (p. 394).

Index . . . . . 397—411

NOTES ON THE HISTORY OF THE  
CITY OF BOSTON

The first settlement in Boston was made in 1630 by a group of Puritan settlers from England. They came to the city in search of religious freedom and a place to practice their faith. The city was founded on a small island in the harbor, and the settlers built a fort to protect themselves from the Native Americans. The city grew rapidly, and by 1640 it had a population of over 1,000 people. The city was the center of the Puritan movement in New England, and it played a major role in the development of the American colonies.

The city was the center of the Puritan movement in New England, and it played a major role in the development of the American colonies. The city was the center of the Puritan movement in New England, and it played a major role in the development of the American colonies. The city was the center of the Puritan movement in New England, and it played a major role in the development of the American colonies.

The city was the center of the Puritan movement in New England, and it played a major role in the development of the American colonies. The city was the center of the Puritan movement in New England, and it played a major role in the development of the American colonies. The city was the center of the Puritan movement in New England, and it played a major role in the development of the American colonies.

The city was the center of the Puritan movement in New England, and it played a major role in the development of the American colonies. The city was the center of the Puritan movement in New England, and it played a major role in the development of the American colonies. The city was the center of the Puritan movement in New England, and it played a major role in the development of the American colonies.



# PART I

## MEANS OF DIAGNOSIS

THE following abbreviations will be used in this work :

T. Tension of the eyeball.	r. Punctum remotum or far point.
E. Emmetropia.	p. l. Perception of light.
M. Myopia.	P. Pupil.
H. Hypermetropia.	' Sign for a foot.
m. H. Manifest hypermetropia.	" Sign for an inch.
l. H. Latent hypermetropia.	m. Metre.
Pr. Presbyopia.	cm. Centimetre.
As. Astigmatism.	mm. Millimetre.
A. Accommodation.	D. Dioptré, the unit in the metrical system of measuring lenses.
V. Acuteness of vision.	y. s. Yellow spot of the retina.
p. Punctum proximum or near point.	

---

## CHAPTER I

### OPTICAL OUTLINES.

1. Rays of light are deviated or refracted when they pass from one transparent medium, *e.g.* air, into another of different density, *e.g.* water or glass.

2. If the deviation in passing from vacuum into air be represented by the number 1, that for crown glass (of which ordinary lenses are made) is 1.5, and for rock crystal ("pebble" of opticians) 1.66. Each of these numbers is the "refractive index" of the substance. Every ray is refracted except the one which falls perpendicularly to the surface (Fig. 1 *a*).



3. In passing from a less into a more refracting medium the deviation is always towards the perpendicular to the refracting surface; in passing from a more into a less refracting medium it is always,

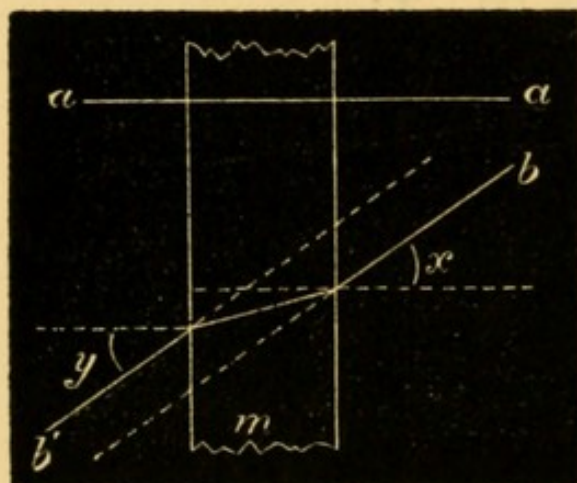


FIG. 1.—Refraction by a medium with parallel sides.

and to the same extent, away from the perpendicular (Fig. 1 *b*), *i. e.* the angle  $x$  in the Figure = the angle  $y$ .

4. Hence, if the sides of the medium (Fig. 1 *m*) be parallel, the rays on emerging (*b'*) are restored to their original *direction* (*b*), and if the medium be thin very nearly to their original *path*.

5. But if, as in a prism, the sides of *m* form an angle (Fig. 2 *a*) the angles of incidence and emergence ( $x$  and  $y$ ), still being equal, *b'* must also form an angle

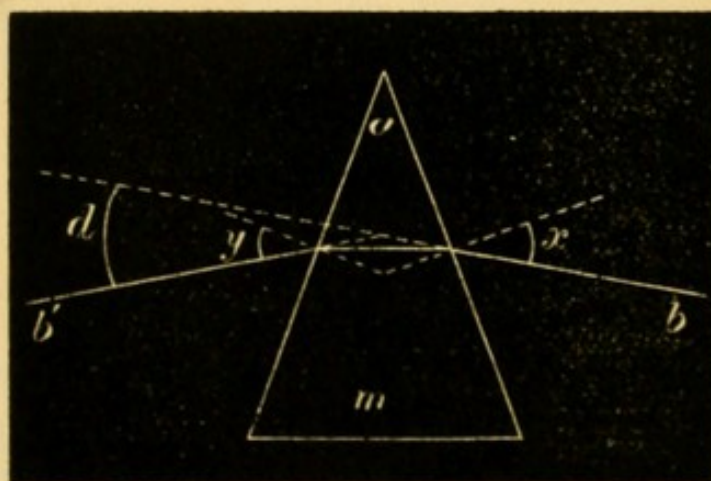


FIG. 2.—Refraction by a prism.

with *b*. The angle *a* is the “refracting angle” or edge of the prism; the opposite side is the “base.” The figure shows that light is always deviated *towards the base*. Crown glass prisms cause a deviation (represented by the angle *d*) equal to about half the refracting angle of the prism. The *rela-*



*tive* direction of the rays is not changed by a prism; if parallel or divergent before incidence they are parallel or similarly divergent after emergence (Fig. 3.).

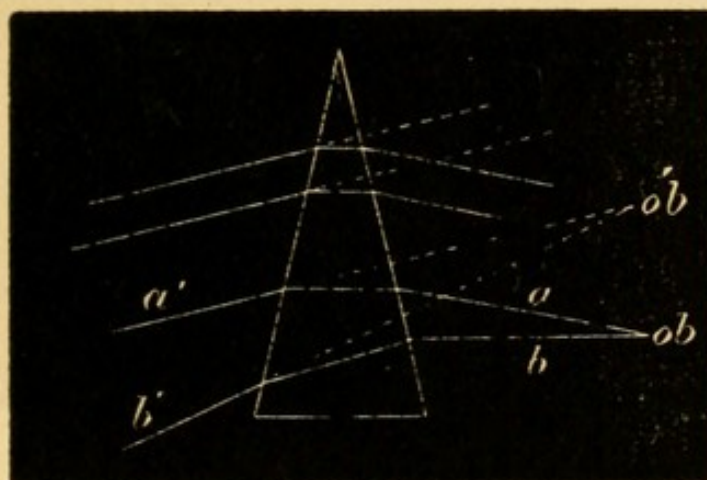


FIG. 3.—Apparent displacement of object by a prism.

6. Every object seems to lie, or is “projected,” in the direction of the rays *as they enter the eye*; *ob* (Fig. 3), seen by an eye at *a'* or *b'*, seems to be at *ob'*, where it would be if the rays *a' b'* had undergone no deviation.

7. For very thin *prisms* the deviation ( $\alpha$  and  $\beta$ , Fig. 4) remains the same for varying angles of incidence. For thin *lenses* this is expressed by saying that the angle  $d$ , Fig. 5, is the same for the rays *a a'*, *b b'*, and *c c'*, incident at different angles, but at the *same distance from the axis*.

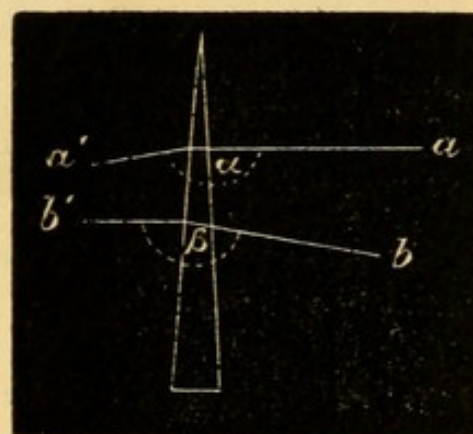


FIG. 4.—Refraction the same for different angles of incidence.

8. An ordinary lens is a segment of a sphere (plano-convex or plano-concave), or of two spheres whose centres are joined by the axis of the lens (biconvex or biconcave).

9. A lens is regarded as formed of an infinite number of minute prisms, each with a different refracting angle. Fig. 6 shows two such elements of a



convex lens, in which the angle ( $\alpha$ ) of the prism at the edge of the lens is larger than the angle ( $\beta$ )

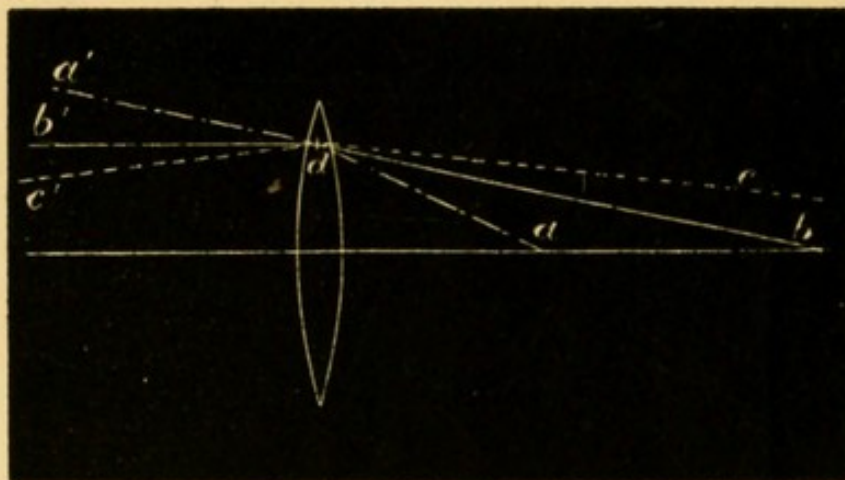


FIG. 5.—Refraction by a thin lens the same for all rays incident at the same distance from the axis.

of the prism nearer the axis. Hence, of the two parallel rays ( $a$  and  $b$ )  $a$  will

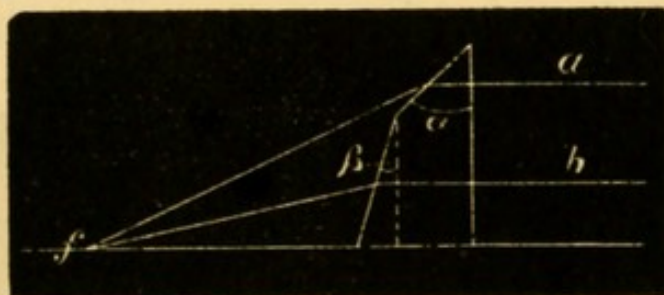


FIG. 6.—Prismatic elements of a convex lens.

(see § 5) be more refracted than  $b$ , and the rays will, after emergence converge and meet at  $f$ . Fig. 7 shows the corresponding facts for a concave lens, by which parallel rays are made divergent.

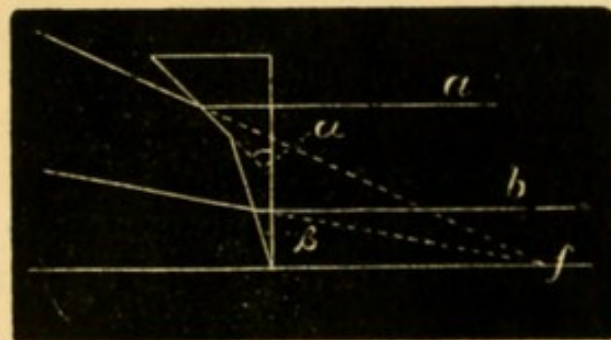


FIG. 7.—Prismatic elements of a concave lens.

10. The only ray not refracted by a lens is the one passing through the centre of each surface (compare § 2), which is the *principal axis* ( $ax$ , Fig. 8). *Secondary axes* are rays (such as  $s. ax$ ) entering and emerging at points on the lens parallel to each other, and hence (see § 4) not altered in direc-



tion; all rays which pass through the central point of the lens are secondary axes (except the principal axis).

11. The *principal focus* ( $f$ , Fig. 10) of a lens is the point to which rays parallel before incidence ( $aa$ ) converge after refraction, the deviation of each ray varying directly with its distance from the principal axis (Fig. 6).

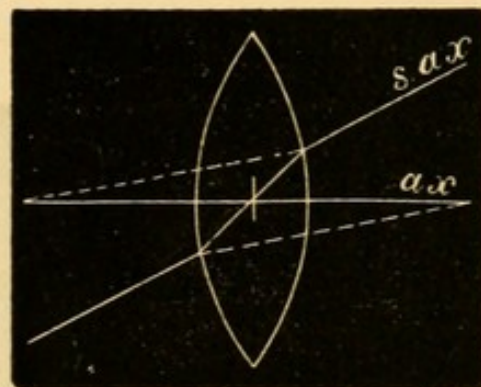


FIG. 8.—Axes of a lens.

But this is only approximately true. In an ordinary lens the rays ( $a$ , Fig. 9) which traverse the margin are disproportionately refracted, and meet sooner than the rays ( $b$ ) which lie nearer the axis; and the result is, not one focus but, a number

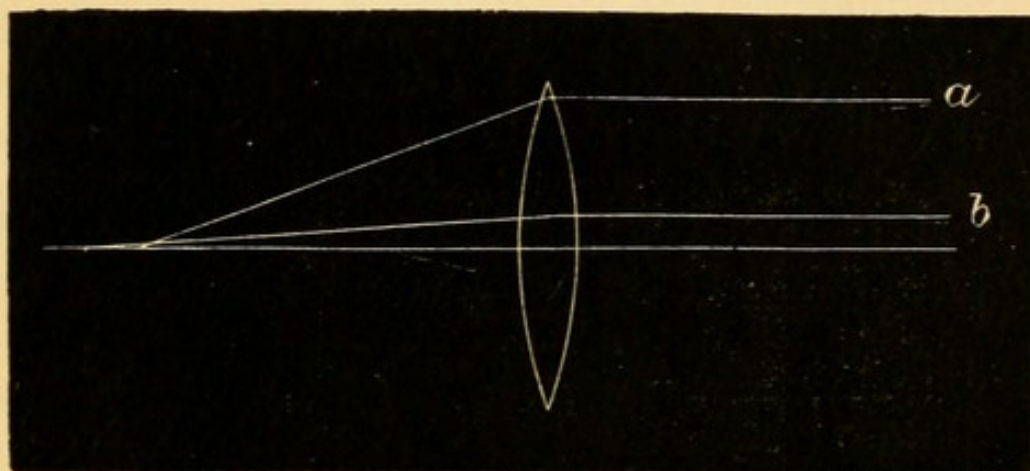


FIG. 9.—Spherical aberration.

of foci. This "spherical aberration" increases with the size of the lens. In the eye it is, to a great extent, removed by the iris, which prevents the light from passing through the marginal parts of the crystalline lens.

If parallel rays are incident from the side towards  $f$  (Fig. 10) they will be focussed at  $f'$ , at the same distance from the lens as  $f$ ; hence every lens has two principal foci—anterior and posterior.

12. The *path* of a ray passing from one point to another is the same, whatever its *direction*; the path of the ray  $bb'$  (Fig. 10) is the same, whether it pass from  $cf$  to  $c'f'$ , or in the opposite direction.



13. From § 7 it follows that in Fig. 10 the angles  $a$  and  $a'$  are equal, and hence the ray  $b$ , diverging from  $cf$ , will not meet the axis at  $f$ , but at  $c'f'$ ;

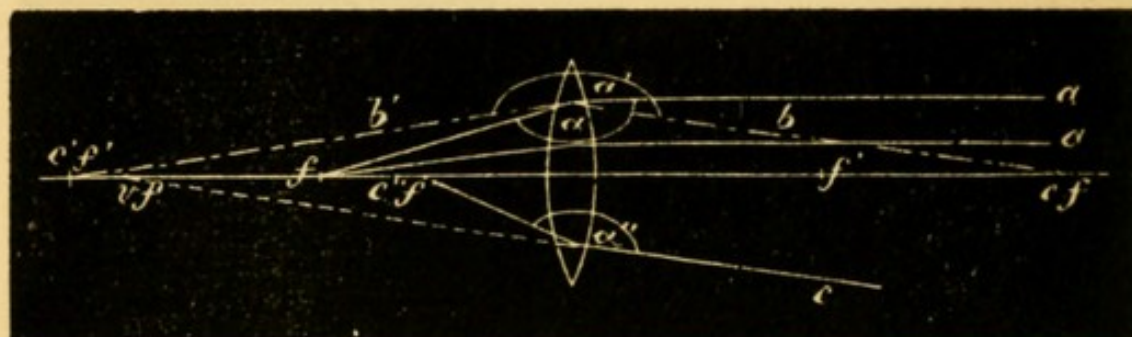


FIG. 10.—Foci of a convex lens.

$cf$  and  $c'f'$  are *conjugate points*, and each is the *conjugate focus* of the other. The angle  $a$  or  $a'$  remaining the same, then if  $cf$  be further from the lens  $c'f'$  will approach it. A ray ( $c$ ) converging to the axis will be focussed at  $c''f''$ , because  $a'' = a$ ; no real point conjugate to  $c''f''$  exists; but if the ray start from  $c''f''$  it will, on taking the direction  $c$ , appear to come from  $vf$ , which is the *virtual focus* of  $c''f''$  (see § 6).

14. Concave lenses have only virtual foci. In Fig. 11,  $a$ , parallel to the axis, is made divergent (see

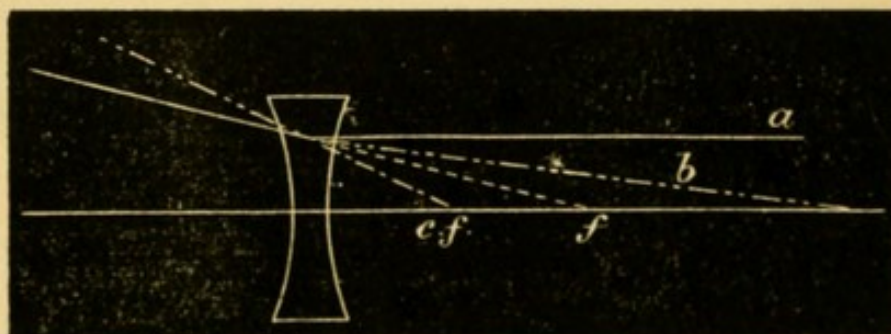


FIG. 11.—Foci of a concave lens.

Fig. 7), its virtual focus being at  $f$ ; similarly  $cf$  is the virtual conjugate focus of the point emitting the ray  $b$ .

15. In equally biconvex or biconcave lenses of crown glass the principal focus is at the centre of curvature of either surface of the lens.

16. *Images*.—The image formed by a lens consists of foci, each of which corresponds to a point on the



object. Given the foci of the boundary points of an object, we have the position and size of its image.

In Fig. 12 the object  $a b$  lies beyond the focus  $f$ .

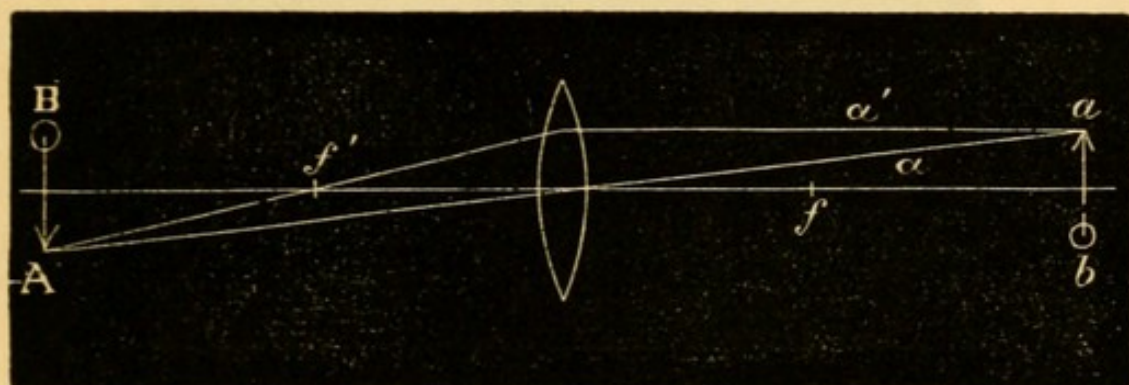


FIG. 12.—Real inverted image formed by a convex lens.

From the terminal point  $a$  take two rays  $a$  and  $a'$ , the former a secondary axis, and therefore unrefracted, the latter parallel to the principal axis, and therefore passing after refraction through the principal focus  $f'$ . These two rays (and all others which pass through the lens from the point  $a$ ) will meet at  $A$ , the conjugate focus of  $a$ . Similarly the focus of the point  $b$  is found, and the real inverted conjugate image of  $a b$  is formed at  $A B$ . The relative sizes of  $a b$  and  $A B$  vary as their distances from the lens.

If  $a b$  be so far off that its rays are virtually parallel on reaching the lens, its image  $A B$  will be at  $f'$ , and very small. If  $a b$  be at  $f$  its rays will be parallel after refraction (§ 11 and 12), and no image be formed. If  $a b$  lie between  $f$  (or  $f'$ ) and the lens, the rays will diverge after refraction, and again no image be formed (see Fig. 10,  $c'' f''$ ).

But in the two last cases a virtual image is seen by an eye so placed as to receive the rays. In Fig. 13 two rays from  $a$  take after refraction the course shown by  $a$  and  $a'$ , virtually meeting at  $A$  (see Fig. 10,  $v f$ ); and an observer at  $x$  will see at  $A B$  a virtual, magnified, erect image of  $a b$ .

The enlargement (in Fig. 13) is greater the nearer  $a b$  is to  $f'$ , and greatest when it is at  $f'$ . But, as  $A B$  has no real existence, its apparent size varies with



the known, or estimated, distance of the surface against which it is projected. A uniform distance

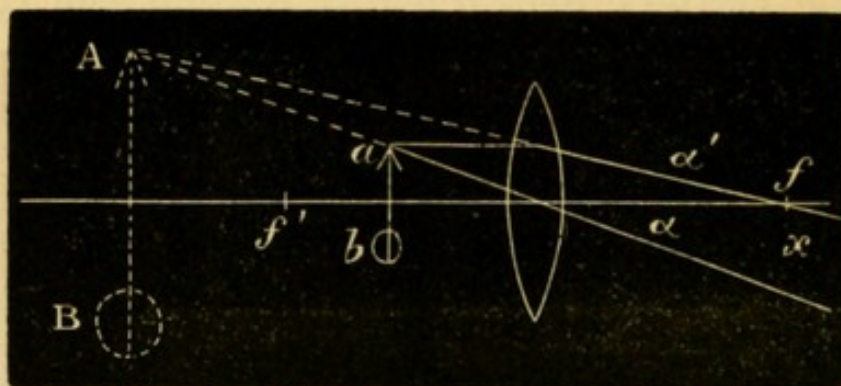


FIG. 13.—Virtual erect image formed by a convex lens.

of projection of about 12" (30 cm.) is taken in comparing the magnifying power of different lenses.

When  $ab$  is at  $f'$  (Fig. 13) we shall find on trial that the image  $AB$  can be seen well only by bringing the eye close up to the lens. At a greater distance only part of the object will be seen, and this part will be less brightly lighted, facts of importance in direct ophthalmoscopic examination (p. 52). Thus in Fig. 14

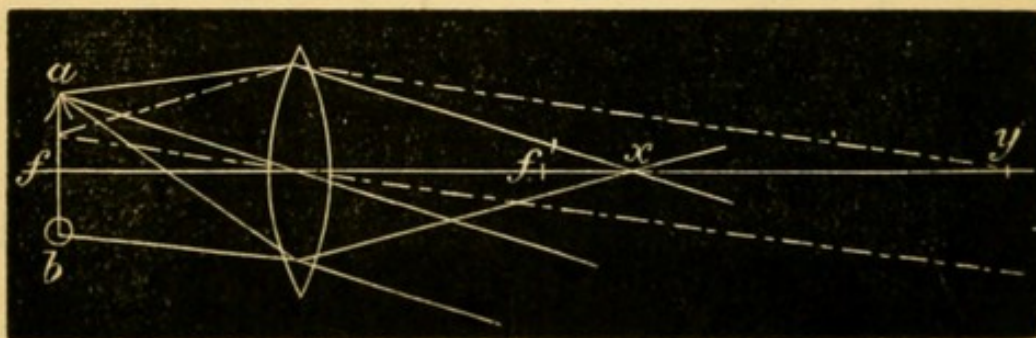


FIG. 14.—Virtual image; result of observer varying distance of his eye from the lens.

an observer placed anywhere between the lens and  $x$ , receiving rays from every part of  $ab$ , will see the whole image. But if he withdraw to  $y$ , his eye will receive rays only from the central part of  $ab$ , and will therefore not see the ends of the object.

It is easily shown by similar constructions that the images formed by concave lenses are always virtual, erect, and diminished, whatever the distance of the object (Fig. 15). (Compare Fig. 11).



17. The size of the image (whether real or virtual) varies with (1) the focal length of the lens, and (2) the distance of the object from the principal focus.

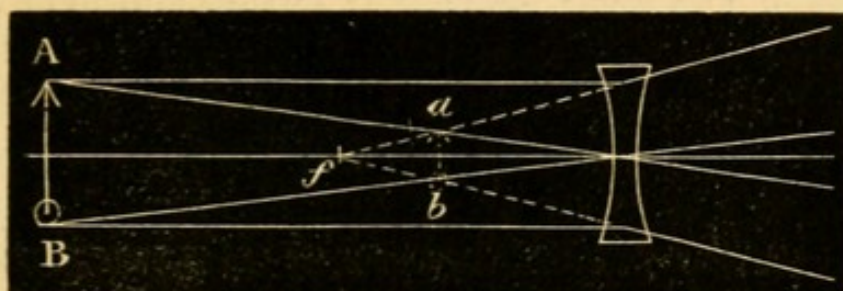


FIG. 15.—Image formed by a concave lens.

(1) The shorter the focus of the lens, the greater is its effect or the “stronger” it is; *the refractive power of a lens varies inversely as its focal length.*

(2) For a *convex* lens, the image (whether real or virtual) is larger (*i.e.* the effect greater) the nearer the object is to the principal focus (whether within or beyond it).

For a *concave* lens the image is smaller (*i.e.* the effect greater) the further the object is from the lens (whether within or beyond the focus).

18. *Prisms.*—Any object viewed through a prism seems displaced towards the edge of the prism, and to a degree which varies directly as the size of the refracting angle (§§ 5 and 6). The eye is directed towards the position which the object now seems to take, and this fact may be utilised for several purposes:—1. *To lessen the convergence* of the visual lines without removing the object further from the eyes. In Fig. 16 the eyes,  $R$  and  $L$ ,

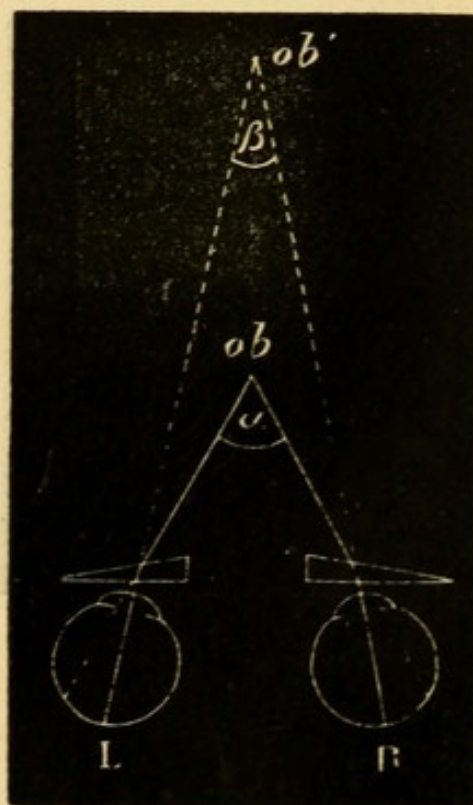


FIG. 16.—Effect of prisms in lessening convergence.



are looking at the object ( $ob$ ) with a convergence of the visual lines represented by the angle  $a$ . If prisms be now added with their edges towards the temples they deflect the light, so that it enters the eyes under the smaller angle  $\beta$ , as if it had come from ( $ob'$ ), and towards this point the eyes will be directed, though the object still remains at  $ob$ . The same effect is given by a single prism of twice the strength before one eye, though the actual movement is then limited to the eye in question. If spectacle lenses be placed so that the visual lines do not pass through their centres they act as prisms, though the strength of the prismatic action varies with the power of the lens and the amount of this "decentration" (see § 9, Figs. 6 and

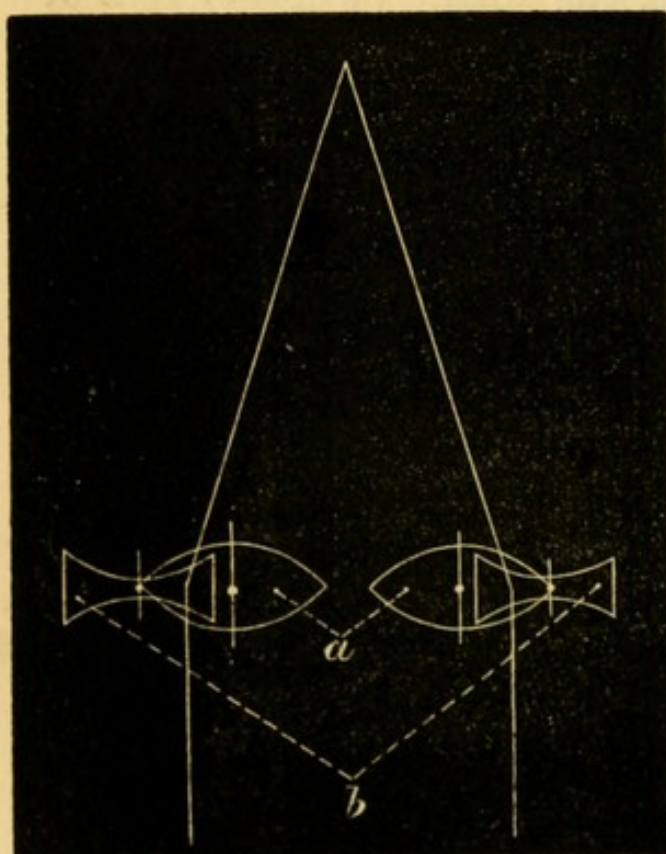


FIG. 17.—Lenses acting as prisms.

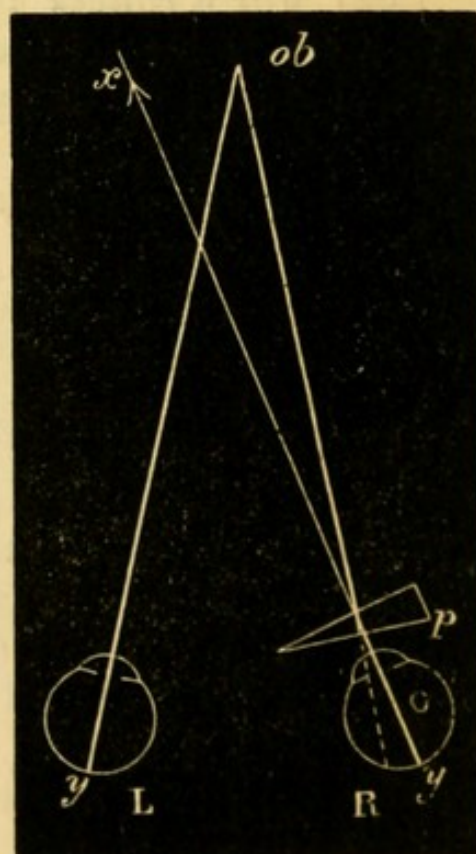


FIG. 18.—Diplopia removed by prism.

7). In Fig. 17 the visual lines pass outside the centres of the convex lenses ( $a$ ) and inside those of the concave lenses ( $b$ ). Each pair therefore acts as a prism with its edge outwards.—2. *To remove double*



vision caused by slight degrees of strabismus. The prism so alters the direction of the rays as to compensate for the abnormal direction of the visual line. In Fig. 18,  $R$  is directed towards  $x$  instead of towards  $ob$ , and two images of  $ob$  are seen (see Chap. XXI). The prism ( $p$ ) deflects the rays to  $y$ , the yellow spot, and single, binocular vision is the result.—3. *To test the strength of the ocular muscles.* In Fig. 19 the prism at first causes diplopia by displacing the rays from the yellow spot ( $y$ ) of the eye ( $R$ ) (Chap. XXI). By a compensating rotation of the eye (cornea) outwards, shown in the Fig. by the change of the transverse axis from 1 to 2,  $y$  is brought inwards to the situation of  $im$ , the images are fused and single vision restored; the effect of the prism is overcome by the action of the external rectus. This "fusion power" of the several pairs of muscles may be expressed by the strongest prism that each pair can overcome. The fusion power of the two external recti is represented by a prism of about  $8^\circ$ ; that of the two internals by  $25^\circ$  to  $35^\circ$  or more; that of the superior and inferior recti, acting against each other, by only about  $3^\circ$ .—4. *Feigned blindness of one eye* may often be exposed by means of the diplopia (unexpected by the patient) produced by a prism. The prism should be stronger than can be overcome by any effort, *e.g.*  $8^\circ$  or  $10^\circ$ , base upwards or downwards. The patient is often best thrown off his guard by holding the prism before the sound eye.

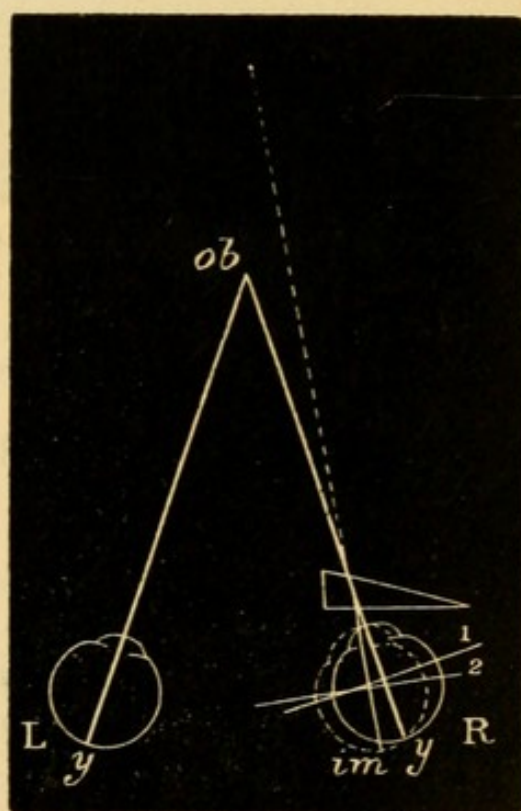


FIG. 19.—Prism used for testing strength of muscle.



If he now exclaims that he sees double he must of course be seeing with both eyes.

19. *Refraction of the eye.*—The eye presents three refracting surfaces:—the front of the cornea,\* the front of the lens, and the front of the vitreous; and in the normally formed or *emmetropic* eye, with the accommodation relaxed, the principal focus (§ 11) of these

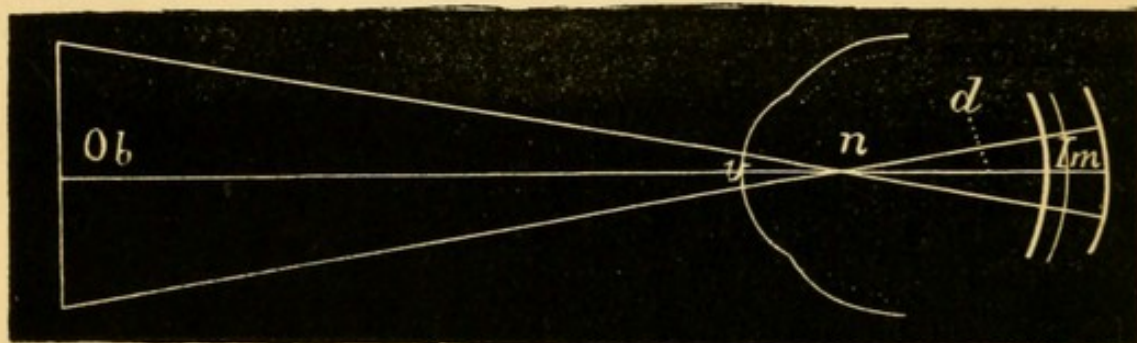


FIG. 20.—Visual angle and retinal image. *Ob*, object; *v*, visual angle; *n*, nodal point where the axial rays cross; *d*, distance from *n* to the retina. The position of the retina is shown by the three curved lines at the right-hand end, *H.* being represented by the line nearest to, and *M.* by the one furthest from *n*, whilst the middle thin line shows the retina in *E.*

combined dioptric media falls exactly upon the layer of rods and cones of the retina, *i.e.* the eye in a state of accommodative rest is adapted for parallel rays. The point at which the secondary axial rays (see § 10, Fig. 8) cross, the “posterior nodal point” (*n*, Fig. 20) lies, in the normally formed eye, at 15 mm. in front of the yellow spot of the retina, and very nearly coincides with the posterior pole of the crystalline lens. The angle included between the lines joining *n* with the extremities of the object (*ob*) is the *visual angle* (*v*). If the distance (*d*), from *n* to the retina, remain the same, the size of any image

\* The posterior surface of the cornea being parallel with the anterior, causes no deviation; and the aqueous has the same refractive power as the cornea. Hence the refractive effect of the cornea and aqueous is the same as if the corneal tissue extended from the front of the cornea to the front of the lens.



(*Im.*) on the retina will depend on the size of the angle  $v$ , and this again on the size and distance of *ob.* But if the distance ( $d$ ) alters, the size of the image (*Im*) is altered without any change in  $v$ . Now the length of  $d$  varies with the length of the posterior segment of the eye; it is greater in myopia (M.) and less in hypermetropia (H.); and hence the retinal image of an object at a given distance is as the Fig. shows larger in myopia and smaller in hypermetropia than in the normally formed eye. The length of  $d$  also varies with the position of  $n$ , and this is influenced by the positions and curvatures of the several refractive surfaces.  $n$  is advanced very slightly by the increased convexity of the lens during accommodation, but much more so if the same change of refraction is induced by a convex lens held in front of the cornea: hence convex lenses by lengthening  $d$ , enlarge the retinal images. Concave lenses put  $n$  further back, and, by thus shortening  $d$ , lessen the images. If the lens, which corrects any optical error of the eye, be placed at the "anterior focus" of the eye,\* 13 mm., or half an inch, in front of the cornea,  $n$  moves to its normal distance (15 mm.) from the retina, and the images are therefore reduced or enlarged to the same size as in the emmetropic eye.

The length of the *visual axis*, a line drawn from the yellow spot to the cornea in the direction of the object looked at, is about 23 mm. The centre of rotation of the eye is rather behind the centre of this axis, and 6 mm. behind the back of the lens. The focal length of the cornea is 31 mm., and that of the crystalline lens varies from 43 mm. with accommodation relaxed, to 33 mm. during strong accommodation.

\* The anterior focus is the point where rays, which were parallel in the vitreous, are focussed in front of the cornea.



The *optical conditions of clear sight* are as follows :

(1) The image must be formed exactly on the retina, *i.e.* the retina must lie exactly at the focus of the dioptric media for the object looked at. (2) The image must be formed at the centre of the yellow spot (Chap. II, § 11). (3) The image must have a certain size, and this is expressed by the size of the corresponding visual angle ( $v$ , Fig. 20) ; with average light  $v$  must be equal to at least five minutes ( $\frac{1}{12}$ th of a degree) in order that the form of the image may be perceived ; an object subtending any smaller angle (down to about one minute) is still visible, though only as a point of light.—*Influence of the pupil.*—Other things being equal the larger the pupil the worse is the sight, the clearness of the images being lessened by the spherical aberration caused by the marginal part of the lens (Fig. 9). For the same reason troublesome distortion of the images is often caused by the operation of iridectomy.

The smaller the pupil the less is the spherical aberration (p. 5), and, *cæt. par.*, the better the V. Also the smaller the pupil the less is the accommodation needed for near vision. If the pupil be so small as to subtend an angle ("angle of divergence") of not more than 5 minutes with any point on the object, the latter will be clearly seen without effort of accommodation at its full distance D. (p. 32). By calculation it appears that if the pupil had a diameter = .66 mm. it would subtend an angle of divergence of 5 minutes at about .5 m. (18"); *i.e.* with a pupil of .66 mm. the finest point should be clearly seen (with strong light) at 18" without any accommodation. This may be successfully demonstrated by looking through a hole of the above size in a thin card held as close as possible to the eye.

*Numeration of spectacle lenses.*—Some system of numbering is required which shall indicate the refractive power of the lenses used for spectacles. Two systems are current.—In the *first system*, which was till lately universal, the unit of strength is a strong lens of 1" focal length. As all the lenses used are weaker than this, their relative strengths can be



expressed only by using fractions. Thus, a lens of 2" focus being half as strong as the unit (§ 17, 1), is expressed as  $\frac{1}{2}$ ; a lens of 10" focus is  $\frac{1}{10}$ ; of 20" focus  $\frac{1}{20}$ ; and so on. The objections are, that fractions are inconvenient in practice; that the intervals between the successive numbers are very unequal; and that the length of the inch is not the same in all countries, so that a glass of the same *number* has not quite the same focal length when made by the Paris, English, and German inches respectively.\* —In the *second system*, which is fast displacing the old one, the metrical scale is used, and the unit is a weak lens of 1 metre (100 cm.) focal length, and is known as a dioptré (D); the lenses differ by equal refractive intervals. A lens twice as strong as the unit, with a focal length of half a metre (50 cm.), is 2 dioptrés (2 D), a lens of ten times the strength, or one tenth of a metre focus (10 cm.), is 10 D, and so on. The weakest lenses are .25, .5, and .75 D, and numbers differing by .5 or .25 D are also introduced between the whole numbers. A slight inconvenience of the metrical dioptric system is that the number of the lens does not express its focal length. This, however, is obtained by dividing 100 by the number of the lens in D; thus the focal length of 4 D =  $\frac{100}{4} = 25$  cm. If it is desired to convert one system into the other, this can be done, provided that we know what inch was used in making the lens whose equivalent is required in D. The metre is equal to about 37" French and 39" English or German; a lens of 36" French (No. 36 or  $\frac{1}{36}$  old scale), or of 40" English or German (No. 40 or  $\frac{1}{40}$ ), is very nearly the equivalent of 1 D. A lens of 6" French ( $\frac{1}{6} = \frac{6}{36}$ ) will therefore be equal to 6 D; a lens of 18" French ( $\frac{1}{18} = \frac{2}{36}$ ) = 2 D, &c.; a lens of 4 D =  $\frac{4}{36} = \frac{1}{9}$ , *i. e.* a lens of 9" French, &c.

\* 1" English = 25.3 mm., 1" French = 27 mm., 1" Austrian = 26.3 mm., 1 Prussian = 26.1 m.m.



The following lenses are used for spectacles, and are, therefore, necessary in a complete set of trial glasses. The first column gives the number in D, the second the focal length in centimetres, the third the approximate numbers on the French inch scale, the denominator of each fraction showing the focal length in French inches. In some cases there are no equivalent lenses made on the inch system.—In this table, and throughout the book, convex lenses are indicated, according to custom, by the + sign; concave lenses by the — sign.



1. No. in D. + (Convex) or - (Concave).	2. Focal Length in cm.	3. No. and Focal Length in Paris inches.
0.25.....	400.....	.....
0.5.....	200.....	$\frac{1}{7\frac{1}{2}}$
0.75.....	133.....	$\frac{1}{5\frac{1}{3}}$
1.....	100.....	$\frac{1}{3\frac{1}{2}}$
1.25.....	80.....	$\frac{1}{3\frac{1}{3}}$
1.5.....	66.....	$\frac{1}{2\frac{1}{4}}$
1.75.....	57.....	$\frac{1}{2\frac{1}{2}}$
2.....	50.....	$\frac{1}{1\frac{1}{3}}$
2.25.....	44.....	$\frac{1}{1\frac{1}{6}}$
2.5.....	40.....	$\frac{1}{1\frac{1}{4}}$
2.75.....	36.....	$\frac{1}{1\frac{1}{3}}$
3.....	33.....	$\frac{1}{1\frac{1}{2}}$
3.5.....	28.....	$\frac{1}{1\frac{1}{5}}$
4.....	25.....	$\frac{1}{9}$
4.5.....	22.....	$\frac{1}{8}$
5.....	20.....	$\frac{1}{7}$
5.5.....	18.....	.....
6.....	16.....	$\frac{1}{6}$
7.....	14.....	$\frac{1}{5\frac{1}{2}}$
8.....	12.5.....	$\frac{1}{4\frac{1}{2}}$
9.....	11.....	$\frac{1}{4}$
10.....	10.....	$\frac{1}{3\frac{1}{2}}$
11.....	9.....	.....
12.....	8.3.....	$\frac{1}{3}$
13.....	7.7.....	.....
14.....	7.....	$\frac{1}{2\frac{3}{4}}$
15.....	6.7.....	$\frac{1}{2\frac{1}{2}}$
16.....	6.2.....	$\frac{1}{2\frac{1}{4}}$
18.....	5.5.....	$\frac{1}{2}$
20.....	5.....	.....





## CHAPTER II

## EXTERNAL EXAMINATION OF THE EYE

(1.) To detect *irregularity of the corneal surface*; whilst the patient follows with his eyes some object, *e.g.* the uplifted finger, moved slowly in different directions, watch the reflection of the window from the cornea; it will be suddenly broken by any irregularity, such as an abrasion or ulcer.

(2.) To estimate the *tension of the eyeball* (T.); the patient looks steadily down, and gently closes the eyelids; the observer then makes light pressure on the globe through the upper lid, alternately with a finger of each hand, as in trying for fluctuation, but much more delicately. The finger-tips are placed very near together, and as far back over the sclerotic as possible. The pressure must be gentle, and be directed vertically *downwards, not backwards*. It is best for each observer to keep to one pair of fingers, not to use the index at one time and the middle finger at another. Patient and observer should always be in the same relative position, and it is best for both to stand and face one another. Always compare the tension of the two eyes. Be sure that the eye does not roll upwards during examination, for if this occur a wrong estimate of the tension may be formed. Some test both eyes at once with two fingers of each hand. Normal tension is expressed by T. n. The degrees of increase and decrease are indicated by the + or - sign, followed by the figure 1, 2, or 3. Thus T.+1 means decided increase; T.+2, greater increase, but sclerotic can still be indented; T.+3, eye very hard, cannot be indented



by moderate pressure; T.—1—2—3 indicate successive degrees of lowered tension. A note of interrogation (T.? + or ?—) for doubtful cases, and T. n. for the normal, give nine degrees, which may be usefully distinguished. Equally good observers often differ in regard to the minor changes of tension. Apart from variations in delicacy of touch it is to be remembered that eyes deeply set in the orbits are more difficult to test, and that T. in a few cases really does change at short intervals, *e. g.* within half an hour. Increased rigidity of the sclerotic, which occurs naturally in old age and sometimes from disease, alters the apparent tension, though the internal pressure may be normal or even too low. When a blind eye contains bone it feels like wood covered with washleather.

(3.) The *mobility of the eyeball* may be impaired in any or every direction, and in any degree. Commonly only one eye is affected. First, to test the lateral and vertical movements, direct the patient with both eyes open to look successively towards, or follow a pencil or finger moved in each of, the four directions, up, down, right and left; next, to test the convergence power he looks at the object held vertically in the middle line, rather below the horizontal, and gradually approached from 2' to about 6". In each position we must notice both eyes; thus, when the patient looks to his right we have to note the outward movement of his right and the inward movement of his left. The fixed marks for the inward and outward movements are the inner and outer canthi, and as the apparent range of movement judged in this way varies a little in different people, the corresponding movements of the two eyes should always be compared. In looking strongly outwards the corneal margin does not in all persons quite reach the outer canthus, but it always reaches the inner canthus during inward rotation. In children and stupid people the movements are often defective simply from



inattention. In very myopic eyes the movements are somewhat defective in all directions. The vertical movements are best shown by noting the position of the cornea in relation to the border of the lower lid; the border of the upper lid is less trustworthy, since there may be some ptosis or other cause of inequality between the two sides.

(4.) *Squint or strabismus* exists if the visual axes are not both directed to the same object. A squint may be the result either of over-action, or of weakness or paralysis, of a muscle. The internal recti by excessive contraction often cause convergent squint; most other forms of strabismus result from actual defect of nervous or muscular power.

When a squint is well marked there is no difficulty in identifying the squinting eye as the one which is misdirected when an object is held up to the patient's attention: in most cases the patient always squints with the same eye, but a few persons can squint with either indifferently (*alternating squint*). Nor is there often any doubt as to whether the squint is internal (convergent) or external (divergent), *i.e.* whether the axis of the squinting eye crosses that of its fellow between the patient and the object he looks at, or crosses it beyond this object, or even positively diverges from it; upward or downward squint, though less common, is almost as evident. But to prove beyond doubt which is the squinting eye, direct the patient to look at a pencil held up in the middle line at about 18" from his face, and with a card or piece of ground glass cover the apparently sound, or "working" eye; the squinting eye will at once move so as to look at, or "fix," the pencil, proving that it had previously been misdirected. If the sound eye be watched behind the screen it will be seen to squint as soon as the affected eye "fixes" the object; this is known as the *secondary squint*, and its direction is the same as that of the original or *primary squint*. Thus, if the primary squint is



convergent, the secondary will also be convergent. In squint from overaction, or from mere disuse of one muscle, the secondary and primary deviations are equal, but in paralytic squint the secondary often exceeds the primary. If the squinting eye retains full range of movement, *i. e.* moves in companionship with its fellow in all directions, the squint is termed *concomitant*, in contradistinction to *paralytic*; hence in every case of squint it is necessary to test the mobility of the eyes. It is also important to note whether the squint is constant or only occasional (*periodic*).\*

(5.) *Diplopia* (*double sight*) is almost always a result of squint, but the most troublesome diplopia is often caused by a deviation too slight to be perceptible. Diplopia caused by squint is of course binocular, and disappears when one eye is covered. Uniocular diplopia (double sight with one eye), however, often occurs in commencing cataract, and has been described in some cases of cerebral tumour. In the former it has a physical cause in the crystalline lens (*see* Cataract); in the latter it must depend upon some cerebral change.

To find out what defect of movement is causing binocular diplopia, darken the room, and ask the patient to follow with his eyes a lighted candle, held about 6' from him, moved successively into different

\* It is necessary to be aware that an *apparent squint*, either external or internal, is sometimes met with. The *optic* axis of the eye passes from a point rather to the inner side of the y. s. through the centre of the cornea, and forms a small angle ("angle *a*") with the *visual* axis, the line which joins the y. s. to the object looked at and commonly cuts the cornea rather within its centre. As we judge of the apparent direction of a person's eyes by the centres of his corneæ (*i. e.* by the *optic* axes), a slight apparent outward squint will be produced if the angle *a* be (as in many hypermetropic eyes) larger than usual, and an apparent convergent squint if, as in myopia, it be smaller. Apparent squint is always slight, and the screen test described in the text gives a negative result.



positions, and to describe the relative places of the double images in each position. Ascertain which of the two images belongs to each eye by placing before one eye a strongly coloured glass, or by covering one eye and asking which image disappears. In many cases the image formed in the squinting eye (the "false" image) is less bright or distinct, and this difference gives a valuable means of distinguishing the sound from the affected eye; but the patient does not always notice such a difference between the two images, and it may then be difficult to be sure which eye is at fault. The patient's replies should be recorded on such a diagram as that shown at Fig. 114; the radii may of course be increased for intermediate positions. The false image is marked by the dotted line, the true one by the unbroken line. We have thus a graphic representation of the candle as it appears to the patient, and can deduce from the apparent position of the false image what movements of the corresponding eye are at fault, and, consequently, which muscle or muscles are defective. It is *essential that the patient should not move his head* during the examination, and that he remain throughout at the same distance from the candle. Remember that, in the extreme lateral movements, the nose interferes, and eclipses one image. When the double images are very wide apart the patient sometimes fails to notice the false image.

For the diagnosis of a case of diplopia it is often sufficient to ask in which directions the double sight is most troublesome, and how the images appear in respect to height, lateral separation, and apparent distance from the patient (Chap. XXI).

(6.) *Protrusion (proptosis) and enlargement of the eye.*—Unequal prominence of the two eyes is best ascertained by seating the patient in a chair, standing behind him, and comparing the summits of the two corneæ with each other, and with the bridge of the nose, or the line of the eyebrows. The appearance of



prominence or recession, as seen from the front, depends very much on the quantity of sclerotic exposed; thus, slight ptosis gives a sunken appearance to the eyes, and in slight cases of Graves's disease the proptosis seems to increase when the upper lids are spasmodically raised. It is to be remembered that real prominence of the eye may depend on enlargement of the eyeball (myopia, staphyloma, intra-ocular tumour), as well as on its protrusion, and that if only one eye be myopic, the appearance will be unsymmetrical. Decided proptosis may follow tenotomy or paralysis of one or more ocular muscles. In hypermetropia, in which the eyeball is too short, and in the rare cases of paralysis of the cervical sympathetic, the eye often looks sunken.

(7.) Information derived from *the blood-vessels visible on the surface of the eyeball*.—Three systems of vessels have to be considered in disease; they are, however, usually too small to be seen to perfection in health. (1) The vessels proper to the conjunctiva (*posterior conjunctival vessels*), in which it is not important to distinguish between arteries and veins (Fig. 21, *Post. Conj.*, and Fig. 22). (2) The *anterior ciliary vessels*, lying in the subconjunctival tissue, and which, by their perforating branches, supply the sclerotic, iris, and ciliary body, and receive blood from Schlemm's canal and the ciliary body, the perforating branches of the *arteries* (Fig. 21 A) are seen in health as several comparatively large tortuous vessels which stop short about  $\frac{1}{12}$ " or  $\frac{1}{8}$ " from the corneal margin (Fig. 23); their episcleral non-perforating branches are invisible in health, but so numerous as to form, when distended, a pink zone of fine, nearly straight, very closely-set vessels round the cornea (Fig. 21 A and Fig. 24) ("ciliary congestion," "circum-corneal zone," see Iritis and Diseases of Cornea); the perforating *veins* are very small, but more numerous than the perforating arteries (Fig. 21v), and their episcleral twigs form a closely-meshed



network (Fig. 25). (3) The vessels proper to the margin of the cornea and immediately adjacent zone of conjunctiva (*anterior conjunctival vessels*, and their *loop plexus on the corneal border*, Fig. 21 *l* and Fig. 48);

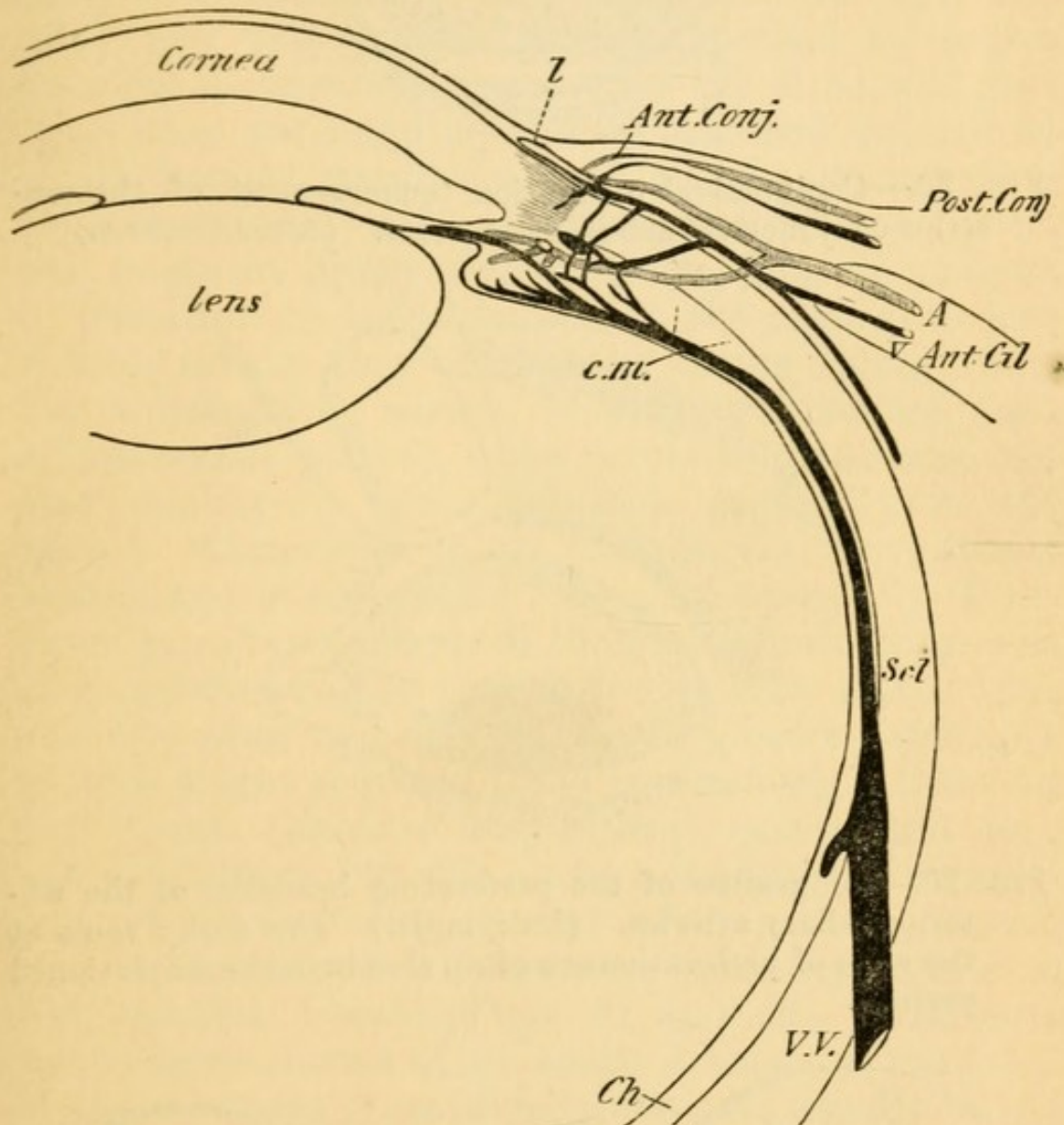


FIG. 21.—Vessels of the front of the eyeball. *c.m.* Ciliary muscle. *Ch.* Choroid. *Scl.* Sclerotic. *V.V.* Vena vorticiosa. *l.* Marginal loop-plexus of cornea. *Ant.* and *Post. Conj.* Anterior and posterior conjunctival vessels. *Ant. Cil. A.* and *V.* Anterior ciliary arteries and veins. (Simplified and altered from Leber.)

by these numerous minute branches, which are offshoots of the anterior ciliary vessels, Systems 1 and 2 anastomose.

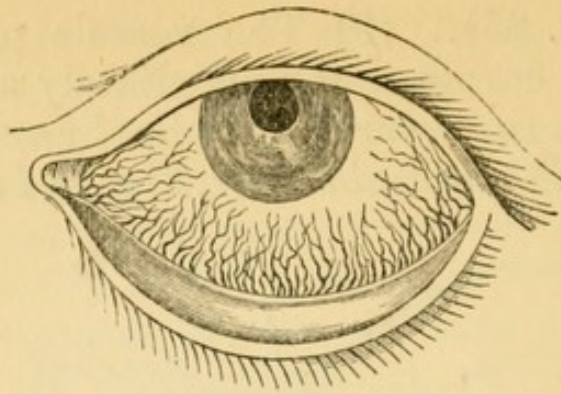


FIG. 22.—Conjunctival congestion (engorgement of the posterior conjunctival arteries and veins. (After Guthrie.)

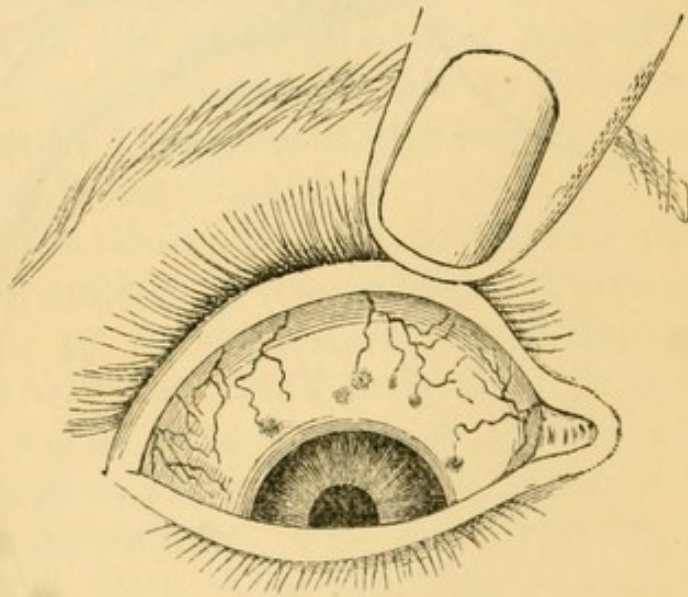


FIG. 23.—Congestion of the perforating branches of the anterior ciliary arteries. (Dalrymple.) The dusky spots at the seats of perforation are often seen in dark-complexioned persons.

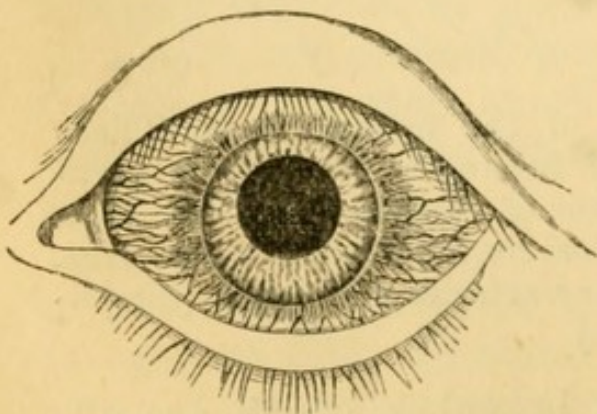


FIG. 24.—“Ciliary congestion” (engorgement of episcleral twigs of anterior ciliary arteries). (After Dalrymple.)

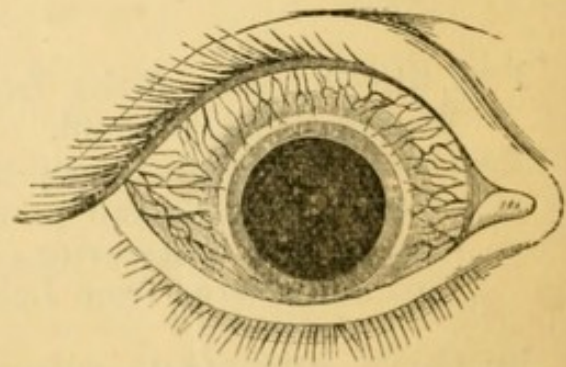


FIG. 25.—Congestion of anterior ciliary veins (episcleral venous plexus). (After Dalrymple.)



Speaking generally, congestion composed of tortuous, bright-red (brick-red) vessels (System 1) moving with the conjunctiva when it is slid over the globe, and least intense just around the cornea (Fig. 22), indicates a pure conjunctivitis (ophthalmia), and will usually be accompanied by mucopurulent or purulent discharge. (2) A zone of pink congestion surrounding the cornea, and formed by small, straight, parallel vessels, closely set, radiating from the cornea, and not moving with the conjunctiva (anterior ciliary *arterial* twigs, Fig. 24), points to irritation or inflammation of the cornea, or iris. A more scanty zone of dark or dusky colour (Fig. 25), which, when severe, is finely reticulated (*episcleral venous plexus*), often points to glaucoma, but may accompany other diseases, especially in old people. Congestion in the same region, more deeply seated, and of a peculiar lilac tint, especially if unequal in different parts of the zone, shows cyclitis or deep scleritis. (3) Congestion in the same zone, and also composed of small vessels, but superficially placed, bright red, and often encroaching a little on the cornea (*anterior conjunctival vessels* and *loop plexus of cornea*, Fig. 48), shows a tendency to irritable but often superficial corneal inflammation. Localised or fasciculated congestion generally points to phlyctenular disease (Figs. 41 and 42). Although in the severe forms of all acute diseases of the front of the eye these types of congestion are usually mixed and but imperfectly distinguishable, much information may often be derived from attention to the leading forms described.

(8.) Note the *colour of the iris*, and compare it with that of the fellow eye. In some persons the irides, although healthy, are of different colours, one blue or grey, the other brown or greenish; and sometimes one iris shows large patches of lighter or darker colour than its fellow (piebald). But if the iris of an inflamed eye looks greenish while its fellow



is blue we should suspect iritis; and if the iris of a defective eye be different from its fellow some morbid changes should be suspected (Chap. VIII).

(9.) *The pupils* are to be examined as to (1) equality, (2) size in ordinary light, (3) mobility, (4) shape. The pupils are often large and inactive, and sometimes oval, in amaurotic patients, in glaucoma, and in paralysis of the circular fibres of the iris (supplied by the third nerve). They may be too large but quite active in myopia and in conditions of defective nerve-tone. Wide dilatations of one or both pupils, with dimness of sight of a few days' duration, and without ophthalmoscopic signs of disease, is usually traceable to atropine or belladonna, used by accident or design, causing paralysis of accommodation. When very small the pupil is seldom quite round.

The centre of the pupil usually lies a little to the nasal side of the corneal centre.\* The pupils should be round and, when equally lighted, equal in size. When one eye is shaded its pupil should dilate considerably, and on exposure contract quickly to its former size ("*direct reflex action*") : during this trial the other pupil will act, but to a much less extent ("*indirect reflex action*"). The pupils contract when the gaze is directed to a near object (say 6" distant), *i.e.* during accommodation and convergence, and dilate in looking at a distant object; but the range of this "*associated action*" is much less than that of the reflex action. The pupil dilates when painful impressions are made on the sensory nerves of the skin, *e.g.* by the faradaic brush or by pricking with a pin. The pupils may be motionless to light and shade from iritic adhesions (p. 116) or from atrophy of the iris in glaucoma or other local disease; such conditions should be carefully noted or excluded. Reflex action

\* This natural eccentricity varies much both in degree and exact position in different persons. (Compare Irregular Astigmatism.)



is lost when the eyes are blind from disease of the optic nerves or retinae; if only one eye be blind the direct action of its pupil will be lost, but (unless there be disease of its third nerve also) the indirect action will be much greater than in health. When one eye is blind its pupil is often rather larger than the other. Reflex action may also be lost without any affection of sight, and *without loss of associated action* (Chap. XXIII).

The dilatation effected by atropine is often less in old than in young people. Permanent inequality of pupils without disease is rare, unless the two eyes differ widely in refraction (Chap. XX); but temporary dilatation of one pupil is not uncommon. When very active pupils are suddenly exposed after being shaded they often oscillate for a few seconds before settling, and finally remain a little larger than at the first moment of exposure. Considerable differences, both in *range* and *rapidity* of action of the pupils, are compatible with health; in general, however, the pupils become smaller and lose both in range and rapidity with advancing years. Marked inactivity, with small size, should excite suspicion of spinal or cerebral disease. The pupils are smaller whenever the iris is congested, whether this be a merely local condition (*e.g.* in abrasion of cornea), or form part of a more general congestion, as in typhus fever\* and in plethoric states, or be caused by venous obstruction, as in mitral regurgitation and bronchitis. They are large in anæmia, and in cases where the systemic arteries are badly filled, such as aortic insufficiency,† and during rigors.

(10.) *The field of vision* is the entire surface from

\* The small pupil of typhus and the frequently large pupil of typhoid are ascribed by Murchison to the differences in the vascularity of the iris (as a part of the whole eyeball) in the two diseases. 'Continued Fevers,' 541.

† See an article on "The Indications afforded by the Pupil," 'Medical Examiner,' March 2, 1879.



which, at a given distance, light reaches the retina,\* the eye being stationary (Fig. 26). If each part of the field is equidistant from the part of the retina to which it corresponds, the field will be hemispherical, with its inner or concave surface towards the eye; it may, however, be projected on to a flat surface, and for many clinical purposes this is sufficient. For roughly testing the field, *e. g.* in a case of chronic glaucoma, or of atrophy of optic nerve, or of hemianopsia, the following is generally enough. Place the patient with his back to the window; let him cover one eye, and look steadily at the centre of your face or nose at a distance of 18" or 2'. Then hold up your hands with the fingers spread out in a plane with your face, and ascertain the greatest distance from the central point at which they are visible

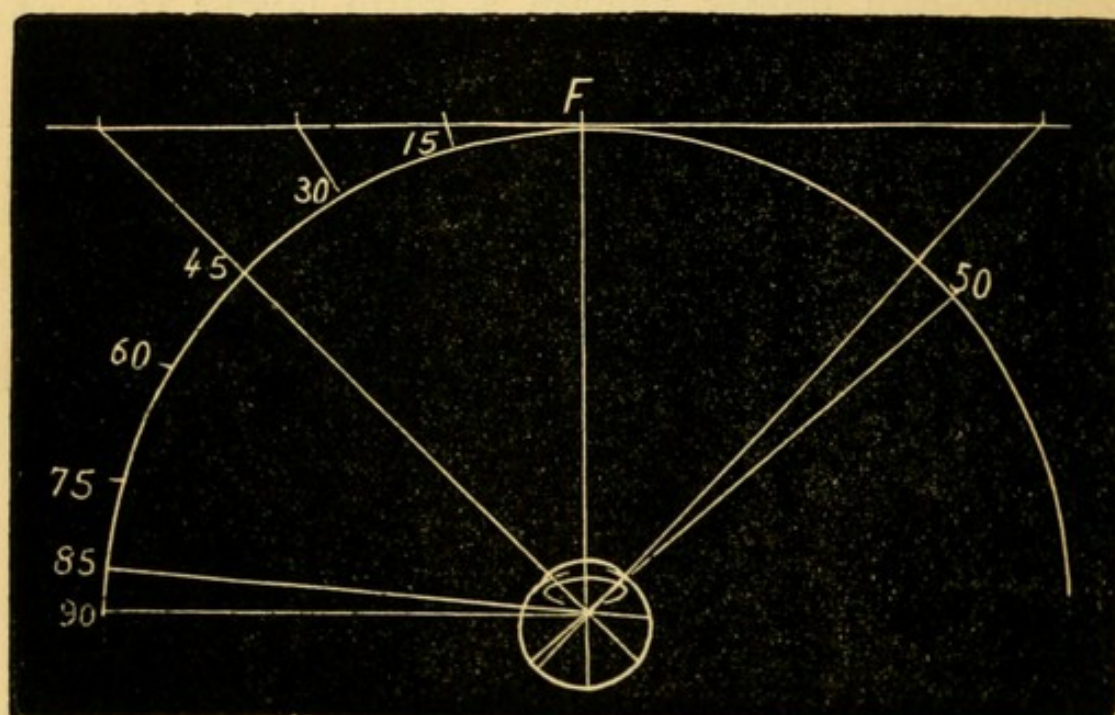


FIG. 26.—Field of vision with radius of 12", projected up to 45° on to a flat surface two feet square. F, fixation spot.

in various directions—up, down, in, out, and diagonally. It is essential that the patient should look

\* Strictly "the percipient part of the retina." It now seems established that the most peripheral zone of the retina is not sensitive to light. (Landolt.)



steadily at the face, and not allow his eye to wander after the moving fingers.

A more exact method is to make patient gaze, with one eye closed, at a white mark (the "fixation spot") on a large black board at a distance of 12" or 18", and to move a piece of white chalk set in a long black handle from various parts of the periphery towards the fixation spot, until the patient exclaims that he sees something white. If a mark be made on the board at each of about eight such peripheral points, a line joining them will give with fair

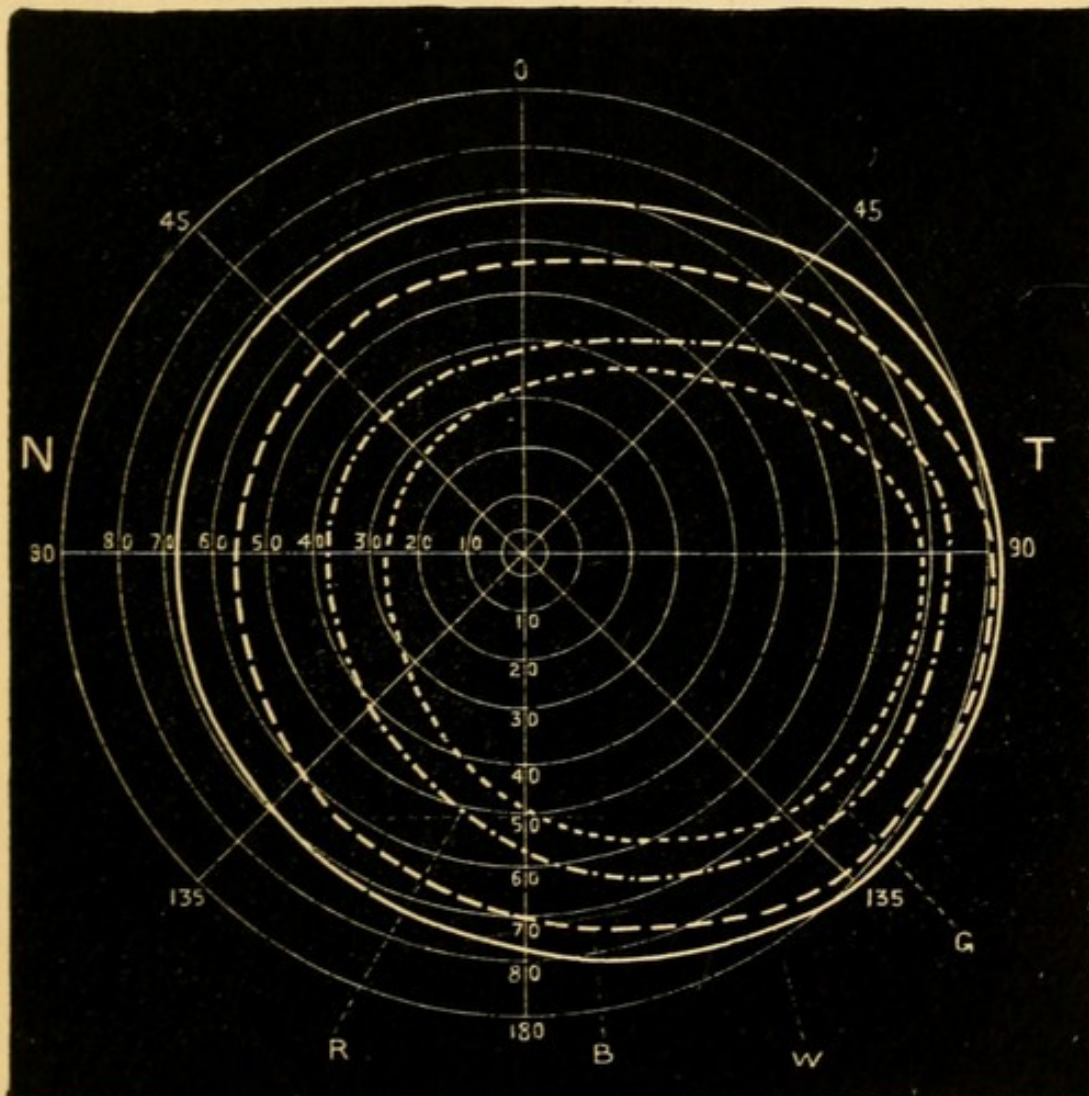


FIG. 27.—Field of vision of right eye as projected by the patient on the inner surface of a hemisphere, the pole of which forms the object of regard. T, temporal, N, nasal side. W, boundary for white, B, for blue, R, for red, G, for green. (Landolt.)



accuracy the boundary of the visual field if it be not larger than  $45^\circ$  in any direction; but beyond that angle the object, if on a flat surface, will be much too far from the eye to make the test accurate (see Fig. 26). A true map, unless the field be much contracted, can be made only by means of an instrument, the perimeter, which consists essentially of an arc marked in degrees, and moveable around a central pivot on which the patient fixes his gaze. Thus taken the field covers a somewhat oval portion of the hemisphere, the smaller end being upwards and inwards (Fig. 27). From the fixation point it extends  $90^\circ$  or more in the outward direction, but only about  $65^\circ$  or rather less inwards, upwards, and downwards.

(12.) *Testing the acuteness of sight.*—By acuteness of sight (V. or S.) is meant the power of distinguishing *form*, and, as commonly used, the term refers only to the centre of the visual field, the peripheral parts of the retina having a very imperfect power of distinguishing form and size. V. varies considerably in different persons whose eyes are normal. It is said to diminish somewhat in old age, without disease of the eyes (Donders). The standard taken as normal is the power of distinguishing square letters that subtend a visual angle of 5 minutes (Fig. 20), the limbs of which are of uniform thickness, each limb subtending an angle of 1 minute (Snellen's Test Types). Rays forming so small an angle are very nearly parallel, and may be considered as coming from an object at an infinite distance. The types are made of various sizes, each being numbered according to the distance (in feet or metres), at which it subtends a visual angle of 5 minutes. Thus, No. XX subtends this angle at 20' (= No. 6 at 6 m.), No. X at 10' (= No. 3 at 3 m.), No. II at 2' (= No. .6 at .6 m.). Numerically, acuteness of vision is expressed by a fraction, of which the denominator is the number of the type D, and the



numerator the greatest distance ( $d$ ) at which it can be read,  $V = \frac{d}{D}$ ; if No. 6 is read at 6 m.  $\frac{d}{D} = \frac{6}{6}$  or 1, *i. e.*  $V$  is normal; if only No. 18 can be read at 6 m.  $\frac{d}{D} = \frac{6}{18}$ ; if only 60 then  $\frac{d}{D} = \frac{6}{60}$ . Any distance greater than about 3 m. may be selected for this test, *i. e.* No. 3 read at 3 m., or No. 5 at 5 m., generally show the same acuteness as 6 read at 6 m. But at distances less than 3 m. the accommodation comes into play, and the illumination is often brighter, hence No. 1 at 1 m. ( $\frac{1}{1}$ ) does not practically show the same state of sight as 6 at 6 m. ( $\frac{6}{6}$ ). It is, therefore, best to record the fractions unreduced so that the distance at which the test was used may be known. For testing near vision, Snellen's types are thought by many to be practically inferior to those of Jaeger and others, in which the letters have the form and proportions found in ordinary type. (See Appendix.) If  $V$ . be very bad (less than  $\frac{6}{60}$  or  $\frac{1}{10}$ ), it may be expressed accurately enough by noting the distance at which the outspread fingers can be counted when exposed to a good light and against a dark background. Below this point we can still distinguish good from bad, or uncertain, perception of light and shade (*p. l.*), by alternately exposing and shading the eye with the hand, without touching the face.

(13.) *Accommodation* ( $A$ .) is tested clinically by measuring the nearest point (*punctum proximum*,  $p$ .) at which the smallest readable type (Snellen's .5 or Jaeger's 1) can be clearly seen. The *region* of accommodation is the space in which it is available (*see Presbyopia*). The *amplitude*, *power*, or *range* of  $A$ . is expressed in terms of the convex lens, whose focal length is = the distance from the cornea\* to  $p$ ., this being the lens which adapts  $V$ . in an eye without  $A$ . from the farthest point of distinct vision (*punctum remotum*,  $r$ .) to  $p$ .: thus in Fig. 28 let  $p$ . be at 10 cm.;

\* Strictly from a point about  $\frac{1}{2}$ " in front of the cornea, since the glass cannot be placed upon the eyeball.



if A. be then relaxed, *i. e.* the eye be adapted for parallel rays, the rays from *p.* will be focussed at C. F., behind the retina; but V. will again be clear

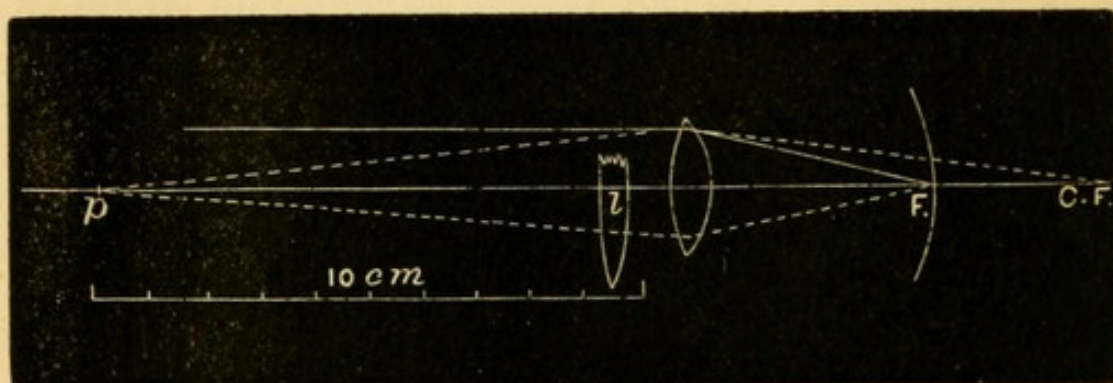


FIG. 28.—Accommodation represented by a convex lens.

at 10 cm. if a lens, *l*, of 10 cm. focus ( $= 10$  D., see p. 15) be held close to the cornea; because rays from that point will be made parallel before entering the eye (§§ 11 and 12), and will therefore be focussed on the retina.

The convergence of the visual axes upon a point at any given distance is always naturally associated with accommodation for the same distance. The two functions can, however, be partially dissociated to a degree which varies with age and in different persons; *i. e.* the accommodation can be either relaxed a little or increased a little, without changing any given position of the visual axes; this independent portion is known as the *relative accommodation*.

(14.) *The apparent size* of an object depends, in the first place, on the size of its *retinal image*, and this, as already shown (§ 19, p. 13), depends upon (a) the size of the visual angle, and (b) the distance of the retina from the nodal point. It is clear that in Fig. 20 a smaller object placed nearer to the eye or a larger one placed further off might subtend the same angle as *ob*, and therefore have a retinal image of the same size. There are, however, other factors contributing to our estimate of the size of objects, especially contrast of size and shade, estimation of distance, and effort of accommodation.



A white object on a black ground looks larger than a black object of the same size on a white ground. The further off an object is judged to be, the larger does it look. The greater the accommodative *effort* used, whatever may be the distance of the object, the smaller does it appear; thus, patients whose eyes are partly under the influence of atropine, and presbyopic persons whose glasses are too weak, complain that near objects if looked at intently for a short time become much smaller; whilst when one eye is under the action of eserine (causing spasm of the accommodation) objects appear larger than if held at the same distance from the other eye. Prisms with their bases towards the temples seem to diminish objects seen through them by necessitating excessive convergence of the eyes (the converse of Fig. 16).

(15.) *Colour perception* is best examined by testing the power of discriminating between various colours without naming them. The best test-objects are a series of skeins of coloured wool, or, for pocket use, smaller strips of coloured paper, or coloured stuffs. A colour-blind person will expose his defect by placing together or "confusing" as similar, certain colours, usually mixed tints, which to the normal eye appear quite different. The set of wools now in common use was introduced by Professor Holmgren, of Upsala\* (see Appendix). Acquired colour-blindness (from atrophy of the optic nerves) may often be detected quite well by asking the names, if the patient has been well trained in colours. But in congenital colour-blindness the "confusion test," without naming the colours, is far safer; because, in the first place, such persons often learn to distinguish correctly between many common coloured objects by differences of *shade* (*i. e.* differences in the quantity of white light which they reflect), and hence may escape detection unless tested with a large series of different colours in many shades, some of which,

\* 'De la Cécité des Couleurs,' &c., 1877.



containing equal quantities of white, will look exactly alike; and secondly, though such persons often use the names for colours freely, the words do not to them convey the same meaning as to those with normal colour-sense, and hopeless confusion results from an examination so made. For details see Chapter XV and Appendix.

(16.) *The uses of prisms* have been explained at p. 9.



## CHAPTER III

## EXAMINATION OF THE EYE BY ARTIFICIAL LIGHT

THIS includes (1) examination by focal or oblique light ; (2) examination by the ophthalmoscope.

(1.) In using *focal, oblique, or lateral illumination* the anterior parts of the eye are examined with the light of a lamp concentrated by a convex lens. The method is used to detect or examine opacities of the cornea, changes in the appearance of the iris, alterations in the outline and area of the pupil from iritis, and opacities of the lens. Such an examination is to be made by routine in every case before using the ophthalmoscope. We require a somewhat darkened room, a convex lens of two or three inches focal length (one of the large ophthalmoscopic lenses), and a bright, naked lamp-flame.

The patient is seated with his face towards the light, which is at about 2' distance. The lens, held between the finger and thumb, is used like a burning-glass, being placed at about its own focal length from the patient's cornea and in the line of the light, so as to throw a bright pencil of light on the front of the eye at an angle with the observer's line of sight. Thus all the superficial media and structures of the eye can be successively examined under strong illumination, the distance of the lens being varied a little, according as its focus is required to fall on the cornea, the iris, or the anterior or posterior surface of the crystalline lens (Fig. 29). By varying the position of the light and of the patient's eye, making him look up, down, and to each side, we can examine all parts



of the corneal surface, of the iris, of the pupillary area (*i.e.* the anterior capsule of the lens), and of the lens-substance. If the light be thrown at a very

acute angle on the cornea or lens, opacities are much more visible than if it fall almost perpendicularly. By habitually magnifying the illuminated parts by a second lens held in the other hand, much additional information can be gained.

For complete exploration of all parts of the crystalline lens the pupil must be dilated with atropine, but careful examination without atropine will generally

enable us to detect opacities lying in or near the axis of the lens even if deeply seated. In examining the posterior pole of the lens the light must be thrown almost perpendicularly into

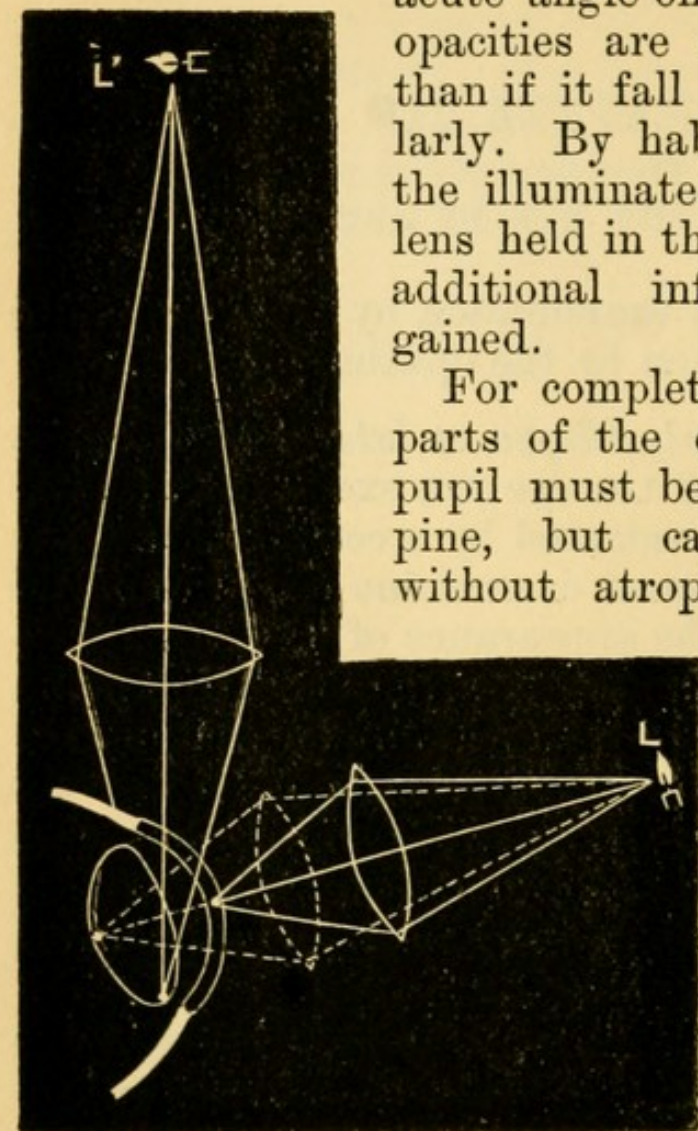


FIG. 29.—Focal illumination.

the pupil, and the observer must place his eye as nearly in the same direction as is possible without intercepting the incident light. Opacities of the cornea and anterior layers of the lens appear whitish, deep opacities in the lens, especially in old people, look yellowish, by focal light. Tumours, large opacities in the vitreous, and retinal detachments may be seen by this method if they lie close behind the lens. Minute foreign bodies in the cornea will often be seen by focal light when invisible, because covered by hazy epithelium, in daylight.



## (2.) *Ophthalmoscopic Examination*

The ophthalmoscope enables us to see the parts of the eye behind the crystalline lens, by making the observer's eye virtually the source of illumination for the observed eye.—Rays of light entering the pupil in a given direction are partly reflected back by the choroid and retina, and on emerging from the pupil take the same or very nearly the same course that they had on entering (p. 6, § 12). Hence the eye of the observer if so placed as to receive these returning rays must also be so placed as to cut off the entering rays; as, therefore, no light can enter in the necessary direction, none can return to the observer's eye. This is why the pupil is usually black. Although with a large pupil, especially in a hypermetropic or myopic eye, the observer receives some of the returning rays (because he does not intercept all the entering light), and in this way sees the pupil of a fiery red instead of black, still for any useful examination the observer's eye must, as already stated, be in the central path of the entering (and emerging) rays.—This end is gained by looking through a small hole in a mirror, by which light is reflected into the patient's pupil, and this perforated mirror is the ophthalmoscope. There are two ways of seeing the deep parts of the eyeball by its means.

A. *The indirect method* of examination, by which a clear, real, inverted image of the fundus, somewhat magnified, is formed in the air between the patient and the observer.

The following simple experiment will show how this is effected:—Take two convex lenses of about 2" focal length each; hold one in the left hand, at about 2" from this print; take the other in the right hand, and, moving your head a few inches back, hold the second lens at about its focal length in front of the first; you will then see an inverted image



of the print slightly magnified. *a.* Observe that in order to see this image clearly you have to make an effort, and that you cannot see both the image of the print and the print itself, clearly at the same moment; this is because the eye of the observer (*obs*, Fig. 30) cannot be adjusted for the image (*im*) and the more distant object (*ob*) at the same time. The fundus of the eye seen on this principle is magnified

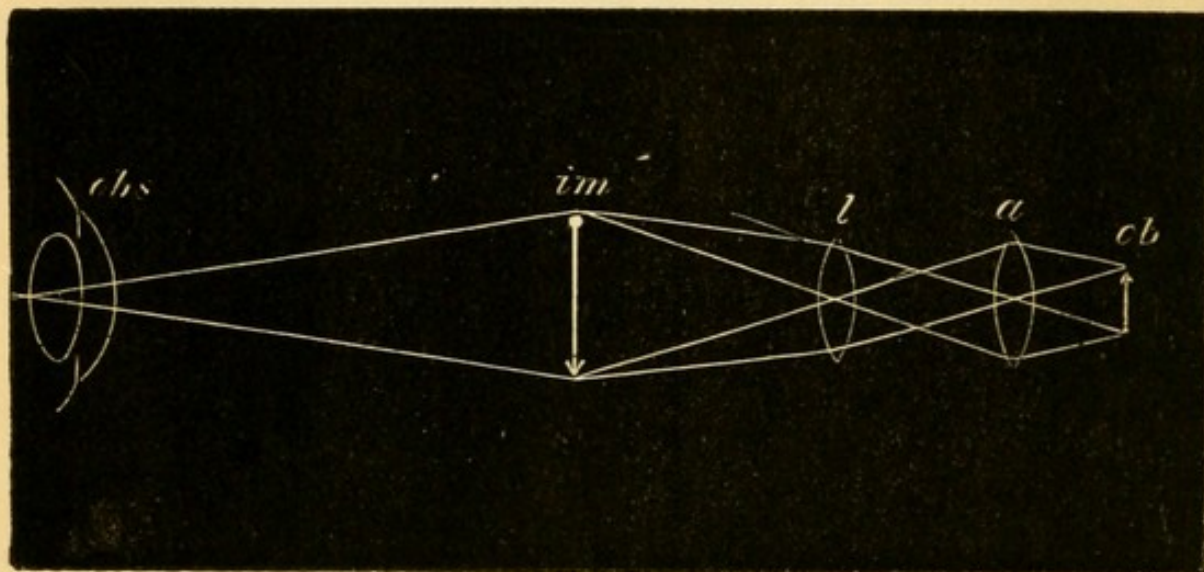


FIG. 30.—*ob* is the object. *a.* The first lens. *l.* The second lens. *im.* The magnified inverted image of *ob* viewed by the observer, *obs*.

about five diameters, if the eye be normal. The image is larger in H and smaller in M. *b.* Notice that if the observer's head be moved slightly from side to side, the image will appear to move in the opposite direction.

*B. The direct method* of examination by which (except when the eye is myopic) a virtual, erect image is seen, more magnified than in the former method and situated behind the patient's eye.

The conditions are the same as those under which a magnified image of any object is seen through a convex lens (Fig. 13), as in the following experiment:—Hold a convex lens of, say 3" focal length, at any distance from this page not greater than 3", and place your eye close to the lens. The print will be



magnified and seen in its true position, *i. e.* "erect."  
*a.* The enlargement will be more the greater the distance of the lens from the page up to 3" (§§ 16 and 17, p. 7). If the distance be further increased the print will not be seen clearly. The image is a "virtual" one, because it is the image which would be formed if the rays which enter the eye in a diverging direction, could be prolonged backwards until they met behind the lens (Figs. 13 and 33). *b.* If the lens be placed just at its focal length from the paper the image will be seen clearly only if the accommodation be completely relaxed. *c.* If it be nearer to the page, more or less accommodation must be used, or else the observer must withdraw his head further from the lens. *d.* If, keeping the lens quite still, the observer withdraw his head, the field of view will be lessened (Fig. 14) whilst the image will appear to increase in size (without really doing so), and these changes will be greater the nearer the lens is to its focal distance from the paper; if it be almost exactly at its principal focal distance, only a very small part of the print will be seen when the head is withdrawn. *e.* If the head be moved a little from side to side the image will appear to move in the same direction.

The emmetropic eye, with the accommodation fully relaxed, is adjusted for distant objects, *i. e.* parallel rays, and receives a clear image of such objects on the layer of rods and cones of the retina (p. 12).—A clear image of the *fundus of the eye*, *i. e.* the retina, optic disc, and choroid, can be obtained in such an eye (as in the experiment just described, where the distance of the lens from the paper was equal to or less than its focal length) on condition that the eyes, both of patient and observer, be adjusted for infinite distance, *i. e.* for parallel rays; in other words, that the accommodation of both be relaxed. The fundus so seen is magnified about 20 diameters.

In order to use the ophthalmoscope\* it is first

\* For choice of instruments see Appendix.



necessary to learn to manage the mirror and light. (1) Seat the patient in a darkened room and place a lamp with a large, steady, naked flame on a level with his eyes, a few inches from his head, and about in a line with his ear. The lamp may be on either side, but is usually placed on his left, and it is better to keep to the same side until practice has given steadiness to the various combined movements which are necessary. (2) Sit down in front of the patient with his face fronting your own, feature to feature. It is most convenient for the observer's face to be a little higher than that of the patient. (3) Take the mirror of the ophthalmoscope (without any lens behind, and without the large lens) in your left hand for examining the patient's left eye (and *vice versâ* for his right eye), hold it, mirror towards the patient, close to your own eye, and with the sight-hole placed so that (with your other eye closed) you see the patient through it. Now rotate the mirror slightly towards the lamp until the light reflected from the flame is thrown into the patient's pupil, and open your other eye. (4) You will so far have seen nothing except the front of the patient's eye, unless atropine have been used, for he will have looked at the centre of the mirror, and his pupil, strongly contracted, will look either black or very dull red. (5) Now tell him to look steadily a little to one side, into vacancy, or at an object on the other side of the room. The pupil will now become red—bright fiery red if it be rather large; a duller red if it be small or the patient's complexion be dark. In one position, when the eye under examination looks a little inwards, the red will change to a yellowish or whitish colour, and this indicates the position of the optic disc. (6) Learn to keep the light steadily on the pupil, during slow movements backwards and forwards and from side to side (taking care that the patient keeps his eye all the time in the same position, and does not follow the movements of the mirror); the test of steadiness



will be that the pupil remains of a good red colour in all positions. Up to this point the examination may be made without atropine; and so far only a uniform red glare will have been seen, no details of the fundus being visible, unless the patient be either myopic or considerably hypermetropic.

In order to see the details of the fundus it is best to begin by learning the *Indirect Method* (Fig. 31), for, though rather less easy, it is more generally useful than the direct.

Take the mirror without any lens behind it in one hand,\* and one of the large convex "objective" lenses corresponding to *l* in Fig. 30 in the other. Always, if possible, have the pupil dilated with atropine, for by this means you learn to see the fundus much more quickly and easily. In examining the patient's right eye apply the mirror with your right hand to your right eye, holding the lens in your left hand; it is best to reverse everything for his left eye, but the position of the light need not be changed. The hand which carries the lens should be steadied by resting the little or ring finger against the patient's brow or temple.

We usually begin by looking for the optic disc, which is one of the most important and easily seen parts. As the disc lies to the nasal side of the posterior pole of the eye, the cornea must be rotated a little inwards, *i. e.* the back of the eye outwards, in order to bring the disc opposite the pupil, when the observer is immediately in front; the right eye, *e. g.*, must be directed to the observer's right ear, or to the uplifted little finger of his mirror-hand. The patient must turn his eye, not his head, in the required direction. The lens should be held about

\* But many learn to see the image more quickly and easily by placing a convex lens of 4 D. behind the mirror. If the observer wears glasses for reading he should wear them, or put a lens of the same strength behind the mirror, for the indirect examination.



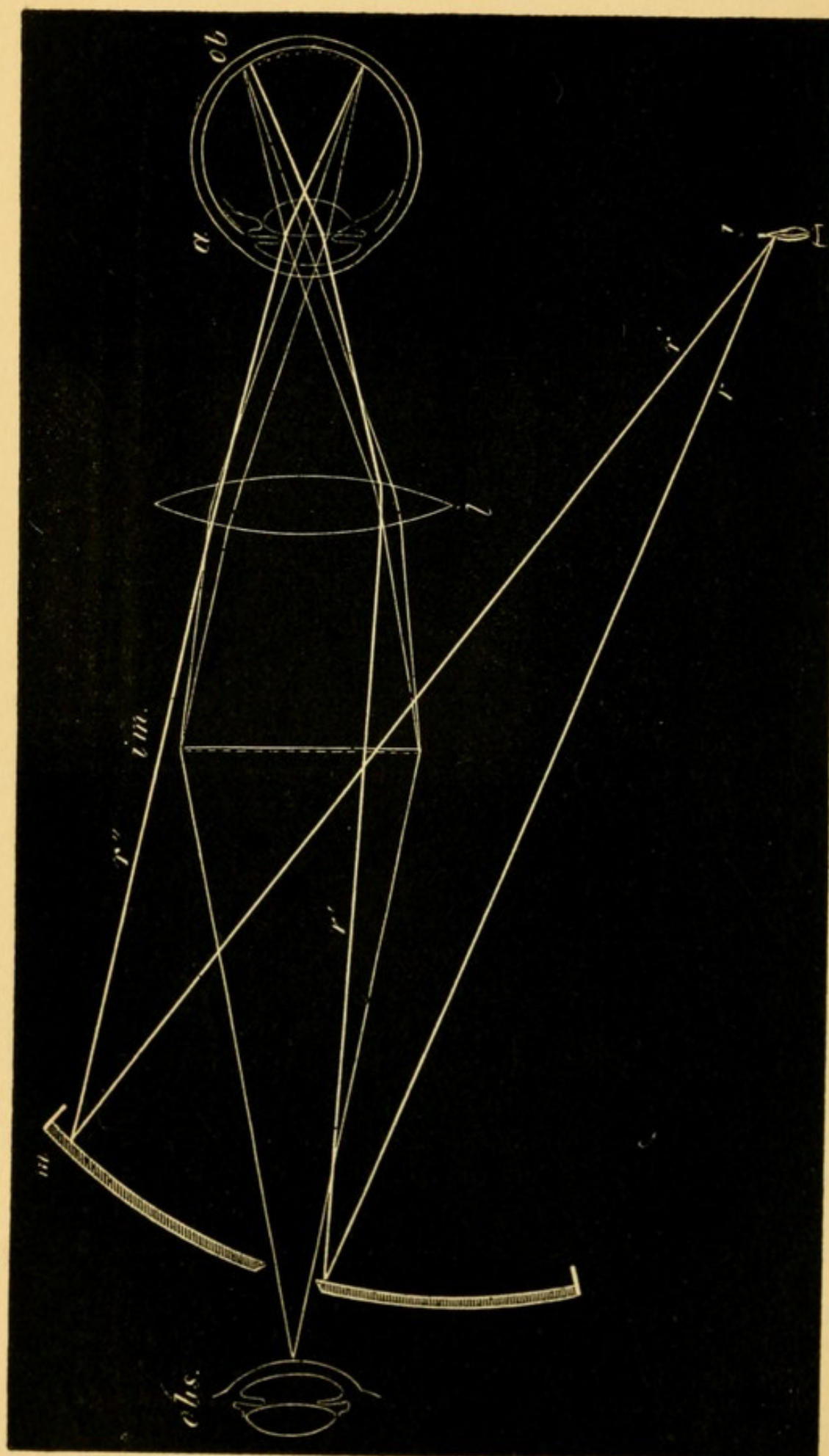


FIG. 31.—Ophthalmoscopic examination by the "indirect method." Lettering as for Fig 30. In addition, the thick lines  $r'$ , rays from the lamp, are reflected from the mirror  $m$ , in the directions  $r''$ , traverse the lens  $l$ , and are focussed in front of the retina  $ob$ , on which they therefore throw a diffused light. From the fundus thus lighted, pencils of rays (shown by thin lines) are given off, which emerge from the eye parallel and form a clear inverted image,  $im$ , at the focus of the lens  $l$ ; this image is viewed through the sight-hole by the observer  $obs$ . The distance between  $obs$  and  $im$  is about  $10''$ , and from  $im$  to  $a$  about  $5''$ .



2"—3", and the observer's eye be about 15", from the patient's eye; the image of the fundus being formed in the air 2" or 3" in front of the lens will thus be situated about 10" from the observer.

The bright red glare (from the *choroid*) will be obvious enough; but most beginners find some difficulty in avoiding the reflection of the mirror from the patient's cornea, and in adjusting the accommodation and the distance of the head, so as to see the image clearly. The head must be slowly moved a little further from or nearer to the patient, and at the same time an attempt made to adjust the eyes (both being kept open) for a point between the observer and the lens. As a rule the disc and retinal vessels are seen clearly at the first sitting.

The *optic disc*—ending of the optic nerve in the eye above the lamina cribrosa, *optic papilla* (Figs. 32 and 34)—is round, well defined, much lighter in colour than the fiery red of the surrounding fundus, and numerous blood-vessels are seen to radiate from its centre, chiefly upwards and downwards. As soon as the disc can be easily seen the student must pass on to the study of the most important details of this part itself, and of the other parts of the fundus. Some of these will be described here and others in the chapters on the Diseases of the Choroid and Retina, and on the Errors of Refraction.

The colour of the disc, as a whole, is greyish pink with an admixture of yellow. It is nearly circular, but seldom perfectly so, being often apparently oval or slightly irregular. Two differently coloured parts are noticeable—a central patch, whiter than the rest, and into which most of the blood-vessels dip; and a surrounding part of pink or greyish pink. In many eyes, especially in old persons, we distinguish a third part, a narrow boundary line of lighter colour, which represents the border of the sclerotic (*scleral ring*). (Fig. 32.) The blood-vessels consist of several large trunks and a varying number of small twigs; the



large trunks emerge from the central white part of the disc, and often bifurcate once or twice on its area; the small twigs may emerge separately from various parts of the disc, or form branches of the large trunks.

*Variations.*—The colour of the disc appears paler or darker according to the colour of the surrounding choroid, the brightness of the light used, and the patient's age and state of health. A curved line of dark pigment often bounds a part of the circumference of the disc (Fig. 34) and has no pathological meaning. The central white patch varies greatly in size, position and distinctness; it may be so small as hardly to be perceptible, or very large; may shade off gradually or be abruptly defined; may be central or eccentric; when large it generally shows a greyish stippling or mottling. (Fig. 34.) This central white patch represents a hollow, the *physiological cup* or *pit* (compare Figs. 34 and 35), left by the nerve-fibres as they radiate out from the centre of the disc towards the retina, like the tentacles of an open sea-anemone; and through it the chief blood-vessels pass on their way between the nerve and the retina. This depression is generally shaped like a funnel or a dimple with gradually sloping sides (Fig. 35); but sometimes the sides are steep, or even over-hanging; in other eyes it is wide, shallow, and enlarged towards the outer side of the disc. The physiological pit is whiter than the rest of the disc, because the greyish-pink nerve-fibres are absent at this part, and we can therefore see down to the opaque, white, fibrous tissue which, under the name of *lamina cribrosa*, forms the floor of the whole disc (Fig. 35). The stippled appearance often noticed in the pit is caused by the holes in this lamina, through which the bundles of nerve-fibres pass on their way to the retina; the holes appear darker because filled by non-medullated nerve-fibres, which reflect but little light.



*The other parts of the fundus.*—The groundwork is of a bright fiery red (the choroid *not the retina*); in many eyes this colour is nearly uniform, but in persons of very light or very dark complexion we see a pattern of closely-set, tortuous, red bands (vessels of the choroid), separated by spaces either of darker or of lighter colour (Fig. 32). (For details see Chap. XII.)

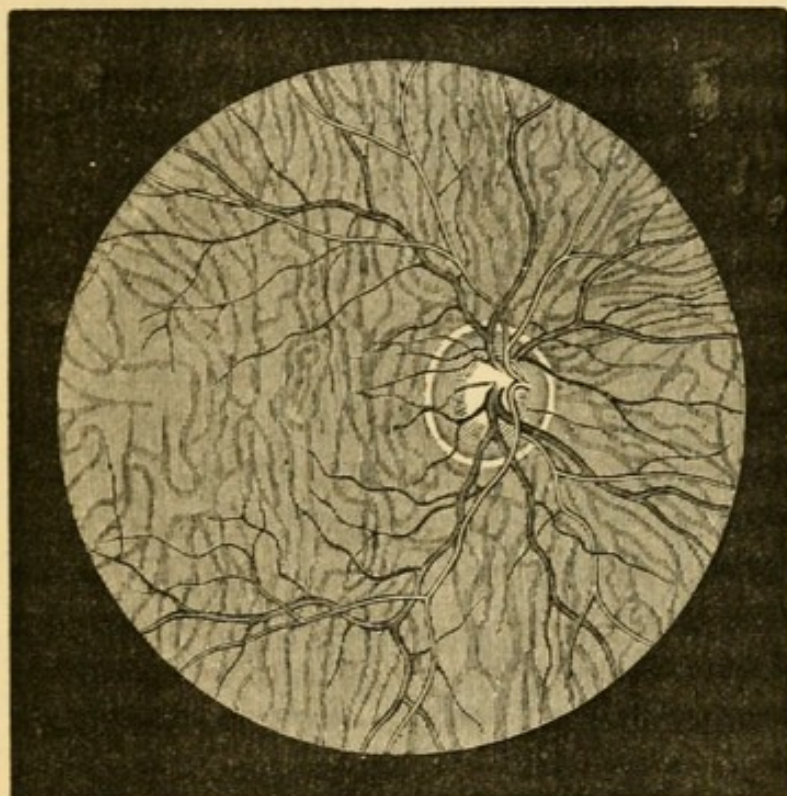


FIG. 32.—Ophthalmoscopic appearances of healthy fundus in a person of very fair complexion. Scleral ring well marked. Left eye, inverted image. (Wecker and Jaeger.)

Upon this red ground the vessels of the retina divide and subdivide dichotomously. It will be noticed that the chief trunks pass almost vertically upwards and downwards, and that no large branches go to the part *apparently* inwards from the disc (to the left in the Fig.); that the visible retinal vessels are comparatively few and are widely spread; that they become progressively smaller as they recede from the optic disc; and that they never anastomose with each other. Special attention must be given to the part, apparently to the inner (nasal) side of the optic



disc (really to its outer, temporal side), which is the region of most accurate vision, the yellow spot (y. s., *macula lutea*, or shortly "macula"). In this region, which comes into view when the patient looks straight at the ophthalmoscope, the choroidal red is duller and darker than elsewhere. It is skirted by large retinal vessels, which give off numerous twigs towards its centre, though none of them can be seen quite to reach that point (compare Fig. 72, Chap. XIII). In many eyes nothing but these indefinite characters mark the y. s.; but in some, especially in dark eyes and young patients, a minute bright dot occupies its centre and is encircled by an ill-bounded dark area, round which again a peculiar, shifting, white halo is seen. The minute dot is the *fovea centralis*, the thinnest part of the retina. The neighbourhood of the disc and y. s. form the *central region* of the fundus. The *peripheral parts* are explored by telling the patient to look successively up, down, and to each side, without moving his head. To see the extreme periphery the observer must move his head as well as the patient his eye. Towards the periphery the choroidal trunk-vessels are often plainly visible even when none were distinguishable at the more central parts.

The vessels of the retina are easily distinguished from those of the choroid by their course and mode of branching; by the small size of all except the main trunks; by their sharper outline and clearer tint; but especially by the presence of a light streak along the centre of each (Fig. 32), which gives them an appearance of roundness, very different from the flat band-like look of the choroidal vessels. They are divisible into two sets—a darker, larger, somewhat tortuous set—the veins; and a lighter, brighter red, smaller, and usually straighter set—the arteries; the diameter of corresponding branches being about as 3 to 2. The arteries and veins run pretty accurately in pairs. Pressure on the eyeball, through the



upper lid, causes visible pulsation of the arteries on disc.

The indirect method of examination is most generally useful, because it gives a large field of view, under a low magnifying power (about five diameters), and thus allows us to appreciate the general character and distribution of any morbid changes better than if we begin with the direct method, in which the field of view is smaller and the magnifying power much greater. It has also the great advantage of being equally applicable in all states of refraction, whereas if the patient be myopic his fundus cannot be examined by the direct method without the aid of a suitable concave lens, found experimentally, placed behind the mirror (p. 53). The inversion of the image seen by the indirect method is such that what appears to be upper is lower, and what appears to be R. is L.

In the *Direct Method*, the examination is made by the mirror alone, or with the addition of a lens in the clip or disc behind it, but without the intervention of the objective lens.

By this method the parts (unless the eye be myopic) are seen in their true position (Fig. 33) the upper part of the image corresponding to the upper part of the fundus, the right to the right, &c, it is therefore often called the method of the "erect" or "upright" image; though, as will be seen below, these terms are not strictly convertible with "direct examination." It is used—(1) to detect opacities in the vitreous humour and detachments of the retina;—(2) To ascertain the condition of the patient's refraction, *i. e.* the relation of his retina to the focus of his lens-system; (3) For the minute examination of the fundus by the highly magnified, virtual, erect image (Fig. 34).

(1.) To examine the vitreous humour. The patient is to move his eye freely in different directions, whilst the light is reflected into it from a distance of a foot



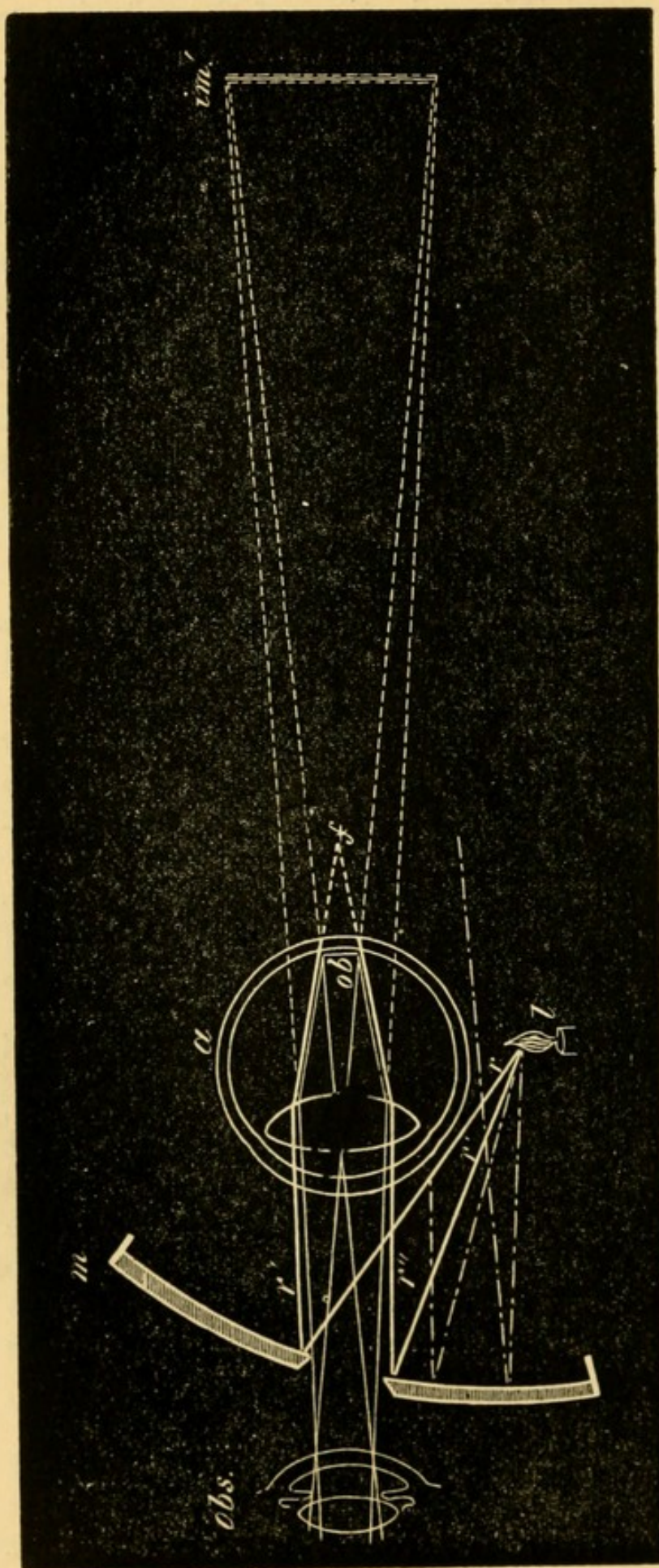


FIG. 33.—Examination of virtual erect image ("direct method"). Lettering as in Fig 31. The rays  $r'$   $r''$  entering the eye divergent would be focused behind the retina, as at  $f$ , and hence illuminate the fundus diffusely. The returning pencils (thin lines) are parallel or divergent (according as the eye is E. or H.) on leaving the eye, and appear to proceed from a highly magnified erect image  $im'$ , behind the eye. It is seen that only those lamp-rays which strike close to the sight-hole are available; if the hole be too large no rays will enter the pupil and the fundus will not be illuminated.



or more (for details see Diseases of Vitreous): detachments of the retina are seen in the same way. Opacities in the vitreous and folds of detached retina, being situated far within the focal length of the refractive media, are seen in the erect position under the conditions mentioned at p. 41 c., the observer being at a considerable distance from the eye.

(2.) To ascertain the refraction. If when using the mirror alone *at a distance of 12"—18", or more,* from the patient's eye, we see some of the retinal vessels clearly and easily, the eye is either myopic or hypermetropic. If, when the observer's head is moved slightly from side to side, the vessels seem to move in the same direction, the image seen is a virtual one and the eye hypermetropic. The eye is myopic if the vessels seem to move in the contrary direction; the image in M. is, indeed, formed and seen in the same way as the inverted image seen by the "indirect" method of examination (compare Figs. 31 and 99), but except in the highest degrees of M. it is too large and too far from the patient to be useful for detailed examination. In low degrees of M. this inverted image is formed so far in front of the patient's eye as to be visible only when the observer is distant perhaps 3' or 4'; whilst in E. and in the lower degrees of H. the erect image will not be easily seen at a greater distance than 12" or 18" (p. 41 d, and Fig. 14).—If, therefore, in order to get a clear image by the direct method, the observer has to go either very near to, or a long way from, the patient, no great error of refraction can be present.

The above tests only reveal qualitatively the presence of either M. or H., but by a modification of the method, the quantity of any error of refraction, *e. g.* H., can be determined with great accuracy—(*Determination of the refraction by the ophthalmoscope*).—In E., as already stated at p. 41, the erect image can be seen only if the observer be near to the patient, and



also completely relax his accommodation; for, in experiment *d* there described, when the head was withdrawn from the lens the field of view and illumination rapidly diminished. The same occurs with the eye, but in a much greater degree, and hence in E. no useful view can be gained by the direct method without going very near to the eye.

In H., where the retina is within the focus of the lens-system, the erect image is seen when close to the patient's eye only by an effort of accommodation in the observer, just as in the same experiment when the lens was within its focal length from the page (p. 41 c.). And as in that experiment the print was also seen easily, even when the head was withdrawn, so in H. the erect image is seen at a distance as well as close to the patient.

If now the observer, instead of increasing the convexity of his crystalline, place a convex lens of equivalent power behind his ophthalmoscope mirror, this lens will be a measure of the patient's H., *i.e.* it will be the lens which, when the patient's accommodation is in abeyance, will be needed to bring parallel rays to a focus on his retina. If a higher lens be used, the result will be the same as when in the experiment the convex lens was removed beyond its focal length from the print; the fundus will be more or less blurred.

Hence to measure H.:—(1) the accommodation of both patient and observer must be fully relaxed (usually by atropine in the patient and by voluntary effort in the observer); (2) the observer must go as close as possible to the patient; (3) he must then place convex lenses behind his mirror, beginning at the weakest and increasing the strength till the highest is reached, which still permits the details of the optic disc to be seen with perfect clearness.—By practice the distance between the corneæ of patient and observer may be reduced to about 1". The light must be on the same side as the eye under examination, so



as to avoid much rotation of the mirror. The right eye must examine the right, and *vice versâ*.

In the same way, though with less accuracy in the high degrees, M. can be measured by means of concave lenses; the lowest lens with which a clear erect image is obtained being slightly more than the measure of the M.

It is sometimes useful to know how much lengthening or shortening of the eye corresponds to a given neutralising lens. The following numbers, slightly altered from Knapp, are sufficiently near the truth. The distance between the eye of the observer and that of the patient is supposed to be not more than 1 inch.

H. of 1 D. represents shortening of .3 mm.

"	2	"	"	.5	"
"	3	"	"	1.	"
"	5	"	"	1.5	"
"	6	"	"	2.	"
"	9	"	"	3.	"
"	12	"	"	4.	"
"	18	"	"	6.	"

M. of 1 D. represents lengthening of .3 "

"	2	"	"	.5	"
"	3	"	"	.9	"
"	5	"	"	1.3	"
"	6	"	"	1.75	"
"	9	"	"	2.6	"
"	12	"	"	3.5	"
"	18	"	"	5.	"

Astigmatism (As.) may also be measured by this method, the refraction being estimated successively in the two chief meridians by means of corresponding retinal vessels (*see Astigmatism*).

This application of the direct method needs much practice. For convenience the lenses, of which there are twenty or more, are placed in a thin metal disc, which can be revolved behind the mirror so as to bring each lens in succession opposite the sight-hole. There are many forms of these "refraction ophthalmoscopes," varying in minor details of construction (*see Appendix*).



(3.) The erect image is very valuable, on account of the high magnifying power (about 20 diameters

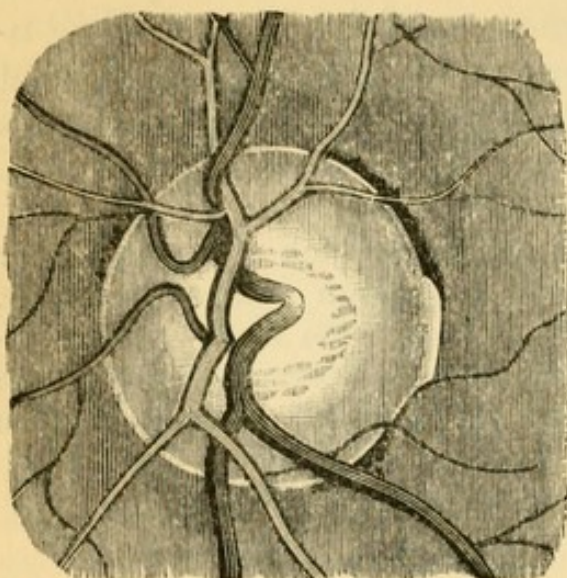


FIG. 34.—Ophthalmoscopic appearance of healthy disc, as seen in the erect image. Dark vessels, veins. Physiological pit stippled.  $\times 15$  diameters (after Jaeger).

in the E. eye), for the examination of the finer details of the fundus. The disc looks less sharply defined, because more magnified, than when seen by the indirect method; both the disc and the retina often show a faint radiating striation (the nerve-fibres); the *lamina cribrosa* is often more brilliantly white; and the pigment epithelium of the choroid can be recognised as a fine uniform dark stippling.

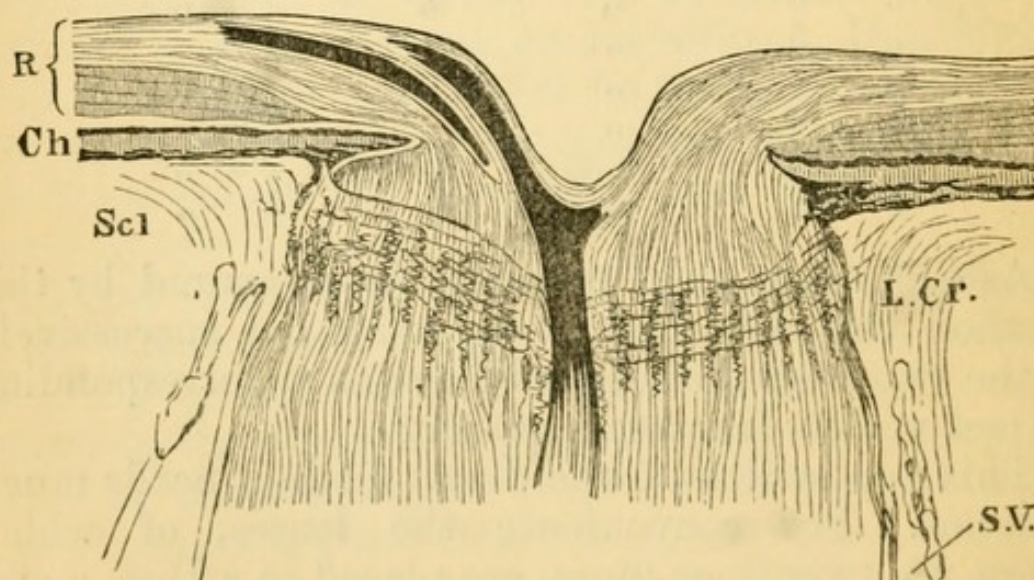


FIG. 35.—Vertical section of healthy optic disc, &c.  $\times$  about 15. *R.* Retina, outer layers shaded vertically, nerve-fibre layer shaded longitudinally. *Ch.* Choroid. *Scl.* Sclerotic. *L. Cr.* Lamina cribrosa. *S.V.* Subvaginal space between outer and inner sheath of optic nerve. The central vein and one of the divisions of the central artery are seen in the nerve and disc.



If the refraction be E. or H. no lens is needed behind the mirror; if M., a concave lens must be placed in the clip behind the mirror, of sufficient strength to give a good, clear, erect image. The observer must come as near as possible to the patient.

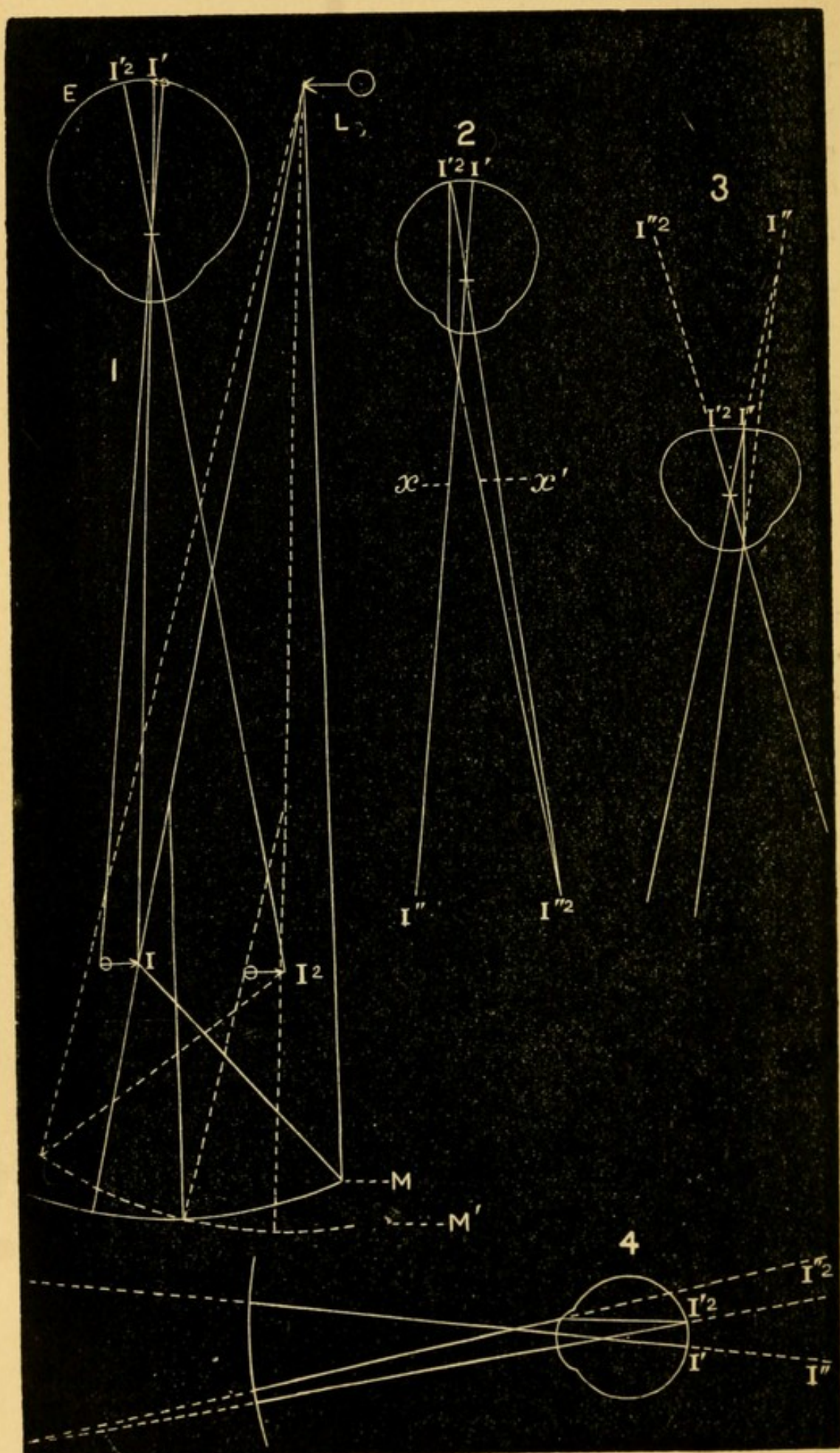
By reference to Fig. 33 it will be seen that only those rays are useful which strike near the centre of the mirror, none others entering the patient's pupil; hence, if the aperture in the mirror be too large the fundus will not be well lighted. It should not be larger than 3 mm., nor smaller than 2 mm.

### *Keratotomy, Retinoscopy, or Pupilloscopy.*

In this method the refraction is determined by noticing in which direction the light (*i.e.* the image of the lamp-flame), thrown by the mirror on the fundus, moves when the mirror is rotated in any given direction. The exact degree of any error of refraction is measured by the lens, which put close to the patient's eye in a case of ametropia, renders the movement, and the other characters, of the image the same as in emmetropia. The test is really most accurate when used at a great distance from the patient; in practice a distance of about 1 m. (100—120 cm., or 3'—4') is chosen. Observation is directed to the boundary line between the lighted and adjacent non-lighted area, *i.e.* to the movement of the dark shadow rather than of the flame-image. If the observer, being at 120 cm. (4') from the patient and using an ordinary concave mirror of 22 cm. (9") focus, throw the light into the patient's pupil\* and slightly rotate the mirror between the finger and thumb, he will see a dark shadow pass across the illuminated field of the pupil. The edge of this shadow has the same direction as the axis on which the mirror is turned. In E., H. and very low M. the

\* The pupil should whenever possible be dilated by atropine.







shadow moves in the direction opposite to that in which the mirror is rotated (or "against" the mirror); in M. of more than 1 D it moves in the same direction as the mirror (or "with" the mirror). The light should be thrown as nearly as possible in the direction of the visual axis, and the lamp be placed immediately over the patient's head rather than to one side.

In Fig. 36, 1, the eye E is lighted by the inverted image of the flame L, formed at I by the mirror M. Of the image I a second image I', again inverted, is formed on the fundus of E. I' will be accurately focussed if the eye E is adapted for the image I, but will be more or less out of focus in every other case. The observer, placed behind M, sees an image of I' formed in the same way as the image of the fundus seen by the direct method (p. 41), and therefore either inverted and real, or erect and virtual, according as the eye is M or H (p. 51.) If the observer's eye be accurately adapted for this image of I' he will indeed see, not only the light and shadow, but the retinal vessels; but he neglects these in attending to the movements of the shadow.

If the mirror M be rotated into the position shown by the dotted line M', I will move in the same direction, viz. to I<sub>2</sub>, and its retinal image will move in the opposite direction from I' to I'<sub>2</sub>; and this movement of the *retinal* image will be the same, whatever may be the refraction of the eye. In the following description we disregard L, I, and I<sub>2</sub>, and look upon I', or I'<sub>2</sub>, as the source of light.

If E be *myopic* (Fig. 36, 2) the image of I, seen by the observer, is real, inverted, and formed at I'', the far point of the patient's eye (*compare* Fig. 99); and it corresponds in definition and brightness with I'. If I' move to I'<sub>2</sub>, I'' will move to I''<sub>2</sub> in the contrary direction, *i.e.* the image seen by the observer moves in the same direction as (or "with") the mirror.



If the eye  $E$  be hypermetropic (Fig. 36, 3) or emmetropic, the observer sees an erect, virtual image of  $r'$  at  $r''$ , the virtual focus of  $r'$  (compare Fig. 13). If  $r'$  move to  $r'_2$ ,  $r''$  will seem to move to  $r''_2$ , i.e. the image seen, moves in the contrary direction to (or "against") the mirror.

The above statement for myopia is true only if the observer is beyond the far-point of the observed eye. In M. of 1 D. the far-point is situated 1 M. (100 cm. or 3') from the patient's eye (see Myopia), and the image seen will have the characteristic M. movement if the observer be a little further off (120 cm. or 4'). But if the observer be within the far-point of the myopic eye (Fig. 36, 4) the rays will be referred towards  $r''$  and  $r''_2$  respectively (§ 6, p. 3), and the image (which will be seen out of focus, because the rays from it will be focussed in front of the observer's retina) will have the same movement as in hypermetropia or emmetropia. At the ordinary distance of 3'—4' (100—120 cm.) this occurs if the observed eye have M. of less than 1 D., e.g. with M. of 0.5 D. the images  $r''$  and  $r''_2$  in Fig. 36, 2, would be formed at 2 m. (6') from the patient, far behind the mirror, as in 4, Fig. 36. Hence at a distance of about 1 m. movement "against" the mirror may indicate M. of about 1 D., or E. or H. The lowest M. which can give the characteristic M. movement at this distance is slightly more than 1 D., say 1.25 D.

In employing retinoscopy the patient is armed with a trial frame, into which lenses (+ if the shadow move "against" the mirror, generally showing H.; — if it move "with" the mirror, always showing decided M.) are successively put until one is reached which just reverses the movement. This lens indicates nearly, but not quite, the refraction of the eye under observation. (1) If the uncorrected shadow moves "against," but with the addition of + 2 D. just moves "with," we know that the M. movement so produced indicates at least 1 D. of M., or rather



more ; the refraction of the eye is therefore not  $H. = 2 \text{ D.}$ , but  $H. = 2 - 1 = 1 \text{ D.}$  Hence when the shadow moves "against" (H.) we subtract 1 D. from the lowest + lens, which makes it move "with." (2). The uncorrected shadow moves "with;" there is M.; the addition of  $- 2 \text{ D.}$  makes the shadow just move "against." We know that this movement is still consistent with M. of about 1 D.; the refraction is therefore not  $M. = 2 \text{ D.}$ , but  $M. = 2 + 1 = 3 \text{ D.}$  Hence when the shadow moves "with" we add 1 D. to the lowest  $-$  lens, which makes it move "against."

Astigmatism is easily detected, and its amount measured by observing, on rotating the mirror, first from side to side, then from above downwards, whether the shadow has the same movement and characters in each direction; or by noting that when the shadow in one meridian is "corrected" by a lens, the meridian at right angles to it still shows decided ametropia. The lens is then found which corrects the latter meridian, and the As. equals the difference between the two lenses.

Apart from the *direction* in which the image (and shadow) moves, something may be learnt from variations in (1) its brightness; (2) its rate of movement; (3) the form, straight or crescentic, of its border. The image is brightest, its movement quickest and most extensive, in very low M. and in Em. The higher the ametropia, whether M. or H., the duller is the illumination, the slower and less extensive its movement, and the more crescentic its border. The *brightness* of the image depends on how clearly  $r$  (Fig. 36, 1) is focussed on the retina; the more accurately  $r'$  is an image of  $r$ , the brighter and larger will  $r''$  (Fig. 36, 2 or 3) be; and as the flame is rectangular, the borders of the image will be nearly straight. These conditions occur when the eye is exactly adapted for the distance of  $r$ , *i. e.* in M. of about 1 D. If the M. be higher than 1 D,  $r'$  will be out of focus, and therefore be spread over a larger area, and being formed



by the same number of rays as before, it will therefore be less bright. The image  $r''$  (Fig. 36, 2) will be correspondingly diffused and dull, and being formed nearer to the patient's eye, as for example at  $x$ , it will move only from  $x$  to  $x'$  in the same time as  $r''$  takes in moving to  $r''_2$ , and hence its movement is slower and less extensive. The same is true in H. (3, Fig. 36), because the higher the H. the more diffused is  $r'$  and the nearer is  $r''$  to the patient's eye. In both cases, high M. and high H., the border of the shadow is crescentic because the diffused image forms a nearly round area on the retina.

This is not the place in which to discuss the relative merits of Retinoscopy and direct Ophthalmoscopic determination of refraction. Retinoscopy is without doubt a very delicate and accurate means of determining the refraction. It is also easily learnt and quickly applied, and in certain cases it gives decidedly more accurate results than the other method is capable of.



# PART II

## CLINICAL DIVISION

---

### CHAPTER IV

#### DISEASES OF THE EYELIDS.

THE border of the lid, which contains the Meibomian glands, the follicles of the eyelashes, and certain modified sweat-glands and sebaceous glands, is often the seat of troublesome disease. Being half skin and half mucous membrane, it is moist and more susceptible than the skin itself to irritation by external causes; being a free border, its circulation is terminal, and therefore especially liable to stagnation. Its numerous and deeply-reaching glandular structures, therefore, furnish an apt seat for chronic inflammatory changes.

*Blepharitis* (ophthalmia tarsi, tinea tarsi, sycosis tarsi) includes all cases in which the border of the eyelid is the seat of subacute or chronic inflammation. There are several types. The skin is not much altered, but chronic thickening of the conjunctiva near the border of the lid is generally observed. The disease may affect both lids or only one, and the whole length or only a part.

In the commonest and worst form the glands and eyelash-follicles are the principal seats of the disease. The symptoms are, firm thickening and dusky congestion of the border region, with exudation of sticky secretion from its edge, gluing the



lashes together into little pencils. Very mild cases present merely overgrowth of lashes and excess of Meibomian secretion. But generally the disease progresses; little excoriations, and ulcers covered by scab, form along the free border, and often minute pustules appear; the thickening and vascularity increase; the lashes are loosened, and free bleeding occurs if they are pulled out. After months or years of varying activity some or all of the hair-follicles become altered in size and direction, or quite obliterated; stunted, misplaced, or deficient lashes, being the result. As the thickening gradually disappears, little lines, or thin seams, of scar form just within the edge of the lid, and often cause slight eversion. The resulting exposure of the marginal conjunctiva, added to the scantiness of the cilia, causes the disagreeably raw and bald appearance termed *lippitudo*; and epiphora, from eversion, tumefaction, or narrowing of the puncta, is another common result. Often, however, the disease leads to nothing worse than the permanent loss of a certain number of the lashes.

In another type the changes are quite superficial—marginal eczema; the patient is liable, perhaps through life, to soreness and redness of the borders of the lids, little crusts, scales, or pustules, form at the roots of the lashes, the growth of the lashes not being much interfered with. In such people the eyes look weak or tender; the condition is made worse by exposure to heat, dust, and wind, and by long spells of work.

Ophthalmia tarsi generally begins in childhood, and an attack of measles is the commonest exciting cause. It seldom becomes severe or persistent except from neglect of cleanliness in a child with sluggish circulation; the patients are generally anæmic, often scrofulous, and the condition is then often the result of some previous more acute ophthalmia. In adults severe sycosis of the eyelids may accompany



sycosis of the beard, but, as a rule, no tendency to such disease of the skin is observed.

*Treatment.*—When the inflammatory symptoms are severe nothing has such a marked effect as pulling out all the lashes. Cases of a few weeks' standing may be cured and recurrences in older cases very much relieved, by one or two such epilations, together with local remedies. Local applications are always needed (1) for the removal of the scabs, (2) to subdue the inflammatory symptoms. A warm alkaline and tar lotion, with which the lids are to be carefully soaked for a quarter of an hour night and morning, followed by a weak mercurial ointment applied along the edges of the lids after each bathing, is an efficient plan if the mother will take pains. In bad cases painting, or pencilling, the border of the lid with nitrate of silver, either in strong solution, or the diluted stick, or the use of weak copper drops is very useful in addition to the ointment. In old cases with much epiphora the canaliculus is to be slit up. The patients generally need a long course of iron. (F. 1, 2, 3, 6; 14, 15; 20, 21, 22).

A *stye* is the result of suppurative inflammation of the connective tissue, or of one of the glands, in the margin of the lid. Owing to the close texture of the tarsus and the vascularity of the parts, the pain and swelling are often severe, and even alarming to the patient. The matter generally points around an eyelash; but if seated in a Meibomian gland, it may point either to the border of the lid or to the conjunctiva, rarely to the skin.

Styes almost always show some derangement of health, especially of the stomach or reproductive organs. Over-use of the eyes, especially if ametropic, is the exciting cause in some cases; exposure to cold wind in others. Styes are very apt to recur, singly or in crops, for several weeks or months.

*Treatment.*—A stye may sometimes be cut short if seen quite early, by the vigorous use of an antiphlo-



gistic lotion. A little later the attack may be shortened by thrusting a fine point of nitrate of silver into the orifice of the gland, if this can be identified, the corresponding eyelash being first drawn out. But often poulticing gives most relief until the styne points, when it should be opened. The health always needs attending to, and a purgative iron mixture often suits better than anything else.

Some persons are subject to very small pustules or styes, much more superficial than the above, and less closely associated with derangement of health.

A Meibomian gland is often the seat of chronic overgrowth, a little tumour in the substance of the lid being the result (*Meibomian cyst, chalazion*). In a few weeks or months the growth becomes as large as a pea, forming a firm, hemispherical, painless swelling beneath the skin. It generally causes thinning of the tissues towards the conjunctiva, and is then recognisable by a dusky patch on the inner surface of the lid. The deeper part of the gland is the usual seat of disease; if, as sometimes happens, the part near the edge of the lid is affected, the tumour usually remains very small. The skin is freely moveable over the tumour, but occasionally the growth pushes forwards and adhesion occurs; even then it is easily distinguished from a sebaceous cyst by the firmness of its deep attachment. During its course the cyst may inflame and even suppurate, and in the latter case it forms one variety of "stye." The same tumour may inflame several times, and finally suppurate and shrink. Like styes, these tumours are apt to continue forming one after another. They are much commoner in young adults than earlier or later in life, but they are now and then seen in infants. Patients as often apply for the disfigurement, as for any discomfort, which these little growths occasion.

*Treatment.*—The cyst is to be removed from the inner surface of the lid; in the rare case, where



it points forwards, the incision may be in the skin. The tumour generally consists of a soft, pinkish, gelatinous mass, or of a gruelly or puriform fluid; there is no cyst-wall. (*See Operations.*)

Small yellow dots are sometimes seen on the inner surface of the lids, due to little cheesy collections in the Meibomian glands, and causing irritation by their hardness. They should be picked out with the point of a knife.

*Warty formations* are not very common on the border of the lid, and are of little consequence except in elderly people, in whom they should be looked upon with suspicion as possible starting-points of rodent cancer. A small fleshy, yellowish-red, flattened growth is sometimes met with just upon the tarsal border, and apparently seated at the mouth of a Meibomian gland. It causes some irritation, and should be pared off. Small pellucid cysts are also not uncommon on the lid border. Cutaneous horns are occasionally seen on the skin of the eyelids.

*Molluscum contagiosum* is partly an ophthalmic disease, because so often seated upon the eyelids. One or more little rounded prominences, showing a small dimpled orifice at the top, usually plugged by dried sebaceous matter, are seen in the skin, varying from the size of a mustard seed to a cherry, but usually not larger than a sweet pea; at first they are hemispherical, but afterwards become constricted at the base. The skin is tightly stretched, thinned, and adherent. The larger specimens sometimes inflame, and their true nature may then, without due care, be mistaken. Each molluscum must be removed, the white, lobulated, gland-like mass which forms the growth being squeezed out through the incision made by a knife or scissors.

*Xanthelasma palpebrarum* appears as one or more yellow patches like pieces of washleather in the skin, varying from mere dots to the size of a kidney bean, quite soft in texture, and very little raised. The dis-



ease is commonest near the inner canthus, and unless symmetrical, is usually on the left side. It occurs chiefly in elderly persons who have previously been subject to become very dark around the eyes when out of health. The patches are due to infiltration of the deeper parts of the skin by groups of cells loaded with yellow fat. The frequency of xanthelasma in the eyelids is, perhaps, related to the normal presence of certain peculiar granular cells, some of which contain pigment, in the skin of these parts.

The *pediculus pubis* (crab-louse), if it happens to reach the eyelashes will flourish there. The lice cling close to the border of the lid, and look like little dirty scabs. Their eggs are darkish, and may also be mistaken for bits of dirt. The absence of inflammation and the rather peculiar appearances will lead, in doubtful cases, to the use of a magnifying glass, by which the question will be at once settled.

*Ulcers on the eyelids* may be malignant, or lupous, or syphilitic; and in the last case the sore may be either a chancre or a tertiary ulcer.

*Rodent cancer* (rodent ulcer, flat epithelial cancer) is by far the commonest form of carcinoma affecting the eyelids; although cases of eyelid cancer occasionally present both the clinical and pathological characters of ordinary epithelioma. The peculiarities of rodent cancer are, that it is very slow, that ulceration almost keeps pace with the new growth, and that it does not cause infection of lymphatics. It seldom begins before, generally not until considerably after, middle life, and its course often extends over many years. Beginning as a "pimple" or "wart," it slowly spreads, but years may pass before the ulcer is as large as a sixpence. When first seen we generally find a shallow ulcer, covered by a thin scab, most often involving the skin at the inner end of the lower lid. Its edge is raised, sinuous, nodular, and very hard, but neither inflamed nor tender. Slowly extending both in area and depth, it attacks all tissues.



alike, finally destroying the eyeball and opening into the nose. In a few very chronic cases the disease remains quite superficial, and cicatrisation may occur at some parts of the ulcerated surface. Now and then a considerable nodule of growth forms in the skin before ulceration begins.

The diagnosis is generally quite easy. A long-standing ulcer of the eyelids in an adult is nearly certain to be rodent cancer. *Tertiary syphilitic ulcers* are much less chronic, more inflamed and punched out, and devoid of the very peculiar, hard edge of rodent ulcer; moreover, they are very rare. *Lupus* seldom occurs so late in life as rodent cancer, presents more inflammation and much less hardness, and is often accompanied by lupus elsewhere on the cutaneous or mucous surfaces. Lupus is seldom difficult to distinguish on the eyelids from tertiary syphilis, the latter being more acute, more dusky, and showing more loss of substance, with none of the little, ill-defined, soft tubercles seen in lupus.

When a *chancre* occurs on the eyelid the induration and swelling are usually very marked; the surface is abraded and moist, but not much ulcerated; the glands in front of the ear and behind the jaw become much enlarged. The same glands enlarge, either with or without suppuration, in lupus and in many inflammatory conditions of the lid.

Several cases are on record in which a hard chancre formed on the palpebral conjunctiva, so far from the border of the lid as to be quite concealed. I have seen two such, and Mr. Jas. Adams has recorded one. In each of these three cases the swelling bore considerable resemblance to a large Meibomian cyst. In all there were enlarged glands and well-marked constitutional symptoms.

*Treatment of rodent cancer.*—Early removal is of great importance, and probably the more so in proportion to the youth of the patient. Chloride of zinc paste or the actual cautery is necessary in addition



to the knife in bad cases ; scraping may also be employed. The disease is very apt to return locally. Even in very advanced cases, where complete removal is impossible, the patient may be made much more comfortable, and life probably prolonged, by vigorous and repeated treatment.

*Congenital ptosis* is a not very rare affection. It may be double or unilateral, is stated to have been present at birth, and its causation is unknown. I believe it is never complete. It sometimes diminishes markedly in the first few years of life, but probably seldom disappears. Although the lid droops the skin, in these cases, is often scanty, and the lid tight and deficient in the natural folds. Operations have been devised for shortening the deeper tissues by means of cicatricial bands, caused by passing subcutaneous sutures from the brow to the tarsus (Bowman, Pagenstecher, Wecker). These procedures avoid the risk of further shortening of the lid which attends the ordinary operation of removing an elliptical fold of skin ; they are, however, rather severe operations.

*Epicanthus* is a rare condition, in which a fold of skin stretches across from the inner end of the brow to the side of the nose and hides the inner canthus. If it does not disappear as the child's nose develops, an operation—removal of a piece of skin from the bridge of the nose (sometimes combined with canthoplasty)—is indicated.



## CHAPTER V

## DISEASES OF THE LACRIMAL APPARATUS

THESE may be divided into the affections of the secreting parts—the lacrimal gland and its ducts; and those of the drainage apparatus—the puncta, canaliculi, lacrimal sac, and nasal duct. In the great majority of cases the fault lies entirely in the drainage system.

The flow of tears over the edge of the lid, “watery eye,” has been called *epiphora* when due to excessive secretion by the gland, and *stillicidium lacrimarum* when caused by obstruction to the outflow. No useful purpose is served by keeping the two names, and only the former will be here used. *Lacrimation* is a convenient term for the increased flow which often accompanies inflammation of the eyeball. (For Diseases of the Lacrimal Gland see Chapter XIX.)

*The drainage system* may be at fault in any part from the puncta to the lower end of the nasal duct.

The slightest change in the position of the lower punctum causes epiphora. In health the punctum is directed backwards against the eye; if it look upwards or forwards the tears do not all reach it, and some will then flow over a lower part of the lid. Thus in paralysis of the facial nerve the patient sometimes comes to us for epiphora before he notices the other symptoms; the watering is caused partly by loss of the compressing and sucking action of the punctum which is effected in winking, by the fibres of the orbicularis lying in relation with the lacrimal sac, partly by a slight falling of the lid away from



the eye and a consequent displacement of the punctum. The various chronic diseases of the border of the lids (ophthalmia tarsi), and also granular disease of the conjunctiva (granular lids), are fertile sources of (1) tumefaction with narrowing, of the puncta and canaliculi; (2) cicatricial stricture of the same parts; and in both cases the puncta are displaced as well as constricted. Narrowing, even to complete obliteration, of the puncta, is sometimes seen as the result of former inflammation, of which all traces have long since passed away. Wounds by which the canaliculi are cut across cause their obliteration, and epiphora is the result.

In all the above cases the epiphora is accompanied by a visible change in the size or position of the punctum, none of the signs of inflammation in the lacrimal sac or stricture in the nasal duct being present; and simple division of the canaliculus will cure, or much relieve, the watering (*see Operations*). This is, however, seldom necessary in the epiphora of facial paralysis.

The canaliculus is occasionally plugged by the growth in it of a mycelial fungus, which, mingled with pus cells and mucus, forms a yellowish, or greenish, putty-like concretion. These masses sometimes calcify, and are then called "dacryo-liths."

Epiphora not explained by any of the above changes is in most cases caused by obstruction in the nasal duct, with or without disease of the lacrimal sac.

*Disease of the sac* is rarely primary. It is generally due either to retention of secretion caused by stricture of the duct below, or to the mucous membrane participating in a chronic inflammation of the conjunctiva or of the Schneiderian membrane.

*Obstruction of the nasal duct* is usually caused by chronic thickening of the mucous and submucous tissues lining the canal. Dense, hard thickening causes a stricture, often very tight and unyielding;



but obstruction is common with the canal of full size or apparently even dilated,\* and in these cases excess of mucus seems to be the chief cause. Disease of the duct occurs at all ages, and is much commoner in females than males.† In some cases the change evidently forms a part of a chronic disease of the neighbouring mucous membrane, but in many no cause can be assigned. Sometimes stricture is the result of periostitis or of necrosis, and of these conditions syphilis (either acquired or inherited), scarlet fever, and smallpox are the commonest causes. Injuries to the nose account for a few cases.

A stricture may be seated at any part of the duct, but the upper end, where there is often a natural narrowing, is the commonest spot.

Obstruction of the nasal duct, by preventing the escape of tears, leads to *distension of the lacrimal sac*, to chronic thickening of its lining membrane, and increased secretion of mucus. The mucus may be clear or turbid. At length a point is reached at which the distension can be seen as a little swelling under the skin at the inner canthus (*mucocoele* or *chronic dacryo-cystitis*). This swelling can generally be dispersed by pressure with the finger, the mucus and tears either regurgitating through the canaliculi or being forced through the duct into the nose. In cases of old standing the sac is often much thickened, and may contain polypi, and the swelling cannot then be entirely dispersed by pressure.

A mucocoele is always very apt to inflame and suppurate, the result being a *lacrimal abscess*. Most cases of lacrimal abscess, indeed, have been preceded by mucocoele. Its formation gives rise to great pain, and to tense, brawny, dusky swelling, which, extending for a considerable distance around the sac, is

\* There can be little doubt that the healthy nasal duct varies much in size in different persons (Noyes).

† In a group of 113 consecutive cases, I find 89 females and 24 males.



sometimes mistaken for erysipelas. The matter always points a little below the tendo palpebrarum; the pus often burrows in front of the sac, forming little pouches in the cellular tissue, and, if allowed to open spontaneously, a fistula, very troublesome to cure, is likely to follow. If seen early, before there is decided pointing, it is best to open the abscess by slitting the lower canaliculus freely into the sac, and passing a knife down the nasal duct; anæsthesia is usually necessary. If interference be delayed the skin over the sac soon becomes thinned, and the abscess is then best opened through the skin, by a free puncture inclined downwards and a little outwards; no anæsthetic is necessary, and the resulting scar is insignificant. When the thickening has subsided, under the use of warm lead lotion dressing, the stricture of the duct is to be treated; but the mucocele will form again, and another abscess may occur at any time, unless a free passage can be restored down the nasal duct.

*Treatment of mucocele and lacrimal stricture.*—The object aimed at is the permanent dilatation of the stricture; but whether this can be gained or not, a free opening from the canaliculus into the sac should be maintained, so that the secretions may be often and easily squeezed out.

Dilatation by probing (*see Operations*) is the ordinary and best treatment for all strictures, whether there be mucocele or not, the rule being to use the largest probe that will pass readily. The probing is repeated every few days or less often, according to the duration of its effect, and often needs to be continued for weeks or months. The patient may sometimes learn to use the probe himself. When the stricture is tough and tight it is best at once to divide it by thrusting a strong backed, narrow knife down the duct, and afterwards to use probes. In cases where the stricture is quite soft, and the obstruction due rather to general thickening of the mucous membrane



and over secretion of mucus, than to dense fibrous thickening, the occasional passage of a very large probe, or frequent washing out of the duct with water, or weak astringents, by means of a lacrimal syringe, is beneficial. The diligent and long use of astringent lotions to the conjunctiva is also useful, particularly in soft strictures, as some of the lotion reaches the sac and duct. In cases of long standing, where all other treatment has failed and the lacrimal sac is much thickened, its complete obliteration by the actual cautery gives great relief; extirpation of the lacrimal gland is also occasionally practised. For refractory children and for patients who cannot be seen often, a style of silver or lead, passed in exactly the same way as a probe, but worn constantly for many weeks, is sometimes very useful; but it may slip into the sac out of reach unless furnished with a bend or head so large as to be somewhat unsightly. As a rule, probing should not be begun until the inflammatory thickening and tenderness following a lacrimal abscess have subsided. If the probe be used too often, or with much violence, or if false passages be made, the symptoms may easily be aggravated, or fresh inflammation be set up.—It must be confessed, indeed, that in a considerable proportion of lacrimal cases, whether the stricture be soft or firm, the final results of all treatment are but palliative, and that the benefit obtained is not always worth the pain and inconvenience.

Suppuration of the lacrimal sac, on one or both sides, sometimes takes place in new-born infants without apparent cause; if there be much redness the abscess should be opened, but the suppuration is sometimes chronic, and will cease under the use of astringent lotions. The cases of epiphora with contracted punctum, which are sometimes met with in older children, may perhaps be the consequences of this infantile suppuration.

Cases in which the sac or duct is obliterated by injury can seldom be relieved.



## CHAPTER VI

## DISEASES OF THE CONJUNCTIVA

It is convenient to distinguish those which, from the outset, are general and affect the whole membrane, ocular and palpebral alike, and of which the various forms of contagious ophthalmia are examples, from others which primarily affect either the ocular or the palpebral part alone. *The term "ophthalmia" includes all inflammations of the conjunctiva, and should not be applied to any other diseases.*

## GENERAL DISEASES

The conjunctiva, like the urethra, is subject to purulent inflammation, and, like the respiratory mucous membrane, is liable to the muco-purulent, and to the membranous or diphtheritic forms of disease. All cases in which there is yellow discharge are in greater or less degree contagious. The congestion, which forms a part of conjunctivitis, is much influenced by age; the younger the patient the less is the congestion in proportion to the discharge, a fact to be borne in mind in examining patients at both ends of the scale.

*Purulent ophthalmia* (O. neo-natorum, Gonorrhœal O., Blennorrhœa of the conjunctiva) is generally due to contagion from the same disease, or from an acute or chronic discharge from the urethra or vagina, which may, or not, be gonorrhœal. Muco-purulent ophthalmia when quickly passed on from one to another, under conditions of health favorable to suppuration (*e.g.* weakness after acute exanthems), may be intensified into the purulent form. Gonor-



rhœa has been experimentally produced by inoculation with pus from purulent ophthalmia. Some animals are subject to purulent ophthalmia, but it is said that the discharge from the human disease, and even from gonorrhœa, gives no result on the conjunctiva of rabbits. Like gonorrhea, purulent ophthalmia may occur more than once. It varies greatly in severity, but is, on the whole, much milder in babies than in older persons. The quality of the infecting discharge no doubt has much influence, severe forms being generally caused by inoculation from a recent or severe case; but chronic discharge may also give rise to a severe attack. The health of the recipient and the previous condition of the eyelids exert an important influence; if the lids be granular, various slight causes sometimes bring on severe purulent ophthalmia.

The disease sets in from twelve to about forty-eight hours after inoculation; in infants the third day after birth is almost invariably given as the date when discharge was first noticed. Itchiness and slight redness of conjunctiva soon pass on to intense congestion of conjunctiva, with chemosis, tense inflammatory swelling of the lids, great pain and discharge. The discharge at first is serous, or like turbid whey, but soon becomes more profuse, creamy (purulent), and yellow, or even slightly greenish. Dark, abrupt ecchymoses are often present. The lids, always swollen, hot and red, in bad cases become very tense and dusky. The upper lid hangs down over the lower, and is often so stiff that it cannot be completely everted. The conjunctiva is succulent and easily bleeds.

The disease if untreated declines spontaneously, and the discharge almost ceases in about six weeks, the palpebral conjunctiva being left thick, relaxed, and more or less granular. Cicatricial changes, identical with, but less severe than, those resulting from chronic granular lids, and analogous to what occurs



in stricture of the urethra sometimes follow; considerable permanent thickening of the ocular conjunctiva may also occur.

There is a great risk to the cornea in this disease, partly from strangulation of the vessels, partly from the local influence of the discharge. If within the first two or three days the cornea becomes hazy and dull, like that of a dead fish, there is great risk that total or extensive sloughing will occur. In many of the milder cases ulcers form a little below the centre, and rapidly cause perforation. In other cases clear deep ulcers form close to the edge of the cornea. In a large number of the infantile cases no corneal damage occurs. Either one or both eyes may be attacked; in adults one eye often escapes; in infants, where the inoculation occurs during birth, both eyes almost always suffer.

*Treatment.*—If only one eye be affected, and the patient be old enough to obey orders, the sound eye must be covered up with the shield introduced by Dr Buller; take two pieces of india-rubber plaster, one  $4\frac{1}{2}$ " the other 4" square, cut a round window in the middle of each, and stick them together, with a small watch-glass inserted into the window. The plaster is fixed by its free border, and by other strips, to the nose, forehead and cheek, and the patient looks through the glass, the lower-outer angle is left open for ventilation; particular attention is to be paid to the fastening on the nose. All concerned are to be warned as to the risk of contagion and the means of conveying it. The essential curative measures are—(1) Frequent removal of the discharge by the free use of water. Every hour, day and night, the lids are gently opened and the discharge removed with soft bits of moistened rag or cotton wool; or a syringe or irrigation apparatus may be used. In adults, where the swelling is often extreme and very brawny, the cleansing must be done very gently lest we should increase the congestion and irritability. (2) The



frequent anointing of the lids with a simple ointment. (3) The use of astringent or antiseptic lotions once an hour, or every two or three hours, according to the case and the nature and strength of the solution. (F. 3, 17, 18, 19, 23, 24, 25.) Iodoform in the form of ointment (F. 16) has also been well spoken of; I have been disappointed by the apparent uncertainty of its action in the purulent ophthalmia of babies. Many surgeons greatly prefer weak nitrate of silver (F. 3) to all other solutions. (4) Strong solutions of nitrate of silver, or the mitigated solid nitrate (F. 1 and 2), are of great service in shortening the attack and lessening the risks, and, whatever other treatment be adopted, they should be used in all severe cases unless specially contraindicated. A ten- or twenty-grain solution is brushed freely over the conjunctiva of the lids, everted as well as possible, and freed from discharge. If the mitigated stick is used more care is needed; and to prevent too great an effect, it is to be washed off with water, after waiting about fifteen seconds. These strong applications must be made by the surgeon. The pain caused by them is lessened, and the benefit increased, by free bathing with cold, or iced water afterwards. The application is not to be repeated until the discharge, which will be markedly lessened for some hours, has begun to increase again; once a day is usually enough. (5) Local cold by iced water or thin iced compresses; in severe cases to be used almost constantly, in milder cases frequently for periods of half an hour. This plan, but little adopted in our hospital practice, is very highly spoken of as most efficacious, *if begun early and carried out well*, but if only half done it is useless and disagreeable. Hot fomentations are sometimes better than cold. (6) In the early stage, in adults, several leeches to the temple will give relief, or, if the swelling be very tense, we may divide the outer canthus with scissors or knife, and thus both bleed and relax the parts at the



same time. Scarification of the ocular conjunctiva by radial incisions, and removal of the ring of conjunctiva overlapping the cornea, may be tried. Mr Critchett in a very bad case, divided the upper lid vertically across, and kept its two halves turned upwards by sutures fastened to the forehead, in order to relieve the tension of the lids and to make the conjunctiva more accessible.

The following additional precautions are important:—Strong nitrate of silver applications are unsafe in the earliest stage, before free discharge has set in, and also in cases where, even later in the disease, there is much hard, brawny swelling of the ocular conjunctiva, and comparatively little discharge; cases, in fact, approaching the condition known as diphtheritic ophthalmia. In these, either very cold or very hot applications, leeches, cleanliness, and weak lotions, should be chiefly relied upon. Ice and leeches are seldom advisable for infants. It is of extreme importance to begin treatment very early, for the cornea is often irreparably damaged within two or three days. The patients, if adults, are often in feeble health, and need supporting treatment. Ulceration of the cornea does not contraindicate the use of strong nitrate of silver if the discharge is abundant. Treatment must be continued so long as there is any discharge, for a relapse of purulent discharge often takes place if remedies are discontinued too soon.

*Muco-purulent ophthalmia.*—The commonest and best characterised of the acute ophthalmiæ is the so-called *catarrhal ophthalmia*. The name is a bad one, for neither does the disease form part of a general catarrh of the respiratory tract, nor does it show the tendency to relapse so characteristic of catarrh, nor does it seem to be caused by cold. The disease attains its height very quickly, almost always attacks both eyes, and gets well spontaneously in about a fortnight. There is great congestion, much gritty



pain, which often prevents sleep, spasm of the lids, free muco-purulent discharge, and, in many cases, ecchymotic patches in the conjunctiva. The lids are somewhat swollen and red, but never tense, and the cornea seldom suffers.

This disease seems to be much oftener communicated from person to person than purulent ophthalmia, for which it is sometimes mistaken. It varies much in severity, even in different members of the same household, who catch it almost at the same time, but attacks all ages indiscriminately. It is, I believe, commonest in warm weather. or perhaps at the change from cold to warm. It is rare to find that the patient has suffered from the disease before. Any mild astringent lotion will cut it short, nitrate of silver (F. 3) being the best.

Troublesome *ophthalmia, with muco-purulent discharge*, is common in children *after exanthemata*, especially measles. It runs a less definite course than the preceding disease, shows but little tendency to spontaneous cure, and is very often complicated with phlyctenular ulcers of the cornea, blepharitis and eruptions on the face; and the patients are frequently strumous. The discharge is seldom so abundant as in the disease just considered. The treatment is often troublesome, and many changes have to be tried; weak nitrate of silver lotions (F. 3), with the use of the yellow ointment (F. 11, 12, or 13), or boracic acid ointment, both to the skin and conjunctiva, or calomel dusted into the eye, are the best local means; atropine alone often increases the irritation. Careful attention to health is necessary. The patients should not be confined to the house, but, with a large shade over both eyes, should take plenty of exercise in fine weather. *The eyes should not be bandaged in any form of ophthalmia, and poultices are very seldom suitable.*

Some forms of acute conjunctivitis, with little or no discharge, are seen both in children and adults, which do not conform to the above types, and are of



comparatively slight importance. Many such appear to depend on changes of weather or exposure to cold, and are complicated with phlyctenulæ. A few are distinctly rheumatic. The conjunctiva is involved more or less in herpes zoster of the ophthalmic division of the fifth nerve, in erysipelas of the face, in the early stage of measles, and slightly in eczema of the face. Slight degrees of chronic conjunctivitis are set up by various local irritants, dust, smoke, cold wind, &c., and by the strain attending the use of the eyes without glasses in cases of hypermetropia. Mention must be made of the cases sometimes seen in children, where an ophthalmia appears to form part of an impetiginous or herpetic eruption on the face, with which it is simultaneous. These again differ from the commoner cases, in which the lids, cheek, and lining membrane of the nose are irritated into an eruption by tears and discharge from a pre-existing conjunctivitis.

Muco-purulent ophthalmia, of any kind, becomes a very important affair if it breaks out in schools or armies, &c., where granular disease of the eyelids is prevalent (p. 82).

*Membranous and diphtheritic ophthalmia.* In a few cases of ophthalmia, either purulent or muco-purulent, the discharge adheres to the conjunctiva in the form of a membrane (*membranous or croupous ophthalmia*). Still more rarely, in addition to membrane on the surface, the whole depth of the conjunctiva is stiffened by solid exudation, which much impairs the mobility both of the lids and eyeball, and, by compressing the vessels, prevents the formation of free discharge, and places the nutrition of the cornea in great peril. It is to the latter cases that the term *diphtheritic* is limited by most authors; but we find many connecting links between the two types above defined, and between each of them and the ordinary purulent and muco-purulent cases.

It is of much consequence in practice, both for



prognosis and treatment, to recognise the presence of membranous discharge and of solid infiltration, in any case of ophthalmia; for the liability to severe corneal damage is much increased by either these conditions, but especially by the latter. The membrane may cover the whole inside of the lids, or it may occur in separate, or in confluent, patches; it often begins at the border of the lid, and is seldom found on the ocular conjunctiva. It can be peeled off, the conjunctiva beneath bleeding freely unless infiltrated and solid; in the latter case the membrane is more adherent, the conjunctiva is of a palish colour, and scarcely bleeds when exposed, and there is little or no purulent discharge. In most cases the solid products, whether membrane or deep infiltration, pass after some days into a stage of liquefaction, with free purulent secretion. In rare cases the membrane forms and re-forms for months. As regards cause, (1) very rarely the process creeps up to the conjunctiva from the nose in cases of primary diphtheria, or is caused by inoculation of the conjunctiva with membrane; whilst in a few the ophthalmia forms the first symptom of general diphtheria, or of masked, or anomalous scarlet fever. (2) Much more commonly it is part of a diphtheritic type of inflammation following some acute illness. (3) It may be caused by the over-use of caustics in ordinary purulent ophthalmia (p. 78). (4) It may be due to contagion, either from a similar case or from a purulent ophthalmia, or a gonorrhea, the diphtheritic type depending on some peculiarity in the health or tissues of the recipient. Membranous and diphtheritic ophthalmiæ are seen most often in children from two to eight years old, less commonly in adults and infants. It is commoner in North Germany than in other parts of Europe, but very severe and even fatal cases occur in our own country. In two cases I have seen essentially the same disease attack the skin of the eyelids and cause sloughing patches.



In *treatment* the cardinal point is not to use nitrate of silver in any form when there is scanty discharge and much solid infiltration of the conjunctiva. The agents to be relied upon are (1) either ice or hot fomentations; ice, if it can be used continuously and well; fomentations, to encourage liquid exudation and determination to the skin if the cold treatment cannot be carried out, or fails to make any impression on the case; (2) leeches, if the patient's state will bear them; (3) great cleanliness. The presence of membrane is no bar to the use of caustics, provided that the conjunctiva is succulent, red, and bleeds easily. Mr Tweedy strongly advises quinine lotion used very frequently (F. 23).

The local use of atropine sometimes gives rise to a peculiar inflammation of the conjunctiva and skin of the lids—"atropine irritation." The conjunctiva of the lids becomes vascular, thickened, and even granular, and usually the skin reddened, slightly excoriated, and somewhat shining. This effect of atropine is commonest in old people. Some persons are very susceptible, and cannot bear even a drop or two without suffering in some degree. Daturine and duboisin cause less irritation and may be used instead, unless it be safe to disuse all mydriatics for a few days. An ointment containing lead and zinc should be applied to the lids, and zinc or silver lotion to the conjunctiva; sometimes glycerine suits better than ointment. Eserine sometimes causes identical symptoms. I have not found that the addition of carbolic acid (.1 per cent.) has, as alleged, prevented an atropine solution from causing irritation.

#### PARTIAL DISEASES.

*Granular ophthalmia* (trachoma) is a very important malady, characterised by slowly progressive changes in the conjunctiva of the eyelids, in consequence of which this membrane becomes thickened, vascular, and roughened by firm elevations, instead



of being pale, thin, and smooth. The change usually begins in the follicular structures of the conjunctiva of the lower lid, extending to the papillæ and the submucous tissue of both lids at a later period, and giving rise to the growth of much organised new tissue in the deep parts of the conjunctiva. This tissue is afterwards partly absorbed and partly converted into dense, tendinous scar, which by very slow shrinking often gives rise to much trouble. It is important to remember that the conjunctiva in this disease does not ulcerate, and that the prominences are not "granulations" in the pathological sense.

The disease is first shown by the presence, on the lower lid, of a number of rounded, pale, semitransparent bodies like little grains of boiled sago, or sometimes looking like vesicles; the so-called "vesicular," or "sago-grain," or "follicular" granulations (Fig. 37). Some of these appear to be lymphatic, others tubular mucous, follicles. They are, to a certain degree, normal, and are seen, especially on the lower lids, in many young persons with slight ophthalmia who never afterwards suffer from true granular lids. Such mild cases in which no parts deeper than the follicles and papillæ are affected, and in which recovery takes place without cicatricial changes, are by some distinguished authors placed, under the name of *conjunctivitis follicularis*, in a separate category from the granular disease. The latter disease is held on this hypothesis to depend on a different morbid process, the growths or "granulations" bearing no relation to lymph-follicles. But the frequent coincidence of transition forms in the same case, the fact that both follicular conjunctivitis and well-

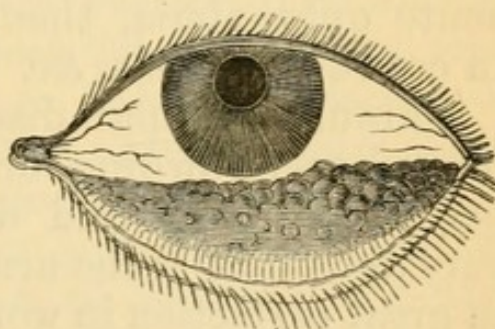


FIG. 37.—Granular lower lid (after Eble).



marked granular disease admittedly occur under the same general conditions, and that in a given case the distinctions between "follicles" and "granulations" often cannot be made until it is known whether or not cicatricial changes will occur, certainly much lessen the clinical value of the asserted pathological difference.

Granular disease is very important because it greatly increases the susceptibility of the conjunctiva to take on acute inflammation and to produce contagious discharge; makes it less amenable to treatment, and very liable to relapses of ophthalmia for many years; and often gives rise to deformities of the lid and to serious damage of the cornea. So vulnerable is the granular conjunctiva that it is rare in ordinary practice to see granular lids of long standing without the history of a previous attack of acute ophthalmia, though many such may be seen in crowded schools, &c.

Chronic granular disease is the result (1) of prolonged overcrowding, or rather of long residence in badly ventilated and damp rooms; it used to be very abundant in the army and navy, and is still seen in great perfection in workhouse schools; (2) a generally low state of health, no doubt, increases the susceptibility to it; (3) it is, *cæteris paribus*, commonest and most quickly produced in children; (4) certain races are peculiarly liable to suffer, *e.g.* the Irish, the Jews and some other Eastern races, and some of the German and French races. The Irish and Jews carry it with them all over the world, and transmit the liability to their descendants wherever they live. Negroes in America are said to be almost exempt; (5) damp and low-lying climates are more productive of it than others; thus it is rare in Switzerland. Possibly what are now race tendencies may be the expression of climatal conditions acting on the same race through many generations. When accompanied by discharge the disease is contagious, but



probably not otherwise\* ; and it is generally held that the discharge from a case of trachoma is specific, *i. e.* that it will give rise by contagion, not only to muco-purulent or purulent ophthalmia, but to the true granular disease. This point is a very difficult one to decide, but my own experience inclines me to accept the view, at least for some cases.

Those who practise in the army, or who have charge of such institutions as pauper schools, will find that in practice, the causes of the chronic granular condition are inextricably mixed up with all kinds of facilities for contagion, and that it will be necessary to fight against two enemies—the causes of spontaneous\* chronic granular disease, and the sources of contagious discharge. The former is to be combated by improved hygienic conditions, especially by free ventilation, dry air, abundant open-air exercise, and improvement of the general vigour. The sources of contagion are endless, especially since, as has been stated, granular patients are liable to relapses of muco-purulent discharge from almost any slight irritation. Frequent inspection of all the eyes, rigid separation of all who show any discharge or are known as especially subject to relapses, arrangements for washing such as will prevent the use of towels and water in common, extreme care against the introduction of contagious cases from without,—such are the chief preventive measures. Extra precautions will be needed in time of war or famine, or when measles or scarlet fever are prevalent, or during marches through hot, sandy, or windy districts.

The *curative treatment*, when discharge is present, does not differ from that of the acute ophthalmiæ

\* It is right to state, however, that some high authorities have for long held that the chronic disease is contagious, and even communicable at a distance through the air, without the presence of any appreciable discharge. Recently, Sattler has published researches which, he believes, prove that trachoma is caused by a micrococcus.



already given. The use of strong astringents (solid sulphate of copper) or caustics (nitrate of silver in strong solution, or in the mitigated solid pencil), however, is generally needed in order to make much impression on the granular state of the lids. The lids being thoroughly everted, are touched all over with one or other application, and this is repeated daily, or less often; some experience being required before we can decide how often to touch the eyelids in each case. By careful treatment on this principle most patients may be kept comfortably free from active symptoms, many relapses may be prevented, the duration of the disease shortened, and the risks of secondary damage to the cornea much lessened. Do what we will, however, granular disease when well established is most tedious, and fastens many risks and disabilities on its subjects for years to come.

For routine treatment on a large scale nothing is so effectual as nitrate of silver, either a ten- or twenty-grain solution, or the mitigated solid point (F. 1 and 2). But silver has the disadvantage of sometimes permanently staining the conjunctiva after long use, and in very chronic cases I think either sulphate of copper or the lapis divinus (F. 5) is to be preferred,

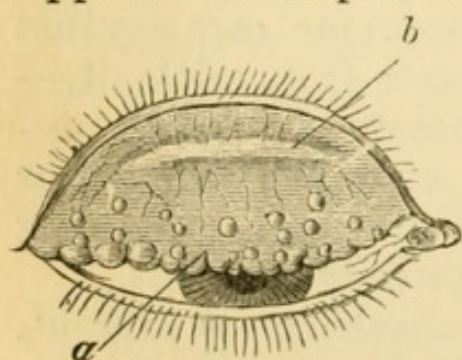


FIG. 38.—Granular upper lid. *a*. Granulations. *b*. Line of scar in typical position, parallel with border of lid.

especially as the patient may sometimes be taught to evert his own lids and use it himself. The solid mitigated nitrate of silver needs washing off with water at first (p. 77), but in old cases it is often better not to do so.

*Results of granular disease.*

—Friction by the granulations of the upper lid (*a*, Fig. 38), especially in cases of long standing where some scarring is present (*b*),



often causes cloudiness of the cornea, partly from ulceration, but mainly from the growth of a layer of new and very vascular tissue, just beneath the epithelium (*pannus*) (Fig. 39). In later periods the conjunctiva and deeper tissues are shortened and puckered by the scar following absorption of the "granulations." (Fig. 38, *b.*) These changes, when severe, often lead to inversion of the border of the lid (*entropion*);

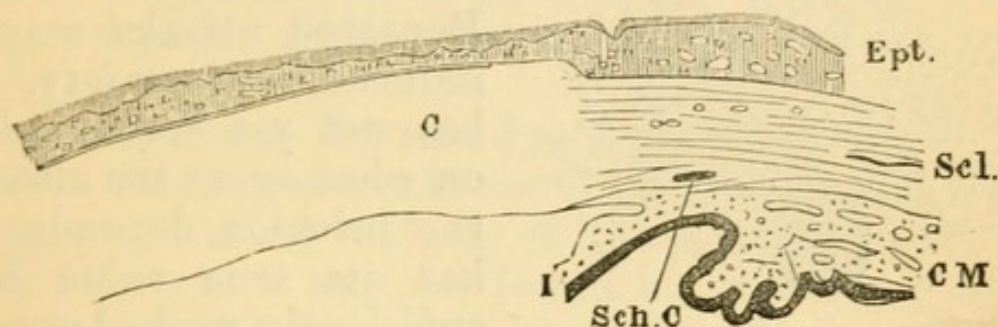


FIG. 39.—Section showing layer of new and vascular tissue (*pannus*) between epithelium (*Ept.*) and cornea (*C.*). *Scl.* sclerotic. *C M.* Ciliary muscle. *Sch. C.* Schlemm's canal. *I.* Iris.  $\times$  about 10 diameters.

when slighter, some or all of the lashes may be distorted so as to rub against the cornea, without actually turning inwards (*distichiasis*, *trichiasis*); and these conditions are often combined with pannus. Pannus begins beneath the upper lid, its vessels are superficial and continuous with those of the conjunctiva, and are distributed in relation to the parts covered by the lid, not in reference to the structure of the cornea (Fig. 40). The proper corneal tissue suffers but little except where ulcers occur; but when the vascularity is extreme it may soften and bulge, even without ulcerating.

Pannus disappears when the granular lid, or the displacement of lashes is cured. Very severe and universal pannus is sometimes best treated by artificial inoculation with purulent ophthalmia, the inflammation being followed by obliteration of vessels and clearing of the cornea; but this treatment needs great judgment and caution. More recently an in-



fusion of the seeds known in commerce as "Jequirity" (F. 37) has been introduced into Europe by De Wecker. It acts in the same way as pus from purulent ophthalmia, but much more mildly; a mild very acute attack of purulent ophthalmia comes on a few hours after it has been used, lasts a few days, and

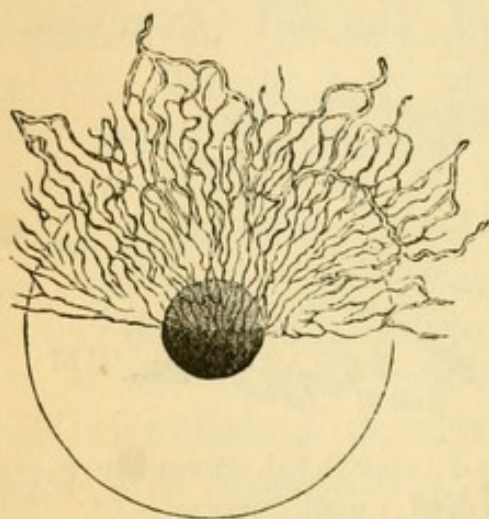


FIG. 40.—Pannus affecting upper half of cornea.

is followed by more or less shrinking of the trachoma bodies and of the vessels. Repeated attacks may be induced with safety. It has not yet been decided on what agent the effect of the infusion depends, nor has its true value been sufficiently worked out. In my own hands it has so far given very satisfactory results. Removal of a zone of conjunctiva and subconjunctival tissue (*syndec-*

*tomy, peritomy*) from around the cornea is free from risk and sometimes very beneficial in old cases which, though severe, are not bad enough for inoculation. In old cases of granular disease, even where no complications have arisen, the upper lids often droop from relaxation of the loose conjunctiva above the tarsal cartilage, and the patient acquires a sleepy look.

For the cure of the displaced lashes and incurved eyelid we may;—(1) repeatedly pull out the lashes with forceps; (2) extirpate all the lashes by cutting out a narrow strip of the marginal tissues of the lid; or (3) attempt by operation to restore the lashes to their proper direction (*see Operations*); such operations well selected and carefully performed give very good results; but as the inner surface of the lid continues to shorten, and this shortening tends to reproduce the original state of things, some of these procedures give only temporary relief.



*Chronic conjunctivitis*, chiefly of the lower lid, is a common disease, especially in elderly people. There is more or less soreness and smarting, redness and papillary roughness of the inner surface of the lid or of both lids, but very little discharge and no trachoma granulations. The caruncle is red and fleshy, as it is in all forms of palpebral conjunctivitis, and there is often soreness of the lids at the canthi. Lapis divinus is one of the best applications, and yellow ointment is sometimes useful (F. 5 and 11).

The rare disease described as Amyloid of the Conjunctiva seems not yet to have been noticed in this country. Detailed accounts of its clinical and pathological characters may be found in Knapp's "Archives of Ophthalmology," vols. x and xi, and an excellent abstract of one of these papers appeared in the 'Ophthalmic Review,' for Aug., 1882.



## CHAPTER VII

## DISEASES OF THE CORNEA

*A. Ulcers and non-specific inflammatory diseases*

INFLAMMATION of the cornea may be circumscribed or diffuse, and, though usually affecting the proper corneal tissue, may be limited to the epithelium on either of its surfaces. It may be a local process leading to formation of pus, or to ulceration; or the expression of a constitutional disease, such as inherited syphilis; or it may form part, and perhaps only a minor part, of disease involving also the deeper parts of the eyeball—the iris (kerato-iritis), or sclerotic (sclero-keratitis), for example.

The different varieties of corneal ulceration and suppurative inflammation form a very large and important contingent of ophthalmic cases. The cornea, although a fibrous structure, is further removed from the blood-vessels than almost any other tissue, and its delicate surface is much exposed; it is therefore extremely susceptible both to disturbances of nutrition from defective supply, or bad quality, of blood, and to irritation by external agencies. Lastly, its surface is so delicate, and its perfect transparency and regularity so important, that slight injuries and irritations are of more moment here than in any other part of the body.

When inflamed the cornea always loses its transparency. If only the anterior epithelium is involved, the surface loses its polish and looks like clear glass which has been breathed upon—"steamy," or finely pitted. This steaminess occurs in many states of disease.



Thickening of the epithelium, and still more, exudation into the corneal tissue, is shown by a white, greyish, or yellowish tint.

If the corneal tissue be opalescent, while the surface is at the same time "steamy," the term "ground-glass" gives a good idea of the appearance, though to make the simile correct the glass ought to be milky throughout, as well as ground on the surface. Rapid suppurative inflammation is preceded by a stage of diffused opalescence, and this appearance is therefore a very dangerous sign in such diseases as purulent ophthalmia, severe burns, or paralysis of the fifth nerve.

Before describing the most important types of corneal ulcer, it is convenient to mention the principal *changes attendant on ulceration of the cornea* in general.—An ulcer of the cornea is preceded by a stage of infiltration, and the inflamed spot is generally a little raised. After the centre of the spot has broken down into an ulcer, the extent, density, and colour of the infiltration at its base and edges are important guides to the future course of the case. When the ulcer heals it leaves a hazy or opaque spot (*leucoma* if dense, *nebula* if faint), which is slight and will often disappear entirely if superficial, but will in part be permanent if it result from a deep ulcer. These opacities are likely to clear, *cæteris paribus*, in proportion to the youth of the patient; time also is a very important element, *nebulæ* often continuing to clear slowly for years. Local stimulation aids in the removal of the opacities, one of the best applications being the ointment of yellow oxide of mercury (F.11,12). Some ulcers have scarcely any infiltration, and these for the most part heal slowly with little or no opacity; but they often cause permanent loss of substance, and this is shown by the presence of a facet, or flattened spot, at the seat of disease. Such facets destroy the regular curvature of the cornea, and thus often cause more



damage to vision than a considerable degree of mere clouding. During repair, blood-vessels often form and pass from the nearest part of the corneal edge to the ulcer, to disappear when healing is complete; phlyctenular ulcers, however, are vascular from the beginning. Corneal opacities and facets are of course most serious when situated over the pupil.

The chief *symptoms* of corneal ulceration are ; (1) *photophobia*, with its consequence, spasm of the orbicularis, *blepharospasm* ; (2) *congestion* ; (3) *pain*. All three symptoms vary extremely in degree in different cases.—As a broad rule, with many exceptions, we may say that intolerance of light is worse in children than in adults, worse with superficial than with deep ulcers, and worse in persons who are strumous and irritable than in those with healthy tissues and good tone. Photophobia should always lead to a careful inspection of the cornea, and we shall then sometimes be surprised to find how slight a change gives rise to this symptom in its severest form.—The degree of congestion varies with the seat and cause of the ulcer, and with the patient's age, being usually greatest in adults. The visible congestion is, as in iritis, due especially to distension of the subconjunctival twigs of the *ciliary zone* (Fig. 21, Ant. Cil., and Fig. 24), but there is often congestion of the conjunctival vessels as well. In some forms of marginal ulcer only those vessels which feed the diseased part are congested. Great pain in and around the eye often attends the earlier stages of corneal abscess, and is common in many acute ulcers ; as a symptom, it of course always needs careful attention ; it is generally relieved by those local measures which are best for the disease itself.

#### TYPES OF CORNEAL ULCERATION

(1.) One of the simplest forms is the *small central ulcer* often seen in young children. A little greyish-white spot forms in the central part of the cornea,



at first elevated and bluntly conical, afterwards showing a minute shallow crater; the congestion and photophobia vary, but are often slight. The ulcer is usually single, but is apt to recur in the same, or the other eye. The infiltration in many of these cases extends into the corneal tissue, and the residual opacity often remains for a long time, if not permanently. The patients are always badly nourished. In most cases the ulcer quickly heals, but now and then the infiltration passes into an abscess, or a spreading, suppurating ulcer.

(2.) Less commonly one, or a succession of, central ulcers occur of a much more chronic character, and attended with little or no infiltration. After lasting for months the loss of tissue is only partly repaired, and a shallow depression or a flat facet is left with perhaps scarcely any loss of transparency. Some of the best examples are seen in anæmic, or strumous, patients with granular lids of long standing.

(3.) *Phlyctenular ophthalmia* and *phlyctenular ulcers* of cornea (*phlyctenulæ*, *herpes corneæ*, *pustular ophthalmia*, *marginal keratitis*, "strumous ophthalmia"). The formation of little papules, or pustules, on or near the corneal margin is exceedingly common, either independently, or as a complication of some existing ophthalmia. Although there are many varieties and degrees of phlyctenular inflammation in respect to the seat, extent, and course of the disease, the following features are common to all. They show a strong tendency to recur during several years; they are seldom seen in very young children, and comparatively seldom after middle life; they occur so often in strumous subjects that we are justified in strongly suspecting scrofulous tendencies in all who suffer much from them; *ophthalmia tarsi* is often seen in the same patients; the first attack often follows closely after an acute exanthem and especially after measles; the cases are much influenced by climate and weather, and their condition often



varies extremely from day to day without making either progress or regress.

An elevated spot, like a papule, commonly about the size of a small mustard seed, is seen either on the white of the eye near the cornea, or upon, or just within, the corneal border. It is preceded and accompanied by localised congestion. Its top sometimes becomes as yellow as that of an acne pustule, but more often when seen it has become abraded, flat, and aphthous looking. Pustules at a little distance from the cornea (Fig. 41), although generally larger

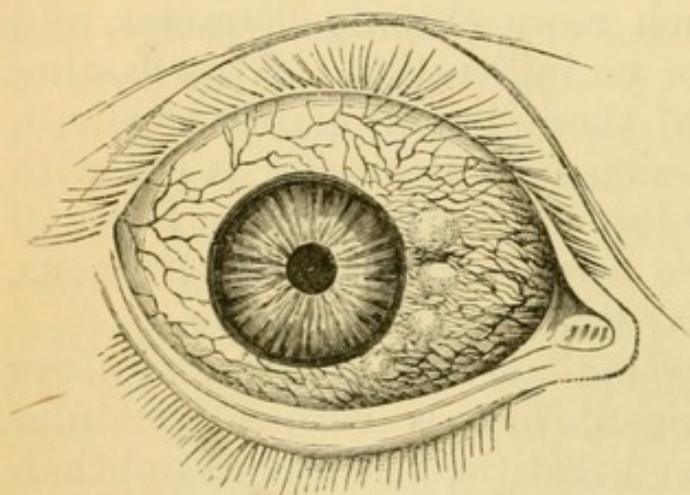


FIG. 41.—Phlyctenular ophthalmia, conjunctival form (Dalrymple).

than those seated on the corneal border, occasion less photophobia, and are more easily cured. Pustules at the corneal border, though often very small, cause troublesome, and even very severe, photophobia; they are troublesome in

proportion rather to their number than their size, and if numerous enough to form a ring round the cornea, their cure is often most tedious.

A pustule is always liable, even when it has begun on the conjunctiva, to advance as a superficial ulcer on to the cornea, though it never extends in the opposite direction over the sclerotic. Such a *phlyctenular ulcer*, if it do not stop near the corneal border, will make, in an almost radial direction, for the centre, carrying with it a leash of vessels which lie upon the track of opacity left in the wake of the ulcer (Fig. 42). Finally, the ulceration stops, the vessels dwindle and disappear, but the path of opacity seldom clears up entirely. The term *recurrent*



*vascular ulcer* is used when such ulcers are solitary ; but they are often multiple as well as recurrent, and the cornea may then finally be covered by a thin, irregular network of superficial vessels on a patchy, uneven, hazy surface, the so-called "*phlyctenular pannus*."

A variety of phlyctenular inflammation, aptly called *marginal keratitis* ("spring-catarh" of continental authors), occurs in mild degrees in the form of a slight, granular-looking, often vascular, swelling, beginning crescentially above or below, but often ex-

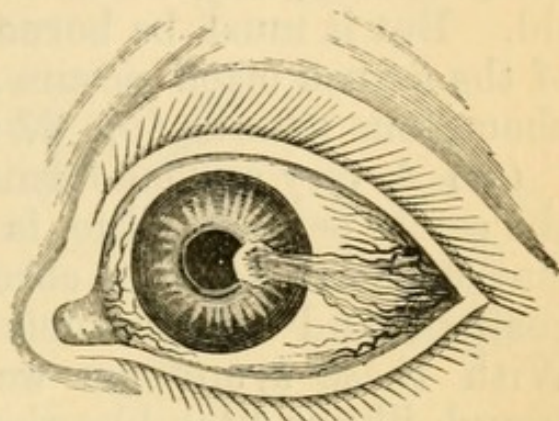


FIG. 42.—Phlyctenular ulcer (Travers).

tending all round the edge of the cornea. If the process continues the cornea is encroached upon by a densely vascular, superficially ulcerated, and yet somewhat thickened zone. It is to be distinguished from a deeper variety of marginal keratitis alluded to at p. 107.

In another variety a single pustule just within the border of the cornea ulcerates deeply, becomes surrounded by swollen and infiltrated tissue, and may perforate ; such cases are seen in weakly women and strumous children.

In very rare cases, what appears to be an ordinary conjunctival pustule persists, grows deeply, and may even perforate the sclerotic in the form of an ulcer ; or it may infiltrate the sclerotic and the ciliary body beneath, forming a soft, semi-suppurating tumour, whence the inflammation is likely to spread to the vitreous and destroy the eye. Stopping short of these extreme results, such a case forms one type of episcleritis (p. 125).

The corneal changes produced by the friction of



granular lids have been considered under that subject. The pannus of granular lids can usually be distinguished from the "phlyctenular pannus" just mentioned, by the greater uniformity and closeness of its vessels, and by its being worst under the upper lid (Fig. 40); any doubt is dispelled by everting the lid. But it must be borne in mind that ulceration of the cornea often occurs as a complication of trachomatous pannus (pp. 87 and 93, 2).

(4.) A very serious form of disease, commonest in the senile period of life, is the *serpiginous ulcer*. It may be either acute or chronic. There is much congestion, and often much pain and photophobia. With these symptoms we find either a marginal trough-like or ditch-like ulcer, with crescentic borders, or a more central ulcer, with nearly circular outline and a varying amount of infiltration of its walls. If the ulcer have lasted some little time a portion of its border, usually that nearest the edge of the cornea, will be partly healed and bevelled off, the floor of the ulcer becoming gradually deeper towards opposite side, which will be infiltrated, sharply cut, and perhaps overhanging.

Slight cases, taken early, generally give little trouble, especially if the infiltration is insignificant. But such an ulcer, if neglected, is very likely to increase in all dimensions, to become complicated with iritis and hypopyon, and to lead to perforation of the cornea; or to spread slowly over the whole cornea, and leave a dense scar. In either event the eye is much damaged, if not destroyed.

(5.) *Abscess of the cornea* and *acute suppurating ulceration* are common diseases. Abscess may occur at any age, but is commonest in elderly or senile people, in whom an abrasion, or some slight injury by a foreign body, is not an uncommon cause, especially if near the centre of the cornea. The little grey central ulcers of young children (p. 92), and the serpiginous ulcer just described, sometimes go on to



abscess. It will very often be noticed that in corneal abscess, as well as in the serpiginous ulceration, the patients are either senile or under-fed; or if vigorous and full-blooded, that they show signs of being damaged by drink. Abscess of the cornea is attended by great pain and congestion, and the case, therefore, usually comes under care tolerably early. The spot itself is generally small and circumscribed; it usually bursts forwards, and is converted into an ulcer, but it may perforate the posterior surface of the cornea. There is always some haziness of the entire cornea, and the purulent infiltration may, if the case do badly, spread and involve almost its whole extent.

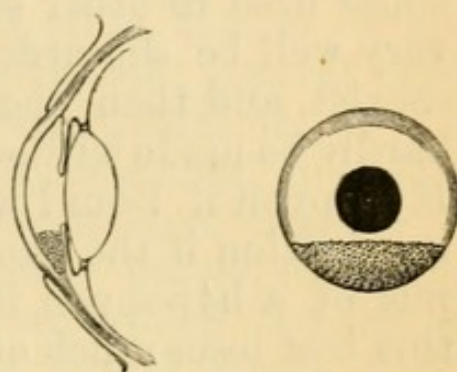


FIG. 43.—Hypopyon, seen from the front, and in section, to show that the pus is behind the cornea.

*Hypopyon* signifies a collection of pus or purulent lymph at the lowest part of the anterior chamber; its upper boundary is usually, but not always, level (Fig. 43). It may occur with any acute ulcer, whether deep or not, which is accompanied by purulent infiltration of the surrounding cornea; or with corneal abscess; or with any corneal ulcer, chronic or acute, in which there is iritis. The pus may be derived either from an abscess breaking through the posterior surface of the cornea, or from suppuration of the epithelium covering Descemet's membrane, or from the surface of the iris. Simple iritis now and then gives rise to hypopyon. The diameter of the anterior chamber is a little greater

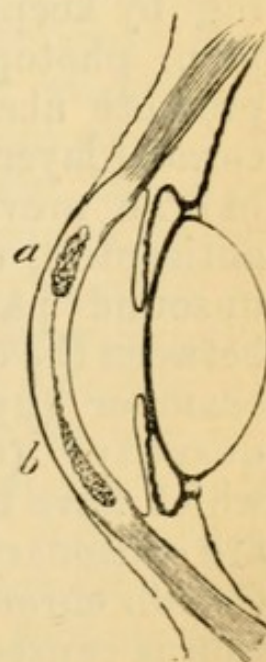


FIG. 44.—  
a. Abscess.  
b. Onyx.



than the apparent diameter of the clear cornea, and thus a very small hypopyon may be hidden behind the overlapping edge of the sclerotic.

In many cases of severe corneal suppuration (*a*, Fig. 44) the pus sinks down between the lamellæ of the cornea (*b*). To this condition the term *onyx* is applied, and should be limited, though it is sometimes used in other senses. The term, however, may very well be discarded. Onyx and hypopyon often coexist, and then the distinction between them can hardly be made without tapping the anterior chamber. Hypopyon if liquid will, but onyx will not, change its position if the patient lies down; as however, the pus of a hypopyon is often gelatinous or fibrinous, this test loses much of its value. The distinction can sometimes be made by means of oblique illumination, the cornea being clear in front of a hypopyon.

#### *Treatment of ulcers of the cornea.*

The principles of local treatment for the various types of corneal ulceration are:—(1) To favour healing by keeping the surface at rest. (2) To relieve pain, photophobia, and severe congestion. (3) To promote absorption of purulent infiltration in the corneal layers, and of pus in the anterior chamber. (4) To prevent the ulceration from spreading, by antiseptics, or by scraping away or destroying the unsound parts. (5) By incision to evacuate pus between the corneal layers (abscess), or in the anterior chamber (hypopyon), when increasing or in large quantity. (6) To stimulate the surface of ulcers which have begun to heal, or of indolent ones which are stationary. (7) Counter-irritation by a seton in certain chronic cases. (8) When the corneal ulceration is caused by granular lids or associated with any form of acute ophthalmia, the treatment of the conjunctiva is usually more important than that of the cornea.



The choice of one or another of the above plans is easy enough in a large proportion of cases. In others, especially the severer cases, a good deal of judgment is needed; and it is sometimes impossible to predict with certainty what will be best, owing largely to the incompleteness of our knowledge as to the mode of action of the various means at our disposal.

Ulcers of the cornea are so often a sign of bad health that the improvement of the general state should always receive most careful attention.

Treating the matter clinically we shall find that local stimulation (6) is best for a large number of the cases as they first come under notice, including phlyctenular cases, chronic superficial ulcers of various kinds, and even many recent ulcers if not threatening to suppurate. As a general rule, this plan alone is not suitable when there is much photophobia, but exceptions occur, especially in old-standing cases. The most convenient remedy is the ointment of amorphous yellow oxide of mercury (F. 11 and 12), of which a piece about as large as a hemp-seed is to be put inside the eyelids once or twice a day. If smarting continue for more than half an hour the ointment should be washed out with warm water; and if the eye become more irritable after a few days' use of the ointment, this must be weakened or discontinued. The same ointment, combined with atropine as a local anodyne, gives excellent results in cases of superficial ulcer with much photophobia (F. 13). Calomel flicked into the eye daily or less often is also an admirable remedy. Nitrate of silver in the form of solid mitigated stick is useful if carefully applied to large conjunctival pustules, and occasionally to indolent corneal ulcers; its use, however, needs some skill, and is seldom really necessary. Solutions of from 5 to 10 grains to the ounce may be cautiously used by the surgeon instead of the yellow ointment, and are particularly valuable in old vascular ulcers and in ulcers with conjuncti-



vitis.—When in doubt it is best to depend for a few days on atropine alone, used once or twice a day.

Severe and obstinate photophobia, in young children, may well be treated by division of the outer canthus with scissors; this renders spasm impossible for a time, and allows the remedies to be efficiently used. Free douching of the head and face, by putting the child's head under a tap of cold water, is sometimes very successful. In all cases of corneal disease attended with intolerance of light, the patient is to wear a large shade over *both* eyes, or, better, a pair of "goggles;" a little patch over one eye does not relieve photophobia. Many a child is kept within doors, to the injury of its health, who, with suitable protection, can go out daily without the least detriment to its eyes.

In chronic and relapsing cases, with photophobia and irritability, where other methods have had a fair trial, a seton gives the best results, whether or not there be much congestion of the eye. A double thread of thick silk is used, and is inserted amongst the hair of the temple or behind the ear, so that the resulting scar may be hidden; at least an inch of skin is to be included between the punctures. The seton is to be moved daily, and if acting badly may be dressed with savin ointment; it should be worn at least six weeks. Severe inflammation, and even abscess, sometimes sets in a few days after the insertion of the thread, and in very rare cases secondary bleeding has occurred from a branch of the temporal artery. To avoid wounding the artery in inserting the seton in the temple, the skin is to be held well away from the head.

Very severe, recent phlyctenular cases, are occasionally difficult to influence, and remain practically "blind" with spasm of the lids for weeks. There is seldom any risk, provided that the cornea be examined at intervals of a few days, and in the end such cases do well. Calomel dusted on the cornea sometimes



helps more than any other local measure, and change of air, especially to the seaside, frequently effects a more rapid cure than any local treatment.

Cases for which the stimulating treatment is suitable seldom need the eye to be bandaged, though, as mentioned, they often need a shade or goggles.

The remaining methods are applicable to the severer forms of ulceration ;—the serpiginous ulcer, deep suppurating ulcers, abscess, and generally all ulcers with hypopyon, and all acute ulcers in elderly persons. In many cases of severe type, at an early stage, the pain may be relieved and the ulceration stopped by very hot fomentations (of water, poppyhead, or belladonna) to the eyelids for twenty minutes every two hours, the eye being tied up in the intervals with a large pad of cotton wool and bandage ; the patient must rest, have good food, and often alcohol, and take quinine, or bark and ammonia. If, nevertheless, the ulceration spread, or a hypopyon form or increase, incision of the cornea and the use of topical remedies are called for. Corneal section relieves pain by relaxing the corneal surface, and so, by encouraging sleep, favours healing ; it lets out pus, if present, from between the layers of the cornea, or from the anterior chamber, and by reducing tension perhaps accelerates the natural currents of fluid through the eye. It is doubtful whether removal of a portion of iris (iridectomy) has any antiphlogistic effect not possessed by a simple, free opening into the anterior chamber ; but there seems no objection to it. In simple corneal section a large incision (made with a Graefe's cataract knife, Fig. 141) may either be carried across the ulcer from side to side through the whole thickness of the cornea, leakage being maintained for a few days, until the ulcer shows signs of healing, by reopening the wound with a probe every day or two (Saemisch's method) ; or a similar wound may be made a little above the lower margin of the cornea without refer-



ence to the situation of the ulcer, and be kept open in the same way, if desired (Teale, Little). Pus or lymph which does not escape from the anterior chamber should be removed with smooth-ended iris forceps. Theoretically the latter incision is the better, being more favorable to escape of hypopyon, less dangerous to the lens, and perhaps less likely to cause infection of the iris by matters carried in from the diseased corneal tissue. A mere puncture at the edge of the anterior chamber seems often quite successful, but is so, perhaps, chiefly in cases where the formation of pus in the anterior chamber has already stopped. The free corneal sections should not be employed except in severe cases, where the addition of the linear operation-scar will be unimportant. In a recent case of perforated ulcer, with prolapse of iris through the hole, the iris should be drawn out with forceps (Fig. 139), and as large a piece as possible removed, in order that the cut ends may retract from the perforation, and anterior synechia be avoided. Of antiseptics boracic acid is the best, because it causes neither irritation nor pain. It may be used in saturated solution (20 grains to the ounce) as a hot fomentation, being also put into the conjunctival sac, and the eye tied up with it; or better, may be freely dusted or rubbed, in the form of impalpable powder, on the ulcerated surface as often as three times a day. I have lately seen several rapidly extending purulent ulcers stop under this treatment, after the surface and edges of the ulcer had been scraped as clean as possible with a small sharp steel spoon. Quinine lotion (F. 23) is also very useful, and is perhaps to be preferred to boracic acid lotion if there is much conjunctival discharge.

Use of atropine and eserine in severe ulcers of the cornea.—Formerly either atropine, or belladonna lotion, was used for nearly every case of severe corneal ulcer. Atropine often relieves pain, prevents or lessens iritis, and probably lessens engorgement



of the vessels of the iris and ciliary region; but it tends to increase any existing conjunctival inflammation and corneal infiltration; and by narrowing the area and contracting the vessels of the iris, it probably retards, rather than hastens, the absorption of pus in the anterior chamber. During the last few years eserine has been largely employed in many cases which would formerly have been treated by atropine. Acute suppurating ulcers, accompanied by much haze of the surrounding cornea, with or without hypopyon, are the most suitable for treatment by eserine. It probably acts in great measure by enlarging the surface of the iris and dilating the ciliary arteries, and thus favouring absorption; possibly, also, it acts locally on the ulcerated surface. There is no proof that it lowers the tension unless this were previously increased, as it seldom is in corneal ulcers. Eserine causes congestion of the deep vessels of the ciliary region, and after a time increases the photophobia and irritability of the eye; these symptoms usually coincide with disappearance of the corneal infiltration, and the commencement of vascularisation of the ulcer, and when this stage is reached the eserine should be discontinued. In severe cases we are seldom justified in omitting hot fomentations, compress, and other measures, and it is therefore difficult to assign to atropine and to eserine their true shares in the result. I have, however, satisfied myself that a few cases of acute infiltrated ulcer have done well under eserine alone (F. 31), used from three to six times a day, and I now employ it largely. When there is much conjunctival discharge, a ten-grain solution of nitrate of silver put inside the lower lid with a brush once a day will generally suit well; it must be begun sparingly and its effect watched: if the irritability should increase the silver must be discontinued.

Iodoform is highly spoken of in the treatment of



many ulcers of the cornea, both chronic and acute, but I have not yet used it much in these cases. It must be *very finely powdered*, and may be used either in substance or made into an ointment (F. 16).

I have occasionally seen a good result from the use of cold evaporating lotions in irritable superficial ulcers, with much spasm of lids, which have resisted other treatment.

*Conical cornea.*—In this condition the central part of the cornea very slowly bulges forwards, forming a bluntly conical curve. The focal length of the affected part of the cornea is thereby shortened, and the eye becomes myopic (*see Myopia*). The curvature, however, is not uniform, and hence irregular astigmatism complicates the myopia.

The disease, which is rare, occurs chiefly in young adults, especially women, suffering from chronic dyspepsia; its onset is sometimes dated from a severe, exhausting illness; it appears to be due to defective nutrition of that part of the cornea which is furthest from the blood-vessels. In advanced cases the protrusion of the cornea is very evident, whether viewed from the front or from the side, but slight degrees are less easily distinguished from ordinary myopic astigmatism. In high degrees the apex of the cone, which is situated rather below the centre of the cornea, often becomes nebulous. The disease may progress to a high degree, or stop before great damage has been done. Concave glasses alone are of little use; but they are sometimes useful in combination with a screen, perforated by a narrow slit or small central hole so as to allow the light to pass only through the centre, or through some one meridian, of the cornea. In advanced cases an operation is needed (Chap. XXII).



### B. *Diffuse keratitis.*

#### *Syphilitic, interstitial, parenchymatous, or "strumous" keratitis.*

In this disease the cornea in its whole thickness undergoes a chronic inflammation, which shows no tendency either to the formation of pus or to ulceration. After several months the inflammatory products are either wholly or in great part absorbed, and the transparency of the cornea restored in proportion.

The changes in the cornea are usually preceded for a few days by some ciliary congestion and watering. Then a faint cloudiness is seen in one or more large patches, and the surface, if carefully looked at, is found to be "steamy" (p. 90). These nebulous areas may lie in any part of the cornea. In from two to about four weeks the whole cornea has usually passed into a condition of white haziness with steamy surface, of which the term "ground glass" gives the best idea. Even now, however, careful inspection, especially by focal light, will show that the opacity is by no means uniform, that it shows many whiter spots, or large denser clouds, scattered among the general mist; in very severe cases the whole cornea is quite opaque and the iris hidden; but, as a rule, the iris and pupil can be seen, though very imperfectly (Fig. 45). In many cases iritis takes place, and posterior synechiæ are formed.

—Blood-vessels derived from branches of the ciliary vessels (Fig. 21) are often formed in the layers of the cornea (Fig. 46); they are small but set thickly, and in patches; as they are covered by a certain thickness of hazy cornea, their bright scarlet is toned down to a

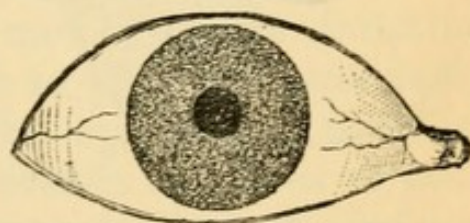


FIG. 45.—Interstitial keratitis.



dull reddish-pink colour ("salmon patch" of Hutchinson). The separate vessels are visible only if magnified (p. 37), when we see that the trunks, passing in

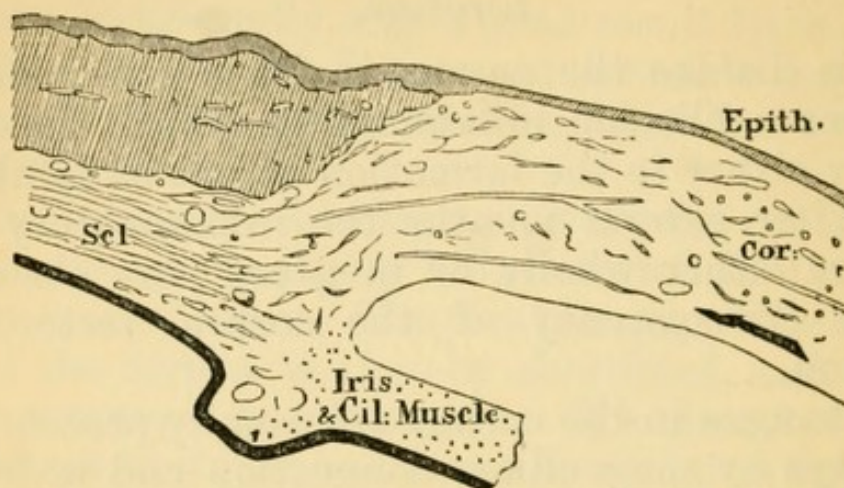


FIG. 46.—Thickening of cornea and formation of vessels in its layers in syphilitic keratitis. Subconjunctival tissue thickened.  $\times$  about 10 diameters. (Compare with Fig. 36.)

from the border, divide at acute angles into very numerous twigs, lying close to each other and taking

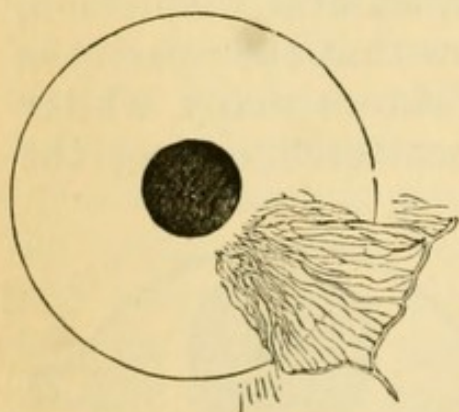


FIG. 47.—Vessels in interstitial keratitis.

a nearly straight course towards the centre (Fig. 47). These salmon patches are of no constant form, but when small are often crescentic, but if large tend to assume a sector-shape.—In another type the vascularity begins as a narrow fringe of looped vessels which are continuous with the loop-plexus of the corneal margin (Fig. 48, compare Fig. 21 l), and gra-

dually extend from above and below towards the centre. The vessels in these cases are somewhat more superficial, and the corneal tissue in which they lie is always swollen by infiltration. This type, which forms a variety of "*marginal keratitis*" (compare p. 95), usually occurs in syphilitic subjects, but



I believe that some of the patients are at the same time strumous. A similar disease, ending in loss of the eye, sometimes from glaucoma, occurs now and then in elderly people.—In extreme cases of either type of vascular keratitis the vessels cover the whole cornea, except a small central island.

The degree of congestion and the subjective symptoms in syphilitic keratitis vary very much; as a general rule there is but moderate photophobia and pain, but when the ciliary congestion is great these symptoms are sometimes very severe and protracted.

The attack can be shortened and its severity lessened by treatment; but the disease is always slow, and from six to twelve months may be taken as a fair average for its duration from beginning to end. Very bad cases with excessively dense opacity sometimes continue to improve for several years, and reach a very unexpected degree of sight. Perfect recovery of transparency is less common, even in moderate cases, than is sometimes supposed, but the slight degree of haziness which so often remains does not much affect the sight. The epithelium usually becomes smooth before the cornea becomes transparent; but in severe cases irregularities of surface and straggling vessels may remain and render the diagnosis difficult.

Syphilitic keratitis is almost always symmetrical, though an interval of a few weeks commonly separates its onset in the two eyes; rarely the interval is several months, a year or even more. It generally occurs between about the ages of 6 and 15; sometimes as early as  $2\frac{1}{2}$  or 3 years, and very rarely as

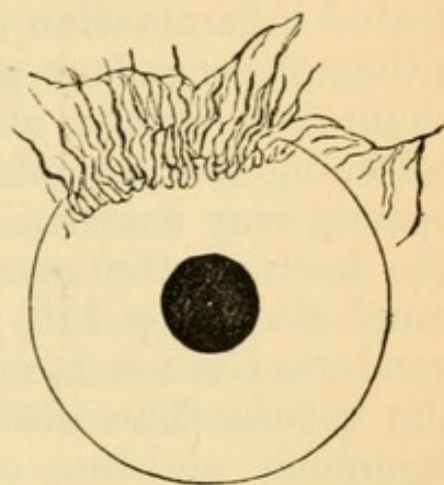


FIG. 48.—Marginal vascular keratitis.



late as 35. If it occur very early the attack is generally mild. Relapses of greater or less severity are common. Not only does iritis occur with tolerable frequency, but we occasionally meet with deep-seated inflammation in the ciliary region, giving rise either to secondary glaucoma, or to stretching and elongation of the globe in the ciliary zone, or to softening and shrinking of the eyeball.\* Dots of opacity may sometimes be seen on the lower part of the back of the cornea before the cornea itself is much altered (p. 110); sometimes, too, the interstitial exudation is much more dense at the lower part of the cornea than elsewhere. Syphilitic keratitis in strumous children often shows more irritability, photophobia, and conjunctival congestion, than in others; but it is very seldom that ulceration occurs, and although in the worst cases the cornea becomes softened and yellowish, and for a time seems likely to give way, actual perforation is one of the rarest events. Pannus from granular disease may coexist with syphilitic keratitis.

*Treatment.*—A long but mild course of mercury is certainly of use. It is customary to give iodide of potassium also, and it probably has some influence. If the patients are very anæmic, and they often are so, iron, or the syrup of its iodide, is more advisable than iodide of potassium as an adjunct to the mercury. Locally it is well to use atropine by routine until the disease has reached its height, on the ground that iritis may be present. Setons in my experience are seldom of use; but in cases attended by severe and prolonged photophobia and ciliary congestion iridectomy is occasionally followed by rapid improvement; this operation, however, is

\* When the cornea has cleared, ophthalmoscopic signs of past choroiditis (p. 167) are often found at the fundus. The choroiditis often dates much further back than the keratitis, but there is little doubt that it may relapse, or occur as an accompaniment of the corneal disease. (Chap. XXIII.)



seldom needed or justifiable unless there be decided glaucomatous symptoms. When all inflammatory symptoms have subsided, the local use of yellow ointment or calomel (F. 10 and 11), appears to aid the absorption of the residual opacity.

The form of keratitis above described is caused by *inherited* syphilis. In rare cases it has been seen as the result of secondary *acquired* syphilis. Other cases of diffuse keratitis occur in which syphilis has no share, but they are seldom symmetrical, nor do they occur early in life. That diffuse, chronic keratitis, affecting both eyes of children and adolescents, is, when well characterised, almost invariably the result of hereditary syphilis, is proved by abundant evidence. A large proportion of its subjects show some of the other signs of hereditary syphilis in the teeth, skin, ears (deafness), physiognomy, mouth, or bones. When the patients themselves show no such signs a history of infantile syphilis in the patient or in some brothers or sisters, or of acquired syphilis in one or other parent, may often be obtained.\* That this keratitis stands in no causal relation to struma is clear, because the ordinary signs of struma are not found oftener in its victims than in other children, because persons who are decidedly strumous do not suffer from this keratitis more often than others, and because the forms of eye disease which are universally recognised as "strumous" (ophthalmia tarsi, phlyctenular disease, and relapsing ulcers of cornea) very seldom accompany this diffuse keratitis. (Illustrations of the teeth in inherited syphilis are given in Fig. 151, Chap. XXIII.)

\* I have found other personal evidence of inherited syphilis in 54 per cent. of my cases of interstitial keratitis, and evidence from the family history in 14 per cent. more; total 68 per cent.; and in most of the remaining 32 per cent. there have been strong reasons to suspect it.



*Other forms of Keratitis.*

Inflammation of the cornea forms a more or less conspicuous feature in several diseases where the primary, or the principal, seat of mischief lies in another part of the eye. It is important for purposes of diagnosis to compare these *secondary or complicating forms of keratitis* with the primary diseases of the cornea already described.

In iritis the lower half of the cornea often becomes steamy, and more or less hazy. In some cases a number of small, separate, opaque dots are seen on the posterior elastic lamina (Descemet's membrane), often so minute as to need a hand-lens for their detection (p. 37). These dots are sharply defined, the large ones looking very like minute drops of cold gravy-fat, the smallest like grains of grey sand; in cases of long standing they may be either very white or highly pigmented. They are generally arranged in a triangle, with its apex towards the centre and its base at the lower margin of the cornea, the smallest dots being near the centre (Fig. 49); but in some cases (sympathetic ophthalmitis especially) the dots are scattered over the whole area. They are of course difficult to detect in proportion as the corneal tissue itself is hazy.

The term *keratitis punctata* is used to express this accumulation of dots on the back of the cornea; and by some authors is allowed to include also allied cases in which small spots with hazy outlines are seen in the cornea proper. *Keratitis punctata* is, almost without exception, secondary to some disease of the cornea, iris, or choroid and vitreous. But a

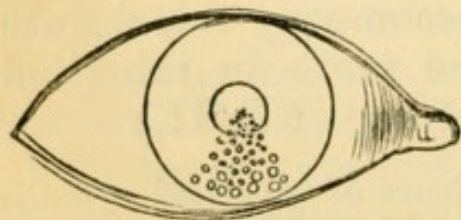


FIG. 49.—Keratitis punctata.

few cases are seen, chiefly in young adults, where the corneal dots form the principal, if not the sole, visible



change; the number of these cases diminishes, however, in proportion to the care with which other lesions are sought (p. 129).

It is now and then difficult to say whether the iritis or keratitis in a mixed case has been the initial change; but when this doubt arises the cornea has generally been the starting-point; and with care we are seldom at a loss to decide whether the case is one of syphilitic keratitis with iritis, or of scleritis with corneal mischief and iritis, or of primary iritis with an unusual degree of corneal haze. (*See* Chaps. VIII and IX.)

Slight loss of transparency of the cornea occurs in most cases of *glaucoma*. The earliest change is a fine, uniform, steaminess of the epithelium. In very severe, acute cases the cornea becomes hazy throughout, though not in a high degree. The same haze occurs in chronic cases of long standing with great increase of tension, but the epithelial "steaminess" often then gives place to a coarser "pitting," with little depressions and elevations (vesicles), especially on the part which is uncovered by the lids.

In *Buphthalmos* (*Hydrophthalmos*) the corneal changes are often very conspicuous, although not essential. In this rare and very peculiar malady there is a general and slowly progressive enlargement of cornea, anterior part of sclerotic, and iris, together with extreme deepening of the anterior chamber and slight increase of tension. The cornea often becomes hazy or semi-opaque. The disease, which may perhaps be looked upon as a congenital or infantile form of glaucoma, is either present at birth or comes on in early infancy, and usually causes blindness. Operative treatment generally fails, but eserine is said to be useful. (*See* Glaucoma.)

A peculiar and rare form of corneal disease, seen in elderly or prematurely senile persons, is the *transverse calcareous film*, an elongated patch of light grey opacity, looking when magnified like very fine



sand, placed beneath the epithelium, and running almost horizontally across the cornea. It consists of minute crystals, chiefly calcareous.

*Arcus senilis* is caused by fatty degeneration of the corneal tissue just within its margin (Fig. 50).

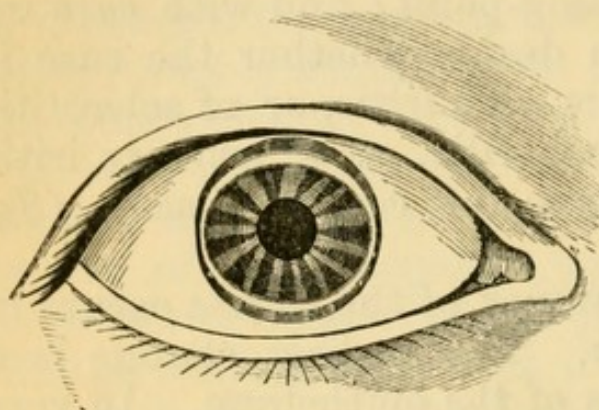


FIG. 50.—Arcus senilis (Canton).

It first appears beneath the upper lid, next beneath the lower, thus forming two narrow, white, or yellowish crescents, the horns of which finally meet at the sides of the cornea; it always begins, and remains most intense, on a line slightly

within the sclero-corneal junction, and the degeneration is most marked in the superficial layers of the cornea, beneath the anterior elastic lamina; in other words, the change is greatest at the part most influenced by the marginal blood-vessels. It is not found to interfere with the union of a wound carried through it, though the tissue of the arcus is often very tough and hard. Nevertheless, its occurrence chiefly at an advanced age, and its frequent co-existence with fatty degeneration, both in distant parts and in the blood-vessels and muscles of the eyeball, mark it as a truly senile change.

Less regular forms of arcus are seen as the result of prolonged or relapsing inflammations near the corneal border, whether ulcerative or not. It is generally easy to distinguish such an arcus, because the opacity is denser, more patchy, and its outlines less regular than in the primary form; when arcus is seen unusually early in life it is generally of this inflammatory kind, for simple arcus is rare below forty.

Opacity of a very characteristic kind is likely to follow the use of a lotion containing *lead* when



the surface of the cornea is abraded. An insoluble, densely opaque, very white film of lead salts is precipitated on, and adheres very firmly to, the ulcerated surface; the spot is sharply defined, and looks like white paint. If precipitated on a deep and much inflamed ulcer, the layer of tissue to which the film adheres is often thrown off, but when there is only a superficial abrasion or ulcer, the lead adheres very firmly, and can only be scraped off imperfectly. But even in the latter cases the film is probably after a time thrown off or worn off, if we may judge by the fact that nearly all the lead opacities which come under notice are comparatively new. The practical lesson is, never to use a lead lotion for the eye when there is any suspicion that the corneal surface is broken. Powdered acetate of lead rubbed into the conjunctiva (a treatment which has been used for granular lids), is not, in my experience,\* attended by risk of corneal opacity, even though there be ulceration; the lead is precipitated at once, and adheres for weeks to the granular surface.

The prolonged use of *nitrate of silver*, whether in a weak or strong form, is sometimes followed by a dull, brownish-green, permanent discoloration of the conjunctiva, and even the cornea may become slightly stained.

\* 'Brit. and Foreign Med.-Chir. Rev.,' Jan., 1875.



## CHAPTER VIII

## DISEASES OF THE IRIS.

*Iritis.*

INFLAMMATION of the iris may be caused by certain specific blood diseases, especially syphilis; or may be the expression of a tendency to relapses of inflammation in certain tissues under the influence largely of climate and weather—rheumatic iritis; it often occurs in the course of ulcers, and of wounds and other injuries, of the cornea; also with diffuse keratitis and sclerotitis. Iritis also forms a very important part of the remarkable and serious disease known as sympathetic ophthalmitis.

Acute iritis, from whatever cause, is shown by a change in the colour of the iris, by indistinctness or “muddiness” of its texture, by diminution of its mobility, and by the formation of adhesions (*posterior synechiæ*) between its posterior (uveal) surface and the capsule of the lens; there is, besides, in most cases, a dulness of the whole iris and pupil, caused partly by slight corneal changes (p. 110), partly by muddiness of the aqueous humour. The eyeball is congested and sight is almost always defective. There may, or may not be pain, photophobia, and lachrimation.

The congestion is often nearly confined to a zone, about one twelfth or one eighth of an inch wide, which surrounds the cornea, its colour being pink (not raw red), the vessels small, radiating, and nearly straight, and lying beneath the conjunctiva (*ciliary or circumcorneal congestion*, Fig. 23). These are the episcleral branches of the anterior ciliary arteries (Fig. 21). Quite the same congestion is seen in many other



conditions, *e. g.* corneal ulceration (p. 92) ; whilst on the other hand, in some cases of iritis, the superficial (conjunctival) vessels are congested also, especially in their anterior divisions, which are chiefly offshoots of the ciliary system. We therefore never diagnose iritis from the character of the congestion alone ; but the disease being proved by the other symptoms, the kind and degree of congestion help us to judge of its severity.

The altered colour of the iris is explained by its congestion, and by the effusion of lymph and serum into its substance ; a blue or grey iris becomes greenish, whilst a rich brown one is but little changed. The inflammatory swelling of the iris also accounts both for the blurring (muddiness) of its beautifully reticulated structure, and for the sluggishness of movement, indicating stiffness of its tissue, noticed in the early period. After a few days lymph is thrown out at one or more spots on its posterior surface, and still further hampers its movements by adhering to the lens-capsule ; and most cases do not come under notice till such synechiæ have formed. The quantity of solid exudation, whether on the hinder surface, or into the structure, of the iris, varies much ; it is usually greatest in syphilitic iritis, when distinct nodules of pink, or yellowish, colour are sometimes seen projecting from the front surface. In rare cases pus thrown out by the iris into the aqueous, subsides and forms hypopyon ; a corresponding deposit of blood constitutes hyphæma. Firm adhesions to the lens-capsule may be present without much evidence of exudation into the structure of the iris. Exudative changes are usually most abundant at the inner ring of the iris, where its capillary vessels are far the most numerous (Fig. 51).

Apparent discoloration of the iris is, however, often due entirely to suspension of blood-corpuscles, or inflammatory products, in the aqueous humour ; sometimes this altered fluid coagulates into a slightly



turbid gelatinous mass, which almost fills the chamber ("spongy exudation"). The aqueous sometimes becomes yellow without losing transparency.

The tension of the eyeball may be a little increased in acute iritis; rarely it is considerably diminished,

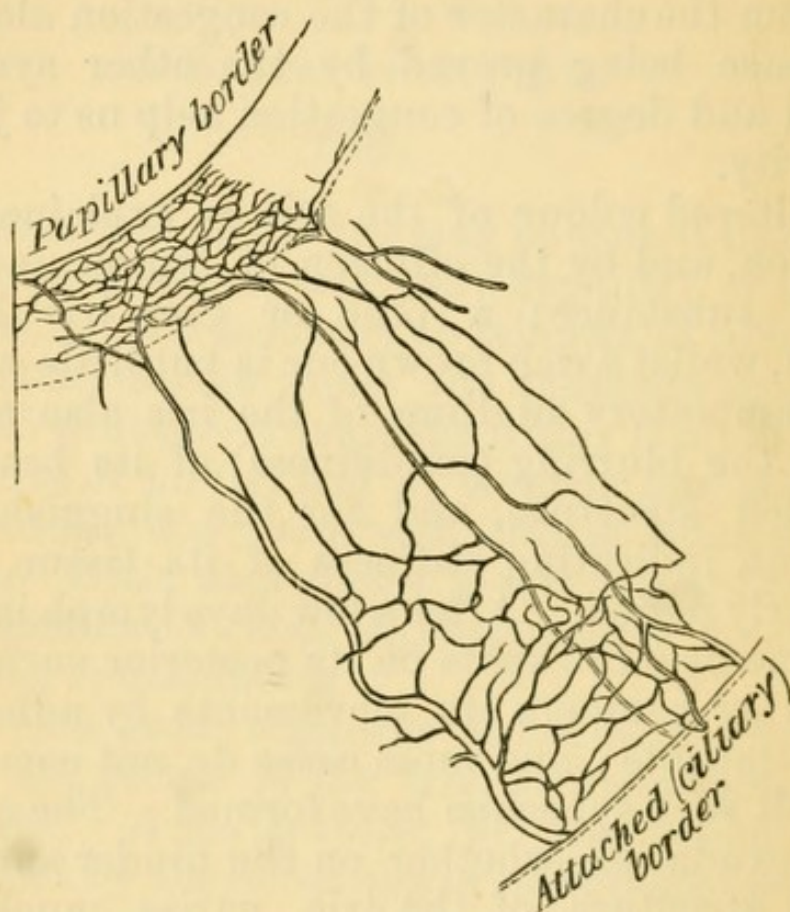


FIG. 51.—Vessels of human iris artificially injected; capillaries most numerous at pupillary border, and next at ciliary border.

and in such cases there are generally other peculiarities.

The condition of the pupil alone is diagnostic in all except very mild or incipient cases of iritis. It is sluggish or quite inactive, and not quite round; it is also rather smaller than its fellow (supposing the iritis to be one-sided), because the surface of the iris is increased (and the pupil, therefore, encroached on) whenever its vessels are distended (p. 29). Atropine causes it to dilate between the synechiæ; the synechiæ, being fixed, appear as angular projections when the iris on each side of them has retracted. If



there be only one adhesion it will merely notch the pupil at one spot; if the adhesions be numerous the pupil will be crenated or irregular (Fig. 52). If the whole pupillary ring, or still more, if the entire posterior surface, of the iris be adherent, scarcely any dilatation will be effected; the former condition is called annular or circular synechia, and its result is "*exclusion*" of the pupil; the latter is known as *total posterior synechia*. If the synechiæ are new and the lymph soft the repeated use of atropine will cause them to give way, and the pupil will become round; but even then some of the uveal pigment, which is easily separable from the posterior surface of the iris, often remains behind, glued to the lens-capsule by a little lymph (Fig. 53). The presence of one or more such spots of brown pigment on the capsule is always conclusive proof of present or of past iritis. The pupillary area itself in severe iritis is often filled by greyish or yellowish lymph, which spreads over it from the iris. The iris may be inflamed without any lymph being effused from its hinder surface, and then the pupil, though sluggish, acting imperfectly to atropine, and never dilating widely, will present no posterior synechiæ nor any adhesion of pigment-spots to the lens, but it will always be discoloured (serous iritis); iritis of this kind often occurs with ulceration of the cornea. When exudation into the pupil becomes organised, a dense white

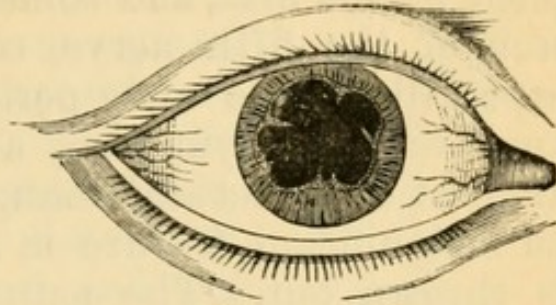


FIG. 52.—Iritic adhesions (posterior synechiæ) causing irregularity of pupil. (Wecker and Jaeger.)

the lymph soft the repeated use of atropine will cause them to give way, and the pupil will become round; but even then some of the uveal pigment, which is easily separable from the posterior surface of the iris, often remains behind, glued to the lens-capsule by a little lymph (Fig. 53). The presence of one or more such spots of brown pigment on the capsule is always conclusive proof of present or of past iritis. The pupillary area itself in severe iritis is often filled by greyish or yellowish lymph, which spreads over it from the iris. The iris may be inflamed without any lymph being effused from its hinder surface, and then the pupil, though sluggish, acting imperfectly to atropine, and never dilating widely, will present no posterior synechiæ nor any adhesion of pigment-spots to the lens, but it will always be discoloured (serous iritis); iritis of this kind often occurs with ulceration of the cornea. When exudation into the pupil becomes organised, a dense white

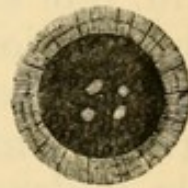


FIG. 53.—Spots of pigment and lymph at seat of former iritic adhesions.



membrane or a delicate film, often, however, presenting one or more little clear holes, is formed over the pupil (*"occlusion" of the pupil*).

Pain referred to the eyeball and to the parts supplied by the first, and sometimes by the second, division of the fifth nerve, commonly occurs in iritis, especially in the early period of the attack. It is a very variable symptom, and gives no clue to the amount of structural change, being sometimes quite an insignificant feature in a case where much lymph is thrown out. The pain is seldom constant, but comes on at intervals, is often worst at night, and is described as shooting, throbbing, or aching. It is commonly referred to the temple or forehead, as well as to the eyeball; sometimes also to the side of the nose and to the upper teeth. Photophobia and watering are generally proportionate to the pain.

The duration of acute iritis varies from a few days when mild to many weeks when severe. The defect of sight is proportionate to the haziness of the cornea, aqueous, and pupillary space, but in some cases is increased by changes in the vitreous. Iritis sometimes sets in very gradually, causing no marked congestion or pain, but slowly giving rise to the formation of tough adhesions, and often to the growth of a thin membrane over the pupillary area; in some of these the iris becomes thickened and tough, and its large vessels undergo much dilatation, whilst in others keratitis punctata occurs (*see Cyclitis*, p. 129; *Diseases of Cornea*, p. 110; and *Sympathetic Ophthalmitis*, p. 133).

*Results of iritis.*—Such of the results as are permanent need separate notice. Reference has been made to the adhesions, which are often permanent, and to the spots of uveal pigment on the lens-capsule, which are always so. Either of these conditions tells a tale of past iritis which is often a valuable aid to diagnosis. A blue iris which has undergone severe inflammation may remain greenish.



When the pupil is "excluded" or "occluded," the remainder of the iris being free, fluid collects in the posterior aqueous chamber, and by bulging the iris forwards, and diminishing the depth of the anterior chamber, except at its centre, gives the pupil a funnel-like appearance; if the bulging be partial, or be divided by bands of tough membrane, the iris looks cystic. *Secondary glaucoma* is likely to follow, and the tension of the globe should, therefore, be carefully noted whenever this bulging is present. "Total posterior synechia" always shows a severe, though often a chronic, iritis; it is often accompanied by deep-seated disease, and followed by opacity of the lens (secondary cataract), and in some cases ultimately the lens becomes absorbed. Relapses of iritis are believed to be induced by the presence of synechiæ, even when there is no protrusion of the iris by fluid; but their influence in this direction has, I believe, been much overrated.

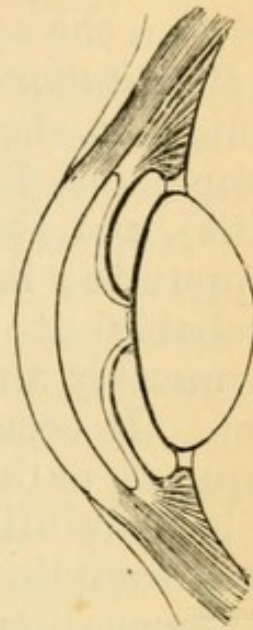


FIG. 54. — Diagram to show bulging of iris by collection of aqueous humour behind it, when the pupillary border of the iris is completely adherent to the lens-capsule (exclusion of pupil).

It must, however, be observed that there is still much difference of opinion on the point last referred to. The iritis of syphilis is still held by some to be very liable to recur, and to be by no means limited to the secondary stage; and we still often hear it stated that iritic adhesions, by preventing free movement of the iris, operate as sources of irritation, and thus predispose to relapse. I have seldom succeeded in getting a history of recent syphilis in cases of recurring iritis, whilst in a number of cases of old iritis with the history of inflammation during secondary syphilis years before, I have scarcely found one with well-marked history of relapses. Lastly, I have several times seen severe relapses in rheumatic cases after iridectomy had been performed as a preventive. All the evi-



dence seems to me to favour the view that recurrences of iritis depend, as a rule, upon the constitutional cause of the disease.

The following are the most important points as to the causes of iritis, and the chief clinical differences between the several forms.

*Constitutional causes.* — *Syphilis.* — The iritis is acute; it shows a great tendency to effusion of lymph and formation of vascular nodules (plastic iritis), and the nodules, when very large, may even suppurate; it is symmetrical in a large proportion, probably at least two thirds, of the cases. But asymmetry and absence of lymph-nodules, are common. It occurs only in secondary syphilis (either acquired or inherited), and seldom relapses. It is to be carefully distinguished from the iritis which often complicates syphilitic keratitis (p. 105).

*Rheumatism* is the cause of most cases of relapsing unsymmetrical iritis; there is but little tendency to effusion of lymph, and nodules are never formed, but there is occasionally fluid hypopyon (pp. 97 and 115); the congestion and pain are often more severe than in syphilitic iritis. A single attack is rarely symmetrical, though both eyes commonly suffer by turns. It relapses at intervals of months or years. Even repeated attacks sometimes result in but little damage to sight. *Gout* is apparently a cause of some cases of both acute, and insidious chronic, iritis. It is perhaps doubtful whether the gout or the chronic rheumatism from which the same patients sometimes suffer is the cause of the iritis. In its tendency to relapse, and to affect only one eye at a time, gouty resembles rheumatic iritis. The children of gouty parents are occasionally liable to a very insidious and destructive form of chronic iritis, with disease of the vitreous, keratitis punctata and glaucoma (p. 130) (see also Chap. XXIII).

*Chronic iritis (plastic irido-choroiditis)*, (see also p. 129). — In a few cases symmetrical iritis, of a chronic, progressive and destructive character, is compli-



cated with choroiditis, disease of vitreous and secondary cataract. These cases, for which it is at present impossible to assign any cause, either general or local, are chiefly seen in young adults, and, I think, oftenest in women.

*Sympathetic iritis.*—See Sympathetic Ophthalmitis.

*Local causes.*—*Injuries.*—Perforating wounds of the eyeball, particularly if irregular, contused, and complicated with wound of the lens, are often followed by iritis. Perforating wounds are more likely to be followed by iritis in old than in young persons. If the corneal wound suppurate, or become much infiltrated, the iritis is likely to be suppurative, and the inflammation to spread to the ciliary processes and cause destructive panophthalmitis. Iritis may follow a wound of the lens-capsule without wound of the iris, and with only a mere puncture of the cornea. Examples of traumatic iritis from these several causes are seen after the various operations for cataract. The iritis (or more correctly irido-capsulitis) following extraction of senile cataract is often prolonged, attended by chemosis, much congestion, and the formation of tough membrane behind the iris (see "Cataract").—Iritis may also follow superficial wounds and abrasions of the cornea, or direct blows on the eye; but it is of great importance whenever the question of injury comes in, to ascertain whether or not there has been a perforating wound. Iritis often accompanies ulcers and other inflammations of the cornea especially when deep, or complicated with hypopyon, or occurring in elderly persons. Iritis may be secondary to deep-seated disease or tumour in the eye.

*Treatment.*—(1.) In every case where iritis is present atropine is to be used often and continuously, in order to break down adhesions which have formed, and to allow any lymph subsequently formed to be deposited outside the ordinary area of the pupil. A strong solution (four grains of sulphate of atro-



pine to one ounce of distilled water) is to be dropped into the conjunctival sac every hour in the early period. Even if the synechiæ are, when first seen, already so tough that the atropine has no effect on them, it may prevent the formation of new ones on the same circle. Atropine also greatly relieves pain in iritis, and lessens the congestion, and through these means it no doubt helps materially to arrest exudation. Mild acute iritis may sometimes be cured by atropine alone.

(2.) If there be severe pain with much congestion, three or four leeches should be applied to the temple, to the malar eminence, or to the side of the nose. They may be repeated daily, in the same or smaller numbers, with advantage for several days, if necessary; or after one leeching repeated blistering may be substituted. Some surgeons use opiates instead of, or in addition to, leeches. Leeches occasionally increase the pain.—Severe pain in iritis can nearly always be quickly relieved by artificial heat; either fomentations or dry heat, as hot as can be borne, to the eyelids. To apply dry heat, take a piece of cotton wool the size of two fists, hold it to the fire, or against a tin pot full of *boiling* water, till quite hot, and apply it to the lids; have another piece ready and change as soon as the first gets cool; continue this for twenty minutes or more, and repeat it several times a day.\* Paracentesis of the anterior chamber should be resorted to in severe iritis if the aqueous tumour remain turbid after a few days of other treatment; the wound is to be reopened daily until there is marked improvement.

(3.) Rest of the eyes is very important. Many an attack is lengthened out, and many a relapse after partial cure is brought on, by the patient continuing at, or returning too soon to, work. It is not in most cases necessary to remain in a perfectly dark room;

\* I owe my knowledge of the value of dry heat, so applied, to Mr. Liebreich.



to wear a shade in a room with the blinds down is generally enough, provided that no attempt be made to use the eyes. Work should not be resumed till at least a week after all congestion has gone off.

(4.) Cold draughts of air on the eye and all causes of "catching cold" are to be very carefully avoided, by keeping the eye warmly tied up with a large pad of cotton wool.

(5.) The cause of the disease is to be treated, and into this careful inquiry should always be made. If the iritis be syphilitic, treatment for secondary syphilis is proper, mercury being given just short of salivation for several months, even though all the active eye symptoms quickly pass off. The rheumatic and gouty varieties are less definitely under the influence of internal remedies; iodide of potassium, alkalies, colchicum, salicylate of soda, and turpentine, each have their advocates; when the pain is severe tincture of aconite is sometimes markedly useful; mercury is seldom needed, but in protracted and severe cases it may be given with advantage. It is sometimes advisable to combine quinine or iron with the mercury in syphilis, or to give them in addition to other remedies in rheumatic cases.

(6.) As a rule no stimulants are to be allowed, and the bowels should be kept well open.

(7.) Iridectomy is needed for cases of severe iritis where judicious local and internal treatment have been carefully tried for some weeks without marked relief to the symptoms, and whether or not there be increased tension. It is chiefly in cases of constitutional origin, either syphilitic or rheumatic, and in the iritis accompanying ulcers of the cornea, that iridectomy is useful; it is not admissible in sympathetic iritis, nor in iritis after cataract extraction.—In reference to iridectomy it is to be borne in mind that unless necessary it is injurious, by producing an enlarged and irregular pupil through which, for



optical reasons (p. 5), the patient will often not see so well as through the natural pupil, even though this be partially obstructed. The effect of the operation in abating the inflammation is occasionally very marked, but in order to be sure that the effect is due to the operation we must have first tried fairly the other means of cure. In regard to all methods of local treatment we must bear in mind that acute iritis occurs in all degrees of severity, and that the mildest cases often need only atropine and rest.

*Traumatic iritis*, in a very early stage, is best combated by atropine, continuous cold, obtained by laying upon the closed eyelids pieces of lint wetted in iced water and changed every few minutes; and by leeches. *Cold is not to be used to any other form of iritis.*

*Congenital irideremia* (absence of iris) is occasionally seen, and is often associated with other congenital defects of the eye.

*Coloboma of the iris* (congenital cleft in the iris) gives the effect of a very regularly made iridectomy. It is always downwards or slightly down-in, and usually, but not always, symmetrical. There are many varieties in degree, and sometimes there is nothing more than a sort of line or seam in the iris. It often occurs without coloboma of the choroid.

Persistent remains of the pupillary membrane have sometimes to be distinguished from iritic adhesions. They form thin shreds or loops of tissue, in colour resembling the iris, to the *anterior* surface of which, close to its pupillary border, they are attached. They are longer and slenderer than posterior synechiæ, and are not attached to the lens-capsule.\* I have once seen well-marked remains of this membrane complicated with equally unequivocal iritic adhesions, in a case of acute iritis.

\* When remains of pupillary membrane are complicated with old iritic adhesions in children, there has probably been intra-uterine iritis.



## CHAPTER IX

## DISEASES OF THE CILIARY REGION.

THIS chapter is intended to include cases in which the ciliary body itself, or the corresponding part of the sclerotic, or the episcleral tissue, is the sole seat, or at least the headquarters, of inflammation. From the abundance of vessels and nerves in the ciliary body, and the importance of its nutritive relations to the surrounding parts, we find that many of the morbid processes of the ciliary region show a strong tendency to spread, according to their precise position and depth, to the cornea, iris, or vitreous, and by influencing the nutrition of the lens to cause secondary cataract. Although alike on pathological and clinical grounds it is necessary to subdivide the class into groups, we may observe that the various diseases of this part show a general agreement in some of their more important characters; thus all of them are protracted and liable to relapse, and in all there is a marked tendency to patchiness, the morbid process being most intense in certain spots of the ciliary zone, or even occurring in quite discrete patches. It is convenient to make three principal clinical groups, the differences between which are accounted for to a great extent by the depth of the tissue chiefly implicated. The most superficial may be taken first.

(1.) *Episcleritis* (more correctly *Scleritis*) is the name given to one or more large patches of congestion, with some elevation of the conjunctiva from thickening of the subjacent tissues, in the ciliary region. The congestion generally affects the conjunc-



tival as well as the deeper vessels, and the yellowish colour of the exudation tones the bright blood-red down to a more or less rusty tinge, which is especially striking at the centre of the patch, where the thickening is greatest. The latter varies in amount, but seldom causes more than a low, widely spread mound of swelling.

Episcleritis is a rather rare disease. It occurs chiefly on the exposed parts of the ciliary region, and especially near the outer canthus; but the patches may occur at any part of the circle, and exceptionally the inflammation is diffused over a much wider area than the ciliary zone, extending far back, out of view. The iris is often a little discoloured and the pupil sluggish, but actual iritis is the exception. There is often much aching pain. The disease is subacute, reaching its acme in not less than two or three weeks, and requiring a much longer time before absorption is complete. Fresh patches are apt to spring up while old ones are declining, and so the disease may last for months; indeed, relapses at intervals and in fresh spots are the rule. It usually affects only one eye at a time, but both often suffer sooner or later. After the congestion and thickening have disappeared a patch of the underlying sclerotic, of rather smaller size, is generally seen to be dusky as if stained; it is doubtful whether such patches represent thinning of the sclerotic from atrophy, or only staining; it is but seldom that they show any tendency to bulge as if thinned.

In rare cases the exudation is much more abundant, and a large hemispherical swelling is formed, which may even contain pus; such cases pass by gradations into conjunctival phlyctenulæ, and are generally seen in children (compare p. 95).

Episcleritis is seldom seen except in adults, and is commoner in men than women. Inquiry often shows that the sufferer is, either from occupation or temperament, particularly liable to be affected by



exposure to cold or by changes of temperature. Some of the patients are rheumatic, some gouty. Similar patches, but of a brownish, rather translucent appearance, are occasionally caused by tertiary syphilis, acquired or inherited ("*gummatous scleritis*").

In the treatment, protection by a warm bandage, rest, the yellow ointment (Fig. 11), the use of repeated blisters, and local stimulation of the swelling, are generally the most efficacious. Atropine is very useful in allaying pain. Internal remedies seldom seem to exert much influence, except in syphilitic cases. Salicylate of soda has been highly spoken of by some.

Lately systematic kneading of the eye through the closed lids ("massage"), and also scraping away the exudation with a sharp spoon, after turning back the conjunctiva, have been highly spoken of, and are certainly worth trial.

(2.) *Sclero-keratitis and sclero-iritis* ("scrofulous scleritis," "anterior choroiditis").—A more deeply-seated, very persistent, or relapsing, subacute inflammation, characterised by, congestion of a violet tint (deep scleral congestion, p. 27, 2), abruptly limited to the ciliary zone, and affecting some parts of the zone more than others (tendency to patchiness). Early in the case there is a slight degree of bulging of the affected part, due partly to thickening; whilst patches of cloudy opacity, which may or may not ulcerate, appear in the cornea close to its margin. Iritis generally occurs later. Pain and photophobia are often severe. After a varying interval, always weeks, more often months, the symptoms recede. At the focus of greatest congestion, or it may be around the entire zone, the sclerotic is left of a dusky colour, sometimes interspersed with little yellowish patches, and permanent haziness of the most affected parts of the cornea remains. The disease is almost certain to relapse sooner or later; or a succession of fresh inflammatory foci follow each other



without any intervals of real recovery, the whole process extending over months or years. After each attack more haze of cornea and fresh iritic adhesions are left. The sclerotic, in bad cases of some years' standing, becomes much stained, and bulges decidedly (ciliary or anterior staphyloma), and the cornea becomes both opaque and altered in curve; the eye is then useless, though but seldom liable to further active symptoms.

The characteristic appearance of an eye which has been moderately affected is the dusky colour of the

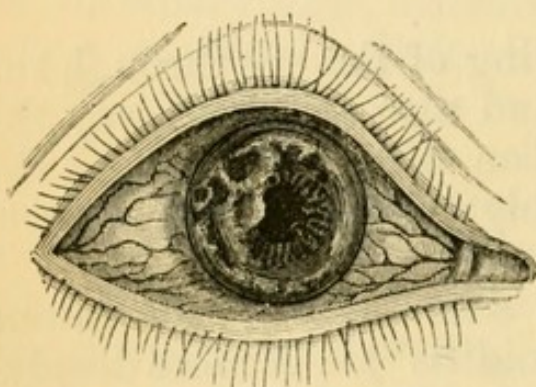


FIG. 55.—Relapsing Sclero-keratitis (from nature).

sclerotic and the irregular, patchy opacities in the cornea (Fig. 55), which are often continuous with the sclerotic. The disease does not occur in children, nor does it begin late in life; most of the patients are young or middle-aged adults, and, unlike the former variety, most are wo-

men. It is not associated with any special diathesis or dyscrasia, but generally goes along with a feeble circulation and liability to "catch cold;" in some cases there is a definite family history of scrofula or of phthisis. Predisposed persons are more likely to suffer in cold weather, or after change to a colder or damper climate, or after any cause of exhaustion, such as suckling.

*Treatment* is at best but palliative. Local stimulation by yellow ointment or calomel is very useful in some cases, particularly in those which verge towards the phlyctenular type. In the early stages, especially when the congestion is very violent and altogether subconjunctival, atropine often gives relief, and it is, of course, useful for the iritis. Repeated blistering



is also to be tried, though not all cases are benefited by it. I have not seen much benefit from setons. Warm, dry applications to the lids are, as a rule, better than cold. Mercury, in small and long-continued doses, is certainly valuable when the patient is not anæmic and feeble, but it is to be combined with cod-liver oil and iron. Protection from cold and bright light by "goggles" is a very important measure, both during the attacks and in the intervals between them. There is no rule as to symmetry; both eyes often suffer sooner or later, but sometimes one escapes whilst the other is attacked repeatedly. Transition forms occur between this disease and episcleritis.

(3.) *Cyclitis with disease of vitreous and keratitis punctata* (chronic serous irido-choroiditis).—A small but important series of cases, in which there is congestion, as in mild iritis, and dulness of sight, but usually no pain or photophobia. Flocculi are found in the anterior part of the vitreous, or numerous small dots of deposit are seen on the posterior surface of the cornea (keratitis punctata, Fig. 49); the anterior chamber is often too deep, and insidious iritis usually follows. Patches of recent choroiditis (p. 170) are often to be seen at the fundus. Persistence and liability to relapse are features as marked here as in the other members of the cyclitic group. The tension is often slightly augmented at the beginning, and the eye sometimes passes into a permanent state of chronic glaucoma from blocking of the ligamentum pectinatum with cells, without the intervention of plastic iritis (*see Glaucoma*); but usually the final condition depends on the extent of the iritic adhesions, for when the synechiæ are numerous and tough, and the iris is much altered in structure, or the pupil blocked by iritic membrane, secondary glaucoma is likely to arise from imprisonment of fluid behind the iris (Fig. 54). When seen quite early the diagnosis will probably be "serous iritis"



or "ciliary congestion," unless the eye be carefully examined ; for the pupil is generally free in all parts, or shows, at most, one or two adhesions after atropine has been used. In a few cases the punctate deposits on the back of the cornea constitute almost the only objective change (simple keratitis punctata), but these are very rare (p. 110) (compare Chronic Iritis, p. 120).

The cases occur in adolescents or young adults, and the disease is always sooner or later symmetrical. Many mild cases recover perfectly, and in most others the final result is satisfactory. In respect to cause, there is strong reason to believe that many of these cases are the result of gout in a previous generation, the patient himself never having had the disease (Hutchinson). The disease seems often to be excited in predisposed persons by prolonged overwork or anxiety, combined with underfeeding, or defective assimilation ; the patients often describe themselves as delicate ; some are phthisical. On the other hand, in some of the worst cases, leading to secondary cataract and ultimately to shrinking of the eyes (p. 120), the patient appears to be, from first to last, in good health, and free from any ascertainable morbid diathesis.

In the *treatment* prolonged rest of the eyes is important. Atropine is usually necessary, but if there be increase of tension its effect must be carefully watched, and in cases where there are no iritic adhesions, eserine may have to be substituted. If the increase of tension keeps up, and seems to be damaging the sight, iridectomy is necessary. Small doses of iodide of potassium and mercury appear to be useful in the earlier stages, given with proper precautions, and accompanied by iron and cod-liver oil. Change of climate would probably often be very beneficial. In the worst cases, where the changes are like those resulting from sympathetic ophthalmitis, no treatment seems to have any effect.



Cases of acute inflammation are occasionally seen in which most of the symptoms resemble those of acute iritis, but with the iris so little affected, that it is evidently not the headquarters of the morbid action. The tension may be much reduced, whilst repeated and rapid variations, both in sight and objective symptoms, occur. The term "*idiopathic phthisis bulbi*" has been applied to some of these. Again, some cases of syphilitic inflammation, which are classed as syphilitic "iritis," might more correctly be called "cyclitis." In some cases of heredito-syphilitic keratitis there is much cyclitic complication (p. 108), and these are always difficult to treat.

Plastic inflammation of the ciliary body, following injury (*traumatic iritis* or *iridocyclitis*), is the usual starting-point of the changes which set up sympathetic inflammation of the fellow eye; the tension is often lowered, and the symptoms subacute. The onset of *purulent traumatic cyclitis* (*panophthalmitis*) is signalled by congestion, pain, chemosis, and swelling of lids. The inflammation quickly spreads to the fibrous capsule of Tenon and the muscles, the eye becoming glued to the surrounding parts, protruded and fixed. If the lens be transparent a yellow or greenish reflection is, after a few days, sometimes seen behind it, indicating the presence of pus in the vitreous humour; but usually the cornea and aqueous are too turbid, even should the lens be clear, to allow deep inspection.

#### SYMPATHETIC IRRITATION AND SYMPATHETIC OPHTHALMITIS.

Certain morbid changes in one eye may set up either functional disturbance or destructive inflammation in its fellow. The term *sympathetic irritation* is given to the former, and *sympathetic ophthalmitis* (or *ophthalmia*) to the latter. Though these conditions may be combined, they more often occur separately, and it is very important to distinguish between them.



Although at present the exact nature of the changes which precede sympathetic inflammation is unknown, and their path has not been fully traced out, we are sure (1) that the changes start from the region most richly supplied by branches of the ciliary nerves (composed of fibres from the fifth, sympathetic, and third), viz. the ciliary body and iris; (2) that their first effects are generally seen in the same part of the *sympathising eye*; (3) that the *exciting eye* has nearly always been wounded, and in its anterior part; and that decided plastic inflammation of its uveal tract is always present; (4) that inflammatory changes have in some cases been found in the ciliary nerves and optic nerve of the exciting eye.

The morbid influence has of late years been generally believed to pass along the ciliary nerves; but the earlier hypothesis of transmission along the optic nerve has recently been revived, and, further, the blood-vessels, lymphatics, and even the blood itself, are at the present time claimed by different authors as probable channels. The histology of the subject has not yet been fully worked out by the most modern methods.

In almost every case sympathetic inflammation is set up by a perforating wound, either accidental or operative, in the ciliary region of the other eye, *i.e.* within a zone, nearly a quarter of an inch wide, surrounding the cornea. The risk attending a wound in this "dangerous zone" is increased if it be lacerated, or heal slowly, or if the iris or ciliary body be engaged between the lips of the sclerotic, or if the eye contain a foreign body; under all conditions, indeed, which make the occurrence of plastic or purulent irido-cyclitis probable. Sympathetic inflammation may also be set up by a foreign body lodged in the eye, whether the wound be in the ciliary region or not; by an eye containing a tumour, though probably not unless the eye has been operated upon; by a purely corneal wound, or a perforating ulcer, if



complicated by adhesion of the iris, with dragging on the ciliary body.

*Symptoms in the Exciting eye.*—The exciting eye, when it is causing sympathetic *irritation*, generally shows ciliary congestion and photophobia, and often suffers neuralgic pain. In an eye which is causing sympathetic *inflammation*, iritis, often with lowered tension, is always present; but the iritis is often painless and without noticeable congestion, and thus may easily be overlooked; it is especially important to remember that the exciting eye, though its sight is always damaged, need not be blind, and that under certain circumstances, it may in the end be the better eye of the two.

*Symptoms in the Sympathising eye.*—*a. Sympathetic Irritation.*—The eye is, in common speech, “weak” or “irritable.” It is intolerant of light, and easily flushes and waters if exposed to bright light or if much used; the accommodation is weakened or irritable, so that continued vision for near objects is painful or even impossible, and the ciliary muscle seems liable to give way suddenly for a short time, the patient complaining that near objects now and then suddenly become misty for a while. Neuralgic pains, referred to the eye and side of the head, are also common. Temporary darkening of sight, indicating suspension of retinal function, and more lasting defect of sight without ophthalmoscopic changes, are spoken of as occurring in certain cases. Such attacks may occur again and again in varying severity, lasting for days or weeks, and finally ceasing without ever passing on to structural change. Sympathetic irritation is always, and as a rule promptly, cured by removal of the exciting eye; but occasionally the symptoms persist for some time afterwards.

*b. Sympathetic Inflammation (Ophthalmitis).*—The disease may arise out of an attack of “irritation,” but much more commonly it sets in without any such warning. It may be acute and severe, or so insidious



as to escape the notice of the patient until well advanced. It is in all cases a prolonged and a relapsing disease; when once started it is self-maintaining, and its course usually extends over many months, or even a year or two. In mild cases a good recovery eventually takes place, but in a large majority the eye becomes blind. The disease usually takes the form of a plastic irido-cyclitis or irido-choroiditis, with exudation from the entire posterior surface of the iris, leading to total posterior synechia (p. 117). Its chief early peculiarities are a great liability to dotted deposits on the back of the cornea (p. 110), dusky ciliary congestion with marked engorgement of the large vessels which perforate the sclerotic in the ciliary region, and thickening and muddiness of the iris, causing shallowness of the anterior chamber; if the pupil allows of ophthalmoscopic examination we shall find the vitreous clouded by floating opacities, and there is often neuro-retinitis. In acute and severe cases the congestion is intense, there is severe pain, photophobia, and tenderness on pressure, and the iris, besides being thick, is changed in colour to a peculiar buff or yellowish brown, and shows numerous enlarged blood-vessels. Attacks of intense neuralgia of the fifth nerve characterise some cases. In cases of all degrees, the tension is often increased, the eye becoming decidedly glaucomatous for a longer or shorter time. Many dotted opacities appear in the lens, which afterwards becomes completely cataractous and in some cases is finally quite absorbed. In the worst cases the eye finally shrinks, but in many it remains glaucomatous with total posterior synechia corneal haze and more or less ciliary staphyloma. In the mildest cases (the so-called "serous" form), the disease never goes beyond a chronic iritis with punctate keratitis, disease of the vitreous, and sometimes (perhaps usually) neuro-retinitis.

Sympathetic ophthalmitis generally begins about



two or three months after the injury to the exciting eye; very seldom sooner than three weeks, *i.e.* not until time has elapsed for well-marked inflammatory changes to occur at the seat of injury. On the other hand, the disease may set in at any length of time, even many years, after the injury or other disease of the exciting eye, particularly if the latter contain a foreign body. It occurs at all ages, but children are considered to be more liable than adults. Distinct inflammatory changes are always present in the exciting eye, but, as already stated, these may be manifested by but very slight subjective symptoms. When carefully observed, these changes are found to precede by some days, if not longer, the onset of structural disease in the sympathising eye, the morbid process apparently taking some time to travel from one eye to the other.

*Treatment.*—By far the most important measure refers to prevention. When once sympathetic inflammation has begun we can do little to modify its course. The clear recognition of this fact leads us to advise the excision of every eye which is at the same time useless and liable to cause sympathetic mischief, *i.e.* of all eyes which are blind from injury or disease of the anterior segment of the globe; and to give this advice most urgently when the blind eye is already tender or irritable, or is liable to become so, when it has been lost by wound, and when it is probable that it may contain a foreign body. Any lost eye in which there are signs of past iritis, even if there be no history of injury, is best removed, especially if shrunken. But much judgment is needed if the damaged eye, though irritable and likely to cause mischief, still retains more or less sight. Every attention must then be paid to the exact position of the wound, the evidence as to its depth, the evidence of hæmorrhage, and especially to the condition of the lens, and to the presence of the yellowish haziness behind the lens, which indicates



lymph or pus in the vitreous (p. 131). The date of the injury and the condition of the wound, whether healed by immediate union, or with scarring, puckering or flattening, are very important points. *Irritation* of the fellow eye may set in a few days after the injury; but since *inflammation* very seldom begins sooner than two or three weeks, we may, if we see the case early, watch it for a little time. Complete and prolonged rest in a darkened room is a very important element in the prevention of sympathetic irritation and inflammation, and should always be insisted on when we are trying to save an injured eye (compare p. 122). In rare cases sympathetic inflammation sets in *after* the removal of the exciting eye, even after an interval of several weeks, a contingency which emphasises the importance of excising every condemned eye at the earliest possible moment.

*When sympathetic ophthalmitis has set in* we can do comparatively little.

A. *The exciting eye*, if quite blind or so seriously damaged as to be for practical purposes certainly useless, is to be excised at once, though the evidence of benefit from this course is slender. But it is not to be removed if there is reason to hope for restoration of useful sight in it; if there be simply a moderate degree of subacute irido-cyclitis with or without traumatic cataract, and with sight proportionate to the state of the lens, the eye is to be carefully treated, since it may very probably in the end be the better of the two (p. 133).

B. *The sympathising eye*. The important measures are (1) atropine, used very often, as for acute iritis; (2) absolute rest and exclusion of light by residence in a dark room and with a black bandage over the eyes; (3) repeated leeching if the symptoms are severe, or counter-irritation by blisters or by a seton in chronic cases. (4) Mercury is believed by some to be beneficial. Quinine is sometimes given. (5) No operation is permissible whilst the disease is still



active, since iridectomy, performed whilst there are active symptoms, is followed by closure of the gap with fresh lymph. Operations in severe cases which have become quiet are seldom of use, the eye being generally then past recovery.

The *prognosis* is, as will be gathered, very grave; even in the mildest cases, when seen quite early, we must be very cautious, for the disease often slowly progresses for many months.



## CHAPTER X

## INJURIES OF THE EYEBALL.

A CLEAR distinction is to be made between contusion and concussion injuries, and wounds of the eyeball.

(1.) *Contusion and concussion injuries.*—*Rupture of the eyeball* is commonly the result of severe direct blows. The rent is nearly always in the sclerotic, either a little behind, or close to the corneal margin, with which it is concentric; the cornea itself is but seldom rent by a blow. The rupture is usually large, involves all the tunics, and is followed by immediate hæmorrhage between the retina and choroid, and into the vitreous and anterior chambers; often the lens and of some of the vitreous escape; sight is usually reduced to perception of light or of large objects. The conjunctiva, however, often escapes untorn, and in such a case if the lens pass through the rent in the sclerotic, it will be held down by the conjunctiva, and form a prominent, rounded, translucent swelling over the rupture. The diagnosis of rupture is generally easy, even if the rent be more or less concealed. The eyeball often shrinks; but occasionally it recovers with useful vision. Immediate excision is generally best when the wound is "compound;" but if the conjunctiva be not torn, and occasionally even when it is, we should wait a few days until the disappearance of the blood from the anterior chamber allows the deeper parts to be seen. The treatment is the same as for wounds of the eye (p. 143).

It may here be mentioned that copious hæmor-



rhage, accompanied by severe pain, sometimes occurs between the choroid and sclerotic as the result of sudden diminution of tension, either by an operation, such as extraction of cataract or iridectomy, or by a glancing wound of the cornea. Eyes in which this occurs are for the most part already unsound and often glaucomatous.

Blows often cause *internal damage without rupture of the hard coats* of the eye. The iris may be torn from its ciliary attachment (*coredialysis*), so that two pupils are formed (Fig. 56) or the lens be loosened or displaced (p. 165) by partial rupture of its suspensory ligament, so that the iris, having lost its support, will shake about with every movement (*tremulous iris*). Such lesions are likely to be obscured for a time by bleeding into the anterior chamber and into the vitreous. The lens

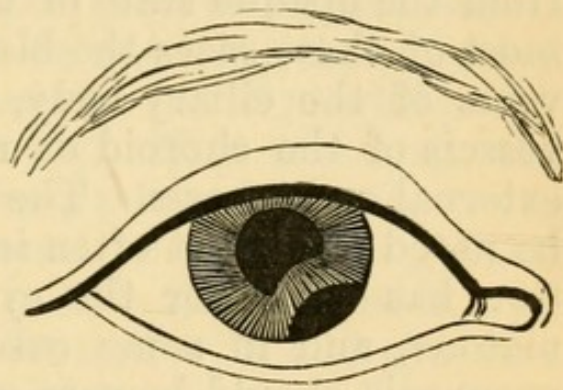


FIG. 56.—Separation of iris following a blow (after Lawson).

often becomes opaque afterwards (p. 157). Detachment of the retina is often found after severe blows, which have caused hæmorrhage into the vitreous.—Blows on the front of the eye may cause *rupture of the choroid*, or hæmorrhage from choroidal or retinal vessels. These changes are found at the central part of the fundus, often almost exactly at the yellow spot, thus causing much damage to sight. The rents in the choroid appear, after the blood has cleared up, as lines or narrow bands of atrophy bordered by pigment, and often slightly curved towards the disc (Fig. 69). Hæmorrhages from the choroidal vessels without rupture of the choroid, usually leave some residual pigment after absorption.—*Paralysis of the iris and ciliary muscle*, with partial and often irregular, dila-



tation of the pupil are sometimes the sole results of a blow on the eye. The defect of sight can be remedied by a convex lens. When uncomplicated these symptoms are seldom permanent. (*For Traumatic Iritis, see p. 121.*)

Great defect of sight following a blow, and neither remedied by glasses nor accounted for by blood in the anterior chamber, will generally mean copious hæmorrhage into the vitreous, with or without the other changes just mentioned in the retina and choroid. The red blood may sometimes be seen by focal light, but often its presence can only be inferred from the opaque state of the vitreous. Probably in most of these cases the blood comes from the large veins of the ciliary body, but sometimes from the vessels of the choroid or retina. There may be no external ecchymosis. The tension of the globe is to be noted; it is not often increased unless inflammation has set in or the eye was previously glaucomatous, and in some cases it is below par. The prognosis should be very guarded whenever there is reason to think, from the opaque state of the vitreous, that much bleeding has taken place, or when the iris is tremulous or partly detached, or if any rupture of the choroid can be made out. Blood in the anterior chamber is often completely absorbed in a day or two; but in the vitreous humour absorption, though rapid, is less complete, and permanent opacities are often left. The use of atropine, the frequent application of iced water, or of an evaporating lotion, to the lids, and occasional leeching if there are inflammatory symptoms, will do all that is possible for the first week or two after a severe blow with internal hæmorrhage. If the lens be loosened it may at any time act as an irritating foreign body, or set up a glaucomatous inflammation (p. 165). Now and then optic neuritis occurs in the injured eye as the immediate effect of the blow. Hæmorrhage behind the choroid is believed to account for certain well-



known cases in which, after a blow, there is defect of sight without visible change, or with localised, temporary haze of retina ("*commotio retinæ*"). Temporary myopia or astigmatism may also follow a blow on the eye; they depend on altered curvature of the lens, and are sometimes entirely removed by paralysing the ciliary muscle with atropine (*see also Hysterical Amblyopia*).

(2.) *Wounds*.—A. Superficial *abrasions* of the cornea cause much pain, with watering, photophobia, and ciliary congestion. They are frequently due to a scratch by the finger nail of a baby at the breast. The abraded surface is often very small and shows no opacity; it is detected by watching the reflexion of a window from the cornea (p. 19), whilst the patient slowly moves his eye. Now and then the symptoms return after a long interval of cure.

Minute fragments of metal or stone flying from tools, &c., often partly imbed themselves in the cornea ("*foreign body on the cornea*"), and give rise to varying degrees of irritability and pain. The fragment soon becomes surrounded by a hazy zone of infiltration, but it remains easily visible unless it be very small or covered by mucus or epithelium. When in doubt always examine the cornea by focal light with magnifying power (p. 37).

The pupil is often smaller than its fellow, and the colour of the iris altered in cases of superficial injury to the cornea, indicating congestion of the iris (p. 29). Actual iritis sometimes occurs, but not unless the corneal wound inflames.

*Treatment*.—(For removal of foreign bodies, *see Operations*). After surface injuries a drop of castor oil may be applied and the eye kept closed for the day with a pad of wadding and a bandage. Atropine is required if there is much irritation or threatened iritis. If hypopyon appear the case becomes one of hypopyon ulcer (p. 96).

Foreign bodies often adhere to the inner surface



of the upper lid; whenever a patient states that he has "something in his eye" and nothing can be found on the cornea, the upper lid must therefore be everted and examined.

Large bodies sometimes pass far back into the upper or lower conjunctival sulcus, and lie hidden for weeks or months, causing only local inflammation and some thickening of the conjunctiva. Search must be made, if needful, with a wire loop or probe whenever the suspicion arises (*see Orbit*).

B. *Burns, scalds, and injuries by caustics, &c.*—The conjunctiva and cornea are often damaged by splashes of molten lead, or by strong alkalies or acids, of which lime, either quick or freshly slaked, is one of the commonest. The eyeball is not often scalded, the lids closing quickly enough to prevent entrance of the steam or hot water. In none of these cases is the full effect apparent for some days, and a cautious opinion should, therefore, always be given when the case is seen very early.

The effects of such accidents are manifested by (1) inflammation of the cornea passing into suppurative keratitis, with hypopyon in bad cases; (2) scarring and shortening of the conjunctiva, and in bad cases adhesion of its palpebral and ocular surfaces, *symblepharon*.

The most superficial burns whiten and dry the surface, and in a few hours the epithelium is shed. This is shown on the cornea by a sharply outlined, slightly depressed area. The surface is clear if the damage be quite superficial and recent, but more or less opalescent, or even yellowish, if the case be a few days old, and the burn be deep enough to have caused destruction or inflammation of the true corneal tissue. When there is much opacity it does not completely clear, and considerable flattening of the cornea and neighbouring sclerotic often occurs at the seat of deep and extensive burns. The conjunctival whitening is followed by mere desquamation and vascular reaction, or by



ulceration and scarring, according to the depth of the damage.

*Treatment.*—In recent cases, seen before reaction has begun, a drop of castor oil once or twice a day, a few leeches to the temple, and the use of a cold evaporating lotion, or of iced water, will sometimes prevent inflammation. If seen immediately after the accident, the conjunctival sac is to be carefully searched for fragments, or washed with very weak acid or alkaline solution if a liquid caustic of the opposite character have done the damage. If inflammatory reaction is already present when the case comes to notice, treatment by compress, hot fomentations, and the other means recommended for suppurating ulcers (p. 101), is most suitable. There is often much pain and chemosis. Buttons of granulation forming on the floor of a healing burn of conjunctiva should be snipped off.

*c. Penetrating wounds and gun-shot injuries.*—When a patient says that his eye is wounded, the first step is to examine the seat, extent and character of the wound, ascertain the interval since the injury, and test the sight of the eye; the next, to make out all we can about the wounding body, and especially whether any fragment has been left within the eyeball.

Very large foreign bodies, such as pieces of glass, sometimes lie for long in the eye without causing much trouble, the large wound having given exit to the contents of the globe, and been followed by rapid shrinking without inflammation.

*Treatment.*—Penetrating wounds are least serious when they implicate the cornea alone, or the sclerotic behind the ciliary region, *i. e.* when situated at least  $\frac{1}{4}$  inch behind the cornea. Penetrating wounds of the cornea, without injury to the iris or lens, and without any prolapse of iris are rare; they generally do very well, and if the case be not seen until one or two days after the injury, the wound will often have



healed firmly enough to retain the aqueous, and it may be difficult to decide whether the whole thickness of the cornea have been penetrated or not. Wounds of the sclerotic seldom unite without the interposition of a layer of lymph; when seen early they should, if gaping, clean, and uncomplicated by evidence of internal injury, be treated by the insertion of one or two fine sutures, followed by the use of ice (p. 124).

But penetrating wounds are usually very serious to the injured eye; the iris is frequently lacerated and included in the track of the wound; the lens is punctured and becomes swollen and opaque from absorption of the aqueous humour (*traumatic cataract*, p. 157), and liable in its swollen state to press on the ciliary processes, and cause grave symptoms; extensive bleeding perhaps takes place into the vitreous; a few days later plastic or purulent cyclitis may destroy the eye (p. 131). The fellow eye is, of course, often in danger of sympathetic inflammation.—Every case has therefore to be judged from two points of view, the damage to the injured eye and the risk to the sound one; and the question whether to sacrifice, or attempt to save, the former is sometimes very difficult to decide.

(I.) In the two following cases the eye should be excised at once. (1) If the wound, lying wholly or partly in the “dangerous region” (p. 132), be so large and so complicated with injury to deeper parts that no hope of useful sight remains. (2) If, even though the wound be small, it lie in the dangerous region, and have already set up severe iritis, pp. 121 and 131).

(II.) There is the large class of cases in which it is certain or very probable that the eye contains a foreign body, although the injury is not of itself fatal to sight and has not as yet led to inflammation or to shrinking of the eye.

The first question then is whether the foreign body



can be seen, the second whether or not it is steel or iron, and therefore possibly removable by a magnet. A foreign body, if lying on or embedded in the iris, the lens being intact, should be removed, usually with the portion of iris to which it is attached; if loose in the anterior chamber it may be difficult to remove. If it can be seen imbedded in the lens and the condition of the eye be otherwise favorable, a scoop extraction may be done in the hope of removing the fragment with the lens; or the lens may be allowed, or by a needle operation (p. 159) induced, to undergo partial absorption and shrinking, so as to enclose the foreign body more firmly, and when subsequently extracted, to bring it away. If we are certain that the foreign body has passed into the vitreous, whether through the lens or not, and whether by gunshot or not, we can seldom save the eye. The foreign body can in such a case seldom be seen, but a track of opacity through the lens with blood in the vitreous, or even the latter alone, with conclusive history that the wound was made by a fragment or a shot, and not by an instrument or large body, will generally decide us in favour of excision.—These rules now need some modification when the foreign body is of iron or steel, since it has been found possible in certain cases, by means of a strong electro-magnet, to remove such fragments, even when lying in the vitreous. This may be done either through the wound of entrance, more or less enlarged, or through a fresh wound made where the body is seen, or believed, to lie. Many forms of magnet have been employed, the most successful, however, usually being those in which a small spatula instrument, powerfully magnetised by being attached to the core of an electro-magnetic coil, is introduced into the eye in search of the body. The spatula in the instrument used at Moorfields will, when the circuit is complete, lift nine ounces. Though a considerable number of eyes have now been saved



with useful sight by means of the magnet, it must be remembered that the extraction of the foreign body does not ensure the safety of the eye; that the eye may inflame or shrink, and remain as potent a source of sympathetic disease as before, especially so if iritis or threatened panophthalmitis were present at the time of operation.\* Foreign bodies occasionally become imbedded at the fundus, beyond the dangerous region, without causing any further trouble.

(III.) There remain cases of less severe character, in which there is no foreign body in the eye; (1) the wound is in the dangerous region and complicated with traumatic cataract; (2) in the dangerous region without traumatic cataract; (3) there is traumatic cataract, but the wound is corneal, and, therefore, out of the dangerous zone. In group (2) there will often be much difficulty in deciding what to do, it being presumed that the wounded eye shows no iritis or other signs of severe inflammation; some of the most difficult cases are those of wounds by sharp instruments close to the corneal border, with considerable adhesion of the iris, or in which there is evidence that the track lies between the lens and the ciliary processes, the lens not being wounded, and useful sight remaining. If the patient be seen within two or three weeks of the injury, and the sound eye shows no irritation, we may safely watch the case for a few days. If decided sympathetic irritation (p. 133) be present, and do not yield after a few days' treatment, excision is advisable, even though the lens of the wounded eye be uninjured. In regard to group 1, excision is without doubt the safest course in all cases, whether or not the eye be causing sympathetic symptoms or be itself especially irritable; for there is little prospect of regaining

\* Mr Snell, of Sheffield, who has probably had a larger experience of this method than anyone else, has published (June, 1883), an excellent monograph, in which all the cases hitherto recorded are given, in addition to his own.



useful vision in an eye with a ciliary wound and traumatic cataract. In group 3, excision is justifiable only in the rare cases where severe iritis and threatened panophthalmitis come on. The patient in all open cases must be warned, and must be seen every few days for many weeks.

When sympathetic ophthalmitis has set in before the patient asks advice, the rule as to excision of the exciting eye is different (p. 136).

The treatment of wounded eyes which are not excised is the same as for traumatic iritis and cataract, viz. atropine, rest, and local depletion (*see* p. 124 and 157). If seen before inflammation (iritis) has begun ice is to be used. If the iris has prolapsed into the wound the protrusion should be drawn further out and a large piece of iris cut off, so that the ends when replaced by the curette may retract and remain quite free from the wound (*see* Iridectomy); this may be done as much as three or four days after the injury. If seen a few hours after the wound, the prolapse can sometimes be returned, or made to retract by eserine.

It is sometimes important to determine whether an excised eye contains a foreign body. If nothing can be found in the blood or lymph, &c., by feeling with a probe, it is best to crush the soft parts, little by little, between finger and thumb, when the smallest particle will be felt. If a shot has entered and left the eye, the counter-opening may, if recent, be found from the inside, although no irregularity be noticeable outside the eyeball.



## CHAPTER XI

## CATARACT.

CATARACT means opacity of the crystalline lens, and is due to changes in the structure and composition of the lens-fibres. The capsule is often thickened, but otherwise not much altered. The changes seldom occur throughout the whole lens at once, but begin first in a certain region, *e.g.* the centre (*nucleus*) or the superficial layers (*cortex*), whilst in some forms of partial cataract the change never spreads beyond the part first affected.

*Senile changes in the lens.*—With advancing age the lens, which is from birth firmest at the centre, becomes harder, and acquires a very decided yellow colour; its refractive power usually decreases, its surface reflects more light, and its substance becomes somewhat fluorescent. The result of all these changes is that at an advanced age the lens is more easily visible than in early life, the pupil becoming greyish instead of being quite black. This greyness of the pupil may easily be mistaken for cataract, but ophthalmoscopic examination shows that the lens is transparent, the fundus being seen without any appreciable haze. It has hitherto been supposed that the lens became smaller in old age, but the researches of Priestly Smith have lately shown that the lens continues to increase in all dimensions, so long as it remains transparent. As a rule, however, cataractous lenses are undersized.

The consistence of a cataract depends chiefly on the patient's age. The wide physical differences between cataracts depend less on variations in the



cause, position or character of the opacity, than on the degree of natural hardness proper to the lens when the opacity sets in. Below about thirty-five all cataracts are "soft."

*Forms of General Cataract.*

(1.) *Nuclear cataract.*—The opacity begins in, and remains more dense at, the nucleus of the lens, thinning off gradually in all directions towards the cortex (Fig. 59); the nucleus is not really opaque, but densely hazy. As the patients are generally old, nuclear cataract is usually senile and hard, and also often amber-coloured or light brownish, like "peasoup" fog.

(2.) *Cortical cataract.*—The change begins in the superficial parts, and generally takes the form of sharply defined lines or streaks, or triangular patches, which point towards the axis of the lens, and whose shape is dependent on the arrangement of the lens fibres (Fig. 60). They usually begin at the edge (*equator*) of the lens where they are hidden by the iris, but when large enough they encroach on the pupil as whitish streaks or triangular patches. They affect both the anterior and posterior layers of the lens, and the intervening parts may be quite clear. Sooner or later the nucleus also becomes hazy (mixed cataract), and the whole lens eventually gets opaque.

Some cases of the large class known as "senile" or "hard" cataract are nuclear from beginning to end, *i. e.* formed by gradual extension of diffused opacity from the centre to the surface; more commonly they are of the mixed variety.

A few cataracts beginning at the nucleus, and many beginning at the cortex, are not senile in the sense of accompanying old age, and are, therefore, not hard. Some such are caused by diabetes, but in many it is impossible to say why the lens should have become diseased.\* Many of them are known as

\* Lowered blood-supply from atheroma of the carotid has



“soft” cataracts when complete. They generally form quickly, in a few months. A few are congenital. Whether nuclear or cortical, they are whiter and more uniform looking than the slower cataracts of old age, and the cortex often has a sheen like satin or mother-of-pearl, or looks flaky like spermaceti.

In some cortical cataracts we find only a great number of very small dots or short streaks (dotted cortical cataract). Occasionally a single large wedge-shaped opacity will form at some part of the cortex and remain stationary and solitary for many years. Sometimes in suspected cataract, though no opaque striæ are visible by focal illumination, one or more dark streaks (“striæ of refraction”—Bowman) are seen with the mirror, altering as its inclination is varied, and having much the same optical effect as cracks in glass. These “flaws” should always be looked on as the beginning of cataract.

#### *Partial Cataract.*

Three forms need special notice.

(1.) *Lamellar (zonular) cataract* is a peculiar and well-marked form in which the superficial laminæ and the nucleus of the lens are clear, a layer or shell of opacity being present between them (Fig. 62). It is probable that the opacity is present at birth; it certainly never forms late in life. The great majority of its subjects suffer from infantile convulsions. The size of the opaque lamella or shell, and, therefore its depth from the surface of the lens, is subject to much variation, and it may be much smaller than is shown in the Figure. The opacity is often stationary for years, perhaps for life; and though it is stated that the cataract, if left, eventually becomes general, cases in which this can be proved are rare.

(2.) *Pyramidal cataract*.—A small, sharply-defined spot of chalky-white opacity is present in the middle lately been suggested as a cause in some cases (Michel). Cataract does not seem to be often related to renal disease.



of the pupil (at the *anterior pole* of the lens), looking as if it lay upon the capsule. When viewed sideways it seems to be superficially imbedded in the lens, and also sometimes stands forwards as a little nipple or pyramid (Fig. 57). It consists of the degenerated products of a localised inflammation just beneath the lens-capsule, with the addition of organised lymph derived from the iris and deposited on the front of the capsule, the capsule itself being puckered and folded (Fig. 58). It is always stationary, and never becomes general.

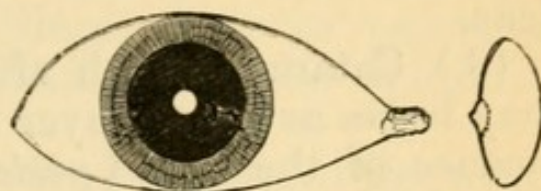


FIG. 57.—Pyramidal cataract seen from the front and in section.

Pyramidal cataract is the result of central per-

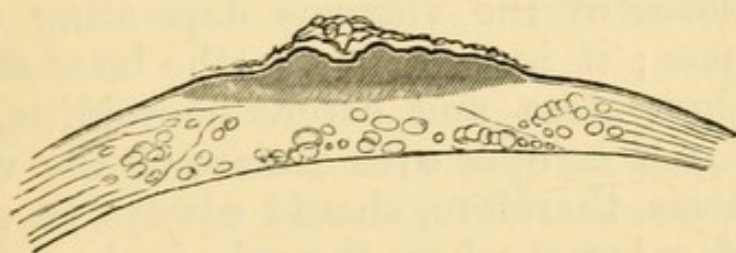


FIG. 58.—Magnified section of a pyramidal cataract. The fine parallel shading shows the thickness of the opacity, the double (black and white) outline is the capsule; on each side are the cortical lens-fibres, many being broken up into globules beneath the opacity. Lying upon the puckered capsule over the opacity is a little fibrous tissue, the result of iritis.

forating ulceration of the cornea in early life, and of this ophthalmia neonatorum is nearly always the cause; it is therefore often associated with corneal nebula. The contact between the exposed part of the lens-capsule and the inflamed cornea, which occurs when the aqueous has escaped through the hole in the ulcer, appears to set up the localised subcapsular inflammation. Iritis in very early life may also



cause similar opacities at the points of adhesion between the iris and lens.

The term *anterior polar cataract* is applied both to the form just described and to certain rare cases in which general cataract begins at this part of the lens.

(3.) Cataract, which afterwards becomes general, may begin as a thin layer at the middle of the hinder surface of the lens (*posterior polar cataract*) (Fig. 61). There are many varieties, but in general the pole itself shows the most change, the opacity radiating outwards from it in more or less regular spokes. The colour appears greyish, yellowish, or even brown, because seen through the whole thickness of the lens. Sometimes the opacity is due to formations adherent to the back of the capsule, *i. e.* in front of the vitreous; but this cannot be proved during life. —Cataract beginning at the posterior pole is often a sign of disease of the vitreous depending on choroidal disease; it is common in the later stages of retinitis pigmentosa and severe choroiditis, and in high degrees of myopia with disease of the vitreous. The prognosis, therefore, should always be guarded in a case of cataract where the principal part of the opacity is in this position.

When a cataract forms without known connection with other disease of the eye, it is said to be "*primary*." The term *secondary cataract* is used when it is the consequence of some local disease, such as severe iridocyclitis, glaucoma, detachment of the retina, or the growth of a tumour in the eye. Primary cataract is almost always symmetrical, but an interval, which may even extend to several years, usually separates its onset in the two eyes. Secondary cataract, of course, may or may not be symmetrical.

*Diagnosis of cataract.*—The subjective symptoms of cataract depend almost solely on the obstruction and



distortion of the entering light by the opacities. Objectively cataract is shown in advanced cases by the white or grey condition of the pupil at the plane of the iris; in earlier stages by whitish opacity in the lens when examined by focal light (p. 37) and by corresponding dark portions (lines, spots or patches) in the red pupil when examined by the ophthalmoscope mirror.

Both subjective and objective symptoms differ with the position and quantity of the opacity. When the whole lens is opaque the pupil is uniformly whitish; the opacity lies almost on a level with the iris, no space intervening, and consequently, on examining by focal light we find that the iris casts no shadow on the opacity; the brightest light from the mirror will not penetrate the lens in quantity enough to illuminate the choroid, and hence no red reflex will be obtained. Such a cataract is said to be mature or "ripe," and the affected eye will be in ordinary terms, "blind." If both cataracts be equally advanced, the patient will be unable to see any objects; but he will distinguish quite easily between light and shade when the eye is alternately covered and uncovered in ordinary daylight (good perception of light, *p. l.*), and will tell correctly the *position* of a candle flame. The pupils should be active to light and not larger than usual, and the tension normal.

In a case of incipient cataract the patient complains of gradual failure of sight, and we find the acuteness of vision (p. 32) impaired, probably more in one eye than in the other, and more for distant than for near objects. In the earliest stages of senile cataract some degree of myopia may be developed (Chap. XX), or owing to irregular refraction by the lens, the patient may see two or more images, close together, of any object with each eye (*polyopia uniocularis*). If he can still read moderate type, the glasses appropriate for his age and refraction, though giving some help, do not remove the defect. If, as is usual, he be presbyopic,



he will be likely to choose over-strong spectacles, and to place objects too close to his eyes, so as to obtain larger retinal images (p. 13), and thus compensate for want of clearness. In nuclear cataract, as the axial rays of light are most obstructed, sight is often better when the pupil is rather large, and such patients tell us that they see better in a dull light or with their backs to the window, or when shading the eyes with the hand. In the cortical and more diffused forms this symptom is less marked.

On examining by focal light (after dilating the pupil with atropine) an *immature nuclear cataract* appears as a yellowish, rather deeply-seated haze, upon which a shadow is cast by the iris on the side from which the light comes (3, Fig. 59). On now using the mirror this same opacity appears as a dull blur in the area of the red pupil, darkest at the centre, and gradually thinning off on all sides, so

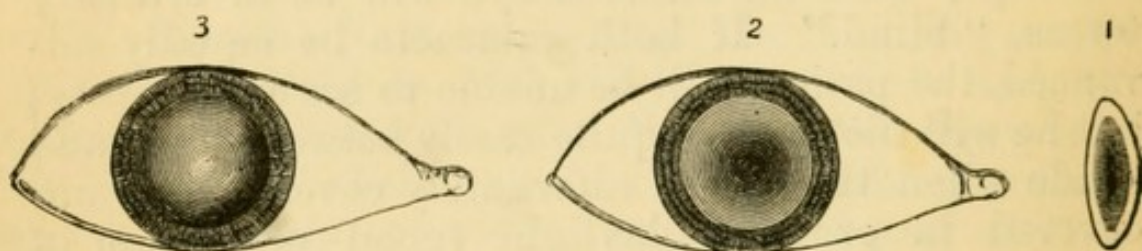


FIG. 59.—Nuclear cataract. 1. Section of lens; opacity densest at centre. 2. Opacity as seen by transmitted light (ophthalmoscope mirror) with dilated pupil. 3. Opacity as seen by reflected light (focal illumination). The pupil is supposed to be dilated by atropine.

that, at the margin of the pupil, the full red choroidal reflex may still be present; the details of the fundus, if still visible, are obscured by the hazy lens, the haze being thickest when we look through the centre of the pupil (2, Fig. 59). If the opacity is very dense and large, only a faint dull redness is visible quite at the border of the pupil.

*Cortical opacities*, if small and confined to the equator (or edge) of the lens, do not interfere with



sight; they are easily detected with a dilated pupil by throwing light very obliquely behind the iris. When large and encroaching on the pupil they are visible in ordinary daylight. They occur in the form of dots, streaks, or bars: seen by focal light they are white or greyish, and more or less sharply defined,

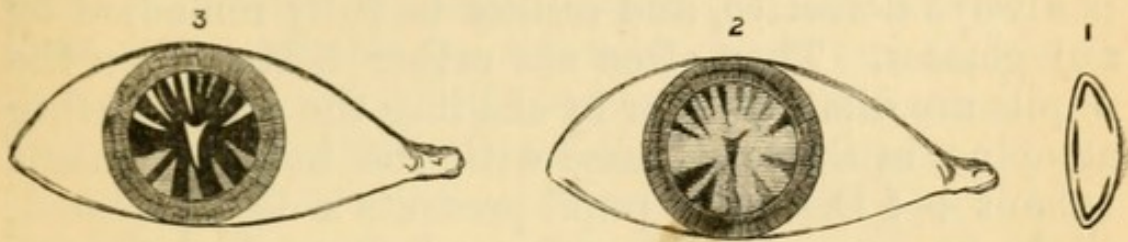


FIG. 60.—Cortical cataract. References as in preceding figure.

according as they are in the anterior or posterior layers (3, Fig. 60). With the mirror they appear black or greyish, and of rather smaller size (2, Fig. 60), and if the intervening substance is clear, the details of the fundus can be seen sharply between the bars of opacity.

*Posterior polar opacities* are seldom visible without careful focal illumination, when we find a patchy or stellate figure very deeply seated in the axis of the lens (3, Fig. 61); if large it looks concave like the bottom of a shallow cup. With the mirror it is seen as a dark star (2, Fig. 61), or network, or irregular patch, but smaller than when seen by focal light.

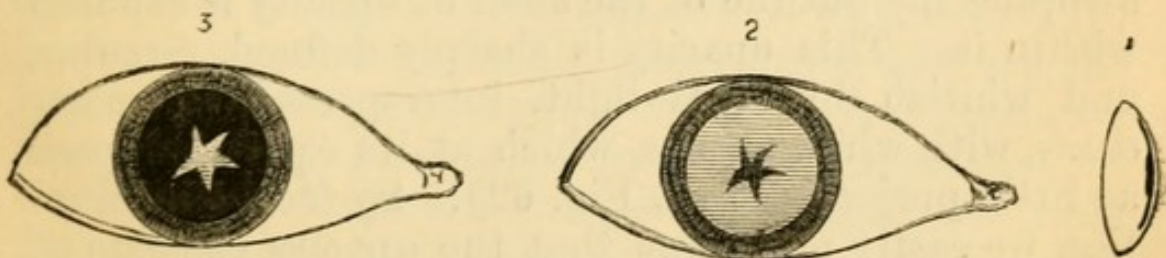


FIG. 61.—Posterior polar cataract. References as before.

The diagnosis of *lamellar cataract* is easy if its nature be understood, but by beginners it is often diagnosed as “nuclear.” The patients are generally children or young adults; they complain of “near



sight" rather than of "cataract;" for the opacity is not usually very dense, and whether the refraction of their eyes be really myopic or not, they (like other cataractous patients) compensate for dull retinal images by holding the object nearer, and so increasing the size of the images (p. 13). The acuteness of vision is always defective, and cannot be fully remedied by any glasses. They often see rather better when the pupils are dilated either by shading the eyes or using atropine, in the latter case with the help of glasses (about + 4 D.). The pupil presents a deeply-seated, slight greyness (4, Fig. 62), and when dilated with

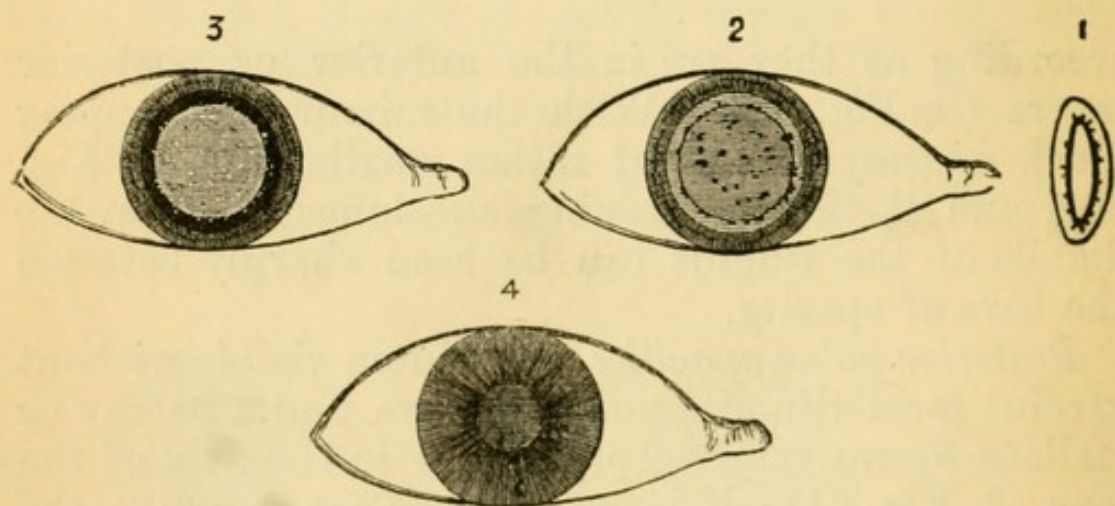


FIG. 62.—Lamellar cataract. Figs. 1, 2, 3, as before. Fig. 4 shows *slight* greyness of the undilated pupil owing to the layers of opacity being deeply seated.

atropine the outline of the shell of opacity is exposed within it. This opacity is sharply defined, circular, and whitish by focal light, interspersed, in many cases, with white specks, which at its equator appear as little projections (3, Fig. 62). By focal illumination we easily make out that the opacity consists of two distinct layers, that there is a layer of clear lens substance (cortex) in front of the anterior layer, and that the margin (equator) of the lens is clear. By the mirror the opacity appears as a disc of nearly uniform greyish or dark colour, sometimes with projections, or darker dots, and surrounded by a zone of



bright red reflexion from the fundus corresponding to the clear margin of the lens (2, Fig. 62). The opacity often appears rather denser at its boundary, a sort of ring being formed there; and in some cases quite large spicules or patches project from this part. Not only does the size of the opaque lamella, and, therefore, its depth from the surface of the lens, differ greatly in different cases, but its thickness or degree of opacity varies also. The disease is nearly always symmetrical in the two eyes. Occasionally there are two shells of opacity, one within the other, separated by a certain amount of clear lens substance.

The lens may be cataractous at birth (*congenital cataract*). This form, of which there are several varieties, is nearly always symmetrical, and generally involves the whole lens. Often the development of the eyeball is defective, and though there are no synechiæ, the iris often acts badly to atropine.

*Traumatic cataract*.—Severe blows on the eye may be followed by opacity of the lens, the suspensory ligament being generally torn in some part of its circle (*concussion cataract*) (p. 131), but I am not aware that cataract ever follows injury to the head without direct injury to the eye.

Traumatic cataract proper is the result of wound of the lens-capsule; the aqueous passing through the aperture is imbibed by the lens-fibres, which swell up, become opaque, and finally disintegrate and are absorbed. The opacity begins within a few hours of the wound; it progresses quickly in proportion as the wound is large, and the patient young; but both the symptoms and consequences are often more severe in old persons. A free wound of the capsule followed by rapid swelling of the whole lens, may give rise, especially after middle life, to severe glaucomatous symptoms and iritis. In from three to six months a wounded lens will generally be absorbed, and nothing but some chalky-looking detritus remain



in connection with the capsule. A very fine puncture of the lens is occasionally followed by nothing more than a small patch or narrow track of opacity, or by very slowly advancing general haze.—The objects of *treatment* are to prevent iritis and posterior synechiæ by atropine, and by ice and leeching if there be severe inflammatory symptoms (p. 121). It is usually safest to allow the lens to become absorbed, but we must be prepared to extract it by linear operation or suction, at any time, should glaucoma, iritis, or severe irritation arise.

*Prognosis of cataract.*—*a. Course.*—Although opacities in the lens never clear up, they advance with very varying rapidity in different cases. As a rough rule, the progress of a general cataract is rapid in proportion to the youth of the patient. Cataracts in old people commonly take from one to three years in reaching maturity—sometimes much longer. If the lens be allowed to remain for long after it is opaque, further degenerative changes generally occur; it may become harder and smaller, calcareous and fatty granules being formed in it; or the cortex may liquefy whilst the nucleus remains hard (*Morgagnian cataract*). A congenital cataract may undergo absorption and shrink to a thin, firm, membranous disc. Soft cataract in young adults, from whatever cause, is generally complete in a few months.

*b. Sight.*—The prognosis *after operation* is good when there is no other disease of the eye, and when the patient (although advanced in years) is in fair general health. It is not so good in diabetes, nor when the patient is in obviously bad health, the eyes being then less tolerant of operation.—In the lamellar and other congenital varieties, it must be guarded, for the eyes are often defective in other respects, and sometimes very intolerant of operation; the intellect, too, is sometimes defective, rendering the patient less able to make proper use of his eyes.—In traumatic cataract of course everything depends



on the details of the injury (pp. 139, 143), but as a rule the younger the patient the better the prospect of a quiet and uncomplicated absorption of the lens.

In every case of immature cataract, the vitreous and fundus should be carefully examined by the ophthalmoscope, and the refraction ascertained. The presence of high myopia is unfavorable, and the same is true of opacities in the vitreous, indicating, as they usually do, that it is fluid. Any disease of the choroid or retina will, of course, be prejudicial in proportion to its position and extent. In every case, the tension of the eye, and size and mobility of the pupils to light and atropine, are to be carefully noted.

*Treatment.*—In the early stages of senile and nuclear cataract sight is improved by keeping the pupil moderately dilated with a weak atropine solution (half a grain to the ounce), used about three times a week. Dark glasses, by allowing some dilatation of the pupil, sometimes give relief. Stenopaic glasses are sometimes useful. With these exceptions, nothing except operative treatment is of any use.—The management of lamellar cataract requires separate description.

*Operations for the removal of cataract* are of three kinds: (1) *Extraction of the lens entire* through a large wound in the cornea, or at the sclero-corneal junction, the lens-capsule remaining behind. By a few operators the lens is removed entire in its capsule. (2) For soft cataracts, *gradual absorption*, by the agency of the aqueous humour admitted through needle punctures in the capsule, just as after accidental traumatic cataract (needle operations, *solution, discission*). The operation needs repetition two or three times, at intervals of a few weeks, and the whole process therefore occupies three or four months. (3) For soft cataracts, *removal by a suction syringe or curette*, introduced into the anterior chamber through a small wound near the margin of



the cornea, the whole lens having, if thought necessary, been freely broken up by a discission operation a few days previously (Chap. XXII).

Extraction is necessary for cataracts after about the age of forty. The lens from this age onwards is so firm that its absorption after discission occupies a much longer time than in childhood and youth; moreover, as already stated, the swelling of the lens after wound of the capsule is less easily borne as age advances, and hence solution operations become not only slower but attended by more danger. Indeed, though suction and solution operations are applicable up to about the age of thirty-five, extraction is often practised in preference at a much earlier age. Suction is difficult, and unless well performed is attended by more risk of irido-cyclitis than the "solution" operation; its advantage lies in the saving of time, almost the whole lens being removed at one sitting.

If one eye presents a complete cataract whilst the sight of the other is still perfect, or at least serviceable, removal of the cataract will confer little immediate benefit to the patient. Indeed, if one eye be still fairly good, the patient will often be dissatisfied by finding his operated eye less useful than he expected, perhaps even not so useful as the other. In senile cataract, therefore, it is usually best not to operate so long as the lens of the other eye remains nearly clear; but so soon as it becomes sufficiently affected to interfere seriously with vision, extraction of the cataract from the first eye is advisable, provided that the patient has a fair prospect of life. The cataract in the first eye may be over-ripe and less favourable for operation if it be left until the second eye be quite ready. The removal of a single cataract in young persons is often expedient on account of appearance. In all cases of single cataract it must be explained that after the operation the two eyes will not work to-



gether, on account of the extreme difference of refraction. (*See Anisometropia.*)

Even when both cataracts are mature at the same time, it is safer to remove only one at once, because the after treatment is more easily carried out upon one eye than both, and because after the double operation any untoward result in one eye adds to the difficulty of managing its fellow; while a bad result after single extraction enables us to take especial precautions, or to modify the operation, for the second eye. Even if the patient be so old or feeble that the second eye may never come to operation, we shall consult his interests better by endeavouring to give him one good eye than by risking a bad result in attempting to give him both at the same time.

Cataract can seldom be safely extracted until it is complete or ripe (p. 153). The transparent portions of an immature cataract cannot be completely removed, partly because they are sticky, partly because they cannot be seen; and, remaining behind in the eye, they act as irritants and often set up iritis. Incomplete juvenile cataract (*e.g.* lamellar cataract) may be, and often is, artificially ripened by tearing the capsule with a needle (*see* Discission and Suction); but hard cataract cannot be so treated because the lens is too hard to absorb the aqueous well, and the senile eye is intolerant of injury to the lens (p. 157). But a procedure has lately been introduced by Förster for hastening the completion of very slow senile cataracts. Förster performs an iridectomy and then bruises the lens by rubbing the cornea firmly over the pupil with a cataract spoon or other smooth instrument; the capsule is not ruptured, but the lens-fibres are broken up or so changed that they often become opaque a few weeks or months after. This method has not yet been tried largely enough to warrant any conclusions.



The *principal causes of failure* after extraction of cataract are—

(1.) *Hæmorrhage* between the choroid and sclerotic, coming on, usually with severe pain, immediately after the operation. The blood fills the eyeball, and often oozes from the wound and soaks through the bandage.

(2.) *Suppuration*, beginning in the corneal wound, and in most cases spreading to the whole cornea, to the iris and vitreous, and ending in total loss of the eye. It occasionally takes a less rapid course, and stops short of a fatal result. The alarm is given in from twelve hours to about three days after operation by the occurrence of pain, inflammatory œdema of the lids (particularly the free border of the upper lid), and the appearance of some muco-purulent discharge. On raising the lid the eye is found to be greatly congested, its conjunctiva œdematous, the edges of the wound yellowish, and the cornea steamy and hazy. In very rapid cases the pupil, especially near to the wound, will already be occupied by lymph. Suppuration is probably often caused by infection. Chronic dacryocystitis (p. 71) is a very dangerous condition, the pus escaping through the puncta and infecting the wound. Suppuration is more probable if the wound lie in clear corneal tissue than if it be partly scleral. Often, however, we are quite at a loss to account for this disaster (*see* p. 158).

The use of hot fomentations for an hour three or four times a day, leeches, if there be much pain, and internally a purge, followed by quinine, ammonia, and wine or brandy, should be at once resorted to. As to other measures, opinions differ. Von Graefe employed a very firm compressive bandage between the bathings. It is more usual now to employ one of the antiseptic lotions, or eserine, without tight bandaging. Some have gone so far as to reopen the wound, scrape its edges, and remove any lymph or pus from the anterior chamber. But the great



majority of these cases go on to suppurative panophthalmitis, or to severe plastic irido-cyclitis with opacity of cornea and shrinking of the eyeball.

(3.) *Iritis* may set in between about the fourth and tenth days. Here also pain, œdema of the eyelids, and chemosis are the earliest symptoms. There is lachrimation, but no muco-purulent discharge, and the cornea and wound remain clear and bright. The iris is discoloured (unless it happen to be naturally greenish brown), and the pupil dilates badly to atropine. Whenever, in a case presenting such symptoms, a good examination is rendered difficult on account of the photophobia, iritis should be suspected. If the early symptoms are severe, a few leeches to the temple are very useful. Atropine and warmth are the best local measures. If atropine irritates (p. 82), daturine or duboisine should be tried (F. 28, 29).

This inflammation is plastic, ending in the formation of more or less dense membrane in the pupil. Such membrane by contracting and drawing the iris with it towards the operation scar, often contracts and displaces the pupil (Fig. 148 shows this in an extreme degree). The membrane is formed partly by exudation from the iris and ciliary processes (*iritis*, *cyclitis*), partly by the lens-capsule and its proliferated endothelial cells (*capsulitis*).

(4.) The iris may prolapse into the wound at the operation, or a few days afterwards by the reopening of a weakly united wound. When iridectomy has been done the prolapse appears as a little dark bulging at one or both ends of the wound, and often causes prolonged irritability, without actual iritis. The protrusion in the end generally flattens down, but sometimes it needs to be punctured or even removed. The occurrence of prolapse is a reason for keeping the eye tied up longer.—*After operations* are needed if the pupil be much obstructed by capsular opacities or by the results of iritis; but nothing should be done until active



symptoms have subsided and the eye been quiet for some weeks.

*Sight after the removal of cataract.*—In accounting for the state of the sight we have to remember that the acuteness of sight naturally decreases in old age (p. 32); that slight iritis, producing a little filmy opacity in the pupil, is common after extraction; and that some eyes, with good sight, remain irritable for long after the operation, and therefore cannot be much used. Thus, putting aside the graver complications, we find that, even of the eyes which do best, only a moderate proportion reach anything like normal acuteness of vision. Cases are considered good when the patient can with his glasses read anything between Nos. 1 and 14 Jaeger and  $\frac{6}{18}$  Snellen; but a much less satisfactory result than this is very useful. About 5 per cent. of the eyes operated upon are lost from various causes.—The eye is rendered extremely hypermetropic by removal of the lens, and strong convex glasses are necessary for clear vision; these should seldom be allowed until three months after the operation, and at first they should not be continuously worn. Two pairs are needed; one makes the eye emmetropic and gives clear distant vision (+ 10 or 11 D.); the other (about + 16 D.) is for reading, sewing, &c., at about 10" (25 cm.), as during strong accommodation. As all accommodation is lost, the patient has no *range* of distinct vision.

*Lamellar cataract.*—If the patient can see enough to get on fairly well at school, or in his occupation, it is often best not to operate; but when the opacity is dense enough to interfere seriously with his prospects, something must always be done. The choice lies between artificial pupil when the clear margin is wide and quite free from spicules, and solution or extraction when it is narrow, or when large spicules of opacity project into it from the opaque lamella (Fig. 62). It is very difficult to say which



method gives on the whole the better results, and we must judge each case on its own merits. If atropine, by dilating the pupil, improves the sight, an artificial pupil, made by removing the iris quite up to its ciliary border, will generally be beneficial; the clear border of the lens is thus exposed in the coloboma, and light passes through it more readily than through the hazy part. A very good rule is to operate on only one eye at a time, thus allowing the choice of a different operation on its fellow.

When a cataractous eye is absolutely blind (no p.l., see p. 33) some more deeply seated disease must be present, and no operation should be undertaken.

*Dislocation of the lens* in its capsule is usually caused by a blow on the eye, but may be spontaneous, or congenital. It is usually downwards, and only partial; the iris may be tremulous where its support is lost (p. 139), but is often bulged forward at some other part where the lens rests against it; the free edge of the lens can be seen through the dilated pupil by focal light, or still better with the ophthalmoscope, as a curved line passing across the pupil. More rarely the dislocation is complete either into the vitreous or into the anterior chamber. A full-sized lens dislocated into the anterior chamber causes acute glaucoma. Glaucoma, acute or chronic, may also follow at any time after a dislocation, either partial or complete, into the vitreous. Dislocated lenses often become opaque and shrunken and then either remain loose, or become adherent, and in either event are likely sooner or later to set up irritation and pain. Such a lens may sometimes be made to pass at will through the pupil by altering the position of the head. The edge of a transparent lens in the vitreous appears (by the mirror) as a dark line; when in the anterior chamber it appears as a bright line (by focal illumination). Congenital dislocation of the lens is often accompanied by other defects of development, such as coloboma.



## CHAPTER XII

## DISEASES OF THE CHOROID.

THE choroid is, next to the ciliary processes, the most vascular part of the eyeball, and from it the outer layers of the retina, and probably the vitreous humour also, mainly derive their nourishment. Inflammatory and degenerative changes often occur, some of them entirely local, as in myopia, others symptomatic of constitutional, or of generalised disease, such as syphilis and tuberculosis. Choroiditis, unlike inflammation of its continuations, the ciliary body and iris, is seldom shown by external congestion or severe pain; and as none of its symptoms are characteristic, the diagnosis rests chiefly on ophthalmoscopic evidence.

Blemishes or scars, permanent and easily seen, nearly always follow disease of the choroid, and such spots and patches are often as useful for diagnosis as cicatrices on the skin, and deserve as careful study. The retina lying over an inflamed choroid often takes on active changes, or becomes atrophied afterwards; but in other cases, apparently as severe, it is uninjured. Indeed, it is sometimes far from easy to say in which of these two structures the disease has begun, especially as changes in the pigment epithelium, which is really part of the retina, are as often the result of deep-seated retinitis, or retinal hæmorrhage, as of superficial choroiditis. Patches of accumulated pigment, though usually indicating spots of former choroiditis, are sometimes the result of bleeding, either from retinal or choroidal vessels, and their correct interpretation is sometimes difficult.



*Appearances in health.*—The choroid is composed chiefly of blood-vessels and of cells containing dark brown pigment. The quantity of pigment varies much in different eyes, and to some degree in different parts of the same eye; it is very scanty in early childhood, and in persons of fair complexion; more abundant in persons with dark or red hair, brown irides, or freckled skin; more plentiful in the region of the yellow spot than elsewhere. In old age the pigment epithelium becomes paler. When examining the choroid we need to think of four parts: (1) the retinal pigmented epithelium (which is for ophthalmoscopic purposes choroidal), seen in the erect image as a fine darkish stippling; (2) the capillary layer (chorio-capillaris), just beneath the epithelium, forming a very close meshwork, the separate vessels of which are not visible in life; (3) the larger blood-vessels, often easily visible; (4) the pigmented connective-tissue cells of the choroid proper, which lie between the larger vessels.

In the majority of eyes these four structures are so toned as to give a nearly uniform, full red colour by the ophthalmoscope, blood-colour predominating. In very dark races the pigment is so excessive that the fundus has an uniform slaty colour. In very fair persons (and young children) the deep pigment (4) is so scanty that the large vessels are separated by spaces of lighter colour than themselves (Fig. 32). In dark persons these same spaces are of a deeper hue than the vessels, the latter appearing like light streams separated by dark islands (*see* upper part of Fig. 65). Near to the disc and y. s. the vessels are extremely abundant and very tortuous, the interspaces being small and irregular; but towards and in front of the equator the veins take a nearly straight course, converging towards the *venæ vorticosæ*, and the islands are larger and elongated. The veins are much more numerous and larger than the arteries (Fig. 64), but no distinction can be made



between them in life. The vessels of the choroid, unlike those of the retina, present no light streak along the centre (*cf.* p. 48). The pigment epithelium and the capillary layer tone down the above contrasts, and so in old age, when the epithelial pigment is bleached, or if the capillary layer is atrophied after superficial choroiditis (Fig. 65, *a*), the distinctions described are particularly marked.

A vertical section of naturally injected human choroid is shown in Fig. 63; the uppermost dark line is the pigment epithelium (1); next are seen the capillary vessels, cut across (2); then the more deeply-seated large vessels (3), and the deep layer of stellate pigment-cells of the choroid proper (4).—Fig. 64 is from an artificially injected human choroid seen from the inner surface. The shaded portion is intended to represent the general effect produced by all the vessels and the pigment epithelium. The lower part shows the large vessels with their elongated interspaces, as may be seen in a case where the pigment epithelium and chorio-capillaris are atrophied (Fig. 65 *b*); in a dark eye these interspaces would be darker than the vessels. The middle part shows the capillaries without the pigment epithelium. Both figures are magnified about four times as much as the image in the indirect ophthalmoscopic examination.

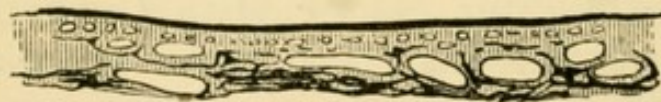

FIG. 63.—Human choroid, vertical section. Naturally injected.  
× 20.

### *Ophthalmoscopic Signs of Disease of the Choroid.*

The changes usually met with are indicative of *atrophy*. This may be partial or complete; primary, or following inflammation or hæmorrhage; in circumscribed spots and patches, or in large and less abruptly bounded areas. Secondary changes are



often present in the corresponding parts of the retina. The chief signs of atrophy of the choroid are—(1) the substitution of a paler colour (varying from pale red to paper-white), for the full red of health, the subjacent white sclerotic being more or less visible where the atrophic changes have occurred ;

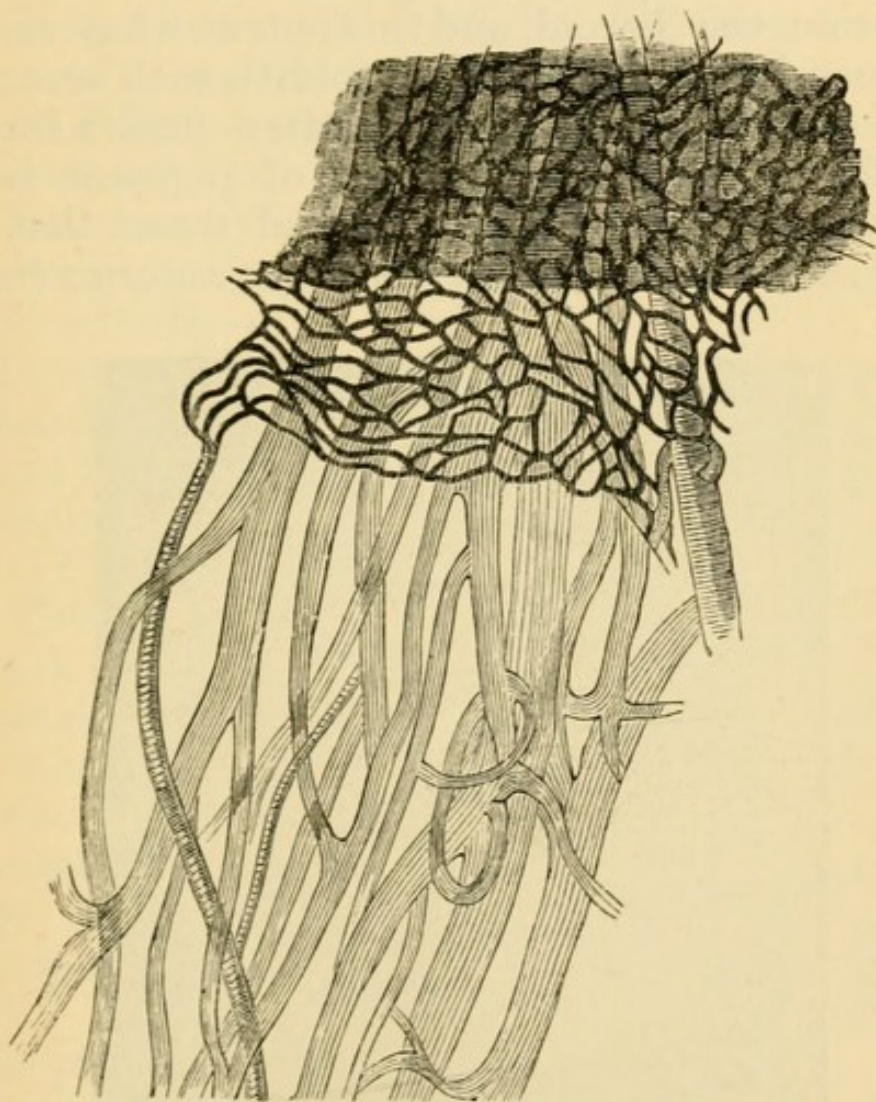


FIG. 64.—Vessels of human choroid artificially injected. Arteries cross-shaded. Capillaries too dark and rather too small. The uppermost shaded part represents the effect of the pigment epithelium.  $\times 20$ .

(2) black pigment in spots, patches, or rings, and in varying quantity upon, or around the pale patches. These pigmentations result, 1st, from disturbance and heaping together of the normal pigment, 2nd, from increase in its quantity, 3rd, from blood-colour-



ing-matter left after extravasations. Patches of primary atrophy (*e.g.* in myopia) are never much pigmented unless bleeding have taken place. The amount of pigmentation in atrophy following choroiditis is closely related to that of the healthy choroid, *i. e.* to the complexion of the person.

Pigment at the fundus may lie in the retina as well as in, or on, the choroid, and this is true whatever may have been its origin, for in choroiditis with secondary retinitis the choroidal pigment often passes forward into the retina. When a spot of pigment is distinctly seen to cover over a retinal vessel that spot must be not only in, but very near the anterior (inner)

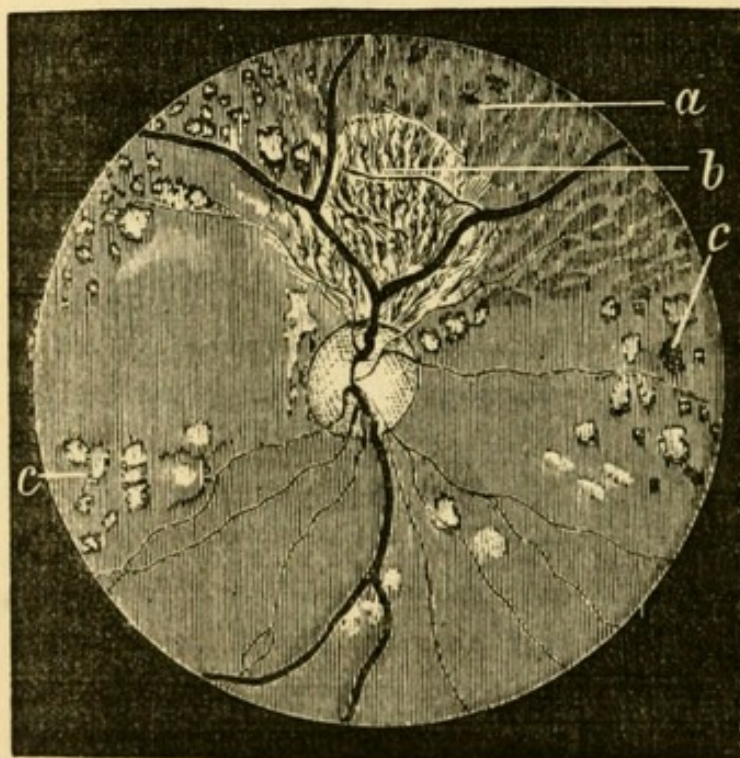


FIG. 65.—Atrophy after syphilitic choroiditis, showing various degrees of wasting (Hutchinson). *a.* Atrophy of pigment epithelium. *b.* Atrophy of epithelium and chorio-capillaris; the large vessels exposed. *c.* Spots of complete atrophy, many with pigment accumulation.

surface of, the retina; and when the pigment has a linear, mossy or lace-like pattern (Fig. 75), it is always in the retina; these are the only conclusive tests of its position.



It is important, and usually easy, to distinguish between partial and complete atrophy of the choroid. In *superficial atrophy*, affecting the pigment epithelium and capillary layer, the large vessels are peculiarly distinct (Fig. 65 *a* and *b*). Such "capillary" or "epithelial" choroiditis often covers a large surface, the boundaries of which are sometimes well defined, sinuous and map-like, but are as often ill marked; in the latter case we must carefully compare different parts of the fundus, and also make allowance for the patient's age and complexion. Complete atrophy is shown by the presence of patches of white or yellowish-white colour of all possible variations in size, with sharply-cut, circular, or undulating borders, and with or without pigment accumulations (Figs. 65 *c* and 66). The retinal vessels pass unobscured over patches of atrophied choroid, proving that the appearance is caused by some change deeper than the surface of the retina.



FIG. 66.—Atrophy after choroiditis (Magnus).

If the patient comes with *recent choroiditis* we also often see patches of palish colour, but they are less sharply bounded and frequently of a greyer or whiter (less yellow) colour than patches of atrophy; moreover, the edge of such a patch is softened, the texture of the choroid being dimly visible there, because only partly veiled by exudation. If the overlying retina is unaffected its vessels are clearly seen over the diseased part, but if the retina itself is hazy or opaque



the exact seat of the exudation often cannot be at once decided; and this difficulty is often increased by the hazy state of the vitreous.

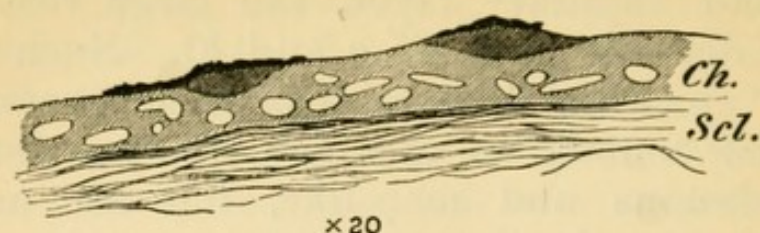


FIG. 67.—Minute exudations into inner layer of choroid in syphilitic choroiditis. Pigment epithelium adherent over the exudations, but elsewhere has been washed off. *Ch.* Choroid. *Scl.* Sclerotic.

Syphilitic choroiditis begins in and is often confined to, the inner (capillary) layer of the choroid (Fig. 67), and hence it often affects the retina. In miliary tuberculosis of the choroid the overlying retina is clear, and the growth is, for the most part, deeply seated (Fig. 68). After very severe choroiditis, or extensive hæmorrhage, absorption is often

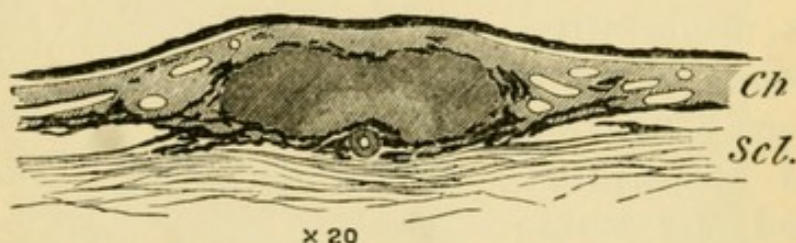


FIG. 68.—Section of miliary tubercle. Inner layers of choroid comparatively unaffected. The lighter shading, surrounding an artery in the deepest part of the tubercle, represents the oldest part, which is caseating; an artery is seen cut across in this part of the tubercle.

incomplete; we then find, in addition to atrophy, grey or white patches, or lines, which, in pattern and appearance, remind us of keloid scars in the skin, or of patches and lines of old thickening on serous membranes.

Very characteristic changes are seen after *rupture of the choroid* from sudden stretching caused by blows on the front of the eye. These ruptures, always situated in the central region, occur in the form of



long tapering lines of atrophy, usually curved towards the disc, and sometimes branched (Fig. 69); their borders are often pigmented. If seen soon after the blow the rent is more or less hidden by blood, and the retina over it is hazy.

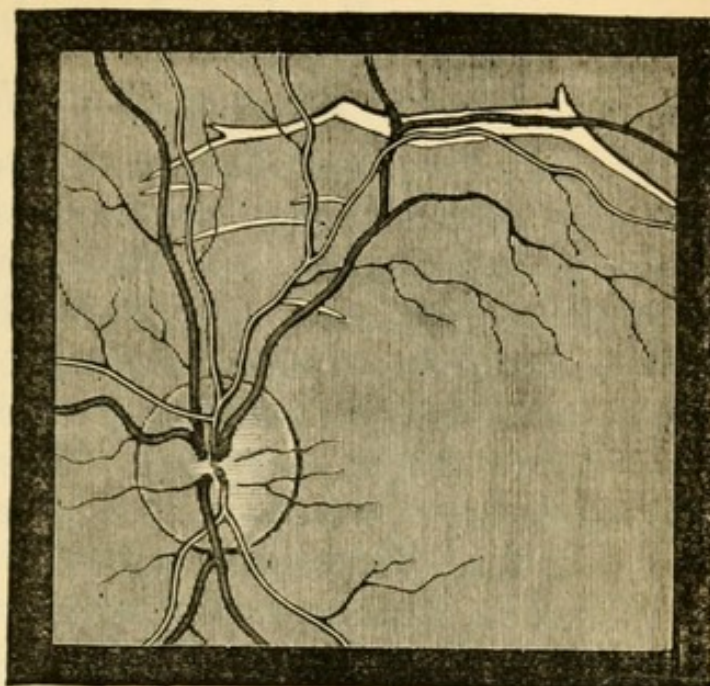


FIG. 69.—Ruptures of Choroid (Wecker).

The pathological condition known as “colloid disease” of the choroid consists in the growth of very small nodules, soft at first, afterwards becoming hard like glass, from the thin *lamina elastica*, which lies between the pigment epithelium and chorio-capillaris. It is common in eyes excised for old inflammatory mischief, and in partial atrophy after choroiditis (Fig. 70.) But little is known of its ophthalmoscopic equivalent, or its clinical characters. Probably it may result from various forms of choroiditis, and may also be a natural senile change.

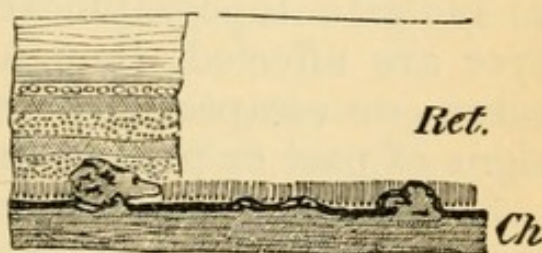


FIG. 70.—Partial atrophy after syphilitic choroiditis. Minute growths from inner surface of choroid, showing how they disturb the outer layers of the retina.  $\times 60$ .

*Hæmorrhage* from the choroidal vessels is not so often recognised as from those of the retina, but may be seen sometimes, especially in old people and in highly myopic eyes.



The patches are more rounded than retinal hæmorrhages, and we can sometimes recognise the striation of the overlying retina. Occasionally they are of immense size. Patches of atrophy may follow.

*Clinical forms of Choroidal Disease.*

(1.) Numerous discrete patches of choroidal atrophy (sometimes complete, as if a round bit had been punched out, in others incomplete, though equally round and well defined) are scattered in different parts of the fundus, but are most abundant towards the periphery; or, if scanty, are found only in the latter situation. They are more or less pigmented, unless the patient's complexion is extremely fair (Figs. 65 *c* and 66).

(2.) The disease has the same distribution, but the patches are confluent; or large areas of incomplete atrophy, passing by not very well defined boundaries into the healthy choroid around, are interspersed with a certain number of separate patches; or without separate patches there may be a widely-spread superficial atrophy with pigmentation (Fig. 65 *a* and *b*).

These two types of *choroiditis disseminata* run into one another, different names being used by authors to indicate topographical varieties. Generally both eyes are affected, though unequally; and in some cases one escapes. The retina and disc often show signs of past or present inflammation.

Syphilis is by far the most frequent cause of symmetrical disseminated choroiditis. The choroiditis begins from one to three years after the primary disease, whether this be acquired or inherited; occasionally at a later period.

The discrete variety (Fig. 65 *c*), where the patches, though usually involving the whole thickness of the choroid, are not connected by areas of superficial change, is the less serious form, unless the patches are very abundant. A moderate number



of such patches confined to the periphery, cause no appreciable damage to sight. The more superficial and widely-spread varieties in which the retina and disc are inflamed from the first, are far more serious. The capillary layer of the choroid seldom again becomes healthy, and with its atrophy, even if the deeper vessels be not much changed, the retina suffers, passing into slowly progressive atrophy. The retina often becomes pigmented (Fig. 75), its blood-vessels extremely narrowed, and the disc passes into a peculiar hazy yellowish atrophy ("waxy disc," Hutchinson—"choroiditic atrophy," Gowers). The appearances may closely imitate those in true retinitis pigmentosa, and the patient, as in that disease, often suffers from marked night-blindness. Such patients continue to get slowly worse for many years, and may become nearly blind.

Syphilitic choroiditis generally gives rise, at an early date, to opacities in the vitreous; they are either of large size and easily seen as slowly floating ill-defined clouds, or so minute and numerous as to cause a diffuse and somewhat dense haziness ("dust-like opacities," Förster) (Chap. XVI). Some of the larger ones may be permanent. In the advanced stages, as in true retinitis pigmentosa, posterior polar cataract is sometimes developed.

There are no constant differences between choroiditis in acquired and in inherited syphilis; in many cases it would be impossible to guess, from the ophthalmoscopic changes, with which form of the disease we had to do. But there is, on the whole, a greater tendency towards pigmentation in the choroiditis of hereditary than in that of acquired syphilis, and this applies both to the choroidal patches and to the subsequent retinal pigmentation.

In the treatment of syphilitic choroiditis we rely almost entirely on the constitutional remedies for syphilis—mercury and iodide of potassium. Cases



which are treated early in the exudation stage are very much benefited in sight by mercury, the visible exudations quickly melting away; but I believe that even in these, complete restitution seldom takes place, the nutrition and arrangement of the pigment epithelium and bacillary layer of the retina being quickly and permanently damaged by exudations into or upon the chorio-capillaris (as in Fig. 67). In the later periods, when the choroid is thinned by atrophy, or its inner surface roughened by little out-growths (Fig. 70), or adhesions and cicatricial contractions have occurred between it and the retina, nothing can be done. A long mercurial course should, however, always be tried if the sight be still failing, even if the changes all look old; for in some cases, even of very long standing, fresh failure takes place from time to time, and internal treatment has a very marked influence. In acute cases rest of the eyes in a darkened room, and the employment of the artificial leech or of dry cupping at intervals of a few days, for some weeks, are useful. But it is often difficult to ensure such functional rest, for the patients seldom have pain or other discomfort.

Disseminated choroiditis sometimes occurs without syphilis, chiefly at about the age of puberty. It is thought that exposure to bright light may sometimes cause it.

In choroiditis from any cause iritis may occur (*cf.* p. 129).

(3.) The choroidal disease is limited to the central region. There are many varieties of such localised change.

In *myopia* the elongation which occurs at the posterior pole of the eye very often causes atrophy of the choroid contiguous to the disc, and usually only on the side next the yellow spot (*see Myopia*). The term "*posterior staphyloma*," is applied to this form of disease when the eye is myopic, because the atrophy is a sign of posterior bulging of the sclerotic. The



term "*sclerotico-choroiditis posterior*" is also used. A similar crescent, but seldom of great width, is very commonly seen, bounding the lower margin of the disc, in astigmatic eyes; its widest part nearly always corresponds accurately with the direction of the meridian of greatest curvature of the cornea, and thus often assists us in determining the direction of the axis of the correcting cylindrical lens (Chap. XX). A narrow and less conspicuous crescent, or zone, of atrophy around the disc is seen in some other states, notably in old persons, and in glaucoma (Fig. 90). Separate round patches of complete atrophy ("punched-out" patches) at the central region may occur in myopia with the above-mentioned staphyloma, and must not then be ascribed to syphilitic choroiditis; in other cases of myopia ill-defined partial atrophy is seen about the y. s., sometimes with splits or lines running horizontally towards the disc.

*Central senile choroiditis.*—Several varieties of disease confined to the region of the y. s., and disc are seen, and chiefly in old persons. A particularly striking and rather rare form is shown in Fig. 71. In others a larger, but less defined, area is affected. Some of these appearances undoubtedly result from large choroidal or retinal extravasations, but the nature of the disease in such as Fig. 71 is obscure.—In another form, along with superficial atrophy, the large deep vessels are much narrowed, or even converted into white lines and devoid of blood column, by thickening of their coats.—In another form the central region is occupied by a number of very small, white, or yellowish-white dots, sometimes visible only in the erect image. This form in typical cases is very peculiar, and appears to be almost stationary; the discs are often decidedly pale; when very abundant the spots coalesce, and some pigmentation is found. The pathological anatomy and general relations of this disease are incompletely known; it has been clinically described by Hutchinson and Tay, and is tolerably



common. It is symmetrical and the changes may sometimes be mistaken for a slight albuminuric retinitis (p. 185). No treatment seems to have any

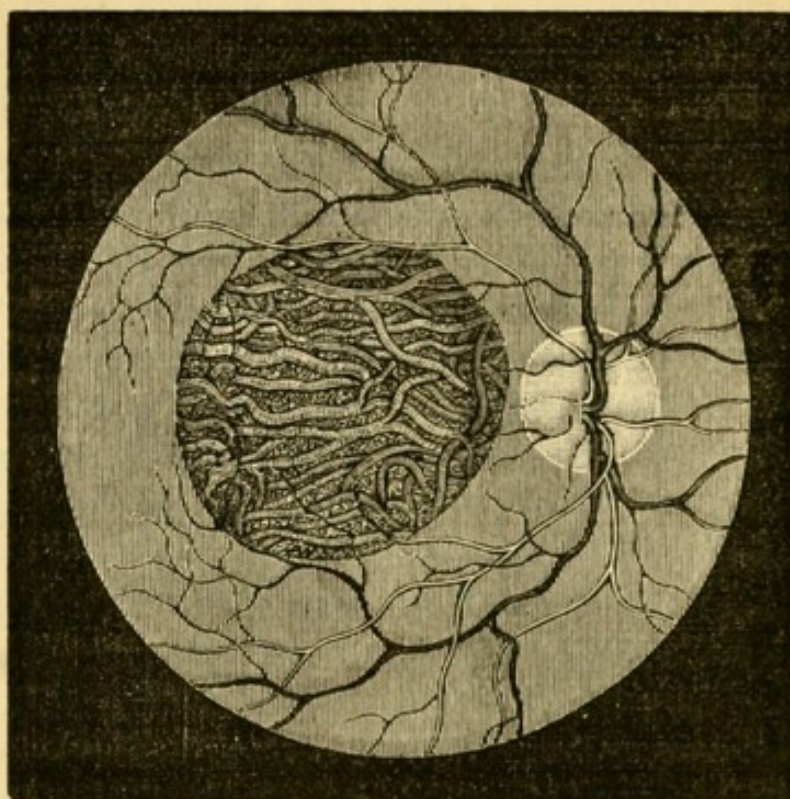


FIG. 71.—Central choroiditis (Wecker and Jaeger).

influence. Every case of immature cataract should, when possible, be examined for central choroidal changes.

(4.) *Anomalous forms of choroidal disease.*—Single, large patches of atrophy, with pigmentation, and not located in any particular part, are occasionally met with. Probably some of them have followed the absorption of tubercular growths in the choroid, while others are the result of large spontaneous hæmorrhages (p. 173); such patches towards the front of the fundus may follow blows by blunt objects on the overlying sclerotic, which caused hæmorrhage, or inflammation, and subsequent atrophy. —Single large patches of exudation are also met with, and are, perhaps, tubercular (*see* p. 128).—*Choroidal disease* in disseminated patches seems sometimes to depend upon numerous scattered hæmor-



rhages into the choroid, sometimes occurring repeatedly at different dates, and leading to patches of partial atrophy with pigmentation. The local cause of such hæmorrhages is obscure; the disease may occur in one eye or both, and in young adults of either sex. It may perhaps be called hæmorrhagic choroiditis (Chap. XVI). Although the changes produced are very gross, some of these patients regain almost perfect sight, a fact, perhaps, pointing to the deep layers of the choroid as the seat of disease. It is possible that over-use of the eyes, or exposure to great heat or glare, sometimes causes choroiditis (p. 176 and 201).

Single spots of choroidal atrophy, especially towards the periphery, should, no less than abundant changes, always excite grave suspicion of former syphilis, and often furnish valuable corroborative evidence of that disease. The periphery cannot be fully examined unless the pupil be widely dilated. A few small, scattered spots of black pigment on the choroid or in the retina, without evidence of atrophy of the choroid, often indicate former hæmorrhages. Such spots are seen after recovery from albuminuric retinitis with hæmorrhages, after blows on the eye, and sometimes without any relevant history.

Congestion of the choroid is not commonly recognisable by the ophthalmoscope. That active congestion does occur is certain, and it would seem that myopic eyes are especially liable to it, particularly when exposed to bright light and great heat. Serious hæmorrhage may undoubtedly be excited under such circumstances. In conditions of extreme anæmia the whole choroid becomes unmistakeably pale.

*Coloboma* of the choroid (congenital deficiency of the lower part) is shown ophthalmoscopically by a large surface of exposed sclerotic, often embracing the disc (which is much altered in form, and may be hardly recognisable), and extending downwards to



the periphery, where it often narrows to a mere line or chink. The surface of the sclerotic, as judged by the course of the retinal vessels, is often very irregular, from bulging of its floor backwards. The coloboma is occasionally limited to the part around the nerve, or may form a separate patch. Coloboma of the choroid is often seen without coloboma of the iris, and when both exist, a bridge of choroidal tissue generally separates them in the region of the ciliary body.

*Albinism* is accompanied by congenital absence of pigment in the cells of the pigmented epithelium and stroma of the whole uveal tract (choroid, ciliary processes, and iris). The pupil looks pink, because the fundus is lighted, to a great extent, indirectly through the sclerotic. Sight is always defective, and the eyes photophobic and usually oscillating. Many almost albinotic children become moderately pigmented as they grow up.



## CHAPTER XIII

## DISEASES OF THE RETINA.

OF the many morbid changes to which the retina is subject, some begin and end in this membrane, such as albuminuric retinitis and many forms of retinal hæmorrhage; in others, the retina takes part in changes which begin in the optic nerve (neuro-retinitis), or in the choroid (choroido-retinitis); very serious lesions also occur from embolism or thrombosis of the central retinal vessels. The retina may be separated ("detached") from the choroid by serous fluid or blood. The retina may also be the seat of malignant growth (glioma), and probably of tubercular inflammation.

In health the human retina is so nearly transparent as to be almost invisible by the ophthalmoscope during life, or to the naked eye if examined immediately after excision. We see the retinal blood-vessels, but the retina itself, as a rule, we do not see. The main blood-vessels are derived from the *arteria* and *vena centralis*, which enter the outer side of the optic nerve, about 6 mm. behind the eye; the veins and arteries are generally in pairs, the veins not being more numerous than the arteries; all pass from or to the optic disc (Fig. 32). At the disc anastomoses, chiefly capillary, are formed between the vessels of the retina and those of the choroid and sclerotic. As no other anastomoses are formed by the vessels of the retina, the retinal circulation beyond the disc is terminal; and, further, as the vessels branch dichotomously, and the branches anastomose only by means of their capillaries, the circulation of



each considerable branch is terminal also. The capillaries, which are not visible by the ophthalmoscope, are narrower and less abundant than those of the choroid, and their meshes become much wider towards the anterior and less important parts of the retina. At the y. s. (Fig. 72), the only part used for accurate sight, they are, however, very abundant (compare Fig. 64); but at the very centre of this region (*fovea centralis*), where all the layers except the cones and outer granules are excessively thin, there are no vessels, the capillaries forming fine, close loops just around it (Fig. 72).

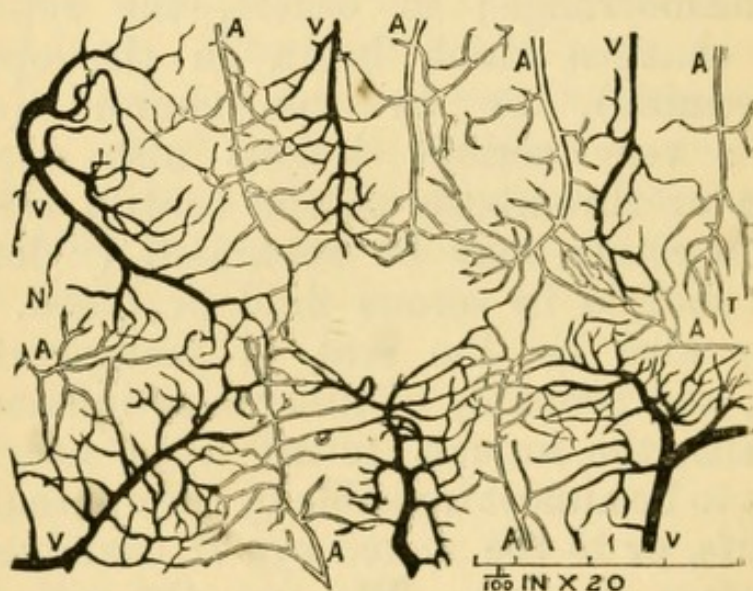


FIG. 72.—Blood-vessels of human retina at the yellow spot (artificial injection). The central gap corresponds to the Fovea centralis. A. Arteries; V. Veins; N. Nasal side towards disc; T. Temporal side. The meshes are much wider at the periphery of the retina.

In children, especially those of dark complexion, a peculiar, white, shifting reflexion, or shimmer, is often seen at the y. s. region, and along the course of the principal vessels. It changes with every movement of the mirror, and reminds one of the shifting reflexion from "watered" and "shot" silk. Around the y. s. it takes the form of a ring or zone, and is known as the "halo round the macula" (p. 48). When the choroid is highly pigmented, even if this



shifting reflexion be absent, the retina is visible as a faint haze over the choroid like the "bloom" on a plum. Under the high magnifying power of the erect image the nerve-fibre layer is often visible near the disc, as a faintly-marked radiating striation. The sheaths of the large central vessels at their emergence from the physiological pit (p. 46) show many variations in thickness and opacity.

In rare cases the medullary sheath of the optic nerve-fibres, which should cease at the lamina cribrosa, is continued through the disc into the retina, and causes the ophthalmoscopic appearance known as "opaque nerve-fibres." This congenital peculiarity may affect the nerve-fibres of the whole circumference of the disc, or only a patch or tuft of the fibres; it may only just overleap the edge of the disc, or may extend far into the retina, where even separate islands of opacity are sometimes seen. It is to be particularly noted that the central part (physiological pit) of the disc is never affected, because it contains no nerve-fibres. The affected patch is pure white, and quite opaque, its margin thins out gradually, and is striated in fine lines, which radiate from the disc like carded cotton wool; the retinal vessels may be buried in the opacity, or run unobscured on its surface, and are of normal size. The deep layers of the affected part of the retina being obscured by the opacity, an enlargement of the normal "blind-spot" is the result. One eye, or both, may be affected. There is seldom any difficulty in distinguishing this condition from opacity due to neuro-retinitis.

#### *Ophthalmoscopic signs of Retinal Disease.*

*Congestion.*—No amount of capillary congestion, whether passive or active, alters the appearance of the retina; and as to the large vessels, it is better to speak of the arteries as unusually large or tortuous, or of the veins as turgid or tortuous, than to use the



general term congestion. Capillary congestion of the optic disc may undoubtedly be recognised; but even here great caution is needed, and much allowance must be made for differences of contrast depending on differences in the tint of the choroid, for the patient's health and age, and for the brightness of the light used, or, what is the same thing, for the size of the pupil. Caution is also needed against drawing hasty inferences from the slight haziness of the outline of the disc, which may often be seen in cases of hypermetropia, and which is certainly not always morbid.

The only ophthalmoscopic proof of true *Retinitis* is loss of transparency of the retina, and two chief types are soon recognised according as the opacity is diffused, or consists chiefly of abrupt spots and patches. Hæmorrhages are present in many cases of retinitis; but they also often occur without inflammation. The state of the disc varies much, but it seldom escapes entirely in a case of extensive or prolonged retinitis. In a large majority of cases of recent retinitis the visible changes are limited to the central region, where the retina is thickest and most vascular.

(1.) The lessened transparency which accompanies *diffused retinitis* simply dulls the red choroidal reflex, and the term "smoky" is fairly descriptive of it. The same effect is given by slight haziness of any of the anterior media, but a mistake is excusable only when there is diffused mistiness of the vitreous from opacities which are too small to be easily distinguished (Chap. XVI), and the difficulty is then increased because this very condition of the vitreous often coexists with retinitis. A comparison of the erect and inverted images is often useful; for if the diffused haze noticed by indirect examination be caused by retinitis, then by the direct examination what before seemed a uniform haze may now appear as well-marked spotting or streaking. When the



change is pronounced enough to cause a decidedly white haze of the retina there is no longer any doubt. The retinal arteries and veins are sometimes enlarged and tortuous in retinitis, and in severe cases they are generally obscured in some part of their course. These forms of uniformly diffused retinitis are usually caused either by syphilis or embolism.

(2.) Near the y. s. a number of small, intensely white, rounded spots are seen (Fig. 73), either quite

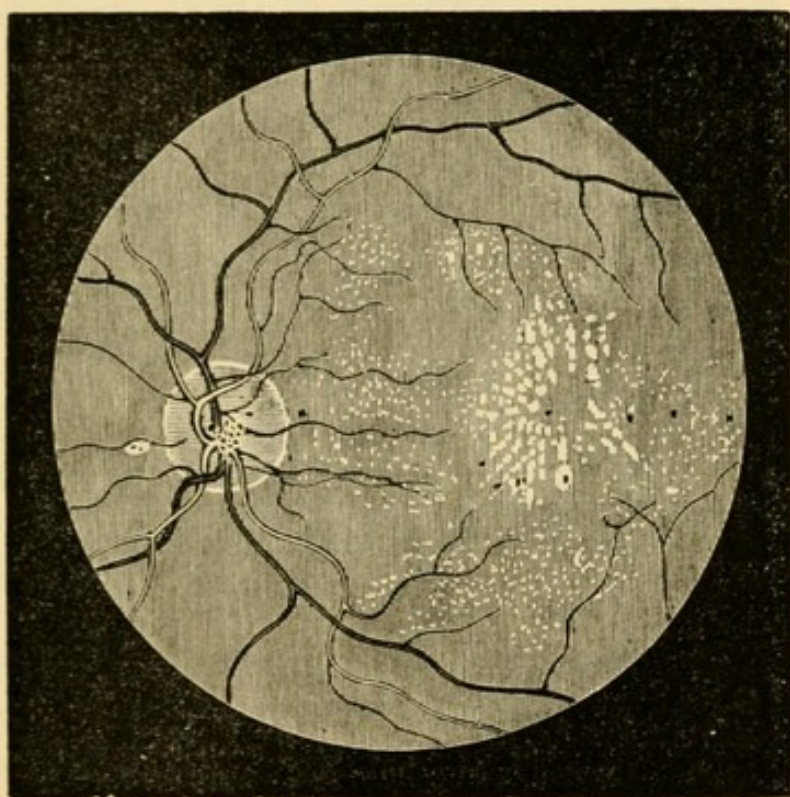


FIG. 73.—Renal retinitis at a late stage (Wecker and Jaeger).

discrete or partly confluent. When very abundant and confluent they form large, abruptly outlined patches, with irregular borders, some parts of these patches being striated, others stippled.

(3.) A number of separate patches are scattered about the central region, but without special reference to the y. s. They are of irregular shape, white or pale buff, and sometimes striated (Fig. 74); they are easily distinguished from patches of choroidal atrophy (p. 168) by their colour, the comparative



softness of their outlines, and the absence of pigmentation.

In types 2 and 3, some hæmorrhages are usually present; the retina generally may be clear, but more often there is diffused haze and evidence of swelling. The hæmorrhages may be so numerous and large as

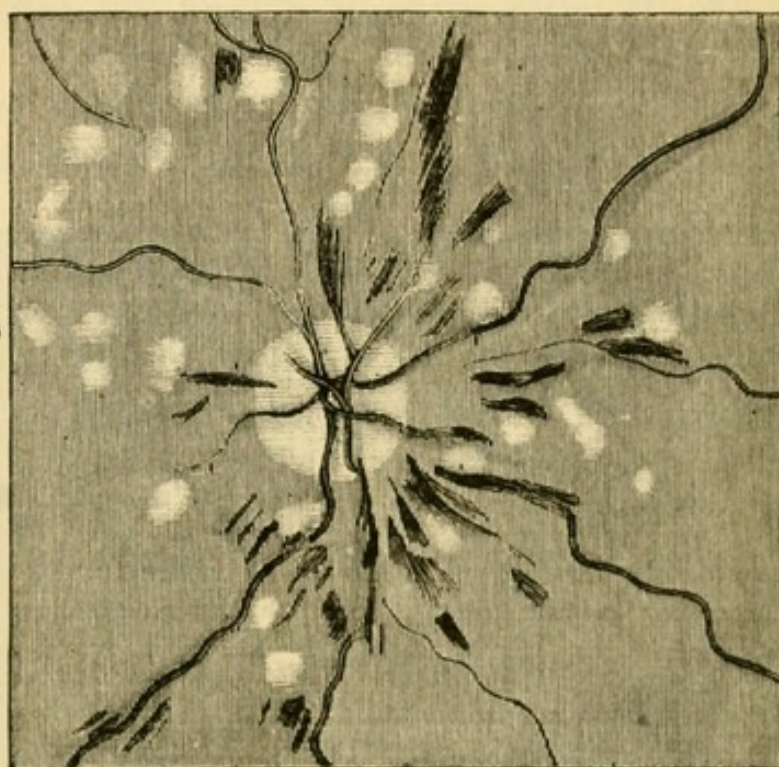


FIG. 74.—Recent severe retinitis in renal disease (Gowers).

to form the chief feature, the retinal veins being extremely tortuous and dilated.

Forms 2 and 3, which nearly always affect both eyes, are generally associated with albuminuria, but in rare cases similar changes are caused by cerebral disease and other conditions.

(4.) Rarely a single large patch or area of white opacity is seen with softened, ill-defined edges, any retinal vessels that may cross it being obscured. Such a patch of retinitis is usually caused by choroidal exudation beneath (p. 168).

*Hæmorrhage* into (or beneath) the retina is known by its colour, which is darker than that of the average choroid; but redder and lighter than that of a very dark choroid. Blood may be effused into any



of the retinal layers, and the shape of the blood patches is mainly determined by their position. When effused into the nerve-fibre layer, or confined by the sheath of a large vessel, the extravasation takes a linear or streaked form and structure, following the direction of the nerve-fibres; extravasations in the deeper layers are rounded. Very large hæmorrhages, many times as large as the disc, sometimes occur near the yellow spot, and probably all the layers then become infiltrated, while sometimes the blood ruptures the anterior limiting membrane of the retina and passes into the vitreous.

Retinal hæmorrhages may be large or small, single or multiple; limited to the central region or scattered in all parts; linear, streaky or flame-shaped, punctate or blotchy; they may lie alongside large vessels, or have no apparent relation to them. The hæmorrhage may, as already mentioned, be the primary change, or may only form part of a retinitis or papillo-retinitis. A hæmorrhage which is mottled and of dark, dull colour, is generally old. The rate of absorption varies very greatly; hæmorrhages after blows are very quickly absorbed, while those depending on rupture of diseased vessels in old people, or accompanying albuminuric retinitis, generally last for months, and often leave permanent traces.

*Pigmentation of the retina* has been referred to in connection with choroiditis (p. 170). Whenever pigment in the fundus forms long, sharply-defined lines, or is arranged in a mossy, lace-like or reticulated pattern, we may always safely infer that it is situated in the retina, and generally that it lies along the sheaths of the retinal vessels (compare Fig. 75 with Fig. 72). Pigment in or on the choroid never takes such a pattern, being usually in blotches or rings. The two types, however, are often mingled in cases of choroiditis with secondary affection of the retina; indeed, in every case where we decide that the retina



is pigmented the choroid must be carefully examined for evidences of former choroiditis.

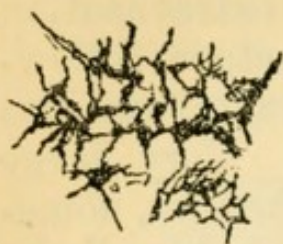

FIG. 75.— Study of pigment in the retina in a specimen of secondary retinitis pigmentosa, seen from the inner (vitreous) surface.

Spots of pigment may be left after the absorption of retinal hæmorrhages. Such spots can generally be distinguished from those following choroiditis by their more uniform appearance and by the absence of signs of choroidal atrophy.

*Atrophy of the retina*, of which pigmentation of the retina, when present, is always a sign, has for its most constant indication a marked shrinking of the retinal blood-vessels and thickening of their coats. When the atrophy follows a retinitis or choroido-retinitis (retinitis pigmentosa, syphilitic choroido-retinitis, &c.) all the layers are involved, and the outer layers (those nearest the choroid) earlier than the inner; but when it is secondary to disease of the optic nerve (optic neuritis, progressive atrophy, and glaucoma) only the layers of nerve-fibres and ganglion-cells are atrophied, the outer layers being found perfect, even after many years. A retina atrophied after retinitis often does not regain perfect transparency, and if there have been choroiditis the retina remains especially hazy in the parts where this has been most severe.

The disc in atrophy following retinitis or choroido-retinitis always passes into atrophy, often of peculiar appearance, being pale, hazy, homogeneous-looking, and with a yellowish or brownish tint (p. 175).

*Detachment (separation) of the retina*.—As there is no continuity of structure between the choroid and retina, the two may be easily separated by effusion of blood or serous fluid, the result either of injury or disease, by morbid growths, and by the traction of fibrous cords in the vitreous. Such fibrous bands and strings develop in the vitreous in some cases of



irido-cyclitis, and perhaps in myopic eyes without signs of inflammation. Occasionally rents may be seen in the separated retina. It has been suggested that such rents occurring whilst the retina was still *in situ* might initiate the detachment by allowing the intrusion of vitreous between the retina and choroid; and this explanation may possibly hold good in very myopic eyes. The retina is separated at the expense of the vitreous (which is proportionately absorbed), but always remains attached at the disc and ora serrata, unless as the result of wound or great violence. The depth, area, and situation of the detachment are subject to much variety. Fig. 76 shows a diagrammatic section of an eye in which the lower part of the retina is separated.

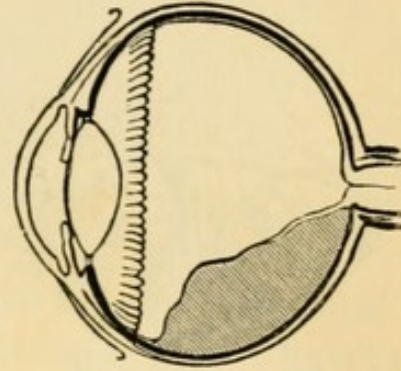


FIG. 76.—Section of eye with partial detachment of retina.

The separated portion is usually far within the focal length of the eye; its erect image is, therefore very easily visible by the direct method (p. 49, 1), when it appears as a dark grey, or whitish reflexion in some part of the field, the remainder being of the natural red colour; the detached part is grey or whitish, because the retina has become opaque. With care we can accurately focus the surface of the grey reflexion, see that it is folded, and see one or more retinal vessels meandering upon it in a tortuous course; they appear small and of dark colour. If the separation be deep the outline of its more prominent folds (Fig. 77) can be seen standing out sharply against the red background, and in some cases the folds flap about when the eye is quickly moved. In extreme cases we can see the detached part by focal light. When the detachment is recent, especially if shallow, the red choroid is still seen



through it; the diagnosis then rests on the observation of whether the vessels in any part become darker, smaller, and more tortuous, and upon ophthalmoscopic

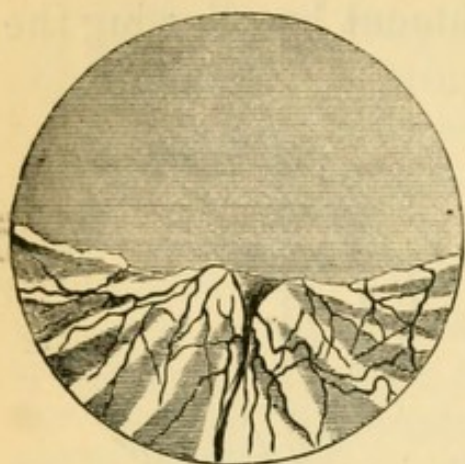

FIG. 77. — Ophthalmoscopic appearance of detached retina (erect image) (after Wecker and Jaeger).

estimation of the refraction of the retinal vessels (p. 51) at different parts of the fundus, for the detached part will be much more hypermetropic than the rest. In very high myopia a shallow detachment may still lie behind the principal focus, and therefore not yield an erect image without a suitable concave lens; in such a case, and in others where minute rucks or folds of detachment are present, examination by the indirect method

leads to a right diagnosis; the image of the detached portion is not in focus at the same moment as its surrounding parts, *parallactic movement*\* is obtained, and the vessels are tortuous. Deep and extensive detachment is often associated with opacities in the vitreous or lens, or with iritic adhesions; and any of these conditions interfere with the conclusive application of the above tests. The treatment of detachment of the retina is very unsatisfactory. Puncture of the sclerotic over the detachment, or of the separated retina itself, allowing the fluid to escape from the eye in the one case or into the vitreous in the other, have been repeatedly tried. Lately profuse sweating and salivation, induced by pilocarpine (F. 35) has been recommended in recent cases.

\* On closing one eye and viewing two objects, one beyond the other but in the same line, one object seems to move over the other when the head is moved from side to side.



*Clinical forms of Retinal Disease.*

The symptoms of retinal disease relate only to the failure of sight which they cause, and this may be either general or confined to a part of the field, according to the nature of the case. Neither photophobia nor pain occurs in uncomplicated retinitis.

*Syphilitic retinitis* is generally associated with and secondary to choroiditis (p. 175), but in a few cases retinitis of the same kind is primary. The vitreous in this disease, as in syphilitic choroiditis, is often hazy, and the opacities are sometimes seated very deeply, just in front of the retina. The changes are those of diffuse retinitis (p. 184, 1), with slight "smoky" haze, often confined to the region of the yellow spot or disc; but in bad cases the haze passes into a whiter mistiness, and extends over a much larger region; sometimes long, branching streaks or bands of dense opacity are met with, and hæmorrhages may occur. The disc is always hazy, and at first too red, while the retinal vessels, both arteries and veins, are somewhat turgid and tortuous; rarely the disc becomes opaque and swollen (papillitis). At a late period, in unfavorable cases, the vessels shrink slowly, almost to threads, and the retina often becomes pigmented at the periphery, the pigmented epithelium of the choroid at the same time disappearing..

Syphilitic retinitis is one of the secondary symptoms, seldom setting in earlier than six, or later than eighteen, months after the primary disease. It occurs in congenital as well as acquired syphilis. It generally attacks both eyes, though often with an interval. Its onset is often rapid, as judged by its chief symptom, failure of sight, and it may be stated that, as a rule, the degree of amblyopia is much higher than would be expected from the ophthalmoscopic changes. Night-blindness is often a pronounced symptom. Its course is chronic, seldom



lasting less than several months, and it shows a remarkable tendency for many months to repeated and rapid exacerbations after temporary recoveries, but with a tendency to get worse rather than permanently better. Amongst the early symptoms is often a "flickering," and this with the history of variations lasting for a few days, and of marked night-blindness, often leads to a correct surmise before ophthalmoscopic examination. There is, however, nothing pathognomonic in any of the symptoms. An annular defect in the visual field ("ring scotoma,") may often be found if sought; in the late stages the field is contracted.

Mercury produces most marked benefit, and when used early it permanently cures a large proportion of the cases; but in a number of cases, perhaps in those where there is most choroiditis, the disease goes slowly from bad to worse for several years, in spite of very prolonged mercurial treatment. Of the efficacy of prolonged disuse of the eyes, and of local counter-irritation or depletion, strongly recommended by many authors, I have had but little experience.

*Albuminuric retinitis (papillo-retinitis).* — The changes are strongly marked, and so characteristic that it is [possible, in most cases, to say from an ophthalmoscopic examination alone that the patient is suffering from chronic kidney disease.

The earliest change (the stage of œdema and exudation) is a general haze, of greyish tint, in the central region of the retina, generally with some hæmorrhages and soft-edged white patches (3, p. 185), and with or without haze and swelling of the disc. In this stage the sight is often unimpaired, and so the cases are seldom seen by ophthalmic surgeons till a few weeks later, when the translucent, probably albuminous, exudations in the swollen retina have passed into a state of fatty or fibrinous degeneration, a change which affects both the nerve-fibres and connective tissue.



In this, the second stage, we find a number of pure white dots, spots, or patches, in the hazy region, and especially grouped around the yellow spot. Their peculiarity is their sharp definition and pure, opaque, white colour; indeed, when small and round, they are quite glistening. When not very numerous they are generally confined to the yellow spot region, from which they show a tendency to radiate in lines (Fig. 73); when very small and scanty they may be overlooked, unless we examine the erect image; but in most cases large patches are formed by the confluence of small spots, and the borders of these patches are striated, crenated, or spotted. At this stage the soft-edged patches (Fig. 74) have often to a great extent disappeared or become merged into more general opacity of the retina; the disc is hazy and somewhat swollen, especially just at its margin, and the retina, as judged by the undulations of its vessels, and confirmed by post-mortem examinations, is much thickened. Hæmorrhages are generally still present in greater or less number, and occasionally constitute the most marked feature of the case; they are usually striated. Sometimes an artery is seen sheathed by a dense white coating.\* In another group papillitis (p. 203) is the most marked change, though some bright white retinal spots are always to be found by careful examination.

The usual tendency is towards subsidence of the œdema, and absorption of the fatty deposits and extravasations, generally with improvement of sight—the third stage, or stage of absorption and atrophy. In the course of several months the white spots diminish in size and number until only a few very small ones are left near the yellow spot, with, perhaps, some residual haze: the blood-patches are slowly absorbed, often leaving pigment spots, and

\* Illustrations of this are given in Gowers's 'Medical Ophthalmoscopy,' pl. xii, fig. 1, and in 'Trans. Ophth. Soc.,' vol. ii, pl. ii.



the retinal arteries may be shrunken. In cases of only moderate severity almost perfect sight is restored. But when the optic disc suffers severely (severe papillitis), or if the retinal disease is excessive and attended by great œdema, sight either improves very little, or, as the disc passes into atrophy and the retinal vessels contract, it may sink to almost total blindness. Such a condition may be mistaken for atrophy after cerebral neuritis; but the presence of a few minute bright dots or of some superficial disturbance of the choroid, at the yellow spot, or of some scattered pigment spots left by extravasations, will generally lead to a correct inference (p. 188). In the cases attended by the greatest swelling and opacity of retina and disc, death often occurs before retrogressive changes have taken place.

Albuminuric retinitis is symmetrical, but seldom quite equal in degree or result in the two eyes. In extreme cases it may cause detachment of the retina.

The kidney disease in the malady under consideration is always chronic. The retinitis may occur in any chronic nephritis, and in the albuminuria of pregnancy. Whatever be the form of the kidney disease, the retinitis seldom occurs without other signs of active kidney mischief, such as headache, vomiting, loss of appetite, and often anasarca. The quantity of albumen varies very much. In the absence of anasarca the symptoms are often put down to "biliousness," and as in such cases the failure of sight is the most troublesome symptom, the ophthalmoscope often leads to the correct diagnosis. A second attack of retinitis sometimes occurs in connection with a relapse of renal symptoms. Many of the best marked cases of albuminuric retinitis occur in the albuminuria of pregnancy, and the prognosis for sight is good in many of these if the symptoms come on late in the pregnancy; but some of them (probably cases of old kidney disease) do very badly, and pass into atrophy of the nerves.



(For the changes which occur in the retina in other chronic general diseases, *e.g.* diabetes, pernicious anæmia, and leucocythæmia, see Chapter XXIII.)

The term *retinitis hæmorrhagica* has been given to certain rare cases, where very numerous, linear or flame-shaped retinal hæmorrhages are found all over the fundus, with extreme venous engorgement. It usually occurs in only one eye at a time, and comes on rapidly. The patients are often gouty. Thrombosis of the trunk of the *vena centralis retinæ* is probably the determining cause of the condition.\*

Other cases are seen where extravasations, varying much in size, number and shape, are scattered in different parts of the fundus of one or both eyes. Some of them are probably allied to the above, but often the nature of the case is obscure, or the hæmorrhages are related to senile degeneration of vessels. Such cases are often called *retinitis apoplectica*.

Lastly, in an important group, a single very large extravasation occurs from rupture of a large retinal vessel, probably an artery. The hæmorrhage is generally in the yellow spot region; in process of absorption it becomes mottled, the densest parts remaining longest, and, if seen in that condition for the first time, the case may be taken for one of multiple hæmorrhages. These large extravasations cause great defect of sight, which comes on in an hour or two, but not with absolute suddenness. Absorption, in the several groups of cases just mentioned, is very slow.

Hæmorrhages may occur from blows on the eye. They are usually small and quickly absorbed, differing in the latter respect very much from the cases before described.

*Embolism of the central artery* of the retina, or of one or more of its main divisions, gives rise to a cha-

\* Hutchinson; Michel, Graefe's 'Arch. f. Ophth.,' xxiv, 2.



racteristic retinitis, the cause of which can in most cases be recognised at once if it be recent ; whilst in old cases the appearances, taken with the history, lead to a right diagnosis. *Thrombosis* of the artery causes similar changes.

The leading symptom of embolism is the occurrence of an instantaneous defect of sight, which is found on trial to be limited to one eye ; sometimes the feeling is as if one eye had suddenly become "shut," the blindness being as sudden as that from quickly closing the lids ; but whether the defect amounts to absolute blindness or not, depends on the position and size of the plug. In any case, owing to the temporary establishment of collateral circulation by the capillary anastomoses at the disc (p. 181), the patient often notices an improvement of sight a few hours after the occurrence. But this improvement is only very slight, the collateral channels being quite insufficient to meet the demand fully ; nor is it often permanent, because the retina suffers very quickly from the almost complete stasis, œdema and inflammation rapidly setting in and leading to permanent damage.

If the case be seen within a few days of the occurrence, the red reflex of the choroid around the yellow spot and disc is quite obscured, or partially dulled, by a diffused and uniform white mist. The opacity is greatest just around the centre of the yellow spot, where the retina is very vascular (Fig. 72), and where its cellular elements (ganglion and granule layers) are more abundant than elsewhere ; but at the very centre of the white mist a small, round, red spot is generally seen, so well defined that it may be mistaken for a hæmorrhage ; it represents the *fovea centralis*, where the retina is so thin that the choroid continues to shine through it when the surrounding parts are opaque ; it is spoken of by authors as the "cherry-red spot at the macula lutea." This appearance is very seldom seen except after sudden arrest



of arterial blood supply, by embolism or thrombosis of the arteria centralis, and perhaps by hæmorrhage into the optic nerve compressing the vessels; and of these causes embolism appears to be the commonest. The haze surrounds and generally affects the disc also, which soon becomes very pale. The small veins in the yellow-spot region often stand out with great distinctness, partly because enlarged by stasis, and partly from contrast with the white retina. Small hæmorrhages are often present. The larger retinal vessels, both arteries and veins, are more or less diminished at and near the disc, the arteries in the most typical cases being reduced to mere threads; both arteries and veins are, however, sometimes observed to increase in size as they recede from the disc. The arteries, however, are not always extremely shrunk in cases of retinal embolism, the variations depending upon the position and size of the plug, *i. e.* upon whether it causes complete occlusion or not. The sudden and complete failure of supply to a single branch of a retinal artery is sometimes followed by its emptying and shrinking to a white cord almost immediately. In other cases the branch may for a time be little, if at all, altered in size, and yet its blood column be quite stagnant, as is proved by the impossibility of producing pulsation in it by the firmest pressure on the globe, whilst the other branches respond perfectly to this test (p. 48). But in other cases, this pressure test, which showed blockage of some or all branches shortly after the onset, again produces pulsation a few days later, without any visible evidence of collateral circulation.

In from one to about four weeks the cloudiness clears off, and the disc passes into moderately white atrophy; the arteries, or some of them (according to the position of the plugging), are either reduced to bloodless white lines, or are simply narrowed considerably, whilst still pulsating easily on pressure.

Sight is almost always lost, or only perception of



large objects retained, whatever be the final state of the blood-vessels. In the rare cases, where an embolus passes beyond the disc, and is arrested in a branch at some distance from it, the changes are confined to the corresponding sector of the retina, and a limited defect of the field is the only permanent result. It is scarcely necessary to say that no treatment can be of any use in cases of lasting occlusion of the retinal arteries.

In a few cases where instantaneous blindness of *both* eyes has been associated with extremely diminished arteries ("*ischæmia retinæ*"), iridectomy has been followed by return of sight; lower tension causing re-establishment of circulation. These cases generally occur after whooping cough. (*See also* Quinine blindness.)

*Retinitis pigmentosa* is a very slowly progressive symmetrical disease, leading to atrophy of the retina, with collection of black pigment in its layers and around its blood-vessels, and secondary atrophy of the disc.

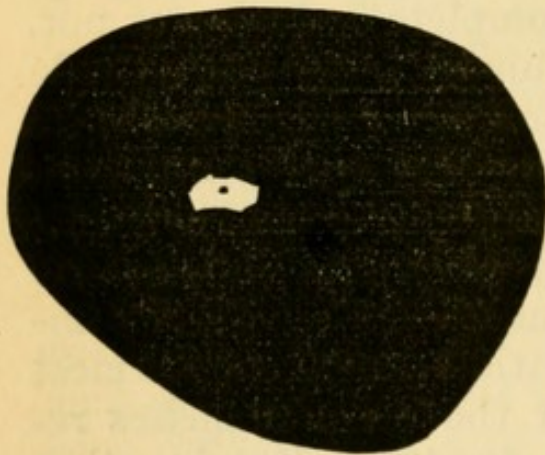


FIG. 78.—Extreme concentric contraction of field of vision (R.) in a case of advanced retinitis pigmentosa. The central dot shows the fixation point. The black shows the part lost.

The earliest symptom is inability to see well at night, or by artificial light (night-blindness, *nyctalopia*). Concentric contraction of the visual field soon occurs (Fig. 78). These defects may reach a high degree, whilst central vision re-

mains excellent in bright daylight. The symptoms are noticed at an earlier stage by patients in whom the choroid is dark, and absorbs much light.

Ophthalmoscopic examination, where these sym-



ptoms have been present for some years, shows:— (1) at the equator or periphery a greater or less quantity of pigment, arranged in a reticulated or linear manner (Fig. 75), often with some small, separate dots; (2) in advanced cases, evidence of removal of the pigment epithelium, but never any patches of choroidal atrophy; (3) that the pigment is arranged in a belt, which is generally uniform, the pattern being most crowded at the centre, and thinning out towards the borders of the belt; (4) that the changes are always symmetrical, and the symmetry very precise. These appearances are quite characteristic of true retinitis pigmentosa. In addition, we find (5) diminution in size of the retinal blood-vessels, the arteries in advanced cases being mere threads; (6) a peculiar hazy, yellowish "waxy" pallor of the optic disc (p. 175); (7) sometimes the pigmented parts of the retina are quite hazy; (8) posterior polar cataract and disease of the vitreous are often present in the later stages. The latter changes (5 to 8), however, are found in many cases of late retinitis consecutive to choroiditis, and are not peculiar to the present malady.

The disease begins in childhood or adolescence, progresses slowly but surely, and, as a rule, ends in blindness some time after middle life. A few cases of apparently recent origin are seen in quite aged persons, and a few are considered to be truly congenital. The quantity of pigment visible by the ophthalmoscope varies much in cases of apparently equal duration, and is not in direct relation to the defect of sight; cases even occur, which certainly belong to the same category, in which no pigment is visible during life, the retina being merely hazy, and in one such case microscopical examination revealed abundance of minutely divided pigment (Poncet). The pathogenesis of the disease is not finally settled; it is at present doubtful whether there is from the first a slow sclerosis of the connective-tissue



elements of the retina, with passage inwards of pigment from the pigment epithelium, or whether the disease begins in the superficial layer of the choroid and the pigment epithelium. Its cause is obscure. It is undoubtedly strongly heritable, and many high authorities believe that it is really produced by consanguinity of marriage, either between the parents, or near ancestors of the affected persons. Many of its subjects are of full mental and bodily vigour; but others are badly grown, suffer from progressive deafness, and are defective in intellect. Although want of education, as a consequence of defective sight and hearing, may sometimes account for this result, we cannot thus explain the various defects and diseases of the nervous system which are not unfrequently noticed in kinsmen of the patients. That the subjects of this disease should be discouraged from marrying is sufficiently evident.

In a few cases galvanism has been followed by improvement both of vision and visual\* field, but no other treatment has any influence.

Complications such as cataract and myopia are not uncommon, and must be treated on general principles.

It is sometimes very difficult to distinguish widely-diffused and superficial choroiditis, with pigmentation of retina and atrophy of the disc, from true retinitis pigmentosa. The question will generally relate to cause, as between retinitis pigmentosa and choroido-retinitis from syphilis (p. 174). But other cases of choroido-retinal disease are sometimes met with, which though differing in ophthalmoscopic appearance from typical retinitis pigmentosa, are, like it, related to some general disease of the nervous system in the patient or his parents, and not to syphilis.

*Retinal disease from intense light.*—A number of

\* Gunn, 'Oph. Hosp. Reports,' x, 161.



cases have now been observed in which blindness of a small area at the centre of field has been caused by staring at the sun, usually during an eclipse. Corresponding to this functional defect ophthalmoscopic evidence of choroiditis or choroido-retinitis have been found at the yellow spot. The defect often lasts for months, if not permanently.\* (*Compare* blindness from snow, electric light, &c., p. 226.)

\* For accounts of recent cases and experiments on this affection see 'Lond. Med. Record,' Oct., 1883; also 'Ophthalmic Review,' April and May.



## CHAPTER XIV

## DISEASES OF THE OPTIC NERVE.

THE optic nerve is often diseased in its whole length, or in some part of its course, either within the skull, in the orbit, or at its ocular end.

The effect of disease of the optic nerve in producing (1) ophthalmoscopic changes in its visible portion (the optic disc, or *papilla optica*), and (2) defect of sight, varies greatly according to the seat, nature, and duration of the disease. The appearance of the disc may be entirely altered by œdema and inflammation, without the nerve-fibres losing their conductivity, and, therefore, without loss, or even defect, of sight; on the other hand, inflammatory or atrophic changes, causing destruction of the nerve-fibres, may arise in the nerve at a distance from the eye, and, whilst producing great defect of sight, cause little or no immediate change at the disc. Although we are here concerned chiefly with the ophthalmoscopic and visual sides of the question, a few words are needed as to the morbid changes in the nerve.

The pathological changes to which the optic nerve is liable include those which affect other nerve tissues. Inflammation varying in seat, cause and rapidity, and resulting in recovery or atrophy, may originate in the nerve itself, may pass down it from the brain (descending neuritis), or may extend into it from parts around; atrophy may occur from pressure by tumours, or distension of neighbouring cavities (*e. g.* the third ventricle), or from laceration or compression after fracture of the optic canal; and the optic



nerve is very subject to the change known as "grey degeneration" or "sclerosis."

Lastly, the optic nerve being surrounded by a lymphatic space ("subvaginal space"), which is continuous through the optic foramen with the meningeal spaces in the skull and is bounded by a tough, fibrous "outer sheath," is liable to be affected by morbid processes going on in that space. This subvaginal or inter-sheath space, bounded externally by the outer sheath of the optic nerve, is lined internally by the inner sheath which is closely adherent to the nerve itself (Fig. 35). Fluid retained or secreted in the subvaginal space is often found there *post mortem*, in cases of the optic neuritis about to be described as so commonly associated with intracranial disease, and has been held to explain the occurrence of this neuritis. Recent microscopical researches, however, have shown that inflammatory changes can be traced along the whole course of the optic nerves from their intra-cranial part to the eye. The occurrence of *optic papillitis*\* in intracranial disease is probably, therefore, explained in all cases by an extension of inflammation from the brain or its membranes either along the interstitial connective tissue of the nerve or down the inner nerve-sheath, or perhaps, in some cases, along the intrinsic blood-vessels of the optic nerve. This explanation by "descending neuritis" has always been accepted for the papillitis caused by meningitis. But other hypotheses, which have been, or seem likely to be, given up, have hitherto been held by most authorities to be more applicable to the papillitis caused by cerebral tumour, because in this form the signs of inflammation in the nerve above the disc and in the membranes at the base of the brain, if present at all, are so slight as to require a careful

\* "Papillitis" has been proposed by Leber to designate the ophthalmoscopic appearances of the inflamed or swollen *disc*, without reference to theories of causation, or to the state of the nerve trunk.



microscopical examination for their detection. The part taken by the fluid which, as stated above, is often present in the subvaginal space of the nerve and in greatest quantity close to the eye, is not yet known. It may possibly act in either or both of two ways; mechanically by compressing the nerve and hindering return of blood from the retina, and thus complicating an already existing neuritis, or vitally by carrying inflammatory germs from the cranial cavity to the optic nerve. It is not yet fully known how cerebral tumours set up descending optic neuritis when the absence of fluid in the sheath precludes any appeal to its influence; but many facts point to the probability that they do so by lighting up irritation with increase of cell-growth in the surrounding brain substance, and local meningitis. Nor is it fully understood why the other cranial nerves are so seldom damaged, at least permanently.\*

As already stated in previous chapters, inflammation may extend into the disc from the retina or choroid near to it, and may occur in consequence of the sudden arrest of the blood-current caused by embolism and thrombosis of the central retinal vessels, in their course through the nerve.

*The ophthalmoscopic signs of papillitis* are caused by varying degrees of œdema, congestion and inflammation of the disc. It is no longer useful to maintain the old ophthalmoscopic distinction between "swollen disc," or "choked disc," and "optic neu-

\* For a full and masterly statement of this difficult subject, enriched with many new facts, the reader is referred to Dr Gowers's 'Manual and Atlas of Medical Ophthalmoscopy.' In a recent careful paper Drs Edmunds and Lawford maintain that basal meningitis is probably always the starting point of optic neuritis, even in cases of cerebral tumour, and that the inflammation usually travels down the inner sheath of the optic nerve, 'Trans. Ophth. Soc.,' vol. iii, 1883. See also the papers by Drs Stephen Mackenzie, Brailey and others in the first volume of the same 'Trans.,' 1881, and in the 'Trans. of Internat. Med. Congress,' 1881.



ritis." The latter term was formerly reserved for cases showing little œdema, but much opacity, changes which were supposed especially to indicate inflammation passing down the nerve from the brain; but if œdema and venous engorgement predominated ("choked disc"), the changes were attributed to compression of the optic nerve by fluid in its sheath-space, or with less reason to pressure on the ophthalmic vein at the cavernous sinus. The changes are often mixed, or vary at different stages of the same case. The terms "neuritis" and "papillitis" will be here used to the exclusion of "choked disc."

The most important early changes in optic papillitis are blurring of the border of the disc by a greyish opalescent haze, distension of the large retinal veins, and swelling of the disc above the surrounding retina. Swelling is shown by the abrupt bending of the vessels, with deepening of their colour and loss of the light streak—they are, in fact, seen foreshortened; also by noticing that slight lateral movements of the observer's head, or lens, cause an apparent movement of the vessels over the choroid behind, because the two objects are on different levels ("parallactic test," p. 190). The patient may die, or the disease may, after a longer or shorter time, recede at this stage. But further changes generally occur; the haziness becomes decided opacity, which more or less obscures the central vessels and covers and extends beyond the border of the papilla (Fig. 79), so that the disc appears enlarged; its colour becomes a mixture of yellow and pink with grey or white, and it looks striated or fibrous, appearances due to a whitish opacity of the nerve-fibres mingled with numerous small blood-vessels and hæmorrhages. The veins become larger and more tortuous, even kinked or knuckled; the arteries are either normal or somewhat contracted; there may be blood-patches. The swelling of the disc may



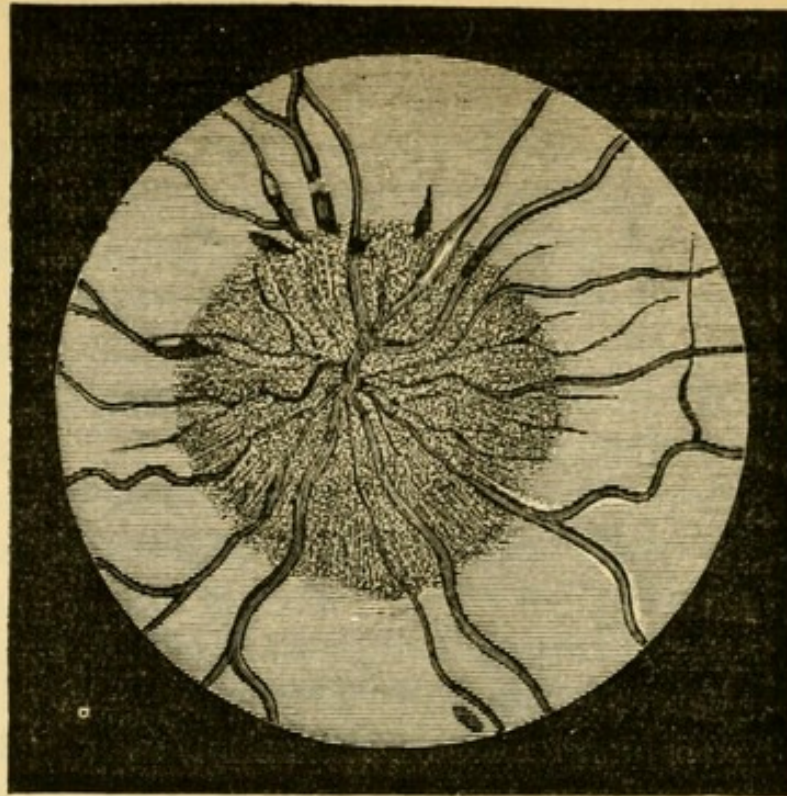


FIG. 79.—Ophthalmoscopic appearance of severe papillitis. Several elongated patches of blood near border of disc. (After Hughlings Jackson.) Compare with Fig. 80.

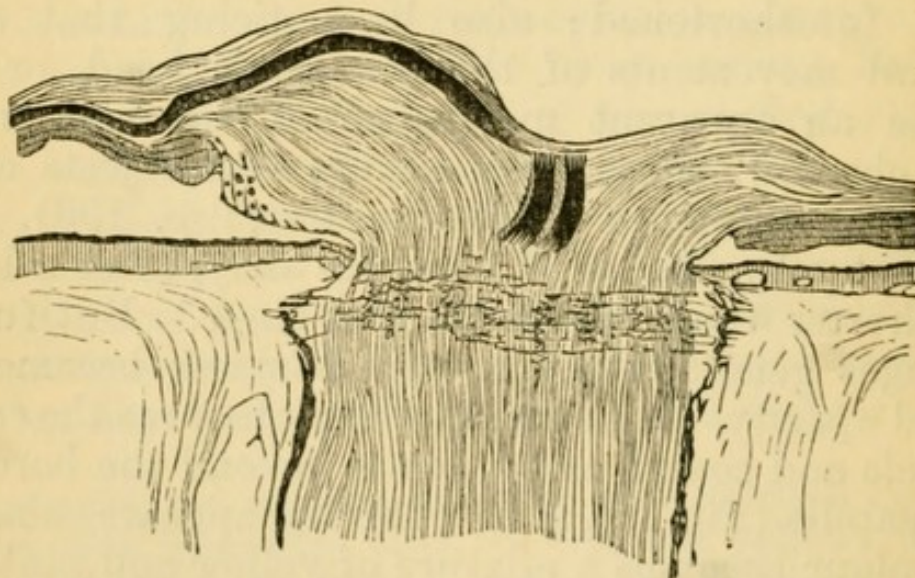


FIG. 80.—Section of the swollen disc in papillitis, showing that the swelling is limited to the layer of nerve-fibres (longitudinal shading); other retinal layers not altered in thickness. (Compare with Fig. 35.)  $\times$  about 15.

be very great, and is appreciated either by the above-mentioned foreshortening of the vessels, by the paralactic test, or by ophthalmoscopic measurement (p. 53).



Such changes may disappear, leaving scarcely a trace; or a certain degree of atrophic paleness of the disc, with some narrowing of the retinal vessels and thickening of their sheaths, or other slight changes, may remain. But in many cases the disc gradually, in the course of weeks or months, passes into a state of "post-papillitic," or "consecutive," atrophy; the opacity first becomes whiter and smoother looking ("woolly disc"); then it slowly clears off, generally first at the side next the yellow spot, and the retinal vessels simultaneously shrink to a smaller size, though they often remain tortuous for a long time (Fig. 81). As the mist lifts, the sharp edge, and finally the whole surface of the disc, now of a staring-white colour, again comes into view. A slight haziness often remains, and the boundary of the disc is often notched and irregular; but upon these signs too much reliance must not be placed.

Sight is seldom much affected\* until marked papillitis has existed some little time. If the morbid process quickly cease, often no failure occurs; or sight may fail, may even sink almost to blindness, for a

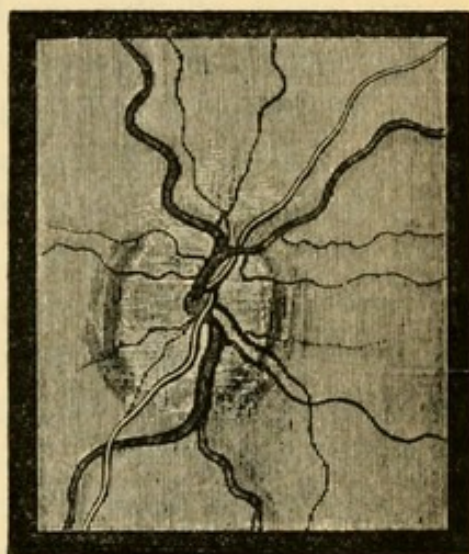


FIG. 81.—Atrophy of disc after papillitis. Upper and lower margins still hazy; veins still tortuous; arteries nearly normal; disturbance of choroidal pigment at inner and outer border. Sight in this case remained fairly good. The disc is not represented white enough.

\* Dr Hughlings Jackson was the first to insist on the frequency of papillitis without failure of sight. The value of this discovery is very great, since double papillitis without other changes in the eye is one of the most important signs we possess of the existence of tumour or inflammation within the skull.



short time, and recovery take place if the changes cease before compression of the nerve-fibres have given rise to atrophy. Gradual failure late in the case, when retrogressive changes are already visible at the disc, is a bad sign. The sight seldom changes, either for better or worse, after the signs of active papillitis have quite passed off, and though the relations between sight and final ophthalmoscopic appearances vary, it is usually true (1) that great shrinking of the central retinal vessels indicates a high grade of atrophy and great defect of sight, and is generally accompanied by extreme pallor, with some residual haziness, of the disc (advanced post-papillitic atrophy); (2) that considerable pallor, and other slight changes, such as white lines bounding the vessels, or streaks caused by increase of the connective tissue of the disc, are compatible with fairly good sight, if the central vessels are not much shrunk.

Advanced atrophy, undoubtedly following papillitis, does not, however, always show signs of the past violent inflammation; the appearances may, indeed, be indistinguishable from those caused by primary atrophy (p. 210).

Papillitis is double in the great majority of cases. If single, it generally indicates disease in the orbit; but single papillitis, from intra-cranial disease, is occasionally seen. In the double cases, however, there are often inequalities, in time, degree, and final result, between the two eyes.

The changes are not always limited strictly to the disc and its border (pure papillitis), for in some cases a wide zone of surrounding retina is hazy and swollen, exhibiting hæmorrhages and white plaques, or lustrous white dots (*papillo-retinitis*, *neuro-retinitis*). It is not always easy to say, in such a case, whether the changes are due to renal disease, with great swelling of the disc (p. 193), or to some intra-cranial malady. In renal cases there is always albuminuria,



the patient is seldom a young child, and the cases with most severe neuro-retinitis occur in an advanced stage of the kidney disease;\* in the cases of neuro-retinitis most closely resembling renal cases, but caused by cerebral disease, there is no albumen, and the changes seldom closely resemble those caused by kidney disease until they have existed for long and caused very great defect of sight.

*Etiology.*—Papillitis occurs chiefly in cases of irritative intracranial disease, viz. in meningitis, both acute and chronic, and in intracranial new growths of all kinds, whether inflammatory (syphilitic gummata), tubercular, or neoplastic. It is very rare in cases where there is neither inflammation nor tissue growth, as in cerebral hæmorrhage and intracranial aneurysm. Further, it must be stated that no constant relationship has been proved between papillitis and the seat, extent, or duration of the intracranial disease. Papillitis has occasionally been found without coarse disease, but with widely diffused minute changes, in the brain. Thus, the occurrence of papillitis, although pointing very strongly to organic disease within the skull, and especially to intracranial tumour, is not of itself either a localising or a differentiating symptom. Inflammation about the sphenoidal fissure, thrombosis of the cavernous sinus, and tumours and inflammations in the orbit, are occasional causes of papillitis, which is then usually one-sided, and often accompanied by extreme œdema and venous distension; in some of these there is protrusion of the eye and affection of other orbital nerves, and the exact seat of the disease may be obscure.

Other occasional causes of double papillitis, with or without retinitis, are lead poisoning, the various exanthemata (including recent syphilis), sudden suppression of menstruation, simple anæmia, and, perhaps, exposure to cold. In a few cases well-

\* Gowers, p. 187.



marked double papillitis occurs without other symptoms, and without assignable cause.

Certain cases of failure of sight, often in only one eye, with slight neuritic changes at the disc, followed by recovery or by atrophy, must be referred to a local, primary neuritis, originating some distance behind the eye (*retro-bulbar neuritis*). The changes are clinically very different from any of those above described (*see* p. 219, 3).

Syphilitic disease within the skull is a common cause of papillitis, but the eye changes alone furnish no clue to the cause, nor to its mode of action, which may be:—(1) by giving rise to intracranial gumma not in connection with the optic nerves, but acting as any other tumour acts (*see* above); (2) by direct implication of the chiasma or optic tracts in gummatous inflammation; (3) in rare cases neuritis, ending in atrophy and blindness, occurs in secondary syphilis, with severe head symptoms pointing to acute meningitis.

The condition of the pupil in neuritic affections depends partly on the state of sight and partly on the rapidity of its failure. As a rule, in amaurosis from atrophy of the discs after papillitis the pupils are for a time rather widely dilated and motionless; after a while they often become smaller, and unless the blindness be complete they regain a certain amount of mobility to light.

#### ATROPHY OF THE OPTIC DISC.

By this is meant atrophy of the nerve-fibres of the disc, and of the capillary vessels which feed it. The disc is too white; milk-white, bluish, greyish, or yellowish in different cases. Its colour may be quite uniform, dead, or opaque looking, or some one part may be whiter than another; the stippling of the *lamina cribrosa* (p. 46) may be more visible than in health, or, on the other hand, entirely absent, as if covered or filled up by white paint (Figs. 82 and



83). The central retinal vessels may or may not be shrunk. The choroidal boundary is too sharply defined, or, as in Fig. 81, too hazy; it may be even and circular, or irregular and notched. The sclerotic ring (p. 45) is often seen with unnatural clearness, being even whiter than the nerve which it encircles. The large retinal vessels are to be carefully noted as

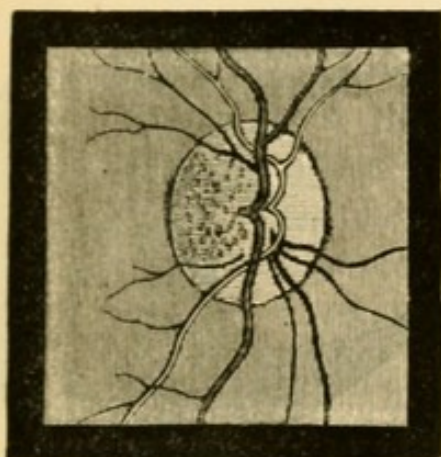


FIG. 82.—Simple atrophy of disc. Stippling of lamina cribrosa exposed. (Wecker.)

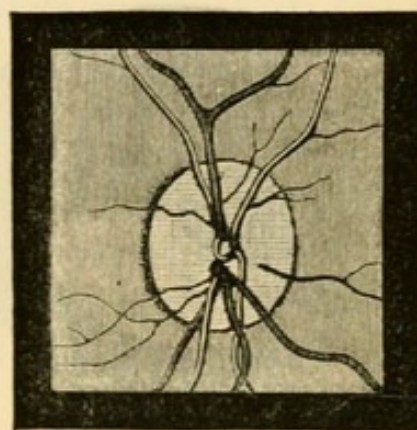


FIG. 83.—Atrophy of disc from spinal disease. Lamina cribrosa concealed. Vessels normal. (Wecker.)

to size and tortuosity, both points being important in the diagnosis of cause, and for prognosis. Mere pallor of the disc, as is present in extreme general anæmia, must not be mistaken for atrophy; the change is then one of colour only, without unnatural distinctness, loss of transparency, or disturbance of outline.

*Varieties.*—(1.) The nerve-fibres undergo atrophy during the absorption and shrinking of the new connective tissue formed during severe neuritis (post-papillitic atrophy, p. 207).

(2.) When the disc participates secondarily in inflammation of the retina or choroid it also participates in the succeeding atrophy (pp. 175, 188).

(3.) Atrophy of any part of the optic nerve or chiasma, from pressure—as by a tumour or by distension of the third ventricle in hydrocephalus—from injury, or local inflammation, leads to secondary



atrophy, which sooner or later reaches the disc. Such cases often show the conditions of pure atrophy, without adventitious opacity or disturbance of outline, and often without change in the retinal vessels. They are not very common.

(4.) The optic nerves are liable to chronic sclerotic

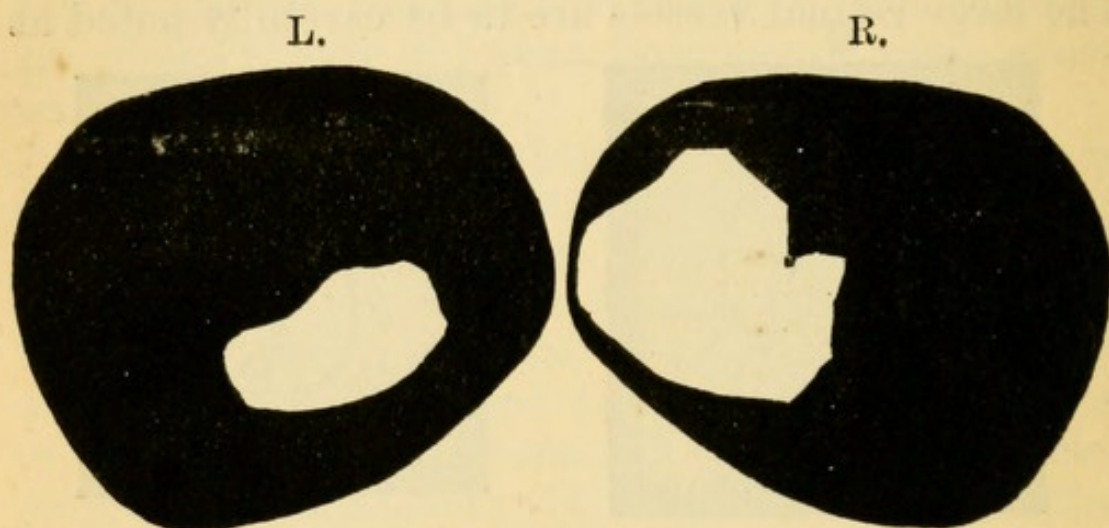


FIG. 84.—Irregular contraction of fields of vision in a case of progressive atrophy of optic nerves. The loss is symmetrical, but more advanced in the L., where it has extended over the fixation point; in the R. it has just reached the fixation point at one place. The black represents the parts lost.

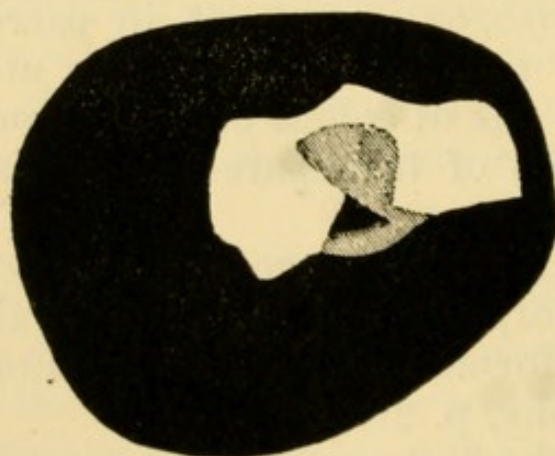


FIG. 85.—Irregular contraction, with central loss, of L. visual field, from progressive atrophy of optic nerve in locomotor ataxy. The black represents the blind parts; the shading shows partial loss of vision.

changes, with thickening of the connective-tissue framework and atrophy of the nerve-fibres, without



the occurrence of papillitis. The change in these cases appears to begin at the disc, but the exact order of events is not fully known in this large and important group.—Groups 3 and 4 furnish the cases which are known clinically as “primary” or “progressive” atrophy of the optic disc.

*Clinical aspects of Atrophy of the Discs.*—As in optic neuritis, so in atrophy and pallor of the disc, there is no invariable relation between the appearance (especially the colour) of the disc and the patient's sight. A considerable degree of pallor, which it may be impossible to distinguish from true atrophy, is sometimes seen with excellent central vision (p. 32), though usually accompanied by some defect of the visual field. Again, the discs often look alike, although the sight is much better in one eye than the other. (See p. 219, 4.)

Patients with atrophy of the disc come to us because they cannot see well or are quite blind. There are usually no other local symptoms except such as are furnished by the pupils, and these present many variations. In post-papillitic atrophy the pupils are generally too large, and sluggish or motionless to light; in most cases of primary progressive atrophy they are of ordinary size, or smaller than usual, and act very imperfectly (Chap. XXIII). When only one eye is affected, the other being quite healthy, the pupil of the amaurotic eye has no direct action to light (p. 28) and is often a little larger than its fellow.

The visual field, in cases of atrophy, is generally contracted, or shows irregular invasions, or sector-like defects (Figs. 84 and 85). Colour-blindness is a marked symptom in nearly all cases, but is not always proportionate to the loss of vision, being in some much greater and in others much less than the state of vision would lead us to expect (*see also* Chap. XV). Green is the colour lost soonest in nearly all cases, and red next.



A. Cases in which both discs are atrophied may be conveniently classified as follows in regard to diagnosis and prognosis.

(1.) If the changes point decidedly to recently past papillitis (p. 207), there is some prospect of improvement; but, on the other hand, sight may for a time get worse. The case must, of course, be investigated most carefully as to the cause of the neuritis. If sight has been stationary for some months further change is unlikely.

(2.) If the retinal arteries are much shrunken, whether neuritis have occurred or not, the prognosis is bad (p. 208).

(3.) If the most careful examination leaves it uncertain whether previous papillitis have occurred, inquiry should be made for previous symptoms of intracranial disease; since consecutive cannot always be distinguished from primary atrophy (p. 208.)—But in a large number of those cases which present no ophthalmoscopic evidences of previous papillitis, the history will be quite negative as to cerebral symptoms;—and these will, for the most part, fall into the two following groups.

(4.) There are symptoms of chronic disease of the spinal cord, usually of locomotor ataxy; or, much more rarely, symptoms of general paralysis of the insane.

(5.) No cause can be assigned for the atrophy; these are less common than has been supposed.

The sclerosis leading to atrophy of the discs in locomotor ataxy (4) usually comes on early in that disease, often before well-marked spinal symptoms have appeared. The optic atrophy always becomes symmetrical, though it generally begins some months sooner in one eye than in the other; it always progresses, though sometimes not for years, to complete, or all but complete, blindness. The discs are usually characterised by a uniformly opaque, grey-white colour, the lamina cribrosa being often concealed,



although neither the central vessels nor the disc margin are obscured in the least (Fig. 83). The central vessels are often not materially lessened in size, even when the patient is quite blind.

Cases of progressive atrophy are seen which resemble the above, but where no signs of spinal-cord disease are present, even though the patient has been long blind (5). It is known that in some of these patients ataxic symptoms come on sooner or later, and it is highly probable that, could the cases be followed up for a sufficient number of years, this termination would be found to be common.\* Indeed, preataxic optic atrophy is now a recognised method of onset of the disease. Cases of Classes 4 and 5 are far commoner in men than women.

In making the prognosis of cases of progressive, uncomplicated amblyopia or amaurosis, with more or less atrophy of discs, special attention is to be paid to whether or not the failure was synchronous, and whether it is now equal in the two eyes. The state of the field of vision in cases seen early is also of much importance; peripheral contraction, as distinguished from central defect, is a bad sign, for progressive atrophy seldom begins with defect in the centre of the field. Cases of gradual, uncomplicated failure of sight, in which the symptoms have, from the beginning, been equally symmetrical, will generally show but slight atrophic changes in proportion to the defect of sight (p. 219, 4).

**B.** Single amaurosis with atrophy of the disc, in a majority of cases, indicates former embolism of the central artery (p. 195), or some local affection of the trunk of the optic nerve (pp. 210, 219). The latter cases often give a history of having suffered from severe localised headache or neuralgia. But

\* I have found decided spinal symptoms in 58 of a series of 76 consecutive cases of progressive atrophy, and of the remaining 18, several showed one or more symptoms which were probably of spinal origin.



here it must be remembered that in cases of progressive atrophy, accompanying or preceding spinal disease, a very long interval occasionally separates the onset of the disease in the two eyes,\* and we may see the first eye before the commencement of disease in the second.

Single amaurosis following immediately after injury to the head, and leading in a few weeks to atrophy, indicates damage to the nerve from fracture of the optic canal (pp. 211, 3). The blow has generally been on the front of the head, and on the same side as the affected eye.

\* This interval may be three or four years, and an interval of from one to two years is not very rare.



## CHAPTER XV

## AMBLYOPIA AND FUNCTIONAL DISORDERS OF SIGHT.

THE term amblyopia means dulness of sight, but its use is generally restricted to cases of defective acuteness of sight (p. 31), short of blindness, in which there is little or no ophthalmoscopic change. Amaurosis indicates a more advanced affection—complete blindness without apparent cause. These terms are essentially clinical, whilst papillitis and atrophy imply easily recognised pathological changes in the disc. Amblyopia may depend upon disease in the retina, in any part of the optic nerve or tract, or in the optic centres; and it may be temporary or permanent. It is always most important to distinguish single from symmetrical cases.

Two common and important forms of unsymmetrical amblyopia may be considered first.

(1.) *Amblyopia from suppression of the image* in one eye, in cases of squint. A squinting person, in order to avoid the inconvenience of double vision (p. 22), suppresses the consciousness of the image formed in the squinting eye. If this process be continued the sensorium becomes permanently blunted for images in this eye; we say that the eye is amblyopic when we ought to say that the corresponding centre loses perception. This defect, though often very great, affects only that part of the visual field which is common to both eyes and is therefore least marked in the outer part of the field. It continues though the squint be cured, *i. e.* though both eyes are again directed to the same object; but it can be to some extent improved, by oft-repeated



separate practice of the defective eye, the sound eye being closed. The suppression is much more easily effected by some persons than others, and early in life than later; hence those who have squinted constantly since early childhood seldom have diplopia when they come for advice several years afterwards, while if squint be acquired later, diplopia lasts for years if not for life. When the suppression is temporary, even though often repeated, as in cases of alternating and of periodic squint, no amblyopia results.\*

(2.) *Amblyopia from defective retinal images.*—In cases of high hypermetropia or astigmatism, when clear images have never been formed, the correction of the optical defect by glasses at the earliest practicable age often fails, at any rate for a time, to give full acuteness of sight. Want of education in the appreciation of clear images is probably the chief cause, though defective development of the retina may also come into play. We may explain in the same way the common cases in which, with anisometropia (p. 303), the sight of the more ametropic eye even when corrected by the proper glasses, remains defective, although no squint have ever existed; and in some degree also the defect often observed after perfectly successful operations for cataract in children. When discovered late in life this defect is seldom altered by correcting the optical error, but in children the sight may improve when the suitable glasses are constantly worn.

In cases of amblyopia not belonging to either of these categories a definite date of onset will generally be given. Two principal divisions may be formed, according as the defect is single or double.

\* It should be stated that the above, commonly received, explanation of the amblyopia of eyes which have squinted from early life has been assumed on the theory of congenital (rather than acquired) "correspondence" between the two retinae, and that it is doubted by so high an authority as Prof. Schweigger.



It must here be noted, however, that defect or blindness of one eye often exists unknown for years, until accidentally discovered by closing the sound eye. This ignorance of the defect is most common when the failure has been gradual, painless, and not accompanied by any change in the appearance of the eye. The patient is naturally alarmed at the sudden discovery of the defect, and believes it to be recent, but much caution must be used in accepting his belief. *Sudden* failure of one eye is as a rule dated correctly; and the same is true of gradual failure of the right eye in a man used to rifle shooting, or to "sighting" for any purpose.

(3.) Cases of recent failure of one eye with little or no ophthalmoscopic change occur but rarely, and generally in young adults; the onset is often rapid, with neuralgic pains, sometimes very severe, in the same side of the head. There may be pain in moving the eye, or tenderness when it is pressed back into the orbit. The degree of amblyopia varies much, but is often especially marked at the centre of the field. The disc of the affected eye is sometimes hazy and congested. The attack is often attributed to exposure to cold. Most of the cases recover under the use of blisters and iodide of potassium, but in a certain number the defect is permanent, and the disc becomes atrophied. A *retrobulbar neuritis*, often slight and transient, most likely occurs (p. 210), and the cases are perhaps analagous to peripheral paralysis of the facial nerve.

(4) Much commoner is a progressive and equal failure in both eyes, often amounting in a few weeks, or months, to great defect (14 or 20 Jaeger, or V. from  $\frac{1}{3}$  to  $\frac{1}{10}$ ), with no other local symptoms except perhaps a little frontal headache, but often with nervousness, general want of tone, and loss of sleep and appetite. Ophthalmoscopic changes, never pronounced, may be quite absent. At an early period the disc is often decidedly congested, and slightly



swollen and hazy, but these changes are all so ill-marked that competent observers may give different accounts of the same case. Later the side of the disc next the y. s., and finally in bad cases, the whole papilla, becomes pale, and the diagnosis of incomplete atrophy is given. The defect of sight is described as a "mist," and is usually most troublesome in bright light and for distant objects, being less apparent early in the morning and towards evening. The pupils are normal, or at most rather sluggish to light. The defect of V. is limited to, or much greater at, the central part of the field (causin

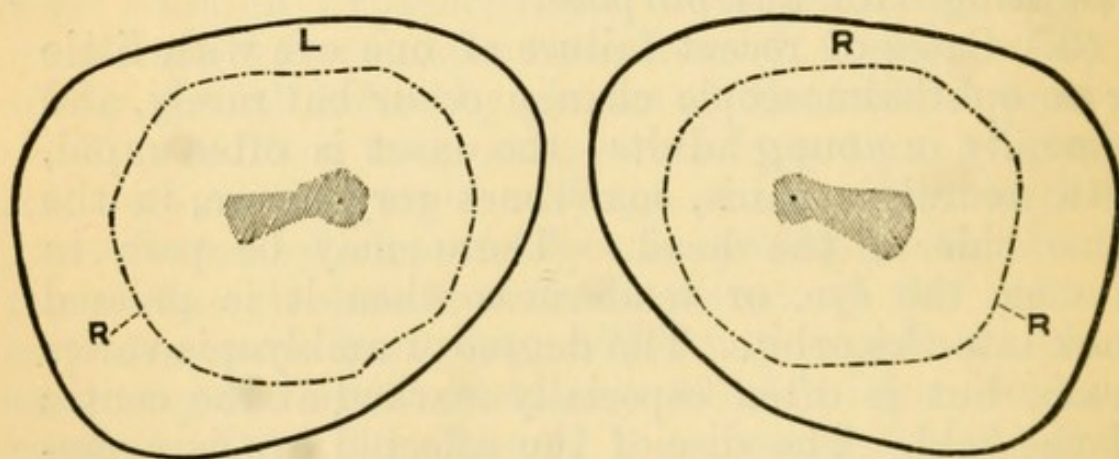


FIG. 86.—R. right, L. left, visual field in a case of central amblyopia from tobacco smoking. The shaded area is the part over which acuteness of vision and colour-perception are lowered (relative central scotoma), no part of the field being absolutely blind. The dotted line marked R. shows the boundary of the field for red (*see* Fig. 27).

a *central scotoma*), and occupies an oval patch from the fixation point (corresponding to the y. s. outwards to the blind spot (corresponding to the optic disc), on which area the perception of green and red is also defective or absent. This symptom may often be detected by moving a red or green spot (from 5 to 15 mm. square) from the fixation point in different directions, the patient steadily fixing the upheld finger or other object with one eye; the colour of the spot will be seen best (if at all) at a little distance from



the fixation point (compare p. 230); in many cases no colour defect is apparent if the patient be tested with large masses of colour. The periphery of the field being good, no difficulty is experienced by the patient in going about, the large surrounding objects being visible; hence the patient's manner differs from that of one with progressive atrophy, who finds difficulty in walking about, &c., because his visual field is contracted (p. 213).

The patients are almost without exception, males, and at or beyond middle life. With very rare exceptions they are smokers, and have smoked for many years, and a large number are also intemperate in alcohol.—The exceptions occur chiefly in a very few patients in whom a similar kind of amblyopia is hereditary, is liable to affect the female as well as the male members, and sometimes comes on much earlier in life. The etiology of these cases is obscure, and in some few of them there is no evidence of heredity.

In the common cases it is now generally agreed that tobacco has a large share in the causation, and in the opinion of an increasing number of observers it is the sole excitant. The direct influence of alcohol, and of the various causes of general exhaustion, such as anxiety, underfeeding, and general dissipation, is still to some extent an open question (*see* Chap. XXIII, Diabetes). My own opinion, based on the examination of a large number of cases, is that tobacco is the essential agent, and that the disuse or greatly diminished use of tobacco is the one essential measure of treatment. It is important to remember that the disease may come on when either the quantity or the strength of the tobacco is increased, or when the health fails and a quantity which was formerly well borne becomes excessive. Hence cases of *central amblyopia* may, as a rule, except in the rare form above mentioned, be named *tobacco amblyopia*.

The prognosis is good if the patient come early, and if the failure have been comparatively quick.



In such cases really perfect recovery may occur, and very great improvement is the rule. In the more chronic cases, or cases where already the whole disc is pale, a moderate improvement, or even an arrest of progress, is all we can expect. If smoking be persisted in no improvement takes place, and the amblyopia increases up to a certain point, but complete blindness very seldom, if ever, occurs. In the treatment, disuse of tobacco is the one thing essential. Drink should, of course, be moderated. It is usual to give strychnia, subcutaneously or by mouth, for a considerable period, but whether any medicine acts otherwise than by improving the general tone is doubtful; subcutaneous injections of strychnia, carefully carried out, have not given definite results in my own cases. There is reason to believe that the disease depends on a chronic inflammation of the central bundles of the optic nerve, beginning at a distance from the eye.\*

*Hemianopia* (usually called *hemiopia*) denotes loss of half the field of vision. When uniocular the defect is seldom quite regular, and generally depends upon detachment of the retina or a very large retinal hæmorrhage.—It is usually binocular, and then indicates disease at or behind the optic chiasma. In the great majority of cases the R. or L. lateral half of each field is lost (Fig. 87). Sometimes only a quarter of each field is lost. The line of separation between the blind and the seeing halves of each field may pass vertically straight through the fixation point, but more commonly it deviates a little, leaving intact a small area of the field around the fixation point, so that central vision is not impaired; the transition from the seeing to the blind half may be quite abrupt, or rather gradual. Loss of the R. half of each *field*, meaning loss of function of the L. half of each *retina*, points to disease of the L. optic

\* Trans. Ophth. Soc., vol. i, p. 124, and iii, p. 160.



tract\* or its continuations, or of the convolutions forming the L. occipital lobe and angular gyrus. Loss of the two nasal halves is extremely rare.

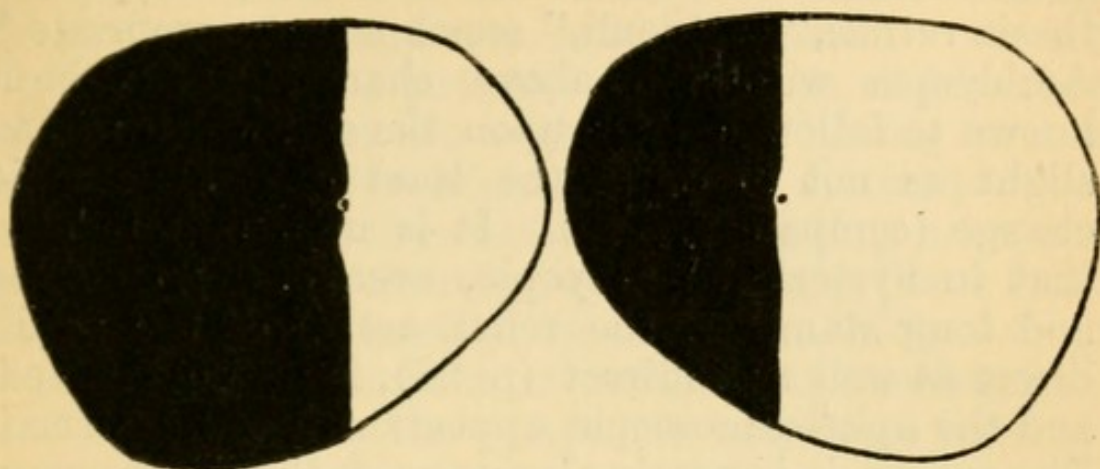


FIG. 87.—Fields of vision in a case of L. homonymous lateral Hemianopia. The dividing line comes within one or two degrees of the fixation point (shown by the central dot) in each eye. The lesion causing this hemianopia is probably in the optic tract, or not higher than the corpora geniculata.

Loss of the two temporal halves (temporal hemianopia) points to disease at the anterior part of the chiasma. Even when hemianopia has lasted for years the optic discs seldom show any change. When lateral hemianopia coexists with hemiplegia the loss of sight is on the paralysed side; “the patient cannot see to his paralysed side” (Hughlings Jackson).

*Hysterical amblyopia and amaurosis* take various forms, and real defect is sometimes mixed up with conscious feigning.—In hysterical hemianæsthesia the eye on the affected side is sometimes defective, or quite blind. In other cases of hysteria both eyes are defective, but one worse than the other; there is concentric contraction of the visual fields, sometimes with, sometimes without, colour-blindness, a varying degree of defective visual acuteness, and sight is often disproportionately bad by feeble light (hence

\* Because the L. optic tract consists of fibres which supply the L. half of each retina, those of them destined for the R. eye crossing over at the optic commissure.



the term, "anæsthesia of the retina," is sometimes used). There may, however, be, in addition, irritative symptoms—watering, photophobia, and spasm of accommodation—and then the term, "hyperæsthesia retinæ," or "oculi," seems more appropriate.\* Amblyopia with the above characters has been known to follow a blow upon the eye, which was so slight as not to cause the least ophthalmoscopic change (compare p. 140). It is important to note that in hysterical amblyopia, even of high degree and long standing, the reflex action of the pupil, direct as well as indirect (p. 28), is fully preserved, and the ophthalmoscopic appearances quite normal. The prognosis is nearly always good, though recovery is sometimes slow, and relapses may occur. In some of the worst cases I have seen, there has been considerable ametropia (Chap. XX.)

True hysterical amblyopia seems allied, from the ophthalmic standpoint, with a much larger and more important class, best epitomised by the term *asthenopia*, in which photophobia, irritability, and want of endurance of the ciliary muscle (*accommodative asthenopia*), or sometimes of the internal recti (*muscular asthenopia*) with some conjunctival irritability, are the main symptoms, acuteness of sight being usually perfect, and the refraction nearly or quite normal.—Of the retinal, conjunctival, and muscular factors, any one may be more marked than the others, and it would seem that, given a certain state of the nervous system, which may be described as impressionable or hyperæsthetic, over-stimulation of any one is liable to set up an over-sensitive state of the other two.—These patients often complain also of dazzling, pain at the back of the eyes, and headache, or neuralgia in the head. All the symptoms are worse after the day's work, and sometimes on first waking in the morning, and they are liable to vary

\* These cases correspond to the "kopiopia hysterica" of Förster.



much with the health. Artificial light always aggravates them, because it is often flickering and insufficient, but especially because it is hot. The symptoms often last for months or years, causing great discomfort and serious loss of time.

*Causation.*—The patients are seldom children or old people. Most are women, either young or not much past middle life, often very excitable, and often with feeble circulation. If men, they are emotional, fussy, and often hypochondriacal. Some local cause can also generally be traced, such as a long spell of close application at needlework, reading, &c., and in such cases the symptoms may come on very suddenly, the patient becoming, within a day or two, quite incapacitated for reading. Sometimes bright colours, glittering things, or exposure to kitchen fire, seem specially injurious. Or, again, there is a history of phlyctenular ophthalmia, or superficial ulcers, which have left the fifth nerve permanently unstable.

*Treatment.*—The refraction and the state of the internal recti should always be carefully tested, and any error corrected by lenses, which may often be combined with prisms, with their bases towards the nose (p. 9). Plain coloured glasses are sometimes useful. But glasses will not cure the disease, and we must not promise too much from their use. The patient may be assured that there is no ground for alarm, and that the symptoms will probably pass off sooner or later. He should be discouraged from thinking about his eyes, and he need seldom be quite idle. The artificial light used should be sufficient and steady (not flickering), and should be shaded to prevent the heat and light from striking directly on the eyes. Bathing the eyes freely with cold water, and the occasional employment of weak astringent lotions, are useful, and cold air often acts beneficially. The eyes are often much better after a rest of a day or two. Out-door exercise, and only moderate use of the eyes therefore should be en-



joined. General measures must be taken according to the indications, especially in reference to any ovarian, uterine, or digestive troubles, or to sexual exhaustion in men.

#### FUNCTIONAL DISEASES OF THE RETINA.

*Functional night-blindness (endemic nyctalopia)* is caused by temporary exhaustion of the retinal sensibility from prolonged exposure to diffused, bright light.—The circumstances under which it occurs usually imply not only great exposure to bright light, but lowered general nutrition, and probably some particular defect in diet. It often co-exists with scurvy. Sleeping with the face exposed to bright moonlight is believed to bring it on. It is commonest in sailors after long tropical voyages under bad conditions, and in soldiers after long marching in bright sun. In some countries it prevails every year in Lent when no meat is eaten, and again in harvest time. It is now but rarely indigenous in our country, but scattered cases occur, especially in children,\* and it still occasionally prevails in large schools.

In this malady two little dry films, consisting of fatty or sebaceous matter and epithelial scales, often form on the conjunctiva at the inner and outer border of the cornea. Their meaning is obscure, but they are sometimes absent in this disease and present in other conditions. There are no ophthalmoscopic changes. This night-blindness is soon cured by protection from bright light and improvement of health, and especially by cod-liver oil. That the affection is local in the eye is shown by the fact that darkening one eye, with a bandage, during the day, has been found to restore its sight enough for the ensuing night's watch on board ship, the unprotected eye remaining as bad as ever.—*Snow-blindness (or ice-blindness)* is essentially the same disease, with

\* Snell reports numerous cases from near Sheffield. 'Transactions of the Ophthalmological Society,' vol. i, 1881.



the addition of congestion, intense pain, photophobia, contraction of pupils, and sometimes of conjunctival ecchymoses. These peculiarities doubtless depend chiefly on powerful and prolonged stimulation of the whole retina, leading to congestion of its own vessels and those of the choroid, and subsequently of the whole eyeball; something may also be due to the effect of the reflected heat upon the conjunctiva. Snow-blindness is effectually prevented by wearing smoke-coloured glasses. Attacks, apparently identical with snow-blindness, but of shorter duration, sometimes occur in men engaged in trimming powerful electric lights. The symptoms do not come on until several hours after exposure to the light.\* (See p. 201.)

*Hemeralopia* (*day-blindness*) occurs in certain cases of congenital amblyopia.

*Micropsia*.—Patients sometimes complain that objects look too small. When not due to insufficiency of accommodative power (*excessive effort*, p. 34) it is generally a symptom of disease of the outer layers of the retina, especially in the central region, and syphilitic retinitis is the commonest cause (p. 191). Both micropsia and its opposite, megalopsia, are sometimes seen in hysterical amblyopia.

By *Muscae volitantes* are understood small dots, rings, threads, &c., which move about in the field of vision, but do not actually cross the fixation point, and never interfere with sight. They are most easily seen against the sky, or a bright back-ground such as the microscope field. They depend upon minute changes in the vitreous, which are present in nearly all eyes, though in much greater quantity in some than others. They vary, or seem to vary, greatly with the health and state of the circulation, but are of no real importance. They are most abundant and troublesome in myopic eyes.

*Diplopia*, see Chap. XXI; also pp. 22 and 153 for Unocular Diplopia.

\* 'Ophthalmic Review,' April, 1883.



For Affections of Sight in Megrin and Heart Disease, see Chap. XXII.

*Malingering.*—Patients now and then pretend defect or blindness of one or both eyes, or exaggerate an existing defect, or sometimes secretly use atropine in order to dim the sight. The imposture is generally evident enough from other circumstances, but detection is occasionally very difficult. Malingering and intentional injuries of the eye are very rare here but common in countries where the conscription is in force.

The pretended defect of sight is usually confined to one eye. If the patient be in reality using both eyes, a prism held before one (by preference “the blind” one) will produce double vision (p. 11). The stereoscope, and also coloured glasses, may be made very useful. Another test, when only moderate defect is asserted, is to try the eye with various weak glasses, and note whether the replies are consistent; very probably a flat glass or a weak concave may be said to “improve” or “magnify” very much. Again, atropine may be put into the *sound* eye, and when it has fully acted the patient be asked to read small print; if he reads easily with both eyes open the imposture is clear, for he must be reading with the so-called “blind” eye. If absolute blindness of one eye be asserted, the state of the pupil will be of much help (unless the patient have used atropine); for if its direct reflex action be good (p. 28) the retina and nerve cannot be much diseased (but as to this point compare Hysterical Amblyopia, p. 224).

Pretended defect of both eyes is more difficult to expose, and, indeed, it may be impossible to absolutely convict the patient if he is intelligent and has got up the subject. The state of the pupils, of the visual fields and of colour perception, are amongst the best tests.

*Colour-blindness* may be congenital or acquired. When acquired it is symptomatic of disease of the



optic nerve, or, as for example in hysterical amblyopia, of some affection of the visual centre.

Congenital colour-blindness is not often found unless looked for. According to recent and extended researches in various countries, a proportion varying from about 3 to 5 per cent. of the males are colour-blind in greater or less degree, and it appears to be more common in the lower than in the upper classes. These facts show the importance of carefully testing all men whose employment renders good perception of colour indispensable, such as railway signalmen and sailors. Colour-blindness is usually partial, *i.e.*, for only one colour or one pair of complementary colours, but is occasionally total. The commonest form is that in which pure green is confused with various shades of grey and of red (red-green-blindness); blindness for blue and yellow is very rare. The blindness may be incomplete, perception of very pale, or very dark, red or green, *e.g.* being enfeebled, whilst bright red and green are well recognised; or it may be complete for all shades and tints of those colours. Congenital colour-blindness is very often hereditary, but nothing further is known of its cause. It is very rare in women (0·2 per cent.). The acuteness of vision (*i.e.* perception of form) is normal. Both eyes are affected.\*

The detection of colour-blindness, either congenital or acquired, is easy, if, in making the examination, we bear in mind the two points already referred to at p. 35, viz.:—(1) Many persons with perfect colour *perception* know very little of the *names* of colours, and appear colour-blind if asked to name them; (2) The really colour-blind often do not know of their defect, having learnt to compensate for it by attention to difference of shade and texture. Thus a signalman may be colour-blind for red and green; yet he may, as a rule, correctly distinguish the green from the red light, because one appears to him “brighter”

\* But on this point further research is needed.



than the other. The quickest and best way of avoiding these sources of error has been mentioned at p. 35. A certain standard colour is given to the patient without being named, and he is asked to choose from the whole mass of skeins of wool all that appear to him of nearly the same colour and shade (no two being really quite alike). If, for example, he cannot distinguish green from red he will place the green test skein side by side with various shades of grey and red. Wilful concealment of colour-blindness is impossible under this test if a sufficient number of shades be used.

As it is necessary to detect slight as well as high degrees, the first or preliminary test should consist of very pale colours, and a pale pure green is to be taken as the test (No. 1 of the series given in the Appendix). For ascertaining whether the defect be of higher degree or not, stronger colours are then used; a bright rose colour, *e. g.* may be confused with blue, purple, green, or grey of corresponding depth (Nos. 7 to 11); and a scarlet with various shades and tints of brown and green (Nos. 12 to 17).

It may here be noted that the visual field is not of the same size for all colours (Fig. 27), green and red having the smallest fields, and that the perception of all colours is, like perception of form (p. 32), sharpest at the centre of the field. With diminished illumination some colours are less easily perceived than others, red being the first to disappear, and blue persisting longest, *i. e.* being perceived under the lowest illumination; but in dull light the colours are not confused, as in true colour-blindness. In congenital colour-blindness, as we have seen, red-green-blindness is the commonest form; and in cases of amblyopia from commencing atrophy of the optic nerve green and red are almost always the first colours to fail, blue remaining last.



## CHAPTER XVI

## DISEASES OF THE VITREOUS.

THE vitreous humour is nourished by the vessels of the ciliary body, retina, and optic disc, and is probably influenced by the state of the choroid also; and in most cases disease of the vitreous is associated with (and dependent on) disease of one or other of the structures named.

Thus, in connection with various surrounding morbid processes, the vitreous may be the seat of inflammation, acute or chronic, general or local, and of hæmorrhage. It may also degenerate, especially in old age, its cells and solid parts undergoing fatty degeneration, become visible as opacities, whilst its general bulk becomes too fluid. The only change which we can directly prove in the vitreous during life is loss of transparency from the presence of opacities moving, or more rarely fixed, in it, but according as such opacities move quickly or slowly we infer that the humour itself is, or is not, more fluid than in health.

Opacities in the vitreous may take the form of large dense masses, or of membranes like muslin, crape, "bees' wings" of wine, bands, knotted strings, or isolated dots; and they may be either recent, or the remains of long antecedent exudations or hæmorrhages. Again, the vitreous may become more uniformly misty, owing to the diffusion of numberless dots ("dust-like" opacities), which need careful focussing by direct examination, with a convex lens (about + 8 D.) behind the mirror, to be separately seen.



Opacities in the vitreous are usually detected, with great ease, by direct ophthalmoscopic examination at from 10" to 18" from the patient, but are generally situated too far forward (*i.e.* too far within the focus of the lens-system) to be seen clearly at a very short distance without a + lens behind the mirror (p. 49). If the patient moves his eye sharply and freely from side to side and up and down, the opacities will be seen against the red ground, as dark figures which continue to move after the eye has come to rest; they are thus at once distinguished from opacities in the cornea or lens, or from dimly-seen spots of pigment at the fundus, which stop when the eye stops. The opacities in the vitreous move just as solid particles and films move in a bottle after the bottle has been shaken, and the quickness and freedom of their movement in the one case, as in the other, depends very much on the consistence of the fluid. When the opacities pass across the field quickly, and make wide movements, we may be sure that the vitreous humour is too fluid; if they move very lazily, its consistence is probably normal. In some cases only one or two opacities may be present, and may only come into view now and then. Moving opacities in the vitreous obscure the fundus both to the direct and indirect ophthalmoscopic examination, in proportion to their size, density, and position; a few isolated dots scarcely affect the brightness of the ophthalmoscopic image.

The opacities may lie quite in the cortex of the vitreous, and be anchored at the fundus, so as to have but little movement. Such opacities, generally single, are found lying over or near to the disc, and may be the result either of inflammation or of hæmorrhage; they are often membranous, more rarely globular, and not perfectly opaque. Such an opacity should be suspected when, by indirect ophthalmoscopic examination, a localised haze or



blurring of some part of the disc or its neighbourhood is noticed. The observer must then search for it by the direct method, the patient's eye being at rest; by altering his distance from the patient, or by turning on various convex lenses (or concave, if the eye be very highly myopic), the opacity will come sharply into view. The refraction of the patient's eye must be approximately known in order to make this examination properly (p. 49). Densely opaque white membranes may also form over the disc or upon the retina, the nature and situation of which are diagnosed in the same way.

Diffused haziness of the vitreous causes a corresponding degree of dimness of outline and darkening of the details, of the fundus, as if these were seen through a thin smoke. The disc, in particular, appears red, without really being so. Much the same appearances are caused by diffused haze of the cornea or lens, but the presence of these changes will, of course, have been excluded by focal illumination. There are even cases of vitreous disease where no details can be seen, even by careful examination, though plenty of light reaches and returns from the fundus. In these the light is scattered by innumerable little particles, each of which is transparent, so that the light, without being absorbed, is distorted and broken up, as in passing through ground glass, or white fog, or a partial mixture of fluids of different densities, such as glycerin and water. This fine general haze is found chiefly in syphilitic choroido-retinitis, in which infiltration of the vitreous with cells is known to occur. It is not always easy, nor indeed possible, to distinguish with certainty between diffuse haze of the vitreous and diffuse haze of the retina (p. 184).

Crystals of cholesterin sometimes form in a fluid vitreous, and are seen with bright illumination as minute, dancing, golden spangles, when the eye moves about (*sparkling synchysis*). They proportionately



obscure the fundus. Large opacities just behind the lens may be seen by focal light in their natural colours. In rare cases of choroido-retinitis, minute growths, consisting chiefly of blood-vessels, form on the retina, and project into the vitreous; they are rather curiosities, than of practical importance.

*Parasites* (*cysticercus cellulosæ*) occasionally come to rest in the eye, and in development penetrate into the vitreous; they are rarely seen in England, but are commoner on the Continent. Very rarely a foreign body may be visible in the vitreous.

The following are the conditions in which disease of the vitreous is most commonly found:—

(1.) Myopia of high degree and old standing; the opacities move very freely, showing fluidity of the humour, and are sharply defined. They are often the result of former hæmorrhage.

(2.) After severe blows, causing hæmorrhage from the vessels of the choroid, or ciliary body. When recent, and situated near the back of the lens, the blood can often be seen by focal light; if very abundant, it so darkens the interior of the eye that nothing whatever can be seen with the mirror.

(3.) After perforating wounds. The opacity will be blood if the case be quite recent. Lymph or pus in the vitreous gives a yellow or greenish-yellow colour, easily seen by focal light, or even by daylight (p. 131), and usually most dense towards the position of the wound.

(4.) In rare cases large hæmorrhages into the vitreous occur spontaneously in healthy eyes, with hæmorrhages into the retina (not to be confused with retinitis hæmorrhagica, p. 195). Relapses often occur, and detachment of retina may come on. The subjects are generally young adult males liable to epistaxis, constipation, and irregularity of circulation (Eales); gout may have some influence (Hutchinson). There may be a relation between these and certain cases of choroidal disease (referred to at p. 179).



In all of the above cases detachment of the retina is likely to occur sooner or later, and if present, the difficulty of diagnosis between the two conditions may be considerable (p. 190).

(5.) Syphilitic choroiditis and retinitis. There is often diffuse haze, in addition to large, slowly floating opacities. The change here is due to inflammation, and the opacities may entirely disappear under treatment (pp. 175, 184, 191).

(6.) Some cases of cyclitis and cyclo-iritis (p. 129). The opacities are inflammatory.

(7.) In the early stage of sympathetic ophthalmitis. The opacities are inflammatory.

(8.) In various cases of old disease of choroid, usually in old persons, and without proof of syphilis. No doubt many of these indicate former choroidal hæmorrhages.

(9.) The vitreous is believed to become repeatedly and quickly hazy in the active stages of glaucoma. The point is difficult to settle clinically, because the cornea and aqueous are nearly always, and the lens often, hazy at the same time, and the opportunity of examining specimens of uncomplicated recent glaucoma scarcely ever occurs.



## CHATER XVII

## GLAUCOMA.

IN this peculiar and very serious disease, the characteristic objective symptom is increased tightness of the eye-capsule (sclerotic and cornea), "increased tension;" all the other phenomena peculiar to the disease depend upon this condition. The disease is much commoner after middle life, when the sclerotic becomes less distensible, than before; and it is commoner in hypermetropic eyes, where the sclerotic is too thick, than in myopic eyes, where it is thinned by elongation of the globe.

Glaucoma may be primary, coming on in an eye apparently healthy, or the subject of some disease, such as senile cataract, which has no influence on the glaucoma; or it may be secondary, caused by some still active disease of the eye, or by conditions left after some previous disease, such as iritis. It is always important, and seldom difficult, to distinguish between primary and secondary glaucoma.

Glaucoma differs in severity and rate of progress from the most acute to the most chronic and insidious form. But in all its varieties glaucoma is a progressive disease, and unless checked by treatment goes on to permanent blindness. It generally attacks both eyes, though not simultaneously, the interval varying from a few days to several years.

It is customary to speak of glaucoma as either acute, subacute, or chronic, and this arbitrary division is useful in practice. But many intermediate forms are found, and the same eye may, at different stages in its history, pass through each of



the three conditions. We may, indeed, here observe that acute and subacute outbursts are generally preceded by a so-called "premonitory" stage, in which the symptoms are not only chronic and mild, but remittent; the intervals of remission becoming shorter and shorter, till at length the attacks become continuous, and the glaucomatous state is fully established. Rapid increase of presbyopia (Chap. XX), shown by the need for a frequent change of spectacles, is a common premonitory sign, though often overlooked.

*Chronic glaucoma* sets in with a cloudiness of sight, or "fog," which is liable to variations, and often quite clears off for days, or even weeks ("premonitory stage"). But in some cases, according to the patient, the failure progresses without remissions from first to last. During the attacks of "fog" artificial lights are seen surrounded by coloured rings ("rainbows" or "halos"), which are to be distinguished from those due to mucus on the cornea. The attacks of fog are often noticed only after long use of the eyes, as in the evening or when exhausted, the sight being better in the early part of the day and after food. The disease has to be distinguished from incipient nuclear cataract, disease of the optic nerve, syphilitic retinitis, and attacks of megrim. Even when the sight has become permanently cloudy, complete recovery no longer occurring between the attacks, variations of sight still form a marked feature. There is no congestion, and often no pain.

If we see the patient during one of the brief early fits of cloudy sight, or after the fog has settled down permanently, the following changes will be found. A greater or less defect of sight in one eye, or if in both, more in one than the other, and not remedied by glasses; the pupil a little larger and less active than normal; the anterior chamber may be shallow, and there is usually slight dulness of the eye from steaminess of cornea, or haze of the aqueous humour, and



some engorgement of the large perforating vessels at a little distance from the cornea (Figs. 21 and 23); the tension will be increased (usually about + 1, p. 19) and the field of vision may be contracted, especially on the nasal side.—The optic disc will be found normal, pale, or sometimes congested, in early cases; pale and cupped (p. 241) at a later stage. The cupping usually occupies the whole surface, but sometimes takes the form of a central depression, indistinguishable from a large steep-sided physiological cup (p. 54). There may be spontaneous pulsation of all the vessels on the disc; or the arteries, if not pulsating spontaneously, will do so on *very slight* pressure on the eyeball (p. 48).—If the case be of old standing the tension will often be much increased, the pupil dilated and sluggish, though not motionless, the lens hazy, the field of vision much contracted (Fig. 88), acuteness of vision extremely defective, the cornea sometimes clear, in other cases dull. In nearly all cases of glaucoma the temporal part of the field (nasal part of the retina) retains its function longest; and in advanced cases the patient will often show this by his manner or statements.

An eye in which the above symptoms have set in may progress to total blindness in the course of months or several years without a single “inflammatory” symptom, without either pain or redness—*chronic painless glaucoma (glaucoma simplex)*; and since the lens often becomes partially opaque, and of a greyish or greenish hue, cases of chronic glaucoma are sometimes mistaken for senile cataract.

But more commonly, in the course of a chronic case, periods of pain and congestion occur, with more rapid failure of sight; or the disease sets in with “inflammatory” symptoms at once. In these cases of *subacute glaucoma*, besides the symptoms named above, we find dusky reticulated congestion of the small and large episcleral vessels in the ciliary region (Fig. 25), with pain referred to the eye, the side of



the head, or nose, and rapid failure of sight. The increase of tension, steaminess and partial anæsthesia of the cornea, enlarged and sluggish pupil, and shal-

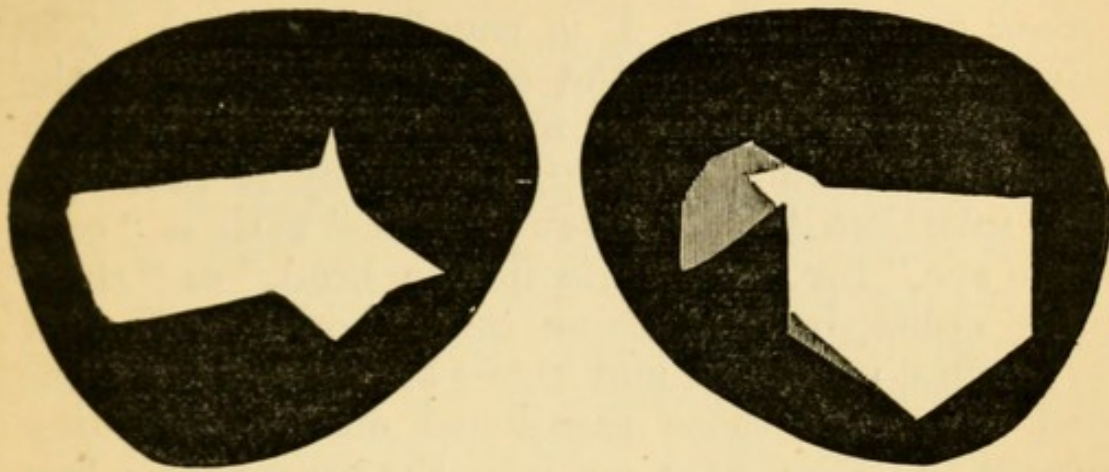


FIG. 88.—Irregular contraction of R. and L. fields of vision in chronic glaucoma; from two different cases. The black parts show complete loss; the shaded area shows partial loss. Each field remains best in the outer part. (Compare with Figs. 84 and 85.)

lowness of the anterior chamber, are all more marked than is usual in chronic cases, and the media are too hazy to allow a good ophthalmoscopic examination.

These symptoms, ending after a few weeks or months in complete blindness, may remain at about the same height for months afterwards with slight variations, the eye gradually settling down into a permanent state of severe, but chronic, non-inflammatory glaucomatous tension. In other cases a subacute attack passes off only to return in greater severity a few weeks or days later (*remittent glaucoma*).

*Acute glaucoma* differs from the other forms only in suddenness of onset, rapidity of loss of sight, and severity of congestion and pain. The congestion, both arterial and venous, is intense; in extreme cases the lids and conjunctiva are swollen, and there is photophobia, so that the case may be mistaken for an acute ophthalmia. All the specific signs of glaucoma are intensified; the pupil considerably dilated and motionless to light, the cornea very



steamy, the anterior chamber very shallow, and tension + 2 or 3. Sight will fall in a day or two down to the power of only counting fingers, or to mere perception of light, and if the case have lasted a week or two even p. l. is usually abolished. The pain is very severe in the eye, temple, back of the head and down the nose; not unfrequently it is so bad as to cause vomiting, and many a case has been mistaken for a "bilious attack" with a "cold in the eye," for "neuralgia in the head," or "rheumatic ophthalmia." Some cases, however, though very acute, are mild and remit spontaneously; but such cases, like those mentioned on the preceding paragraph, often pass on into the severe type just described.

*Absolute glaucoma* is glaucoma which has led to permanent blindness. Such an eye continues to display the tension and other signs of the disease, and remains liable to attacks of pain and congestion for varying periods, but in many "absolute" cases, especially those which follow acute forms of glaucoma, changes occur sooner or later, leading to staphylomata, cataract, atrophy of iris, and finally to softening and shrinking of the globe. The term "*glaucoma fulminans*" denotes extremely severe acute glaucoma, abolishing sight in a few hours.

As a rule glaucoma runs the same course in the second eye as in the first, but sometimes it will be chronic in one and acute or subacute in other.

*Explanation of the symptoms.*—The causes which produce the temporary attacks or "premonitory symptoms" lead, if continued, to atrophy of the inner layers of the retina (p. 188) and of the disc, and to consequent blindness. The increase of tension damages the retina both by direct compression and by impeding its circulation, the latter being probably the more important factor in the early stages. If the media are clear enough to allow a good view the retinal arteries are seen to be narrowed, and often to pul-



sate spontaneously, and the veins are engorged. The periphery of the retina suffers soonest and most from this lowering of arterial blood supply, and hence probably the contraction of the visual field. But the inner layers (compare p. 188) of the retina, over its whole extent suffer if the pressure be kept up (1) from this same insufficiency of arterial blood, and the changes, including hæmorrhage, which follow impeded venous outflow; (2) from stretching and atrophy of the nerve-fibres on the disc. The floor of the disc (*lamina cribrosa*), being the weakest part of the eye-capsule, is slowly pressed backwards, the nerve-fibres being dragged upon, displaced, and finally atrophied; the direct pressure on the nerve-fibres, as they bend over the edge of the disc, helps in the same process. Hence finally the disc becomes not only atrophied, but hollowed out (Fig. 89) into the well known "glaucomatous

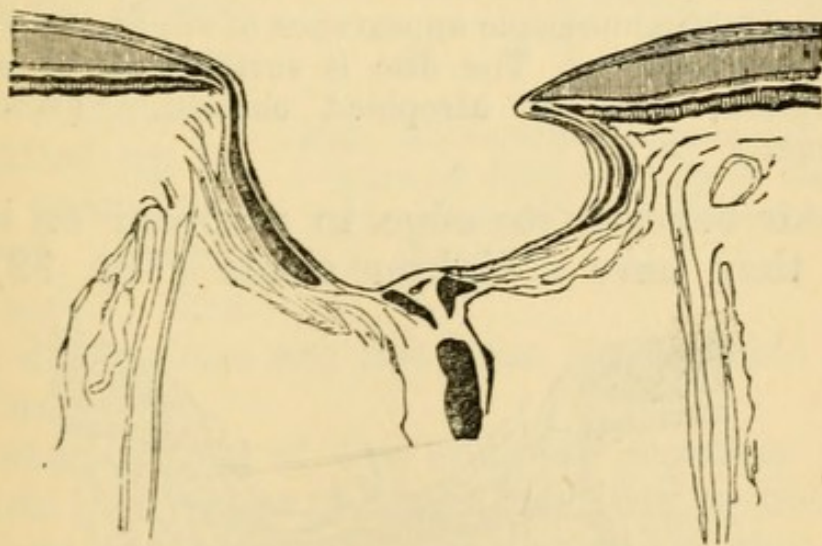


FIG. 89.—Section of very deep glaucoma cup. (Compare Fig. 35.)

cup." This cup, when deep, has an overhanging edge, because the border of the disc is smaller at the level of the choroid than at the level of the *lamina cribrosa*; its sides are quite steep even when the cup is shallow (Fig. 91).

With the ophthalmoscope this cupping is shown by a sudden bending of the vessels just within the



border of the disc, where they look darker because foreshortened (Fig. 90); if the cup be deep they may

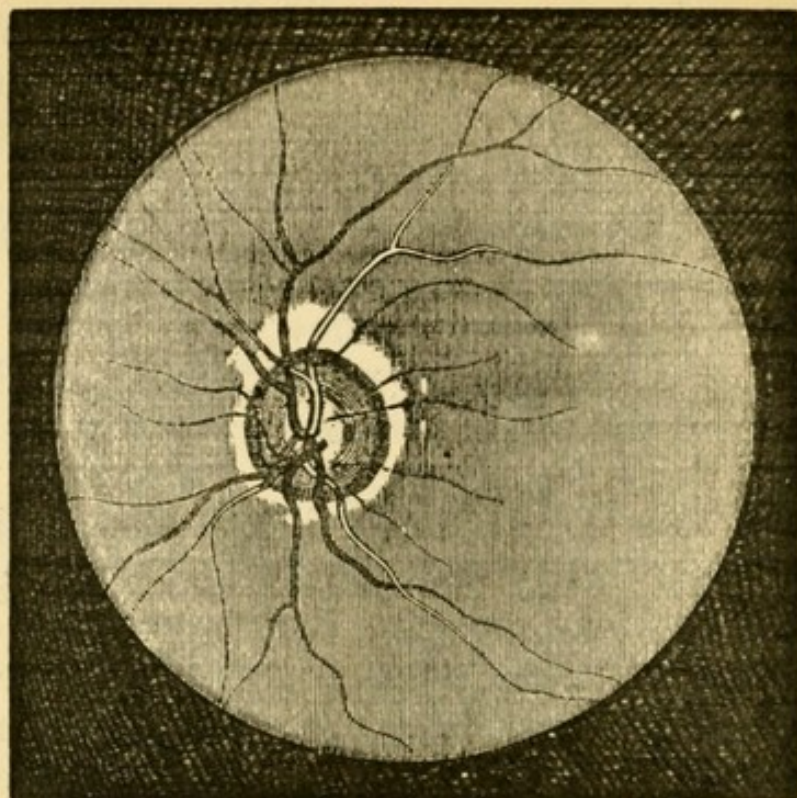


FIG. 90.—Ophthalmoscopic appearance of slight cupping of the disc in glaucoma. The disc is surrounded by a narrow, irregular, zone of atrophied choroid. (Wecker and Jaeger.)  $\times 7$ .

disappear beneath its edge to reappear on its floor, where they have a lighter shade (Fig. 92). The

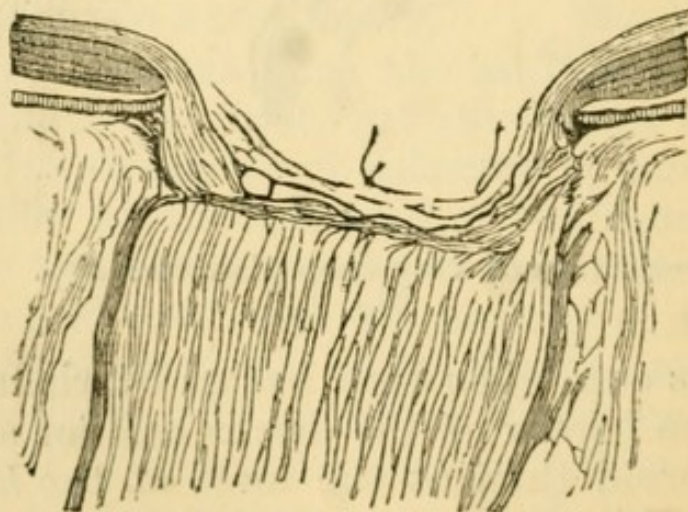


FIG. 91.—Section of less advanced glaucoma cup.

vessels seldom all bend with equal abruptness, some parts of the disc being more deeply hollowed than



others, or some of the vessels spanning over the interval instead of hugging the wall of the cup. Increase of tension must be maintained for several months to produce cupping recognisable by the ophthalmoscope. When recent acute glaucoma has been cured by operation, the disc, though not cupped often becomes very pale. — Although usually the excavation extends from the first over the whole surface of the disc, it appears sometimes to begin at the thinnest part (the physiological pit), and spread centrifugally thence towards the border (p. 238). A deep cup is sometimes partly filled up by fibrous tissue, the result of chronic inflammation, and its true dimensions are not then appreciable by the ophthalmoscope.

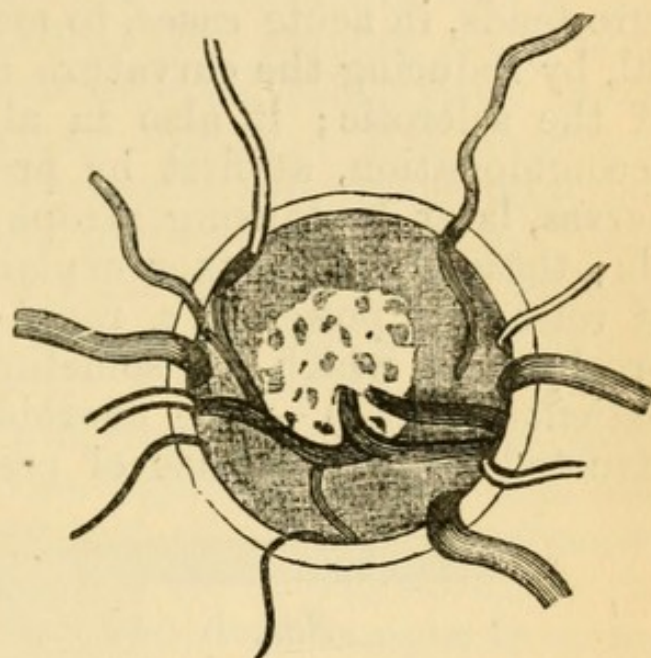


FIG. 92. — Ophthalmoscopic appearance of deep cupping of the disc in glaucoma (altered from Liebreich).  
× about 15.

The shallowness of the anterior chamber is probably due to advance of the lens; it is by no means a constant symptom. Compression of the ciliary nerves accounts, in early cases, for the dilated and sluggish pupil, and for the corneal anæsthesia. In old-standing cases the iris is often atrophied and shrunk to a narrow rim; in uncomplicated glaucoma iritic adhesions are never seen. The corneal changes depend partly on "steaminess" of the epithelium, partly upon haze of the corneal tissue from œdema (Fuchs). In recent cases, especially if acute, the aqueous humour and the lens appear to become



somewhat turbid. In old cases, as already stated, the lens often becomes slowly cataractous. It is generally stated that the vitreous humour becomes hazy during the attacks, especially in severe cases, but since it is just in these cases that the cornea and aqueous are most dull, the statements about the vitreous are conjectural (p. 235). The internal pressure tends, in acute cases, to make the globe spherical, by reducing the curvature of the cornea to that of the sclerotic; it also in all cases weakens the accommodation, at first by pressing on the ciliary nerves, later by causing atrophy of the ciliary muscle; these facts together explain the rapid decrease of refractive power (*i. e.* rapid onset or increase of presbyopia) which is sometimes noticed by the patient (p. 237).—The choroidal circulation is obstructed by the increase of pressure, and in severe

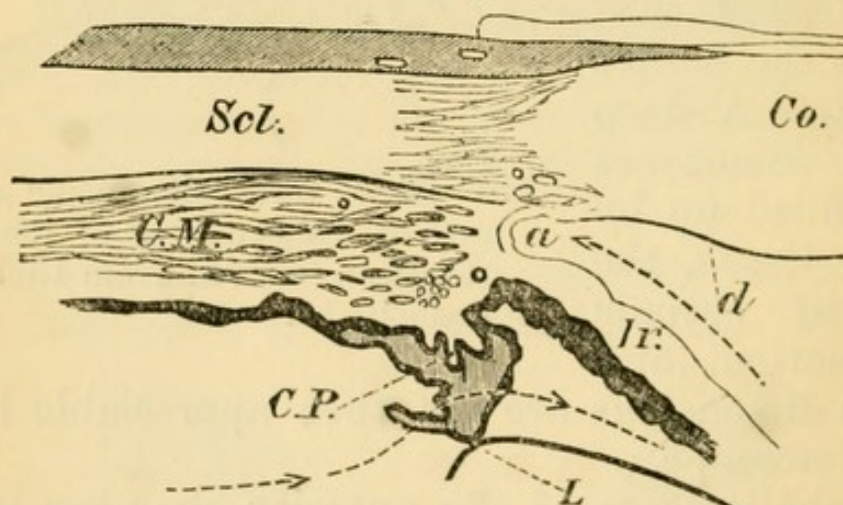


FIG. 93.—Section through the ciliary region in a healthy human eye. *Co.*, cornea; *Scl.*, sclerotic; *C.M.*, ciliary muscle; *C.P.*, two ciliary processes, one larger than the other; *Ir.*, iris; *L*, the marginal part of the crystalline lens; *a*, angle of anterior chamber; *d*, membrane of Descemet, which ceases (as such) before reaching the angle *a*. The dotted line shows the course probably taken by fluid from the anterior part of the vitreous into the posterior aqueous chamber, where it is augmented by aqueous humour secreted by the anterior part of the ciliary process, thence through the pupil (not shown) into the anterior aqueous chamber, to the angle *a*. Suspensory ligament of lens not shown.  $\times 10$ .



glaucoma, especially of old standing, the *anterior ciliary veins* (forming the episcleral plexus) (Figs. 21 and 25), as well as the arteries (Fig. 23), become very much enlarged.

*Mechanism of glaucoma.*—The increased tension is due to excess of fluid in the eye-ball. Impeded escape is probably the chief cause of this excess, and recent research has proved that changes are present in nearly all glaucomatous eyes, which must lessen, or prevent, the normal outflow. But increased secretion, and internal vascular congestion, undoubtedly play an important part in certain cases. Both conditions would have most effect when the sclerotic was most unyielding, *i. e.* in old age, and in hypermetropic eyes (p. 236). Normally there is a constant movement of fluid from the vitreous humour through the suspensory ligament of the lens, and also from the anterior part of the ciliary processes into the anterior chamber in the course shown by the dotted line in Fig. 93. The fluid escapes from the anterior chamber into the lymphatics, and perhaps into the veins, of the sclerotic, through the meshes of the *ligamentum pectinatum* (*Fontana's spaces*), which close the angle *a*; and it has been proved that very little fluid can pass through any other part of the cornea. In glaucoma the angle *a* is nearly always closed, in recent cases by contact, in old cases by permanent cohesion, between the periphery of the iris and the cornea (Figs. 94 and 95). No complete explanation of this advance of the iris has yet been given. Dr Adolf Weber holds that the ciliary processes becoming swollen from various causes, push the iris forwards and so start the glaucomatous state. Priestly Smith believes the primary obstruction to depend upon narrowing, or even obliteration, of the circular chink ("circumlental space") between the edge of the lens and the tips of the ciliary processes, and that this proceeds mainly from a progressive increase in the size of the lens which occurs



in old age ;\* obstruction of this space leads to rise of pressure in the vitreous, followed by advance of the lens

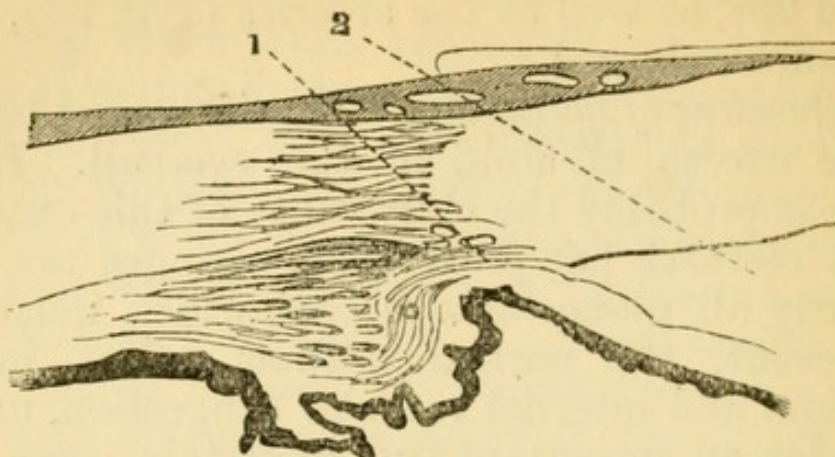


FIG. 94.—Ciliary region from a case of acute glaucoma of one month's duration. (1 and 2, situations of iridectomy wounds in two cases.)  $\times 10$ .

and ciliary processes, pressure on the iris, and closure of the angle ; swelling of the ciliary processes would be a contributory cause. Brailey holds that a chronic

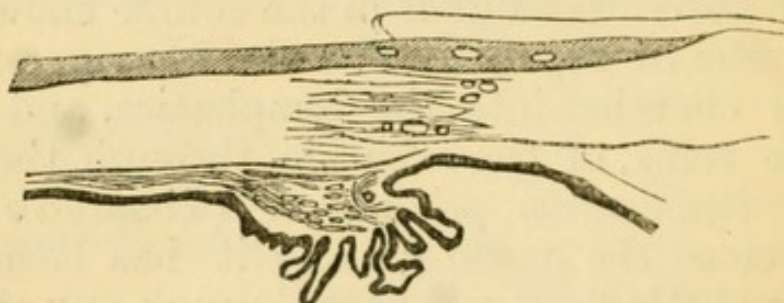


FIG. 95.—Ciliary region in chronic glaucoma of three years' standing.  $\times 10$ .

inflammation of the ciliary muscle and processes, and of the iris, quickly passing on to atrophic shrinking, leads to narrowing of the angle and initial rise of tension ;† in a later paper, however, he agrees to some extent with the view of Weber, above referred to.‡ (For other causes see Secondary Glaucoma, p. 253.)

An over-supply of fluid affects the tension differ-

\* Priestly Smith 'On Glaucoma,' 1879; 'Oph. Hosp. Reports,' x, 25, 1880; Int. Med. Congress, 1881. This growth of the lens has now been established beyond doubt by Smith's further researches; 'Trans. Ophth. Soc.,' vol. iii, 1883.

† Brailey, 'Ophth. Hosp. Reports,' x, pp. 14, 89, 93 (1880).

‡ Brailey, *ibid.*, p. 282 (1881).



ently in different cases. Congestion and ordinary inflammations of the retina and uveal tract do not cause glaucoma, and dilatation of the arteries by vaso-motor paralysis is said to be accompanied by diminished tension. But tumours in, and even upon, the eye often give rise to secondary glaucoma, and probably one important factor in these cases is the active congestion and transudation which occur near to quickly growing tumours; certainly the glaucoma stands in no constant relation either to the size or position of the tumour. A relation is observed in some cases between glaucoma and neuralgia of the fifth nerve; and T. is said to be lowered in paralysis of this nerve. Probably the pain acts by causing associated congestion, and thus setting up glaucoma in a predisposed eye.

*General and diathetic causes.*—In an eye predisposed, by the changes above mentioned at the rim of the anterior chamber, any cause of congestion may precipitate an acute attack. Vascular engorgement of the eyes in connection with digestive disturbances, gout, or neuralgia, or the same result brought on by the over-use of presbyopic eyes without suitable glasses, or a blow, or prolonged ophthalmoscopic examination, may all bring it about. Atropine has sometimes caused an attack, probably because, by lessening the width, it increases the thickness, of the iris, and so crowds it into the angle of the anterior chamber. Iridectomy on one eye occasionally sets up acute glaucoma in the other, probably by causing general excitement and disturbance. Glaucoma is much commoner after than before the age of forty;\* the rare cases seen in young adults and children are generally chronic and associated with other changes in the eyes, particularly myopia. Acute cases are often dated from a period of over-work of the eyes, or want of sleep, as from sitting up nursing, &c. There is not unfrequently a history of gout. Patients

\* Of 130 cases nearly four fifths occurred after 40.



who have had glaucoma in one eye should be emphatically warned as to the danger of over-using the eyes, or of working without proper glasses, and against dietetic errors. Glaucoma as a whole is rather commoner in men than women, but of acute cases a large majority are in women, whilst the greater number of the chronic and subacute cases occur in men.\*

*Treatment.*—Iridectomy or an equivalent operation, is, with very few exceptions, the only curative treatment. Eserine (the alkaloid of Calabar bean) used locally, however, diminishes the tension in acute glaucoma, and some few attacks have been permanently cured by its means alone. But although seldom really curative, eserine is of great temporary value in cases where an operation has to be deferred. It has little or no effect on the tension unless it cause marked contraction of the pupil. Eserine acts (1) by stretching the iris and drawing it away from the angle of the anterior chamber; (2) by the contraction of the ciliary muscle which it causes the meshes of the tissue bounding this angle are more widely opened. Eserine causes congestion of the ciliary processes, and probably this explains why, if it do not soon relieve glaucoma, it sometimes aggravates all the symptoms. It is of use chiefly in recent, and especially in acute, cases; a solution of half a grain or a grain of the sulphate in the ounce is to be used once, twice, or oftener, in the day. If in a few hours it increase the pain and do not lessen the T. it should be abandoned. The pain in acute cases may be much relieved by leeching, warmth to the eye, derivative treatment such as purgation and hot-foot baths, and soporifics.

\* In 130 consecutive cases of primary glaucoma I find 54% M., 46% F.; of the males alone 25% were acute, and 75% chronic of the females alone 48% were acute, and 52% chronic.

Some numbers quoted from Schmidt and Laqueur in Graefe and Saemisch's 'Handbuch,' v, I, 65, give the following. Of 123 cases, 53% M., 47% F.; of males 10% acute, 90% chronic or subacute; of the females 30% acute, 70% chronic and subacute.



Iridectomy cures glaucoma by permanently reducing the tension to the normal or nearly normal degree. It is found, that to ensure success: (1) the path of the incision must lie in the sclerotic from 1 to 2 mm. from the apparent corneal border (Fig. 94); (2) the wound should be large, allowing removal of about a fifth of the iris; (3) the iris should be removed quite up to its ciliary attachment; this is best done by first cutting one end of the loop of protruding iris, then tearing it from its ciliary attachment along the whole extent of the wound, and cutting through the other end separately. (*See Operations.*) Evacuation of the aqueous humour by paracentesis of the anterior chamber gives only temporary relief.

A mere wound in the sclerotic, differing but little in position and extent from that made for iridectomy, is sufficient to relieve + T., and to cure many cases of glaucoma permanently, and this operation (*subconjunctival sclerotomy*) has been largely adopted by some operators within the last few years. Iridectomy, however, will probably remain the better operation for most cases, partly at least because it is easier to perform well. Sclerotomy is open to objection: (1) because the position and length of the wound are not perfectly under control; if too far forward and too short the incision is insufficient, if too far back and too long there is risk of wounding the ciliary processes and getting hæmorrhage into the vitreous; even shrinking of the operated eye and sympathetic inflammation of the other have occurred; (2) because the iris may prolapse into the wound, and need removal, and the operation then becomes an iridectomy; (3) when the anterior chamber is very shallow sclerotomy cannot be supposed to aid the exit of fluid so much as the removal of a piece of the iris.

Several other operations, the principle of which is to make a puncture at the sclero-corneal junction,



have been tried, but have not gained general confidence.

Whichever operation be employed in glaucoma the formation of the operation scar in the sclerotic is certainly a most important factor.

Iridectomy in acute glaucoma no doubt acts, at first, by removing a portion of the iris from the blocked angle (Fig. 94), and thus allowing the normal escape of fluid. It is held by some high authorities, however, that its permanent effect is due to the formation, at the seat of the wound, of a layer of tissue more pervious to the eye-fluids than the sclerotic ("filtration-scar"). The fact that an iridectomy for glaucoma which heals rather slowly, is thought by many to be more favorable than one which heals immediately, *i. e.* with no new tissue, and that a slight bulging of the scar is believed by some surgeons to be rather a good thing than otherwise, are probably expressions of the real value of the new tissue formed during somewhat slow healing. The curative effect of sclerotomy points in the same direction. Such a porous scar never forms if the incision be in the cornea.

An operation, usually iridectomy, is to be done in all cases of acute and subacute glaucoma, whether there be great pain or not, so long as some sight still remains, and even if all p. l. be lost, provided that the blindness be of only a few days' duration. Even if the eye be permanently quite blind, iridectomy or sclerotomy is sometimes preferable to excision of the globe, for the relief of pain (pp. 252 and 260).

In very chronic glaucoma, when well developed, the rule is less clear, for it is well known that the effect of operation in such cases is far less constant, especially if the visual field be already much contracted. As no other treatment is of use, and operative treatment is certainly often beneficial, it should, as a rule, be adopted, the patient's judgment being allowed a fair weight in the decision. The same



difficulty occurs in some of the so-called "premonitory attacks," which are in truth transient attacks of slight glaucoma. When once it is clear that such attacks of temporary mistiness and rainbows are glaucomatous, and that they are getting more frequent, the operation should seldom be deferred; but if the patient can be seen at short intervals eserine should have a fair trial before operation is resorted to. It is to be remembered that iridectomy done when sight is still nearly perfect may, by allowing light to pass through the margin of the lens, cause an increase of the defect (p. 14); and this, though not of necessity a contra-indication, must be carefully taken into account.\* The patient's prospect of life must also be allowed for in chronic glaucoma; if he be old and feeble, life may end before the disease has in its natural course caused blindness.

*The prognosis* after operation is, in general terms, better in proportion as the disease is acute and recent. If operated on within a few days of the onset of acute symptoms, provided that there be at least good p. l. at the time of operation, sight is often restored to the state in which it was at the onset, i.e. if the disease be recent, nearly perfect sight will be restored. Even in cases combining the maximum of acuteness and severity (*glaucoma fulminans*), in which for a day or two all p. l. has been abolished, the operation may be successful. But the prognosis is not always so favourable in acute glaucoma, especially if the patient's health be much broken down. If an acute attack occur in a chronic case sight will be improved more or less; if the case be entirely chronic we can only hope, as a rule, to prevent it from getting worse.

The full effect of the operation is not seen for

\* I now usually perform sclerotomy in chronic glaucoma if the anterior chamber be of fair depth, the pupil act well to eserine, and acuteness of vision be good. In acute glaucoma I always prefer iridectomy.



several weeks, though a marked immediate effect is produced in acute cases. In cases of long standing T. may remain permanently rather + after operation, without bad effect, provided it be very much less than before the operation; the eye tissues can in some degree adapt themselves to increased pressure.

A second iridectomy in the opposite direction, or a sclerotomy, should be done if the T., having been reduced to normal, or very slightly +, after the first operation, rises definitely, and is accompanied by a return of other symptoms; but several weeks should generally elapse, for slight waves of glaucomatous tension may occur before the eye has fully recovered from the first operation, and these may generally be relieved by other means. Cases which relapse definitely, or which steadily get worse after the first operation, are always very grave, and the second operation must not be confidently expected to succeed. If after iridectomy in acute glaucoma the symptoms are not relieved even for a time, or become worse, some complication is to be suspected, such as hæmorrhage from the retina or choroid, or a tumour. (*See Secondary Glaucoma.*)

*Other treatment.*—If we are obliged to delay the operation, the other means mentioned at p. 248 should be prescribed, including eserine. The diet should as a rule be liberal, unless the patient be plethoric. It is very important to insure sound sleep and mental calm. After the operation, until the eye has become quiet, all causes likely to induce congestion must be carefully avoided, such as use of the eyes, stooping, or straining, and prolonged ophthalmoscopic examination. Atropine must never be used. We should be on the alert for the earliest symptoms in the second eye after operation on the first (p. 247), and the use of eserine may be advisable as a prophylactic.

In a few cases of very chronic or subacute character, with great increase of T., iridectomy seems to aggra-



vate the disease, being followed, not even by temporary benefit but, by persistence of + T., increased irritability, and still further deterioration of sight ("*glaucoma malignum*"). It is believed that the tilting forward of the lens, which sometimes follows iridectomy, may help to account for these symptoms.

Glaucoma may occur independently in cataractous eyes; and in eyes from which the lens has been extracted, with or without iridectomy.

*Secondary glaucoma* may be acute or chronic, according as it is a consequence of active disease or of sequelæ. It may be caused by circular iritic synechia with bulging of the iris (p. 119). Various forms of chronic irido-keratitis and irido-cyclitis (p. 125), especially the sympathetic form (p. 134), are liable to be accompanied by it; in the former it is due to choking of the spaces of Fontana by inflammatory products, and perhaps to excessive secretion from the ciliary processes; in the sympathetic disease, to total posterior synechia. It may follow perforation of the cornea with large anterior synechia. The eye often becomes temporarily glaucomatous in the course of traumatic cataract from the pressure of the swollen lens on the iris and ciliary processes, especially in patients past middle life (p. 157). In none of these cases is there much danger of mistaking secondary for idiopathic glaucoma.

But secondary glaucoma may result from various deeper changes. When the lens is dislocated (p. 165), either behind or in front of the iris, it often sets up glaucoma, and sometimes of a very severe type, apparently by pressing on the ciliary processes or iris. There is generally the history of a blow; and in posterior dislocation, even if the edge of the displaced lens cannot be seen, the iris is usually tremulous and its surface concave or flat at one part, whilst bulging or prominent at another. If we are sure that a lens dislocated into the vitreous is causing the symptoms, it should be extracted with a scoop (*see Operations*); and



if lying in the anterior chamber should also usually be removed. If the eye become glaucomatous immediately after a severe blow (p. 139) the condition of the lens may not be ascertainable, and then an iridectomy must be done and the eye be watched; vitreous is very likely to escape at the operation if there be dislocation of the lens, for the latter condition implies rupture of the suspensory ligament.—Hæmorrhage into an eye whose retina is detached (*e.g.* in high degrees of myopia) may give rise to acute glaucoma with severe pain.—A glaucomatous attack generally occurs during the growth of an intraocular tumour (p. 260). It is often impossible to distinguish such a case from one of idiopathic glaucoma of the same severity and standing; for, even if the lens be not opaque, and it often is so, the other media will probably be too hazy to allow an ophthalmoscopic examination, and the growth is usually dark in colour. In almost every case, however, the glaucoma will be “absolute”, and will be known to have been so for weeks or months, and there will also be the negative fact that the fellow-eye shows no signs of glaucoma. If a glaucomatous eye, which has been absolutely blind for several months, remains painful and congested, and its media too opaque for ophthalmoscopic examination, it should always be excised as likely to contain a tumour. Tumours in the eyes of children may cause secondary glaucoma, but there is seldom any difficulty in making the diagnosis; the patient is far below the age for primary glaucoma, and the growth is usually conspicuous, from its whitish colour.—Secondary glaucoma now and then supervenes in cases of albuminuric retinitis, and of embolism or thrombosis of the retinal vessels, and perhaps in cases of retinal hæmorrhage from other causes (“*hæmorrhagic glaucoma*”). In the last-named cases the diagnosis can sometimes be completed only after an unsuccessful operation has shown that the case is not a simple one.



## CHAPTER XVIII

## TUMOURS AND NEW GROWTHS OF THE EYEBALL.

A. *Tumours and Growths of the Conjunctiva and Front of the Eyeball.*

*Cauliflower warts*, like those on the glans penis, are sometimes seen on the ocular and palpebral conjunctiva. They have narrow pedicles, and are flattened like a cock's comb. They should be snipped off, but fresh ones are apt to spring up.

*Lupus of the conjunctiva* is generally accompanied by lupus of the skin, and sometimes of the oral mucous membrane. The conjunctiva is thickened, irregularly tubercular, and very vascular. The disease very seldom attacks the ocular conjunctiva, and is usually confined to a part of one eyelid. It is much benefited by the usual local treatment for lupus.

The eyelid, and especially the tarsus, is now and then the seat of diffused gummatous inflammation in the tertiary stage of syphilis. The infiltration gives rise to a hard, indolent swelling of the whole lid (*syphilitic tarsitis*).—Chancres and tertiary syphilitic ulcers may occur on the lids (p. 66).

*Pinguecula* is a small yellowish spot, looking like adipose tissue, in the conjunctiva, close to the inner or outer edge of the cornea. It consists of thickened conjunctiva and subconjunctival tissue, and contains no fat. It is commonest in old people, and in those whose eyes are much exposed to local irritants. It is of no consequence, though advice is often asked about it.

*Pterygium* is a triangular patch of thickened ocular conjunctiva, the apex of which encroaches upon the



cornea ; it is almost always seated on the exposed part of the eye. It varies much in thickness and vascularity, and is sometimes stationary, in other cases progressive. It is to be distinguished from opacity of the cornea, and from the cicatricial band (symblepharon) which often forms between lid and globe after burns or wounds of the conjunctiva. It is rarely seen except in those who have spent some years in hot countries. The best treatment is, after dissecting up the growth to double it inwards upon itself, drawing its apex into the chink between sclerotic and conjunctiva by means of a deep suture, which is brought out again near the caruncle ; or to transplant the growth into a cleft in the conjunctiva below the cornea ; excision or ligature are less effectual. Adhesion of swollen conjunctiva to a marginal ulcer of cornea is the starting-point of pterygium ; the reason of its subsequent progress is obscure.

*Small thin cysts*, with clear watery contents, sometimes elongated and beaded, are not uncommon in the ocular conjunctiva near to one of the canthi. They are formed by distension of valved lymphatic trunks.

*Dermoid tumours (solid)* of the eyeball are much scarcer than the cystic dermoids of the eyebrow (p. 270). They are whitish, smooth, hemispherical and firm. They generally lie in the palpebral fissure and are either wholly conjunctival and moveable, or partly corneal and fixed. They are solid, and hairs may grow from their surface. They may be combined with other congenital anomalies of the eye or lids. The corneal portion of such a tumour cannot always be perfectly removed.

The swelling in some cases of *episcleritis* may be mistaken for a tumour. (See p. 126).

A congenital *fibro-fatty growth* sometimes occurs in the form of a yellowish, lobulated, tongue-like protrusion between the lid and the globe, and usually at the outer and upper side of the orbit.



*Cystic tumours* may be met with beneath the palpebral conjunctiva. The very rare form known as *Dacryops* is a bluish tumour caused by occlusion and distension of a duct of the lacrimal gland ; but other cystic conjunctival tumours are met with which cannot be so explained (p. 269). Fibrous, and even bony tumours are occasionally seen in the substance of the upper lid, perhaps starting from the tarsus ; and soft pedunculated (polypoid) growths have been met with in the sulcus between lid and globe.

*Malignant tumours* arise much less commonly on the front of the eye than in the choroid or retina. They may be either epithelial or sarcomatous. An injury is often stated to be the cause of the growth.

*Epithelioma* may begin on the ocular conjunctiva, in which case it remains moveable, or at the sclero-corneal junction, when it quickly encroaches on the cornea, infiltrates its superficial layers and becomes fixed. It may be pigmented. When such a growth is not seen until late it may perhaps be as large as a walnut, may cover or surround the cornea, and present a papillary or lobulated surface. The glands in front of the ear may be enlarged.

*Sarcoma* in this region may or may not be pigmented. It generally arises at the sclero-corneal junction, and when small the conjunctiva is traceable over the growth. But in advanced cases it may be impossible from the clinical features to diagnose the nature of a tumour in this part.

Moveable tumours (epithelioma) not involving the cornea may be cut off, but are very likely to recur ; and recurrence is still more likely in the case of growths fixed to the cornea or sclerotic. Removal of the eyeball at an early date, especially in the case of sarcomata, is the best course in the majority of cases.

The lacrimal sac is occasionally the seat of new growth, which may be mistaken for chronic mucocele,



B. *Intraocular Tumours.*

By far the commonest forms are glioma of the retina and sarcoma of the choroid.

*Glioma of the retina* is a disease of infancy or early childhood, the patients being generally under three years old when first brought for treatment; it may, however, be present at birth, and is said occasionally to begin as late as the eleventh or twelfth year. Glioma is very soft, composed of small, round cells which grow from the granule layers of the retina, and it either grows outwards, causing detachment of the retina, or inwards into the vitreous; often several, more or less separate, lobules are present. It often fills the eyeball in a few months, and then spreads by contact to the choroid, and to the sclerotic and orbit. It is especially prone to travel back along the optic nerve to the brain; and it may cause secondary deposits in the brain and in the scalp, and more rarely in distant parts. If the eye be removed before either the optic nerve or the orbital tissues are infiltrated the cure is radical, but in the more numerous cases, where the patient is not seen till what may be called, clinically, the second stage (*see below*), a fatal return in the orbit or within the skull is the rule. Glioma sometimes occurs in both eyes, and in several children of the same parents.

The earliest symptom is a shining whitish appearance deep in the eye, and the eye is soon noticed to be blind; as there is neither pain nor redness, advice is seldom sought at this stage. T. is n. or rather—. When the peculiar appearance has become very striking, or the eye becomes painful, the child is brought. In this (the second) stage there is generally some congestion of the scleral vessels, and a white, pink, or yellowish reflexion from behind the lens (which remains clear), steaminess of the cornea, mydriasis, T. +, anterior chamber shallow and of uniform depth; there may be enlargement or pro-



minence of the eyeball. On focal examination some vessels can generally be seen on the whitish background, and white specks, indicating calcareous degeneration, are sometimes present.

In young children the above appearances are sometimes simulated by inflammatory changes in the vitreous, with detachment of the retina; and the differential diagnosis is occasionally very difficult. In these cases of *pseudo-glioma* iritic adhesions are usually present, T. is —, the eye somewhat shrunken, the anterior chamber deep at its periphery, whilst absent or shallow at the centre. There is often the history of some illness with a definite inflammation of the eye before the peculiar appearance came in the pupil. When in doubt the eye should be excised. Snell\* records a remarkable case in which “*pseudo-glioma*” was diagnosed in both eyes; one eye afterwards shrunk to a mere stump after first enlarging somewhat; the other progressed steadily to a fatal termination from true glioma.

*Sarcoma of the choroid and ciliary body* is a growth of late or middle life, being rarely seen below the age of thirty-five. The majority of these tumours are pigmented (melanotic), some being quite black, others mottled or streaked. A few are free from pigment. Some are spindle-celled or mixed, others composed of round cells; some are truly alveolar, but in many specimens there is very little connective tissue stroma, and no very defined arrangement of the cells. These tumours are moderately firm but friable; some are very vascular, and hæmorrhages often occur into them. The tumour grows from a broad base, and usually forms a well-defined rounded prominence, pushing the retina before it; blood or serous fluid is effused round its base, so that the retinal detachment is more extensive than the tumour. These tumours often grow slowly so long as they are wholly contained within

\* Ophthalmological Soc., 1883-4.



the eye, and two, three, or more years may pass before the growth passes out of the eye and invades the orbit. Though orbital infection does not usually occur till the globe is filled to distension by the growth, it may happen much earlier, the cells passing out along the sheaths of the perforating blood-vessels and producing large extraocular growths, while the primary intraocular tumour is still quite small. The lymphatic glands do not enlarge, but there is great danger of secondary growths in distant parts, especially in the liver, a risk not entirely absent, even when the eye tumour is small. Hence early removal of the globe is of the utmost importance, and a good, though not too confident, prognosis may be given when the optic nerve and tissues of the orbit show no signs of disease.

*Symptoms and course.*—If the case be seen early, when defect of sight is the only symptom, the tumour can often be seen and recognised by its well-defined rounded outline, some folds of detached retina often being visible near it; the pupil, cornea, and tension will probably be natural. But sooner or later the tumour in its growth sets up symptoms of acute or subacute glaucoma and sometimes iritis; subsequently secondary cataract forms. It is in this glaucomatous (second) stage that relief is usually sought. Unless some part of the tumour happen to be visible outside the sclerotic, or project into this anterior chamber, a positive diagnosis often cannot now be given, owing to the opacity of the media, although by exclusion we may often arrive at great probability. If the eye be left alone, or iridectomy be performed, glaucomatous attacks and pain will recur, and the eye will enlarge and gradually be disorganised by the increasing growth, which will then quickly fill the orbit and fungate. But sometimes a deceptive period of quiet follows the glaucomatous attack, and perhaps even some shrinking and reduction of tension may occur, after which the growth



will make a fresh start and become apparent. It is chiefly in very old patients that this slow course is noticed. Sarcoma is especially likely to form in eyes previously injured, or already shrunk from disease.

Thus it is apparent that in a majority of cases of choroidal tumour we can only guess at the truth. We suspect a tumour and urge excision in the following cases: (1) When an eye that has been for some time failing or blind from deep-seated disease becomes painful, congested, and glaucomatous (there being no glaucoma of the other eye), and particularly if there be secondary cataract (*see* p. 254). (2) Similar eyes with normal or diminished tension are best excised as possibly containing tumour. (3) In extensive detachment of retina confined to one eye, without history of injury or evidence of myopia, the patient should be warned, or the eye excised, according to circumstances.

In all cases of suspected glioma or sarcoma the eye should be opened at once, and if a tumour be found the cut end of the optic nerve of the excised eye should be carefully looked at; if this be pigmented or thickened, another piece should be at once removed, and the orbit searched by the finger for evidence of growth; the surface of the eye should also be carefully examined for external growths. When infection of the nerve or orbit is suspected the orbit should be cleared out and chloride of zinc paste applied (as at p. 270).

*Tubercular growths* of large size may occur in the choroid or iris. The diagnosis may be uncertain till after excision, and the treatment differs in no way from that of malignant growths. The patients are generally children above five. Iritis and acute inflammatory symptoms are commoner than in the cases of malignant growth; there is often great congestion and T. is usually either n. or — (*see* p. 178).



*Tumours of the iris* are rare. Melanotic as well as unpigmented sarcomata are occasionally met with.\* Sebaceous or epithelial tumours are also seen; they are nearly always the result of transplantation of epithelium, or of a hair, into the iris through a perforating wound of the cornea.—In rare cases cystic tumours with thin walls are formed in connection with the iris, particularly in eyes which have been operated on for cataract.

The term *granuloma* has been applied to several forms of non-malignant tumour of the iris, some of which were large tubercles, some syphilitic gummata, and some true granulation tissue following wounds. These forms are all usually accompanied by iritis.

\* A well-reported case, with numerous references, is given by Little, in 'Trans. Ophth. Soc.,' vol. iii, 1883.



## CHAPTER XIX

## INJURIES, DISEASES, AND TUMOURS OF THE ORBIT.

(1.) *Contusion and Concussion Injuries.*—*Ecchymosis* of the eyelids from direct blows ("black eye") is to be distinguished from extravasation into the orbital cellular tissue, following fracture of the walls of the orbit. In ordinary "black eye" the ecchymosis is superficial, and, if it affect either the palpebral or ocular conjunctiva, does not pass far back. The ecchymosis following orbital fracture is deep-seated, often entirely beneath, rather than in, the skin and conjunctiva, diminishes in density towards the front and borders of the lids, and when considerable, may cause proptosis. The two forms may be combined when fracture is caused by direct violence to the orbit.

Fracture of the inner wall of the orbit into the nose, the sinuses opening into it, or the nasal duct, is often followed by *emphysema of the orbital cellular tissue*. This can occur only when the mucous membrane is torn. The emphysema comes on quickly from "blowing the nose," and is shown by a soft, whitish, doughy swelling of the lids, which crepitates finely under the finger; the globe is more or less protruded and its movements limited. The emphysema disappears in a few days if the lids be kept rather firmly bandaged. These fractures are usually caused by blows over the inner angle of the orbit, but occasionally by blows on the malar region.

*Partial ptosis* is an occasional result of blows upon the upper lid. It is generally accompanied by paralysis of accommodation and dilatation of



the pupil, and it seldom lasts more than a few weeks.

(2.) *Orbital abscess* and *orbital cellulitis* may follow injuries, but are often of apparently spontaneous origin. Cellulitis may spread to the orbit from the face in erysipelas, or from the throat in severe tonsillitis.—Diffused acute inflammation of the cellular tissue is difficult to distinguish from acute orbital abscess, since in both there are the signs of deep inflammation, with displacement of the eye and limitation of its movements, chemosis of the conjunctiva, and brawny swelling and redness of the lids. An acute abscess soon points between the globe and some part of the rim of the orbit, but even in cellulitis the swelling may be greater at some one part, and give rise to a feeling deceptively like fluctuation.

Orbital abscess may be very chronic, and may simulate a solid tumour until the pus nears the surface; even then we may not be able to distinguish it from a cystic tumour until an exploratory incision sets the question at rest. Abscess of the orbit, whether acute or chronic, is very often the result of periostitis, and a large surface of bare bone is often found with the probe.

In acute cases, as soon as fluctuation is certain, an incision is to be made with a narrow, straight knife, generally through the skin, or, if practicable, through the conjunctiva. As the pus is often curdy, it is best not to use a grooved needle. Chronic cases of doubtful nature may be watched for a time. It may be necessary to go deeply into the orbit, either with the knife, probe, or dressing forceps, before matter is reached. A drainage tube should be inserted if the abscess be deep. The proptosis does not always disappear when the abscess is opened, for, in addition to hæmorrhage caused by the operation, there may be much thickening of the tissues. Sight may be injured or lost by stretching of, or pressure on, the optic



nerve, and the cornea may become anæsthetic, and ulcerate from damage to the ciliary nerves behind the globe.

The lacrimal gland is occasionally the seat of acute or of chronic inflammation, and in either case an abscess may form. In chronic cases the enlarged gland is distinctly felt projecting, and can generally be recognised by its well-defined and lobulated border; but the enlargement cannot always be distinguished from that caused by a morbid growth in the gland, or corresponding part of the orbit. In acute inflammation there are the usual signs, local heat, tenderness, and pain, with swelling, which may obscure the boundaries of the gland. If the enlargement be great, the eyeball is displaced, and the oculo-palpebral fold of the conjunctiva in front of the gland is pushed downwards, and projects more or less between the lid and the eye.

When an abscess forms, it usually points to the skin, and should seldom be opened from the conjunctival surface. If it be allowed to burst spontaneously through the skin, a troublesome fistula may follow.

A little abscess sometimes forms in one of the separate anterior lobules, the main body of the gland remaining free. There is limited swelling and tenderness of the lid at the upper-outer angle, not passing back beneath the orbital rim. The abscess points through the conjunctiva, above the outer end of the tarsal cartilage, and is thus distinguished from a suppurating Meibomian cyst.

(3.) *Wounds*.—Wounds of the *eyelids* need no special treatment, beyond very careful apposition by sutures, sometimes with a small hair-lip pin, so as to secure primary and accurate union. Lacerated wounds of the ocular conjunctiva need a few fine sutures, if extensive, and they seldom lead to any deformity. When a rectus tendon has been torn



through I have never succeeded in getting the ends to unite.

*Penetrating wounds through the lids or conjunctiva*, which pass deeply into the orbit, may be much more serious than they appear at first sight, since the wounding body may have caused fracture of the orbit, and damage to the brain-membranes, or a piece of the wounding instrument may have been broken off and lie embedded in the roomy cavity of the orbit, without at first exciting disturbance or causing displacement of the eye. Some most extraordinary cases are on record, in which very large foreign bodies have lain in the orbit for a long time undetected. The optic nerve is occasionally torn across without damage to the globe. Every wound of the eyelids or conjunctiva should, therefore, be carefully explored with the probe, and, whenever possible, the instrument which caused the wound should be examined.

When a foreign body is suspected or known to be firmly embedded, and is not removable through the original wound, it is generally best to divide the outer canthus, and prolong the incision into the conjunctiva; in some cases an incision through the skin over the margin of the orbit, at the situation of the foreign body, will be preferable. Single shot corns, embedded and causing no symptoms, should not be interfered with unless they can be easily reached.

Wounds of the orbit, by gunshot or other explosives, when extensive and caused by numerous shots or fragments of sand, gravel, &c., driven into the tissues, are serious, because the eyeball itself is often injured. Such injuries may cause tetanus.

#### TUMOURS OF THE ORBIT.

A tumour of any notable size in the orbit always



causes protrusion of the eye (proptosis), with or without lateral displacement and limitation of its movement. As a rule there are no inflammatory symptoms. An exact diagnosis of the seat, attachments and nature of an orbital tumour is, of course, often impossible before operating.

A tumour in the orbit may originate in some of the loose orbital tissues, in the lacrimal gland, in the periosteum, upon or within the eyeball, or from the optic nerve; or it may have encroached upon the orbit from one of the neighbouring cavities. Tumours in the orbit, when fluctuating, may be either cystic or ill-defined, and may or may not pulsate. They may be solid, and either moveable or fixed by broad attachments to the wall of the cavity. Sight is often damaged or destroyed in the corresponding eye by compression or infiltration of the optic nerve.

(1.) *Distension of the frontal sinus* by retained mucus causes a well-marked, fixed, usually very chronic swelling, not adherent to the skin, at the upper-inner angle of the orbit above the *tendo oculi*. Hard at first, it fluctuates when the bony wall has been absorbed. Its course is usually slow, but acute suppuration may supervene, and the swelling be mistaken for a lacrimal abscess (p. 71). There is generally a remote history of injury. The aim of treatment is to re-establish the opening, closed probably as the result of fracture between the floor of the sinus and the nose. The most prominent part of the swelling is freely opened; a finger is then passed up the nostril, and the floor of the sinus perforated on the finger by a trocar passed from above through the incision. A seton or drainage-tube is then passed through the hole, and brought out at the nostril; it must be worn for several weeks or months.

(2.) *Pedunculated ivory exostoses* sometimes grow from the walls of the same sinus or its neighbour-



hood; beginning early in life they increase very slowly, cause absorption of their containing walls, and often in the end undergo spontaneous necrosis and fall out. Their removal while still fixed is difficult and dangerous, owing to the proximity of the dura mater.

(3.) Tumours encroaching on one or both orbits from the base of the skull, the antrum, the nasal cavity, or the temporal fossa, generally admit of correct diagnosis.

The suspicion of tumour on the inner or lower wall of the orbit should always lead to an examination of the palate, pharynx, and teeth, of the permeability of each nostril, of the functions of the cranial nerves, of the state of the glands behind the jaw on both sides, and to an inquiry as to epistaxis or discharge from the nose.

(4.) *Pulsating tumours of the orbit* and cases of *proptosis with pulsation* are in most cases due to arterio-venous intercommunication in the cavernous sinus, in consequence of which the ophthalmic vein and its branches become greatly distended with partly arterialised blood. In a large proportion the symptoms follow rather gradually after a severe injury to the head. In others they come on suddenly with pain and noises in the head, without apparent cause, and these idiopathic cases are usually in senile persons. In several examples of both forms a communication has been found, post-mortem, between the internal carotid and the cavernous sinus, the result of wound from fracture of the base of the skull in the traumatic cases, and of rupture of an aneurysm in the idiopathic ones. The typical symptoms are proptosis, with chemosis, pulsation of the eyeball, paralysis of orbital nerves, a soft pulsating tumour under the inner part of the orbital arch, and a bruit. A bruit with proptosis and conjunctival swelling may be present, without demonstrable tumour or pulsation. Ligature of the common



carotid has been practised with good results in a large number of cases; subsequent excision of the eye and evisceration of the orbit for a dangerous return of symptoms in one or two. An unruptured aneurysm of the internal carotid does not cause the symptoms just described. Aneurysm of the intraorbital arteries and arterio-venous communications in the orbit, if they occur, are excessively rare.—Erectile tumours, well-defined and separable, but not causing decided pulsation, are sometimes met with in the orbit, and can be dissected out.

(5.) A fluctuating tumour which does not pulsate, is not inflamed, and not connected with the frontal sinus, may be a chronic orbital abscess (p. 264), a hydatid, or a cyst containing bloody or other fluid and of uncertain origin. An exploratory puncture should be made after sufficiently watching the case, and the further treatment must be conditional. Perfectly clear, thin fluid probably indicates a hydatid, and in this case the swelling is likely to return after a puncture and the cyst will need removal through a free opening. The echinococcus hydatid often contains daughter-cysts, some of which escape puncture. Suppuration may take place around any species of hydatid.

(6.) Examination leads to the diagnosis of a *solid tumour limited to the orbit*. We must try to determine whether the growth began in the eyeball or optic nerve, or in some of the surrounding tissues. We therefore examine the globe for symptoms of intraocular tumour (p. 258).

Solid growths independent of the eyeball may arise as follows:—(a) From the *periosteum*; these are firmly attached by a broad base, are generally malignant, and seldom admit of successful removal. (b) The *lacrimal gland* (compare p. 265) is the seat of various morbid growths, including carcinoma; a great part of the growth is in the position of the gland, and can be explored by the finger. Although



such a growth is often attached firmly to the orbital wall, its position, lobulated outline, and well-defined boundary will often lead to a correct diagnosis. Tumours of the lacrimal gland should always be removed if they are increasing, for we can never feel sure that they are innocent. (c) Solid tumours originating in some of the softer orbital tissues, especially the form known as cylindroma, or plexiform sarcoma, occur more rarely. (d) Tumours of the optic nerve, usually myxomatous, occur, though rarely; they generally cause neuro-retinitis and blindness, but no absolutely pathognomonic symptoms; they may sometimes be extirpated without removing the globe.

When an orbital tumour is found during operation to be adherent to bone or to infiltrate the soft parts, chloride of zinc paste (18a) should be applied on strips of lint, either at once, or the next day when oozing has ceased. If the periosteum be affected it is to be stripped off, and the paste applied to the bare bone. Hæmorrhage from the depth of the orbit can always be controlled by perchloride of iron and a firm graduated compress.

In every case of suspected primary orbital tumour the question of syphilis must be carefully gone into; although neither periosteal nor cellular nodes are common in the orbit, both are known to occur and disappear under proper treatment.

*Nævus* may occur on the eyelids, and in the orbit, and implicate the conjunctiva, both of the lids, and eyeball. Deep nævi may degenerate, and become partly cystic.

*Dermoid tumours (cystic)* are not uncommon at the outer end of the eyebrow; more rarely they occur near the inner canthus. Lying deeply, beneath the orbicularis, they are not adherent to the skin, like sebaceous cysts; the subjacent bone is sometimes hollowed out. They often grow faster than the surrounding parts, and should then be extirpated, the



thin cyst wall being carefully and completely removed through an incision parallel with, and situated in, the eyebrow. They usually contain sebaceous matter and short hairs; occasionally, clear oil.



## CHAPTER XX

## ERRORS OF REFRACTION AND ACCOMMODATION.

As stated at p. 12, § 19, when the length of the eye is normal, and the accommodation relaxed, only parallel rays are focussed on the retina, and, conversely, pencils of rays emerging from the retina are parallel on leaving the eye (Fig. 96, and p. 5, §§ 11

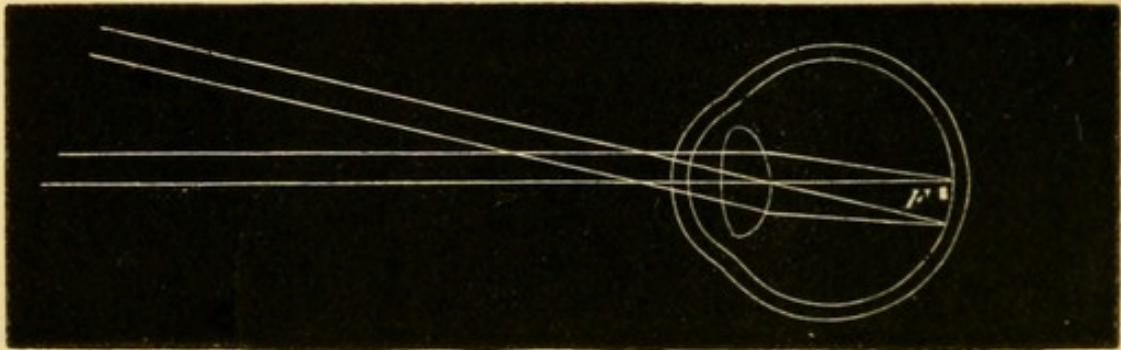


FIG. 96.—Pencils of parallel rays entering, or emerging from, an emmetropic eye.

and 12), and this, the condition of the normal eye in distant vision, is called emmetropia (E.). All permanent departures from the condition in which, with relaxed accommodation, the retina lies at the principal focus, are known collectively as ametropia.

In E. rays from any near object, *e. g.* divergent

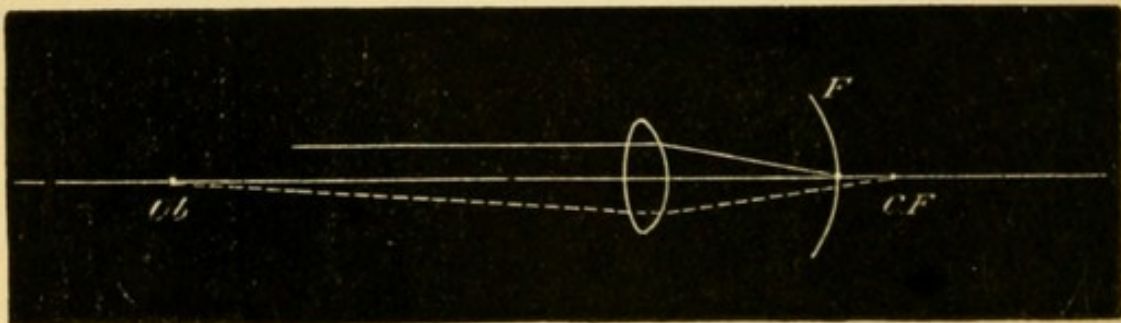


FIG. 97.—Emmetropia.—Distant objects (parallel rays) focussed on retina; near objects (divergent rays) focussed behind retina.



rays from *Ob*. Fig. 97, are focussed behind the retina at *cf*, every conjugate focus being beyond the principal focus (p. 6, § 13). Reaching the retina before focussing, such rays will form a blurred image, and the object *Ob* will therefore be seen dimly. But by using accommodation the convexity of the crystalline lens can be increased and its focal length shortened, so as to make the conjugate focus of *Ob* coincide exactly with the retina (*cf*, Fig. 98). Under this condition the object *Ob* will be clearly seen, whilst

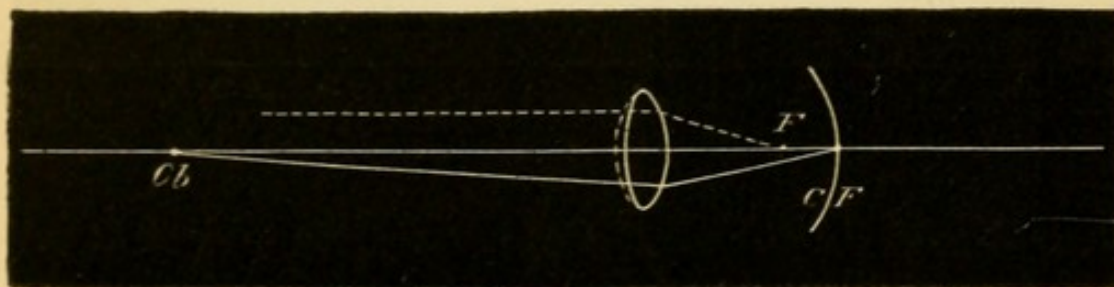


FIG. 98.—Eye during accommodation.—Near objects (divergent rays) focussed on retina; distant objects (parallel rays) focussed in front of retina. The dotted line in front of the lens shows its increase of convexity.

the focus of a distant object, which in Fig. 97 was formed on the retina, will now lie in front of it (*F*, Fig. 98), and the distant object will appear indistinct. The nearest point of distinct vision (*p*) and the farthest (*r*) have been defined at p. 33.

#### MYOPIA (M.).

In Fig. 97, if the retina were at *cf* instead of at *F*, a clear image would be formed of an object at *Ob*, without any effort of accommodation, whilst objects farther off would be focussed in front of the retina. This state, in which the posterior part of the eyeball is too long, so that, with the accommodation at rest, the retina lies at the conjugate focus of an object at a comparatively small distance, is called Short sight or Myopia (M.) (*Axial Myopia*).



In Fig. 99 the inner line at  $R$  is the retina, and  $F$  the principal focus of the lens-system, *i. e.* the position of the retina in the normal eye. Rays emerging from  $R$  will, on leaving the eye, be convergent, and, meeting at the conjugate focus  $R'$ , will form a

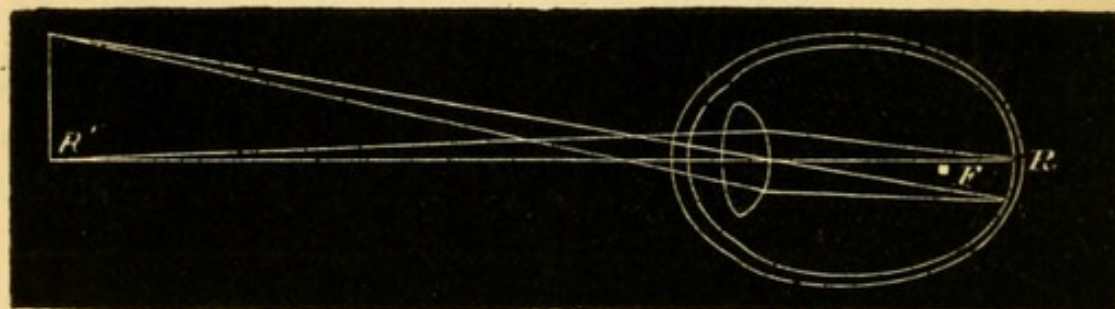


FIG. 99.—Myopia.—Retina beyond principal focus, hence only near objects (divergent rays) focussed on retina.

clear image in the air. Conversely, an object at  $R'$  will form a clear image on the retina ( $R$ ) (*compare* Figs. 10 and 12). The image of every object at a greater distance than  $R'$  will be formed more or less in front of  $R$ , and every such object must, therefore, be seen indistinctly. But objects nearer than  $R'$  will be seen clearly by exerting accommodation, just as in the normal eye (Figs. 97 and 98).

In *M.* the indistinctness of objects beyond the far point ( $r$ ) is lessened by partially closing the eyelids. This habit is often noticed in short-sighted people who do not wear glasses, and from it the word myopia is derived.

The distance of  $r$  ( $R'$ , Fig. 99) from the eye will depend on the distance of its conjugate focus  $R$ , *i. e.* upon the amount of elongation of the eye. The greater the distance of  $R$  beyond  $F$ , the less will be the distance of its conjugate focus  $R'$  ( $= r$ ); in other words, the higher will be the *M.*, and the more indistinct will distant objects be. If the elongation of the eye be very slight,  $R$  nearly coinciding with  $F$ ,  $R'$  ( $= r$ ) will be at a much greater distance (*compare* p. 7, § 16), and distant objects will be less indistinct.



As the retinal images formed in a myopic eye are larger than normal (p. 13), myopic persons can distinguish smaller objects at the same distance than those with normal eyes.

*Symptoms of M.*—In low degrees the patient's complaint is that he cannot see distant objects clearly; in moderate and high degrees it is rather that he can see distinctly only when things are held very close, for objects a few feet off are so indistinct that many such persons neglect them. Adults often tell us that their distant sight was good till about eight or ten years of age, that it then began to shorten, and that the defect after increasing for several years at length became stationary.

In many cases, no other complaint is made; but in a certain number complications are present. There is often intolerance of light, an additional cause for the half-closed lids and frowning expression so often noticed. Aching of the eyes is a very common and troublesome symptom and is especially frequent if the M. be increasing; it is often brought on, and always made worse, by over use of the eyes, but sometimes it is very troublesome when quite at rest, and even in bed at night. One or both internal recti often act defectively, so that convergence of the optic axes for near vision becomes difficult, painful, or impossible, and various degrees of divergent strabismus result; this occurs oftenest, but by no means only, in the higher degrees of M. where  $r$  is so near that binocular vision involves a strong effort of convergence. When this "muscular asthenopia," or "insufficiency of the internal recti," is slight or intermittent it causes indistinctness, or "dancing of the print," and sometimes actual diplopia, besides the other discomforts above mentioned; but diplopia is seldom present when a constant divergent squint has been established. The lower degrees of M. are sometimes accompanied by involuntary contraction



of the ciliary muscle ("spasm of accommodation") by which M. is temporarily increased; and the habitual approximation of objects which thus becomes necessary, is one cause of still further elongation of the eye and increase of the structural M. Floating specks (*muscæ volitantes*, p. 227) are especially common and troublesome in myopia.

*Objective signs and complications.*—In high degrees of M. the sclerotic is enlarged in all directions (Fig. 100); the eye being too large often looks too prominent and its movements are somewhat impeded. But apparent prominence of the eye may depend on many other causes (p. 23, 6).

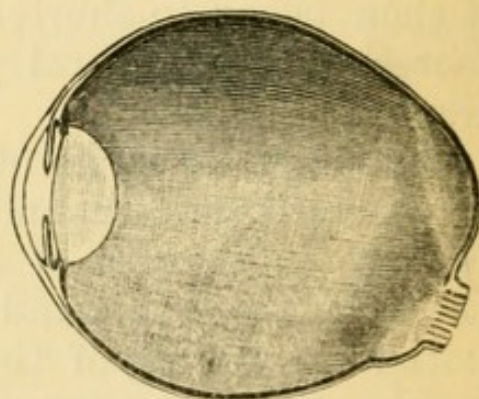


FIG. 100.—Section of a highly myopic eyeball. The retina has been removed.

The existence of M. is made certain by the ophthalmoscope in four different ways.—(1) By direct examination, the image of the fundus formed in the air (Fig. 99) is clearly visible to the observer, if he be not nearer to it than his own near point. The image is inverted and magnified, the enlargement being greater the further it is formed from the patient's eye, *i. e.* the lower the M. (p. 9, § 17). For very low degrees this test is not easy to use, because of the great distance (3' or 4' *e. g.*) that must intervene between observer and patient; but it is easily applied if the image be not more than 2' in front of the patient (p. 51, 2).

(2.) By indirect examination the disc in M. appears smaller than usual. If now, the object lens be gradually withdrawn from the patient's eye the disc will seem to grow larger. This appearance, which depends on a real increase in the size of the



aërial image, is less evident the lower the M. (Fig. 102, *bis*, C).

(3.) By direct examination no clear view of the fundus is obtained if the distance between patient and observer be less than that between patient and inverted aërial image (Figs. 30 and 99 R'); and as R' is in front of the myopic eye, the image will always be invisible if the observer go close to the patient. Hence, if on going close to the patient the observer cannot, either by relaxing or using his accommodation (*see* p. 51), see any details of the fundus clearly, the patient is myopic (opacities of the media being, of course, excluded). This test is applicable to all degrees of M., accommodation being completely relaxed.

4. By *retinoscopy* (p. 55), the shadow obtained on rotating the mirror moves in the direction of rotation. The tests (1), (2), and (4) are, on the whole, most generally useful for beginners.

In a large proportion of cases, the elongation of the eye causes atrophy of the choroid on the side of the optic disc next to the y. s. (the apparent inner side in indirect examination).

This atrophy gives rise to a crescentic patch (Fig. 102) of yellowish-white or greyish colour, whose concavity is formed by the border of the disc, whilst its convex side curves towards the y. s.; it is known as a "myopic crescent," also as a "posterior staphyloma" (p. 176), because it indicates a localised bulging of the sclerotic (Fig. 100). It varies in size from the narrowest rim to an area

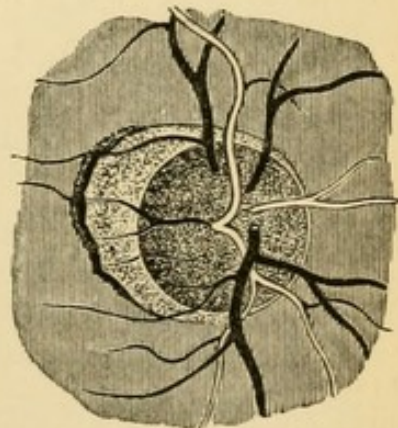


FIG. 102.—Myopic crescent or small posterior staphyloma. (Wecker and Jaeger.)

several times that of the disc, and may form a zone entirely surrounding the disc (Fig. 103), instead of a crescent; there may also be several spots of



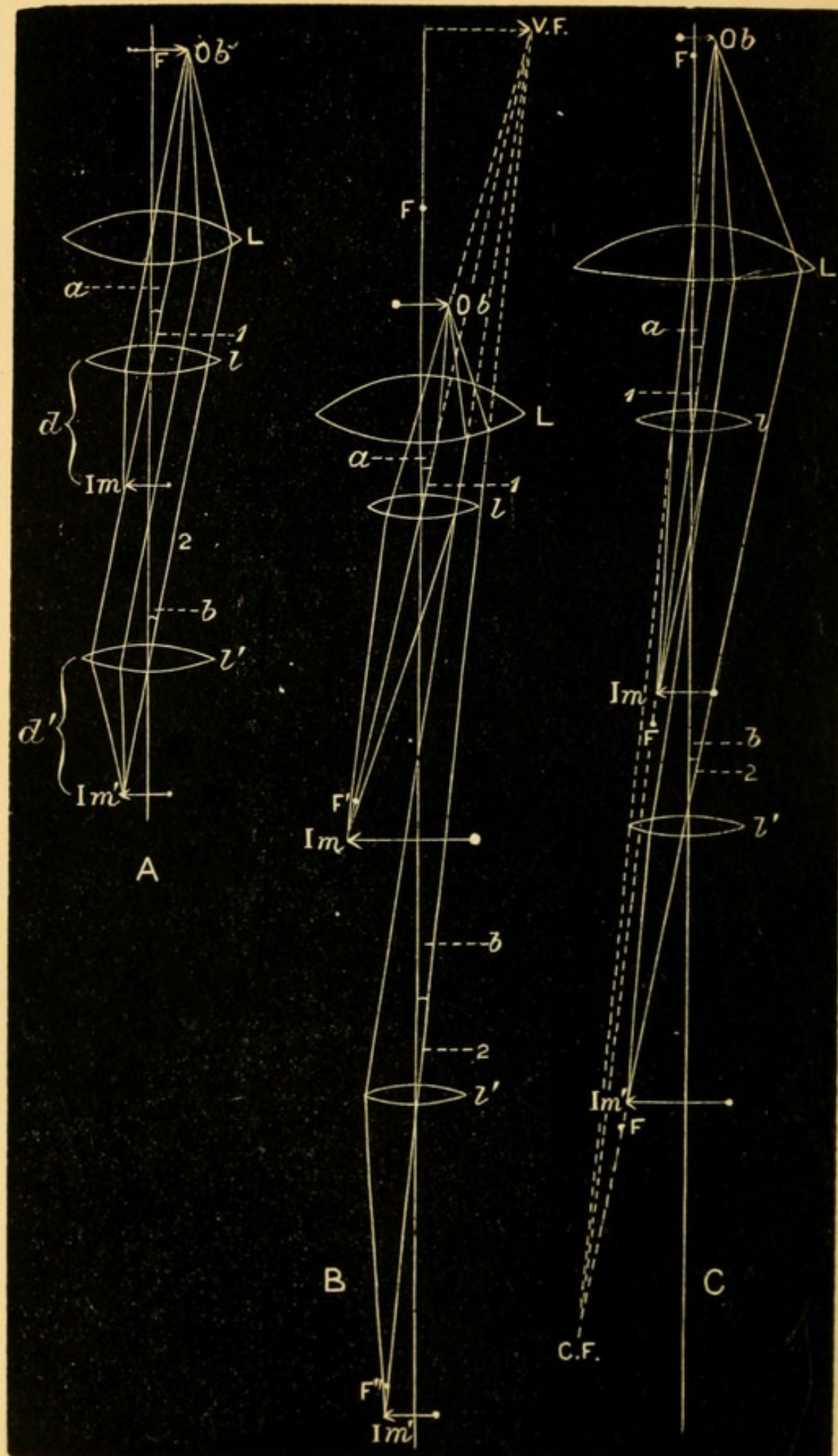


FIG. 102, bis.



Description of Fig. 102, *bis*, which shows the effect on the size of the inverted image caused by withdrawing the objective lens from the eye, in the indirect ophthalmoscopic examination.

FIG. A shows that in emmetropia the image remains of the same size on withdrawal of the lens. *Ob* is the retina lying at the principal focus of the dioptric media of the eye, represented by *L*; *l* and *l'* show the objective lens at different distances from the eye; *Im* and *Im'* the ophthalmoscopic images formed in each case.—Rays from any point on *Ob* emerge from *L* parallel, and are united by *l* at the point *Im* (the principal focus of *l* for the rays indicated) on the secondary axis 1 which forms with the principal axis the angle *a*. If *l* be removed to *l'* it will still intercept some of the same bundle of parallel rays, and these will be united in *Im'*, at the same distance as before, on the secondary axis 2 which forms with the principal axis the angle *b* = the angle *a*. The relative sizes of *Im* and *Im'* depend on (1) their respective distances *d* and *d'* from the lens, and (2) on the size of the angles *a* and *b*. As in the present case *d* = *d'* and *a* = *b*, *Im* must = *Im'*.

FIG. B shows the diminution of the image in hypermetropia. The lettering is as before, but *F* is the principal focus of *L*, and *V.F.* the virtual focus of the retina *Ob*. The letters *d* and *d'* are omitted, but can easily be supplied. The angle *b* is now smaller than *a* because the rays emerge from *L* divergent (as if from *V.F.*), and hence (*d* and *d'* being nearly equal) *Im'* must be smaller than *Im*.

FIG. C shows the increase of the image in myopia; the retina, *Ob* is now beyond *F*; *C.F.* is the "far point" of the eye, conjugate to *Ob*. The angle *b* is now larger than *a* because the rays emerge from *L* convergent (towards *C.F.*), and hence (*d* and *d'* still being nearly equal) *Im'* must be larger than *Im*.



atrophy, or diffused thinning of the choroid, beyond the bounds of the crescent, especially in a horizontal

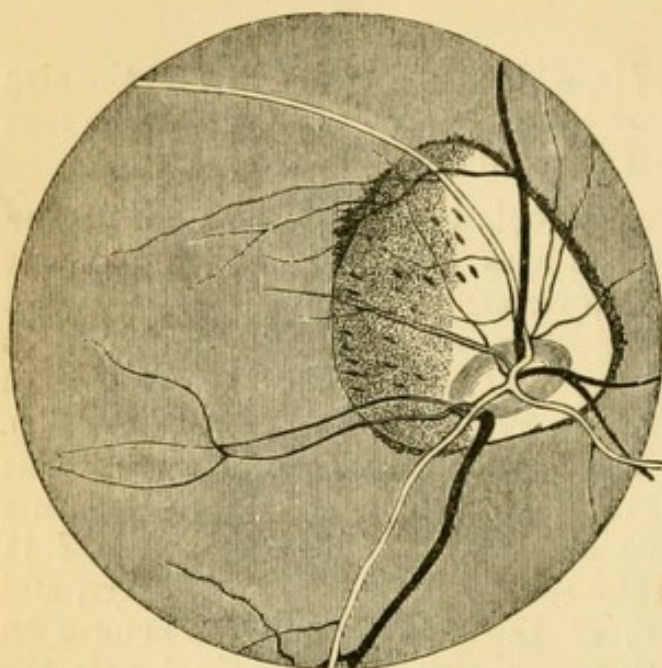


FIG. 103.—Large annular posterior staphyloma (Liebreich).

direction towards the y. s. As a rule, the higher the M. the more extensive are these choroidal changes, but the relation is by no means constant, and occasionally even in high degrees we find no crescent. Hæmorrhages may occur from the choroid in the same region, and leave some residual pigment (pp. 169 and 173).

Owing to the steepness of the bulging, the disc is often tilted, and appears oval, because seen at "three quarter face" instead of "full face" (Fig. 103). It is sometimes very pale on the side next the y. s. when the staphyloma is large.

There is in M. a great liability to liquefaction of, and the formation of opacities in the vitreous, and, still worse, to detachment of the retina. A large proportion of all the retinal detachments occur in myopic eyes. A blow on the eye sometimes appears to have caused the detachment, though often not until after a considerable interval. In high degrees of M. the lens frequently becomes cataractous, the cataract generally being cortical and complicated with disease of the vitreous (pp. 152, 188, &c.).

Thus we arrive at a sum total of serious difficulties and risks to which myopic persons are subject, especially when the myopia is of high degree. It is only when the degree is low (2 D. or less), and the con-



dition stationary, that the popular idea of "short sight" being "strong sight" is at all borne out, or that the later onset of Presbyopia (p. 303) counter-balances the disadvantages of bad distant vision.

*Causes.*—M. is sometimes present at birth, but much more commonly the eye begins to elongate during childhood. Though M. is strongly hereditary, it may also begin independently, especially from the prolonged use of the eyes for near work. The strain on the internal recti, counterbalanced, it may be, by a corresponding tension on the external recti, is believed to act by compressing the eyeball, and thus causing the unprotected posterior pole of the sclerotic to bulge. The concomitant tension of the ciliary muscle probably aids by bringing on congestion of the uveal tract (as it certainly appears to do of the disc), and thus predisposes to softening and yielding of the tunics; to this congestion the habit of stooping over the book or work contributes by retarding the return of blood. It is evident that if such causes are able to start the disease they must constantly tend to increase it. M. seldom increases after the age of twenty-five, unless under special circumstances; but general enfeeblement of health, as after severe illness or prolonged suckling, seriously increases the risk of its progress, even after middle life. Any condition in which during childhood better vision is gained by holding objects very close is likely to bring on M.; and so we find it disproportionately common amongst those who from childhood have suffered from corneal nebulæ, partial (especially lamellar) cataract, severe choroiditis, or a high degree of astigmatism. A bad supply, or bad arrangement, of light, bad print, and seats or desks so proportioned as to encourage children to stoop over their lessons, are now generally believed to be answerable for much of the acquired myopia met with. It is however to be noted that some of the very worst cases occur in



persons who have never used their eyes for close observation of any kind.

The *treatment* is divisible into (1) prophylactic and (2) remedial—1. Much may be done to prevent M., or to check its increase when it has begun, by regulating the light, books and desks, used by children, so as to remove the temptations to stooping. Children should not be allowed to read or work by flickering or dull light; and as we write and read from L. to R., it is best, whenever possible, to admit the light from the left, so that the shadow of the pen is thrown towards the right, away from the object looked at. A myopic child should not be allowed to fully indulge his bent, which is generally strong, for excessive reading.—2. By means of suitable glasses (*a*) distant objects may be seen clearly, *i.e.* the eye be rendered emmetropic, (*b*) reading and working become possible at a greater distance. The strain on the internal recti usually ceases when the gaze is directed into the distance, whether vision be distinct or not; glasses for distant vision have therefore no effect on the progress of the myopia, and are of value only for educational purposes, that the patient may see what is about him as clearly as other people; their use is therefore to a great extent optional. But if we can increase the distance of the natural far point (*r*) from the eyes, we lessen the tension on the internal recti in near vision, diminish the temptations to stooping and to reading by bad light, and so help to check the progress of the disease; hence glasses for near work are very important in the higher degrees of M. (3 D. and more) in early life. When M. has been stationary for years, however, the decision even on this point may be left to the patient.

Before ordering glasses for either purpose we must measure accurately the degree of M. In Fig. 104 let *r* be the far point, and let it be 25 cm. in



front of the patient's eye, so that he can see nothing clearly at a greater distance than 25 cm. (a) He is required to see distant objects (objects seen under parallel rays) clearly. A concave lens is interposed of strength sufficient to give to parallel rays a degree of divergence, as if they came from  $r$  (Fig. 11). The focal length of this lens will be the same as its distance from  $r$ ; and, as it is placed close to the eye, its focal length will be very nearly the same as (a little shorter than) the patient's far point. Therefore, if we measure the distance of  $r$  from the patient's eye, a lens of nearly the same focal length will neutralise his M. He will choose a

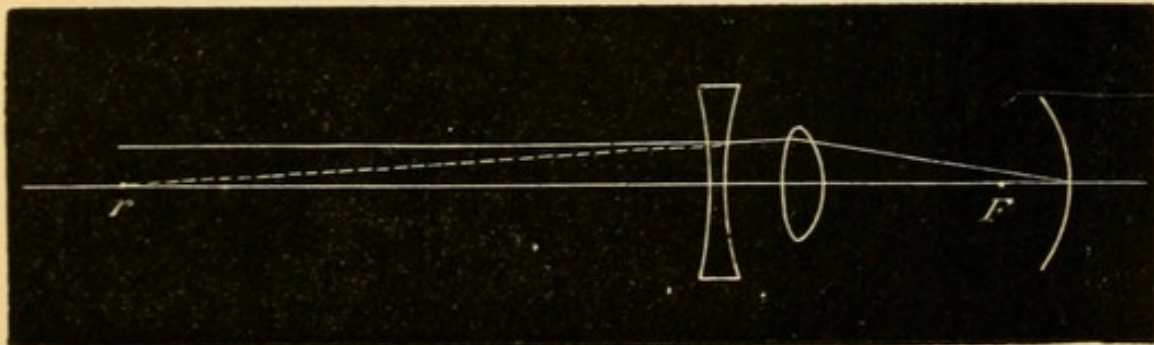


FIG. 104.—Myopia corrected by concave lens.

lens rather higher than this test would lead us to expect, if the M. be uncomplicated;\* whilst if, owing to complications, there be considerable defect of vision, he will often choose a somewhat lower glass. Hence it is a good rule to begin the trial with a lens weaker than the one which, judging by the above test, we expect the patient to choose, and to try successively stronger ones till the best result is reached. The weakest concave glass which gives

\* It is sometimes stated that the glass chosen for distance is rather *weaker* than is indicated by the distance of  $r$  from the crystalline lens, the accommodation causing an apparent increase of M. This is true only in low degrees of M., and not always in them; most patients choose a rather *stronger* lens than is indicated by  $r$ , *i. e.*, a lens whose focus is shorter by the distance between its own central point and the cornea.



the best attainable sight for the *distant* test types (p. 32) is the measure of the M., and this glass, *but not a stronger one*, may be safely worn for distant vision. Beginners often test M. patients with concave glasses for near types; neither + nor - glasses give any information about the *refraction* when used for near objects, since they merely either substitute, or call into use, the *accommodation*.

(b) A glass is needed with which the patient will be able to read or sew at a distance greater than his natural far point. Theoretically the fully correcting glass (a) would suit, since it gives to all rays a course which, in relation to the myopic eye, is the same as that of the rays entering a normal eye. But this glass can seldom safely be allowed in the higher degrees of M. The lens which fully corrects the myopia diminishes the size of the retinal images so much (p. 13) that the patient is tempted to enlarge them again by bringing the object nearer; again, the accommodation is often defective in the higher degrees of M., and, as the fully correcting lens requires full accommodation, it will lead to over-straining if this function be weakened, and so cause discomfort, if nothing worse. For these two reasons, the rule is to give, for near work, a glass which will diminish the myopia, but not fully correct it.

Let M. be 7 D. then  $r$  will be at 14 cm. (p. 15) from the eye. If a glass be required with which the patient shall be able to read at 30 c.m., or which shall remove  $r$  from 14 cm. to 30 cm., *i.e.* shall leave the patient with M. 3 D., we must correct the difference between 7 D. and 3 D. ( $7\text{ D.} - 3\text{ D.} = 4\text{ D.}$ ); a concave lens of 4 D. will make rays from 30 cm. diverge as if they came from 14 cm. But even this partial correction may diminish the images so much that, if vision be imperfect, from extensive choroidal changes, reading at the increased distance will be difficult, and the patient will prefer to bring the object nearer again at the expense of his accommodation,



and will thus be inconvenienced instead of bettered; it is, therefore, often advisable, even for partial correction, to order a weaker lens than is optically correct.

Aching from preponderance of the external over the internal recti (insufficiency of the internal recti, p. 275), if not cured by partially correcting glasses, is often best treated by division of the external rectus of one or both eyes. This operation may always be done when there is a marked divergent squint, even if the squint be variable.—Prismatic spectacles (p. 9), the bases of the prisms being towards the nose, are very serviceable for reading, in cases of slight muscular insufficiency. By deflecting the entering light towards their bases (Fig. 16) the prisms give to rays from a certain near point a direction as if they came from a greater distance, and thus lessen the need for convergence of the optic axes. The prisms may be combined with concave lenses.

M. may also be caused by an increase of the curvature, or of the refractive power, of the media (*myopia of curvature*). Thus, in conical cornea (p. 104) the curvature of the central part of the cornea is increased (*i. e.* its focal length shortened), and the principal focus of the lens-system lies in front of the retina, often very far in front, without any change of place of the parts at the back of the eye. M. usually of low degree often comes on in commencing senile cataract (p. 153) from a shortening of the focal length of the crystalline lens, but whether this is due to increase of convexity, or of refractive index (p. 1) is uncertain. M. is sometimes simulated in H., and actual M. increased, by needless and uncontrollable action of the ciliary muscle.

#### HYPERMETROPIA. (H.)

H. is optically the reverse of M. It is one of the commonest conditions we have to treat. The eyeball



is too short (*axial hypermetropia*), so that when the accommodation is relaxed the retina lies within the principal focus of the eye. As rays from an object within the principal focus of a convex lens emerge from the lens divergent (Figs. 10 and 13), so pencils of rays leaving a hypermetropic eye are divergent (Fig. 108); and, conversely, only rays already convergent can be focussed on the retina. H. always dates from birth and does not afterwards increase, except slightly in old age. But it may diminish and even give place to M. by elongation of the eye. In fig. 105 the curved line representing the retina is in front of F (*compare* Fig. 96). Parallel rays will,

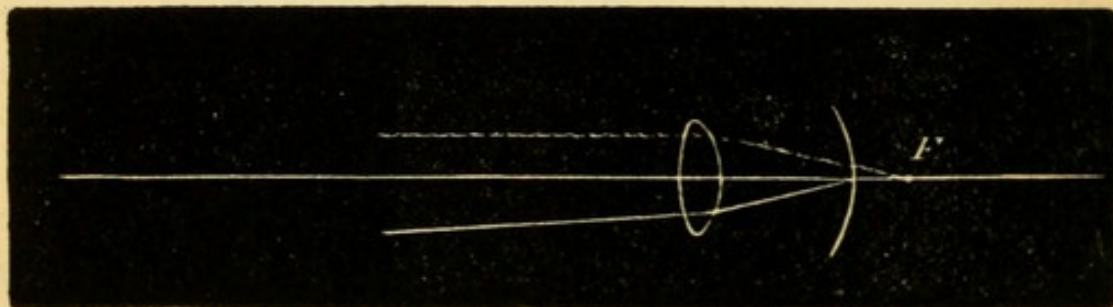


FIG. 105.—Hypermetropia. Parallel rays focussed behind retina. Rays already convergent focussed on retina.

after passing through the lens, meet the retina before focussing and form a blurred image, whilst divergent rays, meeting the retina still further from their focus, will form an even worse image (*compare* Fig. 97); hence neither distant nor near objects will be seen clearly. But by using accommodation the focal length can be shortened until the focus falls upon the retina

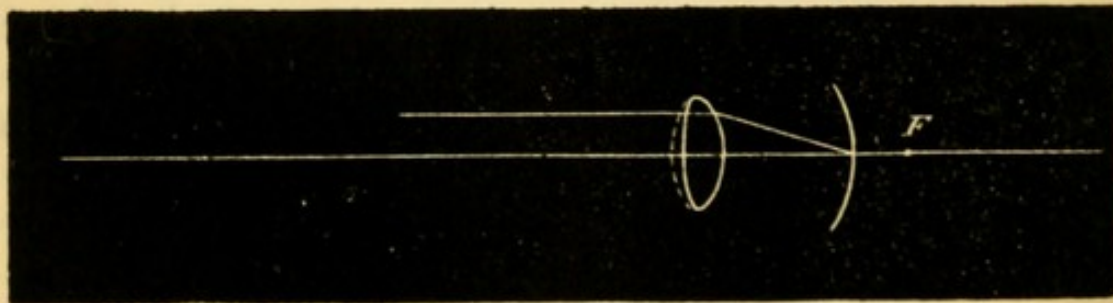


FIG. 106.—Hypermetropia corrected by accommodation. Parallel rays focussed on retina.

(Fig. 106), and distant objects are then seen clearly ;



and additional accommodation will give also distinct vision of near objects (*compare* Fig. 98). A little consideration will show that the competence of the ciliary muscle to give these results will depend in any given case : (1) on the degree of advancement of the retina in front of  $F$ , *i. e.* on the degree of shortening of the eye; and (2) on the strength of  $A$ , *i. e.* on the extent to which the focal length of the lens can be altered.

The same result may be gained by placing a convex lens in front of the eye, instead of using the accommodation. In a given case,  $A$ . being relaxed, let the ray ( $a$ , Fig. 107) on leaving the eye diverge from the axis, as if it proceeded from a

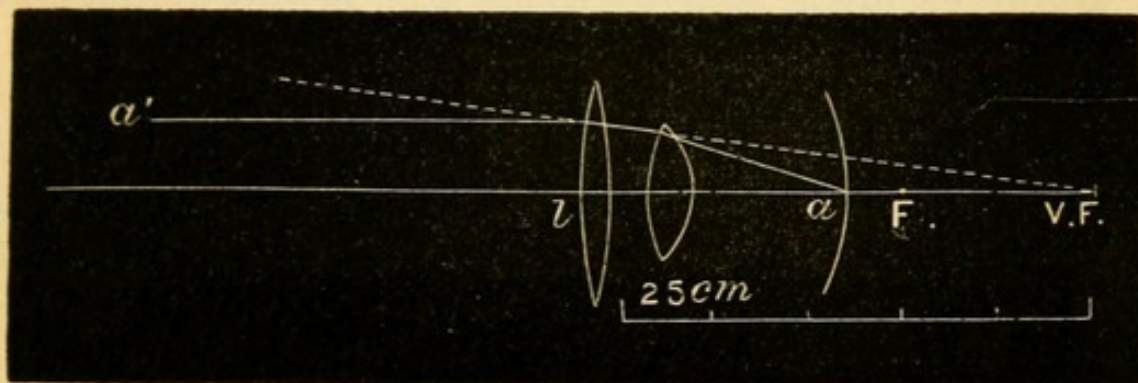


FIG. 107.—Hypermetropia corrected by a convex lens, whose focus coincides with the virtual focus of the retina.

point  $V. F.$  (*compare* Fig. 13) 25 cm. behind the cornea. If the ray  $a'$ , parallel with the axis, pass through a convex lens,  $l$ , of 25 cm. focal length held close to the eye, it will be made to converge towards this same point, and therefore in accordance with § 12 (p. 5) will be focussed on the retina at  $a$ .

Fig. 108 may be taken for a section of a very highly hypermetropic eye, the rays emerging from which are divergent. The image formed on the retina of a hypermetropic eye is smaller than that of the same object placed at the same distance from a normal eye (p. 13).

In old age the refractive power of the crystalline lens normally diminishes, and, therefore, an eye



originally emmetropic is now unable to focus parallel rays on the retina; this condition causes

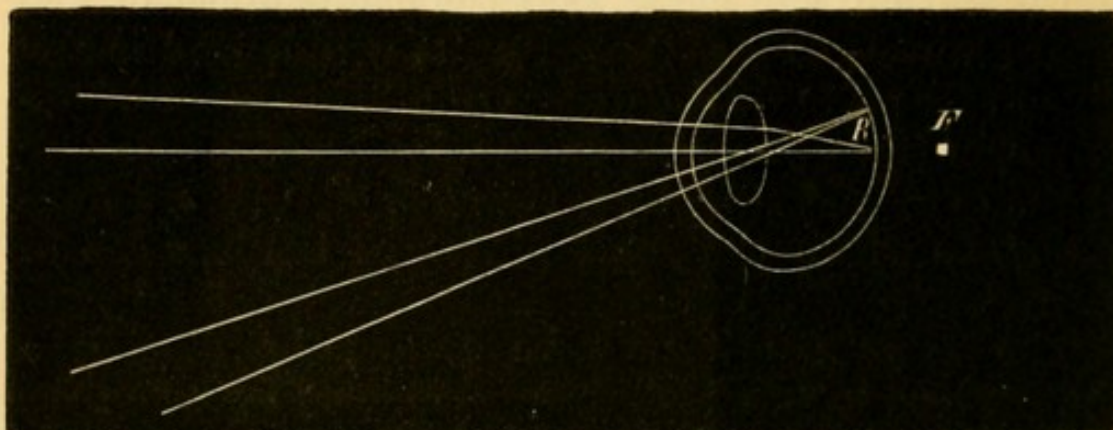


Fig. 108.—Course of the rays emerging from a hypermetropic eye.

slight *acquired hypermetropia*, and begins at the age of 65.

*Symptoms and results of H.*—The *direct* symptoms are due to insufficiency of the accommodation; for distinct vision of any object, whether near or distant, requires A. proportionate to the degree of shortening of the eye, and the absolute power (amplitude) of A. is not increased in H., at any rate not enough to meet the demand.

If H. is slight or moderate and A vigorous, no inconvenience is felt either for near or distant vision. But if A. have been weakened by disease or ill health, or have failed with age, the patient will complain that he can no longer see near objects clearly for long together; that the eyes ache or water, or that everything “swims” or becomes “dim,” after reading or sewing for a short time (*accommodative asthenopia*). There is not usually much complaint of defect for distant objects. Many slight or moderately H. patients find no inconvenience till 25 or 30 years of age, when A. has naturally declined by nearly one half. Women are often first troubled after a long lactation, and other persons after prolonged study or desk-work, or when suffering from chronic exhausting



diseases. Children often complain of watering, blinking, and headache, rather than of dimness.

In very high degrees of H., as a large part of the A. is always needed from childhood upwards for distant sight, even the strongest effort does not suffice to give clear images of near objects, which consequently such a person never sees well. Such patients often partly compensate for the dimness of near objects by bringing them still nearer, thus enlarging the visual angle and increasing the size of the retinal images (p. 13). This symptom may be mistaken for M., but can be distinguished by the want of uniformity in the distance at which the patient places his book, and by his being often unable, at any distance whatever, to see the print easily or to read fluently. In the highest degrees even distinct distant vision is not constantly maintained, the patient often being content to let his accommodation rest, except when his attention is roused.

As age advances, a point is reached, even in moderate degrees of H., at which A. no longer suffices even for distant, and much less for near, vision. Such persons tell us that they early took to glasses for near work, but add that lately the glasses have not suited, and that they are now unable to see clearly either at long or short distances. Ophthalmoscopic examination shows no change except H., and suitable convex glasses at once raise distant vision to the normal.—Occasionally photophobia, conjunctival irritation, and redness are present in H., but the first-named symptom is less common than in M. (See p. 224.)

The most important *indirect result* of H. is *convergent strabismus*. To understand this we must remember that there is a certain constant relation between the action of the ciliary muscles and of the internal recti,—that A. can be exerted only to a very limited degree without convergence of the optic axes,



and that for every degree of A. there is, in the normal state, a constant amount of convergence (*compare* p. 34). In H. accurate near sight needs, as we have seen, an excess of A., thus, *e. g.* with H. of 2 D., clear vision of an object at 50 cm. will require as much A. as vision at 25 cm. by a normal eye, and this A. cannot be exerted without converging for 25 cm. (or nearly so). Such a person, therefore, has to do two things at once—to look at an object distant 50 cm., and to make his optic axes meet at 25 cm. The former he does by directing one eye (*e. g.* the R.) to the object 50 cm. off; the latter by converging the visual axes so that the L. meets the R. at 25 cm., instead of 50 cm. In this case the L. eye will squint inwards, but *both* internal recti will act equally in bringing about the convergence, and both eyes will use as much A. as a pair of normal eyes would do at 25 cm.

This “concomitant” convergent strabismus (p. 22, § 4) generally comes on early in childhood, as soon as the child begins to look attentively and use A. vigorously in regarding near objects. In examining cases we shall be struck by finding that: (1) in some the squint is noticed only when A. is in full use, that it appears and disappears under observation, according as the child fixes its gaze on a near object or looks into space (*periodic squint*); (2) in others the squint is constant, but is more marked during strong A.; (3) it is constant, invariable, and of high degree; (4) in most cases the squint always affects the same eye, and this is generally accounted for by some original defect of the eye itself (such as a higher degree of H., or As., or a corneal opacity), which leads to its fellow being chosen for distinct sight; but patients who see equally well with each eye often squint with either indifferently (*alternating squint*). The squint causes diplopia (homonymous, p. 308), and to avoid this inconvenience, patients for the most part soon learn to



ignore (or "suppress") the image formed in the squinting eye, the result usually being that this eye becomes very defective (p. 217). This power of suppressing the false image is learnt most easily in very early life. In alternating squint no permanent suppression occurs, and consequently both eyes remain good.

It will soon be noticed that squint is not present in every case of H. In very low degrees the necessary extra A. can be used without any extra convergence (relative accommodation p. 34). In very high degrees, on the other hand, the effort needed for distinct vision, even of distant, and *à fortiori* of near, objects, is so great that the child often sacrifices distinctness to comfort and binocular vision, using only so much A. as can be employed without overconvergence. The squint sometimes disappears spontaneously as the child grows up; this might be explained by an increased power of dissociating A. from convergence, or by a diminution of H. from elongation of the eye, or by a general tendency in all persons, and of this there is other evidence, to weakening of the internal recti with advancing age.

The *treatment* of H. consists in removing the necessity for overuse of A. by prescribing convex spectacles which, in proportion to their strength, supply the place of the increased convexity of the crystalline lens induced by A. In theory, the whole H. ought to be corrected by glasses in every case, and the eye be rendered emmetropic. But in practice we find it often better to give a weaker glass, at least for a time.

If A. in a H. eye be in abeyance (paralysed by atropia) vision for distant objects will be distinct only if the rays pass through a convex lens, held in front of the eye, whose focus coincides with the virtual focus of the retina (p. 287). The strength of this lens is the measure of the H.; thus the patient



has H. 2 D. if a convex lens of 50 cm. focal length is necessary for this purpose.

But if A. be intact, then, as it has constantly to be used for distant sight, the patient is often unable to relax it fully, when a corresponding convex lens is placed in the front of the eye; he will relax only a part, and this part will be measured by the strongest convex lens with which he can see the distant types clearly. That part of the H. which can be detected by this test is called "manifest," (m. H.). The part remaining undetected, because corrected by the involuntary use of A., is latent (l. H.). The sum of the m. H. and l. H. is the total (H.).

Now, most H. people can habitually use some A. for distance (and a corresponding excess for near vision) without inconvenience, and hence the full correction of H. is by no means always needful, or even agreeable to the patient. In many cases the correction of the m. H. is enough to relieve the asthenopic symptoms, at any rate for a considerable time; but we often find that after wearing these glasses for some weeks or months the symptoms return, and a fresh trial will then show a larger amount of m. H., which must then again be corrected by a corresponding increase in the strength of the glasses. This process may have to be repeated several times until after a few months the total H. becomes manifest, and may be corrected. This method is most suitable for adults in whom the use of atropine to paralyse A., and allow the immediate estimation of the total H., is inconvenient or impossible; or for whom the glasses which correct the total H., as estimated by the ophthalmoscope, without atropinisation, are found, if ordered at once, to be inconveniently strong. But for children there is seldom any gain, and often no little inconvenience, from following this gradual plan; with them the better way is to estimate the total H., and to order glasses slightly (1 D.) weaker than that amount.



*To examine for H.*—(1.) For m. H. Note the patient's vision for distant types at 6 m., then hold in front of his eyes a very weak convex lens (+ .5 D.), and if he sees as well, or better, with it, go to the next stronger lens, and so on until the strongest has been found which allows the best attainable distant vision; this lens is the measure of the m. H.

(2.) For H. (total).—The easiest and most certain plan is to direct the patient to use strong atropine drops (F. 26) three times a day for at least two days, and then to test his distant vision with convex glasses. As in (1), the strongest lens which gives the best attainable sight is the measure of the H.

*Ophthalmoscopic tests.*—(3) The image of the disc seen by the indirect method becomes smaller when the lens is withdrawn from the eye (Fig. 102, *bis*, B.).

(4.) The retinoscopic test is described at p. 55.

(5.) By direct examination an erect image is seen at whatever distance the observer be from the patient (p. 51). The observer may learn, as stated at p. 51, to estimate H. with almost as great accuracy with a refraction ophthalmoscope as by trial lenses, and this plan, like retinoscopy, is extremely valuable with children who are too young or too backward to give good answers. The total, or nearly the total, H. may be found in this way without atropine if the examination be made in a dark room, for then A. is generally quite relaxed, however persistently it may have acted when the patient was able to look attentively at objects in the light. The objective estimates (4 and 5), however, are more easily made after the use of atropine.

The next question is, whether the glasses are to be worn always, or only when A. is specially strained, *i. e.* in near work. They are to be worn constantly (1) whenever we are attempting to cure a squint by their means; (2) in all cases of high H. in children, whether with or without strabismus. But patients



who come under care for the first time as young adults, in whom the H. is, as a rule, of moderate or low degree, may generally be allowed to wear them only for near work. Elderly persons require two pairs—one for distance, neutralising the m. H., the other stronger, neutralising the presbyopia also, for near work (p. 303); the use of the former may, however, be left to the patient's choice.

*Treatment of convergent hypermetropic squint.*

(1.) If the squint be periodic (p. 290), it can be cured by the constant use of the spectacles which correct the total H.

(2.) The same is true in some cases where the squint, though constant, varies in degree, being greater during A. for near, than for distant, objects. It is best to use atropine in all such cases, and if under its use the squint disappear, or be much lessened, glasses will cure it. We shall, however, often be disappointed to find the squint as marked as ever, even with complete paralysis of A., and then, as a rule, it is not curable by glasses.

(3.) If the squint be constant in amount and of some years' standing, operation is usually necessary. As the squinting eye is then usually very defective (p. 217), the removal of the deformity is the chief object of the operation, binocular vision being comparatively seldom restored. Hence, in view of the tendency to spontaneous cure already mentioned, it is better not to operate on very young children, especially as in them we cannot easily tell whether or not the squint is still periodic. The most rational treatment for children under 4 (when glasses may often be begun) is to cover the eyes alternately with a blind for some hours daily, to ensure each eye being alternately used (p. 218); but this plan can seldom be carried out. When operation is decided upon it is a safe rule to divide only one internal rectus at a sitting. At the end of a few weeks, if



the squint still be considerable, the operation is performed on the other eye. Muscular asthenopia is very likely to come on some years later if both tendons are needlessly divided. It is safer to leave slight convergence than to run this risk. (*See also Divergent strabismus.*)

#### ASTIGMATISM (As.).

In the preceding cases (M. and H.), the refracting surfaces of the eye (the front of the cornea and the two surfaces of the lens) have been regarded as segments of spheres.

All the rays of a cone of light which issue from a round spot and pass through such a system are (neglecting "spherical aberration" (Fig. 9)) equally refracted, and meet one another at a single point—the *focus* of the system. For if such a cone of incident light be looked upon as composed of a number of different planes of rays, situated radially around the axis of the cone, the rays situated in any plane (say the vertical) will, after passing through the lens-system, meet behind it at its focus, whilst those forming any other plane (as the horizontal) will meet at the same point; and the same will be true of all the intermediate planes.

But let the curvature, and, therefore, the refractive power, of one of the media (for instance, the cornea) be greater in one meridian, say the vertical, than in the horizontal, then the vertical-plane rays will meet at their focus, whilst the horizontal-plane rays at the same distance will not yet have met, and if received on a screen will form a horizontal line of light. If the intermediate meridians had regularly intermediate focal lengths, they would form, at the same place, lines of intermediate lengths, and the image of the round spot of light, if caught on a screen at this distance, would form a horizontal oval. To a retina receiving such an image, the round point of light would appear drawn out horizontally. Such



an eye is called astigmatic, because unable to see a point as such, all round points appearing drawn out more or less into lines.

A little reflection will show that in the same case, at the focal point of the horizontal-plane rays, the rays of the vertical plane will already have met and crossed, and that the image at this point will form a vertical oval.

If the screen be placed midway between these two extreme points, the image will be circular, but blurred, because the vertical-plane rays will have crossed, and begun to separate, while the horizontal ones will not yet have met, and each set will be equally distant from its focus. The meridians of the astigmatic medium which refract most (shortest focus) and least (longest focus) are the "*principal meridians*." The distance between their foci is the "*focal interval*," and represents the degree of astigmatism.

The astigmatism of the eye may be *regular* or *irregular*. In *regular astigmatism*, the meridians of greatest and least refractive power, "*principal meridians*," are always at right angles to each other; and every meridian is nearly a segment of a circle. Of the principal meridians, the most refractive (the one with shortest focal length) is, as a rule, vertical, or nearly so, and the least refractive, therefore, horizontal, or nearly so. The cornea is the principal seat of this asymmetry. The crystalline lens, however, is also astigmatic, to a less degree, and its meridians of greatest and least curvature are usually so arranged as in some degree to neutralise those of the cornea; it thus partially corrects the corneal error.

Regular astigmatism is corrected by a lens which equalises the refraction in the two principal meridians. Such a lens must be a segment of a cylinder, instead of, like an ordinary lens, a segment of a sphere. Rays traversing a cylindrical lens in the plane of the axis of the cylinder are not refracted,



since the surfaces of the lens in this direction are parallel; but rays traversing it in all other planes are refracted, more or less, and most in the plane or meridian at a right angle with the axis.

*Irregular astigmatism* may be caused either by irregularities of the cornea, arising from ulceration or conical cornea\* (p. 104); or by various conditions of the crystalline lens, such as differences of refraction in its various sectors, tilting or lateral dislocation of the lens, so that its axis no longer corresponds, as it should nearly do, with the centre of the cornea. Irregular astigmatism causes much distortion of the ophthalmoscopic image, especially when the lens is moved from side to side. It is seldom much benefited by glasses.

Returning to *Regular Astigmatism*, it will be seen that the optical condition of the eye depends upon the position of the retina in respect to the focal interval. In the following diagram (Fig. 109) let the most refracting meridian be vertical, and its focus be called *a*, the least refracting meridian horizontal and its focus *b*. (The astigmatism is here re-

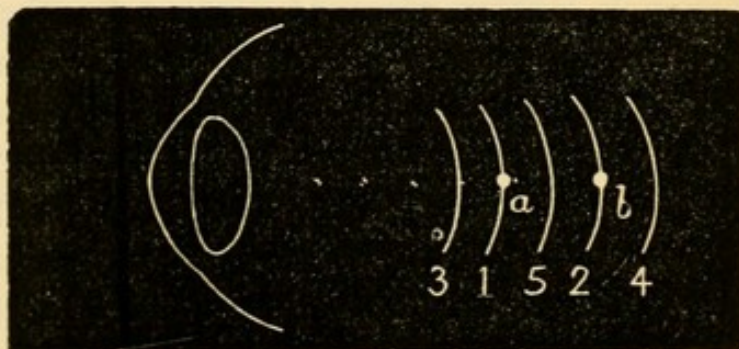


FIG. 109.

presented as caused by altered *position of the retina* in different planes, instead of by altered *curvature of the cornea* in different planes, the diagram being, of course, only intended to aid the comprehension

\* There can be little doubt from clinical observation with a refraction ophthalmoscope, that corneal As., is often still more complicated owing to the curvature of each meridian being permanently and naturally more or less elliptical instead of circular, and this without any tendency towards "conical cornea," as commonly understood.



of the principle.) (1) Let  $a$  fall on the retina (1, Fig. 109), and  $b$ , therefore, behind it. There is E. in the vertical meridian, and therefore H. in the horizontal meridian; this is simple H. As. (2) Let  $b$  fall on the retina (2, Fig. 109), and  $a$  in front of it. The horizontal meridian is, therefore, E., and the vertical meridian M.; simple M. As. (3) Let  $a$  and  $b$  both lie behind the retina (3, Fig. 109). There is H. in both meridians, but more in the horizontal than the vertical meridian; compound H. As. (4)  $a$  and  $b$  are both in front of the retina (4, Fig. 109). There is M. in both meridians, but more in the vertical than the horizontal; compound M. As. (5)  $a$  is in front of the retina, and  $b$  behind it (5, Fig. 109). There is M. in the vertical and H. in the horizontal meridian; mixed As.

The general symptoms of As. are of the same order as those caused by the simpler defects of refraction; but attention to the patient's complaints, and to the manner in which he uses his eyes, will, in the higher degrees, often give the clue to its presence. Low degrees, especially of simple H. As., often give rise to no inconvenience till rather late in life. As. is most commonly met with in connection with H., because H. is so much commoner than M. But it is said to occur with greater *relative* frequency in M., when, if complications be present, it may, if not of high degree, be readily overlooked unless specially sought for. The higher grades of As. cause much inconvenience, no objects being seen clearly; and spherical glasses, though of use if the As. be compound, are nearly useless if it be simple. As. is always to be suspected if, with the best attainable spherical glasses, distant vision is less improved than it ought to be (supposing, of course, that no other changes are present to account for the defect). No definite rule can be laid down as to the degree of defect which should raise the suspicion of As.; indeed, in the higher degrees of even simple M. and



H., acuteness of vision is often below normal (pp. 218 and 280).

As. may be measured either by trial with glasses, by retinoscopy (p. 55), or by ophthalmoscopic estimation (p. 53) of the refraction of the retinal vessels in the two chief meridians. A comparatively easy qualitative test is found in the apparent shape of the disc, which instead of being round, is more or less oval. In the erect image the long axis of the oval corresponds to the meridian of greatest refraction, and is therefore as a rule nearly vertical (Fig. 110).

In the inverted image (Fig. 111) the direction of the oval is at right angles to the above, provided that the object lens be nearer than its own focal

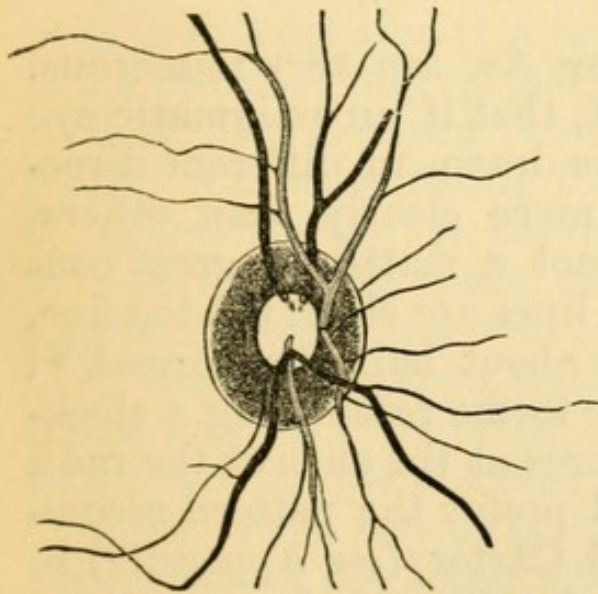


FIG. 110.—Erect image of disc in Astigmatism with meridian of greatest refraction nearly vertical (Wecker and Jaeger).

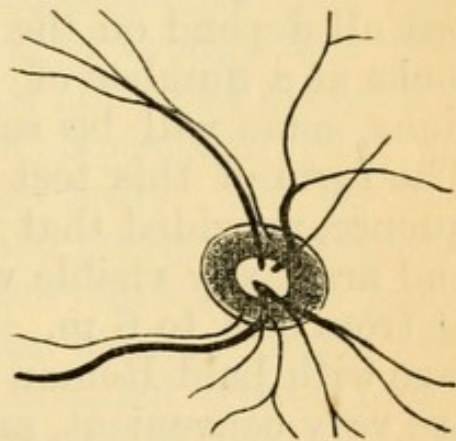


FIG. 111.—The same disc, seen by the indirect method (Wecker and Jaeger).

length to the eye. As. is suspected when in the erect image, an undulating retinal vessel appears clear in some parts, and indistinct in others, an appearance which may be taken for retinitis if the examination be confined to the erect image. It may be imitated by looking at a wavy line through a cylindrical lens.



In the indirect examination the shape of the disc changes on withdrawing the lens from the patient's eye. It will be remembered that in M. the image increases as the lens is withdrawn (p. 276, 2), that in E. its size remains the same, whilst in H. it diminishes (Fig. 102, *bis*). Thus, in a case of simple M. As. in the vertical meridian, that dimension of the disc which is seen through the vertical meridian will enlarge on distancing the lens; from being oval horizontally, when the lens is close to the eye, it becomes first round and then oval vertically on withdrawing the lens. In the other forms of As. the same holds true; the image enlarges, either absolutely as in M. As., or relatively as in H. As., in the direction of the most refracting meridian.

The subjective tests for As. are very numerous, but all depend on the fact, that if an astigmatic eye looks at a number of lines drawn in different directions, some will be seen more clearly than others. The form of this test is not a matter of great consequence, provided that the lines are clear, not too fine, and are easily visible with about half the normal V. at from 3 m. to 6 m. The forms resembling a clock-face with bold Roman figures at the ends of the radii are very convenient, and I prefer the pattern recommended by Mr Brudenell Carter (*see Appendix*) to any other that I have used. On this face are three parallel black lines separated by equally wide white spaces, and which collectively form a "hand" that can be turned round into the positions of best and worst vision.

The easiest case for estimation is one of simple H. As., in which the eye is under atropine. Many cases of simple M. As. are almost as easy to test. In a given case let the eye be E. in the vertical meridian, and H. in the horizontal. With A. paralysed, rays refracted by the vertical meridian will be accurately focussed on the retina, whilst the focus of



those refracted by the horizontal meridian will be behind the retina (Fig. 109, 1), and consequently form on it a blurred image. Now the rays which strike in the plane of the vertical meridian are those which come from the borders of horizontal lines; hence the patient under consideration will see the lines at a distance of 3 m. to 6 m. quite clearly when the "hand" is horizontal, except their ends, which will be blurred. The rays which strike in the plane of the horizontal meridian are those which proceed from the sides of vertical lines, and as this meridian is hypermetropic the lines in the "hand," when placed vertically, will be indistinct, except their ends, which will be sharply defined. We now leave the "hand" vertical, and test the refraction for the lines in this position (*i. e.* for the horizontal meridian) in the ordinary way (p. 293, 2), and find, *e.g.* that with + 2 D. they are seen most clearly, though not perfectly. On substituting for the spherical glass, + 2 D. cylinder with its curvature horizontal (*i. e.* its axis vertical) the lines of the hand, and all the figures on the clock will be seen perfectly; the vertical lines and figures being seen through the horizontal meridian corrected by the cylinder lens; the horizontal figures through the unaided vertical meridian, the rays which pass through the cylinder in this meridian not being refracted.

In a case of simple M. As. in the vertical meridian the lines of the "hand" will be dull or invisible when horizontal, whilst when vertical they will be clear. On trial a concave cylinder will be found, which, with its curvature vertical (axis horizontal), makes the lines of the hand quite clear when horizontal, and all the figures quite plain.

The cases of compound and mixed As. are less easily dealt with by this test. It is generally best first to find in the usual way the spherical glass which gives the best result for the distant types, and then, arming the eye with this glass, to test for As., with



the clock-face and cylindrical lenses, as in the simple cases described above.

We may use, instead of a cylindrical glass, a narrow slit in a round plate of metal, which can be placed in the direction of either of the chief meridians, the spherical glass being then found with which, in each meridian, the patient sees best. One chief meridian may be ascertained by finding the direction of the slit which gives the best sight with the spherical glass chosen in the preliminary examination, and the other meridian by finding the glass which gives the best result with the slit at a right angle to the former direction.

Another method (that of Javal) consists in making the patient highly myopic for the time being, by means of a convex lens (unless he be myopic already); then accurately finding his far point for the least myopic meridian, and, lastly, finding the concave cylinder which is needed to reduce the opposite meridian to the same refraction. A special apparatus is needed.

Ophthalmoscopic estimation and retinoscopy, however, save much time, especially in mixed As.

Whatever means be employed, the degree of As. is expressed by the difference between the glasses chosen for the two chief meridians; or by the cylindrical lens which, added to the chosen spherical, gives the best result for the lines or the distant types. When cylindrical glasses are ordered the whole of the astigmatism should be corrected. It is not usually necessary to correct astigmatism of less than 1 D.; but exceptions to this rule are not uncommon, some patients deriving marked relief from the correction of lower grades.

Vision is often defective in As., and in the high degrees we are often obliged to be content with a very moderate improvement at the time of examination. This may sometimes be explained by the retina never having received clear images, *i. e.*



never having been accurately practised (p. 218); V. in such cases often improves after proper glasses have been worn for some months. In other cases, irregular As. is the cause of the defect. Much also depends on the intelligence of the patient; some persons are far more appreciative of slight changes in the power, or in the direction of the axis, of the cylinder than others, and this apart from the absolute acuteness of sight.

*Unequal refraction in the two eyes (An-iso-metropia).*—It is common to find that one eye has more H., more M., or more As., than its fellow; or that one is normal, while the other is ametropic. When the difference is not more than is represented by 1.5 D., and V. is good in both (see p. 218), the refraction may with advantage be equalised by giving the glasses which correct each eye, and the development of divergent squint (p. 311, 3) may sometimes be prevented by the increased stimulus to binocular vision thus given. But equalisation is seldom possible if the difference be greater, though, especially in myopic cases, advantage is sometimes gained by partial equalisation. When no attempt is made to harmonise the eyes, the spectacles ordered should suit the *less* ametropic eye. Often, when one eye is E. and the other M., each is used separately for different distances, and both remain perfect; but if one be As. or very H. it is generally defective from want of use.

#### PRESBYOPIA (Pr.).

Presbyopia (old sight, often called "long sight") is the result of the gradual recession of  $p$ , which takes place as life advances, and which causes curtailment of the range or amplitude of A (p. 33). From the age of ten (or earlier) onwards,  $p$  is constantly receding from the eye. When it has reached 9" (22 cm.), *i. e.* when clear vision is no longer possible at a shorter distance than 22 cm., Pr. is said to have



begun. The standard is arbitrary, 22 cm. having been fixed by general agreement as the point beyond which  $p$  cannot be removed without some inconvenience, the point where age begins to tell on the practical efficiency of the eyes unless glasses are worn. In the normal eye this point is reached soon after forty, and the rate of diminution is so uniform that the glasses required to bring  $p$  to 22 cm. may often, if necessary, be determined merely from the patient's age. But, as there are exceptions to this rule, even for normal eyes, allowance has to be made for any error of refraction (H. or M.), and it is unsafe in practice to rely upon age except as a general guide.

The slow failure of A., causing Pr., depends upon senile changes in the lens, which render it firmer and less elastic, and therefore less responsive to the action of the ciliary muscle. There can be little doubt, however, that failure of the ciliary muscle itself, or of its motor nerves, also forms an important factor in those cases where Pr. comes on earlier or more quickly than usual (*see also* p. 237).

As Pr. depends on a natural recession of the near point, it occurs in all eyes, whether their refraction be E., M., or H. In M., however, Pr. sets in later than in a normal eye, because for the same *range* of A. the *region* is always nearer than in the normal eye. In H., on the contrary, Pr. is reached sooner than is normal, because for the same *range* of A. the *region* is always further than in the normal eye. Thus, in an E. eye a power of A. = 4.5 D. gives a *range* from  $r = \text{infinity}$  to  $p = 22$  cm. (the focal length of 4.5 D., *see* p. 33), *i.e.* Pr. is just about to begin. In a case of M. 2 D., with the same *range*, the *region* of A. lies between 50 cm. (the  $r$  for this eye) and 15.5 cm. (= focal length of  $2 + 4.5$ , or 6.5 D.); Pr. has not yet begun. In a case of H. 2 D. with the same *range*, 2 D. of A. are used in correcting the H., *i.e.* in bringing  $r$  to infinity, and only 2.5 D. of A. re-



mains;  $p$  is therefore at 40 cm. (= focal length of 4.5 — 2, or 2.5 D.), and a + lens of 2 D. is needed to bring  $p$  to 22 cm.; there is Pr. = 2 D. The only cases in which Pr. cannot occur are in M. of more than 4.5 D. Thus if  $M = 7$  D.,  $r$  is at 14 cm., and though, with advancing years,  $p$  will recede to 14 cm., it cannot go further, cannot reach 22 cm.; the patient, who never could see at a greater distance than 14 cm., has simply lost the power to see at a shorter distance.

*Treatment.*—Convex spectacles are found, by the aid of the Table given below, with which the patient can read at 22 cm.

In practice it is always proper to examine for H. or M., by taking the distant vision, and trying the patient for m. H. (p. 293) and M. (p. 283). If m. H. be found, arm the patient with the glass which neutralises it and makes him E., and then add the convex glass that should, by the Table, be required to bring  $p$  to 22 cm. If M. be found, subtract its amount from the corresponding convex glass.

In prescribing for Pr. we must often order rather less than the full correction. For instance, if A. be almost entirely lost,  $p$  is practically removed to  $r$ , and the glass which will bring  $p$  to 22 cm. will also bring  $r$  to the same, or nearly the same point, and the patient will be able to see clearly only just there. Now 22 cm. is too near for sustained vision, and such patients often prefer a glass which gives them a near point of from 30 to 40 cm. (12" to 16"), though in choosing it they sacrifice some degree of sharpness of sight. The difficulty experienced by these patients in reading with glasses which give  $p = 22$  cm. depends on the unaccustomed strain which is thereby thrown on the internal recti; and it may be removed or lessened by adding to the convex glasses prisms, with the bases towards the nose (Fig. 16); or by decentring the ordinary convex lenses inwards (Fig. 17).



*Presbyopia Table for Emmetropic Eyes.*

Age.	Distance of <i>p</i> .		Pr., expressed by the lens necessary to bring <i>p</i> to 22 cm. or 9".	
	cm.	Inches.	Dioptries	Paris Inch scale.
40.....	22.....	9.....	0.....	0
45.....	28.....	11.....	+1.....	+ $\frac{1}{3.6}$
50.....	43.....	17.....	2.....	$\frac{1}{1.8}$
55.....	67.....	27.....	3.....	$\frac{1}{1.2}$
60.....	200.....	72.....	4.....	$\frac{1}{9}$
65.....	infinity.....		4.5.....	$\frac{1}{8}$
70.....	acquired	H.=1 D.	5.5.....	$\frac{1}{6\frac{1}{2}}$
75.....	"	" 1.5 D.	6.....	$\frac{1}{6}$
80.....	"	" 2.5 D.	7.....	$\frac{1}{5}$



## CHAPTER XXI

## STRABISMUS AND OCULAR PARALYSIS.

STRABISMUS exists whenever the two eyes are not (as they ought to be) directed towards the same object. The eye is "directed towards" an object when the image is formed on the most sensitive part of the retina (the yellow spot); the straight line joining the centre of this image with the centre of the object is the "visual axis" (*see* footnote to p. 22). In health the action of the ocular muscles is such as to keep both visual lines always directed to the object under regard, and binocular but single vision is the result. Although each eye receives its own image, only one object is perceived by the sensorium, because the images are formed on parts of the retinæ which "correspond" or are "identical" in function, *i.e.* which are so placed that they always receive identical and simultaneous stimuli.

But if, owing to faulty action of one or more of the muscles, one eye deviate and the visual lines cease to be directed towards the same object, the image will no longer be formed on the y. s. in both eyes. In one of them it must fall on some other and non-identical part of the retina, and the result is that two images of the same object are seen (*Diplopia*, p. 22). In Fig. 112 *y* is the y. s. in each eye, and the visual line of the R. eye (the thick dotted line) deviates inwards; hence the image of the object (*ob.*) which is formed at *y* in the L. eye, will in the R. eye fall on a non-identical part to the inner side of *y*. *Ob.* will be seen in its true position by the L. eye. To the R. eye, however, it will appear to be at *F. ob.*, because the part of the R. retina which now receives



the image of *ob.* was accustomed, when the eye was normally directed, to receive images from objects in

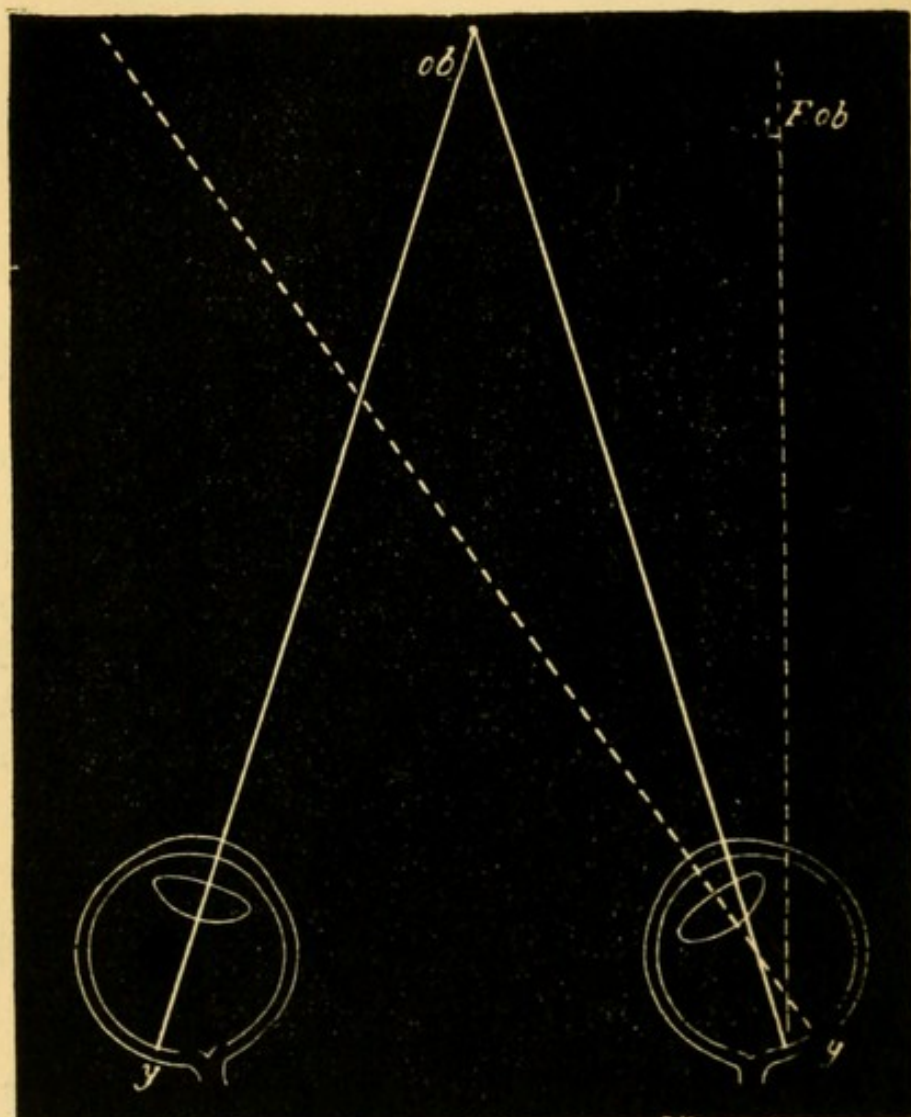


FIG. 112.—Shows the position of the double images in diplopia from convergent or crossed strabismus. The images are homonymous, or correspond in position to the eyes.

the position of *F. ob.*; and in consequence of this early habit *F. ob.* is the position to which every image formed on this part of the retina is referred.

Hence if the eye deviate towards its fellow (convergent squint—as in Fig. 112), the false image will seem to the squinting eye to be in the opposite direction; the image (*F. ob.*) for the R. eye being referred to the patient's R., and that for the L. eye (*ob.*) to his L.; in convergent or crossed strabismus the double images correspond in position to the eyes, or



are *homonymous*.—Similar reasoning will show that if the eye deviate from its fellow (Fig. 113, divergent squint), the position of the double images must be

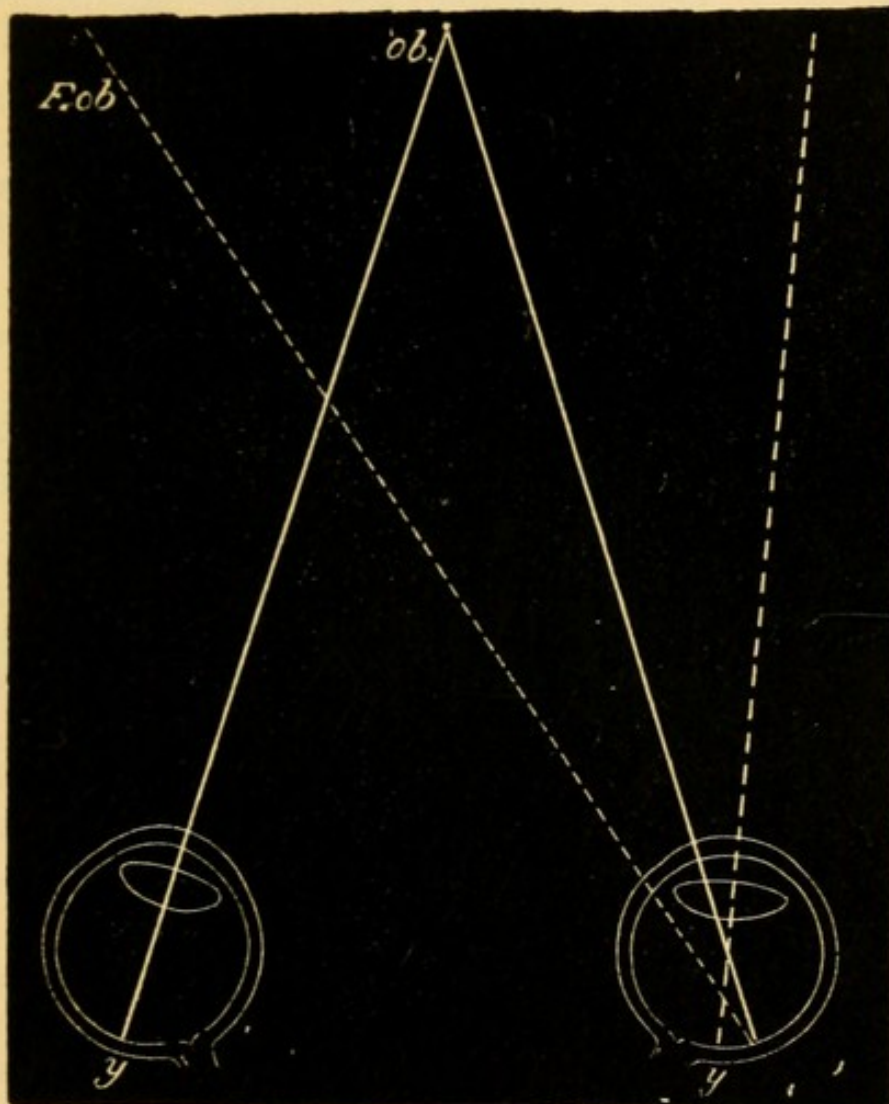


FIG. 113.—Position of double images in divergent strabismus.  
The images are crossed.

reversed, and the image belonging to the R. eye appear to be to the left of the other; hence in divergent squint the double images are *crossed*.

Since the image of *ob.* in the squinting eye is formed on a portion of the retina, more or less distant from the most perfect part (the *y. s.*), it will not appear so clear or so bright as the image formed at the *y. s.* of the sound (or “working”) eye; it is called the “false” image, that formed in the working eye being the “true” one. The greater the deviation



of the visual line (*i. e.* the greater the squint) the wider apart will the two images appear and the less distinct will the "false" image be.

[The y. s. (*y*) of the R. eye will receive an image of some different object lying in its visual line (shown by the thick dotted line); this image, if sufficiently marked to attract attention, will be seen, and will appear to lie upon the image of *ob.* seen by the "working" (L.) eye; two equally clear objects will be seen superimposed. But, as a rule, only one of these images is attended to, the perception of the other being habitually suppressed, even sooner than that of the "false image" (p. 217); the suppressed image always belongs to the squinting eye.]

Squinting is not always accompanied by double vision because:—(1) if the deviation be extreme, the false image is formed on a very peripheral part of the retina, and is so dim as not to be noticed; conversely, the less the squint the more troublesome is the diplopia, when present; (2) as already mentioned (p. 217), after a time the "false image" is suppressed.

For the method of examining for strabismus and diplopia, *see* pp. 21 and 22.

Strabismus may arise from any one of the following muscular conditions:—(1) over-action; (2) weakness, following over-use; (3) disuse of an eye whose sight is defective; (4) stretching and weakening of a tendon after tenotomy; (5) from paralysis of one or more of the muscles.

(1.) Over-action of the internal recti gives rise to the convergent squint of hypermetropia (p. 289). Occasionally convergent squint occurs in myopia. Both forms are concomitant (p. 22), but in cases of long standing the range of movement of the squinting eye is often deficient.

(2.) Strabismus from weakness (*muscular asthenopia*, pp. 224 and 275) always depends on weakening



of the internal rectus, and is consequently divergent. It is commonest in M., but is not infrequent in H., and even in Em. The eye can be moved into the inner canthus, even in extreme cases, by making the patient look sideways, though not by efforts at convergence, and it is thus but rarely that these cases simulate paralysis. Tenotomy of the external rectus and "advancement" of the weakened muscle are often needed.

(3.) Strabismus from disuse is also nearly always divergent, depending, as it does, on relaxation of the internal rectus. It occurs in cases where convergence is no longer of service, as when one eye is blind from opacity of the cornea or other cause, or where the refraction of the two eyes is very different (p. 303). Treatment is seldom useful, but tenotomy of the external rectus may be called for.

(4.) Stretching and weakening of the internal rectus after division of its tendon for convergent squint may give rise to divergence, simulating that caused by paralysis of the internal rectus. The caruncle in these cases, however, is generally much retracted, and this, together with the history of a former operation, will prevent any mistake in diagnosis. Such a squint can always be lessened, and often quite removed, by an operation for "readjustment" or "advancement" of the defective muscle.

(5.) *Paralytic squint*.—The deviation is caused by the unopposed action of the sound muscles. When the palsied muscle tries to act, the eye fails, in proportion to the weakness, to move in the required direction. In many cases there is only slight paresis, and the resulting deviation is too little to be objectively noticeable; but in such cases the diplopia, as mentioned already, is very troublesome, and it is for this symptom that the patient comes under care. Further, in these slight cases the symptoms often vary with the effort made by the patient. In paralysis of the third nerve the several branches



are often affected in different degrees, and the strabismus and diplopia are then complex. When paralysis is of long standing, secondary contraction of the opponent seems sometimes to occur, still further complicating the symptoms. Lastly, the sound yoke-fellow\* of the paralysed muscle sometimes acts too much in obedience to efforts made by the latter, and in this way the squint may occasionally, even when both eyes are uncovered, affect the sound instead of the paralysed eye, *i. e.* it may alternate. (*Compare* Secondary squint, p. 21.)

The commonest forms of paralytic squint are due to affection, separately, of the external rectus (sixth nerve), superior oblique (fourth nerve), or of one or all of the muscles supplied by the third nerve (internal, superior and inferior recti, inferior oblique, levator palpebræ).†

*Paralysis of the external rectus (sixth nerve)* causes a convergent squint from preponderance of the internal rectus; and this, except in the slightest cases, is very noticeable. Movement straight outwards is impaired, and if the paralysis be complete the eye cannot be moved outwards beyond the middle line of the palpebral fissure. There is homonymous diplopia; the two images, when in the horizontal plane, are upright and on the same level; the distance between them increases as the object is moved towards the paralysed side, but it diminishes, or the images even coalesce, in the opposite direction. Thus, in paralysis of the left external rectus (Fig. 114, uppermost figure), the images separate more as the object is moved to the patient's left, but approach one another,

\* Yoked or conjugate muscles are the muscles of opposite eyes which act together in producing lateral and vertical movements; *e. g.* the internal rectus of one eye acts with the external rectus of the other in movement of the eyes to the R. or L.

† In 77 cases of paralysis of a single oculo-motor nerve I found the third nerve affected in 31 cases, the fourth in 9, and the sixth in 37.



and finally coalesce, as it is moved over to his right. In slight cases the diplopia ceases when the patient looks at an object a few inches off, but reappears when he gazes straight forwards at a distant object. In the upper part of the field the false image is sometimes lower, and in the lower part of the field higher than the true one. I have many times noticed that the pupil is larger in the affected eye than in the other, a condition which we should not expect.

In *paralysis of the superior oblique (fourth nerve)* there is either no visible squint, or only a slight deviation upwards and inwards. But when the eyes are directed below the horizontal, very troublesome diplopia arises from the defective downward and outward movement, and loss of rotation of the vertical meridian inwards, to which the lesion gives rise. In downward movements, especially downwards and towards the paralysed side, the eye remains a little higher than its fellow; in trying to look straight down (inferior rectus and superior oblique) the unopposed action of the inferior rectus carries the cornea somewhat inwards (convergent squint), and at the same time rotates the vertical axis outwards, whilst the cornea remains on a rather higher level than its fellow; in following an object from the horizontal middle line down-outwards it will be seen that the vertical meridian of the cornea does not, as it should, become inclined inwards.

In many cases, however, the slight defects of movement caused by paralysis of the superior oblique are not clearly marked, and the diagnosis has to be based on the characters of the diplopia (*compare p. 22*). In all positions below the horizontal line the false image is below the true one, and displaced towards the paralysed side (homonymous); thus, if the R. muscle be at fault the false image will be below and to the patient's R. (Fig. 114, arrow-head figure); further, it is not upright, but leans towards the true image. The difference in height between the images is



greatest in movements towards the sound side; the lateral separation is greater the further the object is moved downwards; the leaning of the false image is greatest in movements towards the paralysed side. When the patient looks on the floor, *i. e.* projects the images on to a horizontal surface, the false image seems nearer to him than the true one. The images are always near enough together to cause inconvenience, and as the diplopia is confined to, or is worst in, the lower half of the field, the half most used in daily life, paralysis of the superior oblique is very annoying, especially in going up or down stairs, in looking at the floor, counting money, eating, &c.

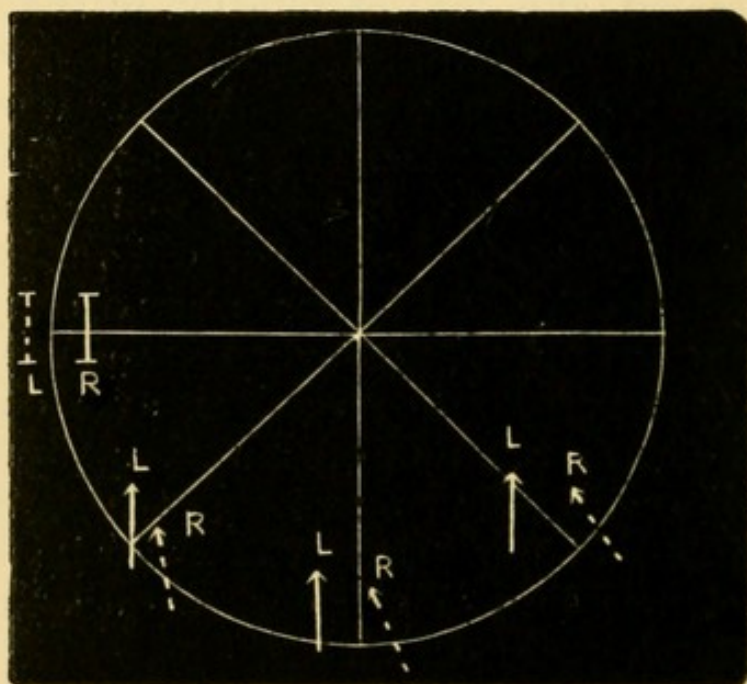


FIG. 114.—Chart showing position of double images, as seen by the patient, in paralysis of L. external rectus and R. superior oblique.

*Paralysis of the third nerve*, when complete, causes ptosis, loss of inward, upward, and downward movements, loss of accommodation, and partial mydriasis, well-marked divergent strabismus from unopposed action of the external rectus, and crossed diplopia. The downward and outward movement, with rotation of the vertical meridian inwards, effected by the



superior oblique remains. The mydriasis is much less than that produced by atropine. In many cases the paralysis is incomplete, affecting some branches (and muscles) more than others, and the symptoms are then less typical. Isolated paralysis of a single third nerve muscle is rare.

*Peculiarities of paralytic strabismus.*—(1.) If a patient suffering, *e. g.* from paresis of one external rectus, look at an object distant about two feet, and the sound eye be then covered by holding a card (or a piece of ground glass) before it, the paralysed eye will make an attempt (more or less successful according to the degree of palsy) to look at the object. The movement effected will call for a greater effort than if the sixth nerve were healthy, and as the eye muscles always work in pairs, the same effort will be transmitted to the internal rectus of the healthy eye. The latter will, in consequence, describe a larger movement than the paralysed eye, *i. e.* the secondary squint will be greater than the primary (p. 22). This test is sometimes of use in distinguishing which is the faulty eye, in cases where the squint is slight, and the patient unable to distinguish between the false and true images (p. 23). (2.) Giddiness is often present when the patient walks with the sound eye closed. This symptom depends on an erroneous judgment of the position of surrounding objects, which is caused by the weakened muscle not being able to achieve a movement of the eye corresponding in magnitude to the effort made. It is absent when both eyes are open, and when the paralysed eye is covered. It often gives us more aid than the former symptom in determining which is the faulty eye; but it varies much in severity in different cases, and may be quite absent. Patients with ocular palsy often keep one eye closed, *nearly always the paralysed one*, to avoid diplopia.

Paralysis of the ocular muscles is seldom symmetrical; in the rare cases where it is so, the disease is



usually intracranial, and in most cases nuclear, though symmetrical disease of nerve trunks sometimes occurs. In certain cases of symmetrical paralysis of all the ocular muscles ("*ophthalmoplegia externa*"), which depend on nuclear disease, other cranial nerves (especially the optic and fifth) are often involved, and symptoms of spinal or bulbar disease often present (p. 318).

*Paralysis of the internal muscles of the eyeball.*

The three internal muscles are supplied by two nerves; the ciliary muscle and sphincter of the pupil by the third nerve (short root of lenticular ganglion), the dilator of the pupil by the sympathetic, but whether from the lenticular ganglion, or by branches independent of that structure, is uncertain. The following paralytic states of these three muscles are to be distinguished.

A. *Iris affected alone.*—(1.) Paralysis of the dilator. The pupil in moderate light is equal to, or rather smaller than, the other; in a bright light it contracts a little, but when shaded does not dilate, and hence, if the eyes be examined in a dull light, the paralysed pupil is much smaller than its fellow (*paralytic miosis*); accommodation is not affected. This state of the pupil occurs in paralysis of the cervical sympathetic; in a certain degree it is common in old age. In intrathoracic aneurysm it often occurs from destructive compression of the sympathetic trunk; it should, therefore, always be regarded as a symptom calling for investigation. Dilatation from spasm of the dilator, owing to irritation of the same nerve, is said to occur in similar cases, and would equally demand attention. (2.) Paralysis of the sphincter alone (*paralytic mydriasis*) causes moderate dilatation; the pupil remains of the same size in the brightest light, and accommodation is unaffected. It is very rare. (3.) Paralysis of both iridian muscles without affection of accommodation (*iridoplegia*).



The pupil is of medium size, and uninfluenced by variations of light (reflex iridoplegia); but its associated action (p. 28) is usually retained, except in very advanced cases.

B. *Ciliary muscle paralysed alone (Cycloplegia).*—Accommodation is lost without any change in the activity of the pupil. The term is applied only to cases of nervous origin, not to presbyopia. The condition is very rare, except after diphtheria, when paralysis (often only paresis) of accommodation, with little or no affection of iris, is common.

C. *Ciliary muscle and iris affected.*—(1) *Mydriasis with cycloplegia*; partial dilatation of the pupil (to about 4 or 5 mm.), with loss of accommodation. The condition is seen in complete paralysis of the third nerve. In rare cases it occurs without failure of any other part of the nerve, and then the pupil is sometimes widely dilated. (2.) Paralysis of all the three internal muscles ("*ophthalmoplegia interna*") ; loss of accommodation, no movement of iris either "associated" or "reflex," pupil of medium size; it is often a later stage of iridoplegia (A, 3).

*Causes of ocular paralysis.*—It is convenient to separate the external and mixed forms from those in which only the internal muscles are involved, since the local lesions are, as a rule, different in the two groups.

Paralysis of the third, fourth, or sixth nerve, may be the result of tumours or other growths in the orbit, but in such cases, as a rule, the paralysis forms only one amongst other well-marked local symptoms. In the vast majority of uncomplicated ocular palsies there is nothing in the state of the eye, or the orbital parts, to guide us as to whether the seat of disease lies in the orbit or within the cranium. Meningitis, morbid growths, and syphilitic periostitis at the base of the skull, or involving the sphenoidal fissure, often cause ocular palsy, seldom



confined to one nerve, and aneurysm of the internal carotid in the cavernous sinus occasionally does so. Syphilitic gumma of the nerve trunk is probably the commonest cause of single paralysis; the intracranial portion of the nerves is known to be often the seat of such growths, but small neural gummata probably occur also on the orbital part of the nerves. Fractures of the skull often lead to ocular paralysis by compression of a nerve, either by displacement of bone or by inflammatory exudation afterwards thrown out. Pain in the temple or front of the head is very common in ocular palsies due to periostitis and gummata. In certain cases neither the symptoms nor history enable us to locate the seat, or prove the cause, of the paralysis. The term "rheumatic" is often applied to such cases on the assumption that the palsy is peripheral and caused by cold, that it is, in fact, to be compared to peripheral paralysis of the facial nerve; no doubt some of these are in reality syphilitic. Paralysis, usually of short duration and affecting only one nerve, is not uncommon at an early stage of locomotor ataxy. Ophthalmoplegia externa generally sets in slowly, is permanent, and indicates sclerotic disease of the nerve centres, usually caused by syphilis; but it is sometimes caused by tumour centrally placed. Occasionally it is "functional," and passes off.

In respect to the causation of the internal paralyses we have but little positive knowledge. Mydriasis with cycloplegia and no other paralysis, would be accounted for by disease of the short (third nerve) root of the lenticular ganglion. Iridoplegia and ophthalmoplegia interna are probably the result of chronic, very strictly localised, disease of the centres for the pupil and accommodation (Gowers), which have been shown to form separate parts of the nucleus of the third nerve. Complete ophthalmoplegia interna would also occur if the lenticular ganglion (Hutchinson), or the intraocular gan-



glionic cells of the choroid (Hulke), were disorganised; but such changes have not yet been proved *post-mortem*.

*Treatment of ocular paralyses.*—In estimating the results of treatment it is well to remember that some cases recover spontaneously, that in many the defect is a paresis rather than paralysis, and that in the latter cases the symptoms often vary in severity from day to day, or even whilst under observation at a single visit, according to the attention and effort given by the patient. The questions of syphilis and of injury to the head are always to be carefully inquired into, especially when only one nerve is paralysed. When several nerves are involved, tumour, aneurysm, or syphilis (either gummatous inflammation at the base, or sclerotic nuclear disease) are to be suspected; in the nuclear cases there is usually bilateral symmetry. Iodide of potassium and mercury are the only internal remedies likely to be beneficial, and unless syphilis be quite out of the question they should have a full trial; many cases recover quickly under moderate doses of iodide. Faradisation of the paralysed muscles is sometimes used.

*Nystagmus* (involuntary oscillating movement of the eyes) is generally associated with serious defect of sight dating from very early life, such as opacity of the cornea after ophthalmia neonatorum, congenital cataract, choroido-retinitis, or disease of the optic nerve. It is, however, also seen in cases of infantile amblyopia without apparent cause, and constantly in albinos. Nystagmus is often developed during adult life, in coal miners; it has been attributed to the insufficiency of light furnished by the safety lamps, and with more probability to the necessity which the miner is under of constantly looking in an unnatural direction, upwards or sideways for example. It is often present only when the collier takes up his mining posture. Nystagmus also forms a symptom in some cases of disseminated sclerosis.



Usually both eyes oscillate, but when only one eye is defective, it alone may oscillate.—The movements in nystagmus, whatever may be the cause of the condition, vary much in rapidity, amplitude and direction in different cases, and even in the same case at different times; they are generally worse when the patient is nervous, and often there is a particular position of the eyes in which the oscillation is least. Nystagmus often becomes much less marked as life advances. Treatment is useless.



## CHAPTER XXII

## OPERATIONS.

## A. OPERATIONS ON THE EYELIDS.

1. *Epilation of eye-lashes*.—Position: patient seated; surgeon standing behind. The forceps to be broad-ended, with smooth, or very finely roughened, blades which meet accurately in their whole width. Stretch the lid tightly by a finger placed over each end. Pull out the lashes at first quickly in bundles, and finish by carefully picking out the separate ones that are left.

2. *Eversion of upper lid*.—Position as for 1, or the surgeon may stand in front. The patient looks down, a probe is laid along the lid above the upper edge of the “cartilage;” the lashes, or the edge of the lid, are then seized by a finger and thumb of the other hand, and turned up over the probe, which is simultaneously pushed down. After a little practice the probe can be dispensed with, and the lid everted by the forefinger and thumb of one hand alone, one serving to fix and depress the lid, the other to turn it upwards.

3. *Removal of Meibomian cyst*.—Position as for 1. Instruments: a small scalpel or Beer’s knife (Fig.




FIG. 115.—Meibomian scoop.

147) and a curette, or small scoop (Fig. 115, and 143). (1) Evert the lid; (2) make a free crucial incision into the tumour from the conjunctival surface; (3) remove the growth either by squeezing the lid between finger- and thumb-nail, or by means of the



scoop. The cavity fills with blood, and may thus for a few days be larger than before. These tumours have no distinct cyst-wall.

4. *Inspection of cornea* in purulent ophthalmia, &c. Position: if the patient be a baby or child, the back of its head is to be held between the surgeon's

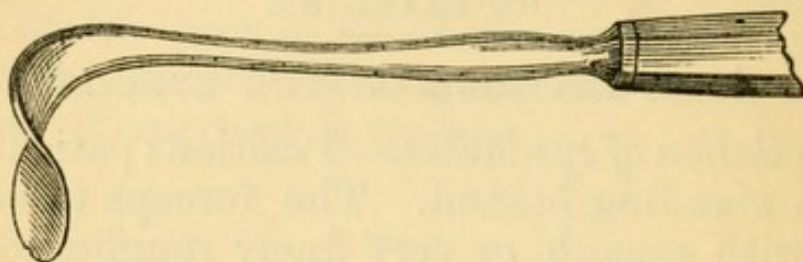


FIG. 116.—Desmarres' lid elevator.

knees, its body and legs being on the nurse's lap; if an adult, the same as for 1. If the lids cannot be

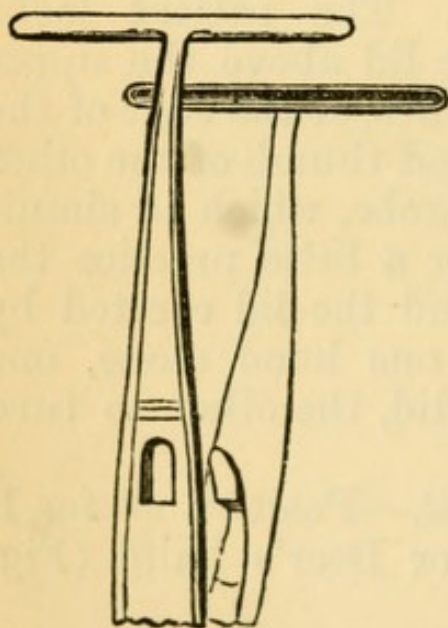


FIG. 117.—Entropion forceps.

easily separated by a finger of each hand, enough to allow a view of the cornea, retractors should be used (a convenient pattern is shown in Fig. 116), by which one lid, or both, can be raised and held away from the globe. If this instrument be gently used we avoid all risk of causing perforation of the cornea should a deep ulcer be present; an accident which may happen in cases attended by much swelling or spasm of the lids if the fingers are used.

5. *Entropion*.—*Spasmodic entropion of the lower lid*, with relaxed skin, in old people. Position as for 1. Instruments:—T forceps (Fig. 117), scissors (Fig. 128), toothed forceps. (1.) With the T forceps pinch up a fold of skin as close as possible to the edge of the lid, and of width proportionate to the



degree of inversion, and cut it off close to the forceps; (2) with the toothed forceps pinch up the orbicularis muscle now exposed, and cut out a small piece. Sutures need not be used.

6. *Organic entropion and trichiasis*.—When the whole row of lashes is turned inwards, and the inner surface of the lid much shortened by scarring, the radical extirpation of all the lashes is the quickest and most certain means of giving permanent relief, but it leaves an unsightly baldness and exposes the cornea to unnatural risk from dust, &c. Position: recumbent; the surgeon stands behind the patient. Anæsthesia seldom necessary. Instruments: a horn or bone lid-spatula (Fig. 119, s), or a lid clamp (Fig. 118), a Beer's knife (Fig. 147), and forceps. Make an incision from end to end (beginning just outside the punctum) between the hair-follicles and Meibomian ducts, as if to split the lid into two layers. Then make a second incision through the skin and tissues, about a twelfth of an inch from the border of the lid, parallel with, but in a plane at right angles to, the first. The strip of skin and tissues included between these two cuts will now be almost free, except at its ends, which are to be united by a cross-cut, and the strip dissected off; it should include the hair-follicles in their whole depth. Examine the white edge of the "cartilage," now exposed, for any hair-follicles accidentally left behind; they will appear as black dots, and are to be carefully removed.

In the same or slighter cases, the inversion of the

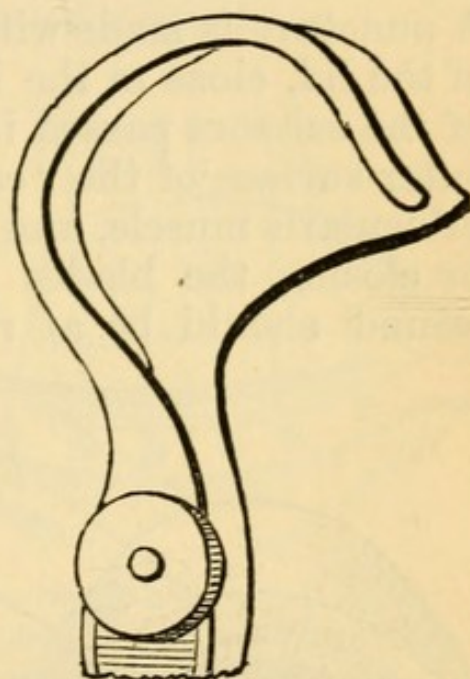


FIG. 118. — Snellen's lid clamp (for the R. upper lid).



border of the lid may be much lessened by complete division of the "cartilage" from the conjunctival surface along a line parallel with, and 3 mm. from, the free border (Burow's operation) (Fig. 120, Bu). The wound gapes and the inverted border of the lid falls forward and is kept in its natural place by the cornea. The only instruments needed are a scalpel and scissors. Position as for 1, or recumbent. The lid is kept well everted whilst the incision is being made. A puncture is made with the knife parallel to the edge of the lid, close to the inner or outer end, one blade of the scissors passed in and made to run along the outer surface of the "cartilage" between it and the orbicularis muscle, and then the "cartilage" divided by closing the blades parallel to the border. The wound should be at right angles to the surface.

A bluish line should be seen through the skin on replacing the lid. This operation gives complete relief for the time, but may need repetition in a few months.

Various operations are performed for transplantation of the displaced lashes forwards and upwards, so as to restore their natural direction. *Arlt's operation*. — The free border of the lid is split from end to end (leaving the punctum), as for extirpation of the lashes, but more deeply

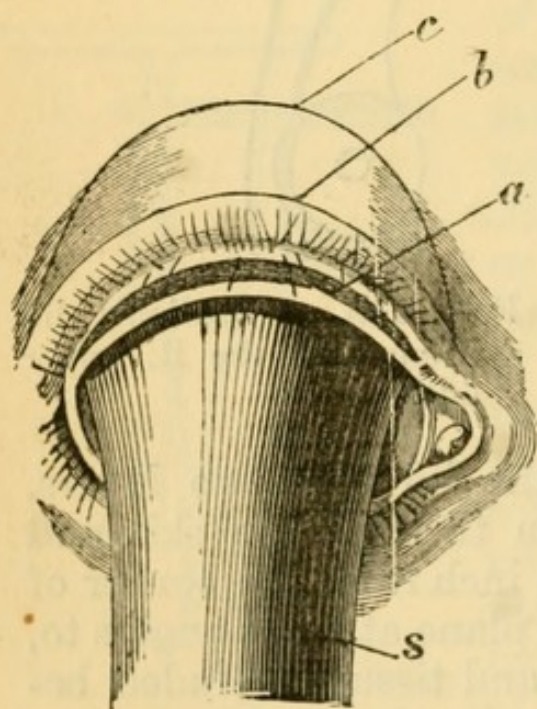


FIG. 119.—Arlt's operation for trichiasis (after Schweigger).

(Fig. 119, *a*). A second incision (*b*), extending beyond the ends of the first, is now made through the skin parallel to, and about two lines from, the border of the lid, and down to, but not through the "carti-



lage ;" thirdly, a curved incision (*c*) is made, joining *b* at each end and including a semilunar flap of skin, of greater or less width according to the effect desired ; fourthly, this flap is dissected off without injury to the orbicularis, and the wound, bounded by the lines *b* and *c*, closed by sutures. The anterior layer of the lid border, which contains the lashes, is thus tilted forwards and drawn upwards.

A third operation (Streatfeild's) consists in the simple removal of a wedge-shaped strip of the "carti-

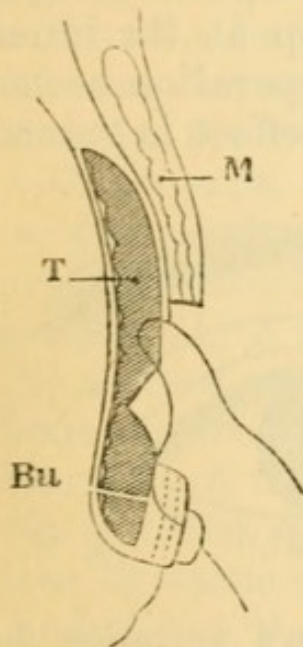


FIG. 120.—Diagrammatic section of upper lid; showing Snellen's operation, and line of section in Burow's operation (Bu). (Altered from Wecker.)

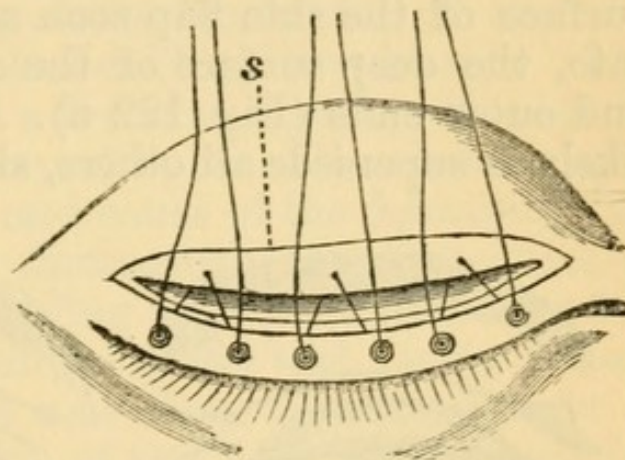


FIG. 121.—Snellen's operation for trichiasis. (After Wecker.)  
s. Edge of retracted skin and muscle.

lage" (with its superjacent skin and muscle), from the whole length of the lid, at a distance of a line or two from its border (*b*, Fig. 119). No sutures are used.

Snellen operates as follows :

—The incision (*b*, Fig. 119) is carried down to the tarsus, the muscle and skin separated from it and pushed upwards, and a wedge, shown by the groove in Fig. 120, cut from the exposed tarsus, as in Streatfeild's operation. The border of the lid is now everted, and kept in its new position by passing two or three threads, as shown in Figs. 120 and 121,



and tying them over beads. The skin wound need not be sutured.

All these operations (except 1) are apt to need repetition sooner or later.

Another, and newer, operation (Spencer Watson,\* Dianoux, Story†), has for its object to make the marginal strip containing the lashes change place with a strip of skin immediately above, which is dissected up and passed beneath it, both strips remaining attached at their ends, and being kept in their new places by fine sutures (Fig. 122). The cuticular surface of the skin flap soon adheres to, and merges into, the deep surface of the cilia flap at its inner and outer ends (Fig. 122 B). This operation seems likely to supersede all others, since its effect is gained

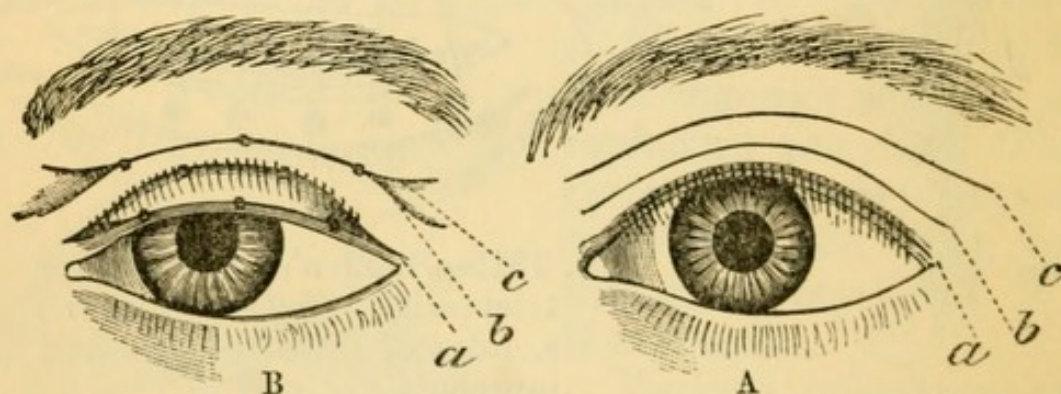


FIG. 122.—Modification of Spencer Watson's operation for trichiasis (Story, Dianoux). A, lines of incision. B, operation completed.

without the removal of any tissue. Occasionally, however, the strips, or one of them, slough.

7. *Ectropion*.—Ectropion from thickening of the conjunctiva, aided by relaxation of the tissues of the lower lid, seen chiefly in old people, may be treated by the removal of a V-shaped piece of the whole thickness of the lid, the edges being brought together with a hare-lip pin. Another plan is to exercise a horizontal fold of the palpebral conjunctiva corre-

\* Spencer Watson—'Roy. Lond. Oph. Hosp. Rep.,' vii, 440 (1873).

† Story—'Ophthalmic Review,' ii, 37 (1883).



sponding to the most everted part; the contraction of the scar draws the margin of the lid into place; or the everted mucous membrane may be drawn back into the sulcus between lid and globe by a suture, passed into the conjunctiva at two points  $\frac{1}{3}$  inch apart, passed deeply, brought out on the cheek, and tied over a bit of india-rubber tube; the thread is tightened from day to day until it has nearly cut through.

For ectropion from cicatricial changes in the skin a plastic operation is generally needed. At the same time the eyelids should be united by fine sutures, after paring a narrow strip from the border of each lid within the line of the lashes (blepharoplasty). The lids may be separated a few weeks later.—The operation for the cure of the ectropion will naturally vary with the seat, extent, and cause of the deformity, but we may conveniently distinguish three varieties of organic ectropion, according as the condition has followed: (1) a wound of the eyelid with faulty union; (2) a deeply adherent scar from abscess, disease of bone, or deep ulceration of the lid; or (3) extensive scarring of the face from burns, lupus, &c. When the cause is quite localised, and there is not much loss of tissue (groups 1 and 2), the scar may be included in a V-shaped incision, the flap separated and pushed up till the lid is in position, and the lower part of the wound then brought together by a pin or sutures, so that what was a V now becomes a Y, the edges of the flap being attached by sutures to the limbs of the Y. As the lid has generally become too long, from prolonged eversion, we often have, at the same time, to shorten it by removing a small triangle from its outer end, and uniting the edges of the gap. When the position of the deformity prevents the above operation, it is necessary to introduce new skin into the gap, made by dissecting out the cicatricial tissue and putting the everted lid into position. This may be done by bringing a flap with a broad pedicle, either by sliding or twisting, into the gap; or by the



method (introduced into our country by Dr Wolfe) of transplanting from a distant part a single graft of skin without a pedicle, large enough to fill the gap; or again, by filling the gap with several small pieces of skin (dermic grafts). Where there is extensive destruction of skin (group 3), these grafting methods seem particularly valuable. If a single large graft be used the important points are to make it considerably larger than the deficiency it is to supply, to free the under surface of the graft very thoroughly of all subcutaneous tissue, to unite it by fine sutures, and apply warm dressings. The single graft operation has now been tried many times, and with a very good proportion of successes.

8. *Ptosis* (chiefly the congenital form) may be treated by the removal of an oval of skin from the upper lid, parallel to its length, the muscle not being touched. Sutures are to be carefully inserted, and every effort made to get immediate union. More complicated operations, intended to raise the lid by producing contraction of the subcutaneous tissues without the removal of any skin, have been recommended by Pagenstecher and De Wecker.

9. *Canthoplasty*.—For lengthening the palpebral fissure at the outer canthus. The canthus is divided by scissors, or a bistoury, as far as may seem necessary. The contiguous ocular conjunctiva is then attached by sutures to the cut edges of the skin, so as to prevent reunion, one suture being placed in the angle of the wound, one above, and one below.

10. *Peritomy*, for obstinate cases of partial pannus. Anæsthesia is necessary. Instruments:—Speculum (Fig. 127), fixation forceps (Fig. 129), scissors, and Beer's knife (Fig. 147). With the knife a circular incision is carried through the conjunctiva, round the cornea, at 5 mm. ( $\frac{1}{5}$ "), or less, from its border. The zone of conjunctiva so included, together with the whole of its subconjunctival tissue down to the sclerotic, is now carefully removed by the scissors.



The bare surface thus left granulates, and finally contracts to a narrow band of white scar-tissue, by which the vessels running to the cornea are obliterated. The subconjunctival fascia is often found much thickened in these cases. Care must be taken not to make the incision too far from the cornea, lest the insertions of the recti be damaged. The zone of tissue should be removed in one piece. The symptoms are generally made worse for a time, and the final result is not reached for several months. In some cases the operation has, in my experience, been very successful, whilst in others, without apparent reason, it has quite failed of its purpose.

#### B. OPERATIONS ON THE LACRIMAL APPARATUS.

1. *Lacrimal abscess.* (See p. 71).
2. *Slitting up the lower canaliculus.*—This is best done by means of a knife with a blunt or probe point, and a blade narrow enough to enter the punctum. The best forms of these knives are Weber's knife, with a probe end (Fig. 124); Bowman's,




FIG. 124.—Weber's canaliculus knife.

with nearly parallel borders and a rounded end (Fig. 125), and Liebreich's (Fig. 126). Position as for 1. (1) The lower lid is drawn tightly outwards and downwards by the thumb. (2) The canaliculus knife is passed *vertically* into the punctum, then turned horizontally and passed on through the neck of the canaliculus till it reaches the bony (inner) wall of the lacrimal sac. It is then raised up from heel towards point, and thus made to

FIG 123.—Canaliculus director.



divide the canaliculus, care being taken that the neck is freely divided. Liebreich's knife cuts its own way without being raised. The lower canaliculus may also be divided with a Beer's knife (Fig. 147), which is run along a fine grooved director (Fig. 123),

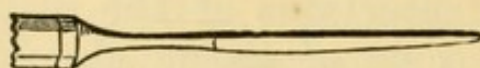


FIG. 125.—Bowman's canaliculus knife.

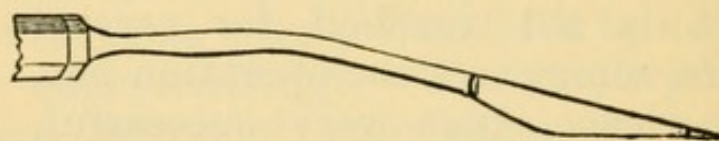


FIG. 126.—Liebreich's knife for canaliculus and nasal duct.

previously introduced. In cases of mucocele, it is good practice to divide the wall of the sac freely, and to divide the upper, as well as the lower, canaliculus.

3. *Probing the nasal duct.*—After dividing the canaliculus pass a good-sized lacrimal probe horizontally along its floor till it strikes the inner (bony) wall of the sac. Then raise it to the vertical position, and push it steadily down the duct (downwards and a little outwards and backwards) till the floor of the nose is reached. Bowman's earlier probes were in six sizes, of which the largest was  $\frac{1}{20}$ th in. in diameter. Mr. Bowman afterwards adopted much larger probes with bulbous ends; and several such patterns are now in use. The probe used should be the largest that will pass easily.

4. *A stricture of the duct* may be incised with any of the canaliculus knives, although Weber's and Bowman's are too slender to be used with safety. Liebreich's is intended to be so used, and a special knife for the purpose had previously been introduced by Stilling. The knife is used as a probe, being pushed quite down the duct, then partly withdrawn, turned in another direction, and pushed down again. There is generally bleeding from the nose.



In all these procedures we must be certain that the probe or knife rests against the bony (nasal) wall of the lacrimal sac before it is raised into the vertical direction. If the probe be stopped at the entrance of the canaliculus into the sac (as may easily happen if the canal be not thoroughly slit in its whole length), the lid will be pulled upon and puckered whenever the instrument is pushed towards the nose; but if the probe have reached the sac, backward and forward movements will not usually cause puckering of the lid. If in the former case the instrument be turned up, and an attempt made to pass it down the duct, a false passage will be made.

The direction of the two nasal ducts is either parallel or such that if prolonged upwards they would converge slightly; they very seldom diverge. The probe when in the duct should, even if, as usual, its lower end be curved forwards, rest against and indent the eyebrow; if it stands forwards from the brow it is usually in a false passage.

### C. OPERATIONS FOR STRABISMUS.

*Tenotomy.*—The object is to divide the tendon close to its insertion into the sclerotic. In this country the operation is usually done subconjunctivally, but in the operations of Graefe and Snellen the tendon is more or less exposed to view. The internal and external recti are the only tendons commonly divided, the internal far the more frequently. Anæsthesia is seldom necessary except for children. Position recumbent.—The operator usually stands on the patient's right whether for right or left eye; but some prefer to stand behind, using curved scissors. Instruments: Stop speculum (Fig. 127 shows a convenient and common pattern), straight scissors, with blunted points (Fig. 128), toothed fixation forceps (Fig. 129), strabismus hook (Fig. 130). There are several forms of hook, differ-



ing in the length and sharpness of the curve, and the shape of the tip. In some the tip is bulbous ;

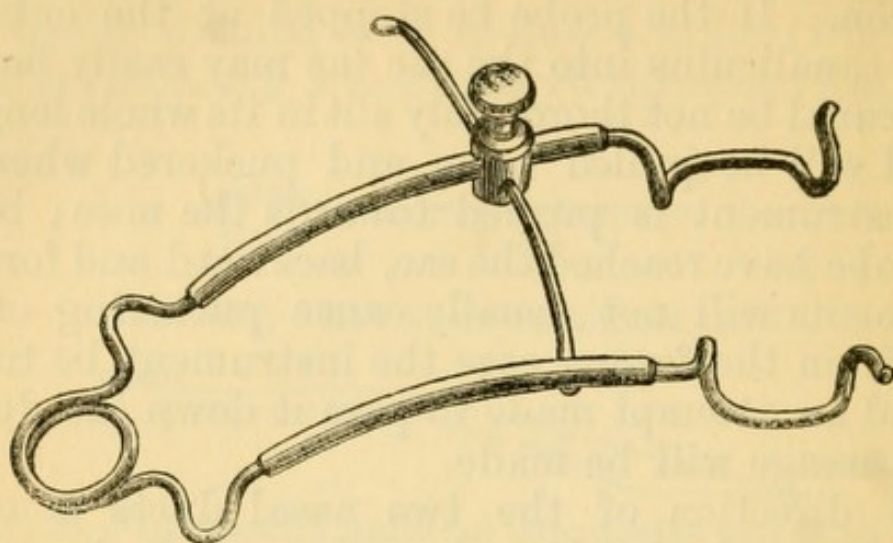


FIG. 127.—Stop spring speculum.

in others the hook is flattened sideways, but not enlarged at the end.

*Operations.*—*Critchett's operation.*—(1) After introducing the speculum, take the fixation forceps in the left hand, and pinch up a fold of conjunctiva over the lower border of the tendon (say of the right internal rectus) at its insertion. With the scissors make a small opening in this fold close to the end of the forceps, and parallel with the tendon. A layer of fascia (capsule of Tenon) is now exposed, and easily recognised ; it is to be pinched up, and an opening made in it corresponding to the conjunctival wound. By taking deep hold with the forceps, both conjunctiva and fascia may sometimes be divided at one stroke. As a rule, both conjunctiva and Tenon's capsule are thicker in children than adults.

(2.) Take the hook in the right hand (holding the wound open with the forceps in the left), and pass it, concavity downwards and point backwards, through the opening in the fascia, as far as its elbow, keeping its end always flat against the sclerotic. Next turn the end of the hook upwards, still



FIG. 128.—Strabismus scissors (drawn too thick in the blades).

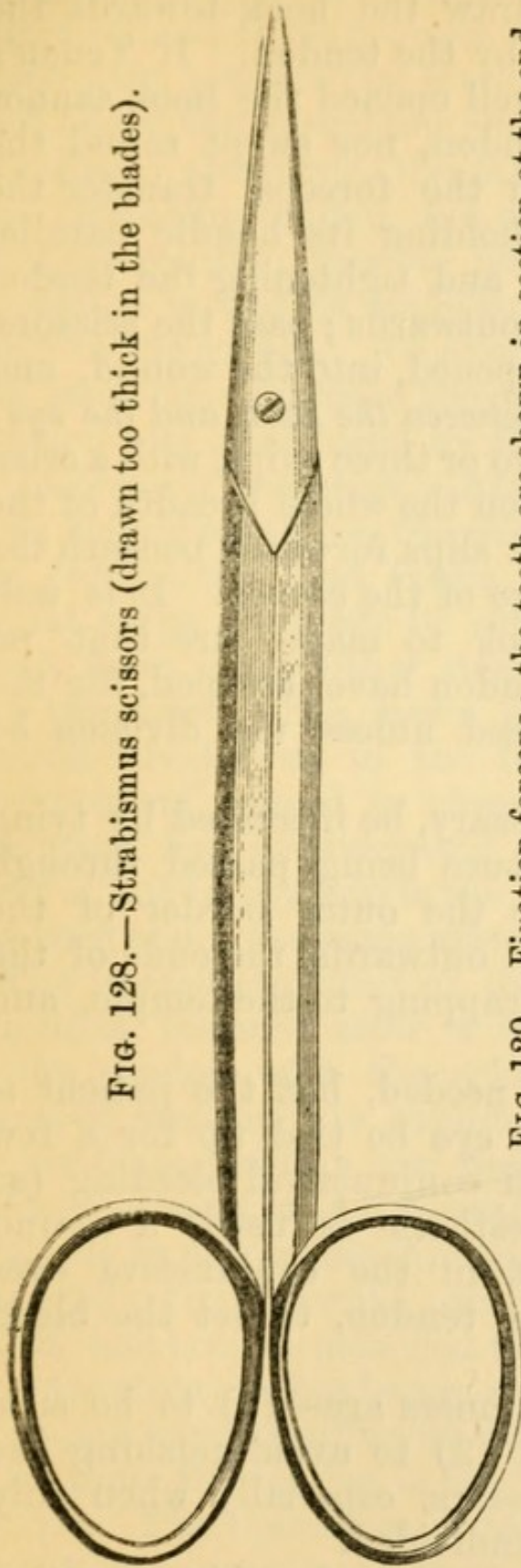


FIG. 129.—Fixation forceps; the teeth are shown in section at the end.





FIG. 130.—Strabismus hook (the bent part is represented too thin).



guided by the sclerotic, between the tendon and the globe, until its end is seen projecting beneath the conjunctiva, above the upper border of the tendon.



On now attempting to draw the hook towards the cornea it will be stopped by the tendon. If Tenon's capsule have not been well opened the hook cannot be passed beneath the tendon, nor swept round the sclerotic.—(3) Lay down the forceps, transfer the hook to the left hand, holding its handle parallel with the side of the nose and tightening the tendon by traction forwards and outwards; pass the scissors, with the blades slightly opened, into the wound, and push them straight up *between the hook and the eye*; the tendon is divided at two or three snips, with a crisp sound and feeling. When the whole breadth of the tendon is divided the hook slips forwards beneath the conjunctiva up to the edge of the cornea. It is well by reintroducing the hook to make sure that no small strands of the tendon have escaped, for the operation does not succeed unless the division be complete.

The effect may, if necessary, be increased by tying the eye out; a stout suture being passed through the conjunctiva, close to the outer border of the cornea and the eye drawn outwards, the ends of the thread are attached by strapping to the temple, and left for two days.

No after treatment is needed, but the patient is more comfortable if the eye be tied up for a few hours. If there be much conjunctival bleeding (as is common when no anæsthetic is used) a second small hole may be cut in the conjunctiva over the upper border of the tendon, to let the blood escape.

The difficulties for beginners are—(1) to be sure of opening the fascia; (2) to avoid pushing the tendon in front of the scissors, especially when only the upper part remains undivided.

Division of one internal rectus by this operation diminishes the squint by about two lines (4 mm.).

After the operation just described the tendon, in retracting, draws with it, to a varying extent, the



neighbouring parts of Tenon's capsule and the conjunctiva, and these indirect but wide attachments, on their part, prevent the tendon from retracting fully, and hence the maximum effect of its division is not obtained; moreover, the caruncle is drawn back by the retreating tendon, and a hollowness at the inner canthus results; this is, however, very slight if the operation wound be made small, and as near as possible to the cornea. To avoid this deformity, and at the same time increase the effect, the following modification was introduced by Mr. Liebreich.

*Liebreich's operation.*—After making the conjunctival wound as above, the scissors are passed between the conjunctiva and fascia, and by repeated horizontal snips are made to separate these membranes freely from one another over the tendon, as far as the caruncle. The fascia is then opened, and the tendon divided as in the former operation. The conjunctival wound is closed by a suture. This operation has considerably more effect than Critchett's, but in my hands the sinking of the caruncle has been about the same after both operations.

The immediate effect of the tenotomy of a rectus muscle is lessened after a few days by the reunion of the tendon with the sclerotic, but after a few weeks or months it is sometimes again increased by the stretching of this new tissue.

*Readjustment or Advancement* consists in bringing forwards to a new attachment the tendon of a rectus (generally the internal, occasionally the external), which has become attached too far back after a previous tenotomy, or has become weakened, *e.g.* in myopia. There are several different operations, but in nearly all of them the tendon is held in its new position by sutures. The operation is tedious and painful, and the patient must always be under an anæsthetic. The instruments are the same as for tenotomy.

I generally perform the operation as follows (essentially by Critchett's method):—A vertical incision



is made about 4 mm. from the cornea, exposing the whole width of the tendon, but the conjunctiva is not extensively dissected up from it. The tendon is then divided on a hook in the usual way. Two or three double-needled sutures are then passed from within outwards, through the flap formed by the tendon, fascia, and conjunctiva, at a considerable distance from its free edge, and the flap then shortened by cutting off its free border. The deep ends of the sutures are next passed, by means of their remaining needles, from within outwards, through fascia and conjunctiva, close to the border of the cornea, taking as broad a hold as possible. At this stage the external rectus is to be divided, and a stout traction suture introduced at the outer side of the eye (*see* p. 334), by which it can be drawn in. The tendon sutures are now tied, and the eye kept as far inwards as possible by fastening the traction suture to the bridge of the nose with strapping. The traction suture cuts out in a day or two; the tendon sutures should be left in a week. The pain and swelling, which for a few days are sometimes considerable, are best relieved by ice, or a spirit lotion, to the lids. The final result is not reached for several weeks (p. 311, 4).

#### D. EXCISION OF THE EYE.

Instruments as for squint, but the scissors curved on the flat. The operator may stand either behind or in front. (1) Divide the ocular conjunctiva all round, close to the cornea. (2) Open Tenon's capsule, and divide each rectus tendon and the neighbouring fascia on the hook; the two obliques are seldom divided on the hook. (3) Make the eye start forwards by pressing the speculum back behind the equator of the globe. (4) Pass the scissors backwards along the sclerotic till their open blades can be felt to embrace the optic nerve (recognised



by its toughness and thickness), and divide it by a single cut, while steadying the globe with a finger of the other hand. Finish by dividing the oblique muscles and remaining soft parts, close to the globe. Apply pressure for a minute or two, and then tie up tightly for six or eight hours with an elastic pad of small sponges overlaid by cotton wool. There is scarcely ever serious bleeding. The artificial eye may be fitted in from two to three weeks.\*

After some weeks or months a button of granulation tissue occasionally grows from the scar at the bottom of the conjunctival sac, and should be snipped off.

The operation is more difficult when the eye is ruptured or shrunken, or the surrounding parts much inflamed and adherent. The order of division of the muscles is immaterial. The important points are to leave as much conjunctiva as possible, so as to form a deep bed for the glass eye, and by keeping the scissors close to the globe during the whole operation, to avoid unnecessary laceration of the tissues.

When, as in some cases of intraocular tumour, it is desired to remove another piece of the optic nerve, the nerve should be felt for with the finger, seized and drawn forward with the forceps, and cut off further back with the scissors.

*Abscission* is the removal of a staphylomatous cornea with the front part of the sclerotic, leaving the hinder part of the globe, with the muscles attached, to serve as a movable stump for carrying the artificial eye. Four or five semicircular needles carrying sutures are made to puncture and counter-puncture the sclerotic, just in front of the attachments of the recti; the part of the globe in front of the needles is cut off, the needles drawn through, and

\* The glass eye must be renewed as often as it gets rough, generally at least once a year. Some persons have much difficulty in tolerating it, and they must be content to wear it for only a part of the day. It is always to be removed at bedtime.



the sutures tied. The operation is admissible only when the ciliary region is free from disease, and has therefore a very limited application; even in the most favourable cases the stump is not entirely free from the risk of setting up sympathetic inflammation, and I therefore never perform it. It is said that if the sutures are passed only through the conjunctiva or the muscles, the risk is less than when they are passed through the sclerotic.

The recently revived operation of *optico-ciliary neurotomy*, in which the optic nerve and all the ciliary nerves are divided without removal of the globe, with the view of preventing sympathetic disease, appears to me to be bad surgery. The sensibility of the cornea, abolished by the operation, often returns, proving that the ciliary nerves have reunited. The cut ends of the optic nerve have also been found reunited. The operation therefore cannot be relied upon to destroy these, nor, it may be added, any of the other possible paths (p. 132) along which sympathetic irritation and inflammation may travel; indeed, sympathetic inflammation has been observed to follow the operation in at least one case.

#### E. OPERATIONS ON THE CORNEA.

*Removal of foreign bodies.*—Position as for 1. Instruments: a steel spud (Fig. 131), or a broad

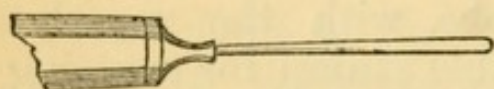


FIG. 131.—Corneal spud.

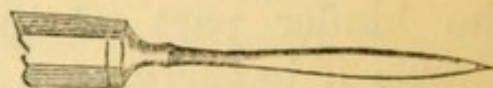


FIG. 132.—Broad needle.

needle with double cutting edge (Fig. 132). The eyelids are held open by the index and ring fingers, and the eyeball steadied by the middle finger placed against the temporal side of the globe. The chip is gently picked or tilted off by placing the edge of the spud beneath it, or, if firmly embedded, a certain amount of scraping may be necessary. The first few



touches, by which the epithelium is removed, cause the most pain. If the foreign body be barely embedded in the epithelium, a touch with a little roll of blotting paper will often detach it. When a fragment of iron has been present for more than a couple of days, its corneal bed is usually stained by rust, and a little plate or ring of brown corneal slough can often be picked off after the removal of the chip; but, as a rule, this minute slough may be left to separate spontaneously. *After-treatment.*—Tie the eye up so as to protect the corneal surface from friction and irritation; a drop or two of castor oil placed in the conjunctival sac lubricates the cornea and lessens the irritation. Atropine is to be used if there be marked congestion and photophobia.

When a splinter is deeply and firmly embedded, especially if it has penetrated the cornea and is projecting into the anterior chamber, its removal is often very difficult. Unless great care be taken the splinter in such a case may be pushed on into the chamber, and the iris or lens be wounded. This may sometimes be prevented by passing a broad needle through the cornea at another part and laying it against the inner surface of the wound, so as to form a guard or foil to the foreign body, the latter being removed by spud or forceps from the front.

A foreign body in the anterior chamber should, in recent cases, always be removed, and the piece of iris on which it lies must generally be excised. In cases of old standing we may judge by the symptoms whether to operate or not.

*Paracentesis* of the anterior chamber.—Position as for 1, or recumbent; anæsthesia seldom necessary. Instruments: a paracentesis needle (Fig. 133) with a very small, short, triangular blade bent at an obtuse angle (like a minute bent keratome); or a broad needle (Fig. 132). The former is more safe, as the blade is too short to reach the iris or lens, even



if the patient should jerk his head. If the contents of the chamber do not follow the needle on its withdrawal, a small probe (Fig. 133) is passed

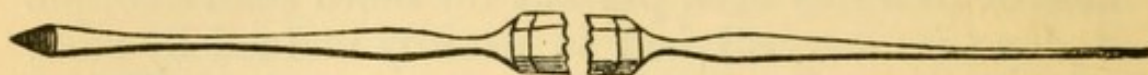

FIG. 133.—Paracentesis needle and probe mounted on same handle.

into the wound. In cases where the operation needs repetition every day or two the original wound can generally be re-opened with the probe. Speculum and fixation forceps should be used unless the patient has good self-control.

*Corneal section* for Hypopyon ulcer.—Position recumbent. Anæsthesia not usually needed. Instruments: a Graefe's or Beer's cataract knife (Figs. 141 and 147), speculum and fixation forceps. The incision is carried through the whole thickness of the cornea from one side of the ulcer to the other, being both begun and finished in sound tissue. Or it may be placed entirely in sound cornea, or at the sclero-corneal junction (p. 101), leaving the ulcer untouched; the last position avoids all risk of wounding the lens.

The knife is entered at an angle with the plane of the iris, its edge straight forwards; when its point is seen, or judged, to have perforated the cornea, the handle is depressed until the back of the knife lies parallel with the iris, and the blade then pushed straight across the ulcer to the point chosen for counter-puncture; often in practice it is simply pushed on till it cuts out. The aqueous ought not to escape until the point of the knife is engaged in its counter-puncture, but an earlier escape cannot always be avoided. If it is desired to keep the wound open, its edges are to be separated by a probe every second or third day. The wound closes quickly at first,



unless kept open, but after having been opened a few times, it sometimes remains patent for longer.

*Operations for conical cornea.*—The object is to produce a scar at the apex of the cone, which by contracting shall reduce the curvature, and so diminish the high degree of irregular myopic astigmatism to which the condition gives rise.

There are three methods. (1.) Graefe's operation consists in first carefully shaving off the apex of the cone without entering the anterior chamber, and then producing an ulcer by touching the raw surface with solid mitigated nitrate of silver (F. 1) and so obtaining a scar. The application needs great care, and the after-treatment is troublesome, as there is the risk that more inflammation than is wished for may set in. (2.) In another operation the apex of the cone is cut off with a cataract knife, the anterior chamber being entered, and the wound either left to close or united by sutures; there are several different modes of removing the little piece. (3.) Mr. Bowman removes the outer layers of the cone by means of a very delicate cutting trephine, and leaves the surface to heal and contract. I believe that No. 2 gives on the whole the best results.

*After-treatment.*—Atropine and compressive bandage until the wound has closed; antiphlogistic treatment, and heat locally, if inflammatory symptoms arise.

All operations for conical cornea are difficult to perform and somewhat uncertain in result, but in many cases vision improves from barely seeing very large letters before operation, to reading small print afterwards. The final result is never gained for several months. An artificial pupil may be necessary if a large corneal opacity finally remains.



## F. OPERATIONS ON THE IRIS.

A portion of the iris is very often removed by operation (iridectomy), and with various objects. The principal of these are—(1) the direct improvement of sight by altering the position and size of the pupil (artificial pupil); (2) to influence the course of an active disease—glaucoma, iritis, ulcer of cornea with hypopyon; (3) to remove the risks attending “exclusion” and “occlusion” of the pupil, by restoring communication between the anterior and posterior chambers; (4) as a stage in the extraction of cataract.

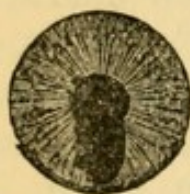

FIG. 134. — Iridectomy downwards for artificial pupil. (The line of incision is intended for extraction of cataract.) (Wecker.)

*Artificial pupil.*—The object is to remove the portion of iris in the position best adapted to sight; thus, in cases of leucoma the iridectomy is made opposite the clearest part of the cornea. When the state of the cornea allows it, the new pupil should be made down-inwards or straight downwards; the next best place is outward or out-upward; and straight upwards is, of course, least useful, because the new pupil will be covered by the lid. The coloboma

should generally be small, and often only the inner (pupillary) part of the chosen portion is to be removed, the outer (ciliary) part being left (Fig. 134), so as to prevent the light from passing through the margin of the lens (p. 14). After such an operation the pupil will be oval or pear-shaped, and widest towards the centre. The incision should lie in the corneal tissue, if only the pupillary part of the iris is to be removed; but if only a narrow zone of cornea remain clear the incision must lie a little outside the sclero-corneal junction lest its scar should interfere with the transparency of the remaining clear cornea. The loop of iris should be cut off with a single snip.



In *iridectomy for glaucoma* the coloboma is to be large, the iris to be removed quite up to its ciliary attachment, and the incision to lie as far back in the sclerotic as possible (1 to 2 mm. from the border of the cornea is not too far). The coloboma should be wider towards the incision than towards the pupil ("key-hole pupil") (Fig. 135). The loop of iris, when drawn out, is usually cut first in one angle of the wound, then torn from its ciliary attachment by carefully drawing it over to the other angle of the wound, and its other end cut, the points of the scissors being pushed just within the lips of the wound to ensure removal of the largest possible portion.




FIG. 135.—  
Iridectomy for  
glaucoma  
(Wecker).

The difficulty of making an artificial pupil (for optical purposes) of the best shape, *i.e.* broad towards the natural pupil and narrow towards the circumference, is, owing to the small size of the parts, much greater than would be at first supposed, and several methods are in use. In Mr Critchett's *iridodesis* the loop of iris is drawn out through a small opening, and strangulated by a fine ligature tied round it just over the incision; the little loop soon drops off, and the result is a pear-shaped pupil, with its broad end towards the centre. The inclusion of iris in the track of the wound has sometimes set up severe irritation, and even destructive irido-cyclitis, and on this account the operation is now but seldom performed. Another plan is to draw out a small loop of iris with a blunt hook (Tyrrell's hook), and to cut off only the pupillary portion; this method is uncertain, but, on the whole, it gives good results. Mr Carter cuts out a V-shaped bit of iris by introducing a pair of blunt-ended iridotomy scissors through the corneal incision, opening the blades, and cutting out just as much iris as is intruded between them by the gush of the escaping aqueous. This operation requires much nicety, and



entails some risk of wounding the lens, but when well performed it gives an excellent artificial pupil.

*Iridotomy (iritomy).*—In this operation an artificial pupil is formed by the natural gaping of a simple incision in the iris. It is only applicable when the lens is absent. Through a small incision in the cornea, between the centre and margin, the scissors (shears) shown at Fig. 136 are passed; the more pointed blade is passed behind the iris as far as is deemed necessary, and the iris and false membrane divided by a single closure of the blades. It is sometimes necessary to make a second cut at an angle with the first, so as to include a V-shaped tongue of iris which will shrink and allow a larger pupil.

Iridotomy is most useful when the iris has become tightly drawn towards the operation scar by iritis occurring after cataract extraction (Fig. 148). The line of the cut in the iris should lie, as nearly as may be, *across* the direction of its fibres, and should always be as long as possible. In cases of this sort, or when, without much dragging of the iris towards the scar, the pupil is filled by iritic or cyclitic membrane after cataract extraction, iridotomy yields a better pupil than iridectomy, and with less disturbance of, and no dragging upon, the ciliary body.

*The operation of iridectomy.*—Position recumbent; the operator usually stands behind. Anæsthesia is always advisable, though in urgent cases iridectomy can be successfully performed by an adept without it. Instruments: stop speculum (Fig. 127), fixation forceps, bent keratome (Fig. 137), iris forceps, bent at various angles according to the position of the iridectomy (Fig. 139), iris scissors with elbow bend (Fig. 138), of which some patterns have one or both blades probe pointed, a curette (Fig. 143) for replacing the cut ends of the iris, and preventing their incarceration in the angles of the wound. The iri-



dotomy scissors (Fig. 136) are very convenient, especially for downward and inward operations, and for the left hand. Graefe's cataract knife (Fig. 141) is preferred to the triangular keratome, by some operators, in iridectomy for glaucoma.

The conjunctiva is held by the fixation forceps near the cornea, at a point opposite to the place selected for puncture. (1.) The keratome is to be entered slowly, steadily pushed on across the anterior chamber till the wound is of the desired size, then slowly withdrawn, and, in withdrawal, its blade carefully turned to one side, so as to lengthen the internal wound. Two points need attention:—as soon as the point of the knife is visible in the anterior chamber, it must be tilted slightly forwards to avoid wounding the iris and lens; and care must be taken not to tilt it sideways, for if this be done the wound, instead of lying parallel with the border of the cornea, will lie more or less across that line. The incision is made almost as much by lifting the eye against the knife with the fixation forceps, as by pushing the knife against the eye. The forceps are now laid down, or if fixation be still necessary, they are given to an assistant, who is to gently draw the eye into the position required for the next step; in so doing, he is to draw away from the eye, not to push the ends of the forceps against the sclerotic. (2.) The iris forceps are introduced, closed,

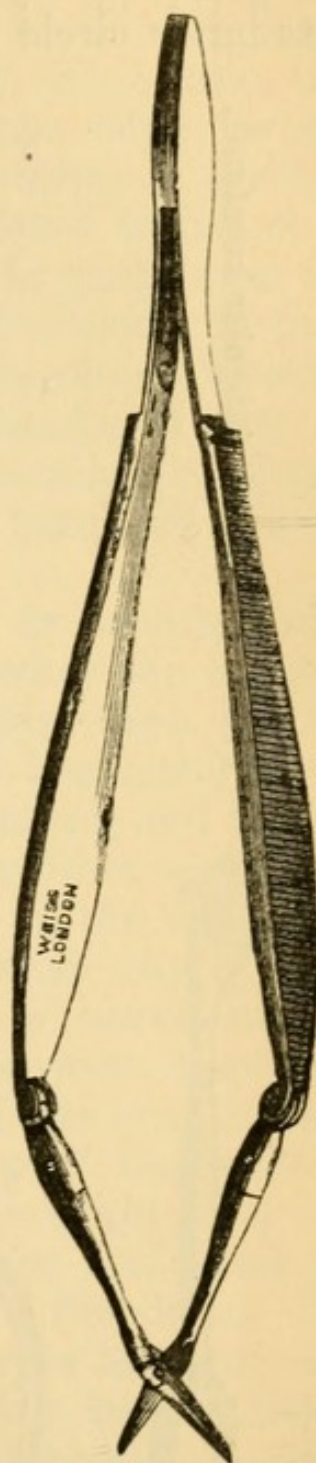


FIG. 136. — Iridectomy scissors.



into the wound, and passed very nearly to the pupillary border of the iris, before being opened and made to grasp it. By seizing the pupillary part of the iris, its inner circle is certain to be brought outside the

FIG. 137.—Bent triangular keratome.

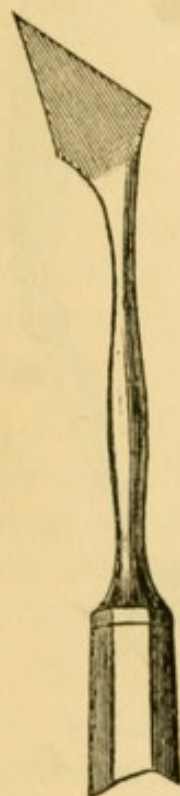

FIG. 138.—Iridectomy scissors.

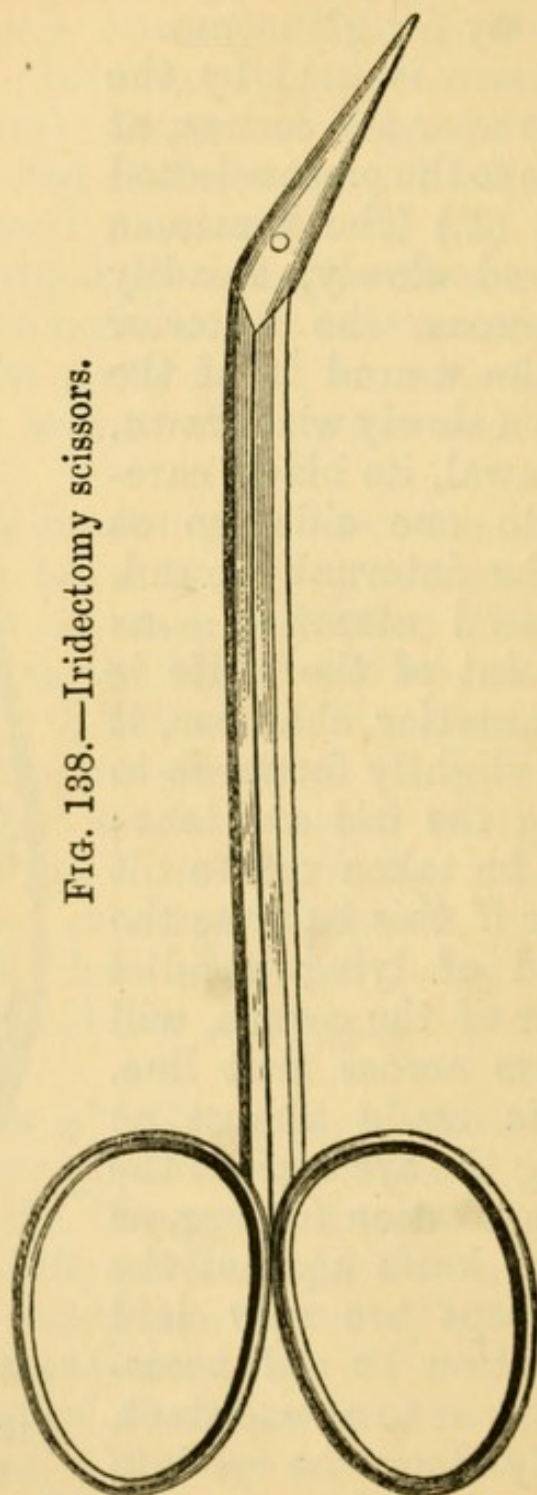
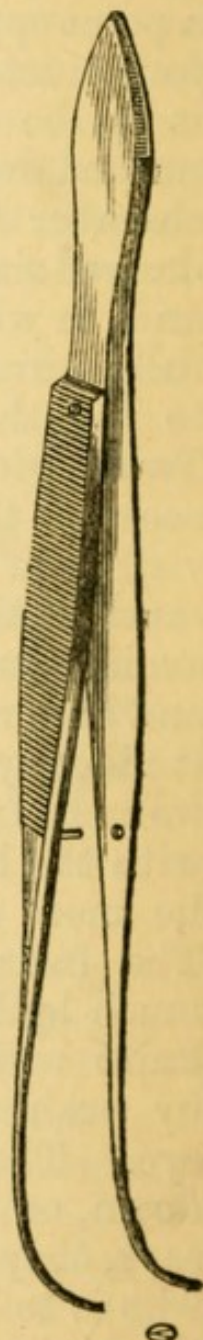


FIG. 139.—Iris forceps.



wound, when the forceps are now withdrawn; if the iris be seized in the middle of its breadth, a button-hole may be cut out, and the pupillary part left



standing. Often the iris is carried into the wound by the gush of aqueous as the keratome is withdrawn, and it is then seized without passing the forceps so far into the chamber. (3.) The loop of iris having been cut off, either at a single snip, or by cutting first one end and then the other, as in glaucoma (p. 343), the tip of the curette is gently introduced into each angle of the wound to free the iris, should it be entangled; this little precaution is of importance in order to prevent inclusion of the iris in the track of the wound. The speculum is now removed, and the eye, or both eyes, bandaged over a pad of cotton wool, either with a four-tailed bandage of knitted cotton, or two or three turns of a soft cotton or flannel roller.

The anterior chamber is refilled in twenty-four hours, except in cases of glaucoma, when the wound frequently leaks more or less for several days. It is as well in all cases to keep the eye bandaged for a week, the wound being but feebly united, and likely to give way from any slight blow or other accident. When the incision lies in, or partly in, the sclerotic, some bleeding generally occurs; when the eye is much congested, this hæmorrhage is considerable, and the blood may run into the anterior chamber either during or after the excision of the iris; it can be drawn out by depressing the lip of the wound with the curette, but if the chamber again fills, no prolonged efforts need be made, since the blood is usually absorbed without trouble in a few days. In diseased, especially glaucomatous, eyes however, its absorption is often slow. Secondary hæmorrhage sometimes occurs from a diseased iris several days after the operation.

*Sclerotomy* is an operation for dividing the sclerotic near to the margin of the cornea. It is employed in glaucoma, instead of iridectomy, or after iridectomy has failed. The pupil is to be contracted as much as possible by eserine before the operation. It is



performed subconjunctivally, a Graefe's cataract knife (Fig. 141) being entered through the sclerotic near the margin of the cornea\*, passed in front of

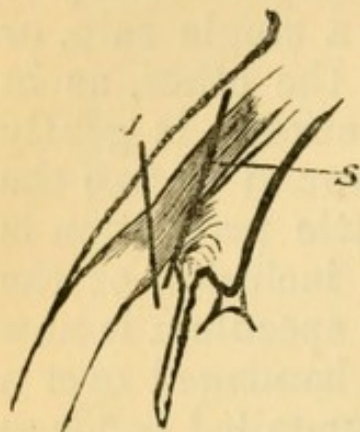


FIG. 140.—Diagrammatic section of ciliary region, showing path of wound in iridectomy for glaucoma (*I*) and in sclerotomy (*S*). (*Compare* Fig. 94, 1 and 2.)

the iris, and brought out at a corresponding point on the other side, so as to include nearly one-third of the circumference; the puncture and counter-puncture are then enlarged by slow sawing movements; the central quarter of the sclerotic flap, and the whole of the conjunctiva (except at the punctures) are left undivided. The knife is then slowly withdrawn. The whole operation is to be done very slowly, that the aqueous humour may escape gradually; any rush of fluid is likely to carry the iris into the wound and cause a permanent prolapse, and this is considered by nearly all operators

as very undesirable, if not a source of danger. If decided prolapse occur the iris should be excised, and the operation then becomes a very peripheral iridectomy. A moderate degree of bulging and separation of the lips of the two scleral wounds takes place for a week or two, when the scar flattens down, and finally a mere bluish line is left. Sclerotomy is difficult to perform well; if the incision be too long and too far back there is danger of hæmorrhage into the vitreous and even of puckering and inflammation of the scar and sympathetic ophthalmitis of the other eye; in other cases it may be too short or too far forward, and then it is no better than an incision for iridectomy. In Fig. 140 *I* shows the line of incision in iridectomy for glaucoma, and *S*

\* Wecker makes it 1 mm. from the clear cornea. In my own operations the distance is generally about 2 mm.



the line in sclerotomy. Comparison with Fig. 94, however, will show that the incisions for iridectomy in glaucoma vary in position a good deal in different cases.

#### G. OPERATIONS FOR CATARACT.

1. *Extraction of cataract* has been systematically practised for nearly a century and a half. The operation has passed through many important changes, and many different procedures are still in use. There is also much diversity of practice in regard to anæsthesia, but a large number of the most experienced operators frequently dispense with it. All the operations are difficult to perform well, and much practice is needed to ensure the best prospect of success. The sources of possible failure are many, and, as in avoiding one we are very apt to fall into another, it cannot be expected that any one operation will, in all its details, ever be universally adopted. At present the majority of surgeons adhere more or less closely to the operation known as the "modified linear" method of von Graefe.

All operations for extraction of hard cataract agree in the following points:—(1) An incision is made in the cornea, at the junction of cornea and sclerotic, or even slightly in the sclerotic, large enough to give exit to the crystalline lens unbroken, and not altered in shape. The knife now almost




FIG. 141.—Graefe's cataract knife.

universally employed is the narrow, thin, straight knife of von Graefe (Fig. 141). (2) The capsule is freely opened with a small, sharp-pointed instrument (cystotome or pricker, Fig. 143). (3) The lens is removed through the rent in the capsule (the latter structure remaining behind), either by pressure and manipulation outside the eye, or by means



of a traction instrument (scoop or spoon, Fig. 142) passed into the eye just behind the lens. Most operators have abandoned the habitual use of the scoop, reserving it




FIG. 142.—Cataract spoon.

FIG. 143.—Cystotome (upper end), and curette (lower end).



for certain emergencies and special cases. —(4) Iridectomy is very often performed as the second stage, not with the primary object of facilitating the exit of the lens, but to lessen the after risks of iritis; since it has been found that, if no iridectomy be done, the portion of iris traversed by the lens is often so bruised or stretched, as to become the starting-point of severe traumatic iritis. The following are the chief varieties of operation at present practised.

(a.) *Linear extraction* (best described here, though not applicable to hard cataract).—A small incision (4 to 6 mm.) is made by a keratome (Fig. 137) well within the margin of the cornea. It is often better, though not essential, to make a small iridectomy. After opening the capsule the lens is squeezed out piecemeal, or coaxed out by depressing the outer lip of the wound with the curette (Fig. 143). Only quite soft cataracts, or those in which the nucleus, though firm, is very small, can be so dealt with.

The wish to extend the principle of a straight wound to {full-sized hard cataracts led von Graefe, in 1865, to introduce (b) the “*modified linear*” or “*peripheral linear*” extraction, in which the



incision lies slightly beyond the sclero-corneal junction (Fig. 145, 2), and consequently involves the conjunctiva, of which a flap is made. The incision is intended to form an arc of the largest possible circle, *i. e.* of the scleral, not of the corneal, curve; its plane, therefore, must lie as nearly as may be in a radius of the scleral curve, and at a considerable angle with that of the iris (Fig. 146, 2). A large iridectomy is performed as the second stage. The incision is made with the Graefe knife (Fig. 141), which is at first directed towards the centre of the pupil and then brought up to the seat of counter-puncture. The edge is turned somewhat forward during the greater part of the proceeding, and the cut completed by sawing movements. The iridectomy is occasionally made several weeks before the extraction ("preliminary iridectomy"), the parts being allowed to become perfectly quiet in the interval. The disadvantages of the peripheral linear extraction are;—the frequency of bleeding from the conjunctiva into the anterior chamber, the parts being thus obscured; a considerable risk of loss of vitreous, owing to the peripheral position of the wound, and sometimes a difficulty in making the lens present well; a small but appreciable risk that the operated eye will set up sympathetic inflammation, the wound lying in the "dangerous region" (p. 132); lastly, there is a tendency to make the wound rather too short in order to avoid some of these risks, and thus difficulties are introduced in the clean removal of the lens. Its great advantage lies in the very small attendant risk of suppurative inflammation.

A variety of this operation consists in placing the incision rather further down, and at the same time giving it a somewhat sharper curve, so that it forms an arc of a smaller circle than before, but is still not concentric with the cornea (Fig. 145, 3, upper section). The puncture is directed somewhat down-



wards (as at the right-hand end of the Figure), and its plane, which at the puncture and counter-puncture is almost parallel with the iris, alters to nearly a right angle at the summit of the flap. The track of the wound, if shaded, would appear as in the figure.

(c) *Short flap* (de Wecker).—The incision, made with the same knife, lies exactly at the sclero-corneal junction, and is of such an extent that it has a height of about 3 mm. ( $\frac{1}{4}$  of the diameter of the cornea) (Fig. 144). A narrow rim of conjunctiva remains attached to the flap. The iridectomy is small (as in Fig. 134). For very bulky cataracts this incision is not quite large enough.

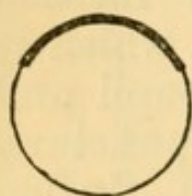


FIG. 144.—  
Short flap.

(d.) The incision has nearly the same curve and plane as in b, but the greater part of it lies considerably within the margin of the cornea (*corneal*

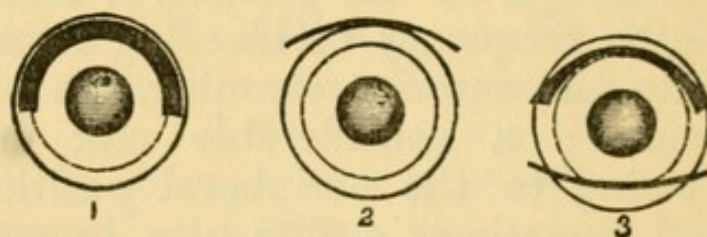


FIG. 145.—Paths of incision for extraction of cataract. 1, old flap; 2, peripheral linear; 3 (upper fig.), a variety of the peripheral linear; (lower fig.) corneal section. The wound appears as a narrow slit (2) or a broad tract (1), when seen from the front, according to the inclination of its plane. The dotted circle shows the average outline of the lens. Compare Fig. 146.

*section*), and iridectomy is usually dispensed with. Liebreich and Bader make the section downwards, its plane forming an angle of about  $45^\circ$  with that of the iris (Fig. 145, 3, lower section). In Lebrun's corneal operation an almost identical section is made upwards; the upper section of 3, Fig. 145, if placed further in the cornea, would nearly represent it. The corneal operations, without iridectomy, are comparatively easy to perform, even without anæsthesia,



but their results are often marred by extensive adhesion of the iris to the scar. It is unlikely that they will gain general adoption.

It is an advantage to use eserine for a day or two after the operations *c* and *d*, so as to lessen the risk of the iris becoming permanently engaged in the wound.

(*e*) *Flap extraction* (Daviel, Beer).—The incision is slightly within the visible margin of the cornea, concentric with it, and equal to at least half its circumference (1, Fig. 145), thus forming a large arc of a small circle. The plane of the incision is parallel with that of the iris (1 Fig. 146). No iridectomy is made. The incision is made with the triangular knife of Beer (Fig. 147), in which the blade near its heel is somewhat wider than the height of the flap, the section being completed by simply pushing the knife across the anterior chamber flat with the iris, its back corresponding to the base of the intended flap. The inner length of the wound is less than the outer by the thickness of the obliquely cut cornea at each end (1, Fig. 145).

The flap operation is usually done without anæsthesia, and neither speculum nor fixation forceps are

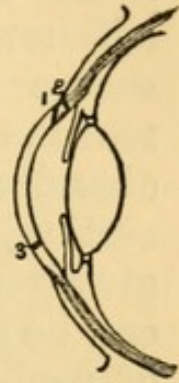


FIG. 146.—The same sections seen in profile, showing the plane of the incision in 1, 2, and the lower section of 3.

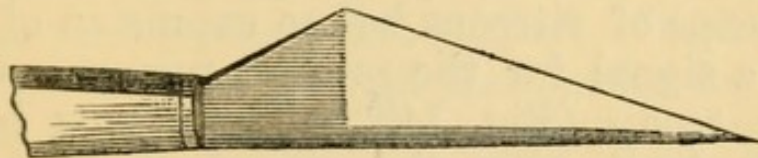


FIG. 147.—Beer's cataract knife.

needed. The after treatment is troublesome, but when everything does well the result is almost perfect, the pupil retaining its natural size, shape, and mobility. But the great height of the flap, in proportion to its width, renders it very liable to gape



or even to fall forwards, and this, with the fact that the whole wound lies in corneal tissue, considerably increases the risk of rapid suppurative inflammation of the cornea; the iris often prolapses and becomes adherent to the wound, and even apart from this, severe iritis is a common occurrence. For these reasons the old flap extraction has been almost abandoned in favour of the peripheral linear, corneal section, and short flat operations, which, though giving perhaps a smaller percentage of results that can be called "perfect," yield a much larger average of useful eyes.

Historically, the flap operation was the earliest; then came the linear operation; thirdly, the modified or peripheral linear operation, with iridectomy; and lastly, the modern corneal operations and short flap, the aim of which is to gain the substantial advantages both of the old flap and the modified linear methods, without the great risks of the former or the imperfections of the latter.

Of other operations the most important is Pagenstecher's, in which the lens is removed by a scoop in its unbroken capsule. It is most applicable to cataracts which are over-ripe or are complicated with old iritis, and to Morgagnian cataract (p. 158).

The chief *complications* which may arise *during extraction of cataract* are :—(1) too short an incision; this is best remedied by enlarging with iris scissors. (2) Escape of vitreous before expulsion of the lens; this is a signal for the prompt removal of the lens with a scoop (Fig. 142), the vitreous being then cut off level with the wound by scissors. (3) Portions of the lens remaining behind after the chief bulk has been expelled; they should be coaxed out by gentle manipulation after removal of the speculum.

*After treatment of extraction by the modified linear, short flap, and corneal operations.*—The patient is best



in bed for from four to seven days. The dressing consists of a piece of soft linen overlaid by a pad of cotton wool, and kept in place by a four-tailed bandage of knitted cotton, or a narrow flannel roller. Both eyes are to be bandaged. The room should be kept nearly dark for at least a week, all dressings and examinations being made by the light of a candle. The dressings are removed and the lids gently cleansed with warm water twice a day, their edges being separated by gently drawing down the lower lid, so as to allow any retained tears to escape; this cleansing is very grateful to the patient. Some surgeons open the lids and look at the eye the day after the operation; but many prefer to leave them closed for several days unless there are signs that the case is doing badly (p. 162).<sup>\*</sup> It is a good practice to use one drop of atropine daily after the third day, to prevent adhesions should iritis set in. During the first few hours there will be some soreness and smarting, and at the first dressing a little blood-stained fluid, but after this there should be no material discomfort, and nothing more than a little mucous discharge, such as old people often have. When first examined (from two to seven days after operation) the eye is always rather congested from having been tied up; but there should be no chemosis, the wound should be united so as to retain the aqueous, and its edges clear. The pupil is expected to be black unless it is known that portions of lens matter have been left behind. If all be well, the bandage may be left off during the daytime at the end of a week or ten days, a shade being worn; but it should be re-applied at night for the first two

<sup>\*</sup> Old people occasionally get delirious during the confinement in bed after iridectomy or extraction of cataract, and for such patients the rules as to bandaging and darkness should be relaxed. Some operators of large experience have abandoned dark rooms for all cataract cases; and a few bandage only the operated eye, leaving the other open.



or three weeks to prevent accidents from movements during sleep. At the end of a fortnight, if the weather be fine, the patient may begin to go out, the eyes being carefully protected from light and wind by dark goggles, and he may be out of the surgeon's hands in from three to four weeks.

*After-operations.*—When iritis occurs (p. 162) the pupil becomes more or less occluded by false mem-

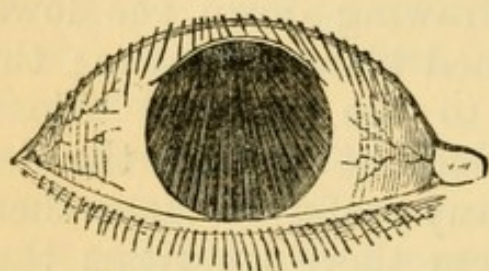


FIG. 148.—Diagram of occlusion and displacement of pupil from iritis, after upward extraction of cataract.

brane, and the subsequent contraction of this membrane, may draw the iris towards the scar, so that the pupil is at once blocked and displaced (Fig. 148). In slight cases sight is greatly improved by simply tearing across the membrane and capsule with a fine needle, and treating the case as after discission of

soft cataract. But in severer cases an artificial pupil must be made, either by iridectomy or iridotomy (p. 342).

2. *Solution (Discission) operations.*—In these the lens is gradually absorbed by the action of the aqueous humour admitted through a wound in the capsule (pp. 157 and 159).—(1) The pupil is fully dilated by atropine; (2) an anæsthethic is given unless the patient is old enough to control himself well, for the slightest movement is attended by risk; (3) the lids are held open by the fingers, or a stop speculum and fixation forceps used; (4) a fine cataract needle (Fig. 149)




FIG. 149.—Cataract needle.

is directed to a point a little within the border of the cornea (usually the outer border), and when close to its surface is plunged quickly and rather obliquely



into the anterior chamber. Its point is then carried to the centre of the pupil (Fig. 150), dipped back through the lens-capsule, and a few gentle movements made so as to break up the centre of the anterior layers of the lens; (6) the needle is then steadily withdrawn. Special care is taken not to wound, nor even touch, the iris, either on entering or withdrawing the needle, and not to stir up the lens deeply nor too freely.

*After-treatment.* — The pupil to be kept widely dilated with atropine (F. 26), a drop being applied after the operation, and at least six times a day afterwards, or much oftener if there be threaten-

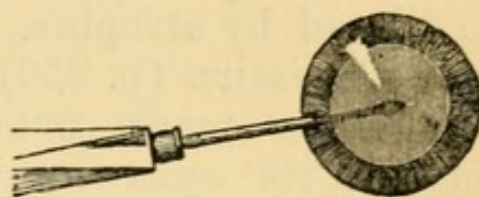


FIG. 150.—Discission of cataract.

ing of iritis. Ice or iced water is in every case to be applied constantly for forty-eight hours after the operation,\* as for traumatic iritis (p. 124), and the patient to remain in bed in a darkened room for a few days. A little ciliary congestion for two or three days need cause no uneasiness, but the occurrence of pain, increase of congestion, and alteration in the colour of the iris (commencing iritis), are indications for the application of leeches near the eye and the more frequent use of atropine.

If the cataract were complete, no marked change will be seen for some weeks; if partial (*e.g.* lamellar), in a day or two the part of the lens near the needle wound, and in a few days the whole lens, will become opaque. In from six to eight weeks the lens will have become notably smaller (flattened or hollowed on the front surface). If the eye be perfectly quiet, but not unless, the operation may now be repeated in exactly the same way, and with the same after-treatment and precautions, but the

\* I have to thank my colleague, Mr. Gunn, for this valuable suggestion.



needle may be used more freely. The bulk of the lens will generally disappear after the second operation, but the needle has often to be used a third or a fourth time for the disintegration of small residual pieces, or in order to tear the capsule if it has not retracted enough to leave a clear central pupil. A small whitish dot remains in the cornea at the seat of each needle puncture.

3. *Extraction by suction*.—This operation is applicable to completely soft cataracts. The pupil is to be dilated by atropine. The lens-capsule is opened as in Discission (p. 356), but more freely. Then an incision is made obliquely through the cornea between its centre and margin, with a keratome (Fig. 137) or broad needle (Fig. 132), and the nose of the syringe passed through the wound and gently dipped into the lacerated lens-substance. By very gentle suction the semifluid lens-matter is then drawn gradually into the syringe. The instrument is not to be passed behind the iris in search of fragments. Nearly the whole of the lens is removed. The after-treatment is the same as for needle operations. Two forms of syringe are in use: Teale's, in which the suction is made by the mouth applied to a piece of flexible india-rubber tubing; Bowman's, in which the suction is obtained by a sliding piston worked by the thumb moving along the syringe. It is often better, and in lamellar cataract necessary, to break up the lens freely with a fine needle a few days before using the syringe, and thus allow it to be thoroughly macerated and softened in the aqueous humour; atropine and ice must be used freely in the interval between this needle operation and the suction; and the surgeon must be prepared to interfere before the day appointed for the suction should inflammatory symptoms be set up by the rapid swelling of the lens (p. 157). Suction is a very delicate operation, but in my experience highly satisfactory.



## PART III

### DISEASES OF THE EYE IN RELATION TO GENERAL DISEASES.

---

#### CHAPTER XXIII

IN stating very shortly the most important facts bearing on the connection between diseases of the eye and of other parts of the body, it is convenient to make the following subdivisions:—(A) the eye changes occur as part of a general disease; (B) the ocular disease is symptomatic of some local malady at a distance; (C) the eye shares in a local process, affecting the neighbouring parts.

(For the clinical details of the various eye diseases referred to in this chapter, see Part II.)

**A.** General diseases, in which the eye is liable to suffer.

*Syphilis* is, directly or indirectly, the cause of a large proportion of the more serious diseases of the eye.

1. *Acquired syphilis*.—Primary stage. Hard chancres are occasionally seen on the eyelid, and even far back on the conjunctiva (p. 67).

Secondary stage (sore throat, shedding of hair, eruption and condylomata).—*Iritis* is common between two and eight or nine months, and does not occur later than about eighteen months, after the contagion; in from two-thirds to three-fourths of the cases both eyes suffer; there is a marked tendency



to exudation of lymph (plastic iritis), shown by keratitis punctata, haze of cornea, and less commonly by lymph-nodules on the iris. In some cases there are symptoms of severe cyclitis, leading to detachment of retina and secondary cataract, and but little iritis; but the cyclitis of acquired syphilis does not give rise to ciliary staphyloma (*compare* p. 128). Syphilitic iritis, though sometimes protracted, rarely relapses after complete subsidence.—*Choroiditis* and *retinitis* generally set in rather later, from six months to about two years after the chancre; seldom as late as four years.\* The two conditions are most often seen together, but either may occur singly; and in each the vitreous generally becomes inflamed. These conditions are essentially chronic, the retinitis being often, and the choroiditis sometimes, liable to repeated exacerbations or recurrences; whilst in some cases the secondary atrophic changes progress slowly for years almost to blindness, often with pigmentation of the retina. Syphilitic choroiditis and retinitis usually affect both eyes, but often in an unequal degree, and even when severe the disease is occasionally limited to one eye.—*Keratitis*, indistinguishable from that of inherited syphilis, is amongst the rarest events in the acquired disease; when it occurs it is usually in the secondary stage of the disease.

Later periods.—Ulceration of the skin and conjunctiva of the lids, gummatous infiltration of the lids and sclerotic, and nodes in the orbit (whether cellular or periosteal) occur but rarely. *Oculo-motor paralysis* is one of the frequent ocular results of syphilis. It may depend upon gumma (syphilitic neuroma) of the affected nerve or nerves in the orbit or in the skull, or upon gummatous inflammation of the dura mater at the base of the skull, matting the nerves together, or on disease of nerve centres.

\* A few cases are on record in which it appeared not to have begun till about ten years after infection.



The gummatous nerve lesions seldom occur very late in tertiary syphilis.

The optic disc is often inflamed or atrophied as an indirect result of syphilitic disease of the eye or of the nervous system; but the terms "syphilitic optic neuritis" or "syphilitic optic atrophy" are seldom applicable in any more direct sense.—The retinitis of the secondary stage affects the disc, and, when atrophy of the retina and choroid occur, the disc becomes wasted in proportion; whilst in rare cases the retinitis of secondary syphilis is replaced by well-marked papillitis. Such cases must not be confused with others, still more rare, in which double papillitis, passing into atrophy, occurs with all the symptoms of severe meningitis in secondary syphilis. Tertiary syphilitic disease, anywhere within the cranium, commonly causes optic neuritis, in the same way as do other coarse intra-cranial lesions (p. 203); but neuritis may also be caused more directly by gummatous inflammation of the trunk of the optic nerve, or of the chiasma.—Primary progressive atrophy of the discs occurs in association with locomotor ataxy and ophthalmoplegia externa of syphilitic origin; probably in a few instances the optic atrophy occurs alone, or for a time precedes the other changes in syphilitic, as it is known to do in non-syphilitic, ataxy.

2. *Inherited syphilis*.—In the secondary stage.—*Iritis* corresponding to that in the acquired disease is seen in a small number of cases, and occurs between the ages of about two and fifteen months. It often gives rise to much exudation, leading to occlusion of the pupil, and is frequently accompanied by deeper changes (cyclitis and disease of vitreous). It is very often symmetrical, and is much commoner in girls than boys.—*Choroiditis* and *retinitis*, of precisely the same forms as in acquired syphilis, occur at the corresponding period of the disease, *i.e.* between six months and about three years of age; and they show as much (some observers think more) tendency



to the degenerative and atrophic results already described; in severe cases there are not uncommonly signs of cerebral degeneration. In the later stages, *keratitis*, which is the commonest eye disease caused by inherited syphilis, occurs. It is commonest between six and fifteen years old, but is sometimes seen as early as two or three years, and is occasionally deferred till after thirty. The disease is frequently complicated with iritis and cyclitis, and, though tending to recovery, shows a considerable liability to relapse. It almost always attacks both eyes, though sometimes at an interval of many months. When the patient is unusually young, the disease as a rule runs a mild and short course.—The *oculo-motor palsies* occur but rarely in inherited syphilis but a few well authenticated cases are on record.

*Smallpox* causes inflammation and ulceration of the cornea, leading, in the worst cases, to its total destruction, but in a large number to nothing worse than a chronic vascular ulcer. The corneal disease comes on some days after the eruption (tenth to fourteenth day from its commencement), and after the onset of the secondary fever. Iritis, uncomplicated and showing nothing characteristic of its cause, sometimes occurs some weeks after an attack of smallpox. Only in very rare cases do variolous pustules form on the eye, and even then they are always on the conjunctiva, not on the cornea.

*Scarlet fever, typhus*, and some other exanthemata may be followed by rapid and complete loss of sight, lasting a day or two, showing no ophthalmoscopic changes, and ending in recovery. Such attacks are believed to be uræmic, or at any rate dependent on some toxic condition of the blood. A peculiarity of these cases is the preservation of the action of the pupils to light.—Very severe purulent or diphtheritic ophthalmia sometimes occurs during scarlet fever.

*Diphtheria*.—By far the commonest result is para-



lysis (often incomplete) of both the ciliary muscles (*cycloplegia*); the pupils are not affected except in severe cases, when they may be rather large and sluggish.\* The symptoms generally come on from four to six weeks after the commencement of the illness, last about a month, and disappear completely. Diphtheritic cycloplegia is usually, but not invariably, accompanied by paralysis of the soft palate. In most of the cases seen by ophthalmic surgeons the attack of diphtheria has been mild, sometimes extremely so, the case often being described as "ulcerated throat;" but inquiry often yields a history of other and severer cases in the family, and of general depression and weakness in the patient out of proportion to his throat symptoms. We find that most of the patients who apply with diphtheritic cycloplegia are hypermetropic, doubtless because those with normal (and *à fortiori*, with myopic) refraction are much less troubled by paresis of accommodation, and often do not find it necessary to seek advice. Concomitant convergent squint is sometimes developed in hypermetropic children during the diphtheritic paresis, owing to the increased efforts at accommodation (p. 289). Paralysis of the external muscles is occasionally seen; I have never myself seen any except the external rectus affected, and recovery has been rapid.

*Diphtheritic and membranous ophthalmia* are occasionally caused by direct inoculation of the conjunctiva of the attendant by diphtheritic material from the patient's throat; or in the patient himself by extension up the nasal duct to the conjunctiva. But in many cases of "diphtheritic" and "membranous" ophthalmia the disease seems to be local, the inflammation taking on this special form without ascertainable relation to any infectious disease. No doubt there is often something peculiar in the

\* Further observations are wanted.



patient's health, or in the state of his eye-tissues, which gives a proclivity to this kind of inflammation. Thus diphtheritic ophthalmia of all degrees is more common in young children than in adults: the worst cases generally occur after measles, or during or after scarlet fever, broncho-pneumonia, or severe infantile diarrhœa: old granular disease of the conjunctiva also confers a liability to a diphtheritic type of inflammation, and the same tendency is sometimes seen in ophthalmia neonatorum and in gonorrhœal ophthalmia. As there seems but seldom any reason to look upon diphtheritic ophthalmia as the local manifestation of a specific blood disease, the term "diphtheria of the conjunctiva" should, I think, seldom be used.

*Measles* is a prolific source of ophthalmia tarsi in all its forms, and of corneal ulcers, particularly of the phlyctenular forms. It also gives rise to a troublesome muco-purulent ophthalmia, and under bad hygienic conditions this may be aggravated by cultivation and transmission, into destructive disease of purulent, membranous, or diphtheritic type.

*Chicken-pox* is sometimes followed by a transient attack of mild conjunctivitis.

*Whooping-cough* often, like measles, leaves a proneness to corneal ulcers. In a few rare cases the condition known as *ischæmia retina* (sudden, temporary, arterial bloodlessness) has occurred.

*Malarial fevers*, especially the severe forms met with in hot countries, are sometimes the cause of retinal hæmorrhages (often large and periarterial), and even of considerable neuro-retinitis; when there is much pigment in the blood, the swollen disc may have a peculiar grey colour. When renal albuminuria is caused by malarial disease, albuminuric retinitis may occur.

*Relapsing fever* is sometimes followed, during convalescence, by inflammatory symptoms with opacities



in the vitreous (cyclitis) with or without iritis; recovery takes place. These cases are commoner in some epidemics than in others.

*Epidemic cerebro-spinal meningitis* also, in a few cases, gives rise to acute choroiditis, with pain, chemosis, and great tendency to rapid exudation of lymph into the vitreous and anterior chambers, and often leading to disorganisation of the eye, and blindness.\* It is believed that the inflammation may extend to the eye along the optic nerve, or may occur independently in the brain and the eye. Deafness from disease of the internal ear is even commoner than the eye disease.

*Purpura* has been observed in a few cases to be accompanied by retinal or subretinal hæmorrhages; they are sometimes perivascular and linear, and in other cases form large blotches. They have also, but rarely, been found in *Scurvy*.

In *Pyæmia* one or both eyes may be lost by septic emboli lodging in the vessels of the choroid or retina, and setting up suppurative panophthalmitis. The symptoms are, swelling of the lids, loss of sight, congestion, especially of the perforating ciliary vessels (Fig. 23), chemosis, discoloration and dulness of aqueous and iris. There may or may not be some protrusion and loss of mobility, and conjunctival discharge. Pain, sometimes very severe, may be almost absent; probably, its presence indicates rise of tension. A yellow reflex is often seen from the vitreous. The eyeball generally suppurates if the patient lives long enough. Sometimes both eyes are affected, together or with an interval.—In cases of *Septicæmia* abundant retinal hæmorrhages of large size may occur in both eyes; they come on a few days before death and are thus of grave significance. As they are not present in typhoid and other fevers

\* Possibly a few of the cases in which similar eye conditions are seen without apparent cause may be the accompaniments of slight and unrecognised meningitis. (See *Pseudo-glioma*, p. 259.)



of corresponding severity, their presence is sometimes an aid in differential diagnosis.\*

*Lead poisoning* is an occasional cause of optic neuro-retinitis leading to atrophy, of atrophy ensuing upon chronic amblyopia, and of rapid, usually transient, amblyopia. The two former are the most common; the atrophy, whether primary or consecutive to papillitis, is generally accompanied by very marked shrinking of retinal arteries, and great defect of sight or complete blindness; it is generally symmetrical, but one eye may precede the other. Other symptoms of lead poisoning, usually chronic, but occasionally acute, are nearly always present. Care must be taken not to confuse albuminuric retinitis from kidney disease induced by lead, with the changes here alluded to, which are due in some more direct manner to the influence of the metal.

The deposition of lead upon corneal ulcers has been referred to at p. 112.

*Alcohol*.—Some observers still hold that alcohol, especially in the form of distilled spirits, may cause a particular form of symmetrical amblyopia (the so-called *amblyopia potatorum*). The difficulty of arriving at the truth depends chiefly upon the fact that most drinkers are also smokers, and that tobacco, whether smoked or chewed, is allowed by all authorities to be one of the causes (or as most now hold, the sole cause) of a similar disease. The question of whether alcohol directly causes disease of the optic nerves will not be settled until observers are much more careful than they have hitherto been to record as typical cases of alcoholic amblyopia, only those in which the patient does not use even the smallest quantity of tobacco in any shape. Magnan thinks alcoholic amblyopia less common than some have supposed.†

*Tobacco*.—Whatever may be the truth (and it is

\* Gowers, 'Medical Ophthalmoscopy,' 2nd edit., p. 255.

† Magnan 'On Alcoholism,' Greenfield's translation.



confessedly difficult to arrive at) as to the direct influence of alcohol, and of the various substances often combined with it, there is no doubt whatever that tobacco, whether smoked or chewed, does act directly on the optic nerves, and in such a manner as to give rise to definite, and usually very characteristic, symptoms. The amblyopia seldom comes on until tobacco has been used for many years. The quantity needed to cause symptoms is, *cæteris paribus*, a matter of idiosyncrasy, and very small doses may produce the disease in men who, in other respects also, are unable to tolerate large quantities of the drug. Predisposing causes exert a very important influence: amongst these are to be especially noted increasing age; nervous exhaustion from overwork, anxiety, or loss of sleep; chronic dyspepsia, whether from drinking or other causes; and probably sexual excesses, and exposure to tropical heat (or light). A large proportion of the patients drink to excess, and thus make themselves more susceptible to tobacco, both by injuring the nervous system and the stomach. But some remarkable cases are seen in men who have for long been total abstainers, in others who have lately become abstainers without lessening their tobacco, and in yet others who are strictly moderate in alcohol, are in robust health, and in whom increasing age is the only recognisable predisposing cause. The strong tobaccos produce the disease far more readily than the weaker sorts, and chewing is more dangerous than smoking. Probably alcohol in very moderate doses counteracts, rather than increases, the injurious effect of tobacco on the nervous system and optic nerves (Hutchinson).

*Quinine*, taken in very large doses, at short intervals, has in a few cases caused serious visual symptoms. Sight in both eyes may be totally lost for a time, but recovery, more or less perfect, takes place eventually, sometimes in a few days, sometimes not for months. There is great contraction of



the visual field even after perfect recovery of central vision; the discs are pale and the retinal arteries extremely diminished. The symptoms are therefore those of almost arrested supply of arterial blood to the retina.

*Kidney disease.*—The common and well-known retino-neuritis, associated with renal albuminuria, and of which several clinical types are found, has been already described. It need only be noted that the disease is commonest with chronic granular kidneys and in the kidney disease of pregnancy, but that it is also seen in the chronic forms following acute nephritis and in lardaceous disease; and that it is rare in children. Detachment of the retina is an occasional result in extreme cases. The prognosis as regards vision is best in the cases depending on albuminuria of pregnancy. The retinal œdema and exudation are probably caused by the blood-state; but the disease of the small blood vessels, and the cardiac hypertrophy, no doubt add to and complicate the changes. Indeed the different types of retinal disease which are met with probably depend in great measure on the varying parts played by the three factors alluded to. The failure of sight caused by abuminuric retinitis has often led to the correct diagnosis of cases which had been treated for dyspepsia, headache, or “biliousness.”

*Diabetes* sometimes causes cataract. In young or middle-aged patients the cataract usually forms quickly, and is of course soft. As it is always symmetrical, the rapid formation of double, complete cataract, at a comparatively early age, should always lead to the suspicion of diabetes. In old persons the progress of diabetic cataract is much slower, and often shows no peculiarities. The relation of the lenticular opacity to the diabetes has not been satisfactorily explained: the presence of sugar in the lens, the action of sugar or its derivatives dissolved in the aqueous and vitreous, the abstraction of water



from the lens owing to the increased density of the blood, and, lastly, degeneration of the lens from the general cachexia attending the disease, have all been offered in explanation.—In a few cases retinitis occurs attended by great œdema and copious (probably capillary) hæmorrhages into the retina and vitreous.—In other cases central amblyopia from disease of the optic nerves has been observed, but hitherto only in patients who were smokers.\*

*Leucocythæmia* is often accompanied by retinal hæmorrhages, less commonly by whitish spots bordered by blood, and consisting of white corpuscles; these spots may be thick enough to project forwards. Occasionally there is general haziness of the retina. In severe cases the whole fundus is remarkably pale, whether there be other changes or not.† The changes are usually symmetrical.

*Progressive pernicious anæmia* is marked by a strong tendency to retinal hæmorrhages; these are usually grouped chiefly near the disc, and are striated (Gowers). White patches are also common, and occasionally well-marked neuritis occurs. I have seen hæmorrhages of different dates, and in one case, shown to me by Dr Sharkey, there had evidently been a large extravasation from the choroid at an earlier period. The disc and fundus participate in the general pallor.

*Heart disease* is variously related to changes in the eyes and alterations of sight. Aortic incompetence often produces visible pulsation of the retinal arteries. This pulsation often differs from that seen in glaucoma in extending far beyond the disc, and in not being so marked as to cause complete

\* See a paper by Dr Edmunds and the author, 'Trans. Ophth. Soc.,' vol. iii, 1883.

† For a full account of the changes see Gowers' 'Medical Ophthalmoscopy.' Dr Sharkey has shown me a case with diffuse retinitis, very numerous punctiform hæmorrhages, chiefly peripheral, and dilatation with extreme tortuosity of the veins.



emptying of the larger vessels during the diastole. In glaucoma the pulsation is confined to the disc. The difference is explained by the different mode of production in the two cases; in the one incomplete closure of the aortic orifice lowers the pressure in the whole blood-column during the diastole, and allows a reflux of blood from the eye; in the other heightened intraocular tension, telling chiefly on the comparatively yielding tissues of the optic disc, increases the resistance to the entrance of arterial blood. Valvular disease of the heart is generally present in the cases of sudden lasting blindness of one eye, clinically diagnosed as embolism of the arteria centralis retinæ; but in some of these thrombosis of the artery or of its companion vein, or blocking of the internal carotid\* and ophthalmic arteries, has been found *post-mortem*. Brief temporary failure, or even loss, of sight may occur in the subjects of valvular heart disease, and in some persons who are liable to recurring headaches (*see* Megrin). Repeated attacks of this kind sometimes lead to permanent blindness of one eye, and atrophy of the disc comes on; possibly repeated temporary failures of retinal circulation at length give rise to thrombosis. In another group of cases which needs investigation, sight fails during successive pregnancies or lactations, recovering between times; some of these may be cases of renal retinitis; others may be mere accommodative asthenopia (p. 288). It is probable that high arterial tension predisposes to intraocular hæmorrhage in cases where the small vessels are unsound, and that the frequent association of retinal hæmorrhage with cardiac disease is thus explained.

*Tuberculosis* is sometimes accompanied by the formation of tubercles in the choroid. These may occur in acute miliary tuberculosis, whether the meninges be involved or not, but owing to the difficulty of thorough ophthalmoscopic examination in

\* Gowers' 'Medical Ophthalmoscopy,' p. 29.



such patients, and the frequently very small size of the choroidal growths, they are much more often seen after, than before, death. Chronic tubercular tumours of the brain may be accompanied by tubercles of slow growth and larger size in the choroid, and occasionally these attain such dimensions, and cause such active symptoms, as to simulate malignant tumours.\* (p. 261). It is also probable that certain cases of localised choroidal exudation, not accompanied by serious general symptoms or by inflammatory symptoms in the eye, may be of tubercular nature (p. 178).

Barlow† has seen tubercles in the choroid *post-mortem*, in 16 cases; in 13 with, 3 without, tubercular meningitis. Sometimes they took the form of extremely minute dots, "tubercular dust." In 44 children who died of tubercular disease (42 showing miliary tubercles in the meninges) Dr Money‡ found tubercles in the choroid of one or both eyes in 14.

*Rheumatism.*—In acute rheumatism Dr Barlow informs me that he has more than once seen well-marked congestion of the eyes and photophobia; but neither iritis nor other inflammatory changes occur. The subjects of chronic rheumatism are, however, subject to relapsing iritis. Some of these patients give a history of acute articular rheumatism as the starting-point of their chronic troubles, others of a prolonged subacute attack, lasting for many months, whilst in others again the articular symptoms have never been severe. In yet another series a liability to fascial or muscular rheumatism, or to recurrent neuralgia from exposure to cold or damp, are the only "rheumatic" symptoms of which a

\* For interesting cases of and remarks on choroidal tuberculosis in its various forms and relations, *see* communications by Mackenzie, Barlow, Coupland, and others in 'Trans. Ophth. Soc.,' vol. iii, p. 119 et seq. (Oct., 1882).

† Barlow, *Ibid.*, p. 132. ‡ Money, 'Lancet,' 1883, ii, 813.



history is given; in some of these the neuralgia is probably gouty. It is to be remembered that the eye is now and then the first part to be attacked by an inflammation, which later events show to be clearly related to rheumatism or to gout.

Gonorrhœal rheumatism is not unfrequently the starting-point of relapsing iritis as well as of chronic relapsing rheumatism. Rheumatic iritis occurring for the first time in the primary attack of gonorrhœal rheumatism is, in my experience, more often symmetrical than other forms of arthritic iritis, or than the later attacks of iritis in the same patient; a fact which sometimes make the distinction between rheumatic and syphilitic iritis difficult.

I have full notes of 13 cases in which iritis occurred for the first time during or after gonorrhœal rheumatism; none had had rheumatism before the gonorrhœa, but one had had gout. In 7 of these, the first attack of iritis occurred in both eyes during or within a few months of gonorrhœa; in 2 others, the first iritis, though symmetrical, occurred several years after the gonorrhœa. In only 4 was the first iritis single. Of the 9 in which the first attack was double, relapses occurred in 5, but never in more than one eye at a time.

It is believed that rheumatism is the cause of some cases of non-suppurating orbital cellulitis, and of relapsing episcleritis. Rheumatism is also believed to cause some of the ocular paralyses.

*Gout.*—Gouty persons are not very unfrequently the subjects of recurrent iritis indistinguishable from that which occurs in rheumatism. Rheumatism and gout seem sometimes so mixed that it is not always possible to assign to each its right share in the causation of iritis; but that the subjects of true "chalk gout" are liable to relapsing iritis is undoubted. There is, on the whole, more tendency to insidious forms of iritis in gout than in rheumatism. It is also generally believed that the subjects of gout, or persons whose near relatives suffer from it, are particularly subject to glaucoma; acute glaucoma was



indeed the "arthritic ophthalmia" of earlier authors. Hæmorrhagic retinitis is also commoner in gouty persons than in others; it may be single or double, and is to be distinguished from albuminuric retinitis. —It has also been observed that the children or descendants of gouty persons, without being themselves subject to gout, are sometimes attacked, in early adult life, by an insidious form of irido-cyclitis often leading to secondary glaucoma and serious damage to sight;\* both eyes are attacked sooner or later. The cases in this group probably seem rarer than they are, from the impossibility in many instances of getting a full family history.

Several different clinical types may be recognised in the large group of maladies referred to in this section under the name of "iritis." Besides cases of pure iritis, we meet with examples of cyclitis, in some cases with increase, in others with decrease of tension; in other groups either the sclerotic or conjunctiva are chiefly affected (true "rheumatic ophthalmia" without iritis); a fourth group, in which the pain is disproportionately severe, may be spoken of as neuralgic. In a large majority, however, the iris is the headquarters of the morbid action. All arthritic eye diseases are marked by a strong tendency to relapse; they usually attack only one eye at a time, though both suffer sooner or later; and they are all much influenced by conditions of weather, being commonest in spring and autumn.

*The strumous condition* is a fruitful source of superficial eye diseases, which are for the most part tedious and relapsing, are often accompanied by severe irritative symptoms, but, as a rule, do not lead to serious damage. The best types are—(1) the different varieties of ophthalmia tarsi; (2) all forms of phlyctenular ophthalmia ("pustular" or "herpetic" diseases of the cornea and conjunctiva); (3) many superficial

\* Hutchinson, the 'Lancet,' Jan., 1873.



relapsing ulcers of cornea in children and adolescents, though not distinctly phlyctenular in origin, are certainly strumous ; (4) many of the less common, but very serious, varieties of cyclo-keratitis in adults occur in connection with lowered health, susceptibility to cold, and sluggish but irritable circulation, if not with decidedly scrofulous manifestations.

*Entozoa* sometimes come to rest and develop in the eye or orbit. The commonest intraocular parasite is the *cysticercus cellulosæ* ; it is excessively rare in this country, but commoner on the Continent. The *cysticercus* may be found either beneath the retina, in the vitreous, or upon the iris, and may sometimes be recognised in each of these positions by its movements. The parasite has been successfully extracted from the vitreous ; when situated on the iris its removal involves an iridectomy. Sometimes it develops under the conjunctiva, where I have seen it set up suppurative inflammation. The *echinococcus* hydatid with multiple cysts may develop to a large size in the orbit and cause much displacement of the eyeball.

**B.** Eye disease, or eye symptoms, indicative of local disease at a distance.

*Megrim* is well known to be sometimes accompanied, or even solely manifested, by temporary disorder of sight. This generally takes the form of a flickering cloud ("flittering scotoma" of German authors) with serrated borders, which, beginning near the centre of the field, spreads eccentrically so as to produce a large defect in the field, a sort of hemianopsia ; the borders of the cloud may be brilliantly coloured. It is referred to both eyes, and is visible when the lids are closed. The attack lasts only a short time, and perfect sight returns. In many patients this amblyopia is the precursor of a severe sick headache, but in others it constitutes the whole attack ; it scarcely ever follows the headache.



Less definite and characteristic symptoms (dimness, cloudiness, or *muscæ*) are complained of by some patients (*compare* p. 370).

*Neuralgia* of the fifth nerve, especially of its first division, in a few cases precedes or accompanies failure of sight in the corresponding eye with neuritis or atrophy of the disc (p. 219, 3). A liability to neuralgia of the face and head is not unfrequently observed in persons who subsequently suffer from glaucoma.—Intense neuralgic pain in the face or head sometimes causes dimness of sight of the same eye whilst the pain lasts.—The old belief that injury to branches of the fifth nerve can cause amaurosis is not borne out by modern experience,\* injury to the optic nerve by fracture of the skull furnishing the true explanation of such cases (p. 216).

Sympathetic ophthalmitis is the only known instance in which inflammation of the eyeball is caused by local disease of an independent part.

*Diseases of the central nervous system* may be shown in the eye either at the optic disc (papillitis and atrophy), or in the muscles (strabismus and diplopia).

The diseases which most often cause *papillitis* are intracranial tumours, syphilitic growths and meningitis. Abscess of the brain and softening from embolism and thrombosis less commonly cause it, and cerebral hæmorrhage scarcely ever. Papillitis has been found in a few cases of acute and sub-acute myelitis;† it does not occur in spinal meningitis.

In a very large proportion (Dr Gowers thinks at least four-fifths) of all the cases of *cerebral tumour* (including syphilitic growths) neuritis occurs at

\* References to many of the earlier cases supposed to prove this relation between the fifth and optic nerves are given by Brown-Séquard in Holmes's 'System of Surgery,' 3rd ed., vol. ii, p. 206.

† Gowers, loc. cit., p. 161; Dreschfeld, 'Lancet,' Jan. 7, 1882.



some period. The severity and duration of the neuritis vary much, and probably depend in many cases on the rate of progress, as well as on the character, of the morbid growth. It not uncommonly sets in at no long interval before death, whilst in other cases it is very chronic. There is very little in the characters or course of the papillitis to help us in the localisation of intracranial tumour; and although a very high degree of papillitis, with signs of great obstruction to the retinal circulation, generally indicates cerebral tumour, there are many cases in which the presence of papillitis does not help us to decide the nature of the intracranial disease, whether tumour, meningitis, or syphilitic disease. Tumours also sometimes cause simple optic atrophy by pressing upon or invading some part of the optic fibres.

*Intracranial syphilitic disease* is a common cause of papillitis, the disease being either a gummatous growth in the brain, or a growth or thickening beginning in the dura mater, or basilar meningitis. The prognosis is much better than in cerebral tumours if vigorous treatment be adopted early; indeed in all cases of papillitis, where intracranial disease is diagnosed and syphilis even remotely possible, mercury and iodide of potassium should be promptly given.

*Meningitis* often causes papillitis, but in this respect much depends on its position and duration. Meningitis limited to the convexity, whatever its cause, is seldom accompanied by ophthalmoscopic changes; on the other hand basic meningitis very often causes neuritis. The neuritis in basic meningitis is probably proportionate to the duration and intensity of the intracranial mischief, being comparatively slight in acute and rapidly fatal cases, whether tubercular or not. In tubercular meningitis, papillitis is very common\* and its occurrence seems especially related to the presence of inflammatory

\* Garlick found it in 23 of 26 fatal cases, 'Med.-Chir. Trans.,' vol. 62. Money (loc. cit.) discovered it in only 16 of 42 fatal



changes about the chiasma (Gowers); and even the neuritis occurring in cases of cerebral tumour seems often to be caused by secondary meningitis set up by the growth.\* In a form of meningitis in young children named by Drs Gee and Barlow "posterior basic," optic neuritis is infrequent, though the patients often live some little time. When patients recover from meningitis the neuritis may pass into atrophy and cause amaurosis; such cases are well known to ophthalmic surgeons; it is probable that some of them may be instances of recovery from tubercular meningitis.—In rare cases papillitis occurs with severe head symptoms, ending in death, but without macroscopic changes in the brain or membranes. Microscopical changes in the brain substance, justifying the term cerebritis, have been found in one such case by Dr Sutton, and in another by Dr Stephen Mackenzie.† It must not be forgotten that optic neuritis may be caused by various altered conditions of the blood; and that it is occasionally seen without any evidence either of central nervous disease or of blood changes.

*Hydrocephalus* rarely causes papillitis, but often at a late stage causes atrophy of the optic nerves from the pressure of the distended third ventricle on the chiasma. Dr Barlow informs me that he has several times seen a very gross form of choroiditis ending in immense patches of atrophy; I have recorded one such case and seen others.

The diseases most commonly causing *atrophy not preceded by papillitis* are the chronic progressive diseases of the spinal cord, especially locomotor ataxy. The atrophy in these cases is slowly progressive, double, though seldom beginning at the same time

cases. Slight papillitis is very easily overlooked in delirious or fretful children.

\* Edmunds and Lawford, 'Trans. of Ophth. Soc.,' iii, 138 (1883).

† Also a case by Dr Silk, 'Brit. Med. Journ.,' May 26, 1883.



in both eyes, and it always ends in blindness, although sometimes not until after many years. Similar atrophy sometimes occurs in the early stages of general paralysis of the insane, but chiefly in cases complicated by marked ataxic symptoms. It is also, but much more rarely, seen in lateral and in insular sclerosis. In the latter, amblyopia with slight neuritic changes is occasionally seen, and sight may improve or almost recover after having been defective for some time. In cases of homonymous lateral hemianopia we find that sometimes the blind half of the field is separated from the seeing half by a straight line which passes through the fixation point (Fig. 87), whilst more commonly this dividing line deviates towards the blind half in the central part of the field, thus leaving a small central area of perfect vision. Ferrier has suggested that in the former cases the lesion is probably situated in the tract, and that in the latter it lies in some part of the cortical visual centre.

*Motor disorders of the eyes.*—Some of the commoner causes of ocular palsy have been already given. It may be mentioned here that basilar meningitis often causes paralysis of one or more of the ocular nerves with squinting (and double vision if the patient be conscious), and, further, that the palsy in such cases often varies, or appears to vary, from day to day.

Locomotor ataxy and general paralysis of the insane are sometimes preceded by paralysis (usually, but not always, temporary) of one or more of the eye muscles, causing diplopia; and there may for years be nothing else to attract attention. The same diseases may also be ushered in by internal ocular paralysis. The most frequent variety is loss of the reflex action of the pupils to sensory stimulation of the skin and to light, whilst their associated action remains, "reflex iridoplegia;" when shaded and lighted they remain absolutely motionless, but they dilate when accommodation is relaxed and con-



tract when it is in action (p. 28) ("Argyll Robertson symptom").\* This phenomenon is often, though by no means always, associated with a contracted state of the pupils, and hence the term "spinal miosis" is often, but incorrectly, used. This reflex paralysis of the iris is one of the most valuable of the early signs of locomotor ataxy. We do not, however, yet know how often it may occur in healthy persons or without eventual spinal disease; it certainly has comparatively little significance in old persons. Recent observations show that, at least in general paralysis of the insane, loss of reflex dilatation to sensory stimulation of the skin (p. 28) is probably the earliest pupillary change.† The complementary symptom, loss of associated, with retained reflex, action of the pupils has not been fully studied. Any of the other internal paralyses may also in certain cases occur as precursors of ataxy.—Paralysis of one-third nerve coming on with hemiplegia of the opposite side may, but does not necessarily, indicate disease of the crus cerebri on the side of the palsied third nerve.‡—Ophthalmoplegia externa has been already mentioned; it may here be added that cases occur in which this condition appears to be "functional," in which at any rate the symptoms come on quickly and pass off completely, recurring perhaps at a later period; of these cases, I have seen several in young adults.

Double ophthalmoplegia externa is the extreme type of a large and important class of ocular palsies, to which much attention has been given recently, characterised by the paralysis of certain *movements* (usually associated movements of the two eyes) not of the *muscles* supplied by a certain nerve. There may be, *e.g.* loss of power of both eyes to look upwards (both superior recti) or loss of power to look

\* Argyll Robertson, 'Edinburgh Med. Jour.,' 1869, 703.

† Bevan Lewis, 'Trans. Ophth. Soc.,' vol. iii, 1883.

‡ For exceptions *see* Robin, 'Troubles Oculaires dans Mal. de l'Encéphale,' 1880, p. 95.



to the right (R. external and L. internal rectus); and yet in the latter case the L. internal rectus if differently associated, as with the R. internal during convergence, may act perfectly well. Such associated paralyses are explained by lesions (usually sclerotic, occasionally tumour) affecting the centres for certain combined movements, which are more central anatomically and higher physiologically, than the centres of origin of the nerve-trunks. Cases of paralysis of both third or both sixth nerves, and also of complete ophthalmoplegia, are sometimes due to symmetrical coarse disease (syphilitic gummata, for instance) of the affected nerve-trunks. The symptoms in all the cases referred to in this paragraph may be temporary or permanent, acute or chronic, and caused by various fine or coarse anatomical changes; and they are frequently associated with other and graver nervous symptoms. It is of great importance in cases of multiple and associated ocular paralysis to make out, if we can, whether the symptoms point to peripheral disease (disease of nerve-trunks), or to disease of the nuclei of origin of the nerves, or to lesion of the centres for certain movements.

Insular (disseminated) sclerosis is often accompanied by nystagmus, characterised by irregularity, both of the amplitude and rapidity of the movements.

There appears to be an intimate relation between the occurrence of *Convulsions* and the formation of lamellar cataract, this form of cataract being scarcely ever seen, except in those who have had fits in infancy. A very striking deformity of the permanent teeth is also nearly always present, depending upon an abruptly limited deficiency, or absence, of the enamel on the part furthest from the gum (Fig. 151, 7). The teeth affected are the first molars, incisors, and canines, of the permanent set. The dental changes are quite different from those which are pathognomonic of



inherited syphilis, although mixed forms are sometimes seen. The relation between the convulsions, the cataract, and the defective dental enamel has not been satisfactorily explained. Mr Hutchinson has collected many facts in favour of the belief that the dental defect is due to stomatitis interfering with the calcification of the enamel before the eruption of the teeth, and that mercury is the commonest cause of this stomatitis. On this hypothesis the coincidence of the dental defect and the cataract is due to mercury having been usually prescribed for the infantile convulsions from which these cataractous children suffer. It seems, however, reasonable to suppose that the defect of the crystalline lens and of the enamel, both of them epithelial structures, may be caused by some common influence; although the facts that the peculiar teeth are often seen without the cataract, and the cataract occasionally seen with perfect teeth, appear to weaken this view.

C. Cases in which the eye shares in a local process affecting the neighbouring parts.

In *herpes zoster* of the first division of the fifth nerve the eye participates. When only the supra-orbital or supra-trochlear branches are attacked, the eyeball usually escapes, or is only superficially congested. But if the eruption occur on the parts supplied by the nasal branch (*i. e.* if the spots extend down to the tip of the nose), there is usually inflammation of the proper tissues of the eyeball (ulceration or infiltration of cornea, and iritis); for the sensitive nerves of the cornea, iris, and choroid are derived, through the long root of the ophthalmic ganglion, from the nasal branch. Occasionally the eye suffers, however, when the nasal branch escapes. The pain and swelling of the herpetic region are often so great that the attack gets the name of "erysipelas." In rare cases atrophy of the optic nerve, and paralysis of the third and other neighbouring nerves, occur with the herpes.



In *paralysis of the first division of the fifth* the cornea and conjunctiva are anæsthetic; the cornea may be touched or rubbed without the patient feeling at all. In many cases ulceration of the cornea, usually uncontrollable and destructive in character, takes place. It is doubtful whether this is due directly to paralysis of trophic fibres running in the trunk of the fifth, or indirectly to the anæsthesia. In regard to the latter, it is certain that the loss of feeling (1) allows injuries and irritations to occur unperceived, and (2), by removing the reflex effect of the sensory nerves on the calibre of the blood-vessels, permits inflammation to go on uncontrolled.

In *paralysis of the facial nerve* the eyelids cannot be shut, and the cornea remains more or less exposed. When a strong effort is made to close the lids the eyeball rolls upwards beneath the upper lid. Epiphora is a common result of facial palsy. Severe ulceration of the cornea may result from the exposure.

*Paralysis of the cervical sympathetic* causes some narrowing of the palpebral fissure from slight drooping of the upper lid, apparent recession of the eye into the orbit, and more or less miosis from paralysis of the dilator of the pupil (p. 316). No changes are observed in the calibre of the blood-vessels of the eye, or in the secretion of tears. The pupil is said to be less contracted after division of the sympathetic trunk than when the trunk of the fifth (and with it the oculo-sympathetic fibres) is cut, and knowledge of this may be now and then useful in diagnosis.

In *exophthalmic goitre* (Graves's disease) the eyeballs are too prominent, and the protrusion is almost invariably bilateral, though not unfrequently greater on the right side. It is often apparently increased in slight cases by an involuntary elevation of the upper lids when looking forwards, and by the lids not following the cornea, as they should do, when the patient looks down.



In severe cases the proptosis may be so great as to prevent full closure of the lids, and in these dangerous ulceration of the cornea is to be feared. In such cases it is beneficial to shorten the palpebral fissure by uniting the borders of the lids at the outer canthus, or even to unite the lids in their whole length (p. 327). No changes are present in the fundus, excepting sometimes dilatation of arteries and spontaneous arterial pulsation. The seat of the lesion causing this peculiar malady is not yet known. It has been generally supposed to be due to some morbid condition of the sympathetic, but recent speculations point to a localised central lesion, probably in the medulla oblongata, as being more likely.\*

*Erysipelas* of the face sometimes invades the deep tissues of the orbit and causes blindness by affecting the optic nerve and retina; on recovery the eye is found to be blind and the ophthalmoscope shows either simple atrophy of the disc, or signs of past retinitis also. Other forms of orbital cellulitis may lead to the same result.

*Note on the Teeth in Inherited Syphilis, with Description of Fig. 151.*—None of the *first set* of teeth are characteristically altered, though the incisors frequently decay early.

In the *permanent set* only two teeth, the central upper incisors, are to be relied upon; but the other incisors, both upper and lower, and the first molars, are often deformed from the same cause. The characteristic change in the upper central incisors appears to depend upon defective formation of the dentine, and in a less degree of the enamel, of the central lobe of the tooth (Fig. 151, 2, 5, and 6). Soon after the eruption of the tooth this lobe wears away, leaving at the centre of the cutting edge a

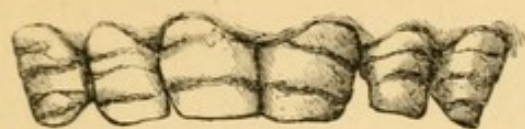\* See an able paper by Dr W. A. Fitz-Gerald in the 'Dublin Jour Med. Sci.,' for March and April, 1883.



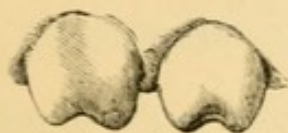vertical notch (Fig. 1). If the cause have acted so intensely as entirely to prevent the development of the central lobe, we find, instead of the notch, a narrowing and thinning of the cutting edge in comparison with the crown, and this, according to its degree, produces a resemblance to a screw-driver, or to a peg (Figs. 3 and 4). The teeth are also usually too small in every dimension, so that the incisors are often separated from one another by considerable spaces. In extreme cases all the incisors are peggy and much dwarfed. The changes are usually symmetrical, but Fig. 5 shows one tooth typically deformed and the other normal.

Figs. 151—7, shows in an extreme degree the changes due to absence of enamel in cases of Lamellar Cataract (p. 380) ("mercurial," "stomatitic," "strumous," and "rickety" teeth). The change occurs in lines running horizontally across the whole set of permanent incisors and canines. When slight it affects only the part near the edge, the enamel beginning as a sudden terrace or step a little distance from the edge; in bad cases several such "terraces" are present and the whole tooth is rough, pitted, and discoloured. The first permanent molars show a corresponding change on the grinding surface.

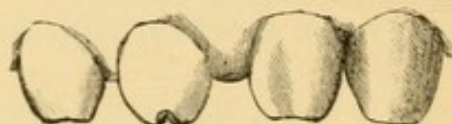



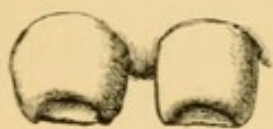7



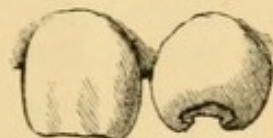
1



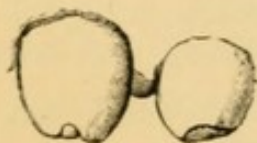4



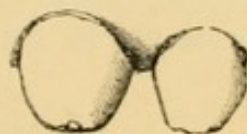6



5




2



3







# APPENDIX

## FORMULÆ, ETC.

### NITRATE OF SILVER.

#### 1. *Mitigated Solid Nitrate of Silver :*

Nitrate of Silver  $\mathfrak{z}$  i

Nitrate of Potash  $\mathfrak{z}$  ii

Fused together and run into moulds to form short, pointed sticks.

Used for granular lids and purulent ophthalmia.

The strength above given is known as No. 1, and is that which I generally use ; three weaker forms are made, known as Nos. 2, 3, and 4, containing respectively 3,  $3\frac{1}{2}$ , and 4 parts of Nitrate of Potash to 1 of Nitrate of Silver.

Pure Nitrate of Silver is never to be used to the conjunctiva.

#### 2. *Solutions of Nitrate of Silver :*

- (1) Nitrate of Silver gr. x or xx,  
Distilled Water  $\mathfrak{z}$  j.

Used by the surgeon for purulent ophthalmia, granular lids and chronic conjunctivitis, and some cases of ulcer of the cornea.

3. (2) Nitrate of Silver gr. j or ij,  
Distilled Water  $\mathfrak{z}$  j.

Used by the patient in various forms of ophthalmia ; only a few drops to be used at a time, and not more than three times a day.

All solutions of Nitrate of Silver should be kept either in a deep blue bottle, or in a dark place.

### SULPHATE OF COPPER.

4. A crystal of *Pure Sulphate of Copper*, smoothly pointed, may be used for touching granular lids of old standing.

#### 5. *Lapis Divinus :*

Sulphate of Copper 1,

Alum 1,

Nitrate of Potash 1.

Fused together, and Camphor equal to  $\frac{1}{10}$  of the whole added.







14. *Red Oxide of Mercury :*

Red Oxide of Mercury gr. iij,  
Vaseline ʒj.

Used for ophthalmia tarsi &c. Was formerly used for corneal ulcers and nebulæ; but the Yellow Oxide, which being made by precipitation is not crystalline, is now generally preferred because less irritating.\*

15. *Nitrate of Mercury (Citrine Ointment) :*

Unguentum Hydrargyri Nitratis (B. P) ʒj,  
Vaseline or Prepared Lard ʒvij.

Used in the same cases as 14.

16. *Iodoform :*

Iodoform may be used either in substance or as an ointment made with Vaseline.

Iodoform gr. x to gr. xxx,  
Vaseline ʒj.

In either case, it is essential that the *finest* powder should be used in order to avoid mechanical irritation.

## SULPHATE OF ZINC :

17. Sulphate of Zinc gr. j or ij,  
Water or Rose Water ʒj.

## CHLORIDE OF ZINC :

18. Chloride of Zinc gr. ij,  
Water ʒj,  
If there is a deposit, add of Dilute Hydrochloric Acid, just enough to make a clear solution.

18a. *Chloride of Zinc Paste (Caustic) :*

- (1) Chloride of Zinc 1,  
Wheat Flour 2, 3, or 4,  
Water, enough to make a thick paste (St Thomas's Hospital).
- (2) Allow solid Chloride of Zinc to deliquesce, add a little glycerine, and make into a paste with powdered Sanguinaria. The glycerine prevents hardening on keeping (St Thomas's Hospital).

---

\* The ointment known as "Singleton's Golden Eye Ointment" appears to contain the crystalline red oxide in fine powder as its active ingredient. A sample kindly analysed for me by Mr S. Plowman, contained 70 grains of the oxide to the ounce or nearly 9 grains in a drachm.



- (3) Chloride of Zinc 480 grains (8).  
Wheat Flour 180 grains (3).  
Water, or Liquor Opii Sedativus  $\text{ʒfl j.}$  (8)  
(Middlesex and Moorfields Ophthalmic Hospitals).
- (4) Chloride of Zinc 1,  
Freshly-burned Plaster of Paris 2, made  
into a paste with a few drops of water.  
(Druitt's 'Vade Mecum,' 9th Ed.)
- (5) Chloride of Zinc 1,  
Oxide of Zinc 1,  
Wheat Flour 2,  
Water enough to make a stiff paste, which  
is made into caustic points. (Squire,  
13th Ed.)

It would seem from the above that the exact composition of the paste is not of much importance. It would be desirable to have the point settled.

#### ALUM :

19. Alum gr. iv to gr. x,  
Water  $\text{ʒj.}$

The above lotions are in common use in the milder forms of acute and chronic ophthalmia. The Chloride of Zinc occasionally irritates; it is specially used in purulent and severe catarrhal ophthalmia instead of the weak Nitrate of Silver lotions. The stronger Alum lotion is often used in the same cases. The Alum and Sulphate of Zinc lotions may be used unsparingly to the conjunctiva; the Chloride, even in severe cases, not more than six times a day.

#### CARBONATE OF SODA :

20. Carbonate of Soda gr. x,  
Water  $\text{ʒj.}$

Used for softening the crusts in severe ophthalmia tarsi. A small quantity of the lotion, diluted with its own bulk of hot water, to be used for soaking the edges of the eyelids for ten or fifteen minutes night and morning.

#### TAR AND SODA :

21. Carbonate of Soda  $\text{ʒiss,}$   
Liquor Carbonis Detergens  $\text{ʒj to ʒss,}$   
Water to Oj.

Used in the same cases as the last.

#### BORAX :

22. Biborate of Soda gr. x to xx,  
Water  $\text{ʒj.}$

Used in the same cases as the last.



## QUININE LOTION :

23. Sulphate of Quinine gr. iij,  
Acid. Sulph. dil. (B. P.), just enough to dis-  
solve.  
Water ℥j.

Used in diphtheritic ophthalmia.

## BORACIC ACID LOTION :

24. Boracic Acid 4,  
Water 100 by weight.

Used as an antiseptic before and after operations on the eye-ball, and in the treatment of suppurating ulcers of the cornea.

Boracic Acid in very fine powder may be used for dusting on to the cornea in cases of severe suppurating ulcer; it causes scarcely any pain and may be applied as often as three times a day (p. 102). The crystals are difficult to powder finely, but an almost impalpable amorphous powder, obtained by preventing regular crystallization, can be had.

Mr Martindale has made for me some soluble styles containing about 60 per cent. of boracic acid for use in cases of lacrimal obstruction with much secretion of mucus (p. 73).

## CARBOLIC ACID LOTION :

25. Absolute Phenol 5,  
Water by weight 100.

Used in purulent ophthalmia. It is important to use absolutely pure carbolic acid for the conjunctiva. Severe irritation often follows if any other varieties are employed.

## MYDRIATICS AND MIOTICS :

26. (1) *Strong Atropine Drops* :  
Liquor Atropiæ Sulphatis (B. P.),  
(Sulphate of Atropia gr. iv,  
Distilled water ℥j).

Used in all cases where the rapid and full local action of the drug is required. Atropine (a single drop, of 2 grains to ℥j, or about .5 per cent.) begins to dilate the pupil in about fifteen minutes, and to paralyse the accommodation a few minutes later; it produces full dilatation of the pupil (9 mm.) in 30 to 40 minutes, and full paralysis of accommodation in about 2 hours. Both remain at their height for 24 hours, and the effect does not pass off entirely till from 3 to 7 days, the accommodation recovering rather sooner than the pupil. If stronger solutions be used several times, the action continues longer. Atropine is absorbed into the aqueous humour and acts locally upon the iris. The effects of Atropine are only very temporarily over-



come by Eserine. Atropine slightly lowers the tension of the healthy eye, but usually increases the tension in glaucoma.

27. (2) *Weak Atropine Drops:*

Sulphate of Atropia gr.  $\frac{1}{4}$  to  $\frac{1}{40}$ ,  
Distilled water  $\mathfrak{z}\text{j}$ .

Used when, for optical purposes, it is desired to keep the pupil dilated for a long time, as in immature nuclear cataract. A single drop about three times a week will generally suffice.

Solutions of Sulphate of Atropine keep for an indefinite time; the flocculent sediment which often forms does not impair their efficiency. The addition of 1 part of carbolic acid to 1000 of the solution is said to prevent "atropine irritation."—The *Liquor Atropiæ* (B. P.), which contains rectified spirit, is irritating to the eye and should not be used. The mydriatics may also be used in the form of ointment with vaseline, and a smaller percentage of the drug is then necessary.

28. *Daturine:*

Sulphate of Daturia gr. iv,  
Distilled Water  $\mathfrak{z}\text{j}$ .

Used as a mydriatic in cases where Atropine causes conjunctival irritation.

29. *Duboisine:*

Sulphate of Duboisia gr. j,  
Distilled Water  $\mathfrak{z}\text{j}$ .

A new mydriatic, acting more quickly and powerfully, and passing off in a shorter time, than atropine. Is tolerated in cases where Atropine causes conjunctivitis. To be used with caution, as well-marked toxic symptoms are sometimes caused.

Duboisine begins to act on the pupil and accommodation in less than 10 minutes, produces full mydriasis in less than 20 minutes, and complete cycloplegia in about 1 hour. The maximum effect does not last quite so long as, and the effect passes off completely rather sooner than, that of Atropine. Duboisine seldom breaks down iritic adhesions which have already resisted Atropine. Its chief use seems to be for cases in which Atropine causes irritation.

30. *Homatropine:*

Hydrobromate of Homatropine gr. iv,  
Distilled Water  $\mathfrak{z}\text{j}$ .

A new mydriatic, acting rather more quickly and passing off much sooner than Atropine; very convenient, therefore, for dilating the pupil for ophthalmoscopic examination.



Homatropine begins to act on the pupil and accommodation in from 5 to 10 minutes; the greatest dilatation of pupil (usually, however, rather less than that obtained by Atropine) is reached in about 35 minutes, and complete or nearly complete cycloplegia in an hour or rather less (with a solution of gr. iv to ʒj). The full effect is only maintained, however for an hour, more or less, and both pupil and accommodation usually recover completely in 24 hours or less.

31. *Eserine* (the Alkaloid of Calabar Bean):

Sulphate of Eseria gr. iv,  
Distilled Water ʒj.

Used in mydriasis and paralysis of the accommodation whether caused by Atropine or by nerve lesions, in some forms of corneal ulcer, and in acute glaucoma.

32. A weaker solution (gr. j to ʒj) is often better borne.

Eserine begins to contract the pupil and cause spasm of the accommodation in about 5 minutes; its maximum effect is reached in 15 to 30 minutes. Its effect on the accommodation lasts only an hour or two, but the pupil does not completely recover for many hours, sometimes 2 or 3 days. After several weeks' use the effects last longer, but never so long as those of Atropine. A very weak solution acts more on the pupil, than on the accommodation. Eserine causes pain in the eye and head, arterial ciliary congestion, and twitching of the orbicularis; the pain, sometimes severe, seldom lasts long. Eserine slightly increases the tension of the healthy eye, but often lessens the tension in primary glaucoma.

All the mydriatics and miotics may be obtained in the form of small gelatine discs of known strength (made by Savory and Moore), which are sometimes more convenient than the solutions. Of the mydriatics, Homatropine and Duboisine are much the most expensive. Eserine sulphate is also expensive.

33. *Belladonna Fomentation*:

Extract of Belladonna ʒj to ʒij,  
Water Oj.

Warmed in a cup or small basin and used as a hot fomentation in suppurating and seriginous ulcers of cornea.

34. *Pilocarpine for Subcutaneous Injection*:

Hydrochlorate of Pilocarpine gr. v,  
Distilled Water ʒj.

Dose, miiij, gradually increased, to be injected daily or less often.

Used in cases of retinal detachment, choroiditis and retinitis.



35. *Pilocarpine Drops* gr. iv to ʒj.

Pilocarpine is a miotic like Eserine, but its action is much weaker.

36. *STRYCHNIA for Subcutaneous Injection:*

Liquor Strychniæ (B. P.) gr. iv to ʒj.

Dose, 2 minims ( $\frac{1}{80}$  grain), gradually increased, for subcutaneous injection. To be injected once a day.

37. "Jequirity" seeds, obtained from a leguminous plant, are used in South America for the cure of granular lids (p. 88). They can now be readily obtained either whole or in moderately fine powder. The infusion is made as follows:—The broken seeds, freed from shell, are infused for 2 hours in cold water in the proportion of 1 to 50 (about 9 grains to the ounce); the softened seeds are then further powdered and soaked in the same water for 24 hours longer and filtered. Probably a shorter soaking will suffice if they can be ground to very fine powder before being wetted.

38. *BANDAGES* for the eyes may be of thin flannel or soft calico. A linen or knitted cotton bandage, about ten inches long, with four tails of tape, or a loop of tape embracing the back of the head (Liebreich's bandage), is very convenient after the more serious operations. An ordinary narrow flannel bandage is better when much pressure is wanted, or if the patient be unruly.

When absolute exclusion of light is desired, it is best to use a bandage made of a double fold of some thin black material.

Fine old linen is better than lint for laying next the skin in dressings after operations.

39. *SHADES* may be bought at the opticians' and chemists'; or may be made of thin cardboard covered with some dark material, or of stout dark blue paper, like that used for making grocers' sugar bags. Shades of black plaited straw are also very light and convenient.

Shades, to be effectual, should extend to the temple on each side, so as to exclude all side light.

40. *PROTECTIVE GLASSES.*

Various patterns of glasses are made for the purpose of protecting the eyes from wind, dust, and bright light. The glasses are either flat, or hollow like a watch glass, and are coloured in various shades of blue or smoke tint. The most effectual are the ones known as "goggles;" in these the space between the glass and the edge of the orbit is filled by a carefully fitting framework of fine wire gauze or black crape, by which



side-wind and light are excluded. A small air-pad of thin india-rubber tubing makes the frame fit still more closely.

Other forms, known as "horseshoe" or "D," and "domed" or "hollow," glasses are also in common use.

#### 41. TEST TYPES.

Snellen's types for testing both near and distant vision under an angle of 5 minutes can be obtained, in several languages, in the form of a small book, from Williams and Norgate, 14, Henrietta Street, Covent Garden.

The types which I generally use for testing near vision are those used at the Moorfields Hospital, where they may be obtained. They can also be bought, conveniently mounted, of Millikin and Co., Instrument Makers, Albert Embankment, S.E. These types nearly resemble those of Jaeger, and, though less correct theoretically than the corresponding types of Snellen's scale, are more convenient in practice for testing the reading power. There are several other sets of test-types which it is unnecessary here to particularise.

A convenient set of tests, small enough to be carried in the pocket, has been arranged for me by Mr Hawksley, 300, Oxford Street. It consists of types for near and distant vision, a pupilometer for measuring the pupil, a set of coloured stuffs for colour blindness, and a small series of lenses for testing refraction. This case is intended chiefly for ward work and general medical cases. It may be also bought without the lenses.

#### 42. OPHTHALMOSCOPES :

It is impossible to say that any ophthalmoscope is the best. When expense is not a great object it is always better to have one of the so-called "refraction ophthalmoscopes." In these a number of small lenses are placed in a disc behind the mirror, the disc being made to revolve by the pressure of the finger against its edge so as to bring the lenses one after another opposite the sight-hole. The use of the lenses is explained at p. 51. For medical ophthalmoscopy it is not essential to have so many lenses ; about four concave and two convex will enable an erect image to be easily obtained in most cases ; Liebreich's "small" ophthalmoscope and Oldham's ophthalmoscope are both very convenient forms for such use, and cost less than half as much as the refraction instruments. Every ophthalmoscope case should contain two large "objective" lenses for the indirect examination, focal illumination, and magnifying ; one may be of  $2\frac{1}{2}$  the other  $3\frac{1}{2}$  focus. For the detection of incipient opacities in the lens, and for direct examination with-



out atropine a plane mirror is very useful in addition to the ordinary concave one. It gives a weaker illumination.

Of the refraction ophthalmoscopes there are now a great many patterns differing in the number and size of the lenses, the size of the mirror and lens-bearing disc, and other details. Usually the disc contains 20 to 24 lenses, and one empty circle. In the simpler forms about half the lenses are + and half -. But in others the number of powers is immensely increased by combining lenses of different strengths, *e.g.* the disc may contain 24 + lenses, whilst a single movable - lens, rather stronger than the highest + is placed behind the disc over the sight-hole; by using it alone and placing it in succession over the various + lenses, a series of 25 - powers, or 49 in all, will be obtained. In order to avoid the error caused by looking obliquely through a lens, some of the more elaborate instruments (*e.g.* Loring's, Couper's, Purves's as modified by Lang and others) are so arranged that the mirror can be sufficiently inclined to receive the light, whilst the lens-bearing disc remains at right angles to the observer's line of sight. Generally speaking the English and American instruments are much better made than the French. Of the simpler forms the one introduced by Dr Gowers, and made for two guineas by Coxeter, of Grafton Street, W.C., is in my experience (with one or two minor alterations) very convenient and efficient. Of the more expensive forms several very good ones, derived from an early model by Mr Laidlaw Purves, one made by Mr W. Ferrier, 56, Beresford Street, Walworth, S.E. The latest form of this instrument, made by Mr Ferrier, for myself, has 3 mirrors mounted on a rotating carriage like the "nose-piece" of a microscope; it is extremely convenient and accurate. For the application of the "nose-piece" principle to the ophthalmoscope we are indebted to Mr Lindsay Johnson. In a good refraction ophthalmoscope the mirror should be thin and the sight-hole perforated; the lens-disc thin and working as close to the back of the mirror as possible; the lenses evenly mounted, centred truly, either thoroughly covered up or easily accessible for cleaning, and not less than 5 mm. in diameter.

43. The "CLOCK-FACE" for testing astigmatism (p. 300) can be had from Carpenter and Westley, 24, Regent Street, Waterloo Place, and from Pickard and Curry, 195, Great Portland Street, W.

44. The set of COLOURED WOOLS recommended by Prof. Holmgren, of Upsala, for testing colour blindness, can be obtained for about five and sixpence from P. Dörrfel, Unter den Linden 46, Berlin. A less perfect set is sold by Pickard and



Curry, 195, Great Portland Street, W. Stilling's coloured letters, printed on a ground-work of the confusion colours, may be obtained through Williams and Norgate.

The coloured slips at the end of this Appendix show some of the commonest colours of various shades which are confused together by persons whose perception of red and green is defective or wanting. Most of the colours here given were carefully chosen for me, from various pattern books, by a colour-blind medical man, though in some few instances I have not been able to get from the paper makers *precise* duplicates of the tints which he chose.

On the *first page*, No. 1 (pale green) is likely to be confused with such buffs and pinks as Nos. 2, 3, and 4; or No. 5 may be confused with a chocolate nearly like No. 6.

On the *second page*, the test colour, No. 7 (rose), will be confused, in well-marked cases, with one or both of the next two Nos., and by complete red-green-blind persons with grey and green of corresponding depth. The grey and green (Nos. 10 and 11), though very likely to be confused together, are too light to be mistaken for No. 7; no pure grey paper of sufficient depth could be found in the trade.

On the *third page* the test colour is a bright red (12). This, in well-marked cases, will be confused with some two or three of the others, *e.g.* with the lighter brown and green (13 and 16), or with the darker shades (14, 15, 17); but it will seldom be confused with all.

To detect low degrees of colour defect a much larger series, especially of the weak colours, more or less like Nos. 1 to 6, and Nos. 10 and 11, is required.

The manner in which a colour-blind person behaves will often excite suspicion of his defect. He will perhaps take two skeins of wool represented by Nos. 1 and 3, place them side by side to see whether or not they are alike, and finally decide that they are not quite of the same colour, though "rather alike." In such cases, and again in others where the patient perhaps does not understand what is wanted, we may often make the diagnosis certain in the following manner:—taking two colours, say Nos. 5 and 6, over which the patient is stumbling, or on which he cannot express himself, to them add a third (*e.g.* 16) of the same *colour* as one of them, but of markedly different *shade*. Now ask him which *pair* is more alike, Nos. 5 and 6 or Nos. 5 and 16; if he says Nos. 5 and 6 he is of course colour-blind, and is judging by the *shade*, *i.e.* the amount of white, not by the *colour*. The same may be tried with Nos. 1, 3, and 16, with Nos. 12, 14, and 17, Nos. 10, 11, and 5, &c.

It must be understood that the colours here given are merely illustrations taken from one particular case; if the same test



colours (Nos. 1, 7, and 12) be used it will be found that different colour-blind persons by no means always choose exactly the same confusion colours; and hence to make this test tolerably certain it is necessary to have a large series of tints and shades, and these can most easily be obtained in Berlin wools.

A special arrangement of the wools enabling a quick, accurate, and uniform record of colour perception to be made has been designed by Dr Wm. Thomson, of Philadelphia ('Trans. Amer. Ophth. Soc.,' 1880, p. 142).

Of the many other tests for colour-blindness the following may be mentioned:—

Stilling's tables, consisting of coloured letters or patterns printed on a groundwork of one of the "confusion colours." They are preferred by some to Holmgren's wools.

Donders determines the colour-sense (or colour defect) quantitatively, by means of a light of known intensity, which passes through apertures filled by differently coloured glasses; these are recognised at a specified distance if the colour-sense is normal.

Bull (of Christiania) has introduced a quantitative test, based upon the smallest amount of colour which, mixed with grey, can be recognised by the normal eye (to be obtained from Trübner and Co.) Rows of coloured spots, those in each row containing a different quantity of grey, are painted in oil colours on a black back-ground. The normal eye will distinguish the colours even in the greyest row; the colour-blind will, according to the degree of defect, confuse complimentary colours in some, or all of the rows. I find Bull's tables very useful but like all painted and lithographed surfaces they reflect too much light, and thus, unless held exactly in the right position, they shine and their colour is altered. Unless very carefully used they are, I think, less trustworthy than a good set of wools.

---



1

2

3

4

5

6







7


8

9

10

11







12

13


14

15

16

17







# INDEX

---

- Aberrations, 1
- Abrasion of cornea, 141
- Abscess of cornea, 96
  - — episcleral, 126
  - — lacrimal gland, 265
  - — — sac, 71, 73
  - orbital, 264
- Abscission, 337
- Accommodation, errors, 272
  - examination, 33
  - in myopia, 275
  - influence of age, 303
  - — — refraction, 304
  - paralysis, 317, 363
  - relative, 34
- Accommodative asthenopia, 224, 288
- Acuteness of sight, 31
- Advancement of muscle, operation, 355
- Albinism, 180
- Albuminuric retinitis, 368
- Alcohol, amblyopia, 366
- Amaurosis, 217
- Amblyopia, 217
  - alcohol, 366
  - central, 220
  - diabetic, 369
  - from defective retinal images, 218
  - — suppression, 217
  - hysterical, 223
  - potatorum, 366
  - quinine, 367
  - tobacco, 366
- Ametropia (*any permanent error in refraction of the eye*), 272
- Anæmia, pernicious, eye diseases, 369
- Anæsthesia of retina, 224
- Anisometropia, 303
- Anterior chamber, foreign body, 339
  - — paracentesis, 339
- Anterior focus of eye, 13
  - polar cataract, 152
  - staphyloma, 128
- Apparent size of objects, 34
- Arcus senilis, 112
  - inflammatory, 112
- Arlt's operation, 324
- Arterial pulsation, 238
- Artificial eye, 337
  - pupil, 342
- Asthenopia (*weakness of eyes; any condition in which the eyes cannot be used for long together*).
  - accommodative, 224, 288
  - muscular, 224, 275
- Astigmatism, 295
  - clock-face for, 300
  - irregular, 297
  - methods of testing, 300—302
  - regular, 297
  - traumatic, 141
  - visual acuteness, 302
- Atrophy of choroid in myopia, 277
  - optic (*see also* Neuritis), 210
  - — after embolism, 215
  - — clinical aspects of, 213
  - — consecutive, 207, 211
  - — in ataxy, 214



- Atrophy, optic, postpapillitic, 207, 211  
 — — primary, 213  
 — — prognosis in, 214  
 — — progressive, 213  
 — — pupils in, 213  
 — — sight in, 213  
 — — in hydrocephalus, 377  
 Atropine, action on healthy eye, 28, 29, 389  
 — effects on tension, 390  
 — irritation, 82  
 — in cataract, 159  
 — — corneal ulcers, 99, 102  
 — — glaucoma, 247  
 — — iritis, 121  
 Axial myopia, 273  
 Axis, optic of eye, 22  
 — principal of a lens, 4  
 — secondary of a lens, 4  
 — visual of eye, 13, 22  
  
 Bandages, 391  
 — after cataract operations, 355  
 — — excision of eye, 337  
 — in iritis, 123  
 — — ophthalmia, 79  
 — — ulcers of cornea, 101  
 Basedow's disease, 382  
 "Black eye," 263  
 Blennorrhœa of conjunctiva, 74  
 Blepharitis, 61  
 Blepharoplasty, 327  
 Blepharospasm, 92  
 Blindness of one eye, undiscovered, 219  
 Blood-vessels of choroid, 167  
 — — eye, external, 24  
 — — retina, 181  
 Blows on the eye, 139  
 Bone in eye, 20  
 Bony tumour of lid, 257  
 Brain (*see* Cerebral).  
 Buller's shield, 76  
 Buphthalmos, 111  
 Burns of eye, 142  
  
 Burow's operation, 324  
  
 Canaliculus, diseases of, 69  
 Canthoplasty, 328  
 Cataract, 148  
 — atropine in, 159  
 — concussion, 157  
 — congenital, 157  
 — cortical, 149  
 — diabetic, 369  
 — diagnosis, 152  
 — dotted cortical, 150  
 — discission, 356  
 — extraction, 349  
 — — after operations, 356  
 — — history, 354  
 — glasses, 164  
 — hard, 149  
 — in myopia, 159  
 — lamellar, 150  
 — mature, 153  
 — mixed, 149  
 — Morgagnian, 158  
 — nuclear, 149  
 — operations, 160, 349  
 — over-ripe, 158, 160  
 — primary, 152  
 — polar, anterior, 152  
 — — posterior, 152, 199  
 — prognosis, 158  
 — pyramidal, 150  
 — secondary, 152  
 — sight after removal, 163  
 — soft, 149  
 — solution, 356  
 — suction, 358  
 — symptoms, 152  
 — traumatic, 157  
 — treatment, 159  
 — zonular (*see* Lamellar), 150  
 Catarrhal ophthalmia, 78  
 Caustics, injuries by, 142  
 Cellulitis of orbit, 264, 383  
 Central choroiditis, 176  
 — nervous system eye diseases, 375  
 — scotoma, 220, 369



- Centre of rotation of eye, 13  
 Cerebral tumour, neuritis in, 209, 375  
 — syphilis, neuritis in, 210, 376  
 Cerebritis, neuritis in, 377  
 Cerebro-spinal meningitis, eye diseases, 365  
 Chalazion, 64  
 Chancre on eyelids, 67, 359  
 Chemosis, 75  
 Cherry-red spot, 196  
 Chloride of zinc paste, 395  
 Cholesterine in vitreous, 233  
 Choroid, appearances in disease, 168  
 — atrophy of, 168  
 — colloid of, 173  
 — coloboma of, 179  
 — congestion of, 179  
 — diseases of, 166  
 — healthy, 167  
 — hæmorrhages in, 280  
 — myopic changes, 176  
 — rupture, 172  
 — sarcoma, 259  
 — tubercle, 172, 178, 370  
 Choroidal atrophy in myopia, 177  
 — exudation, 178  
 — disease with cataract, 178  
 — hæmorrhages, 172, 173, 280  
 — — results, 178  
 Choroiditic atrophy of disc, 175, 188  
 Choroiditis, central senile, 177  
 — disseminata, 174  
 — hæmorrhagic, 179  
 — in hydrocephalus, 377  
 — senile, 177  
 — syphilitica, 172  
 Chronic conjunctivitis, 89  
 Ciliary body, sarcoma of, 259  
 — congestion, 24, 115  
 — muscle, paralysis of, 139, 317  
 — region, diseases of, 125  
 Circum-corneal zone, 24  
 Clear sight, optical conditions, 14  
 Cold in iritis, 123, 124  
 Coloboma of choroid (*congenital cleft in choroid*), 179  
 — — iris (*cleft in iris, congenital or the result of iridectomy*), 124  
 Colour blindness, 228  
 — in atrophy, 213  
 — tests, 394  
 Colour perception, testing, 35  
 Colours, fields of vision for, 230  
 “*Commotio retinae*,” 141  
 Congenital absence of iris, 124  
 — cataract, 157  
 — coloboma, 124, 179  
 — dermoid cysts, 270  
 — — tumour, 256  
 — fibro-fatty growths, 256  
 — irideremia, 124  
 — ptosis, 68  
 Congestion choroidal, 179  
 — ciliary, 24, 92, 114  
 — circum-corneal, 24  
 — conjunctival, 26  
 — episcleral, 27  
 — in iritis, 114  
 — of retina, 183  
 — of optic disc, 181, 204  
 — varieties of, 27  
 Conical cornea, 104, 341  
 Conjunctiva, diseases, 74  
 Conjunctivitis (*see Ophthalmia*).  
 Contagion, conjunctival, 74  
 Convergent squint (*see strabismus*)  
 Convulsions and lamella cataract, 380  
 Coredialysis, 139  
 Cornea, abrasion, 141  
 — abscess, 96  
 — conical, 104, 341  
 — diseases, 90  
 — focal length, 13  
 — foreign body, 338  
 — inspection, 322  
 — lead deposit, 113  
 — operations, 338



- Cornea, steaminess, 90  
 — transverse calcareous film, 111  
 — ulceration, 91, 92  
 — — atropine in, 92, 102  
 — — eserine in, 102  
 — — fomentation, 101  
 — — paracentesis, 101  
 — — phlyctenular, 94, 95  
 — — recurrent, 95  
 — — section for, 101  
 — — serpiginous, 101  
 — — seton for, 100  
 — — suppurating, 101  
 — — treatment, 98  
 Crescents in astigmatism, 177  
 — myopia, 176, 277  
 Crystalline lens, spherical aberration of, 5, 14  
 — focal length of, 13  
 Cup physiological, 46  
 — in Glaucoma, 238, 241  
 Cutaneous horn, 65  
 Cyclitis, 129  
 — traumatic, 129  
 — suppurative, 131  
 — syphilitic, 360  
 Cyclo-iritis (*see* Sclero-)  
 — keratitis (*see* Sclero-)  
 Cycloplegia (paralysis of ciliary muscle), 317, 363  
 — diphtheritic, 363  
 Cysticercus, 374  
 — Cellulosæ, 234  
 Cystic tumours in lids and orbit, 268, 270  
 Cysts of conjunctiva, 256, 257  
 — of iris, 262  
  
 Dacryo-cystitis, chronic (*inflammation of lacrymal sac*), 71  
 Dacryo-liths, 70  
 Dacryops, 270  
 "Dangerous zone," 132  
 Daturin, 82  
 Day blindness, 227  
 Decentred lens, 10  
 Delirium after eye operations, 355  
 Dermoid cysts of eyebrow, 270  
 — tumour of eyeball, 256  
 Detachment of retina, 139  
 — — — in myopia, 280  
 Diabetes, eye diseases, 368  
 Diabetic amblyopia, 369  
 — cataract, 368  
 — retinitis, 369  
 Dioptre, 15  
 — Dioptric system of spectacle lenses, 15  
 Diphtheria, eye disease, 362  
 Diphtheritic paralysis of accommodation, 363  
 — — recti muscles, 363  
 — ophthalmia, 363  
 Diplopia (*see also* strabismus and paralysis), 22, 307  
 — binocular, 22  
 — crossed, 309  
 — homonymous, 290, 309  
 — uniocular, 22  
 Direct examination, 40, 49  
 Discission of cataract, 356  
 Dislocation of lens, 139, 165  
 Disseminated choroiditis, 174  
 — sclerosis, eye diseases, 378, 380  
 Distichiasis, 87  
 Double sight, 22  
 Duboisin, 82  
  
 Ecchymosis in catarrhal ophthalmia, 79  
 — of eyelids, 263  
 Echinococcus, 374  
 Ectropium, operations, 326  
 Eczema, marginal, 62  
 Embolism of eye in pyæmia, 365  
 — central artery, 195  
 Emmetropia, 272  
 Emphysema of orbit, 263  
 Endemic nyctalopia, 226



- Entozoa in eye, 374  
 Entropion, organic, 87, 323  
   — spasmodic, 322  
   — operations for, 322, 323  
 Epicanthus, 68  
 Epilation, 63, 321  
 Epiphora, 69  
 Episcleritis, 125  
 Epithelioma of conjunctiva, 257  
 Erysipelas of face, blindness from, 383  
 Eserine, action on healthy eye, 391  
   — in extraction of cataract, 353  
   — — glaucoma, 248  
   — — mydriasis, 390  
   — — ulceration of cornea, 102  
 Eversion of upper lid, 321  
 Examination, focal, 37  
   — of blood-vessels of eye, 24  
   — — colour perception, 35, 229  
   — — cornea, 19  
   — — eye, external, 19  
   — — field of vision, 29  
   — — mobility of eye, 20  
   — — pupils, 28  
   — — refraction of eye, 51, 272  
   — — tension, 19  
   — ophthalmoscopic, 39  
   — — direct, 40, 49  
   — — indirect, 39, 43  
 Excision of eye, 336  
   — — — rules for, 144, 254, 261  
   — — — in sympathetic disease, 133, 136  
 Exclusion of pupil, 117  
 Exophthalmic goitre, 382  
 Exostoses, ivory, of orbit, 267  
 Extraction of cataract (*see* Cataract), 356  
 Eye disease in relation to general diseases, 359  
 Eye, protrusion of, 266  
   — refracting surfaces, 12  
 Eyelids, diseases, 61  
   — wounds, 265  
 Facial nerve, paralysis, 382  
 "False image," 23, 308  
 "Far point," 33  
 Feigned blindness, 29, 30, 213  
 Field of vision, 29, 30, 213, 238  
 Fifth nerve paralysis, 382  
 Filtration scar, 250  
 Flap extraction, 353  
 Flittering scotoma, 374  
 Focal illumination, 37  
   — interval, 276  
 Focus, anterior of eye, 13  
   — conjugate of a lens, 6  
   — principal of a lens, 5  
   — virtual of a lens, 6  
 Foreign body in eye, 144  
   — — — orbit, 266  
   — — on cornea, 141  
 Förster's operation, 161  
 Fourth nerve paralysis, 313, 317  
*Fovea centralis*, 48, 182  
 Fracture of orbit, 263  
 Frontal sinus, distension of, 266  
 Functional diseases, 217  
 Fundus of eye, examination, 43  
   — — — definition, 41  
 Fungus in canaliculus, 70  
 Fusion power of ocular muscles, 11  
  
 Gelatinous exudation in anterior chamber, 116  
 General diseases causing eye disease, 359  
 General paralysis of insane, eye diseases, 378  
 Giddiness from ocular paralysis, 315  
 Glasses, protective, 392  
   — (*see* Spectacles).  
 Glaucoma, 236  
   — absolute, 240  
   — acute, 239  
   — after extraction of cataract, 253  
   — atropine in, 252  
   — causes, 240, 247  
   — chronic, 237  
   — cornea in, 111



- Glaucoma, cupping, 238, 241  
 — eserine in, 248  
 — fulminans, 240  
 — hæmorrhagic, 254  
 — “inflammatory,” 238  
 — malignum, 253  
 — mechanism of, 245  
 — neuralgia preceding, 375  
 — operations, 248, 343  
 — premonitory stage, 237  
 — primary, 236  
 — prognosis, 251  
 — remittent, 239  
 — secondary, 253  
 — — to anterior synechiæ, 253  
 — — — cataract extraction, 253  
 — — — dislocation of lens, 253  
 — — — posterior synechiæ, 119, 129  
 — — — sympathetic iritis, 134  
 — — — tumour, 258, 260  
 — second operation, 252  
 — simplex, 238  
 — subacute, 238  
 — theory of iridectomy, 250  
 — treatment, 248  
 — vitreous humour in, 244  
 Glioma of retina, 258  
 Goitre, exophthalmic, 382  
 Gonorrhœal ophthalmia, 382  
 Gout, eye diseases, 373  
 — cyclitis, 130, 373  
 — iritis, 120, 372  
 Grafting, 328  
 Granular lids, 82  
 — ophthalmia, 82  
 — — results of, 86  
 Granuloma of iris, 262  
 Graves’s disease (*see* Goitre).  
 Gummatous scleritis, 127  
 — tarsitis, 255  
 Gunshot injuries, 143, 265  
  
 Hæmorrhage, after extraction, 162  
 — conjunctival, 79  
 Hæmorrhage, choroidal, 169, 173, 179, 280  
 — in iritis, 115  
 — — renal retinitis, 193  
 — into anterior chamber, 115, 139  
 — — optic nerve, 197  
 — vitreous, 140, 234  
 — intraocular, 139  
 — orbital, 263  
 — retinal, 187, 369  
 — — in blood diseases, 369  
 — secondary, after iridectomy, 347  
 — glaucoma, 254  
 — retinitis, 373  
 Hard cataract, 149  
 Heart disease, eye diseases, 369  
 Hemeralopia (*day blindness*), 227  
 Hemianopia, 222  
 Hemiopia, 222  
 Hereditary amblyopia, 221  
 — disease of retina, 198  
 — syphilis, eye diseases, 361  
 — gout, eye diseases, 373  
 Herpes of conjunctiva, 80  
 — — cornea, 93  
 — Zoster, eye diseases, 381  
 Homonymous diplopia (*see* Diplopia).  
 Hyalitis (*inflammation of vitreous*) (*see* Vitreous).  
 Hydatid of orbit, 268  
 Hydrocephalus, optic atrophy, eye diseases, 377  
 Hydrophthalmos, 111  
 Hyperæsthesia of retina, 224  
 Hypermetropia, 285  
 — acquired, 287  
 — haze of disc, 184  
 — tests for, 293  
 Hyphæma (*blood in lower part of anterior chamber*), 115  
 Hypopyon (*pus in lower part of anterior chamber*), 97, 115



Hypopyon, ulcer, corneal section,  
340

Hysterical amaurosis, 223

Ice blindness, 226

Idiopathic phthisis bulbi, 131

Images formed by lenses, 7

— retinal, influence of lenses on,  
13

Indirect examination, 39, 43

Injuries of eyeball, 138

— — orbit, 263

Insufficiency muscular, 275

Intraocular tumours, 258

— hæmorrhage (*see* Hæmorrhage)

Iodoform in purulent ophthalmia, 77

Iridectomy, 344

— distortion of image after, 14

— exciting glaucoma in other  
eye, 247

— in cataract extraction, 350

— — corneal opacity, 242

— — — ulcer, 101

— — glaucoma, 248, 343

— — iritis, 123

Irideremia, congenital, 124

Irido-choroiditis, 129

— — plastic, 121

— -cyclitis, 131

— — traumatic, 131

Iridodesis, 343

Iridoplegia (*paralysis of iris*),  
317

— reflex, 317

Iridotomy, 344

Iris, colour, 27

— cysts, 262

— diseases, 114

— epithelial tumour, 262

— granuloma, 262

— operations, 342

— paralysis, 317

— tremulous, 139

— tubercle, 261

— tumours, 261

Iritis, 114

— after extraction, 163

— atropine, 121

— chronic, 120

— cold in, 124

— gelatinous exudation, 116

— glaucoma secondary to, 119,  
129

— gonorrhæo-rheumatic, 372

— gouty, 120, 372

— heat in, 122

— heredito-gouty, 120, 373

— in corneal ulcer, 96, 121

— — interstitial keratitis, 105

— iridectomy, 123

— leeches in, 122

— with nodules, 115, 120

— paracentesis, 122

— plastic, 120, 134

— pupil in, 116

— recurrent, 120

— results, 118

— rheumatic, 120, 371

— serous, 117

— suppurative, 115, 131, 162

— sympathetic, 134

— syphilitic, 120

— traumatic, 121

— treatment, 121

Iritomy, 344

Ischæmia retinæ, 198

Ivory exostosis, 267

Jequirity in trachoma, 88

Keratitis, diffuse, 105

— interstitial, 105, 362

— — iritis in, 105, 108

— marginal, 93, 95, 106

— parenchymatous, 105

— *punctata*, 110, 129, 134

— secondary forms, 110

— strumous, 93, 105

— syphilitic, 105, 362

Keratotomy, 55

Kidney disease, eye diseases,  
368



- Kopiopia hysterica*, 224
- Lacrimal apparatus, diseases, 69  
 — canaliculi „ 70  
 — gland „ 265  
 — — abscess, 265  
 — obstruction, 69, 70, 71  
 — punctum, alterations, 69  
 — sac, diseases, 70  
 — — abscess, 71, 329  
 — stricture, 72, 330
- Lacrimation, 69
- Lamellar cataract, 150, 155  
 — — treatment, 164  
 — — and convulsions, 380
- Lamina cribrosa*, 46
- Lateral sclerosis, eye diseases, 378
- Lead-opacity of cornea, 113  
 — poisoning, eye diseases, 366
- Lebrun's extraction, 352
- Leeches in iritis, 122  
 — — purulent ophthalmia, 77
- Lens, axes of, 4  
 — concave, 16  
 — crystalline, changes preceding cataract, 150  
 — — dislocation, 165, 253  
 — — examination, 38  
 — — myopia due to changes in, 285  
 — — senile changes, 148  
 — decentred, 9  
 — definition, 3  
 — foci of, 5, 6  
 — images formed by, 6  
 — refraction by, 4  
 — refractive power of, 8  
 — signs for convex and concave, 16  
 — spherical aberration, 5
- Lenses, numeration of, 14  
 — table of spectacle, in dioptries and inches, 17
- Leucocythæmia, eye diseases, 369
- Leucoma, 91
- Lice on eyelashes, 66
- Light, effect of intense, 201
- Limeburn, 142
- Linear extraction, 350
- Lippitudo, 62
- Locomotor ataxy, cycloplegia, 378  
 — diplopia, 378  
 — iridoplegia, 378  
 — optic atrophy, 210, 212, 377
- Lupus, 67  
 — conjunctival, 255
- Lymphatic cyst of conjunctiva, 256
- Macula lutea*, 48
- Magnet for removal of piece of iron, 145
- Malarial fever, eye diseases, 364
- Malignant tumours (*see* Tumours).
- Malingering, 11, 228
- Marginal keratitis, 93, 95, 106
- Measles, eye-diseases, 364
- Megalopsia, 227
- Megrim, eye-symptoms, 374
- Meibomian concretions, 65  
 — cyst, 64, 321
- Membranous ophthalmia, 80, 363
- Meningitis, epidemic cerebro-spinal, 365  
 — eye diseases, 365, 376  
 — ocular paralysis, 317  
 — optic neuritis, 376  
 — recovery with optic atrophy, 377  
 — syphilitic, 376  
 — tubercular, 371, 376
- Mercurial teeth, 381
- Micrococcus of trachoma, 85
- Micropsia, 227
- Miosis (*persistent contraction of pupil*), 382  
 — paralytic, 316, 382  
 — in spinal disease, 379
- Miotics, action, 389



- Mobility of eye, examination, 20  
 — — in myopia, 21  
 Molluscum contagiosum, 65  
 Moon-blindness, 226  
 Morgagnian cataract, 158  
 Mucocele, 71  
 Muco-purulent ophthalmia, 78  
 Muscæ volitantes, 227  
 Muscular asthenopia, 224, 275  
 Mydriasis (*persistent dilatation of pupil*) paralytic, 315, 316  
 — traumatic, 140  
 Mydriatics, action, 389  
 Myopia, 273  
 — accommodation in, 275  
 — axial, 273  
 — causes, 281  
 — choroidal changes, 176, 377  
 — complications, 276  
 — crescent, 277  
 — from conical cornea, 285  
 — — incipient cataract, 285  
 — of curvature, 285  
 — spectacles in, 282  
 — strabismus in, 275, 311  
 — tests for, 276  
 — traumatic, 141  
 — treatment, 282  
  
 Nævus of lids and conjunctiva, 270  
 Nasal duct, diseases of, 70  
 — — probing, 330  
 "Near-point," 33  
 Nebula, 91  
 Nerve-fibres, optic, opaque, 183  
 Nerve, facial, paralysis, 69, 382  
 — fifth, paralysis, 382  
 — fourth, paralysis, 313, 317  
 — optic, inflammation (*see Neuritis*)  
 — — atrophy (*see Atrophy*)  
 — sixth, paralysis, 312, 317  
 — sympathetic, paralysis, 382  
 — third, paralysis, 314  
  
 Neuralgia, eye symptoms, 375  
 — preceding glaucoma, 375  
 — — neuritis, 375  
 Neuritis, optic, appearances, 204  
 — — descending, 202, 203  
 — — in cerebral tumour, 375  
 — — — cerebritis, 377  
 — — — lead-poisoning, 366  
 — — — meningitis, 376  
 — — — syphilitic brain diseases, 376  
 — — pathology, 203  
 — — retro-bulbar, 210, 219  
 Neuro-retinitis, 208  
 Neurotomy, optico-ciliary, 338  
 Night-blindness, 198  
 — functional, 226  
 Nitrate of silver in corneal ulcer, 99  
 — — — ophthalmia, 77, 78  
 — — staining conjunctiva, 113  
 Nodal point of eye, 12  
 Nyctalopia (*night-blindness*) 198  
 — endemic, 226  
 Nystagmus, 319  
 — in disseminated sclerosis, 380  
 — miner's, 319  
  
 Objects, apparent size of, 34  
 Oblique illumination, 37  
 Occlusion of pupil, 118  
 Ocular paralysis (*see Paralysis*)  
 Onyx, 98  
 Opaque optic nerve-fibres, 183  
 Operations, 321  
 — for abscess of orbit, 264  
 — — abscission of eye, 337  
 — — artificial pupil, 342  
 — — canthoplasty, 328  
 — — cataract, 349  
 — — — after operations, 356  
 — — — causes of failure, 162  
 — — — extraction, 349  
 — — — needle, 356  
 — — — solution, 356  
 — — — suction, 358



- Operation for distended frontal sinus, 266
- — division of canthus, 328
  - — ectropion, 326
  - — entropion organic, 323
  - — — spasmodic, 322
  - — epilation, 321
  - — eversion of eyelid, 321
  - — excision of eye, 336
  - — foreign body on cornea, 338
  - — inspection of cornea in photophobia, 92, 322
  - — iridectomy, 342
  - — iridodesis, 343
  - — iridotomy, 344
  - — lacrimal abscess, 71, 329
  - — — stricture, 330
  - — Meibomian cyst, 321
  - — paracentesis of anterior chamber, 339
  - — peritomy, 328
  - — ptosis, 328
  - — sclerotomy, 347
  - — slitting canaliculus, 329
  - — strabismus, 331
  - — trichiasis, 323
  - — readjustment, 335
  - lacrimal, 329
  - on cornea, 338
  - — eyelids, 321
  - — iris, 342
- Ophthalmia, 74
- after exanthems, 79
  - catarrhal, 78
  - chronic, 89
  - croupous, 80
  - diphtheritic, 80, 363
  - follicular, 83
  - from atropine, 82
  - — cold, 80
  - — eserine, 82
  - — irritants, 80
  - gonorrhœal, 74
  - granular, 82
  - impetiginous, 80
  - in eczema, 80
- Ophthalmia in erysipelas, 80
- — herpes zoster, 80, 381
  - membranous, 80, 363
  - muco-purulent, 78
  - *neonatorum*, 74
  - phlyctenular, 80, 93
  - purulent, 74
  - pustular, 93
  - rheumatic, 80, 371
  - sympathetic, 131
  - *tarsi*, 61
- Ophthalmitis, sympathetic, 131
- Ophthalmoplegia externa*, 316, 379
- *interna*, 317
- Ophthalmoscopes, 393
- Ophthalmoscopic examination, 39
- — direct method, 40, 49
  - — — — in myopia, 49
  - — indirect method, 39, 43
- Optic disc, atrophy, 210, 377
- — congestion, 184
  - — healthy, 45
  - nerve, diseases of, 202  
(see also Neuritis and Atrophy).
  - — — from syphilis, 210, 361
  - — pathological changes, 202
  - — sclerosis, 212
  - — tumours, 261, 266
- Optical outlines, 1
- Optico-ciliary neurotomy, 338
- Orbicularis, spasm, 92
- paralysis, 69, 382
- Orbit, abscess of, 264
- cellulitis of, 264
  - diseases of, 263
  - emphysema of, 263
  - foreign body in, 265
  - tumours, 266
  - wounds of, 265
- Oscillation of pupil, 29
- Pannus (*extensive superficial vascularity of cornea*), 87



- Pannus, phlyctenular, 95  
 — trachomatous, 87  
 Panophthalmitis, 131  
 — purulent, 131, 162  
 — pyæmic, 365  
 — sympathetic, 131  
 — traumatic, 144  
 Papillitis (*inflammation of optic disc*) (*see* Neuritis).  
 Papillo-retinitis, 192, 208  
 Paracentesis of anterior chamber, 102, 339  
 — for corneal ulcer, 101, 102  
 — — glaucoma, 349  
 — — iritis, 122  
 Parallax movement, 190  
 Paralysis, associated, 379  
 — central, 375  
 — diphtheritic, 363  
 — in spinal disease, 378  
 — ocular, 307  
 — of cervical sympathetic nerve, 316  
 — — ciliary muscle, 139, 317, 363  
 — — external ocular muscles, 311  
 — — rectus (6th N.), 312  
 — — facial nerve, eye disease, 382  
 — — fifth nerve, eye disease, 382  
 — — internal ocular muscles, 139, 316  
 — — iris, 139, 316  
 — — superior oblique (4th N.), 313, 317  
 — — third nerve, 314  
 — peripheral, 380  
 — syphilitic, 360, 362, 380  
 Paralytic miosis, 316  
 — mydriasis, 316  
 Pediculus pubis, 66  
 Perforating conjunctival ulcer, 95  
 Perimeter, 32  
 Periostitis of orbit, 264  
 Peritomy, 88, 328  
 Phlyctenular affections, 79, 93  
 — pannus, 95  
 Photophobia, 92, 100  
 Phthisis bulbi, idiopathic, 131  
 Physiological cup, 46  
 Pigment in retina, 198, 200  
 — on choroid, 166, 169, 200  
 Pilocarpine for detached retina, 190  
 Pinguecula, 255  
 Polyopia uniocularis, 153  
 Polypus, lacrimal, 71  
 Posterior nodal point, 12  
 — polar cataract, 155  
 — staphyloma, 277  
 — synechia, 114  
 — — total, 117  
 Preliminary iridectomy, 342, 351  
 Presbyopia, 303  
 — in myopia, 304  
 — table, 306  
 Primary optic atrophy, 213, 377  
 Prism, action of, 9, 35  
 — uses of, 9  
 Prismatic spectacles, 285  
 Probing nasal duct, 330  
 Projection, 3  
 Prolapse of iris, 163  
 — — — in cataract extraction, 163, 354  
 — — — in sclerotomy, 249, 348  
 Progressive optic atrophy, 213, 377  
 Proptosis, 23, 24, 266  
 — in orbital disease, 267  
 Protective glasses, 392  
 Pseudo-glioma, 259, 365  
 Pterygium, 255  
 Ptosis (*falling of upper lid*)  
 — congenital, 68  
 — from granular lids, 88  
 — operations, 328  
 — paralytic, 314  
 — traumatic, 263



- Pulsation, retinal, in aortic disease, 369  
 Pulsating tumour of orbit, 267  
 Pupil (*see also* Iris, Synechia)  
   — actions, in health, 28  
   — contraction from congestion, 29  
   — examination, 28  
   — exclusion, 117  
   — influence on sight, 14  
   — in diphtheritic cycloplegia, 363  
   — — optic atrophy, 210, 213  
   — — iritis, 116  
   — — neuritis, 210  
   — — spinal disease, 378  
   — occlusion, 118  
   — total posterior synechia, 117, 253  
   — why black, 39  
 Pupillary membrane, remains of, 124  
 Pupilloscopy, 55  
 Purpura, eye disease, 365  
 Pustular ophthalmia, 93  
 Pyæmia, eye disease, 365  
  
 Quinine amblyopia, 367  
   — lotion in diphtheritic ophthalmia, 82  
  
 “Rainbows” in glaucoma, 237  
 Readjustment of ocular muscles, 335  
 Recurrent vascular ulcer, 94  
 Reflex iridoplegia, 378  
 Refraction, 1  
   — by a prism, 2  
   — determination by ophthalmoscope, 51  
   — — retinoscopy, 55  
   — errors, 272  
   — of light, 1  
   — — the eye, 12  
 Refractive index, 1  
 Relapsing fever, eye diseases, 364  
  
 Relative accommodation, 34  
 Renal disease, eye diseases, 192, 368  
 Retina, anæsthesia, 224  
   — appearances in disease, 183  
   — — health, 47, 181  
   — atrophy, 188  
   — blood-vessels, 48, 181  
   — concussion, 141  
   — congestion, 183  
   — detachment, 139, 188  
   — diseases, 181  
   — functional diseases, 226  
   — glioma, 258  
   — hyperæsthesia, 224  
   — pigmentation, 198, 200  
   — tubercle, 181  
   — white patches, 185, 193  
 Retinal embolism, 195, 370  
   — hæmorrhage, 186, 370  
   — — in blood diseases, 364, 369  
   — image, 12, 13, 14  
   — — in myopia, 13  
   — — influence of lenses on size, 13  
   — thrombosis, 195, 370  
 Retinitis, albuminuric, 185, 192, 368  
   — apoplectica, 195  
   — diffused, 185  
   — hæmorrhagic, 195, 373  
   — from anæmia, 369  
   — — lead, 366  
   — — leucocythæmia, 369  
   — — malarial disease, 366  
   — *pigmentosa*, 198  
   — renal (*see* Albuminuric).  
   — syphilitic, 191, 360  
   — with choroiditis, 191, 200  
   — — optic neuritis, 192, 208  
 Rheumatism, eye diseases, 371  
 Ring-scotoma, 192  
 Ripening cataract, operation, 161  
 Rodent ulcer, 66  
 Rotation of eye, centre, 13



- Rupture of choroid, 139  
 — — eyeball, 138
- Saemisch's operation, 101
- Sago-grain granulations, 83
- Salmon patch, 106
- Sarcoma of choroid, 259  
 — — ciliary body, 259  
 — — iris, 262  
 — — sclerotic, 257
- Scalds of eye, 152
- Scarlet fever, eye disease, 79, 362
- Scarring of conjunctiva, 87
- Scleral ring, 45
- Scleritis, 125
- Sclero-iritis, 127  
 — keratitis, 127
- Sclerosis of optic nerves, 212
- Sclerotic, rupture, 138
- Sclerotic - choroiditis posterior, 177
- Sclerotitis, 125
- Sclerotomy, 249, 347
- Scotoma (*an area of defect or blindness in the visual field*), 220  
 — central, 220  
 — fluttering, 374
- Scrofulous eye-diseases, 371  
 — sclerotitis, 127, 374
- Scurvy, eye disease, 365
- Secondary cataract, 152  
 — glaucoma, 119  
 — keratitis, 110  
 — operations for cataract, 356  
 — squint, 21
- Senile changes in accommodation, 304  
 — — — choroid, 177  
 — — — lens, 148  
 — failure of vision, 31
- Septicæmia, eye diseases, 365
- Serous iritis, 117
- Serpiginous ulcer, 96
- Setons in ulcers of cornea, 100  
 — — syphilitic keratitis, 108
- Shades, 100, 392
- Short sight, 273
- Sight, acuteness, 32  
 — — testing, 32  
 — after cataract operations, 164  
 — field, 29  
 — — for colours, 31  
 — in optic atrophy, 213  
 — — — neuritis, 207  
 — optical conditions of clear, 14
- Silver staining of conjunctiva, 113
- Sloughing of cornea, 76
- Smallpox, eye disease, 362
- Snow-blindness, 226
- Soft cataract, 150
- Solution of cataract, 356
- Sparkling synchysis, 233
- Spasm of accommodation, 275
- Spectacles in astigmatism, 300  
 — — hypermetropia, 291  
 — — myopia, 282  
 — — presbyopia, 305  
 — — unequal eyes, 303  
 — prismatic, 225, 285  
 — lenses, table of, 17
- Spinal cord disease, eye diseases, 377
- Spongy exudation in iritis, 116
- Spring catarrh, 95
- Squint (*see* Strabismus).
- Staphyloma (*a bulging of the sclerotic or cornea*).  
 — anterior, 128  
 — posterior, 176, 277
- Stillicidium lacrimarum*, 69
- Stomatitic teeth, 381
- Strabismus, alternating, 21, 290  
 — apparent, 22 (footnote)  
 — causes, 310  
 — concomitant, 290  
 — convergent, 21, 289  
 — definition and varieties, 21  
 — divergent, 21  
 — examination, 21  
 — in hypermetropia, 289



- Strabismus in myopia, 275, 311  
 — paralytic, 311  
 — periodic, 290  
 — primary, 21, 315  
 — secondary, 22, 315  
 — spontaneous disappearance of, 291  
 Strumous eye diseases, 373  
 — ophthalmia, 93  
 Sty, 63  
 Suction of cataract, 358  
 Suppression of image, 217  
 Suppuration after extraction, 162  
 Sycosis tarsi, 61  
 Sympathetic inflammation, 131  
 — irritation, 131  
 — nerve, paralysis, 382  
 — ophthalmitis, 131  
 Symblepharon, 142  
 Synchysis, sparkling, 233  
 Syndectomy, 88  
 Synechia (*adhesion of iris*), anterior, 144  
 — — causing glaucoma, 253  
 — posterior, 115, 129  
 Syphilis, acquired, choroiditis, 360  
 — — eye diseases, 359  
 — — iritis, 359  
 — — keratitis, 360  
 — — ocular paralysis, 318  
 — — retinitis, 191, 360  
 — — brain disease, 209, 210, 361  
 — inherited, choroiditis, 361  
 — — eye diseases, 361  
 — — iritis, 361  
 — — keratitis, 105, 362  
 — — ocular paralysis, 362  
 — — retinitis, 361  
 — orbital disease, 269  
 — scleritis, 127  
 — tarsitis, 255  
 — ulcers of eyelids, 67  
 Syphilitic teeth, 383  
 Tarsitis, syphilitic, 255, 360  
 Teeth in lamellar cataract, 380  
 — syphilitic, 109, 383  
 Tenotomy, 331  
 Tension of the eyeball, examination, 19  
 — — diminished, 131  
 — — increased, 246  
 — — in glaucoma, 238, 240, 246  
 — — — iritis, 116, 129  
 — — — paralysis of fifth nerve, 247  
 — — variation, 20  
 Test types, 32, 33, 392  
 Third nerve paralysis, 314  
 Thrombosis of retinal artery, 196  
 — — vein, 195  
*Tinea tarsi*, 61  
 Tobacco amblyopia, 221, 366  
 Total posterior synechia, 117, 119  
 Toxic amblyopia, 367  
 Trachoma, 82  
 Traumatic astigmatism, 141  
 — cataract, 144  
 — cycloplegia, 139  
 — irido-cyclitis, 121, 131  
 — irido-plegia, 139  
 — iritis, 121  
 — myopia, 141  
 — panophthalmitis, 121  
 — ptosis, 263  
 Trichiasis, 88, 323  
 Tubercle of choroid, 261  
 — — iris, 261  
 Tuberculosis, eye diseases, 370  
 Tumours, intraocular, 258  
 — of eye, 255  
 — — eyelids, 255  
 — — front of eyeball, 255  
 — — orbit, 263  
 Typhus, eye disease, 362  
 Ulcers of cornea (*see Cornea*).  
 — lids, syphilitic, 67



- Ulcers of lids, lupus, 255  
— — rodent, 66  
Undiscovered blindness of one eye, 219  
Unequal refraction of the two eyes, 303  
Uræmic amaurosis, 362  
*Venæ vorticosæ*, 167  
Virtual image, size, 7  
Vision (*see* Sight).  
— field (*see* Field and Sight).  
Visual angle, 12  
— axis, 13, 307  
Vitreous humour, cholesterin, 233  
— diseases of, 231  
— dust-like opacities, 175  
— examination, 49, 232  
— hæmorrhage, 234  
— — traumatic, 138  
— in choroiditis, 175, 235  
Vitreous humour in glaucoma, 235, 244  
Vitreous humour in irido-cyclitis, 129, 235  
— — myopia, 234  
— — retinitis, 235  
— opacities, 231  
Warts, 65  
— conjunctival, 255  
Watered-silk appearance of retina, 182  
Watery eye, 69  
Waxy disc, 175, 199  
Whooping cough, eye diseases, 364  
Woolly disc, 207  
Wounds of eyeball, 143  
— — eyelids, 265  
— — orbit, 265  
*Xanthelasma palpebrarum*, 65  
Yellow spot, 48  
Zonular cataract, 150, 164, 380







J. & A. CHURCHILL'S  
MEDICAL CLASS BOOKS.

---

ANATOMY.

*BRAUNE*.—An Atlas of Topographical Anatomy, after Plane Sections of Frozen Bodies. By WILHELM BRAUNE, Professor of Anatomy in the University of Leipzig. Translated by EDWARD BELLAMY, F.R.C.S., and Member of the Board of Examiners; Surgeon to Charing Cross Hospital, and Lecturer on Anatomy in its School. With 34 Photo-lithographic Plates and 46 Woodcuts. Large Imp. 8vo, 40s.

*FLOWER*.—Diagrams of the Nerves of the Human Body, exhibiting their Origin, Divisions, and Connexions, with their Distribution to the various Regions of the Cutaneous Surface, and to all the Muscles. By WILLIAM H. FLOWER, F.R.C.S., F.R.S. Third Edition, containing 6 Plates. Royal 4to, 12s.

*GODLEE*.—An Atlas of Human Anatomy: illustrating most of the ordinary Dissections and many not usually practised by the Student. By RICKMAN J. GODLEE, M.S., F.R.C.S., Assistant-Surgeon to University College Hospital, and Senior Demonstrator of Anatomy in University College. With 48 Imp. 4to Coloured Plates, containing 112 Figures, and a Volume of Explanatory Text, with many Engravings. 8vo, £4 14s. 6d.

*HEATH*.—Practical Anatomy: a Manual of Dissections. By CHRISTOPHER HEATH, F.R.C.S., Holme Professor of Clinical Surgery in University College and Surgeon to the Hospital. Fifth Edition. With 24 Coloured Plates and 269 Engravings. Crown 8vo, 15s.



**ANATOMY**—*continued.*

**HOLDEN.**—**A Manual of the Dissection of the Human Body.** By LUTHER HOLDEN, F.R.C.S., Consulting-Surgeon to St. Bartholomew's Hospital. Fifth Edition, by JOHN LANGTON, F.R.C.S., Surgeon to, and Lecturer on Anatomy at, St. Bartholomew's Hospital. With Engravings. 8vo. *[In preparation.]*

*By the same Author.*

**Human Osteology : comprising a Description of the Bones, with Delineations of the Attachments of the Muscles, the General and Microscopical Structure of Bone and its Development.** Sixth Edition, revised by the Author and JAMES SHUTER, F.R.C.S., late Assistant-Surgeon to St. Bartholomew's Hospital. With 61 Lithographic Plates and 89 Engravings. Royal 8vo, 16s.

ALSO,

**Landmarks, Medical and Surgical.** Third Edition. 8vo, 3s. 6d.

**MORRIS.**—**The Anatomy of the Joints of Man.** By HENRY MORRIS, M.A., F.R.C.S., Surgeon to, and Lecturer on Anatomy and Practical Surgery at, the Middlesex Hospital. With 44 Plates (19 Coloured) and Engravings. 8vo, 16s.

**The Anatomical Remembrancer ; or, Complete Pocket Anatomist.** Eighth Edition. 32mo, 3s. 6d.

**WAGSTAFFE.**—**The Student's Guide to Human Osteology.** By WM. WARWICK WAGSTAFFE, F.R.C.S., late Assistant-Surgeon to, and Lecturer on Anatomy at, St. Thomas's Hospital. With 23 Plates and 66 Engravings. Fcap. 8vo, 10s. 6d.

**WILSON — BUCHANAN — CLARK.** — **Wilson's Anatomist's Vade-Mecum : a System of Human Anatomy.** Tenth Edition, by GEORGE BUCHANAN, Professor of Clinical Surgery in the University of Glasgow, and HENRY E. CLARK, M.R.C.S., Lecturer on Anatomy in the Glasgow Royal Infirmary School of Medicine. With 450 Engravings, including 26 Coloured Plates. Crown 8vo, 18s.



**BOTANY.**

**BENTLEY.—A Manual of Botany. By Robert**

BENTLEY, F.L.S., M.R.C.S., Professor of Botany in King's College and to the Pharmaceutical Society. With 1185 Engravings. Fourth Edition. Crown 8vo, 15s.

*By the same Author.*

**The Student's Guide to Structural,  
Morphological, and Physiological Botany. With 660 Engravings.  
Fcap. 8vo, 7s. 6d.**

ALSO,

**The Student's Guide to Systematic  
Botany, including the Classification of Plants and Descriptive  
Botany. With 350 Engravings. Fcap. 8vo.**

**BENTLEY AND TRIMEN.—Medicinal Plants:**

being descriptions, with original Figures, of the Principal Plants employed in Medicine, and an account of their Properties and Uses. By ROBERT BENTLEY, F.L.S., and HENRY TRIMEN, M.B., F.L.S. In 4 Vols., large 8vo, with 306 Coloured Plates, bound in half morocco, gilt edges, £11 11s.

---

**CHEMISTRY.**

**BERNAYS.—Notes for Students in Chemistry;**

being a Syllabus of Chemistry compiled mainly from the Manuals of Fownes-Watts, Miller, Wurz, and Schorlemmer. By ALBERT J. BERNAYS, Ph.D., Professor of Chemistry at St. Thomas's Hospital. Sixth Edition. Fcap. 8vo, 3s. 6d.

*By the same Author.*

**Skeleton Notes on Analytical Chemistry,  
for Students in Medicine. Fcap. 8vo, 2s. 6d.**

**BLOXAM.—Chemistry, Inorganic and Organic;**

with Experiments. By CHARLES L. BLOXAM, Professor of Chemistry in King's College. Fifth Edition. With 292 Engravings. 8vo, 16s.

*By the same Author.*

**Laboratory Teaching; or, Progressive  
Exercises in Practical Chemistry. Fourth Edition. With 83  
Engravings. Crown 8vo, 5s. 6d.**



**CHEMISTRY**—*continued.*

**BOWMAN AND BLOXAM.**—**Practical Chemistry**, including Analysis. By JOHN E. BOWMAN, formerly Professor of Practical Chemistry in King's College, and CHARLES L. BLOXAM, Professor of Chemistry in King's College. With 98 Engravings. Seventh Edition. Fcap. 8vo, 6s. 6d.

**BROWN.**—**Practical Chemistry: Analytical Tables and Exercises for Students.** By J. CAMPBELL BROWN, D.Sc. Lond., Professor of Chemistry in University College, Liverpool. Second Edition. 8vo, 2s. 6d.

**CLOWES.**—**Practical Chemistry and Qualitative Inorganic Analysis.** An Elementary Treatise, specially adapted for use in the Laboratories of Schools and Colleges, and by Beginners. By FRANK CLOWES, D.Sc., Professor of Chemistry in University College, Nottingham. Third Edition. With 47 Engravings. Post 8vo, 7s. 6d.

**FOWNES.**—**Manual of Chemistry.**—*See WATTS.*

**LUFF.**—**An Introduction to the Study of Chemistry.** Specially designed for Medical and Pharmaceutical Students. By A. P. LUFF, F.I.C., F.C.S., Lecturer on Chemistry in the Central School of Chemistry and Pharmacy. Crown 8vo, 2s. 6d.

**TIDY.**—**A Handbook of Modern Chemistry**, Inorganic and Organic. By C. MEYMOTT TIDY, M.B., Professor of Chemistry and Medical Jurisprudence at the London Hospital, 8vo, 16s.

**VACHER.**—**A Primer of Chemistry**, including Analysis. By ARTHUR VACHER. 18mo, 1s.

**VALENTIN.**—**Chemical Tables for the Lecture-room and Laboratory.** By WILLIAM G. VALENTIN, F.C.S. In Five large Sheets, 5s. 6d.



**CHEMISTRY**—*continued.*

**VALENTIN AND HODGKINSON.**—A Course of

Qualitative Chemical Analysis. By W. G. VALENTIN, F.C.S. Fifth Edition by W. R. HODGKINSON, Ph.D. (Wurzburg), Demonstrator of Practical Chemistry in the Science Training Schools. With Engravings. 8vo, 7s. 6d.

**WATTS.**—Physical and Inorganic Chemistry.

By HENRY WATTS, B.A., F.R.S. (being Vol. I. of the Thirteenth Edition of Fownes' Manual of Chemistry). With 150 Wood Engravings, and Coloured Plate of Spectra. Crown 8vo, 9s.

*By the same Author.*

**Chemistry of Carbon - Compounds, or**

Organic Chemistry (being Vol. II. of the Twelfth Edition of Fownes' Manual of Chemistry). With Engravings. Crown 8vo, 10s.

---

**CHILDREN, DISEASES OF.**

**DAY.**—A Treatise on the Diseases of Children.

For Practitioners and Students. By WILLIAM H. DAY, M.D., Physician to the Samaritan Hospital for Women and Children. Crown 8vo, 12s. 6d.

**ELLIS.**—A Practical Manual of the Diseases

of Children. By EDWARD ELLIS, M.D., late Senior Physician to the Victoria Hospital for Sick Children. With a Formulary. Fourth Edition. Crown 8vo, 10s.

**SMITH.**—On the Wasting Diseases of Infants

and Children. By EUSTACE SMITH, M.D., F.R.C.P., Physician to H.M. the King of the Belgians, and to the East London Hospital for Children. Fourth Edition. Post 8vo, 8s. 6d.

*By the same Author.*

**Clinical Studies of Disease in Children.**

Second Edition. Post 8vo.

[*In preparation.*]

**STEINER.**—Compendium of Children's Dis-

eases; a Handbook for Practitioners and Students. By JOHANN STEINER, M.D. Translated by LAWSON TAIT, F.R.C.S., Surgeon to the Birmingham Hospital for Women, &c. 8vo, 12s. 6d.

---



## DENTISTRY.

**GORGAS.**—**Dental Medicine :** a Manual of Dental Materia Medica and Therapeutics, for Practitioners and Students. By FERDINAND J. S. GORGAS, A.M., M.D., D.D.S., Professor of Dentistry in the University of Maryland; Editor of "Harris's Principles and Practice of Dentistry," &c. Royal 8vo, 14s.

**SEWILL.**—**The Student's Guide to Dental Anatomy and Surgery.** By HENRY E. SEWILL, M.R.C.S., L.D.S., late Dental Surgeon to the West London Hospital. Second Edition. With 78 Engravings. Fcap. 8vo, 5s. 6d.

**STOCKEN.**—**Elements of Dental Materia Medica and Therapeutics, with Pharmacopœia.** By JAMES STOCKEN, L.D.S.R.C.S., late Lecturer on Dental Materia Medica and Therapeutics and Dental Surgeon to the National Dental Hospital; assisted by THOMAS GADDES, L.D.S. Eng. and Edin. Third Edition. Fcap. 8vo, 7s. 6d.

**TAFT.**—**A Practical Treatise on Operative Dentistry.** By JONATHAN TAFT, D.D.S., Professor of Operative Surgery in the Ohio College of Dental Surgery. Third Edition. With 134 Engravings. 8vo, 18s.

**TOMES (C. S.).**—**Manual of Dental Anatomy, Human and Comparative.** By CHARLES S. TOMES, M.A., F.R.S. Second Edition. With 191 Engravings. Crown 8vo, 12s. 6d.

**TOMES (J. and C. S.).**—**A Manual of Dental Surgery.** By JOHN TOMES, M.R.C.S., F.R.S., and CHARLES S. TOMES, M.A., M.R.C.S., F.R.S.; Lecturer on Anatomy and Physiology at the Dental Hospital of London. Third Edition. With many Engravings, Crown 8vo. *[In the press.*

---

## EAR, DISEASES OF.

**BURNETT.**—**The Ear: its Anatomy, Physiology, and Diseases.** A Practical Treatise for the Use of Medical Students and Practitioners. By CHARLES H. BURNETT, M.D., Aural Surgeon to the Presbyterian Hospital, Philadelphia. With 87 Engravings. 8vo, 18s.

**DALBY.**—**On Diseases and Injuries of the Ear.** By WILLIAM B. DALBY, F.R.C.S., Aural Surgeon to, and Lecturer on Aural Surgery at, St. George's Hospital. Second Edition. With Engravings. Fcap. 8vo, 6s. 6d.



**EAR, DISEASES OF**—*continued.*

**JONES.**—**A Practical Treatise on Aural Surgery.** By H. MACNAUGHTON JONES, M.D., Professor of the Queen's University in Ireland, late Surgeon to the Cork Ophthalmic and Aural Hospital. Second Edition. With 63 Engravings. Crown 8vo, 8s. 6d.

*By the same Author.*

**Atlas of the Diseases of the Membrana Tympani.** In Coloured Plates, containing 59 Figures. With Explanatory Text. Crown 4to, 21s.

---

**FORENSIC MEDICINE.**

**OGSTON.**—**Lectures on Medical Jurisprudence.**

By FRANCIS OGSTON, M.D., late Professor of Medical Jurisprudence and Medical Logic in the University of Aberdeen. Edited by FRANCIS OGSTON, Jun., M.D., late Lecturer on Practical Toxicology in the University of Aberdeen. With 12 Plates. 8vo, 18s.

**TAYLOR.**—**The Principles and Practice of Medical Jurisprudence.** By ALFRED S. TAYLOR, M.D., F.R.S. Third Edition, revised by THOMAS STEVENSON, M.D., F.R.C.P., Lecturer on Chemistry and Medical Jurisprudence at Guy's Hospital; Examiner in Chemistry at the Royal College of Physicians; Official Analyst to the Home Office. With 188 Engravings. 2 Vols. 8vo, 31s. 6d.

*By the same Author.*

**A Manual of Medical Jurisprudence.**  
Tenth Edition. With 55 Engravings. Crown 8vo, 14s.

ALSO,

**On Poisons, in relation to Medical Jurisprudence and Medicine.** Third Edition. With 104 Engravings. Crown 8vo, 16s.

**TIDY AND WOODMAN.**—**A Handy-Book of Forensic Medicine and Toxicology.** By C. MEYMOTT TIDY, M.B.; and W. BATHURST WOODMAN, M.D., F.R.C.P. With 8 Lithographic Plates and 116 Wood Engravings. 8vo, 31s. 6d.

---



**HYGIENE.**

**PARKES.**—A Manual of Practical Hygiene.

By EDMUND A. PARKES, M.D., F.R.S. Sixth Edition by F. DE CHAUMONT, M.D., F.R.S., Professor of Military Hygiene in the Army Medical School. With 9 Plates and 103 Engravings. 8vo, 18s.

**WILSON.**—A Handbook of Hygiene and Sani-

tary Science. By GEORGE WILSON, M.A., M.D., F.R.S.E., Medical Officer of Health for Mid Warwickshire. Fifth Edition. With Engravings. Crown 8vo, 10s. 6d.

---

**MATERIA MEDICA AND THERAPEUTICS.**

**BINZ AND SPARKS.**—The Elements of Thera-

peutics; a Clinical Guide to the Action of Medicines. By C. BINZ, M.D., Professor of Pharmacology in the University of Bonn. Translated and Edited with Additions, in conformity with the British and American Pharmacopœias, by EDWARD I. SPARKS, M.A., M.B., F.R.C.P. Lond. Crown 8vo, 8s. 6d.

**OWEN.**—A Manual of Materia Medica; in-

corporating the Author's "Tables of Materia Medica." By ISAMBARD OWEN, M.D., Lecturer on Materia Medica and Therapeutics to St. George's Hospital. Crown 8vo, 6s.

**ROYLE AND HARLEY.**—A Manual of Materia

Medica and Therapeutics. By J. FORBES ROYLE, M.D., F.R.S., and JOHN HARLEY, M.D., F.R.C.P., Physician to, and Joint Lecturer on Clinical Medicine at, St. Thomas's Hospital. Sixth Edition. With 139 Engravings. Crown 8vo, 15s.

**THOROWGOOD.**—The Student's Guide to

Materia Medica and Therapeutics. By JOHN C. THOROWGOOD, M.D., F.R.C.P., Lecturer on Materia Medica at the Middlesex Hospital. Second Edition. With Engravings. Fcap. 8vo, 7s.

**WARING.**—A Manual of Practical Therapeu-

tics. By EDWARD J. WARING, C.I.E., M.D., F.R.C.P. Third Edition. Fcap. 8vo, 12s. 6d.

---



**MEDICINE.**

**BARCLAY.—A Manual of Medical Diagnosis.**

By A. WHYTE BARCLAY, M.D., F.R.C.P., late Physician to, and Lecturer on Medicine at, St. George's Hospital. Third Edition. Fcap. 8vo, 10s. 6d.

**CHARTERIS.—The Student's Guide to the**

Practice of Medicine. By MATTHEW CHARTERIS, M.D., Professor of Materia Medica, University of Glasgow; Physician to the Royal Infirmary. With Engravings on Copper and Wood. Third Edition. Fcap. 8vo, 7s.

**FENWICK.—The Student's Guide to Medical**

Diagnosis. By SAMUEL FENWICK, M.D., F.R.C.P., Physician to the London Hospital. Fifth Edition. With 111 Engravings. Fcap. 8vo, 7s.

*By the same Author.*

**The Student's Outlines of Medical Treatment.** Second Edition. Fcap. 8vo, 7s.

**FLINT.—Clinical Medicine: a Systematic Treatise**

on the Diagnosis and Treatment of Disease. By AUSTIN FLINT, M.D., Professor of the Principles and Practice of Medicine, &c., in Bellevue Hospital Medical College. 8vo, 20s.

**HALL.—Synopsis of the Diseases of the Larynx,**

Lungs, and Heart: comprising Dr. Edwards' Tables on the Examination of the Chest. With Alterations and Additions. By F. DE HAVILLAND HALL, M.D., F.R.C.P., Assistant-Physician to the Westminster Hospital. Royal 8vo, 2s. 6d.

**SANSOM.—Manual of the Physical Diagnosis**

of Diseases of the Heart, including the use of the Sphygmograph and Cardiograph. By A. E. SANSOM, M.D., F.R.C.P., Assistant-Physician to the London Hospital. Third Edition. With 47 Woodcuts. Fcap. 8vo, 7s. 6d.

**WARNER.—Student's Guide to Medical Case-**

Taking. By FRANCIS WARNER, M.D., F.R.C.P., Assistant-Physician to the London Hospital. Fcap. 8vo, 5s.

**WEST.—How to Examine the Chest: being a**

Practical Guide for the Use of Students. By SAMUEL WEST, M.D., M.R.C.P., Physician to the City of London Hospital for Diseases of the Chest, &c. With 42 Engravings. Fcap. 8vo, 5s.



**MEDICINE**—*continued.*

**WHITTAKER.**—Student's Primer on the Urine.

By J. TRAVIS WHITTAKER, M.D., Clinical Demonstrator at the Royal Infirmary, Glasgow. With Illustrations, and 16 Plates etched on Copper. Post 8vo, 4s. 6d.

---

**MIDWIFERY.**

**BARNES.**—Lectures on Obstetric Operations,

including the Treatment of Hæmorrhage, and forming a Guide to the Management of Difficult Labour. By ROBERT BARNES, M.D., F.R.C.P., Obstetric Physician to, and Lecturer on Diseases of Women, &c., at, St. George's Hospital. Third Edition. With 124 Engravings. 8vo, 18s.

**CLAY.**—The Complete Handbook of Obstetric

Surgery; or, Short Rules of Practice in every Emergency, from the Simplest to the most formidable Operations connected with the Science of Obstetrics. By CHARLES CLAY, M.D., late Senior Surgeon to, and Lecturer on Midwifery at, St. Mary's Hospital, Manchester. Third Edition. With 91 Engravings. Fcap. 8vo, 6s. 6d.

**RAMSBOTHAM.**—The Principles and Practice

of Obstetric Medicine and Surgery. By FRANCIS H. RAMSBOTHAM, M.D., formerly Obstetric Physician to the London Hospital. Fifth Edition. With 120 Plates, forming one thick handsome volume. 8vo, 22s.

**REYNOLDS.**—Notes on Midwifery: specially

designed to assist the Student in preparing for Examination. By J. J. REYNOLDS, L.R.C.P., M.R.C.S. Fcap. 8vo, 4s.

**ROBERTS.**—The Student's Guide to the Practice

of Midwifery. By D. LLOYD ROBERTS, M.D., F.R.C.P., Physician to St. Mary's Hospital, Manchester. Third Edition. With 2 Coloured Plates and 127 Engravings. Fcap. 8vo, 7s. 6d.

**SCHROEDER.**—A Manual of Midwifery; includ-

ing the Pathology of Pregnancy and the Puerperal State. By KARL SCHROEDER, M.D., Professor of Midwifery in the University of Erlangen. Translated by CHARLES H. CARTER, M.D. With Engravings. 8vo, 12s. 6d.

**SWAYNE.**—Obstetric Aphorisms for the Use of

Students commencing Midwifery Practice. By JOSEPH G. SWAYNE M.D., Lecturer on Midwifery at the Bristol School of Medicine. Seventh Edition. With Engravings. Fcap. 8vo, 3s. 6d.

---



## MICROSCOPY.

**CARPENTER.**—**The Microscope and its Revelations.** By WILLIAM B. CARPENTER, C.B., M.D., F.R.S. Sixth Edition. With 26 Plates, a Coloured Frontispiece, and more than 500 Engravings. Crown 8vo, 16s.

**MARSH.**—**Microscopical Section-Cutting: a Practical Guide to the Preparation and Mounting of Sections for the Microscope, special prominence being given to the subject of Animal Sections.** By Dr. SYLVESTER MARSH. Second Edition. With 17 Engravings. Fcap. 8vo, 3s. 6d.

**MARTIN.**—**A Manual of Microscopic Mounting.** By JOHN H. MARTIN, Member of the Society of Public Analysis, &c. Second Edition. With several Plates and 144 Engravings. 8vo, 7s. 6d.

---

## OPHTHALMOLOGY.

**HIGGENS.**—**Hints on Ophthalmic Out-Patient Practice.** By CHARLES HIGGENS, F.R.C.S., Ophthalmic Surgeon to, and Lecturer on Ophthalmology at, Guy's Hospital. Second Edition. Fcap. 8vo, 3s.

**JONES.**—**A Manual of the Principles and Practice of Ophthalmic Medicine and Surgery.** By T. WHARTON JONES, F.R.C.S., F.R.S., late Ophthalmic Surgeon and Professor of Ophthalmology to University College Hospital. Third Edition. With 9 Coloured Plates and 173 Engravings. Fcap. 8vo, 12s. 6d.

**NETTLESHIP.**—**The Student's Guide to Diseases of the Eye.** By EDWARD NETTLESHIP, F.R.C.S., Ophthalmic Surgeon to, and Lecturer on Ophthalmic Surgery at, St. Thomas's Hospital. Third Edition. With 157 Engravings, and a Set of Coloured Papers illustrating Colour-blindness. Fcap. 8vo, 7s. 6d.

**WOLFE.**—**On Diseases and Injuries of the Eye: a Course of Systematic and Clinical Lectures to Students and Medical Practitioners.** By J. R. WOLFE, M.D., F.R.C.S.E., Senior Surgeon to the Glasgow Ophthalmic Institution; Lecturer on Ophthalmic Medicine and Surgery in Anderson's College. With 10 Coloured Plates, and 120 Wood Engravings, 8vo, 21s.

---



## **PATHOLOGY.**

**JONES AND SIEVEKING.**—**A Manual of Pathological Anatomy.** By C. HANDFIELD JONES, M.B., F.R.S., and EDWARD H. SIEVEKING, M.D., F.R.C.P. Second Edition. Edited, with considerable enlargement, by J. F. PAYNE, M.B., Assistant-Physician and Lecturer on General Pathology at St. Thomas's Hospital. With 195 Engravings. Crown 8vo, 16s.

**LANCEREAUX.**—**Atlas of Pathological Anatomy.** By Dr. LANCEREAUX. Translated by W. S. GREENFIELD, M.D., Professor of Pathology in the University of Edinburgh. With 70 Coloured Plates. Imperial 8vo, £5 5s.

**VIRCHOW.**—**Post-Mortem Examinations: a Description and Explanation of the Method of Performing them, with especial reference to Medico-Legal Practice.** By Professor RUDOLPH VIRCHOW, Berlin Charité Hospital. Translated by Dr. T. B. SMITH. Second Edition, with 4 Plates. Fcap. 8vo, 3s. 6d.

**WILKS AND MOXON.**—**Lectures on Pathological Anatomy.** By SAMUEL WILKS, M.D., F.R.S., Physician to, and late Lecturer on Medicine at, Guy's Hospital; and WALTER MOXON, M.D., F.R.C.P., Physician to, and Lecturer on the Practice of Medicine at, Guy's Hospital. Second Edition. With 7 Steel Plates. 8vo, 18s.

---

## **PSYCHOLOGY.**

**BUCKNILL AND TUKE.**—**A Manual of Psychological Medicine: containing the Lunacy Laws, Nosology, Ætiology, Statistics, Description, Diagnosis, Pathology, and Treatment of Insanity, with an Appendix of Cases.** By JOHN C. BUCKNILL, M.D., F.R.S., and D. HACK TUKE, M.D., F.R.C.P. Fourth Edition, with 12 Plates (30 Figures). 8vo, 25s.

**CLOUSTON.**—**Clinical Lectures on Mental Diseases.** By THOMAS S. CLOUSTON, M.D., and F.R.C.P. Edin.; Lecturer on Mental Diseases in the University of Edinburgh. With 8 Plates (6 Coloured). Crown 8vo, 12s. 6d.

**MANN.**—**A Manual of Psychological Medicine and Allied Nervous Disorders.** By EDWARD C. MANN, M.D., Member of the New York Medico-Legal Society. With Plates. 8vo, 24s.



**PHYSIOLOGY.**

**CARPENTER.**—**Principles of Human Physiology.** By WILLIAM B. CARPENTER, C.B., M.D., F.R.S. Ninth Edition. Edited by Henry Power, M.B., F.R.C.S. With 3 Steel Plates and 377 Wood Engravings. 8vo, 31s. 6d.

**DALTON.**—**A Treatise on Human Physiology :** designed for the use of Students and Practitioners of Medicine. By JOHN C. DALTON, M.D., Professor of Physiology and Hygiene in the College of Physicians and Surgeons, New York. Seventh Edition. With 252 Engravings. Royal 8vo, 20s.

**FREY.**—**The Histology and Histo-Chemistry of Man.** A Treatise on the Elements of Composition and Structure of the Human Body. By HEINRICH FREY, Professor of Medicine in Zurich. Translated by ARTHUR E. BARKER, Assistant-Surgeon to the University College Hospital. With 608 Engravings. 8vo, 21s.

**SANDERSON.**—**Handbook for the Physiological Laboratory :** containing an Exposition of the fundamental facts of the Science, with explicit Directions for their demonstration. By J. BURDON SANDERSON, M.D., F.R.S.; E. KLEIN, M.D., F.R.S.; MICHAEL FOSTER, M.D., F.R.S.; and T. LAUDER BRUNTON, M.D., F.R.S. 2 Vols. with 123 Plates. 8vo, 24s.

**YEO.**—**A Manual of Physiology for the Use of Junior Students of Medicine.** By GERALD F. YEO, M.D., F.R.C.S., Professor of Physiology in King's College, London. With 301 Engravings. Crown 8vo, 14s.

---

**SURGERY.**

**BELLAMY.**—**The Student's Guide to Surgical Anatomy ;** a Description of the more important Surgical Regions of the Human Body, and an Introduction to Operative Surgery. By EDWARD BELLAMY, F.R.C.S., and Member of the Board of Examiners ; Surgeon to, and Lecturer on Anatomy at, Charing Cross Hospital. Second Edition. With 76 Engravings. Fcap. 8vo, 7s.

**BRYANT.**—**A Manual for the Practice of Surgery.** By THOMAS BRYANT, F.R.C.S., Surgeon to, and Lecturer on Surgery at, Guy's Hospital. Fourth Edition. With about 700 Engravings (nearly all original, many being coloured). 2 Vols. Crown 8vo.  
[In the press.]



**SURGERY**—*continued.*

**CLARK AND WAGSTAFFE.** — **Outlines of**

Surgery and Surgical Pathology. By F. LE GROS CLARK, F.R.C.S., F.R.S., Consulting Surgeon to St. Thomas's Hospital. Second Edition. Revised and expanded by the Author, assisted by W. W. WAGSTAFFE, F.R.C.S., Assistant Surgeon to St. Thomas's Hospital. 8vo, 10s. 6d.

**DRUITT.** — **The Surgeon's Vade-Mecum; a**

Manual of Modern Surgery. By ROBERT DRUITT, F.R.C.S. Eleventh Edition. With 369 Engravings. Fcap. 8vo, 14s.

**FERGUSON.** — **A System of Practical Surgery.**

By Sir WILLIAM FERGUSON, Bart., F.R.C.S., F.R.S., late Surgeon and Professor of Clinical Surgery to King's College Hospital. With 463 Engravings. Fifth Edition. 8vo, 21s.

**HEATH.** — **A Manual of Minor Surgery and**

Bandaging, for the use of House-Surgeons, Dressers, and Junior Practitioners. By CHRISTOPHER HEATH, F.R.C.S., Holme Professor of Clinical Surgery in University College and Surgeon to the Hospital. Seventh Edition. With 129 Engravings. Fcap. 8vo, 6s.

*By the same Author.*

**A Course of Operative Surgery: with**

Twenty Plates drawn from Nature by M. LÉVEILLÉ, and Coloured. Large 8vo, 30s.

ALSO,

**The Student's Guide to Surgical Diag-**

nosis. Second Edition. Fcap. 8vo, 6s. 6d.

**MAUNDER.** — **Operative Surgery.** By Charles

F. MAUNDER, F.R.C.S., late Surgeon to, and Lecturer on Surgery at, the London Hospital. Second Edition. With 164 Engravings. Post 8vo, 6s.

**PIRRIE.** — **The Principles and Practice of**

Surgery. By WILLIAM PIRRIE, F.R.S.E., late Professor of Surgery in the University of Aberdeen. Third Edition. With 490 Engravings. 8vo, 28s.



**SURGERY**—*continued.*

**SOUTHAM.**—**Regional Surgery :** including Surgical Diagnosis. A Manual for the use of Students. Part I., the Head and Neck. BY FREDERICK A. SOUTHAM, M.A., M.B. Oxon, F.R.C.S., Assistant-Surgeon to the Royal Infirmary, and Assistant-Lecturer on Surgery in the Owen's College School of Medicine, Manchester. Crown 8vo, 6s. 6d.

---

**TERMINOLOGY.**

**DUNGLISON.**—**Medical Lexicon :** a Dictionary of Medical Science, containing a concise Explanation of its various Subjects and Terms, with Accentuation, Etymology, Synonyms, &c. By ROBERT DUNGLISON, M.D. New Edition, thoroughly revised by RICHARD J. DUNGLISON, M.D. Royal 8vo, 28s.

**MAYNE.**—**A Medical Vocabulary :** being an Explanation of all Terms and Phrases used in the various Departments of Medical Science and Practice, giving their Derivation, Meaning, Application, and Pronunciation. By ROBERT G. MAYNE, M.D., LL.D., and JOHN MAYNE, M.D., L.R.C.S.E. Fifth Edition. Crown 8vo, 10s. 6d.

---

**WOMEN, DISEASES OF.**

**BARNES.**—**A Clinical History of the Medical and Surgical Diseases of Women.** By ROBERT BARNES, M.D., F.R.C.P., Obstetric Physician to, and Lecturer on Diseases of Women, &c., at, St. George's Hospital. Second Edition. With 181 Engravings. 8vo, 28s.

**COURTY.**—**Practical Treatise on Diseases of the Uterus, Ovaries, and Fallopian Tubes.** By Professor COURTY, Montpellier. Translated from the Third Edition by his Pupil, AGNES M'LAREN, M.D., M.K.Q.C.P. With Preface by Dr. MATTHEWS DUNCAN. With 424 Engravings. 8vo, 24s.

**DUNCAN.**—**Clinical Lectures on the Diseases of Women.** By J. MATTHEWS DUNCAN, M.D., F.R.C.P., F.R.S.E., Obstetric Physician to St. Bartholomew's Hospital. Second Edition, with Appendices. 8vo, 14s.

**EMMET.**—**The Principles and Practice of Gynæcology.** By THOMAS ADDIS EMMET, M.D., Surgeon to the Woman's Hospital of the State of New York. With 130 Engravings. Royal 8vo, 24s.

---



**WOMEN, DISEASES OF**—*continued.*

**GALABIN.**—**The Student's Guide to the Diseases of Women.** By ALFRED L. GALABIN, M.D., F.R.C.P., Obstetric Physician to, and Lecturer on Obstetric Medicine at, Guy's Hospital. Third Edition. With 78 Engravings. Fcap. 8vo, 7s. 6d.

**REYNOLDS.**—**Notes on Diseases of Women.** Specially designed to assist the Student in preparing for Examination. By J. J. REYNOLDS, L.R.C.P., M.R.C.S. Second Edition. Fcap. 8vo, 2s. 6d.

**SMITH.**—**Practical Gynæcology: a Handbook of the Diseases of Women.** By HEYWOOD SMITH, M.D., Physician to the Hospital for Women and to the British Lying-in Hospital. With Engravings. Second Edition. Crown 8vo. [*In preparation.*]

**WEST AND DUNCAN.**—**Lectures on the Diseases of Women.** By CHARLES WEST, M.D., F.R.C.P. Fourth Edition. Revised and in part re-written by the Author, with numerous additions by J. MATTHEWS DUNCAN, M.D., F.R.C.P., F.R.S.E., Obstetric Physician to St. Bartholomew's Hospital. 8vo, 16s.

---

**ZOOLOGY.**

**CHAUVEAU AND FLEMING.**—**The Comparative Anatomy of the Domesticated Animals.** By A. CHAUVEAU, Professor at the Lyons Veterinary School; and GEORGE FLEMING, Veterinary Surgeon, Royal Engineers. With 450 Engravings. 8vo, 31s. 6d.

**HUXLEY.**—**Manual of the Anatomy of Invertebrated Animals.** By THOMAS H. HUXLEY, LL.D., F.R.S. With 156 Engravings. Post 8vo, 16s.

*By the same Author.*

**Manual of the Anatomy of Vertebrated Animals.** With 110 Engravings. Post 8vo, 12s.

**WILSON.**—**The Student's Guide to Zoology: a Manual of the Principles of Zoological Science.** By ANDREW WILSON, Lecturer on Natural History, Edinburgh. With Engravings. Fcap. 8vo, 6s. 6d.

---

11, NEW BURLINGTON STREET.



B/f.



## Date Due

Demco 293-5			



RE46  
884N

Accession no.  
11891

Author  
Nettleship, E.  
Diseases of the  
eye.

Call no.

RE46  
884N

19th CENT.



