

Catalogue of preparations, &c.; in morbid anatomy and experimental physiology : contained in the Museum of the Army Medical Department, Fort Pitt, Chatham / edited by George Williamson.

Contributors

Great Britain. Army Medical Services. Museum, Chatham.
Williamson, George, 1819-1865.
Harvey Cushing/John Hay Whitney Medical Library

Publication/Creation

London : Printed by Smith, Elder, and Co., 1845.

Persistent URL

<https://wellcomecollection.org/works/s63hvgfz>

License and attribution


This material has been provided by This material has been provided by the Harvey Cushing/John Hay Whitney Medical Library at Yale University, through the Medical Heritage Library. The original may be consulted at the Harvey Cushing/John Hay Whitney Medical Library at Yale University. where the originals may be consulted.

This work has been identified as being free of known restrictions under copyright law, including all related and neighbouring rights and is being made available under the Creative Commons, Public Domain Mark.

You can copy, modify, distribute and perform the work, even for commercial purposes, without asking permission.

**wellcome
collection**

Wellcome Collection
183 Euston Road
London NW1 2BE UK
T +44 (0)20 7611 8722
E library@wellcomecollection.org
<https://wellcomecollection.org>





R. L. Huntington

Staff Surgeon.

1833.

Fort Pitt.





Presented by
Sir James M^cGrigor
From The Medical Officers
of The Army.

CATALOGUE

OF

PREPARATIONS, &c.

IN

MORBID ANATOMY AND EXPERIMENTAL
PHYSIOLOGY,

CONTAINED IN

THE MUSEUM

OF

THE ARMY MEDICAL DEPARTMENT,

FORT PITT, CHATHAM.

EDITED BY

GEORGE WILLIAMSON, M.D.,

ASSISTANT-SURGEON TO THE FORCES.

LONDON :

PRINTED BY SMITH, ELDER, AND CO., 65, CORNHILL.

1845.

78027



19th
Cent
A 891
G7
C6
1845

TO
THE RIGHT HONORABLE
SIDNEY HERBERT, M.P.
SECRETARY AT WAR,

This Volume is respectfully Inscribed,

BY THE MEDICAL OFFICERS OF THE ARMY,

IN PROOF OF WHAT *THEY*

BY ZEAL AND A DISCREET APPLICATION OF THE VERY LIMITED

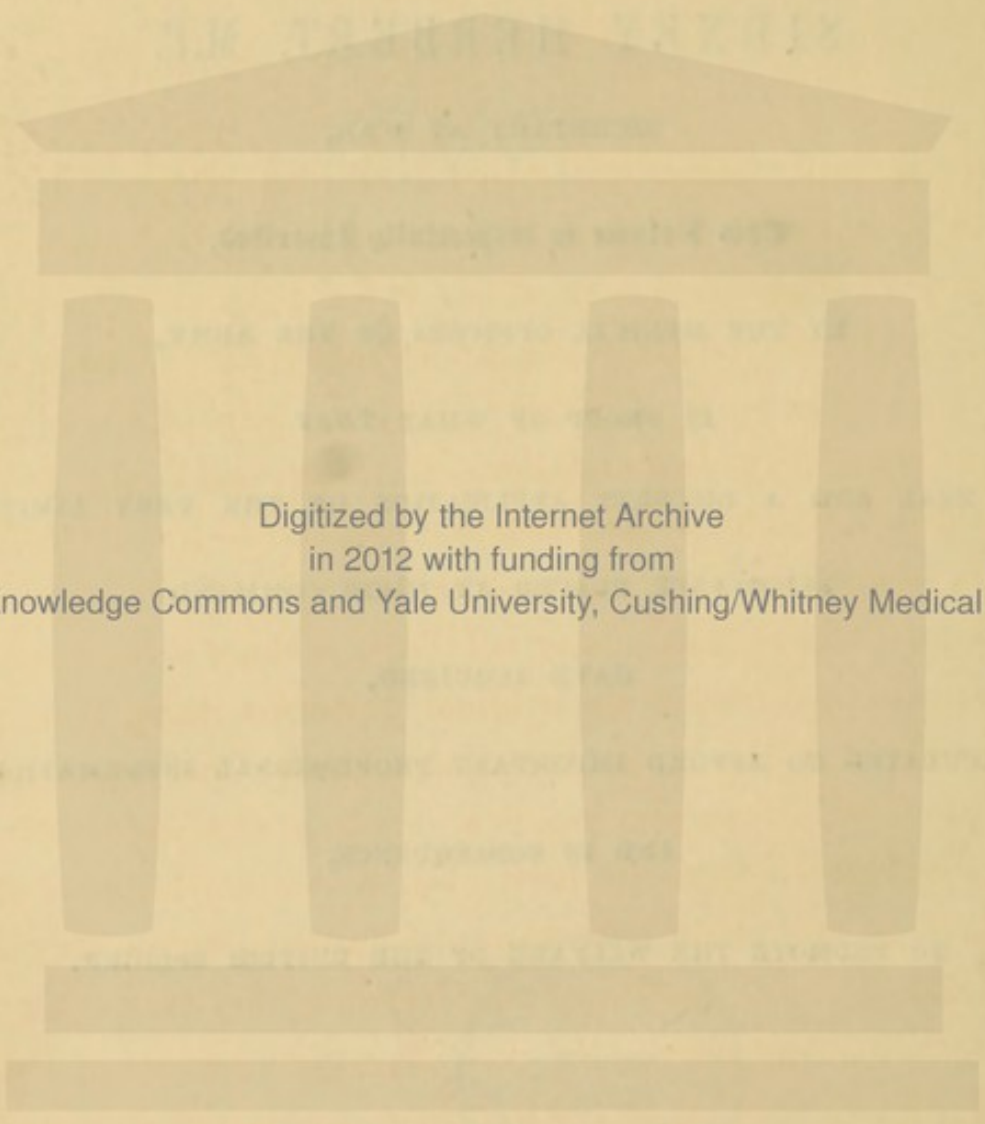
ALLOWANCE PLACED AT THEIR COMMAND

HAVE ACQUIRED,

CALCULATED TO AFFORD IMPORTANT PROFESSIONAL INFORMATION,

AND IN CONSEQUENCE,

TO PROMOTE THE WELFARE OF THE BRITISH SOLDIER.



Digitized by the Internet Archive
in 2012 with funding from
Open Knowledge Commons and Yale University, Cushing/Whitney Medical Library

NOTICE.

THE earliest attempt by medical officers of the army, to form a collection in morbid anatomy, was made in 1810, under the superintendence of the present Director General, then Inspector of Hospitals at Portsmouth. That effort, however, was only of short duration, and produced not more than fifty preparations—a result no doubt to be ascribed, in a great measure, to the removal to the Peninsula of its originator and chief promoter. After 1811 nothing appears to have been done till 1816, when a second effort was made by desire of the original projector, then Director General; and the York Hospital, Chelsea, was selected as the place where the preparations were to be deposited. Here a few specimens were acquired; but it was not till after the removal of the infant collection to Chatham, where the only General Hospital continued to exist after the conclusion of the war, that the forming of the collection so anxiously desired by the chief of the department was seriously undertaken. The requests and recommendations issued at that time from Head Quarters to the medical officers of the army generally, were honourably responded to almost immediately, and the same spirit which was evinced, now seventeen years ago, has continuously prevailed ever since; and

the result has been the acquirement of an extensive, a varied, and a valuable collection of morbid preparations.

The present volume is intended to communicate to the officers of the department, in as few words as possible, the natures and number of the preparations in the collection, which has been effected principally by their zeal, and thus to enable them to understand what yet requires to be supplied by their further exertions. The names of the contributors of preparations, it will be observed, are regularly given in the body of the work; hence it is only necessary here to remark, that the department is greatly indebted to the exertions of the several able officers who have successively superintended the Hospital establishment at Chatham, viz., the late Dr. Forbes,—Drs. Skey, Clarke, Davy, and Smith, and to the successive curators,* for the able manner in which the preparations have been prepared, but more especially to Mr. Gulliver, now Surgeon of the 1st Life Guards, and Dr. Williamson, Staff-Assistant Surgeon, the officer who has had the charge of the collection for the last four years, and who has edited this publication.

* The late Mr. J. D. Millar, Mr. Ford, Dr. Bushe, Mr. Gulliver, Mr. Fagg, Dr. Caw, Dr. M'Crae, Mr. Calder, Mr. Atthill, Mr. Stewart, Mr. Staunton, and Dr. Williamson.

CONTENTS.

CLASS I.

ORGANS OF CIRCULATION.

DIVISION I.

DISEASES AND INJURIES OF THE PERICARDIUM AND HEART.

	Page
SECT. I. Inflammation and Effusion of Lymph on the Pericardium and Heart	1
II. Bony Deposit in the Heart and Pericardium	7
III. Hypertrophy, Dilatation, and Atrophy of the Heart	8
IV. Heart's Tissue Diseased	11
V. Aneurisms of the Heart	13
VI. Diseased States of the Valves	14
VII. Injuries of the Heart	21
VIII. Preternatural Apertures and Malformations of the Heart	21

DIVISION II.

DISEASES OF THE ARTERIES.

SECT. I. Inflammation, Atheromatous and Bony Deposits in the Arteries	24
II. Aneurism of the Arteries	30
III. Coagula from Aneurisms	54
IV. Fibrinous Coagula in Arteries	55
V. Abnormal Appearance consequent on Injury and Ligature	56
VI. Malformations and Varieties of Arteries	58

DIVISION III.

DISEASES OF THE VEINS.

SECT. I. Inflammation, Ulceration, and Fibrinous Coagula in Veins and Sinuses	60
---	----

CLASS II.
ORGANS OF RESPIRATION.

DIVISION I.

DISEASES AND INJURIES OF THE LARYNX, TRACHEA, BRONCHI, BRONCHIAL
THYROID, AND THYMUS GLANDS.

	Page
SECT. I. Inflammation and Effusion of Lymph in the Larynx, Trachea, and Bronchi	65
II. Œdema of the Larynx	67
III. Ossification of the Cartilages of the Larynx	67
IV. Ulceration of the Larynx	68
V. Ulceration of the Trachea and Bronchi	73
VI. Diseases of the Bronchial, Thyroid, and Thymus Glands	74
VII. Injuries of the Larynx and Trachea	78

DIVISION II.

DISEASES OF THE LUNGS.

SECT. I. Tubercles in the Lungs	79
II. Tubercular Cavities in the Lungs	81
III. Medullary Deposit in the Lungs	86
IV. Cartilaginous and Bony Deposits in the Lungs	86
V. Hydatids in the Lungs	87
VI. Melanosis of the Lungs	87
VII. Apoplexy of the Lungs	87
VIII. Emphysema of the Lungs	88
IX. Inflammation and Hepatization of the Lungs	89
X. Hypertrophy of the Pulmonary Tissue	91
XI. Abscesses of the Lungs	91
XII. Gangrene of the Lungs	91

DIVISION III.

DISEASES OF THE PLEURA.

SECT. I. Inflammation, Ecchymosis, Effusion of Lymph on the Pleura, and Compression of Lung from Various Causes	92
II. Cartilaginous Thickening of the Pleura	96
III. Bony Deposits in the Pleura	97
IV. Fatty Deposits in the Pleura	97
V. Tubercular Deposits in the Pleura	97
VI. Abscesses in or connected with the Pleural Cavity	98

CLASS III.
ORGANS OF SENSATION.

DIVISION I.

DISEASES OF THE DURA MATER.

	Page
SECT. I. Blood effused on and under the Dura Mater	99
II. Thickening and Effusion of Lymph on the Dura Mater	100
III. Bony Deposit in the Dura Mater	100
IV. Tubercular Deposit in the Dura Mater	101
V. Tumours of the Dura Mater	102
VI. Absorption and Reticulated Appearance of the Dura Mater	104

DIVISION II.

DISEASES OF THE PIA MATER AND ARACHNOID.

SECT. I. Vascularity, Thickening, and Effusion of Lymph on the Arachnoid and Pia Mater	105
II. Calcareous Deposits in the Arachnoid and Pia Mater	106

DIVISION III.

DISEASES AND INJURIES OF THE BRAIN.

SECT. I. Ramollissement of the Brain	107
II. Apoplectic Cells in the Brain	108
III. Abscesses in the Brain	109
IV. Tubercular Deposit in the Brain	111
V. Serous Cysts in the Brain	111
VI. Hydatids from the Brain	113
VII. Tumours from the Brain	113
VIII. Dilatation of the Ventricles and Rupture of the Septum Lucidum	115

DIVISION IV.

DISEASES OF THE SPINAL CHORD AND NERVES	117
---	-----

DIVISION V.

DISEASES AND INJURIES OF THE ORGANS OF THE SENSES.

SECT. I. Diseases of the Eye	119
II. Diseases of the Ear	120
III. Diseases of the Nose	121
IV. Diseases of the Tongue	122
V. Diseases of the Skin	123

CLASS IV.
ORGANS OF DIGESTION.

DIVISION I.

DISEASES OF THE MOUTH, PHARYNX, AND ŒSOPHAGUS.

	Page
SECT. I. Diseases of the Lips	131
II. Diseases of the Gums and Teeth	131
III. Diseases of the Palate	132
IV. Inflammation, Effusion of Lymph, and Ulceration of the Pharynx and Œsophagus	132
V. Tumours of the Œsophagus	133

DIVISION II.

DISEASES, INJURIES, AND WOUNDS OF THE STOMACH.

SECT. I. Inflammation, Petechia, Softening and Erosion of the Mucous Membrane of the Stomach	135
II. Hypertrophy of the Coats of the Stomach	136
III. Carcinomatous Ulceration of the Stomach	136
IV. Ulceration of the Stomach	139
V. Perforation of the Coats of the Stomach by the action of its own Secretions	141
VI. Sloughing of the Coats of the Stomach	141
VII. The Effects of Poison on the Coats of the Stomach	142
VIII. Wounds of the Stomach	142

DIVISION III.

DISEASES, WOUNDS, RUPTURES, AND MALFORMATIONS OF THE SMALL
INTESTINES.

SECT. I. Inflammation, Petechia, Effusion of Lymph, and Ulceration of the Small Intestines	143
II. Gangrene of the Small Intestines	151
III. Intus-susception	152
IV. Hernia	153
V. Strictures and Contractions of the Small Intestines	156
VI. Tumours of the Small Intestines	156
VII. Wounds and Ruptures of the Small Intestines	157
VIII. Malformations of the Small Intestines	158

DIVISION IV.

DISEASES, INJURIES, WOUNDS, AND MALFORMATIONS OF THE LARGE INTESTINES.

	Page
SECT. I. Inflammation and Effusion of Lymph on the Large Intestines	159
II. Ulceration of the Large Intestines	161
III. Sloughing of the Large Intestines	168
IV. Scirrhus and Contractions of the Large Intestines	170
V. Fistula in Ano	171
VI. Wounds of the Large Intestines	172
VII. Malformations of the Large Intestines	172
VIII. Intestinal Concretions	172
IX. Intestinal Worms	173

DIVISION V.

DISEASES OF THE PERITONEUM.

SECT. I. Inflammation, Ecchymosis, and Effusion of Lymph on the Peritoneum	175
II. Tubercular Degeneration of the Peritoneum	176
III. Hydatids and Tumours in the Peritoneum	179
IV. Injuries of the Peritoneum	180

CLASS V.

SECRETING ORGANS SUBSERVIENT TO DIGESTION.

DIVISION I.

DISEASES AND INJURIES OF THE SUBMAXILLARY GLAND	181
---	-----

DIVISION II.

DISEASES AND INJURIES OF THE PAROTID GLAND	181
--	-----

DIVISION III.

DISEASES AND INJURIES OF THE TONSILS.

SECT. I. Sloughing of the Tonsils	181
---	-----

DIVISION IV.

DISEASES, INJURIES, AND MALFORMATIONS OF THE LIVER.

SECT. I. Inflammation and Abscesses in the Liver	182
--	-----

	Page
SECT. II. Cicatrices in the Liver	188
III. Dilatation of the Biliary Ducts	189
IV. Enlargement of the Liver	189
V. Fatty and Oily Matter in the Liver	189
VI. Common Tubercle in the Liver	190
VII. Scirrhus Tubercle, with Hypertrophy of the White Substance of the Liver	191
VIII. Medullary Deposit in the Liver	194
IX. Melanotic Deposit in the Liver	195
X. Cartilaginous and Calcareous Deposits in the Liver	196
XI. Cysts, Hydatids, and Worms in the Liver	196
XII. Rupture of the Liver	199
XIII. Malformations of the Liver	200
XIV. Diseases, and Malformations of the Gall Bladder, including Biliary Calculi	200

DIVISION V.

DISEASES, INJURIES, AND MALFORMATIONS OF THE SPLEEN.

SECT. I. Inflammation and Abscess of the Spleen	204
II. Induration of the Spleen	204
III. Enlargement of the Spleen	205
IV. Spleen diminished in size	205
V. Tubercular Deposit in the Spleen	206
VI. Melanotic Deposit in the Spleen	207
VII. Cartilaginous and Bony Deposits in the Spleen, and its Capsule	207
VIII. Rupture of the Spleen	208
IX. Malformations of the Spleen	208

DIVISION VI.

DISEASES OF THE PANCREAS	209
------------------------------------	-----

DIVISION VII.

DISEASES AND MALFORMATIONS OF THE LYMPHATIC VESSELS AND LYMPHATIC
GLANDS.

SECT. I. Diseases of the Lymphatic and Lacteal Vessels	210
II. Lymphatic Glands enlarged and filled with Tuberculous Matter	211
III. Calcareous Deposit in the Lymphatic Glands	212

CLASS VI.
URINARY ORGANS.

~~~~~  
DIVISION I.

|                                                            | Page |
|------------------------------------------------------------|------|
| DISEASES AND MALFORMATIONS OF THE SUPRARENAL CAPSULE . . . | 213  |

DIVISION II.

DISEASES, INJURIES, AND MALFORMATIONS OF THE KIDNEYS.

|                                                                                    |     |
|------------------------------------------------------------------------------------|-----|
| SECT. I. Softening of the Substance of the Kidneys . . . . .                       | 214 |
| II. Dilatation of the Pelvis and Infundibula . . . . .                             | 214 |
| III. Contraction, Thickening, and complete Obliteration of the<br>Ureter . . . . . | 215 |
| IV. Blood effused in the Substance of the Kidney . . . . .                         | 216 |
| V. Tuberculous Deposit in the Kidney . . . . .                                     | 216 |
| VI. Granular Degeneration of the Kidney . . . . .                                  | 219 |
| VII. Cysts, and Hydatids in the Kidney . . . . .                                   | 220 |
| VIII. Calculi in the Kidney . . . . .                                              | 223 |
| IX. Rupture of the Kidney . . . . .                                                | 225 |
| X. Malformations of the Kidney . . . . .                                           | 226 |

DIVISION III.

DISEASES AND INJURIES OF THE BLADDER INCLUDING URINARY CALCULI.

|                                                                                        |     |
|----------------------------------------------------------------------------------------|-----|
| SECT. I. Hypertrophy of the Coats of the Bladder . . . . .                             | 228 |
| II. Ulceration, and Fungoid Tumours of the Mucous Membrane<br>of the Bladder . . . . . | 229 |
| III. Abscesses in the Coats of the Bladder . . . . .                                   | 231 |
| IV. Serous Cysts attached to the Bladder . . . . .                                     | 232 |
| V. Sacculi in the Bladder . . . . .                                                    | 233 |
| VI. Blood effused between the Coats of the Bladder . . . . .                           | 233 |
| VII. Rupture of the Bladder . . . . .                                                  | 233 |
| VIII. Urinary Calculi . . . . .                                                        | 234 |

DIVISION IV.

DISEASES, AND INJURIES OF THE PROSTATE GLAND.

|                                                            |     |
|------------------------------------------------------------|-----|
| SECT. I. Enlargement of the Prostate Gland . . . . .       | 240 |
| II. Scrophulous Deposit in the Prostate Gland . . . . .    | 240 |
| III. Abscesses and Sinuses in the Prostate Gland . . . . . | 241 |

## DIVISION V.

## DISEASES, INJURIES, AND MALFORMATIONS OF THE URETHRA.

|                                                                 | Page |
|-----------------------------------------------------------------|------|
| SECT. I. Strictures and False Passages in the Urethra . . . . . | 242  |
| Sacculi in the Urethra . . . . .                                | 240  |

## CLASS VII.

## GENITAL ORGANS OF THE MALE.

## DIVISION I.

## DISEASES, INJURIES, AND MALFORMATIONS OF THE PENIS AND SCROTUM.

|                                                                       |     |
|-----------------------------------------------------------------------|-----|
| SECT. I. Ulceration, and Sloughing of the Penis and Scrotum . . . . . | 247 |
| II. Verrucae on the Penis . . . . .                                   | 247 |
| III. Elephantiasis of the Scrotum . . . . .                           | 248 |
| IV. Malformations of the Penis and Scrotum . . . . .                  | 248 |

## DIVISION II.

## DISEASES, AND INJURIES OF THE TUNICA VAGINALIS, AND TUNICA ALBUGINEA TESTIS.

|                                                                                                          |     |
|----------------------------------------------------------------------------------------------------------|-----|
| SECT. I. Hydrocele . . . . .                                                                             | 249 |
| II. Hæmatocele . . . . .                                                                                 | 251 |
| III. Cartilaginous, and Ossific Deposit in the Tunica Vaginalis and<br>Tunica Albuginea Testis . . . . . | 251 |
| IV. Soft, Cartilaginous, and Bony Substances attached to the<br>Tunica Vaginalis Testis . . . . .        | 252 |
| V. Cysts attached to the Tunica Vaginalis Testis . . . . .                                               | 253 |
| VI. Fungoid Growths from the Tunica Albuginea Testis . . . . .                                           | 253 |

## DIVISION III.

## DISEASES, INJURIES, AND MALFORMATION OF THE TESTICLE.

|                                                                        |     |
|------------------------------------------------------------------------|-----|
| SECT. I. Chronic Enlargement, and Induration of the Testicle . . . . . | 255 |
| II. Scrophulous Deposit, and Abscesses in the Testicle . . . . .       | 255 |
| III. Fungous Growths from the Testicle . . . . .                       | 257 |
| IV. Atrophy of the Testicle . . . . .                                  | 258 |
| V. Imperfect Descent of the Testicle . . . . .                         | 259 |

## DIVISION IV.

## DISEASES OF THE EPIDIDYMIS, VAS DEFERENS, AND VESICULA SEMINALIS.

|                                                                                 | Page |
|---------------------------------------------------------------------------------|------|
| SECT. I. Scrophulous Deposit in the Epididymis and Vesicula Seminalis . . . . . | 260  |
| Atrophy of the Vesicula Seminalis . . . . .                                     | 260  |

## CLASS VIII.

## GENITAL ORGANS OF THE FEMALE.

## DIVISION I.

## DISEASES, INJURIES, AND MALFORMATIONS OF THE OVARIA, FALLOPIAN TUBES AND ROUND LIGAMENTS.

|                                                                                          |     |
|------------------------------------------------------------------------------------------|-----|
| SECT. I. Cysts in the Ovaria, and Fallopian Tubes . . . . .                              | 261 |
| II. Scrophulous Deposit in the Ovaria . . . . .                                          | 263 |
| III. Conversion of the Ovaria into a Fatty Substance containing Hair and Teeth . . . . . | 264 |
| IV. Tumours in the Ovaries . . . . .                                                     | 264 |
| V. Corpora Lutea, Extra Uterine Pregnancy, &c. . . . .                                   | 265 |

## DIVISION II.

## DISEASES, INJURIES, AND MALFORMATIONS OF THE UTERUS.

|                                                                      |     |
|----------------------------------------------------------------------|-----|
| SECT. I. Inflammation, and Effusion of Lymph in the Uterus . . . . . | 266 |
| II. Hydatids in the Uterus . . . . .                                 | 267 |
| III. Ulceration, Cancer, and Fungoid Growths in the Uterus . . . . . | 268 |
| IV. Fibrous Tumours of the Uterus . . . . .                          | 268 |
| V. Fleishy Tumours of the Uterus . . . . .                           | 269 |
| VI. Uterus with the Fœtus in the Passages . . . . .                  | 270 |
| VII. Rupture of the Uterus . . . . .                                 | 270 |
| VIII. Moles . . . . .                                                | 270 |
| IX. Bones from the Uterus . . . . .                                  | 271 |

## DIVISION III.

## DISEASES OF THE VAGINA, AND EXTERNAL PARTS OF GENERATION.

|                                                   |     |
|---------------------------------------------------|-----|
| SECT. I. Tumours attached to the Vagina . . . . . | 272 |
| II. Tumours from the Labia . . . . .              | 272 |
| III. Elephantiasis of the Labia . . . . .         | 272 |

CLASS IX.  
LACTIFEROUS ORGANS.

---

DIVISION I.

DISEASES OF THE MAMMA.

|                                                          | Page |
|----------------------------------------------------------|------|
| SECT. I. Scirrhus of the Mamma . . . . .                 | 273  |
| II. Medullary Sarcoma and Fungous Hæmatodes of the Mamma | 274  |
| III. Hypertrophy of the Mamma of the Male . . . . .      | 275  |

---

CLASS X.  
ORGANS OF LOCOMOTION.

---

DIVISION I.

DISEASES, INJURIES, AND MALFORMATIONS OF THE JOINTS.

|                                                                                                                                                                       |     |
|-----------------------------------------------------------------------------------------------------------------------------------------------------------------------|-----|
| SECT. I. Diseases of the Synovial Membrane . . . . .                                                                                                                  | 276 |
| II. Hypertrophy of the Cartilages . . . . .                                                                                                                           | 279 |
| III. Atrophy, and Softening of the Cartilages . . . . .                                                                                                               | 281 |
| IV. Ulceration, principally affecting the Synovial Aspect of the<br>Cartilage . . . . .                                                                               | 286 |
| V. Ulceration, principally affecting the aspect of the Cartilage<br>next the Bone . . . . .                                                                           | 289 |
| VI. Caries of the Articular Surfaces, the Bones otherwise healthy                                                                                                     | 291 |
| VII. Caries of the Articular Surfaces, and an irregular deposition of<br>Adventitious Osseous Matter, on the Surface of the Bones<br>external to the Joints . . . . . | 292 |
| VIII. Caries of the Articular Surfaces, complicated with Necrosis .                                                                                                   | 295 |
| IX. Modifications of Form in the Articular Extremities ; shortening<br>of the Neck of the Femur ; and Eburnations of the Sur-<br>faces . . . . .                      | 297 |
| X. Caries of the Articular Extremities, attended with Disease of<br>the Cancellous Structure ; the Bones softened, and their<br>Earthy part diminished . . . . .      | 301 |
| XI. Anchylosis . . . . .                                                                                                                                              | 302 |
| XII. Appearances exhibited by Joints in Scurvy . . . . .                                                                                                              | 304 |

|                                                                                               | Page |
|-----------------------------------------------------------------------------------------------|------|
| SECT. XIII. Rheumatic and Gouty Deposits in the Joints and Tissues external to them . . . . . | 304  |
| XIV. Injuries of the Joints . . . . .                                                         | 305  |

## DIVISION II.

## DISEASES OF THE BONES.

|                                                                     |     |
|---------------------------------------------------------------------|-----|
| SECT. I. Inflammation, and thickening of the Periosteum . . . . .   | 307 |
| II. Abscesses in the Bone . . . . .                                 | 307 |
| III. Caries . . . . .                                               | 308 |
| IV. Necrosis . . . . .                                              | 324 |
| V. Bone after Amputation . . . . .                                  | 334 |
| VI. Scrophulous Deposit in Bone . . . . .                           | 334 |
| VII. Melanotic Deposit in Bone . . . . .                            | 335 |
| VIII. Spina Ventosa . . . . .                                       | 335 |
| IX. Interstitial Absorption . . . . .                               | 335 |
| X. Mollities Ossium . . . . .                                       | 337 |
| XI. Atrophy and Diminution of the Earthy part of the Bone . . . . . | 337 |
| XII. Hypertrophy of Bone . . . . .                                  | 338 |
| XIII. Exostosis, including Venereal Nodes . . . . .                 | 340 |
| XIV. Cellular Exostosis . . . . .                                   | 343 |
| XV. Osteo Sarcoma . . . . .                                         | 344 |
| XVI. Medullary Sarcoma and Fungus Hæmatodes . . . . .               | 346 |
| XVII. Malformations of Bone . . . . .                               | 349 |

## DIVISION III.

## INJURIES OF THE BONES.

|                                 |     |
|---------------------------------|-----|
| SECT. I. Fractures . . . . .    | 350 |
| II. Gunshot Fractures . . . . . | 368 |

## DIVISION IV.

## DISEASES, AND INJURIES OF THE MUSCLES AND TENDONS.

|                                                                                    |     |
|------------------------------------------------------------------------------------|-----|
| SECT. I. Cartilaginous, and Bony Deposit in the Muscles and Tendons                | 371 |
| II. Fatty, Scrophulous, and Melanotic Deposit in the Muscles and Tendons . . . . . | 372 |
| III. Entozoa in Muscle . . . . .                                                   | 372 |
| IV. Rupture of Muscles . . . . .                                                   | 372 |

CLASS XI.  
TUMOURS.

-----  
DIVISION I.

|                           | Page |
|---------------------------|------|
| ADIPOSE TUMOURS . . . . . | 374  |

DIVISION II.

|                               |     |
|-------------------------------|-----|
| SARCOMATOUS TUMOURS . . . . . | 374 |
|-------------------------------|-----|

DIVISION III.

|                                                    |     |
|----------------------------------------------------|-----|
| FIBROUS, AND FIBRO-CARTILAGINOUS TUMOURS . . . . . | 376 |
|----------------------------------------------------|-----|

DIVISION IV.

|                                    |     |
|------------------------------------|-----|
| OSTEO-SAROMATOUS TUMOURS . . . . . | 377 |
|------------------------------------|-----|

DIVISION V.

|                                       |     |
|---------------------------------------|-----|
| CALCAREOUS AND BONY TUMOURS . . . . . | 378 |
|---------------------------------------|-----|

DIVISION VI.

|                            |     |
|----------------------------|-----|
| VASCULAR TUMOURS . . . . . | 378 |
|----------------------------|-----|

DIVISION VII.

|                             |     |
|-----------------------------|-----|
| MELANOTIC TUMOURS . . . . . | 379 |
|-----------------------------|-----|

DIVISION VIII.

|                                                  |     |
|--------------------------------------------------|-----|
| MEDULLARY SARCOMA AND FUNGUS HÆMATODES . . . . . | 379 |
|--------------------------------------------------|-----|

DIVISION IX.

|                            |     |
|----------------------------|-----|
| ENCYSTED TUMOURS . . . . . | 382 |
|----------------------------|-----|

-----  
CLASS XII.

|                         |     |
|-------------------------|-----|
| MALFORMATIONS . . . . . | 384 |
|-------------------------|-----|

|                         |     |
|-------------------------|-----|
| MISCELLANEOUS . . . . . | 388 |
|-------------------------|-----|

---

|                            |             |
|----------------------------|-------------|
| CASTS AND MODELS . . . . . | Page<br>391 |
|----------------------------|-------------|

|                     |     |
|---------------------|-----|
| PAINTINGS . . . . . | 395 |
|---------------------|-----|

## DRAWINGS.

### CLASS I.

#### ORGANS OF CIRCULATION.

##### DIVISION I.

|                                                              |     |
|--------------------------------------------------------------|-----|
| DISEASES AND INJURIES OF THE PERICARDIUM AND HEART . . . . . | 399 |
|--------------------------------------------------------------|-----|

##### DIVISION II.

|                                                 |     |
|-------------------------------------------------|-----|
| DISEASES AND INJURIES OF THE ARTERIES . . . . . | 401 |
|-------------------------------------------------|-----|

### CLASS II.

#### ORGANS OF RESPIRATION.

##### DIVISION I.

|                                                                     |     |
|---------------------------------------------------------------------|-----|
| DISEASES AND INJURIES OF THE LARYNX, TRACHEA, AND BRONCHI . . . . . | 403 |
|---------------------------------------------------------------------|-----|

##### DIVISION II.

|                                 |     |
|---------------------------------|-----|
| DISEASES OF THE LUNGS . . . . . | 404 |
|---------------------------------|-----|

##### DIVISION III.

|                                  |     |
|----------------------------------|-----|
| DISEASES OF THE PLEURA . . . . . | 405 |
|----------------------------------|-----|



## CLASS III.

## ORGANS OF SENSATION.

## DIVISION I.

|                                                                | Page |
|----------------------------------------------------------------|------|
| DISEASES OF THE DURA MATER, PIA MATER, AND ARACHNOID . . . . . | 406  |

## DIVISION II.

|                                              |     |
|----------------------------------------------|-----|
| DISEASES AND INJURIES OF THE BRAIN . . . . . | 407 |
|----------------------------------------------|-----|

## DIVISION III.

|                                                                |     |
|----------------------------------------------------------------|-----|
| DISEASES AND INJURIES OF THE SPINAL CHORD AND NERVES . . . . . | 407 |
|----------------------------------------------------------------|-----|

## DIVISION IV.

## DISEASES AND INJURIES OF THE ORGANS OF SENSE.

|                                        |     |
|----------------------------------------|-----|
| SECT. I. Diseases of the Eye . . . . . | 408 |
| II. Diseases of the Ear . . . . .      | 409 |
| III. Diseases of the Nose . . . . .    | 409 |
| IV. Diseases of the Tongue . . . . .   | 409 |
| V. Diseases of the Skin . . . . .      | 409 |

## CLASS IV.

## ORGANS OF DIGESTION.

## DIVISION I.

|                                                         |     |
|---------------------------------------------------------|-----|
| DISEASES OF THE MOUTH, PHARYNX, AND ŒSOPHAGUS . . . . . | 413 |
|---------------------------------------------------------|-----|

## DIVISION II.

|                                                |     |
|------------------------------------------------|-----|
| DISEASES AND INJURIES OF THE STOMACH . . . . . | 414 |
|------------------------------------------------|-----|

## DIVISION III.

|                                            |     |
|--------------------------------------------|-----|
| DISEASES OF THE SMALL INTESTINES . . . . . | 415 |
|--------------------------------------------|-----|

## DIVISION IV.

|                                                         |     |
|---------------------------------------------------------|-----|
| DISEASES AND INJURIES OF THE LARGE INTESTINES . . . . . | 415 |
|---------------------------------------------------------|-----|

## DIVISION V.

|                                      |     |
|--------------------------------------|-----|
| DISEASES OF THE PERITONEUM . . . . . | 417 |
|--------------------------------------|-----|

## CLASS V.

## SECRETING ORGANS SUBSERVIENT TO DIGESTION.

## DIVISION I.

|                                                           | Page |
|-----------------------------------------------------------|------|
| DISEASES AND INJURIES OF THE SUBMAXILLARY GLAND . . . . . | 418  |

## DIVISION II.

|                                                      |     |
|------------------------------------------------------|-----|
| DISEASES AND INJURIES OF THE PAROTID GLAND . . . . . | 418 |
|------------------------------------------------------|-----|

## DIVISION III.

|                                                |     |
|------------------------------------------------|-----|
| DISEASES AND INJURIES OF THE TONSILS . . . . . | 418 |
|------------------------------------------------|-----|

## DIVISION IV.

|                                              |     |
|----------------------------------------------|-----|
| DISEASES AND INJURIES OF THE LIVER . . . . . | 418 |
|----------------------------------------------|-----|

## DIVISION V.

|                                              |     |
|----------------------------------------------|-----|
| DISEASES AND INJURIES OF THE SPLEEN. . . . . | 418 |
|----------------------------------------------|-----|

## DIVISION VI.

|                                                 |     |
|-------------------------------------------------|-----|
| DISEASES AND INJURIES OF THE PANCREAS . . . . . | 418 |
|-------------------------------------------------|-----|

## DIVISION VII.

|                                                                                  |     |
|----------------------------------------------------------------------------------|-----|
| DISEASES AND INJURIES OF THE LYMPHATIC VESSELS AND LYMPHATIC<br>GLANDS . . . . . | 418 |
|----------------------------------------------------------------------------------|-----|

## CLASS VI.

## URINARY ORGANS.

## DIVISION I.

|                                              |     |
|----------------------------------------------|-----|
| DISEASES OF THE SUPRARENAL CAPSULE . . . . . | 419 |
|----------------------------------------------|-----|

## DIVISION II.

|                                                                |     |
|----------------------------------------------------------------|-----|
| DISEASES, INJURIES, AND MALFORMATIONS OF THE KIDNEYS . . . . . | 419 |
|----------------------------------------------------------------|-----|

## DIVISION III.

|                                                                 | Page |
|-----------------------------------------------------------------|------|
| DISEASES AND INJURIES OF THE BLADDER, INCLUDING URINARY CALCULI | 420  |

## DIVISION IV.

|                                                       |     |
|-------------------------------------------------------|-----|
| DISEASES AND INJURIES OF THE PROSTATE GLAND . . . . . | 420 |
|-------------------------------------------------------|-----|

## DIVISION V.

|                                                |     |
|------------------------------------------------|-----|
| DISEASES AND INJURIES OF THE URETHRA . . . . . | 420 |
|------------------------------------------------|-----|

## CLASS VII.

## GENITAL ORGANS OF THE MALE.

## DIVISION I.

|                                                          |     |
|----------------------------------------------------------|-----|
| DISEASES AND INJURIES OF THE PENIS AND SCROTUM . . . . . | 421 |
|----------------------------------------------------------|-----|

## DIVISION II.

|                                                        |     |
|--------------------------------------------------------|-----|
| DISEASES OF THE TESTICLE AND SPERMATIC CHORD . . . . . | 421 |
|--------------------------------------------------------|-----|

## CLASS VIII.

## GENITAL ORGANS OF THE FEMALE.

## DIVISION I.

|                                                      |     |
|------------------------------------------------------|-----|
| DISEASES OF THE OVARIA AND FALLOPIAN TUBES . . . . . | 422 |
|------------------------------------------------------|-----|

## DIVISION II.

|                                  |     |
|----------------------------------|-----|
| DISEASES OF THE UTERUS . . . . . | 422 |
|----------------------------------|-----|

## DIVISION III.

|                                                                   |     |
|-------------------------------------------------------------------|-----|
| DISEASES OF THE VAGINA AND EXTERNAL PARTS OF GENERATION . . . . . | 423 |
|-------------------------------------------------------------------|-----|

## CLASS IX.

|                              |     |
|------------------------------|-----|
| LACTIFEROUS ORGANS . . . . . | 423 |
|------------------------------|-----|

## CLASS X.

## ORGANS OF LOCOMOTION.

## DIVISION I.

|                                               |      |     |
|-----------------------------------------------|------|-----|
| DISEASES AND INJURIES OF THE JOINTS . . . . . | Page | 424 |
|-----------------------------------------------|------|-----|

## DIVISION II.

|                                 |     |
|---------------------------------|-----|
| DISEASES OF THE BONES . . . . . | 424 |
|---------------------------------|-----|

## DIVISION III.

|                                 |     |
|---------------------------------|-----|
| INJURIES OF THE BONES . . . . . | 425 |
|---------------------------------|-----|

## CLASS XI.

|                   |     |
|-------------------|-----|
| TUMOURS . . . . . | 427 |
|-------------------|-----|

## CLASS XII.

|                         |     |
|-------------------------|-----|
| MALFORMATIONS . . . . . | 429 |
|-------------------------|-----|

|                         |     |
|-------------------------|-----|
| MISCELLANEOUS . . . . . | 430 |
|-------------------------|-----|

|                  |     |
|------------------|-----|
| PRINTS . . . . . | 432 |
|------------------|-----|

## EXPERIMENTAL PHYSIOLOGY.

|                                                            | Page |
|------------------------------------------------------------|------|
| SECT. I. Bone, Cartilage, and Joints . . . . .             | 433  |
| II. Tendon and Muscle . . . . .                            | 447  |
| III. Brain and Organs of Sense . . . . .                   | 448  |
| IV. Integuments and subjacent Cellular Substance . . . . . | 449  |
| V. Heart, Artery, and Vein . . . . .                       | 449  |
| VI. Miscellaneous . . . . .                                | 451  |

CLASS I.  
ORGANS OF CIRCULATION.

DIVISION I.

*DISEASES AND INJURIES OF THE PERICARDIUM  
AND HEART.*

SECTION I.—INFLAMMATION AND EFFUSION OF LYMPH ON THE  
PERICARDIUM AND HEART.

1. Heart covered with a thin layer of false membrane, deposited in granular patches ;—also a cluster of enlarged bronchial glands, containing calcareous matter, situated behind the aorta and pulmonary arteries.—Donor, Mr. Bradford, A. S. 56th Regt.

2. Heart exhibiting a delicate granular and lace-like deposition of lymph on the serous surface.—Printed Cat. page 47, No. 85.

3. Coagulable lymph effused on the serous surface of the pericardium, exhibiting a granular and lace-like appearance.—Printed Cat. page 35, No. 16.

4. Effusion of lymph in flakes and granules on the surface of the heart ;—also calcareous deposit on the external surface and in the substance of the pericardium which adheres at the posterior part to the right auricle.

5. Heart with coagulable lymph effused on its surface, more particularly on the right auricle where it presents a granular appearance, and the portion of the pericardium opposed to it exhibits a number of irregular elevations and depressions.

6. Surface of the heart and pericardium coated with coagulable lymph, varying in thickness in different situations and presenting a minute granular appearance.—Printed Cat. page 34, No. 10.

7. Coagulable lymph effused on the surface of the heart, producing a granular and lacelike appearance; the pericardium adheres partially to that organ.—York Hospital, Chelsea.—Printed Cat. page 32, No. 1.

8. Shows a considerable quantity of coagulable lymph effused on the serous surfaces of the heart and pericardium and which, near the base of the heart and along its anterior aspect, presents a well-marked lacelike or honeycombed appearance. The pericardium is thickened and large masses of lymph are seen hanging from its serous membrane.—Donor, Dr. Connel, A. S. Rifle Brigade.

9. Heart coated with a thick layer of coagulable lymph which, on the anterior surface, has a granular appearance; the pericardium is thickened and partially adheres by shreds of the same.—Printed Cat. page 34, No. 11.

10. Serous surface of the heart and pericardium covered with a thick layer of lymph having a fur-like appearance. Pericardium much enlarged and thickened.—Donor, Mr. Taylor, A. S. 58th Regt.

11. Heart coated with a fur-like deposit of lymph.—Donor, Dr. Henderson, Surgeon 78th Regt.

12. Heart exhibiting effusion of lymph on its surface which presents in some places a fur-like, in others a lace-like, appearance.

13. Lymph effused on the serous surfaces of the heart and pericardium, producing fur-like and lace-like appearances.

14. Heart enlarged;—lymph effused on the serous surfaces of the heart and pericardium, organized, and varying much in density and character,—being reticulated, honeycombed, granular, and in masses.—MS. Cat. vol. i. page 115, No. 96.

15. Serous surfaces of the heart and pericardium coated with a fur and velvet-like deposit of lymph, which has become organized.

The parietes of the right ventricle are slightly hypertrophied ; those of the left very much—Donor, Mr. Walker, Surgeon 92nd Regt.

16. Pericardium thickened and its serous membrane covered with organized lymph which, especially over the auricles and origins of the great vessels, is extended into numerous shreds and flocculent prolongations.—Donor, Mr. Winterscale, Surgeon 2nd Dragoons.

17. Serous surfaces of the heart and pericardium coated with a thin stratum of lymph, presenting an appearance much resembling the pile of plush.—York Hospital, Chelsea.—Printed Cat. page 32, No. 3.

18. Pericardium thickened, lined with firm reticulated lymph, and connected posteriorly to the surface of the heart (which is also covered with lymph) by round cords, their length varying from half an inch to two inches.—Print. Cat. page 36, No. 21.

19. Serous surfaces of the heart and pericardium covered with a loose flaky deposit of coagulated lymph. Pericardium greatly thickened.—Donor, Dr. Shanks, A. S. 82nd Regt.—Printed Cat. page 46, No. 79.

20. Heart and pericardium coated with lymph varying in character, being reticulated and in masses.

21. A very thick layer of lymph covering the heart and inner surface of the pericardium ; on some places thin and lace-like, on others in shreds and masses. Pericardium enlarged and much thickened.—Donor, Mr. Warren, I. G. H.

22. The entire surface of the heart and a portion of the pericardium covered with a copious deposit of soft spongy lymph, presenting a reticular and flocculent appearance,—the result of acute inflammation.—Donor, Mr. O'Brien, A. S. 7th Regt.—MS. Cat. vol. i. page 117, No. 102.

23. Lining membrane of the pericardium and surface of the heart coated with a thick layer of plastic lymph by which, in many places, particularly at the apex of the left and at the upper and back part of the right ventricles, they are closely united. The



opposed serous surfaces at the anterior aspect of the heart are smooth. The pericardium itself is much thickened, apparently from inflammation of long duration. The parietes of the right ventricle are much thinned.—Print. Cat. page 35, No. 13.

24. Serous surfaces of the heart and pericardium covered with a thick layer of lymph, deposited in lamellar masses and shreds. Below the lining membrane of the aorta there is a considerable quantity of atheromatous deposit.

25. Pericardium thickened;—its inner surface, as well as the surface of the heart, presenting numerous papillæ and pendulous excrescences of lymph, most remarkable along the thin edge of the heart.—Donor, Mr. Davidson, A. S. 21st Regt.—Print. Cat. page 43, No. 61.

26. Serous surfaces of the heart and pericardium covered with an extremely thick layer of lymph, particularly on the left ventricle where it measures an inch. Heart enlarged, and pericardium much thickened.

27. Serous surfaces of the heart and pericardium coated with a flocculent and reticulated deposit of lymph; the pericardium partially adherent.—Print. Cat. page 34, No. 9.

28. Surface of the heart covered with a layer of coagulable lymph, presenting a strongly marked lace-like appearance; the portions of the heart from which the lymph is detached was, in the recent preparation, highly vascular.—MS. Cat. vol. i. page 141, No. 163.

29. Serous surfaces of the heart and pericardium coated with coagulable lymph, which presents a very fine reticulated and lace-like appearance.—Donor, Mr. Fraser, A. S. Staff.

30. Exhibits a deposit of lymph, in the form of a continuous layer, on the whole serous surfaces of the heart and pericardium; the lymph on the former is minutely injected.—Donor, Mr. Ford, A. S. Staff.—Print. Cat. page 46, No. 77.

31. Heart exhibiting effusion of lymph on its surface; the pericardium adheres to it by many bands of the same.

32. Heart and pericardium coated with lymph, which is reticulated and in shreds; the lymph is minutely injected.—Print. Cat. page 42, No. 59.

33. Exhibits the serous membranes of the heart and pericardium coated with lymph, surfaces adherent around the apex; an opening in the inferior part of the pericardium communicating through the diaphragm (a part of which is attached in a sloughing state,) with an abscess which occupied almost the whole of the right lobe of the liver; below the lining membrane of the aorta there is a large atheromatous deposit. The pericardium was found filled with pus.—Donor, Mr. Ford, A. S. 72nd Regt.—MS. Cat. vol. i. page 125, No. 121.

34. Inflammation of the serous membrane covering the heart, also of that lining the ventricles, recent effusion of lymph on the serous covering, ecchymosed patches from rupture of a vein beneath it,—and two pendulous sacs (which now appear corrugated, but when recent were filled with turbid serum) suspended from the upper and back part of either auricle. Hypertrophy and dilatation of the left ventricle; ossification, thickening, and contraction of the aortic valves, the septum between two of them is nearly obliterated, so that they present the appearance of one long fold or valve. Cartilaginous thickening of mitral valves and of chordæ tendiniæ, foramen ovale open. Weight 16 ounces. From a boy 12 years of age.—Donor, Dr. Ely, Rochester.—MS. Cat. vol. i. page 138, No. 157.

35. Inflammation of the lining membrane of the right auricle.—MS. Cat. vol. i. page 41, No. 110.

36. Heart exhibiting a large white patch on the anterior surface of the right ventricle. Donor, Mr. Ford, A. S. 72nd Regt.—Print. Cat. page 45, No. 75.

37. A well-defined deposit of lymph on the serous membrane covering the right ventricle;—a portion of the adventitious membrane is turned down, leaving the true membrane smooth and entire beneath.—Donor, Mr. Gulliver, A. S. 71st Regt.—Print. Cat. page 45, No. 72.

38. Two large white patches of lymph on the anterior surface of

the right ventricle, and four of a smaller size on the left.—Print. Cat. page 80, No. 35.

39. Portion of heart, showing a number of granular-looking white spots on the external surface of the right auricle, enlargement of the Eustachian valve, and a cribriform state of the valve of the coronary vein.—MS. Cat. vol. i. page 127, No. 125.

40. Heart exhibiting effusion of lymph and partial adhesion to the pericardium. Donor, Dr. Skey, I. G. H.—Print. Cat. page 17, No. 35.

41. Enlargement and thickening of the pericardium, which contained three pints of pus.—Donor, Dr. Davey, A. S. 7th Regt.—MS. Cat. vol. i. page 114, No. 93.

42. Dilatation of the pericardium, which adheres firmly to the apex and posterior part of the heart. The pericardium contained about three pints of pus.—Donor, Mr. Fraser, A. S. Staff.

43. Partial adhesion of the pericardium to the left auricle of the heart.

44. A number of loose bands of firm lymph extending between the serous membrane of the heart and pericardium; the surface of the former is covered with several opaque white spots.—Donor, Mr. Gulliver, A. S. 71st Regt.—Print. Cat. page 44, No. 71.

45. Adhesion of the pericardium to the surface of the heart, and a spicula of bone in that membrane.—MS. Cat. vol. i. page 114, No. 91.

46. Universal adhesion of the pericardium to the surface of the heart, with coagulable lymph effused on the surface of the pleura attached.

47. Pericardium firmly adherent to the surface of the heart; the mitral valves thickened.

48. Universal and firm adhesion of the pericardium to the sur-

face of the heart ; hypertrophy of the left ventricle, attended with a cartilaginous degeneration of the mitral valve.—Print. Cat. page 41, No. 54.

49. Universal adhesion of the pericardium to the surface of the heart, with hypertrophy and dilatation of the right ventricle.—Print. Cat. page 49, No. 90.

50. Pericardium adhering firmly and universally to the surface of the heart ; plates of bony matter deposited below the lining membrane of aorta. Heart enlarged.

51. Heart and pericardium firmly agglutinated by a layer of lymph ; the left ventricle dilated.—Print. Cat. page 34, No. 12.

52. Universal adhesion of the pericardium to the surface of the heart, with thickening of the auriculo-ventricular valves. Heart enlarged.

53. Pericardium firmly united to the surface of the heart by a layer of lymph. Heart enlarged.

54. Exhibits universal adhesion of the pericardium to the surface of the heart. Heart enlarged. Walls of the right ventricle thinner than usual.—Print. Cat. page 35, No. 15.

55. Heart and pericardium firmly agglutinated by a layer of lymph ; left ventricle dilated.

56. Adhesion of the pericardium to the surface of the heart.—MS. Cat. vol. i. page 130, No. 134.

57. Serous surfaces of the heart and pericardium closely united by coagulable lymph ; the right lung being collapsed and adhering to the outer surface of the latter.—Print. Cat. page 33, No. 8.

## SECTION II.—BONY DEPOSIT IN THE HEART AND PERICARDIUM.

58. Portion of the heart exhibiting a large bony deposit on the

exterior of the right ventricle with adhesion of the pericardium.—Donor, Mr. Ford, A. S. 72nd Regt.

59. Membrane lining the interior of the right ventricle converted into patches of a cartilaginous consistence in three places.—MS. Cat. vol. i. page 127, No. 126.

60. A small deposit of osseous matter under the lining membrane of the left ventricle. From a woman aged 98.—Donor, Dr. Davy, A. I. H.

61. Semi-cartilaginous looking bodies developed in the serous covering of the heart, in the form of distinct round elevations.—MS. Cat. vol. i. page 130, No. 135.

62. Ossification of a large portion of the pericardium; the ossific matter almost entirely surrounds both auricles, is a quarter of an inch in thickness, and in some places an inch and a-half in breadth.—Donor, Mr. Stanley, St. Bartholomew's Hospital, London.

63. Ossification of a portion of the pericardium, situated over the right auricle; the ossific matter is about three inches in length, and a quarter of an inch in thickness.—Donor, Mr. Whitfield, Surgeon, R. A.

### SECTION III.—HYPERTROPHY, DILATATION, AND ATROPHY OF THE HEART.

64. Shows general enlargement of the heart, but more especially dilatation and hypertrophy of the left ventricle,—thickening of the semilunar valves of the aorta,—atheromatous deposit beneath its lining membrane,—and a number of large, opaque white spots on the external surface of the heart.—MS. Cat. vol. i. page 119, No. 111.

65. Dilatation and hypertrophy of the left ventricle of the heart and vegetation on the semilunar valves of the aorta.—Donor, Sir James McGrigor, Bart., Director General.

66. Active aneurism of the left ventricle; also calcareous deposit between the coats of the aorta.

67. Dilatation of both ventricles, more especially of the left, with thinness of the parietes of the right; there are likewise enlargement of both auriculo-ventricular openings, a diseased state of the semilunar valves of the aorta, an incipient aneurism in one of the sinuses of Valsalva, which extends below the valves, and the lining membrane of the aorta and upper part of the left ventricle diseased.—Donor, Mr. Ford, A. S. 72nd Regt.—MS. Cat. vol. i. page 123, No. 116.

68. Immense dilatation of the left auricle of the heart, with the corresponding auriculo-ventricular opening very much contracted from cartilaginous and osseous deposit.—Donors, Messrs. Shelly and Stillwell, Epsom.—MS. Cat. vol. i. page 28, No. 129.

69. Heart enlarged, with dilatation of the arch of the aorta and thickening of its coats.—Donor Mr. Stewart, Surgeon 84th Regt.

70. Heart enlarged, with great thickening of the walls of the left ventricle, and two opaque white spots,—one on the right ventricle, and the other on the pulmonary artery.—Print. Cat. page 48, No. 89.

71. Heart enlarged, with dilatation of the left ventricle, and a number of white granular-looking spots on its external surface.—Print. Cat. page 47, No. 83.

72. Heart enlarged, with dilatation of all the cavities, but more especially of the left ventricle, incipient aneurism in one of the sinuses of Valsalva, atheromatous deposit below the lining coat of the aorta, and a number of white granular-looking spots on the external surface of the heart.—Donor, Dr. Munro, A.S. 7th Regt.

73. Heart enlarged, with great dilatation and thickening of the walls of the left ventricle; surface of the heart covered with shreds of lymph.

74. Heart showing great dilatation of the left ventricle, with thickening of its parietes; surface of the heart covered with a number of white spots, aortic valves thickened, and atheromatous de-

posit beneath the lining membrane of the vessel.—Donor, Mr. Rogers, Surgeon 10th Hussars.

75. Heart enlarged, with dilatation and thickening of the walls of the left ventricle and atheromatous deposit beneath the lining membrane of the aorta.

76. Heart very much enlarged; a large opaque white spot on the anterior surface of the right ventricle, and two or three of a smaller size on the posterior surface of the heart;—a tumour about the size of a pigeon's egg situated above the vena cava inferior, immediately at its termination in the right auricle.—Print. Cat. page 66, No. 1.

77. Great enlargement of the heart, with dilatation of all the cavities, but more especially of the left ventricle the walls of which are also much thickened; surface of the heart covered with a number of large white granular-looking spots, and below the lining membrane of the aorta there is a deposit of atheromatous and bony matter.—MS. Cat. vol. i. page 132, No. 141.

78. Enlargement of the heart, with dilatation of the cavities, more especially of the left ventricle; the inner surface of the arch of the aorta is studded with ossific matter.—MS. Cat. vol. i. page 133, No. 142.

79. Left ventricle of the heart much dilated and its walls thickened; muscoli pectinati, situated immediately below the auriculo-ventricular opening on the posterior aspect of the heart, have a white tendinous and glistening appearance. There are also two oblique openings leading from one ventricle to the other, through the ventricular septum; inner surface of the aorta thickened.—Donor, Dr. M'Crae, A.S., 6th Dragoons.—MS. Cat. vol. i. page 127, No. 127.

80. Heart enlarged; left ventricle dilated and its walls thickened, with a hollow fibrinous concretion at its inferior part; surface of the heart covered with a number of white granular spots; and below the lining membrane of the aorta there are a number of large patches of ossific matter.—Donor, Mr. Carey, Australia.

81. Hypertrophy, with dilatation of the left ventricle of the heart; atheromatous deposit under the serous tunic of the aorta; and a number of white spots on the external surface of the heart.—Donor, Mr. Ford, A. S. 72nd Regt.—Print. Cat. page 44, No. 70.

82. Dilatation of the left ventricle of the heart, with albuminous deposition in its muscular substance, and partial adhesion of the pericardium.—Donor, Mr. Fraser, A. S. Staff.

83. Active aneurism of the left ventricle of the heart, the walls of that organ containing tubercles; external surface of the heart covered with shreds of lymph.—Print. Cat. page 38, No. 35.

84. Heart enlarged, and its external surface covered with shreds of lymph; margins of the semilunar valves of the aorta thickened.—Print. Cat. page 48, No. 86.

85. Slight dilatation of the left ventricle, with ossification and ulceration of the aortic valves.—Print. Cat. page 38, No. 35.

86. Cavities of the heart filled with wax, to exhibit a considerable enlargement of that organ.—Donor, Mr. Rolston, A. S. Staff.—Print. Cat. page 37, No. 26.

87. Heart of small size, the walls of the left ventricle thickened.—Print. Cat. p. 36, No. 24.

#### SECTION IV.—HEART'S TISSUE DISEASED.

88. Tuberculous matter deposited beneath the serous membrane covering the heart.—Donor, Mr. Squair, Surgeon 93d Regt.—MS. Cat. vol. i. page 124, No. 119.

89. Fibrinous clots, in the muscular substance of the right ventricle of the heart, which contained purulent matter.—Necrol. Reg. vol. v. folio 290.

90. Portion of the right ventricle of the heart, exhibiting circumscribed deposits of organized lymph in its substance and on its external



surface.—Donor, Mr. Grant, A. S. 71st Regt.—MS. Cat. vol. i. page 140, No. 160.

91. Part of the left ventricle of the heart, exhibiting two hollow fibrinous concretions; the one that is laid open contained a pus-like fluid.—MS. Cat. vol. i. page 129, No. 132.

92. A portion of the right ventricle of the heart, with fibrinous concretions both in its substance and attached to the lining membrane; in some of them are cavities which contained purulent matter.—Donor, Dr. Cooper, A. S. 29th Regt.—MS. Cat. vol. i. page 137, No. 154.

93. A portion of heart with several fibrinous clots in its substance, and on its internal surface;—one of them was collapsed, as if its contents had escaped, the rest were filled with a serous-looking fluid.—MS. Cat. vol. i. page 135, No. 147.

94. A portion of the right ventricle of the heart, near its apex, exhibiting fibrinous clots in a state of softening in substance and on internal surface.—MS. Cat. vol. i. page 132, No. 140.

95. A small fibrinous concretion, with delicate parietes and smooth exterior, which contained a puriform-looking fluid, and adhered to the columnæ carneæ of the left ventricle.—MS. Cat. vol. i. page 129, No. 131.

96. The sac of a small abscess in the parietes of the left ventricle, near the origin of the aorta; extensive verrucous excrescences from the aortic semilunar valves. A small ulcer in the centre of the mitral valve, atheromatous deposit in the coats of the aorta, with hypertrophy and dilatation of the left ventricle.—Donor, Mr. Ford, A. S. 72nd Regt.—MS. Cat. vol. i. page 124, No. 117.

97. Sac of an abscess situated in the muscular substance at the apex of the heart, which was filled with a reddish white purulent fluid. The thickness of the parietes of the heart are reduced at the very apex to a quarter of an inch. The sac is lined by a layer of lymph, rough internally, smooth externally, and susceptible of being easily detached from the surrounding muscular substance.—MS. Cat. vol. i. page 141, No. 162.

98. Ulceration of the inner surface of the apex of the left ventricle, this cavity is dilated and its parietes thickened.—Print. Cat. page 46, No. 76.

99. Heart enlarged, a large calcareous concretion in its substance, and its external surface covered with shreds of lymph.—Print. Cat. page 37, No. 28.

100. The cyst of a large tumour situated over the right auricle. Heart enlarged; pericardium adherent, and the aorta ossified at several points.—Print. Cat. page 36, No. 23.

101. Heart of a child, *ætat.* 7 months, exhibiting ecchymosis.—Donor, Mr. Gulliver, A. S. 71st Regt.

102. Portion of heart affected with incipient melanosis.—Donor, Dr. Davy, A. I. H.—Print. Cat. page 40, No. 47.

103. Section of the heart of an ox, the right auricle of which shows a large fibrinous tumour growing from its inner surface.—Donor, Mr. Stanley, Surgeon St. Bartholomew's Hospital.

104. An hydatid situated in the left ventricle of the heart of a cow.—Donor, Dr. Davy, A. I. H.

#### SECTION V.—ANEURISMS OF THE HEART.

105. Aneurismal dilatation situated at the apex of the left ventricle of the heart. The cavity of the aneurism is occupied by an irregularly shaped fibrinous coagulum about the size of a filbert, which, at its most inferior part, is separated from the cavity of the pericardium by the walls of the sac, which measures only about a line in thickness. Attached to the external surface of the apex of the ventricle in the situation of the aneurism, and extending for some distance beyond its limits, are seen the remains of adhesions which connected the apex of the heart with the inner surface of the corresponding portion of the pericardium.—Donor, Mr. Lamert, Surgeon 1st Veteran Battalion.—Print. Cat. page 39, No. 37.

106. An aneurismal tumour, about the size of a very large lemon, arising from the left ventricle, and communicating with its cavity by a circular opening about an inch in diameter. The opening presents a smooth rounded edge, and is situated midway between the base and apex of the ventricle. The aneurismal tumour is fully equal in dimensions to that of the left ventricle, and covered by a false membrane of considerable density. The walls of the tumour at its outer side adhere to the adjoining portion of the pericardium and lung. The thinnest portion of the tumour is that corresponding to a depression at its inner, upper, and back part.—Printed Cat. page 39, No. 38.

#### SECTION VI.—DISEASED STATES OF THE VALVES.

107. Heart exhibiting ossification, thickening, and contraction of the mitral valve; the auriculo-ventricular opening is hardly large enough to admit the point of the little finger. External surface of the heart covered with a number of irregular granular-looking white spots.—Print. Cat. page 38, No. 32.

108. Heart exhibiting deposition of bony matter in the mitral valve, by which the auriculo-ventricular opening is nearly obliterated; also extensive dilatation of both auricles.—Donor, Mr. Fraser, A. S. Staff.—Print. Cat. page 44, No. 67.

109. Osseous deposit, under the lining membrane of the left auricle, which involves a great part of the circumference of the left auriculo-ventricular opening and base of the mitral valve. On the auricular aspect of the opening a considerable portion of the osseous surface is bare and ragged, the endo-cardiac membrane being completely absorbed.—Donor, Dr. Nicholson, Surgeon 42nd Regt.—MS. Cat. vol. i. page 117, No. 104.

110. Extensive deposition of bony matter in the mitral valve, by which the auriculo-ventricular opening is almost entirely obliterated. The osseous matter has a granular appearance, and bare, the endocardiac membrane being absorbed.—Donor, Mr. Hume, A.S. 43d Regt.

111. Ossification of the mitral and semilunar valves of the aorta, with thickening of the tricuspid; heart generally enlarged.—Donor, Mr. Ford, A. S. 72nd Regt.—MS. Cat. vol. i. page 121, No. 114.

112. An irregular deposition of calcareous matter in the substance of the mitral valve.—MS. Cat. vol. i. page 137, No. 153.

113. Extensive deposition of bony matter in the mitral valve, which has an irregular granular appearance, and uncovered by the lining membrane of the heart.—MS. Cat. vol. i. page 128, No. 130.

114. Extensive osseous deposit in the mitral valve.—Donor, Dr. Pearson, Surgeon 87th Regt.—MS. Cat. vol. i. page 139, No. 158.

115. Mitral valve thickened and ulcerated with wart-like excrescences attached to its upper surface.

116. Two pendulous wart-like excrescences attached to the upper margin of the left auriculo-ventricular opening, there are also several others of a smaller size around their base. The auricular aspect of the mitral valve has also a slight warty appearance.—Donor, Dr. Knox, Edinburgh.

117. Disease of the mitral and semilunar valves of the aorta, with slight atheromatous deposit in the coats of that vessel; also general adhesion of the pericardium to the heart. The apex of one of the divisions of the mitral valve presents a large fringe of fleshy excrescences, with small growths of a similar character attached to several of the chordæ tendineæ. The surface of other portions of the valve likewise exhibits several excrescences near its apex, around which its structure is somewhat thickened. The semilunar valves of the aorta are at many points thickened, and present on their free margins wart-like excrescences interspersed with nodules of bony matter.—Print. Cat. page 37, No. 29.

118. A number of wart-like excrescences attached to the mitral valve, with slight hypertrophy of the left ventricle.—Donor, Dr. Shean, Surgeon 7th Regt.—MS. Cat. vol. i. page 137, No. 152.

119. Abundant deposition of earthy matter in the mitral valve by which the auriculo-ventricular opening is very much contracted.—Print. Cat. page 45, No. 73.

120. Ossification, thickening, and contraction of the margin of the mitral valve. Heart enlarged.

121. Warty excrescences on the auricular aspect of the tricuspid valve.—Print. Cat. page 36, No. 25.

122. Ossification and ulceration of the left auriculo-ventricular opening.

123. Extensive ossification and ulceration of the semilunar valves of the aorta, one of the valves is entirely destroyed, and in the sinus of Valsalva corresponding to it, there is a large mass of calcareous matter overhanging an ulcerated cavity filled with the same substance. In the base of another valve there is an irregular ulcerated opening. Heart enlarged.—MS. Cat. vol. i. page 142, No. 164.

124. Aortic valves, more or less thickened, especially along their free margins. The septum between two of them is much thickened, and converted into bone the surface of which is covered by the lining membrane; below the inner coat of the aorta there is a copious deposit of atheromatous matter.

125. Warty excrescences involving the whole of the free margin of the aortic valves, and containing a copious deposit of calcareous matter. The interior surface of two of the sinuses of Valsalva presents numerous small warty irregularities, interspersed with opaque spots, resulting from deposition of atheromatous matter. In the bottom of the middle sinus there is an oblique fissure which extends through the whole thickness of the aortic coats; this sinus is considerably dilated externally, and near the most convex point exists the fissure above described.—Donor, Mr. Martin, Surgeon 73d Regt.—MS. Cat. vol. i. page 176, No. 103.

126. Semilunar valves of the aorta, with osseous matter deposited at their base.—Print. Cat. page 63, No. 67.

127. Ossification and thickening at the junction of two of the semilunar valves of the aorta, ulceration in the centre of another, and several pendulous excrescences hanging from it.

128. Thickening ossification and ulceration of the septum, between two of the semilunar valves of the aorta.

129. Margins of two of the semilunar valves of the aorta partially ossified.—Donor, Dr. Davy, A. I. H.

130. Semilunar valves of the aorta, with osseous deposit at their base.

131. Thickening and elongation of the septum connecting two of the semilunar valves of the aorta.—Print. Cat. page 62, No. 66.

132. Margins of the semilunar valves of the aorta somewhat thickened.—Donor, Mr. Nicholson, Surgeon 42d Regiment.

133. Ulceration and thickening of the aortic and mitral valves, with dilatation of the left ventricle.—Donor, Dr. Dobson, surgeon.—Print. Cat. page 39, No. 36.

134. Bony deposit in the semilunar valves of the aorta, with wart-like excrescences growing from their surfaces. Walls of the left ventricle thickened and dilated.—Donor, Mr. Marshall, Staff Surgeon.

135. Semilunar valve of the aorta, corresponding to the sinus from which the left coronary artery arises, extensively ruptured at its base, widely separated from the inner surface of the aorta, and loaded with a fringe of warty excrescences, one of which is remarkable for its size and the slender pedicle by which it is suspended in the cavity of the ventricle. The mitral valve is also slightly thickened at some points, and there are two pendulous wart-like excrescences at its base.—Print. Cat. page 37, No. 30.

136. Wart-like excrescences fringing the whole extent of the margin of the left auriculo-ventricular opening, and a band about an inch in breadth of similar ones, extending from the above opening, along the inner surface of the left auricle, for the distance of nearly

an inch and a-half. There is also a similar state of the free margins of the mitral and aortic valves, the former of which is likewise slightly thickened throughout its whole extent. The chordæ tendinæ, besides showing several pendulous excrescences, appear generally thickened and whiter than usual, as if from a deposition of lymph under the endo-cardiac membrane. On the surface of the columnæ carneæ, particularly at their extremities, the membrane is opaque and thickened, apparently from the same cause.—Donor, Mr. Ford, A. S. 72nd Regt.—MS. Cat. vol. i. page 122, No. 115.

137. Shows portions of the semilunar valves of the aorta in a fibro-cartilaginous state, and studded with pieces of bony matter. Also an aneurism involving one of the sinuses of Valsalva, a portion of the upper part of the left ventricle, and semilunar valves. The sinus of Valsalva is considerably dilated, and there exists at the lower part of its external surface, a distinctly rounded opening, the edges of which are thinned and irregular. At the upper and inner part of the tumour, near the common point of attachment of two of the valves, the internal membrane appears to have given way; the blood, by its reflux towards the ventricle during the resistance of the arterial system, seems to have raised the edge of the lacerated membrane, to have passed under the base of one of the valves towards the ventricle, and at a situation immediately inferior to the valves, to have then, caused a tumour, covered by the endo-cardiac membrane. The latter is proved by the fact, that the lining membrane of the ventricle is reflected over the root, and continued along the uninjured portions of the surface of the mass of fibrinous coagula.—Donor, Dr. Calvert, A. I. H.—Print. Cat. page 43, No. 63.

138. Pendulous vegetations from the semilunar valves of the aorta, rupture of one of the valves extending about half its breadth, with several spots of atheromatous deposit in the coats of the aorta.—Print. Cat. page 58, No. 46.

139. Large pendulous and fungoid excrescences attached to the semilunar valves of the aorta, also dilatation of one of the sinuses of Valsalva.

140. Osseous deposit within and along the free margins of the aortic valves, conjoined with warty excrescences. A large osseous

mass, partially covered by membrane on its upper and lower aspect and having an irregular surface, involves the free margin and inner half of one of the valves, which, from the weight of the matter deposited, is dragged downwards in the direction of the ventricle. There are also wart-like excrescences, disposed in a circular manner, extending over about two-thirds of the circumference of the arterial opening, and attached to the endo-cardiac membrane immediately below the valves, as well as around the orifice corresponding to one of the coronary arteries.—Print. Cat. page 50, No. 4.

141. A large mass of fungoid and warty excrescences attached to the semilunar valves of the aorta, and containing many deposits of bony matter.—Donor, Dr. Roe, Surgeon, 28th Regt.—Print. Cat. page 58, No. 47.

142. Warty and fungoid excrescences attached to the semilunar valves of the aorta.

143. Fungoid excrescences adhering to the semilunar valves of the aorta, with great dilatation of the left ventricle.—Donor, Dr. Mahony, Staff Surgeon.

144. Ulceration and fungoid degeneration of the semilunar valves of the aorta ; heart enlarged ; arch of the aorta dilated.

145. Fungoid excrescences attached to one of the semilunar valves of the aorta, with thickening of the other two. The mitral valve has also a number of wart-like excrescences attached to it. Heart enlarged.—Print. Cat. page 49, No. 1.

146. Cartilaginous verrucæ on the edges of the aortic and mitral valves.—Print. Cat. page 45, No. 74.

147. Wart-like excrescences arising from the free margins of the semilunar valves of the aorta.—Print. Cat. page 100, No. 73.

148. A number of wart-like excrescences on the semilunar valves of the aorta ; also surrounding the orifice of the left auriculo-ventricular opening. A cartilaginous concretion in the substance of the mitral valves, and softening of the parietes of the left ventricle.—



Donor, Mr. Ford, A. S. 72nd Regt.—MS. Cat. page 117, No. 105.

149. Thickening, with bony deposit, in the mitral and semilunar valves of the aorta. Heart enlarged, left ventricle dilated and its walls thickened.—Print. Cat. page 20, No. 48.

150. An ulcerated opening, about three lines in diameter, in one of the sigmoid valves of the aorta. The valves are thickened and rigid, particularly along their free margins, and contain a considerable quantity of ossific matter.—Donor, Mr. Allan, A. S. 87th Regt.—MS. Cat. vol. i. page 206, No. 199.

151. Two ulcerated openings of considerable size in one of the semilunar valves of the aorta; these valves, as also the aorta from its commencement to within an inch of the termination of its arch, are considerably thickened, from a deposition of atheromatous matter. The openings of the different arteries given off from the aorta are more or less contracted and puckered.—Donor, Mr. Ford, A. S. 72nd Regt.—MS. Cat. vol. i. page 184, No. 130.

152. Semilunar valves of the aorta thickened, and the septum between two of them very much elongated, so that internally they almost seem as one distinct valve.—MS. Cat. vol. i. page 191, No. 152.

153. Semilunar valves of the aorta thickened and ossified, with atheromatous deposit in the coats of that vessel; left auriculo-ventricular opening cartilaginous and ulcerated, with fungoid excrescences on the auricular aspect of the opening. Hypertrophy and dilatation of the left ventricle.

154. Laceration of two of the semilunar valves of the aorta, thickening of these valves from bony deposit, coats of the aorta studded with scales of ossific matter, some of which are quite bare, whilst others are still covered by the attenuated lining membrane. Slight hypertrophy of the walls of the left ventricle.—Donor, Mr. Whitfield, Surgeon, R. A.

155. A round cartilaginous body at the point of junction of two

of the semilunar valves of the aorta.—MS. Cat. vol. i. page 189, No. 146.

#### SECTION VII.—INJURIES OF THE HEART.

156. Heart exhibiting a wound, the instrument having penetrated the right ventricle through the diaphragm.

157. A punctured wound of the right ventricle, close to the apex of the heart.—Donor, Mr. Hill, Staff Surgeon.—Print. Cat. page 46, No. 78.

#### SECTION VIII.—PRETERNATURAL APERTURES AND MALFORMATIONS OF THE HEART.

158. Deficiency of the septum auriculorum, and general enlargement of the heart.—Donor, Mr. Lightbody, Surgeon 80th Regt.—Print. Cat. page 47, No. 81.

159. Foramen ovale open,—diameter of the opening an inch and a half; heart enlarged, with a number of white glistening spots on its surface.—Print. Cat. page 33, No. 7.

160. Heart with the foramen ovale unclosed; diameter of the opening three-quarters of an inch.—Print. Cat. page 33, No. 5.

161. Heart with two small openings at the anterior part of the fossa ovalis.—Print. Cat. page 13, No. 17.

162. Heart of an adult, with the foramen ovale open, and the Eustachian valve perfect.—Print. Cat. page 40, No. 44.

163. Heart with the foramen ovale imperfectly closed; there are two openings, the largest of which is one-fourth of an inch in diameter. The external surface of the heart is covered with a number of large white spots, as from lymph effused under the serous covering.—Print. Cat. page 32, No. 4.

164. Heart exhibiting the foramen ovale open.—Donor, Dr. Blake, Surgeon 7th Dr. Gds.—Print. Cat. page 43, No. 62.

165. Septum auriculorum, with the foramen ovale of considerable size.—Donor, Dr. McLean.—MS. Cat. vol. i. page 125, No. 120.

166. The membrana ovalis attenuated and cribriform.

167. Foramen ovale capable of admitting the little finger.—MS. Cat. vol. i. page 135, No. 149.

168.—Foramen ovale capable of admitting a large bougie; also a number of smaller foramina through the fossa.

169. Foramen ovale open, with a number of fine tendinous cords passing from the Eustachian valve to the opposite side of the auricle. Donor, Dr. Davy, A. I. H.—MS. Cat. vol. iii. page 194, No. 24.

170. An enlarged and cribriform state of the Eustachian valve.—MS. Cat. vol. i. page 126, No. 123.

171. A cribriform state of the Eustachian valve.—MS. Cat. vol. i. page 134, No. 144.

172. Eustachian valve reticulated.—MS. Cat. vol. i. page 135, No. 148.

173. A reticulated appearance of Eustachian valve.—MS. Cat. vol. i. page 134, No. 143.

174. A portion of the right auricle of the heart, showing an unusual net-like structure connected with the Eustachian valve and coronary vein.—Donor, Dr. Jackson.—MS. Cat. vol. i. page 121, No. 113.

175. The opening of the coronary vein of large size, and a varicose vein situated along the border of the fossa ovalis laid open.—Donor, Dr. McCrae, A. S. 6th Drs.—MS. Cat. vol. i. page 128, No. 128.

176. A membrane similar to the Eustachian valve in the left auricle.—MS. Cat. vol. iii. page 200, No. 71.

177. Shows a reticulated appearance of the valve at the mouth of the coronary vein.

178. Foramen ovale open, with two large openings in the septum ventriculorum :—from an acephalous foetus.

179. Foetus, exhibiting malformation of the heart; the aorta arising from the right ventricle which communicates with the left, immediately below the origin of that vessel.—Donor, Dr. Scott, Surgeon Rifle Brigade.

## DIVISION II.

### *DISEASES OF THE ARTERIES.*

---

#### SECTION I.—INFLAMMATION, ATHEROMATOUS AND BONY DEPOSITS IN THE ARTERIES.

180. Lining membrane of the aorta of a deep red colour, affording a fine specimen of aortitis; also two large opaque white spots, slightly raised above the rest of the lining membrane, with a well-defined margin.—MS. Cat. vol. i. page 173, No. 97.

181. Dilatation and thickening of the aorta, with adventitious matter deposited beneath its inner coat, producing a very irregular granulated-looking surface.—Donor, Mr. Cathcart, A. S. 7th Dr. Gds.—MS. Cat. vol. i. page 182, No. 126.

182. Atheromatous deposit beneath the inner membrane of the ascending aorta.—Donor, Dr. Davy, A. I. H.—Print. Cat. page 62, No. 62.

183. Abundant deposition of atheromatous matter beneath the internal coat of the ascending aorta.—Donor, Mr. Fiddes, Surgeon 85th Regt.

184. Portion of aorta, immediately above the semilunar valves, thickened and indurated from atheromatous deposit.

185. Aorta, immediately above the semilunar valves, exhibiting a deposition of atheromatous matter beneath the inner tunic.—Print. Cat. page 57, No. 43.

186. Portion of aorta, with thickening and cartilaginous induration of the inner membrane, affording an example of that form of disease termed "tuberculate steatoma."—Print. Cat. page 58, No. 44.

187. Great thickening and induration of the lining membrane of the aorta, immediately above the semilunar valves.—Donor, Mr. O'Brien, A. S. 7th Fusiliers.—MS. Cat. vol. i. page 177, No. 112.

188. A portion of aorta containing atheromatous deposit, several of the vessels arising at the chief points of deposition are much contracted in diameter at their origin.—Donor, Mr. O'Brien, A.S. 7th Fusiliers.

189. Portion of the thoracic aorta; its internal membrane, which is much thickened, is dissected from the middle coat, showing that the latter is quite free from disease.

190. Portion of the ascending aorta, presenting tubercular deposit between the circular fibres of the vessel and its inner membrane.—Donor, Mr. Gulliver, A. S. 71st Regiment.—Print. Cat. page 58, No. 45.

191. Atheromatous deposit beneath the inner membrane of the thoracic aorta; calibre of the vessel much enlarged.—Donor, Mr. Fiddes, Surgeon 85th Regt.—Print. Cat. page 64, No. 76.

192. Atheromatous deposit beneath the inner membrane of descending aorta, with considerable dilatation of its coats.—Donor, Mr. Martin, Surgeon 73rd Regt.

193. Section of aorta discoloured by melanotic matter.—Donor, Dr. Davy, A. I. H.—Print. Cat. page 40, No. 47.

194. Osseous deposit in the obliterated ductus arteriosus. From a boy *ætat.* 5 years.

195. Osseous deposit in the obliterated ductus arteriosus of a man.

196. Partial ossification of a portion of one of the coronary arteries of the heart.—Donor, Dr. Davy, A. I. H.—MS. Cat. vol. i. page 172, No. 91.

197. Portion of aorta, exhibiting osseous deposit between its tunics.—Donor, Dr. Davy, A. I. H.—Print. Cat. page 64, No. 74.

198. Extensive ossification of the aorta, attended with dilatation of that vessel.—Donor, Dr. Davy, A. I. H.

199. Ossific matter deposited in the ascending aorta.—Donor, Dr. Mahony, Surgeon 7th Fusiliers.

200. Exhibits abundant deposition of bony matter beneath the inner coat of the aorta, with thickening of the semilunar valves.—Print. Cat. page 65, No. 81.

201. An irregular ridge of ossific matter in the coats of the aorta immediately above the sinuses of Valsalva, with partial thickening and ossific deposit in the sigmoid valves.—Print. Cat. page 50, No. 5.

202. Aorta, exhibiting ossification and dilatation; mitral valve of the heart thickened; pericardium adherent to that organ.—Print. Cat. page 51, No. 12.

203. Arch of the aorta dilated, and its coats thickened from atheromatous and bony deposits. Heart enlarged.—Donor, Dr. Connell, A.S. Rifle Brigade.—Print. Cat. page 48, No. 88.

204. A number of large plates of ossific matter deposited under the lining membrane of the arch of the aorta, with great dilatation of that vessel. Heart small, and a large white patch of lymph on the anterior surface of the right ventricle.—Donor, Dr. Davy, A. I. H.—MS. Cat. vol. i. page 179, No. 121.

205. A portion of the thoracic aorta, with ossific matter beneath its lining membrane.—Donor, Dr. Nicholson, Surgeon 42nd Regt.

206. Partial obliteration of the mouths of the intercostal arteries, from deposition of bony and atheromatous matter beneath the inner coat of the aorta.

207. Ossific matter deposited beneath the inner membrane of the aorta and iliac arteries; semilunar valves of the aorta slightly

thickened.—Heart small, and its coronary vessels large and tortuous. From a man *ætat.* 98.—Donor, Dr. Davy, A. I. H.

208. Portion of aorta, exhibiting abundant deposit of bony and atheromatous matter beneath the inner coat.—Donor, Mr. Fiddes, Surgeon 85th Regt.

209. Portion of aorta, showing large plates of bony deposit beneath the inner tunic.—Print. Cat. p. 48, No. 89.

210. Exhibits ossification of a portion of the thoracic aorta; the inner membrane in some places is absorbed, leaving the bony matter bare.—Donor, Dr. Davy, A. I. H.

211. Coats of the aorta dissected, exhibiting numerous points of calcareous deposit between its internal and middle tunics.—Print. Cat. p. 50, No. 8.

212. Ossific deposit on the inner surface of the abdominal aorta; the lining membrane is ulcerated around these deposits, leaving the bony laminae bare; in the space between the osseous plates the coats of the aorta are studded with atheromatous deposit.—Donor, Dr. Davy, A. I. H.

213. Diameter of the origin of the cœliac artery diminished by the existence of atheromatous deposit between the coats of the aorta.—Necrol. Reg. vol. v. folio 290.

214. Atheromatous deposit beneath the lining membrane of the abdominal aorta.

215. Portion of the lining membrane of the aorta, exhibiting osseous deposit.

216. A small portion of aorta with a deposit of osseous matter on the external surface of the inner tunic.—Print. Cat. page 65, No. 79.

217. A portion of aorta exhibiting osseous deposit between its tunics.—Print. Cat. page 17, No. 37.



218. Internal surface of the arch of the aorta entirely covered with ossific matter deposited in large bony plates, some of them having a granular appearance; with dilatation of the arch.—Donor, Dr. Cotton, Surgeon 12th Regt. — MS. Cat. vol. i. page 213, No. 220.

219. Large plates of ossific matter deposited between the coats of the ascending aorta, with dilatation of the arch.—MS. Cat. vol. i. page 179, No. 123.

220. Inner surface of the arch of the aorta studded with ossific deposit.—Donor, Dr. Davy, A. I. H.

221. Osseous deposit on the inner surface of the aorta immediately above the semilunar valves.—Donor, Dr. Stewart, A. I. H.—MS. Cat. vol. i. page 187, No. 137.

222. Thoracic aorta partially ossified, from a man *ætat.* 84.—Donor, Dr. Davy, A. I. H.

223. Portion of abdominal aorta, with a number of ossific patches on its inner coat.—Donor, Dr. Whitfield, Surgeon, R. A.

224. Ossific matter deposited beneath the inner membrane of the aorta.—Print. Cat. page 65, No. 79.

225. Portion of abdominal aorta, showing several osseous deposits under its lining membrane.—Donor, Dr. Melvin, Surgeon 60th Regt.

226. Abdominal aorta and common iliac arteries ossified in many places.—Donor, Dr. Davy, A. I. H.—MS. Cat. vol. i. page 173, No. 93.

227. Ossific deposit in the abdominal aorta and celiac artery.—Donor, Dr. Davy, A. I. H.—MS. Cat. vol. i. page 173, No. 95.

228. Obliteration of the left common iliac artery, calibre of the right also greatly diminished; the coats of the latter vessel and the abdominal aorta are thickened from atheromatous deposit. Donor, Dr. Davy, A. I. H.—Print. Cat. page 62, No. 61.

229. Bony deposit beneath the inner tunic of the common iliac artery.—Donor, Dr. Davy, A. I. H.—Print. Cat. page 64, No. 75.

230. Inner membrane of the femoral artery thickened, ridged, and puckered.—MS. Cat. vol. i. page 194, No. 164.

231. Partial ossification of the superficial femoral artery.—Donor, Dr. Davy, A. I. H.—MS. Cat. vol. i. page 172, No. 88.

232. Portion of the femoral artery exhibiting osseous matter beneath the inner tunic, with opacity of the latter.

233. Portion of the femoral artery exhibiting several points of ossification.—Print. Cat. page 54, No. 25.

234. Inner coat of the femoral artery, thickened, puckered and ossified.—MS. Cat. vol. i. page 195, No. 170.

235. A portion of the posterior tibial artery completely ossified. From an old man.—Donor, Dr. McCrae, A. S. Staff.

236. Thickening of the lining membrane of the arteria innominata, and occlusion of the vertebral artery.

237. Right internal carotid artery, exhibiting at its origin a cartilaginous deposit and sacculus—Donor, Dr. Martin, Surgeon 73rd Regt.

238. Small granular excrescences on the internal coat of the vertebral artery before uniting to form the basilar. — MS. Cat. vol. i. page 198, No. 182.

239. Ossification of the internal carotid arteries and their branches.—Donor, Dr. Davy, A. I. H.

240. Partial ossification of the basilar artery and its branches. From a Maltese, ætat. 95.—Dr. Davy, A. I. H.

241. Closure of the posterior communicating artery of the cerebrum by deposition on its inner coat.

242. Arteries of the brain, presenting ossific deposit extending even to their minutest branches.—Necrol. Reg. vol. vi. page 156.

243. Partial ossification of the arteries of the brain.—Donor, Dr. Davy, A. I. H.—MS. Cat. vol. i. page 172, No. 86.

244. Partial ossification of the internal carotid arteries and their branches.—From a Maltese, ætat. 95.—Donor, Dr. Davy, A. I. H.

245. Partial ossification of the internal carotid arteries; and some of the branches forming the circle of Willis obstructed by coagula.—Donor, Dr. White, Surgeon Rifle Brigade.—MS. Cat. vol. i. page 172, No. 90.

246. Ossification of the principal branches of the internal carotid arteries. From a woman ætat. 98.—Donor, Dr. Davy, A. I. H.

## 2. ANEURISM OF THE ARTERIES.

247. Aneurism at the origin of the aorta, involving the upper and back part of the septum cordis and projecting into the right auricle so as materially to encroach on the dimensions of that cavity, and slightly on the right auriculo-ventricular opening. One of the aortic valves is widely separated in the direction of the apex of the heart from the usual attachment of its base, for a depth measuring nearly two inches from the free margin of the valves. The curtain thus formed between the aneurismal cavity and that of the left ventricle, projects considerably along its whole length into the latter, and presents, about the middle of its perpendicular measurement at one side, an extensive irregular opening having its edges fringed with elongated verrucose excrescences. The coats of the portion of the aorta around the opening into the aneurismal sac, as well as the sinuses of Valsalva, contain a copious deposit of atheromatous matter.—MS. Cat. vol. i. page 130, No. 136.

248. An aneurism about the size of an orange, situated at the origin of the aorta, which burst into the upper part of the right ventricle; the opening into it is moderately regular and somewhat polished, measuring one-third of an inch at its extreme diameter. The aneurism projects extensively into the upper part of the ventricle, so as to occupy the greater part of the diameter of the upper

third of that cavity, as well as of the commencement of the pulmonary artery, one of the valves of which is much thinned, and extended over the convex surface of the tumour. The sinuses of Valsalva contain atheromatous deposit; and two of the semilunar valves are thickened, around the situation of the corpora aurantii, from the same cause. A portion of the semilunar valve, corresponding to the sinus with which the aneurism is connected, projects in a mammillated form downwards, and rather backwards, towards the cavity of the left ventricle. The mammillated projection is opaque, and appears somewhat thickened, even from its base, by atheromatous deposition.—Donor, Dr. Burrell, Surgeon 77th Regt.—MS. Cat. vol. i. page 211, No. 212.

249. An aneurism about the size of a plum, situated at the base of one of the semilunar valves of the aorta, and projecting downwards into the ventricle between the endo-cardium and the muscular substance of the heart. The ventricular septum forms the internal, and the semilunar valve the external wall of the sac; in the latter there are two large openings, each a quarter of an inch in diameter, between the aneurismal sac and the left ventricle.—Donor, Mr. Allan, 2nd Staff Surgeon.—MS. Cat. vol. i. page 214, No. 223.

250. An aneurismal tumour about the size of a large plum, connected with the right side of the aorta immediately above the semilunar valves, which burst into the pericardium. The opening by which the aneurism communicated with the aorta is circular, about an inch in diameter, and its edges rounded and moderately regular. Within the coats of the aorta, near to the verge of the opening at its back part, there is some trace of atheromatous deposit; and a similar deposition, but to a much greater extent, in the coats of the thoracic aorta. The tumour projects into the upper part of the right auricle, surmounts considerably the upper limits of that cavity, and presents a ragged opening capable of admitting a goose-quill, through which the blood escaped into the pericardium. No coagulum was found in the sac.—Donor, Mr. Allan, A. S. Staff.—MS. Cat. vol. i. page 136, No. 151.

251. An aneurismal tumour, capable of containing a middle-sized peach, projects from the posterior part of the aorta which is dilated for the extent of two inches and a-half from its origin. In the

posterior part of the enlarged vessel is an oval opening one inch and three-quarters in extreme diameter leading into the aneurismal tumour. The edge of the opening projects,—is smooth, polished, and firm, like fibro-cartilage. At the upper and right part of the tumour is a lacerated opening an inch long, to a portion of the circumference of which adheres the upper margin of the right auricle, which is thrown considerably upwards and to the right side; the tumour projects backwards to some extent between the right and left auricles in such a manner as, in a certain degree, to force their respective walls towards each other.—Donor, Dr. Dyce, A. S. Staff.—MS. Cat. vol. i. page 177, No. 111

252. An aneurism the size of a large plum, situated immediately above the semilunar valve of the aorta, which burst into the pericardium. The opening leading into the tumour from the vessel is about two inches in its longest diameter; its edge is round and projecting, and the inner surface of the sac is smooth and polished. There is a considerable quantity of atheromatous matter deposited beneath the lining membrane of the aorta above the aneurism.—Donor, Mr. Stanley, Surgeon St. Bartholomew's Hospital.

253. An aneurism about the size of a pullet's egg, situated at the anterior part of the origin of the aorta, which burst into the pericardium; the opening which allowed the blood to escape is capable of admitting a goose-quill.—Donor, Dr. Roe, Staff Surgeon.—MS. Cat. vol. i. page 209, No. 207.

254. An aneurism about the size of a pigeon's egg, situated about three inches above the commencement of the aorta, which burst into the pericardium; the communication between the vessel and tumour will only admit a common probe; the inner surface of the aorta is much thickened, and presents very irregular elevations and depressions from atheromatous deposition.—MS. Cat. vol. i. page 188, No. 145.

255. An aneurism the size of a walnut, situated two inches above the semilunar valves, which burst into the pericardium. The opening from the aorta into the sac is in the form of an irregular slit about four lines in length, the edges of which are rounded and covered by the lining membrane. The parietes of the sac towards

its upper part are of considerable thickness, but elsewhere attenuated, and near to their lowermost point there is a small opening capable of admitting a bougie, the consequence of rupture, which was followed by immediate death. Half an inch higher in the vessel and on the concave side of its arch, there is a second aneurism about the size of a hazel-nut, round the opening into which the internal membrane of the vessel is fissured in one or two places. The whole of the inner surface of the ascending aorta is thickened, corrugated, and closely studded with atheromatous matter. — Donor, Dr. Davy, A. I. H.

256. Aneurism of the aorta, immediately above the semilunar valves, which burst into the pericardium; the opening between the vessel and sac is about half an inch in diameter, and its edges round and smooth. The tumour encroaches to a considerable extent on the dimensions of the right auricle and upper part of the right ventricle. The inner surface of the aorta is studded with atheromatous deposit.—Donor, Mr. Allan, A. S. Staff.—MS. Cat. vol. i. page 214, No. 222.

257. An aneurism, about the size of a horsebean, situated an inch above the semilunar valves. The aorta at its origin is likewise irregularly dilated, and there is atheromatous deposit between its coats; the semilunar valves are coated with warty excrescences, and a number of smaller vegetations of the same description exist in one of the sinuses of Valsalva. The sac of the aneurismal tumour consists simply of the external coat of the aorta, the two others having been destroyed by ulceration, and the ulcerated opening (the consequence of the destruction of the two internal coats) is of an irregular form, with inverted and jagged edges. Around the edges, as well as in the sinus of Valsalva immediately below them, are also numerous minute ulcerated points.—Donor, Dr. M'Donnell, Surgeon 57th Regt.

258. An aneurism of the aorta about the size of a walnut, situated immediately above the semilunar valves and involving the right coronary artery, which burst into the pericardium. The parietes of the sac are thin, particularly at its superior part, and close to the opening by which it communicates with the aorta. The arch of the aorta is studded with atheromatous deposit, and at

the concavity of the arch, and nearly opposite the origin of the left subclavian artery, there is an ulcerated spot half an inch in length, with irregular fungous edges.—Donor, Dr. Stevenson, A. S.—Print. Cat. page 52, No. 13.

259. A large aneurism, of the ascending portion of the arch of the aorta, which burst into the pericardium by a small opening capable of admitting a bougie. The tumour is formed by general dilatation of the convex side of the vessel, commencing about the middle of the ascending aorta and terminating at the origin of the left subclavian artery; the inner surface of the sac is rough and irregular, and the serous membrane of the vessel is continued entire over a great part of it. The arteria innominata and left carotid arteries are completely obliterated. There are also two smaller aneurisms at the commencement of the aorta; one about the size of a large plum, the other the size of a horsebean.—MS. Cat. vol. i. page 189, No. 148.

260. Aneurism of the aorta situated immediately above the semi-lunar valves, which caused death by bursting into the pericardium; the tumour is about the size of a hen's egg; its walls are thin, and the opening through which the blood escaped is capable of admitting a bougie. There is also another pouch of a smaller size in its neighbourhood; the inner surface of the arch of the aorta is studded with atheromatous matter, and the parietes of the left ventricle somewhat thickened.—Donor, Dr. Jones, 1st Dr. Gds.—MS. Cat. vol. i. page 194, No. 163.

261. Shows general dilatation of the convex border of the ascending portion of the arch of the aorta, which burst into the pericardium by an opening capable of admitting a probe. The inner surface of the sac and vessels are covered by a number of large white osseous deposits.—MS. Cat. vol. i. page 198, No. 181.

262. An aneurism about the size of a pigeon's egg, situated an inch above the semilunar valves of the aorta; the opening into the sac is an inch in diameter, its edges are round and smooth. The inner surface of the aorta is studded with atheromatous matter.

263. An aneurism the size and shape of a pigeon's egg, situated

immediately above the semilunar valves of the aorta ; the communication between the vessel and sac is capable of admitting a crow-quill ; the walls of the sac are of considerable thickness, and lined with coagula. The coats of the aorta are rough and irregular, from the deposition of atheromatous matter. About ten ounces of blood were found in the pericardium.—Donor, Dr. Stewart, A. I. H.—MS. Cat. vol. i. page 186, No. 133.

264. Two aneurisms of the arch of the aorta, one of which commences by a circular aperture, one inch in diameter, immediately above the semilunar valves ; has its sac formed in the anterior wall of the left auricle ; the auricle is considerably diminished in size, in consequence of the bulging inwards of its anterior parietes ; the tumour is lined by firm coagula, and the opening by which the blood found its way into the pericardium was capable of admitting a goose-quill. The other aneurism commences about two inches higher up, by a small opening capable of admitting a bougie ; the sac is about the size of an orange, and its walls thinned in some places by absorption. The coats of the aorta are corrugated and studded with atheromatous deposit. Heart enlarged.—Donor, Dr. Roe, Surgeon 38th Regt.—MS. Cat. vol. i. page 193, No. 162.

265. An aneurism the size of a billiard-ball, on the anterior surface of the arch of the aorta, situated opposite to the commencement of the arteria innominata ; the opening into the sac is of an oval form, two inches in its longest diameter, with smooth, round, projecting edges ; the walls forming the most prominent part of the tumour are thin and transparent, and the rest of the sac is lined by a few clots of blood. There is also atheromatous matter deposited beneath the lining membrane of the aorta.—Donor, Dr. Gillice, A. S. Staff.

266. A large aneurism of the arch of the aorta ; the communication between the vessel and sac is about two inches in diameter, its edge round, smooth, and projecting ; the walls of the tumour are in many places very thin, and contain a large coagulum. Heart enlarged, pericardium thickened, and the serous membrane of both covered with lymph.—Donor, Dr. McDonnell, Surgeon 57th Regt.—Print. Cat. page 54, No. 28.

267. An aneurism the size of an orange, situated immediately be-



low the origin of the left subclavian artery ; the opening from the aorta into the sac is about an inch in diameter, with round projecting edges ; the walls of the sac are thin, and gave way at the lower part ; the inner surface of the aorta is studded with atheromatous deposit. Heart enlarged, with a few flakes of lymph on its surface. Print. Cat page 52, No. 14.

268. An aneurism situated on the concave side of the arch of the aorta, opposite to the origin of the arteria innominata.

269. Aneurism of the aorta about the size of a plum, situated immediately above the semilunar valves and containing a coagulum, with osseous matter in the coats of the vessel.

270. A small incipient aneurism situated at the origin of the aorta, and another small dilatation between the valves and the left ventricle ; the valves are covered with large fungous excrescences.

271. An aneurism of the ascending aorta the size of a billiard-ball ; the communication between the vessel and the tumour is about an inch and a-half in diameter ; the aorta, immediately beyond the origin of the aneurism, is much contracted and its coats studded with atheromatous matter.—Donor, Dr. Davy, A. I. H.—Print. Cat. page 61, No 58.

272. An aneurism the size of a plum, situated immediately above the semilunar valves of the aorta, on the concave side of the vessel, and pressing upon the right pulmonary artery in such a manner as almost entirely to obstruct it ; the opening into the tumour from the vessel is of an oval form, and two inches in its longest diameter, its edges smooth and round, and the serous membrane of the vessel is continued entire over the inner surface of the sac ; coats of the aorta studded with atheromatous deposit.—MS. Cat. vol. i. page 195, No. 169.

273. A large aneurism of the anterior portion of the ascending aorta commencing, about an inch and a-half above the semilunar valves, by an opening three inches in diameter, with smooth round edges ; the tumour contains a quantity of coagula, and is attached anteriorly to two of the ribs on the right side of the chest. The

aorta, in the situation of the aneurism and immediately above it, is much dilated, its coats puckered, and studded with atheromatous deposit.—Donor, Dr. Davy, A. I. H.

274. A large aneurism of the ascending portion of the arch of the aorta laid open; its internal surface is rough and irregular, and its walls in many places very thin.—Albany Hospital, Isle of Wight.

275. Exhibits the interior of the sac of an aneurism of the arch of the aorta.—Donor, Mr. Jamieson, 10th Regt.

276. Aneurism of the convex surface of the arch of the aorta; the vessel and sac are quite continuous, there being no distinct opening, but the one running gradually into the other; the inner surface of the dilated portion is lined by a few layers of coagula, and at some points the walls of the sac are very thin. The pressure of the tumour has caused obliteration of the superior vena cava.—Donor, Mr. Fraser, A. S. Staff.—Print. Cat. page 57, No. 41.

277. A large aneurism of the arch of the aorta, commencing about three inches above the semilunar valves, terminating at the origin of the left subclavian artery, and formed by general dilatation of all the coats of almost the entire circumference of the vessel; the internal membrane of the aorta is continued over the greater part of the sac, and its walls in some places are very thin. The aorta, both above and below the aneurism, is rough and irregular from atheromatous deposit.—MS. Cat. vol. i. page 191, No. 154.

278. Extensive aneurism, occupying the whole of the arch of the aorta and ascending on the trachea and œsophagus for a considerable distance; the walls of the sac are very thin, and filled with concentric laminæ of coagula.—Print. Cat. page 56, No. 31.

279. A large aneurism of the arch of the aorta which presses upon the trachea and œsophagus; the walls of the sac are thin in many places and filled with concentric layers of coagula.—Donor, Mr. Collier, D. I. H.

280. A small aneurism at the commencement of the arteria innominata, and another about the size of a billiard-ball, situated at the

termination of the arch; the coats of the tumour are thin and lined with coagula; the opening between the vessel and sac is of an oval form, the edges round, smooth, and projecting, and measuring in diameter one inch and a quarter; the tumour is firmly attached to the œsophagus. The coats of the arch and upper part of the thoracic aorta are studded with atheromatous matter, thickened, puckered, and irregular, with a number of small dilatations.—Donor, Mr. Ford, A. S. 72nd Regiment.—MS. Cat. vol. i. page 182, No. 128.

281. Extensive aneurismal dilatation of the arch of the aorta, embracing the whole of the vessel from its commencement to the origin of the left carotid artery and pressing posteriorly on the trachea and bronchial tubes, with some layers of coagulum deposited on the anterior wall of the sac. The pericardium adheres firmly to the surface of the heart.—Print. Cat. page 64, No. 71.

282. Great dilatation of the arch of the aorta, but particularly of the ascending and upper part of the descending aorta. The internal coat presents numerous opaque spots, from atheromatous deposit.—MS. Cat. vol. i. page 191, No. 153.

283. Dilatation of the ascending portion of the arch of the aorta: the lining membrane is rough, from the deposition of atheromatous and bony matter; two of the semilunar valves are also thickened.—MS. Cat. vol. i. page 195, No. 165.

284. Dilatation of the arch of the aorta, with atheromatous deposit under its lining membrane.—MS. Cat. vol. i. page 198, No. 183.

285. A false aneurism of the arch of the aorta, and a true one of the descending portion of that vessel. The false aneurism is the size of a large orange, of an oblong shape, attached anteriorly to the first bone of the sternum, posteriorly to the trachea at and immediately above the part where this tube divides into the two bronchi, the calibre of the lower part of the trachea being diminished by the pressure of the aneurism. The left carotid and subclavian arteries are unconnected with the tumour, but the arteria innominata arises from its summit, and is plugged up by one of the layers of coagula which form the walls of the sac. The true

aneurism is about the size of a small egg, and commences about half an inch below the origin of the left subclavian artery, lies parallel with the division of the trachea, and here, in consequence of pressing on the œsophagus, has diminished its calibre at least one-third.—MS. Cat. vol. i. page 174, No. 102.

286. A large aneurism of the arch of the aorta which burst into the right pleural cavity. The tumour commences about two inches above the semilunar valves, and terminates at the origin of the left subclavian artery; it is firmly united posteriorly to the trachea and bronchial tubes; the walls are in some places very thin and lined with a few concentric layers of coagula. Atheromatous matter deposited below the lining membrane of the aorta, both above and below the aneurism. Surface of the heart covered with a number of large white glistening spots.—Donor, Dr. Williams, Surgeon 68th Regt.—MS. Cat. vol. i. page 188, No. 144.

287. An aneurismal tumour, of the transverse portion of the arch of the aorta, laid open anteriorly to show the perpendicular septum by which it is separated from the artery. The septum consists of the two inner coats of the latter, and the sac of the aneurism generally of the external coat, which had been detached by the blood from the outer surface of the middle coat. The opening through which the blood reached the aneurismal sac is nearly three-quarters of an inch in diameter, almost circular, and situated in the upper half of the septum. The edges of this opening are rounded, and coated with the lining membrane of the aorta, which membrane is also continued for a short distance on the outer surface of the septum. The interior of the aorta is much thickened by atheromatous deposit, particularly opposite the left subclavian artery. There is also an appearance as if a second aneurism had been about to form at the upper part of the descending aorta.—Donor, Mr. Martin, Surgeon 73rd Regt.—Print. Cat. page 64, No. 72.

288. Three aneurisms of the arch of the aorta. The first, about the size of a hen's egg, is situated on the concave side of the arch, opposite to the left carotid and subclavian arteries; the opening into the sac from the vessel is about one inch and a-half in diameter, its edges round and smooth; the walls of the sac are thin, and its cavity almost filled with coagula. About an inch and a-half below the

origin of the subclavian artery, on the convex side of the arch, there is a small digital depression, formed by dilatation of all the coats. The third, and largest, aneurism is situated at the lower part of the arch, about the size of an orange and almost entirely filled with coagula; the outer surface of the sac is covered by a portion of the left lung, and the opening from the vessel into the tumour is circular, with smooth, round edges. The inner surface of the vessel is rough and irregular, from atheromatous deposit.—Donor, Mr. Ford, A. S. 72nd Regt.—MS. Cat. vol. i. page 182, No. 127.

289. Aneurism of the arch of the aorta communicating with the right lung; the tumour is about the size of a billiard ball, attached posteriorly to the inferior part of the trachea bronchi and root of the right lung; the opening into it from the vessel is about a quarter of an inch in diameter, and its edges smooth and round. The lower part of the arch of the aorta is contracted, and its inner surface studded with atheromatous matter. There are several ulcerated points at the commencement of the left bronchus.

290. Shows three aneurisms of the arch of the aorta. The first, about the size of a plum, situated an inch and a-half above the semilunar valves, and the opening leading into it is half an inch in diameter. The second, about the size of an orange, is situated on the anterior side of the arch, and rests externally on the inferior lobe of the left lung; its walls are thin, and lined with coagula; the irregular opening in the sac was produced by forcible separation from the sternum to which it firmly adhered. The third aneurism is of smaller size, formed on the posterior aspect of the arch, situated between the two other tumours, and the opening into it has a very irregular appearance. There is also ossific matter deposited in the semilunar valves and below the lining membrane of the aorta.—Print. Cat. page 60, No. 53.

291. An aneurism of the arch of the aorta, the size of an orange, which burst into the trachea by a granular-looking opening, capable of admitting a crow-quill. The aorta is dilated, thickened, rough, and irregular from the deposition of atheromatous matter.—Donor, Mr. Stanley, Surgeon St. Bartholomew's Hospital.

292. An aneurism of the arch of the aorta, the size of a duck's

egg, which burst into the trachea by an opening large enough to admit a goose-quill. The communication between the vessel and sac is two inches in diameter; its edges smooth and round, with the exception of a portion of the lower margin which is ulcerated. The aorta is studded with atheromatous matter.

293. An aneurism of the arch of the aorta, the size of a hen's egg; the walls of the sac are formed laterally by condensed cellular tissue, posteriorly by the trachea and œsophagus; two of the rings of the former are ulcerated, and the mucous membrane partially destroyed and pushed into the tube by a coagulum. The communication between the vessel and sac is situated opposite to the left carotid artery, and so small as scarcely to admit a probe. A large coagulum hangs into the vessel, and is suspended by a small neck to the opening. The walls of the sac are lined by coagula.—Donor, Dr. Gordon, A. S. 35th Regt.—MS. Cat. vol. i. page 211, No. 211.

294. A small aneurism of the arch of the aorta which burst into the trachea, a little above its bifurcation, by an opening about the size of a crow-quill. The coats of the vessel are dilated and loaded with atheromatous matter; at the root of the left subclavian artery is situated a pouch of size sufficient to contain a walnut; the left subclavian, for about two inches from its origin, is considerably dilated; the right subclavian and common carotid arteries are given off separately.—MS. Cat. vol. i. page 202, No. 193.

295. An aneurism arising from the transverse arch of the aorta, the size of a pigeon's egg, closely connected to the trachea behind and bounded by the brachio-cephalic trunks in front, one of which (the innominate artery) makes a deep indentation in the sac; the opening into it is circular and measures half-an-inch in diameter, its edges are round and covered by the lining membrane, which spreads out for some distance on the interior of the sac. The great sinus of Morgagni is considerably dilated, and there are two small pouches immediately above the semi-lunar valves, one of which is capable of containing a hazel-nut; the coats of the vessel in these situations are much infiltrated with atheroma.—MS. Cat. vol. i. page 204, No. 195.

296. An aneurismal tumour, the size of a walnut, situated between the origins of the left carotid and innominata arteries and communicating with the aorta, by an opening three-quarters of an inch in diameter, the edges of which are smooth and round. The sac is partially filled with organised coagula or fibrine; the transverse portion of the arch of the aorta is closely studded with thin bony plates situated between its middle and internal coats, except where the latter has disappeared, which is the case at many points. The trachea is pressed backwards, contracted in calibre, and two of its cartilaginous rings widely separated from each other. The mucous membrane, at the point of separation, is very thin and elevated into a tumour the size of a horse-bean.—MS. Cat. vol. i. page 196, No. 171.

297. Two aneurisms, with dilatation and discoloration of the arch of the aorta; one aneurism is situated at the origin of the arteria innominata, about the size of a hazel-nut, filled with coagula, and attached posteriorly to the trachea through which there is an ulcerated opening capable of admitting a bougie. The second aneurism is situated on the concave aspect of the arch, filled with coagula, and a little larger than the other tumour. There are also two depressions of a smaller size in the arch of the aorta, and its whole internal surface is studded with atheromatous matter.—MS. Cat. vol. i. page 192, No. 159.

298. A large aneurism of the arch of the aorta, attached posteriorly to the trachea, in which there are two small openings and the mucous membrane of this tube is studded with numerous minute ulcers.—Donor, Dr. Stewart, A. S. 70th Regt.—MS. Cat. vol. i. page 201, No. 190.

299. An aneurism, the size of a large orange, arising from the transverse portion of the arch of the aorta, and extending two and a half-inches above the bifurcation of the trachea, against which it presses. The coats of the sac are thin, particularly at the summit of the tumour which is pointed and lies to the left of the trachea. The large brachio-cephalic trunks are in front of the tumour. The opening from the aorta into the sac is large, its edges are rounded, and situated posterior to the above-named vessels.—MS. Cat. vol. i. page 202, No. 192.

300. Aneurism of the arch of the aorta, the size of an orange, attached posteriorly to the trachea, the mucous membrane of which is ulcerated in three places, but the rings of this tube are entire. The left carotid and subclavian arteries arise from the summit and the arteria innominata from the lower part of the tumour, the two former vessels being separated from the latter by a distance of three inches. The walls of the sac are of considerable thickness, and the descending portion of the arch is contracted, thickened, puckered, and infiltrated with atheromatous matter.—Donor, Dr. Davy, A. I. H.

301. Two aneurisms of the arch of the aorta. One about the size of a plum, situated on the posterior part of the vessel, between the arteria innominata and left carotid artery, burst by an oval opening into the trachea, one of the rings of which is stretched half across the aperture quite denuded of membrane, as is also the aneurismal surface of four others. The second tumour is situated on the anterior part of the aorta, and only separated from the former by a duplicature of the coats of the vessel, the sac is about the size of a hazel-nut, and its walls very thin. The inner surface of the aorta is studded with atheromatous deposit.—Donor, Dr. Henderson, A. S. 78th Regt.—MS. Cat. vol. i. page 173, No. 99.

302. An aneurism the size of a duck's egg, situated at the upper part of the thoracic aorta, attached posteriorly to the left bronchus into which it burst by an aperture capable of admitting a bougie. The communication between the vessel and sac is about one inch in diameter, its edges smooth and slightly puckered, and on each side of which there are two small depressions, about the size of horse-beans; the lining membrane surrounding the opening is thickened and irregular.—Donor, Dr. Burrell, A. S. 94th Regt.—MS. Cat. vol. i. page 178, No. 113.

303. An aneurism, situated at the descending portion of the arch of the aorta, which has its sac composed of all the coats of the vessel. The tumour burst into the left bronchus by two small round openings each about the size of a crow-quill. The coats of the aorta are thickened and contain much atheromatous deposit.—Donor, Mr. Martin, Surgeon 73rd Regt.—MS. Cat. vol. i. page 177, No. 108.

304. An aneurism of the arch of the aorta, situated on the left side of the trachea, which burst into the œsophagus by a large open-



ing. The communication between the vessel and sac is about a quarter of an inch in diameter, and filled with coagula. The orifices of the left carotid and subclavian arteries are somewhat diminished in size, by calcareous deposit within the coats of the aorta, about their points of origin.—Donor, Dr. Drysdale, A. S. 24th Regt.—MS. Cat. vol. i. page 210, No. 209.

305. A large aneurism of the arch of the aorta, attached posteriorly to the trachea, the mucous membrane covering three rings of which is absorbed. The sac is partially filled with concentric layers of coagula; the arteria innominata arises from its summit, and is about three inches apart from the origin of the left carotid artery.—Donor, Dr. Roe, Surgeon 28th Regt.—Print. Cat. page 59, No. 50.

306. A large aneurism of the ascending aorta, the opening into which is situated one inch and a-half above the semilunar valves, is one inch in diameter, and its edges smooth and hardened by calcareous and atheromatous deposition. The tumour measures from before backwards seven and a-half inches; projects beyond the thoracic parietes to the height of three inches, having destroyed a portion of the right side of the sternum, and of the second, third, and fourth ribs to the extent of four inches of their length. The sac is filled with laminated coagula, and occupies a considerable part of the right pleural cavity, to the parietes of which it is closely adherent. A transverse incision is made into the sac, to show the coagulum.—Donor, Mr. Montgomery, Surgeon R. N.—MS. Cat. vol. i. page 189, No. 147.

307. Two aneurisms of the descending and upper part of the thoracic aorta. The superior one is small, and the communication between the vessel and sac is of an oval form, with rough and irregular edges. The inferior tumour is about the size of a pigeon's egg, and situated at the side of the left bronchus, the coats of which are ulcerated; there are two openings in the sac,—one of a large size, on its most prominent part, with irregular ragged edges; and the other, smaller, situated on the right side of the tumour. The inner surface of the vessel is coated with atheromatous deposit.

308. A very large aneurism of the arch and upper part of the

thoracic aorta, with rupture of the sac, which shows an immense mass of hollow concentric coagula; the walls of the tumour are thin, and the inner surface of the vessel is studded with atheromatous matter: the bodies of the neighbouring vertebræ and heads of the adjoining ribs were carious.

309. Aneurism of the thoracic aorta, which burst into the left cavity of the chest. The tumour extends more to the right than to the left side of the spine: an incision is made into it on the right side, which exhibits the sac filled with concentric layers of coagula. Part of the left lung adheres to the front of the tumour, where the rupture which proved fatal is observed to be about an inch in diameter, and plugged up with a coagulum. The arch of the aorta is thickened and infiltrated with atheromatous deposit, and on its summit there is a pouch the size of a pigeon's egg.—Print. Cat. page 61, No. 59.

310. Aneurism of the thoracic aorta; showing a large and nearly circular opening of communication into the sac measuring one inch and a-half in its perpendicular, and one inch in its transverse diameters, the edges of which are smooth, callous, and rounded. The parietes of the sac are closely attached to the sides of the bodies of the third, fourth, fifth, sixth, and seventh dorsal vertebræ, and also to the heads of the corresponding ribs, which are denuded and rough from absorption. The lung adheres intimately to the front and side of the sac on the right side of the chest, and immediately behind the adhesions there is a large lacerated opening in the sac, through which the blood was effused into the lower lobe of the lung. The coats of the aorta are much thickened by atheroma, and at the junction of the transverse and descending parts of the arch there is an incipient aneurismal dilatation.—Donor, Mr. Ford, A. S. 72nd Regt.—Print. Cat. page 59, No. 51.

311. Aneurism of the descending aorta, which burst into the base of the left lung. The tumour arises from the anterior part of the vessel, is attached posteriorly to the dorsal vertebrae, two of the bodies of which are partially absorbed, has insinuated itself under the œsophagus, and pushed that tube forward. A portion of the left lung is attached to a bulging of the sac, which protrudes into the left cavity of the chest, where the rupture took place.—

Donor, Dr. M'Donnell, Surgeon 57th Regt.—Print. Cat. page 54, No. 29.

312. An aneurism of the thoracic aorta, about the size of a billiard-ball, which burst into the left pleural cavity. The sac is filled with loose coagula; and two of the dorsal vertebræ were partially absorbed. The arch of the aorta is dilated and studded with atheroma.—Donor, Dr. Robertson, R.N.—Print. Cat. page 56, No. 33.

313. Aneurism of the thoracic aorta, which burst into the left pleural cavity; it extended from the third to the eighth dorsal intervertebral cartilage, the intervening vertebræ, and the heads and necks of the corresponding ribs on each side, were denuded and partially absorbed. The pleura formed the most external covering of the tumour, at the most prominent part of which, on the left side, an irregular ragged opening of the membrane, about an inch in length, had given egress to the effusion of blood. The large deficiency in the posterior aspect of the tumour was closed in the natural state by the vertebræ and ribs. The communication between the aorta and sac is of a square form, and embraces nearly half the circumference of the vessel, the inner membrane of which is studded with atheromatous deposit.—Donor, Mr. Ford, A. S. 72nd Regt.—MS. Cat. vol. i. page 181, No. 125.

314. An aneurism of the descending portion of the arch of the aorta, about the size of a hen's egg, attached posteriorly to three of the dorsal vertebræ, with numerous points of ossification in the coats of the aorta. An irregularity occurs in the origin of the vessels arising from the arch, the left vertebral artery taking its rise from the aorta, between the left carotid and left subclavian arteries.

315. Aneurism of the thoracic aorta, with absorption of four of the dorsal vertebræ; the superior lesion shows the point at which the sac burst into the right side of the chest; the others were made on removing it from the body. The inner surface of the sac is studded with calcareous deposit.—Donor, Dr. Mahony, Staff Surgeon.—MS. Cat. vol. i. page 212, No. 219.

316. A large aneurism of the posterior part of the thoracic aorta, which has produced partial absorption of seven of the dorsal verte-

bræ, and entire absorption of two of the heads of the ribs on the right side, and corresponding transverse processes. The whole of the thoracic aorta and part of the sac are loaded with calcareous deposit.—Donor, Dr. Arthur, D. I. G. H.

317. Aneurismal tumour at the posterior portion of the aorta, immediately below its arch, capable of containing a pigeon's egg. The tumour has caused absorption of the lower and anterior surface of the fourth,—the whole anterior surface, to the depth of a quarter of an inch, of the fifth,—and in a less degree of the upper part of the body of the sixth,—dorsal vertebræ. These bones form the posterior boundary of the aneurism, and were covered by laminated coagula only; the sac is closely adherent to the sides of the vertebræ, and thus effusion of blood into the posterior mediastinum was prevented. A free communication exists between the aneurism and the vessel, and the coats of the latter are much thickened from a deposition of atheromatous matter.—MS. Cat. vol. i. page 208, No. 205.

318. An aneurism of the thoracic aorta about the size of an orange, immediately below the termination of its arch, which had produced superficial absorption of the bodies of two of the dorsal vertebræ. The opening from the aorta into the aneurism is large and nearly circular; its edges rounded and covered by the lining membrane of the vessel, which membrane is also visible for some distance on the inner surface of the sac. The parietes of the sac posteriorly are thin and show a large irregular and lacerated opening, through which blood to the amount of eight pints had escaped into the left cavity of the chest; the lung on this side was greatly compressed; the coats of the aorta are loaded with atheromatous deposit.—MS. Cat. vol. i. page 197, No. 177.

319. A very large aneurism of the thoracic aorta, which lies to the left of the spine, and has caused absorption of the bodies of four of the vertebræ; the intervertebral cartilages are entire and project into the sac, which is very rough and irregular. The tumour pressed posteriorly on the œsophagus, anteriorly against the sternum part of which had become absorbed, and also formed extensive adhesions with the adjoining viscera. No rupture of the sac took place. The arch of the aorta is greatly dilated, and infiltrated with atheromatous deposit.—Donor, Dr. Paterson, A. S. 52nd Regt.—Print. Cat. page 55, No. 30.

320. An aneurism of the thoracic aorta, commencing about an inch below the left subclavian artery and embracing five inches of the course of the vessel. The lining membrane of the aorta is thickened and studded with atheromatous and bony deposit.—Necrol. Reg. vol. v. page 303.

321. A dissecting aneurism of the arch and thoracic aorta; to the left of the origin of the left subclavian artery is a small fissure, involving only the inner and middle coats of the aorta, through which fissure a piece of brass wire has been passed to indicate more clearly its situation. The outer or cellular coat of the aorta is free from rupture, but extensively separated from the two inner coats. The separation of the former from the latter is limited to about a third of the circumference of the vessel, and extends from the origin of the aorta throughout the whole length of the portion preserved in the preparation. The exterior wall of the receptacle formed for the blood effused between the coats of the vessel, seems to have given way into the interior of the pericardium. To point out the extent of the dissection produced by the effusion of blood, as well as the situation of the opening into the pericardium, a long whalebone probe has been passed between the separated coats of the vessel through the opening into the pericardium. The coats of the aorta are loaded with atheromatous deposit, and at some points present portions of calcareous matter. The left carotid arises from the trunk of the arteria innominata.—Donor, Dr. Power, A. S. 51st Regt.—MS. Cat. vol. i. page 210, No. 210.

322. An aneurism the size of a small melon, arising from the abdominal aorta and involving the cœliac axis; the sides of the sac are thickened by fibrinous deposit on its inner surface, but much attenuated on the fore part, where it burst. The opening of communication between the vessel is oblong, its edges are rounded and smooth, and there is much atheromatous deposit around and below it, so as to contract considerably the orifices of the mesenteric and renal arteries. The fore part of the aorta is dilated into a pouch at and around the orifices of these arteries; below this dilatation, the vessel is much contracted. Death took place suddenly, from extravasation of blood into the abdomen.—Donor, Mr. Bradford, A. S. 56th Regt.

323. An aneurism the size of a duck's egg, situated on the ante-

rior surface of the abdominal aorta, immediately above the cœliac axis. The vessel communicates with the sac by two oval openings, each about a quarter of an inch in diameter, and separated from each other by a portion of the aorta half an inch in breadth; the edges of the openings are smooth, and covered by the lining membrane of the vessel which, in the neighbourhood of the apertures, is puckered and irregular. The tumour burst into the cavity of the chest and posterior mediastinum.—MS. Cat. vol. i. page 199, No. 187.

324. An aneurism the size of a duck's egg, of the abdominal aorta, situated above the cœliac axis and bulging between the crura of the diaphragm. The opening between the vessel and sac is about three-quarters of an inch in diameter, with smooth polished edges; the inner surface of the aorta is loaded with atheromatous deposit. The sac burst into the left cavity of the chest.—Donor, Mr. Fox, A. S. 47th Regt.—Necrol. Reg. vol. vi. folio 47.

325. A large aneurism of the posterior part of the abdominal aorta, which has produced absorption of two of the bodies of the vertebræ, leaving the intervertebral cartilage entire. The communication between the vessel and sac is by a round opening, an inch in diameter, with smooth polished edges. The inner coat of the aorta is studded with atheromatous deposit. The sac burst by the fissure seen at the upper part of the preparation, close to the bodies of the vertebræ, into the cavity of the chest.—Donor, Mr. Stanley, Surgeon St. Bartholomew's Hospital.—MS. Cat. vol. i. page 179, No. 119.

326. An aneurism of the anterior part of the abdominal aorta, situated immediately below the origin of the cœliac axis. The tumour is about the size of an orange, its walls thick and lined with coagula, except at the lower and fore part, where it has burst by a fissure half an inch in length. The communication between the vessel and sac is of a square form, with smooth edges, and occupies almost the whole of the anterior part of the aorta. The superior mesenteric artery arises from the anterior part of the tumour, and is plugged up by coagula.—MS. Cat. vol. i. page 186, No. 135.

327. An aneurism about the size of an orange, of the abdominal aorta, embracing about two and a-half inches of its anterior surface,

commencing immediately below the coeliac artery; and the superior mesenteric artery arises from the centre of the tumour. A portion of the upper part of the sac, the size of a pigeon's egg, appears externally to form a distinct aneurism, but on a more careful examination, is found to communicate with the larger portion of the sac. The tumour burst below the inferior portion of the duodenum.—MS. Cat. vol. i. page 213, No. 221.

328. An aneurismal tumour of the abdominal aorta about the size of a plum; the communication between the vessel and sac is about an inch and a-half in diameter, and the lining membrane of the former is continued for a considerable distance into the latter; the inner surface of both is studded with atheromatous matter.—Donor, Mr. Whyte, Surgeon 69th Regt.

329. Aneurism of the anterior part of the abdominal aorta, immediately above the superior mesenteric artery; the sac is about the size of a large orange, the walls thin and lined with a few coagula; the communication between the vessel and sac is about an inch in diameter, and its edges smooth and round.—Albany Hospital, Isle of Wight.

330. Aneurism of the anterior part of the abdominal aorta, situated immediately above the origin of the renal arteries; the walls of the sac are thin, and lined with a few layers of coagula; the communication between the vessel and sac is about an inch and a-half in diameter, and the lining membrane of the former is continued for some distance on the interior of the latter. The tumour burst into the cavity of the abdomen.

331. Aneurism of the abdominal aorta, situated opposite to the origin of the coeliac axis; the opening from the vessel into the sac is about an inch in diameter, and its edges smooth, round and polished.—Donor, Dr. Collier, D. I. H.

332. Aneurism of the abdominal aorta, with ulceration of the bodies of the lumbar vertebræ; affording a well-marked specimen of dilatation of the external coat of the artery, after destruction of the inner and middle tunics. The basis only of the sac, which was of prodigious magnitude, is preserved. Notwithstanding the exten-

sive ulceration of the vertebræ, the interposed fibro-cartilages are intact. The opening into the sac is about half-an-inch in diameter.—Donor, Mr. Baynton, Curator of the Museum of St. Bartholomew's Hospital.

333. An immense aneurism arising from the left and back part of the thoracic and abdominal aorta, opposite to the eleventh and twelfth dorsal and first lumbar vertebræ. The tumour extends along the left side of the spine, having produced absorption of the two last dorsal and two first lumbar vertebræ, as low as the crest of the ilium and brim of the pubis, and also projects to a great extent in the left lumbar region filling up the space between the ilium and ribs. The sac is bounded posteriorly by the left half of the two last dorsal, all the lumbar vertebræ, lumbar muscles and os innominata; about ten pounds weight of coagula were extracted from the sac.—Print. Cat. page 53, No. 17.

334. A large aneurism of the right external iliac artery, for the cure of which the aorta was tied; the tumour, when exposed in dissection, extended from an inch and a half below Poupart's ligament to within an inch and a-half of the bifurcation of the aorta, overlapping the left common iliac artery, occupying the whole of the right iliac fossa and pressing the kidney nearly double. An incision has been made into the aneurism, which is filled with concentric layers of coagulable lymph deposited on its inner surface, and in the recent state contained loose coagula and thin sanies. The iliacus and psoas muscles were in a state nearly approaching to putridity, and the aneurismal sac itself had been on the point of giving way at two different parts—viz., at its upper part behind the peritonæum by sloughing, and at its lower and anterior part it was nearly bursting into the cavity of the abdomen from the extreme distention and attenuation of its parietes, where it was most prominent. By simple inspection of the inner surface of the aneurismal sac, it was difficult to discover the communication with the artery. A probe was attempted to be introduced into it from the femoral artery, but the crural was so much contracted as not to admit of its passing. By blowing into the femoral, however, with a blow-pipe, an opening was discovered at about half an inch above Poupart's ligament; but from this upwards there was no continuation of the external iliac; the place of communication with the upper part of the artery was only ascer-



tained by passing the end of the blow-pipe around, and blowing at the same time gently through it, till a part was found from whence the common iliac became inflated, which was more than three inches above the lower opening. In the intervening space between them no trace of the tube of the external iliac was discernible. Around the upper aperture several small spiculæ of osseous matter were discovered. At first it appeared as if nearly the whole of the external iliac was disorganized and involved in the aneurism; but after careful dissection, about two inches of its tube were disentangled from the condensed cellular tissue forming the outer layers of the sac, in a sound state, after which it became confounded with the walls of the aneurism. The whole of the lower part of this artery, together with the crural and nearly an inch of the femoral, is in a diseased state and implicated in the tumour. The aorta is tied at three or four lines above its bifurcation, and about an inch below the inferior mesenteric artery. The ligature is well placed and includes no extraneous substance, except two small bits of detached nervous fibre, that had probably been torn from the aortic plexus. The aorta is distended with wax injection to within about one-third of an inch of the ligature, a clot of blood intervenes between them; beyond the ligature neither size nor wax had passed, and no particle of either was discernible in any of the iliac or femoral arteries, or in any of their branches. The patient survived the operation scarcely twenty-three hours.—Donor, Dr. Murray, D. I. H.—London Medical Gazette, Session 1834–35, No. 1.

335. Aneurismal sac the size of a billiard-ball, of the left femoral artery, immediately below Poupart's ligament. The lining membrane of the vessel is continued over the greater part of the inner surface of the sac.—Donor, Dr. Shean, Surgeon 7th Fusiliers.—MS. Cat. vol. i. page 203, No. 194.

336. Left thigh injected and dried showing an aneurism of the popliteal artery, for the cure of which the operation of tying the superficial femoral was performed successfully; but aneurism recurred from anastomosis with other branches. The superficial femoral for about three inches is completely obliterated, and converted into a cord-like process where the ligature was applied; the artery immediately below this point is filled with injection, and continues so until it reaches the aneurismal sac; it is again filled with

injection where it leaves the aneurism. The artery between the obliterated part and the aneurism is nothing diminished in size, and the circulation has evidently been restored by the perforating branches of the profunda, which are large and tortuous, and join the artery at this part.—Donor, Dr. Bradford, Surgeon 56th Regt.

337. Aneurism of the popliteal artery the size of a duck's egg, with an opening in the sac.

338. Diffused aneurism of the right popliteal artery; the tumour occupied the right ham and lower part of the thigh, in the latter direction it burst and profuse hæmorrhage took place. The superior extremity of the vessel is pervious and communicates with the sac, the inferior is plugged up with coagulable lymph for about three inches of its course.—Print. Cat. page 61, No. 60.

339. A small diffused aneurism of the popliteal artery.

340. Aneurism of the popliteal artery about the size of a duck's egg, the walls of which in some places are very thin. The communication between the artery and sac is about an inch and a-quarter in length.—York Hospital, Chelsea.

341. Aneurism (probably of the popliteal artery) about the size of a hazel-nut, the walls of which are of moderate thickness and lined by the inner membrane of the vessel. — Donor, Dr. Forrest, A. S. Staff.

342. A large aneurism of the arteria innominata, which extends as high as the upper part of the thyroid cartilage. The walls of the sac are in many places very thin, though no rupture has taken place, and its inner surface is partially divided into two compartments by a fold of the coats; the lining membrane of the vessel is continued smooth and entire over a considerable distance of the inner surface of the sac. The communication between the vessel and sac is of an oval form and measures about an inch in its longest diameter. The vena cava descendens and internal jugular vein were partially obstructed by firm adhering lymph. The right Parvagum, where most pressed on, was nearly obliterated. The tumour contained a considerable quantity of coagula.—Donor, Dr. Portelli.—MS. Cat. vol. i. page 186, No. 134.

343. Aneurism of the arteria innominata, which burst into the lung at the spot where a small part of that viscus is visible in the preparation. The aorta and the other vessels connected with it are tolerably healthy.—Donor, Dr. McMunn, A. S. 10th Regt.

344. An aneurism the size of an orange, arising from the superior part of the left subclavian artery, its walls are thick and lined with a few coagula. The communication between the artery and sac is about an inch in length. The vertebral artery at its origin is involved in the tumour and arises from its upper part.

345. A large aneurism of the right axillary artery in the first part of its course. The walls of the sac are generally very thin; the communication between the vessel and sac is about two inches in length with smooth round edges. The tumour must have occupied the whole of the axillary space: four of the ribs are preserved and form the internal walls of the sac. The man died from its rupture.—Donor, Dr. Portelli.

346. A small aneurism about the size of a pigeon's egg, the walls of which are of moderate thickness and lined internally with a few coagula. The communication between the vessel and sac is capable of admitting a goose-quill; and a large nerve firmly adheres to the external surface of the tumour.

### SECTION III.—COAGULA FROM ANEURISMS.

347. Section of a fibrinous coagulum, exhibiting a laminated structure and a cavity which was filled with fluid blood.—MS. Cat. vol. i. page 192, No. 155.

348. Section of a coagulum showing its concentric layers.—MS. Cat. vol. i. page 190, No. 149.

349. Coagulum taken from an aneurismal sac of the thoracic aorta.—Necrol. Reg. vol. v. fol. 303.

350. A large and firm coagulum taken from an aneurism of the arch of the aorta, with a canal in it through which the blood had to pass in order to reach the arteria innominata.

351. Organized lymph from an aneurism of the arch of the aorta.—Donor, Dr. Williams, Surgeon 68th Regt.—MS. Cat. vol. i. page 185, No. 131.

352. Coagulum taken from an aneurism of the arch of the aorta.—Donor, Mr. Martin, Surgeon 73rd Regt.—Print. Cat. page 64, No. 78.

353. Section of a coagulum, showing the concentric layers.

#### SECTION IV.—FIBRINOUS COAGULA IN ARTERIES.

354. Two masses of fibrine about the size of filberts attached to the inner surface of the arch of the aorta, with dilatation and atheromatous deposit on the inner surface of the vessel.—MS. Cat. vol. i. page 200, No. 188.

355. The branches of the right pulmonary artery obstructed by fibrinous clots softened in the centre.—MS. Cat. vol. i. page 209, No. 208.

356. Pulmonary artery obstructed by fibrinous clots.

357. Portion of the descending aorta presenting two coagula internally softened.—MS. Cat. vol. i. page 195, No. 168.

358. Femoral artery and profunda obstructed by a coagulum.—Print. Cat. page 54, No. 25.

359. Coagula in the internal carotids firmly adhering to their sides, with dilatation of the vertebral and basilar arteries.—Donor, Dr. Dix, Surgeon 94th Regt.—MS. Cat. vol. i. page 179, No. 109.

360. Basilar artery, right carotid, and some of the branches forming the circle of Willis, more or less obstructed by fibrinous clots.—MS. Cat. vol. i. page 208, No. 206.

261. Basilar artery and principal branches of the internal carotids completely obliterated from the effusion of lymph.—MS. Cat. vol. i. page 192, No. 160.

SECTION V.—ABNORMAL APPEARANCE CONSEQUENT ON INJURY  
AND LIGATURE.

362. Rupture of the aorta at its origin three lines in length parallel to the course of the vessel. The internal and middle coats appear as if divided by a sharp instrument, and a small coagulum resembling a lumbricus passes through the opening;—the interior of the vessel is slightly affected with incipient atheroma; and the external is separated from the middle coat for a short distance around the opening.—Print. Cat. page 51, No. 11.

363. Two ruptures of the aorta. One of which is situated immediately above the valves; the internal and middle coats are lacerated nearly throughout the whole circumference of the vessel, and a very narrow slip of the middle coat only connects them at the posterior part; the external or cellular coat is also extensively lacerated and separated from the others. Close to the left subclavian artery a second laceration of all the coats of the artery has taken place, involving one-half of the circumference of the vessel. At the concavity of the arch, nearly opposite to the origin of the large vessels, there are a few spots of atheroma.—Print. Cat. page 51, No. 10.

364. Arch of the aorta laid open to expose a rupture, of its middle and internal coats, which runs transversely and occupies more than half the circumference of the vessel. The margins of the lesion are smooth and inverted as if cut by a pair of scissors. The external coat of the vessel is sound, and separated for some distance from the middle coat by a stratum of coagulated blood. The pericardium was filled with blood, but the opening through which it entered was not detected. The preparation furnishes a good illustration of dissecting aneurism.—Donor, Dr. MacLauchlan, A. S. 97th Regt.—MS. Cat. vol. i. page 204, No. 197.

365. Rupture of the aorta immediately above one of the semi-lunar valves, in consequence of fungiform disease of its structure. Around the rupture the coats of the vessel are thickened from morbid deposition; the rupture measures five lines in length, and the cellular coat of the artery is raised and forms an elevated ring round the margin of the external orifice.

366. The sac of an abscess, situated at the base of the cranium, which caused ulceration of the coats of the internal carotid artery and back of the pharynx. The sac of the abscess is close to the base of the skull, about an inch behind the condyles of the lower jaw, and an inch in diameter; a large bougie is passed along the internal carotid artery and through the rupture in its coats into the back of the pharynx. Fatal hæmorrhage took place in a few minutes, by the blood escaping from the internal carotid into the back of the pharynx.—MS. Cat. vol. i. page 212, No. 218.

367. Rupture of the middle meningeal artery at different points, caused by a fall, followed by effusion, compression and death.—MS. Cat. vol. i. page 206, No. 200.

368. Abdominal aorta exhibiting a horizontal wound through its coats, caused by the point of a bayonet.—Donor, Dr. Strachan, I. G. H.—Print. Cat. page 63, No. 70.

362. Femoral artery on which a ligature had been applied below the arteria profunda, for secondary hæmorrhage after amputation of the thigh.—Donor, Dr. White, A. S. Staff.—Print. Cat. page 60, No. 55.

370. Complete obliteration of the femoral artery after ligature for popliteal aneurism.—Donor, Dr. Hennan, D. I. H.—Print. Cat. page 53, No. 21.

371. An ulcerated opening in the brachial artery, almost an inch in extent, the consequence of the application of a ligature to that vessel.—MS. Cat. vol. i. page 180, No. 124.

372. Brachial artery obliterated by ligature; a plug of lymph extends up to the nearest branch.—Print. Cat. page 63, No. 68.

373. The ulnar artery and nerve, after amputation of the fore-arm at the superior third, the former, from which the ligature had been removed is not obliterated, and the cut extremity of the latter is thickened.—MS. Cat. vol. i. page 200, No. 189.

374. An artery and nerve; the former with a ligature attached, which had not come away four months after amputation.—MS. Cat. vol. i. page 201, No. 191.

## SECTION VI.—MALFORMATIONS AND VARIETIES OF ARTERIES.

375. Aorta with only two semilunar valves, each of which is larger than natural.

376. Pulmonary artery with only two semilunar valves, each valve is larger than natural. The right coronary artery is scarcely perceptible and completely impervious, whilst the left is much about the usual size.—Donor, Mr. Allan, 2nd Staff Surgeon.—MS. Cat. vol. i. page 214, No. 224.

377. A cribriform state of the margin of one of the semilunar valves of the aorta, with a loose band passing from its centre to its junction with the aorta.

378. Arch of the aorta, exhibiting the arteria innominata of unusual length. The aorta from its commencement to its termination, is generally thickened and its serous coat presented many opaque spots. The inner coat of a part of the thoracic aorta is dissected off, so as to show this.—MS. Cat. vol. i. page 192, No. 159.

379. Left carotid artery arising from the lower part of the arteria innominata.

380. Arteria innominata and left carotid arising by a common mouth from the arch of the aorta.

381. Arteria innominata and left carotid arising by one common trunk.—Donor, Mr. Allan, A. S. Staff.

382. Left carotid artery and nervus vagus smaller than the right.—Donor, Dr. Davy, A. I. H.—MS. Cat. vol. iii. page 195, No. 37.

383. Vertebral artery unusually small.

384. Upper portion of the vertebral artery very small.

385. Vertebral artery unusually large.—Donor, Dr. Davy, A. I. H.

386. A small band passing across the mouth of the vertebral artery.

387. A small band passing across the mouth of the vertebral artery.

388. Calibre of the basilar artery intersected by a broad transparent band.

389. A small band of lining membrane passing across the basilar artery near its divisions.

390. A small sacculus at the termination of the internal carotid artery.

391. Basilar artery and its branches, the right vertebral being much smaller than the left.—Donor, Mr. Martin, Surgeon 73rd Regt.—Print. Cat. page 64, No. 73.

392. Ulnar artery arising from the axillary opposite the lower margin of the scapula, and proceeding down to the elbow-joint, along with the radial and there separating from it and continuing its course over the flexors of the fore-arm to the space between the flexor sublimus and flexor carpi ulnaris, runs over the annular ligament and is distributed in the usual manner to the fingers.

393. Radial artery at first lying between the coraco-brachialis and biceps, and then proceeding along the inner side of the latter to the elbow-joint, when it takes its usual course in the fore-arm.—Donor, Mr. M'Beath, Edinburgh.

394. Specimen of a superficial interosseus artery, which ran in the course of and accompanied the median nerve, and terminating by joining the superficial palmar arch formed by the ulnar artery. The superficialis volæ was very small, and distribute solely to the muscles of the ball of the thumb. The ulnar and radial arteries were of the natural size, and followed their usual course. The vessels only are preserved.—Donor, Dr. Stubbs.

395. Left hypogastric artery unusually small, with corresponding development of the right. From a monster fœtus.

396. Left obturator artery arising from the internal epigastric, and winding behind Gimbernaut's ligament to the obturator foramen.—Donor, Dr. Williamson, A. S. Staff.



## DIVISION III.

*DISEASES OF THE VEINS.*SECTION I.—INFLAMMATION, ULCERATION, AND FIBRINOUS  
COAGULA IN VEINS AND SINUSES.

397. Portion of vein with a number of wart-like excrescences attached to its lining membrane, the effect of inflammation.—Donor, Dr. Knox, Edinburgh.

398. Median vein showing the effects of Phlebitis.—Donor, Dr. Stewart, A. I. H.—MS. Cat. vol. i. page 226, No. 17.

399. Ulceration of the femoral vein at the point where the vena saphena enters.—Print. Cat. page 67, No. 3.

400. Large coagulum surrounding the aorta and vena cava, effused by ulceration of the latter vessel which also has lymph poured out on its inner surface.—Donor, Dr. Murray, Staff Surgeon.

401. Sides of the left iliac vein united by adhesion, with the exception of two small apertures through which bristles are passed.—MS. Cat. vol. i. page 231, No. 38.

402. Obliteration of the iliac vein by adhesion.—MS. Cat. page 228, No. 24.

403. External iliac vein and artery, the former obliterated by a substance resembling lymph; from a woman who died of Phlegmasia Dolens.—Donor, Dr. Jones, Surgeon 1st Dr. Guards.

404. Left iliac and femoral vein, with its continuation to the ankle plugged up with coagulum.—Donor, Dr. Scott, Surgeon Rifle Brigade.—Print. Cat. page 68, No. 12.

405. Left iliac and femoral vein obstructed by coagulum.—Donor, Mr. Martin, Surgeon 73rd Regt.—MS. Cat. vol. i. page 226, No. 15.

406. Femoral vein, containing coagulable lymph; a ligature had been placed on the femoral artery on account of secondary hæmorrhage after amputation.—Donor, Dr. White, A. S. Staff.

407. Femoral vein plugged up by fibrinous coagula which adheres to its sides; the fibrine does not extend beyond the entrance of the saphena vein, but there is a small portion of coagula in the external iliac vein, which, however, does not adhere to the sides of the vessel nor fill its calibre. At the entrance of the saphena the femoral is very much contracted, having assumed a cord-like appearance. From a man who died of Phlebitis, Beri Beri and Phlegmasia Dolens.—Donor, Dr. Mouat, Surgeon 13th Lt. Dragoons.

408. Femoral vein, for the space of about three inches completely plugged up by fibrinous coagula which adheres to its lining membrane. A short distance above this the vein is partially obstructed by adhesion of its opposite sides. From a patient who died of Anasarca, Phlebitis and Beri Beri.—Donor, Dr. Mouat, Surgeon 13th Lt. Drs.

409. Cartilaginous and bony concretions from the pudic veins of a man who died of Amentia.—MS. Cat. vol. i. page 230, No. 36.

410. Phlebolites from the uterine veins of a maniac.—Necrol. Reg. vol. v. fol. 284.

411. A portion of the vena cava ascendens, exhibiting in one spot deposition on the inner coat; iliac glands much enlarged, some of them excavated and contained purulent matter.—Donor, Dr. Davy, A. I. H.—MS. Cat. vol. i. page 226, No. 18.

412. Coagulum in the femoral vein exhibiting internal softening.—Necrol. Reg. vol. v. fol. 58.

413. Fibrinous clot in the femoral vein, partially softened and adhering to the lining membrane.—Necrol. Reg. vol. v. fol. 114.

414. Portion of the inferior vena cava containing a coagulum which descends into the iliac veins, completely closing the right canal.—Donor, Mr. Lightbody, Surgeon 80th Regt.—Print. Cat. page 68, No. 9.

415. Coagulum in the vena cava.

416. Lower end of the vena cava and iliac veins occupied with a firm coagulum, partly fibrine, partly cruor, internally softened, at some points villous looking, and presenting a trace of puriform matter.—Necrol. Reg. vol. v. fol. 58.

417. Fibrinous clot firmly adhering to the membrane of the vena cava.—MS. Cat. vol. i. page 23, No. 34.

418. Fibrinous clot firmly adhering to the inside of the left iliac vein.—Donor, Dr. Martin, Surgeon 73rd Regt.

419. External iliac vein completely obstructed by fibrinous coagula which adheres to its sides.—Donor, Dr. Burrill, A. S. Staff.—MS. Cat. vol. i. page 227, No. 19.

420. Laminated fibrinous clot softened in the centre, occupying the vena cava and iliac veins. The iliac and femoral veins of the left side are irregularly contracted.—MS. Cat. vol. i. page 231, No. 40.

421. Femoral vein exhibiting a large clot of fibrine, filling the entire calibre of the vessel and firmly adhering to its inner surface; the clot has undergone a process of softening.—Necrol. Reg. vol. v. fol. 107.

422. Femoral vein filled with fibrinous coagula which adheres to

its sides.—Donor, Dr. Burrell, A. S. Staff.—MS. Cat. vol. i. page 92, No. 75.

423. Popliteal vein filled with a fibrinous clot, at most places firmly adherent to the inner tunic of the vessel;—the absorbent glands contain several small purulent cavities.—MS. Cat. vol. i. page 194, No. 164.

424. Popliteal vein completely filled by a sanguineous coagulum.—Donor, Dr. Bushe, A. S. Staff.—Print. Cat. page 67, No. 6.

425. Vein exhibiting a softened fibrinous clot adhering to its inner surface.

426. Vein filled with coagulum.

427. A portion of the splenic vein filled with coagulable lymph, and its coats partially ossified.—Donor, Dr. Burrell, A. S. Staff.—MS. Cat. vol. i. page 226, No. 14.

428. Trunk of the vena porta, with the coagulum which obstructed it.—Donor, Dr. Dix, 94th Regt.—MS. Cat. vol. i. page 226, No. 16.

429. A fibrinous clot adhering to the mouth of one of the pulmonary veins.

430. Lower portion of the right internal jugular vein near its junction with the subclavian, containing a clot of fibrine softened in the centre.—Necrol. Reg. vol. v. page 346.

431. A fibrinous clot in the longitudinal sinus.

432. A coagulum in the longitudinal sinus, partly clot and partly fibrine, the latter of a semifluid consistence resembling pus.

433. Portion of the femoral vein, after the removal of a coagulum, showing that they do not depend on any morbid condition of the lining membrane of the vessel.

434. Portions of vein exhibiting varix.—Donor, Dr. M'Donnell, Surgeon 57th Regt.—Print. Cat. page 67, No. 4.

435. Superior mesenteric vein, opening into a large sac. The vein is indicated by a piece of bougie.—Donor, Mr. Lightbody, Surgeon 80th Regt.—Print. Cat. page 68, No. 10.

436. Vena cava abdominalis, situated on the left side of the aorta; the right common iliac vein passes behind the origin of the left common iliac artery, and unites with its fellow on the left side at the bifurcation of the aorta. The vena cava thus formed, ascends along the left side of the aorta until opposite the origin of the superior mesenteric artery, where, crossing from left to right in front of the latter vessel, it perforated the right lobe of the liver and preserved its natural course.

CLASS II.  
ORGANS OF RESPIRATION.

DIVISION I.

*DISEASES AND INJURIES OF THE LARYNX,  
TRACHEA, BRONCHI, BRONCHIAL, THYROID, AND  
THYMUS GLANDS.*

SECTION I.—INFLAMMATION AND EFFUSION OF LYMPH IN THE  
LARYNX, TRACHEA AND BRONCHI.

437. Lining membrane of the trachea and bronchial tubes in a state of great vascularity.

438. Bronchial membrane highly inflamed, with grey hepatization of the pulmonic tissue which is also studded with numerous tubercles.—Print. Cat. page 10, No. 11.

439. Larynx and trachea, showing the false membrane formed in croup; the layer of lymph is of considerable thickness, effused principally on the posterior surface of the tube, and extends from the larynx to within a quarter of an inch of the bifurcation of the trachea.

440. Larynx and a portion of the trachea lined by a false membrane formed in croup; the lymph is of a dark colour, with several small elevations on its surface, the largest of which (situated at the lower part of the thyroid cartilage) is laid open and shows a cavity in its substance; below this point the lymph is of great thickness,

and formed of several layers.—Donor, Mr. Ford, A. S. 72nd Regt.—MS. Cat. vol. i. page 28, No. 15.

441. Coagulable lymph deposited on the lining membrane of the larynx and trachea, with destruction of the mucous membrane of the epiglottis.—Donor, Dr. Connell, A. S. Rifle Brigade.—Print. Cat. page 8, No. 37.

442. Mucous membrane of the larynx and a portion of the trachea thickened, covered with lymph and varioloid pustules.—Print. Cat. page 5, No. 16.

443. Larynx and a portion of the trachea, showing the remains of numerous varioloid pustules, and a granular deposit of lymph on the lining membrane.—Donor, Dr. Tuthill, A. S. 52nd Regt.—Print. Cat. page 8, No. 35.

444. Mucous membrane of the larynx and trachea coated with lymph; these tubes in the recent state were highly inflamed.—Print. Cat. page 6, No. 31.

445. Larynx and a portion of the trachea coated with lymph, and the mucous membrane in a state of ulceration.

446. Mucous membrane of the larynx and a portion of the trachea coated with a thick layer of lymph; the tonsils and pharynx are also covered with a layer a quarter of an inch in thickness, which hangs down on each side over the epiglottis.—Donor, Dr. Kinnis, A. S. Staff.—MS. Cat. vol. i. page 2, No. 44.

447. Mucous membrane of the trachea thickened and coated with lymph, the effect of small-pox.—Print. Cat. page 5, No. 16.

448. Two portions of coagulable lymph, hollow in their centres, and dividing into numerous prolongations, which are likewise tubular, resembling the subdivisions of the bronchial tubes.—Donor, Dr. Gahan, A. S. Staff.—MS. Cat. vol. i. page 55, No. 142.

449. Trachea of a fowl almost closed by a false membrane.—Donor, Mr. Shower.—MS. Cat. vol. i. page 28, No. 14.

## SECTION II.—ŒDEMA OF THE LARYNX.

450. Extensive œdema of the glottis and epiglottis.—Donor, Mr. Martin, Surgeon 73rd Regt.—MS. Cat. vol. i. page 2, No. 45.

451. Œdema of the glottis and epiglottis.

452. Œdema of the glottis and abrasion of the mucous membrane of the epiglottis.—Print. Cat. page 2, No. 5.

453. Œdema of the glottis and rima glottidis.—Print. Cat. page 4, No. 13.

454. Œdema of glottis, epiglottis and surrounding cellular tissue; and a deep excavated ulcer at the posterior part of the right vocal chords.—Donor, Dr. Logan, A. S. 53rd Regt.

455. Larynx œdematous, and the sacs of two small abscesses situated immediately behind and beneath the left inferior chordæ vocales.—MS. Cat. vol. i. page 3, No. 52.

456. Œdema of the glottis and epiglottis, with effusion of lymph on the mucous membrane of the pharynx and larynx.

457. Œdema of the larynx and enlargement of the tonsils.

458. Œdema of the glottis and epiglottis, with great thickening and slight ulceration of the mucous membrane of the larynx.—Print. Cat. page 4, No. 12.

459. Œdema of the glottis and epiglottis;—thickening of the mucous membrane of the larynx;—the cavity of an abscess in the substance of the tongue;—and an opening between the third and fourth rings of the trachea made in tracheotomy.—Donor, Dr. Kemlo.

## SECTION III.—OSSIFICATION OF THE CARTILAGES OF THE LARYNX.

460. Thyroid and cricoid cartilage almost completely ossified.



461. Thyroid cartilage almost entirely ossified.

462. Thyroid cartilage generally bony, with partial necrosis of the posterior part of the inner surface of the left ala, also of the anterior part of both alæ. The sequestrum is at the bottom of the bottle.—Donor, Dr. Stephenson, Rochester.—MS. Cat. vol. i. page 3, No. 55.

463. Cartilages of the larynx almost entirely ossified, with a few points of bony matter at the root of the epiglottis.—Donor, Mr. Alexander, A. S. Staff.—MS. Cat. vol. i. page 2, No. 46.

#### SECTION IV.—ULCERATION OF THE LARYNX.

464. Two ulcers on the posterior surface of the larynx; œdema of the glottis, and effusion of lymph in the larynx and upper part of the trachea, caused by small pox.—Donor, Dr. Lightbody, Surgeon 80th Regt.

465. Epiglottis entirely destroyed by ulceration, with thickening and ulceration of the mucous membrane of the larynx.—Donor, Dr. Stewart, A. I. H.—MS. Cat. vol. i. page 2, No. 48.

466. Epiglottis almost entirely destroyed by ulceration, with ulceration and effusion of lymph on the mucous membrane of the larynx which has a peculiar granulated appearance.

467. Extensive ulceration of the epiglottis and right chordæ vocales, also several ulcerated patches in the trachea; with œdema of the glottis.—Print. Cat. page 2, No. 3.

468. Extensive ulceration of the mucous membrane of the larynx, with destruction of nearly one-half of the epiglottis.—Donor, Dr. Stewart, Surgeon 71st Regt.—Print. Cat. page 1, No. 1.

469. Extensive ulceration of a portion of the posterior aspect of the epiglottis and upper part of the larynx.—Necrol. Reg. vol. v. page 349.

470. Deep and extensive ulceration of the mucous membrane of

the larynx, which has destroyed the chordæ vocales and exposed a portion of the anterior part of the thyroid cartilage.

471. Ulceration of the larynx;—situated immediately above the vocal chords are two small elevations, with an aperture on their summit which leads each into a cavity in their substance; a deep ulcer at the posterior angle of the vocal chords on either side, that on the left has laid bare the base of the arytenoid cartilage; the mucous membrane covering the superior vocal chords and epiglottis has a peculiar granulated appearance. Glottis thickened and œdematous.

472. Fungoid ulceration of the right side of the larynx, and inferior chordæ vocales.—Donor, Mr. Power, A. S. Staff.

473. A very deep excavated ulcer which has destroyed almost the whole of the right chordæ vocales; mucous membrane of the glottis and epiglottis thickened and œdematous.—Print. Cat. page 1, No. 2.

474. The cavity of the larynx very much diminished in size, in consequence of the enlargement of the mucous follicles, which, with the lining membrane of the larynx, upper and posterior part of the trachea, are in a state of ulceration. Glottis much thickened.—Donor, Dr. Burke, I. G. H.

475. Ulceration of the mucous membrane of the epiglottis and larynx, thickening of the mucous membrane of the upper part of the trachea; with œdema of the glottis.—Print. Cat. page 3, No. 9.

476. Mucous membrane of the epiglottis and larynx thickened and extensively ulcerated.—Donor, Mr. Whyte, Surgeon 69th Regt.—Print. Cat. page 8, No. 39.

477. Extensive ulceration of the mucous membrane of the epiglottis, larynx and upper part of the trachea.—Print. Cat. page 3, No. 8.

478. Slight ulceration of the mucous membrane of the epiglottis and chordæ vocales.—MS. Cat. vol. i. page 6, No. 65.

479. Ulceration of the chordæ vocales on both sides, and œdema of the rima glottidis.—MS. Cat. vol. i. page 3, No. 51.

480. Fungoid ulceration of the posterior aspect of the larynx, also immediately below the right chordæ vocales, with œdema and thickening of the glottis.

481. Several well-defined ulcers on the mucous tunic of the larynx and upper part of the trachea.—Print. Cat. page 7, No. 32.

482. Great thickening of the glottis and epiglottis, and extensive ulcers on both of the thyroid cartilages, that on the right side communicating by a sinus situated between the thyroid cartilage and os hyoides, with the integuments of the neck.—Donor, Dr. McMunn, A. S. 10th Regt.—Print. Cat. page 8, No. 41.

483. Extensive ulceration of the mucous membrane of the posterior surface of the epiglottis and chordæ vocales which are entirely destroyed, and in their site on either side are two round elevations, that on the right side has a circular aperture on its summit.

484. Ulceration of the mucous membrane on right side of the epiglottis, as well as the upper margins of the chordæ vocales and velum pendulum palati. Œdema of the glottis and enlargement of the tonsils.—Donor, Dr. Kinnis, A. S. Staff.

485. Ulceration of the two inferior chordæ vocales, and upper part of the trachea.

486. A large deep ulcer of the mucous membrane at the angle of the thyroid cartilage, extending outwards on each side beneath the chordæ vocales. There are also some small ulcers at the upper part of the trachea.—MS. Cat. vol. i. page 4, No. 56.

487. Small superficial ulcers of the mucous membrane of the epiglottis, larynx and trachea.—MS. Cat. vol. i. page 5, No. 62.

488. Two large excavated ulcers in the larynx; one situated op-

posite to the Pomum Adami, which has almost entirely destroyed the left inferior vocal chords; the other at the posterior angle of the right vocal chords; there is also an ulcer on the right side of the trachea which has perforated the fifth and sixth rings of that tube.

489. Ulceration of the glottis, and partial exposure of the left arytenoid cartilage; thickening of the mucous membrane of the larynx, with numerous small ulcers in the upper part of the trachea.—Donor, Dr. Shean, Surgeon 7th Fusiliers.—MS. Cat. vol. i. page 6, No. 66.

490. Posterior surface of the epiglottis rough and irregular, presenting the appearance of cicatrization. Glottis œdematous.—MS. Cat. vol. i. page 3, No. 53.

491. Arytenoid cartilages completely denuded of soft parts, and nearly separated from their attachments; mucous tunic of the larynx thickened, rough and irregular.—MS. Cat. vol. i. page 4, No. 57.

492. Mucous membrane of the epiglottis and larynx much thickened.

493. A large deep excavated ulcer at the posterior angle of the right vocal chords, with numerous small ulcers in the larynx and upper part of the trachea.—MS. Cat. vol. i. page 3, No. 54.

494. A large irregular ulcer immediately above the left vocal chords which has partially destroyed them; and another of a smaller size and circular form in the same situation on the right side; the right chordæ vocales are much thickened, and there are numerous minute ulcers in other parts of the larynx, and two of a large size on the posterior surface of the trachea.—Print. Cat. page 2, No. 3.

495. A large deep excavated ulcer at the posterior angle of the right vocal chords, and several others of a smaller size in different parts of the larynx.—Print. Cat. page 3, No. 10.

496. Extensive ulceration and thickening of the mucous membrane of the larynx and trachea, and the body of the cricoid carti-

lage is denuded of soft parts. Glottis œdematous.—Print. Cat. page 6, No. 30.

497. Ulceration of the mucous membrane of the epiglottis and larynx; also a large ulcerated surface at the posterior part of the cricoid cartilage and upper part of the trachea; a portion of the cricoid cartilage, and several rings of the trachea are bare and quite denuded of soft parts. Vocal chords on either sides thickened but more particularly the right. Glottis œdematous.—Print. Cat. page 7, No. 34.

498. A deep excavated ulcer at the posterior part of the cricoid cartilage on the left side; body of the cricoid cartilage quite denuded of soft parts. Glottis œdematous and the diameter of the larynx much contracted.

499. Left half of the cricoid cartilage ossified and denuded of soft parts, lying loose in a triangular-shaped ulcerated cavity, having its base posteriorly and apex anteriorly; this cavity also contains a portion of the cricoid cartilage in a cartilaginous state about an inch in length, attached anteriorly to the opposite ala of the cricoid cartilage, the remainder of it is loose and bare. The piece of detached bone is of a triangular form, resembling in shape and size one-half of the cricoid cartilage, ossified and necrosed, the laryngeal aspect and superior border of which are smooth and polished, the external and remaining margins are rough and irregular. The right half of the cricoid cartilage is also partially ossified.—Donor, Mr. Rogers, Surgeon 10th Hussars.—Print. Cat. page 8, No. 42.

500. An ulcer with everted callous edges on the upper and inner surface of the cricoid cartilage on each side, immediately below the inferior vocal chords.—MS. Cat. vol. i. page 5, No. 61.

501. Mucous membrane of the larynx and trachea studded with an immense number of oval-shaped ulcers, some of them having coalesced.—Print. Cat. page 2, No. 6.

502. Mucous membrane of the larynx and upper part of the trachea thickened, and presenting a peculiar cribriform appearance, caused by a number of small minute ulcers. Body of the cricoid cartilage denuded of soft parts, and its surface rough and granular.

503. Extensive ulceration and thickening of the mucous membrane of the epiglottis and larynx, one large oval ulcer laying bare a portion of the thyroid cartilage on the right side, which is partially ossified, and its inner layer appears as if about to exfoliate. The whole of the cricoid cartilage on the same side, and the posterior half of that of the left is also quite denuded of soft parts.—Print. Cat. page 14, No. 14.

504. Ulceration of the right sacculus laryngis, destruction of the right vocal chords, œdema of the glottis, and a number of small oval ulcers some of them coalescing, in the larynx and upper part of the trachea.—Donor, Mr. Ford, A.S. 72nd Regt.—MS. Cat. vol. i. page 7, No. 67.

505. Extensive ulceration of the mucous membrane of the larynx, commencing immediately below the vocal chords, also of the upper part of the trachea; and the base of the left arytenoid cartilage is laid bare by a small deep excavated ulcer of an oval shape.

506. A round polypus excrescence attached to the left inferior vocal chord so as nearly to close the opening of the glottis.

#### SECTION V. ULCERATION OF THE TRACHEA AND BRONCHI.

507. Extensive ulceration of the trachea; many of its cartilages are denuded of soft parts and partially destroyed.—MS. Cat. vol. i. page 31, No. 25.

508. Mucous membrane of the larynx, but more particularly that of the trachea and bronchi, extensively ulcerated. Conglobate glands at the bifurcation of the trachea greatly enlarged.

509. Extensive ulceration of the trachea and larynx.—MS. Cat. vol. i. page 28, No. 17.

510. Mucous membrane of the trachea and bronchial tubes thickly studded with oblong transverse ulcers, also eight or ten of a smaller size and round shape on the lower surface of the epiglottis, and

another on the right inferior vocal chord. The whole mucous membrane in the recent state was of a dark livid colour.—MS. Cat. vol. i. page 32, No. 29.

511. Extensive ulceration of the trachea and larynx, with partial destruction of many of the cartilages of the former.—MS. Cat. vol. i. page 31, No. 26.

512. A large irregular ulcerated opening on the anterior and upper part of the trachea; several rings of this tube are destroyed, and others of them quite denuded of soft parts.—MS. Cat. vol. i. page 29, No. 21.

513. An ulcerated opening situated on the posterior surface of the trachea, about an inch and a-half below the cricoid cartilage, capable of admitting a large bougie, which communicated with the œsophagus.—Print. Cat. page 9, No. 2.

514. A portion of lung showing obliteration of one of the bronchi, and the cicatrix of an ulcer.

#### SECTION VI.—DISEASES OF THE BRONCHIAL, THYROID AND THYMUS GLANDS.

515. A large oval opening situated between the thyroid cartilage and first ring of the trachea, which communicated with the empty cavity of an abscess in front of this tube; immediately below which there are two or three enlarged glands filled with cheesy matter. There are also two small ulcers on the posterior part of the inferior vocal chords.—MS. Cat. vol. i. page 31, No. 28.

516. A small ulcerated opening at the lower part of the trachea, through which the contents of a diseased bronchial gland was being discharged. Glands enlarged and of a dark colour, and the margin of the ulcerated opening has the same appearance.

517. A large irregular opening situated in the lower part of the trachea, and another in the right bronchus; below this the parts are puckered and contracted. The two ulcerated openings communicate

with a cavity in one of the bronchial glands, which is filled with calcareous matter, situated in front of the trachea and bronchi. Bronchial glands enlarged, and of a dark colour.—MS. Cat. vol. i. page 31, No. 27.

518. Extensive ulceration of the right bronchus at its commencement. An ulcerated opening communicates with the excavation left by the breaking up of tuberculated bronchial glands.—MS. Cat. vol. i. page 55, No. 144.

519. The cyst of an abscess the size of a pullet's egg, formed in a mass of enlarged bronchial glands situated at the bifurcation of the trachea, having opened into the right bronchus and destroyed the cartilages in nearly their whole circumference. A loose calcareous mass covered with dark matter of a melanotic character was found in the lower part of the bronchus almost wholly obstructing its canal. The sac of the abscess also communicates with the left bronchus by an aperture about a quarter of an inch in diameter, having (particularly at its superior part) a fungous edge projecting into its canal to the extent of nearly one-eighth of an inch; the sac also opens into the œsophagus; and there is a small ulcer at the inner edge of the descending cornua of the thyroid cartilage on the right side.—Donor, Mr. Tice, A. S. 8th Regt.—MS. Cat. vol. iv. No. 13.

520. A cyst, with thick parietes attached to the lower part of the right side of the trachea, which contained an albuminous-looking substance. The bronchial glands are likewise somewhat enlarged, and one which contains a yellow cheesy-looking substance communicates by a small ulcerated opening with the right bronchus.—MS. Cat. vol. i. page 56, No. 151.

521. Albuminous substance which was contained in a cyst of diseased bronchial glands.—MS. Cat. vol. i. page 56, No. 152.

522. A mass of enlarged bronchial glands situated at the bifurcation and along the right side of the trachea, immediately behind the arch of the aorta.—Print. Cat. page 18, No. 43.

523. Bronchial glands on the right side and posterior part of the



trachea at its bifurcation, and along the course of the bronchi for a considerable distance, much enlarged from tubercular deposit in them, which has in many places begun to soften and break down.—Donor, Mr. Logan, A. S. 53rd Regt.—MS. Cat. vol. i. page 52, No. 131.

524. A dark-coloured spot about a quarter of an inch in diameter, situated at the lower part of the trachea which is nearly perforated by the softened tuberculous matter of a bronchial gland.—MS. Cat. vol. i. page 30, No. 22.

525. Bronchial gland containing tuberculous matter.—MS. Cat. vol. i. page 247, No. 4.

526. Enlarged conglobate glands at the bifurcation of the trachea.

527. An enlarged lymphatic gland, filled with cheesy matter, situated over the bifurcation of the trachea.—Donor, Dr. Scott, Surgeon 2nd Batt. Rifles.—MS. Cat. vol. i. page 28, No. 13.

528. Bronchial glands much enlarged, and showing the empty cyst of an abscess.—Donor, Mr. Henderson, A. S. 78th Regt.

529. Bronchial glands attached to the thoracic aorta enlarged and filled with scrofulous deposit, one of which situated along the course of the descending aorta is partially empty.—Donor, Mr. Logan, A. S. 53rd Regt.—MS. Cat. vol. i. page 53, No. 134.

530. An enlarged bronchial gland, filled with scrofulous matter, occupying the angle of bifurcation of the trachea, and several others of a smaller size surrounding it.—MS. Cat. vol. i. page 30, No. 24.

531. Bronchial glands at the bifurcation and along the anterior surface of the trachea enlarged, some of them containing a yellow cheesy-looking substance, and others of them partially empty.—MS. Cat. vol. i. page 57, No. 153.

532. Bronchial glands enlarged, and some ossific deposit in their

substance.—Donor, Dr. Cathcart, Surgeon 7th Dragoons.—MS. Cat. vol. i. page 67, No. 199.

533. Bronchial glands enlarged and studded with a copious earthy deposit.—Print. Cat. page 10, No. 10.

534. Bronchial glands, with abundant deposition of osseous matter.—Print. Cat. page 10, No. 9.

535. A tumour the size of a walnut, which contained a fluid resembling whey attached to the fore part of the trachea.—Donor, Dr. Scott, Surgeon 2nd Batt. Rifles.—MS. Cat. vol. i. page 28, No. 10.

536. Great enlargement of the thyroid gland, more especially of the left lobe which descended as low as the bifurcation of the trachea, with osseous deposit and several small empty cysts in its substance.—Donor, Sir A. West.

537. An enlarged and hardened condition of the thyroid gland, with inflammation of the lining membrane of the larynx and trachea.—Donor, Mr. Burton, A. S. 68th Regt.—MS. Cat. vol. i. page 28, No. 16.

538. Enlargement of the thyroid gland.

539. Thyroid gland somewhat smaller than usual, in its right lobe there is a small cyst which contained a cheesy substance. The glandulæ Morgagni of the larynx are well developed, the left is laid open and appears to be of a conglomerate nature.—MS. Cat. vol. iii. page 228, No. 110.

540. A coagulum of blood of a circular form and somewhat larger than a hazel nut, encysted in the lower part of the left lobe of the thyroid gland.—Necrol. Reg. vol. iv. page 35.

541. Left lobe of the thyroid gland deficient; close to the trachea and attached to it on this side is a vesicle filled with a transparent fluid.—Necrol. Reg. vol. vi. page 128.

542. Thymus gland with a tubercle the size of a garden pea

situated in its left lobe.—Donor, Mr. Calder, A. S. Staff.—MS. Cat. vol. i. page 56, No. 150.

#### SECTION VII.—INJURIES OF THE LARYNX AND TRACHEA.

543. Comminuted fracture of the cricoid cartilage, in consequence of the kick of a horse.—Donor, Dr. Annesley, Surgeon 72nd Dr. Gds.—MS. Cat. vol. i. page 2, No. 43.

544. An extensive wound of the thyroid cartilage, extending from its lower and anterior part obliquely upwards and backwards nearly to the larger cornua, completely separating the epiglottis from its attachment; with considerable œdema of the glottis.—Donor, Dr. Davies, E. I. C. Service.—Print. Cat. page 6, No. 28.

545. Shows the result of an operation for the cure of a fistulous opening, following an attempt at suicide; the cut made by the patient was situated above the os hyoides, between the epiglottis and base of the tongue. On the external surface there is a triangular portion of skin, which was removed from below the chin, adapted to the opening, and secured by means of sutures to the adjacent parts which are puckered and contracted; on the inner surface at the root of the tongue is an oval depression which is thin and transparent on the right side.—Print. Cat. page 5, No. 26.

546. The os hyoides separated from the thyroid cartilage, by a suicide; the wound has divided the whole of the thyro-hyoid membrane from one cornua of the thyroid cartilage to the other, separated the epiglottis from its attachments, and entered the back of the pharynx, cutting the thyroid arteries; neither of the carotids however were wounded, the right is preserved in the preparation, showing that it is untouched.—Print. Cat. page 3, No. 11.

547. A kidney bean impacted in the trachea of a child, which caused suffocation.—Halifax Museum.

## DIVISION II.

### *DISEASES OF THE LUNGS.*

---

#### SECTION I.—TUBERCLES IN THE LUNGS.

541. A portion of lung, with a number of minute tubercles in their early stage.—MS. Cat. page 63, No. 179.

549. A portion of right lung, studded with miliary tubercles.—MS. Cat. vol. i. page 70, No. 204.

550. A portion of lung, studded with miliary tubercles.

551. A portion of lung, studded with granular tubercles. Pleura pulmonalis thickened, and agglutinated by intervening lymph to that covering the pericardium.

552. A portion of lung, with a number of small tubercles situated close to the minute blood-vessels, some of them adhering to the coats of the vessels.—MS. Cat. vol. i. page 64, No. 181.

553. A portion of lung, studded with miliary tubercles, and its parenchyma highly vascular.—MS. Cat. vol. i. page 44, No. 113.

554. Section of lung, showing miliary tubercles.

555. Portion of lung, its substance condensed by the existence of numerous crude tubercles.—York Hospital, Chelsea.

556. Portion of lung consolidated and filled with miliary tubercles.—Print. Cat. page 14, No. 25.

557. Portion of lung consolidated and filled with miliary tubercles, and a small quantity of lymph on pleura.—Print. Cat. page 11, No. 3.

558. Portion of left lung studded with miliary tubercles some of which have coalesced and in one situation a vomica is formed which is lined by highly vascular parietes. The preparation is minutely injected; but the tubercular matter exhibits no distinct trace of vascularity.—Donor, Mr. Gulliver, A. S. Staff.—Print. Cat. page 25, No. 68.

559. Tubercles of the lungs in their first and second stages of development, with the parts surrounding them in a state of inflammation.—MS. Cat. vol. i. page 44, No. 112.

560. Portions of lung containing common grey tubercles; parenchyma of the lungs injected; but the tubercular matter does not show any trace of vascularity.—Donor, Professor Partridge, King's College.

561. Portion of lung condensed, and presenting different stages of tubercular deposit. The bristle denotes the communication between a bronchial tube and a small vomica. In this preparation an attempt has been made to inject the tubercles; the false friable membrane which lined the excavations having been washed away, showing how highly vascular their parietes are.—Print. Cat. page 25, No. 67.

562. Lungs of a dog studded with tubercles from the size of a pin's head to that of a common bean.—Donor, Mr. Shower, Apoth.—MS. Cat. vol. i. page 47, No. 120.

563. A portion of lung (minutely injected) from the *Mecacus Rhesus* pervaded by tubercles.—Donor, Mr. Gulliver, A. S. Staff.—

564.—Portion of lung, in the substance of which are situated tubercles of a large size and firm consistence; in one of them there is a central cavity which communicates with a bronchial tube.—MS. Cat. vol. i. page 55, No. 146.

565. A large tubercle situated in the upper lobe of the left lung; a section is made through its centre, showing that it consists of cheesy-looking matter contained in a distinct sac which is smooth and polished internally.

566. Portion of lung thickly studded with tubercles in different

stages of maturation, with a number of small vomicæ.—Donor, Dr. Burke, Surgeon Rifle Brigade.

567. Portion of lung studded with tubercles and vomicæ.

568. Lungs of a monkey, affected with tubercular phthisis in all its stages.—Donor, Mr. Ford, A. S. 72nd Regt.

569. A portion of lung having a cavity filled with tubercular matter soft towards its circumference.—MS. Cat. vol. i. page 63, No. 180.

570. Portion of left lung with two large scrofulous deposits quite isolated; the surrounding pulmonary tissue is quite healthy.—Print. Cat. page 29, No. 89.

571. The whole of left lung converted into a mass of yellow cheesy matter, without the slightest vestige of its original structure remaining. Pleura thickened.—Print. Cat. page 19, No. 47.

572. Portion of left lung hepatized and having a slight cerebri-form appearance, with two small vomicæ in its substance.—Necrol. Reg. vol. v. page 331.

## SECTION II.—TUBERCULAR CAVITIES IN THE LUNGS.

573. A portion of lung with two empty vomicæ; the surrounding pulmonary substance is studded with tubercles and consolidated.

574. A large cavity intersected by several bands in a portion of the right lung, the anterior part of which is studded with tubercles and adheres to the parietes of the thorax.—Print. Cat. page 20, No. 50.

575.—Portion of the upper lobe of right lung, with a tubercular excavation, on the side of which is a fine band; and in the centre of this band there is a vessel of considerable magnitude, which at one part presents a ruptured opening communicating with the excavation. The cavity was filled with coagulated blood.—MS. Cat. vol. i. page 56, No. 147.

576. Portion of lung with several vomicæ, their walls firm and cartilaginous, and the intermediate pulmonic structure consolidated.—Print. Cat. page 12, No. 8.

577. Portion of lung with a vomica having its walls firm and cartilaginous, and the remaining portion consolidated; pleura thickened and covered with lymph.—Print. Cat. page 13, No. 19.

578. A portion of the walls of a tubercular cavity lined by a deposit of false membrane.—MS. Cat. vol. i. page 66, No. 191.

579. Portion of right lung with a large tubercular excavation, lined by a tough semi-cartilaginous membrane in which are several openings of bronchial tubes.—Print. Cat. page 23, No. 60.

580. A large tubercular cavity, lined by a thick firm membrane, in a portion of lung the substance of which is studded with tubercles and the pleura thickened.

581. An induration, larger than a hen's egg situated in the upper lobe of the left lung, filled with small grey semi-transparent tubercles, in the centre of which there are two caverns (which were filled with dark coagula) communicating freely with each other, one capable of holding a walnut the other about half its size; there are also several smaller vomicæ in the mass; the walls of the larger excavation had in the recent preparation a rough broken-down aspect as though recently lacerated and no lining membrane. The openings of the bronchial tubes, into these cavities, four or five in number, were filled with clotted blood, and there is a ruptured vessel presenting a gaping orifice, easily admitting a large probe and situated near the centre of the larger excavation.—Donor, Dr. Maclachlin, A. S. 79th Regt.—Edin. Med. and Surg. Journal, vol. lii. page 144, year 1839.

582. Portion of the upper part of the lung, in which there is a large cavity lined by a firm smooth membriform matter; surrounding pulmonic tissue healthy.—MS. Cat. vol. i. page 59, No. 162.

583. Two portions of right lung, each presenting an aperture leading from a vomica, which communicated with the pleural cavity causing pneumo-thorax.—Necrol. Reg. vol. v. page 290.

584. Portion of the surface of the lung, showing a small rounded aperture leading into a vomica; the pleura is thickened and semi-cartilaginous.—MS. Cat. vol. i. page 59, No. 161.

585. A large rounded aperture in the pleura investing the upper part of the lung, continuous with a bronchial tube which traverses a tubercular cavity.—MS. Cat. vol. i. page 60, No. 166.

586. Portion of lung with two caverns communicating freely with each other, bounded externally by the thickened pleura and internally by the pulmonary tissue, which is studded with tubercles. One of the bronchial tubes is obliterated and others compressed.

587. A large irregular tubercular excavation, in the inferior lobe of left lung, lined by a fine membrane, with a number of fleshy bands intersecting it. And several other cavities of a smaller size in the upper lobe. Pleura thickened and covered with lymph.—Print. Cat. page 19, No. 46.

588. Several irregular tubercular cavities situated immediately beneath the pleura of left lung, pulmonary tissue studded with tubercles and hepatized; pleura much thickened.—Print. Cat. page 17, No. 36.

589. A very large irregularly excavated tubercular cavity, immediately beneath the pleura of right lung, occupying nearly three-fifths of its anterior surface. Lung compressed and studded with tubercles.—Print. Cat. page 13, No. 17.

590. A portion of lung, with numerous vomices, filled with tubercles and hepatized;—the mucous lining of the bronchi is extensively ulcerated.—Print. Cat. page 15, No. 31.

591. Root of lung with a large cavity lined by a false membrane at some parts semi-cartilaginous.—Print. Cat. page 14, No. 24.

592. An immense irregular tubercular excavation, lined by a firm semi-cartilaginous membrane, occupying one-half of the upper lobe of left lung, a strong fleshy band divides it into two unequal parts; the remainder of this lung was condensed and tuberculated, with the



exception of a small portion of margin of inferior lobe.—MS. Cat. vol. i. page 71, No. 207.

593. Section of lung showing several irregular excavations and consolidation of the contiguous tissue by abundant tubercular infiltration, forming a very good example of grey hepatization.—Print. Cat. page 25, No. 69.

594. A tubercular excavation the size of a billiard ball intersected by several bands; lung studded with tubercles and compressed; pleura thickened.—Print. Cat. page 13, No. 15.

595. A large cavity in the middle lobe of the lung communicating with the pleural cavity by an opening in the fissure between inferior and middle lobes. Pleura thickened and covered by soft unorganized lymph.—MS. Cat. vol. i. page 61, No. 171.

596. A large tubercular cavity in the upper part of a lung, with several large bronchial tubes opening into it and lined by a thick semi-cartilaginous membrane.

597. Several large irregular tubercular excavations in the right lung, pulmonary tissue consolidated and studded with tubercles. Pleura much thickened and covered with shreds of lymph.—Print. Cat. page 21, No. 56.

598. Section of lung showing three tubercular cavities lined by firm semi-cartilaginous membranes. Pleura thickened.—Donor, Dr. Munro, A. S. Coldstream Gds.

599. A large tubercular excavation in the apex of right lung and a moderate sized bronchial tube opening into it; pulmonary tissue loaded with tubercular matter. Pleura much thickened.—Print. Cat. page 27, No. 80.

600. A large tubercular cavity lined by a false membrane and traversed by many bands; pleura thickened.—Print. Cat. page 14, No. 20.

601. Left lung containing numerous large and irregular vomiceæ, with firm semi-cartilaginous cysts, communicating freely with each other and the bronchial tubes; pulmonary tissue consolidated; pleura thickened.—Print. Cat. page 19, No. 44.

602. A small rounded opening, the size of the blunt extremity of a probe on the pleura, near the inner, anterior and lower margin of the inferior lobe of the left lung, leading into a tubercular cavity in its neighbourhood, also several small bulging points apparently about to burst on the surface of the lung. Pleura much thickened.—MS. Cat. vol. i. page 71, No. 206.

603. A portion of the left lung with a tubercular cavity in it, which communicated by a fistulous opening with the cavity of the chest, causing pneumo-thorax. Pleura covered by a thick layer of recently effused lymph.—MS. Cat. vol. i. page 38, No. 103.

604. Right lung with numerous irregularly-shaped cavities and condensation of its substance. Pleura thickened and opaque.—Print. Cat. page 18, No. 42.

605. A very large tubercular cavity, traversed by bands in the apex of the left lung, having destroyed the whole of the pulmonary tissue leaving nothing but the pleura for its walls; there are also two others of a smaller size in the lower part of the lung. Pleura costalis firmly adhering to the surface of the lung.—Print. Cat. page 30, No. 96.

606. Lung with two vomiceæ traversed by bands and communicating with the bronchi; substance of the lung studded with tubercles. Pleura thickened and covered with lymph.—Print. Cat. page 11, No. 5.

607. One irregular tubercular excavation in the apex and another in the base of left lung, the latter traversed by numerous bands; pulmonary tissue in a state of grey hepatization. Pleura thickened and covered with lymph.—Print. Cat. page 20, No. 51.

608. A small tubercular cavity in apex of left lung having

a bronchial tube leading into it, and communicating by a small rounded opening with the cavity of pleura, causing pneumothorax; surface of pleura covered with recently effused lymph.—Donor, Dr. Lea, Surgeon 5th Foot.—MS. Cat. vol. i. page 52, No. 126.

609. Several very large irregular tubercular excavations communicating freely one with the other and intersected by bands; a large mass of chalky concretion in substance of lung, pleura very much thickened, with numerous points of ossific deposition on its surface.—Print. Cat. page 11, No. 2.

610. An immense cavity occupying four-fifths of the lung, the pulmonary tissue being entirely destroyed, leaving nothing but the pleura for its walls.—Donor, Dr. Jackson, H. E. I. C.

611. A large irregular tubercular excavation, in a portion of the lung, lined by a thick semi-cartilaginous membrane, with several bronchial tubes opening into it; pleura thickened.

### SECTION III.—MEDULLARY DEPOSIT IN THE LUNGS.

612. A portion of lung containing a well-defined deposit of medullary matter, about the size of a hen's egg, of a soft pulpy texture approaching very nearly the structure of foetal brain, possessing no capsule but appearing to be in immediate contact with the contiguous healthy pulmonic tissue.—Print. Cat. page 24, No. 65.

### SECTION IV.—CARTILAGINOUS AND BONY DEPOSITS IN THE LUNGS.

613. Posterior part of the left lung converted into a cartilaginous substance about an inch and a-half in thickness.—Print. Cat. page 26, No. 72.

614. Tumour about the size of a pigeon's egg, of a cartilaginous and bony structure found in right lung.

615. Superior lobe of right lung containing a fibrous deposit in its substance without any trace of tubercles.

616. Portion of lung, to the surface of which is attached a small rounded cartilaginous body.—Donor, Dr. Stephenson, Rochester.—MS. Cat. vol. i. page 58, No. 157.

617. Portion of lower lobe of left lung containing a large earthy deposit.—Print. Cat. page 28, No. 83.

618. Three bony concretions which were expectorated from the lungs of a man ætat. 60 otherwise healthy.—Donor, Mr. Starkie, Apothecary.

619. Portion of lung of a sheep altered in structure, and containing several masses of osseous deposit.—Donor, Dr. Athill, A. S. Staff—MS. Cat. vol. ii. page 146, No. 170.

#### SECTION V.—HYDATIDS IN THE LUNGS.

620. Portion of the lung of a sheep filled with large hydatids.

#### SECTION VI.—MELANOSIS OF THE LUNGS.

621. Portion of right lung containing extensive melanotic deposit.

622. Section of lung showing spurious melanosis.—Donor, Dr. Munro, A. S. Coldstream Gds.

623. Portion of lung loaded with black carbonaceous matter, probably taken from the body of a coal-miner.—Donor, Dr. Wm. Thompson, Edinburgh.

#### SECTION VII.—APOPLEXY OF THE LUNGS.

624. A specimen of pulmonary apoplexy.

625. Portion of lung showing pulmonary apoplexy.—MS. Cat. vol. i. page 41, No. 110.

626. Portion of lung showing two cysts remaining after the absorption of blood effused in pulmonary apoplexy.

627. Specimen of pulmonary apoplexy probably of long standing.—MS. Cat. vol. i. page 47, No. 118.

628. Portion of lung shewing pulmonary apoplexy.—MS. Cat. vol. i. page 68, No. 200.

629. A fine specimen of pulmonary apoplexy.—Print. Cat. page 20, No. 48.

#### SECTION VIII.—EMPHYSEMA OF THE LUNGS.

630. Two small portions of emphysematous lung dried and divided so as to show the distended nature of the air cells.—MS. Cat. vol. i. page 56, No. 148.

631. Two small portions of emphysematous lung dried and divided so as to show the distended nature of the air cells.—MS. Cat. vol. i. page 56, No. 149.

632. A large emphysematous vesicle in the anterior and inferior part of the edge of the upper lobe of left lung.—MS. Cat. vol. i. page 65, No. 187.

633. A dried specimen illustrative of emphysema of the lungs.

634. Section of a portion of lung showing two cul-de-sac dilatations of the bronchial tubes (which constitutes lobular emphysema) and tubercles in their second stage of development.—Donor, Mr. Gulliver, A. S. Staff.—Print. Cat. page 24, No. 63.

635. Two large cul-de-sac dilatations, of the extremities of the bronchial tubes, communicating freely with each other.—Print. Cat. page 28, No. 84.

636. Portion of lung with an emphysematous vesicle the size of a cherry attached to it.—MS. Cat. vol. i. page 65, No. 188.

637. Interlobular emphysema of a portion of the lung.—MS. Cat. vol. i. page 65, No. 189.

638. External appearance of a portion of lung in interlobular emphysema; the effused air has separated the pleura from the parenchyma and produced a number of fissures between its lobes.—Donor, Mr. Cavet, A.S. 97th Regt.—Print. Cat. page 31, No. 97.

639. Shows the condition of the lung in interlobular emphysema when the pleura covering it is dissected off; the enlarged and ruptured bronchial cells and the fissures between the lobules, are very distinctly seen.—Print. Cat. page 22, No. 59.

640. Portion of pleura pulmonalis raised by an effusion of air underneath.

#### SECTION IX.—INFLAMMATION AND HEPATIZATION OF THE LUNGS.

641. Portion of lung showing inflammation of its parenchyma.—MS. Cat. vol. i. page 42, No. 111.

642. Portion of lung showing "Hepaticization rouge."—MS. Cat. vol. i. page 45, No. 114.

643. Complete consolidation of a portion of lung in consequence of repeated attacks of subacute inflammation.—MS. Cat. vol. i. page 45, No. 115.

644. Shows the greater part of a lung in progress of passing from the condition of red to grey hepaticization.—MS. Cat. vol. i. page 50, No. 125.

645. The lower lobe of left lung in a state of grey hepaticization with no vestige whatever of cellular structure, texture smooth and solid, with one or two patches which appear to have a tendency to softening and forming a remarkable contrast in colour and density to the upper lobe, which is otherwise healthy with the exception of being œdematous.—MS. Cat. vol. i. page 70, No. 205.

646. Section of lung showing consolidation.—Print. Cat. page 13, No. 16.

647. Portion of right lung consolidated, with a small abscess situated beneath the pleura, which in the recent state was extremely vascular.—Print. Cat. page 21, No. 55.

648. Consolidation of a portion of left lung.—Print. Cat. page 14, No. 22.

649. Section of lung showing grey hepatization.—Print. Cat. page 12, No. 6.

650. Section of lung showing grey hepatization.—MS. Cat. vol. i. page 67, No. 195.

651. Consolidation of a portion of lung.—Print. Cat. page 14, No. 21.

652. Portion of lung showing consolidation.—Print. Cat. page 13, No. 12.

653. Portion of lung showing hepatization and cicatrization, with thickening of the pleura.

654. Portion of the inferior lobe of left lung exhibiting grey hepatization.

655. Section of a portion of lung dried to show complete obliteration of the pulmonary tissue, which takes place in "Hepatization rouge."—MS. Cat. vol. i. page 46, No. 114.

656. Grey hepatization of a portion of lung; pleura costalis thickened and adherent.—Print. Cat. page 14, No. 23.

657. Portion of lung showing red hepatization passing into grey softening.—MS. Cat. vol. i. page 49, No. 123.

658. Hepatization of a portion of the lung, and the bronchi filled with lymph.

659. Portion of lung consolidated.—Print. Cat. page 12, No. 7.

660. Consolidation of a portion of lung.—Print. Cat. page 11, No. 1.

## SECTION X.—HYPERTROPHY OF THE PULMONARY TISSUE.

661. Consolidation of a portion of lung in consequence of hypertrophy of its vesicular texture, the exterior of the viscus appears healthy but the whole section of its interior is studded with minute granules, the diseased structure differs from the "*Hepaticization grise*" of Laennec by containing no pus and by being much less porous; Andral terms it the "*Hypertrophie du poumon*," and Boyle "*La Granulation Pulmon.*"—Print. Cat. page 26, No. 70.

662. Hypertrophy of a small portion of the parenchyma of the lung, its section appears studded with minute granules, but no appearance of pus, its length is about two inches and breadth one, forming a good specimen of the "*Hypertrophie du poumon*" of Andral.—MS. Cat. page 40, No. 105.

## SECTION XI.—ABSCESSSES OF THE LUNG.

663. A phlegmonoid abscess, about the size of a pigeon's egg, in a portion of the lung, which burst into the pleural cavity.—Donor, Mr. Ore, A. S. 8th Lt. Drs.—Print. Cat. page 29, No. 88.

664. Section of right lung showing a phlegmonoid purulent cysts.—Print. Cat. page 21, No. 54.

## SECTION XII.—GANGRENE OF THE LUNGS.

665. Gangrene of a portion of lung with a partially separated slough adhering to it.—Print. Cat. page 27, No. 79.

666. Gangrene of a portion of lower lobe of left lung about two inches in length and an inch and a-half in breadth.—MS. Cat. vol. i. page 49, No. 124.

667. Gangrenous eschar of the lung.



## DIVISION III.

*DISEASES OF THE PLEURA.*

## SECTION I.—INFLAMMATION, ECCHYMOSES, EFFUSION OF LYMPH ON THE PLEURA, AND COMPRESSION OF LUNG FROM VARIOUS CAUSES.

668. Portion of pleura costalis very vascular.—MS. Cat. vol. i. page 48, No. 122.

669. Pleura costalis greatly ecchymosed and lined in many parts by thin layers of coagulated blood.—Print. Cat. page 28, No. 87.

670. Portion of pleura costalis thickened and covered by a layer of coagulable lymph.—Donor, Mr. Ford, A. S. 72nd Regt.—MS. Cat. vol. i. page 52, No. 128.

671. Portion of the pleura costalis covered with an extensive deposition of coagulable lymph, having a slightly lace-like and flocculent appearance.—Donor, Mr. O'Brien, A. S. 7th Regt.—Print. Cat. page 30, No. 93.

672. Pleura pulmonalis covered with a deposition of coagulable lymph, having a well-marked lace-like appearance. Lung consolidated.—Print. Cat. page 21, No. 53.

673. Pleura pulmonalis covered by a delicate thin and lace-like deposition of lymph not completely organized.—Print. Cat. page 20, No. 52.

674. Portion of pleura thickened and covered with lymph deposited in a lace-like form.—Print. Cat. page 31, No. 99.

675. A portion of the pleura covered with two distinct layers of adventitious membrane; one is of a firm cartilaginous structure; the second is of recent formation and deposited in a lace-like form.—MS. Cat. vol. i. page 54, No. 140.

676. Pleura costalis thickened and covered with organized coagulable lymph having a lace-like appearance.—Print. Cat. page 23, No. 61.

677. Portion of diaphragmatic pleura covered with an extensive deposition of coagulable lymph in a tuberculated and slightly granulated form.—Donor, Mr. O'Brien, A. S. 7th Regt.—Print. Cat. page 30, No. 94.

678. Portion of pleura covering diaphragm coated with a layer of newly formed granular lymph.—Print. Cat. page 22, No. 58.

679. Portion of the pleura costalis thickened from deposition of lymph on its serous surface; the adventitious membrane has acquired very considerable toughness.—Print. Cat. page 24, No. 62.

680. Portion of diaphragmatic pleura coated with coagulable lymph, having attached to it a large loose pear-shaped portion of lymph which only adheres by a slender peduncle.—Print. Cat. page 26, No. 75.

681. Costal and diaphragmatic pleura coated with a very abundant deposition of lymph, having a flocculent appearance and at some parts nearly an inch in thickness.—Print. Cat. page 26, No. 74.

682. Pleura pulmonalis covered with flocculent lymph and the lung compressed.—Donor, Mr. Ford, A. S. 72nd Regt.—MS. Cat. vol. i. page 52, No. 129.

683. A large mass of flocculent coagulated lymph which was found in the left cavity of the thorax.—MS. Cat. vol. i. page 55, No. 141.

684. Several granular clusters of coagulable lymph on the diaphragmatic pleura.

685. Pleura pulmonalis and costalis of left side, more particularly the latter, coated with a thick layer of lymph. Lung compressed, and three openings in it by which the air had escaped into the pleural cavity.—Print. Cat. page 15, No. 32.

686. Left half of thorax, with a portion of its walls excised so as to illustrate the pathology of pneumo-thorax, diaphragmatic and a portion of the pulmonary pleura covered with a thick layer of granulated lymph. Two small openings at external margin of inferior lobe of lung communicating with the pleural cavity; lung compressed, pushed upwards and adhering to the parietes of the chest, leaving a large empty sac between the inferior border of the lung and diaphragm.—MS. Cat. vol. i. page 54, No. 138.

687. Left cavity of thorax very much enlarged; lung compressed and condensed in consequence of empyema; both the pleura pulmonalis and costalis are much thickened and their surface covered with a quantity of coagulable lymph. At the lower part of the lung the lymph has assumed the form of long shreds which seems to be partly organized.—Print. Cat. page 30, No. 95.

688. Left cavity of the chest enlarged; lung compressed; pleura pulmonalis and costalis thickened and covered with coagulable lymph, having a lace-like appearance and in the form of shreds.—Print. Cat. page 31, No. 98.

689. Pleura covering left lung thickened and coated with a layer of flocculent lymph; lung compressed and a free communication between a large sized bronchus and its surface through the medium of a small tubercular excavation.—MS. Cat. vol. i. page 55, No. 143.

690. Pleura pulmonalis and costalis of the left lung covered with flocculent lymph. Lung compressed.—Print. Cat. page 21, No. 57.

691. Lung covered with lymph, with a fistulous opening which communicates with the pleural cavity.

692. Lung coated with a thick layer of granulated lymph and compressed.—Print. Cat. page 11, No. 4.

693. Right lung coated with lymph, compressed and having a cavity in its superior lobe.

694. Right lung covered with a thin layer of lymph and compressed.—Donor, Mr. O'Brien, A. S. 7th Regt.—Print. Cat. page 30, No. 92.

695. Pleura pulmonalis and costalis thickened and contained a collection of air.—Donor, Dr. White, A. S. Staff.—Print. Cat. page 28, No. 82.

696. Pleura pulmonalis and costalis adhering together by means of a layer of lymph, at some parts one inch in thickness.—Print. Cat. page 28, No. 85.

697. Diaphragmatic pleura and that covering the pericardium thickened and adhering to the right lung by means of a soft yellow cheesy-looking deposit. Lung studded with tubercles.—Print. Cat. page 28, No. 86.

698. Pleura costalis thickened, adherent and lined with a thick yellowish layer of lymph having a slightly tuberculated appearance.—Albany Hospital, Isle of Wight.

699. Pleura thickened.—Donor, Mr. Ford, A. S. 72nd Regt.—MS. Cat. vol. i. page 52, No. 130.

700. Pleura pulmonalis and costalis thickened, covered with lymph and adherent.—MS. Cat. vol. i. page 53, No. 132.

701. Pleura costalis thickened and adherent.—Print. Cat. page 12, No. 10.

702. A number of long loose thread-like adhesions between the pleura covering the pericardium and lung, also between the latter and costal pleura.—Donor, Mr. Lightbody, Surgeon 80th Regt.

703. Long loose adhesions between a portion of left lung and the anterior part of second rib.—Donor, Dr. Bradford, A. S. 56th Regt.

704. Portion of lung exhibiting the effect of pressure from aneurism; some of the substance of the lung appears to be absorbed.—MS. Cat. vol. i. page 62, No. 173.

SECTION II.—CARTILAGINOUS THICKENING OF THE PLEURA.

705. Portion of lung with the pleura pulmonalis attached, the latter is an inch thick and converted into a substance of a fibro-cartilaginous nature.—MS. Cat. vol. i. page 58, No. 160.

706. Pleura pulmonalis and costalis adherent, of a fibro-cartilaginous structure and about half an inch in thickness. Lung compressed.—Print. Cat. page 26, No. 73.

707. Part of the diaphragmatic pleura of an oval form about five inches in length and two in width converted into cartilage.—MS. Cat. vol. i. page 39, No. 104.

708. A small portion of the pleura pulmonalis about the size of a half-penny converted into cartilage, with four or five small rounded elevations on its surface.—MS. Cat. vol. i. page 41, No. 108.

709. Portion of diaphragmatic pleura thickened from a deposition of a cartilaginous substance, about the sixth of an inch in thickness, a portion of which is raised.

710. An adventitious cartilaginous substance, a quarter of an inch in thickness, glueing the pleura costalis and pulmonalis together.—Albany Hospital, Isle of Wight.

711. Portion of pleura costalis considerably thickened, of a cartilaginous consistence and having a peculiar smooth and glistening surface.—MS. Cat. vol. i. page 53, No. 137.

712. Portion of lung with a number of small white dots on its surface consisting of animal matter and phosphate of lime.—Donor, Dr. Davy, A. I. H.—Print. Cat. page 29, No. 90.

713. Fibro-cartilage developed on the surface of the pleura and containing between its layers some bony matter.

## SECTION III.—BONY DEPOSITS IN THE PLEURA.

714. Pleura pulmonalis, with a number of large ossific deposits in it.—Donor, Dr. Stewart, A. I. H.

715. Part of the pleura costalis, with ossific deposit of large size and irregular shape. The bony matter is deposited in sharp acuminate points.—MS. Cat. vol. i. page 58, No. 158.

716. A large ossific deposition on the external surface of the pleura costalis; lung consolidated and adhering to it.—Print. Cat. page 12, No. 11.

717. A large osseous deposit in a portion of the pleura.

718. Osseous deposit in the pleura pulmonalis; lung consolidated.

## SECTION IV.—FATTY DEPOSITS IN THE PLEURA.

719. Portion of pleura, with several fatty appendages attached to it.—Donor, Dr. Stevenson, Rochester.—MS. Cat. vol. i. page 57, No. 154.

## SECTION V.—TUBERCULAR DEPOSITS IN THE PLEURA.

720. A part of the diaphragmatic pleura studded with numerous granular tubercles.—MS. Cat. vol. i. page 40, No. 106.

721. Two small tubercular deposits in an adhesive band which extends between the superior and middle lobes of the right lung.—MS. Cat. vol. i. page 55, No. 145.

722. Numerous small tubercles in a strong band of adhesion which connected the upper lobe of right lung to the parietes of the chest.—MS. Cat. vol. i. page 54, No. 139.

723. Numerous tubercles in the pleura costalis, also in a

strong band of adhesion between the lung and pleura, with several loose flakes of lymph adhering to both.—Donor, Dr. Davy, A. I. H.—MS. Cat. vol. i. page 47, No. 119.

724. A large mass of tubercular matter occupying the space between the edge of right lung and front of diaphragm.

SECTION VI.—ABSCESSSES IN OR CONNECTED WITH THE  
PLEURAL CAVITY.

725. Sac of an abscess situated between the inferior lobe of the lung and the diaphragm. Pulmonary and diaphragmatic pleura coated with lymph.

726. Sac of a circumscribed abscess in the left cavity of the thorax, with a fistula opening externally between the eighth and ninth ribs; pleura thickened.—Print. Cat. page 32, No. 102.

727. An abscess, the size of a billiard-ball, situated beneath the pleura costalis of the left side and protruding into the thoracic cavity.—MS. Cat. vol. i. page 68, No. 201.

728. A large cyst attached to the costal pleura, and filled with hydatids.

729. A conical cyst about the size of a pigeon's egg, projecting from the diaphragm into the left pleural cavity.—Donor, Mr. Ford, A. S. 72nd Regt.—Print. Cat. page 27, No. 76.

730. A loose filamentous tissue, which connected the left lung to the walls of the chest, containing many vesicles varying in size from a pea to a marble and containing a clear serous-looking fluid.—MS. Cat. vol. i. page 58, No. 159.

CLASS III.  
ORGANS OF SENSATION.

DIVISION I.

*DISEASES OF THE DURA MATER.*

SECTION I.—BLOOD EFFUSED ON AND UNDER THE DURA  
MATER.

731. A large mass of coagulum adhering to the external surface of the dura mater which lined the right temporal bone.—Print. Cat. page 142, No. 32.

732. A thin stratum of blood effused on the external surface of a portion of the dura mater.—Donor, Mr. White, A. S. Staff.—Print. Cat. page 143, No. 33.

733. Portion of dura mater with a layer of coagulated blood of a dark colour adhering to its outer surface.—Donor, Mr. Smyth, A. S. 85th Regt.—Print. Cat. page 144, No. 41.

734. Blood effused on the inner surface of the dura mater which covered the right hemisphere of the brain.—Donor, Dr. Davy, A. I. H.—MS. Cat. vol. iii. page 2, No. 51.

735. A thin stratum of blood effused on the inner surface of the dura mater.—MS. Cat. vol. iii. page 5, No. 128.



SECTION II. — THICKENING AND EFFUSION OF LYMPH ON THE  
DURA MATER.

736. Thickening of the anterior portion of the dura mater which covered the left hemisphere of the brain; also a soft cheesy body about the size of a pea deposited on its inner surface.—MS. Cat. vol. iii. page 13, No. 79.

737. Large patches of coagulable lymph thrown out on the inner surface of the dura mater along the course of the superior longitudinal sinus.—Print. Cat. page 138, No. 7.

738. Two portions of dura mater with yellow lymph effused on their inner surface, at several parts the lymph is deposited in thick patches.—Print. Cat. page 139, No. 20.

739. A thick oval patch of yellow lymph, consisting of several layers, deposited on the outer surface of the dura mater.—Print. Cat. page 139, No. 20.

740. Falx major adhering firmly and extensively to the arachnoid membrane.—MS. Cat. vol. iii. page 14, No. 82.

SECTION III.—BONY DEPOSIT IN THE DURA MATER.

741. A spicula of bone in the dura mater situated close to the longitudinal sinus.—Donor, Mr. Lightbody, Surgeon 80th Regt.—Print. Cat. page 144, No. 44.

742. Large irregular masses of bone in the dura mater along the course of the longitudinal sinus on both sides.—Donor, Mr. Grasset, Staff Surgeon.

743. Large irregular plates of bony matter in the dura mater on either side of the longitudinal sinus.—MS. Cat. vol. v. page 4, No. 120.

744. Several spiculæ of bone on the dura mater along the course

of the longitudinal sinus on both sides, also a large mass in the falx major.—Print. Cat. page 143, No. 34.

745. Spiculæ of bone in the dura mater along the course of the longitudinal sinus on both sides.—Donor, Mr. Allan, A. S. Staff.

746. An osseous deposit, somewhat larger than a pea, situated on the inner surface of the dura mater which covered the anterior and superior part of the left hemisphere of the brain. Also another deposit of nearly the same size attached to the left side of the anterior part of the falx major. The surfaces of both the portions of bone are irregular.—Donor, Dr. Williams, Surgeon 68th Regt.

747. A large patch of bony matter deposited in the anterior part of the falx major, also another of smaller size a little posterior to its centre.—Donor, Mr. Allan, A. S. Staff.

748. A large mass of osseous deposit, three inches in length and one inch in depth, situated in the anterior part of the falx cerebri.—Donor, Dr. Melvin, Staff Surgeon.—MS. Cat. vol. v. page 5, No. 130.

749. Three large osseous deposits in the falx cerebri.—Donor, Dr. Montgomery.—MS. Cat. vol. iii. page 233, No. 140.

750. Three osseous deposits, the size of large peas, situated in the anterior part of falx major which is also reticulated.—MS. Cat. vol. iii. page 12, No. 73.

751. A bony deposit in the anterior and inferior margin of the falx major which is also reticulated.—Donor, Dr. Caw, A. S. Staff.—MS. Cat. vol. v. page iii. No. 116.

752. Two osseous deposits in the anterior part of falx cerebri.

#### SECTION IV.—TUBERCULAR DEPOSIT ON THE DURA MATER.

753. A thick layer of tuberculous matter deposited on the inner surface of the dura mater which covered the left anterior lobe of the brain.



754. A number of tumours of a tubercular character, from the size of a pea to that of a cherry, attached to the inner surface of the dura mater. Sections are made of some of them showing their structure to be of a firm homogeneous nature.—Print. Cat. page 137, No. 1.

755. Scrofulous matter deposited in the falx cerebri near crista galli.

756. Adventitious matter of a scrofulous character deposited on the external but particularly on the internal surface of the dura mater, in the latter situation it is at one part nearly a quarter of an inch in thickness and adheres to the surface of the brain.—Donor, Mr. Ford, A. S. 72nd Regt.—MS. Cat. vol. iii. page 8, No. 64.

757. Section of the previous preparation showing adventitious deposit on the outer but particularly on the inner surface of the dura mater which adheres to the brain through its intervention.—Donor, Mr. Ford, A. S. 72nd Regt.—MS. Cat. vol. v. page 8, No. 64.

#### SECTION V.—TUMOURS OF THE DURA MATER.

758. Soft fleshy excrescences, apparently of coagulable lymph of a pale yellow colour, adhering to the inner surface of a portion of the dura mater which was situated opposite to the inferior part of the right, anterior and middle lobes of the brain.—Print. Cat. page 141, No. 26.

759. A large adventitious deposit, at one part about an inch in thickness, attached to the inner surface of the dura mater which covered the anterior part of the cerebrum. The tumour projected into the substance of the anterior lobe.—Print. Cat. page 14, No. 24.

760. Three fleshy tumours larger than horse-beans and several others the size of millet seeds attached to and imbedded in the substance of the dura mater on each side of the falx cerebri, some of them arising from the external and others from the internal surface of this membrane.—Necrol. Reg. vol. vi. page 1.

761. A fleshy excrescence, about the size of a shilling, attached to the inner surface of a portion of the dura mater.

762. A spongy and wart-like tumour, about the size of a large pea, attached to the inner surface of the dura mater.—MS. Cat. vol. iii. page 17, No. 100.

763. A tumour, about the size of a pea, attached to the inner surface of the dura mater.—Donor, Dr. Williams, 68th Regt.—MS. Cat. vol. iii. page 2, No. 68.

764. A tumour, about the size of a hen's egg and of a medullary consistence and appearance, attached to the inner surface of the dura mater and projected into the surface of the brain.—Print. Cat. page 137, No. 3.

765. A tumour, about the size of a plum and of a homogeneous texture at some parts softened and broken up, which was found attached to the dura mater.—Donor, Dr. Davy, A. I. H.—Print. Cat. page 138, No. 8.

766. A tumour of a medullary character which takes its origin between the layers of the dura mater; it pressed on the anterior lobe of the right hemisphere of the brain. The globe of the right eye was also occupied by a tumour the size of a pigeon's egg partly of a melanotic and partly of a medullary nature.—Preparation No. 880.—Necrol. Reg. vol. v. page 255.

767. A tumour, about the size of a hen's egg and of a firm fleshy consistence, attached to a portion of dura mater and projected into the substance of the brain.—Print. Cat. page 138, No. 5.

768. A firm fleshy tumour, about the size of a plum and of a homogeneous texture, attached to the dura mater, it was imbedded in the left middle lobe of the cerebrum.—MS. Cat. vol. iii. page 18, No. 102.

SECTION VI.—ABSORPTION AND RETICULATED APPEARANCE  
OF THE DURA MATER.

769. Portion of dura mater thinned and perforated at the parts which corresponded to bony projections on the inner surface of the cranium.—Necrol. Reg. vol. v. page 249.

770. Dura mater which covered the convex surface of the brain absorbed at several places, presenting an appearance as if it had been gnawed by insects.—Print. Cat. page 139, No. 13.

771. Two large circular apertures in the dura mater, close to the anterior extremity of the longitudinal sinus which is destroyed at this part; there are two other openings in the dura mater which covered the lateral part of the anterior lobes of the brain, that on the left side being about two inches in length and that on the right side one inch.—MS. Cat. vol. iii. page 16, No. 90.

772. Anterior extremity of the dura mater on each side of the longitudinal sinus absorbed, edge of the falx major has a ragged appearance from shreds of lymph hanging on it, the arachnoid covering of anterior lobes of brain adhered to the inner surface of the dura mater as did the falx to the portion of arachnoid opposed to it.—MS. Cat. vol. iii. page 12, No. 74.

773. A large opening in, with a cribriform state of, the falx major; dura mater in the neighbourhood of the falx also attenuated in several places.—MS. Cat. vol. ii. page 12, No. 72.

774. Two large apertures in, with a cribriform state of, the falx major.

775. A cribriform appearance of the falx major.

## DIVISION II.

### *DISEASES OF THE PIA MATER AND ARACHNOID.*

~~~~~

SECTION I. — VASCULARITY, THICKENING AND EFFUSION OF LYMPH ON THE ARACHNOID AND PIA MATER.

776. Portion of arachnoid membrane presenting a small blood-vessel branching through its substance. The vessel was full of red blood but has lost its colour by drying.—MS. Cat. vol. iii. page 14, No. 84.

777. Veins of a portion of the pia mater and arachnoid congested.

778. Thickening of the pia mater and arachnoid which covered the upper surface of the cerebrum.—Donor, Mr. Davey, A.S. 7th Regt.—MS. Cat. page 2, No. 53.

779. The arachnoid and pia mater covering a portion of brain thickened.—Donor, Mr. Millar, Staff Surgeon.

780. Portion of the right hemisphere of the brain showing thickening of the arachnoid and enlargement of the glandulæ Pacchioni.—Print. Cat. page 144, No. 40.

781. Two superficial sections of the hemispheres of the cerebrum, with deposition of lymph on the arachnoid and enlargement of the glandulæ Pecchioni.—Print. Cat. page 142, No. 31.

782. Portion of pia mater from the upper surface of one of the

hemispheres with the cerebral substance firmly adhering to it.—MS. Cat. vol. iii. page 12, No. 75.

SECTION II.—CALCAREOUS DEPOSITS IN THE ARACHNOID AND
PIA MATER.

783. A small calcareous deposit attached to a portion of pia mater which covered the left hemisphere of the brain.—Necrol. Reg. vol. vi. page 98.

784. Calcareous deposits the size of large peas in the inferior part of each choroid plexus.—MS. Cat. vol. iii. page 14, No. 83.

785. Calcareous concretions the size of peas from the inferior part of each choroid plexus.—Necrol. Reg. vol. ii. page 344.

786. Calcareous concretions the size of horse-beans in the inferior part of each choroid plexus.—Donor, Dr. Scott, Surgeon Rifle Brigade.—MS. Cat. vol. iii. page 8, No. 63.

DIVISION III.

DISEASES AND INJURIES OF THE BRAIN.

SECTION I.—RAMOLLISSEMENT OF THE BRAIN.

787. Softening of the cortical substance of a portion of brain.

788. Softening of the cortical substance of a portion of brain; an oval ulcerated opening, about two inches in length divided into two parts by a narrow band, situated in the dura mater corresponding to the softened portion of brain.—Print. Cat. page 143, No. 36.

789. Well marked ramollissement of a portion of the right hemisphere of the brain.—Print. Cat. page 144, No. 39.

790. Ramollissement of a portion of right lobe of the cerebrum; the dura mater is thickened and adheres to the arachnoid by the intervention of an abundant deposition of lymph on its internal surface. In the recent preparation the dura mater and arachnoid included small collections of viscid pus, which were depressed into the substance of the softened brain.—Print. Cat. page 141, No. 27.

791. Section of brain showing the anterior part of the right corpus striatum completely broken down in consequence of ramollissement.

792. Section of brain showing ramollissement and breaking up of the anterior part of the left corpus striatum and medullary substance in the neighbourhood on its external side; these parts in the recent preparation were of a dark colour.—Donor, Mr. Ford, A. S. 72nd Regt.—MS. vol. iii. page 2, No. 54.

SECTION II.—APOPLECTIC CELLS IN THE BRAIN.

793. Right hemisphere of the brain of a paralytic idiot, showing a large apoplectic cell on its external surface situated between the anterior and middle lobes.—Donor, Mr. Fraser, A. S. Staff.—Print. Cat. page 140, No. 22.

794. A large apoplectic cell, about four inches in length, two and a-half in breadth and depth, situated in the right hemisphere of the brain, and extending into the inferior and posterior cornu of the lateral ventricle; the cavity contains a few coagula and its walls are soft and broken down; this hemisphere appears much larger than the left on account of the effusion and distension having caused compression of the surrounding cerebral substance. Ecchymosis beneath the arachnoid and pia mater covering the inferior and posterior part of the anterior lobe.

795. A large apoplectic cell, lined with a few coagula, in the left hemisphere of the brain external to the corpus striatum, opening into the lateral ventricle; also another apoplectic effusion in the anterior part of the cerebellum and upper surface of the crura cerebri; extravasation of blood beneath the membranes covering superior surface of the left hemisphere.—Print. Cat. page 48, No. 89.

796. Portion of brain showing a small apoplectic cell in the inferior part of the middle lobe of the right hemisphere, in its neighbourhood blood is effused beneath the arachnoid membrane which is thickened; corpus striatum softened.—Donor, Mr. Ford, A. S. 72nd Regt.—MS. Cat. vol. iii. page 8, No. 62.

797. An apoplectic cell occupying the greater part of the anterior lobe of the right hemisphere of the brain and has destroyed the anterior part of the corpus striatum; there is also blood effused beneath the membranes covering the inferior part of this lobe.

798. An apoplectic cell in the upper part of the left hemisphere of the brain.—Print. Cat. page 145, No. 47.

799. A large apoplectic cell in the anterior part of right hemi-

sphere of the brain containing a clot of blood about the size of a hen's egg.

800. Portion of cerebrum containing an apoplectic deposit.

801. An apoplectic cell, containing a clot, situated in the right hemisphere on the external and posterior part of the optic thalamus.—MS. Cat. vol. v. page 5, No. 127.

802. An apoplectic cell in the right corpus striatum.—MS. Cat. vol. v. page 5, No. 128.

803. An apoplectic cell filled with coagula in the left optic thalamus and corpus striatum.—Necrol. Reg. vol. vi. page 156.

804. Small apoplectic effusion in the medulla oblongata and pons Varolii.

805. An apoplectic cell, filled with coagulum, situated in the anterior parts of the cerebellum and fourth ventricle, immediately above the pons Varolii.—Print. Cat. page 48, No. 89.

806. An ancient laceration of the surface of the left hemisphere of the brain.—MS. Cat. vol. iii. page 4, No. 56.

SECTION III.—ABSCESSSES IN THE BRAIN.

807. A depression, about the size of a pigeon's egg which contained purulent matter, situated on the superior part of the middle lobe of the cerebrum between arachnoid and pia mater.

808. Cyst of an abscess, about the size of a hazel nut not having well defined parietes and contained a greenish puriform matter, situated in the centre of posterior lobe of right hemisphere.—Donor, Mr. Ford, A. S. 72nd Regt.—MS. Cat. vol. iii. page 3, No. 55.

809. Cyst of a large abscess situated in the inferior and posterior part of the left anterior lobe of the cerebrum, anterior to the fissures of Sylvius and immediately below the corpus striatum. The cavity is lined by a distinct membrane some parts of it having a granular

appearance, there is an aperture inferiorly, capable of admitting a common quill, the margins of which adhered to the orbital plate of the frontal bone and from this part an opening descended into the left nasal cavity.—Preparation No. 887.—MS. Cat. vol. iii. page 258, No. 216.

810. Cyst of an abscess, about four inches in length, two inches in breadth and one in depth, situated in the left hemisphere of the brain, extending from before backward and lined by a distinct membrane.

811. Cyst of an abscess, the size of a plum, situated in the right hemisphere of brain external and superior to the corpus striatum, lined by a distinct membrane and projecting into the anterior cornu of the lateral ventricle.—Print. Cat. page 138, No. 4.

812. Section of brain showing the cyst of an abscess, about two inches in length and half an inch in breadth, lined by a fine cellular membrane several delicate bands of which pass across the cavity, situated in the right corpus striatum.

813. An incysted abscess, about the size of a plum, in the cerebellum immediately above the fourth ventricle. The interior of the cavity is smooth and lined by a distinct membrane.—MS. Cat. vol. iii. page 16, No. 93.

814. Section of brain showing the cyst of an abscess the interior of which is rough and broken down.

815. Portion of brain showing the cyst of an abscess, the size of a pigeon's egg, lined by a distinct membrane.—Donor, Dr. Williams, Surgeon 68th Regt.

816. Sac of an abscess, the size of a pea, in the right lobe of the cerebellum its contents were of a cheesy nature, a section is made of the cavity and bristles are placed so as to indicate more clearly the opposite portion of its walls.—Print. Cat. page 143, No. 37.

817. A cavity, the size of a horse-bean, in the right side of the tuber-annulare.—Necrol. Reg. vol. v. page 323.

SECTION IV.—TUBERCULAR DEPOSIT IN THE BRAIN.

818. Section of the left hemisphere of the brain showing a large well-defined tubercular deposit with a delicate cellular structure existing between the brain and adventitious matter. In the recent preparation the cellular structure had a slight yellow tinge.—Print. Cat. page 141, No. 28.

819. Portion of the right hemisphere of the cerebrum showing a small tubercle, bristles are so placed as to indicate more clearly its size.—Print. Cat. page 142, No. 28.

820. A large scrofulous tumour in the middle lobe of the left hemisphere near the surface, with separation of the convolutions and considerable softening of the medullary structure.—Donor, Mr. O'Brien, A. S. 7th Regt.—MS. Cat. vol. v. page 2, No. 110.

821. Two scrofulous tubercles in their second stage of maturation in the substance of the cerebrum.—Donor, Richard Partridge, Esq., King's College, London.

822. A scrofulous tumour, the size of a large plum, situated in the inferior part of the left lobe of the cerebellum and pressing on the medulla oblongata.—Donor, Mr. Stanley, St. Bartholomew's Hospital.

823. A large tubercle partly broken down which was situated on the left lobe of the cerebellum and surrounded by about half a drachm of pus-like fluid.—MS. Cat. vol. iii. page 15, No. 89.

SECTION V.—SEROUS CYSTS IN BRAIN.

824. Portion of anterior lobe of left hemisphere of brain showing the upper surface of a cavity lined by a fine cellular membrane which was filled with serous fluid.—MS. Cat. vol. iii. page 13, No. 79.

825. Portion of anterior lobe of left hemisphere of brain showing

the floor of a cavity lined by a fine cellular membrane which was filled with serous fluid.—MS. Cat. vol. iii. page 13, No. 79.

826. Portion of one of the hemispheres of the brain showing a long deep cavity on its surface, situated between the arachnoid and pia mater which contained two drachms of serum.

827. Section of a cyst, the size of a hazel nut which contained serous fluid, situated in the posterior lobe of the cerebrum immediately behind the posterior cornu of the right lateral ventricle.—MS. Cat. vol. iii. page 11, No. 71.

828. A vesicular body, the size of a pea, situated in the anterior part of the velum interpositum.—Print. Cat. page 144, No. 38.

829. Pineal gland enlarged and a small cavity in it which was distended with serous fluid.

830. Pineal gland larger than usual with a cavity in it which contained a brownish fluid.—Donor, Mr. O'Brien, A. S. 7th Regt.—MS. Cat. vol. iii. page 5, No. 57.

831. Substance of the pineal gland destroyed and its investing membrane was filled with fluid.—Necrol. Reg. vol. v. page 377.

832. Pineal gland enlarged with several yellow coloured spots on its surface.—Donor, Dr. Davy, A. I. H.—MS. Cat. vol. iii. page 2, No. 50.

833. Calcareous concretions about the size of small peas which were attached to the pineal gland.—Necrol. Reg. vol. v. page 369.

834. A large cyst, in the anterior and superior surface of the left upper lobe of the cerebellum, lined by a distinct membrane which was filled with a straw-coloured fluid. A tumour about the size of a horse-bean is attached to the anterior wall of the cavity; a coloured thread is passed through the tumour the better to point it out.—Donor, Mr. Gulliver, A. S. Royal Horse Guards.—MS. Cat. vol. v. page 6, No. 131.

835. A large gelatinous-looking vesicle, of an opaque white colour, from the brain; the man died with symptoms of cerebral compression.—Donor, Mr. Roberts, A. S. 59th Regt. — London Medical Gazette, 1838.

SECTION VI.—HYDATIDS FROM THE BRAIN.

836. Portion of pia mater with a hydatid attached; the cyst is laid open and the animal exposed.—MS. Cat. vol. iii. page 14, No. 85.

837. Hydatid which was found imbedded in the right corpus striatum; it is a cephalo cyst, and has a small depression in the appendix.—MS. Cat. vol. iii. page 14, No. 86.

838. Hydatid from the brain laid open; there is a small opaque granular-looking body within it, and corresponding to this in its parietes is a small aperture.—MS. Cat. vol. iii. page 15, No. 87.

839. Cyst from which the hydatid forming the previous preparation was taken. Preparations 836, 837, 838, and 839 were taken from the same patient, and were situated chiefly on the surface of both hemispheres immediately beneath the pia mater.—MS. Cat. vol. iii. page 15, No. 88.

840. Small cysticercus which was situated loosely between the dura mater and neighbouring investments of the convolutions at the base of the brain near to the optic nerve. It appears to be the cysticercus cellulosa, and the four preceding preparations are apparently of the same species.

841. An immense number of hydatids from the membranes and substance of the brain.—Donor, Dr. Bell, Surgeon 26th Regt.—MS. Cat. vol. iii. page 18, No. 103.

SECTION VII.—TUMOURS FROM THE BRAIN.

842. A tumour about the size of a walnut in the substance of the right optic thalamas. The tumour was in the recent preparation of

a darker colour and harder texture than the rest of the brain; its borders were well defined, and in their vicinity the vessels had become enlarged.—MS. Cat. vol. iii. page 6, No. 59.

843. Portion of a tumour, of a firm fibrous consistence, which occupied the whole of the superior and middle part of the right hemisphere and descended as low as the corpus callosum. The parietal bone covering the tumour was completely absorbed for the space of two inches.—Donor, Dr. Bell, Surgeon 26th Regt.—MS. Cat. vol. iii. page 18, No. 104.

844. Tumour about the size of a plum and of a cheesy consistence; removed from the brain.—Royal College of Surgeons, Edinburgh.—Print. Cat. page 139, No. 10.

845. Four tumours about the size of walnuts and of a fibrous texture; taken from the brain.—Donor, Mr. Booty, A. S. Staff.—Print. Cat. page 138, No. 6.

846. Tumour of a firm consistence which was situated in the substance of the cerebrum, a little anterior to its right crus. The tumour had no cyst, and the portion of brain surrounding it was softened.—Donor, Mr. Davey, A. S. 7th Regt.—MS. Cat. vol. iii. page 2, No. 52.

847. A tumour about the size of a hazel-nut and of a firm cheesy consistence; taken from the brain.—MS. Cat. vol. iii. page 17, No. 101.

848. Several tumours of a fibrous consistence which were situated on the superior surface of middle lobe of left hemisphere. The pia mater and arachnoid are thickened and adherent.—Donor, Mr. Malcolm, A. S. 72nd Regt.

849. Tumour of a pale yellow colour and firm fibrous consistence which occupied the upper and anterior part of right lobe of the cerebrum. It is firmly attached to the dura mater, which is at some parts absorbed, as was also the corresponding portion of the frontal bone.—Donor, Mr. Wyer, 74th Regt.—MS. Cat. vol. iii. page 10, No. 66.

850. Tumour about the size of a plum and of a medullary structure attached to the cerebellum. From a soldier who died of a fever.—Donor, Mr. Lightbody, Surgeon 80th Regt.

851. Pituitary body enlarged and of a firm consistence, with a small cavity in its substance. The infundibulum is likewise better developed and firmer than natural.—MS. Cat. vol. iii. page 13, No. 77.

852. Tumour about the size of a pigeon's egg which was situated in the left anterior lobe of the brain. The tumour is of a firmer texture than the surrounding medullary substance and has well defined borders; both the tumour and cerebral substance adhere firmly to the dura mater and scalp, on which there is a large cicatrix: the os-frontis was perforated by a circular aperture and allowed the tumour and a portion of brain to protrude, forming hernia cerebri. Preparation, No. .—Print. Cat. page 145, No. 48.

SECTION VIII.—DILATATION OF THE VENTRICLES AND RUPTURE OF THE SEPTUM LUCIDUM.

853. Great dilatation of the foramen of Munro. The lateral ventricle contained about four ounces of limpid serum.—Print. Cat. page 142, No. 30.

854. Fifth ventricle of a large size, both laminæ of the septum lucidum are separated throughout their whole extent and much thickened. All the ventricles were distended with serous fluid.—MS. Cat. vol. iii. page 12, No. 74.

855. Dilatation of the fifth ventricle.—Donor, Dr. Davy, A. I. H.—Print. Cat. page 146, No. 49.

856. A large opening in the septum lucidum with several bands of medullary matter passing across it.—MS. Cat. vol. iii. page 17, No. 99.

857. Septum lucidum much enlarged and a circular opening about an inch in diameter at its anterior part. In the recent preparation

two small blood vessels were observed to run through the aperture. The lateral ventricles were very much distended with serous fluid.—Donor, Mr. Gulliver, A. S. Staff.—MS. Cat.* vol. iii. page 13, No. 78.

858. A longitudinal opening about an inch in length in the septum lucidum. The lateral ventricles were distended with serous fluid.—MS. Cat. vol. iii. page 16, No. 91.

859. Almost the whole of the septum lucidum broken down, with only a few bands passing across the aperture.

DIVISION IV.

DISEASES OF THE SPINAL CHORD AND NERVES.

860. Spinal chord; which in the recent preparation was highly vascular, from a child 38 days old who died of Pneumonia.—Donor, Dr. Davy, A. I. H.

861. A large tumour, occupying the spinal canal, situated opposite to the two last lumbar vertebræ and upper part of the sacrum; on the front of the sacrum there is a circular opening, half an inch in diameter to which was attached a tumour the size of a large filbert, leading into the spinal canal; on the posterior part of the sacrum the tumour has destroyed the greater part of the bones on each side of the spinous processes, those of the lumbar vertebræ have been removed to expose the tumour which is soft, broken down, of a dark red colour and granular appearance and occupies the sheath of the spinal chord, the nerves lie on its posterior surface and those proceeding out of the sacral foramina appear quite healthy.—MS. Cat. vol. iii. page 20, No. 10.

862. Stump of the arm:—exhibiting the bulbous tumours frequently found on the extremities of nerves after amputation.—Print. Cat. page 171, No. 35.

863. Portion of the ulnar nerve terminating in a bulb; the nerve is imperfectly injected.—MS. Cat. vol. ii. page 19, No. 4.

864. Part of the median terminating in a bulb. The enlargement appears to result from adventitious deposit rather than enlargement of the nervous texture or neurelima.—MS. Cat. vol. iii. page 19, No. 5.

865. Part of the median nerve terminating in a bulb. The swelling is of firm fibrous texture intersected by lines of tendinous lustre.—MS. Cat. vol. iii. page 19, No. 6.

866. Ulnar nerve terminating in a bulb.

867. Two bulbous tumours, one situated a little above the other at the extremity of the ischiatic nerve, the bulbs are of a dense firm homogeneous texture apparently distinct from that of the nerve or neurelma, and is not to be considered a disease, as nerve always presents this appearance at the end of a stump.—Donor, Mr. Stanley, St. Barthomew's Hospital.

868. Posterior tibial nerve increased in size from deposition of lymph between its fibrils. The surrounding structures were very much condensed on account of an old foul irritable ulcer.—MS. Cat. vol. iii. page 21, No. 12.

869. Atrophy of both optic nerves, particularly the left, from a patient who had an amaurotic affection of the left eye.—Donor, Dr. Jones, 1st Dragoons.—MS. Cat. vol. i. page 194, No. 163.

870. Trunk of the nervus vagus intimately connected with that of the great sympathetic.—Donor, Dr. Davy, A. I. H.—MS. Cat. vol. iii. page 19, No. 3.

DIVISION V.

DISEASES AND INJURIES OF THE ORGANS OF THE SENSES.

SECTION I.—DISEASES OF THE EYE.

871. Atrophy of one of the left optic nerves anterior to the commissure.—MS. Cat. vol. iii. page 27, No. 4.

872. Eye the humours of which having been discharged and its coats have collapsed to the size of a pea. A section displays the most complete disorganization with a trace of the pigmentum nigrum remaining in its centre. The orbit was loaded with fat and the muscles of the eye-ball were sensibly atrophied, the result of an inquiry some years previous to the death of the patient; from the same subject as the previous preparation.—MS. Cat. vol. iii. page 27, No. 4.

873. Eye collapsed and contracted from the escape of its humours with atrophy of the corresponding optic nerve. The disease originated in an injury of the eye.—Donor, Mr. O'Brien, A. S. 7th Regt.—MS. Cat. vol. iii. page 28, No. 6.

874. Partial ossification of the sclerotic coat of the eye.—Donor, Dr. Davy, A. I. H.—MS. Cat. vol. iii. page 27, No. 2.

875. A deposit of bony matter in the choroid of the right eye; the retina with the hyaloid membrane pass from behind forwards in the centre of the eye, the humours having been absorbed.—Necrol. Reg. vol. vi. page 98.

876. Complete obliteration of the pupil from the effusion of lymph and consequent adhesion of the pupillary margin of the iris. The cornea was opaque but did not adhere to the iris.—MS. Cat. vol. iii. page 27, No. 3.

877. Diseased crystalline lens from the eye of a patient operated on for staphyloma. The lens on its first removal from the eye was of unusually hard texture and much compressed in its antero-posterior diameter. Viewed between the eye and a bright light its whole substance appeared somewhat opaque but not uniform in point of colour, for at different points were observed radii of a deep amber colour emanating as it were from the centre and diverging towards the circumference; since the immersion of the preparation in spirit the latter of these appearances has not been evident.

878. Lens and hyaloid membrane of a child, discharged by a perforation of the cornea caused by an ulcer following small-pox.—Donor, A. Stewart, A. S. Staff.—MS. Cat. vol. iii. page 28, No. 8.

879. Symblepharon of lower eyelid to the cornea.—MS. Cat. vol. iii. page 27, No. 1.

880. Globe of right eye occupied by a malignant tumour composed of two distinct structures one of which is of a medullary and the other of a melanotic character, the right optic nerve was also involved in the disease, of a dark colour, harder and smaller than the left.—Preparation No. 766.—Necrol. Reg. vol. v. page 227.

881. Malignant disease of the eye-ball, the exterior of which is firm and cartilaginous and the interior filled with calcareous matter.

SECTION II.—DISEASES OF THE EAR.

882. Caries of the petrous portion and mastoid process of the right temporal bone, the greater part of the latter, the small bones of the ear and the anterior surface of the former are destroyed; about an ounce of pus was found between the petrous portion of

the temporal bone and the dura mater.—Print. Cat. page 148, No. 19.

883. Caries of the external and anterior walls of the meatus auditorius of the right temporal bone, also of the mastoid process where there was an abscess which communicated with the internal ear; the membrana tympani and all the ossicula auditus except the stapes, were destroyed.—Print. Cat. page 156, No. 100.

884. Caries of the internal meatus and petrous portions of the left temporal bone.—Print. Cat. page 156, No. 100.

885. A carious cavity the size of a horse-bean situated at the outer extremity of the petrous portion of the left temporal bone on its internal surface.

SECTION III.—DISEASES OF THE NOSE.

886. A polypous excrescence from the nose of a man who had one removed once before.—MS. Cat. vol. iii. page 245, No. 189.

887. An immense gelatinous polypus arising from the septum nasi on both sides also adhering to the base of the cranium, the cerebral surface of which presents an oblong tumour extending from the ethmoid bone to the foramen magnum; the whole of the ethmoid (with the exception of the crista galli) body of the sphenoid, basilar process of the occipital, petrous portions of the temporals, more especially that of the right, are entirely absorbed without the slightest vestige of bony matter remaining and occupied by a soft elastic tumour covered only by the dura mater; it is five inches in length, two and a-half in breadth and protrudes upwards at the sphenoid for an inch and a-quarter. A probe is passed down into the left nostril through an opening situated between the posterior part of the ethmoid, orbital plate of the frontal and small wing of the sphenoid bones, the margins of the superior part of this opening are thickened and to which adhered the arachnoid and pia mater covering the left anterior lobe of the brain in which was a large abscess. Preparation No. 809. Two large pendulous bodies hang, from that part of the tumour attached to the septum, into the back of the

pharynx ; the one on the left side is the size of a hen's egg and extended down as far as the epiglottis and pushes the palate forwards, the lower part of this tumour is of a dark colour and ulcerated, that on the right side is the size of a walnut, the two being separated from each other by a deep notch, in the bottom of which is the remains of the septum of the nose, superiorly and anteriorly they form one distinct mass. The frontal and maxillary bones of right side are removed to show the tumour which is attached to all the parts formerly mentioned with the addition of the entire septum of the nose and is continuous at the base posteriorly with the smaller tumour which hangs into the back of the pharynx ; it rests inferiorly on the palate, the bones of which are entirely destroyed with the exception of the alveolar processes. The bones of the nose on this side were absorbed, the base of the orbit very thin, nasal process of the maxillary entire but much expanded, turbinated bones completely absorbed but the mucous membrane which contained them was quite perfect as were also the walls of the antrum. The tumour in the left nasal cavity is rather larger than that in the right, has the same attachment and separated by a deep depression from the larger portion of the tumour which hangs into the pharynx. All the bones are in a similar manner absorbed as those on the opposite side.—MS. Cat. Vol. iii. page 258, No. 216.

888. Thickening of the lining membrane of the right maxillary antrum and the left antrum is much larger than the right.—Donor, Mr. Cathcart, Surgeon 7th Dragoons.—MS. Cat. vol. iii. page 213, No. 60.

SECTION IV.—DISEASES OF THE TONGUE.

889. Lenticular papillæ of the tongue in a state of hypertrophy.—MS. Cat. vol. ii. page 4, No. 20.

890. Mucous membrane of the tongue ulcerated in several places.—MS. Cat. vol. ii. page 4, No. 19.

891. A deep excavated cancerous ulcer in a portion of the tongue which was removed by operation.—Donor, Mr. O'Brien, A. S. 7th Regt.

892. Malignant ulceration which has destroyed the greater part of the right side of the tongue.—Donor, Mr. Fraser, A. S. Staff.—Print. Cat. page 70, No. 6.

SECTION V.—DISEASES OF THE SKIN.

893. Portion of skin showing warts to be a disease of the cutis as well as cuticle.

894. Two portions of skin showing warts, one portion is deprived of cuticle.

895. Condylomatous excrescences the size of walnuts removed from the vicinity of the verge of the anus.—Donor, Mr. Athill, A. S. Staff.—MS. Cat. vol. iii. page 241, No. 176.

896. A toe deprived of its cuticle and showing a circumscribed enlargement of the papillæ of the chorion in a corn.

897. Toe deprived of its cuticle, exhibiting a circumscribed enlargement of the papillæ and the surface of the chorion elevated. This preparation and the previous one are minutely injected and the enlargement and increased vascularity of the papillæ are very distinct. The appearances described show the state of the cutis in corns after the thickened cuticle has been removed. This is a pathological appearance in the human subject but a structure resembling this disease may be seen to be the natural state in some animals when there is a very thick and much used cuticle. In the other museum this may be seen in some injections of the vascular layer of the planter cutis vera of the dog.

898. A corn, of which a section is made including the subjacent parts, situated over the articulation between the first and second phalanx of the second toe; there is also a well-defined bursa in the cellular tissue immediately beneath the chorion.—MS. Cat. vol. ii. page 197, No. 19.

899. A corn of which a section is made, situated on the inner side of the great toe over the metatarso phalangeal articulation, and in the

cellular substance immediately beneath the chorion there is a well-defined bursa.—Donor, Mr. Gulliver, A. S. Staff.—MS. Cat. vol. ii. page 197, No. 20.

900. Piece of the integument of the leg in which the granulations of an ulcer are injected.—Donor, Mr. Gulliver, A. S. Staff.—MS. Cat. vol. ii. page 199, No. 29.

901. Portion of the cutis vera in which an ulcer is situated, the part is minutely injected.—Donor, Mr. Gulliver, A. S. Staff.

902. Portion of cutis vera showing a small irregular deficiency in its substance the base of which is very vascular as are also its margins where the papillæ are enlarged. The depression is the cicatrix of an ulcer of the leg which had been completely healed and covered with cuticle, six weeks before the man's death. The preparation illustrates how slow the cutis vera is to reproduce any loss of substance.

903. Several small cicatrices on the cutis vera. The hair bulbs have not been reproduced; if the preparation be looked at in profile the deficiency of the hairs will be plainly seen. From the leg of a middle-aged man who had ulcers of the part for at least twelve months before his death.

904. Portion of cutis vera from a stump showing a cicatrix of a very firm, shining and almost tendinous texture. In the cicatrix are some of the appendages of the skin.—MS. Cat. vol. iii. page 19, No. 6.

905. Portion of skin with a thickened and elevated cicatrix the effect of frequent corporeal punishment.—Donor, Dr. Davy, A. I. H.

906. Portion of cutis vera from which the cuticle is detached showing a thickened elevated and gelatinous-looking cicatrix. From the thigh of a man aged 28.—Donor, Dr. Davy, A. I. H.

907. Portion of skin showing the thickening of the cutis in a cicatrix.—MS. Cat. vol. ii. page 202, No. 46.

908. Portion of dermis, showing an old cicatrix, injected, the

vessels shooting from the contiguous parts into the newly-formed substance are of much smaller size and less numerous than those surrounding the cicatrix.

909. Portion of skin injected the cuticle and rete mucosum are separated from the vascular layer of the dermis and a number of varioloid pustules are situated between them, the inner surface of the rete mucosum has a peculiar lace-like appearance; also several white slightly depressed spots on the external surface of the dermis, the parts surrounding them are highly injected. From a patient who died of variola.

910. Portion of skin injected, showing the vascular layer of the dermis with a number of depressed white spots on its surface. From a patient who died of variola.

911. Portion of skin injected; the cuticle is separated from the rete mucosum which is attached to the vascular layer of the dermis, with several white depressions on their surface. From a patient who died of variola.

912. Portion of skin showing the pustular character of the eruption in small-pox.—Donor, Mr. O'Brien, A. S. 7th Regt.

913. Portion of integument from the sole of the foot from which the cuticle is detached, between the layers of which there are a number of varioloid pustules, some of them large and distended, others of them have burst leaving deep depressions; on the surface of the dermis there are several circular depressions with small spots of lymph in their centres. The patient died about the eighth day.—Donor, Dr. Davy, A. I. H.

914. Portion of skin minutely injected, the cuticle is partially detached and on its inner surface there are a number of circular depressions some of them coalescing, also a number of dark yellow spots on the chorion. From a patient who died of small-pox.—Donor, Richard Partridge, Esq., King's College.

915. Portion of the cuticle from the palm of the hand presenting on its inner surface a number of irregular depressions and at some

parts a lace-like appearance. From a patient who died of small-pox.—Donor, Richard Partridge, Esq., King's College.

916. Portion of the cutis vera of the face showing ulcerative absorption of its surface which is thus rendered very irregular and as it were deeply eroded or worm-eaten. From a young man who died of confluent small-pox.—Donor, Dr. Millar, Surgeon 51st Regt.—MS. Cat. vol. ii. page 200, No. 32.

917. Portion of true skin of a limb exhibiting some brown or blackish discolorations of its surface with no destruction of it except at one or two points. From a patient who died of small-pox.—Donor, Dr. Millar, Surgeon 51st Regt.—MS. Cat. vol. ii. page 200, No. 32.

918. Portion of true skin from the sole of the foot studded with the bases of varioloid pustules, apparently effused lymph somewhat dark-coloured.—Donor, Dr. Millar, Surgeon 51st Regt.—MS. Cat. vol. ii. page 200, No. 32.

919. Cuticle from the sole of the foot separated in many places into two layers between which several varioloid pustules are imbedded apparently by destruction of the inner layer.—Donor, Dr. Millar, Surgeon 51st Regt.—MS. Cat. vol. ii. page 200, No. 32.

920. Portion of skin and cellular substance completely infiltrated with coagulated blood, the cuticle is partially detached from the surface of the dark sanguinous deposit, the border of the sound skin where it is in contact with the diseased is thickened, and at some parts of a purple colour. From the shoulder of a man who died of purpura.—Donor, Dr. Burrell, A. S. Staff.—MS. Cat. vol. ii. page 198, No. 21.

921. Portion of skin and cellular substance infiltrated with coagulated blood, cuticle detached, margins of healthy skin thickened and of a dark colour. From the shoulder of a man who died of purpura, section of previous preparation.—Donor, Dr. Burrell, A. S. Staff.—MS. Cat. vol. ii. page 198, No. 21.

922. Infiltration of blood into a portion of the skin and cellular substance: from a patient who died of scorbutus.

923. A mass of coagulated blood about the size of a walnut effused into the cellular substance immediately beneath the skin which is also infiltrated and of a dark colour. The effects of scurvy.

924. Copious effusion of lymph in the hairy scalp also below the cranial aponeurosis where it is nearly half an inch in thickness, the result of erysipelas.—MS. Cat. vol. ii. page 204, No. 49.

925. Portion of hairy scalp much thickened by an abundant deposit between it and the cranial aponeurosis.

926. Portion of integument injected showing the process of separation between the dead and living parts.—Donor, Mr. Howship.—Print. Cat. page 129, No. 9.

927. An oval portion of skin four inches in length and one inch and three-quarters in breadth, affected with ichthyosis, the diseased part is of a dark brown colour, and the excrescences stand out from the skin like the pile of plush, soft and pliable, the dermis is not affected, and it is a disease entirely of the epidermis.—Donor, Mr. T. Berry, Staff Surgeon.—MS. Cat. vol. ii. page 196, No. 8.

928. Sebaceous gland very much enlarged; taken from the neck.—Necrol. Reg. vol. v. page 255.

929. Portion of true skin showing the effect of tattooing; the colouring matter sinks deep into the chorion as is seen by a section of the tattooed part.

930. Portion of tattooed skin.

931. Tubercular melanosis of the integuments and cellular membrane of the foot with the exception of that covering the heel. A section is made of the foot and shows the new deposit to be one inch and a-half in thickness; on the external surface there are a number of black tubercles from the size of a pea to that of a cherry. The dis-

case first appeared in the sole of the foot; the leg was amputated above the knee.—Print. Cat. page 199, No. 26.

932. Skin and cellular membrane affected with tubercular melanosis. This is a section of the previous preparation.

933. Several large masses of melanotic matter deposited in a tubercular form on the integuments and cellular substance of the leg.—Print. Cat. page 199, No. 26.

934. A foot affected with elephantiasis; all the phalanges of the toes with the exception of the first phalanx of the great toe have dropt off, leaving the articular surfaces of the metatarsal bones much thickened; the skin of the ball of the toes has a granular appearance, as if from ulceration. Sections are made into it, showing the thickness of skin and cellular substance.—Donor, Dr. Tuthill, A. S. 2nd W. I. Regt.

935. Section of the skin of a foot affected with elephantiasis. From the previous preparation.

936. Portion of skin from the sole of the foot affected with elephantiasis; the cuticle is about one-third of an inch in thickness, the section of which presents a number of ridges running perpendicularly from the inner to the outer surface, and a distinct notched line of separation between it and the chorion. From preparation No. 934.

937. Portion of skin from the sole of the foot affected with elephantiasis; the cuticle is of considerable thickness, and shows the same grooves and ridges as the previous preparation.—From preparation No. 934.

938. Left foot enormously enlarged from tubercular elephantiasis; the extremities of the toes are large, some of them the size of a hen's egg; an extensive deep excavated ulcer with thickened tubercular edges situated on the dorsum of the foot opposite the metatarso-phalangeal articulations, none of the bones of which however are caries or absorbed. The skin presents on the outer aspect a cluster of round hard bodies, from the size of a pin's head to that of a horse-bean, planter arch rounded like a ball. The whole skin

as far as the knee was thickened and scaly ; the limb was removed above the knee, and the patient an English artilleryman recovered from the operation, but it is not known how long he survived it or if the disease recurred in other parts. Donor, Mr. Shelly, Surgeon, Epsom.—MS. Cat. vol. ii. page 202, No. 47.

939. Portion of skin affected with elephantiasis ; its external surface presents a granular and scaly appearance. From the same subject as the preceding preparation.

940. Portion of skin affected with tubercular elephantiasis, and showing numerous tubercles of different sizes on its surface. From the same patient as No. 938.

941. Portion of skin showing tubercular elephantiasis.—From the same patient as No. 938.

942. Portion of the leg affected with tubercular elephantiasis. The tibia and fibula are quite sound. From the same patient as No. 938.

943. Portion of the foot of a patient who was affected with *Bucnemia tropica*.—Donor, Dr. Sillery, A. S. Staff.

944. Small tumour from the shoulder, its structure is analagous to that of the integuments.—Donor, Mr. Fiddes, Surgeon 85th Regt.

945. Upper lip and chin destitute of hair as was also the pubis, the testicles did not exceed those of a child of six months and the vasa deferentia were impervious and terminated in the cellular substance of the scrotum. From a man aged fifty-eight.—MS. Cat. vol. iii. page 226, No. 105.

946. Dracunculus extracted from the scrotum.—Donor, Lewis Grant, Esq.—MS. Cat. vol. iii. page 217, No. 65.

947. Dracunculus with its cyst which was removed by operation from the scrotum.—Donor, Dr. Grogan, A. S. Staff.—MS. Cat. vol. iii. page 248, No. 206.

948. Dracunculus extracted from the calf of the leg.—Donor, Lewis Grant, Esq.—MS. Cat. vol. iii. page 217, No. 66.

949. Dracunculus extracted from the foot.—Donor, Lewis Grant, Esq.—MS. Cat. vol. iii. page 217, No. 66.

950. Dracunculus extracted from the foot.—Donor, Lewis Grant, Esq.—MS. Cat. vol. iii. page 217, No. 68.

951. Dracunculus extracted from the foot.—Donor, Lewis Grant, Esq.—MS. Cat. vol. iii. page 217, No. 69.

952. Portions of dracunculus extracted from the ankle. The last portion, the end of which is seen in the upper part of the bottle, was removed at once, about six inches in length, easily coming away entire; immediately after removal it was seen to wriggle about occasionally.—Donor, Mr. Gulliver, A. S. Staff.—MS. Cat. vol. iii. page 222, No. 96.

953. Dracunculus extracted from the foot.—Donor, Mr. Hall, A. S. Staff.—MS. Cat. vol. iii. page 235, No. 154.

954. Dracunculus which was removed from the integuments of the head.—Donor, Dr. Bace, 45th Regt.

955. Great toe with a peculiar elongation of the nail.—Donor, Dr. Davy, A. I. H.—MS. Cat. vol. ii. page 196, No. 13.

956. Remarkable thickening of the roots of the nails with ulceration of their anterior half.—MS. Cat. vol. iii. page 239, No. 169.

CLASS IV.

ORGANS OF DIGESTION.

DIVISION I.

DISEASES OF THE MOUTH, PHARYNX, AND ÆSOPHAGUS.

SECTION I.—DISEASES OF THE LIPS.

957. Portion of lower lip removed by operation, showing cancer with slight ulceration of its margin.—Donor, Dr. Powell, A. S. Staff.—MS. Cat. vol. iii. page 242, No. 177.

958. A large portion of lower lip removed by operation, showing an extensive circular cancerous ulcer, with everted thickened edges, which has perforated the mucous membrane.—MS. Cat. vol. iii. page 248, No. 205.

SECTION II.—DISEASES OF THE GUMS AND TEETH.

959. A carious molar tooth, with a portion of the alveolar process attached, which was broken off in the extraction of the diseased tooth.—Donor, Dr. Powell, A. S. Staff.

SECTION III.—DISEASES OF THE PALATE.

960. An oval opening in the right side of the soft palate a quarter of an inch in its smallest diameter, with smooth round edges, and two others of a size to admit the head of a large probe, anterior to the larger; also four or five cicatrices on the inferior surface of the palate.—MS. Cat. vol. ii. page 5, No. 22.

961. An ulcerated oval opening in the soft palate.

962. An ulcerated opening, extending completely across the soft palate having detached the uvula from its superior connections, the margins of which have become cicatrized.—Donor, Mr. O'Brien, A. S. 7th Regt.

963. Velum pendulum palati completely destroyed by ulceration.—Print. Cat. page 70, No. 7.

SECTION IV. — INFLAMMATION, EFFUSION OF LYMPH AND
ULCERATION OF THE PHARYNX AND ŒSOPHAGUS.

964. Inflammation of the tongue, trachea and œsophagus.—Print. Cat. page 69, No. 3.

965. A portion of the interior of the œsophagus highly vascular.—MS. Cat. vol. ii. page 2, No. 13.

966. Mucous membrane of the œsophagus very much congested and lined by an unorganized false membrane.—MS. Cat. vol. ii. page 2, No. 14.

967. Mucous membrane of the œsophagus lined by a rough granular layer of lymph.—Donor, Mr. Tuthill, A. S. 52nd Regt.—Print. Cat. page 70, No. 8.

968. A large ulcer on the left side of the pharynx, which has laid bare the cornu of the thyroid cartilage; the glottis and epiglottis are very much thickened and œdematous.—Donor, Dr. Dyce, A. S. Staff.—MS. Cat. vol. ii. page 2, No. 12.

969. Abrasion of the mucous membrane of the œsophagus.—Print. Cat. page 70, No. 5.

970. Carcinomatous ulceration and contraction of the lower third of the œsophagus with thickening of the lining membrane of the middle third; likewise adhesion of portions of the lung in its vicinity, with effusion of lymph on the serous surface of the heart and pericardium.—Preparation 988.—Donor, Mr. Ford, A. S. 72nd Regt.—MS. Cat. vol. ii. page 3, No. 16.

971. Ulceration and stricture of the middle third of the œsophagus.—Donor, Mr. Campbell, A. S. 25th Regt.—Print. Cat. page 69, No. 1.

972. Two large oval ulcers on the interior of the œsophagus, one of which communicates with a diseased bronchial gland at the division of the trachea.—MS. Cat. vol. ii. page 2, No. 11.

973. An ulcer on the mucous membrane of the œsophagus; the lymphatic glands exterior to it are deeply impregnated with tubercular matter.—MS. Cat. vol. ii. page 4, No. 18.

974. An ulcer of the œsophagus which communicated by a sinus with the posterior mediastinum.—Donor, Dr. Scott, Surgeon Rifle Brigade.—Print. Cat. page 70, No. 9.

SECTION V.—TUMOURS OF THE ŒSOPHAGUS.

975. Numerous small cysts which contained pus, situated between the œsophagus, larynx and trachea.—Print. Cat. page 69, No. 2.

976. An oval tumour occupying the whole circumference of the œsophagus, commencing about an inch and a-half above the cardiac orifice of the stomach, extending upwards about two inches and across the centre measuring two and a-half inches in breadth: the calibre of the lower part of the œsophagus would scarcely admit a common-sized bougie; glottis and epiglottis œdematous.—Donor,

Mr. Pilkington, Surgeon 21st Regt.—MS. Cat. vol. ii. page 5, No. 21.

977. A small tumour situated on the mucous membrane of the œsophagus.—Donor, Mr. O'Brien, A. S. 7th Regt.—MS. Cat. vol. ii. page 4, No. 17.

DIVISION II.

DISEASES, INJURIES, AND WOUNDS OF THE STOMACH.

~~~~~

#### SECTION I.—INFLAMMATION, PETECHIA, SOFTENING AND EROSION OF THE MUCOUS MEMBRANE OF THE STOMACH.

978. Stomach, the mucous membrane of which, in the recent preparation was highly vascular; coats of the great curvature much distended, bulging and thinned, the mucous membrane covering it is eroded,—the remainder of the lining membrane corrugated.—Donor, Dr. Dease, Staff Surgeon.—Print. Cat. page 73, No. 16.

979. Petechial spots on the stomach, the mucous membrane is thickened and irregular.—Print. Cat. page 71, No. 5.

980. Mucous membrane of the stomach, with a number of small elevations and depression on its surface, the result of inflammatory action.—Donor, Dr. Alexander, Staff Surgeon.—MS. Cat. vol. ii. page 14, No. 27.

981. Mucous membrane of the stomach having a granular appearance; the man died of yellow fever.—Mr. Bradford, A. S. 56th Regt.—MS. Cat. vol. ii. page 15, No. 33.

982. Mucous membrane of the great arch of the stomach abraded, the muscular coat laid bare, the walls of the viscus generally thin and some of its vessels distended with coagulated blood.—MS. Cat. vol. ii. page 18, No. 50.

983. Partial thickening and a peculiar corrugated appearance of the mucous membrane of the stomach, chiefly confined to the pyloric extremity.—MS. Cat. vol. ii. page 18, No. 47.

## SECTION II.—HYPERTROPHY OF THE COATS OF THE STOMACH.

984. General hypertrophy of the coats of the stomach, with a small ulcer on its mucous surface.—Donor, Dr. Dix, Surgeon 94th Regt.—MS. Cat. vol. ii. page 16, No. 44.

985. Hypertrophy of the coats of the stomach particularly in the neighbourhood of the pylorus, with deposition of yellow lymph in the cellular coats.—MS. Cat. vol. ii. page 17, No. 45.

986. Portion of stomach showing hypertrophy of all the coats, with a thick deposition of yellow lymph in the cellular tunic which has a honey-combed appearance.—Donor, Dr. Arthur, D. I. H.

## SECTION III.—CARCINOMATOUS ULCERATION OF THE STOMACH.

987. Carcinomatous ulceration of the cardiac orifice of the stomach and termination of the œsophagus, which is in consequence very much contracted and the coats thickened.

988. Carcinomatous ulceration of the cardiac orifice of the stomach continued from the œsophagus; portions of lung, aorta, diaphragm and pancreas adhere to its outer surface; there is also an abscess situated between its posterior surface and the aorta, with thickening and contraction of the pyloric orifice. The stomach is considerably diminished in size and highly vascular, its coats thinned and the mucous surface in some places is abraded.—Donor, Mr. Ford, A. S. 72nd Regt.—MS. Cat. vol. ii. page 3, No. 16.

989. A large deeply-excavated carcinomatous ulceration at the cardiac extremity of the stomach, which has destroyed at some parts all the coats and its contents were only prevented from escaping by an adhesion to the liver.—Donor, Dr. Gordon, A. S. 35th Regt.

990. A carcinomatous excrescence, about the size of a hen's egg with several others of a smaller size in its neighbourhood, situated on the mucous membrane of the stomach, which around the tumour is ulcerated and thickened.—Donor, Dr. Smith, Staff Surgeon.

991. A large oval carcinomatous ulceration of the stomach with smooth round edges at one extremity a quarter of an inch in depth, the coats of the viscus are thickened and indurated.—Donor, Richard Partridge, Esq., King's College.

992. A very large irregular carcinomatous ulceration of the stomach, the edge of the ulcer is much thickened and several nipple-like processes project from its margin.—MS. Cat. vol. ii. page 20, No. 58.

993. Fungoid excrescences of a carcinomatous character, of the mucous membrane of the stomach, ulceration has commenced on the surface of some of them, particularly on those near the cardiac orifice.

994. Cancerous ulceration of the lesser arch of the stomach, the cardiac orifice of which is contracted.—Donor, Dr. Titus Berry, Staff Surgeon.—Print. Cat. page 74, No. 20.

995. Extensive carcinomatous excrescences and ulceration of the stomach, which has perforated all the coats by two large openings, the margins of which are much thickened and indurated.—Donor, Mr. Gillice, A. S. Staff.—MS. Cat. vol. ii. page 15, No. 35.

996. Extensive carcinomatous ulceration of the stomach, the surface of which is very irregular, with a number of shreds of membrane and flocculi hanging from it, the edges of the ulcers at some parts are much thickened.

997. Large soft vegetations surrounding the interior of the pyloric orifice of the stomach, the vegetations are in many places nine or ten lines in thickness, and extend from an inch and a-half to two inches round the pylorus; they appear to be produced from the mucous membrane.—Donor, E. Stanley, Esq., Surgeon, St. Bartholomew's Hospital, London.

998. Very extensive carcinomatous ulceration of the mucous membrane of the pylorus, the coats of which are much thickened and contracted. Omentum agglutinated into one mass of an irregular tuberculated appearance.—Donor, Dr. Jameson, A. S. 10th Regt.

999. Two large carcinomatous tumours at the pyloric extremity of the stomach, one the size of a hen's egg, the other much smaller; the mucous membrane covering them and in their neighbourhood is ulcerated, with a number of detached shreds of membrane hanging from its surface; the coats of this extremity of the stomach are much thickened, with a deposition of lymph in the cellular tunic.—Donor, Dr. Jameson, A. S. 10th Regt.

1000. Scirrhus ulceration of the pylorus with thickening of its coats.—Donor, Mr. O'Brien, A. S. 7th Regt.

1001. Scirrhus ulceration of the pylorus, with thickening, contraction and effusion of lymph in its cellular coat, which has a honey-combed appearance.

1002. Scirrhus of the pyloric orifice of the stomach, the opening into the duodenum is so small as hardly to admit a crow-quill, two large tumours of a similar nature also project from its mucous surface.—Print. Cat. page 74, No. 22.

1003. Extensive ulceration of the stomach in the neighbourhood of the pyloric orifice, the margin of the ulcer is thickened, elevated, and very irregular, also several fungoid tumours in the duodenum.—Donor, Dr. Davy, A. I. H.—MS. Cat. vol. ii. page 29, No. 126.

1004. General hypertrophy of all the coats of the stomach particularly at the pyloric orifice, which is much contracted and affected with carcinomatous ulceration.—Donor, Dr. O'Brien, A. S. 7th Regt.—MS. Cat. vol. ii. page 16, No. 41.

1005. Pyloric orifice of the stomach contracted and in a scirrhus state, coats much thickened.—Print. Cat. page 71, No. 1.

1006. Contraction of the pyloric orifice of the stomach.—Donor, Mr. Cathcart, Surgeon 7th Dr. Gds.—MS. Cat. vol. ii. page 15, No. 37.

1007. A number of irregular ulcers about the size of peas, and deep fissures separating them, situated at the pyloric orifice of the stomach, which is contracted and its coats much thickened, also

a cicatrice on the mucous surface of this viscus, several inches from the orifice.—Donor, Mr. Martin, Surgeon 73rd Regt.

1008. An enlarged gland about the size of a walnut, situated between the coats of the stomach at the pyloric orifice which is in a scirrhus condition, and shows an oval opening on its surface.—MS. Cat. vol. ii. page 15, No. 39.

1009. A scirrhus condition of the pyloric orifice of the stomach, with an ulcerated opening through its coats, which at this part are much thickened and contracted.—Donor, Mr. Jones, Ordnance Medical Department.

1010. Extensive malignant ulceration of the pyloric extremity of the stomach, involving deeply the surrounding parts; the liver is firmly adherent to the peritoneal coat opposite the points of ulceration, the omentum is much thickened and contains numerous heterogeneous deposits.—Donor, E. Stanley, Surgeon, St. Bartholomew's Hospital, London.

1011. An extensive ulcer, with elevated firm edges, situated on the convex surface of the stomach near the pyloric orifice.—Print. Cat. page 71, No. 3.

1012. Extensive ulceration of a carcinomatous nature which has perforated all the coats of the stomach by a large round opening, with thickening of the pyloric extremity.—Donor, Dr. Chermiside, Surgeon 10th Hussars.—Print. Cat. page 71, No. 4.

1013. A large deeply excavated ulcer, with everted thickened edges, on the great extremity of the stomach which is adherent to and communicates with the spleen.—Print. Cat. page 71, No. 6.

#### SECTION IV.—ULCERATION OF THE STOMACH.

1014. A deep excavated ulcer capable of containing a pigeon's egg on the mucous surface of the stomach, which adheres to the liver.



1015. A large oval ulcer, at the pyloric orifice of the stomach, which has perforated all its coats.—Print. Cat. page 73, No. 19.

1016. Ulceration of the pylorus.—Print. Cat. page 73, No. 17.

1017. An oval ulcer half an inch in its longest diameter, with very defined edges, which extends through all the coats at the pyloric extremity of the stomach.—Donor, Mr. Frazer, A. S. Staff.—Print. Cat. page 73, No. 18.

1018. A large irregular ulcer half an inch in diameter, situated on the lower margin of the pylorus, also a small spheroid tumour in the coats of the latter having an orifice on its summit leading into a small sac; texture of tumour firm.—MS. Cat. vol. ii. page 22, No. 65.

1019. An ulcerated opening at the pyloric extremity of the stomach, with general thickening of its coats. The stomach adhered to the lobulus Spigelii of the liver.—Donor, Mr. Portelli, Malta.—MS. Cat. vol. ii. page 14, No. 31.

1020. Extensive ulceration of the mucous membrane of the stomach at the pyloric extremity, portions of the lining membrane hang in shreds from different parts of the ulcerated surface.—MS. Cat. vol. ii. page 17, No. 46.

1021. A large oval ulcer situated on the smaller curvature between the cardiac and pyloric orifices of the stomach, and presenting near its posterior extremity a projection resembling in shape and size the nipple of the female breast, the section of which shows it to consist of a portion of the pancreas; at its anterior extremity there is a rounded opening, capable of admitting a large bougie. The contents of the stomach had during life been prevented from escaping by an effusion of lymph and adhesion of the edges of the opening to the liver. The small curvature of the stomach is very much contracted, and the neighbouring parts much thickened.—MS. Cat. vol. ii. page 21, No. 64.

1022. An ulcerated opening about an inch in diameter on the smaller curvature of the stomach, which allowed the escape of its contents.—Donor, Mr. Shoreland, Surgeon 96th Regt.

1023. A perforation, the size of a common quill, of the coats of the stomach situated at the posterior part of the inferior curvature, having the appearance as though a portion had been cut out.—Donor, Dr. Innis, A. S. 84th Regt.

1024. Perforation of the lesser curvature of the stomach, the opening is capable of admitting a crow-quill.

1025. Perforation of the coats of the stomach, the opening is capable of admitting a large bougie.—Necrol. Register, vol. iv. folio 58.

1026. Perforation of the stomach which leads to an extensive deposition of tuberculous matter between it and the liver; by this opening the tuberculous matter had been partly evacuated.—MS. Cat. vol. ii. page 18, No. 48.

1027. Stomach, in the mucous membrane of which, particularly towards its pyloric extremity, are situated some small livid depressions which might be mistaken for the cicatrices of former ulceration, but the real nature of which is doubtful.—MS. Cat. vol. ii. page 18, No. 49.

#### SECTION V.—PERFORATION OF THE COATS OF THE STOMACH BY THE ACTION OF ITS OWN SECRETIONS.

1028 Destruction of the whole of the great arch of the stomach by the action of its own secretions, after sudden death.—Donor, Mr. Smyth, A. S. 85th Regt.—Print. Cat. page 30, No. 91.

1029. A stomach perforated in five places after death by the action of its secretions.—Donor, Mr. Bradford, A. S. 56th Regt.—MS. Cat. vol. ii. page 15, No. 32.

1030. Extensive solution of continuity of the large curvature of the stomach, probably by the action of its own secretion after death.

#### SECTION VI.—SLOUGHING OF THE COATS OF THE STOMACH.

1031. Portion of stomach showing abrasion, ulceration and a

superficial slough on its mucous membrane.—Donor, Dr. Barclay, Surgeon 21st Regt.—MS. Cat. vol. ii. page 14, No. 29.

SECTION VII.—THE EFFECTS OF POISON ON THE COATS OF THE STOMACH.

1032. Stomach showing erosion and several dark coloured elevations on the mucous membrane of the bulging extremity; the affected part is about two inches in circumference; the result of swallowing a drachm of the oxymuriate of mercury and half an ounce of laudanum.—Donor, Mr. Martindale, Surgeon 17th Regt.—Print. Cat. page 72, No. 11.

1033. Two large irregular elevations, of a dark colour, on the mucous membrane of the pyloric extremity of the stomach, the rest of the internal coat is of a dark grey colour; produced by swallowing an ounce of the oxymuriate of mercury.—Donor, Mr. Colclough, Surgeon 9th Lancers.—Print. Cat. page 74, No. 21.

1034. Mucous membrane of the stomach of a dark brown colour thickened, granular and at some parts eroded; the effects of poisoning from arsenic.—Donor, Mr. Cavat, late A. S. 97th Regt.—MS. Cat. vol. ii. page 21, No. 62.

SECTION VIII.—WOUNDS OF THE STOMACH.

1035. A gunshot wound of the larger curvature of the stomach; the man lived eight hours after the accident.—Donor, Dr. White, Surgeon Rifle Brigade.

### DIVISION III.

#### *DISEASES, WOUNDS, RUPTURES AND MALFORMATIONS OF THE SMALL INTESTINES.*

---

#### SECTION I.—INFLAMMATION, PETECHIÆ, EFFUSION OF LYMPH AND ULCERATION OF THE SMALL INTESTINES.

1036. Mucous membrane of the ileum highly vascular.—Print. Cat. page 82, No. 55.

1037. Petechiæ and vibices situated under the muscular coat of the duodenum.—Donor, Dr. Alexander, Staff Surgeon.

1038. Petechiæ between the coats of the ileum.—Print. Cat. page 80, No. 35.

1039. Portion of small intestine highly congested. From a patient who died of measles.

1040. A portion of ileum near its termination with a copious deposit of coagulable lymph on the valvulæ conniventes which are considerably enlarged.—Print. Cat. page 82, No. 54.

1041. A portion of ileum the mucous membrane of which is covered with a copious deposit of coagulable lymph. From a

patient who died of dysentery.—Donor, Mr. Bradford, A. S. 56th Regt.

1042. Mucous membrane of the lower portion of the ileum and commencement of cœcum coated with granular lymph. From a man who died of dysentery.—Donor, Mr. Bradford, A. S. 56th Regt.

1043. Portion of ileum with the valvulæ conniventes covered with lymph and several small ulcers on their surface.

1044. Portion of ileum with the mucous membrane thickened and coated with granular lymph.—Donor, Mr. Fiddes, Surgeon 85th Regt.—MS. Cat. vol. ii. page 26, No. 111.

1045. Corrugation of the mucous membrane of the ileum, copious deposit of highly vascular lymph, and ulcerations of old date, the basis of which are studded with miliary tubercles.—Donor, Mr. Gulliver, A. S. 71st Regt.—Print. Cat. page 82, No. 57.

1046. A portion of the small intestines, with great enlargement of Peyers patches which are ulcerated in their centres.—Donor, Mr. Martindale, Surgeon, 17th Regt.—Print. Cat. page 78, No. 22.

1047. Portion of ileum, the glandulæ solitariæ, and aggregatæ, are very much enlarged and the surfaces of two of them are slightly ulcerated.—Donor, Dr. White, A. S. Staff.—Print. Cat. page 87, No. 83.

1048. Enlargement of the glandulæ aggregatæ with ulceration of their surfaces, the edges of which are thick and everted.—Donor, Mr. Martindale, Surgeon 17th Foot.—Print. Cat. page 78, No. 22.

1049. Great prominence and slight ulceration of two patches of the glandulæ aggregatæ, with the same state of some of the glandulæ solitariæ.—Print. Cat. page 89, No. 97.

1050. Portion of ileum showing great prominence of the glandulæ solitariæ and aggregatæ, with ulceration particularly of the latter.

1051. Great enlargement and prominence of the glandulæ aggregatæ, glandulæ solitariæ less so, the surfaces of two of the former are ulcerated.

1052. Enlargement and ulceration of two of the glandulæ aggregatæ, also a circular spot at which all the tunicæ are deficient except the peritoneal.—Donor, Dr. Davy, A. I. H.—Print. Cat. page 87, No. 81.

1053. Enlargement and ulceration of the glandulæ aggregatæ.—Donor, Mr. Martindale, Surgeon.—Print. Cat. page 78, No. 22.

1054. Great prominence and slight ulceration of the glandulæ aggregatæ of a portion of ileum.

1055. Portion of ileum with enlargement of the glandulæ aggregatæ and superficial ulceration of their surface, also two deep ulcers of a somewhat circular form with raised edges.—Print. Cat. page 89, No. 95.

1056. Thickening of the coats of the ileum with enlargement of the glandulæ aggregatæ and solitariæ, and incipient ulceration particularly of the former.—Donor, Mr. Gulliver, A. S. Surgeon 71st Regt.—Print. Cat. page 83, No. 59.

1057. Enlargement of the glandulæ solitariæ of the ileum, also incipient ulceration in the form of small round points.

1058. Superior half of the duodenum with the glandulæ solitariæ enlarged and ulcerated, the ulcers are in one or two places well defined but for the most part they present irregular edges, are of a burrowing nature and have undermined the mucous tunic for some distance around.—MS. Cat. vol. ii. page 38, No. 156.

1059. Portion of ileum with enlargement of the glandulæ solitariæ and effusion of lymph on the mucous tunic.—Donor, Dr. Davy, A. I. H.—Print. Cat. page 90, No. 103.

1060. Glandulæ aggregatæ enlarged and filled with tubercular matter.

1061. Tubercular degeneration, in the site of the glandulæ aggregatæ, which precedes ulceration in phthisis pulmonalis.—Print. Cat. page 86, No. 79.

1062. A portion of ileum :—an ulcer with ragged edges on its mucous membrane and an entire tubercle about the size of a bean, in the second stage of development under it.—Donor, Dr. Scott, Surgeon 2nd Battalion Rifles.—MS. Cat. vol. ii. page 30, No. 127.

1063. Portion of ileum with several deep ulcers which have undermined the mucous membrane, and at one place perforated all the coats.—Donor, Dr. White, A. S. Staff.—Print. Cat. page 87, No. 83.

1064. Portion of ileum presenting several ulcers, with thick everted edges, on the mucous membrane.—Donor, Dr. Hennen, D. I. H.

1065. Several large irregular ulcers with ragged edges on the inner tunic of a portion of small intestine.—Donor, Dr. Bushe, A. S. Staff.—Print. Cat. page 77, No. 15.

1066. An ulcer, with ragged edges having scrofulous matter deposited in its base, on the mucous membrane of a portion of the ileum.

1067. Several ulcers with ragged edges on the mucous membrane of the upper part of the jejunum.—Donor, Dr. Scott, Surgeon Rifle Brigade.

1068. An ulcer on the mucous tunic of the ileum, the base of which is studded with tuberculous matter. The preparation is injected.—Print. Cat. page 84, No. 63.

1069. Injected ulcers of the mucous membrane of the ileum.—Print. Cat. page 84, No. 65.

1070. Portion of ileum with a large ulcer on its mucous tunic, the basis of the lesion is formed by abundant tubercular matter which

elevates the serous coat of the gut in a granular form. The preparation is minutely injected, and highly vascular, but none of the colouring matter of the injection has entered the tubercular substance.—Print. Cat. page 85, No. 69.

1071. Several large oval ulcers, the basis of which are studded with small caseous tubercles, situated in the mucous membrane of the ileum, the surfaces of the ulcers are highly vascular and villous. The preparation has been minutely injected and affords a good example of exaggerated vascularity by the inflammatory process. The tubercular accretions elevate the peritoneum immediately opposite the ulcers of the mucous tunic.—Donor, Mr. Gulliver, A. S. Staff.—Print. Cat. page 83, No. 62.

1072. Ulceration and the highest vascularity of the mucous membrane of a portion of the ileum. The preparation shows myriads of anastomoses the result of minute injection; the gut is most vascular in the situation of the ulcers.—Donor, Mr. Gulliver, A. S. Staff.

1073. Incipient ulceration of the mucous membrane of the ileum, the preparation is highly injected and the mucous tunic is excessively vascular round the ulcers.—Donor, Mr. Gulliver, A. S. 71st Regt.—Print. Cat. page 85, No. 71.

1074. Injected portion of ileum, presenting ulcers of the inner membrane.—Donor, Mr. Gulliver, A. S. 71st Regt.—Print. Cat. page 85, No. 72.

1075. Ulceration of the mucous membrane of a portion of the ileum.—Donor, Mr. O'Brien, A. S. 7th Regt.

1076. Portion of ulcerated ileum. — Donor, Dr. Hennen, D. I. G. H.

1077. Portion of ileum with a small ulcer on the mucous tunic which has destroyed all the coats; on the opposite peritoneal coat is a deposit of lymph, thrown out to prevent the consequences of perforation.—Print. Cat. page 89, No. 98.

1078. Portion of jejunum with several ulcers on the mucous mem-



brane and a number of dark-coloured spots on the valvulæ conniventes as if from the effusion of blood below the inner tunic.—Guy's Hospital.—MS. Cat. vol. ii. page 37, No. 153.

1079. Portion of ileum, the mucous and muscular coats of which were in the recent preparation of a deep-red colour from sanguineous infiltration, the former is ulcerated and abraded.—Donor, Dr. Burrell, A. S. Staff.—MS. Cat. vol. ii. page 36, No. 152.

1080. A deep excavated ulcer on the ileum.—Donor, Dr. Hennen, D. I. G. H.

1081. Two large excavated ulcers, which nearly embrace the whole circumference of the ileum, with thickened irregular edges.

1082. Numerous small ulcers on the mucous membrane of the ileum which is thickened and irregular.—Print. Cat. page 77, No. 12.

1083. A portion of ileum ulcerated; the result of remittent fever.—Donor, Dr. Mahoney, Surgeon 7th Regt.

1084. Large irregular livid ulcers with ragged edges, some of them completely surrounding the gut.—MS. Cat. vol. ii. page 45, No. 186.

1085. Several large irregular ulcers, on the mucous membrane of the ileum, completely surrounding the gut, with dark coloured spots in their centre.—MS. Cat. vol. ii. page 35, No. 146.

1086. Two large oval ulcers, covered with lymph, edges thickened and everted, on the mucous membrane of a portion of the ileum.—Print. Cat. page 81, No. 46.

1087. A large oval ulcer, coated with lymph, on the mucous membrane of the ileum.—Print. Cat. page 78, No. 17.

1088. Portion of jejunum with several large ulcers, on the inner tunic, the edges of which are much thickened and irregular; in the

centre of one of them, are two small round openings from perforation of all the coats.—Print. Cat. page 79, No. 28.

1089. Large ulcers, at the termination of the ileum, the surfaces of which are covered with granular lymph and the edges thickened.

1090. Portion of ileum near the ilio colic valve extensively ulcerated and in a sloughing state, with a perforated opening, capable of admitting a common probe, through all the coats; higher up in the ileum is a well defined ulcer of a dark brown appearance.—Print. Cat. page 89, No. 96.

1091. Extensive ulceration, at the termination of the ileum, with deposition of adventitious matter at their basis.

1092. Extensive ulceration embracing the whole circumference of the termination of the ileum, also affecting the ilio colic valve.—MS. Cat. vol. ii. page 35, No. 147.

1093. Extensive ulceration and thickening of the mucous membrane at the termination of the ileum.—Print. Cat. page 81, No. 45.

1094. Ulceration of the mucous membrane at the termination of the ileum.—Donor, Mr. Gulliver, A. S. 71st Regt.

1095. A circular perforation capable of admitting a crowquill at the upper part of the duodenum.—Donor, Mr. Pilkington, Surgeon 21st Regt.—MS. Cat. vol. ii. page 40, No. 164.

1096. An ulcerated opening in the duodenum which communicated with an abscess in the liver.—Donor, Mr. O'Brien, A. S. 7th Regt.—MS. Cat. vol. ii. page 29, No. 124.

1097. A perforation of the duodenum arising from ulceration; with an almost impervious state of the ductus communis chole-  
dochus.—Donor, Dr. Diver, Surgeon 91st Regt.—MS. Cat. vol. ii. page 33, No. 136.

1098. A small ulcerated perforation of the ileum.—Donor, Dr. Davy, A. I. H.—Print. Cat. page 79, No. 29.

1099. A portion of ileum perforated by ulceration.—Donor, Dr. Trigance, Surgeon 30th Regt.

1100. A large ulcerated perforation of the ileum, the omentum adheres to the margin of the opening, the cœcum is also ulcerated.—MS. Cat. vol. ii. page 28, No. 117.

1101. An ulcerated perforation of the ileum.—Donor, Dr. Henderson, Surgeon 48th Regt.—MS. Cat. vol. ii. page 27, No. 119.

1102. Perforation of the ileum from ulceration, also a layer of coagulable lymph on its peritoneal surface.

1103. A large irregular ulcer, with two small perforations through its centre, in a portion of the ileum.—Donor, Mr. James Cavet, Surgeon.

1104. Perforation from ulceration of all the coats of the ileum, also a deep excavated ulcer a little above it; mucous membrane thickened.—Donor, Mr. Lightbody, Surgeon 80th Regt.—Print. Cat. page 87, No. 86.

1105. Three large ulcerated perforations in the ileum, also several ulcers on the mucous membrane.—Donor, Dr. Diver, Surgeon 91st Regt.—MS. Cat. vol. ii. page 31, No. 129.

1106. Two ulcerated perforations of the ileum.—Donor, Mr. Lightbody, Surgeon 80th Regt.

1107. A small perforation in the ileum caused by ulceration, lymph effused on the peritoneal coat.—Donor, Dr. Burrell, A. S. 94th Regt.

1108. Fold of small intestine united by coagulable lymph and on the adhesion being partially separated an ulcerated opening one-fourth of an inch in diameter presented itself.—MS. Cat. vol. ii. page 45, No. 187.

1109. Perforation by ulceration of a portion of small intestine, the opening is about an inch in length and embraces the whole cir-

cumference of the gut.—Donor, Mr. Wood, Surgeon, Edinburgh.—MS. Cat. vol. ii. page 41, No. 165.

## SECTION II.—GANGRENE OF THE SMALL INTESTINES.

1110. A large portion of the jejunum in a state of inflammation and congestion approaching to gangrene.—MS. Cat. vol. ii. page 30, No. 128.

1111. Portion of jejunum with an oval perforation in it, the result of mortification, the parts in the neighbourhood are thickened and of a dark colour, and a long thick layer of lymph about an inch in breadth is effused on the peritoneal coat along the course of the gut.—MS. Cat. vol. ii. page 33, No. 141.

1112. A sphacelated portion of the jejunum adhering to the peritoneum at the internal abdominal ring, which is enlarged and the peritoneum relaxed.—MS. Cat. vol. ii. page 33, No. 141.

1113. A large opening embracing nearly the whole circumference of the ileum, a small slip of the peritoneal coat alone remains to connect the two ends of the gut ; the result of sphacelus.

1114. Portion of ileum presenting a round sphacelated opening one-fourth of an inch in diameter with shreds of membrane hanging from it, and another opening capable of admitting a common probe in its neighbourhood.—Donor, Mr. Lindsay, Surgeon 18th Regt.—Print. Cat. page 85, No. 75.

1115. Sphacelated spots on the jejunum, one about the size of a shilling embracing all the coats, the other is considerably smaller and only embracing the two internal tunics of the gut ; the sloughs are partially separated, in both of them. The coats of the intestine are much thickened.—Donor, Mr. Titus Berry, Staff Surgeon.—Print. Cat. page 82, No. 56.

1116. Portion of small intestine about seven inches in length, voided per anum ; the muscular fibres of the gut are distinctly

visible.—Donor, Mr. Job, Surgeon 13th Lt. Drs.—Print. Cat. page 82, No. 53.

1117. Portion of intestines about eight inches in length, passed per anum, the muscular fibres are distinctly visible.—Donor, Mr. Strahan, I. G. H.

### SECTION III.—INTUS-SUSCEPTION.

1118. Intus-susception of a portion of the jejunum.

1119. A large portion of ileum intus-suscepted and protruding through an extensive ulcerated opening in the inferior part of the gut.—Donor, Dr. Davy, A. I. H.—MS. Cat. vol. ii. page 29, No. 123.

1120. Intus-susception of a portion of the ileum.

1121. Portion of ileum intus-suscepted.—Print. Cat. page 76, No. 4.

1122. Intus-susception of a portion of small intestine.—Donor, Dr. Burke, I. G. H.

1123. Intus-suscepted portion of intestine withdrawn, to show an adhesion between the peritoneal coats covering the two portions of gut.—Print. Cat. page 76, No. 7.

1124. Portion of ileum intus-suscepted.—Donor, Mr. Lightbody, Surgeon 80th Regt.

1125. Intus-susception, about two inches in length, of a portion of jejunum.—MS. Cat. vol. ii. page 45, No. 188.

1126. Portion of intus-suscepted ileum.—Print. Cat. page 77, No. 9.

1127. Intus-susception of a portion of ileum, and a layer of coagulable lymph on the mucous membrane of the inverted portion.

1128. Intus-susception of a portion of small intestine.—Donor, Mr. Stephenson, A. S. 89th Regt.—Print. Cat. page 88. No. 90.

1129. Intus-susception of a portion of the ileum.

1130. Portion of ileum and cœcum intus-suscepted into the colon.—Print. Cat. page 93, No. 14.

1131. Cœcum and a considerable portion of the ileum intus-suscepted into the colon.—Print. Cat. page 94, No. 20.

1132. A large portion of the colon intus-suscepted, with thickening of the coats at this part; below the inverted portion there are two irregularly perforated openings through all the tunic.—Donor, Dr. Caw, A. S. Staff.—MS. Cat. vol. ii. page 85, No. 162.

#### SECTION IV.—HERNIA.

1133. Sac of a congenital hernia.—Donor, Mr. E. Stanley, Surgeon, St. Bartholomew's Hospital.

1134. Sac of a congenital hernia.

1135. Sac of a congenital hernia. The commencement of the hernia at the interior abdominal ring is shown with the internal epigastric artery coursing along its pudic border.—Donor, Mr. E. Stanley, Surgeon, St. Bartholomew's Hospital.

1136. Congenital, inguinal hernia.—Donor, Mr. E. Stanley, Surgeon, St. Bartholomew's Hospital.

1137. Oblique inguinal hernia of the right side, the contents of the sac consisted of omentum only, a portion of which is seen passing through the abdominal ring.—Print. Cat. page 89, No. 94.

1138. Shows the manner in which the peritoneum forms the sac of a hernia;—at the posterior part is the appendix vermiformis of unusual breadth and thickened but not more than half the usual length, the walls of the cœcum are also much thickened.—Donor, Dr. Davy, A. I. H.—MS. Cat. vol. ii. page 27, No. 113.

1139. Scrotal hernia of the right side, which commenced as an oblique inguinal hernia, the vas deferens and spermatic vessels by behind the sac and the epigastric artery winds round its neck and runs up along its inner side.—MS. Cat. vol. ii. page 77, No. 132.

1140. A small oblique inguinal hernia.—Donor, Mr. E. Stanley, Surgeon St. Bartholomew's Hospital.

1141. Oblique inguinal hernia of the left side, a bougie is passed into the internal epigastric artery which hooks round the neck of the sac, the fibres of the cremaster muscle are seen descending nearly to the lower part of the scrotum enveloping the testicle.

1142. Oblique inguinal hernia with a fold of intestine lying in the canal, but does not protrude through the external opening, the specimen is dried and the vessels injected, the internal epigastric artery and vein are seen winding round the neck of the sac and running along the internal border.

1143. Double oblique inguinal hernia, one of the sacs is laid open to show a portion of intestine lying in it. The vessels are injected, the preparation dried and the epigastric arteries hook round the rings and run along their internal border.—Donor, Mr. Allan, A. S. Staff.—MS. Cat. vol. iii. page 251, No. 211.

1144. Double oblique inguinal hernia.—Donor, E. Stanley, Surgeon St. Bartholomew's Hospital.

1145. Direct inguinal hernia, the spermatic cord lies on the outer side of the sac.—Donor, Mr. E. Stanley, Surgeon St. Bartholomew's Hospital.

1146. Oblique inguinal hernia (female).—Donor, E. Stanley, Surgeon St. Bartholomew's Hospital.

1147. Femoral hernia, omentum lying in and adhering to the sac (female).—Donor, E. Stanley, Surgeon St. Bartholomew's Hospital.

1148. Large sac of a femoral hernia of the right side (male).—Donor, E. Stanley, Surgeon St. Bartholomew's Hospital.

1149. An umbilical hernia about the size of an orange a large portion of the omentum is contained in the sac, to which it at some parts firmly adheres.—Donor, Mr. Fagg, A. S. Staff.

1150. A small umbilical hernia, the sac is filled by a portion of omentum.

1151. Sac of an umbilical hernia about the size of a hen's egg, the sac presents no very distinct neck.

1152. Diaphragmatic hernia, the greater part of the transverse arch of the colon with the omentum are situated above the diaphragm, the opening in which is in the muscular portion and about an inch in diameter.

1153. Displays the whole of the stomach and greater part of the transverse arch of the colon (both rather small) with the omentum, situated in the lower and anterior part of the left cavity of the thorax. The anterior surface of the stomach is firmly attached to the lower lobe of the lung; the lung of this side as might be expected, has become much reduced in size and occupies the superior and posterior part of its proper cavity. The right lung is smaller than the left from the circumstance of the heart being much displaced by the stomach and colon, and instead of extending across from the second rib of the right side to the sixth of the left as this viscus naturally does, it now lies nearly parallel to the spine, having the apex almost on a line with the coronary ligament of the liver and being of natural size must have proved much less yielding during inspiration than the stomach and colon on the other side of the chest. The opening in the diaphragm extends in a transverse direction near to the centre of the dorsal attachments of the left side of this muscle, and the objects forming the hernia have contracted adhesions with the diaphragm and other parts, and the peritoneum lining the former is in many places continuous with that covering the colon. From a soldier in whom a musket-ball entered close to the nipple of the left breast and passed out at the back between the eighth and ninth ribs, the anterior wound soon healed but the posterior did not do so for a considerable period. This preparation in whatever light it is viewed whether as a congenital malposition or the result of a wound of the diaphragm is singular, inasmuch as he enjoyed good health previous



to the accident and even after it to such an extent as to enable him to do his duty for nearly twenty-two years.—Donor, Dr. Dowse, A. S. 88th Regt.—MS. Cat. vol. iii. page 214, No. 63.

1154. Small intestines strangulated by a portion of omentum which had formed adhesions round the root of the mesentery.—Print. Cat. page 78, No. 19.

1155. A portion of ileum of a horse showing hypertrophy of its muscular tunic and protrusion of the mucous coat between the muscular fibres. The mucous lining is dissected from the muscular tunic.—MS. Cat. vol. ii. page 41, No. 168.

#### SECTION V.—STRICTURES AND CONTRACTIONS OF THE SMALL INTESTINES.

1156. Portion of jejunum about six inches from its commencement, with a well-marked stricture, it has the appearance as if a cord had been firmly tied round the gut; the mucous membrane is quite healthy.—Print. Cat. page 86, No. 76.

1157. Stricture of the jejunum, the inner surface of which presents a small white glistening depression encircling the gut, the mucous membrane seems as if it stopped abruptly at the groove superiorly, but it runs more gradually into it inferiorly—Print. Cat. page 86, No. 77.

1158. Portion of jejunum near the commencement very much contracted, with thickening of the coats in the site of the stricture.—MS. Cat. vol. ii. page 42, No. 170.

#### SECTION VI.—TUMOURS OF THE SMALL INTESTINES.

1159. Portion of ileum with a pedunculated body hanging from its mucous surface, the pedicle is about three-fourths of an inch in length and the tumour attached to it is about the size of a horse-bean it appears to be of a simple tissue, possibly an hypertrophied and enlarged follicle.—Guy's Hospital.

1160. A vascular tumour about the size of a bean situated below the mucous membrane of a portion of the small intestine.—MS. Cat. vol. ii. page 40, No. 162.

1161. Portion of small intestine with a fatty tumour imbedded in its coats.

#### SECTION VII.—WOUNDS AND RUPTURES OF THE SMALL INTESTINES.

1162. Gunshot wound of the small intestines terminating in artificial anus. The ball entered on the left side below the ribs wounded the intestine which here protrudes and passed out through the second false rib of the same side, a quill is inserted into the upper part of the gut. The bowel was impervious below the wound but healthy above; the fæces were voided through the preternatural opening.—Donor, Dr. Roe, Surgeon 28th Regt.—Print. Cat. page 85, No. 74.

1163. Gunshot wound of the small intestines and mesentery, the former wounded in three places and the latter in one.—Donor, Mr. Tighe, A. S.—Print. Cat. page 86, No. 78.

1164. A ruptured opening about half an inch in diameter in the small intestine, produced by a fall.—Donor, Mr. Whyte, Surgeon 69th Regt.—Print. Cat. page 87, No. 87.

1165. A ruptured opening capable of admitting a crow-quill in a portion of the ileum; the mucous membrane is separated on one side for some distance around the aperture and is rough and granular; produced by the blow of a capstan bar. The patient died forty-eight hours after the accident.—Donor, Dr. Trigance, Surgeon 30th Regt.

1166. A portion of ileum ruptured by a fall into the ditch of Fort Victoria, the opening is capable of admitting a large bougie and situated in the centre of an ulcer, there is also another oval ulcer with thickened edges close to the former.—Donor, Dr. Trigance, Surgeon 30th Regt.

## SECTION VIII.—MALFORMATIONS OF THE SMALL INTESTINES.

1167. A small digital appendix, attached to a portion of the jejunum, continuous with the calibre of the intestine.

1168. Portion of small intestine with a diverticulum about the size of a pigeon's egg, with several ulcers on its mucous surface and a small tumour projecting from it.—Donor, Mr. O'Brien, A. S. 7th Regt.—MS. Cat. vol. ii. page 26, No. 110.

1169. Diverticulum of a portion of the same intestine.

1170. Diverticulum about the size of a plum, of a portion of the ileum.—Donor, Dr. Montgomery, A. S. Staff.

1171. Diverticulum the size of a pigeon's egg of a portion of the small intestine.

1172. A diverticulum of the ileum laid open and the mucous membrane at its orifice and that of the intestine in its immediate neighbourhood is ulcerated.—Donor, Mr. Lightbody, Surgeon 80th Regt.—MS. Cat. vol. ii. page 33, No. 137.

## DIVISION IV.

### *DISEASES, INJURIES, WOUNDS AND MALFORMATIONS OF THE LARGE INTESTINES.*

---

#### SECTION I. — INFLAMMATION AND EFFUSION OF LYMPH ON THE LARGE INTESTINES.

1173. Portion of large intestine, the mucous membrane inflamed and covered with granular lymph.—Print. Cat. page 100, No. 73.

1174. Portion of colon with the mucous membrane covered by a thin stratum of lymph.—MS. Cat. vol. ii. page 68, No. 167.

1175. Mucous membrane of a portion of colon covered by coagulable lymph.

1176. Copious effusion of granular and flocculent lymph on the lining membrane of a portion of the colon which is also ulcerated.—Print. Cat. page 92, No. 4.

1177. Portion of colon covered with a granular layer of lymph. Print. Cat. page 100, No. 73.

1178. Lining membrane of a portion of colon covered with a granular layer of lymph.—Print. Cat. page 100, No. 73.

1179. A flocculent and granular effusion of lymph on the mucous membrane of the colon, which is also thickened and ulcerated.—Print. Cat. page 93, No. 10.

1180. A layer of lymph effused on the lining membrane of the colon, which is also slightly abraded.

1181. Mucous membrane of a portion of the colon covered with large masses of granular lymph.

1182. Two portions of colon, the lining membrane of one of them is entirely covered with masses of granular lymph and the coats much thickened; the mucous membrane of the other is ulcerated, rough and irregular.—Donor, Mr. Dowse, A. S. 88th Regt.

1183. Lining membrane of a portion of colon thickened and universally covered by granular lymph. — Donor, Dr. Hennen, D. I. H.—Print. Cat. page 99, No. 66.

1184. Mucous membrane of a portion of sigmoid flexure of colon inflamed, thickened, and entirely covered by a granular deposit of lymph.—Print. Cat. page 99, No. 64.

1185. Inner membrane of a portion of colon, thickened, puckered, ulcerated, and covered by granular lymph.

1186. Coats of a portion of the colon very much thickened and the inner surface covered by a granular layer of lymph.—Print. Cat. page 103, No. 90.

1187. Coats of the caput cœcum coli much thickened and the mucous membrane covered with lymph, at some parts ulcerated and hanging in shreds. The interior is very irregular and thrown into large folds.—Donor, Mr. Whitefield, Surgeon, R. A.

1188. Mucous membrane of the cœcum and ascending colon thickened very irregular and covered by granular lymph; the termination of the ileum is quite healthy.—Print. Cat. page 104, No. 91.

1189. Portion of colon with the mucous membrane thickened and universally covered by well-marked granular lymph.—Print. Cat. page 100, No. 70.

1190. Portions of large and small intestine the inner membranes of which are coated with organized lymph but more particularly the former.—Print. Cat. page 100, No. 73.

1191. Mucous membrane of a portion of colon covered with lymph, and to which are attached a number of wart-like excrescences; coats thickened.

1192. Cæcum and portion of ilium very much thickened from effusion of lymph between their coats and on the lining membrane, which is ulcerated and presents a granular appearance.

1193. Large masses of yellow lymph effused below the mucous membrane of a portion of colon, the lining membrane is abraded at several places.

1194. Lymph effused beneath the mucous membrane of the colon, causing it to project in the form of excrescences about the size of beans.—Print. Cat. page 102, No. 83.

1195. Portion of colon much contracted, its mucous surface is covered by a peculiar gelatinous-looking secretion and tuberculous matter.—Donor, Dr. Dyce, A. S. Staff.—MS. Cat. vol. ii. page 79, No. 142.

1196. Mucous membrane of vermiform appendix of cæcum lined by a pseudo membrane and its sides completely adherent about an inch from its termination. A well marked example of adhesion in a mucous canal, it contained pus.—MS. Cat. vol. ii. page 80, No. 144.

1197. Appendix vermiformis divided in two nearly equal compartments by adhesion of the mucous membrane.—Necrol. Reg. vol. v. page 361.

## SECTION II.—ULCERATION OF THE LARGE INTESTINES.

1198. Lining membrane of the cæcum and appendix vermiformis in a state of ulceration.—Donor, Mr. Jackson, A. S. 42nd Regt.—MS. Cat. vol. ii. page 76, No. 123.

1199. A large irregular ulcerated opening at the apex of the vermiform process. The mucous membrane of the cæcum and termination of ilium is thickened, ulcerated and projects in the form of wart-like excrescences.

1200. Appendix vermiformis of a large size, with a number of excavated ulcers on the lining membrane.—Donor, Mr. Martin, A. S. 73rd Regt.—MS. Cat. vol. ii. page 71, No. 104.

1201. Ulceration of the mucous membrane of the vermiform process, also several broad bands covered by the lining membrane, passing across it.—MS. Cat. vol. ii. page 78, No. 135.

1202. Appendix vermiformis much enlarged and ulcerated internally.—Donor, Dr. Nicholson, Surgeon 42nd Regt.—MS. Cat. vol. ii. page 74, No. 116.

1203. Vermiform appendix much dilated and ulcerated, the mucous membrane is detached at the apex, and a round tumour about the size of a small cherry projects from its base—it contained pus.

1204. Appendix vermiformis of unusual size, its coat thickened and the mucous lining of it as also that of the cæcum and a portion of the ileum are in a state of inflammation.—Donor, Mr. Melvin.

1205. An ulcer of the cæcum nearly cicatrized, the appendix vermiformis is greatly elongated and was very much distended with flocculent matter, its opening is involved in the cicatrix and much contracted.—MS. Cat. vol. ii. page 79, No. 141.

1206. Mucous membrane of a portion of the sigmoid flexure of the colon, of a dark colour and ulcerated.—Donor, Mr. Calvert, A. I. H.—Print. Cat. page 100, No. 68.

1207. Portion of colon ulcerated and petechial spots under the mucous tunic. A sequela of remittent fever.—Donor, Dr. Mahony, Surgeon 7th Regt.

1208. Inner membrane of the colon having a reticulated appearance from ulceration.—Print. Cat. page 93, No. 5.

1209. Portion of colon with marks of old ulcers and wart-like excrescences on the mucous membrane—Print. Cat. page 94, No. 17.

1210. Mucous membrane of a portion of colon ulcerated, and its coats thickened.

1211. Portion of colon with superficial ulceration of the mucous tunic and abundant deposition of fatty matter in the appendices epiploicæ.—Print. Cat. page 97, No. 50.

1212. Numerous small deep ulcers on the inner tunic of a portion of colon, coats much thickened from fatty deposit beneath the peritoneum.—Print. Cat. page 98, No. 58.

1213. Ulceration of a portion of colon.—Print. Cat. page 96, No. 38.

1214. Ulceration of a portion of colon.—Print. Cat. page 95, No. 28.

1215. Portion of ulcerated colon, the ulcers at some parts are small and in clusters, at others large and irregular with the mucous membrane at their margins hanging in shreds.

1216. Portions of colon extensively ulcerated.

1217. Large irregular ragged ulcers on the mucous lining of the caput cœcum. The man died of remittent fever.—Donor, Dr. Mahony, Surgeon 7th Regt.

1218. Extensive ulceration of the caput cœcum and copious effusion of lymph an inch in thickness in its coats and neighbourhood.—Print. Cat. page 21, No. 57.

1219. Caput cœcum and a portion of colon with a number of irregular ulcers with well defined edges on its inner membrane.—Print. Cat. page 96, No. 33.

1220. Mucous membrane of colon and a portion of ileum covered with a number of large irregular ragged ulcers.



1221. Portion of colon near its commencement with ragged irregular ulcerations scattered over the mucous membrane.—Print. Cat. page 92, No. 3.

1222. Mucous membrane of the cœcum, appendix vermiformis and portion of colon extensively ulcerated and the coats at some parts thickened and at others thinned.—Donor, Mr. Booty, A. S. Staff.—Print. Cat. page 72, No. 7.

1223. Cœcum very much contracted and the inner membrane of it and the termination of the ileum ulcerated.—Print. Cat. page 104, No. 97.

1224. Portion of colon with nearly the whole of the mucous membrane destroyed by ulceration, leaving only small prominent detached patches; there is also an abundant deposition of fatty matter below the peritoneum.

1225. Large intestine showing thickening, and irregular ulceration of the mucous tunic, the remaining portions in many places present the appearance of fleshy verrucæ.—Donor, Mr. Gulliver, A. S. 71st Regt.—Print. Cat. page 102, No. 81.

1226. Two large ulcers with well defined, thickened and everted edges, in the centre of one of them perforation of the serous coat appears to have been prevented by a small coagulum of blood.—MS. Cat. vol. ii. page 79, No. 140.

1227. Irregular ulcers with defined, thickened edges on the mucous membrane of a portion of colon.—MS. Cat. vol. ii. page 79, No. 139.

1228. A large ulcer with irregular edges on the mucous membrane of a portion of colon, the ulcerated surface has a peculiar granulated appearance.—MS. Cat. vol. ii. page 76, No. 126.

1229. An oval ulcer in a healing state with defined thickened edges on the lining membrane of a portion of colon.—Donor, Mr. Davey, A. S. 7th Regt.—MS. Cat. vol. ii. page 71, No. 106.

1230. Mucous membrane of the cœcum and colon very extensively

ulcerated and presenting a peculiar granulated appearance.—Print. Cat. page 98, No. 57.

1231. Lining membrane of the caput cœcum and portion of colon almost entirely destroyed by ulceration, and the portion of the inner coat that remains is thickened and projects in the form of fungus. The appendix vermiformis is doubled up in an adhesion which it has contracted with the omentum majus.—MS. Cat. vol. ii. page 77, No. 133.

1232. Portion of ascending colon, the mucous membrane of which is in a state of fungus ulceration embracing the whole circumference of the gut.—MS. Cat. vol. ii. page 78, No. 134.

1233. Extensive ulceration of the inner membrane of a portion of colon.—Print. Cat. page 105, No. 100.

1234. Very extensive ulceration of the inner membrane of the cœcum and colon.—Necrol. Reg. vol. v. page 361.

1235. Almost the whole of the mucous membrane of the cœcum and a portion of colon destroyed by ulceration, and presenting a peculiar granulated appearance.—Donor, Mr. Simpson, Malta.

1236. Portion of colon, with extensive ulceration on its internal surface.—Print. Cat. page 103, No. 89.

1237. Several ulcers of a large size, and an immense number varying in size from a pin's-head to that of a bean, on the mucous membrane of a portion of colon, which presents a peculiar reticulated appearance,—coats thickened.—Print. Cat. page 93, No. 12.

1238. Very extensive ulceration of the mucous membrane of a portion of the colon.—Print. Cat. page 94, No. 15.

1239. Numerous small ulcers which have coalesced, on the mucous membrane of a portion of colon.—Print. Cat. page 97, No. 47.

1240. Ulceration and a peculiar granulated appearance of a portion of colon.

1241. A number of small round ulcers on the lining membrane of the colon, this membrane is thickened and has a granular appearance.

1242. Extensive granular ulceration of the inner coat of a portion of the colon.—Print. Cat. page 94, No. 16.

1243. Mucous membrane of a portion of the colon ulcerated and granular.

1244. Very extensive ulceration of the mucous membrane of a portion of the colon, also a number of wart-like excrescences on this membrane.—Print. Cat. page 95, No. 22.

1245. Ulceration and fleshy excrescences on the mucous surface of a portion of colon.

1246. A number of irregular ulcers with a warty appearance of the inner membrane of a portion of the colon.—Coats thickened.—Donor, Mr. Hamilton, A. S.—Print. Cat. page 100, No. 69.

1247. Extensive ulceration with a granulated appearance of the inner tunic of a portion of colon.—Print. Cat. page 99, No. 61.

1248. Extensive ulceration and thickening of the mucous membrane of a portion of the colon, which is at some parts completely separated from the muscular layer; and abundant deposition of fatty matter below the peritoneal coat.—Print. Cat. page 96, No. 34.

1249. Extensive ulceration of the inner membrane of a portion of colon which hangs in shreds from its surface.—Donor, Mr. Bradford, A. S. 56th Regt.—MS. Cat. vol. ii. page 73, No. 109.

1250. Portion of the transverse arch of the colon, with ulceration, effusion of lymph, and extensive separation of the mucous from the muscular coat.—Donor, Mr. Fiddes, Surgeon, 85th Regt.

1251. Portion of large intestine with the mucous membrane separated in large detached portions and hanging in shreds.—Donor, Mr. Lightbody, Surgeon 80th Regt.—Print. Cat. page 103, No. 85.

1252. Portion of colon showing a large opening through which the contents of an hepatic abscess was discharged.—Print. Cat. page 95, No. 24.

1253. Cæcum adhering to the parietes of the abdomen in which is situated a fœcal abscess communicating with the gut by an opening capable of admitting a large bougie; there is also another perforation the same size about an inch lower down opening into the cavity of the abdomen, the mucous membrane between these openings is ulcerated, the extremity of the vermiform process adheres to the ileum with which it communicates internally, as also with the cæcum.

1254. A large perforation from ulceration of the caput cæcum.—Donor, Dr. Romley, A. S. Staff.

1255. Ulceration of the colon which has perforated all the coats.—Print. Cat. page 95, No. 25.

1256. An oval ulcerated opening about one and a-half inches in diameter, extending through all the coats of a portion of the colon, which are also thickened.—Print. Cat. page 99, No. 59.

1257. Ulceration which has in two places perforated all the coats of the colon.

1258. Extensive ulceration of the colon and rectum, which at one spot perforated all the coats.—Print. Cat. page 105, No. 99.

1259. Upper part of rectum perforated by ulceration, the opening is capable of admitting the forefinger, also extensive ulceration of the remainder of the mucous lining.—MS. Cat. vol. ii. page 84, No. 159.

1260. A number of large irregular ulcers on the mucous membrane of the colon and rectum.

1261. Mucous lining of colon and rectum covered by a number of small oval ulcers, coats thickened.—Print. Cat. page 96, No. 32.

1262. Mucous membrane of a portion of colon ulcerated and the coats are about two and a-half inches in thickness from a deposition of fatty matter beneath the peritoneum.

1263. Two small well defined ulcers on the mucous tunic of a portion of large intestine. The preparation is injected and shows the vascularity of the bases of the ulcers.—Donor, Mr. Gulliver, A. S. 71st Regt.—Print. Cat. page 101, No. 78.

1264. An ulcer on the inner membrane at the verge of the anus, minutely injected.—Donor, Mr. Gulliver, A. S. 71st Regt.—Print. Cat. page 101, No. 79.

1265. Extensive ulceration of the lining membrane of the rectum.

1266. Mucous membrane of the rectum ulcerated, and covered by many prominent granulations.—Donor, Mr. Martin, Surgeon 73rd Regt.—MS. Cat. vol. ii. page 74, No. 114.

1267. Extensive ulceration of the rectum; the ulcers burrow beneath the mucous membrane which presents a reticulated appearance, and there are several wart-like excrescences attached to it.—Print. Cat. page 94, No. 17.

1268. Ulceration of the rectum.

1269. Ulceration and effusion of lymph on the mucous tunic of a portion of colon, and rectum.—Print. Cat. page 97, No. 48.

1270. Rectum ulcerated and lymph effused on the inner membrane.—Donor, Dr. Calvert, A. I. H.—Print. Cat. page 100, No. 67.

### SECTION III.—SLOUGHING OF THE LARGE INTESTINES.

1271. Appendix vermiformis with a portion of cœcum, separated by sloughing; they were found detached from the intestine, and adhering only by the upper end of the appendix where it is connected to the mesentery.—Donor, Mr. Martin, Surgeon, 73rd Regt.

1272. Perforation by sloughing of appendix vermiformis where it communicates with cœcum.—Donor, Dr. Sibbald, Maidstone.—MS. Cat. vol. ii. page 79, No. 131.

1273. Appendix vermiformis gangrenous, and numerous perforations extending through all its coats.—MS. Cat. vol. ii. page 80, No. 145.

1274. Ulceration, effusion of lymph, and a sloughing state of the mucous membrane of a portion of colon.—Donor, Mr. O'Brien, A. S. 28th Regt.—Print. Cat. page 98, No. 55.

1275. Mucous lining of a portion of colon ulcerated, partly gangrenous and pelicles of lymph effused on its surface.—Donor, Mr. Martindale, Surgeon, 70th Regt.—Print. Cat. page 97, No. 39.

1276. Portion of colon with sloughing of the inner membrane, which hangs in loose shreds from its surface.—Print. Cat. page 96, No. 35.

1277. Cœcum and adjoining portion of ileum ; the mucous tunic of the former is extensively sphacelated so as to expose the muscular fibres ; and a large portion of the inner membrane hangs loose in the jar. An ulcerated aperture extends through all the coats of the large intestines ; in the ileum there are several patches of ulceration.—Print. Cat. page 101, No. 79.

1278. Ulceration and sloughing of the inner tunic of the cœcum which hangs in loose shreds from its surface ; coats much thickened.

1279. Portion of colon with ulceration and sloughing of the inner membrane which is separated from the muscular and hangs in shreds.

1280. Lower part of colon and part of the rectum presenting ulceration and sloughing of the mucous membrane which hangs in long loose shreds.

1281. Sloughing phagedæna of the mucous membrane of a por-

tion of colon.—Donor, Dr. Davy, A. I. H.—Print. Cat. page 98, No. 52.

1282. Numerous sloughing ulcers in the mucous membrane of a portion of colon.—Donor, Dr. Trigance, Surgeon 30th Regt.—Print. Cat. page 103, No. 86.

1283. Extensive ulceration and a sloughing state of the mucous membrane of the rectum which hangs in shreds, and perforation of all the coats at several places.—Print. Cat. page 105, No. 102.

1284. Portion of the inner coat of the caput cœcum detached by sloughing and found in the colon; from a dysenteric patient.—Donor, Mr. O'Brien, A. S. 7th Regt.

1285. Portion of the mucous membrane of the rectum voided by stool.—Donor, Dr. Hutchinson, Surgeon 11th Light Drs.

1286. Portion of the inner membrane of the rectum voided by stool.—Donor, Dr. Hutchinson, Surgeon 11th Lt. Drs.

#### SECTION IV.—SCIRRHOUS AND CONTRACTIONS OF THE LARGE INTESTINES.

1287. Scirrhus of the ileo colic valve; the opening from the ileum is completely obstructed by coagulable lymph, the mucous membrane is thickened, softened in some places and ulcerated in others, with hypertrophy of it and the submucous tissue, to such a degree as very considerably to diminish the calibre of the gut.—The man died of continued fever.—Donor, Dr. O'Hallaran, Surgeon 77th Regt.

1288. Meso-colon and transverse arch of the colon in a carcinomatous state, the former is converted into a large scirrhus mass; the coats of the latter are much thickened and indurated, and there is an ulcerated opening nearly in the centre of the transverse arch, through which its contents were discharged into the abdominal cavity.—Donor, Dr. M'Andrew, Surgeon 14th Foot.—MS. Cat. vol. ii. page 71, No. 107.

1289. Great thickening of the coats of the sigmoid flexure of the colon with diminution of its calibre to such a degree as only to admit a quill, the opening seen in the preparation is a rupture of the intestine made on removal.—Print. Cat. page 102, No. 84.

1290. Two contractions, one at each extremity of the transverse arch, by which the gut is reduced to half its usual calibre—MS. Cat. vol. ii. page 72, No. 108.

1291. Transverse arch of the colon much contracted with many vascular rounded projections from its peritoneal surface apparently the result of a yielding of the coats.—Print. Cat. page 103, No. 88.

1292. Aperture of the appendix vermiformis partially obliterated and its cavity of the usual size.—MS. Cat. vol. ii. page 82, No. 154.

#### SECTION V.—FISTULA IN ANO.

1293. A fistulous sinus extending up along the coats of the rectum for about an inch and a half where it opens into the gut.—MS. Cat. vol. ii. page 83, No. 155.

1294. Extensive ulceration of all the coats of the rectum which communicates by two fistulous openings with the fundus of the bladder, one of them a small circular opening capable of admitting a common probe situated immediately behind the prostate gland, the other a little posterior will admit a quill, coats of the bladder thickened.—MS. Cat. vol. ii. page 83, No. 157.

1295. Numerous fistulæ in the cellular substance at each side of the anus; about one inch and a half from the verge there is a short stricture and a communication, between the gut and the prostatic portion of the urethra, capable of admitting a tolerably large goose quill.—MS. Cat. vol. ii. page 73, No. 110.



## SECTION VI.—WOUNDS OF THE LARGE INTESTINES.

1296. A large perforation of the posterior part of the coats of the rectum caused by a fall on the handle of a broom which entered the anus perforated the rectum and made an opening into the cavity of the abdomen.—Donor, Mr. Smyth, A. S. 85th Regt.—Print. Cat. page 104, No. 94.

## SECTION VII.—MALFORMATIONS OF THE LARGE INTESTINES.

1297. Caput cœcum of very large size with appendix of unusual length.—Donor, Mr. Fiddes, Surgeon 85th Regt.—Print. Cat. page 105, No. 101.

1298. Appendix vermiformis shorter than usual, attached to the lower part of the ileum and bound down to its coats by the peritoneum.—Donor, Mr. Fiddes, Surgeon 85th Regt.—Print. Cat. page 105, No. 98.

1299. Imperforate anus, the cul de sac in which the rectum terminates was found loose in the pelvis, pointing downwards and following its natural course.—Donor, Mr. Allman, Apothecary to the Forces.—MS. Cat. vol. ii. page 84, No. 158.

## SECTION VIII.—INTESTINAL CONCRETIONS.

1300. A ball, the size of a large plum composed of hair, having a smooth polished surface; taken from the stomach of a sheep.—Donor, Mr. Ford, A. S. 72nd Regt.

1301. Two immense alvine concretions from the colon of an aged horse. Sections are made of both of them showing that the nucleus is principally composed of hair.—Donor, Mr. Home, Vet. Surg. 2nd Life Guards.

## SECTION IX.—INTESTINAL WORMS.

1302. Larvæ discharged by vomiting from the stomach of a woman.—Donor, Dr. Hacket, Staff Surgeon — Johnson's Medico-Chirurgical Review, vol. v. page 367.

1303. Cæcum of a boy, ætat. 2, having a large number of worms (*Tricocephalis dispare*) adhering to its lining membrane. A vast number of lumbrici were found in the substance of the liver, gall bladder and duodenum.—Preparation, No. —Donor, Dr. Davy, A. I. H.—MS. Cat. vol. ii. page 135, No. 119.

1304. Section of the skull showing several *Ascaris lumbricoides* in the left cavity of the nose, in the æthmoid and sphenoid cells, and one in the right nasal cavity. A great many lumbrici were also found in the stomach and bowels. Those seen in the preparation most probably procured their present position by vomiting.—From a Maltese woman, ætat. 56.—Donor, Mr. O'Brien, A. S. 7th Regt.

1305. *Ascaris lumbricoides* in the appendix vermiformis the mucous membrane of which is highly inflamed.—Donor, Dr. Davy, A. I. H.—MS. Cat. vol. ii. page 75, No. 121.

1306. Appendix cœci enlarged and containing an *Ascaris lumbricoides*.

1307. *Ascaris lumbricoides* from a child aged 2 years.—Donor, Dr. Davy, A. I. H.

1308. Numerous *Ascaris lumbricoides* voided per anum by a child.—Donor, Mr. Alexander, A. S. Staff.

1309. *Tænia solium* complete; in the centre of the head is a projecting papilla armed with a double circle of hooks, and around this are four apertures or suckers placed at equal distances which constitute the true mouth by which nourishment appears to be imbibed. The segments towards the head are very slightly indicated but are more marked lower down where they become sub-quadrangle and at length elongated, so that the length of each seg-

ment exceeds the breadth ; each of the joints are also furnished with a pore situated in the centre of a small prominent papilla which are believed to be connected with the generative system.—MS. Cat. vol. ii. page 46, No. 191.

1310. *Tænia solium* complete.—Donor, Mr. Finnie, Surgeon 1st Regt.

1311. *Tænia solium* complete.

1312. *Tænia solium* incomplete passed per anum.

1313. *Tænia solium* incomplete.

1314. *Tænia solium* large and incomplete.

1315. *Tænia solium* small and incomplete.

1316. *Tænia solium* incomplete.

1317. *Tænia solium* incomplete.

1318. *Tænia solium* incomplete.—Donor, Dr. Benza, A. S. Staff.

1319. *Tænia solium* incomplete eighteen feet in length, passed per anum.—Donor, Mr. Cavet, A. S. 97th Regt.

## DIVISION V.

### *DISEASES OF THE PERITONEUM.*

---

#### SECTION I. — INFLAMMATION, ECCHYMOSIS, AND EFFUSION OF LYMPH ON THE PERITONEUM.

1320. A portion of peritoneum exceedingly vascular, and studded with a number of small osseous bodies.—MS. Cat. vol. ii. page 32, No. 130.

1321. Numerous ecchymosed spots of a black colour under the peritoneum.—MS. Cat. vol. ii. page 39, No. 159.

1322. Extensive ecchymosis of a black colour which in one place forms a continuous layer.—MS. Cat. vol. ii. page 39, No. 160.

1323. Portion of sigmoid flexure of colon with effusion of lymph on its serous surface and ecchymosis between the peritoneum and muscular fibres.—Print. Cat. page 102, No. 82.

1324. Gastro-colic omentum converted into a large and dense granular mass from effusion of lymph between its layers and on its surface.—Donor, Mr. Ford, A. S. 72nd Regt.—MS. Cat. vol. ii. page 75, No. 118.

1325. Portion of mesentery converted into a solid mass from deposition of lymph between its layers and on its free surface.—Donor, Dr. Milligan, Surgeon 51st Regt.

1326. Omentum much thickened from deposition of lymph between its layers.—MS. Cat. vol. ii. page 86, No. 166.

1327. Portion of omentum with its margin much thickened from deposition of lymph between its layers.

1328. Portion of omentum with its margin thickened and effusion of lymph between its layers.—Print. Cat. page 104, No. 96.

1329. Small intestines agglutinated and covered with coagulable lymph which is at some parts one-eighth of an inch in thickness.

1330. Small intestines united and covered by a thick layer of lymph.

1331. Convolutions of small intestines matted together by a thick adventitious layer of lymph on the serous surface of the peritoneum and by the deposition of large fleshy masses.—Donor, Mr. Gulliver, A. S. Staff.—Print. Cat. page 83, No. 61.

1332. A strong band of adhesion, extending between a portion of intestine and the walls of the abdomen, about one inch and a half in breadth and a quarter of an inch in thickness where it adheres to the gut, as it proceeds it divides into two round cords before reaching the abdominal walls.

## SECTION II.—TUBERCULAR DEGENERATION OF THE PERITONEUM.

1333. A long thin band of adhesion connecting the left lobe of the liver to the omentum. The omentum is infiltrated with tuberculous matter, and there is also a similar deposit beneath the serous covering of the liver.—MS. Cat. vol. ii. page 77, No. 129.

1334. Portion of stomach with large masses of tubercular deposit beneath the peritoneal coat which also adheres to the liver.

1335. Portion of the termination of the ileum with tubercular matter deposited in a granular form on the serous covering.—Print. Cat. page 90, No. 106.

1336. Portion of ileum presenting a deposition of tubercular matter in a granular form on the external surface.—Print. Cat. page 91, No. 107.

1337. Numerous tubercular deposits, from the size of a pin's head to that of a horse-bean, in their second stage of development on the peritoneal coat of the small intestines; convolutions at some parts adhering by coagulable lymph.

1338. Peritoneum covering the convolutions of the small intestines adhering and studded with tubercles.—Print. Cat. page 82, No. 51.

1339. Tubercular deposit under the peritoneal coat of the small intestines, convolutions adherent.—Print. Cat. page 81, No. 47.

1340. Numerous small tubercular deposits on the peritoneum of a portion of ileum, convolutions adherent by coagulable lymph, which at some parts hangs in loose shreds.—York Hospital, Chelsea.—Print. Cat. page 81, No. 43.

1341. Tubercular accretions beneath the peritoneum, with agglutination of the small intestines by coagulable lymph, which hangs in loose shreds.—Print. Cat. page 83, No. 60.

1342. Many crude tubercles of large size, attached to the serous surface of the jejunum, by an accidental tissue of a loose filamentous nature.—MS. Cat. vol. ii. page 38, No. 157.

1343. Extensive tubercular deposit in the peritoneum.—Print. Cat. page 81, No. 49.

1344. Tubercular deposit in the second stage of maturation in the peritoneum.—Print. Cat. page 81, No. 49.

1345. Peritoneum thickened, with tubercular deposit in its structure.

1346. A portion of ileum attached to the omentum, with tubercles in both.—Donor, Dr. Davy, A. I. H.—MS. Cat. vol. ii. page 29, No. 125.

1347. Tubercular accretions of the peritoneum, the omentum being the part principally involved in the disease, which is at some parts an inch in thickness, and firmly agglutinated to the transverse arch of the colon. Coats of the stomach much thickened.—Print. Cat. page 88, No. 91.

1348. Serous covering of small intestines and mesentery studded with minute tubercles, and shreds of a loose filamentous tissue hanging from it.

1349. Small intestines agglutinated by coagulable lymph, which hangs in loose shreds from their surface, with tubercles of various sizes below the serous membrane.—Donor, Dr. Shanks, A. S. 82nd Regt.—Print. Cat. page 80, No. 36.

1350. Portion of sigmoid flexure of the colon and the upper part of the rectum, with numerous tubercles of various sizes beneath the peritoneal covering, and shreds of lymph hanging from its surface; there is also a pedunculated body about two inches in length, attached to the external surface likewise filled with tubercles.—MS. Cat. vol. ii. page 78, No. 13.

1351. Large masses of tubercular deposit beneath the peritoneum of a portion of colon, as also in the omentum, which is nearly two inches in thickness.—MS. Cat. vol. ii. page 75, No. 120.

1352. Portion of peritoneum lining the walls of the abdomen, studded with a granular-looking deposit of tuberculous matter.—MS. Cat. vol. iii. page 261, No. 217.

1353. Portion of abdominal peritoneum thickened from a deposit of tuberculous matter.—MS. Cat. vol. ii. page 46, No. 189.

1354. Portion of the anterior wall of the abdomen, beneath the peritoneal surface of which are situated some small tubercles.—MS. Cat. vol. ii. page 78, No. 138.

1355. Extensive deposition of tuberculous matter beneath the peritoneal lining of the abdomen.—MS. Cat. vol. ii. page 35, No. 148.

1356. Numerous minute tubercles in the omentum.—Donor, Dr. Davy, A. I. H.

1357. Tubercles the size of horse-beans in a portion of omentum.—Donor, Mr. Fiddes, Surgeon, 85th Regt.

### SECTION III.—HYDATIDS, AND TUMOURS IN THE PERITONEUM.

1358. Hydatids (*Echinococcus Rudolphi*) attached to the omentum of a rabbit.—Donor, Mr. Gulliver, A. S. Staff.

1359. A small osseous deposit, with several tubercles in its neighbourhood, situated under the peritoneum lining the abdominal parietes.—MS. Cat. vol. ii. page 78, No. 36.

1360. A large calcareous deposit beneath the peritoneum covering the colon.

1361. A fatty tumour the size and shape of a large pear, attached to the sigmoid flexure of the colon.—Print. Cat. page 97, No. 51.

1362. Two fatty appendages the size of cherries, attached to the mesentery; ileum much contracted.—Donor, Mr. Ford, A. S. 72nd Regt.—MS. Cat. vol. ii. page 33, No. 138.

1363. Omentum majus, much thickened from a deposition of numerous small tumours of a sarcomatous nature.—Donor, Mr. Taylor, A. S. 58th Regt.—MS. Cat. vol. ii. page 75, No. 119.

1364. Three small-sized bodies of a sarcomatous nature, attached to each other in a pediculated manner, and to the serous coat of the jejunum by a common stalk-like process.—MS. Cat. vol. ii. page 38, No. 135.

1365. Portion of peritoneum with a small fibrous tumour situated under the peritoneal coat.—Donor, Dr. Davy, A. I. H.

1366. A small tumour of a steatomatous character beneath the peritoneum of a portion of rectum.—MS. Cat. vol. ii. page 76, No. 125.



1367. Portion of gastro colic omentum, with a cartilaginous cyst containing scrofulous matter, attached to the loose margin.—Donor, Mr. Ford, A. S. 72nd Regt.—Print. Cat. page 101, No. 80.

1368. Portion of jejunum, the peritoneal surface of which is irregularly elevated by vascular deposits beneath it; some of these growths project from the free surface of the peritoneum, and appear to be almost entirely composed of bloodvessels. The preparation is minutely injected.—T. Wormald, Esq. Demonstrator of Anatomy, St. Bartholomew's Hospital.—MS. Cat. vol. ii. page 39, No. 158.

#### SECTION IV.—INJURIES OF THE PERITONEUM.

1369. Laceration of the mesentery, caused by the individual being thrown violently from his horse against a tree.—Donor, Dr. Kinnis, A. S. Staff.

CLASS V.

SECRETING ORGANS SUBSERVIENT TO  
DIGESTION.

---

DIVISION I.

*DISEASES AND INJURIES OF THE SUBMAXIL-  
LARY GLAND.*

---

DIVISION II.

*DISEASES AND INJURIES OF THE PAROTID  
GLAND.*

---

DIVISION III.

*DISEASES AND INJURIES OF THE TONSILS*

---

SECTION I.—SLOUGHING OF THE TONSILS.

1370. Left tonsil one entire slough, in the centre of which an entozoa (*Tricocephalis Affini* of Rudolphi) of minute size was found, the first instance of its having been met with in the human subject. —Preparation No. 1771.—MS. vol. ii. page 221, No. 93.

## DIVISION IV.

### *DISEASES, INJURIES, AND MALFORMATIONS OF THE LIVER.*

---

#### SECTION I.—INFLAMMATION AND ABSCESSES IN THE LIVER.

1371. Section of liver, softened in texture, and containing several cavities of small abscesses.—Donor, Mr. Colclough, Surgeon 9th Lancers.—Print. Cat. page 112, No. 47.

1372. Numerous large cavities of abscesses in the liver, which was of an enormous size, and protruded so high into the right thoracic cavity as to compress the lung, and thrust the heart far to the left side. In removing the viscus one large abscess burst; the remaining solid and fluid parts weighed fourteen pounds, whereof probably nearly three-fourths consisted of purulent matter.—Donor, Dr. Thomson, A. S. 26th Regt.—Print. Cat. page 117, No. 87.

1373. Cavity of a large abscess in the upper part of the right lobe of the liver; surrounding structure broken down, with portions of it hanging from the inner surface of the sac, which is covered with granular lymph. The patient died of acute hepatitis after ten days' illness.—Donor, Mr. Cathcart, Surgeon 38th Regt.

1374. Portion of liver having the sac of an abscess situated in the right lobe, near its convex surface.—Donor, Mr. Davy, A. S. 7th Regt.

1375. Sac of an abscess the size of a billiard ball, removed from the convex surface of the liver: the diaphragm adheres to it and forms its anterior wall.—Donor, Dr. Strachan, I. G. H.

1376. Sac of an abscess situated in the convex surface of the right lobe of the liver; the peritoneum covering it is thickened and coated with lymph.

1377. Sac of an abscess situated in the right lobe of the liver, near its convex surface, which contained one pint of yellowish-brown pus; the gall-bladder was filled with vitiated bile; shreds of lymph on the peritoneal coat.—Print. Cat. page 108, No. 9.

1378. Sac of an extensive abscess in the right lobe of the liver, near its convex surface, and lined by a distinct firm membrane; peritoneal coat thickened and covered with lymph.

1379. Sac of a large abscess situated in the right lobe of the liver, near its convex surface; inner surface rough and broken up; weight of liver eleven pounds.—Print. Cat. page 106, No. 1.

1380. Sac of an abscess in the right lobe of the liver, near its convex surface, surrounding structure broken up.—Print. Cat. page 107, No. 6.

1381. Cavity of a large abscess in the right lobe of the liver, with a strong band of hepatic structure passing across it; inner surface rough, and lined with lymph; diaphragm adherent. The patient died hectic.—Donor, Mr. Frazer, A. S. Staff.

1382. Sac of a large abscess situated in the right lobe of the liver; cyst of a dense fibrous structure, and secreting surface coated with layers of flocculent lymph; abdominal surface of diaphragm adhering to convex surface of liver, while the thoracic aspect is coated with lymph, and a portion of lung adheres; there is likewise an opening through the diaphragm, by which the abscess communicated with the right plural cavity.—Donor, Mr. Ford, A. S. 72nd Regt.—MS. Cat. vol. ii. page 138, No. 132.

1383. Sac of an abscess in the right lobe of the liver, near its convex surface, communicating with the right lung, which adheres to the diaphragm, and also with the pericardium by a large irregular aperture. Serous surface of the heart and pericardium covered with granular lymph.

1384. Sac of a large abscess situated in the right lobe of the liver, communicating with the inferior lobe of the right lung by a circular aperture half an inch in diameter, through the diaphragm to which the lung adheres.—Print. Cat. page 107, No. 5.

1385. An oval opening, about one inch in diameter, through the diaphragm, from the convex surface of the liver into the right pleural cavity; the result of the bursting of an hepatic abscess, which contained a sero-purulent fluid; the fluid, after finding its way into the cavity of the chest, was confined in a limited space by a preternatural adhesion of the pleura pulmonalis to the diaphragm; a small portion of lung is attached.—Donor, Mr. Fiddes, Surgeon 85th Regt.

1386. Cavity of an abscess in the right lobe of the liver, communicating by an ulcerated opening through the diaphragm with the base of the right lung; the upper surface of the liver, and the inferior surface of the lung, adhere intimately to the diaphragm, and around the passage of communication in each organ there is induration from effusion of lymph.

1387. A large sac of an abscess in the right lobe of the liver, which contained seventeen ounces of a thick yellow purulent matter; peritoneum lining the inferior surface of the diaphragm adheres to that covering the liver, and on detaching a small portion of the adhering diaphragm, the peritoneal coat of the liver was found completely absorbed, and at a nipple-like process, which projects into the thorax, both peritoneal coats are destroyed; the abscess must have soon made its way through the diaphragm into the base of the right lung to which it adhered.—MS. Cat. vol. ii. page 154, No. 198.

1388. Sac of a large abscess in the right lobe of the liver, communicating with the right lung, the base of which forms a large part of the walls of the sac, its internal surface is rough and covered with lymph.—Print. Cat. page 107, No. 2.

1389. Sac of a large abscess situated in the right lobe of the liver, near its convex surface, which penetrates the diaphragm and communicates with the right lung; a bougie is passed from a large

bronchial tube into the cavity, the inner surface of which is rough and lined with lymph ; liver enlarged.—MS. Cat. vol. ii. page 154, No. 197.

1390. Sac of an enormous abscess occupying the whole of the right lobe of the liver, which contained four pints of pus mixed with blood ; structure softened, and the white texture preternaturally developed. The organ is very much enlarged ; it extended across the epigastric into the left hypochondriac region downwards below the umbilicus, and upwards into the chest as far as the fourth rib. The most prominent point of it was at the seventh rib, which is displaced from its cartilage, and a portion of it carious. An opening in the diaphragm, capable of admitting a common quill, leads from the sac into the cavity of the chest, which contained three pints of pus. Ascending colon intimately connected with the sac of the abscess, the pus of which has penetrated its outer coat.—MS. Cat. page 129, No. 105.

1391. Liver exhibiting the sac of an abscess of considerable size, the diaphragm adheres to the convex surface ; a bougie is passed through an incision in the integuments into the cavity of the abscess ; the evacuation of the matter gave temporary relief.—Donor, Mr. Lightbody, Surgeon 80th Regiment.

1392. Cavity of an abscess the size of an orange, situated in the right lobe of the liver, about an inch from its convex surface, which was filled with liquid and curdled pus, inner surface of sac rough and covered with lymph.—MS. Cat. vol. ii. page 155, No. 201.

1393. Cavity of an abscess in the liver ; the surrounding parenchyma is broken down, and hangs in loose shreds.

1394. Liver showing the sac of an abscess, situated in the thin margin of right lobe, lined by a firm fibrous membrane with shreds of lymph attached to it ; the diaphragm adheres to the convex surface, and also to the base of the lung.

1395. An irregular sac of an abscess in a portion of the liver.

1396. A portion of liver, showing the cavities of two abscesses, the inner surfaces of which are rough and granular.—Donor, Dr. Hodson, Surgeon 95th Regiment.

1397. Section of liver, showing the cavities of a number of small abscesses having no lining membrane, and the hepatic structure surrounding them is soft and broken up.—Preparation No. 1384.—Print. Cat. page 109, No. 16.

1398. Portion of liver, exhibiting the sac of an abscess, the internal surface of which is rough, with shreds of lymph attached to it.

1399. Cavity of an abscess in the liver; surrounding structure broken down and hanging in loose shreds.

1400. Sac of a large abscess taken from the liver, and everted to show its internal surface, which is lined by a smooth membrane; the walls are thick and fibrous.—Print. Cat. page 112, No. 40.

1401. Portion of a liver, showing two cavities of abscesses situated in the anterior part of the right lobe, lined by a distinct firm membrane, and communicating with each other by an opening capable of admitting a common quill.—Donor, Mr. Turnbull, 98th Regiment.

1402. Part of the sac of an abscess taken from the inferior portion of the right lobe of the liver; its inner surface is rough and granular, its walls a quarter of an inch in thickness; it contained two pints of viscid matter.—Donor, Dr. Scott, Surgeon Rifle Brigade.—Print. Cat. page 118, No. 96.

1403. Several cavities of abscesses in both lobes of the liver, with shreds of lymph on its peritoneal covering.—Print. Cat. page 119, No. 98.

1404. Cavities of abscesses of various sizes in both lobes of the liver; structure surrounding them soft, broken up and hanging loose.

1405. Portion of the left lobe of the liver, showing a sac about the size of a plum, which contained fluid resembling pus, but without its globular characters.—Donor, Mr. Melvin, Surgeon 60th Regt.—MS. Cat. vol. ii. page 137, No. 131.

1406. Liver showing two abscesses, one of a large size, situated in the concave aspect of the right lobe, lined by flocculent lymph which contains sixteen ounces of thick pus; the other about the size of a walnut, situated near the convex surface is coated with lymph, and adhered to the diaphragm; a long groove on the upper surface running from the anterior to the posterior margin.—MS. vol. ii. page 129, No. 104.

1407. Liver much enlarged and weighing five pounds four ounces; left lobe indurated, and the cavity of an abscess in the right which contained two pints of pus, surrounding structure broken down and hanging in loose shreds; peritoneal covering coated with lymph.—Print. Cat. page 113, No. 50.

1408. Portion of liver, showing the cavity of an abscess, which communicates with the stomach, close to the pyloric orifice, by a circular aperture one inch in diameter; mucous membrane surrounding it softened.

1409. Sac of an abscess in the concave aspect of the left lobe of the liver, inner surface of the sac broken down, and portions of it hanging loose: stomach adhering, and forming part of the wall of the sac; a portion of the peritoneal coat of the stomach destroyed by ulceration.—Print. Cat. page 107, No. 7.

1410. Portion of liver, showing the sac of an abscess, which communicates with the stomach by a large irregular opening about three inches in diameter; stomach and part of the transverse arch of the colon adherent, the coats of the former surrounding the opening much thickened, and the mucous membrane granular.—Print. Cat. page 101, No. 12.

1411. A cavity, the size of a walnut, in the lower part of the right lobe of the liver, in which lay a needle of a dark colour, two and a half inches long, having its point upwards, and embedded in the substance of the liver; the cavity communicates with the duodenum immediately below the pyloric orifice of the stomach. It is



stated that the patient swallowed a needle two years previous to his death.—Donor, Mr. Allan, A. S. Staff.—MS. Cat. vol. ii. page 152, No. 192.

1412. Section of liver, showing a portion of the sac of a large abscess, capable of containing a pint of matter which was situated in the right lobe, and communicated with the corresponding angle of the colon; structure surrounding the cavity soft, and broken up.—Preparation 1252.—Print. Cat. page 95, No. 24.

1413. Cavity of an extensive irregular abscess in the liver, situated between the two lobes, with shreds of membrane and lymph hanging from its inner surface, communicating inferiorly with a cavity formed by adhesion of the concave surface of the liver to the upper surface of the stomach.—Donor, Dr. Burrell, Surgeon 77th Regt.—Necrol. Reg. vol. vi. page 47.

1414. Sac of an hepatic abscess (dried), which contained seven and a half pints of pus.—Print. Cat. page 111, No. 36.

1415. Sac of an hepatic abscess (dried), which contained seventeen pints of purulent matter; the abscess became perceptible externally, and was opened, when three pints of serous fluid flowed out, but no pus; he died two days afterwards of peritonitis.—Print. Cat. page 111, No. 37.

## SECTION II.—CICATRICES IN THE LIVER.

1416. Liver enlarged and lobulated, structure condensed, and presenting puckering and marks of old suppurating cavities.—Print. Cat. page 107, No. 8.

1417. Portion of liver having a depressed, puckered, white cicatrix on its surface.—Print. Cat. page 111, No. 35.

1418. A long deep irregular groove of an old cicatrix, extending backwards along the upper surface of the right lobe of the liver, for about six inches; the structure of the gland contiguous to it is semi-cartilaginous, and the remainder is firm, and presents a smooth, oily appearance; there are also several other depressions of a smaller

size in different parts of both lobes; liver small, weight one pound fifteen ounces.—MS. Cat. vol. ii. page 156, No. 202.

### SECTION III.—DILATATION OF THE BILIARY DUCTS.

1419. Portion of liver, showing great dilatation of the hepatic ducts, one of which is capable of admitting a large bougie. Preparation No. 1431.—MS. Cat. vol. ii. page 150, No. 185.

1420. Section of liver, exhibiting dilatation of the hepatic ducts; one of those is of a large size, and contains a dark brown biliary fluid of the consistence of cream, and small gritty bodies of a black colour resembling biliary calculi; peritoneum covering the liver coated with lymph.—MS. Cat. vol. ii. page 142, No. 154.

1421. A small portion of liver in which is an hepatic duct very much dilated, and containing a dark brown biliary fluid; the coats of the duct are firm and fibrous.—MS. Cat. vol. ii. page 142, No. 155.

### SECTION IV.—ENLARGEMENT OF THE LIVER.

1422. Liver very much enlarged and elongated; weight eight pounds fourteen ounces; structure firmer than usual. Preparation No. 2302.—Print. Cat. page 164, No. 147.

1423. Liver enormously enlarged, lobulated, and having a deep notch separating the two lobes posteriorly; with large scrofulous tubercles deposited in its substance; weight ten and a half pounds. Preparation No. 1707.—Print. Cat. page 113, No. 51.

### SECTION V.—FATTY AND OILY MATTER IN THE LIVER.

1424. Portion of a liver, containing a large quantity of oily matter, which is seen floating on the surface of the spirits, also small globules on the section; the external surface presents a tuberculated appearance.

1425. A considerable quantity of oil collected from the liver, forming preparation No. 1424.

## SECTION VI.—COMMON TUBERCLE IN THE LIVER.

1426. Portion of liver, containing a small circumscribed deposit of tuberculous matter.—MS. Cat. vol. ii. page 152, No. 190.

1427. A well defined tubercle, of a cheesy consistence, and about the size of a cherry, situated in the right lobe of the liver, near its convex surface; peritoneal covering coated with lymph.—Necrol. Reg. vol. vi. page 356.

1428. Portion of liver, showing several tubercles of a caseous consistence near its surface.

1429. A large well-defined tuberculous deposit, slightly softened towards its margin, situated in a portion of the liver.

1430. Portion of liver, showing two tubercles in their second stage of development. No tubercles were found in any other organ of the body.—MS. Cat. vol. ii. page 135, No. 122.

1431. Portion of liver, containing four well-defined tubercular deposits, the layers of which are arranged concentrically. A biliary duct passes through one of these masses. Preparation No. 1419.—MS. Cat. vol. ii. page 150, No. 186.

1432. Portion of liver, showing two caseous tubercles. From a man *ætat.* twenty-five, who died of phthisis.

1433. Portion of the liver, of the *Macacus Rhesus*, pervaded by tubercles in their first and second stages of development; minutely injected.—Donor, Mr. Gulliver, A. S. Royal Horse Guards.

1434. Two large tubercular deposits, slightly softened and broken up, situated in a portion of the liver. Preparation No. 1529.—Print. Cat. page 115, No. 67.

1435. Portion of liver, showing a cavity filled with softened tubercular matter; a strong band of adhesion unites it to the dia-

phragm, and its peritoneal covering is coated with lymph.—Necrol. Reg. vol. vi. page 84.

1436. A tubercle, situated in an adventitious band, which connected the inferior surface of the right lobe of the liver to the corresponding part of the transverse arch of the colon. Preparation No. 1342.—MS. Cat. vol. ii. page 38, No. 157.

1437. Portion of liver infiltrated with tuberculous matter, also containing several cavities having distinct lining membranes.—Donor, Mr. Turnbull, Surgeon 98th Regt.

1438. Portions of liver containing tuberculous matter, minutely injected.—Donor, Mr. Patridge, King's College.

#### SECTION VII.—SCHIRROUS TUBERCLE, WITH HYPERTROPHY OF THE WHITE SUBSTANCE OF THE LIVER.

1439. Section of the common tuberculated liver of hard drinkers; the round bodies are of a firm texture, and of a brownish or dirty yellow colour; external surface presents numerous elevations from the size of a pea to that of a bean, with shreds of lymph attached to it; what the exact nature of these bodies (which have improperly been termed tubercles) is, does not seem to have been properly explained. Andral considers this condition to depend on hypertrophy of the white tissue, and others are of opinion that it is owing to the deposition of a new substance. From a man who died of acute dysentery.

1440. Portion of tuberculated liver, having attached to its external surface a globular mass of similar structure. From a man who died of chronic dysentery.

1441. Section of a tuberculated liver, the greater number of the round firm bodies are of large size, and in an advanced state of development.

1442. Portion of tuberculated liver.—Necrol. Reg. vol. v. page 246.

1443. Liver tuberculated, small, weight two pounds five ounces. From a man *ætat.* 30, a hard drinker, who had a pulmonic complaint of eight months' duration, of which he died.

1444. Right lobe of the liver small and thickly studded with schirrous tubercles.—*Print. Cat.* page 111, No. 38.

1445. Tuberculated liver of a habitual drunkard, right lobe small, shreds of lymph attached to its peritoneal covering; a deep depression on its convex surface and a portion of diaphragm adherent; its internal structure presents (besides the small elevated bodies) a peculiar cribriform appearance.—*Donor, Dr. Sillery, A. S. Staff.*

1446. Portion of tuberculated liver.

1447. Portion of liver showing a well defined schirrous tubercle about the size of a plum.

1448. Portion of liver studded with schirrous tubercles.

1449. Liver small, weight two pounds fifteen ounces, structure condensed from the deposition of schirrous tubercles, external surface very irregular from numerous projecting eminences, varying in size from a pea to a cherry; posterior part of the convex surface of the right lobe adherent to the diaphragm.—*Preparation No. 1559.*—*MS. Cat.* vol. ii. page 171, No. 45.

1450. Section of an indurated liver, showing great hypertrophy of the white substance. When the liver is in this condition, there is generally considerable diminution of its size, and ascites is almost always concomitant. It is most frequently observed at this place in subjects who have died of chronic dysentery, contracted in tropical climates.—*Preparation 1211.*—*Print. Cat.* page 97, No. 50.

1451. Portion of liver, exhibiting the cirrhosis of Laennec; the white tissue is preternaturally developed, and of a yellow colour.—*MS. Cat.* vol. ii. page 133, No. 117.

1452. Section of liver showing well-marked hypertrophy of the

white substance ; peritoneal coat thickened, rough, and cartilaginous.—MS. Cat. vol. ii. page 136, No. 129.

1453. Portion of tuberculated liver ; the section presents a slightly reticulated appearance.—Donor, Mr. Bradford, A. S. 56th Regt.—MS. Cat. vol. ii. page 129, No. 103.

1454. Portion of liver affected with cirrhosis ; in the centre the diseased portions have become absorbed, and present a reticulated appearance.—MS. Cat. vol. ii. page 136, No. 126.

1455. Portion of liver showing hypertrophy of the white substance, which in the centre has begun to break down, leaving small cavities.

1456. Section of a liver, exhibiting interstitial absorption of its centre, those parts in which the process of absorption has not commenced are studded with scirrhus tubercles, the whole of the centre of the specimen resembles an empty honey-comb, owing to the absorption of these bodies, and the cellular cysts which enclosed them still remaining.—Donor, Dr. Whitfield, Surgeon, Royal Artillery.

1457. Portion of liver exhibiting interstitial absorption.—Section of No. 1456.

1458. Section of liver, showing hypertrophy of the white substance, and containing numerous cavities which present a honey-combed appearance.

1459–1460–1461. Three portions of liver, each presenting a peculiar cribriform or honey-combed appearance, from small cavities in their substance. These cavities are not lined by any membrane, and they did not contain any fluid ; structure soft and homogeneous, and had in the recent state a bluish or leaden hue ; only in one portion of the liver was there any tuberculated appearance, and that faint ; weight of liver, three pounds and a half. Disease of the liver was not suspected during life. Preparation No. 1111.—MS. Cat. vol. ii. page 33, No. 141.

## SECTION VIII.—MEDULLARY DEPOSIT IN THE LIVER.

1462. Section of liver injected, and containing numerous medullary deposits of various sizes.—Donor, Mr. Partridge, King's College.

1463. Portion of liver, showing many large white medullary deposits in its substance, the intervening structure soft and of a black colour.—Donor, Dr. Lander, Surgeon, 7th Hussars.

1464. Right lobe of the liver indurated and condensed; a large encephaloid tumour in its thin edge which adhered to the arch of the colon and communicated with it by two ulcerated openings; the tumour when recent was of a melanotic colour externally, the surface having several openings through which some dirty brown-coloured fluid exuded; internally it consisted of masses of light-coloured caseous or tubercular pulp, intersected by dark brown melanotic-looking matter, the whole being contained in a well defined cyst of dense texture; gall bladder enlarged and was distended with bile; peritoneum covering the liver thickened and coated with lymph.—Donor, Mr. Ford, A. S. 72nd Regt.—MS. Cat. vol. ii. page 139, No. 133.

1465. A large cerebriform tumour, imbedded in the upper and posterior part of the right lobe of the liver, portions of the mass are softened and broken down.—MS. Cat. vol. ii. page 148, No. 177.

1466. Portion of liver, showing injected medullary tumours in its substance.—Donor, Mr. Stanley, St. Bartholomew's Hospital.

1467. Portion of liver, filled with medullary tubercles of various sizes, all the masses are softened and broken down in their centres, leaving large cavities. Injections of different colours were thrown into the vessels of the liver, some of each are extravasated in and around the tubercles, but the medullary structure itself is only imperfectly injected, and chiefly from the hepatic artery. The liver was much enlarged. From a middle-aged woman, in whom the disease progressed very rapidly.—Donor, Mr. Moon, Guy's Hospital.

1468. Portion of liver, containing several medullary tumours, injected.—Donor, Mr. Howstrip, London.

SECTION IX.—MELANOTIC DEPOSIT IN THE LIVER.

1469. Portion of liver, showing melanotic degeneration; the deposits are of various sizes, from that of a pea to that of a cherry, the intervening structure is of a dirty white colour.

1470. Portion of liver highly melanosed, the section of which shows that many of the deposits are of a deep black colour, others of a bluish-brown hue, and the intervening substance of a dirty cream colour; the peritoneal surface presents numerous black elevations. Presented by the Royal College of Surgeons, Edinburgh.—Print. Cat. page 110, No. 25. Edinburgh Medical and Chirurgical Transactions, vol. i. page 271.

1471. Section of No. 1470, studded with melanotic deposits, but more widely separated from each other than in the former; the rest of the substance is of a pale yellow colour and homogeneous texture.

1472. Two portions of liver, showing numerous melanotic deposits intermingled with cerebriform matter. In one portion the black melanotic masses are well defined, varying in size from that of a pea to that of a walnut, in different stages of advancement. In the other there are several small, and one very large melanotic mass, the centre of which is soft and broken down; the liver weighed five pounds. A tumour of a melanotic and encephaloid structure was found to occupy the right eye.—Preparation No. 880.—MS. Cat. vol. ii. page 147, No. 173.

1473. Portion of liver studded with melanotic deposits from the size of a pea to that of a cherry, injected.—From a middle aged woman who had a melanotic tumour on the right side, which was removed by operation; there were a few tubercles in the lungs and sternum.—Donor, Mr. Partridge, King's College.

1474. Portion of liver filled with large black melanotic tumours;



the liver weighed fifteen pounds.—From the body of a Greek in whom the liver, pancreas, aorta, and integuments were affected with the same disease.—Preparations Nos. 102, 193, and 1602.—Donor, Dr. Davy, A. I. H.

1475. Portion of liver, studded with melanotic and cerebriform deposits.—Donor, Mr. Stanley, St. Bartholomew's Hospital.

#### SECTION X.—CARTILAGINOUS AND CALCAREOUS DEPOSITS IN THE LIVER.

1476. Small tumour of a cartilaginous consistence, taken from the liver, where it was imbedded in a fibrous cyst.—From a Maltese who died of tetanus.—Donor, Dr. Davy, A. I. H.

1477. Portion of liver, with a cartilaginous deposit on its surface, and several small gritty bodies about the size of pin-heads in its substance.—Preparation No. 1566.—Print. Cat. page 116, No. 85.

1478. Portion of liver with a calcareous deposit in its substance.—Print. Cat. page 114, No. 65.

1479. Section of liver presenting a very hard calcareous deposit, about the size of a pea in its substance.

1480. Portion of a hard calcareous deposit, taken from the surface of the liver.

#### SECTION XI.—CYSTS, HYDATIDS, AND WORMS IN THE LIVER.

1481. Cyst, about the size of a large plum, situated in the thin margin of the liver, and lined by a distinct smooth membrane.—Donor, Dr. Raich, Surgeon 67th Regt.—MS. Cat. vol. ii. page 131, No. 106.

1482. Portion of liver showing a fibro-cartilaginous cyst about the size of a small orange, situated in the superior and posterior part

of the right lobe, containing one or more hydatids, much compressed, which at the time they were discovered appeared to have been some time dead. Filling up the space existing between the folds of the hydatid or hydatids, is a yellowish matter somewhat resembling the partially broken up yolk of a hard boiled egg, which, on being analyzed, was found to contain a considerable quantity of cholesterine. The upper aspect of the cyst is connected to the diaphragm by an elongated band of adhesion. The liver weighed five pounds, and possessed throughout an unusual density of structure.—MS. Cat. vol. ii. page 151, No. 187.

1483. A thick fibro-cartilaginous cyst, found in the left lobe of the liver, which contained several hydatids in a live state; a portion of the diaphragm is attached by a long narrow band of adhesion.—From the same subject as Preparation No. 1482.—MS. Cat. vol. ii. page 151, No. 187.

1484. A very large fibro-cartilaginous cyst, rough and irregular internally, situated in the posterior and convex aspect of the right lobe of the liver, which contained a large hydatid.—Preparation No. 1502.—From a patient who died of ascites, with which he had been afflicted for four months.

1485. A fibro-cartilaginous cyst, about the size of an orange, situated in the thin margin of the liver, containing an hydatid.

1486. A cyst, situated in the posterior and convex aspect of the liver, part of the walls of which are encrusted with calcareous matter; it was filled with hydatids; part of the diaphragm and lung adhere.—Print. Cat. page 109, No. 15.

1487. A large, thick, fibro-cartilaginous sac, the interior of which presents a number of irregular elevations and depressions; it contained a large hydatid. Preparation No. 1501.—Donor, Mr. Bace, A. S. 45th Regt.

1488. Cyst, from the substance of the liver, containing a number of hydatids; interior rough and granular from the effusion of lymph.

From a man who died of fever, complicated with jaundice.—Donor, Mr. Bardin, A. S. 53rd Regt.

1489. A small cyst containing an hydatid, situated near the convex aspect of the liver.—Print. Cat. page 119, No. 101.

1490. Cyst about the size of a duck's egg, filled with hydatids, situated in the posterior part of the concave surface of the liver. From a man who died of phthisis.

1491. Cyst in the thin margin of the liver containing several hydatids.—Print. Cat. page 109, No. 17.

1492. A very distinct fibrous cyst, about the size of a walnut, containing hydatids, situated near the convex surface of the right lobe of the liver. From a man who died of hæmoptysis.—Donor, Dr. Renny, Surgeon, 67th Regt.

1493. Portion of liver containing a large hydatid cyst, lined by a distinct smooth membrane.

1494. Cyst of an hydatid in a portion of liver, the structure of which is studded with scirrhous tubercles.—Donor, Mr. Martin, Surgeon, 73rd Regiment.

1495–1496. Two sections of the liver of a pig, presenting a peculiar honeycombed appearance, from innumerable small cysts containing hydatids.—Donor, Mr. Partridge, King's College.

1497. Portion of liver of a sheep, containing a number of cysts filled with hydatids; hydatids were also found in the lungs and spleen. Preparation No. 620.

1498. Hydatids from the liver of a cow; the parent cyst is unopened and the second cyst appears through its diaphanous texture.—Donor, Dr. Athill, A. S. Staff.

1499. Hydatids from the liver of a bullock, situated in the right lobe and contained in a cyst; when first removed they presented evident symptoms of vitality.—Donor, Mr. Ford, A. S. 72nd Regt.

1500. Three hydatids from the liver.

1501. Hydatid of large size, from the liver; the surface of the hydatid is rough and granular, from a number of small ash-coloured concretions beneath its outer membrane. Preparation No. 1487.—Donor, Mr. Bace, A. S. 45th Regt.

1502. A large hydatid from the surface of the liver. Preparation No. 1484.

1503. A vast number of lumbrici, in the substance of the liver, around which small abscesses had formed; also in the gall bladder, biliary ducts, duodenum, and stomach. Numerous small worms (*Tricocephalis disparis*) were found in the cœcum. Preparation No. 1303. From a Maltese boy ætat. 2, who died of dysentery.—Donor, Dr. Davy, A. I. H.

#### SECTION XII.—RUPTURE OF THE LIVER.

1504. Rupture of a portion of the liver, about an inch from the suspensory ligament, the lesion on the surface is about four inches in length and extends far into its substance, the section of which shows a small quantity of coagulated blood; the result of a blow by the pole of a waggon on the abdomen near the scrobiculus cordis; the patient lived thirty-six hours after the accident.—Donor, Dr. Dyce, A. S. Staff.—MS. Cat. vol. ii. page 133, No. 116.

1505. Rupture of the liver, in consequence of a fall from a height of forty-five feet on board ship, right side having come in contact with some packing-cases on deck. The patient died six hours after the accident.—Donor, Dr. Stewart, A. I. H.

1506. Extensive laceration of the convex surface of the right lobe of the liver; from a gun-shot wound.

1507. Section of the liver of a horse, showing effusion of blood in its substance. The liver was four times its natural size, generally very soft and immensely distended with coagulated blood.—MS. Cat. vol. ii. page 148, No. 175.

## SECTION XIII.—MALFORMATIONS OF THE LIVER.

1508. Portion of liver, having numerous nodules and supplementary lobes, and containing a considerable quantity of oily matter.—Donor, Dr. Ingham, Surgeon, 29th Regt.

1509. Portion of liver having many supplementary lobes, from the size of a pea to that of a plum. From a man who died suddenly of pulmonary apoplexy.—Donor, Mr. Orr. A. S. 95th Regt.

1510. Left lobe of the liver extremely small, so as at first sight to appear altogether absent, right lobe also small and attached to the diaphragm, by many firm membranous bands; structure dense and studded with scirrhus tubercles; weight of liver with a portion of diaphragm two pounds five ounces. From a man *ætat.* 34, who died of ascites.—Donor, Mr. Nicholson, Surgeon, 42nd Regt.

1511. The left lobe of the liver is wanting. There are however two supplementary lobes of the size of walnuts, situated to the left of the longitudinal fissure, and there is moreover a rim of substance firm to the touch and covered by peritoneum, occupying the site of the left lobe; this is about three inches long from right to left and is connected to the diaphragm by a *ligamentum latum*. The right lobe was of normal size and tuberculated, not from the tubercular matter of phthisis being deposited, but from the white portion of the liver being hypertrophied.—From a man *ætat.* 24, who died of phthisis.

## SECTION XIV.—DISEASES AND MALFORMATIONS OF THE GALL-BLADDER, INCLUDING BILIARY CALCULI.

1512. Hypertrophy of the coats of the gall bladder, which contained four calculi.—Donor, Mr. O'Brien, A. S. 7th Regt.—MS. Cat. vol. ii. page 132, No. 110.

1513. Coats of the gall bladder very much thickened.—Donor, Dr. Strachan, I. G. H.

1514. Hypertrophy of the coats of the gall bladder. From a

man who had long been affected with jaundice.—Donor. Mr. Duke, A. S. 12th Regt.

1515. Coats of the gall bladder thickened and cartilaginous, with bony deposit in its fundus.—Donor, Mr. Fiddes, Surgeon 85th Regt.

1516. A number of oblong yellow spots on the lining membrane of the gall bladder, the largest of which occupies the fundus, and part of the softened membrane hangs loose from its surface.—MS. Cat. vol. ii. page 155, No. 199.

1517. Gall bladder divided into compartments by transverse bands, one of these at the fundus contains a fungoid warty tumour, about the size of a cherry; two biliary calculi were also found in the gall bladder.—Preparation No. 1542.—Necrol. Reg. vol. v. page 292.

1518. Biliary ducts much dilated, more especially the hepatic and ductus communus cholidochus; caused by the pressure of a calculus.—From a woman ætat. 98.—Donor, Dr. Davy, A. I. H.

1519. A lumbricus in the ductus communus cholidochus and hepatic duct.—Donor, Dr. Davy, A. I. H.

1520. Gall bladder partially divided by two membranous septa.

1521. Shows a supernumerary hepatic duct, which joins the ductus communus cholidochus about one inch from its commencement, the biliary ducts are considerably enlarged.—Donor, Mr. O'Brien, A. S. 7th Regt.

1522. Gall bladder containing two large soft calculi, one is white and composed of cholesterine, the other is also white externally and dark brown internally.

1523. A biliary calculus about the size of a cherry, of a dark slate colour with small white deposits on its surface; impacted in the neck of the gall bladder.

1524. Gall bladder containing three large dark brown calculi.

1525. Gall bladder completely filled with numerous small angular calculi.—Donor, Dr. Heisse, A. S. 35th Regt.

1526. Four large and ten small calculi from the gall bladder.—Donor, Dr. Stephenson, Rochester.

1527. Many biliary calculi, two of which are of large size.

1528. Six biliary calculi. From a woman *ætat.* 98.—Donor, Dr. Davy, A. I. H.

1529. Biliary calculus which was impacted in the neck of the gall bladder.—Print. Cat. page 115, No. 67.

1530. Biliary calculi.

1531. Calculus from the gall bladder.

1532. Section of a biliary calculus.

1533. Two calculi from the gall bladder. From a man who after an apoplectic fit became idiotic, and died so at the end of six years.

1534. Biliary calculus.

1535. Two biliary calculi.

1536. Several large smooth and numerous small angular biliary calculi.

1537. Numerous small angular biliary calculi.

1538. Numerous small angular biliary calculi.

1539. Numerous small angular biliary calculi.

1540. Biliary calculus about the size of a cherry.

1541. A smooth white biliary calculus about the size of a cherry. From a man who died of remittent fever, and who was attacked with cholic shortly before his death.—Donor, Dr. M'Munn, A. S. 10th Regt.

1542. Sections of two biliary calculi.—From Preparation No. 1517.—Necrol. Reg. vol. v. page 292.

1543. Section of a biliary calculus chiefly composed of cholesterine.—Donor, Mr. Lloyd, A. S. Rifle Brigade.

1544. Two small white biliary calculi, the lower one was impacted in the commencement of the cystic duct.—Donor, Dr. Davy, A. I. H.

1545. Biliary concretion about the size of a pigeon's egg; the external crust is black, and the one beneath is of a dark brown colour. — Donor, Dr. Stephenson, Rochester. — MS. Cat. vol. ii. page 146, No. 168.

1546. Biliary calculus about the size of a cherry, of a deep black colour. From a man who died of chronic pericarditis.—Donor, Dr. Taylor, A. S. 58th Regt.

1547. Two biliary calculi about the size of beans, and several others of a smaller size, and of a deep black colour.

1548. Several black biliary calculi.

1549. Minute biliary calculi of a black colour, and rough exterior.—Donor, Dr. Knox, Edinburgh.

1550. Five small biliary calculi.

1551. Two black irregular biliary calculi.—MS. Cat. vol. ii. page 106, No. 172.

1552. Eight small black irregular biliary calculi.—Print. Cat. page 114, No. 63.

1553. Small black biliary calculi; when recent their surfaces were regular and highly polished; they are very light and friable. From a woman *ætat.* 90.—Donor, Dr. Stephenson, Rochester.



## DIVISION V.

*DISEASES, INJURIES, AND MALFORMATIONS  
OF THE SPLEEN.*

## SECTION I.—INFLAMMATION, AND ABSCESSSES OF THE SPLEEN.

1554. Spleen slightly lobulated, and a large abscess in its substance, near the convex surface of the inferior angle, the interior of the sac is lined by granular lymph. — Print. Cat. page 120, No. 6.

1555. Several sacs of abscesses near the convex surface of the spleen, each lined by a distinct firm membrane.—Print. Cat. page 120, No. 2.

1556. A large sac of an abscess surrounding the spleen, the interior of which, as also the peritoneum covering this organ, is coated with a thick layer of granular lymph.—Print. Cat. page 120, No. 3.

## SECTION II.—INDURATION OF THE SPLEEN.

1557. Structure of spleen firm and indurated, peritoneal covering thickened, with numerous white semi-cartilaginous spots on its surface, and shreds of lymph attached.

1558. Section of an indurated spleen, minutely injected.—From a man who died of ague in India.

## SECTION III.—ENLARGEMENT OF THE SPLEEN.

1559. Spleen very much enlarged, weight four pounds two ounces; it extended from the 8th rib to the crust of the ilium; structure condensed, peritoneum covering it a quarter of an inch in thickness, firm, and cartilaginous.—MS. Cat. vol. ii. page 172, No. 45.

1560. Spleen much enlarged, weight two pounds five ounces; structure condensed, peritoneal coat thickened, with large white glistening cartilaginous spots on its surface, and portions of lymph attached.—Print. Cat. page 120, No. 10.

1561. Spleen enlarged, weight one pound eight ounces; structure firm; investing membrane thickened and entirely covered by a thick uniform layer of lymph, which is at some parts semi-cartilaginous.

1562. Spleen much enlarged, weight one pound eight ounces; structure condensed: capsule thickened, with shreds of lymph attached.—Print. Cat. page 121, No. 14.

1563. Spleen enlarged and lobulated, weight one pound six ounces.

## SECTION IV.—SPLEEN DIMINISHED IN SIZE.

1564. Spleen exceedingly small, weight two ounces two drachms; capsule thickened and partially converted into cartilage.—From a Maltese, ætat. 84, whose arteries were generally ossified.—Donor, Dr. Davy, A. I. H.

1565. Spleen exceedingly small, weight two ounces four drachms; structure firm.—From a man who had been addicted to the use of ardent spirits.—Donor, Mr. Stewart, Surgeon 84th Regt.

1566. Spleen small, weight two ounces four drachms; structure firm, and its capsule at parts opaque.—Print. Cat. page 116, No. 85.

## SECTION V.—TUBERCULAR DEPOSIT IN THE SPLEEN.

1567. Section of spleen studded with extremely minute miliary tubercles.—Necrol. Reg. vol. vi. page 20.

1568. Portion of spleen studded with minute miliary tubercles; texture firmer than usual.—MS. Cat. vol. ii. page 171, No. 44.

1569. Spleen containing numerous miliary tubercles; shreds of lymph attached to its peritoneal coat.

1570. Portion of spleen of a child, pervaded throughout by tubercles about the size of peas. — Donor, Mr. Gulliver, A. S. R. H. Gds.

1571. Spleen studded with tubercles.

1572. Section of spleen containing numerous tubercles about the size of peas; the spleen weighed two pounds.—From a man who died of phthisis; almost every organ of the body showed tubercular degeneration in an advanced stage.

1573. Spleen studded with large caseous tubercles, which at several places cause elevations on the surface, where they are only covered by the peritoneum.—From a patient who died of phthisis.

1574. Portion of spleen pervaded by large cheesy tubercles.

1575, 1576. Two sections of an enlarged and indurated spleen, having a large white tubercle in its substance near the surface, where it is partially softened and contained in a distinct sac.—Donor, Dr. Bradford, Surgeon 56th Regt.

1577. Tuberculous deposit in the spleen.—From a man *ætat.* 39, who died of phthisis.

1578. Portion of spleen having two large white tubercles in its substance, near the convex surface, which is of a dark red colour from the effusion of blood beneath its capsule.

1579. Portion of spleen condensed and containing a large tubercular deposit; external surface of a deep purplish red colour.—Preparation No. 136.—Donor, Mr. Ford, A. S. 72nd Regt.—MS. Cat. vol. i. page 122, No. 115.

#### SECTION VI.—MELANOTIC DEPOSIT IN THE SPLEEN.

1580, 1581, 1582. Three portions of spleen containing large black masses of melanotic matter; in the centre of some of them there is a deposit of white medullary substance, which is slightly softened and broken down; the spleen was much enlarged and weighed three pounds. The mammæ, sternum, liver and kidneys were affected with the same disease.—Preparation No. 2050.—Donor, Mr. Melville, Staff Surg.—MS. Cat. vol. iii. page 223, No. 99.

#### SECTION VII.—CARTILAGINOUS, AND BONY DEPOSITS IN THE SPLEEN, AND ITS CAPSULE.

1583. Spleen studded with numerous calcareous bodies about the size of pin-heads; structure firm; shreds of lymph attached to the peritoneal coat.—MS. Cat. vol. ii. page 174, No. 46.

1584. Spleen showing great thickening of its capsule, which at one part is half an inch in thickness and cartilaginous.—Donor, Mr. O'Brien, A. S. 7th Regt.

1585. Structure of spleen dense and firm; capsule covering its convex surface about three-quarters of an inch in thickness and cartilaginous.—MS. Cat. vol. ii. page 170, No. 37.

1586. Portion of spleen having several small cartilaginous bodies in its capsule.—Donor, Dr. Davy, A. I. H.

1587. A mass about an inch and a half in thickness, taken from the external surface of the spleen, consisting partly of a dense fibro-cartilaginous substance and partly of bone; a small portion only of the vascular structure of the spleen remains, occupying the concavity of the substance seen in the preparation.—From a very old man.—Donor, Mr. Gulliver, A. S. Staff.

1588. Part of 1587, dried and preserved in turpentine, exhibiting the extent of the osseous matter.—Donor, Mr. Gulliver, A. S. Staff.

#### SECTION VIII.—RUPTURE OF THE SPLEEN.

1589. Spleen ruptured across its centre.—From a sailor who fell from the masthead and was killed. The abdomen was found full of grumous blood.—Donor, Mr. Fraser, A. S. Staff.

1590. Spleen showing well-defined sanguineous coagula in its structure.

#### SECTION IX.—MALFORMATIONS OF THE SPLEEN.

1591. Spleen small, and having four supplementary spleens about the size of walnuts.—Printed Cat. page 18, No. 42.

1592. Spleen of an unusual form, being elongated and consisting of two equal portions, joined by a narrow neck.—From the body of an insane officer who committed suicide.—Donor, Mr. Thomas, Surgeon Ordnance Medical Department.

1593. A supplementary spleen, about the size of a walnut, situated in the splenic omentum.

1594. Five supernumerary spleens, from the size of a pea to that of a cherry, situated in the splenic omentum.


1595. Supernumerary spleen about the size of a walnut.

1596. Two supernumerary spleens about the size of cherries. The spleen itself was very much enlarged in consequence of the patient having suffered from remittent fever.

1597. A supernumerary spleen.—Donor, Dr. Davy, A. I. H.

## DIVISION VI.

### *DISEASES OF THE PANCREAS.*



1598. Pancreas containing tubercular and calcareous deposit.

1599. A cancerous tumour in the pancreas ; another of the same nature was found in the capsule of Glisson in the liver ; when recent, both the tumours were very vascular, and had all the characters of carcinoma.—Donor, Mr. Gulliver, A. S. R. H. Gds.—MS. Cat. vol. ii. page 127, No. 8.

1600. Portion of pancreas in a scirrhus condition, and its external surface presents numerous round elevations about the size of peas.

1601. Pancreas condensed and of a homogeneous texture, having little or no trace of its granular structure.—MS. Cat. vol. iv. page 10, No. 127.

1602. Portion of pancreas exhibiting melanosis.—Preparations Nos. 102, 193, 1474.—Donor, Dr. Davy, A. I. H.—Print. Cat. page 40, No. 47.

1603. Pancreas enlarged ; structure condensed ; when recent its enveloping membrane had a dark melanosed appearance.—Necrol. Reg. vol. v. page 246.

1604. Atrophied pancreas, with a peculiar sacculated state of the opening of its duct into the duodenum ; there are no villous folds at the entrance of the ductus communis choledochus into the intestine ; each of these ducts enter the duodenum separately.—From a man, ætat. 18, who was exceedingly emaciated and died of diabetes.

## DIVISION VII.

### *DISEASES, AND MALFORMATIONS OF THE LYMPHATIC VESSELS, AND LYMPHATIC GLANDS.*

---

#### SECTION I.—DISEASES OF THE LYMPHATIC AND LACTEAL VESSELS.

1605. Upper part of the thoracic duct containing a coagulum of blood.—Donor, Dr. Davy, A. I. H.

1606. Portion of small intestine with a part of the mesentery attached, in which are varicose lacteals.—From a man, ætat. 37, who died of phthisis.

1607. Portion of small intestine, showing a varicose lacteal.—From a man who died of phthisis.

1608. Portion of small intestine, exhibiting varicose lacteals, with enlargement of the mesenteric glands.—From a man who died of phthisis.

1609. Portion of jejunum, with mesentery attached, exhibiting the lacteal vessels distended with a soft curd-like matter; the mesenteric glands are also enlarged and filled with tuberculous matter.—From a man, ætat. 30, who died of phthisis.

1610. Portion of jejunum showing a lacteal vessel laid open, which is filled with curdy matter; also an enlarged mesenteric gland containing scrophulous matter.—From a man, ætat. 29, who died of phthisis.

1611. Part of ileum and mesentery, exhibiting a varicose state of the lacteals; mesenteric glands enlarged and containing scrophulous matter.—Donor, Dr. Bushe, A. S. Staff.—Print. Cat. page 77, No. 15.

SECTION II.—LYMPHATIC GLANDS ENLARGED AND FILLED  
WITH TUBERCULOUS MATTER.

1612. Mass of mesenteric glands, very much enlarged and filled with tuberculous matter, softened in the centre. In this case death took place from marasmus.—Donor, Mr. Fraser, A. S. Staff.

1613. Enlarged mesenteric glands, containing tuberculous matter, some of them softened in the centre.—MS. Cat. vol. ii. page 127, No. 10.

1614. Mesenteric glands enlarged and filled with tuberculous matter.—Donor, Sir James Grant, I. G. H.

1615. Lymphatic glands, which were situated in the gastro-hepatic omentum, much enlarged, and deeply infiltrated with tuberculous matter. From a man, ætat. 24, who died of phthisis.

1616. Lymphatic glands, which were situated over the cœliac artery, much enlarged and filled with scrophulous matter.—From a man who died of phthisis.—Donor, Dr. Scott, Surgeon Rifle Brigade.

1617. Mesenteric glands, much enlarged, and containing tuberculous matter, with shreds of lymph attached to the peritoneum.—Print. Cat. page 88, No. 89.

1618. Mesenteric glands, enlarged and filled with tuberculous matter.

1619. Mesenteric glands, enlarged and filled with scrophulous matter.

1620. Mesenteric glands, enlarged and infiltrated with tubercular matter.



1621. Mesenteric glands, enormously enlarged, altered in structure, and containing serophulous deposit.—Donor, Mr. Cotton, A. S. 12th Regt.—MS. Cat. vol. iv. page 118, No. 11.

1622. Lumbar glands, much enlarged and filled with tubercular matter.—Donor, Mr. Martin, Surgeon 73d Regt.

1623. Portion of an inguinal gland, removed from an ulcerated cavity of a bubo: one side appears of a darker colour than the other owing to the application of potassa fusa previous to excision.

### SECTION III. — CALCAREOUS DEPOSIT IN THE LYMPHATIC GLANDS.

1624. Mesenteric glands, enlarged and containing calcareous and tubercular matter.—From a man, ætat. 18, who died of phthisis.

1625. Mesenteric glands, enlarged and filled with calcareous matter.

1626. Mesenteric gland filled with calcareous deposit.—From a man, ætat. 45, who died of pneumonia.

1627. Two concretions from a tuberculous mesenteric gland, composed of carbonate of lime with a small quantity of phosphate.

### SECTION. IV.—MALFORMATIONS OF THE LYMPHATIC VESSELS.

1628. Receptaculum chyli and a portion of the thoracic duct, exhibiting an unusual cellular structure in their interior; the course of the duct is preserved by means of small openings in the cells —From a Maltese, ætat. 95.—Donor, Dr. Davy, A. I. H.

1629. Unusual course of the thoracic duct across the aorta.—Donor, Mr. Martin, Surgeon, 73rd Reg.

## CLASS VI.

### URINARY ORGANS.

---

#### DIVISION I.

#### *DISEASES AND MALFORMATIONS OF THE SUPRA-RENAL CAPSULE.*

---

1630. Right supra renal capsule enlarged, and having tuberculous matter deposited in its substance, and on its external surface.—From a man, ætat. 24, who died of phthisis.

1631. Supra renal capsule enlarged, and a tubercular deposit, about the size of a cherry, in its substance.

1632. Supra renal capsule enlarged, and studded with tuberculous matter.

1633. Cyst, about the size of a walnut, which contained a grumous, sanguineous fluid, situated in the left supra renal capsule. Preparations Nos. 970, 988.—Donor, Mr. Ford, A. S. 72nd Regt. MS. Cat. vol. ii. page 3, No. 16.

## DIVISION II.

### *DISEASES, INJURIES, AND MALFORMATIONS OF THE KIDNEYS.*

---

#### SECTION I.—SOFTENING OF THE SUBSTANCE OF THE KIDNEYS.

1634. Section of a kidney, the cortical and part of the tubular portions of which are softened, and of a fine yellow colour.—MS. Cat., vol. ii. page 187, No. 69.

#### SECTION II.—DILATATION OF THE PELVIS, AND INFUNDIBULA.

1635. Section of an enlarged kidney, injected; the infundibula and pelvis are very much dilated. The right kidney was found converted into a sac, which contained a pint and a half of pus. The bladder, except at its cervix, presented a complete surface of ulceration.—Donor, Mr. Howship, London.—Print. Cat., page 125, No. 23.

1636, 1637. Right and left kidneys enlarged, ureters, pelvis, and infundibula, very much dilated, the latter forming large sacs in their substance, some of them are capable of containing a walnut. From a Maltese, ætat. 22.—Donor, Dr. Portelli.

1638. Kidney, exhibiting dilatation of its pelvis, and infundibula, with trophy of its substance. From a man, ætat. 30, who died of urinary fever, succeeding stricture of the urethra, and retention of urine. The other kidney was in the same state.—Donor, Dr. Stephenson, Rochester.

1639. Kidney enlarged, pelvis and infundibula very much dilated, the latter forming numerous cells in the lower half of the organ, the structure of which is absorbed. From a man who died of phthisis; no symptom of disease of the kidney was observed during life.

1640. Kidney, showing dilatation of the pelvis and infundibula, the latter forming large sacculi in its substance.

1641. Kidney, exhibiting dilatation of the infundibula, pelvis, and ureter; the substance of the gland is nearly absorbed. The bladder was punctured from the rectum, in consequence of retention of urine, from structure of the urethræ. After death, the whole of the urinary organs were found in a state of disease.

1642. Substance of the right kidney, almost entirely absorbed; pelvis and calyces greatly dilated. From a man, *ætat.* 34, who had, some years before, been cut for stone in the bladder. He had been long subject to nephritic complaints, and a few days before his death, he was attacked with total suppression of urine, with violent constitutional symptoms. He died on the sixth day. The whole mucous tissue of the kidneys was highly vascular, and of a dark red colour; the pelvis, and infundibula of left kidney, were distended with calculi, and bloody pus. Preparations Nos. 1716, 1722, 1723, 1877.—Donor, Dr. Stephenson, Rochester.

1643. Remarkable dilatation of the pelvis, and infundibula of a kidney, with almost complete absorption of its parenchymatous substance.—Donor, Dr. Hunt, A. S. Staff.

### SECTION III.—CONTRACTION, THICKENING, AND COMPLETE OBLITERATION OF THE URETER.

1644. Ureter contracted, coats much thickened, and lined with coagulable lymph.

1645. Kidney partly absorbed, ureter obliterated in consequence of the pressure of an aneurism. Preparation No. 333.—Print. Cat., page 53, No. 17.

SECTION IV.—BLOOD EFFUSED IN THE SUBSTANCE OF THE  
KIDNEY.

1646. Left kidney, showing a mass of coagulated blood, about the size of a cherry, effused in its substance near its surface; also several others of a smaller size, and numerous small cysts containing soft yellow caseous matter.—Donor, Dr. Power, A. S. 51st Regt.

SECTION V.—TUBERCULOUS DEPOSIT IN THE KIDNEY.

1647. A tuberculous deposit near the surface of the kidney.

1648. Section of a kidney, having two small tuberculous deposits near its surface.

1649. Section of an enlarged kidney, with numerous small tubercles deposited on its surface, immediately beneath the capsule. From a man, *ætat.* 33, who died of phthisis.

1650. A large tubercular deposit, softened in the centre, situated in the upper part of the left kidney.

1651. Portion of a kidney, studded with tuberculous matter which is partially softened. From a man of a strumous diathesis who died of phthisis.

1652. Kidney enlarged, numerous deposits of caseous tuberculous matter, contained in distinct cysts, and situated in the substance of the organ; the surface of the gland is very irregular from similar deposits, one of which is about the size of a cherry, and is filled with softened tubercle.—Donor, Dr. Power, A. S. 51st Regt.

1653. Portions of the left kidney, having a large tubercular deposit, slightly softened, in its substance.—Necrol. Reg., vol. ii. page 331.

1654. Tubercular deposit in the kidney; pelvis and infundibula enlarged, their coats thickened, and lined with granular lymph.

1655. Tubercular deposits, softened in the centre, situated in the tubular portion of the kidney, with a cyst at its superior angle.

1656. Kidney enlarged, and infiltrated with tuberculous matter, portions of which are softened and broken up, and the structure of the organ presents a homogeneous texture.

1657, 1658. Two kidneys, containing many small cavities, filled with pus, situated near the surface of the organs. The lungs, prostate gland, and vesiculæ seminales, also contained tubercles and pus.—Donor, Dr. Davy, A. S. 7th Regt.

1659. Structure of a kidney, almost entirely disorganized, containing several small cavities, and surrounded by very firm, white adipose, and cellular substance, which adheres strongly to the external surface of the gland: ureter enlarged.

1660. Kidney enlarged, and exhibiting a large fibrous cyst filled with softened scrophulous matter, situated in its inferior angle; a portion of the capsule of the organ is thickened, with small depressions on its surface.—Preparations Nos. 2479, 2480, 2481, 2482, Print. Cat. page 126, No. 30.

1661. Kidney, exhibiting a fibrous cyst about the size of a walnut, which contained a thick white cheesy deposit. From a lad, ætat. 15 years, who died of mesenteric disease, after amputation for a scrophulous affection of the knee joint.

1662. Kidney enlarged, and infiltrated with tuberculous matter, which is softened in the centre.

1663. Kidney much enlarged, weight fifteen ounces; structure studded with tuberculous matter, which is softened and broken up, leaving large cavities in its substance. From the same subject as No. 1662.

1664. Left kidney much enlarged, weight ten ounces four drachms; substance studded with numerous small tubercular deposits, some of them solitary, others in clusters and softened in their centres: those situated on the convex surface where the outer covering of the organ is taken off, have open mouths, and the matter which they contained was only prevented from escaping by the capsule of the kidney, which, in consequence, is very rough and irregular: the infundibula, pelvis, and ureter are much dilated, coats thickened, and lined by a thick layer of granular lymph; these tubes were filled with purulent matter.—Preparation, No. 1754.—MS. Cat. vol. ii. page 194, No. 104.

1665. Kidney much enlarged, weight thirteen ounces; tubercular degeneration in different stages, and numerous cavities of abscesses in its substance, some opening on the external surface; capsule thickened, ureter dilated, and lining membrane also thickened.—Preparation, No. 1768.—Donor, Mr. Ford, A. S. 72nd Regt.—Necrol. Reg. vol. vi. page 47.

1666. Right kidney, showing the cavities of two irregular scrophulous abscesses in its superior angle.—From a man, ætat. 27, who died of scrophula.—Preparation 2276.—MS. Cat. vol. iii. page 114, No. 45.

1667. Kidney, showing tubercular deposits, and cavities which contained matter, communicating with the pelvis: the substance of the organ is of a pale yellow colour, and homogeneous appearance; the infundibula, pelvis, and ureter are much dilated; coats thickened, and lined with a granular curdy substance, firmly adhering to their surfaces.—Print. Cat. page 125, No. 27.

1668. Kidney, containing many cavities, which were filled with softened tuberculous matter: the whole of the structure of the organ is destroyed.—From a man who died of tubercular disease, affecting the lungs, peritoneum, and kidneys.—Donor, Mr. Badenoch, Staff Surgeon.

1669. Right kidney, containing numerous cavities, which were filled with a cheesy-like albuminous matter: structure of the organ entirely destroyed.—Necrol. Reg. vol. iv. page 186.

## SECTION VI.—GRANULAR DEGENERATION OF THE KIDNEY.

1670. Kidney, showing granular degeneration: external surface rough and tuberculated. From a man who died of dysentery complicated with scurvy.

1671, 1672. Right and left kidneys enlarged, and showing granular degeneration; infundibula, pelves, and ureters much dilated. From a man, *ætat.* 38, who had hemiplegia dextra and incontinence of urine; he died on the sixth day with symptoms of apoplexy.

1673. Right kidney enlarged, weight nine ounces and a quarter, exhibiting well marked granular degeneration; several of the tubular masses are absorbed. From a man, *ætat.* 38, who died of phthisis, complicated with general anasarca.—*Necrol. Reg.* vol. iv. page 176.

1674. Kidney small, weight two ounces three drachms, showing granular degeneration.

1675. Kidney small, weight two ounces seven drachms, affected with granular degeneration; almost the whole of the tubular portion is absorbed, and the external surface is very irregular: the cortical portion is very narrow.—From the same subject as the preceding.

1676. Kidney, exhibiting granular degeneration; external surface rough and tuberculated.—*Print. Cat.* page 127, No. 11.

1677. Kidney enlarged, weight six ounces, showing well marked granular degeneration: a number of irregular elevations, with two serous cysts on the external surface.

1678. Kidney, showing granular degeneration in its advanced stage; the tubular portions are almost entirely destroyed, and the external surface presented numerous elevations about the size of peas.—From the same subject as Preparation No. 1677.



1679. Kidney enlarged, and affected with granular degeneration in its advanced stage. Almost the whole of the tubular masses have disappeared.

1680. Kidney, showing well marked granular degeneration in the third stage; the whole of the tubular portion is absorbed; infundibula and pelvis dilated.—Print. Cat. page 124, No. 18.

#### SECTION VII.—CYSTS, AND HYDATIDS IN THE KIDNEY.

1681. Left kidney much atrophied, weight six drachms; a small cyst, situated in the upper part of its convex border, immediately beneath its fibrous tunic, which contained a clear serous fluid.—From a maniac, *ætat.* 29, who died of phthisis.

1682. A large cyst in the substance of a kidney, and innumerable small ones, about the size of pin heads, immediately beneath its capsule. From a woman, *ætat.* 98, who died of peritonitis.—Donor, Dr. Davy, A. I. H.

1683. Kidney, containing innumerable small serous cysts, near its external surface.—From the same subject as No. 1682.—Donor, Dr. Davy, A. I. H.

1684. Kidney, having several serous cysts, near its external surface.—Print. Cat. page 123, No. 9.

1685. Kidney, containing many serous cysts.—From a man who died of phthisis.—Donor, Dr. Scott, Surgeon Rifle Brigade.

1686. Two cysts; one, about the size of a walnut, situated at the inferior angle of the kidney, and another, of a smaller size, in the convex surface.—Print. Cat. page 123, No. 13.

1687. Left kidney much enlarged, weight ten ounces; having a cyst, about the size of a cherry, on its anterior surface, which contained one hundred and five small calculi. From a man, *ætat.* 24,

who died of phthisis; the patient never had any symptom of renal disease.—Preparation Nos. 1688, 1720, 1721.

1688. Cyst, attached to the lower portion of the right kidney, which contained two ounces of clear yellow serum, also many other cysts of a smaller size filled with a similar fluid, situated near the convex surface. The pelvis contained a large calculus.—Preparation Nos. 1687, 1720, 1721.

1689. Section of a kidney, showing a cyst, about the size of a walnut, on its anterior surface; it contained a quarter of an ounce of dark coloured fluid.—From a man, *ætat.* 39, who died of chronic dysentery. No symptom of any derangement of the urinary organs during life.

1690. Right kidney, having three serous cysts in its substance, near the convex surface, one of which is about the size of a hen's egg. From a man, *ætat.* 49, who died of scorbutus.

1691. Kidney, with many cysts in its substance, varying from the size of a pea to that of a walnut.—From a man, *ætat.* 22, who died of acute hepatitis; had no symptom of any disease of the kidney.—Donor, Mr. Henry, A. S. 14th Dragoons.

1692. Kidney, showing a cyst in its superior angle, with granular degeneration of its substance.—Print. Cat. page 125, No. 25.

1693. Kidney, showing two small serous cysts, in its external surface, with granular degeneration of its substance.—Print. Cat. page 128, No. 41.

1694. A sac, the size of an orange, lined by a firm smooth membrane, situated in the centre of a kidney, and having no communication with the substance of the organ. The patient had been under treatment for rheumatism and bowel complaint, of which he died. The lungs were tuberculated, and the large intestines ulcerated.

1695. Section of a kidney, throughout the interior of which there are numerous cysts, filled with serous fluid.—Donor, Mr. Stanley, Surgeon St. Bartholomew's Hospital.

1696. Section of the left kidney, much enlarged and exhibiting numerous adventitious serous cysts.—Preparation No. 1699.—Print. Cat. page 127, No. 31.

1697. Kidney much enlarged, weight twelve ounces, three drachms, completely filled with cysts of various sizes.—Donor, Mr. Blinkens, A. S. Gr. Gds.—MS. Cat. vol. ii. page 193, No. 100.

1698. Kidney enlarged, weight fifteen ounces, structure entirely destroyed and studded with serous cysts of various sizes.

1699. Right kidney much enlarged, weight two pounds three ounces, and every where converted into cysts filled with a dark grumous substance, and the parenchymatous structure entirely destroyed by the adventitious developments.—Preparation No. 1696.—Print. Cat. page 127, No. 31.

1700, 1701. Two kidneys enormously enlarged, weight of right, two pounds two drachms; left, two pounds eight ounces and a half; thickly studded with serous cysts varying in size from a pea to that of an orange.—Donor, Dr. Shanks, Surgeon 55th Regt.—MS. Cat. vol. ii. page 191, No. 91.

1702. A very large sac, which was filled with a white semi-fluid matter resembling pus, communicating with the pelvis of the kidney, by an ulcerated opening, and by a similar aperture with another sac of a smaller size, situated above the kidney. This latter sac and the pelvis, were distended with a whitish matter of the consistence of butter; the sciatic nerve passes through the inferior portion of the larger cavity. Kidney small, structure almost entirely destroyed, pelvis and infundibula dilated, ureter almost impervious, and its opening from the kidney was quite closed by coagulable lymph. From a man, ætat. 44, of very intemperate habits, who died suddenly of delirium tremens.—Donor, Mr. O'Brien, A. S. 7th Regt.

1703. A very large cyst, attached to the lower angle of a kidney, which was filled with hydatids.—Preparation No. 1705.—Print. Cat. page 122, No. 2.

1704. A very large firm fibrous cyst, containing hydatids and gelatinous fluid, attached to the superior extremity of the kidney.—Donor, Dr. Sweeny, A. I. H.

1705. Hydatids, taken from the cyst, forming preparation No. 1703.—Print. Cat. page 122, No. 2.

#### SECTION VIII.—CALCULI IN THE KIDNEY.

1706. Calcareous matter in the pelvis of a kidney. The patient died of phthisis.

1707. A number of small calcareous concretions, in the pelvis of a kidney; structure affected with granular degeneration.—Preparation No. 1423.—Donor, Mr. Howel, Staff Surgeon.—Print. Cat. page 113, No. 51.

1708. Pelvis of a kidney, containing a large quantity of calcareous matter.

1709. Kidney, having a calculus in its pelvis, at the commencement of the ureter.—Print. Cat. page 124, No. 15.

1710. Parenchyma of a kidney, entirely destroyed; infundibula and pelvis very much dilated, and contain soft calculi.—From a man, *ætat.* 40, admitted with pain in the head, thirst, and purging of a thin yellow matter. Three days afterwards, he became comatose, and died the following day.

1711. Left kidney small, and containing three soft white calculi; two of them, about the size of peas, are situated in the infundibula, and the third, of the form and size of a walnut, occupies the pelvis.—From a man, *ætat.* 27, who died of phthisis. There was no symptom of nephritic disease.

1712. Kidney enlarged, pelvis and infundibula dilated, and containing large irregular-shaped calculi.—MS. Cat. vol. ii. page 190, No. 87.

1713. Kidney enlarged, structure destroyed, infundibula dilated and forming cysts, about the size of walnuts, which are lined by granular lymph, and contain two dark brown calculi.—From a man, who died of dropsy succeeding intermittent fever.

1714. Kidney enlarged, parenchyma almost entirely absorbed, pelvis and infundibula very much dilated, forming cells which contain numerous oval brown calculi.—From a hemiplegic patient, who had also disease of the heart.

1715. Right kidney, exhibiting two calculi of a brownish black colour, one about an inch in length and half an inch in breadth, the other about the size of a pea, both situated in the infundibula; one-third of the gland is converted into adipose matter.—Preparation No. 1777.—MS. Cat. vol. ii. page 195, No. 105.

1716. Left kidney enlarged, ureter, pelvis, and infundibula very much dilated, the latter forming large sacs, which were occupied by calculi; mucous membrane is thickened, and surrounding the aperture of the infundibula there is a considerable quantity of calcareous deposit.—Preparations Nos. 1642, 1722, 1723, 1877.—Donor, Dr. Stephenson, Rochester.

1717. Kidney enlarged, parenchyma almost entirely absorbed, capsule alone remaining; pelvis and infundibula very much dilated, forming large sacs, and having a large calculus in the mouth of the ureter.

1718. Kidney very much enlarged, structure greatly destroyed, pelvis and infundibula much dilated, forming a sac which contains a large irregular dark brown calculus, having three prolongations proceeding from one common centre. The cavity of an abscess, situated on the anterior aspect of the organ, with two ragged apertures leading into the abdominal cavity; the sac, however, does not communicate with the kidney.—Donor, Mr. Pearson, Surgeon 87th Regt.—Necrol. Reg. vol. vi. page 48.

1719. An oval calculus, about the size of a large bean, impacted in the left ureter, an inch from its vesical extremity; above the calculus, the ureter is much dilated as also the pelvis and infundibula

of the kidney, which is very small, its structure being almost entirely absorbed and forming a sac. The man died of phthisis pulmonalis, with no symptom of urinary disease.—Donor, Dr. Stewart, A. I. H.

1720. One hundred and five small calculi, composed of oxalate of lime and lithic acid, found in a cyst which was situated in the parietes of the left kidney.—Preparation Nos. 1687, 1688, 1721.

1721. Calculus, found in the pelvis of right kidney, consisting of ammoniaco, magnesian phosphate, uric acid and oxalate of lime.—Preparation Nos. 1687, 1688, 1720.

1722. Calculi, from the kidney composed of triple phosphate.—Preparation Nos. 1642, 1716, 1723, 1877.—Donor, Dr. Stephenson, Rochester.

1723. Fine crystalline sand, and some gravel, composed of triple phosphate, from the kidney.—Preparation Nos. 1642, 1716, 1722, 1877.—Donor, Dr. Stephenson, Rochester.

1724. Calculus, found in the commencement of the ureter; the dark nucleus of which is composed of oxalate of lime; the enveloping parts consist of phosphate of lime and magnesia, a little carbonate of lime, and lithic acid; the lithic acid is in distinct layers.—From a man, ætat. 68, who died of phthisis.

1725. Calculi from the kidney.

1726. Two renal calculi.

1727. One oval calculus, from the left ureter, weighing thirty-one grains.

#### SECTION IX.—RUPTURE OF THE KIDNEY.

1728. Right kidney ruptured; the inferior angle is almost entirely detached, and only connected by a few bands of cellular membrane.

## SECTION X.—MALFORMATIONS OF THE KIDNEY.

1729. Left kidney enlarged, and was found in its usual position : right kidney entirely wanting, as was also the supra renal capsule.—From a young man who died of phthisis.—Donor, Mr. Bannatine, A. S. 58th Regt.

1730. Left kidney and ureter extremely small, and rudimentary, the former about the size of a large bean ; right kidney normal.—From a boy, *ætat.* 15.—Donor, Dr. Cotton, Surgeon 12th Regt.

1731. A single kidney, somewhat lobulated ; it was found resting on the right margin of the pelvis, partly projecting into this cavity, and occupying the triangular space formed between the belly of the psoas magnus muscle, and the promontory of the sacrum. Its anterior surface filled up the space usually observed between the caput cœcum coli and the right side of the bladder, to the latter of which it was connected by a fold of peritoneum.

The ureter occupies a groove in the lower and inner part of the front of the kidney, and thence proceeds to the bladder. The renal arteries, two in number, arise from the lower and front part of the abdominal aorta, about an inch and a half from its division into the common iliacs ; one renal vein proceeds from the kidney and terminates near the commencement of the vena cava.—From a man, *ætat.* 20, who died of common continued fever.

1732. Lobulated kidney, situated in the pelvis opposite to the left sacro iliac synchondrosis ; its convex surface is attached to the sacrum by cellular substance. There are three small renal arteries, one of which arises from the angle of the aorta at its division, and proceeding downwards enters the groove in the superior angle of the kidney ; the other two arise from branches of the internal iliac artery, one of these proceeds to the groove in the inferior angle of the organ, and the other enters on the convex surface of the kidney ; veins emerge from the kidney, accompany the respective arteries, and then join their accompanying veins.

1733. Two kidneys, united at their inferior angles so as to resemble a horse-shoe.

1734. Two kidneys united inferiorly, so as to resemble a horse-shoe; besides the two usual renal arteries, there are four others, of a smaller size, which arise from the aorta, and enter the substance of the gland at the place where the two kidneys are united.

1735. Horse-shoe kidney, much enlarged, with three ureters, each terminating in the bladder.

1736. A horse-shoe kidney, slightly lobulated.

1737. Kidney enlarged, lobulated, and in the form of a horse-shoe.

1738. Two kidneys, united so as to resemble a horse-shoe.

1739. Two kidneys, united so as to resemble a horse-shoe, having five renal arteries.



### DIVISION III.

#### *DISEASES, AND INJURIES OF THE BLADDER, INCLUDING URINARY CALCULI.*

---

##### SECTION I.—HYPERTROPHY OF THE COATS OF THE BLADDER.

1740. Coats of the bladder contracted, and thickened.—Donor, Dr. Davy, A. I. H.

1741. Bladder contracted, mucous membrane corrugated, which in the recent preparation, was of a bluish grey mottled appearance.—MS. Cat. vol. ii. page 214, No. 57.

1742. Bladder, which contained a calculus, viscus enlarged, and the coats thickened towards its neck.—Donor, Mr. T. Berry, Staff Surgeon.

1743. Hypertrophy of the muscular coats of the bladder.

1744. Hypertrophy of the coats of the bladder, mucous membrane corrugated, and a circumscribed thickening of the velum, extending between the entrance of the two ureters; prostate gland enlarged, especially the middle lobe, on the surface of which there is a round aperture. The left kidney contained a calculus.—From a man who died of phthisis.

1745. Bladder contracted, muscular coats hypertrophied.

1746. Bladder, which contained a calculus, contracted, coats much thickened, with fleshy excrescences of the mucous membrane,

lining the superior fundus.—Donor, Mr. Robertson, Surgeon, R. N.—MS. Cat. vol. ii. page 220, No. 87.

1747. General hypertrophy of the coats of the bladder, more especially of the muscular larger; mucous lining of the membranous portion of the urethra destroyed, and a sinus in the left lobe of the prostate; the bladder and urethra contained small calculi.—From a man, ætat. 31, who had been some time under treatment for stricture.—Donor, Mr. Maynard, Surgeon Coldstream Guards.

1748. Bladder, which contained a calculus, showing general hypertrophy of its coats, more particularly of the muscular layer; mucous membrane much corrugated. The walls of the bladder are about one inch in thickness.—MS. Cat. vol. ii. page 219, No. 82.

1749. Hypertrophy of the coats of the bladder: the muscular layer is about an inch in thickness, mucous membrane rough, and irregular: stricture of the urethra a little anterior to the bulb.—Donor, Dr. Bell, Surgeon 26th Regt.—MS. Cat. vol. ii. page 217, No. 76.

1750. Bladder enlarged, general hypertrophy of its coats, more especially of the muscular layer: mucous membrane corrugated, at several parts abraded, of a dark red colour, and coated with lymph mixed with sandy deposit: the bladder was filled with bloody urine.—Donor, Dr. Pitcairn, Surgeon 49th Regt.—MS. Cat. vol. iv. page 220, No. 104.

## SECTION II.—ULCERATION, AND FUNGOID TUMOURS, OF THE MUCOUS MEMBRANE OF THE BLADDER.

1751. Ulceration of the mucous membrane of the bladder, which is much contracted.

1752. Several ulcers on the mucous membrane covering the neck of the bladder.—Donor, Mr. Fiddes, Surgeon 85th Regt.

1753. Internal surface of the bladder, much ulcerated, with shreds

of membrane, and lymph hanging from it; several round fleshy excrescences of the mucous membrane lining its fundus.—From a woman who died of phthisis.—Donor, Dr. Scott, Surgeon, Rifle Brigade.

1754. Mucous membrane of the bladder almost entirely destroyed by ulceration, and presents numerous irregular ridges, which in the recent state were of a dark red colour: left ureter dilated and lined by granular lymph.—Preparation No. 1664.—MS. Cat. vol. ii. page 194, No. 104.

1755. Almost the whole of the mucous membrane of the bladder destroyed by ulceration, leaving the muscular fibres quite bare, some of which are also destroyed, the peritoneal coat alone remaining: the portions of the mucous membrane that still exist are of a dark red colour. Numerous small circular ulcers, on the mucous membrane covering the prostate and neck of the bladder. Right ureter dilated, coats thickened, and lined internally with lymph: vesiculæ seminales distended with scrophulous matter. A fistulous opening capable of admitting a common quill, situated in the membranous portion of the urethra, which opened externally, about an inch and a half in front and a little to the right side of the raphe: the parts surrounding the fistula are firm and cartilaginous.—MS. Cat. vol. iv. page 219, No. 103.

1756. Mucous membrane of the bladder, entirely destroyed by ulceration, and the internal surface very rough and irregular; ureter, pelvis, and infundibula of left kidney thickened, dilated, and lined with granular lymph: kidney much enlarged, and infiltrated with tuberculous matter.—Donor, Dr. Calvert, A. I. H.

1757. Coats of the bladder thickened, mucous membrane covering the lower fundus and neck of the viscus, ulcerated and coated with lymph.

1758. Bladder small, and very much contracted, mucous membrane ulcerated; ureter, pelvis, and infundibula of kidney very much dilated, coats thickened and lined with lymph; gland lobulated, and large sacs formed in its substance, in consequence of the dilatation of the infundibula.—Donor, Dr. Stewart, A. I. H.

1759. Bladder enlarged, parts of the coats thickened, internal surface extensively ulcerated, and covered with lymph: with several sinuses situated between the mucous and muscular layers.—Donor, Mr. O'Brien, A. S. 7th Regt.

1760. Coats of the bladder thickened, and a large ulcerated opening, through its walls into the vagina; a cyst, about the size of a plum, in the left ovarium.—From a woman, *ætat.* 26, who had a copious fetid discharge from the vagina.—Donor, Mr. Martin, Surg. 73rd Regt.

1761. Hypertrophy of the coats of the bladder, more particularly of the muscular layer, with fleshy excrescences from its mucous membrane.—Print. Cat., page 130, No. 1.

1762. Bladder, exhibiting large fleshy growths from its mucous membrane.—Donor, Mr. Dempster, A. S. Staff.

1763. A large fungoid, soft, gelatinous growth, arising from the superior fundus of the bladder, through which exists a communication with a large sac, situated between the bladder and peritoneum; the walls of the sac are thin, and lined with lymph.

1764. A large fungoid growth, from the inner surface of the bladder.—Donor, Dr. Ingham, Surg. 29th Regt.

### SECTION III.—ABSCESSSES IN THE COATS OF THE BLADDER.

1765. Two sacs of abscesses in the coats of the bladder; one, the size of a pigeon's egg, at the superior fundus, and another, much larger, and very irregular, situated on the left of the inferior fundus, between the prostate and vesicula seminalis, communicating with the bladder by several apertures; right ureter, immediately before it enters the bladder, very much dilated; vesicula seminalis enlarged and filled with fluid; bladder contracted, coats thickened, and in the recent preparation the mucous membrane was ecchymosed.—MS. Cat., vol. ii. page 223, No. 97.

1766. A large sac, situated at the posterior and superior fundus

of the bladder, external to its walls, containing a small irregular shaped piece of bone, with sharp points and edges, and of a greenish black colour. The sac communicated with the bladder by two openings, situated a little to the inner side of the entrance of the right ureter; one, of a size to admit a common quill, and the other capable of receiving a probe; the mucous membrane of the bladder is of a slate colour, and of a soft pulpy consistence. The sigmoid flexure of the colon adhered to the sac, and communicated with it by an ulcerated opening, about the size of a crown piece, with ragged irregular edges; the piece of bone had probably been swallowed, became entangled in the folds of the intestine, and produced ulceration.—MS. Cat., vol. iv. page 223, No. 106.

1767. Sac of a large abscess, situated to the left side between the bladder and rectum, communicating with the former, by an opening capable of admitting a common quill, above and between the entrance of the ureters; the surface of the rectum is very irregular, much ulcerated, and communicates with the sac by five large apertures; the consequence of dysentery of four months' standing; disease confined to the rectum.—Donor, Dr. Dawson, A. S. 42nd Regt.

1768. Sac of an abscess, about the size of a walnut, situated in the cellular substance at the superior fundus of the bladder, external to its walls; the coats of this viscus are contracted, and hypertrophied, and about half an inch in thickness; mucous membrane of a brownish red colour, soft, and ulcerated at its base, immediately behind the cervix; orifice of the urethra closed, to the size of a small probe, by a congenital membranous septum. Preparation No. 1665. — Donor, Mr. Ford, A. S. 72nd Regt. — Necrol. Reg., vol. vi. page 47.

#### SECTION IV.—SEROUS CYSTS ATTACHED TO THE BLADDER.

1769. Bladder of a sheep, having a serous cyst, the size of a walnut, attached to the external surface of its fundus.—Donor, Dr. Davy, A. I. H.

## SECTION V.—SACculI IN THE BLADDER.

1770. A large sac, situated at the inferior fundus of the bladder, extending from the entrance of the ureters to the bulb of the urethræ, the mucous membrane covering it is very irregular from ulceration; at one part, both the mucous and muscular coats are destroyed, and a thick layer of lymph, mixed with sandy deposit, adheres to the whole of its surface. This sac contained a large irregular-shaped calculus. The coats of the bladder are much thickened, more especially the muscular layer, mucous membrane of a dark red colour; bladder and sac contained a quantity of milky urine mixed with pus. Right tunica vaginalis, rough, vascular, and coated with lymph, the effect of a hydrocele, which burst two days before death.—Preparation No. 1801.—MS. Cat., vol. ii. page 224, No. 101.

## SECTION VI.—BLOOD EFFUSED BETWEEN THE COATS OF THE BLADDER.

1771. Inner surface of the urinary bladder, showing a number of warty excrescences, of a black colour, from the size of a pea to that of a cherry, caused by the effusion of blood below the mucous membrane.—Preparation No. 1370.—MS. Cat. vol. ii. page 221, No. 93.

## SECTION VII.—RUPTURE OF THE BLADDER.

1772. Rupture of the fundus of the bladder, from external violence; the patient lived five days after the accident.—Donor, Mr. Fraser, A. S. Staff.

1773. Bladder ruptured at its superior fundus, in consequence of a fall on an iron cot, whilst the subject of it was in a state of inebriety; he died forty-eight hours after the accident.—Donor, Mr. Trigance, Surgeon 30th Regt.

## SECTION VIII.—URINARY CALCULI.

1774. Coats of the bladder thickened, and containing a large, oval, flattened calculus.

1775. Coats of the bladder much hypertrophied, the muscular layer being about an inch in thickness, and contains a large, soft, white calculus.—Donor, Dr. Portelli, A. S. Staff.

1776. Coats of the bladder thickened, and contracted, so as to resemble an hour-glass, and containing a large calculus, which has assumed the same form.—Donor, Dr. Piper, Surgeon 83rd Regt.—Print. Cat. page 131, No. 19.

1777. Bladder, containing a small, oval, flattened calculus; ureters dilated.—Preparation No. 1715.—MS. Cat. vol. ii. page 223, No. 99.

1778. Urinary bladder of a small bitch, completely filled by a large white calculus.

1779. A large urinary calculus.

1780. A large oval flattened urinary calculus.

1781. Section of a urinary calculus.

1782. Sections of a urinary calculus, composed of lithic acid.

1783. Sections of a urinary calculus, weighing one and one-seventh of an ounce, successfully removed by operation.—Print. Cat. page 132, No. 25.

1784. Section of a urinary calculus.

1785. Section of a large urinary calculus.

1786. Sections of an enormous urinary calculus, weighing seven-

teen ounces, which filled the whole of the pelvis: the coats of the bladder were much thickened, and its vessels so distended that at first sight it resembled a uterus. The patient had suffered from stone in the bladder for twenty years previous to his death, and had taken every lithontriptic that had acquired any character.—London, Med. Journal, vol. v. for the year 1784.

1787. Urinary calculus.

1788. Urinary calculus.

1789. Section of a urinary calculus.

1790. Urinary calculus.

1791. Urinary calculus.

1792. Urinary calculus, of a conoid shape, and rough exterior, extracted from the urethra of a woman, ætat. 35.—Donor, Dr. Calder, A. S. Staff.—MS. Cat. vol. ii. page 216, No. 70.

1793. Four small round urinary calculi, about the size of beans.

1794. Two urinary calculi, taken from the bladder of a pig.

1795. Urinary calculus, passed from the urethra.

1796. An irregular oblong calculus, from the prostate gland, composed of phosphate of lime.—Donor, Dr. Stephenson, Rochester.

1797. Two small concretions, from the prostate gland.

1798. Section of a large urinary calculus.

1799. A large rough flattened urinary calculus, which passed into the vagina, through an ulcerated opening; after which the patient recovered. She was supposed to have cancer of the uterus.

1800. Section of a urinary calculus.



1801. A large, irregular shaped, urinary calculus, resembling the superior extremity of the left femur, with a distinct head, neck, and trochanter major: the superficial layer of which has a white crystalline appearance, and seems to be composed of triple phosphate, and the one underneath of uric acid.—Preparation No. 1770.—MS. Cat. vol. ii. page 224, No. 100.

1802. Two sections of a urinary calculus, composed of ammoniaco-magnesian phosphate, and uric acid.—Donor, Dr. Stephenson, Rochester.

1803. Two sections of calculus, composed of phosphate and triple phosphate of lime.—From the urinary bladder of an old man.

1804. Calculus, composed of phosphate of lime, with a crust of ammoniaco-magnesian phosphate.—From the bladder of a male.—Donor, Dr. Stephenson, Rochester.

1805. Section of a calculus, from the bladder of a male, composed of triple phosphate, and a trace of lithic acid.—Donor, Dr. Stephenson, Rochester.

1806. Two sections of urinary calculus, composed of triple phosphate.

1807. Section of a urinary calculus, composed of phosphate of lime, ammoniaco-magnesian phosphate, and carbonate of lime, with a trace of lithic acid, and animal matter.—Removed by operation by Mr. Gulliver, A. S., R. H. G.

1808. Urinary calculus.

1809. Two sections of a fusible calculus, with a nucleus of lithic acid.—From the body of a negro.—Donor, Dr. Burke, I. G. H.

1810. Five urinary calculi, removed by operation, a section is made of one of them.—Donor, Dr. Barden, A. S. Staff.

1811. Urinary calculi.

1812. Section of a urinary calculus.

1813. Fragments of a urinary calculus.

1814. Urinary calculus.

1815. Section of a urinary calculus.

1816. Three small calculi, from the bladder of a pig, composed of carbonate of lime and animal matter.—Donor, Dr. Davy, A. I. H.

1817. Crystals, found in the urinary bladder of a fox hound, composed of phosphate of lime, and ammoniaco-magnesian phosphate, no trace of lithic acid.—Donor, Mr. Gulliver, A. S., R. H. G.

1818. Calculi, from the bladder of an ox, composed of carbonate of lime and animal matter.—Donor, Dr. Williams, Surgeon 68th Regiment.

1819. Two sections of urinary calculus.

1820. Section of a urinary calculus; nucleus composed of uric acid, and the rest of ammoniaco-magnesian phosphate.

1821. Section of a urinary calculus, nucleus composed of uric acid, the external layer of ammoniaco-magnesian phosphate.

1822. Section of a urinary calculus, nucleus composed of oxalate of lime, and the external layer of ammoniaco-magnesian phosphate.

1823. Section of a urinary calculus, nucleus consists of oxalate of lime, surrounded by ammoniaco-magnesian phosphate.

1824. Sections of a large urinary calculus, the brown central part composed of oxalate of lime, and the outer white layer of ammoniaco-magnesian phosphate.—Donor, Dr. Fraser, Surgeon 60th Rifles.

1825. Section of a urinary calculus, nucleus composed of oxalate of lime, surrounded by ammoniaco-magnesian phosphate.

1826. Sections of a urinary calculus, nucleus composed of oxalate of lime, and the external layer of ammoniaco-magnesian phosphate.

1827. Section and fragments of a urinary calculus, nucleus composed of oxalate of lime, surrounded by triple phosphate.—Removed by operation, by Dr. Dawson, Staff Surgeon.—MS. Cat. vol. ii. page 220, No. 89.

1828. Section of a calculus, nucleus composed of oxalate of lime, surrounded by a layer of uric acid, then by ammoniaco-magnesian phosphate.

1829. Section of a urinary calculus, nucleus composed of oxalate of lime, surrounded by a mixture of ammoniaco-magnesian phosphate and uric acid.

1830. Section of a urinary calculus, nucleus of oxalate of lime, and the external layers of ammoniaco-magnesian phosphate.

1831. Section of a urinary calculus; the crust is composed of oxalate of lime, phosphate of lime, niphine or animal matter. The body, uric acid, urate of ammonia, phosphate of lime, and niphine. The nucleus, oxalate of lime and niphine. The phosphate of lime exists in very minute quantities.—Removed after death from a man, ætat. 84, who had suffered from symptoms of calculus for many years, but would not submit to an operation.—Donor, Mr. Fooker, A. S. Staff.

1832. Section of a urinary calculus, composed of oxalate of lime.

1833. Section of a urinary calculus, composed of oxalate of lime.

1834. Sections of urinary calculus, principally composed of oxalate of lime; removed by operation from a boy aged 8 years: he was quite well twenty years after, and never had any return of the disease.—Donor, Mr. Fooker, A. S. Staff.

1835. Mulberry calculus, of a globular form, weight one ounce and a half and thirty grains.—Removed by Dr. Williamson, A. S. Staff.—MS. Cat. vol. iv. page 216, No. 102.

1836. Sections of mulberry calculus.

1837. Small mulberry calculus.

1838. Urinary calculus, the body of which is of a white colour ; with a dark brown granular deposit of a mulberry appearance on its surface.

1839. Section of a urinary calculus, principally composed of oxalate of lime.

1840. Section of a urinary calculus, composed of oxalate of lime.

1841. A rough urinary calculus, about the size of a bean, and of dark brown colour.

1842. Small calculus, passed from the urethra of a child.—Donor, Mr. Nicholson, Staff Surgeon.

## DIVISION IV.

### *DISEASES, AND INJURIES OF THE PROSTATE GLAND.*

#### SECTION I.—ENLARGEMENT OF THE PROSTATE GLAND.

1843. Prostate gland much enlarged, middle lobe projecting slightly into the neck of the bladder; this viscus is dilated, and coated with lymph.—Donor, Dr. Shean, Surgeon 7th Regt.

1844. Prostate gland very much enlarged, middle lobe forming a transverse ridge at the cervix of the bladder; coats of the bladder hypertrophied, more particularly the muscular layer, mucous membrane rough and irregular, ureters dilated.—Donor, Dr. Shanks, A. S. Staff.

1845. Third or middle lobe of the prostate gland enlarged to about the size of a pigeon's egg, and projecting into the neck of the bladder, in the form of a valve; coats of the bladder thickened, particularly the muscular layer, mucous membrane corrugated, with a number of irregular ridges and small sacculi in its surface; ureters dilated.—Donor, Mr. Allan, A. S. Staff.—MS. Cat., vol. ii. page 220, No. 90.

1846. Prostate gland enlarged, especially the middle lobe, which is about the size of a plum, and projects into the cervix of the bladder, in the form of a valve.—From a man who died suddenly from disease of the aortic valves.—Donor, Mr. Allan, A. S. Staff.

#### SECTION II.—SCROPHULOUS DEPOSIT IN THE PROSTATE GLAND.

1847. A scrophulous tubercle, in the prostate gland; vesicula seminalis very small.—From a man, ætat. 24, who died of scrophula.—Preparation No. 1938.

1848. Prostate gland enlarged, and scrophulous matter deposited in its substance. The mesenteric glands, and kidneys, also contained similar deposits.

1849. Prostate gland, vesiculæ seminales, and termination of the vasa deferentia, very much enlarged, and filled with softened scrophulous matter, which has become broken up, leaving large cavities in their substance; bladder contracted, and the muscular coat much thickened.—From a man who died of amentia.

### SECTION III.—ABSCESSSES, AND SINUSES IN THE PROSTATE GLAND.

1850. Cavity of an abscess, in the right lobe of the prostate, compressing the prostatic portion of the urethra; muscular coat of the bladder thickened.

1851. Cavity of a large abscess, in the left lobe of the prostate gland, communicating with the urethra by an opening, about an inch and a half in length; mucous membrane of the bladder entirely destroyed by ulceration.—Donor, Mr. Ford, A. S. 72nd Regt.

1852. Sinus, in the prostate gland, communicating with the urethra.—Donor, Dr. Scott, Surgeon Rifle Brigade.

## DIVISION V.

### *DISEASES, INJURIES, AND MALFORMATIONS OF THE URETHRA.*

#### SECTION I.—STRICTURES, AND FALSE PASSAGES IN THE URETHRA.

1853. Stricture of the urethra, about an inch from the orifice, and a dilatation of the canal, capable of holding a bean, immediately behind the contraction.

1854. A narrow stricture of the urethra, about three inches from the orifice, a bristle is passed behind a white glistening band, which intersects the canal.—Print. Cat. page 134, No. 5.

1855. A firm, narrow stricture of the urethra, about three inches from the orifice; urethra behind the stricture dilated; bladder contracted, muscular coat hypertrophied.

1856. A firm, narrow stricture, about five inches from the orifice; urethra behind the contraction dilated; prostate gland enlarged.

1857. Urethra, for about four inches of its extent from the orifice, completely obliterated, and a fistula communicating with the scrotum; a large portion of the integuments of which are destroyed, and a portion, about the size of a shilling, of the body of the penis is ulcerated; the urethra behind the stricture is very irregular, from a number of small pits and grooves on its surface.—Print. Cat. page 135, No. 15.

1858. Stricture of the urethra, close to the bulb; a piece of whalebone is passed into the contracted portion, which is about two inches in extent; muscular coat of the bladder hypertrophied.

1859. A narrow stricture of the urethra, situated a little anterior to its bulb.

1860. Stricture of the urethra, anterior to the bulb: the surface of the canal is very irregular.—From a soldier who had laboured under severe stricture, which had been relieved by caustic.—Donor, Mr. Fiddes, Surgeon 85th Regt.

1861. A firm semi-cartilaginous stricture, about an inch in length, situated immediately anterior to the bulb of the urethra.—Donor, Dr. Taylor, A. S. 58th Regt.

1862. A narrow stricture of the urethra, opposite to the bulb; behind the contraction, the canal is dilated, the inner surface of which is irregular, and a bristle is passed behind a transverse fold of the mucous membrane. From a man, *ætat.* 25, who never complained of any thing connected with the urinary organs.

1863. Stricture of the urethra, immediately anterior to the bulb, with injury of the canal, from the use of bougies.

1864. Stricture of the urethra, anterior to the bulb; a false passage made by the improper use of the catheter; dilatation of the canal behind the stricture, also enlargement of the prostatic ducts. The patient died from infiltration of urine into the surrounding parts.—Donor, Mr. Fraser, A. S. Staff.

1865. Stricture of the urethra, opposite to the bulb; and a false passage leading into the latter.—Print. Cat. page 134, No. 3.

1866. Stricture of the urethra, opposite to the bulb, and a false passage to its right side; an instrument could not be introduced into the bladder. The urine was drawn off, by puncturing this viscus above the pubis, a piece of whalebone is introduced into the opening made into the bladder.—From a man, *ætat.* 32, who died of phthisis.

1867. Stricture of the urethra, opposite to the bulb; a fistulous



opening, anterior and another posterior to the contraction; the membranous and prostatic portions of the urethræ are dilated, ulcerated and coated with lymph; the coats of the bladder are thickened, the mucous membrane at several parts ulcerated, and lymph adhering to its surface; ureter, pelvis, and infundibula of both kidneys much dilated.

1868. Stricture of the urethra, opposite to the bulb; two fistulæ communicating with the perineum, one situated anterior to the contraction, and the other posterior to it; this latter fistula proceeds from a large ulcerated cavity, on the right side of the membranous portion of the urethra; canal behind the stricture dilated; coats of the bladder hypertrophied. The patient died of gangrene, caused by the escape of urine into the cellular substance of the perineum.

1869. Stricture of the urethra, opposite to the bulb, dilatation of the membranous and prostatic portions of the urethra, and a large sac of an abscess, in the situation of the prostate gland, and vesiculæ seminales; bladder enlarged, hypertrophy of its coats, particularly of the muscular layer, numerous small pits or sacculi in its mucous membrane; great dilatation of the ureter, pelvis, and infundibula of left kidney.—Donor, Mr. O'Brien, A. S. 7th Regt.—MS. Cat. vol. ii. page 219, No. 85.

1870. Stricture of the urethra, opposite to the bulb, and a false passage anterior to the contraction, and another in the membranous portion of the urethra, which is dilated, and presents a number of longitudinal bands on its surface; coats of the bladder much thickened, particularly the muscular layer, and numerous small sacculi in the mucous membrane.—Print. Cat. page 136, No. 18.

1871. Two fistulous openings, capable of admitting bougies, situated in the membranous portion of the urethra, and communicating with the rectum; the mucous membrane of the gut is very irregular, and there are several other sinuses leading from it into the surrounding cellular substance.

1872. Ulceration, and a sloughing condition of the mucous membrane, along the whole course of the urethra; an opening near the

glans penis, the result of an incision, made during life, to divide a stricture; coats of the bladder very much thickened.

1873. Urinary organs, of a negro, showing extensive cavities of abscesses, in the prostate gland, and neck of the bladder; also another, close to the bulb, which communicates with the urethra, and opens externally by two apertures; almost the whole mucous membrane, along the course of this canal, is destroyed by ulceration; bladder contracted and coats hypertrophied.

1874. Stricture of the membranous portion of the urethra, and a large cavity of an abscess, involving the bulb and membranes of the urethra, with which it communicates; also two other cavities of abscesses, in the lateral lobes of the prostate gland, a piece of whalebone is passed from one into the other. The bladder is immensely distended, its parietes are thickened, and there are a number of small pits or sacculi, situated in the mucous membrane, on its posterior aspect.—Donor, Mr. Calder, A. S. Staff.—MS. Cat. vol. ii. page 215, No. 65.

1875. A sinus, in the left side of the urethra, leading into an ulcerated cavity, three inches in length, which is of a dark slate colour, situated in the bulb and corpus spongiosum urethra. Another false passage, in the membranous portion of the urethra, communicating with a large cavity the size of an egg, having the same dark hue as the former, situated behind the prostate gland, and extending upwards as far as the reflection of the peritoneum from the bladder on to the rectum; both cavities the result of the forcible use of the catheter: bladder contracted, coats thickened, mucous and muscular layer on the posterior fundus, to the extent of about an inch, destroyed by ulceration; this viscus contained a quantity of urine mixed with pus and mucous. Two portions of omentum, attached to the left side of the bladder, forming a loop, about four inches in circumference, which enclosed several folds of small intestines, which were of a dark gangrenous hue; a knuckle of intestine also adhered to the posterior aspect of the bladder.—MS. Cat. vol. ii. page 228, No. 24.

1876. Mucous membrane, along the whole course of the urethra, much thickened, contracted, rough, and coated with lymph; a cavity

of a large irregular abscess, involving the bulb, membranous portion of the urethra and prostate gland : several ulcers on the mucous membrane of the bladder ; ureter, pelvis, and infundibula of left kidney much dilated, rough, and coated with lymph ; capsule of the gland thickened, and an irregular cavity of an abscess in its superior angle.—Print. Cat. page 135, No. 9.

#### SECTION II.—SACCULI IN THE URETHRA.

1877. Bladder of a man, who had some years before been cut for stone, exhibiting a sacculus, about the size of a pigeon's egg, situated in the prostatic portion of the urethra, with a fistulous opening leading from it into the cellular substance between the bladder and rectum.—Preparations Nos. 1642, 1716, 1722, and 1723.—Donor, Dr. Stephenson, Rochester.

1878. A large sacculus, capable of containing a walnut, situated in the bulbous portion of the urethra : at the anterior and posterior extremities of the sac there are two fleshy excrescences, the anterior one being about the size of a hazel nut, and the posterior a little larger : the mucous membrane of the urethra lines the interior of the sac. A fistula in the right side of the rectum.—Donor, Mr. Paynter, A. S. 60th Regt.—MS. Cat. vol. ii. page 226, No. 23.

CLASS VII.  
GENITAL ORGANS OF THE MALE.

---

DIVISION I.  
*DISEASES, INJURIES, AND MALFORMATIONS  
OF THE PENIS AND SCROTUM.*

---

SECTION I.—ULCERATION, AND SLOUGHING OF THE PENIS  
AND SCROTUM.

1879. Extensive ulceration of the glans penis and prepuce, with paraphymosis.

1880. Loss of the integuments of the scrotum, and lower half of the penis, the testicles being left quite bare: two sinuses leading from the root of the penis to the verge of the anus.—Print. Cat. page 189, No. 16.

SECTION II.—VERRUCÆ ON THE PENIS.

1881. A large cluster of verrucæ, of two years' growth; removed by operation, from the prepuce.

1882. Portion of the penis covered by warty excrescences.

1883. Large warty excrescences on the glans penis, and prepuce.—Donor, Mr. Whitfield, Surgeon, Royal Artillery.

1884. Immense verrucous excrescences on the penis.—Donor, Dr. Sillery, A. S. Staff.

1885. Large warty excrescences on the glans penis. Sections are made of this and Preparation No. 1884, showing that their structures are firm and fibrous, and the verrucæ appear to arise from the fibrous membrane of the corpus cavernosum.

### SECTION III.—ELEPHANTIASIS OF THE SCROTUM.

1886. Scrotum, weighing six pounds twelve ounces, affected with elephantiasis; the vessels and nerves are seen to be much enlarged, and the testicles atrophied. Taken from the body of a negro.

### SECTION IV.—MALFORMATIONS OF THE PENIS AND SCROTUM.

1887. Penis, of a small size; congenital phymosis of the prepuce, the opening in which scarcely exceeds that of the orifice of the urethra, the glans penis does not adhere to the prepuce: integuments covering the pubis devoid of hair.—From a maniac, ætat. 58, who died of phthisis.—Preparations Nos. 1959, 1960, 1965.—MS. Cat. vol. iii. page 227, No. 108.

1888. Congenital phymosis, the opening in the prepuce is only capable of admitting a common probe.—Donor, Mr. Allan, A. S. Staff.

1889. Congenital malformation of the generative organs; about half an inch of the lower surface of the urethra, and frænum preputii deficient, and the scrotum bifid.—From a child a month old.—Donor, Dr. Kinnis, A. S. Staff.

## DIVISION II.

### *DISEASES, AND INJURIES OF THE TUNICA VAGINALIS, AND TUNICA ALBUGINEA TESTIS.*

---

#### SECTION I.—HYDROCELE.

1890. Exhibits fine injection of the tunica vaginalis testis, affected with hydrocele: a small soft body attached to the testicle; the sac contained at least four ounces of fluid. The patient had never undergone any treatment for the complaint.—Donor, Mr. Gulliver, A. S. 71st Regt.

1891. Sac of a hydrocele of the tunica vaginalis testis, with separation of the epididymis from the body of the gland.

1892. Sac of a hydrocele, showing the relative position which the testicle bears in that disease.

1893. Sac of a hydrocele of the tunica vaginalis testis. The patient attributed this affection to a blow received a month previously.

1894. Sac of a hydrocele of the tunica vaginalis.—Preparation No. 1899.

1895. Sac of a hydrocele of the tunica vaginalis, and the cavity of a large abscess, at its lower part.—Donor, Dr. Sillery, A. S. Staff.

1896. Sac of a hydrocele of the right tunica vaginalis, the left

testicle has formed adhesion in the groin, and does not descend into the scrotum.

1897. Section of the pelvis, exhibiting the sacs of a double hydrocele.

1898. Sac of a hydrocele, with thickening of the right tunica vaginalis; two small pendulous bodies, attached to the surface of the testicle.—From a maniac, ætat. 73.

1899. Sac of a hydrocele of the tunica vaginalis, exhibiting thickening of its parietes, and effusion of lymph in the cavity: a small puncture, is seen passing through the inferior part of the tunica albuginea into the substance of the testicle, made by the point of a trochar. In the attempt at a radical cure by injection, part of the injected fluid, having accidentally been infused into the cellular tissue of the scrotum, the irritation produced inflammation, sloughing, and a low fever, of which the patient died. The man was 35 years of age and had hydrocele of both vaginal tunics.—Preparation No. 1894.

1900. Numerous adhesive bands, stretching across the cavity of the tunica vaginalis, and connecting that portion of it which lines the scrotum to that which covers the testicle.

1901. Partial adhesion of the tunica vaginalis lining the scrotum, to that covering the testicle, and several membranous bands passing across the cavity.

1902. Adhesion of the lower part of the tunica vaginalis lining the scrotum, to that covering the testicle: no operation in this case had been performed for the cure of the hydrocele.—Donor, Dr. Stewart, A. I. H.

1903. Adhesion of the lower part of the tunica vaginalis lining the scrotum, to that covering the testicle; the upper part of the sac is enlarged, and was filled with serous fluid; the vaginal tunic covering the gland is much thickened and of cartilaginous firmness.

1904. Tunica vaginalis much thickened, and semi-cartilaginous, with almost complete obliteration of the sac.

1905. Right testicle somewhat enlarged, and indurated; cavity of the tunica vaginalis obliterated, excepting a small portion of its upper part: both it, and the tunica albuginea are considerably thickened; a section exhibits the structure of the testicle much changed from the effusion of lymph.—MS. Cat. vol. iii. page 178, No. 55.

1906. Testicle, of small size, and substance very soft; vaginal tunic obliterated by a delicate filamentous tissue, which, in the recent preparation, was so easily torn, that there hardly appeared to be any adhesion, although the action of the spirits has rendered it very plain. An example of obliteration of a serous sac without inflammation.—From a very old man.

1907. Adhesion of the sac of the tunica vaginalis, and thickening of the tunica albuginea. The operation for the radical cure of hydrocele was the cause of the obliteration of the sac.—From a young man who died of compound fracture of the leg.—Donor, Mr. Gulliver, A. S. 71st Regiment.

## SECTION II.—HÆMATOCELE.

1908. Tunica vaginalis very much thickened, semi-cartilaginous and filled with coagulated blood: a piece of whalebone is passed through an aperture, which was made in puncturing the sac.—Donor, Dr. Pearson, Surgeon 87th Regt.—MS. Cat. vol. v. page 146, No. 94.

## SECTION III.—CARTILAGINOUS, AND OSSIFIC DEPOSIT IN THE TUNICA VAGINALIS, AND TUNICA ALBUGINEA TESTIS.

1909. Tunica vaginalis thickened, and fibro-cartilaginous; the inner surface of the sac is rough, and irregular from the effusion of lymph.

1910. Sac of a hydrocele, with a plate of ossific matter deposited in the tunica vaginalis, the interior of which is rough, and irregular.



—Donor, Mr. Stanley, Surgeon, St. Bartholomew's Hospital, London.

1911. Partial ossification of the tunica albuginea testis, and obliteration of the vaginal sac.—From a man, *ætat.* 98, in whom most of the arteries were ossified.—Donor, Dr. Davy, A. I. H.

1912. Portion of the tunica albuginea testis, with ossific matter deposited in it.—From the same subject as Preparation No. 1911.—Donor, Dr. Davy, A. I. H.

#### SECTION IV.—SOFT, CARTILAGINOUS, AND BONY SUBSTANCES ATTACHED TO THE TUNICA VAGINALIS TESTIS.

1913. A small, round, red coloured body, attached by a slender pedicle to the tunica vaginalis, covering the testicle; in the recent preparation, a vessel could be seen entering into the little tumour, and its substance appeared like a clot of blood.—From a middle aged man who died of phthisis.

1914. A small sized body, of soft consistence, attached by a pedicle to the upper part of the tunica vaginalis covering the testicle.—From a man, *ætat.* 22, who died of ascites.

1915. A small cartilaginous body, attached to the upper part of the vaginal tunic covering the testicle: the cavity contained a small quantity of fluid.

1916. A small cartilaginous body, attached by a pedicle to the tunica vaginalis covering the upper part of the testicle: the cavity contained a small quantity of fluid.

1917. A cartilaginous body, hanging by a pedicle from the vaginal tunic covering the caput epididymis.

1918. Four small cartilaginous bodies, found loose in the cavity of the tunica vaginalis of Preparation No. 1917.

1919. A small pedunculated body of an ossific nature, attached to the vaginal tunic covering the globus minor.

1920. Two small bony concretions, from the tunica vaginalis.

SECTION V.—CYSTS ATTACHED TO THE TUNICA VAGINALIS TESTIS.

1921. Four small pedunculated bodies of an encysted nature, (which contained a fluid slightly opaque) attached to the tunica vaginalis covering the caput epididymis.

1922. A small serous cyst, attached by a slender neck to the vaginal tunic covering the caput epididymis.—From the same subject as Preparation, No. 1921.

1923. A small cyst, attached by a pedicle to the tunica vaginalis covering the epididymis.

1924. Three small cysts, attached by pedicles to the tunica vaginalis covering the epididymis.

1925. Tunica vaginalis testis, presenting a delicate adventitious cyst, which was distended with straw-coloured serum, connected by a broad base to the loose portion of the vaginal sac, and by a narrow one to the reflected part on the surface of the testicle; beneath and behind this cyst may be seen another of very small size, wholly attached to the loose portions of the vaginal sac.—Necrol. Reg. vol. iv. page 259.

1926. Tunica vaginalis testis enlarged; a large cyst, containing serum, situated between the layers of the vaginal tunic, where it is reflected on to the testicle.—MS. Cat. vol. iii. page 184, No. 82.

SECTION VI.—FUNGOID GROWTHS FROM THE TUNICA ALBUGINEA TESTIS.

1927. Fungus growth, from the tunica albuginea of left testicle;

substance of the gland nearly absorbed ; the white line visible in the preparation is the cut edge of the tunica albuginea ; some induration of the integuments covering right testicle.—Donor, Mr. Ford, A. S. 72nd Regt.—Print. Cat. page 189, No. 20.

1928. Testicle, removed by operation, exhibiting a fungoid growth, from the tunica albuginea testis, with absorption of the substance of the gland.—Print. Cat. page 188, No. 8.

### DIVISION III.

#### *DISEASES, INJURIES, AND MALFORMATIONS OF THE TESTICLE.*

---

##### SECTION I.—CHRONIC ENLARGEMENT, AND INDURATION OF THE TESTICLE.

1929. Left testicle slightly enlarged, and indurated, with thickening and condensation of the surrounding cellular tissue.

1930. Section of left testicle, exhibiting enlargement and induration; capsule much thickened; removed by operation.—Donor, Dr. Grant, A. S. Staff.—MS. Cat. vol. v. page 146, No. 93.

1931. Right testicle much enlarged, weight fourteen ounces: structure indurated; sac of an abscess in its inferior angle; prolongations of the tunica albuginea much thickened: tunica vaginalis covering the gland presents a granulated appearance. Removed by operation; the patient recovered perfectly from the operation, but died some time after, from extensive disease within the abdomen.

##### SECTION II.—SCROPHULOUS DEPOSIT, AND ABSCESSES IN THE TESTICLE.

1932. Miliary tubercles in the substance of a testicle, and crude tubercular matter in the epididymis. — Print. Cat. page 190, No. 24.

1933, 1934. Two testicles, from the same subject, somewhat enlarged, structure slightly disorganized, and numerous crude tubercles deposited in their substance; cavities of the tunica vaginalis obliterated.

1935. Testicle slightly enlarged, with scrophulous matter deposited in its substance; tunica vaginalis thickened and obliterated.—From a man who died of phthisis.

1936. Left testicle slightly enlarged, and tuberculous deposit, about the size of a bean, in its anterior surface.

1937. Several scrophulous tubercles in the substance of the left testicle, with a cicatrix in the integuments, which adhere to the gland.—Print. Cat. page 191, No. 30.

1938. Testicle containing scrophulous tubercles; tunica vaginalis and integuments adhering to the gland.—From a man, *ætat.* 24, who died of scrophula.—Preparation No. 1847.

1939. Testicle enlarged, and indurated, with scrophulous matter deposited in its substance.—From a soldier affected with secondary syphilis, who had taken much mercury.

1940. Left testicle enlarged; tuberculous deposit in its substance.—From a man, *ætat.* 30, who died of phthisis.

1941. Two testicles; in the substance of one of them there is a large mass of cheesy tuberculous matter; in the other the scrophulous matter is infiltrated through its substance.

1942. Testicle and epididymis considerably enlarged; in the former numerous miliary tubercles are deposited, and the latter is so completely infiltrated with tuberculous deposit that all trace of the vas deferens is gone.—From a man, *ætat.* 30, who died of phthisis.

1943. Testicle much enlarged; structure infiltrated with scrophulous matter, and its section presents a soft cheesy homogeneous texture.

1944. Left testicle considerably enlarged, and converted into a soft cheesy mass of a homogeneous texture; an ulcerated opening, about an inch in diameter, in the integuments.—From the same subject as Preparation No. 2356.

1945. Testicle enlarged, structure infiltrated with scrophulous matter, of a pale yellow colour, and of a soft caseous consistence.—Donor, Dr. Williams, Staff Surgeon.

1946. Testicle filled with scrophulous matter, of a soft cheesy consistence, and of a pale yellow colour.

1947. Testicle containing tuberculous matter, which is softened and broken up.

1948. Testicle enlarged, with softened tubercular matter in its substance.

1949. Right testicle much enlarged, and filled with softened tuberculous matter, structure broken up.—Donor, Mr. Lightbody, Staff Surgeon.—MS. Cat. vol. iii. page 185, No. 86.

1950. Testicle much enlarged, infiltrated with scrophulous matter, which is partially softened and broken up. From a man who injured the testicle in riding, after which he had frequent attacks of inflammation, rendering its extirpation necessary.

1951. Testicle very much enlarged, structure entirely destroyed, and converted into a soft laminated mass, parts of which are softened and broken up.

### SECTION III.—FUNGOUS GROWTHS FROM THE TESTICLE.

1952. A fungous growth, from the body of the testicle, a section of which presents a smooth homogeneous texture of a pale yellow colour.

1953. Testicle enlarged and scirrhus; the lower half of its body is converted into a fungus, which protruded through an ulcerated

opening in the scrotum; the upper part of the vaginal cavity is dilated into a pouch, which contained a thick fluid like honey. Removed by operation. The other testicle had been extirpated for the same disease. The last operation was followed by a speedy and perfect cure.—Donor, Mr. Lightbody, Staff Surgeon.

1954. A large fungous growth, from the posterior aspect of the testicle; the part attached was previously removed, with the hope of destroying the fungus, but without effect. Tunica vaginalis divided into two compartments by a membranous septum.

1955. Right testicle infiltrated with serophulous matter, and a fungus arising from its body. Removed by operation.—Print. Cat. page 191, No. 31.

1956. Extensive carcinoma of the right testicle, involving the scrotum and part of the penis, with a large fungous growth arising from them; the left testicle, which appears at the posterior and inferior part of the preparation, is also much indurated. Preparation No. 612, and Drawings Nos. 2925, 2926.—Print. Cat. page 24, No. 64.

#### SECTION IV.—ATROPHY OF THE TESTICLE.

1957. Penis, scrotum, and a section of the bladder, exhibiting the testes diminished in size; vesiculæ seminales enlarged and distended with fluid.

1958. Testes, and vesiculæ seminales very small. From a man who died of phthisis; according to the account of his comrades, he never had any desire for female society.

1959, 1960. Arrested development of the testicles, they do not exceed the size of a child's at six months old; the vas deferens in Preparation No. 1959 is impervious, and terminated in the cellular tissue of the scrotum, at a distance from the epididymis, with which it had no connection. The testis, in No. 1960, is laid open, its structure displayed, which appears quite natural; the vas deferens

(which is cut away) had a similar termination to the other. From a maniac, ætat. 58.—Preparation Nos. 1887, 1965.—MS. Cat. vol. iii. page 226, Nos. 105, 106.

SECTION V.—IMPERFECT DESCENT OF THE TESTICLE.

1961. Testicle, small and lying close to the abdominal ring.



## DIVISION IV.

### *DISEASES OF THE EPIDIDYMIS, VAS DEFFERENS AND VESICULA SEMINALIS.*



#### SECTION I. — SCROPHULOUS DEPOSIT IN THE EPIDIDYMIS AND VESICULA SEMINALIS.

1962. Epididymis enlarged, and filled with scrophulous matter.

1963. A yellow cheesy deposit of scrophulous matter, in the globus minor of both testicles, also a similar deposit in the tunica vaginalis of one of them; vas deferens of one obliterated, structure of the glands healthy. From a young man, who had suffered severely from hernia humoralis, three years previous to his death, which took place from disease of the brain.—Donor, Mr. Gulliver, A. S. Royal Horse Guards.

#### SECTION II.—ATROPHY OF THE VESICULA SEMINALIS.

1964. Vesiculæ seminales, one unusually small.—From a man who died of phthisis.

1965. Prostate gland and vesiculæ seminales remarkably small, the latter perfectly empty; vasa deferentia at their termination impervious; veins of the prostatic portion of the urethræ have a varicose appearance.—Preparation Nos. 1887, 1959, and 1960.—MS. Cat. vol. iii. page 226, No. 105.

## CLASS VIII.

### GENITAL ORGANS OF THE FEMALE.

---

#### DIVISION I.

#### *DISEASES, INJURIES, AND MALFORMATIONS OF THE OVARIA, FALLOPIAN TUBES, AND ROUND LIGAMENTS.*

---

##### SECTION I.—CYSTS IN THE OVARIA, AND FALLOPIAN TUBES.

1966. Section of an ovary very much enlarged, and containing numerous serous cysts; injected yellow. The whole mass weighed twenty-six pounds. It shows the reflected character of some of the adventitious cysts, and the vascularity of their membranes: when recent, both the venous and arterial capillaries were distinctly visible.—Donor, Dr. Ashwell, Guy's Hospital.

1967, 1968. Two portions of an ovary, containing numerous serous cysts; injected with red injection.—Donor, Mr. Key, Guy's Hospital.

1969. Section of an encysted ovarium.—Donor, Dr. J. Munro, A. S. Coldstream Guards.

1970. Ovary very much enlarged, with numerous large cysts in its substance, which were filled with white pultaceous matter.

1971. Ovarium, exhibiting a dropsical cyst, which contained three ounces of limpid fluid; also one which is filled with flaky pus.—From a middle-aged woman. — Donor, Mr. Gulliver, A. S. 71st Regt.

1972. Dropsical cysts in both ovaria; the cyst on the right side contained a brownish fluid in which floated smaller cysts.—Donor, Mr. Lizars, Surgeon, Edinburgh.

1973. A very large serous cyst in the right ovary.

1974. Cyst, situated in the left ovary, capable of containing ten ounces of fluid; its walls are thin, and its interior is lined by a glistening serous membrane.—Donor, Mr. Stanley, St. Bartholomew's Hospital.

1975. Portion of an ovarian cyst, that had been spontaneously relieved by rupture, months before death; its walls are of considerable thickness.—Donor, Mr. Addison, Guy's Hospital.

1976. Ovarium with a small cyst attached to it.—From a woman who died from parturition.—Donor, Dr. Scott, Rifle Brigade.

1977. A large collection of cysts, of various sizes, connected with the ovaries; the uterus and ovaries adhered to the diseased mass, but did not appear to be involved in it. A large sac was found, extending from the pelvis in various directions, on cutting into which, much yellow gelatinous fluid escaped, and the cysts came into view.—From a woman, *ætat.* 23, who, when the disease had existed about three years, was tapped five or six times.

1978. Ovary of small size, and a serous cyst, about the size of a pea, attached to the extremity of the Fallopian tube.—From a woman, *ætat.* 80, who died from the effects of ulceration and partial sloughing of the labia. She had borne children.—Preparation Nos. 1990, 2022.—Donor, Dr. Stephenson, Rochester.

1979. Uterus and ovaries: one of the Fallopian tubes obstructed, the other pervious, and a small cyst attached to its extremity.—From a young unmarried woman, who never had children.—Donor, Dr. Connell, A. S. Rifle Brigade.

1980. Two serous cysts, attached by pedicles to the left Fallopian tube, near its corpus fimbriatum.—Donor, Mr. Bradford, A. S. 56th Regt.

## SECTION II.—SCROPHULOUS DEPOSIT IN THE OVARIA.

1981. Ovarium enlarged, and presenting tough, fibro-cartilaginous cysts, which contain softened scrophulous matter. The intestines were found matted together by abundant effusion of lymph, and the peritoneum was tubercular.—From a middle-aged woman, who died of ascites.—Donor, Mr. Gulliver, A. S. 71st Regt.

1982. Ovarium, partly converted into fleshy substance, and cysts containing cheesy and softened tuberculous matter.

1983. Left ovarium enlarged, and filled with cheesy scrophulous matter. When an incision was made into the ovary, some cavities were found in it, containing a viscid fluid.—From a woman, ætat. 32, who died of dropsy.

1984. Right ovarium very much enlarged, and containing many cavities, filled with softened tuberculous matter, and a viscid fluid.—Preparation No. 1983.—Donor, Dr. Davy, A. I. H.

1985. The uterus and ovaries; the latter much enlarged and filled with a yellow cheesy tuberculous matter, with a few serous cysts in their substance.

SECTION III.—CONVERSION OF THE OVARIES INTO A FATTY  
SUBSTANCE CONTAINING HAIR, AND TEETH.

1986. Ovary enlarged, and containing sebaceous matter and hair, also a molar tooth imbedded in the walls of the sac.—From an elderly female, who, after long and severe suffering, sunk from hæmorrhage and copious purulent discharge.—Preparation No. 2010.—Donor, Mr. Cavet, Surgeon.

1987. Ovary enlarged, and containing in its centre a cyst, filled with hair mixed with sebaceous matter: the substance of the ovary presents throughout cells filled with fat. — College of Surgeons, London.

1988. Ovary enlarged, and converted into a cyst, the interior of which is rough and irregular, with two molar teeth attached to its walls: the sac has formed adhesions to the parietes of the abdomen, and opens externally by an aperture capable of admitting a bougie. —Donor, Dr. Munro, A. S. Coldstream Guards.

SECTION IV.—TUMOURS IN THE OVARIES.

1989. Section of a large fibro-cellular tumour, from the ovary, which weighed four pounds and three quarters, its structure is intersected by white glistening fibres. From a woman, ætat. 96, who had been married, and had three children.—Donor, Mr. Wood, Surgeon, Edinburgh.

1990. Fibro-cellular tumour, of a white colour, round and smooth on the surface. Its structure is irregularly intersected by white fibres, having a dense tissue of a similar colour interposed. The tumour was attached to the left Fallopian tube, between it and the round ligament.—Preparation Nos. 1978, 2022.—Donor, Dr. Stephenson, Rochester.

1991. Ovarium, containing an osseous deposit in its substance.—Donor, Mr. Alexander, A. S. Staff.

SECTION V.—CORPORA LUTEA, EXTRA UTERINE PREGNANCY,  
&c.

1992. Right ovary, presenting two corpora lutea.—Donor, Mr. Cavet, Surgeon.

1993. Ovary, in the substance of which is a circumscribed deposit, apparently of coagulated lymph; the peritoneal and fibrous tunics were perfectly entire, and no mark through which an ovulum might have escaped.—From a patient, *ætat.* 25, who poisoned herself with laudanum. She had one child, when about 20 years of age.—Preparation No. 2000.—Donor, Dr. Stephenson, Rochester.

1994. Shows adhesion of the left Fallopian tube to the ovary of the same side.—From a woman, who died of chronic raving mania.—Preparation No. 2001.

1995. Fallopian pregnancy, with rupture of the left tube, some fibrine still adheres to the part; sections are made of the ovaries, and in one of them appear corpora lutea; the rupture was occasioned by medicine taken to procure abortion.—From a Negress who died very suddenly from hæmorrhage.—Donor, Dr. Stewart, A. I. H.

1996. Uterus and its appendages: the ovarium of one side is deficient, and the one present is extremely small; just above the os uteri was a false membrane, which closed the passage.—Donor, Dr. Davy, A. I. H.

## DIVISION II.

### *DISEASES, INJURIES, AND MALFORMATIONS OF THE UTERUS.*

---

#### SECTION I.—INFLAMMATION, AND EFFUSION OF LYMPH IN THE UTERUS.

1997. Internal and external surfaces of the uterus, covered with coagulated lymph.—From a woman, who died of peritoneal inflammation, on the eighth day after her delivery.—Donor, Dr. Davy, A. I. H.

1998. Uterus, rough internally, and lined with lymph; Fallopian tubes partially obstructed, and one of them contained pus. From a woman, *ætat.* 18, who died of peritonitis, fifteen days after delivery.—Donor, Dr. Davy, A. I. H.

1999. Uterus, lined by a false membrane; ovaries adhering to its walls; no appearance of corpora lutea; marks of old ulceration on the mucous membrane of the rectum. From a woman, *ætat.* 46, the mother of several children.—Donor, Dr. Davy, A. I. H.

2000. Fundus of the uterus, lined by a loose spongy substance; the uterus was opened under water, but nothing like an ovum could be detected.—Preparation No. 1993.—Donor, Dr. Stephenson, Rochester.

2001. Uterus, exhibiting a small fibrinous substance, attached to its mouth : in the recent preparation, the mucous membrane of the os, and cervix uteri, had a red congested appearance, with a thin covering of a yellow fluid, resembling pus.—Preparation No. 1994.

2002. Uterus enlarged, its interior is rough, and lined with coagulated lymph.—Donor, Dr. Monro, A. S. Coldstream Guards.

2003. Uterus enlarged, rough on the internal surface, from the effusion of lymph ; small, round cysts in one of the Fallopian tubes, which is much dilated. The ovaries presented corpora lutea and vesicles. Probably from a woman shortly after delivery.

2004. Obliteration of the os uteri. From a woman, ætat. 92.—Donor, Dr. Davy, A. I. H.

2005. Diseased uterus of a bitch ; in the recent preparation, the necks and mouths of the uterus were of a cartilaginous firmness, and the lining membrane highly vascular ; the right cornu presented two large oval expansions, which contained blood mixed with pus, and the mucous lining is soft, pulpy, and of a purple colour. In one of these cavities were also found two small substances, resembling portions of cranial bones. The left cornu is divided into numerous small sacculi, throughout its whole length, within which thin greenish-yellow purulent fluid was found ; its lining tunic was highly vascular and dark coloured.—Preparation No. 2031.—Donor, Mr. Ford, A. S. 72nd Regt.

## SECTION II.—HYDATIDS IN THE UTERUS.

2006. Uterus, having several hydatid cysts, attached to its body.—Donor, Dr. Grant, Second Class Staff Surgeon.—MS. Cat. vol. iii. page 193, No. 59.



SECTION III.—ULCERATION, CANCER, AND FUNGOID GROWTH IN THE UTERUS.

2007. Inner surface of the uterus and vagina extensively ulcerated, and an opening, about the size of a crown piece, leading from the uterus into the bladder.—Donor, Dr. Sibbald, A. I. H.—MS. Cat. vol. iii. page 186, No. 24.

2008. Malignant ulceration of the neck of the uterus and vagina, which communicate with the rectum, by an opening, capable of admitting a bougie. The patient died of hectic fever.—Donor, Mr. Fraser, I. G. H.

2009. Cancerous ulceration of the neck of the uterus, which communicates with the bladder, by an opening about the size of a crown piece.—Donor, Dr. Munro, A. S. Coldstream Guards.

2010. Fundus uteri, in a carcinomatous state, the vagina, bladder, and rectum were thrown into one cavity by ulceration.—Preparation No. 1986.—Donor, Mr. Cavat, Surgeon.

2011. A large fungoid growth, arising from the os tinæ, and upper part of the vagina.—Donor, Dr. Davy, A. I. H.

SECTION IV.—FIBROUS TUMOURS OF THE UTERUS.

2012. A large fibrous tumour, occupying the cavity of the uterus, and three others of a smaller size, attached to the external surface of this organ; a section is made of one of the ovaries, which is a little altered in structure.—From a woman 50 years of age.—Donor, Mr. Baynton, St. Bartholomew's Hospital.

2013. Cavity of the uterus, occupied by a large fibrous tumour, and two others of a smaller size, attached to its outer surface. The section of the largest tumour, presents a white, greyish colour, intersected by glistening, filamentous laminæ, arranged in irregular concentric layers, and in several places has the appearance as if it

were composed of smaller tumours compressed together.—From a woman *ætat.* 58.

2014. Section of a uterus, exhibiting a fibrous tumour in its walls.—Donor, Dr. J. Monro, A. S. Coldstream Guards.

2015. Two large fibrous tumours, situated in the anterior wall of the uterus, and occupying its cavity; also two of a smaller size, one attached to the posterior aspect of the uterus, and the other to its neck.—Donor, Mr. Stanley, St. Bartholomew's Hospital.

2016. A large fibrous tumour, situated in the anterior wall of the uterus, the neck of which is remarkably elongated.—Donor, Mr. Stanley, St. Bartholomew's Hospital.

2017. Section of a uterus, presenting fibrous tumours of various sizes, intersected by many white glistening fibrous bands; the structure of the uterus surrounding these tumours is much compressed.—Donor, Dr. Bright, Guy's Hospital.

2018. Tumour of a very dense, fibrous texture, round in form, and regular on the surface; it was attached to the cervix uteri.

2019. Section of uterus, which is occupied by a large fibrous tumour.—Donor, Dr. J. Monro, A. S. Coldstream Guards.

#### SECTION V.—FLESHY TUMOURS OF THE UTERUS.

2020. Fleshy tumour, which projected into the abdomen, from the external surface of the fundus uteri.—From a middle aged woman, who died during childbirth.—Donor, Dr. Robertson, Surgeon R. N.

2021. A small, fleshy growth, attached to the fundus of the uterus, in the walls of which there is some scrophulous deposit; left ovary converted into a cyst, which contained a serous fluid; right enlarged and containing a serous cyst.

2022. Neck of the uterus, occluded by adhesion of its sides, and

by a small fleshy growth, which projects into the cavity of the viscus: in the substance of this tumour, are numerous small vesicles, which are also seen in the lower part of the cervix uteri, and os tinctæ; these vesicles present the appearance of enlarged mucous follicles, but there is no depression observable in their centres. Before slitting up the neck of the uterus, a small probe could not be passed through it, and the adhesions, which have been separated at the commencement of the tumour, were very firm.—Preparation Nos. 1978, 1990.—Donor, Dr. Stephenson, Rochester.

#### SECTION VI.—UTERUS, WITH THE FŒTUS IN THE PASSAGES.

2023. Uterus, and vagina, with a fœtus at the ninth month, in the passages; the posterior surface of the urinary bladder has given way from the pressure of the child's head.—From a Negress who died in childbirth.—Donor, Dr. Hardie, A. S. Staff.

#### SECTION. VII.—RUPTURE OF THE UTERUS.

2024. Rupture of the right side of the uterus; the membranes, and placenta adhere to the internal surface, at the point of rupture. The left side of the uterus is occupied by a fibrous tumour.—Donor, Mr. Moline, A. S. 22nd Regt.—MS. Cat. vol. v. page 167, No. 69.

2025. Transverse rupture of the uterus, immediately above its cervix: the edges of the rupture are livid, from effused blood.—From a dwarfish woman ætat. 24, three feet eight inches in height; she was exhibited as such in a travelling caravan; she had completed her full period of pregnancy; embryotomy was attempted and the uterus gave way.—Donor, Dr. Sibbald, A. I. H.—MS. Cat. vol. iii. page 188, No. 33.

#### SECTION VIII.—MOLES.

An organized mass, with membranes attached; expelled from the uterus, about the third month of pregnancy, after much uterine action and hæmorrhage.—Donor, Mr. Ford, A. S. 72nd Regt.

2027. Oval-shaped coagulum, which is rather larger than a hen's egg, having a small cavity in its centre, which is lined by a delicate membrane, and contained a bloody fluid.—Passed per vaginam by a woman, who supposed herself three months gone with child.—Donor, Mr. Denny, A. S. Staff.

2028. Organized mass, discharged from the uterus : it is difficult to say, whether it is the membranes of the ovum containing a coagulum of blood, or not.—From a woman *ætat.* 35, who was supposed to be three months gone in pregnancy.—Donor, Mr. A. Stewart, A. S. Staff.—MS. Cat. vol. iii. page 188, No. 30.

2029. Coagulum, expelled from the uterus, after suppressed menstruation.—Print. Cat. page 192, No. 3.

2030. A clot of blood, which seems to have become partly organized, expelled from the uterus, three months after an attack of uterine hæmorrhage.—Donor, Mr. Allan, A. S. Staff.

#### SECTION IX.—BONES FROM THE UTERUS.

2031. Portion of cranial bone, from the uterus of a bitch.—Preparation No. 2005.—Donor, Mr. Ford, A. S. 72nd Regt.

2032. Bones, evacuated from the vagina, uterus, and stomach of a girl.—Donor, Dr. Calvart, D. I. G.—Print. Cat. page 199, No. 24.

### DIVISION III.

#### *DISEASES OF THE VAGINA, AND EXTERNAL PARTS OF GENERATION.*

---

##### SECTION I.—TUMOURS ATTACHED TO THE VAGINA.

2033. Tumour, of dense fibrous texture, and a peculiar crescentic figure, arising from the left side of the vagina, and nearly encircling the rectum; one extremity of the tumour pushes the vagina before it, and caused a projection of the labia.—Donor, Dr. Stewart, A. I. H.

##### SECTION II.—TUMOURS FROM THE LABIA.

2034. A large fibrous tumour, from the labia pudendi.

2035. Adipose tumour, from the labia pudendi, of a middle aged woman.—Donor, Mr. Stanley, St. Bartholomew's Hospital.

##### SECTION III.—ELEPHANTIASIS OF THE LABIA.

2036, 2037. Elephantiasis of the labia pudendi, the mass weighs forty pounds; excised, by Dr. Birrell, A. S. Staff, from a Negress; twelve days after the operation she was discharged from hospital cured.—Drawings No. 2890, 2891, 2892, 2893.—Donor, Dr. Dease, Staff Surgeon.—Print. Cat. page 192, No. 4.—Edinburgh Medical and Surgical Journal, vol. xxiii. page 257.

## CLASS IX.

### LACTIFEROUS ORGANS.

---

#### DIVISION I.

#### *DISEASES OF THE MAMMA.*

---

##### SECTION I.—SCIRRHUS OF THE MAMMA.

2038. Mamma, affected with scirrhus in its early stage, the nipple very much retracted.—Donor, Dr. M'Crea, A. S. Staff.

2039. Scirrhus mamma in its early stage; a small gland at the posterior and superior part of the preparation is also affected with the same disease, which was of eighteen months' duration.—Removed by operation from a woman, ætat. 30.—Donor, Dr. M'Crea, A. S. Staff.—MS. Cat. vol. iii. page 211, No. 49.

2040. Section of a scirrhus mamma injected to show the condition of its capillaries; removed from a woman who had borne one child; she died twenty-one days after the operation, from bronchitis; the affection was said to have been of three years' duration, and to have commenced in the skin.

2041. Scirrhus mamma; removed from an unmarried woman,

ætat. 44, who assigned a blow, received seven months previously, as the cause of its formation.—Donor, Mr. T. Berry, Staff Surgeon.

2042, 2043. Two sections of a mamma, exhibiting a mixture of scirrhus and adipose tissue.—Donor, Mr. Fraser, A. S. Staff.

2044. Section of a scirrhus mamma, skin covering it in a state of ulceration.

2045. Scirrhus tumour; from the breast of Captain D—, who was slightly wounded in the breast, by a musket ball, while serving in Spain; some time after the wounded part healed, this tumour appeared and was extirpated with a favourable result.—Donor, Mr. Hosack, Staff Surgeon.

## SECTION II.—MEDULLARY SARCOMA, AND FUNGUS HÆMATODES OF THE MAMMA.

2046. Medullary sarcoma of the mamma, nipple much retracted.—From a woman, ætat. 45.—Donor, Mr. F. Berry, Staff Surgeon.

2047. Section of a mamma, affected with medullary sarcoma; portions of the structure are soft and broken up, some parts are also firm, and of a scirrhus character.—From a middle aged woman, whose breast, while nursing, acquired a very considerable size from fungus hæmatodes, which was removed; but a tumour again formed, nearly as large as the former, and she died six months after the removal of the first.—Royal College of Surgeons, Edinburgh. }

2048. Section of medullary sarcoma of the mamma.—Royal College of Surgeons, Edinburgh.

2049. Two sections of a mamma, affected with medullary sarcoma. In the medullary matter, there are several serous cysts, also small, round gelatinous looking bodies.—From a married lady, ætat. 65, who had no complaint until five months previous to its extirpation.—Donor, Mr. Wood, Surgeon, Edinburgh.

2050. Fungus melanodes of the right mamma; the tumour is

large and of a deep bluish-black colour; a fungous growth of the same dark hue arises from the skin covering it.—Preparations Nos. 1580, 1581, 1582.—Donor, Mr. Melville, Staff Surgeon.—MS. Cat. vol. iii. page 223, No. 99.

### SECTION III.—HYPERTROPHY OF THE MAMMA OF THE MALE.

2051. Hypertrophy of the left mamma; when an incision was made into it after death, a few drachms of a clear mucous fluid escaped, from the cut extremities of numerous small ducts. The tumour was of some months' duration and occurred spontaneously.—From a man, ætat. 26.

2052. Mamma unusually developed, but without any apparent alteration of structure.—From a man who died of phthisis pulmonalis.—Donor, Mr. O'Brien, A. S. 7th Regt.

2053. Mamma in the male unusually large.



## CLASS X.

### ORGANS OF LOCOMOTION.

---

#### DIVISION I.

#### *DISEASES, INJURIES, AND MALFORMATIONS OF THE JOINTS.*

---

##### SECTION I.—DISEASES OF THE SYNOVIAL MEMBRANE.

2054. Synovial membrane surrounding the condyles of the femur thickened, and much coagulated lymph is deposited on its free surface; the cartilage is quite sound.

2055. Loose portion of the synovial membrane of left knee joint much enlarged, thickened, and covered by a layer of coagulable lymph, having a granulated appearance, which also adheres to the cartilage on the internal condyle; a small portion of the cartilage on the external condyle appears to be absorbed and atrophied; the remainder of the articular surfaces are perfectly sound. The capsule contained a considerable quantity of yellow pus; two large abscesses were found in the muscles of the thigh, immediately above the joint.—Preparation No. 2341.—MS. Cat. vol. iii. page 109, No. 147.

2056. Synovial membrane of the ankle joint thickened, and the

articular surfaces coated by a layer of coagulated lymph.—Print. Cat. page 167, No. 6.

2057. Synovial membrane of the knee joint much thickened, and encroaching over the margins of the articular cartilages: a thin layer of coagulated lymph adheres to one part of the articular surface of the femur, but the cartilage covering this bone, as also that of the tibia, is healthy.—Removed from a boy, 10 years of age, who had suffered from the disease upwards of eight months.

2058. Synovial membrane of knee joint thickened: adhesions between the articular surfaces of the femur and tibia, and a delicate membraniform layer on the cartilage of the inner condyle of the femur. The patella is lying at the bottom of a cavity, the sides of which are formed by the thickened synovial membrane, which protrudes over the circumference of that bone: the cartilage is healthy.—Donor, Dr. Scott, Surgeon Rifle Brigade.—Print. Cat. page 172, No. 44.

2059. The whole of the synovial membrane of the knee joint much thickened and pulpy. All the articular surfaces of the bones composing the joint are completely invested by a layer similar to the thickened synovial membrane, from which the morbid growth appears to have extended: a portion of the cartilage of the patella is quite healthy; the crucial ligaments are also thickened, and the semilunar cartilages destroyed.—Print. Cat. page 172, No. 40.

2060. Synovial membrane of wrist joint generally thickened, and projecting over the margins of the articulation. The cartilages are entire, but partly covered by a delicate membranous exudation, and cellular membranous bands extend, in one situation partially, and in another entirely, across the articular extremity of the radius. The synovial membrane covering the carpal bones is also much thickened, and coated with granular lymph. This joint exhibits the commencement of one form of an ankylosis.—Removed by operation from a man, *ætat.* 23, who had for above six months been affected with swelling of the wrist, accompanied with sinuous ulcers in the surrounding soft parts and hectic fever.

2061. Synovial capsule of left knee joint very much enlarged,

with numerous fatty appendages of various sizes, and filamentous fringes hanging from the inner surface of the synovial membrane around the condyles of the femur: these appendages and fringes are apparently continuous with the synovial membrane. The cartilages covering the internal condyle of the femur, as also that covering the semilunar depressions of the tibia, are absorbed at these parts; the surfaces of the bones are smooth and polished, but appear otherwise healthy; some adventitious deposit of bony matter around the margin of the external condyle of the femur. The internal semilunar cartilage is destroyed.—Donor, Mr. Allan, A. S. Staff.

2062. Proximal extremity of the radius, around the neck of which numerous rounded tumours are hanging into the articular capsule, some by fine, and others by broader pedicles. These growths are of the colour and consistence of fat, varying in size from an eighth to a third of an inch in diameter; they have a smooth surface, continuous, and apparently identical with the synovial membrane. The articular cartilage is entire, and presents many filiform processes arising from its surface.—From a man who died of gangrene of the foot. The motions of the joint were impaired during life.—Donor, Mr. Martin, Surgeon 73rd Regt.

2063. A number of fatty appendages, from the size of a millet seed to that of a bean, suspended, some by fine and others by broad pedicles, from the inner surface of a bursa, which was extirpated from the back of the hand.—Donor, Mr. Allan, A. S. Staff.

2064. Condyles of the femur, exhibiting a small pedunculated body, and a filamentous fringe projecting from the synovial membrane on the upper margin of the articular surface, into the cavity of the joint; other filamentous bodies project from the very centre of the articular cartilage of one of the condyles.—From a man who died of phthisis.—Preparation Nos. 2109, 2110.—Necrol. Reg. vol. v. page 151.

2065. Lower articular end of the femur, exhibiting a thickened fold of synovial membrane close to the margin of the cartilage of the inner condyle.—From a man who died of phthisis.—Necrol. Reg. vol. v. page 225.

2066. Lower articular extremity of the ulna, on the cartilage of which are some superficial furrows. In the fossa olecronalis is a portion of bone, connected only to its site by slender cellular tissue: and in the pit for the coronoid process, is a smaller cartilaginous body similarly attached.—From a man, ætat. 58, who died of phthisis; he had long been completely idiotic.—Preparation No. 2112.

2067. A portion of a flattened cartilaginous body, about three quarters of an inch in length, and half an inch in breadth: its surface is smooth, and apparently covered by synovial membrane.—Extracted from the inner side of the knee joint, where it was attached by a broad base, and hung loose into the cavity of the joint, from which during the operation much synovial fluid escaped; the patient after the operation never had a bad symptom.—From a man, ætat. 30, who had for some time complained of weakness, and pain in both knees, which he said swelled on exertion.

2068. Section of a roundish cartilaginous body, about an inch in diameter, having a central portion of bony matter about the size of a bean. Its surface is smooth, polished, and irregularly nodulated.—Extracted from the knee joint of a man, ætat. 44, who had long been affected with lameness, consequent on an injury received some years previously.—Preparation No. 2069.—MS. Cat. vol. iii. page 88, No. 58.

2069. Section of Preparation No. 2068, dried to show its osseous nucleus.—MS. Cat. vol. iii. page 88, No. 58.

2070. Cartilaginous body, about the size of a bean, extracted from the knee joint.

2071. An enlarged subcutaneous bursa, the walls of which are thickened and coated with lymph; it contained a thin purulent fluid.—Donor, Mr. O'Brien, A. S. 7th Regt.

## SECTION II.—HYPERTROPHY OF THE CARTILAGES.

2072, 2073. Two patellæ, exhibiting thickening of their carti-

lages, extending transversely across the centres of their articular surfaces. The surfaces of the swelled cartilages are unchanged, except where their continuity is irregularly interrupted by fissures penetrating deeply into their substance.—From a man, ætat. 31, who was admitted with phthisis pulmonalis.—MS. Cat. vol. iii. page 91, No. 71.

2074. Patella, showing thickening and cracking of its cartilage.—From a man, ætat. 24, who died of pulmonary consumption. There was no alteration in the external appearance of the joints, and they contained the usual quantity of synovia, the synovial membrane appearing perfectly healthy.—Preparation No. 2075.—Necrol. Reg. vol. v. page 313.

2075. Hypertrophy of the cartilage of the patella. A transverse section of the bone and cartilage has been made, in order to exhibit the extent to which the latter is thickened.—Preparation No. 2074.

2076, 2077. Two patellæ, exhibiting well defined swelling of their cartilages at their inner margins. These preparations are put up to show the simultaneous existence of this change, in precisely the same parts of the two corresponding joints.—From a man, ætat. 27, who died of phthisis pulmonalis.—Necrol. Reg. vol. v. page 9.

2078. Cartilage of the patella, somewhat swelled and softened, with irregular depressions on its surface.—From a man, ætat. 47, who died of pneumonia, and had no tubercular disease.—Preparation No. 2136.—Necrol. Reg. vol. v. page 10.

2079, 2080. Upper extremities of the tibiæ, the cartilages of which present villous surfaces, having brushlike projections, which appear to be the cartilaginous fibres elongated and hypertrophied.—From a man, ætat. 76; his lower extremities were particularly well formed, and he was never known by his friends to have complained of his joints. Notwithstanding, on examining the joints after death, previously to opening them, it was concluded that there was certainly loss of substance in the cartilage of one of them, and probably also to a less extent in the other. This opinion was formed, from a crackling being perceived in the first, when the limb was sharply flexed and extended, the hand being firmly placed on the front of the

joint, and in the second a roughness was perceptible.—Preparations Nos. 2089, 2103.

### SECTION III.—ATROPHY, AND SOFTENING OF THE CARTILAGES.

2081, 2082. Two patellæ, exhibiting small portions of the cartilages at their margins, softened and villous, and their fibres elongated.

2083. A small portion of the cartilage of the patella near its margin, thinned, and softened, and having a deep depression in its surface.—From a man who died of phthisis.—Preparation No. 2093.

2084. A pit on the border of the patella (filled with red injection) formed by the absorption of the cartilage; the synovial membrane, however, is entire and lines this pit.

2085. Patella, the articular cartilage of which is generally thinned and villous on the surface.—From a man, ætat. 74, who often complained of rheumatism, and latterly suffered severely from it.—Preparations Nos. 2088, 2096, 2102.—Donor, Dr. Stephenson, Rochester.

2086. Atrophy and villosity of the cartilages covering the patella.

2087. Patella, exhibiting softening and alteration of its articular cartilage.—Preparations No. 2104, 2114, 2190, 2191.

2088. Patella, the cartilage of which is generally thinned and villous; a section is made of the cartilage to show its thickness.—Preparations Nos. 2085, 2096, 2102.

2089. Left patella, in which the cartilage across the middle of the bone is thinned, and the base of the thin part is softened, and short fibres project from it, towards the cavity of the joint.—Preparations Nos. 2079, 2080, 2103.

2090. Patella, exhibiting slight thickening of its cartilage, on the middle and external part of the bone, with well marked thinning,

villosity and softening extending thence to the left side of the bone. From a man, *ætat.* 32, who died of tubercular consumption. Previously to his admission into the lunatic asylum at Fort Clarence, he had been three years confined to bed after an attack of remittent fever, succeeded by amentia. During the whole period of his mental disease, he was listless and sullen, in consequence of which he was indisposed to move. The lower extremities became emaciated and partially paralytic. There was no alteration in the external appearance of the joints; the synovial membrane contained about the usual quantity of synovia.—Preparations Nos. 2095, 2097, 2100.—Necrol. Reg. vol. iv. page 210.

2091. Patella, showing a softening and thinning of its cartilage, exactly opposite and corresponding in form to a synovial fringe.—From a man, *ætat.* 90, who died of a bronchitic attack of a few days standing. His limbs were well formed, and no disease of the joints was suspected during life, although he used often to complain of rheumatism. There was a very distinct crepitus perceptible on moving the surfaces together, which accordingly enabled the state of the cartilages to be predicted.—Preparations Nos. 2092, 2099, 2101.

2092. Patella, exhibiting partial atrophy, softening, and villosity of a portion of the cartilage extending across the bone, and in a situation to which in certain positions of the joint the extremity of a synovial fringe was in contact.—Preparations Nos. 2091, 2099, 2101.

2093. Patella, a portion of the cartilage of which is thinned, softened, and villous.—Preparation No. 2830.—MS. Cat. vol. iii. page 101, No. 115.

2094. Patella, exhibiting a partial thinning, softening, and disintegration of its cartilages.—From a man, *ætat.* 28, who died of phthisis pulmonalis.—Preparation No. 2115.—Necrol. Reg. vol. iv. page 253.

2095. Upper articular end of the tibia, exhibiting softening and alteration of the cartilage in the lunar depressions, in one of which

the cartilage presents a fibrous appearance.—Preparations Nos. 2090, 2097, 2100.

2096. Portion of the lower articular end of the femur, exhibiting a circumscribed thinning, and fibrous degeneration of the cartilage between the condyles.—Preparations Nos. 2085, 2088, 2102.

2097. Condyles of the femur, exhibiting a circumscribed thinning and softening of the cartilages.—Preparations Nos. 2090, 2095, 2100.

2098. Patella and condyles of the femur; a portion of the cartilage of the former is thinned, softened, and villous, and a part of that between the condyles of the latter is entirely absorbed.—From a man, *ætat.* 44, who died of phthisis.—Necrol. Reg. vol. v. page 143.

2099. Lower articular end of the femur, exhibiting thinning and a velvet appearance of the cartilage.—Preparations Nos. 2091, 2092, 2101.

2100. Knee joint, exhibiting a circumscribed thinning and softening of the cartilage on the external condyle of the femur, also on the opposing surface of the patella; the synovial membrane and cartilages in other respects natural.—Preparations Nos. 2090, 2095, 2097.

2101. Distal end of the femur, exhibiting thinning, softening, and villosity of the cartilage; on one of the condyles the cartilage is entirely absorbed, leaving the bones quite bare.—Preparations Nos. 2091, 2092, 2099.

2102. Lower extremity of the femur, exhibiting wasting of a part of the cartilage on one of the condyles. In the centre of the articular surface are some granules, of the colour and texture of cartilage, firmly attached to the bone; these granules give the idea of reproduction, however partial, of articular cartilage.—Preparations Nos. 2085, 2088, 2096.

2103. Right patella, exhibiting deficiency of its articular car-



tilage in one situation, and exposure of the bone apparently healthy beneath; the cartilage around the deficiency is thinned and fibrous.—Preparations Nos. 2079, 2080, 2089.

2104. Condyles of the femur, in which there is a deficiency of the greater part of the cartilage of the outer condyle, the exposed bone being slightly smoother than usual, and the margins of the remaining cartilage even and very abrupt. The cartilage is elsewhere of the usual thickness and texture, but numerous delicate filiform processes project from its surface towards the cavity of the joint.—From a man, 78 years of age, whose knee was deformed, and projected much inwards. He walked tolerably well, and simply attributed the deformity to the gradual effect of hard work. He broke stones on the road up to the period of his admission into the poor-house with diseased bladder, of which he died.—Preparations Nos. 2087, 2104, 2114, 2188, 2189.

2105. Exhibits complete absorption of large portions of the cartilages covering the condyles of the femur, and margins of the tibia; on the former, isolated patches of cartilages are observed, thick in their centre, and thin at their circumference; the exposed bone is smooth, polished, and apparently healthy.—Donor, Mr. Stanley, St. Bartholomew's Hospital.

2106. Cartilage covering the head of the humerus, and the glenoid cavity, thinned, and almost completely absorbed; only two small stripes of cartilage remain on the former, and a rim round the margin of the latter bone; the portions of the exposed bones are smooth, polished, and apparently healthy.—Preparation No. 2368.—MS. Cat. vol. iii. page 102, No. 118.

2107. Upper articular extremity of the humerus, exhibiting a deficiency of its cartilage on the posterior part of its surface. A similar appearance, but of less extent, presented in the other humerus.—From a man, *ætat.* 47, an idiot, who died of phthisis.—Necrol. Reg. vol. iv. page 260.

2108. Absorption of a portion of the cartilage covering the head of the femur; the exposed bone appears smooth and natural.

2109, 2110. Upper articular end of two radii, exhibiting a circumscribed deficiency of their cartilages near their circumference; the disease in No. 2110 is farthest advanced.—From a man, *ætat.* 58, who died of phthisis.—Preparation No. 2064.—Necrol. Reg. vol. iv. page 151.

2111. Partial absorption of the cartilage covering the inner condyle of the right humerus.—Preparation No. 2588.—MS. Cat. vol. iii. page 134, No. 106.

2112. Upper articular end of the ulna, exhibiting some superficial furrows on its cartilage, a small portion of which is also absorbed.—Preparation No. 2066.

2113. Articular extremity of the metacarpal bone of the great toe, exhibiting thinning, partial absorption and separation of the articular cartilage from the subjacent bone.—From a man, *ætat.* 50, who died of chronic dysentery. He was invalided from India in consequence of chronic rheumatism.—Necrol. Reg. vol. v. page 215.

2114. External semilunar cartilage of the knee joint, softened, ragged, and approaching in character to cellular tissue.—Preparations Nos. 2087, 2104, 2190.

2115. Patella, a part of the cartilage of which is converted into a puckered fibrous tissue somewhat like a cicatrix.—Preparation No. 2094.—Necrol. Reg. vol. v. page 253.

2116. Distal end of the femur, presenting a small but well defined depression on the cartilage of the inner condyle. The base of the depression is smooth, and formed of a very thin layer of cartilage; its margins are also smooth and rounded. The depression, which differs in many respects from the ordinary atrophy of articular cartilage, may probably be regarded as the cicatrix of an ulcer.—From a middle-aged man who died of dysentery, contracted in the West Indies. After his death, it was observed that the knee joint was contracted, and could not be extended by ordinary force, but nothing further is known about the case.

SECTION IV.—ULCERATION, PRINCIPALLY AFFECTING THE SYNOVIAL ASPECT OF THE CARTILAGE.

2117. Cartilages covering a portion of the head of the femur, and corresponding surface of the acetabulum absorbed, and the round ligament detached from the bone.—Donor, Mr. Stanley, St. Bartholomew's Hospital.

2118. Destruction of the round ligament of the hip joint, with softening of the cartilage covering the head of the femur. — Donor, Mr. Stanley, St. Bartholomew's Hospital.

2119. Left acetabulum of a deep port wine colour, and exhibiting extensive thinning, and ulceration of its articular cartilage, with destruction of the ligamentum teres; the joint contained a few drachms of bloody sanies. — Preparation Nos. 2120, 2121. — MS. Cat. vol. iii. page 96, No. 89.

2120. Head of the left thigh bone, exhibiting extensive thinning, and ulceration of its articular cartilage: the reflected synovial membrane, as well as the head of the bone, had the same dark port wine colour as No. 2119.—Preparation No. 2121.

2121. Ulceration of the internal half of the articular cartilage covering the distal extremity of the radius.—Preparation No. 2119, 2120.

2122. Ankle joint, exhibiting ulceration of the greater part of the cartilaginous surfaces, extending to the subjacent bones. The cartilage around the ulcerations appears to have suffered no change; its margins are smooth, and it is firmly adherent to the bone. The exposed part of the latter, between the ulcer on its surface and the smooth edge of the cartilage, appears to be natural. The posterior part of the capsule presents a layer of coagulable lymph on its synovial aspect. The ulcerated surface of the bones, as well as the adventitious matter on the synovial membrane, is shown by injection to be very vascular.—From a man, ætat. 28, of a strumous habit,

who died of phthisis. Some weeks before death, a fistulous ulcer formed in the integuments of the outer ankle, from which issued a copious sanious discharge sometimes mixed with curdy matter.

2123. Hip joint, exhibiting ulceration of the cartilage covering the head of the femur; an abundant deposition of lymph around its neck, on the inner surface of the capsule and in the acetabulum; the latter is in consequence nearly filled up, but the head of the femur is not dislocated. The soft parts around the joint are very much thickened.—From a man, *ætat.* 23, who contracted the disease from exposure to wet and cold. After seven months' treatment he sunk under colliquative diarrhoea. On dissection, slight ulceration of the mucous membrane of the small intestines was found.

2124. Synovial membrane of the knee joint, much thickened and coated with lymph; semilunar cartilage entirely destroyed, crucial and lateral ligaments also very much diseased; upper extremity of the tibia denuded of cartilage and carious. A deposition of scrophulous matter in the cancelli of the inner condyle of the femur, of which a section has been made; a portion of the cartilage covering the patella is ulcerated, the bone exposed and carious; the part of the cartilage that remains is comparatively smooth and natural, with a small quantity of lymph deposited on its surface.—From a man, *ætat.* 30, who died of extensive scrophulous abscesses in the breast and back, as well as of the knee joint; the lungs contained tubercles.—Donor, Dr. White, Surgeon Rifle Brigade.

2125, 2126, 2127, 2128. Bones composing the knee joint, the surfaces of which are throughout invested with a thick granular layer of lymph. The cartilages are entirely destroyed, except a small extent on the posterior part of the condyles of the femur; portions of the bones are exposed and carious. The disease extends into the articulation between the tibia and head of the fibula.—Donor, Dr. Burrell, A. S. Staff.—MS. Cat. vol. iii. page 92, No. 75.

2129. Ankle joint, exhibiting ulceration of the cartilages and coagulable lymph deposited on the eroded surfaces; portions of the bones are exposed, and carious. Removed from a lad, in whom the disease was consequent on an injury.

2130. Ankle joint, exhibiting ulceration of the cartilages; deposition of coagulable lymph on their surfaces and on the synovial membrane.—Removed by operation from a man, who had an ulcer communicating with the joint.

2131. Left ankle and several of the tarsal joints, exhibiting ulceration of their cartilages: the synovial membranes as well as the cartilages are soft, thickened, and covered with coagulable lymph.—MS. Cat. vol. iii. page 105, No. 130.

2132. Ankle and tarsal joints, showing destruction of the cartilages between the astragalus, os calcis, and the cuboid bone: a small quantity of coagulated lymph appears on the surface of the ankle joint, but the cartilages are entire. The ulcerated surfaces are generally covered by very vascular coagulated lymph, as shown by the injection, and a portion of the cancelli of the os calcis is exposed and apparently necrosed.—From a man, *ætat.* 31, who attributed the disease to a sprain; the limb was amputated, and he became very healthy afterwards.

2133. Ankle and tarsal joints, showing ulceration of the cartilages between the navicular bone and astragalus, and between the cuboid and os calcis; the cartilages of the ankle joint are entire, but on that of the astragalus there is a deposition of lymph.—Print. Cat. page 169, No. 21.

2134. Ulceration of the cartilages between the astragalus and os calcis; the sac of an abscess between the tendo Achillis and ankle joint.—MS. Cat. vol. iii. page 106, No. 132.

2135. Section of a foot, exhibiting complete destruction of the cartilages of the astragalus, and navicular bone, and coagulated lymph deposited between them. From a man, aged 21, whose leg was amputated successfully on account of this disease.

2136. Shoulder joint, lined throughout by a pseudo-membranous substance, and the cartilage much thickened, softened, and easily separated from the bone.—Preparation No. 2078.—Necrol. Reg. vol. v. page 10.

2137. Elbow joint, exhibiting ulceration of the cartilages, and an irregular deposition of granulated coagulable lymph on the ulcerated surface, with thickening of the synovial membrane. From a man, ætat. 23, who had been twelve months afflicted with the disease, from which he was relieved by amputation of the limb. The case was considered of a scrophulous nature.

2138. Ulceration of the cartilages of the elbow-joint: a deposit of coagulated lymph on its eroded surfaces, and on the synovial membrane, which is much thickened.

2139. Wrist and carpal joints, showing ulceration of the cartilages, coagulable lymph deposited on their surfaces and on the synovial membrane, which is much thickened: bones carious. Disease of eight months' duration.—Donor, Dr. M'Loughlan, A. S. 79th Regt.

2140. Ulceration of the cartilages forming the carpo-metacarpal articulation of right thumb; synovial membrane thickened and coated with lymph, with subluxation of the metacarpal bone.—Necrol. Reg. vol. vi. page 70.

SECTION V.—ULCERATION, PRINCIPALLY AFFECTING THE ASPECT OF THE CARTILAGE NEXT THE BONE.

2141. Hip joint, exhibiting ulceration of the cartilage, and destruction of the round ligament. On the head of the femur the cartilage is extensively separated from the head of the bone by the ulcerative process; the former, however, still retains its smooth synovial surface: coagulable lymph is deposited around the neck of the femur and in the acetabulum.—From a man who attributed the disease to having kicked his foot against some inequality in the ground; he died after nine weeks' treatment.—Donor, Mr. Egan, A. S. 19th Lancers.

2142. Pelvis and hip joints, exhibiting ulceration of their cartilages, destruction of the round ligaments, and an irregular deposit

of coagulated lymph on the inner surface of the synovial membrane. The cartilage is in many places separated from the bone, particularly from the right femur, where the greater part of the cartilage is detached in one continuous layer; the thigh bones are much wasted. From a boy, aged 7, who had suffered from the disease for eighteen months.

2143. Hip joint, presenting ulceration of the entire surface of the cartilages. Some shreds hang loose from the head of the femur, which appear to be partly the remains of the cartilage, and partly coagulated lymph. The ligamentum teres is softened and shreddy, separated from the femur, but still retaining connection with the acetabulum; the capsule is also very much thickened. The joint was filled with brick-coloured grumous fluid, and the ulcerated surface presented the highest vascularity. — *Print. Cat.* page 170, No. 32.

2144. Hip joint, showing ulceration of the entire surface of its cartilage. The head of the femur is enlarged, and the acetabulum presents a corresponding increase in size; no part of the round ligament, or its pit in the head of the bone or acetabulum are perceptible; the capsule is much thickened and coated with lymph. The disease was attributed by the patient to a fall, eight months before admission into hospital.

2145. Knee joint, exhibiting ulceration of almost the entire surface of the cartilage, and caries of the exposed bones. The portions of cartilage that remain, still retain their smooth, synovial surface; the semilunar cartilages are destroyed; the crucial and lateral ligaments are also much diseased, and the femur is partially dislocated inwards. When first opened, the joint was filled with a black, putrid, offensive fluid, giving the articular surface the appearance of having been immersed in ink; this appearance is, in a great measure, destroyed by maceration. — *MS. Cat.* vol. iii. page 104, No. 128.

2146. Elbow joint, exhibiting caries of the upper end of the ulna, and of the inner condyle of the humerus; a thin layer of coagulated

lymph on the cartilage of the outer condyle ; thickening and induration of the soft parts around the joint.—Print. Cat. page 168, No. 20.

SECTION VI.—CARIES OF THE ARTICULAR SURFACES, THE BONES OTHERWISE HEALTHY.

2147. Hip joint, the cartilages and round ligament of which are entirely destroyed, and the bones carious. The ulceration has extended deeply into the cancelli of the bones, and completely through the bottom of the acetabulum ; the capsule and soft parts around the joint are much thickened and consolidated.

2148. Hip joint, the surfaces of which are throughout carious, and the greater part of the bottom of the acetabulum is destroyed. On the outer surface of the ilium and ischium, near to the socket, is a scanty deposit of adventitious bone.—From a man, who was reported to have been attacked at sea with acute rheumatism, succeeded by affections of the hip and knee joint, and pulmonary disease.

2149. Head of the femur, the cartilage entirely destroyed, and its surface throughout carious.—Donor, Dr. Alexander, Staff Surgeon.—Print. Cat. page 173, No. 47.

2150. Knee joint, the cartilages of which are entirely destroyed, and the bones throughout carious.

2151. Knee joint, exhibiting caries of the articulating surfaces of the femur and tibia, extending deeply into their cancelli ; the posterior parts of the condyles of the femur are destroyed, as also the semilunar cartilages ; two deep ulcerated excavations in the head of the tibia ; ankylosis of the patella to the inner condyle of the femur, where a portion of the latter bone is smooth and polished.

2152. Caries of the distal articulating surfaces of the radius and ulna, and a small quantity of adventitious deposit of bony matter around the margin of the radius.



SECTION VII.—CARIES OF THE ARTICULAR SURFACES, AND AN IRREGULAR DEPOSITION OF ADVENTITIOUS OSSEOUS MATTER, ON THE SURFACE OF THE BONES EXTERNAL TO THE JOINTS.

2153. Caries of the articular surfaces of the hip joint, and of the trochanters. A great part of the head of the femur is destroyed, and the acetabulum is enlarged. There is extensive deposition of adventitious bone around the acetabulum, and on the external surface of the ilium; and directly above the great ischiatic notch is a circumscribed deficiency of the new bone, apparently from ulceration.—From a man, who was admitted with pain in the hip, of twelve months' duration; suppuration took place in the joint, and the case proved fatal.

2154. Articular surface of the hip joint throughout carious, and a small portion of the bottom of the acetabulum destroyed; around the outer part of its margin a considerable quantity of adventitious bone is deposited, which extends in the form of a crust over nearly the whole of the iliac fossa, also around the neck of the femur and upper part of the shaft.—From a man, ætat. 27. The disease was of about twenty months' duration, suppuration was very abundant for some time before death.—Preparation No. 2155.—MS. Cat. vol. iii. page 43, No. 179.

2155. Section of the head and neck of the femur, the former carious, and the whole a little more spongy than in the healthy bone.—Preparation No. 2154.—MS. Cat. vol. iii. page 43, No. 179.

2156. Hip joint, the surfaces of which are throughout carious; a quantity of adventitious bone is deposited around the posterior and upper part of the acetabulum, also on the anterior surface of the femur between the trochanters.—The patient was twenty months under treatment for the disease. It was caused by a fall from his horse.

2157. Hip joint generally carious; the acetabulum is remarkably extended in the direction of the thyroid foramen, on which it

encroaches considerably; the bottom of this socket is remarkably thin and cribriform, and around its superior margin there is a quantity of adventitious deposit, as well as on the anterior surface of the neck of the femur between the trochanters. The head of the femur is partly destroyed.

2158. Hip joint, the surfaces of which are throughout carious. The head of the femur is partly destroyed and much flattened; a large quantity of adventitious osseous deposit around the margin of the acetabulum, particularly at its posterior part, also on the anterior surface of the neck of the femur. The disease made its appearance without any assignable cause.—The patient died hectic after nine months' treatment.

2159. Extensive caries of the acetabulum, which at its internal part is very thin, and perforated in many places; a deposition of adventitious bony matter around its margin and on the external surface of the ilium.—From a man who died of phthisis pulmonalis.

2160. Caries of the acetabulum; a very extensive deposition of adventitious osseous matter around its margins and on the external surface of the ilium, where there are three circumscribed deficiencies of the new bone, apparently from ulceration; also a few granules of new bony matter in the internal part of the bottom of the acetabulum, and a thin crust in the inner surface of the ilium.

2161. Caries of the entire articular surface of the femur, and a deposition of adventitious bony matter on its anterior aspect, between the trochanters.

2162. Caries of the head of the femur, a considerable portion of which is destroyed; an adventitious osseous deposit around its neck, and along the anterior inter-trochanteric line.

2163. Extensive caries of the head of the femur, a great part of which is destroyed; a deposit of adventitious bony matter around its neck, and extending for a considerable distance down the shaft of the bone.

2164. Knee joint, exhibiting caries; small portions of the cartilage still remain on each of the bones; a considerable quantity of adventitious osseous deposit round the margins of the femur and tibia, as also on the external surface of the patella.

2165. Very extensive caries of the distal extremities of the tibia and fibula, with ossific deposit around the joint, which extends for a considerable distance upwards; shaft of the tibia thickened, and consolidated.

2166. Lower extremities of the tibia and fibula, exhibiting caries of their articular surfaces, with a deposition of adventitious osseous matter on the internal malleolus and posterior aspect of the tibia, also on the external surface of the fibula.—Preparation No. 2671.—Painting 2804.—Print. Cat. page 160, No. 120.

2167. Caries of the articular surface of the right humerus, exposing the cancelli, with several small cavities in its upper part; numerous spiculæ of new osseous matter, shooting from the tuberosities and neck of the bone, also adventitious bony matter deposited for a considerable distance down the shaft.—From a man, ætat. 31, affected with scrophulous disease of the shoulder joint of four years' duration. Numerous sinuses communicated with the diseased bone. The arm was amputated with a favourable result.—Donor, Dr. Williamson, A. S. Staff. — MS. Cat. vol. iii. page 73, No. 337.

2168. Elbow joint, exhibiting caries of the articular surfaces, and irregular deposition of new osseous matter on the external surface of the bones around the joint.

2169. Caries of the articular surfaces of the humerus and ulna, with new osseous matter on the periosteal parts of the bones around the joint, extending for a considerable distance up the humerus.

2170. Caries of the articular surfaces of the elbow joint; large spicular exostoses on the olecranon, also adventitious deposit on the bones around the articulation. The effect of an injury received six-

teen months previously ; the patient was a highly scrophulous subject. The limb was amputated.

2171, 2172. Elbow joints exhibiting caries of the articular surfaces. Numerous spiculæ of new bone, shooting from the coronoid processes and from the olecranons. Adventitious osseous matter is also deposited on the condyles of the arm bones, from which it extends upwards on their shafts.—No. 2171 was removed by operation.—Preparation No. 862.—Print. Cat. page 171, No. 35.

2173. Right elbow joint exhibiting caries of the articular surfaces. Numerous sharp spiculæ of new osseous matter shooting from the coronoid and olecranon processes of the ulna, also from the condyles of the humerus ; a thin deposit of bony matter around the neck of the radius.—Removed from a man, ætat. 22, disease of thirteen months' duration ; he died of gangrene of the stump on the sixth day after the operation. — Donor, Dr. Williamson, A. S. Staff.—MS. Cat. vol. iii. page 75, No. 340.

2174. Left elbow joint, exhibiting caries of the articular surfaces. A large exostosis, about two inches in length, on the coronoid process ; very extensive adventitious osseous deposit on the olecranon, upper part of radius, and condyles of the humerus ; in the olecranon fossa of the latter there is a large circular ulcerated opening, extending completely through the bone, and from it a smaller ulcerated canal leads upwards towards the outer margin of the bone.—Donor, Mr. Roberts, Surgeon, Chester.

#### SECTION VIII.—CARIES OF THE ARTICULAR SURFACES, COMPLICATED WITH NECROSIS.

2175. Hip joint exhibiting the head of the femur partly destroyed by caries ; and a portion of necrosed bone, about an inch and a half long and three quarters broad, lying at the posterior and upper part of the bottom of the acetabulum. The dead part is nearly detached, and its articular surface is smooth : the internal part of the acetabulum is also smooth, polished, and apparently sound, but the brim of the socket is carious. On the posterior and internal surface of

the ilium, there is an incrustation of new bone; and immediately above the ischiatic notch there is a circumscribed deficiency of the adventitious bone, apparently from ulceration, which has extended into the outer table of the old bone. The patient died of phthisis pulmonalis.

2176. Knee joint exhibiting caries of the whole extent of the articular surfaces, with thickening of the synovial membrane and neighbouring soft parts. A portion of the articular extremity of the tibia is dead, and nearly detached; some necrosed fragments appear to have separated from the posterior part of one of the condyles of the femur.—From a phthisical subject. In the neighbourhood of the knee, abscesses formed. He died twelve months after the commencement of the disease.—Donor, Mr. Cavat, A. S. 97th Regt.

2177. Knee joint showing extensive caries of the articular surfaces; on the external lunar depression of the tibia, a portion of the bone is dead and nearly detached. There is some deposit of new bone, on the outer part of the femur and tibia, and the fibula is ankylosed to the latter.—From a soldier, ætat. 40, admitted with the disease on his arrival from India. The limb was amputated, four months after which he died of disease of the lungs.

2178. Knee joint presenting numerous excavations in the articular extremities. Small parts of the surfaces of the inner condyle of the femur and the tibia have assumed an ivory-like polish. The excavations are probably the result of exfoliations of dead portions of the epiphyses. The disease is reported to have been the effect of scrophula.

2179. Distal extremity of the femur, showing extensive destruction of its articular surface from caries, and two excavations probably the result of exfoliations of dead portions of bone.

2180. Shoulder joint exhibiting caries of the articular surfaces exposing the cancelli; in the head of the humerus is a cavity containing a portion of the articular extremity of the bone, dead and nearly detached. The entire scapula is thickened, its inferior border, and the posterior part of the glenoid cavity, present nu-

merous spiculæ of new bone. On the upper part of the shaft of the humerus, there is also some adventitious bony matter; and in one situation there is a circumscribed deficiency of the new bone, apparently from ulceration. The patient ascribed the disease to a fall from his horse; there were many large ulcers in the shoulder and side, communicating with the bones and joint.

2181. Shoulder joint exhibiting caries extending deeply into the articular surface of the bones. Some irregular exostoses around the glenoid cavity of the scapula; the bone is throughout thickened by an incrustation of new osseous matter on both its surfaces, and the tubercles and upper part of the shaft of the humerus are enlarged, and coated with a similar deposit. In the inferior and posterior part of the glenoid cavity there is an excavation of large size, and smaller depressions appear on the head of the humerus; necrosed portions of bone, which had separated from these excavations, were found loose in the cavity of the joint.—From a man, *ætat.* 25, who had ulceration of this joint of seventeen months' duration; he died after being worn out from diarrhoea and profuse discharge from the joint.

2182. Articular surface of the right humerus, almost entirely destroyed by ulceration. Two large excavations in the head of the bone, the posterior and larger of which is smooth and polished; the other is soft, spongy, and irregular, in which is a portion of necrosed bone quite loose and detached; its surface is smooth where it was in contact with the scapula, and porous where it was attached to the humerus. There are several other smaller cavities immediately above the large tubercle penetrating deep into the surface of the bone.—From a man, *ætat.* 28; disease of eighteen months' standing. Numerous sinuses communicated with the joint. Amputation was performed successfully.—Donor, Mr. Ford, 2nd Staff Surgeon.—MS. Cat. vol. iii. page 69, No. 324.

SECTION IX. — MODIFICATIONS OF FORM IN THE ARTICULAR EXTREMITIES; SHORTENING OF THE NECK OF THE FEMUR; AND EBURNATIONS OF THE SURFACES.

2183. Hip joint presenting remarkable shortening of the neck of the femur, flattening and expansion of its head, with a correspond-

ing change of form in the acetabulum. The head of the bone is enlarged, principally around its inferior border, as if from expansion; its upper and front part being flattened, so that the articular surface extends anteriorly close to the shaft, while the neck presents a greater extent posteriorly. The acetabulum is much widened, and remarkably shallow, corresponding to the alteration of shape in the head of the bone. A longitudinal section of the thigh bone exhibits the centre of the neck hardly half an inch long. There is no appreciable diminution in the density and strength of the bone, and the compact shell of its neck, as well as the cancellous structure, appear throughout perfectly natural. The articular cartilage, as far as can be ascertained from a dry but imperfectly macerated preparation, appears of its usual thickness, and without traces of ulceration.—Donor, Dr. Dempster, A. S. 38th Regt.—MS. Cat. vol. v. page 74, No. 149.—Edinburgh Medical and Surgical Journal, No. 129, page 313.

2184. Hip joint, exhibiting shortening of the neck of the thigh bone. The head is flattened and expanded considerably, and approximates to the shaft so as to be considerably below the trochanter. The acetabulum is diminished in depth, but enlarged laterally, so as to correspond with the altered shape of the head of the femur. The cartilage of the articulation presents throughout its usual thickness and consistency, and is generally smooth; the round ligament is also entire. A longitudinal section is made of the femur, which exhibits the upper and lower shell of what remains of the neck, to be formed of compact bone, equal to the ordinary thickness in this situation, and the reticular texture of the bone is more dense for some distance from the edges, so as to form an indistinct line on either side of the most contracted part towards the centre. The cancelli were filled with caseous matter, in some places nearly colourless, in others tinged with dark grumous blood. The other hip joint was quite natural.—Preparation No. 2185.—Edinburgh Med. and Surgical Journal, No. 120, page 99.—MS. Cat. vol. v. page 76, No. 150.

2185. Section of the preceding femur, presenting shortening of its neck; the head is approximated to the shaft, and depressed very considerably below the trochanter major.

2186. Section of the upper end of the femur, its head flattened, and compressed considerably below the trochanter major; the neck much shortened, and the head approximated to the shaft; a large adventitious portion of osseous matter at the inferior part of its head; articular surface pitted and rough.—From a man, *ætat.* 74, who had been ten years lame; the limb was shortened, and a little inverted; the joint ankylosed, or rather converted into an articulation like that of the sacro-iliac symphysis. It was caused by a fall on the trochanter major; he walked about at first, but gradually became lame. Any person who had seen the case during life, would probably have pronounced that there had been fracture of the convex femoris.

2187. Upper part of the femur, its neck somewhat shortened, and forming nearly a right angle with its shaft, the upper part of the head being just level with the summit of the great trochanter; some adventitious bony matter near the trochanter at the base of the neck, and an increase of density and thickness of the upper part of the shaft.—MS. Cat. vol. v. page 78, No. 152. — Edinburgh Med. and Surg. Journal, No. 128, page 99.

2188. Portion of the head of the femur forming the preceding preparation, showing the round ligament which had apparently been detached from the head of the bone, and acquired a new connection near to its original site. The capsule of the joint appeared unimpaired.

2189. Great toe of the right foot directed outwards, beneath the other toes, at a right angle with its metatarsal bone. — From a lunatic pensioner, *ætat.* 73.

2190. Section of the outer condyle of the femur (Preparation No. 2104), exhibiting a portion of its articular surface, somewhat smooth and polished, and its whole margin slightly expanded by a deposition of new bone.—Preparation Nos. 2087, 2114, 2191.

2191. Upper articular end of the tibia, showing great obliquity of the external articular cavity, and a smoothness of the bone in this situation giving the idea of its having been worn away by attrition.



— Preparation Nos. 2087, 2104, 2114, 2190. — MS. Cat. vol. iii. page 88, No. 61.

2192. Lower end of the femur and patella, the anterior part of the outer condyle of the former is smooth, highly polished, and very hard, with superficial grooves on its surface; the corresponding surface of the patella is in the same condition. The margins of the condyles of the femur are expanded and everted by an adventitious deposit of new osseous matter.—From a man, *ætat.* 30, who died of phthisis pulmonalis; he never made any complaint of the knee joint.

2193. Cartilages covering the articular surfaces of the astragalus, calcaneum, cuboid, and navicular bones entirely destroyed; portions of their articular extremities are highly polished, very hard, and converted into an ivory-like substance, while other parts of their substances are carious.—MS. Cat. vol. iii. page 106, No. 135.

2194. Upper end of the humerus, the head of which is flattened; very hard, highly polished, and converted into a porcelain-like substance; around this ivory-like part there is a deposit of adventitious bony matter.—From Dr. Davy's analysis of the shaft, of the adventitious bone, and of the polished ivory-like articular surface; the following are the results, viz.:

Composition of the shaft,—

|                        |         |       |
|------------------------|---------|-------|
| Phosphate of lime, &c. | . . .   | 58·8  |
| Animal matter          | . . . . | 41·2  |
|                        |         | <hr/> |
|                        |         | 100·0 |
|                        |         | <hr/> |

Composition of the polished articular surface,—

|                        |         |       |
|------------------------|---------|-------|
| Phosphate of lime, &c. | . . .   | 54·2  |
| Animal matter          | . . . . | 45·8  |
|                        |         | <hr/> |
|                        |         | 100·0 |
|                        |         | <hr/> |

Composition of new bone around the articular surface,—

|                        |         |       |
|------------------------|---------|-------|
| Phosphate of lime, &c. | . . .   | 48·8  |
| Animal matter          | . . . . | 51·2  |
|                        |         | <hr/> |
|                        |         | 100·0 |
|                        |         | <hr/> |

SECTION X. — CARRIES OF THE ARTICULAR EXTREMITIES, ATTENDED WITH DISEASE OF THE CANCELLOUS STRUCTURE ; THE BONES SOFTENED, AND THEIR EARTHY PART DIMINISHED.

2195. Knee joint, in which the epiphyses are very light, and softer than natural. Ulceration of the cartilages appears to have commenced in several places. An example of the early stage of the scrophulous disease which commences in the cancelli.—From a lad 12 years of age.

2196, 2197. Ankle joint, the bones of which are softened, and their articular surfaces carious. The diminution of earthy matter is shown from the analysis of a portion of the tibia by Dr. Davy, who found its composition as follows :

|                        |           |       |
|------------------------|-----------|-------|
| Phosphate of lime, &c. | . . .     | 38·2  |
| Animal matter          | . . . . . | 61·8  |
|                        |           | 100·0 |
|                        |           | ---   |

From a lad, aged 7 years, of delicate appearance, and scrophulous habit, who had been upwards of two years affected with the disease. There were sinuses communicating with the joint, accompanied by profuse discharge, and, latterly, hectic fever. The limb was removed, and twenty days after the operation, when the stump had nearly healed, he died of inflammation of the membranes of the brain.

2198. Portion of foot, exhibiting softening of the articular extremities of the tarso-metatarsal bones, the cancelli exposed by the ulcerative process, and some fragments dead and in progress of separation. The articulations of the os calcis and astragalus to the cuboid and navicular bones are perfectly healthy. From a man, ætat. 31, who had for a long time been annoyed with ill-conditioned ulcers on the back of the foot, in consequence of external injury. The ulceration extended, and sinuses formed in every direction, communicating with the diseased bones. The limb was amputated, and the man did well.

2199. Ankle joint exhibiting ulceration extending into the cancelli. The bones are very light, and so soft as to admit easily of being cut with a knife. The diminution of the earthy matter is shown by an analysis by Dr. Davy of a portion of the tibia, which was found to be composed as follows, viz. :—

|                              |       |
|------------------------------|-------|
| Phosphate of lime, &c. . . . | 39·6  |
| Animal matter . . . .        | 60·4  |
|                              | 100·0 |
|                              | ----- |

From a middle-aged man who had laboured under the disease for some years.—Donor, Mr. Gulliver, A. S. 71st Regt.

#### SECTION XI.—ANCHYLOSIS.

2200. Occipital bone and atlas consolidated together by osseous matter.—From a Negro, who died of phthisis; he never complained of any inconvenience from the anchylosis.—Donor, Dr. Heman, D. I. G. H.

2201. Hip joint, in which there is anchylosis between the upper part of the acetabulum and the remaining part of the head of the femur. The lower half of the acetabulum is empty, and a large deficiency in its bottom communicates with the cavity of the pelvis. The os innominatum and the thigh bone are much wasted, and adventitious osseous matter deposited on the inner surface of the former, and on the shaft of the latter.—From a tailor, who, having laboured under this disease many years, died ultimately hectic.—Donor, Mr. Fraser, A. S. Staff.

2202. Section of knee joint, the bones of which are anchylosed, and the capsule obliterated, dense cellular tissue occupying the interspaces of the articular surfaces. Immediately above the condyle of the femur the shaft of the bone appears to have been fractured, and around this fracture there is a very abundant deposition of new osseous matter; from the posterior part of the condyles a large shell of bony matter arises and proceeds upwards on the femur for

about five inches.—Preparation No. 2203.—Necrol. Reg. vol. v. page 141.

2203. Section of 2202, macerated and dried, showing that the cancelli of the femur and tibia are continuous; showing also the adventitious deposit of bony matter more distinctly than in the preceding preparation.—Necrol. Reg. vol. v. page 141.

2204. Section of a knee joint, the bones of which are completely ankylosed, and the capsule obliterated, dense cellular tissue occupying the interspaces of the articular surfaces.—From a man, aged 35, who received a gunshot wound in the knee joint, while on service in India. The ball entered the back part of the joint, and shattered the patella in its exit. Twenty-six months after the injury he died at Fort Pitt, of an enormous abscess of the liver.—Preparation No. 2205.—Edinburgh Medical and Surgical Journal, No. 130, page 163.

2205. Section of a knee joint, in which the soft parts have been removed, showing the cancelli of the femur and tibia, and of the former and the patella, completely continuous.—Preparation No. 2204.

2206. Knee joint, in which there is ankylosis of the patella and tibia to the femur, and of the fibula to the tibia. A longitudinal section has been made, showing the complete continuity between the cancelli and femur. A churchyard specimen.—Donor, Mr. Gulliver, A. S. 71st Regt.

2207. Portion of the right foot, showing ankylosis of the three internal metatarsal bones to the cuneiform bones, also of the latter to the navicular; the posterior concave surface of which is much enlarged, and its margin surrounded by adventitious osseous deposit. A longitudinal section is made of the preparation to show the cancelli of the metatarsal, cuneiform and navicular bones to be continuous.—From a man, *ætat.* 61, who died of amentia. No mention was made of his ever having had any disease of the foot.

2208. Elbow joint exhibiting ankylosis of the humerus to the ulna. The head of the radius is enlarged and carious, as also the

corresponding articular surfaces. A longitudinal section is made of the humerus and ulna, showing the cancelli of these two bones to be continuous.

#### SECTION XII.—APPEARANCES EXHIBITED BY JOINTS IN SCURVY.

2209. Cartilaginous surfaces of the astragalus of a dark brownish red colour, and the synovial membrane thickened, and coated with pale yellow lymph.—From a patient who died of scorbutus.

2210. Cartilages of the astragalus of a dark brown red colour.—From a patient who died of scorbutus.

#### SECTION XIII. — RHEUMATIC AND GOUTY DEPOSITS IN THE JOINTS, AND TISSUES EXTERNAL TO THEM.

2211. Condyles of the femur, and patella, exhibiting deposits on their articular surfaces, analysed by Dr. Davy, and found to be lithate of soda.—From a man, *ætat.* 36 ; during the last four years of his life, he suffered from what was termed rheumatism, affecting not only the large joints, but also the articulation of the hands and feet.—Preparation Nos. 2213, 2214.—Necrol. Reg. vol. v. page 259.

2212. Patella with a deposit of lithate of soda on its inner surface.—From a man, *ætat.* 31, who died of chronic catarrh.—Necrol. Reg. vol. v. page 149.

2213. Lithate of soda, deposited on the articular surface of the distal extremity of first metatarsal bone.—Preparation Nos. 2211, 2214.—Necrol. Reg. vol. v. page 259.

2214. Elbow joint exhibiting lithate of soda on its articular surfaces.—Preparation Nos. 2211, 2213.

2215. Hand deformed by large nodosities of gouty tophus around the joints of the fingers, on the palmar aspect of their extremities,

and on the back of the metacarpus. The cartilages of the carpus are incrustated with a thin layer of the concretions, but they present their usual thickness.—Preparation Nos. 2216, 2217, 2218.—Donor, Mr. Galeani, A. S. 43rd Regt.—Print. Cat. page 167, No. 11.

2216. Section of a thumb, exhibiting the seat of the gouty matter principally in the cellular substance external to the periosteum and to the articulations, and particularly at the extremity of the member. The masses of the adventitious deposit have no communication with the articular cavities. The cartilages of the latter are of the natural thickness, except in a part of the joint between the metacarpal bone and the first phalanx. — Preparation Nos. 2215, 2217, 2218. — Donor, Mr. Galeani, A. S. 43rd Regt.—Print. Cat. page 167, No. 11.

2217. Counterpart to the preceding, exhibiting a bursa between a mass of the adventitious deposit and the external part of the articular capsule.—Preparation Nos. 2215, 2216, 2218.

2218. Piece of a flexor tendon of one of the fingers, with some of the muscular fibres attached to it. In the substance of both some deposits of gouty matter are presented.—Preparation Nos. 2215, 2216, 2217, are from the same subject. These concretions have been examined by Dr. Davy, who found their composition in the dry state as follows, viz. :—

|                                                  |       |
|--------------------------------------------------|-------|
| Super-lithate of soda . . . . .                  | 94·5  |
| Phosphate and carbonate of lime . . . . .        | 4·5   |
| Animal matter, chiefly cellular tissue . . . . . | 1     |
|                                                  | <hr/> |
|                                                  | 100·0 |

—Donor, Mr. Galeani, A. S. 43rd Regt.—Print. Cat. page 167, No. 11.

#### SECTION XIV.—INJURIES OF THE JOINTS


2219. Hip joint, in which there is a fracture of the posterior part of the rim of the acetabulum, and displacement of the head of the femur on the dorsum of the ilium. The round ligament is ruptured near to its attachment to the pit in the thigh bone. On dissection the psoas and iliacus muscles were found on the stretch, the quadra-

tus entire, the superior fibres of the obturator externus and the posterior part of the glutæus minimus lacerated, the superior gemellus completely, the pyriformis partially torn through, these muscles being carried upwards by the head of the bone; the obturator internus was entirely rent asunder, the gemellus inferior was perfect. The limb was shortened, semiflexed, and inverted.—From a robust young man who fell from the Castle Wall of Edinburgh into Princes Street gardens, from the effects of which fall it is probable that he instantly died.—Donor, Mr. Gulliver, A. S. 71st Regt.—MS. Cat. vol. iii. page 126, No. 71.

2220. Elbow joint exhibiting dislocation of the radius and ulna backwards, behind the condyles of the humerus. The coracoid process is lodged in the fossa olecranal. The brachialis anticus muscle is partly lacerated, and about a third of its attachment to the coracoid process of the ulna separated from the bone, and the biceps is much stretched, both lateral ligaments are also severed, but the coronary ligament remains entire. The arm was in a state of semiflexion and the hand supine; the olecranon projected in a marked manner behind, and the condyles of the humerus formed a large tumour in front. The anterior part of the capsular ligament of the joint was also extensively lacerated.—From a man, ætat. 41, who being inebriated, fell into the trench of a fort from a high building. Exclusive of this dislocation he had received the following injuries: fracture of the sternum, femur, bones of the ankle joint and distal end of the radius; also rupture of the liver. He was taken up moribund and died in an hour.—Preparation No. 2557.—Donor, Mr. Gulliver, A. S. 71st Regt.—Print. Cat. page 184, No. 52. London Medical Gazette, vol. iii. page 733.

## DIVISION II.

### *DISEASES OF THE BONES.*



#### SECTION I.—INFLAMMATION, AND THICKENING OF THE PERIOSTEUM.

2221. Tibia exhibiting a circumscribed thickening of the periosteum covering its inner aspect. The thickening appears to be the effect of deposition between the layers of the membrane; and the bone is perfectly healthy beneath.—From a patient who had been salivated for visceral and venereal disease. He died of scurvy contracted on his voyage from India.

2222. Section of tibia; the periosteum covering its anterior aspect is thickened, and the bone in this situation enlarged from deposition of osseous matter. There is an ulcer on the lower part of the adventitious bone, and another higher up which has apparently cicatrized.—From a patient who had taken much mercury in India.

#### SECTION II.—ABSCESSSES IN THE BONE.

2223. Cavity of an abscess in the lower jaw of a rabbit, the internal and external laminae of the bone are expanded, and thin.—Donor, Mr. Gulliver, A.S. Staff.

2224. Cavity of an abscess in the cancellous structure of the posterior superior spinous process of the right ilium.



2225. Right ilium, exhibiting the cavity of an abscess in the cancellated structure of the posterior superior spinous process.—MS. Cat. vol. iii. page 48, No. 201.

2226. Section of a tibia, showing the cavity of an abscess about three quarters of an inch in diameter, in the cancellous structure of its upper extremity, communicating obliquely with the surface of the bone at its tubercle.

2227. The whole of the cancellous structure of the upper extremity of the tibia destroyed by a scrophulous abscess. The cartilage covering the head of the bone is entire and perfectly healthy. The greater part of the shell of the bone is also destroyed, and a large portion is loose and detached. The surrounding soft parts are much diseased, softened, and broken up by purulent matter.

2228. Section of a tibia, showing the cavity of an abscess in the cancellated structure of its distal extremity.—From a man ætat. 26, in whom the disease was of ten months duration when the limb was amputated.—Donor, Mr. Gulliver, A.S. Staff.

### SECTION III.—CARIES.

#### *Bones of the Cranium and Face.*

2229. Calvarum, showing jagged ulcers of both tables, but chiefly of the external, some of them completely penetrating the bone; in one of the ulcers on the left parietal bone, there is a portion of bone partially necrosed.

2230. Caries and partial necrosis of the external table of the os frontis, the bone is thickened, and on its internal surface there are marks of increased vascularity.

2231. Portion of cranium, exhibiting numerous ulcers on the external table of the frontal and parietal bones; the internal table is much grooved by vascular canals.

2232. Portion of cranium much thickened, with extensive caries and partial necrosis of the external table of the frontal and parietal

bones; at some parts the ulceration extends through the whole thickness of the skull. The internal table shows marks of great vascularity.—Donor, Dr. Pearson, Surgeon, 87th Reg., M. S., Cat. vol. iii. page 68, No. 322.

2233. Portion of skull, presenting a large ulceration of the external table of the frontal bone, extending to the upper parts of the nasal and superior maxillary processes. The anterior wall of the frontal sinuses is completely destroyed. The margins of the ulcer are smooth, and rounded, its base is partly cancellated and partly smooth. The effect of scrophula.

2234. Frontal bone exhibiting a portion of the superciliary ridge and orbital process, much eroded and partially detached. The edges of the bone around the diseased part are smooth and rounded, and there is not the slightest deposition of new osseous matter.—From a patient who died of phthisis.—Preparation No. 2289.

2235. Calvarium thickened, consolidated, and exhibiting extensive ulceration of the external table of the frontal and right parietal bones; the diploë obliterated by osseous deposit.—From a man who died of epilepsy.

2236. Extensive absorption of the external table of the skull, which is thus irregularly pitted; the margins of the depressions are generally smooth; in the right side of the occipital bone complete perforation has taken place, and the bones are thickened from deposition of new osseous matter.—From a man *ætat.* 30, who was two months in hospital with pulmonary consumption and diarrhœa, of which he died; he had long been affected with pain in the head, particularly severe about the frontal sinuses and forehead, he was also subject to epistaxis, and large fetid coagula often escaped from the left nostril; he had also insomnium with great depression of spirits. No external appearance of disease or injury was ever detected in the integuments of the head.

2237. Portion of the left parietal bone, showing extensive caries of the internal and external tables, with deposition of new bone on the surface of the former.

2238. Cranium exhibiting extensive ulceration with partial ne-

erosis of the frontal bone; in some situations both tables of the skull are perforated, and the frontal sinuses are opened. The bones of the nose and palate, and the right malar bone are also destroyed by ulceration.—Print. Cat. page 149, No. 30.

2239. Calvarium in which there is an ulcer equally affecting both tables; on the inner surface there is a net-work of vascular canals surrounding the ulcerated part.

2240. Cranium exhibiting erosion of the external table of the frontal bone, its internal table presenting marks of increased vascularity; a large ulcerated opening in the palatine plates of the superior maxillary bones.—Print. Cat. page 163, No. 141.

2241. Cranium presenting ulceration and partial necrosis of the external table of the os frontis; also an ulcerated opening in the posterior part of the palatine plates of the superior maxillary bones.

2242. Caries and partial necrosis of the external table of the frontal bone, the internal surface of which presents marks of great vascularity. The superior maxillary bones and their palatine plates are carious, and portions necrosed and in process of separation.—MS. Cat. vol. iii. page 70, No. 327.

2243. Cranium presenting numerous superficial ulcers on the external table, with marks of increased vascularity on its internal surface.—From a man whose tibia was affected in a similar manner. On his admission, elevated blotches of a livid colour were observed over his body; he had ulcerated throat, and had undergone eight courses of mercury.—Preparation No. 2313.

2244. Calvarium, on which there are some superficial circular ulcers; one of these, of large size, is smooth, and apparently cicatrized, though with loss of substance. The internal table opposite to the ulcers is much perforated, and grooved by vascular canals.

2245. Calvarium exhibiting incipient ulceration of the external table of the frontal bone, with enlargement, in several places on the inner table, of the small vascular canals and foraminæ.

2246. Calvarium much thickened, and consolidated, with several deep rounded ulcerated pits in the external and internal tables; some of them having penetrated both tables, contain small portions of dead bone.

2247. Calvarium very thick and dense, and exhibiting a small oblong perforation with round edges through the left parietal bone, which corresponded with tumours of the dura mater.—From a Lascar who died of pneumonia. His companions stated that he had formerly fallen from the mast-head of a ship, and had been stunned for a moment, but that he never afterwards complained of his head.—Donor, Mr. Fraser, A. S. Staff.

2248. Calvarium exhibiting depression on its external table, and cicatrices of ulcers; some of these are perfectly compact and smooth like the neighbouring bone; others are rough, and penetrate the outer table more abruptly. Reported to be the result of the use of mercury.

2249. Calvarium exhibiting ulceration of the internal table of the parietal bones on each side of the sagittal suture: the margin of the ulcer presents marks of increased vascularity, and in its centre there is a defined aperture, capable of admitting a quill, which completely penetrates the bone.

2250. Skull-cap, in which are several excavations in the diploë of the parietal bones; opposite to some of the cavities the inner table is absorbed, with numerous vascular canals on its surface; the external table is also excessively thin.

2251. Internal table of the calvarium presenting marks of great vascularity, its surface being rough and granular, with tortuous linear elevations forming grooves in the tabula vitrea. — *Print. Cat.* page 158, No. 110.

2252. Calvarium, the internal table of which presents numerous deep, narrow, and tortuous vascular grooves. The bones on each side of the mesial line are affected at exactly corresponding parts, where they are also slightly thickened.

2253. Malar bone, and zygoma, exhibiting ulceration of their

outer surfaces, with numerous vascular canals on the internal table of the frontal bone.

2254. Cranium showing the palatine plate of the right superior maxillary bone, the inferior turbinated bone, and part of the vomer, destroyed by ulceration, and a large excavation in the mastoid process of the left temporal bone. A depression on the outer surface of the frontal bone, the site of former ulceration; the left superciliary arch is also thickened.—Print. Cat. page 165, No. 153.

2255. Extensive ulceration of the anterior surface of the left superior maxillary bone.


2256. Greater part of the right superior maxillary and malar bones, as also the bony palate, destroyed by carcinomatous ulceration. The eroded surfaces are irregular and sharp.—From a man, ætat. 39, admitted with carcinoma of the face; a large fungous zone was situated over the right cheek, and connected with the antrum of the same side. He died greatly emaciated.—Drawing No. 2971.

2257. The whole of the osseous palate and anterior part of the alveolar processes of both superior maxillary bones, right turbinated bones, and part of the vomer, destroyed by ulceration. Supposed to have been induced by the use of mercury.—MS. Cat. vol. iii. page 65, No. 310.

2258. Destruction of the whole of the bony palate, anterior part of the alveolar processes of both superior maxillary bones, also of the turbinated bones and lower part of the vomer. The result of secondary syphilis.—MS. Cat. vol. iii. page 67, No. 319.

2259. Æthmoid bone and osseous parietes of the nares destroyed by caries. A nidus, containing myriads of very small but lively maggots, occupied the place of the sphenoidal cells; immense numbers of these were also discharged with purulent matter during life. In the right anterior lobe of the brain existed an abscess which contained about an ounce of pus.—Donor, Dr. Fogarty, Surgeon, 22nd Reg. MS. Cat. vol. iii. page 47, No. 197.

2260. Lower jaw, the right half of which has been absorbed, the



eroded surface of the remaining portion is very rough and sharp. The effect of a carcinomatous fungus.

*Bones of the Trunk.*

2261. Ulceration of the lower portion of the body of the second cervical vertebra, with a slight deposit of osseous matter on the surface of the third.

2262. Ulceration of the anterior surface of three of the dorsal vertebræ, a considerable portion of the articular surface of one of them is destroyed.—Donor, Dr. Henderson, Surg. 48th Reg.

2263. Two dorsal vertebræ, the greater part of the body of one of which is destroyed by ulceration, as also a part of the contiguous one, with ankylosis of their oblique processes.

2264. Ulceration of the bodies of the two last cervical, and all the dorsal vertebræ, with large deep cavities in their substance; the seventh and eighth dorsal are ankylosed, the greater part of the body of the eleventh is destroyed, and united to the twelfth by osseous matter, from the surface of which bony spiculæ project. The ulceration principally affects the fronts of the bones, leaving their articular surface undiminished in extent.

2265. Ulceration of the front of the bodies of the ten inferior dorsal vertebræ; the upper half of the body of one of them is entirely destroyed.—From a patient who died of lumbar abscess.

2266. Ulceration of the front of the bodies of seven of the dorsal vertebræ; the greater part of the body and articular surface of one of them is destroyed, and the corresponding oblique processes are ankylosed; on the bodies and transverse processes of some of them there is a deposit of new osseous matter.

2267. Portion of spine exhibiting destruction of the bodies of the eighth and ninth dorsal vertebræ by ulceration. The disease has also commenced in the front of the bodies of two other vertebræ.—

From a man ætat. 35, who was admitted with paralysis of the lower extremities; he died of phthisis.

2268. Spine and part of the parietes of the chest. There has been destruction of the bodies of some of the vertebræ, and consequent excurvation of the spine. An abundant deposit of coagulated lymph has taken place around the front and sides of the diseased bones, as well as on the dura mater of the cord. The canal is not narrowed at the situation of the curve. The preparation exhibits the first stage of the curative process. Bony anchyloses has not yet taken place, but the parts are rendered steady and firmly kept in a favourable position by the coagulated lymph.—From a child six years old who died of diarrhœa.

2269. Ulceration of the front of the bodies of nearly the whole dorsal vertebræ, with several cavities in their substance, and absorption of some of the intervertebral cartilage.—From a patient who died hectic consequent on puncturing an abscess, which pointed externally in the right lumbar region.

2270. Absorption of the bodies of the dorsal vertebræ, also of several of the heads of the corresponding ribs and transverse processes. The bodies of four of the vertebræ are almost completely destroyed, particularly on the left side, where there is a large opening into the spinal canal. The cartilaginous substances of the vertebræ are entire, but shrivelled by drying. Caused by the pressure of an aneurism of the aorta; although the spinal cord was exposed there was no paralysis.—Donor, Mr. Fraser, I. G. H.

2271. Ulceration of the bodies of the dorsal vertebræ, with deposition of new bony matter on their surfaces; an osseous band unites the front of the bodies of two of them; a considerable portion of the body of one of these two is destroyed.

2272. Ulceration of the front of the bodies of the six inferior dorsal vertebræ, with deposition of new osseous matter on parts of their surfaces, and a cavity in the substance of the eleventh and twelfth.

2273. Ulceration of the bodies of the five inferior dorsal verte-

bræ, extending deep into the cancellous structure ; also of the transverse processes on the left side of the lower vertebræ.—Donor, Mr. Cathcart, Surgeon, 7th Dragoons.—M.S. Cat. vol. iii. page, 114, No. 46.

2274. Lower half of the body of the ninth, the whole of the tenth, and a great part of the eleventh dorsal vertebra, destroyed by ulceration, with ankylosis of the latter to the twelfth. The intervertebral substance is also absorbed ; part of one of the bodies remains in its situation dead, and nearly separated.—From a patient *ætat.* 21, who had been several times in hospital for pains in the loins, latterly he became paraplegic and died comatose.—Donor, Dr. Alexander, Staff Surgeon.

2275. Bodies of the two last dorsal vertebræ, almost completely destroyed by ulceration, and exposing a large portion of the spinal canal ; with new osseous deposit on the surface of what remains of their bodies ; caused by the pressure of an aneurism.—Donor, Dr. Lander, Surgeon, 59th Regiment.

2276. Ankylosis of the bodies of two of the last cervical vertebræ ; lower half of the body of the fifth dorsal extensively destroyed by ulceration, a large cavity in the substance of the sixth, which contains a portion of necrosed bone ; superficial caries of the bodies of the three last dorsal, and first lumbar vertebræ ; the greater part of the body of the twelfth has been destroyed, and is ankylosed to the eleventh dorsal, and first lumbar. Inferior half of the last lumbar vertebræ, and corresponding surface of the sacrum, also destroyed by caries. Partial ankylosis of the right sacro-iliac sychondrosis. Caries of the articular surfaces of the left hip joint ; in the posterior part of the bottom of the acetabulum there is a large portion of necrosed bone in process of separation, the surface of which is smooth and polished, and close to its outer margin there is a small cavity, which contained a portion of dead bone. The part of the head of the femur, corresponding to the piece of necrosed bone, is also smooth and polished. Around the margin of the acetabulum on the internal and external surfaces of the ilium, as also along the anterior inter-trochanteric line of the femur, there is an abundant deposition of new osseous matter. On the inner surface of the ilium there are circumscribed depressions, apparently caused by the ab-



sorption of the adventitious deposit.—Preparation No. 1666, MS. Cat. vol. iii. page 114, No. 45.

2277. Ulceration of the front part of the bodies, and transverse processes of the lumbar vertebræ, as also of their articular surfaces; with absorption of two of the intervertebral cartilages, and deposition of new osseous matter on their bodies.—From a patient who died of lumbar abscess.—Donor, Dr. McClure, A.S. 59th Regiment.

2278. Ulceration of the articular surfaces of the bodies of the lumbar vertebræ and sacrum; a cavity in the substance of one of the vertebræ, containing a portion of necrosed bone.—The result of a severe contusion on the loins.—Necrol. Reg. vol. v. page 154.

2279. Two lumbar vertebræ, exhibiting ulceration of the front and articular surfaces of their bodies; a small cavity in the cancellous structure of one of them, with osseous deposit on their surfaces.

2280. Left side of the bodies of the last dorsal and first lumbar vertebræ, extensively destroyed by ulceration, the intervertebral cartilages remaining entire.—From a man, ætat. 37, who died of lumbar abscess.

2281. Almost the whole of the first lumbar vertebra destroyed by ulceration, with the cyst of a large abscess attached.

2282. Almost the whole of the body of the second lumbar vertebra destroyed by ulceration, as also a great part of the third, and what remains of them are ankylosed. The first is extensively diseased, having a cavity in its substance, which contains a portion of necrosed bone; on their surface there is an extensive deposition of new bone; a large extent of the spinal canal is exposed.

2283. Ulceration of the articular surface of the last lumbar vertebra, and os sacrum. The intervertebral substance appears to be completely destroyed.

2284. Two lumbar vertebræ, the fronts of the bodies of which are connected by an abundant deposition of new osseous matter; several apertures are seen leading through the adventitious deposit, be-

tween their articular surface, and into the substance of one of them, which is in a state of ulceration.

2285. Ulceration of the bodies of two of the lumbar vertebræ; the fronts of which are connected by a ridge of adventitious bone situated a little to the left side.

2286. Extensive ulceration of the fronts of the bodies of the four lower lumbar vertebræ, as also of the anterior surface of the sacrum; there are cavities in the cancellous structure of some of them, which contain portions of necrosed bone. An abundant deposition of new osseous matter, of an archlike form, on their surfaces, by which the three upper are connected; the third and fourth are also partially ankylosed.—MS. Cat. vol. iii. page 113, No. 39.

2287. Ulceration of the articular surface of the body of the last lumbar vertebra, and of the corresponding part of the sacrum, as also of their anterior surfaces, which are connected by two strong broad arches of adventitious bone.

2288. Left os innominatum, exhibiting an abundant deposition of new osseous matter on the inner surface of the ilium, which is in a carious state. A large opening about an inch in diameter, extending completely through the bone, about an inch from the crest of the ilium, opposite to the sacro-iliac synchondrosis.—From a man who died of scrophula.—MS. Cat. vol. iii. page 60, No. 279.

2289. Portion of a rib, the entire circumference of which is irregularly eroded, and nearly detached from the surrounding parts. Around the diseased portion is a deposit of caseous matter.—From a patient who died of phthisis pulmonalis.—Preparation No. 2234.—Donor, Mr. Miller, Staff Surgeon.

2290. Upper part of the sternum, opposite to the first rib on the left side, deeply ulcerated, and a portion completely detached, with deposition of caseous matter around the ulceration.—From a man, ætat. 37, who was several years affected with scrophula. He died of pulmonary phthisis; caseous matter also pervaded the mesenteric glands, kidneys, and prostate.—Print. Cat. page 126, No. 29.

2291. Sternum completely divided into two portions, opposite to the fourth rib, by the ulcerative process. A considerable quantity of coagulable lymph is deposited on the posterior part of the bone, as well as on the ulcerated surface. A small aperture, is seen situated between the cartilages of the second and third ribs of the left side, which communicated with the anterior mediastinum.—From a man, ætat. 30, who had long been affected with mania, and died of sanguineous apoplexy. There was a large abscess, opposite to the carious part of the bone, of long standing.—Necrol. Reg. vol. iv. page 55.

*Bones of the Superior Extremities.*

2292. Absorption of a part of the posterior aspect of the clavicle.—From a man, ætat. 40, who died from rupture of an aneurism of the right subclavian artery.—Donor, Dr. Portelli.

2293. Scapula very thin, soft, and light; part of the acromion process has been destroyed by ulceration; deposition of new osseous matter on the anterior surface of the bone, immediately below the supra-scapular notch; the adventitious bone is also ulcerated.—Preparation No. 2294.—Print Cat. page 165, No. 154.

2294. Extensive ulceration of the neck and upper part of the shaft of the humerus, around which there is a deposit of new osseous matter; some portions of the cancellous structure are partly detached. The cartilage covering the head of the bone is entire.—Preparation No. 2293.—Print. Cat. page 165, No. 154.

2295. Head and neck of the right humerus, which was excised on account of caries, consequent on a gunshot wound; the large deep groove, seen in the preparation (the course of the ball) is ulcerated; a little below the groove, there is an aperture about one-fourth of an inch in diameter, situated on the inner aspect of the bone, leading into the medullary cavity. The tubercles, and upper part of the shaft are enlarged from deposition of new osseous matter.—Donor, Dr. Williamson, A. S. Staff.—MS. Cat. vol. iii. page 72, No. 336.

2296. Ulceration of the distal half of the left humerus, princi-

pally affecting the posterior aspect of the bone; with deposition of new osseous matter in a cellular form.

2297. Humerus exhibiting a circular ulceration on the posterior part of the lower end of the shaft, and some enlargement of the bone on the anterior part opposite to the ulceration.

2298. External condyle of the humerus, and the greater part of its articular surface, for the head of the radius destroyed by ulceration, with a slight deposition of new osseous matter along the line leading to the external condyle; cartilages covering the bone composing the elbow joint slightly eroded.—Donor, Dr. Gordon, A. S. 35th Regt.

2299. Humerus exhibiting ulceration of a great part of the external condyle, not implicating the articular surfaces. The base of the ulcer is formed by a portion of the cancellous structure apparently necrosed, and there is a deposition of new bone above and behind this part, as also on the olecranon process and internal condyle.

2300. Bones of the right fore-arm: the upper third of the ulna is much enlarged, its structure soft and porous, and at parts carious, with new osseous matter deposited on its surface; the articular cartilage is also destroyed, distal half of radius much thickened, and at several parts in a state of ulceration; around its articular extremity there is a deposit of adventitious bony matter.—From a patient who died of scrophula, conjoined with secondary syphilis. — Preparation Nos. 2301, 2321, 2322.—MS. Cat. vol. iii. page 57, No. 253.

2301. Upper and middle thirds of the left ulna very much enlarged and thickened, with several points of ulceration on its posterior aspect, and new osseous matter deposited around its upper articular extremity.—Preparation Nos. 2300, 2321, 2322, —MS. Cat. vol. iii. page 57, No. 253.

2302. Bones of the fore-arm: the whole of the ulna, with the exception of about an inch at its distal extremity, is much enlarged and thickened from the deposition of new osseous matter on its sur-

face, and an ulcer on the posterior aspect near its carpal extremity. The posterior aspect of the inferior third of the radius is also enlarged, and slightly ulcerated.—From a man who died of chronic dysentery; two years previously he had primary syphilis, and soon after an attack of fever, followed by ulceration of various parts of the body.—Preparation No. 2453.

2303. Arm; radius and ulna very much thickened by an irregular deposition of bony matter, and at parts extensively ulcerated, particularly the upper third of the radius, which is in consequence much smaller than usual. Portions of the cartilages of the elbow-joint are absorbed, and coagulable lymph deposited on their surfaces. The surrounding tissues are softened and broken up by purulent matter. The arm is injected, to show the vascularity of the parts.—Print. Cat. page 150, No. 34.

2304. Bones of the right carpus and metacarpus, showing scrofulous ulceration of their structure.—From a man, ætat. 24, who died of phthisis.

2305. Caries of the entire shaft of the metacarpal bone of the right thumb, and a thin shell of new bone completely surrounding it, with the exception of a portion on its posterior aspect, where there is a large aperture leading to the diseased bone. The articular cartilages are quite sound and entire. The metacarpal bone alone was excised, leaving the phalanges of the thumb. A very severe attack of erysipelas ensued: the patient ultimately recovered, but without any useful motion of the member. — MS. Cat. vol. iii. page 68, No. 321.

2306. Presents loss of a great part of the metacarpal bone of the left middle finger, the first phalanx is also imperfect, and united to it by an intermediate ligamentous substance. — From a soldier, a maniac, from whom no account of the lesion could be procured.

2307. Second phalanx of the middle finger, almost entirely destroyed by ulceration, only a small part of the shaft and the distal articular extremity remain. The finger was removed when in a state of gangrene, the result of paronychia.—Donor, Dr. Berry, Staff Surgeon.

*Bones of the Inferior Extremities.*

2308. Upper part of right femur exhibiting extensive ulceration of the great trochanter, and some adventitious osseous deposit around the ulcerated part.

2309. Left femur exhibiting some ulcerated openings extending deeply into the substance of the trochanter major, and a specular deposit of osseous matter on its surface. The head of the bone is much rarified.

2310. Left femur exhibiting an irregular deposit of new bone, in a craggy form, along the whole of the shaft, particularly on the inner aspect of the lower third, with some ulcers extending deeply into the old bone. Reported to be the result of secondary syphilis, which was treated by the extensive use of mercury.

2311. Right tibia, exhibiting an irregular granular deposition of new bone on the anterior aspect of its upper and middle thirds. The enlarged parts are, in many places, excavated by ulceration of the adventitious deposit and shaft of the old bone.

2312. Upper half of the right tibia, which is ulcerated at several places; around the ulcers there is an irregular deposit of new bone. Reported to be the effect of mercury.

2313. Left tibia and fibula much thickened from a deposition of new osseous matter in a cancellous form on their surfaces; the centres of the enlarged parts are in many places excavated by ulceration, and in the bases of some of the ulcers are small portions of bone, apparently necrosed, and nearly detached.—From a man whose cranium was similarly affected.—Preparation No. 2243.

2314. Bones of the leg irregularly thickened by a deposition of new osseous matter, which is loose and cancellated, and in some situations excavated by deep ulcers. The lower end of the fibula is enlarged, and fistulous apertures communicate with large excavations in its centre.

2315. Tibia thickened by deposition of osseous matter on its surface. On one side the new bone presents a cellular form, on the other it is arranged in longitudinal lines, and is generally perforated by minute foramina, apparently penetrating at right angles with the longitudinal axis of the bone. The new bone is but loosely attached to the surface of the old.

2316. Section of tibia thickened from deposition of new osseous matter, with ulcers on its surface, which are confined to the new bone. In the lower half of the shaft, the bone is generally enlarged and spongy; in the upper the cancelli are somewhat rarified, so that the epiphysis affords but little resistance to the knife. This part according to the analysis of Dr. Davy consists of—

|                        |     |
|------------------------|-----|
| Phosphate of lime, &c. | 60  |
| Animal matter          | 40  |
|                        | —   |
|                        | 100 |

The disease is said to have been produced by mercury.

2317. Tibia exhibiting an osseous node on its shaft, and an excavated ulcer on the inner malleolus, surrounded by new bony matter.—From a soldier who had been five times salivated for venereal complaints.

2318. Section of tibia thickened by deposition of adventitious osseous matter. In one situation there is an aperture leading from an ulcerated part of the surface into the centre of the bone. Near to the middle of the shaft the parietes of the old bone are visible, the new bone being deposited on its outer and inner surfaces. Lower down all traces of the old shaft have disappeared, the loose cellular structure of the new bone only being apparent.—Said to be the effect of mercury.

2319. Portion of tibia much thickened from an adventitious deposit of bony matter; the surface of which is extensively ulcerated.—From a patient who had taken much mercury in India, and had suffered from chronic dysentery.

2320. Lower third of the tibia, exhibiting an irregular ulcer on its surface, surrounded by new osseous matter. The disease was the

effect of anthrax, some portions of the bone were exfoliated.—He died of general anasarca.—Necrol. Reg. vol. iv. page 14.

2321, 2322. Lower thirds of the right and left tibia much enlarged and thickened from a deposition of new osseous matter on their surfaces, which are in a state of ulceration.—No. 2321 is a wet, and the other a dry specimen.—Preparation Nos. 2300, 2301.—MS. Cat. vol. iii. page 57, No. 252.

2323. Portion of tibia, exhibiting a deep ulcer on its external wall; on the surface of the ulcer there is a deposit of coagulated lymph, and it is surrounded by some new osseous matter. The periosteum is thickened, and also coated with lymph. From a man who had undergone several courses of mercury in India for liver complaints. The cranium and both tibiæ were diseased. The liver was tuberculated.—Preparation No. 2326.

2324. Section of a tibia with investing soft parts, in which is a very large deep ulcer with a well defined edge, and great thickening and induration of the integuments. The preparation is minutely injected, and the ulcerated surface of the bone is partly coated by coagulated lymph, and partly by very vascular villi.—Donor, Mr. Partridge, King's College, London.

2325. Tibia on the shaft of which is an ulcer, surrounded by some adventitious osseous matter, and presenting a small portion of necrosed bone at its base.—Print. Cat. page 163, No. 145.

2326. Portion of tibia much thickened, and consolidated with the fibula. The walls of the former are very dense and depressions filled partly by osseous and partly by fibrous tissue denote the site of old ulceration.—Preparation No. 2323.

2327. Ulceration of the external and inferior aspects of the os calcis.

2328. Caries of the navicular bone of the horse.—Donor Dr. McKenzie, A.S. 1st Dragoon Guards.



## SECTION IV.—NECROSIS.

*Bones of the Head and Face.*

2329. Cranium exhibiting large irregular depressions, and various degrees of deficiency of its parietes, in some places comprehending both tables, and in others the external only; chiefly affecting the left side. The exposed surface of the inner table is quite smooth and compact, as well as the margins of the depressions. The effect of various exfoliations succeeding to a sabre wound of the left parietal bone. The patient was an African negro, a maniac with occasional violent paroxysms; disease of four years' duration.—Donor, Mr. Gunning, I.G.H.

2330. Cranium exhibiting at some parts caries and at others necrosis; over the sagittal suture the external table to the extent of a crown piece is necrosed, and in process of separation, and corresponding to this on the internal surface there are apertures communicating with the dead portion of bone. Ulceration of the external table of the right parietal, as also of the greater part of the frontal bone, which is much thickened. The internal surface of the cranium, presents marks of increased vascularity, and at parts incipient ulceration.—MS. Cat. vol. iii. page 66, No. 311.

2331. Calvarium thickened and consolidated, with some superficial circular ulcers of the external table, in the centres of which there are portions of bone necrosed and in process of separation. The internal surface also presents deep excavated ulcers, with enlarged vascular canals and foramina.

2332. Calvarium, in the os frontis of which there is a large circular foramen with smooth edges; the effect of exfoliation; there was hernia cerebri. The patient ætat. 25, had been long subject to epilepsy, and at length sunk under reiterated attacks of the affection.

2333. Calvarium exhibiting necrosis of part of nearly the entire thickness of the frontal bone, the surface of the sequestrum is rough and irregular; it is completely detached, but incarcerated by a thin remaining layer of the outer table of the living bone, and a project-

ing ridge of the inner table. Another piece of the bone is apparently dead and in process of separation.

2334. Frontal bone, a large portion of the entire thickness of which is necrosed and detached; on the internal surface of the bone there is a net work of vascular canals, surrounding the opening from which the dead bone has come away.—Donor, Dr. Brown, Surgeon, 87th Regt., Print. Cat. page 156, No. 102.

2335. Parietal bone, from which a large portion of the entire thickness has exfoliated. The deficiency is filled by membranous matter, and some new bone is formed around the edges of the old, as also in the substance of the membranous matter quite detached from the old bone. This preparation illustrates the formation of new bone at a distance from the old, a fact at variance with the opinions of Haller and Dethleef.—From a man, who had lost his palate bones, and penis from syphilis; disease of two years' duration. He had been several times salivated.

2336. Exfoliated portions of frontal bone, one of which is about three inches in length, and the other of smaller size.—Casts No. 2786, Print. Cat. page 155, No. 69.

2337. Ulceration of the malar bones, and external angular processes of the frontal bone; in the bases of the ulcers there are portions necrosed, and in process of separation.

2338. Cranium, the posterior part of the alveolar process of the right superior maxillary bone exfoliated.

2339. Superior maxillary bones, the front parts of which are dead, and nearly detached. Portions of the orbital and palatine processes have been separated, as well as the ossa unguis. There is not the slightest deposition of new bone.

2340. Portion of cranium, exhibiting considerable absorption of the cribriform plate of the ethmoid bone, and to a less degree in the left malar, and right upper jaw bones, a portion of the alveolar pro-

cess of which latter is dead and just detached.—Preparation No. 758, Print. Cat. page 141, No. 26.

2341. Necrosis of the right angle of the lower jaw, including the whole thickness of the bone, and extending up to the roots of the condyle and coronoid process. The portion of dead bone is detached, and the two last molar teeth are still imbedded in it.—Preparation No. 2055, MS. Cat. vol. iii. page 109, No. 147.

2342. Necrosed portion of lower jaw, with the alveolar process and some of the molar teeth. The consequence of an injury in extracting a carious tooth.

2343. Sequestrum from the lower jaw, which separated fourteen months after the commencement of the disease.

2344. Necrosed portion of lower jaw and alveolar process, with some of the molar teeth. From a child three years of age who had an abscess in the gum which discharged copiously for a considerable time, when the bone was detached, and the patient did well.

2345. A portion of necrosed alveolar process from the right side of the lower jaw, containing a temporary molar tooth, and the rudiments of two permanent teeth. Exfoliation was induced by mercury exhibited in yellow fever.—MS. Cat. vol. iii. page 66, No. 309.

2346] Portion of necrosed alveolar process with a molar tooth.

#### *Bones of the Trunk.*

2347. Necrosis of the anterior part of the ring of the atlas, the portion of dead bone is loose and detached. The processus dentatus of the second cervical vertebra is in a state of ulceration.—Donor, Dr. Dyce, A. S. Staff.—MS. Cat. vol. iii. page 110, No. 28.

2348. Body of one of the lumbar vertebra almost completely de-

stroyed by ulceration, and in the centre of the cavity thus formed, a large portion of bone is dead and nearly detached.

2349. Third lumbar vertebra exhibiting a bony exostosis on the front of its body; death and partial separation of part of the cancellated structure of the articular surface.—MS. Cat. vol. iii. page 111, No. 31.

2350. A cavity in the cancellated structure of a lumbar vertebra, in which several dead portions of bone are contained, with irregular osseous deposit on the anterior surface of the body. A cavity of an abscess capable of containing six ounces of matter was found on the inner surface of both the psoas muscles; small portions of necrosed sacrum were detected in the right sac; and in the left, the transverse processes and bodies of the lumbar vertebræ were ulcerated. The psoas muscles were converted into a fibro-cartilaginous substance.

2351. Lumbar vertebra, exhibiting a smooth circular excavation in the front of its body, which contained a portion of necrosed bone.

2352. A cavity in the body of one of the lumbar vertebra, containing a portion of necrosed bone; on the surface of the vertebra there is a considerable quantity of new osseous deposit.—From a patient who died of psoas abscess.

2353. Ulceration of the front of the bodies of the lumbar vertebræ, and a cavity in the substance of two of them, which contain portions of necrosed bone.—Donor, Dr. Davidson, A. S. 42nd Regt.

2354. Rib exhibiting a perforation through its substance, made in the operation for empyema; the margin of the opening is necrosed, with a small quantity of adventitious bone around it. The pleura is thickened and coated with lymph.—Preparation No. 685.—Print. Cat. page 15, No. 32.

2355. Two small portions of necrosed bone, the upper of which came away on the fourteenth day after perforating the rib for empyema; the lower one was found in the wound after death.—From

a man who died of empyema, complicated with tubercles in the lungs.

2356. Upper piece of the sternum, near the right sterno-clavicular articulation, a large portion of which is necrosed and nearly detached. There is a small bridge of new bone, extending posteriorly from below the dead portion to the clavicle, the sternal end of which is ulcerated.

2357. Necrosis of the body of the sternum, and an abundant deposition of new osseous matter on both surfaces, but chiefly on the dorsal aspect.

2358. Sternum; a large circular portion of the left side of its body is black, dead, and nearly detached. There is scarcely any attempt at regeneration of new bone.—From a man, ætat. 24, who died of phthisis. He had strumous abscesses in different parts of the body.

2359. Necrosis of the lower part of the body of the sternum, and a deposit of new osseous matter surrounding it, especially on the dorsal aspect.—From a man, ætat. 24, who died of phthisis with scrophulous abscesses in different parts of the body.—MS. Cat. vol. iii. page 71, No. 322.

*Bones of the Superior Extremities.*

2360. Several large exfoliations from the clavicle.

2361. Stump of the humerus, presenting a detached necrosed portion several inches in length. The surface of the dead portion is eroded, and there is a considerable thickening of the shaft of the bone from adventitious osseous deposit.

2362. Stump of the humerus, presenting necrosis of the inner layer of the amputated extremity of the bone. The sequestrum, which is about four inches in length, is nearly detached. The outer layer of the bone surrounding the sequestrum is enlarged, and pierced

by several cloacæ. A portion of it has been cut out to expose the sequestrum. — From a man in whom the disease was of twelve months' duration. He recovered after a second amputation. The preparation being the bone which was removed on that occasion.

2363. Humerus; a superficial portion of the anterior surface of the shaft is necrosed and partly detached, with an extensive osseous deposit around the dead piece.

2364. Inferior half of the humerus, exhibiting ulceration and necrosis of large portions of its shaft. There is a very abundant deposition of new osseous matter around the diseased parts, which also extends as low as the elbow joint.—Donor, Dr. Gordon, A. S. 35th Regt.

2365. Shows deficiency of a large portion of the lower part of the shaft of the humerus, from necrosis, in consequence of a gunshot wound.—Donor, Dr. Henderson, Surgeon 48th Regt.

2366. Humerus and bones of the arm. In the middle and outer aspect of the former there is an oval opening leading into a cavity in the shaft; also another cavity in the external condyle, situated between the articular surface for the head of the radius and olecranon fossa. The distal extremity of the ulna is enlarged from a deposition of new osseous matter, with a cavity in its substance. These excavations contained portions of necrosed bone.

2367. Distal extremity of the left radius much enlarged, from a deposition of new osseous matter, which extends for about four inches up the shaft, in the centre of which there is a large cavity containing portions of necrosed bone; the cavity communicates with the wrist joint; the cartilage covering the extremity of the radius is destroyed. A portion of the shaft of the ulna is also enlarged. Amputated with success.—Donor, Dr. Williamson, A. S. Staff.—MS. Cat. vol. iii. page 73, No. 338.

2368. Bones of the fore-arm, exhibiting necrosis of the distal extremity of the ulna, involving the articular surface: the dead portion is nearly detached, and the bone surrounding it is enlarged from

osseous deposit. Removed by operation.—Preparation No. 2106.—MS. Cat. vol. iii. page 102, No. 118.

2369. Proximal phalanx of the finger ; the entire shaft of which is eroded, diminished in size, and partly surrounded by an irregular shell of new bone. Although the shaft of the old is partially absorbed, and there is an abundant deposit of new osseous matter, it is uncertain whether the remaining part of the shaft is yet dead. There is a considerable space between the new and the old bone.

2370. Necrosis of the distal phalanx of the middle finger, caused by paronychia, succeeding to frost-bite.—Donor, Mr. Stewart, A. S. Staff.—MS. Cat. vol. iii. page 62, No. 302.

2371. Proximal phalanx of the thumb ; the posterior aspect of the shaft of which is partly destroyed by ulceration, and its distal articular surface is necrosed, and partially detached : the effect of injury.—Removed by operation.

#### *Bones of the Inferior Extremities.*

2372. Femur presenting necrosis of its shaft. The sequestrum comprehends nearly the whole length of the shaft, and is very rough on the surface ; it is completely detached, and surrounded by a tolerably thick and uneven shell of new bone, abundantly pierced by cloacæ, so as extensively to expose the dead part.—From a man admitted with a gun-shot wound of two years' standing ; the ball had lodged, but had been cut out a month afterwards. On admission there were two openings between the ham-strings ; his general health was very bad, and he died after ten weeks' treatment.

2373. Stump, the lower half of which is necrosed and nearly separated. At the extremity, the sequestrum comprehends the entire thickness of the bone ; the surface on which the saw acted is smooth and unchanged : higher up, the dead bone appears to consist of the inner circumference only, and its surface is rough and eroded. A

large osseous case, presenting numerous perforations, surrounds the necrosed part.

2374. Lower half of the femur, exhibiting necrosis of the anterior circumference of its shaft. The sequestrum, is rough on the surface and loosely contained in a cavity, formed by an abundant deposit of new bone, which is pierced by numerous foramina.—From a gunshot injury.

2375. Lower half of the femur enlarged by an abundant deposition of new osseous matter on its external part, and presenting some large irregular excavations in its centre, which communicate with the surface by rounded apertures, especially at the condyles where the openings are very extensive, and in some situations the surrounding articular cartilages appear to be but little changed. Amputated on account of this disease; the case proved fatal after the femoral artery had been tied for secondary hæmorrhage.—Preparation Nos. 362, 406.—Donor, Dr. White, A. S. Staff.

2376. Os femoris, the shaft of which is curved, prodigiously thickened, and very heavy. In the centre are some cavities, from which sequestra have probably been detached. The head and neck of the bone appear to be unchanged, but the lower articular surface is irregular.—Found in a church-yard in Scotland.—Donor, Mr. Hennen, A. S. 57th Regt.

2377. Necrosis of the amputated extremity of the femur. The dead portion is partly detached, but the surface on which the saw has acted is not at all smoothed or altered, although it was embedded in the soft parts one hundred days after the operation. The patient died of hectic fever and diarrhœa.—Donor, Mr. Fraser, I. G. H.

2378. Femur, the shaft of which presents a fracture running for a considerable extent in a longitudinal direction. The external part of the bone, at the fractured extremities, is apparently dead and in progress of separation from the living bone.

2379. Upper extremity of the head of the tibia, exhibiting a



large portion of cancellous structure necrosed, and nearly detached. On the external wall of the bone is a considerable deposit of new osseous matter, and a rounded opening communicates with the internal necrosed part. The articular surface is sound.—From a man *ætat.* 23, who had an attack of rheumatism from which he recovered, but the knee remained diseased and was amputated.

2380. Necrosis of the greater part of the cancellated structure of the upper extremity of the tibia, with a copious deposit of new osseous matter surrounding it, and a large opening exposing the dead part. The articular surface is sound.—MS. Cat. vol. iii. page 71, No. 330.

2381. Necrosis of the shaft and cancellated structure of the head of the tibia. The sequestrum comprehends the entire thickness of the shaft, except to a small extent on its posterior aspect, where reparation has been attempted by a spongy shell of living bone, but on the anterior aspect there has been no reproduction of osseous matter.—Donor, Mr. O'Brien, A. S. 7th Regt.

2382. Tibia exhibiting deficiency of a great part of the circumference of its shaft (in consequence of necrosis) which is much shortened by approximation of the epiphyses, these are softened and connected by two portions of spongy bone. This specimen is a good example of how little reparation is to be expected when the entire thickness of the shaft of a bone, at least in the human subject, becomes necrosed. From a boy *ætat.* 11. It was necessary to amputate the limb, after the dead bone was detached.—Donor, Dr. Stephenson Rochester, Preparation No. 2383.

2383. Sequestrum, which separated spontaneously from the tibia, and comprehended the entire circumference of the shaft.—Preparation No. 2382.

2384, 2385. Sections of a tibia, the periosteum injected; showing necrosis of a portion of its shaft, which is generally enlarged, also several ulcers on its surface. The sequestrum (surrounded with a new vascular membrane) is small, rough, and detached, and protrudes through a cloaca. Portions of dead bone had been removed

some years previously. From a young man in whom the disease was upwards of two years standing. Donor, Mr. Robertson, Surgeon, R. N.

2386. Tibia much thickened, and presenting a cavity in its substance, from which a sequestrum has been detached, with several cloacæ.—From a gunshot injury.

2387. Tibia exhibiting necrosis of the lower part of the shaft and cancellous structure; a large opening in the surrounding new bone exposes part of the sequestrum, which appears in this situation to comprehend the entire thickness of the shaft. The case of new osseous matter is very abundant.—From a man, ætat. 49. The disease was of twelve months' duration, and came on without any obvious cause. The limb was amputated, and the man did well.

2388. Tibia exhibiting the commencement of the process of exfoliation. A large superficial portion of the shaft is dead, very white and hard, and already marked out by a groove formed in the neighbouring living bone.

2389. Necrosed portions of the shafts of long bones, apparently of the femur and tibia; some of them appear to be examples of internal exfoliation after amputation, the sequestrum being principally composed of the inner shell, but comprehending the entire thickness, just at the extremity divided by the saw.

2390. Fibula, the upper extremity of which has exfoliated; the surface of the extremity of the fibula and the corresponding part of the tibia are rough, and there is very little deposition of new osseous matter around them.—From a man, ætat. 25, who died of phthisis. When admitted, he had ulcers on the outer part of the leg, communicating with the head of the fibula. The knee joint was perfectly sound.

2391. Portion of the fourth metatarsal bone, the external surface of which is extensively ulcerated, and a portion of its shaft partially necrosed.—From a man who had suffered from secondary syphilis

for fifteen months. The bone was removed, and the patient did well.

#### SECTION V.—BONE AFTER AMPUTATION.

2392. Stump of a humerus, the extremity of which is rounded and encircled by some new osseous matter; the medullary canal is not completely closed.

2393. Stump of a femur, showing an exostosis arising from the *linea aspera*, a part of the growth has been broken off, but its base still remains. The medullary canal is still open. The patient died exhausted, in consequence of the spicula of bone projecting into the nerves of the stump.—Donor, Mr. Gulliver, A. S. Staff.

2394. Stump of a femur, the extremity of which is rounded by a considerable deposition of new osseous matter, particularly in the situation of the *linea aspera*; the medullary canal is nearly closed. Four years elapsed between the operation and the death of the individual.—Preparation No. 2575.—Print. Cat. page 179, No. 19.

2395. Stump of a femur, the extremity of which is rounded, and the medullary canal but partially closed by new osseous matter, some of which is also deposited around the end of the stump, particularly in the situation of the *linea aspera*.

2396. Stump of a femur, the amputated extremity rounded, the medullary canal nearly closed by new osseous matter, some of which is also deposited around the end of the stump.

#### SECTION VI.—SCROPHULOUS DEPOSIT IN BONE.

2397. Section of the inferior part of the spine, rendered very light by interstitial absorption. The medullary substance of the cancelli is deficient, and some caseous matter is deposited in its place.—Print. Cat. page 176, No. 21.

## SECTION VII.—MELANOTIC DEPOSIT IN BONE.

2398. Section of a spine, exhibiting melanotic deposit in the cancellous structure of the bodies of the vertebræ.—Donor, Mr. Stanley, Surgeon, St. Bartholomew's Hospital.

## SECTION VIII.—SPINA VENTOSA.

2399. Pelvis and bones of the posterior extremity of the Red American Fox (*Canis Fulvus*), showing spina ventosa of the femur and tibia; the structure of the bones have been entirely destroyed, and converted into a membranous bag, which is coated internally with a thin layer of osseous matter.

## SECTION IX.—INTERSTITIAL ABSORPTION.

2400. Hydrocephalic skull of a child. The divergent arrangement of the osseous spiculæ, and their mutual insertion at the sutures are well seen.—Donor, Mr. Grant, A. S. 71st Regt.

2401. Exhibits extensive destruction of the anterior part of the right parietal bone close to the coronal suture, from the pressure of a subjacent tumour. The opening is of an irregular form, and its margins are everted.—Preparation No. 843.—MS. Cat. vol. iii. page 18, No. 104.

2402. Frontal bone, through the anterior part of which is a circular opening, with smooth and rounded edges.

2403. Cranium exhibiting a foramen, about five lines in diameter, its edge smooth and depressed, situated in the superior part of the occipital bone, probably the effect of pressure. It was not known during the life of the patient.

2404. Deficiency of the inner and middle tables of the skull, over a lunated circumscribed space; the dura mater corresponding to it is also absorbed.

2405. Presents absorption of several parts of the internal table of the skull; these depressions are the effect of pressure of fungi from the dura mater.

2406. Calvarium presenting absorption of various parts of the internal table, from the pressure of growths from the dura mater.

2407. Skull cap exhibiting small circumscribed attenuations of the inner table at the vertex, extending also in some points through the outer table; probably the effect of growths from the dura mater. The bone is also lighter than usual.

2408. Cranium presenting great enlargement and absorption of the osseous parietes of the nares. The whole of the turbinated bones, the vomer, osseous palate, anterior part of the alveolar process of the superior maxillary bones, the internal wall of the right antrum and orbit are destroyed; from the pressure of a polypus growth. The man died of pulmonic disease.

2409. Lower jaw exhibiting a regular circumscribed cavity in the external part of its ramus, the shell of which is expanded and thin. The fangs of the molar teeth are exposed. Probably from the pressure of a tumour.

2410. Upper portion of the sternum, the internal surface of which presents a cup-like excavation throughout its whole extent; from absorption of its internal lamella and cancellous structure, with some perforation of the outer plate. Caused by the pressure of an aneurism.

2411. Spinal column showing lateral curvature. There are two curves, one to the right and the other to the left side, the bodies of the four superior dorsal vertebræ project to the left side, and the

fifth, sixth, seventh, eighth, and ninth project to the right side, with corresponding hollows on either aspect of the spine.

2412. Lower fragment of tibia fractured by the action of the absorbents. The surface of the broken extremity presents a cellular appearance, and the longitudinal canals of the compact substance of the bone are preternaturally large. A small quantity of new osseous matter around its extremity.

#### SECTION X.—MOLLITIES OSSIUM.

2413. Section of the upper part of the femur, exhibiting mollities ossium. The whole of the earthy matter of the bone is wanting, and converted into a soft homogeneous white substance. The walls of the bone are no longer visible, nothing but a dense fibrous tissue with a very small proportion of osseous matter occupying their place. The articular cartilage is healthy, and of the natural thickness.—From a girl upwards of thirty years of age.—Donor, Mr. Howship, Surgeon, London.

#### SECTION XI.—ATROPHY AND DIMINUTION OF THE EARTHY PART OF THE BONE.

2414. Bones of the hand, with lower third of the radius and ulna extremely attenuated, fragile and light. The atrophy has extended from within outwards, the dimensions and external form of the bones being preserved by a very thin shell. The phalanges of the thumb are almost entirely absorbed. The part was removed by amputation from a patient affected with the leprosy of Ceylon.—Donor, Mr. West, A. S. Staff.

2415. Bones of the leg extremely attenuated, fragile and light. The size and form of the bones are preserved by [a very thin shell, while the internal parts are completely deficient; some deposit of new osseous matter on their surfaces which are also at parts

ulcerated. The cartilage covering the head of the tibia is entire, and apparently sound.—From a patient affected with the leprosy of Ceylon.

2416. Lower third of the tibia and fibula, with several of the tarsal and metatarsal bones, extremely light and so brittle as to be easily broken up into powder, by pressure between the finger and thumb. The bones are of their usual size, and the cancellous structure still remains; on the surface of some of them there is a slight deposit of new osseous matter.—From a man affected with elephantiasis. The limb was removed by operation.—Preparation Nos. 938, 2417.—Donor, Mr. Shelly, Surgeon, Epsom.—MS. Cat. vol. ii. page 202, No. 47.

2417. Section of a tibia and astragulas (in spirits), structure extremely light, soft, and brittle.—Preparation Nos. 938, 2416.—Donor, Mr. Shelly, Surgeon, Epsom.—MS. Cat. vol. ii. page 202, No. 47.

2418. Bones of the foot ankylosed, their structure remarkably light and soft, and easily cut with a scalpel.—From a patient who died of lumbar abscess.

2419. Sections of two metacarpal bones, which contain very little animal matter, and are remarkably light.—From a patient affected with scrophula.

## SECTION XII.—HYPERTROPHY OF BONE.

2420. Cranium throughout much thickened, being about half an inch in thickness and very dense. The inner table is regular, and the vascular grooves are of the usual depth.—From a man who died of phthisis.

2421. Cranium of small size, very heavy, and its parietes unusually thick, particularly the frontal and upper part of the parietal bones.—From a man, ætat. 42, who died of dropsy.

2422. Calvarium very thick, and the grooves of the middle

meningeal arteries so deep as to extend nearly through the outer table. The inner table, particularly of the frontal bone, presents irregular elevations and depressions, from the deposition of new osseous matter.—From a Maltese woman, ætat. 98.

2423. Calvarium much thickened and consolidated, and the grooves for the middle meningeal arteries very deep, and at some parts presenting osseous canals.

2424. Skull exhibiting thickening of the outer and upper part of the parietal bones, also of the malar and orbital aspects of the frontal bone. The new osseous matter presents numerous depressed points, and tortuous linear indentations on their surfaces. Apparently the skull of a female. A churchyard specimen.—Donor, Dr. Boyes, A. S. Staff.

2425. One half of the skull exhibiting hypertrophy, particularly at the upper part of the frontal bone and vertex. Its structure is porous, light, and very white, so that it resembles a good deal a bone that had been exposed to intense heat. The section also presents at several points portions of a smooth white ivory-like deposit. The internal surface of the skull is very irregular, and shows marks of increased vascularity. All the sutures are obliterated, with the exception of the squamous and inferior part of the lambdoidal sutures, where the disease seems to have terminated. The diploë of the frontal, parietal, and occipital bones, are continuous. The late Dr. Spurzheim had a specimen of the same disease, which he valued very highly on account of its rarity.—Donor, Dr. Munro, Professor of Anatomy, Edinburgh.

2426. Cranium; the superior maxillary and nasal bones are much expanded, and converted into a loose cancellated texture. The enlargement affects the whole of these bones, except the malar processes and posterior part of the palatine plate of superior maxillary bones.—The skull appears to be that of a young negress from Sierra Leone.—Donor, Dr. Sweeny, D. I. G. H.

2427. Section of two ribs, very much enlarged and thickened



from interstitial deposition; the pleura is also greatly thickened.—Donor, Dr. Sharpe, University College, London.

SECTION XIII.—EXOSTOSIS, INCLUDING VENEREAL NODES.

2428. Calvarium; on the inner surface of the frontal bone there are some smooth, dense, osseous exostoses, with absorption at two places of the internal table.

2429. Cervical vertebræ, exhibiting solid exostoses from the front of their bodies.

2430. Last dorsal and lumbar vertebræ, presenting osseous deposit on the right side of their bodies.

2431. The three lower lumbar vertebræ and sacrum, presenting some irregular osseous deposits on the anterior surface of their bodies.—From a man, ætat. 24, who died hectic, from copious discharge of matter from an opening in the left groin, with fixed pain in the lumbar region and pelvis.

2432. Portion of rib, showing an exostosis on its external aspect opposite to its tubercles.

2433. Humerus exhibiting a bony growth from the inner and upper part of the surface of the shaft.—Print. Cat. page 116, No. 119.

2434. A large exostosis, arising from the horizontal ramus of the pubis, and descending down in front of the hip joint. In the outer part of the osseous tumour there is a smooth polished canal, which contained the femoral artery and vein; another bony mass, attached to the trochanter minor and inner aspect of the femur immediately below its neck, which proceeds to the former tumour. Also two other osseous deposits, one on the linea aspera, and the other on the margin of the obturator foramen.—MS. Cat. vol. iii. page 72, No. 333.

2435. Femur exhibiting exostoses along the whole course of the anterior and external aspects of its shaft.

2436. Lower part of the femur, exhibiting a pointed bony growth from its external surface.—Preparation No. 2475.

2437. Shaft of the femur, very much thickened and enlarged from deposition of new osseous matter. Donor, Mr. Roberts, Surgeon, Chester.

2438. Patella with a bony projection from its lower margin.

2439. Tibia exhibiting a bony growth from its upper and back part; the adventitious bone is very dense and compact near to its base, and cellular on its surface.

2440. Fibula exhibiting a bony exostosis, about two inches long and one broad. The growth is dense and smooth towards its base, cellular and nodulated elsewhere.

2441. A small bony exostosis from the great toe, with a portion of the integuments which covered it, presenting a corn, and several small bursæ mucosæ in the cellular substance between the osseous projection and the indurated integuments. — Donor, Dr. Davy, A. I. H.

2442. Leg of a horse exhibiting a small pointed exostosis (a splint). — Donor, Dr. Dartnell, A. S. 41st Regt.

2443. Radius considerably thickened and consolidated from the deposition of adventitious bone on its surface. Reported to have been produced by mercury.

2444. Upper third of the radius, much enlarged and thickened by the deposition of bony matter.

2445. Radius thickened by irregular deposition of bony matter on the surface of its shaft.

2446. Distal extremity of the radius, considerably thickened and consolidated from deposition of adventitious bony matter. Reported to have been produced by mercury.

2447. Shaft of the tibia, much consolidated and thickened by the deposition of new osseous matter on its surface, in which there are numerous fissures.

2448. Bones of the leg on which are some osseous nodes. The new bone is rendered very spongy by the interposition of numerous cells or fissures, and the surfaces of the ridges are generally perforated by small rounded foraminæ. Said to be the result of mercury.

2449. Tibia and fibula thickened by rather dense osseous depositions, with points of ulceration.

2450. Bones of the leg, the lower part of the tibia much thickened by new osseous matter, which is much cancellated, and perforated by minute holes.—From a soldier, who had undergone repeated salivations for rheumatism and venereal disease.

2451. Tibia much thickened from deposition of new bony matter on its surface, in which there are numerous fissures and foraminæ. A section is made of the bone, to show that the structure of the node is dense and firm.—Print. Cat. page 164, No. 150.

2452. Bones of the leg thickened by deposition of new osseous matter on their surfaces, in some places presenting a cellular, in others a linear arrangement.

2453. Tibia, the shaft of which is much thickened by a deposition of new bone on its surface.—Preparation No. 2302.

2454. Lower half of the tibia thickened by deposition of new bone on its surface. The adventitious osseous matter is separated by fissures or cells, the former in many places very long, deep, and regular, so as to give a linear arrangement to the new bone; and the surface of the ridges thus formed, are generally penetrated by numerous small holes, for the most part at right angles with the axis

of the shaft.—From a soldier who had used much mercury for syphilis.

2455. Shaft of tibia much consolidated, and presenting some dense osseous nodes on its surface.—From a soldier who had been repeatedly salivated for syphilitic and other complaints.

2456. Tibia exhibiting a circumscribed thickening of its shaft. The new osseous matter is penetrated by numerous minute foraminæ. From a maniac who died of phthisis.

2457. Shaft of the tibia much thickened and consolidated.

2458. Tibia, on which there is a very dense osseous node.—From a subject, whose cranium was ulcerated. He had taken much mercury for rheumatic affections.

2459. Tibia, the anterior surface of which is thickened and very dense.

2460. Tibia, on the posterior aspect of which there is a dense osseous node.

2461. Fibula, the lower part of which is thickened by adventitious osseous matter. The upper part of the bone is preternaturally curved.

#### SECTION XIV.—CELLULAR EXOSTOSIS.

2462. Skull of a Negro, showing a very large osseous tumour, arising from the anterior wall of the antrum of the left maxillary bone; the external and posterior boundaries of this cavity are in a natural condition. The substance of the tumour is divided by bony plates into several compartments, and its outer shell is formed of very dense bone.

2463. Left half of the lower jaw, to the outer surface of the horizontal ramus of which is attached a tumour, partly composed of

bone and partly of dense fibrous tissue. The surface of the tumour is smooth, and its base is encircled in a thin shell of bone, extending from the jaw. The disease was of eighteen months' duration, and occurred in a middle-aged soldier who died of phthisis.—Preparation No. 2464.

2464. Right half of the lower jaw, being a section of the preceding preparation, which has been macerated, to show the thin shell of bone more distinctly arising from the jaw, and the structure of the tumour to be divided into numerous cells by bony plates.

#### SECTION XV.—OSTEO SARCOMA.

2465. Section of a round tumour, arising from the side of the proximal digital phalanx. A thin bony shell extends from the surface of the bone, and envelopes the tumour, the structure of which is composed of a cartilaginous substance, with a few osseous spiculæ interposed throughout it. Removed by operation.

2466. Section of a round tumour, arising from the palmer aspect of the proximal digital phalanx. The tumour is very firm, and composed partly of bone and partly of cartilaginous substance. Its base extends to the outer shell of the bone, the inner wall having disappeared, and the osseous growth takes its origin from the cancelli. A slight cellular cyst surrounds the tumour, the integuments are simply distended and thinned.

2467. A large tumour, composed partly of bone, of a fibro-cartilaginous substance, and of encephaloid matter, from the upper part of the femur, to the external surface of which the tumour was attached.—From a man, ætat. 23, who had osteo-sarcomatous disease of the left thigh, which in a year proved fatal.—Preparation Nos. 2468, 2469.—Donor, Dr. Reach, A. S. 10th Hussars.

2468. Femur, the neck of which is completely destroyed, and the trochanters and upper part of the shaft eroded. A small quantity of new bone is deposited on the shaft below the eroded part. The

tumour No. 2467 was attached to this bone, which for seven inches of its length was engaged in the origin and growth of the tumour. The head of the bone remained attached to the acetabulum by the round ligament, but had no connection with the shaft; the lower part was healthy.—Donor, Dr. Reach, A. S. 10th Hussars.

2469. Os innominatum, porous, much diminished in density, and presenting a small quantity of new bony matter on various parts of its surface. Its periosteum was thickened and easily detached.—Preparation Nos. 2467, 2468.—Donor, Dr. Reach, A. S. 10th Hussars.

2470. Shaft of the femur, to which is attached a large osteosarcomatous tumour. The bone is enlarged, and its surface very rough and irregular from the deposition of new osseous matter in the form of soft laminæ and spiculæ. There is a portion of the mass of a light spongy and friable texture, which was detached during maceration; previous to which a fibro-cartilaginous substance was interposed between the bony plates.—Donor, Dr. Gordon, D. I. G.

2471. Tibia exhibiting enlargement of the medullary canal, and thinning of its walls. From the external part of the latter, there is much new bone arising at right angles from the old, and in most places assuming the form of continuous layers, formed by the approximation of spicula; probably the effect of osteo sarcoma.

2472. Section of the posterior extremity of a dog, exhibiting osteosarcomatous tumours arising from the upper and lower extremities of the tibia, the shaft of the bone being quite free from the disease. The tumours are composed partly of spiculæ of osseous matter arising from the surface of the bone, and partly of a soft fibrous substance. The articular cartilages of the knee joint are entire and sound, although one of the tumours extends considerably beyond the extremity of the tibia.—Donor, Mr. Stanley, Surgeon, St. Bartholomew's Hospital.

2473. Cranium exhibiting destruction of the bones of the right side of the face and base of the skull, by an osteo-sarcomatous tumour; on the surface of the ramus of the lower jaw, there is

a slight deposit of new osseous matter.—Preparation No. 2658.—  
Necrol. Reg. vol. v. page 178.

SECTION XVI.—MEDULLARY SARCOMA AND FUNGUS  
HEMATODES.

2474. Cranium and lower jaw, in which there are numerous large circular perforations, with rough edges. Every bone of the head is more or less engaged, with the exception of the malar and maxillary bones. In some bones the disease seems as if it had commenced in the diploë; the frontal and parietal bones have suffered the greatest destruction. On the right side of the cranium the perforations are most numerous; they are, generally speaking, of a circular form, their edges shelving from without inwards, the absorption being greater in the external than in the vitreous table. Many of the apertures are entirely destitute of adventitious osseous deposit, others are surrounded on the outer surface with a few perpendicular bony plates. The lower jaw also shows extensive absorption of the alveolar processes on both sides, and of the substance of the jaw itself.—Figured by Sir George Ballingall, Trans. Edin. Med. Chirur. Society, vol. iii. part i. page 252.—Donor, Dr. A. Stewart, Staff Surgeon.—MS. Cat. vol. iii. page 77, No. 341.

2475. Cranium, in which are numerous large jagged openings and cribriform perforations through various parts of its parietes. The ulcerative process has extended in several situations between the tables, and the inner surface of the skull opposite to some of the lesions is studded with fine short osseous spiculæ.—From a man, *ætat.* 32, who had been five years in the West Indies, where he had had repeated attacks of ague and dysentery, and was five times salivated. He affirmed that he had never been affected with venereal disease. He had also enlargement of the elbow joint.—Preparation No. 2436.

2476. Calvarium exhibiting a large tumour of soft medullary substance, arising from the diploë and extending equally through the outer and inner tables; the dura mater is firmly attached to the

tumour. The patient's intellectual faculties were unimpaired.—Preparation No. 2484.—Donor, Mr. Allan, A. S. Staff.

2477. Portion of a frontal bone, exhibiting a tumour of a soft fleshy consistence arising from the diploë and extending equally through the external and internal tables.—Donor, Mr. Howship.—Print. Cat. page 147, No. 1.

2478. Destruction of the bones of the left side of the face, from fungus hæmatodes of the antrum. An unsuccessful attempt had been made to remove the tumour, before admission into the civil hospital, Mauritius.—Donor, Dr. Montgomery, A. S. Staff.

2479. Pelvis very fragile and light, and exhibiting various excavations in the cancellous texture of its different bones. The left pubis and part of the right ilium are completely destroyed. The deficient parts were filled with encephaloid matter, which in some situations formed tumours like Nos. 2481, 2482, 2483.—London Medical Gazette, vol. iii. page 41.—Print. Cat. page 126, No. 30.

2480. Two lumbar vertebræ, the osseous tissue is very fragile, light, soft, and expanded. When recent, their interstices were occupied with brain-like matter.—Preparation Nos. 1660, 2479, 2481, 2482, 2483.

2481. First and second ribs, between which a tumour is situated about as large as a hen's egg. The tumour is composed principally of brain-like matter, with spiculæ of bone shooting into it from the cancelli and external surface of the ribs.—Preparation Nos. 1660, 2479, 2480, 2482, 2483.

2482. Rib exhibiting partial dilatation of its parietes and deposition of encephaloid matter in the cancelli. The bone is so fragile at the diseased part that it has been broken in making a section of it.—Preparation Nos. 1660, 2479, 2480, 2481, 2483.

2483. Rib, a part of which is rarified, with numerous openings into its cancelli, and osseous laminæ growing from its internal sur-



face.—Preparation Nos. 1660, 2479, 2480, 2481, 2482.—Print. Cat. page 126, No. 30.

2484. Section of the foot affected with medullary sarcoma. All the tarsal and metatarsal bones, with the exception of a small portion of the calcaneum, are entirely destroyed, and converted into a soft brain-like substance. The cartilage covering the extremity of the tibia is softened, and nearly separated from the bone. Removed by amputation below the knee, from a native of India. The disease returned a few months after in the stump, glands of the thigh and groin, and also in the cranium. He died two years after the operation.—Preparation No. 2476.—Donor, Mr. Cotton, A. S. 12th Regt.

2485. Upper part of the humerus enlarged, and throughout converted into a texture partly fleshy and partly osseous. In the cancelli of the head of the bone is a deposit apparently of encephaloid matter. The articular cartilage is healthy.—Donor, Dr. Watson, Staff Surgeon.

2486. Small portion of the shaft of the femur extremely thin and fragile. A piece of a white dense, and apparently homogeneous tumour, is attached to the bone. The wasting of the small portion of bone seen in the preparation, seems to have proceeded regularly from the medullary cavity outwards, the external shell of the bone being entire. The disease is probably the albuminous carcinoma of some authors.—From a woman, *ætat.* 33.—Royal College of Surgeons, London.

2487. Sacrum exhibiting deposition of encephaloid matter in its substance. The structure of the bones is converted into a soft fleshy texture of medullary character.—From a woman, *ætat.* 60, who had been confined to her bed for nearly two years. There were spontaneous fractures of the right clavicle and humerus, and of left femur. A similar deposit was found in all the bones, which have been preserved in the Richmond Hospital Museum, Dublin.—Donor, Mr. O'Brien, A. S. 7th Regt.

## SECTION XVII.—MALFORMATIONS OF BONE.

2488. Cranium, the lateral halves of which are not symmetrical. The left side of the os frontis and vertex is much depressed, and the left half of the base of the cranium is lower than the right. At the posterior part of the skull are two small perforations, with smooth rounded edges.—From a man, *ætat.* 31, who died of ascetes. Nothing is known of his intellectual powers worthy of remark.

2489. Portion of cranium with a deep oval depression in front of the crista galli.

2490. Sternum exhibiting a foramen capable of admitting the little finger, in the inferior part of its middle portion, probably dependent on accidental arrest of development at that part.—From a man, *ætat.* 23.

2491. Sternum broader than usual, and where the manubrium unites with the body, it projects considerably forwards.

2492. Fifth rib on the right side broader than usual, and bifid at its sternal extremity, the fourth rib on each side have also double cartilages.

## DIVISION III.

### *INJURIES OF THE BONES.*

---

#### SECTION I.—FRACTURES.

##### *Bones of the Cranium and Face.*

2493. Cranium with comminuted fracture of the left parietal bone and os frontis, extending through the roof and floor of the orbit. There is no displacement of the fragments.—From a man, who was thrown from his horse against a stone wall, and died four days after the accident. On dissection it was found that the middle meningeal artery was ruptured; that there was a coagulum between the dura mater and the bone, and that an abscess existed in the substance of the brain.—Donor, Dr. Bell, A. S. 94th Regt.

2494. Cranium exhibiting comminuted fracture of the os frontis, extending to the ethmoid and nasal bones, and nasal processes of the superior maxillary bones; terminating fatally on the twelfth day after the accident.

2495. Skull, in which is a fissure traversing horizontally to the left side of the frontal bone, across both tables of the frontal sinus and terminating in the right orbital plate; also another fissure in the left side of the temporal bone, which terminates at the pterygoid processes.

2496. Portion of cranium, with a fissure in the left side of the frontal bone, extending through the orbit to the sphenoid. Fractured by a smoothing-iron thrown at the man. When first admitted,

symptoms of fracture were not observable, but in twenty-four hours violent delirium supervened, and he died in forty hours after the accident.—Donor, Mr. Anderson, A. S. 82nd Regt.

2497. Fracture of the right side of the cranium, extending from the lower part of the coronal suture, obliquely upwards through the left parietal bone, and across the sagittal suture to the right parietal. Caused by a fall; the patient died twenty-four hours after the accident. The middle meingeal artery was ruptured, and firm coagula were found between the dura mater and bone.—Preparation No. 367.—MS. Cat. vol. i. page 206, No. 200.

2498. Cranium, in which is a fissure running across the vertex and terminating in the wings of the sphenoid, just behind its orbital plates; separation of the inferior parts of the lambdoidal suture.

2499. A fissure in the posterior part of the right parietal bone, a portion of which was removed by the trephine.

2500. Calvarium presenting a horizontal fissure extending from the coronal suture across the middle of the left parietal bone, and terminating posteriorly at the lambdoidal suture; between these two points both tables of the skull are involved in the fracture. The fissure, which externally seems to terminate in the coronal suture, is internally continued beyond that suture into the frontal, for about an inch and a half, thus presenting a fracture only of the inner table. Branching off from the principal fracture, in the situation of the left parietal protuberance, and extending downwards and forwards to the anterior and inferior angle of the bone, is a fracture which involves only the external table. There is also separation of the coronal suture, and a fissure in the inferior angle of the right parietal bone.—From a man who fell from a height of twelve feet, while in a state of intoxication: symptoms of cerebral compression appeared, and he died about six hours after the accident.

2501. Skull-cap, showing separation of the left half of the coronal suture, also of the sagittal suture, and a fissure extending from the disastasis in the latter suture traversing into the right parietal bone. The suture appears to be consolidated where the separation ceases and the fracture commences.—From a man who was thrown from his horse

when at full speed. He, however, rose, and endeavoured to remount, but died a few hours afterwards. An immense quantity of blood was effused on the surface of the brain.—Donor, Mr. Campbell, A. S. 17th Lancers.

2502. Calvarium presenting separation of the left half of the coronal, and of a part of the sagittal suture and a fissure extending from the termination of this separation, partly across the right parietal bone.—Donor, Dr. White, A. S. Staff.

2503. Calvarium exhibiting a circular depressed fracture of the right parietal bone, and a fissure extending from it upwards, across the sagittal suture into the left parietal bone. The dura mater on the right side is separated for a considerable distance from the bone.

2504. Calvarium exhibiting a fracture of the right parietal bone extending across the coronal suture into the frontal, also across the sagittal to the left parietal bone. Caused by a blow on the left side of the head by a comrade; both middle meningeal arteries were ruptured, and a coagulum, about three ounces weight, was found on the right side, as well as one about an ounce on the left, between the dura mater and the bone. He lived four days after the accident.—Donor, Dr. Alexander, A. S. Staff.

2505. Right parietal bone, in which there is a perpendicular fissure about three inches long, partly consolidated by osseous matter and partly open. In the latter situation a small portion of bone is slightly depressed, and has apparently been detached and reunited, and the under surface of this piece is rough, from deposition on it of new bony matter—From an epileptic lunatic of taciturn, morose, and violent habits, who had been twelve months insane.

2506. Calvarium showing an oval depressed fracture of the left side of the frontal bone. The fragments are reunited; the centre of the depression is about half an inch from the original level of the bones, and the longest diameter of the fractured piece is about two inches.—From a man, *ætat.* 30, who received a blow with the handle of a broom two years before his death; he had symptoms of compression from which he recovered, but was ever after subject to

fits of epilepsy, in one of which he died.—Donor, Dr. Munro, Staff Surgeon.

2507. Section of cranium, showing a depressed fracture of both tables of the frontal bone, firmly united by osseous matter.—Donor, Mr. Kenny, Surgeon, 12th Lancers.—Print. Cat. page 182, No. 43.

2508. Calvarium presenting an oval depressed fracture of the right parietal bone. The fracture of the inner table is of greater extent than that of the outer.—From a Caffre.—Donor, Dr. Forbes, I. G. H.

2509. Calvarium very thin, and presenting a small circular depressed fracture of the left parietal bone. The internal table is more extensively fractured than the external.—Donor, Dr. Blake, Surgeon 7th Dragoon Guards.

2510. Calvarium showing a small circumscribed smooth depression on the outer table of the frontal bone, and the opposite inner table raised to a much greater extent. The fracture is perfectly consolidated.—From a man, ætat. 33, who was confined on account of mania.—Necrol. Reg. vol. iv. page 53.

2511. Skull cap exhibiting an old reunited fracture of the frontal bone. The inner table is considerably depressed, without corresponding depression of the outer table.—From a soldier who was wounded in the head in Spain, several years before his death.

2512. Portion of cranium, exhibiting a depressed fracture of the squamous portion of the temporal and part of the parietal bone. The fragments are completely reunited by bone. The centre of the depression is about three quarters of an inch from the original level of the bones, and the diameter of the fractured pieces is about three inches.—From a soldier who died of fever, three years after the injury. He had recovered so perfectly from the effects of the fracture, that he continued his employment as an officer's servant until within a few days of his death.—Donor, Dr. Jameson, A. S. Royal Dragoons.

2513. Punctured fracture of the occipital bone, the opening is ca-

pable of admitting a common quill; the internal table is very much comminuted. Caused by a blow with a bridle bit. The patient died from inflammation and suppuration of the brain.—Donor, Dr. Cole, A. S. 20th Regt.

2514. Left orbit exhibiting a small punctured fracture of the orbital plate of the frontal bone, just above the os unguis. The margins of the fracture are driven inwards. Produced by an accidental wound by a bayonet. The wound in the skin was very small and soon healed, but the patient had pain in the head, fever, then coma, and death on the twelfth day after the injury. A small triangular portion of the fracture was elevated inwards, and sticking in the dura mater, and the membranes of the brain were inflamed near the wound, and covered with puriform matter.—Donor, Dr. Young, Surgeon 95th Regt.

2515. Portion of skull showing an oval opening half an inch in its longest diameter, situated in the left orbital plate of the frontal bone. Caused by the subject of the specimen falling, while drunk, with a tobacco pipe in his hand, the stem of which passed through the orbit, without injuring the eye, and penetrated the optic thalamus and lateral ventricle. He lived five days after the accident; cause of death only discovered on dissection.—Donor, Dr. Dawson, A. S. 42nd Regt.

2516. Skull cap exhibiting comminuted fracture of the occipital and right parietal bones.—Donor, Dr. Tighe, A. S. 75th Regt.

2517. Cranium presenting comminuted fracture of both temporal bones, and extending completely across the base of the cranium; on the left side, portions of the temporal and occipital bones are much depressed.

2518. Cranium exhibiting extensive fracture. The fracture extends from the squamous portion of the right temporal bone, through the mastoid and petrous portion, crossing the auditory canal from behind forwards, into the sphenoid and ethmoid bones. There is also a fissure traversing the occiput close behind the condyles, from one mastoid process to the other. The trephine was

applied to the anterior and inferior part of the right parietal bone, when the greater part of the squamous portion of the temporal was removed. The dura mater is separated from the bone, in the right temporal fossa, forming a cavity as large as an orange, which was filled with blood partly coagulated. The central meningeal artery is torn throughout two inches of its course. The dura mater is also separated from the occipital bone throughout its whole extent, forming a cavity which contained three ounces of semi-coagulated blood; at these places the brain was much compressed. Caused by a heavy cart having passed over the patient's head. He died soon after the operation.—Donor, Mr. Allan, A. S. Staff.—MS. Cat. vol. iii. page 137, No. 118.

2519. Cranium presenting separation of the left half of the coronal suture, with a fissure in the temporal bone of the same side, which extends through the root of the zygoma to the base of the skull. Caused by a fall.—MS. Cat. vol. iii. page 134, No. 105.

2520. Skull presenting a fissure extending downwards from the left parietal bone, and terminating at the pterygoid process.—Donor, Mr. Alexander, A. S. Staff.

2521. Skull in which is a fissure, extending from the right parietal bone downwards through the temporal bone and its external auditory meatus, and terminating at the foramen lacerum anticum.—Donor, Dr. Calvert, A. I. G.

2522. Cranium exhibiting a fissure in the posterior and inferior angle of the left parietal bone, extending through the external auditory meatus into the body of the sphenoid, with separation of the inferior part of the lambdoidal suture.

2523. Skull exhibiting separation of the lambdoidal suture; from which a fissure extends across the lateral sinus, detaching the mastoid process and part of the petrous portion of the temporal bone, traversing the external auditory meatus and terminating in the squamous portion of the bone.—Donor, Mr. Colclough, Staff Surgeon.—Print. Cat. page 181, No. 38.

2524. Skull exhibiting a fissure extending perpendicularly



through the occipital bone and articular surface of the atlas; complete fracture transversely of the petrous portion of the right temporal bone, detaching the carotid foramen and internal auditory meatus. The atlas ankylosed to the occiput.

2525. Cranium presenting fracture of the occipital bone on the left side, with separation of the inferior part of the lambdoidal suture. The petrous portion of the left temporal bone is completely detached. Caused by a fall from a height of forty feet. The patient died forty-eight hours after the accident. Blood was effused at the base of the brain.

2526. Cranium presenting a fissure in the posterior and inferior angle of the left parietal bone, traversing the temporal bone immediately behind the mastoid process, and condyle of the occipital bone. A second fissure, a little anterior to the former, extends through the parietal and mastoid processes of the temporal to the digastric groove, but does not embrace the internal table of the skull. Caused by a fall from a height, on the right temporal bone, whilst the subject of the specimen was in a state of intoxication; the trephine was applied without relief, and he survived the accident six days, and was conscious to near his death. Blood was effused on right hemisphere of the brain.—Donor, Dr. Dawson, A. S. 42nd Regt.

2527. Skull showing separation of the inferior part of the left lambdoidal suture, extending into the posterior lacerated foramen. Caused by a fall from a height of forty feet. The patient died forty hours after the accident. Blood was effused at the base of the brain.—Donor, Dr. Dawson, A. S. 42nd Regt.

2528. Cranium exhibiting fracture with slight depression of the posterior part of the right parietal bone, and separation of the inferior part of the lambdoidal suture of the same side. Caused by a fall on the occiput, whilst descending a stair in a state of intoxication; he died almost instantly. Blood was found effused at the base of the brain.—MS. Cat. vol. iii. page 141, No. 121.

*Bones of the Trunk.*

2529. Portion of spine, showing fracture of the laminæ at the root of the spinous process of the fifth cervical vertebra, with dislocation forwards of the body of the fourth. The membranes of the spinal cord are uninjured.

2530. Fracture of the body of one of the dorsal vertebra, a portion of bone is detached, and is seen lying in a cavity between two of them; the fracture has encroached considerably upon the spinal canal.—Donor, Mr. Stanley, Surgeon, St. Bartholomew's Hospital.

2531. Spine exhibiting fracture with displacement of two of the lower dorsal vertebræ. The lower part of the fracture projects backwards so as nearly to obliterate the canal and divide the cord, the upper and back edge of these vertebræ press the cord towards the arch. A mass of adventitious bone is deposited on the lateral part of the bodies of the vertebræ, on either side of the fracture. In this preparation, as also in No. 2532, the cord is indented by the body of the vertebræ and not by the arch.—From Captain ———, 58th Regt., who received the injury in the West Indies from a fall, and died ten months after the accident.

2532. Spine exhibiting fracture with displacement of the tenth and eleventh dorsal vertebræ. The lower part of the fracture is driven backwards so as nearly to obliterate the canal, and divide the spinal cord, the upper part of the body of the vertebræ being jammed against the arch. This preparation, as also 2531, exhibits a form of injury, in which it would be useless to attempt to remove pressure from the cord, by trepanning the arches of the vertebræ, as proposed by Mr. Cline.—From a soldier who fell into a deep well; he survived the injury two months, during which time the lower extremities were paralysed.—Donor, Mr. Maynard, Surgeon, Coldstream Guards.

2533. Section of the fourth rib, which has been transversely fractured. A case of new bone is formed around the fracture, but the extremities are yet disjoined: there does not appear to be any new osseous matter deposited in the cancelli. The external callus

is very intimately connected with the old bone at some distance from the fracture, but there is no connection between the external surface of the extremities of the fragments and the new bone.—Preserved in turpentine.—From a woman, *ætat.* 46, a maniac, who died of pulmonary disease.—Preparation Nos. 2534, 2535, 2536.—Necrol. Reg. vol. iv. page 127.

2534. Counterpart of the preceding.‡ The tough ligamentous matter connecting the extremities of the fracture is here shown, and the cancelli are obliterated by a substance of cartilaginous texture.—Preserved in spirits.—Preparation Nos. 2533, 2535, 2536.—Necrol. Reg. vol. iv. page 127.

2535. Section of the fifth rib, exhibiting the form and extent of the callus after fracture. The new bony matter is not quite consolidated, and extends in the form of an arch from one fragment to the other, but has not yet united the opposite extremities of the fracture.—Preserved in turpentine.—Preparation Nos. 2533, 2534, 2536.—Necrol. Reg. vol. iv. page 127.

2536. Counterpart of the preceding, exhibiting the fibro-cartilaginous substance, interposed between the broken ends of the bone and between the external portions of the new bone.—Preserved in spirits.—Preparation Nos. 2533, 2534, 2535.—Necrol. Reg. vol. iv. page 127.

2537. Two ribs transversely fractured, about four inches from their anterior ends: some new bone around the outer surface of the fracture connects the fragments, but the callus is not completely consolidated opposite the fractured extremities.—From a patient who died imbecile and paralytic.

2538. Seventh rib separated from its cartilage. No reunion has taken place, and the extremity of the rib is ulcerated, but no change is exhibited in the corresponding part of the cartilage.

2539. Portion of the seventh rib from the left side, showing a transverse fracture united.—From a maniac.

2540. Sternum perforated by a pen-knife, the blade of which projects half an inch beyond the posterior surface of the bone.—From a soldier who killed himself by wounding the heart with the knife.

2541. Section of pelvis exhibiting fracture through the horizontal ramus of the os pubis and the ramus of the ischium on right side; also of the sacrum close to its junction with the ilium; the latter is a comminuted fracture.—From the passing of the wheel of a stage-coach over the pelvis. The patient survived the injury twelve hours.—Donor, Dr. Jones, Surgeon 1st Dragoon Guards.

2542. Os innominatum exhibiting a fracture through both branches of the pubis, and through the posterior part of the ala ilii.—Apparently from an adult, who did not long survive the injury.

*Bones of the Superior Extremities.*

2543. Portion of scapula broken from the body of the bone, and exhibiting stillated fracture of the glenoid cavity.

2544. Clavicle fractured in its centre, with great lateral separation of the fragments, and subsequent reunion by new bone.—Donor, Dr. Scott, Surgeon Rifle Brigade.

2545. Clavicle in the middle of which is an old oblique fracture, very firmly consolidated, with some overlapping of the broken extremities.

2546. Clavicle transversely fractured about its centre, with overlapping of the broken ends. A considerable quantity of new bone is deposited in the cavity formed by the displaced fragments, but the fracture is not yet consolidated. Thirty-one days after the injury, when the patient died of fever.

2547. Humerus, the head of which is broken from the shaft, and

wedged in a longitudinal fracture of the latter, which is reunited by an abundant deposition of new bone.—Donor, Mr. Fraser, I. G. H.

2548. Humerus, the shaft of which is fractured, with overlapping of the fragments, the lower one in front of the other. Reunion has taken place by a dense ligamentous structure. Hardly any new osseous matter has been formed, merely a very thin layer on the broken surface of the lower fragment, at a distance from its fractured extremity. Removed by amputation from a soldier who received a compound fracture of the arm at Waterloo.

2549. Shaft of the humerus fractured transversely, and reunited by a large quantity of new bone around the outer surface of the fragments, and a small quantity in the medullary canal. The fractured surfaces of the fragments are not yet consolidated. The external callus may in some places be easily separated from the surface of the old bone. This preparation shows the state of the callus 128 days after the injury. According to the analysis of Dr. Davy, the comparative composition of the shaft of the bone and the callus is as follows, viz. :—

|                            | Shaft. | Callus. |
|----------------------------|--------|---------|
| Animal matter . . . .      | 38·60  | 38·8    |
| Phosphate of lime, &c. . . | 61·40  | 61·2    |
|                            | <hr/>  | <hr/>   |
|                            | 100·00 | 100·0   |

2550. Distal end of the humerus, in which is a comminuted fracture extending into the joint. None of the fractured extremities exhibit any change since the injury.—From a man who was drunk, and jumped from a height of forty feet. He sustained various injuries. The arm was amputated on the fifth day, and he died on the sixth.

2551. Lower articular end of the humerus, exhibiting transverse fracture immediately above the condyles, and the latter broken into three fragments; one fracture extends into the middle of the joint. Neither the fractured ends of the bone nor the cartilage seem to have undergone any change.—From a soldier, fourteen days subsequent to the injury.—Donor, Dr. Bradford, A. S. 56th Regt.

2552. Internal condyle of the humerus broken off; the fractured surfaces are coated with a fibrous substance.

2553. Humerus of a fowl which has been fractured; the fragments much separated laterally, and reunited by a broad yoke of new bone.—Donor, Dr. Clarke, A. I. H.

2554. Section of a radius, which has been fractured, firmly united by bone, and the medullary canal completely re-established. There is a little displacement of the fragments, and on the surface of the concave side, the provisional callus has become permanent.—From a man, ætat. 30, who lived four years after the injury.—Donor, Mr. Gulliver, A. S. Staff.

2555. Section of an ulna, which has been fractured, completely reunited, and the medullary canal re-established.—From the same forearm as No. 2554.—Donor, Mr. Gulliver, A. S. Staff.

2556. Radius exhibiting transverse fracture of its distal end, with fissures extending through the lower fragment into the carpo-radial joint. The lower fragment is displaced, being situated behind the upper.—Donor, Mr. Lightbody, Surgeon 80th Regt.

2557. Radius, the distal end of which is fractured transversely, with splintering of the fragments. The fracture extends into the articulation between the radius and ulna.—Donor, Mr. Gulliver, A. S. 71st Regt.—Print. Cat. page 184, No. 51.

2558. Radius exhibiting comminuted fracture of its distal end extending into the joint.

2559. Hand exhibiting fracture of the metacarpal bones, one of them united by bone, with ulceration and necrosis of parts of them. The distal articular cartilage of one of the bones is also ulcerated, and the exposed surface of the bone is shown by injection to be preternaturally vascular. Ankylosis of the radius, carpal, and metacarpal bones.—Print. Cat. page 177, No. 2.

2560. Metacarpal bone of the sheep exhibiting reunited fracture.

The accident took place at two years old, and at the age of three years the animal was killed. The bone had been set in splints at the time of the accident.—Donor, Dr. Burton, Staff Surgeon.

*Bones of the Inferior Extremities.*

2561. Coxo-femoral articulation, exhibiting an ununited fracture of the neck of the left femur, within the capsular ligament; also an oblique fracture through the trochanter; the superior fragment overlaps the inferior, and their extremities are united by an abundant deposition of callus.—From a maniac, ætat. 31, who leaped from a window five months previous to his death.—Necrol. Reg. vol. vi. page 70.

2562. A recent fracture of the neck of the femur entirely within the capsular ligament; it extends from the base of the head obliquely downwards and inwards.—Donor, Mr. Stanley, Surgeon, St. Bartholomew's Hospital.

2563. Femur exhibiting a fracture extending completely through its neck. There appears to have been an attempt at reparation.—From a man, ætat. 28, who fell from a height of twenty feet, injured his spine, and broke his thigh. He died of tetanus nineteen days after the accident.—Donor, Mr. Richardson, A. S. 18th Regt.

2564. Recent fracture of the neck of the left femur within the capsular ligament; the fracture extends obliquely downwards and inwards to the smaller trochanter.—Preparation No. 362.—Print. Cat. page 51, No. 10.

2565. Head and part of the neck of the femur separated by fracture, which extends transversely about half through the junction of the head to the neck, and then in the direction of the axis of the latter through its whole length.—From a man who sustained the injury by a fall on the hip. No attempt at reparation ensued, the limb became wasted and useless, and he died five months after the accident of dropsy.—Donor, Mr. M'Dermott, Surgeon, 4th Regt.

2566. Section of femur, exhibiting transverse fracture of its neck,

which is forced into the shaft of the bone below the trochanter major.—Donor, Mr. Stanley, St. Bartholomew's Hospital.

2567. Coxo-femoral articulation. The femur exhibits fracture of the neck at its junction with the shaft, the fracture extending downwards and backwards through the great to the base of the little trochanter, thus detaching the posterior part of the former, and the whole of the latter process with the upper fragment. The head of the bone is considerably depressed, but the fracture is firmly consolidated by abundant deposition of new osseous matter, an arch of which extends from the anterior inferior spinous process of the ilium, across the front of the joint to the upper part of the shaft of the femur. This portion of adventitious bone became detached during the process of maceration, having been connected only by fibro-cartilaginous substance to the neighbouring bones, a circumstance which shows the facility with which bone may be formed in the soft parts contiguous to a fracture, when displacement of the fragments or any other cause excites a high degree of ossific action.—From an insane officer, aged 39, who fell on his right hip and fractured the neck of the thigh bone. Shortening and inversion of the limb immediately followed, and remained until his death, which took place from disease of the lungs eleven months after the accident.—Edin. Med. and Surg. Journal, No. 129.

2568. Femur obliquely fractured below the great trochanter. About three inches of the line of fracture run longitudinally down the shaft of the bone. The external surface of the edge of the fractured extremities is white, dense, and apparently in process of separation from the neighbouring bone, which is porous.

2569. Femur exhibiting an oblique fracture which extends from the base of the trochanter major downwards and inwards, for a considerable distance below the trochanter minor. The fractured extremities are firmly reunited by bone.

2570. Femur exhibiting oblique fracture in the upper third of the shaft. The fracture has reunited with great overlapping of the fragments, the upper one being situated exactly in front of the other.



2571. Femur exhibiting oblique fracture of its shaft about two inches below the trochanter. The fractured extremities are smooth and disunited; but there is an abundant deposit of new bone, particularly on the inferior fragment, and some splinters of large size, which have been detached, are completely reunited to the shaft by bony callus. Complete consolidation took place, but the limb was one inch shorter than the other. The patient, *ætat.* 32, died eight months after the accident, from general debility and effusion of blood in the cellular membrane of both limbs. Several deaths took place about the same period, at the Mauritius, from the same complaint, without any accident. The reunion of the fractured femur, was broken by the application of moderate force. This weakness of union, it may be conjectured, was in part the effect of the fatal disease, analogous to what has been said to take place in scurvy.—Case of Private A. Henny, 97th Regt., in annual return of 99th Regt. for 1836.—MS. Cat. vol. iii. page 146, No. 127.—Donor, Mr. Montgomery, A. S. Staff.

2572. Femur, the shaft of which has been fractured just below the trochanter, and firmly reunited, with great distortion; the inferior extremity of the lower fragment being displaced upwards and forwards, and the head and great trochanter depressed backwards. The shaft of the bone is throughout vastly thickened by adventitious osseous matter on its surface; the boundaries of the old bone being visible in the section.—From a vault in Spain.—Donor, Mr. Fraser, A. I. G. H.

2573. Femur, in which has been an oblique fracture in the upper third of the shaft, with bony reunion. There is great overlapping of the fragments, the upper is situated on the outside of the lower, which is everted. It is evidently an old injury. From Dr. Davy's analysis the comparative composition of the shaft of the bone and the callus is as follows,—

|                          | Shaft. | Callus. |
|--------------------------|--------|---------|
| Animal matter . . . .    | 40·15  | 47·63   |
| Phosphate of lime, &c. . | 59·85  | 52·37   |
|                          | <hr/>  | <hr/>   |
|                          | 100·00 | 100·00  |
|                          | <hr/>  | <hr/>   |

2574. Femur, which has been fractured obliquely in the upper third of the shaft, and reunited by a very abundant deposit of new bone. There is great overlapping of the fragments, the upper is situated on the inner side of the lower, and the bone is much curved.—Donor, Mr. O'Brien, A. S. 7th Regt.

2575. Femur exhibiting fracture of its neck at the juncture with the head, and of the middle of the shaft. Both fractures are firmly consolidated by bone, in the former the head of the bone is depressed, so as nearly to touch the little trochanter, in the latter there is great overlapping of the fragments. The fracture of the neck of the bone appears to have been wholly within the articular capsule. The other thigh-bone may be referred to for comparison.—No. 2394. The analysis of Dr. Davy shows the comparative composition of the shaft of the bone and of the callus to be as follows, viz. :—

|                                | Shaft. | Callus. |
|--------------------------------|--------|---------|
| Animal matter . . . . .        | 38·8   | 37·2    |
| Phosphate of lime, &c. . . . . | 61·2   | 62·8    |
|                                | 100·0  | 100·0   |
|                                | 100·0  | 100·0   |

From a man, ætat. 31, who died of phthisis. Four years previously, in America, he fractured both his thighs by a fall from a horse : one limb was amputated.—Print. Cat. page 179, No. 19.

2576. Shaft of the femur obliquely fractured at its lower third, and reunited by bone. The fragments overlap considerably ; the lower is twisted outwards, and the upper is situated on the front and inner side. From the analysis of Dr. Davy the comparative composition of the shaft of the bone and of the callus is as follows, viz. :—

|                                | Shaft. | Callus. |
|--------------------------------|--------|---------|
| Animal matter . . . . .        | 44·12  | 49·63   |
| Phosphate of lime, &c. . . . . | 55·88  | 50·37   |
|                                | 100·00 | 100·00  |
|                                | 100·00 | 100·00  |

From a man, ætat. 43, who died of erysipelas. The injury took place five years before his death.

2577. Shaft of a femur, which has been fractured, and firmly reunited by abundant new osseous matter. There is great overlapping of the fragments, the upper presenting exactly in front of the lower. The injury had evidently taken place a very long time before death. From the analysis of Dr. Davy it appears that the comparative composition of the shaft of the bone and of the callus is as follows, viz. :—

|                                | Shaft.                                    | Callus.                                   |
|--------------------------------|-------------------------------------------|-------------------------------------------|
| Animal matter . . . . .        | 40·6                                      | 41·7                                      |
| Phosphate of lime, &c. . . . . | 59·4                                      | 58·3                                      |
|                                | <hr style="width: 50%; margin: 0 auto;"/> | <hr style="width: 50%; margin: 0 auto;"/> |
|                                | 100·0                                     | 100·0                                     |
|                                | <hr style="width: 50%; margin: 0 auto;"/> | <hr style="width: 50%; margin: 0 auto;"/> |

2578. Femur, the shaft of which has been obliquely fractured, with an attempt at a preternatural articulation. Large irregular masses of new bone are connected with the fractured ends; large portions of the shaft have been split off longitudinally from the lower fragment, and firmly reunited by bone to the rest of the shaft, in which there is a large cavity which probably contained portions of necrosed bone.

2579. Femur, the shaft of which has been fractured, and firmly reunited by new osseous deposit. The fragments overlap, the upper being situated in front of the lower.—Donor, Mr. Roberts, Surgeon, Chester.

2580. Patella exhibiting a small portion of its lateral part detached perpendicularly, and reunited by dense ligamentous matter.—Preparation No. 2581.

2581. A superficial section of No. 2580, showing the form of the external surface of the fragments.

2582. Section of tibia, showing fracture of its upper extremity extending into the knee-joint; the fracture is united. There is a cavity of an abscess in the cancellated texture, which contained a portion of necrosed bone.—Donor, Mr. Partridge, King's College.

2583. Oblique fracture of the shafts of the tibia and fibula firmly reunited by bone.—From a man, *ætat.* 45, who died of chronic dysentery.

2584. Oblique fracture of the shaft of the tibia, reunited by osseous deposit; the bone is much deformed and bent backwards.—Donor, Mr. Roberts, Surgeon, Chester.

2585. Bones of the leg broken near the lower third of their shafts. The fractures are firmly consolidated by bone, with much deformity, the upper fragment of the fibula being united to the lower fragment of the tibia.—From a young man, who had a compound fracture, and in whom the limb was amputated two months after, on account of excessive suppuration.—Donor, Mr. Gulliver, A. S. Staff.

2586. Transverse fracture of the shaft of the tibia ununited.—From a boy, *ætat.* 14. The limb was amputated on the fifth day after the accident, when tetanus had taken place. The patient died.—Donor, Dr. Gordon, A. S. 35th Regt.

2587. Tibia and fibula, exhibiting fracture of internal and external malleoli extending into the ankle joint. The internal malleolus is partially reunited by bone. The lower extremity of the fibula, with a small portion of the anterior and outer margin of the tibia are broken off.

2588. Oblique fracture of the distal extremity of the fibula, ununited, with deposition of new bone on the surface of the upper fragment, as also on the posterior aspect of the tibia close to the ankle joint.—Preparation No. 2111.—MS. Cat. vol. iii. page 134, No. 106.

2589. Distal end of the tibia and fibula, exhibiting a comminuted fracture extending into the joint. The injury was accompanied by compound dislocation, occasioned by a fall from a height of thirty feet; the limb was amputated.—Donor, Dr. Davy, A. I. H.

2590. Inferior extremity of the tibia and fibula separated by

transverse fracture. A perpendicular fracture also extends through the tibia into the ankle joint.

## SECTION II.—GUNSHOT FRACTURES.

2591. Cranium exhibiting the track of a musket ball, from the lower and inner side of the right orbit to the carotid canal in the petrous portion of the left temporal bone. The internal carotid artery was ruptured, and the ball lay near the opening. Spiculæ of bone were entangled in the substance of the left hemisphere of the brain, and suppuration had commenced in this part. The patient was a smuggler, who survived the injury ten days, when hæmorrhage took place, and he died in a few minutes.—Donor, Mr. Fraser, A. S. Staff.

2592. Skull cap exhibiting two perforations made by a pistol ball, in the anterior and right side of the frontal bone, and in the posterior part of the left parietal bone. The ball entered in the former situation and lodged in the latter. The first opening is round and smooth, the second is regular on the inner table, but the outer is torn up to an extent much larger than the ball, which is lodged in front of the splinters.—From an officer who was killed in a duel.—Donor, Mr. Tighe, A. S. 75th Regt.

2593. Portion of cranium, in which is a circular perforation made by a musket ball at Waterloo. The external margin of the hole is sharp, but the internal is rounded and of somewhat longer diameter than the former. The ball lodged in the brain. The man, however, became convalescent, until he was attacked with apoplexy, fifteen weeks after the wound, and died. The ball was found loose in the lateral ventricle, having shifted its original position.

2594. Skull cap exhibiting a smooth circumscribed deficiency of the outer table of the right parietal bone. The inner table is quite unchanged. Said to be the result of gunshot injury.

2595. Skull cleft by a sabre cut through the occipital and right parietal bones.

2596. Cranium exhibiting an extensive wound of the occipital bone supposed to have been made by a cutting instrument during life.—Donor, Mr. Dyce, A. S. 81st Regt.

2597. Lower jaw exhibiting a circumscribed deficiency of the alveolar process.—From a man who was wounded by a buck-shot which lodged at the base of the tooth, and produced caries of the remainder; it was extracted twelve months after the injury.—Donor, Mr. Fiddes, Surgeon 85th Regt.

2598. Dorsal portion of the spine showing a bullet lodged in the canal. The ball appears to have entered exactly through the centre of the arch, which with the spinous process is partly broken away.—From a sergeant of the 5th Dragoon Guards, who was shot by a private of the regiment.—Donor, Mr. Badenock, Staff Surgeon.

2599. Fifth dorsal vertebra, exhibiting fracture of part of the right side of its arch, by a pistol ball which is lodged in the canal. The ball entered the right deltoid muscle, and proceeded downwards on the outside and upper part of the chest near to the spine, and finally lodged in the canal. The course of the ball was not known till the death of the patient, which took place thirty days after the injury. The body and limbs below the navel were deprived of sensation and motion, the urine required removal by the catheter, or dribbled away, and the fæces were passed involuntarily; followed by sloughing of the integuments of the sacrum and trochanters.—From an officer who was wounded in a duel.—Donor, Mr. Young, Surgeon 95th Regt.

2600. Humerus, the shaft of which has been shattered by gun-shot, and firmly consolidated by osseous matter. A large splinter, which was completely detached, has become perfectly reunited to the fragments.—Donor, Dr. Brown, Surgeon 87th Regt.—Print. Cat. page 183, No. 49.

2601. Radius, the shaft of which has been fractured by gun-shot, and reunited by new osseous matter, and firmly consolidated thereby to the ulna.

2602. Bones of the fore-arm fractured by musket shot. The ball

having entered in front, shattering the bones and tearing the extensor tendons in its exit. The wound made by the ingress of the ball is much smaller than that of its egress.—From a sergeant who received the wound from his own musket. The limb was amputated about an hour after the injury.—Donor, Dr. Coghlan, Surgeon.

2603. Hand and carpus, exhibiting the track of a musket-ball through the latter, entering on the palmar aspect, dislocating and fracturing some of the carpal bones in its exit. The hand was amputated.—Donor, Dr. Henderson, Surgeon 48th Regt.

2604. A matchlock ball firmly lodged in the head of the femur. The ball entered opposite to the trochanter major, and passed through the brim of the acetabulum. The wound in the skin soon cicatrized, but the patient died of lockjaw and general tetanus, six weeks after the receipt of the injury.—Donor, Dr. Stewart, A. S. 86th Regt.

2605. Upper part of the femur obliquely fractured through the great trochanter by a musket ball, which is firmly imbedded in the cancelli at the base of the neck of the bone.—Donor, Dr. Gibson, A. S. Staff.

2606. Upper end of the femur, exhibiting a cavity at the base of the great trochanter containing a grape shot, which is quite loose, the cavity being considerably larger than the ball.

2607. Condyles of the femur and patella fractured by a carabine ball, which in its entrance has comminuted the point of the patella, split the bone longitudinally, lodged between the condyles, and broken off the inner one.—Donor, Dr. Barlow, Surgeon 3rd Light Dragoons.—Print. Cat. page 186, No. 68.

## DIVISION IV.

### *DISEASES AND INJURIES OF THE MUSCLES AND TENDONS.*



#### SECTION I.—CARTILAGINOUS, AND BONY DEPOSIT IN THE MUSCLES AND TENDONS.

2608. Portion of diaphragm degenerated into fibro-cartilage, and adherent to a portion of the liver.—Donor, Mr. O'Brien, A. S. 7th Regt.

2609. Portion of psoas muscle, exhibiting fibro-cartilaginous induration.—From a patient who died of lumbar abscess.

2610. Portion of the vastus externus muscle, in the substance of which and in the tendinous part are several plates of osseous matter.—MS. Cat. vol. iii. page 150, No. 7.

2611. Portion of diaphragm immediately above the spleen, exhibiting a deposit of bony matter in its substance.—Preparation No. 217.—Donor, Dr. Twining, A. S. Staff.

2612. An irregular piece of bone taken from the substance of the triceps adductor muscle.

2613. Stylo-hyoid ligament, in the centre of which is situated a splint of compact bone; a distinct ligamentous substance about an inch in length intervening between it and the styloid process.



SECTION II.—FATTY, SCROPHULOUS AND MELANOTIC DEPOSIT IN  
MUSCLES AND TENDONS.

2614. A portion of the soleus muscle converted into fat, only a very thin layer of muscular fibres remaining.—From a limb which had been amputated, in consequence of a very general change of structure of its muscles.—Donor, Mr. Stanley, Surgeon, St. Bartholomew's Hospital.

2615. Masses of scrophulous matter deposited in the substance of the muscles of the arm.—Preparation No. 374.—Necrol Reg. vol. v. page 206.

2616. A large cyst in the tibialis anticus muscle, which contained six ounces of semi-pellucid, gelatinous matter. The tumour was caused by a kick of a horse, several months before the patient died. It increased gradually, and caused no inconvenience to the patient.

2617. Melanotic deposition in muscle.—From a white horse. The disease was observed in various parts of the body, particularly in the left lumbar region close to the aorta, and descending into the pelvis, where masses of melanotic matter were as large as a child's head.—Edin. Medico-Chirurgical Trans. vol. i. page 264.

SECTION III.—ENTOZOA IN MUSCLE.

2618. Portion of muscle, in which are situated small white cysts of the trichina spiralis.—From College of Surgeons, London.

2619. Trichina spiralis, and young of Filaria Medinens.—College of Surgeons, London.

SECTION IV.—RUPTURE OF MUSCLES.

2620. Portion of diaphragm, exhibiting a solution of continuity. The coats of the stomach had also given way, and part of their contents were found in the left pleural cavity.—From a soldier who

was killed by a fracture of the skull.—Preparation No. 1028.—Print. Cat. page 30, No. 91.

2621. A portion of the rectus abdominis muscle ruptured, in consequence of the abdomen having been struck by the pole of a waggon. The liver was also ruptured.—Preparation No. 1504.—MS. Cat. vol. ii. page 133, No. 116.

2622. Portion of left rectus abdominis muscle ruptured. The ruptured part, as well as the sheath of the muscle as high as the umbilicus was occupied with coagulated blood.—From a man, ætat. 24, who died of phthisis; he was extremely emaciated, had frequent vomiting and irritability of stomach. The rupture was not known during life.

2623. Rupture of the gastrocnemius muscle, with blood effused between its fibres.

2624. Portion of the long supinator muscle, exhibiting a cicatrix after its division. The cicatrix is formed by very dense tough fibrous substance, and was connected by firm and somewhat dense cellular substance to the cut end of the radius.—The man's arm was amputated five years before his death.—Preparation Nos. 865, 866.

2625. Adductor longus femoris muscle, which has apparently been ruptured, and the rupture followed by reunion, by means of a tough, white, fibrous substance.—MS. Cat. vol. iii. page 152, No. 13.

CLASS XI.  
TUMOURS.

---

SECTION I.—ADIPOSE TUMOURS.

2626. A large fatty tumour, from a Negro.

2627. A fatty tumour, removed from the thigh of a man who died of fever.

2628. Fatty tumour, removed from the shoulder of a girl, *ætat.* 18. The tumour was situated over the supra spinatus muscle, to the fibres of which it was attached.

2629. An adipose tumour, removed from the thigh; it appears to have been attached by a narrow pedicle.—Donor, Dr. Sibbald, A. I. H.

2630. An adipose tumour of an irregular warty appearance, removed from the foot of a convict.—Donor, Mr. Robertson, Surgeon R. N.

2631. A large fatty tumour, from the omentum of a sheep.

SECTION II.—SARCOMATOUS TUMOURS.

2632. Tumour, of a uniform smooth and compact texture; a

groove in its posterior aspect, in which lay the saphena vein. Removed from the thigh of a young female; the tumour began to increase rapidly when of three years' growth.—Donor, Dr. M'Crae, A. S. Staff.

2633. Sarcomatous tumour of uniform, white, homogeneous texture, removed from the parietes of the abdomen, a little above and to the right side of the umbilicus. The tumour had been excised several times previously, when its size much exceeded that seen in the preparation. The wound was completely cicatrized in three weeks, and there was no appearance of a return of the disease.—Donor, Mr. Staunton, A. S. Staff.

2634. A very large sarcomatous tumour in the neck of a fowl; texture smooth and compact and of a yellow colour. The bird was much emaciated.

2635. Sarcomatous tumour, of a smooth, uniform, compact texture, and of a white colour, removed from the inferior angle of left scapula. The tumour had been observed to exist for five months, and for the last two months lancinating pains were experienced in it, with discoloration of the integuments, which became adherent to the tumour.—Donor, Dr. Foulis, A. S. 20th Regt.

2636. Sarcomatous tumour, about the size of an egg, of a uniform white texture, and firm consistence.

2637. Tumour situated under the cartilages of left ear, external to the parotid gland, texture smooth, compact, and spongy.—Preparation No. 2748.—MS. Cat. vol. iii. page 236, No. 159.

2638. Tumour of a smooth, uniform, compact texture, and enclosed in a cyst of cellular substance. The surface is ulcerated, and discharged sanies, and on one occasion four ounces of blood.—From the thigh of a man, ætat. 24, who first perceived the growth twelve months previously to its extirpation.

2639. Section of a sarcomatous tumour, removed from the arm.

2640. Tumour, from the inside of the knee, consisting of numerous small granules of a uniform, smooth, firm texture, connected by cellular membrane, and presenting the appearance of pancreatic sarcoma.—Donor, Mr. Whitfield, Surgeon R. A.

SECTION III.—FIBROUS, AND FIBRO-CARTILAGINOUS TUMOURS.

2641. A very large fibrous tumour, which was situated behind the sternum, and protruded between the first and second ribs. Part of the trachea, bronchial tubes, pericardium, and aorta are attached, which are much compressed by the pressure of the tumour. The patient suffered much from cough, expectoration and difficulty of breathing.—Preparation No. 2642.—Donor, Mr. Turnbull, A. S. 98th Regt.

2642. Section of preceding preparation, showing the structure of the tumour to be firm, dense, and intersected by fibrous bands.—Donor, Mr. Turnbull, A. S. 98th Regt.

2643. Fibrous tumour, about the size of an egg, which was attached to the integuments by a narrow pedicle.—Donor, Sir James M'Grigor, Bart., Director General.

2644. Fibrous tumour, which was connected with the periosteum of the upper and inner part of right tibia, by a narrow pedicle, in the centre of which ran an artery as large as the digital. The surface of the tumour is ulcerated, and healthy-looking pus was discharged from it.—From a middle-aged woman, who had been affected with the growth for nine years; it caused little pain except when the subject of it walked much, when it was very troublesome.—Donor, Mr. Gulliver, A. S. Staff.

2645, 2646. Small fibrous tumours, removed at different times from the tuberosity of the left ischium.—No. 2645 was first removed, and some time after the disease again returned.

2647. Fibrous tumour, removed from the lumbar region of a man, ætat. 28; the tumour was of three years' growth.—Donor, Dr. Davy, A. I. H.

2648. A fibro-cartilaginous tumour, removed from the outer aspect of the trochanter major of a man, ætat. 30. The swelling had existed for two years, and had been punctured with a large needle, under the supposition that it was an enlarged bursa.—Donor, Mr. Gulliver, A. S. Staff.

2649, 2650. Two fibro-cartilaginous tumours, removed from over each trochanter major, to which they partly adhered. The patient had observed these growths for five months; they caused little inconvenience.

2651. Fibro-cartilaginous tumour, removed from the neck.

2652. Fibro-cartilaginous tumour, removed from the natis, where it adhered to the gluteus maximus muscle.

2653. Fibro-cartilaginous tumour.

2654. Tumour of a cartilaginous structure; removed from the natis.

2655. One of a congeries of fibro-cartilaginous tumours, taken from the natis, showing the development of a bursa between two of the tumours.

2656. Tumour of a cartilaginous structure, removed from over the ligamentum patellæ of a young female; the growth was of three months' standing, and latterly began to increase rapidly.—Donor, Mr. Stewart, A. S. Staff.

2657. Tumour of a cartilaginous structure, removed from a man's thigh.—Donor, Dr. Davy, A. I. H.

#### SECTION IV.—OSTEO-SARCOMATOUS TUMOURS.

2658. Section of a tumour of an osteo-sarcomatous character, composed partly of bone, and partly of firm fibrous substance.—From the right side of the face. The tumour extended into the

orbit, enveloping the optic nerve, and had destroyed the superior maxillary bone, orbital plate of the frontal, and wings of the sphenoid.—Preparation No. 2473.—MS. Cat. vol. iii. page 236, No. 158.

#### SECTION V.—CALCAREOUS AND BONY TUMOURS.

2659. A large osseous tumour, which was situated partly within the pelvis, closely surrounded by and adhering to the peritoneum on all sides. The large intestines were much reduced in size.—From an aged female who had suffered long from constipated bowels, and died ultimately of complete obstruction of them.—Preparation No. 2660.—Donor, Dr. Sibbald, D. I. G.

2660. A small tumour, partly composed of bone, and partly of firm fibrous substance. This tumour was attached to Preparation No. 2659.—Donor, Dr. Sibbald, D. I. G.

2661. Tumour containing calcareous and bony matter, removed from the arm near the insertion of the deltoid muscle.—From a girl, aged 17 years.—MS. Cat. vol. iii. page 247, No. 203.

#### SECTION VI.—VASCULAR TUMOURS.

2662. Base of the skull exhibiting a large vascular tumour, occupying a considerable portion of the space which contains the middle lobes of the brain. The surface of the tumour is lobulated, its substance composed of numerous vascular cells, and it is firmly attached to the dura mater; that portion of it which rests on the sella turcica has completely destroyed this part of the sphenoid bone, and the roots of the tumour extend forwards through the sphenoid into the superior part of the æthmoid cells.—Preparation No. 888. MS. Cat. vol. iii. page 213, No. 60.

2663. Tumour in a state of ulceration, composed chiefly of cells filled with coagula; removed from a black soldier.—Donor, Mr. Draper, I. G. H.

2664. Tumour of a vascular character arising from a portion of the integuments of the arm.

#### SECTION VII.—MELANOTIC TUMOURS.

2665. Melanotic tumour the size of a walnut, removed from the face of a woman, *ætat.* 50; a small tumour of the same character had been removed from her eye.

#### SECTION VIII.—MEDULLARY SARCOMA AND FUNGUS HÆMATODES.

2666. Medullary tumour the size of an adult head, situated between the superficial and deep layer of muscles in the calf of the right leg, externally the tumour is lobulated, and is covered with a fine cyst, to which in many places it firmly adheres; in others again it is easily separated. The structure of the mass is generally of an ash colour, with streaks of red as if from coagulated blood, and in many places composed of brain-like substance. In one spot there is a small portion of a cartilaginous and bony consistence. The tumour has no connection with the tibial nerves and vessels, being separated from them by the deep fascia, and no vessels of any magnitude enter the diseased mass. The soleus and gastrocnemius are stretched and much attenuated, forming an envelope to the tumour.—From a woman, *ætat.* 65; the tumour was of three years' growth when the thigh was amputated.—MS. Cat. vol. iii. page 221, No. 89.—Donor, Dr. M'Crae, A. S. 6th Dragoons.

2667. A very large tumour exhibiting encephaloid structure, from the abdomen; it appears to have originated from the capsule of the left kidney, which is seen attached to the diseased mass. The kidney is small and compressed; its structure is, however, healthy.—From a girl, *ætat.* 16 years.—Donor, Dr. Wood, A. S. Staff.—MS. Cat. vol. iii. page 240, No. 175.

2668, 2669. Sections of a large medullary tumour, which was situated in right superior maxillary bone. Its substance is inter-



sected by strong cellular bands.—From a child, *ætat.* 14 months.—Donor, Dr. Ponder, Surgeon, Chatham.—MS. Cat. vol. iii. page 220, No. 88.

2670. Section of a fibro-medullary tumour situated at the lower part of the calf of the leg, between the superficial and deep layer of muscles. The preparation is injected, and the diseased mass is at one part highly vascular. The limb was amputated below the knee, and the patient died of inflammation of the veins ten days after the operation.—MS. Cat. vol. iii. page 240, No. 174.

2671. A large cerebriform tumour arising from the inferior part of the great toe. Fungous excrescences spring from its surface, which is covered by a foul black crust, the removal of which always gave rise to hæmorrhage. The structure of the tumour is composed of brain-like substance and coagula intersected with cellular bands. The leg was amputated successfully.—Preparation No. 2166.—Painting No. 2804.—Print. Cat. page 160, No. 120.

2672. Tumour composed of a firm scirrhus substance and partly of a soft brain-like substance. Excised from the ham.—Preparation No. 2674.—Donor, Mr. Gulliver, A. S. Staff.

2673. A large tumour of soft cerebriform texture injected, and showing at some parts great vascularity.—From a soldier who, when at the Cape of Good Hope, where he served eleven years, enjoyed good health until he received a blow on the left side, when the tumour made its appearance, and increased so rapidly that the patient died about eight months after.

2674. A large tumour, partly of firm and apparently albuminous matter, and partly of softened brain-like substance. The tumour was situated in the upper and outer part of the popliteal space.—From the same patient as the tumour No. 2672, to which this mass succeeded after nine months; it bled repeatedly and profusely, and the patient beginning to sink, the limb was removed successfully just below the smaller trochanter.—From a woman, *ætat.* 51.—Donor, Mr. Gulliver, A. S. Staff.

2675. A large irregular lobulated tumour, composed of a cerebri-form substance, at parts softened and broken up; it weighed sixteen ounces, and was attached to the elbow.—From a man, *ætat.* 49, who, having fallen from his cart and bruised his right arm, shortly after perceived a small tumour on his elbow, which was removed, and the wound united by the first intention. Four or five years afterwards this tumour began to form on the same part.—Drawings No. 2954.—Donor, Mr. T. Berry, Staff Surgeon.

2676, 2677. Sections of a tumour taken from the neck of a sheep, presenting a great variety of structure; divided into irregular compartments by strong membranous septa, some of them containing brownish masses irregularly broken down; also spiculæ of bone and coagula.—Preparation No. 2678.

2678. Portion of the tumour, forming the two preceding preparations, after maceration, showing light plates and spiculæ of bony matter, resembling crystallization.

2679. A tumour about the size of an egg, composed of a cerebri-form substance; its surface is ulcerated and showed a considerable tendency to bleed; removed from the back of the leg, where it had been observed for nine years, and did not acquire a size larger than an almond. During the last nine months, however, the tumour progressively enlarged to its present size.

2680, 2681. Two sections of a large tumour which was removed from the shoulder, presenting a variety of structure, being partly composed of medullary matter, and partly of a gelatinous substance intermixed with serophulous matter. The preparations have been injected, and show considerable vascularity at some points.

2682. A large tumour attached to the external surface of the pericardium; its texture is composed of a uniform smooth cerebri-form matter, at some parts softened and broken down.

2683. A large tumour surrounding the left side of the lower jaw. The tumour is composed partly of soft medullary matter and partly of a firm fibrous substance; it adheres to the jaw, where a fissure



extends through the body of the bone. The integuments and mucous membrane of the cheek are ulcerated, and communicate with a cavity which contained a quantity of bloody pus.—Donor, Mr. Allan, A. S. Staff.—MS. Cat. vol. iii. page 250, No. 210.

2684. Foot of a cock, showing a large tumour of a cerebriform texture; its surface is ulcerated. The bird, after the removal of the disease, became very large and plump.—Donor, Mr. O'Brien, A. S. 7th Regt.

#### SECTION IX.—ENCYSTED TUMOURS.

2685. Shows the cyst and contents of an atheromatous tumour, removed from the cheek.

2686. Cyst of an atheromatous tumour; when first opened it contained a white soft substance, in which were a few fine hairs; removed from under the integuments of a man, *ætat.* 35.

2687. A small atheromatous tumour, removed from a female breast.—Donor, Mr. Menzies, A. S. Staff.

2688. Cyst of an atheromatous tumour, about the size of a walnut, with its contents; removed from the axilla of a healthy young woman. The tumour was of eighteen months' standing, and caused no uneasiness.—Donor, Dr. Burrell, Surgeon 77th Regt.

2689. Cyst of a steatomatous tumour, with its contents; removed from the neighbourhood of the parotid gland.—From a man, *ætat.* 24; the tumour was of nine months' growth, and occasioned very severe pain and derangement of the general health.—Donor, Dr. Davy, A. I. H.

2690. Steatomatous tumour, taken from the scalp.—Donor, Mr. Gulliver, A. S. Staff.

2691. Steatomatous tumour the size of a walnut, removed from the scalp, where there were several others of various sizes; this tumour was of six years' growth.—From a man, *ætat.* 39.

2692. Cyst of a tumour with its bed; the matter contained in the sac was of a soft albuminous nature; taken from the scalp.—Donor, Dr. Scott, Surgeon Rifle Brigade.

2693. Cyst, from the inner surface of which some hairs grew, and which was distended with pus; it had existed for eighteen months, and was situated under the integuments covering the scapula of a child, *ætat.* 2 years.—Donor, Dr. Davy, A. I. H.

2694. Tumour, consisting of a sac containing hair; excised from the neck of a horse.—Donor, Mr. Draper, D. I. G. H.

2695. Capsule of a very large encysted tumour; the inner surface of the sac is lined with layers of lymph.

## CLASS XII.

### MALFORMATIONS.

---

2696. Anencephalous fœtus.

2697. Anencephalous fœtus.

2698. Face of an anencephalous fœtus, showing deficiency of the optic nerve.

2699. A monstrous fœtus; the bones of the upper and back part of the head are deficient, as also the posterior wall of the spinal canal; the brain and spinal cord are only covered by a thin membrane.

2700. Fœtus showing a large cyst filled with medullary matter, communicating with the interior of the cranium at its posterior part, where the tumour is attached to the brain.

2701. Fœtus showing deficiency of the abdominal parietes. The child lived two hours after birth.—Donor, Mr. Frazer, A. S. Staff.

2702. Two fœtus united by the thorax and abdomen; the monstrosity possessed two tracheæ, one lung to each body filling up the entire cavity of the thorax, two hearts, two œsophagi, one stomach, one intestinal canal, two kidneys, one urinary bladder, one uterus, one vagina, and one anus. The monster was dead on delivery, two

hours after which a living child was born, which died the following morning.—Donor, Dr. Pizano, Malta.—MS. Cat. vol. iii. page 203, No. 86.

2703. Fœtus exhibiting the following *lusus*; the inferior extremities attached to the back; the placenta forming the base of the abdomen; the larynx and œsophagus descending on the left side of the spine, which is very much distorted to the right; the heart below the sternum, covered by its serous membrane; and the parietal portion of the peritoneum only covering the intestines.—Donor, Mr. Lightbody, Surgeon 80th Regt.

2704. Hand of an infant, with six fingers; the thumb wanting, the corresponding extremity in a similar condition. The child was nine months old.—Preparation No. 2705.—Donor, Dr. Davy, A. I. H.

2705. Foot of an infant, with six toes; the corresponding foot exhibited the same phenomena.—From the same subject as No. 2704.

2706. Displays the two toes next the great toe, of both feet, almost entirely united.

2707. Œsophagus wanting; the pharynx terminating opposite to the cricoid cartilage.—Taken from an encephalous fœtus.

2708. Pelvis of a fœtus exhibiting an imperforate anus; the gut is pervious to within an inch of its termination. The child lived two hours after birth.

2709. Stomach and part of the duodenum of a child, the former without a pylorus, the latter deficient at its upper portion, and connected with the stomach by cellular membrane only.—From a child who lived five days after birth.—Donor, Dr. Scott, Surgeon Rifle Brigade.

2710. The bladder, ureters, and right kidney from a fœtus at the full period of utero-gestation. The kidney is very small and des-

titude of the lobulated surface usually present in the foetus. The ureters are greatly dilated, and that of the right side somewhat bent upon itself. The bladder is laid open from behind, much dilated, thickened, and of a tough fibro-cartilaginous appearance. The ureters and bladder were found distended with urine. The dilatation does not appear to have been connected with any obstruction, either in the termination of the ureters, or in the urethra.—Donor, Mr. Gulliver, Royal Horse Guards.

2711. Foetal calf with two heads.—Donor, Mr. White, Staff Surgeon.

2712. A kid with two bodies and one head.

2713. A pig with two faces.—Donor, Mr. Lamont, Surgeon 91st Regt.

2714. Two foetal pigs, united by the thorax and abdomen.

2715. Foetal pig having two bodies and one head.

2716. Foetal pig with eight legs.

2717. Foetal pig exhibiting deficiency of the abdominal cavity; a kidney and some rudimentary intestines are seen lying close to the thoracic viscera; the ribs are absent, the heart and lungs are seen covered only by thin serous membrane; the umbilical vein passed directly to the heart. There are three extremities situated close to the lower jaw, and one between the ears.—Donor, Mr. Staunton, A. S. Staff.

2718. A kitten with two bodies and one head.

2719. Kitten having one head and two bodies united above the umbilicus, but distinct below that point.

2720. Kitten with two faces.

2721. Kitten with two faces.

2722. Kitten exhibiting monstrosity of the head; there are two faces and three eyes.—Donor, A. Stewart, A. S. Staff.

2723. Duckling with double head and neck.

2724. A young duck with two bills and four legs.

2725. A chicken with two bills.

2726. Chicken with one head and two bodies.

2727. Two chicks joined by their bodies.

2728. A young turkey with four legs.

2729. A young duck with four legs.

2730. A duckling with three legs.

2731. A chicken with three legs.

2732. A young duck with three legs.

2733. A chicken with a supernumerary leg.

2734. Fœtal shark with two heads; removed from the mother with thirteen others.



## MISCELLANEOUS.

---

2735. Section of the muscular substance of the leg, presenting well defined effusions of blood beneath the integuments, and between the muscles.—From a man, *ætat.* 41, who died of scorbutus.—Print. Cat. page 200, No. 29.

2736. Section of a large coagulum found between the peritoneum and abdominal muscles.—From a man on whom the operation of paracentesis abdominis had been performed between the crest of the ilium and the umbilicus.

2737. Portion of integuments from the foot, exhibiting the cavity of an abscess, with its external opening; the sac is injected.

2738. Portion of adipose substance from the foot, in which the sac of a small abscess is situated; the preparation is injected.

2739. Caseous matter deposited between the peritoneum and abdominal muscles.—From a sailor who died of marasmal wasting.—Donor, Mr. Fraser, A. S. Staff.

2740. Portion of cellular tissue, presenting a large quantity of bony matter deposited in its substance.—Royal College of Surgeons, London.

2741. Ulceration of the foot, after partial amputation; the parts are injected and show high vascularity of the ulcerated surface.—Donor, Mr. Stanley, Surgeon of St. Bartholomew's Hospital.

2742, 2743. Sections of the leg exhibiting fungus hæmatodes of the soft parts in front of the tibia. The preparations are injected,

and show the fungous growths to be highly vascular.—From a man, *ætat.* 56, whose limb was amputated above the knee; six months previously, he had received a contusion on the tibia; ulceration took place and to it succeeded a fungus, which was growing rapidly and bleeding profusely. The stump healed in three weeks and the disease had not returned nine months after the operation.—Donor, Mr. Bushe, A. S. Staff.

2744, 2745. Fungus hæmatodes of the leg, with ulceration of the tibia. The parts are injected and show great vascularity.—From a man, *ætat.* 37, the disease commenced in Ceylon, ten months previously to admission, in the form of a tumour of a purple colour, succeeded by ulceration. A pale fungus then sprouted up, which assumed a dark purple colour and constantly bleeding; the limb was amputated with apparent success.

2746. Thumb much enlarged from the deposition of medullary matter in the sheath of the flexor tendons; the bones are sound; the integuments are ulcerated; the preparation is injected, and shows great vascularity of the adventitious deposit.

2747. Hand and part of the bones of the fore-arm of a Chinese, exhibiting many large deep ulcers: removed by amputation.—Donor, Dr. Kinnis, A. S. Staff.

2748. Extensive carcinomatous ulceration affecting the left side of the face, and having destroyed a considerable portion of the lower jaw.—Preparation No. 2637.—M.S. Cat. vol. iii. page 236, No. 159.

2749. Portion of umbilical cord, exhibiting the ulcerative process which causes its separation.—Donor, Dr. Davy, A. I. H.

2750. Foot of a Negro, supposed to exhibit the effects of dry gangrene. The greater number of the phalanges have dropt off, and those that remain with the metacarpal bone of the great toe, are denuded of periosteum, and are of a dark colour.

2751. Foot, which was removed immediately above the ankle, in consequence of dry gangrene.—Donor, Dr. Dyce, A. S. Staff.

2752. A small tumour attached by a slender pedicle to the inner surface of the basilar artery.

2753. Calibre of the basilar artery intersected by a band, enlarged in the middle, and attached by either end to the inner surface of the vessel.—From a man who died of pneumonia.

2754. Two tumours, which were found loose in the right pleural cavity. They consist of two oval compressed sacs, filled with cheesy matter. The pleural cavity also contained two points of bloody serum. From a man, *ætat.* 33, who died of phthisis pulmonalis.—Donor, Dr. Cotton, Surgeon 12th Regt.

2755. Exhibits the buffed coat of blood, taken from a patient labouring under continued fever.

2756. Coagulum expelled from the stomach of a man, after eating a breakfast of bread and milk, violent symptoms of gastric and enteritic inflammation succeeded, from which the patient recovered.

2757. One hundred and eighty-two pebbles and two pieces of flint, which had been swallowed with a suicidal object, by an insane patient, in the Military Lunatic Asylum, and passed by stool without prejudice to his health.

2758. Opium, which was swallowed with intention of suicide, and was brought off the stomach by emetics of sulphate of zinc.—Donor, Dr. Williams, Surgeon 68th Regt.

2759. Foot of a mummy.

2760. Coins removed from the thigh of an officer.—Donor, Sir James McGregor, Bart. Director-General.—Hennen's Principles of Military Surgery, page 82.

## CASTS AND MODELS.

### *CALCULI.*

---

2761. A very large calculus taken from the bladder of Sir Thomas Adams, Bart., Lord Mayor of London, ætat. 81. The calculus weighed five ounces, and is now in the Laboratory at Cambridge.—Donor, W. I. Iliff, Esq.

2762. A large calculus, taken from the bladder of a man after death.—Donor, W. I. Iliff, Esq.

2763. A large urinary calculus.

2764. A large urinary calculus.—Nos. 2765, 2766, 2767, 2768, 2771, are from calculi in the Norfolk and Norwich Hospitals.—Donor, Mr. Steel, Surgeon 1st Dragoons.

2765. An oval urinary calculus.

2766. Nine oval urinary calculi, from a man, ætat. 59; the calculi weighed four ounces.—The patient was cured by operation.

2767. Five triangular urinary calculi.—The patient was cured by operation.

2768. Two urinary calculi.

2769. Four urinary calculi.

2770. Section of an urinary calculus which had a musket-ball for a nucleus.—Donor, Sir G. Ballingall, Edinburgh.

2771. A large mulberry calculus.—The patient was cured by operation.

2772. Mulberry calculus, removed by the lateral operation, by the donor, from the bladder of a patient, *ætat.* 49.—The patient made a rapid recovery; the calculus weighed four ounces and two scruples, and had been forty years in the bladder.—Donor, W. Fergusson, Esq. Professor of Surgery, King's College, London.

#### TUMOURS, &c. &c.

2773. An enormous sarcomatous tumour springing from the lower jaw.—Donor, Sir George Ballingall, Professor of Military Surgery.

2774. Bust of a person affected with glanders; the eyes are closed by a swelling of the eyelids, forehead, and scalp; tumours exist in the superior maxillary regions and the left upper eyelid.—A case similar to this is described in vol. i. of Guy's Hospital Reports.—From the Museum of Guy's Hospital.

2775. Sarcomatous tumour in the superior maxillary bones.—Drawings, No. 2952, 2953.

2776. Sarcomatous tumour in the cheek.—The tumour of which this is a cast was removed from Hugh Nevison, *ætat.* 51, by the Donor, Sir George Ballingall, Professor of Military Surgery.—Vide Clinical Lecture delivered at the Royal Infirmary, July 1827, page 21.

2777. Sarcomatous tumour, situated behind the angle of the right lower jaw. The tumour when removed was found adherent to the mastoid processes of the temporal bone; in dissecting it out the facial artery was divided, and the trunk of the carotid laid bare for nearly an inch and a half of its course. It was of a dense sarcomatous structure, and contained within it several large cells, filled with bloody fluid. The patient, a fine young woman, made a speedy recovery.—Donor, Sir George Ballingall, Professor of Military Surgery.

2778. Fungous tumours in the left groin.—Taken after death

from Robert Auld, an idiot boy.—Edinburgh Medical and Surgical Journal, for October 1827.

2779. Large firm condylomatous excrescence, occupying the perineum and parts surrounding the anus. The morbid growths were excised, but returned again some months afterwards.—Donor, Dr. Williamson, A. S. Staff.—MS. Cat. vol. ii. page 204, No. 51.

2780. Shaft of the femur, very much enlarged, from the effect of medullary sarcoma; head flattened and below the level of the trochanter major, and its neck much shortened, from interstitial absorption. Amputation was performed at the hip joint by Dr. Handyside of Edinburgh. The patient, a boy, 14 years of age, was affected six years previously with pain in the thigh, subsequently to scarletina. The wound healed for the most part by the first intention, and the patient left the hospital six weeks after the operation. The disease however returned in the left orbit, left hypochondriac regions, the stump, and lymphatic glands.—London and Edinburgh Monthly Journal, No. xxxvii. page 85.—Preparation No. 2781.—Donor, Dr. O'Brien, A. S. Ceylon Rifles.

2781. Stump after amputation at the hip joint.—Preparation No. 2780.—Donor, Dr. O'Brien, A. S. Ceylon Rifles.

2782. Large tumour involving the whole of the left buttock.

2783. Great enlargement of the lower extremity of the femur, and head of the tibia, with great relaxation of the ligaments of the knee joint.—Donor, Dr. Williamson, A. S. Staff.

2784. Inguinal hernia of the left side. Donor, Dr. Hennen, A. S. Staff.

2785. Head of a boy, *ætat.* 5 years and 4 months, who was affected with hydrocephalus. He enjoyed good health for about fourteen months previously to the cast being taken. The body was well developed, the bregma closed, the pupils rather dilated, but contractile on exposure to light, and vision perfect. His disposition was mild and intellect precocious beyond his years.—Donor, Dr. Ore, A. S. 8th Hussars.

2786. A large fossa in the forehead, caused by necrosis, and separation of a great part of the os frontis.—Preparation No. 2336.—Donor, Dr. Hennen, A. S. Staff.

2787. Right foot, after the astragalus was removed.—From a woman, *ætat.* 28, who was thrown from a baggage cart, and received a compound dislocation of the astragalus, which was removed as it was found impossible to reduce it; the os calcis was pushed up into the articular surface of the tibia, and the wound dressed with compresses; she recovered rapidly and has now a good foot.—Donor, Dr. Rawson, Carlow.

2788. Dislocation of the radius and ulna backwards and outwards; several attempts at reduction had been made but without success.—Donor, Dr. Williamson, A. S. Staff.

2789. Case containing fifteen glass models illustrative of morbid affections of the eye.—Donor, Mr. Allan, A. S. Staff.

2790. Cast of the breech and screw of a fowlingpiece, which had been driven by the bursting of the gun, into the frontal sinus, and remained embedded in the nasal fossa, during the space of eight years, the greater part of which time a portion of the metal protruded through the palate into the mouth. Extracted after death from an officer of the Ceylon Rifles.

## P A I N T I N G S.

---

2791. Exhibits an impervious state of the pulmonary artery, with four vicarious pulmonary branches, one of them aneurismal.—Painted by Dr. Schetky, D. I. G. H.

2792. Brain, exhibiting hydrocephalus internus. The right side of the brain is laid open, and some of the fluid still left: the septum lucidum is perforated by an irregular, ragged opening, showing the depth of the fluid in the left ventricle, and divided (without dissection) into two layers, one of which is folded, and supported by a hook: the plexus choroides is seen coming up from the cornu ammonis, and passing through the foramen of Monro: bloodvessels inosculate round the thin walls of the ventricle.—From a child, seven years of age.—Painted by Dr. Schetky, D. I. G. H.

2793. Ulceration of the stomach and intestines, also tubercular deposit in the lung.—Preparation No. 1015.—Print. Cat. page 73, No. 19.—Painted by Dr. Schetky, D. I. G. H.

2794. Stomach, liver, small intestines, and urinary bladder, affected with large masses of vesicular structure growing from their peritoneal coat, and sending down pendulous portions, supported by processes of peritoneum.—Painted by Dr. Schetky, D. I. G. H.

2795. Vesicular masses in the omentum and colon, from the same subject as 2794.—Painted by Dr. Schetky, D. I. G. H.



2796. An ulcerated opening in the left side of the perineum, the result of lithotomy.

2797. View of the base of the cranium, greatly enlarged from hydrocephalus.—From a young fisherman, *ætat.* 20 years.—The skeleton is preserved in Mr. Liston's Museum.

2798. Anterior and posterior view of the cranium, in which there are numerous large perforations with rough edges.—Preparation No. 2474.—MS. Cat. vol. iii. page 77, No. 341.

2799. Extensive ulceration of the outer table of the frontal bone, extending to the upper part of the nasal and superior maxillary processes.—Painted by Dr. M'Diarmid, A. S. Staff.

2800. Skull of a Negro, showing a large osseous tumour arising from the anterior wall of the antrum of the left maxillary bone.—Preparation No. 2462.

2801. Shows disease of the ankle-joint.

2802. Transverse fracture of the patella, with partial necrosis of the upper fragment.—Magnified from a preparation in the collection of Mr. Liston.—Donor, Mr. Gulliver, A. S. Staff.

2803. Medullary sarcoma in the leg, also a section of a small fungus hæmatodes. The former tumour adhered but slightly to the surrounding parts: the gastrocnemius and soleus muscles were pale and attenuated, stretched over the tumour, and perforated by it, at a spot where a fungus had begun to appear; one coagulum of blood was obvious. The mass was intersected by septa of a consistence not firm enough to resist forcible tearing; from these the different portions could be turned out with the fingers. Two such portions are represented. Amputation being performed, the man did well. The fungus hæmatodes was also successfully extirpated from the calf of the leg.

2804. Fungus hæmatodes, springing from the under surface of the great toe.—From the same subject as 2671, taken in an earlier

stage of the disease.—Donor, Dr. Logan, Surgeon 5th Dragoon Guards.—Print. Cat. page 160, No. 120.

2805. Exhibits molluscum pendulum in the face, accompanied by a tubercular affection of the back and upper extremities. The principal tumour, which was soft and moveable, was appended to the right eyelid. When extirpated, its structure was found to be cellular and moderately vascular. It was not ascertained whether regeneration subsequently took place. This disease occurred in a weaver, a patient in the Royal Infirmary, Edinburgh; was of long standing, free from pain, and of imperceptible origin.—Painted by Dr. Schetky, D. I. G. H.

2806. Elephantiasis of the right lower extremity.—From a woman, a patient in the Royal Infirmary, Edinburgh, in whom the disease appeared suddenly after a slight febrile attack at Gibraltar, and in a few days attained the size which is here represented.—Painted by Dr. Schetky, D. I. G. H.

2807. Exhibits pustular eruption on the face; with pustules and ulcers on the shoulders and upper extremities.—From a woman, ætat. 50, who had been profusely salivated ten years before, for a supposed syphilitic affection. The eruption rapidly disappeared by appropriate treatment, terminating by desquamation.—Painted by Dr. Schetky, D. I. G. H.

2808. Exhibits pustular eruption, mixed with encrusted ulcers, diffused over the whole surface of the body; also a female head, with ulceration of the tongue and under lip.—Preparation No. 467.—Painted by Dr. Schetky, D. I. G. H.—Print. Cat. page 2, No. 7.

2809. Exhibits ulceration of the buttocks.—Painted by Dr. Schetky, D. I. G. H.—Print. Cat. page 202, No. 9.

2810. Exhibits deep ulceration in the nates.—Donor, Professor Lizars, Edinburgh.

2811. Cancerous ulcer on the hand and fore-arm of a woman. The arm was amputated, and the disease had not returned two months after the operation. This picture also represents a fungoid malignant ulcer above the heel. — Painted by Dr. Schetky, D. I. G. H.

2812. Fœtal monster, from a preparation in the collection of Dr. William Campbell, Edinburgh. — Donor, Dr. Stewart, A. S. 2d Dragoons.

## DRAWINGS.

---

### CLASS I.

### ORGANS OF CIRCULATION.

---

#### DIVISION I.

#### *DISEASES AND INJURIES OF THE PERICARDIUM AND HEART.*

##### SECTION I.—PERICARDITIS.

2813. Universal adhesion of the pericardium to the surface of the heart; heart enlarged. Right auricle and ventricle laid open. A yellow semi-transparent substance, occupying a considerable space in the right auricle, and extending into the ventricle, where it may be seen entangled with the tricuspid valves and carneæ columnæ.

2814. Exhibits the left auricle and ventricle, with the aorta laid open, of the same heart as No. 2813. The mitral valve presents a granulated appearance from the deposition of calcareous matter in its substance. A similar fleshy mass to what was observed in the preceding drawing, may be seen passing through and behind the chordæ tendineæ.

2815. Pericardium thickened, lined with firm reticulated lymph, and connected posteriorly to the surface of the heart (which is also covered with lymph) by round cords, their length varying from half

an inch to two inches.—Preparation No. 18.—Donor, Dr. Schetky, D. I. G. H.—Print. Cat. page 36, No. 21.

## SECTION II.—HYPERTROPHY AND DILATATION.

2816. Heart enormously hypertrophied, with dilatation of its cavities, also adhesion of the pericardium to the surface of the heart. Weight nine pounds.—Donor, Mr. O'Hara, A. S. Staff.

2817. Simple dilatation of the cavities of the heart, with an injected state of the right auricular appendix; inflammation of the internal coat of the origin of the pulmonary artery; inflammation of the internal surface of the aorta, with atheromatous deposit between the inner and middle coats, also corrugation of its semilunar valves.—Donor, Dr. Callow, Surgeon 6th Dragoons.

## SECTION III.—HEART'S TISSUE DISEASED.

2818. Tubercular deposit, in the substance of the heart, in two places. The organ itself is enlarged, and thickened, more particularly at the diseased parts. There is a considerable vascular turgescence on the surface of one side.—From a woman, between 20 and 30 years of age, of low character and bad habits, who expired suddenly without previous indication of disease, having been always represented as a remarkably healthy person.—Donor, Dr. M'Intosh, Edinburgh.

2819. Exhibits ulcers on the surface of right auricle.—Drawn by Mr. Steele, Surgeon 16th Regt.

2820. Apoplexy of the heart; several ecchymoses are seen on the left ventricle, immediately under its external serous covering, and an opening on its surface, communicating with the left ventricle, from which the [hæmorrhage proceeded, causing death. Calcareous deposit in the mitral valves.—From a woman, ætat. 60, who had for several years all the signs of dilatation with hypertrophy. The heart was found surrounded with coagulated blood, exactly moulded round the organ, some fluid blood also existed. — Donor, Dr. Pitcairn, A. S. 58th Regt.

2821. Appearance of the heart in purpura hæmorrhagica. — Donor, Dr. Dyce, A. S. Staff.

SECTION IV.—ANEURISM OF THE HEART.

2822. Aneurismal dilatation, situated in the apex of the left ventricle. — Preparation No. 105. — Drawn by Dr. M'Diarmid, A. S. Staff.

---

DIVISION II.

*DISEASES AND INJURIES OF THE ARTERIES.*

SECTION I.—ANEURISMS.

2823. An aneurism, about the size of a plum, situated at the base of one of the semilunar valves of the aorta, and projecting downwards into the ventricle, between the endo-cardium and muscular substance of the heart. — Preparation No. 249. — Donor, Mr. Allan, 2nd Class Staff Surgeon. — MS. Cat. vol. i. page 214, No. 223.

2824. Aneurism, arising by a very narrow neck from the arch of the aorta, between the left carotid and subclavian arteries.

2825. Rupture of the aorta into the œsophagus, also several openings in the right bronchial tube, out of which blood seemed to have been poured at the same time. The patient died after vomiting an immense quantity of blood, without any previous symptom of the disease. — Donor, Dr. Pitcairn, A. S. 58th Regt.

2826. View of the cavity of an aneurism of the aorta.

2827. An immense aneurism, arising from the left side and back part of the thoracic and abdominal aorta, opposite to the eleventh

and twelfth dorsal and first lumbar vertebræ.—Preparation No. 333. Print. Cat. page 53, No. 17.!

2828. External view of a carotid aneurism.—Donor, Mr. Stratford, A. S. Staff.

2829. Diffused aneurism of the right popliteal artery. — Preparation, No. 338.—Donor, Mr. Rolland, A. S. 4th Regt.—Print. Cat. page 61, No. 60.

#### SECTION II.—VARICOSE ANEURISM.

2830, 2831. Two views of the parts connected with a varicose aneurism. The brachial artery divides into the radial and ulnar high up in the arm; these arteries communicate by a transverse branch below the aneurism, and then again proceed separately. A ligature has been placed on both the radial and ulnar arteries. — Donor, Mr. Franklin.

#### SECTION III.—ANEURISM BY ANASTOMOSIS.

2832. Aneurism by anastomosis, situated in the region of the right malar bone.—Donor, Dr. Dartnell, A. S. Staff.

2833. Aneurism by anastomosis situated in the right cheek, which was treated by ligature.—Donor, Dr. Marlow, A. S. 28th Regt.

2834. Aneurism by anastomosis, situated in the lower eyelid successfully treated by ligature.—Donor, Dr. Marlow, A. S. 28th Regt.

2835. External and internal view of the effect of torsion of arteries.

CLASS II.  
ORGANS OF RESPIRATION.

~~~~~  
DIVISION I.

*DISEASES AND INJURIES OF THE LARYNX, TRACHEA,
AND BRONCHI.*

~~~~~  
SECTION I.—INFLAMMATION AND EFFUSION OF LYMPH IN THE  
LARYNX, TRACHEA, AND BRONCHI.

2836. Exhibits the appearance of the trachea and bronchial tubes, in acute and chronic bronchitis.—Drawn by Dr. Schetky, D. I. G. H.

2837. Mucous membrane of the larynx and trachea, highly vascular, and a fistulous opening between the thyroid and cricoid cartilages; produced by an attempt at suicide with a razor. The wound healed, with the exception of the opening shown in the drawing. The patient died a month afterwards of acute bronchitis, brought on by the continued irritation produced by the opening.—Donor, Dr. Brown, Surgeon 87th Regt.

2838. Shows varioloid pustules on the mucous membrane of the tongue, larynx, and trachea, which is also highly vascular.—Drawn by Mr. Rolland, A. S. 4th Regt.



SECTION II.—ULCERATION OF THE LARYNX, TRACHEA,  
AND BRONCHI.

2839. Ulceration of the glottis, with great vascularity of the epiglottis.—Donor, Dr. Williams, Surgeon 63rd Regt.

2840. Ulceration of the epiglottis and larynx, with inflammation of the lower part of the trachea and bronchial tubes. — Donor, Dr. Williams, Surgeon 63rd Regt.

2841. Great vascularity, and extensive ulceration of the trachea and bronchial tubes; the upper part of the former has been perforated by one of the ulcers.—Donor, Dr. Dartnell, A. S. Staff.

2842. Two views of necrosis, and perforation of the cricoid cartilage; arytenoid cartilages much thickened, and the muscles infiltrated with lymph and pus.—From a patient, who after an attack of pneumonia, was seized with acute pain in the larynx, followed by difficulty of breathing and articulation, with a croupy voice and cough. He died of asphyxia, fifteen days after the commencement of the symptoms of dyspnoea. — Donor, Dr. Pitcairn, A. S. 58th Regt.

---

DIVISION II.

*DISEASES OF THE LUNGS.*

SECTION I.—TUBERCLES IN THE LUNGS.

2843. Inflammation of the parenchyma of the lung, which is also studded with tubercles.—Donor, Dr. Williams, Surgeon 63rd Regt.

2844. Section of right lung, exhibiting tubercles in different stages.—Donor, Dr. Williams, Surgeon 63rd Regt.

2845. Portion of lung, showing tubercular depositions, the bronchial tubes are much dilated and open into vomicæ. — Donor, Dr. Dodds, A. S. Staff.

SECTION II.—EMPHYSEMA.

2846. Portion of the anterior edge of left lung, showing a large emphysematous vesicle. — Preparation No. 632. — Donor, Mr. Macready, A. S. 52nd Regt.

---

DIVISION III.

*DISEASES OF THE PLEURA.*

SECTION I.—THICKENING AND ADHESION OF THE PLEURA  
PULMONALIS TO THE PLEURA COSTALIS.

2847. Pleura pulmonalis very much thickened; hepatization of the lung, with carbonaceous deposit throughout its structure, and tubercles in an early stage.—Donor, Dr. Williams, Surgeon 68th Regt.

2848. Elongated adhesions between the pleura pulmonalis and costalis.—From a girl 13 years of age.

CLASS III.  
ORGANS OF SENSATION.

---

DIVISION I.

*DISEASES OF THE DURA MATER, PIA MATER, AND  
ARACHNOID.*

---

SECTION I.—INFLAMMATION, ULCERATION, AND TUBERCULAR DEPOSIT IN THE DURA MATER, PIA MATER, AND ARACHNOID.

2849. External surface of the dura mater, which invested the right temporal bone, exhibiting ulceration.

2850. Internal surface of the dura mater, of No. 2849, exhibiting great vascularity, in the course of the ulceration.

2851. Two drawings, exhibiting inflammation and tubercular deposit in the arachnoid and pia mater.—From a patient, ætat. 29, who was habituated to all excesses; he had stupor, lividity of face, could not answer questions, skin was very sensible, and pulse natural. The disease was principally confined to the base of the brain, which was slightly softened; the tubercles were hollow.—Donor, Dr. Pitcairn, A. S. 58th Regt.

## DIVISION II.

*DISEASES AND INJURIES OF THE BRAIN.*

## SECTION I.—INFLAMMATION AND RAMOLISSEMENT OF THE BRAIN.

2852. External appearance of the left hemisphere of the brain, exhibiting venous congestion on the surface, and a portion of the dura mater adherent; also a section of the brain in a state of softening, with bloody puncta in its substance. The longitudinal sinus was almost obliterated, near the point of lesion seen in the drawing, by thickening and induration of its parietes, and an exudation of lymph, mixed with a hard coagulum of blood, which led to the enlargement of the veins beyond the obstruction. These were filled with coagulated blood, and their coats thickened and inflamed. Rupture had taken place in many points on its surface, and also in the substance of the brain itself.—From a lady, who died three weeks after childbirth.—Donor, Dr. M'Intosh, Edinburgh.

---

## DIVISION III.

*DISEASES AND INJURIES OF THE SPINAL CHORD AND NERVES.*

## SECTION I.—INFLAMMATION AND EFFUSION OF PUS IN THE MEMBRANES OF THE SPINAL CHORD.

2853. Inflammation of the membranes of the spinal chord; on laying open the spinal canal, it was observed that the medulla spinalis was unusually soft, and at the situation of the first dorsal, and two lower cervical, vertebræ, the theca was discovered to be at least three times its natural thickness, and highly vascular, whilst the chord itself was converted into a dusky semi-transparent, yel-

lowish substance, somewhat resembling paste, or jelly, both in colour and consistence.—From a man, who, having received a contusion on the loins, by a fall from his horse, became paraplegic; he lingered in this state above a year, and sunk at length from an accumulation of sloughing bed sores.—Drawn by Dr. Schetky, D. I. G. H.

2854. Pus situated in the subarachnoid cellular tissue of the spinal chord and cerebellum.—From a child eighteen days old, who had hydrocephalus; it had neither paralysis nor convulsions.—Donor, Dr. Pitcairn, A. S. 58th Regt.

## SECTION II.—APOPLEXY OF THE SPINAL CHORD.

2855, 2856, 2857. Three views of apoplexy of the spinal chord.—Donor, Dr. Pitcairn, A. S. 58th Regt.

---

## DIVISION IV.

### *DISEASES AND INJURIES OF THE ORGANS OF SENSE.*

#### SECTION I.—DISEASES OF THE EYE.

2858. Dense cataract of the right eye.—From a soldier in whom the disease had been many years forming.—Drawn by Mr. Rolland, A. S. 4th Regt.

2859. An opaque cataract of the right eye, with adhesion of the pupillary margin of the iris to the capsule.—From a soldier, who was sent home from Bermuda with this disease, the result of ophthalmia, caused by the accidental application of paint to the eye.

2860. Transparent staphyloma of the left cornea, the conse-

quence of an attack of ophthalmia in the West Indies.—From a soldier, ætat. 27.—Drawn by Mr. Rolland, A. S. 4th Regt.

2861. Exhibits leucoma of the left cornea.—Drawn by Mr. Rolland, A. S. 4th Regt.

2862. Eye affected with fungus hæmatodes.—Drawn by Mr. Macready, A. S. 52nd Regt.

SECTION II.—DISEASES OF THE EAR.

SECTION III.— „ „ „ NOSE.

SECTION IV.— „ „ „ TONGUE.

SECTION V.— „ „ „ SKIN.

2863. Exhibits vaccinia in two sisters.—Donor, Mr. Williams, Surgeon 68th Regt.

2864. Pustular eruption, accompanying vaccination.—From a woman who, two days after vaccination, was attacked with vomiting and pain in the limbs; on the ninth day the vaccine vesicles appeared on the arm, and on the thirteenth the eruption delineated in the drawing made its appearance.—Drawn by Mr. Rolland, A. S. 4th Regt.

2865. Variolar pustules.—Drawn by Mr. Rolland, A. S. 4th Regt.

2866. Face of an infant covered with the pustules of confluent smallpox in an advanced stage.—Drawn by Mr. Rolland, A. S. 4th Regt.

2867. Confluent smallpox on the back of the hand.—From a soldier, ætat. 21, a case of severe smallpox, which terminated favourably.—Drawn by Mr. Rolland, A. S. 4th Regt.

2868. Pustular eruption on the upper part of the face.—From a

soldier who had been vaccinated in early life.—Donor, Mr. Lyons, Staff Surgeon.

2869. Herpes zoster, on the side, in an advanced stage; the vesicles have matured and scabbed, and lost their characteristic appearance.—From a soldier, ætat. 40; the disease was extremely well marked, and was ushered in with considerable fever.—Drawn by Mr. Rolland, A. S. 4th Regt.

2870. Acne punctata, extensively spread over the back; the eruption had appeared some time before and slowly increased.—From a young man of fair complexion.—Drawn by Mr. Rolland, A. S. 4th Regt.

2871. Purpura hæmorrhagia on the inner surface of the arm.—Drawn by Mr. Dartnell, A. S. Staff.

2872. Purpura simplex in a child 8 years of age.—Donor, Mr. Dodds, A. S. Staff.

2873. Appearance of a pestilential carbuncle, from one of the cases which occurred in 1813 in Malta.—Drawn by Dr. Calvart, D. I. G. H.

2874. Papular eruption, connected with syphilis.—From a soldier, who had been treated for primary syphilis with mercury; two months afterwards, the eruption here delineated made its appearance; and at the same time he was attacked with ulceration in the septum narium and in the pharynx.—Drawn by Mr. Rolland, A. S. 4th Regt.

2875. Exhibits an eruption in a case of secondary syphilis.—Donor, Mr. Williams, Surgeon 68th Regt.

2876, 2877. Two coloured drawings from the same individual, exhibiting one of the forms of secondary syphilitic eruption.

2878. Arm exhibiting rupia prominens (syphilitic).—From a patient in the Lock Hospital, Edinburgh.—Drawn by Mr. Bannatine, A. S. Staff.

2879. Leg of a patient affected with syphilis consecutiva, illustrating rupia prominens.—Drawn by Mr. Bannatine, A. S. Staff.

2880. Exhibits cachexia syphiloidea.—Donor, Dr. Graham, Surgeon 75th Regt.

2881. Another drawing from the same patient as No. 2880, but at a period subsequent to the preceding.—Donor, Dr. Graham, Surgeon 75th Regt.

2882. Syphilitic ulceration on the back of the hand.—Drawn by Dr. Dodds, A. S. Staff.

2883. Ulceration of the toes and soles of the feet.—From a patient who was admitted with ulcers on the penis, followed by ulceration of the tonsils, and pustular eruption. The disease in the foot appeared while the patient was under the influence of mercury, but did not heal on its omission.—Drawn by Dr. Schetky, D. I. G. H.

2884. Malignant ulceration on the nose, cheeks, and upper lip.—Drawn by Mr. Rolland, A. S. 4th Regt.

2885. Presents small abscesses with livid integuments surrounding them, in different parts of the body. The disease was accompanied by marasmus; the abscesses terminated in ill-conditioned ulcers.—From a young soldier.

2886. Exhibits phagedenic ulceration in the left groin, knee, and foot. The femoral artery ulcerated, and was tied above Poupart's ligament. The patient died twenty days afterwards of mortification of the knee and foot.—Drawn by Mr. Rolland, A. S. 4th Regt.

2887. Drawing of tubercular elephantiasis affecting the face.—Donor, Dr. Kinnis, A. S. 90th Regt.

2888. Tubercular elephantiasis principally affecting the face and upper extremities.—From Sergeant Bibby, ætat. 35.—Edin. Med. and Surg. Journal for January 1844.—Donor, Dr. Kinnis, Staff Surgeon.



2889. Elephantiasis affecting the left leg.—Donor, Dr. Dartnell, A. S. Staff.

2890, 2891. Anterior and posterior views of elephantiasis of the labia pudendi. The diseased mass was successfully excised by Dr. Birrell, A. S. Staff, from a Negress, who stated that, eleven years previous to the operation, she had been affected with gonorrhœa and chancres, for which she was severely salivated. The discharge continued for some time from the vagina, and on its cessation, the morbid action which led to the tubercular growth commenced. During the progress of the disease, her health was generally good, except that she was subject to slight febrile attacks every six weeks; and during the last two years ulceration of the tumour, attended with superficial hæmorrhage, occurred several times, producing great debility; on the twelfth day after the operation, she walked out of the hospital.—Preparation No. 2034.—Edin. Med. and Surg. Journal, vol. xxiii. page 257.—Donor, Dr. Dease, Staff Surgeon.

2892. Shows the state of the labia, immediately after the removal of the morbid growth forming the subject of the preceding drawings.—Donor, Dr. Dease, Staff Surgeon.

2893. Shows the parts of generation after the final healing of the wound made in the operation, for the removal of the diseased mass, forming Nos. 2890, 2891, 2892.

CLASS IV.  
ORGANS OF DIGESTION.

~~~~~  
DIVISION I.

DISEASES OF THE MOUTH, PHARYNX, AND ŒSOPHAGUS.

~~~~~  
SECTION I.—DISEASES OF THE TONGUE.

2894. Tongue exhibiting a morbid secretion, the edge of a crimson colour, its centre white, furred and rough.—From a phthisical patient.—Drawn by Mr. Rolland, A. S. 4th Regt.

SECTION II.—STRICTURE OF THE ŒSOPHAGUS.

2895. Anterior view of a stricture of the œsophagus near its termination in the stomach, accompanied by excrescences growing externally from the duodenum.—Drawn by Dr. Brown, Surgeon 2d Dragoon Guards.

2896. Posterior view of the same as No. 2895, with part of a soft fungoid excrescence growing from the internal surface of the stomach at its cardiac orifice. In this case the stomach was highly vascular; the inferior extremity of the œsophagus was thickened,

and discoloured for about three inches, tapering gradually downwards to the cardia, where it was so constricted as to admit with difficulty the passage of the smallest catheter. The fungous excrescence, represented in the second drawing, grew from the cardiac portion of the mucous tunic of the stomach; it was about ten inches round at the outer edge, and half an inch thick in the centre, gradually becoming thinner towards its circumference, and resembling a longitudinal section of a bunch of grapes half grown. There was also a morbid enlargement of the ductus communis chole-dochus, produced by a fungus growth at its entrance into the duodenum. Two opaque caseous excrescences likewise grew from, and were firmly attached by, broad vascular bands to the same viscus, the base of the largest being fastened to the cardiac end of the stomach, by a fine pellucid membrane spread along its upper curvature.—Donor, Dr. Brown, Surgeon, 2nd Dragoon Guards.

---

## DIVISION II.

### *DISEASES AND INJURIES OF THE STOMACH.*

#### SECTION I.—THE EFFECTS OF POISON ON THE STOMACH AND INTESTINES.

2897. Stomach and duodenum, exhibiting the result of swallowing a drachm of the oxymuriate of mercury and half an ounce of laudanum.—Preparation No. 1032.—Print. Cat. page 72, No 11.—Donor, Dr. M'Intosh, Edinburgh.

2898. Exhibits the morbid condition of the colon, contrasted with the comparatively healthy condition of the jejunum.—From the same subject as No. 2897.—Donor, Dr. M'Intosh, Edinburgh.

2899. Shows the state of the termination of the colon, and whole of the internal surface of the rectum; also the appearance of the gums after death.—From the same subject as Nos. 2897, 2898.—Donor, Dr. M'Intosh, Edinburgh.

## DIVISION III.

*DISEASES OF THE SMALL INTESTINES.*

## SECTION I.—INFLAMMATION AND ULCERATION OF THE SMALL INTESTINES.

2900. Mucous membrane of a portion of the ilium, exhibiting ulceration and great congestion, with enlargement of a mesenteric gland, which contains pus; in a case of yellow fever.—Dr. M'Diarmid, A. S. Staff.

2901. Two views of perforations of the small intestines.—Donor, Dr. Pitcairn, A. S. 58th Regt.

2902. Fig. 1. External surface of a portion of ilium, with cheesy excrescences attached to it.

Fig. 2. Portion of liver intersected by numerous ligamentous substances.

Fig. 3. Portion of colon exhibiting the state of its mucous surface. The whole from the same subject, being the effects of long residence in India, and habitual intemperance.—Drawn by Mr. Steele, Surgeon 16th Regt.

## DIVISION III.

*DISEASES AND INJURIES OF THE LARGE INTESTINES.*

## SECTION I.—INFLAMMATION AND ULCERATION OF THE LARGE INTESTINES.

2903, 2904. Two drawings showing the mucous membrane of portions of the colon in different patients, in acute dysentery.—Drawn by Mr. Steele, Surgeon 16th Regiment.

2905. Exhibits the effects of acute dysentery; the mucous membrane of the colon is vascular, thickened and ulcerated.—Drawn by Mr. Steele, Surgeon 16th Regiment.

2905. Fig. 1. Portion of the colon, exhibiting ulceration and perforation, in a case of dysentery, supervening on acute hepatitis.

Fig. 2. Portion of caput coli, in the same disease.—Drawn by Mr. Steele, Surgeon 16th Regiment.

2907. Portion of colon in chronic dysentery, showing inflammation, and ulceration of the mucous membrane.—Drawn by Mr. Steele, Surgeon 16th Regiment.

2908. Shows a portion of the colon in a gangrenous state, some small projections of the meso-colon attached are much distended with a yellow gelatinous fluid.—Drawn by Mr. Steele, A. S. 1st Dragoons.

2909. Portion of the descending colon, exhibiting three marked states of disease, existing at the same period, viz., inflammation, ulceration, and gangrene.—Drawn by Mr. Steele, A. S. 1st Dragoons.

2910. Colon exhibiting many ulcers in a granulating state, also sloughing of certain parts of the mucous membrane.—Drawn by Mr. Rolland, A. S. Staff.

2911. Portion of colon, showing increased vascularity of its mucous membrane, and small circular ulcers having a pustular character: the inner surface of the rectum studded with similar ulcers, and a part of the lining membrane of the ilium in which well-defined ulcers also exist.—From a child who died of smallpox.

2912. Lower part of the rectum and part of the walls of a cavity, which communicated with the gut by an opening caused by a wound with a poker.—Drawn by Mr. Thom, A. S. 11th Regiment.

2913. Drawing of the abdominal viscera in a state of gangrene.—Donor, Dr. Leslie, A. S. 45th Regiment.

2914. Represents a portion of ilium, strangulated in an abnormal aperture of the mesentery.

## DIVISION IV.

*DISEASES OF THE PERITONEUM.*SECTION I.—EFFUSION OF LYMPH, AND TUBERCULAR DEPOSIT IN  
THE PERITONEUM.

2915. View of the peritoneal surface of a portion of ilium, exhibiting inflammation, and granular effusion of lymph.—Drawn by Mr. Rolland, A. S. 4th Regiment.

2916. Shows complete agglutination of the intestines to each other, and also to the peritoneum lining the walls of the abdomen, with large deposits of tubercular matter in the serous membrane.—Drawn by Dr. Dartnell, A. S. Staff.

2917. Peritoneum thickened, with much tuberculous matter deposited in its substance, also complete agglutination of the intestines to each other.—Drawn by Dr. Dartnell, A. S. Staff.

2918. Shows a tumour of medullary structure in the mesentery.—Donor, Dr. Williams, Surgeon 68th Regiment.

CLASS V.

SECRETING ORGANS SUBSERVIENT TO  
DIGESTION.

---

DIVISION I.

*DISEASES AND INJURIES OF THE SUBMAXILLARY  
GLAND.*

DIVISION II.

*DISEASES AND INJURIES OF THE PAROTID GLAND.*

DIVISION III.

*DISEASES AND INJURIES OF THE TONSILS.*

DIVISION IV.

*DISEASES AND INJURIES OF THE LIVER.*

---

SECTION I.—MEDULLARY DEPOSIT IN THE LIVER.

2919. Section of liver showing medullary matter deposited in its substance.—Donor, Dr. Williams, Surgeon 68th Regiment.

---

DIVISION V.

*DISEASES OF THE SPLEEN.*

DIVISION VI.

*DISEASES OF THE PANCREAS.*

DIVISION VII.

*DISEASES AND INJURIES OF THE LYMPHATIC VESSELS  
AND LYMPHATIC GLANDS.*

CLASS VI.  
URINARY ORGANS.

---

DIVISION I.  
*DISEASES OF THE SUPRARENAL CAPSULE.*

DIVISION II.  
*DISEASES, INJURIES, AND MALFORMATIONS OF THE  
KIDNEYS.*

---

SECTION I.—GRANULAR DEGENERATION OF THE KIDNEY.

2920. Section of a kidney, showing granular degeneration.—From a patient who died of fever: the specific gravity of the urine was 1015.—Donor, Dr. Adolphus, A. S. 98th Regiment.

2921. Section of a kidney, representing granular degeneration.—From a patient who died of phthisis pulmonalis, the specific gravity of the urine was 1010.—Dr. Adolphus, A. S. 98th Regiment.

2922. Shows granular degeneration of the kidney, which is also smaller than usual.—Donor, Dr. Dodds, A. S. Staff.

2923. Kidney much enlarged, and shows granular degeneration of its structure.—Donor, Dr. Williams, Surgeon 68th Regiment.



## DIVISION III.

*DISEASES AND INJURIES OF THE BLADDER, INCLUDING  
URINARY CALCULI.*

## DIVISION IV.

*DISEASES AND INJURIES OF THE PROSTATE GLAND.*

## DIVISION V.

*DISEASES AND INJURIES OF THE URETHRA.*

CLASS VII.  
GENITAL ORGANS OF THE MALE.

---

DIVISION I.

*DISEASES AND INJURIES OF THE PENIS AND SCROTUM.*

---

SECTION I.—THICKENING OF THE PREPUCE.

2924. Indurated thickening of the prepuce, accompanied with ulceration.—Donor, Dr. Williams, Surgeon 68th Regt.

---

DIVISION II.

*DISEASES OF THE TESTICLE AND SPERMATIC CHORD.*

SECTION I.—CARCINOMA OF THE TESTICLE.

2925. Carcinoma of the testis and scrotum. — Preparation Nos. 612, 1956.—Drawn by Mr. Rolland, A. S. 4th Regt.—Print. Cat. page 24, No. 64.

2926. Presents a more advanced stage of the same disease as No. 2925.—Drawn by Mr. Rolland, A. S. 4th Regt.

2927. Induration, enlargement, and discoloration of the scrotum; with fungous ulceration arising from the right testicle.—Drawn by Mr. Rolland, A. S. 4th Regt.

2928. Encysted hydrocele of the spermatic chord.—Donor Dr. Williams, Surgeon 68th Regt.

CLASS VIII.  
GENITAL ORGANS OF THE FEMALE.

---

DIVISION I.

*DISEASES OF THE OVARIA AND FALLOPIAN TUBES.*

---

SECTION I.—CYSTS IN THE OVARIA.

2929. Fig. 1. Represents dropsy of the ovary.  
„ 2. Inflammation of the Fallopian tubes.—Drawn by  
Dr. O'Brien, A. S. Ceylon Rifles.

2930. Represents the Fallopian tubes and ovaries, filled with an opaque, white substance, of a cheesy consistence; a cyst about the size of a walnut filled with a limpid fluid situated on the anterior aspect of the right ovary. About an inch from the termination of the rectum, a small cyst containing a similar cheesy deposit was observed, which, when subjected to the microscope, appeared to consist of minute granular bodies of a hexagonal shape, as shown at the bottom of Fig. 1. Fig. 2.—Dropsy of the ovaries.—Drawn by Dr. O'Brien, A. S. Ceylon Rifles.

---

DIVISION II.

*DISEASES OF THE UTERUS.*

SECTION I.—TUMOURS OF THE UTERUS.

2931. Fig. 1. Semi-cartilaginous tumour in the uterus.  
„ 2. Polypus of the uterus.—Drawn by Dr. O'Brien,  
A. S. Ceylon Rifles.

## DIVISION III.

*DISEASES OF THE VAGINA AND EXTERNAL PARTS OF  
GENERATION.*

## SECTION I.—ULCERATION OF THE LABIA PUDENDI.

2932. Exhibits ulceration, induration, and discoloration of the labia pudendi. — From a child between three and four years of age: the disease appeared six weeks after an attack of measles, which had been attended with much pulmonary and intestinal irritation, and proved fatal in fourteen days.—Donor, Dr. McIntosh, Edinburgh.

2933. A scirrhus tumour of the left labia in a state of ulceration. The tumour was removed, and on being cut into showed the true scirrhus structure. It involved the posterior wall of the vagina and part of the rectum. The patient had syphilitic sores two or three years before the operation, for which she never underwent any treatment.—Drawn by Dr. Bannatine, A. S. Staff.

---

  
CLASS IX.

## LACTIFEROUS ORGANS.

CLASS X.  
ORGANS OF LOCOMOTION.

---

DIVISION I.

*DISEASES AND INJURIES OF THE JOINTS.*

---

SECTION I.—DISLOCATIONS.

2934. Two views of a dislocation of the radius and ulna backwards.—Preparation No. 2220.

2935. Luxation of the head of the femur into the ischiatic notch, with fracture of the posterior edge of the brim of the acetabulum.—Preparation No. 2219.—Drawn by Mr. McDiarmid, A. S. Staff.—MS. Cat. vol. iii. page 126, No. 71.

---

DIVISION II.

*DISEASES OF THE BONES.*

SECTION I.—NECROSIS.

2936. Cranium exhibiting large irregular depressions, and various degrees of deficiency of its parietes, the effect of exfoliation.—Preparation No. 2329.—Drawn by Mr. McDiarmid, A. S. Staff.

2937. Represents sphaecelus of the middle finger of the right hand.—From a man, ætat. 28, a groom, in whom the disease ap-

peared soon after having been engaged in cleaning the feet of a greasy horse: the drawing was taken six weeks after the commencement of the disease, at which time the finger was amputated. The patient made a speedy recovery.—Drawn by Dr. Dodds, A. S. Staff.

2938. Sternum, a large circular portion of the left side of the body of which is dead, and nearly detached.—Preparation No. 2358.—Drawn by Mr. Rolland, A. S. 4th Regt.

2939, 2940. Two views of a femur, presenting necrosis of nearly the whole length of the shaft.—Preparation No. 2372.—Drawn by Dr. Dartnell, A. S. Staff.

## SECTION II.—MEDULLARY SARCOMA.

2941. A large medullary tumour arising from the right shoulder-joint.—Drawn by Dr. Marlow, A. S. 28th Regt.

2942. Upper part of the humerus affected with medullary sarcoma.—Preparation No. 2485.—Drawn by Dr. M'Diarmid.

2943. Cranium and lower jaw, in which there are numerous large circular perforations with rough edges.—Preparation No. 2474.—Donor, Dr. Stewart, Staff Surgeon, MS. Cat. vol. iii. page 77, No. 341.

---

## DIVISION III.

### *INJURIES OF BONES.*

#### SECTION I.—FRACTURES.

2944. Fracture of the left parietal bone.

2945. Fracture of a considerable extent in the left side of the base of the cranium.—From the same subject as No. 2944.

2946. Deficiency of the greater part of the left parietal bone ; brain exposed. This bone was removed by operation for the cure of long-continued head-ache, consequent on a fall on the head, but without any beneficial result.—Donor, Dr. Armstrong, Staff Surgeon.

2947. Four views of an injury of the head.—Drawn by Mr. Rolland, A. S. 4th Regt.

#### SECTION II.—GUNSHOT FRACTURES.

2948. Remarkable deformity of the face, caused by a gunshot wound in attempted suicide, during a paroxysm of insanity. The muzzle of the musket was applied below the chin, and the shot entering behind the symphysis of the lower jaw, passed upwards and outwards, and made its exit through the centre of the nose, destroying in its passage the hard and soft palate, a portion of the posterior part of the tongue, and the bones of the nose, leaving both eyes wholly uninjured.—Drawn by Dr. Dartnell, A. S. Staff.

CLASS XI.  
TUMOURS.

---

2949. Congenital tumour in the left arm of a child, *ætat.* 14 days. At birth, it was about half the size here delineated, which was as follows: length four and a half inches, circumference eleven inches, external surface five inches and three quarters.—Drawn by Dr. Schetky, D. I. G. H.

2950. Represents a tumour of the maxillary antrum.— Drawn by Dr. Dartnell, A. S. Staff.

2951. Shows an immense tumour of the maxillary antrum in a Malabar boy.—Drawn by Dr. Dartnell, A. S. Staff.

2952. Extensive sarcomatous tumour in the mouth, occupying nearly the whole of this cavity, and sending processes downwards to the back of the pharynx. It apparently had its origin in the left maxillary antrum. It was firm, and somewhat moveable, and divided into two portions by a deep fissure.—Casts No. 2775.

2953. Shows the same tumour as the preceding in a more advanced stage.—Drawn by Mr. Wyer, Surgeon 74th Regt.

2954. A large irregular lobulated tumour of a cerebriiform texture, attached to the elbow.—Preparation No. 2675.—Donor, Mr. T. Berry, Staff Surgeon.

2955. Section of a tumour removed from the leg; it weighed three pounds seven ounces.—Donor, Dr. Menzies, A. S. 16th Regt.



2956, 2957. Two views of an osteo-sarcomatous tumour occupying the region of the ankle. — Donor, Dr. A. Smith, Staff Surgeon.

2958. Fungus hæmatodes involving the left eye of a boy.— Drawn by Dr. Dodds, A. S. Staff.

2959. Shows the inner aspect of a lower extremity affected with fungus hæmatodes.— Drawn by Mr. Leslie.

2960. Outer view of No. 2959.— Drawn by Mr. Leslie.

## CLASS XII.

### MALFORMATIONS.

---

2961. Encephaloid tumour growing from the right side of the head, accompanied by an enormous fissure in the palate. The head was of a conical shape, the tumour resembled a kidney, being  $11\frac{5}{8}$  inches in its longest surface, and 8 in its lateral superficies. It was soft and pulpy to the touch, without pulsation, and of low temperature; it appeared to contain the greater part of the cerebrum. The orbicularis muscle of the right eye was exposed, the eye itself disorganised, the left eye was imperfect, the palate was divided from the extremity of the nose by a fissure directly back to the pharynx; the velum pendulum, uvula, and tonsils were all deficient. The nose had a horny prominence near its extremity, the tongue was thick and large. There was also malformations of the fingers and toes, some wanting phalanges, others partially or entirely deficient in nails, others having interdigital membranes. The child lived forty-five days.—Donor, Mr. Pargeter, Chatham.

2962, 2963. Front and back views of a monster, consisting of the junction of the superior parts of two female fœtus.—Drawn by Calvart, D. I. G. H.

2964. Dwarf remarkably deformed. The upper extremities are nearly absent, a small portion of the humerus being alone present. Height 2 feet  $2\frac{2}{10}$  inches, girth below the axilla 2 feet 4 inches, height of body from the sacrum to the top of the shoulder, 1 foot 7 inches.—Drawn by Dr. Dartnell, A. S. Staff.

## CLASS XIII.

### MISCELLANEOUS.

---

2965. Exhibits dorsal abscess, connected with ulceration of the vertebræ. The abscess was situated in front of the spine, extending from the sixth cervical to the eighth dorsal vertebræ and contained eighteen ounces of purulent matter. The aorta and œsophagus were anterior to this large sac, the bodies of the vertebræ were in a carious state, and the intervertebral substance was in a great degree absorbed.—From a man, ætat. 23, a feeble scrophulous subject, admitted with fistula in ano. A slight curvature in the dorsal region was perceptible with tumefaction but without sense of fluctuation. The patient died of acute bronchitis.—Drawn by Mr. Shetky, D. I. G. H.

2966. Represents a large lumbar abscess, pointing in the left thigh.—Drawn by Dr. Dartnell, A. S. Staff.

2967. Exhibits loss of all the toes, with ulceration and exposure of all the metatarsal bones, the effect of congelation.—From a Negro whose feet were frostbitten, on his voyage to England.—Drawn by Mr. Rolland, A. S. 4th Regiment.

2968. Exhibits whitlow in the index finger of the left hand, consequent on a puncture with a needle.—The finger became contracted, but was restored to a permanent state of extension, by removal of a portion of the tendon of the flexor digitorum profundus. The finger, which under many other circumstances would have proved an inconvenience, was thus rendered tolerably useful to the patient in the

exercise of his trade as a shoemaker.—Drawn by Mr. Bannatine, A. S. Staff.

2969. Shows the cicatrix of a sloughing ulcer, situated on the left side of the neck.—The patient lost during the progress of the disease nearly twenty pounds of blood, from the inferior thyroid artery.—Donor, Dr. Adolphus, A. S. 98th Regiment.

2970. Malignant ulceration of the lower jaw.—Drawn by Mr. Rolland, A. S. 4th Regiment.

2971. Carcinoma on the cheek. — Preparation No. 2256.—Drawn by Mr. Rolland, A. S. 4th Regt.—Print. Cat. page 154, No. 57.

2972. Exhibits chronic hydrocephalus in a child, *ætat.* two years and four months; it enjoyed good health until the period of dentition, when it suffered very severely. About the same time, or soon after, the child's head began to enlarge and gradually increased until it had attained its present magnitude, viz., circumference thirty-four inches and a half, and from ear to ear twenty-one inches and three-fourths. There was mesenteric enlargement, and general wasting, conjunctiva injected, and eyelids devoid of hair as also the superciliary ridges: pressure had caused ulceration at the posterior part of the head.—Donor, Mr. O'Brien, A. S. 7th Regiment.

2973. Two views of a stump after amputation at the shoulder-joint. — Preparation No. 2167.—Donor, Dr. Williamson, A. S. Staff.

## PRINTS.

---

2974. Two views of a fatal polypus in the right side of the heart.—Donor, Mr. Stewart, A. S. Staff.

2975. Represents inflammation of the theca of the medulla spinalis. The vessels in the spinal chord were gorged with blood and the theca was very red, the inflammation however did not extend to the substance of the spinal marrow itself.—From a man, ætat. 60, admitted into hospital, moribund, with gangrenous swelling of right arm. Previous to death, which took place in a few hours, he became affected with tetanus.

2976. Tumour arising from the perineum, excised by Mr. Liston.—Donor, Mr. P. D. Murray, A. S. Staff.

2977. Congenital tumour in the arm of a child.—Drawing No. 2949.—Donor, Dr. Neale, A. I. H.

2978. Represents a case of ichthyosis, which made its appearance about five or six weeks after birth.—The subject of this disease was the youngest but one of ten children, the rest of the family were quite healthy.

## EXPERIMENTAL PHYSIOLOGY.

---

### SECTION I.—BONE, CARTILAGE AND JOINTS.

2979. Tibia of a rabbit exhibiting abundant deposition of new bone around the old shaft, which is dead, and apparently in course of separation from the living bone. These phenomena are the result of an injury inflicted on the inner surface of the bone and medullary canal, a month previous to the death of the animal.—Donor, Mr. Gulliver, A. S. Staff.

2980. Section of a tibia of a young rabbit, seven weeks after fracture. The deposition of new bone is abundant, and the extremities of the broken bone are passed beyond each other.—Donor, Mr. Gulliver, A. S. Staff.

2981. Tibia of a rabbit, exhibiting some thickening of its parietes; and in the centre of the upper part appear the remains of the old shaft or of its inner shell. The effect of injury to the medullary cavity, inflicted six months before the death of the animal. About three months after the injury to the centre of the bone, it was much enlarged, and about two-thirds of the circumference of the cylinder of new bone, and upwards of an inch in length, having been removed, a larger portion of dead bone was extracted. The greater part of the inferior portion of the bone has therefore been regenerated, and so nicely adjusted in appearance to the rest, as to exhibit hardly any difference. The experiment was made upon a young animal, about half grown.—Donor, Mr. Gulliver, A. S. Staff.

2982. Tibia of a peacock which had suffered a comminuted fracture a few hours after death. The medullary canal is blocked up by coagulated blood, and there is ecchymosis of the periosteum and neighbouring soft parts.—Donor, Mr. Gulliver, A. S. Staff.

2983. Humerus of a rabbit, about sixty-five hours after it had been fractured, exhibiting lymph between the broken portions, an appearance considered by John Hunter as simply owing to the abstraction of the red part of the extravasated blood.—Donor, Mr. Gulliver, A. S. Staff.

2984. Forearm of a rabbit, the fourth day after fracture. The soft parts around the fragments are consolidated and swollen, and the lymph is particularly abundant on the concave side of the fracture.—Donor, Mr. Gulliver, A. S. Staff.

2985. Section of fracture of the thigh bone of a rabbit, exhibiting the same state of the neighbouring soft parts as No. 2983, also lymph between the fractured ends, and in the medullary canal. The preparation is injected, but it does not appear that any bloodvessels yet exist in the lymph. The fifth day after fracture.—Donor, Mr. Gulliver, A. S. Staff.

2986. Humerus of a rabbit six days after fracture. The periosteum is thickened, there is lymph between the fragments, and the old bone at a distance from the fracture is somewhat softened and thickened, which is well shown a little below the middle of the upper portion.—Donor, Mr. Gulliver, A. S. Staff.

2987. Section of a fractured thigh bone of a rabbit, exhibiting consolidation of the soft parts contiguous to the injury; lymph in the medullary canal and between the fragments. The sixth day after the injury.

2988. Section of the fractured humerus of a rabbit. There is a fibro-cartilaginous substance around the fracture apparently continuous with the thickened periosteum. In the centre of the cartilaginous substance is a nucleus of ossific matter, which has no connection with the old bone. The medullary canal is occupied by a tough substance, in which no new bone is apparent.—Donor, Mr. Gulliver, A. S. Staff.

2989. Counterpart of No. 2988. It will be observed that the work of reparation is principally confined to (or rather more active on) the concavity of the curve, formed by the displaced fragments, which is also exhibited in Nos. 2990, 2991, 3002, 3005, a provision not unlike that observed by Mr. Stanley in ricketty bones.—Donor, Mr. Gulliver, A. S. Staff.

2990. Section of a fractured tibia of a rabbit. There is abundant fibro-cartilaginous deposition around the fracture, and in the medullary canal. In the former situation ossification is proceeding, and the process is also advancing from the old bone at points distant from the line of fracture, which is thus becoming connected by a sort of arch or clasp of new bone.—Donor, Mr. Gulliver, A. S. Staff.

2991. Counterpart of No. 2990, dried so as to show more perfectly the extent and direction of the ossific process. In this specimen the osseous matter in the medullary canal at the ends of the fragments is well shown.—In Nos. 2990, 2991, the injury was inflicted thirteen days before the death of the animal.—Donor, Mr. Gulliver, A. S. Staff.

2992. Section of the ulna of a dog, which had suffered fracture. New bone is seen connected and apparently proceeding from the external surface of the old, but the new formation has not yet advanced over the extremities of the fragments. Osseous matter has also been deposited in the medullary canal. The preparation is minutely injected, and the callus shown to be vascular. The injury was inflicted fourteen days before the death of the animal—Donor, Mr. Gulliver, A. S. Staff.

2993. Section of the fractured tibia of a rabbit. A firm cartilaginous substance surrounds the fracture, and in the medullary canal something like lymph is observed; no cartilage or new bone, although the latter is very well marked in the upper fragment, connected with the old bone, and situated at a considerable distance from the end of the fracture. The external callus appears to be continuous or identified with the periosteum. The injury



was inflicted twelve days before the death of the animal.—Donor, Mr. Gulliver, A. S. Staff.

2994. Section of an overlapping fracture of the tibia of a rabbit. The fragments are widely separated, but a yoke of new bone extends from one to the other. A ring of new bone is situated around the shafts of the fragments, at a distance from the extremities of the fracture, particularly in the lower portion. There is also some new bone in the medullary canal, and the inner layer of the old bone presents the appearance of thickening from the addition of new bone. The injury was inflicted twenty-four days previous to the death of the animal.—Donor, Mr. Gulliver, A. S. Staff.

2995. Counterpart of No. 2994, showing the new ossific matter in a matrix of fibro-cartilaginous appearance, and coagulated lymph in the centre.—Donor, Mr. Gulliver, A. S. Staff.

2996. Section of a fractured thigh bone of a rabbit.—The external deposit of new bone is very abundant, and shown to be remarkably vascular, by injection. A detached splinter from the shaft of the bone has become firmly imbedded in the new osseous matter. Twenty-three days after the injury.—Donor, Mr. Gulliver, A. S. Staff.

2997. Section of a fractured os femoris of a rabbit. The medullary canal at the extremities of the fracture is closed by new bone, which is also forming around the injury. The callus is injected. Fourteen days after the injury.—Donor, Mr. Gulliver, A. S. Staff.

2998. Counterpart of No. 2997 dried, showing the form, extent, and great vascularity of the external callus.—Donor, Mr. Gulliver, A. S. Staff.

2999. The upper fragment of the fractured tibia of a rabbit. The external callus is seen at a distance from the fractured end, and at a corresponding situation in the medullary canal, and also at the extremity by which the tube is closed. The new bone is very successfully injected. The fracture was made fourteen days before the death of the animal.—Donor, Mr. Gulliver, A. S. Staff.

3000. Section of the fractured tibia of a rabbit. The deposition

of new bone has been very abundant, particularly on the concave side of the bone, and the medullary canal is completely obliterated. The new bone is shown to be very vascular by injection. Twenty-eight days after the injury.—Donor, Mr. Gulliver, A. S. Staff.

3001. Section of the fractured tibia of a rabbit. The new bone is very abundant, and is shown by injection to be more vascular than the old bone. Thirty-three days after the injury.—Donor, Mr. Gulliver, A. S. Staff.

3002. Section of the fractured os femoris of a rabbit. The callus is minutely injected, and is so deposited as to fill up the concavity formed by the overlapping fragments. Twenty-four days after the injury.—Donor, Mr. Gulliver, A. S. Staff.

3003. Counterpart of No. 3002, showing ligamentous matter between the extremities of the fragments and centre of the external callus. There would therefore be motion allowed, so that in this stage the parts resemble the condition presented by the second kind of accidental articulation.—Donor, Mr. Gulliver, A. S. Staff.

3004. Section of the fractured os femoris of a rabbit, exhibiting the same condition of parts as No. 3003, but in a more advanced stage. Ossification has here partially extended into the ligamentous texture between the fragments, which are thus partially united. The preparation has been very successfully injected, and the injection has run freely between the callus and periosteum. Twenty-seven days after the injury.—Donor, Mr. Gulliver, A. S. Staff.

3005. Exhibits the vascularity of callus, in the tibia of a rabbit. Forty-three days after the injury.—Donor, Mr. Gulliver, A. S. Staff.

3006. Portion of the os femoris of a dog, exhibiting a deposit of new osseous matter on its surface. For further particulars see No. 3011.—Donor, Mr. Gulliver, A. S. Staff.

3007. Counterpart of No. 3006. There is new bony matter closing up the end of the tube of the bone, as is also the case in the preceding preparation.—Donor, Mr. Gulliver, A. S. Staff.

3008. Inflammation of the external surface of the lower portion of the thigh bone of a dog. The new bone is highly injected. For further particulars, see No. 3011.—Donor, Mr. Gulliver, A. S. Staff.

3009. Portion of ulna of a dog exhibiting the effects of inflammation of its external surface. The new bony matter is very successfully injected. For further particulars, see No. 3011.—Donor, Mr. Gulliver, A. S. Staff.

3010. Portion of the tibia of a dog, exhibiting a deposition of new bony matter on its external surface in the form of small cells. The new bone is highly injected. For further explanation, see No. 3011.—Donor, Mr. Gulliver, A. S. Staff.

3011. Radius of a dog, presenting new bone on a part of its external surface, in which situation it is minutely injected. This preparation and the five preceding ones, afford examples of proper inflammation of the osseous tissue. In the experiments a portion of tinfoil was introduced between the periosteum and the bone, in order to afford an opportunity of examining the effects of inflammation in the bony structure, distinct from the appearances resulting from lesions of the periosteum. However, these preparations exhibit just the same change in the osseous tissue as that generally assigned to inflammation of the periosteum, and frequently indeed, in the human subject, to the effects of mercury. Mr. Howship pointed out the existence of minute longitudinal canals in the compact parts of the long bones, and showed that the common effects of inflammation of bone was, first, increased vascularity of the delicate web lining the canals, and then an apparent dilatation of their size. Nos. 3006, 3007, 3008, appear to present an enlargement of the external longitudinal canals of the bone, with a true hypertrophy of its texture—a sort of unravelling or exaggeration of the natural state of parts.—Donor, Mr. Gulliver, A. S. Staff.

3012. Tibia of a rabbit, into the medullary canal of which a portion of the metatarsal bone of the same animal has been introduced. The foreign bone is apparently quite unchanged, either in form or density, although it had remained in the living part upwards of seven weeks. The walls of the surrounding living bone are

simply thickened, except in one place at the posterior and upper part, where a portion appears to be about removal by death or absorption, so as to admit of the egress of the foreign bone, which is favoured by the exuberant growth of a vascular substance in the medullary canal, tending to push away the dead bone. In the back of the bottle hangs a portion of the same organized substance, which was interposed between the surface of the foreign bone and the other half of the shaft. Thus the dead bone was long surrounded by a texture very favourable to absorption.—Preparation No. 3031.—Donor, Mr. Gulliver, A. S. Staff.

3013. Section of the tibia of a rabbit, exhibiting the sac of an abscess in the upper part of the medullary cavity, communicating with a cyst outside the bone; the cyst contained very thick pus. The walls of the bone are thickened, and lymph occupies the lower part of the medullary canal. The effect of irritation of a foreign body, which had been introduced into the medullary cavity, and allowed to remain there thirty-four days previous to the death of the animal.—Donor, Mr. Gulliver, A. S. Staff.

3014. Section of the tibia of a rabbit, exhibiting abundant deposition of new bony matter around the upper part of the shaft. In the upper part of the tibia the old bone is in progress of separation; in the lower part, the new bone is situated both on the internal and external surfaces of the old bone, and the former is seen to be continuous with the old shaft. This preparation is the other half of No. 3013 macerated.—Donor, Mr. Gulliver, A. S. Staff.

3015. Tibia of a rabbit, exhibiting great thickening and vascularity of the periosteum, with lymph situated between it and the bone. The periosteum has been turned off, and some of the lymph is attached to the membrane, and some adheres to the new bone. The effect of a foreign body introduced into the medullary canal three days previous to the death of the animal.—Donor, Mr. Gulliver, A. S. Staff.

3016. Section of the patella of a rabbit, exhibiting fracture which has reunited by dense fibrous substance, and another fracture united

by bone. The bone was broken transversely in two places, forty-eight days before death.—Donor, Mr. Gulliver, A. S. Staff.

3017. Counterpart of No. 3016, dried.

3018. Section of the left patella of a rabbit, exhibiting a transverse fracture, which has united by bone. The line of fracture is visible. The fracture was made thirty days previous to the death of the animal. Section of No. 3019.—Donor, Mr. Gulliver, A. S. Staff.

3019. Counterpart of No. 3018, dried and preserved in turpentine.—Donor, Mr. Gulliver, A. S. Staff.

3020. Section of the right patella of a rabbit, exhibiting a transverse fracture united by dense fibrous tissue. The fracture was made fifty-four days previous to the death of the animal. Section of No. 3021.—Donor, Mr. Gulliver, A. S. Staff.

3021. The other half of the preceding, dried and preserved in turpentine.

3022. Transverse fracture of the patella of a rabbit, reunited by very short fibrous substance. The fracture was made forty-six days previous to the death of the animal.—Donor, Mr. Gulliver, A. S. Staff.

3023. Tibia of a rabbit exhibiting the process of exfoliation. New bone is deposited around the margin of that about to exfoliate. This deposit seems to be preparatory to the action of absorption between the dead and living bone.—Donor, Mr. Gulliver, A. S. Staff.

3024. Tibia of a rabbit exhibiting the commencement of the process of exfoliation.—Donor, Mr. Gulliver, A. S. Staff.

3025. Sections of the tibia of a rabbit, exhibiting layers of new bone on the old shaft; the former having but a slender connection with the latter. The effect of irritation of the medullary substance.

3026. Two portions of the tibia of a rabbit, one a bit of the compact shell of the shaft, the other a spongy and light portion from near the extremity. These bits of bone had been introduced into the medullary canal of the foregoing bone, No. 3025, and allowed to remain there twenty-eight days before the death of the animal. There was profuse suppuration. No diminution had taken place in the weight of these splints of bone; on the contrary, the spongy portion was one-tenth of a grain heavier than when first introduced. The pencil marks by which Dr. Davy noted the weight on the surfaces of these portions of bone are not obliterated.—Donor, Mr. Gulliver, A. S. Staff.

3027. Tibia of a rabbit, exhibiting a deposit of new bone on its external and internal surfaces. At the bottom of the bottle is the fibula of another rabbit, which had been introduced into the medullary canal of the tibia thirty-six days previous to the death of the animal. The adventitious bone was not weighed, but it does not appear to have been acted on by the absorbents, although a portion of new bone has been deposited on one of its ends, and is firmly connected with it. The groove, marking the boundary of the new osseous deposit, by which the adventitious bone was imprisoned is well marked in one of the sections.—Donor, Mr. Gulliver, A. S. Staff.

3028. Tibia of a rabbit, the shaft of which is nearly detached, and completely surrounded by a shell of new bone, in which are several apertures leading to the sequestrum.—Donor, Mr. Gulliver, A. S. Staff.

3029. A portion of the cylinder of a new bone from No. 3028, exhibiting a soft pulpy membrane lining its internal surface. The periosteum is prodigiously thickened.—Donor, Mr. Gulliver, A. S. Staff.

3030. Tibia of a rabbit, into the medullary canal of which the lint was introduced twenty days previous to the death of the animal. There is a deposit of new osseous substance on the surface of the shaft of the bone, to which new matter has but a slender connection, some of it having been torn off with the periosteum.—Donor, Mr. Gulliver, A. S. Staff.

3031. Section of the tibia of a rabbit, exhibiting a shell of new bone around the old shaft. In the inferior part of the medullary canal much new bone is also deposited, and in this situation the old and new bone seem to be incorporated. This is the counterpart of No. 3012 macerated.—Donor, Mr. Gulliver, A. S. Staff.

3032. Tibia of a rabbit, with a portion of human tibia. The latter had been introduced into the medullary canal of the former twenty-five days previous to the animal's death; the limb was then macerated for twelve weeks, and found not to have suffered any change.—Donor, Mr. Gulliver, A. S. Staff.

3033. Tibia of a rabbit, in the medullary canal of which a portion of human tibia is situated. The latter is firmly united to the former by true osseous matter, verified by the analysis of Dr. Davy, and the rabbit's bone is perfectly healthy. The adventitious bone was introduced some weeks before the death of the animal; after death the limb was twelve weeks subjected to the putrefactive fermentation.—Donor, Mr. Gulliver, A. S. Staff.

3034. Sections of a tibia of a rabbit, exhibiting a shell of new bone around its middle and in the medullary canal.—Donor, Mr. Gulliver, A. S. Staff.

3035. Portion of the tibia of a rabbit, which had been introduced into the preceding tibia, No. 3034, seven weeks before the death of the animal. When removed after the maceration of the part, this adventitious bit of bone presented some small deposit of new bone on its surface, which were analysed by Dr. Davy, and found to be true bone. The pencil marks of the weight of the foreign bone remained without obliteration, and may yet be seen. This portion of bone had increased in weight.—Donor, Mr. Gulliver, A. S. Staff.

3036. Sections of the tibia of a rabbit, into the medullary canal of which portions of bone had been introduced seven weeks before. It will be seen that the bones are unaltered; the bits of bone were unchanged in weight, and the animal grew fast and was healthy and active.—Donor, Mr. Gulliver, A. S. Staff.

3037. Transverse fracture of the patella of a rabbit; the fragments are connected by ligamentous matter, and new bone is deposited on their broken surfaces, so that the fragments present the appearance of two symmetrical patellæ.—Donor, Mr. Gulliver, A. S. Staff.

3038. Transverse fracture of the patella of a rabbit, exhibiting the same state as No. 3037. The new bone deposited on the fractured extremities is well marked.—Donor Mr. Gulliver, A. S. Staff.

3039. Transverse fracture of the patella of a rabbit, which has reunited by bony matter.—Donor, Mr. Gulliver, A. S. Staff.

3040. Transverse fracture of the patella of a dog, exhibiting the same change as Nos. 3037, 3038. The preparation is minutely injected, and the new bone sprouting from the extremities of the fracture, as well as the interposed membranous texture, is shown to be very vascular.—Donor, Mr. Gulliver, A. S. Staff.

3041. Patella of a dog, transversely fractured, and reunited by ligamentous matter, nearly half an inch long. This interposed substance is very vascular, as shown by injection.—Donor, Mr. Gulliver, A. S. Staff.

3042. Section of the patella of a dog, which has been fractured transversely. The aponeurotic fibres in front of the bone were not divided. The union is yet entirely ligamentous, and no new bone has appeared. Twenty-eight days after the injury.—Donor, Mr. Gulliver, A. S. Staff.

3043. Patella of a rabbit transversely fractured. The union is by ligamentous matter, but there is a copious deposit of new bone on the fractured extremities, by which they are placed in contact. Fifty days after the injury.—Donor, Mr. Gulliver, A. S. Staff.

3044. Patella of a dog which has been transversely fractured. The fragments are completely consolidated by bone, but a deficiency of osseous matter is observed on the inner surface marking the line of fracture. This may also be seen less distinctly on the sides of the



patella. One hundred and twenty days after the fracture.—Donor, Mr. Gulliver, A. S. Staff.

3045. Patella of a dog which had been transversely fractured. The fragments are perfectly consolidated by bone, and the situation of the fracture is well marked on both surfaces of the bone. One hundred and seventy days after the injury. Both this and preparation No. 3044 were boiled upwards of twelve hours, without in the least affecting the uniting medium.—Donor, Mr. Gulliver, A. S. Staff.

3046. Patella of a dog, exhibiting fracture of its inner table, a portion of which has been detached and is now perfectly reunited by osseous matter. One hundred and one days after the injury. This bone was boiled several hours without affecting the uniting medium.—Donor, Mr. Gulliver, A. S. Staff.

3047. Ribs of a rabbit, from one of which a portion of the entire circumference of the bone was removed with the periosteum. The extremities of the fracture present a scanty deposit of bone, the intervening space, of about a quarter of an inch, being occupied by membranous matter. Two months after the injury. The animal was about half grown at the time of the experiment.—Donor, Mr. Gulliver, A. S. Staff.

3048. Radius of a dog, exhibiting a transverse fracture. A deposition of new bone is seen on the external surface of the fragments around the fracture. The new bone has not yet become consolidated opposite to the fracture. In the medullary canal, there is hardly any osseous deposit, corresponding to the external callus. Before drying, the extremities of the fragments admitted easy motion on each other, being united only by tough membranous matter as were also the extremities of the external osseous substance. Thirty-two days after the injury.—Donor, Mr. Gulliver, A. S. Staff.

3049. Tibia of a dog, exhibiting fracture of its shaft. There is an abundant deposit of new bone on the external surface of the fragments, commencing at a great distance from the broken extremities, and extending upwards and downwards towards the line of fracture,

opposite to which there is a deficiency of the deposit. In the medullary cavity there is no plug of osseous matter. Thirty-nine days after the injury. This and the preceding preparation are minutely injected, and exhibit the vascularity of the new bone, and of the membrane which surrounds it.—Donor, Mr. Gulliver, A. S. Staff.

3050. Radius of a rabbit, exhibiting a fracture of its shaft, and an abundant deposit of new bone at a distance from the fracture. The broken extremities are hard and pointed so as to fit each other exactly. Fifteen days after the injury, which was an overlapping fracture, the broken extremities projecting into the surrounding soft parts. It will be observed that the fractured ends are neither softened nor rounded.—Donor, Mr. Gulliver, A. S. Staff.

3051. Femur of a fowl, exhibiting an overlapping fracture, reunited by an exuberant osseous callus. Some fragments of the shaft are detached, one of which is consolidated with the new bone at the distance of about a quarter of an inch from the old bone.—Donor, Mr. Calder, A. S. Staff.

3052. Section of the tibia of a dog, from which a superficial layer of the shaft has exfoliated. The surface from which the dead portion had been detached is very vascular, as also the medullary tissue opposite.—Donor, Mr. Gulliver, A. S. Staff.

3053. Section of the tibia of a dog, the shaft of which is necrosed and in progress of separation. The new bone deficient on one side, where the shaft is entirely necrosed, but reparation has made some progress on the opposite side.—Donor, Mr. Gulliver, A. S. Staff.

3054. Distal end of a dog's femur, from which a portion of the cartilage had been removed five days previous to the death of the animal. No change has supervened; apparently no more than if you paired off a portion of a hoof or nail.—Donor, Mr. Gulliver, A. S. Staff.

3055. A similar specimen to No. 3054, in which a thin layer of cartilage from the edge of one of the condyles had been removed thirteen days previous to the death of the animal. The cut surface

is a little smoother than at first.—Donor, Mr. Gulliver, A. S. Staff.

3056. Another specimen similar to Nos. 3054, 3055, twelve days subsequently to the removal of the cartilage from the front and edge of the condyle.—Donor, Mr. Gulliver, A. S. Staff.

3057. Section of the tibia of a dog, exhibiting an internal necrosis. The sequestrum is just detached, and is rough and irregular on its surface. The new membrane lining the cavity from which the dead portion is separated, is very well marked and extremely vascular. An abundant deposit of new bone, of great strength. Four months after the injury to the medullary tissue.—Donor, Mr. Gulliver, A. S. Staff.

3058. Section of the tibia of a dog, exhibiting an early state of necrosis of the shaft. The periosteum is thickened, there is an abundant thickening by new osseous matter of the shaft around the necrosed part, and the process of separation of the latter has commenced, the line of disjunctive absorption being well marked and very vascular.—Donor, Mr. Gulliver, A. S. Staff.

3059. Inferior maxillary bone of a pig fed on madder root. The bony part of the teeth is coloured, while the enamel is free from stain.—Donor, Dr. Williamson, A. S. Staff.

3060. Tibia of a pig fed on madder root; a wire was passed round it thirty-two days before the death of the animal. The bone exhibits absorption at the site of the wire, which is covered by firm lymph; above and below this point the bone is thickened from the deposition of new osseous matter.—Donor, Dr. Williamson, A. S. Staff.

3061. Tibia of a pig fed on madder root; two holes were bored in it and filled with shot, the distance between the holes being one inch and three-tenths, and the entire length of the tibia five inches. Twenty-one days after, the animal was killed and the distance between the shot found to be the same as at the time of the experiment; the tibia has, however, increased in length a fourth of an inch, now

measuring five inches and a fourth.—Donor, Dr. Williamson, A. S. Staff.

## SECTION II.—TENDON AND MUSCLE.

3062. Exhibits the first step of reparation in the ruptured tendo-Achillis. The ends are separated, blood and lymph extravasated between, and into the tissue around them, and the neighbouring structures are becoming very vascular as seen in the neurilema of the posterior tibial nerve. The tendon was divided three days previous to the death of the animal.—Donor, Mr. Gulliver, A. S. Staff.

3063. Tendo-Achillis of a rabbit, which had been divided at its junction with the muscular fibres. A long piece of membranous substance is interposed between the divided ends, and the tendon is enlarged. Divided thirty days before the death of the animal.—Donor, Mr. Gulliver, A. S. Staff.

3064. Tendo-Achillis of a dog, which had been divided forty-one days before the death of the animal. The divided ends of the tendon are apparently unchanged, and the interposed new substance connecting them is without fibres, presenting a smooth, homogeneous appearance on its cut surface.—Donor, Mr. Gulliver, A. S. Staff.

3065. Tendon of a dog, which had been divided twenty-one days before his death. The divided extremities are retracted about an inch (or rather the upper extremity), the interspace being occupied by coagulated lymph, in the substance of which some ecchymoses are apparent. The substance of the tendon appears to have undergone no change. The preparation has been minutely injected, and the adventitious deposit is shown to be vascular, and vessels are every where branching through the substance of the tendon.—Donor, Mr. Gulliver, A. S. Staff.

3066. Tendon of a dog, which had been divided four months before his death. The divided extremities are somewhat bulbous, and extremely tough and dense. The uniting medium is slender, and apparently a cellulo-fibrous tissue. It is shown to be vascular by injection.—Donor, Mr. Gulliver, A. S. Staff.

3067. Tendon of a dog, which had been divided sixty-three days before his death. The divided extremities are hardly altered, and the uniting medium is a dense fibrous tissue, similar to the contiguous tendon.—Donor, Mr. Gulliver, A. S. Staff.

3068. Tendon of a rabbit, some of the fibres of which had been divided, and a seton passed between them five days before its death. The divided ends are somewhat enlarged, and covered with a white deposit. Suppuration was established.—Donor, Mr. Gulliver, A. S. Staff.

3069. Tendon of a dog, through the substance of which a seton was passed six days before his death. The tendinous fibres appear to be unchanged, but the cellular tissue contiguous to the injury is swollen and infiltrated with lymph.—Donor, Mr. Gulliver, A. S. Staff.

3070. Tendon of a dog, which was divided three months before his death. A slight swelling marks the extremity of the upper fragment, which was retracted about three quarters of an inch. The injury is repaired by a texture very nearly approaching to that of tendon.—Donor, Mr. Gulliver, A. S. Staff.

3071. A portion of No. 3070 dried, so as to show the arrangement of the bloodvessels, which are seen to penetrate into the substance of the new part.—Donor, Mr. Gulliver, A. S. Staff.

### SECTION III.—BRAIN AND ORGANS OF SENSE.

3072. Median nerve of a dog, which was divided four days before his death. The extremities of the divided nervous fibrils are somewhat enlarged, but there is no evident alteration in the neurilema.—Donor, Mr. Gulliver, A. S. Staff.

SECTION IV.—INTEGUMENTS AND SUBJACENT CELLULAR  
SUBSTANCE.

3073. Portion of skin from the leg of a dog, exhibiting a newly-formed cicatrix. There was no destruction of parts, some vessels of small size, shooting from the margin of the cicatrix, anastomose with others of larger size forming a plexus in the centre.—Donor, Mr. Gulliver, A. S. Staff.

SECTION V.—HEART, ARTERY AND VEIN.

3074. Exhibits a wound in the carotid artery of a dog closed externally by coagulable lymph.—Donor, Dr. Davy, A. I. H.

3075. A wound in the carotid artery of a dog almost entirely healed.—Donor, Dr. Davy, A. I. H.

3076. Portion of the carotid artery of a dog, which had been divided for more than half its diameter, and healed. The vessels in these experiments were partially divided transversely, and the bleeding arrested by the application of compresses (moderate pressure as on a vein after blood-letting) moistened with water. The experiments were made with a view to determine the credit due to a celebrated styptic,—Acqua Binelli,—and the result shows the efficacy of simple pressure in stopping hæmorrhage from large vessels, and that the Acqua Binelli is of no more utility in arresting hæmorrhage than water.—Dr. Davy, in Edinb. Med. and Surg. Journal, vol. xl. page 31.

3077. Posterior extremity of a dog, in which the femoral artery was tied. The bloodvessels are filled with coarse injection.—Donor, Mr. Alexander, A. S. Staff.

3078. Femoral artery of a dog, around which a ligature was placed four days previous to the death of the animal. A very small clot is formed, not extending to the nearest branch above the ligature.

3079. A similar specimen to No. 3078, six days subsequent to the tying of the vessel. Here also the clot does not nearly extend to the nearest branch above the ligature.

3080. Femoral artery of a dog, upon which two ligatures had been placed at a distance from each other so as to include a clot within the portion of the vessel between the ligatures. Through this clot a seton has been passed. The result appears to be nearly complete removal of the clot, and effusion of lymph around the vessel, with shrinking of the latter.

This experiment was made four days before the death of the animal. There was much pus around the vessel, but none within it.

3081. Median cephalic vein, three days after phlebotomy.—From a man, *ætat.* 24, who died of phthisis.

## MISCELLANEOUS.

---

3082. Sac of an abscess, exhibiting its vascularity, and the deposition in its cavity of a substance apparently (at least in consistence) intermediate between pus and tubercle.—From a rabbit, in the leg of which the tumour had existed for six weeks, in consequence of irritation kept up in the centre of the tibia.—Donor, Mr. Gulliver, A. S. Staff.


3083. Exhibits two tumours from a rabbit, the upper of which is similar to No. 3082, but the lower has become very vascular, apparently from organization of the white substance contained in the sac. This lower tumour was soft like the other in its early stage, but became gradually harder.—From the tibia of a rabbit, in consequence of irritation kept up in the centre of the bone.—Donor, Mr. Gulliver, A. S. Staff.




MIRIAM'S STORY

The first of the two volumes of the story of Miriam is a history of the people of Israel from the time of the Exodus to the time of the Babylonian Captivity. It is a history of the people of Israel as a nation, and it is a history of the people of Israel as a people. It is a history of the people of Israel as a nation, and it is a history of the people of Israel as a people.

The second volume of the story of Miriam is a history of the people of Israel from the time of the Babylonian Captivity to the time of the return to the land of Israel. It is a history of the people of Israel as a nation, and it is a history of the people of Israel as a people. It is a history of the people of Israel as a nation, and it is a history of the people of Israel as a people.





Accession no. 32917

Great Britain,  
Author  
Army Medical...

Catalogue of prep.  
in Fort Pitt, Chatham.

Call no.

19th A891

Cent 67

C5

1845

BOUND BY  
WESTLEYS &  
CLARK.  
LONDON.

