

Oral anaesthesia; local anaesthesia in the oral cavity : technique and practical application in the different branches of dentistry / by Kurt Hermann Thoma.

Contributors

Thoma, Kurt H. 1883-
Harvey Cushing/John Hay Whitney Medical Library

Publication/Creation

Boston, Mass. : Ritter & Flebbe, [1914], [©1914]

Persistent URL

<https://wellcomecollection.org/works/e7xtg4m4>

License and attribution

This material has been provided by This material has been provided by the Harvey Cushing/John Hay Whitney Medical Library at Yale University, through the Medical Heritage Library. The original may be consulted at the Harvey Cushing/John Hay Whitney Medical Library at Yale University. where the originals may be consulted.


This work has been identified as being free of known restrictions under copyright law, including all related and neighbouring rights and is being made available under the Creative Commons, Public Domain Mark.

You can copy, modify, distribute and perform the work, even for commercial purposes, without asking permission.


**wellcome
collection**

Wellcome Collection
183 Euston Road
London NW1 2BE UK
T +44 (0)20 7611 8722
E library@wellcomecollection.org
<https://wellcomecollection.org>


RK510
.T36
1914




TRANSFERRED TO
YALE MEDICAL LIBRARY









ORAL ANAESTHESIA

LOCAL ANAESTHESIA IN THE ORAL CAVITY

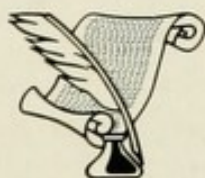TECHNIQUE AND PRACTICAL APPLICATION IN
THE DIFFERENT BRANCHES OF DENTISTRY

BY

KURT HERMANN THOMA, D.M.D.

Assistant in Anaesthesia, Harvard Dental School, Harvard University
Assistant in Dental Anatomy, Harvard Medical School, Harvard University
Fellow of the Harriet N. Lowell Society for Dental Research of Harvard
University


Member of National, State and Local Dental Societies



BOSTON, MASSACHUSETTS
RITTER & FLEBBE
120 BOYLSTON STREET

(The right of reproduction of the original illustrations is strictly reserved.)

Copyrighted at the Registry of Copyrights, Washington, D. C., 1914. All rights reserved.



CONTENTS

	Page
I. INTRODUCTION	7
II. ANATOMY OF THE ORAL CAVITY	9
1. OSTEOLOGY	9
Maxilla	9
Mandibula	14
2. NEUROLOGY	25
The Ophthalmic nerve	25
The Maxillary nerve	25
The Spheno-palatine ganglion	28
The Mandibular nerve	31
III. TOPOGRAPHY	35
The Mucous membrane of the mouth	35
The Pterygo-mandibular space	38
IV. PHARMACOLOGY	39
1. NOVOCAIN	39
2. SUPRARENIN SYNTHETICUM	41

	Page
3. NOVOCAIN SUPRARENIN COMBINED	44
Seidel's 16 Theses	44
Seidel's method	47
Ampules	47
Solutions	47
Tablets, Author's method	48
4. PHYSIOLOGICAL SALT SOLUTION	50
5. DISTILLED WATER	50
V. INSTRUMENTARIUM	54
1. INSTRUMENTS	54
2. TABLETS	54
VI. PREPARING OF THE SOLUTION	58
Requirements of a solution prepared from tablets	58
VII. LOCAL ANAESTHESIA	60
A. SURFACE ANAESTHESIA	62
Nasal Anaesthesia	63
B. INFILTRATION ANAESTHESIA	63
The infiltration method in the maxilla	63
Preparing of the patient	64
Preparing of place for insertion of the needle	65
1. Injection on the labial and buccal sides	66
2. Injection on the palatal side	68
The infiltration method in the mandibula	69
1. Injection on the labial side of lower incisors	70
2. Injection on the lingual side of lower incisors	70
Horizontal injection	70

	Page
C. CONDUCTIVE ANAESTHESIA	71
The Conductive method in the Mandible	73
1. Pterygo-mandibular injection	74
2. Mental injection	81
3. Buccinator injection	84
The Conductive method in the maxilla	85
1. Zygomatic injection	85
2. Infra-orbital injection	86
3. Incisive injection	89
4. Posterior-palatine injection	90
5. Spheno-maxillary injection	90
D. GANGLION ANAESTHESIA	91
Injection into the Gasserian ganglion	91
VIII. FAILURES AND ILL-EFFECTS IN LOCAL ANAESTHESIA	93
True failures and Ill-effects	93
a. No anaesthesia is obtained	93
b. Undesirable symptoms during the anaesthesia	94
c. After-effects	96
Oedema	96
After-pain	97
Prolonged anaesthesia	97
Psychological Effects	98
Ill-Effects due to other sources	99
VIII. PRACTICAL APPLICATIONS OF LOCAL ANAESTHESIA IN DIF- FERENT BRANCHES OF DEN- TISTRY	101
Table I: Infiltration anaesthesia for the teeth only	102
Table II: Infiltration anaesthesia for the teeth and soft tissues	103
Table III: Conductive anaesthesia for the teeth only	104
Table IV: Conductive anaesthesia for the teeth and soft tissues	105

	Page
1. OPERATIVE DENTISTRY	106
Cavity preparations	106
Removal of normal pulps	107
Removal of calcified pulps	111
Removal of pulps with pulp stones	111
Removal of hypertrophied pulps	111
Removal of inflamed pulps	112
Removal of inflamed pulps complicated with periodontitis	112
Acute alviolar abscess at the Apex	112
Chronic Alviolar abscess	113
Pericemental abscess	114
Diagnosis	114
2. CROWN AND BRIDGE WORK	116
Fitting of bands and cementing bridges	116
Grinding and Devitalizing	118
3. EXODONTIA	120
4. ORAL SURGERY.	121
Operation for granulum, root and apex amputations.	122
Impacted teeth	130
Fractures of the jaws	131
Cysts, Tumors, Necrosis, Odontoma	131
Cleft palate, Hare lip, Amputation of the alviolar process, and Resection of jaws	133

I. INTRODUCTION

IN these days of nervousness, hysteria and competition, the dentist stands before the question: How can I accomplish my work with the least discomfort to the patient, in the shortest time and with the most perfect result? Local anaesthesia fulfills these three requirements in the most ideal manner. If there is no interfering pain, there is no reason why we should not accomplish much better work in much less time.

Does general Anaesthesia or Analgesia fulfill these requirements? Certainly not. How can we perform delicate dental operations, if we have to watch a more or less complicated machine, as well as the action of the narcotic on the patient, and how unpractical is general anaesthesia for exodontia and minor oral surgery in the mouth. Mouth prop, inability of the patient to coöperate, obscured field of operation by saliva and blood, which is swallowed and inhaled, endless sponging prolonging the operation, are only some of the disadvantages. This created the desire for something better.

But not only in dentistry, also in surgery arose the demand for something safer with less strain, discomfort and danger to the patient. Professor Bier of Berlin developed the infiltration anaesthesia with cocaine. Cocaine anaesthesia was then introduced successfully into the different branches of Medicine. In dentistry cocaine was injected with much force through a very short needle, directly into the gum, producing a velum of white appearance. This decreased the pain considerably in extraction. A new way of using cocaine in dentistry was introduced by Professor Briggs of Boston in 1890. His method is called pressure anaesthesia. A pellet of cocaine is placed upon the exposure of a pulp and pressed in with a small piece

of unvulcanized rubber, causing anaesthesia of the pulp for purpose of devitalization. Professor Braun of Zwickau worked out a new technique and system of local anaesthesia, which aroused promptly great interest in our profession. On account of the idiosyncratic behavior of cocaine, men of science looked for a substitute. Among several hundred preparations, "Novocain," discovered by Professor Einhorn of Munich was found the best. The dentists of Germany were quick in realizing the advantages of the new technique combined with the new drug. In utilizing for our profession, Braun's original ideas, different methods of injection, and various ways of preparing of the anaesthetic solution developed. The most distinguished German authors are Braun, Haertel, Fischer, Seidel, Buente, Moral, Steinkamm and Hauptmeyer.

Local Anaesthesia is based upon thorough knowledge of the oral Anatomy, scrupulous asepsis, fresh drugs, and exact technique.

II. ANATOMY OF THE ORAL CAVITY

Only those structures of the Anatomy of the oral cavity which are intimately connected with Local Anaesthesia shall be considered in this book.

I. OSTEOLOGY

The formation and make-up of the maxilla and mandibula, the two bones containing the teeth, is of somewhat different character. The mandible resembles more a flat bone; it even could be compared with a rib, while the maxilla is of irregular type, containing the principal air sinuses of the face.

The maxillary bone encloses a large cavity, the **Maxilla** maxillary sinus (O. T. Antrum of Highmore). Its walls, therefore, are very thin. Of the four surfaces the anterior and infra-temporal are of special interest to us, also the alviolar, zygomatic and palatal processes, and the infra-orbital, posterior alviolar and posterior palatine foramina.

a. The Anterior surface (O. T. external or facial surface) presents an eminence over the root of the cuspid, called the canine eminence, which separates the incisive from the canine fossa. Above this lies the infra-orbital foramen under which the levator anguli oris takes its origin. The incisive fossa gives origin to the compressor nasi, above and below and more to the median line, to the depressor septi (O. T. depressor alae nasi).

b. The Infra-temporal surface (O. T. posterior or zygomatic surface) is convex, directed backwards and inward. It

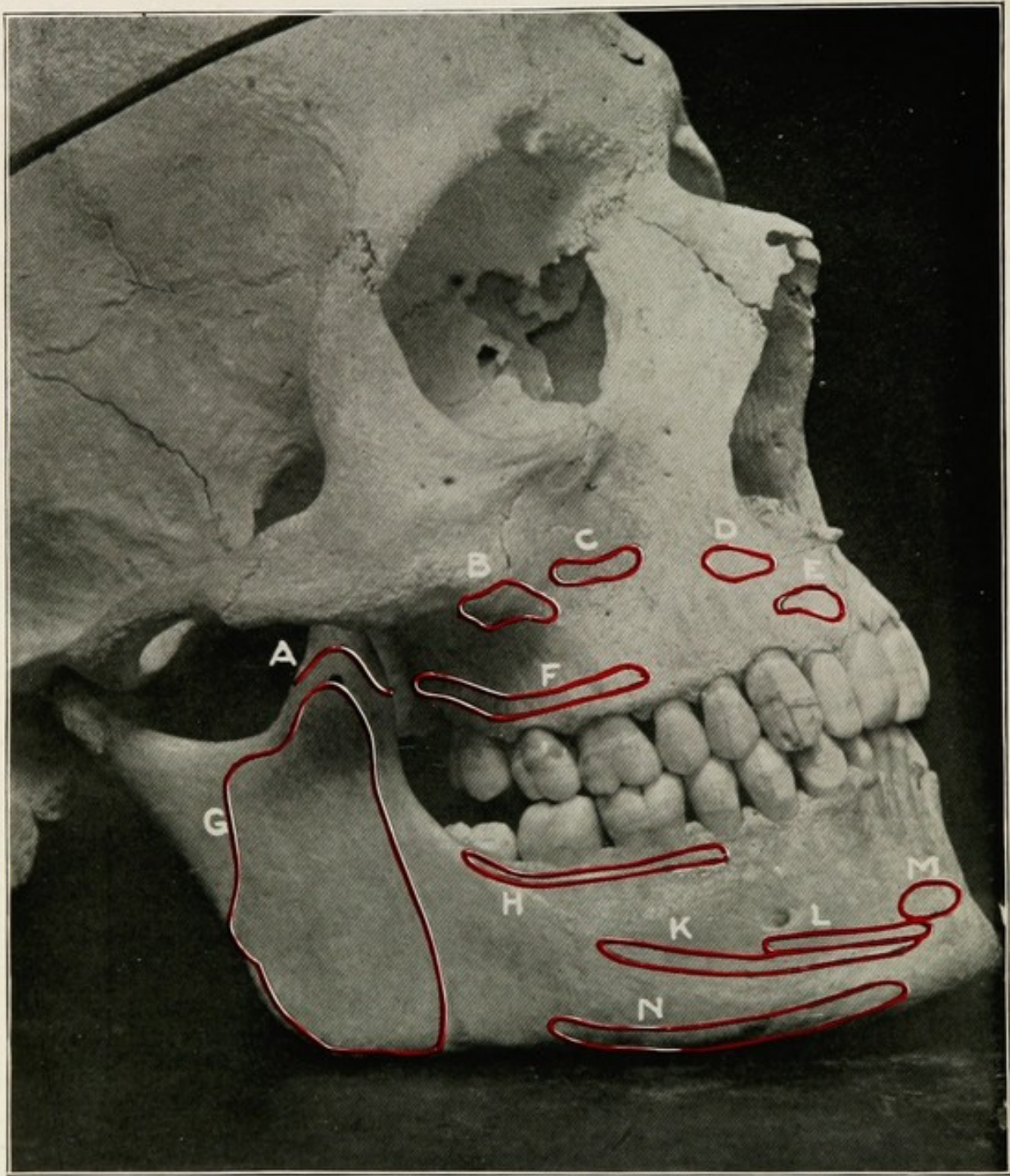


FIG. 1. Outer surface of Maxilla and Mandibula showing attachments of muscles. A: m. Temporalis; B: m. Masseter; C: m. Levator anguli oris; D: m. Compressor nasi; E: m. Depressor septi; F @ H: m. Buccinator; G: m. Masseter; K: m. Depressor anguli oris; L: m. Depressor labii inferior; M: m. Depressor menti; N: m. Platysma myoides.

forms part of the zygomatic fossa. It is separated from the anterior surface by the zygomatic process. It contains the posterior alviolar foramina. At its posterior and inferior part is a rounded eminence, the tuber maxillare. This gives attachments to a few fibers of the external pterygoid muscle.

c. The Zygomatic process (O. T. Malar process) extends from over the second molar to articulate with the malar bone. Its posterior surface is convex and forms part of the zygomatic fossa.

d. The Alviolar process is made up of an inner and outer plate, which are connected with numerous septa of cancellated bone. *The outer plate* is continuous with the anterior and infra-temporal surfaces and is marked by vertical ridges corresponding with the roots of the teeth. It is quite thin and frail over the incisors, cuspids and bicuspid, containing numerous small foramina, giving the bone a porous appearance. A very thin plate of bone separates the maxillary sinus from the canine fossa. Further back in the region of the molars, the process becomes thicker and a cortical airia, with very few foramina is usually found at the root of the zygomatic process. The posterior extremity forms the tuberosity which again is very porous around the alviolus for the wisdom tooth. *The inner plate* of the alviolar process is much heavier and stronger, small pores are evenly distributed throughout its extent. At its upper extremity it joins the palatal process. The alviolar process gives origin to the buccinator muscle at the posterior part of its outer plate, near its upper margin, which reaches as far forward as the first molar or second bicuspid.

e. The palatal process projects horizontally inward to form the roof of the mouth together with a portion of the palatal bone. In the median line of the anterior part, we find the incisive foramen, at the posterior and external sides are the two palatine foramina.

f. The Infra-orbital foramen is situated immediately below the center of the infra-orbital ridge and near the upper

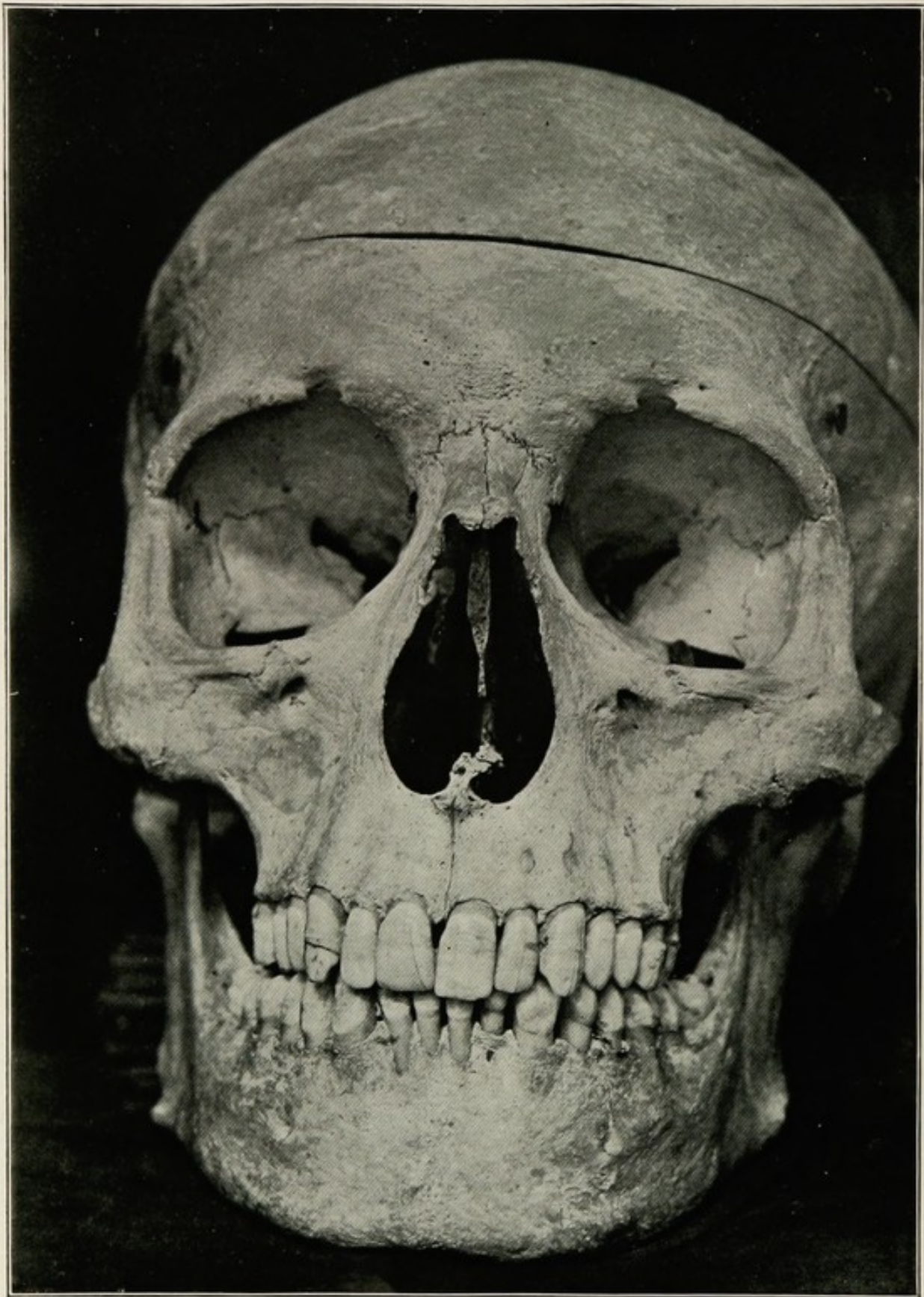

FIG. 2. Skull showing small foramina in the incisor region of the maxilla and mandibula. Note also Infra-orbital and mental foramina.

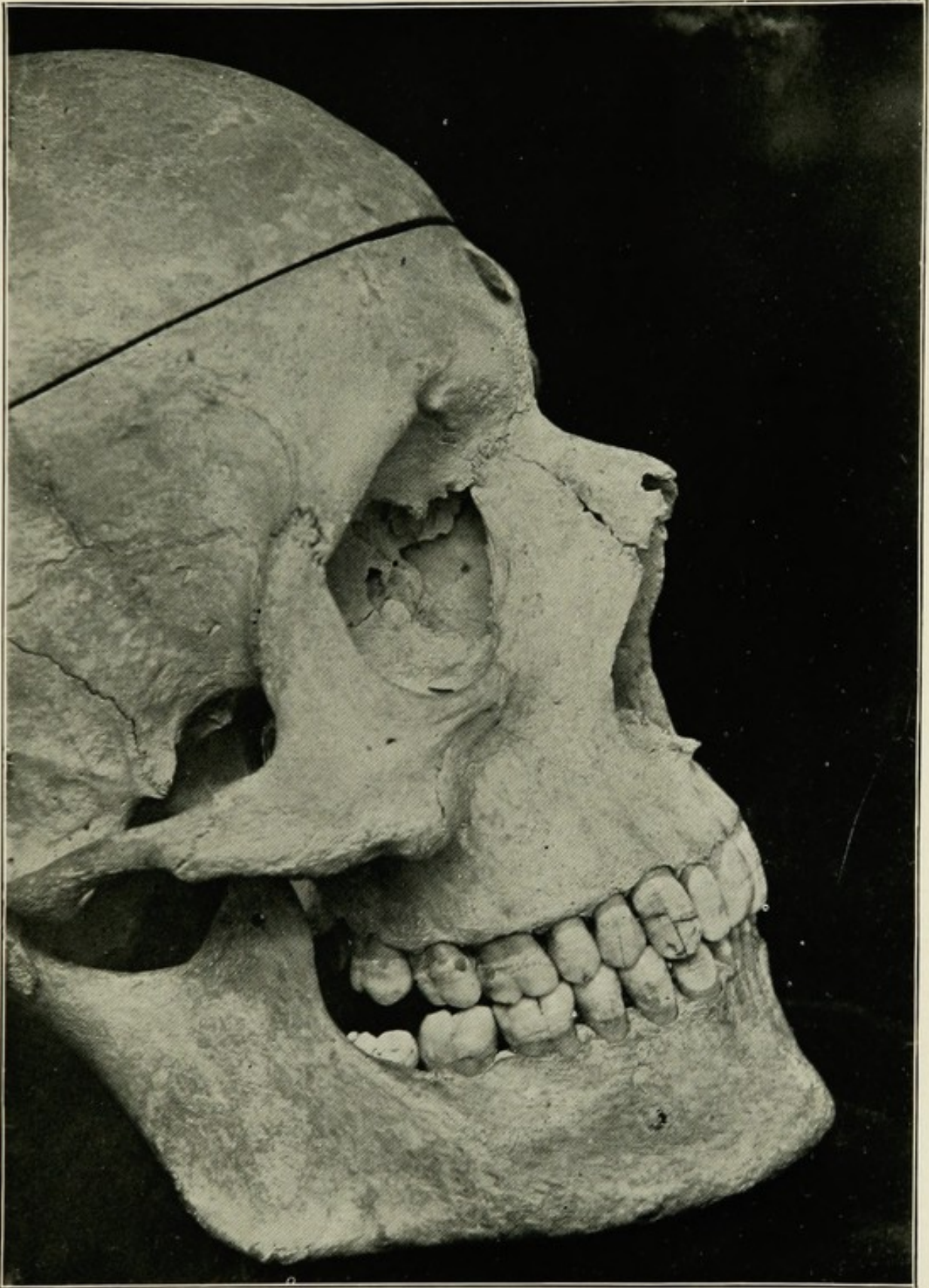


FIG. 3. Skull showing foramina in the cuspid, bicuspid and molar regions of the maxilla and absence in the mandibula.

margin of the canine fossa, above the root of the first bicuspid. It is oval in shape and transmits the infra-orbital nerve and blood vessels.

g. The posterior alviolar foramina are situated at the posterior part of the infra-temporal surface, and are usually two in number. They lead into canals of the same name which transmit the posterior alviolar vessels and nerves.

h. The Incisive foramen lies immediately behind the incisor teeth in the median line. It is formed by four canals, two lateral ones for the descending palatine arteries, and two, one in front and one behind, in the median line, for the naso-palatine nerves.

i. The Palatine Foramina. There is a larger and a smaller foramen, the first transmits the anterior palatine nerves and vessels, the other lies almost immediately behind it and transmits the middle palatine nerve and vessels, which supply the soft palate. The larger palatine foramen is situated at the level of the third molar or in children at the level of the last molar present. It is the outlet of the palatine canal made up of the maxillary and palatine bones.

j. The Maxillary sinus (O. T. Antrum of Highmore), varies considerably in shape, size and capacity. Its posterior wall is crossed by the posterior alviolar nerves, which they enter by special foramina. On its external wall we find a canal for the middle alviolar nerve, which runs downward and forward to the bicuspid region, and on its anterior wall we find the anterior alviolar canal, in which the anterior alviolar nerves descend. It runs inward towards the nose and downward towards the incisors. The superior surface is formed by the floor of the orbit, which contains the infra-orbital canal.

This bone is much denser than the maxilla, and
Mandibula also has much thicker and very cortical layers.

It is divided into a body and two rami. The body of the mandible consists of an external and internal surface, and of the alviolar process.

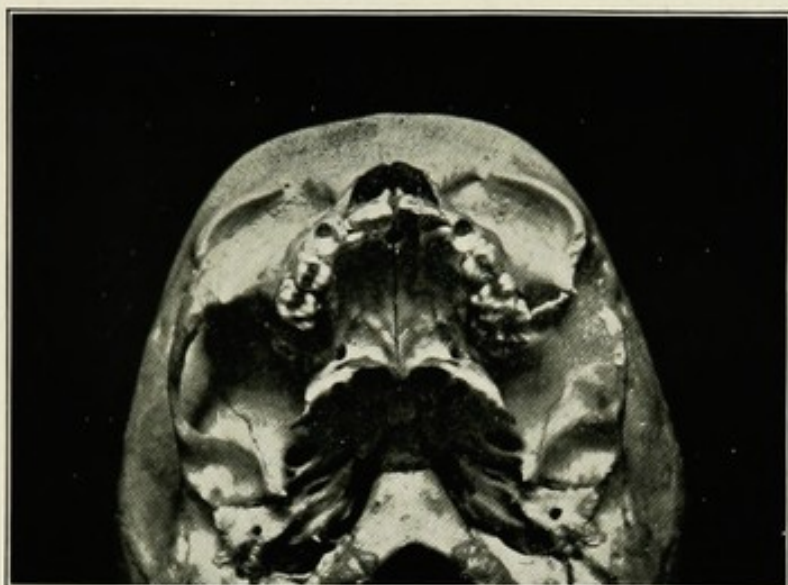


FIG. 4. Palate of a child 6-7 years, note location of incisive and palatine foramina.

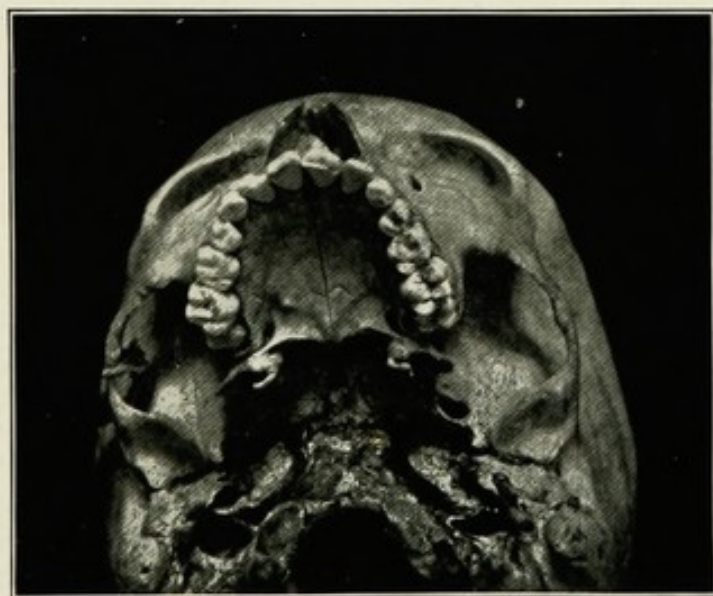

FIG. 5. Palate of a child 11-12 years, note location of incisive and palatine foramina.

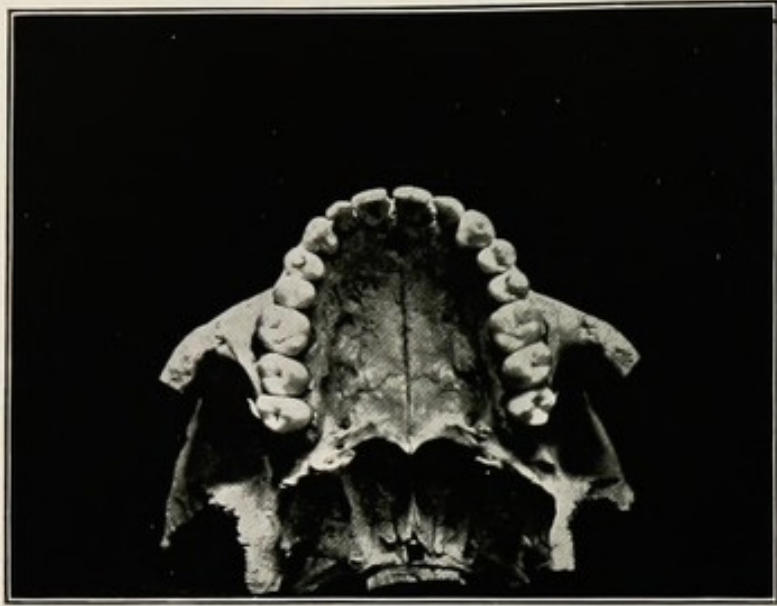

FIG. 6. Palate of an adult, note location of incisive and palatal foramina.

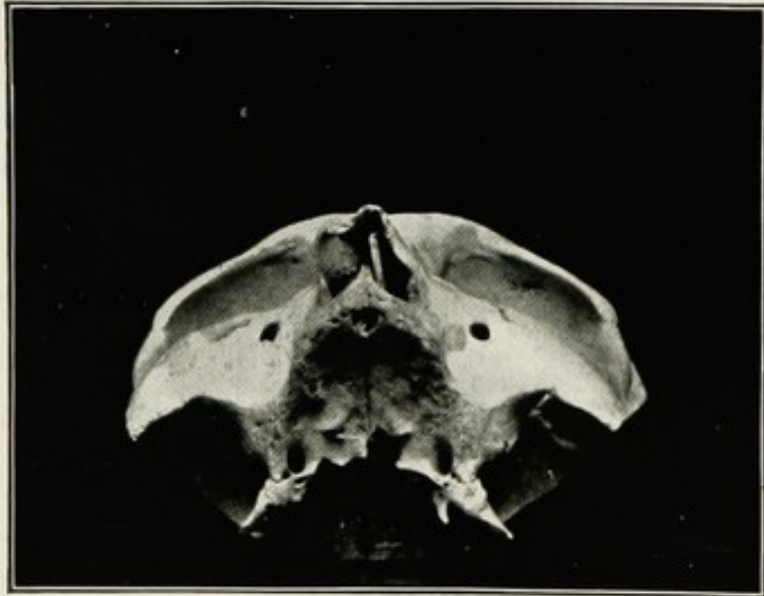

FIG. 7. Palate of senile skull, note location of incisive and palatine foramina.

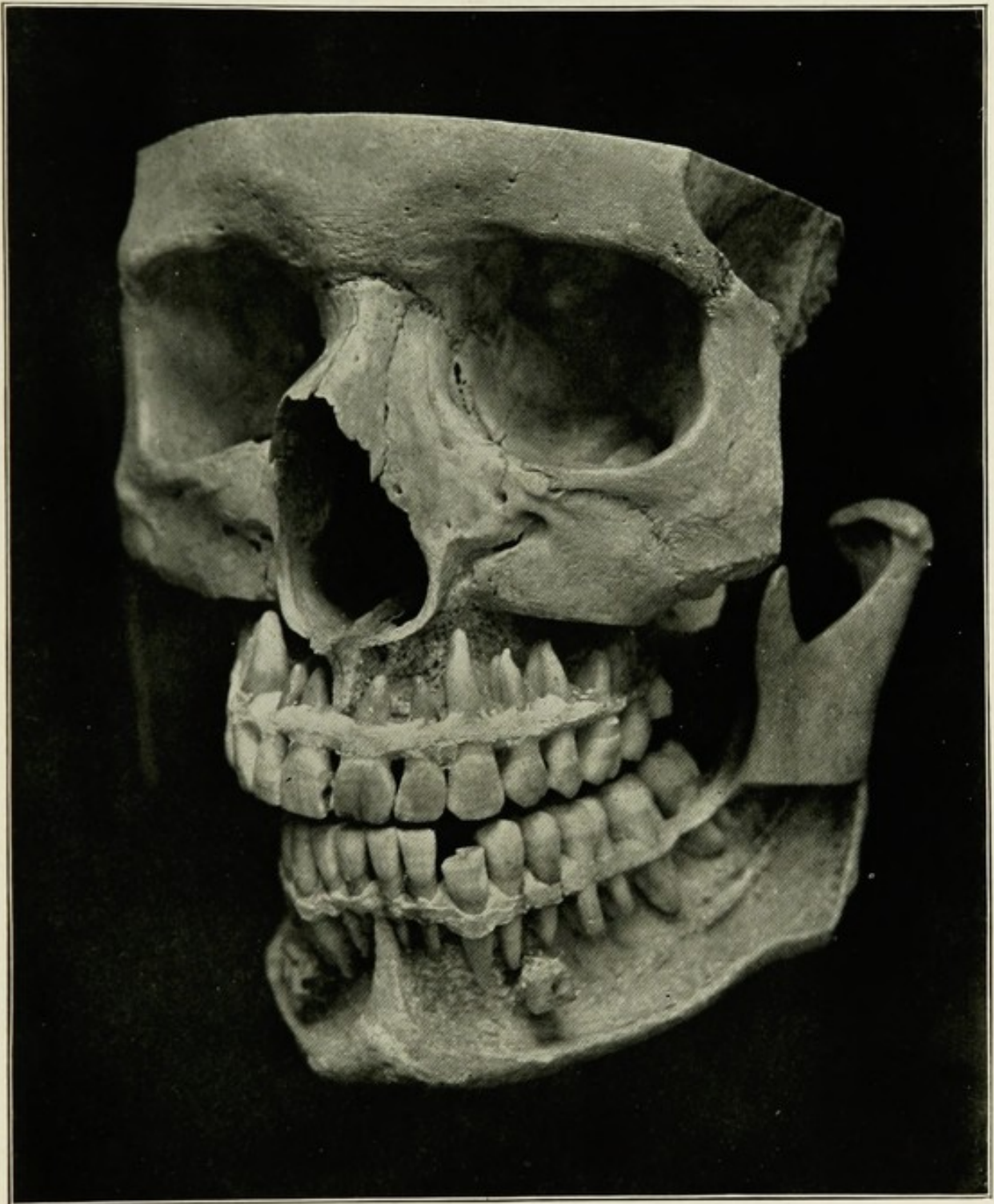


FIG. 8. Skull with dissected anterior superior alveolar canal.

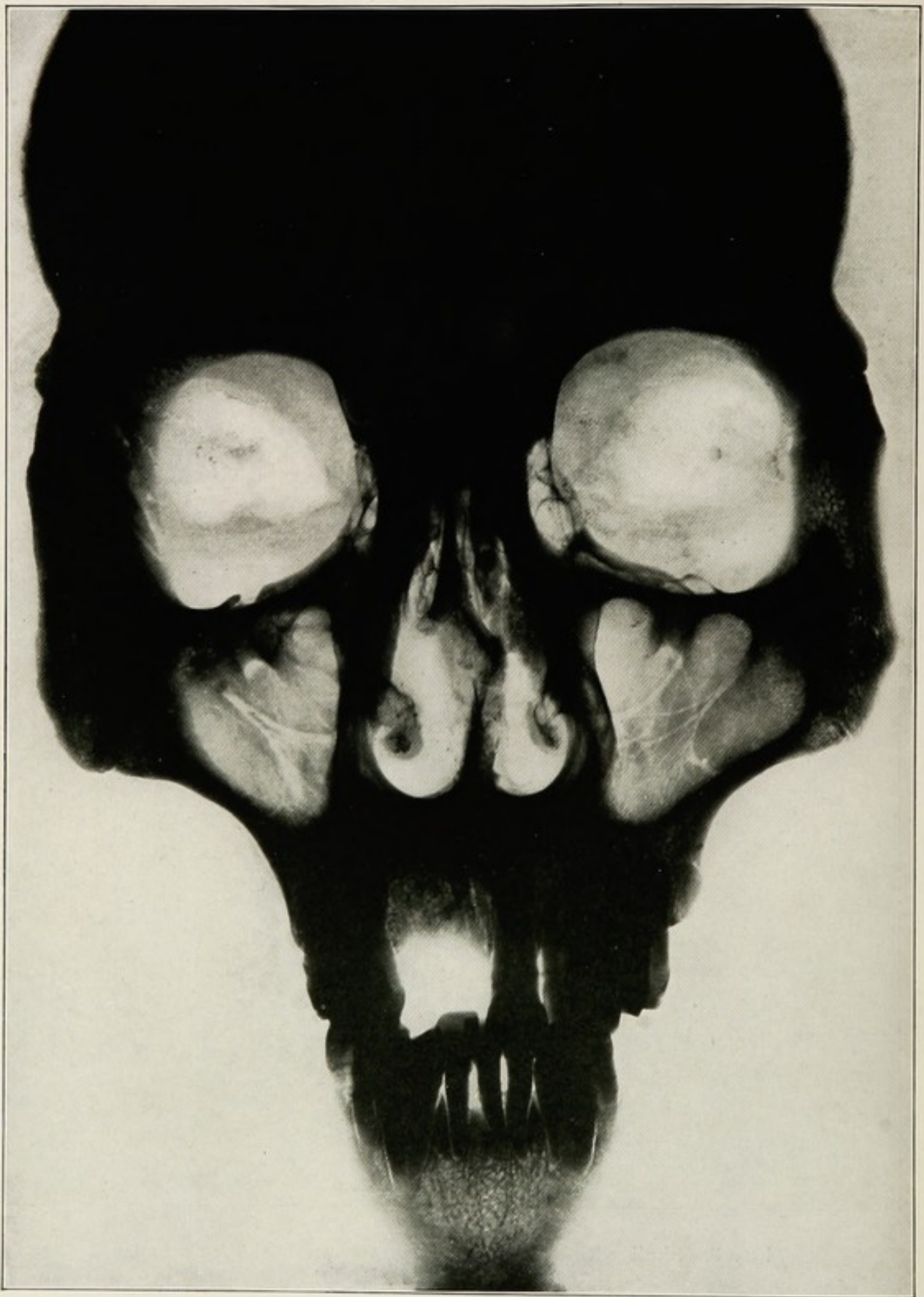

FIG. 9. Radiograph showing a frontal aspect of the maxillary sinus. Anterior middle and infra-orbital canals, infra-orbital foramen and superior alviolar plexus.

THE BODY OF THE MANDIBLE

a. **The External surface** of the body of the mandible presents the two mental foramina, one on either side, the external oblique line which is continuous from the ramus, and the mental fossa. The mental fossa lies directly beneath the incisor teeth, and is very porous. Showing many small foramina similar to the ones around the roots of the maxillary teeth. These are

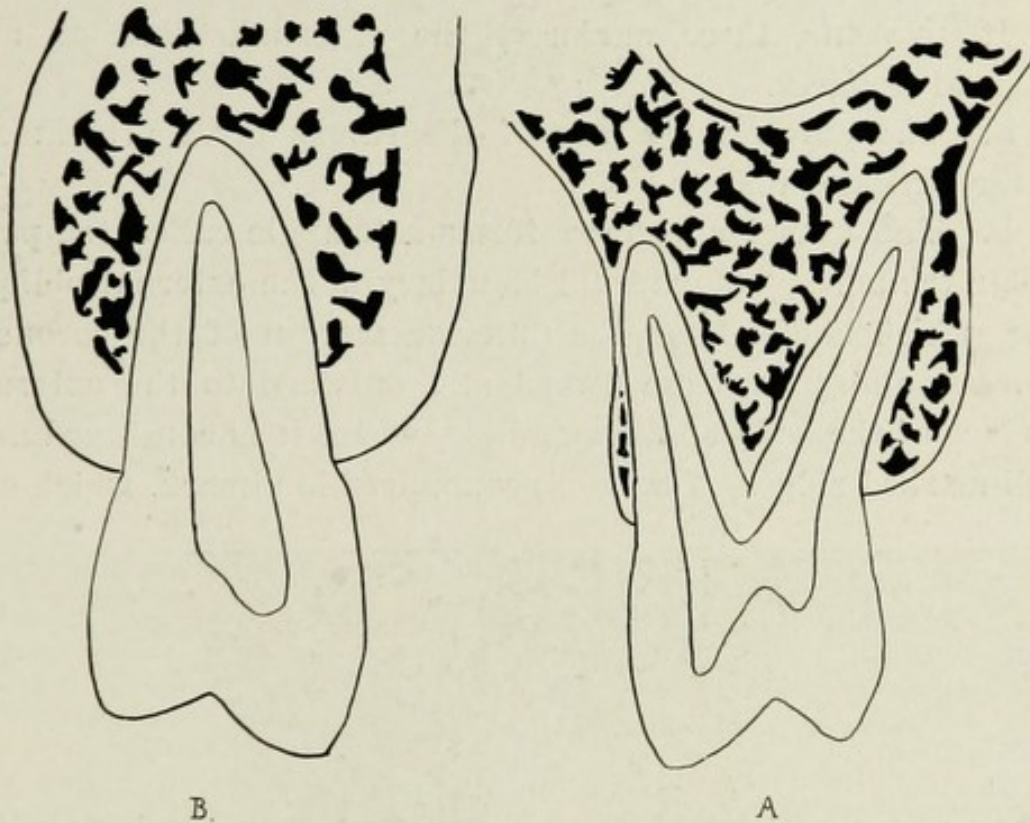


FIG. 10. Cross section through maxilla and mandibula showing difference in makeup of the bone. A. Frontal section through maxillary alveolar process. B. Frontal section through mandibular alveolar process. Both in the bicuspid region.

made use of for the infiltration method of local anaesthesia. The rest of the surface is almost one cortical mass.

b. **The Internal surface** of the body likewise is made up of a very heavy layer of bone, with the exception of the region of the genial tubercles, where we find a caniculated area.

c. **The alviolar process** of the mandibula is much stronger than the alviolar process of the maxilla. In the molar region it is even reënforced by the external and internal oblique lines. The alviolar ridge shows perforations, especially well marked in the bicuspid and incisor regions, but the part near the roots and over the apices of the teeth is non-caniculated with the exceptions mentioned, on both sides of the incisor teeth.

THE RAMUS OF THE MANDIBLE

It presents three surfaces, the external, anterior and internal surfaces.

a. **The external surface** of the ramus gives attachment to the Masseter muscle.

b. **The anterior surface** forms a triangle called the post-molar triangle. Its external boundary is the external oblique line, which starts from the anterior margin of the coronoid process, and passes downward and outward to the external surface of the body of the mandible, where it is continued as a well-marked ridge. This is a pronounced landmark, which can

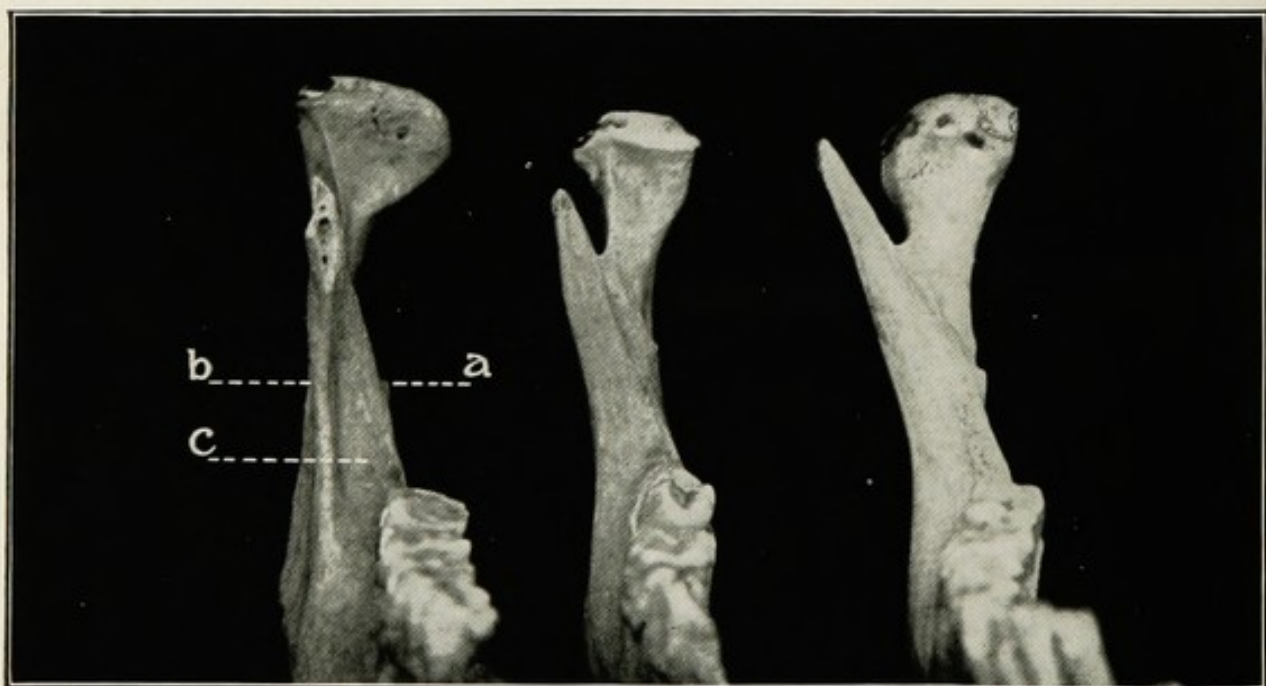


FIG. 11. Three mandibles showing different construction of the post-molar triangle. a Internal oblique line. b External oblique line. c Post-molar triangle.

be easily palpitated in the mouth. The internal boundary of the post-molar triangle is the internal oblique line, which is varying, sometimes well marked, other times rounded, and hard to find. The base is formed by the wisdom tooth. The triangle is concave and can be easily felt with the tips of the fingers. It lies behind and externally to the last molar.

c. The internal surface of the ramus presents about its center the mandibular foramen. This is the opening into the mandibular canal. The margin of the foramen presents at its anterior side a prominent lingula, the mandibular tongue. To this is attached the speno-mandibular ligament. The mandibular tongue is varying in size from a tongue like to a thickened process. From this a decided groove starts, running obliquely downward, for the mylohyoid nerve and artery. At the angle of the ramus, we find rough oblique ridges, to give insertion to the internal pterygoid muscle. This muscle covers the mandibular foramen completely, with the exception of a circular space. This space is called *pterygo-mandibular space* from its position between the pterygoid muscle and the mandible. Its outline is the *sulcus mandibularis*, a groove found around the foramen.

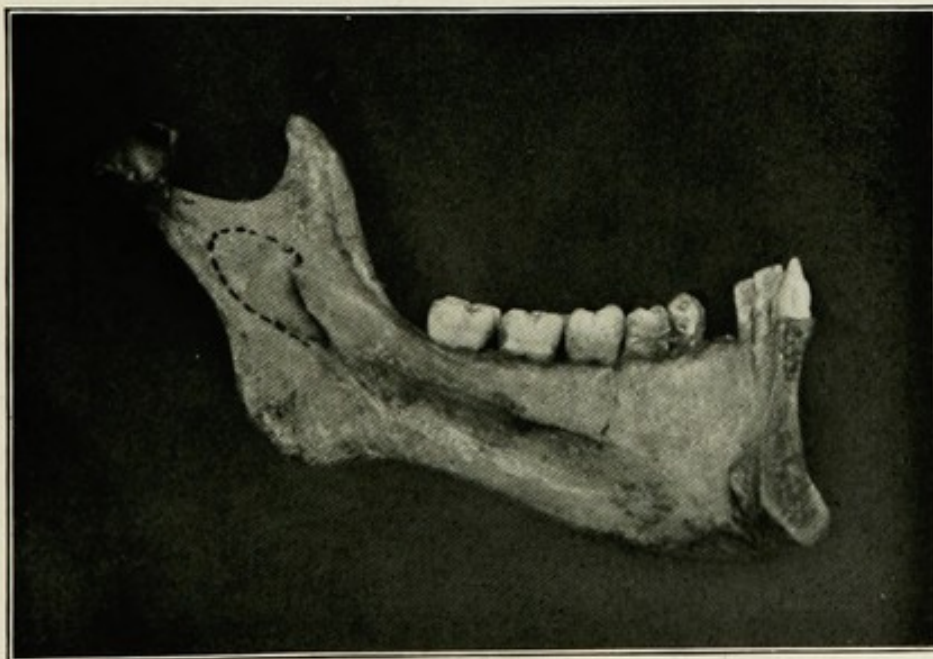

FIG. 12. Sulcus mandibularis enclosed by the dotted line.

d. The Mandibular canal (O. T. Inferior dental canal) runs obliquely downward and forward in the substance of the ramus, and then horizontally forward in the body of the mandible. It lies close to the inner compact layer, immediately under the alviolae into which small branches extend, given off from the main canal, for the nerves and vessels which supply the teeth. In the median line anastomosis with the opposite side takes place.

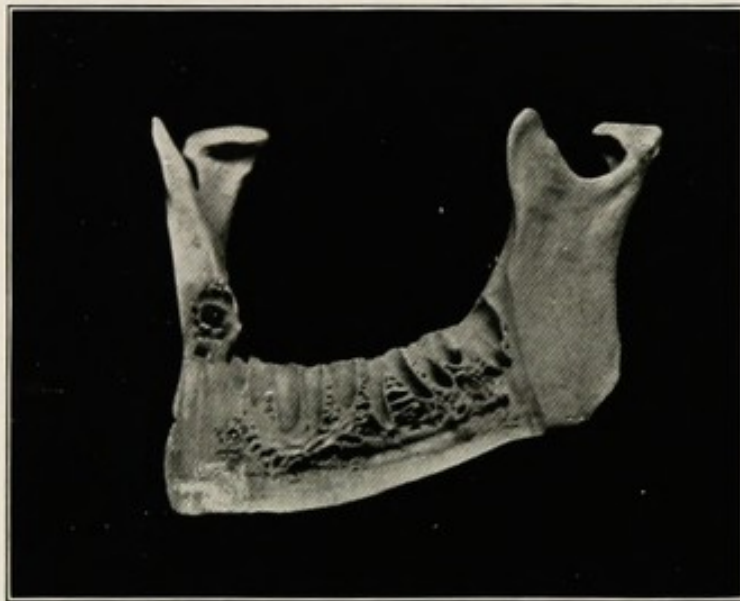


FIG. 13. Specimen showing dissected mandibular canal.

e. The Mandibular Foramen (O. T. Inferior dental foramen) is situated about the middle of the internal surface of the ramus, halfway between the anterior and posterior border (in a horizontal line varying slightly between the alviolar border and the coronal surface of the molars). Viewing the mandible from in front, it seems covered by the internal oblique line on account of the angle of the ramus to the median line, which varies in different individuals. The inferior alviolar nerves and vessels are protected by the lingula, when entering the foramen, and therefore an injection for this nerve has to be made above the lingula, into the pterygo-mandibular space.

f. The **Mental foramen** lies below and between the first and second bicuspids, usually nearer and sometimes entirely

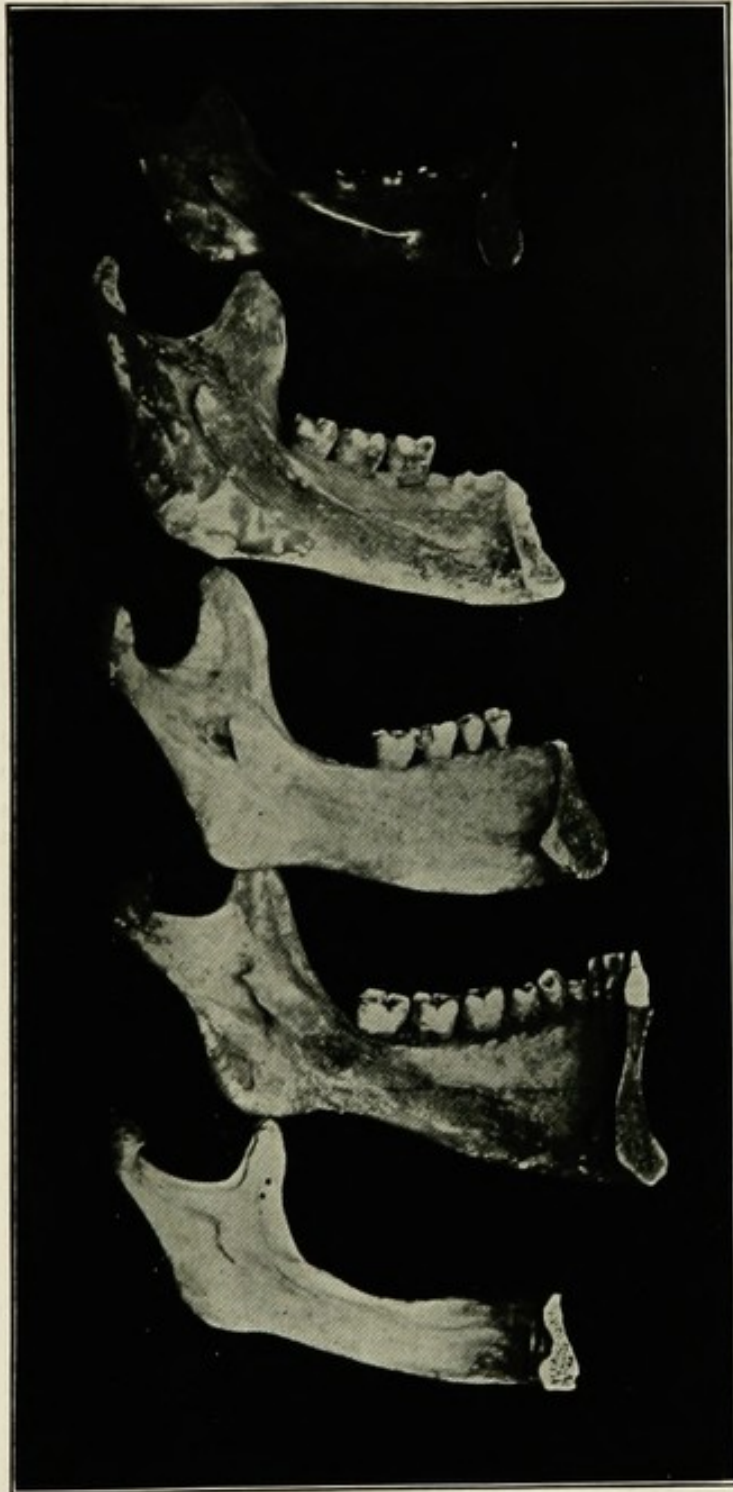

FIG. 14. Variations of the internal surface of the ramus mandibularis. Note the lingula, sulcus mandibularis, and mandibular foramina in the different specimen. The first from a young the last from a senile individual.

below the second bicuspid. It is the communication with the mandibular canal, and gives exit to the mental nerve and vessels.

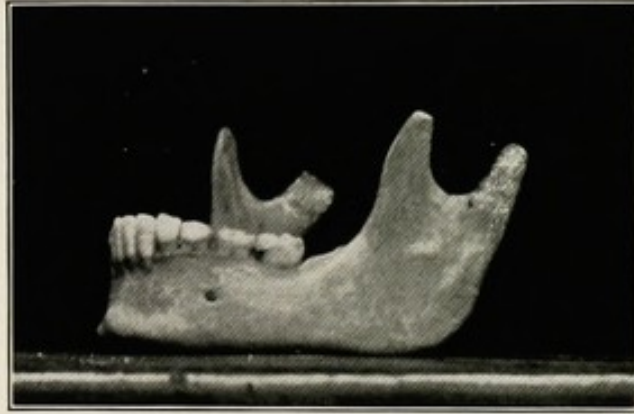


FIG. 15. Location of mental foramen in a child.

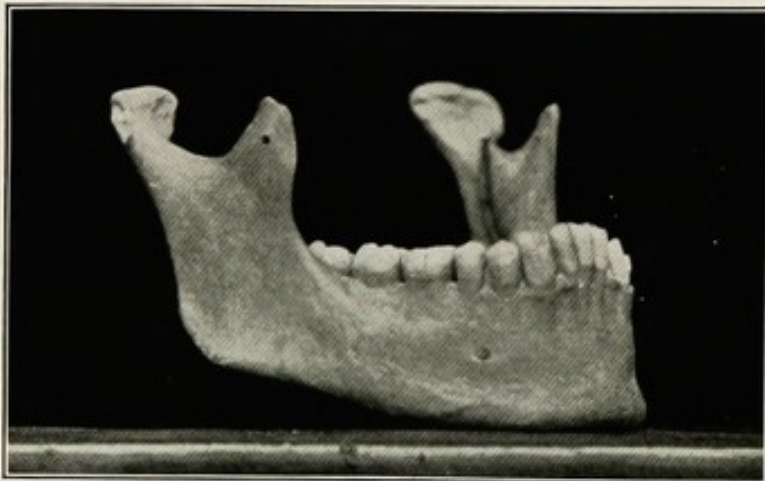

FIG. 16. Location of mental foramen in adult.

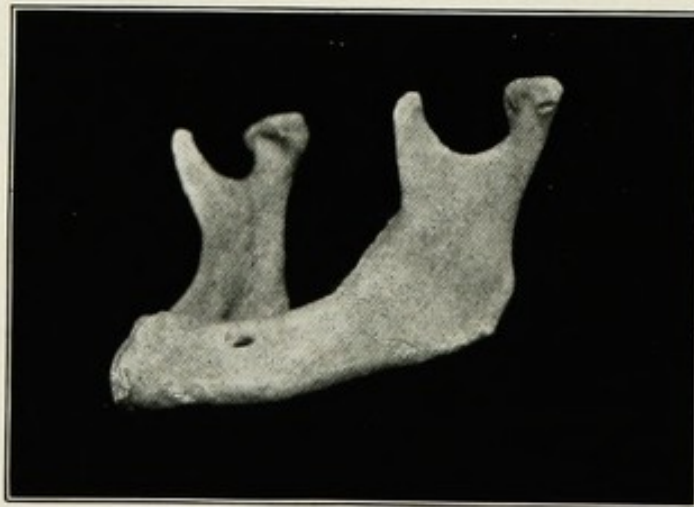


FIG. 17. Location of mental foramen in senile skull.

2. NEUROLOGY

The trigeminal or Vth cranial nerve has a larger, or sensory, and a smaller, or motor root. The large root forms the semi-lunar ganglion. The Vth nerve is divided into

1. Ophthalmic nerve.
2. Maxillary nerve (O. T. Superior maxillary).
3. Mandibular nerve (O. T. Inferior maxillary).

The Ophthalmic Nerve The Ophthalmic nerve supplies no tissue in the oral cavity. It supplies the eye-ball, the lacrimal gland, the lining of the eye, and nasal fossa, the skin of the eyebrow, forehead and nose. It is only so far of interest to us as in some cases of neuralgia the pain is referred to this branch.

The Maxillary Nerve The maxillary nerve comes from the foramen rotundum entering the speno-maxillary fossa. Here it gives off—

The zygomatic branch, supplying the skin of the side of the forehead and of the cheek.

The speno-palatine nerves, which form the sensory, or short, roots of the speno-palatine ganglion.

The posterior superior alviolar rami are given off just before the nerve enters the infra-orbital canal. They are two or three in number, but often have a common trunk, and then divide and pass downward on the tuberosity of the maxilla. They give off twigs to the buccal part of the gum and mucous membrane of the cheek; these are called the superior gingival branches. The posterior alviolar branches enter from the infra-temporal surface of the maxilla into the posterior alviolar canals. They supply the mucous membrane of the maxillary sinus, and then take part in the formation of the superior dental plexus, supplying the molar teeth, the alviolo-dental membrane and the gum.

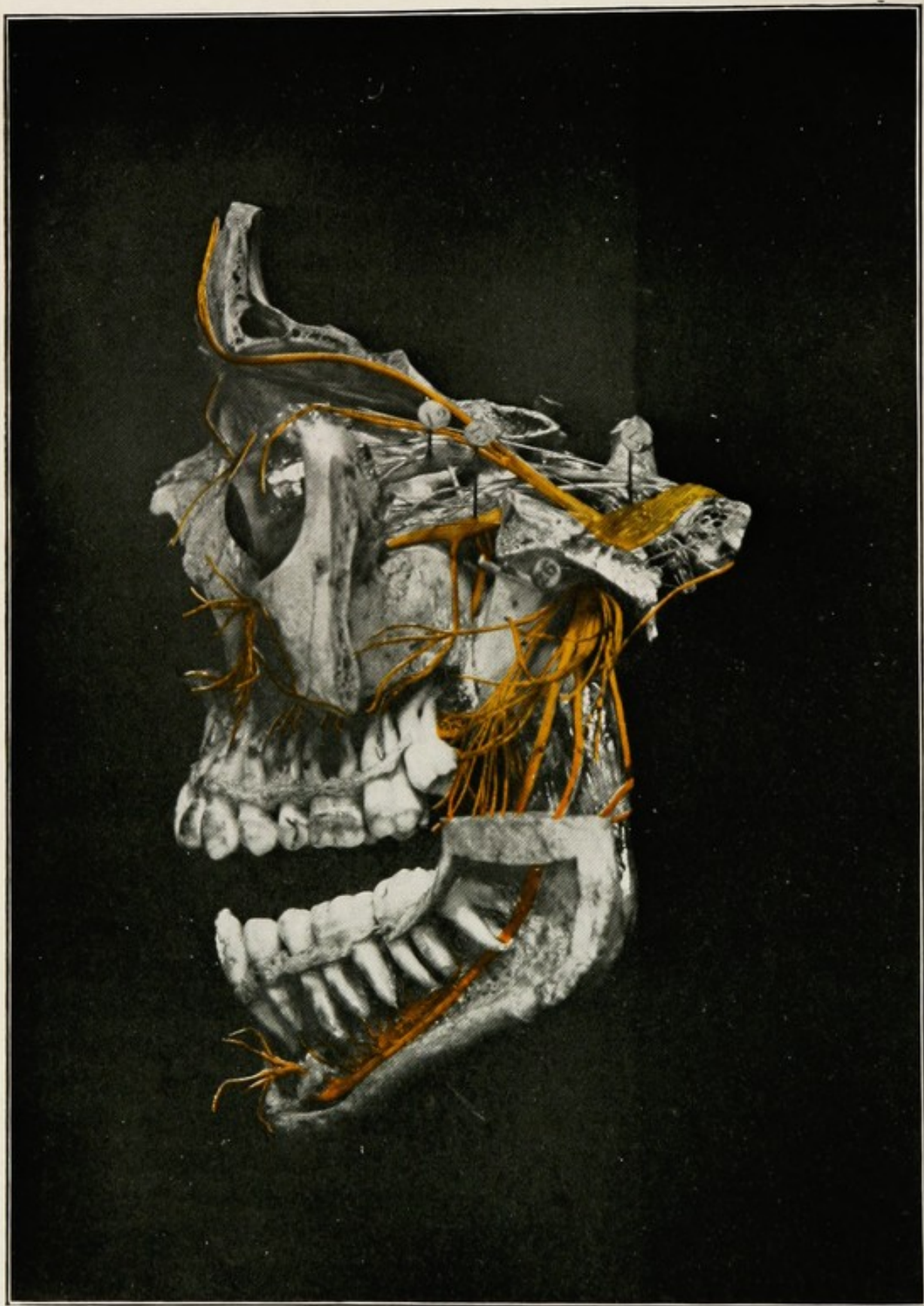

FIG. 18. Nervus trigeminus; (Vth cranial nerve) 12. N. opticus; 14. ganglion semilunare; (Gasseri) 15. N. maxillaris; 26. N. mandibularis.

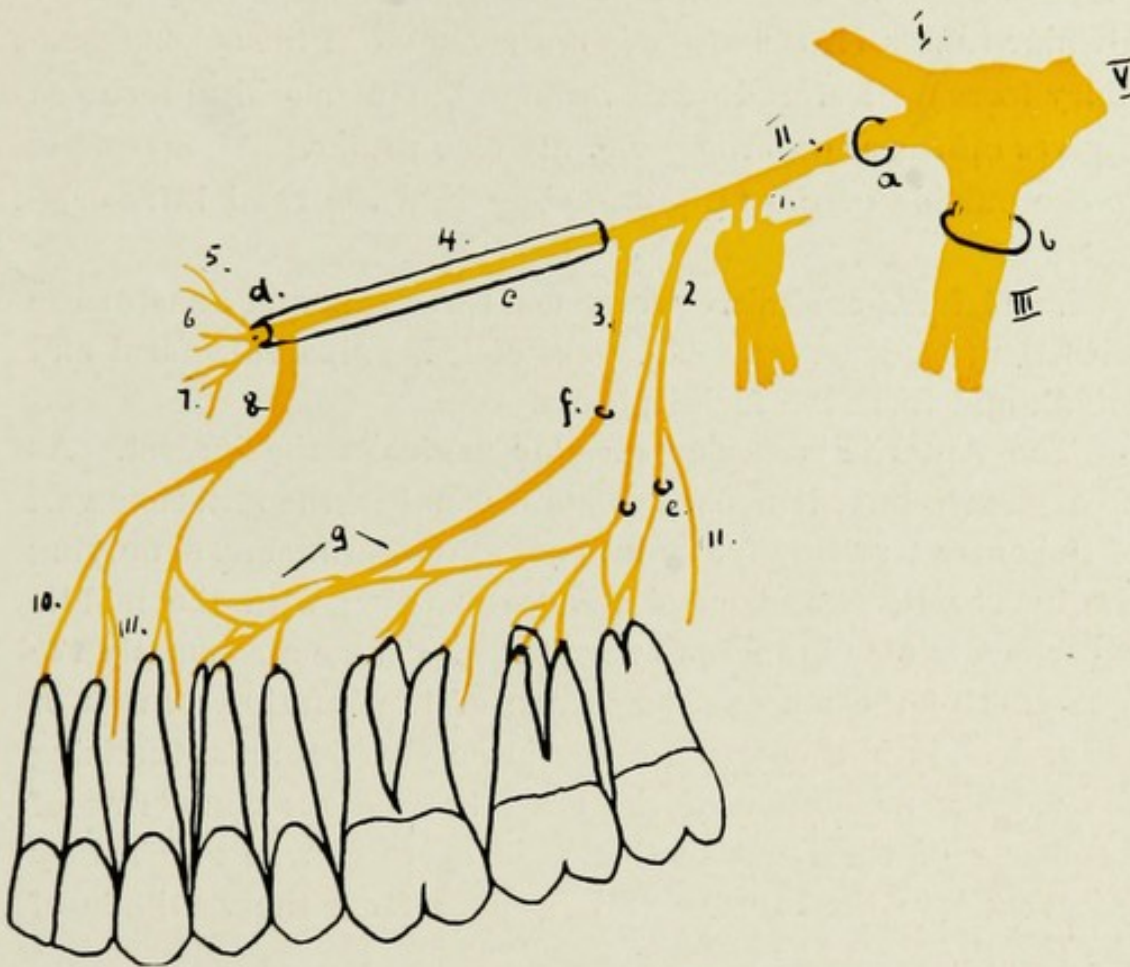


FIG. 19. Schematic drawing of the Nervus maxillaris. V. Ganglion semilunare; I. N. ophthalmicus; II. N. maxillaris; III. N. mandibularis; 1. Nn. speno-palantine; 2. Rami alviolares superiores posteriores; 3. Ramus alviolaris superior medius; 4. N. infra-orbitalis; 5. Rami palpebrales; 6. Rami nasales; 7. Rami labiales; 8. Rami alviolares superiores anteriores; 9. Plexus dentalis superior; 10. Ramus dentalis superior; 11. Ramus gingivalis superior; a. F. rotundum; b. F. ovale; c. Canalis infra-orbitalis; d. F. infra-orbitalis; e. Foramina alviolaria posteriores.

The middle superior alviolar ramus is given off from the maxillary nerve just before it enters the infra-orbital canal or from the infra-orbital at its beginning. It runs downward and forward in a special canal on the outer wall of the maxillary sinus, which it often enters on the infra-temporal surface of the maxillary bone. It joins into the superior dental plexus, to supply the bicuspid teeth.

The Infra-orbital nerve. This is the name of the second division, after it enters the infra-orbital canal. It follows the

course of the artery, and soon gives off the middle superior alviolar ramus (if the latter is not given off in the speno-maxillary fossa). Before its exit through the infra-orbital foramen it gives off the anterior superior alviolar ramus. After coming to the outside of the face, it divides into the rami infra-orbitales.

Rami infra-orbitales. These are three sets and anastomose with the facial nerves. They are called, palpebral, nasal and labial, and form the facial plexus.

The Anterior superior alviolar ramus is the largest. As a common trunk, it runs through a canal in the anterior wall of the antrum; then divides into a series of branches, supplying the incisor teeth and cuspids, anastomosing with the middle superior alviolar branches by a plexus. These also supply the fore part of the mucous membrane of the inferior meatus of the nose. It is a common observation that by anaesthetizing the mucous membrane of the nose, the patient complains of numbness of the front teeth. This nerve can be reached by injecting into the infra-orbital foramen from the vestibule of the mouth.

Superior dental plexus. As described, it is formed by the three superior alviolar branches. From it come the branches that supply the teeth and the alviolar process.

Superior dental rami. They are the small nerve fibers that enter the root of the teeth by the apical foramen to take part in the formation of the pulps, supplying also the alviolo-dental membrane.

Superior gingival rami. They are the branches that pass into the alviolar process and supply the gum.

THE SPHENO-PALATINE GANGLION

This is deeply placed in the speno-maxillary fossa. It is heart shaped and lies just below the maxillary nerve from which it receives its two sensory roots. The motor root comes

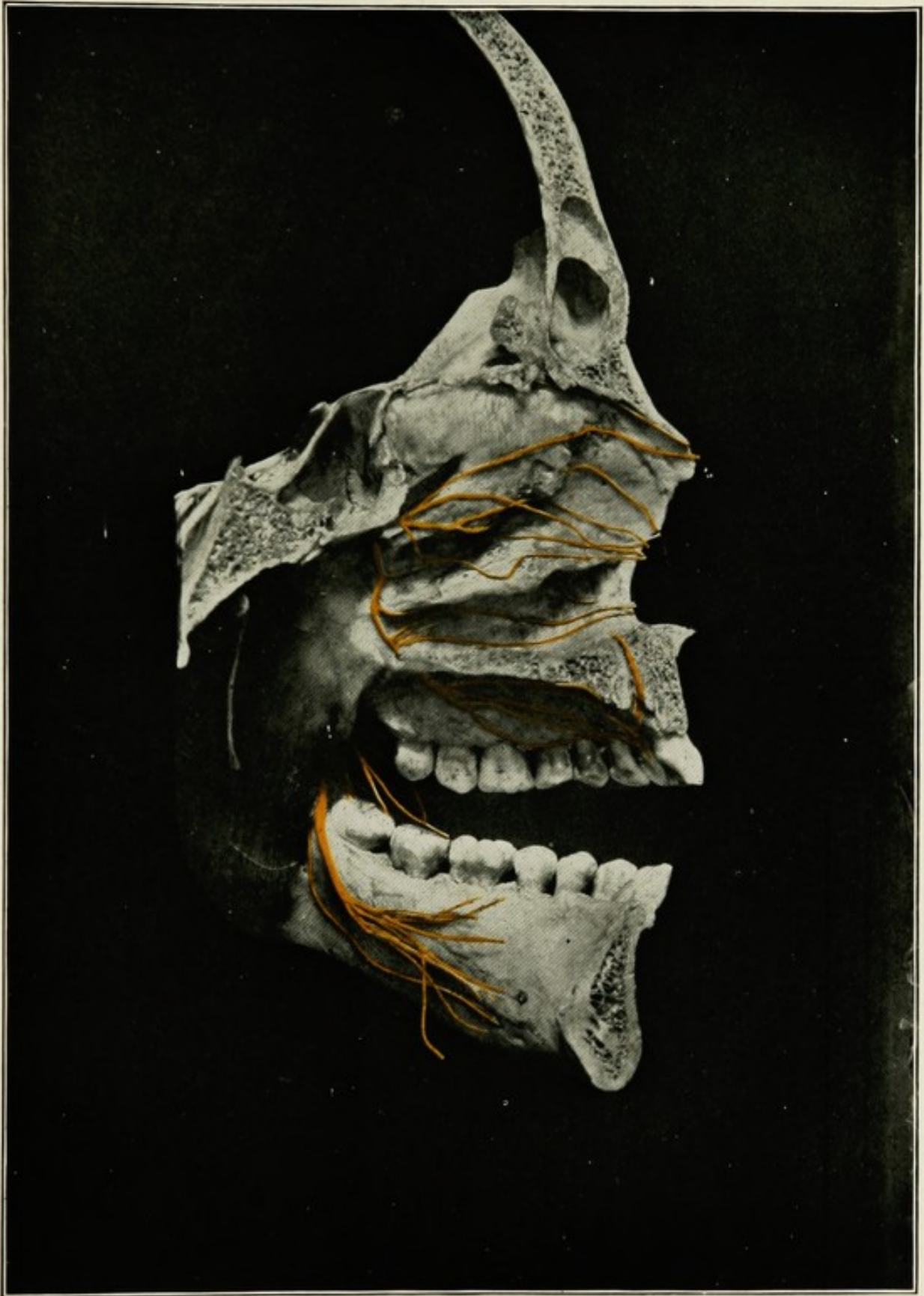


FIG. 20. Nervus trigeminus (Vth cranial nerve). In the maxilla; nasopalatine part. In the Mandibula: lingual nerve.

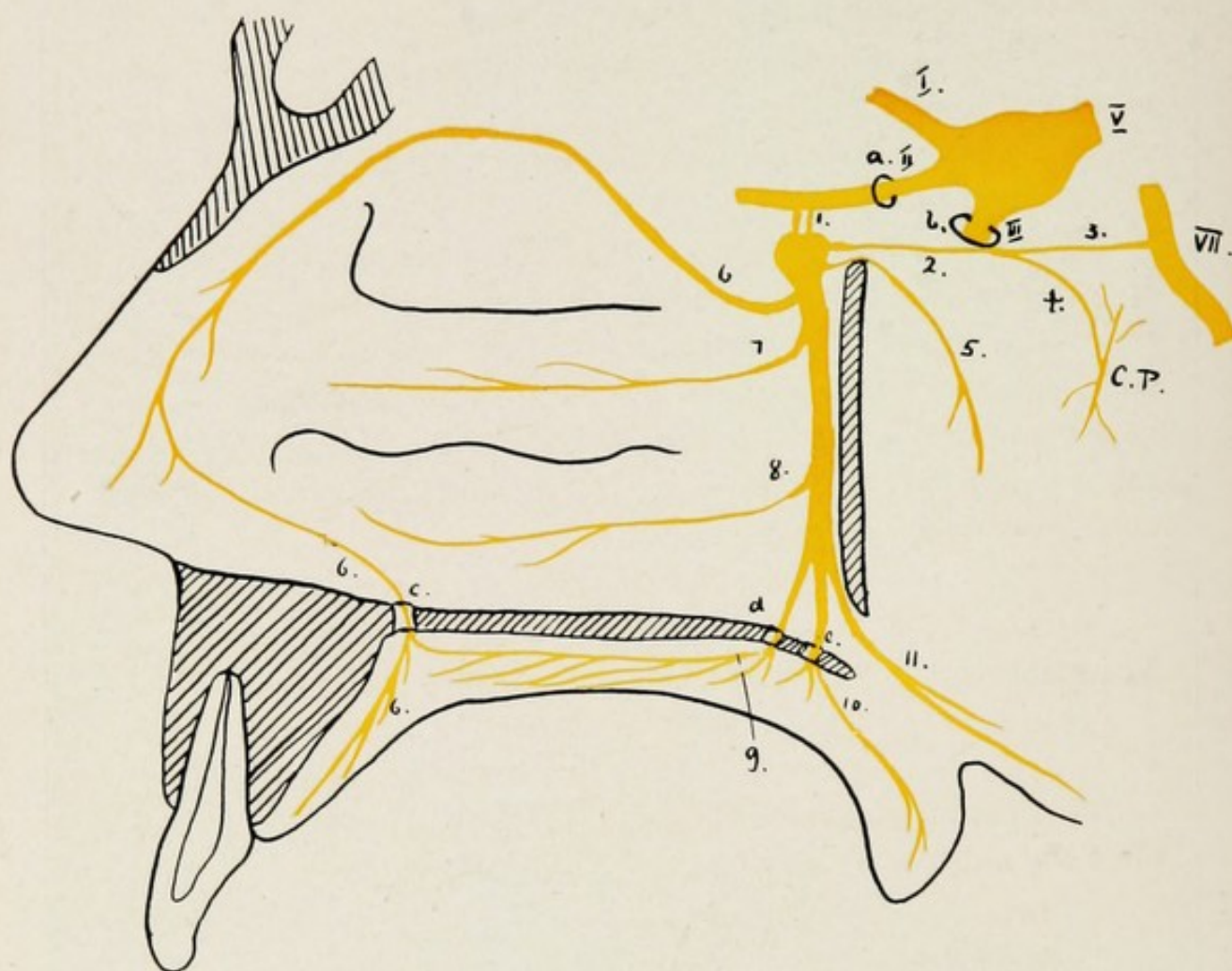


FIG. 21. Schematic drawing of ganglion sphenopalatinum. V. ganglion semilunare; I. N. ophthalmicus; II. N. maxillaris; III. N. mandibularis; 1. Nn. sphenopalatini; 2. N. vidii; 3. N. petrosus superficialis major (from N. facialis); 4. N. petrosus profundus (from carotid plexus); 5. N. pharyngis; 6. N. nasopalatinus; 7. 8. Rami nasales; 9. N. palatinus anterior; 10. N. palatinus medius; 11. N. palatinus posterior; a. F. rotundum; b. F. ovale; c. F. incisivum; d. F. palatinum majus; e. F. palatinum minor.

from the facial nerve, and is called the large superficial petrosal; the sympathetic root comes from the carotid plexus, and is called the deep petrosal. They join and form the Vidian nerve. From the branches of the sphenopalatine ganglion there are of interest to us.

The Anterior palatine nerve, which passes through the palatine canal, and emerges through the palatine foramen. It is accompanied by the artery, and supplies the hard palate, as far forward as the cuspid teeth.

The Middle palatine nerve. This emerges through the accessory palatine foramen, supplying the soft palate, uvula and tonsils.

The posterior palatine nerve, supplying the muscles of the soft palate.

The naso-palatine nerve. This takes the course from the spheno-palatine foramen across the inside of the roof of the nose until it reaches the septum. From here it passes downward and forward between the periosteum and the mucous membrane to reach the incisive foramen. It is distributed over the anterior part of the hard palate, anastomosing with the anterior palatine nerve.

The Mandibular Nerve

The mandibular nerve is made up of a large, or sensory, and a small, or motor, part. It takes its exit from the skull through the foramen ovale. Immediately afterwards it divides into an anterior and a posterior part.

The anterior branch is nearly all motor nerves, and supplies the muscles of mastication. Its branches are

Internal pterygoid nerve.

Masseter nerve.

Deep temporal nerve.

Buccinator nerve.

External pterygoid nerve.

Auriculo-temporal nerve.

The posterior part consists of

Lingual nerve.

Inferior alviolar nerve.

Of these we want to consider :

Buccinator nerve. This nerve passes forward from between the two heads of the external pterygoid muscle, then through the temporal muscle to the surface of the buccinator muscle. It divides into two branches—

Superior ramus, to supply integument and the superior part of the buccinator muscle.

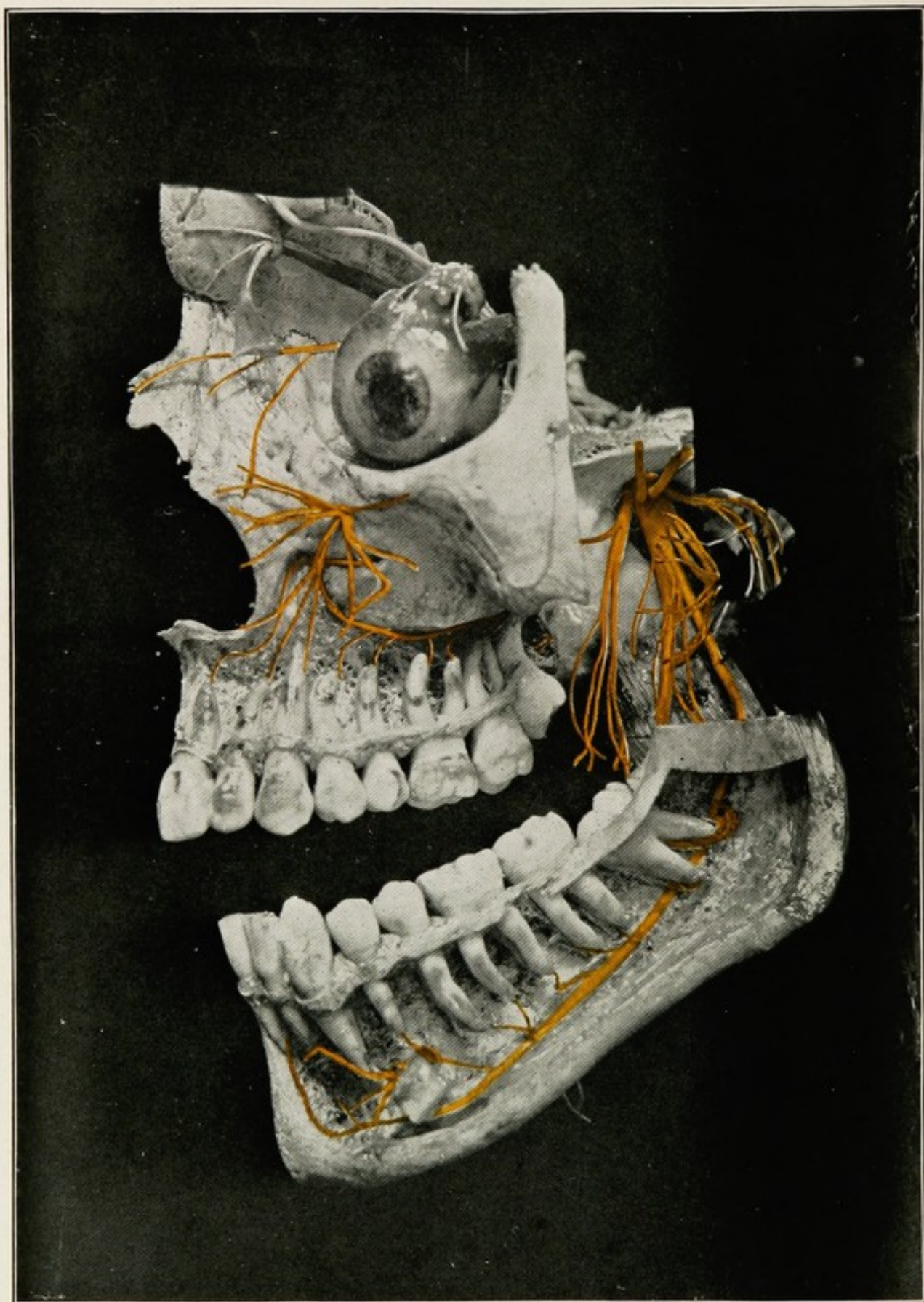


FIG. 22. Nervus trigeminus: (Vth cranial nerve). In the Maxilla showing the anterior part of the N. maxillaris. In the mandibula showing the N. mandibularis.

Inferior ramus, which passes forward to the angle of the mouth. It supplies the integument of the muscle, and the mucous membrane of the cheek, also the buccal side of the gum in the lower jaw between the first bicuspid and second molar.

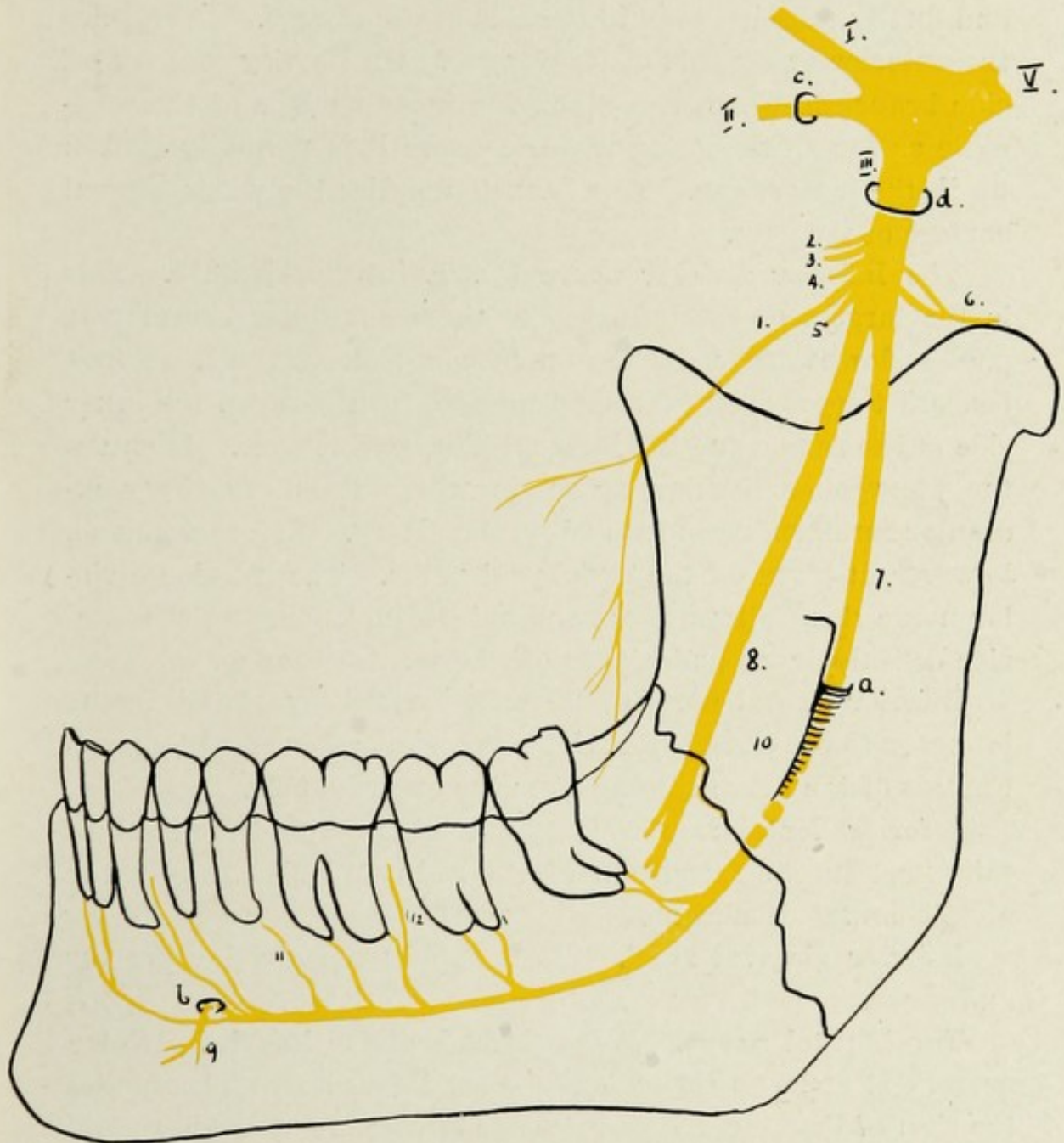


FIG. 23. Schematic drawing of nervus mandibularis. V. ganglion semilunare; I. N. ophthalmicus; II. N. maxillaris; III. N. mandibularis; 1. N. buccinatorius; 2. N. massetericus; 3. Nn. temporalis profundus; 4. N. pterygoideus externus; 5. N. pterygoideus internus; 6. N. auriculo temporalis; 7. N. alviolaris inferior; 8. N. lingualis; 9. N. mentalis; 10. N. mylohyoideus; 11. Ramus dentalis inferior; 12. Ramus gingivalis inferior; a. F. mandibularis; b. F. mentalis; c. F. rotundum; d. F. ovale.

The Lingual nerve. This first runs with the inferior alviolar nerve, situated on its inner side, but soon passes further forward and descends between the ramus of the mandible and internal pterygoid muscle, passing down at its anterior margin, and finally crossing over to the side of the tongue. It supplies the anterior two-thirds of the tongue. On its way it gives off side branches, which run along the inner surface of the mandible as far as the anterior part, where it is minutely broken up in the periosteum. This branch supplies the whole lingual surface of the gum.

The Inferior alviolar nerve (O. T. inferior-dental). This is the largest of the branches of the mandibular nerve. It passes downward with the inferior alviolar artery, at first beneath the external pterygoid muscle, then between the inner side of the ramus and the internal pterygoid muscle. It enters the pterygo-mandibular space, in which it enters the mandibular foramen, accompanied by the artery. Before doing so, however, it gives off the mylohyoid nerve. The inferior alviolar nerve then follows the mandibular canal, forming the inferior dental plexus and giving off the mental branch.

Inferior dental plexus. This is formed by the different branches to the teeth and alviolar process, and in front by anastomosis of the nerve coming from the opposite side.

Inferior dental rami. They enter the roots of the teeth to take part in the formation of the pulp and also supply the alviolo-dental membrane.

Inferior gingival rami. They supply the alviolar process and gums.

The Mental nerve. It is a branch of the inferior alviolar nerve. It emerges through the mental foramen, and supplies the skin of the chin and the mucous membrane of the lower lip and the anterior labial part of the gum, communicating freely with the facial nerve.

III. TOPOGRAPHY

It is of importance to know the makeup of the soft tissue of the mouth, and the relations of the structures we have to deal with. The mucous membrane lines the entire oral cavity. It consists of epithelium and tunica propria. Underneath this and forming the deeper part is the submucosa.

The submucosa consists of thick connective tissue bundles containing numerous elastic fibers, which extend into the periosteum, but become finer towards the tunica propria. In the gums, the submucosa is very dense, binding the mucous membrane down closely to the periosteum. As it passes into the mucous membrane of the cheek and lip it becomes less dense, and under the reflection of the mucous membrane the submucosa is a thick layer of loose connective tissue. The same is true on the palatal side. The angle formed by the alviolar and palatal process is filled in with a large amount of connective tissue, containing fat cells and the palatal mucous glands. Over the central portion of the hard palate, the submucosa is again very thin and extremely fibrous.

The tunica propria is made up of a mass of dense connective tissue bundles, and papillae are extending into the epithelium.

The epithelium is the thick covering of the mucous membrane.

The blood supply is very free, larger branches are found in the submucosa giving off capillaries, which extend into the papillae of the tunica propria, where they freely ramify and anastomose. These give the mucous membrane its reddish color.

Nerves are numerous. Primitive nerve fibers extend from the submucosa into the papillae of the tunica propria. The

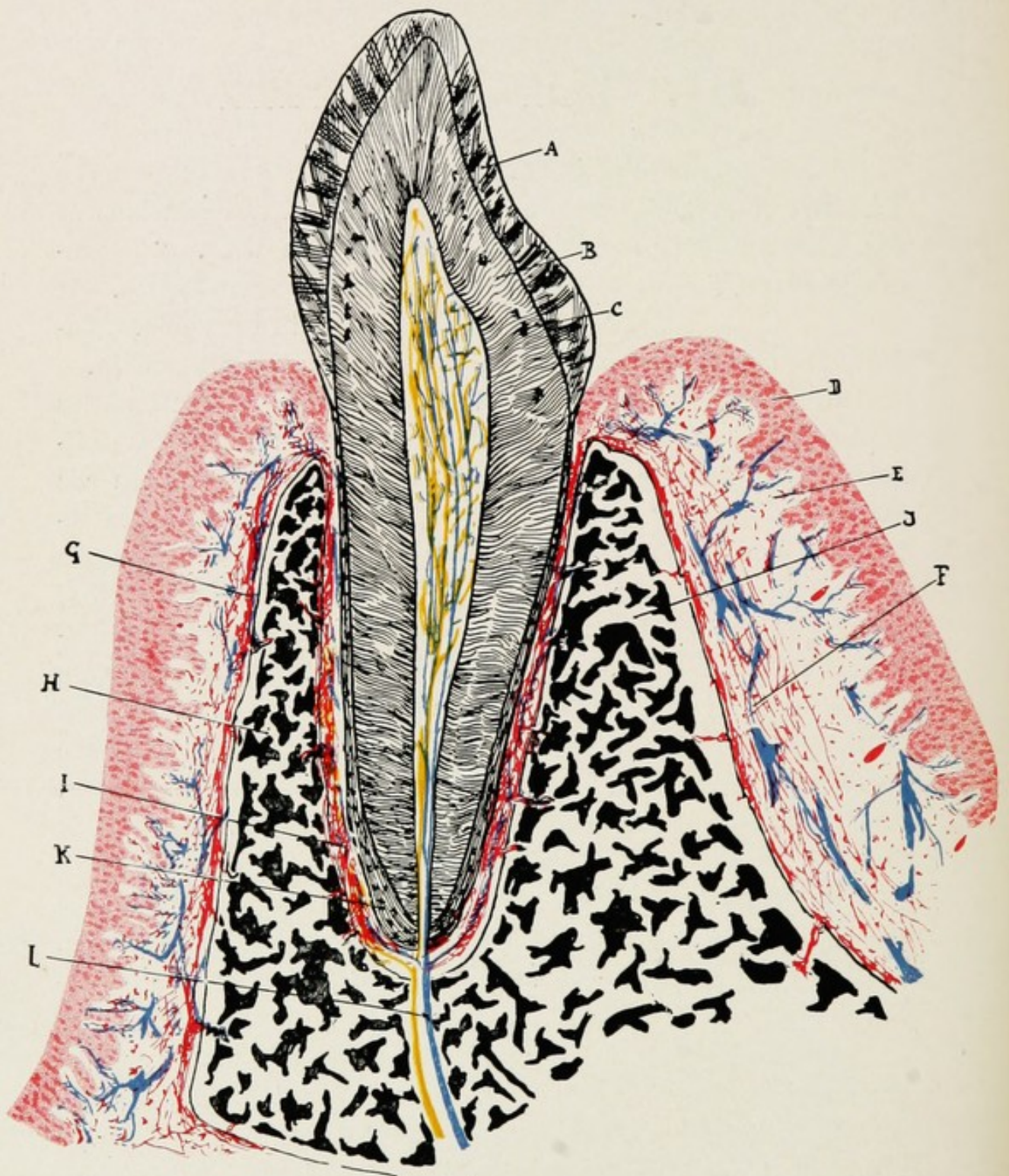


FIG. 24. Section through the upper jaw in the incisor region. A. Enamel; B. Dentin; C. Interglobular spaces; D. Epithelium; E. Tunica propria; F. Submucosa; G. Periosteum; H. Outer Plate of alviolar process; I. Inner Plate of alviolar process; K. Cement; L. Dental nerves and vessels.

nerve supply seems to be more abundant in the anterior part of the mouth, while the molar region of the gum, and the membrane over the ramus is hardly sensitive.

Injections should be made into the loose parts of the submucosa, where the solution is taken up easily with little force.

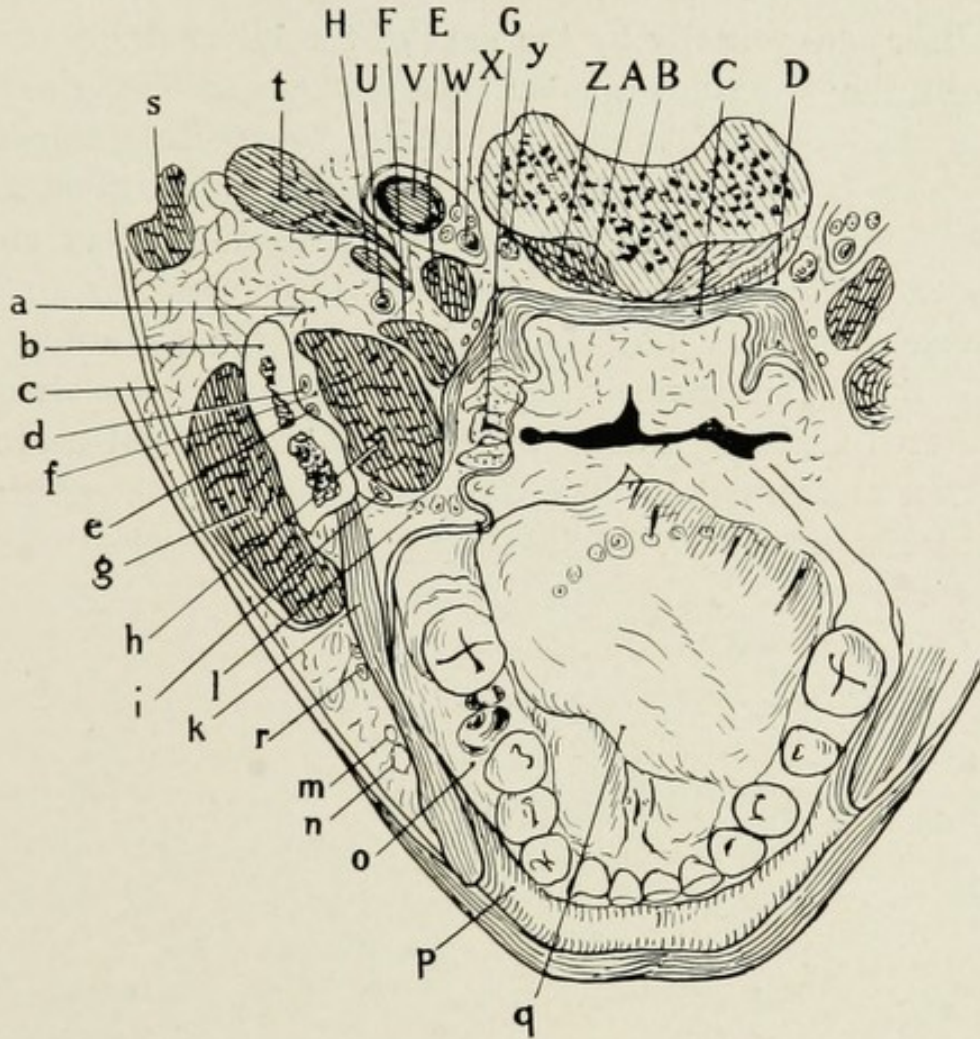


FIG. 25. Horizontal section through human head in the plane in which mandibular conductive anaesthesia is best accomplished. a. Glandula parotis; b. Ramus mandibulae; c. Fascia parotideomasseterica; d. Nervus alveolaris inf.; e. A. and V. alveolaris inf.; f. Spatium pterygomandibulare; g. M. masseter; h. M. pterygoid int.; i. Nervus lingualis; k. M. buccinator; l. Glandulae palatinae; m. Art. maxillaris externa; n. Glandulae buccalis; o. Gingiva; p. Labium inferius; q. Lingua; r. Glandulae buccalis; s. M. masseter; t. M. Diaphragmaticus; u. Art. carotis externa; v. Vena jugularis interna; w. N. vagus, glossopharyngeus and hypoglossus; x. Art. carotis interna; y. Ganglion cervicale superior; z. M. longus capitis.

A. M. rectus capitis anterior; B. Epistropheus; C. M. constrictor pharyngis superior; D. Fascia praevertebralis; E. M. stylopharyngeus; F. M. styloglossus; G. Tonsilla palatina; H. M. stylohyoideus.

Injecting into the dense submucosa of the gum, as in the old method, requires much pressure and is incorrect.

It also is important not to inject into one of the vessels. This can be avoided by moving the syringe slightly forth and back.

The Pterygo-Mandibular Space The pterygo-mandibular space is bounded externally by the part of the internal surface of the mandibular ramus, enclosed in the sulcus mandibularis, internally by the internal pterygoid muscle. It is a bag-like space filled with connective tissue. In it the alviolar nerve and artery enter the mandibular foramen. The artery lies anteriorly to the nerve and is protected by the lingula, the nerve is more to the median line and posteriorly to the artery. The inferior alviolar vein forms a plexus around the artery. The lingual nerve is seen in a section cut through the pterygo-mandibular space at the anterior margin of the internal pterygoid muscle.

IV. PHARMACOLOGY

I. NOVOCAIN

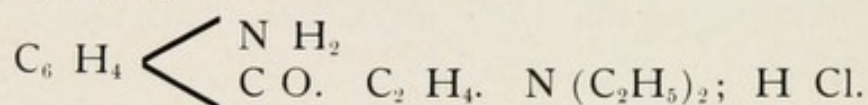
There is no reason today why cocaine, for which so many patients have an idiosyncrasy, should still be used in any branch of medicine. The toxicity of cocaine was not so clearly understood in the beginning, and occurring deaths were first thought to be due to overdoses. But experience showed that in some cases, very large doses could be administered without any bad effects, while other cases were reported where death occurred from as small a dose as 0.01 gram. Besides the danger of idiosyncrasy, there are a number of diseases where cocaine is contra-indicated on account of its toxic action on the general system, especially on the nerves, kidneys, and heart. These are anaemia, chlorosis, neurasthenia, nephritis, heart diseases, arterio sclerosis and general weakness, often illness. It is also a great disadvantage that cocaine decomposes partly when boiled, losing much of its anaesthesia producing power.

Therefore a large number of men of science searched for years for a substitute. Professor Braun, the "father of Local Anaesthesia," formulated the following requests, qualities, which the new preparation should possess.

1. The substitute shall not be inferior to cocaine in its anaesthesia producing power.
2. It shall be relatively non-toxic.
3. It shall have no irritating action, even on the most delicate tissues.
4. It must be easy to combine it with suprarenin and combined, it should not lose of its anaesthesia producing power, neither should it affect the action of the suprarenin.
5. It must be boilable.

Among the many preparations, which have all been thoroughly tested out by men like Professor Braun and Professor Bier, Novocain was found to be by far the best.

It was prepared by Professor Einhorn in Munich, and is the "hydrochlorid of the p-Aminobenzoyldiethylaminoethanol" with the formula:



Production It is produced through the action of "diethylamin" upon "p-Aminobenzoëacidchlorethylester."

Chemical Properties It occurs in small, colorless and tasteless crystals, soluble in water (1:1), and less soluble in alcohol (1:30). It is also soluble in glycerine at 20 Centigrades (1:5). Melting point 156 Centigrades. It can be heated without decomposition to 120 Centigrades.

Reactions It shows the general alcaloid reactions, tincture of iodine produces a brown, picric acid, a yellow precipitate. Alkalies produce a white precipitate, which is soluble in alcohol and ether.

If one mixes a solution of 0.1 gram Novocain in 5 c.c. of water, and three drops of dilute sulphuric acid with five drops of potassiumpermanganate, we find that the violet color disappears at once. This distinguishes Novocain from Cocaine.

Physiological Properties Novocain possesses the same action upon peripheral sensory nerves as cocaine. The 0.25 per cent solution is sufficient to completely anaesthetize even the thick nerve trunks in about ten minues.

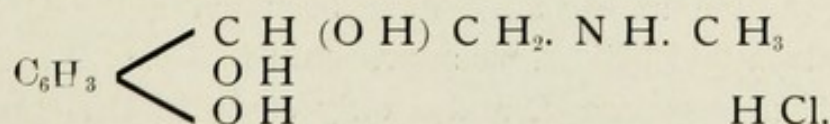
Clinical Tests (Pharmacological institute of the University in Breslau.) Locally applied there is no irritation, even if Novocain is brought upon the most sensitive tissue in strongly concentrated solutions, as upon the cornea. General effects upon the system after its absorp-

tion are scarcely perceptible, neither the circulation nor the respiration suffers, the blood pressure is not increased. From experiments it was found that Novocain is seven times less toxic than cocaine.

The best solution for our purpose is the two per cent **Dosage** solution, for the infiltration as well as for the conductive method. A change of strength is not required for special cases, and I have used it most successfully in cases where cocaine and ether anaesthesia was contra-indicated on account of cardiac, pulmonary or other diseases. The maximal dose is 0.5 gram (Fischer) for subcutaneous injections, but as much as 2 gram has been used subcutaneously, without causing any damage. But in our specialty such a quantity is never called for, and the maximal dose which allows 24 c.c., or 12 syringes full of a two per cent solution is hardly ever reached.

2. SUPRARENIN SYNTHETICUM

Suprarenin has a great anaemia producing power, and is a strong astringent. It is added to the anaesthetic solution for one of two, or two purposes. First to contract the capillaries and tissue locally, to prevent absorption and infiltration into the soft tissue, therefore increasing duration and strength of the anaesthesia. Secondly, it is added to decrease bleeding in certain operations. It is much superior to adrenoline, or any of the organic substances gained from the suprarenal glands, as it is more staple, keeps better and is less toxic. It is the "Hydrochlorid of O-Dioxyphenylethanolmethylamin," and has the chemical formula:



Production Chloracetobrenzkatechin is transformed by methylamin into Methylaminacetobrenzkatechin.

By reducing this keton we receive the secondary alcohol called synthetic suprarenin.

Synthetic Suprarenin is a grayish white powder. **Chemical Properties** It does not dissolve easily in cold nor in hot water, and is insoluble in alcohol and ether. Melting point 207-208 Centigrades.

Titrated with diluted acids it is very easily soluble and gives a watery clear solution. It is in the market diluted 1:1000.

Synthetic suprarenin is very sensitive. Free alkali, air and especially heat cause its decomposition. **Reactions** It has to be kept in bottles made of special alkali free glass, and should not be exposed to air unnecessarily. It has the advantage over the organic preparation that it can be boiled to some extent. Slightly discolored solutions have toxic or irritating effects.

It is the strongest Haemastatic and astringent known. **Physiological Properties** It causes anaemia and contraction of capillaries and tissues locally, while when introduced into the circulation it increases the blood pressure. This comes partly from increased heart action, and partly from contraction of the arteriols in the whole body.

Clinical experiences in different institutions and hospitals of Europe proved Suprarenin Synthetic to be the best substitute for the organic preparation. **Clinical Experiences**

Different than with Novocain, I found it of great importance to vary the amount of Suprarenin for individual cases. **Dosage** I have been using the E tablets, which contain 0.000,05 grams suprarenin to 1 c.c., if a two per cent solution is prepared, and I only came to the conclusion that so high a percentage of Suprarenin is not necessary, while treating a patient with grave cardiac and pulmonary disorders. He was referred to me for treatment under local anaesthesia, by another dentist. Considering the seriousness of the situa-

tion, I prepared a special solution containing two per cent Novocain and 0.000,01 gram Suprarenin to 1 c.c. I used the infiltration and conductive methods in the upper and the conductive method in the lower jaw, with perfect result, and to my surprise I found that the time of anaesthesia was not decreased. I then tried the new solution on a patient, which had slight toxic effects, immediately after the injection of a solution containing 0.000,05 gram Suprarenin, with encouraging result. In conductive anaesthesia of the mandible, we sometimes find that the lip feels perfectly numb, that the dentine is sufficiently desensitized, but the pulp only partly anaesthetized. Fischer agreed with me that this is probably due to the fact that the tooth in question is supplied by the central nerve fibers of the nerve trunk, which are not reached by the anaesthetic. This teaches two things, first, that we should allow time enough for the drug to act, and second, that the suprarenin should be used in small percentage for conductive anaesthesia, on account of its astringent action, probably preventing in high concentration the infiltration of the nerve trunk to its center.

Conclusively I lay the cause of slight toxic effects, post-operative pain in extraction, post-operative infection, and oedema as after-effect, as well as incomplete conductive anaesthesia to a too large percentge of suprarenin.

For general use I found a solution containing 0.000,015-0.000,02 gram of synthetic suprarenin, to 1 c.c. or a 0.0015-0.002% solution of suprarenin the best.

For cases where a deep anaemia is desired, a higher percentage of 0.000,05 gram per 1 c.c. or 0.005% is recommended.

For patients with heart diseases, arterio-sclerosis, nephritis and hysteria a lower percentage of suprarenin is advisable. Use not more than 0.000.01 gram to 1 c.c., or 0.001%.

3. NOVOCAIN SUPRARENIN COMBINED

At a congress of German dentists held in Muenster, Germany, at which the German authorities on local anaesthesia met, Seidel proposed sixteen theses formulating use and dosage of the Novocain-Suprarenin solutions. The problem was thoroughly discussed by Fischer, Apffelstaedt, Moral, Steinkamm, Hauptmeyer, Buente, Friedmann, Heinemann, Endres, Rilke and Heinze during the two days' meeting and finally accepted by unanimous vote as follows:

SEIDEL'S 16 THESES

I. The fresher a Novocain-Suprarenin solution is, the less is its toxicity, and the greater is its anaesthesia producing power. Therefore when examining preparations scientifically, one should only use freshly self-prepared solutions. One can only get a clear picture of the power of the Novocain-Suprarenin solutions, if one is sure that the solution used contains Novocain and Suprarenin pure, and not products of deterioration.

II. Fresh Novocain and Suprarenin either separate or mixed (solutions) should be clear as water.

III. For the practice a Novocain solution should only be considered "fresh" and fully active, if clear and colorless.

IV. The same is true for solutions of suprarenin. Solutions of suprarenin are less stable the more diluted they are.

V. Mixed Novocain-Suprarenin solution is only to be considered "fresh" directly after the mixing of the dissolved parts.

Already in ten minutes a Novocain-Suprarenin solution will show discoloration (from high temperature, action of light or air), diminishing its power and increasing its toxicity.

VI. A sterile Novocain-Suprarenin solution cannot be made lasting through addition of antiseptics, because the yellow discoloration of the Novocain, and the red discoloration of the suprarenin are due to chemical processes (oxydation) and not bacterial influences.

Therefore a Novocain-Suprarenin solution should be sterile, but an antiseptic character is not required.

VII. Antiseptic additions [*e. g.*, Thymol, and others, as in patented preparations (author)] are not only unnecessary but directly injurious. At the present time there is no antiseptic known which is entirely non-irritant in a concentration powerful enough to have sufficient antiseptic properties.

VIII. Individualizing the concentration of Novocain is not required for the small doses used for dental purposes and, contrary to cocaine, it makes no difference whether a certain dose is injected in weak or strong concentration, as long as the total doses of 0.2 grams is not transgressed.

IX. In dentistry where the part to be anaesthetized (bone and tooth) cannot be infiltrated directly, but where in contrary a diffusion is required, a solution of a comparatively high percentage can be used only.

X. The best solution for dental purposes is the two per cent solution.

XI. The suprarenin concentration has to be changed in many cases. This is required because:

1. The toxicity of the suprarenin is dependent from the concentration in which a certain dosis is given. This is important in arterio-sclerosis and when unintentionally injecting into a vessel.

2. In many cases a strong anaemia of the field of operation is required, in others bleeding is desirable.

XII. In normal cases the best results are obtained if the two per cent Novocain solution contains 0.000,02 grams Suprarenin per 1 c.c.

XIII. In arterio-sclerosis or cardiac disorders a decrease of the suprarenin dosis to 0.000,01 gram is recommended. If strong anaemia is desired an increase to 0.000,05 grams is required.

XIV. The question what percentage of salt should be added to the solution to make it isotonic is not yet scientifically solved.

The material presented by Buente and Moral, as well as by Fischer, is not sufficient.

XV. In practice we find no difference if 0.6 or 0.9 gram salt is added to a two per cent solution of Novocain. The amount which also fulfills the theoretical requirements is not yet known.

XVI. The above requirements cannot be fulfilled in practice by the use of ampules or tablets, ready for a solution of one certain percentage. The operator should prepare and mix the solution himself, as with the method described by Seidel or similar ones.

SEIDEL'S METHOD

Seidel's Method* of preparing the solution is a very scientific one. He originated an instrumentarium consisting of an apparatus to produce distilled water and a sterilizer to sterilize the bottles, and other instruments used; also to sterilize the two per cent Novocain solution, which is kept in a special bottle. The suprarenin solution 1:1000 can be bought in Germany in small original bottles of 5 c.c., from this the normal pipette constructed as a bottle is filled. Before injecting he prepares the solution by measuring the amount of Novocain solution, and adding as many normal drops of Suprarenin solution as required for the individual case.

This method no doubt is ideal, but the preparing and sterilizing of the solution takes time, and the responsibility is too great to leave in charge of any office help. Also the sensitiveness of the Suprarenin solution is to be considered. In this country, we have not the facility to get this ingredient directly and in shortest time. If injections are not frequently used there is also a great deal of waste, as the Suprarenin solution does not keep long after the bottle has been opened. The danger to use Suprarenin, the toxicity of which has been increased through influences of air, heat, light or age, is too great to take chances.

AMPULES

Ampules containing mixtures of Novocain and Suprarenin are in the market, also patented preparations containing other ingredients. Seidel's Theses VI and VII discard the latter, the former are also quite far from the ideal, Theses V calling a mixed solution of Novocain fresh only directly after the mixing. Often the solutions gained from ampules are actually discolored and, what is worse, it is hard to control their age.

SOLUTIONS

Solutions put up in bottles are still more undesirable than the ampules. After the bottle is once opened the rest deterior-

* Deutsche Monatschrift fuer Zahnheilkunde Heft. 8-1913.

ates quickly from bacterial invasion, and chemical processes (light, air, heat.) See Theses VI and VII, also II, V and IX.

TABLETS: AUTHOR'S METHOD

I have used solutions prepared from tablets in private practice and school clinics entirely, with the exception only of short periods when I tried out other methods. The tablets of Farbwerke Hoechst I found very satisfactory, they are carefully and scientifically made and very reliable. Professor Braun examines them every year and finds that they are always sterile. This of course is of first importance. I used and recommended the E tablet, but, as explained in a previous chapter, I found that they contain too much Suprarenin, and that it is necessary to vary the amount of Suprarenin. I therefore prepared solutions from the D and F tablets. This of course is somewhat complicated for general use. To simplify the technique of preparing the solution, Farbwerke Hoechst was kind enough to produce a new tablet. I therefore use now, and recommend for general use, Tablet T.

Tablets T For all anaesthesia in the oral cavity, either for
for purely dental or for surgical operations, the solu-
General Use tion is prepared from the T tablets. This tablet
dissolved in 1 c.c. of salt solution gives a solution
containing two per cent Novocain and 0.000,02 gram of Supra-
renin to 1 c.c.

Tablets E If deep anaemia is desired, as in cases of diffi-
for Deep cult surgical operations (root amputations, im-
Anaemia impacted third molars, etc.), the E tablets can be
used to prepare the solution. This tablet dis-
solved in 1 c.c. of physiological salt solution gives a solution
containing two per cent of Novocain and 0.000,05 gram of Su-
prarenin to 1 c.c.

Tablet F combined with Tablet E For abnormal cases, arterio-sclerosis, nephritis, grave cardiac disorders, hysteria, use two F tablets plus one E tablet dissolved in 6 c.c. of salt solution. This gives a two per cent solution of Novocain containing only 0.000,009 gram of Suprarenin to 1 c.c.

These solutions I find very satisfactory, and they also come very close to the fulfillment of the Sixteen Theses of Seidel. The solution prepared by dissolving the tablets in the salt solution, just before the injection is made fulfills the requirements of Theses I to X. Thesis V discards solutions of Suprarenin and Novocain, which are not mixed by the operator immediately before the injection. In the tablets the two ingredients are mixed in a dry state, in which they are better preserved, and as long as no moisture penetrates into the tube, which is prevented by the rubber stopper, they do not deteriorate. When the tablets are dissolved we get a water clear solution which, in accord with Thesis II, is to be considered "fresh." Theses XI, XII, and XIII call for different Suprarenin concentrations. There are three concentrations required, the normal strength being 0.000,02 grams, which we get with the "T" tablet; the increased strength being 0.000,05 grams which we get with the "E" tablet; and the decreased strength being 0.000,01 gram, which is only recommended for very serious disorders. If such a solution is required it can be obtained by dissolving two F tablets and one E tablet in 6 c.c. of salt solution, this gives a two per cent Novocain solution with 0.000,009 gram Suprarenin. Theses XIV and XV have to do with the salt solution, and Thesis XVI advocates Seidel's method, which certainly is ideal, but not adaptable for us.

I have proved to my satisfaction that the "tablet method" is very little behind the method of "separate solutions," if the solution is prepared conscientiously, and if we vary the strength of Suprarenin.

4. PHYSIOLOGICAL SALT SOLUTION

The question whether a 0.6 or 0.9% salt solution with two per cent Novocain is isotonic, is theoretically not yet solved, as seen from Theses XIV and XV. In practice, however, I found Braun's solution very satisfactory; he recommends to add a very small amount of dilute hydrochloric acid to offset the derogatory action of the glass alkali and to prevent oxidation of the Suprarenin. His solution is:

Sodii chloridi puriss.....	2.0
Acidi hydrochlorid. Diluti.....	gtt.1
Aquae dest	300.0

Fill the bottle with this solution and boil it fifteen minutes. Lately, however, a new solution, called Ringer solution, has been recommended. It contains the salts found in the blood, and is claimed to fulfill the requirements better still. It contains Calcium chloride, which was found by Professor Guerber, Director of the Pharmacological Institute, Marburg, to improve the process of absorption in the tissue, and to stimulate the action of the leukozytes. I have been using the Ringer solution for the last three months; it contains:

Sodium chloride	0.50
Calcium chloride	0.04
Potassium chloride	0.02
Aquae dest	100.00

There are Ringer tablets on the market, which are dissolved in distilled water: ten tablets to 100 c.c. aqua dest. The solution is then boiled for fifteen minutes. These simplify the self-production of the salt solution.

5. DISTILLED WATER

The greatest difficulty for the conscientious practitioner is to get perfectly distilled water. The druggist does not keep

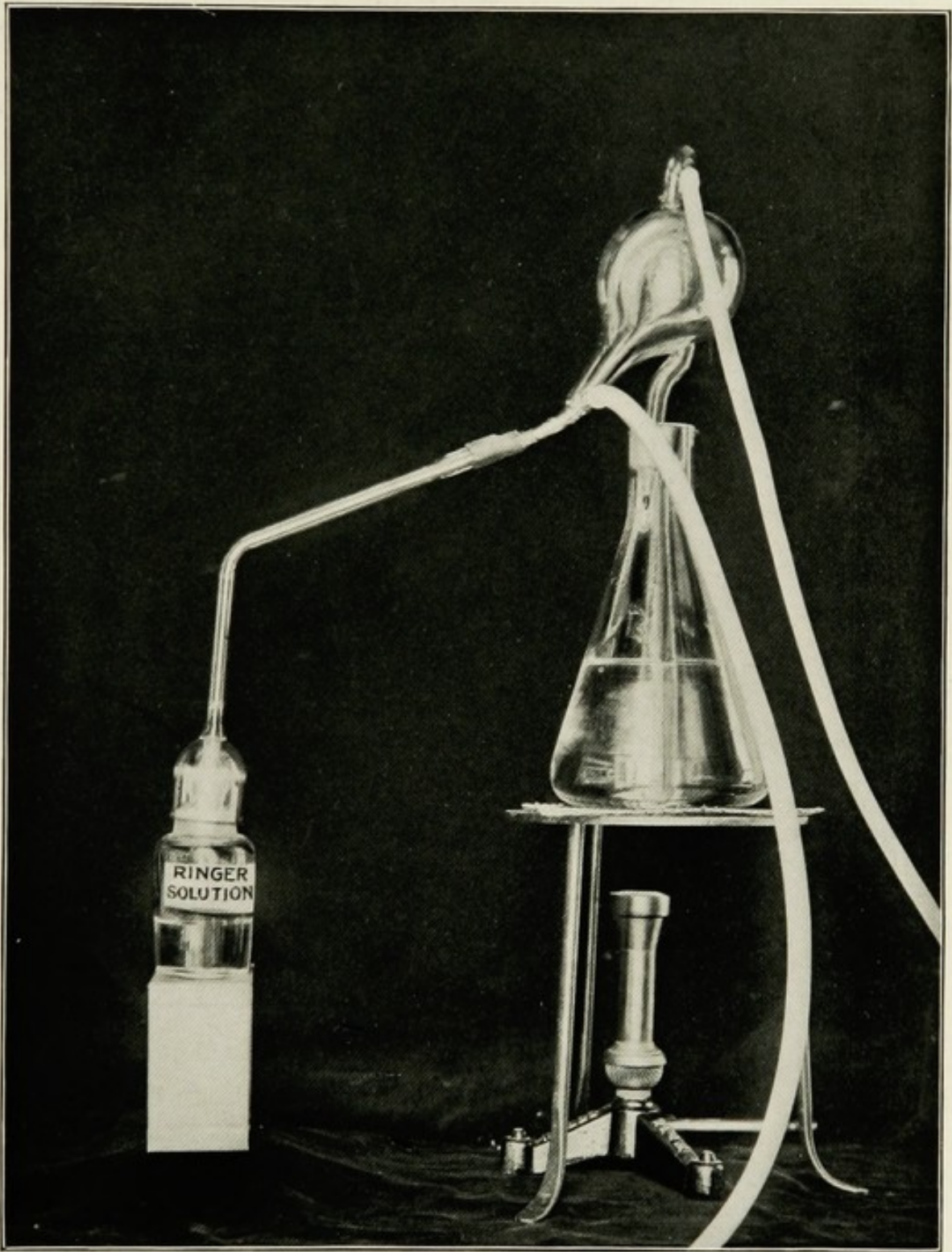


FIG. 26. Femel Apparatus to produce distilled water.

the distilled water in aseptic condition, and in a short time it becomes impure by the growth of all kinds of fungi and their products. Vegetations of these often can be seen with the naked eye, swimming around in the bottle. Although the fungi themselves are killed when dissolving the tablets, there are still the dead cells and the previously formed toxins to be con-

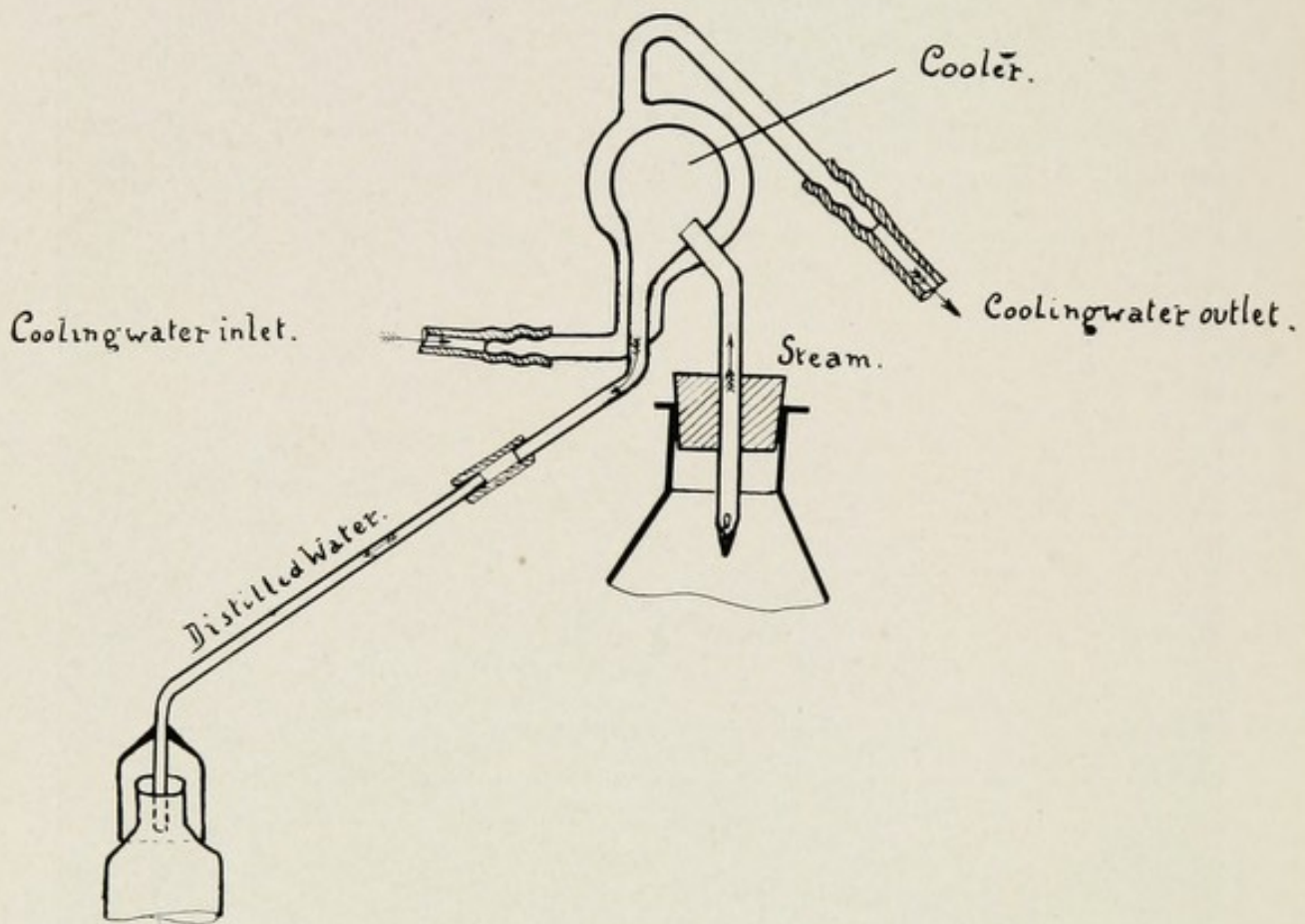


FIG. 27. Schematic drawing of distilled water apparatus.

sidered. Ehrlich found that Infusions of Salvarsan made with commercial distilled water, caused toxic effects which did not occur if fresh, sterile, distilled water was used.

It is therefore commendable to have special distilled water prepared by a reliable druggist, which then is measured into the well-cleaned and dealkalied bottle. After adding the Ringer tablets cook it for fifteen minutes.

For large clinics, it is advisable, and in private practice possible, to produce sterile, toxin-free, distilled water with the Femel Apparatus.* The handling is very simple. Bottle A is filled with commercial distilled water, and the cooler is mounted with a rubber stopper. Cooling water is connected to the inlet and a tube takes care of the overflow. The outlet for the distilled water is connected by a special glass tube to the bottle. The gas is lit under bottle A (without letting the cooling water run) to produce steam, which sterilizes the whole outfit. Now the cooling water is opened carefully and allowed to run very slowly. The distilled water runs into the bottle, into which the Ringer tablets are added.

* F. and M. Lautenschlager, Berlin N. 39; Chausseestrasse 92.

V. INSTRUMENTARIUM

The instruments required for quick, safe, and aseptic work are:

Two Fischer syringes, one mounted in a short hub with a 26 mm., the other in a long hub with a 45 mm. iridio-platinum needle. I prefer iridio-platinum needles because it simplifies matters, in that they do not need to be boiled before use, can be used again, and therefore can always be mounted on the syringe ready for use. These do not break. If steel needles are used, which often show specks of rust and oxide, one has to boil them and should only use them once. The platinum needles have to be sharpened from time to time with a round engine stone.

The syringes are kept in a *glass jar* with absolute alcohol, placed on a *stand*, together with two porcelain dissolving cups.

The dissolving cups are graduated, one up to three, the other up to 10 c.c., and are used to measure, dissolve and sterilize the anaesthetic solution. They are made of porcelain, which can be cleaned with dilute hydrochloric acid.

The bottle double corked, contains the Ringer solution.

A glass tray is used to keep tablets and reserve needles. Also an engine stone to sharpen the needles.

TABLETS

Novocain-Suprarenin Synthetic Tablet T.*

Novocain	0.02	gram.
Suprarenin Synthetic	0.000,02	gram.

Novocain-Suprarenin Synthetic Tablets E.*

Novocain	0.02	gram.
Suprarenin Synthetic	0.000,05	gram.

* Farbwerke Hoechst Co., 111 Hudson Street, New York.



FIG. 28. Bottle for Ringer solution. Jar with tight-fitting cover filled with absolute alcohol. Syringes and dissolving cups are placed on a nickel-plated stand and kept in the jar. Glass tray with cover to keep drugs and reserve needles.

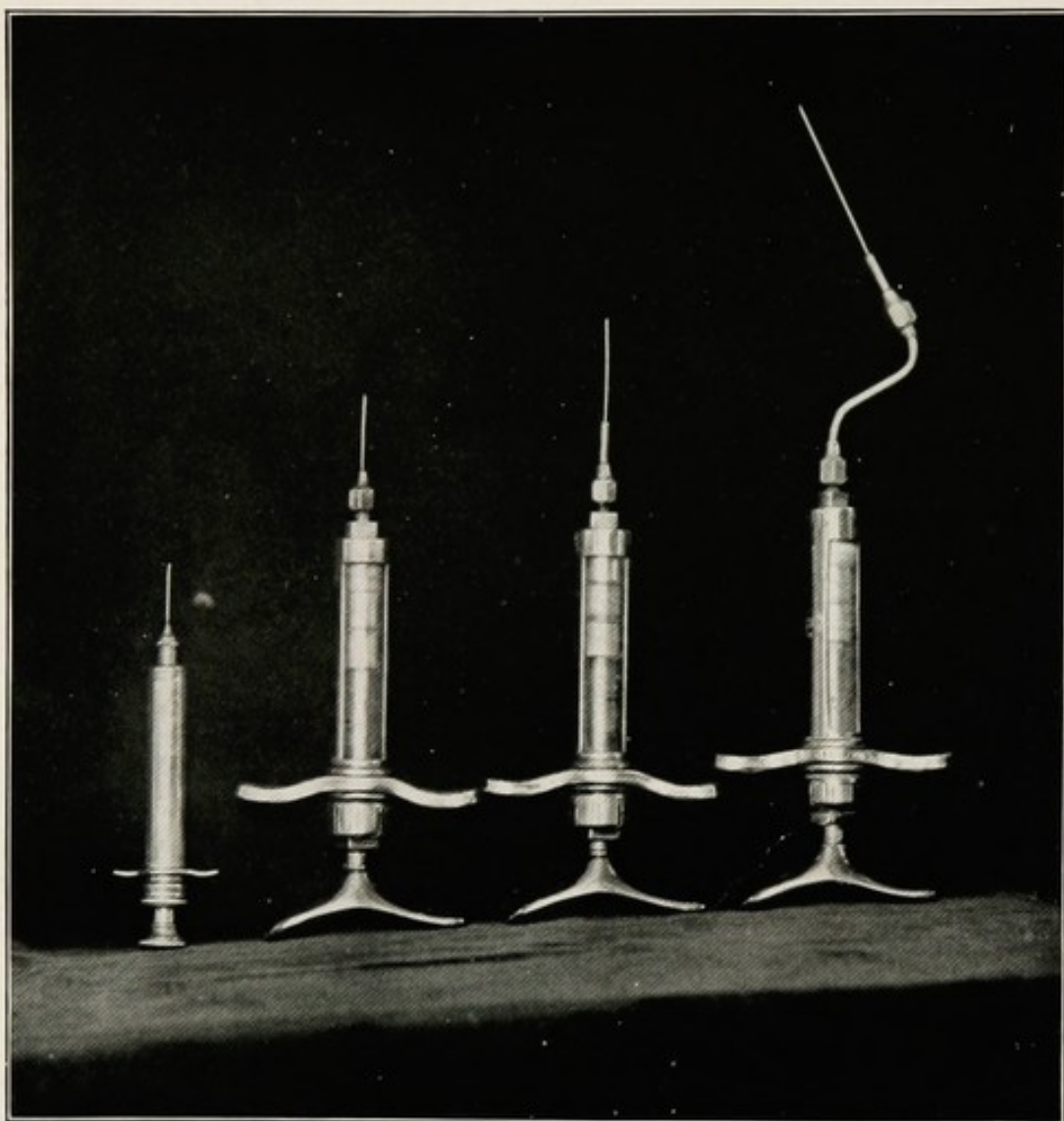


FIG. 29. Syringes. The small syringe with 27 gauge platinum needle for mucous anaesthesia previous to injecting with the large syringe. The next syringe is Fischer's syringe mounted with the short needle. The third is mounted with the 45mm. long needle, and the last one is mounted with the bayonet piece and a 60mm. long needle.

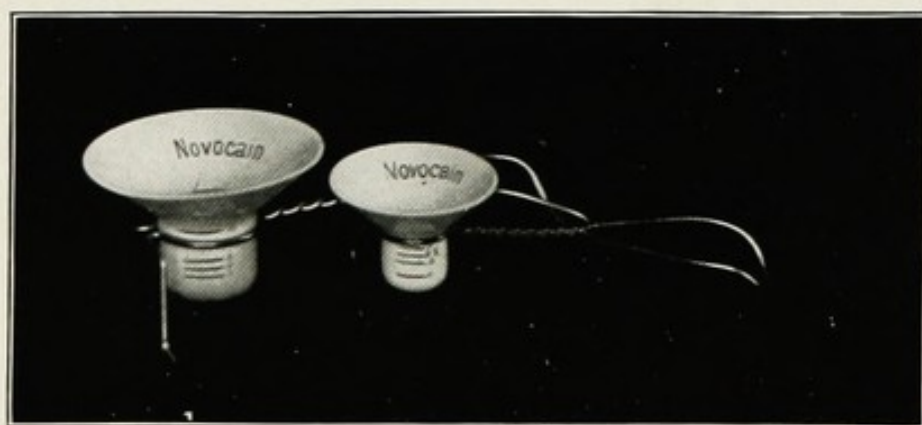


FIG. 30. Large and small dissolving cups.

Novocain Tablets F* (for special cases only to combine with the E Tablets).

Novocain0.05 gram.

Ringer Tablets*

Sodium Chloride0.050 gram.

Calcium Chloride0.004 gram.

Potassium Chloride0.002 gram.

Dissolve ten tablets in 100 c.c. of aqua dest and sterilize.

* Farbwerke Hoechst Co., 111 Hudson Street, New York.

VI. PREPARING OF THE SOLUTION

Remove the stand from the jar and wash the cup and syringe in distilled water, to remove all traces of alcohol. Fill cup with Ringer solution to the mark required.

Heat the solution over the flame to boiling.

Add tablets as follows:

For normal cases: One T tablet to each c.c. This gives a solution with:

Novocain2%
Suprarenin0.000,02 gr. to 1 c.c.

For deep anaemia: One E tablet to each c.c. This gives a solution with:

Novocain2%
Suprarenin.....0.000,05 gr. to 1 c.c.

For abnormal cases: Two F tablets and one E tablet to 6 c.c. This gives a solution with:

Novocain2%
Suprarenin.....0.000,009 gr. to 1 c.c.

Draw the cup through the flame till the tablets are dissolved.

Sterilize needle on the syringe in the flame.

Fill the syringe and avoid touching the needle.

REQUIREMENTS OF A SOLUTION PREPARED FROM TABLETS

1. It should be immediately used after it has been prepared.
2. The solution should not come in contact with anything except the porcelain cup and the syringe.

It should not be left longer than absolutely necessary in the dissolving cup nor in the syringe. The solution is very sensitive, being affected and chemically changed by air, heat, light, and especially by alkalies.

3. The tablets should not be touched with hands nor instruments, and the tube should be closed immediately after use, with the rubber stopper. The tablets are chemically changed by air, light, and especially by moisture.

4. The tablets should be white; sometimes the uppermost one discolors from chemical changes, caused by improper handling of the tube.

5. The solution gained from the tablets should be clear as water.

If it shows any light pink color, it should be discarded.

The manufacturing of the T tablets will be delayed on account of the war. Use instead:

For normal cases: One F and one E tablet to 3.5 c.c. This gives a solution with

Novocain	2%
Suprarenin.....	0.000,015 gram to 1 c.c.

VI. PREPARING OF THE SOLUTION

Remove the stand from the jar and wash the cup and syringe in distilled water, to remove all traces of alcohol. Fill cup with Ringer solution to the mark required.

Heat the solution over the flame to boiling.

Add tablets as follows:

For normal cases: One T tablet to each c.c. This gives a solution with:

Novocain	9.0%
Supracain	

REQUIREMENTS OF A SOLUTION PREPARED FROM TABLETS

1. It should be immediately used after it has been prepared.
2. The solution should not come in contact with anything except the porcelain cup and the syringe.

It should not be left longer than absolutely necessary in the dissolving cup nor in the syringe. The solution is very sensitive, being affected and chemically changed by air, heat, light, and especially by alkalies.

3. The tablets should not be touched with hands nor instruments, and the tube should be closed immediately after use, with the rubber stopper. The tablets are chemically changed by air, light, and especially by moisture.

4. The tablets should be white; sometimes the uppermost one discolours from chemical changes, caused by improper handling of the tube.

5. The solution gained from the tablets should be clear as water.

If it shows any light pink color, it should be discarded.

VII. LOCAL ANAESTHESIA

Local Anaesthesia has successfully progressed not only in minor but also in major surgery since we have been enabled, with the later methods, to obtain a really total anaesthesia. For this progress we are principally indebted to Professor Braun.

There are now different possibilities to produce local anaesthesia, named according to that part of the sensory nerve supply into which we decide to inject.

- a. The Surface Anaesthesia.
- b. The Infiltration Anaesthesia.
- c. The Conductive Anaesthesia.
- d. The Ganglion Anaesthesia.
- e. The Spinal Anaesthesia.

The Surface anaesthesia is only used upon mucous membranes which absorb it rapidly.

The Infiltration method anaesthetizes the peripheral nerve endings.

The Conductive method intercepts a whole nerve trunk supplying a certain area.

The Ganglion anaesthesia is obtained by injecting into a ganglion, anaesthetizing all the regions supplied by its branches.

The Spinal anaesthesia consists of mixing the anaesthetic solution with the liquor cerebrospinalis, and re-injecting of both into the spine. With this method much larger areas can be anaesthetized, but it is only practical in the lumbar part of the body, and therefore of no use in oral surgery.

In the oral cavity we have mainly to deal with the V Cranial nerve, which offers many possibilities for local anaesthesia.

Often the question is asked whether local anaesthesia has any bad effects on the pulp of the tooth, or the tissue in general. Both questions can be answered in the negative. A tooth, if anaesthetized properly by the infiltration or one of the other

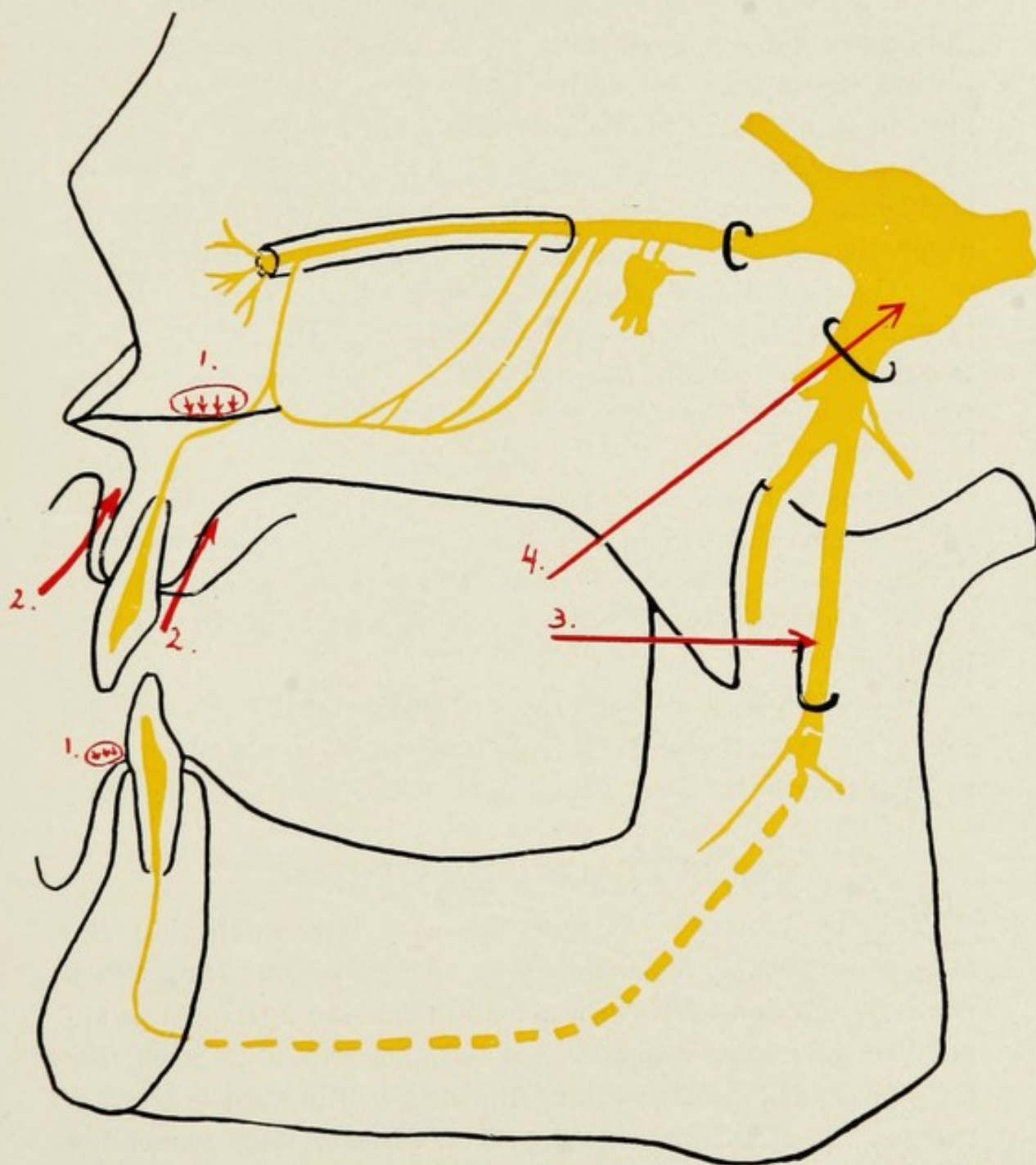


FIG. 31. Schematic illustration of the methods of local anaesthesia recommended for dental surgery. 1. Surface anaesthesia. 2. Infiltration anaesthesia. 3. Conductive anaesthesia. 4. Ganglion anaesthesia.

methods named in this book, is not in danger. We only anaesthetize the nerve fibers, while the circulation of the pulp is not interfered with to any extent, unless an extremely large amount of Suprarenin should be used. Also the surrounding tissues do not suffer, unless irritant antiseptics are added to the solution, as in some preparations which are on the market. We always inject into connective tissue from which the solution absorbs in one hour to one hour and a half, unless the amount of Suprarenin is too high. It is different, however, if we inject accidentally the whole amount into muscle tissue. From this, absorption takes place very slowly, it sometimes requires several days till all is absorbed, during which time the muscle is stiff, sometimes somewhat swollen, and causes, if it is a muscle of mastication, false ankylosis. This disappears without treatment. The danger of injecting into a nerve or vessel is also often questioned. To inject into a nerve trunk has no consequences other than a prompt action of the anaesthetic. Arteries are thick walled and elastic, and therefore are not easy to puncture, they rather go out of the way; veins and capillaries can be avoided if we move the syringe forth and back while injecting.

In modern local anaesthesia it is a principle to separate the act of anesthetizing from the operation proper, having a waiting time in between, during which the anaesthesia deepens.

A. SURFACE ANAESTHESIA

This method depends upon the absorbing quality of the mucous membrane. It has generally no deep action. If a twenty per cent solution of Novocain made from the F tablets is applied to the gum it causes superficial anaesthesia sufficient for fitting bands in bridge work or finishing a filling at the cervical margin. It also can be used previous to the insertion of the needle. There is, however, one method of surface anaesthesia which gives good results, this is the anaesthesia from the nose.

NASAL ANAESTHESIA

Place a piece of cotton saturated with a twenty per cent solution of Novocain into the inferior meatus of the nasal cavity. In a short time the solution will penetrate through the mucous membrane of the nose and anaesthetize the incisor teeth of the respective side.

B. INFILTRATION ANAESTHESIA

This method depends upon diffusion of the solution through the pores of the bone, thus reaching the dental nerve, before it enters the tooth.

For dental anaesthesia use:

For single-rooted teeth, labial or buccal injections.

For multi-rooted teeth, buccal and palatal injections.

For surgical anaesthesia use:

For all teeth, labial or buccal and palatal injections.

The solution is injected into the submucosa, from where it penetrates into the bone, depending upon the action of the Suprarenin to prevent quick absorption. Anaesthesia can be produced in five minutes and lasts one hour. It is at its best in ten minutes, and after half an hour it disappears gradually, the solution being absorbed slowly.

The Infiltration Method in the Maxilla

The maxilla is (as we have seen in another chapter) especially well adapted for the infiltration method, on account of the thin construction of the outer alviolar plate, and its porous make-up. This method can be used for any teeth in the upper jaw. The bicuspids and incisors are the easiest to anaesthetize; next come the cuspids and third molars, while the first and second molars sometimes show some difficulties on account of the zygomatic process forming a cortical mass over these teeth.

PREPARING OF THE PATIENT

If local anaesthesia is to be used on a patient the operator has never injected for, or in an entirely strange patient, one should inquire while leisurely conversing whether the patient has any severe illness, requiring a decrease in the percentage of suprarenin. If the subject of injection is opened, the

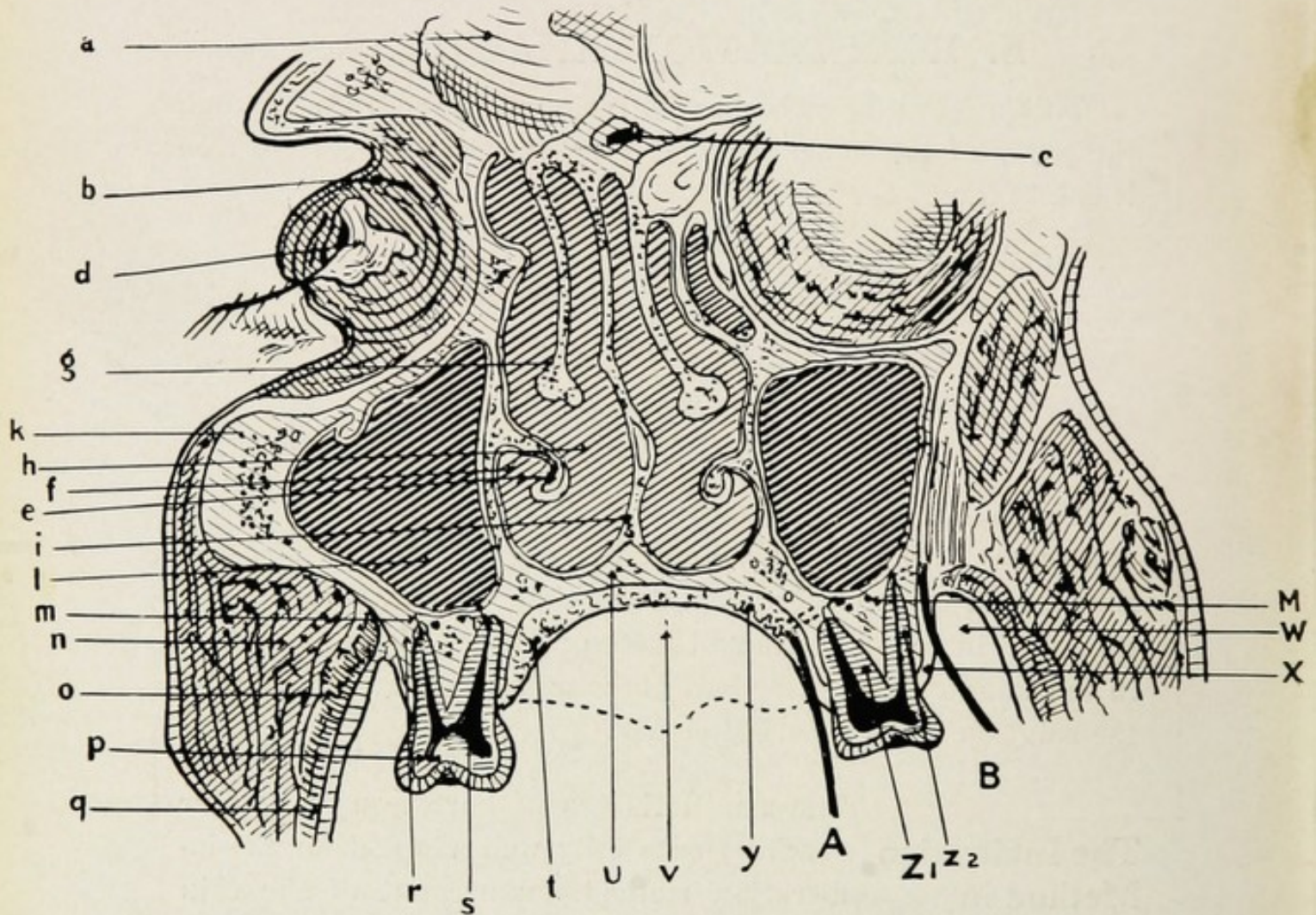


FIG. 32. Frontal section through the molar region showing buccal and palatal injection by the infiltration method.

A. Position of needle for palatal injection; B. Position of needle for buccal or labial injection. a. Sinus frontalis; b. M. orbicularis oris; c. Cellula ethmoidalis; d. Bulbus oculi; e. Concha nasalis inf.; f. Meatus nasi inferior; g. Concha nasalis media; h. Meatus nasi medius; i. Septum nasi; k. Processus zygomaticus; l. Sinus maxillaris; m. Plexus dentalis superior; n. M. masseter; o. M. buccinator; p. Dens molaris primus; q. Membrana mucosa buccalis; r. Processus alveolaris; s. Pulpa dentis; t. Membrana mucosa palatinae; u. Processus palatinus; v. Cavum oris; w. Cavum buccalis; x. Membrana mucosa alveolaris; y. Glandulae palatinae; z. (1) Radix palatinae; z. (2) Radix buccalis.

patient usually mentions of his own accord previous disagreeable experiences, if he has had any, and the operator can conduct himself accordingly. This is also the time to assure the patient of the safety of this anaesthetic, and of the great advantage to both the patient and the operator, sparing the first the pain, and allowing the latter to use his best ability to perform the operation.

PREPARATION OF PLACE FOR INSERTION OF THE NEEDLE

An unclean mouth should first be sprayed out with an anti-septic solution. Hold the lip away from the gum, and with a short cotton roll wipe all the mucus from the field of operation. Then with a little bit of cotton dipped in campho-phenique, or solution of aconite and iodine, equal parts, sterilize and anaesthetize the part where the needle is to be inserted. In very sensitive patients I use a small hypodermic syringe, with a very fine and sharp platinum needle, and inject a few drops of Novocain solution previous to the regular injection.

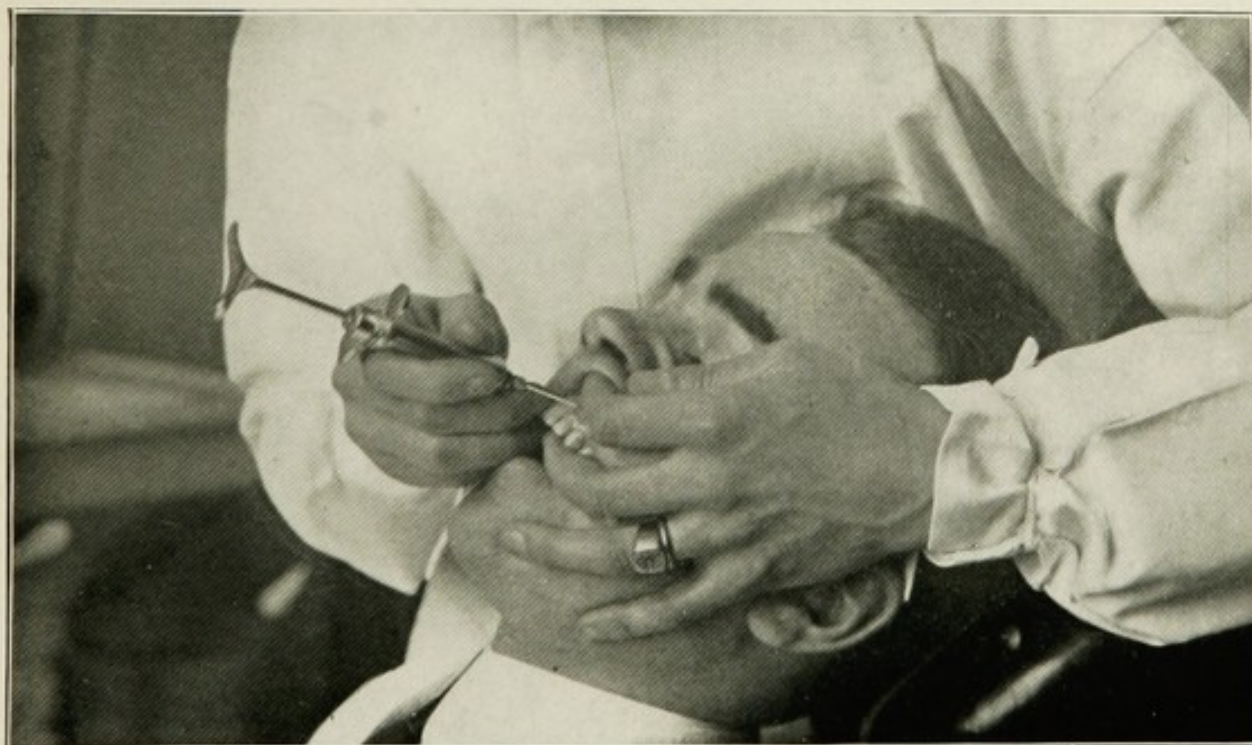


FIG. 33. Position of operator when injecting for an upper tooth by the infiltration method.

1. Injection on the labial and buccal side of the Maxilla.

The point of insertion on the labial and buccal side is half-way between the gum margin and apex of the root. For cuspids it is advisable to start higher up, and for the molars one should start over the mesial root, or still farther forward, pushing the needle obliquely backward and upward, to reach a point between and a little higher than the apices of the buccal roots.

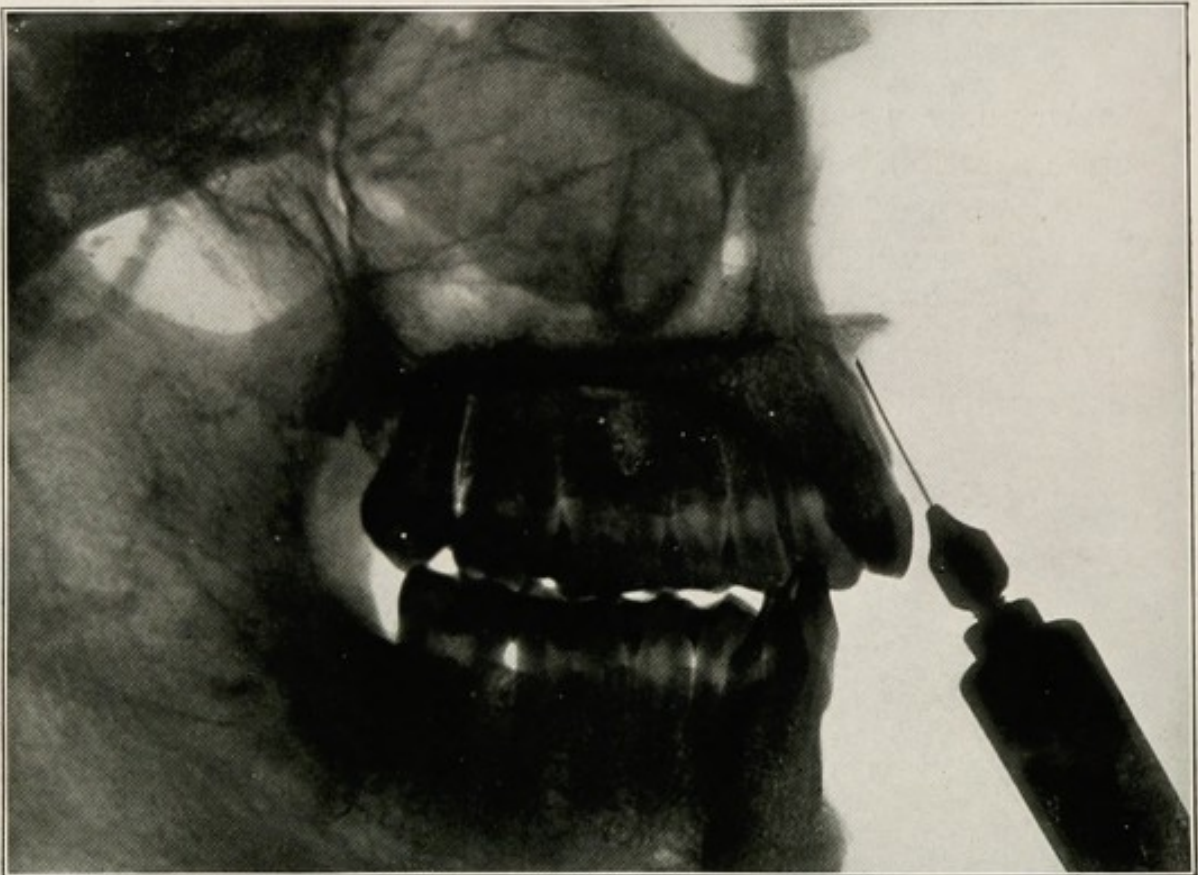

FIG. 34. Radiograph showing the infiltration method for an upper incisor.

This to overcome technical difficulties. The upper wisdom tooth is sometimes hard to reach, its neck is usually well set in and at a higher level than the other molars. In these cases it is best to use the long needle, insert it very high at the level of the apex, but further forward over the twelve-year molar, and push it backward and inward in horizontal direction. The process around the third molar is very porous and anaesthesia

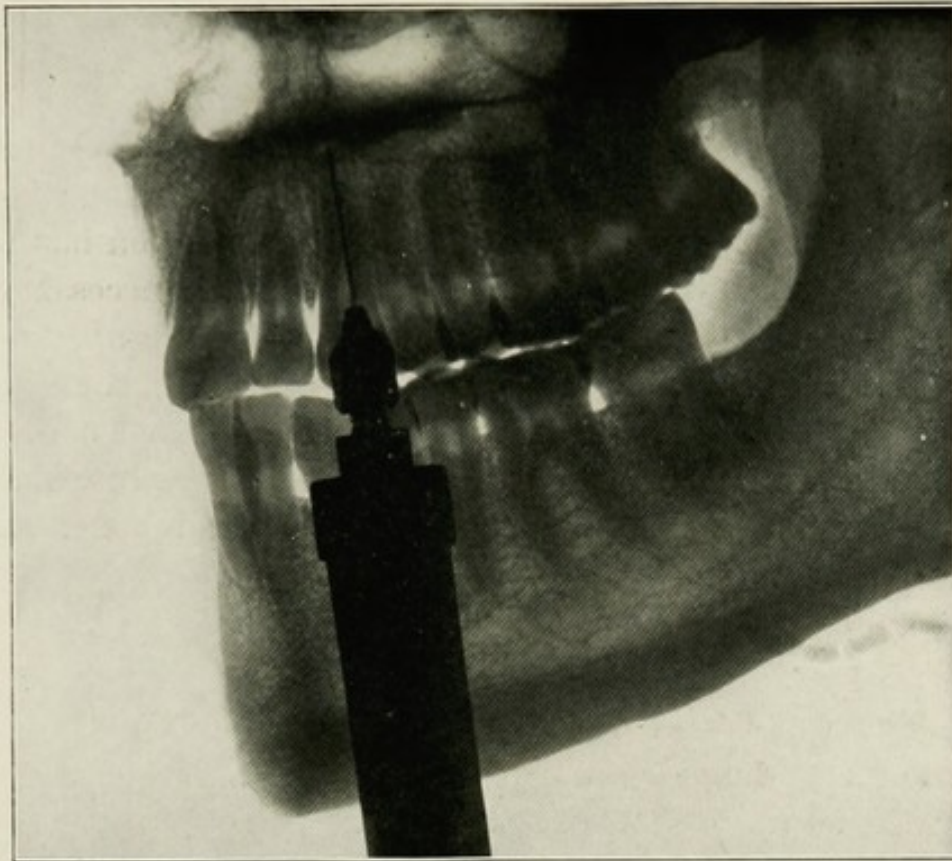


FIG. 35. Radiograph showing the infiltration method for an upper cuspid.

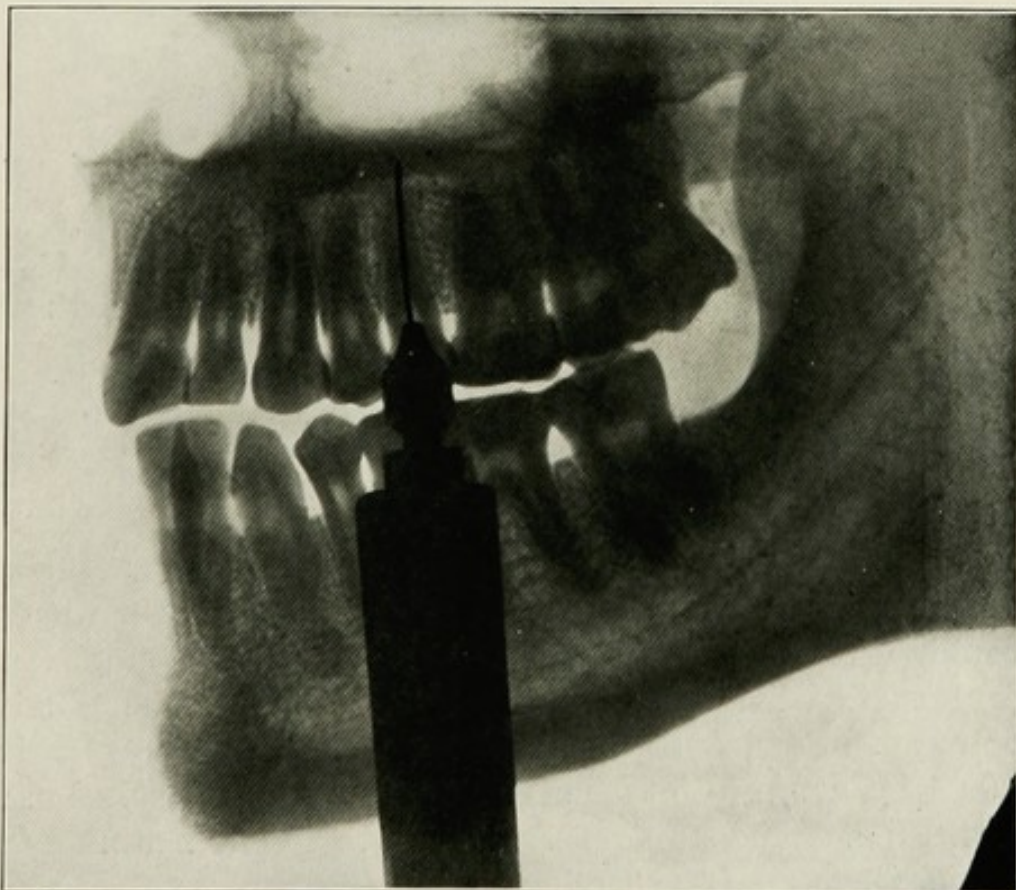


FIG. 36. Radiograph showing the infiltration method for an upper bicuspid.

usually takes easy effect. Generally the short needle is used. Push it, opening directed toward the bone, down to the periosteum. A drop or two is injected. Now the syringe is best held like a writing pen, and after the first injection has taken effect, push it slowly and carefully upwards, if necessary, injecting as you go along, till you are opposite the apex of the root. Here inject slowly and evenly, moving the syringe slightly forth and back, to avoid injecting into a small vein. In this manner a depot of 1 to $1\frac{3}{4}$ c.c. is deposited, into the submucous tissue between mucous membrane and bone. Little

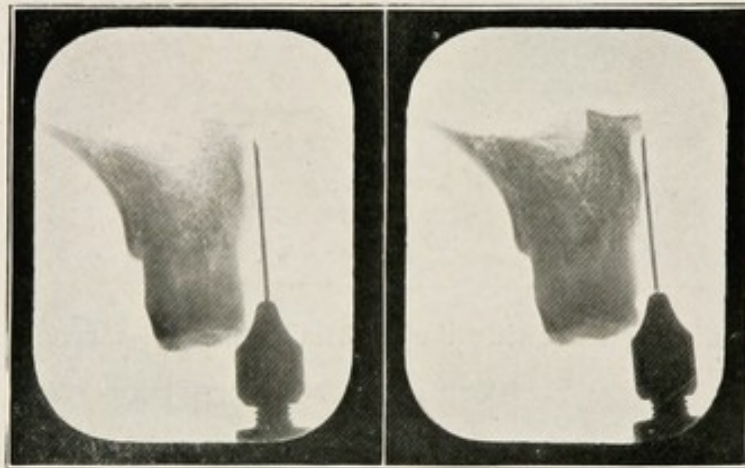


FIG. 37. Wrong position of needle.

FIG. 38. Right position of needle opening pointing towards the bone.

force is needed to inject. After five to eight minutes, anaesthesia occurs in the tooth injected for, sufficient to extirpate the pulp without pain. (See Table I.)

2. Injection on the palatal side of the maxillary teeth.

The palatal gum of the maxilla is supplied by the anterior palatine and naso-palatine nerves, therefore for surgical operations an additional injection to produce anaesthesia of the soft parts is required. Also for the molars, and often for the first bicuspid, a palatal injection is needed to anaesthetize the palatal root. For these injections we start at the gingival margin, push the needle down parallel with the process, and inject 0.25 c.c. again into the part which takes up the solution the easiest, the submucous tissue. After five to eight minutes anaesthesia occurs. (See Table II.)

**The Infiltration
Method in
the Mandibula**

We have studied the lower jaw and found it porous only in the mental fossa, and at the genial tubercles, while in the region of the back teeth the bone is very dense. The infiltration method, therefore, is not advisable for the lower jaw, except for the four incisors.

For dental anaesthesia use labial injections.

For surgical anaesthesia use labial and lingual injections.

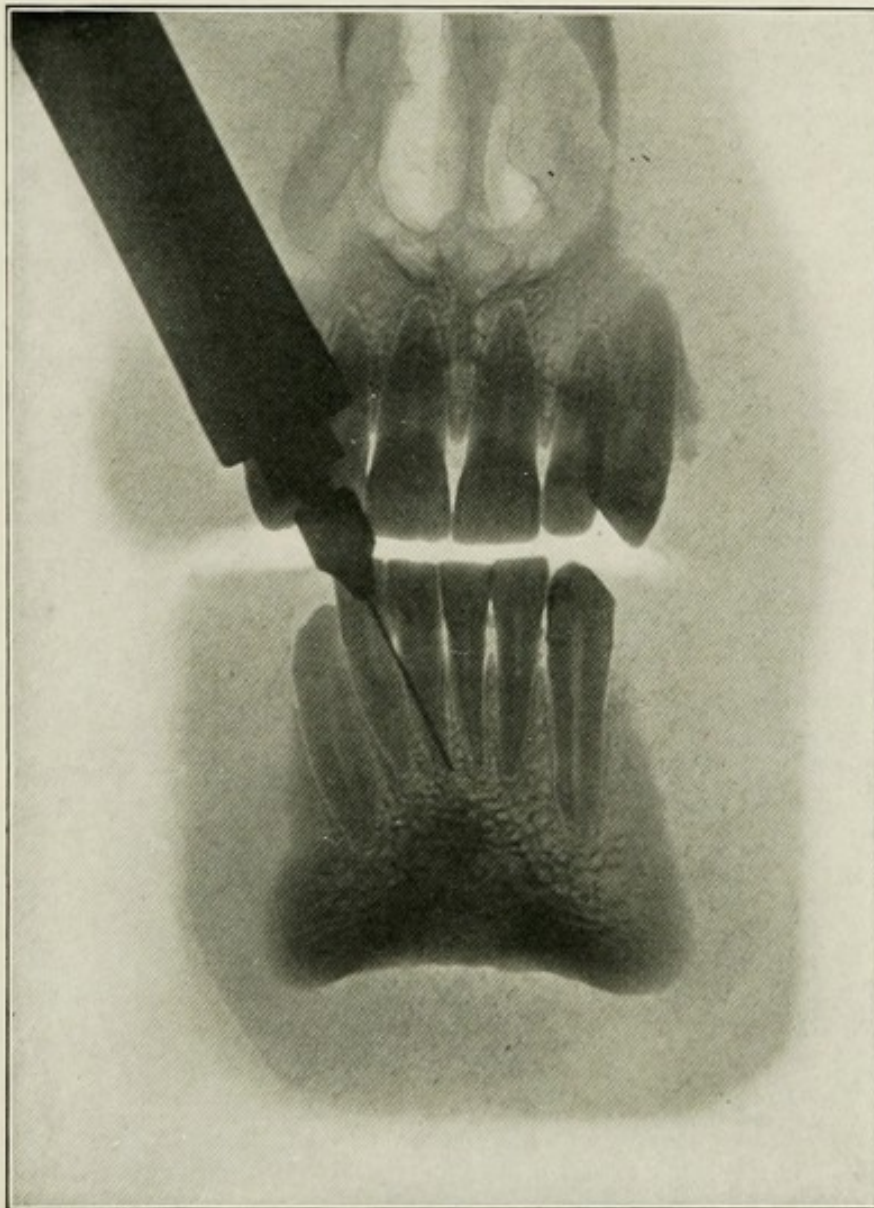


FIG. 39. Radiograph showing the infiltration method for a lower incisor.

1. Injection on the labial side of the mandibular incisors.

Here the procedure is very much like in the maxilla, often, however, it is easier to insert the needle over the tooth next to the one we wish to anaesthetize, pushing it obliquely toward the apex of the tooth in question. (See Table I.)

2. Injection at the lingual side of the mandibular incisors.

The procedure is very much like that at the palatal side of the maxilla. The lingual gum is supplied by the lingual nerve. This injection is only necessary in case of extraction of the lower incisors. (See Table II.)

To avoid repeated puncture of the mucous membrane, if several adjoining teeth are to be anaesthetized from the labial or buccal side by the infiltration method, the long needle is inserted over the apex of the root of the tooth farthest forward or nearest the operator. After having injected for this

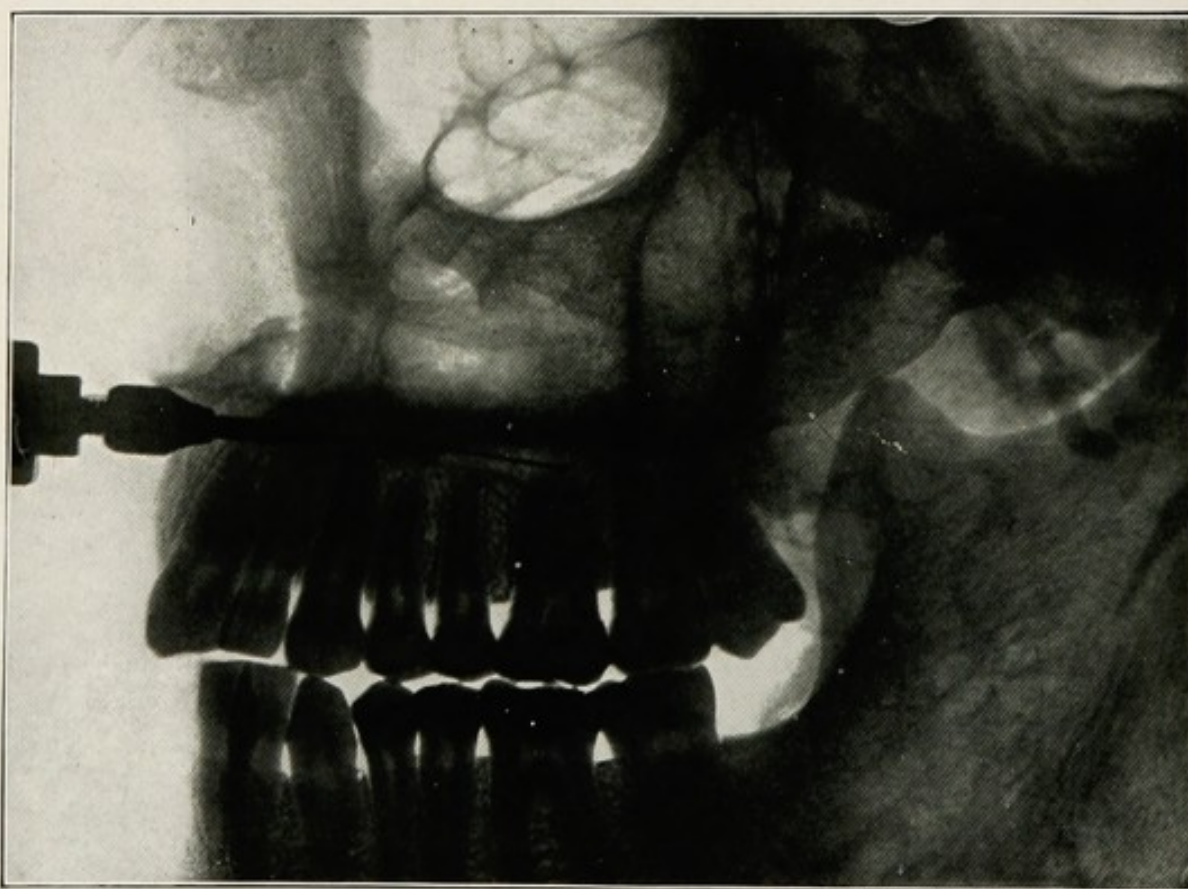


FIG. 40. Radiograph showing the horizontal injection for bicuspid and molar region.

first tooth, push the needle along the bone in horizontal direction, till you have reached the place opposite the apex of the second tooth; here again deposit some of the solution and proceed in same manner for the next tooth. This method can be used for a series of teeth in the incisor region, in the upper as well as in the lower jaw, and for anaesthetizing adjoining maxillary bicuspids and molars. The use of the horizontal injection is only advisable in healthy tissue. It is easy to see

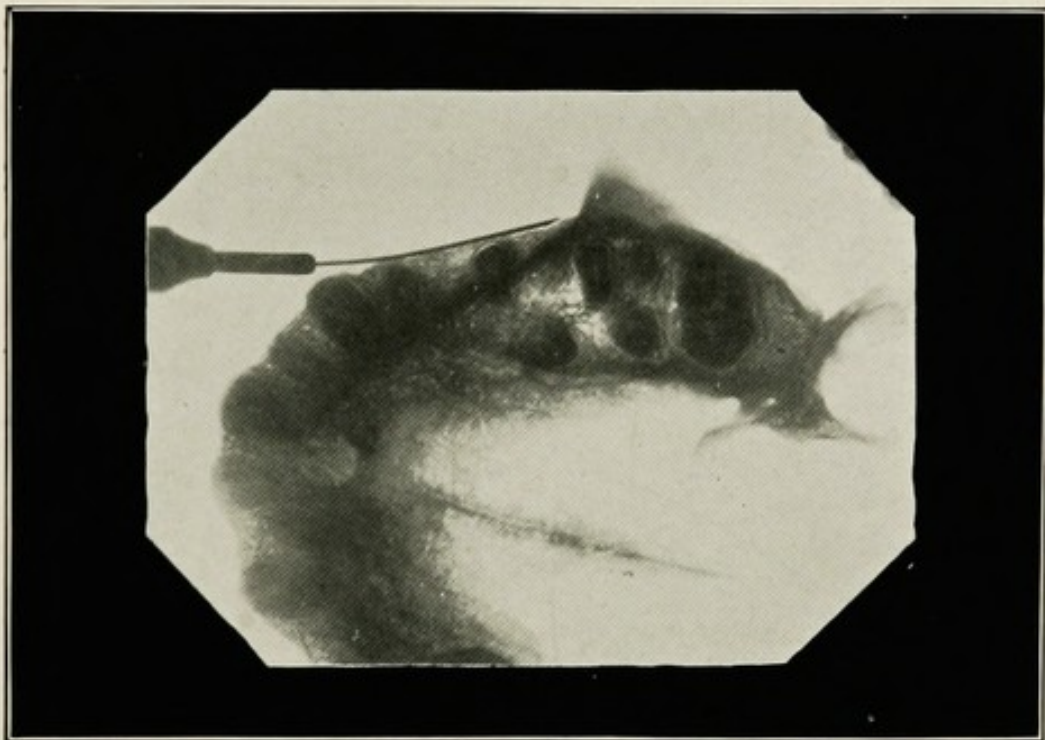


FIG. 41. Radiograph showing the horizontal injection in a coronal section.

how we would spread an infection, if the needle was passed through an abscess, while anaesthetizing the first tooth, all the area would be inoculated. For infected areas we resort to the conductive method. For surgical anaesthesia use the conductive method at the palatal side.

C. CONDUCTIVE ANAESTHESIA

In the conductive method the conductivity of the main trunk of the nerve supplying the teeth and tissues in the oral cavity

is intercepted or blocked at a convenient point, while in the infiltration anaesthesia the drug acts on the peripheral nerves. As the place of insertion is usually quite removed from the field of operation, we resort to this method, if the infiltration method is contra-indicated on account of septic conditions. It is used if the infiltration method cannot be applied,

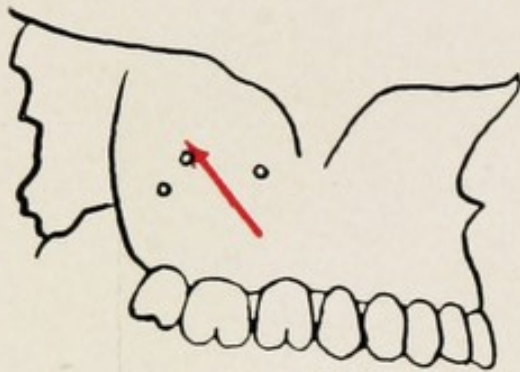


Fig. 1.

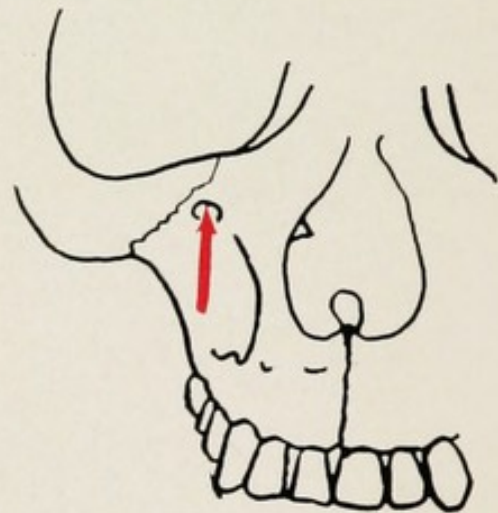


Fig. 2.

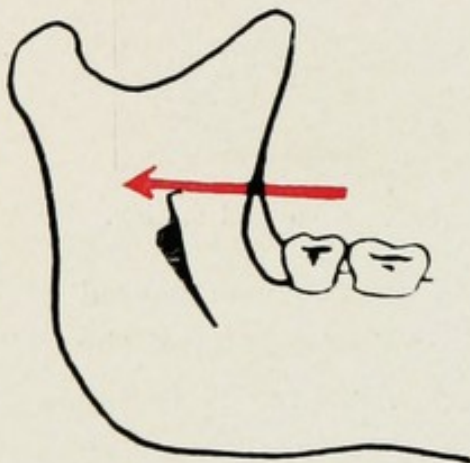


Fig 3.

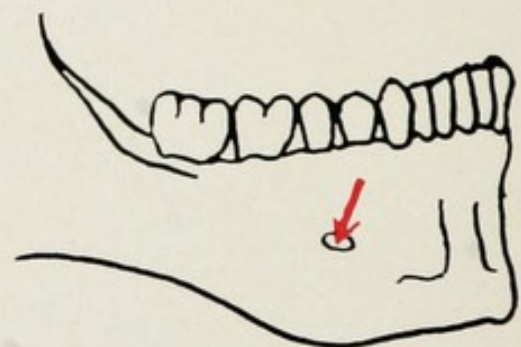


Fig. 4.

FIG. 42. Conductive Anaesthesia. 1. Zygomatic injection; 2. Infra-orbital injection; 3. Pterygo-mandibular injection; 4. Mental injection.

on account of the anatomical structure of the jaw. We may resort to it if several teeth supplied by one nerve trunk are to be operated upon, and we use it in combination with the infiltration method for large surgical operations, to combine extensive anaesthesia with anaemia of the field of operation. Halsted (1885) was the first to use conductive anaesthesia, blocking off the inferior alviolar nerve at the mandibular foramen.

FOR DONTAL OPERATIONS

Conductive Method in the Mandible For purely dotal operations we need only anaesthesia of the nerve which supplies the teeth. It enters the mandible through the mandibular foramen. For anaesthesia of the molars and bicuspid on one side, one injection over the mandibular foramen into the pterygo-mandibular space is sufficient. The cuspid and two incisors are sometimes also anaesthetized, sometimes remain slightly sensitive on account of the anastomosis from the other side. Another injection into the mental fossa, or over the mental foramen of the opposite side is needed in the latter case. For anaesthesia of all the lower teeth, one should use two injections, one over each of the mandibular foramina.

FOR SURGICAL OPERATIONS

For surgical operations we need not only anaesthesia of the teeth, but also of the soft tissue surrounding them. On the inner side this region is supplied by the lingual nerve; on the buccal side, by the inferior alviolar nerve; and by the buccinator nerve in the region of the first and second molar and second bicuspid. Therefore we need anaesthesia of the lingual and buccinator nerve in addition to the alviolar. The inferior alviolar and lingual nerves can be anaesthetized with the same injection, and often also the buccinator nerve is reached, especially if a large amount is injected. Most frequently, however, it is necessary to inject for the buccinator nerve.

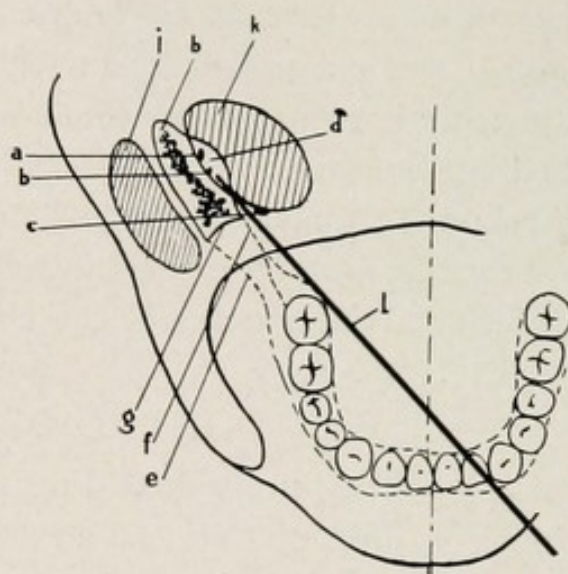


FIG. 43. Diagram showing injection into the pterygo-mandibular space.

a. N. alviolaris inf.; b. A. alviolaris inf.; c. N. lingualis; d. Spatium pterygo-mandibulare; e. Linea obl. externa; f. Linea obl. interna; g. Trigonium retro-molare; h. Ramus mandibulae; i. M. masseter; f. M. Pterygoid int.; l. Position of needle.

I. PTERYGO-MANDIBULAR INJECTION

For the right side, stand in front of the patient, palpitate the external oblique line of the ramus, then the internal oblique line with the thumb of the left hand, and finally place the tip of the thumb into the depression between, the post-molar triangle. The thumb is left there to guide the insertion of the needle and the other fingers fix the jaw.

For the left side, place the left arm around the patient's head and palpitate the post-molar triangle with the tip of the index finger. On this side, the index finger serves as guide for the insertion of the needle, while the other fingers are used to hold the jaw.

Prepare the place of insertion in the usual manner. This injection is the least painful, but, as in all cases of conductive anaesthesia, sterilization of the place where the needle is inserted and scrupulous asepsis is of utmost importance.

Place the syringe, mounted with the long iridio platinum needle (45 m.m.) between cuspid and first bicuspid of the

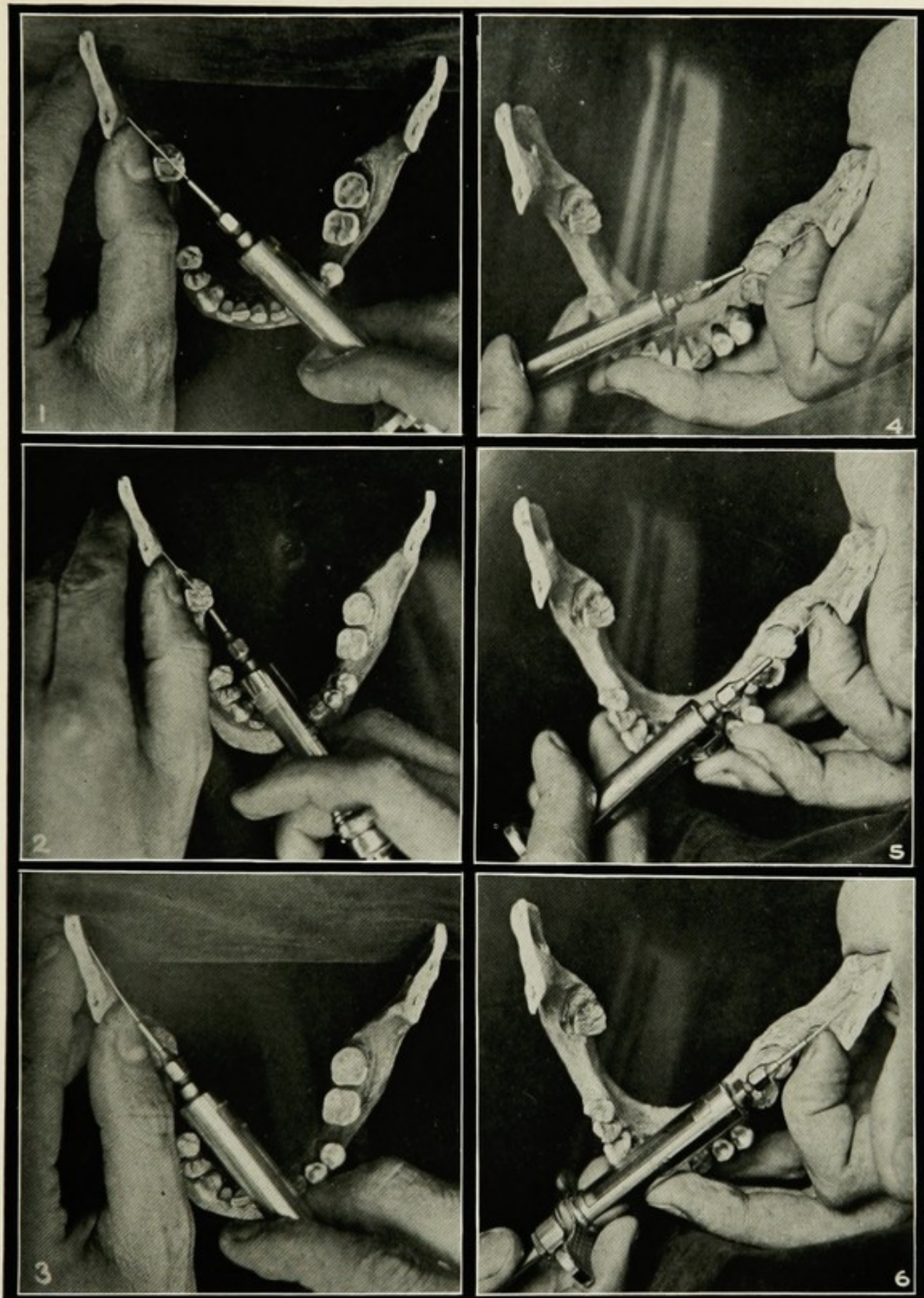


FIG. 44. Technique of inserting the needle for the Pterygo-mandibular injection. 1, 2 and 3, on the right side; 4, 5 and 6, on the left side. 1 and 4, feeling of the internal oblique line. 2 and 5, adjusting position of the syringe parallel with the ramus. 3 and 5, reaching the pterygo-mandibular space.

opposite side, and insert the needle into the mucous membrane 1 cm. over the last molar, and close to the finger nail. Inject a small quantity to anaesthetize the superficial structures.

Push the needle forward till you feel the internal oblique line. If you do not find it, it is because you are too far to the

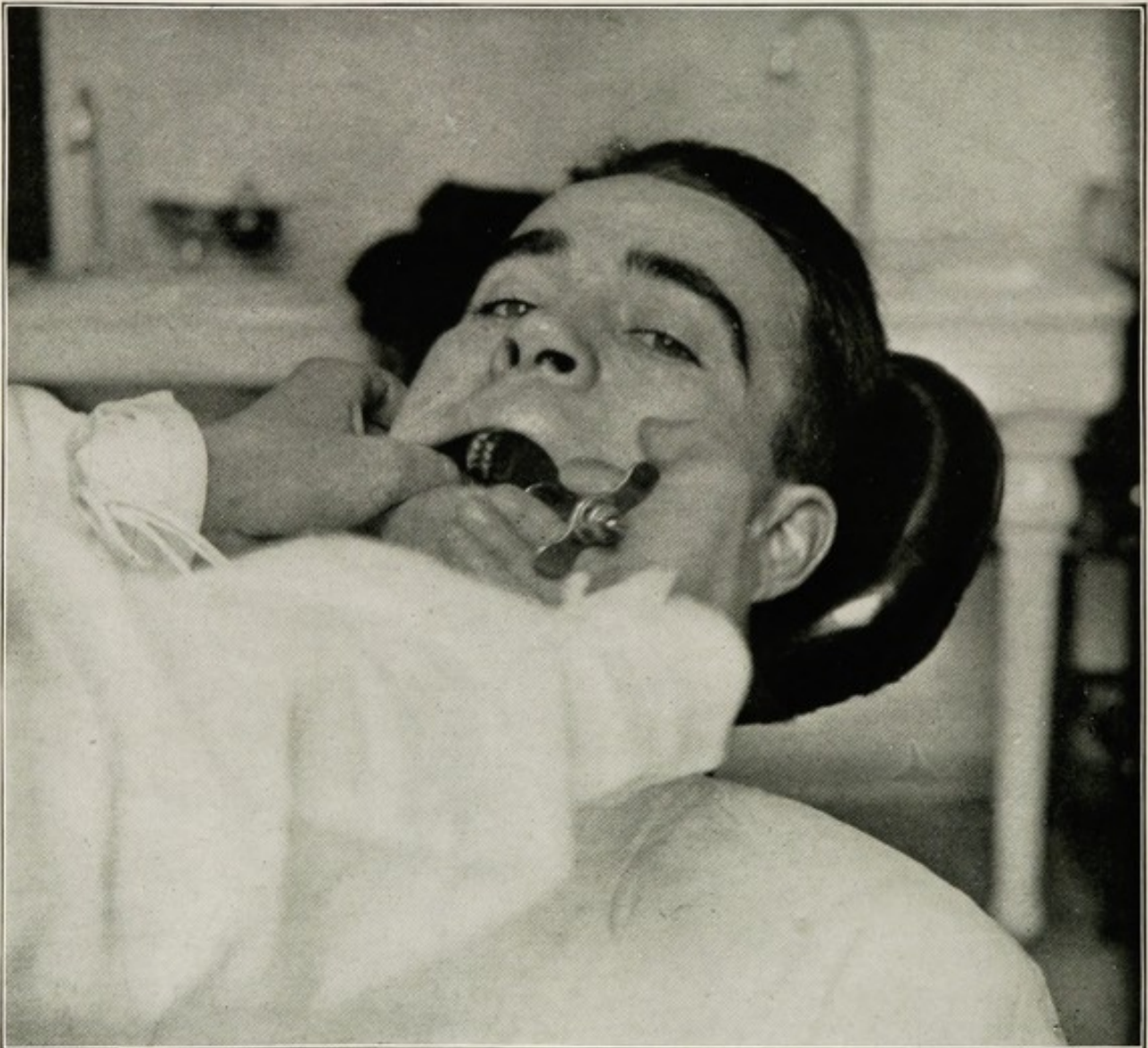

FIG. 45. Pterygo-mandibular injection on the right side; position on patient.

median line, in which case the error can be corrected by puncturing the mucous membrane at a place more to the outside.

Push the needle slowly forward and change the direction of the syringe, so as to bring it parallel with the ramus. This

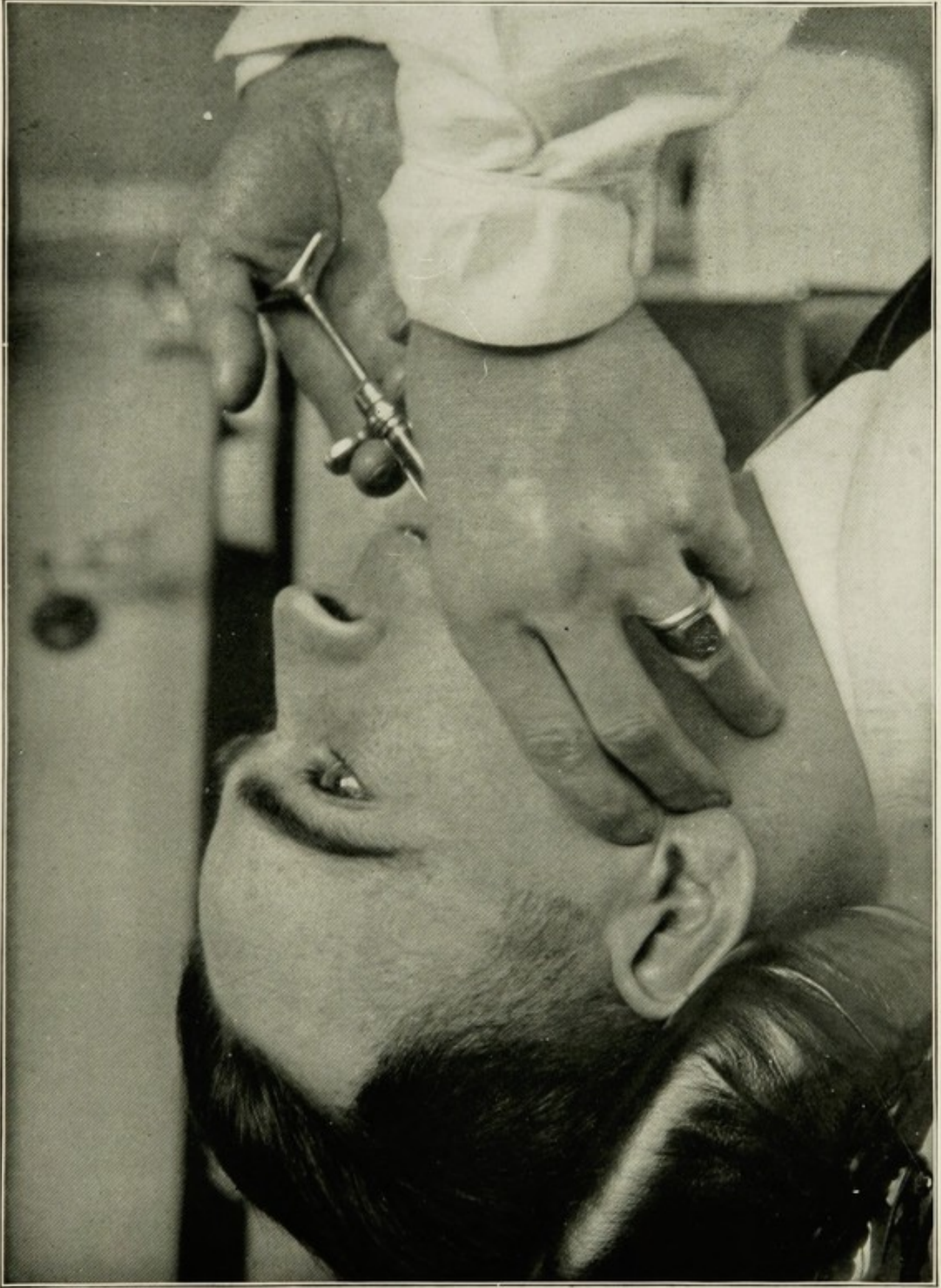


FIG. 46. Pterygo-mandibular injection on the right side; position on patient.

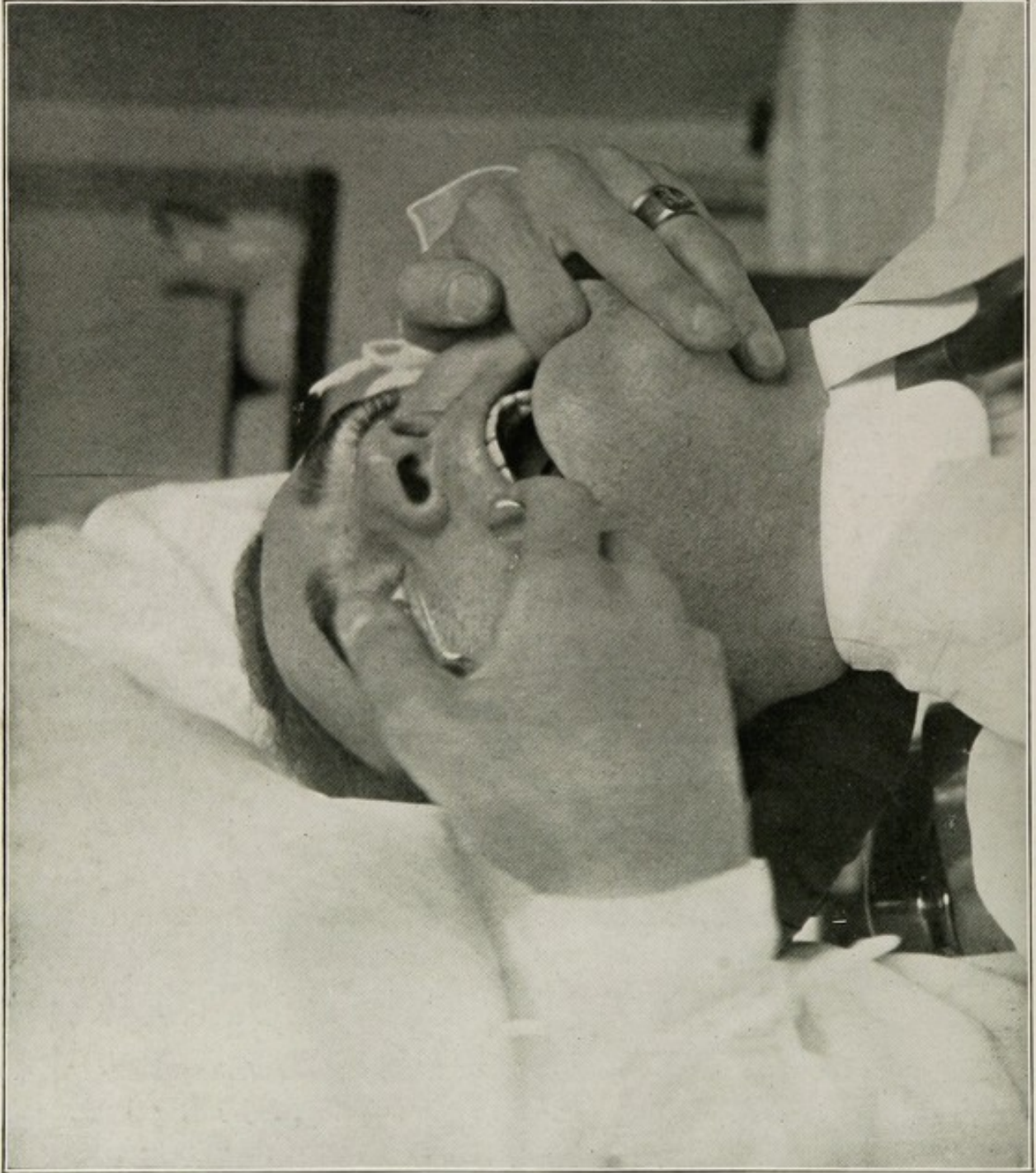


FIG. 47. Pterygo-mandibular injection on the left side; position on patient.

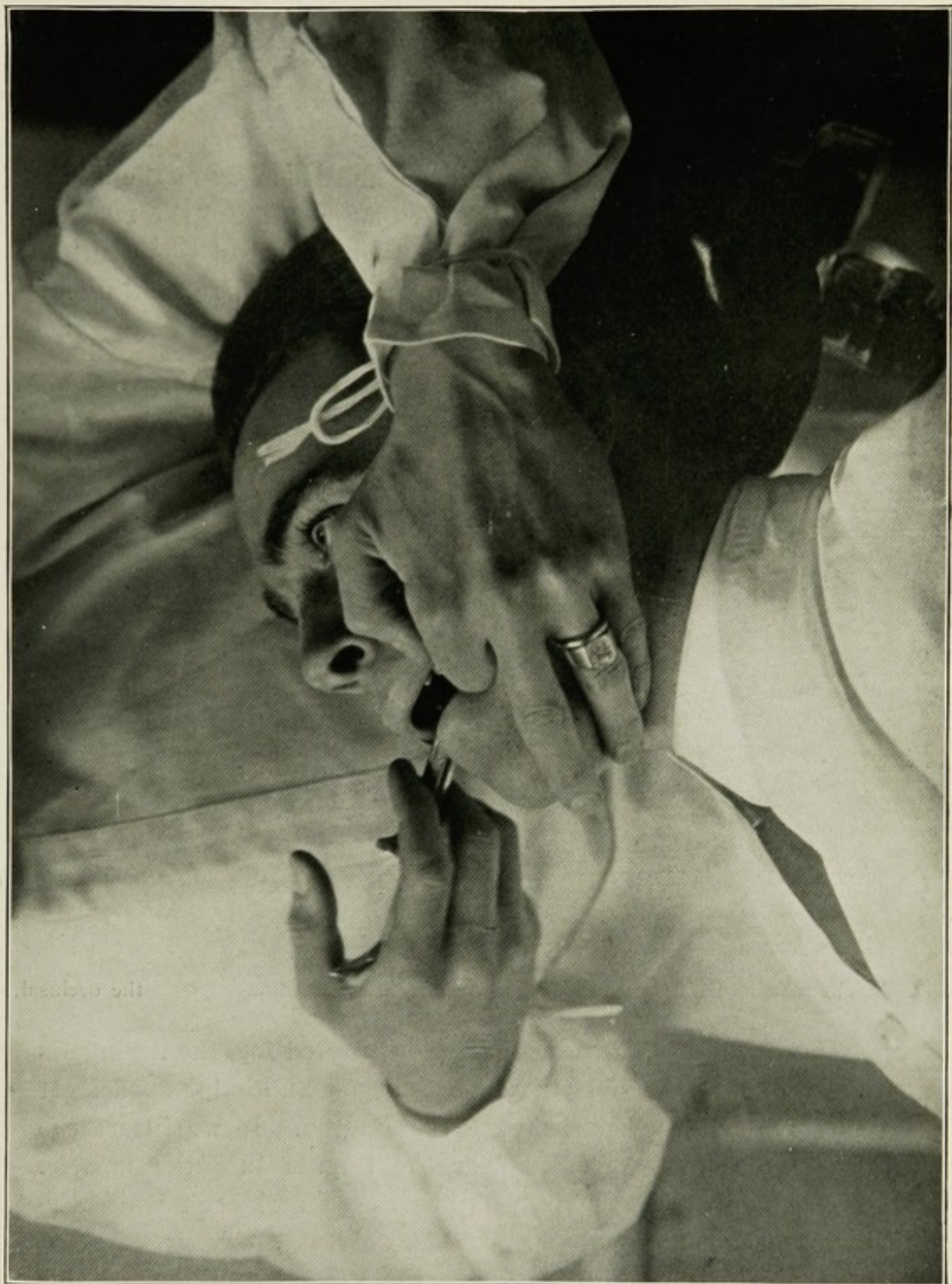

FIG. 48. Pterygo-mandibular injection on the left side; position on patient.

changes the position of the back part of the syringe, bringing it over the incisors, or further back over the bicuspid.

Now comes the distinction for dental and surgical anaesthesia. The lingual nerve lies anterior and medially of the alviolar nerve, halfway between the alviolar nerve and the mucous membrane. Therefore, by depositing one-third of the solution when the needle is halfway in, we will anaesthetize the lingual nerve.

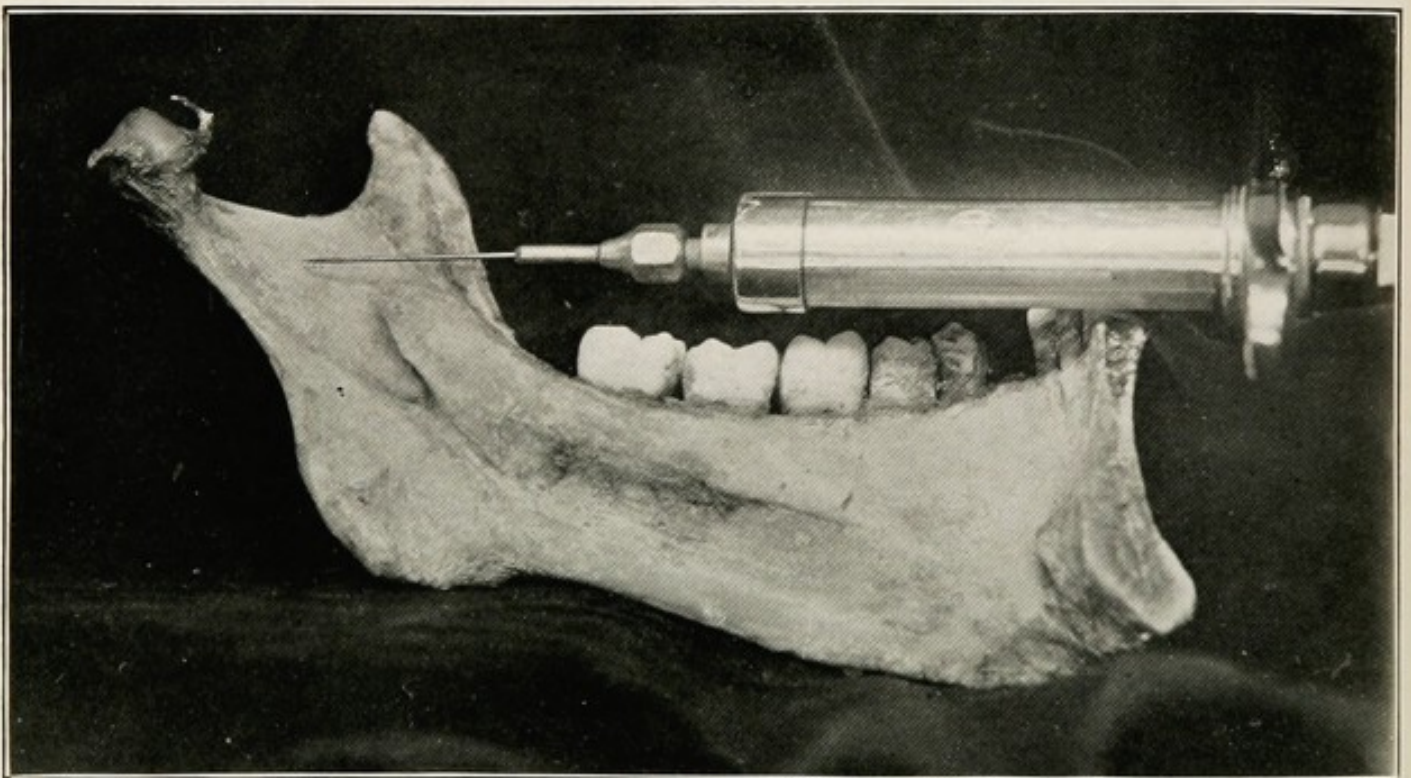


FIG. 49. Sulcus mandibularis with needle, which is inserted one centimeter over the occlusal surface.

After the lingual nerve has been injected for, the syringe is pushed along the bone into the pterygo-mandibular space. It should reach the space above the lingula. If we insert the needle too low, it passes over the lingula into the muscle. The needle is now moved slightly forth and back while the injection is made.

In this way we anaesthetize the lingual and the inferior alviolar nerve. If we want anaesthesia of the teeth only, we do not inject till we have reached the pterygo-mandibular space,

where we deposit 1.5 to 2 c.c. In this manner, we avoid anaesthesia of the lingual nerve.

It is of double advantage not to inject while inserting the needle. The danger of infiltrating muscle bundles is decreased, and the whole amount of the solution can be utilized to anaesthetize the inferior alviolar nerve.

Anaesthesia occurs in fifteen to twenty minutes, and lasts at least one hour.

In children the needle should be directed slightly downward; in old patients slightly upward on account of the different relation of the mandibular foramen. (See Figure 14.)

For longer anaesthesia inject two syringes full, or 4 c.c. at once. (See Tables III and IV.)

The first sign the patient experiences is numbness of the lower lip and, if the lingual nerve is anaesthetized, also numbness of the tongue. These are signs of a successful injection, and occur in a very short time. It is important in this anaesthesia, especially for nerve extractions, to wait till it has reached its deepest stage; this sometimes takes thirty minutes, working from the median line backwards.

Failures in this injection occur if the internal oblique line is ignored, if the needle loses the contact with the inner side of the ramus, or if the injection is too low. It is important to inject in a horizontal plane one centimeter over the last molar to reach the pterygo-mandibular space above the lingula. If we insert the needle along the bone too far down, we find that a projecting lingula guides the needle directly into the muscle, and this we want to avoid.

2. MENTAL INJECTIONS

For the injection into the mental foramen, we insert the needle into the reflexion of the mucous membrane, below the first bicuspid. Holding the finger tip over the foramen, compress the mucous membrane, and push the needle down and slightly back along the bone for several millimeters. When

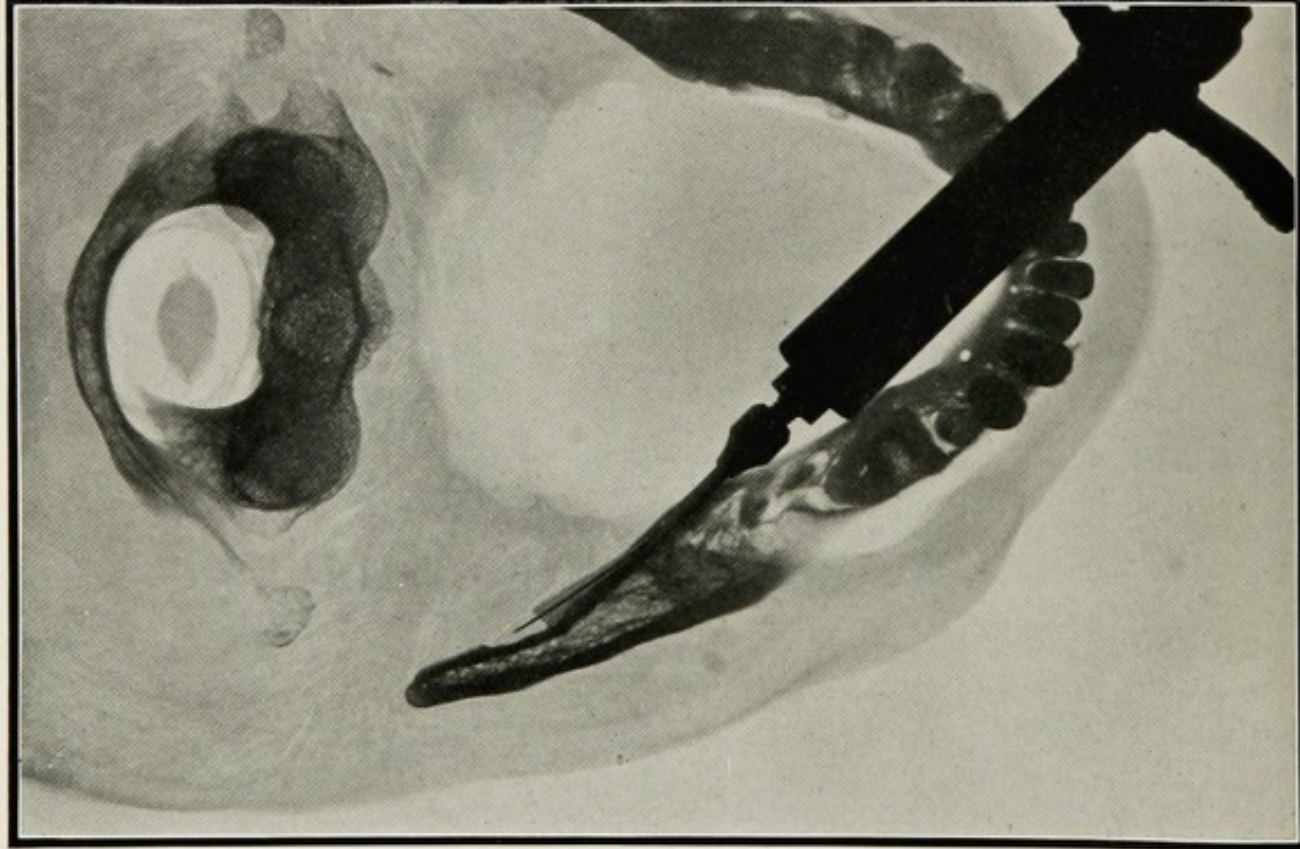


FIG. 50. Radiograph showing needle inserted in right position above the lingula.

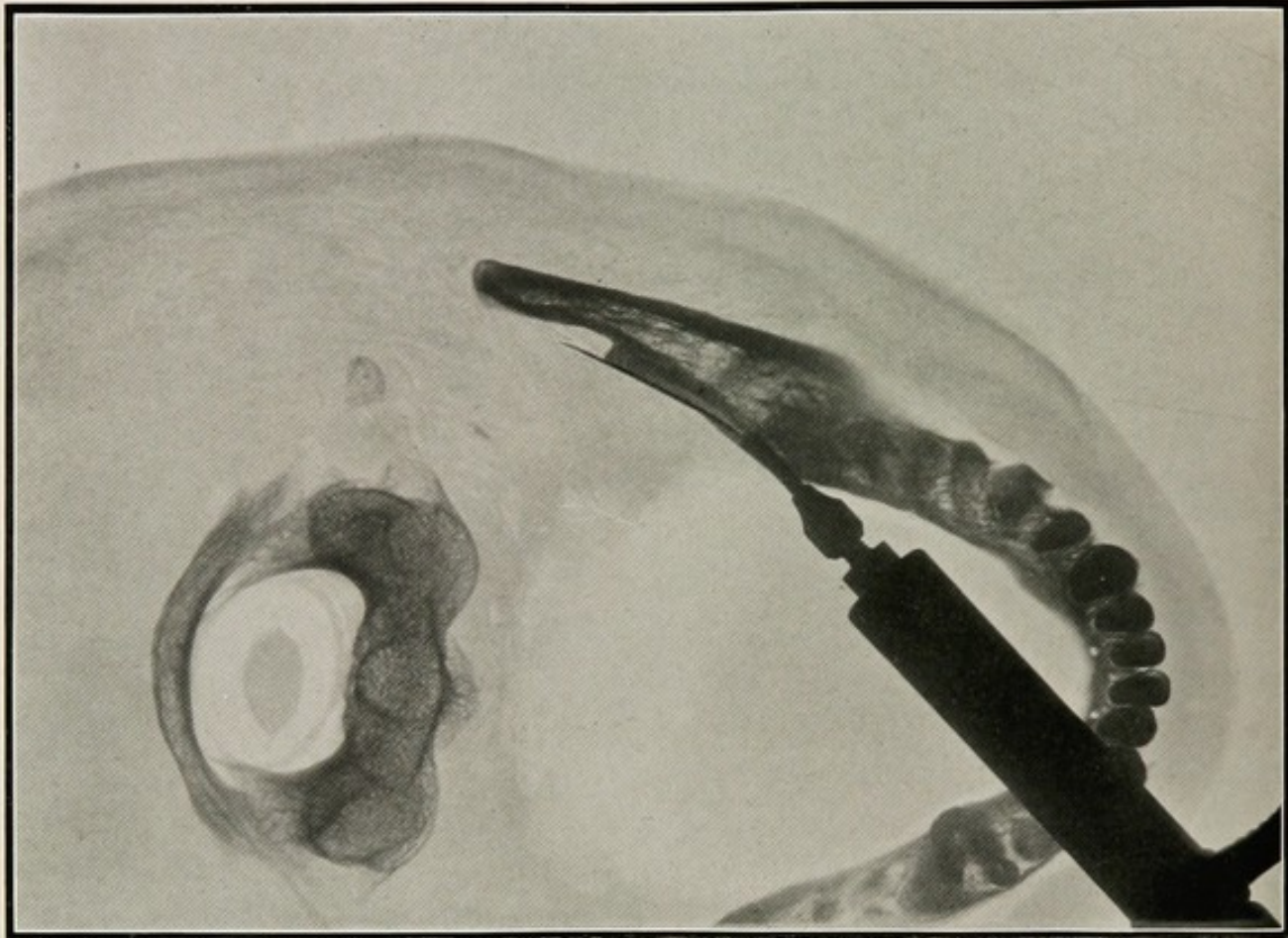


FIG. 51. Radiograph showing needle inserted too low sliding along the lingula into the muscle.

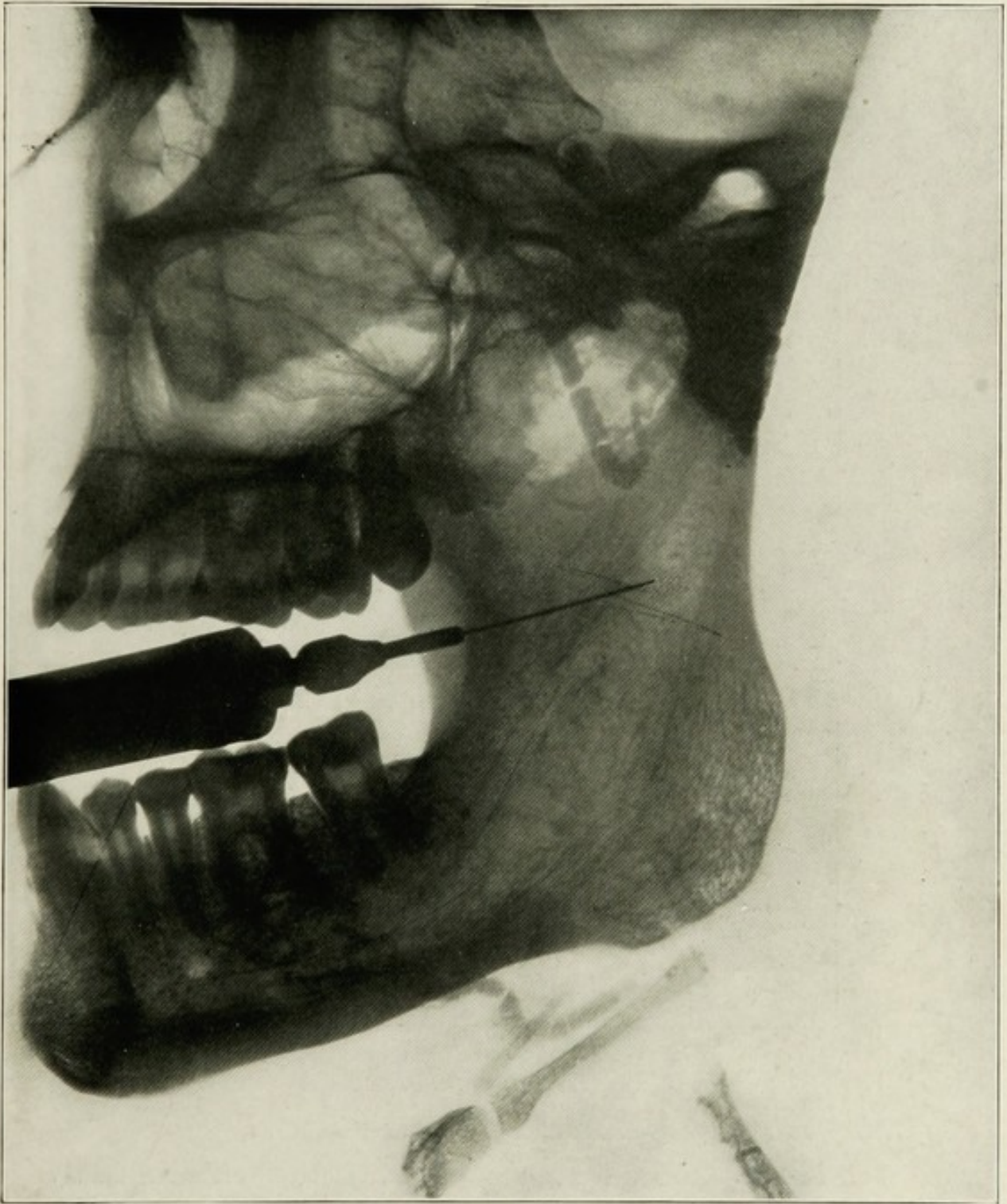


FIG. 52. Radiograph showing the pterygo-mandibular injection.

felt under the finger inject into the foramen 1 c.c. Pressing while injecting will direct the solution through the mental foramen into the mandibular canal. (See Tables III and IV.)

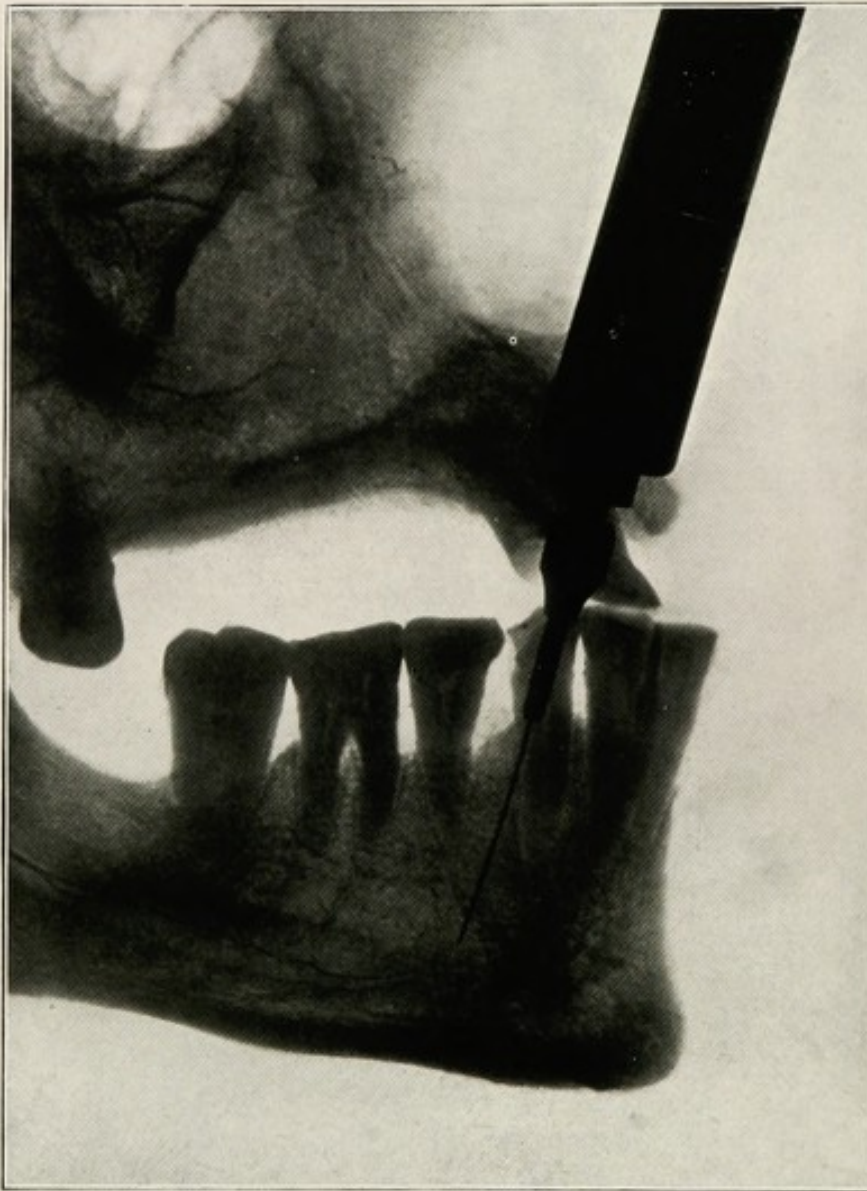

FIG. 53. Radiograph showing injection into the mental foramen.

3. BUCCINATOR INJECTION

For the buccinator nerve make one injection, either directly into the mucous membrane supplied by it or, in case of inflammation by conductive anaesthesia, inserting the needle just below the Stenson's duct, pushing it backward toward the

ramus. The area supplied by the buccinator nerve varies in different individuals, and it is not always necessary to inject for this nerve specially. Often it is also reached with the pterygo-mandibular injection.

We have studied the nerve supply in the maxillary bone and found it much more complicated than in the mandible. The method to anaesthetize the maxillary nerve after it comes from the foramen rotundum is very difficult and therefore, we usually prefer to use two injections to block the sensation carried by the superior alviolar nerves, and two injections to anaesthetize the soft tissue of the palate.

For dental anaesthesia use to anaesthetize:

Maxillary molars and bicuspid: zygomatic injection.

Maxillary incisors and cuspids: infra-orbital injection.

For surgical anaesthesia use to anaesthetize:

Posterior part of maxilla: zygomatic and posterior palatine injection.

Anterior part of maxilla: infra-orbital and incisive injection.

For large surgical operations use to anaesthetize:

Whole maxilla: speno-maxillary injection.

1. ZYGOMATIC INJECTION

Palpitate the zygomatic process of the maxilla, preparing the place of insertion as above and sliding the long needle, keeping close to the bone, upward, backward and inward, depositing the solution while injecting. In this manner the two posterior superior branches and often also the middle superior branch are crossed by the direction of the needle, and anaesthetized by the solution, desensitizing the molars and, in favorable cases, also the bicuspid. It is often advisable to

inject in two directions to reach all the superior alviolar branches. The horizontal direction will reach the posterior superior alviolar branches, while the more vertical direction will reach the middle superior alviolar nerve, in the case this is given off before the maxillary nerve enters the infra-orbital canal. The zygomatic injection gives also anaesthesia of the buccal part of the gum. Inject 2 c.c. Anaesthesia occurs in ten minutes and lasts one hour. (See Tables III and IV.)

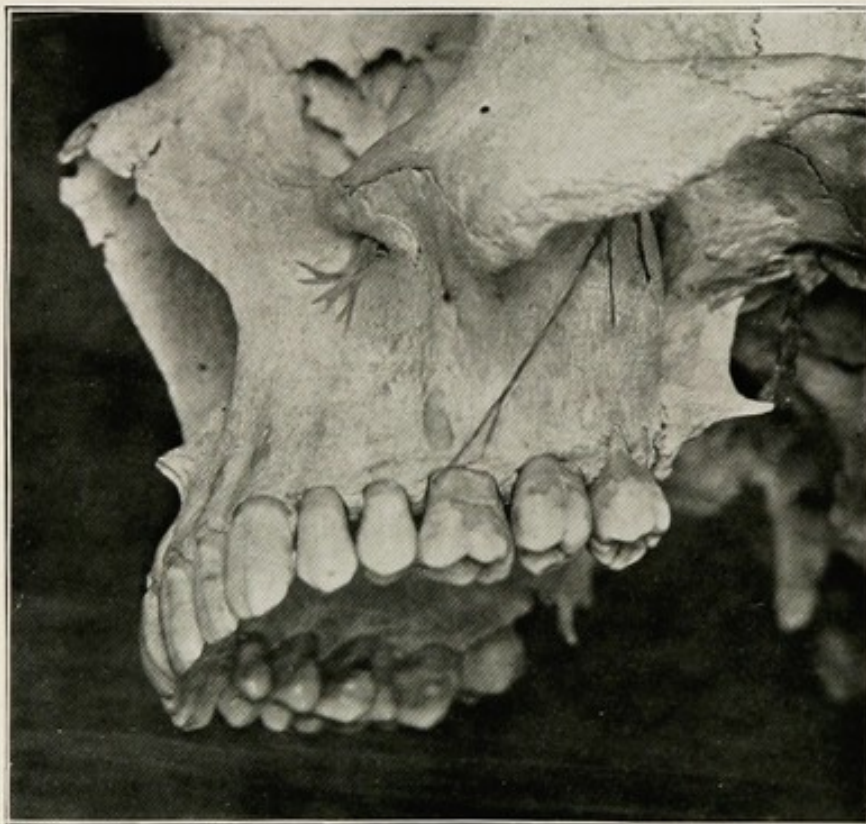

FIG. 54. Infra-temporal surface of the maxilla. The posterior superior alviolar branches are shown entering the foramina. One branch is a gingival branch.

2. INFRA-ORBITAL INJECTION

Palpitate the infra-orbital foramen and place upon it the tip of the thumb or index finger. With one of the other fingers retract the upper lip and after preparing the place, insert the long needle in the canine fossa, as high as the reflection of the mucous membrane allows. Push it along the bone until felt under the finger. While compressing the soft tissue over the

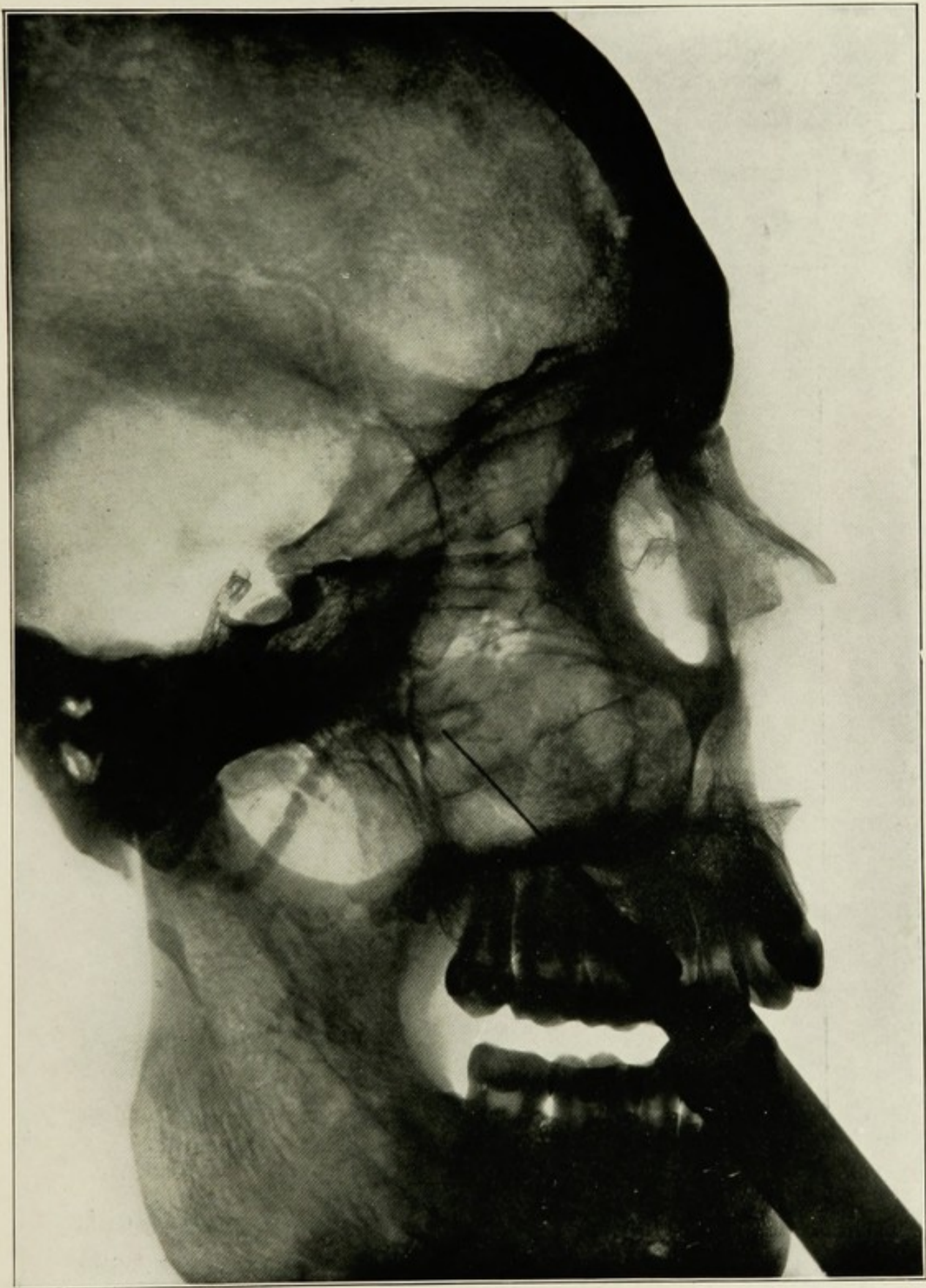


FIG. 55. Radiograph showing zygomatic injection.

foramen with the finger, inject slowly and evenly 1 c.c. In this manner the solution is pressed into the infra-orbital canal where it reaches the anterior superior alviolar nerve. Anaes-

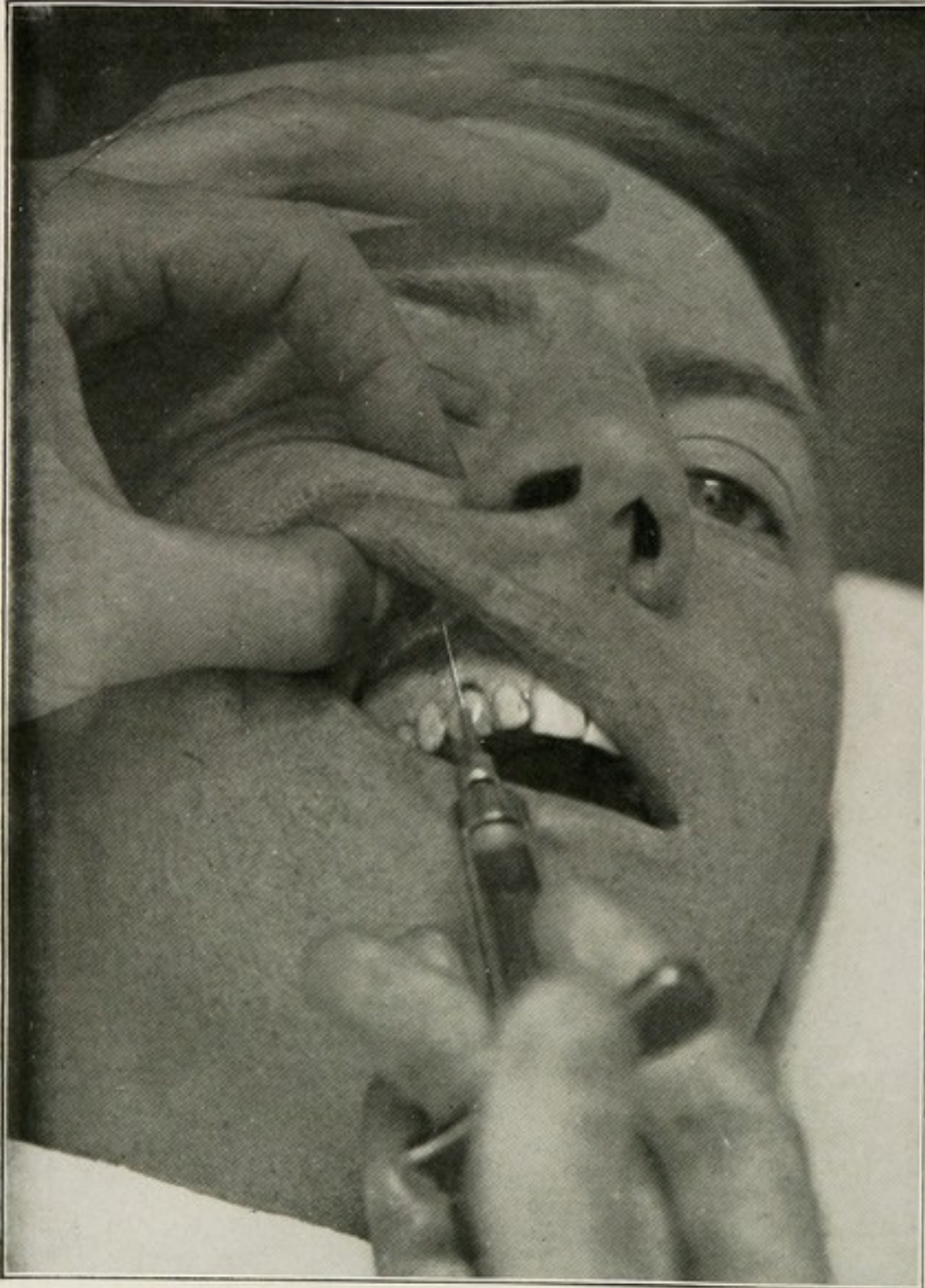


FIG. 56. Infra-orbital injection on the right side.

thesia occurs in the incisors and cuspid. This injection is only indicated in alviolar abscesses and larger surgical operations. (See Tables III and IV.)

3. INCISIVE INJECTION

If anaesthesia of the anterior part of the palate and palatal gum is desired, we insert the needle in the median line, between the two upper central incisors. Push it along the bone and you

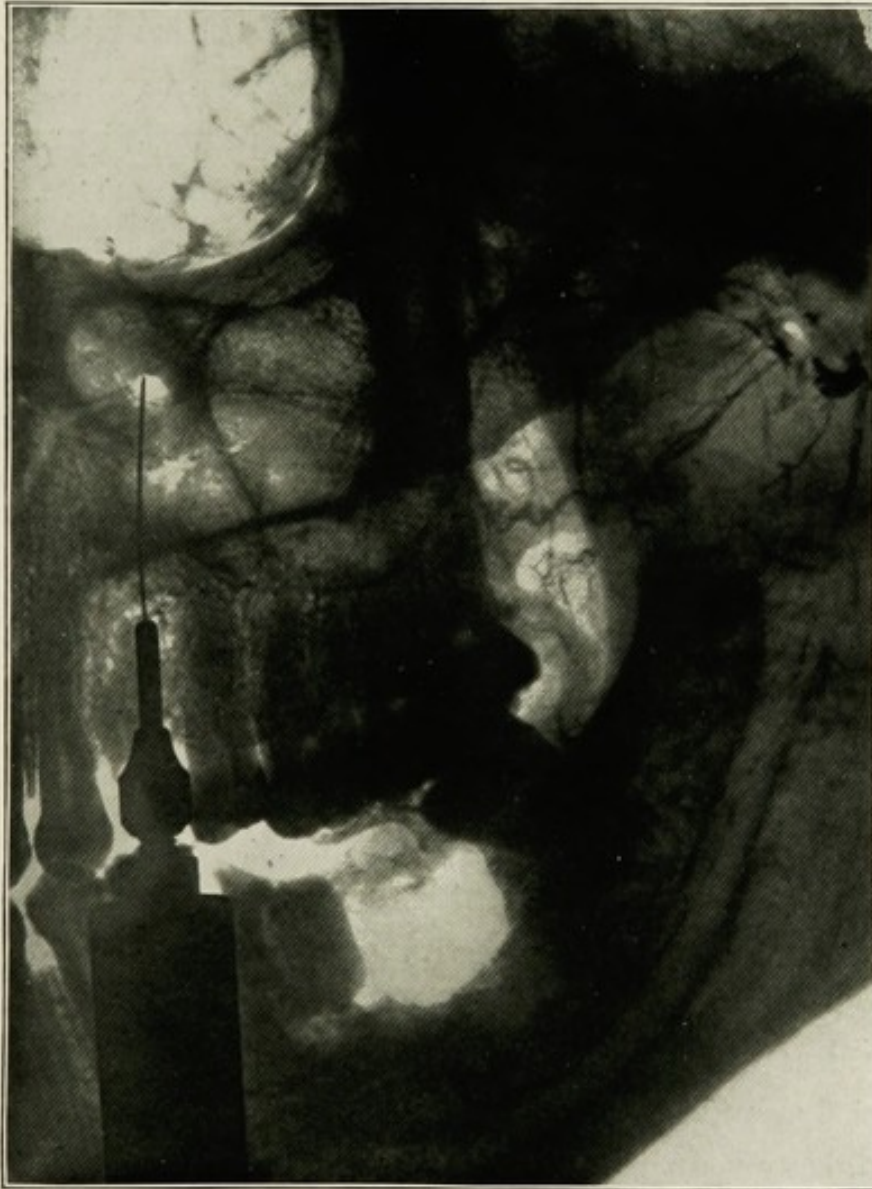

FIG. 57. Radiograph showing Infra-orbital injection.

cannot fail to get into the incisive foramen. A few drops produce anaesthesia in the palatal part of the gum behind the maxillary incisors and cuspids, in five minutes. (See Table IV.)

4. POSTERIOR PALATINE INJECTION

To get anaesthesia of the posterior part of the palate and palatal part of the gum, the needle is inserted near the gingival margin of the mesial part of the third molar (in children, of the last molar present.) Push it slightly upward and backward, till the palatal process is reached. The main trunk of the nerve passes forward in a groove between the alviolar and palatal process, and if the foramen is not reached exactly, we are sure to anaesthetize the anterior palatine nerve. Inject only a few drops; if more than 0.3 c.c. is injected, anaesthesia of the soft palate occurs, which is undesirable. The anaesthesia occurs in a few minutes and reaches as far forward as the cuspid teeth. (See Table IV.)

5. SPHENO-MAXILLARY INJECTION

In large cases of oral surgery and especially if the entire region of the maxilla is in a pathological condition, we can take resort to the speno-maxillary injection, anaesthetizing the whole second division of the trigeminal nerve in the speno-maxillary fossa after it emerges from the foramen rotundum. The point of insertion is below the junction of the zygomatic process of the maxilla and the malar bone. Keeping in close contact with the infra-temporal surface of the maxillary bone, the needle is advanced carefully, obliquely upwards, for four centimeters. (This injection requires a special needle of larger size and five and one-half centimeters in length, mounted most advantageously on the bayonet-shaped piece in the long hub.) Inject a small amount as you go along till you reach the speno-maxillary fossa, where the main injection is made. The doses should not be too small, 4 c.c. of a two per cent solution will give complete anaesthesia in fifteen minutes. (See Table IV.)

D. GANGLION ANAESTHESIA

Haertel* describes in his article some of the largest surgical operations of the face as resections of the maxilla, large tumor operations, and also cases of neuralgia, where he used ganglion anaesthesia of the Vth nerve with great success, either with Novocain or in neuralgia with alcohol. The anaesthesia was mostly produced on both sides by a double injection.

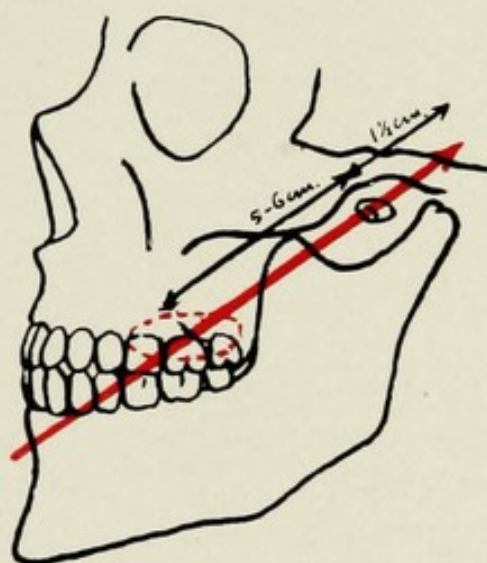


FIG. 58. Schematic drawing showing the injection into the Gasserian Ganglion.

INJECTION INTO THE GASSERIAN GANGLION

Insert the needle in the cheek (after preparing the place in the usual manner) opposite the gingival margin of the second maxillary molar, after anaesthetizing the tissue superficially, push the needle upward between the upper jaw and ramus of the mandible till it reaches the base of the skull striking the planum infratemporale. While inserting the needle we place the index finger of the left hand into the superior part of the vestibulum oris to prevent the needle from piercing the mucous membrane of the mouth. After having reached the base of the skull, the direction of the needle is adjusted by the following rules: If we look at it from front, we find that it points in the

* Haertel: Fortschritte auf dem Gebiete der Local Anaesthesie. Zeitschrift fuer aertzliche Fortbildung. 1914. 1.

direction of the pupil of the eye of the same side, and if we look at it from the side it points towards the tuberculum articulare of the zygomatic arch. Feeling our way forward along the bone we reach the third division of the fifth nerve, where it emerges from the foramen ovale. The patient will give a sign of pain when the nerve is reached. The distance up to this

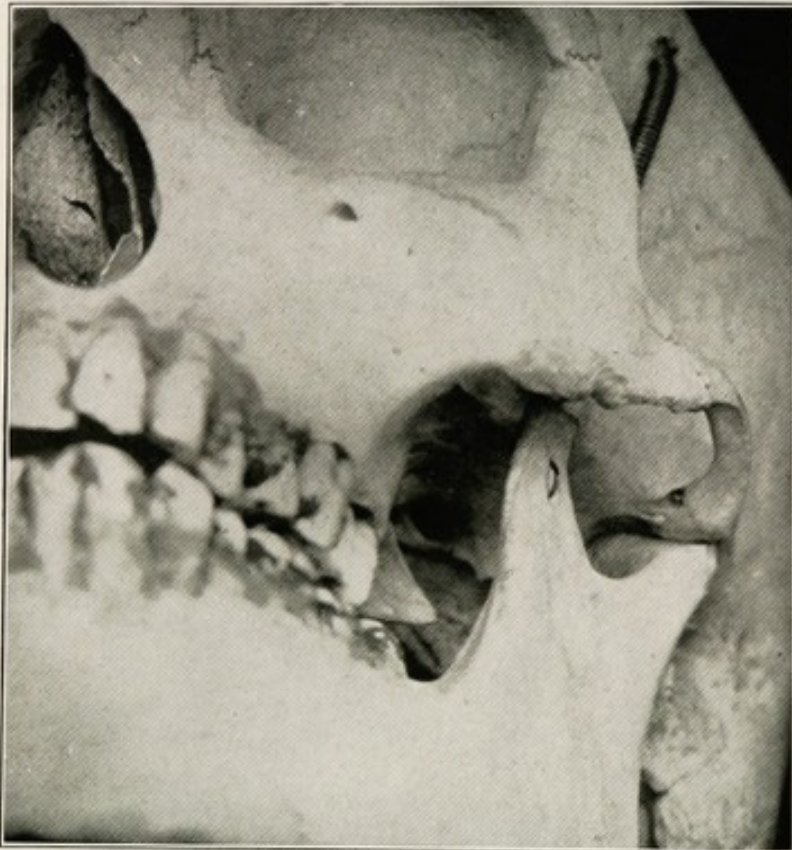

FIG. 59. Foramen ovale in the skull seen from the position of the operator.

point is five to six centimeters. Now the needle is inserted one and one-half centimeters into the substance of the ganglion. Inject 1 c.c. of a two per cent solution of Novocain containing 0.000,02 gram of Suprarenin to 1 c.c. Scrupulous asepsis is of greatest importance.

VIII. FAILURES AND ILL-EFFECTS IN LOCAL ANAESTHESIA

Although failures in *general anaesthesia* might have grave results, failures in *local anaesthesia* do not endanger the patient's life as long as the maximal dose is not reached. If we consider the ability local anaesthesia gives us to improve the quality of our work, saving the patient suffering at the same time, and the possibility to do away with the dangers, handicaps, discomforts, and after-effects of general anaesthesia for exodontia and minor surgical operations in the oral cavity, the small percentage of failures forms a negligible factor, which can be almost entirely eliminated with perfected technique, reliable anaesthetics and careful elimination of infection during and after the operation. We meet failures and ill-effects in local anaesthesia of various kinds:

- A. True failures and ill-effects.
- B. Psychological effects.
- C. Ill-effects due to other sources.

True Failures and Ill-Effects Failures and ill-effects very frequently occur not from the injection, but from the psychic attitude of the patient, or other causes, which we will consider later. True failures can be classified as follows:

- a. No or insufficient anaesthesia is obtained.
- b. Undesirable symptoms during anaesthesia.
- c. After-effects.

a. No anaesthesia is obtained. This can be entirely eliminated, if the cause is ascertained. If no anaesthesia oc-

curs, if it is not sufficiently deep, or if it does not last long enough, we can repeat the injection, avoiding the second time the probable error. In the infiltration method it is important to use the same puncture, not only to avoid unnecessary damage to the mucous membrane, but also because the solution might be lost through the first puncture, if a second one is made close by. Failures of result usually come from:

1. Insufficient knowledge of the anatomy of the oral cavity.

2. Insufficient apparatus or technique. The anatomy and technique should be clearly in the mind of the operator. After some practice these sources of failure are soon eliminated. In the infiltration method the most frequent causes are, if the part opposite the apex of the root is not reached, or if the contact with the bone is lost. In conductive anaesthesia, if we inject into muscle tissue instead of into the connective tissue surrounding the nerve trunks. This is especially true in the pterygo-mandibular injection, where we are sure to infiltrate the internal pterygoid muscle, if we lose the contact with the ramus or insert the needle too low. In the case where we are too low down, we slide over the lingula into the muscle, this should be avoided. The insertion should be made one centimeter over the last molar, this is above the lingula.

3. Inefficient drugs or drugs deteriorated through age, chemical or bacteriological influences. If the solution shows a slight pinkish color it is a sign of changes that have taken place. Anything that deteriorates the drugs decreases their anaesthesia producing power. The anaesthetic should be fresh and the solution water clear.

4. Too large percentage of suprarenin is liable to interfere with the infiltration of the center of thick nerve trunks, on account of its astringent properties.

b. Undesirable symptoms during the anaesthesia. It is hard sometimes to distinguish whether such symptoms are due

to psychological effects, or to the anaesthetic. In this chapter we will consider the latter:

LOCAL SYMPTOMS

There is pain experienced during the injection. This is due:

1. From injecting a too cold or hot solution. The solution ought to be of blood temperature. This can be easily obtained by my described method, where the solution is specially prepared every time before use.

2. From drugs (antiseptics) added to the solution to keep the solution sterile. Seidel found in applying the velum test on the cutis of the arm that thymol added to solution produces in some cases severe pain.

3. From the solution not being isotonic with the blood, too high or too low a percentage of salt causes osmotic pressure.

4. From injecting into an acute abscess, this should be avoided from obvious reasons.

GENERAL SYMPTOMS

The heart action may be increased, sweating may occur or a queer feeling in the extremities. If these are not of psychological origin they can only come from:

1. The suprarenal substances. In the beginning I used adrenolin solution 1:1000, which of course deteriorates much quicker than the synthetic suprarenin. I injected into one patient a solution of two per cent Novocain, and three drops of Adrenolin to 1 c.c. After only injecting 0.2 c.c. for a maxillary cuspid, the above-mentioned symptoms appeared in extreme degree, cold sweating and muscular pains lasted two hours. I credit the cause to toxic effects from the adrenolin, which I received fresh from the drug store. It was slightly discolored. Since using synthetic suprarenin I have had no more such grave experiences, but in some patients I observed every time

slight effects of sweating on the forehead or queer feeling in the fingers. I credit this to too high percentage of Suprarenin contained in the E tablets, and have therefore asked for the manufacturing of a new tablet, which I recommend for all normal cases. This, the T tablet, contains only 0.000,02 gram Synthetic Suprarenin to 1 c.c.

Potassium bromide or "valyl" highly recommended by Professor Kionka, in Breslau, may be given in these cases. The latter is valuable in cases of increased pulse and heart action and trembling. It also can be given as a preventive, one-quarter to one-half hour before the operation, to counteract nervousness.

In cases of fainting, tip the patient's head between his knees, give aromatic spirits of ammonia, strong black coffee, oil of camphor, or strychnine sulphate. Some of these agents should always be kept handy. Black coffee is a splendid stimulant on account of its lasting action.

c. After-effects. We must consider that after-effects frequently occur after operation or extraction, from other reasons than the injection. These will be considered in another chapter. After-effects are oedema and after-pain.

Oedema. This is a simple swelling caused by infiltration of serum. It may be caused:

1. By solutions which are not isotonic. By traumatism, caused by inserting the needle several times in the same part, correcting the direction. In conductive anaesthesia, by piercing the inferior pterygoid muscle or injecting into the same. This also may cause ankylosis of the mandibula and difficult deglutition.

2. Through toxic or irritating effects upon the protoplasm from deteriorated drugs, antiseptics or other unnecessary additions to the anaesthetic solution. Also to large percentage of Suprarenin in very sensitive tissue.

3. From injection into muscles. Although an anaesthetic solution is absorbed quickly and without disturbance from connective tissue, if the percentage of suprarenin is not too high, it is a different question, however, if muscles are infiltrated. Here the absorption is sluggish, and takes sometimes two or three days. This may cause swelling. In conductive anaesthesia of the mandible, there is great danger to inject into the internal pterygoid muscle, which causes swelling and often also false ankylosis and difficult deglutition.

Oedema not complicated by infection will disappear without treatment.

After-pain. In treating pain after injections, we have to consider that post-operative pain frequently occurs from causes which have nothing to do with the injection. These are considered later. Pain from the injection can only be ascertained after a purely dental operation. After-pain very seldom occurs from the injection. Causes are:

1. Deteriorated drugs.
2. Unnecessary additions to the solution, such as anti-septics.
3. Infection from non-sterile solution, syringe or needle.
4. Infection taken up by the needle, from the mucous membrane or fluids of the mouth.
5. Infection of the puncture during the anaesthesia.
6. Infection of the puncture after the operation.

PROLONGED ANAESTHESIA

Cases of prolonged anaesthesia have been reported lasting for several days or weeks. These, however, can always be traced to:

1. Injury of a nerve during operation, as in the lower jaw, if the tooth sockets come in contact with the mandibular canal. Especially in impacted wisdom teeth, there is danger of injuring the inferior alviolar nerve.

2. Injury of the mandibular canal. Loosening a piece of bone which, if pressed downward, can cause anaesthesia by pressing upon the nerve.

3. Injecting of alcohol causes prolonged anaesthesia, it is therefore important to remove the alcohol carefully from the syringe and dissolving cups.

In nervous and hysteric persons, the patient's **Psychological** mind and imagination plays a great part in **Effects** the success of the injections and operator, and it is well to say a few words in regard to the attitude of the operator towards the patient.

We get so accustomed to our work that we neglect to realize the fear and terror some sensitive patients experience previous to an operation. We forget that many people make it their pastime to talk about nothing else but symptoms, cures and operations of diseases, and that some are walking encyclopedias of the ill-effects, accidents, or after-effects of drugs, and spread their knowledge among their friends. Some associate every syringe with cocaine, and are terrified of cocaine poisoning, and others are alarmed by the numbness produced by an anaesthetic, confusing it with paralysis.

Sometimes the respiration is increased, and the patient perspires on the forehead. This very frequently is fear, and often is seen after insertion of the needle before a drop is injected.

The best example is one of the cases I demonstrated on at the Massachusetts State Society Meeting of 1913. While explaining the technique of the injection to the audience, the patient, a mail-carrier of about 30-35 years, collapsed. I had not made any injection, but the patient, which was weakened from severe pain, collapsed from fear caused by the explanation and description of the operation.

Dr. Frohman had a case for extraction of two wisdom teeth, with somewhat similar experience. Only that the patient fainted after the injection; he succeeded, however, in extracting

one wisdom tooth, and when the patient came back (after two weeks) for extraction of the other wisdom tooth, he hesitated to give an anaesthetic. He used the ethyl-chloride spray for a very short time, and at once the same symptoms appeared.

It is fear which we have to conquer, in all these cases, and the antidotes are, convincing attitude, sureness of result, confidence of the operator in himself, and in his success, which will result in confidence of the patient towards the operator. It is well to tell the patient that Novocain has absolutely nothing in common with cocaine and is entirely harmless. Tell them what parts are going to feel numb, so that this does not alarm them.

**Ill-Effects
Due to Other
Sources**

Post-operative pain and inflammation may occur after an operation, not caused by the injection but directly from the wound. It can come:

1. From a septic wound.
2. From a wound infected during the operation.
3. From a wound infected after the operation by the fluid of the oral cavity. A wound in the mouth cannot be kept aseptic, and is exposed to secondary infection.

To avoid this inflammation and pain after operations, infected tooth sockets should be curetted and washed out with an antiseptic solution. Also the suprarenin should not be administered in the anaesthetic in too high percentage, because the danger of infection is increased through too deep anaemia. For normal cases 0.000,02 gram Suprarenin to 1 c.c. is sufficient, allowing enough bleeding to protect the wound.

The severest part of post-operative pain is usually eliminated by the long duration of the anaesthesia. Dressing the wound with gauze containing Novocain powder, after thorough curetting will be found beneficial, still better is Tribel's:

℞	Chloral-hydrat	2.0
	Camphor	1.0
	Novocain	0.5
	Misce exactissime	

or Euroform paste:

R	Orthoform	40.0
	Europhen	60.0
	Liquid petroleums. q. to make paste	

Internally administer: Trigeminin,* Aspirin or Pyramidon.*

Failure and ill-effects therefore can almost always be traced back to the incorrect technique of deteriorated drugs, infection, and fear. And these can be eliminated almost entirely.

I have used local anaesthesia in children, and in adults up to eighty, in patients which collapsed from cocaine, and which have been warned not to have another injection, and I have repeatedly used it on patients with severe heart and pulmonary disorders of all kinds, with excellent result, and I have the full appreciation of the patients.

* Farbwerke Hoechst Co., 111 Hudson Street, New York.

IX. PRACTICAL APPLICATION OF LOCAL ANAESTHESIA IN DIFFERENT BRANCHES OF DENTISTRY

The various operations which can be performed under "Local Anaesthesia" have been mentioned shortly in a previous chapter. To make it clearer what special method is best adapted for a certain case, and to bring out variations beneficial for certain cases, the author adds this chapter. It also is intended to be of a more practical nature, suggesting operations, as the amputation of roots, which through local anaesthesia are brought into the realm of the general practitioner.

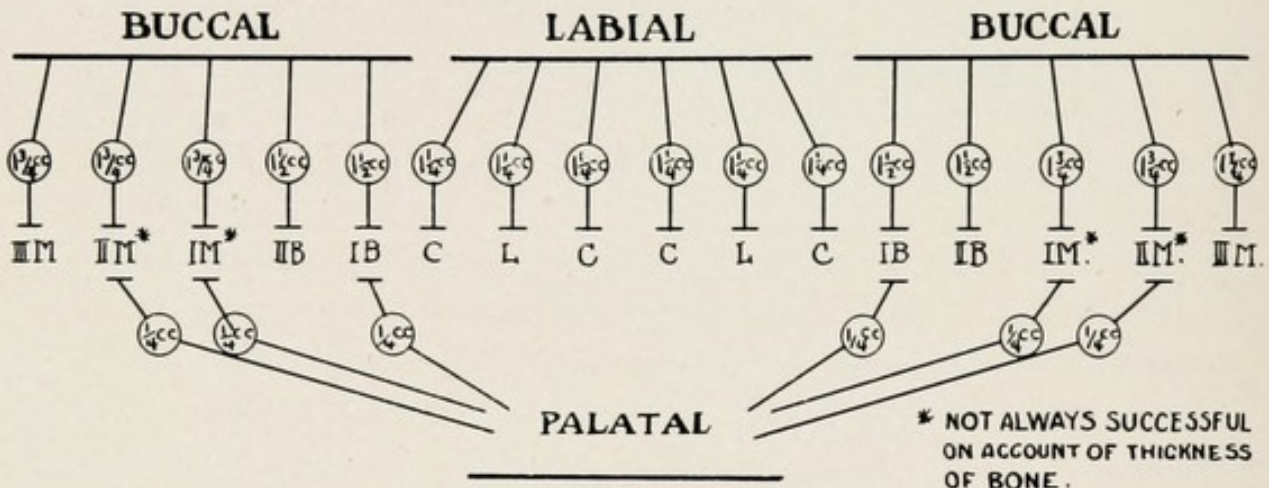
Two general rules for selecting the method of injection :

1. Use always the simplest and surest method.
2. Avoid injecting into pathological tissue.

The four following tables show what teeth, and what tissue, we can anaesthetize with the infiltration and with the conductive method :

TABLE I. INFILTRATION ANAESTHESIA FOR THE TEETH ONLY

I. MAXILLA



II. MANDIBULA

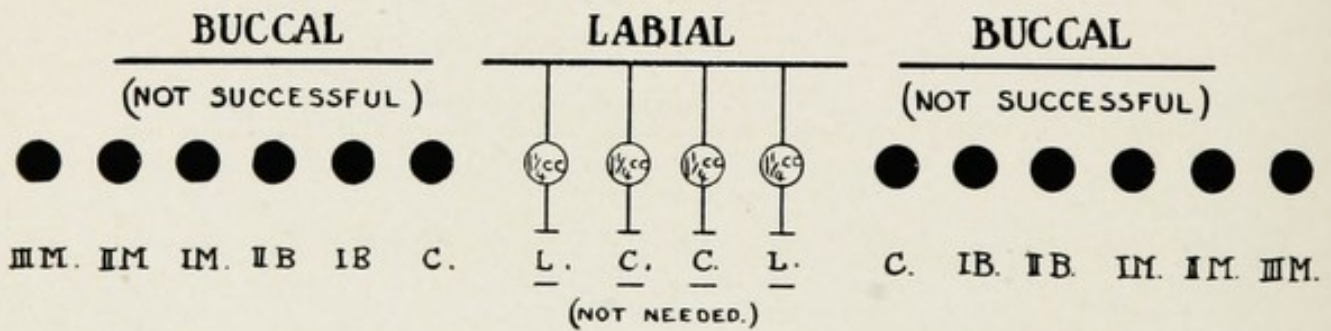
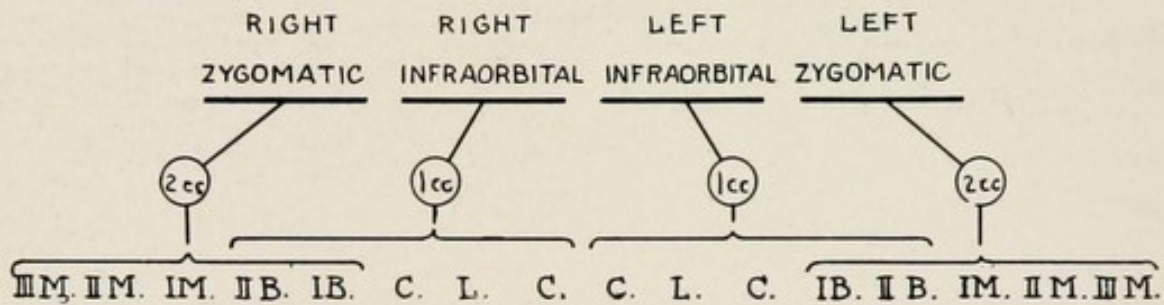


TABLE III. CONDUCTIVE ANAESTHESIA OF THE
TEETH ONLY

I. MAXILLA



II. MANDIBULA

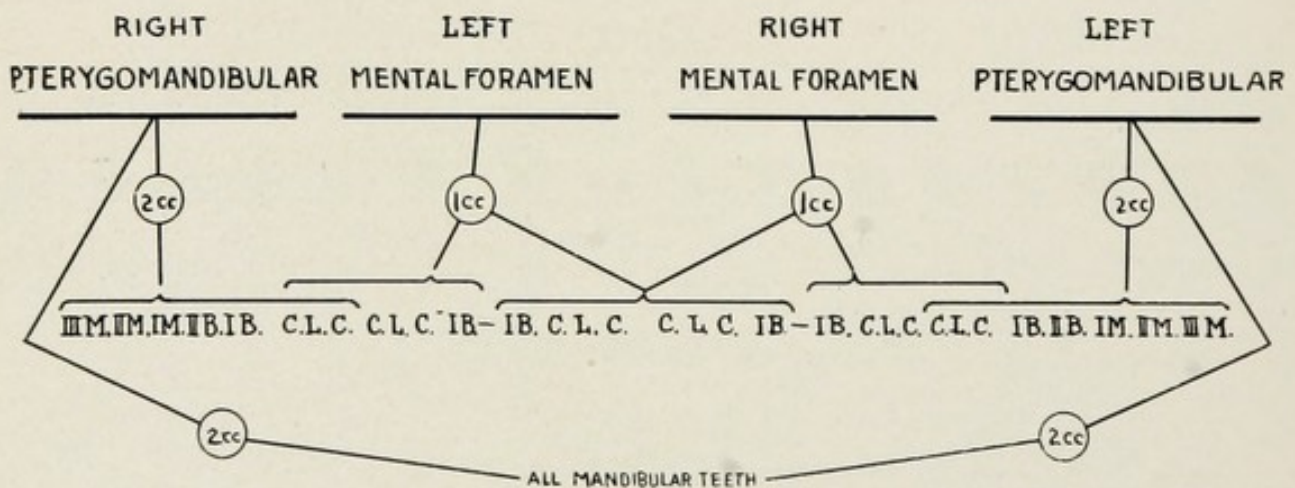
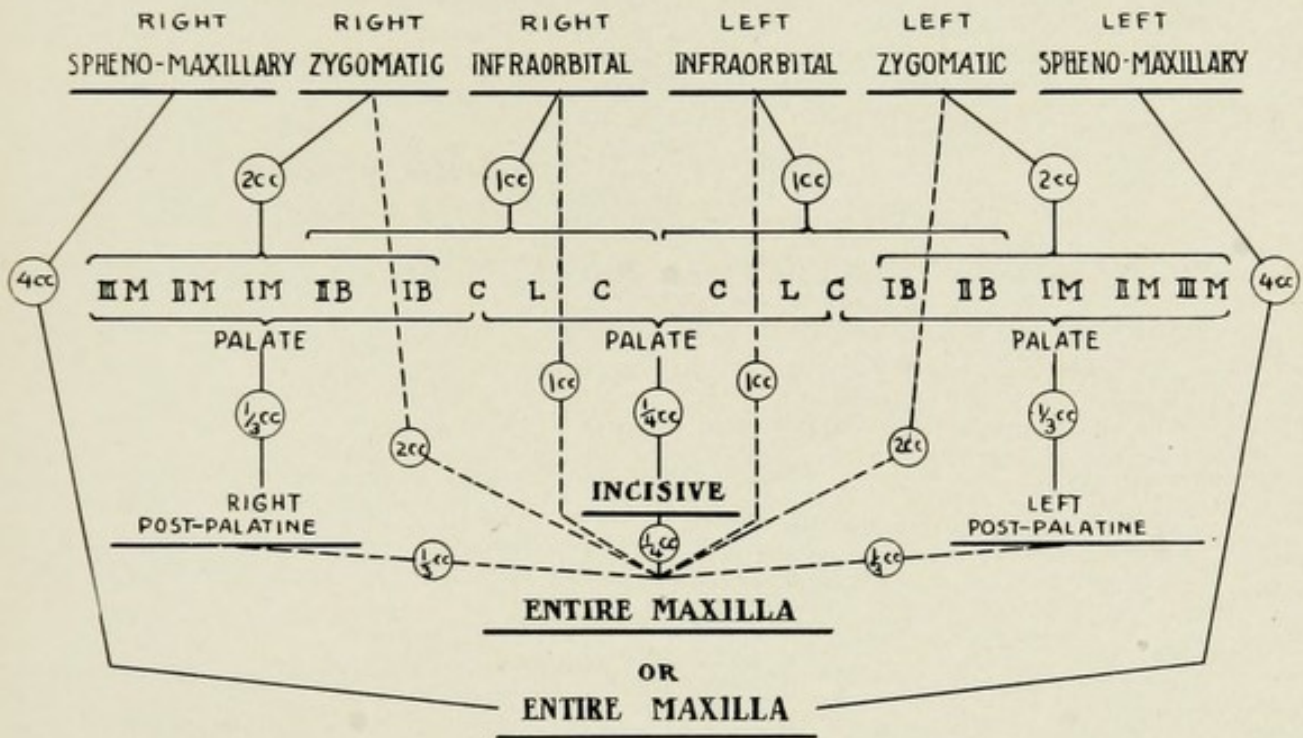
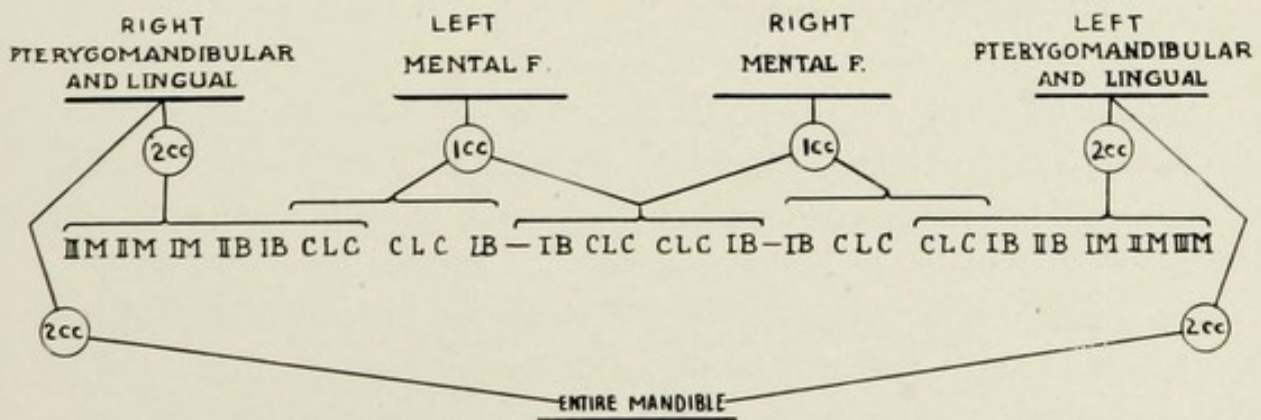


TABLE IV. CONDUCTIVE ANAESTHESIA OF THE TEETH AND SOFT TISSUES

I. MAXILLA



II. MANDIBULA



1. OPERATIVE DENTISTRY

Cavity Preparations

To remove caries and prepare cavities with normal pulps, for fillings, we need usually anaesthesia of the teeth only. But if the gum has to be retracted for cervical cavities, anaesthesia of the gum is advisable to allow the proper adjustment of the clamp.

The first and second maxillary molars sometimes do not respond to the infiltration method, especially in patients with massive bone formations. If the zygomatic process extends far down, it prevents the infiltration of these teeth from the buccal side; in these cases conductive anaesthesia by the zygomatic method is advisable. If the infiltration method has been used and proves a failure, apply the conductive method at once. If two or three adjoining teeth need to be anaesthetized, use the horizontal injection, proceeding from one tooth to the other without removing the needle.

The lower molars and bicuspid cannot be anaesthetized singly, the few pores around the alviolar margin are not sufficient to assure deep enough anaesthesia, the success is too uncertain to make it practical. If there is a cavity in an incisor in addition to cavities in the posterior teeth of the same side, use the conductive anaesthesia up to the median line, and though the pulp might not be entirely anaesthetized in the incisors, on account of the anastomosis, the dentine usually is desensitized to allow cavity preparation. Should the anaesthesia be unsatisfactory, inject by the infiltration method into the mental fossa, this will anaesthetize the incisor tooth in question completely, in five minutes. The waiting time of fifteen minutes seems objectionable to some men, but it should be remembered that this is made up easily because the anaesthesia allows us to work much quicker afterwards. If there are several cavities on one side they can be prepared in one sitting, and the most anterior one should be taken first, because the

anaesthesia begins in front and works backward. Three, four or five teeth sometimes can be prepared for fillings with one injection. (Tables I and III.)

When preparing a cavity for a filling under anaesthesia, we should be careful that the tooth does not heat up, thermal shocks, though not felt by the patient, may burn the delicate pulp tissue, cause inflammation and subsequently a dead pulp. Also one should bear in mind the anatomy of the tooth because we have put asleep the guard pain, which gives us warning when we approach the pulp-chamber. The pulp-chamber in young patients is of large size, it decreases with age, and in pyorrhetic and gouty patients, it sometimes has receded under the gum line.

If the cavity is extensive, it is of great value to ascertain the outline of the pulp-chamber by the radiograph, and in all cases it is well to seal the dentinal tubules with carbolic ether rosin after the cavity preparation is completed. This will prevent irritation from the filling, be it permanent, with or without cement lining, or be it temporary. In the latter case we also have the danger of infection, if the filling gets loose or is partly chewed out. Besides protecting the cavity rosin eliminates also the pain caused by the cement when the permanent filling (inlay) is set.

Removal of Normal Pulp To remove a normal pulp, the anaesthesia is accomplished in the same manner as described for cavity preparations (Tables I and III).

Sometimes from some reason or other we do not get complete anaesthesia of the pulp, especially when anaesthetizing the lower teeth with the conductive method. Not making a special injection for the incisors, we find that the pulp can be exposed, but on account of the anastomosis from the other side, it is still somewhat sensitive. In these cases the anaesthesia is completed surprisingly easy by pressure anaesthesia. Place half of a pugglet of Novocain over the ex-

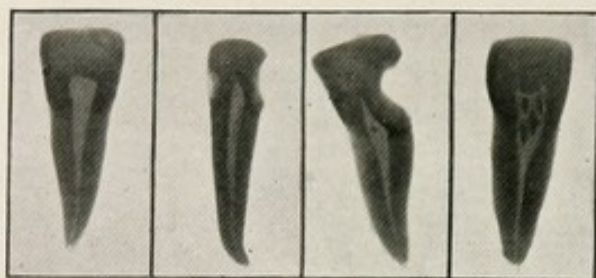

FIG. 60. Radiograph of maxillary incisors showing variation of the pulp chamber. Note how the pulp recedes in the region of decay.

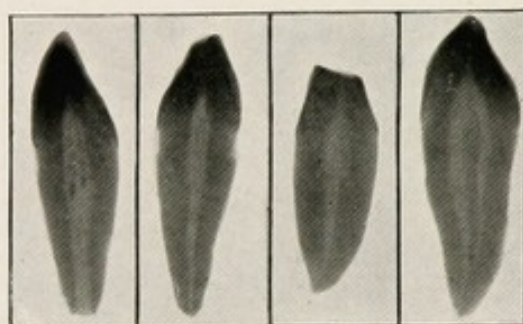

FIG. 61. Radiograph of cuspids. Note the open apical foramen in No. 1, and the division of the root canal in No. 4.

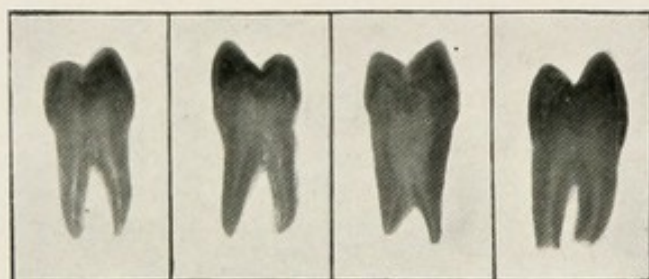


FIG. 62. Radiograph of maxillary first bicuspsids. Note large apical foramen in the young tooth No. 4.

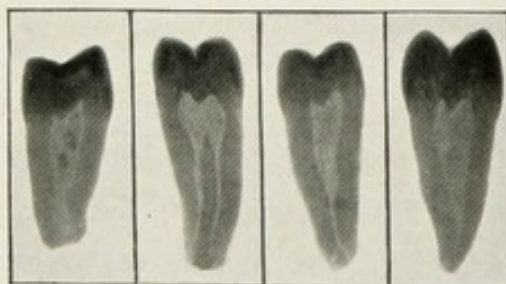

FIG. 63. Radiograph of maxillary second bicuspsids. Note variations of the root canals. No. 1 with open apical foramen. No. 3, showing two apical canals.

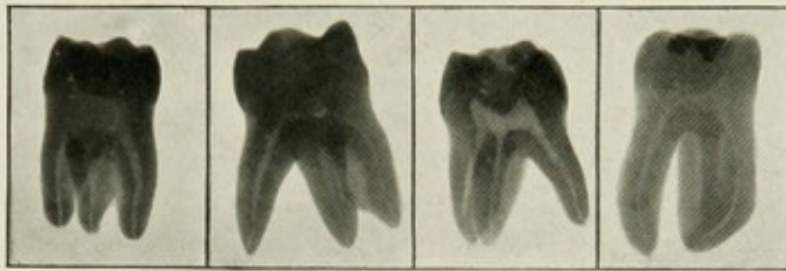


FIG. 64. Radiograph of maxillary molars. Normal pulp chamber in No. 1. Almost entirely calcified pulp chamber in No. 2. Two apical canals in the palatal root of No. 3. Bent buccal root in No. 4.

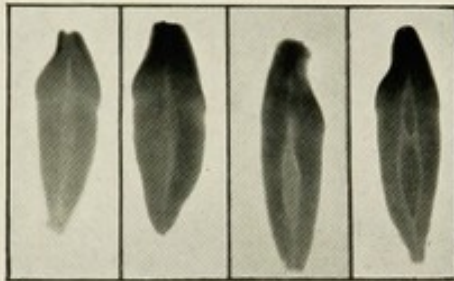


FIG. 65. Radiograph of mandibular incisors. Note variations.

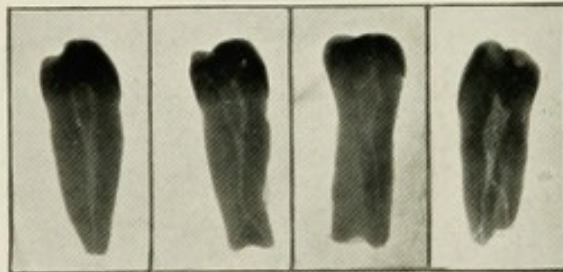


FIG. 66. Radiograph of mandibular bicuspid, showing many abnormalities.

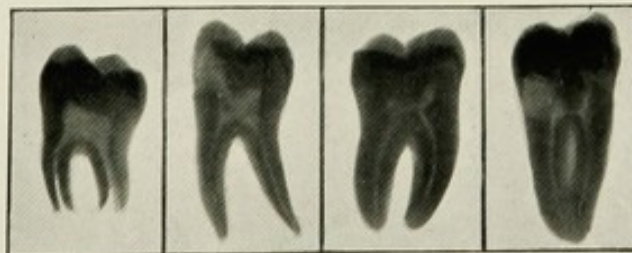


FIG. 67. Radiograph of mandibular molars. No. 1, young tooth with open foramen. No. 3 and 4 show calcified pulp chambers.

posure, do not add water but let it dissolve in the moisture secreting from the pulp. When it has become of the consistency of a paste, press it down with unvulcanized rubber. No pain is caused and the action occurs at once.

When extracting the pulp one must realize that also the tissue around the tooth is anaesthetized, and should be careful not to injure the tissue beyond the apical foramen, this often causes peridontitis. Insert the broach to the end of the root canal and extirpate the pulp. Use sulphuric acid or sodium potassium treatment to remove all organic tissue from side canals and accessory foramina. The root canals should not be filled the same sitting unless one ascertains the procedure and completion of the filling with a liberal amount of radiographs. On account of the anaesthesia the coöperation of the patient is lost, and we have no guide to tell us when the filling has penetrated through the apex.

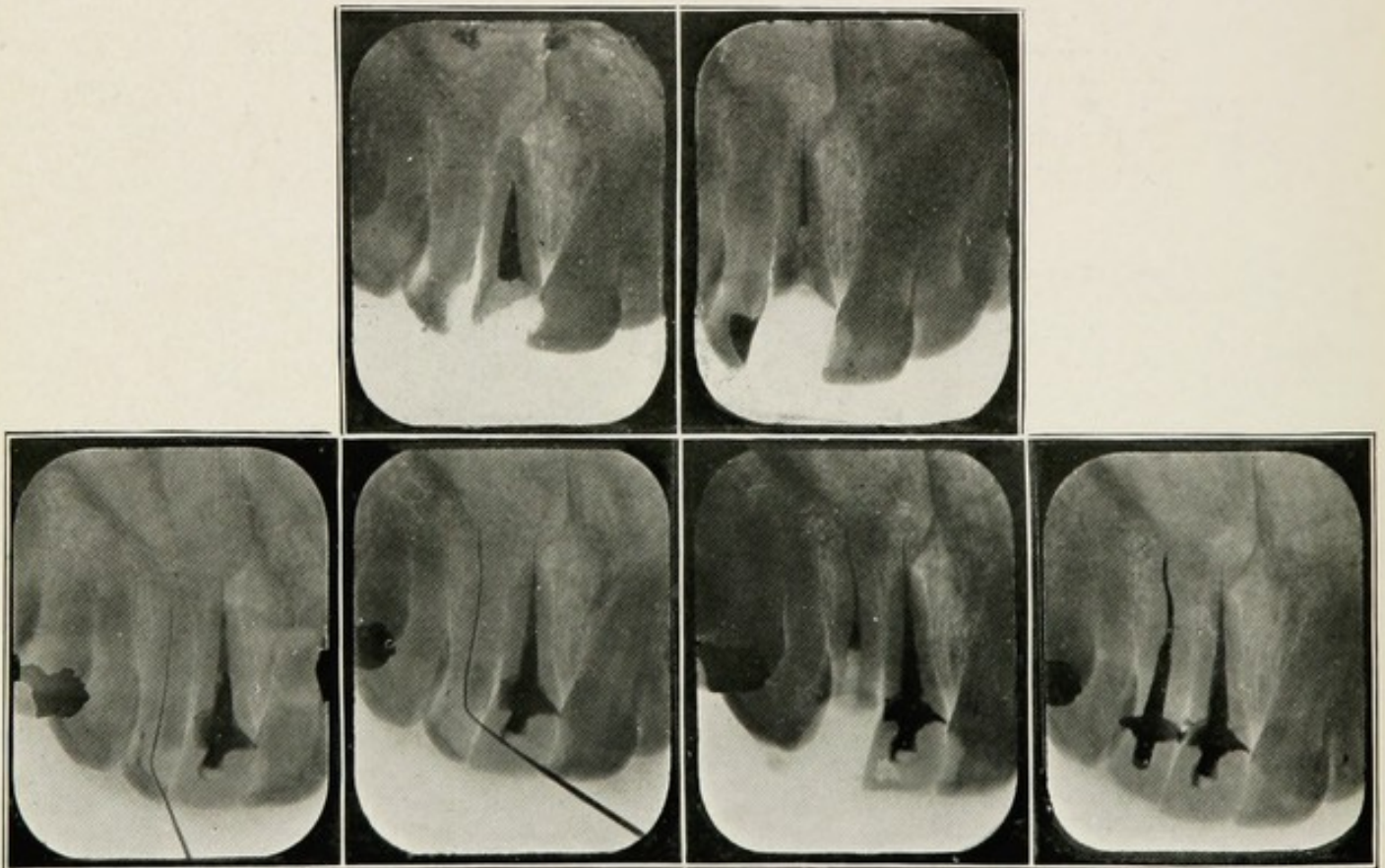


FIG. 68. Central incisor with chronic abscess (lead filling), lateral incisor with pulpitis. Infiltration method was used to extirpate the pulps.

**Removal of
Calcified Pulp**

In some patients all the teeth have a great amount of secondary dentin deposited in the root canals, which are sometimes entirely obstructed, the circulation is interfered with, but nerve fibers extend throughout the pulp chamber. It is impossible to anaesthetize a pulp of that sort with pressure anaesthesia, also arsenic preparations are most frequently unsuccessful. Local anaesthesia is ideal for these cases and, guided by a radiograph, we can open them up to the apex with root canal instruments and drugs or both combined. The method of anaesthesia is the same as above.

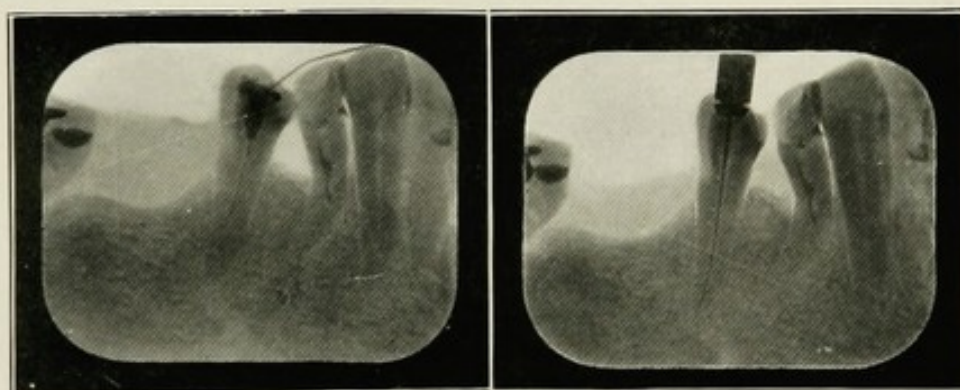


FIG. 69. Root of lower second bicuspid. Its lower end was extremely sensitive and inaccessible. Conductive anaesthesia was used to ream the root canal to the apex. The first bicuspid shows the same condition but is complicated on account of a badly bent root.

**Removal of
Pulps with
Pulp Stones**

Another case where pressure anaesthesia is unsuccessful is, if obliteration of the root canals or pulp chamber has taken place. These are ascertained with the radiograph and removed under local anaesthesia.

**Removal of
Hypertrophied
Pulps**

Often and most frequently in the six-year molars of children who neglected their teeth, we find the pulp hypertrophied and extending way out of the pulp chamber. The blood supply is increased and sensitiveness prevails in the root canals. Inject by the infiltration method, which is

preferable whenever it can be applied, but use the E tablet with 0.000,05 gram of Suprarenin to 1 c.c. In the lower posterior teeth produce anaesthesia with the conductive method, using the T tablet, and after anaesthesia has occurred inject solution made with the E tablet directly into the pulp. The high percentage of Suprarenin in the E tablet causes anaemia. This is the only operation in operative dentistry where we wish to combine anaesthesia with anaemia. Remove the hypertrophied pulp and cauterize if necessary.

Removal of Inflamed Pulp If the inflammation of the pulp has not gone beyond the apical foramen, anaesthesia is produced as for normal pulps. (Tables I and III.) The pain will stop as soon as the anaesthesia occurs. The pulp then is removed under great care not to infect the area beyond the foramen. (Fig. 68, lateral incisor.)

Removal of Inflamed Pulp Complicated by Periodontitis The peridental membrane is inflamed, the tooth feels long, and pain is increased if the tooth is touched. The outer plate of the alviolar process has not yet been affected. Inject by the infiltration or conductive method (Tables I and III). The pain will stop and the root canal can be opened.

Acute Alviolar Abscess at the Apex The alviolar plate is usually destroyed, sinus may be present or not, which usually determines the amount of pain. The infiltration method in these cases is contra-indicated on account of the danger of deep infection, and producing of pain through increased pressure. Many writers recommend to inject around the periphery of the abscess, but it is not necessary to take this chance, as we get best results with the conductive methods. (Table IV.) The area of infection can usually be entirely avoided. The palatal and lingual gum

needs only to be anaesthetized if the abscess points towards the palatal or lingual part of the mouth. In acute alviolar abscesses, we produce an artificial sinus, and establish the possibility of thorough irrigation from the tooth through the apex and sinus to the mouth. This is easily done under local anaesthesia.

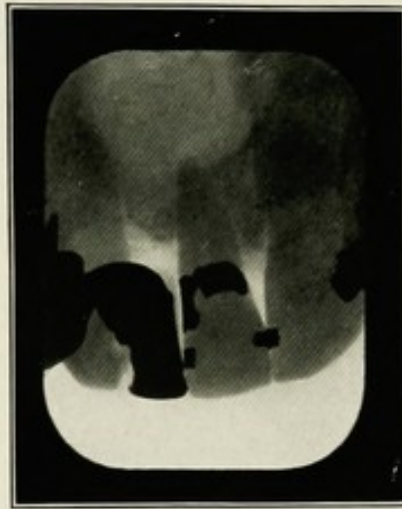


FIG. 70. Acute alviolar abscess of a central incisor. The tooth was very loose and very painful on percussion. Nasal anaesthesia was used to open into the pulp chamber and lance the abscess.

Chronic Alviolar Abscess In chronic alviolar abscesses there is usually no sensation in the tooth, and the treatment can be applied to the root canal without anaesthesia. Very frequently, however, there is a granulum at the apex which does not always yield treatment from the root canal, and has to be removed surgically. If it is treated from the root canal there is usually no need of anaesthesia, except the tooth be sensitive on percussion. The surgical treatment consists in opening up and curdettling the apex of the tooth and cavity thoroughly. Amputation of the apex of the root is only necessary if it is infected, partly absorbed or gangrenous.

Usually there is little inflammation and the infection is confined to the region of the apex of the alviolus. In these

cases the infiltration method can be used and anaesthesia can be produced as in Table II. In cases where the inflammation covers a larger field, the conductive method is preferable. (Table IV.)

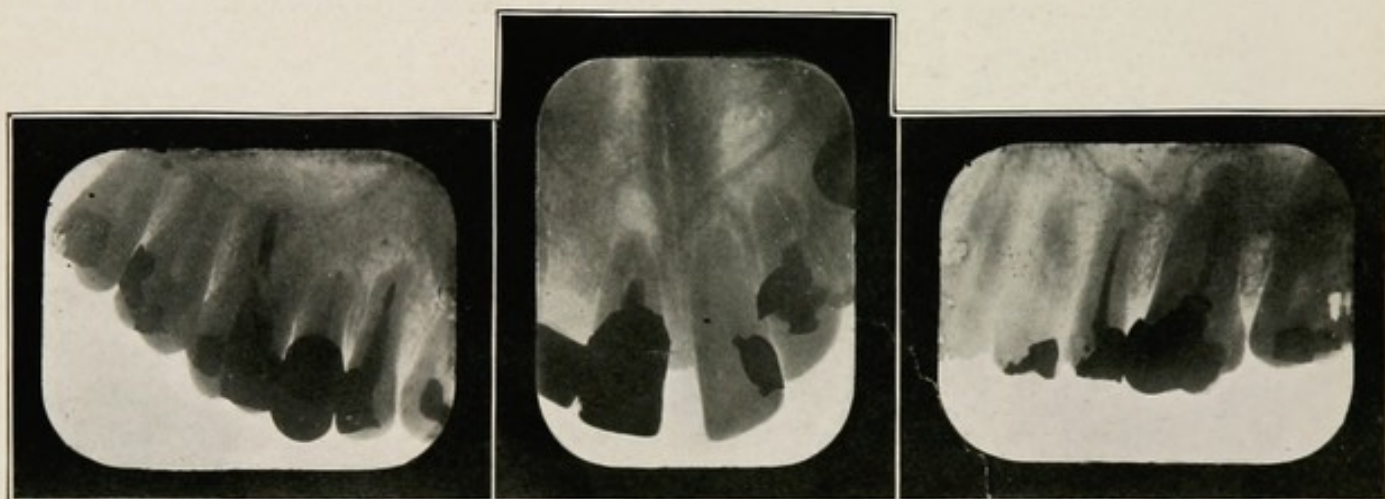

FIG. 71. Chronic alveolar abscesses. No. 1 shows chronic abscess on first and second bicuspid. No. 2 shows chronic abscess on left central carrying a bridge. Right central pulp chamber almost entirely calcified, filling extending into middle of tooth, abscess on the apex. Right lateral shows also a chronic abscess. Patient suffers of rheumatism. No. 3. Chronic abscess on second bicuspid. Small cyst on six-year molar. Teeth feel lame from time to time.

Abscesses are not always originated from infected pulps, but often occur on the side of the **Pericemental Abscess** root from pockets, perforations or foreign material. These have to be curetted and cleaned, which is a painful process and should be done under local anaesthesia. The gum only needs to be anaesthetized, after Table II or IV, as required for individual cases.

Sometimes there is obscure pain either of neural-**Diagnosis** gic character, from mild pulpitis or impacted teeth. In the latter case the radiograph can be used for diagnosis, but in the former it is of little use. The pain may be referred to another part, and can be located with local anaesthesia. Inject for the suspected tooth, if your diagnosis was correct the pain will stop.

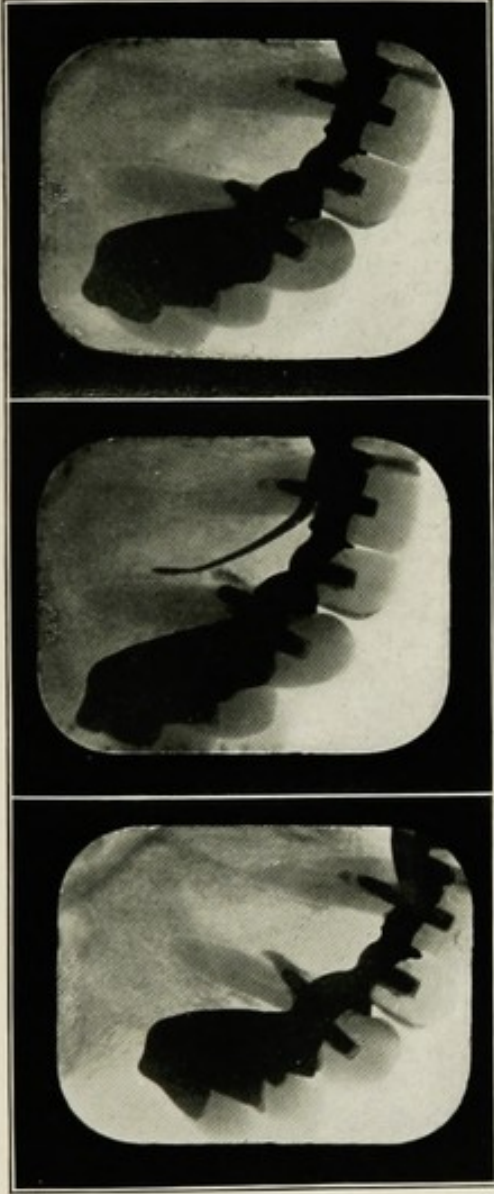


FIG. 72. Pericemental abscess caused by perforation of the tooth by a post. The infiltration method was used in this case to remove the irritating cement. No. 1, before; No. 2, during; No. 3, after the operation.

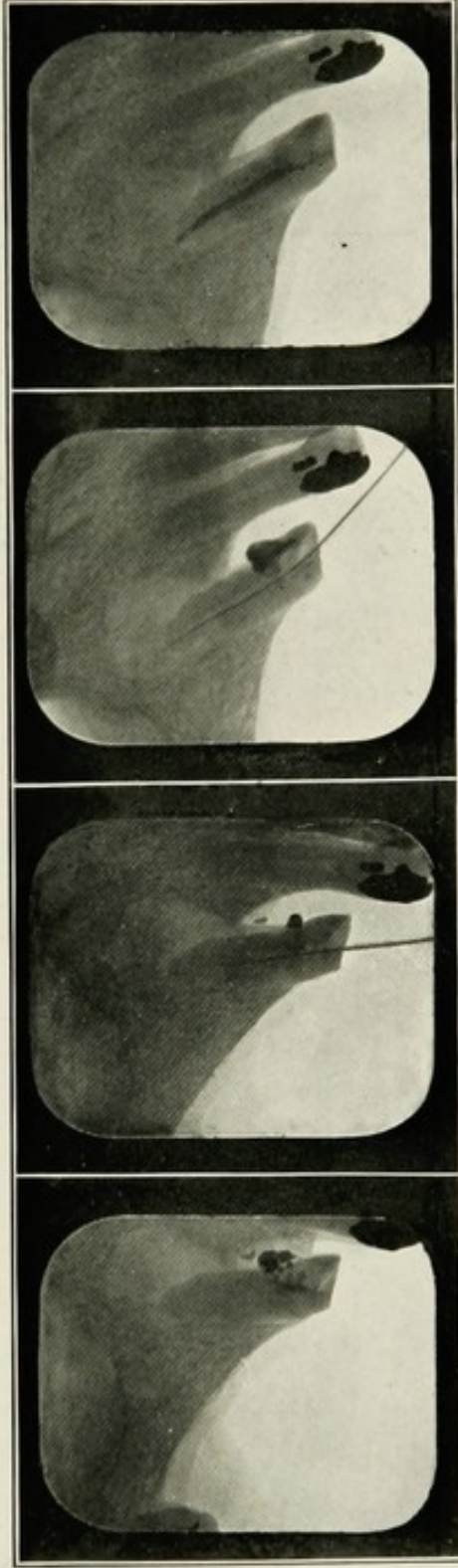


FIG. 73. Pericemental and alviolar abscess on a maxillary cuspid. The tooth has a very horizontal direction and the root has been perforated when the operator prepared it for a post crown. The root canal was filled with putrescent sensitive tissue. Under local anaesthesia I curetted the pericemental abscess and cleaned the root canal. The serie shows the tooth at different stages of the treatment.

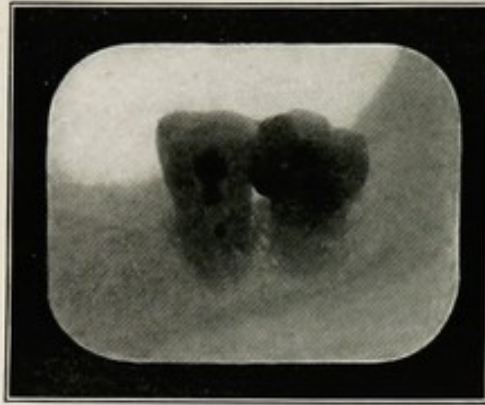


FIG. 74. Patient between 70-80 suffered for years with severe pains of neuralgic character. The Radiograph shows pulp stones in the first and second mandibular molars. I used the pterygo-mandibular injection and removed the pulps from both teeth. The pain did not recur.

2. CROWN AND BRIDGE WORK

In crown and bridge work we perform the most radical dental operations. Not only do we have to cut off more tooth substance than when excavating, but it is especially the grinding which causes a great deal of pain and discomfort. Also it is frequently necessary to devitalize sound teeth. The fitting of bands and cementing of the crown or bridge is also a painful process. At the other hand, it is of greatest importance that this work be performed exactly, because if a tooth is not perfectly prepared it is impossible to fit a crown which does not irritate nor invite decay. One can safely say that failures in bridge work result more from not being radical enough, than from any other cause, and this again in most cases is due to pain.

Fitting Bands and Cementing Bridges There is only very superficial anaesthesia required for fitting bands and cementing bridges. Injections into the gingival margins are sufficient, but are usually more or less painful. One also can inject between the gum and tooth, this requires great pressure. A sufficient way is to apply a twenty per cent solution of Novocain with brush or cotton.

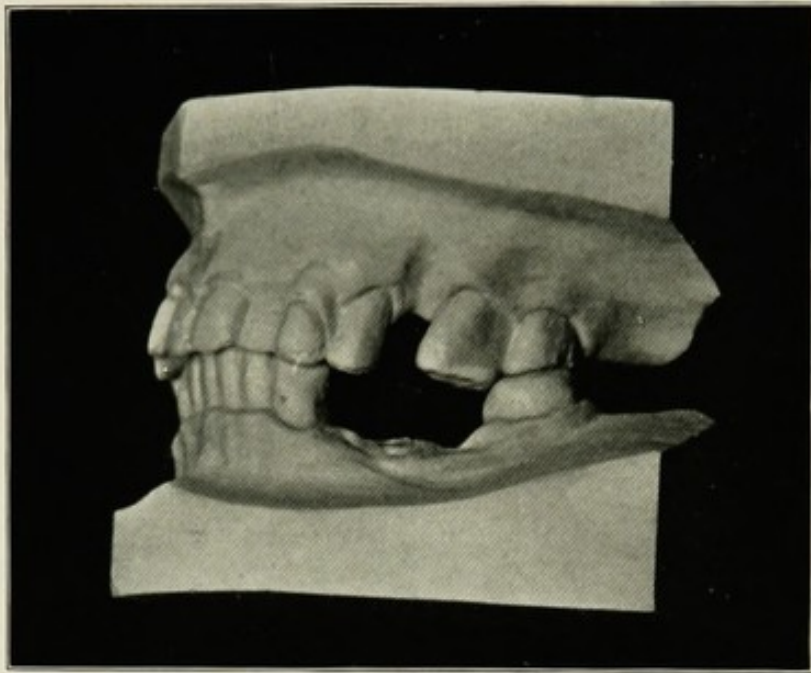


FIG. 75. Crown and bridge case I, before treatment.

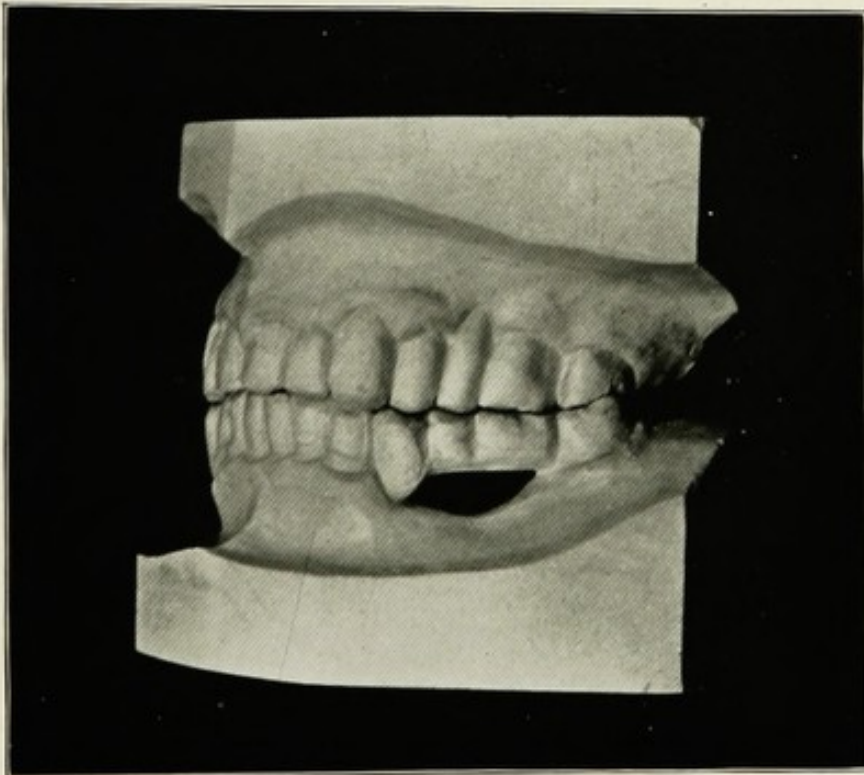


FIG. 76. Crown and bridge case I, after treatment.

In bridge work there is usually more than one **Grinding and Devitalizing** tooth to be operated upon. The conductive method is therefore an ideal help. Also the infiltration method is sometimes advisable. Usually it is of benefit to anaesthetize both the teeth and soft tissues. Injections given in Tables I, II, III or VI can be used as required.

Case I. The author prepared with one pterygo-mandibular injection, all the left mandibular teeth to serve as abutments in case figure 75. The lower second molar was devitalized, cuspid and lateral ground for open-faced crowns, and one bicuspid root extracted, all in one sitting. In the upper jaw I injected for the two bicuspids on the buccal side by the infiltration method, separate for each tooth. I devitalized and cut these off for banded post crowns to be attached together, with a dummy on either side. Figure 76 shows case finished; in the lower jaw a sanitary bridge, with porcelain chewing surface from lower left lateral to second molar.

Case II. (Fig. 77.) I have used the zygomatic injection to devitalize the first maxillary molar. It was repaired with a large hand-carved porcelain crown to fill in the spaces on either side. The two maxillary bicuspids I devitalized with the infiltration method horizontal injection. The central lateral and cuspid were anaesthetized by the horizontal injection, combined with the incisive injection to extract the two latter on account of their position. The central incisor I devitalized for a banded post crown. In the lower jaw I used the pterygo-mandibular injection, to prepare the second molar for an all metal crown, to devitalize the first bicuspid for a banded post crown, and the cuspid for a half crown with post. All the grinding and most of the fitting was done under local anaesthesia. Fig. 78 shows the case completed.

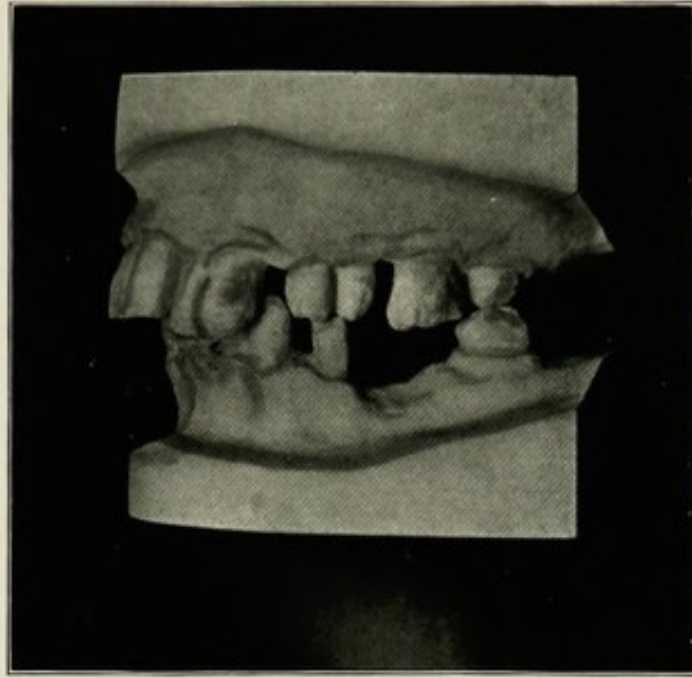


FIG. 77. Crown and bridge case II, before treatment.

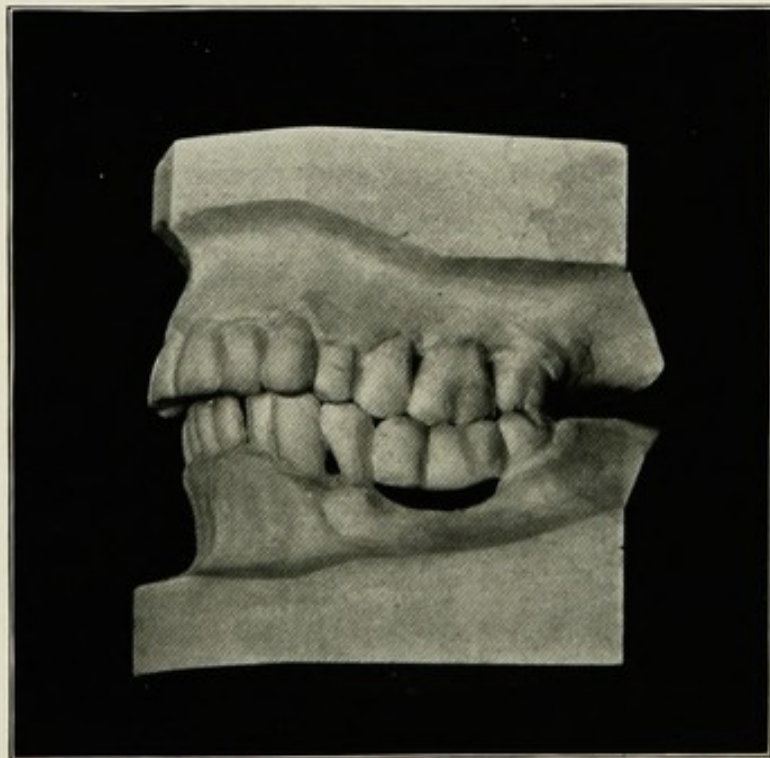


FIG. 78. Crown and bridge case II, after treatment.

EXODONTIA

Many general practitioners gave up extracting on account of the disturbances which often accompany the administration of a general anaesthetic. The patients, however, have great trust in the family dentist, and very much prefer to have him do the extracting instead of being sent to a specialist. This has as a consequence that frequently roots are suffered to be left in the mouth, being there a continuous source of infection and condemnation. The general practitioner also frequently fears to take upon himself the responsibility of administering a general anaesthetic, and is not sure to be able to accomplish under the unfavorable circumstances of such an anaesthetic a successful operation. Under local anaesthesia the most difficult extractions are easily accomplished. Everything is favorable, there is plenty of time to cut the gum to get access to badly decayed roots, and if a root is broken there is lots of time and the best possibilities to get it out.

Extractions always have been accomplished more or less painlessly with injections into the gum producing a gingival velum. This of course anaesthetized as a rule the soft tissues only, and was painful on account of the pressure required for the injection. The extraction itself was only partly painless because the dental ramus supplying the tooth and alviolo-dental membrane was not reached, and the anaesthesia was worthless if a broken-off root had to be taken out, especially so in the lower jaw.

For extraction the tooth as well as the soft tissue has to be anaesthetized. If there are only few teeth to be extracted, and these are not adjoining, the infiltration method can be used (Table II) if it is not contra-indicated on account of putrescent conditions or location. For the lower posterior teeth, infected areas or extensive operations, use the conductive method (Table IV.) The anaesthesia does not only allow the extracting, but also curetting of the sockets, which in most cases is of greatest

importance. The tendency of late has been to use too high a percentage of suprarenal substances causing too great anaemia. This is a false principle. The bleeding should be normal or almost normal, as this is the natural cleaning process of the wound, toxins and other products of inflammation are carried out with the blood. The disadvantage of interfering with the normal blood circulation is also obvious, if we consider that a wound in the mouth is continuously exposed to infection, antiseptic dressings of tooth sockets being not advisable, as the healing process should be that of organization of a blood clot.

If we diminish the blood circulation of the wound we diminish also the natural protection against infection; we give the bacteria one-half or one hour's time to multiply and take possession. When the anaesthesia and anaemia wears finally off, we find complications, post-operative pain on account of post-operative infection. This can be avoided easily if we use the T tablets, which contain only 0.000,02 gram of Suprarenin to 1 c.c.

ORAL SURGERY

There are today only very few cases of dental surgery where local anaesthesia is not used to greater advantage, with more safety, promising greater success of the operation, and less discomfort to the patient than general anaesthesia. The only cases where it cannot be used are cases complicated with ankylosis of the mandible.

To put patients to the strain and danger of ether, chloroform, or similar general anaesthetics, with their psychic, and physic pre- and after-effects, for ordinary cases of exodontia or oral surgery confining a patient for days to the hospital or the bed, is no more justifiable. If we compare two operations, side by side, one under general anaesthesia, with mouth props, general relaxation of the patient, the field of operation being continuously obscured by increased venous bleeding and saliva, not to speak of blood and pus, which is swallowed and pene-

trates into the lungs, the operation being prolonged by endless sponging, which takes up more than half of the time; and compare the other under local anaesthesia with a clear view, bleeding almost obliterated, and coöperation of the patient, we find it easy to choose; and it also makes it clear why it is for the operator to choose, and not for the patient.

Since the introduction of conductive and spinal anaesthesia general anaesthesia has become less popular. The progress which local anaesthesia has made in modern surgery is shown in the report of the university clinics of Marburg and Heidelberg, where of all operations fifty respectively fifty-four per cent have been performed under local anaesthesia. It is especially used on the head (cranium and face) neck, ribs, hemorrhoids and all operations on the extremities.* Also the public has quickly become accustomed to local anaesthesia, and has great faith in this new method, which is less disagreeable and less dangerous.

For large surgical operations ganglion anaesthesia is used; for smaller operations the conductive method is recommendable. But it should be combined, however, with the infiltration method, to anaesthetize the anastomosis from buccinator, facial or infra-orbital nerves, and in some cases to get anaemia of the field of operation. Use the T tablets for conductive and ganglion anaesthesia; the T or E tablets for infiltration anaesthesia; the T tablet if anaemia is not required; the E tablet if the bleeding needs to be decreased so as to give a better view of the field of operation.

Operation for Granulum, Root and Apex Amputations Local anaesthesia gives the general practitioner the possibility of using his skill for delicate surgical operations, which in some cases are the only means to retain a tooth without endangering the general health of the patient. Since the physician as well as the dentists have become familiar with the grave significance

* Haertel: Fortschritte auf dem Gebiete der Local Anaesthesie. Zeitschrift fuer aeztliche Fortbildung 1914. 1.

of an infected apical granulum, which often is the focus of general diseases of toxic or infectious cause, and since the radiograph has become such a simple and popular means of diagnosis preventing the unconscientious dentist to ignore such cases with placid remarks, we come to realize that our treatment of these conditions with medicines placed into the root canal is not sufficient, and that we have to extract the tooth and curette the socket, or perform on it a delicate operation, which on account of its present importance I will describe in detail.

Indication. 1. Surgical treatment is indicated in all teeth worth saving where treatment through the root canal is unsuccessful, as in all cases where the root is affected, absorbed or gangrenous. No tooth should remain in the mouth with granulating peridontitis, giving symptoms of soreness, lameness or pain continuously or at intervals. So-called gum boils, which enlarge from time to time, or sinuses, come under the same head, and are of severer nature than the first named.

2. Surgical treatment is indicated in cases of well-fitting crowns or bridges, where we find the root canal of an abutment only partly filled.

3. Surgical treatment is indicated in roots which on account of their curving, or on account of obstructions, cannot be filled to the apex.

4. Surgical treatment is indicated in teeth which have been perforated at the apical part by root canal instruments.

5. Surgical treatment is indicated if root instruments have been broken off in the root canals, and cannot be removed from the pulp chamber.

Difficulties. These operations can be performed in all, but are easier in single-rooted teeth. If working at the buccal roots of the upper teeth one should be careful not to perforate the floor of the antrum. In the lower bicuspid the mental

nerve must be considered. The lower second and third molars and the upper third molars are the most unfavorable teeth to operate upon on account of their position.

Anaesthesia. Use the conductive combined with the infiltration method wherever practical, but either can be used alone. Inject as to Tables II and IV, and in difficult cases use the E tablet for the infiltration injection to get anaemia.

INJECTION FOR OPERATION ON THE LEFT MAXILLARY LATERAL INCISOR

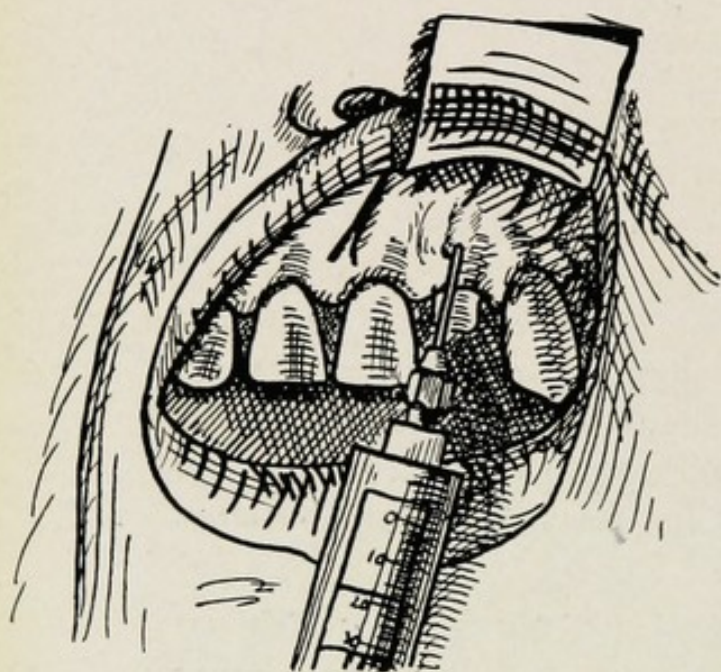


FIG. 79. Labial injection.

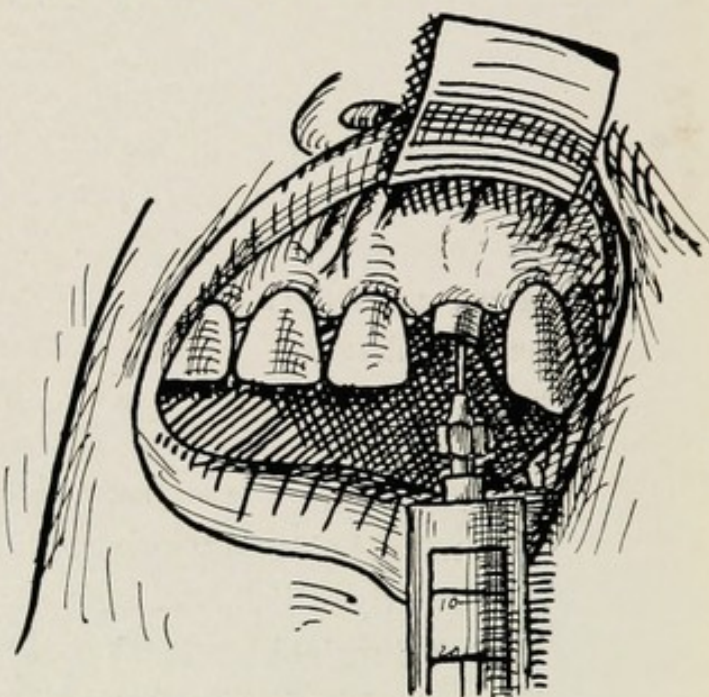


FIG. 80. Palatal injection.

Operation. The operation varies according to the cause. If we operate for a granulum it is sometimes sufficient to curette the apex and the socket, removing all granulated tissue. If the root is affected, partly absorbed or gangrenous, if the root filling does not extend through the apical foramen, or if the apex is perforated, it is necessary to amputate the apical part of the root. If a foreign body is to be removed, it is often sufficient to cut a window on the front surface of the root, and remove it through the pulp chamber.

Technique of Granulum Operation. The root canal should be treated before the operation is performed. The canal can be filled either before or during the operation. Sterilize with iodine, and be sure to have the root filling germ proof and sealed tight, or the filling will be pressed out if a crown with post is cemented on. This is accomplished by pumping thinly mixed

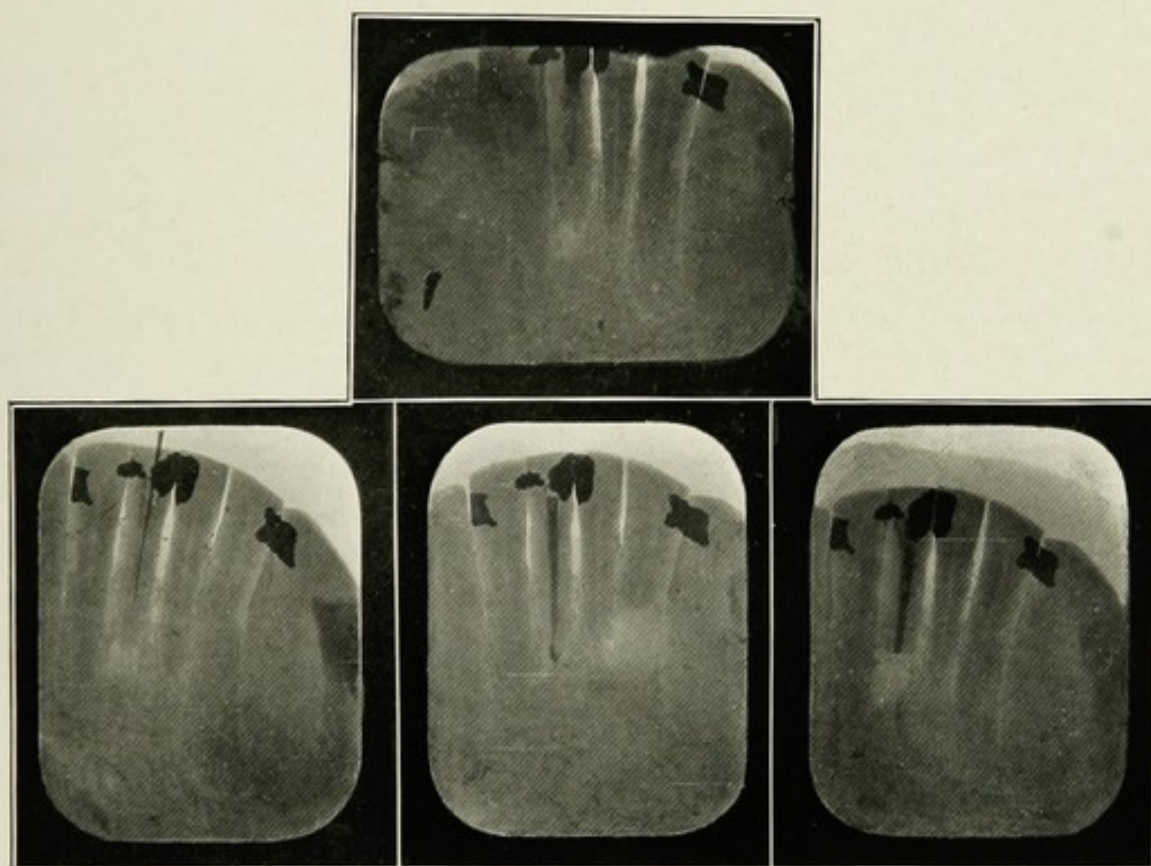


FIG. 81. Serie showing amputation of the apex of the lower incisor. No. 1 (top) Diagnosis of the granulated condition. Nos. 2 and 3, Treatment before the operation. No. 4, Result after the operation.

phosphate cement into the canal, and by moistening the gutta-percha point with the same mixture, before inserting it. The gutta-percha point is packed down into the root canal with a suitable instrument to get a close fit on the walls. If there is a wide apical foramen, or an artificial perforation at the apex, the cement and also the point will extend beyond, if the foramen and part of the apical root canal is calcified, the root

should be amputated at the place where the filling ends. Previous to and after the root canal filling, we take a radiograph for guide and control of the work.

Instruments used :

1. Retractor.
2. Knife.
3. Pliers.
4. Periosteal Raspatorium.
5. Sharp retractor.
6. Chisel and mallet or fissure and round burrs.
7. Small curette.
8. Scissors.
9. Sewing outfit.

To perform the surgical part of the operation, paint the line of incision with tincture of iodine, and make a half-round incision to cut loose a flap which is separated from the bone with the sharp raspatorium; it is then retracted with the sharp retractor upward in the upper jaw, and downward in the lower jaw. If a sinus is present it is well to let the incision go through it. The retractor is held by an assistant. Remove the alviolar plate to uncover the infected area.

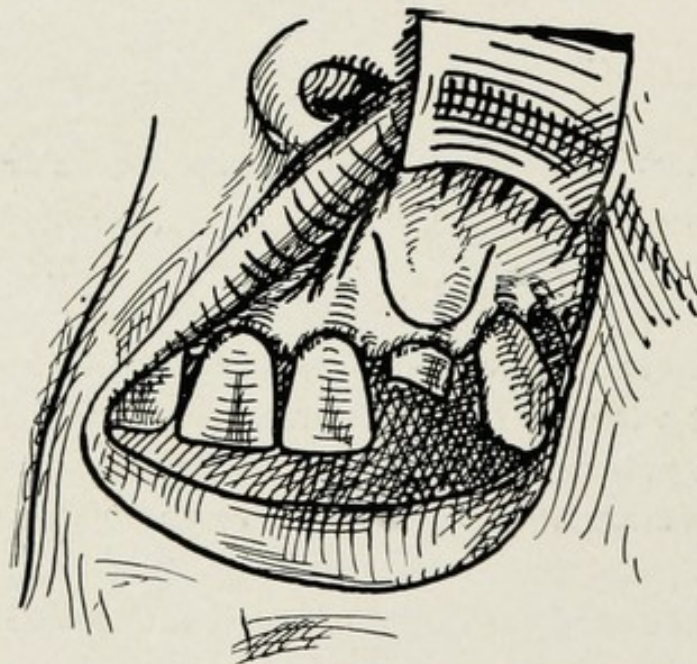


FIG. 82. Showing incision for operation on the left maxillary lateral incisor.

This is easy as the bone is usually partly destroyed. It is important to have a clear view of the whole extent of the apex of the root.

1. Curetting only necessary. If the apex is not affected curette the root and alviolar socket and remove all pathological tissue, with suitable curettes. The most difficult part to reach is the part behind the root, which can be curetted with a large spoon excavator.

2. Amputation is not necessary, but Apical part of root canal is not filled. If the root serves as abutment of a bridge, the removal of which is not wished, but the root canal is only partly filled, amputation is sometimes not advisable because it would weaken the abutment. In these cases we can, after removing the granulum, slit the root with a round burr from front, starting from the apex, till we reach the root filling. This part of the root canal is then thoroughly sterilized, best with iodine, dried out and carefully filled with amalgam. Cotton is placed in the cavity to prevent parts of the amalgam to remain unseen in the wound. The amalgam is thoroughly smoothed, the cotton removed and the wound washed out.

WINDOW OPERATION TO REMOVE BROKEN OFF BROACH
IN ROOT CANAL

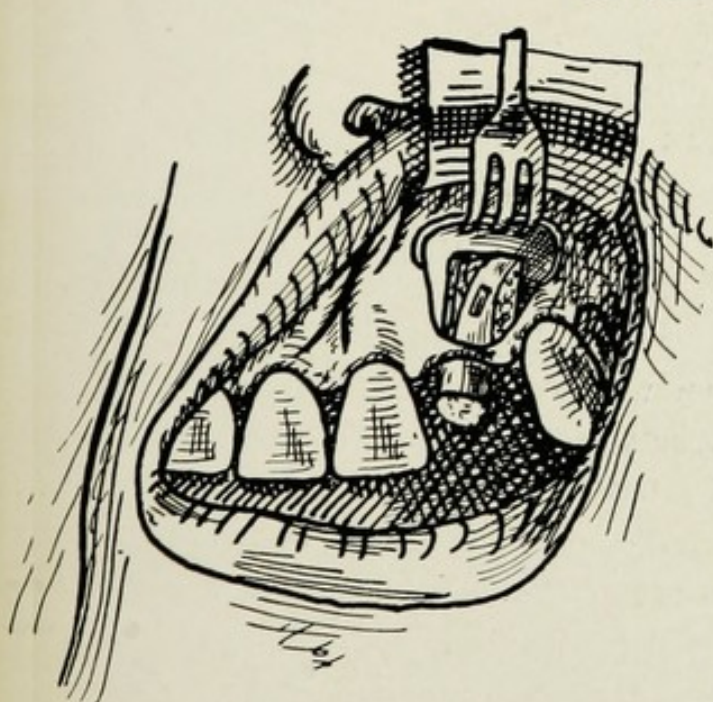


FIG. 83. After the window is cut and the broach exposed.

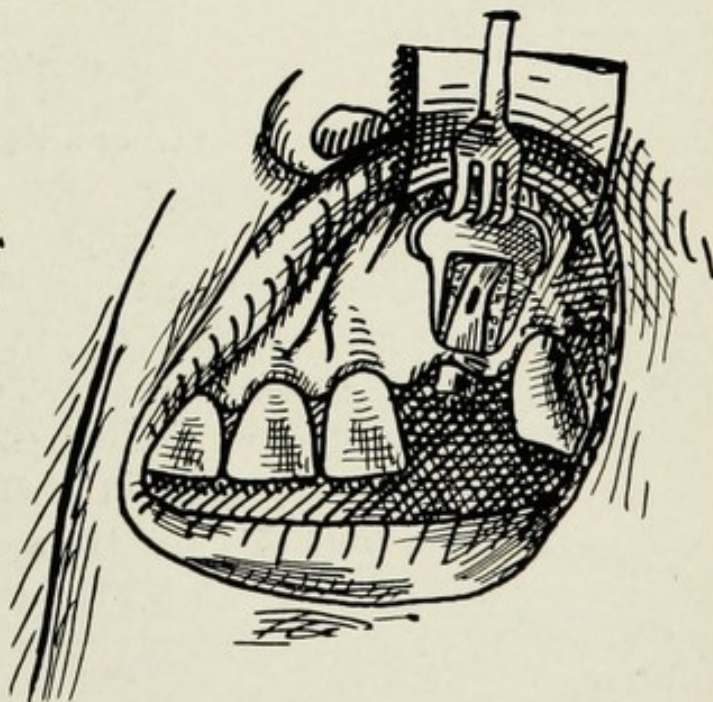


FIG. 84. After filling of the window.

3. Window Operation. If there is a perforation, we cut it smooth and for retention. If a foreign body is lodged in the root canal, we locate it with the Radiograph, cut a window over it and with a suitable instrument push it into the pulp chamber. Place a piece of cotton into the cavity to prevent it from falling out unseen. A smooth broach of sufficient size is now placed into the canal, and the window is filled with amalgam, which is smoothed off carefully. Again prevent amalgam from falling into the wound, wash out and close the wound. Remove the broach carefully after the amalgam is hard and fill the root canal at a subsequent sitting.

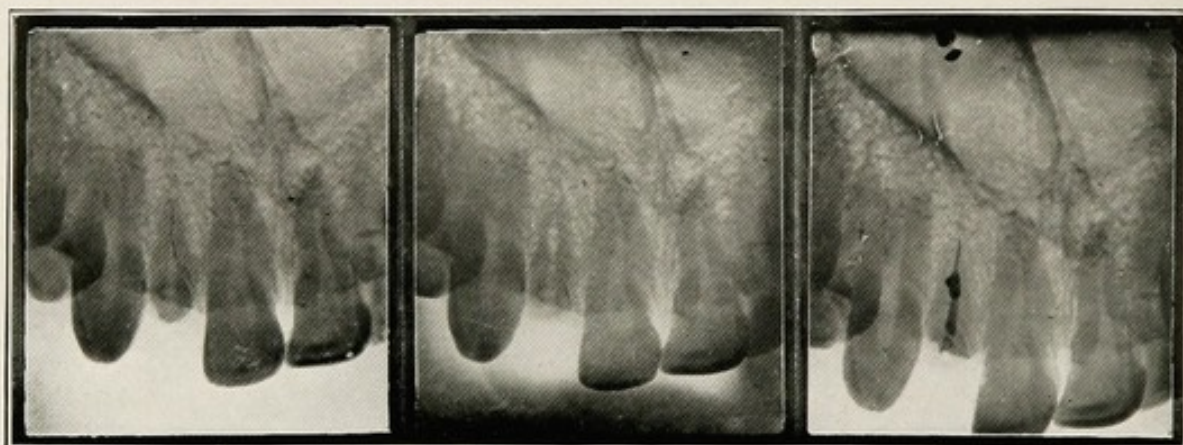


FIG. 85. Radiographic serie illustrating the window operation. No. 1, shows broken instruments. No. 2, instrument removed. No. 3, root canal and window filled.

4. Root amputation and Apex amputations. In molars, especially in pyorrhoeic conditions or cervical caries, it becomes sometimes necessary to amputate an entire root, as the palatal or one buccal root of an upper molar, or the mesial root of a lower molar. This is an easy operation. To amputate the apex only requires more skill. When we have the apical part of the root in plain view, we diagnose whether it is pathological. With a fissure burr we cut it off crossways at a point where it is healthy, and to which the root filling extends. Now comes the most important act, the removal of the granulation tissue. This is removed with a curette till healthy bone is visible on

OPERATION FOR APEX AMPUTATION

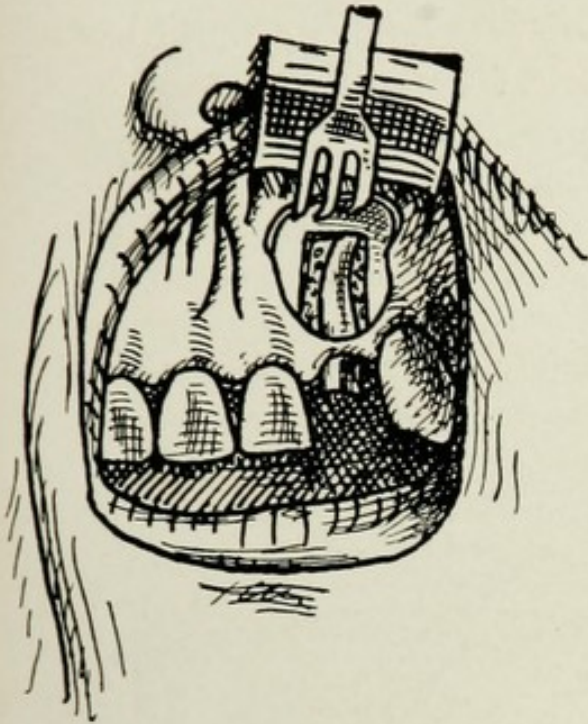


FIG. 86. Root of the tooth is exposed.

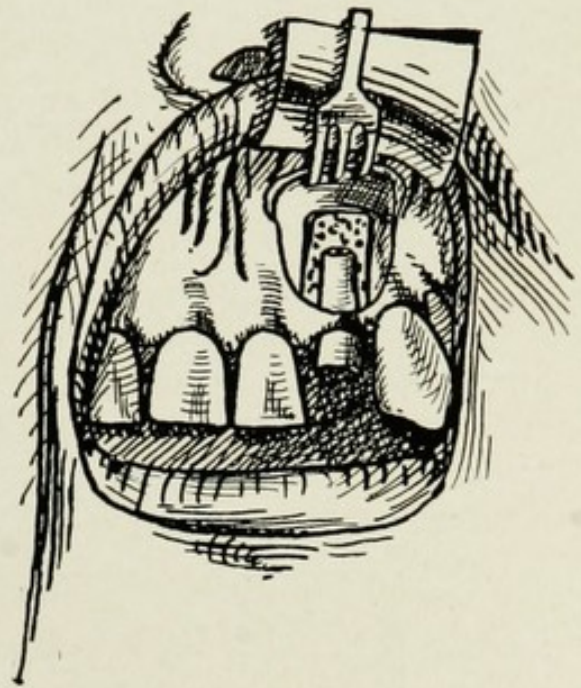


FIG. 87. After amputating the root and curetting of the cavity.

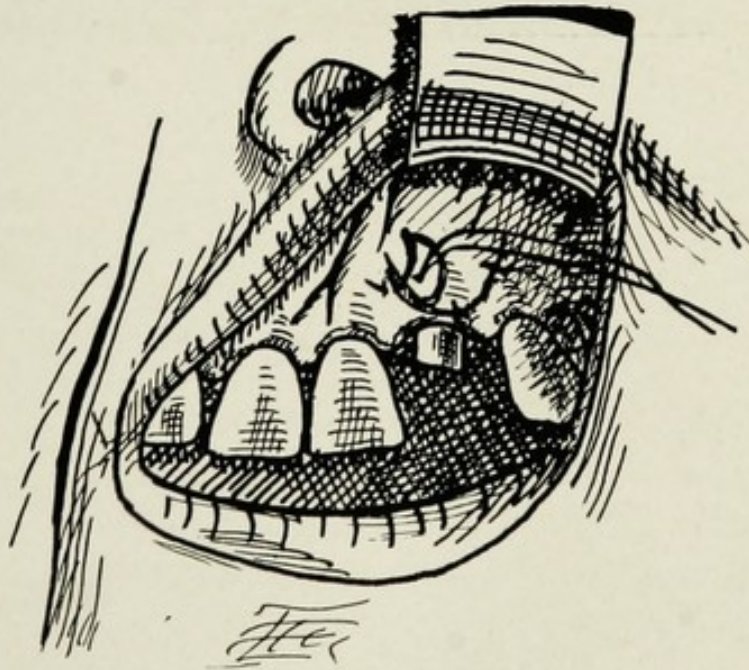


FIG. 88. Sewing of the wound.

all sides. All margins and sharp points are then smoothed with a round burr, and the cavity is thoroughly washed out with a mild antiseptic solution. This is dried up. Before sewing, stimulate the wound with a small instrument, to invite bleeding for the formation of a blood clot. Draw the flap down and sew it back carefully with horsehair stitches. If a wound heals by first intention, the stitches can be removed in three days. For swelling of the soft tissue, which frequently occurs after such an operation, apply dry heat. If the blood clot should become septic, the stitches have to be removed and the cavity is packed with iodoform gauze to let the wound heal from the inside out. This is not an ideal result, but sufficient for the preservation of the tooth.

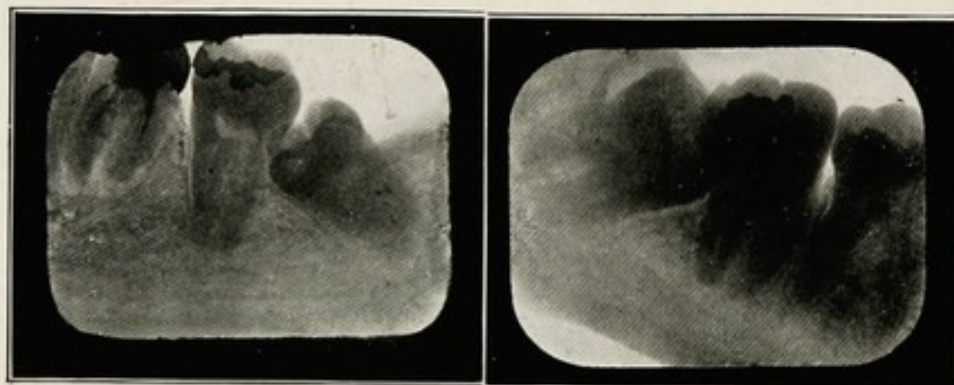


FIG. 89. Impacted lower third molars. Both have been removed with the pterygo-mandibular injection.

Impacted Teeth Difficult extractions and especially the removal of impacted teeth are operations which become more and more frequent as civilization progresses. The conductive methods are advisable for anaesthesia, and it is usually not necessary to produce special anaemia. (Tables II and IV.) If we do, we should be careful, however, to prevent post-operative infections. The injuries caused by these operations are usually very deep, and if we have anaemia of the field of operation, packing of the wound with:

Euroform paste

R	Orthoform	40
	Europen	60
	Liquid petroleum.....	s. q. to make paste

is recommended. In all cases, frequent rinsing of the wound by the patient and washing out daily by the operator is advisable. If the wound has been packed one can stimulate it at a future sitting to bleeding, to get a blood clot filling the cavity. Then there is no anaemia, and infection will be taken care of by natural means.

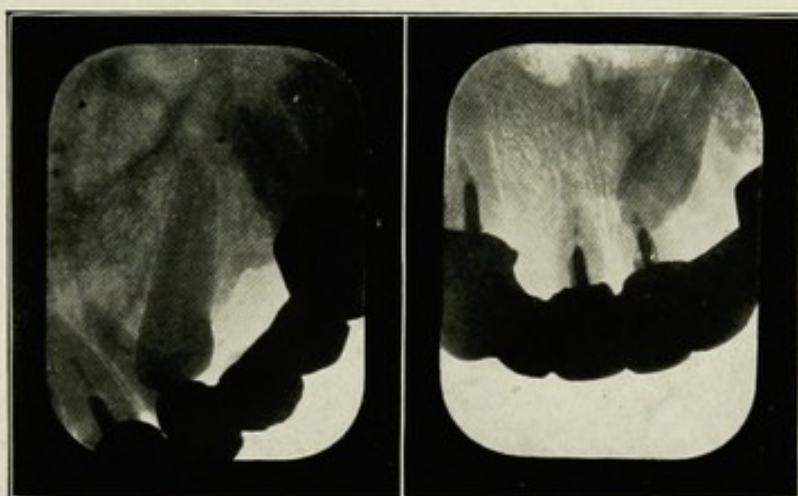


FIG. 90. Impacted cuspids under bridgework.

To set fractures of the upper or lower jaw, we use local anaesthesia to advantage. Whenever the conductive method can be used it is to be preferred. The pterygo-mandibular space can be reached from the outside, starting at the inner surface of the lower border of the mandible, directing the needle straight upward into the pterygo-mandibular space. Also the infra-orbital nerve can be reached from the outside, extending the needle directly in and injecting into the infra-orbital canal. Also the infiltration method gives sometimes good results.

Cysts, Tumors, Necrosis, Odontoma To remove small growths on the jaws, palate, cheeks, or lips, we again use the conductive method combined with infiltration around the tissue to be removed.

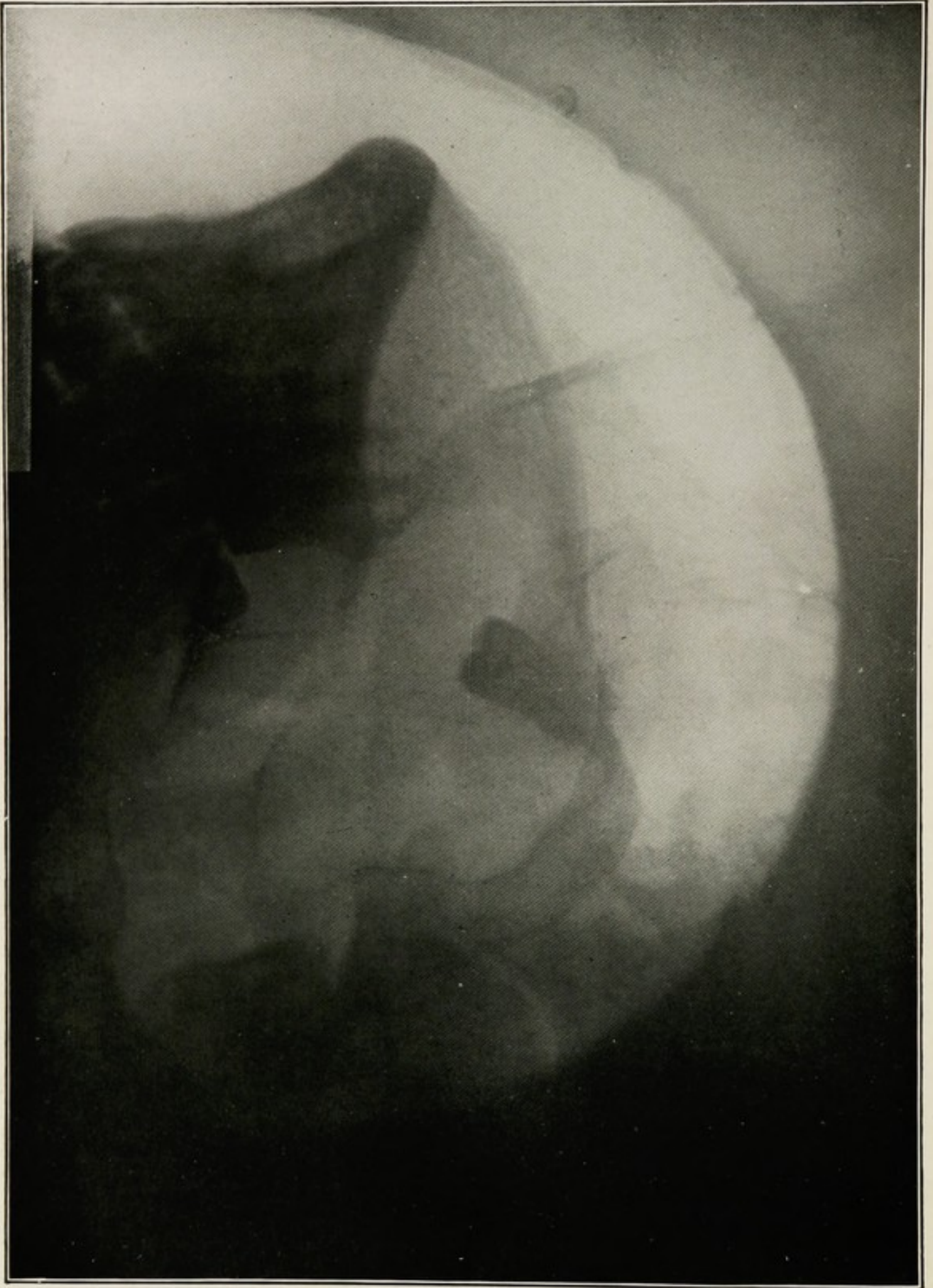

FIG. 91. Large mandibular cyst with unerupted third molar. One root of the third molar extends below the lower margin of the mandible.

**Cleft Palate, Hare Lip,
Amputation of the
Alviolar Process,
Resection of Jaws**

For more extensive operations it is usually necessary to anaesthetize the whole division of the fifth nerve, supplying the region in question. For cleft palate we anaesthetize the second division with the speno-maxillary injection. Injections into the incisive, posterior and accessory palatine foramina are also indicated. For amputation of the superior alviolar process, the zygomatic, infra-orbital, incisor and post palatine injections are sufficient. For amputations of the lower alviolar process, use the pterygo-mandibular injection, and in both cases combine the conductive with the infiltration method. For larger operations, as amputations of the upper or lower jaw, Haertel* (clinic of the University of Berlin) recommends the Ganglion anaesthesia. He describes the following operations, which have been performed successfully under ganglion anaesthesia: Six resections of the upper jaw, two extirpations of the tongue, two sarcoma of the nasopharynx, on orbital tumor, and three smaller operations about the jaws.

* Archiv fuer Klinische Chirurgie, Dezember, 1912.

INDEX

A

- ABSCISS, pericemental, 114
- Adjoining teeth, anaesthesia of, 106
- After-effects, 96
- After-pain, 97
- Alcohol jar, 54
- Alviolar abscess, acute, 112
- Alviolar abscess, chronic, 113
- Alviolar process of the mandible, 12
- Alviolar process of the maxilla, 11
- Ampules with Novocain Suprarenin solution, 47
- Amputation of alviolar process, 133
- Amputation of root, 128
- Amputation of root apex, 128
- Anaesthesia, conductive, 60, 71
 - ganglion, 60, 91
 - infiltration, 60, 63
 - not obtained, 93
 - prolonged, 97
 - spinal, 60
 - surface, 60, 62
 - undesirable symptoms, 94
- Anaemia in extraction, 120
- Anatomy of the oral cavity, 9
- Apex amputation, 128
- Antidotes for fainting, 96
- Antrum of Highmore, 14
- Arterio sclerosis, 49
- Author's method of preparing the solution, 48

B

- BICUSPIDS, anaesthesia of mandibular, 106
- Bier, 7
- Braun, 8, 60

- Braun's requirements of a substitute for cocaine, 39
- Buccinator injection, 84
- Buente, 8

C

- CALCIFIED pulps, removal of, 111
- Canine fossa, 9
- Cardiac disorders, 49
- Cavity preparations, 106
- Cementing bridges, 116
- Chronic alviolar abscess, 113
- Cleft palate, 133
- Cocaine, 7, 39
- Conductive anaesthesia, 71
 - in the mandible, 73
 - in the maxilla, 85
- Conductive method, 60
- Crown and bridge work, 116
- Cups to prepare solution, 54
- Curetting of alviolar sockets, 120
 - technique, 127
- Cysts, 131

D

- DISTILLED water, 50
 - Femel apparatus, 51
- Devitalization of normal teeth, 107, 118
- Diagnosis of pain, 114

E

- EINHORN, 8, 39
- Euroform paste, 100, 130
- Exodontia, 120
- External oblique line, 20
- Extraction of teeth, 120

F

- FAILURES and ill-effects in "Local Anaesthesia," 93
 Fainting, 96
 Fear, 98
 Femel apparatus, 51
 Fischer, 8
 Fitting bands, 116
 Foramen, incisive, 14
 infra-orbital, 11
 mandibular, 21, 22
 mental, 19, 23
 palatine, 14
 posterior superior alviolar, 14
 Foreign body in root canal, 128
 Fractured jaws, 131

G

- GANGLION anaesthesia, 60, 91
 "General Anaesthesia" versus "Local Anaesthesia," 7, 93, 121
 Granulum of the alviolo-dontal membrane, 113
 Granulum operation, 122
 technique, 125

H

- HAERTEL, 8, 133
 Halsted, 73
 Hare-lip, 133
 Hauptmeyer, 8
 Hypertrophied pulps removed, 111

I

- ILL-EFFECTS in Local Anaesthesia, 93, 99
 Impacted teeth, 130
 Incisive foramen, 14
 injection, 89
 Incisors, anaesthesia of mandibular, 106
 Infection from injection, 97
 post-operative, 99, 121
 Infiltration anaesthesia, history, 8
 method, 60, 63
 in the mandibula, 69
 in the maxilla, 63

- Inflamed pulps, removed, 112
 Infra-orbital foramen, 11
 injection, 86
 Injection, buccinator, 84
 Gasserian ganglion, 91
 horizontal, 70
 incisive, 89
 infra-orbital, 86
 mental, 81
 on labial and buccal side of the maxillary teeth, 66
 on labial side of mandibular incisors, 70
 on lingual side of mandibular incisors, 70
 on palatine side of maxillary teeth, 68
 posterior palatine, 90
 pterygo-mandibular, 74
 rules, 101
 spheno-maxillary, 90
 tables, 102, 103, 104, 105
 zygomatic, 85
 Insertion of needle, preparing place for, 65
 Instrumentarium, 54
 Internal oblique line, 21
 pterygoid muscle, 21
 Introduction, 7

J

- JAR for syringe, 54
 Jaws fractured, 131
 Jaws, resection of, 133

K

- KALIUM bromide—See potassium bromide

L

- LOCAL Anaesthesia, 60
 versus general anaesthesia, 7, 93, 121

M

- MANDIBULA, 14
 body, 19
 ramus, 20

Mandibular nerve, 31
 Maxilla, 9
 Maxillary nerve, 25
 Maxillary sinus, 14
 Mental fossa, 19
 injection, 81
 Molars, anaesthesia of mandibular, 106
 anaesthesia of maxillary, 106
 Moral, 8
 Mucous membrane of the mouth, 35

N

NASAL anaesthesia, 63
 Necrosis, 131
 Needle for injection, 54
 Nephritis, 49
 Nerves, anterior palatine, 30
 anterior superior alviolar ramus, 28
 buccinator, 31
 inferior alviolar, 34
 inferior dental plexus, 34
 inferior dental rami, 34
 inferior gingival rami, 34
 infra-orbital, 27
 infra-orbital rami, 28
 lingual, 34
 mandibular, 31
 maxillary, 25
 mental, 34
 middle palatine, 31
 middle superior alviolar ramus, 27
 naso palatine, 31
 ophthalmic, 25
 posterior palatine, 31
 posterior superior alviolar rami, 25
 spheno-palatine, 25
 spheno-palatine ganglion, 28
 superior dental plexus, 28
 superior dental ramus, 28
 superior gingival ramus, 28
 zygomatic, 25
 Neurology, 25
 Novocain, 39
 clinical tests, 40
 discovered, 8
 dosage, 41
 physiological properties, 40
 production, 40
 pugglets, 107
 reaction, 40

Novocain-Suprarenin combined, 44
 Suprarenin in ampules, 47
 Suprarenin in solution, 47
 Suprarenin in tablets, 48

O

ODONTOMA, 131
 Oedema, 96
 Operation for granulum, 122
 for granulum, technique, 125
 Operative dentistry, 106
 Ophthalmic nerve, 25
 Oral surgery, 121
 Osteology, 9

P

PAIN post-operative, 99, 121
 Pericemental abscess, 114
 Peridontitis removal of pulps, 90
 Posterior palatine injection, 90
 Potassium bromide, 96
 Practical application of Local Anaesthesia, 101
 Preparing of the solution, Author's method, 48
 Preparing of the solution, Seidel's method, 47
 Pulp chamber of teeth changes, 101
 Pulps, calcified, removal of, 111
 hypertrophied, removal of, 111
 inflamed, removal of, 112
 normal, removal of, 107, 118
 with pulp stones, removal of, 111

Q

QUANTITY of solution to be injected at one time, 41

R

RAMUS of mandible, 20
 Removal of calcified pulps, 111
 hypertrophied pulps, 111
 inflamed pulps, 112
 normal pulps, 107
 pulps with pulp stones, 111
 pulps with peridontitis, 112
 Requirements of a solution prepared from tablets, 58

Resection of jaws, 133
 Ringer solution, 50
 Ringer tablets, 50, 57
 Root amputations, 128
 Root canal with foreign body, 128
 Rules for injections, 101

S

SEIDEL, 8
 Seidel's Sixteen Theses, 44
 method to prepare Novocain Suprarenin solution, 47
 Sharpening of the needle, 54
 Solution, preparing of, 58
 requirements if prepared from tablets, 58
 preparing, Author's method, 48
 Spheno-maxillary ganglion, 28
 injection, 90
 Spinal anaesthesia, 60
 Steinkamm, 8
 Submucosa of mucous membrane, 35
 Substitute for cocaine, Braun's requirements, 60
 Sulcus mandibularis, 21
 Suprarenin syntheticum, 41
 chemical properties, 42
 clinical experiences, 42
 dosage, 42
 physiological properties, 42
 production, 41
 reaction, 42
 Surface anaesthesia, 60, 62
 Symptoms, during anaesthesia, undesirable, 94
 Syringes, 54, 56

T

TABLE I. Infiltration anaesthesia of the teeth only, 102
 Table II. Infiltration anaesthesia of the teeth and soft tissue, 103
 Table III. Conductive anaesthesia of the teeth only, 104
 Table IV. Conductive anaesthesia of the teeth and soft tissue, 105
 Tablets of Novocain Suprarenin, 48
 Tablets E, 49, 54
 F, 49, 54
 F + E, 57
 Ringer, 50, 57
 T, 48, 54
 Teeth impacted, 131
 Topography, 35
 Tuber maxillare, 11
 Tumors, 131

U

UNDESIRABLE symptoms during anaesthesia, 94

V

VALYL, 96

W

WAITING time of anaesthesia, 106
 Window operation, 128
 Wisdom teeth impacted, 130

Z

ZYGOMATIC fossa, 11
 injection, 85
 process, 11


LIST OF ILLUSTRATIONS


FIG.	PAGE
1. Outer surface of maxilla and mandibula showing attachments of muscles	10
2. Skull showing small foramina in the incisor region of the maxilla and mandibula	12
3. Skull showing foramina in the cuspid, bicuspid and molar regions of the maxilla and absence in the mandibula	13
4. Palate of a child 6-7 years	15
5. Palate of a child 11-12 years	15
6. Palate of an adult	16
7. Palate of senile skull	16
8. Skull with dissected anterior superior alviolar canal	17
9. Radiograph showing a frontal aspect of the maxillary sinus	18
10. Cross section through maxilla and mandibula showing difference in make-up of the bone	19
11. Three mandibles showing different construction of the post molar triangle	20
12. Sulcus mandibularis enclosed by the dotted line	21
13. Specimen showing dissected mandibular canal	22
14. Variations of the internal surface of the ramus mandibularis	23
15. Location of mental foramen in a child	24
16. Location of mental foramen in adult	24
17. Location of mental foramen in senile skull	24
18. Nerves trigeminus; (Vth cranial nerve)	26
19. Schematic drawing of the Nervus maxillaris	27
20. Nervus trigeminus (Vth cranial nerve)	29
21. Schematic drawing of ganglion sphenopalatinum	30
22. Nervus trigeminus: (Vth cranial nerve). In the maxilla showing the anterior part of the N. maxillaris. In the mandibula showing the N. mandibularis	32
23. Schematic drawing of nervus mandibularis	33


FIG.	PAGE
24. Section through the upper jaw in the incisor region	36
25. Horizontal section through human head in the plane in which mandibular conductive anaesthesia is best accomplished	37
26. Femel apparatus to produce distilled water	51
27. Schematic drawing of distilled water apparatus	52
28. Bottle for Ringer solution. Jar filled with absolute alcohol. Syringes and dissolving cups, and glass tray	55
29. Syringes	56
30. Large and small dissolving cups	56
31. Schematic illustration of the methods of local anaesthesia recommended for dental surgery	61
32. Frontal section through the molar region showing buccal and palatal injection by the infiltration method	64
33. Position of operator when injecting for an upper tooth by the infiltration method	65
34. Radiograph showing the infiltration method for an upper incisor	66
35. Radiograph showing the infiltration method for an upper cuspid	67
36. Radiograph showing the infiltration method for an upper bicuspid	67
37. Wrong position of needle	68
38. Right position of needle, opening pointing towards the bone	68
39. Radiograph showing the infiltration method for a lower incisor	69
40. Radiograph showing the horizontal injection for bicuspid, and molar region	70
41. Radiograph showing the horizontal injection in a coronal section	71
42. Conductive Anaesthesia: 1. Zygomatic injection. 2. Infra-orbital injection. 3. Pterygo-mandibular injection. 4. Mental injection	72
43. Diagram showing injection into the pterygo-mandibular space	74
44. Technique of inserting the needle for the pterygo-manidbular injection	75
45. Pterygo-mandibular injection on the right side; position on patient	76
46. Pterygo-mandibular injection on the right side; position on patient	77
47. Pterygo-mandibular injection on the left side; position on patient	78
48. Pterygo-mandibular injection on the left side; position on patient	79
49. Sulcus mandibularis with needle	80
50. Radiograph showing needle inserted in right position above the lingula	82
51. Radiograph showing needle inserted too low, sliding along the lingula into the muscle	82

FIG.	PAGE
52. Radiograph showing the pterygo-mandibular injection	83
53. Radiograph showing injection into the mental foramen	84
54. Infra-temporal surface of the maxilla	86
55. Radiograph showing zygomatic injection	87
56. Infra-orbital injection on the right side	88
57. Radiograph showing infra-orbital injection	89
58. Schematic drawing showing the injection into the Gasserian ganglion	91
59. Foramen ovale in the skull seen from the position of the operator	92
60. Radiograph of maxillary incisors	108
61. Radiograph of cuspids	108
62. Radiograph of maxillary first bicuspid	108
63. Radiograph of maxillary second bicuspid	108
64. Radiograph of maxillary molars	109
65. Radiograph of mandibular incisors	109
66. Radiograph of mandibular bicuspid	109
67. Radiograph of mandibular molars	109
68. Central incisor with chronic abscess (lead filling), lateral incisor with pulpitis	110
69. Root of lower second bicuspid	111
70. Acute alviolar abscess of a central incisor	113
71. Chronic alviolar abscesses	114
72. Pericemental abscess caused by perforation of the tooth by a post	115
73. Pericemental and alviolar abscess on a maxillary cuspid	115
74. Patient suffered with severe pains of neuralgic character. The Radiograph shows pulp stones	116
75. Crown and bridge, case I, before treatment	117
76. Crown and bridge, case I, after treatment	117
77. Crown and bridge, case II, before treatment	119
78. Crown and bridge, case II, after treatment	119
79. Labial injection	124
80. Palatal injection	124
81. Serie showing amputation of the apex of the lower incisor	125
82. Showing incision for operation on the left maxillary lateral incisor	126
83. After the window is cut and the broach exposed	127

FIG.	PAGE
84. After filling of the window	127
85. Radiographic serie illustrating the window operation	128
86. Root of the tooth is exposed	129
87. After amputating the root and curetting of the cavity	129
88. Sewing of the wound	129
89. Impacted lower third molars	130
90. Impacted cuspids under bridge-work	131
91. Large mandibular cyst with unerupted third molar	132







Date Due

YALE MEDICAL LIBRARY

AUG 27 1993
YALE

17 MEDICAL

LIBRARY

Demco 38-297



WORLD MEDICAL LIBRARY

3 9002 01073 9275



