

**Diseases of the nose and its accessory cavities / With special sections on diseases of the skin of the nose, on injuries, on rhinoplastic operations, and on ear-affections in their relation to intra-nasal diseases, by Robert Liveing, William Adams, and A. E. Cumberbatch.**

### **Contributors**

Watson, W. Spencer 1836-1906.  
Harvey Cushing/John Hay Whitney Medical Library

### **Publication/Creation**

London : Lewis, 1890.

### **Persistent URL**

<https://wellcomecollection.org/works/fa7xvu88>

### **License and attribution**


This material has been provided by This material has been provided by the Harvey Cushing/John Hay Whitney Medical Library at Yale University, through the Medical Heritage Library. The original may be consulted at the Harvey Cushing/John Hay Whitney Medical Library at Yale University. where the originals may be consulted.

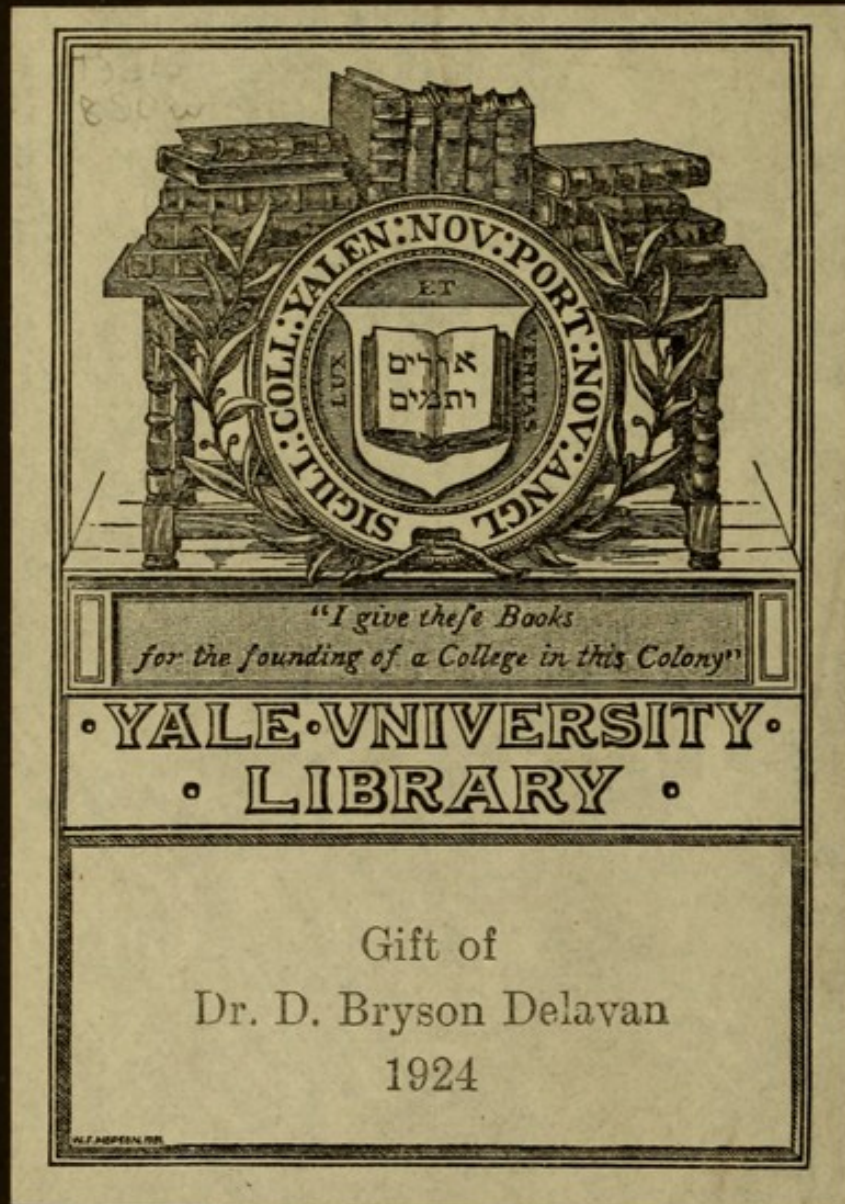
This work has been identified as being free of known restrictions under copyright law, including all related and neighbouring rights and is being made available under the Creative Commons, Public Domain Mark.

You can copy, modify, distribute and perform the work, even for commercial purposes, without asking permission.

**wellcome  
collection**

Wellcome Collection  
183 Euston Road  
London NW1 2BE UK  
T +44 (0)20 7611 8722  
E [library@wellcomecollection.org](mailto:library@wellcomecollection.org)  
<https://wellcomecollection.org>






TRANSFERRED TO  
YALE MEDICAL LIBRARY



6

DISEASES OF THE NOSE  
AND ITS  
ACCESSORY CAVITIES



# DISEASES OF THE NOSE

AND ITS

## ACCESSORY CAVITIES

BY

W. SPENCER WATSON, F.R.C.S.Eng., B.M.Lond.

SURGEON TO THE THROAT DEPARTMENT OF THE GREAT NORTHERN CENTRAL HOSPITAL;  
SENIOR SURGEON TO THE ROYAL SOUTH LONDON OPHTHALMIC HOSPITAL; FORMERLY  
ASSISTANT-SURGEON TO KING'S COLLEGE HOSPITAL; FELLOW OF THE ROYAL  
MEDICAL AND CHIRURGICAL SOCIETY; MEMBER OF THE OPHTHALMOLOGICAL  
SOCIETY OF GREAT BRITAIN AND IRELAND; MEMBER OF THE  
WEST LONDON MEDICAL AND CHIRURGICAL SOCIETY, &C

WITH SPECIAL SECTIONS ON

*DISEASES OF THE SKIN OF THE NOSE, ON INJURIES, ON RHINOPLASTIC  
OPERATIONS, AND ON EAR-AFFECTIONS IN THEIR RELATION  
TO INTRA-NASAL DISEASES*

BY

DR. ROBERT LIVEING, MR. WILLIAM ADAMS AND  
MR. A. E. CUMBERBATCH.

*SECOND EDITION*

WITH NUMEROUS ENGRAVINGS AND LITHOGRAPHIC PLATES

LONDON

H. K. LEWIS, 136 GOWER STREET

1890



RF 341  
890W

Gift of Dr. A. B. D. Elavan

## PREFACE TO THE SECOND EDITION.

---

DURING the period which has elapsed since the publication of the first edition of this work many improvements have been made in our diagnostic methods and appliances, and in rhinological therapeutics and rhinal instruments. The use of *cocaine* has of itself revolutionized the operative treatment of many hitherto intractable forms of intra-nasal disease. Several important additions to the physiology of the sense of smell are due to the recent observations and experiments of Drs. Hughlings Jackson, Ferrier, Althaus, Beevor, and others. In this department, and in that of the anatomy of the organ of smell, I have received great help from Dr. T. P. Smith, who has revised the whole of the First Section, and brought it up to a level with the present advanced state of the physiology of the nose as a sense-organ and as a part of the respiratory apparatus. The pathology of the sensory apparatus is treated of more fully than in the First Edition, in the Sections on Anosmia and on Reflex Neuroses. With regard to the new matter in the general body of the work, the chief additions have been made in the Sections on Post-Nasal Catarrh, on Hypertrophic Rhinitis, and on Adenoid Vegetations of the Naso-Pharynx; while in the Section on Diseases of the Skin, Dr. Robert Liveing has been good enough to contribute a valuable article on Lupus Erythematosus. Several Sections have been much curtailed, and those on the Hygienic and Medico-legal relations of the sense of smell have been altogether omitted. An entirely new Section by Mr. A. E. Cumberbatch on the connection between Nasal and Aural Diseases forms the last but not the least important article. The Appendix of Cases of the First Edition has been omitted from the Second; many of the cases being embodied in the Sections to which they belong, while many new ones have been intercalated in an abbreviated form. The

illustrations are more numerous than in the First Edition, and of those now added, some have been drawn from recent specimens by my son, Mr. George Spencer Watson, and several of the lithographic plates have also been drawn under my directions by the same hand. I have endeavoured to acknowledge the assistance I have derived from numerous authors in the body of the book. The literature of the subject, however, has become so extensive during the last few years, that I think it not improbable that some important points of rhinological research may have escaped my notice, and I trust that any authors who are not quoted by name will attribute the omission to want of space, and the necessity of condensation.

HENRIETTA STREET, W.

*July, 1890.*

## TABLE OF CONTENTS.

---

SECTION I.	PAGES
The Anatomy and Physiology of the Nose and Nasal Fossæ . . . . .	1—23
SECTION II.	
Preliminary Remarks; A. On Rhinoscopy, Anterior, Median and Posterior, and on Digital Exploration of the Nares and the use of Cocaine; B. On Nasal Stenosis; C. On Fœtor from the Nostrils; D. On Discharges from the Nostrils . . . . .	24—40
SECTION III.	
<i>Sub-Section</i> 1. Catarrh; 2. Post-Nasal Catarrh; 3. Strumous Rhinorrhœa; 4. Syphilitic Coryza; 5. Dry Catarrh 6. Rhinitis Atrophica and Ozæna; 7. Rhinitis Caseosa; 8. Diphtheritic Rhinitis . . . . .	41—65
SECTION IV.	
<i>Sub-Section</i> 1. Chronic Hypertrophic Rhinitis; 2. Cysts in the Nasal Fossæ and Naso-pharynx . . . . .	66—78
SECTION V.	
<i>Sub-Section</i> 1. Gelatinous Polypi; 2. Epistaxis; 3. Foreign Bodies; 4. Rhinoliths; 5. Entomozoaria and "Peenash" . . . . .	79—112
SECTION VI.	
Ulcerative Affections of the Nasal Fossæ. <i>Sub-Section</i> 1. Erosive Ulcers of Syphilitic Origin; 2. Lupoid Ulcers; 3. Eczematoid Ulcers; 4. Ulcers, the Sequelæ of Fevers; 5. Glanders; 6. Scorbutic Ulcers; 7. Ulcers in Paresis of the Fifth Pair of Nerves; 8. Tuberculous Ulcers . . . . .	113—130
SECTION VII.	
Adenoid Vegetations of the Naso-Pharynx . . . . .	131—142
SECTION VIII.	
Necrosis of the Bones and Cartilages of the Nose. Certain Affections of the Septum Nasi . . . . .	143—147
SECTION IX.	
Diseases of the Frontal, Ethmoidal, and Sphenoidal Sinuses, and of the Lachrymal Sac . . . . .	148—158
SECTION X.	
Diseases of the Antrum of Highmore in its Relations to Diseases of the Nasal Fossæ . . . . .	159—184

	PAGES
SECTION XI.	
Diseases of the Skin and Subcutaneous Tissues of the Nose. <i>Sub-Section</i> 1. Herpes; 2. Eczema; 3. Comedones, Acne, Sycosis, Gutta Rosea; 4. Lupus; 5. Lupus Erythematosus ( <i>Dr. R. Liveing's article</i> ); 6. Epithelioma, Rodent Ulcer; 7. Lipoma, Rhinoscleroma; 8. Chilblain, Frostbite, Gangrene; 9. Intermittent Hyperæmia and Dyspeptic "Red-Nose"; 10. Erysipelas . . . . .	185—217
SECTION XII.	
Tumours of the Nasal Fossæ and of the Naso-Pharynx. <i>Sub-Section</i> 1. Fibroma; 2. Sarcoma and Recurrent Fibroid Tumours; 3. Treatment of Fibroma and Sarcoma in the Nasal Fossæ and Naso-Pharyngeal Cavity; 4. Malignant Polypi of the Nasal Fossæ; 5. Bony and Cartilaginous Tumours of the Nasal Fossæ . . . . .	218—241
SECTION XIII.	
Recent Injuries of the Nose, with Cases in Illustration. <i>Sub-Section</i> 1. Contusions and Wounds; 2. Fractures and Dislocations of the Bones of the Nose ( <i>Mr. W. Adams' Article</i> ); 3. Injuries with the Lodgement of Foreign Bodies	242—254
SECTION XIV.	
On Malformations, Distortions and Mutilations of the Nose Rhinoplastic Operations. <i>Sub-Section</i> 1. Malformations and Distortions of Congenital Origin, or the Results of Injuries; 2. Defects and Mutilations due to Disease or Injuries, and Mechanical Appliances for their Relief; 3. Rhinoplastic Operations; 4. On Dressings, Bandages, etc. . . . .	255—277
SECTION XV.	
Anosmia and other Functional Derangements of Olfaction . . . . .	278—290
SECTION XVI.	
Reflex Neuroses depending on Intra-Nasal Disease . . . . .	291—295
SECTION XVII.	
Neuroses of the Nose. <i>Sub-Section</i> 1. Sneezing; 2. Spasmodic Twitching; 3. Neuralgia; 4. Paralysis of Common Sensation; 5. Nasal Cough and the existence of a Sensitive Area in the Nose . . . . .	296—300
SECTION XVIII.	
Mental and Intra-Cranial Complications of Intra-Nasal Diseases	301—307
SECTION XIX.	
Mr. Cumberbatch's Article on the <i>Diseases of the Ear</i> in connection with Nasal Disease . . . . .	308—312

## LIST OF WOODCUTS.

		PAGE		
Fig. 1.	Cells of the regio olfactoria in man. (After Fisk and Ecker).	4		
" 2.	Cells of the olfactory region of the frog. (From Frey's Histology)	5		
" 3.	Cells of the olfactory region of man. (After Lockhart Clarke)	7		
" 4.	Syphon-douche apparatus	24		
" 5.	Higgenson's syringe for use as a nasal douche	25		
" 6.	Wray's syphon-douche bottle	25		
" 7.	Post-nasal syringe	26		
" 8.	Rumbold's intra-nasal syringe	27		
" 9.	The position of the surgeon and patient in anterior rhinoscopy	28		
" 10.	Watson's nasal dilator	28		
" 11.	Fränkel's speculum	29		
" 12.	Türck's tongue depressor	30		
" 13.	White's palate-hook	30		
" 14.	Semon's electric lamp for the pharynx	31		
" 15.	Rumbold's intra-nasal mirror	32		
" 16.	Goodwille's speculum	53		
" 17.	Author's canula for the application of caustics	69		
" 18.	Author's guarded spring electric cautery knife	71		
" 19.	Author's ring-knife	72		
" 20.	Author's nasal plugs	73		
" 21.	} Illustrations of hypertrophic growths on the turbinated bodies	} 74		
" 22.			} Illustrations of hypertrophic growths on the turbinated bodies	} 75
" 23.				
" 24.	} Illustrations of hypertrophic growths on the turbinated bodies	} 75		
" 25.				
" 26.	Dr. G. Johnson's case of cyst in the naso-pharynx	76		
" 27.	Illustration of Dr. G. Johnson's case (same case as in fig. 27)	77		
" 28.	(No figure 29)			
" 29.	S. Watson's insufflator for the nose	86		
" 30.	Krause's snare for polypi	87		
" 31.	Hook for drawing forward naso-pharyngeal growths	88		
" 32.	Author's sliding polypus forceps	90		
" 33.	Morell Mackenzie's temporary sponge-tampon	94		
" 34.	Bellocq's canula	97		
" 35.	} Rose's epistaxis plug	} 99		
" 36.				
" 37.	Forceps with separable blades for the removal of foreign bodies	102		
" 38.	Author's long crocodile forceps	105		
" 39.	Justi's cutting-spoons for adenoid vegetations	138		
" 40.	Guy's ring-knife	139		
" 41.	Löwenberg's forceps	139		
" 42.	Author's forceps for adenoid vegetations in children	139		
" 43.	Bowman's canaliculus knife	158		
" 44.	} Nasal duct probes	} 158		
" 45.				
" 46.	Stilling's nasal duct knife	158		
" 47.	Conical nasal duct probe	158		
" 48.				

	PAGE
Fig. 49. External wall of nasal fossa. (After Giraldès)	159
„ 50. External wall of nasal fossa. (After Giraldès)	160
„ 51. } Illustration of a case of abscess of the antrum.	168
„ 52. }	
<i>(The numbering of the woodcuts is here interrupted by a gap, there being no other woodcuts till fig. 61.)</i>	
„ 61. Auspitz's microscopic section of skin affected with lupus	197
„ 62. Neumann's microscopic section of the skin affected with lupus erythematosus	202
„ 63. Wm. Adams' ivory nasal plugs	243
„ 64. Author's nose truss	246
„ 65. Wm. Adams' forceps for straightening septum	247
„ 66. } Wm. Adams' curved forceps for elevating depressed nasal	248
„ 66A. } bones	
„ 67. Wm. Adams' steel screw compressor for deviations of the septum	250
„ 68. Wm. Adams' nose truss	251
„ 69. } Stump's silver artificial nose	259
„ 70. }	
„ 71. }	
„ 72. }	
„ 73. } Various artificial noses adapted by Mr. Stump	( 258
„ 74. }	&
„ 75. }	( 259
„ 76. }	
„ 77. Result of rhinoplastic operation by Mr. John Wood	265
„ 78. Swaardemaker's olfactometer	279

LIST OF LITHOGRAPHIC PLATES.

Plate I. Fig. 1. Relative position of patient and surgeon in posterior rhinoscopy; fig. 2. Position of pharyngeal mirror and tongue depressor in posterior rhinoscopy	opposite page 33
Plate II. Various figures illustrating intra-nasal growths and posterior rhinoscopic views	opposite page 81
Plate III. Eight figures illustrating diseases of the antrum	opposite page 174
Plate IV. Seven figures numbered from between fig. 2 to fig. 8	between pages 192 and 193
Plate V. Three figures illustrating skin diseases of the nose	opposite page 208

## SECTION I.

---

# THE ANATOMY AND PHYSIOLOGY OF THE NOSE AND NASAL FOSSÆ.

---

### THE ANATOMY OF THE NOSE AND NASAL FOSSÆ.

THE *nose*, the central, most prominent region of the face, is normally symmetrical, and divided by a median plane into a right and left half. Each half consists of a bony and cartilaginous framework, covered externally by integument and subcutaneous muscles, and internally by mucous membrane. At the lower and anterior part of each is an aperture (the nostril) by which the surface communicates with a cavity—the nasal fossa.

The *nasal fossæ* are symmetrically formed, one on either side of a median vertical septum (the septum nasi), by which they are divided into a right and left nasal fossa. Each is bounded externally by the nasal, superior maxillary, ethmoid, lachrymal, inferior spongy, palate bones, and pterygoid plates of the sphenoid, with their mucous coverings; above by the cribriform plate of the ethmoid in the centre, by the frontal and nasal bones in front, and by the body of the sphenoid and part of the palate bone at the posterior part; below by the palate; and in front by the union of the nasal bones and by the articulation of the nasal cartilages with the septum. Each fossa is capable of being narrowed laterally and expanded by means of the muscles lying external to the cartilage; and by the peculiar arrangement of the mucous membrane covering the middle turbinated bone and a corresponding line of thickening of the septum, the cavity is divisible, when contracted, into two distinct and separate channels, an upper one passing towards and along the



olfactory region—the olfactory channel, and a lower or respiratory channel. The mucous membrane covering the middle turbinated bone is prolonged into an elevation anteriorly, described by Meyer as the *agger nasi*. Its direction is almost parallel with the dorsal ridge of the nose, running forwards and downwards, till it reaches very nearly to the anterior aperture of the nostril. This *agger nasi* approaches very near to a thickened portion of the septum, and a very slight lateral compression, as by the action of the compressor naris muscle, brings them into actual contact, and so divides the fossa into the two channels above alluded to. This arrangement will be found to be important in reference to the anosmia associated with facial palsy, and will be referred to in a future page.

Besides the anterior openings (the nostrils) by which they communicate with the external air, the nasal fossæ have each a posterior opening (the posterior nares), which makes their cavities continuous with that of the pharynx.

The furrows or depressions on the outer wall of each fossa formed by the projecting turbinated bones are termed meatuses. They are three in number—the superior, middle, and inferior.

Each fossa communicates with four sinuses, the frontal, above, opening, with the anterior ethmoidal cells, into the middle meatus through the infundibulum; the sphenoidal, behind, opening into the superior meatus; the maxillary or antrum Highmorianum, opening indirectly into the middle meatus at the lower part of the infundibulum (see Giraldès' treatise, "Des Cystes Muqueux"); and the posterior ethmoidal, opening into the superior meatus (see Figs. under Section on Antrum).

Each fossa also communicates with the conjunctival surface by a continuation of the mucous membrane of the inferior meatus through the nasal duct, lachrymal sac, and the canaliculi and puncta lachrymalia.

#### *The Functions and Minute Anatomy of the Nasal Fossæ.*

The nose and its fossæ may be regarded in four different aspects—1, as a *sense organ*; 2, as a part of the *respiratory apparatus*; 3, as part of the *face* and of the *mechanism of expression*; 4, as part of the *vocal mechanism*.

First, regarded as a *sense organ*, it must be divided into (a) the *olfactory region proper*, or that part of the mucous lining of

the nostrils upon which the olfactory nerves are distributed, and which is endowed with the sense of smell; and (b) the *Schneiderian* or *pituitary region*, comprising the remaining and by far the larger portion of the nasal cavities possessing only common sensation. These two regions differ in their structure as well as in their vital properties. The *olfactory region* is limited to the upper half of the septum, the superior turbinated bone, and perhaps half of the middle turbinated bone, together with the under surface of the cribriform plate of the ethmoid. The mucous membrane covering these bones is distinguishable, even to the naked eye, from that of the rest of the nasal cavities, by the presence of a yellowish or sepia-brown pigment, and by its evident thickness and softness as compared with the contiguous surface. Examined microscopically, this region is seen to be bounded by a tolerably well-defined, toothed or undulated border. The differences of structure depend upon the character of the epithelium, the occurrence of peculiarly constructed glands (Bowman's glands),\* and upon the relations of the nerves. The epithelium is *not ciliated*. It is also thicker than in the Schneiderian region, so that in the sheep, whose ciliated epithelium is 0.03'' in thickness, it measures 0.05'', and in the rabbit the one is 0.04'' thick, and the other 0.07''. Notwithstanding this thickness, it is remarkably soft and delicate, and is so much affected by almost all reagents as to allow of its being studied only with considerable trouble.

The nerves are the terminal ramifications of the first pair, and begin in the olfactory bulbs, which lie, one on each side, immediately on the *lamina cribrosa* of the ethmoid bone, not being separated therefrom by any cerebro-spinal fluid. The structure of the bulbs shows that they are to be regarded as

\* In men they are certainly not so numerous as in other mammalia; on the contrary, they are in part replaced by the ordinary clustered mucous glands. Their occurrence in men generally is nevertheless demonstrated. (Frey, "Histology," s. 597.)

It is probable that these glands may be more numerous in dark-skinned than in fair individuals; and hence they may be hardly discoverable in some specimens and abundant in others. It is one of their functions, apparently, to exude a pigmented secretion on the surface of the olfactory mucous membrane, as is seen in the olfactory region of the fox (see Ecker's plates), and it seems probable that in fair men, the pigment secreting function being feebly developed throughout, the olfactory region would partake of the general deficiency.

portions of the cerebral substance. The filaments which arise from their under surface are enveloped in sheath prolongations of the dura mater, and are arranged in two sets. The inner set is directed to the septum nasi, while the outer set is distributed to the lateral walls of the nasal fossæ. The sheaths derived from the dura mater are continuous with the periosteum.

The filaments as they pass through the cribriform plate are found to be composed of delicate transparent connective tissue bundles, enclosing many cellular elements, between which are imbedded the minute prolongations of the olfactory nerves. These latter are from 3-7 $\mu$  broad, pale, and slightly granular on the surface, and consist of a delicate membrane either structureless or minutely striated with longish nuclei, and investing a tenacious semi-fluid substance which oozes out in drops when the cut surfaces are compressed.

Schultze's researches have proved that these tube-like structures do not contain a homogeneous fluid, but are composed of many extremely delicate fibrillæ, easily obliterated, and less than 1 $\mu$  in diameter. The tubes, therefore, represent secondary bundles, enclosed in sheaths, and the fine fibrillæ are axis-cylinders of the most delicate kind, and devoid of medullary matter. These fibrillæ pass to the periphery, and in all probability are connected with the epithelial cells on the surface of the nasal mucous membrane, which require a somewhat minute description.

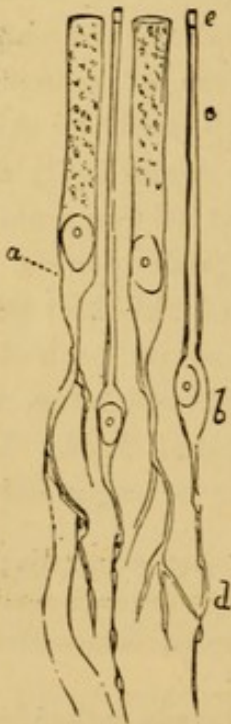


Fig. 1.  
(after Fick and Ecker.)  
Cells of the regio olfactoria  
of man. *a*, Epithelial  
cell; *b*, "olfactory cell,"  
with the descending pro-  
cess *d*, and the peripheral  
rod *c*, beyond which pro-  
jects a short off-set *e*.

The epithelium covering the olfactory region resembles in form the cylindrical ciliated cells found in the remaining portions of the nose; but the cells of the former are much longer, and between them are scattered certain cellular structures which are absent from the rest of the mucous membrane. (See fig. 1.) The cells in question differ in various animals as regards the possession of ciliæ. These exist in the lower part of the nasal cavity

in all classes of animals; but in the olfactory region they are wanting in mammalia generally. On the other hand, in birds, amphibia and certain classes of fishes, that region is either partially or entirely lined by ciliated epithelium. *Goblet-cells* are absent from the olfactory region, whereas they are very abundant among the ciliated cells. Observers are pretty well agreed that there is a direct connection between the fibres of the olfactory nerve and the cells lining the olfactory region. According to Max Schultze, the cells may be divided into two categories, the olfactory cells and the supporting cells, the distinction being easily made out in the frog. (See fig. 2.) In this animal, the supporting cells are conical in shape; their peripheral extremities, directed towards the nasal cavity, are marked by well-developed margins furnished with cilia. The body of the cell is short and contains a nucleus with nucleoli, and is prolonged below into a riband-shaped extremity, presenting irregular dilatations and many lateral branches, and considerably exceeding the length of the cell itself. In the majority of the supporting cells, however, the body of the cell is considerably developed at the expense of the extremity; the nucleus is at some distance from the free surface, the cell is laterally compressed and presents no decided margin beneath the row of cilia. Both kinds of cells contain yellow pigment granules in their protoplasm, and it is to these that the colour of the mucous membrane is due.

Between these supporting cells are those which belong to the second category, the so-called olfactory cells. (See fig. 2, *b*.) These are spindle-shaped and contain only enough protoplasm to cover their oval nuclei, which are furnished with nucleoli. Each of the extremities of these cells forms a long delicate prolongation. One of the latter is extremely minute, but frequently swollen at intervals, and passes downwards, without dividing, into the connective tissue basis of the mucous membrane. The other extremity is thicker

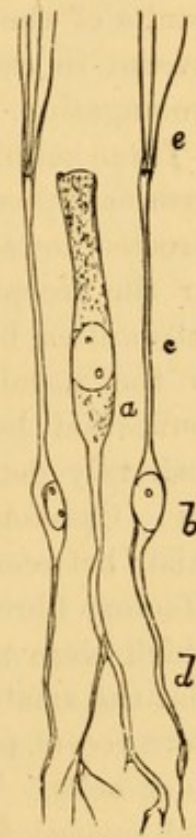


Fig. 2.  
(from Frey's Histology.)  
Cells of the olfactory region of the frog. *a*, epithelial cell; *b*, "olfactory cell;" *c*, peripheral rod of olfactory cell; *e*, cilia; *d*, central process of "olfactory cell."

and more conspicuous, and passes upwards to the free surface of the mucous membrane, where it ceases on the same level as the bases of the supporting cells. Each cell has a corona of delicate ciliæ, which are more minute and fragile, and longer than those of the cells situated beyond the boundary of the olfactory region, but not distinguishable, by any peculiarities, from those of the supporting cells. In other amphibia, and in many birds, the peripheral extremities of the olfactory cells are similarly coated with ciliæ; but in fishes and mammalia, we find only very short rod-shaped prolongations (see fig. 1, *e.*), with regard to which it is doubtful whether they are not the results of the mode of preparation. Two nuclei are sometimes present in each cell, the second being situated in the lower prolongation.

These cellular structures are regarded by M. Schultze as the terminal apparatus of the olfactory nerves; their prolongations directed towards the nasal cavities, represent the mechanism for the reception of the odorous materials, while their lower extremities, beneath the mucous membrane, are to be regarded as the terminal fibrils of the olfactory nerve itself. The connection between the cells and the fibrillæ has not been positively demonstrated; but the theory is a very probable one. Opinions vary, however, as to whether any difference exists between the two kinds of cells. Ecker thought that the olfactory fibres passed into the lower extremities of those cells which were regarded as "supporting" by M. Schultze, and that the smaller cells (the olfactory cells of the latter) were of more recent formation, and intended to supply the place of the older cells. This view has been adopted by other observers, and several forms of cells have been discovered, intermediate between the two kinds. Exner believes that he has demonstrated the connection between the epithelium of the olfactory region and the olfactory fibrils; he states that the prolongations of protoplasm from the lower extremities of the supporting cells form a network lying on the mucous membrane, from the strands of which the supporting and the olfactory cells arise, and into which all the fibres of the olfactory nerve are continuously implanted.

Closely analogous appearances have been seen and described by Lockhart Clarke (*Medico-Chir. Rev.*, 1862, vol. i, p. 521),

(fig. 3), who states that the olfactory nerve fibres on reaching the base of the epithelial layer, divide into finer and still finer fibrils to form a network with numerous interspersed nuclei, through which they are probably connected with the olfactory cells (*f*, in fig. 3), although he has never been able satisfactorily to convince himself of such connection. According to Dr. Ferrier, the *cerebral olfactory centre* is situated in the *gyrus uncinatus*, on the inner side of the temporo-sphenoidal lobe; it is closely connected with the gustatory centre.

Although the ciliated cells of the nasal fossæ are much more readily affected by water than those of other situations, this is true to an even greater extent as regards the cells of the olfactory region, and the destructive effect of the filling of the nasal cavities with water and other fluids is thus easily accounted for; as, also, on the other hand, is the ready transudation of volatile substances through the epithelium rendered intelligible. For the moistening and protection of the epithelium throughout the region in which it exists, it is furnished with a great number of the "glands of Bowman," a fact which is the more remarkable, because the immediately contiguous, ciliated, mucous membrane is but scantily supplied with glands,\* or is wholly without them. These glands are simple cylinders, either straight or slightly convoluted at the lower end, and 0.08"—0.1" in length, or elongated pyriform follicles, situated principally between the larger branches of the olfactory nerves, in crowded rows, in part, however, more isolated, as at the lower boundaries of the olfactory region. . . . Their canals, 0.014"—0.025" wide, are lined by a beautiful simple epithelium, composed of rounded polygonal cells, 0.006" to 0.008" in size, containing more or fewer yellowish or brownish pigment granules, to which is due the varying colour of the olfactory mucous membrane. Their excretory ducts are rather more contracted than the glandular canals, and ascend, always lined by rounded larger cells, straight through the epithelium, in order to terminate on the surface with rounded

\* According to Fick (p. 91) the Schneiderian membrane has numerous clustered mucous glands.

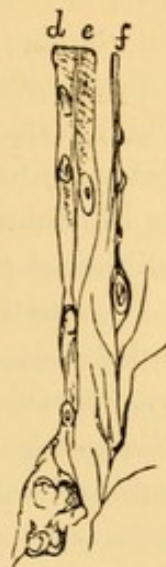

Fig. 3.  
(after Lockhart  
Clarke.)  
Cells of the olfactory region of man. *d*, *e*, the proper epithelial cylinders; *f*, the peripheral rod of the "olfactory cell."

orifices surrounded by a few large cells. The tissue beyond these glands is, as in other regions, soft connective tissue without elastic elements.

The ciliated portion of the mucous membrane, or "Schneiderian membrane," is that part of the mucous membrane which lines the remainder of the nasal cavities. Its structure varies in different parts, though the epithelium is ciliated over its whole extent. We may conveniently divide it into the *thicker* glandular mucous membrane of the proper nasal fossæ, and the *thinner* membrane of the accessory sinuses and of the interior of the spongy bones. Under the ciliated epithelium is a true *membrana mucosa*, wholly without elastic elements, or, at all events, very scantily supplied with them, and composed chiefly of common connective tissue. In the proper nasal fossæ there are embedded in this membrane very numerous larger and smaller racemose mucous glands of the usual kind, so that in places, especially at the borders of the septal cartilages and on the inferior spongy bones, it presents a thickness of 1"—2". The thickness of the mucous membrane of these regions, however, does not depend upon the glands alone, but also, especially at the border and posterior extremity of the inferior spongy bone, upon *abundant, almost cavernous plexuses* in its interior.

In the accessory cavities the glands are probably less numerous, and, according to Kölliker, almost wanting, but in the antrum of Highmore they may be found in great abundance by macerating the membrane in a solution acidulated by nitric acid and afterwards in simple water. Numerous opaque yellowish glands can then be seen with the naked eye, arranged in regular lines on the internal wall of the cavity and more unequally distributed in other parts. Dr. Giraldès describes them as being so close set on the inner wall that five or six may be counted in a space of half a square centimètre (about one-sixth of an inch). (See Giraldès' "Des Cystes Muqueux.") (See Plate I, fig. 3.)

Except in these places the mucous membrane of the accessory cavities is extremely delicate and inseparable as a distinct membrane from the periosteal lining therein; and the same may be said of it in the nasal fossæ themselves, particularly in the glandular parts, notwithstanding the intimate connection of the two. (Kölliker's "Human Histology," vol. ii, p. 417.)

The vessels in the true nasal fossæ are very numerous, less

so in the accessory cavities, where the colour of the lining membrane is extremely pale, and more like a serous membrane in appearance. The branches of the arteries and veins enter into free anastomoses, the veins especially forming a spongiform plexus, most strongly developed along the lower margin and posterior extremity of the inferior turbinated bone. The dilated almost cavernous veins in this region give the mucous membrane an almost erectile character, and render it very liable to alterations in bulk in congested conditions, and especially in the hyperæmia of a common catarrh. There are no true papillæ in the nasal mucous membrane, though the vessels give that appearance, where they form loops and numerous anastomoses. The amount of watery vapour constantly passing from these vascular surfaces is enormous, and according to Bosworth of New York amounts to 16 fluid ounces of fluid in the 24 hours. (See Paper by Bosworth on "Asthma," *American Journal of Medical Sciences*, Sept., 1889.)

The *nerves* are—1. Branches of the fifth pair (ethmoidal, posterior nasal, and a branch of the anterior dental), which supply especially the ciliated region, but also extend to the olfactory region. 2. The olfactory nerves, which supply only the non-ciliated olfactory region. 3. The Vidian and nasopalatine, which supply the septum. 4. The anterior palatine, which supplies the middle and lower spongy bones. The *arteries* are the anterior and posterior ethmoidal, from the ophthalmic; the sphenopalatine, from the internal maxillary; and the alveolar branch of the internal maxillary. The *veins* form a close network beneath the mucous membrane. Some of them pass with the veins accompanying the sphenopalatine artery, and others, through the alveolar branch, join the facial vein; a few communicate with the veins in the interior of the skull, through the foramina in the cribriform plate of the ethmoid bone. (Gray's "Anatomy," p. 582.) The *lymphatics* join the retro-pharyngeal glands (two small glands placed in front of the spine upon the *recti capitis antici majores* muscles) and others beneath the upper part of the sterno-mastoid. (*B. Fränkelin Ziemssen's Cyclopedia*, vol. iv, p. 126, and *Ed. Simon's Jahresbericht*, 1872, i, S. 45.) Some also enter glands situated on the surface and in the substance of the parotid gland. (Curnow's *Goulstonian Lectures on the Lymphatic System and its Diseases*, *Lancet*, 1879, vol. i, p. 833.)



*Physical and Chemical Characters of Nasal Mucus.*—The secretion of the mucosa of the nostrils, or nasal mucus, is the viscid and almost transparent semi-fluid which is familiar to everyone. In health, however, it seldom attracts attention, being secreted in such small quantity, and often drying up so completely, that it only requires to be removed at very long intervals in the form of semi-solid pellets or scales. If collected as a semi-fluid from the nostrils and evaporated, it remains in the basin as a yellow, somewhat glistening and tolerably transparent coating. It contains epithelial cells and a few mucous corpuscles, the latter being rounded granular nucleated cells of about the size of white blood corpuscles, and rendered transparent by the addition of dilute acetic acid, by which reagent their nuclei (from 3 to 5 or 6 in number) are rendered more distinct. It is not soluble in water, but if it remains in contact with that fluid for a considerable time it yields some mucin, in consequence of which, the addition of acetic acid to the water produces a very slight turbidity. It is neutral to test paper, and salt to taste, but is said by Simon to be slightly alkaline.

The following is an analysis of normal nasal mucus by Berzelius. In 1000 parts:—

Water . . . . .	930·7
Mucin . . . . .	53·3
Alcohol extractive and alkaline lactates	3·0
Chlorides of sodium and potassium .	5·6
Water extractive with traces of albumen and phosphates . . . . .	3·5
Soda combined with mucus . . . . .	3·9

Berzelius finds *no fat* in normal mucus, but according to J. E. Bowman, a trace of fat is found, and Simon also gives a small proportion of fat as present in healthy mucus.

The physical and chemical properties of *nasal* mucus do not differ in any important respect from those of the mucus of the bronchial and air passages generally.

From a consideration of the foregoing details, we may realize the admirable adaptability of these fossæ for the purposes of the sense of smell: all the properties and structures of the different parts, and their relative position, and the position of each with regard to other adjacent organs, tending towards the protection of the sense-organ or towards the perfection of its special

function. And here I must notice that the sense of taste owes much more to the olfactory sense than has hitherto been acknowledged, until, indeed, Dr. Wm. Ogle\* pointed out that the idea of flavours is essentially a matter of olfaction and not one of taste. He adduces cases in which, when the sense of smell is entirely lost, all sense of flavours is also lost, though the ideas of salt, sweets, sour, or bitters may still be appreciated; and, on the other hand, shows that when access to the *olfactory regions* by the *anterior nares only* is closed, though there may be no appreciation of flavours or scents of any kind held to the nostrils, yet under such circumstances the flavours of meats and wines are perfectly recognized as long as the posterior nares are in free communication with the pharynx and mouth.

It is probably superfluous to insist on the fact that the olfactory region proper is alone the seat of the organ of smell, but for those who wish for evidence on this point I may refer to M. Deschamp's work on "Diseases of the Nasal Fossæ," pp. 62 *et seq.*, and to Dr. Hippolyte Cloquet on "Osphrésiologie," where the whole evidence is brought forward most clearly and conclusively on pp. 350 *et seq.*

The experiments of Valentin ("De Functionibus Nervorum Cerebrantium," etc., Bernæ, 1839) add still further confirmation of the same point. Two dogs with their eyes bandaged, one having the olfactory nerves and ganglia sound, and the other having had them destroyed, are brought into the neighbourhood of a dead decomposing animal; the former will examine it by its smell, the latter, even if he touches it, will pay no attention to it. This experiment, several times repeated by Valentin, always gave the same results. Hence it is evident that the olfactory region alone, to which only the olfactory nerves are distributed, has the faculty of olfaction.

It is remarkable that the sense of smell is, with very few exceptions, only excited by organic bodies, or the products of their decomposition. With the *inorganic* world the sense of smell has little to do, except, as it would seem, incidentally, as, for instance, when a gas is so powerful and dangerous in its properties that its chemical effect on the olfactory region gives rise to a peculiar scent, in a manner analogous to, and possibly

\* See *Medico-Chirurgical Transactions*, vol. liii, article "Anosmia," on pp. 263 *et seq.*

identical with, that of the electric current. All the other senses are affected equally by the *organic* and the *inorganic* world, but the sense of smell seems specially devoted to the detection of differences in organic substances and their products.\* Few mineral substances, even in a gaseous state, have any smell at all. Ammonia, chlorine, iodine, bromine, nitrous acid, nitric oxide, sulphuretted hydrogen, arseniuretted hydrogen, arsenic, seleniuretted hydrogen, and a few other gases, have each distinct odours, but it is probable that their effect on the mucous membrane of the olfactory region is of a chemical nature, and differs materially from the ordinary process of olfaction. Even among these few instances, we find four at least that may be regarded as commonly derived from the decomposition of *organic* substances, viz., sulphuretted hydrogen, ammonia, iodine, and bromine. The sense of pungency, common alike to strong acid vapours and strong alkaline ammoniacal vapour, is produced probably by irritation of the nerves of common sensation rather than those of smell, and seems designed rather as a protective to the lungs than as a means of discriminating the varieties of odoriferous articles of food.

Professor Graham † seems to be of opinion, that in the process of olfaction, there is always chemical change, and that this change consists in oxygenation of the odorous substance within the nostrils. This theory harmonises well with the fact that odorous substances are derived chiefly from the organic world, and that "odorous substances in general are such as can be readily acted on by oxygen." Chemical action, no doubt, gives rise to sensation on sentient surfaces, and the pituitary membrane is probably affected chemically by those substances that have the quality of pungency, such as ammonia and sulphurous acid; but this is not the kind of chemical change which Professor Graham supposes to be essential to the process of olfaction. He shows that gases which are not capable of oxygenation at ordinary temperatures are inodorous, and gives

\* Butyric acid, *if much diluted*, produces the well-known *disagreeable* smell of tainted butter. If the nose be held over *fresh butyric acid*, and a strong inspiration be taken, there is a sensation of smell which may be described as *pungently acid*. It appears, therefore, that concentrated gaseous butyric acid excites particularly the nerves of common sensation, and, when diluted, those of smell.—Fick, p. 103.

† See "The Senses and the Intellect," by Alexander Bain, M.A. 2nd Edition. London, 1864. Page 168.

two instances in proof of this, viz., carburetted hydrogen, which is found in mines mixed mechanically with oxygen, but uncombined, and hydrogen which is also odourless, and does not combine with oxygen at any temperature endurable by the human tissues.

Of the most strongly odorous gases, sulphuretted hydrogen is a good example, and this is rapidly decomposed by the action of the oxygen of the atmosphere. In like manner, the hydrocarbons, such as the ethers, alcohol, and the essential oils, are all easily oxidizable. It is also shown that certain of the combinations of hydrogen have been actually decomposed in the act of producing smell. Thus when a small quantity of seleniuretted hydrogen passes through the nose, the metallic selenium is found reduced upon the lining membrane of the cavities. The action on the sense is very strong, notwithstanding the minuteness of the dose; there is an intensely bad smell as of decaying cabbage, and the irritation of the membrane causes catarrh.

The last mentioned circumstance points to an irritant action on the pituitary membrane generally, and seems to indicate that the olfactory region is in this instance only secondarily affected in consequence of chemical action, the primary action being an irritation of the nerves of common sensation, and of the mucous surface generally.

Taking into consideration these two features common to most odoriferous bodies, viz. (1), their organic origin, and (2) their ready oxidizability, we may perhaps conclude, that *tendency to change* of a chemical kind is an essential quality of odorous bodies; and it may be that when the tendency is towards the return to inorganic matter, the odour being disagreeable or disgusting repels the animal affected by it, but that, when the tendency to change is in a direction favourable to the assimilability of the product with the animal tissues, the impression on the olfactory organ is of an agreeable and attractive kind. So that foetid and nauseating odours are significant of putrescent change, the advanced stage in the progress of the organic towards the inorganic world, while fragrant, aromatic ethereal, alcoholic, ambrosiac (*e.g.*, musk and amber) and alliaceous odours, indicate only the first stage of this progress, and are significant of the extreme maturity of organic growth immediately preceding incipient decay, rather than of an actual commencement of decay itself.

However much we may hesitate to conclude, from Professor Graham's observations, that olfaction consists essentially in an oxygenation of the odorous substance, and in the stimulant effect of that chemical process upon the sentient nerves of the olfactory region, we may yet look hopefully upon this theory as the germ of a rational classification of odours. Professor Graham has already shown with regard to taste, that a certain class of mineral substances (the sesquioxides of the metals) can be placed in a class as sapid substances, viz., as sweet; possibly odorous substances may be capable of classification in a similar way as fragrant, foetid, aromatic, etc., according to their chemical constitution. At present the only attempts at classification of odours have been based on conjecture or the merest fancy, and have been utterly useless for scientific purposes.

A theory entirely opposed to that of Professor Graham, which may be called the chemical theory of olfaction, is that propounded by Dr. William Ogle, who has suggested the idea that odorous impressions may be the result of vibrations, basing his views on the fact that pigment is present in the olfactory region, and that this pigment is essential to perfect olfaction. Admitting Dr. Draper's views as to the absorption of luminous vibrations by the choroidal pigment to be correct, may not a similar function, he asks, attach to the pigment of the nose and ear? (*Medico-Chirurgical Transactions*, vol. liii, pp. 289 and 290.) It is reserved for future physiologists to solve this difficult problem.

A classification of odours based upon the chemical qualities of odorous matters, offers a prospect of overcoming the great difficulty which metaphysical classifications will always present. Whether an odour be agreeable or offensive will depend upon individual idiosyncrasies, and these are often the result of the association of ideas. An odour that may be agreeable to most persons, may from some accidental association of ideas in an individual affected by it, be most repulsive to that individual. The child who has been cajoled into taking medicines by the pleasant odour of some aromatic vehicle will henceforth have a special aversion to that particular scent. So a perfume may become repulsive from the circumstance of its having been used by a person whose character or appearance is disagreeable to us from some other cause, the two ideas of the scent and

the repulsive person being on all future occasions indissolubly connected.

The essential conditions for olfaction are the following:—

1. The nervous apparatus of olfaction must be perfect. The centre of olfaction (probably situated in the first temporo-sphenoidal lobe, according to Dr. Ferrier), the olfactory tracts and bulbs, and the nervous expansion on the olfactory region within the nostrils must be healthy and without breach of continuity. According to Dr. Hughlings Jackson, it is probable that *both* sides must be in the normal condition, for anosmia, or loss of the sense of smell, is, according to that physician, *usually double*.

2. The odoriferous matter must be conveyed to the olfactory region.

Numerous experiments show that no sense of smell is excited by the presence of highly odorous vapours in the sinuses leading to the nostrils, the olfactory region being artificially excluded, nor in the cavity of the nostrils when the olfactory nerves have been destroyed.

3. The mucous membrane of the olfactory region must not be too dry.

4. The mucous membrane of this region must not be too moist.

5. In mammalia and birds, and probably in reptiles, the odorous matter must be brought to the olfactory region in a state of vapour, or at least in a state of very fine powder. In *fishes* the sense of smell is exercised upon substances dissolved *in water*. In their case, therefore, the only apparent difference between smell and taste is that the mechanical and vital apparatus of the two functions are situated in different regions.\* But it is important to note that, the nervous distribution being

\* The odorous matters are contained in the water; but in what form—whether dissolved in the same manner as the gases absorbed by water—is uncertain. The solution of these matters in water is clearly no reason for denying the sense of smell to fishes, or for placing the sense of taste in their nares; for the essential characteristic of the sense of smell consists, not in the gaseous nature of the odours, but in the special sensibility of certain nerves, and in its difference from the sensibility with which the nerves of taste are endued. The matters of odours also must in all cases be dissolved in the mucus of the mucous membrane before they can affect the olfactory nerves, and their state in the mucus must be the same as that in which they are contained in water.—*Müller's Physiology of the Senses*, p. 1312.

different in these two regions, we must look for some difference of function. Mr. Herbert Spencer suggests that this difference consists in the adaptability of the olfactory region to the detection of gases held in solution in the water, while the gustatory surface deals only with the saline and crystalloidal substances. The former, therefore, can perceive odorous substances at a greater distance on account of the more rapid and extensive diffusibility of the gaseous substances through the water, as compared with the slower diffusibility of the sapid substances, sweets, sour, bitters, and salines. Certain it is that sharks and other fishes seem to be able to smell animal substances at long distances, and to be attracted powerfully by odours that can only reach their olfactory regions dissolved in or diffused through the element in which they live. Aristotle's view was as follows:—He regards *smell* as standing midway between touch and taste on the one hand, and sight and hearing on the other. It resembles taste, in that odour is to the one what flavour is to the other; but it differs from both taste and touch in being carried on through a medium that intervenes, *whatever that medium may be*, instead of by contact with the object. The *medium* Aristotle finds it difficult to determine. It is something without a name, common to air and water. (*Psychology*, ii, 11, 12.)

6. The *nutrition* of the mucous membrane of the nostrils generally, and of the olfactory region in particular, must be good, and as an essential part of the nutrition the pigment of the olfactory region must be unimpaired. (See Section on Functional Derangements of the Sense of Smell.) Various circumstances, such as inflammation, catarrhal swelling, or excessive secretion of mucus, will interfere more or less with the perfection of the sense, and the excessive dryness of this region, in cases of injury or disease of the fifth pair, leads to a greatly diminished *acuteness of smell*, as well as to a total loss of *sensibility to irritants*, such as pungent vapours, snuffs, etc.

7. In animals, living in air, the sense of smell is rendered more acute by rapid *movement* of the odorous emanations across the sentient surface, and some amount of movement of the odorous matter is essential to the production of a sense of smell. The reason why rapid inspirations should increase odorous impressions is not so evident as might at first consideration appear. No doubt the current of air is drawn

towards the olfactory region; but some other condition must be fulfilled, inasmuch as Bidder has shown that when air, charged with odorous matters, is directly injected through a tube in the nares into the olfactory region, at most a very faint impression is created. Rapid inspirations must, therefore, have some other action which is necessary to perfect the sensation, and it would appear that the inferior turbinate bone plays an important part in this latter respect. Absence of this bone results in very decided diminution or even suspension of the power of receiving odorous impressions. The presence of this bone would appear, therefore, either to facilitate the passage of odorous materials to the sentient surface or to increase the irritability of the olfactory fibrils. It has been supposed to act as a kind of dam and to direct the current of air towards the roof of the nose. Some authorities have thought that the folds of mucous membrane belonging to the bone serve to divide the current of air into fine streamlets, while, according to another view, the bone narrows the nasal passages and causes the air to enter under increased pressure. The author would suggest that, in addition to other possible effects, the mucous surface of the bone warms and moistens the air-currents, and thus renders odorous materials more capable of perception. Frequent and rapid inspirations through the nose must tend to change the air in the upper parts of the cavities.

8. *Warmth* favours the impression of scent. This is probably due to the increased rapidity of the *volatilization* of the odorous matter.

Next, considered as a part of the *respiratory apparatus*, the nostrils offer in the first place a *double aperture*\* for the admission of air, and the nasal cavities present several different structural peculiarities, evidently designed to ensure the admission of air suitable for respiration, and to prevent the admission of gases or pulverised solids into the lungs and air

\* The utility of a *double aperture* and *two* olfactory regions is not apparent. The perfection of the odorous impressions is, as far as we know at present, as perfect when one nostril is occluded as when both are free and patent. When we contrast this with the phenomena of vision there seems an unaccountable discrepancy. Binocular vision not only gives greater *acuteness* of vision, but also renders the impression of *solidity*. Does bi-rrhinal afford any corresponding advantage over mono-rrhinal olfaction? Possibly the doubleness of the nasal organ has reference chiefly to its importance as a part of the respiratory apparatus.



passages :—*a.* The vibrissæ, or fine hairs, at the entrance of the nostrils catch all the coarser particles floating in the air. *b.* The moist and sensitive ciliated mucous membrane catches any finer particles, and by the secretion of mucus entangles them and ultimately extrudes them. *c.* Irritant gases or vapours excite the nutritional and sensory nerves of the ciliated region, and sneezing and a flow of sero-mucus are at once set up, the pain and irritation at the same time exciting voluntary efforts against the further respiration of the offending gas. *d.* The sense of smell placed in the direct current of inspiration warns us against gases or air tainted with foul or putrescent odours, and so likely to be injurious to the whole system as well as the lungs. *e.* The great extent and complexity of the mucous surface, largely supplied with freely anastomosing blood vessels, warms and moistens the inspired air.

Thirdly. The nose may be regarded as part of the *mechanism of expression*. And in this aspect we note that its frame-work is partly bony and immovable, viz., that formed by the nasal bones, the vomer, the perpendicular plate of the ethmoid, and nasal processes of the superior maxillary bones, and partly cartilaginous and movable, viz., that formed by the superior lateral, lower lateral, and sesamoid cartilages at the sides and by the septal cartilage internally. Though, however, the upper bony portion of the framework is immovable, the skin covering it is capable of some amount of motion, and is actually moved by the subcutaneous muscles, and thus the whole external organ is a very important part of the organ of expression.

The muscles are the *pyramidales nasi*, continuous with the fibres of the *occipito-frontalis*, and descending on either side to become blended by a tendinous expression with the *compressor naris*; the latter being a small thin triangular muscle arising by its apex from the superior maxillary bone (a little above and external to the *incisive fossa*), and inserted into a thin aponeurosis which is attached to the fibro-cartilage of the nose, and continuous on the bridge of the nose with the muscle of the opposite side.

The levator labii superioris alæque nasi, the dilatator naris posterior, the dilatator naris anterior, the depressor alæ nasi, and the compressor narium minor, are all described in detail in anatomical works. All these muscles are supplied by the facial nerve.

The *skin of the nose* is thin, and loosely connected with the subjacent parts on the dorsum and sides, but is thicker and more firmly adherent at the tip and lobes and alæ. It is furnished with a large number of sebaceous follicles, especially at the furrow between the alæ and cheek, and along the curved outline of the alæ. As the skin passes into the interior of the nostrils, it becomes thinner and furnished with numerous hairs (*vibrissæ*); as it advances into the nostrils proper it loses its cuticular epithelium, and becomes covered with soft, ciliated mucous cells, at the same time also losing its cutis vera and subcutaneous areolar tissue.

Even viewed as an organ of expression, the sense-organ cannot be disregarded. We see in the characteristic expression of disgust (without perhaps any physical cause for the mental attitude) the habitual movements by which a foul or offensive odour is repelled. The mouth is closed, the nostrils expanded and the alæ raised, and an expiratory effort is made, as if to thrust from the olfactory region the offending odour. In animals (especially in those gifted with highly-organized olfactory organs, *e.g.*, the dog, and other hunting carnivora) the nostrils, when raised and expanded, indicate attention and vigilance. So, too, in man, the connection between the respiratory function and the nostrils leads to a habitual movement of the latter, associated with a mental condition primarily affecting the thoracic viscera, but finding its expression partly in the face. Anxiety and expectation quicken the breathing and the heart's action, the nostrils rapidly expand and contract, for the purpose of admitting as full a stream of air as possible. Thus an expression of anxiety and expectation is depicted on the countenance, involuntarily, automatically, and as a consequence of the *associated movements* of the nostrils, as part of the respiratory apparatus, with those of the more essential parts of the same apparatus.

Fourthly. The nasal fossæ and sinuses have an important effect on the tone (*timbre*) of the *voice*. If the voice passes unobstructed through the nasal cavities it has the ordinary or normal tone, but if the posterior nares are cut off from the pharynx by voluntary raising, firm closing of the soft palate, or by swelling of the parts, a peculiar modification of the voice is produced, and M. Lespagnol\* seems to have proved that

\* Lespagnol, "Dissertation sur l'Engastrinisme," Paris, 1811.

ventriloquists produce their peculiar effects by a forcible closing of the posterior nares by elevating and fixing the soft palate against the back of the pharynx. The reverberation of the vocal sounds in the sinuses seems to have a somewhat analogous effect to that produced by the fossæ of the os hyoides in the howling monkeys (*Cebus Seniculus* and *Cebus Beelzebut*).

The effect on the voice of partial obstructions of the posterior nares is well known in ordinary catarrh, in which there is a peculiar thickness in the articulation; and the sounds of *m* and *n* are specially altered into the sounds *b* and *d*: thus, *nose* is *doze* and *music* is converted into *boozic*. The same kind of thickness and indistinctness of utterance is observed in cases of *adenoid vegetations* and in other diseases causing *nasal stenosis*.

Besides the four different functions of the nose already considered, a fifth subsidiary and incidental one is the modification of sound conveyed from the mouth to the ear, due to the intervention of spaces and cells containing air between the teeth and the auditory apparatus; and also the diminution of shock and vibration on the brain during mastication, due to the same arrangement.

The *psychological* aspect of this sense requires a passing notice. There is no other sense so intimately associated with *memory*. *Ideas* that have occurred to the mind simultaneously with certain scents are often recalled to the mind automatically, as it were, after long intervals of time by the accidental presence of the same scent. The association of ideas or mental images with peculiar scents seems to affect animals, and especially dogs in a remarkable way. The dog seems to have so acute a perception of odours which to us are unrecognizable, that he can smell out his master among a crowd of other individuals even after the lapse of a considerable period of time, and "The Autocrat of the Breakfast Table" (Oliver Wendell Holmes) thinks there is a physical reason for this strange "connection between the sense of smell and the mind." The olfactory nerve is, as he remarks truly, the only one directly connected with the hemispheres of the brain. To speak more truly, the olfactory "*nerve*" is not a *nerve* at all, but a part of the brain in intimate connection with its anterior lobes.

#### THE VITAL PROPERTIES OF THE NASAL FOSSE.

The vital properties of the nasal fossæ direct their actions and regulate them even in the conditions of disease. Sensitive-

ness is a vital property of the nasal fossæ under three forms:—

1. Nutritive sensitiveness, or reflex irritability. This is the property of all organs and parts of the body, but it is more developed in the mucous membranes of the eye, nose, mouth, and the secreting glands than in the general surface.

2. Common sensation, or tactile sensibility. The nasal cavities possess this in common with the surface of the skin, but probably in a less degree than the lips, tongue, and hands, but have sufficient acuteness of sensation to resent the intrusion of foreign bodies or irritant gases.

3. Special sensation, viz., smell; this property being confined to the olfactory region already described.

By virtue of nutritive sensitiveness, a secretion of lymphoid or mucous fluid constantly lubricates and moistens the surfaces and cavities of the nasal fossæ, and thus renders them fit for the reception of odorous impressions. In the normal condition the liquid exhaled is diffused as vapour in the air traversing the nasal passages, and is so carried away by it that it would at first sight appear to be altogether absent; but if any irritation is set up in the nostrils, as for instance by plugging them with lint, or *charpie*, or by taking snuff, the liquid increases rapidly, and soon runs down in a stream if the irritant cause is persistent.

The discomfort occasioned by excessive dryness of the nostrils, whether produced by a sharp attack of inflammation, or by rapidly inspiring cold dry air, is a sufficient demonstration of the utility of the secretion of fluid as it exists in health. On the other hand, impaired function is produced by an excessive secretion of moisture, as in the case of common catarrh, in which it is probable that the ends of the nerve fibres, which in the normal condition come into actual contact with the odorous particles, are so bathed in moisture that olfaction is rendered impossible. The altered character of the secretion in catarrh and in the different forms of coryza gives rise to much irritation of the mucous membrane and the skin of the aperture of the nostrils, but the true cause of this changed condition is not yet sufficiently demonstrated. It probably depends upon the presence of ammonia.

The mucous glands in the pituitary membrane exude a stringy, transparent, and inodorous fluid; this becomes thicker

on exposure to the air, and if not got rid of by blowing the nose, as when secreted in rather large quantity during the night, becomes hard, and often dries into the form of crusts, moulded upon the surfaces whence they have been secreted.

#### THE DEVELOPMENT OF THE NOSE.

The external nose in the foetus, and in children, is much less prominent and more flattened out than in the adult, and, in consequence of the absence of the frontal eminences and sinuses, it forms with the forehead a much more acute angle: the depressed line, in the profile of the infant, being replaced in the adult by a more or less prominent one.

The nasal fossæ are relatively smaller in size, and much less complex than in the adult, and the whole olfactory apparatus is later in coming to maturity than the senses of hearing and sight; their vertical diameter is remarkably small, the sinuses being not yet formed, and the lateral masses of the ethmoid being still cartilaginous. The cribriform plate of the ethmoid, at birth, is a mere membranous plate continuous with the falx cerebri of the dura mater, and attached behind to the partially ossified body of the sphenoid. The vertical plate of the ethmoid is cartilaginous at this period, but the vomer is already ossified; some months after birth the nasal fossæ extend in all their diameters, and the different sinuses are developed. At the age of two years the frontal sinuses and ethmoidal cells have begun to form, and the hollowing out of the antrum Highmorianum goes on simultaneously. The antra appear as cavities at an earlier period than any other of the sinuses, the development commencing about the fourth month of foetal life, and at birth have a rounded form, which later on becomes irregularly pyramidal. In a foetus at about the seventh month of gestation, though there were no traces of the ethmoidal or sphenoidal or frontal cells, the antrum was large enough to hold a split pea, but had its walls in contact nearly in its whole extent. Its cavity therefore presented a flattened irregularly ovoid shape. The greater part of the upper maxillary bones was at this time cartilaginous in this foetus, and the cribriform plate of the ethmoid and its vertical plate were also cartilaginous. The sphenoidal cells are the latest to make their appearance, and are often not yet formed at the period of birth.

It is obvious that this late development of the central por-

tions of the base of the skull provides in the first place for a certain amount of mobility in the bones during parturition, and especially in the antero-posterior or long diameter, but also to a certain extent transversely; so that the head in the course of its passage through the maternal structures is compressed laterally and in an antero-posterior direction, and elongated vertically without injury to the parts. This would be impossible if the parts were perfectly rigid. The partially cartilaginous condition of the ethmoid and sphenoid has the effect of a hinge upon which the parietals and frontals move laterally, and the occipitals and frontals in the opposite direction. A second object attained by this flexible and compressible condition is, that the alteration of bulk of the surrounding bones and cavities in the process of growth, can go on without any rigid impediment in the centre, and the full development of the soft tissues, and especially of the nerves, is possible without the risk of compression by the encroachment of bony deposits on the channels for their transmission.

On the other hand, it is probable that the late development of the bone in this region occasionally favours the formation of tumours and outgrowths in the nasal and orbital cavities, and that some of the malformations of the face are due to arrest of development of these parts during fœtal life.

## SECTION II.

## A. PRELIMINARY REMARKS ON RHINOSCOPY AND DIGITAL EXPLORATION OF THE NASO-PHARYNX.

*Methods of Cleansing the Mucous Membrane as a preliminary to Rhinoscopy.*

BEFORE employing rhinoscopy we must ascertain that the mucous membrane is free from secretions or discharge of any kind.

Hence it is often desirable to use the syringe or nasal douche (fig. 6) before attempting to examine the nostrils. Slightly warm water, with a little carbonate of soda or common salt in it, is less irritating as a douche than pure water. The simplest form of douche is that known as the syphon douche (fig. 4). The nozzle is made of vulcanite, and is perforated by a single hole. It should be made to fit the nostril exactly. The syphon end of the tube is placed in a jug or basin of solution at some height above the patient's head, and the water is drawn down by suction into the nostril. The water will now continue

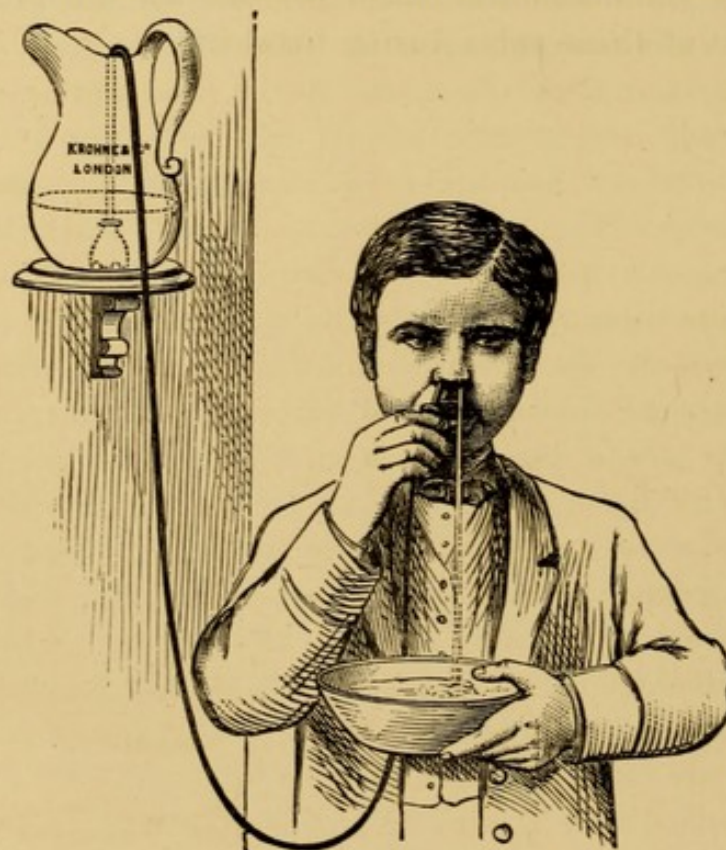


Fig. 4.

to flow until the jug is emptied, and the force of the stream can be varied by varying the height at which the jug is placed. If the patient be instructed to keep his mouth open, and breathe entirely through his mouth, the stream of water will find its way from one nostril to the other without passing down the pharynx, and the two nostrils will thus be subject to a continuous cleansing stream. If desired, the current can be reversed by putting the nozzle into the opposite nostril, and allowing the water to escape by the one through which it at first entered.

Higginson's syringe can easily be converted into a most efficient nasal douche by having one of the douche (soft rubber) nozzles fitted to it; for many cases it will only be necessary to use an ordinary syringe to the front part of the nasal fossæ, or to snuff up some warm saline solution from the palm of the hand, and very often the use of the handkerchief will be sufficient.

Mr. Chas. Wray has invented a very useful modification of the syphon douche. It allows of "starting" the flow through the nozzle by blowing down the shorter tube, and so avoiding the inconvenience of drawing the stream into the nostril by suction (fig. 6).

It must not be assumed that the douche is necessary or even desirable in all cases of rhinitis with obstruction. Dr. Rumbold, of St. Louis (see "St. Louis Medical and Surgical Journal" and "The Chicago Medical Journal and Examiner" of 1872), has used a spray of vaseline heated to liquefaction, and combined

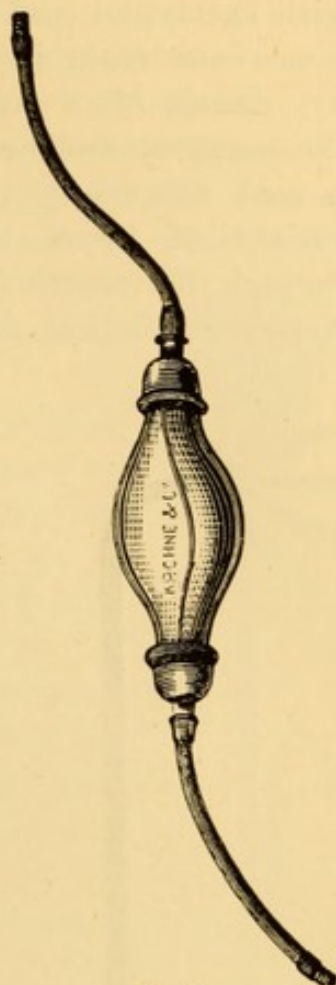


Fig. 5.

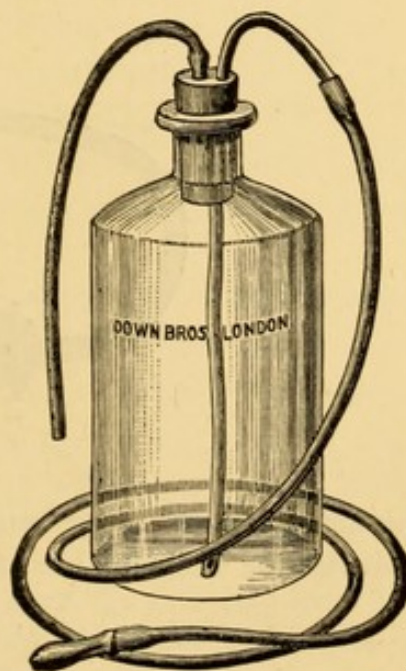

Fig. 6.

Wray's Syphon Douche-bottle.



with eucalyptol and gualteria mixtures, and alternated with pinus canadensis in glycerine. The hot vaseline is applied by means of a spray apparatus specially designed for the purpose, and used according to Dr. Rumbold's method, is said effectually to cleanse the nasal fossæ in a great variety of forms of rhinitis. The spray is introduced through the mouth into the naso-pharynx ("Journal of the American Medical Association," January, 1889. Article by

Dr. Ely McClellan), and if the spray appears anteriorly, the fact of the nostril being unobstructed is clearly demonstrated. This is the more necessary in those very common cases in which the septum has a lateral deviation, and generally whenever the parts near the choanæ can be only feebly illuminated.

Whether used for cleansing purposes or therapeutically, the fluid employed should always be warm, of a temperature varying from 95° F. to 100° F., and some saline substance should be in solution, pure water

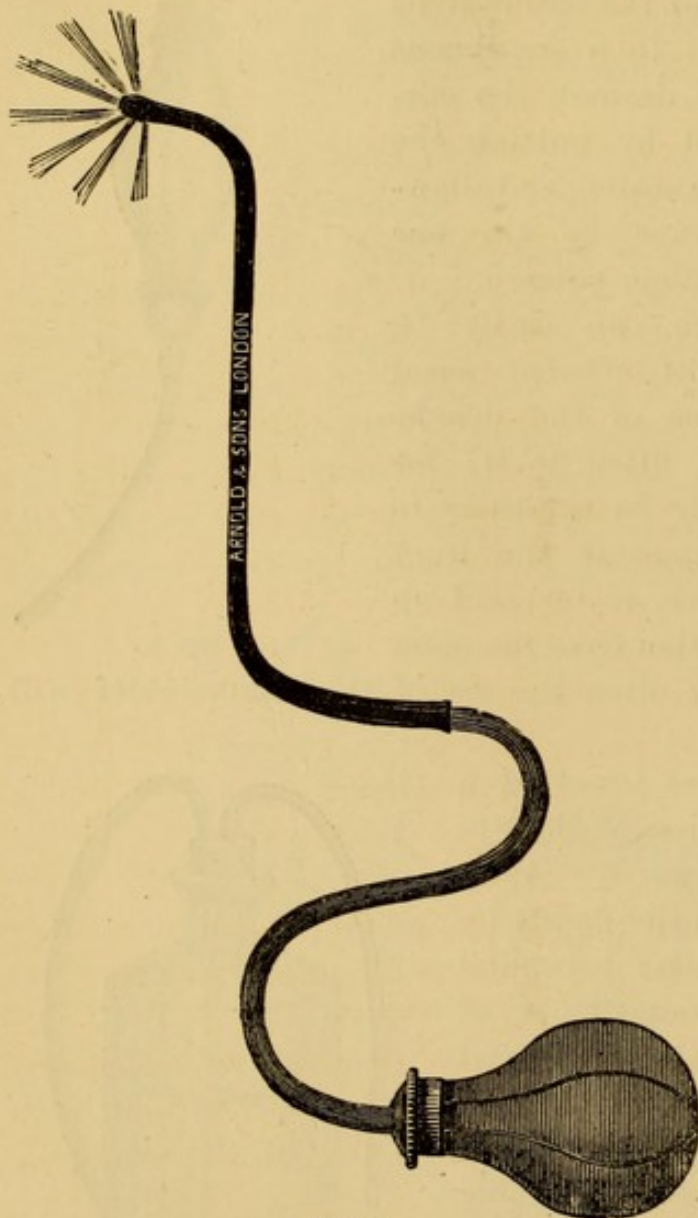


Fig. 7.

being much more irritating to the mucous membrane than a solution of bicarbonate of soda, or common salt, or borax.!

*Method of Cleansing the Nostrils before Posterior Rhinoscopy.*

When the posterior nares are to be examined, and the channel is too much obstructed by growths or hypertrophy to

allow of the employment of the douche, the post nasal syringe should be used (see fig. 7), passed through the mouth and behind the soft palate. But Rumbold's syringe (see fig. 8) for the posterior nares is more effectual and less difficult of application if the obstruction in the anterior nares will allow of its being passed along the floor of the nose till it reaches the choanæ. In either case Sajous' solution is a very efficient cleansing lotion for this purpose (see Section on Chronic Hypertrophic Rhinitis).

*Best Methods of Illumination.*—For inspection of the nostrils the most perfect light (next to sunlight,\* which, when obtainable, is by far the best) can be derived from the use of a Welsbach gas-burner. This light is perfectly steady and white, and when concentrated on the parts under examination by means of a concave six-inch-focus-mirror illuminates them as well or better than an ordinary glow electric light such as is supplied with the Trouvé photophore lamp. The Welsbach gas-burner should be fitted on a double-jointed Morell Mackenzie bracket (see fig. 9). I also think highly of the *albo-carbon gas-light*, arranged as used by Dr. Sajous, of Philadelphia (see Sajous' "Lectures on the Diseases of the Nose and Throat," fig. 5, page 6), but there are certain practical objections to this light. It must be lighted for about half-an-hour before use, the perfection of the light being unattainable until the receptacle has become thoroughly heated, and under certain conditions an unpleasant odour is given off.

*For anterior rhinoscopy* we require that the *frontal concave mirror* should be attached by a ball-and-socket joint to a spectacle frame, and that it have an oval central perforation,

\* The chief objection to sunlight is its uncertainty; the next is the varying angle at which it strikes the operator's room at different seasons of the year and different hours of the day. This last objection can be overcome by the use of a *large plane mirror* set on a stand, to which it is fixed by a central ball-and-socket joint. The sun's rays can by reflection from this mirror be rendered horizontal, no matter at what altitude the sun may be at the time. I have had such a mirror, with a diameter of one foot, in use for some years, and have often found it very efficient for the purpose indicated.




Fig. 8.

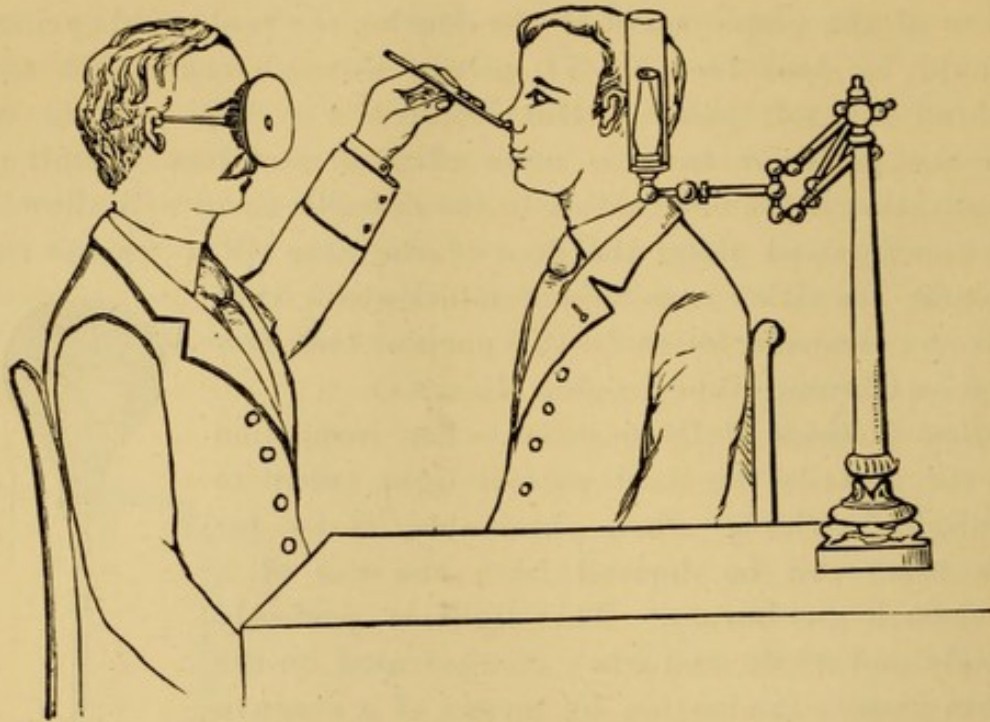


Fig. 9.

through which the observer looks. The eye of the observer is thus exactly in the central line of the converging focus of light-rays, and is in the most favourable position for seeing the deeper parts of the nostril. When direct sunlight is available a plane mirror, also with a central perforation, may be substituted for the concave mirror. If the mirror be attached to a head band, the ball-and-socket joint must be attached to a stem to allow the mirror to come down to a level with the surgeon's eye. The mirror on the spectacle frame is more suitable for rhinoscopy than that fitted with a head band. The observer's eye should be on a level with the observed nostril, and the surgeon should sit on a lower chair than the patient, in order to obtain the full advantage of the reflected image.

The lamp should be behind the patient and a little to his left side, and on a level with the ear. The rhinoscopist sits in front of and somewhat to the left of the patient (see fig. 9).

In anterior rhinoscopy the patient's head should be directed forwards, and the tip of his nose tilted upwards by means of a nasal dilator (Spencer Watson's). After this view has been examined, the head may be inclined first forward, and at the same time the upper lip drawn




Fig. 10.  
Watson's  
Nasal-  
dilator.

downwards. By this manœuvre a view of the floor of the nostril is obtained, the roof of the nostril can be viewed to a slight extent, and the anterior part of the middle turbinated bone can be seen. Several different kinds of specula should be provided. Goodwillie's trivalve, Duplay's, Metz's, Schuster's, and Fränkel's are all good. It is also well to provide several probes, set in handles, and a few of *Watson's stylets*\* for applying cocain on cotton wool. This is a much more convenient way of anæsthetizing the nostrils than that by the spray bottle. It is also well to have a syphon douche, or other douche-apparatus, and some warm antiseptic solution for cleansing the parts. Cotton wool (dry) on the above stylets is also required for cleansing purposes in some cases.

The other essentials are two or three basins with hot antiseptic solutions, into which the instruments must be placed immediately after using, and spray apparatus for applying medicated solutions. Napkins, handkerchiefs, and towels should be supplied in abundance. Under favourable circumstances, the healthy mucous membrane can be seen directly backwards for a distance of an inch and a half or two inches, the smooth, flat surface of the septum on the inside, and the rounded surface of the anterior part of the inferior turbinated bone and the inferior meatus on the outside, all the surfaces being of a uniform rosy tint, and slightly moist. When the head is tilted backwards the anterior part of the middle turbinate is also seen.

The extent of mucous membrane visible from the front varies very much, according to the capacity of the nasal fossæ. Czermak states that in one instance, in which the nasal cavity was very capacious, he succeeded in getting a view of the posterior part of the pharyngo-nasal cavity. The inferior turbinated bone and the inferior meatus are, in ordinary cases, visible to the depth of one-third of an inch from the orifice, and a much larger portion of the septum comes easily into view. In order to confirm or correct the visual impression conveyed by the view obtained near the hinder orifice through the anterior

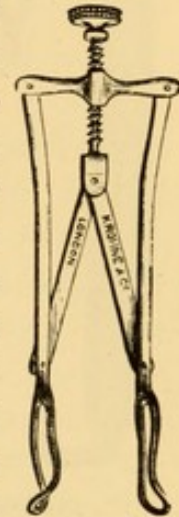


Fig. 11.  
Fränkel's  
Speculum.

\* These stylets are made (by Messrs. Wright, of Bond Street) of about six inches in length, and finished off with the worm of a screw at the free end, on which the cotton wool can be wound and securely fixed.

nares, and to make sure whether or not the pharyngeal aperture

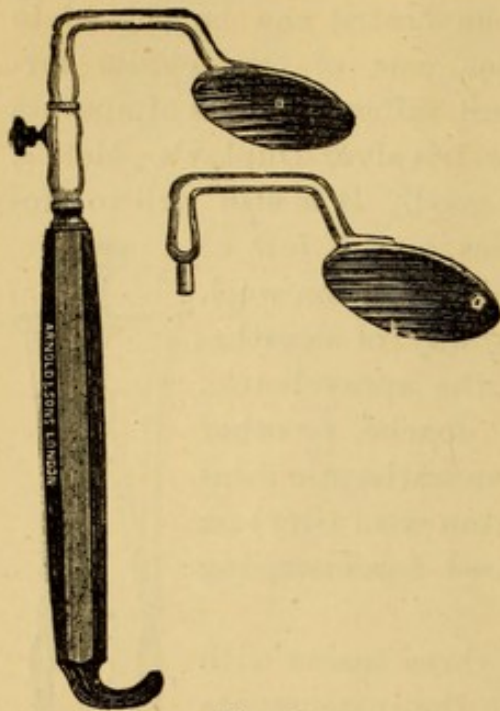


Fig. 12.  
Turck's Tongue Depressor.

is within view, the patient should be directed to articulate the vowel sounds. The muscles of the soft palate are thus thrown into play, and, if there be no obstruction towards the pharyngeal orifice, will be seen in action by the observer. This confirmatory evidence is of great value when polypi have been removed and when others are suspected to be lying in the deeper parts.

For *posterior rhinoscopy* the following additional requisites should be ready:—

1. A tongue depressor. Rum-

bold's or Türeck's rectangular tongue depressor may be used indifferently. After being placed in position either can be kept there by the patient if he is intelligent and well under control (see fig. 12).

2. Faucial rhinoscopic mirrors in handles of two sizes.

3. A *spray bottle* with solution of cocain.

4. An india rubber stout thread (or, still better, staylaces that have been steeped in mucilage and dried) of about one foot or 18 inches long. These are intended for passing through the nostrils into the pharynx and out through the mouth, and used to draw forward the soft palate when it cannot be brought forward by other means.

5. Palate-hooks are seldom of any use. If any palate-hook is employed, that invented by Dr. White, of Philadelphia, and made by Messrs. Down Bros., is the most likely to be effectual. The best method of getting the soft palate forward, with which I am acquainted, is to make the patient respire rapidly and as if "panting for breath." He should not, however, take deep inspirations, and his *attention* should be directed




Fig. 13.  
White's Palate-hook.

to his chest movements and *not* to his throat. When this method does not succeed cocaine should be applied, and it may then be possible to use palate-hooks. For posterior rhinoscopy the patient's head should be above the level of the rhinoscopist's, and he should, therefore, sit on a chair about two inches higher during the examination.

*Methods of Illumination.*—The lamp employed for posterior may be the same as that used for anterior rhinoscopy. It is manifestly inconvenient to change the kind of illumination in the middle of a sitting. Or we may employ the electric light to illuminate the posterior nares with advantage. With this light the mirror can be fixed on the forehead, and thus we have the advantage of the use of both eyes for examining the image on the faucial mirror. It is often possible, however, to get a clear image of the posterior nares with precisely the same mirror and means of illumination as those described for anterior rhinoscopy, viz., a Welsbach gas-burner and a 6-inch focus concave mirror (see Plate I, fig. 1). Semon's laryngeal electric mirror (made by Schall) is also exceedingly good for posterior rhinoscopy when the pharynx is capacious (see fig. 14).\*

For the purpose of *median rhinoscopy*, Voltolini and Rumbold use small mirrors set on stems and introduced along the floor of the nostrils with a view to obtaining by double reflection a view of the lateral and upper walls of the cavity. They are rarely employed, but may sometimes be useful for examining the hollow under the tip of the nose immediately within the vestibule (see fig. 15).

For examining the naso-pharynx and the deeper parts of the nares through the anterior aperture, Zaufal's speculum is required. It consists of a tube terminating anteriorly in a funnel-shaped orifice. Zaufal's tubes are made in three sizes to suit the requirements of particular cases. The orifices of the Eustachian tubes can be viewed by this means.

*Anterior Rhinoscopy with Light Transmitted from Behind.*—Cresswell Baber describes an ingenious method of



Fig 14.

\* It is, however, not altogether free from danger. A lamp of this kind, on a recent occasion, cracked and flew to pieces—fortunately, however, before it had been introduced into the throat.

anterior rhinoscopy with transmitted light. It was devised and recommended by Voltolini. The observer inspects the nasal cavity from the front whilst an assistant illuminates the naso-pharynx by holding a rhinoscopic mirror in the ordinary position and concentrating a strong light upon it. Mr. Cresswell Baber has simplified the method by attaching the rhinoscopic mirror to Trouve's electric photophore, and thus enables the observer to do without the aid of an assistant. Schall's photophore (see fig. 14 supra) and mirror will no doubt answer the same purpose.

*Palate Hooks.*—In posterior rhinoscopy palate hooks can rarely be used unless the parts have been anæsthetized by cocaine. White's palate hook is the best (see fig. 13 supra). That described by Rumbold is also good.


*Method of Tying Forward the Velum.*—The best method I am acquainted with for drawing the palate forward mechanically is that advised by Störk, Wales, and Bosworth, and introduced into this country by Mr. Walsham, though in a slightly modified form. White cords (those sold as stay-laces answer well) are prepared by steeping them in mucilage and allowing them to dry. They are then firm but flexible rods. One of these cords is passed through the anterior



nares, and when it reaches the pharynx is seized by forceps and drawn through the mouth. The two ends are then gently but firmly pulled forwards and held by an assistant while rhinoscopy and any subsequent operation is performed.

*Author's Method of Controlling the Palate.*—The mechanical methods, however, are all inferior to that of directing the patient to *breathe rapidly in short gasps*, and at the same time diverting his attention from his throat and concentrating it on his chest movements. This is a method suggested by myself, and often succeeds when other plans have failed.

In case of failure by this method, it is sometimes possible to get a good view of the posterior nares by leaving the patient without any instructions whatever. The velum may then assume a vertical position spontaneously. In other cases a favourable position is assumed when the patient attempts to blow or hiss through the nose. In others the pronunciation





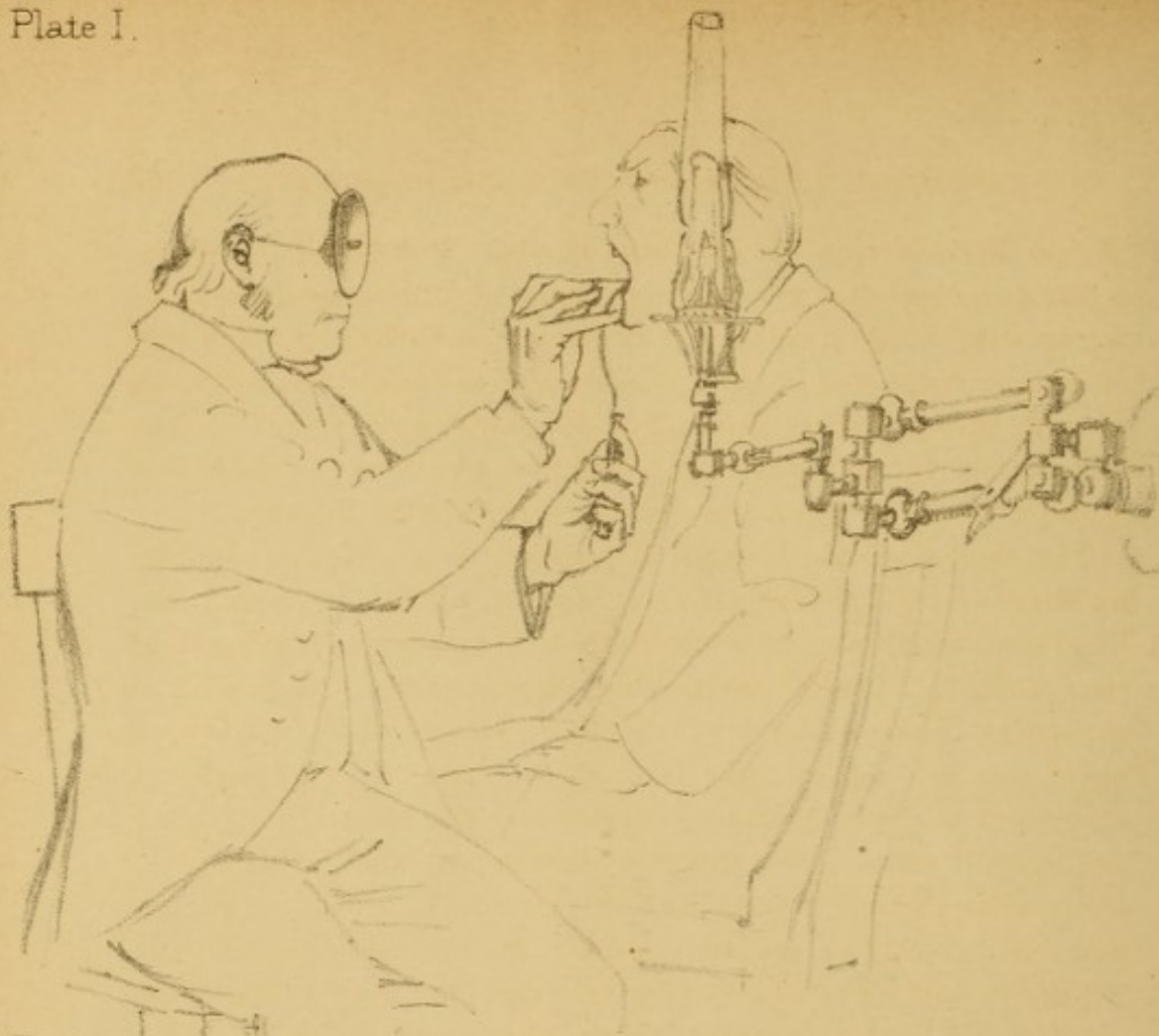


Fig. 1

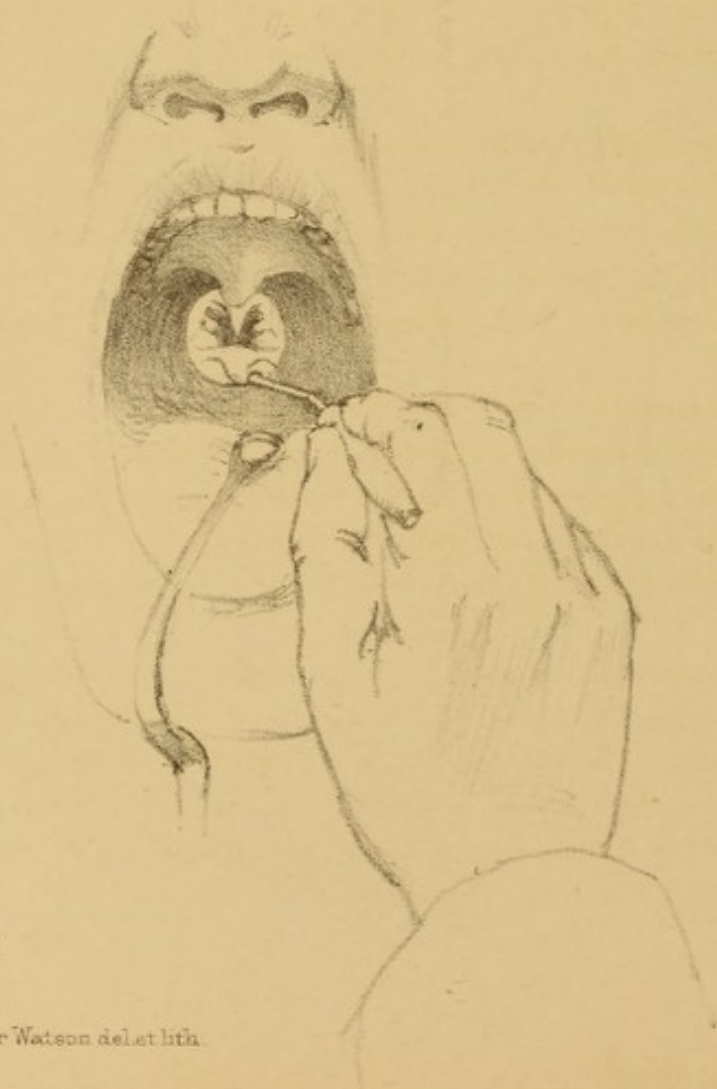


Fig. 2

of the French nasal vowel *en* succeeds. The *tongue*, however, is the principal obstacle in many cases, and its spasmodic arching resists most forcibly all attempts, whether the tongue-spatula is employed or not. If, after several trials and intervals of rest, this obstinate arching of the dorsum continues, it may be subdued by firm pressure continued for thirty seconds or a minute, until the rigid muscles are overcome by fatigue.

The tongue should be kept in position by a rectangular long-handled spatula (Rumbold's or Türck's, see fig. 12 supra), the handle of which can be sometimes left to the management of the patient. Under favourable circumstances, and with a capacious pharynx, the turbinated bones, the two upper meatuses, the septum, the roof of the pharynx, the posterior surface of the velum, and the orifices of the Eustachian tubes, can be well seen. The superior turbinated bone is often only seen indistinctly. According to Czermak, it is sometimes possible to see the posterior aspect of the nasal bones and the under surface of the lamina cribrosa (the view being taken parallel with the septum), when the nasal fossæ are very capacious.

The relative positions of the patient and surgeon are shown in Plate I, fig. 1, and the position of the faucial mirror in fig. 2.

To those who are not accustomed to the use of the rhinoscope, a good idea of the anatomical relations of the posterior nares and their general appearance is gained from the figure (Plate II, fig. 2) taken from a view illustrating Professor Czermak's treatise (New Sydenham Society's Translation, p. 77.)

When attempts at posterior rhinoscopy fail (as they very often do in young children and persons with narrow pharynges and spasmodic tongues or palates), *digital exploration* may succeed in giving a certain amount of information.

*Digital exploration of the choanæ* may be carried out as follows:—

1st. The patient is seated on a low chair, if an adult, with the surgeon behind him, the patient's head resting against the surgeon's chest. (If the patient is a young child its best position is on the nurse's knees and with its head on the surgeon's knees, the latter sitting facing the nurse, who must control the child's movements.)

2nd. The mouth must be kept open by a firm, resisting gag. A ready form of gag is made by thrusting a portion of a folded towel between the molar teeth. It can be held in position by an assistant or by the surgeon's left hand.

3rd. The forefinger of the right hand is passed rapidly behind the soft palate, and the tip of the finger turned upwards and forwards in the direction of the choanæ. Choking spasmodic movements are almost inevitable. It is better to withdraw the finger if they are severe, and then again introduce it to complete the examination after a short interval of rest.

The roof, walls, and sides of the naso-pharynx can be explored at the same examination.

## B. PRELIMINARY REMARKS ON NASAL STENOSIS.

The term *nasal stenosis* is a convenient one. It implies a narrowing or occlusion of the nasal passages from any cause, either within or without. Turgescence of the vascular membrane over the turbinated bones, temporary (as in catarrh) or permanent (as in chronic hypertrophy), hypertrophy of the turbinated bones, the presence of polypi or other growths, adenoid vegetations of the naso-pharynx, tumours or abscesses or cysts of the adjacent cavities, congenital or traumatic deflections or distortions of the septum, congenital adhesions of the lateral walls or anterior or posterior apertures, cicatricial adhesions after injuries, the presence of foreign bodies, are some of the principal causes of *nasal stenosis*. Several of these causes of stenosis may coexist in the same case. There may, for instance, be chronic hypertrophic rhinitis with polypi; distortions of the septum with polypi; hypertrophy of the bony structure of the turbinated bones with deflection of the septum and polypi; papillomata of the turbinated bodies with polypi; chronic rhinitis and consequent temporary "stenosis" from turgescence with any form of permanent "stenosis." Hence it is not sufficient to have discovered one form of obstruction, such as a polypus, in order to form a complete diagnosis, the polypus being in many cases only a late development of a primary "stenosis" of a more serious kind. Nor is it sufficient to have discovered hypertrophy of the turbinated bones, which is often only part of a general narrowing of the nasal fossæ, and that from a variety of different causes. The symptoms vary as the obstruction is partial or complete, one-sided or bilateral, tem-

porary or permanent. When incomplete, the breathing through the nostril is noisy and "snuffling," giving rise to the common term "snuffles," as in the coryza of infants; and this symptom in infants at the breast is associated with more or less difficulty in taking the breast. The incomplete form in these cases going on to complete occlusion, "sucking" becomes impossible. In all cases of complete stenosis "oral" respiration is observed, and gives a peculiar and characteristic expression to the face of the sufferer. If unrelieved, this complete stenosis in children and young adults leads to further complications. The "nasal voice," or inability to articulate the *m* and *n* sounds, which are replaced by the *b* and *d* sounds, is noticeable from the first. The breathing at night is "snorting" and sonorous, and is sometimes associated with fits of choking, especially in the cases due to naso-pharyngeal obstruction. Later on the chest becomes laterally contracted. The child or youth is "pigeon-breasted." He is delicate and liable to pulmonary and bronchial complications. He is often considered dull and stupid, and unable to concentrate his attention on his studies (aprosexia), and his growth is often stunted. Not uncommonly, attacks of *asthma* are superadded to his other troubles, or he becomes subject to *hay-fever*. One or other of these two maladies may last on to adult life or even old age. According to Bosworth, of New York, even partial and unrecognized stenosis may be the cause of asthma or hay-fever, and the cure of these depends essentially on the removal of the obstruction from any of the usual causes of stenosis. Among the other symptoms of stenosis, anosmia, or impaired sense of smell, is always noticed in adults, and is associated with impairment of taste or the perception of flavours.

Rhinoscopy and digital exploration are the principal means of *diagnosis*, and local *treatment* is all-important for the relief or cure, as will be shown hereafter (see Section V, Sub-section 1, on Nasal Polypi; Section III, Sub-section 3, on Strumous Rhinorrhœa; and Section VII, on Adenoid Vegetations of the Naso-pharynx).

### C. PRELIMINARY REMARKS ON FŒTOR OF THE NOSTRILS.

No symptom is so distressing to the patient and those about him as fœtor of the breath. It is important, therefore, to dis-

tinguish the sources from which the breath acquires its bad odour. The odour may come from the mouth, when the nostrils are closed, and it is then important to determine whether it proceeds, as is so often the case, from decayed teeth, or from the naso-pharynx, or from the larynx, or trachea and bronchial tubes. All these parts, and (in cancerous disease) the œsophagus also, may give rise to offensive breath. The diagnosis can only be determined by rhinoscopic and laryngoscopic examination, the parts being viewed—firstly, before the use of antiseptics and deodorants, and, secondly, after they have been thoroughly cleansed by antiseptic sprays and gargles. Two or more causes may coexist, and it is then less easy to decide which part is chiefly at fault, but the presence of secretions of a mucous or purulent character in the naso-pharynx will be conclusive as to this part being one source, at least, of the bad odour. The nostrils will then be examined with the mouth closed, and the odour, if present, is evidently due to naso-pharyngeal or intra-nasal disease. When the odour is slight or imperceptible to the surgeon, the patient himself may yet notice it, and it is then due to one of two causes. It may proceed from the discharge escaping intermittently from one of the accessory cavities (as in abscess of the antrum), or it may be due to “subjective” causes, such as are sometimes observed in “epileptics” and in cases of intra-cranial disease involving the olfactory nervous centres.

Should it proceed from discharges from the accessory cavities, the examination of the nostril after first cleansing it, and then placing the patient's head in a downward position (as described in the article on Diseases of the Antrum), will generally give evidence of the presence of a fœtid discharge in the position corresponding to the source of the mischief, *i.e.*, in the middle meatus if the case be one of disease of the antrum, or frontal sinuses; and in the naso-pharynx if the discharge is from the sphenoidal sinus or posterior ethmoidal cells.

If, however, the fœtor is perceptible to the surgeon at once, the inspection of the nostrils will reveal the usual signs of rhinitis with retention of secretions (described under the head of Ozœna and the various forms of rhinitis). The stench of ozœna proper is characteristic and very easily recognized, and is remarkable from the fact of its extending into the air around the patient for several yards, and for its persistence

often after the use of powerful antiseptic douches. The odour from caries or necrosis within the nostrils is quite as offensive, but less penetrating, and can be palliated or removed completely by antiseptic douches; that from rhinitis caseosa is so strong as to be described by Cozzolino as intolerable, and in the two cases that have come under my observation I can confirm this description. In one of them, while removing some polypi complicating rhinitis caseosa, I was so much affected by the stench that I could with difficulty restrain myself from vomiting. Yet in this case, after the free use of antiseptics and the removal of the malodorous contents of the nasal fossæ, the stench entirely ceased.

The same thing occurs in cases of supposed ozæna due to retained and decomposed crusts of mucus. Free douching and the removal of the dry crusts completely removes the fœtor. The removal of diseased bone and foreign bodies also frees the nostrils of the offensive odour.

When the larynx, trachea, or œsophagus are the sources of the odour the laryngoscope will show ulcerative disease involving cartilage or bone, and in some cases open cancers; and in these cases the nasal and pharyngeal or oral lesions will be absent. I think it probable that in all cases of fœtor from the nostrils some form of parasitic micro-organism is present, and Hajek of Vienna has intimated that the *bacillus fœtidus* is the essential and specific cause of the odour of true ozæna, cultivations of this bacillus giving a similar odour in the cultivated growth. He states that the coccus of Friedländer also exists sometimes in the discharges of ozæna (*Berlin Klin. Woch.*, 1888, No. 32).

#### D. PRELIMINARY REMARKS ON THE DISCHARGES FROM THE NOSTRILS—(1) LIQUID, (2) SEMI-SOLID (3) SOLID.

(1.) Liquid—*a*, clear fluid; *b*, turbid or mucoid; *c*, mucopurulent; *d*, purulent; *e*, blood; *f*, sero-sanguineous or sanious.

(2.) Semi-solid—*a*, viscid mucus; *b*, clots and serum; *c*, clots and pus; *d*, cheesy.

(3.) Solid—*a*, mucoid crusts; *b*, dark greenish or yellowish crusts; *c*, diphtheritic membrane; *d*, blood-crusts; *e*, rhinolithes or chalky concretions; *f*, sloughs and sequestra; *g*, entomozoaria or parasites.

The nature of the nasal discharge is often an important factor in the formation of a diagnosis of nasal diseases, and the changes in their character at different stages give valuable indications of the progress of the disorder either towards recovery or aggravation. It would be difficult to lay down any precise description of the amount of moisture passing from the nostrils in health. There is a considerable physiological variation in almost all individuals according to the variations of the atmosphere, whether the air is moist, dry, hot, or cold. It may be laid down that any moisture that escapes from the nose so frequently or so copiously as to be troublesome to the person affected, is pathological and abnormal. Perhaps a rough test is the number of pocket-handkerchiefs required in the day. Copiousness is the chief irritative quality, offensiveness is the next, and discoloration is the next most significant abnormality.

(1.) *a. Clear fluid* is only abnormal as a discharge when it is so copious as to come away in drops and at frequent short intervals, or when it comes away in a stream on lowering the head, or placing it to one side. If the flow is from one nostril only, the conclusion is that its origin is from one or more of the sinuses communicating with the nostril so affected. It must not, however, be concluded that because the clear fluid discharge comes from one nostril only that its source is therefore one of the sinuses or the antrum. Fourteen cases of *nasal hydrorrhœa* have been collected by Bosworth, and the conclusion at which he arrives is, that the excessive flow of clear fluid (whether from one nostril only or from both) is most frequently the result of lesions of the trifacial, and that in another class of cases the sympathetic nerve is over-stimulated; basing his theory on the observations of Dr. Julius Althaus. (See *Med. Chir. Trans.*, vol. lii, p. 39.) The fact that polypi are sometimes associated with the hydrorrhœa does not clearly establish the connection between the two phenomena as cause and effect, and it seems not improbable that the polypi when present may be a consequence of the hydrorrhœa rather than its cause. There is also a possibility of the fluid being cerebro-spinal, and that it escapes through a fissure in the cribriform plate of the ethmoid. That such an origin is the true one can only be after a severe injury, and as a consequence of a fracture of the base of the skull. The microscopic and chemical

analysis of the fluid will aid in the diagnosis. The known qualities of the cerebro-spinal fluid, and its specific gravity, may be conclusive, but cases have occurred in which the distinction between the two possible sources of the flow has not been quite so clear as it might be thought. The specific gravity of the serous effusion in chronic catarrh of the antrum is so low and its other chemical characters so closely resemble those of the cerebro-spinal fluid, that from analysis alone diagnosis is still doubtful. (See Sir James Paget's "Case of Polypi of the Antrum," *Clinical Society's Transactions*, vol. xii, p. 47, alluded to below in Section on Antrum.) The history of a recent injury is a much safer guide to a correct diagnosis.

b. Turbid or mucoid fluid indicates simple catarrh, which in its various stages may become, (c) muco-purulent, or (d) purulent, though in the latter condition it is probably due to specific purulent infection, especially when it occurs in newly-born infants. When the discharge is bloody or sero-sanguineous, there is probably ulceration of the membrane at some part, or some accidental injury has caused a temporary lesion. The separation of crusts of dried mucus often gives rise to this form of discharge. (Epistaxis is treated of in Section V, Sub-sect. 2.)

(2.) The *semi-solid* viscid secretions in their various forms indicate a chronic catarrh, such as is observed in hypertrophic and atrophic rhinitis.

(3.) *Dry crusts* of a dirty greenish, or yellowish colour, are also commonly discharged in all forms of chronic rhinitis, and are often the cause of obstruction and fœtor from their long retention in the nasal fossæ. They require active treatment for their speedy and frequent removal, by means of douches and antiseptic sprays or lotions used by means of the injecting syringe. c, *Diphtheritic membrane* in the nostrils is one of the symptoms of diphtheria, the disease sometimes commencing in this cavity. The swelling of the whole of the lining membrane rarely allows an inspection, but the irritating quality of the sanious discharge, and the excoriation of the upper lip, are characteristic; and when the glands behind the angle of the jaw and along the posterior border of the sterno-mastoid are found enlarged and tender, the diagnosis of intra-nasal diphtheria is clearly arrived at. The appearance of shreds of membrane after syringing the nostrils with antiseptic solutions



confirms the suspicions of the true nature of the case. *d*, *Rhinolithes* or *chalky concretions* are found as moulds of the lower or middle meatus and sometimes attain large dimensions. They are accompanied by a foetid sanious or purulent discharge, and may give rise to a suspicion of necrosis or caries. *e*, Sloughs of mucous membrane occur in glanders and diphtheria, and also after the application of caustics or the actual cautery. They may be mistaken for dry crusts of mucus, but on placing them in water their fibrous character and tenacity at once distinguish them from mucus, which after soaking becomes easily disintegrated. Sequestra of bone, the results of injury or disease, can only be confounded with rhinolithes by very careless observers, but the possibility of both forms of solids being associated in the same case must be borne in mind. Rhinolithes occupy the lower and presenting parts of the nostril, whereas sequestra from caries or necrosis proceed from the deeper parts, and have a characteristic worm-eaten, or spongy surface when detached. Both of these solid discharges may be accompanied by excessively offensive sero-sanguineous liquid or mucoid discharges, and occasionally by epistaxis. *Rhinolithes* sometimes have as their nucleus a foreign body around which mucus and layers of phosphates are closely agglutinated into a hardened mass. *f*, Entomozoaria in the nostrils appear to be of common occurrence in some parts of India, and this affection, known as *Peenash*, is alluded to in Section V.

## SECTION III.

THE VARIOUS FORMS OF CATARRH OF THE  
NASAL FOSSÆ.

- SUB-SECTION 1. Simple Catarrh. "Cold in the head."  
 „ 2. Chronic Post-nasal Catarrh, American Catarrh, Naso-  
 palatine Gland Disease (Sir Andrew Clark), or  
 "Follicular Disease of the Naso-pharyngeal Space"  
 (Beverley Robinson).  
 „ 3. Strumous Rhinorrhœa.  
 „ 4. Syphilitic Coryza.  
 „ 5. Dry Catarrh.  
 „ 6. Rhinitis Atrophica and Ozæna.  
 „ 7. Rhinitis Caseosa.  
 „ 8. Diphtheritic Rhinitis.

## SUB-SECTION 1.

*Nasal Catarrh : its Pathology, Causes, Symptoms, and Treatment.*

THE first stage of catarrh in the mucous membrane of this, as of all other regions, is that of *hyperæmia*. The perifollicular blood-vessels become congested and the adjacent tissues swollen by increased flow of blood. This is followed by hypersecretion of the follicular glands, and the result is a *lymphadenitis*. The secretion, at first mucous in character, soon assumes a suppurative form, and a *suppurative follicular lymphadenitis* is thus induced.

*Causes.*—Cold applied to the surface is the cause commonly given for "catching cold." This cause alone, however, is obviously insufficient in a healthy condition of the system. The *circulation* must be *feeble* in the individual who suffers, and the *nervous tone* lowered by insufficient or faulty nutrition. It is impossible, without taking into account the different vitality of different individuals, to account for the fact that persons exposed to the same atmospheric conditions will be affected so differently as we commonly observe them to be. Ill-fed children and delicate women will suffer severely from this troublesome and common affection, while healthy and robust adults entirely

escape. The lowered vitality of the former renders them unequal to the effort of equalizing the circulation in the part irritated, and the consequent congestion and inflammatory swelling of the mucous membrane is the result.

To the irritant effect of cold there is often superadded another source of irritation, viz., the suspension in the atmosphere of foreign particles of soot and foul gases; and hence the frequency of catarrh in the London fogs so prevalent during the autumn and winter. The closely-allied condition, *epidemic catarrh* or *influenza*, is attributed to altered states of the atmosphere, whether from excessive proportion of ozone or from some low organisms of a vegetable kind. But the excessive and early nervous prostration in this form of catarrh points to a much more general blood-poisoning of the system than in the simple form. Nevertheless, it is probable that common sporadic catarrh may be due to the absorption of a small dose of the same kind of poison which in a larger dose and more widely spread might give rise to an epidemic of influenza.

Dr. Weber, of Halle, affirms that the excitant of disease in influenza is a fungus which was discovered some years ago to exist in nasal secretions. *The Times*, January, 1890.

While, however, the common catarrh partakes of the character of influenza, it also resembles another form of nasal catarrh, viz., hay-fever, and as this latter affection has been almost demonstrated to depend upon the presence of low vibrio-like\* organisms in the nasal mucous membranes, we have, in this circumstance, another reason for supposing that some similar cause is in operation in the production of the similar train of effects here observed.

Chemists and druggists find that the inhalation of chlorine vapour produces nasal catarrh very rapidly, and Professor Schönbein was affected in the same way by inhaling ozone. The inhalation of the powder of ipecacuanha and of tobacco are also occasional causes of catarrh. Any irritant, such as common snuff, will produce similar temporary catarrh, and it is easy to conceive that a continuous irritation, as from breathing damp fog loaded with minute particles of coal-dust, soot, and irritant products of combustion will produce a lasting impression, and give rise secondarily to the constitutional disturbances associated with the local inflammation.

\* See Professor Binz on Hay Fever, *Practitioner*, April, 1874, p. 269 et seq.

According to M. Cloquet ("Osphrésiologie," p. 601), the most common determining cause of this affection is coldness and rawness of the atmosphere and sudden changes from warm to cold air. "Nothing," he says, "is more evident at Paris and London, where the temperature is most variable."

Dampness and cold applied to the feet are also supposed to have a peculiar influence in producing ordinary catarrh.

*Symptoms.*—The subjective symptoms of catarrh are well known: a general feeling of lassitude, with aching of the limbs and back, and perhaps violent sneezing, is soon followed by a sense of stiffness and obstruction in the nostrils and region of the frontal sinuses; the sense of smell is impaired, and taste suffers at the same time; then follow coryza and the associated use of the pocket-handkerchief. The hearing is sometimes affected from the associated inflammation or congestion of the pharynx. If the catarrhal inflammation has extended to the adjacent sinuses, there will be headache and aching pains about the cheeks or orbit, and should the nasal duct be involved, obstruction of the tear passages and, perhaps, lachrymal abscess or mucocele may result. The obstruction to breathing through the nostrils renders the voice muffled, and gives rise to the well-recognized "nasal voice," or difficulty of pronouncing the *m* and *n* sounds. The disinclination for exertion and feeling of *malaise* are now greater than before. Occasionally an eruption of herpes appears on the upper lip, about the third or fourth day after the commencement of the fever. The skin having from the first been dry, after the first day or two becomes abnormally hot. Thirst and loss of appetite are generally associated with this train of symptoms. If the discharge from the nostrils continue unchecked, it assumes a more tenacious consistence and yellow colour, as if from admixture of pus with the ordinary mucus. At this stage there is greatly increased debility, and the nose and eyelids and adjacent parts become much swollen, and the eyes appear congested and have an overflow of lachrymal secretion.

*Characters of Mucus in Catarrh.*—The secretion during a catarrh being at first thinner than the healthy mucus, of course contains a larger proportion of water during the early stages of the complaint; later on it becomes thicker, in consequence of the increase in the number of mucus corpuscles. The reaction is alkaline, and generally more strongly so than in health; the

fat is increased, and contains cholesterin, and there is an excess of albumen.

According to Hueten, micrococci of a characteristic form are found in catarrhal mucus, and he considers them as the essential cause of the coryza. Hajek (*Berlin Klin. Woch.*, 1888, No. 32) states that acute coryza is often accompanied by the presence of bacilli, and among them the streptococcus pyogenes and the staphylococcus pyogenes aureus.

The following analysis of nasal mucus, in a man *æt.* thirty years, is given by Dr. F. Simon. It came away in the form of thick, tough yellow lumps, and was only discharged from one nostril. It was devoid of odour, alkaline, and, moistened with water, exhibited an extraordinary number of epithelial and a few mucous cells, connected by a pretty thick membrane of coagulated mucus. In 1,000 parts :—

Water . . . . .	880·0
Solid constituents . . . . .	120·0
Fat containing cholesterin . . . . .	6·0
Caseous matter, with pyin or mucin in solution . . . . .	13·2
Extractive matters with lactates and chloride of sodium . . . . .	12·0
Albumen, cells, and coagulated mucus	84·0

The clinical features of the case, from which the above analysis was derived, point to a somewhat peculiar condition and are not those of an ordinary catarrh, but the increased proportion of fat and albumen and the increased alkalinity have been observed in the mucus of catarrh of the common kind. Gruby and Simon have observed in nasal mucus during a common cold, "large cells, which had eight times the diameter of blood corpuscles, consisting of a delicate transparent capsule and an inner round cell with a nucleus twice as large as a blood corpuscle." These were found in the gray or yellow streaked gelatinous mucus from the air passages and the nostrils.

In very severe catarrhs with some amount of inflammation of the mucosa, the mucus has a yellowish colour and loses its transparency, or has its transparency mottled or streaked with lines or masses of a yellow colour. This is due to an admixture of pus with the mucus; but the microscopic features of this modified mucus are not materially different from those of healthy or catarrhal mucus, the pus corpuscle being very similar to the

mucus corpuscle, and behaving in a similar way with reagents. If any *considerable* quantity of pus is mixed with the mucus, it may be detected by the tests for albumen; the liquor puris containing a much larger proportion of albumen than ordinary mucus, and therefore giving much more decided evidence of its presence on the addition of nitric acid or the employment of the ebullition test.

Nothing very satisfactory has been made out as to the chemical changes in nasal mucus, to which its irritating qualities are attributable. We sometimes find in the course of a catarrh that the upper lip and margins of the nostrils become reddened and excoriated. This may be partly due to an extension of the hyperæmia and swelling of the mucous to the cuticular membrane, but it is probably due in part to some irritating quality in the secretion. The increased alkalinity alone would seem hardly sufficient to account for this, and it is probable that it undergoes some other changes, with the nature of which we are as yet unacquainted. If the discharge has continued for a long period, it will become fœtid and offensive in many persons, and in a few it will have this character from the first; thus constituting what is termed simple or *accidental ozæna*; but the odour in these cases is very different from that in constitutional ozæna.

In the scrofulous, this long-continued discharge may be succeeded or accompanied by superficial excoriations of the margins of the nostrils and the upper lip, and both these parts become swollen and red. The adjacent parts of the cheeks, too, are often irritated by the flow of the foul discharge, and an eczematous eruption may then make its appearance, and not yield to treatment till the disease in the nostrils has subsided. As a rule, however, in healthy persons this malady ceases in a period varying from a few days to a fortnight, the swelling of the mucous membrane subsides, the discharge ceases, and a healthy condition is restored.

*Complications.*—Swelling of the lymphatic glands beneath the sterno-mastoids, over the parotid and in its substance, retro-pharyngeal abscess, mucocele, dacryocystitis, polypus, abscesses in the frontal sinus, or antrum of Highmore, pharyngeal troubles, and obstruction of the Eustachian tubes are all possible complications of severe or repeated attacks of ordinary catarrh. Extension of inflammation to the chest or larynx is also a

possible complication, and not very uncommon in neglected "colds in the head."

*Treatment.*—A cold is difficult to cure because few people will submit to the restraint and regimen necessary for cure, and very few place themselves under medical treatment at all for what is often considered a trivial, if a troublesome, ailment. There is, nevertheless, some aid afforded by the judicious use of warmth, quietude, careful dieting, and sudorific medicines. In a few cases, especially in spare people with languid circulation and chilly extremities, a common cold can be cut short by a dose of laudanum, and in some cases Dr. Sidney Ringer has found frequently repeated doses of tincture of aconite effectually stop the progress of a common cold. The inhalation of carbolic acid is sometimes very soothing, if used in the following formula, known as Dr. Hagner's Olfactory, highly spoken of by Dr. Brand in the *Berlin. Klin. Wochenschrift*:—

R Acid. Carbolic . . . . .	gr. v.
Sp. Vin. Rect. . . . .	℥ xx.
Liq. Ammoniaë . . . . .	℥ v.
Aq. Destill. . . . .	℥ x.

"A few drops to be used for inhalation on a cone of bibulous paper."

The inhalation of menthol and eucalyptol is equally pleasant and efficacious in all stages.

Many remedies have been brought forward for the relief and cure of catarrh during the last few years. Among these "Ferrier's snuff" holds a prominent place. It consists of a powder of white sugar, bismuth and morphin. acet. (gr. iv to 1 oz.). It gives considerable relief in many cases. With this, cocain, hydrochlor, may be combined in the proportion of 2 grs. to the ounce. The mere application of a solution of cocain (5 to 10 per cent.) also gives great relief in the hyperæmic stage. Salicylate of soda given internally in gr. x or gr. xv doses is a most valuable remedy, but requires careful watching, as in some persons a full dose is apt to give rise to faintness and disturbance to the stomach. I have also great confidence in full doses of quinine given the last thing at night. Two or four grains of the sulphate or hypophosphite may be given at bed-time and smaller doses during the day. At the same time warm baths and suitable sudorifics with rest in bed and avoid-

ance of exposure to cold will materially cut short the attack in most cases.

Among other remedies salicylic acid in fine powder combined with subnitrate of bismuth used as a snuff is said to be a speedy and reliable remedy in this troublesome ailment.

The following formula for a snuff is given by J. Moure in his treatise on "Maladies des Fosses Nasales" (p. 45) :—

Chlorhydrate de Cocaine . . . . .	15 or 20 Centigr.
Chlorhydrate de Morphine . . . . .	5 „
Benzoin pulvérisé . . . . .	25 „
Trisnitrate de Bismuth pulvérisé . . . . .	10 grammes.

To be used as a snuff occasionally during the day.

According to Dr. McClellan, of Chicago, the hot vaseline spray, combined with eucalyptol and gualteria, is very useful in all forms of nasal catarrh (see p. 31, preface). Dr. McClellan states that the results in his hands have been "invariably good," and that "he has abandoned the water douche entirely." "The applications should be made at intervals of from 12 to 24 hours, until the severity of the symptoms is relieved, and then every second or third day as necessity demands."

Periodate crystals used both as a snuff and given internally are also credited with having great influence in checking catarrhal symptoms, and especially in epidemic influenza (Dr. O'Connor, *Med. Press and Circular*, January, 1890).

Sulphate of atropia in doses of  $\text{mss}$  to  $\text{mii}$  of the *Liq. Atropiæ* is valuable in arresting the progress of coryza (Dr. Gentilhomme, *Practitioner*, December, 1882, p. 456).

Many other remedies besides those enumerated have been extolled as efficacious, and the difficulty of choosing from among them is therefore great. Multiplicity of remedies in this, as in other diseases, implies either a tendency to spontaneous recovery without remedies or a doubtful efficacy of many of the remedies themselves.

In persons subject to this form of nasal catarrh, it is often possible to check the tendency by improving the diet and keeping up the general circulation by warmer clothing, and avoiding exposure to cold and wet; at the same time taking care to enforce healthful exercise in the open air, and the avoidance of everything likely to disturb the digestive and assimilating functions.



## SUB-SECTION 2.

*Post-nasal Catarrh, Retro-nasal Catarrh, or American Catarrh.*

Whether this form of chronic nasal catarrh should be described as being pathologically distinct from ordinary chronic catarrh is a disputed point. I am inclined to regard it as a climatic\* variation of ordinary catarrh. Beverley Robinson describes it as a distinct affection under the name of "*Follicular disease of the naso-pharyngeal space.*" Sir Morell Mackenzie and many other specialists of equal authority give in their adhesion to the view that there *is* such a disease having special characters of its own, and widely disseminated over the American continent. Dr. Bosworth, on the other hand, regards it as merely a form of nasal catarrh, and states that the *pharyngeal* is always associated with disease of the *nasal* mucous membrane. The first English physician to call attention to this form of pharyngeal catarrh was probably Dr. Dobell, who read a paper on "*Post-nasal Catarrh*" at the Abernethian Society of St. Bartholomew's Hospital in 1854. Sir Andrew Clark ("London Hospital Reports," vol. i, p. 1860) also describes a similar, or probably the same, disease under the term *naso-palatine gland disease*, which he describes as follows:—

The glands of the mucous membrane in the naso-pharyngeal region are very numerous in the neighbourhood of the posterior nares and the Eustachian tubes. Sir Andrew Clark † describes them "as racemose, saccular, and compound follicular. The place of each is indicated by a slight prominence, in the centre of which is a round, thick-lipped opening. This opening leads to a general cavity, with communicating recesses. In health they secrete a yellowish viscid mucus, which has the power of converting starch into sugar. They are subject to three kinds of morbid change. 1. The production of an excessive quantity of viscid mucus. 2. The formation and discharge of pus-like fluid. 3. Retention of either of the foregoing in the cavities of the glands, and its conversion into fœtid, cheesy

\* Under the term "*climate*" I should include not merely the variations of temperature, of moisture, and what is generally denominated "*weather*," but also its secondary effects on the inhabitants, such as social habits, dress, food, habitations, and also its tertiary effects, such as "*racial*" temperament, physical conformation, and powers of endurance.

† See "*London Hospital Reports*," vol. i.

masses, which are from time to time extruded through the nose or mouth. The symptoms are discomfort, aching, or pain in the neighbourhood of the soft palate and posterior nares; tingling or sense of fulness about the root of the nose; frontal headache; a mawkish or fœtid taste in the back of the mouth; a thick mucous, purulent or cheesy secretion discharged at intervals, chiefly through the mouth, by means of snorting nasal inspirations, followed by hawking; slight perversions of taste and smell; alterations of voice; sometimes temporary deafness from obstruction of one or both Eustachian tubes; and an abundant secretion of wax in the external ear. The presence of the disease is demonstrated by the rhinoscope." Sir Andrew Clark has found that some benefit is derived from the following plan of treatment. First he directs the patient to irrigate the posterior nares with a solution of chlorate of potash, by snuffing up the solution through the nostrils, the level of the nostrils being placed under that of the solution. He then applies a strong nitrate of silver solution with a camel's-hair brush on a stem properly curved for the purpose; and lastly, again irrigates the parts with solutions of tannin and alum. The results of treatment are, however, not always very satisfactory, the disease being very obstinate, and resisting treatment for a long period. Constitutional remedies do not seem to have much influence over the local affection. I look upon this disease as closely allied to, if not identical with, the chronic pharyngeal catarrh described by Beverley Robinson as Post-Nasal Catarrh.

Assuming for the moment that there is a clinically distinct affection included under the above designations, the essential physical changes may be briefly described as a mamillated condition of the anterior wall and vault of the pharynx with a thickening of the membrane covering the posterior third of the septum (Solis Cohen and Beverley Robinson). This appearance can be discovered by the rhinoscopic method and by digital exploration. Examined by digital exploration, the mamillations are felt as a roughened surface, which gives to the finger a sensation like that of Russian leather (Beverley Robinson).

Whether the conditions above described are to be regarded as pathognomonic of chronic post-nasal catarrh is somewhat doubtful, for some American physicians, who recognize the disorder as a distinct form of chronic catarrh, are silent as

to the peculiar mamillated surface of the naso-pharynx and the thickening of the septum.

The treatment is that of ordinary catarrh modified by local conditions. 1. By spraying with the post-nasal spray tube for several days every three hours with an alkaline spray containing menthol, eucalyptol, and gualteria (Warner's pastilles dissolved in hot water) until the viscosity of the mucus is reduced, and the parts become less coated. 2. I then use the post-nasal syringe, with a more stimulating lotion, containing iodine and carbolic acid, with borax, until a healthier condition is produced. It is sometimes necessary to employ a douche, but not often, and only when the crusts encroach on the nasal fossæ and cause much obstruction to nasal breathing. The treatment may extend over many weeks or months, and consequently a variety of remedies may be necessary as the aspect of the pharynx changes. 3. The use of solution of nitrate of silver, applied by means of the throat brush, in strengths of gr. iii to f.  $\bar{3}$ i, or up to gr. x to f.  $\bar{3}$ i, is very efficacious in the later stages, and this should be applied night and morning. 4. Hazeline as a spray is also useful in the later stages. Meanwhile, the constitutional treatment of catarrh and change of climate will do much to complete the cure. The internal medicines recommended by American physicians are—(1.) *Cubebæ* in powder, three grains in syrup of ginger and water, taken after meals; or the *oleosin*, 15 drops on a lump of sugar, three times a day, after meals (Sajous). (2.) *Ammoniacum*, in very small doses (gr. i-iii), administered with an expectorant such as ipecacuanha or carbonate of ammonia (Beverley Robinson). (3.) *Quinine* in cases complicated by malaria. A warm, dry climate (such as that of the Auvergne) is the best, while the damp cold climates and the seaside are to be avoided.

### SUB-SECTION 3.

*Strumous rhinorrhœa* is chiefly met with in ill-nourished children with feeble digestion and languid circulation, and is associated with chronic enlargements of the lymphatic glands, eczematous eruptions on the face or head, and phlyctenular ophthalmia and keratitis. The discharge is muco-purulent, often offensive, and the nostrils are obstructed partly by the swollen mucous lining and partly by greenish yellow crusts of the dried and congealed mucus.

In the treatment it is important—1st, to remove the crusts from the nostrils at least once or twice in the day. For this purpose the camel's hair pencil answers better in young children than the nose douche. The crusts do not extend deeply into the nasal fossæ, and the employment of the douche will only cause increased irritation, not to speak of the difficulty of employing it in such young subjects. Glycerine and water, with a little carbolic acid (one part in sixty or eighty), applied to the crusts themselves by means of the brush will soon soften them, and they can then be washed away by a gentle stream of warm salt and water from a syringe; 2nd, to apply some form of soothing and non-irritant ointment, of which the ung. zinci benzoati is perhaps the best; and 3rd, to improve the general health by good diet, warm clothing, healthy exercise, cod-liver oil, and steel tonics, giving an occasional aperient when necessary. In many children thus affected there is some irritating condition of the bowels manifested by mucous discharges and the presence of ascarides. Treatment must of course be directed towards removing these irritant conditions, and the occasional use of clysters of salt and water or infusion of quassia is very useful in the attainment of this result. The combination of powdered bark with carbonate of soda, given two or three times a day, will often help very much in the same direction. The diet should be nutritious, but not stimulating, and pastry and excess of sugar in any form should be especially avoided. Ripe sound fruit, cooked or uncooked, should be given daily whenever it can be obtained, and good milk is absolutely essential.

Associated with this chronic rhinorrhœa of strumous children, and sometimes succeeding it, there is often a *thickening of the mucous membrane* and the submucous tissues, especially of the covering of the inferior turbinated bones. The mucous membrane along the lower borders of these bones is thickened and overhangs the inferior meatus, reaching inwards almost to the septum, impeding the child's breathing, producing snuffling and a peculiar thickness of the voice, and often causing the surgeon to suspect a polypus.

This form of stenosis is not unfrequently associated with rickets, and in such cases a considerable deformity of the chest may result from the strained inspiratory efforts. The ribs will in some cases sink inwards along the whole width of the carti-

lages, forming a deep groove between the bony portions and the sternum, and thus giving rise to a permanent deformity and diminished calibre of the thorax. A typical case of this kind occurred to me at the Great Northern Hospital on March 15th, 1877, in a child *æt.*  $2\frac{1}{2}$  years. There was almost complete stenosis of the nostrils, and some enlargement of the tonsils, not, however, sufficient to cause serious impediment to breathing (as Dr. Bridges allowed). The ribs were beaded and deeply grooved; legs and arms not deformed, the child never having attempted to put its feet to the ground; prominence of the lumbar region of spinal column.

In sucklings the severe dyspnœa caused by the stenosis during the act of sucking is also present during sleep, the habitual position of the tongue in young children being in contact with the roof of the mouth, and hence the child is constantly waking up half-stifled by the habitual position of the tongue. All refreshing sleep is thus prevented, and very soon great exhaustion and prostration ensue. In some children asthmatic attacks are thus brought on, and similar attacks are caused even in adults by the same cause, as also by other forms of obstruction of the nostrils, such as polypi or tumours. It is said by Kussmaul that the vigorous attempts at inspiration made by sucklings affected with stenosis in the acts of sucking and during sleep give rise to acute hyperæmia of the lungs, and that this is one cause of the suffocative attacks so commonly observed in such children. (Ziemssen's "Cyclopedia of Medicine," vol. iv. Fränkel on "Dis. of Nose," pp. 112 *et seq.*)

The *diagnosis*, however, will not be difficult if the nostril be examined in a good light with Fränkel's speculum, when the broad base of the growth will become evident. The strumous aspect and the age of the patient will generally aid us in forming a correct opinion as to the true nature of the disease.

*Treatment of stenosis in strumous rhinorrhœa.*—The use of astringent applications, such as glycerine of tannin, solution of chloride of aluminium (gr. iv to f.  $\bar{3}$  j), or nitrate of silver (gr. v to f.  $\bar{3}$  j) solution by means of a camel's hair pencil, and the careful regulation of the diet as above described for strumous rhinorrhœa, will generally suffice in the less severe cases to reduce the swelling of the membrane.

If, however, there is some amount of induration as well as enlargement, and if the mischief has been going on for a long

period and causes much discomfort from the difficulty of breathing through the nostrils associated therewith, and especially if both nostrils are simultaneously affected, it will

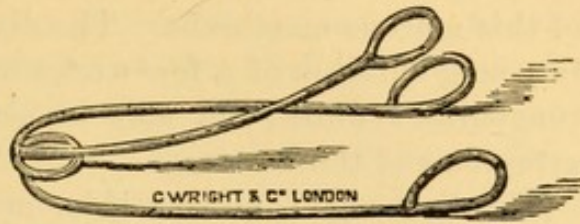

Fig. 16.  
Goodwillie's Speculum.

be good practice to cauterize the membrane by means of the galvanic cautery. The nostrils can be kept open and distended during the operation by means of Fränkel's or some other speculum, such as that of Goodwillie (see fig. 16), and the caustic (if chromic acid or nitric acid be used) may be passed into nostril through my platinum canula (see fig. 17, Section IV).

If, after removal of the growth and cicatrization of the wound, there is still obstruction, it will probably be overcome by the application of chromic acid passed through a canula, and applied along the surface of the inferior turbinated bone at intervals of about a week or ten days. Ledran employed *catgut* bougies for the purpose of dilating the cavity, introducing them along the floor of the nostril, and leaving them until they increased in size by the absorption of moisture, and gradually increasing the size of the bougie until the required amount of dilatation was obtained. Professor Boyer employed *gum elastic canulæ* with the same object, making the patient wear them day and night for a long period. This plan may be adopted at short intervals for children at the breast, but I cannot recommend it for general adoption in all cases. For adults Adams' ivory plugs, or those made of vulcanite (as figured in Section IV, Sub-Section 1), of several sizes may be worn for at first an hour, then two hours a day, and sometimes can be worn without discomfort for many hours in the day. They should always have a silk cord attached to their free end, which should be fixed by a loop over the ear of the same side if worn during the night. *Laminaria* bougies can sometimes be used with very good effect. Small bougies of the size of a No. 3 catheter should be used at first, and left in the nostril for about half-an-hour. The size employed can be increased gradually until dilatation has been established.

#### SUB-SECTION 4.

*Syphilitic coryza*, dependent upon mucous tubercles, is a connecting link between the ulcerative and non-ulcerative diseases

of this mucous membrane. The disease is most commonly seen in young children of a few weeks or months old, affected with congenital syphilis, and may be associated with all the other symptoms of the disease.

The discharge is at first thin, muco-purulent, and offensive, but soon becomes thicker. The nostrils appear swollen and red at the edges, and the child is constantly affected with "snuffles," *i.e.*, a noisy respiration and snuffling sound is heard with each inspiration and expiration, due to the swollen state of the mucous membrane and the crusts of dried mucus covering it and obstructing its passages.

In the worst cases the nostrils become completely obstructed, and the child can only breathe through its mouth. In sucking, therefore, the child is constantly obliged to stop to get its breath, and respiration becomes very much impeded. Hence it is very necessary to remove the crusts at this stage, and the child will probably have to be fed by means of a spoon, the action of sucking being rendered so difficult as to be almost impossible.

In addition to the disease within the nostrils the external parts of the nose at the edges of the alæ are often the seat of pustules, fissures, and deep ulcerations, and the larynx and other parts of the throat are often similarly affected, so that the voice becomes dull, hoarse, and disagreeable, or may be even entirely lost. The discharge meanwhile becomes thin, sanious, and sometimes tinged with blood. The ulcers may go on to caries and ulceration of the bones and cartilages. The general health is at the same time becoming more and more influenced by the constant inhalation of fœtid gases from the putrifying crusts in the nostrils, as well as from the progress of the constitutional disease, and death often ensues from this combination of adverse circumstances. Hæmorrhage from the nostrils, consequent on the efforts made by the child in respiration and the detachment of the crusts with some violence, is an occasional complication.

Syphilitic coryza or rhinorrhœa is distinguishable from ordinary catarrhal rhinorrhœa by the history of syphilis in the parents, by the presence of ulcers or fissures of the alæ nasi, upper lip or pharynx, and by the hoarseness or loss of voice, indicating similar ulcers or tubercles of the larynx. It is often the *first* symptom of syphilis that shows itself in new-born infants; we may therefore not have any of the usual symptoms

of the disease, such as copper-coloured eruptions, etc., to guide us in diagnosis. In "snuffles" of this kind the cleansing of the nostrils by means of the nose-syringe with warm douches is still more necessary than in simple coryza, and if the discharge is very offensive a weak solution of permanganate of potash, or aluminium chloride will be very useful. After that cleansing, then the grey oxide of mercury ointment, diluted with benzoated lard, should be passed into the nostrils, and this must be repeated twice or thrice in the day. Meanwhile constitutional treatment by means of mercury will be absolutely necessary, either by means of inunction or by giving grey powder internally. After a course of mercury, cod-liver oil and iodide of iron will generally suffice to complete the cure. If, after the acute symptoms have subsided, the mucous membrane is still swollen and semi-ulcerated, a weak solution of nitrate of silver (gr. ij to f. ℥j), applied by means of a camel's hair pencil, will be very useful in most cases.

Syphilitic coryza in adults is of the same kind, but is much more obstinate, and will generally be found to be associated with ulcers. For these patients constitutional treatment by mercury is not often requisite. In all probability they have already undergone a course during an earlier stage of the malady. Hence iodide of potassium, or sodium, or ammonium, will be generally more likely to benefit the patient than a mercurial course. Dr. Prosser James speaks highly of the iodide of calcium in the treatment of ozæna, and prefers it to iodide of potassium on account of its taste being less nauseous. The local treatment by the douche is absolutely essential, and probably the best solution for this purpose is a weak solution of carbolic acid and sulpho-carbolate of soda, ℥iii of the latter and ℥xx of the former to a pint of warm water. A stronger solution can be used if the weaker one is found to be insufficient as a deodorizer.

#### SUB-SECTION 5.

##### *Dry Catarrh.*

This is a form of rhinitis to which persons whose occupation compels them to inhale a dry, dusty atmosphere are especially liable.

*Symptoms.*—A sense of tingling and dryness of the nostrils, without discharge, and a faint, musty odour are the principal



symptoms. The nostrils have a dry coating of mucus, but no obstruction to breathing. It may be the sequel of any form of chronic rhinitis, or may be a temporary attack originating in an exposure to some dry, irritating vapour in the rooms occupied by the patient. The air of a concert or ball-room is especially liable to cause this in persons subject to ordinary catarrhal attacks. In the worst cases there is pain of a sharp tingling character in the nose, and extending up to the forehead. The dry secretions or crusts form an additional source of discomfort, and require the frequent use of the pocket-handkerchief for their detachment. If the vault of the pharynx is involved crusts also form there, and on detachment the mucous surface has a dry, parchment-like aspect.

*Treatment.*—The first thing to be done is to remove the morbid secretions. For this purpose the nasal spray apparatus, charged with a saline solution containing borax and carbonate of soda, is the principal and most efficient means. If the crusts form in the posterior nares and pharynx, the posterior nasal syringe, charged with a similar warm solution, will be necessary. If this is not sufficient, a pharyngeal brush, with solution of nitrate of silver (gr. iv to ʒi), or of solution of glycerine of iodine and carbolic acid, applied three or four times a day, will be necessary. In some of the worst cases a slender pair of forceps (see fig. 39) must be used for the detachment of the adherent crusts, and the spray solution of borax applied soon after and repeated several times a day.

Bosworth relies much on the use of stimulating snuffs, and gives the following formulæ :—

- (1) Pulv. Sanguinaria,  
Pulv. Myrrhæ, aa. ʒi.  
Lycopodii, ʒii.
- (2) Pulv. Galangæ,  
Pulv. Amyli, aa. ʒi.
- (3) Pulv. Galangæ ?  
Pulv. Myrrhæ,  
Pulv. Acaciæ, aa. ʒi.

If these are found too irritating, he uses the following :—

- (4) Acid. Salicylic, ʒi.  
Lycopodii, ad ʒss.

- (5) Potass. Bromid., ʒi.  
Sacch. Alb., ʒiii.
- (6) Pulv. Myrrhæ,  
Lycopodii, aa. ʒi.
- (7) Pulv. Belladonnæ,  
Magnes. Calcin., aa. ʒss.
- (8) Sodæ Salicylat., ʒss.  
Sod. Bicarb., ʒi.  
Pulv. Amyli, ʒss.

In using these snuffs they may be either snuffed up from a quill or blown in by means of an insufflator (see fig. 30). For application to the pharynx, however, the insufflator of Rauchfuss is better.

Should the dry catarrh be unrelieved by these methods the condition is probably that of atrophic rhinitis, of which an account is given in the next Sub-Section.

#### SUB-SECTION 6.

*Rhinitis Atrophica ; Ozæna ; Idiopathic or Constitutional Ozæna of Trousseau ; Fætid Chronic Rhinitis (Gottstein).*

Though *ozæna* is rather a symptom than a morbid entity or disease in itself, it has been classed clinically as a form of rhinitis from the fact that the prominent symptom, fætor of the breath, is an essential and striking character of atrophic rhinitis. It consists essentially in typical cases of an atrophy of the mucous membrane, with expansion of the nasal cavities, in which crusts of dry mucus accumulate and give rise to an offensive odour, recognizable as the "ozænic stench" or "punaisie."

*Causes.*—A. *Predisposing causes.*—There is probably an hereditary ozænic diathesis in most cases. The patients have depressed nasal bridges, inherited from their parents, and there are sometimes several persons affected in the same family. Chronic catarrh and hypertrophic changes are also common predisposing causes. In many cases the family has a phthisical tendency, one or more members either having died of phthisis or being affected with it.

B. *Occasional causes.*—Any obstructive disease of the nasal fossæ, due to congenital distortion of the septum or to hyper-

trophic enlargements or displacements of the turbinated bodies which in their turn give rise to chronic catarrh and subsequent formation and retention of dry crusts.

The *symptoms* vary according to the stage of the disease. When fully formed, the atrophic rhinitis is associated with a peculiar physiognomy due principally to the depression of the bridge of the nose (*nez ecrasé*). This is not exactly the scrofulous "facies," though it somewhat resembles it. I do not find the thick, scrofulous upper lip common in ozænic patients. There is a wide expanded nostril sometimes presenting the aperture forwards instead of downwards, and a thin flat ala without the rounded contour and with a marked absence of the deep sulcus separating the ala from the cheek, so that the transition from the one to the other is almost imperceptible. The nose, in fact, looks more like "a snout" than the natural organ, and has a marked want of expression.

Some authors describe the "ozænic" as delicate looking, but they may be seen with healthy, fresh complexions and well-nourished, as often as with pasty and muddy-looking faces. The "ozænic odour" is characteristic and can be recognized in a room many yards from the patient, and even in a room in which he has been sitting. It is peculiarly penetrating and sickening, and keeps at a distance the unfortunate sufferer's most intimate friends and relations. Sometimes the patients suffer from severe frontal headaches. They are generally depressed in spirits as if from a constant sense of their malady.

The crusts that form in the nostrils are most troublesome in the morning. If neglected the nostrils become completely blocked by them, and it is then often difficult to get them away by the use of the handkerchief.

They form a lining of the cavities and of the pharynx, and when detached by hawking and spitting have a brownish-green colour and are sometimes tinged with blood. The pharynx has a dry shining appearance when free from secretions. The sense of smell is either much deteriorated or wholly lost, and the hearing is often very imperfect.

The secretions of the nostrils are at times very much more fluid than at others and require the use of a pocket-handkerchief at very frequent intervals, and when fluid the secretions are thick and mucopurulent in character.

After a free use of antiseptic douches, the cavity of the

nostrils may be examined rhinoscopically and is found to be very wide, so that the pharyngeal apertures can be easily seen in anterior rhinoscopy, the outer wall being widely separated from the septum by reason of the atrophy of the inferior turbinated bone. It is not unusual in the early stages of the disease to find atrophy on one side and perhaps hypertrophy on the other, the latter condition being in fact but the early stage of the former. The whole membrane is seen covered with a dirty yellowish lining of mucus, and when this is detached by forceps or douches the subjacent membrane is seen to be thin and glistening, the natural velvety surface being absent, especially from the outer wall, though it may have a congested and reddened appearance in parts, and be occasionally streaked with blood. There are no ulcerations, however, in the typical cases.

*Pathology.*—According to Zaufal, the secretions being retained and putrifying are the essential cause of the fœtor. The large size of the nasal fossæ prevents the usual cleansing effects of a strong current of expired air. The diminution of the humidity consequent on the retarding action of the normal narrowness of the passage and its sinuosities causes a drying up of the secretions. The character of the secretions is viscid and still further retards their separation. Accumulation and decomposition of the crusts with undue pressure on the membrane affected still further prevents the normal action of healthy gland secretion, and so on in a vicious circle. The fœtidity of the secretion seems to be due to a pungent acrid form of decomposition of morbid secretion in which fatty matter is very abundant. Molecules of disintegrated fat cells are very abundant in the crusts according to the researches of Krause. Krause gives details of two autopsies of cases of ozæna proper, *i.e.*, not complicated by ulcers or diseased bone, and sums up the results as follows:—“The most remarkable circumstance, however, is the demonstration that the infiltration cells in the mucous membrane have undergone disintegration and have been converted into a copious fatty detritus, and that numerous large fat cells have been formed. The occurrence of these changes may serve to explain the origin of the fœtor in ozæna.” (See Virchow’s “Archiv.,” Bd. 85). Hajek,\* of Vienna, states that the coccus of Fried-

\* Berlin, *Klin. Woch.*, 1888, No. 32, in *Journal of Laryngol.*, October, 1888.

lander is *sometimes* present in the secretions in ozæna, but that the "fœtid bacillus" is constant and specific, and that this bacillus, when cultivated, gives the special odour of ozæna. Moure (*op. cit.*, p. 102) suggests that the principal cause of all the symptoms is a specific inflammation of the glands of the mucous membrane. He, nevertheless, agrees that there may be present (according to Löwenberg) a particular form of *coccus*, that (according to Ziem) there may be a special *ferment*, a *microbe* (as described by Bresgen), and also *fatty acids*, as described by Krause. All these separate morbid conditions may coexist, and are not incompatible one with the other. They point to a condition of the mucous surface allied to *lupus erythematosus* of the skin.

*Diagnosis.*—In well-marked cases there can be no difficulty—the stench from the nostrils, the persistent formation of dry crusts, the atrophic membrane, the long continuance of the symptoms, the absence of caries, ulcer, or necrosis, and the age of the patients, viz., childhood, or early adult life, all clearly point to the condition of atrophic rhinitis. When *hypertrophic rhinitis* is for a time associated with atrophy in the opposite nostril, some temporary difficulty must be experienced in forming the diagnosis. The progress of the case clears up all ambiguity.

*Prognosis and Treatment.*—The prognosis is almost always unfavourable. The lost tissue elements cannot be restored, and the structure of the blood vessels cannot be reproduced. All that can be done is to remove the secretions, and disinfect them when decomposed; or prevent their decomposition by the use of antiseptics; or finally by energetic cauterization alter the structure of the superficial layers of the membrane where the cell proliferation is more especially active.

In all cases the patients and friends should be cautioned against any prospect of a speedy recovery, even when the remedies are most assiduously applied. It is safe, however, in the case of children, to promise that after the period of puberty the symptoms are more likely to diminish in severity, and that in time they may altogether disappear. Moore (*op. cit.*, p. 185) asserts that he has completely cured patients of from 12 to 16 years of age, and that these patients have discontinued all treatment, and yet remain free from all symptoms of atrophic rhinitis. My own experience has not been so favourable. I

have cured only one case, and that a doubtful case of atrophic rhinitis.

The first and essential thing is to cleanse the nasal fossæ. This can be done by copious douches and by irrigation with sprays of an antiseptic character. The douche may be used either by means of the syphon or by the syringe (see *ante*). The solutions employed should be of a temperature of about 96° F., and I prefer the following as a convenient form of solution:—

Sod. Biborat. ℥iii.

Sod. Sulpho Carbol. ℥iii.

Acid Carbohc Crystall. gr. v.

Aq. Destill. f. ℥viii.

f. ℥ii with f. ℥iv of hot water to be used as a douche.

The above is not a complete solution until the hot water has been added, but the mixture is more convenient in this form. As a spray, the same solution can be used three or four times a day, the douche only being applied early in the day, and whenever the crusts have accumulated. Warner's antiseptic pastilles, prepared according to Dr. Carl Seiler's formula, are extremely useful from their portability, easy solubility, and accurate dosage. In the evening the nostrils should be anointed with an Iodoform ointment (3 grains to ℥i).

If the pharynx is covered with crusts, and the douche fails to detach them, they should be detached by means of a pharyngeal brush containing an antiseptic solution. A mixture of Iodine and Carbohc Acid (℥ii of each to f. ℥viii of water) makes a very efficient lotion for this purpose. The retro-nasal syringe will also be necessary in some cases. If the odour is not controlled by these remedies, a chlorine gargle may be used. It should be freshly prepared by the action of strong Hydrochloric Acid on dry pulverized Chlorate of Potash, to which distilled water is then added. Iodine vapour may also be inhaled in the very obstinate cases.

In a very obstinate case under my care at the Great Northern Hospital, after the failure of other antiseptics, I succeeded with a spray containing a strong solution of Sulphurous Acid (in the proportion of one part of the Pharmacopeia Solution to five parts of water). The handkerchiefs used by the patient should be at once disinfected by steeping them in some antiseptic solution.

It has often been noticed that in young girls the odour from the nostrils is more intense at the time of the monthly periods, and during this time the remedies must be applied more frequently. At other times a douche night and morning will perhaps be sufficient, with a spray occasionally in the middle of the day, but during the monthly periods the douching and spraying must be more frequently and thoroughly used.

If the patient complains of headache or frontal pain immediately after using the douche, it should be changed for a different kind of antiseptic. I think that too large a douche is sometimes employed, and that when the crusts have disappeared at the commencement of the douche it should then be discontinued. As soon as a more healthy state of the parts has been induced, the douches should be altogether omitted, and sprays substituted. The more healthy the mucous membrane the more sensitive it becomes, and whenever irritation of the eyes, and pain in the upper part of the nostril is complained of after or during the douche, it is desirable to intermit it or substitute a simple alkaline solution without antiseptics. I dislike the use of dry powders by insufflation in these cases. They seem to cause a coagulation of the secretions, and obstruct their detachment, but as the secretions become less viscid, powdered Iodol may be used occasionally.

Some practitioners recommend the use of Solutions of Nitrate of Silver freely to the mucous surfaces, and even destroy the membrane by means of the galvanic cautery. I have no experience of this method of treatment, and on *à priori* grounds should not advise it. It is, however, strongly advised in very obstinate cases. In one case recorded in Virchow-Hirsch's Jahresbericht the accidental inoculation of the nostril by gonorrhœal virus set up violent catarrhal inflammation, and when this was cured by the application of Solution of Nitrate of Silver the ozæna had disappeared.

The general health should be regulated, and tonics given whenever necessary. Free exercise in the open air is in all cases to be recommended, and, if possible, change to a dry climate. The moist atmosphere of the sea-side seems to aggravate the symptoms, and residence in a dry inland place of high altitude is generally beneficial. The body should be kept warm, and especially the loins and lower limbs, and warm

or tepid baths, with friction of the surface with rough towels after bathing, are very helpful in this direction.

#### SUB-SECTION 7.

##### *Rhinitis Caseosa.*

This rare affection was first described by Professor Cozzolino in 1884. He had seen, when he last reported on the subject (October, 1889), three cases only. It is not to be confounded with merely retained secretions, nor should it be regarded as a complication, nor as a symptom, but as a true "morbid entity." The etiology is not clear, but according to Cozzolino it should be regarded as a desquamative rhinitis peculiar to scrofulous persons, brought about by the presence or passage of parasites into the nasal fossæ, the scrofulous condition affording a favourable soil for their multiplication and accumulation. The principal symptoms are: (1) occlusion of the nasal fossæ; (2) an intolerable fœtidity; and (3) an escape from time to time both from the nares and from the choanæ of almost gelatinous masses which detach themselves from the principal mass and simulate a single mass occupying the nasal cavity. These masses sometimes, when they fall into the throat, cause a sensation of suffocation, after which the patient gets temporary relief. In the second period, owing to the increased volume of these masses, pressure outwards on the osseous walls of the nasal cavity gives rise to deformity of the face with osseous and cartilaginous lesions and pains which make the diagnosis more difficult. In some cases polypi occur in the later stages. Examined by the rhinoscope, a formless, softish, greyish-yellow substance is seen streaming from the cavity and with a fœtid odour worse than that of ozæna, but with less tendency to diffuse itself into the surrounding air. When a probe is thrust into this substance it can be easily broken up and can then be washed away by means of naso-pharyngeal syringing. There is generally a dull red colour of the mucous membrane, but no ulceration, though the epithelium may be wanting over a great part of the surface. In the later stage myxomatous growths may be found, and also osseous and cartilaginous lesions. The microscopic examination of the caseous mass reveals large numbers of cocci, spores, and rectilinear bacteria somewhat



resembling the bacilli of tuberculosis, a great number of white corpuscles, and a mass of fatty cells and crystals of stearine pyramidally or radially disposed and embedded in an amorphous substance.

*Treatment.*—This consists of removing the caseous substance and cleaning out the cavities by antiseptic irrigation.

If the latter stage has been reached more formidable surgical procedures will become necessary. This account is taken from Professor Cozzolino's communication to the Laryngological Congress of Paris in September, 1889. One case of this kind came under my notice about four years ago. Removal of the substance from the nostrils and subsequent douching with antiseptic solutions effectually cured the patient, a man of forty years of age. I have seen this patient at intervals since and he remained perfectly well.

#### SUB-SECTION 8.

##### *Diphtheritic Coryza.*

The early recognition during an epidemic of the symptoms of diphtheria in particular cases is obviously very important. If there be in any suspicious case any nasal symptoms, such as snuffling and coryza during the prevalence of diphtheria, the following are the steps to be taken in forming a *diagnosis*:—  
“The finger should be placed behind the angle of the lower jaw, behind the lobe of the ear, and thence down the side of the neck, and if swelling of the cervical glands be noticed, it renders it probable that there is a false membrane in the nares. If, further, the upper lip be reddened exclusively under *one* nostril, and that on the side of the glandular swelling, or if the swelling exists on both sides, but unequally, and if the lip is correspondingly reddened, the probability that there is nasal diphtheria is converted into a certainty, since ordinary coryza acting equally on both nostrils produces equal redness of both sides of the upper lip” (*Bretonneau, 5th Memoir, Syd. Soc. Trans.*, p. 196, 197). It is rarely possible to obtain a view of the mucous membrane itself, but if the swelling is slight and the discharge can be thoroughly washed away, the characteristic dirty grey membrane may be seen lining the fossæ.

*Treatment.*—The use of carbolic and alkaline douches followed by repeated sprays of recently made chlorine solution, which should also be applied as a gargle and by the posterior nasal

syringe, must be at once carried out. In the case of children, the best way of applying the chlorine solution is by passing a stylet armed with cotton wool saturated with it along the floor of the nostrils and into the posterior nares through the mouth. There is a risk, however, in applying these stimulating antiseptics, of bringing on dangerous epistaxis. This is more particularly liable to occur in young children, and is often very uncontrollable and may even prove fatal. These local remedies must be supplemented by supporting regimen and tonics, into the details of which it would be out of place to enter in this work.

## SECTION IV.

SUB-SECTION 1. Chronic Hypertrophic Rhinitis.

,, 2. Cysts in the Nasal Fossæ and Naso-Pharynx.

## SUB-SECTION 1.

*Chronic Hypertrophic Rhinitis.*

*Etiology.*—Hypertrophy of the mucous membrane of the nose may result from repeated attacks of acute rhinitis, from irritation of any kind such as the application of caustics or strong solutions in the form of sprays or douches, and from the neglected chronic simple rhinitis. A scrofulous disposition favours the morbid process and aggravates any local causes such as those specified. In some cases it seems to be idiopathic.

*Pathology.*—In uncomplicated simple chronic rhinitis the mucous membrane is uniformly swollen, the submucous cavernous tissue being congested but capable of being reduced in bulk by pressure, and returning at intervals to its normal condition; but in the chronic hypertrophy, not only is the epithelial layer thickened, but the cavernous erectile tissue covering the turbinated bones, and sometimes the submucous covering of the septum, become permanently distended and lose the power of recovering their normal bulk. The surface of the membrane also becomes corrugated and raised into folds or villous prominences, the posterior thirds of the middle and inferior turbinated bodies being most frequently affected in this way. The anterior extremity of the inferior turbinate and occasionally the anterior part of the middle turbinate, when hypertrophied, are generally uniformly swollen, and when pressed by the probe do not recede. Sometimes the anterior parts have also wart-like outgrowths on their surface, but these are not frequent and occupy only one or two spots or surfaces, differing from those on the hinder parts, where they are uniformly distributed over a considerable surface.

*Symptoms.*—The symptoms are those of stenosis more or less complete. In the advanced cases the breath-channel may be completely occluded; in less advanced stages one or both nostrils may admit of a forced snuffling respiration. There is

a constant flow of mucus from the anterior nares, and a backward flow into the naso-pharynx, where the viscid secretions form adherent crusts, which are only detached with difficulty and much "hawking" and coughing. There is, in addition, the usual distress of stenosis, the habitual oral breathing, the snoring and distress of breathing at night, the nasal voice, impairment of hearing, of smell and taste, and asthmatic attacks, with occasional implication of the larynx. The uvula and velum become thickened, and the elongation of the former gives rise to chronic irritative cough. The breath is sometimes offensive from the accumulation of the mucous secretions in the naso-pharynx, and there may be chronic pharyngitis due to the same cause.

*Progress, duration, and termination.*—The progress of the disease is slow, and once established rarely terminates in recovery or even in mitigation. Nevertheless, there are variations in the intensity of the symptoms, the onset of cold, damp weather causing increased obstruction, and dry weather bringing with it a reduction of the bulk of the growths and temporary relief, so that the breath-channel becomes comparatively free, and the sense of smell to some extent restored. There is reason to believe that in some instances the case develops into chronic atrophic rhinitis with ozæna and all its attendant discomforts. It may, however, continue in the hypertrophic form and become associated with multiple polypi. (See Cases II. and III., pp. 73, 74.) Chronic hypertrophic rhinitis is not commonly observed after the age of 45.

*Diagnosis.*—In order to form a differential diagnosis from simple chronic rhinitis, anterior rhinoscopy must be aided by the use of the probe, and the application of cocain. If there is simple chronic rhinitis the tissues yield under the probe, and cocain sensibly reduces the bulk of the membrane covering the turbinated bones; but in chronic hypertrophic rhinitis the pressure of the probe is resisted, and the mucous membrane speedily returns to its original bulk, and there is little shrinking by the action of cocain. When posterior rhinoscopy can be satisfactorily employed the dirty grey colour of the protruding hinder extremities of the turbinated bodies \* may be seen from

\* Most commonly the inferior turbinate only is seen, its great bulk occupying the greater part of the aperture, and presenting either a greyish white or a purple red rounded and nodulated prominence.

the posterior nares. If digital exploration is employed these prominent bodies can be felt, and their villous mulberry-like surface recognized.

The complications of chronic hypertrophy are polypi, tumours, or deviations of the septum, and any intranasal disorders that give rise to obstruction. When any such complications exist, it is difficult to say which is the primary cause of the disorder. They may be synchronous in origin, or one may have preceded the other. Such complications are very frequent, and therefore noteworthy, as having a distinct bearing upon the treatment. That polypi are sometimes the result of chronic hypertrophy seems probable from cases that have come under my notice, in which such growths of an unusual form were associated with hypertrophy of the turbinates. The form of the polypus in these cases was "nummular," *i.e.*, flattened, and with a very short narrow pedicle. I removed several such polypi, varying in size from that of a pea to that of a horse bean, in a case in which I also removed the hinder extremity of the inferior turbinated bone. (See Case III.) The leaf-like shape of the polypi was precisely that of the papillomatous or "petaloid" growths seen in another case of chronic hypertrophy. (See Case II, figs. 21 to 24.) It happens now and again that these cases are treated as "multiple polypi," and yet the obstruction continues after their removal. In a case related by Mr. Milligan, of Northampton (*Brit. Med. Journal*, Nov. 16, 1889), polypi had been removed twenty-six times by the late Mr. Kirby Smith and by Mr. Milligan, and yet the patient was very little better. Mr. Milligan then "wrenched away the superior (*inferior?*) and middle turbinated bones as completely as possible; on the portions of bone removed he found innumerable little polypi, showing that as soon as the large ones were removed these would grow and fill up the nose again." The result of this operation was that the patient could "breathe perfectly through her nose, which for twelve years she had been unable to do."

The complication of cleft palate in one of my cases is noteworthy. The chronic naso-pharyngitis common in cases of cleft palate may have had much to do with the hypertrophic changes in the hinder extremity of the turbinate.

The superior turbinate may be not only enlarged, but converted into a bony cyst, and pressing the septum towards the

opposite side. This complication, therefore, may give rise to a diagnosis of a bony tumour. (See *Zuckerkanndl's Anatomie and Pathologie der Nasenhohle.*)

The hypertrophy may affect one side only, but most commonly it is bilateral. It may be associated with partial atrophy.

In young children the usual effects of nasal stenosis may be observed. (See Stenosis, Section II, supra.)

*Treatment.*—The early stages may be mitigated by the use of mild astringent and antiseptic solutions applied by means of the nasal syringe. Sprays are not often useful, and the soft nasal syringe is generally necessary in order to reach the accumulated mucous and dry or viscid secretion that accumulates in the naso-pharynx. A Rumbold's nasal syringe can sometimes be passed through the anterior nares, and the perforated extremity then in the naso-pharynx allows a stream of the solution to be distributed in that region. Sajous' Solution is as follows:—Iodine  $\zeta$ ss, Acid. Tannic  $\zeta$ ss, Aq. Oss, Nux filter and evaporate to  $\zeta$ ii, then add Glycerin  $\zeta$ iv, Acid Carbohc Liquid  $\eta$ ii. This forms a clear solution, which remains in contact with the membrane for a considerable period on account of its oily consistence. It should be applied several times a day. Douches are rarely admissible. As a spray, when it can be effectually employed, Hazeline (the spirit of Witch-hazel) is very good after the removal of the coating of mucus and other secretions has been carried out. In some few slight cases cure may thus be effected, but in by far the majority these measures must be regarded only as preliminaries, and as facilitating a free inspection of the fossæ. No permanent reduction of the hypertrophy can be hoped for without the use of more active agents. These are (1) the use of Caustics, viz., Nitric Acid, Chromic Acid, Glacial Acetic Acid, the Acid Pernitrate of Mercury. To apply these effectually I use a platinum canula (see fig. 17), passed into the nostril, which is dilated by a

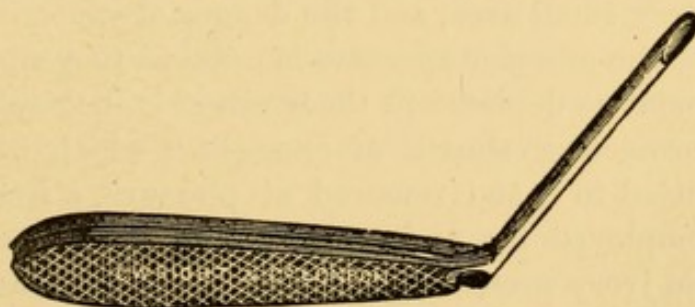


Fig 17.

Author's Canula for application of Caustics.

speculum. The best "carrier" for the fluid caustics is a strip of *cane* or *deal* of about eight inches in length, and with the end beaten somewhat into the form of a pointed brush. This woody substance absorbs a sufficient quantity of the acid without permitting it to drip from the end, as glass or metallic probes will do. It is well, however, to dry the end of the "carrier" on blotting-paper to ensure that there is no superfluous acid on its end. The ordinary silver probe heated in a spirit lamp and dipped into the Chromic Acid, is perhaps a better carrier for this caustic. The nostril is illuminated by the frontal mirror, and the canula is thus guided towards the spot which it is desired to act upon. The application should be made on the most prominent parts of the inferior turbinated body, and a spray of saturated Solution of Carbonate of Soda must be used immediately after the withdrawal of the canula. There is some pain, which goes off after a few hours, but if cocain is first applied the pain is insignificant. Should it be necessary to apply the caustic to the septum as well as the turbinate it will be well to guard against adhesions of the opposed surfaces by passing a probe between them at intervals of a few days after each application. This method requires repetition after about a fortnight, and may again need to be repeated as many as four, six, or eight times. A few days after each application a superficial slough forms and separates, and the resulting cicatrix reduces the bulk of the membrane in proportion to the extent of the area cauterized.

(2). The Electric Cautey.—This is altogether a more rapid, less painful, and more effectual method.

Various forms of snares and knives have been devised. I may particularly recommend Schech's snares, and for linear cauterizing my guarded spring electric cautey knife. (See fig. 18.) It enables the operator to limit the action of the cautey to a very small area, and the danger of cauterizing the alæ or edges of the anterior aperture is reduced to a minimum. The instrument as depicted in the woodcut is incomplete without a further protecting sheath of *crow-quill*, which in actual use can be fitted to it and renewed at pleasure, a fresh sheath thus being employed for each case. When the space available is ample, an ivory protecting sheath is screwed on at B.

The guarded spring cautey instrument is designed for the application of the cautey to the deeper parts of the nose and

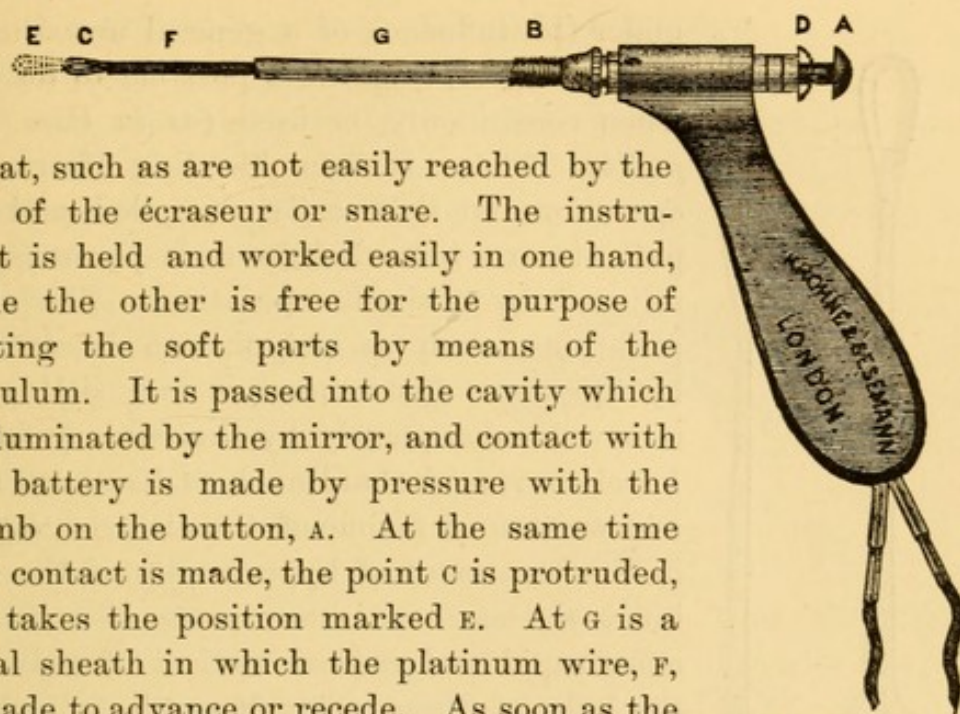


Fig. 18.

throat, such as are not easily reached by the loop of the *écraseur* or snare. The instrument is held and worked easily in one hand, while the other is free for the purpose of dilating the soft parts by means of the speculum. It is passed into the cavity which is illuminated by the mirror, and contact with the battery is made by pressure with the thumb on the button, A. At the same time that contact is made, the point C is protruded, and takes the position marked E. At G is a metal sheath in which the platinum wire, F, is made to advance or recede. As soon as the cautery has acted sufficiently, pressure is removed from the button, A, when the point E again recedes to its position, C, and at the same time, contact being cut off, the wire speedily becomes cool, and the instrument can then be removed without danger of cauterizing the healthy parts. It is sometimes desirable to cover the part of the instrument between B and C with a quill, and thus still further protect the parts (the end of the quill at C being open either laterally or terminally, and thus allowing the heated point to protrude and recede within a non-conducting channel). This instrument can be used with a three or four cell bichromate battery. A shield in the form of an ivory tube can be screwed on to the metal at B. This apparatus is made by Messrs. Krohne and Sesemann.

In all the foregoing directions I have only had in view the treatment of the anterior third of the hypertrophied parts.

(3). For the treatment of the hypertrophied posterior extremity of the turbinated bones, either the cold wire snare (Jarvis' by preference) or the Schech's snares will be available.

(4). In the worst cases, however, when there are extensive papillomatous growths occupying the greater part of both the inferior and middle turbinated bones, it is better to remove them rapidly by the *ring-knife* (see fig. 19), the patient being



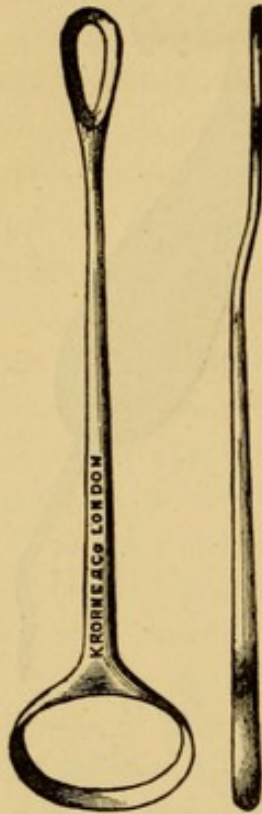


Fig. 19.  
Author's ring-knife.

under the influence of a general anæsthetic. It is, however, sometimes possible to do this when cocain only is used (*as in Case III, p. 74*). There is free bleeding after this operation, but it is easily controlled, and the patients are immediately and permanently relieved by a single operation. The complications, such as polypi, can be treated by the same instrument at one sitting, or removed subsequently by the cauterizing snare. I feel convinced that, much as has been said and written in favour of the electric cauterizing in the treatment of hypertrophy of the turbinates, there are many cases in which a more rapid and radical method of reducing the bulk of these parts is much to be preferred. The cauterizing should be reserved for those cases in which the hypertrophy is limited to the anterior third of the inferior or middle turbinates, and even of them to those only in which the amount of hyper-

trophy is slight in degree, and not accompanied by thickening of the bones themselves. In some specimens which I have removed, the bones were much thickened, and could not have been removed by any method short of the action of a strong cutting instrument. I have been obliged in some cases to use a small bone-cutting pliers and the nasal saw before completely establishing the breath channel.

I think it probable that Dr. Woakes' "nasal plough" may be useful in some of these cases of anterior hypertrophy, but not for cases of hypertrophy of the posterior  $\frac{2}{3}$  of the inferior turbinate, and not at all for those affecting the middle turbinate.

(5). After the principal obstructing growths have been removed by any of the above-described methods or by combinations of two or more of them, there will still be a tendency on the part of the membrane to a chronic inflammatory swelling, and in this stage spraying the parts with hazeline is very useful. I also at this stage use nasal plugs for the purpose of widening the breath channel at those parts which have not yielded to the treatment already employed. The space

between the septum and the middle turbinate is often unaffected, and the opposing mucous membranes remain in contact long after the lower part of the breath channel has become comparatively free, and the reduction in bulk of the middle turbinate may be affected by the use of the plugs (see fig. 20), beginning at first with the smaller and thinner No. 1, and gradually increasing the size up to No. 6, the thickness of course being varied as the peculiarities of the case may indicate. There is a remarkable tolerance of these plugs in hypertrophic rhinitis which is very surprising. Patients will allow the plugs to remain in all night, sleeping soundly. I recommend their use, however, for the day, and especially during the evening, for one, two, or even six hours when necessary.

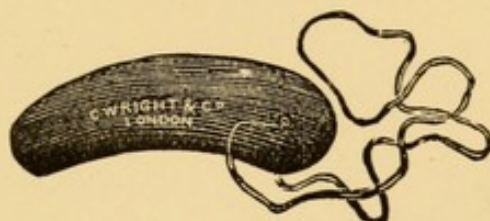


Fig. 20.  
Half actual size.  
Author's Nasal Plug. No. 2 size.

#### *Cases in Illustration.*

CASE I.—Mrs. E., æt. 54 years, very tall and stout, and with symptoms of stenosis and prominence of eyeballs. Great mental depression and fainting fits. Much difficulty of breathing at night.

Extensive hypertrophy of both inferior turbinates.

Ether given, and inferior turbinates removed entirely from end to end at two operations.

Great relief. In the course of next few months caustics applied and subsequently *vulcanite plugs* for reduction of the hypertrophy of the middle turbinates.

Much satisfaction expressed by the patient. The improvement remained for several years, but whenever there were threatenings of a return of stenosis the *plugs* were resorted to, and with much relief on many occasions.

CASE II.—A gentleman's gardener, æt. 35 years. Symptoms of stenosis for six years. Operations for polypus, but without relief. Fimbriated outgrowth seen from anterior nares on the anterior third of the inferior turbinate. No posterior rhinoscopic view obtainable, but by digital exploration soft growths felt protruding into pharynx from choance.

By ring-knife operation (under anæsthetic) the growths

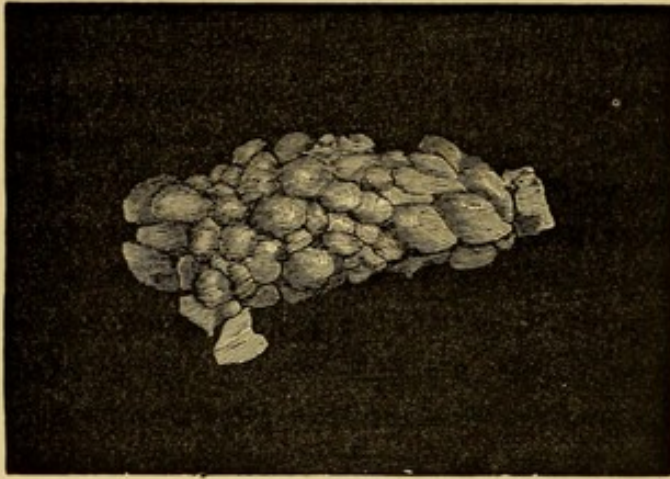


Fig. 21.

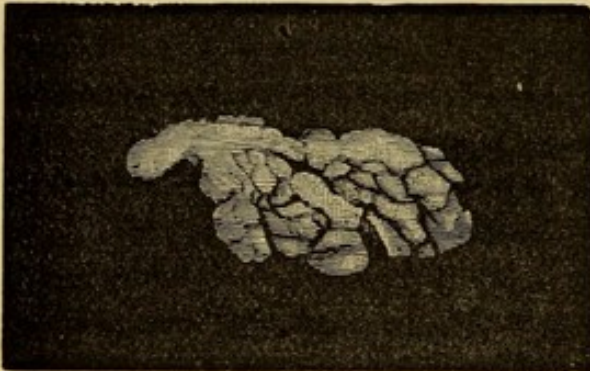

Fig. 22.

depicted in cuts removed at two operations, figs. 21 and 22 being growths from the left, and figs. 23 and 24 growths from the right nostril of the same patient. Three years after the patient remained perfectly free from nasal trouble, and immensely improved in health, the commencement of his relief dating from the time of the operations, and having steadily continued ever since.

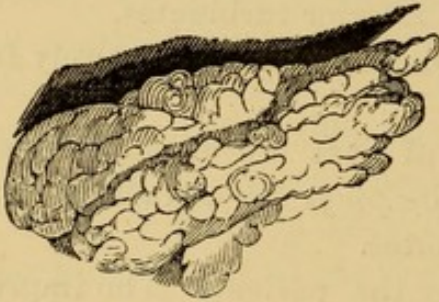


Fig. 23.

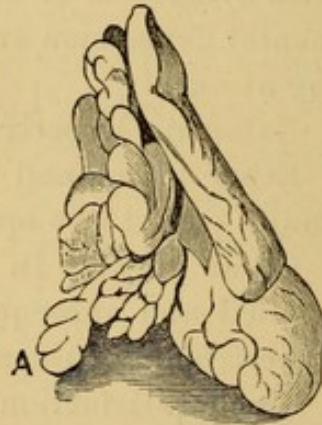


Fig. 24.

CASE III.—Mr. H., *æt.* 50 years. Symptoms of aggravated stenosis for years. Cleft palate. Good rhinoscopic view of growths on hinder extremities of inferior turbinates, complicated with nummular polypi.

Cocain (20% solution) applied freely and thoroughly. Numerous polypi removed by cold wire snare. Ring-knife operation on inferior turbinates. Portion of the hinder extremity of the inferior turbinate of the right nostril shown

in woodcut (fig. 25). The size of this growth is somewhat exaggerated in the cut. It was, however, extraordinarily large. The results of treatment were excellent and lasting. The polypi removed were some of them *nummular* in shape.

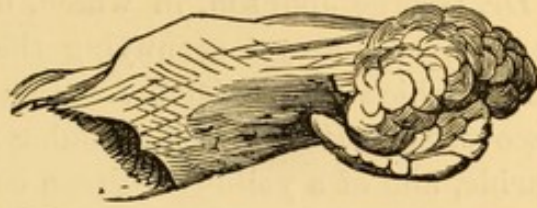


Fig. 25.

CASE IV.—A young gentleman, æt. 23, of no occupation. Obstruction in right nostril for about a year. Much disturbed in mind by this, and also in great discomfort, especially in attempting to swallow. The rhinoscope showed a globular body in right posterior naris. No obstruction in left nostril, and nothing abnormal in left posterior naris.

Nitrous oxide gas and ether given. Globular swelling caught by snare. It burst, and proved to be a cyst. Two days later rhinoscopy revealed a nodulated mulberry-like purple growth, occupying right posterior naris. Cocain applied and cold wire snare again passed. The globular mulberry-like mass shown in woodcut (see fig. 26) was withdrawn. Good results followed.

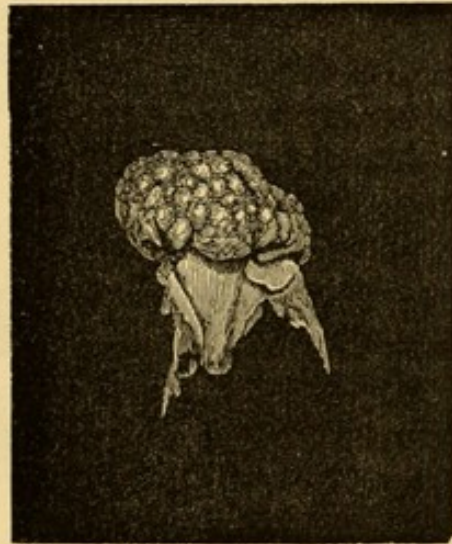


Fig. 26.

#### SUB-SECTION 2.

##### *Cysts in the Nasal Fossæ and Naso-pharynx.*

The nasal cavities proper are seldom the seat of cysts originating in their own lining membrane, though they are occasionally invaded by cystic growths in the antrum and the

other accessory sinuses. A remarkable case, however, occurred to Dr. George Johnson, in which, by the use of the rhinoscope, he discovered a cyst occupying the right side of the posterior nares, which had existed for two years without having been discovered. It formed a globular tumour as big as a full-sized marble, and of a yellowish-green colour. By introducing forceps along the floor of the right nostril, the cyst was grasped and burst, and the patient got immediate relief (see figs. 27 and 28).

*Dr. G. Johnson's Case, reported in "British Medical Journal," in May, 1874.*

"A gentleman, twenty-four years of age, consulted me on account of an obstruction in the right nostril, which had existed for two years. On examination with the mirror, the posterior opening of the right nasal fossa was seen to be obstructed by a globular tumour (fig. 27), as large as a full-sized marble, and of a yellowish-green colour. I asked my colleague, Mr. John Wood, to devise a plan for removing the tumour. He introduced a slender curved polypus-forceps through the anterior opening of the nostril, and grasped the tumour, which burst, and discharged a glairy fluid, like white of egg. The patient felt immediately that the obstruction was removed; and, on rhinoscopic examination, the shreddy remains only of the tumour

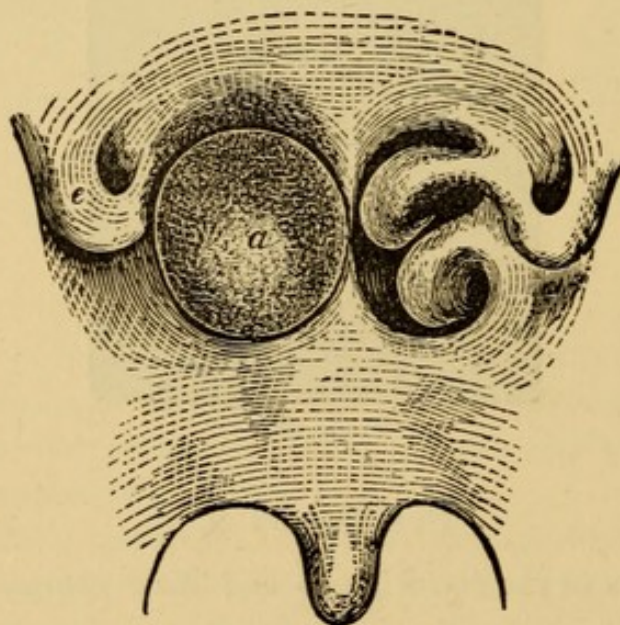


Fig. 27.

Posterior view of the uvula, soft palate, and nares, as seen by rhinoscopy. *a.* A globular tumour obstructing the posterior opening of the right nasal fossa. *c.* The orifice of the right Eustachian tube.

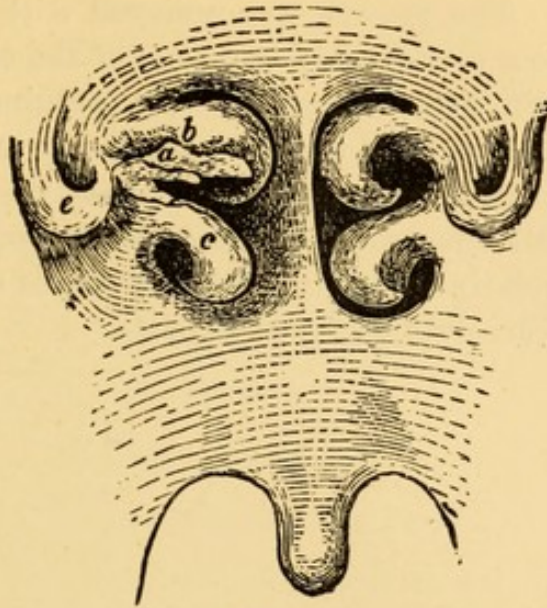


Fig. 28

The posterior nares, after the removal of the tumour represented in fig. 6. *a*. The abraded surface from which the tumour was torn. *b*. The middle, and *c*, the inferior turbinated bone. *e*. The Eustachian Tube.

were seen attached to the middle turbinated bone, which had before been concealed by the tumour (fig. 28). The tumour had evidently been a mucous cyst. This case occurred ten years ago; and I heard only a few days ago that there has been no return of the disease. The practical value of rhinoscopy in this case can scarcely be questioned. It is doubtful whether, by any other mode of examination, the position and nature of the tumour could have been determined with sufficient certainty to warrant an operation for its removal."

A similar form of cyst occurred to me some years ago. It was associated with villous growths on the posterior extremity of the inferior turbinate body (see Case IV in Sub-section I of this Section).

In Zuckerkandl's work on the diseases of the nasal fossæ, he gives a section of the bones of the nasal fossæ showing a *cystic hypertrophy* of the middle turbinate.

In the *Proceedings of the Med. Soc. Lond.* (vol. iii, p. 134), a case of mine is recorded which might be more properly described as a *cyst-bearing polypus* than as a cyst. It was that of a girl, æt. 15 years, who had been troubled with a discharge from the left nostril for several years, together with steadily-increasing stenosis of this side. Examination revealed a polypus, which arising in the region of the middle turbinate, had displaced the nasal process of the superior maxillary bone outwards to a

certain extent. The growth was removed with the snare, and was found to be a *multilocular cyst*, some of the cavities being as large as a split pea. The cavities contained mucus and columnar epithelium. A tumour afterwards made its appearance high up in the right nostril. It is not very uncommon to meet with small adenomata which have undergone cystic degeneration in gelatinous polypi, but they are so small, as a rule, that they are scarcely recognized as cysts.

## SECTION V.

- SUB-SECTION 1. Gelatinous Polypi.  
 „ 2. Epistaxis.  
 „ 3. Foreign Bodies.  
 „ 4. Rhinolithes or Nasal Calculi.  
 „ 5. Entomozoaria.  
 „ 6. Peenash.

## SUB-SECTION 1.


*Gelatinous or Mucous Polypi.*

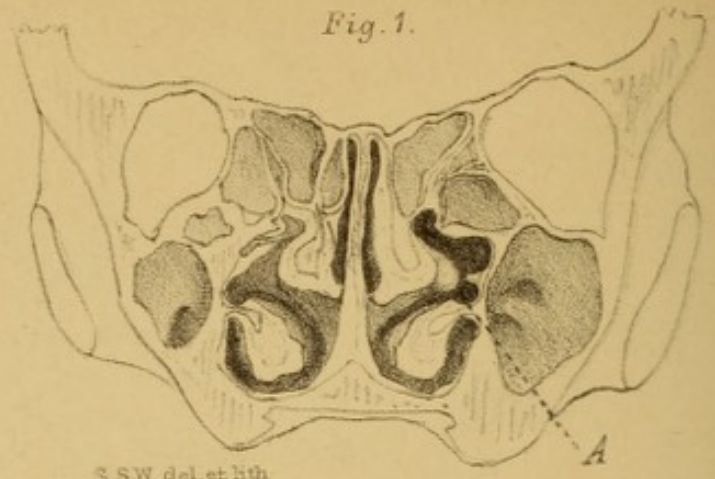
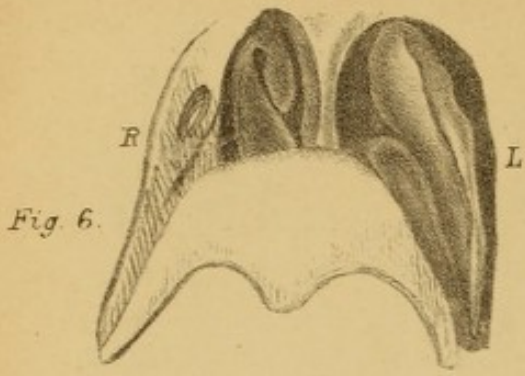
THESE growths form a class intermediate between the simple hypertrophy of the mucous membrane and the tumours springing from it. They may, in fact, be regarded either as local hypertrophies of the mucous membrane and submucous tissue, or as myxomata or sarcomata of the submucous areolar tissue, with the possibility in some cases of being adenomata of the mucous membrane itself. Their most common seat is the outer wall of the middle meatus, but they may, in fact, spring from any part\* of the nasal fossæ or their sinuses, except the floor and roof, though there is no recorded instance of a mucous polypus growing from the septum nasi, except one specimen in the museum of St. Thomas's Hospital (Section I, 3). Polypi occur in the course of various forms of catarrhal rhinitis, *e.g.*, chronic coryza, hypertrophic and caseous rhinitis. According to one author they are frequently associated with "necrosing ethmoiditis," and in a paper read by him before the Medical Society of London, specimens of bone from the ethmoid were exhibited, showing erosions and necroses of the bones. My own experience does not confirm this view, and I have reason to believe that this condition of the bones is not at all common in association with gelatinous polypi. Probing the ethmoid in search of bare spots of bone is a somewhat doubtful means of diagnosis, and this kind of examination may possibly excite the necrosing ethmoiditis which is subsequently discovered. They

\* See Plate III, fig. 4, where there is polypus springing from the lip of the orifice of the antrum of Highmore. There is a specimen in King's College Museum of a polypus hanging down into the nostril, the pedicle of which springs from the frontal sinus. (See Plate III, 1st edition of this work, fig. 7.)

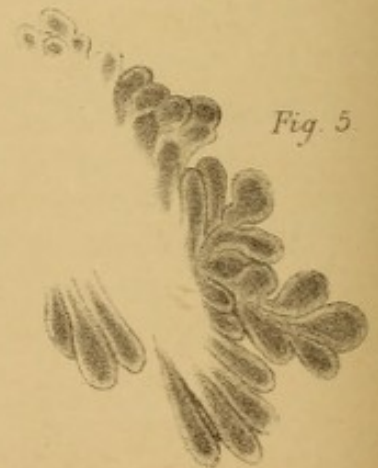
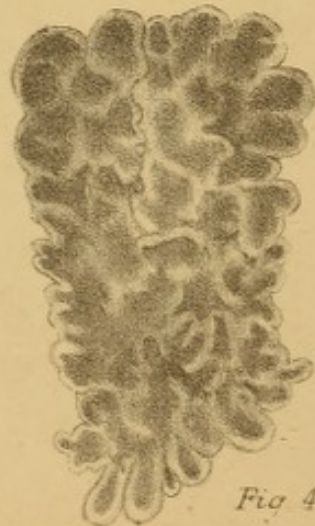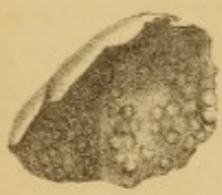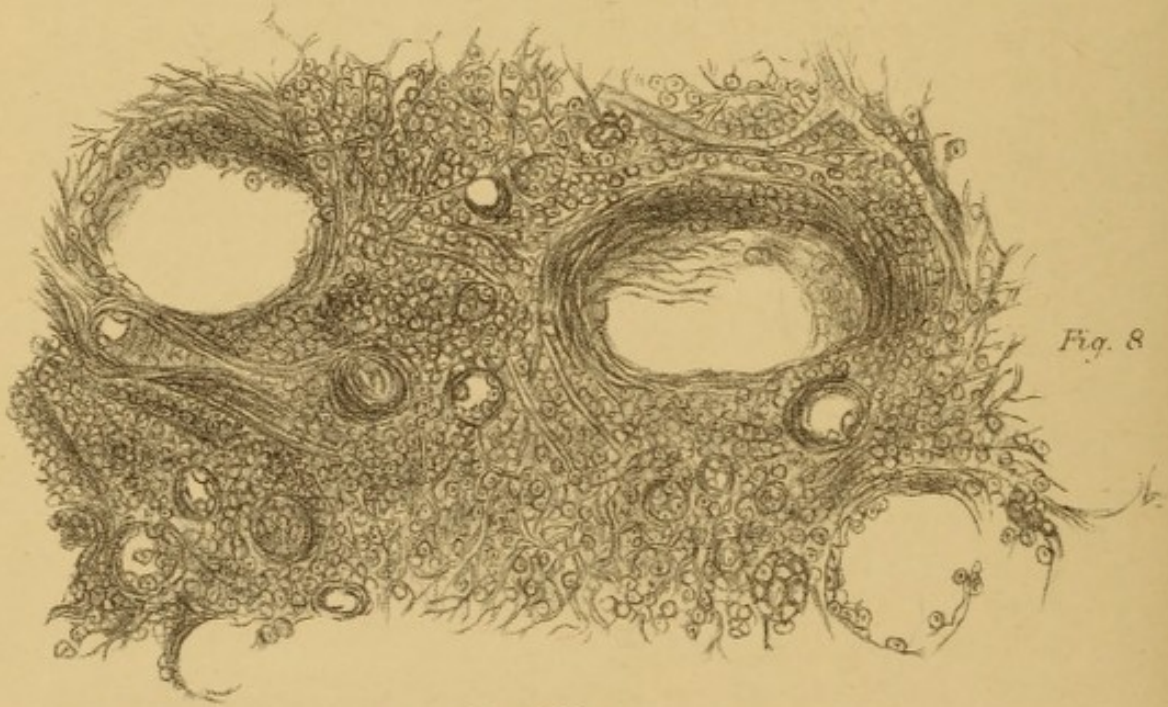
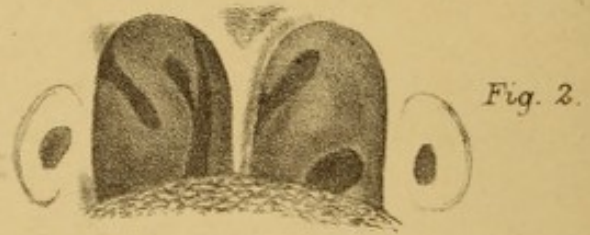
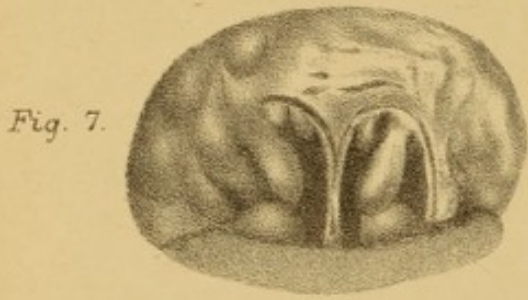


vary in form, but for the most part are attached to the mucous membrane by a narrow pedicle or neck, and have the free extremities bulbous or pear-shaped. According to Zuckerkandl (p. 75, on Intra-Nasal Inflammatory Affections and Intra-Nasal Growths), the following are the principal points of attachment of polypi:—(a) On the lips of the hiatus semilunaris (*op. cit.*, Plate I, fig. 3 b); (b) On the infundibulum (*op. cit.*, Plate IV, fig. 18 b); (c) On the ostium ethmoidale; (d) On the ostium frontale or maxillare (see woodcut, fig. 60 b); (e) On the border of the middle turbinated bone (middle and lateral edge of the lower border); (f) On the lips of an accessory groove which is sometimes found on the medial surface of the middle turbinated bone; (g) On the *Bulla ethmoidalis* (see woodcut, fig. 61 d); (h) In the labyrinth of the æthmoid; and (i) On the septum, consequently in a predominant degree in the *respiratory portion* of the nasal cavities. He has not met with polypi originating either from the inferior or superior boundaries of the nostril, nor on the lower turbinated bone. Out of 39 cases of nasal polypi, Zuckerkandl states that in 29 instances the growths sprang from portions of the lateral wall. In regard to the instances of growths *from the bottom of the infundibulum* he remarks on the difficulty of extirpating such growths. "It is a well-known fact," he continues, "that *nasal polypi often recur*, and that such recurrence is not always due to one and the same cause. It is easy to overlook small, deeply-seated polypi, and when the large ones are removed, any growth which sooner or later appears is regarded as a recurrence of a polypus presumably not fully removed." "I will now endeavour to criticize my own cases and compare them with this statement. In the case of growths originating at the edge of the middle turbinated bone or at the lips of the semilunar fissure, I will allow that the surgeon can get at the insertion of the pedicle, and radically remove the tumour, though it will not be easy to do this when dealing with polypi with broad pedicles. I will also admit the possibility of reaching the base of a polypus springing from the angular borders of the superior meatus; but in the case of polypi springing from the bottom of the infundibulum, from the ostium frontale, maxillare or ethmoidale, or from the fundus of the superior meatus, it is ridiculous to suppose that they can be fully removed either by evulsion or by means of the snare. In polypi of this kind a portion of the pedicle always remains.





S.S.W. del. et lith.



*Description of Plate II.*

Fig. 1. A vertical section through the middle of the nasal fossæ, in which there is hypertrophy of the turbinated bodies on both sides, and a small polypus (marked A) in the middle meatus of one side (after Zuckerkandl).

Fig. 2. A rhinoscopic view of the posterior nares, showing the superior and middle meatus, the turbinated bones, and the orifices of the Eustachian tubes (after Czermak.)

Fig. 3. A portion of the lining membrane of the antrum, near its orifice of communication with the nostrils, after preparation by soaking in dilute nitric acid; the glands are seen as described in the text, magnified 2 diameters (after Giraldès).

Fig. 4. A gland from a portion of the same (magnified 60 diameters) (after Giraldès).

Fig. 5. A portion of a gland from the same (magnified 80 diameters) (after Giraldès).

Fig. 6. Rhinoscopic view of the posterior nares and of the velum palati, on the side (R) the orifice of the Eustachian tube is seen, which, on the other side (L) is covered by two tumours (after Czermak).

Fig. 7. Adenoid vegetations in the naso-pharyngeal cavity, cylindrical vegetations on right lateral wall of the naso-pharyngeal cavity, covering the opening of the Eustachian tube; remains of vegetations after operations on fornix and left lateral wall (after W. Meyer).

Fig. 8. Microscopical view of a section of the adenoid vegetation from the fornix in the case represented in fig. 7 (magnified 300 diameters) (after Dr. W. Meyer).

Faint, illegible text, possibly bleed-through from the reverse side of the page. The text is too light to transcribe accurately.

Under the most favourable circumstances the edges of the semilunar fissure and of the superior meatus can be reached by the snare; any portion of the pedicle which is attached above these edges, always remains behind, and when polypi are thus inserted, there is always a cause for recurrence after every operation. In my opinion, a radical removal of such polypi is possible only when the *nest* can be exposed to which the pedicle is attached, unless after the ordinary operation it were possible, aided by rhinoscopy, to penetrate into the furrows and destroy the remainder of the growths. I think that *in dealing with such growths, the forceps will prove more effectual than the snare.*" I quite endorse this opinion, and think besides, that when polypi are thus situated the removal of portions of the middle and sometimes of the inferior turbinated bone will much facilitate the complete extirpation of the growths, and especially in those not uncommon instances in which hypertrophy of these bones is associated with the polypi. For this purpose my *ring-knife* is a very efficient instrument, and can be used rapidly and safely (see Plate II, fig. 1.)

With regard to their form, polypi may be lobulated, or may occur as single pear-shaped or oval masses, and their size may vary from that of a pea or smaller, to the size of a walnut or even larger. The surface is smooth, moist, and covered with a continuation of the mucous covering of the nasal fossæ, but their aspect, when seen from the anterior nares, is different from that of the normal mucous membrane. They have a semi-transparent greyish-yellow colour, with a tense distended appearance, as if from being full of serum, though with a certain proportion of vessels ramifying upon them. When touched they do not easily bleed at their free extremities, but the attached pedicle is very vascular, and bleeds when touched or pulled. There are generally several in the nostril at the same time, very seldom a single one by itself. If they are attached near the anterior nares, they in process of growth make their appearance at the orifice, or they distend the nostrils, and press them outwards, encroaching upon the adjacent bones and pushing the walls of the antrum before them, distending the whole of the upper part of the face and cheek, and producing a hideous deformity of the features quite characteristic of intranasal growths (though not specially of mucous polypi), which is known by surgeons as the "frog face." Lastly, if attached

further back, these growths encroach upon the pharynx and block up the posterior nares, hanging down even below the level of the soft palate.

*Minute Structure.*—There are two varieties—1, the simple sarcoma\* of the submucous tissue, overspread by mucous membrane with pavement epithelium with vibratile cilia; and 2, the adenomatous form. These latter have the mucous glands of the part very much multiplied and hypertrophied, and in them also there is a great increase in the submucous areolar tissue. The mucous surface is in this variety also covered with ciliated epithelium. In both there is an œdematous condition of the areolar tissue, of which they are principally composed. They are sometimes cystiform, the soft gelatinous or semifluid interior being hollowed out into one or more areolar spaces; but this is an exceedingly rare condition in the simple mucous polypus. They are sometimes called *vesicular*, but this name is applied equally to both varieties. It is not difficult to account for their shape and pendulous condition. Being composed in great part of serous fluid, there is a constant tendency for this fluid to gravitate to the bottom of the growth; and the neck is stretched, compressed, and narrowed by the extension thus made on it. The shape of the nasal fossæ also favours the production of the pear shape, there being more room for expansion at the lower part of the cavity than above.

The section of a simple mucous polypus is semi-transparent, as if the meshes of the areolar tissue were filled with clear serum, but in a few cases there is also a more opaque tissue occupying some portion of the growth, and this is more particularly observed in those in which the polypus has recurred again and again after removal. It is also asserted that simple myxomatous polypi are sometimes transformed into malignant tumours, in which epitheliomatous processes are found invading the simpler original growth.

Dr. F. Schiffers, of Liege (*Memoire lu au Congrès International de Laryngologie et d'Otologie de Paris, Septembre, 1889*), gives two well-marked instances in point. Whenever,

\* The use of the term "sarcoma" to describe the gelatinous form of polypus is in the sense of its being a hyperplasia of a normal simple tissue, as distinguished from the more complex growths developed in glandular structures. It is very commonly described as myxoma, and the microscopic structure certainly justifies this designation.

therefore, in an elderly person one nostril only is obstructed by a growth having the outward characters of a simple myxomatous polypus, it is well to be cautious in our diagnosis and prognosis, and especially if the growth is implanted on the septum or floor or roof of the cavity. Dr. John Harley kindly examined a tumour of this kind removed by me at King's College Hospital, in July, 1864. The opacity of a part of the growth in this case was due to the organization of the fine molecular matrix in which the ordinary mucous corpuscles are embedded. The microscopic structure was the same in the opaque white parts, and in the transparent jelly-like parts, being composed of round or oval, granular, sometimes poli-nucleated corpuscles, of the average diameter of  $\frac{1}{3000}$  of an inch. They are separated by intervals of less than half their width (fig. 8 on Plate IV), being embedded in a faintly granular or faintly fibrous matrix. On loosening the corpuscular mass, the granular matrix is found to envelop the corpuscles, and to be separable into soft fusiform fibres, in the centre of which the corpuscles lie, forming distinct nuclei to them. The diameter of these fibres is at their widest part a little more than that of the corpuscle. The attenuated extremities of the spindle-shaped mucous fibres are often prolonged into clear homogeneous structureless membrane; the fibres measure the  $\frac{1}{8000}$  of an inch. (Fig. 8, Plate IV.).

A third variety occasionally occurs in the form of small papillomata (soft warts), but these are exceedingly rare, unless indeed the early stage of the ordinary polypus appears under this form. (Billroth's "Surgical Pathology and Therapeutics," p. 616). (See Section IV, Sub-Section 1, figs. 21 to 24.)

*Symptoms.*—The first symptoms are similar to those of a slight nasal catarrh. The patient experiences a feeling of fulness and discomfort in the nostril affected, and he feels a constant desire to expel something that obstructs his breathing and the free current of air through it. He has continual snuffling respiration, the sense of smell is deadened, and the voice becomes nasal in character. By-and-bye the nostril becomes completely obstructed, and then the finger passed up meets with the polypus, which is now also visible on inspection by the surgeon. If both nostrils are equally affected at the same time, the obstruction to breathing is very inconvenient, and the patient is obliged to keep his mouth constantly open; but, as a rule, the obstruction is not allowed to involve both sides without some surgical



aid having been rendered in time to prevent this. If the growth increases, it may obstruct the nasal duct, and a lachrymal abscess then forms and bursts on the cheek, or at least the tear passage becomes so much obstructed that there is constant overflow from the eye on to the cheek (epiphora), and very possibly mucocele of the lachrymal sac. When the patient blows his nose violently, he can force the growth lower down towards the orifice of the nostril, and by a deep inspiration those polypi that are nearest the posterior nares may be drawn down into the pharynx. They become less bulky in dry warm weather, and more so in cold and damp weather; so that the patient experiences much more discomfort in the latter, and great relief in the former. They are not accompanied by pain, and grow very slowly. They give rise, however, to great discomfort, especially in the impediment to respiration and the loss of smell with which they are accompanied, and occasionally deafness is added to the other discomforts. In common with other forms of nasal stenosis polypi give rise to asthma. (See Dr. Bosworth on Asthma, with an analysis of eighty cases with especial reference to its relation to local diseases of the upper air tract. *American Journal of the Medical Sciences* for September, 1888.) (See also *infra*, Section XII.)

Epistaxis is an occasional symptom, and sneezing is apt to occur in sudden changes of temperature of the air.

In the very advanced stages, the extension of the growth may obstruct the free passage of the tears down the nasal duct; and, still later, may press upon the contents of the orbit, and thrust the eyeball partly out of its normal position, causing exophthalmus.

An unusual effect of the long continuance of polypi is to cause thickening of the nasal bones and cartilages, as well as their lateral expansion. In a large nasal polypus operated on by Sir W. Fergusson, at King's College Hospital, and recorded in the *Medical Times and Gazette* for October 19, 1867, this unusual thickening of the bones and cartilages was remarked upon by Sir William, as being an exceedingly rare condition. As a rule, they are very much thinned as well as expanded.

*Diagnosis.*—The above detailed symptoms lead to an almost certain conclusion, that we have to deal with a mucous polypus, but rhinoscopy, generally of the anterior nares only, without any aid from the speculum, will make the matter clear to a surgeon.

who is familiar with the appearance of these growths. The greyish-yellow or greenish shining surface projecting from the upper part of the nares is unmistakable in most cases. But there are a few occasionally seen in the early stage in which it is not so easy to say at once whether the growth is a mucous polypus, or one of a fibro-sarcomatous nature. The latter, however, are generally more dense-looking, of a deeper tint, and firmer to the touch. The simple mucous polypus when touched by the probe lightly, dimples and at once returns to its former shape, yielding before the probe as if soft and elastic; whereas the fibro-sarcomatous polypus when touched, offers much more resistance, and is very likely to bleed.

A chronic thickening of the mucous membrane covering the lower turbinated bone sometimes simulates polypus. This will be distinguished after thoroughly cleansing the part with the syringe, by observing its red colour and dense aspect; and by passing a probe along its attached border it will be found to extend a considerable distance into the nostril, and to have no narrow pedicle, such as is almost invariably the case with mucous polypi.

Other growths, such as malignant, osseous, or cartilaginous tumours and foreign bodies, will be distinguished by their colour and hardness, as well as by the previous history and present condition of the patient.

Cases of distension of a portion of the ethmoidal cells by mucus, may sometimes present to the eye the appearance of mucous polypi. Two specimens in St. Thomas's Hospital Museum illustrate this point of diagnosis ("Museum Catalogue," Section I, Nos. 14 and 15). In the first is seen "immediately above the foramen into the antrum, a smooth, rounded, convex projection from the roof of the middle chamber; a section through this prominence has been made, showing it to depend simply upon an enlargement of one of the posterior ethmoidal cells."

In the second specimen, "projecting from the roof of the middle chamber at the anterior part, is a smooth, regularly convex, oval tumour, measuring seven lines in its long diameter, and four lines in breadth. This tumour was considered to be of the nature of ordinary polypus of the nose, but is shown on section to depend simply upon an enlarged and dilated condition of one of the anterior ethmoidal cells."

The diagnosis would be easily made in such cases by using

the probe, when the surface would be found to be hard and resistant, and a puncture would confirm it, by allowing the escape of pent-up mucus.

Abscess or blood tumour of the septum, or chronic thickening of this part, may occasionally so far obstruct the nostril, that it is at first difficult to ascertain where the swelling springs from. It will be better, under such circumstances, to use a probe as an aid in diagnosis, and by passing it around the swelling it will be ascertained that the base is broad and comes from the inner wall of the fossa. It is besides of a red colour in the early stage, and later on the associated heat and pain of the surrounding parts point distinctly to inflammation as the cause of the swelling.

Besides ascertaining the nature of the polypus, it is important, if possible, to ascertain exactly its point of attachment. This can only be done by passing up a probe, curved to any form thought most convenient, and endeavouring to hook it round the pedicle; where it meets with resistance it is evident that that is the point at which the polypus is attached.

It is also well to ascertain whether there are several polypi or only a single one. As a rule they are multiple, and not unfrequently after the removal of the growth visible through the anterior nares, others come into view sooner or later; a single polypus is a very rare thing.

*Treatment.*—Various dessicative applications have been used for the purpose of drying up the smaller varieties, and in the early stages they have an undoubted efficacy. Mr. Bryant has employed finely powdered tannin for this purpose with great success, and Mr. Banks, of Liverpool, also speaks highly of this method of treatment. The powder is blown into the nostrils by means of a small tube to which an india-rubber ball is attached (fig. 30). It is probable that the small vesicular polypi, and those of a papillomatous nature are the varieties in which this method of treatment has been successful; and in

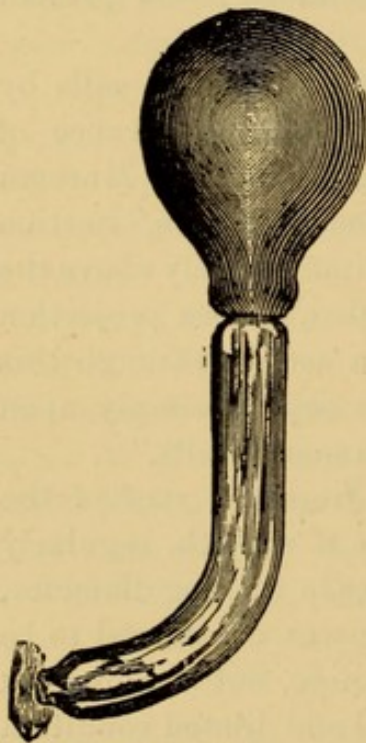


Fig. 30.  
S. Watson's insufflator, made  
by Messrs. Krohne and  
Sesemann.

all cases in which the tumour is small and soft, there is every prospect of a temporary relief, if not of a permanent cure, by steadily using the tannin powder for a few weeks, two or three times a day. If, however, the polypus has attained to any size, it becomes very difficult to apply powder efficiently, and we must then resort to more decided measures.

As a preliminary to all operations for the removal of nasal polypi when a general anæsthetic is not desirable, I employ a solution of cocain. The best way of applying this is to saturate a pledget of cotton wool fixed firmly on the end of a Watson's stylet, with a 10 or 20 per cent. solution. The solution used should be freshly made, and an addition of an equal proportion of glycerine to the water gives it a greater viscidty, and enables it to penetrate deeper into the cavity. It should be applied not only on the growths, but freely over the septum, and floor, and walls of the cavity, and if possible beyond the seat of implantation of the polypus. This stylet is made by Messrs. Wright, of Bond Street.

Tearing away the polypus by means of the forceps is a safe and efficient measure, taking care to seize the neck or pedicle as close as possible to its attachment and twisting it off at this point. Very free bleeding always follows, but this is easily arrested by syringing with cold water, or even by causing the patient to snuff up water by forced inspirations.

The best form of snare is that known as Krause's. It has the advantage that the loop of wire is easily fitted and quickly re-adjusted after use. The length of the tube is also an advantage, as the hand of the operator is kept well out of the line of sight (fig. 31).

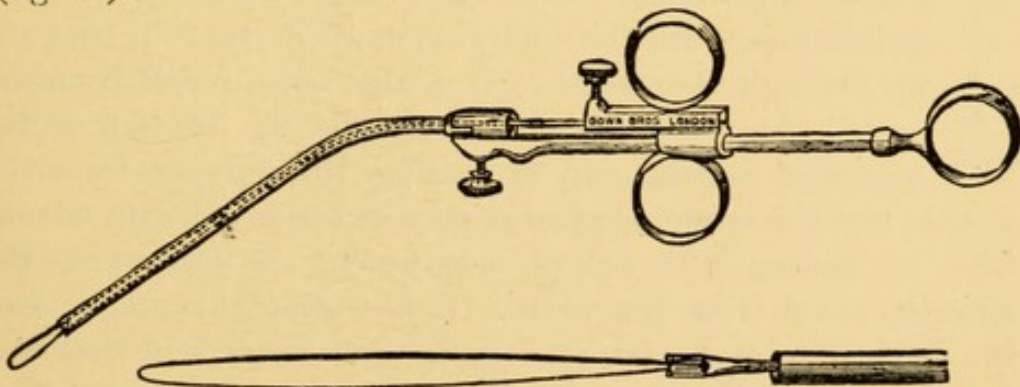


Fig 31.  
Krause's Snare.

In order to get the loop of thin piano wire well up round the pedicle of the polypus, it is necessary to ascertain the point of

attachment very accurately, and then to guide it over the bulbous extremity, pushing it well home by means of a fork-shaped guide. The pedicle can then be strangulated by tightening the wire loop; and if this is done slowly and cautiously, the bleeding may be reduced to a mere nothing. In the case of polypi presenting through the posterior nares and hanging down into the pharynx, it is necessary, as a preliminary step, to get the loop of the wire snare through the floor of the nose into the pharynx, and to draw it into the mouth by means of the finger passed behind the soft palate, or by catching it with a pair of forceps as soon as it appears in the back of the throat. A still better method, however, is—(1) to pass Bellocq's sound, the eye of the stylet of which is armed with a stout silk thread, through the nares; (2) to seize with forceps the thread as soon as it appears in the pharynx and draw one end out of the mouth; (3) to withdraw the sound through the nose, bringing with it the other end of the thread; (4) to attach the nasal end of the thread to the wire loop of the snare, and by pulling upon the



Fig. 32.

end of the thread hanging from the mouth, draw it along the floor of the nares into the pharynx. Though this description is somewhat long, the actual performance of these manœuvres is a matter of a very few seconds, provided no unusual difficulties present themselves. The loop is then slipped over the polypus and the wire withdrawn into the nasal fossæ. A ligature then passed through the pharyngeal end of the polypus and brought out at the mouth will facilitate its removal after the pedicle has been cut through by the wire; but if this cannot be accomplished, it may be allowed to fall down into the pharynx, and will then be coughed up through the mouth. If within easy reach from the mouth, the cork-screw shaped tractor (fig. 32) is a useful means of seizing and extracting the polypus from the mouth, and the same instrument may be employed with advantage in dealing with polypi, whether by the forceps or the anterior snare from the nares. It has some advantages over the beaked forceps: 1st, it occupies less space, and does not interfere with the view of the parts; 2nd, it holds more firmly and can be made to twist the tumour on its own axis by a simple movement of the operator's fingers, the movement by means of forceps necessitating a much firmer

grip and the growth being more likely to slip away during the twisting manœuvre. I scarcely ever use the galvanic cautery wire snare, as it can only be employed in exceptional cases and when the patient is very well under control.

When it is desirable to remove portions of the turbinated bodies with the polypi (as in the cases of multiple papillomata, Section IV, Sub-Section 1), I believe the use of a general anæsthetic is almost always necessary, and the "*ring-knife*" is the best instrument for the purpose. It is more effectual, thorough, and rapid than any other instrument, and though there is considerable bleeding after its use, the relief afforded is so complete and so speedy that in these not very uncommon cases it is by far the best method of operating. I have in one or two cases operated by this method without a general anæsthetic, but by a previous free application of a strong (20 per cent.) solution of cocain to the parts (fig. 9, Section IV).

When the patient is well under control the *galvanic cautery snare* (Sajous' or Schech's) may be used with effect. Bleeding is not so free when this instrument can be employed. But the most successful operators with the galvanic cautery snare require much patience, and many repetitions of the operation are necessary.

At the meeting of the British Medical Association in August, 1886, Dr. Wolston, of Edinburgh, one of the most successful operators with the electric cautery, brought forward a table of 34 cases of nasal polypi to show the results of this method of treatment. In some of these the number of polypi removed seems very large. In Case 27, 90 polypi were removed; in Case 8, 83; in Case 5, 68; in Case 4, 51; in Case 21, 76; in Case 11, 76. I think these figures will stand rather for the number of *pieces* of polypi cut off than for the number of polypi removed with their pedicles, and the obvious conclusion is that the operations must have consisted in a number of successive introductions of the cautery snare at each sitting. This method, therefore, however successful in its results, must be very tedious and trying to the endurance of both patient and operator.

The multiplicity of instruments devised for the purpose of treating polypi surgically, sufficiently demonstrates that very great difficulties in dealing with them are often experienced. I do not rely on any one method, but when operating

take care to provide myself with several sets of instruments, and when baffled by the failure of one method resort to some other which seems better adapted to meet the special difficulties of the case. For I think it will be allowed that in no cases are the circumstances met with precisely similar. Some unexpected complication, such as the presence of a distorted septum or a hypertrophied inferior turbinated bone, or a cartilaginous or bony outgrowth, is almost sure to present itself; and this complication, whatever it may be, must be dealt with on the spot and by some deviation from the original plan of the proposed operation. I desire to speak with considerable favour of Jarvis' snare. It is, next to Krause's, the most easily worked, and in some respects it is an improvement on Krause's, as it enables the operator to strangulate the pedicle very gradually and so avoids hæmorrhage.

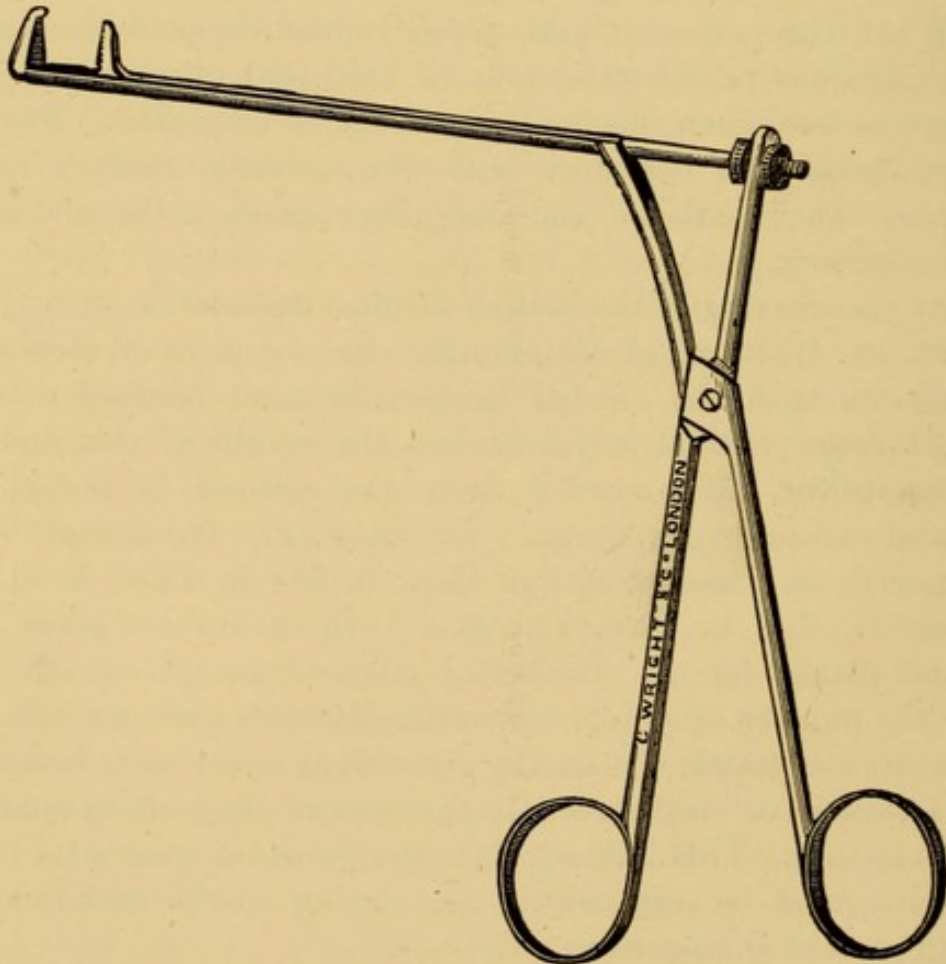


Fig. 33.  
Author's sliding polypus forceps.

I have often found the *sliding polypus forceps* (see fig. 33), made under my directions by Messrs. Wright, of Bond Street, useful

for removing polypi high up in the middle meatus and where forceps with larger blades could not be introduced. The pointed ends give a great advantage in enabling the operator to insinuate them into a very narrow channel.

By whatever method the polypi have been removed there is always a possibility that some portion of the pedicle or some smaller lobules remain behind. As soon, therefore, as the bleeding has ceased, the nasal fossæ should be thoroughly washed out by means of the douche syringe, and the region to which the polypus has been attached carefully examined. Any smaller growths should then be touched freely with chromic acid passed through a canula, either by means of the ordinary caustic holder or the jointed caustic holder (Earle's), and the pedicle treated in the same way. For the purpose of applying caustic to the posterior nares, a curved probe coated with a film of nitrate of silver is the best instrument, and if the pharynx is suitable for the use of the rhinoscope, its aid should be called in for the performance of this delicate operation. Subsequently the occasional use of finely powdered tannin, by means of the insufflator, will suffice to prevent any growths that are beyond the reach of caustic from taking on an active growth, and we may thus succeed in causing them to shrivel up entirely, and rid the patient of a very troublesome malady.

Sometimes polypi of very considerable size have been reduced to very small dimensions, and even destroyed by the use of powerful astringents. A very interesting instance of a case of a large polypus hanging behind the uvula in the throat successfully treated by the injection of a solution of perchloride of iron through the anterior nares, is recorded in the *New York Medical Record* of October 1st, 1868.

The description so far given of the treatment refers only to the more numerous class of cases met with in practice in which the polypi have only attained such dimensions that it is possible to reach them through the normal apertures of the nasal fossæ, either in front or from behind; but it every now and then happens that the disease has been allowed to go on to such an extent that the whole of the tissues, including the surrounding bones, have been thrust out and distended in every direction, the whole cavity being occupied by a closely-packed mass of lobulated polypi, some portions of them protruding from the nasal orifices in front and others hanging down in the pharynx.



Even under these circumstances it is well to attempt the removal of the mass without dividing any of the tissues with the knife; and if the ordinary polypus forceps cannot be introduced through the anterior nares, a pair with separable branches jointed like the ordinary midwifery forceps, may be used; each branch being passed separately, and the two united at the joint after they have been adjusted to the proper position with their points at the pedicle. A portion of the mass having been torn away, even though the whole of the polypus seized may not have come away in the first attempt, more room will be available for subsequent attempts, and in this way very large mucous polypi have been extracted.

It is very rarely necessary for the removal of mucous polypi, however large, to enlarge the anterior aperture of the nares, but if it is found impossible to reach them by any of the means mentioned in consequence of their having expanded the bones and become almost embedded in the upper jaw, encroaching upon the antrum in their progress, then the division of the ala in the line of the sulcus near the cheek will give a good deal more available space. The resulting scar after this operation is insignificant, and the proceeding does not add anything to the dangers or difficulties of the case. Dr. Thudichum, in order to make room for the introduction of instruments, dilates the nostril by introducing into it as many strips of *laminaria digitata* as are required to fill it. They swell up by the imbibition of moisture and effect a gradual distension of the cartilaginous parts. He also advises in some cases forcible dilatation by means of strong forceps made somewhat in the form of Liston's speculum. (See *Lancet* for Sept. 5, 1868.) It has been found necessary, when very large polypi are situated very far back in the nostrils, to make a button-hole opening in the soft palate and draw the polypus down through it into the mouth. Such a case occurred to M. Manne, a surgeon of Avignon, in 1747. The polypus filled the nostril, projected into the fauces, and completely closed the opening of the nares in front. Manne attempted to extirpate the posterior mass, but the soft palate, tightly distended by the tumour, presented invincible obstacles to his doing so, so that he determined to lay open the soft palate, in the median line. He then cut off several portions of the tumour, and passed threads through the part remaining. By pulling on the threads at the same time that he pushed it forwards with

his fingers in the fauces behind the mass, he at length broke through the pedicle, and the noise made by its sudden escape through the aperture was like that of drawing a cork out of a bottle. A second polypus showed itself soon after; this was removed and the cure was complete. The method of removing polypi simply by means of the fingers has been practised by Morand and Sabatier, and also by Professor Gross. One finger is passed into the nostril in front and another through the posterior nares behind, and by alternately pushing backwards and forwards the pedicle at length gives way. The cases of large firm growths are those most suitable for this proceeding, and it cannot be applied as a rule to mucous polypi, nor to those that are attached high up in the nares, nor to those with very broad or very firm pedicles. Professor Gross's case was one of a large gelatinoid polypus, with a very narrow foot-stalk (attached to the posterior extremity of the inferior spongy bone), which was therefore easily torn asunder. This, therefore, was an exceptionally favourable case for this method of treatment.

Various other methods of snaring, ligaturing, cauterising, and burning off polypi are described by authors: some of these will be referred to in speaking of the fibroid and fibrous growths that are occasionally found in the nostrils and naso-pharyngeal region, and to the treatment of which they are more especially applicable.

#### SUB-SECTION 2.

*Epistaxis: its Varieties, Causes, Treatment—occasionally Symptomatic.*

Bleeding from the nose, being in the majority of instances either salutary or unimportant, is brought strikingly under the notice of the surgeon only when its copiousness, frequency, or persistence render it alarming to the patient and his friends.

It is, perhaps, the commonest of all hæmorrhages met with in medical or surgical practice, and when we consider the delicate structure of the nasal mucous membrane, the number of vessels with which it is supplied, and their very superficial course, the slight support afforded them by the surrounding parts, their continual exposure to irritating foreign bodies, and to great changes of temperature and moisture in the

atmosphere, it is not to be wondered at that this region is so frequently the seat of hæmorrhagic fluxes.

*Traumatic epistaxis* is the result of direct blows, or internal abrasions, the presence of foreign bodies, or such slight injuries as picking the nose, blowing the nose, or even violent sneezing. It comes on with a sudden gush, and, in most cases, soon ceases spontaneously. According to the nature and force of the injury, it may be more or less copious, and may come from one or both nostrils. When due to violent injury involving fracture of the base of the skull, the complication of bleeding from the ears is associated with it, and the epistaxis becomes merely symptomatic and unimportant as compared with the graver cerebral symptoms co-existing.

It sometimes happens after an injury that blood escaping from the posterior part of the nares finds its way down into the pharynx, and thus the patient may be losing a great quantity without any flowing through the nostrils, and without any visible cause for his growing pallor and faintness. It generally happens, however, that when the blood has been swallowed in any considerable quantity vomiting occurs, and coagulated blood appears in the vomit. But even this may not be sufficient to point to the real source of the hæmorrhage. So that, in all cases of obscure hæmatemesis, the possibility of some lesion in the pharynx or the posterior nares should be inquired for, and, if necessary, local pressure by plugging should be had recourse to.

In troublesome post-nasal flow during an operation on the anterior nares the use of a *temporary sponge-plug*, such as that shown in fig. 34, will be found very useful, especially in young children.

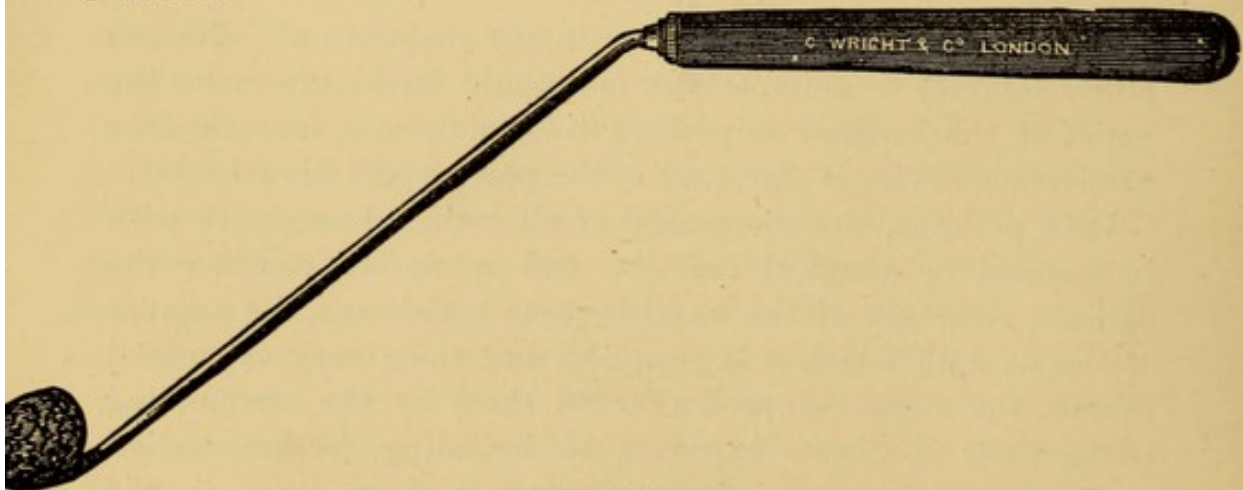


Fig. 34.  
Temporary sponge tampon.

*Spontaneous epistaxis* may be due to local causes, such as tumours, polypi, ulceration, or violent irritating powders that have found their way into the nostrils; or it may be due to obstructions in the general circulation, such as occurs in heart-disease, or splenic leucocythæmia, or uræmia. It is also occasionally a symptom of leucæmia, purpura, and scurvy, in which there is weakening of the vessels as well as a want of coagulability of the blood. Hæmophilia is also a cause, and in this disease there may be many members of the same family who habitually bleed from the nose. In acute vascular disease with retinal hæmorrhages, epistaxis is often a prominent symptom.

*Vicarious epistaxis* occurs in women whose menstrual flow is suppressed, and in persons of both sexes in whom an habitual discharge of blood is stopped from any cause. When the epistaxis is vicarious of the menstrual flow, it recurs at regular monthly intervals, and thus the diagnosis becomes clear.

According to Puech (*Moure's Manuel Pratique des Maladies des fosses nasales*, p. 225), bleeding from the nose is the most infrequent of the hæmorrhages that are observed in functional derangements of the uterus. He found that hæmorrhage from the stomach occurred 32 times, from the breast 25 times, from the lungs 24 times, and only 18 times from the nasal fossæ.

There is a tendency to epistaxis in boys and girls at about the age of puberty. In plethoric persons this gives relief, but if it becomes habitual it may lead to troublesome anæmia and other consequences.

*Epidemics of Epistaxis*.—A very fatal *epidemic*, characterized by bleeding from the nose, is recorded as having occurred in Etruria and Romandiola in the year 1200 (Morgagni, "De Sedibus et Causis," etc., epist. i, No. 25); and Gillchrist also mentions *epidemics* of nose bleeding.

Epistaxis is frequently the immediate cause of death in children with diphtheria. Dr. Thomas Parker Smith relates that he saw an epidemic of diphtheria when he was resident surgeon of the Stafford Infirmary in 1859 or 1860. Out of nearly 30 cases under his care, most of whom were children, about 12 died from epistaxis, and, in consequence of the age of the patients and the state of the fauces, it was impossible to plug the posterior nares. Dr. Parker Smith tried styptics of all kinds, and the patients were in every respect well cared for, but the results of treatment were very unsatisfactory. It is not

unlikely that the epidemics of epistaxis recorded by Morgagni and Gillchrist may have been diphtheria epidemics, that disease not having been accurately described or recognized at the periods of the outbreaks alluded to.

Epistaxis is also a common symptom in fevers and exanthemata, either as an early occurrence or in the crisis.

*Treatment.*—The principal function of the practitioner when called upon to treat a case of epistaxis is to decide whether interference is safe or desirable, and in the majority of cases he will decide in the negative.

When the epistaxis is vicarious, either of the menstrual flow or of some habitual hæmorrhage, as, for instance, from old standing piles, it will be improper in the first instance to attempt to check the flow of blood. Our first efforts in such cases must be towards restoring the habitual or normal evacuation. This done, the vicarious bleeding will cease of its own accord.

In plethoric persons of advanced years with indications of atheromatous disease of the arteries, bleeding from the nose is often rather salutary than otherwise, and it is unwise to check the flow unless it becomes alarming from its persistence or frequent recurrence.

Epistaxis following blows upon the nose is very seldom important, and in most instances may be stopped by causing a stream of cold water to be drawn up the nostrils by a forced inspiration. Cold applied to the root of the nose will assist the other remedy.

When from whatever cause the amount of blood lost is alarming, it becomes an important part of the surgeon's duties to allay terror and excitability on the part of the patient, and by a calm manner and soothing words to prevent him from increasing the difficulties of the case by restlessness and nervous agitation. The air of the room must be kept cool with a free current of air circulating around him, and, unless the weather happen to be unusually cold, he may be placed in a "thorough draught" without any danger. He should sit or stand with his head erect, his shoulders thrown well back, and his throat denuded of all neckcloths, or tight bands of any kind. Meanwhile the trickling of blood from the nostrils will cause a constant inclination on the part of the patient to bend the neck forwards. This must be resisted, and the dress protected by towels round the upper part of the chest and a sponge held up

to the nose. If, however, the attack of epistaxis occurs in a weakly person, and especially if much blood has been lost, the semi-recumbent posture will be more suitable, the shoulders being raised and supported between the scapulæ. Ice, if at hand, may be given by the mouth, thrust up the nostrils, and applied to the root of the nose and forehead. Any form of ice-bag will be convenient for applying the cold to the outside of the nose.

Dr. Chapman has found warmth applied to the back of the neck (by means of water in his india-rubber bag at a temperature of 115°) have a very decided effect in stopping hæmorrhage from the nose. And in some obstinate cases *hot water irrigation* of the nostrils will succeed.

M. Anquier mentions a case in which he was called to a young man of twenty who had been suffering for *three hours from violent epistaxis*. The patient had been subject to such attacks from infancy. M. Anquier tried in vain to stop the bleeding by means of cold water, plugging the nares, mustard plasters, etc. At last he irrigated the nose with *very hot water* with instant success. During the next night and day the friends of the youth were able by this means to stop at the outset several fresh outbreaks. The author thinks the hot water acted by producing a reflex contraction of the bleeding vessels, and not by encouraging the flow and so causing depletion of the superficial vessels, as has been supposed in reference to stoppage of the uterine vessels (*Practitioner*, February, 1883, p. 184).

When the bleeding is alarming, the posterior nares must be plugged, and in that case Bellocq's instrument will be required, or a gum elastic catheter, with a double loop of stout ligature thread passed down its channel and out at the eye of the instrument. This is carried along the floor of the nostrils, and the loop seized and drawn through the mouth; the catheter is then withdrawn from the nose leaving the thread lying within it,

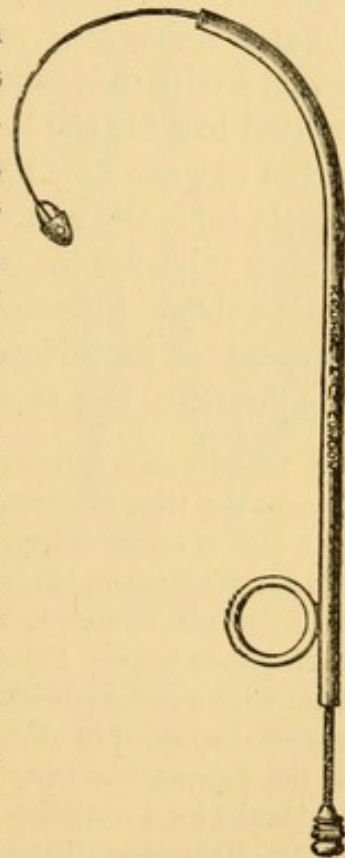


Fig. 35.  
Bellocq's Canula.

and passing out of the mouth. A dossil of lint of about the size of a man's thumb, is now tied in the middle of the double thread, one end of which is left hanging from the mouth, while the lint is drawn backwards by pulling upon the two ends passing from the nostrils (fig. 7, Plate IV). The lint becomes thus wedged tightly against the posterior aperture, and the escape of blood posteriorly is completely stopped. A plug of lint is now placed across the anterior aperture of the nostrils, and the two ends hanging from the nostril tied tightly over it. This answers the double purpose of keeping the posterior plug in position, and of plugging the anterior nares at the same time. It may then be necessary to plug the other nostril in the same way. At the end of thirty-six,\* or at latest forty-eight hours, the plugs should be removed, and the nasal fossæ syringed with a weak solution of alum or with cold water, until the clots are detached. Various ingenious contrivances have been suggested and devised, with a view to simplify the operation of plugging the posterior nares. The best apparatus of the kind is that invented by Dr. A. Cooper Rose, of Hampstead, and made under his direction by Mr. Coxeter, of Grafton Street. It consists of a gum elastic tube about 5 inches long, with lateral perforations near the end, and covered with thin caoutchouc membrane in the form of a spirally twisted bag for the last 3 or 4 inches of its length. The cavity of the bag can now be injected with air or water from the gum elastic tube, the end of which has fitted to it a piece of india-rubber tube, for the purpose of connecting it with a syringe or india-rubber injector. Practically, the mouth answers the purpose of an inflator for this instrument. To use it the membranous bag is smoothly folded over the contained tube,

\* There is some danger of inducing blood-poisoning if the plugs are retained beyond the time necessary to cause the formation of firmly adherent clots. In a case of severe epistaxis in the course of leucocythæmia, recorded by the late Dr. Habershon, plugging of the posterior nares was followed by death from pyæmia, though in this instance the plugs were removed at the end of twenty-four hours; the sinuses of the dura mater being found after death filled with a green pus-like fluid. (*Lancet*, Feb. 27, 1875.) The same result has also happened in other instances on record; but the constitutional state of the patient has more influence in determining these results than the accidental local condition due to plugging. I may mention, on the authority of Dr. Habershon, that among the accidents of plugging tetanus is said to have once followed.

and the whole being oiled is passed along the floor of the nares till it reaches the pharynx. The bag is now inflated or injected with water, and the expansion of the bag both in front and behind suffices to completely close both apertures (figs. 36 and 37).

If a stop-cock is fitted, the air or water is kept in by turning it as soon as sufficient tension is obtained, but the same object may be attained by tying the india-rubber connecting tube tightly up.

This is a much better, as well as much simpler apparatus than that of M. Martin St. Anges, in which the tube communicates with the bag at one end only, the bag itself hanging loose from the extremity of the tube, so that in order to introduce it into the nostrils it is necessary to push it along the floor of the nose on the end of a probe.

When it is desired to remove the plug, the water is let out by untying the india-rubber connecting tube or by turning on the stop-cock. The instrument is at once set free and removed without difficulty. This plan offers two advantages: the plug is more readily introduced and more easily withdrawn than by the method of plugging with Bellocq's instrument. If a sponge-tent is at hand, it may be used as a plug, leaving it in the nostril till the warmth of the part expands it. In removing it, however, there is some difficulty, as the rough surface of the sponge becomes somewhat closely united with the inequalities of the mucous surfaces, and hence it is only in cases of great urgency that this form of plug should be employed.

Another and easier method of plugging the posterior nares is the following. It is attributed by Dr. Ed. Hamilton (*Brit. Med. Journal*, May 8, 1880) to the late Josiah Smyly. I give the description of this method in Dr. Hamilton's words:—"I take a strip of linen material, three feet long; the width will be in proportion to the fineness of the texture; the coarser it is, the

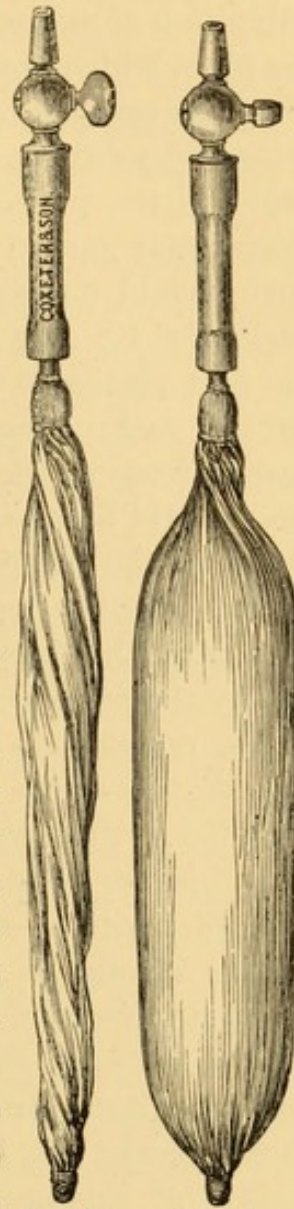


Fig. 36.

Fig. 37.



narrower it may be. We may take one inch wide as the standard. This may be soaked in some domestic astringent at hand, tea, alum-water, saturnine solutions; oil may be used, but it should be sparingly, as, although it greatly facilitates the introduction of the material, yet, as it interferes with the imbibition of moisture, it prevents the subsequent expansion of the plug, which is useful in checking the escape of blood by its compressing effect. The best of all fluids, if at hand, is a saturated solution of gallic acid in glycerine, which may be kept for the purpose. This has the advantage of combining astringency and styptic quality with lubrication. This strip of linen should be regarded as consisting of *three parts*, each intended for its own special position in the nostril. The end of the first portion should be grasped in the blades of a dressing forceps, and conveyed along the floor of the nostril to the posterior termination of that cavity; the remainder, about one foot, should be rapidly 'paid' by the finger and thumb into the cavity of the nostril. The solid mass thus formed should be forced along the floor of the nose, first with the little finger, and then with the dressing forceps or a pencil, until it is found to occupy the posterior nostril, and distinctly felt in it by *the finger, hooked round the soft palate*. This is far the most important part of the entire proceeding, being, as it were, the basis of operations. The second portion should now be paid into the nostril in the same way, and pressed by the finger and forceps into its position—the roof of the nose. The third and last portion should be pushed into the nostril, so as to occupy a position in front of and below the other two, and, being caught within the edge of the alar cartilage, will usually retain its position without trouble. I think it desirable that the material should not be cut, but retained as one continuous piece for the facility of subsequent removal; but too much care cannot be taken in disposing of the first portion."

It will not be necessary nor desirable to leave the plug in the nostril more than 24 hours.

Dr. Negrier, of Angers, France, has called the attention of the profession to a remedy which he has employed frequently and with uniform success in the treatment of epistaxis. It consists simply in causing the patient, in a standing posture, suddenly to raise one or both arms perpendicularly upward, and to retain them for a short time in this position. If only

one is raised it should be that of the side from which the hæmorrhage proceeds, and then the patient may compress the bleeding nostril with the other hand. In young children the surgeon may perform both offices for the patient. The remedy has always succeeded, even in very bad cases, when all other means had failed. The effect is almost instantaneous, and usually continues permanent, if the patient has lost a certain quantity of blood—say from six to nine ounces. The elevated position of the arm should be sustained a few minutes, in order to give the blood in the bleeding orifices time to coagulate.

Dr. Negrier explains the result by the consideration that as the blood in the erect position of the arm requires a much greater force to sustain it than when the arm is pendent, the energy of the heart's contraction must be in the same proportion diverted from the carotid to the subclavian. ("Archiv. Générales," 3me sér. xiv, 168: Wood's "Practice of Medicine," vol. ii, p. 294.)

Dr. T. Parker Smith found this method succeed in several cases while in India in charge of the 104th Regiment.

Sometimes pressure of the side of the nostril against the septum will arrest the bleeding, if it come from the lower part of the septum itself, as there is reason for thinking it not unfrequently does.

Mr. Banks, of Liverpool, has pointed out that in some rare instances the bleeding surface is situated in the upper part of the pharynx and behind the soft palate. In an obstinate case of this kind plugging the posterior nares failed to stop the bleeding, and there was evidently a flow of blood down the pharynx even after the nares were plugged, though there was no defect in the method of plugging or the efficiency with which it was carried out. Under these circumstances the plug was removed, and a strong solution of perchloride of iron was injected by means of the spray apparatus through one nostril, the other nostril being at the time closed and the mouth also kept closed. This method, persevered in for a fortnight, quite stopped the bleeding, and on its recurring was again resorted to with an equally good result.

In the epistaxis coming on during an attack of diphtheria, the treatment by the spray of perchloride of iron would be a valuable means of applying styptics, though in the young

patients, who are so often the subjects of this disease, it is very difficult to keep them quiet enough to admit of the required manipulation. In adults and manageable children, however, it can be employed with great advantage.

### SUB-SECTION 3.

*Foreign bodies* are often thrust up the nostrils by young children, and sometimes by the insane. It is then often impossible to obtain any history of the cause, and if the foreign body has been long in the nostril, the patient may be brought to us with symptoms of chronic ulcerative rhinitis, and with a fetid sanious or purulent discharge from the nostril. The nature of the foreign body is quite unknown, perhaps; it may be a button, or a stone, or a pea, or bean. It may be embedded in an ulcerated cavity with granulations springing up around it, and masking its characteristic form. If it be a pea or bean, it will, perhaps, have swollen up and germinated, and so given rise to complete occlusion of the nostril. The diagnosis can, however, always be made by means of the rhinoscope and the probe.

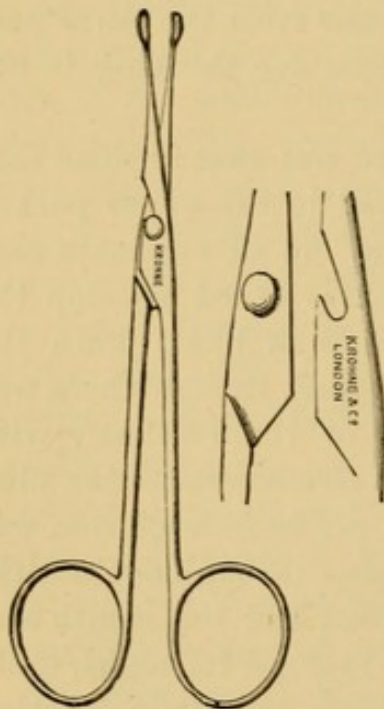


Fig. 38.  
Forceps with separable blades for  
removal of foreign bodies.

*Treatment.*—If seen early, the foreign body may be removed by exciting a fit of sneezing by tickling the anterior nares, or administering a pinch of snuff. Those means failing, the posterior nasal douche with a strong stream of water may be more successful. If seen later, Gross's ear-curette or an ear scoop will be most likely to dislodge it; and if it be larger than these instruments can deal with, a pair of forceps with separable blades, which can be interlocked after being passed separately, will probably succeed (see fig. 38).

Dr. Sajous suggests for the removal of foreign bodies far back (see *Sajous' Lectures on the Diseases of the Throat and Nose*, page 213) the following plan:—"A piece of slender wire is passed along the floor of the nose as far back as the

pharynx, withdrawing the end out of the mouth with forceps. A tampon of cotton wool or linen being securely attached to it, and drawn up behind the palate into the posterior nares, it is pulled through the nasal cavity along with the foreign body. In a case" (he continues) "in which a pebble could not be grasped, I passed two wires, one above and one under it, into the mouth, then tied a strong piece of tape between the two ends, thus forming a loop with which the foreign body was withdrawn as a cork is pulled out of the body of a bottle."

#### SUB-SECTION 4.

##### *Nasal Calculi—Rhinoliths.*

The concretions occasionally found in this cavity, and especially in the lower portion, under the inferior turbinated bone, are for the most part foreign bodies, around which mucous and phosphatic deposits have become agglutinated and hardened in successive layers. Graefe considers that the gouty dyscrasia favours the formation of these concretions; but it is unlikely that any true calculus, apart from the accidental presence of a nucleus consisting of a foreign body introduced from without, or projected from the pharynx in the process of deglutition, has ever been formed in this cavity. It is just possible that the crusts formed in chronic ozæna may, when retained for a lengthened period, become consolidated, and subsequently encrusted with carbonates and phosphates of lime, and hence give rise to a tolerably dense earthy mass; but such instances are extremely rare.

There is often associated with the concretion a distortion of the bones due to some congenital or traumatic cause of old standing. The obstruction due to a distorted septum favours the accumulation of inspissated mucus.

*Diagnosis.*—The account given by the patient of having introduced a foreign body into the nostrils will often guide the surgeon, but the probe and ocular inspection will be necessary before any certainty of the nature of the case can be arrived at. The diagnosis in some cases may be very difficult; a pea that had sprouted in the nasal cavities having been, in one recorded instance, mistaken for a polypus.

*Symptoms.*—(1). Fœtid discharge from one nostril which is

obstructed. (2). A greyish or brownish-green substance seen in the anterior nares which, when touched by the probe, is hard and rough on the surface, and embedded in a granulating surface. (3). This body may be movable. (4). There is sometimes severe pain and there may be reflex neuroses. In one case (Schmiegelow's case, vide infra) there was perspiration limited to one-half of the face, continuing for a long time. (5). A history of a foreign body having been introduced is rare. (6). The bulk of the calculus may thrust the septum to the opposite side.

*Treatment.*—The application of cocain (10 % solution) will greatly facilitate the extraction of the calculus both by causing local anæsthesia and by reducing the hyperæmia and swelling of the mucous membrane around it. It may then be seized and dislodged by the fenestrated scoop, or the fenestrated forceps with separable blades (see fig. 38, supra, in Sub-Section 3). But if too large to be extracted entire without lacerating the parts, it must be broken up by a drill or strong forceps, and extracted piecemeal, as we find was actually done in a case related in the *Gazette des Hôpitaux* for 1859. The patient suffered from attacks of severe pain, at first supposed to be neuralgic, but afterwards attributed to necrosis of the nasal bones. The calculus was at last discovered and crushed by lithotripsy at four sittings, and ultimately got rid of, but with some deformity of the nose remaining. It is hardly possible to lay down any universally applicable rules for the treatment of cases so varied in their circumstances, and so rarely met with in practice, but the fact that such cases as that last alluded to may be met with should be taken into account in the formation of a diagnosis in obscure cases. As another alternative in the treatment of large or firmly-fixed concretions, we may endeavour to thrust them backwards into the pharynx, if it is found that they are more movable in that direction than towards the anterior aperture.

The following cases illustrate the methods of treatment of this form of malady:—

*Author's Case of Rhinolith.*

A gentleman, æt. about 35 years, had an injury to his nose when about six years of age. The tip of the nose has been somewhat depressed ever since, but there is a good bridge and

the depression is due to some shrinking in the cartilaginous septum, which is curiously distorted. For some time past fragments of what the patient regarded as bone have from time to time escaped from the right nostril. On examining the nostril a piece of loose, hard substance was found occupying the floor of the nostril. It was slightly movable when touched by the probe. The canula forceps was employed and a piece of the substance, which was very brittle, removed. Another piece was broken away and removed by the same instrument. The patient then blew his nose rather forcibly and expelled a hard mass the size of a horse-bean, with very ragged and irregular surfaces, and with blood and pus occupying the hollows and interstices. Dr. Burnet made a careful examination of the fragments removed and could find *no bone-structure* in them. He regarded it as a concretion of earthy material.

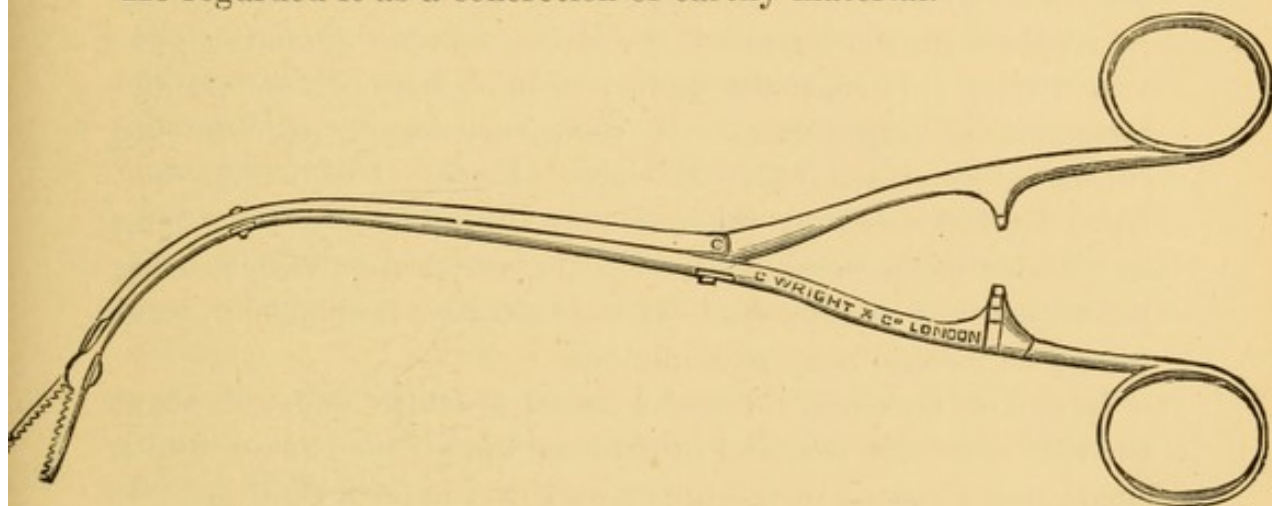


Fig. 39.  
Author's long crocodile forceps.

Two cases are reported by Dr. Chiari, Docent of the University of Vienna (*Annales des Maladies de l'oreille*, etc., January, 1890, p. 18 and *seq.*). In the first case, that of Mdlle. A. St.—æ. 22 years, the greyish-brown gritty substance covered with foetid mucus had as its nuclei *fragments of cork*, of the introduction of which into the nose the patient could give no account. In the second case (a little girl of 12 years of age), the calculus consisted of carbonate of lime in the centre of which was a hard round body which on microscopic examination consisted of *wood fibres and cellulules*. In both cases abundant *cocci* were found in the depressions on the surface of the calculus and in the foetid mucus covering them. Dr. Chiari suggests that the foreign bodies introduced into the nose form a surface of attraction for these

bacteria, which in their turn attract the lime salts of the mucus and favour their accumulation on the foreign body. Dr. Chiari reported another case of rhinolith (see *British Medical Journal*, October 31, 1885), the nucleus of which was a *metal button*. Mr. Cresswell Baber (*British Medical Journal*, October 17, 1885), reports a case of a calculus which consisted of a *boot button* encrusted with phosphates and carbonates. The patient was an adult, and the boot button must have been introduced when he was about four or five years of age. Dr. Schmiegelow, of Copenhagen, describes a remarkable case in the *Nordiskt. Medic. "Archiv."* (*British Medical Journal*, October 3, 1885). The patient was a man of 58 years of age, who had suffered for 16 years from a foetid purulent discharge from the left side of the nose, with complete obstruction. The obstructing body proved to be a calculus as large as a walnut, and required for its removal the employment of a strong *écraseur* extending over two sittings. It consisted mainly of phosphate of calcium and phosphate of magnesium, with some carbonate of calcium and traces of chlorides. Dr. Moriarty (*British Medical Journal*, April 10, 1886) relates the case of a large calculus occurring in a Mahomedan woman, *æt.* 24 years, which required crushing before it could be removed. It weighed two drachms and contained no foreign body as a nucleus.

In one of my cases I found a small greenish body, of about the size of a split pea, and in external appearance not unlike a small pea, situated in the upper part of the lachrymal sac. It was easily removed by making a small incision, and when cut across presented the appearance of hard putty, the earthy matter being held together by hardened mucus.

A very similar case is recorded in the *Pathological Transactions* (vol. xxiii, p. 293). A substance removed from the lower canaliculus resembled in shape, size, and colour a green pea. It appeared in the lower eyelid as a red inflammatory swelling projecting on both aspects, and forming a most unsightly prominence about the size of a hazel nut. The young lady from whom it was removed thought it was the *identical pea* which she had once when at school *thrust up her nostril*, and had never been able to get out again. It is clear, however, from the microscopic examination made by Dr. J. S. Bristowe, that it was nothing more than a mass of inspissated pus mixed with, and

held together by, vegetable organisms of a low type. It consisted, according to Dr. Bristowe's report, "first, of immense numbers of lowly vegetable organisms; and, second, large numbers of small, roundish or angular bodies, which, from their size, arrangement, optical properties, and behaviour, seem to be dead and disrupted nuclei of cells. The vegetable organisms, are, I think," says Dr. Bristowe, "chiefly dead and motionless bacteria, and fine confervoid filaments. The nuclei, or fragments of nuclei, are doubtless derived from pus or epithelium."

M. Cloquet ("Osphrésiologie," p. 627) gives the following instances of nasal calculi recorded by different authors. Th. Bartholin relates that a young Danish woman, after suffering from pains in the head for a long period, expelled from the nose several calculi of the size and shape of date-stones. Gab. Clauder saw a woman of 60, of a catarrhal constitution, who passed by the same passage a rounded, very hard concretion of the size of a hazel-nut. J. F. Khern witnessed the escape of four pea-shaped calculi from the nostrils of a young female suffering from violent headache, and whom he treated by the administration of errhines. Riedlin, D'Ulm, Buchner, Plater, and several others, have recorded instances of this remarkable affection.

Some remarkable cases are recorded by the late Mr. Cæsar Hawkins, in his "Contributions to Pathology and Surgery" (vol. i, p. 225).

In one of his cases, bodies like half-formed cartilage came away every now and then, looking as if they had been moulded to the superior spongy bone. The patient in this case was delicate and subject to hæmoptysis, and the nostril was usually obstructed for a day or two previously to their discharge.

In another case, a body presented in one nostril, looking exactly like a malignant polypus, associated with some external swelling of the parts and causing pain and obstruction in both nostrils; at last a substance projected lower than usual in the nostril, and a surgeon pulled out several substances like chalk in consistence, and exceedingly fœtid, and which were also in shape exactly like the spongy bones; they were probably composed of phosphate, or perhaps carbonate of lime, with fœtid mucus.



## SUB-SECTION 5.

*Maggots and other living foreign bodies in the nasal fossæ:  
“Peenash.”*

*Living foreign bodies* have been found in these cavities. In tropical countries, and more especially in British India, many instances have been recorded of persons having discharged larvæ from the nostrils after having experienced disturbances referable to the region of the frontal sinuses. Saltzmann thinks that the eggs of these worms enter the nostrils when in the act of smelling flowers or fruits in which they have been deposited by the moth. From the researches of Coquerel, a surgeon in the French Navy, who was temporarily stationed at Cayenne in French Guiana, and from those of his brother-officers St. Pair and Chapuis, it appears that in South America the maggots found in the nose are the larvæ of the *lucilia hominivora*. In 1862 the French Government having sent an expedition into Mexico, the nature of the disease of “myasis” of the nose was elucidated by the researches of Morel, Jacob, and Weber. Morel thinks the fly (*lucilia hominivora*) always enters the nostril during sleep, and that the persons attacked are for the most part patients suffering from *ozæna*. The mucous membrane becomes reduced to a pulp by the deposition of the eggs and the hatching of the larvæ. This disease attacks most commonly persons affected with *ozæna* or some form of foetid rhinitis; the flies being probably attracted by the stench proceeding from the nostrils.

The *symptoms* caused by the presence of maggots or larvæ in the nose are very striking, but not sufficiently so to lead to an unfailling diagnosis. Pain, sometimes violent, but always very troublesome, is felt in the front of the head, near the root of the nose. It sometimes extends to the temples or occiput. At one time there is only a tingling; at others an intolerable pain that causes fainting, vertigo, and even sudden and temporary blindness. Patients have been seized with maniacal delirium which has only stopped when the worms have been expelled. Pozzi and Schneider have both reported examples of this singular kind of mania. It is thought that the alternate calm and accessions of pain depend on the repose or movements of the insect.

Sometimes the nostril is dry; most commonly a foetid sanious discharge is the prominent symptom. Some patients have frequent sneezing and a continual desire to scratch the nose; some thrust their fingers continually into their nostrils; others dribble from the mouth; others again are tortured by the constant presence of foetid odours. Sleeplessness and delirium of a maniacal character are observed in the advanced stages. The headache is severe, and in some cases is continuous. If the disease is unchecked by treatment, the mucous membrane, bones and skin of the nose are all in turn destroyed. Convulsions, followed by coma, generally terminate the life in fatal cases.

*Treatment.*—This disorder is very difficult to recognize in the early stages, and consequently very difficult to treat, but the douche apparatus with the head inclined to one side and lower than the rest of the body, would offer some chance of dislodging the insects; and one saline solution having failed, the effect might be varied by trying another. Common salt is generally very distasteful to most grubs, caterpillars, and insects; but if this did not succeed, the permanganates or carbolic acid in very weak solution might be tried. The most effectual remedy is that proposed and employed by Dauzat, viz., inhalations and injections of chloroform, and this will probably supersede all others.

“Pure chloroform may be injected into the nostrils when inhalations are not effective, a procedure harmless to the membrane,” (Sajous, *op. cit.*, p. 215). In order to avoid the pain caused by the injection of pure chloroform the patient should be first put under the anæsthetic influence of the vapour of chloroform by inhalation.

Dr. W. R. Lawson states (*Medical Times and Gazette*, Feb. 6th, 1875) that in the case of a white soldier at Demerara, after the failure of injections of various descriptions, the insufflation of snuff produced a speedy cure, the tobacco acting as a poison on the maggots.

We are told, in the “*Ephemerides des Curieux de la Nature*,” that after an attack of epistaxis, a worm in the form of a leech came from the nostrils. This, however, was most probably only a clot of blood.

In the “*Annales de la Société Entomologique de France*” we find an account of a condemned prisoner, who died from the effects of a quantity of the larvæ of a fly (*Lucilia hominivora*)

having been deposited in his frontal sinuses and nasal fossæ. “Facts of this kind appear to be common at Guyane. M. Saint-Pair has observed six such cases. In one more than 300 larvæ were extracted by means of injections, but it was impossible to get them all out; they soon were seen invading the eyeball, and creeping between the eyelids; the lower eyelid became gangrenous, and fell down on the cheek, leaving the margin of the orbit exposed. The worms attacked the mouth and gums, and denuded the superior maxilla. The patient died eighteen days after admission to the hospital.”

*Peenash.*—According to a correspondent of the *Medical Times and Gazette* (Jan. 30, 1875) on the subject of “Native Practice in Rajpootana,” worms in the nose or “peenash” is an ordinarily common malady; not only in human beings, but also in camels, caused by the ring-hole in the nasal septum of the latter ulcerating and becoming a nidus for the deposit of larvæ. But with human beings, or at least with men, who do not wear nose-rings, there is not this excuse ready to hand for the entrance of flies; but doubtless most have witnessed the apathy with which the natives permit clusters of flies round the eyes and nostrils. Probably maggots may arrive at maturity without any previous ulceration. A case is related by the author of the above report in the *Indian Medical Gazette*, Aug. 18, 1874.

*A Case of Maggots in the Nose, causing its complete destruction and the death of the Patient* (“*Indian Medical Gazette*,” August, 1871).

“A man, during a period of insensibility from a remittent, had maggots breed in his nostrils, and, notwithstanding all that could be done, the case went on from bad to worse. Notwithstanding injections of various kinds—black wash (generally very efficacious), carbolic acid, turpentine and oil, etc., the worms gradually destroyed the bridge of the nose itself, ultimately opening the pharynx and displaying in the ethmoidal cells, or rather in the position of the latter, a moving, loathsome mass of maggots and decaying tissue. Very many worms were daily, or even hourly destroyed by the constant use of injections, or by picking them out with forceps. But their name was legion, and the destruction of those in front seemed only to clear the way for the appearance of increased numbers. Ultimately coma supervened, and death

took place under this condition. The author remarks, 'I have treated many cases of peenash, and previously witnessed fatal terminations in persons brought after the disease had far advanced, but I never before treated the malady from the commencement when, in spite of all endeavours, it persistently continued from bad to worse. But this result may probably be attributed to the very weak state of the constitution before the man became the victim of worms in the nose.'"

Dr. Moriarity reports from Mooltan a case of maggots in the posterior nares, causing erysipelas of the nose (*Indian Medical Gazette*, Oct. 1, 1877, p. 263). A private in the 70th Regiment, the subject of constitutional syphilis, had an attack of swelling of an erysipelatoid character of the face and nose, and a sanious discharge from the nostrils. The nose was plugged with lint saturated with perchloride of iron. After a few days the sanious discharge from the nose became more abundant, and a few maggots were spat up. An inspection of the fauces disclosed a large collection of maggots situated beneath the folds of the isthmus faucium. These maggots were extracted in large numbers, and perchloride of iron freely applied to the fauces. Ultimately, after about four weeks of treatment, the man recovered. Some of the maggots removed developed into flies, the body and wings of which had a *bright metallic lustre*, while the head was of a dirty brown colour. They were a quarter of an inch in length.

In all these cases occurring in tropical climates, the *lucilia hominivorax* seems to be the insect, the eggs of which are deposited by the fly in the nostril, and the maggots of which become developed in some part of the nasal fossæ or its sinuses.

But even in temperate climates insects or grubs are sometimes found in the nostrils. Thus an extraordinary story is told by Dr. Razoux, of Nismes: A woman was attacked with a fever, with violent headache, which, in spite of remedies, made continual progress. About the fourth or fifth day she began sneezing, and expelled some small white worms. Her headache diminished sensibly as the worms came out. Seventy-two of them were expelled in the course of a few hours, and the patient was completely cured. These worms were exactly like those that are found in the frontal sinuses of sheep (*æstrus*

*ovis*), and as the woman had, the day before her attack, drunk of some water at a pond to which sheep were in the habit of being led, the author of this record thinks that she was infected by the worms in this way.

This, however, is not an isolated case, for Sir Morell Mackenzie quotes another reported by Kirchmann (*Wien. Med. Wochenschrift*, 1881, Dec. 3):—"A peasant woman was attacked with bleeding from the nose which lasted three days. The blood came from the left nostril, and the corresponding side of the face was enormously swollen. The hæmorrhage was arrested by injections of perchloride of iron, and this treatment was followed by the expulsion of a mass of maggots of the *œstrus ovis*. The patient made a good recovery."

Sir Morell Mackenzie also quotes two cases in which the maggots of the *leather-eater* are said to have been found in the nose. ("Diseases of the Throat and Nose," vol. ii, p. 458).

Besides the cases recorded as being of not uncommon occurrence in India and South America of the true "Peenash," there are scattered cases mentioned as having occurred in various European countries. Petrequin observed one in a hospital at Sienna. Anthelmintic remedies were given internally and by inhalation, and in the course of eight days fifty-eight maggots were expelled, and subsequently developed into *luciliae*. Mankiewickz, a medical practitioner in Berlin, published the following case:—In a delicate boy, æt. 9 years, suffering from scrofulous ozæna, enormous quantities of maggots were seen adhering to the septum. They were removed by smearing them over with a solution of Balsam of Peru, and a complete cure was effected, though the boy lost the tip of his nose.

Moquin-Tandon also records two cases, one in Aix (Provence), under the care of D'Astros of Aix, and a second which occurred in a girl 9 years of age, who was cured by the use of cigarettes of Arsenite of Soda. Prince, of Jacksonville (U.S.), has recorded a case as occurring in a farmer with ozæna (*Philadelphia Medical News*, Oct. 14, 1882, p. 445).

Other living creatures, such as *centipedes*, *earwigs*, and *leeches*, have occasionally found their way into the nasal fossæ, and have given rise to severe symptoms. *Ascarides* have been found in the nose after death, and there are a few instances in which the worms were expelled from the nose during life. Many interesting cases and references are given by Cloquet in his "Osphrésiologie," at pp. 615 to 625.

## SECTION VI.

## ULCERATIVE DISEASES OF THE MUCOUS MEMBRANE OF THE NASAL FOSSÆ.

- SUB-SECTION 1. Erosive Ulcers of Syphilitic Origin.—Rouge's Ozæna.
- „ 2. Lupoid Ulcers.
- „ 3. Eczematoid Ulcers.
- „ 4. Ulcers as the Sequelæ of Fevers.
- „ 5. Glanders.
- „ 6. Scorbutic Ulcers.
- „ 7. Ulcers in Paresis of the Fifth Pair of Nerves (Neuro-paralytic Ulcers).
- „ 8. Tuberculous Ulcers.

## SUB-SECTION 1.

*Syphilitic Ozæna.*

THE observations of Dr. Rouge, of Lausanne, embodied in a pamphlet entitled “Nouvelle Méthode Chirurgicale pour le traitement Chirurgical de l'Ozène, Lausanne, 1873,” throw some doubt upon the possibility of true ozæna being present without some affection of the bones. He is of opinion that it is impossible to have “punaisie” without some lesion of the skeleton of the nasal cavities, but these views are not generally accepted, the *ozæna* (see Sect. II, Sub-Section 4) of *chronic fœtid rhinitis* with atrophy of the mucous membrane being remarkable for the absence of ulceration and necrosis.

*Syphilitic Ozæna* depends upon tertiary syphilitic ulcers of the mucous membrane, often demonstrable in the anterior nares, and sometimes in the posterior. These ulcers may be preceded or followed by caries or necrosis of the bones, and the stench is then more horribly sickening than in any other form of this disgusting malady.

Among the less common, but possible causes of the same symptom, are eczematous inflammation of the mucous membrane, cancerous or scorbutic ulcers, necrosis, as the result of injuries or the presence of foreign bodies, and ulcers or retained secretions with or without necrosed bone in the antrum Highmorianum or frontal sinuses.

Mr. Cæsar Hawkins (see "Contributions to Pathology and Surgery," vol. i, p. 228) is of opinion that ozæna (using the term in its most comprehensive sense so as to include all kinds of ulcers, or inflammations of the Schneiderian membrane, with or without a foetid discharge) may be caused by inoculation from any animal poison, whether "from glanders or from inoculation with putrid and foul meat. The consequence of this state of system is that from whatever cause it may arise, ozæna is accompanied by a variety of symptoms such as would at one time have been considered decidedly syphilitic, but which may be met with as a consequence of any poisonous or other cachectic cause whatever."

Having the authority of so distinguished a surgeon as the gentleman I have just quoted for the great variety of causes of the disease, it is very important that we should not hastily classify our cases in one or other of the categories I have mentioned. There will, as I have often observed in my own practice, be cases to which it is impossible to give a distinctive name and classification, and we must then be content with placing them under the large and comprehensive class of The Cachectic.

*Erosive Syphilitic Ulcers* occur during the latter stages of syphilis, *i.e.*, as tertiary symptoms; and it is of course very important to recognize the early stages of the disease, and to gain, if possible, a clear history of the primary manifestations of syphilis. We must, however, in the absence of a clear previous history, be on our guard against concluding that a case is syphilitic, as the early stage of this is not unlike that of the idiopathic ozæna.

There is some amount of pain and tenderness in the part, and often a good deal of constitutional disturbance. There is a sense of stuffed nostrils, and fulness of the forehead and bridge of the nose; diminution or deprivation of the sense of smell; debility, emaciation, and irritation; nocturnal restlessness; sleeplessness; complaints of pains in the limbs, with chilliness and occasional heats and flushings. In women, at the menstrual periods all the symptoms are aggravated, and the discharge becomes more abundant and offensive.

If the ulcers are within view we may gain a good deal of information as to the true nature of the disease. Generally they are easily seen both in the anterior nares and by posterior

rhinoscopic examination, and it is often noticed that they have a peculiar serpiginous outline, the spreading edge of the ulcer being lunated, and the healing edge shelving off from it into the sound mucous membrane.

These ulcers often spread down into the pharynx and over the pillars of the fauces. When they have gone so far as to excavate the bones, or perforate the septum nasi, as they sometimes do, their appearance is still more characteristic.

These serpiginous ulcers, however, are not absolutely pathognomonic of syphilitic ozæna. The ozæna may depend upon disease originating primarily in the bones, and then a ragged ulcer with excavated edges and sloughy base will be seen in the nares; or, the ulcer may not be within view at all; or, lastly, there may be mere superficial excoriations, like the psoriasis of the mouth, which may be of truly syphilitic origin, and may give rise to chronic disease with fœtor of the breath.

The examination of the posterior nares may disclose similar ulcers of the middle or lower turbinated bones and septum, and it is probable that the same condition extends upwards to the ethmoidal cells and frontal sinuses, as well as downwards to the larynx. It is sometimes attended with headache, loss of smell, and great alteration of the voice.

The secretion of the nostrils, though at first somewhat more abundant than natural, is replaced in the later stages by the constant formation of dry greenish crusts, which tend to cause a feeling of stuffiness and obstruction. This secretion and these crusts have a very offensive and sickening odour, which is quite characteristic.

There is in the majority of these cases a history of constitutional syphilis, though in many it is impossible to trace the cause of the disease. Where, however, there is no history of acquired syphilis, it is probable that a congenital taint may be present.

The *diagnosis* in adults must therefore depend partly upon the character of the ulcers, but also in great part upon the history and general appearance of the patient.

If in infancy there has been snuffles from a very early period, say within a few months of the birth, and with this traces of excoriations about the anus and the angles of the mouth; above all, if there are the characteristic notched teeth and nebula of



the corneæ, or a co-existing keratitis interstitialis, it is almost certain that we have before us an instance of constitutional hereditary syphilis.

I am bound to say, however, that though I have seen a large number of cases of supposed hereditary syphilis in youth and young adult life marked by the above characteristics, I have not seen many of these patients with erosive ulcers of the nostrils. In many of them, however, there is a very decided flattening of the bridge of the nose. Hence it is probable that there has been disease of the cartilages in early infancy in such patients, and these are the cases alluded to in the first section as being the subjects of syphilitic coryza.

In the very young infants who are the subjects of this coryza it is very difficult to ascertain whether any true ulcers have formed in the deeper parts of the nostrils, and the small size of the anterior nares rarely allows a good view of the front part of the cavity, while posterior rhinoscopy is utterly out of the question. But it is beyond doubt that in the worst cases of infantile syphilis, ulcers, and even perforating ulcers, form within the nostrils, and in the later stages the bones become affected and fragments are discharged among the crusts of mucus. In these instances the discharge is frequently sanious in character, and there are fissures, excoriations, and ulcers on the external surface of the nostrils. Ulcers of the throat are a frequent complication, and the larynx may also be affected, as is evident from the dull, hoarse, or even almost extinct voice of the child. Bleeding from the nostrils sometimes complicates the disease very seriously, and, if the discharge from the ulcers becomes dried up, the infant's breathing will be much obstructed by the accumulated crusts, sucking becoming an impossibility, and the nutrition suffers more and more until the child sinks and dies of exhaustion. Some of these infants with syphilitic coryza die from the absorption of the putrid gases they are constantly breathing. The discharges collecting in the nostrils become putrid, and the decomposing gases find their way to the lungs by the aid of the inspirations, the energy and frequency of which are doubled by the obstacles that impede them, and the child is slowly poisoned by its own breath.

The *diagnosis* of the disease in infancy will not be difficult. The coryza is generally associated with some affection of the skin, psoriasis or excoriations of the anus, the hoarse voice, etc.,

and the parents' previous history will be tolerably clear without going very deeply into all particulars.

In the *treatment* of this disease, whether in infants or adults, the free use of the douche and the application of antiseptic solutions are as necessary as in the cases already referred to. It is, however, as well to apply, by means of a camel's hair pencil, as a preliminary to injections, a solution of carbolic acid (gr. i to 60) mixed with an equal part of glycerine. This is to be applied two or three times daily, in order to soften and detach the dry crusts. When this result has been obtained, the injection of weak iodine solutions and chlorides will be required, and in addition to these, the inhalation through the nostrils of iodized spray from a Siegle's steam spray inhaler, or of iodine vapour,\* will be very useful in deodorizing the breath of the patient.

In ulcerative syphilitic ozæna in adults, one or more courses of mercury have most probably been taken during the primary or secondary stages; but if there is reason to believe that mercury has been insufficiently tried, it will be well to employ the calomel vapour bath on the plan so successfully carried out by Mr. Henry Lee, keeping the patient steadily under this treatment for three or four weeks, and directing the vapour especially to the cavities of the nostril, the head being now and then, during the time of the bath, held over the neck-opening of the cloak and the vapour inhaled through the nostrils. In this way the very finely divided calomel powder becomes deposited upon the surfaces of the ulcers.

The effect of mercury, however, requires to be very carefully watched in these cases, because it so often happens that there is with the syphilitic a scrofulous taint in the constitution: this particular combination of diatheses rendering the system more liable to the ulceration of mucous membranes than either by itself; and it is well known that scrofulous persons do not bear

\* Viz., Tr. Iodi. ʒiii, water ʒiv, to be warmed and inhaled, the bottle containing the solution being placed in a basin of hot water, while the whole apparatus is surrounded by a towel arranged in a conical form, and the top of the cone being left open the patient inhales from that aperture; or a phial containing iodine or Tr. Iodi. may be employed, the heat of the hand on the outside of the phial being sufficient to volatilize the iodine; or a few drops may be put into any suitable inhaler, those made of porcelain being most appropriate.

mercury so well as those untainted with that constitutional weakness. Hence if the gums rapidly show decided signs of mercurial action, the baths should be at once discontinued, and if necessary, recommenced after an interval.

In cases in which mercury has been given freely and efficiently during the primary or secondary stages it will be found desirable to give a course of iodide of potassium, beginning with 4-grain doses and going on to 20 or 30 grains, and combining with this sarsaparilla in the form of liquid extract. If after a few days or a week of this plan of treatment there is no amendment in the symptoms, it will be better to give up specific treatment altogether and to rely upon topical applications and the internal administration of cod-liver oil and iodide of iron. Sometimes perchloride of iron and bitter tonics will be required alternately with the cod-liver oil; and in all cases, whether specifics are given or not, a supporting regimen should be made a *sine qua non*.

*A Case of Erosive Syphilitic Ulcers of the Nostrils and Alæ Nasi : Treatment by Iodide of Potassium and applying the Solid Nitrate of Silver, under the care of the Author.*

Mr. G. D., an artist and man of letters, aged thirty-eight years, came to me with tertiary serpiginous ulcers just within the left ala nasi.

Eight years previously he had a primary chancre, and has had secondary eruptions, for which he took mercury. Lately he has been smoking and drinking very freely, and his general health has suffered in consequence of his late hours and the great strain on his system from literary work at night.

The left ala is much swollen and erythematous, and inside the left nostril are several ulcerated patches covered with scabs, and with red swollen edges.

At first the cachectic appearance of the patient induced me to treat him with tonics (steel and mineral acids) and with soothing local applications. In the course of three weeks, however, the ulcers were evidently spreading, their edges were swollen and tuberculous, and the whole nose red and inflamed. He was still smoking to excess and drinking a good deal of whisky.

He now began iodide of potassium and decoction of sarsaparilla internally, and the solid nitrate of silver was applied to

the edges of the sores. In another fortnight a very marked improvement in the aspect of the case was noticed. The ulcers on the outside had quite healed; those within were no longer spreading. His general health, too, had much improved. He continued the iodide and sarsaparilla for some months, and on September 15th the discharges had all ceased, and the ulcers quite healed. The septum had unfortunately become perforated by an ulcer of about the size of a fourpenny piece. The lower part of the nose was slightly flattened, but was not deformed to a noticeable extent.

This gentleman subsequently suffered from periostitis of the orbit, from which he recovered very rapidly under full doses of iodide of potassium.

In the case of children, I find the mercurial ointment more manageable than any other preparations, and in most cases very effective, provided sufficient attention has been given to cleansing the nostrils of crusts previously by the use of the syringe.

M. Trousseau prefers injections for children, and specifies the following four as those most likely to be serviceable:—

No. 1. Eau Phagédénique, or Yellow Wash, <i>i.e.</i> Corrosive Sublimate	1 grain to 1 fluid-ounce of Lime Water.
No. 2. Chlorate of Potash	. 5 grains.
Distilled Water	. 1 fluid-ounce.
No. 3. Nitrate of Silver	. 5 grammes.
Distilled Water	. 100 grammes.
No. 4. Sulphate of Copper	. 24 grains.
Distilled Water	. 1 fluid-ounce.

The strength of No. 3 Solution is much greater than is ordinarily used under such circumstances, and represents, in our measure, about 24 grains to the fluid ounce. Such a solution would, in my opinion, be highly irritating, not only to the ulcers themselves, but also to the sound parts of the mucous membrane, and even to the skin of a young infant. It is better, therefore, to commence with a solution of about 5 grains to the fluid ounce, and, if necessary, to increase its strength by degrees. If the ulcers are within reach, I much prefer to apply the lotions by means of a camel's hair pencil, as by this plan the diseased parts only are stimulated, and the adjacent

mucous membrane is not irritated; but if this be impracticable, as it often is, the weaker solutions, or the ointments above mentioned, are more manageable and generally quite as efficient.

Caustics as a rule may be safely used in the form of the mitigated nitrate of silver sticks, suitable caustic holders with long flexible stems being best adapted for this purpose, and I much prefer this plan, or the use of a sponge on a long stem, to the employment of strong solutions of nitrate of silver for the reasons above mentioned.

In case of bone disease being satisfactorily made out, it will become a question whether any operation for the removal of sequestra can be safely undertaken, but the consideration of this point is deferred to a later section.

*Primary Syphilitic Ulcers* within the nostrils are of course extremely rare. The only case that has occurred in my practice was that of a monthly nurse (sent to me by Dr. A. E. Sansom), whose nostril became infected during her attendance on a lady in her confinement, the latter at the time suffering from the disease in question. There was, when I first saw her, complete occlusion of the nostril by a fleshy-looking growth, having a cartilaginous hardness. With great difficulty, on account of the swelling, I was able to get a view of the ulcerated surface. The surrounding parts of the cheek and ala were thickened and swollen. The glands under the jaw were also enormously enlarged, and very painful. The patient was in high fever, and in great pain and distress. Under a course of mercury, continued for many weeks, and subsequent treatment by Iodide of Potassium, the symptoms were all subdued, but not without the appearance of a well-marked secondary eruption.

There are no absolutely pathognomonic symptoms in the early period of primary intranasal ulcer. The best guide to a diagnosis will be a clear history of all possible sources of infection. The appearance of a secondary eruption is only of use later on as a confirmation of the diagnosis. As compared with other ulcers in the nostrils, primary syphilitic ulcers are harder and more sluggish-looking—having, in fact, the characteristic appearance of the true Hunterian chancre.

## SUB-SECTION 2.

*Lupoid Ulcers* are probably present in some cases of ozæna, occurring in persons of a tuberculous or phthisical constitution, and it becomes a point of great importance in practice to distinguish between these cases and the true syphilitic ulcers.

The *diagnosis* is important for many obvious reasons. The presence of marked phthisis or tuberculosis, or of lupus in any one of the family will afford a strong presumption in favour of the view that the ozæna is dependent upon lupoid ulcers, and the character, standing, and past history of the patient will confirm or throw doubt upon the probability of this being the correct diagnosis.

Lupus of the conjunctiva is not a very uncommon malady. A case of the kind was under my care at the Central London Ophthalmic Hospital, in which a distinct and separate lupoid ulcer was present on the conjunctiva, associated with similar ulcers on the skin of the nose and cheek; and Arlt has recorded cases of *primary lupus* of the conjunctiva. There is, therefore, no great improbability in the occurrence of the same kind of ulceration within the nostrils,\* though from its situation it may be difficult to discover its position or recognize its form. Though, however, we may assume that some cases of ozæna in young and delicate adults, and especially in young women, are true instances of lupus, it is also not uncommon to meet with cases of a mixed kind, viz., of lupoid ulceration engrafted on a syphilitic constitution, or of a combination of phthisical and scrofulous dyscrasia in the same individual, and the symptoms of the disease will be modified in accordance with each of these constitutional peculiarities. In all the varieties of this disease, its obstinate continuance, in spite of all remedies, offers a strong presumption in favour of the case being of the lupoid variety.

*Treatment.*—Topical applications, though of great value in promoting the comfort of the patient and accelerating the cure of the disease, are not to be relied on alone. Nevertheless, the cleansing of the nostrils with some antiseptic solution, either a weak solution of Condy's fluid, or a weak carbolic acid

\* Virchow mentions, as examples of isolated foci of lupus, "Primary lupus of the nasal mucous membrane and of the conjunctiva." "Die krankhaften Geschwülste," vol. ii, p. 482.

solution, or a solution of chloride of aluminum, or iodine in vapour or as an injection, are very important aids to the constitutional remedies. Residence in a warm climate, sea-air and sea-bathing, and the administration of cod-liver oil, iron, arsenic, and quinine, in succession or in combination, will be the most important features of the medical treatment. Warm clothing and good diet, with a moderate allowance of wine, are also absolutely necessary, and all exhausting or exciting occupations are to be studiously avoided. Cheerful society and a good deal of out-of-door exercise with early hours, are equally to be insisted on, if by any means attainable.

When there are visible ulcers within the nostrils, which is rarely the case, they should be touched with a strong solution of nitrate of silver (grs. x or xx to f. ʒi), or with a finely pointed stick of the nitrate of silver and nitrate of potash moulded together; and, if the edges of the ulcer are spreading, the strong caustic, or potassa fusa should be applied freely and firmly to those parts of the ulcer which are evidently extending. They should be anointed frequently with a dilute mercurial ointment.

If the ulcers be continuous, with a patch of lupus upon the skin, its depth being great, and the edge comparatively indolent in character, it is a case either for the galvanic wire or the free use of Volkmann's spoon.

If, on the other hand, the edge of the ulcer is swollen, red, irritable, and easily bleeds when touched, a soothing plan with antiseptic douches and mild ointment, such as ung. zinci, will be more suitable to the case. At the same time, in this irritable form of lupus, the part should be protected from the irritation of cold and the external air by being covered up with cotton wool and occasional poultices, whenever they can be used without obstructing the nostrils, with or without some antiseptic. Later on Volkmann's spoon may be required.

After the ulcers have healed, there is often a sense of rawness and tenderness of the nostrils, depending upon chronic inflammation, and it is useful to employ mild astringent lotions for some time after the ulcerative action has ceased, and as Mr. Durham suggests, in his admirable essay in Mr. Holmes's "System of Surgery," to plug the nostrils with loose dossils of lint, so as to obviate the irritation from the passage of cold air.

Glycerine of tannin is a very useful application under these circumstances.

### SUB-SECTION 3.

The *eczematous* form of nasal ulcers is seen most frequently in young children who have the eczematous eruption on the upper lip and cheeks, and very often chronic blepharitis and tinea tarsi, and not unfrequently follows the exanthemata, especially measles. But it is occasionally seen in older persons of an eczematous diathesis. The odour from the nostrils is seldom very pronounced in these cases. In children the usual faults of feeding, such as over-indulgence in pastry and unwholesome sweets, are generally the chief sources of disturbance, and there are often ascarides irritating the lower bowel. The bowels must be cleared out and then steel and bitters given, with a simple nourishing diet, and plenty of fresh vegetables.

The nostrils require to be cleansed with the saline warm douche or syringe night and morning, and the zinc ointment applied constantly.

If the crusts collect in such a mass that it is impossible to apply the ointment effectually to the underlying mucous membrane, it will be useful to employ first the glycerine of borax by means of a camel's hair pencil, and then when the crusts have been removed after softening, the nitrate of silver solution (gr. ii to f. ʒi) and the zinc ointment can be used with effect. In adults there are often serious faults of digestion and assimilation to be contended with. It is generally necessary to restrict the diet to plain joints and vegetables, and to forbid sweets and rich dishes of all kinds. The local treatment is of the same kind as for children, and the following mixture will be useful:—

Magnes. sulphatis ʒiv.  
 Acid sulph. dil. ʒss.  
 Ferri. sulphatis, gr. viii.  
 Sp. Chlorof. ℥xv.  
 Aq. Pimentæ ad ʒviii.

One-eighth part to be taken thrice daily.

In each individual, however, there will be some peculiarity of temperament, which will have to be met by its appropriate method of treatment. In the majority there is a tendency to



deposits of lithates in the urine, and a disinclination to take healthful exercise, with drowsiness after dinner, and an habitually torpid condition of mind and body.

#### SUB-SECTION 4.

The *fevers* which give rise to ulcers in the nostrils, with more or less implication of the bones and cartilage, are measles, scarlatina, small-pox, and typhus. The symptoms may commence by the usual swelling, pain and tenderness, followed by ulceration and purulent discharge. They must be treated on the principles already indicated, and with a supporting regimen.

Occasionally after severe *catarrh*, simple ulcers near the orifices of the nostrils occasion great irritation, and require the local application of some stimulant, such as a solution of nitrate of silver (gr. v to fl. oz. i) applied by means of a camel's hair pencil, and followed by the constant use of ungu. zinci oxid. The glycerine of tannin is also very useful.

*Fissures* often form at the orifices of the nostrils, either at the anterior junction of the septum with the alæ, or at the posterior angle of the alæ. At the same time the skin around the tip and the sides of the nose is swollen and red, and the whole organ is so excessively irritable and painful, that the patient is constantly applying the ends of the fingers to the part and rubbing or picking off the scabs as they form, thus increasing the mischief and hindering the healing process. These symptoms are generally accompanied by some gastric or intestinal irritation, and, when children are the subjects, ascarides are often found in great numbers in the stools. Hence, in the treatment, our first indication is to clear out the bowels by a dose or two of some saline aperient, and to follow this up with bitter tonics and steel. The fissures themselves should then be touched lightly once a day with a solution of nitrate of silver (gr. v to f. ʒi), or with the solid stick of sulphate of zinc, and the ointment of yellow oxide of mercury used occasionally. At the same time the hands and fingers must be restrained from picking and irritating the parts by wearing gloves constantly, unless the patient's self-control is sufficient without them. As soon as the redness and irritability have subsided, and healthy granulations have sprung up in the fissures, all stimulating applications must be discontinued, and simple cerate, or ungu. zinci oxid. benzoati applied instead. The

constitutional treatment should be continued for some time after the fissures have healed, and especial attention to the bowels will be necessary in most cases.

#### SUB-SECTION 5.

##### *Glanders.*

In 1821, Dr. Schilling, of Berlin, made the first positive observation of a case of glanders in the human subject, but Dr. Elliotson seems to have been the first to call attention in this country to the fact that this disease is communicable by inoculation from the horse to man, and again from man to the horse and the ass.

The human subject is probably not liable to the disease unless a wound or abraded surface is actually inoculated with pus from an ulcer or abscess, or with nasal discharge of a glandered animal; but as there is some difference of opinion as to the possibility of the absorption of the virus by the *unbroken* mucous membrane in animals, it is not certain that the latter mode of infection may not be possible in the human subject.

*Symptoms.*—The symptoms commence in many cases by pains, often described as rheumatic, in some part of the trunk, back, or limbs, with dyspnoea and tightness of the chest, with rigors, headache, feeling of lassitude, frequency of pulse, and often by vomiting and diarrhoea and great irritability of stomach and depression of spirits, the form of fever assuming a typhoid character of extreme violence.

About this time, or from the first onset of the disease, a pimple or wound, before unnoticed, becomes hot, painful, swollen and suppurating, and the parts around become swollen and red. If the pimple happen to be on the face, the eyelids, nose, and cheek become puffed up to such an extent that the eyes cannot be opened (see Plate V, fig. 2). The eyelids may then become red, hot, dry, and shining, and the nose dark coloured and perhaps gangrenous (see Plate V, fig. 2). *Soon from the nostrils flows a thick discharge of a deep yellow colour, here and there a little bloody*, and in several cases it has been noticed that the discharge was much more copious from one than from the other nostril. Hard phlyzacious pustules

appear on and around the nose, and on various parts of the trunk and extremities. The temperature and pulse are high, the tongue white and dry, the respiration quick and difficult. Then come delirium, and in the course of a few hours swellings of a red colour upon the legs and more pustules about the face, the original pustules having by this time assumed a purple tint. Diarrhœa and profuse sweating, and restlessness with increased delirium, are soon followed by exhaustion and death.\* After death purulent deposits are found in the site of the swellings on the limbs and trunk, or in the viscera, and perhaps pneumonia, with suppuration in the pleura. On examining the nostrils an ulcer or ulcers are found resembling those seen in glandered horses, and in some cases the bones of the nose are necrosed and the soft parts gangrenous. In one case (recorded by Mr. Brown, surgeon of the 2nd Regiment of Dragoons) the following appearances were noted:—"A cluster of tubercles was found in the cellular membrane, exterior to the pericranium of the left superciliary ridge, and in the right frontal sinus, exactly (according to the veterinary surgeon of the regiment) similar to those observed in the frontal and other sinuses of the horse after acute glanders." On dividing the various livid tumours of the surface down to the bone, "the muscles appeared perfectly decomposed and of a dark liver colour, exhaling a peculiar fœtid odour, with points of purulent matter, as it were, infiltrated everywhere through their entire substance, resembling much a hepatized or tuberculated lung," and under each "was a cluster of the grey circular tubercles, the whole composed of fine cellular tissue, enclosed in small cysts, proportionate in size and consistency to the extent and duration of the tumour, and firmly attached to the periosteum." In another case, "the various tumefactions were full of pus, underneath which, in many, a number of small white granules were seen; and these, in several instances, were closely attached to the periosteum or perichondrium. The frontal sinuses contained a jelly-like secretion and a number of similar granules."

\* A case is recorded by Dr. Elliotson in the *Med.-Chir. Trans.* vol. xviii, p. 201 *et seq.*, and illustrates the difficulty of diagnosis in those cases in which the first symptoms noticeable are those of gangrenous erysipelas and sometimes mortification. This form of the disease is especially seen in the parts adjacent to the nose and eye.

It will at once strike the pathologist that this disease, in its advanced stages, bears a close resemblance to pyæmia or acute tuberculosis, in some of its symptoms and pathological phenomena, with the addition of the peculiar affection of the nostrils and the specific form of ulcer there found.

The disease is of course of rare occurrence, and is therefore chiefly interesting to the practitioner in reference to *diagnosis*. The chief characteristics are the inflamed pustule on the skin in the early stage, and the copious yellow, sometimes viscid, discharge from one or both nostrils. The pustule or ulcer alone, apart from any specific history, is not sufficiently characteristic to justify a diagnosis, but the rapid swelling of all the parts around it, the extension of inflammation along the lymphatics, and the rapid formation of swellings and phlyzacious pustules around the original pustule, would at once arouse the suspicion of a specific poison, and the history would help to elucidate its nature. *Carbuncle* and *malignant pustule* would both be suggested by the appearance. The former would, however, be distinguished by its great size, extreme painfulness, and induration; and the latter by its being, for some days at least, a purely local affection and unaccompanied by any constitutional disturbance, whereas glanders more frequently commences with pains in the hypochondrium or chest, or with rheumatic pains in the limbs, and with severe constitutional disturbance before the local mischief has attracted much attention. *Primary syphilitic ulceration* within the nostril (an extremely rare but still a possible contingency) gives rise to much local swelling, which, however, is one-sided and associated with less constitutional disturbance, though with more pain, than is observed in glanders. The history may throw light on the diagnosis. *Cancrum oris*, or *noma*, might present some features resembling those of glanders; but this is a disease almost entirely confined to childhood, in which glanders would not be likely to occur, and the absence of any pustules and of the nasal discharge would be sufficient to distinguish it (see T. Holmes's "Syst. Surg.," vol. i, pp. 639, 641, 644). As, however, *erysipelas* with *gangrenous* complications may occur in the adult, it is quite possible to mistake the nature of such a case; and Virchow mentions that in a case of Von Graefe's, with acute exophthalmus, he after death discovered glanderous nodules in the choroid, and thus established

the true character of the disease, which had not been suspected during life.

*Prognosis.*—"Acute glanders and acute farcy, when accompanied by the characteristic eruption, are almost necessarily fatal. One case of acute glanders, and several of acute farcy, have been recorded, in which recovery took place. In farcy unaccompanied by the eruption the prognosis is much more favourable, recovery being the rule and not the exception. Chronic glanders, especially when complicated by farcy, is almost invariably fatal." (Messrs. Gamgee, *op. cit.*, p. 709, vol. i.) In chronic glanders, recovery has occasionally taken place, after a long series of abscesses extending over two or three years.

The *treatment* should be directed first to supporting the strength and eliminating powers of the system by quinine, brandy, and frequent administration of good soup and eggs, milk, etc. Then the nostrils and sorès should be washed thoroughly and frequently with carbolic acid lotions. Dr. Elliotson considered a weak solution of creasote extremely valuable as an injection into the nostrils, and mentions the recovery of two patients under this treatment carried on sedulously for a few weeks. It seems doubtful, however, whether these could have been such severe cases as those in which scattered abscesses had already formed, with severe constitutional symptoms resembling those of pyæmia. Dr. Tilbury Fox mentions arsenic and strychnine as medicines recommended upon good authority, and hypo-sulphites and perchloride of iron have also been spoken favourably of in this disease, of the treatment of which few medical men have had much experience.

#### SUB-SECTION 6.

*Scorbutic Ulcers* are extremely uncommon in the mucous membranes of the nose, except as the result of some accidental irritation in the course of scurvy, or when associated with sloughing of the whole or a great part of the tissues composing the lips, gums, and portions of the cheek. Dr. Buzzard remarks (see Dr. R. Reynolds's "System of Medicine," vol. i, p. 744) that "In confirmed scurvy the slightest pressure suffices to open the skin and to give rise to an ulcer, whose edges are hard, thick,

and shining, and the surface fungoid and bleeding. Its tendency is to increase rapidly in size, and to invade the neighbouring structures. An intolerably offensive odour is emitted from it. \* \* \* The lips and nostrils are occasionally the seat of this ulceration, and the patient then presents a ghastly appearance, much like that of an aggravated case of lupus. The exhaustion attendant upon these spreading ulcers is often fatal."

#### SUB-SECTION 7.

##### *Ulcers in connection with Paresis of the Fifth Pair of Nerves (Neuro-Paralytic Ulcers).*

The influence on nutrition associated with the sensory function of the fifth pair of nerves has been made the frequent subject of experiment, and is often illustrated in clinical observations. It is especially noticed that when one side of the face loses its sensation, that the eyeball of that side is liable to become inflamed, and the cornea to ulcerate. It has not, however, been so frequently noticed that ulcers of the other mucous surfaces are likely to come on. Such is, however, the case, and is due to the same cause, as I conceive. The reflex nutritional irritability of the part is bound up with its sensational activity, and whenever there is any irritant cause the part is unable to call forth its reparative powers, and the result is a slow molecular necrosis.

In a case formerly under my care, the lining membrane of the nostrils was excoriated in patches varying from the size of a split pea to that of a sixpence. The ulcers were dry and sluggish, and showed no tendency either to healing or to spreading, though, as the result proved, they did actually increase in size from day to day. The skin of the nose, near the margin of the nostrils, was only slightly invaded by the ulcers, and at this part was slightly redder than the surrounding skin. The woman suffered very much from bleeding from this side of the nose, and was anosmic also on this side. The ulcerations probably extended quite up to the region of olfaction, though it is by no means certain that that region was actually invaded; the anosmia being satisfactorily accounted for by the swelling and occlusion of the nostril, due to the absence of muscular action in the ala.

Little can be done in such a case by way of local treatment. It is, however, well to cover the mucous membrane with some soothing ointment, such as the benzoated lard, and protect the parts from exposure to the weather when the atmosphere is cold and damp. The main treatment must, of course, be directed to the restoration of the nerve function, and in the meanwhile the general nutrition should be kept up by generous, but not stimulating diet, and by avoiding exposure to cold.

In the case above alluded to, attention to these points again and again resulted in healing of the ulcers, while neglect almost invariably brought a recurrence of the same mischief. These ulcers being painless, they were consequently very little noticed by the patient herself, and hence her neglect of remedies was easily accounted for.

#### SUB-SECTION 8.

##### *Tuberculous Ulcers.*

Tuberculosis of the nasal fossæ is a very rare disease. It occurs under two forms—the *Simple* and the *Hyperplastic* form. The septum seems to be the favourite seat of the ulcer, but it may attack one of the turbinated bones. The *simple* tuberculous ulcer has a whitish grey surface, even with the surrounding mucous membrane, and with an irregular but not raised margin. The *hyperplastic* form has raised edges from deposition of morbid material in the submucous tissue. In neither form is there any *pus* of the normal character secreted, there is a tendency to bleeding, and the whitish-grey surface of the ulcer is liable to be coated with crusts of mucus and discoloured by foreign particles.

The treatment best adapted to check the progress of the ulcer is that of extirpation, either by the galvanic cautery or the knife. If, however, the ulcer is small, applications of lactic acid may be first tried. As these ulcers occur in persons of phthisical constitutions and tendencies, the general treatment for phthisis must be added to the other remedies.

## SECTION VII.

## ADENOID VEGETATIONS OF THE NASO-PHARYNX.

*Preliminary Remarks.*—In 1860 Czermak found some small growths in the naso-pharynx, and his discovery excited considerable attention, and was followed by marked results. The naso-pharynx soon attracted the attention of anatomists, physiologists, pathologists, and therapeutists; and adenoid vegetations formed the subject of a host of pamphlets and monographs. The abundance of material thus produced renders the task of condensation difficult; but I trust I shall be able to prove that the advance of surgery in this region has been commensurate with the numbers, earnestness, and ability of the explorers. It may be regarded as certain that many thousands of young persons who would otherwise have been going about wholly or partially deaf, with their mouths wide open and a look of idiocy, and creating a nightly nuisance by their loud snoring, are now freed from such distressing facial characteristics, and no longer disturb their friends and neighbours. Such, then, are the beneficent results that have flowed from Czermak's discovery.

This affection of the naso-pharynx was scarcely recognized in this country before Dr. Meyer, of Copenhagen, called attention to it in a paper published in vol. liii of the *Med. Chir. Trans.*, in 1870. Czermak, however, noticed these growths as early as 1860 (*Du Laryngoscope, etc., Ed. Française, Paris, 1860*), and Löwenberg mentions and describes them in an article in the *Archives d'Otologie* in 1865.

The disease consists of a morbid growth of the closed ductless glandular structures of the pharynx (Plate II, Figs. 7 and 8).

*Anatomy of the Pharyngeal Tonsil.*—These disseminated closed follicles, described by Kölliker in 1859 as the *pharyngeal tonsil*, occupy the roof and posterior wall of the pharynx, line the hollows of Rosenmüller's fossæ, and pass over the swelling caused by the termination of the Eustachian tubes. The normal maximum thickness of the pharyngeal tonsil, according



to Luschka, is 7 mm. It contains many roundish follicles and racemose glands; its structure is similar to that of the tonsils. Kölliker states that the pharyngeal tonsil in new-born and young children is as hyperæmic as the tonsil itself.

*General Character of Adenoid Vegetations.*—The adenoid growths vary in form and consistence; in some cases being solid and firm, and in others soft, highly vascular, and prone to bleed. Sometimes they are uniformly distributed over the vault and posterior wall in the form of a velvety cushion. Sometimes they occupy one side exclusively. They are sometimes conical in shape, sometimes villous, rarely pedunculated. When they occupy the whole of the naso-pharyngeal space, they give to the finger the sensation of “soft masses like a bunch of earth-worms.” Their colour is a light pink, but on irritation by the probe or the use of the douche, they assume a bright red colour. The discharge varies in quality, according to the stage of the disease. In early stages it is a thick, whitish, gluey substance, while in advanced cases it assumes a purulent character, and tends to form crusts, which are “hawked” up, and have a blood-stained surface. After a digital exploration of the pharynx, the finger is often stained with blood, the vegetations being highly vascular and easily bleeding. They occur most often in young children with scrofulous tendencies, more rarely in adolescents, and quite exceptionally in old people. Cold and moist climates seem to favour their production. They are more prevalent in Denmark, in America (Northern States), in the North of Germany and France, and in England; less so in warm and dry climates. Scrofula appears to be a frequent predisposing cause, and some observers mention syphilis and straining the pharynx in singing and speaking as further causes.

*Symptoms.*—The symptoms are most pronounced in young children. In the small pharynx of a child a small growth produces much obstruction; in the more capacious cavity of the adult there is less sign of obstruction, but a greater facility for rhinoscopic inspection.

The mouth is habitually and constantly kept open. If the patient be told to keep his mouth shut, he can do so only for a few seconds. He is unable to breathe through the nostrils, or does so very imperfectly, and with obvious difficulty and noise,

and the oppression of breathing is much greater after active exercise and during a meal. The nostrils are flattened laterally, so that "the nose appears compressed, and the patients have a peculiar way of pouting or twisting their lips, toying with them as it were" (Meyer, *loc. cit.*).

In the case of young children, it is very commonly stated by the parents that the child's pillow is often found in the morning stained with blood and mucus, which has run from the nostrils or mouth; perhaps from both. In adults there is often a collection of dry viscid secretion in the morning, which can only be got rid of by hawking and spitting. The mucus expelled is often partially blood-stained. Wheezing and snoring during sleep are also commonly noticed and complained of by others sleeping in the same room. There is headache, and a sensation of fulness and obstruction in the back of the throat. The patients are especially liable to catarrh in the nostrils, and swelling of the inferior turbinate.

*Effects on the Physiognomy.*—Besides the open mouth and lateral compression of the nose,\* there is a dull look about the eye, and a stupid listless expression of the face generally. The dull gaze is attributed by Justi in part to the extension of inflammation to the lachrymal gland and conjunctiva, and in part to the headache, which most often occurs when the growths are on the roof of the pharynx.

*Deafness Common.*—This is more marked in children, and in all in whom deafness is an associated symptom. The deafness may depend on pressure upon the pharyngeal orifices of the Eustachian tubes, but is often the result of extension of inflammation along the tubes to the middle ear. This happens more especially in those cases in which the morbid growths are on the sides of the pharynx.

*Effects on the Voice and Articulation.*—The voice is generally more or less muffled, and nasal in tone, and the speaking indistinct. In some of the worst cases the *m*, *n*, sounds can only be pronounced as *b* or *d* and *l*. So that "moon" is pro-

\* The falling in of the alæ of the nose is due to their habitual inactivity and consequent wasting of their muscles in patients who breathe only through the mouth. Nasal respiration is associated with rhythmical expansion and compression of the alæ, and when these alternate movements no longer take place, wasting of the muscles is the consequence.

nounced “bood,” and “common,” “cobbod,” and “nose,” “loze” or “doze.”\*

“In some cases the position of the growths can be determined from the alteration in the speech, according as it is nasal, or dull and weak, or characterized by the inability to pronounce the nasal consonants. The alteration of the voice is due partly to the closure of the nose, partly to alteration in the uvula and diminution of the naso-pharyngeal space” (article by Dr. Justi, No. 125 of Volkmann’s “Sammlung”). In estimating the effects on the voice it is well to bear in mind that a thickened velum, which is a secondary consequence of adenoid growths, may influence the tone of the voice, even after the growths have been removed, and when most of the troublesome symptoms have been either altogether dismissed, or much alleviated. As long as the nostrils are occluded posteriorly no sonorous vibrations are communicated to the air which they contain, and this must have the effect of deadening the tones of the voice.

*Effects on the Sense of Smell.*—The smell is often dulled (dys-osphresia) and often abolished (anosmia) in advanced cases. The sense of smell is affected probably in two ways—1st, by the alteration of the mucous membrane, both in the pituitary and the olfactory region; and 2nd, by the occlusion of the naso-pharynx cutting off the odorous emanations, and preventing their free circulation.

*Effects on the Inspired Air.*—This is common with other obstructive intranasal diseases, tends to impair the purity, as well as to diminish the temperature of the inspired air.

*Effects on the Development of Infants.*—The interference with development may begin even while the infant is at the breast. Obstruction to nasal breathing is then most disastrous; sucking becomes almost impossible, and the constant efforts to inspire through obstructed channels sometimes give rise to attacks resembling asthma, and are, according to Niemeyer, a cause of spasmodic croup, inasmuch as the exclusively buccal respiration tends to produce abnormal dryness of the glottis.

\* The English and German *ng* becomes *gh* hard, thus “Klingel” is converted into “Kligghel;” “song” into “soggh,” “morning” into “bordiggh.”

The French *nasal vowels* are either replaced by the simple vowels, so that “penchant” is pronounced “pacha,” or a *g* sound is added to the simple vowel, and “penchant” becomes “pague-chague.”

*Effects on the Mental Condition of Children and Young Adults.*—The mental condition of children in whom this disease has been allowed to go on unchecked, is much below the average. They become listless and disinclined to study, and have, in common with all patients affected with nasal stenosis, the condition of mind to which Guye of Amsterdam has applied the term "aprosexia," a want of power to fix the attention on any subject long enough to be able to master it or commit it to memory. The deafness so often associated with the other symptoms aggravates the general dulness of the intellect, and so retards the progress of all educational efforts.

*The Varying Degrees of Intensity of the Symptoms.*—The symptoms thus enumerated may vary in number and intensity as the growths vary in size, position, and extent. The symptoms are much less marked when there are only small velvety growths, than in those cases in which the whole nasopharynx is occupied by a mass of prominent highly vascular tumours.

*Prognosis.*—From the circumstance that these growths rarely occur after the age of thirty, we must conclude that there is a strong tendency in this disease to get well of itself; that in fact the children and adolescents affected with it "grow out of it." This may be so. Nevertheless its effects may be so serious and so lasting that early treatment should be always advised. In the worst cases the treatment must also be active.

*Diagnosis.*—*Digital exploration* is the most universally applicable method of arriving at a conclusive diagnosis. In many cases it is the only method, for in the majority the use of the faucial mirror is impossible. Sometimes the bulk of the growths in the pharynx is so great that the uvula is visibly thrust forwards, and portions of the posterior wall can be seen with villous growths upon them. Digital exploration, however, carried out as described in Preliminary Remarks A, Section II, is most reliable in all cases. The pharynx is less sensitive than in the healthy condition, and bears the movements of the finger well. In order to make a thorough exploration of both sides, as well as the roof of the naso-pharynx, it is better to use first the right forefinger and then the left. The points to be ascertained are the positions of the growths on the several walls, and their size and character.\*

\* Semon, Schech, and Bosworth advocate as a substitute for digital exploration the injection of a stream of warm water by means of a ball syringe,

When there is any doubt left, or if there are objections of any kind to digital exploration, the best method is to employ Schall's mirror with the electric lamp, as modified by Dr. Felix Semon (see fig. 14), using a palate hook (such as White's) (see fig. 13) to draw forward the velum. Before proceeding to the examination of the pharynx by the mirror, the secretions must be thoroughly washed away by means of the nasal douche if the nostrils are not completely obstructed, or by means of Rumbold's post-nasal douche, or by the Rumbold's syringe, the long nozzle of which can generally be passed along the floor of the nostril till it reaches the pharynx (see fig. 8). Zaufal's speculum is said to be useful in exploring the pharynx, and especially in ascertaining the position and extent of the growths in the neighbourhood of the Eustachian orifices. There are, however, great difficulties in young children (the most numerous of these patients) in introducing Zaufal's tubes through the nostrils. In some cases the co-existence of hypertrophy of the turbinates makes their use impossible. They are likely to be serviceable only in adults with capacious nostrils.

There is rarely any difficulty in the diagnosis, the symptoms objective and subjective being quite characteristic.

#### *Differential Diagnosis.*

1. From *simple chronic coryza*.—The symptoms presented by chronic coryza in common with adenoid vegetations are,—a persistent snuffling, an alteration of the voice, abnormal secretion, sometimes abundant flow of mucus, sometimes the difficult hawking up of dry and adherent crusts. The senses of smell and taste and sometimes of hearing are affected. The breath is often offensive.

Unless the pharynx is explored by the rhinoscope and the through one nostril. If the water does not escape from the other nostril, but flows from the mouth, they consider that there is certainly an obstruction in the naso-pharynx. It is, however, obvious that obstructions of some other kind in one or both nostrils may give the same result, and so lead to an erroneous diagnosis. And on the other hand, even when no obstruction exists either in the nostril or naso-pharynx, the stream may be drawn into the mouth by the patient's omission to shut off the naso-pharyngeal cavity at the moment of injection.

finger it is impossible to be sure that these symptoms may not indicate the presence of adenoid vegetations.

2. From *enlarged tonsils*.—When the usual symptoms of adenoid vegetations are present and some amount of enlargement of the tonsils also, but not sufficient to account for the obstruction to nasal respiration, it is at once evident that the enlargement of the tonsils is not the sole cause, and we are led at once to examine the pharynx. When, however, the tonsils are very much enlarged the diagnosis is less obvious. In many cases in my experience chronic follicular tonsillitis is associated with adenoid vegetations of the pharynx. The two conditions often appear to me to be part of one general pharyngitis, and it is therefore essential, before commencing the treatment of any case of enlarged tonsils, to make a careful exploration of the pharynx. It is, however, by no means invariable to find the two conditions associated; and there may be enlarged tonsils with no obstruction to nasal respiration and no *characteristic* affection of the voice and articulation such as we find in cases of adenoid vegetation alone.

3 and 4. From polypi and naso-pharyngeal polypi the diagnosis is comparatively easy, using the anterior and posterior methods of rhinoscopy. The only difficulty would be when one of these two conditions is combined with adenoid vegetations in the same individual. The diagnosis is then of less consequence, however, though it will make the treatment more complicated. The effects on the voice, smell, and hearing produced by naso-pharyngeal polypi are precisely those observed in adenoid disease.

*Diagnosis as Preliminary to Operative Treatment*.—Whenever the patient is difficult to control I invariably give an anæsthetic before confirming my diagnosis, and get the patient or his friends to consent to the operation for removal being performed while the patient is still under its influence and as soon as I have made my diagnosis.

*Treatment*.—This consists in the removal of the growths. Various methods have been employed. The ring-knife of Meyer was the method I first adopted. I now employ Guye's (see fig. 41) ring-knife and my own forceps (see fig. 43) for children, and for adults Löwenberg's forceps. Löwenberg's and Justi's cutting spoons are also sometimes useful for removing growths on the lateral walls, whether they occur in children or adults (see fig. 40).

*Use of Cocain as an Anæsthetic.*—In adults the parts should be

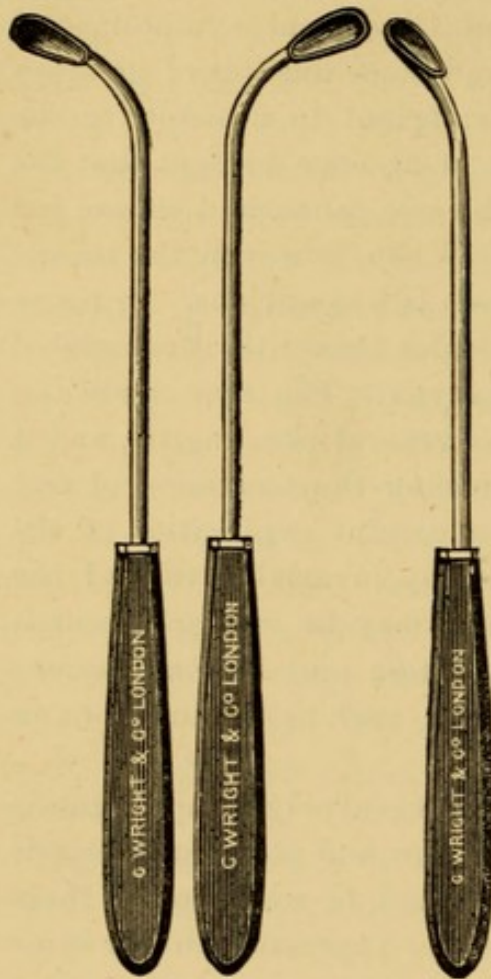


FIG. 40.  
Justi's cutting spoons for adenoid  
vegetations.

prepared by a free application of a 4% or even a 10% solution of cocain, applied (by means of S. Watson's stylets armed with absorbent cotton wool) to the soft palate and pharynx, at intervals of a minute for about 10 minutes or until the palate becomes thoroughly benumbed. If the anæsthesia is incomplete a 20% solution may be used. It should be quite recently prepared, and the cocain should be dissolved in equal parts of glycerine and water.\* A gag (Mason's or some similar form) is then introduced and held by an assistant, the patient sitting opposite the operator with his head supported by a second assistant. I then introduce the Löwenberg's forceps, the tongue being depressed by a spatula which can be removed when the forceps is in position.

The growths are felt by the finger of the left hand and the forceps guided to them, and by successive closure and opening of the blades, the growths are pinched off. There is no necessity for removing the forceps from the mouth frequently, as the portions removed will be either coughed up or swallowed. There is free hæmorrhage which can be controlled by the application of perchloride of iron on cotton wool, and by ice-water syringed through the nostrils. Afterwards the ring-knife or cutting spoon is used for the removal of the smaller growths.

In the case of young children, I prefer to operate while the patient is under the influence of a general anæsthetic, and chloroform is the preferable anæsthetic for these cases. It is

\* Justi used a solution of morphia and chloroform to paint the pharynx, and speaks favourably of its action as an anæsthetic.

important, however, to have the patient's head hanging well over the edge of the operating table, and to turn it completely over to one side. In very few children can the operation be completed at one sitting without the use of a

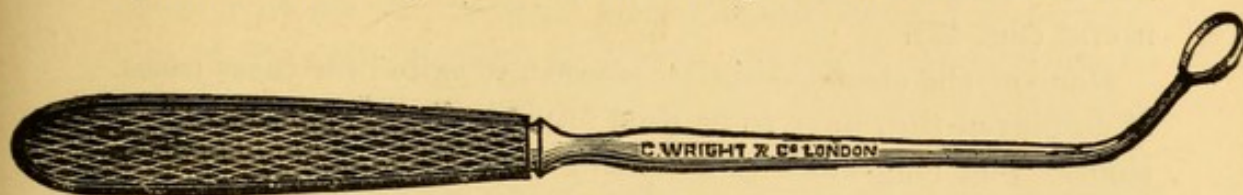


Fig. 41.  
Guye's ring-knife for adenoid vegetation.

general anæsthetic. Guye's ring-knife (see fig. 41) is a most reliable and efficient instrument for these cases, but Justi's and

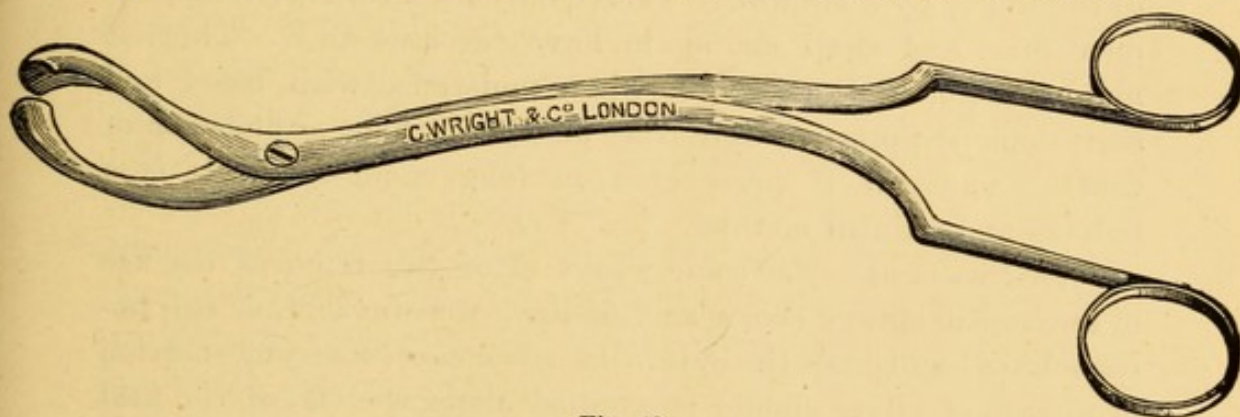

Fig. 42.  
Löwenberg's forceps.

Löwenberg's cutting spoons are also very useful; the former especially for operating on the lateral parts and Löwenberg's for isolated growths on the roof and posterior wall.

I have used Meyer's ring-knife, passed through the nostril

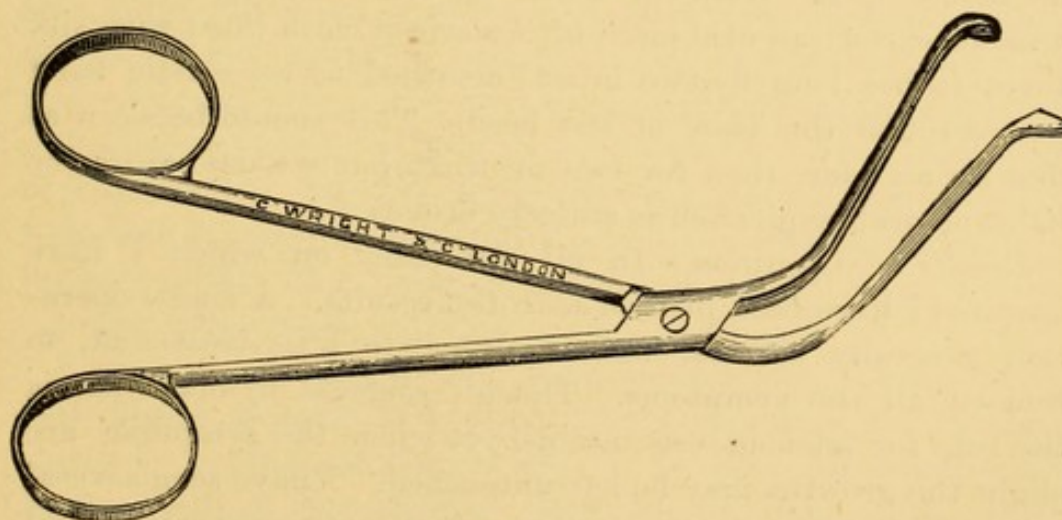


Fig. 43.  
Author's forceps for adenoid vegetations.



and guided by the left fore-finger in the pharynx, but it is difficult to pass the instrument through the nostril in most cases. Small growths can be removed by the finger nail, and in young children the forceps of the pattern shown is often useful (fig. 43).

None of the electric cautery snares are suited for these cases. If employed they have to be used on eight or ten different occasions. The ring-knife and cutting spoon act sufficiently as a rule in one or at most two sittings. Capart, of Brussels, uses a curette attached to the finger by means of a double cylinder, which also acts as a finger shield, and Sir F. Dalby has invented for these operations an artificial finger nail fastened to the finger by a thimble. I have only used this latter instrument once and shall not again have recourse to it. There is much danger of the thimble when moistened with blood and secretions slipping off into the pharynx. The application of caustics succeeds if persevered in long enough, but it is a tedious and painful method.

*After-treatment.*—For some weeks after the removal the use of antiseptic sprays (boric acid, iodine, carbolic acid, or sulphocarbolates) will help the cure. In some cases a strong solution of nitrate of silver should be applied about the end of the first week. It is then necessary to deal with complications, and especially those involving the ear.

The Politzer's bag will be especially useful in many of these cases. It will also be necessary to get the patient accustomed to nasal respiration, and to break him of his habit of keeping his mouth open. With this view it is useful to make him wear a mouth-cover (an oval piece of American cloth lined with silk three inches long by two broad) attached to an elastic band passed round the back of the head. This should be worn at first for an hour, then for two or three hours a day, until the habit of oral respiration is entirely broken.

*Results of Operation.*—In all the cases on which I have operated I have been pleased with the results. A single operation generally suffices, with appropriate after-treatment, to remove all the symptoms. Though removal by operation is the rule for adenoid vegetations, yet when the symptoms are slight the growths may be left untoached. I have seen several cases in which, by the application of local antiseptic sprays, and by the use of Hazeline as a spray through the nostrils and

directly to the pharynx, the slight symptoms have been kept in check, and the difficulty of nasal respiration has been overcome. If the age of puberty is reached without any serious affection of the ear or voice, and with only occasional obstruction of the nostrils, there is every prospect of the vegetations dwindling in size as the walls of the pharynx develop and expand.

There is, however, great danger in leaving the growths whenever the hearing is affected, and when the rhinoscope reveals the presence of large growths in the neighbourhood of the pharyngeal orifices of the Eustachian tubes. The patients, too, may suffer from frequent attacks of rhinitis, and there may be laryngeal complications, and if there is complete occlusion of the nostrils for any length of time, and the characteristic physiognomy above described, the operation is urgently required. Persistent headache is another symptom calling for early and prompt treatment. The late effects of neglected cases are lateral flattening and widening of the chest with, in some patients, an indrawing of the middle ribs and prominence of the sternum (pigeon-breast, or pectus carinatum), and a dwarfing of the general development, not only of the body, but of the intellect as well (Löwenberg, see "Tumeurs Adenoides," p. 23). Guye, of Amsterdam, has called attention to a peculiar hebetude or inability to concentrate the mind on any subject of study in cases of chronic nasal disease (Aprosexia). In these cases of neglected adenoid vegetations, this hebetude of the mind is particularly marked. Dr. Rumbold, of St. Louis, has also noticed in cases of chronic rhinitis very marked "melancholia, inability to think consecutively; to recollect the common affairs of life; to add up a column of figures; to remember immediate relations' names, etc." (Rumbold, "The Treatment of Catarrh," p. 240). I have observed similar mental hebetude both in children and adults in cases of chronic obstructive disease within the nostrils, dependent either upon polypi, adenoid vegetations, or other causes of stenosis.

*Literature.*—Czermak, *Du Laryngoscope*, etc., Paris, 1860; Löwenberg, *Archives d'Otologie*, 1865; Löwenberg, *Les Tumeurs Adenoides du Pharynx Nasal*, 1879; J. O. Roe, *Adenoid Growths in the Vault of the Pharynx*, *Med. Record*, Sept. 13th, 1879; Meyer, *Med. Chirurgical Trans.*, vol. liii; Virchow, *Pathologie des Tumeurs*; Rindfleisch, *Lehrbuch der Pathologischen Gewe-*

*belehre*; Stofft, in *Canstatt Jahresbericht*, etc., 1863; B. Wagner, *Archiv D. Heilkunde*; Cornil and Ranvier, *Manuel d Histologie Pathologique*; Storcke de Vienne, *Congres de Gratz*, 1875; Robert, *Memoire in Bulletin Gen. de Thérapeutique*; J. P. Cassells, *Shut your Mouth and Save your Life*, Edin., 1877; Grehaut, *Recherches Physiques sur la Respiration de l'homme*, Paris, 1864; Rayer, Billard, *Zeitschr. Rat. Medicin*, 1865; Bouchert, Dupuytren, Brücke, Blake of Boston, Rumbold of St. Louis; Justi, *Adenoid Growths in Naso-Pharynx* (No. 125 of Volkmann's *Sammlung*), 1878; Bresgen, Gerhardt, Lassegue, Catlin, Politzer, Fick, Wendt, in Ziemssen's *Handbuch der Speciellen Pathologie und Therapie*; Zaufal (*Archives d'otologie und Prager Medicin. Wochenschrift*); Michel, Lorrain, Gosselin, Morell Mackenzie, Lennox Browne, F. Semon, Cousin, Wilde of Dublin, Carl Stoenk of Stuttgart, Graham, Gottstein, Weber, Guye of Amsterdam, Triquet, Moure of Paris, Cresswell Baber, *Rhinocopy*; Bosworth, *Adenoma of the Naso-Pharynx*, *Journal of Otology*, Jan., 1882; and *Growths in the Nasal Passages*, *Med. Record*, Jan. 13th, 1883; Fränkel, *Ueber adenoide vegetationen*, *Deutsche Med. Woch.*, 1884; Chatellier, *Des Tumeurs Adenoides*, etc., Paris, 1886; Hooper, *Boston Med. and Surg. Journal*, March 15th, 1888.

## SECTION VIII.

## NECROSIS AND CARIES; CERTAIN AFFECTIONS OF THE SEPTUM.

*Necrosis* of the bony walls, or of the deeper-seated bones in the fossæ, is liable to occur under a variety of circumstances. Severe injuries, leading to abscesses, with detachment of the periosteum, not unfrequently leave the bones in a necrosed condition. The abscess, after it has been opened, or has discharged itself spontaneously, remains open as a sinus, and, on probing this sinus, portions of denuded bone are discovered. In the course of time—sometimes weeks, or even months after the injury, the bare bone is found to be lying loose in the cavity of the abscess, and either comes away in the discharge or is removed by the forceps.

*Abscesses* following the exanthemata and erysipelas are often associated with necrosis of some of the more superficial bones. The same thing occurs occasionally as a result of lachrymal abscess, especially if the opening of the abscess has been long delayed, and if the patient has a scrofulous constitution. These abscesses are very liable to come on after the different fevers, especially measles and scarlatina in children of a weakly habit or badly nourished.

In most cases of long-standing syphilitic ozæna, and in many of idiopathic ozæna, in which treatment, perseveringly and steadily carried out, has failed to remove the offensiveness of the discharge, there is reason to believe that some dead portion of bone is locked up in the intricate mazes of the ethmoidal cells, or in one or other of the sinuses communicating with the nasal fossæ. The necrosis in these cases will have arisen either from the isolation of a fragment by ulceration having extended in various directions around it or from the original severity of an acute inflammatory attack.

The *diagnosis* is uncertain and difficult in all cases, unless the part affected happen to be within view by rhinoscopic examination or within reach of the probe. Some indication of the nature of the case may be afforded by the occasional escape of

small fragments of sequestrum in the discharge, but no reliance can be placed upon the reports of patients on this head, and it is often impossible to gain any clue to the actual condition of the more deep-seated bones. The free use of the douche is of course a great aid in making a rhinoscopic examination, and its immediate effect will be some aid in diagnosis. If, after a free use of the douche, the stench from the nostrils disappears, it is a strong evidence not only that no necrosed bone is present, but it also makes it nearly certain that there is no actual caries of the bone. In such a case the stench is probably due to the decomposition of the retained crusts of discharge. If, on the other hand, the stench remains after a thorough douching, or very quickly returns, there is probably necrosis, and almost certainly ulceration or caries.

The hitherto insurmountable obstacle to reaching the offending sequestrum has been the small space offered for manipulation and examination by the limited aperture of the anterior nares. This difficulty might no doubt be overcome by slitting up the nostrils along the line of junction of the alæ with the cheek, or by dividing the middle line of the nose and reflecting back the alæ, one or both, to the sides; but these are formidable proceedings, inasmuch as there is an inevitable scar left after either of them.

Hence it has been proposed by Dr. Rouge, of Lausanne (in a work entitled *Nouvelle Methode Chirurgicale pour le Traitement de l'Ozène*), to accomplish the same object by lifting the upper lip and nostrils together, having first freed them by incisions through the mucous membrane of the mouth and divided the cartilages at their attachment to the upper jaws. The anterior bony nares are thus completely exposed, and a very good view is obtained of the interior of the nasal fossæ, with a large space for the introduction of instruments.

I do not think Rouge's method has been very often adopted, and have not myself performed his operation. The great difficulty of reaching the deeper and higher parts of the fossæ is due to the narrowness of the bony walls and not to the overlapping of the soft tissues. It is, therefore, obvious that any instruments that will pass through the former will not be impeded in their passage through the external apertures. Very large sequestra can be and have been removed through the natural passages, and if they are too large to pass, they can be

removed piecemeal. At the same time, Rouge's operation is sometimes attended with considerable hæmorrhage, which causes a good deal of embarrassment to the operator, and is not altogether free from danger.

*Dr. Rouge's Case of Ozæna treated by Operation—Meningitis—Death.*

Mdlle. W—, twenty-eight years of age (having undergone a previous operation with only partial success in October), was again operated on on the 11th of December. It was performed for the purpose of removing a necrosed and carious piece of the ethmoid, which had not been perceived in the previous operation. To this was due the persistence of some amount of odour. The ozæna was so far removed that the patient requested, with some urgency, to be relieved entirely by a new operation. The probe reached the ethmoid, which gave a dry bruit. On the 11th December, chloroform. The bistoury follows the cicatrix in the upper gingivo-labial furrow. I detach the nose according to my method, cutting the attachment of the nostrils on both sides; with the gouge I take away the whole of the perpendicular plate of the ethmoid, so that the finger passes directly to the under surface of the horizontal plate of that bone. This done, I feel on the right side, high up, *an ulceration of the os planum*, which I gouge over an area of about one centimetre; the finger introduced through this aperture passes into the cavity of the orbit behind the eyeball. The nasal fossæ are washed out with a full stream of water to remove blood and clots. The ulcers are touched with nitrate of silver; the nose and lip are now replaced. In the evening, tumefaction of the eyelids on the right side, temperature  $37.2^{\circ}$  (Reaumur). On the 12th temperature  $37^{\circ}$ ; ecchymosis of the eyelids, which are so swollen as to hide the eyeball; no pain; the general condition excellent. In the evening, temperature  $38.4^{\circ}$ . On the 13th, in the evening, the patient complained of headache and was restless in the night. On the 14th, great excitement, incoherence of ideas, complains of the head and of a pain between the shoulders. Ice to the head; blister to the nape of the neck; calomel, 5 centigrammes every hour. In the evening, temperature  $38.2^{\circ}$ ; the restlessness continues during the night. On the 15th, unconscious; 16th, coma; 17th, death, with a temperature of  $41^{\circ}$ .

The autopsy disclosed an obstruction of the ophthalmic vein by a clot containing globules of pus, and general suppurative meningitis, all the veins being very much dilated and as if varicose and gorged with blood. There was no fissure of the ethmoid, the lamina cribrosa was intact; no purulent focus in its neighbourhood; the bone was healthy around the limits of the operation, which had been performed on the vertical plate and the os planum.

Though in this case the result was unfortunate, yet in a number of other cases the result has been excellent in Dr. Rouge's hands.

The *septum* is liable to various accidents of the diseases described in Section VI., and more especially to ulceration of syphilitic origin. Whenever the bones of the nose are attacked in the course of syphilitic ozæna, some portion of the septum is generally involved in this mischief. Ulceration of this part is very difficult to arrest; necrosis of the exposed bone very often follows, and perforation of the septum is not an unfrequent result. The ulcers, if spreading rapidly, should be touched on their growing edges with strong solution of nitrate of silver, or with the acid pernitrate of mercury, and an ointment of dilute nitrate of mercury, or the grey oxide, kept applied in the intervals. Douching with a weak solution of sulpho-carbolates must be kept up several times daily, and constitutional treatment will of course have to be rigidly attended to. Calomel vapour for inhalation is very useful in these cases.

Lupoid ulcers within the nose, and true lupus from without, are equally liable to invade the septum nasi. They must be treated in accordance with the principles to be hereafter laid down (Section XI). The ulcers resulting from glanders are very characteristic. Simple abscesses may form under the mucous membrane covering the septum; blood tumours, the result of contusions, may also occur on one or both sides of the bone or cartilage, or both. In the case of abscesses, the sooner the pus is let out the better, as there is less chance of the periosteum or perichondrium being stripped off by the progress of the purulent effusion. But in the case of blood tumour, it is better to leave the blood in its position, unless from the great bulk of the effused blood the respiration is impeded. It may not be easy to distinguish between these two

conditions, but the precedent injury and the comparatively sudden appearance of the swelling will be some guide to the diagnosis, and the heat and redness, which would be present in the case of abscess, would be absent in the case of injury. In the former fluctuation is easily made out, in the latter it is scarcely appreciable, unless the amount of blood effused is very considerable.



## SECTION IX.

- SUB-SECTION 1. Diseases of the Frontal Sinuses.
- „ 2. Diseases of the Ethmoidal Sinus.
- „ 3. Diseases of the Sphenoidal Sinus.
- „ 4. Diseases of the Lachrymal Sac and Nasal Duct in their relations to Diseases of the Nasal Fossæ.

## SUB-SECTION 1.

*Diseases of the Frontal Sinus.*

THE rare cases in which these sinuses are affected possess considerable interest on account of the difficulties of diagnosis, and also from the close proximity of the parts involved to the cranial contents. The *diagnosis* in the early stage of abscess is extremely obscure; and even when the walls of the sinus have become considerably protruded, only the seat of the malady is clearly established, while the nature of the contents of the cavity may remain as uncertain as ever. It is only when there is manifest fluctuation, with protrusion and thinning of the walls of the cavity, that abscess can be clearly detected. Even at this stage the swelling and redness of all the surrounding parts may be so great that the aspect is not unlike that of erysipelas or of acute abscess of the lachrymal sac. From erysipelas it differs in being associated at an early period with severe pain and tenderness in the frontal region, and from the absence of the polished and shining surface peculiar to that disorder. From lachrymal abscess it differs in the primary seat and extent of the swelling, and in the absence of any but very slight interruption to the free escape of the tears through the excreting lachrymal passages. Abscess in the frontal sinus is often associated with or preceded by an offensive discharge from the nostril, and in some cases all sense of smell is lost. Neither of these conditions is observed in connection with ordinary abscess of the lachrymal sac; but they may both be present exceptionally if the bones of the nasal fossæ are involved, and the lachrymal abscess is only a secondary result of this condition. The removal of pieces of necrosed bone from the walls of the sinus has often been accomplished, but should never be attempted until they

are found to be lying quite or nearly loose and detached. In the following cases the portions of diseased bones occupied the anterior wall of the sinuses; but in any cases in which the posterior walls are involved it is extremely dangerous to attempt the removal of sequestra, the dura mater being very liable to be ruptured in the act of tearing away the partially detached bone. I have, however, never seen this accident happen, nor have I ever known or read of any case in which fatal results have followed an operation of this kind.

*Case 1.—A Case of Necrosis of the Orbital Plate of the Frontal Bone following an Acute Abscess of the Frontal Sinus.*

J. E. L., aged thirty-two years, a perfumer's assistant, married, had always been in good health, never having had a day's illness, and never having had venereal or other disease till January, 1874, when he was suddenly seized with severe pain in the head, forehead, and across the eyes. He had not had any fall or injury, nor was he aware of anything having happened to him likely to have produced this condition. The pain he describes as having been so severe that he was unable to keep still for a moment, but "kept rolling himself about in agony." In a day or two this was succeeded by swelling, redness, and heat of the forehead and eyelids, and it was supposed that he was suffering from erysipelas; and at length a swelling formed over the inner side of the orbit, which at last broke. From the time of the outbreak of erysipelas, and up to the time that I first saw him in April, he was very frequently annoyed by the *escape into his nostrils of some very foul-smelling discharge*, but no bone had escaped. When seen by me, on April 29, 1874, there was a swelling of about the size of half a walnut immediately under the inner extremity of the superciliary ridge, the skin over this being red and inflamed, and perforated near its centre by a sinus, from which thick, foul-smelling pus was constantly flowing. On probing this sinus I found several pieces of bone lying loose in the frontal sinus. I therefore suggested that an operation should be performed for the removal of these sequestra. Bichloride of methylene was given, and the sinus was then enlarged and two fragments of bone easily drawn out. The larger of the two pieces was about three-quarters of an inch across, about the thickness of an egg-shell, and concavo-convex in form. Having compared

the fragments with the bones in this region, they evidently came from the orbital plate of the frontal bone at its junction with the inner extremity of the superciliary ridge. Very free arterial hæmorrhage followed the removal of the dead bone, but this was easily controlled by pressure. The cavity was dressed with dry lint. In a few days all the swelling had subsided, and by the use of carbolic acid lotion as an injection, all offensive odour was soon destroyed; healthy granulations sprang up, and the wound gradually contracted, leaving a depressed cicatrix, however, and a fistulous opening that only closed about the end of August or early in September. When seen in October no opening remained, the general health was very good, and there was no distortion of the eyelid, as I had at one time anticipated. He still *occasionally notices an offensive smell coming into his nostrils from the part.*

*Case 2.—Case of Necrosis of the Frontal Bone following Abscess.*

Thomas C., aged twenty-six years, came to King's College Hospital under my care in May, 1864, with an ulcer occupying the left side of the root of the nose, and a swelling of that part of the forehead corresponding to the frontal sinus of the same side. A *foul-smelling discharge* had commenced nine months before *to come down his nostrils*, and had continued ever since. There was great tenderness over the frontal swelling. He denied ever having had syphilis. All his symptoms rapidly subsided after the escape of a piece of necrosed bone that had evidently formed part of the anterior wall of the frontal sinus.

In some rare instances such as the following a spontaneous discharge of the pus makes its way through the nostril:—

*Case 3.—A Case of Abscess of Frontal Sinus opening into the Nostril. (Demarquay on Diseases of the Orbit.)*

A woman, fifty years of age, who had suffered from syphilis, had on the anterior part of her frontal bone a fluctuating and indolent tumour. When pressure was made on this tumour, and continued for some time, it caused it to empty itself; *a large quantity of pus then flowed from the nose.* An affection of the frontal sinus, with destruction of the anterior wall of the sinus, was diagnosed. There were besides three exostoses on the arms and forearms.

This woman died from albuminuria, and at the autopsy the frontal sinus was found to be much dilated and full of pus; its anterior wall was destroyed to a great extent; around this perforation the osseous tissue was thickened and condensed. The diplöe had disappeared, the entire thickness of the bone being made up of a compact and very hard tissue.

*Fractures of the bones forming the walls of the sinus do not generally lead to what is strictly an abscess, though, if the injury be compound, suppuration will almost always follow, and the extent of the mischief will depend greatly upon the position of the lines of fracture with regard to the cranial contents. If the upper or posterior walls of the sinus are not involved, very transient effects may be produced, and the simplest treatment only be required in the majority of such instances. An open suppurating sinus, with discharge of clotted mucus and blood, has sometimes been mistaken for an injury involving protrusion of brain substance; but a careful consideration of the anatomical relations of the injured parts and a microscopic examination of the discharged matters will soon clear up the apparent difficulty of diagnosis. There is another possible source of error—when the integument and bony portion of the anterior wall of the sinus have been removed or displaced, leaving the periosteal lining exposed. Under these circumstances, the air entering the nasal passages will give rise to movements of a rhythmical kind in the membrane in question; and this movement is so similar to that of the cerebral convolutions that it has been mistaken for the latter. In these cases auscultation and percussion might be employed if the other means of diagnosis failed to eliminate the possible sources of obscurity, and further evidence might be afforded by the use of concentrated light brought to a focus on the protruding membrane. A membrane distended by air has a certain amount of translucency which would be entirely absent from protruded brain substance. In a case reported by Mr. Harrison to the *British Medical Journal* (November 27, 1869), the injury occurred in a boy of 15 years. The swelling extended from the root of the nose beyond the frontal eminences, and the margins of this swelling gave, on pressure, the peculiar crackling sensation characteristic of emphysema. There was a circular opening in the anterior wall of the right sinus, into which the tip of the little finger nearly fitted, and through which, on each*

expiration, a visible impulse was given to the air still remaining beneath the skin.

The remote effects of injuries in the region of the frontal sinuses are sometimes more serious than the abscesses of traumatic origin already alluded to. The immediate effects of a blow on the forehead may be so trifling that the injury after a few days is forgotten, and months or years may elapse before the attention of the patient or his friends is called to the part by the occurrence of alarming symptoms, perhaps indicating intracranial mischief; or, in other instances, by the occurrence of swelling and pain in the region of the sinuses. The late occurrence of symptoms was well marked in an instance recorded by Demarquay, in which the patient had been struck on the forehead by a fragment of iron two years before any serious mischief showed itself. At the expiration of that time, enormous swelling came on, rapidly followed by drowsiness, aphasia, and paralysis, and in less than a week the patient was dead. After death it was found that an abscess of the frontal sinus had burst through the posterior wall into the cranial cavity, and a large abscess had formed in or under the cerebral hemispheres. An early opening of the abscess in this case would, in all probability, have saved the patient.

*Foreign bodies* sometimes set up great irritation in the sinuses, and occasionally cause suppuration, though remarkable instances are recorded of the slight amount of mischief caused by the permanent lodgment of bullets and large pieces of metal in this cavity. Among the less common causes of abscess in these sinuses glanders may be enumerated. Glanderous nodules and subsequent ulcers are almost always found in the frontal sinuses after death from glanders. During life, severe typhoid symptoms, with frontal pain and a discharge of sanious pus from the nostril, are the leading features of this disease in the human subject. The use of injections of solutions of creosote has been followed by cure in some cases; in any case the use of antiseptic solutions by means of the douche apparatus, and a supporting diet with quinine, are the chief points of treatment likely to be attended with success.

*Chronic abscess of the frontal sinuses* sometimes arises from accidental occlusion of the passage into the nasal fossæ. The diagnosis of these cases is somewhat difficult, on account of the very slow rate of expansion of the walls of the cavity, and the

striking resemblance of the swelling, when formed, to that of an osteo-sarcomatous or malignant tumour of the same region.

The swelling commences imperceptibly, and goes on increasing slowly for months (and in one case for twelve years), until at length considerable deformity is produced, with exophthalmos from encroachment of the tumour upon the orbital cavity. To the touch the swelling presents in the early stage a nodulated uniformly bony surface; later on there are interspaces between bony islets, where a softer and fluctuating surface is perceived. Ultimately pointing takes place through one of these softened parts, and the abscess either discharges itself or is opened by the knife.

In a case under the care of Mr. H. A. Reeves and myself conjointly at the Central London Ophthalmic Hospital, a woman of forty-six years of age had such a swelling, with displacement of the eyeball, which had been coming on for three months at least before admission. It was punctured, and a quantity of muco-purulent fluid in stringy masses escaped. An opening of communication was then made between the cavity of the sinus and the nostril of the same side, and this was kept open by probing and syringing with iodine lotions from time to time. The cavity gradually contracted, but the eyeball retained its abnormal position for a considerable time afterwards, and a fistulous opening lying at the bottom of a funnel-shaped depression above the orbit was very troublesome, and resisted all attempts to close it permanently.

In dealing with any disease of the frontal sinuses, we ought to be aware of the danger of the mischief extending backwards towards the cranial cavity. Among the earliest symptoms of involvement of the cranial contents, anosmia and optic neuritis are, perhaps, the most formidable. It is well, therefore, to test the sense of smell and to examine the eye with the aid of the ophthalmoscope in all cases. In a case of enlargement of the frontal sinuses under my care, associated with purulent discharge from the nostrils and anosmia, well-marked optic neuritis was also present.

## SUB-SECTION 2.

*Diseases of the Ethmoidal Sinuses.*

Acute catarrhal inflammation sometimes running on to suppuration occasionally attacks the ethmoidal sinuses in the course of acute rhinitis. The early symptoms are extremely indefinite, and pain in the region of the upper part of the nostril, and at the inner orbital region, are the only ones leading to a diagnosis of the case. In the later suppurative stage offensive pus coming from the upper part of the nostril, and trickling down into the naso-pharynx, with perhaps exophthalmus and orbital abscess, will be the principal indications. Later on meningitis may be occasioned by extension of periosteal mischief through an ulcerated surface of the bone. In more favourable circumstances a bony sequestrum forms, and may be removed through the nostril.

The treatment in the early stages is mainly by antiseptic injections and sprays, the offensive discharge being thoroughly and frequently washed away. Sequestra when discovered can generally be removed either whole or piecemeal through the natural passage. Woakes regards "*necrosing ethmoiditis*" as a common initial stage of polypous growths. I cannot endorse this view. In my experience there is rarely any necrosis of the bones in cases of polypi. The diseases most commonly associated with abscess of these sinuses are Tertiary Syphilis, Scrofula, and Tuberculosis. Local injury and the lodgment of foreign bodies, as in the case of "*Peenash*," are also occasionally the starting-points of abscess and ulceration in these cavities. The simpler forms are rarely dangerous, but when abscess of the orbit is associated with the other symptoms, the case may go on to a fatal termination. Polypi, when allowed to go on to the stage of full distension of the nostrils, may give rise to inflammation and necrosis of the ethmoid in common with the other bones forming the walls of the nostrils. The same remark will apply to other intranasal tumours.

## SUB-SECTION 3.

*Diseases of the Sphenoidal Sinus.*

The sphenoidal cells being in direct communication with the nasal fossæ, all those morbid processes that affect the latter

may extend to the former. Catarrhal affections, chronic inflammatory thickenings, polypoid excrescences, and even, according to Virchow, necrosis and caries with perforation of the base of the skull, may thus be found in the walls of these cavities. Diphtheritic ulceration of its mucous membrane has been reported. Chronic inflammation has been said by Michel to be the most frequent cause of so-called ozæna. Accumulation of serous fluid in the form of a cystic osteoma, is reported by A. J. B. Holland, of Montreal, as occurring (*Gazette Medicale de Montreal*, Aug., 1889) in this sinus. A woman of 26 years of age had an obstruction of the nose dating from her fourth year. The obstruction was almost complete, and accompanied by loss of smell and of memory and by violent headache. A convex bony tumour was discovered in the nasopharynx. This was perforated, and gave issue to an abundant serous fluid. The symptoms of obstruction all disappeared, and the patient made a good recovery.

The *sphenoidal sinus* when inflamed, gives rise to one-sided deep-seated pain in the face and jaws of the same character as that observed in abscess of the antrum (see Section X.). There is an escape of bright yellow pus from the nostril of the affected side, which finds its way backwards into the nasopharynx. In one or two recorded cases exophthalmus has been a prominent symptom, and amaurosis dependent upon necrosis of the lesser wing of the sphenoid.

#### SUB-SECTION 4.

##### *Diseases of the Lachrymal Sac and Nasal Duct in relation to Intra-Nasal Diseases.*

Extension of the inflammation of rhinitis to the *lachrymal sac* is a common feature of almost every kind of inflammation of the nasal fossæ. The following case is a good illustration of this. It may be taken as a typical one. Similar cases occur not unfrequently in hospital practice, but it too often happens that the patient becomes tired of the necessarily prolonged course of treatment, and is lost sight of before the cure is complete.

Mr. C., forty-five years of age, came to me with watering of the right eye, associated with a feeling of obstruction in the



right nostril. He had at that time a pallid, anæmic aspect, and a languid and feeble gait; his gums were sore and inclined to bleed. Four years before, he had suffered from an attack of inflammation of the eyes in the course of secondary syphilis, the primary symptoms having occurred two months before. About nine weeks before presenting himself, he noticed the watering of his right eye, and the escape of a yellowish-red discharge from the right nostril, which he felt to be obstructed. He had also at times a severe pain (described by him as neuralgic), which affected the head as from an ordinary cold. Traces of iritis were visible in both eyes. On passing a nasal speculum, an ulcer of the septum was seen running obliquely downwards and forwards, the adjacent parts of the mucous membrane being thickened, so that the edges of the ulcer were somewhat steep and abrupt. The surface of this sore was covered with a dirty grey lymph-like serum, which seemed inclined to dry into a scab. A yellowish matter exuded from the nostril, and had *a somewhat fætid odour*, but not such as is generally associated with dead or carious bone.

Under a course of mercury and nasal douches his general health improved, the obstruction in the nostril diminished, the ulcer became more healthy-looking, and the discharge less copious and less offensive; but, notwithstanding these signs of general amelioration, the lachrymal sac became much swollen about March 4, and the increased fulness and hardness in this region prevented its being emptied by pressure. Up to this time the patient had always been able to press the accumulated mucus downwards into the nose, and so to cause the disappearance of the swelling.

I now laid open the lower canaliculus of the right eye, and passed a probe, but not into the sac itself.

On March 5 I succeeded in passing a probe into the sac, and on the 8th quite into the nasal duct.

From this date the progress continued steadily and slowly. The ulcers in the nostril gradually healed, and on June 10 he had discontinued the mercury for some weeks, having commenced the syrup of the iodide of iron. At this time there was little or no discharge, and no overflow of tears from the lachrymal sac. Probes had been passed from time to time, until a full-sized Watson's probe was passed easily. The douche

was still used night and morning, and although there was occasional fetor, it had very much diminished.

October, 1877.—During the latter part of 1876 he continued to have probes passed occasionally, and up to this date they had been used about once in six or eight weeks. He has no epiphora, and wishes the probe to be passed rather as a precaution, and to prevent the possibility of a return of the stricture. He continued the iodide of iron for some months, and then resorted to cod-liver oil. His health became rapidly re-established, and is now excellent.

A somewhat similar case to the above was under my care at the Central London Ophthalmic Hospital. In this case both nostrils were affected, and the septum had become perforated by ulceration before the commencement of treatment. Under a course of iodide of potassium with mild mercurials the condition of the nostrils rapidly improved, and the treatment by mechanical dilatation of the nasal ducts (both of which in this case were affected) was proceeded with. The patient was perfectly relieved, though before the use of remedial measures the obstruction in the lachrymal passages had led to large abscesses and fistulæ in both lachrymal sacs.

*Remarks.*—From these and other similar cases I am inclined to think that the constitutional treatment of lachrymal obstructions is quite as important as the mechanical measures, and that the condition of the whole tract of mucous membrane from the conjunctiva to the nostrils is at fault in the worst forms of mucocele; that the obstruction, in fact, depends rather upon a uniform narrowing of the whole extent of the series of channels, than upon a stricture limited to one or two points. Nevertheless, there can be no doubt that in the later stages there are certain points in the lachrymal sac which are more likely to become permanently closed, and hence we often find a tight stricture either at the opening of the canaliculi into the sac, or at about the lower third of the sac itself. When, however, there is a strongly marked syphilitic or scrofulous swelling of the mucous tract, it will be very difficult to overcome the epiphora, or to heal up the fistulæ of an abscess, without very careful attention to constitutional treatment. When the constitutional condition has improved, mechanical treatment will often be necessary, and will have a much better chance of

succeeding than if attempted without this preparation. (Reported in full in *Med. Times and Gazette*, Jan. 10th, 1878.)



Fig. 44.  
Bowman's  
Canaliculus  
Knife.

It was recently (Nov. 15th, 1889) stated by Dr. Adolf Bronner that "in about 80 per cent. of cases of mucocele or abscess of the lachrymal sac, the corresponding side of the nose was affected." ("Report of Laryngological Society's Proceedings.") Hence the importance of examining the nostrils in all such cases, and commencing the treatment from the nostrils rather than from the conjunctival surface. The starting-point of *lachrymal sac* disease, however, is sometimes

the conjunctiva. The pressure from gelatinous polypi often causes obstruction in the lachrymal sac, and ultimately produces mucocele or chronic abscess. In the early stages the



Fig. 47.

cure of the intranasal disease may put a stop to that within the sac; but should abscess form, it will be necessary to open the sac either through the cheek, or, if possible, through the canaliculi on their conjunctival aspect. Rare cases of polypi and of rhinoliths have been reported as invading or originating within the sac. The treatment must be regulated by general principles, but in almost every case it will be found necessary to employ means of dilating the nasal duct, and as a preliminary to this the use of a canaliculus-knife (see fig. 44) and a set of probes (see figs. 45 and 46) will be necessary, and sometimes the duct must be divided by means of Stilling's knife (see fig. 47), and larger probes used (see fig. 48).

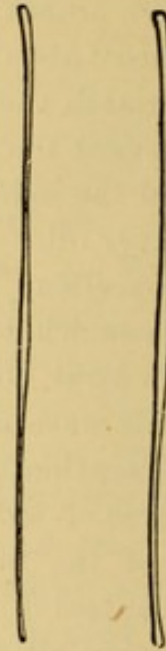


Fig. 45. Fig. 46.  
Author's probes  $\frac{1}{2}$  of  
actual size.



Fig. 48.

## SECTION X.

## DISEASES OF THE ANTRUM.

*Anatomy of Antrum.*—Without entering minutely into the anatomy of this cavity, the insertion of the accompanying figures from Giraldès' classical work will serve to indicate the position of the antrum and its relations to the nasal fossæ. For a more complete description I must refer to systematic treatises on general anatomy. A fair *résumé* of the anatomy of this cavity will be found in the Section on Diseases of the Antrum in the First Edition of this work.

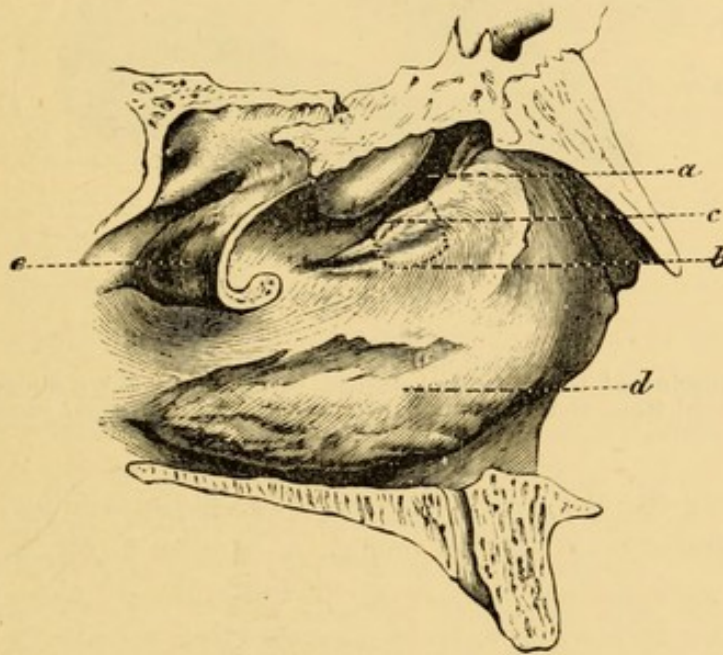


Fig. 49.

External wall of the nasal fossæ.

*a.* Infundibulum. *b.* Dotted line showing the course of the canal between the maxillary sinus and the nasal fossæ. *c.* Bony spur of the infundibulum. *d.* Inferior turbinated bone. *e.* Middle turbinated bone of which the anterior  $\frac{3}{4}$  have been cut away.

Diseases of the *Antrum of Highmore* have a much more intimate connection with intranasal disease than those of either of the other accessory cavities.

*Abscess of, or suppuration in, the Antrum,* may be induced by extension of severe catarrhal, syphilitic, herpetic, or variolous inflammation from the neighbouring nasal fossæ, and is probably, in such cases, partly due to the accidental closure of the

aperture into the nostril by the swelling of the surrounding mucous membrane, or possibly by the plugging of the aperture with inspissated mucus. Caries of the teeth, the roots of which are in communication with the cavity; caries or necrosis of the alveolar ridge; the thrusting of a tooth into the sinus in an endeavour to extract it; injuries and lodgment of foreign bodies—these are all exciting causes of suppuration in the

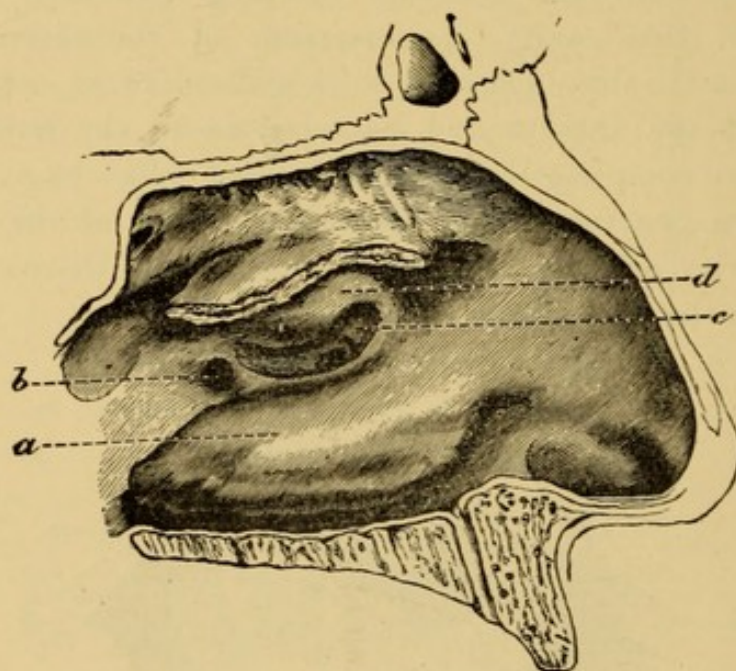


Fig. 50.

External wall of the nasal fossæ.

*a.* Inferior turbinate bone. *b.* Pathological perforation making a communication between the nasal fossæ and the maxillary sinus. *c.* Infundibulum much enlarged. *d.* Bulla ethmoidalis.

antrum. *By far the most frequent cause appears to be the extension of suppuration from the root of a carious tooth, or from the periosteum surrounding it.* A good instance of this is to be found in the following case of suppuration within the antrum in a scrofulous child, associated with necrosis of the alveolar ridge, which came under the care of the author.

CASE I.—A child, æt. 5, was brought to me with an ulcerated aperture in the cheek, opposite the left malar bone. The child had a very unhealthy, scrofulous aspect, and the lower eyelid was completely everted by a cicatrix, the result of an old scrofulous abscess on the cheek, by which the eyelid itself had become in great part destroyed; the skin of the cheek being terminated at its upper part by an abrupt cicatricial adhesion to the lower margin of the orbit. The probe passed into the fistulous opening on the cheek, met with bare bone, and, when

thrust on, entered the antrum. Inside the mouth the left superior alveolar ridge was found to have a bare, ragged, and evidently necrosed surface, opposite two of the molar teeth.

On February 26th, the probe being passed into the aperture in the cheek, found its way through an opening into the mouth by the side of the molar teeth. Two of these teeth being found to be quite loose, they were extracted, and with them came away the necrosed portion of the alveolar ridge. This left a free opening into the antrum, from which a discharge freely escaped.

Dr. White, of Philadelphia, in the "Dental Cosmos," also gives the following account of a case of abscess of the antrum, caused by a decayed tooth. Dr. Garretson cites this case at p. 423 in his work on "Diseases of the Mouth and Jaws."

CASE II.—Mr. S—, æt. 20, light complexion (peculiar whiteness of the skin, a characteristic of the family), had been complaining for some time of a foetid discharge from the right nostril, of heat, and a sense of tension in the right superior maxilla. He applied to his physician, who gave him a wash, with the belief that the parts would speedily return to their normal condition, he supposing the affection to be merely an increased discharge depending upon a slight local hyperæmia, the result, perhaps, of the bad state of the weather at the time. The parts, however, did not recover, the discharge became much more foetid, and evidently was principally composed of unhealthy pus, though it was not as copious as it had been previously; the pain was not severe, but the heat of the parts more elevated, and the sense of tension increased. The patient was irritable and pale; the heat of the body was rather above the average temperature. This was the condition of the patient when he came under the care of Dr. White.

Upon examining the anterior nares nothing could be discovered to account for the discharge, the mucous membrane being a little inflamed, but not sufficient to occasion it. A diseased state of the antrum was suspected, and the mouth was examined to ascertain if a diseased tooth could be the cause. The second molar, upper jaw, right side, was unsound; part of the crown was decayed away; the bulbous portion of the nerve and the filaments of the buccal roots were dead, but that in the palatine root was living, and occasioned the patient pain. A little arsenical paste was applied to destroy it. No sign of

alveolar abscess was present in it or any other tooth; a careful inspection was now made, and important information was received. *Upon examining the right nostril with a speculum, a little pus was seen in the middle meatus.* The patient was requested to incline his head towards the left side; he did so, and upon looking at the parts again a large amount of pus was found. This, together with facts stated already in this paper, and that there was no other assignable cause of the discharge, were deemed sufficient to establish the diagnosis—abscess of the antrum, probably caused by the unsound second molar tooth.

Extraction was advised and submitted to. Upon the removal of the tooth no pus escaped. A probe was introduced into the alveolus previously occupied by one of the buccal roots, and readily passed on into the antrum; pus now followed the withdrawal of the instrument. The cure was completed on general principles. Dr. White concludes his description by remarking that this gentleman had repeatedly visited a *horse* belonging to his father, which had a profuse discharge from the nose, and which was thought to be *glanders*. The horse's malady was prior to that of the patient, and, of course, could only have caused him to fear that he had contracted the disease from it.

The retention of mucus from any cause is not uncommonly associated with or followed by suppuration. Polypi of the nasal fossæ, or of the antrum itself, and tumours of any kind in its cavity or neighbourhood, may excite suppuration, and so complicate the case as to render the diagnosis very difficult. The following case of abscess, depending upon the presence of polypi in the antrum, occurred in my practice in 1868.

CASE III. J. M—, æt. 31, a fruit and fish hawker, in good general health and well nourished, applied at the hospital with a sinus and ragged ulcer, situated near the lachrymal sac of the right side, but a little external to it.

*History.*—He said that he had for some time suffered from a watery eye, and that about Christmas last a swelling had formed in the region now occupied by the ulcer, which was opened two or three months ago by a surgeon and proved to be an abscess. This sinus was probed on several occasions by this surgeon, and about a month ago a small piece of very thin bone of about half the size of the thumb-nail escaped from it.

At or about this time a foetid discharge commenced from the right nostril, and this had continued ever since. His sight was little or not at all affected.

*Present condition, May 29th, 1868.*—In addition to the ulcer and sinus there is a slight fulness of the upper part of the cheek and side of the nose, and the eyeball is thrust a little towards the temporal side of the orbit. There is little or no overflow of tears. A probe passed into the sinus finds its way easily directly backwards to the apex of the orbit, and reaches a depth of a little over three inches. On a subsequent probing the same sinus was found to communicate with the antrum and nostril. No bare bone was felt in either direction. The nostril is obstructed, and there is a very offensive discharge constantly escaping from it.

*Treatment and Progress.*—Injections of a lotion containing one part of tincture of iodine to five parts of water were used with the india-rubber-bottle syringe, and the effect was to cause a free flow of mixed lotion and pus from the right nostril. This was done twice or three times a week till the morning of June 23rd, when he suddenly felt something in his throat and posterior nares, which he managed to cough up with much effort, and almost choking in the attempt. The material which he brought up consisted of four or five dirty-white lumps of soft, pulpy material, varying in size from that of a cobnut to that of a large walnut, and having the most abominably stinking odour. In the choking efforts to bring this up he swallowed some portion of the mass, after which he felt very sick, vomited several times, and was so much prostrated as to be obliged to keep his bed for the rest of the day. From this time, however, the sinus began to heal up, and by July 20th had quite closed. There was still a slight discharge from the nostril at this date, but his health had so much improved, and he suffered so little inconvenience, that he ceased attending the hospital.

The examination of the decomposed mass which had been coughed up gave no evidence of any structure whatever.

In the *Edinburgh Medical Review* (October, 1867) a case is recorded as having been under M. Demarquay with symptoms of abscess (such as "the discharge of large quantities of pus through fistulous openings into the mouth and through the sockets of several teeth"), in which he removed the whole upper jaw, and, on examining the diseased part, found a bony



tumour lying loose in the antrum, like the kernel of a nut in its shell.

The general health of the patient is almost always in fault. Scrofula, and the furuncular cachexia, are the most common forms of constitutional debility in which purulent inflammation of the antrum is likely to occur. Syphilis does not appear to be commonly associated with it, but the abuse of mercury is thought to have a predisposing influence, though the evidence on this point is very insufficient.

Abscess of the antrum has been caused in a newly-born infant from injuries received during parturition, the face having presented itself under the pubes (Druitt's "Surgeon's Vade Mecum," p. 431; and *Medical Times and Gazette*, N.S., vol. iv, p. 860). I have myself seen two cases of abscess of the antrum in very young children, in whom I had reason to suppose the mischief was connected with injuries received during parturition.

*Symptoms.*—The physical signs of suppuration in this cavity will necessarily differ according to the exciting cause, and when there is a means of exit for the discharge, either through the natural opening into the nasal fossæ, or through a socket of a tooth, or a fistulous opening elsewhere, there will not be the pain, swelling, and distension which are usually the accompaniments of a confined abscess.

In some cases the only indications of suppuration going on in the antrum are the ozænic stench and the occasional discharge of pus from one nostril only. The fœtor is noticed by the patient sooner and more constantly than by those about him, and sometimes he complains of a putrid taste in the mouth, with nausea and want of appetite. Pain is complained of in various parts of the cheek, and at the root of the nose, but not constantly, and in some cases there is pain of a neuralgic kind in the region of the frontal sinus. There is also sometimes depression of spirits, inability and disinclination for, mental work, and general malaise. Trousseau relates that he was consulted, on account of ozæna, by a gentleman of forty years of age, who was in good health, except for this source of discomfort. When told to close his mouth and breathe through his nose, Trousseau could detect no bad odour. This gentleman then said that he could produce the stench at will; he sat down, with his head inclined very much downwards, and discharged

into his pocket-handkerchief a large quantity of horribly stinking pus. There was probably some necrosed bone in the antrum with suppuration, but without occlusion of the antral orifice into the nasal fossæ. This case may be taken as typical of the class, there being no pain nor distension, and no external objective signs whatever of the presence of pus in the antral cavity; occasional or constant ozæna, and occasional discharge of offensive pus, being the only signs of the disease. The position of the head during the discharge of pus, when this is capable of control (as in the case of Trousseau's patient), is a very conclusive evidence of the seat of the disease. It is not, however, an invariable or even common symptom, though, when present, it is one of great value.

*Diagnosis.*—In a case of occasional or intermittent discharge of foetid pus from one nostril only, especially if the discharge only takes place when the head is held downwards, or to one side, there is probably suppuration within the antrum, and this may depend upon a necrosed piece of bone lying loose, or in process of separation from the sound parts, or upon a decayed tooth, the fang of which communicates with the cavity. In most instances the abscess will be found to be associated with a decayed tooth, one fang of which perhaps is protruding into the cavity. It is not, however, invariably from this cause. There may be a foreign body of some kind lying loose in the cavity, irritating the lining membrane, but the condition of the teeth must be very closely examined, and in the event of one of them being decayed and tender to the touch, there is every probability of its being the source of the mischief in the antrum.\* Examination of the nostrils, by means of the speculum, should not be omitted, though the evidence conveyed by it may be merely negative. But it may disclose a trickling of pus into the middle meatus, and if, on inclining the patient's head to the opposite side and again examining the nostril, we find that the flow of pus into the middle meatus is very much increased, the diagnosis is rendered much clearer as to the antrum being the part involved.

\* Bosworth, following Zuckerkandl, states that in the late stages of abscess of the antrum, teeth whose roots project in the floor of this cavity become carious, and expresses the opinion that in some of these cases the carious teeth, instead of being the cause of the abscess, are really one of its results. (Bosworth "On the Nose and Naso-pharynx," p. 471).

Examination by this method may be made more conclusive if the nostril is first thoroughly cleansed, and when quite free from discharge the patient's head is lowered, and kept with the suspected side uppermost, in the lowered position, for about 20 seconds. The presence of a stream of pus in the middle meatus after this preliminary treatment will be an almost certain indication that its source is the antrum. The patients sometimes complain that during sleep, or when lying on their backs, the unpleasant discharge escapes into the throat, and that when the head is bent forwards it flows from the nostril of the affected side.

There are, however, four conceivable conditions under which the diagnosis may still remain obscure, even after a careful inspection by anterior rhinoscopy. First the case of suppuration in the frontal sinus. Here we may have purulent discharge from one nostril, fœtor chiefly noticed by the patient, though also as a rule noticed by others, and a general melancholic aspect of the patient. Even after inspection, as the pus from the frontal sinus flows naturally into the middle meatus, there is no way of distinguishing the case from one of abscess of the antrum. The second condition is that of abscess with or without a piece of necrosed bone in the ethmoidal cells. These also open into the middle meatus, and present the same appearances and symptoms. The third condition is that in which the frontal sinus and ethmoidal cells are both affected, and the fourth that in which all the sinuses are affected at the same time, as well as the antrum.

*Treatment.*—The cause being discovered, if it should be concluded that a decayed and tender tooth is at fault, it should be extracted, and the cavity can then be opened through the socket. If pus escape from this opening, it may be syringed out, freely and frequently, with a hope of bringing away any irritating piece of necrosed bone, a misplaced tooth, or foreign body. But in the event of the discharge continuing, the opening must be enlarged, and the antrum thoroughly explored with the probe, remembering that there may be incomplete septa running across the cavity, and that a foreign body may easily be concealed in one of those compartments or fossæ that are so commonly seen in the antrum. The possibility of polypi or other tumours being present, and being themselves the exciting causes of the suppuration, should be borne in mind, and the treatment

will have to be modified as the circumstances of the case require.

*Symptoms of Abscess when the matter is confined.*—When there is undoubted obstruction in the orifice, the symptoms are those of confined pus, and resemble the condition of true abscess within bony structures elsewhere, but with some special features peculiar to the region involved.

There is dull, aching pain in the jaw extending up to the orbit, sometimes to the frontal region between the eyes, and along the alveolar processes. This may be ushered in with rigors, and associated with general febrile disturbance in acute cases, but more commonly the pain remains as the only symptom for some time, and then a gradual swelling of the jaw comes on, pain becomes more acute and throbbing, and rigors, increased temperature, restlessness, and febrile irritability are speedily developed. As the jaw-bone is expanded, various alterations in the shape and relations of the surrounding parts are noticed. The malar bone is elevated, the molar teeth are thrust downwards, so as to appear elongated in the mouth; the hard palate is depressed, and becomes flat or even convex downwards; the nostril of the side affected becomes narrowed or entirely obstructed; the eyeball is thrust upwards and outwards. Mr. Salter has recorded instances in which, besides the protrusion of the eyeball in advanced cases of abscess of the antrum, there was also amaurosis, consequent upon periosteal inflammation extending into the orbit and involving the sheath of the optic nerve (see Mr. S. James A. Salter's article "On the Teeth," etc., in Holmes' "System of Surgery;" and the article in *Medico-Chirurgical Transactions*, vol. xlv, by the same author).

When expansion has gone on to the extent described—though it by no means follows that all the above symptoms will be present in every case—there will very often be some spot or space on the anterior surface, or in the hard palate, at which fluctuation is perceptible. In almost all such cases a molar tooth is decayed, and has been the cause of the mischief. It must be looked for, but if there be no such offender we must look out for some presenting soft point of the swelling, and, though no fluctuation may be felt, there may be some portion of the walls so thin that they yield under pressure, giving to the finger the sensation of dry, tightly-stretched parchment.

If in doubt as to the presence of fluid, a fine trocar and canula thrust into the presenting part will generally solve the mystery, and also give evidence of the kind of fluid contained in the cavity.

It sometimes happens that the abscess in the antrum is associated with very extensive disease of the bones of the base of the skull, and in such instances meningitis and death have occurred. In the case of scrofulous abscess of the orbit, from which the two woodcuts were taken, the antrum was found after death to be full of fœtid pus, and the floor of the orbit was carious. It was probable, however, that the disease of the antrum was only secondary to the original mischief in the orbit in this case, which terminated in meningitis and death.

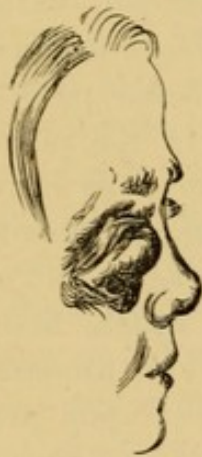

Fig. 51.

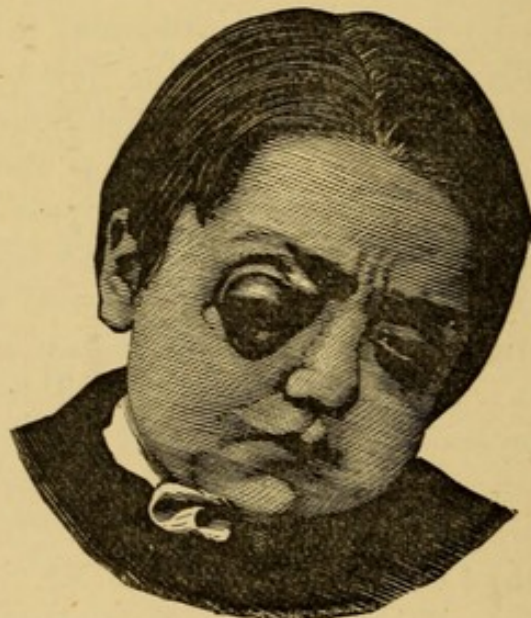

Fig. 52.

*Diagnosis.*—The symptoms, in the early stages of the malady, are somewhat indefinite and unreliable. There is a dull aching pain of the cheek and jaw, and sometimes pain in the frontal region, and the former is referred to the whole of the jaw and the floor of the orbit, and not to the alveolar ridge only, as in ordinary periostitis of the alveolus, preceding gumboil, or that associated with carious teeth. There is also some swelling of the soft parts, and tenderness spread over the whole antral region, and not confined to one spot or region of the jaw, nor to the region of the lachrymal sac. The nostril of the side affected is drier than usual, and sometimes obstructed; there is

heat of the parts, but no superficial redness. Nearly always one tooth, a bicuspid or a molar of the affected side, is decayed and painful, or diseased in some less obvious way.

Later on, the distortion of the surrounding parts indicates the region whence the enlargement has started, but in the early stages, unless some part of the bony walls has become much attenuated, the nature of the enlargement is less obvious, and, in some cases, the distension of the sinus goes on for years so slowly and painlessly, and with so complete an absence of febrile disturbance, that the idea of abscess is not prominently suggested. Hence it has, on more than one occasion, been supposed that a tumour of the upper jaw was present, and the most careful and experienced surgeons have been led into an error of diagnosis on this point.

In M. Dubois' case of simple accumulation of mucus in the antrum (Mackenzie on "Diseases of the Eye," p. 69), the patient, when a boy of seven years of age, was observed by his parents to have a hard round tumour, about the size of a filbert, near the root of the nasal process of the left upper maxillary bone. *The nostril was almost completely closed, and the nose was twisted to the right.* The cheek was prominent; and the skin below the lower eyelid, and covering the upper part of the tumour, was of a livid colour, and seemed ready to give way. The upper lid was pushed upwards, and the whole length of the gums on the left side had advanced beyond the level of those of the right. Breathing, speech, mastication, and sleep were impeded. Sabatier, Pelletan, and Boyer being called in to consultation, the *unanimous opinion* appears to have been that it was a case of *fungus* of the *maxillary sinus* requiring an operation. An opening, however, was made in the most prominent part of the swelling, the ichorous discharge evacuated, and as a result the abscess was ultimately cured, and no tumour was found.

The importance of arriving at a certain conclusion as to the presence of pus in the antrum under similar circumstances, before proceeding to any operation for the removal of a tumour, cannot be too strongly insisted on, and it should therefore be the rule before operating always to perforate the cavity, either through the socket of a molar tooth, or through some expanded part of the anterior wall, or through the outer wall of the

nasal fossa. This proceeding has, on two or three occasions, saved the surgeon from the discredit of removing the upper jaw for an abscess of the antrum.

Electric *transillumination* (Semon) of the bones of the face, as suggested by Voltolini, and carried into effect by Heryng, promises to give us very valuable aid in the diagnosis of abscess in the antrum. For this purpose Heryng has recently (1890) employed a small incandescent lamp, of *at least* five volts, passed on a tongue-depressor into the patient's mouth. The lamp is protected by a double glass envelope, the outer one being in communication with the air beyond the patient's lips. The room must be perfectly dark. The patient closes his mouth, and the electric current is established, when the bones of the face, according to Heryng's experience, are perfectly lit through, and appear up to the orbit bright red. If there should be empyema of the antrum the affected side *remains dark*, and the diagnosis is secured. Heryng has employed this method in ten cases; in only one did he fail in his diagnosis. (Dr. F. Semon, paper read before the Odontological Society of Great Britain, Jan., 1890.) A somewhat similar method of diagnosis for dental disease was employed by Dr. Bruck, junr., in 1876, the Drummond limelight being used by him (see *Medical Times and Gazette*, April 15, 1876).

The rare complication of abscess with tumour must not be overlooked, for several instances of the kind are on record. In the College of Surgeons' Museum there is a specimen of fibrous tumour of the upper jaw, and occupying the antrum, removed by Mr. Liston. Before the operation for its removal, the antrum had been perforated and pus evacuated, and at the upper part of the preparation there is a small cavity, which contained pus.

At later stages of the case the eyeball may be protruded, in common with all the structures surrounding the cavity, but exophthalmus is not invariably observed even in this period of the malady. The lachrymal sac and nasal duct are not uncommonly obstructed, and the eye on the affected side is watery.

*The prognosis* is almost always favourable; it is only when the surrounding bones are extensively involved, and especially when there is reason to believe that the bones at the base of the skull are carious or necrosed, that there is any reason to

anticipate danger to life. If, however, in the course of a fever or erysipelas, or after an operation on the jaws, such as tooth-drawing, or an injury to any of the bones of the antral walls, a sudden access of pain and distension in the cheek and jaw, with protrusion of one or both eyeballs, and delirium, convulsions, or coma, or other cerebral symptoms make their appearance, there is some reason to fear that intracranial abscesses and meningitis have set in, and the issue may be fatal within a very few days.

But such instances are exceedingly rare, and can only occur when the patient is in a very unhealthy state, or is exposed to some unhealthy influences, such as pyæmic infection or the poisons of contagious fevers.

The *treatment* was laid down by John Hunter, and his rules will hold good for the majority of cases we have to deal with.\*

“The first part of the cure, as well as of that of all other abscesses, is to make an opening, but not in the part where it threatens to point, for that would generally be through the skin of the cheek. If the disease is known early, before it has caused the destruction of the fore-part of the bone, there are two ways of opening the abscess: *one by perforating the partition between the antrum and the nose, which may be done*; and the other by drawing the first or second grinder of that side and perforating the partition between the root of the alveolar process and the antrum, so that the matter may be discharged for the future that way. But if the fore-part of the bone has been destroyed, an opening may be made on the inside of the lip, where the abscess most probably will be felt; but this will be more apt than the other perforation to heal, and thereby may occasion a new accumulation, which is to be avoided, if possible, by putting in practice all the common methods of preventing openings from healing or closing up; but this practice will prove rather troublesome; therefore the drawing the tooth is to be preferred, because it is not so liable to this objection.”

Several different kinds of antrum-perforators have been contrived (see Erichsen's Surgery). If the walls are thin a strong trochar will be sufficient, but for perforating in the canine fossa, or indeed in any part of the walls retaining their

\* The works of John Hunter, F.R.S., edited by James F. Palmer, vol. ii, p. 78.



normal thickness, a carpenter's gimlet, or some similar instrument, is more appropriate.

Having made an opening, the probe should be introduced with a view to ascertain whether there is any foreign body or necrosed bone in the cavity. If there be, it will be necessary to enlarge the opening, by cutting away portions of the bony walls to an extent sufficient to allow of the introduction of a scoop, forceps, or such other instruments as may be required, and to facilitate the removal of the offending body when found.\* If, however, no foreign substance can be found, the sinus must be injected with some antiseptic lotion daily, until the secretion becomes healthy in character and insignificant in quantity. The aperture, if made through the socket of a tooth, can be kept open by introducing a soft silver or leaden lachrymal style, and securing the end by means of silver wire wound round the adjacent teeth. Great care must be taken not to allow this plug to slip into the antrum, and in order to avoid this, it is better to employ for the purpose one of the old-fashioned and now disused styles with a button at the end.

It has been proposed by Lamorier to make the opening below the malar process, but there is the obvious objection that this is not the most depending part of the sinus, and, consequently, not the part most favourable for allowing the free escape of the discharge.

*Cysts of the Antrum.*—In dealing with the subject of cysts, in this cavity, there is a difficulty in the nomenclature, which imports some confusion of ideas. The old name of *dropsy of the antrum* seems to include clinically a variety of different pathological conditions not quite clearly defined, but of these different conditions we may, I think, safely exclude two varieties as being distinct from the others, viz., the *dentigerous cysts* and the *subendosteal cysts*, of which the pathology and etiology are pretty well understood; whilst the simple *serous*

\* The existence of separate fossæ or recesses within the antrum, formed by the projection of imperfect dissepiments across it, will sometimes prevent the probe or finger reaching a foreign substance, if the latter happen to be lodged behind one of these partitions. Hence a curved scoop is very useful for the purpose of exploring the interior, and by hooking it round any projecting bony plates or columns that present themselves, the foreign body can be easily extracted.

*cysts* of William Adams,\* the *mucous cysts* of Giraldès, the *vesicular polypi* of Virchow, and the *polypi* of Sir Benjamin Brodie and Sir James Paget are all, I think, of one and the same kind; all these being included in the term *dropsy of the antrum*, under circumstances which may accidentally arise in particular cases. Provisionally, however, it will be convenient to consider the descriptions of the various authors alluded to, as if they related to distinct affections, *i.e.*, till such time as further observations may satisfy us that we have to deal with varying aspects of the same disease.

*Solitary cysts* occurring in this cavity have most frequently been found to be dentigerous, *i.e.*, a misplaced tooth-sac has found its way, through the alveolar ridge, into the cavity of the antrum, and has there developed into a cyst in the process of growth. (Plate III, figs. 3, 4, 5, and 7.)

With regard to the *dentigerous cysts*, it has been proved by Mr. James Salter ("On the Impaction of Permanent Teeth in the Substance of the Maxillary Bones," by S. J. A. Salter, in "Guy's Hospital Reports," vol. v, 3rd series) that "the cysts only arise when the tooth or teeth associated with them are embedded in the jaw-bone; they do not occur after the tooth has pierced the gum."

There is, however, another form of cystic growth, described by Virchow as *vesicular polypus*, which, from the tendency which all polypi have to increase in bulk, is probably in some cases the commencement of those enlargements of the antrum that are generally described as dropsy, a designation, by the way, altogether inappropriate, implying, as it does, a false notion of its pathological significance and etiology. They are thus described by the author above named—


"We find in the wall of the maxillary sinus, vesicles sometimes solitary, sometimes multiple, which are filled with a clear or opaque mucus, or with a purulent or epithelial mass. These vesicles spring up by degrees from the surface, take on the form of molluscous growths and polypi, and these polypi become at last so large as to fill up the whole of the cavity. These large vesicles have not ordinarily such thick contents; the mucus softens and forms a thinner and more watery liquid. If the morbid product increases more and more, the sinus can sometimes no longer hold it, and dilatation therefore results,

\* See figs. 3 and 6 on Plate III, specimens in St. Thomas' Hospital.

accompanied by atrophy of the bone. This condition appears to be that one which has often been described as *hydrosy of the sinus*; at least, there is no observation showing that *free hydrosy* could attain, in the antrum, to such a development, and I consider as probable, that which M. Giraldès has been the first to note, that a mistake has usually been made as to the origin of these cysts. At the time that the polypus has become so largely developed, it is possible, on opening the sinus, to reach immediately the cavity of the polypus, without perceiving that the liquid was contained in a special envelope, exactly as, when one cuts into the sac of an echinococcus, the vesicle of the animal is at the same time incised.\*

*Polypi of the Antrum, with persistent dropping of clear Fluid from the Nostril.*—Of the same kind as the *vesicular polypi* of Virchow is Sir James Paget's remarkable case ("Clinical Society's Transactions," vol. xii, p. 47). If we compare the figs. 3 and 6 of Plate III with fig. 7, which is reproduced from Sir James Paget's coloured illustration in the "Clinical Society's Transactions" above alluded to, the resemblance in the characteristics of the *simple serous cysts* of the former to the polypi of the latter will be at once apparent. Perhaps the mucous cysts, described by Giraldès, depicted in figs. 1 and 2, are not precisely of the same kind. In Sir James Paget's case, when first brought forward (Nov. 22nd, 1878), the diagnosis was very obscure. The striking symptom was the copious *dropping of a clear fluid from one nostril*. Various opinions were expressed as to the significance of this symptom. Being present at the meeting in question I ventured to suggest that in this and in two similar cases that had come under my observation the dropping of fluid from one nostril was due to *chronic catarrh of the antrum*. (*Lancet Report*, Nov., 1878). I founded my diagnosis on the fact that the flow of fluid being from *one nostril* its most probable source was from the antrum on the same side. The subsequent history of the case proved that I had made a fortunate guess of the true state of the case; for in Sir James Paget's supplement he relates how, the patient having died in the interval, the following conditions were brought to light at the post-mortem inspection of the head. "The whole base of the skull, the cribriform plate of the ethmoid bone, the olfactory bulbs, and the dura mater in

\* Virchow, "Die krankhaften Geschwülste," Vol i, p. 245.



*Description of Plate III.*

Figs. 1 and 2. Sections of the upper jaw with cysts in the antra (from Giraldès' Treatise "sur des Kystes Muqueux des Sinus Maxillaire").

Fig. 3. A specimen of cyst in the antrum, in St. Thomas' Hospital Museum. In the same specimen there is a polypus of the nasal fossa. The lining membrane of the antrum is slightly thickened at the point of attachment of the cyst. The first molar tooth is decayed in the fang opposite the attached parts of the cyst; the other teeth are all healthy; the fang of the carious tooth is exposed on the alveolar ridge externally, showing that otitis and subsequent absorption of bone tissue have been going on.

Fig. 4. The opposite side of the specimen represented in fig. 3, to show the polypus (much shrunk by the long immersion in spirit) attached below the orifice of the antrum in the middle meatus.

Fig. 5. An imperfect cyst in the antrum, with a carious molar tooth immediately beneath it (from a specimen in St. Thomas' Hospital Museum).

Fig. 6. Simple serous cysts of the antrum. The mucous membrane of the nose appears to have been inflamed (from a specimen in St. Thomas' Hospital Museum).

Fig. 7. A specimen of osseous cyst containing a loose tooth, in the possession of Mr. Samuel Cartwright (from Mr. Cattlin's paper on the "Antrum," in the *Odontological Society's Transactions*, 1857-60, p. 38).

Fig. 8. Sir James Paget's case of polypi in the antrum. Specimen No. 3944 in the Catalogue of the Museum of the Royal College of Surgeons.

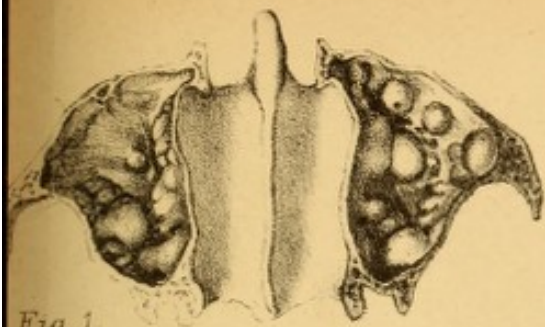


Fig. 1

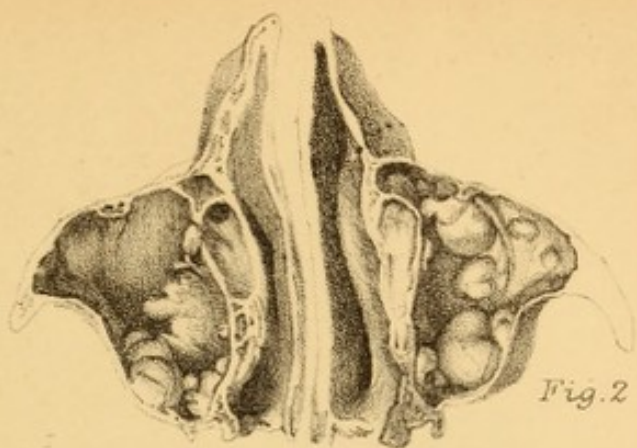


Fig. 2

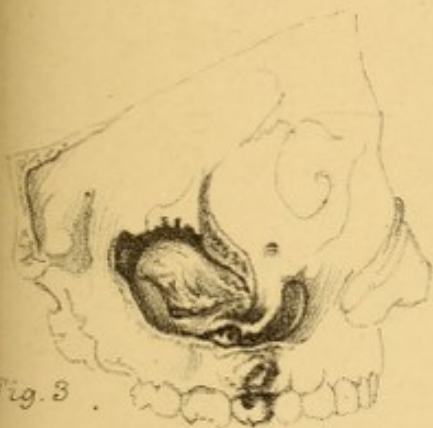

Fig. 3

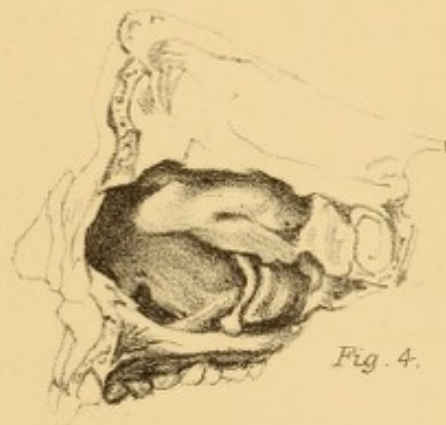


Fig. 4.

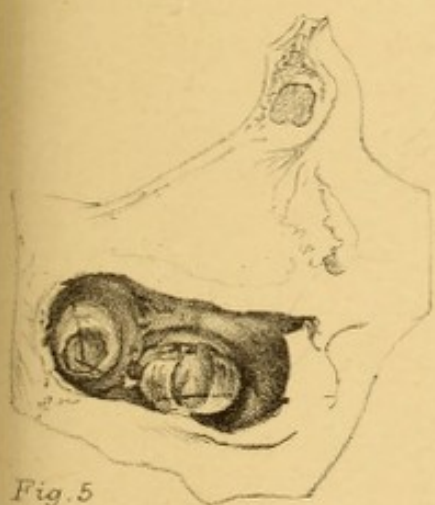

Fig. 5

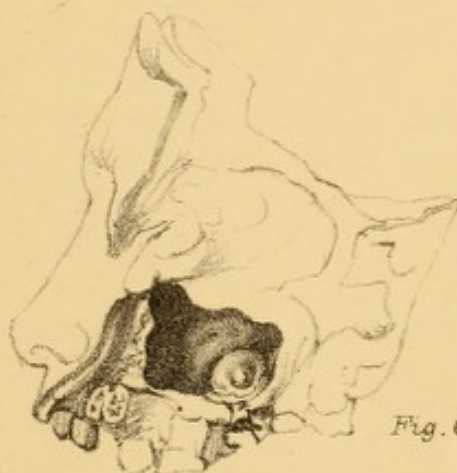


Fig. 6.

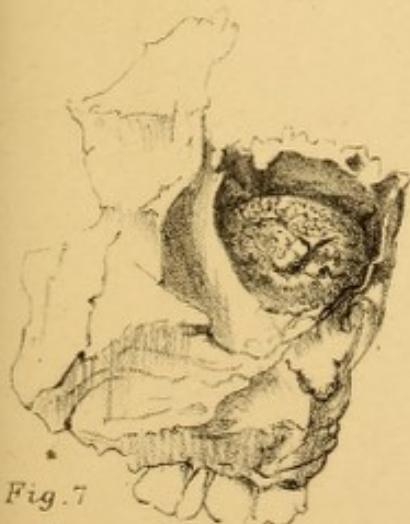

Fig. 7

George Spencer Watson lith.

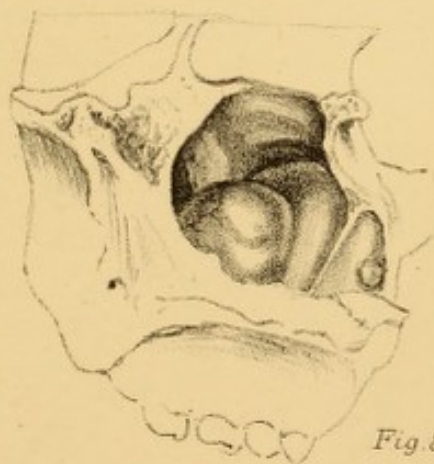



Fig. 8.

West, Newman imp



relation with these were completely healthy. The examination was made the more carefully because of a suspicion that it might have been subarachnoid fluid which had dropped from the nostril. Nothing in evidence of such a supposition could be found. The lining of all the nasal cavities and sinuses, except that of the left antrum, appeared quite healthy. Of this antrum the bony walls were unchanged; its shape and size were natural, and nothing external indicated any change within. But its floor was covered with *two broad-based convex polypoid growths*, deep clear yellow, with the fluid infiltrated in their tender tissue, and covered with branching blood-vessels. They were of rounded shapes, about  $\frac{2}{3}$  of an inch in diameter and  $\frac{1}{2}$  an inch in depth; *they looked like very thin-walled cysts, but were formed of very fine membranous or filamentous tissue, infiltrated with serum.* On the outer wall of the antrum were flattened soft yellow masses which appeared as the residue of one or more similar polypoid bodies, collapsed after breaking or accidental injury, and the escape of the greater part of the serous fluid. The rest of the mucous membrane lining the antrum was thick, pale, soft, and rather coarsely granular, *changed, as one might expect it to be, in chronic catarrh.*" This appears to be the only case in which the explanation of the dropping of fluid from one nostril has been arrived at by the results of post-mortem inspection, no mention of this symptom as being indicative of polypi or of cysts in the antrum having been previously made by any author on the subject.

Under the head of "*Nasal Hydrorrhœa*," Dr. F. H. Bosworth, of New York, has collected fourteen cases of profuse watery discharge from the nose. These he divides into two classes. In a certain number the escape of watery fluid is purely passive and painless, while in others the flow of water gives rise to symptoms of intense irritation, such as we observe in ordinary cases of hay fever. In the first class he thinks that "the essential lesion consists of an ablation of function of the trifacial nerve, which, as we know, exercises an inhibitory action upon the serous exosmosis which takes place normally in the nasal mucous membrane. The paralysis of sensation connected with loss of function of the trifacial, accounts for the absence of irritation. This was a striking feature in Dr. Althaus' case (see *Brit. Med. Journal*, 1878, vol. ii, p. 831; also *Med. Chir. Trans.*, vol. lii, p. 29), in which the patho-



logical lesion seems to have been thoroughly recognized, and the diagnosis established, of neuritis involving the fifth pair on both sides." Bosworth regards the existence of polypi in the antrum in Sir James Paget's case as "the result of the persistent hydrorrhœa," and suggests "that the essential lesion consisted of some obscure condition at the base of the brain, which gave rise subsequently to an attack of acute meningitis, to which the patient succumbed." "In another class of the cases, we see that the watery discharge gives rise to an intense irritation of the nasal mucous membrane, as manifested by the peculiar formication and sneezing which becomes a source of exceeding great distress" (*Bosworth, Diseases of the Nose and Throat*, New York, 1889, vol. i, pp. 258 to 271). In this second class of cases of hydrorrhœa there is probably some disturbance or irritation of the sympathetic system of nerves. I have seen one case of this kind. A married lady, of about 30 years of age, the wife of an officer in the Indian army, had very persistent flow from both nostrils, with intense irritation, and fits of sneezing. The symptoms were associated with excessive nervousness and melancholy. It was therefore impossible to make a thorough examination of the nostrils, as the patient shrank away directly any instruments were produced. I saw this lady several times, and used cocain to the nostrils, at the same time giving tonics internally. No improvement, however, took place, and I have since lost sight of the patient.

Mr. Priestley Smith, of Birmingham, has recorded two cases of "persistent dropping of fluid from the nostril associated with atrophy of the optic nerves, and other brain symptoms" (*Ophthalmic Review*, Jan. 3rd, 1883), and in one of these there were *polypoid growths in the nostril*. It is a fair inference that there may have been similar growths in one or other of the sinuses, and possibly in the antrum of the side affected. The association of optic nerve atrophy with these cases of cystic or polypoid growths has been noticed by Nettleship, and a case has also been recorded by myself.

*Author's Case of Cyst of the Antrum associated with Optic Nerve Neuritis and Atrophy.*—Ann C., aged 29, a servant, well nourished, and with dark hair and complexion, came to the hospital on July 14th, 1879. She had noticed failure of sight in her right eye, with a severe pain in the eyeball

for about six days. Under treatment elsewhere, the sight had become much deteriorated. She had pains and tenderness of the shin bones, but no symptoms indicating a syphilitic history. There was an exostosis of the right lower jaw opposite the bicuspid. The eyeball had normal tension, the pupil being round and contractile and the texture of the iris good. When the left eye was covered, the right pupil remained partially dilated, though exposed to strong light. Vision amounted to 20 Jäger. On ophthalmoscopic examination, the optic disc was seen to be blurred, and the surrounding retina œdematous. No note was made of any swelling of the upper jaw at this period of the case.

The treatment consisted of mercurials, by internal doses of liquor hydrargyri perchloridi and Plummer's pill, and the inunction of a mercurial liniment on the brow and temple, with an occasional opiate at night. This was continued with slight variations till the middle of September. No improvement of vision was obtained, but the congested and œdematous state of the retina subsided, and the optic disc became pale. The patient was now put upon a course of iodide of potassium. In January, 1880, the eye remained in much the same condition, and there was now swelling of the right upper jaw, visible through the cheek. This swelling she had noticed to be on the increase for the last year, and it had now (January 20th) become extremely painful, the pain extending up to the side of the head. Inside the mouth and opposite the upper molars, and on the outer alveolar ridge, a swelling of a fluctuating character presented itself. On puncturing this, a clear yellow fluid exuded; it contained abundant cholesterine crystals. The swelling of the cheek now subsided, and a ragged opening in the antrum could be felt with the point of the finger. The cavity was syringed out from time to time with solutions of sulphate of zinc, and latterly of iodine; and the character of the fluid gradually changed to a mere sero-pus. An opening large enough to admit the point of a probe still remains (May 14th, 1880), and the cavity is still extensive enough to allow an inch and a half of the probe to pass upwards and inwards towards the floor of the orbit. There is still considerable pain of a neuralgic kind in the side of the head and around the eye. The sight of the eye remains as before, the optic disc being permanently atrophied.

Up to the present date (June 14th) there has been no improvement in the vision. The nostril on the side affected was not obstructed, nor was there ever any discharge from it.

*Diagnosis of Vesicular Cysts or Polypi of the Antrum.*—It is not easy to lay down any definite rules of diagnosis for such rare cases. The fact of a persistent dropping of a clear fluid from one nostril, if unexplained by any visible morbid change in the nostril, leads to a strong presumption that cysts or polypi, or at least chronic catarrh due to some cause, exists in the antrum of the side affected. If there be optic neuritis under the same circumstances the diagnosis is strengthened. The long continuance of a serous discharge of low specific gravity does *not* indicate a fissure in the cribriform plate of the ethmoid. The fluid examined in the Paget case was of low specific gravity—one specimen being sp. gr. 1009·3 and another 1010·4. One hundred parts of the liquid contained 1·5 of solid matter in solution. There was “proteid matter,” but no indication of grape sugar.

There seems to have been cerebral disturbance on the cessation of the flow of fluid both in Sir James Paget's case and in those of Mr. Priestley Smith. This symptom, therefore, would be significant in any future cases of the kind. Distension of the walls of the antrum is seldom observed in these cases.

The *treatment* of the cases of cysts or polypi in the antrum must at present be regarded as unsatisfactory. In Sir James Paget's case above alluded to sulphate of zinc was given, both internally and as an injection into the nostril; and this plan having been continued for six weeks the dropping of fluid gradually diminished, and in two or three weeks more completely ceased. The same thing happened in a similar case recorded by Dr. Elliotson and Sir Benjamin Brodie (*Med. Times and Gazette*, Sept. 19th, 1857, and in the 3rd volume of Sir Benjamin Brodie's works, page 665). It would, therefore, be worth while to try this plan of treatment in any similar case of the kind. Where, however, there are any nerve lesion, as in Dr. Althaus' case,\* the treatment of the case will have to be conducted in accordance with the diagnosis of the symptoms referable to the supposed lesion. Dr. Bosworth cured a case of nasal hydrorrhæa by the use of the galvanic current locally applied (*op. cit.*, p. 270).

\* *Brit. Med. Journ.*, 1878, vol. ii, p. 831

*Mucous Cysts.*—M. Giraldès, of Paris, seems to have first pointed out that the so-called *dropsy of the antrum* is often only the result of the formation of a large single cyst or multiple cyst, and that the seat of the disease was, in such instances, in the mucous glands of the lining membrane of this cavity. These glands lie in great numbers, especially along the inner wall of this sinus, and when, from any cause, the orifice of the glandular canal becomes obliterated, the secretion is retained, collects and forms a cyst. M. Giraldès divides these cysts into two kinds:—1. The miliary cysts, formed by the dilatation of the peripheral part of the excretory duct. 2. Cysts of a larger bulk, and formed by the dilatation of the whole follicle. The first kind are only of importance as being occasionally the starting point of the larger cysts. These latter, of which specimens are seen in St. Thomas' Hospital Museum, placed there by Mr. William Adams, even before the treatise of M. Giraldès called attention to their significance, are variable in number, sometimes single, sometimes multiple. (Plate III, figs. 1 and 2.)

In another specimen the "lining membrane of the antrum at the base of the cyst is slightly thickened, but healthy in other parts, excepting that, at a little posterior to the above-described cyst, it appears to be split into two layers, which are separated from each other, the outer layer having a central perforation, presenting therefore somewhat the appearance of a cyst with a central aperture." ("Catalogue of St. Thomas's Hospital Museum," p. 194; description of specimen I, 22.)

In the next specimen (I, 23 in the Catalogue), a somewhat similar condition of the posterior part of the lining membrane of the antrum is described; it "is seen to be split into two layers at two places, the layers being separated to the extent of one-eighth of an inch, and connected by loose but abundant areolar tissue."

M. Giraldès, in his paper on this subject, describes two cases of cyst in the antrum illustrating the multiple form of cyst in an early stage of development.

Their size varies from that of a large pea to that of a pigeon's egg, and even larger. Their colour is not uniform: sometimes transparent, of a whitish yellow, sometimes opaque, yellowish at the centre, and transparent at their circumference. The matter contained in them is generally viscid, thick, stringy,

transparent, and sometimes yellowish. In some instances it is a thick opaque mass, occupying the central region of the tumour. In the larger cysts the matter seems to have undergone a certain amount of alteration; it is more liquid, of a yellowish-white, sometimes but slightly transparent, of a syrupy consistence, and loaded with crystals of cholesterine. The matter from these cysts dries up rapidly when exposed to the air, and then assumes the appearance of gum arabic. Chemically, it contains much the same constituents as mucus, but with a little more albumen. Microscopically, it contains granules, altered blood globules, fat globules, *débris* of epithelium, but, above all, a large quantity of crystals of cholesterine.

*Symptoms and Progress.*—As the cysts increase in bulk they fill, and ultimately distend the cavity occupied by them, and thrust the walls of the antrum towards the cheek, the orbit, the nostrils, or the mouth, and sometimes in all these directions at the same time, causing thereby great facial deformity and displacement of the neighbouring organs. The walls become thin and fibrous in consistence, so that when pressure is made on the cheek a crackling sensation, as if from the yielding of parchment, is experienced. In all respects, therefore, the symptoms resemble those of so-called dropsy of the antrum.

*Diagnosis of Cysts.*—The same external distortion and enlargement of the jaw occurs in the advanced stages, as in distension of the walls of the antrum from any other cause, and in the early period these features will be altogether absent. An exploratory incision in the most prominent part of the swelling, through the mucous membrane, will not fail to clear up any doubt as to the presence or absence of fluid and as to its nature, but it may not quite satisfy us as to its position, unless care be taken to explore the cavity with a probe after letting off its fluid contents: for it is not very uncommon to meet with cystic growths in the mouth quite external to the walls of the antrum, and it would not be satisfactory to conclude, from the mere presence of fluid in such a cyst, that we were therefore dealing with an antral cyst. Sir James Paget described a case occurring in a woman, of a soft elastic swelling, which pushed out the thin mucous membrane of the upper jaw, producing externally an appearance somewhat similar, at first sight, to distension of the antrum. An incision into the cyst allowed the escape of nearly an ounce of turbid brownish fluid, contain-

ing crystals of cholesterine. Sir James then found that "the cyst rested in a deep excavation on the surface of the alveolar border of the upper jaw; an adaptation of shape attained as the result of long-continued pressure of the cyst, which had existed six years."

*Sub-endosteal Cysts.*—It sometimes happens that a tooth-socket communicates with the antrum though separated from its mucous cavity by the periosteal and mucous linings. Under these circumstances the fluids of the mouth find their way into the sub-endosteal space, and gradually separate the lining of the cavity as they accumulate. This rare form of cyst is distinguished from the other varieties by the ascertained presence of a perforation in the tooth-socket, through which fluid of a *peculiarly pungent and fetid* odour escapes. The *diagnosis* of this kind of fluid accumulation may be very difficult in the early stage, the aperture into the antrum being sometimes extremely small and, perhaps, covered over by a crust of tartar. Even at a later period there may be little local tenderness or pain, and, in fact, nothing to point to the particular tooth-socket which is at fault. A careful inspection and repeated probings of suspicious points will alone lead the surgeon to the true source of the mischief.

*Treatment of Cysts with Distension of the Walls of the Antrum.*—A puncture should be made in the most prominent part of the cyst wall, and, after removal of the contained fluid, the aperture sufficiently enlarged to allow of the whole cystic growths being scraped away from their attachments. The opening must be made, if possible, within the mouth, in order to avoid a disfiguring scar on the cheek, and also because the cavity of the antrum can be better reached at this part, about half an inch above the second molar tooth, or at the most prominent part of the tumour near that point. If, however, there is a carious molar that requires removal, it should be extracted, and the antrum can then be perforated through the socket. In whichever way an opening is made, it should be sufficiently large to allow of the introduction of some instrument, such as a gouge, for the purpose of extracting the cystic contents. If the opening be made in the outer wall, a portion of the bone should be removed by means of cutting pliers.

The sinus being opened widely and emptied of its contents, it may be syringed out daily with some stimulating injection,

such as iodine solution, or boric acid lotion (gr. viii to f. ʒi) and the aperture kept open by being stuffed with eucalyptus gauze or some terebinthinate antiseptic plug.

A still better method of making a large orifice in the wall of the antrum is that suggested by Dr. Weber, viz., to cut the bony wall in the form of a trap-door, leaving the upper part of the flap united by the periosteum, as a sort of hinge. This allows of a sufficient opening, and the vitality of the bone will be preserved, so that when it is thought desirable to close the orifice, the bone can be restored to its normal position and no permanent aperture will be left. If the walls of the sinus have become much attenuated before treatment is commenced, it is possible that a seton may be passed through the expanded and softened portions, and allowed to remain until suppuration has become established; but this method is open to the objection that we cannot judge of the exact nature of the cyst unless we have a considerable opening, through which the probe or finger can be passed; and considering the very frequent occurrence of some irritating foreign body or loose tooth in connection with these enlargements of the antrum, considering also the fact that the cyst, if multiple or if formed of a tough membrane, should be removed in order to prevent its refilling, it is much better in all cases to make a larger opening than could be done by the use of the seton thread only. It is rarely necessary to make any incisions through the integuments in order to reach the expanded walls of the antrum; and this is only justifiable when the cystic growth is partly solid. It is probable that in Sir John Fife's case the incisions were made through the integuments in the expectation of meeting with a solid growth, though it was afterwards found that the only contents of the antrum were "two teeth and about four ounces of gelatinous amber-coloured fluid." The case is instructive, as illustrating the desirability of making preliminary or exploratory incisions into the growth within the mouth before proceeding to make large incisions through the skin.

*Diphtheritic disease of the Antrum* sometimes occurs at an early stage of diphtheria when the nostril is the part first attacked. (See case related in Bretonneau's Memoirs, translated for the *New Sydenham Society*, 1859, p. 180).

*Worms and other living creatures in the Antrum.*—Insects have found their way into the antrum. Thus Mr. Heysham, of Car-

lisle, relates that he removed a dead insect, more than an inch long and thicker than a common crow-quill, from a woman's antrum. The patient was sixty years of age and had been a great snuff-taker; and though there were no symptoms of abscess or of any other disease of the antrum, the pain referred to this region was so severe that Mr. Heysham was induced to open the cavity with a trocar and syringe it out through the aperture, the result being that on the fifth day the insect was removed, and a few hours after two others followed (see Mr. Lane's Ed. of Cooper's "Surg. Dict.," vol. i, p. 252).

Bordenave ("Mem. de l'Academ. de Chir.," p. 381) relates a case in which several whitish worms, together with a piece of fetid fungus, were discharged from the antrum after an opening had been made in it for an abscess. Deschamps also describes a worm like the *Ascaris lumbricus* as having been found in the antrum of a soldier whose body he was dissecting; it was four inches long. Probably in all these cases the worm was the *Linguatula tænioides*, which is occasionally found in the frontal sinuses.

The Solid Tumours of the Antrum are (1) Erectile or Cavernous Tumours; (2) Bony Cysts; (3) Polypi; (4) Fibrous and Fibro-sarcomatous growths; (5) Osteosarcoma; (6) Recurrent Fibroid; (7) Medullary Sarcoma; (8) Myeloid; (9) Osseous; (10) Carcinoma. These are all treated of exhaustively in works on general surgery and more particularly in Christopher Heath's *Diseases of the Jaws*. Any detailed account of these and other affections of the bones of the face involving the antrum would be out of place in this work.

Weber gives the relative frequency of tumours of the antrum as follows:—Out of 307 cases there were: Carcinoma, 133; Sarcoma, 84; Osteoma, 32; Cystoma, 20; Fibroma, 17; Enchondroma, 8; Gelatinoid polypus, 7; Melanotic Sarcoma and Carcinoma, 5; Angioma, 1. He remarks that carcinoma occurs too frequently in the list; doubtless from its having been frequently confounded with medullary sarcoma (Dr. Lefferts' article in Ashurst's *International Cyclopedia of Surgery*).

*The Differential Diagnosis between Diseases of the several Accessory Cavities.*

It is often difficult to ascertain from which cavity a discharge of pus escapes into the nose. When there is a closure of the



orifice of the sinus there is still greater difficulty of diagnosis, and the seat of the disease is first, perhaps, indicated by enlargement or displacement of one of the neighbouring regions, such as the orbit, for instance, in the case of the *ethmoidal sinus*, of the *maxillary bone*, in the case of abscess of the *antrum*, and *displacement of the eyeball downwards and outwards* in the case of abscess of the *frontal sinus*. When there is a flow of pus into one nostril, the position of the pus is, to a certain extent, an indication of its source: Thus, if it is most abundant in the middle meatus, and escapes from the nostril more freely when the head is lowered or inclined to the opposite side, the probability is that the discharge is from the *antrum*. When it is from the other cavities, as, for instance, the frontal, ethmoidal or sphenoidal, the upright position of the head favours its flow from the nostril. When the pus is seen in the middle meatus, but falling more over the posterior end of the middle turbinate, and escaping more freely into the nasopharynx than through the anterior nares, there is probably disease of the ethmoidal or sphenoidal sinuses. The most common indication of ethmoidal disease is proptosis, and in some rare cases emphysema of the orbit. The later stages will be marked by the presence of carious bone in the nostril, and consequent excessive discharge and fœtor. The distension of the sphenoidal sinus may sometimes be ascertained by examining by posterior rhinoscopy. Abscess of this sinus is often associated with that of the posterior ethmoidal cells.

Pain is referred to the cheek and jaw most frequently in antral abscess, but is also occasionally referred to the frontal region as well. In abscess of the frontal sinus it is referred more particularly to the frontal region, and in ethmoidal and sphenoidal affections to the deeper parts of the orbital region. In all these cases it is unilateral. Amaurosis may occur in antral, sphenoidal, or frontal abscesses.

Fœtor of the nostrils is present in all, but is most pronounced in the later stages of ethmoidal disease, when large portions of the bone have become carious, and occupy an abscess cavity.

The use of the transillumination test, as described in the Section on the Antrum, promises to be very useful in the diagnosis of abscess in this cavity, and in differential diagnosis from ethmoidal and sphenoidal disease.

## SECTION XI.

DISEASES OF THE SKIN AND SUBCUTANEOUS  
TISSUES OF THE NOSE.

- SUB-SECTION 1. Herpes.  
 „ 2. Eczema.  
 „ 3. Comedones, Acne, Sycosis, Gutta Rosea.  
 „ 4. Lupus.  
 „ 5. Lupus Erythematosus. (Dr. Robert Liveing's article).  
 „ 6. Epithelioma, Rodent Ulcer.  
 „ 7. Lipoma, Rhinoscleroma.  
 „ 8. Chilblain, Frostbite, Gangrene.  
 „ 9. Intermittent Hyperæmia and Dyspeptic "red-nose."  
 „ 10. Erysipelas of the Face, commencing in the nasal cavities.

## SUB-SECTION I.

*Herpes* of catarrh frequently affects the upper lip and the adjacent parts of the alæ and mucous membrane of the nose. It appears in the form of a group of vesicles, each about the size of a millet-seed or a split pea, and is accompanied with general febrile heat, thirst, rapid pulse, and local irritation. In a few days the vesicles dry up into thin scabs, which are sometimes confluent, and not generally surrounded by any redness of the skin. An eruption of herpes on the upper lip and adjoining portion of the nose frequently accompanies attacks of intermittent and other fevers.

*Herpes zoster facialis*, when it invades the region of the ophthalmic division of the fifth pair, sometimes involves the nasal branch, and this branch is occasionally attacked alone. In the former case there is congestion of the conjunctiva, intolerance of light, irritation of the eyeball, and acute neuralgic pain in the whole of the region of the eye and side of the nose. In the course of twenty-four or forty-eight hours, an eruption of vesicles appears in the forehead, eyelids, and side of the nose, and generally ulceration of the cornea and great vascular congestion of the sclerotic. Serious impairment of sight is too often the ultimate result, and sometimes complete destruction of vision ensues. The nasal branch of the nerve

may, however, be the only part involved, and the eruption is then confined to the side of the nose, and the eyeball is not affected. The eruption having become developed, the severe pain ceases or becomes much mitigated in most cases.

*Diagnosis.*—Before the eruption makes its appearance, the aspect is that of an acute neuralgic attack, and as it often follows exposure to cold in persons of very feeble habit of body, it may be set down to rheumatism of the parts. But the vesicular eruption appearing on one side only of the face or nose, the appearances are characteristic.

*Treatment.*—In the commencement of the case soothing local applications, such as powdered starch, or liquid extract of opium, are indicated. At the same time, in the febrile form of the disease, effervescing salines may be given internally. When there is acute neuralgia, morphia or opium in some form will be necessary to relieve the pain. The hypodermic injection of morphia, as the most speedy means of relief, will be generally preferred. Gouty or dyspeptic conditions are not uncommonly associated with herpes, and must be met by appropriate remedies. Later on, in the cases of herpes zoster, if there are, as very commonly occurs, superficial ulcers in the site of the eruption, they may be dressed with zinc ointment or benzoated lard, or any simple cerate.

The treatment of simple catarrhal herpes consists simply in protecting the surface by dusting it over with finely-powdered starch, or applying zinc ointment, until the scabs have died and desquamated. Ulcerations rarely occur in the catarrhal form, and it is often so simple an eruption that no treatment is required, apart from that directed against the associated catarrhal symptoms.

## SUB-SECTION 2.

### *Eczema.*

This affection, known also as *porrigo larvalis* and *crusta lactea*, often occurs on the alæ of the nose, at the point of junction of the skin with the mucous membrane, and extends both up the nostrils and on the adjacent surfaces of the lips and cheeks. The nose thus becomes enlarged, the surface reddened, and the passage of the air through the nostrils impeded. Eczema also originates on the mucous membrane, and the passage thus

becomes obstructed by crusts and swollen membrane. It has been commonly asserted that this affection is peculiar to the strumous and strumo-rachitic diathesis, but according to Neumann's statistics, this opinion is hardly borne out by facts. (See Neumann's "Text-Book of Skin Diseases" translation by Dr. Pullar, p. 137.) He is rather inclined to regard it as associated with dyspepsia and disordered menstruation in the majority of cases, though in many its origin is obscure. The late Dr. Tilbury Fox regarded it as a catarrhal affection of the skin, and it is remarkably frequent in association with ordinary catarrh, and after those exanthemata, and particularly measles, in which there is a previous catarrhal flow from the nasal mucous membrane. Possibly, the strumous diathesis predisposes to catarrhal affections, and hence eczema may be looked upon as one of the indirect accidents of struma, though it may not be necessarily a consequence of the constitutional condition.

*Treatment.*—The local treatment in acute eczema must be directed towards moderating the excessive heat and inflammatory action of the part. Cold douches, or linen wet with cold water will be most suitable at this stage. Soda has a tendency to allay the feeling of itching and heat, and it may be added to the water. After the subsidence of the heat and redness, the crusts may be dressed with ungu. zinci.

These applications are also suitable to the chronic form, but in addition the crusts must be softened once a day by smearing with potash-soap and washing with warm water.

In the case of gouty eczema, the secretions must be carefully regulated during the paroxysms of inflammatory swelling and redness, and especial attention must be given to the state of the urine. After the acute stage has subsided, tonics, and especially steel and chalybeate waters, will be required.

### SUB-SECTION 3.

#### *Comedones, Acne, Sycosis, Gutta Rosea.*

*Comedones* appear frequently in young persons at about the period of puberty, on the alæ and bridge of the nose, though they also infest the forehead, chin, cheeks, and shoulders. The comedo consists of a distended hair-follicle, the secretion of which, instead of passing upwards with the hair and lubricating it and the surrounding skin, becomes dry, indurated, and moulded

to the form of the follicle. Its upper extremity, lying at the level of the orifice of the follicle, is marked as a black spot (of the size of the point of a pin, and sometimes as large as a pin's head or larger) visible to the naked eye. These spots sometimes become surrounded by a small elevation, which marks the distension of the follicle with its retained secretion, and sometimes the skin over this raised surface becomes inflamed, suppurates, and forms a pustule. This later stage of the *comedo* constitutes *acne*.

In the earlier stage, before redness and inflammatory swelling have come on, the contents of the follicle can be squeezed out between the two thumb nails in the form of a whitish-yellow worm-like thread, of about the thickness of a piece of sewing cotton, and in some cases of the thickness of a piece of whipcord. These worm-like threads consist of closely-packed epidermic scales, which here and there exhibit an opaquely-dotted appearance, due to the presence of oil globules and a few free oil globules. The black spot on the top of this yellowish mass, which comes away with it, consists of a large superficial layer of epidermic scales impregnated with dirt. Among the contents of the obstructed follicle is a small six-legged parasite, the *steatozoon* or *acarus folliculorum*, described accurately by Dr. Beale,\* Sir Erasmus Wilson,† and others.

This morbid condition occurs in persons whose skin is naturally greasy, whose hair and nails grow fast, and whose heads are full of scurf. It is part of a general disorder of the whole cutaneous surface, the secretion of the follicles being

\* *Journal of Cutaneous Medicine*, vol. iii, No. 2, October, 1869.

† He gives a detailed description of it in his work on "Diseases of the Skin" (p. 508 of 1st edition). He has also discovered the ovum and embryo of the steatozoon. The following are the extremes of measurement of the perfect animal in fractions of an English inch, according to Sir E. Wilson:—

Entire Length.	Length of Abdomen.	Breadth of Thorax.
$\frac{1}{135}$	$\frac{1}{227}$	$\frac{1}{555}$
$\frac{1}{64}$	$\frac{1}{88}$	$\frac{1}{555}$

Neumann also describes them as existing very commonly in the sebaceous follicles of the normal skin.

excessive, while the parts of the subcutaneous tissue around them are deficient in activity.

*Treatment* consists first in remedying any constitutional defect that may be manifest. The secretions are always more or less unhealthy, and a combination of steel and aperients is generally useful. Amenorrhœa, or leucorrhœa or dyspepsia, will be met by remedies appropriate to each particular case. With regard to local treatment, the skin may be stimulated by gentle friction, kneading, and by the application of hot fomentations without soap. Those comedones which are evidently hard and dry and cannot be removed without mechanical aid, may be gently pressed out, and subsequently friction with fine oatmeal and borax lotion will, in most cases, very soon improve the general condition of the cutaneous surface. Later on, bichloride of mercury, with almond emulsion, alkaline washes, alum lotion, and lastly the weak hypochlorite of sulphur ointment, may be used with much benefit.

*Acne* consists of retention of the secretion of the hair follicles, as in comedones, with the addition of perifollicular inflammation. It may occur as a complication of *comedones* and *milia*, or as a sequel of the former, and frequents the same regions of the cutaneous surface. At the outset of the disease it appears as raised conical points, exactly similar to those of comedones, and is then termed *acne punctata*; whereas in the later stages, when inflammation around the base of the swelling has come on, it is described as *acne indurata*; and still later, when the swelling and induration are succeeded by vascular congestion and suppuration, as *acne vulgaris*.

The nose is not so frequently affected by *acne vulgaris* as the parts of the face adjacent to it.

*Etiology*.—At the period of puberty, the time at which acne is most commonly observed, there is greatly increased development of hair all over the body; the hair follicles therefore become more active, and, consequently, if there is any constitutional defect of nutrition, they become congested and inflamed. The acne pimple or pustule is the result. Want of cleanliness, exposure to cold, with general languor of the circulation, are associated causes. Dyspepsia, mental depression, disorders of the generative organs, and especially uterine affections, are among the more prominent primary defects leading to the local disorder.

*Treatment.*—The treatment must be directed to three points. (1) The relief of local hyperæmia; (2) the improvement of the nutrition of the skin of the part; (3) the improvement of the general nutrition.

The local hyperæmia and irritation will be best allayed by soothing applications to the part, and by stimulation of the secreting activity of the internal organs.

Alterative tonics, combined with gentle aperients, will be required in the cases of atonic dyspepsia so often associated with this affection, and subsequently steel or quinine may be required. Locally, the application of a lotion containing oxide of zinc and calamine powder suspended in water, with a small quantity of bichloride of mercury (gr. i to  $\bar{z}$ viii), will be very useful when applied warm to the face. The later stages will require more stimulant applications, and in obstinate cases the general health will require a course of arsenic or iron, or the two in combination, before the debilitated digestive organs will recover their proper condition. Soap should not be used in acne vulgaris.

General hygienic considerations are all-important in the treatment; and especial care must be taken to attend to ventilation, exercise, and diet. The latter should be unstimulating, but abundant and varied. Excess of sugar and alcoholic stimulants containing sugar are particularly hurtful, and pastry and rich dishes are to be avoided. Great cleanliness of the skin generally should be observed, and warm baths containing potash are especially efficacious in this respect.

*Sycosis* sometimes attacks the roots of the hair within the entrance to the nostrils. It presents at first the appearance of tubercles (of the size of a millet seed, pea, or even larger) developing into pustules, which dry up into circumscribed irregular crusts. The pustules are each traversed by a hair, the root of which, on being pulled out, is swollen, bent, and bathed with pus. The surrounding skin is considerably swollen and œdematous, and subsequently abscess may form and the sub-maxillary lymphatic glands become enlarged.

*The treatment* should be local only. First, the crust should be softened by oily or watery applications, and then removed. The hairs must then be pulled out, and red precipitate ointment (gr. i to  $\bar{z}$ i) applied, using also soap and water as a douche occasionally, during the change of dressings. Persons liable to

acne and sycosis should avoid the use of scented soaps. If it is necessary to apply soap to the face, the best common yellow soap (known as "Knight's Pale Primrose") or Pears' Transparent Soap, is far better for all purposes than the mixtures sold as scented soaps. Some of these latter have been proved to cause affections of the skin. Fine oatmeal rubbed gently over the face offers the best substitute for soap.

*Gutta rosea* is a condition resembling *acne vulgaris* in certain points, but differing from it materially in others. It resembles acne in attacking the hair-follicles of the face, and particularly of the alæ of the nose and the adjacent parts of the cheek; but it differs from it in being a disease of the middle or rather late period of life. It is rarely seen in young adults. By some dermatologists, it is considered a variety of *acne*, and the spots are very similar in appearance to those of *acne*, whence it is sometimes called *acne rosacea*, but they are more spread out and less sharply defined at their circumference, and the cutaneous structures around are more uniformly involved in the same congested condition with which the pimples themselves commence. They sometimes become confluent, the whole of the alæ and adjacent parts of the nose being of a uniform rose-red colour, with here and there a few isolated elevations marking the position of the original pimples. In very severe cases, the whole of the nose, including the tip, becomes involved in a bright rose-red swollen eruption, giving the patient a truly Bardolphian aspect. In these extreme cases, the condition is very different from that of a simple inflammatory swelling and infiltration of the perifollicular structures, such as the early stages present. The whole cutis and subcutaneous areolar tissue of the part affected become congested and infiltrated with plastic exudation, and the surrounding skin is more or less œdematous in the worst cases. The raised spots dotted here and there over the surface have a shining, almost translucent texture, and every now and then pustules or raised vesicles form on the most prominent parts. The heat and sense of tension in the part is always increased after eating, and whenever the digestion is out of order. The eruption is sometimes accompanied by cracks or fissures at the margins of the nostrils, and extending somewhat into the nasal fossæ, and these cause great irritation, the patient being very apt to pick or scratch them with his fingers, and so increase the mischief.



*Etiology.*—This condition is almost always associated with dyspepsia, due to various causes. It occurs not unfrequently in persons who have been living highly, dining on rich food, and taking three or four full meals a day without sufficient exercise. It may also occur in persons who have been living moderately or even poorly, if they have indulged too freely in the sugar-containing articles of food and sweets, with an insufficiency of animal food and fresh vegetables. Sedentary habits and mental uneasiness or anxiety increase the tendency to dyspeptic malaise, and thus to an aggravation of the chronic disorder in the nose and face. It is also occasionally associated with disordered menstruation in women about the time of the cessation of the catamenia.

*Treatment.*—In the milder and earlier stages of gutta rosea much benefit will be derived by improved habits of diet, increased exercise, and the use of occasional aperients and antacid tonic medicines. The lotion of oxide of zinc and calamine powder is very grateful, when applied locally to the spots, and may be occasionally changed for Goulard water and eau de Cologne and water whenever the heat and tension indicate some cooling application.

Free purging is essential in the commencement of treatment, the saline purgatives, such as sulphate of magnesia and sulphate of soda, or the Carlsbad salts, being of great value in all cases of the kind. Later on, a combination of mineral acids and cinchona, or steel with mineral acids, will generally be required, the patients being very often debilitated and their powers of assimilation weakened by long-continued dyspeptic ailments. Friction of the surface, tepid bathing, and a mild climate are important aids to the other remedies. In some cases arsenic combined with steel will be useful, when the simpler forms of tonics have failed to restore the healthy secretive activity of the skin. Alcohol should be allowed sparingly, and the lighter wines, such as hock and moselle, or Vin de Grave, are preferable to richer and stronger kinds; while malt liquors are to be strictly forbidden. The local treatment of this disorder is of quite secondary importance, and is directed chiefly towards allaying irritation and protecting the part from exposure to cold and external irritants.




Fig. 2.

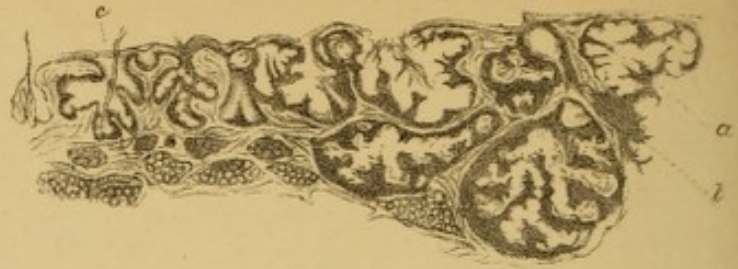

Fig. 3.



Fig. 4.



Fig. 5.



Fig. 6.



Fig. 7.

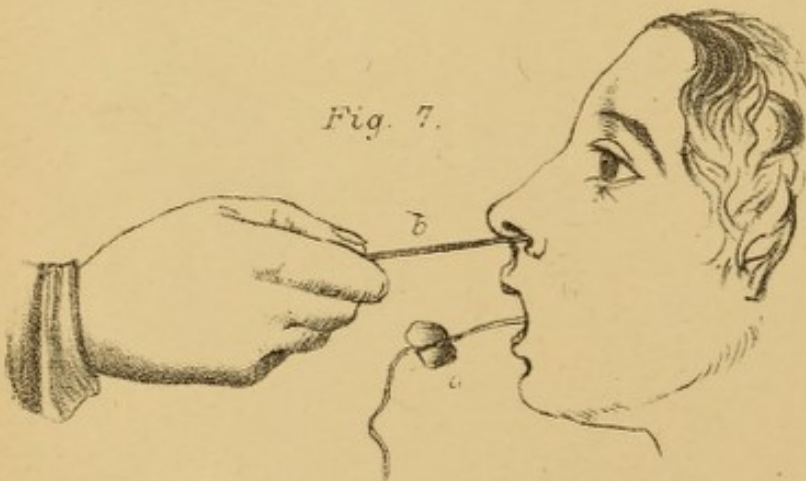
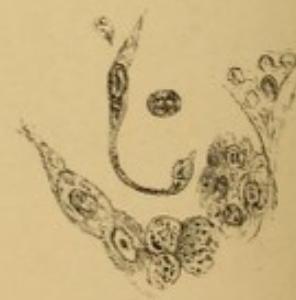

Fig. 8.



X 320

*Description of Plate IV.*

Fig. 2. Vertical section of skin affected with lupus, showing the passage of the healthy skin into that which is most infiltrated. *a*, acinous nodules; *b*, embryonic tissue of the lupus nodule; *c*, altered hair sacs and sebaceous glands (after Rindfleisch).

Fig. 3. Portrait of a patient of Dr. J. Swift Walker, with (so-called) lipoma nasi before operation (from a photograph).


Fig. 4. Portrait of the same patient after removal of the tumour (from a photograph).

Fig. 5. A patient of Dr. J. Swift Walker, who had suffered from malignant pustule, ending in destruction of the tip of the nose and portions of both alæ (from a photograph). The disease was contracted by the patient, a farmer in Staffordshire, from one of his own oxen, the body of which he was examining, and which had died while affected with "black quarter."

Fig. 6. Portrait (from a photograph) of the same patient after Dr. Swift Walker had performed a plastic operation by bringing down a flap from the forehead.

Fig. 7. A diagram to illustrate the method of plugging the posterior nares for the arrest of epistaxis. A plug at *a*, about to be lodged firmly in the posterior nares by means of the ligature *b*. This having been done, the double ligature *b'* is tied over a plug placed over the orifice of the anterior nares or, if necessary, wedged into them.

Fig. 8. A microscopic drawing, by Dr. John Harley, of a section of a gelatinous polypus of the nostril ( $\times 320$ ).



## SUB-SECTION 4.

*Lupus.*

Though *lupus* may attack various parts of the skin of the general surface, it more often selects the face, and very commonly the nose and adjacent parts of the cheek. Under the forms designated as *lupus non-exedens* and *lupus exedens*, it may be described as a tuberculous affection of the skin with a great tendency to destruction of the parts attacked, either by ulceration or an interstitial absorption. Pathologically considered, it is well described as "the slow disorganization of all the structures comprising the cutis and cuticle attacked by it, in consequence of the deposition in the cutis vera of a neoplasm of low vitality; the tendency to shrinking or atrophy of the parts affected, or in other cases to their destructive ulceration, being due to the presence of this new deposit."

The primary seat of this neoplastic formation has been a subject of dispute among dermatologists, but the variation in their descriptions is probably due to their describing different varieties under the same name.\*

*Lupus non-exedens* occurs in patches occupying the *alæ nasi*, and the adjacent parts of the face. It commences as a tubercle or tubercles slightly raised above the surface, of a dull-red colour, shining surface, and semitranslucent texture.† Other similar tubercles appear in their immediate neighbourhood, and a congeries or patch of them is thus formed, the whole mass often becoming confluent and presenting a red shining surface somewhat uneven and tuberculated at its edges, which are raised above the surrounding parts. These tubercles give rise to no pain or irritation, and may remain almost stationary for months. Sometimes they present a scaly surface, which peels off and is replaced by a new skin having a more cicatricial appearance. The skin gradually assumes a cracked and scaly aspect over the whole patch, and as it separates the

\* For the pathology of *Lupus* and the account of the so-called giant-cells of *lupus*, see Dr. Thin's paper in the *Med. Chir. Transactions*, read in March, 1879.

† This semitranslucent shining appearance is due to the increased succulence of the tissues associated with dilatation of the capillaries and lymphatics, and also to some amount of œdema following this dilated condition.

surface below becomes more and more flattened and depressed until it ultimately is actually below the normal level of the skin, and in time assumes a white scarlike appearance. Meanwhile new tubercles have been springing up at the outer margins of the patch, and perhaps new ones have formed at a little distance, being separated by healthy skin from the original growth. These new tubercles are generally arranged in a somewhat circular, or semicircular form, spreading as the new crops arise in this form continually repeated, and becoming parts of a larger circle on each occasion.

*Diagnosis.*—Some syphilitic eruptions have a certain coarse resemblance to lupus, and leave depressed cicatrices, but with *dark* coloured stains. But the concomitant conditions will be important means of distinguishing the two diseases. The syphilitic eruptions will be associated with other symptoms of constitutional syphilis, such as scars of old ulcers on the forehead, cheeks, or palate, or stains of ulcers of old spots on the same parts; lupus, on the other hand, appears as a merely local manifestation, being commonly confined to the narrow region of the nose and cheeks. There is no associated syphilitic cachexia, and the complexion remains perfectly bright and ruddy.

*Lupus Exedens.*—In this variety there is the same aggregation of tubercles as in other forms, but as it progresses there is marked ulceration of the central portion, which at first softens, then becomes crusted over, and when the crusts separate, presents an indolent form of ulcer. There is less transparency preceding the ulceration than in lupus non-exedens, and the base is harder, giving the ulcerated surface the appearance of being composed of a rotten cheesy deposit. It affects the whole thickness of the skin, and the glandular and hair-forming apparatus, and all the parts involved are destroyed by its ulcerative action, the cartilages and bones of the nose being sometimes ultimately eroded by it in the worst forms, hence distinguished as *L. vorax*. The entire nose has been seen to be destroyed in less than a month. The excavation of the centre of the growth is bounded by successive new crops of tubercles which form a raised border, varying in height according to the greater or less depth of the erosion. The ulcers, as well as the tubercles, are remarkable for the absence of severe pain.

*Diagnosis.*—The age of the patient (generally between five and thirty years), the gelatinous aspect of the sore with the continual reproduction of crusts over the surface of the ulcer, the dull red raised edge, and the form of the cicatrices; the absence of any general affection of the lymphatic glands, and the often florid, rarely cachectic, look of the patient, together make up a very clear concurrence of diagnostic indications.

*Epitheliomatous* ulcers have hard everted edges and a prominent fungoid surface, and in the advanced stages the glands become affected. The surface exudes a foul discharge, and crusts are rarely formed over it. This form of disease seldom affects the nose, and when it does, it is seen in elderly people, and there is generally a marked cachexia.

In Plate VI, fig. 1, is seen an instance of lupus exedens, having a slight superficial resemblance in its local developments to epithelioma. The prominence of the ulcerated surface here was due to the swelling of the parts beneath and around the ulcer, and not to fungoid protrusion of the diseased growth itself. In this respect the face depicted as fig. 3 on the same Plate offers a striking contrast. Here we have a well-marked case of epithelioma with much fungoid protrusion of the ulcerated surface distinctly referable to the morbid growth itself, and not at all due to infiltration of the surrounding parts.

Ulcers of *syphilitic* origin are generally associated with tertiary symptoms of the disease elsewhere, and with an earthy cachectic complexion and broken health. The syphilitic lupoid ulcer is not surrounded by the characteristic soft rounded raised edge peculiar to true lupus; on the contrary, its edges are sharply cut and everted, its surface being foul, dirty, and sloughy, and surrounded by a copper-coloured areola. The history of the case is generally conclusive.

*Syphilitic acne* sometimes assumes an aspect very closely resembling lupus exedens; when, for instance, the acne pimples have become confluent and ulcerated, and especially if caustics have been applied. Separate acne pimples on the neighbouring parts and the existence of other symptoms of constitutional syphilis, such as periosteal nocturnal pains and scars of old ulcers on the face or in the throat or mouth, will sufficiently indicate the true nature of the case.

*Rodent ulcer* is associated with pain; it occurs in old age. It



has only a slight tendency to healing, and its course is very chronic.

*The causes* of lupus are not very clearly defined. It is seen most frequently during the period of life between five and thirty-five years of age, and in persons of tuberculous tendencies, and sometimes in phthisical subjects. Possibly, it is due to a combination of two or more associated diatheses. "It is more common in the country than in town, and in the female than in the male sex. Devergie found that twenty-five out of forty-seven cases were females, and Hutchinson forty-six out of seventy-four. Its selective seat is the face. In sixteen cases, according to Devergie, out of forty-four cases, the nose was affected; the nose and other parts of the face together in twenty-six cases. It is a disease of the poor rather than of the rich." (Dr. Tilbury Fox, "Diseases of the Skin," p. 372.)

*Pathology.*—That a morbid deposit resembling granulation tissue is constantly present in some portion of the integument is acknowledged by all the pathologists who have studied the minute anatomy of lupus. Some difference of opinion, however, exists as to the primary seat of this deposit. According to Rindfleisch, the disease consists essentially of an adenoma of the sudoriferous and sebaceous follicles of the skin, the surrounding structures being secondarily affected (see Plate IV, fig. 2). "The cells of the lupoid tubercle are, on the whole, of small size, and held together by a mucoid cement, and may be called embryonic tissue." In a section, such as that in fig. 2, Plate IV, the gradual transition of the healthy sebaceous gland at *c* into the various stages of disease, as seen in the central portions of the section, is well illustrated. The extreme periphery of the affected area is marked when seen from the surface by white shining nodules, which correspond to the sebaceous glands in the first stage of degenerative change, accompanied by swelling of the gland tissue. This swelling is due partly to proliferation of the glandular elements, and partly to the fact that the cells, instead of undergoing fatty degeneration, grow large and vesicular, distending the body of the gland even to five times its normal bulk. The proliferation of the corpuscular elements, according to Rindfleisch, begins in the interstitial and capsular connective tissue of the sebaceous and sudoriferous glands, and extends thence into the surrounding parts, often deeply into the subcutaneous connective tissue along

the afferent vessels. In the ulcerative stage, the parenchyma proper of the glands undergoes fatty degeneration, while the intermediate granulation tissue is converted into pus. The little abscesses thus formed burst and discharge their contents, leaving as the result an ulcerated surface.

According to Auspitz, however, in ordinary lupus non-

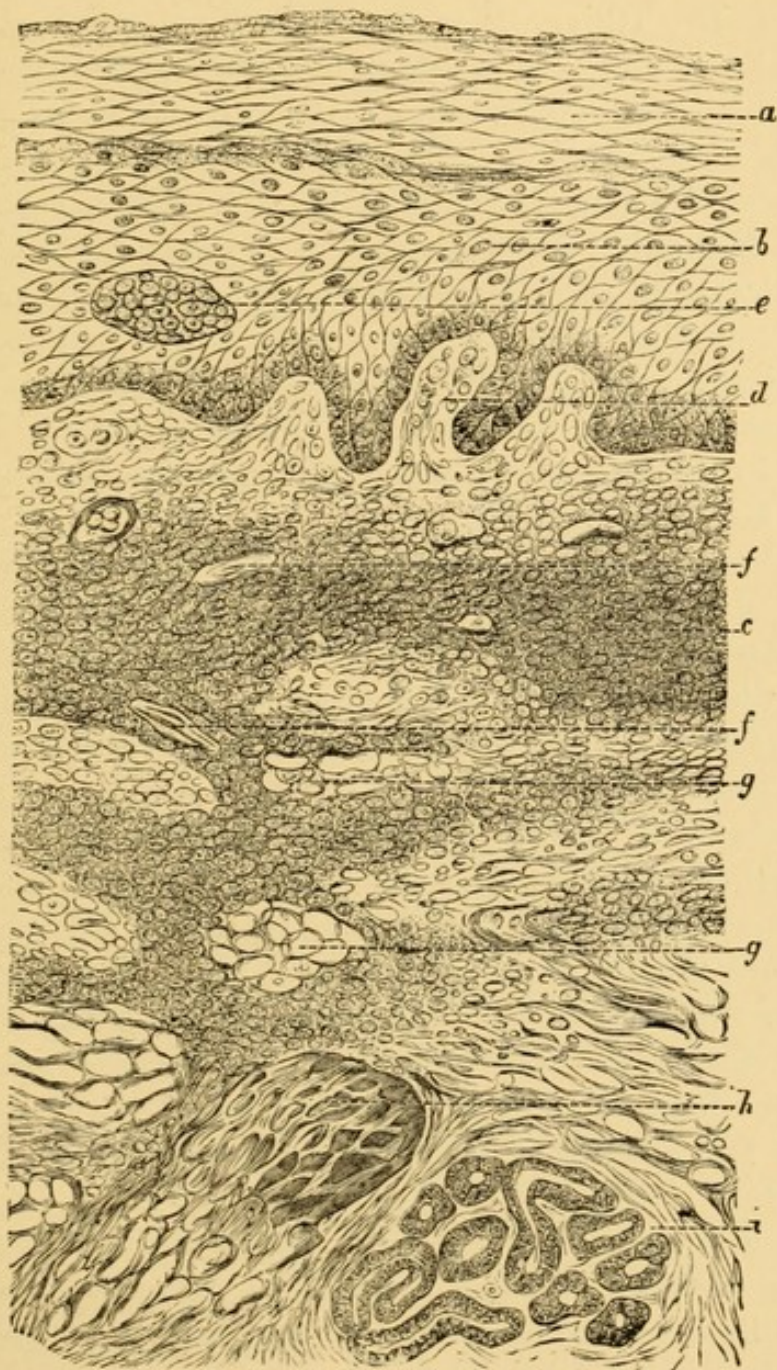


Fig. 61 (after Auspitz.)

Vertical section through a lupus nodule of the face, treated with dilute acetic acid.  $\times 300$ .  
*a* Horny layer of epidermis. *b*. Rete. *c*. Corium filled with cells of new formation.  
*d*. Papillary layer. *e*. Transversely-cut papilla. *f*. Transversely-cut vessel of corium.  
*g*. Transversely-cut connective tissue bundles. *h*. A cut muscle. *i*. A sebaceous gland coil.

exedens, in an early stage, the corium is the primary seat of the new deposit, which consists of oval cells with a nucleus more or less distinct, and varying in diameter from  $\cdot 003$  to  $\cdot 005$  inches. These cells seem to originate from the connective tissue corpuscles, as held by Virchow.

The subjoined illustration from Dr. Auspitz's work\* shows the above-mentioned changes.

The late Dr. Tilbury Fox (to whom I am indebted for the opportunity of using the woodcut, fig. 61) adopted these views as being more correct in reference to the ordinary forms of lupus. "In cases of lupus in which the disease consists not so much of tubercles as in a superficial infiltration, Dr. Auspitz noticed that the rete Malpighii was increased to twice or three times its normal thickness, its cells having undergone fatty change. The papillæ were filled with the lupus cells, which were especially abundant along the capillary vessels therein, the vessels themselves being dilated and coiled to a marked extent, and surrounded by an increased amount of connective tissue." (Dr. Tilbury Fox, *op. cit.* p. 372.)

*Prognosis.*—In the non-ulcerative forms there is a very fair prospect of cure without any serious disfigurement, though a white cicatricial shrinking of the skin will mark the site of the original disease. The ulcerative forms are more obstinate, resist treatment for months or years, and often lead to great permanent disfigurement.

*Treatment.*—In dealing with lupus, constitutional remedies are sometimes valuable, and the medicines most in favour are cod-liver oil and iodide of iron. In some cases iodide of potassium and sarsaparilla are more efficacious, and in others arsenic has been found to succeed after the failure of the other remedies. Locally, caustics are only to be applied to the scaly edges, and only in the form of solutions. A solution of nitrate of silver (gr. x to f.  $\frac{3}{4}$  i) applied by means of a camel's-hair brush is very useful.

In the ulcerative forms the solid nitrate of silver or chloride of zinc in the form of paste, or moulded into a stick with sulphate of lime, will be necessary for the purpose of destroying the lupous tissue.

The *caustic* most in favour with Hebra and Kaposi is that

\* Ueber die Zellen-infiltrationen der Lederhant bei Lupus Syphilis und Scrofulose. Wien, 1864.

known as *Cosme's paste*. The formula for it is R arsenici albi grana decem, cinnabaris factitiæ drachmam semis, unguent rosati unciam semis. The paste is spread on linen to the thickness of the back of a knife. Strips, a finger's breadth in width, are cut off from this and applied to the part, charpie or wadding being placed over them. The dressing is left on for twenty-four hours, and is then renewed with fresh paste on the same plan as before. At the end of the second day the paste is again applied for the third time, as before, and is removed at the end of the third day. The great advantage which attends the use of this paste consists in the fact that the healthy skin is not in the least affected by it, not even excoriated, whilst each individual lupus nodule is invariably and thoroughly destroyed. After three to five days the eschars formed by its use are thrown off by suppuration. ("New Sydenham Society's Translation of Hebra's and Kaposi's 'Diseases of the Skin,'" vol. iv, pp. 101, 102.)

*Pencils of chloride of zinc* are very inconvenient, if used without admixture, on account of their deliquescence and brittleness. The sticks formed after the plan suggested by Kobner and Bruno are to be preferred. They are made by fusing together one part of chloride of zinc; a half, a fifth, or a tenth part of nitrate of potash; a half or a tenth part of chloride of potassium, and moulding into sticks one-and-a-half to two inches long. They should be then wrapped in tin foil and kept in a well-corked bottle. ("New Sydenham Society's Translation of Hebra and Kaposi's 'Diseases of the Skin,'" p. 108.) Chloride of zinc penetrates quite as readily as nitrate of silver into the lupus nodules, and acts just as slightly on the healthy tissues. It causes less severe, and more transitory, pain than the nitrate (*op. cit.*).

Volkman employs a sharp-edged steel spoon for the purpose of scraping away the diseased tissue, and subsequently makes a number of superficial cuts into the raw surface till it bleeds freely. This must be done while the patient is under the influence of an anæsthetic.

The galvano-caustic offers many advantages:—(1) the heat can be regulated to any required degree; (2) the effect can be produced rapidly, and (3) more effectually than with the chemical escharotics. A convenient instrument for this purpose is that supplied by Messrs. Krohne and Sesemann. (See Fig. 18.)

Caustics or other means for the destruction of the diseased tissues should only be employed when the disease is evidently extending, and only to those parts in which the ulcers are most perceptibly advancing. In some cases, however, there are indications for withholding caustics. They are those particularly in which there is great irritability, redness, and swelling of the surrounding skin, and excessive tenderness of this irritable part. Under such circumstances soothing applications and poultices should be employed for a time, and caustics used only after the surrounding redness has subsided. In all cases the parts should be carefully excluded from cold air, and in the winter cotton wool should be applied over the other dressing. The dressing of the ulcerated surface should be non-irritating in most cases. The grey oxide of mercury ointment has appeared to agree well with those cases that have been under my care.

*Complications of Lupus.*—When the cheek is affected simultaneously with the nose, the glands in the sub-maxillary region and certain small glands in front of the ear may become inflamed and suppurate, giving exit to whey-like pus and a cheesy friable material. Sinuses and indurated nodules subsequently form in the region of these abscesses, and give rise to hard, prominent cicatricial lines or nodules. *Erysipelas* sometimes occurs as a complication of lupus erythematoses, even when no caustics have been applied. In lupus vulgaris it rarely occurs spontaneously, but when the health of the patient is favourable to its occurrence, the application of caustics not unfrequently excites erysipelalous inflammation of the neighbouring skin.

#### SUB-SECTION 5.

*Erythematous Lupus.* By Dr. Robert Liveing, F.R.C.P., Consulting Physician to the Skin Department at Middlesex Hospital.

Syn.: Lupus Erythematoses.

“Erythematous lupus was first described under that name by Casenave, although the disease had been previously noticed by several writers under different names. At the present time some writers regard the disease as quite distinct from any form of lupus; this view is not, however, generally accepted. The

severer forms of the disease lead to a gradual destruction of tissues, which removes the disease from the class of simple chronic inflammations. The association of erythematous lupus with polymorphic erythema has not been sufficiently noticed by writers. It is very common to find patches of chilblain-like erythema of the fingers in those who suffer from erythematous lupus of the nose and cheeks. Patches of erythema also appear on the face, extending far beyond the lupus, and show their nature by disappearing quickly and entirely, but leaving behind the more limited permanent lupus patch.

“*Symptoms.*—Lupus erythematosus is as a rule confined to the head, and it is especially liable to attack the nose, where it often forms a butterfly-shaped patch, extending across the bridge to the cheeks on both sides; the ears are also sometimes affected, and when it attacks the scalp it leaves permanently bald scars; the mucous membrane of the nose may be involved, but more commonly the disease is limited to the skin. When the disease first appears it closely resembles an ordinary inflammation of an erythematous kind; more rarely it presents the appearance of a dry superficial eczema; it is in this early stage that the diagnosis is most difficult. Later on the sebaceous glands become involved in the inflammation, and the free secretion of sebum is prevented; this gives the peculiar dotted appearance so often seen round the margin of a patch of erythematous lupus. The disease spreads slowly at its margin, which is recognized as the more active part by its slightly raised appearance and brighter colour; as the disease extends, the old or central portion undergoes changes by which a very superficial layer of scar tissue is formed in the skin, giving it a white atrophic appearance, which contrasts with the reddish colour of the more active portions of the patch; in course of time the lupus tissue may cease to develop, and then all that remains is a very superficial thin scar, which in mild cases slowly disappears; in the more severe forms of the disease, however, the scar is permanent. The disease is painless, but attended with itching, which in some instances is well marked.

“The *etiology* of erythematous lupus is obscure. It is met with chiefly in adults, between the ages of twenty and fifty; rarely in children. It is more common in women than in men, and is especially associated with what is called feeble venous circulation in the extremities; that is, people who suffer from

cold hands and feet are more liable to it than those not so affected. Some inflammations of the skin appear to excite its development, especially chilblains on the nose and ears, and sometimes eczema. The writer has met with several cases where it followed very slight injuries, but in most instances all these exciting causes are absent, and the disease arises without any apparent cause. This form of lupus is in no way connected with scrofula, and in this respect it probably differs from lupus vulgaris.

*Pathology.*—Some recent German observers regard lupus erythematosus as simply a peculiar form of inflammation of the skin followed by degeneration and atrophy. The general opinion is, however, in favour of the older view, that there is a cellular new growth, and that the disease is really a form of lupus. The structural changes that occur in the scalp and ears would certainly render the latter view probable. There are, moreover, such a vast number of intermediate forms between

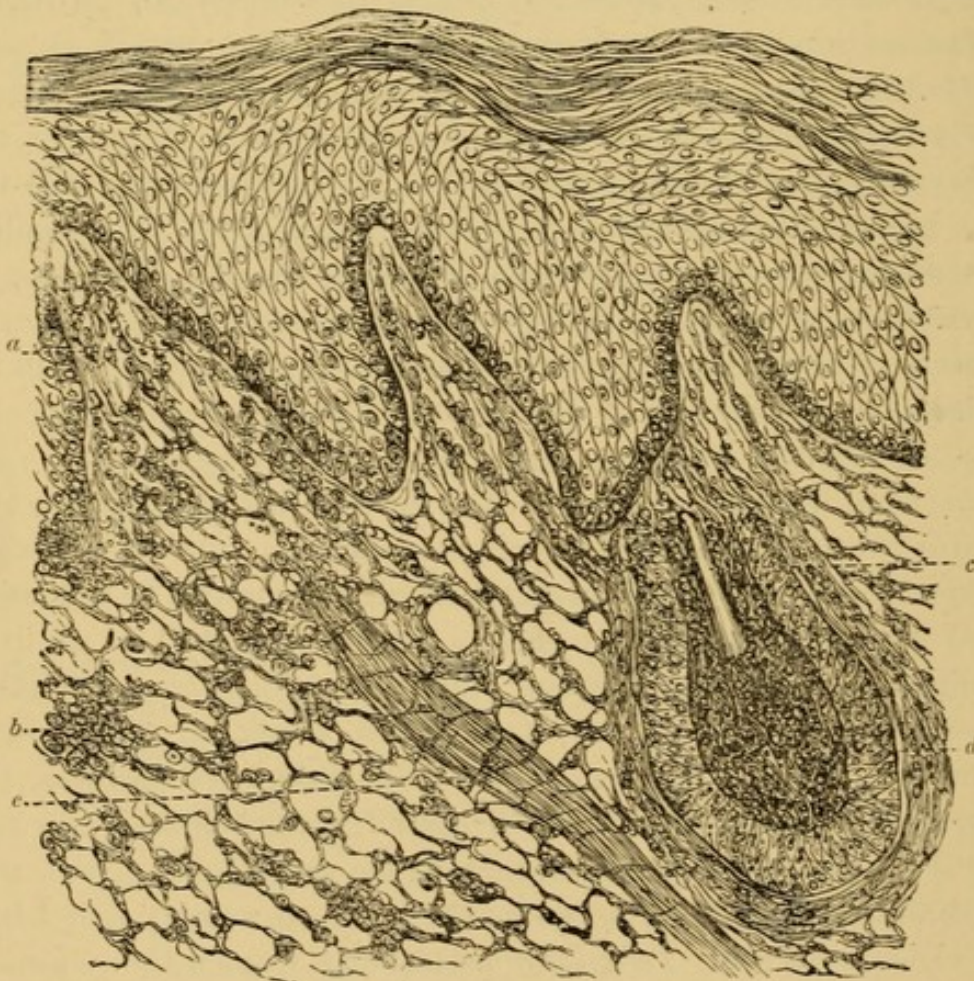


Fig. 62 (after Neumann).

a. Enlarged papilla with cell infiltration. b. Accumulation of cells. c. Hair cut.  
d. Sebaceous gland with infiltration. e. Arrector pili.

typical lupus erythematosus, where the inflammatory symptoms are very striking, and those forms of superficial lupus in which the new tissue growth is admitted by everyone that we can easily form a complete series without any well-defined break."

In fig. 62 (which I am enabled to make use of by the kindness of the late Dr. Tilbury Fox) we see that the papillæ are changed in form and much enlarged, that the sebaceous glands are infiltrated and have assumed a globular form, having lost their acinous shape, their excretory ducts becoming obstructed by the altered secretion and the new formation. The glands, thus obstructed and enlarged, are thrust towards the surface, where they are visible to the naked eye as minute yellow deposits, and are soon destroyed by ulceration, their friable contents forming part of the *débris* discharged from the surface.

"*Diagnosis.*—Lupus erythematosus may be mistaken for erythema, gutta rosea, eczema, psoriasis, or lupus vulgaris. In arriving at a diagnosis the following characters of erythematous lupus will be of value. (1) The parts especially liable to be affected are the nose, cheeks, and the lobes of the ears. (2) The disease is more or less symmetrical. (3) The eruption has a well-defined and slightly raised margin. (4) The sebaceous glands are especially liable to be affected, and this is usually best seen at the margin of the patch. (5) The disease forms superficial atrophic scars usually more developed on the ears or scalp than on the cheeks. (6) The age at which the disease appears, as well as its very superficial character, helps to distinguish it from lupus vulgaris.

"*Treatment.*—The general treatment of erythematous lupus is not very satisfactory. There is no medicine which has any certain curative effect. In some cases arsenic, and in others the salts of iodine do good, but the favourable action of these medicines is by no means so certain as to give much encouragement to the patient. When there is indigestion and constipation, as there often is, a rational plan of internal treatment is at once indicated. External remedies are rather more satisfactory. Amongst the most useful are tincture of iodine, preparations of salicylic acid, and oleate of mercury ointment (one per cent.); astringent lotions are also sometimes useful. When all the ordinary remedies fail, recourse may be had to linear scarification; instruments may be obtained which are especially made for this purpose. The effect of thorough scarification is



greatly to hasten nature's process of cure, that is, the atrophic scarring of the lupus tissue is quickly produced."

#### SUB-SECTION 6.

##### *Epithelioma. Rodent Ulcer.*

*Epithelioma* occurs as a disease of the nose occasionally in the form of warty or fungous excrescences, or in the shape of a roundish ulcer, with hard indurated sinuous edges. It may commence as a hard subcutaneous lump,\* which subsequently ulcerates, or as a warty growth, which, in consequence of irritation and scratching, becomes in time an irritable sore, and develops the hard edges and base of epithelioma. There is a tendency in each form to involve the neighbouring tissues in the same kind of growth, and in neglected cases the whole nose becomes a mass of fungoid tissue, which involves besides the nearest parts of the cheek and lip, and extends into the nostrils. A case of this kind from a specimen and cast in Middlesex Hospital is represented in Plate V, fig. 3.

*Diagnosis.*—It occurs late in life, and this at once distinguishes it from lupus, and the character of the sore is entirely different from that of lupus. There is occasionally some similarity observed between primary syphilitic, and even tertiary syphilitic ulcers and those of epithelial cancer. It is highly improbable that syphilitic sores would occur on the nose, but in the immediate neighbourhood primary and tertiary sores have not unfrequently been observed. The primary indurated chancre is very characteristic, and is distinguished principally by the sharp and defined outline of the indurated base, while the neighbouring lymphatic glands are enlarged and indurated from a very early date. The soft form of chancre and the tertiary syphilitic sore would have less resemblance to epithelial cancer from the absence of an indurated base and edges; and there would, in their case, be enlarged glands in the sub-maxillary region at an early stage, while, in the case of epithelioma, the glands become affected only in the very latest stage of the disease.

*Treatment.*—Extirpation of the growth by the knife, caustics,

\* An interesting example of this variety is related by Sir James Paget ("Lectures on Surgical Pathology," vol. ii, p. 430).

or the actual cautery are the only rational means to be employed for the removal of this disease. The galvanic cautery ecraseur might be used with advantage in the fungoid forms of the disease, such as that represented in Plate V, fig. 3, but in other cases the knife or caustics are preferable. In cases in which the glands have become diseased, operative interference will not be desirable, and only palliative treatment can be employed.

*Rodent Ulcer.* Syn.: Flat or superficial epithelial cancer (Thurich). A Form of Cancroide (Sebert). Rodent Cancer (Moore). Jacob's Ulcer (Jacob).

The precise pathological position of *Rodent ulcer* has been a matter of controversy, some observers regarding it as only a "phase of epithelioma," the late Dr. Tilbury Fox and Dr. Colcott Fox often looking upon it as "an intractable, ulcerating, non-cancerous growth, sui generis" (Sir James Paget and Mr. Jonathan Hutchinson). The weight of evidence seems to me to be in favour of the view that it is a phase or modification of epithelioma. Mr. Hulke regards it as "a variety of epithelioma" (*Med. Times and Gazette*, 1873). Dr. Thin stated "that in rodent ulcer the primary and chief feature was an epithelial growth of new formation" (*Pathological Transactions*, vol. for 1878-9). There appear to be two recognized varieties—the tubular, or cylindrical, and the alveolar forms. In either case the newly-formed epithelial cells are most abundant and earliest found in the immediate strata below the epidermis, though Dr. Thin has found them invading the sweat glands in two cases, and Drs. Tilbury and Colcott Fox found them as bud-like processes from the hair follicles, which those observers regard as the starting point of the disease. The *rete mucosum* is only invaded at a very late period of the ulceration, and is not infiltrated with the new cell growth at any period. The clinical features are well marked in typical examples, and there are very few recorded instances in which there can be much difficulty in distinguishing rodent ulcer from epithelioma, the growth of the latter being as a rule much more rapid, and always sooner or later infecting the lymphatic glands. It may commence as an irritable wart or pimple, which, as the patient grows old, becomes an almost painless ulcer, and then spreads *slowly*, until it may, if unchecked, destroy a large portion of the face, including bones and muscles. It attacks frequently

the side or bridge of the nose, and the adjacent parts of the cheek and lower eyelid.

This ulcer is seldom seen below the upper two-thirds of the face—that part, in fact, on which, if we except the eyebrows and eyelashes, there is a much less development of hair than on the lower part.

The edge of the ulcer is indurated and raised, but not undermined and everted. The surface is dry, clean, glossy, and does not exude any large amount of secretion. It does not invade the neighbouring tissues by infiltrating them with deposit, but it slowly eats its way into them. It does not affect the lymphatic glands, nor do similar tumours occur in other parts of the body.

The late Mr. Moore (in his work on “Rodent Cancer”) inclined to the belief that rodent ulcer is not a fibrous degeneration, but a form of epithelial cancer, composed, however, “of a more feebly vital material.”

Continental observers make no distinction between epithelioma and rodent ulcer, but it will be found practically convenient to regard the two diseases as distinct clinically; for the rodent ulcer is different in appearance from that of epithelioma, its edges not being undermined, and it does not affect the lymphatic glands.

*Treatment.*—Extirpation of the disease by the knife or caustics, or both, is safe and effectual even in the late stages, and should be urgently advised as the only means of giving a chance of cure to the patient.

For instances of successful treatment by these means in cases which would formerly have been considered hopeless, in which the whole nose and adjacent parts of the face had been eroded, leaving in their places huge gaping chasms, I must refer to Mr. Moore’s monograph on the subject. It is important in operating to remove the whole of the disease, and to apply caustics to any surfaces from which there is any difficulty in removing the growth by the knife. Instructive illustrative cases will be found in the late Dr. Tilbury Fox’s and Dr. Colcott Fox’s contribution to the *Pathological Society’s Transactions* for 1879.

## SUB-SECTION 7.

*Lipoma. Rhinoscleroma.*

*Lipoma*, so called from the pendulous and lobulated aspect of the growth, consists of a hypertrophic enlargement of all the structures of the alæ and tip of the nose, but does not, as its name would imply, contain any true fat. It is more properly described as a *cutaneous* outgrowth (Paget, "Lectures on Pathology," vol. ii, p. 105), with excess of fibro-cellular tissue and enlargement of the sebaceous glands. In well-marked examples pendulous growths of a bluish red colour, and varying in size from that of a small cob-nut to that of a walnut, with a rounded lobulated surface studded with minute crypt-like depressions, hang from the alæ and tip of the nose, to which they are attached by broad bases or pedicles. There are generally three lobes to the tumour, two lateral and one in front. They grow slowly and painlessly, and become fully developed at an advanced period of life. It has been called *Rhinophyma*, or *Hammer-Nose*, by Dr. Balmanno Squire.

The pathology of this disease is not well understood, but the structure of the parts after removal is that of uniform hypertrophic thickening of the whole of the tissues involved, especially of the cutis and integumental glands, the sebaceous crypts being sometimes distended so as to form cysts as big as a bean. The subcutaneous areolar tissue is also much thickened, and the minute blood-vessels greatly dilated. The disease, therefore, consists of a local fibroma, and in some respects resembles elephantiasis, but with the addition of cystic enlargement of the sebaceous glands. It is possible that in some cases it represents an exaggerated condition of acne rosacea in its later stages. According to Balmanno Squire, alcoholized persons are not more liable to this affection than other people. He regards it as simply one of the degenerations of advanced age. These tumours, being very unsightly, may be removed without difficulty or danger. The hæmorrhage is somewhat free, but never so abundant as to excite apprehension. In a case operated on by my friend Dr. Swift Walker (see Plate IV, fig. 3), the result, as seen in Plate IV, fig. 4, is eminently satisfactory. Several other instances have come under my notice in which equally good results have been obtained. In a case under my


care in 1876 (Mr. R., *æt.* about 55 years), with well-marked enlargement of the tip and alæ, the patient, a somewhat gross-looking, stout man, with acne around the nose, had had the GOUT. He was a beer-drinker, and thought beer agreed with him, and with exception of the gout never had a day's illness. In this case the growths occupied the whole of the tip and alæ continuously, and the diseased part shaded off into the healthy skin imperceptibly, there being no distinct line of demarcation. I, therefore, advised that no operation should be attempted, but that the patient should abjure beer, and use a calaminic lotion, and glycerine of starch, with oxide of zinc. Whether the association of *gout* with lipoma in this case was anything more than an accidental one is open to question.

In performing the operation for the removal of cutaneous outgrowths, the chief point to be attended to is to preserve the alar cartilages intact. This may be best effected by making an incision down the median line of the nose until the septal cartilage is exposed, then carefully dissecting the growths off the alar cartilages on each side, guiding the incisions by distending the nostril with the forefinger, so avoiding the possibility of cutting too deeply, and by saving as much healthy skin as possible in order to form flaps to cover the exposed cartilages, and give sufficient prominence to the tip of the nose.

A layer of cotton wool, saturated with styptic colloid, forms a very convenient dressing; it is not bulky, and, when dry, makes a kind of case to the parts, and keeps the edges of the flaps well in apposition until union is effected.

*Rhinoscleroma.*—Hebra has described this disease as a peculiar new formation about the nose, in the *Wiener Medizinische Wochenschrift*, January, 1870. He says:—

“To form an idea of it, a substantial syphilitic sclerosis of the prepuce *in optimâ formâ* may in imagination be transplanted to the external nasal structures, in one case even to the alæ nasi, and in another to the nasal ridge; to the mucous surfaces which form the borders of the nasal cavity; or lastly, to the skin of the parts surrounding the nose, as the upper lip and forehead. Among nine observed cases there were only two which presented the disease on the nose, cheek, and forehead simultaneously; in the others it was confined to the nose and upper lip alone. As a flat swelling it projected as much as  $1\frac{1}{2}$  lines in some places, its extent being always limited by a



*Description of Plate V.*

Fig. 1. A case of lupus terebrans, under the care of the late Professor Partridge at King's College Hospital.

Fig. 2. A case of glanders, from a wax cast in King's College Anatomical Museum.

Fig. 3. A wax cast, in the Museum of Middlesex Hospital, from a patient with epithelioma of the nose.

The patient was a woman, *æt.* 60 years. The museum contains a specimen, in spirit, of the whole of the diseased mass removed after death. The growth occupied the entrance of the nostrils, and extended a short distance within them.



Fig. 1.

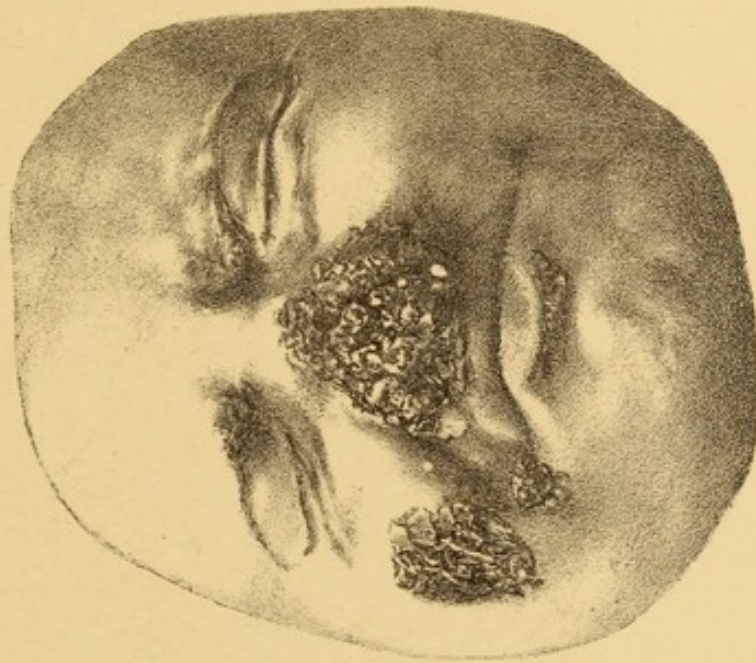

Fig. 2.

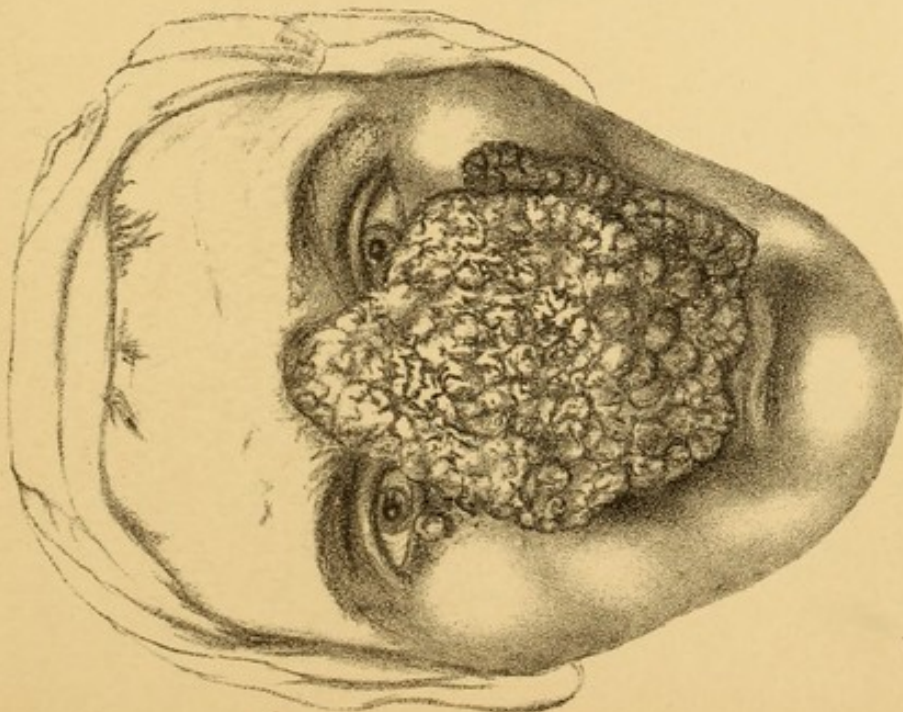



Fig. 3.





sharp border with steep edges. The colour of this new formation varied from normal skin colour to a dark reddish-brown. The upper surface of the diseased places was always smooth, rarely shining. The most striking objective symptom consisted in the extraordinary complete induration of the affected places, which had an almost ivory-like feel. Besides this, the patients experienced but little pain, and only when the formation presented itself localized on the inner surfaces of the nose, and when these prominences were pressed. In all cases the development progressed very slowly, requiring several years before the trouble had acquired dimensions which obliged the patient to seek medical aid.

Characteristics common to all forms of the disease are seen :—

1. In their constant seat on the nose and sometimes in its immediate vicinity.

2. In the extraordinary induration of the affected parts.

3. In the exceedingly slow development of the pathological product, which appears either in the form of brownish-red tubercles or knuckles, or as induration of the normal-appearing tissue.

4. In the sharp margination of these indurations, and the absence of all œdema or inflammatory symptoms in the vicinity.

5. In the absence of all apparent metamorphosis of the new formation, as it neither degenerates, softens, ulcerates, nor is absorbed.

6. In the failure of all internal treatment, even with the strongest agents.

7. In the absence of all danger to the system at large, even in case of its existence for many years.

8. Lastly, in the insensibility and painlessness, when the diseased parts are left untouched ; severe pain, on the contrary, when the dark red tubercles are pressed.

Microscopic examination showed this growth to be "cell infiltration of the upper layers of the corium and the whole papillary body. The normal structure of the affected tissue has thus far suffered by the massively accumulated new formative elements, so that the connective-tissue structure of the papillæ and upper part of the corium is forcibly separated and crowded out, and its elements are renewed. The cells appeared well pre-

served, with sharp contour, and distinct nucleus, and imbibed carmine well."

A most interesting and exhaustive account of rhinoscleroma appears in the "New Sydenham Society's translation of Dr. Hebra's and Kaposi's work on 'Diseases of the Skin,'" published 1875. An analysis of the characters of fifteen cases is there given. "The patients were all in the middle period of life, between 20 and 40, belonged to various nations, and followed very different occupations. No cause can be assigned for the production of the disease." Various *complications* of the disorder are mentioned, such as ulceration of the uvula, perforation of the hard palate, aphonia and laryngeal spasm, a peculiar alteration of the palate and pharynx, etc., but in none of these was there any clue to the constitutional condition of which the local disorder was a manifestation. The changes in the mucous membranes were clearly of the same character as those on the skin. Neither was there any further indication deducible from any of these cases for the successful treatment or cure of the disease. The *diagnosis* depends upon the characteristic hardness and the strict localization of the growth. Syphilitic nodules, though at first indurated, soon soften and ulcerate, and yield ultimately to appropriate anti-syphilitic remedies, which have no influence whatever upon true rhinoscleroma.

Dr. Payne, of St. Thomas' Hospital, discovered in October, 1885, a micro-organism associated with this disease. (Pathological Society, October, 1885.) The bacillus was small and required prolonged staining in methyl-violet to develop the colour. The bacilli appeared to be within the cells in some parts, but not universally. In the same specimen in which the bacillus was discovered the histological examination showed that the skin and the upper part of the mucous membrane were invaded by a small-celled growth resembling granulation-tissue, with an admixture of some larger cells of a different form. The epidermis was also altered in a peculiar manner, producing concentric masses with some resemblance to the "nests" of epithelioma. There were also firm masses of fibrous tissue. The whole structure was entirely different from epithelioma or sarcoma, or any other definite tumour-formation, but formed a growth more resembling the granulation-tumours, such as lupus, syphilis, or tubercle, than anything else, though quite

distinct from any of these. It was remarkable for the absence of any evidence of atrophy or degeneration. The histological appearances were, in the main, the same as had been observed in all cases of rhinoscleroma, though these appearances had been differently interpreted by different observers.

Cornil has found a small rod-like bacillus inclosed in a hyaline capsule, closely resembling Friedländer's pneumococcus. Frisch also describes a small rod-shaped bacillus in the round cells. It is interesting to note that the disease has been reproduced in animals, from culture of the bacilli, by Stepanow. (Bosworth, "Diseases of the Nose and Throat," vol. i, p. 383.)

Obstruction of the nasal respiration is one of the chief *complications*, and may require an operation. Sir Morell Mackenzie succeeded in perforating such an obstruction (in a case reported by him, March 21st, 1885, in the *Brit. Med. Journal*) by means of the galvanic cautery. In this case both nostrils were before the operation completely shut off from the pharynx. Only one side could be penetrated by the cautery instrument, but this gave great relief as the septum was already partially destroyed by the disease.

One case, that of Doustrepoint (*Deut. Med. Woch.*, 1887, No. 5, p. 85) stands by itself as having been cured. A man, *æt.* 34, with the appearances of rhinoscleroma on the upper lip, the septum, and one ala, was treated by the local inunction of corrosive sublimate in lanolin. The disease completely disappeared in three months and a half, with the exception of a small nodule on the septum. All other cases are reported as having resisted treatment, and the disease is generally regarded as incurable.

#### SUB-SECTION 8.

##### *Chilblain, Frostbite, Gangrene.*

*Chilblain* on the nose is not uncommon in this temperate climate. It is the first stage of frostbite. The same persons are liable to chilblains on the nose as those who suffer from the same troublesome complaint on the fingers and toes. The symptoms are the same, and treatment also. It is well, however, to take more especial care in this region, because a frequent recurrence of *chilblain* may bring on a permanent

discoloration and swelling. All sudden changes and all extremes of temperature should of course be avoided by people with the predisposition to chilblain, for the complaint is very liable to recur. Extra clothing, moderate exercise, and some change for the better in the diet are the best prophylactics.

*Frostbite* rarely affects any other part of the face in healthy persons in this country, or in any temperate climate. The nose and ears are affected with acute inflammation running on to gangrene after prolonged exposure, rarely enough in this country; while in Canada and Russia during the extreme severity of winter, these parts are very frequently destroyed by cold, so that in the former country it is considered imprudent to venture out of doors when the thermometer is standing below a certain degree.

I am informed by my friend Dr. J. Walters, of Reigate, that in Canada persons do not consider it too cold to go out with the thermometer standing at  $20^{\circ}$  below zero, provided the air is still; the danger is when without extreme cold there is a strong wind. In severe climates the ears are frostbitten more frequently than the nose.

There are three degrees of frostbite, the first characterized by redness or blueness of the skin, the second by vesication, and the third by gangrene. In the first degree, the nose becomes at first pale and numbed, and pinched or contracted in bulk; after a time, these symptoms pass off, and are succeeded by redness and swelling, with great itching and pricking. This condition is, in fact, the same *as that of chilblain*. This redness in general passes off without treatment, but it is considered dangerous to apply sudden or great warmth to the part under these circumstances, and in an attack of this kind of frostbite it is better to restore the natural heat of the part very gradually, *e.g.*, by rubbing with snow at first, and then gradually allowing it to be influenced by warmth applied with the hand. The redness, however, may remain permanent, the capillaries never regaining their contractile power, and this is especially likely to occur in frostbites of the nose and ears.

Professor Billroth relates the case of a young man whom he treated without success for a permanently *dark-blue nose*, the result of frostbite. The application of collodion made the organ paler for a time, but gave an unpleasant polish to it, almost as disagreeable as the blue tint; and as the blue tint returned

when it was removed, the plan of treatment was abandoned for the application of dilute nitric acid. This produced a yellow discoloration, which was also only transitory. Tincture of iodine and nitrate of silver were next tried. The one gave the organ a brownish-red and the other a brownish-black colour. The patient bore all these changes of colour like a hero, but the end of his chequered career was that his nose remained true blue to the last. Professor Billroth thought of trying cold as a last remedy, but, fearing that the patient's condition might be made worse, gave up the project.

In this country, and in temperate climates generally, the parts most exposed to cold and in which frostbite is threatened are always of a red colour during the preliminary stage, as it affects the nose, cheek, and ears; but in the severe northern climates, and in intense cold, the part affected by the cold becomes of a pale colour; and it is by this colour that the bystander often warns the person affected of the accident that has befallen him, though he himself is generally unconscious of it, the part being so benumbed by the anæsthetic influence of the cold. This change of colour is accompanied with a stiffness and numbness of the part in which it occurs. Dr. Fletcher (D. J. Thomson, "Lectures on Inflammation," London, 1825, p. 640), who had been physician to the Emperor of Russia, relates "that when a man tells another that he is frozen, he asks whereabouts; and is informed that it is in this place or that, but commonly the nose, the upper part of the cheek, or perhaps the tip of the ear. He then usually rubs it well with snow, and lets it thaw by degrees, else if without that preparation he should go immediately into the stove, he would be in danger of losing his nose or other frozen part."

All authors are agreed as to the danger of rapidly applying warmth when a part has been frozen, and most agree in the advisability of using snow as a local application, with friction, in the first instance.

*Gangrene* of the tip of the nose may occasionally arise independently of local injury or obstruction. Disease of the internal organs, leading to extreme exhaustion, has in some cases been associated with it. For example, in October, 1874, a patient of the late Dr. Hardinge's in the Great Northern Hospital was dying from phthisis pulmonalis. A week or ten days before her death a dark bluish-black discoloration made its appear-

ance at the tip of her nose, which, in the course of a few days, spread to the size of a shilling and involved the whole of the tip, but did not extend to the alæ. This was not due to ecchymosis, but to venous stasis, and Dr. Hardinge believed that if the patient had lived a few days longer the tip of the nose would have sloughed. He had observed only three or four similar cases in the course of his experience.

The same causes must have operated in a case of which there is a preparation in the College of Surgeons' Museum (No. 1,821), presented by Mr. Swan. A man cut his throat, and suffered so great a loss of blood that the nutrition of one of those parts, to which the blood is sent with most difficulty, became impossible. Before he died his nose sloughed. (Paget, "Lectures on Pathology," vol. i, p. 35.)

A case of partial and superficial *gangrene* of the tip of the nose and ear occurred to me at the Great Northern Hospital in the winter of 1874-75. The patient was a delicate girl of eighteen years of age, with all the evidences of cyanosis of congenital origin. Her lips were always of a bluish colour and her complexion correspondingly dull, and tinted by the excess of venous blood circulating in the arterial system. The weather at the time was exceedingly cold, and the small patches of gangrene, one on the upper edge of the concha of the ear and the other on the side of the tip of the nose, were due no doubt to the effects of cold on parts already in a state of very deficient vitality. The treatment consisted in keeping the parts constantly covered with cotton wool and in supporting the system by tonics and improved diet. Under this plan the gangrenous patch did not extend deeper than the superficial layers of the corium, and a very limited area was affected. The case demonstrates the danger of exposing persons with the languid circulation of cyanosis to severe cold.

When there is complete loss of sensation, with persistent bluish-white discoloration, followed after a few days by vesication and bluish-black discoloration around the vesicle and beneath it, the third degree of frostbite has been reached, and a slough is inevitable. Little can be done by way of treatment. Poultices of linseed meal and powdered charcoal, or lotions of chlorine water, or chloride of lime, or soda, will be the appropriate local applications until the slough separates, and the surface of the stump must be dressed with some mild form of

ointment, such as ceratum cetacei or adeps benzoatus, with occasional stimulation by means of lotions of sulphate of zinc or copper. The resulting deformity may generally be remedied by means hereafter to be alluded to under the head of rhinoplastic operations (Section XIV.).

#### SUB-SECTION 9.

*Intermittent Hyperæmia of the skin and subcutaneous tissues, probably due to reflex neuroses. Dyspeptic "red-nose."*

One case only has been under my observation. I note it, however, as a remarkable one. References to such cases are scattered throughout medical literature. Thus: "Dr. Graves mentions that he once met with a singular affection in connection with gout, and quotes the case of an elderly lady of gouty habit, who was liable to a daily paroxysm of the following character. About three o'clock in the afternoon her nose became hot, and the heat continued for four or five hours, the skin being first of a bright red, then of a purplish colour; this redness spread to the upper part of the cheeks, and was accompanied by uneasiness, but no pain, and always subsided about the same hour in the evening." (Dr. Garrod on "Gout," p. 453.)

In my case there was no history of *gout*, nor do I believe my patient, a clergyman, of about 60 years of age, had any symptoms of, or hereditary tendency to, gout. He was of a highly nervous temperament, and was constantly in attendance on a brother who was suffering from "shaking palsy." He had been for 25 years in Demerara, but had not suffered from fever nor from any liver disease while in that climate. He had had for two years past daily paroxysms at a certain hour of the day, which varied somewhat, but generally towards evening, of the following kind: He had a sense of "creeping" and heat, and of a rush of blood to the nose and cheeks. At these times there was visible redness of the nose and shining, prominent, tinged veins. The whole organ became crimson.

When I saw this gentleman the external appearance of the nose was not remarkable, though, perhaps, rather bulky laterally. The mucous membrane was remarkably dry, but not encrusted, and there was no fœtor of the breath.



Various palliative local remedies were used with some relief of the more urgent symptoms, and internal tonics were given. Considerable relief was obtained by applying dry cold at the time of the paroxysms and in the interval. The uncomfortable feeling of dryness within the nostrils was relieved at first by the use of ordinary snuff, and afterwards by the use of veratrum in powdered sugar. Though I saw this gentleman at intervals for about three years, the paroxysms he described never came on in my presence. During that time no perceptible increase in the bulk of the nose took place. I am inclined, therefore, to think that the hyperæmia as described must have been slight, and that the subjective sensations of "heat" and of a flow of blood were due to vaso-motor disturbance and to local hyperæsthesia, both being due to some reflex irritation. I used the rhinoscope frequently, but never discovered any morbid change in the mucous membrane beyond an excessive dryness.

The cases in which the integument is affected with a kind of erythema as a consequence of, or as a reflex irritation due to, hypertrophic rhinitis, are of a different kind. They lead sometimes to permanent redness of the nose, and at the same time to hyperplasia of the corium, as a consequence of the increased blood-supply.

Neither are the cases of dyspeptic "*red-nose*" to be confounded with these. There seems to be a close connection between gouty dyspepsia and this form of *red-nose*. These cases are best treated on general principles as laid down in systematic treatises in medicine. Undue redness of the nose in women is often due to disordered menstruation.

#### SUB-SECTION 10.

##### *Erysipelas of the Face of Nasal Origin.*

The spreading of erysipelas from the nose and throat is so frequent that a passing allusion is here admissible. I am not aware that there is anything specific in the particular form of throat and nose affection giving rise to erysipelas of the face. It is, however, generally seen in patients of broken-down constitution, and comes on with an attack of acute quinsy and severe fever and prostration. It is in this form of infecting quinsy that the disease sometimes spreads to several members

of a family or household. It assumes a very severe type, and is often fatal. It is no doubt due to some form of bacillus or microbe which becomes lodged in the nares and fauces.

In these cases the importance of antiseptic nasal douches and sprays cannot be too strongly insisted upon. A freshly-made chlorine gargle used as a spray for the nostrils, both in front and behind, is extremely valuable. The douche of sulphocarbolates and carbolic acid is very useful, unless the nostrils are completely blocked, when the spray alone must be depended upon.

## SECTION XII.

## TUMOURS OF THE NASAL FOSSÆ, AND NASO-PHARYNGEAL POLYPI.

- SUB-SECTION 1. Fibroma.
- „ 2. Sarcoma and Recurrent Fibroid Tumours.
- „ 3. Treatment of Fibroma and Sarcoma in the Nasal Fossæ and Naso-Pharyngeal Cavity.
- „ 4. Malignant Polypi of the Nasal Fossæ.
- „ 5. Bony and Cartilaginous Tumours of the Nasal Fossæ. Osteoma and Enchondroma of the Septum.

## TUMOURS OF THE NASAL FOSSÆ, AND NASO-PHARYNGEAL POLYPI.

MUCOUS and Gelatinous Polypi having been already considered (in Section III), there remain for consideration (1) Fibrous Polypi, (2) Sarcomatous Tumours, (3) Malignant or Carcinomatous Tumours, (4) Osseous and Cartilaginous Tumours. It has been usual to describe naso-pharyngeal polypi as a special and distinct class, and clinically it is often convenient to regard those hard or sarcomatous tumours which present themselves in the pharynx as of a different nature from those originating more anteriorly in the nasal fossæ, and to place the typical instances of naso-pharyngeal polypus in a different class from the ordinary nasal polypi. The fibrous and sarcomatous tumours in this region more often extend, as they grow, towards the pharynx than forwards, and more often occupy the pharynx from the commencement than the nasal fossæ. Nevertheless, the presenting part of the tumour being a mere accident of its growth, and the implantation of its pedicle being its most important feature in a surgical point of view, it is better to classify them according to their histological affinities and characteristics rather than to accidental modifications due simply to their position of origin, or the point at which they are most prominent in the course of their growth.

There are certain *symptoms* common to all the varieties of intra-nasal tumours. In the initial stage of the disease we have disagreeable sensations and irritation of the mucous membrane, necessitating the frequent desire to blow the nose, and perhaps

a muco-purulent discharge, with occasional hæmorrhages. The respiration is slightly impeded at first, but as the bulk of the tumour increases, one or both nostrils become completely obstructed, the sense of smell is destroyed on one or both sides, and the voice becomes nasal in character. The next stage is that of distension. The nasal bones are expanded, the antrum encroached upon, the palate depressed, the pharynx obstructed, and deafness produced by irritation of the Eustachian tube. In other cases the orbits are encroached upon, and the eyeball displaced, double vision being thereby occasioned. Sometimes respiration and deglutition are both seriously impaired, and in other cases the lachrymal sac becomes obstructed and inflamed, and fistulous openings appear on the cheek. In the very worst and most advanced cases, the whole of the face is hideously disfigured by the expansion of the antral walls and the whole nasal region; severe pains attack the head, the jaws, the eyes, the teeth, and the forehead, and in the last stage the brain becomes affected by pressure upon its base, and convulsions and coma usher in the termination of the patient's earthly troubles. This description, however, only applies to the most formidable and neglected kinds, such as the case described by Paletta\* of an enormous polypous mass situated in the nasal fossæ and sphenoidal sinuses, which distended the left antrum, expanded the bones of the nose, ulcerated the skin on each side of it, expanded the palate bones, thrust down the palate in its passage into the pharynx, pushed the tongue out of the mouth, and the eyes partially out of the orbits. The adjacent bones were dilated and destroyed, and the polypus itself had an extreme degree of hardness.

#### SUB-SECTION 1.

##### *Fibroma.*

Any part of the walls of the nasal fossæ and the adjacent region of the pharynx may be the seat of implantation of a fibrous tumour, but the roofs of these cavities are most frequently thus affected, and next in frequency the outer walls of the nasal fossæ, and especially the inferior turbinated bone. It is in most cases impossible to decide whether they have origi-

\* "Exerc. Path.," p. 8. Milan, 1820.

nally sprung from the aponeurotic coverings of the bones, or from the periosteum itself, and in many it may be uncertain whether or not the bones have been primarily or only secondarily involved. The naso-pharyngeal polypus is the typical form of fibrous tumour in this region, and may be implanted by a single broad pedicle or by several separate roots springing from the root of the pharynx or the lateral walls of the posterior nares.

In the course of the discussion at the Paris Chirurgical Society, some years ago, M. Robert asserted that these tumours spring from the foramen lacerum anterius; others declare that they sometimes arise from the whole basilar surface of the sphenoid and occipital bones, and even from the atlas and superior cervical vertebræ, from whence they gradually protrude into the pharynx, nares, etc. Their primary attachment is most commonly by a single broad pedicle from some part of the basilar surface, and the occasional occurrence of several pedicles supporting one tumour is due to ulceration of the opposed surfaces of the tumour and mucous membrane against which they abut; these ulcerated surfaces becoming subsequently united by granulation and cicatrization. They consist of more or less dense tedinous or fibrous tissue, the fibres interlacing in every possible direction, so as to form nodular masses with smooth rounded surfaces.

*Symptoms.*—The early symptoms are those of obstructive disease of the nostrils, with occasional epistaxis, the origin of which may be overlooked at this period. As the tumour increases in size it is seen or felt projecting into the pharynx as a hard rounded mass, and later on manifests its presence in the nostrils as a fleshy-looking obstruction visible anteriorly. When the pedicle is attached to the anterior part of the basilar surface, it may be visible in the anterior nares from the commencement or at a very early stage.

As it advances, the bones of the nose become flattened and spread out laterally, and the orbits invaded, the eyeballs being displaced outwards in proportion to the extent to which these cavities are affected. In one rare instance recorded by Mr. Prescott Hewett (*Medico-Chirurgical Transactions*, vol. xxxiv, p. 43), the tumour, instead of advancing anteriorly through the nostrils, made its way through the sphenomaxillary fissure into the orbit and the pterygo-maxillary fossa, and ultimately occupied the outer and anterior aspect of the upper jaw, thus giving

the appearance of a tumour springing from the antrum. In those cases in which the roof of the nostrils is the original seat of the growth, there is, from an early period, an obstruction in the nostril affected, and the bones of the nose are very soon seen to be displaced. Some displacement of the eyeball is also seen as soon as the cavity of the orbit has become encroached upon.\* If one nostril only is occupied by the tumour the septum nasi is gradually pushed over by it to the opposite side, and sometimes, on looking into the mouth, the palate may be seen to be depressed on the side affected. In these cases the growth may not be visible in the pharynx, and even the finger may fail to reach any projecting tumour in the posterior nares. Posterior rhinoscopy, however, will probably detect the obstruction, and its extent in the backward direction.

*Diagnosis.*—From gelatinous or mucous polypi fibrous tumours differ, 1st, in their firmer consistence when touched by the finger or probe; 2nd, in their seat of implantation being generally higher up and further back in the first instance; 3rd, in their denser and more opaque aspect when their presenting parts are visible in the anterior or posterior nares; 4th, in their immobility when the patient is told to blow violently through the affected nostril while the other is closed; 5th, in the absence of any changes in their bulk from atmospheric causes; 6th, in their microscopic appearances after removal.

They differ from carcinomatous or recurrent sarcomatous diseases by their firmness and comparatively slow growth, by the absence of any affection of the lymphatic glands, and by their non-recurrence when completely removed. But this latter point of difference is by no means a reliable means of testing their pathological character, for it often happens that a tumour appears to have been entirely removed, and that a recurrence nevertheless takes place in consequence of some unavoidable incompleteness in the first operation.

*Syphilitic nodes* or scrofulous abscesses in the pharynx may simulate fibroma. The history and concomitant conditions will

\* A case is mentioned by Velpeau ("Dictionnaire des Trente Volumes," vol. xxii, p. 317) of a fibrous tumour of the pharynx which encroached upon and filled the whole orbit; and M. Gerdy ("Des Polypes," p. 30) relates a case of a fibrous polypus of the nostril and antrum which partly thrust up the floor of the orbit, but was successfully removed by Dupuytren through incisions into the mucous membrane of the mouth.

be the chief reliable means of distinguishing the two diseases. The following case is an illustration of this point:—

*A Case of supposed Syphilitic Sarcoma of the Pharynx and Upper Jaw, simulating Naso-Pharyngeal Polypus, under the care of the Author.*

Susannah F., an apparently healthy girl, with a fresh colour and clear skin, aged 10 years, was first brought to me at King's College Hospital, in April, 1863, on account of obstruction of the nostrils and a flattening out of the bridge of the nose, accompanied with severe pain. The flattening of the bridge of the nose and stuffiness of the nostrils had been noticed by the girl's mother about four months, and during this period several of the girl's teeth had become loose and had fallen out, so that she had lost all the incisors and bicuspid. She still, however, continued well nourished.

Her mother was a weakly, haggard-looking woman, who had three other living children, and had had two miscarriages. The girl Susannah, when an infant, had suffered from sores about the anus soon after her birth, but her milk teeth were sound and good, and there had been no eruption on her body.

The two nasal bones were both thrust forwards, the right being most prominent. She could force air through the nostrils with difficulty, there was nothing abnormal visible through the anterior nares. Posterior rhinoscopy was attempted, but failed. She had a muco-purulent discharge, sometimes offensive, from the nostrils; there was a softening and yielding of the front part of the alveolar ridge.

Passing the forefinger behind the soft palate, a firm nodular mass was felt projecting from the posterior aperture of both nostrils, but chiefly from the right. On the anterior aspect of the third and fourth cervical vertebræ a distinct enlargement was felt projecting into the pharynx. In February, 1864, the flattening of the nasal bridge and the distance between the eyes had increased, and the posterior nares had become still more obstructed, while the tumour in front of the vertebræ projects more and extends higher. There is now much difficulty in swallowing.

*March, 1864.*—All the teeth have now fallen out of the upper jaw. She complains of severe pain at the back of the neck, but is otherwise in good health.

*January 20, 1865.*—A nodal swelling has appeared over the left side of the frontal bone; this swelling is very tender on pressure. The intra-nasal and pharyngeal tumours remain in much the same condition. The nodal swelling suppurated, and ultimately cicatrized.

*January, 1866.*—She has grown much taller and thinner, but the nasal tumour remains unaltered in bulk or consistence.

*March, 1873.*—I had lost sight of this patient till she was again sent to me at the Great Northern Hospital, eleven years after I had first seen her. In this time she had grown very tall, but was miserably thin and cachectic. Her forehead was marked by numerous white cicatrices along the line of the eyebrows, the upper jaw was much shrunk and contracted, and her soft palate was perforated by several apertures and ragged openings, the results of old cicatrized ulcers. She says her nostrils are completely closed, but she can still breathe a little through the left. She has occasional bleeding from the nostrils and often very severe headaches.

*Tumours coming from the antrum* may present some of the appearances of the later stages of similar growths springing from the nasal fossæ, but the history of the early stages of the disease will in some measure serve to distinguish it. An antral growth will cause at first some swelling on the cheek, and will only secondarily lead to obstruction within the nostril; whereas the fibrous growths in the nasal fossæ cause obstruction in the early stages, and involve the surrounding parts only at the later periods. In the very rare cases in which the pharyngeal growth passes round the posterior aspect of the upper jaw, and ultimately reaches its anterior surface and compresses the antrum, it may be very difficult to make an accurate diagnosis. The rare conditions of the lodgment of foreign bodies (as in the case of a pea having germinated in the nostril), and the impaction of displaced teeth in unusual positions, must be borne in mind in forming our diagnosis; but these sources of error are so rare, and the symptoms likely to be presented so uncertain, that it would be impossible to lay down any definite rules for the purposes of diagnosis in regard to them.

*Fractures and displacements* of the bones sufficient to cause obstruction of the nares may assume the superficial aspects of a tumour, but the use of the rhinoscope and the probe will soon



enable us to detect the true nature of the obstruction in such cases.

Having satisfied ourselves of the fibrous character of a growth, we have next to ascertain its seat of implantation.

In the early stage the rhinoscope and speculum will enable us to ascertain whether the growth is confined to the nostrils properly so called, or springs from some parts of the walls of the pharynx. The exact seat of the growth, if confined to the nostrils, can also be discovered by the same means; using a powerful light and sending a concentrated beam by means of a lens or a concave mirror into the deeper recesses of the rhinal cavity. The use of the probe will also aid us in the same direction. In the later stages distortion of the various parts and the actual protrusion of the growth either anteriorly or posteriorly, or in both directions at once, will give us some evidence of its extent and seat of origin.

The possibility of a tumour which has originated *within the cranium* presenting in the nostrils, and simulating a fibrous nasal polypus, is not altogether imaginary. A very remarkable instance of the kind is cited by M. Gerdy ("Des Polypes," p. 110). A fibrous tumour of the second division of the fifth pair of cranial nerves was mistaken for a nasal polypus, and treated on this supposition by several ineffectual operations, with a fatal result. A very careful consideration of the symptoms in such a case would have given some clue to the origin of the tumour, and in any doubtful case it will always be well to ascertain whether there are any paralytic conditions or loss of sensation in those parts to which the cranial nerves are distributed.

Another singular case illustrating the extreme difficulty of diagnosis is referred to by Cruveilhier. A mass having the appearance of a fibrous polypus occupied the right nostril, and was, on post-mortem examination, found to consist of a portion of dura mater, thickened, exhibiting a fungous surface, and containing within it the corresponding parts of the arachnoid and pia mater along with some cerebral substance and pus, the whole forming a hernia through the cribriform plate of the ethmoid bone.

A similar case is described as a congenital disease under the name of *hydrencephalocèle*, by Virchow.

*Case of Palato-Nasal Hydrencephalocele.* (Virchow, "Die krankhaften Geschwülste," vol. i, p. 785, *Explanatory Note of the Woodcut.*)

A palatine hydrencephalocele in a new-born infant. From the gaping mouth projects an irregular-shaped, nodular tumour of the size of a small apple, and appearing to be fixed to the roof of the mouth. On making a slit it is seen that the palate and the vomer are bent outwards and upwards by the tumour, and that the tumour itself comes out of the cranial cavity by a large opening situated immediately in front of the sphenoid, and behind the still cartilaginous ethmoid. The front of the sphenoid is displaced downwards and forwards; its relations with the vomer are interrupted and the latter only articulates with the ethmoid. The anterior portion of the pouch (the tumour) consists of a cavity with smooth walls lined by the dura mater. There are besides several irregular cavities towards the lower and anterior parts; at its uppermost part a mass of brain substance is found, and this is continuous with the main portion of the brain within the skull. The brain itself is much compressed at its base, while the greater portion of the superior space is filled with liquid which is enclosed in a large cavity, partly surrounded by a thick membrane.

The same form of tumour is described as a *rhinencephalocele*, when it presents, as it sometimes has been known to do, at the root of the nose, or in the nasal fossæ. In almost all such cases the congenital origin of the growth will be a sufficient means of diagnosing the case; pulsations synchronous with the cerebral pulsations and the fluid contents generally recognizable will clear up any doubts remaining in ambiguous cases. Tumours may also arise in dangerous proximity to the brain without actually starting from within the cranium, and in all cases in which there are symptoms indicating an encroachment on the orbital cavity, such as displacement or protrusion of the eyeball, there is a possibility that the tumour may be attached to the cribriform plate of the ethmoid, or to the parts of the sphenoid in its immediate neighbourhood (see a case by the late Mr. Cooper Forster, *Clinical Society's Transactions*, vol. iv, p. 152). In any case in which the bones of the inner wall of the orbit are involved there is *some* danger in surgical interference, but this is greatly increased when the cribriform plate of the

ethmoid is immediately adjacent to the attachment of the polypus, and hence the importance of the diagnosis of such cases. Fibrous polypi differ from the malignant tumours in this neighbourhood, by their comparatively slow growth, and by the absence of severe pain, and a sanguineous or fœtid discharge in the early stages. They are also very generally pedunculated, whereas the malignant growths have a very broad base of attachment, often as large as the free surface of the tumour.

#### SUB-SECTION 2.

*Sarcoma and Recurrent Fibroid Tumours* spring from the same parts of the nasal fossæ as the fibrous polypi, but they are less commonly seen as naso-pharyngeal polypi. The lardaceous form is generally a degenerated state of the mucous polypus, having a greyish white, opaque aspect, and very soft and easily-broken texture; their consistence being often like that of very soft cheese. They have some vascularity towards the base, and present vascular points here and there on section. It often happens that after a gelatinous polypus has been removed once or twice, the recurrent polypus assumes the lardaceous opaque condition. Its microscopic characters are then found to have undergone a corresponding change, the embryonic cellular tissue having been replaced by closely aggregated spindle-cells or round cells with little or no intercellular tissue of a fibrous kind. Occasionally the true fleshy sarcoma is the original tumour, and many of the naso-pharyngeal tumours, and the more rapidly growing tumours of the nasal fossæ, are of this kind.

Their consistence and colour vary so much that nothing general can be said about them; they may be as hard as cartilage or of gelatinous, nearly fluid consistence. On incision they may appear bright red, white, yellowish, brown, grey, black, dark red, and different shades of all these colours may appear on the same cut surface, apart from the pigmentation; this variation of colour depends upon their greater or less vascularity, and also the more or less recent extravasations of blood into their tissue. They are attached by one or more broad pedicles. They differ from carcinoma by being distinctly encapsuled in most instances, but in all cases having no tendency to infiltration of the neighbouring parts. The naso-pharyngeal polypi, when not pure fibromata, are of the variety termed fibrosarcoma.

They are very vascular, and hence bleed very readily when touched or incised.

*Progress.*—Left to take their natural course, the fibrous and sarcomatous tumours, whether in the nose or pharynx, tend to destruction of the patient by gradually encroaching upon the adjacent parts, and often by causing absorption of the bones at the base of the cranial cavity and setting up brain mischief. The naso-pharyngeal tumours as they increase in bulk expand the bony palate and form a tumour visible in the mouth, or in rare instances extend into the pterygo-maxillary fossa; while those arising in the nasal fossæ expand the nasal and upper maxillary bones, and displace the contents of the orbits, or even penetrate those cavities after causing absorption of their walls by pressure; sometimes the bridge of the nose is destroyed by ulceration and the tumour presents through the opening. After operations for their removal they are very likely to return in the form of sarcoma of a medullary type, and then softening and ulceration of the diseased mass ensues, with very offensive discharge from the nostrils. Typhoid symptoms or some form of blood-poisoning is soon developed, and the patient generally dies either comatose or after a series of convulsions. If, however, the growth has been removed by an early and effectual operation, it is not likely to recur, and the recovery of the patient is permanent.

*Diagnosis.*—As in the case of fibrous tumours, similar affections of the upper jaw and of the antrum may make their appearance in the nostril or pharynx, and at a late stage the case will present some of the aspects of a tumour originating in the pharynx. But the same distinctions will be applicable here as in the case of fibrous tumours, though when we are dealing with a rapidly-growing sarcoma the stages are much shorter, and the diagnosis will be correspondingly difficult.

The following case illustrates the course of recurrent fibroid growths.

Robert J., aged 55, a labourer in the country, came to the Great Northern Hospital, in June, 1873, with an expansion of the bones and walls of the left nostril, which he said had been obstructed for seven years. The swelling had increased during the last eighteen months, and very rapidly within the last six weeks, the surface had become of a slightly red colour, and

the tears now constantly flow over the cheek in consequence of the obstruction of the lachrymal sac caused by the growth of the tumour. The left nostril is occupied by a reddish growth, which looks and feels, when touched with the probe, much firmer than the ordinary gelatinous polypus. It bleeds very readily when touched, and when an attempt was made by a surgeon in the country to remove it by avulsion with the forceps, very free bleeding came on.

The evident firmness of the growth, as compared with the gelatinous variety, and its probably high attachment, made it extremely probable that this was a fibro-sarcoma, and forbade the hope of removing it by the avulsion method, or by the snare or ligature. The following operation was therefore performed, the patient being under the influence of chloroform, on June 18th.

The left ala was separated from the cheek by an incision commencing from the inside of the nostril, and carried through the thickness of its attached border and upwards along the groove between the ala and cheek towards the inner canthus. The arteries divided in this incision were then tied and the flap reflected inwards, exposing a fibrous tumour of about the size of a walnut. Its high attachment could not be reached, however, without dividing the bone at about the junction of the nasal process of the superior maxillary and the nasal bone. This done, the root of the polypus was easily torn away by passing the forefinger behind it and thrusting it forwards. It was attached by a very broad base to the anterior and upper part of the outer walls and to a small portion of the cribriform plate of the ethmoid; the inner wall of the antrum had become much compressed and flattened in an outward direction, and one attachment of the tumour was at the margin of the orifice of the antrum, the two upper turbinated bones having been pushed aside and in part absorbed. Several separate gelatiniform masses were removed from the turbinated bones. The bones at the upper part of the cavity were well scraped by the gouge, and strong perchloride of iron solution was then applied freely to the surface of attachment. The edges of the wound were brought together with stout silver wire sutures, and the line of incision covered with lint saturated with carbolized oil (1 in 40).

The nostril was syringed out daily with a weak solution of

carbolic acid (1 in 80), the discharge being for some days very offensive. There was also a slight threatening of erysipelas about the third day, which, however, soon passed off under the stimulant treatment with perchloride of iron, and thenceforward the progress of the case was perfectly satisfactory.

Six months after the operation he returned to the hospital; the wound had been healed entirely some time, and the scar was only perceptible above the ala. The nostril was quite free from obstruction, and there was not the slightest overflow of tears. The patient expressed himself as being perfectly comfortable, and very pleased with the result of the operation.

The tumour, however, showed signs of a return about February, 1874, and a foul-smelling discharge began to escape from both nostrils. About the middle of April both nostrils were obstructed, and in the left there was a visible tumour of a greyish colour, which bled on the slightest touch. Towards the end of the month he began to suffer from severe frontal and occipital headache, for the relief of which morphia was prescribed, first as pills, and then in the form of hypodermic injections, but with only partial relief.

On April 29th, chloroform having been administered by Mr. Eastes, the old line of incision was reopened, and a large soft polypus exposed, occupying the whole nasal cavity as far back as the sphenoidal cells and pterygoid processes. The deeper portion of the tumour came from the sphenoidal cells, and in order to reach them it was necessary to split up the nasal bones and to cut away a portion of the nasal process of the superior maxillary. The whole mass of the tumour removed was of the size of a small hen's egg, but it was so friable that it was removed piecemeal by tearing and gouging, and the knife was not required. The bleeding from the superficial parts was very free, and there was also considerable oozing from the deep attachments; but the application of the actual cautery to the former, and of a plug of cotton wool to the latter, effectually checked it. On the following day he was quite free from the pain, and expressed himself as greatly relieved, having slept well with the aid of morphia. On the 15th day the superficial wound had healed, but the discharges from the nostrils were very offensive, in spite of the use of frequent injections of solution of permanganate of potash.

On June 17th he became delirious, and in a few days died

with symptoms of intracranial disease, the nostrils having, during the last few weeks, become again completely obstructed.

The nodules of the tumour, after removal on the second occasion, presented on section a white mottled surface with bloody points of extravasation, and had very much the aspect of brain tissue. Microscopically examined, they consisted of closely aggregated cells with granular contents and with no distinct nuclei. These cells had every variety of shape, and seemed to have assumed their various forms in consequence of very close packing. There was no intercellular matrix. A few of the cells were fusiform with large nuclei, but the majority were those of embryonic connective tissue, and, though very various in shape, were tolerably uniform as to size. The above description is taken partly from my own observations and partly from those of Dr. Thomas Parker Smith, who kindly undertook the microscopic examination of the tumour for me.

I look upon the tumour as fibroid or sarcomatous, and as resembling the recurrent forms of epulis or fibro-plastic tumours of the gums.

The very rare occurrence of sarcomatous tumours originating in the frontal sinus, and ultimately finding their way into the posterior nares and pharynx (see a case in the *Medical and Surgical Journal of Edinburgh*, July, 1826), may complicate the diagnosis. If such a case were seen by the surgeon only at a late stage of the disease it would be difficult to arrive at a true diagnosis, but the history would show that protrusion of the frontal region and encroachment on the walls of the orbit, with more or less displacement of the eyeball, had been early symptoms in the case, and this would be against the supposition of the disease being originally within the nasal fossæ proper.

### SUB-SECTION 3.

#### *Treatment of Fibroma and Sarcoma in the Nasal Fossæ and Naso-Pharyngeal Cavity.*

The first point to be considered is whether any means should be adopted for the removal of the tumour. No operation should be attempted for the removal of tumours evidently coming from the cranial cavity, *i.e.*, in which some symptoms of cerebral disturbance, such as paralysis or anæsthesia of parts supplied by

the cranial nerves, are present. Nor, as a general rule, should any operation be attempted when the displacement of the eyeball has been an early symptom in the case; for under such circumstances the tumour is very probably implanted on the bones of the basilar surface near to the cribriform plate of the ethmoid or the orbital plate of the frontal, and any attempt to remove the tumour may cause fatal injury to these parts (see a case by the late Mr. Cooper Forster, *Clinical Society's Transactions*, vol. iv, p. 159). Those tumours that are evidently connected with nodal swellings elsewhere can only be treated by constitutional remedies.

Under the condition of advanced softening, and perhaps fungous protrusion through ulcerated openings on the cheek, the case is not generally favourable for an operation, but the general health of the patient being good and the glands of the neck being unaffected, an operation may be recommended even under these circumstances.

In some cases the embarrassment and danger of hæmorrhage into the pharynx may be prevented by plugging the posterior nares before commencing the cutting part of the operation. M. Verneuil has operated in this way, and considers the preliminary plugging very useful in many operations on the nose and upper jaw. Whenever possible, the plugging should be performed before the administration of chloroform, because the co-operation of the patient is useful. It is obvious that, when the pharynx is occupied by a tumour, the preliminary plugging would either be impossible or very likely to impede rather than facilitate the subsequent steps of the operation.

The great variety of methods of operating testifies to the difficulties experienced in dealing with these tumours.

Fibrous tumours presenting in the nostrils may sometimes be reached by the wire snare forceps and removed through the anterior aperture, and they may also be removed in the same way or by ligature when presenting in the pharynx, if with a long and somewhat narrow peduncle; but when they are situated higher up in the nostrils, and are attached by a broad base, it is impossible to remove them without preliminary incisions through the soft parts, and in most instances separation of portions of the bones.

For tumours of this kind Dr. Rouge's operation, already described, may sometimes be of service. If, after lifting up



the face by this method, sufficient space is not obtained, the nasal bone and the nasal process of the superior maxillary of the side affected may be partly detached and turned upwards with the skin-flap; in this way combining the advantages of Rouge's and Langenbeck's operations. Langenbeck's operation is performed as follows:—An incision commenced at the centre of the root of the nose is carried vertically downwards along its ridge till it reaches the lower third; a transverse sweep outwards is then carried along the upper margin of the alar cartilage. The flap thus formed is dissected outwards, and the nasal and superior maxilla exposed, their periosteum, however, being left untouched. The cartilage is now separated by an incision through its junction with the lower edges of the nasal and nasal process of the superior maxillary. In order to divide the bones at the median junction with those of the opposite side, a saw may be used, or the bone-cutting pliers, one blade being passed into the nostril and the other external to it. The nasal process of the superior maxillary is separated from its junction with the body of the bone in the same way by transverse incisions either with the saw or the cutting pliers. By means of an elevator, these bones are separated from their other lateral and posterior attachments, and turned upwards; only their periosteal and mucous coverings then remain to unite them with the frontal. The upper part of the nasal cavity is thus completely laid open, and tumours attached to the basilar surface of the sphenoid can be easily extracted through the aperture thus made.

In those cases in which the tumour is attached to the outer wall of the nasal fossæ either of the above-described operations will give sufficient room for its complete removal. A third method, however, described by Mr. Croft, at a meeting of the Medical and Chirurgical Society, offers very great advantages whenever the tumour has extended much towards the antrum. Under these circumstances an incision is made along the ala nasi up to the lower part of the nasal process of the superior maxillary bone, and carried thence along the margin of the orbit. The nasal process of the superior maxillary is then cut through with forceps, and the periosteum stripped off the anterior surface of the body of the bone. A piece of bone is removed from this surface, making a window into the antrum. The tumour can then be reached and removed, and the

periosteum and skin replaced. The bone is soon regenerated by the periosteal flap, and a less amount of deformity is left than would be expected from the amount of bone necessarily removed.

If, as often happens, the nasal bones are very much expanded and thinned by the pressure of the growth beneath, the upper part of the nasal cavity may be exposed by division of the soft parts along the line of the junction of the ala nasi and cheek, and subsequently cutting through the nasal bone by means of the bone-cutting pliers, or even in some cases with a pair of strong scissors.

The object of these operations being to afford room for the introduction of instruments, the choice of the kind of incision will in a great measure depend upon the size of the tumour and the depth at which its pedicle is attached.

If the pedicle is single, and occupies some portion of the roof or sides of the pharyngeal cavity, and can be clearly defined by exploration with the finger, it is unnecessary to make any preliminary incisions. Under these circumstances the *wire of the ecraseur* can be passed through the nose into the pharynx, and the neck of the pedicle caught within the loop by manipulation with the finger through the mouth. The wire loop may sometimes be passed more easily round the pedicle through the mouth into the pharynx. Sometimes the tumour has depressed the soft and hard palate, and it can then be reached more easily after making an incision through the palate at the time of the operation for the removal of the tumour (Boutonniere Palatin of Maisonneuve), or through an aperture made in a preliminary operation some days before, as practised by Nelaton. Whichever way is practised, the wire of the ecraseur can be more easily passed round the polypus through the mouth in those cases which are clearly fibrous in texture, and when sarcomatous and soft they may be separated from their attachments by means of the toothed scissors, or even by the finger, without any other instruments. The actual cautery is sometimes useful in checking hæmorrhage after these operations, and when the attachments are very broad it is a means of destroying any portion of the pedicle which has escaped the wire of the ecraseur or the other instruments employed.

In some few instances there is no possibility of exposing and

extirpating the tumour without removing the upper jaw or a great portion of it. The orbital plate of the upper maxillary bone can always be left entire in these operations, and in some cases the alveolar ridge can also be saved. This operation gives a much greater freedom for operating on the deep attachments of the growth, and, by enabling the operator to remove the whole of the base of the pedicle, prevents the liability to a recurrence.

The *galvanic ecraseur* has been of late years much employed for fibrous polypi, but the cases to which it is adapted are far from frequent. The principal advantage is that it divides the tissues with a very slight amount of bleeding, but on the other hand it is often so difficult to adjust the wire to the pedicle, that the tumour can only be removed piecemeal. Successive portions are ensnared and divided, and in this way many successive slices can be removed, each slice making more room for subsequent applications. It is also difficult in dealing with deeply-seated pedicles to avoid cauterizing the healthy tissues at the same time that the disease is being attacked; but notwithstanding all these disadvantages, the galvanic ecraseur is becoming daily more and more useful in this department of surgery, and is especially adapted for the removal of tumours accessible from the anterior nares.

Strangulation by a *ligature* passed round the pedicle is only to be preferred whenever the more expeditious proceedings already described cannot be employed. It is an extremely painful method, and sometimes excites much inflammation and tumefaction of the surrounding parts, and may be attended with a profuse foetid discharge and dangerous constitutional disturbance. The cure, too, is very slow, and there is a risk of poisoning by the passage of putrid fluids into the stomach. It is claimed on behalf of the ligature that it is not attended by hæmorrhage, but its inconveniences and dangers far outweigh this single advantage.

#### SUB-SECTION 4.

##### *Malignant Polypi of the Nasal Fossæ.*

True *carcinoma* is described as one of the diseases occurring within the nostrils; but the instances in which the so-called malignant tumours here met with have been proved to belong

histologically to the class of carcinomatous disease are very rare. The recorded cases are for the most part either fibrous or sarcomatous tumours that have undergone some kind of softening and degeneration with perhaps fungous protrusion, or cases of encephaloid disease originating in the meninges, or cranial bones, and making its way through the ethmoid and sphenoid bones into the orbit and nostril.

From a scientific point of view, and, perhaps, in some respects practically, it is important to make a distinction between the mere accidents of ulceration and compression of neighbouring parts arising from the presence of a tumour in itself free from malignant qualities, and those results due, in an early stage of the disease, to the special malignancy of carcinoma.

The following *clinical features* are attributed to, and supposed to be characteristic of, malignant growths. They are attached to a large surface by a broad base. They are accompanied from the very beginning by severe frontal and rhinal pain. They bleed very easily when touched, and often give rise to spontaneous epistaxis. A fœtid ichorous or sanguineous discharge flows from the nostril at an early stage. The bulk of the tumour increases very rapidly. The glands in the neck are early affected.

Some of these malignant growths are hard, immovable, and incompressible; others are soft, very vascular, and easily broken down, and have the characteristics of encephaloid cancer. They appear to grow always from the bones, and never from the mucous membrane or periosteum. The microscopic appearances differ in no respect from the cancers of the same kind in other parts of the body.

*Cases.*—One of the most striking instances of this disease is recorded in the "Catalogue of St. George's Hospital Museum" (Series xvi, 47 and 48). A malignant tumour, described as firm, and inelastic, was removed from the left nostril of a child æt. four years. The disease reappeared in various parts of the body, and the patient died six months after the operation. A vertical antero-posterior section of the nasal cavity shows it to be filled with a deposit of malignant nature; the cavity of the antrum is occupied by a similar growth. The zygomatic fossa, the cerebral surface of the frontal bone, the palate bone and the superior maxillary, are all more or less involved in the disease.

The body of the sphenoid has been completely absorbed and its position is occupied by part of the tumour, which has penetrated the cribriform plate of the ethmoid in the upward direction. The parts of the dura mater in contact with the disease were much thickened, but the brain was healthy.

This case illustrates the fact that most of the malignant growths in this region are recurrent. In the first instance the disease appeared to be of a fibrous nature, and was attached to the outside of the nostril of a healthy child. Sir Benjamin Brodie was the operator in this case, and his diagnostic acumen being so well-known and appreciated, the fact of his not having recognized the malignant nature of the growth demonstrates the great difficulty of arriving at a satisfactory conclusion in such cases.

In the case of a woman sixty years of age under my care in 1871, the early symptoms of the polypus in the nostril were those of simple obstruction with muco-purulent but not offensive discharge. In the course of a few months protrusion of one eyeball and lachrymal abscess and fistula were developed, and I then made an attempt to remove a portion of the polypus, but finding that it bled very readily and had a broad base of attachment, I removed only a very small portion of the disease. On microscopic examination the tumour proved to be of an epithelioid nature, the cells of which it was made up being closely aggregated and presenting great varieties of form as if from very close packing. The tumour increased rapidly after this partial operation, and the pain also became very severe, necessitating the frequent use of opiates. She died within a year from the commencement of the disease.

An exactly parallel case is reported in the "Ophthalmic Hospital Reports" (vol. iv, p. 38), and in that instance the tumour was removed twice before any malignant symptoms developed themselves, excepting that very severe hæmorrhage occurred on the first occasion, and about a year after this a slightly tender lymphatic gland of the size of a horse-bean was felt behind the angle of the lower jaw. The tumour removed by the second operation (performed by the late Mr. Moore) was to all appearances a simple sarcoma; nevertheless very shortly after the enlarged gland above alluded to increased in size, softened, and presented a characteristic cancerous ulcer. The

orbit also became involved in a similar ulceration, and the patient died nine months after the second operation.

*Diagnosis.*—The chief points of diagnosis between benign and malignant polypi have been already stated (see Sub-Sections 1 and 4). Too much reliance, however, cannot be placed on any of the signs of malignancy, and in the earliest stages an exact diagnosis is sometimes very difficult. Here it will be necessary only to allude to the occasional occurrence in the nostrils of tumours of intracranial origin.

The instance from Cruveilhier's practice under Sub-Section 1, is also applicable in reference to malignant tumours, but the meningeal cancers (so called) which penetrate the base of the cranium towards the orbit and upper part of the nares are those most likely to be looked upon as true cancer of the nares.

Out of fifty-one cases of meningeal cancer analyzed by Velpeau, seven presented in the orbito-nasal region, and in several of these the tumour presented in the nostrils and caused symptoms commonly referable to malignant polypus.

It may *à priori* have been supposed that intra-cranial disease would necessarily give rise to symptoms striking enough to call attention to the seat of the mischief; but this is far from being universally the case. Pain in the head, for instance, may be referred to a particular region, and yet after death a tumour is discovered in a position quite remote from the seat of pain, and tumours have many times been discovered within the skull without any subjective or objective symptoms during life that in any way raised a suspicion of their presence.

Recently, it is true, the ophthalmoscope has occasionally thrown light on these obscure cases, and in certain instances of so-called optic neuritis discovered by its use the physician has been enabled to diagnosticate intra-cranial tumour; but it has happened that very serious lesions of nerves, and of most important structures within the skull have given no external sign whatever. Professor Bérard (*Theses de Paris*, No. 23, 1826) has related a case in which *the olfactory nerves were destroyed by the pressure of a tumour*, and yet the patient, according to the positive affirmation of the occupants of the beds adjoining his, enjoyed to the last the faculty of smell. This, too, was a case in which the tumour protruded through the ethmoid into the

nares, and in which the sense of smell might be supposed to have been affected by the presence of the intra-nasal portion of the tumour.

The diagnosis, therefore, on this point must always be very guarded, and too much reliance must not be placed on negative evidence. When positive paralysis or anæsthesia is present the evidence of intra-cranial lesion is of course very much stronger.

*Treatment.*—The majority of cases of so-called malignant tumour being only instances of recurrent sarcoma, there is no reason why properly-selected cases should not be submitted to operative interference.

Softening of the presenting part of the tumour, and perhaps fungous protrusion through the cheek or the nostril, with considerable distortion of the features and even displacement of the eyeballs, need not forbid the attempt to relieve the patient of a most serious and (if left to itself) fatal disease; but when a tumour has *from the first* grown rapidly and been associated with severe frontal pain and ichorous discharge from the nostrils, and especially if on examination the base is broad and largely adherent to the roof of the nares and pharynx, and bleeds on the slightest touch, no prudent surgeon would think of meddling with it in the way of operation. Our efforts must be mainly directed to relief of pain and preparing the patient for an euthanasia.

#### SUB-SECTION 5.

*Bony and cartilaginous tumours* are occasionally met with in the nostrils, but rarely, if ever, originating from the bones of the nasal fossæ themselves. They spring sometimes from the posterior ethmoidal cells, or the frontal sinuses, and invade all the surrounding cavities in their progress. According to Dr. Thudichum, exostosis of the turbinated bones is an occasional complication of nasal polypus (*Lancet*, September, 1868), and he has succeeded in detaching such growths by means of the galvanic cautery wire, the loop of which is heated to whiteness. From my own experience I cannot recommend such a means of attempting the removal of a genuine bony tumour, for though I am satisfied that it is possible to cut through a narrow pedicle of bone by means of this instrument, yet there are great difficulties.

in the way of doing so, and the wire is very apt to break, when heated to whiteness, if any strain is put upon it during the operation. If, however, the exostosis is attached by a fibrous or cartilaginous pedicle, there is no difficulty in cutting it through by the heated wire, though under such circumstances a pair of scissors would answer equally well or even better.

Several cases of bony tumours occupying the nasal fossa and the adjacent antrum have been recorded in the *Pathological Transactions*, and elsewhere, presenting some of the symptoms of ordinary nasal polypi. Dr. Duka's case (*Pathological Transactions*, vol. xviii, p. 256 *et seq.*) is the best illustration of this rare and curious condition.

A Mahomedan woman, about twenty-six years of age, presented herself with the right side of the face much disfigured by a well-marked swelling of the infra-orbital region extending downwards and inwards, both the nose and eye being encroached upon. There was an oozing of muco-purulent fluid from the right nostril; the roof of the mouth was in its normal condition; the difficulty of breathing through the nose was considerable. On introducing a probe into the nostril it was stopped in its progress by a hard bone-like structure, which on inspection presented a rounded blackened extremity about a quarter of an inch from the edge of the ala and septum nasi. Seizing it with the forceps, it appeared quite movable, as if on a pivot from above downwards, and to a certain extent from side to side, but it resisted all efforts at traction forwards. On laying open the ala nasi, Dr. Duka found that a bony mass occupied the nasal fossa, and was retained in it by its bony walls; he therefore removed the palatine and alveolar portion of the superior maxilla, and succeeded in extracting a mass of compact, ivory-like bone, weighing 1,060 grains. This was lying loosely embedded in a cartilaginous deposit, but had no apparent connection with any of the living tissues. It is, therefore, impossible to say whence this tumour originated.

In a somewhat similar case in the *Mémoires de la Société de la Chirurgie de Paris*, vol. ii, a bony tumour was removed from the nasal fossa by M. Michou. This tumour, however, was attached to the orbital plate of the superior maxillary bone, and to the vomer. In such cases as the two above alluded to, and in any case in which the tumour is evidently loose, an attempt to remove it would probably be successful, and free



from excessive danger to the life of the patient. In other instances, however, the deep attachments of the bone are to the base of the cranium, and in one case (*Pathological Transactions*, vol. xix, p. 311) a portion of the large bony mass, which visibly occupied the orbital and nasal cavities, was found after death to extend through the sphenoid and ethmoid bones into the middle fossa of the cranial cavity, and to be lying in contact with the under surface of the brain.

*Cartilaginous* tumours in the orbital nasal region sometimes cause frightful deformity of the face; and as they are, as a rule, attached to the base of the skull, and parts of them lie in contact with the under surface of the brain, surgery is quite helpless in attempting to relieve the patient.

In a case reported in "Cooper's Surgical Dictionary," "the upper part of the nose had been expanded to an enormous size, while below the left nostril was immensely dilated. The distance between the eyes was more than four inches. \* \* \* After death, a good deal of the tumour was found to be of a cartilaginous consistence, and a portion of it as large as an orange extended within the cranium, where it had annihilated the anterior lobe of the left hemisphere of the brain. Notwithstanding this, till a few hours before his decease, the boy was not comatose, nor insensible. All the surrounding bones had been more or less absorbed, and the place where the excrescence first grew could not be determined."\*

*Enchondroma and osteoma of the septum* are not uncommon. They are easily recognized by anterior rhinoscopy, and are seen to obstruct the passage by a rose-pink obstacle on the septal side, the probe indicating their seat of implantation. Sometimes the growth invades one nostril only, and it is then important to ascertain whether the fellow nostril has a depression corresponding to the protuberance, as if so, the obstruction is obviously due to an abnormal formation, or "bulging" of the septum without a tumour. The seat of enchondroma and of osteoma is most commonly at the lower part of the septum about one-third of an inch from the entrance, and extending backwards and upwards towards the protuberance.

The *symptoms* are those of obstruction with increased secretion and chronic catarrh.

\* See also a case by Prochaska, "Disquisitio Anatomico-Physiologica Organismi Corporis Humani," p. 172. Vienna, 1812. Translated and cited in Mackenzie, on "Diseases of the Eye," p. 62.

*Treatment* :—Enchondromatous growths, which, however, often prove to be partly bony, should be removed by the galvanic wire cauterizing snare if the growth is small and pedunculated; but, as this is seldom the case, I prefer the knife, and when the growth is partly bony, a small saw and cutting-bone pliers will be required. In any case, the patient must be placed under the influence of an anæsthetic.

His head should be placed lower than the level of the chest during the operation in order to allow of the blood passing into the mouth and not into the air passages.

After the operation very little dressing is required beyond the insertion of a piece of lint smeared with an antiseptic; but later on, when the cicatrization is going on, ivory or vulcanite plugs should be inserted, and worn for several hours each day in order to prevent the tendency to contraction.

## SECTION XIII.

## RECENT INJURIES OF THE NOSE, WITH CASES IN ILLUSTRATION.

- SUB-SECTION 1. Contusions and Wounds.  
 „ 2. Fractures and Dislocations of the Bones of the Nose  
 (*Mr. W. Adams' Article*).  
 „ 3. Injuries with the Lodgment of Foreign Bodies.

## SUB-SECTION 1.

*Contusions and Wounds.*

A BLOW on the nose ordinarily gives rise to nothing worse than a transient epistaxis, easily checked by the application of cold applied externally, or by causing the patient to draw up cold water into the nostril by an inspiratory effort. In the event of this plan not succeeding, pressure of the ala nasi against the septum by the finger commonly stops the flow of blood, the bleeding being frequently from ruptured capillaries on the septum near the junction of the bony with the cartilaginous portion.

In the more severe contusions, the septum is occasionally affected with the peculiar blood-tumour already described in Section VIII.

*Incised and lacerated* wounds of the nose require no special treatment, the parts being in most cases easily adapted, and uniting well either by first intention, or by primary union.

Incised wounds resulting in partial or total separation of a portion of the nose have often been followed by complete union of the severed part, even after it has been separated from the main portion of the organ for a considerable time. It is a matter of history that Garengoet was scoffed and sneered at for having stated that a portion of the nose that had been completely severed, on being restored to its natural situation, had been made to adhere. In this case the portion of the nose had been bitten off, and was recovered from a sewer into which it had fallen. That such an adhesion of a separated part is possible is now undisputed, and in any case in which the

surgeon should neglect to attempt the readjustment of parts so severed, he would be justly blamed. It is related in Costello's "Cyclopædia of Surgery," vol. iii, p. 231, that a pugilist having bitten off his adversary's nose in a fit of fury, swallowed it. The surgeon who was called in was blamed for not administering an emetic, in order to recover the severed portion with a view to attempt its re-union. Possibly he might have thought that the piece belonged to the biter by right of conquest. In Carlini's case (recorded in the *Medical Gazette*, 1834, No. 40), the detached portion had been five-and-a-half hours completely separated, yet it united perfectly. It is impossible to say how long after complete severance of the flap the surgeon should give up all hope of re-union: but in any doubtful case it will be wise to give the patient the benefit of the doubt, and after carefully cleansing the detached piece in warm water, and perhaps revivifying the raw surface of the stump by scarification, to adapt the parts and retain them in position by sutures and strapping, or by the application of a layer of cotton wool steeped in styptic colloid, or collodion. It is better, if possible, to avoid the use of sutures, and the styptic colloid offers the advantage of forming when dry a firm crust around the parts, which supports them in position better than any less solid application.

An intimate friend of my own had the misfortune, when a child, to cut off a portion of the end of his nose with a carving-knife. His mother, with great presence of mind, instantly replaced it, and kept it in position by means of an extemporized plaster composed of brown paper smeared with soap and sugar. The severed part completely united, and my friend's nose, a rather handsome one, retained its perfect form in adult life, a depressed cicatricial line, scarcely visible to ordinary observation, being the only trace of the injury.

*Punctured wounds* do not often present any peculiar features in this region. A somewhat singular accident is related by Dr. Garretson (*op. cit.*, p. 495):—

"A young man slipped while standing on a stall in a market-house. Falling forward and downwards upon one of the hooks, it entered his mouth, breaking off three of his upper teeth, perforating his hard palate, and passing by its point into the right nostril. There was no fracture of bone save a few trifling spiculæ about the circumference of the puncture. The

broken teeth were removed, and on the fourth day three small pieces of bone escaped. The wound healed perfectly by the twenty-fourth day."

When, however, the instrument with which the wound is made penetrates the roof of the nostrils, the case becomes complicated by the injury to the cranial contents, and death may possibly ensue. Dr. G. Williamson ("Notes on the Wounded from the Mutiny in India," p. 20) notices a case in which the end of a cane entered the nostril by the left ala, and penetrated the base of the skull immediately below the left optic nerve, carrying before it the left posterior clinoid process. Death followed two days after the accident. The broken extremity of the cane was found in the wound after death.

In *medico-legal inquiries* as to the cause of death, it is sometimes important, in the absence of any external injury, but with evidence of intra-cranial lesions, to search for penetrating wounds of the interior of the nostrils. In the case of young children the cartilaginous condition of the body of the sphenoid makes it very possible that a sharp-pointed instrument might find its way into the brain without any external wound, and symptoms of cerebral lesions, with fatal termination in a few days, might come on without any suspicion of injury until the interior of the nostrils had been examined.

#### SUB-SECTION 2.

*Fractures* of the bones of the nose may be trifling in importance as regards the life of the patient, if the injury does not extend beyond the facial portion of the organ, though they often occasion very considerable distortion from permanent displacement of the fragments. The lachrymal bone is occasionally fractured by direct blows on the nose or edge of the orbit, and in such cases the ordinary signs of contusion are sometimes accompanied by emphysema of the eyelids and the cellular tissue of the orbit, due to the escape of air from the nostrils through the fractured edges of the bone. These symptoms pass off, as a rule, in the course of a week or ten days under the simplest treatment, the patient being cautioned not to blow his nose until the injured bone has become firmly united; it has sometimes happened, if this precaution has not been observed, that there has been a fresh escape of air into the cellular tissue

while the patient has been using his pocket-handkerchief, and a repetition of this accident is very likely to lead to a permanent opening of communication through the lachrymal bone into the cellular tissue of the orbit, and to subsequent occasional attacks of emphysema.

The *nasal bones* are often broken by direct blows of great violence, but the swelling and ecchymosis may make it difficult or impossible at the time of the accident to detect the fracture. If the loose fragments are felt at the time, they should be replaced by passing a director or female catheter into the nostrils and lifting them forwards into their normal position. During the first few days after the injury there is so much swelling and tenderness of the parts, that plugging of the nostril can rarely be endured by the patient, but if the bones be much displaced and show a tendency to falling inwards, an attempt should be made to keep them in position. A plug of cotton wool coated with wax, or a tuft of wax-coated cotton, may be inserted, and replaced after the swelling has subsided by an ivory or vulcanite plug, or by Mr. Adams's ivory plugs (see fig. 63).

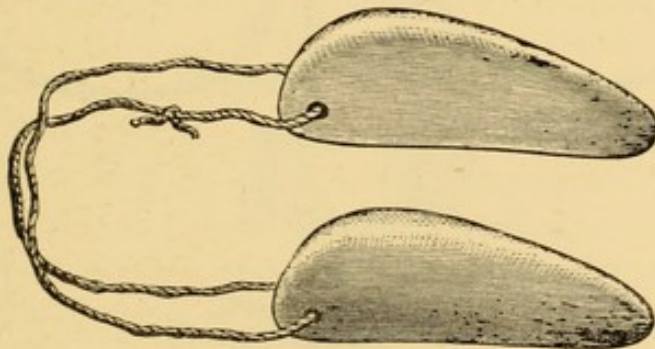


Fig. 63.  
Mr. Adams's Ivory Plugs.

When, after all swelling has subsided, the bones are found to retain their normal position, it is better to avoid the use of any plugs whatever, as they cause much discomfort to the patient and are not necessary for the cure.

The displacement upwards of the septum nasi, and with it of the crista galli and cribriform plate of the ethmoid, with or without fracture of the nasal bones, is a most serious injury, the displaced bones being driven into the anterior lobes of the brain, and attended with hæmorrhage and perhaps escape of cerebral tissue. The symptoms attending such an injury are those of fracture of the base of the skull, and the fracture and

displacement of the nasal bones will be of secondary importance, though valuable as an indication of the probable seat and extent of the deep-seated lesion.

*Lateral dislocation of the nasal bones* from blows requires immediate reduction by pressure, and it is generally easy to replace them, but unfortunately they very easily slip back into their faulty position. I have devised a nose-truss for the purpose of keeping the bones in their place after dislocation, and this instrument, which I prefer to Adams's instrument, should be worn for about a fortnight after the reduction has been effected. The woodcut explains the method of using it (see fig. 64).

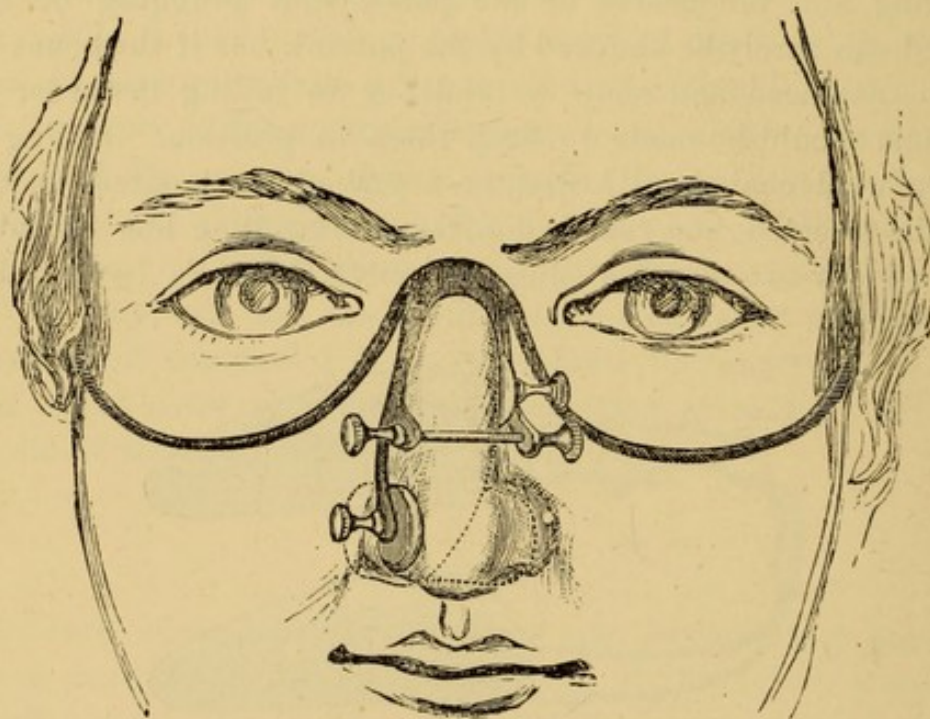


Fig. 64.  
Author's Nose-truss.

For recent dislocations, I prefer this instrument to Adams's truss (see fig. infra) on account of its greater lightness of construction, and because with the spectacle-frame resting on the bridge of the nose, there is less danger of the whole frame shifting laterally. The band round the forehead in Mr. Adams's truss can only be kept in firm position by being very tightly fitted and buckled round the head. When, however, the injury is of such a nature that the spectacle-frame cannot be worn, Adams's nose-truss is the preferable apparatus.

If the septum is much distorted, the bony and cartilaginous portions may be separated, or the cartilaginous portion forcibly

broken by means of Mr. W. Adams's forceps designed expressly for this purpose (see fig. 65).

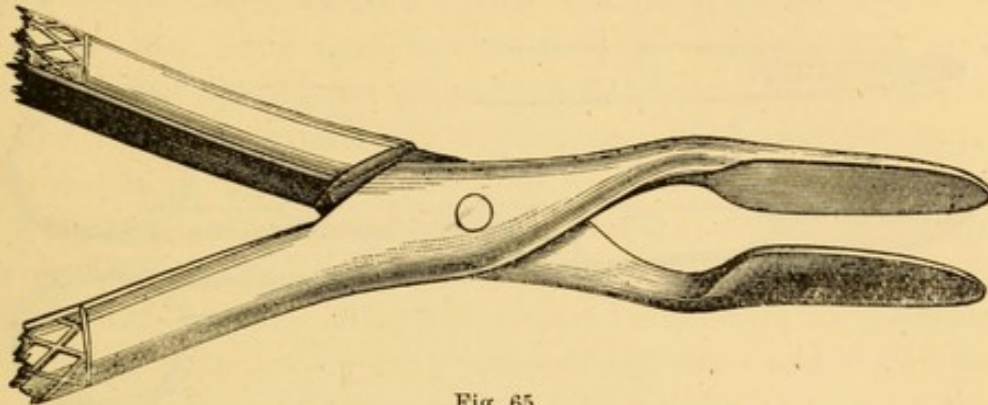


Fig. 65.  
Forceps for straightening the septum nasi.

Mr. W. Adams has favoured me with the following account of the principles which have guided him in the treatment of these cases, when of traumatic origin:—

“All cases of so-called *broken nose* may be divided into two classes, viz.:—

“1st. Those in which the injury is limited to the anterior, or cartilaginous portion of the nose, and consists essentially of depression, with lateral bending of the cartilaginous septum, probably also with a partial displacement of this septum from its attachment to the bones; and

“2ndly. Those in which the nasal bones are fractured, with more or less depression, and lateral displacement, in addition to depression and lateral bending of the cartilaginous septum.

“Many examples of both these forms of injury have fallen under my observation in private practice, but all the cases in which I have been consulted have been at periods varying generally from one to six months after the accident. In one case, however, that of a young lady, eleven years of age, the accident had occurred six years previously in a fall down a sloping bank forty feet in height.

“In all these cases the principle of treatment which I have adopted has been, whilst the patient is under chloroform, to straighten the bent cartilaginous septum with a pair of strong forceps, with flat parallel blades.\* In some cases the two blades

\* “These forceps should not be used by simply closing the blades; but by keeping them apart when in the nasal chamber and twisting them sideways, so as to re-break the septum, which has probably been split as well as bent, and by this means it can be brought straight in the median line.”



when closed may be forced up each nostril, under the lower portion of the nasal bones, and lateral pressure may be made externally by the thumb, at the same time that the bones are

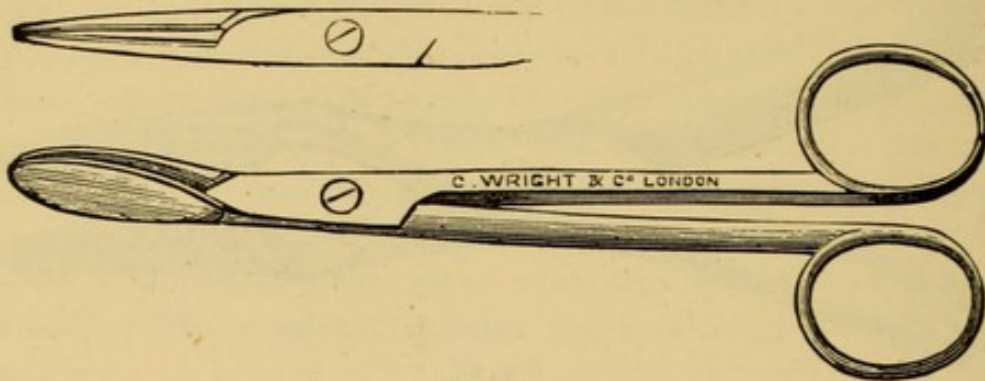


Fig. 66.  
Mr. Adams's curved forceps for elevating nasal bones.

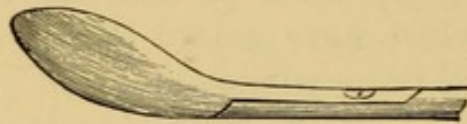


Fig. 66A.  
Side-view of Adams' curved forceps

raised from within.\* This was done in the case reported below, that of C. R., in which sufficient force was employed to re-fracture the left nasal bone."

*Mr. Adams's Case of Fracture of the Nasal Bones with Depression and Bending of the Cartilaginous Septum, much improved by Forcible Straightening Six Months after the Accident.*

This case was of a more severe character than that reported in the *Brit. Med. Journal* of Oct. 2, 1875, and which was the first case operated on, its date being July, 1861.

"C. R., aged 22, an officer in the army, first consulted me on the 6th June, 1871, having sustained a severe injury to the nose by a fall in the previous December. This gentleman was wearing one of the new-fashioned Ulster coats, and having both hands in the pockets fell down flat at a railway station, the nose coming in contact with an iron rail. The nasal bones had been fractured, and projected towards the left side. The cartilaginous septum was also much depressed and bent, projecting

\* "For the purpose of elevating the depressed and often comminuted margins of the nasal bones, I prefer to use forceps with very narrow curved blades, as shown in fig. 66. This can be moved about more freely in the narrow portion of the nasal chamber, and elevates the nasal bones more effectually."—(W. Adams).

into the left nostril, whilst the tip of the nose was directed towards the right side, somewhat in the shape of a half-moon, giving to the face altogether a most unsightly appearance. In this case, also, more than one surgeon of eminence had been consulted, and the opinion given was that no treatment could be adopted with any probability of success. I advised the same treatment as in the former case, and this was assented to.

“ *On the 9th June* I performed the operation, chloroform being administered by Mr. Braine. The cartilaginous septum was straightened, but very little improvement effected in the position of the nasal bones. The steel screw-compressor was used continuously for three days and nights, followed by the use of the ivory plugs. The improvement, so far as the front part of the nose and cartilaginous septum were concerned, was satisfactory, but the nasal bones being still depressed and displaced towards the left side, I directed Mr. Blaise to construct a kind of steel truss (represented in fig. 68) to pass round the head, having a small oval pad connected with the front part, and capable of accurate adjustment by means of two cog-wheels, so as to be applied to the left nasal bone, as a retentive apparatus, after the bone had been forcibly bent or re-broken—an operation which I performed *on the 21st June*, when chloroform was again given by Mr. Braine. In this operation considerable force was employed in the attempt to bring the nasal bones into their natural position, by a firm and long-continued pressure on the left nasal bone. Very considerable improvement was effected, and the steel truss and pad were immediately applied as a retentive apparatus. I also more completely straightened the cartilaginous septum, and the steel screw-compressor, followed by the ivory plugs, was used to support the septum, at the same time that the truss was applied to support the nasal bones externally.

“ After this operation the progress was satisfactory, and the improvement very marked and well maintained; still, however, from the severity of the case and its duration neither the depression nor the lateral deviation of the nasal bones was entirely removed, and

“ *On the 5th July, 1871*, I again repeated the operation, chloroform being given by Mr. Braine; still further improvement was gained with very little force, and the retentive apparatus used, as before, for several weeks.

“ *On the 27th November*, when I saw him for the last time, I

found the improvement had been well maintained, and the appearance of the nose so much improved that it would scarcely attract attention, and the result was considered to be very satisfactory.

“After this operation of forcibly straightening the nose, I employ a retentive apparatus, consisting of the steel screw compressor, represented in fig. 67, which is applied so as to support the septum, one blade being introduced into each nostril, and the screw tightened just sufficient to hold it in position, and bring the blades in contact with the septum, but without making any pressure upon it. This apparatus can be worn two or three days and nights without removal. After this, I introduce the ivory plugs represented in fig. 63, which the patients can remove at pleasure, and re-introduce, so that both nostrils are kept moderately distended, and support given to the cartilaginous septum.

“It would not be possible to support the nasal bone by anything introduced in the upper part of the nasal cavity, from its small size and the sensitive character of the lining membrane. When the nasal bones have been fractured, I have employed a

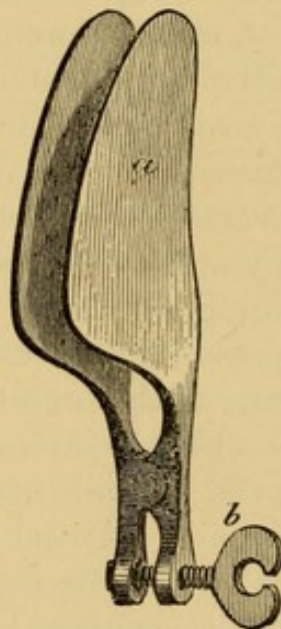


Fig. 67.  
Steel Screw Compressor.\*

retentive apparatus, externally, by means of two small pads attached to steel levers and adjusted by cog-wheels, and attached

\* This instrument has been modified lately. The blades are now made of ivory, almost rectangular in shape, while the rack and pinion are inclined obliquely to the blades.

to the front part of a steel-band passing round the head, forming a kind of nose-truss, if it may be so termed.\* This apparatus is represented in fig. 68, and was first used in the case of C. R. (see above), and found to answer extremely well. This truss can be worn day and night for two or three weeks, according to the severity of the case. In the case above referred to it was worn for a still longer period.

“The operation of forcibly straightening the nose does not require to be repeated, except in cases of great severity, but it may, in some instances, have to be repeated once or twice, the retentive apparatus being afterwards employed.”



Fig 68.

Mr. W. Adams's Nose-truss. (The cut is taken, by Mr. Ernst's permission, from his book on "The Choice of Orthopædic Appliances.")

*Dislocation* of both nasal bones backwards is a very rare accident. It cannot occur without fracture or dislocation of the septum, and may be associated with fracture of the cribriform plate of the ethmoid, which would probably be driven upwards into the base of the brain. Such a displacement of the nasal bones can be reduced by passing a curved director up the nostrils and thrusting them forwards, but more force will be

\* One pad attached to a short lever can be used to make slight pressure on the convex side of the displaced nasal bones, whilst the other pad, attached to a longer lever, may act as counter-pressure, resting against the nasal process of the superior maxillary bone low down.

required to effect this than in the case of fractures, the displaced bones being locked between the nasal processes of the superior maxillary bones. Once replaced, however, no plugs will be required to keep them in position. In a case under the care of Mr. Adams, a permanent deformity resulted from unreduced dislocation of the nasal bones backwards occurring in a young child. In this case there is great prominence of the nasal processes of the superior maxillæ, and a consequent widening of the whole nose.

*Mr. Adams's Case : both Nasal Bones evenly depressed between the Nasal Processes of the Superior Maxillary Bones, producing Flattening of the upper part of the Nose. Cartilaginous Septum also depressed and bent, projecting into the Right Nostril. The tip of the Nose deviating towards the left side.*

“Miss F., aged 11, was sent to me by my friend, Mr. Walter Coulson, on the 9th June, 1874, and the nose then presented the general appearance indicated in the above description. The accident occurred six years previously, when she was only five years of age, by her falling down a sloping bank forty feet in height, the nose coming in contact probably with a stone when she first rolled off the embankment.

“In addition to the external deformity the breathing was very much interfered with in this case. The voice was also much altered, and an offensive discharge constantly occurred from the nostrils, as in ordinary ozæna. No evidence of necrosis of bone could be obtained by examination with the probe, nor was this indicated by any tenderness to pressure externally. I therefore advised the operation of straightening as in the preceding cases.

“On the 10th June, chloroform being administered by Mr. Braine, I straightened the cartilaginous septum with the steel forceps, and to some extent succeeded in improving the position of the nasal bones. The steel screw compressor and ivory plugs were worn without inconvenience, and on the 2nd July I endeavoured still further to raise the depressed nasal bones, with the assistance of Dr. Sliman, of Hackney, who administered chloroform. The blades of the forceps were carried directly upwards, in a direction to elevate the nasal bones, and a firm lateral pressure, applied externally, at the same time. A marked improvement in the shape of the

nose was thus produced, and the same retentive apparatus employed; but it was difficult to maintain sufficient lateral pressure externally. The general improvement in the form and shape of the nose was considerable, and much of the depression removed. The offensive discharge from the nostrils entirely ceased, and both the breathing and voice were much improved. The nasal bones, however, still remain somewhat depressed."

*Lateral displacement the result of injury.*—When the lateral displacement is of old standing, no immediate treatment having been adopted, or, if adopted, having failed from some cause, it becomes a question whether the bones may not be *refractured* and *readjusted*. Mr. Wm. Adams has succeeded in so doing. He employs a stout steel rod of ten inches in length, and about  $1\frac{1}{2}$  inches in diameter at its upper extremity, tapering at the lower end to a diameter of an inch. Both ends are flat, and the lower covered with a firm india-rubber pad. The lower end of the rod is placed against the bone it is desired to bring into position, and the upper end is then struck a sharp blow with a wooden mallet. The septum is then adjusted by means of the septum forceps, and the nose truss applied as in a case of recent injury. I have had no opportunity of testing this method, but believe it to be perfectly sound in principle, and safe in skilful hands, such as those of the gentleman who has devised the operation.

### SUB-SECTION 3.

*Injuries with the lodgment of foreign bodies* in the nostrils are most frequently the result of gunshot wounds or explosions. The symptoms of obstruction and often an offensive discharge after an injury are not always at once recognized by the surgeon in attendance as diagnostic of the presence of a foreign body. If, however, these symptoms continue for a lengthened period, the use of a probe will generally discover the cause of the obstruction.

Dr. G. Williamson relates the case of an officer who lived seven years after an injury to the forehead and nose. After death the breech and screw of a fowling-piece were found lodged in the forehead and nasal cavities. The anterior portion of the right hemisphere of the brain rested on the flat part of

the breach, and was only separated from it by a false membrane.

In a case reported by Mr. Lawson, a foreign body, which had remained unsuspected in the nostril for 12 years, and weighed 2 oz., was discovered and removed successfully during the life of the patient (Lawson, "On Diseases and Injuries to the Eye," p. 335).

For the removal of foreign bodies accidentally introduced into the nostrils, the rules of treatment have been already laid down in Section V, Sub-Section 3.

*Burns* and *Scalds* of the nose do not require any treatment at all different from that of injuries of a similar kind occurring in other parts of the body. It is well, however, to prevent, if possible, contraction of the orifices of the nostrils during the healing of sores following such injuries, for the amount of shrinking is sometimes very considerable. Ivory or vulcanite tubes adapted to the nostrils may succeed in preventing this in some cases; in others a plastic operation will be necessary for the restoration or widening of the aperture; in others no remedies will be of any avail.

## SECTION XIV.

MALFORMATIONS, DISTORTIONS, AND MUTILATIONS OF THE NOSE—  
RHINOPLASTIC OPERATIONS.

- SUB-SECTION 1. Malformations and Distortions of Congenital Origin, or the Result of Injuries.
- „ 2. Defects and Mutilations due to Disease or Injury, and Mechanical Appliances for their Relief.
- „ 3. Rhinoplastic Operations.
- „ 4. On Dressings, Bandages, &c.

## SUB-SECTION 1.

*Congenital defects of the nose* are of three kinds—(1) Those of deficiency of the whole or part of the organ; (2) Imperforate nostrils (*Atresia narium*); (3) Distortions and Fissures; (4) Double Noses.

*Absence of the nose or of part of its integument* is extremely rare, unless we include under this head the cleft extending through the palate and upper jaw, associated with harelip. In this malformation the floor of the nose is almost entirely absent, and the septum or column either wanting or displaced forwards, together with the intermaxillary portion of the alveolar ridge. In this condition the alæ are flattened and expanded laterally, and the tip of the nose depressed, the abnormal column projecting downwards and forwards in an unsightly manner, sometimes giving the appearance of a pendulous tumour attached to the under part of the tip of the nose. Complete absence of the nose and nostrils probably only occurs in cyclopians, such as are rarely seen in museums. In these a rudimentary nose without perforation projects from the middle of the forehead above the single orbital cavity.

*Imperforate nostrils* are also extremely rare, and may be remedied by making an incision into the obstructing tissue; the aperture being kept open during cicatrization by plugs, or tubes of vulcanite or ivory. If the obstruction extends deeply into



the nostrils, as in cases of rhinoscleroma of the palate, the hard material causing the obstruction may sometimes be removed by operation.

*Lateral displacements* of congenital origin are not uncommon. The septum alone may be displaced while the columna and ala remain in their normal position, so that on examining one nostril it is found to be obstructed by what at first sight appears to be a polypus or tumour, while the other is seen to have an unusually large capacity. The septum is sometimes set across the nares obliquely, in such a way that one nostril is obstructed below and the other above. Under these circumstances the voice is rendered nasal in character, and respiration is much interfered with, but when only one nostril is obstructed there may be very little, if any, alteration of the voice.

*Treatment of lateral deviations of the septum of congenital origin.*—The choice of operations for the restoration of the normal position of the septum must depend upon the position and extent of the deflection. If the deflection is slight and unaccompanied by any considerable thickening, a simple incision through the cartilage in the direction of the long axis of the prominent part will be sufficient; but it must be followed by the use of plugs worn constantly for a long period during the process of healing. When there is thickening, a portion of the cartilage must be removed by Ingal's method. The mucous membrane is first denuded from the surface on the prominent side and the thickened cartilage removed, after which the mucous membrane can be replaced in its previous position. In cases in which the bone is thickened as well as the cartilage, a chisel or saw will be necessary for the division and removal of the obstructing bone, and, in some cases, bone-cutting scissors will be required. Blandin's method consists in the use of a *punch* fitted to forceps, of the form used by Mr. Wm. Adams. Each blade is passed into the corresponding nostril, and on the closure of the blades the septum is perforated. Various forms of *punch-heads* are provided to meet the variety of forms of deviation. The shapes recommended for this purpose by Dr. Sajous are elliptical, arrow-shaped, and star-shaped.

Soft carbolized plugs should be worn for the first week after the operation, and subsequently vulcanite or ivory plugs can be employed for a period of two or three months.

*Clefts in the alæ*, whether of *congenital* or *traumatic* origin, and perforations of any part of the walls of the nose, can be closed by paring the edges of the cleft or aperture, and bringing them together by harelip pins or wire sutures. Very few examples of *double nose* are recorded. In one case\* a little tumour, like a second nose, grew on the root of the principal or normal nose. Pierre Borel† mentions the case of a carpenter who had a double nose, and adds that he was called "the man with two noses," but gives no further details. Whether in such cases any operation for the removal of the superfluous organ is desirable or not, must depend upon the connections of the part. Possibly an *encephalocoele* presenting at the root of the nose may have given rise to the idea of a second nose being present, and in such a case no surgical interference would be admissible.

#### SUB-SECTION 2.

##### *Defects and Mutilations due to Disease or Injury, and Mechanical Appliances for their Relief.*

Disease often destroys the whole of the external parts of the nose, and even of the adjacent parts of the cheek, leaving a most repulsive-looking gap in the middle of the face. The ravages of lupus, syphilitic erosive ulcers, malignant pustule, or frostbite, may be such as to render the patient's life very miserable from the hideous deformity thus produced. But, besides the deformity, the articulation is more or less affected and the sense of smell is lost.

The loss of the whole or a portion of the nose is sometimes in part remedied by the employment of an artificial substitute made of metal, vulcanite, or some other modification of india-rubber, coloured to imitate the natural skin. This can be fixed on to the sound parts of the face by means of a prominent portion which passes into the gap, and the application of gum to the cheeks where the natural and the artificial parts come in contact; or the artificial member may be fixed to a pair of spectacles which can be worn in the usual way.

There are several mechanics in London who have made very successful adaptations of artificial noses, and of these Mr. Stump, of Bolsover Street, and Messrs. Krohne and Tesemann, of Duke Street, are about equally skilful. For the full par-

\* Bartholini, "Hist. Anat." Cent. i, Hist. 25. † Cent. iii, Obs. 43.

particulars of Mr. Stump's methods of adaptation, and for the particulars of some excellent results, I must refer to a description in the *British Medical Journal* for April 4th, 1868. He claims to have improved on the hard and stiff noses worn with spectacles, by adapting flexible noses attached without spectacles,

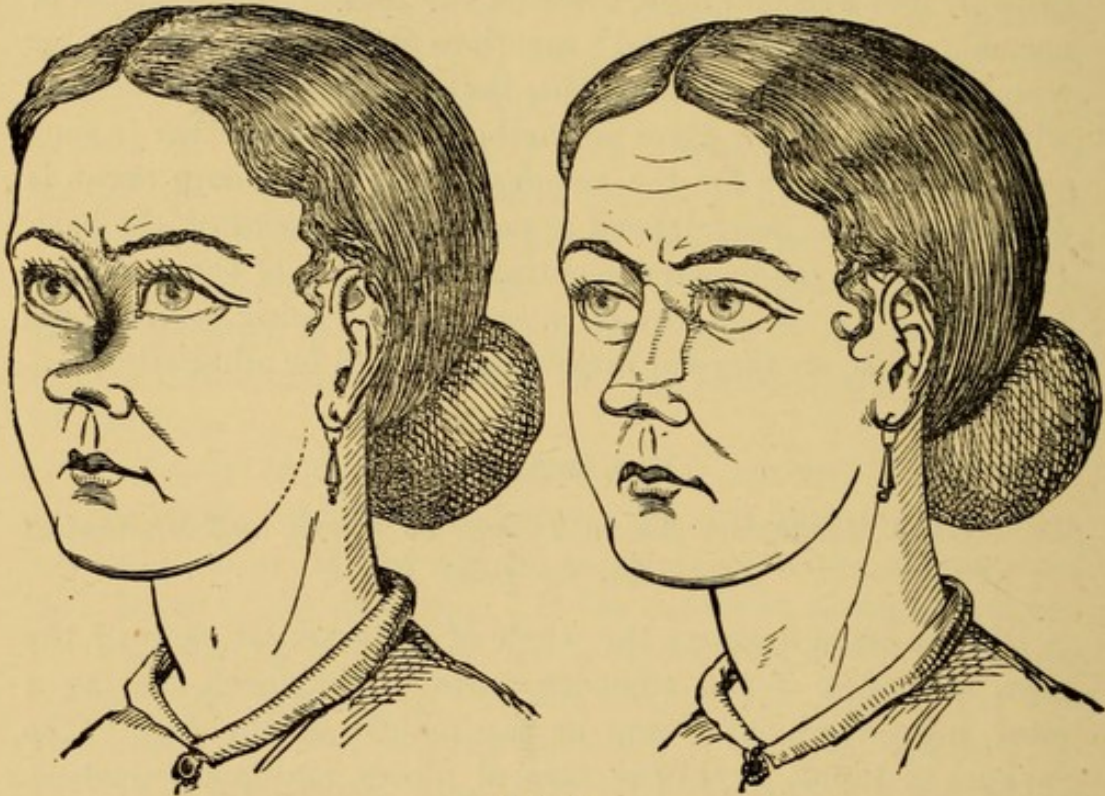


Fig. 71.

Drawing No. 71 represents one of three very similar cases; it is of a young lady who has suffered from hereditary syphilis, which, after raging between the nose and corner of the eye for many years, at last yielded to skilful medical treatment and healed, but leaving an orifice, leading into the head, one inch and a half high by five-eighths of an inch wide; and the contraction of the skin in healing has drawn down the sides of the orifice, the brow, the corner of the eyelid, and the bridge of the nose, giving the girl a frightful profile. Mr. Stump has covered the orifice and made up the bridge of the nose with a piece resting on the tip of the nose, which has remained intact, thereby doing away with the necessity of wearing a black riband tied round the face; it keeps the cold air out of the head, and, coloured to match the complexion of the surrounding parts, it is a vast improvement.

Drawing No. 72 represents a case of entire loss of the nose as a feature; it being from a side view perfectly gone.

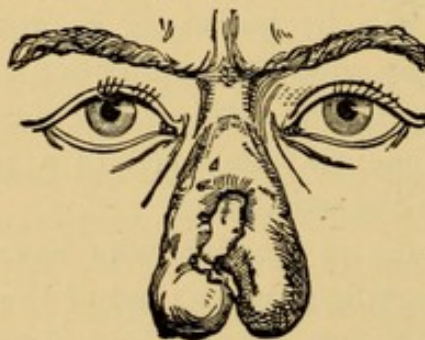

Fig. 72.

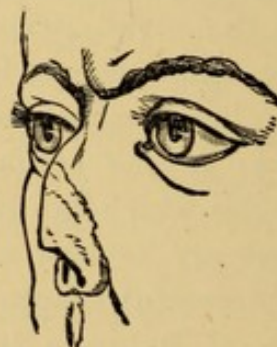

Fig. 73.

Drawing fig. 73 is of a case in which disease was arrested after the loss of the tip of the nose only, and the falling in of the nostrils consequent on the loss of the support of the septum.

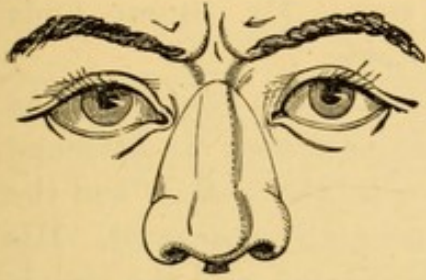

Fig. 74.

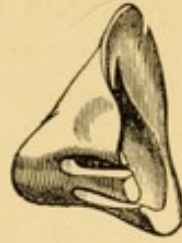


Fig. 75.

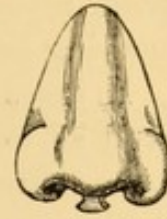


Fig. 76.

Drawing fig. 74 is a Case fitted with one of Mr. Stump's noses (*British Medical Journal*, April 4th, 1868).

and which follow the movements of the face. They are made of a material allied to india-rubber, and are attached to the face by means of collodion or strong gums (see figs. 71 to 76).

Nevertheless Mr. Stump has constantly to fit cases in which the disease is still active, and in which, by reason of tenderness and for fear of other and obvious consequences, the surgeon cannot allow the use of the strong gum. It is, therefore, necessary in such cases to resort to a nose modelled in silver, and kept in position by spectacles (see figs. 69 and 70).

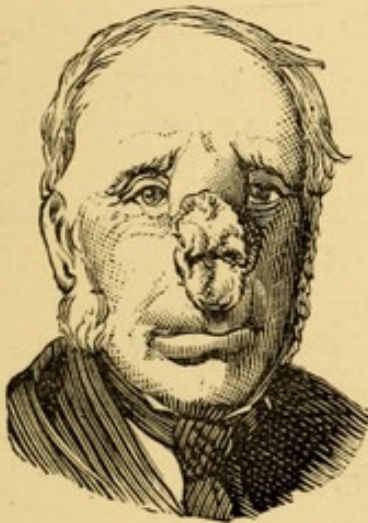

Fig. 69.



Fig. 70.

Figs. 69, 70 illustrate the use of the silver artificial nose adapted by Mr. Stump to cases of active disease.

In fitting these cases Mr. Stump tells me that he goes through the same careful process as that which he adopts in the modelling and fitting of the flexible nose; thus ensuring an equal pressure of the thin edge on the parts that will bear it, and allowing of easing away at tender spots, and withal giving a feature suggested by and suitable to the face for which it is intended.

In cases involving a large part of the face (including perhaps

nose, mouth, and even one or both eyes), Mr. Stump finds nothing but the *silver plate mask* practicable.

In cases in which there is a deficiency in the hard palate as well as loss of the nose, the artificial nose may be attached to an obturator fitted to the aperture in the palate, and the patient's condition will thus be very materially improved. His articulation and deglutition will be facilitated, and the nose is retained in position without the use of any external support except, perhaps, a pair of spectacles. A very successful case, in which this plan was adopted, is cited in Dr. Garretson's work on "Oral Diseases and Surgery," pp. 672 *et seq.*\*

"A young man, aged twenty-six years, had lost by disease the entire external nose, the nasal processes of the superior maxillary bones, and a large portion of their palatine processes. The approximal parts of the palatine plates of the palate and the turbinated bones were also destroyed, but the soft palate, uvula, and tonsils were uninjured. \* \* \* The artificial nose and obturator were made of vulcanite in two pieces, the larger piece forming the external nose, the septum, and a horizontal plate above the palate, and the second piece occupying the roof of the mouth, and being fitted to the upper piece by means of a staple and slide bolt, which was fastened or released in the roof of the mouth. This was so arranged that the patient could, by passing the finger into the mouth, firmly secure or detach the parts of the apparatus at will. It was afterwards found necessary to adapt a pair of spectacles to the part corresponding to the root of the nose to obviate an unpleasant vibratory movement, which was communicated to the external nose by the movements of the tongue in the acts of deglutition and speech. This apparatus was worn with ease and comfort by the patient."

One remarkable result of the use of these artificial noses is that the sense of smell is to some extent restored. The covering up of the aperture of the nostrils warms the air, retains the moisture of the nasal fossæ, and directs the current of air upwards towards the olfactory region; the organ thus regaining three of the conditions essential to the perfection of its functional activity, and for the want of which it had no doubt lost it.

Formerly artificial noses were made of silver, but the metallic

\* Cases in illustration have also been published by Mr. Lund, of Manchester, and by Mr. Edgar Browne, of Liverpool.

nose is decidedly inferior cosmetically to the india-rubber or celluloid organ; the india-rubber, on the other hand, requires frequent removal, and the celluloid has the dangerous quality of being explosive if brought near a flame.\*

### SUB-SECTION 3.

#### *Rhinoplastic Operations.*

Whenever the gap in the face is due to the original malformation or to injury—provided there are sufficient tissues around it, and the gap is not too large in proportion to the surrounding healthy structures—the prospect of being able to fill it up by a plastic operation is in the highest degree hopeful. But in cases of deficiency resulting from disease there is always the possibility of an unhealthy condition of the parts remaining, and consequently of a defective result or of complete failure. In any case, whether congenital, traumatic, or morbid in origin, the general health of the patient should be closely inquired into; and all lowering or weakening causes removed before any attempt is made to improve his condition by an operation.

There are two principal methods of operating for the restoration of the nose when completely destroyed—(a) The Taliacotian or Italian operation, and (b) The Indian.

(a) *The Italian or Taliacotian operation* is now seldom performed. It consists in transplanting a piece of skin from the inner side of the arm on to the gap in the face. The proceeding necessitates the providing a *helmet*, a *breast-plate*, and an *arm-plate* all of leather, carefully fitted to the patient and connected and kept in place by suitable straps. It involves a fixation of the arm on the head for a period of a fortnight or more. The discomfort of this enforced position of the arm is alone sufficient to deter surgeons from recommending this method, but its uncertainty and danger are not inconsiderable.

(b) *The Indian operation* was introduced by Lucas, in 1803, and revived by Carpue in 1814.

The first step in the *Indian operation* is to cut out of paper, sticking-plaster, or a thin sheet of wax, a pattern corresponding

\* Some very useful information on the subject of "Oral Deformities" will be found in Mr. Norman W. Kingsley's work on the subject (London, Lewis, 1889).

in size and shape to the intended new nose. This pattern being spread out and laid on the forehead in a reversed position with the part corresponding to the tip, *alæ* and *columna* uppermost, the flap is marked in ink with the pattern as a guide, but of dimensions about one-third larger than its actual size. This is necessary, in order to allow for subsequent shrinking of the flap, the borders of which corresponding to the *alæ* and *columna* should be well rounded off, and of very ample proportions. No acute angles should be made at any part of the circumference of the transplanted portion of skin; for it has been generally observed that sloughing is apt to occur at any angular projections of a large flap. The shaping out of the nostrils must be left to a subsequent step.

If the height of the forehead is not sufficient to give the necessary length to the flap, a larger one may be obtained by giving it a more oblique position on the forehead, its long diameter being inclined to one side instead of being placed vertically.

These preliminaries having been arranged, and anæsthesia induced, the edges of the gap are made raw by dissecting off the cicatricial tissue to the extent of a quarter-of-an-inch in width all round. The frontal flap is then formed by making an incision through the skin of the forehead in the lines previously marked, and dissected from off the periosteum. Langenback\* removed the periosteum with the skin, but this can rarely be done with safety or advantage. The dissection being carried down to the root of the nose, a bridge of skin is there left undivided, but the incision on one side is carried down and made continuous with the raw surface prepared for the reception of the flap on the margin of the gap. The flap is then reversed and adapted to these edges and retained in position by means of sutures. The flap having become firmly united, and its circulation being healthy, the twisted neck at the root of the nose will in most cases form an unsightly prominence, and in order to diminish this, a further operation will be required. In dividing or dissecting off any portion of this part of the flap, care must be taken to save the main channels of its nutrition. The frontal and superior nasal branches of the ophthalmic artery will be the principal nutrient arteries if the neck of the flap has been taken from above the inner end of the eyebrow, and if the

\* "Deutsche Klinik" for 1869.

lateral incision towards the nose has been well planned the angular artery of one side will also have supplied it. In dividing the root or neck of the flap, therefore, it is well, if possible, to make incisions as nearly vertical and as much in the median line as possible, and by this means one or all of the arteries mentioned will remain undivided.

This is the simplest form of procedure, but it often fails to give a good result from the absence of any central support to the flap, which in the course of time sinks inwards and presents too flat a surface on the dorsal aspect, and leaves the artificial alæ much distorted. But excellent results may be obtained by this method when the septum or a great portion of it remains. An instance in point is delineated in Plate IV, fig. 5, from the practice of Dr. Swift Walker of Hanley. The patient had lost the tip and some portions of the alæ by the destructive effects of malignant pustule. The flap formed from the forehead was sufficient in this case to fill up the gap completely, and the result is faithfully represented in the figure (Plate IV, fig. 6).

In cases, however, in which the septum is completely destroyed, there is no support for the flap brought down from the forehead, and the flattening consequent on subsequent contraction renders the artificial member very imperfect. Under these circumstances Mr. John Wood's operation is more suitable for the worst cases, or those in which the bones as well as the septum are deficient.

In a first operation two different steps are taken with the view to form a central base of support for the frontal flap. In the first place two vertical cuts are made through the upper lip, about half-an-inch on each side of the median line, leaving a central portion free below, but attached above at the alveolar arch. The lateral portions of the lip are now brought together by harelip pins and twisted sutures in the usual way. The upturned portion of the lip is split from below upwards, so as to make the mucous and cutaneous surfaces continuous and facing inwards,\* the raw surface looking outwards. By this proceeding

\* An incidental and unexpected advantage was proved to have been gained by this plan in one of Mr. John Wood's cases (reported in the *Medical Times and Gazette* of June 20, 1867). The tip of the nose in this case was found to remain unusually prominent, which was the more remarkable from the circumstance that there is always a tendency in these cases to recession or shrinking of



the vertical depth of the flap from the lip is nearly doubled. In the next step, the cheeks being dissected from their deep attachment, shaving off all the structures close to the bone, if necessary as far outwards as the malar articulation, the two lateral flaps thus formed are brought together and united in the median line to the upturned lower flap. At the same time long harelip pins are passed through the middle of the cheek flaps and across the nasal cavity in such a way as to approximate their edges and lift them well forwards, the cheeks being of course protected by pads from pressure against the ends of the pins.

The base of support being thus formed, the frontal flap is brought down by a subsequent operation after the lateral and lip flaps have become firmly united in their new position, and after a healthy granulating surface has become established in the centre.

The following case illustrates the above remarks:—

*Mr. John Wood's Case of Rhinoplastic Operation (abridged report.)*

J. P., aged twenty-three, was admitted May 28, 1873, with destruction of the entire nose, the result of lupoid ulceration.

The patient is of a strumous habit, and is a native of South Wales. The whole of the nose has disappeared—skin, cartilage, and the bony structures—so that a chasm is left extending back to the muscles of the soft palate, which can be seen in action during deglutition. All sense of smell is lost.

June 7th.—Chloroform was administered, and Mr. Wood performed the first operation, which consisted in making a columna for the new nose, and also in bringing the cheeks closer together, and thus diminishing the size of the opening on the principles laid down in the preceding pages.

16th.—The cheek-flaps have firmly united in the median line. Pin transfixing them removed.

July 2nd.—Two portions of skin about half-an-inch square from the newly-formed flaps immediately over the openings of the future nostrils were respectively reflected and turned in, being kept in position round these apertures previously made raw, in the tip. Mr. Wood attributed this fortunate result to the growth of stiff hairs from the deep or skin surface of the recurved central portion of the upper lip. The patient in this instance was an adult fully-developed man with a strong moustache.

order by the presence of integument to prevent their too great cicatricial contraction, and possible subsequent closure.

August 6th.—Third operation.—A flap with broad pedicle was taken in the usual manner from the forehead, and twisted down—the edges of the opening having first been pared, and the integument covering the newly-formed flaps over the lower part having been dissected from below upwards, so as to expose an extended raw surface on which to implant the forehead flap. Deep and superficial wire sutures were used to keep the parts *in situ*. Warm-water dressing to flap.

8th.—Transplanted flap looks well; no sloughing.

11th.—Some of the wire sutures removed.

18th.—The new nose has united firmly except for an extent of one inch opposite the inner canthus on either side. Wound in forehead granulating vigorously.

21st.—Pedicle of flap divided to-day.

25th.—Wire sutures removed. Circulation in nose quite established, but there is a slight superficial slough, about the size of a fourpenny piece, where the pedicle was divided.

Wound in forehead quite healed. It is interesting to observe that if the point of the nose be touched with anything, such as the end of a pencil, the patient, with his eyes previously and still closed, when told to place his finger on the part irritated, will immediately raise his hand and put his finger on the cicatrix in the forehead.

October 22nd.—Operation for closing the opening on the right

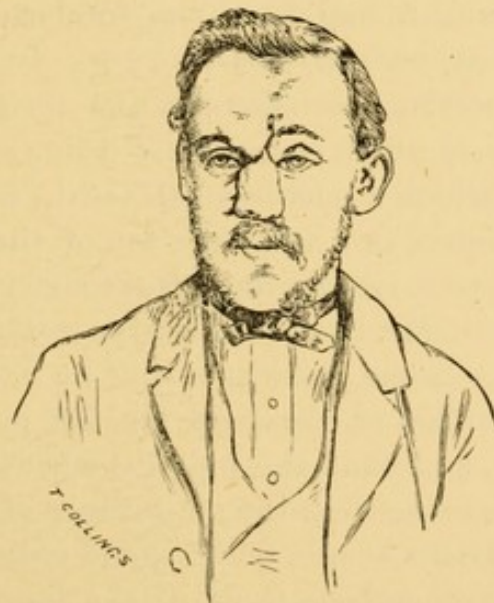

Fig. 77.  
Result of Mr. Wood's Rhinoplastic Operation.

side performed to-day in the same way as that for the left side. The difficulty seems increased by the fact that the patient has been accustomed to breathe through these openings, and therefore the air has a constant tendency to re-open the wound.

29th.—Wire sutures removed from right side. The opening is quite closed.

November 19th.—Patient discharged, with directions to keep the nostrils open by inserting the catheter tubing. His sense of smell is now almost perfect. (Full report in *Medical Times and Gazette*, December 27, 1873, and in Appendix of 1st edition of this work).

The following method of forming the margins of the nostrils was adopted by Dieffenbach with great success, after the union of the frontal flap had been satisfactorily accomplished. In that portion of the skin from the forehead, intended for the columna, he formed on each side a small triangular flap, the apex of which was towards the posterior part of the nostril. It was now reflected forwards and upwards, and, the inside of the nose being previously made raw, the small flap was fixed in its position by a small bent plate of lead, through which a needle was passed, transfixing the flap, and coming out on the ridge of the nose; it was here passed through another leaden plate, and its point twisted to retain all in their proper situations. Wire and small-quilled sutures would answer the same purpose equally well.

Instead of taking a flap from the forehead, Dieffenbach, in three cases at least, took it *from the scalp*. In one only of these three was the operation satisfactory, and for some time it was covered with hairs, which were plucked out as they grew. In another case, in which a portion of the scalp was brought down to form the columna, the main portion of the flap being from the forehead, the part lost its hair after fourteen days, and there was no return of it. Mr. Brudenell Carter related, at the Medical Society of London, some years ago, that he had on one occasion transplanted a portion of the scalp for the purpose of making an artificial nose, and that the only drawback to the complete success of the operation was the appearance of a tuft of hairs at the end of the patient's nose, which could only be got rid of by the use of depilatory embrocations. If the flap is taken from the

scalp there is a much smaller wound in the forehead, and the consequent disfigurement is much less; but it is a question whether the tuft of hairs, possibly not easily removable, at the tip or indeed over a large portion of the new nose would not be an equally disfiguring and embarrassing result of the operation. Hence it is very undesirable to attempt the restoration of the nose by a flap from the scalp, in spite of Dieffenbach's authority to the contrary.

In cases in which there is a loss of the septum and alæ, but the nasal bones remain, Mr. Francis Mason's operation is very useful as a preliminary to the bringing down of a frontal flap. It is described in the *Lancet* for June 10, 1871, and consists in bringing across the gap two lateral and one superior flap of integument as a base of support for the frontal flap. The lateral flaps are formed from the integuments of the cheek, the operation thus differing entirely from that just described, in which the whole thickness of the tissues down to the bone is dissected off and brought forwards. In Mr. Mason's operation the margins of the gap are left entire, and the incisions for the formation of the lateral flap are made in the sound tissues, about half or three-quarters of an inch away from the margin of the opening. The flaps are dissected from without towards the median line, are turned inwards, so that the skin surface is towards the nostrils, and a raw surface presents externally. The edges of the two lateral flaps are then brought together and united by sutures in the middle. The upper part of the aperture is now filled in by a flap from the skin, covering the nasal bones, which is reversed in a similar way, leaving a raw surface externally. The frontal flap can then be brought down either during the same or in a subsequent operation. In taking the skin flap from the nasal bones it is very important to avoid making the incisions so freely to one side that the angular branch of the facial artery is wounded. This artery, on one or both sides, may be required as the nutrient vessel of the frontal flap.

Under the most favourable circumstances, however, and with the greatest skill and care, the results are too often disappointing, so far as the cosmetic effect is concerned. But there is almost always some *improvement* in the patient's appearance, and he also often gains the sense of smell, and improved

articulation and distinctness of speech ; nevertheless, many persons prefer to have an artificial nose, such as those supplied by the mechanician.

In order to prevent the sinking in of the transplanted flap, whether taken from the forehead or cheeks, in cases where the solid framework of the nose has been lost, M. Ollier transplanted the periosteum of the frontal bone with the integuments, and even utilized bone tissue in the form of a flap.\*

A young man, aged seventeen years, had lost the whole framework of the nose from congenital syphilis, leaving an excavation in the nasal region, but with the lower portion of the nostrils and the columna untouched, though they were retracted, and instead of being horizontal were turned upwards and forwards. To remedy this, a portion of the bone of the nose still remaining on the right side, and also a portion of the superior maxillary bone of the same side, were transplanted, and a flap of periosteum taken with the integument from the forehead. The osseous flap remained attached to the adjacent bone by means of its periosteum on its outer aspect, and was engrafted into the central portion of the cleft so as to form the point of the nose. It became firmly united in its new position, and the periosteal flap from the forehead also formed a complete union, and in the course of two months and a half had become hardened from ossific deposit. The nostrils became horizontal and widely patulous, and the whole nose was sufficiently prominent and provided with a firm osseous framework such as would prevent any subsequent sinking in of the integument.†

These results may be considered highly satisfactory, but the transplantation of periosteum cannot always be safely attempted ; the denudation of bone in patients affected with constitutional syphilis being often followed by necrosis, and this occurring in the region of the forehead may lead to very much worse results than those for the relief of which the operation has been undertaken.

Langenbeck, of Berlin ("Deutsche Klinik," 1869), also transplanted the periosteum of the frontal bone in an operation

\* *Gazette de Hopitaux*, Nov., 1861, p. 538.

† Sir William Stokes, of Dublin, has also succeeded in transplanting periosteal flaps from the forehead, and in one case satisfied himself fifteen months after the operation that new bone had been formed by the transplanted flaps.

in 1859, and is therefore the original proposer and practiser of this method.

*The formation of a columna from the upper lip* may be required as a separate operation in cases in which the tip of the nose is depressed from total or partial loss of the lower part of the septum and columna. Dieffenbach's operation may then be employed. It consists in freeing the central portion of the upper lip by two perpendicular incisions carried up into the nasal cavity from the oral margin. The red labial margin is then made raw by a superficial scarification, and turned upwards and adapted to a raw surface, prepared for its reception, under the tip of the nose, where it is united by sutures. The edges of the divided lip, whence the flap has been taken, are united by harelip pins. It is not necessary to twist the flap, so that its mucous surface may be directed upwards, and its cuticular aspect downwards. This was thought necessary by Dieffenbach, and was practised by him in his own operations; but experience has shown that the mucous surface soon assumes a cuticular covering when exposed, and that, on the other hand, the skin surface becomes mucous in quality when inverted and constantly moistened by mucous secretions. If the lip be not deep enough for the operation above described, a columna may be made from a horizontal flap out of the lip, or by one taken from the adjacent part of the cheek.

*Operations for the restoration of depressed noses.*—In cases in which the bony septum and portions or the whole of the nasal bones have been lost, the skin remaining entire, the nose becomes flattened, or even drawn inwards in a concave form, the tip and alæ, however, being still visible below, though much less prominent than in the normal condition.

Under these circumstances, *Dieffenbach's operation* may be performed with advantage.\* It consists of the four following stages:—

*1st Stage.*—The central part of the integument covering the depressed ridge, from the frontal bone down to the apertures of the nostrils, is raised by lateral incisions, in the form of a vertical flap attached above but free below.

*2nd Stage.*—Two lateral flaps are formed by incisions in the cheeks of sufficient width below to allow them to be adapted to

\* A detailed description is given in "Surgical Observations on the Restoration of the Nose." Translated by J. S. Bushman, p. 55.

the central strip in the form of sides and alæ for the new nose. In these flaps the original depressed alæ and the adjacent portions of the cheek are together raised up from the depressed osseous pit into which they had been sunk.

*3rd Stage.*—The margins of these flaps are pared and adapted to one another. And the attached bases of the two lateral flaps are freed still more from the bones in order to allow of their being brought close to the central flap without risk of subsequent contraction.

*4th Stage.*—The edges of the flaps are united by twisted sutures, over entomological pins, or by wire sutures. The new nose is kept forwards during the union of the flaps by two long needles passed under the two alæ and the centre of the bridge, each needle being fastened on the cheeks to leather pads or splints, laid on each side of the nose, and made to press them together. If the columna is altogether wanting, it may be supplied by a subsequent operation from the upper lip, as in the operation already described. My own experience of operations such as the above is by no means favourable. But it is possible that in the cases which have come under my notice the details given by the originator of the method have not been strictly carried out.

*The alæ nasi* may be formed by flaps taken from the cheek, and, in order to avoid the tendency to closing in of the nostrils (a result very difficult to prevent), the edges of the flap must be folded inwards and fixed in that position by sutures. Deficient alæ may also be formed by a modification of the Indian operation by a flap from the forehead, and here also the folding inwards of the edges of the flap will greatly add to the perfection of the resulting nose. For this improvement in rhinoplastic methods surgery is indebted to Dieffenbach, who lays great stress on its importance, asserting that by it alone is the potato-like appearance of the nose, caused by the approximation of the new alæ, to be avoided.

In a case of depression of the ridge between the bridge and the tip of the nose, I have performed Sir Wm. Fergusson's operation, with a modification which I believe to be original. I may describe it as a *subcutaneous rhinoplastic operation*. The sinking in of this part of the nose has been due in the cases that have come under my observation to perforations of the septum and the cicatricial contraction following the healing of

the perforating ulcer. The first part of the method, supposing, of course, that all ulcerative action has long ceased, is to accustom the patient to the wearing of a spring truss, somewhat similar to that employed by Sir Wm. Fergusson in his operation for harelip. The spring is nearly circular, passing round the back of the head and terminating in two pads anteriorly. The pads are so fitted as to press against the sides of the nose at the level of the depressed notch. This truss should be worn for a month or six weeks before the operation, at first for an hour, and as soon as it can be borne, for three, six, or twelve hours at a time. At the same time it is well for the patient to wear an ivory or vulcanite plug in each nostril for some period of the day in order to stretch the soft parts under the depressed notch, and at the same time to render the mucous membrane somewhat "callous," and so less liable to resist instrumental proceedings later on.

The *first step* of the operation is detachment of the skin over the *depression* from the mucous membrane of the lower part as far as the *tip*, and from the bones above it by employing a tenotomy knife, introduced through the nostrils, and dissecting laterally upwards without perforating the skin. 2nd. Bleeding being free, quilled sutures are passed horizontally across the dissected parts from the extreme lateral limits of the dissection, and the deep surfaces of the side-flaps brought into close apposition in the middle line. If the dissection has been carried as far outwards as it should have been, the result of this will be to form a raised vertical ridge, extending from a quarter of an inch above the notch to a similar distance below it. The sutures should be of silver wire, and the ends should be twisted and fastened over a single roll of sticking-plaster on either side of the nose. The ridge thus formed will at first appear much larger than necessary, and this is better, in order to allow of some inevitable shrinking during cicatrization and afterwards. When the sutures are removed, one on about the third or fourth day, and the others about the fifth or sixth day, the roll of sticking-plaster should be still kept in position by means of cotton-wool pads, saturated with *styptic colloid* (Dr. Richardson's). As the styptic colloid dries, a firm splint is left supporting the sides.

At the expiration of a week or ten days the spring truss is applied and worn continuously in order still further to prevent



the tendency of the raw surfaces to separate and fall back into their original positions. Later on pads of lint saturated with collodion are to be substituted for the rolls of sticking-plaster and the first dressings, which need not, however, be disturbed for a fortnight or even later from the day of the operation. The spring truss must be worn for several weeks longer, and the plugs within the nostrils should also be employed at intervals as a support to the raised tissues over the notch.

A case of this kind was recently (February, 1890) under my care at the Great Northern Hospital. The result has been very satisfactory. The patient is a married woman of about 40. Her history points to the perforation of her septum due to injury about two years ago. She now has a very well-shaped nose.

In the case of a young gentleman *æt.* 17 years, with deficiency of the septum, due to some injury during the patient's birth or soon after, I raised the ridge of the nose by an operation similar to that described above, and with an excellent result.

Portions of the lower part of the ridge, or of the lip may be restored by the employment of the frontal flap or by some modification of the Indian method, and in these cases it is generally necessary to split the skin over the nasal bones, and turn it aside, in order to form a place of attachment and channels of nutrition for the frontal flap, the size and shape of which must be modified to suit each particular case.

In all the above-described operations there is a tendency to contraction of the transplanted flaps, and in the *alæ* particularly we notice a drawing together of the margins, so that the nose becomes gradually too rounded at the tip and too narrow at its base of attachment to the cheeks. The excessive roundness of the tip may be much reduced by excising portions of the ridge, a little above the tip, of a myrtle-leaf shape, the long diameter being longitudinal, and the deep aspect of the piece excised being broader than the superficial part. Portions of a similar shape, but with the superficial broader than the deep aspect (the wedge being in fact reverse), are next excised from the lateral aspects of the ridge above the *alæ*. The edges of the wounds are brought accurately together, and when union has taken place a more natural form of the tip and dorsum of the nose will be the result.

In operating for the removal of tumours or cicatrices on the

nose, the possibility of subsequent disfigurement should always be borne in mind. By well-contrived incisions the nose may be, as it were, *reconstructed* by the same operation by which the diseased part is removed. To effect this, the incisions must be made as nearly vertical in direction as possible, and the diseased growth or scar included between two semi-circular or semi-lunar cuts, which should include a wedge-shaped piece of the cartilage as well as of the soft tissues. In order to allow the divided edges to be brought accurately into apposition, it may be necessary to pare away more of the tissue than is absolutely involved in the disease, and to make the union of the lines of incision at as small an angle as possible. If the disease occupies a large extent, the gap will require a transplanted flap from the forehead or cheek, in order to fill it up satisfactorily, and it will generally be better to do this by a subsequent operation.

*Fistulous openings into the accessory cavities*, if they cannot be made to heal by the application of the actual cautery to their edges, may be closed by a plastic operation. The first step, however, is to prevent the flow of discharges through the fistula, by ensuring a free passage through the natural channel. Lachrymal fistula, for example, will not be successfully dealt with by any plastic operation, unless the free escape of tears and mucus through the nasal duct has been previously ensured by the use of internal probing and the removal of internal obstructions; and fistulæ of the antrum or frontal sinus will also remain patulous as long as their contained mucous or purulent secretions have no ready outlet through their normal apertures. Though no general rules can be laid down applicable to the treatment of every kind of fistulous opening, it is probable that in most instances an operation of the following kind will be successful. The skin surrounding the aperture having been divided into two or three flaps, the points or narrowest portions of which meet at the aperture as a centre, and their broadest diameters being most distant, the deep surfaces of two of the opposed flaps are united by quilled sutures, in such a way that a prominent ridge or nodule is left when adhesion has taken place. The third flap, if one has been found necessary, is attached by sutures, above or below the two others, by a line of stitches. In a case of fistula into the antrum, operated on by the author, the closure of the fistula

was complete. The prominent nodule of skin can easily be reduced by a trifling subsequent operation.

*Abridged report of Author's Case of Injury to the Face, leaving a Fistulous Opening into the Antrum, which was closed by a Plastic Operation. Great Deformity of the Features: the Distortion in part remedied by Plastic Operations. (British Medical Journal, Jan. 16, 1875.)*

James C., aged twenty-five, was kicked in the face by a horse, ten years ago. While training the horse, by whipping it round in a circle with a long leading-rein, the animal suddenly backed on him and kicked him violently in the face. He was knocked down, and when picked up the left side of his face was, as he described it, lying on his left shoulder. There was still evidence that both jaws must have sustained compound comminuted fractures; the nose was split open nearly vertically, and the anterior wall of the antrum broken into through the integuments of the cheek. The contraction of the cicatrices formed during the healing of these injuries, resulted in a drawing down of both the left eyelids to a point above the middle of the inner side of the nose, so that the patient was unable to open his left eye by any movement of the muscles attached to the eyelids, though when the palpebral aperture was dilated by the fingers, the eyeball was seen to be perfect, and the sight of the eye itself was unimpaired. The jaws were much distorted, and could only be opened to a limited extent. Nevertheless, mastication and articulation could be very fairly performed. In the middle of the left cheek was an opening communicating with the antrum, and the skin surrounding this opening was drawn down towards it in the form of a funnel-shaped depression.

He was admitted into the Great Northern Hospital in July, 1874.

Operations for the restoration of the eyelids to their normal position having been performed on July 16th and August 26th with very good results, on October 14th the following operation was performed for the closure of the antral fistula, which lay at about the middle of the cheek, in a hollow, close to the side of the nose. Three flaps were taken from the skin of this hollow by dissecting them from the central aperture outwards; the two lowermost flaps were then brought together by

quilled sutures, so that their deep surfaces were in contact, in the form of a raised eminence, over the site of the depression, and the uppermost flap was attached to a point above them near the root of the nose, its lower edge being also attached by sutures to the upper borders of the two lower flaps. Styptic colloid was then applied in the way usually employed at the Great Northern Hospital.

On the fifth day after this operation the crust of colloid fell off, and the flaps were to be seen in good position, and in great part united by primary union. On the fifteenth day the wounds had become completely healed, and no trace of the fistula remained. A prominent nodule of redundant skin marked the union of the two lower flaps by the quilled suture.

When seen some months later, no trace of the fistula remained.—(*The full report of this case is in the Appendix of Cases No. LXA. in the first edition of this work.*)

The *causes of failure in Rhinoplastic Operations* are:—(1) The existence of some constitutional cachexia or dyscrasia; (2) Some local impairment of nutrition, such as *lupus* or *spreading ulcers*; (3) A too free division of the arteries in the necks of the flaps; (4) Insufficient size of the flaps; (5) Excessive pressure on the parts by dressings; (6) Erysipelas and blood poisoning.

Sloughing of the flap is seldom or never due to engorgement or venous stasis, the fear of which seems to have been the bugbear of the surgeons at the beginning of the century, when it was common to hear that, after a rhinoplastic operation, “a pound and a half of blood was taken from the arm,” and “twenty leeches” were applied round the transplanted flap. In one of Dieffenbach’s cases, in which there was free arterial bleeding from the flap at the time of operating, hæmorrhage was allowed to go on at intervals from this bleeding artery for several days. He regarded the blue colour of the flap as a sign of engorgement, and thinking that more blood flowed into it than could be returned from it, encouraged bleeding till it became paler.

A deficient supply of blood is a much more frequent cause of sloughing, and all our efforts should be directed towards ensuring a free arterial supply by so planning our incisions that there shall be one or more principal arterial trunks passing through the neck of the flap. Pressure by bandages or pads must be

especially avoided, and the simplest dressings will hence be the most useful.

#### SUB-SECTION 4.

##### *Dressings, Bandages, Appliances, etc.*

The simplest and lightest forms of retentive apparatus are the best, in all cases of injury, and after all cutting operations, whether for plastic purposes or the removal of tumours. A simple oblong knitted cotton band, five inches long by three inches broad, fastened across the face by means of four tapes attached to its four angles, and passed round the occiput and forehead, will, in most cases, be quite sufficient to retain in position any of the dressings required. The hollows on the sides of the nose should be filled up by pads of cotton wool, and thus all pressure upon the nose itself is avoided.

When the *styptic colloid* (Dr. B. W. Richardson's) and cotton wool steeped in it have been properly applied to an incised wound, with or without stitches, no other retentive apparatus is required. The *colloid*, after it has become hardened by the evaporation of the ether it contains, forms a closely fitting and accurately moulded splint, and keeps the parts in close adaptation without any undue pressure.

The various forms of bandage, such as the *épervier* and the *fronde du nez* described by Cloquet\* and other French surgeons of the early part of the present century, are merely complicated head bandages with, in one case, a sort of pouch for the reception of the nose. A double-headed roller, passed round the face and occiput with properly placed pads, may sometimes be used with advantage to compress the sides of the nose in cases of hæmorrhage from external wounds, but the antiquated forms of bandages above-named are mere curiosities, and a detailed description of them would be entirely out of place in this work. Strips of common diachylon sticking-plaster are more useful in some injuries and after some operations than any other appliance.

When suppuration has come on over a considerable surface, eucalyptus gauze dressing or Alembroth wool will also be required, and must be carefully applied in such a way as to avoid pressure on the prominent parts of the organ.

\* *Op. cit.*, p. 426.

During the first week or ten days after the transplantation of a flap, there will probably be imperfect circulation and consequent blueness of the part, and wet or cold applications have a tendency to increase this. Cotton wool applied without pressure is the most appropriate dressing under these circumstances. It retains the natural heat of the surrounding parts, and so favours the restoration of the circulation in the flap.

## SECTION XV.

## ANOSMIA AND OTHER FUNCTIONAL DERANGEMENTS OF THE SENSE OF SMELL.

It is important in making these experimental observations, and in testing the acuteness of the sense of smell in *all* cases, to apply substances to the nostrils that are truly odoriferous, avoiding all strong, pungent substances, such as ammonia and strong corrosive acids, the action of which is simply irritant or mechanical, and affects only the nerves of common sensation. Peppermint, lavender, musk, asafoetida, and the volatile essential oils generally, are the proper materials for testing the smell in a case of supposed anosmia.

Swaardemaker's newly devised instrument (1889), termed the *Olfactometer*, described in the *Revue Scientifique*, may possibly be a means of estimating the acuteness of the sense with more accuracy than has hitherto been possible, and may be especially useful in testing as to the unilaterality or bilaterality of the supposed anosmia.—(Extract in *Revue Scientifique*, December 28th, 1889, from *Archives Néerlandaises des Sciences exactes et naturelles*.\*) (See fig. 78).

\* Swaardemaker thus describes his olfactometer: "It consists of a *tube* of glass, one end of which, suitably curved, is adapted for insertion into the nostril, while the other end is accurately fitted into the hollow of a *cylinder*, which can be made to slide up and down the tube at will. This *cylinder* has an internal diameter of eight millimetres, and is charged with the odorous substance. When it is moved, so that it overpasses the end of the glass *tube* to a greater or less extent, the air in the latter is brought into communication with the odorous substance. The further, therefore, that the *cylinder* is drawn downwards the stronger will be the scent which it gives off, and the various degrees of smell-power will be found proportionate to the length of the drawn-out part of the tube (but in the inverse ratio, *i.e.*, the greater the length of tube drawn out when the olfactive minimum is reached the less the smell-power). The *degree of acuteness of smell* is discovered by the intensity of the *minimum perceptibility of odour*. The results of our measurements may be interpreted by a vulgar fraction. Supposing  $o$  = olfactus and  $o'$  = the degree of smell-acuteness required, and  $l$  and  $l'$  the tube lengths obtained, it follows that  $\frac{o'}{o} = \frac{l'}{l}$ . If  $o$  be the normal acuteness of

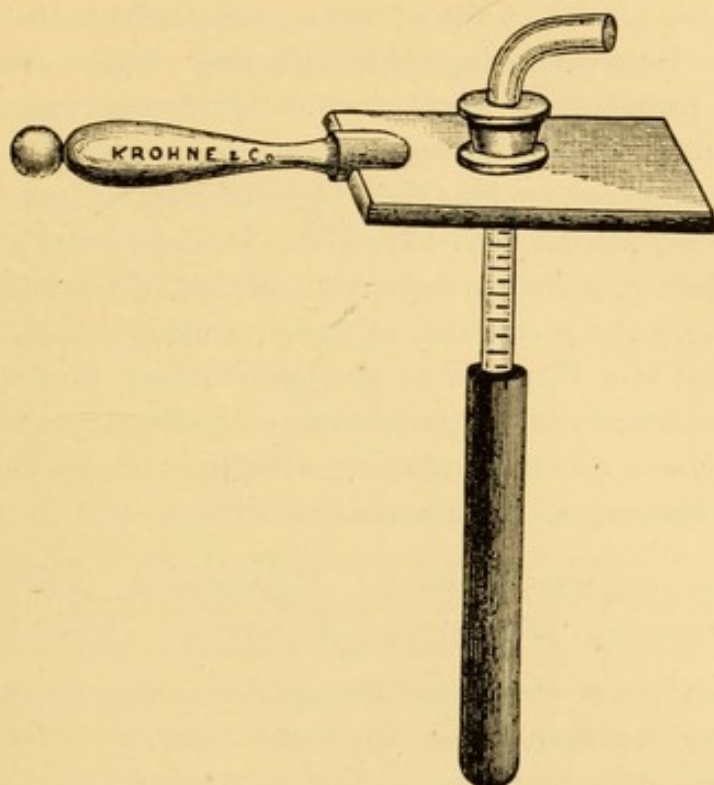


Fig. 78.  
The Olfactometer.

It is also important to distinguish accurately between the sense of taste and that of smell. Persons whose smell is really at fault often declare that they have no sense of taste, because they are unable to detect differences of flavour; which is, in fact, a matter purely of olfaction. Taste only distinguishes the sapid qualities of crystalloidal bodies, such as sweets, sour, salines and bitters, but has no appreciation of flavours, such as those peculiar to different meats, wines, and aromatic fruits. It sometimes happens that the posterior nares are completely obstructed in consequence of adhesion of the soft palate to the back of the pharynx, and in such cases the sense of flavours is completely

smell = 1 the result will be  $o' = \frac{l}{l'}$ . 'My limited experience,' says Swardemaker, 'has furnished me with the remarkable fact that the proportion  $\frac{l}{l'}$ , as a rule is not subject to modification, using instruments made of quite different materials (wax, balsamum toltanum, etc.). From this it must be concluded that in nearly every instance sensibility to different qualities of odour has equally diminished. This is why, for ordinary examination, two olfactometers are sufficient'" (*Lancet*, Jan. 29, 1889). The first of the two tubes forming the set is lined with vulcanized india-rubber, the second with a compound of ammoniacum and gutta-percha. Swardemaker states that the *olfactive minimum* for vulcanized india-rubber bears a constant ratio to that for the ammoniacum compound.



lost, in consequence of the odorous particles from the food being prevented from reaching the olfactory region through the posterior nares; and nasal respiration being impossible, the perception of odours through the anterior nares is also lost. (See two cases reported by Dr. Wm. Ogle in *Medical and Chirurgical Transactions*, vol. liii, pp. 272, 273. In the second of these, an opening being made through the soft palate by an operation, olfaction and the perception of flavours were both restored.)

A partial loss of smell is not uncommon, perhaps in some cases from congenital imperfection, and often in consequence of undue dryness, or undue coating with secretion of the olfactory region in the course of catarrhal affections.

*On Derangements of Smell: Dysosphresia, Anosmia, and Parosmia. Metamorphic Parosmia. Hyperosmia.*

*Anosmia*, loss of smell, and *Dysosphresia*, or impairment of the sense, may be occasioned by three classes of lesions:—1st. Mechanical impediments to the admission of the odorous particles to the olfactory region; 2nd. Impaired function or destruction of the nervous olfactory apparatus, whether in the nostril or within the cranium. 3rd. Impaired nutrition of the Schneiderian membrane.

*Tests for Dysosphresia and Anosmia.*—One side only may be affected in any of these three classes; but it is remarkable that, in the second class, though the lesion of the nervous apparatus may be one-sided, the anosmia is usually double. No sufficient explanation has yet been advanced to account for this anomalous feature. It is suggested, however, by Dr. Althaus that double olfactory neuritis is set up in the olfactory ganglia, which lie close together at the base of the brain. The original lesion being on one side spreads by contiguity from one olfactory bulb to the other. (*Neuritis and Perineuritis of some of the Cranial Nerves*, by Dr. Julius Althaus). In the first and third classes, if there is one-sided loss of function it is not noticed by the patient, and can only be discovered by careful testing, after closing the nostril supposed to be in a sound condition.

Under the *first* head come all those causes that obstruct the nostrils. They may consist of polypi or other tumours; occlusion of the nostril from congenital malformation, such as deflection of the septum with or without hypertrophy of the middle turbinated bone of the side opposite to the deflected

septum or cicatricial adhesions resulting from injury; collapse of the walls of the nostril, due to paralysis of the dilating muscles, such as occurs in connection with paralysis of the portio-dura of the seventh pair; obstruction of the nostrils from dry crusts or secretions, such as we meet in scrofulous or syphilitic coryza; chronic thickening of the pituitary membrane as a sequel of catarrhal or other inflammations, and the presence of foreign bodies.

In almost all these instances the loss of smell may affect only one side of the nose, and in such cases the defect is scarcely noticed by the patient, and can only be detected by experimentally testing the sensitiveness of the olfactory region, after closing the nostril supposed to be in a sound condition.

Under the *second* head come all cases of intracranial disease, or traumatic lesion affecting the olfactory bulbs or the olfactory tracts or the cerebral centre of smell, viz., the tip of the *temporo-sphenoidal* lobe or *subiculum cornu ammonis*, either by destroying them, or by pressing upon them so much as to impair their nutrition and functional activity. Tumours of any kind may involve or compress these parts, and when this is the case there are generally associated with the anosmia other symptoms of cerebral disturbance, and of these, amaurosis is one of the most common. But optic neuritis, without any marked impairment of vision, may be associated with anosmia (see a case by Dr. H. Jackson in the *British Medical Journal*, Aug., 1872), and in some of these instances there is probably olfactory neuritis. The ophthalmoscope will be of great use in forming our diagnosis in such instances, and the fact that the ophthalmoscopic appearances of optic neuritis may be present without any serious defect of vision, renders it more desirable to examine the eyes ophthalmoscopically in all cases of anosmia the origin of which is obscure. Dr. Glynn reported a case (*British Med. Journal*, Sept. 28, 1878, p. 473, Case IV) of a girl affected with double optic neuritis, who became anosmic. She died in a fit (hysterical epilepsy?), and at the autopsy was found "a circumscribed abscess, about two inches in length, involving the *first temporo-sphenoidal convolution*; it extended inwards and downwards towards the base."

Dr. Hughlings Jackson has called attention to effusion into the lateral ventricles as a possible cause of anosmia from intracranial disease. In a case related by him in the *Medical Times*

and *Gazette* for Oct. 17, 1874, there were symptoms of a tumour of the middle lobe of the cerebellum and great enlargement of the head (due apparently to effusion into the lateral ventricles), and in this case there was loss of smell.

Dr. Hughlings Jackson supposed that in this instance, and in another which occurred to Sir William Gull, the loss of smell was due to pressure upon the olfactory lobes and not to any actual disease or tumour in their immediate neighbourhood. In a case under my care some years ago at the Royal South London Ophthalmic Hospital, there was loss of smell and taste, associated with optic neuritis in one eye and a prominence of the region of the frontal sinus. Here the mischief was probably intracranial in part, and the disease might have originally started from the orbit or frontal sinus, and invaded the region of the olfactory bulbs at a later period.

Injuries of the head and, more particularly, severe blows on the occiput, have occasionally been followed by anosmia. Dr. William Ogle, in the essay above referred to, adduces five instances, and in four of them the occiput was the part struck. He suggests that, as Mr. Hilton has pointed out, the olfactory bulbs and the other portions of the brain resting on the anterior cranial fossa are more likely to be injured by blows on the occiput than those parts between which and the skull there is a layer of cerebro-spinal fluid.

A case of mine is reported (in the fourth Volume of the *Ophthalmological Society's Transactions*, p. 269) in which there was double optic neuritis and anosmia following an injury to the head from a fall of forty feet. The youth, a potman of 18 years of age, recovered, but six weeks after the injury the anosmia still remained, though the neuritis had passed off and the sight was good.

In a case of injury to the back of the head from a bicycle accident, recently under my observation, the loss of smell which followed was associated with deafness of one ear. The skull in this case was struck just behind the ear, and the patient was completely insensible for an hour or two after the blow.

The anatomical relations of the olfactory bulbs and of their external roots to the fissure of Sylvius and the third frontal convolution of the brain, would lead us, *à priori*, to expect that lesions of the brain causing aphasia would also occasionally be

associated with anosmia as a complication ; and this is actually the case, as Dr. Hughlings Jackson and Dr. Wm. Ogle and Dr. Althaus\* have pointed out. In the instances of subjective disturbances of smell associated with aphasia, there was also loss of smell, and in Dr. William Ogle's essay two cases are given illustrating this connection of the two sets of symptoms involved in these two functional defects.

From the researches of M. Serres ("Anatom. Comp. du Cerveau," i, 295) it appears that lesion of the external root of the olfactory bulb is more efficacious in determining anosmia than is lesion of the internal root.

Complete loss of smell is sometimes associated with subjective sensations of smell, or *Parosmia*, just as we sometimes have complete loss of sight associated with subjective sensations of flashes of light, in either case the sensation being no doubt due to central irritation of the cerebral tissue where the special nerves have their origin. In the Ophthalmic Hospital Reports, Dr. Hughlings Jackson has recorded two cases of nervous disease in which this curious combination was present, viz., loss of smell and subjective sensations of smell:—"In one case, the patient, a girl, aged 18 years, was deaf, and she was blind also from optic neuritis. This patient one day had a fit. Her mother said the girl's right arm and leg moved, and that she cried out, 'Oh, what a stink; what a dreadful stink in the place.' She fell, and afterwards went into a sound sleep. She could not smell scents."

In other cases *parosmia* may be present without anosmia. An account of a very remarkable case of this kind was read before the Medical Society of London by Drs. Hughlings Jackson and Beevor on February 18th, 1889. At the autopsy "a tumour the size of a small orange was found imbedded in the white matter of the temporo-sphenoidal lobe." The patient was epileptic, the fits being ushered in by an *intellectual aura*, the patient experiencing the sensation of a "horribly nauseous smell." Dr. Anderson has seen a similar case.

Dr. Althaus reports a case of locomotor ataxy with olfactory neuritis in which there was *parosmia* ("a strong smell of phosphorus which overpowered all other accidental smells, and never left him at all for about six weeks") followed by anosmia, but

\* See Dr. Althaus' "Observations on Neuritis and Perineuritis of some of the Cranial Nerves," *Brain*, Parts IV and V.

without loss of taste, though perception of flavours was also lost. Dr. Althaus concludes that in this case the anosmia was "due to a peripheral lesion," "most probably where the olfactory ganglia lie closely together at the base of the brain." Here then we have an instance of *parosmia* existing during the first period, that of irritation, whether due to pressure or approaching inflammatory congestion, and this condition succeeded by complete *anosmia* in the stage of destructive lesion.

Cases of *parosmic aura* preceding epileptic seizures are reported by Dr. Hughlings Jackson, but due indirectly to plugging of the anterior or middle cerebral artery, and others of anosmia, associated with aphasia and right-sided hemiplegia (*Medical Times and Gazette*, August 13, 1864, and *British Medical Journal*, April 30, 1864). When associated with aphasia and right-sided hemiplegia the anosmia is one-sided (the left nostril only being anosmic).

Besides epilepsy, nervous disorders of other kinds are sometimes associated with subjective derangements of olfaction. Dr. Kirkes remarks that it occasionally happens to every one, and especially to nervous persons, "to smell something which is not present and which other persons cannot smell;" and he refers to a case in which the arachnoid was found after death to be studded with pieces of bone, and serofulous cysts were found in the hemispheres.

In some forms of mental disorder Dr. Forbes Winslow\* observes, "the insane are often heard to complain of being exposed to the influence of most noxious and offensive smells." Dr. Lardner, in his work on "Animal Physics," writes that subjective olfactory sensations are not uncommon "with those afflicted with mental derangements," and that insane persons often complain that fœtid or fecal matter has been mixed with their food.

In all these cases Dr. Hughlings Jackson is inclined to refer the temporary derangement of smell to a disturbance of the circulation either of the anterior or of the middle cerebral artery, and in some cases to plugging of one or other of these arteries. It is, however, not improbable that in some at least the lesion is situated in the temporo-sphenoidal convolution. In the *temporary* anosmia observed in the course of typhus and influenza, the fever poison must be spread over a large

\* On "Obscure Diseases of the Brain."

area and often involves the intellectual as well as the sensory centres. In these cases the *anosmia* must be due to the poison directly affecting the *centre of olfaction*.

There are still to be noticed certain rare cases of what may be called (for want of a better term) *metamorphic parosmia*. The patient complains that odours universally recognized by others are by themselves perceived as something entirely different.

Thus Sir Morell Mackenzie gives an instance of a lady to whom the smell of *cooked meat* was so exactly like that of *stinking fish*, that scarcely any animal food could be taken; another in which *violets* smell like *phosphorus*; and another in which *mignonette* has the odour of garlic. In the case of a governess who consulted me, only bacon could be tasted as such; all other food had a nauseous taste. A gentleman who had lost his sense of smell after a severe attack of catarrh said that everything now tasted like *haddock*.

There is a possible source of error in the diagnosis of *parosmia*. A patient may perceive an offensive odour not perceptible by those about him. It may, however, depend upon the presence of antral disease, the discharge from the antrum being only intermittent. A careful exploration of the nostrils, however, will prove this to be peripheral in origin if the discharge lying in the middle meatus is brought away on a probe, and its foetid odour can then be verified.

Under the *third* head come all those cases in which the olfactory region is invaded or destroyed by disease or mechanical lesions. In chronic rhinitis of any kind this region is often involved, whether by ulceration or necrosis. It is seldom, however, that it is destroyed in its entirety, and hence if the carious or necrosed bone is removed, or escapes spontaneously, a restoration of function is effected, and hence also it happens that in many such cases the sense may be impaired without being entirely lost, some portion of the olfactory region being untouched and unobstructed during the progress of the disorder.

Whenever the bones and soft tissues of the front of the nose are destroyed by disease, there is loss of smell, which, however, is restored, when by plastic operations, or by the employment of artificial appliances, the gap is filled up. This singular result can be partly explained by the supposition that, when the

anterior nares are largely exposed to the entrance of air from without, the mucosa of the olfactory region becomes dried up, and so unfitted for the reception of odorous impressions; but that when the aperture is limited by artificial means, sufficient moisture is allowed to accumulate, and there is sufficient warmth in the parts to allow of a restoration of the healthy secretion and nutrition of the tissues, and a consequent return to functional activity. But it is also probably due to the fact that impaired function of the branches of the fifth or seventh pair is under the same circumstances recovered from; and it is also in part due to the alteration in the direction of the current of inspired air; for when the nostrils have a vertical aperture, as in destructive lupus or other ulcerative disease, the inspired air passes directly backwards towards the pharynx; when, however, the nostrils have their apertures horizontal, as in the normal state, and as they should be when an artificial nose is fitted, the breath-current and its contained odours are directed upwards and backwards and into the olfactory region of the nostrils. Certain cases of loss of smell after severe catarrhal attacks with violent sneezing, occurring in elderly women, are, perhaps, due to some local mischief, implicating the fibres of the nerve in the olfactory region. These cases, however, are very obscure, and it is quite possible that in some such instances there may have been hæmorrhage into the olfactory bulbs during the violent paroxysms of sneezing, and the loss of smell may have been due to the consequent destruction of their tissues. If so, this group of cases would come under the second head of classification. It is by no means suggested, however, that the sneezing in these cases is at all traceable to any functional or lesional disturbance of the olfactory bulbs or nerves as a causative influence: on the contrary, it is almost certain that sneezing is induced by irritation of branches of the fifth pair of nerves; but the violent concussion in the act of sneezing may be sufficient in some cases to tear through the connection between the olfactory bulbs and the olfactory nerve-fibres, in the same way that blows on the occiput have been supposed to cause a similar lesion, from the fact that loss of smell has followed the injury. Judging, however, from the analogy of the occasional occurrence of retinal apoplexy under similar circumstances, it is perhaps more within the range of probability that hæmorrhage may have taken place into the substance of the bulbs or beneath them.

But it is only in cases of *sudden* loss of smell *in the course* of severe catarrhal attacks that the above suppositions will serve to explain the phenomena, and then only, when the anosmia is associated with other cerebral lesions, such as amaurosis or aphasia. For the cases in which, *after* a catarrhal attack, there is a more or less gradual loss of smell, associated with obstruction to inspiration through the nostrils, Dr. Wm. Ogle has furnished a sufficient explanation in his essay in the 53rd volume of the *Medical and Chirurgical Transactions*, pp. 370 *et seq.* He there relates the case of a lady who partially lost the power of inspiring through the nostrils after a violent cold or influenza. She could expire through the nose with tolerable ease, but, when she attempted to inspire, she felt as though there were some obstruction, which prevented her doing so with the same ease and fulness as can others, and her voice was slightly nasal in tone. The most strongly smelling substances were placed under her nostrils, while she inspired through the nose, without her perceiving in the least degree their smell. Her perception of flavours remained almost in its integrity. "We have only to suppose," such is Dr. Ogle's explanation, "what is highly probable, that the Schneiderian membrane has been so thickened by chronic inflammation as to bring the septum in contact with the middle turbinated bone and its prolongation, the *agger nasi*, a result which, we have already seen, would require only an excessively slight thickening of the membrane; and, secondly, that this thickening has not only thus cut off the olfactory from the respiratory channel, but that it has also obstructed the former and narrower of these two, the obstruction being of such a kind as entirely to prevent the passage of air inwards, while it allows of the passage of air outwards. We must suppose, that is, that the projecting fold of membrane acts as a valve. That this was the case is rendered almost certain by the fact that the expiration by the nose was much freer than was the inspiration." This satisfactorily explains the absence of olfactory sense when the odorous substance was held under the nostrils, and also the persistence of the perception of flavours, there being no obstruction to the free passage of air from the mouth through the posterior nares.

Disease causing the disappearance of pigment from those parts of the body in which it is normally present, and therefore specially affecting the olfactory region, produces anosmia as one



of its results. A remarkable case quoted by Dr. W. Ogle so well illustrates this, that I shall take the liberty of transcribing it from his essay: "A boy in Kentucky, son of two black slaves, had, up to his twelfth year, a skin of the same dark colour as that of his parents. At this period a white patch appeared near the inner canthus of the left eye. This white patch spread gradually, until in ten years' time it extended over the whole external surface of the body; so that, but for his woolly hair, the boy might have been taken for a very fair European. Later on, some few brownish or copper-coloured spots appeared on the face and hands; but the parts which were not exposed retained permanently their perfect whiteness. At the same time that the boy began to change his colour, he began also to lose the sense of smell, and by the time he had become white, his smell was so seriously impaired that Dr. Hutchinson, who records the case, states it to have been completely lost." (*American Journal of Medical Science*, 1852). This case is important, as presenting us with a pathological condition typical perhaps of a class of similar cases, the manifestations of which are less conspicuous. Mere deficiency of pigment may possibly cause defective perception of odours, and if so, we should expect all albinos, both men and animals, to be deficient in smell or anosmic, and many facts in natural history go to prove that defective perception of odours is one of the many disadvantages under which albino animals labour. If it were established that pigment is altogether absent from the olfactory region of the albino, it would be only logical to expect total loss of smell, or very great impairment of this faculty; but Dr. W. Ogle has pointed out that in most albino animals the pigment remains in the integuments of the nose and ears, and we may therefore assume that it is not altogether absent from the olfactory mucosa; nevertheless it is probable that the olfactory region in albinos partakes to some extent of the general constitutional deficiency, and that they do suffer from an obtuseness in the perception of odours. To this cause (involving as it does an inability to avoid poisonous and unwholesome food) their tendency to die off rapidly in a wild state, or when allowed, though domesticated, to choose their own food, is probably due, as much as to their general delicacy of constitution, and their consequently greater susceptibility to the ravages of disease and climatic influences, and to the attacks of the larger and stronger carnivora. In respect to the last-

named source of danger, the whiteness of their coats renders them more conspicuous to their foes, and therefore adds one more to their other numerous disadvantages in the struggle for existence.

In comparing the case of the negro boy, who became anosmic simultaneously with the loss of the pigment of the skin, with the case of albinos, it is obvious that we are comparing a pathological process with a physiological defect. For the albino animal can hardly be looked upon as suffering from a pathological condition, whole races and breeds being continually reproduced, though they do not ultimately survive in a wild state. Hence, though the two cases are of interest as illustrating the physiology of olfaction, when placed side by side, they do not stand in the relation of varieties of the same pathological process.

The rare cases in which anosmia is associated with lesions of the fifth and seventh pair of nerves may, I think, be classed with the third group, though in complicated cases, in which several cranial nerves are involved, there is always the possibility that the anosmia may be due to lesions in the cerebral substance, and not to trophic defects of the Schneiderian membrane. This difficulty of diagnosis occurred in the case I reported to the Clinical Society in March, 1881.

“A married woman, *æt.* 36, who had suffered from miscarriages, and a severe flooding after a confinement, was seized with neuralgic pain of the left side of the face, with loss of sensation (in the same side of the face), ptosis, and loss of smell, taste, and hearing of the same side. After the symptoms had persisted seven months, twenty grain doses of iodide of potassium were given three times a day with the effect of rapidly relieving the pain in the parts, and restoring the senses of smell, taste, and hearing, and partially restoring the paralyzed upper lid, and the paralyzed ocular muscles. There was a relapse after the relief had persisted for more than a month, and the condition of the patient was still unsatisfactory at the last time of seeing her. The amount of iodide of potassium taken in a continuous course of thirty-one days' duration was between  $3\frac{1}{2}$  and 4 ozs.”

Here the loss of smell was probably due to extension of ulceration over a large surface of the Schneiderian membrane, possibly as far as the olfactory region. There was a constant

dryness of the whole nostril on the side affected. Taste was lost, as well as the sense of smell, and these senses were restored by the treatment. Under these circumstances it might be considered not improbable that some cerebral lesion was also present.

A case has been recorded in which the continual inspiration of the fumes of ether, accidentally, in the course of some experiments on animals, caused a gradual failure of the sense of smell, and at last its total aberration, the effect being attributed to the continuous contact of the sulphuric ether with the minute branches of the olfactory nerve. (Virchow's "Archiv.," iv, 41, 1867).

*Hyperosmia.*—As contrasted with anosmia, it is necessary to refer to cases in which the acuteness of the olfactory sense is abnormally increased. This change is sometimes noticed in hysterical and insane persons, upon whom certain odours occasionally produce very marked effects. The acuteness of the sense of smell may be much heightened by practice; odours undetectable by persons in general are often clearly recognized by those, *e.g.*, medical men and others, who have made a study of them.

*Treatment in Functional Derangements of Smell.*—Whenever the loss of smell can be fairly attributed to temporary loss of functional activity, excitation of the Schneiderian membrane by the passage along it of the constant galvanic current, with interruptions, will sometimes arouse this dormant sense. In the hands of Dr. Cohen, of the Jefferson Medical College, Philadelphia, electricity has sometimes proved adequate for this purpose. (Cohen, "Diseases of the Throat," p. 290). But this method of treatment is not without danger, and may affect the eyesight if the current is too strong. Sir Morell Mackenzie says that a powder containing  $\frac{1}{24}$  grain of strychnia in two grains of starch used as a snuff twice a day will sometimes do good. The strychnia may be increased to  $\frac{1}{16}$  or  $\frac{1}{12}$  of a grain if no effect is produced by the smaller dose. Dr. Althaus has succeeded with this remedy in curing anosmia in two cases. In the intermittent form of anosmia quinine should be given. In the class of cases of anosmia due to mechanical obstructions, the obvious indication is to remove the impediment to the access of the odorous particles, while in those cases in which the cause is central, little or nothing can be done by way of treatment.

## SECTION XVI.

ON REFLEX NEUROSES DEPENDING UPON  
INTRA-NASAL DISEASE.

THE idea of *reflex neuroses* being dependent upon nasal abnormalities, first distinctly formulated by Voltolini in 1871, may very possibly have been suggested by the phenomenon of a "sneeze." This spasmodic affection of the respiratory apparatus is commonly excited by an irritation of the pituitary membrane. The irritation, however, is transient, and the effect also transient. In the case of chronic disease, however, such as polypi, there is an abiding irritation, and the result is a chronic irritability of the respiratory apparatus, with occasional convulsive attacks, such as asthma and spasmodic cough. Since the impetus given by Voltolini, a host of authors have arisen to support and enlarge upon the views propounded by him, and a large number of maladies, hitherto supposed to be dependent upon chronic affections of the nervous system, have been attributed to intra-nasal disease as their primary cause.

In Germany, Hænisch, Hartmann, Shæffer, Fränkel, Hack, Zuckerkandl, Sommerbrodt, Shech, Roth, and Boecker; in Italy, Massini; in America, Mulhall, Todd, Porter, Rumbold, Roe, Elsberg and Bosworth, J. N. Mackenzie, Cohen, etc.; in France, Trousseau, Joal Duplay, Jacquin, G. Moare, Songuet, Cartaz, etc.; and in England, Hunter Mackenzie, McBride, Cresswell Baber, Semon, Morell Mackenzie, De Haviland Hall, Beevor and others, have all in turn called attention to facts bearing upon the subject, and have formulated theories in support of the views propounded. The catalogue of disorders, supposed by Hack to depend upon turgescence of the inferior turbinated body, included *asthma, nightmare, cough, megrim, supra-orbital neuralgia, redness and swelling of the nose and adjacent parts of the face, vertigo, epilepsy, various neuralgic affections of the face, diffuse headache, scotomata and amaurosis.* Hack also feels justified in treating *rheumatic* inflammation of the joints by cauterizing the inferior turbinated body.

In order to judge of the connection between these various affections and intra-nasal disease it is laid down by Hack that when they are so related (to nasal disease) they are associated with transitory nasal obstruction, coryza, and paroxysms of sneezing. He grounds his belief in the causal influence of the nasal disease on the fact that by operating on the turbinated bodies by means of the galvanic cautery he cures the neuroses.

Without committing myself to the views thus laid down, I think there can be no doubt that in certain persons predisposed by an arthritic or some similar diathesis, intra-nasal disease will often produce some of these forms of nervous disorder. Asthma is the form of neurosis most commonly thus produced; about many of the others I feel considerable doubt.

As to the importance of the erectile tissue of the turbinated bodies as a factor in all reflex neuroses of nasal origin, it seems to be now generally agreed that Hack's views are no longer tenable.

As an instance of an unusual kind of reflex neurosis which can hardly be classed under any of the above heads, the following brief abstract may be of interest:—

*Rhinitis with spasmodic "snorting."*—A young woman, age 26, after a great mental shock, was seized with spasmodic inspiratory "snorting," very frequently repeated. This soon became uncontrollable, and continued for many months in spite of treatment, the spasm coming on sometimes every half hour and sometimes every ten minutes during the day, ceasing, however, during sleep. Large doses of bromide were given with temporary good effect; but, on their being discontinued, the "snorting" soon recurred with its original intensity. On rhinoscopic examination, I discovered great thickening of the turbinated bodies, which were partially removed with very good effect. Subsequently nasal plugs were used, and the nostrils were freely sprayed with hazeline. The "snorting" has not recurred since the last operation (in January, 1887); and the smell and taste, which had been much impaired, are now perfect. The general health has also improved. Up to November, 1889, there had been no return of the nervous symptoms. (Case read at a meeting of the *North London Branch of the British Medical Association.*)

Asthma has been proved to be commonly associated with

nasal stenosis, however produced. Dr. Bosworth, of New York, regards asthma as "dependent upon three conditions: 1st, a general neurotic condition as demonstrated by Hyde Salter; 2nd, a diseased condition of the nasal mucous membrane; 3rd, some obscure condition of the atmosphere exciting the paroxysms." According to this author "the most intricate, the most delicate, and the most important part of the whole respiratory tract lies in the nose, in that mass of blood-vessels which we call the turbinated tissues, and which serve to supply the inspired air with moisture, by pouring out upon the surface of the mucous membrane a large amount of water—*sixteen ounces in the course of the day*—by which the inspired air becomes saturated with moisture, this function being necessarily regulated with an extreme degree of nicety of adjustment." "The blood supply in the nose being regulated by the same vaso-motor tract as that which regulates the blood supply in the bronchial tubes, a disturbance in the one region is liable to be followed by a disturbance of the other; a morbid condition in one region renders the other especially susceptible to diseased processes." No case of asthma has occurred in Dr. Bosworth's experience, in which there was not intra-nasal disease of some kind, and he includes in this category hypertrophic rhinitis, nasal polypi, hypertrophic rhinitis with deflected septum, polypi and deflected septum, deflected septum by itself, adenoid and hypertrophic rhinitis, all conditions involving obstruction of the nasal passages. In all but one of the cases treated for the removal of the obstruction, the asthma was either cured or improved. The same causes influenced, according to Dr. Bosworth, all the cases of hay asthma which he had treated, and in all these the results of treatment were either partially or completely successful. Out of 80 cases of perennial asthma and hay asthma, 74 were either cured or improved by mechanical treatment directed towards the removal or cure of the obstructive lesions present in the nose. (Bosworth, on "Asthma," *American Journal of the Medical Sciences*, September, 1888.)

It must be noted that in giving these statistics Dr. Bosworth guards himself from the assertion that asthma is *always* associated with intra-nasal disease. He expressly states that his reputation as a specialist in the department of throat and nose diseases brings such cases almost exclusively under his observa-

tion. Ten cases of reflex neurosis, viz., asthma, spasmodic cough, fits of suffocation and aphonia associated with hypertrophy of the turbinated bodies are reported by M. Hering (in the *Annales des Maladies de l'Oreille*, etc., February, 1886, p. 53). Of these, two were cured by treatment, five were relieved temporarily or permanently, and three were either not treated or only imperfectly treated, the result being that one recovered without treatment and in the other two cases the results were unknown. The treatment consisted chiefly in applying the galvanic cautery or chromic acid to the hypertrophied mucous membrane. In a case of aphonia, reported by Dr. Brebion (*British Medical Journal*, Appendix 3, 1886, p. 661), the voice was recovered after the removal of nasal polypi. In my own experience I have not so often traced the connection between the two conditions, and have not been so successful in the treatment of such cases as I have met with in which they have been clearly associated. I am inclined to the view expressed by Hyde Salter that there is a certain form of asthma dependent on something from within, not from without, in which the cause of the affection is a congenital and possibly an inherited disease. At the same time I think that organic lesions within the nostrils or naso-pharynx are often overlooked by physicians and general practitioners, and that it is always important to look for them carefully in every case of asthma, and to treat the local condition when found by local remedies. In cases of spasmodic cough, aphonia, and laryngeal spasm, in which there is no ascertainable cause referable to the larynx, it will often be found that there is intra-nasal disease and that active treatment directed against the intra-nasal disease brings about a cure of the nervous cough or spasm.

The following works may be consulted with advantage on this subject:—

B. Fraenkel, "Ueber den Zusammenhang von Asthma Nervosum und Krankheiten der Nase" (*Berlin. klin. Wochenschrift*, 16, 17, 1881); also "Von der Nase aus Facialis-Krampf" (*ibid.*, 28, 1884). Hack, *Operative Radical Behandlung bestimmter Formen von Migräne, Asthma, Heufieber sowie Zahlreicher Verwandter Erscheinungen* (Wiesbaden, 1884). Zuckerkandl, "Das Schwellgewebe der Nasenschleimhaut und dessen Beziehungen zum Respirationsspalt" (*Wiener Med. Wochenschrift*, 38, 1884). Hack, "Beiträge zur Extirpation der Nasalen

Schwellkörper" (*Deutsch. Med. Wochenschrift*, 28, 1884; see also *Centralblatt für Laryngologie*, vol. i, p. 106). Sommerbrodt, "Mittheilung von Heilungen pathologischer Zustände welche durch Reflex-vorgänge von der Nase her bewirkt waren" (*Berlin. klin. Wochenschrift*, 10, 11, 1884). Sommerbrodt, "Ueber Nasen Reflex-Neurosen" (*ibid.*, No. 10, 11, 1885). J. N. Mackenzie (*American Journal of Medical Science*, July, 1883). Baber, *A Guide to the Examination of the Nose*, p. 39. Hering, "Des Névroses réflexes déterminées par les affections nasales" (*Annales des Maladies de l'Oreille, du Larynx, etc.*, 2, 3, 1886). Jacobi, "Partial and sometimes General Chorea Minor from Naso-pharyngeal Reflex" (*Internat. Journal of the Med. Sciences*, April, 1886). Semon, German edition of Mackenzie's *Text-book*, p. 500, *et seq.*. Tornwaldt, *Ueber die Bedeutung der Bursa Pharyngea* (Wiesbaden, 1885, pp. 46, 59). Michel, *Zur Behandlung der Krankheiten der Mundrachenhöhle, etc.* (Leipzig, 1880, p. 29). Solis Cohen, *Diseases of the Throat* (New York, p. 164). Schreiber and Naunyn (*Berlin. klin. Wochenschrift*, No. 33, 1885). Schech, *Diseases of the Mouth, Throat, and Nose*, translated by Blaikie, p. 230, *et seq.* *Transactions of the International Medical Congress*, 1884, vol. iv, p. 32, *et seq.* For recent papers see *International Journal of Med. Sciences*, October, 1886, p. 578, *et seq.*; also Boecker (*Deut. Med. Wochenschrift*, 26, 27, 1886). Dr. W. Roth, *The Disorders of the Nasal Mucous Membrane, their relations to the organism in general and their treatment.* F. H. Bosworth, M.D., *Asthma, with an analysis of eighty cases, with special reference to its relation to local diseases of the upper air tract.* Schmiegelow, *Asthma, due to intra-nasal disease.* M. Hering, *Névroses Réflexes in the Annales des Maladies de l'Oreille*, February, 1886.



## SECTION XVII.

## NEUROSES OF THE NOSE.

## SUB-SECTION 1.

*Sneezing.*

THE most common exciting cause of sneezing is a mechanical irritation of the nasal fossæ. The stimulus must be of a delicate kind, coarse or rough irritation being productive of pain. Pustules in the mucous membrane seem to cause sneezing, or a tendency to it in some cases, and violent and persistent fits of sneezing are noted as having been present in cases in which foreign bodies were lodged in the frontal sinuses. The air entering the lungs of new-born infants is supposed to be a cause of sneezing in them, but the simultaneous exposure of the pituitary membrane to a current of air, and the exposure of the face and upper part of the thorax to the light and air may have an equal share in exciting this act.

It comes on often in the commencement of coryza, and is then vulgarly attributed to a chill of the surface, or the suppression of perspiration. It is quite as rational to attribute it to the hyperæsthesia of the mucous membrane of the nose and the greater susceptibility to external impressions, such as a current of cold air, or the entrance of minute foreign bodies. According to Wedelius ("De Medicam. Facultat." p. 211), sneezing often ushers in the access of epilepsy or marks the termination of the fit.

In most cases it is uncontrollable by the will. The muscles once thrown into action, contract in a truly convulsive manner. Few persons can check themselves when they want to sneeze; nevertheless if the attention be suddenly directed to some other object at the very commencement of the preliminary tickling in the nose, the convulsion does not occur. It is also possible to stop the sneeze when the tickling in the nose has only just commenced, by firmly pressing together the alæ nasi against the septum, and stopping the breathing by a strong effort of the will. But this does not always succeed, and it is perhaps

rather a dangerous experiment when it does not, because the act of holding the breath causes great congestion of the head, and there may be some danger of rupture of the cerebral blood-vessels during the sudden convulsion of a sneezing fit, after a prolonged effort of repression.

The effects of sneezing are generally beneficial in various ways. Hoffmann has seen, under its influence, small stones shot from the meatus auditorius, and calculi have been supposed to escape from the kidneys and ureters. But ill effects are occasionally observed, *e.g.*, pulmonary hæmorrhage, menorrhagia, sudden death from rupture of aneurisms; amaurosis from retinal hæmorrhage, epilepsy, apoplexy (Alibert), and perhaps anosmia.

*Dr. Alibert's Case of Apoplexy following a violent fit of sneezing.*

A military man, aged about forty years, excessively stout, gave himself up to drinking, and took no solid nourishment. He was the subject of such violent sneezing, that his face became of a deep purple colour, and his respiration difficult and laborious. One day after twelve or fifteen minutes he was asphyxiated. ("Nouveaux Elémens de Thérap. et de Matière Médic." 4th edit. Paris, 1817, tom. i, p. 136.)

"A man died of cerebral apoplexy, after having sneezed twenty-four times in succession, and at the commencement of the twenty-fifth."\*

Sneezing has caused abortion. It may amount to an actual disease in itself. It has been known to occur several times in the hour, during whole years, without the general health becoming affected ("Ephem. Curios. Nat.," December 2, ann. 6, 1687, Obs. 93). Godefroy Schubart has preserved us the history of a young girl of 17 years, who during several nights suffered from an attack of sneezing, the fits of which were repeated three hundred times and more at each onset (*ibid.*, Dec. 1, ann. 3, 1672, Obs. 138). J. P. Albrecht relates that of an infant in whom it occurred one hundred times an hour, and caused death (*ibid.*, December 2, ann. 6, 1687, Obs. 12). Frequent sneezing has been known to cause blindness, a change of direction of the globe of the eye, and a violent epistaxis.

\* Fannan Strada. Prolusiones Academicæ et Bonnet, lib. i, sect. 20. But the judicious Morgagni ("De Sedibus et Causis Morborum," epist. xiv, No. 16) throws some doubt on the sneezing being the immediate cause of death.

It sometimes occurs as constantly-repeated paroxysms in hysterical young women, and is then best treated by the administration of valerianate of iron and the use of a weak solution of aq. Laurocerasi, snuffed up the nostrils (see letter from Dr. Mayer, of Antwerp, *Lancet*, January 9, 1875).

If there is excessive hyperæsthesia of the pituitary membrane, the use of tobacco snuff is very efficacious, and an instance in which this plan of treatment succeeded in lessening the number and diminishing the violence of the paroxysms was lately recorded by Mr. Gray, of Edinburgh (*Lancet*, January 16, 1875). In this case the patient was a lady of slightly hysterical temperament.

In fevers, and especially typhus, sneezing has been considered a prognostic sign of death for the patients in whom it was observed (Thucyd., "De Bello Pelopon."). It is on this account that the custom of saluting people and invoking the assistance of heaven against this kind of danger is supposed to have arisen. This custom, however it may have originated, has existed among all nations. The Spaniards found it established in Florida when they made the conquest of that district. Others recognize in sneezing something sacred, and this is the opinion of most of the ancients, who regarded the head as the most noble part of the body. Xenophon, in the story of his expedition, relates that when anyone sneezed in the presence of the King of Persia, everyone prostrated himself as if to adore a god. Tiberius required that under similar circumstances those present should pay him homage, and Aristotle inquires why sneezing has been made a divinity rather than cough and belching. At the commencement of convalescence sneezing is considered a sign of good omen, and formerly in the hospitals of Paris a patient who sneezed was considered to have gained sufficient strength to return home. *Sternuit, salva res est, et nosocomio expelli debet*, said the physicians proverbially.

#### SUB-SECTION 2.

*Spasmodic twitching of the nose* is sometimes seen as a form of chorea, and is then generally associated with similar convulsive movements of muscles in other parts of the face or body. It is a very formidable malady to those afflicted with it, and, if it has been of long standing, very difficult to cure. If seen early,

the treatment by those methods best adapted for chorea in other parts will be most suitable in this part. In some cases the movement is, in the first instance, a mere trick, and becomes from the constant repetition a confirmed habit. The same sort of origin accounts for the habit of snuffing, to which some persons are addicted, probably in the first instance excited by a cold in the head.

### SUB-SECTION 3.

*Neuralgia of the nose* is a symptom often complained of. It is generally associated with some intra-nasal growth, and exostosis of the septum or of the bony walls is the condition that most often gives rise to persistent neuralgia. It is also a common symptom of disease of the antrum and the frontal sinuses. Herpes Frontalis, when it attacks the side of the nose, leaves behind it an exaggerated sensitiveness of the skin and a pain which is persistent and neuralgic in character. Under these circumstances the cicatricial marks on the side of the nose affected will point to the origin of the pain. The white cicatrices affecting one side of the nose and the forehead of the same side are very characteristic. Local sedatives, such as a morphia and glycerine paste, applied frequently, give some relief, and tonic treatment is indicated.

### SUB-SECTION 4.

*Paralysis of common sensation in the nose* from disease or injury of the fifth nerve is indicated by the inability to distinguish the pungency of vapours, such as ammonia or acetic acid fumes. Ulceration may be an indirect result of this insensibility of the mucous membrane. Foreign irritating matters carried into the nostril in ordinary respiration are not felt, and remain unexpelled by sneezing or the use of the handkerchief. Dr. Althaus has recorded a case (*Medical and Chirurgical Transactions*, 1869, vol. lii, p. 27) in which the mucous membrane of the nose was absolutely insensible to the contact of blunt, or even sharp, instruments, and no sneezing was brought on by snuff, yet the sense of smell was perfectly normal. In the Section on ulcerative affections of the nose (supra, p. 129), I have related a case of paralysis of sensation in which intra-nasal ulceration occurred.

## SUB-SECTION 5.

*Nasal cough and the existence of a sensitive area in the nose.* Some allusion to this subject has been made in the Section on Reflex Neuroses; it may, however, be not inappropriate to call attention to this area of hyperæsthesia as described by Dr. J. N. Mackenzie (*American Journal of Medical Sciences*), and to give shortly his conclusions on the subject. 1. In the nose there exists a well-defined sensitive area, the stimulation of which, either through a local pathological process, or through the action of an irritant introduced from without, is capable of producing an excitation which finds its expression in a reflex action or in a series of reflected phenomena. 2. This sensitive area corresponds, in all probability, with the mucous membrane covering the corpora cavernosa of the turbinated bones. 3. Reflex cough is only produced by stimulation of this area, and is only exceptionally evoked when other portions of the nasal mucous membrane are irritated. 4. The most sensitive part is the posterior end of the inferior turbinate and the septum immediately opposite. 5. The tendency to reflex action varies in different individuals, being most pronounced when there is hyperæmia and hypertrophy of the turbinate body. 6. This exaggerated sensitiveness may be physiologically considered a means of guarding the lower air-passages against the entrance of irritant vapours, fluids, or solids.

Having had my attention constantly on the alert as to the alleged existence of this sensitive area, I have not been able to localize it with the precision described by Dr. J. N. Mackenzie. The case related in Section XVI, of *spasmodic inspiratory snorting*, is the only typical instance at all like the condition described, but I regarded that instance as one of spasm induced by the sense of obstruction, and as having given rise to a *habit* in a neurotic woman.

## SECTION XVIII.

MENTAL AND INTRACRANIAL COMPLICATIONS OF  
AFFECTIONS OF THE NOSE, AND ITS ACCESSORY  
CAVITIES.*Melancholy, Hypochondriasis, and Aproxia, in Chronic Nasal  
Disease.*

It has been already shown in Section II on Stenosis, and in that on Adenoid Vegetations of the Naso-pharynx, that considerable mental disturbance is often observed. In all cases of chronic catarrh of the nose and naso-pharynx there is a liability to hypochondriasis, loss of memory, and melancholia, which in the worst cases goes on to a condition undistinguishable from insanity. The "hebetudo" or "aproxia" of children affected with adenoid vegetations is very marked, and assists in giving a characteristic silly expression to the countenance. In adults, with chronic catarrh, the memory is most affected, and the tendency to melancholia is very prominent as a subjective symptom. Delusions and hallucinations are not uncommon in adults whose catarrh has been going on for many years. Thus Rumbold ("Treatment of Nasal Catarrh," p. 240) mentions a case in which the patient had a pain in the arm, and believed that the closure of his hand would produce rupture of the nasal blood-vessels. Another patient, while walking, experienced the sensation that he was sinking into the pavement up to his knees. This feeling was so strong that frequently he was compelled to stop and raise one foot as high as his knee for the purpose of getting on the top of the pavement; this he had done on several occasions. The effect, of course, was to throw him instantly to the ground. In ozæna melancholy is a common symptom. There is a constant tendency in patients so affected to shun society from a sense of their infirmity, and this alone is sufficient to account for their melancholy, though the constant breathing of tainted air may in the early stages have a depressing effect on the digestive organs and the general health.

The occasional occurrence of *maniacal delirium*, with sleeplessness, from the presence of *maggots* in the nose, has been alluded to in Section V. In the fatal cases of "*Peenash*" (see Section V), delirium and coma are the prominent symptoms which precede death.

It has been known from an early period that *inflammatory affections of the bones* of the roof of the nostrils are occasionally associated with severe cerebral symptoms; and when we consider the very thin bony partition constituting at once the floor of the cranial and the ceiling of the nasal chamber, it is not surprising that inflammatory mischief in the one cavity should sometimes extend to the other.

Probably the most frequent cause of meningeal inflammation extending from the nose is caries of the ethmoid. Cases of the kind have been already alluded to in Section VIII, p. 145. Many others not there alluded to have been recorded by various authors. For example, Dr. Abercrombie ("*Pathological and Practical Researches on Diseases of the Brain*," Edinburgh, 1845, p. 39) alludes as follows to the occasional occurrence intracranial disease associated with disease in the nose: "A person who has been liable to pain in the forehead and purulent discharge from the nose, becomes at last forgetful and delirious and dies comatose. The ethmoid bone is found carious, the dura mater corresponding to it is diseased, and there is a deposition of pus betwixt it and the brain, sometimes an abscess in the brain itself. Several cases of this kind are mentioned by Lieutand and Bonetus. Morgagni mentions a priest who, after being affected with fever, delirium, pain in the forehead, and convulsions, fell into coma, from which he was relieved by discharging purulent matter from the nose."

Sir William Gull and Dr. H. G. Sutton have called attention to the occasional occurrence of abscess in the brain in the course of chronic disease within the nostrils. ("*Reynolds' System of Medicine*," vol. ii, p. 579, article on "*Abscess of the Brain*.") In one of the tabulated cases there recorded by Sir William Gull (from "*Guy's Hospital Report*," vol. viii, 3rd series), the patient was a man, aged 43 years, with chronic disease of the mucous membrane of the nose, who was suddenly seized with lightness in the head, followed by convulsion, insensibility, then recovery; and again, convulsion a second time on the same day. On the third day headache, increasing to great intensity on the fifth,

referred to the right side of the forehead, &c. No delirium. Death on the eighth day in coma. After death, acute abscess in the middle lobe of the cerebrum on the right side. In a similar case, also recorded by Sir William Gull, there was softening and ulceration of the convolutions of the anterior lobe of the right hemisphere, the brain symptoms having commenced five weeks before death by vertigo and headache, and culminating in insensibility and paralysis twelve days before the fatal issue.

Injuries leading to necrosis may also be followed by meningitis, and the same thing is very likely to occur after penetrating wounds or fractures of the bones. Foreign bodies lodged in the nasal cavities or the frontal sinuses, may lead to the same complication.

Polypi and other tumours are also sometimes the exciting causes of intra-cranial disease, as in the instance of Mr. Simon's, in which a nasal polypus had by pressure obliterated the trunk of the internal carotid artery and caused absorption of the body of the sphenoid. After death, three abscesses were found in the brain.

“A pale, emaciated man, rather past middle age, was admitted, under Mr. Simon's care, into St. Thomas', on account of profuse bleeding from the nose. He was partially deaf. The left eye squinted inwards, and the right was totally blind, and had been so for some weeks. It appeared that so long as thirty years ago he had been under surgical treatment on account of a polypus in the nostril. Many attempts had from time to time been made to extract the growth, but had never been wholly successful. He was much reduced by loss of blood at the time of his admission, and a few days afterwards had an epileptiform seizure, which left him with incomplete hemiplegia of the left side.

Ten days later another fit occurred, and death in coma followed thirteen hours afterwards. At the autopsy a very interesting and most unusual condition of things was found. In the right cerebral hemisphere were three distinct abscesses, and the brain substance generally was much softer than that of the opposite side. The cause of these was found in the entire obliteration of the internal carotid artery by the compression and irritation of a *large nasal polypus*, which had grown upwards, and caused extensive absorption of the body of the sphenoid bone. It was impossible to trace the carotid artery



through the cavernous sinus, its coats being inseparably blended with the dura mater, and old inflammatory material. *The sphenoidal sinus was occupied by a mucous polypus.* There was not the least reason to consider the polypus of a malignant nature, it being evidently of the ordinary fibrous kind. There were no secondary growths in any part of the body." (*Medical Times and Gazette*, January 19, 1858.)

Almost all the fibroid polypi that are allowed to grow without surgical interference to their full extent ultimately involve the base of the brain, and in their late stages are associated with coma, convulsions, and other cerebral symptoms. Malignant growths also give rise to similar results, and are accompanied with severe frontal headache from an early period.

Abscesses of the frontal sinus may burst into the cranial cavity, and abscess of the antrum may terminate by necrosis of the floor of the orbit, and secondarily involve the base of the brain.

*M. Demarquay's Case of Abscess of the Frontal Sinus bursting through the Wall of the Sinus into the Cranial Cavity.—(Abridged from Demarquay's "Diseases of the Orbit," pp. 86, 87.)*

Symptoms of abscess in the frontal sinus in a man about 50 years of age terminated by coma and death. A probe passed through the opening which had formed during life above the left upper eyelid penetrated through the posterior wall of the sinus into the cranial cavity. Both frontal sinuses were full of pus, and though no opportunity was afforded of examining the interior of the skull, there was no doubt that there was a free communication through the bone into the cranial cavity, the probe moving freely within it when passed through the perforation.

Fatal meningitis from this cause occurred in the case mentioned in Section on Diseases of the Antrum (see p. 168).

Epistaxis has indirectly been a cause of suppurative meningitis (see foot-note on page 98).

Surgical operations in this region are liable to be followed by cerebral complications for the same reasons. It has been noticed that in a case of operation for the removal of a sequestrum from the nostrils by Dr. Rouge's operation (Section VIII,

p. 145), the patient died of pyæmic infection with meningitis. The removal of tumours of various kinds, and especially of hard fibrous or bony tumours, from the frontal sinuses or upper part of the nares is also attended with considerable risk. When they have attained a large size, and have invaded the orbit as well as the nasal cavity, the danger of interfering with them is greatly increased, the more so as there are no certain diagnostic indications of their depth or extent backwards. So that a tumour which has been unaccompanied by any symptoms commonly recognizable as cerebral, and which to external appearance is attached to the external aspect of the bones of the base of the skull, may be found after death to extend through the sphenoidal fissure, or through an absorbed portion of the body of the sphenoid into the base of the skull. Accidental injuries of the bones of the nose, if accompanied with much violence, may lead to cerebral complications. The vomer and cribriform plate of the ethmoid may be fractured, and the fossa of the cranial cavity thus exposed to dangerous communication with the roof of the nasal fossæ; or the vomer may be driven upwards, and with it the cribriform plate of the ethmoid and crista galli carried into the cerebral tissue. This latter accident occurred in a case in the Great Northern Hospital, the nasal bones being at the same time fractured and displaced backwards. The usual symptoms of fractured base of the skull are present in these cases; a persistent flow of blood or serum from the nares was a striking feature in the case referred to. Injuries of the frontal sinus are liable to be followed by inflammatory mischief within the skull, indicated by delirium or coma.

*A Case of Injury of the Frontal Sinus. Fatal termination.—*  
(pp. 92, 93, of M. Demarquay's *Work on "Diseases of the Orbit."*)

A young grenadier of the Horse Guards received, during some cavalry manœuvres, a severe kick from a horse, which divided the integuments of the right eyebrow and fractured the outer wall of the frontal sinus. Severe hæmorrhage followed the blow; the patient lost consciousness and the use of all functions, sensory and motor; but some hours afterwards, when he came to himself, he complained of very acute local pains, and convulsive movements appeared in the lips and jaw. At my first visit I considerably enlarged the wound, which was con-

tused, the parts being torn away from over the eyebrow; I afterwards removed numerous detached fragments of bone which were depressed towards the cavity of the frontal sinus. This operation facilitated the exit of a tolerably large quantity of black blood and clot which had accumulated. During the act of expiration, air escaped by the wound, and immediately afterwards blood flowed from the nose. After the wound had been dressed in the most simple manner possible, the patient was bled from the temporal artery and cupped at the back of the neck and between the shoulders; sinapisms were applied to the legs, and a low antiphlogistic regimen prescribed. During the first days the mental faculties appeared disturbed, the memory was entirely lost, the pains continued. Symptoms of delirium appeared and became very intense, and fever co-existed with the deliriura. Very soon afterwards lethargic stupor set in, and the patient died in convulsions on the nineteenth day after the accident. A post-mortem examination revealed very extensive inflammation, with swelling of the mucous membrane of the frontal sinus and of the nasal fossæ, a crack scarcely perceptible in the posterior wall of the sinus, with severe inflammation of the adjacent portion of the dura mater, and a sanguinolent and serous effusion between that membrane and the anterior right lobe of the brain.

Abscesses in these sinuses or in the antrum, if they are associated with orbital inflammation, are not unlikely to lead to meningitis or cerebral abscess. Intracranial tumours presenting in the nostrils are another source of danger in proposed operations. Meningoceles and encephalocèles have been shown to simulate nasal polypus, and the attempt to remove such tumours could not but be followed by disastrous results. A fibrous tumour involving the second division of the fifth pair was in one case mistaken for a nasal polypus, and attempts to remove it terminated fatally.

*A Case of Fibrous Tumour of the Second Division of the Fifth Pair simulating a Nasal Polypus.*

A blacksmith, with all the symptoms of polypus in the nasal fossæ, died of inflammation of the brain, following several ineffectual operations for the removal of the supposed polypus, when, at the autopsy, the following extraordinary disease was discovered:—"Puriform exudation was found at the base of

the brain. As for the tumour of the nasal fossæ, it was formed by the second division of the fifth pair, which at its exit from the skull increased in size and formed a fibrous tumour, divided into five lobes, of which the two largest were each as big as peach-stones; the other three were smaller, and one of them penetrated the orbit through the sphenomaxillary fissure. This fibrous mass occupied the deep temporal fossa lying between the zygomatic arch, the malar bone, the outer wing of the sphenoid, and the posterior aspect of the superior maxillary bone. The tumour extends thus as far as the alveolar border, above the last molar teeth. There it turned back, penetrated the sphenopalatine foramen, which was enlarged sufficiently to admit the little finger. Arrived at the corresponding nasal fossa, it was reflected, and formed a moveable tumour, which was mistaken for a polypus. None of the prolongations of this fibrous mass were mingled with or involved the nerves given off by the second branch of the fifth pair. The tumour sprang from the neurilemma" (Gerdy, "Des Polypes," p. 110).

Plastic operations on the nose are not free from similar danger. The transplantation of the periosteum is especially liable to be followed by purulent infection, if suppuration of the denuded bone should come on. In other instances sloughing of the flap may lead to similar dangers, and, whenever the patient's constitution is in an unfavourable condition, or the hygienic surroundings are faulty, purulent infection is one of the possible dangers that will have to be taken into account.

In two of Dieffenbach's operations for the restoration of the nose death resulted from this cause.

In Section XV it has been shown that *anosmia* is often associated with other symptoms indicating intracranial disease; among these optic neuritis, with or without amaurosis, aphasia, convulsions, and paralysis are the most common. Deafness is also occasionally present. In a case under my own observation some years ago optic neuritis was associated with loss of smell and taste, and with old-standing purulent discharge from the nostrils, and recent enlargement of the frontal sinuses. Injuries of the occiput may give rise to anosmia from laceration or displacement of the olfactory lobes, and in these cases the primary symptoms may be those of concussion with subsequent and permanent mischief, such as deafness, paralysis, aphasia, coma, or convulsions.

## SECTION XIX.

MR. A. E. CUMBERBATCH ON DISEASES OF THE EAR  
IN THEIR RELATIONS TO NASAL AND NASO-  
PHARYNGEAL DISEASES.

THE injurious influences on the ear of morbid conditions of the pharyngeal mucous membrane are pretty generally recognized, but it is not so generally appreciated, that an unhealthy state of the nasal mucous membrane is nearly as potent a source of mischief. Naso-pharyngeal catarrh, by extension through the Eustachian tube, often produces catarrh of the middle ear of greater or less severity, and the severity of the aural is sometimes out of all proportion to that of the naso-pharyngeal catarrh. Even when the naso-pharyngeal catarrh does not spread beyond the Eustachian tube, the interference with the proper aëration of the tympanic cavity—due to obstruction in the tube—may lead to secondary changes in the tympanum. Enlarged tonsils, adenoid vegetations, and new growths, besides predisposing to catarrhal attacks of the middle ear, may act injuriously by mechanically obstructing the orifice of the Eustachian tube. So also may cicatrices left after ulceration of the pharynx.

It is denied by some writers that difficulty in nasal breathing acts injuriously on the tympanum, by interfering with the proper aëration of that cavity, but there can be no doubt that obstruction in the nasal passages causes, at times, undue rarefaction, at others, undue condensation of air in the tympanum. When the nasal passages are much obstructed, every act of swallowing causes rarefaction of air in the upper pharyngeal cavity, which leads naturally to rarefaction of the air in the tympanum. On the other hand, in every violent expiratory effort, such as sneezing or coughing, the air, unable to escape freely through the nose, may be, and often is, forced with injurious violence through the Eustachian tube, producing condensation in the tympanum.

Hence the danger to the ear of the presence of nasal polypi, hypertrophy of the turbinate bones, deformities, and exostoses of the septum, etc.

In the treatment, therefore, of diseases of the middle ear the surgeon should always examine the naso-pharyngeal cavities, remembering that, while these are in an unhealthy condition, all remedies, directed to the removal of the ear mischief, must more or less fail to effect a complete cure.

*Acute Catarrh of the Middle Ear.*—Although it is customary in text books to divide acute catarrh into purulent and non-purulent varieties, it is neither necessary, nor pathologically correct to do so. At the commencement of an attack, it is often impossible to diagnose the exact nature of the exudation. In both forms, the mucous membrane of the tympanic cavity is acutely inflamed, as is also, in general, the Eustachian tube. Sometimes the inflammation spreads to the mastoid cells.

The most prominent symptom is pain in the ear, more or less intense according to the severity of the inflammation, and radiating over the side of the head, intensified by pressure on the auricle, and by movements of the jaw. There is marked deafness, which increases till the stress of the inflammation is past. There is also rise of temperature, tinnitus, and occasionally vertigo. The appearances presented by the membrana tympani vary with the inflammation. In mild cases, there is a loss of polish, and perhaps undue concavity; a few dilated vessels are seen behind the handle of the malleus, followed sometimes by diffused redness, at the posterior superior periphery. In severe cases, the entire membrane is red; small vesicles may form on its surface, and the outline of the handle of the malleus is lost. Between these extremes there are various gradations, which cannot here be more fully described. As the disease progresses, if the attack be a severe one, the epidermis is loosened by serous exudation, and the membrane bulges, usually at its lower part. After a period of suffering, more or less prolonged, either resolution takes place, or the mucus or pus bursts through the membrane into the meatus. When the discharge is mucus, it soon ceases, and the ruptured membrane speedily heals; when the discharge is purulent, it persists longer, and may become chronic. Should the mastoid process become involved, the skin over it is red, swollen, and tender, and the pinna projects unduly, when viewed from behind.

*Treatment.*—The patient should be confined to the house, and, in severe cases, to bed. A gentle aperient and diaphoretics may be administered with advantage. One or more leeches should

be, according to the severity of the pain, applied to the tragus, followed by hot fomentations, and irrigation of the ear, with water as hot as can be borne. Where the pain is not very great, thirty drops of a mixture of olive oil and chloroform, sprinkled on a piece of wool, and applied over the ear, often gives much relief. Should there be great bulging of the membrane, threatening perforation, tension should be relieved by an incision. If the mastoid is involved, it should be freely leeches, and if this treatment fails to subdue the inflammation, an incision should be made down to the bone.

When acute catarrh ends in suppuration, the ear should be syringed with warm water, two or three times a day, after which the meatus should be carefully dried, and a small quantity of powdered boracic acid blown in. Should this treatment fail, a weak solution of sulphate of zinc, or acetate of lead, may be tried, or, better still, rectified spirits, which should at first be diluted, and gradually increased in strength.

When the Eustachian tube continues more or less closed on the subsidence of the inflammation, the tympanum must be inflated by Valsalva's, or Politzer's, method.

*Chronic Purulent Catarrh.*—This disease is invariably the result of the acute form. Sometimes the discharge is very profuse, sometimes so slight as hardly to be noticed, and sometimes it is intermittent.

The degree of deafness varies. Giddiness is not uncommon, but tinnitus is rare. On examination, it may be seen that almost the entire membrana tympani is destroyed, the tympanic cavity, with its swollen, and sometimes polypoid lining membrane, being readily visible; or the perforation may be so small as to be detected with difficulty. Between these extremes, every degree of loss of membrane may be observed. Sometimes the membrane is little altered in appearance, at others it is œdematous and red, and, (if the perforation be small) may be mistaken for a polypus. Often polypi and granulations of varying size are present. Masses of inspissated pus and skin are frequently found, blocking the deep part of the meatus.

*Treatment.*—The ear should be well syringed with warm water twice a day, or oftener, according to the profuseness of the discharge. If there be any unpleasant smell, boracic acid, or perchloride of mercury, (1 in 1000), should be added to the water. After syringing, rectified spirit, diluted if the ear be

sensitive, may be dropped into the meatus, and retained for five minutes. Should this treatment fail, boracic acid, or iodoform, may be blown in. Polypi or granulations, when present, must be destroyed before there is any prospect of the discharge ceasing.

*Chronic Catarrh of the Middle Ear.*—Many pathological conditions are included under this head—conditions too varied to be fully described, but all having the one prominent symptom, deafness. That in the large proportion of cases, the lesion is due to an extension of catarrh from the naso-pharynx, is undoubted, but there are unquestionably some cases in which there is an absence of catarrhal symptoms. In these, the deafness comes on so gradually, that it is hardly noticeable at first; there is no appreciable abnormality in the nose or pharynx, the membrana tympani often looks healthy, and the Eustachian tube may be patent. There is, however, generally a history of hereditary deafness, rheumatism, gout, or syphilis. From whatever cause proceeding, the deafness slowly increases; there is little if any pain, but frequently tinnitus and occasionally vertigo. In some instances the patient hears better in a noise. On examining the membrana tympani there is sometimes, as has been said, little to be seen amiss with it; oftener it is indrawn, especially in its anterior segment, in which case the processus brevis and the handle of the malleus are very prominent. When, however, the membrane is much thickened, the outline of the handle of the malleus is obscured, or even lost. Opaque patches and calcareous deposits are sometimes found on the membrane, and the Eustachian tube is, in the majority of cases, more or less obstructed. The perception of sound through the cranial bones is intensified, but when the catarrh is of long standing, it generally invades the labyrinth to some extent, and then perosseous conduction may be diminished.

*Treatment.*—Poltzer's bag, or the catheter, should be used to restore the potency of the Eustachian tube, and thus relieve undue tension on the membrana tympani and chain of ossicles, at the same time counteracting the adhesive process going on in the tympanic cavity. When inflation of the tympanum alone is not sufficient, medicated vapours and solutions may be introduced through the catheter. Equally important is the treatment directed to the restoration of the naso-pharynx to a



healthy condition. Constitutional treatment is indicated in gouty, rheumatic, or syphilitic cases.

There are three methods of inflating the tympanic cavity: (1) Valsalva's; (2) Politzer's; and (3) the catheter. 1. Valsalva's method consists in making forcible expiration with the nose and mouth closed. 2. Politzer's method is as follows: The patient takes a mouthful of water and retains it, till told to swallow; the nose-piece of the air-bag is inserted into one nostril, and the unoccupied portion of this, and the other nostril, are carefully closed by the thumb and index finger of the operator. The patient is then directed to swallow; as he does so, the bag is quickly compressed, thus forcing the air into the tympanic cavity. Where any difficulty is experienced in swallowing at a given moment, Gruber's modification may be used, which consists in directing the patient to say, "Huck!" at the moment of compressing the bag.

3. To pass the catheter: Take it lightly between the thumb and forefinger, and introduce it along the inferior nasal passage, with the curve downwards, till the point reaches the posterior wall of the pharynx. Next pull the instrument forward, till the beak hooks against the soft palate. On rotating it outwards and a little upwards, and pushing it onwards, the point of the instrument will enter the Eustachian orifice. Another method is to rotate the catheter towards the median line on its point reaching the back of the pharynx, and drawing it forwards till it hooks against the back of the nasal septum. The instrument is again rotated upwards and outwards through an angle of nearly  $180^{\circ}$ ; this brings the point directly opposite the Eustachian orifice, and a little pressure of the beak outwards will cause it to enter. Yet a third method is to turn the point of the instrument at once outwards and gently withdraw, until the beak is felt to glide over the posterior prominent edge of the Eustachian orifice. The instrument is then turned a little upwards, and its point enters the orifice.

## INDEX.

- Abercrombie, intracranial disease associated with disease of the nose, 302.
- Abscess of the antrum of Highmore, 159.
- of the brain as a result of intranasal disease, 302.
- of the frontal sinuses, 148; chronic, 152; diagnosis and treatment of, 153.
- of the lachrymal sac, 155; treatment, 157.
- of the septum nasi, 146.
- following exanthemata and erysipelas associated with necrosis, 143.
- scrofulous, simulating fibroma in the pharynx, 221.
- Acne of the nose, causes and treatment, 189.
- syphilitic, resemblance of to lupus, 195.
- Adams, W., on fractures and dislocations of bones of the nose, 244. (Special Article.)
- operation for forcibly straightening the nose in distortion of septum, etc., 247.
- plug of ivory for dilating nostrils, 53.
- serous cysts of antrum in St. Thomas' Hospital Museum, 173.
- Adenoid vegetations of naso-pharyngeal region, 131.
- character of, 132; dangers connected with continuance of, 141; diagnosis of, 135; effects of on articulation and voice, 133; on development and mental condition, 134; on physiognomy, 133; on sense of smell, 134; literature with reference to, 141; operations for removal, 138; prognosis of, 135; results of operations, 140; symptoms of, 132; treatment of, 137.
- Agger nasi, as described by Meyer, 2.
- Albinos, defective sense of smell in, 288.
- Alibert, violent sneezing inducing apoplexy, 297.
- Althaus, Dr., on olfactory neuritis as a cause of loss of smell, 280; on parosmia, 283.
- Anatomy and physiology of nose, 1.
- Anosmia and other derangements of smell, 278.
- Antrum of Highmore, abscess of, 159; cases of abscess from inflammation of nasal fossæ, caries of teeth, etc., 160; cases in infants from injuries during parturition, 164; symptoms, diagnosis, and treatment of abscess, 163; symptoms when the matter is confined, diagnosis, etc., 167; treatment, 179; cysts of the, 172, 176; dentigerous cysts of, from embedding of the permanent teeth, 173; subendosteal, 181; with distension of walls of antrum, 181; diagnosis of cysts, 178, 180; diseases of the, 159; insects, etc., in the, 182; mucous cysts of, 173, 179; tumours, solid, of, 183; tumours with abscess, 170.
- Aprosexia, as a symptom of adenoid growths, 141.
- Area, sensitive, in the nose, 300.
- Arteries of the nasal fossæ, 9.
- Articulation, effect of adenoid growths on, 133.
- Asthma, dependent on intra-nasal disease, 293.
- Auspitz, on the primary seat of lupus non-exedens, 197.
- Banks, case of epistaxis, treatment of bleeding from pharynx by spray injection of perchloride of iron, 101.
- Bellocq's instrument, use of in severe epistaxis, 97; sound, use of, in applying ligature to nasal polypi, 88.
- Bérard, case of destruction of olfactory nerves by tumour without injuring sense of smell, 237.
- Berzelius' analysis of normal nasal mucus, 10.
- Billroth, case of frost-bite of nose, 212.


- Binz, on hay-fever, 42.  
 Bleeding from nose (see *Epistaxis*).  
 Blood-tumours of the septum, 146.  
 Bones of the nose, fractures of the, 244; necrosis and caries of, 143.  
 Bony tumours of the nasal fossæ, 238.  
 Bosworth, Dr. F. H., on asthma dependent on intra-nasal disease, 293; on nasal hydrorrhœa, 175.  
 Bowman's glands, in the olfactory region, 3, 7.  
 Bulbs, olfactory, 3.  
 Burns and scalds of the nose, 254.  
 Butyric acid, smell of, and nerves excited by, 12.  
 Buzzard, Dr., on scorbutic ulcers of the nose, 128.
- Calculi, nasal, cases of, 104; causes, diagnosis, and symptoms of, 103; treatment of, 104.  
 Cancer, rodent, of the nose, 205.  
 Canula, author's, for applying caustics to nasal mucous membrane, 69.  
 Carcinoma of the nasal fossæ, 234.  
 Caries of the bones and cartilages of the nose, 143.  
 Cartilaginous tumours of the nasal fossæ, 240.  
 Catarrh, dry, 55; treatment of, 56.  
 — nasal, character of mucus in, 43; causes of, 41; complications of, 45; forms of, 41; symptoms of, 43; treatment of, 46.  
 Catarrh, post-nasal, question as to its special character, 48; symptoms and treatment of, 49.  
 Catheter, Eustachian, methods of passing, 312.  
 Cautery, electric, for nasal mucous membrane, etc., 71, 199; for nasal polypi, 89.  
 Cells of olfactory region, as described by Frey and Lockhart Clarke, 5, 6; by Schultze, 4.  
 Chilblain of the nose, 211.  
 Clarke, Lockhart, on the terminations of the olfactory nerves, 7.  
 Clark, Sir A., on post-nasal catarrh, 48.  
 Cloquet, on cases of nasal catarrh, 43; records of nasal calculi by different authors, 62; the olfactory region the seat of the organ of smell, 11.  
 Cold, common, means of curing, 46 (see also *Catarrh*).
- Comedones in the skin of the nose, 187.  
 Complications, mental and intracranial of nasal diseases, 301.  
 Contusions and wounds of the nose, 242.  
 Coryza, diphtheritic, 64; strumous, 50; syphilitic, 53 (see also *Catarrh*).  
 Cough, nasal, as a reflex neurosis, 291, 300.  
 Cosme's paste in the treatment of lupus, 199.  
 Cozzolino, Prof., on rhinitis caseosa, 63.  
 Crocodile forceps, author's, for removal of nasal calculi, 105.  
 Croft, Mr., operation for removal of tumours from nasal fossæ, 232.  
 Cumberbatch, Mr. A. E. Article on Diseases of the ear and their connection with nasal diseases, etc., 308.  
 Cysts in the nasal fossæ and nasopharynx, 75.  
 Cysts of the antrum of Highmore, 172.
- Dacryocystitis, or abscess of lachrymal sac, 155.  
 Defects of nose due to disease or injury, 257.  
 Demarquay, case of abscess of frontal sinus bursting into cranial cavity, 304; case of injury of frontal sinus, 305.  
 Derangements, functional, of sense of smell, 278.  
 Dieffenbach's rhinoplastic operation, 266, 269.  
 Dilator, nasal, S. Watson's, 28.  
 Diphtheria of the nasal fossæ, 39.  
 Discharges from the nostrils, preliminary remarks on, 37.  
 Diseases of the accessory cavities, differential diagnosis between, 183.  
 Dislocation of the nasal bones, 246.  
 Distortions of the nose, 255.  
 Douche, nasal, syphon form of, 24.  
 Dressings, bandages, etc., for injuries of the nose, 276.  
 Dropsy of the antrum, 172.  
 Dyspeptic "red-nose," 215.  
 Dysphresia, or impairment of the olfactory sense, 280.
- Ear, Diseases of the, in relation to nasal and pharyngeal disorders

- (Mr. A. E. Cumberbatch's Article), 308.
- Eczema of the nose, lips, etc., 186.
- Electric transillumination for the diagnosis of abscess of the antrum, 170.
- Enchondroma and osteoma of the septum, 240.
- Epistaxis, causes, varieties, and treatment of, 93; dangers connected with plugging the nostrils for, 98; epidemics of, 95; in nasal diphtheria, 95; methods of plugging the nares in severe, 97; simple means of arresting by raising the arms, 100; spontaneous, 95; traumatic, 94; treatment of, 96; vicarious, 95.
- Epithelioma of the nose, 204.
- Erysipelas of the face, of nasal origin, 216.
- Erythematous Lupus of the nose (Article by Dr. R. Liveing), 200.
- Ethmoidal sinuses, diseases of the, 154.
- Exploration, digital, of the nasopharynx, 24, 33.
- Ferrier, Dr., on the position of the olfactory centre, 7.
- Fibroma of the nasal fossæ and nasopharynx, 219; diagnosis and symptoms of, 220; treatment of, 230; affections simulating, 221.
- Fistulous openings into accessory cavities, 273.
- Fœtor of the nostrils, preliminary remarks on, 35.
- Forceps, author's, for removal of polypi, 90.
- Foreign bodies in the nose, 102, 253.
- Fractures and dislocations of the bones of the nose, 244 (Mr. W. Adams's Article).
- Frontal sinuses, diseases of the, 148; abscess of the, 150; abscess bursting into cranial cavity, 304; chronic abscess of the, 152; fatal case of injury of, 305; foreign bodies in, 152; fractures of the walls of the, 151; glanders as affecting the, 152; necrosis of the, 149.
- Frostbite of the nose, 212.
- Functional derangements of smell, 278.
- Gangrene of tip of nose, 213; cases of, at Great Northern Hospital, 214.
- Gelatinous or mucous polypi, 79; treatment, 86.
- Glands of Bowman in the olfactory region, 7.
- Glanders, 125; diagnosis of, 127; prognosis of, 128; symptoms of, 125; treatment of, 128.
- Graham, Prof., on the connection of olfaction with the oxygenation of the odorous substance, 12, 14.
- Gull, Sir W., on cerebral abscess due to nasal disease, 302.
- Gutta rosea of the *alæ nasi*, 191.
- Habershon, Dr., case of blood-poisoning from plugging posterior nares, 98.
- Hæmorrhage, nasal (see *Epistaxis*).
- Hagner's, olfactory, for stopping a cold, 46.
- Hay-fever, 42.
- Hebra on pathology of rhinoscleroma, 208.
- Hamilton, Dr. E., on Smyly's method of plugging posterior nares, 99.
- Herpes of the nose and lip, 185.
- Hunter, John, on the treatment of abscesses of the antrum, 171.
- Hydrorrhœa, nasal, as a symptom of chronic catarrh of the antrum, 175.
- Hyperæmia, intermittent, of the skin of the nose, 215.
- Hyperosmia, or increased acuteness of smell, 280.
- Hypochondriasis due to nasal disease, 301.
- Illumination of nasal fossæ, methods of, 27, 31.
- Inflation of middle ear by Politzer's method, 312.
- Injuries of the nose, 242; with lodgement of foreign bodies, 253.
- Insects, etc., lodgement of, in nose, 112.
- Insufflator, author's, for applying tannin to polypi, 86.
- Jackson, Dr. Hughlings, on anosmia associated with optic neuritis, 281; parosmia, cases of, 283.
- Johnson, Dr. George, case of cyst in nasal fossa, 76.
- Krause, Prof., on cause of ozæna, 59.


- Lachrymal sac and nasal duct, diseases of the, 155.
- Langenbeck's operation for removal of tumours from nasal fossæ, 232.
- Lipoma of nose, pathology, symptoms, and treatment, 207.
- Liveing, Dr. Robert, article on Erythematous Lupus, 200.
- Lupus Erythematodes, causes and symptoms of, 201; diagnosis of, 203; pathology of, 202; treatment of, 203.
- Lupus of the nose, 193; exedens, 194; causes of, 196; diagnosis of, 195; pathology of, 196; prognosis and treatment of, 198; non-exedens, 193.
- Mackenzie, Sir M., cases cited by, of insects in the nose, 112; parosmia, 285; treatment of functional derangements of smell, 290.
- Malformations of the nose, 255.
- Malignant growths in nasal fossæ, 234.
- Mason, Mr. F., rhinoplastic operation devised by, 267.
- Mechanical appliances for relief of mutilations and defects, 257.
- Melancholia due to nasal disease, 301.
- Meningeal inflammation, due to caries of ethmoid, 302.
- Mucous membrane of nose, methods of cleansing, 24; of illuminating, 27.
- Mucus, nasal, physical, and chemical characters of, 10; in catarrh, analysis of, 44.
- Mutilations of the nose, 257.
- Nares, plugging of (*see Epistaxis*).  
— posterior, Dr. Johnson's case of cyst in, 76.
- Nasal bones, dislocation of, 251; fracture of, 244.  
— catarrh, 41.  
— ducts, diseases of the, 155.
- Nasal fossæ, anatomy and physiology of, 1.  
— — cartilaginous and bony tumours of the, 238.  
— — cysts in the, 75.  
— — fibroma and sarcoma of the, 218.  
— — functions and minute anatomy of the, 2.  
— — important effects of, on the tone of the voice, 19.
- Nasal fossæ, maggots, etc., in the, 108.  
— — malignant polypi of the, 234.  
— — mucous membrane of, 3.  
— — nerves, arteries, and veins of, 3, 9.  
— — tumours of the, 218.  
— — ulcerative diseases of the, 113.  
— — vital properties of the, 20.
- Nasal hydrorrhœa, possible cause of, 38; Dr. Bosworth's cases of, 175.
- Naso-pharyngeal region, adenoid vegetations in, 131.
- Necrosis and caries of the bones and cartilages of the nose, 143.
- Negrier, Dr., simple means of arresting epistaxis, 101.
- Nerves, fifth pair of, ulcers in connection with paresis of, 129; of the nasal fossæ, 9; olfactory, 3.
- Neumann, connection of eczema of nose with dyspepsia, etc., 187.
- Neuralgia of the nose, 299.
- Neuroses, reflex, dependent on intranasal disease, 291; literature on subject of, 294.
- Nose, absence of the, 255; broken, truss for supporting bones in, 246; burns and scalds of the, 254; congenital defects of the, 256; contusions of the, 242; defects and mutilations of, due to disease or injury, 257; development of the, 22; displacement of the, 256; distortion of the, 255; double, 257; fractures and dislocations of the bones of the, 244; malformations of the, 255; operations for restoration of the, 261; spasmodic twitching of the, 298.
- Nose and nasal fossæ, anatomy and physiology of the, 1.  
— as part of the mechanism of expression, 18.  
— as influencing the tone of the voice, 19.  
— as part of the respiratory apparatus, 17.  
— bleeding from (*see Epistaxis*).  
— contusions and wounds of the, 242.  
— intracranial complications of affections of the, 301.  
— necrosis of the bones and cartilages of the, 143.
- Noses, artificial, 258.

- Nose-truss for dislocation of the nasal bones, 246, 251.
- Nostrils, bougies and plugs for dilating, 53, 73; clefts in the, 257; discharges from the, 37; foreign bodies in the, 102, 253; imperforate, 255; plugging, methods of, in epistaxis, 97.
- Obstructions of the lachrymal sac and duct, 155.
- Ogle, Dr. W., on flavours as connected with the sense of smell, 11; odorous impressions as the result of vibrations, 14; loss of smell after catarrh, 287.
- Olfaction, chemical theory of, 12; essential conditions for, 15.
- Olfactometer, Swardemaker's, 278.
- Olfactory region proper, the, 3; cells of in the frog, 5; epithelial cells of as described by Max Schultze, 4; glands of, 3, 7.
- Operations, rhinoplastic, 261.
- Optic neuritis connected with anosmia, 281.
- Ozæna, causes of, 57; diagnosis of, 60; pathology of, 59; prognosis and symptoms of, 58; summary of the views of Rouge on, 113; treatment of, 60.
- syphilitic, 113; diagnosis of, 115; treatment of, 117.
- Paget, Sir J., case of polypus of the antrum, with persistent escape of clear fluid from the nostril, 174.
- Palate, author's mode of controlling during rhinoscopy, 32.
- Palate-hooks, 30.
- Paralysis of common sensation in the nose, 299.
- Parosmia, or perversion of sense of smell, 283.
- Payne, Dr., on pathology of rhinoscleroma, 210.
- "Peenash," or maggots in the nose, in human beings and camels in India, 110.
- Pigment, disappearance of, connected with anosmia, 287.
- Polypi of the nose, gelatinous or mucous, 79; diagnosis of, 84; forms and appearances of, 81; minute structure of, 82; symptoms of, 83; thickening of mucous membrane simulating, 85; treatment of, 86; usual position of, 79; malignant, of the nasal fossæ, 234.
- Polypus, nasal, causing intra-cranial disease (Mr. Simon's case of), 303.
- Rhinitis atrophica (see *Ozæna*).
- caseosa, 63.
- chronic hypertrophic, 66; cases of, 73; causes and pathology of, 66; diagnosis of, 67; symptoms and progress of, 66, 67; treatment of, 69.
- Rhinoliths, or chalky concretions, 40 (see also *Calculi, nasal*).
- Rhinoplastic operations, 261; author's method, 270; causes of failure in, 275; Dieffenbach's method, 269; Langenbeck's, 262; Mr. F. Mason's, 267; Mr. J. Wood's, 263; Sir W. Fergusson's, 270.
- Rhinorrhœa, strumous, 50; stenosis, caused by, 51; treatment of, 52.
- Rhinoscleroma, Hebra on pathology of, 208.
- Rhinoscopy, anterior, requisites for, 27; methods of illumination for, 31; parts seen during, 29, 33; posterior, 30; preliminary remarks on, 24.
- Ring-knife for growths on nasal mucous membrane, 72.
- Robinson, Beverley, on post-nasal catarrh, 48.
- Rodent ulcer of the nose, 205.
- Rose, Dr. Cooper, method of plugging nares, 99.
- Rouge, Dr., on cause and treatment of ozæna, 113; operation for removal of sequestra from nares (with case), 144.
- Sajous, Dr., on removal of foreign bodies from nose, 102.
- Sarcoma of the nasal fossæ, 226; author's case of, 227; treatment of, 230.
- Schultze, on the minute anatomy of the olfactory region, 4.
- Septum, enchondroma and osteoma of the, 240; injuries of the, 243; lateral deviations of the, 256; ulceration, abscesses and blood tumours of, 146.
- Sinuses (see *frontal, ethmoidal, etc.*)
- Skin and subcutaneous tissue of nose, diseases of the, 185.
- Smell, derangements of, 280.
- loss of, causes of, 280; connected with disappearance of pigment, 287; due to disease of bone and soft tissues, 285; following

- severe catarrhal attacks with violent sneezing, 286.
- Smell, sense of, olfactory region alone, the seat of, 11; organic substances, the principal excitants of, 11.
- Sneezing, as a cause of loss of smell, 286; causes and occasional consequences of, 296.
- Snorting, spasmodic, author's case of, 292.
- Spasmodic twitching of the nose, 298.
- Specula, nasal, various forms of, 29.
- Sphenoidal sinuses, diseases of the, 154.
- Stenosis, nasal, preliminary remarks on, 34.
- Stylets for applying cocain, author's, 29.
- Styptic colloid (Dr. Richardson's), as an application after injuries, etc., 276.
- Subcutaneous rhinoplastic operation, author's, 270.
- Sycosis of the nostrils, 190.
- Syphilitic acne, 195; coryza, 53; syphilitic sarcoma of the pharynx and upper jaw, simulating nasopharyngeal polypus, case of, 222.
- Syphilitic ulcers, erosive, of nostrils (ozæna), 113; case of, 118; diagnosis of, 115; treatment of, 117; primary, of nostrils, 117.
- Taliacotian operation, 261.
- Taste, difference between sense of, and that of smell, 11.
- Teeth, decayed, their connection with abscess of the antrum, 160.
- Tests for acuteness of smell, 278.
- Tongue depressor, Türck's, 30.
- Trousseau, formulæ for topical applications in ozæna, 119.
- Tumour, fibrous, of second division of fifth pair, simulating polypus, 306.
- Tumours of the nasal fossæ, and naso-pharyngeal polypi, 218.
- Tympanum, catarrh of, in connection with nasal and naso-pharyngeal disease, 309; methods of inflating, 312.
- Ulcers of nose, as sequelæ of fevers and catarrh, 124; eczematous, 123; erosive syphilitic, 113; glanderous, 126; in connection with paresis of the fifth pair of nerves, 129; lupoid, 121; rodent, 205; scorbutic, 128; tuberculous, 130.
- Valentin, experiments by, with regard to seat of organ of smell, 11.
- Vegetations, adenoid, of nasopharynx, 131.
- Veins of the nasal fossæ, 9.
- Walker, Swift, successful case of restoration of nose, 263.
- Weber, Dr., method of opening the antrum, 182.
- Wood, Mr. John, case of rhinoplastic operation, 264.
- Worms in the nose, or "peenash" (India), 148.
- Wounds of the nose, 242.
- Zinc, chloride of, in treatment of lupus, 199.
- Zuckerkindl, on intra-nasal growths, 80.







July, 1890.

# CATALOGUE OF WORKS

PUBLISHED BY

## H. K. LEWIS

136 GOWER STREET, LONDON, W.C.

Established 1844.

---

SIR WILLIAM AITKEN, KNT., M.D., F.R.S.  
*Professor of Pathology in the Army Medical School.*

**ON THE ANIMAL ALKALOIDS, THE PTOMAINES,  
LEUCOMAINES, AND EXTRACTIVES IN THEIR PATHOLOGICAL  
RELATIONS.** Second edition, Crown 8vo, 3s. 6d.

---

E. CRESSWELL BABER, M.B. LOND.  
*Surgeon to the Brighton and Sussex Throat and Ear Dispensary.*

**A GUIDE TO THE EXAMINATION OF THE NOSE,  
WITH REMARKS ON THE DIAGNOSIS OF DISEASES OF  
THE NASAL CAVITIES.** With Illustrations, small 8vo, 5s. 6d.

---

JAMES B. BALL, M.D. LOND., M.R.C.P.  
*Physician to the Department for Diseases of the Throat and Nose, and Senior Assistant  
Physician, West London Hospital.*

**A HANDBOOK OF DISEASES OF THE NOSE AND  
NASO-PHARYNX.** Large post 8vo, with illustrations, 6s.

---

G. GRANVILLE BANTOCK, M.D., F.R.C.S. EDIN.  
*Surgeon to the Samaritan Free Hospital for Women and Children.*

I.

**ON THE USE AND ABUSE OF PESSARIES.** Second Edit.,  
with Illustrations, 8vo, 5s.

II.

**ON THE TREATMENT OF RUPTURE OF THE  
FEMALE PERINEUM IMMEDIATE AND REMOTE.** Second  
Edition, with Illustrations, 8vo, 3s. 6d.

III.

**A PLEA FOR EARLY OVARIOTOMY.** Demy 8vo, 2s.

FANCOURT BARNES, M.D., M.R.C.P.

*Physician to the Chelsea Hospital for Women; Obstetric Physician to the Great Northern Hospital, &c.*

**A GERMAN-ENGLISH DICTIONARY OF WORDS AND TERMS USED IN MEDICINE AND ITS COGNATE SCIENCES.**  
Square 12mo, Roxburgh binding, 9s.

ASHLEY W. BARRETT, M.B. LOND., M.R.C.S., L.D.S.E.

*Dental Surgeon to, and Lecturer on Dental Surgery in the Medical School of, the London Hospital.*

**DENTAL SURGERY FOR MEDICAL PRACTITIONERS AND STUDENTS OF MEDICINE.** Second edition, With Illustrations, cr. 8vo, 3s. 6d. [Now ready.]

[LEWIS'S PRACTICAL SERIES.]

ROBERTS BARTHOLOW, M.A., M.D., LL.D.

*Professor of Materia Medica and Therapeutics in the Jefferson Medical College of Philadelphia, &c., &c.*

I.

**A PRACTICAL TREATISE ON MATERIA MEDICA AND THERAPEUTICS.** Seventh Edition, Revised and Enlarged, 8vo, 18s. [Just published.]

II.

**A TREATISE ON THE PRACTICE OF MEDICINE, FOR THE USE OF STUDENTS AND PRACTITIONERS.** Fifth Edition, with Illustrations, large 8vo, 21s.

H. CHARLTON BASTIAN, M.A., M.D., F.R.S.

*Examiner in Medicine at the Royal College of Physicians; Professor of the Principles and Practice of Medicine in University College, London; Physician to University College Hospital, &c.*

**PARALYSES: CEREBRAL, BULBAR, AND SPINAL.**  
A MANUAL OF DIAGNOSIS FOR STUDENTS AND PRACTITIONERS. With numerous Illustrations, 8vo, 12s. 6d.

GEO. M. BEARD, A.M., M.D.

*Fellow of the New York Academy of Medicine. &c.*

AND

A. D. ROCKWELL, A.M., M.D.

*Professor of Electro-Therapeutics in the New York Post Graduate Medical School.*

I.

**A PRACTICAL TREATISE ON THE MEDICAL AND SURGICAL USES OF ELECTRICITY.** Including Localized and General Faradization; Localized and Central Galvanization; Franklinization; Electrolysis and Galvano-Cautery. Sixth Edition. With nearly 200 Illustrations, roy. 8vo, 28s.

II.

**NERVOUS EXHAUSTION (NEURASTHENIA) ITS HYGIENE, CAUSES, SYMPTOMS AND TREATMENT.** Second edition, 8vo, 7s. 6d.

W. M. BEAUMONT.

*Surgeon to the Bath Eye Infirmary.*

**THE SHADOW-TEST IN THE DIAGNOSIS AND ESTIMATION OF AMETROPIA.** Post 8vo, 2s. 6d.

---

E. H. BENNETT, M.D., F.R.C.S.I.  
*Professor of Surgery, University of Dublin.*

AND

D. J. CUNNINGHAM, M.D., F.R.C.S.I.  
*Professor of Anatomy and Chirurgery, University of Dublin.*

**'THE SECTIONAL ANATOMY OF CONGENITAL  
CÆCAL HERNIA.** With coloured plates, sm. folio, 5s. 6d.

---

A. HUGHES BENNETT, M.D., M.R.C.P.  
*Physician to the Hospital for Epilepsy and Paralysis, Regent's Park, and Assistant Physi-  
cian to the Westminster Hospital.*

I.

**A PRACTICAL TREATISE ON ELECTRO-DIAGNOSIS  
IN DISEASES OF THE NERVOUS-SYSTEM.** With Illustrations,  
8vo, 8s. 6d.

II.

**ILLUSTRATIONS OF THE SUPERFICIAL NERVES  
AND MUSCLES, WITH THEIR MOTOR POINTS;** a knowledge  
of which is essential in the Art of Electro-Diagnosis. (Extracted from  
the above). 8vo, paper cover, 1s. 6d.; cloth, 2s.

---

HORATIO R. BIGELOW, M.D.  
*Permanent Member of the American Medical Association; Fellow of the British Gynæ-  
cological Society, &c.*

**GYNÆCOLOGICAL ELECTRO-THERAPEUTICS.** With  
an Introduction by DR. GEORGES APOSTOLI. With Illustrations, demy  
8vo, 8s. 6d.

---

DR. THEODOR BILLROTH.  
*Professor of Surgery in Vienna.*

**GENERAL SURGICAL PATHOLOGY AND THERA-  
PEUTICS.** In Fifty-one Lectures. A Text-book for Students and  
Physicians. With additions by Dr. ALEXANDER VON WINIWARTER, Pro-  
fessor of Surgery in Luttich. Translated from the Fourth German edi-  
tion with the special permission of the Author, and revised from the  
Tenth edition, by C. E. HACKLEY, A.M., M.D. Copiously illustrated,  
8vo, 18s.

---

DRS. BOURNEVILLE AND BRICON.  
**MANUAL OF HYPODERMIC MEDICATION.**  
Translated from the Second Edition, and Edited, with Therapeutic  
Index of Diseases, by ANDREW S. CURRIE, M.D. Edin., &c.  
With Illustrations, crown 8vo, 6s.

---

G. H. BRANDT, M.D.

**HAMMAM R'IRHA, ALGIERS.** A Winter Health Re-  
sort and Mineral Water Cure Combined. With Frontispiece and Map,  
crown 8vo, 2s. 6d.

---

GURDON BUCK, M.D.

**CONTRIBUTIONS TO REPARATIVE SURGERY:**  
Showing its Application to the Treatment of Deformities, produced by  
Destructive Disease or Injury; Congenital Defects from Arrest or Excess  
of Development; and Cicatricial Contractions from Burns. Illustrated  
by numerous Engravings, large 8vo, 9s.

---

MARY BULLAR & J. F. BULLAR, M.B. CANTAB., F.R.C.S.  
**RECEIPTS FOR FLUID FOODS.** 16mo, 1s.

---

STEPHEN SMITH BURT, M.D.  
*Professor of Clinical Medicine and Physical Diagnosis in the New York Post-graduate  
 School and Hospital.*

**EXPLORATION OF THE CHEST IN HEALTH AND  
 DISEASE.** With Illustrations, crown 8vo, 6s.

---

DUDLEY W. BUXTON, M.D., B.S., M.R.C.P.  
*Administrator of Anæsthetics at University College Hospital and the Hospital for Women,  
 Soho Square.*

**ANÆSTHETICS THEIR USES AND ADMINISTRATION.** Second edition, with illustrations, crown 8vo. [*In the press.*]  
 [LEWIS'S PRACTICAL SERIES.]

---

HARRY CAMPBELL, M.D., B.S. LOND., M.R.C.S.  
*Assistant Physician and Pathologist to the North-West London Hospital.*

I.  
**THE CAUSATION OF DISEASE:** An exposition of the ultimate factors which induce it. Demy 8vo, 12s. 6d.

II.  
**FLUSHING AND MORBID BLUSHING: THEIR  
 PATHOLOGY AND TREATMENT.** With plates and wood engravings, royal 8vo, 10s. 6d. [*Now ready.*]

---

ALFRED H. CARTER, M.D. LOND.  
*Member of the Royal College of Physicians; Physician to the Queen's Hospital, Birmingham;  
 late Examiner in Medicine for the University of Aberdeen, &c.*

**ELEMENTS OF PRACTICAL MEDICINE.** Fifth Edition, crown 8vo, 9s.

---

P. CAZEAUX.  
*Adjunct Professor in the Faculty of Medicine of Paris, &c.*

AND

S. TARNIER.  
*Professor of Obstetrics and Diseases of Women and Children in the Faculty of Medicine of  
 Paris.*

**OBSTETRICS: THE THEORY AND PRACTICE;** including the Diseases of Pregnancy and Parturition, Obstetrical Operations, &c. Seventh Edition, edited and revised by ROBERT J. HESS, M.D., with twelve full-page plates, five being coloured, and 165 wood-engravings, 1081 pages, roy. 8vo, 35s.

---

F. H. CHAMPNEYS, M.A., M.D. OXON., F.R.C.P.  
*Obstetric Physician and Lecturer on Obstetric Medicine at St. George's Hospital: Examiner  
 in Obstetric Medicine in the University of London, &c.*

**EXPERIMENTAL RESEARCHES IN ARTIFICIAL  
 RESPIRATION IN STILLBORN CHILDREN, AND ALLIED SUBJECTS.** Crown 8vo, 3s. 6d.

---

W. BRUCE CLARKE, M.A., M.B. OXON., F.R.C.S.  
*Assistant Surgeon to, and Senior Demonstrator of Anatomy and Operative Surgery at,  
St. Bartholomew's Hospital; Surgeon to the West London Hospital; Examiner  
in Surgery to the University of Oxford.*

**THE DIAGNOSIS AND TREATMENT OF DISEASES  
OF THE KIDNEY AMENABLE TO DIRECT SURGICAL IN-  
TERFERENCE.** Demy 8vo, with Illustrations, 7s. 6d.

---

JOHN COCKLE, M.A., M.D.  
*Physician to the Royal Free Hospital.*

**ON INTRA-THORACIC CANCER.** 8vo, 4s. 6d.

---

ALEXANDER COLLIE, M.D. ABERD., M.R.C.P. LOND.  
*Medical Superintendent of the Eastern Hospitals.*

**ON FEVERS: THEIR HISTORY, ETIOLOGY, DIAG-  
NOSIS, PROGNOSIS, AND TREATMENT.** Illustrated with  
Coloured Plates, crown 8vo, 8s. 6d. [LEWIS'S PRACTICAL SERIES.]

---

M. P. MAYO COLLIER, M.B., M.S. LOND., F.R.C.S. ENG.  
*Professor of Comparative Anatomy and Physiology at the Royal College of Surgeons,  
England, &c.*

**THE PHYSIOLOGY OF THE VASCULAR SYSTEM.**  
Illustrations, 8vo, 3s. 6d.

---

WALTER S. COLMAN, M.B., M.R.C.P. LOND.  
*Pathologist and Registrar to the National Hospital for the Paralysed and Epileptic;  
Formerly Assistant to the Professor of Pathology in the University of Edinburgh.*

**SECTION CUTTING AND STAINING: A Practical  
Guide to the Preparation of Normal and Morbid Histological Specimens.**  
Crown 8vo, 3s. [Now ready.]

---

ALFRED COOPER, F.R.C.S.  
*Surgeon to the St. Mark's Hospital for Fistula and other Diseases of the Rectum.*  
**A PRACTICAL TREATISE ON THE DISEASES OF  
THE RECTUM.** Crown 8vo, 4s.

---

W. H. CORFIELD, M.A., M.D. OXON.  
*Professor of Hygiene and Public Health in University College, London.*  
**DWELLING HOUSES: their Sanitary Construction and  
Arrangements.** Second Edit., with Illustrations. Cr. 8vo, 3s. 6d.

---

J. LEONARD CORNING, M.A., M.D.  
*Consultant in Nervous Diseases to St. Francis Hospital.*  
**A PRACTICAL TREATISE ON HEADACHE, NEU-  
RALGIA, SLEEP AND ITS DERANGEMENTS, AND SPINAL  
IRRITATION.** With an Appendix—Eye Strain, a Cause of Headache.  
By DAVID WEBSTER, M.D. Second edition, Demy 8vo, 7s. 6d.

---

EDWARD COTTERELL, M.R.C.S. ENG., L.R.C.P. LOND.  
*Late House Surgeon, University College Hospital.*  
**ON SOME COMMON INJURIES TO LIMBS; their  
Treatment and After-treatment, including Bone-setting (so-called).  
With Illustrations, small 8vo, 3s. 6d.**

---

CHARLES CREIGHTON, M.D.

I.

**ILLUSTRATIONS OF UNCONSCIOUS MEMORY IN DISEASE**, including a Theory of Alteratives. Post 8vo, 6s.

II.

**CONTRIBUTIONS TO THE PHYSIOLOGY AND PATHOLOGY OF THE BREAST AND LYMPHATIC GLANDS.** New Edition with additional chapter, with wood-cuts and plate, 8vo, 9s.

III.

**BOVINE TUBERCULOSIS IN MAN:** An Account of the Pathology of Suspected Cases. With Chromo-lithographs and other Illustrations, 8vo, 8s. 6d.

---

H. RADCLIFFE CROCKER, M.D. LOND., B.S., F.R.C.P.  
*Physician, Skin Department, University College Hospital.*

**DISEASES OF THE SKIN; THEIR DESCRIPTION, PATHOLOGY, DIAGNOSIS, AND TREATMENT.** With 76 Illustrations, 8vo, 21s.

---

EDGAR M. CROOKSHANK, M.B. LOND., F.R.M.S.  
*Professor of Comparative Pathology and Bacteriology in, and Fellow of King's College, London.*

I.

**HISTORY AND PATHOLOGY OF VACCINATION.** Vol. I., A Critical Inquiry. Vol. II., Selected Essays, (Edited) including works by Jenner, Pearson, Woodville, Henry Jenner, Loy, Rogers, Birch, Bousquet, Estlin, Ceely, Badcock, Auzias-Turenne, Dubreuilh and Layet. Two volumes, illustrated with 22 coloured plates, including reproductions of the plates illustrating Jenner's Inquiry, of selected plates from the work of Ceely and others, and with a reduced facsimile of an engraving of Mr. Jesty, a facsimile of the first folio of the manuscript of Jenner's original paper, a facsimile of an unpublished letter from Jenner to Mr. Head, Royal 8vo, 36s.

II.

**MANUAL OF BACTERIOLOGY:** being an Introduction to Practical Bacteriology. Illustrated with Coloured Plates from original drawings, and with other Illustrations in the text. Third Edition, 8vo. [*In preparation.*]

III.

**PHOTOGRAPHY OF BACTERIA.** Illustrated with 86 Photographs reproduced in autotype, and wood engravings, royal 8vo, 12s. 6d.

---

RIDLEY DALE, M.D., L.R.C.P. EDIN., M.R.C.S. ENG.

**EPITOME OF SURGERY,** being a complete compendium of the Science and Art of Surgery. Large 8vo, 10s. 6d.

---

HERBERT DAVIES, M.D., F.R.C.P.  
*Late Consulting Physician to the London Hospital.*

**THE MECHANISM OF THE CIRCULATION OF THE BLOOD THROUGH ORGANICALLY DISEASED HEARTS.** Edited by ARTHUR TEMPLER DAVIES, B.A. (Nat. Science Honours), M.B. Cantab., M.R.C.P.; Physician to the Royal Hospital for Diseases of the Chest. Crown 8vo, 3s. 6d.

---

HENRY DAVIS, M.R.C.S. ENG.

*Teacher and Administrator of Anæsthetics to St. Mary's and the National Dental Hospitals*

**GUIDE TO THE ADMINISTRATION OF ANÆSTHETICS.** Fcap. 8vo, 2s.

---

J. THOMPSON DICKSON, M.A., M.B. CANTAB.

*Late Lecturer on Mental Diseases at Guy's Hospital.*

**THE SCIENCE AND PRACTICE OF MEDICINE IN RELATION TO MIND,** the Pathology of the Nerve Centres, and the Jurisprudence of Insanity being a course of Lectures delivered at Guy's Hospital. Illustrated by Chromo-lithographic Drawings and Physiological Portraits. 8vo, 14s.

---

HORACE DOBELL, M.D.

*Consulting Physician to the Royal Hospital for Diseases of the Chest, &c.*

I.  
**ON DIET AND REGIMEN IN SICKNESS AND** Health and on the Interdependence and Prevention of Diseases and the Diminution of their Fatality. Seventh Edition, 8vo, 10s. 6d.

II.  
**AFFECTIONS OF THE HEART AND IN ITS NEIGHBOURHOOD.** Cases, Aphorisms, and Commentaries. Illustrated by the heliotype process. 8vo, 6s 6d.

---

JOHN EAGLE.

*Member of the Pharmaceutical Society.*

**A NOTE-BOOK OF SOLUBILITIES.** Arranged chiefly for the use of Prescribers and Dispensers. 12mo, 2s. 6d.

---

JOHN ERIC ERICHSEN.

*Ex-President of the Royal College of Surgeons; Surgeon Extraordinary to H.M. the Queen, etc.*

**MODERN SURGERY; its Progress and Tendencies.** Being the Introductory Address delivered at University College at the opening of the Session 1873-74. Demy 8vo, 1s.

---

DR. FERBER.

**MODEL DIAGRAM OF THE ORGANS IN THE THORAX AND UPPER PART OF THE ABDOMEN.** With Letter-press Description. In 4to, coloured, 5s.

---

J. MAGEE FINNY, M.D. DUBL.

*King's Professor of Practice of Medicine in School of Physic, Ireland, &c.*

**NOTES ON THE PHYSICAL DIAGNOSIS OF LUNG DISEASES.** 32mo, 1s. 6d. [Now ready.]



AUSTIN FLINT, M.D., LL.D.

*Professor of Physiology and Physiological Anatomy in the Bellevue Hospital Medical College, New York; visiting Physician to the Bellevue Hospital, &c.*

I.

**A TEXT-BOOK OF HUMAN PHYSIOLOGY.** Fourth edition, Illustrated by plates, and 316 wood engravings, large 8vo, 25s.

II.

**THE PHYSIOLOGY OF THE SPECIAL SENSES AND GENERATION;** (Being Vol. V. of the Physiology of Man). Roy. 8vo. 18s.

J. MILNER FOTHERGILL, M.D., M.R.C.P.

*Late Physician to the City of London Hospital for Diseases of the Chest, Victoria Park, &c.*

I.

**A MANUAL OF DIETETICS.** Large 8vo, 10s. 6d.

II.

**THE HEART AND ITS DISEASES, WITH THEIR TREATMENT;** INCLUDING THE GOUTY HEART. Second Edition, entirely re-written, copiously illustrated with woodcuts and lithographic plates. 8vo. 16s.

III.

**INDIGESTION AND BILIOUSNESS.** Second Edition, post 8vo, 7s. 6d.

IV.

**GOUT IN ITS PROTEAN ASPECTS.** Post 8vo, 7s. 6d.

V.

**THE TOWN DWELLER: His Needs and His Wants.** With an Introduction by B. W. RICHARDSON, M.D., LL.D., F.R.S. Post 8vo, 3s. 6d. [Now ready.]

VI.

**HEART STARVATION.** (Reprinted from the Edinburgh Medical Journal). 8vo, 1s.

FORTESCUE FOX, M.D. LOND.

*Fellow of the Medical Society of London.*

**STRATHPEFFER SPA: Its Climate and Waters.** With OBSERVATIONS HISTORICAL, MEDICAL, AND GENERAL, DESCRIPTIVE OF THE VICINITY. Crown 8vo, with Map and Illustrations, 2s. 6d., *nett.*

ERNEST FRANCIS, F.C.S.

*Demonstrator of Practical Chemistry, Charing Cross Hospital.*

**PRACTICAL EXAMPLES IN QUANTITATIVE ANALYSIS,** forming a Concise Guide to the Analysis of Water, &c. Illustrated, fcap. 8vo, 2s. 6d.

ALFRED W. GERRARD, F.C.S.

*Examiner to the Pharmaceutical Society; Teacher of Pharmacy and Demonstrator of Materia Medica at University College Hospital.*

**ELEMENTS OF MATERIA MEDICA AND PHARMACY.** Crown 8vo, 8s. 6d.

---

HENEAGE GIBBES, M.D.

*Lecturer on Physiology and on Normal and Morbid Histology in the Medical School of Westminster Hospital; etc.*

**PRACTICAL HISTOLOGY AND PATHOLOGY.** Third Edition, revised and enlarged, crown 8vo, 6s.

---

C. A. GORDON, M.D., C.B.

*Deputy Inspector General of Hospitals, Army Medical Department.*

**REMARKS ON ARMY SURGEONS AND THEIR WORKS.** Demy 8vo, 5s.

---

JOHN GORHAM, M.R.C.S.

**TOOTH EXTRACTION:** a Manual on the proper mode of extracting Teeth. Third Edition, fcap. 8vo, 1s. 6d. [Now ready.]

---

GEORGE M. GOULD, B.A., M.D.

*Ophthalmic Surgeon to the Philadelphia Hospital, etc.*

**A NEW MEDICAL DICTIONARY:** including all the words and phrases used in Medicine, with their proper pronunciation and definitions, 8vo, 16s.

---

W. R. GOWERS, M.D., F.R.C.P., M.R.C.S.

*Physician to University College Hospital, &c.*

**DIAGRAMS FOR THE RECORD OF PHYSICAL SIGNS.** In books of 12 sets of figures, 1s. Ditto, unbound, 1s.

---

J. B. GRESSWELL, M.R.C.V.S.

*Provincial Veterinary Surgeon to the Royal Agricultural Society.*

**VETERINARY PHARMACOLOGY AND THERAPEUTICS.** With an Index of Diseases and Remedies. Fcap. 8vo, 5s.

---

SAMUEL D. GROSS, M.D., LL.D., D.C.L. OXON.

*Professor of Surgery in the Jefferson Medical College of Philadelphia.*

**A PRACTICAL TREATISE ON THE DISEASES, INJURIES, AND MALFORMATIONS OF THE URINARY BLADDER, THE PROSTATE GLAND, AND THE URETHRA.** Third Edition, revised and edited by S. W. GROSS, A.M., M.D., Surgeon to the Philadelphia Hospital. Illustrated by 170 engravings, 8vo, 18s.

---

ALLAN McLANE HAMILTON, M.D.

**THE MODERN TREATMENT OF HEADACHES.**

Square 16mo, 2s. 6d.

[Just Published.]

WILLIAM A. HAMMOND, M.D.

*Professor of Mental and Nervous Diseases in the Medical Department of the University of the City of New York, &c.*

I.

**A TREATISE ON THE DISEASES OF THE NERVOUS SYSTEM.** Seventh edition, with 112 Illustrations, large 8vo, 25s.

II.

**A TREATISE ON INSANITY.** Large 8vo, 25s.

III.

**SPIRITUALISM AND ALLIED CAUSES AND CONDITIONS OF NERVOUS DERANGEMENT.** With Illustrations, post 8vo, 8s. 6d.

ALEXANDER HARVEY, M.A., M.D.

*Late Emeritus Professor of Materia Medica in the University of Aberdeen; Consulting Physician to the Aberdeen Royal Infirmary, &c.*

I.

**FIRST LINES OF THERAPEUTICS;** as based on the Modes and the Processes of Healing, as occurring Spontaneously, in Disease; and on the Modes and the Processes of Dying, as resulting Naturally from Disease. In a series of Lectures. Post 8vo, 5s.

II.

**ON THE FŒTUS IN UTERO AS INOCULATING THE MATERNAL WITH THE PECULIARITIES OF THE PATER-  
NAL ORGANISM.** In a series of Essays now first collected. Fcap. 8vo, 4s. 6d.

ALEXANDER HARVEY, M.D.

*Late Emeritus Professor of Materia Medica in the University of Aberdeen, &c*

AND

ALEXANDER DYCE DAVIDSON, M.D., F.R.S. EDIN.

*Late Regius Professor of Materia Medica in the University of Aberdeen.*

**SYLLABUS OF MATERIA MEDICA FOR THE USE OF STUDENTS, TEACHERS AND PRACTITIONERS.** Based on the relative values of articles and preparations in the British Pharmacopœia. Ninth edition, 32mo, 1s. 6d.

K. M. HEANLEY.

*Matron of Boston Cottage Hospital.*

**A MANUAL OF URINE TESTING.** Compiled for the use of Matrons, Nurses, and Probationers. Post 8vo, 1s. 6d.

GRAILY HEWITT, M.D.

*Professor of Midwifery and Diseases of Women in University College, Obstetrical Physician to University College Hospital, &c.*

**OUTLINES OF PICTORIAL DIAGNOSIS OF DISEASES OF WOMEN.** Folio, 6s.

---

C. HIGGENS, F.R.C.S.

*Ophthalmic Surgeon to Guy's Hospital; Lecturer on Ophthalmology at Guy's Hospital Medical School.*

**MANUAL OF OPHTHALMIC PRACTICE.**

Crown 8vo, illustrations, 6s.

[LEWIS'S PRACTICAL SERIES.]

---

BERKELEY HILL, M.B. LOND., F.R.C.S.

*Professor of Clinical Surgery in University College; Surgeon to University College Hospital and to the Lock Hospital.*

I.

**THE ESSENTIALS OF BANDAGING.** With directions for Managing Fractures and Dislocations; for administering Ether and Chloroform; and for using other Surgical Apparatus; with a Chapter on Surgical Landmarks. Sixth Edition, revised and enlarged, Illustrated by 144 Wood Engravings, crown 8vo, 5s.

II.

**CHRONIC URETHRITIS, AND OTHER AFFECTIONS OF THE GENITO-URINARY ORGANS.** Coloured plates, Royal 8vo, 3s. 6d.

---

BERKELEY HILL, M.B. LOND., F.R.C.S.

*Professor of Clinical Surgery in University College; Surgeon to University College Hospital and to the Lock Hospital.*

AND

ARTHUR COOPER, L.R.C.P., M.R.C.S.

*Surgeon to the Westminster General Dispensary.*

I.

**SYPHILIS AND LOCAL CONTAGIOUS DISORDERS.**

Second edition, entirely re-written, royal 8vo, 18s.

II.

**THE STUDENT'S MANUAL OF VENEREAL DISEASES.** Being a Concise Description of those Affections and of their Treatment. Fourth edition, post 8vo, 2s. 6d.

---

C. R. ILLINGWORTH, M.D. ED., M.R.C.S.

**THE ABORTIVE TREATMENT OF SPECIFIC FEBRILE DISORDERS BY THE BINIODIDE OF MERCURY.**

Crown 8vo, 3s. 6d.

---

SIR W. JENNER, Bart., M.D.

*Physician in Ordinary to H.M. the Queen, and to H.R.H. the Prince of Wales.*

**THE PRACTICAL MEDICINE OF TO-DAY: Two**

Addresses delivered before the British Medical Association, and the Epidemiological Society, (1869). Small 8vo, 1s. 6d.

---

GEORGE LINDSAY JOHNSON, M.A., M.B., B.C. CANTAB.

*Clinical Assistant, late House Surgeon and Chloroformist, Royal Westminster Ophthalmic Hospital, &c.*

**A NEW METHOD OF TREATING CHRONIC GLAUCOMA,** based on Recent Researches into its Pathology. With Illustrations and coloured frontispiece, demy 8vo, 3s. 6d.

NORMAN KERR, M.D., F.L.S.

*President of the Society for the Study of Inebriety; Consulting Physician, Dalrymple Home for Inebriates, etc.*

**INEBRIETY: its Etiology, Pathology, Treatment, and Jurisprudence.** Second edition, Crown 8vo, 12s. 6d.

NORMAN W. KINGSLEY, M.D.S., D.D.S.

*President of the Board of Censors of the State of New York; Member of the American Academy of Dental Science, &c.*

**A TREATISE ON ORAL DEFORMITIES AS A BRANCH OF MECHANICAL SURGERY.** With over 350 Illustrations, 8vo, 16s. [Now ready.]

J. WICKHAM LEGG, F.R.C.P.

*Assistant Physician to Saint Bartholomew's Hospital, and Lecturer on Pathological Anatomy in the Medical School.*

I.

**ON THE BILE, JAUNDICE, AND BILIOUS DISEASES.** With Illustrations in chromo-lithography, 719 pages, roy. 8vo, 25s.

II.

**A GUIDE TO THE EXAMINATION OF THE URINE;** intended chiefly for Clinical Clerks and Students. Sixth Edition, revised and enlarged, with Illustrations, fcap. 8vo, 2s. 6d.

III.

**A TREATISE ON HÆMOPHILIA, SOMETIMES CALLED THE HEREDITARY HÆMORRHAGIC DIATHESIS.** Fcap. 4to, 7s. 6d.

ARTHUR H. N. LEWERS, M.D. LOND., M.R.C.P. LOND.

*Assistant Obstetric Physician to the London Hospital; Examiner in Midwifery and Diseases of Women to the Society of Apothecaries of London, &c.*

**A PRACTICAL TEXTBOOK OF THE DISEASES OF WOMEN.** Second edition, Illustrations, crown 8vo, 9s. [Now ready.]  
[LEWIS'S PRACTICAL SERIES.]

DR. GEORGE LEWIN.

*Professor at the Fr. Wilh. University, and Surgeon-in-Chief of the Syphilitic Wards and Skin Disease Wards of the Charité Hospital, Berlin.*

**THE TREATMENT OF SYPHILIS WITH SUBCUTANEOUS SUBLIMATE INJECTIONS.** Translated by DR. CARL PRÆGLE, and DR. E. H. GALE, late Surgeon United States Army. Small 8vo, 7s.

**LEWIS'S POCKET CASE BOOK FOR PRACTITIONERS AND STUDENTS.** Designed by A. T. BRAND, M.D. Roan, with pencil, 3s. 6d. *nett.*

**LEWIS'S POCKET MEDICAL VOCABULARY.** Over 200 pp., 32mo, roan, 3s. 6d.

## LEWIS'S PRACTICAL SERIES.

Under this title Mr. LEWIS is publishing a Series of Monographs, embracing the various branches of Medicine and Surgery.

The volumes are written by well-known Hospital Physicians and Surgeons, recognized as authorities in the subjects of which they treat. The works are intended to be of a THOROUGHLY PRACTICAL nature, calculated to meet the requirements of the practitioner and student, and to present the most recent information in a compact and readable form.

### HYGIENE AND PUBLIC HEALTH.

By LOUIS C. PARKES, M.D., D.P.H. LOND. UNIV., Fellow of the Sanitary Institute; Member of the Board of Examiners; Assistant Professor of Hygiene and Public Health at University College, etc. Second edition, with numerous Illustrations, cr. 8vo, 9s. *[Just published.]*

### MANUAL OF OPHTHALMIC PRACTICE.

By C. HIGGENS, F.R.C.S., Ophthalmic Surgeon to Guy's Hospital; Lecturer on Ophthalmology at Guy's Hospital Medical School. With Illustrations, crown 8vo, 6s.

### A PRACTICAL TEXTBOOK OF THE DISEASES OF WOMEN.

By ARTHUR H. N. LEWERS, M.D. Lond., M.R.C.P. Lond., Assistant Obstetric Physician to the London Hospital; Examiner in Midwifery and Diseases of Women to the Society of Apothecaries of London, etc. Second Edition, with Illustrations, crown 8vo., 9s.

### ANÆSTHETICS THEIR USES AND ADMINISTRATION.

By DUDLEY W. BUXTON, M.D., B.S., M.R.C.P., Administrator of Anæsthetics in University College Hospital and the Hospital for Women, Soho Square. Crown 8vo, 4s.

**TREATMENT OF DISEASE IN CHILDREN: EMBODYING THE OUTLINES OF DIAGNOSIS AND THE CHIEF PATHOLOGICAL DIFFERENCES BETWEEN CHILDREN AND ADULTS.** By ANGEL MONEY, M.D., F.R.C.P., Assistant Physician to the Hospital for Sick Children, Great Ormond Street, and to University College Hospital. Second edition, cr. 8vo, 10s. 6d.

**ON FEVERS: THEIR HISTORY, ETIOLOGY, DIAGNOSIS, PROGNOSIS, AND TREATMENT.** By ALEXANDER COLLIE, M.D. Aberd., Member of the Royal College of Physicians of London; Medical Superintendent of the Eastern Hospitals; Secretary of the Epidemiological Society for Germany and Russia. Illustrated with Coloured Plates, crown 8vo, 8s. 6d.

**HANDBOOK OF DISEASES OF THE EAR FOR THE USE OF STUDENTS AND PRACTITIONERS.** By URBAN PRITCHARD, M.D. Edin., F.R.C.S. Eng., Professor of Aural Surgery at King's College, London; Aural Surgeon to King's College Hospital; Senior Surgeon to the Royal Ear Hospital. With Illustrations, crown 8vo, 4s. 6d.

**A PRACTICAL TREATISE ON DISEASES OF THE KIDNEYS AND URINARY DERANGEMENTS.** By CHARLES HENRY RALFE, M.A., M.D. Cantab., Fellow of the Royal College of Physicians, London; Assistant Physician to the London Hospital; Examiner in Medicine to the University of Durham, etc., etc. With Illustrations, crown 8vo, 10s. 6d.

**DENTAL SURGERY FOR MEDICAL PRACTITIONERS AND STUDENTS OF MEDICINE.** By ASHLEY W. BARRETT, M.B. Lond., M.R.C.S., L.S.D., Dental Surgeon to, and Lecturer on Dental Surgery in the Medical School of, the London Hospital. Second edition, with Illustrations, cr. 8vo, 3s. 6d.

**BODILY DEFORMITIES AND THEIR TREATMENT: A HANDBOOK OF PRACTICAL ORTHOPÆDICS.** By H. A. REEVES, F.R.C.S. Edin., Senior Assistant Surgeon and Teacher of Practical Surgery at the London Hospital; Surgeon to the Royal Orthopædic Hospital, &c. With numerous Illustrations, cr. 8vo, 8s. 6d.

Further volumes will be announced in due course.

T. R. LEWIS, M.B., F.R.S. ELECT, ETC.

*Late Fellow of the Calcutta University, Surgeon-Major Army Medical Staff, &c.*

**PHYSIOLOGICAL AND PATHOLOGICAL RESEARCHES.** Arranged and edited by SIR WM. AITKEN, M.D., F.R.S., G. E. DOBSON, M.B., F.R.S., and A. E. BROWN, B.Sc. Crown 4to, portrait, 5 maps, 43 plates including 15 chromo-lithographs, and 67 wood engravings, 3os. *nett*.

C. B. LOCKWOOD, F.R.C.S.

*Hunterian Professor, Royal College of Surgeons of England; Surgeon to the Great Northern Hospital; Senior Demonstrator of Anatomy and Operative Surgery in St. Bartholomew's Hospital.*

**HUNTERIAN LECTURES ON THE MORBID ANATOMY, PATHOLOGY AND TREATMENT OF HERNIA.** Demy 8vo, 36 illustrations, 5s.

J. S. LOMBARD, M.D.

*Formerly Assistant Professor of Physiology in Harvard College.*

I.

**EXPERIMENTAL RESEARCHES ON THE REGIONAL TEMPERATURE OF THE HEAD,** under Conditions of Rest, Intellectual Activity and Emotion. With Illustrations, 8vo, 8s.

II.

**ON THE NORMAL TEMPERATURE OF THE HEAD.** 8vo, 5s.

WILLIAM THOMPSON LUSK, A.M., M.D.

*Professor of Obstetrics and Diseases of Women in the Bellevue Hospital Medical College, &c.*

**THE SCIENCE AND ART OF MIDWIFERY.**

Third Edition, with numerous Illustrations, 8vo, 18s.

A. W. MACFARLANE, M.D., F.R.C.P. EDIN.

*Examiner in Medical Jurisprudence in the University of Glasgow; Honorary Consulting Physician (late Physician) Kilmarnock Infirmary.*

**INSOMNIA AND ITS THERAPEUTICS.**

Medium 8vo, 12s. 6d.

[*Just Published.*]

**SURGEON-MAJOR C. J. McNALLY, M.D., D.P.H. CAMB.**

*Fellow of the Madras University; Professor of Chemistry, Madras Medical College.*

**THE ELEMENTS OF SANITARY SCIENCE.**

Plates, Demy 8vo, 8s. 6d.

RAWDON MACNAMARA.

*Professor of Materia Medica, Royal College of Surgeons, Ireland; Senior Surgeon to the Westmoreland (Lock) Government Hospital; Surgeon to the Meath Hospital, etc.*

**AN INTRODUCTION TO THE STUDY OF THE BRITISH PHARMACOPŒIA.** Demy 32mo, 1s. 6d. [*Just published*]

---

JOHN MACPHERSON, M.D.

*Inspector-General of Hospitals H.M. Bengal Army (Retired).  
Author of "Cholera in its Home," &c.*

I.

**ANNALS OF CHOLERA FROM THE EARLIEST PERIODS TO THE YEAR 1817.** With a map. Demy 8vo, 7s. 6d.

II.

**BATH, CONTREXEVILLE, AND THE LIME SULPHATED WATERS.** Crown 8vo, 2s. 6d.

---

DR. V. MAGNAN.

*Physician to St. Ann Asylum, Paris; Laureate of the Institute.*

**ON ALCOHOLISM, the Various Forms of Alcoholic Delirium and their Treatment.** Translated by W. S. GREENFIELD, M.D., M.R.C.P. 8vo, 7s. 6d.

---

A. COWLEY MALLEY, B.A., M.B., B.CH. T.C.D.

**PHOTO-MICROGRAPHY; including a description of the Wet Collodion and Gelatino-Bromide Processes, together with the best methods of Mounting and Preparing Microscopic Objects for Photo-Micrography.** Second Edition, with Photographs and Illustrations, crown 8vo, 7s. 6d.

---

PATRICK MANSON, M.D., C.M.

*Amoy, China.*

**THE FILARIA SANGUINIS HOMINIS; AND CERTAIN NEW FORMS OF PARASITIC DISEASE IN INDIA, CHINA, AND WARM COUNTRIES.** Illustrated with Plates and Charts. 8vo, 10s. 6d.

---

PROFESSOR MARTIN.

**MARTIN'S ATLAS OF OBSTETRICS AND GYNÆCOLOGY.** Edited by A. MARTIN, Docent in the University of Berlin. Translated and edited with additions by FAN COURT BARNES, M.D., M.R.C.P., Physician to the Chelsea Hospital for Women; Obstetric Physician to the Great Northern Hospital; and to the Royal Maternity Charity of London, &c. Medium 4to, Morocco half bound, 31s. 6d. *nett.*



WILLIAM MARTINDALE, F.C.S.

*Late Examiner of the Pharmaceutical Society, and late Teacher of Pharmacy and Demonstrator of Materia Medica at University College.*

AND

W. WYNN WESTCOTT, M.B. LOND.

*Deputy Coroner for Central Middlesex.*

**THE EXTRA PHARMACOPŒIA** with the additions introduced into the British Pharmacopœia, 1885, with Medical References, and a Therapeutic Index of Diseases and Symptoms. Sixth Edition, limp roan, med. 24mo, 7s. 6d. [Now ready.]

WILLIAM MARTINDALE, F.C.S.

*Late Examiner of the Pharmaceutical Society, &c.*

**COCA, COCAINE, AND ITS SALTS: their History,** Medical and Economic Uses, and Medicinal Preparations. Fcap. 8vo, 2s.

### MATERIA MEDICA LABELS.

Adapted for Public and Private Collections. Compiled from the British Pharmacopœia of 1885. The Labels are arranged in Two Divisions:—

**Division I.**—Comprises, with few exceptions, Substances of Organized Structure, obtained from the Vegetable and Animal Kingdoms.

**Division II.**—Comprises Chemical Materia Medica, including Alcohols, Alkaloids, Sugars, and Neutral Bodies.

On plain paper, 10s. 6d. *nett.* On gummed paper, 12s. 6d. *nett.*

\*.\* Specimens of the Labels, of which there are over 450, will be sent on application.

S. E. MAUNSELL, L.R.C.S.I.

*Surgeon-Major, Medical Staff.*

**NOTES OF MEDICAL EXPERIENCES IN INDIA** PRINCIPALLY WITH REFERENCE TO DISEASES OF THE EYE. With Map, post 8vo, 3s. 6d.

J. F. MEIGS, M.D.

*Consulting Physician to the Children's Hospital, Philadelphia.*

AND

W. PEPPER, M.D.

*Lecturer on Clinical Medicine in the University of Pennsylvania.*

**A PRACTICAL TREATISE ON THE DISEASES OF CHILDREN.** Seventh Edition, revised and enlarged, roy. 8vo, 28s.

---

Wm. JULIUS MICKLE, M.D., F.R.C.P. LOND.  
*Medical Superintendent, Grove Hall Asylum, London, &c.*

I.  
**GENERAL PARALYSIS OF THE INSANE.**  
Second Edition, enlarged and rewritten, 8vo, 14s.

II.  
**ON INSANITY IN RELATION TO CARDIAC AND  
AORTIC DISEASE AND PHTHISIS.** Crown 8vo, 3s. 6d.

---

KENNETH W. MILLICAN, B.A. CANTAB., M.R.C.S.  
**THE EVOLUTION OF MORBID GERMS: A Contribu-  
tion to Transcendental Pathology.** Cr. 8vo, 3s. 6d.

---

ANGEL MONEY, M.D. LOND., F.R.C.P.  
*Assistant Physician to University College Hospital, and to the Hospital for Sick Children  
Great Ormond Street; Assistant Professor of Clinical Medicine in University  
College, London, &c.*

I.  
**THE STUDENT'S TEXTBOOK OF THE PRACTICE  
OF MEDICINE.** Fcap. 8vo, 6s. 6d. [Just Published.]

II.  
**TREATMENT OF DISEASE IN CHILDREN: EM-  
BODYING THE OUTLINES OF DIAGNOSIS AND THE  
CHIEF PATHOLOGICAL DIFFERENCES BETWEEN CHILD-  
REN AND ADULTS.** Second edition, crown 8vo, 10s. 6d. [Now ready.  
[LEWIS'S PRACTICAL SERIES.]

---

E. A. MORSHEAD, M.R.C.S., L.R.C.P.  
*Assistant to the Professor of Medicine in University College, London.*  
**TABLES OF THE PHYSIOLOGICAL ACTION OF  
DRUGS.** Fcap. 8vo, 1s.

---

A. STANFORD MORTON, M.B., F.R.C.S. ENG.  
*Surgeon to the Royal South London Ophthalmic Hospital.*  
**REFRACTION OF THE EYE: Its Diagnosis, and the  
Correction of its Errors.** Third Edition, with Illustrations, small 8vo.  
3s.

---

C W. MANSELL MOULLIN, M.A., M.D. OXON., F.R.C.S. ENG.  
*Assistant Surgeon and Senior Demonstrator of Anatomy at the London Hospital; formerly  
Radcliffe Travelling Fellow and Fellow of Pembroke College, Oxford.*  
**SPRAINS; THEIR CONSEQUENCES AND TREAT-  
MENT.** Crown 8vo, 5s.

PAUL F. MUNDE, M.D.

*Professor of Gynecology at the New York Polyclinic; President of the New York Obstetrical Society and Vice-President of the British Gynecological Society, &c.*

**THE MANAGEMENT OF PREGNANCY, PARTURITION, AND THE PUERPERAL STATE.** Second edition, square 8vo, 3s. 6d.

WILLIAM MURRELL, M.D., F.R.C.P.

*Lecturer on Pharmacology and Therapeutics at Westminster Hospital; late Examiner in Materia Medica to the Royal College of Physicians of London, etc.*

I.

**MASSOTHERAPEUTICS, OR MASSAGE AS A MODE OF TREATMENT.** Fifth edition, with Illustrations, crown 8vo, 4s. 6d. [Just ready.]

II.

**WHAT TO DO IN CASES OF POISONING.** Sixth edition, royal 32mo, 3s. 6d. [Just published.]

III.

**NITRO-GLYCERINE AS A REMEDY FOR ANGINA PECTORIS.** Crown 8vo, 3s. 6d.

IV.

**CHRONIC BRONCHITIS AND ITS TREATMENT.** Crown 8vo, 3s. 6d.

DR. FELIX von NIEMEYER.

*Late Professor of Pathology and Therapeutics; Director of the Medical Clinic of the University of Tübingen.*

**A TEXT-BOOK OF PRACTICAL MEDICINE, WITH PARTICULAR REFERENCE TO PHYSIOLOGY AND PATHOLOGICAL ANATOMY.** Translated from the Eighth German Edition by special permission of the Author, by GEORGE H. HUMPHERY, M.D., and CHARLES E. HACKLEY, M.D. Revised edition, 2 vols. large 8vo, 36s.

GEORGE OLIVER, M.D., F.R.C.P.

I.

**THE HARROGATE WATERS:** Data Chemical and Therapeutical, with notes on the Climate of Harrogate. Addressed to the Medical Profession. Crown 8vo, with Map of the Wells, 3s. 6d.

II.

**ON BEDSIDE URINE TESTING:** a Clinical Guide to the Observation of Urine in the course of Work. Fourth Edition, fcap. 8vo, 3s. 6d. [Just published.]

SAMUEL OSBORN, F.R.C.S.

*Assistant-Surgeon to the Hospital for Women; Surgeon Royal Naval Artillery Volunteers.*

I.

**AMBULANCE LECTURES: FIRST AID.** Second edition, with Illustrations, fcap. 8vo, 1s. 6d.

II.

**AMBULANCE LECTURES: NURSING.** With Illustrations, fcap. 8vo, 1s. 6d.

---

WILLIAM OSLER, M.D., F.R.C.P. LOND.  
*Professor of Clinical Medicine in the University of Pennsylvania, &c.*

**THE CEREBRAL PALSIES OF CHILDREN.** A Clinical Study from the Infirmary for Nervous Diseases, Philadelphia. Demy 8vo, 5s. [Just Published.]

---

K. W. OSTROM.

*Instructor in Massage and Swedish Movements in the Hospital of the University of Pennsylvania.*

**MASSAGE AND THE ORIGINAL SWEDISH MOVEMENTS.** With illustrations, 12mo, 2s. 6d. nett. [Now ready.]

---

ROBERT W. PARKER.

*Surgeon to the East London Hospital for Children, and to the Grosvenor Hospital for Women and Children.*

I.

**TRACHEOTOMY IN LARYNGEAL DIPHTHERIA,** AFTER TREATMENT AND COMPLICATIONS. Second Edition. With Illustrations, 8vo, 5s.

II.

**CONGENITAL CLUB-FOOT; ITS NATURE AND TREATMENT.** With special reference to the subcutaneous division of Tarsal Ligaments. 8vo, 7s. 6d.

---

LOUIS C. PARKES, M.D., D.P.H. LOND. UNIV.

*Fellow of the Sanitary Institute; Member of the Board of Examiners; Assistant Professor of Hygiene and Public Health at University College, &c.*

**HYGIENE AND PUBLIC HEALTH.** Second edition, with numerous Illustrations, crown 8vo, 9s. [Just Published.]  
[LEWIS'S PRACTICAL SERIES.]

---

JOHN S. PARRY, M.D.

*Obstetrician to the Philadelphia Hospital, Vice-President of the Obstetrical and Pathological Societies of Philadelphia, &c.*

**EXTRA-UTERINE PREGNANCY; Its Causes, Species,** Pathological Anatomy, Clinical History, Diagnosis, Prognosis and Treatment. 8vo, 8s.

---

THEOPHILUS PARVIN, M.D.

*Professor of Obstetrics and Diseases of Women and Children at the Jefferson Medical School.*

**LECTURES ON OBSTETRIC NURSING,** Delivered at the Training School for Nurses of the Philadelphia Hospital. Post 8vo, 2s. 6d.

---

E. RANDOLPH PEASLEE, M.D., LL.D.

*Late Professor of Gynæcology in the Medical Department of Dartmouth College; President of the New York Academy of Medicine, &c., &c.*

**OVARIAN TUMOURS: Their Pathology, Diagnosis, and Treatment,** especially by Ovariectomy. Illustrations, roy. 8vo, 16s.

G. V. POORE, M.D., F.R.C.P.

*Professor of Medical Jurisprudence, University College; Assistant Physician to, and Physician in charge of the Throat Department of, University College Hospital.*

**LECTURES ON THE PHYSICAL EXAMINATION OF THE MOUTH AND THROAT.** With an Appendix of Cases. 8vo, 3s. 6d.

R. DOUGLAS POWELL, M.D., F.R.C.P., M.R.C.S.

*Physician Extraordinary to H.M. the Queen; Physician to the Middlesex Hospital and Physician to the Hospital for Consumption and Diseases of the Chest at Brompton.*

**DISEASES OF THE LUNGS AND PLEURÆ, INCLUDING CONSUMPTION.** Third edition, entirely rewritten and enlarged. With coloured plates and wood engravings, 8vo, 16s.

URBAN PRITCHARD, M.D. EDIN., F.R.C.S. ENG.

*Professor of Aural Surgery at King's College, London; Aural Surgeon to King's College Hospital; Senior Surgeon to the Royal Ear Hospital.*

**HANDBOOK OF DISEASES OF THE EAR FOR THE USE OF STUDENTS AND PRACTITIONERS.** With Illustrations, crown 8vo, 4s. 6d. [LEWIS'S PRACTICAL SERIES.]

CHARLES W. PURDY, M.D. (QUEEN'S UNIV.)

*Professor of Genito-Urinary and Renal Diseases in the Chicago Polyclinic, &c., &c.*

**BRIGHT'S DISEASE AND THE ALLIED AFFECTIONS OF THE KIDNEYS.** With Illustrations, large 8vo, 8s. 6d.

CHARLES HENRY RALFE, M.A., M.D. CANTAB., F.R.C.P. LOND.

*Assistant Physician to the London Hospital; Examiner in Medicine to the University of Durham, etc., etc.*

**A PRACTICAL TREATISE ON DISEASES OF THE KIDNEYS AND URINARY DERANGEMENTS.** With Illustrations, crown 8vo, 10s. 6d. [LEWIS'S PRACTICAL SERIES.]

FRANCIS H. RANKIN, M.D.

*President of the New York Medical Society.*

**HYGIENE OF CHILDHOOD.** Suggestions for the care of Children after the Period of Infancy to the completion of Puberty. Crown 8vo, 3s.

AMBROSE L. RANNEY, A.M., M.D.

*Professor of the Anatomy and Physiology of the Nervous System in the New York Post-Graduate Medical School and Hospital; Professor of Nervous and Mental Diseases in the Medical Department of the University of Vermont.*

**THE APPLIED ANATOMY OF THE NERVOUS SYSTEM.** Being a Study of this portion of the Human Body from a stand-point of its general interest and practical utility in Diagnosis, designed for use as a text-book and a work of reference. Second edit., 238 Illustrations, large 8vo, 21s. [Just published.]

---

H. A. REEVES, F.R.C.S. EDIN.

*Senior Assistant Surgeon and Teacher of Practical Surgery at the London Hospital;  
Surgeon to the Royal Orthopædic Hospital.*

**BODILY DEFORMITIES AND THEIR TREATMENT:**  
A HANDBOOK OF PRACTICAL ORTHOPÆDICS. With  
numerous Illustrations, crown 8vo, 8s. 6d.

[LEWIS'S PRACTICAL SERIES].

---

RALPH RICHARDSON, M.A., M.D.

*Fellow of the College of Physicians, Edinburgh.*

**ON THE NATURE OF LIFE: An Introductory Chapter**  
to Pathology. Second edition, revised and enlarged. Fcap. 4to,  
10s. 6d.

---

W. RICHARDSON, M.A., M.D., M.R.C.P.

**REMARKS ON DIABETES, ESPECIALLY IN REFER-**  
ENCE TO TREATMENT. Demy 8vo, 4s. 6d.

---

SAMUEL RIDEAL, D.SC. (LOND.), F.I.C., F.C.S., F.G.S.

*Fellow of University College, London.*

I.

**PRACTICAL ORGANIC CHEMISTRY; The Detection**  
and Properties of some of the more important Organic Compounds.  
12mo, 2s. 6d. [Just published.]

II.

**PRACTICAL CHEMISTRY FOR MEDICAL STUDENTS,**  
required at the First Examination of the Conjoint Examining Board in  
England. Foolscap 8vo, 2s.

---

E. A. RIDSDALE.

*Associate of the Royal School of Mines.*

**COSMIC EVOLUTION; being Speculations on the Origin**  
of our Environment. Fcap. 8vo, 3s.

---

SYDNEY RINGER, M.D., F.R.S.

*Professor of the Principles and Practice of Medicine in University College; Physician to,  
and Professor of Clinical Medicine in, University College Hospital.*

I.

**A HANDBOOK OF THERAPEUTICS.** Twelfth Edition,  
thoroughly revised, 8vo, 15s.

II.

**ON THE TEMPERATURE OF THE BODY AS**  
A MEANS OF DIAGNOSIS AND PROGNOSIS IN PHTHISIS.  
Second edition, small 8vo, 2s. 6d.

FREDERICK T. ROBERTS, M.D., B.SC., F.R.C.P.

*Examiner in Medicine at the University of London; Professor of Therapeutics and of Clinical Medicine in University College; Physician to University College Hospital; Physician to Brompton Consumption Hospital, &c.*

## I.

**A HANDBOOK OF THE THEORY AND PRACTICE OF MEDICINE.** Seventh edition, with Illustrations, in one volume, large 8vo, 21s.

\*.\* Copies may also be had bound in two volumes cloth for 1s. 6d. extra.

## II.

**THE OFFICINAL MATERIA MEDICA.**

Second edition, entirely rewritten in accordance with the latest British Pharmacopœia, fcap. 8vo, 7s. 6d.

R. LAWTON ROBERTS, M.D., M.R.C.S.

*Honorary Life Member of, and Lecturer and Examiner to, the St. John Ambulance Association.*

**ILLUSTRATED LECTURES ON AMBULANCE WORK.**

Third edition copiously Illustrated, crown 8vo, 2s. 6d.

D. B. St. JOHN ROOSA, M.A., M.D.

*Professor of Diseases of the Eye and Ear in the University of the City of New York; Surgeon to the Manhattan Eye and Ear Hospital.*

**A PRACTICAL TREATISE ON THE DISEASES OF THE EAR,** including the Anatomy of the Organ. Sixth edition, Illustrated by wood engravings and chromo-lithographs, large 8vo, 25s.

ROBSON ROOSE, M.D.

*Fellow of the Royal College of Physicians in Edinburgh.*

## I.

**GOUT, AND ITS RELATIONS TO DISEASES OF THE LIVER AND KIDNEYS.** Sixth Edition, crown 8vo, 3s. 6d.

## II.

**NERVE PROSTRATION AND OTHER FUNCTIONAL DISORDERS OF DAILY LIFE.** Crown 8vo, 10s. 6d.

## III.

**LEPROSY AND ITS TREATMENT:** as Illustrated by Norwegian Experience. Crown 8vo, 3s. 6d.

---

BERNARD ROTH, F.R.C.S.

*Fellow of the Medical Society of London; Member of the Clinical and Pathological Societies  
and of the Medical Officers of Schools' Association.*

**THE TREATMENT OF LATERAL CURVATURE OF  
THE SPINE.** With Photographic and other Illustrations, demy 8vo,  
5s.

---

J. BURDON SANDERSON, M.D., LL.D., F.R.S.

*Jodrell Professor of Physiology in University College, London.*

**UNIVERSITY COLLEGE COURSE OF PRACTICAL  
EXERCISES IN PHYSIOLOGY.** With the co-operation of F. J. M.  
PAGE, B.Sc., F.C.S.; W. NORTH, B.A., F.C.S., and AUG. WALLER, M.D.  
Demy 8vo, 3s. 6d.

---

W. H. O. SANKEY, M.D. LOND., F.R.C.P.

*Late Lecturer on Mental Diseases, University College, London, etc.*

**LECTURES ON MENTAL DISEASE.** Second Edition, with  
coloured plates, 8vo, 12s. 6d.

---

JOHN SAVORY.

*Member of the Society of Apothecaries, London.*

**A COMPENDIUM OF DOMESTIC MEDICINE AND  
COMPANION TO THE MEDICINE CHEST:** Intended as a  
source of easy reference for Clergymen, Master Mariners, and Tra-  
vellers; and for Families resident at a distance from professional assist-  
ance. Tenth Edition, sm. 8vo, 5s.

---

E. SCHMIEGELOW, M.D.

*Consulting Physician in Laryngology to the Municipal Hospital and Director of the Oto-  
Laryngological Department in the Polyclinic at Copenhagen.*

**ASTHMA: Especially in its Relation to Nasal Disease.**  
Demy 8vo, 4s. 6d.

---

DR. B. S. SCHULTZE.

*Professor of Gynecology; Director of the Lying-in Hospital, and of the Gynecological  
Clinic at Jena.*

**THE PATHOLOGY AND TREATMENT OF DIS-  
PLACEMENTS OF THE UTERUS.** Translated by J. J. MACAN,  
M.A., M.R.C.S. and edited by A. V. MACAN, M.B., M.Ch., Master of  
the Rotunda Lying-in Hospital, Dublin. With 120 Illustrations, medium  
8vo, 12s. 6d.



JOHN V. SHOEMAKER, A.M., M.D.

*Professor of Skin Diseases in the Medico-Chirurgical College and Hospital of Philadelphia ;  
Physician to the Philadelphia Hospital for Diseases of the Skin.*

**A PRACTICAL TREATISE ON DISEASES OF THE SKIN.** Coloured Plates and other Illustrations, large 8vo, 24s.

WM. JAPP SINCLAIR, M.A., M.D.

*Honorary Physician to the Manchester Southern Hospital for Women and Children, and  
Manchester Maternity Hospital.*

**ON GONORRHOEAL INFECTION IN WOMEN.**  
Post 8vo, 4s.

A. J. C. SKENE, M.D.

*Professor of Gynecology in the Long Island College Hospital, Brooklyn, New York.*

**TREATISE ON THE DISEASES OF WOMEN, FOR THE USE OF STUDENTS AND PRACTITIONERS.** Nine coloured plates and 251 engravings, large 8vo, 28s.

ALDER SMITH, M.B. LOND., F.R.C.S.

*Resident Medical Officer, Christ's Hospital, London.*

**RINGWORM: Its Diagnosis and Treatment.**  
Third Edition, enlarged, with Illustrations, fcap. 8vo, 5s. 6d.

J. LEWIS SMITH, M.D.

*Physician to the New York Infants' Hospital; Clinical Lecturer on Diseases of Children  
in Bellevue Hospital Medical College.*

**A TREATISE ON THE DISEASES OF INFANCY AND CHILDHOOD.** Fifth Edition, with Illustrations, large 8vo, 21s.

FRANCIS W. SMITH, M.B., B.S.

**THE SALINE WATERS OF LEAMINGTON.** Second Edit., with Illustrations, crown 8vo, 1s. nett.

JOHN KENT SPENDER, M.D. LOND.

*Physician to the Royal Mineral Water Hospital, Bath.*

**THE EARLY SYMPTOMS AND THE EARLY TREATMENT OF OSTEO-ARTHRITIS,** commonly called Rheumatoid Arthritis, with special reference to the Bath Thermal Waters. Sm. 8vo. 2s. 6d.

LOUIS STARR, M.D.

*Clinical Professor of Diseases of Children in the Hospital of the University of Pennsylvania ;  
Physician to the Children's Hospital, Philadelphia, &c.*

**HYGIENE OF THE NURSERY.** Including the General Regimen and Feeding of Infants and Children, and the Domestic Management of the Ordinary Emergencies of Early Life. Second edition, with Illustrations, crown 8vo, 3s. 6d. [Just published.]

---

JAMES STARTIN, M.B., M.R.C.S.

*Surgeon and Joint Lecturer to St. John's Hospital for Diseases of the Skin.*

**LECTURES ON THE PARASITIC DISEASES OF THE SKIN. VEGETOID AND ANIMAL.** With Illustrations, crown 8vo, 2s. 6d.

---

W. R. H. STEWART, F.R.C.S., L.R.C.P. EDIN.

*Aural Surgeon to the Great Northern Central Hospital; Surgeon to the London Throat Hospital, &c.*

**EPITOME OF DISEASES AND INJURIES OF THE EAR,** with a Chapter on Naso-Pharyngeal Diseases causing Deafness. Demy 32mo, 2s. 6d.

---

LEWIS A. STIMSON, B.A., M.D.

*Surgeon to the Presbyterian and Bellevue Hospitals; Professor of Clinical Surgery in the Medical Faculty of the University of the City of New York, &c.*

**A MANUAL OF OPERATIVE SURGERY.**

Second Edition, with three hundred and forty-two Illustrations, post 8vo, 10s. 6d.

---

ADOLF STRÜMPELL.

*Director of the Medical Clinic in the University of Erlangen.*

**A TEXT-BOOK OF MEDICINE FOR STUDENTS AND PRACTITIONERS.** Translated from the latest German edition by Dr. H. F. VICKERY and Dr. P. C. KNAPP, with Editorial Notes by Dr. F. C. SHATTUCK, Visiting Physician to the Massachusetts General Hospital, etc. Complete in one large vol., imp. 8vo, with 111 Illustrations, 28s.

---

JUKES DE STYRAP, M.K.Q.C.P., ETC.

*Physician-Extraordinary, late Physician in Ordinary, to the Salop Infirmary; Consulting Physician to the South Salop and Montgomeryshire Infirmaries, etc.*

I.

**THE YOUNG PRACTITIONER: WITH PRACTICAL HINTS AND INSTRUCTIVE SUGGESTIONS, AS SUBSIDIARY AIDS, FOR HIS GUIDANCE ON ENTERING INTO PRIVATE PRACTICE.** Demy 8vo, 7s. 6d. *nett.*

II.

**A CODE OF MEDICAL ETHICS: WITH GENERAL AND SPECIAL RULES FOR THE GUIDANCE OF THE FACULTY AND THE PUBLIC IN THE COMPLEX RELATIONS OF PROFESSIONAL LIFE.** Third edition, demy 8vo, 3s. *nett.*

III.

**MEDICO-CHIRURGICAL TARIFFS.**

Fourth Edition, 1cap. 4to, revised and enlarged, 2s. *nett.*

IV.

**THE YOUNG PRACTITIONER: HIS CODE AND TARIFF.** Being the above three works in one volume. Demy 8vo, 10s. 6d. *nett.*

C. W. SUCKLING, M.D. LOND., M.R.C.P.

*Professor of Materia Medica and Therapeutics at the Queen's College, Physician to the Queen's Hospital, Birmingham, etc.*

**ON THE DIAGNOSIS OF DISEASES OF THE BRAIN, SPINAL CORD, AND NERVES.** With Illustrations, crown 8vo, 8s. 6d.

JOHN BLAND SUTTON, F.R.C.S.

*Lecturer on Comparative Anatomy, Senior Demonstrator of Anatomy, and Assistant Surgeon to the Middlesex Hospital; Erasmus Wilson Lecturer, Royal College of Surgeons, England.*

**LIGAMENTS: THEIR NATURE AND MORPHOLOGY.** With numerous Illustrations, post 8vo, 4s. 6d.

HENRY R. SWANZY, A.M., M.B., F.R.C.S.I.

*Examiner in Ophthalmic Surgery in the Royal University of Ireland, and to the Conjoint Board of the King and Queen's College of Physicians and Royal College of Surgeons, Ireland; Surgeon to the National Eye and Ear Infirmary, Dublin, etc.*

**A HANDBOOK OF THE DISEASES OF THE EYE AND THEIR TREATMENT.** Third Edition, Illustrated with wood-engravings, colour tests, etc., small 8vo. [In preparation.]

EUGENE S. TALBOT, M.D., D.D.S.

*Professor of Dental Surgery in the Woman's Medical College; Lecturer on Dental Pathology and Surgery in Rush Medical College, Chicago.*

**IRREGULARITIES OF THE TEETH AND THEIR TREATMENT.** With 152 Illustrations, royal 8vo, 10s. 6d.

H. COUPLAND TAYLOR, M.D.

*Fellow of the Royal Meteorological Society.*

**WANDERINGS IN SEARCH OF HEALTH, OR MEDICAL AND METEOROLOGICAL NOTES ON VARIOUS FOREIGN HEALTH RESORTS.** Crown 8vo, with illustrations, 6s. [Now ready.]

JOHN DAVIES THOMAS, M.D. LOND., F.R.C.S. ENG.

*Physician to the Adelaide Hospital, S. Australia.*

I.

**HYDATID DISEASE, WITH SPECIAL REFERENCE TO ITS PREVALENCE IN AUSTRALIA.** Demy 8vo, 10s. 6d.

II.

**HYDATID DISEASE OF THE LUNGS.** Demy 8vo, 2s.

---

---

HUGH OWEN THOMAS, M.R.C.S.

I.

**DISEASES OF THE HIP, KNEE, AND ANKLE JOINTS**, with their Deformities, treated by a new and efficient method. Third Edition, 8vo, 25s.

II.

**CONTRIBUTIONS TO SURGERY AND MEDICINE:—**

PART I.—Intestinal Obstruction; with an Appendix on the Action of Remedies. 10s.

„ 2.—The Principles of the Treatment of Joint Disease, Inflammation, Anchylosis, Reduction of Joint Deformity, Bone Setting. 5s.

„ 3.—Fractures, Dislocations, Diseases and Deformities of the Bones of the Trunk and Upper Extremities. 10s.

„ 4.—The Collegian of 1666 and the Collegians of 1885; or what is recognised treatment? Second Edition, 1s.

„ 5.—On Fractures of the Lower Jaw. 1s.

„ 6.—The Principles of the Treatment of Fractures and Dislocations. 10s.

„ 8.—The Inhibition of Nerves by Drugs. Proof that Inhibitory Nerve-Fibres do not exist. 1s.

(Parts 7, 9 and 10 are in preparation).

---

J. ASHBURTON THOMPSON, M.R.C.S.

*Late Surgeon at King's Cross to the Great Northern Railway Company.*

**FREE PHOSPHORUS IN MEDICINE WITH SPECIAL REFERENCE TO ITS USE IN NEURALGIA.** A contribution to Materia Medica and Therapeutics. An account of the History, Pharmaceutical Preparations, Dose, Internal Administration, and Therapeutic uses of Phosphorus; with a Complete Bibliography of this subject, referring to nearly 200 works upon it. Demy 8vo, 7s. 6d.

---

J. C. THOROWGOOD, M.D.

*Assistant Physician to the City of London Hospital for Diseases of the Chest.*

**THE CLIMATIC TREATMENT OF CONSUMPTION AND CHRONIC LUNG DISEASES.** Third Edition, post 8vo, 3s 6d

---

FREDERICK TREVES, F.R.C.S.

*Hunterian Professor at the Royal College of Surgeons of England; Surgeon to and Lecturer on Anatomy at the London Hospital.*

**THE ANATOMY OF THE INTESTINAL CANAL AND PERITONEUM IN MAN.** Hunterian Lectures, 1885. 4to, 2s. 6d.

---

D. HACK TUKE, M.D., LL.D.

*Fellow of the Royal College of Physicians, London.*

**THE INSANE IN THE UNITED STATES AND CANADA.** Demy 8vo, 7s. 6d.

---

DR. R. ULZMANN.

**ON STERILITY AND IMPOTENCE IN MAN.** Translated from the German with notes and additions by ARTHUR COOPER, L.R.C.P., M.R.C.S., Surgeon to the Westminster General Dispensary. With Illustrations, fcap. 8vo, 2s. 6d.

---

W. H. VAN BUREN, M.D., LL.D.

*Professor of Surgery in the Bellevue Hospital Medical College.*

**DISEASES OF THE RECTUM: And the Surgery of the Lower Bowel.** Second Edition, with Illustrations, 8vo, 14s.

---

RUDOLPH VIRCHOW, M.D.

*Professor in the University, and Member of the Academy of Sciences of Berlin, &c., &c.*

**INFECTION - DISEASES IN THE ARMY, Chiefly Wound Fever, Typhoid, Dysentery, and Diphtheria.** Translated from the German by JOHN JAMES, M.B., F.R.C.S. Fcap. 8vo, 1s. 6d.

---

ALFRED VOGEL, M.D.

*Professor of Clinical Medicine in the University of Dorpat, Russia.*

**A PRACTICAL TREATISE ON THE DISEASES OF CHILDREN.** Third Edition, translated and edited by H. RAPHAEL, M.D., from the Eighth German Edition, illustrated by six lithographic plates, part coloured, royal 8vo, 18s.

---

A. DUNBAR WALKER, M.D., C.M.

**THE PARENT'S MEDICAL NOTE BOOK.**

Oblong post 8vo, cloth, 1s. 6d.

---

JOHN RICHARD WARDELL, M.D. EDIN., F.R.C.P. LOND.

*Late Consulting Physician to the General Hospital Tunbridge Wells.*

**CONTRIBUTIONS TO PATHOLOGY AND THE PRACTICE OF MEDICINE.** Medium 8vo, 21s.

---

W. SPENCER WATSON, F.R.C.S. ENG., B.M. LOND.

*Surgeon to the Great Northern Hospital; Surgeon to the Royal South London Ophthalmic Hospital.*

I.

**DISEASES OF THE NOSE AND ITS ACCESSORY CAVITIES.** Second edition, profusely Illustrated, demy 8vo.

[*In the press.*]

II.

**EYEBALL-TENSION: Its Effects on the Sight and its Treatment.** With woodcuts, p. 8vo, 2s. 6d.

III.

**ON ABSCESS AND TUMOURS OF THE ORBIT.**

Post 8vo, 2s. 6d.

---

FRANCIS H. WELCH, F.R.C.S.

*Surgeon Major, A.M.D.*

**ENTERIC FEVER: as Illustrated by Army Data at Home and Abroad, its Prevalence and Modifications, Ætiology, Pathology and Treatment.** 8vo, 5s. 6d.

---

W. WYNN WESTCOTT, M.B.

*Deputy Coroner for Central Middlesex.*

**SUICIDE; its History, Literature, Jurisprudence, and Prevention.** Crown 8vo, 6s.

---

**E. G. WHITTLE, M.D. LOND., F.R.C.S. ENG.**

*Senior Surgeon to the Royal Alexandra Hospital for Sick Children, Brighton*

**CONGESTIVE NEURASTHENIA, OR INSOMNIA AND NERVE DEPRESSION.** Crown 8vo, 3s. 6d.

---

**JOHN WILLIAMS, M.D., F.R.C.P.**

*Professor of Midwifery in University College, London; Obstetric Physician to University College Hospital; Physician Accoucheur to H.R.H. Princess Beatrice, etc.*

**CANCER OF THE UTERUS: Being the Harveian Lectures for 1886.** Illustrated with Lithographic Plates, royal 8vo, 10s. 6d.

---

**E. F. WILLOUGHBY, M.D. LOND.**

**THE NATURAL HISTORY OF SPECIFIC DISEASES, OR STUDIES IN ETIOLOGY, IMMUNITY, AND PROPHELY-LAXIS.** 8vo, 2s. 6d.

---

**E. T. WILSON, B.M. OXON., F.R.C.P. LOND.**

*Physician to the Cheltenham General Hospital and Dispensary.*

**DISINFECTANTS AND HOW TO USE THEM.** In Packets of one doz. price 1s.

---

**DR. F. WINCKEL.**

*Formerly Professor and Director of the Gynæcological Clinic at the University of Rostock.*

**THE PATHOLOGY AND TREATMENT OF CHILD-BED:** A Treatise for Physicians and Students. Translated from the Second German edition, with many additional notes by the Author, by J. R. CHADWICK, M.D. 8vo, 14s.

---

**BERTRAM C. A. WINDLE, M.A., M.D. DUBL.**

*Professor of Anatomy in the Queen's College, Birmingham; Examiner in Anatomy in the Universities of Cambridge and Durham.*

**A HANDBOOK OF SURFACE ANATOMY AND LAND-MARKS.** Post 8vo, illustrations, 3s. 6d.

---

EDWARD WOAKES, M.D. LOND.

*Senior Aural Surgeon and Lecturer on Aural Surgery at the London Hospital; Surgeon to the London Throat Hospital.*

I.

**ON DEAFNESS, GIDDINESS AND NOISES IN THE HEAD.**

VOL. I.—POST-NASAL CATARRH, AND DISEASES OF THE NOSE CAUSING DEAFNESS. With Illustrations, cr. 8vo, 6s. 6d.

VOL. II.—ON DEAFNESS, GIDDINESS AND NOISES IN THE HEAD. Third Edition, with Illustrations, cr. 8vo. [*In preparation.*]

II.

**NASAL POLYPUS: WITH NEURALGIA, HAY-FEVER, AND ASTHMA, IN RELATION TO ETHMOIDITIS.** With Illustrations, cr. 8vo, 4s. 6d.

---

DAVID YOUNG, M.C., M.B., M.D.

*Licentiate of the Royal College of Physicians, Edinburgh; Licentiate of the Royal College of Surgeons, Edinburgh, etc.*

**ROME IN WINTER AND THE TUSCAN HILLS IN SUMMER.** A CONTRIBUTION TO THE CLIMATE OF ITALY. Small 8vo, 6s.

---

HERMANN VON ZEISSL, M.D.

*Late Professor at the Imperial Royal University of Vienna,*

**OUTLINES OF THE PATHOLOGY AND TREATMENT OF SYPHILIS AND ALLIED VENEREAL DISEASES.** Second Edition, revised by M. VON ZEISSL, M.D., Privat-Dozent for Diseases of the Skin and Syphilis at the Imperial Royal University of Vienna. Translated, with Notes, by H. RAPHAEL, M.D., Attending Physician for Diseases of Genito-Urinary Organs and Syphilis, Bellevue Hospital, Out-Patient Department. Large 8vo, 18s.

---

**Clinical Charts For Temperature Observations, etc.**

Arranged by W. RIGDEN, M.R.C.S. 50s. per 1000, 28s. per 500, 15s. per 250, 7s. per 100, or 1s. per dozen.

Each Chart is arranged for four weeks, and is ruled at the back for making notes of Cases; they are convenient in size, and are suitable both for hospital and private practice.



---

**THE NEW SYDENHAM SOCIETY'S PUBLICATIONS.**

*President* :—W. T. GAIRDNER, M.D., LL.D.

*Honorary Secretary* :—JONATHAN HUTCHINSON, ESQ., F.R.S.

*Treasurer* :—W. SEDGWICK SAUNDERS, M.D., F.S.A.

---

Annual Subscription, One Guinea.

---

The Society issues translations of recent standard works by continental authors on subjects of general interest to the profession.

Amongst works recently issued are "Cohnheim's Pathology," "Henoch's Children," "Spiegelberg's Midwifery," "Hirsch's Historical and Geographical Pathology," "Essays on Micro-Parasites," works by Charcot, Duchenne, Begbie, Billroth, Graves, Koch, Hebra, Guttman, etc.

The Society also has in hand an Atlas of Pathology with Coloured Plates, and a valuable and exhaustive "Lexicon of Medicine and the Allied Sciences."

The Annual Report, with full list of works published, and all further information will be sent on application.

---

**PERIODICAL WORKS PUBLISHED BY H. K. LEWIS.**

**THE BRITISH JOURNAL OF DERMATOLOGY.** Edited by Malcolm Morris and H. G. Brooke. Published monthly, 1s. Annual Subscription 12s. post free.

**THE NEW YORK MEDICAL JOURNAL.** A Weekly Review of Medicine. Annual Subscription, One Guinea, post free.

**THE THERAPEUTIC GAZETTE.** A Monthly Journal, devoted to the Science of Pharmacology, and to the introduction of New Therapeutic Agents. Edited by Drs. H. C. Wood and R. M. Smith. Annual Subscription, 10s., post free.

**THE GLASGOW MEDICAL JOURNAL.** Published Monthly. Annual Subscription 20s., post free. Single numbers, 2s. each.

**LIVERPOOL MEDICO-CHIRURGICAL JOURNAL,** including the Proceedings of the Liverpool Medical Institution. Published twice yearly, 3s. 6d. each number.

**TRANSACTIONS OF THE COLLEGE OF PHYSICIANS OF PHILADELPHIA.** Volumes I. to VI., 8vo, 10s. 6d. each.

**MIDDLESEX HOSPITAL, REPORTS OF THE MEDICAL, SURGICAL, AND Pathological Registrars for 1883 to 1888.** Demy 8vo, 2s. 6d. *nett* each volume.

---

\* \* MR. LEWIS is in constant communication with the leading publishing firms in America, and has transactions with them for the sale of his publications in that country. Advantageous arrangements are made in the interests of Authors for the publishing of their works in the United States.

Mr. Lewis's publications can be procured of all Booksellers in any part of the world.

RF341  
890 W



