

**On dactylitis syphilitica : with observations on syphilitic lesions of the joints / by R.W. Taylor.**

**Contributors**

Taylor, Robert W. 1842-1908.

**Publication/Creation**

New York : F.W. Christern, 1871.

**Persistent URL**

<https://wellcomecollection.org/works/jjtu7tyw>

**License and attribution**

This work has been identified as being free of known restrictions under copyright law, including all related and neighbouring rights and is being made available under the Creative Commons, Public Domain Mark.

You can copy, modify, distribute and perform the work, even for commercial purposes, without asking permission.



Wellcome Collection  
183 Euston Road  
London NW1 2BE UK  
T +44 (0)20 7611 8722  
E [library@wellcomecollection.org](mailto:library@wellcomecollection.org)  
<https://wellcomecollection.org>

ON

# DACTYLITIS SYPHILITICA,

WITH OBSERVATIONS ON

## SYPHILITIC LESIONS OF THE JOINTS.

BY

R. W. TAYLOR, M.D.,

SURGEON TO THE NEW YORK DISPENSARY; DEPARTMENT OF VENEREAL AND SKIN DISEASES.

---

REPRINTED FROM

THE AMERICAN JOURNAL OF SYPHILOGRAPHY AND DERMATOLOGY.

JANUARY, 1871.

---

NEW YORK:

F. W. CHRISTERN, PUBLISHER, 77 UNIVERSITY PLACE.

1871.



Digitized by the Internet Archive  
in 2014

<https://archive.org/details/b2042128x>



ON

DACTYLITIS SYPHILITICA,

WITH OBSERVATIONS ON

SYPHILITIC LESIONS OF THE JOINTS.

---

THE tegumentary structures of the fingers and toes are frequently the seat of various syphilitic lesions in the secondary period. These earlier manifestations, however, are, for the most part, of an ephemeral character, and, as a rule, do not leave any trace of their existence, nor are they the cause of any permanent impairment of these members.

The same superficial structures are also involved in the tertiary period of syphilis, and they are then, very frequently, the seat of destructive changes of a chronic character, which produce considerable functional impairment. It, however, may be stated, almost as a rule, that the tertiary lesions of the integuments of the fingers and toes are never exclusively confined to these organs, but that they are coincident with, or follow, from a direct continuity of tissue, similar affections of the palms or the soles.

There is a marked difference in the appearance of the tertiary lesions of the palmar and plantar surface from those



observed on the dorsal surface. The former consist, for the most part, in a peculiar thickening of the epidermis, with a more or less copious exfoliation, which may or may not involve the nails; whereas in the latter cases, which are less frequent, there is a thickening of the whole structure of the derma, with very little if any affection of the epidermis. The former lesion is known as palmar and plantar psoriasis, and the latter as a non-ulcerating tubercular syphilide, which generally undergoes resolution, but in this position, in rare instances, ulcerates.

The mobility of the parts is, of course, very materially interfered with by these forms of thickening, and, from their rebelliousness to treatment, they are often very formidable affections. Clinical observation has proved that these conditions of the integument occur upon the fingers much more frequently than upon the toes.

It is not intended, however, to enter fully into the consideration of these more superficial lesions, but to present the clinical history of a peculiar and rare manifestation of syphilis in the deeper structures of the fingers and toes. This affection consists in the deposit of the peculiar gummy material of tertiary syphilis in one or all of the deep tissues, and is characterized by peculiar deformities. Its literature is very scanty in details, and of quite recent origin. It has been called, by some observers, syphilitic panaris, and by others, syphilitic dactylitis. The application of the word panaris, which is merely a corruption of the word paronychia, to the affection is neither appropriate nor expressive, as it applies to a simple acute inflammation of that portion only of the fingers upon which the nails are situated; whereas the lesion under consideration is a chronic specific inflammation generally involving more than one and frequently all the phalanges without any affection of the nails. The word dactylitis, from the Greek δάκτυλος, a digit or finger, fully expresses the condition: therefore its use will be retained here, as it applies with equal correctness to the fingers and the toes. The recorded cases of this rare lesion are only five in number, excluding those of Erlack, and the descriptions of it as given in the text-books are very meagre, as they are all based upon



one case reported by Nélaton. In 1859 Chassaignac<sup>1</sup> first called attention to this affection, but his description was not sufficiently comprehensive, neither was it clinical in its character. Nélaton,<sup>2</sup> in 1860, devoted a clinical lecture to its consideration, and reported a case, and referred to another which had been observed by him. In 1866 Professor A. Lüche,<sup>3</sup> of Berne, published the details of two very important cases. M. Archambault,<sup>4</sup> of the Hôpital des Enfants, observed a case, due to hereditary syphilis, and published it in 1869. In the present year, 1870, two other important cases have been published, the one, by Dr. H. Risel,<sup>5</sup> as occurring at the clinic of Prof. R. Volkman, of Halle, the other, by Dr. R. Berg,<sup>6</sup> of Copenhagen. Early in the present year, 1870, this lesion developed in one of my own patients, and since then I have carefully studied its course. My attention has also been called to a very interesting case by Professor B. W. McCready, of Bellevue Hospital, who has kindly given me the notes of it, and allowed me the opportunity of observation. My case is important as presenting some points not observed in the others, and I purpose, from a clinical study of the combined number of cases, to present a history of this rare affection. There can be no doubt of its rarity, for many excellent authors do not even mention it, and others, who do, merely refer to Nélaton's case. Previous to a general consideration of the subject, I will briefly describe my own case, and then, in a succinct manner, present the interesting points of all the other cases.

Edward A., a peddler, aged 44, had the initial lesion of syphilis in July, 1867, which was followed, in about a month, by a large papular syphilide upon the forehead, small papules upon the body, pustules in the scalp, mucous patches in the mouth, and rheumatoid pains. Later in the year he

<sup>1</sup> "De la Dactylite Syphilitique."—*Clinique Européenne*, 1859, p. 238.

<sup>2</sup> "Du Panaris Syphilitique."—*Gazette des Hôpitaux*, 1860, pp. 105, 106.

<sup>3</sup> "Die Syphilitische Dactylitis."—*Berliner Klinische Wochenschrift*, Nos. 50 and 51, 1867.

<sup>4</sup> *L'Union Médicale*, No. 140, 1869.

<sup>5</sup> "Zur Casuistik der Syphilitischen Finger-und Gelenks-Affectionens."—*Berliner Klinische Wochenschrift*, No. 7, 1870.

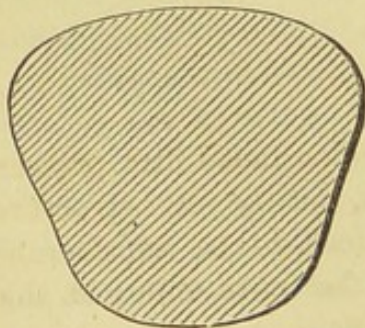
<sup>6</sup> "Fall von Gummöser (Syphilitischer) Dactylitis."—*Archiv für Dermatologie und Syphilis*, No. 2, 1870.



had an iritis. During the years 1868-9 he was troubled with pustulo-crustaceous ulcers upon various parts of the body, which have left their characteristic cicatrices. In the summer of 1869 he had very extensive gummy tumors of the scalp and over the tibiae, which ulcerated and were very rebellious to treatment. He came to me, at the New York Dispensary, in October, 1869, having a non-ulcerating tubercular syphilide above the right eyebrow. At this time he gave me the history detailed above, and with the exception of slight emaciation and weakness, and the tubercles upon the forehead, he presented no other lesion of syphilis. Under the influence of a combination of biniodide of mercury and iodide of potassium with the citrate of quinine and iron his health improved, and his tubercular syphilide subsided and disappeared, leaving a cicatrix. He then had no other syphilitic manifestation until February, 1870, when he complained of a swelling of one of his toes. He stated that he had of late experienced some difficulty in walking, and that, for about a month, he had noticed that the toe gradually grew larger.

Upon examination, the second toe of the right foot was found very much enlarged, and as a consequence it could not maintain its position between the first and third toes, but was elevated more than half an inch above the rest, and rested upon the toes on each side. The circumferential measurement of this toe was three inches, and its transverse and vertical measurement was a little more than an inch, while the same measurements of the corresponding toe of the opposite side were respectively an inch and a quarter, and about five-eighths of an inch. The swelling was perfectly symmetrical along the whole length of the toe, and the integument, which was stretched and shining and not transversely furrowed at the joints, merged, after forming a distinct ridge, into the integument of the foot. When viewed endwise the toe presented a well-marked wedge-shape, its dorsum, which would represent the base, being slightly convex, its sides being flattened and sloping, and its plantar surface or apex was somewhat rounded or truncated, as seen in figure No. 1, which represents

Fig. 1.



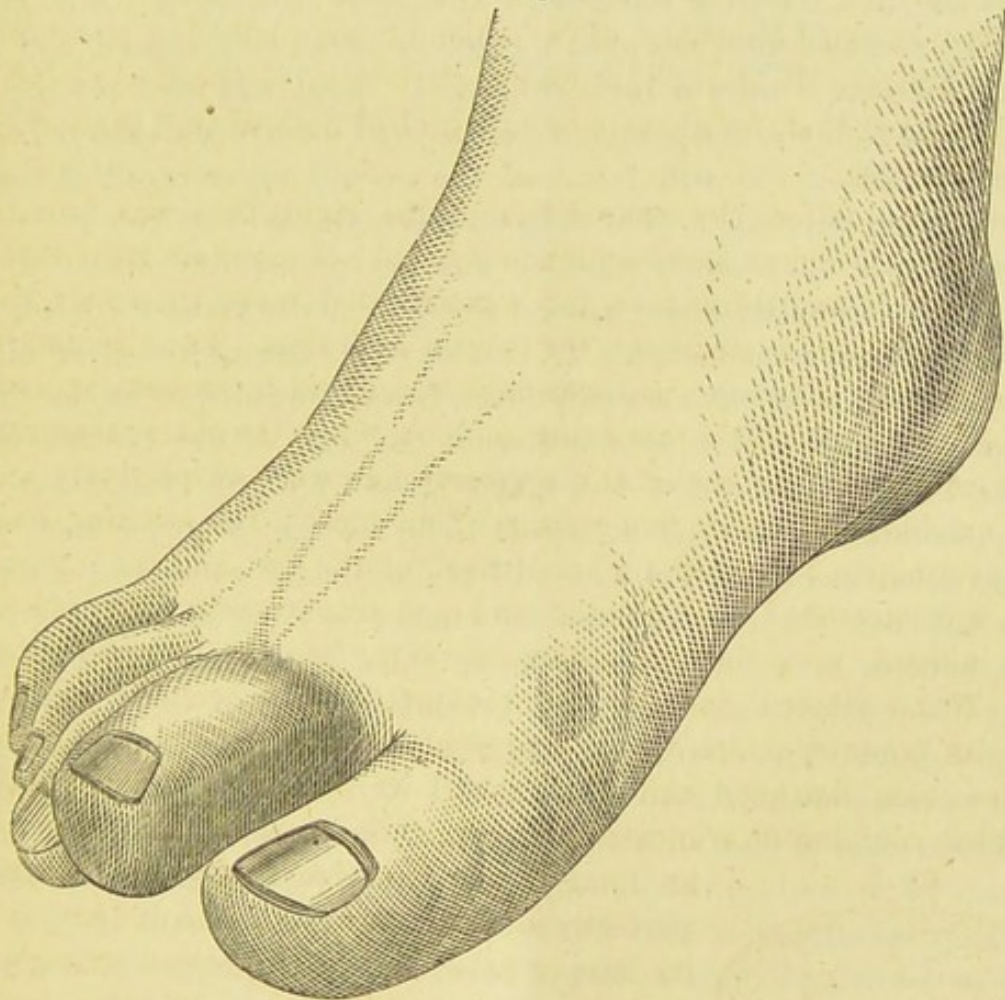
an imaginary transverse section. The nail was perfectly normal, there was no inflammation at its base or sulci, and when pressed strongly upon its flat surface or on its end no pain was produced. The color of the toe was slightly violaceous, evidently from capillary congestion. To the touch it presented, when squeezed, a sensation of firmness combined with elasticity which did not pit. A thermometer placed between the great toe and the

enlarged one indicated a temperature of 93° Fahr., and by the hand no elevation of temperature was felt. It was evident from a careful examination that the distending deposit under the integument was most copiously distributed upon the dorsum and sides of the toe, and very much less upon its



plantar surface, for when the toe was very much elevated the extensor tendon could be felt to be put on the stretch. Though carefully sought for, crepitation could not be elicited at any of the joints. The movements of the phalangeal joints were almost entirely impaired by the thickened condition of the tissues around them, but considerable movement could be produced in the metatarso-phalangeal articulation, particularly when the great and third toes were stretched apart, and then the enlarged toe would fit in between them; but immediately that the foot was placed upon the ground and the normal toes resumed their position, the enlarged one slowly rose until it rested on their sides and dorsum. This condition is shown in figure No. 2.

Fig. 2.



The infiltration was so copious that even long-continued firm pressure failed to clearly reveal the condition of the bones, but the joint structures and the first and second phalanges were noticed to be considerably enlarged, and the first phalanx was thought to be more enlarged than the second. Pain was not present in the toe, neither was it produced when the integument was pinched, nor when the lateral surfaces of the joints were pressed, nor when their articular surfaces were firmly shoved together. The length of the toe was normal.

Being familiar with similar cases, previously reported, and with the pa-



tient's undoubted syphilitic history, I diagnosticated this as one of dactylitis syphilitica. The patient was immediately placed upon the same treatment as before, and directed to cut his shoe in order to prevent chafing, and to favor it as much as possible in walking, but not to apply any external remedies. I have seen the patient at least once a week, during the whole period of the existence of the lesion, and I will briefly note its progress.

The toe remained in the condition above described, without any apparent change, until June, when it was noticed that the infiltration was slightly less, and that it had sunk down a little between the other toes. But slight crepitation had been heard in April. The tension of the integument was less, and the color remained still slightly violaceous. The transverse furrows of the integument at the joints began to reappear, and the articular movements were a little improved. Pain was still absent. It was still found that the first phalanx and its joint were much enlarged. In July the infiltration was still less, and the various other resulting conditions were much improved. The deep structures could now be quite accurately examined; the second phalanx was not perceptibly enlarged, but there was still an enlargement around the first phalanx and its joint, and distinct crepitation was elicited. The iodide of potassium was given alone, during this month, in fifteen-grain doses, in consequence of an obstinate diarrhoea. In August the diminution in the size of the toe was very manifest; but the absorption had taken place from the integument and the deep structures were still enlarged. The toe had resumed its normal position. Distinct crepitation was still plainly heard when the articular surfaces between the first and second phalanges were rubbed upon one another, but not between the second and third phalanges. At this time, fearing a disorganization of the joint, I bandaged the toe very firmly with adhesive plaster. The crepitation could be readily heard from the month of April to the month of November.

The infiltration of the skin has continued to be slowly absorbed, until now, early in December, it is hardly perceptible. The tumefied condition of the deep structures is also slowly subsiding, but it is still slightly perceptible at the first phalanx and its joint, where the crepitation is now much less. The movements of the joints are free, and locomotion is readily accomplished. But lately an arched appearance has been noticed in the long axis of this toe, the most prominent part being at the articulation between the first and second phalanges. This deformity is readily effaced if the toe is elevated by the end of its under surface, but immediately resumes its arched condition when the pressure is removed. There is evidently an unbalanced action between the extensors and flexors, due to disorganization of some part of the joint-structures, and there is a flaccid condition of the ligaments, which is very readily appreciated if traction is made upon the toe, as it then will elongate slightly, and move freely in



various directions. At this time, also, a shallow transverse ridge was seen about the middle of the nail: it was not the result of destructive change, but merely a groove, such as is sometimes observed after adynamic diseases.

The general condition of the patient had improved very much since warm weather, and he had no visible progressive lesion of syphilis.

NÉLATON'S CASE was that of a man aged 50 whose right middle finger swelled upon three occasions. The augmentation in volume was mostly developed in the first phalanx, a little less in the second, and scarcely any in the third. The whole of the first phalanx was involved, and more especially upon the palmar than dorsal aspect. Movement was slightly impaired, and pressure induced slight pain, which, however, existed spontaneously. The integument was stretched and somewhat livid. Under an anti-syphilitic treatment it subsided.

LÜCHE'S CASES :—

1. A syphilitic man, aged 45, having nodes upon the sternum and a swelling of the sterno-clavicular articulation, observed, in April, 1860, that the little finger of his right hand and the great and second toes of the left foot and the second toe of right foot became enlarged. The left knee became swollen and painful, and its articular capsule became thickened, and fluctuation could be felt. Soon after the left little finger enlarged. The swelling in the toes and fingers consisted in a uniform enlargement of all the phalanges except an unusual swelling at the second phalanx of the right great-toe. The integument was red and tense, and the articular cutaneous furrows were effaced. Crepitation was readily heard between the articular surfaces of the phalanges, and abnormal movement existed, particularly in the little finger, the joint of which was quite loose. The patient had, besides, an inflammation of the body and articulations of the fourth cervical vertebra, which interfered with the maintenance of the erect position of the head. Under a mercurial treatment the swelling in the fingers and toes subsided in about three months.

2. A man aged 50, having had very severe syphilitic lesions, particularly gummy deposits in the bone and connective tissue, and painful enlargement of the knee and wrist, noticed that his right great-toe swelled gradually and uniformly, and was soon followed by swelling of the second toe of the left foot. The swelling was due to a uniform enlargement of the phalanges, and a simultaneous thickening of the soft parts. Movement was impaired, but pain was absent. The integument of the toes of this case also was tense and resistant. At first he was treated by mercurial inunctions, which caused some coexisting gummy tumors to disappear, but the swelling in the toes remained. Crepitation could be distinctly heard in the phalangeal articulation of each toe. The gummy tumors, which had healed, became ulcerated again, and the great-toe



became much larger. The phalangeal articulation of the second left toe became opened by ulceration, and a very distinct and harsh crepitation was heard. Under a tonic treatment and the use of iodine, the toes subsided to their normal size in about ten months.

Prof. Lüche also refers to three cases observed by Dr. Erlack, but does not give their details.

1. A syphilitic woman, 48 years of age, had an indolent enlargement of the phalanges of several fingers, which was cured in about eight months.

2. A young woman, having had a general rupial eruption, had a uniform enlargement of several of the articulations of the fingers.

3. A young woman became syphilitic in July, 1855, and in the month of September noticed a thickening of the articulations of the fingers.

BERG'S CASE.—A man aged 35 contracted syphilis in 1854, which manifested itself during the first two years by various cutaneous lesions. In the course of the seven following years he was troubled with recurring syphilides of an ulcerating and serpiginous character, for which he took the bichloride of mercury. In the ninth year of his syphilis, he being then 44 years of age, he observed that the first phalanx of his right middle finger became enlarged; the swelling, however, extended in its whole length, being seated in the bone of the first phalanx and further on in the soft parts. The finger was sensitive to pressure. The swelling of the phalanx rapidly increased during the following weeks. Very soon an hydrarthrosis was observed in the first phalangeal articulation, and a spot formed upon the radial side of the enlarged phalanx which was easily indented, and crepitated slightly. In September the bony tumor had increased in size, but became slightly reduced by compression and external applications. The patient, during the year following, did not pursue an active treatment, and towards the end of the year the phalanx was very much enlarged, and presented a balloon-shaped appearance, measuring in circumference a little more than five inches, while the circumference of the corresponding finger of the opposite side was a little over two inches; it was also much increased in length. The integument and bony structures of the last two phalanges were normal, but the articulation between the first and second phalanges was much distended by fluid, and its ligaments became so loose and flaccid that movement could be produced in various directions, but voluntary motion was absent, and the finger was useless for the performance of its functions. There was no crepitation, and the joint was only slightly sensitive to pressure. It was thought that the ulnar side of the phalanx, near this point, was hypertrophied out of proportion to the rest of the bone. The enlarged finger displaced the other fingers laterally, and it maintained a position always slightly behind them. There was no lesion of the metacarpo-phalangeal joint. The integument over the enlarged pha-



lanx was normal but tense, and could be moved over the bone beneath, which felt as if it was evenly enlarged, but upon its radial side the spot before mentioned became thinner and pitted more upon pressure; still, with slight crepitation and scarcely any pain, gradually resuming, by its elasticity, its distended condition. The bony wall gradually became thinner, and a minute opening was made, giving exit to a clear viscid fluid. Upon probing, a cavity was found, but dead bone was not felt, nor were the parts sensitive. The swelling gradually diminished, especially upon its radial side, and the incisions opened and closed at various intervals, giving exit still to the viscid fluid, which sometimes contained cheesy masses.

Fig. 3.

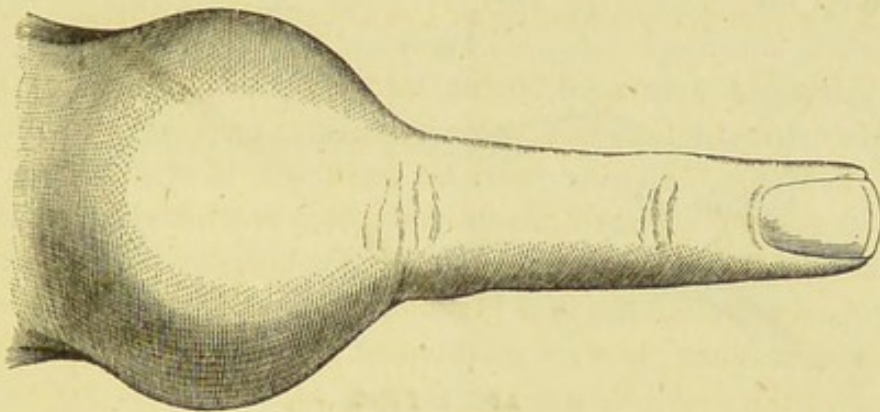
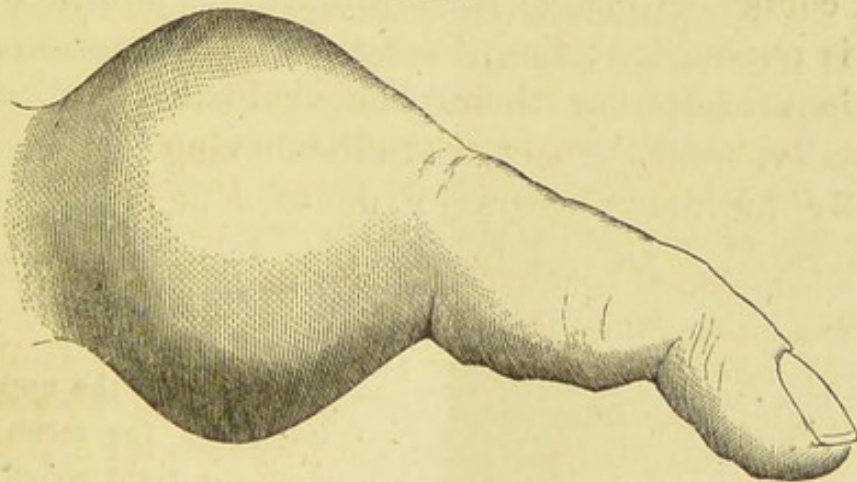


Fig. 4.



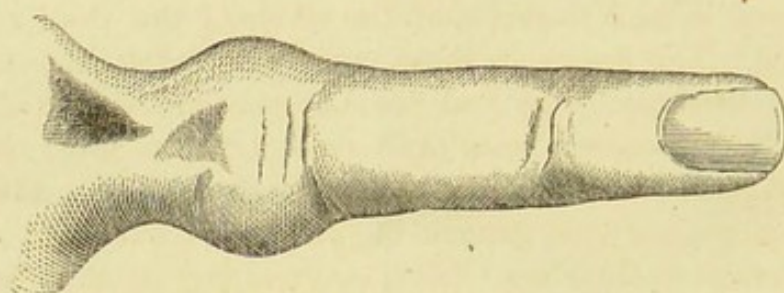
## AFTER BERG.

In March, 1865, the circumference of the phalanx was diminished to a little more than three inches, and its length was shortened about a third of an inch. The joint was still in the same condition. An active inunction treatment was now instituted, and sulphur-water was drunk copiously, and the finger rapidly reduced in size, and the fistulous tract, which had been reopened intentionally, then became permanently closed. In July, 1865 (the lesion having commenced in July, 1863), the phalanx



was much reduced, measuring less than three inches in circumference, and was atrophied in length, measuring about one and one-third inches, while its fellow of the other hand was nearly two inches in length. The end of this finger was a little behind that of the ring-finger, and the distance from the lower portion of the middle joint to the bottom of the interdigital space was slightly less than that of the other hand. The phalanx was constricted at its centre, with a slight depression on its dorsal surface, but there was a little enlargement of the epiphysis. The integument over this phalanx had become wrinkled, and was not adherent to the bone, even at the point of incision, and the periosteum was not painful. The usefulness of the finger was almost wholly restored. Since this time the patient has not suffered from any lesion of syphilis.

Fig. 5.



AFTER BERG.

Volkman's case is evidently one of hereditary syphilis, and though a connected history is wanting, the syphilitic nature of the case is undoubted; first, from the typical course of the osseous lesions and from their peculiar histological structure, and, secondly, from the fact that after having been treated unsuccessfully for many years by non-specific remedies, these affections rapidly yielded to the specific action of iodide of potassium.

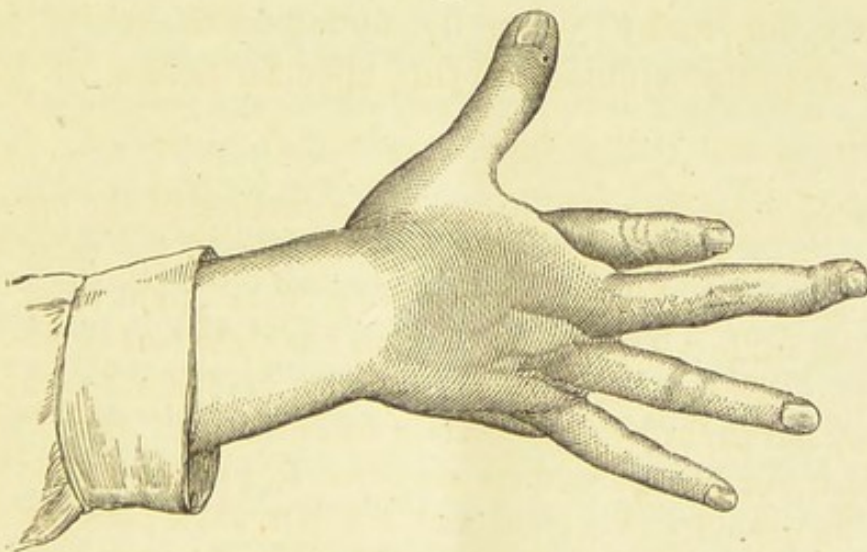
A girl, when fourteen years of age, had a swelling of the upper part of the left ulna, and at her twentieth year, having in the mean time been unhealthy, she noticed a gradual swelling in the right wrist, left knee-joint, and left ankle. Two years after this her right foot swelled; but the skin over the joint was not involved. Motion gradually became impaired until a fixed and slightly flexed position was produced. Spontaneous pain did not exist, but the parts were sensitive to pressure. The knee-joint recovered its mobility in a year, and the left ankle-joint in about five years, whereas the affection in the right ankle disappeared and then recurred with greater severity. This was coincident with pain in the head and limbs. Very soon nodes developed upon the shafts of the tibiæ and on the frontal protuberances. The swelling in the right wrist extended,



after a few weeks, over the dorsum of the hand, involving the first and second phalanges of the thumb and the three adjoining fingers. The thumb and the second and third fingers recovered their normal condition in about three months; but the integument of the index-finger gradually reddened upon its radial side and in about a year opened and discharged a little pus but no bone, then closed, leaving the motion of the finger impaired. In her twenty-eighth year a swelling appeared upon the ulnar side and dorsal surface of the left hand, which, becoming red, extended to the integument of the first and second metacarpal bones. An incision was made into this swelling, which gradually enlarged into an extensive circular ulcer. This healed slowly, leaving a fistula at the base of the metacarpal bone, which healed later on. In the year following (patient then being 29), the first phalanx of the thumb of this hand enlarged, and in a year the last phalanx also became enlarged. Coincidentally the first phalanges of the first and second fingers and the whole of the third right toe became enlarged. The course in these cases was more acute and necessitated several incisions. She had been unsuccessfully treated with non-specific remedies for sixteen years previous to January, 1869. At this time her condition was as follows: The body was ill nourished, there were no cutaneous lesions, nor enlargement of lymphatics, but upon the frontal tuberosity were several nodes. The spleen was very much enlarged. The right wrist was slightly flexed and fixed, and the styloid processes were prominent. The integument over the affected points was tense and in some spots livid. The cicatrices and fistulæ were small and situated upon the dorsal surface of the hands. When a probe was passed into the fistulæ a spongy tissue was felt, but no denuded bone.

The right hand (see figure No. 6) showed the results of the destructive

Fig. 6.



AFTER VOLKMAN.

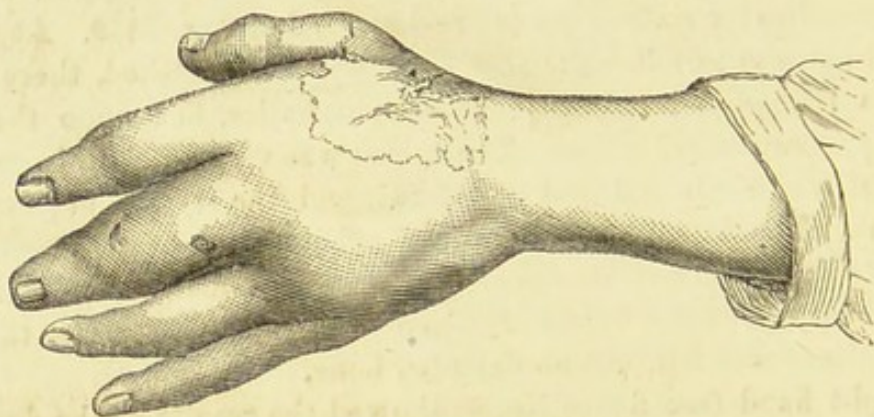
process, the first phalanx of the index-finger was considerably shortened and so constricted at its centre, where a small cicatrix was seen, that the



bone appeared to be divided into two pieces, and the patient had to fix the finger with a glove, so great was the mobility. The two other phalanges were normal. The middle finger was much emaciated, the second phalanx was in a position of super-extension, while the first was slightly flexed. The bones, though unchanged in form, were atrophied, and the integument, joints, and tendons were normal.

In the left hand the lesion was in progress. On the dorsum was a large smooth movable cicatrix, adjoining a small retracted spot at the base of the first metacarpal bone, which was atrophied and produced a marked shortening of the thumb. The first phalanx of the middle finger was very much swollen and obliquely perforated by a sinus, and the bone was completely divided into two parts by an intervening newly-formed tissue. The two phalanges of the thumb and the first phalanx of the index-finger and the first phalanx of the right middle toe were swollen, but there was no sinus nor solution of the continuity of the bone. This is shown in figure 7.

Fig. 7.



AFTER VOLKMAN.

The femur, the knee, and the ankle were normal; but upon the tibiae were numerous nodes, and the shafts of these bones were thickened.

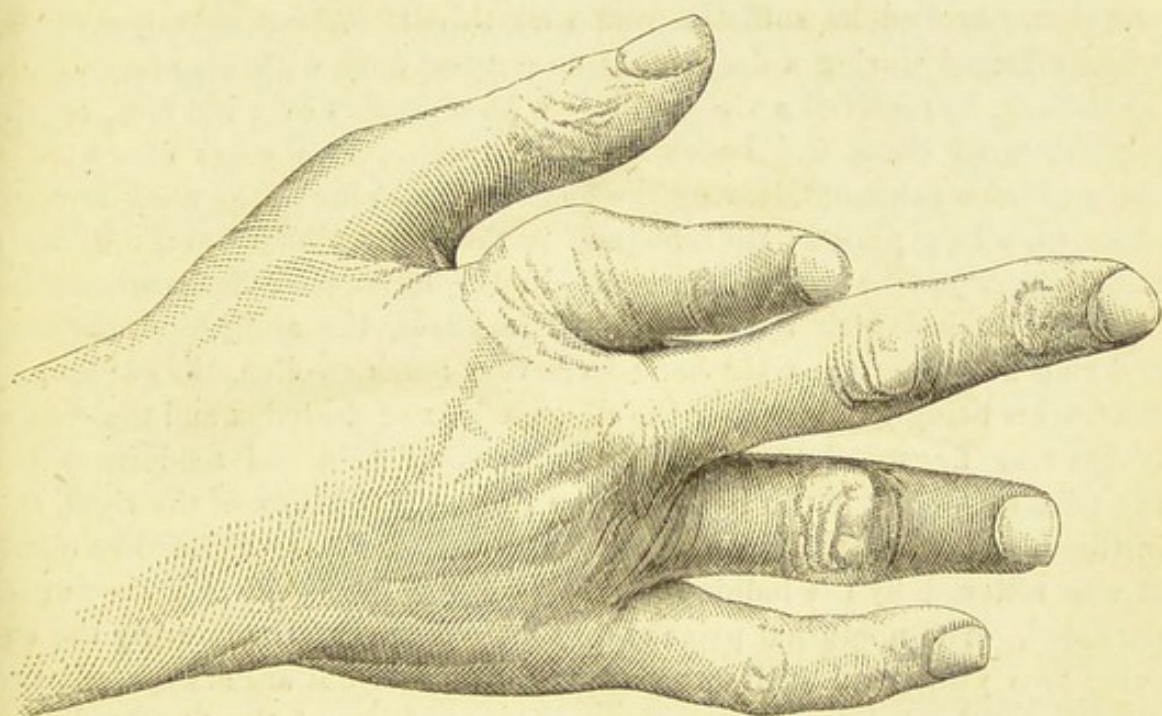
Under the influence of chloroform an incision was made into the last diseased phalanges, and the granular deposit was scraped out. This texture was slightly vascular, soft, yellow, and dry. Pus was not found in it, but was found in the sinuses. This same material was found under the integument of the index-finger. The incision rapidly healed. In the middle finger the shortening increased, and, owing to a retention of pus, an opening was made and the interior of the metacarpo-phalangeal joint could be seen, when the synovial membrane and cartilages were found to be healthy. The swelling of the toe retrograded without local treatment. The patient came under Dr. Volkman's care in January, 1869, and had taken iodide of potassium from that time until the latter part of April, with an astonishing effect upon the osseous lesions. At this time she was seized with very profuse hemorrhage from the stomach and bowels, which resulted in death.



Although McCready's case is wanting in many of the symptoms of syphilis, from the time of contagion to the supervention of osseous lesions, its syphilitic origin cannot be doubted; as it is a well-known fact that we frequently observe late lesions, the syphilitic origin of which is certain, yet we are unable, from a variety of circumstances, to establish a consecutive history of syphilis.

McCREADY'S CASE.—FRANZ Webber, a tailor, born in Germany, aged 43, was admitted Nov. 4th, 1870, into Bellevue Hospital, laboring under an attack of pleurisy with effusion. This presented no unusual feature and soon subsided; but attention was attracted by a peculiar condition of

Fig. 8.



the index and ring fingers of the right hand. The index-finger was deformed and shortened so that its extremity scarcely reached the joint between the first and second phalanges of the middle finger. On careful examination the first phalangeal bone was found to have, in a great measure, disappeared, not more than a fourth or fifth part of its length being left. The metacarpo-phalangeal joint had been destroyed, and a portion of the lower extremity of the metacarpal bone had been absorbed, the new and imperfect joint between it and the phalanx occupying a level a little higher than the line of the knuckles, while the joint between the first and second phalanges was on a level a little lower. The soft parts being in excess, by their bulging, contributed to increase the deformity. The metacarpo-phalangeal joint was quite movable, but the patient had lost control over it, and both flexion and extension were imperfect. In a



similar manner the second phalangeal bone of the ring finger had been reduced to about a fourth part of the length of the same bone on the left hand, the extremity of the finger scarcely reaching to the last joint of that of the middle finger. The loss of substance was confined entirely to the phalangeal bone, though the joint between the second and third phalanges was somewhat swollen and stiffened. (See fig. 8.)

There was no trace of any scar about the fingers, and the patient declared the deformity had supervened on an attack of rheumatism. The patient's father, a strong, healthy man, died after an illness of a few days, aged 50. The mother died at 46, after having been ill three months. He has six brothers and a sister living, all in good health. One brother died at 22, probably of phthisis. He had himself always enjoyed good health, until a few years back. Twenty years ago he had contracted chancre, and had afterwards twice had gonorrhœa; but he had never discovered any eruption, nor had he suffered from sore throat. About February, 1862, while engaged during a dark night on outpost-duty with the army before Vicksburg, he received a violent blow with a musket over the face, breaking the nasal bone, and knocking out a tooth. Two years afterward a piece of bone came out, leaving the peculiar flattening of the nasal arch, so often seen in syphilis. He remained in the army, doing duty, until July 4th, 1864, when he was discharged. In the latter part of the same year he was attacked with rheumatism. The knees, the ankle, and the fore and ring fingers of the right hand were very much swollen, the swelling in the fingers being greatest over the first phalanx of the index and the second of the ring finger. It was attended with some pain and tenderness, but the pain was worst in the length of the tibiæ, particularly of the right, and in the lower fifth of the right ulna and radius, and was aggravated at night. It was relieved by the iodide of potassium, but the swelling of the fingers persisted. The nocturnal pains recurred from time to time during the ensuing two years, and still sometimes trouble him, but are always relieved directly by the iodide of potassium. The swelling of the fingers diminished slightly, and then increased again at intervals of two or three months, but finally subsided after having continued, in all, over two years, leaving the fingers in their present condition. There was never any discharge, nor was the skin of the affected fingers ever broken.

ARCHAMBAULT'S CASE is, of its kind, unique. It occurred as an early lesion of hereditary syphilis. An infant, whose mother had tertiary syphilis, had mucous patches and an enlargement of the last phalanges of the fingers. Being at first regarded as false spina ventosa, it was unsuccessfully treated with anti-strumous remedies; but, when mercury was given, the mucous patches soon disappeared, and the bones were reduced to their normal size.

An analysis of these cases enables us to divide them into



two classes: First, that in which the subcutaneous connective tissue as well as the fibrous structures of the articulations and the phalanges are involved; second, that in which the morbid processes begin in the periosteum and bones, and secondarily implicate the joints, and may or may not be accompanied by deposit in the subcutaneous connective tissue. But it must be remembered that this division is wholly arbitrary, and only adopted for simplicity in description, as they are in fact stages of progress of the lesion and not different varieties of it. But it can be observed upon perusal of the history of the cases that those in which the gummy deposit was developed in the connective tissue, with only slight deposit in the deeper structures, have a different clinical history from those in which the deposit is chiefly in the bones and fibrous structures. Lüche's cases and my own are types of the first variety, and those of Berg, McCready, and Volkman are types of the second variety. It will thus be seen that in the varying phases of the affection all the deeper tissues are involved, and that to complete the history it will be necessary to study the course of the lesion in all of these structures. It would be foreign to the purpose of this article to enter into very minute histological details of the neoplasm which is thus deposited; and I will briefly say that in each instance it is that immature form of connective tissue which is called gummy material.

When this tissue is proliferated amidst the connective tissue of the fingers and toes, we find that the volume of these members becomes materially increased, and that their mobility is thereby much interfered with. In some cases it seems that the deposit is strictly confined to one phalanx, in others that it shades gradually off into the next, and in others again involves all the phalanges. It is impossible to state positively why this gummy material is thus deposited, why it sometimes uniformly enlarges the whole member and in other cases that portion only corresponding to one or more phalanges; but it may be that the inflammation of the bone and joint structures tends to produce inflammation in the connective tissue which immediately surrounds them, and if this was the case we should be able to judge of the intensity of the deep-seated lesion by the greater



or less swelling under the integument; but against this argument we have the clinical fact that the lesion in these cases seems to be more intense in the more superficial than in the deep tissues. It is deposited, as a rule, more copiously over the dorsal than over the palmar and plantar surfaces, Nélaton's case being the only exception; and at the metacarpo- or metatarso-phalangeal articulations, it shades abruptly off into the integument of the hand or foot, forming, as it did in my case, a perfect ridge, and, in one of Lüche's, a kind of ring. The deposit may develop slowly or quite rapidly.

When gummy tumors are developed in localities where the connective tissue is very loose and abundant, as, for instance, over the glutei or gastrocnemii muscles, at an early stage they may be recognized as small, movable, and isolable tumors, over which the integument can be easily moved, and, if followed later on in their course, they will be found to have become adherent to the derma, and perhaps to the very deep tissues, and then to be no longer isolable. But I have observed that this condition is not generally found when these tumors are formed over bony surfaces, where the integument is somewhat closely attached and the connective tissue is not so abundant. Here they are generally found, even at their commencement, to be attached to the deep layers of the corium, which cannot be moved over them; and in some instances they, from the first, appear to reach the periosteum. This condition is readily observed when the deposit occurs over the anterior or subcutaneous surface of the tibia, over the malleoli, and sometimes over the sternum. No observer has as yet found the isolable condition of the gummy tumor in the fingers and toes, but in each instance, in my case particularly, it was adherent to the corium; and I am inclined to think, from the anatomical structure of these organs, that it is generally developed as it is over the tibia, and consequently will not be found as an isolable tumor, over which the integument will freely slide. Like gummy tumors developed elsewhere (we, of course, exclude that rare form in which they are developed over the continuity of a nerve), those of the fingers and toes, as a rule, retain their normal sensation, and are not attended with pain; nor are they particu-



larly sensitive, so that their chief inconvenience is their interference with prehension and locomotion.

Their chronicity is peculiar; for in the various cases it will be seen that they have remained several months, and sometimes shown very little amenability to treatment. This, perhaps, is partially explained by the fact of their density of structure or by their tendency to localize themselves in the dense joint-tissues and phalanges, as will be explained further on. There is also a liability to relapse, as shown by Nélaton's case, and to augment in volume, even, when for a time it has remained indolent, as was shown by one of Lüche's cases.

The usual necrotic tendency of gummy tumor seems to be wanting here; and though Nélaton and Chassaignac hint at such an occurrence, we have not a recorded case in which the phalanges have been denuded by superficial gummy destruction; whereas, though not frequent, this condition is sometimes observed over the dorsal surface of the metacarpal and metatarsal bones. Whether this is to be explained by the peculiar character of the deposit, it being here more highly organized and cellular than when developed elsewhere, or whether it is due to the preponderance of the fibrous tissues of these organs, their great vascularity, and the fact that fat vesicles are not as abundant here as in some other localities, I am unable to say; yet, considering the compactness of the deposit, and the interference to the circulation resulting thereby, and the dependent position when seated in the toes, it is wonderful that it does not produce ulcers. But, in this connection, it must be borne in mind that gummy tumor is not the sole product of late syphilitic inflammation, but that normal cells also are proliferated under the influence of the syphilitic virus. This can be particularly well observed in the fibrous tissues, as, for instance, that of the capsule of the liver. These two conditions, then, often coexist, so that a proliferation of abnormal cells and a hyperplasia of normal cells may take place in the affection under consideration; and this may offer one explanation of the fact that there is a tendency to gradual absorption rather than to molecular death. There exist, moreover, in gummy tumors two causes of decay; the one in their own mechanical obstruction and compression



of the vessels; the other, the inherent tendency of a tissue of a low grade to die. But in the fingers and toes there seems to exist a peculiar reparative tendency, as evinced in the lesions of traumatism; and this may be cited as another reason why they rarely become very much disorganized by syphilitic inflammations.

All the recorded cases in which the morbid process commenced in the subcutaneous connective tissue have presented a violaceous color of the integument, and have been, to the touch, tense and resistant. This state, as said before, is probably owing to the density of the gummy material; but Chassaignac refers to the probability of the deposit being colloid and semi-diffuent, in which case the capillary compression would be much less, and the violaceous appearance of the integument would not be well marked, if at all present. In this diffuent form of deposit, a soft, yielding sensation, approaching in extreme cases almost to a sense of fluctuation, would be felt instead of firm resistance.

The lividity of the integument decreases in proportion with the absorption of the gummy deposit, and in my case remained nearly three months. It is somewhat singular that the tubercular syphilide on the forehead of my patient, which involved the whole thickness of the derma up to its epidermal layer, and which antedated the lesion of the toe about four months, should be of the colloid variety, soft to the touch and very amenable to treatment, and should be followed by a firm deposit of an analogous material in the toe. But we have as yet no clinical fact to prove that the colloid variety of gummy tumor occurs in the fingers and the toes; and although Chassaignac admitted its probability, he reasoned, I think, upon the fact of its occurrence elsewhere, and therefore assumed its liability to occur here.

The nails seem, in general, to escape any synchronous depositive or destructive change. In my own case, it is true, a transverse furrow was observed some months after the commencement of the lesion, upon that portion of the nail which was in process of formation during the progressing period of the gummy deposit, but this was a simple result of the impairment of the nutrition of the nail, and probably the nutrition of the



tegumentary structures was also slightly interfered with, though we have no means of judging of it. The same linear atrophy of the nail is frequently observed after adynamic diseases. We may, therefore, consider it the rule, that in this affection the integument and its modification, the nails, escape any primary implication. Lancereaux remarks that an osteitis or periostitis of the last phalanx may produce destructive changes in the nails, but we have no clinical facts to verify this statement, and observation has shown that when in the tertiary period the nail is destroyed, it is generally by ulcerative tubercular syphilides involving the matrix and sulci of the nail, and it has also shown that we cannot demonstrate an osseous lesion. In most of the cases of syphilitic dactylitis the last phalanx is not enlarged, and in those cases in which it is enlarged, the tissues which underlie and surround the nail are not swollen out of proportion to the rest of the organ, nor are they the seat of more active inflammation. In one of Lüche's cases slight ulceration occurred in the interdigital space, but this was merely produced by mechanical stretching of the integument.

Having now studied the course of the lesion in the connective tissue, its general characters, and the subjective and objective symptoms produced by it, we are prepared to follow its progress in the fibrous structures of the joints and in the bones. Coincidentally with, or soon after, the deposit in the connective tissue, we notice a thickening of one or more phalanges and of the articular capsule, generally but not invariably of the first phalangeal joint. As this thickening of the articular capsule exists in both forms of dactylitis, we will study its course here, and then only incidentally refer to it, when we come to consider the second variety. Pathological observation has fully demonstrated the existence of gummy material in the ligaments, therefore we are warranted in assuming that this enlargement is due to this cause. As a rule, however, it is not copiously deposited, but is disseminated in small portions rather than in large masses through the tissue, and from this distribution it happens that when the material is finally absorbed, or extruded, the whole ligament is not destroyed, but merely those portions which had



been infiltrated. If these structures could be viewed by the naked eye after this process of absorption has taken place, they would be seen to present a honey-comb appearance, the minute holes corresponding to the former seat of gummy deposit. A very similar appearance is presented by bone under the same conditions. This perforated condition of the ligaments, under favorable circumstances, is very soon repaired by a deposit of normal fibrous tissue, which may, as it becomes older, have a tendency to contract, and thus fit more tightly to the bones beneath. The course of this lesion in my own and in Lüche's and Berg's cases shows that in general, although these structures are considerably involved, the final result is not very serious. During its progressive stage it produces a decided impairment of motion of these members, rendering them sometimes immobile: in others preternaturally mobile, so much so that the joint-structures are flaccid, and though the fingers or toes will, by slight force, bend in any direction, they are not at all responsive to volition. Whereas, in its final stage, it may leave the joint either nearly normal or in an impaired condition; as a result of which we see that the phalanges of the fingers and toes are sometimes in the position of superflexion, in others in superextension, or that both conditions are combined in the same members. This is admirably shown by Volkman's case (see fig. 6) and by my own.

This thickened condition and impaired nutrition of the ligaments reacts sometimes upon the tissues lining them, and very often upon that which indirectly derives its nourishment from them: I refer to the synovial membrane and the articular cartilage. In each of the cases in which the deposit has been chiefly subintegumentary there has been evidence of the implication of the articular cartilage, and in none of these cases, which include both of Lüche's cases and my own, has the synovial membrane seemed to participate, as evidenced by an effusion, whereas in Berg's case, which belongs to the second class, and in which the lesion was chiefly osseous, a synovitis was observed. It appears somewhat remarkable that in this first variety of dactylitis, although there is very considerable articular trouble, there should not be an effusion into the joint,



and it remains for future observation to determine whether or not this may occur.

We find it distinctly stated by Lüche that he observed a crepitation, more or less rude in character, in his cases, and it is to be regretted that he does not state the date of the appearance of this symptom. I carefully sought for it from my first examination, and observed it for the first time in the third month of the articular and periarticular trouble. One reliable observation, however, does not warrant an opinion as to the date of development of this symptom. This sound is undoubtedly due to some change in the articular lamellæ of the cartilage, and it is interesting to determine as near as possible what this change is or to what it is due. As we are warranted in assuming that a gummy deposit similar to that of the connective tissue existed in the ligaments, the question arises whether this also pervaded the cartilage. This latter tissue, though non-vascular, we know to be liable to inflammation and its consequent changes, but we have no facts proving it to be the seat of the proliferation of gummy tumors; and various pathological facts, which will be brought out further on, warrant me in concluding that the changes in the cartilage are of a secondary nature, dependent upon those of the articular capsule. Besides these facts, this opinion has the support of anatomical evidence, for the articular lamella of cartilage is nourished by plasma, partly from the vessels of the synovial membrane and partly from those of the ligaments, and does not receive any plasma through the bony lamella underneath; therefore it follows, that any obstruction of the vascularity of the supplying parts interferes with the nourishment of the cartilage, which is a tissue of low grade and readily susceptible of morbid change. Without denying, then, that gummy tumor may occur in articular cartilage (though in the gummy lesions of the trachea and costal cartilage, the deposit is generally between the perichondrium and the cartilage), the crepitation of these joints may be rationally explained by the existence of an impaired nutrition, which produces more or less erosion of this tissue. In my case the changes were slight and temporary, but in one of Lüche's cases the periarticular deposit softened



and was extruded, and the crepitation is described as being rude. We may then conclude that in this affection the articular cartilage undergoes more or less profound nutritional changes, probably in proportion to the extent of peripheral lesion, and that it is capable under favorable circumstances of regeneration to a certain extent.

The synovial sheaths of the tendons have been shown, by the observations of Verneuil<sup>1</sup> and Fournier,<sup>2</sup> to be the seat of inflammation and dropsy in secondary syphilis; but they have not as yet been found to be the seat of gummy deposit, although Van Oordt<sup>3</sup> cites a case of gummy tumor of the third extensor tendon which was seated over the middle of the metacarpal bone.

This variety of dactylitis syphilitica, then, consists in a copious gummy deposit, both in the connective tissue and the fibrous structures of the joints, with a much less copious deposit in the phalanges. It may be developed in a single finger or toe, or it may involve more than one of either of these members, and may even involve one or more of each at the same time. It usually attacks but one joint, and in all but one of the recorded cases—in which it occurred in the second—it has been the first phalangeal joint. The swelling may thus be confined to one phalanx, it may shade off into or wholly involve the second, or may uniformly enlarge the whole of the finger or the toe. As will be seen further on, this variety differs from the second, in the fact that the principal deposit is in the connective and fibrous tissues, whereas in the latter the principal seat of the morbid process is in some portion of the bone. The clinical facts which are now in our possession do not allow us to state decidedly that the lesion of the bone only progresses to a very moderate degree, as shown by a not very extensive enlargement of those structures in Lûche's case and in my own. But it is to be fully taken into account that in all of these three cases an

---

<sup>1</sup> "De l'hydropisie des gâines tendineuses des extenseurs des doigts dans la Syphilis Secondaire."—*Gazette Hebdomadaire*, No. 39, 1868.

<sup>2</sup> "Note sur les lésions des gâines tendineuses dans la Syphilis Secondaire."—*Gazette Hebdomadaire*, No. 41, 1868.

<sup>3</sup> *Des Tumeurs Gommeuses*, Thèse de Paris, pp. 44 and 45. 1859.



active antisyphilitic treatment was quite early adopted, and this perhaps materially held in check the lesion in the bone, whereas, had it not been adopted, the bone-enlargement might have become as formidable as in the cases of the second variety. This lesion generally coexists with grave lesions of the bones, joints, integument, and viscera, and is always the expression of a profound syphilitic dyscrasia. It is generally observed in patients who are past middle age; though in two of Erlack's cases it occurred in young persons. In four out of the seven cases it was observed in men. We are unable to definitely fix its period of evolution, but, in the present state of our knowledge, we may state that it may occur both early and late in the tertiary period.

The deformities produced are not of a very serious character, and can be divided into two classes: first, those of the progressive and stationary period of the lesion; second, those due to the destructive changes in the joint-structures, both of which are shown by my own and Lüche's cases.

We now come to the second variety of dactylitis syphilitica.

In this form the inflammatory action may begin between the periosteum and the bone, being then a specific periostitis; or it may commence in the cancellous tissue around the medulla, and is then an osteo-myelitis. The product of these specific processes is gummy material, which causes the enlargement of the bones. The swelling of the fingers and toes in this variety is very considerable, so that in Berg's case the circumference of a finger at the first phalanx was nearly five inches. As the principal lesion is in the bone and joint-structures and only exceptionally under the integument, the enlargement is nearly limited to the phalanges, which are involved. The recorded cases show us that any, or all, of these phalanges may be attacked by this process: thus, in Berg's case it was the first, in Volkman's it was, respectively, the first and second, and all three at the same time; in McCready's, the first of one finger and the second of another; and finally, in Archambault's, it was all of the last phalanges. According to Volkman's case, the process may be slow in development, or it may run an acute course, as shown by both Volkman's and Berg's cases. In the



thumb of Volkman's patient the first phalanx slowly enlarged, and thus remained a year, before the second was involved, whereas, in the same patient, other fingers swelled so acutely that it was necessary to make incisions into them. So we may conclude that the acute and chronic course may exist in the same patient.

The integument becomes very much stretched by the pressure from within, and the surface-markings and articular furrows in it are effaced, and it can only with difficulty be pinched between the fingers, and it may be so very tense that it can scarcely be moved over the parts beneath. Its color varies from a pink to a decided red, and when the lesion of the bone has been very acute, it may become very much tumefied and sensitive; but this condition is only temporary. In this variety, as in the first, there is no concomitant lesion of the nail, even when the last phalanx is involved. As has been said before, the gummy deposit does not, as a rule, exist under the skin in this variety, though in one of the fingers of Volkman's patient, upon incision, it was found there in very small quantity.

As I have said before, there are two foci of this specific bone-inflammation,\*the one more superficial, the other deeply seated. In Volkman's case it is certain that the process commenced between the bone and the periosteum, for when this membrane was incised, during life, gummy material was scraped from beneath it.

Volkman gives the appearances presented by the tibia, after death, and we may presume that precisely similar changes had taken place in the fingers. The periosteum was loosely attached and readily stripped off, and between it and the bone a small cheesy mass was found. The microscope showed the exterior layers of the periosteum to be normal. Inside of this was a layer of fusiform cells which, further inward, became more numerous, smaller, and rounder, while still further towards the bone they lost their cellular character, and finally presented the appearance of fatty detritus. This cheesy mass was situated immediately upon the bone, projecting by tubular prolongations into the Haversian canals, while upon the bone new periosteum was forming.



These same changes, which Virchow<sup>1</sup> describes as the dry caries of syphilis, and which are generally observed upon the cranium and tibia, existed in the fingers of Volkman's patient. After the deposit of the gummy material, no inflammatory action is excited, but it slowly produces the death of the bone which it infiltrates, and is finally absorbed, leaving a loss of substance which is not again replaced, the whole process being unattended with suppuration.

The swelling, when originally developed, is softer in the acute than in the chronic form, and this is probably due to the tissue which is thus rapidly proliferated being of a colloid character. This variety, of course, produces much deformity, and has a tendency to destructive change; whereas, in the chronic form the swelling is firmer and there is a tendency to remain indolent and infiltrate the bone, and finally be absorbed rather than to break down and to be eliminated.

The clinical details of Berg's case prove that when the lesion begins as an osteomyelitis its course at the commencement may be quite rapid, so that very soon the finger becomes greatly enlarged. The swelling of the bone seems to have been perfectly smooth, and surrounded by a wall composed of compact tissue and periosteum. This latter fact lends weight to the view that the lesion was in reality developed deep in the cancellous tissue, and that coincidently with the rapid proliferation of gummy material, the compact structure and periosteum gradually became expanded, so that they fully accommodated themselves to the very considerably increased pressure from within. But, whether owing to the low organization of the gummy material or to the mechanical effect of its presence, it finally softened, and the investing wall became thinned, and, upon opening, a fluid of the consistency of gummy débris escaped. The facts developed by McCready's case render it probable that its lesion also began as an osteomyelitis, and my friend Dr. Bumstead, who has seen the case, expresses the same opinion. But whether it began as a periostitis or an osteomyelitis, the important clinical fact is brought out by it, that, even if such

---

<sup>1</sup> *Pathologie des Tumeurs* (Trad. Franç.), p. 394. Paris, 1869.



an extensive gummy deposit is formed in bone, it may finally undergo fatty change and be absorbed without softening and being thrown out, so that from all these cases we may infer that both of the conditions of absorption or breaking down may obtain in this lesion. The same remarks which have been previously made as to the varying degrees of maturity of the gummy material, and the consequent tendency to absorption or liquefaction, apply also to this condition. The liquid formed by the degeneration of gummy tumors is a viscid yellowish fluid, containing cheesy flocculi, but no pus. An absence of pus is peculiar to the liquid formed by the degeneration of any gummy deposit, and this as well as its other characteristics are important, as diagnostic points. Microscopical examination of this fluid shows amorphous granular matter, with, sometimes, a few connective-tissue cells, but never, in an unirritated condition, pus-corpuscles. These latter bodies may be found after the gummy ulcer or sinus has been exposed to the air, or has been treated by irritant applications, but never in the original process of softening. The color of the fluid varies from a yellow to a brown; its consistence is also variable, being thin when drawn from a joint and mixed with effusion, and thick and inspissated when formed by the degeneration of connective tissue or bone, and in the latter form it may contain minute bony granules. This same description would apply to the degeneration of the gummy deposit under the integument, should that change possibly occur. The fistulous openings present interesting points also, as showing no tendency to enlarge nor to become thick, bluish, and everted at their orifice,—a condition very frequently observed in the so-called strumous sinuses near joints,—finally, spontaneous closure. But in Volkman's case one of the incisions ulcerated and became quite extensive, and upon healing left a cicatrix, so that we may infer that both of these conditions may obtain.

The fibrous structures of the joints may or may not participate in the morbid process, but as the changes are similar to those occurring in the first variety, it is needless to repeat the description. The articular cartilage also may or may not be profoundly involved, and its altered condition may be in this



variety the result of two causes ; first, the gummy lesion in the ligaments ; second, the same lesion in the underlying bone. In Volkman's case the ligaments were normal, and the trouble in the cartilage was secondary to that of the bone. He states that the articular cartilage had lost its polish and was of a yellowish color. Upon its surface, particularly at the periphery, there were some well-defined, cleanly-cut erosions. Some of them had healed and been replaced by cicatricial tissue, whereas others had a dense sclerotic bone for their bases, while in other spots the cartilage was thin and translucent. The changes in the cartilage were undoubtedly due to disease of the subjacent bone, and not to impaired nutrition from lesion in the joint-capsule. In fact, the process was analogous to that which takes place in fungoid arthritis from osteitis. Volkman mentions having in his museum the tibia of a syphilitic woman, the whole length of which was the seat of gummy deposit. The shaft of this bone was very light and fragile, for the gummy masses had been entirely absorbed, leaving it of a spongy texture. The articular cartilage was for the most part intact, but there were perforations in it which communicated with the bone-tissue by means of sinuses, which in the recent state contained gummy material.

Besides the articular cartilage, the synovial membrane may suffer from morbid changes. In Berg's case, there was a copious effusion into the joint, which probably was caused by inflammatory action in the synovial membrane, set up by gummy deposit in its underlying connective tissue. Richet<sup>1</sup> was the first to describe a thickening of the synovial membrane of the knee, which is accompanied by effusion of an intermittent character and a dull pain, not increased on motion, but worse at night. Lancereaux<sup>2</sup> confirmed Richet's observation by finding, after death, gummy material in the ligaments and beneath the synovial membrane, which lesion, during life, had been attended with the same symptoms. In Berg's case a similar process involved the phalangeal joint, but pain was not present,

<sup>1</sup> "De la tumeur blanche." *Mémoires de l'Académie de Médecine*, vol. 17, pp. 249, 250, 251. 1853.

<sup>2</sup> *Traité historique et pratique de la Syphilis*, page 251. Paris, 1866.



so that, while one case does not prove that pain may not be present, the evidence of analogy would suggest the fact that it may.

The involution of the gummy enlargements of bone is accomplished, as has been previously stated, either by an interstitial absorption, in which there is no lesion of continuity of the overlying soft parts, or by a softening of the deposit and its discharge through a sinus which it forms. As has been said before, even when softening occurs, it is not usually accompanied by a formation of pus. The final results are, that certain portions of the shaft may be wholly absorbed, or the whole shaft may be slightly attenuated. This local absorption completely divided a phalanx in Volkman's patient into two portions, and nearly the whole of a phalanx of one finger, and the whole of a phalanx, its joint, and a portion of the metacarpal bone of another finger in McCready's case. The shafts of the bones may also be rendered light and fragile, or local or general eburnation may take place in them. When the phalanges are divided into two portions, or when the approximative ends of two bones are absorbed, a ligamentous band of connective tissue is formed, which unites them, and in the future serves as a joint. The fact that a whole joint is absorbed, certainly proves that it must previously have been infiltrated with the gummy material. The shortening of the fingers or toes is quite extensive, as Volkman and McCready's cases show, and this may also result from destruction of a part of the metacarpal bone, as well as of the phalanx. A finger with one of these false joints loses its power of grasp, and its function, though not wholly abolished, is much impaired. When very extensive shortening has taken place in a finger, it is remarkable how the integument contracts and adapts itself to the altered condition; it seems that nearly all of the redundant tissue disappears, and that the superficial tissues finally adapt themselves to the decrease. This is very beneficial in giving steadiness and solidity to the false joint. In McCready's case, though very considerable shortening was produced, there was not very much wrinkling of the skin. It is certainly very remarkable that there should be such a small amount, or an entire absence, of pain accompanying



such chronic and profound osseous and articular changes. In all of the recorded cases, the sheaths of the tendons have not been involved.

The *diagnosis* of these lesions is of the utmost importance, for when their syphilitic origin is recognized an appropriate treatment may prevent serious destruction, and at least materially lessen the ultimate deformities. The subcutaneous variety of dactylitis syphilitica might, in its early stage, be mistaken for paronychia or the subperiosteal and subcutaneous inflammation termed whitlow; but the absence of acute inflammatory symptoms, pain especially, would readily eliminate these affections. When the lesion occurs in the great toe it might be regarded as gout, but here, again, the absence of acute invasion and pain would soon point out the error. In the instances in which the lesion is developed in several fingers and toes, particularly when accompanied by trouble in the large joints, it might be looked upon as rheumatoid arthritis, especially as the two lesions are unaccompanied by febrile reaction. But rheumatoid arthritis is essentially a lesion of the joint-structure, not involving the integument. It attacks the metacarpo-phalangeal (and rarely the metatarso-phalangeal) articulation much more frequently than those of the phalanges, involving, in most instances, the sheaths of the tendons, generally the flexors, leaving a deposit of small tophaceous nodules along the course. Its deformity commences with the inception of the lesion, and has a tendency to draw the fingers to the ulnar side of the hand, and to flex and extend them in various positions, and moreover minute tophi are to be found coincidently in the cartilages of the ear. Besides these symptoms the crepitation of rheumatoid arthritis is of a dry, harsh character, and is also observed in the tendinous sheaths, and commences quite early in the affection. In the syphilitic joint-lesion there is generally a history or concomitant symptoms of syphilis; the swelling does not usually involve as many joints, is mostly observed upon the dorsal surface, and rarely if ever upon the palmar surface, or in the sheaths of the flexor tendons; the swelling is at first subcutaneous, and the joint-lesion is usually discovered afterwards; and the crepitation, which is not heard early, is of a softer character.



Enchondroma of the fingers might possibly but rarely be mistaken for dactylitis syphilitica, but with care they can easily be differentiated, as the former involves generally one, and especially the palmar, surface of the bone, increases very slowly, and presents a hard, well-defined tumor. The same remarks apply to exostoses.

The second form of dactylitis syphilitica might perhaps be mistaken for periostitis or the so-called strumous disease of bone. From the former it would be known by its comparative painlessness, its subacute course, and perhaps by the coincidence of syphilitic lesions of larger joints, with their well-marked symptoms as already detailed, as well as a history of syphilis, or the presence of tegumentary lesions of syphilis upon the body. The tendency of the so-called strumous inflammation to localize itself in bone rich in cancellous tissue, particularly those of the carpus and tarsus, and the expanded extremities of long bones, renders it probable that it rarely if ever attacks the phalanges.

The *prognosis* of this affection of the fingers and toes depends entirely upon the accuracy of the diagnosis, and to a certain extent upon the period at which it is recognized, and in the event of its being correct, and as a consequence an appropriate treatment being instituted, it may be stated to be good, for the final impairment of the members is generally not so great as to cause utter uselessness. But if the origin of the lesion is not recognized, the chronic enlargement of the bone, the chronic hydrarthrosis with crepitation, or the latter symptom combined with chronic capsular thickening, might lead the unwary surgeon to pronounce an unfavorable prognosis, and perhaps to institute unnecessary operative procedure. The *treatment* is that of late syphilis, the use of iodide of potassium either alone or combined with a mercurial. The combination always answers best in cases where there is a co-existence of tegumentary lesions, but when these are strictly osseous and ligamentous, our chief reliance is upon the iodide, and we can, if that is inefficient, add the mercury. When the parts are very much distended, a minute incision may be necessary.