

## **Selected papers in gynaecology and obstetrics / by D. Berry Hart.**

### **Contributors**

Hart, D. Berry 1851-1920.

### **Publication/Creation**

Edinburgh : W. & A. K. Johnston, 1893.

### **Persistent URL**

<https://wellcomecollection.org/works/hee9mpas>


### **License and attribution**

This work has been identified as being free of known restrictions under copyright law, including all related and neighbouring rights and is being made available under the Creative Commons, Public Domain Mark.

You can copy, modify, distribute and perform the work, even for commercial purposes, without asking permission.



Wellcome Collection  
183 Euston Road  
London NW1 2BE UK  
T +44 (0)20 7611 8722  
E [library@wellcomecollection.org](mailto:library@wellcomecollection.org)  
<https://wellcomecollection.org>








22500094439





Digitized by the Internet Archive  
in 2015

<https://archive.org/details/b20419855>





SELECTED PAPERS IN GYNÆCOLOGY  
AND  
OBSTETRICS



SELECTED PAPERS IN CYTOLOGY

OF THE

154

SELECTED

PAPERS IN GYNÆCOLOGY

AND

OBSTETRICS

BY

D. BERRY HART, M.D., F.R.C.P.E., ETC.

LATE PRESIDENT, EDINBURGH OBSTETRICAL SOCIETY



W. & A. K. JOHNSTON  
EDINBURGH AND LONDON

1893



774 017

PAPERS IN GYNECOLOGY

GYNÆTRICS

B

M19528

WELLOOM INSTITUTE	
LIBRARY	
Col	W. 10-44
Col	
No	WP 7.
	H 32
	1893



## PREFACE.

---

IN the present volume are collected certain of the Papers I have published in various Medical Journals, chiefly in the Edinburgh Medical Journal, arranged in the natural sequence of Anatomy and Physiology, Pathology and Practice.

In the paper given in Chapter XVII. I had the valuable help of Mr Carter, a well-known anatomical teacher in Glasgow, whose early death has been a great loss to science. I must also specially point out that I am indebted to my Assistant, Dr Lovell Gulland, for his very valuable co-operation in the microscopical part of the research on placental structure.

In conclusion, I have to thank the Publishers, Messrs W. & A. K. Johnston, for the admirable way in which they have executed their part of the work.

D. BERRY HART.

EDINBURGH,  
*Sept.* 24, 1893.



## PLATE 1

The present volume is a reprint of the first edition  
published in 1871. It contains the same material as the  
original, but with some additions and corrections.

The first edition was published in 1871, and the  
present edition is a reprint of the first edition.  
It contains the same material as the original, but  
with some additions and corrections. The present  
edition is a reprint of the first edition, and it  
contains the same material as the original, but  
with some additions and corrections.

The present edition is a reprint of the first edition,  
and it contains the same material as the original,  
but with some additions and corrections.

UNIVERSITY OF TORONTO

LIBRARIES



TO

A. H. F. B.

A VALUED FRIEND

AND CO-WORKER

A. H. R.

1871

1872



## CONTENTS.

### PART I.—ANATOMICAL AND PHYSIOLOGICAL.

#### CHAPTER I.

On Anatomical Methods . . . . .	PAGE 1
---------------------------------	-----------

#### CHAPTER II.

The Nature and Aim of Investigations on the Structural Anatomy of the Pelvic Floor in the Female—The Genupectoral Posture . . . . .	6
---	---

#### CHAPTER III.

On Sacropubic Hernia—Prolapsus Uteri . . . . .	11
--	----

#### CHAPTER IV.

On the Shape of the Empty Female Bladder and its Position . . . . .	25
---	----

#### CHAPTER V.

On Some Points in the Physics of the Bladder, Rectum, and Uterus . . . . .	34
--	----

#### CHAPTER VI.

On the Structure of the Human Placenta, with Special Reference to the Origin of the Decidua Reflexa . . . . .	49
---	----

#### CHAPTER VII.

The Sectional Anatomy of Advanced Pregnancy in Macacus Rhesus . . . . .	63
---	----

### PART II.—MECHANISM OF NATURAL AND MORBID LABOUR.

#### CHAPTER VIII.

The Nomenclature of Positions and Presentations in Labour . . . . .	77
---	----

#### CHAPTER IX.

The Nature and Cause of the Movement of Internal Rotation . . . . .	79
---	----



## CHAPTER X.

On Synclitism . . . . .	PAGE 88
-------------------------	------------

## CHAPTER XI.

A Contribution to the Anatomy and Etiology of Rupture of the Peritoneal Portion of the Vagina during Labour . . . . .	98
---	----

## CHAPTER XII.

The Causation of the Movements of the Head at the Brim of the Rachitic Pelvis	105
---	-----

## CHAPTER XIII.

The Mechanism of the Separation of the Placenta and Membranes during Labour, as well as that of Anomalous Cases where it is expelled before the Child . . . . .	113
---	-----

## CHAPTER XIV.

On Placenta Praevia . . . . .	125
-------------------------------	-----

## CHAPTER XV.

The Anatomy and Mechanism of Early Abortion . . . . .	137
---	-----

## CHAPTER XVI.

On the Dilatation of the Anus and Urethra resulting from Natural Labour . . . . .	141
---	-----

## PART III.—THE PATHOLOGY OF LABOUR.

## CHAPTER XVII.

The Sectional Anatomy of Advanced Extrauterine Gestation . . . . .	147
--	-----

## CHAPTER XVIII.

The Minute Anatomy of the Placenta in Extrauterine Gestation . . . . .	15
--	----

## CHAPTER XIX.

On the Displacement of the Placenta in Extrauterine Gestation and its Relation to those Cases ending in Pelvic Abscess . . . . .	161
--	-----

## CHAPTER XX.

On the Alleged Growth of the Placenta in Extrauterine Gestation after the Death of the Fœtus . . . . .	166
--	-----

## CHAPTER XXI.

A Contribution to the Pathology, Symptoms, and Treatment of Adherent Placenta . . . . .	178
---	-----

## CONTENTS.

xi

### CHAPTER XXII.

	PAGE
Mitral Stenosis and the Third Stage of Labour . . . . .	193

## PART IV.—PRACTICAL PAPERS IN OBSTETRICS AND GYNÆCOLOGY.

### CHAPTER XXIII.

On an Improved Method of Managing the Third Stage of Labour—How can the Accoucheur best Guard the Perineum while the Fœtal Head is Passing? .	197
---	-----

### CHAPTER XXIV.

Four of the rarer Operations of Obstetrics and Gynæcology . . . . .	203
A Contribution to the Pathology of the Lymphatics of the Pelvis. . . . .	216

### APPENDIX.

Presidential Addresses . . . . .	219
----------------------------------	-----

### NOTES.

Bibliography . . . . .	235
------------------------	-----

# LIST OF PLATES.

PLATE I.	.	.	.	.	.	.	to illustrate CHAPTER I.
„ II.	.	.	.	.	.	.	„ „ II.
PLATES III., IV., V.	.	.	.	.	.	.	„ „ VI.
PLATE VI.	.	.	.	.	.	.	„ „ VII.
PLATES VII., VIII.	.	.	.	.	.	.	„ „ IX.
„ IX., X.	.	.	.	.	.	.	„ „ XIII.
„ XI., XII.	.	.	.	.	.	.	„ „ XV.
„ XIII., XIV., XV.	.	.	.	.	.	.	„ „ XVII.
„ XVI., XVII., XVIII., XIX.	.	.	.	.	.	.	„ „ XVIII.
„ XX.	.	.	.	.	.	.	„ „ XXII.



## LIST OF ILLUSTRATIONS IN THE TEXT.

FIG.		PAGE
1.	Diagram of nude female in genupectoral posture . . . . .	11
2.	Frozen section of Pelvis in genupectoral posture . . . . .	14
3.	Sagittal mesial section of Pelvic Floor and Posterior Vaginal Wall . . . . .	17
4.	Sagittal mesial section showing perineal body considerably exaggerated . . . . .	18
5.	Sagittal mesial section showing effect of intra-abdominal pressure . . . . .	19
6.	Diagram showing the hernial nature of prolapsus uteri . . . . .	20
7.	Vertical mesial section showing Y-shape of bladder . . . . .	26
8.	Vertical mesial section of pelvis with bladder contracted—frozen . . . . .	27
9.	Vertical mesial section of pelvis showing peritoneum . . . . .	28
10.	Vertical mesial section of Fœtal female pelvis . . . . .	29
11.	Vertical mesial section of Adult female pelvis . . . . .	31
12.	Vertical mesial section of Woman in labour . . . . .	32
13.	Vertical mesial section of Frozen Cadaver . . . . .	35
14.	Nervous mechanism of Bladder . . . . .	36
15.	Perpendicular section through end of rectum . . . . .	39
16.	Rectum distended by air . . . . .	40
17.	Part of the An.nion Chorion and Placenta of Macacus Rhesus . . . . .	73
18.	Section through the same placenta . . . . .	74
19. } 20. } 21. }	Diagrams to show Synclitic movement of the head . . . . .	89
22.	Bony pelvis in vertical mesial section . . . . .	89
23.	Vertical mesial section of developed parturient canal . . . . .	90
24.	Parturient canal in nature . . . . .	94
25.	Fœtal head moulded by stiff labour . . . . .	95
26.	Child moulded at end of first stage of labour . . . . .	95
27.	Pelvic floor and Uterus at end of gestation . . . . .	99
28.	Pelvic floor during Parturition . . . . .	101
29.	Anterior-parietal-bone presentation . . . . .	106
30.	Posterior-parietal-bone presentation . . . . .	106
31.	Fœtus in Utero . . . . .	110
32.	Third stage Uterus . . . . .	123
33.	Vertical mesial section . . . . .	124
34.	Cervix and lower part of Uterus . . . . .	127
35.	Linear space between reflexa and vera . . . . .	128
36.	Section through the placenta . . . . .	129
37.	Vertical mesial section of Cervix, 4 months' pregnancy . . . . .	130
38.	Section through edge of Placenta, 4 months' pregnancy . . . . .	131
39.	Section through edge of Placenta, 6 months' pregnancy . . . . .	132
40.	Head passing Perineum normally . . . . .	144




FIG.	PAGE
41. Head distending Perineum in Forceps Case . . . . .	144
42. Head distending Perineum in Forceps Case . . . . .	144
43. Placenta of extra-uterine gestation . . . . .	169
44. Placenta of extra-uterine gestation . . . . .	171
45. Sagittal mesial section of Pelvis . . . . .	173
46. Placenta of extra-uterine gestation . . . . .	174
47. Transverse section of Villus . . . . .	176
48. Part of extra-uterine Placenta. . . . .	210
49. Sarcomatous Tumour . . . . .	217



# PART I.

ANATOMICAL AND PHYSIOLOGICAL.



# PART I

ANATOMY OF THE HUMAN BODY



## CHAPTER I.

### A CRITICAL CONSIDERATION OF THE METHODS OF ANATOMICAL RESEARCH WITH SPECIAL REFERENCE TO THE TOPOGRAPHICAL ANATOMY OF THE FEMALE PELVIS.

It may seem, on first sight, an unnecessary proceeding to consider critically the various methods of anatomical research. But although the reputation of the human anatomist for accurate and painstaking work, even to the verge of unnecessary detail, stands high in the profession, it is a fact, nevertheless, that the most widely practised method of anatomical research is far from exact, and that the results gained by newer and more careful investigation have brought out startling errors in many of our text-books. Progress in medical science so much depends on methods of investigation (as is well illustrated by the advance of microscopical science after the use of staining reagents, and of medicine and surgery by the application of the isolation and cultivation of micro-organisms), that it seems to me useful to direct the attention of anatomical teachers and anatomical specialists to the subject indicated in the title of this paper. I feel confident that there is a wide field before anatomists in the subject of the accurate determination of human topographical anatomy, and that the practical branches of the profession will profit by it.

I purpose first taking up the various methods of naked eye anatomical investigation, pointing out their excellences and defects, and, finally, trying to display the topographical relations of the female pelvic floor and pelvic organs, as determined by a trustworthy anatomical method or combination of methods.

The known methods of anatomical research are five in number, as follow :—

1. *Ordinary Dissectional.*
2. *Dissectional or Sectional after Hardening.*
3. *Sectional after Freezing.*
4. *Sectional after Freezing, followed by Fixation in Plaster and careful Dissection.*
5. *Microscopical Sections of Fætuses.*—This gives valuable results, both



for naked eye and microscopic purposes, but I defer further consideration of it at present.

1. *The Ordinary Dissectional Method* must at present be considered in two aspects,—viz., as a means of teaching the student the ordinary facts of anatomy, and, above all, of cultivating his eye and sense of touch; and as a method for the anatomist of ascertaining the facts of anatomy. Its first use is most valuable, and one that fits the student for the practice of his profession better than any other course of study. It teaches him how to observe and how to regulate his muscular action, and educates his touch-sense, all in addition to the anatomical facts he learns or verifies. As a means, however, of ascertaining anatomical relations it is very misleading, owing to the amount of displacement involved in its practice. All anatomists are well aware of this, but its most striking illustrations can be taken from the anatomy of the female pelvis. Thus, in a well-known anatomical text-book (Gray's, seventh edition), deservedly popular among students, there are at least six errors in the drawing of the sagittal section of the female pelvis; and in the drawing of the external genitals, three.<sup>1</sup>

One other illustration will help to show the defects of this method. The ischio-rectal fossa is defined out in the dissection of perineum. The anatomist, however, is unable to do more than learn that its outer boundary is the obturator internus, and its inner the levator ani. In what proportions these form the boundaries, what forms the floor of the fossa, and where and how its apex lies, his method fails to teach him. Sectional anatomy, however, gives these precisely.

2. *Sectional and Dissectional Anatomy after Hardening and embedding in Plaster* has been well described by His of Leipzig. Five to ten litres of a half or one per cent. solution of chromic acid are injected under a mercurial pressure of 100 to 120 mm., until the skin and superficial mucous membranes are coloured yellow. The trunk is then embedded in plaster, so much sawn away as is necessary to expose the region wanted, and then careful dissection or manipulation employed. When a region is thus reached, any structure likely to be displaced by manipulation and adjacent structures may be fixed by plaster of Paris. The results thus attained by His are of great value.

I have practised this method in a modified manner by hardening pelvises in the ordinary mixture of Muller's fluid and spirit used for microscopical specimens, and found that good sections of the pelvic floor could be thus obtained.

<sup>1</sup> These errors are as follow :—

(a) *Sagittal section of female pelvis*—(1) Dilatation of vagina; (2) position of uterus; (3) position of broad ligament; (4) position of Fallopian tube; (5) position of ovary; (6) inclination of pelvic brim in upright posture; (7) length of vaginal walls.

(b) *Genitals*—(1) Representation of labia minora as mucous membrane; (2) fourchette placed as anterior boundary of fossa navicularis instead of posterior; (3) posterior commissure figured as a separate structure instead of being named fourchette.



3. *Frozen Sectional Anatomy* is now much used in this country as a means of investigation, and is probably one of our most accurate methods. The best sections are those made sagittally, or in the coronal direction, and the only objection that can be urged is that the view of parts afforded, especially in transverse sections, is too limited. This disadvantage, however, is quite overcome by the following modification.

4. *Sectional Anatomy after Freezing, followed by Fixation in Plaster, Hardening in Spirit, and careful Removal of Tissues or Structures covering the Parts to be Demonstrated.*—The evident advantages of this are that a slab of any thickness or of any special part can be sawn, accurately fixed in plaster, with one surface free of course, traced, and then, when hardened in spirit and washed, dissected carefully with a minimum of displacement.

The application of this last method to the determination of the topographical anatomy of the female pelvis will now be considered. While much important information as to this has been collected by the clinical work of Schultze, Foster, Van de Warker, Ranney, and others, its accuracy has always seemed to me open to doubt. In the first place, the bimanual method of investigation necessarily displaces the organs before they are fairly grasped and defined by the examining hands. Then the pelvic brim and outlet are difficult to define, and thus errors creep in in the delineation. A more serious objection is, that the anatomy of the pelvic floor cannot be so determined, is usually erroneously figured in pelvic sections clinically determined, and thus gives rise to fresh errors.

The method for the determination of the topography of the female pelvis I recommend is as follows:—The cadaver of a healthy adult woman is taken as a basis for the investigation. The pelvis must be free from cellulitis and peritonitis, and with the bladder and rectum naturally empty.

All these points will be readily granted except the last. It is usual to consider a moderate distension of the bladder and rectum as necessary to render the pelvis normal. Hasse, in his investigation, injected the bladder with water; and His injected the rectum. Now this has always seemed to me wrong. In the first place, it is an artificial disturbance of the body. There is no evidence that artificial distension of the rectum with fluid is the same as its natural distended condition. Then, further, the results obtained on such cadavera cannot be compared with clinical work where the bowel and bladder must be empty for proper investigation. The ridiculous custom of distending the bladder fully before freezing, so as to get a normal (?) condition of parts, need only be mentioned to be condemned.

I was lately fortunate enough to obtain a cadaver fulfilling the conditions already laid down. When frozen, it was first sawn in the middle line. It could then be seen that, while the uterus lay ante-



verted, it was at the same time lying towards the left side, and was consequently cut a little to the inside of its junction with the broad ligament. A lateral sagittal section was then made, so as to cut the uterus mesially. Each slab was fixed in plaster and then hardened in spirit. When hardened, the small intestines were carefully lifted out of the fornices, and then the ovaries and Fallopian tubes exposed *in situ*.

Fig. A in the Plate shows a careful drawing made after the slabs had been placed in apposition.

The points to be noted specially are as follow :—

In regard to the *pelvic floor*: the parallelism of the vagina, urethra, and part of the rectum behind the vagina, to the conjugate of the brim, and the shape of the empty bladder, as well as the length and direction of the anus, are well seen.

In regard to the *uterus*: it has to be specially noted that its cavity is not opened into owing to its left-sided deviation. This, however, is normal, as the uterus is seldom mesial.

The uterus lies within the normal range of position, while the Fallopian tube on the left side runs out horizontally, then vertically, when it turns almost at a right angle to touch the ovary. Probably this last arrangement is uncommon, as His found the ovary lying in a curve or bend of the Fallopian tube usually (*v. B* in Plate I.).

In regard to the *ovary*: it lies on this side of the pelvis with its long axis nearly vertical. When the uterus is central, this holds good for both ovaries, but usually the lateral position of the uterus only allows of the ovary of the side towards which the deviation is, having this direction, the other ovary necessarily lying with its long axis oblique.

Plate I. gives a view of the pelvic floor and uterus with its annexa more perfect than any I have hitherto seen. On some points, however, it varies from the normal. These are—(1) as to the dip of peritoneum, behind the posterior vaginal wall; (2) the relation of the ampulla of the Fallopian tube to the ovary. Probably the arrangement figured by His, and shown at B, is more normal.

PLATE. I.—A. *Sagittal mesial section of female pelvis*: u, uterus; O, ovary; F, Fallopian tube; i p, infundibulo-pelvic ligament; v u p, vesico-uterine pouch; B, bladder; urth, urethra; V, vagina; P, perineal body; l mi, labium minus turned back. B. *Uterus and ovaries seen through brim* (His).

The following NOTE ON THE NAKED-EYE ANATOMY OF THE FEMALE EXTERNAL GENITALS is appended here :—The point I wish to clear up is easily understood. In the anatomical descriptions of the external genitals, the fourchette and labia minora are stated to be mucous membrane. Anatomists have described them thus, in error, owing to the fact that the external genitals in the cadaver soon get altered, and have a misleading appearance to the naked eye. In the living female, however, it can be readily seen that the fourchette is skin and that the labia minora are also skin. If I am asked on what I base this statement, I



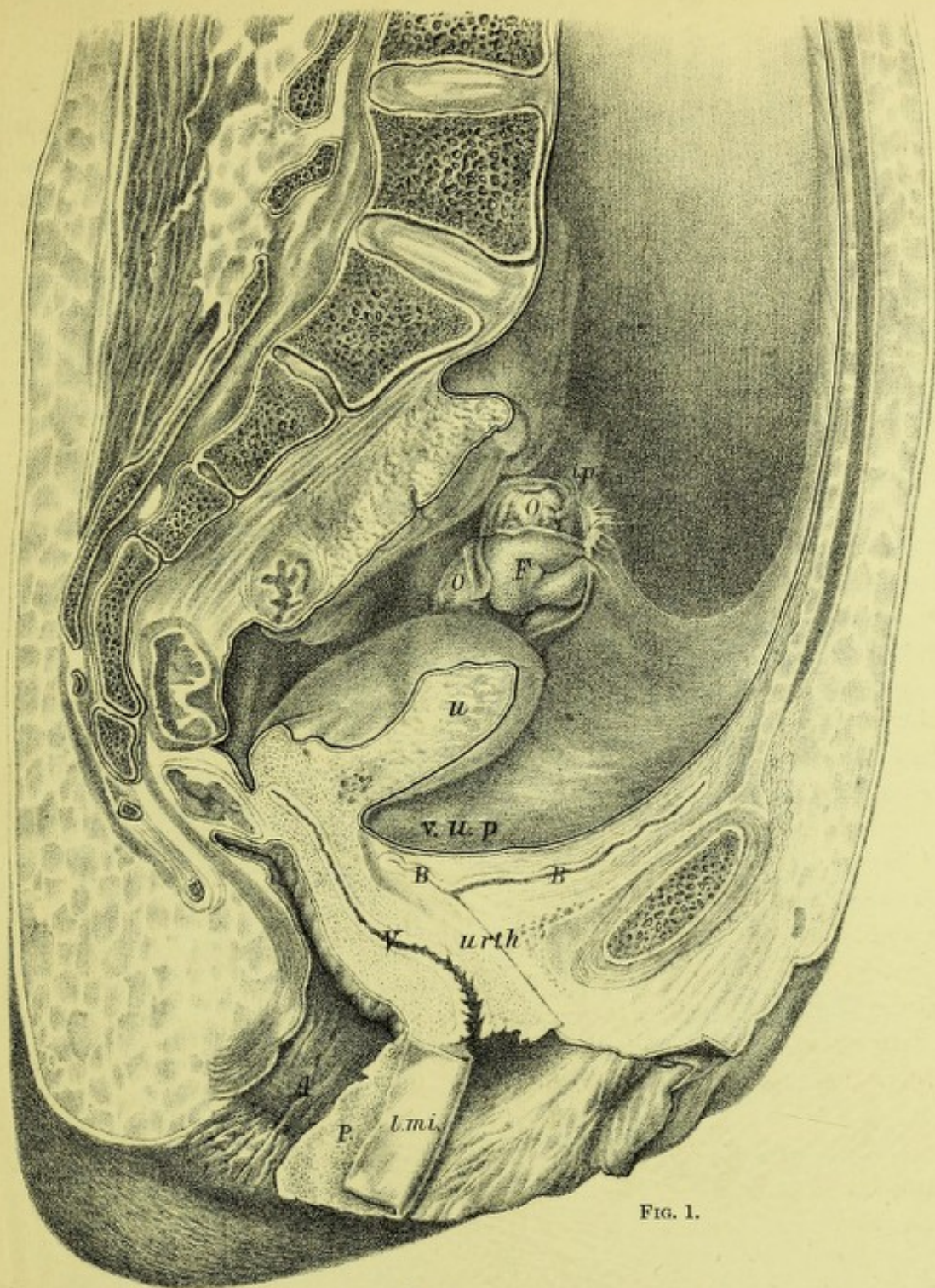


FIG. 1.

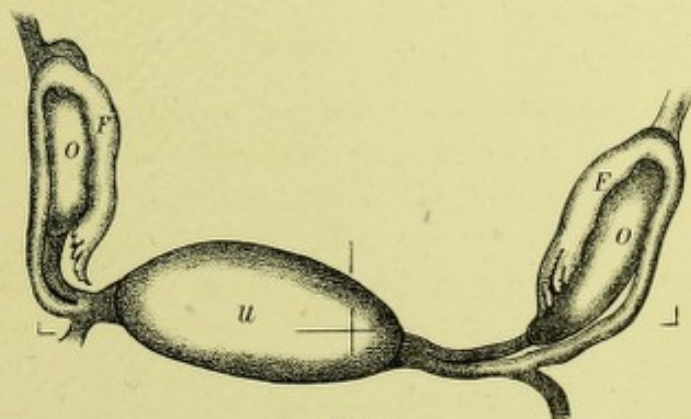


FIG. 2.

W. &amp; A. K. Johnston, Edinburgh &amp; London.

## POSITION OF UTERUS AND OVARIES.

FIG. 1. Sagittal Mesial Section of Pelvis (*Hart*).FIG. 2. Fundus Uteri and Ovaries—Seen through the Pelvic Brim (*His*).





reply that to the naked eye these structures have the appearance of skin; and, further, that the line of separation between skin and mucous membrane can be clearly seen not to include them. Hilton has already noted that at the anal aperture the line of separation between skin and mucous membrane is perfectly distinct, and he terms it the white line. This line is of great importance in determining the fact as to whether piles are external or internal. If the external genitals be looked at carefully, we can trace the line of demarcation between skin and mucous membrane as running along the base of the inner aspect of each labium minus, and passing into the fossa navicularis, separating its skin boundary, the fourchette, from the mucous membrane over the hymen. While Garriguez has drawn attention to the error in the statement that the fourchette is mucous membrane, no one, so far as I am aware, has pointed out the true structure of the labia minora. Turner, however, has described them as muco-cutaneous. The exact relation of the external genitals to one another is of interest. The labia majora have their inner surfaces in contact, whatever posture a woman may assume. The labia minora are also in contact, and the fossa navicularis is artificially made when the fourchette is pulled back. This exact apposition of the external genitals has, of course, a protecting influence on the sensitive organs.





## CHAPTER II.

### THE NATURE AND AIM OF INVESTIGATIONS ON THE STRUCTURAL ANATOMY OF THE FEMALE PELVIC FLOOR—THE GENU-PECTORAL POSTURE.

FOR some years past I have published various communications on what I termed the structural anatomy of the female pelvic floor. At present I wish to define the scope of these researches, to consider some criticisms advanced by others, and to indicate whether or not the opinions advanced have been modified by fresh facts.

This subject will best be considered under the following heads:—

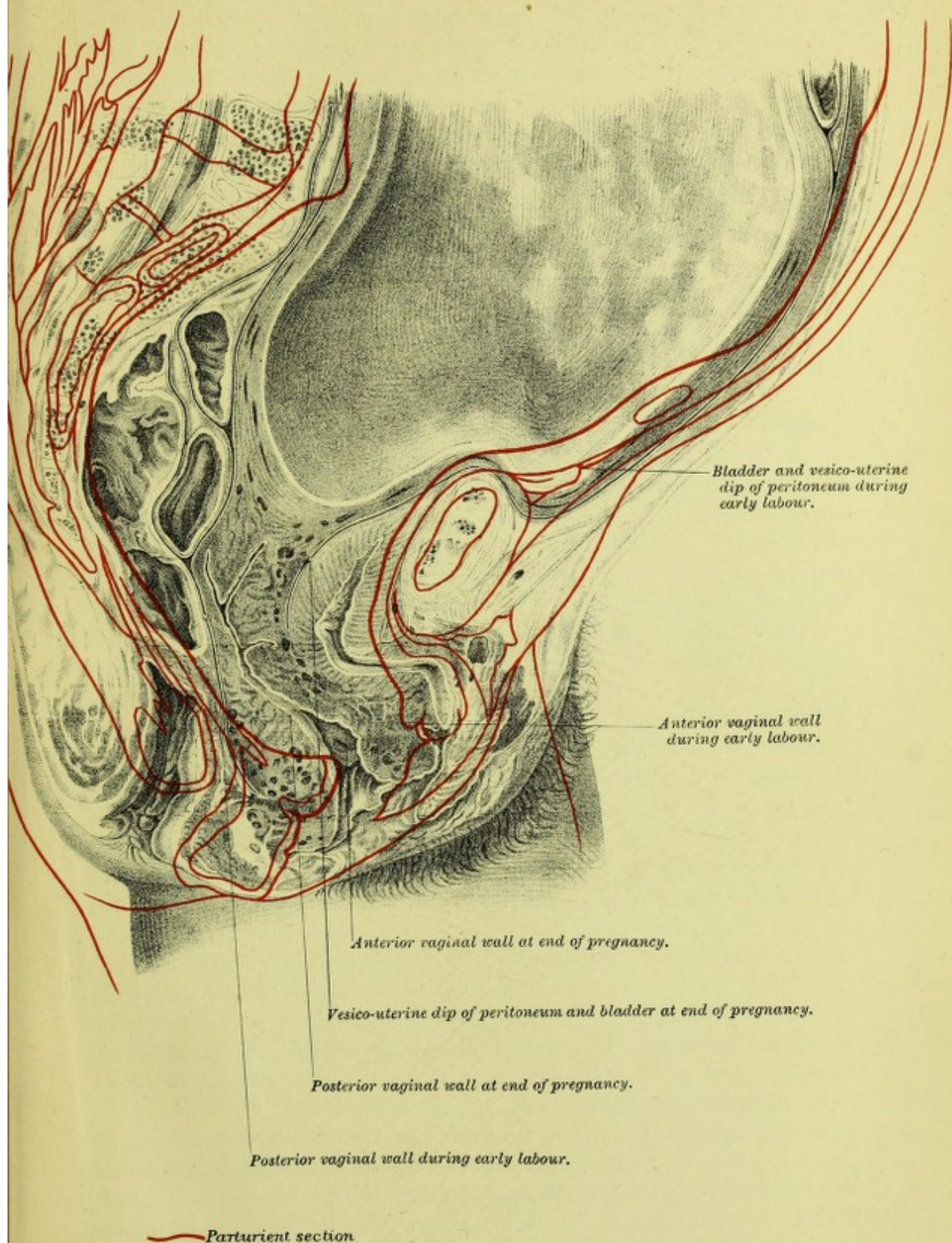
- I. *The Aim of Structural Anatomy.*
- II. *The Methods of Investigation necessary.*
- III. *The Result attained by it.*

I. *The Aim of Structural Anatomy.*—This necessitates, in the first place, a definition of what we mean by the term "Pelvic Floor." As the structural anatomy has its special bearing on the functions of the pelvic floor, it is to be defined so as to satisfy clinical and not dissectional requirements. The abdominal cavity has its inner aspect defined by peritoneum, and therefore I would define the upper aspect of the clinical pelvic floor by the peritoneum covering it, the uterus and appendages being removed of course. For similar clinical reasons the skin of the genitals and parts adjacent define its outer aspect. This gives the pelvic floor the obstetrician has to deal with.


The aim of structural anatomy is to study the mechanism of this pelvic floor, so as to understand the changes taking place in it during labour and the alterations brought about in it by excessive intra-abdominal pressure. Its main object is, therefore, to study the mechanism of parturition and prolapsus uteri, although the functions of the bladder and rectum also come up for consideration.

II. *The Methods of Investigation necessary.*—In no subject is it more necessary to have definite ideas as to methods. Inasmuch as structural anatomy is the anatomy of living function, the relation of parts must be studied in the simplest manner possible. Thus I have always used the following methods. A fresh pelvis is frozen and sawn in definite directions. The direction of a section, so far as the structure of the











pelvic floor is concerned, is of importance. The main directions must be sagittal mesial, sagittal lateral, and axial coronal. The most important are the axial coronal, inasmuch as intra-abdominal pressure acts in the axis of the pelvic inlet, and as the vagina and urethra are at right angles to it we get the proper thickness of tissue. Any obliquity of the section to the pelvic axis leads to error in estimating the relative thicknesses.

When the sections are made and drawn, the next thing is the examination. This must be limited to mere fingering, so that the lines of loose tissue may be recognised. It is often helpful to place the sections under a water-tap, so as to render these lines more evident. In doubtful points microscopic examinations should be made. The ordinary dissectional method is to be avoided, as loose tissue is cut away, the relations disturbed, and lines of cleavage artificially made. Of course dissection has its uses afterwards.

III. *The Results attained by it.*—In the female pelvic floor I described, in sagittal mesial section, a division into pubic and sacral segments, the line of junction being the vagina. The pubic segment was described as mobile, and made up of loose tissue, thus being in direct contrast to the firm sacral segment. The mobility of the pubic segment is due chiefly to its loose attachment to the pubis, where the retro-pubic fat lies. This mobility is so marked that we get the pubic segment displaced (1) even in the genu-pectoral posture; (2) more markedly displaced during labour, when it is in part drawn up; and (3) most markedly of all in prolapsus uteri.

The important displacement is the second one. I first drew attention to it in Braune's section, and since then it has been found well marked in others, viz., Chiara's, Chiari's, Saexinger's. In those of Schroeder and Barbour the labour was too slightly advanced for its production. Clinically it is easily recognised, and has been confirmed by Croom, Barbour, and many others. In Braune's section it was associated with marked thickening of the anterior uterine wall, probably because the woman died during a pain. In none other is the thickening shown, but this agrees with the facts as to the bladder brought out by me; in some the bladder is relaxed, in others contracted.

In considering the changes in the pelvic floor segments produced by the birth of the child at full time, I stated in 1880 that the pubic segment was drawn up "partly above the brim" (p. 15, *Structural Anatomy*, 1880), that this drawing up was "chiefly in the middle line" (p. 16, *ibid.*), and also that the bladder was above the symphysis, even in the first stage of labour. From the statement in one of my papers, that "only the part of the bladder above the pubis is available for the reception of urine," it will be seen that I believed that the entire bladder might not be abdominal. These results were based on an examination of Braune's sagittal mesial section of a woman who died at



the end of pregnancy, another where the labour had advanced to the end of the first stage, and also on Chiara's figure of a case of death during spontaneous evolution of the fœtus. Since that time several sections, both of pregnant and parturient women, have been issued, and we have, in addition, more sections of the pelvis of the non-gravid. There is thus abundance of fresh material for considering the whole question once more, and testing whether the statements made in my thesis are still borne out. To settle this question anatomically we have to consider—

A. *The Relation of the Vagina to the Conjugate in the Non-Gravid and Gravid Woman.*

B. *The Relation of the Os Internum Uteri and Lower Uterine Segment to the Conjugate in the Gravid and Parturient Woman.*

C. *The Action of the Retracting Uterine Muscle on the Pelvic Floor Segments.*

A. *The Relation of the Vagina to the Conjugate in the Non-Gravid and Gravid Woman.*—The vaginal axis in sagittal mesial section is the most convenient topographical line to select, as it is always cut on section, is the boundary line of the pubic and sacral segments, and has a perfectly definite relation to the conjugate. In the non-gravid pelvis it will be found that the vaginal slit in sagittal mesial section lies parallel to the conjugate and  $2\frac{1}{2}$ –3 inches below it. This distance is easily determined by joining the conjugate and vaginal parallels by perpendiculars. In the sections of gravid women at full time (Braune's, Winter's) the same facts hold good, except that the vagina lies on an average of 3 to 4 inches below the conjugate.

The important fact now to be noted is that in a parturient section the vaginal axis of the end of pregnancy can be approximately determined by drawing a parallel to the conjugate  $3\frac{1}{2}$  inches below it. This enables one to see the changes in the segments induced by labour.

B. *The Relation of the Os Internum Uteri and Lower Uterine Segment to the Conjugate in the Gravid and Parturient Woman.*—In the sections of Braune, Waldeyer, and Winter, the os internum is below the conjugate. This is best seen in Waldeyer's section, where, however, a fracture of the pelvis has elevated the parts somewhat. If we take the length of the lower uterine segment as 2 inches, we find further that the upper boundary of the lower uterine segment is also below the conjugate. It may therefore be broadly stated that at the end of pregnancy the lower uterine segment, os internum, cervical canal, and pubic segment are pelvic, *i.e.*, there is no projection of these above the conjugate.

If, now, we take the parturient sections of Braune, Chiari, Chiara, and draw on them the approximate vaginal axis at the end of the preg-



nancy, we find that the pubic segment is above its level, the sacral segment below. This is marked in Braune's section, more marked in Chiari's, and most of all in Chiara's.

But a further point to be noted is as follows. The upper boundary of the distended lower uterine segment is the retraction ring, otherwise known as contraction ring. If we look at the canalised lower uterine segment and cervix in the three parturient sections already quoted, we find the ring at the level of the promontory behind, but 2 inches above the symphysis in front. The vertical diameter between retraction ring and os externum is the same behind as in front, so that it is evident the higher portion in front is due to the higher position of the pubic segment. This displacement is given in detail in Braune's section, where we find bladder, peritoneum, and retro-pubic fat all higher. Braune's drawing is so accurate that there can be no doubt to any eye accustomed to such work; while Chiari's section also shows the peritoneum off the distended and high bladder. In Chiara's section only a small portion of the bladder is not in the abdomen.

While the higher positions of the pubic segment during labour cannot be denied, it has been urged that it is only the bladder that is high, and that further the bladder may be regarded as pushed up, not drawn up. As a mere matter of observation, however, it is not only the bladder but the pubic segment that is drawn on. Indeed the longitudinal uterine muscle directly passes to the cervix, and the cervix to the vaginal walls, which bound and form part of the segments. Traction on them is therefore direct, and the bladder is only indirectly drawn up by its attachment to the cervix and that of the urethra to the anterior vaginal wall.

That the pubic segment, however, is drawn up and not pushed up is evident when we come to consider—

*C. The Action of the Retracting Uterine Muscle on the Pelvic Floor Segments.*—Under this part I wish briefly to consider the method of action of the uterine muscle during labour as well as notice some sections of early labour not yet alluded to.

The dilatation of lower uterine segment, cervical canal, and pelvic floor is accomplished by the upward tension exercised by the longitudinal bundles of muscle during retraction and the dilating power of the fœtus. It is important to note that the round ligaments and utero-sacral folds at any rate, into which longitudinal bundles pass, give, as it were, external fixed points for uterine action. During the pain these external points seem to steady the uterus, and allow of the drawing up by the special bundles passing to the cervix. In the early stages of labour, before full dilatation can occur, the pelvic floor is depressed or bulged down, as Schroeder and Barbour's sections show. When, however, complete canalisation has taken place, the upward tension of uterine



retraction pulls up the pubic segment and gives it the higher position already pointed out. Were it not, indeed, for the upward tension exercised by the uterine muscle there would be for a certainty depression and eversion of the pubic segment before the advancing head. I see, therefore, in all recent sections abundant confirmation of the facts already given in my thesis of 1880, and I maintain still that the pubic segment, in which I of course include the bladder, is drawn up in part into the abdomen during labour; that this is most marked in the second stage of labour; that even in the early part of the first stage the bladder is drawn up as the dilatation of the lower uterine segment begins (Saexinger's section).

In sagittal mesial section a very important line of loose tissue lies between posterior vaginal wall and anterior rectal one. It is here that the posterior boundary of displacement in prolapsus uteri lies. To investigate this subject more fully I made axial coronal sections, and in this way gained fuller information. I found loose tissue separating the pelvic fascia from the organs within it, viz.—bladder, vagina, and anterior wall of rectum. As the drawing up of the pubic segment was a displacement of only part of this portion lying within the pelvic fascia, I considered it advisable to add to the nomenclature by using the terms "entire displaceable" and "entire fixed" segments. The entire displaceable segment is the bladder and urethra with the vaginal walls. The entire fixed portion comprises the tissues lying beyond the pelvic fascia. This is a terminology highly useful, as it puts the matter of so-called prolapsus uteri thus,—“Prolapsus uteri is a displacement of the ‘entire displaceable’ portion past the ‘entire fixed’ portion.”

The “entire fixed” portion coincides exactly with the pelvic floor of some anatomists. In the axial coronal sections one can see the loose side-relations of the pubic segment, and also how, beneath the pubic arch, it is fixed by fascia and muscles. This fixation I also found in microscopical sections.

#### THE CLINICAL FEATURES, ANATOMY, AND USES OF THE GENU-PECTORAL POSTURE.

The contour of the anterior abdominal and pelvic surface of the nude female varies according to the posture she assumes: when erect, the curve of the pelvic floor is markedly convex; and there is a slight bulge of the viscera just above the symphysis (even in the most spare woman), and a lessening of the antero-posterior diameter at the sternum. As a general rule, it may be stated that, whatever posture a woman may assume, the abdominal viscera will bulge at their lowest point with compensatory and equivalent shrinking elsewhere. Under no circumstances have we ever a vacuum in the abdominal and pelvic cavities, so



that all the changes in the contour are just the same as one would get from a homogeneous plastic fluid of the average specific gravity of the abdominal and pelvic viscera. If a woman then be placed in the posture known as the genu-pectoral, and the contour of the pelvic floor and anterior abdominal surface noted, it will be seen that the antero-posterior diameter of the abdomen is increased near the sternum and diminished just above the pubis; that the iliac fossæ are more hollowed, and the pelvic floor, chiefly in the middle line, furrowed and flattened.

The labia majora and minora are still in contact and no further change takes place when they are held apart and the fourchette lifted up. It is only when the hymeneal orifice, the anatomical entrance to the vagina, is opened that we find the vagina becoming a large cavity. The distention of the vagina with air is not, however, the only change following the opening up of the vaginal orifice proper. Coincident with it we get an increase in the antero-posterior diameter of the abdomen at

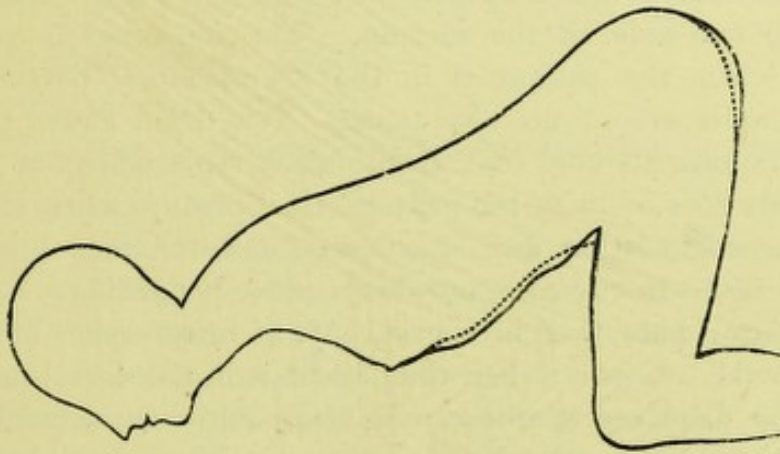


FIG. 1.

DIAGRAM BASED ON FROZEN SECTION AND SILHOUETTE TRACINGS OF NUDE FEMALE IN GENU-PECTORAL POSTURE.

The dotted lines show the contour of the pelvic floor and anterior abdominal surface when the vagina is undilated; the plain line, when vagina is dilated (*Simpson and Hart*).

its sternal end and a coequal lessening of the same just above the pubis. The anterior vaginal wall, lengthened, will be found to follow more or less the contour of the posterior aspect of the symphysis pubis; the posterior, also lengthened, the curve of the sacrum, both thus diverging markedly from the line parallel to the axis of the brim which is the direction of the vagina (leaving out of consideration its upper part) in the undilated and normal condition.

So far the work of observation is easy. The difficult point is to find out the exact changes in the position of the uterus when a patient assumes the genu-pectoral posture and the vaginal orifice is opened.

In the first place, when the uterus is normal in position to begin with, *i.e.*, lying anteverted in a line somewhere between the axis of the brim and a parallel to the horizon, it becomes



more anteverted when the woman is in the genu-pectoral posture, passing down as a whole toward the thoracic diaphragm and up nearer the sacrum. Probably the cervix moves over a greater space, but on this point I am unwilling to dogmatise. The uterus is certainly farther from the vaginal orifice. The finger passed into the vagina touches the cervix therefore with greater difficulty. The most important fact, however, is in regard to the changes in position of the retroverted uterus when a woman assumes the genu-pectoral posture and the vagina is dilated. It will be found to have passed farther from the vaginal orifice and nearer the sacrum. The cervix has certainly moved over a greater space than the fundus, so that the uterus as a whole appears more retroverted. Now, nothing is more often reiterated than that the retroverted uterus becomes anteverted when the patient assumes the genu-pectoral posture and the vaginal orifice is dilated. This I believe is never the case. The fundus may not be felt by the vaginal fingers, but a careful bimanual will show that it is still retroverted, and probably to one side of the sacrum. The bimanual is very easily performed when the patient is in the genu-pectoral posture, as the abdominal walls are in no way tense. Now, I am aware that many eminent gynecologists hold that spontaneous replacement of the retroverted uterus does occur in the genu-pectoral posture when the vaginal orifice is opened to admit air. I can say, however, that I have never seen such a result in any case, nor do I believe it possible.

Any one can note this in a case, say, of retroversion of the three months' gravid uterus. When the patient is in the dorsal posture, the bulge of the displaced uterus can be easily felt. On vaginal examination, when the patient assumes the genu-pectoral posture and the vaginal orifice is opened, the bladder passes down with the intestines, carrying the cervix with it. The heavy fundus lags behind, and passing nearer the sacrum gets jammed and does not replace because the vertical from its centre of gravity falls on the perineal side of the transverse line round which it rotates when it replaces. But, it may be urged, the vagina is not fully distended with air and therefore the uterus does not replace. If a Sims speculum be introduced and the posterior vaginal wall hooked forcibly up, then the fundus will pass to the front and the vagina be found fully distended with air. Quite true. But the air distention is the result of the fundus swinging down, and not the cause. By introducing the Sims speculum fully, and hooking up the posterior vaginal wall forcibly, two things are done. First, the uterus is pushed on, and by the tension of the posterior vaginal wall the cervix pulled towards the perineum. This causes the vertical from the centre of gravity to fall on the intestinal side of the transverse line of rotation, and therefore the fundus drops down so as to lie over the bladder. In a case recorded by Mundé, of New York, the retroverted gravid uterus was replaced by



making the patient assume the genu-pectoral posture and hooking the perineum forcibly up with Sims' speculum. There is no doubt but that Dr Mundé replaced the uterus so. The point to determine is what were the factors of the replacement. I would urge that Mundé, by passing in the Sims speculum and hooking up the posterior vaginal wall, pushed the uterus forward, and that it then gravitated down by its own weight. The vagina became fully distended as the result of this.

Complete replacement of the retroverted uterus can only be obtained when, in addition to the genu-pectoral posture and opening of the vaginal orifice, pressure on the uterus through the rectum, or distending the rectum with air or water, or bringing down the uterus towards the vaginal orifice with a volsella are employed.

To sum up, the clinical features of the genu-pectoral posture are :—

*a. Before the vaginal orifice is opened.*

1. Increase of visceral bulge at sternum, decrease just above pubis, and diminished pelvic floor projection.

*b. After vaginal orifice is opened.*

1. Distention of vagina with air.

2. Slight increase of visceral bulge at sternum and diminution above pubis.

The uterus, when normal in position, alters its position in a way not quite made out. The retroverted uterus does not replace.

In order to understand the anatomy of the genu-pectoral posture, some preliminary matter must be lightly sketched.

If a vertical mesial section of the female pelvic floor be studied, it will be seen that the pelvic outlet is filled up by a thick fleshy layer—the pelvic diaphragm. Running through it parallel to the pelvic brim from skin to peritoneum is the vagina—a mere slit as thus shown. A convenient nomenclature is to consider this pelvic floor as made up of two segments, a pubic and sacral one. These are easily defined. The pubic one is attached to the pubis and ends posteriorly with the anterior vaginal wall. The sacral segment is dovetailed into the sacrum and ends anteriorly with the posterior vaginal wall. (Plate I.) Let us now briefly contrast these two segments. It is evident that the pubic segment is loosely attached to the pubis. The anterior wall of the bladder and urethra meet each other at a right angle, so that we get the space between these and the symphysis pubis filled up with a large amount of loose fat—the retropubic fat. Consequently the pubic segment can revolve round the symphysis as a fixed point. The sacral segment on the other hand is firmly dovetailed into the sacrum and coccyx.

If we examine the relation of the pubic segment to the pubis, we shall find that in the ordinary erect posture the empty bladder is behind and



below the pubis, that the urethra and anterior bladder wall meet each other at about a right angle, that the fat in front of the bladder is retropubic, and that the peritoneum passes from the anterior abdominal wall on to the bladder fundus at the level of the top of the symphysis pubis. (See Pl. I.) The retropubic fat is in its shape and position a rough index to the position of the pubic segment. If the whole pelvic floor be bulged farther down, as it is at the end of pregnancy, the retropubic fat is low down below the subpubic ligament; when the

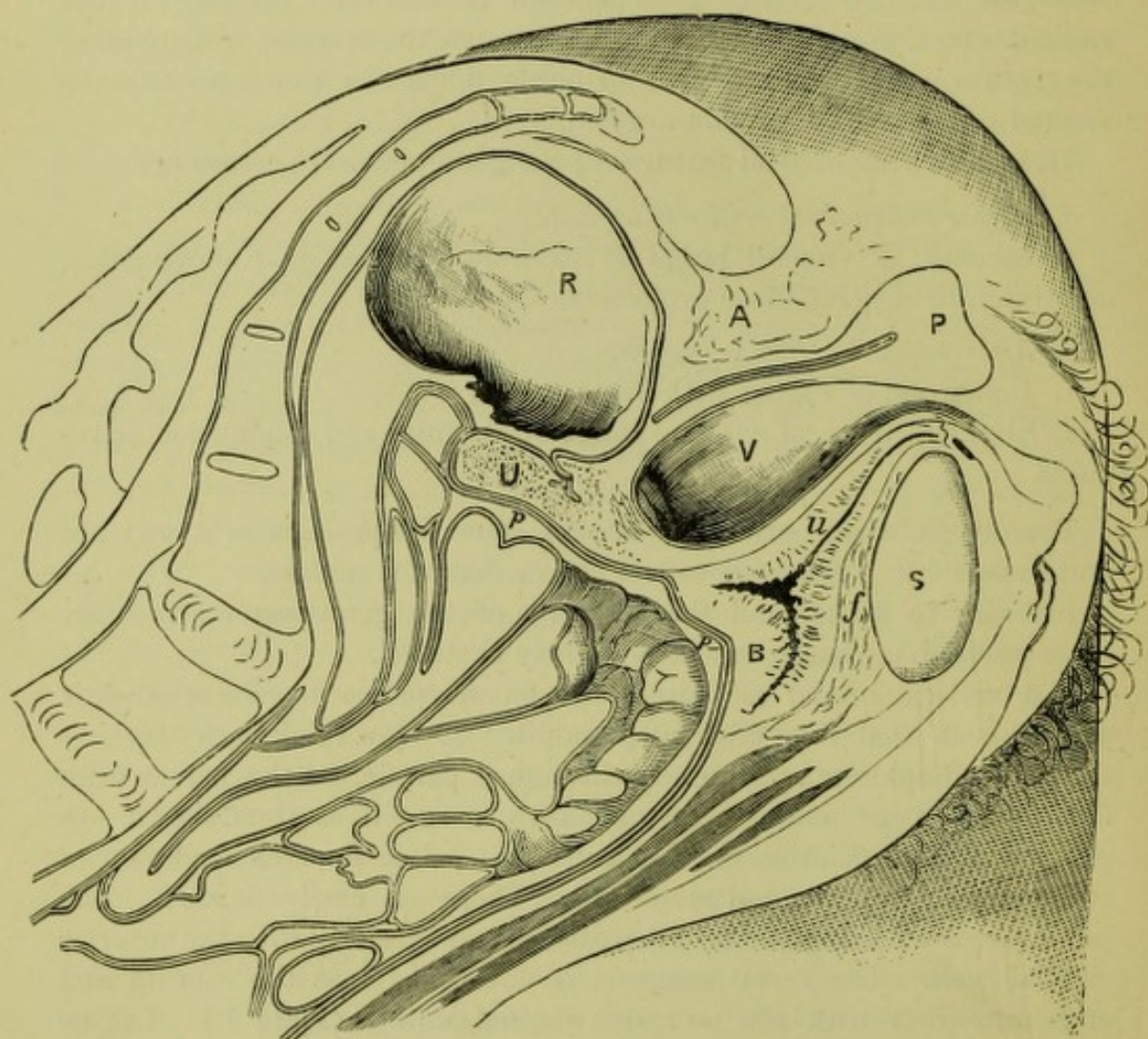


FIG. 2.

Reduced from Simpson and Hart's Frozen Section of Genu-pectoral Cadaver (pelvis shown only).

bladder is drawn up in parturition, the fat is above the symphysis. Thus I was led theoretically to anticipate what Dr Simpson and I actually found in a section of a cadaver frozen in the genu-pectoral posture.

There the bladder proper is above the pubis; the peritoneum passes from the anterior abdominal wall on to the fundus of the bladder more than an inch above the top of the symphysis pubis, the retropubic fat is



partially above the pubis, and the anterior bladder wall and urethra are almost in the same straight line. (Fig. 2.) It is evident, then, that in the genu-pectoral posture, when the hymeneal orifice is stretched, the pubic segment passes down with the viscera, the sacral segment remains behind. In this way we get the vagina dilated. Now what are the factors producing this curious change? Briefly they may be summed up as follows:—

When the patient turns on her knees and droops her head and chest, the viscera bulge at their lowest part, owing to gravitation acting on a plastic mass. The sternal bulge is compensated for by the flattening of the pelvic floor and the diminution of the pubic antero-posterior diameter. Dilatation of the vaginal orifice admits air, makes the pressure on the skin and vaginal aspects of the sacral segment equal, and acting on the vaginal aspect of the loosely attached pubic segment, drives it farther down. By the recoil up of the sacral segment and the drop down of the pubic segment we get the vagina dilated.

In regard to the changes in the uterine position I defer explanation at present.

The physical nature of the abdominal and pelvic contents and walls, the action of gravitation on them, atmospheric pressure, and the anatomical attachment of the pubic and sacral segments of the pelvic floor constitute the factors bringing about vaginal dilatation in the genu-pectoral posture.

The uses of the genu-pectoral posture to the gynecologist are much more limited in my opinion than is generally believed.

For specular examination the semi-prone position (which is a modified genu-pectoral) gives the best view. In the genu-pectoral posture the anterior vaginal wall is more hollowed and more in the shade, especially in its upper part. For the relief of ovarian congestion, in cases of difficult urination, and for the insertion of prolapsus uteri pessaries, the genu-pectoral posture has obvious advantages.

For replacement of the retroverted uterus the genu-pectoral posture is only valuable in so far as gravitation can act on the uterus after the latter is manipulated by rectal pressure, rectal distention, or volsellar traction on the cervix. Otherwise the genu-pectoral posture is disadvantageous for replacement, seeing that the fundus and cervix are farther from the vaginal orifice, and the fundus closer to the sacrum. So far as the patient is concerned, the genu-pectoral posture is an awkward one. To the gynæcologist its consideration is valuable practically, seeing that the study by Marion Sims of this distention with air in this posture of the vagina has given Gynæcology its most valuable speculum and gynæcological science some of its most interesting physical facts.



## CHAPTER III.

### ON SACRO-PUBIC HERNIA—PROLAPSUS UTERI.

IN the formation of the female pelvic floor a structural problem had to be solved, as follows:—The floor had to be constructed so that we should have some method by which it could be opened up to admit of the passage of the child's head; and while this was to be arranged in such a way as not to impede parturition unduly, the pelvic floor was not to be impaired in its structural efficiency, and was to remain sufficiently firm to resist ordinary, and a certain amount of extraordinary, intra-abdominal pressure.

In the erect posture the female vertebral column may be regarded as practically vertical. At the fifth lumbar vertebra the arrangement alters, and the first two bones of the sacrum make an angle backwards with the vertical of about  $60^{\circ}$ . The other vertebræ (3–5 sacral and 1–3 coccygeal) curve gradually forwards, so that the whole sacrum and coccyx form a surface concave forwards. The further continuation of this bony curve is fleshy, reaching to about  $1\frac{1}{4}$  inches from the symphysis pubis, forms what I have already termed the sacral segment of the pelvic floor (fig. 3), and makes an angle of about  $60^{\circ}$  with the horizon. The space between the posterior aspect of the symphysis and the posterior vaginal wall is filled up by the pubic segment of the pelvic floor (fig. 5), whose vaginal aspect closely fits on the anterior aspect of the sacral segment, and is continuous and blended with it on either side of the vaginal slit.<sup>1</sup> Anteriorly the pubic segment has a loose attachment to the symphysis (fig. 5); while posteriorly, where it does not blend with the sacral segment as above given, it is attached to it indirectly through the uterus by the posterior vaginal wall (fig. 4). This forms a strap-like attachment, and is only firmly blended to the sacral segment at the perineum. The peritoneum passes from uterus to sacral segment. Had the sacral segment been prolonged close to the symphysis pubis, it is evident that women would never have had prolapsus uteri; but then parturition, as we know it at present, would have been an impossibility. The pelvic floor is really built so as to support the superincumbent viscera well, and yet not so strongly as to unduly impede the birth of the head. The happy medium of strength sufficient but not too great has been struck.

<sup>1</sup> *V. Chap. II.*, page 10.



Anatomically considered, then, the part of the pelvic floor weak in structure and attachments is the pubic segment, specially in the middle line, and the posterior vaginal wall. So far as displacement of the pelvic floor is concerned, then, we have only to consider the action of the intra-abdominal pressure on this part. There is never any prolapsus of the sacral segment. Rectocele is a distention, and not a hernial phenomenon.

I have spoken of the whole sacral segment as being the supporting one. Usually, however, the perineum is regarded as performing this function. Opinions as to the value of the perineal body vary from

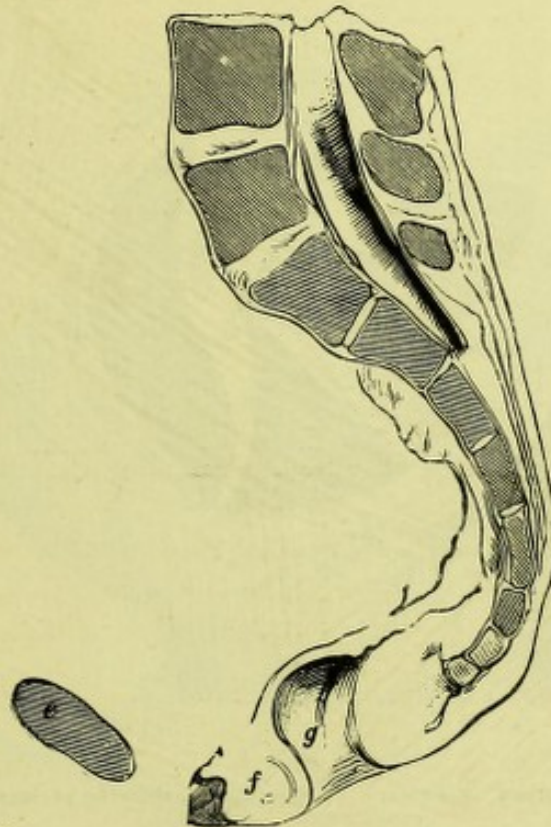


FIG. 3.

THE SACRAL OR SUPPORTING SEGMENT (*f g*) OF THE PELVIC FLOOR AND POSTERIOR VAGINAL WALL IN SAGITTAL MESIAL SECTION. The pubic or displaceable segment, uterus and posterior vaginal wall have been removed.

*e*, Symphysis pubis; *f*, Perineal body; *g*, Anus.—(From nature.)

strong statements that it has nothing to do with prolapsus uteri to equally strong assertions that its existence is the only safeguard against it.

The inferior angle or free edge of the sacral segment is that part of it which is most liable to injury during parturition, since it is the thinnest, and is unsupported by any bony structure (see figs. 3 and 4). It is, therefore, strengthened here by a pyramidal wedge of elastic and muscular tissue known as the perineal body. On vertical section this body is found to be  $1\frac{1}{4}$  inches<sup>1</sup> in height, and to touch with its apex a

<sup>1</sup> This I found as its average height in six vertical sections.



line joining the bottom of the symphysis pubis and sacro-coccygeal joint. The apex of the perineal body is distant about 2 inches from the top of the posterior vaginal wall. I have been thus particular in defining it, since Thomas of New York, in a recent able paper, has unwarrantably exaggerated its dimensions<sup>1</sup> (see fig. 4). The perineal body, therefore, tips and strengthens the inferior angle of the sacral segment like the brass-bound edge of the door-step exposed to much traffic, and acts as a strong attachment to the important perineal muscles. It is erroneous, however, to draw it, as Thomas has done in figure 4, with twice the height and one and a half times the breadth of the reality.

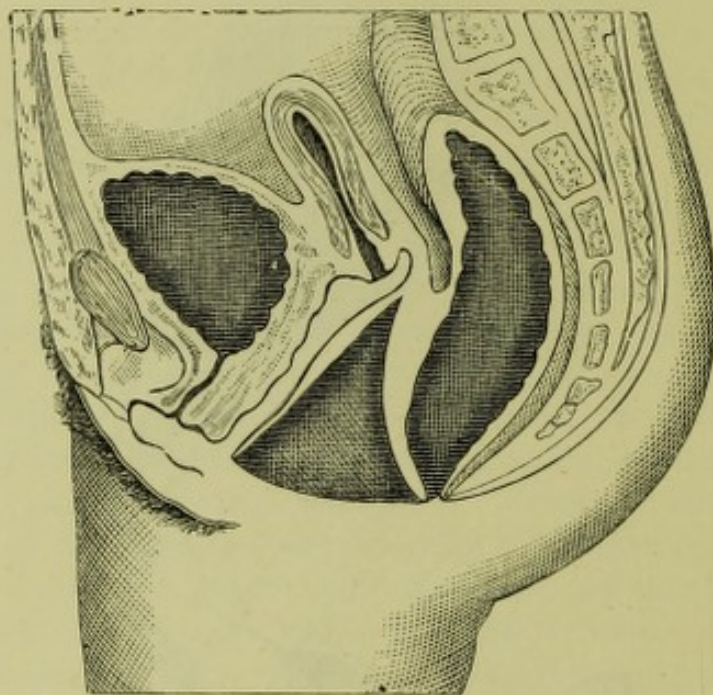


FIG. 4.

SAGITTAL MESIAL SECTION OF FEMALE PELVIC FLOOR, showing perineal body "considerably exaggerated."—(Thomas.)

This gives it the importance of the sacral segment itself—an importance not warranted by fact.

The intra-abdominal pressure acts on the pelvic floor as follows:—We must regard the viscera from the thoracic to the pelvic diaphragm as so much weight of fluid. Atmospheric pressure does not come into consideration, because the atmospheric pressure on the anterior abdominal wall transmitted to the peritoneal surface of the pelvic diaphragm is counteracted by that on the external aspect of the pelvic floor. If we consider the viscera as acting like a fluid, their pressure is at right angles to the limiting surface, *i.e.*, the peritoneal aspect of the pelvic floor. A consideration of fig. 5 will show, then, that part of the intra-abdominal pressure will press the pubic segment of the pelvic floor

<sup>1</sup> *American Journal of Obstetrics*, April 1880, p. 312.



against the sacral (lines 10-14, counting from the symphysis). Another part will have a resultant pressing it in the same way, but also tending to force it down out at the vaginal orifice (lines 8 and 9). A third portion will press it against the symphysis pubis (1, 2, 3), and other moieties will tend to drive it out of the vaginal orifice (6 and 7). As a whole, then, the intra-abdominal pressure will tend to press the pubic segment against the supporting sacral segment and symphysis. The resultants tending to force the pelvic segment past the sacral will be counteracted so far by the want of rigidity of the pubic segment, by the cohesion of the vaginal walls, and the lateral bony attachments of

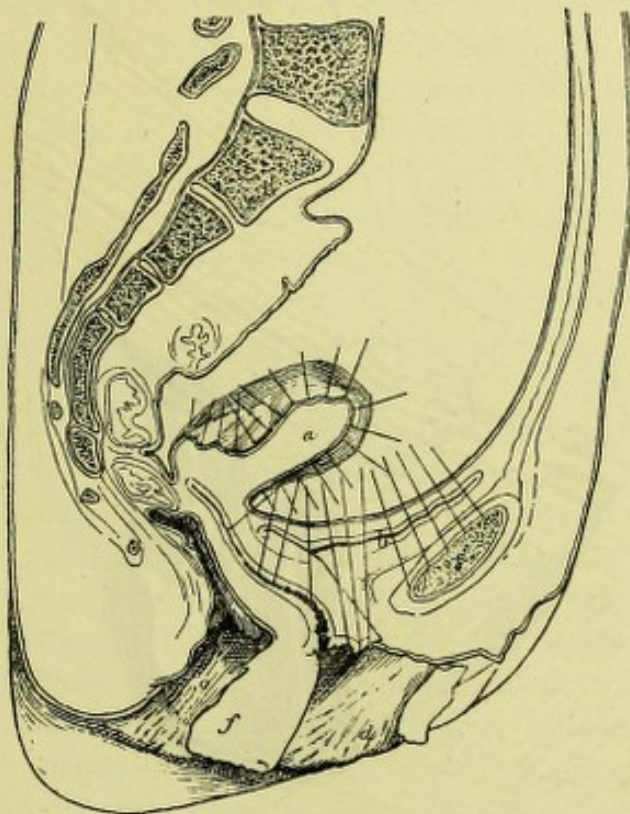


FIG. 5.

SAGITTAL MESIAL SECTION OF FEMALE PELVIC FLOOR, showing effect of intra-abdominal pressure on it.

*b c*, Pubic or displaceable segment.—(From nature.)

the pubic segment. The pelvic floor, however, as already said, is not thoroughly strong. Its weak portion is all that in front of the anterior rectal wall. Any long-continued strong intra-abdominal pressure will therefore tend to displace it, and displace as a whole a definite portion of it, viz., the pubic segment, the uterus, and the posterior vaginal wall. The pubic segment has a weak attachment anteriorly, and its connection to the sacral segment through the posterior vaginal wall is also weak. The uterus lies between, and therefore extra intra-abdominal pressure pushes all three—*i.e.*, pubic segment, uterus, and posterior vaginal



wall—down *en masse*. Anatomically considered, then, all in front of the recto-vaginal line is what intra-abdominal pressure can displace.

The sacral segment is therefore the supporting one, and the pubic segment the displaceable one. It is almost always stated that the posterior vaginal wall is the supporter, and its special sigmoid curve is believed by Thomas to have a special mechanical value in preventing prolapsus. Thomas's mechanical principle is accurate enough, but the fallacy in its application is that he considers intra-abdominal pressure as applied to the top of the vaginal wall. If one wishes to consider the

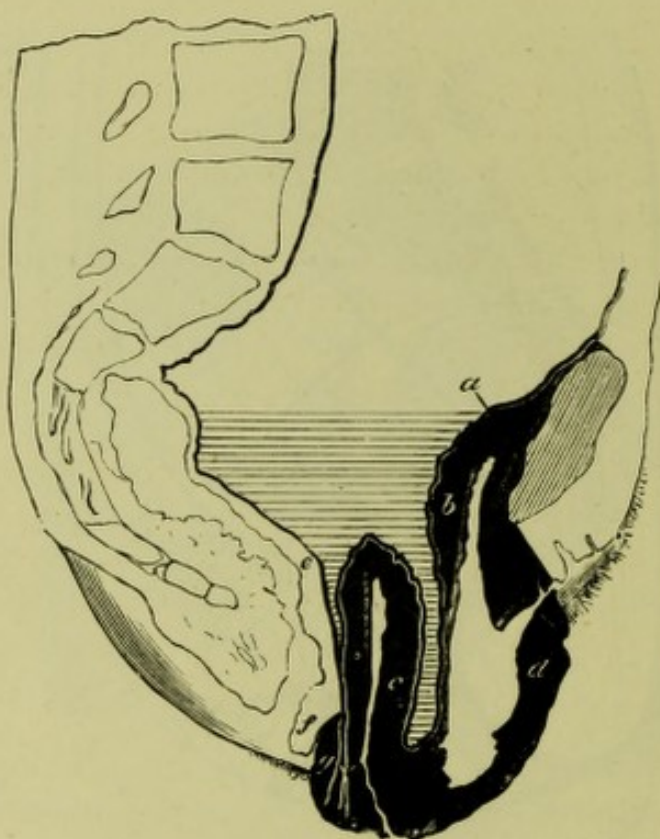


FIG. 6.

DIAGRAM modified from Schütz, showing the hernial nature of prolapsus uteri. The coverings of the hernia are in black; the transverse lines indicate viscera.

*a*, Peritoneal line, i.e., sac; *b d*, Pubic segment; *c*, Uterus; *f*, Remains of perineal body; *g*, Posterior vaginal wall; *e*, Anterior rectal wall.

effect of intra-abdominal pressure on the posterior vaginal wall, one must consider the viscera and pubic segment as pressing like a fluid on the whole posterior vaginal wall and at right angles to it.

To regard the perineum and the posterior vaginal wall as the supporting part is wrong. The perineum is only a certain fraction of the sacral segment, made of a stronger tissue, to be sure, but yet having a value only in proportion to its size and the fact that it gives insertion to many muscles, and is the bit of the sacral segment most usually torn by the foetal head.



We have thus considered the natural structural arrangements of the pelvic floor. This leads us, then, to its pathological displacements, viz. :—

*Hernia through the Front Half of the Pelvic Floor—Sacro-Pubic Hernia, otherwise known as Prolapsus Uteri.*

Hardly any subject in Gynæcology has given rise to more discrepancy of opinion than the pathological condition known as prolapsus uteri. Examination of the opinions advanced by Huguier, Matthews Duncan, Goodell, Marion Sims, Thomas, Protheroe Smith, and many others, will show how widely their views diverge. By some, lesion of the perineum is believed to cause no predisposition to its occurrence, while others seem to imagine that its integrity is the only safeguard against it. It is interesting to note that so many acute observers should hold such divergent opinions. Some of the reasons for this, however, are well worthy of our preliminary attention.

*In the first place*, the stability and structural arrangements of the female pelvic floor have been ignored.

*In the second place*, the importance of the intra-abdominal pressure has been much underrated. The gynæcologist, looking at the stages of a prolapsus uteri occurring in a living woman, is apt to think that the anterior vaginal wall is pulling down the uterus, and the uterus pulling down the posterior vaginal wall, ignoring the reality of the mass of viscera and muscular force above pushing these down as a whole. The uterus is only an insignificant fraction of this mass, and its supra-vaginal cervical portion still more so. The sphere of prolapsus uteri is not in the pelvic floor alone, but reaches up to the diaphragm.

*In the third place*, the term "prolapsus uteri" is a most unfortunate and misleading one. It has led most gynæcologists either to accept without question or to attempt to prove the supposition that the uterus has some important part in causing its own prolapsus; whereas, as I hope to show, it really plays no part in it at all. Had surgeons termed "inguinal hernia" "prolapse of the cremasteric fascia," it is evident they would have been led as far astray as gynæcologists.

*Fourthly*, it has been chiefly studied clinically.

Prolapsus uteri, however, must not only be studied clinically, but also in vertical section on the actual cadaver, as it is only by combining what we learn from these and what we know of the structural arrangement of the pelvic floor that we can obtain true views as to its nature.

We therefore now take up—

A. Clinical Features of Prolapsus Uteri.

B. Anatomical Nature.

C. Explanation of (1) Definite Mechanism; (2) Varying Position of



Uterus during Descent of a Prolapsus Uteri; (3) Enlargement of Uterus.

D. Nature of Prolapsus Uteri.

E. Factors producing Prolapsus Uteri.

F. Nomenclature.

A. *Clinical Features of Prolapsus Uteri*.—If a patient with a complete prolapsus uteri be laid on her side, the whole prolapsed organs replaced,<sup>1</sup> and if she be then bid strain, the following structures will appear and pass out at the vaginal orifice:—The anterior vaginal wall first appears from below upwards. *Pari passu* with its descent the uterus and posterior vaginal wall have come down, the cervix tracing the pelvic curve, and the uterus becoming more and more retroverted, until when the *os uteri* is at the vaginal orifice the uterus lies in the vaginal axis, with the posterior vaginal wall forming a pouch, the half of its own length behind it. Further efforts by the woman will now drive the uterus outside the orifice, and the posterior vaginal wall is now completely everted, its lowest part appearing last.

B. The anatomical features can be studied only in vertical section. Schütz's vertical section of the parts in complete prolapse, from a frozen section, illustrates the description we have given admirably. Figure 6, which is modified from Schütz's drawing, shows that in a nearly complete prolapsus we have from before backwards, pubic segment of the pelvic floor, uterus, and posterior vaginal wall. The rectum is quite in position, and the part of the posterior vaginal wall not prolapsed is that part of it opposite the perineal body where the loose connection between posterior vaginal wall and anterior rectal wall ceases. The peritoneal lining of the displaced structures is well seen.

C. From all we have now gone over it is evident that so-called prolapsus uteri is, as we anticipated anatomically, a displacement downwards *en masse* of all the structures in front of a line drawn between the posterior vaginal wall and anterior rectal one; and if this be considered it will readily be seen why we have always a definite mechanism when viewed at the vaginal orifice.

Two points now come up for consideration, viz., the position of the uterus during the descent of a prolapsus uteri and the relation of the enlargement of the uterus to prolapsus uteri. In regard to the first point, it will be seen that the uterus, while it is being forced down, has the position of its long axis continually altering. This is often expressed by saying that the uterus becomes more and more retroverted as it is forced down. The real fact is, that as the pubic segment is forced down it is stretched chiefly on its peritoneal aspect. In this way tension is made on the cervix uteri, with the effect of throwing the uterus back

<sup>1</sup> This should be done so that what comes down last is replaced first. The order of replacement is therefore posterior vaginal wall, uterus, and anterior vaginal wall.



and making it rest on the retrojacent structures. As these have roughly the pelvic curve, we get the uterus in this way constantly altering its axis-lie.

It is a fact, clinically, that in most cases the uterus in prolapsus is enlarged. At present I am only considering prolapsus uteri in a mechanical aspect; whereas the question of this enlargement is to be settled clinically and by anatomical sections. My own belief is that the enlargement is not purely cervical, but affects the whole uterus and pubic segment too, and that it is a consequence of prolapsus uteri, and not a factor in its production. If we view a prolapsed uterus, with the os at the ostium vaginae, through the pelvic brim, it can be seen that it lies, as it were, at the bottom of a valley, the sides of the valley being the broad ligaments, the bed of the valley the uterus. The parts of the uterus do not lie on the same horizontal plane, but the cervix lies lower. It is evident, then, that the venous supply of the uterus, having a mechanical disadvantage to its return, will have a tendency to stasis most marked at its cervical end. This may lead to areolar hyperplasia at first, and, so far as our present knowledge goes, accounts along with tension for the increased size of the uterus in a prolapsus.

*D. Nature of Prolapsus Uteri.*—The uterus has nothing to do with prolapsus uteri. It is a time-honoured term, but a misleading one. Prolapsus uteri is really a hernia, and is analogous in every point to what we term a surgical hernia, such as femoral hernia, and so on.<sup>1</sup>

Thus it has (1) a *sac*, the peritoneum; (2) a definite road to travel along, whose boundaries are—*a*, in front, the pubic symphysis; *b*, behind, the sacral segment of the pelvic floor—*i.e.*, from anterior wall of rectum back to sacrum; *c*, side walls; (3) definite coverings, viz.—*a*, pubic segment of pelvic floor; *b*, the uterus; *c*, posterior vaginal wall. Like all herniæ, its sac contains intestine (see fig. 6).

What I have already given is sufficient evidence as to the hernial nature of prolapsus uteri. The matter will be made more evident by a consideration of an ordinary oblique inguinal hernia. Here the same structural problem had to be solved, viz., how to get the foetal testicle from the abdominal cavity into the scrotum without unduly impairing the strength of the abdominal wall. Hence we get the spermatic cord lying in an oblique slit, so made that the intra-abdominal pressure presses at right angles to it, *i.e.*, in such a way that the boundaries of the inguinal canal behind the cord are pressed against those in front of it. Still this is the weak point in the wall, and the point where hernia generally occurs. In any such hernia the coverings are thickened, yet no surgeon regards this otherwise than as a result of the hernia itself, caused by excessive intra-abdominal pressure on a part anatomically

<sup>1</sup> I should state that Dr Protheroe Smith and Dr Matthews Duncan urge the hernial nature of prolapsus uteri.



weaker. The same view holds good for a prolapsus uteri. It is a hernia too, and the uterus is only a thickened covering.

If this view be correct, it is clear, then, that the theory of prolapsus uteri, which makes its initial cause lie in the supra-vaginal elongation of the cervix, is open to the objection that it would be the only case of a hernia known where a thickening and hypertrophy of a covering caused the hernia itself. It is unintelligible, too, in other respects, and leads to wrong treatment.

*E. The Factors producing Prolapsus Uteri* are three in number, viz.—  
1. Deficient sacral support ; 2. Deficient tone of pubic segment of pelvic floor ; 3. Intra-abdominal pressure.

1. *Deficient Sacral Support*.—By this I mean that through parturition the sacral segment has got straightened out and notched or deficient at its lower margin—the perineum. It is wrong to imagine that tear of the perineum is everything in prolapsus uteri. The perineum may be considerably torn, but if the sacral segment is still sufficiently curved, and the intra-abdominal pressure not so great, there will be no prolapsus. Tear of the perineum is not everything in prolapsus uteri ; but it is too great a rebound from this view to say that it never has anything to do in bringing it about. Deficient sacral support makes the task of intra-abdominal pressure easier. The bearing of the second and third factors is sufficiently evident. Of all the three, the third, viz., increased intra-abdominal pressure, is the most important, and is sufficient to cause prolapsus even in virgins. The first and second are adjuvant, and almost constantly present.

The etiology of prolapsus may thus be summed up :—1. Intra-abdominal pressure alone may cause it ; 2. An inspection of the figures already given will show that deficiency of the perineum and straightening of the sacral segment will form important factors in prolapsus uteri—*i.e.*, they cannot resist intra-abdominal pressure sufficiently. Want of tone of the pubic segment will make it more easily driven down.

The nomenclature in prolapsus uteri is very embarrassing and deceptive. All such terms as “cystocele,” “prolapse of anterior vaginal wall,” etc., should be avoided. The term sacro-pubic hernia I have proposed, though scientifically correct, will not displace the classical one of prolapsus uteri. The gradations of prolapse are best named by describing how much of the anterior vaginal wall, uterus, or posterior vaginal wall is seen at the vulvar orifice.



## CHAPTER IV.

### I.—ON THE SHAPE OF THE EMPTY FEMALE BLADDER AND II.—ITS POSITION AND DISTENTION.

THE empty female bladder may present one of two shapes. In the large majority of specimens figured it forms with the urethra a Y-shape on sagittal mesial section. The oblique legs of the Y may be about equal in size, or the posterior may be shorter (figs. 7 and 8). This form is so common that it has been accepted hitherto by all authors as the normal one. In certain cases, insignificant in number as compared with the former, the empty bladder cavity forms with the urethra a continuous tube on vertical mesial section (fig. 9). As a whole, in such cases, it is oval in shape, corrugated, and firm to the touch. This latter shape is constantly the one found in the lower animals, such as the rabbit and dog, and is the only one I have ever seen in the human fœtus (fig. 10). If, therefore, the pelvic floor of a woman be viewed on its peritoneal aspect, the fundus of the empty bladder will be found to be almost always large and concave, while in a few cases it is small and convex. In the one case, the inner surface of the upper segment of the bladder, large in area, is in contact with the inner surface of the lower segment; in the other, the anterior and posterior walls, small in area, touch one another.

I wish at present to consider why we should have the bladder presenting two such sharply contrasted forms, to attempt to settle which is the normal one, and to consider the whole question in some practical bearings.

The anterior, posterior, and lateral relations of the bladder are of interest. Anteriorly it is separated from the pubis by a large amount of fat—the retropubic pyramidal fat—(Plate I.). Posteriorly the connection between it and the uterus and upper part of the vagina is also loose. Laterally the bladder is more fixed. The same facts as to looseness of anterior and posterior connections holds good for the male bladder.

The arrangement of the unstriped muscular fibres of the bladder is on the same plan as those of the uterus, *i.e.*, we have external longitudinal unstriped muscular fibres, with their fixed point below; circular ones running at right angles as well as obliquely to these, and an



internal longitudinal layer below the submucous coat. It is evident that their unhindered contraction will give the bladder the cylindrical form which I have described as the one rarely found. So far, then, as the normal arrangements of the bladder go, we see provision made for muscular contraction which shall ultimately bring the anterior and posterior walls, diminished in area, in contact.

I have now to take up the pathologically Y-shaped bladder and explain its occurrence. This can be beautifully studied in the specimen I here show, of which figure 7 is an accurate drawing. In this specimen

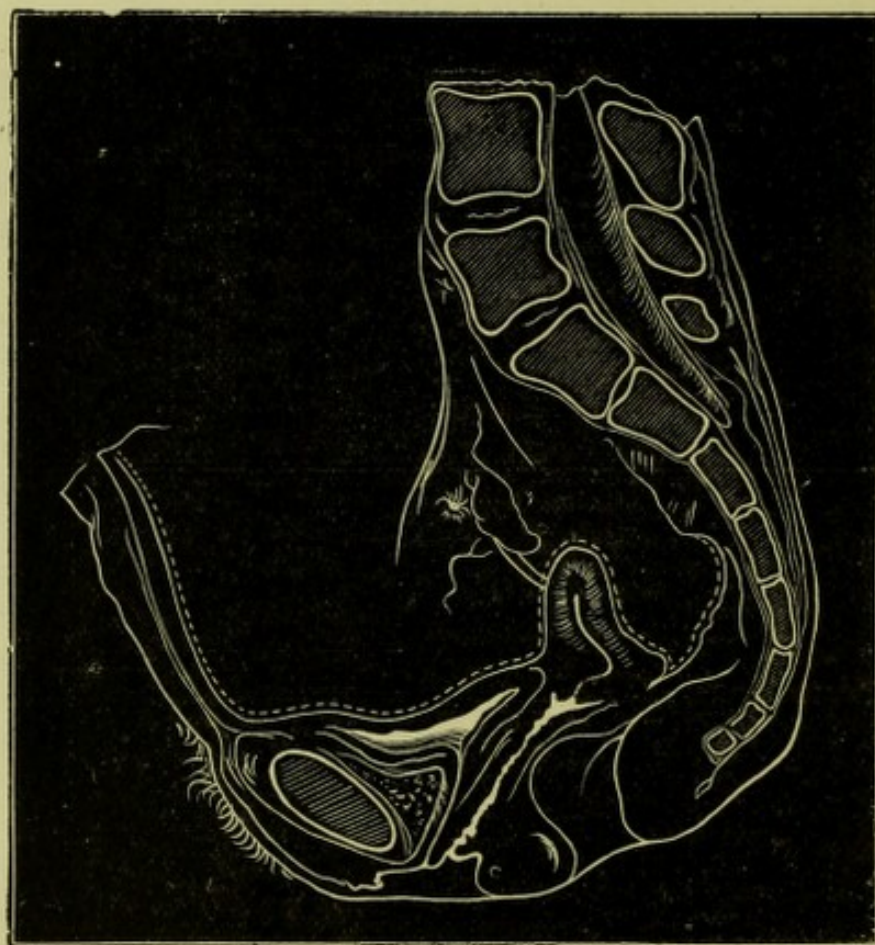


FIG. 7.

VERTICAL MESIAL SECTION OF FEMALE PELVIS (spirit-hardened), showing Y-shape of bladder (b).  
The uterus (a) is anteverted and drawn back by cicatrised utero-sacral ligament.

the Y-shape which the bladder forms with the urethra can be well seen. The causation of this shape is as follows:—

It can be readily seen that the uterus is anteverted. Starting from the posterior angle of flexion, and running to the left and upwards, thickened bands can be seen, the cicatrised left utero-sacral ligament. The shortening of the ligament has had a fourfold effect. It has dragged the uterus backwards and to the left side. Inasmuch as the cervix is fixed in the pelvic floor, and the fundus surrounded by intestine, the effect of this backward drag has been specially spent on the uterine



insertion of the ligament, *i.e.*, the uterus has become anteflexed. A simple experiment will make this clear. If a gum elastic bougie be fixed at either end, and then be grasped between the finger and thumb

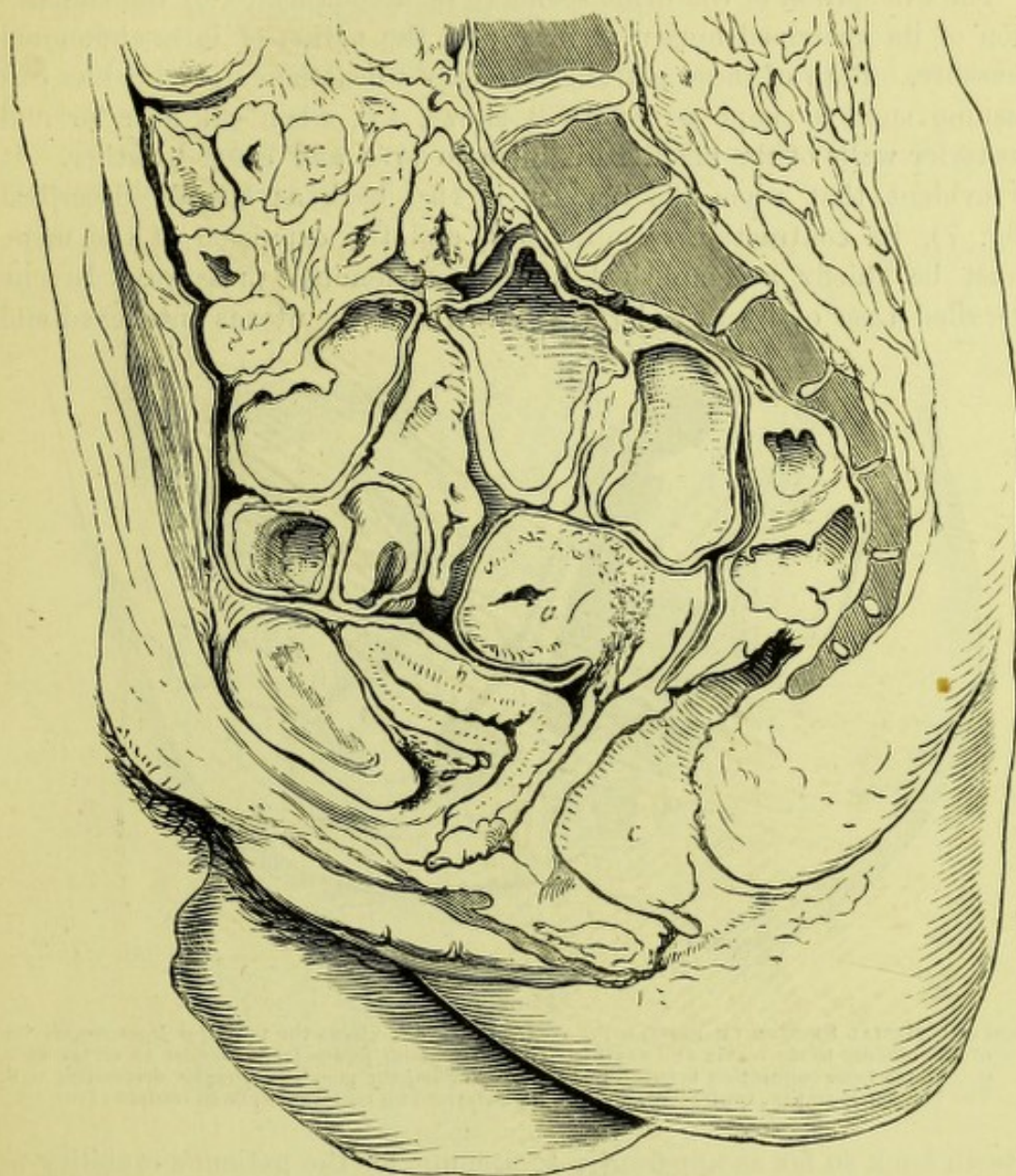


FIG. 8.

VERTICAL MESIAL SECTION OF FEMALE PELVIS (frozen). The Y-shaped bladder (*b*), and the vesico-uterine and retio-uterine pouches, neither of which contains intestine, are well seen.—Fürst, in *Archiv für Gynäkologie*, Bd. vii., S. 407.

*a*, Uterus.  
*b*, Bladder.  
*c*, Rectum.

about two inches above its lower end and pulled back, the bougie will become flexed or bent. In the fourth place, the bladder has been pulled back so as to make its retropubic attachment tense and pull its posterior wall behind the urethra, *i.e.*, to give it the Y-shape seen.

The Y-shape of the bladder exists also in the normal empty bladder.



Fürst has published a beautiful section of a uterus less anteflexed, and a bladder less distorted, bearing out exactly the explanation already given (fig. 8).

The evacuation of the urine seems to be accomplished by the contraction of its unstriped muscular fibre and the action of intra-abdominal pressure. Both of these are effective only when the empty bladder can assume such a shape as figure 9 shows, *i.e.*, when the anterior and posterior walls of the bladder diminish in area and come together. It is evident that when the bladder is tied back as already described (fig. 7), its contraction is minimised, and the expulsion of the urine must be chiefly accomplished by intra-abdominal pressure. In one so-called case of hysterical retention I found the uterus anteflexed and

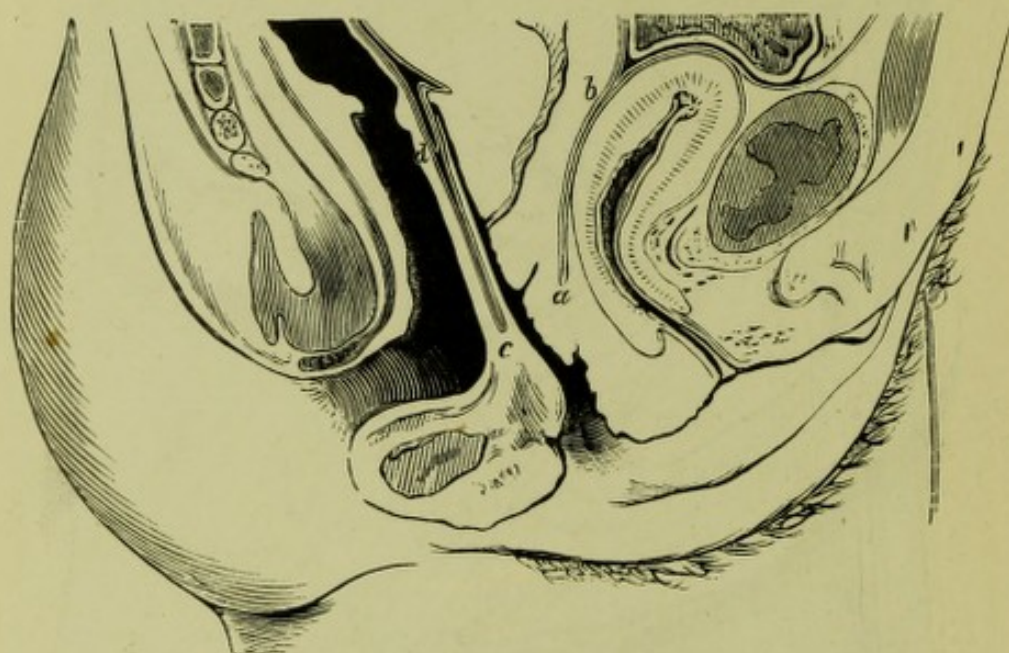

FIG. 9.

VERTICAL MESIAL SECTION OF FEMALE PELVIS (frozen).—*a b*, Shows the posterior loose connection of the bladder to the cervix and vagina. The peritoneum passes from bladder to cervix at *b*. *d c*, Shows loose connection between rectum and vagina, the pouch of Douglas descending to *d*. The bladder is empty, contracted, and has its anterior and posterior walls in contact (*Braune*).

drawn back so far as apparently to account for the patient's inability to micturate oftener than once in one or two days. At the same time, I have seen patients in a like condition where urination was normal.

The practical points I wish to bring out are as follow:—It is now undoubted that the normal uterine position is one of inclination in front of the axis of the brim. I do not believe, however, that the anteversion is so excessive as most German authors allege, as the amount of anteversion they believe in renders necessary the figuring of the Y-shape of the bladder and urethra as normal.

It is evident by examination of plates and specimens that the muscular contraction of the bladder is more marked when the bladder has the cylindrical form than when it has the Y-form. *Braune* figures bladders



of this shape whose walls are antero-posteriorly as thick as those of the unimpregnated uterus (fig. 9). In no bladder with the Y-shape is this nearly the case.

The conclusions advanced are as follow :—

1. The empty bladder in the foetus has always its anterior and posterior walls in contact.
2. In the adult female the same is the normal one for the contracted bladder, but is rarely found.

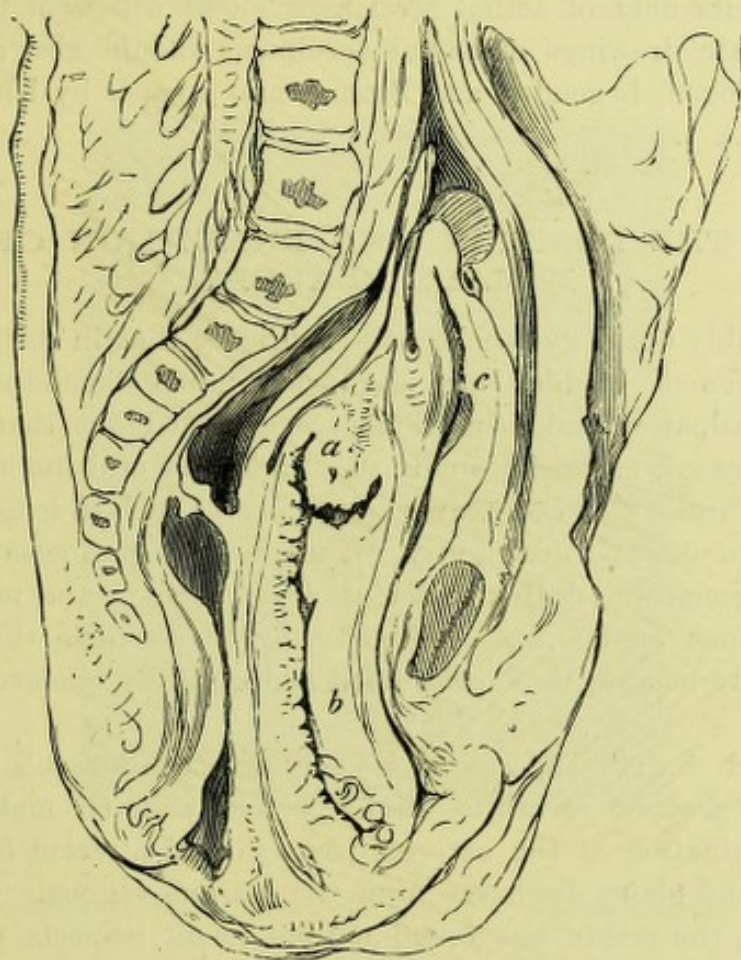


FIG. 10.

VERTICAL MESIAL SECTION OF FETAL FEMALE PELVIS (spirit-hardened).—Empty bladder (*c*) is above pubis; *b* is vagina; *a* uterus cut to one side.

3. The Y-shape can, in certain cases, be traced to a dragging back of the uterus by inflammatory cicatrisation, or to undue anteversion.
4. The Y-shape is, however, found normally in the empty relaxed bladder.

I have not given a vertical section of the female pelvis with the organs placed in what I believe to be the normal posture. Satisfactory attempts, based on clinical investigations and sectional anatomy, have been made by Schultze, His, Schröder, F. P. Foster of New York, and



others. At present, however, gynæcologists have not sufficient data to enable them to be dogmatic in this matter. Clinical investigation of the position of the uterus bimanually gives it an excessive amount of anteversion (well seen in Kocks's plates), owing to the fact that the examiner anteverts it beyond its normal anteversion in order to grasp it, and, in addition, lengthens the vaginal walls. The question of the amount of projection of the soft parts below the pelvic outlet has still to be settled. For this reason I feel that the figuring on my part of any normal diagrammatic section would lead to error. To avoid this I have given woodcuts only of actual sections. Those who wish to see additional accurate drawings of actual specimens should also consult the atlases of Pirogoff, Legendre, and Braune, and a paper by His<sup>1</sup> (*v.*, however, Plate I.).

## II.—ON THE POSITION AND DISTENTION OF THE FEMALE BLADDER.

It is probably every gynæcologist's experience that in certain circumstances the female bladder may seem very much distended, so far as suprapubic palpation and inspection give evidence, but that when the catheter is passed, an unexpectedly small quantity of urine is drawn off. The female urethra is short, averaging only  $1\frac{3}{8}$  inch in length, but yet gynæcologists use, and use rightly, a long flexible gum elastic catheter. Finally, surgeons who deal with retention of urine in the male do not meet with such anomalies. Before trying to reconcile these facts it will be best to narrate three contrasted and carefully observed cases.

CASE I.—A. B., æt. 18, was seen in Professor Simpson's out-patient clinique on account of white discharge and pain on making water. Ocular examination of the external parts showed a recent laceration of the hymen and glairy discharge from the ostium vaginae. On vaginal examination, the cervix was found normal in all respects, except that the os looked downwards and forwards. Bimanually, a fluctuating tumour, reaching up a little above the level of the pelvic brim, was felt in front of the partially retroverted unimpregnated uterus. The catheter introduced drew off 27 oz. of urine (fig. 11).

CASE II. — Mrs C. was admitted to Professor Simpson's ward on

<sup>1</sup> Since writing the above, my friend Dr Milne Murray has made the ingenious suggestion that the bladder has its systole and diastole just as the heart has; that the contracted form in figs. 9 and 10 is the bladder in systole, and the Y-shape in diastole. Of course, this holds good only for cases where there is not posterior pelvic inflammatory cicatrization. One interesting point should be noticed, viz., that the women in whom Braune figures the bladder in systole, i.e., contracted, died violent deaths by suicide (hanging). It is evident that this systole of the bladder, if it exists, must draw the cervix forwards. There is no clinical evidence on these points; and clinical investigation, from its difficulty, would be apt to lead into fallacy. At the same time, carefully conducted examination would lead to some interesting results in regard to urination—a subject not as yet well understood.



account of retention of urine, necessitating catheterism. Bimanual examination showed a large tumour in the hollow of the sacrum, marked elevation of the os uteri above the symphysis, and a fluctuating tumour in the hypogastric region, reaching almost as high as the umbilicus. This physical examination and the history of four months' amenorrhœa made the diagnosis of retroversion of the gravid uterus perfectly plain. What concerns us here, however, is that the bladder contained only about 23 oz. of urine—a less amount than in the previous instance.

CASE III.—Along with Professor Simpson, I saw at the Maternity Hospital a patient with rigidity of os uteri, supposed to necessitate

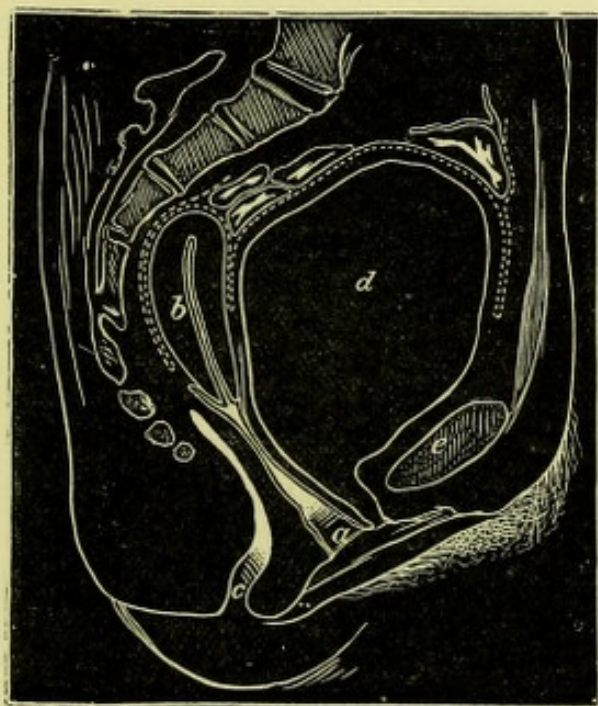


FIG. 11.

VERTICAL MESIAL SECTION OF ADULT FEMALE PELVIS (one-third size), with distended bladder (*Pirogoff*).  
d, Bladder.

early application of the long forceps. Suprapubic inspection and palpation revealed a fluctuating tumour, bluntly triangular in shape, with the apex down. Exact measurements showed that vertically it extended for 4 inches, and transversely for about the same. The catheter, passed deeply up, drew off only  $2\frac{1}{2}$  oz. of clear urine. Some time afterwards, the same apparent distention occurred, when  $3\frac{1}{2}$  oz. were removed. After the bladder was thus emptied the furrow between retraction ring and uterus could be felt two fingers' breadths above the symphysis pubis.

These three cases are typical instances, and evidently call for explanation.

In the first case narrated the bladder was simply distended. It had



pushed the intestines up, tilted the uterus back, but its posterior wall was still in its normal position. The peritoneum was still on the summit of the bladder, but of course was stripped to a certain extent from the lower part of the posterior aspect of the anterior abdominal wall (fig. 11). Thus the bladder, though its summit was only at the level of the brim, was considerably distended.

Now, in the retroversion of the gravid uterus the bladder was certainly distended. Suprapubic palpation, however, misled as to the amount of distention, and for the following reason. The cervix uteri was tilted high up behind the symphysis pubis, and consequently the bladder, to whose posterior angle the cervix is attached, was swung-up, as it were,

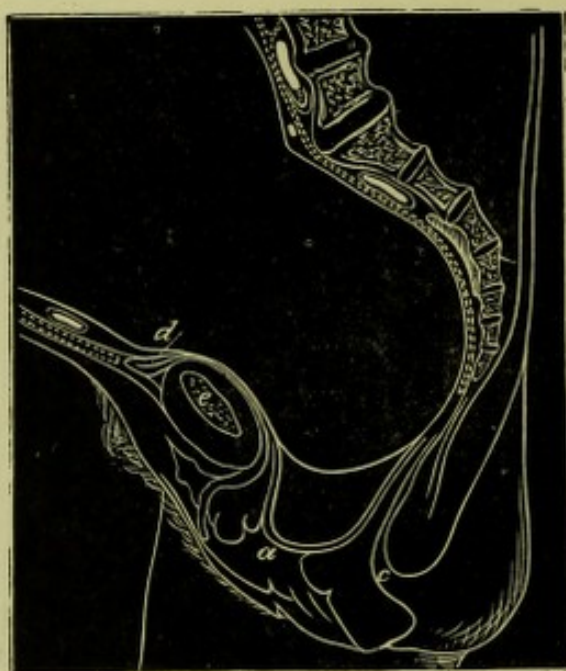

FIG. 12.

VERTICAL MESIAL SECTION OF WOMAN IN LABOUR (*Braune*), a little more than one-fourth size.  
*a*, Symphysis pubis and bladder above, with peritoneum off it.

into the abdominal cavity, a movement permitted by the anatomical relations behind the pubis. The peritoneal relations were the same as in Case I. In the third case the bladder was of course drawn up, as I have already shown,<sup>1</sup> and its relations were as follow:—In front it touched anterior abdominal wall; behind the child's head, the cervix, of course, intervening. In this way the anterior and posterior vesical walls were in contact, and thus a film of urine, as it were, gave the appearance of distention. As I have before pointed out, the peritoneum is stripped off the bladder more or less <sup>2</sup> (fig. 12).

The conclusions advanced are:—1. The retropubic anatomical attachments of the bladder admit of its distention and passage upwards.

<sup>1</sup> = *V.* Chap. II.



2. Suprapubic palpation gives no sure indication of the amount of urinary distention. 3. When the summit of the bladder is above the pubis, it may be—*a*, a pure distention (Case I.); *b*, distention plus a tilting up (Case II.); *c*, drawing up of the bladder, with almost no distention (Case III.).

The reason why gynæcologists use a long gum elastic catheter is very evident. I already described the empty bladder in the non-parturient female as forming a Y-shaped figure on vertical section. During parturition, however, the urethra is elongated, and forms with the bladder, on vertical section, a continuous tube<sup>1</sup> (fig. 9). Only that part of the bladder above the pubis is available for the reception of urine, so that in this way the path for the catheter to travel is increased. In Braune's section of a woman in labour, the distance for the catheter to travel is about  $4\frac{1}{2}$  inches, more than twice what it is normally.

<sup>1</sup> See *Die Lage des Fœtus*; Braune, Tab. C.





## CHAPTER V.

### ON SOME POINTS IN THE PHYSICS OF THE RECTUM, BLADDER, AND PARTURIENT UTERUS.

THE female bladder and rectum lie in the pelvic cavity ; and, from this position, they are exposed to the weight of the superimposed abdominal viscera, and bear, more than other organs, the brunt of intra-abdominal pressure. We have, therefore, to consider the arrangements in the bladder and rectum for storing their temporary contents so as to prevent premature expulsion of them ; and, more difficult still, to study the mechanism by which these viscera expel their contents when desired. In conclusion, it will be of interest to take up rapidly the whole question of the structural anatomy of the pelvic floor—its structure *quâ* intra-abdominal pressure, parturition, and the vesical and rectal functions.

#### THE BLADDER.

The exact explanation of how the urine is retained in and expelled from the bladder, as well as the cause of some connected anomalous phenomena, is by no means settled. It will be most convenient to take up the following heads :—

I. The Position and Shape of the Empty Female Bladder, and the muscular arrangements of bladder and urethra.

II. The Nervous Mechanism of Bladder and Urethra.

III. The Mechanism of the Expulsion of the Urine from the Bladder.

I. *The Position and Shape of the Female Bladder Empty and Distended.*—The female bladder when empty lies *in* the pelvis and *behind* the pubis. The urethra blends with the neck of the bladder at an angle of about  $90^{\circ}$  ; the angular interspace thus formed behind the pubis is filled up with loose fat (Pl. I.). The walls of the bladder are provided with loops of unstriped muscular fibre—external longitudinal fibres, circular fibres within these, and an internal longitudinal layer on which the mucous membrane rests. In the male, the outer layer is arranged in figure-of-eight loops—the smaller loop being, according to Pettigrew, in the prostate, and the larger one in the bladder.



The sphincter vesicæ, in the female, surrounds the urethra; it consists of circular and longitudinal unstriped, and circular (inner) and longitudinal striped muscle; the latter ends  $1\frac{1}{2}$  cm. from the meatus urinarius. In addition, Luschka describes a special sphincter of the vaginal and urethral orifices. In the male, the sphincter vesicæ

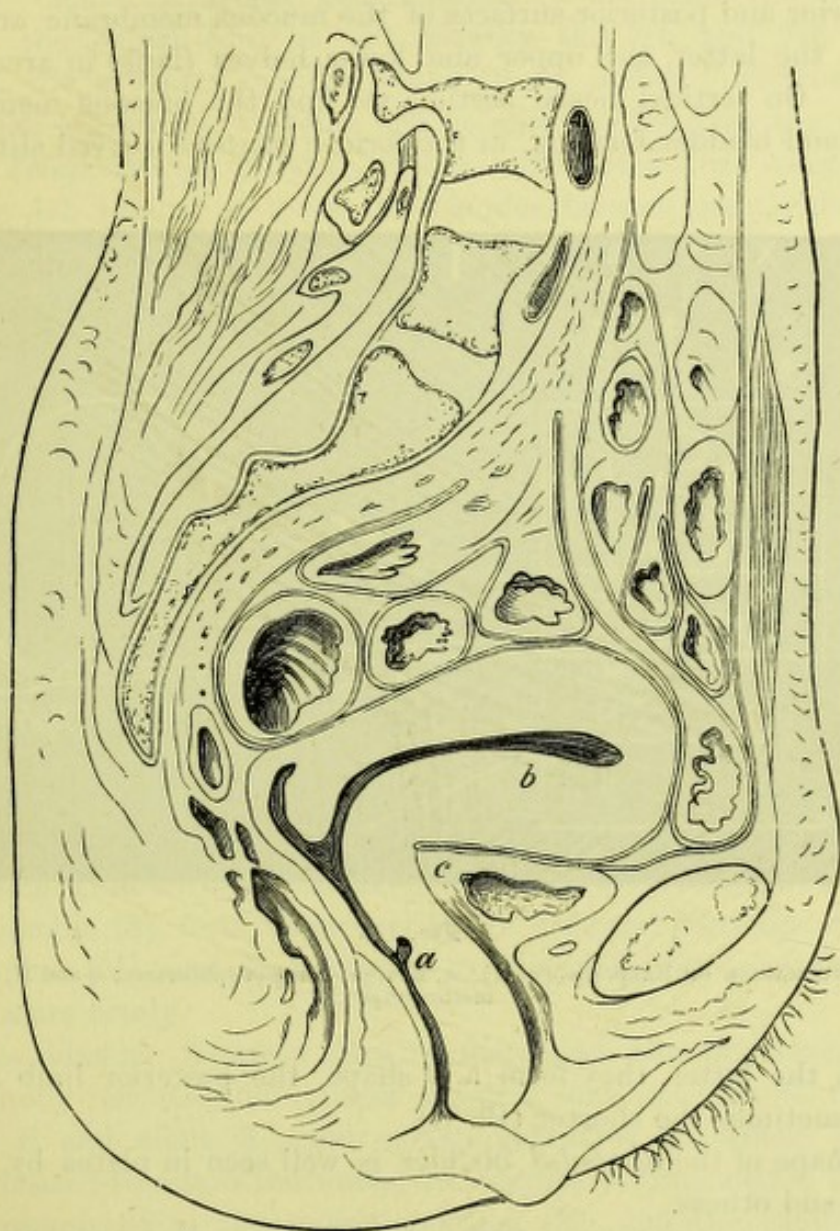


FIG. 13.

VERTICAL MESIAL SECTION OF FROZEN CADAVER (*Pirogoff*). *a*, In front of anterior vaginal wall; *b*, Uterus; *c*, Bladder.

surrounds the prostatic and membranous portions of the urethra—the muscle being both striped and unstriped. In the prostate, the amount of unstriped muscle is large.

The shape of the *empty* female bladder is of interest; I say, specially, “of the empty female bladder,” because I know of no drawing or







II. *The Nervous Mechanism of the Bladder and Urethra.* — The sphincter vesicæ has a certain amount of tone, which has been ascertained as follows:—The abdomen was opened and one ureter ligatured. A canula was passed into the other and water poured in until it passed out at the urethra. In the rabbit a column of water 16 to 20 inches in height was required to overcome the tone. If, however, the spinal cord be cut between the 5th and 7th lumbar vertebræ, the pressure required sinks to six inches. Section at the level of the 4th lumbar vertebra had no effect in lowering the pressure required (*Kupressow*). Further, it has been noted that after section above the 4th lumbar vertebra the bladder became greatly distended, while after section at the 5th or 6th there was incontinence. In the first instance the sphincter centre is intact, but its excito-motor influences cut off; in the 2nd instance the sphincter centre is destroyed (fig. 14).

The *motor* nerves for the bladder are the 3rd and 4th sacral. Stimulation of these, in dogs and rabbits, caused contractions of the sphincter; their section produced paralysis. The *sensory* nerves of the bladder run in the great sympathetic, and thence into the spinal cord.

Further, Budge found that electrical stimulus to the membranous portion of the urethra caused a contraction of the sphincter. Finally, stimulation of the inferior cut surface of the spinal cord at any height causes bladder contractions. From all this, Power in an able article, to which I am mainly indebted for these facts, concludes as follows:—

“In the first place, looking at the ordinary sensations that are experienced as the bladder fills, we may conclude that sensory impressions, rising gradually in intensity, are conveyed (through P) to the sensory ganglia (S), from whence they are reflected (through *d*) to the motor centre (M), and from thence to the sphincter, causing this to contract more firmly.

“If the bladder becomes greatly distended, the impression is no longer wholly reflected, but passes onwards and upwards to the brain (through S and along X), and excites conscious uneasiness or pain. If it be desired to retain the water, an impulse is transmitted by motor fibres (through Z) to the motor ganglion (M), and the excito-motor influence (of S) on the sphincter, is intensified by the will.

“But suppose that, instead of holding the water, it be desired to discharge it—what happens? The phenomena that are then presented seem to necessitate the admission of an inhibitory, restraining, or regulating centre, which must be in close proximity with the excito-motor centre, and, therefore, at the lower part of the spinal cord, for the action of the will in this matter is not, like its own voluntary muscles, rapid and instantaneous, but is exerted only after the lapse of a distinct interval, and the result is a relaxation of the sphincter.



"We may conceive this impulse to pass down special fibres (Y) to an inhibitory centre (I), which may either act directly (through L) on the motor centre (M), or possibly may send branches directly to the sphincter muscles."

So far as this explanation goes, the urine could be expelled by the reflex inhibition of the sphincter's activity, without any contraction of the bladder. There may be, however, a nervous impulse transmitted to the muscular tissue of the bladder also.

III. *Mechanism of the Expulsion of Urine from the Bladder.* — Urination probably occurs in the following way: — Urine trickles along the ureters, which aid its passage by peristalsis, and accumulates in the bladder, which is, for a reason to be given further on, flaccid and non-contracted. As the bladder distends, it assumes the shape seen in plates by Pirogoff, Kohlrusch, and Ruedinger. The vesical sphincter is kept closed by the activity of its motor centre, until the distention reaches the amount causing uneasiness. By a voluntary act the activity of the motor centre for the vesical sphincter is inhibited. The muscular fibre of the bladder by its contraction, aided by the intra-abdominal pressure acting at right angles to its peritoneal surface, expels the urine. When this is accomplished the bladder has the shape seen at fig. 9. At the end of urination we find that the strain has caused the pelvic floor to bulge down; in the inspiration following it rises somewhat.

The bladder does not retain its contracted shape, as this would involve prevention of the entry of the urine from the ureters into it (James), but relaxes, and assumes the Y-shape shown at Pl. I.

Thus the two shapes seen at fig. 9 and Pl. I. are accounted for by the supposition that the bladder has its systole and its diastole, that the shape at fig. 9 is the bladder in systole, fixed by rigor mortis; that the Y-shape shows the bladder in diastole. As to the diastole of the bladder, it is evident that the bladder must relax after its systole, the lower relaxed half taking the shape of the subjacent pelvis, while the upper half drops into this. Further, at all times during distention the bladder has quite the form one would expect from the trickling of a fluid into a viscus having the Y-shape on vertical mesial section already described.

Finally, the existence of systole and diastole explains the anomalous sucking-back of the flexible catheter into the bladder, sometimes experienced at the end of urination. In regard to this I should advance the following explanation:—Let us suppose an ordinary india-rubber catheter passed into the distended bladder; by muscular effort of the bladder, intra-abdominal pressure, and relaxation of the sphincter, the urine is expelled along it until the bladder has the shape seen at fig. 9. As the last drop of urine is expelled, atmospheric pressure acts on the lower end of the catheter, and probably on part of its lower lumen. The



peritoneal surface of the bladder is under less pressure during relaxation, because the ordinary atmospheric pressure transmitted through the abdominal walls is partly counteracted by the elasticity of these walls. At the end of urination the pelvic floor rises somewhat from its bulging-

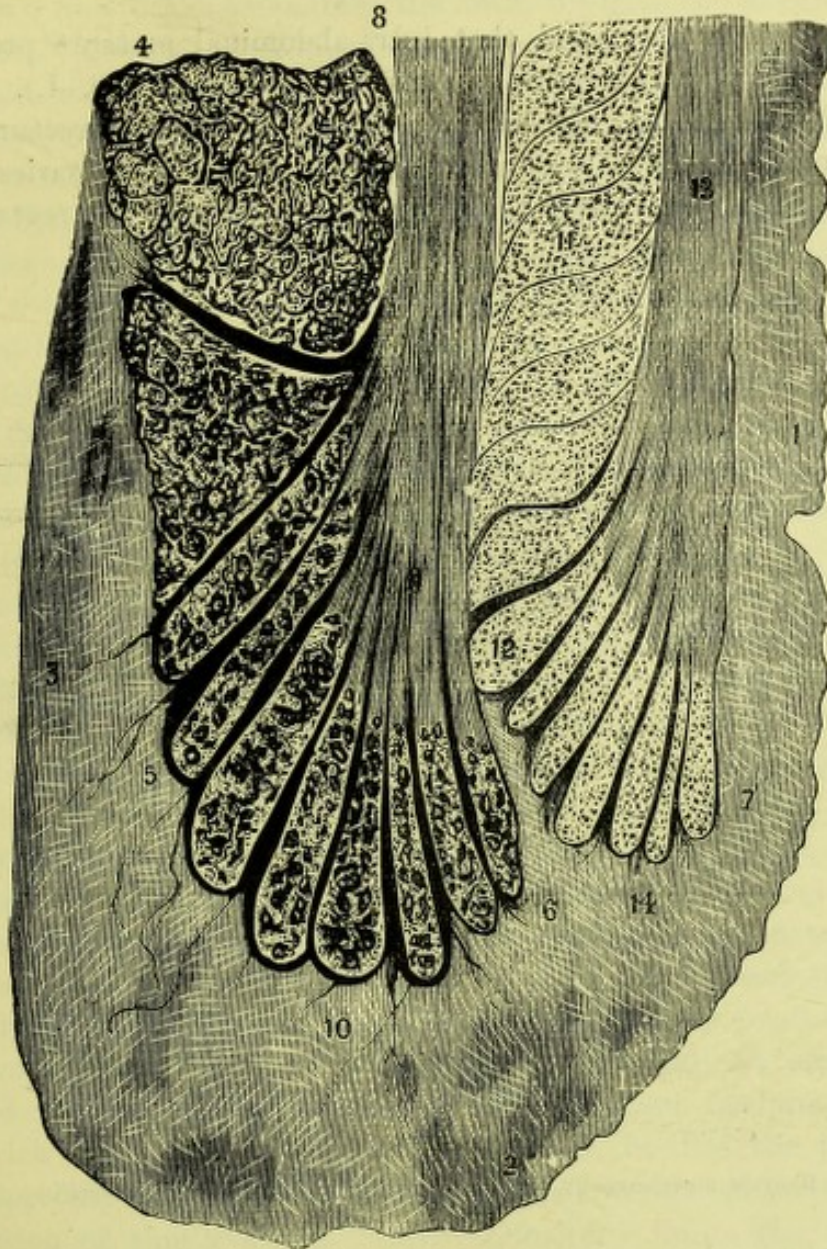

FIG. 15.

PERPENDICULAR SECTION THROUGH THE END OF THE RECTUM (*Ruedinger*).

1. Mucous membrane of the rectum; 2. Boundary between mucous membrane and skin of buttock;
3. Fat; 4. Levator ani; 5. Sphincter ani externus; 6. Fibres of longitudinal layer, separating external sphincter into parts; 7. Sphincter ani internus; 8. Longitudinal muscular fibres, which radiate out at 9; 13. Longitudinal fibres of muscularis mucosæ, which radiate out at 12;
11. Circular fibres of muscular coat; 6, 10, and 14. Slips passing into tissue beyond.

down position; accordingly, the catheter is pushed by atmospheric pressure into the relaxing bladder (now assuming the diastolic form), and becomes coiled up in its lax folds.<sup>1</sup>

<sup>1</sup> The following experiment shows exceedingly well the effect of atmospheric pressure:—Take two test-tubes of such a size that one fits the other easily, but not too easily. Fill the larger half-full



I should, therefore, urge that the urine is expelled by the muscular action of the bladder, aided by intra-abdominal pressure, and that the bladder has its systole, followed by a relaxation.

#### THE RECTUM.

The rectum is so placed that intra-abdominal pressure presses its anterior and posterior walls against one another (Pl. I.). Intra-abdominal pressure does not act in the long axis of the rectum. The clinical proof of this is absolute, inasmuch as vaginal pessaries are not forced out during straining; the vagina lies parallel to the rectum, and,

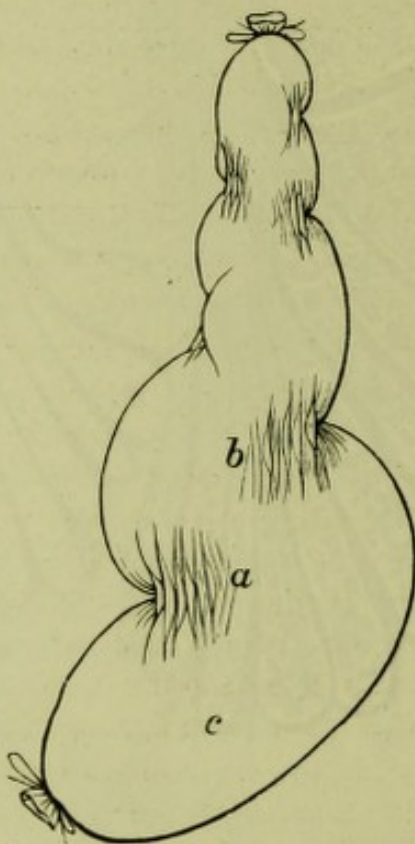


FIG. 16.

RECTUM DISTENDED BY AIR, SHOWING THIRD SPHINCTER (*Chadwick*).

as intra-abdominal pressure presses the vaginal walls together, it must do the same to the rectum.

It is of great interest to note that the anal axis cuts the vaginal and rectal axes at right angles, *i.e.*, it coincides with the direction of intra-abdominal pressure.

The muscular arrangements of the rectum are of importance; we have *muscularis mucosæ*, and unstriped muscular fibres, circular and

with water, and place the other inside. Then invert both, and at once the inner will be pushed up by atmospheric pressure as the water flows out. The full explanation of all the features of this experiment is complex, and I do not enter into it at present.

See also Dr Duncan's paper on the "Retentive Power of the Abdomen."



longitudinal. The anus is guarded by circular sphincters, an internal and an external—the internal partitioned off by fibres from the muscularis mucosæ; the external divided in the same way by longitudinal fibres. Thus, the longitudinal fibres are attached to a fixed point below (fig. 15). About  $2\frac{1}{2}$  inches from the anus, we have the so-called “third sphincter;” this Chadwick describes as two semicircular folds of mucous membrane with circular muscular fibres, lying one above the other, and on opposite sides (fig. 16). So far as we have gone we see that the rectum is so placed that intra-abdominal pressure does not tend to expel its contents, and that the lower end of the bowel is guarded by strong sphincters; when these relax we get the axis of the anal canal running in such a direction that abdominal pressure, coinciding with it, is in the line most favourable for the expulsion of any mass lying in it.

The intestinal contents are propelled on by peristaltic action, the circular fibres of the colon relaxing to allow the mass to pass on, and then contracting to drive it further down. According to Hilton, the sensitive part of the rectum is its last two inches; this exactly corresponds to the part between the anus and third sphincter.

The mechanism of the expulsion of the rectal contents is probably as follows:—We have relaxation of the anal sphincters, and contraction of the longitudinal unstriped muscular fibres of the bowel, which are attached to a fixed point below. The circular fibres of the rectum, especially the sphincter tertius, contract, and intra-abdominal pressure drives the rectum down, causing the pelvic floor to bulge markedly. The rectal contents are thus elongated and driven down, partly by intra-abdominal pressure, but more by the circular fibres and downward eversion of the rectal mucous membrane, until they are brought within the anal canal, where intra-abdominal pressure completes their expulsion. Relaxation of pressure now takes place, and the levator ani helps to reinvert the protruded mucous membrane. Chadwick considers the so-called “sphincter tertius” to act as a detrusor fæcium. I hardly agree with him. The view I should advance is, that the part of the bowel specially engaged in defæcation lies below this sphincter, that the contraction of this so-called “third sphincter” limits the eversion of the mucous membrane of the bowel as well as helps on the passage of the rectal contents, and that it forms an upper boundary to the rectal ampulla on which intra-abdominal pressure acts. It is extremely probable that during the expulsion of the rectal contents the part of the rectum below the sphincter tertius is pulled forward somewhat, *i.e.*, is brought more into an axis favourable to the action of intra-abdominal pressure.

#### STRUCTURAL ANATOMY OF THE FEMALE PELVIC FLOOR.

I have now, in the last place, to state the bearing of all this on the



structural anatomy of the female pelvic floor. The floor is to be considered from three points of view: parturition, intra-abdominal pressure, rectal and vesical functions. In parturition the pubic segment is drawn up, and lies partially above the brim; in the non-parturient woman it is pushed against the sacral segment by intra-abdominal pressure. But the floor is partly made up of bladder and rectum, which contain in their walls circular unstriped fibres, whose contraction diminishes the calibre of these organs. Now, all organs with such an arrangement have their periphery almost entirely unattached. In the pelvic floor this is not the case. There, however, we find the bladder and rectum, where in contact with other structures, have loose tissue intervening. The bladder has, accordingly, loose tissue in front and behind; the urethra has loose tissue in front, while the rectum is loosely tied to the posterior vaginal wall. This is necessary to permit the circular fibres of these organs to contract. This provision, however, introduces the weak structural points in the floor, so that we find intra-abdominal pressure forcing intestine, though rarely, behind the bladder, or between the vaginal and rectal walls. Much more commonly it drives down uterus and pubic segment *en masse*, stripping the posterior vaginal wall from the anterior rectal one.

The special provision for the functions of the rectum has thus introduced an apparently necessary element, which, more than anything else, leads to that troublesome hernia called prolapsus uteri.

#### THE PHYSICS OF THE FULL-TIME AND PARTURIENT UTERUS.

It is only within recent years that sufficient facts have accumulated to enable us to consider the question indicated above. The main points have been ascertained by Bandl, Schroeder and Stratz, Waldeyer, Barbour, Lahs, and others, and are related to the anatomy of the lower uterine segment, the physical conditions of the full-time pregnant and parturient uterus, and the remarkable clinical facts observed in labour by Schroeder and Stratz.

I purpose taking up this question in the present chapter under the following divisions—

1. *The Relation of Uterine Wall to Uterine Contents.*
2. *The Nature and Phases of Uterine Contraction.*
3. *The Physics of the Expulsion of the Fœtus during Labour.*

1. *The Relation of Uterine Wall to Uterine Contents.*—The conditions of the uterine wall must be considered in frozen sections of the entire cadaver, as it is only by studying these that we can attain correct conceptions. This limits one, for pregnancy, to the sections of Braune and Waldeyer, where the entire cadaver was frozen, and the fœtus and other contents lifted out to display the uterine shape.



It will be found then that the uterine wall is passive, and is moulded to the contents by intra-abdominal pressure. The most striking proof of this is given in those cases where the liquor amnii is less abundant, and where the uterine wall accordingly follows more or less the outline of the fœtus. Thus Waldeyer figures a coronal section of an early pregnancy where the uterus can be seen moulded on the leg of the fœtus; while in his drawing of the uterus in advanced pregnancy the uterine wall shows evidence of the pressure of the intestinal coils. In some drawings, such as that by Braune (Tab. B), the uterine wall is smooth in contour, but this merely indicates that the presence of liquor amnii in a certain amount prevents the uterus being moulded on the fœtus, and is in itself proof again of the moulding of the uterine wall on the uterine contents. Further, the posterior wall of the uterus shows evidence of plasticity, inasmuch as it is moulded to the irregularities of the spinal column. The full-time uterus is therefore a slackly-filled sac moulded on its contents by intra-abdominal pressure, and taking in certain cases an impression of its rigid surroundings. In a cast of the pregnant uterus of an ape I found the fœtus distinctly figured (*v.* Chap. VII. and Plate VI.).

2. *The Nature and Phases of Uterine Action.*—Hitherto our notions of this have been extremely crude, and obstetricians have not applied, as they might have done, certain well-known facts in regard to muscular action. In any good text-book of physiology it will be found that the muscular contraction is succeeded by a phase where the muscle resumes its former shape which had been deformed by the contraction. This is due, according to the belief of most physiologists, to the elasticity of the muscle.

The following sentences from a well-known text-book of physiology put the matter briefly. Thus Foster says, "there appears to be a minute diminution of bulk, not amounting to more than one-thousandth." "The shortening, as we have seen, is followed by a relaxation, the muscle returning to its original length. This is brought about by the elastic reaction of the muscular substance itself" (p. 54, 3rd edit.). It may be said that this holds good for striped muscle only, but the same is the case in unstriped muscle. Helme, who investigated the action of the sheep's uterus, found that a contraction curve was made up of

- "(1) The contraction ;
- (2) The maintenance of contraction ;
- (3) The relaxation."

and says—

"The relaxation is probably due therefore to the muscular fibres themselves, either from elastic reaction or active contraction in another plane" (p. 82).



The uterine muscle, whether in a sheep's cornu or a woman's uterus bounds a potential or an actual cavity filled with contents. This cavity has a certain area, and during contraction this area is diminished, while during relaxation it is increased. Helme shows this graphically and obtained tracings recording it. It is of special importance for us to understand this in the uterus immediately *post-partum*. We have then a thick-walled uterus with its characteristic division into retracting portion above the retraction-ring and flaccid thinner portion (lower uterine segment and cervix) below the ring. The retracting portion alone concerns us. Its potential cavity is practically two anterior and posterior triangular surfaces, apex downwards, always in contact. When a contraction comes on, these two have their superficial area diminished and practically slide on one another; when relaxation ensues, their superficial area increases, again the sliding motion occurs, and no hollow cavity is ever formed although the walls may be separated by blood effusion.

In the uterus containing the child or placenta we get a filled cavity; the walls are separate but the space between them always contains fluid, or foetus, or placenta.

We must therefore in practical obstetrics, in an actual pain, distinguish—

(1) *The Retraction*;

(2) *The Relaxation due to Elastic Recoil of the Muscle.*

(1) *The Retraction*.—This is more than a contraction and indicates that in the relaxation the muscle does not resume its original condition but retains a certain amount of its thickening, and diminution of bulk. Retraction is always accompanied by diminution in internal uterine area.

(2) *The Relaxation due to Elastic Recoil of the Muscle*.—I only remark on this head that this phase of uterine action has been strangely neglected in obstetrics and that it is accompanied by increase in internal uterine area. The uterus softens and becomes moulded or impressed, though slightly, by the surrounding organs.

3. *The Physics of the Expulsion of the Foetus during Labour*.—At the beginning of labour we have the slack-walled uterus in the abdomen and moulded by intra-abdominal pressure on its contents, the foetus and liquor amnii. The fundus uteri, on palpation, lies at the level of the margins of the ribs on the right side. The foetus lies doubled up, head usually lowest, and so compacted, that from head to breech, it measures half its length (Ahlfeld).

The well-known foetal attitude is present, *i.e.*, thighs flexed on abdomen, legs on thighs, feet on tibiae; the arms are folded across the chest and the head bent forward on the sternum. It forms thus a compacted ovoid, with the breech touching the fundus and the head at the os internum.



When labour sets in, a very remarkable series of phenomena develops. Our knowledge of these is mainly due to an exceedingly able paper by Schroeder and Stratz, confirmed by the wonderful series of frozen sections of the various stages of labour we now possess. I must confess that I at one time felt sceptical and hostile to their views but I am now convinced of their accuracy and the great ability of the clinical research.

Schroeder and Stratz showed that during labour the fundus uteri remained at nearly the same level as it did at the end of pregnancy. During the pains the uterus erects itself and passes forwards somewhat but the fundus sinks only very slightly.

But, it may be urged, the child is descending; the fundus must sink in proportion. This is precisely where the point lies. It has been shown that during the pains the foetus becomes elongated and straightened, and the original foetal attitude undone by the legs being in part extended. The whole contents, foetus and liquor amnii, are still accurately pressed upon both during the pain and after it. At the end of the second stage therefore there is liquor amnii between the foetus and fundus. This was observed clinically by Schroeder and Stratz and confirmed by Barbour in his section of a woman who died when the foetal head was on the perineum.

A still more remarkable fact is that during the third stage of labour the fundus remains high (provided the patient be chloroformed so as to abolish intra-abdominal pressure) until the placenta is separated and expelled below the retraction-ring.

All these facts can be verified by palpation during labour, and the elongation of the foetus can be ascertained by the use of callipers, one knob being placed on the child's head internally, the other on the breech externally. The measurement between fundus and symphysis is almost a fixed one during the first and second stages, viz., a little more than 24 cm.

In a recent paper Hoffheinz has confirmed these facts exactly.

But by abdominal palpation, interesting points can be made out in regard to the uterus itself. One may map out the retraction-ring, the high position of the bladder and the round ligament, the left usually.

We see therefore that the uterus during the first stage is mainly concerned with the canalisation of the lower uterine segment, cervix and pelvic floor; that during the second stage, intra-abdominal pressure plays a very important part; that in the third stage intra-abdominal pressure is also a great factor in expelling the separated placenta. Thus far for the purely clinical features.

We must trace, however, more exactly what happens during the expulsion in relation to special points.

In the first stage it is during the pain that the uterus takes a



definite shape probably seen in Braune's Plate C. As the result of the pain we get (1) a redistribution of the uterine contents, the liquor amnii forming the fore waters; (2) an elongation of the fœtus and an undoing of the fœtal attitude so that the fœtus becomes rudely quadrupedal and finally almost fully straightened at the end of labour. This is very well shown by Barbour's cast.

When the pain dies off, the firm uterus relaxes, becoming applied to the uterine contents. We have here to consider how this happens. So far as the CONTENTS are concerned the fœtus retains in part the undoing of its attitude, while the liquor amnii becomes distributed into any chinks formed by the fœtus as the uterine compressive power is withdrawn. The liquor amnii is a perfect fluid while the fœtus is semi-plastic and therefore will respond more perfectly to negative pressure changes.

During the pain as we have seen the uterus takes a definite shape but when the pain dies off and it becomes flaccid we get intra-abdominal pressure moulding it again on its contents. The factors here are complex and undoubtedly the elasticity of the canalised tissues as well as the elasticity of the fœtal tissue itself have a bearing not as yet fully grasped.

During this first-stage mechanism there is therefore a general contents pressure established in the fœtus and liquor amnii, but the contents are in the main elongated and therefore lower, as already explained, while the lower uterine segment has become completely, and the pelvic floor in part, canalised.

During the second stage the mechanism has several new features in it.

The uterus undoubtedly acts, but not normally, as a further canalising agent. It establishes tension on the round ligaments and other under-supports of the uterus, and thus grasping the contents, forms, as it were, an ellipsoid for the intra-abdominal pressure to act on during the second stage. The circular muscular fibres are probably active and compressive.

Intra-abdominal pressure is undoubtedly a great factor in expulsion during the second stage. When, by a pain, the head is partially driven deeper into the pelvic cavity, strong reflex intra-abdominal pressure is set up, and the uterus and its contents subjected to a compression that depresses the presenting part markedly. This depression is due to elongation of the fœtus, to some slight depression of the uterus as a whole, and to an actual driving-on of the fœtus as a whole owing to the presence of liquor amnii between the breech and fundus. The exact explanation of this last point is one of great interest. As a matter of fact, the onward progress of the fœtus is in part due to a relative displacement of the uterine contents—the liquor amnii (in part) lying towards the end of labour where it did not lie at the beginning, viz., between the breech and fundus. How is this? It arises, I believe, as



follows. When what we term a second stage pain comes on, the uterus retracts and the presenting part becomes lower. This, however, is slight, as one notes specially when narcosis is too deep. In light anæsthesia, or without it, the patient begins to strain and we get great increase of the intra-abdominal pressure, due to the action of the diaphragm and abdominal muscles. The effect of this addition of intra-abdominal pressure is to cause, usually in a multipara, marked progress of the fœtus. When the pain dies off, the intra-abdominal pressure and intra-uterine pressure fall, the uterine capacity, as well as the purely intra-abdominal capacity, increases, and the upper portion of the fœtus and the liquor amnii responding to this (the head being more fixed), we get passage upwards of the limbs and liquor amnii. This becomes more marked the lower the head descends, as it then is more fixed, so that ultimately, at the very end of labour, we get the fœtus markedly straightened, the limbs more extended, and the bulk of the liquor amnii in the fundal region of the uterus. When the final pain comes on, we get the expulsion of the fœtus caused mainly by the intra-abdominal pressure markedly compressing the uterine contents, and by the effectual pressure, *inter alia*, of the upwardly displaced liquor amnii. All must have noticed frequently the gush of water following the birth of the breech.

I may summarise this question as follows.

*How is the child expelled from the uterus, the fundus remaining throughout at an almost constant level?*

FIRST STAGE.—*Power* here is uterus alone.

*Action*.—Canalisation of lower uterine segment and cervical canal; elongation of fœtus and partial undoing of fœtal attitude; little actual descent of fœtus as a whole, but lowering of presenting part.

SECOND STAGE.

*Action of Uterus*.—This is slight, and consists in its establishing tension on round ligaments mainly and in the continued action of the circular fibres, and in its forming with uterine contents a plastic mass to be compressed by intra-abdominal pressure.

*Intra-abdominal pressure* is main expulsive agent in second stage. By it we get—

- (1) Elongation and straightening of fœtus during the positive pressure.
- (2) Displacement upwards of limbs and of liquor amnii when the pressure falls.
- (3) Ultimate expulsion of fœtus by pressure on displaced fœtal limbs and liquor amnii.

The fundus thus remains practically unaltered in level until the head is born.

The moulding of the fœtus causing its elongation is aided by the grip of the retraction ring.



COMPARISON OF THE EXPULSIVE PHENOMENA PROPER TO THE  
ABDOMINAL CAVITY.

The expulsion of urine, of the rectal contents, and of the fœtus, have all this in common, that the expelled mass is moulded and that the expelling powers are an unstriped muscular organ and intra-abdominal pressure.

In *Urination* we have relaxation of the urethra and expulsion of the markedly moulded stream of urine by vesical action and intra-abdominal pressure. The action of the bladder is put at a minimum by some, and is probably not so active as in the lower animals. The upright posture gives intra-abdominal pressure special advantages, and it is possible that in the evolution of this, the bladder has lost some of its more active function.

In *Defæcation* the expulsive phenomenon is more complex. As already shown, when the fæcal semi-plastic unmoulded mass passes the sphincter tertius, we get uneasy sensations and necessity for expulsion. In this, we get relaxation of the anus, a roofing-in of the lower rectal segment, either by the sphincter tertius or by mere mucous membrane apposition, so that we get a limited muscular expulsive organ formed as it were. By the muscular contraction of this segment, but especially by intra-abdominal pressure, we get the fæcal mass driven out, elongated, and moulded by the anus into the characteristic healthy "stool."

Here the problem of expulsion is more complex than in urination, and less so than in the expulsion of the fœtus, inasmuch as the fæcal mass is discharged in segments.

In *Labour* we get a mechanism of expulsion quite analogous to that of defæcation. There is canalisation of the lower segment, cervix, and pelvic floor, depression of the fœtus by its elongation and moulding, and finally its expulsion mainly by intra-abdominal pressure. In labour, owing to the evident fact that the fœtus is discharged entire, we get a new phenomenon, viz., the relative displacement of uterine contents, so that the lower limbs are extended and the liquor amnii displaced up.

These three expulsive phenomena are thus quite analogous in their mechanism, and the mechanisms of defæcation and the expulsion of the fœtus are identical.



## CHAPTER VI.

### ON THE STRUCTURE OF THE HUMAN PLACENTA, WITH SPECIAL REFERENCE TO THE ORIGIN OF THE DECIDUA REFLEXA.

IN investigating the structure of the advanced extrauterine placenta, one of the authors was struck with the fact that the placenta developed there entirely in connective tissue. In the placenta of advanced normal gestation, it has been supposed by many good observers that the foetal villi, in addition to their own epithelium, derived a covering from the maternal epithelium,—from the surface epithelium of the serotina, or from that of the uterine glands. The generally accepted view in regard to the human placenta has been that the villi of the fertilised ovum grafted themselves on a portion of the hypertrophied mucous membrane, this portion being now termed the decidua serotina; that by the mutual ingrowth of the serotina and villi the placenta was formed; while round the developing ovum there very early grew coalescing folds of decidua, the so-called decidua reflexa. On the one hand were the chorionic villi covered by the foetal epithelium, on the other the connective tissue of the serotina with its special layer of epithelium,—these forming as it were the elements from which the complex placenta was to evolve.

This view is highly unsatisfactory, so far as the human placenta is concerned. It does not explain the overwhelming frequency with which the human fertilised ovum grafts itself on a certain area of the genital tract, viz. in the uterine cavity proper; it assumes a function for the surface epithelium which has never been proved; and, finally, it leaves the origin of the decidua reflexa a complete mystery. Why should decidual folds at the edge of the serotina rise and cover in the ovum, however various its site within the normal limit?

The present investigation was therefore begun to ascertain the part played in the development of the human placenta by the surface epithelium of the decidua serotina; to discover if possible a feasible explanation of the overwhelming frequency with which the fertilised human ovum grafts itself in the cavity of the uterus proper, and, finally, to investigate the nature of the reflexa.

In approaching these questions, we found the greatest help in the invaluable monographs of Sir William Turner, *On the Comparative*



*Anatomy of the Placenta.* The microscopic investigations of Hubrecht, Duval, Langhans, Kastschenko, Minot, Frommel, Gottschalk, and many others, gave us not only valuable facts, but enabled us to compare our own results with theirs.

One of the most important factors in such an investigation as the present is the material at the disposal of the workers, its freshness, and the methods employed for its preservation and examination. In the lower animals, as a rule, the specimen can be obtained immediately after the animal's death, and at once prepared for microscopic examination in the best manner possible. In the case, however, of human uteri it is different, as the specimens are usually obtained from twenty-four to thirty-six hours after death, and thus their value is greatly deteriorated, especially as regards free mucous surfaces, where the epithelial covering soon becomes lost. The authors were specially fortunate in their specimens, as one early pregnant uterus, about the sixth or seventh week, was extirpated from a patient, owing to cancer of the vaginal portion of the cervix, and placed in corrosive sublimate solution a few minutes after its removal. A second specimen of a full time pregnant uterus was obtained from a patient who died suddenly, and on whom *post-mortem* Cæsarean section was performed in the child's interest. The uterus was also removed at the same time, and very shortly afterwards hardened in corrosive sublimate and alcohol. The specimens examined were as follow :—

*Rabbit.*—(1) Unimpregnated uterus ; (2) impregnated ovum at fourth day ; (3) impregnated ovum at eighth ; (4) impregnated ovum at eleventh ; (5) impregnated ovum at fourteenth ; (6) impregnated ovum at twentieth day ; (7) placenta at full time ; (8) post-partum uterus.

*Sheep.*—Unimpregnated uterus, and many very early pregnancies, the dates of which could not be ascertained.

*Rat.*—One near full time (white rat).

*Human.*—(1) Several early abortions ; (2) six weeks' pregnant uterus in complete preservation ; (3) two months' aborting uterus ; (4 and 5) three months' pregnant uteri with foetus expelled (two specimens) ; (6) four months' uterus ; (7) four and a half months' uterus ; (8) two six months' uteri ; (9) full-time pregnancy ; (10) two third stage uteri (full time). All of these were in a good state of preservation, while 2, 8, and 9 were quite perfect.

The method of preparation employed varied in different cases. As fixing agents, Flemming's "strong" solution, a saturated watery solution of picric acid, and a watery solution of corrosive sublimate saturated by boiling, were used in different cases, and to control one another. The early rabbits' uteri were fixed, after cutting them into segments, either unopened in the case of the fourth day uteri, or in the eight days' uteri, after a window had been made in the side away from the mesometrium



to allow the escape of the amniotic fluid and the entrance of the fixing agent. The later rabbits' uteri were all opened before fixing, as were also the sheep's, rat's, and human uteri. All the specimens were hardened in alcohol, and cut in paraffin, the smaller uteri and placentaë being cut in series. The sections were fixed on the slide by the method described by one of the authors (*Journal of Anatomy and Physiology*, 1891); stained, as a rule with hæmatoxylin and eosin (though gentian violet, iodine green, and other anilines, were sometimes used) and mounted in balsam.

RESULTS OF EXAMINATION OF IMPREGNATED OVA OF RABBIT, RAT,  
AND SHEEP.

We do not propose to give a detailed description of the appearances found in these placentaë. This will more appropriately appear at another time; for, while the pregnant uteri of these mammals present many interesting features, the structure of their placentaë differs too much from that of the human placenta to allow of any very profitable comparison. For example, the villi of the rabbit's placenta are totally unlike the human villi; the so-called decidua reflexa of the rat is merely a cup-shaped elevation in which the placenta lies, and though the villi of the sheep's placenta have some points of resemblance to those of the human chorion, the manner of their implantation, in specially differentiated parts of the uterine surface, is so unlike what takes place in the human uterus, that it is doubtful how far one is entitled to institute a comparison.

The following points are the main ones which can be brought into line with facts in the history of the human placenta:—

*Rabbit.*—Here, as Duval, Minot, and others have already shown, the uterine epithelium becomes immensely hypertrophied and degenerated over the two folds of the mucosa next the mesometrium, the site of the future placenta. At that point on the circumference of the blastoderm, which comes in contact with these projecting folds, the foetal ectoderm becomes thickened, and before the mesoderm has grown up to support it, it becomes attached to the degenerated uterine mucosa, which rapidly disappears before it (see Plate IV. fig. 6); very possibly the degenerated epithelial cells are utilised for the nutrition of the "ectoplacenta," as Duval proposes to call this epiblastic proliferation. The mesoderm soon grows into the ectodermic projections, and villi of a sort are formed, but these differ so much from the villi of the human placenta that their history need not be further traced. We need only say that the ectoplacenta loses its distinctness very soon, and seems mainly to be employed to remove the superficial parts of the serotina, if we may so call it.

*Rat.*—The only point of special interest is the ease and completeness



with which the decidual cells, which are here very large, can be shown to be derived from the ordinary connective-tissue corpuscles of the serotina. All intervening stages can be found in the layers of cells lining the so-called decidua reflexa. In other respects the placenta of the rat greatly resembles that of the rabbit, and is not further available for our present purpose.

*Sheep.*—Here the structure of the placenta is modified by pre-existence of the projections on the uterine wall, which combine with the foetal parts to form the cotyledons. These projections, in the non-pregnant uterus, are low, round cylinders with a slightly excavated summit, and are irregularly scattered over the uterine mucous membrane. They consist of a delicate connective tissue whose strands run mainly parallel to the surface, and which is traversed by numbers of long capillaries running mainly at right angles to the surface. They are covered by a single layer of cubical epithelium, and there are no glands, though in the rest of the uterine mucous membrane these are numerous and well-formed. When pregnancy occurs, the blastoderm very rapidly fills up the uterus, and on the parts applied to these projections the epiblast (which has usually two layers) and mesoblast simultaneously form villi, at first very short. The application of these to the surface of the uterine projections is soon followed by the degeneration and disappearance of the uterine epithelium; and the further history of the placenta, so far as we traced it, is comprised in the growth of the villi into the cotyledon and the disappearance of the connective tissue forming this before their growth. No special decidual cells are formed, and the connective tissue does not show any marked appearances of degeneration before its removal. The villi retain their original character.

The only point in which the placentæ of the rabbit and sheep agree is in the way in which the uterine epithelium is removed by the foetal epithelium. The uterine epithelium becomes absorbed or destroyed by the villi which then come in contact with the connective tissue of the mucous membrane. It is possible that the altered epithelium may have a nutritive function for the early ovum.

#### HUMAN PREGNANCY (SIXTH WEEK).

(Fœtus one and a quarter inches long.)—As already explained, this specimen was exceptionally well preserved.

DECIDUA VERA.—Two portions were especially examined (*a*) at the placental edge; (*b*) at the lower uterine segment.

(*a*) *At the placental edge* there is an evident naked-eye division into a compact and a spongy layer. The thickness of the entire decidua is about a quarter of an inch, the compact layer about a twelfth, the spongy layer a sixth. The surface is covered with a single layer of columnar epithelium (*see* Plate V. fig. 11). The cells show no trace of cilia, and have



the appearance of being somewhat degenerated, the intracellular network is swollen, giving the protoplasm a very granular appearance, while the nuclei, though here and there normal, are often irregular and angular in outline, and stain faintly with hæmatoxylin. The compact layer consists mainly of a felted mass of large decidual cells, whose diameter is generally from 18 to 30  $\mu$ , but which vary within even wider limits. Their nuclei are large, and are of a connective-tissue type. Scattered among these are a certain number of leucocytes (not very many) and traversing the layer are numerous thin-walled blood-vessels, and the generally compressed ducts of the glands. The spongy layer is seen to be due to the persistence and dilatation of the uterine glands. The spaces formed in this way are very large (Plate III. fig. 1), and take up most of the layer, the trabeculae of decidual tissue between being comparatively narrow. The epithelium lining these gland-spaces varies considerably in character; that lining the ducts and the spaces nearest to the compact layer is generally somewhat degenerated and flattened, the epithelium of the deeper spaces is cubical and more normal in appearance; while the epithelium of the gland-spaces close to the muscular coat is cylindrical, and is not distinguishable from that of the deep glands of the normal non-pregnant uterus. The spaces generally contain granular debris, degenerated epithelial cells, and leucocytes. In the interglandular tissue the large decidual cells are not so numerous as in the compact layer, and there are proportionately more leucocytes.

(b) *At the lower uterine segment* the decidua is of about the same thickness, but the compact layer is relatively much thicker, and contains fewer ducts, while the spongy layer is not nearly so well defined, nor are the glands so much dilated nor so numerous as at the edge of the placenta. The surface is covered by epithelium having the same characters as that at the placental edge.

DECIDUA REFLEXA.—At its origin where, including the chorionic villi embedded in it, the membrane is about a third of an inch in thickness, this has the same structure as the adjoining vera; it looks indeed as if the compact layer of a part of the decidua vera had been separated from the spongy layer below, and folded back so that the surface epithelium of the reflexa came in contact with that of the vera. Indeed, glands can be seen opening on the outer surface of the reflexa whose deeper expansions are to be found in the vera; the ducts are folded round at the junction just as the surface epithelium is. There are other glands opening on the outer surface of the reflexa, though not very many, whose fundi do not pass out of the reflexa; but these glands are never very long, and there is no trace of a spongy layer anywhere in the reflexa, nor do any glands open on the inner or foetal surface of the reflexa. This surface is of course occupied by the chorionic villi at this stage, and the part of the decidua in contact with them has the structure of the compact



layer, and presents appearances like that of the serotina at the point where the villi are pushing forward into it,—appearances which will presently be described.

The decidua reflexa retains this character for some distance, perhaps half an inch or so from its origin, but as it thins out over the ovum its structure alters. The surface epithelium is lost, all traces of glands disappear, the decidual cells become more and more degenerated and are replaced ultimately by a fibrinous layer which contains immense numbers of leucocytes, most of which are also degenerated. Scattered through this layer are degenerated villi, denuded of epithelium and surrounded by a layer of fibrin. The villi close to the chorion are healthy much further up the decidua than the outlying ones are; but, at the very top, the reflexa consists only of a thin chorion of degenerated foetal connective tissue, with no epithelial covering, and external to this a few strands of fibrinous looking material with numbers of leucocytes.

PLACENTA.—For its examination sections were made from amnion to muscular coat, and in these there are to be seen from within out, amnion, chorion, chorionic villi, maternal portion of placenta, and muscular coat.

The *amnion* is from 30 to 60  $\mu$  in thickness, and made up of flattened epithelium with flattened nuclei on a basis of connective tissue.

The *chorion*, 0.1 to 0.2 mm. thick, is slightly separated from the amnion, but it is difficult to say whether this separation may not be partly artificial, as there seem here and there to be connective-tissue fibres running between the two. The connective tissue of the chorion is of the usual type. The epithelium covering its outer surface varies from place to place along the main chorion. It is perhaps most usually a single layer of low cubical cells, but here and there are to be found two layers, when the appearances are the same as those about to be described in the terminal villi.

The *chorionic villi* are formed of ordinary foetal connective tissue with blood-vessels running through it. The latter are not nearly so wide nor so numerous as they become towards the end of pregnancy. The special point of interest in regard to these villi is, however, their covering, which varies somewhat from place to place. Over the main villus-stems, as over the main chorion, there is often a single layer of cells, but in some places on these larger stems, and almost uniformly over the smaller villi, the epithelium consists of two, sometimes even of three, layers of cells (Plate IV. figs. 2 and 5). The inner of these layers consists of cubical cells, with a large nucleus and relatively clear protoplasm; the outlines of the individual cells can usually be made out. The outer layer consists of cells more or less degenerated, the protoplasm is granular, and stains more deeply with eosin than that of the inner layer of cells, the outline of the cells can seldom be made out, the nuclei are smaller than those of the inner layer, stain deeply, and are often flattened or



angular; there is, in short, every reason to regard this layer as one derived from proliferation of the inner layer. The ectoderm of the fœtus itself in this pregnancy has two layers, and presents appearances almost identical with that of the epithelium covering its villi. The villi of all parts of the placenta which were examined, and the undegenerated villi embedded in the decidua reflexa, all had this structure (except those villi which were embedded in a fibrinous mass, which will be described shortly), and in *none* of the dozens of sections systematically examined was there *any appearance which could give rise to the suspicion that the maternal epithelium had any part in forming the covering of the villi, or that there was anywhere an endothelial covering external to the epithelium.*

The *intervillous spaces* do not seem to contain blood in this specimen; near the chorion they seem indeed to be empty, while near the maternal part their only contents seem to be degenerated débris, apparently the remains of part of the decidua serotina. Here and there in the part of the fœtal placenta next the maternal portion, are islets of this degenerated decidual tissue, in some of which villi are embedded, and these villi, as well as those which are here and there embedded in the surface of the decidua serotina and reflexa, are sometimes without any epithelial covering. The connective-tissue part of the villus is generally surrounded by a ring of fibrinous-looking material, probably the same as that whose origin from the epithelium Minot discusses at length.

There are also in relation to many of the terminal villi, peculiar masses of cells, which will, however, be more appropriately described after the decidua serotina has been discussed.

DECIDUA SEROTINA.—The portion of this layer which remains beneath the rapidly advancing fœtal placenta is only about half the thickness of the decidua vera, and, like it, can be divided into a compact and a spongy layer, with this difference, however, that whilst in the vera the spongy layer is twice as thick as the compact layer, in the serotina the compact layer is at least twice the thickness of the spongy layer, and contains hardly any glands or ducts; these are almost entirely confined to the spongy layer. The compact layer presents other differences from that of the vera; there are many large blood-vessels, apparently veins, in it, with more or less degenerated walls. In some cases the endothelium lining these degenerated vessels has begun to proliferate (Plate V. fig. 12), and in some of these thrombosed vessels the lumen is entirely taken up by young connective-tissue cells—a condition hitherto supposed to come on only after the eighth month of pregnancy (Friedländer, Leopold). The decidual cells present different characters in different parts of the serotina. Next the fœtal placenta they are like those of the decidua vera, but are almost always degenerated, *i.e.*, their nuclei stain faintly, the outline of the cells is more or less blurred, and



their protoplasm is often converted into a fibrinous-looking mass staining a bright pink with eosin. Rather deeper in the serotina the decidual cells are normal, and in still deeper parts, especially between the glands of the spongy layer and just above this layer, the development of the ordinary connective-tissue corpuscles into decidual cells is very beautifully shown. The change consists in a progressive enlargement both of nucleus and cell-body, both of which stain more deeply than usual in the intermediate stage. The above arrangement of the different forms of decidual cells seems to be the typical one, but sometimes irregularities occur, *e.g.*, the intervillous spaces are sometimes bounded by cells still in the young stage. This is probably due to irregularity in the growth of the foetal part of the placenta.

The impression produced by a study of these and of many other preparations is that, as the villi grow, the decidua serotina disappears before them. It is an obvious and well-known fact that the maternal part of the placenta at the end of pregnancy is exceedingly small as compared with the foetal part, and very much smaller than it is in the earlier months, but the cause of this decrease is not so obvious. It must, of course, be evident from what has been said that the degenerating decidua is absorbed, but, Is it absorbed by mother or by foetus? It is difficult to believe that the absorption is carried on by the maternal tissues, for in the first place there are not many lymphatic vessels to be found in the decidua; and in the second place, though leucocytes, the usual removers of dead material, are present in considerable numbers in the decidua, they are to be found rather in the active parts of it than in those already degenerated, and they do not seem sufficiently numerous for the task of absorbing what is relatively such a large mass of tissue. Can the foetal tissues be the absorbing agents? We are inclined to think that they are, in part at least, and would point in support of this to the analogy of the rabbit's placenta, where the foetal epithelium certainly must absorb or cause absorption of the degenerated epithelium and connective tissue of what one may call the serotina there, as we have already pointed out. A further support to this theory is to be found in the existence of a very peculiar set of cells in this placenta, which do not seem to have been described elsewhere. We have already pointed out that the villi tend to have a thicker epithelium towards their extremities, and at the very tips of the villi, where they come in contact with the surface of the degenerating decidua, we find the cells in question, epithelial in character, as figs. 7 and 9 on Plate V. show, and apparently resulting from a proliferation of the epithelium at the extremities of the villi. They are rapidly growing, as the occurrence of numerous mitotic figures among them sufficiently demonstrates, and they have all the characters of embryonic epithelial cells,—a round, deeply staining nucleus, a clear cell protoplasm, and sharply-marked



cell outlines. They remind one in fact most forcibly of the cells of the "ectoplacenta" in the rabbit, the epiblastic epithelium which destroys the degenerated uterine epithelium, and is the forerunner of the true placenta. These masses of cells, which are directly continuous with the epithelium covering the villi, form, in sections, irregularly-shaped projections, often ten or a dozen cells deep, whose surface towards the serotina is usually flattened and rests directly upon the degenerated tissues there, or sometimes even upon young decidual cells. When this occurs, the difference between the two sets of cells is at once apparent. It seems possible that these cells may have to do with the absorption of the degenerated decidua, and that they may even utilise the material obtained from the disintegrating cells for their own nutrition, and at the same time indirectly favour the nutrition of the fœtus by hastening the removal of temporary tissues, and furthering the formation of the true placenta. Probably this epithelium early fulfils its function and itself disappears, as it is not found, at least in the form here described, in any of the later placentæ we have examined, nor does it seem to have been noticed by other authors. In the placenta of a four and a half months' uterus, which we owe to the kindness of Dr William Russell, we found, however, a set of cells at the points where the villi impinge upon the serotina, which apparently represent a later stage of this "trophoblastic" epiblast. One of these points is represented in Plate V. fig. 8, and the cells in question are seen to form a double or treble row of large embryonic-looking cells continuous with the epithelium covering the rest of the villus, which consists at this point of two layers. The portion of the serotina touched by these cells is extremely degenerated. It will be noticed that the connective tissue of the villus is condensed to form a sort of basement membrane below the trophoblastic cells at this stage, which does not occur in the six weeks' pregnancy.

#### OTHER HUMAN PREGNANCIES.

These resolve themselves into two classes—the early abortions, and the later uteri with placentæ *in situ*. The former are not usually suited for the study of the minute relations of parts, as the whole deciduæ and embryo very seldom come away at once, and even when this does exceptionally happen, the relations are almost invariably disturbed by blood extravasations, old or recent. The latter class of preparations in our hands forms an extremely valuable series, but at present we propose only to utilise them to explain the further history of the villi, with special relation to their epithelial covering.

*The Early Abortions.*—We possess several, of dates from one to three months, and the villi in those parts which are least disturbed present appearances identical with those of the six weeks' pregnancy described



at length. All the early specimens indeed show similar appearances, and it is not till we reach the specimen (6, p. 19) that we find any marked change, though the epithelium becomes flatter in the latter specimens.

*Four months' Uterus and Placenta* (see Plate IV. fig. 3).—The villi are covered by a single layer of epithelium, which consists of flattened, deeply-stained nuclei, embedded in a thin protoplasmic layer, in which the cell outlines can no longer be distinguished. Towards the tips of the villi there are sometimes two layers, and at the very extremities there seem sometimes to be several layers; but as our sections of this specimen were not cut in series it is impossible to be certain on this point. At some points on the villi there are patches of that deeply staining substance derived from degenerated epithelium to which Langhans, Minot, and others have given the name of "canalised fibrin." The villi which are actually embedded in the degenerated superficial decidua have no epithelial covering.

*Four and a half months' and six months' Uteri.*—The appearances here are practically identical with those of the four months' uterus.

*Full time Uteri and shed Placentæ* (see Plate IV. fig. 4).—In all of these there is only one layer of epithelium covering the villi, and it is flatter even than in the four months' uterus. The nuclei are almost all degenerated, and the protoplasm in which they are embedded is small in amount. The deeply-stained masses mentioned in the description of the four months' uterus, which have the appearance of being agglomerations of degenerated nuclei, are here much more numerous. The free villi at the deeper part of the placenta do not differ, as far as their covering goes, from those of the more superficial parts; there is no thickening of the epithelium. In the uteri with placentæ still attached there is a relatively large number of villi embedded in what is left of the decidua serotina. These villi have no epithelial covering, and the superficial layer of the decidua in which they lie consists of a degenerated homogeneous-looking connective tissue, in which the remains of decidual cells can here and there be distinguished.

It will be seen from these descriptions that we can fully confirm Minot's dictum (*l.c.*, p. 395) that "the chorionic epithelium advances in its differentiation to a stage equivalent to the two-layered stage of the epidermis, and there stops; whatever further change occurs is degenerative."

The only other important points in which the villi alter histologically are in regard to the connective tissue and blood-vessels. As pregnancy advances the connective tissue becomes more fibrous and generally more fully organised, and the blood-vessels become more numerous, wider, and have more fully differentiated walls.



We have now to consider some questions as to the structure of the human placenta, restricting ourselves to three points :—

1. *The Nature of the Covering of the Villi, and the alleged Rôle, in the Formation of the Placenta, of the Surface Epithelium.*
2. *The probable Nature of the Decidua Reflexa.*
3. *The probable Reason why the Human Ovum grafts itself, as a rule, within a certain Area of the Genital Tract.*

1. *The Nature of the Covering of the Villi, and the alleged Rôle, in the Formation of the Placenta, of the Surface Epithelium of the Serotina.*—In this country no paper has dominated research on these points so much as the classical one of Goodsir, "On the Structure of the Human Placenta," followed up as it has been by the well-known work of Ercolani and Turner.

Goodsir described a double epithelial covering of the villi, and held the outer to be maternal and the inner fœtal. He also figured a distinct space between these, bounded by a limiting membrane, and also an outer limiting membrane to the maternal epithelium. He speaks of part of the decidua serotina being shut off from the main portion by the maternal sinus system, the cells of the two being continuous by the lumen of the threads "which passed in great numbers from the vascular edges of the venous openings, and from the walls of the cavity of the placenta on to the extremities and sides of the villi and tufts of the placenta." He then goes on to say, "This observation led me at once to perceive the real signification of the external cells of the placental tufts. I saw that the great system of cells was a portion of the decidua, all but cut off from the principal mass by the enormous development of the decidual vascular network, but still connected with it by the minute files of cells which fill the cavities of the placental threads. This system of cells, the external cells of the villus, with the external membrane, belong to the organism of the mother."

Turner in his paper, "Some General Observations on the Placenta, with special reference to the Theory of Evolution," represents the maternal epithelium as a fully-developed layer over the villus, stating at the same time that "the layer of fœtal epithelium cannot be seen on the villi of the fully formed placenta" (p. 37, text of fig. 7). He also figures Goodsir's threads as connective-tissue strands joining serotina and villus. From a consideration of our specimens, we believe that the covering of the villi is in the early placenta made up of a multiple layer of epithelium, and that it is epiblastic, *i.e.*, entirely fœtal. It is impossible to look at our specimens, and to come to any other conclusion. We hold that Goodsir's investigation by no means proves that the maternal epithelium is represented on the villus. The recent work on the early relations of the villi and maternal tissue in the bat, rat, and



ruminants, has shown that shortly after ovum-contact the maternal epithelium disappears, *i.e.*, the villi come into immediate relation with the connective tissue. In the paper of Turner's already quoted, the diagrams should, in our opinion, be modified by the obliteration of the maternal epithelium, as this plays no essential part in the formation of the placenta.

The important question has now to be considered as to what condition the serotina is in when the villi graft themselves. The early pregnancy specimen shows *the decidua vera fully completed and covered with columnar epithelium, while the reflexa is also covered in great part with columnar cells.* This tends to show that the ovum has not grafted itself on a fully-formed decidual portion, with its surface epithelium formed, but on the decidua while forming. This point, however, comes up more clearly in our next section (2).

2. *The probable Nature of the Decidua Reflexa.*—William Hunter first pointed out that the human ovum had a decidua arched over it, and he applied the term "reflexa" to this portion. In no human ovum has this been found incomplete, although the general text-book diagram represents the decidua serotina sending folds up to coalesce over the ovum—a purely literary description based on no observation. That there is a decidua reflexa admits of no doubt. Its method of formation has, however, been disputed. Goodsir speaks of it as a cellular decidua formed "of a non-vascular cellular substance, the product of the uterine follicles." Goodsir evidently felt the difficulty of explaining the decidua reflexa from a completed serotina with its surface epithelium fully formed, and clothing the external surface of the villi. Hence his hypothesis, which is just John Hunter's, without the "cellular."

The whole difficulty as to the reflexa disappears if we accept the hypothesis our specimens so strongly indicate. The villi, with their epithelial covering, purely epiblastic and foetal in its origin, graft themselves on the decidua serotina, *while this serotina is forming, prior to its completion, and thus the serotina completes itself over the ovum as it were; the ovum becomes embedded in the serotina, and the reflexa is merely the superficial portion of the serotina. The serotina proper is the deep portion.*

We consider the human ovum to be an embedded one, not attached to the serotinal epithelial surface, and with the epithelial folds of the serotina arching over it to form the so-called reflexa, but one actually growing in the substance of the serotina. This idea of an embedded ovum is of great interest in relation to the development of the placenta in other mammals, but we defer consideration of this point.

3. *The probable Reason why the Human Ovum grafts itself, as a rule, within a certain Area of the Genital Tract.*—It is a



remarkable fact that the human ovum grafts itself normally in a definite and limited area. This area is the triangular surface of the mucous membrane of the body of the uterus, and is bounded below by the os internum, above by the inner openings of the Fallopian tubes. The ovum never grafts below the os internum, and very rarely in the Fallopian tubes. It is also noteworthy that the ovum normally grafts itself only within the limits of that part of the mucous membrane of the uterus denuded of its superficial layer by the menstrual flow, and only rarely in the tubes which do not participate in menstruation so far as providing the menstrual discharge is concerned.

The hypothesis we now advance completely explains all the facts both as to normal and abnormal implantation that are at present at our command. It is briefly this. Suppose the human ovum cannot graft on an epithelial surface but only on connective tissue. We say suppose; but there is strong if not absolute proof for the supposition.

1. In many mammals with a bicornuous uterus it has been clearly demonstrated that the first result of the touch of the villi on the uterine mucous membrane is to cause the disappearance of the epithelial covering, *i.e.*, the villi develop in connective tissue.

2. In the human ovum the villi have never been seen in contact with the surface epithelium of the serotina, although of course pregnant uteri in the very earliest stages have not yet been obtained.

3. The villi of the human ovum have always, in the earliest stages as yet obtained, been seen developing in connective tissue.

Under our hypothesis we understand at once—

1. That menstruation denudes the surface epithelium in the special area for safe-grafting of the ovum.

2. That the ovum, even if fertilised in the Fallopian tube, cannot graft itself there, as the epithelium is intact.

3. That it may graft itself in the Fallopian tube, if the epithelium has been removed by disease and the connective tissue laid bare.

4. The decidua reflexa is at once explained.

In the six weeks' pregnant human uterus, and also in a five months' one, we found at the tips of the villi active phagocytic cells, analogous to those in the villi of the hedge-hog, rabbit, and rat, credited with the power of active absorption of epithelial and connective tissue.

It is therefore possible that, as Hubrecht supposes, we get a process in the early stages of human pregnancy analogous to the hedgehog, *i.e.*, the early epiblastic covering of the ovum grafts itself on a fully formed serotina, destroys the epithelium, embeds itself in the serotina, which closes over it, thus forming the reflexa; and that the villi and intervillous spaces form as in the hedgehog. There are, however, additional facts in regard to human pregnancy, considered as that of the pregnancy in the highest mammal, which must be taken into account in forming



a hypothesis. These are—(1) the occurrence of menstruation, which denudes a certain area of the genital tract of its epithelium monthly; (2) the great danger of Fallopian tube pregnancy; (3) the non-occurrence of pregnancy during suckling when no menstruation goes on.

We have therefore put forward, as a mere working theory, the hypothesis that the human ovum can only graft on connective tissue, a view that can be added as it were to Hubrecht's speculation.

#### DESCRIPTION OF PLATES III., IV., AND V.

The following letters are used in all the figures with the same meaning:—

<i>e.p.</i> = epithelium.	<i>b.v.</i> = blood-vessel.
<i>c.t.c.</i> = connective-tissue corpuscle.	<i>l.</i> = leucocyte.
<i>c.t.f.</i> = connective-tissue fibre.	<i>r.b.c.</i> = red blood corpuscle.
<i>m.</i> = mitotic figure.	<i>deg. dec.</i> = degenerated parts of decidua.

FIG. 1.—Six weeks' pregnancy, human; a section at the point where the decidua reflexa joins the decidua vera and decidua serotina.

*a.* = amnion; *ch.* = chorion; *ch.v.* = chorionic villi, with intervillous space; *v.* = villus; *d.r.* = decidua reflexa; *d.v.* = decidua vera; *com.l.* = compact layer; *sp.l.* = spongy layer; *mus.* = uterine muscle; *gl.* = gland; *dil. gl.* = dilated glands of spongy layer.

FIG. 2.—Transverse section of a villus from placenta of human six weeks' pregnancy. Obj. Zeiss. DD. Oc. 4.

FIG. 3.—Part of a villus from placenta of human four months' pregnancy. Obj. etc. as in fig. 2.

FIG. 4.—Part of a villus from human full-time placenta; *d.n.* = mass formed of degenerated epithelial nuclei. Obj. etc. as in fig. 2.

FIG. 5.—The two layers of epithelium clothing the villi of human six weeks' pregnancy: Obj. Zeiss. Apoc. 2.0 mm. hom. imm. Comp. Oc. 8.

FIG. 6.—Ectoplacenta ("trophoblast") of eight days' pregnancy (rabbit), in its relation to the uterine epithelium; *d.m.ep.* = degenerated maternal epithelium; *ect.* = ectoplacenta, at *a*, passing down to become continuous with the rest of the epiblast. Obj. Zeiss. Apoc. 2.0 mm. Comp. Oc. 4.

FIG. 7.—Trophoblastic(?) epithelium at the extremity of villus in six weeks' pregnancy (human). *y.d.c.* = young decidual cells; *d.b.v.* = blood-vessel with degenerated walls; *d.c.* = degenerated decidual cells; *o.l.* = degenerated outer layer of foetal epithelium. Obj. etc. as in fig. 6.

FIG. 8.—The same, from four-and-a-half months' pregnancy. *b.m.* = basement membrane. Other letters, Obj. etc. as in fig. 7.

FIG. 9.—Part of the trophoblastic epithelium from a section similar to that represented in fig. 7. Obj. Zeiss. Apoc. 2.0 mm. Comp. Oc. 8.

FIG. 10.—Epithelium from a uterine gland in the serotina immediately underlying the villus drawn in fig. 9, under the same power, for comparison. *cil.* = remains of cilia.

FIG. 11.—Epithelium covering the decidua vera in six weeks' pregnancy. *d.c.* = decidual cells. Obj. etc. as in fig. 6.

FIG. 12.—Thrombosed vessel from serotina of same case, surrounded by forming decidual tissue. *fib.* = fibro-blasts; *deg. w.* = degenerating vessel wall. Obj. Pillischer  $\frac{1}{4}$ . Oc. 2.





## CHAPTER VII.

### THE ANATOMY OF ADVANCED PREGNANCY IN MACACUS RHEBUS, STUDIED BY FROZEN SECTIONS, BY CASTS, AND MICROSCOPICALLY.

A FEW months ago I was fortunate enough to obtain a *Macacus Rhesus* in an advanced state of pregnancy. Much work has been done recently in regard to pregnancy in apes by Turner, Waldeyer, and Selenka, so that I was anxious to fill any gap in our knowledge, rather than to follow in the path already so ably and accurately explored by these investigators. Thus it seemed to me that one could accept unhesitatingly what Turner and Waldeyer have told us about the intervillous circulation in the advanced placenta of apes, as well as the dissectional anatomy of Breschet and Selenka.

I therefore determined to investigate in the first place the frozen sectional anatomy of this specimen, to take casts of the uterine cavity and foetus, and to examine the microscopic structure of the placenta. Dr Gulland gave the warning, indeed, that the tissues would be less fitted for microscopical investigation; but though the microscopical sections are less perfect than one would wish, they are definite enough for practical purposes.

The ape was accordingly chloroformed, and when dead, placed in a freezing mixture for several days: it was then sawn mesially and drawn.

While still frozen the foetus and liquor amnii were lifted out and casts taken of the uterine cavity and foetus. Portions of the placenta and uterine wall were then hardened and afterwards cut in paraffin.

I now purpose considering

- I. *The general Anatomy of the Specimen so far as it bears on Pregnancy.*
- II. *The Uterine and Fœtal Casts.*
- III. *The Microscopical Structure of the Placenta.*
- IV. *The general Relations of Apes to Lower Forms and to the Human Female in regard to Menstruation and Pregnancy.*

- I. *The general Anatomy of the Specimen so far as it bears on Pregnancy.*

The ape was evidently a young female, 18 inches from head to breech.



The sagittal mesial section, unfortunately, did not hit the middle line exactly, but by a subsequent cut the pelvis was cut more mesially.

The pregnant uterus measured six inches vertically and four transversely; and antero-posteriorly was oval in shape, and contained the fœtus and liquor amnii. It was probably near full time. The uterine wall measured only  $\frac{1}{8}$  inch on section, and seemed equally thin throughout. The unimpregnated and pregnant uterus in the human female are each about one-half inch thick.

The Fallopian tubes lay vertically in the abdominal cavity, and the ovary lay behind its corresponding tube. In the left ovary there was a *corpus luteum*.

The more mesial section of the pelvis showed the vagina at right angles to the brim, instead of parallel to it as in the human female; the anal, urethral, and vaginal canals were indeed all parallel to one another. The bladder was loosely connected to the pubis and also to the posterior vaginal wall. The glans of the clitoris was grooved in the vertical mesial line.

The cervical canal was peculiar. It was somewhat dilated owing to the plug of mucus having become swollen, and was divided into two parts—a lower portion more dilated than the upper. This is quite different from the cervical canal of the human female, which is a slit-like cavity or section, with its anterior and posterior walls in apposition. This alteration in the cervical canal of the ape may be artificial, but at any rate the cervical canal in this case resembled that of the human female in not being opened up from above by the advancing pregnancy. Other points in relation to the fœtus come up afterwards.

## II. *The Uterine and Fœtal Casts.*

*Fœtal Cast.*—The fœtus presented the head, although in most cases [Turner's, Hunter's] it has at full time presented the breech. The antero-posterior diameter of the head lay in the transverse, and not in an oblique diameter, as it usually does in the human female. The fœtal attitude was quite that of the full-time human fœtus, viz., body with marked dorsal curve, convexity back; arms flexed at elbow, right arm somewhat across body, left arm less so; hands flexed; thighs flexed on trunk, leg on thigh; toes flexed in, big toe also. The tail was flattened on the right leg, and the head turned a little to left shoulder. The whole attitude is practically that of the human fœtus *in utero* at the end of pregnancy, but the condition of the hind paw is of course entirely different. In the human fœtus the foot is so arranged that the dorsum touches the anterior aspect of the leg, an arrangement quite the opposite to that just given in the fœtal ape's hind paw. The doubled-up fœtus measured  $6\frac{1}{4}$  inches.

*The Uterine Cast.*—This cast was of great interest as it showed that



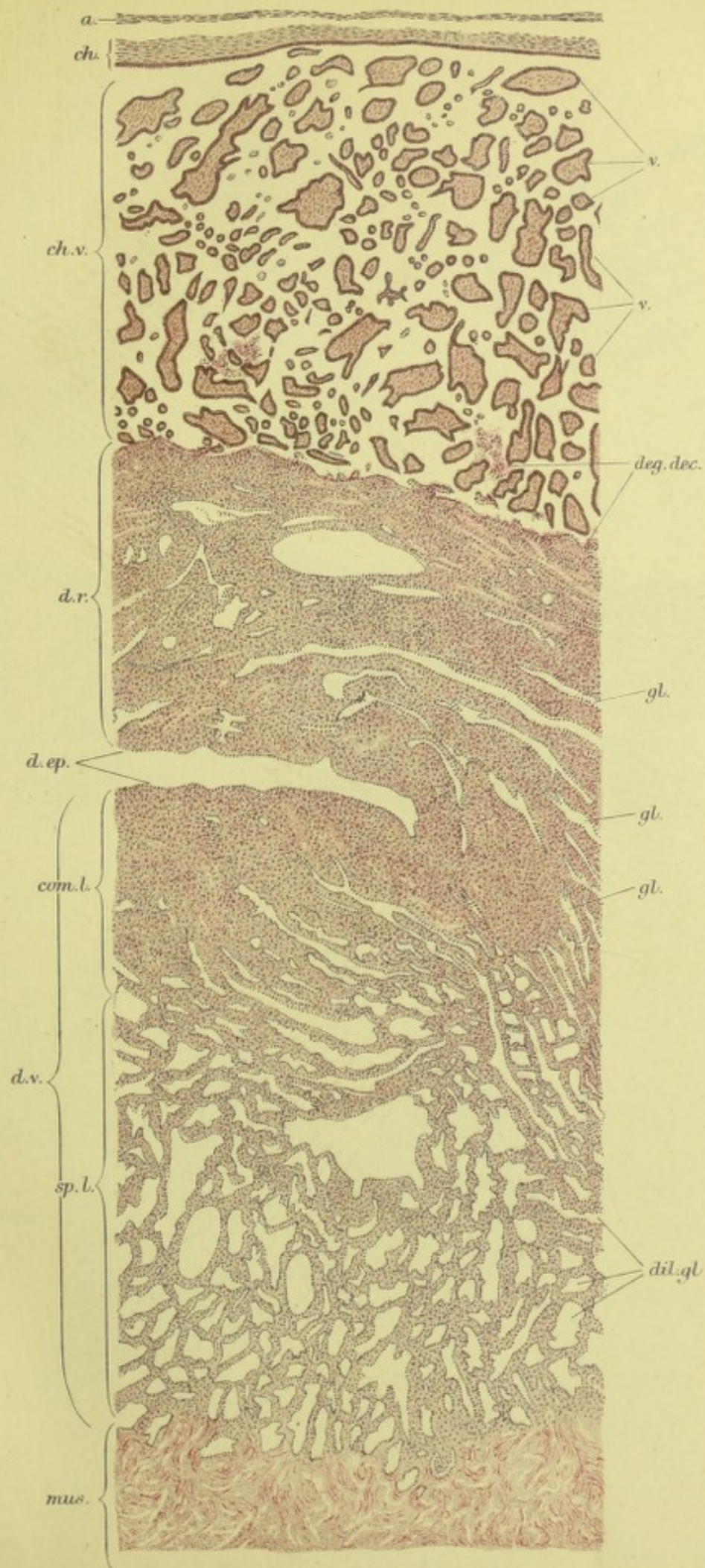








Fig. 2.

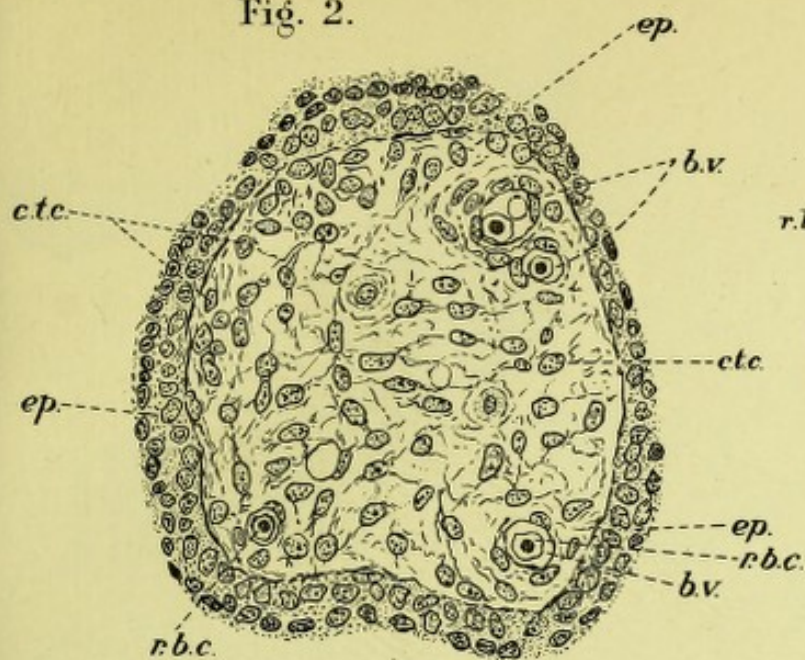


Fig. 3.

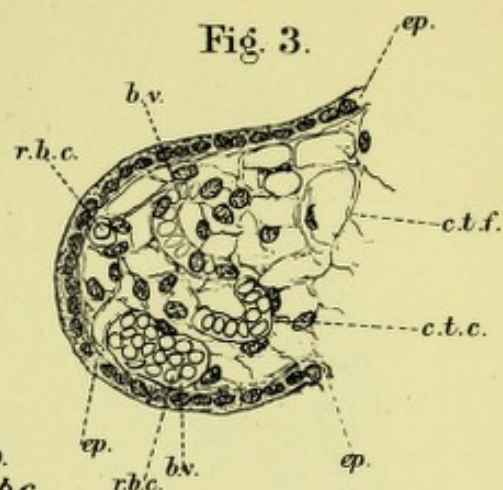


Fig. 5.

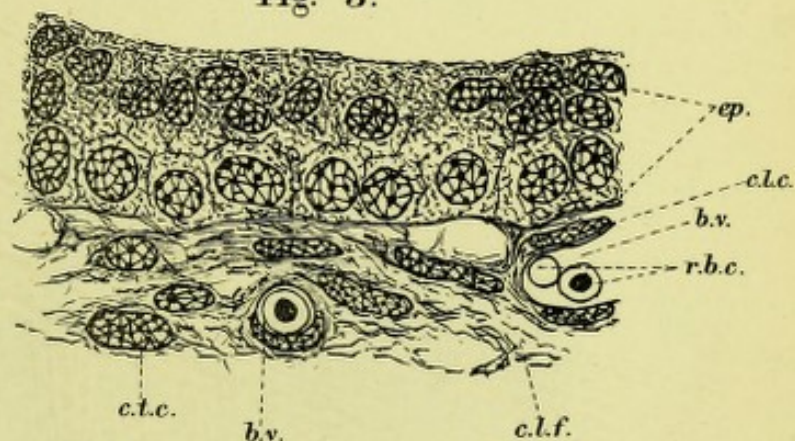


Fig. 4.

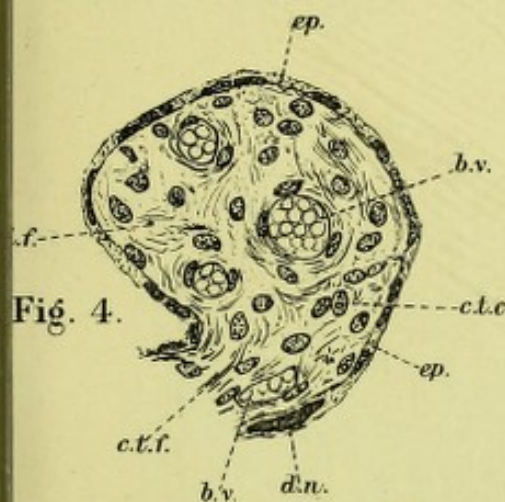
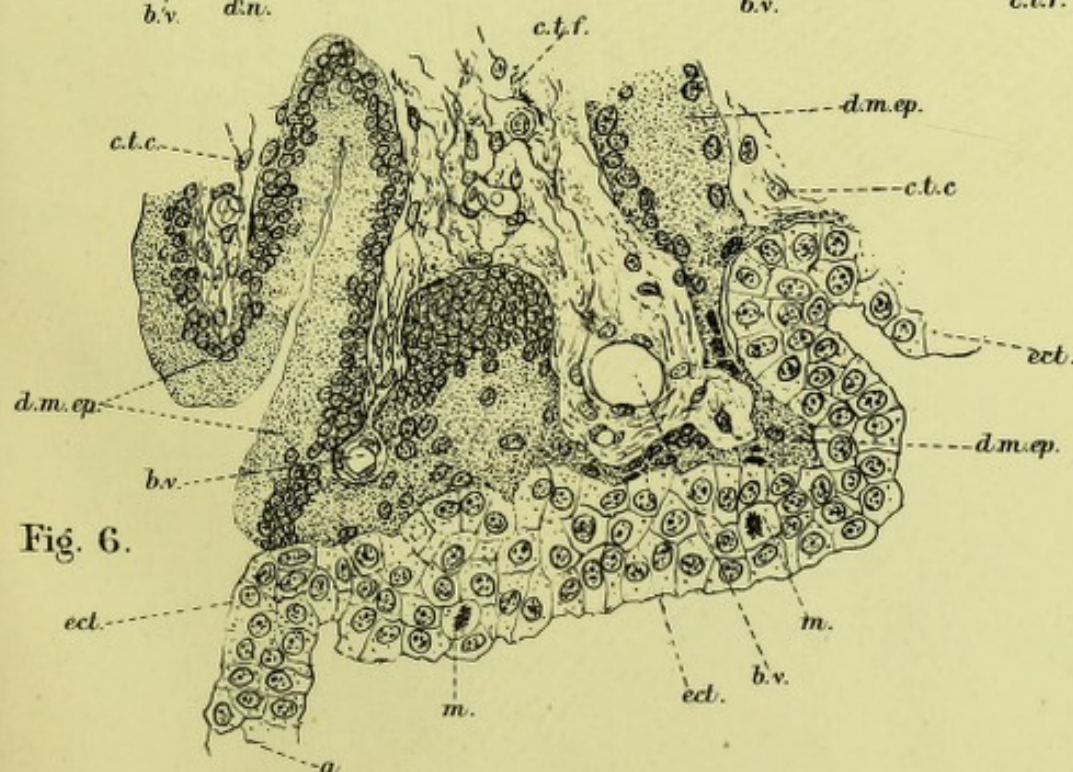


Fig. 6.










Fig. 7.

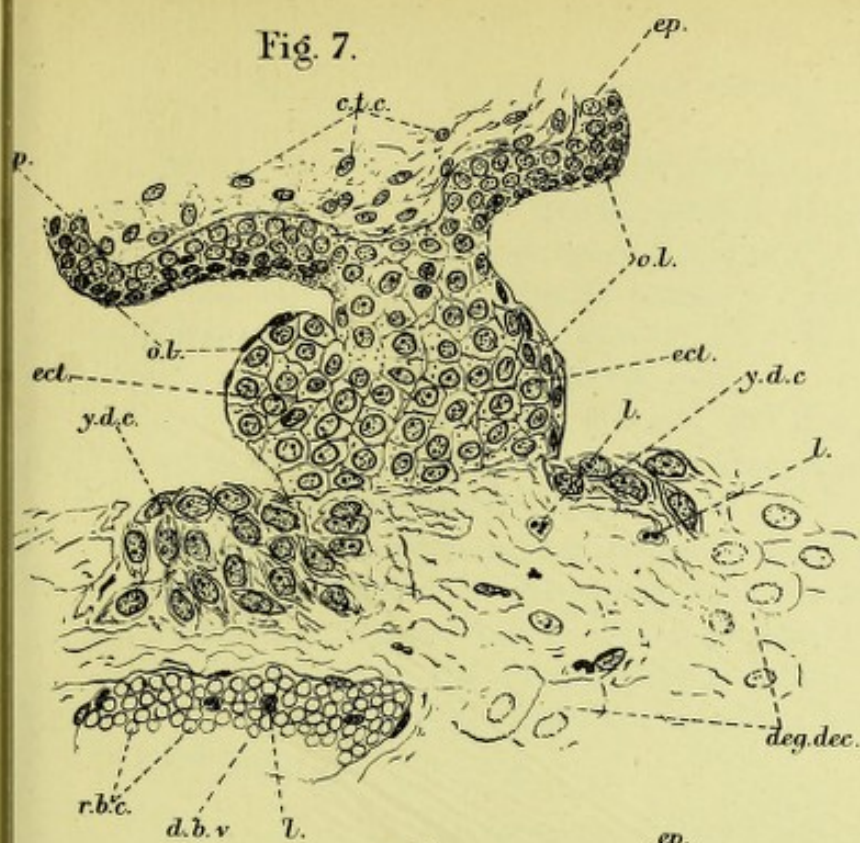


Fig. 9.

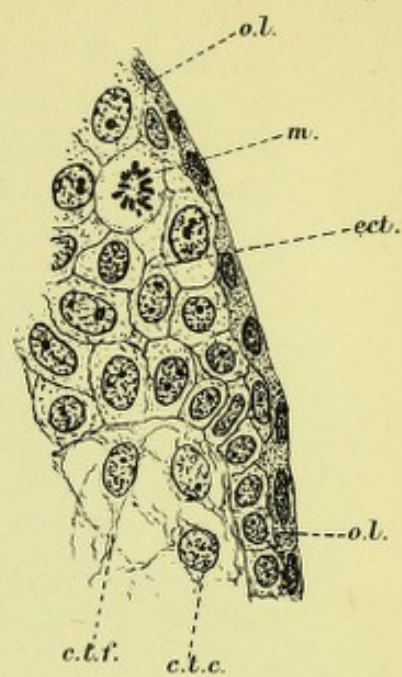


Fig. 8.

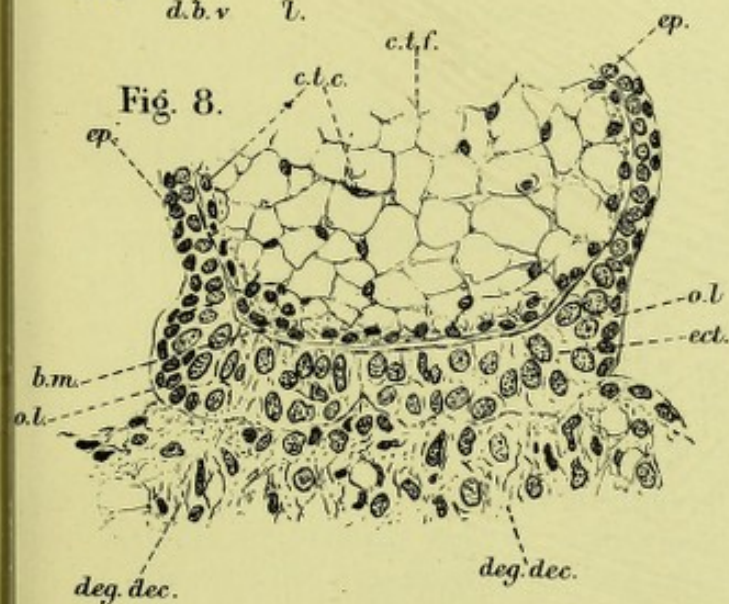


Fig. 10.

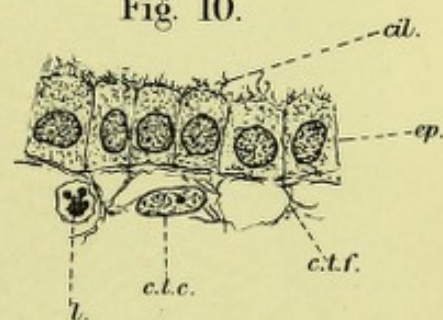


Fig. 11.

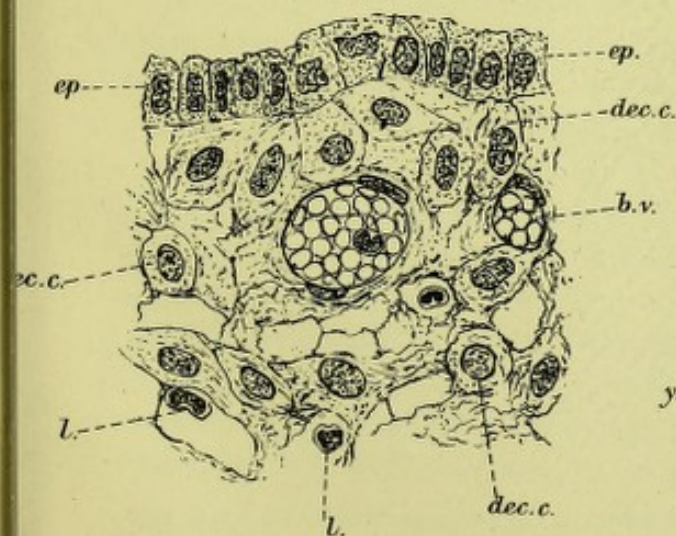
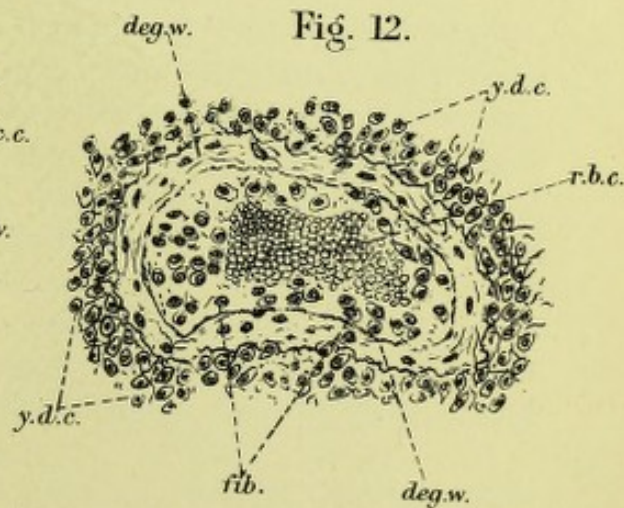



Fig. 12.









the uterine wall was moulded on the uterine contents. Thus one can see the foetal outlines in it; also the groove of the tail. The placental areae of the bilobed placenta are well shown. The lobes lay, as usual, dorsal and anterior (in relation to mother). Their measurements were as follows: dorsal,  $3\frac{1}{2}'' \times 2\frac{1}{2}''$ ; ventral,  $3'' \times 3''$ .

Their relations are well seen in the cast.

The cord was attached to the anterior one, and measured  $4\frac{3}{4}$  inches. The vertices and sides of the placenta were connected by large foetal vessels, two arteries and two veins.

It thus seems that the uterine wall is perfectly passive during pregnancy, and is moulded by intra-abdominal pressure on its contents, a condition exactly the same as in human pregnancy (*v. Chap. V.*).

The behaviour of the uterus during labour is unfortunately not known in these higher mammals, but it is to be hoped this gap will soon be filled up.

### III. *Structure of the Placenta.*<sup>1</sup>

After the freezing, section-cutting, and casting were terminated, parts of the placenta were cut out for microscopic examination. These were left for twenty-four hours in saturated solution of picric acid, thence removed to 50 p.c. alcohol for twelve hours, and then hardened in stronger alcohol embedded in paraffin, and cut with the rocking microtome. The sections were fixed to the slide by the water method, and stained with hæmatoxylin and eosin. Unfortunately the placenta had suffered somewhat by the preliminary processes to which it had been exposed, and the preparations are not so perfect as might be desired. However, although they do not enable one to speak with certainty of the details of cell structure in all parts of the preparation, there is no difficulty in making out the histological relationships of the different tissues, and the appearances we find will, we hope, throw some light on obscure points in connection with this subject.

It is unnecessary to enter into any detailed criticism of the literature bearing upon the placenta of monkeys. This has already been done fully by Waldeyer (*l.c.*), and the only important paper which has appeared since the work of the Berlin Professor is that of Selenka (*l.c.*). The points raised by him, and the questions discussed by Waldeyer, can be best approached in describing the individual parts of the placenta. The amnion and the connective tissue of the chorion and chorionic villi have often been described, and in our specimen present no peculiarities calling for remark. Waldeyer has already noted that the villi are more slender than those of the human placenta, and we can quite confirm this observation.

Waldeyer has also so fully and conclusively proved that the inter-

<sup>1</sup> This part is the work of my assistant, Dr Lovell Gulland, and with his views I entirely agree.



villous spaces contain maternal blood, that it is quite unnecessary to discuss that question further. But when he says (p. 45) that he counts himself among those who accept the view that the intervillous spaces represent dilated capillaries whose walls are preserved, and instead of being penetrated by the villi are simply invaginated by them while the villi permanently retain their covering of foetal epithelium, we join issue with him at once. Apart from the question of the preservation of the capillary walls, which we shall take up immediately, we would ask how it comes, if Waldeyer's view be correct, that this process of dilatation of capillaries has never been observed even in early human pregnancies like those described by Keibel and ourselves, or in the still earlier pregnancies of monkeys described by Selenka, where there was a considerable thickness of decidua serotina still unconverted into placenta?

We fail to understand how the large number of dilated capillaries which are presupposed by this theory, unite into the common intervillous space—a space which extends apparently unbroken, except by the villi, all through the placenta, or at any rate, through large portions of it, and we would point out that we have given reasons for believing that the intervillous space is originally a foetal space, which becomes secondarily only a part of the maternal circulation. That is to say, we have shown that the degenerated decidua serotina is removed by the actively growing epithelium at the tips of the villi, and that the intervillous space behind this attacking line is bounded only by the foetal epithelium covering the villi, which in the early history of the placenta is a double layer, later becomes a single cubical layer, and that this single layer is much flattened and degenerated in the full-time placenta. We are therefore among those who believe that the intervillous spaces are extravascular spaces, and that the maternal blood makes its way into them only after the walls of the maternal vessels in the serotina have been destroyed. This view, or something nearly approaching it, is upheld also by Farre, Kölliker, Langhans, and Heinz (*cf.* Waldeyer, p. 44), and we consider that, in the degeneration of the serotina, the thrombosis of its vessels, and the degeneration of their walls, which we have demonstrated in the early human placenta, we find ample support for our belief. The placenta of the monkey is obviously homologous with that of man, and this homology has been accepted by all writers on the subject, so that we feel justified in taking it for granted that in this matter also the correspondence is complete. That this destruction of vessels by placental growths *can* happen is proved abundantly by every extrauterine gestation, as there maternal blood is invariably extravasated round the villi.

Waldeyer's main reason for regarding the intervillous space as representing dilated maternal vessels seems to be that he finds in the placenta



of Inuus Nemestrinus a single layer of cells which everywhere borders the intervillous space, being continuous with the endothelium of the arteries and veins which open into that space, covering the so-called "decidual hillocks," in which the "Haftzotten," or attaching villi, are embedded, covering the villi and the under side of the chorion. He says that this layer is easily detached from the subjacent tissues, and regards this as a sign that it is endothelium. We see this layer perfectly in the placenta of *Macacus Rhesus*—much better than in any human placenta—and note also how easily it is detached; but we consider that it is the outer layer of the foetal ectoderm, and we shall describe it as such in due course. We would point out, however, that the ease with which it is detached is to our minds a proof rather of its epidermal than of its endothelial nature; nothing is more difficult than to separate a true endothelium from subjacent tissue. The cells have a character totally different from any endothelium—they are cubical, closely set together, and with a considerable cell body; and we know of no instance elsewhere where an endothelium enclosing enormous masses of blood is apposed over a vast area to epithelium, and especially epithelium belonging to another individual, without any trace of connective tissue to support it. Moreover, we know of no force involved in the formation of the placenta which could act so as to dilate capillaries in this imaginary way, nor any reason, logical or histological, why, if all the other tissue-elements of the decidua are removed by the villi or otherwise, the vascular endothelium should be spared entire, and moulded to the surface of the destroying villi.

In the discussion of the relations subsisting in the placenta, too little attention has been paid to the fact that the tissues of two separate individuals are involved in its formation, and it has been taken too much for granted that the uterus had an important part to play in the formation of that organ. Selenka speaks of the embryo as the parasite of the uterus, and in truth all our observations tend to show that the part played by the maternal tissues is mainly a passive one, and that the foetus profits by the degenerative processes which go on in them. Even the formation of the decidua reflexa seems to be really an accident, so to speak, connected with menstruation, and not a true formative process; the fertilised ovum, implanted on the surface bared by the menstrual flow, is covered over by the rapid growth of the uterine mucous membrane, and so is "healed in" as any other non-irritating foreign body would be. When the ovum begins to increase rapidly in size, and to invade and press upon the decidua reflexa, that envelope degenerates in precisely the same way as the serotina, but even more rapidly.

The covering of the chorion and villi is entirely foetal therefore, in our opinion, and, just as in the human placenta, it differs in different places. One point in dispute between different authors is whether the



main or amniotic chorion is covered by a single layer of cells, or by a layer of several cells. Waldeyer, in *Inuus*, found a single layer; Turner, in *Macacus*, layers of several cells. Very possibly, as Waldeyer suggests, the placentæ may have been of different ages, or different parts may have been examined. We certainly find everywhere a many-celled layer, but differ entirely from Turner and Waldeyer in our interpretation of it. These authors seem uncertain whether to regard it as decidual, and representing Winkler's "*Schlussplatte*," or as chorionic and derived from connective-tissue cells. We see every reason to regard it as foetal and ectodermal. It coats the main chorion and the main villi, running along these to become continuous with the so-called "*decidual hillocks*" into which the main villi or "*Haftzotten*" run. These hillocks we regard as expansions of the foetal ectoderm, of the same nature as those we have described in the human placenta, but which seem to be preserved to a later date, relatively, than in man. The cells of this layer are obviously different in character from the true decidual cells. Next the chorion is a layer of fairly columnar cells, then they are disposed more irregularly, and towards the surface—the intervillous space—are somewhat flattened, while the superficial layer, that which Waldeyer regards as an endothelium, is a layer of flat, cubical cells, which, when the villi are cut so that a surface view is obtained, are almost exactly like the layer of epithelial cells covering the amnion. Nowhere in the whole of this layer, either on the chorion or villi or in the so-called "*hillocks*," are there any blood-vessels, leucocytes, or fibres, all of which are invariably present in any modification of the uterine mucous membrane, and the cells (and nuclei) are all very nearly of the same size—a characteristic of epithelium rather than of connective tissue. Perhaps the most conclusive proof of the foetal and epithelial nature of this tissue is the fact that a layer presenting exactly the same characters, but with a thickness of two or three cells instead of six or a dozen, covers the surface of the chorion outside the placenta altogether, and is separated by a layer of degenerated fibrinous-looking material from the remains of the decidua vera, which are quite unlike it in appearance. Where the main villi in the placenta break up into branches this thick layer thins out, gradually or abruptly, and the small villi are covered simply by the single superficial layer, which has the same characters here as over the "*hillocks*" and elsewhere, and these small villi have much the same appearance, therefore, as the villi in a human placenta of about seven months, when the epithelium of the villi has become reduced to a single layer and has begun to degenerate.

The so-called "*decidual hillocks*" require a word or two of description. They are to be found at the points where the main villi come in contact with the serotina, and the old idea in regard to them was that they were masses of decidual cells, *i.e.*, connective tissue cells, which in



some unexplained way formed or were found at these points. Whether the villi tended to attach themselves specially to pre-existing hillocks, or whether they produced these masses of decidual cells by some action of their own, no one seems to have inquired, though the first supposition seems unlikely and the second wellnigh impossible, as the hillocks are based upon degenerated serotinal tissue.

What we see in these structures is that the layer of foetal ectoderm which underlies the main chorion and runs along the main villi becomes thick and massive at the points where the main villi approach the serotina, and the mass of cells forms a cone into whose apex the villus-stem is inserted, and whose base is spread out upon the surface of the serotina. The bases of the cones usually extend somewhat over the surface of the serotina, much more than the corresponding structures in the human placenta do except in the very beginning of its history, and the base of one cone thus generally meets or nearly meets the base of another, as a flattened layer, unless the opening of an artery or vein into the intervillous space breaks the continuity. The layer of flattened epithelium (Waldeyer's endothelium) passes from the villus-stem over the surface of the cone which is turned towards the intervillous space, and runs over the flattened layer between the cones. This fact, as Waldeyer himself half acknowledges, is an important point against his theory, for if this layer really represented the endothelium of dilated vessels which are invaginated before the growing villi, why is this layer not invaginated before the main villi? Waldeyer regards it as a proof of the correctness of his view as to this layer that it is continuous with the endothelium of the arteries and veins opening into the intervillous space, but as this layer bounds the whole of the intervillous space it could hardly but be continuous with the endothelium and continuity cannot imply identity when the two layers are so totally unlike one another. The connective tissue core of the villus leaves the layer behind it at the apex of the cone, and branches and re-branches within the cone without any other covering than the cells of the cone itself. These cells have the epithelial characteristics already mentioned, and we see every reason to regard them as homologous with the masses of foetal epithelial cells at the tips of the villi which we have described in the human placenta. In the monkey this structure evidently persists to a later period than in man,—for what reason we do not venture to surmise. The deep or serotinal surface of these epithelial cones is generally slightly degenerated, especially if the mass of cells in the cone is large, not so much in the flatter expansions, and the tips of the connective tissue branches of the villi, which are usually flush with the serotinal surface of the cones, are always markedly degenerated, the nuclei are lost, the fibrillated character of the connective tissue disappears, and the villus is only recognisable by its difference from the surrounding



structures in the matter of staining. This tendency to degeneration of the surface of the epithelial part of these cones we have noted also, though to a much less extent, in the human placenta, and it is of course a common phenomenon in all many-layered epithelia, especially when exposed to pressure.

It is exceedingly to be regretted that the histological part of Selenka's memoir on the ape's placenta has as yet only the character of a preliminary notice, and that he has not at all discussed the minute structure of the advanced placenta, for his figures show us that between the early stages of the monkey's placenta and that of man there is the most startling similarity. This is especially to be noted in the great development in the monkey of the "trophoblastic" epithelium at the tips of the villi (*cf.* Taf. 35, figs. 5, 11, 12; Taf. 37, fig. 5).

Selenka has indeed entirely missed the significance of this structure, and regards it as a development of the maternal epithelium, because he regards the outer layer of the epithelial covering of the villi as maternal. In this view he stands at the present day almost entirely alone, and his own figures might have shown him his error. As Waldeyer points out, the characters of the two epithelia are totally different. Selenka lays great stress upon the fact that in one specimen the epithelium at the end of a villus was found entering a large dilated gland, but in the figure which he gives of this none of the twenty or thirty other villi which reach the serotina enter glands at all, but are all coated with "trophoblastic" epithelium which is apparently destroying the serotina. His fig. 12 Taf. 35 might have been drawn from some of our preparations of the early human placenta. The view that maternal epithelium enters into the covering of the villi has been abundantly discussed by Minot and ourselves, and need not be further entered into.

The decidua serotina is robbed by us of its "placental layer" (Waldeyer and Turner) which consists of the hillocks. The superficial part of the serotina we find markedly degenerated, sometimes forming simply a fibrinous mass, just as in the human placenta, and the extremities of the mesoblastic core of the villi, themselves degenerated, sometimes penetrate this layer. Below this layer is a true decidua, not very different from the human serotina, except that the cells are never so large. There are many vessels in this layer, whose walls are often considerably degenerated, and beneath it there is a spongy layer, not well developed, but having the same characters as that in the human placenta. Waldeyer doubts the presence of this layer, but here again a difference in the age of the placenta examined may explain the discrepancy.

The decidua vera external to the placenta is very like the serotina, but very much thinner and less vascular.



IV. *The general Relations of Apes to Lower Animals and to the Human Female in relation to Menstruation, the Determination of the Placental Site and the Origin of the Umbilical Cord.*

Under this head I wish to consider some special points of great interest. These are—

- (a) *Menstruation in Apes.*
- (b) *The Determination of the Placental Site.*
- (c) *The Origin of the Umbilical Cord.*

(a) *Menstruation in Apes.*—In the higher apes it is now well known that a periodical discharge of blood takes place from the genitals. The best research is by Bland Sutton who examined the uteri of several macaques and baboons, at various stages. As the animals were killed and the parts at once preserved, no fallacy of *post-mortem* changes came into the observations. Sutton found that the mucous membrane became thickened, that blood escaped (small in quantity) and that there was no shedding of the superficial layer of the mucous membrane, *the epithelium remaining intact although blood was found in the uterine cavity.*

In the human female, however, as is now well known (Kundrat and Engelmann; Leopold), the superficial layer of the uterine mucous membrane is shed, and thus we have a distinct difference between menstruation in apes and the human female. Whether or not in the very highest apes such as the gorilla and chimpanzee, denudation of the mucous membrane occurs, is as yet unknown.

(b) *The Determination of the Placental Site.*—The comparative physiology of this point is one of the greatest interest and value. In *Ruminants* as is well known there are special elevated and thickened parts of the mucous membrane, the cotyledons, on which the villi graft and give the well known polycotyledonary placenta. We have therefore specially developed areas for placental attachment.

In *rabbits* the ovum always grafts itself on two folds—the placental folds—which run parallel and on the side of the line of the broad ligament attachment.

In the *hedgehog*, according to Hubrecht, the ovum attaches itself and the placenta develops in that part of the uterine horn opposite the broad ligament attachment, the mucous membrane being thinnest at the side next the broad ligament in the virgin uterus.

In the *apes* examined by Selenka it was found that there was a special part of the middle of the posterior uterine wall—the *Haftfleck*—where the dorsal lobe of the bilobed placenta developed: the ventral lobe developing on a corresponding portion of the ventral uterine surface a little later. This "*Haftfleck*" had about thirty to forty gland openings in it and increase of the placental site was due to an increase in the "*Haftfleck*."



It is of remarkable interest that in the apes with bilobed placenta and where the uterus is formed on the same plan as the human female, *i.e.*, has Fallopian tubes and a single uterus, pregnancy is made uterine by this arrangement of a "Haftfleck" for the placental site and that in all apes with a bilobed placenta, the placenta is invariably in the same position, the middle portion of the anterior and posterior uterine walls.

In those apes with a single placenta we have no special observations. In the human female the placenta may graft itself normally on any part of the uterine surface proper, *i.e.*, never below the os internum nor outside the inner openings of the Fallopian tubes. If we take the bicornuous uterus as displayed in a ruminant, we find a narrow tube, then the cornua. The implantation of the placenta in the cornua is favoured by the cotyledonary arrangement and no tubal pregnancy has ever been found.

In the human female I have already thrown out the suggestion that the human ovum can only graft on connective tissue, and that menstruation thus bares a safe area. It must be remembered that the Fallopian tube of the human female has a very perfect mucous membrane, and one that can form a serotina like the uterine mucous membrane itself, and it is possible that the menstrual denudation maps out a normal attachment-area in the human female.

(c) *The Origin of the Umbilical Cord.*—The origin of the cord is at present disputed. The view usually adopted is that of Kölliker, *viz.*, that at one period the developing ovum is free but is again moored to the chorion by the outgrowth of the allantois.

His, on the other hand, maintains that at an early stage the developing ovum is in connection with the chorion by its posterior end, the "Bauchstiel," that this forms the cord, the allantois tunnelling it as it were. The covering of the cord is therefore morphologically, skin and not amnion. At first the cord is covered with a single layer of cells; at about the third month this layer is multiple and at the full time, many-layered and flattened. Thus the covering of the cord is morphologically skin but not so completely differentiated as over the foetus.

Hertwig, on the other hand, holds that the developing ovum is attached to the chorion at first by amnion. The closure of the amnion is at the posterior end of the embryo. The allantois grows out, not free into the coelom but along the ventral surface of the amniotic attachment.

Selenka describes this last condition as occurring in the monkey. The question however cannot be considered settled as yet.

I have only a few words now on the relation of this class of apes to the scale of evolution. We regard the main branches of the Mammalia as having diverged from the primitive Monotremes and Marsupials.



Thus we have Monotremes, Marsupials, and then the Primates comprising Lemurs, Apes and Man. We have here a gradation. The Ornithorhynchus has a completely bifid genital tract and lays eggs; the Marsupials have a less bifid uterus and a very imperfect villous attachment of the foetus to the maternal structures; the Lemurs have a bicornuous uterus and diffuse placenta; the lower apes, a single uterus, bilobed placenta and no reflexa; the higher apes and human female, a single uterus, single placenta and reflexa. Looked at from the special point of attachment of the placenta we get

- (a) No attachment of foetal tissues; egg: Ornithorhynchus.
- (b) Very imperfect attachment: Kangaroo.
- (c) More perfect attachment but placenta diffuse and non-deciduate—Lemurs.
- (d) Placenta deciduate but not embedded—lower apes.
- (e) Placenta with reflexa, *i.e.*, ovum embedded at first in maternal tissue—placenta deciduate, higher apes and human female.

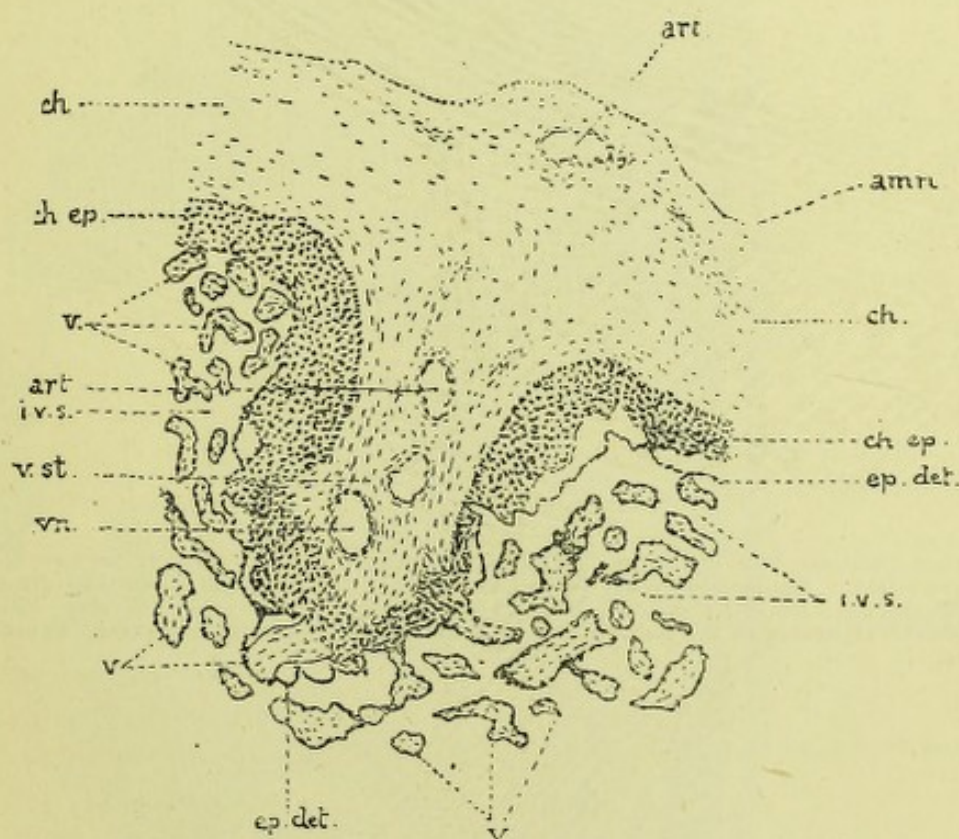


FIG. 17.

PART OF THE AMNION, CHORION, AND PLACENTA OF *Macacus rhesus*:—*am.*, Amnion; *ch.*, Chorion; *ch.ep.*, Foetal epithelium (ectoderm covering the chorion and main villi); *ep.det.*, The superficial layer of the epithelium detached in places (Waldeyer's endothelium); *v.*, Villus; *v.st.*, Villous stem; *art.*, Artery; *vn.*, Vein; *i.v.s.*, Intervillous space containing maternal blood. Ob. §, oc. 4.



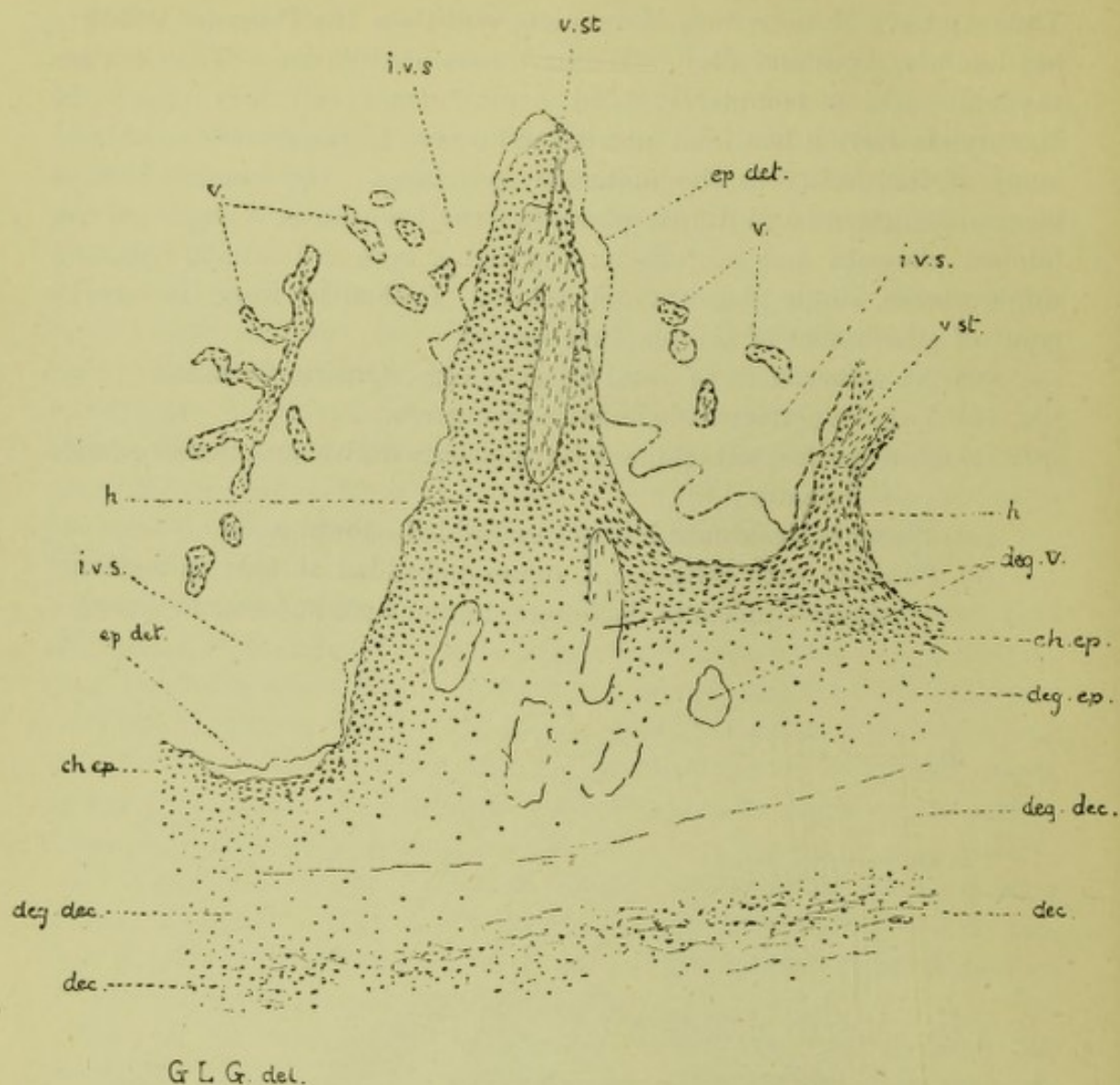
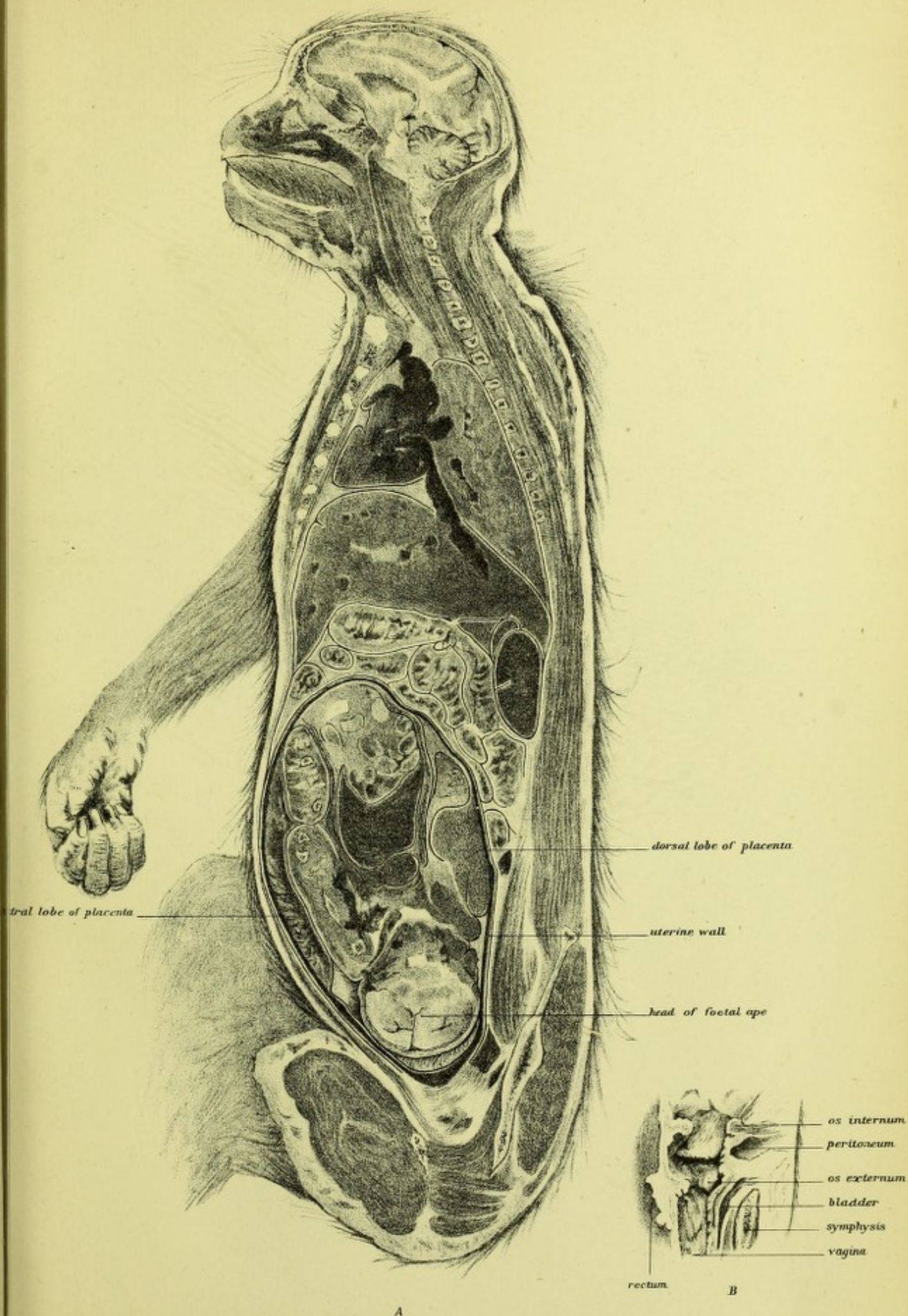


FIG. 18.


SECTION THROUGH THE SAME PLACENTA TO ILLUSTRATE THE ATTACHMENT TO THE DECIDUA SEROTINA:—*deg.v.*, Degenerated villi; *deg.ep.*, Degenerated foetal epithelium on the surface of the trophoblast; *dec.*, Decidua; *deg.dec.*, Degenerated decidua; *h.*, So-called "decidua hillock"—trophoblastic expansion of the foetal ectoderm at the extremities of the main villi. Other letters as in fig. 17.





GRAVID UTERUS, MACACUS.







# PART II.

CONTRIBUTIONS TO THE MECHANISM OF NATURAL  
AND MORBID LABOUR.



W. H. T. 10

THE NEW YORK PUBLIC LIBRARY  
ASTOR LENOX TILDEN FOUNDATION  
1895



## CHAPTER VIII.

### THE INCONSISTENCIES OF THE PRESENT OBSTETRIC NOMENCLATURE FOR POSITIONS.

For the various positions the child may occupy at the beginning of labour, we have at present a nomenclature pretty generally agreed upon. This nomenclature has grown up gradually, and has been specially discussed by the Committee whose formation was suggested by Prof. Russell Simpson at the London International Congress.

In naming the HEAD POSITIONS, the occiput is taken as the factor, and therefore L.O.A. means that "position" where the occiput is to the left and front.

In FACE-CASES, however, the chin is regarded as the guide, and thus we speak of L.M.A., *i.e.*, the face position with the chin to the left and front.

In BREECH CASES, again, the positions are taken from the sacrum, and thus we have L.S.A., meaning that position where the sacrum is to the left and front.

In TRANSVERSE CASES, finally, the nomenclature has varied much. The most common position has been variously termed, dorso-anterior, left cephalo-iliac, or left scapulo-anterior, etc.

Now, in this nomenclature there is no consistency, although there may be convenience, provided one does not go to the root of the matter. To understand the present errors and the way out of them we must recur to the definition of what is termed "position."

"Position" involves two factors, *i.e.*, we must define the relation of a certain part of the child to a certain region of the mother. The latter factor is easily determined, as it is the upper strait of the bony pelvis. In this we take either the ilio-pectineal eminences or sacro-iliac joints, according as the position is anterior or posterior; or where the Solayres' obliquity is not present (the presenting part lying in the transverse) we take the iliac bone itself where the transverse diameter impinges, and use the word "iliac" instead of "ilio-pectineal." To divide the brim into quadrants, as Dr Milne Murray suggests,<sup>1</sup> is met by the difficulty of the occasional absence of Solayres' obliquity—when the occiput, for instance, would occupy two quadrants.

<sup>1</sup> V. *Edinburgh Medical Journal*, 1890, p. 360.



Besides, the real difficulty in defining "position" is the foetal factor. In the ordinary nomenclature it is "occiput" in head cases, "chin" in face cases, "sacrum" in breech cases, and "acromion" in transverse ones. Now head, chin, sacrum, and breech can have no topographical unity. They are so diverse that one is forced to try to define the foetal factor of position in some other way.

I strongly urge a functional definition, and think the best is the following, viz., "*Position is the relation to the upper strait of the pelvis of that portion of the presenting part of the foetus which should first rotate to the front in the movement of internal rotation.*"

This is really no new principle, as evidently in face cases the chin has been chosen as the foetal indicator of position, and apparently because it is of importance that it should rotate to the front in internal rotation.

We can now rearrange the nomenclature as follows:—

Head and face cases retain their nomenclature. In breech we take the hip, and have, therefore—

Dorso-anterior,	.	.	Left coxa-cotyloid.
" "	.	.	Right " "
Dorso-posterior,	.	.	Left " "
" "	.	.	Right " "

For transverse cases we have—

Dorso-anterior,	.	.	Left acromio-iliac.
" "	.	.	Right " "
Dorso-posterior,	.	.	Left " "
" "	.	.	Right " "


It must be noted that "right" and "left" "anterior" and "posterior" refer only to the mother.

This nomenclature is accurate, logical, simple, and it tells the student, moreover, a great fact about internal rotation. The old nomenclature was inaccurate, had no logical consistence, and should of course be altered.

I am not bigoted in regard to this matter. It might, for instance, be possible to define position as "the relation of the dorsal aspect of the presenting part to the upper strait of the pelvis." This would, however, involve the alteration of the nomenclature in face-cases to "left-fronto anterior," etc., and would be an unfortunate necessity, but much better than adhering to a nomenclature that is contradictory and confusing.

The term "PRESENTATION" is best defined as = "and the long axis of the mother and child cut (or coincide)." Breech presentation = Breech in lower uterine segment and the long axis of the uterus and mother coincide. Transverse presentation = Shoulder in lower uterine segment and the long axis of uterus and child intersect.





## CHAPTER IX.

### NATURE AND CAUSE OF THE MOVEMENT OF INTERNAL ROTATION.

ALTHOUGH internal rotation is one of the most striking movements of the part engaging in the pelvis during parturition, we are yet in want, not only of a reasonable explanation of its cause, but also of a detailed description of its nature in the various presentations, normal and abnormal, in which it happens.

In taking up this subject, I purpose considering it under the following divisions :

1. THE HINDRANCES TO A RIGHT CONCEPTION OF THE CAUSATION OF THE MOVEMENT, DUE TO ERRONEOUS ANATOMY AND DESCRIPTION.
2. THE ANATOMY OF THE PARTS CONCERNED IN BRINGING ABOUT ROTATION.
3. A DESCRIPTION OF THE MOVEMENT OF INTERNAL ROTATION IN THE VARIOUS PRESENTATIONS.
4. THE CAUSATION OF THE MOVEMENT OF INTERNAL ROTATION, GENERAL AND PARTICULAR.

1. THE HINDRANCES TO A RIGHT CONCEPTION OF THE CAUSATION OF THE MOVEMENT, DUE TO ERRONEOUS ANATOMY AND DESCRIPTION.

Our knowledge of the cause of rotation has been greatly retarded by the assumption that it must be due to some shape of the bony pelvis. The tissue lining the pelvis has been regarded as having little influence, although in German text-books the pressure of the tissue lining the posterior wall of the pelvis has always been held to be a factor in determining it. Now, mere change of shape in the bony pelvis will not cause rotation ; the only result can be a distortion of the head, *i.e.*, the head will mould itself to the varying capacity of the bony pelvic walls, but not necessarily rotate. This holds even more strongly of the breech. Another very misleading term has been posterior rotation of the occiput in head cases, or chin in face presentations. As I hope to show, no part in the pelvis ever rotates primarily backwards. Rotation is always a forward and inward movement.



## 2. THE ANATOMY OF THE PARTS CONCERNED IN ROTATION.

This must be considered in relation to—

(a) *The Canalised Pelvis and Pelvic Floor.*

(b) *The Fœtal Body, especially the Head.*

(a) *The Canalised Pelvis and Pelvic Floor.*—This may be considered as made up of two parts, one in front of the transverse of the brim and true pelvis, the other behind it. The first is the anterior half of the pelvis and tissues, the second is the posterior half with its tissues.

During the second stage of labour the anterior half of the canalised pelvis is practically the same as that of the bony pelvis, inasmuch as the bladder and retropubic fat are partially drawn out of the pelvis, and it is lined symmetrically with vaginal and cervical tissue.

The posterior pelvic wall, chiefly sacrum and coccyx, is different, however, inasmuch as it has springing from it a segment of the pelvic floor, the sacral segment, attached to the sacrum, coccyx, and edges of the sciatic notches.

This sacral segment is the most important factor in bringing about rotation, and as such must be fully considered.

It is fixed above to the sacrum and coccyx, extends downwards from the bony outlet of the pelvis posterior to the ischial tuberosities, and is unattached at the lower end. It thus includes the posterior vaginal wall and tissues behind it, and has embedded in it parts of the obturator internus, coccygeus and levator ani muscles, as well as the transversus perinei. Part of the strong gluteus maximus also enters into its formation (figs. 1 and 2, Plate VII.).

Owing to its attachments, it can be pulled back and made to recoil, *e.g.*, by Sims' speculum, or driven back by the part of the fœtus engaging in the pelvis. It is the strong segment of the pelvic floor, as will be understood by the following measurements :

Length from tip of coccyx,	.	.	.	3 inches.
Thickness at level of cervix uteri	.	.	.	2 inches.
Do., at anus,	.	.	.	2 inches.

The length is of course increased during labour. The sacro-sciatic ligaments, coccygeus, and levator ani muscles all help to restrain undue driving back of the lower portion of the sacrum and coccyx as well as of the sacral segment.

It is important to consider it divided into two portions—a right lateral and left lateral—lying respectively to the right and left of an imaginary vertical mesial line on the lower portion of the sacrum coccyx and posterior vaginal wall (fig. 2, Plate VII.). The anterior pelvic wall may be considered as the concave aspect of a segment of a circle, on part of which the rotating head or body glides.

One specially important point to be kept in mind is that the anterior



and posterior walls of the canalising pelvis are of very unequal lengths, and that consequently the anterior portion of the presenting part at the brim will touch the sacral segment, and be compressed or pushed forward by it very much sooner than the presenting part lying posteriorly. The recoil of the sacral segment is increased as we pass towards its lower end, as it acts like a lever of the first order (fig. 1, Plate VII.).

(b) *The Fœtal Body, especially the Head.*—The only point I wish to note here, is the relation between the head and canalised pelvic floor so far as mere fitting is concerned. One factor in rotation depends on whether or not the head, for instance, passes through the pelvis easily or the reverse. In the production of malrotated head cases this is an important factor. Another way to put this is as follows. The question as to whether the occiput or sinciput will be deeper in the pelvis depends on whether the relation between the head and pelvis is such that the latter accommodates the suboccipito-bregmatic diameter or the suboccipito-frontal. The head is here considered as made up of the occiput and sinciput—the one begins behind, the other in front of, a coronal plane drawn at the posterior margin of the anterior fontanelle.

### 3. A DESCRIPTION OF THE MOVEMENT OF INTERNAL ROTATION IN THE VARIOUS PRESENTATIONS.

I briefly remark, first, that while the path of the head during rotation is a complex one, and is not exactly known, it is sufficient to describe it as a rotation of the head on an imaginary and varying vertical axis, occurring when the head is at a varying part of the true pelvis, usually below the level of the ischial spines, *i.e.*, when the leading part comes within the sphere of the sacral segment.

Internal rotation takes place in head, face, forehead, breech, and spontaneous expulsion cases. The clinical facts as to internal rotation in each of these is briefly as follows:—

**HEAD.**—In the L.O.A., the occiput, known by its small fontanelle, lies below the brim, opposite the left ilio-pectineal eminence, becomes driven down, and when it strikes the left lateral half of the sacral segment, *i.e.*, when asymmetric to the sacral segment, is rotated through a quarter of a circle to the front and right, so that it lies wholly or partially within the pubic arch, and as it now lies symmetrically to the sacral segment, rotates no further (*a*, fig. 1, Plate VIII.).

In the L.O.A. the occiput rotates to the front and right, *i.e.*, the part deep in the pelvis, and first striking the left half of the sacral segment, becomes rotated to the right and front.

In the R.O.A. the occiput rotates to the front and left through a quarter of a circle, *i.e.*, in the R.O.A., the part deep in the pelvis, and



first striking the right lateral half of the sacral segment, is rotated to the front and left (fig. 1, *b*, Plate VIII.).

In the R.O.P. we may have two rotations—(a) *The normal or long*, and (b) *The abnormal or short*.

(a) *The normal or long* takes place so that the occiput passes from the region of the right sacro-iliac synchondrosis to the pubic arch. Clinically, the occiput is felt leading, and the occiput fits the pelvis accurately—the head is never a small one. In the R.O.P., therefore, when the occiput leads and strikes the right half of the sacral segment before the sinciput touches the left lateral half, it is rotated through three-quarters of a circle to the front and left (fig. 1, *e*, Plate VIII.).

(b) *The abnormal or short rotation* has been greatly misunderstood, owing to erroneous terminology. In R.O.P. cases where the head is small, the sinciput is deep in the pelvis, consequently strikes the left half of the sacral segment first, and is rotated by it to the front and right through a quarter of a circle. Thus the occiput lies in the hollow of the sacrum, and no further rotation of the head takes place, inasmuch as the head is now symmetrically placed to the whole sacral segment (fig. 1, *g*, Plate VIII.). *The malrotated occipito-posterior cases are really rotations forward of the sinciput, occur in cases where the head is small, and can easily be predicted during labour by noticing the deep position of the sinciput, i.e., deep position of anterior fontanelle.* They are best termed, therefore, after rotation, sinciput to pubis cases.

I need not detail the L.O.P., as we have either (a) long rotation of the occiput from left to right (fig. 1, *f*, Plate VIII.) or (b) short rotation of sinciput from right to left (fig. 1, *d*, Plate VIII.).

The rotation of the shoulders is simple. In the L.O.A. the right shoulder is anterior, strikes the right half of the sacral segment first, and is rotated by the pressure on its anterior aspect, to the front and left, through quarter a circle. The head is therefore externally rotated to the left (restitution).

In the R.O.A. the left shoulder is anterior, and is, for reasons already given, rotated to the front and right, causing external rotation to the right (restitution).

In the L.O.P. and R.O.P. either shoulder may strike a lateral half of the sacral segment, and thus rotation of the shoulders may occur to right and front or left and front in each (*v.* Plate VII., fig. 1).

*Internal Rotation in Face Cases.*—We name face cases according to the position of the chin (mentum) as L.M.A., R.M.A., R.M.P., L.M.P. In these positions the rotations are in all respects equivalent to the occipital one, the chin taking the place of the occiput. Thus in the L.M.A., the chin makes the short rotation to the front and right; in the R.M.A., it makes the short rotation to the left and front.



In the R.M.P., however, the normal rotation is the long one from the right sacro-iliac synchondrosis to the pubis; but we occasionally get, not the chin rotating directly to the front, but the forehead making the short rotation to the front. In the L.M.P. we have exactly a similar process. In malrotated face cases, therefore, where the chin after rotation is found in the hollow of the sacrum, we have really a rotation of the forehead forward.

In *Breech Cases* internal rotation is always short, the deeper hip rotating through quarter of a circle to the front. The rotation of shoulder and head is easily known, if the general law, to be stated at the end, is kept in mind.

In *Forehead Cases* rotation usually takes place so that the face lies behind the pubis, after which the occiput passes over the perineum prior to the escape of the face and chin under the pubic arch. Forehead cases are so rare, however, that the particulars in each form of the mechanism is not known with certainty. In the most remarkable form of mechanism known as *Spontaneous Expulsion*, where the doubled-up foetus is driven down into the pelvis shoulder first, and the breech driven over the perineum, we usually get, prior to this delivery of the breech, a rotation of the deep shoulder, so that it passes from the region of the obturator foramen to lie under the pubic arch. A case of this will be presently narrated. Finally, I may note that in the rickety pelvis, where the concavity of the anterior pelvic wall is much diminished, we may get internal rotation occurring as in an occipital case in a normal pelvis; while in the kyphotic pelvis the right occipito-iliac position is common, "the occiput rarely turns forwards, deep transverse position is common, and posterior rotation not uncommon" (Champneys).

#### 4. THE CAUSATION OF THE MOVEMENT OF INTERNAL ROTATION, GENERAL AND PARTICULAR.

It will help greatly to clear up our ideas as to the causation of rotation if we first exclude certain alleged factors.

*Firstly*, The shape of the rotated part can have no essential place in determining this movement, inasmuch as the shoulder in the pelvis, with its soft and varying outline, is rotated in spontaneous expulsions just as the occiput is.

Parts of the foetus of the most variable shape and consistence, if in the pelvis, may become internally rotated. Occiput, sinciput, chin, forehead, buttock, shoulder, all varying from one another markedly in shape, size, and consistence, yet rotate when once they come within the range of a lateral part of the sacral segment.

*Secondly*, The shape of the inner surface of the bony pelvis is not of essential moment; or, to put it in another way, the contour of the



normal inner aspect of the true pelvis is not necessary to rotation. Rotation may occur in the rickety pelvis where there is great loss of concavity in the anterior and posterior bony pelvic walls, and where the much vaunted inclined planes have lost most of their inclination; or in the kyphotic pelvis, where we have changes diametrically opposed to those of the rickety distortion.

The *presence* of the anterior concave pelvic wall, on which posterior pressure may slide the deep presenting part, more than its precise shape, is important. The great factor in producing rotation is the recoil of one lateral half of the sacral segment on the part first touching it. We have seen that the sacral segment in the canalised pelvic floor is fixed above to the posterior portion of the bony pelvic outlet (*viz.*, sacrum and coccyx, and as far forward as ischial tuberosities), while it is free below. It is thus driven back by the successive portions of the foetus, causing the well-known bulging of the perineum. Rotation ceases when the part in the pelvis is symmetrical to the sacral segment, *i.e.*, when the head has rotated so that the occiput is symmetrically placed to the sacral segment, we get no further rotation. *This shows clearly that it is the deep engaging part first striking a lateral half of the sacral segment, driving it back and causing its recoil, along with the guiding influence of the corresponding pubic ramus, which is the essential cause of rotation.*

The recoil of a lateral half of the pelvic floor is not in the conjugate, but as near as may be at right angles to the insertion of that half into the bony pelvic outlet, *i.e.*, more or less parallel to the corresponding half of the anterior segment of the bony pelvis or to the pubic ramus (fig. 2, Plate VIII.). This leads the way to the additional factors. The initial Solayres' obliquity of the head, shortness of the anterior pelvic wall, excess of elastic tissue in the posterior bony wall, and therefore greater friction on, and retardation of, the part lying there—all help to bring about a deep anterior engaging portion which shall strike a lateral half of the sacral segment, and be pushed forward during the pain in a direction nearly parallel to the corresponding half of the anterior segment of the bony pelvis.

We may now apply these general principles to the various instances in which internal rotation occurs.

In the L.O.A. the occiput strikes the left lateral half of the sacral segment early, for the following reasons:—The head with Roederer's obliquity (*i.e.*, occiput deeper at brim than sinciput), and with an antero-posterior diameter in the right oblique of brim (Solayres' obliquity), has its occipital end placed vertically above the left lateral half of the sacral segment, and in consequence of the shortness of the anterior pelvic wall, strikes it early as compared with the sinciput. The latter not only has the longer posterior pelvic wall to travel along



(fig. 1, *x*, Pl. VIII.), but is also hindered by the friction of the greater thickness of tissue there. The left lateral segment, therefore, recoils early on the posterior aspect of the occiput in a direction parallel to the corresponding half of the anterior pelvic wall, *i.e.*, the occiput becomes rotated. The head now lies symmetrically to the sacral segment, with its right and left halves resting on the corresponding halves of the sacral segment, and, therefore, no further rotation takes place. In the R.O.A., for the same reasons, the occiput strikes the right lateral half of the sacral segment, and is rotated to the front and left.

In the R.O.P. we have two possibilities in rotation to explain. There may be first what is termed the normal or long rotation of the occiput inward and to the left, from the region below the sacro-iliac synchondrosis to the arch of the pubis; and the abnormal rotation, where the sinciput rotates from a point below the left ilio-pectineal eminence to the posterior aspect of the pubis, the so-called *posterior rotation of the occiput into the hollow of the sacrum*. This last descriptive term is a very bad one, and should never be used, as both rotations are to the front—the one of the occiput to the front and left (fig. 1, *e*, Pl. VII.), the other of the sinciput to the front and right (fig. 1, *g*, Pl. VII.). The difference in the rotation is due to the relation in point of size or fitting of the head to the pelvis. If the head so fits the pelvis, *i.e.*, is so large that a suboccipito-bregmatic diameter engages in the pelvis, then the occiput first strikes the right lateral half of the sacral segment, and is rotated to the front; whereas, if the head engages in the pelvis with the sinciput low, *i.e.*, if the pelvis can accommodate the occipito-frontal diameter, then the sinciput first strikes the left lateral half of the sacral segment, and is rotated to front and right.

The same reasoning holds for the L.O.P. Usually the occiput first strikes the left lateral half of the sacral segment, and is rotated to the front and right; or the sinciput, when the head is small, first strikes the right lateral half of the sacral segment, and is rotated to the front and left.

In face cases we have in the L.M.A. and R.M.A. the chin leading and being rotated as in the occipital cases. In the R.M.P. and L.M.P. the size of the head is again influential. If the so-called extension is well marked, then the chin first strikes its corresponding half of the sacral segment, and is rotated to the front. The forehead, however, may be deeper, and thus the forehead is rotated to the front, the chin passing indirectly into the hollow of the sacrum. This happens when the fronto-mental diameter is small. I need not go into detail in breech and shoulder cases. In breech cases the anterior hip is deep, the posterior always being retarded, and thus the anterior is always rotated to the front.



The following clinical cases have been noted by me as helping in the clearing up of this problem :—

CASE I.—R.O.P. at brim ; forehead in pelvis, and face at pubic arch. Child's head small, and occiput retarded by posterior pelvic tissue.

CASE II.—Seen with Dr M'Call. Prolapse of funis ; cervical canal admitted three fingers ; ribs presenting. Chloroform being administered, I passed my hand into the vagina and fingers through cervical canal, pulled down a knee, and left the case. An hour afterwards the breech was in the pelvis and leg down, with hips right and left. The leg pulled or rotated to the front, because this part was first pulled against a lateral half of the sacral segment.

CASE III.—Seen with Dr Stanley. Six months' fœtus lying transverse and impacted in pelvis. Shoulder to left and front, and arm protruding. First movement was one of rotation of shoulder to front, and then the body and breech were driven over perineum.

CASE IV.—Seen with Dr Darling. Mento-posterior, with forehead low, and chin ultimately found in hollow of sacrum.

All these cases illustrate the formulæ as to internal rotation, which I now state as follows :—

1. Whatever part of the fœtal head or trunk first strikes a lateral half or lateral part of the sacral segment is rotated internally to the front and in the direction opposite to the lateral half or lateral part of the segment so acting.

2. No part of the fœtus is ever rotated directly into the hollow of the sacrum. The passage of the occiput into the hollow of the sacrum in its so-called posterior rotation is exactly equivalent to the passage of the sinciput into the hollow of the sacrum in normal rotation, and should be excluded from descriptive terminology, as the latter is.

3. The direction of rotation may be predicted in any case by noting what part first strikes persistently a lateral half of the sacral segment.

This view of rotation gives, in my opinion, a more coherent idea of all the rotations than those based on the shape of the head or pelvis only. I do not deny the influence of the shape of the internal surface of the pelvis, but I deny that it alone can determine rotation.

It seems to me, also, that we here see an explanation of the pelvic inclination, Roederer obliquity, Solayres obliquity, and general shape of head and body of fœtus.

The pelvic inclination, as we term it, gives us, by its slope, a short anterior pelvic wall, and may be looked on as due to a slicing away, as it were, of part of the anterior pelvic wall. The kidney shape of the brim, such that the head there does not fully occupy it, and lies with








FIG. 1.

DIAGRAM OF ROTATION  
in Head Cases.

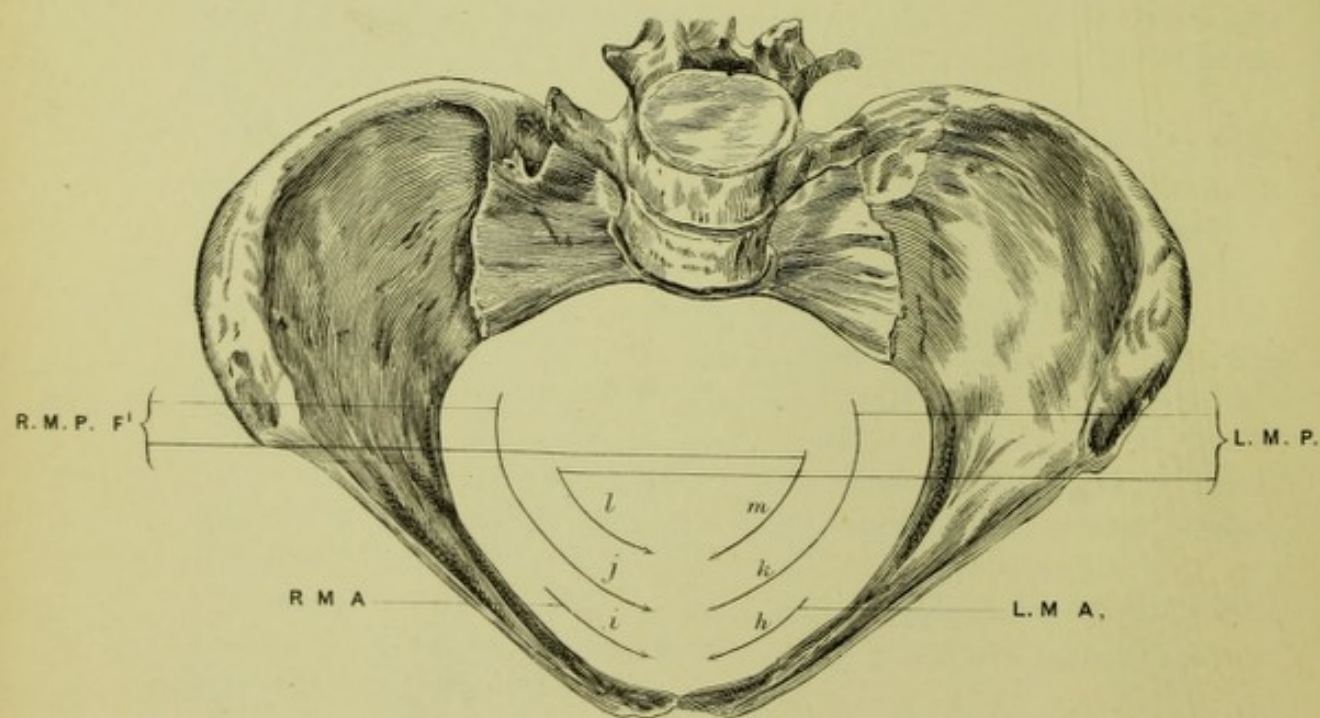
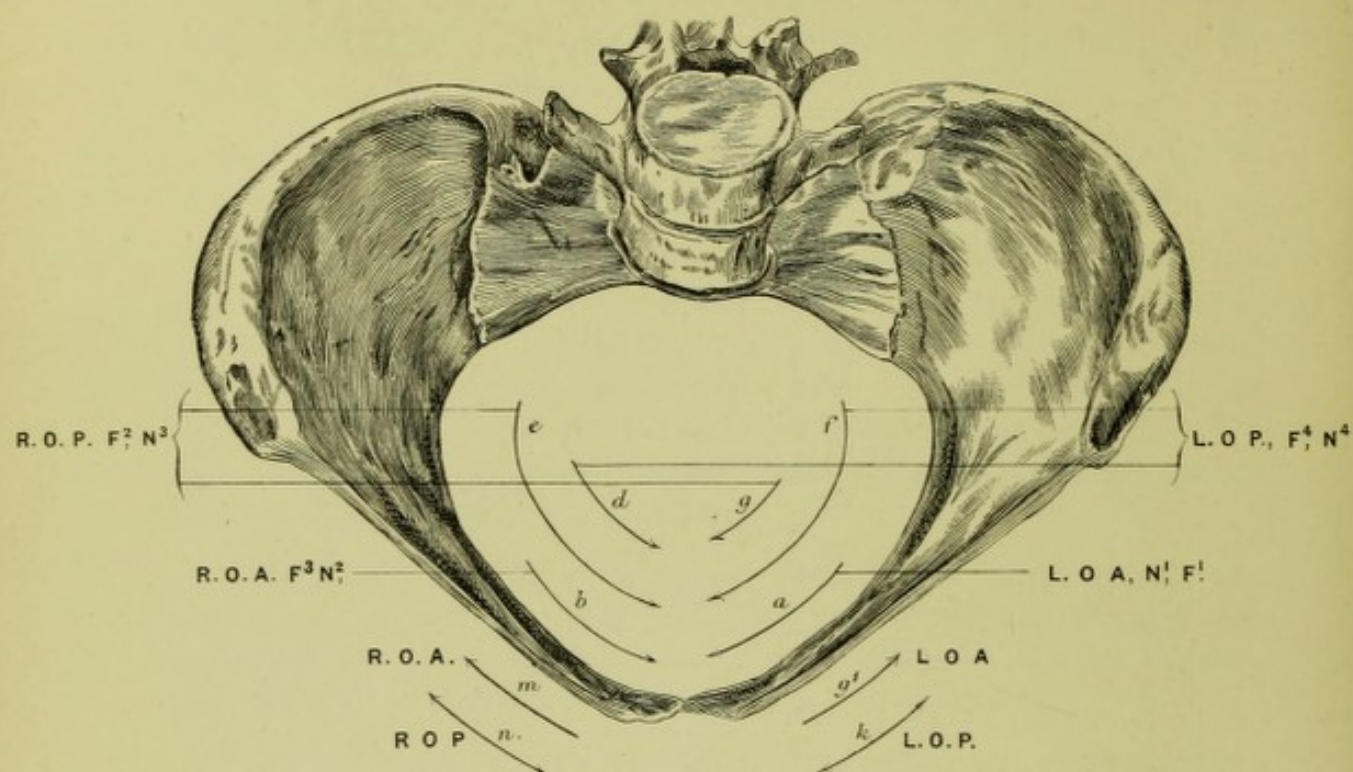



FIG. 2.

DIAGRAM OF ROTATION  
in Face Cases.







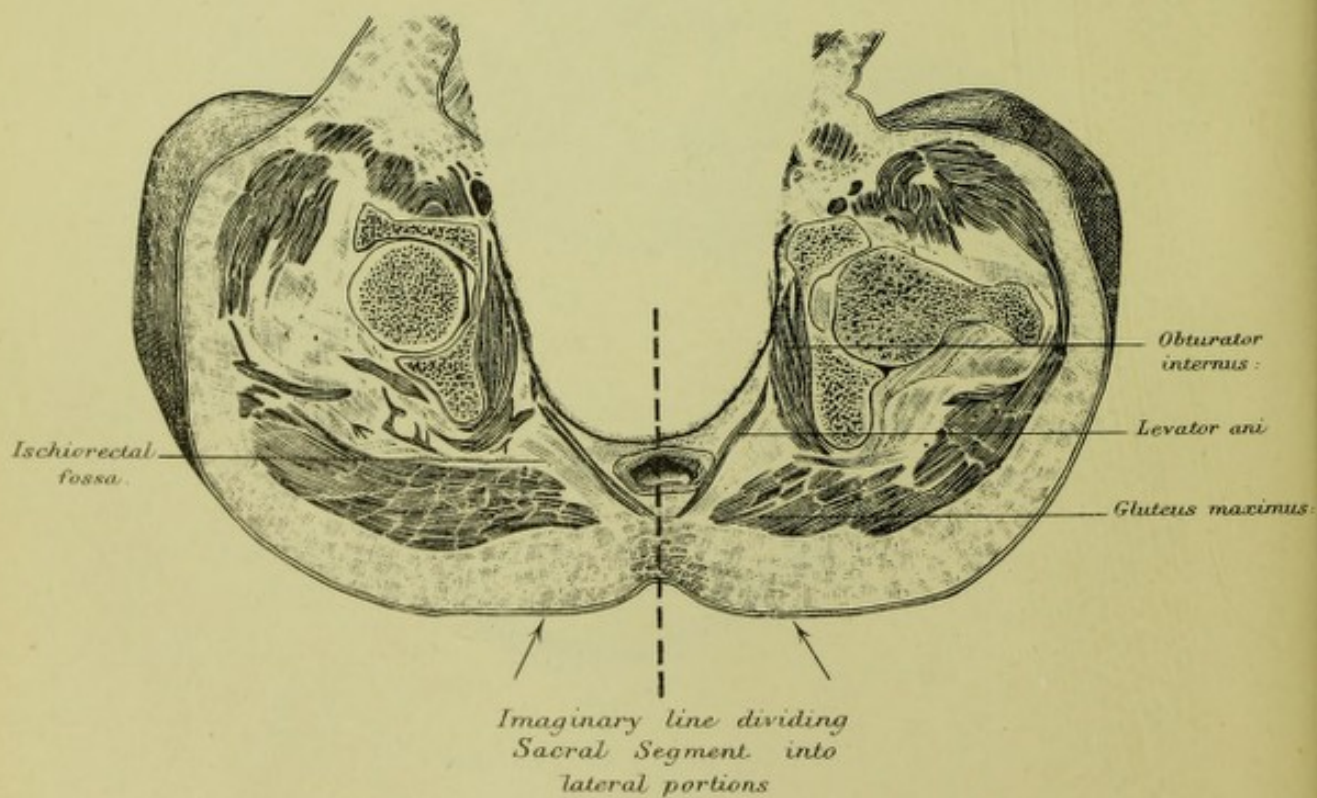
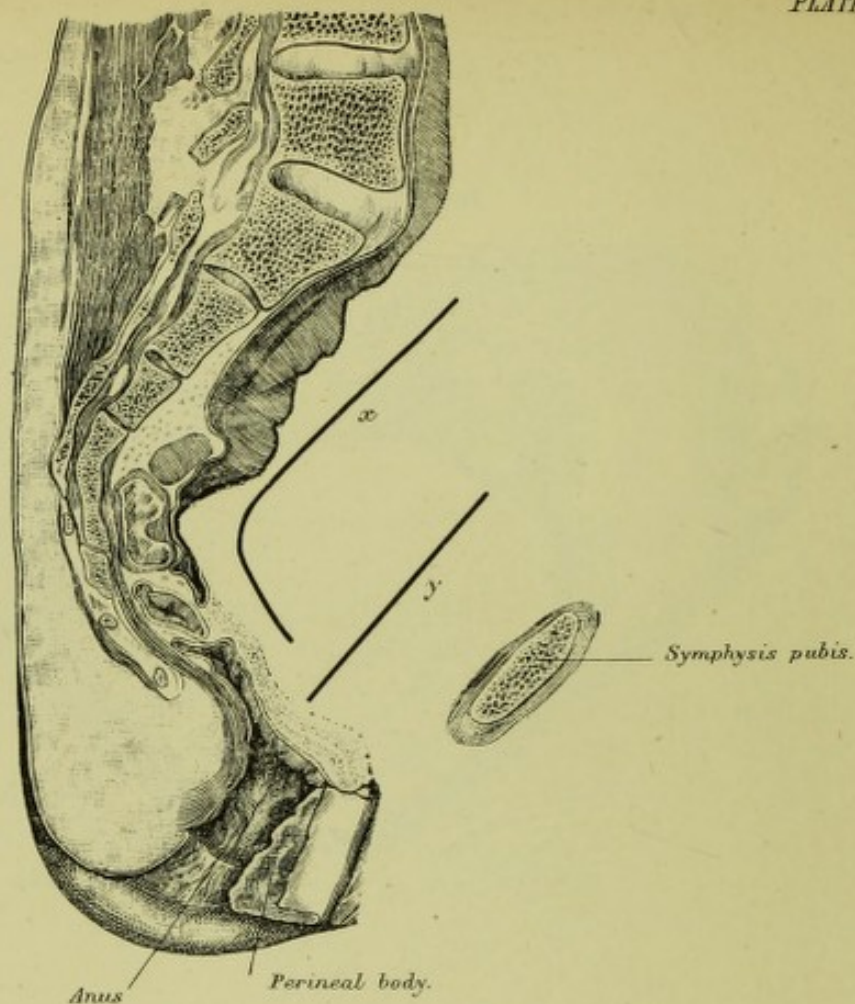


FIG. 2.



the Solayres' obliquity, is necessary for the distention of the bladder during pregnancy; while the shape of the occiput, chin, neck, and sternum allows of Roederer's obliquity in head cases, or extension in face cases, so as to make a part, either occiput or chin, usually lead during labour. The short anterior pelvic wall and oblique and deep position of a part of the foetus (occiput, chin, breech) bring necessarily the foetal part lying anteriorly at the brim early within the reach of a lateral portion of the sacral segment, *i.e.*, tend to cause its early rotation.

## DESCRIPTION OF PLATES.

## PLATE VII.

FIG. 1.—Diagram of Rotation in Head Cases as seen through brim of pelvis. The arrows inside give the direction and amount of Internal Rotation; those outside, the direction of External Rotation.

F<sup>1-4</sup> = first, second, third, or fourth in frequency of occurrence.

N<sup>1-4</sup> = first, second, third, or fourth of Naegele.

Thus L.O.A., N<sup>1</sup>, F<sup>1</sup>. = left occipito-anterior, first in frequency and first of Naegele.

Arrow *a* = amount and direction of Internal Rotation of occiput in L.O.A.

„ *b* = „ „ „ „ „ „ in R.O.A.

„ *c* = „ „ „ „ „ „ in R.O.P.

„ *d* = „ „ „ „ „ „ of sinciput in L.O.P.

„ *f* = „ „ „ „ „ „ of occiput in L.O.P.

„ *g* = „ „ „ „ „ „ of sinciput in R.O.P.

„ *g'* = External Rotation of occiput in L.O.A.

„ *k* (double) = possible External Rotation of occiput in L.O.P.

„ *m* = External Rotation in R.O.A.

„ *n* (double) = possible External Rotation in R.O.P.

FIG. 2.—Diagram of Internal Rotation in Face Cases.

Arrow *h* = amount and direction of Internal Rotation of chin in L.M.A.

„ *i* = „ „ „ „ „ „ in R.M.A.

„ *j* = „ „ „ „ „ „ in R.M.P.

„ *l* = „ „ „ „ „ „ of forehead in L.M.P. (chin to hollow of sacrum).

„ *k* = „ „ „ „ „ „ of chin in L.M.P.

„ *m* = „ „ „ „ „ „ of forehead in R.M.P. (chin to hollow of sacrum).

R.M.P. = right mento-posterior.

## PLATE VIII.

FIG. 1.—Sagittal mesial section of Pelvis to show Sacral Segment.

*x* and *y* = Lengths of paths described by foetal parts lying posteriorly and anteriorly in pelvis.

FIG. 2.—Axial coronal section of pelvis showing sacral segment. The dotted line separates the two lateral divisions; the arrows show the approximate direction of recoil of each lateral half on deep presenting parts of foetus.



## CHAPTER X.

### ON THE ALLEGED SYNCLITIC MOVEMENT OF THE FETAL HEAD.

IN the onward transit of the child's head through the pelvis, the relation of the planes of the foetal head to certain artificially formed planes of the pelvis has claimed attention, and a certain progression of the head has been termed its "synclitic motion." I purpose taking up this theory of the synclitic motion, and testing it by our knowledge of the maternal pelvis, foetal head, and uterine powers.

In the first place it is necessary to define what is meant by synclitic motion, and what are the mechanical conditions permitting or preventing it. These will be best understood by the following simple examples:—

Let us suppose a cylinder, A B (fig. 19), of uniform bore, and with sides whose friction is equal all round, to have a flat disk fitting it and sinking down uniformly by means of a fluid pressure on its upper surface. Now, if the disk, at the beginning of its descent, so lie in the tube that any diameter of its upper surface is always at right angles to the sides of the tube, it is evident it will remain so throughout all the descent. This can be put in another way. If in the diagram we draw a series of transverse lines at right angles to the long axis of the tube, thus dividing it into a number of uniform cross sections or parallel planes, then the disk, descending as already supposed, will have its lower surface always exactly superimposed on a tube-plane. The disk, accordingly, is descending synclitically because it is descending under the conditions necessary for synclitism, viz., a rigid disk or plane is the descending body, uniform pressure on the upper surface of the descending plane is the force, and there is uniform resistance to descent all round on the part of the cylinder.

If we again imagine a series of conditions as already described, with the only difference that the resistance to the descent of the disk is greater on one side of the tube than the other, it is evident that after a certain amount of descent the disk will not coincide with the tube-planes, but will cut them, *i.e.*, the disk will not descend synclitically (fig. 20). Now, further, if an edge of the disk lying against a side of the cylinder be so shaped as to slip down faster where resistance to descent is less; or if during descent the disk becomes distorted, then it is evident that



we cannot have synclitic movement. When a movement of descent not synclitic has begun, it is evident that the fluid column will help to perpetuate synclitic motion, seeing we have a greater height of it above that part of the disk whose edge is lower.

So far we have only considered the downward descent of a disk in a straight cylinder. If the cylinder be curved as at fig. 21, then we get our tube-planes by dividing each side into an equal number of parts, beginning at the top, of course, and then joining these divisions. For the coincidence of the disk with the planes, *i.e.*, for synclitism, the edge of the disk at the concave side must sweep faster round than on the convex one. Now if the concave side of the cylinder, by being roughened, say, give more resistance to descent, and the edge of the disk at that side be so shaped as to slip slower down, synclitic motion is impossible.




FIG. 19.



FIG. 20.

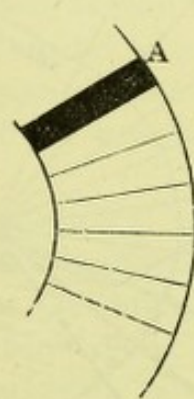


FIG. 21.

We have now to apply these facts to the progress of the foetal head through the maternal canals.

In the first place, what planes of the pelvis are to be taken?

Hodge, who is the chief authority in regard to these planes, describes them as follows:—The first he places at the superior strait of the bony pelvis; the second is on a level with a line joining the subpubic ligament and the middle of the second bone of the sacrum, the third on a level with the spine of the ischia, and so on. All except the first meet anteriorly at the subpubic ligament (fig. 22). Hodge<sup>1</sup> does not divide them, therefore, as I have done in diag. 21. (*See fig. 22.*)

The plane or disk of the foetal head is the parietal one, *i.e.*, that transverse plane of the foetal head which has the right parietal eminence at one edge and the left at the other. The biparietal plane is chosen because it is that part of the head recognisable to the finger of the accoucheur. This defines its lateral points. Its anterior lies at the anterior extremity of the sagittal suture; its posterior at the base of the occiput, and is called by Hodge the cervico-bregmatic plane. More

<sup>1</sup> *System of Obstetrics*, Philadelphia, 1864, p. 26.



recently, however, the suboccipito-bregmatic and occipito-frontal planes have been taken as the foetal planes. The suboccipito-bregmatic<sup>1</sup> plane is the one taken when the head is markedly flexed; the occipito-frontal when this is less pronounced.

Hodge's description of synclitism is as follows:—

“For our illustration, as presenting the most simple view of the mechanism of labour, we still take, not an oblique position of the head, which has some complications, but a direct one, namely, the ‘occipito-pubic position’ of the ‘vertex-presentation,’ the third of Baudelocque,

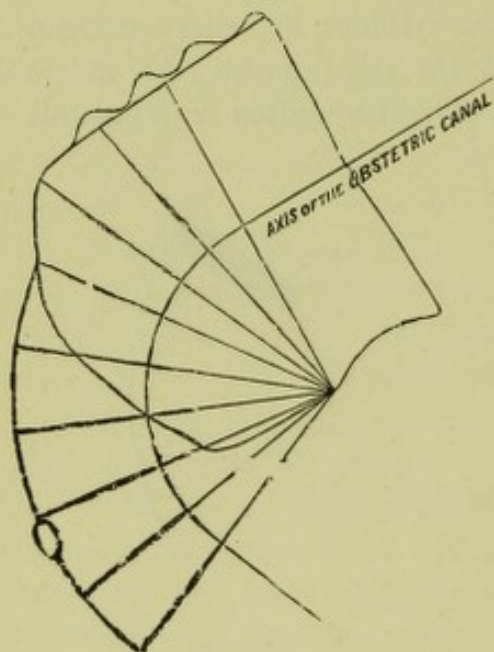


FIG. 22.

BONY PELVIS IN VERTICAL MESIAL SECTION,  
with parallel planes.

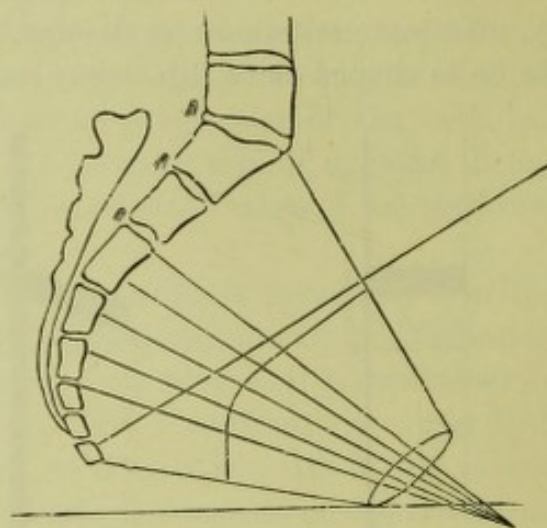


FIG. 23.

VERTICAL MESIAL SECTION OF DEVELOPED  
PARTURIENT CANAL, showing parallel  
plane (*Hodge*).

but which, as we think, has been unnecessarily thrown out of view by M. Nægele.

“By the time the os uteri is nearly or quite dilated, in a primiparous patient, the bag of waters usually ruptures, and the whole force of the contractions of the uterus is immediately directed upon the body of the child, which is therefore compressed into a comparatively small space, the limbs towards the abdomen, while the imperfect flexion of the head becomes gradually increased. If the resistance of the os uteri be considerable this flexion becomes more complete, so that the occipital protuberance will be observed towards the pubis, the lambdoidal sutures converging on either side towards the sagittal suture. In a longer or shorter time the anterior margin of the os uteri slips over the protuberance of the occiput and retracts over the parietal protuberances to the

<sup>1</sup> The suboccipital point is midway between the occipital protuberance and foramen magnum. The bregma=anterior fontanelle.



face or neck of the child. The head is now left engaged in the superior strait, with the base of the occiput towards the top of the pubis, the parietal protuberance opposed to the sides of the brim, while the anterior fontanelle will, with more or less precision, be opposite the promontory of the sacrum. Here there will probably be some delay, as the head is attempting to enter through the short or conjugate diameter of the brim; but in proportion to such delay will be necessary the increase of flexion, for the whole bearing-down force of the mother is, as Dr Duncan<sup>1</sup> well represents it, directed chiefly upon the short arm of the lever of the head through the medium of the spine of the child. The os occipitis, therefore, descends, while the os frontis is resisted by impinging against the promontory of the sacrum. Hence the cervico-bregmatic diameter of the head is parallel to the sacro-pubic diameter of the superior strait, while the bi-parietal or transverse diameter of the head is parallel to the bis-iliac or transverse of the brim, and the occipito-mental is coincident with the axis of the superior strait. Hence the plane of the occipito-bregmatic circumference is parallel to the plane of the superior strait. This is synclitism.

"I can hardly suppose that the statement thus given will meet with any objection, inasmuch as, if the head be not in a state of flexion, as I maintain, the protuberance of the occiput will be at the pubis, and the anterior portion of the os frontis, or forehead, will be at the promontory of the sacrum, in which case the head will be arrested, because the occipito-frontal diameter will be parallel with the short or conjugate diameter of the brim. Then the sagittal suture would run nearly in a direct line from the anterior to the posterior part of the pelvis, and the two fontanelles would be at the same level. When, however, flexion has occurred, the posterior fontanelle will be found lower down and nearer the centre of the strait, and the anterior higher up and nearer the promontory, while the sagittal suture will be found to run not only backwardly, but obliquely upward.

"The process of labour continuing, the child's head descends precisely in the same direction till the sinciput reaches the floor of the pelvis, and the occiput has glided along the posterior or inner surface of the body of the pubis; the whole head descending thus far through a cylinder, as M. Schroeder would express it, the occipito-mental diameter coincident with that of the axis of the brim, and the cervico-bregmatic plane parallel to each plane of such cylinder, till it reaches the level of the third sacral vertebra behind and the top of the arch of the pubis in front. By the time this is accomplished the os frontis has descended below the promontory of the sacrum, and the occiput appears under the arch of the pubis, when, as Dr Dewees would express it, the chin begins to leave the breast, or, more accurately, the process of extension commences.

<sup>1</sup> Hodge is alluding to Dr Matthews Duncan's paper, quoted farther on.



Now the further descent of the head is resisted by the sinciput striking against the floor of the pelvis, and anteriorly by the neck of the child pressing against the pubis. The driving force continues to operate, and chiefly upon the occiput, through the medium of the spine. This portion of the head then descends towards the perineum as far as practicable; but, the resistance here being also great, the head passes off diagonally between these opposing forces, and describes a circular motion on the base of the occiput under the arch of the pubis, where it is comparatively at rest. Hence the process of extension is continually increasing until the occiput has somewhat dilated the vulva, and the parietal protuberances will be perceived on either side at the tubers of the ischia, while through the rectum the anterior fontanelle can be detected at the perineum or coccyx. The head, now partially extended, presents at the inferior strait, with the same diameter and the same planes which were recognised at the brim, and the occipito-mental diameter, which was coincident with the axis of the brim, is now in unison with that of the inferior strait, the chin pointing towards the concavity of the sacrum, while the vertex, as represented by the posterior fontanelle, is at the centre, not of the vulva, but of the inferior strait. The plane, therefore, of the occipito-bregmatic circumference is parallel to the plane of the inferior strait. Now, as the head, moved in this regular manner through the upper or cylindrical portion of the pelvis, presenting its equatorial plane, as Dr Barnes might term it, parallel to the planes of the cylinder, till the sinciput reached the floor of the pelvis, so, during the gradual process of extension through the curved portion of the canal, the same cervico-bregmatic plane became parallel to each successive oblique plane of the curved portion of the canal to the inferior strait. The parietal protuberances will always be found at the sides of the pelvis; and as the occiput gradually advances under the arch of the pubis, the posterior fontanelle is found towards the centre of each plane till it reaches the outlet of the pelvis.

“The bearing-down efforts of the mother now force the child more and more against the perineum, the process of extension continues, till eventually the occiput gets in front of the pubis, the parietal protuberances on either side of the vulva, and the posterior fontanelle is observed clearing the perineum at the centre of the dilated orifice of the vagina, so that again we have the cervico-bregmatic plane engaged, but now parallel to the plane of the orifice of the vagina. Hence the head passes through the canal of the vagina in this circular manner, presenting its equatorial plane parallel to the various oblique planes of the vagina.

“If this representation be correct, the fœtal head ‘at term,’ notwithstanding its apparent irregularity of form, traverses the obstetric canal with as much readiness and precision, continually presenting the same



diameters to the walls of the canal, and the same diameter of the head to the axis of the obstetric canal, as if it were a perfect sphere of about three-and-a-half inches in diameter.

"This seems to me a correct representation of the synclitic movement of the child's head—in other words, the parallelism of the plane of the great occipital extremity—in relation to those of the pelvis and vagina.

"If we now consider the first position of the vertex, the left occipito-anterior, the process is rather more complicated, from two causes. The first is that the head is no longer direct, but oblique, at the superior strait, and subsequently in the cavity of the pelvis; and the second, resulting necessarily from the first peculiarity, is the necessity of a rotatory movement of the head that the occiput may pass under the pubis.

"If the propositions already assumed be granted, these difficulties immediately vanish. For if the head passes through the os uteri in a state of flexion, presenting its cervico-bregmatic circumference to the circle of the os uteri and that of the superior strait, it may practically be regarded as a sphere or ball to be driven through the planes of the canal. Hence it would be a matter of no moment whether it did or did not rotate upon its axis, for diameters of the same length would always be coincident with those of the obstetric passages. Parallelism of planes, therefore, would ensue. To be, however, more precise: In this first position, as in the former, the resistance of the os uteri or the margin of the superior strait against the anterior parts of the head of the child, while the uterine forces are driving down the occiput through the medium of the spine, necessitates flexion of the head to a greater or less degree. Hence, after the os uteri has retreated, the head will be found oblique, not only because it extends diagonally from the left ramus of the pubis to the right sacro-iliac symphysis, but also because the occiput is lower in the pelvis than the forehead and the face. Hence the posterior fontanelle will be found not on the same level with, but lower than, the anterior fontanelle, and the sagittal suture, therefore, not running directly across the pelvis, but obliquely upward as well as backward.

"The parietal protuberances, of course, present obliquely to the right and left sides of the pelvis, while the base of the occiput will be towards the left anterior part of the pelvis, and the anterior fontanelle towards the right sacro-iliac symphysis. Hence we have the cervico-bregmatic diameter parallel to one of the oblique, and the bi-parietal to the other oblique diameter of the brim, while the posterior extremity of the sagittal suture will be found towards the centre of the pelvis, and the chin, being directly opposed to it, will be the most elevated part of the head."

Kueneke's account of synclitism I need not quote, as the description and the facts supporting the theory have already been brought before



our Society and thoroughly refuted in an able paper by Dr Matthews Duncan.<sup>1</sup> To synclitism as defined and defended by Hodge and his followers, however, I have the following objections:—

In the first place, Hodge gives no sufficient reason for his arbitrary parallel planes—parallel because a foetal head plane is alleged to become parallel to them. What puts them completely out of consideration,

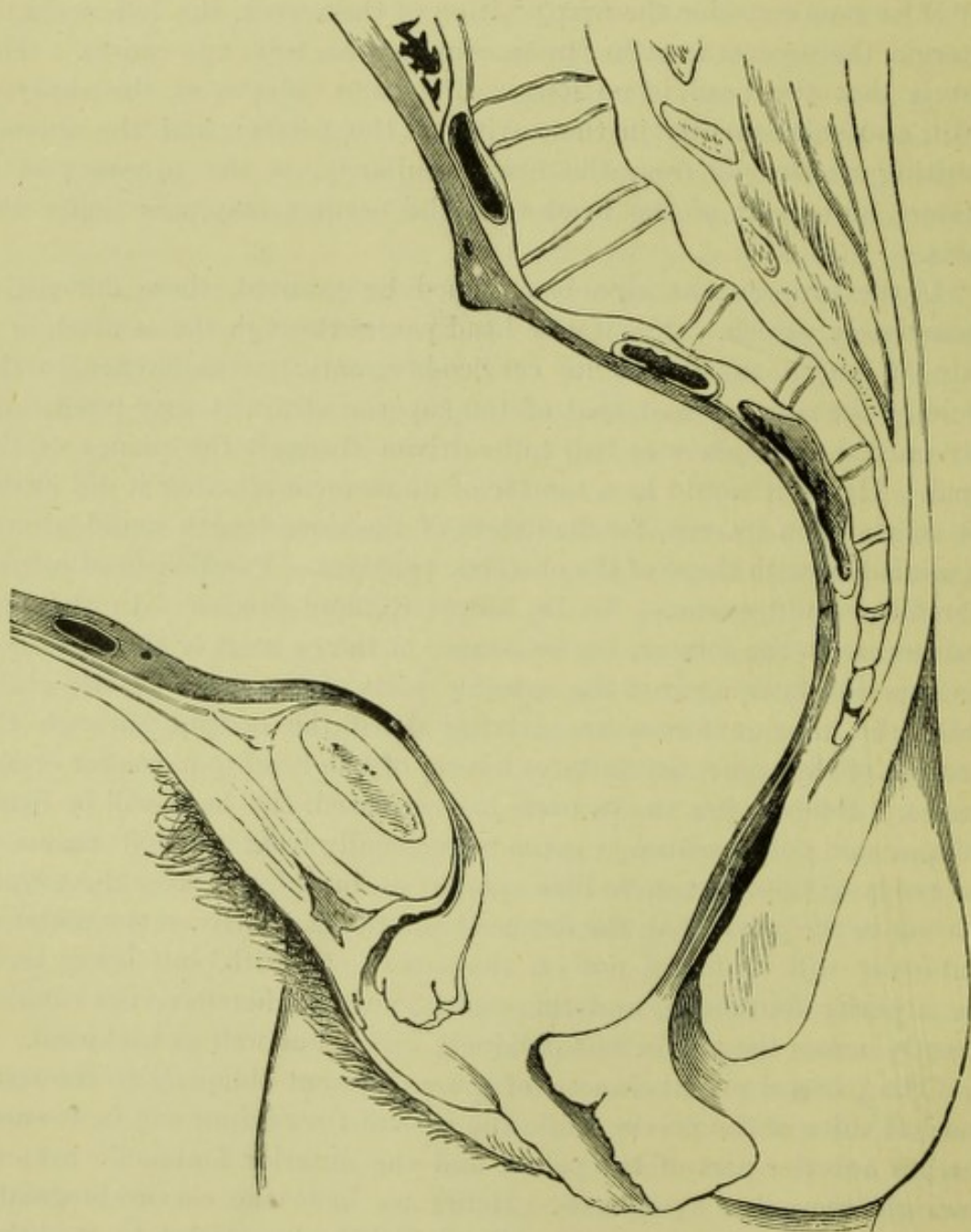


FIG. 24.

THE DEVELOPING PARTURIENT CANAL IN NATURE, showing its elastic lining (after *Braune*).

however, is the fact that they are drawn on the bony pelvis. The mechanism of labour does not take place in a purely bony pelvis. It takes place in a curved bony canal lined by elastic tissue, chiefly lying

<sup>1</sup> *Mechanism of Natural and Morbid Parturition*, Edin., 1875, p. 192.



posteriorly. This important fact is ignored in Hodge's description of synclitism, but a consideration of fig. 24 will show how gross this omission is. As Duncan has shown, this will retard the descent of the side of the non-rotated head lying posteriorly, *i.e.*, will prevent synclitism, which of course demands that the side of the non-rotated head lying posteriorly must, during its whole transit, descend more rapidly than the anterior. Hodge further describes the synclitic movement in a special case that never occurs in nature, viz., with the occipito-frontal diameter of the head always in a conjugate diameter. Such a mechanism, if it occurred, might allow of synclitism, for the following reason:—The greater resistance behind would retard the head in such a manner as to bring about flexion only. Inasmuch as the side walls of the pelvis have

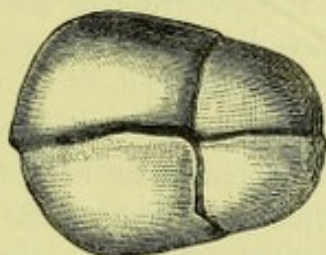


FIG. 25.

FOETAL HEAD MOULDED BY STIFF LABOUR,  
AND PLANES DISTORTED. (Seen from above.)

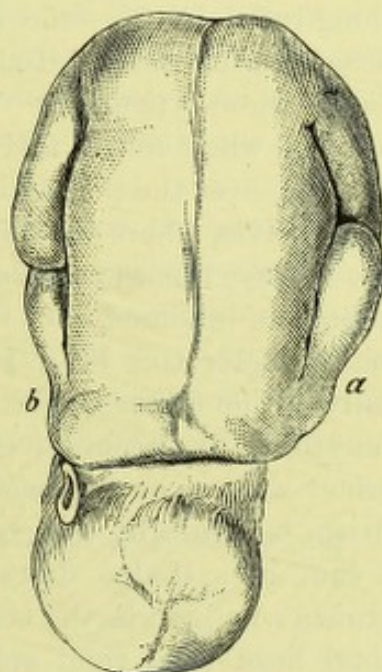


FIG. 26.

CHILD MOULDED AT END OF FIRST STAGE  
OF LABOUR.

*a* and *b*, Grip of retraction ring; *a* Marks  
the side of child lying anteriorly (*Braune*).

equal resistance, and the posterior pelvic resistance would tell equally on the whole forehead, *i.e.*, would not make the head rotate on an occipito-mental diameter, but only on a transverse axis, it is evident that synclitism might occur, although I can quite conceive the cervico-bregmatic plane cutting the parallel planes, even granting all that Hodge assumes. But the head never presents at the brim in the conjugate, unless in some very rare cases (rachitic pelvis: Roberts?) and therefore Hodge's description and reasons based on it fall to the ground. But it may be urged, will this synclitism not occur after the head has rotated from the oblique into a pelvic conjugate diameter, *i.e.*, at the end of Hodge's sacro-pubic case. That it will not do so I shall attempt to show afterwards.



It is assumed further in the description of synclitism that the head is symmetrical during the whole of labour. Hodge even says "it may be practically regarded as a sphere or ball." The answer to this, of course, is that it is not so. The head, in a labour moderately stiff, gets distorted, *i.e.*, has the side lying posteriorly flattened, and accordingly any arbitrary plane in it becomes also distorted (fig. 25). How this will prevent synclitism will be seen shortly. Then the uterine force, further, is alleged to act specially through the foetal spine. Such an assertion is, I believe, utterly erroneous. But it is easy to see how it supports synclitism. The fact of the uterine force acting chiefly or principally through the spine gives a force driving on the head, which, acting at a point equally removed from either side of the head, will not rotate it on a longitudinal axis,—the movement which would destroy synclitism in the sacro-pubic case of Hodge,—but on a transverse one, which may, of course, allow synclitism. The uterine force is, however, conducted through the whole foetus, and distributed over the plane of the girdle of contact, *i.e.*, over the plane surface joining the line of contact between head and pelvis, where the pelvis is resisting the progress of the head. On this theory, then, synclitism will not be favoured, but under certain conditions, be hindered.

Finally, under this head I deny that synclitism can be ascertained clinically. The finger of the accoucheur cannot recognise or trace out with anything like accuracy either a parallel plane in the pelvis of the parturient women, or a special plane in the foetal head. How, then, can synclitism be clinically ascertained?

To sum up: Hodge describes synclitism in a non-existent head-mechanism; he ignores the elastic lining of the pelvic walls; he regards the foetal head as a rigid sphere, and the uterine force as conducted through the spine—all assumptions more or less erroneous. Our knowledge of the factors of labour enables us to say that all of them tend to prevent synclitism.

But a still more valuable fact against synclitism is got by studying the foetus given by Braune in his well-known section. The foetus there has the half of the head lying anteriorly on a lower level than that lying posteriorly, *i.e.*, the head is not lying synclitically in Hodge's superior strait. The posterior resistance, even in the first stage, has begun to tell. Some may urge that this is the remains of Naegele's bi-parietal obliquity at the brim. The occurrence of that in normal labour, however, is exploded (fig. 26).

In the left occipito-anterior position, then, the head progresses as follows:—It lies with its occipito-frontal diameter in the right oblique diameter (Solayres' obliquity) with the occiput lower than the sinciput (Roederer's obliquity), and with no Naegele obliquity. The uterine and abdominal force, transmitted equally through the compact foetus, is



distributed over the plane of the girdle of contact of the head, and forces it down. The occiput slips down faster than the sinciput, because of its special shape and the less pelvic resistance in front as compared with behind, for reasons explained by Dr Simpson<sup>1</sup> in his communication on head flexion. The plane of the girdle of contact is thus lower in front than behind, and, therefore, if the fœtus be considered as a water column, there is a greater height above the occiput, which will further favour the normal antero-posterior flexion. Thus increase of flexion has accompanied descent. But the resistance of the posterior pelvic wall will retard the side of the head there; and thus the occipito-frontal plane of the fœtal head will not coincide with Hodge's plane (the 2nd), but will cut it; the fœtal head plane will be lower anteriorly, will thus have the higher column of fluid, and consequently has all the conditions necessary to its slipping down faster, *i.e.*, to have a lateral flexion to the posterior shoulder, preventing synclitism. The posterior pelvic resistance further flattens the posterior side of the head, giving it that shape which makes it descend less rapidly, and distorting the fœtal head-planes. From certain causes which need not be here enumerated, the head then rotates, and lies with its occipito-frontal diameter in a pelvic conjugate. Here as the head does not rotate perfectly, the pelvic causes in the posterior wall already mentioned will also act in hindering it. I do not, therefore, believe that there is any evidence that at any part of its course the suboccipito-bregmatic plane or occipito-frontal plane of the fœtal head coincides with the so-called parallel pelvic planes.

<sup>1</sup> Head Flexion in Labour: *Contributions to Obstetrics and Gynecology*, p. 116.



## CHAPTER XI.<sup>1</sup>

### A CONTRIBUTION TO THE ANATOMY AND ETIOLOGY OF RUPTURE OF THE VAGINA DURING LABOUR.

RUPTURE of the vagina during parturition is one of the rarer occurrences in obstetrics. Its explanation, however, none the less demands our attention, inasmuch as it is a preventible accident. While Bandl, in his great work on *Rupture of the Uterus*, has given an explanation of most uterine ruptures so clear and comprehensive that little has been added to it, no one has taken up the question of vaginal rupture and tried to show exactly how and why it should ever happen. In this chapter I hope to put the anatomy and causation of rupture of the vagina during parturition on a more exact basis than it has hitherto been.

We therefore consider the position of matters at the beginning of parturition, and the changes which take place in the cervix and pelvic floor as the child is driven through them. At the beginning of parturition we have the child lying in the cavity of the body of the uterus and about to be driven through the lower uterine segment, cervix uteri, and pelvic floor (fig. 27).

The pelvic floor is a thick, unbroken, fleshy layer, divided into anterior and posterior segments by a cleft—the vagina. When the woman is erect this cleft makes an angle of about  $60^{\circ}$  with the ground. On the upper surface of the pelvic floor the uterus lies. It is here made up of the cervix or cervical canal, which has a lower and upper opening. The lower opens into the top of the vagina, the upper into the cavity of the uterus. The length of the cervical canal is about  $1\frac{1}{2}$  inches, and its lumen is such that one could pass his finger into it. Strictly speaking, its anterior and posterior walls are in apposition, and a small portion of its upper end has merged into the uterine cavity. The uterus proper is a large sac containing the fœtus and membranes, and divided into a hemispheroidal lower uterine segment and upper active retracting portion. The only point we have to do with at present is its muscular fibres. For our purpose it is sufficient to consider them as circular and longitudinal. The longitudinal run up the front and down the back of the uterus and pass into the cervix below, probably into the

<sup>1</sup> This chapter has been slightly modified in accordance with the new facts as to the lower uterine segment. For a fuller statement as to the lower uterine segment, v. Chap. XIV.



pelvic floor too. They have other fixed points below, which I omit at present, viz., the broad, round, and utero-sacral ligaments. Thus the uterus proper, cervix, and pelvic floor segments are all continuous. The uterine muscle passes into the lower uterine segment and cervix, the anterior lip of the cervix is attached to the postero-superior angle of the anterior segment of the pelvic floor, the posterior lip of the cervix to the upper and anterior portion of the sacral one. These segments of the pelvic floor differ in their attachment to the bones of the pelvis: the anterior

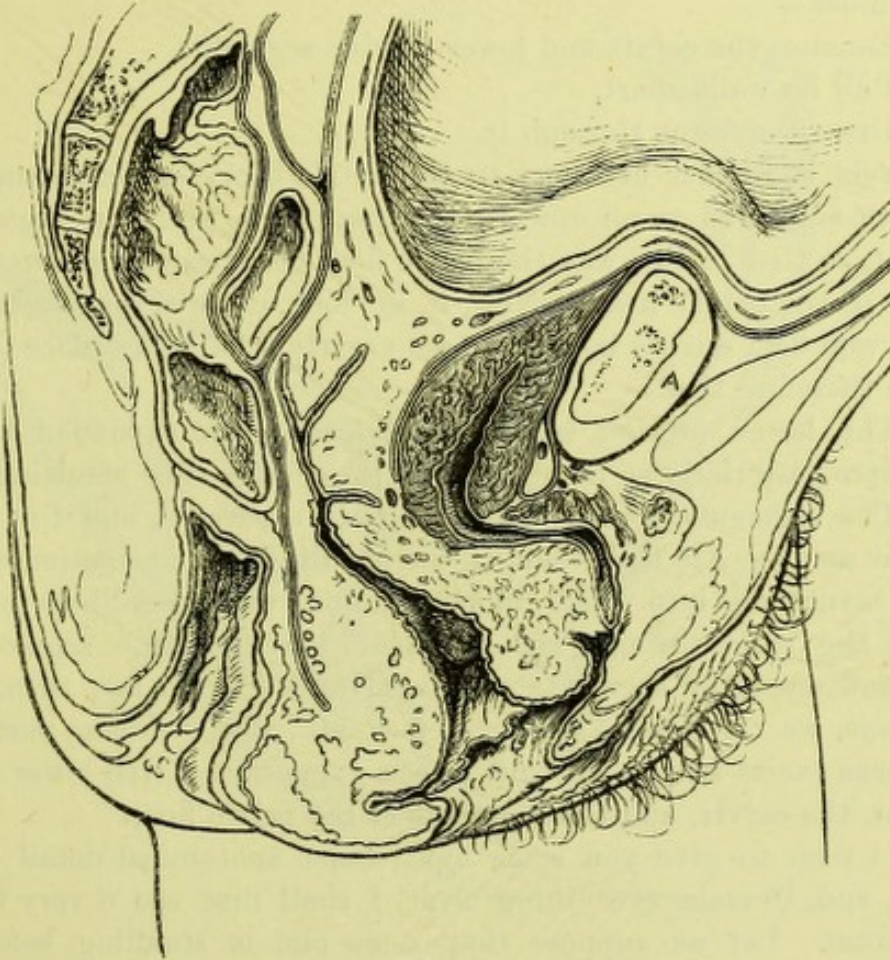


FIG. 27.

PELVIC FLOOR AND UTERUS AT END OF GESTATION (*Braune*).

one is loosely attached to the pelvis, the sacral one firmly to the sacrum and coccyx. Lastly, on this head, note that the long axis of the uterus and that of the vagina are at right angles. The following is a short summary of the condition at the beginning of parturition:—

- (1) Uterine muscle almost quiescent;
- (2) Cervical canal  $1\frac{1}{2}$  inches long and anterior and posterior walls in contact; lower uterine segment hemispheroidal in shape.
- (3) Segments of pelvic floor in apposition, anterior vaginal wall  $2\frac{1}{2}$  inches long, posterior vaginal wall  $3\frac{1}{2}$  inches long.



If the longitudinal unstriped muscle of the uterus shorten, *i.e.*, contract, it must pull on the lower uterine segment and cervix below and also on the segments of the pelvic floor, the resistance of the fœtus lying between fundus and os internum keeping the fundus uteri from being depressed.

Now let us suppose that parturition has begun, and that the uterine muscle contracts. The circular fibres will squeeze the fœtus all round and elongate it, the longitudinal ones will shorten, exert upward tension on the cervix and pelvic floor segments, and thus, having a fixed point below, must—

- (1) Canalise the cervix and lower uterine segment,
- (2) Pull its walls apart,
- (3) Drive the fœtus through it.

The cervix is further attached to the pelvic floor segments, and these, then, are subjected to an upward traction which pulls up the anterior segment, so that in this way the pelvic floor becomes opened up for the passage of the child's head. Now, if we look at an actual section of a woman who died during labour, we see exactly what takes place (fig. 28).

Note therefore that—

(1) The lower uterine segment and cervix are expanded laterally and antero-posteriorly so much that we get a large tube resulting.

(2) The segments of the pelvic floor are separated, and the vaginal walls far apart. All this, then, is the result of uterine action drawing up the structures into which its longitudinal muscular fibres pass, and driving the child through the distensile lower uterine segment and cervix and separable segments of the pelvic floor. So far, then, as we have gone, we can deduce one great fact, *viz.*, that “during parturition the uterus exerts tension on, and causes expansion of, the lower uterine segment, the cervix, and the segments of the pelvic floor.”

But I wish to give you some more exact anatomical detail on this matter, and, to make everything clear, I shall first use a very familiar illustration. Let us suppose that some one is standing before two folding doors, that one of the folding doors has a rope attached at its edge, the other a rope attached near the hinge, and that he has to push some object, say a big box, through them; he can do so best by laying hold of the ropes, one in each hand, putting his foot against the box, and pushing down. The result would, of course, be that he pulled up the one door and drove the box against the other, and thus pushed it through. But suppose that the one rope was double the thickness of the other, and that the latter finally ended in a single strand at the last one-third or so; then, if the box were too big for the doors, the ropes would be pulled on and pulled on till they snapped. Now, which would snap first? The answer is easy: the slender one, at its upper one-third.



Now let me apply this simile. As one sees from figs. 27 and 28, the uterine muscle passes into the lower uterine segment and cervix, and the cervix really into the vaginal walls. We can put this more precisely as follows:—The uterine muscle on the posterior aspect passes into the cervix; the cervix is attached to the top of the vaginal wall. This wall is thinnest at its upper inch; below this the anterior rectal wall strengthens it, and finally the perineal body makes up its powerful inferior part. The anterior uterine muscle passes into the cervix,

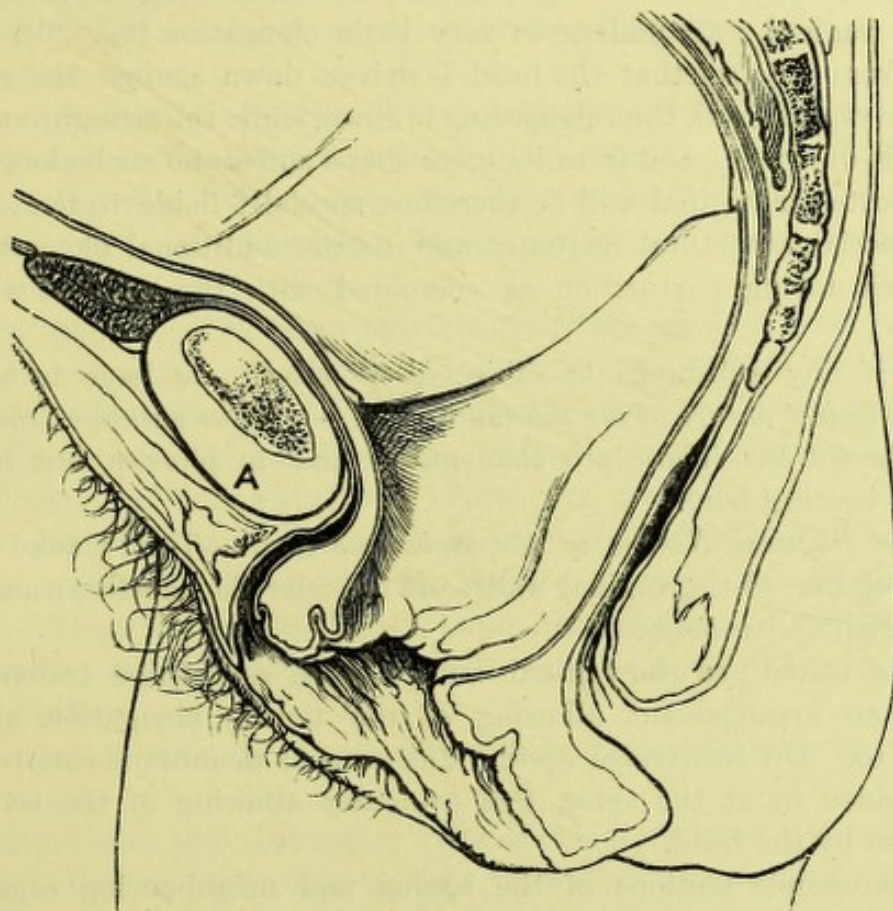


FIG. 28.

PELVIC FLOOR DURING PARTURITION (*Braune*).

and this into the anterior vaginal wall, which is strengthened by the bladder and urethra so as to be very strong. Thus the structures on which the uterine muscle pulls vary in strength; the lower uterine segment and upper part of the posterior vaginal wall are weaker than the other portions of the vaginal wall. You will see at once, then, that where the uterine tension is too great the lower uterine segment or vagina will yield, the part of the vagina yielding being the upper part of the posterior vaginal wall. This is what really happens,—the lower



uterine segment tears more frequently than the vagina, and the upper part of the posterior vaginal wall is the seat of election for a vaginal tear.

These, however, are not the only factors. Thus the size of the head driven on, the existence of uterine obliquity, pendulous abdomen, and the fact that the lower uterine segment bears the stretching from the head first, must, in any given case, be taken into account. These I do not consider now. You will note specially one fact. The posterior vaginal wall is about  $3\frac{1}{2}$  inches long at the beginning of parturition. During parturition, however, it is elongated to about 5 inches (fig. 26), while the anterior vaginal wall undergoes very little elongation (fig. 26). This results from the fact that the head is driven down against the curved posterior vaginal wall, thus elongating it down, while the straight anterior vaginal is drawn up, and from its mere shape suffers no such elongation.

The posterior vaginal wall is, therefore, specially liable to tear, owing to its special structural anatomy and to the additional elongation it undergoes during parturition as compared with the anterior vaginal wall.

Now if any substance is subjected to stress, we have to note—  
1. *The physical nature of the substance itself.* 2. *The nature of the stress it is subjected to.* These are elementary facts in physics, but have a valuable bearing here.

1. *The Physical Nature of the Substance itself.*—This I take up in special relation to the vaginal walls, and consider the naked-eye anatomy and then the microscopic.

To the naked eye the vaginal walls can be seen to be transversely rugous, an arrangement allowing of the tensile elongation already alluded to. On transverse section the mucous membrane can be seen to be folded in at the sides, this evidently allowing of the eccentric dilatation by the head.

If microscopic sections of the vagina and neighbouring organs in a six months' foetus be made, we can study all these relations with the naked eye or with a hand-glass.

If now we examine microscopic sections under higher powers, we find the following structure:—

(1) *T. S. of Foetal Pelvis (6 months) from Pubic Cartilage to Anterior Vaginal Wall.*—Beginning on vaginal aspect, we find many layers of squamous epithelium covering connective tissue papillæ into which bloodvessels project. Outside this lies much fibrous tissue in distinct wavy bundles, and finally a layer of circular unstriated muscle, one of longitudinal, and, lastly, decussating fibrous tissue closely blending the urethra to the vaginal wall.

(2) *L. S. of Foetal Pelvis from Bladder Mucous Membrane to Anterior Vaginal Wall.*—This shows the same structure as already described.



The microscopical structure of the vagina is, therefore, that of a felted substance with strong bands of fibrous tissue and unstriped muscle running in the line of the tension exercised during labour, viz., parallel to the vaginal long axis and at right angles to it.

One additional point of interest comes out in these specimens, viz., that the anatomical fascia may be of two forms, viz., a firm sheet of fibrous tissue, as in the pelvic fascia, and a loose meshwork arrangement of connective tissue in that lying between rectum and vagina and bladder and vagina. The two are functionally contrasted, inasmuch as the one gives attachment to striped muscle, while the other is placed round rectum and bladder to allow of their contraction.

The vaginal walls are, therefore, peculiarly well fitted to stand strain when looked at from a merely mechanical aspect. We must, however, keep in mind that these tissues are vital, *i.e.*, in the intervals of stress they are fed by the abundant blood supply, and their strength and mechanical elasticity kept up.

2. In the second place we must consider the kind of stress to which they are subjected. As Dr James has clearly pointed out to us, we have to consider the amount of stress and the time it is applied. This means that a piece of string may be broken by a sudden tug, and resist a long-continued equable strain. Now, the stress to which the lower uterine segment and vaginal walls are subjected is neither of these. A uterine contraction begins gently, reaches a maximum, and dies away gently. Thus, in this respect, the lower uterine segment and vagina are subjected to as little stress as possible, and yet the driving on power is fairly effective.

Let me now sum up the whole problem before drawing any general conclusions.

I started with this statement, "The problem we have to consider is as follows:—During parturition certain tears of the uterus and vagina are known to occur: how do these happen?"

I showed that the uterine muscle normally pulled on the lower uterine segment and vaginal walls, that these had their special weak points, but were structurally very strong, and that the nature of the stress to which they were subjected was such as to minimise the risk of tear. If you consider the simile of the folding doors pulled open by ropes, and of the box too large to pass, you will at once see that in abnormal positions of the child (cross-births), great enlargement of its head, contracted pelvis, we get a condition of affairs where the uterus will spend its force in elongating the vagina and lower uterine segment, and will ultimately spontaneously tear them.

Tear of the vagina during parturition will happen at the top of the posterior vaginal wall, and usually be transverse.



The whole question may therefore be summed up as follows :—

(1) During labour the uterine muscle exercises an upward tension on the lower uterine segment and pelvic floor segments.

(2) The foetal head exercises a dilating power on the lower uterine segment, cervix, and pelvic floor segments, this dilating force acting at right angles to the long axis of the cervix and vagina.

(3) The vaginal walls are constructed so as to bear longitudinal tension and eccentric strain. This is provided for by the rugæ and the felted structure of the vagina.

(4) The anterior vaginal wall, from its close incorporation with the urethra and loose union with the bladder, is the strong wall.

(5) The posterior vaginal wall is structurally weak at its upper half inch, is more elongated during labour than the anterior one, and, therefore—

*Rupture of the vagina is most common where the posterior vaginal wall is covered by peritoneum, and when it occurs is a tension tear like cervical rupture.*

The precise conditions under which such a vaginal tear happens will vary with each case. The preponderance of the frequency of lower uterine segment over vaginal rupture is marked, and is due in part to the head entering the former first.



## CHAPTER XII.

### THE CAUSATION OF THE MOVEMENTS OF THE HEAD AT THE BRIM OF THE RACHITIC PELVIS.

WHILE a special knowledge of the mechanism of labour in ordinary cases is of the greatest importance to the practitioner, such knowledge becomes imperatively necessary for proper treatment when the pelvis is deformed. It would indeed be profitable, though tedious, to compare, step by step, the wordy warfare that has raged for so many years in regard to the cases suitable for forceps and turning, with the gradual growth of our knowledge of the mechanism of labour in deformed pelves; and to observe how, gradually as the latter increased, the din of words waxed more faint, until unanimity almost has finally prevailed on what was one of the most moot points in obstetrical practice.<sup>1</sup>

At present, however, I purpose simply considering the mechanism of labour in the pelvis known as the rachitic, premising that I deal only with cases where, either spontaneously or by proper treatment, a living child can be extracted.

At the brim of the rachitic pelvis the child's head presents, at the beginning of labour, in a manner strikingly opposed to that in the normal pelvis. It lies with its antero-posterior diameter in the transverse of the pelvis, with its anterior and posterior fontanelles on a level, or nearly so, and with the sagittal suture running transversely near the promontory, much more rarely near the symphysis. The biparietal diameter of the head, or one slightly in front of it, lies in the conjugate of the brim. From this it can be readily understood that, at the beginning of labour, a parietal bone of the child's head presents. Now, as the parietal bones are lateral *quâ* the child's head, we find the German nomenclature a very convenient one. When the sagittal suture is near the promontory, then the anterior parietal bone (anterior *quâ* the pelvis) presents; while, when the sagittal suture runs near the symphysis the posterior parietal bone (posterior *quâ* the pelvis) presents. We can thus speak of—

I. The anterior-parietal-bone presentation. (Fig. 29.)


II. The posterior-parietal-bone presentation. (Fig. 30.)

<sup>1</sup> The controversy of forceps *v.* turning has again revived (1893) owing to the development of the axis-traction forceps.



In each of these we may have two varieties, according to whether the occiput is left or right, but in what proportions is not well known. One or two points, however, must be added. The anterior-parietal-bone presentation is by far the most common. The posterior-parietal-bone presentation is very rare. These two facts are prominent. Litzmann and Veit have more especially called attention to the posterior-parietal-bone presentation. The interest in their papers lies in the fact that this posterior-parietal-bone presentation may occur in a normal pelvis, will then cause delay in the labour, and, as Veit has noted, may lead to undue elongation of the cervix on its posterior aspect.

To sum up, then, in the rachitic pelvis the head most usually presents with the sagittal suture near the promontory, *i.e.*, presents the anterior-



FIGS. 29 and 30.

The upper figure is the anterior-parietal-bone presentation, the lower the posterior-parietal-bone presentation, both in sagittal mesial section.

S, Sagittal suture.

P, Promontory.

parietal. The posterior-parietal rarely presents, and in a rachitic pelvis does not, *per se*, add to the difficulty of the labour. All this may be put more technically by saying that at the brim of the rachitic pelvis the head has neither the Solayres nor Roederer obliquities, but possesses the Naegele obliquity much exaggerated.

After the onset of labour quite a unique series of head movements occurs. Authors such as Goodell, Litzmann, Lahs, Kleinwächter, Schroeder, vary in their description—a matter of no wonder, considering the difficulty of clinically observing these accurately. So far as my experience and reading go, the following is the most accurate account.

In the anterior-parietal-bone presentation the forehead dips slightly or markedly, causing the Michaelis obliquity, as Dr A. R. Simpson has



aptly termed it. The sagittal suture leaves the promontory and approaches the centre of the pelvic brim, *i.e.*, the posterior side of the head, which is above the plane of the brim, rounds the promontory, and the head as a whole becomes shoved to that side of the pelvis towards which the occiput lies. Thus the head passes the conjugate by its bitemporal diameter, or one slightly behind it.

In the posterior-parietal-bone presentation the forehead dips, the side of the head above the plane of the brim rounds the symphysis, and the head as a whole becomes shoved to the side of the pelvis towards which the occiput lies. I have never been able to trace a case of mechanism in the posterior-parietal-bone presentation, but there is indubitable evidence that the head rounds the symphysis, since Litzmann, who first drew special attention to it, described three grades, *viz.*, one where the sagittal suture is above the symphysis, one where it is near it, and one where it lies near the centre of the pelvis. Of course, as Veit has said, these are just the stages of the rounding of the symphysis. Some authors have described the sagittal suture not only as leaving the promontory, but as returning slightly to it, *i.e.*, the head as rounding the promontory and the symphysis too. Thus Goodell says, "Later on, it (the sagittal suture) begins to return towards the sacrum" (p. 780, line 3). More recently Matthews Duncan has confirmed this in some experiments where, by traction on the foot of fetuses brought head last through pelves with contracted conjugates, he was able to demonstrate that a double rotation occurred. Dr Duncan also gives a summary of the various descriptions of the head mechanism in a rickety pelvis, exhibiting the discrepancies already alluded to.

In the last place, Goodell alleges that after the head has been shoved to the occipital side of the pelvis it meets with resistance from the side-wall of the pelvis, and becomes slightly pushed to the forehead side of the pelvis. So far, our knowledge of the movements is as yet fairly accurate.

The explanation of the presentation and head movements is now best taken up under three heads—

- I. The parietal-bone presentation.
- II. The dipping of the forehead and shoving of the head as a whole to the occipital side of the pelvis.
- III. The rounding of the promontory.

#### I.—*The Parietal-Bone Presentation.*

This results from the shape of the head and the conjugate contraction. The mobile head cannot enter the brim, but lies on the promontory and symphysis in stable equilibrium, *i.e.*, with the Naegele obliquity. This is the only position in which it finds stability.



II.—*The Dipping of the Forehead.*

In order to understand this, some preliminary matter is necessary. As the waters are always more or less gone, we have to consider how the foetus is driven on by the uterine and abdominal powers. It is best to take a simple instance first. Let us suppose the foetal head in the right occipito-anterior position and non-rotated, as Braune's plate shows. Part of the head is exposed in the vagina, part is in contact with the elastic tissue lining the pelvis. Here the head meets with resistance to its onward progress, *i.e.*, so much of the pelvic tissue grips and resists its transit. It marks out on the head a girdle which we may call the girdle of resistance. We may define this girdle more accurately, as Lahs has done, by drawing tangents to the head, beginning below at the lowest limits of the contact of head and pelvis. Where the tangents leave the head above gives us the upper limit of the girdle of resistance. The plane section of the head whose outer limits are the girdle of resistance, is the plane of the girdle of resistance. Uterine action, leaving out the consideration of the abdominal powers, compresses the foetus, and as the result of this we get so much fluid pressure over the plane of the girdle of contact, and at right angles to it. The foetus is considered as a plastic fluid, conducting force equally in all directions. All above the plane of the girdle of resistance conducts pressure; all below the girdle of resistance is driven on and passes down in a path determined by the perpendicular fluid pressure on the plane of the girdle of resistance, by the shape of the head and its tenacity, and the friction of the pelvic walls.

Thus, in an ordinary labour, the foetus is a semiplastic mass, and by uterine action has a uniform tension established in it. So much of this tension is distributed equally over the plane of the girdle of contact, and drives on the part of the head lying below its upper limits.

Now, how about the head at the brim of the rachitic pelvis? We have not at first a semiplastic mass of the same shape, but an approach to it. Uterine action moulds the tissues over the sternum closely against the chin, the posterior shoulder touches the side of the head lying above the brim, and thus ultimately we get a compact mass, as in the ordinary case alluded to. If we now draw tangents to the head touching the symphysis and promontory, we define the girdle of resistance, and thus get uterine action establishing a uniform tension over the plane of the girdle of contact. The head tends to be forced down as a whole; but as the superficial area of the plane of the girdle of resistance on the forehead side of the line joining the symphysis and promontory is greater than that on the occipital side, we get the forehead descending—dipping, not extending, as that involves the separation of chin and sternum. After



the forehead has thus dipped, it becomes arrested at some point below the plane of the brim. The plane of the girdle of resistance thus cuts the pelvic brim, and the tension acting at right angles to this oblique plane drives the head as a whole to that side of the pelvis towards which the occiput lies.

The head always delays considerably at the brim—a delay due to the amount of conjugate contraction, but also, I believe, to this fact: The foetus, at first not thoroughly compact, does not transmit uterine action effectively over the forehead side of the plane of the girdle of resistance. While the uterus is thus moulding the foetus, time is lost, and thus the dangerous elongation of the cervix occurs. This seems to me to help to explain why Litzmann's posterior-parietal presentation should cause delay in a normal pelvis.

### III.—*The Rounding of the Promontory.*<sup>1</sup>

Of this no explanation seems to me so good as that given by Lahs. His tangents, drawn with the head at the brim, show the steeper side of the head to be the one with the sagittal suture near the symphysis or promontory. With uniform tension over the plane of the girdle of resistance this steeper side slips down first, *i.e.*, the head rounds the promontory or symphysis, as the case may be. It may be urged that Duncan's experiments tend to disprove this view, seeing this rounding occurred, in his experiments, when the head came last with its sides symmetrical, *i.e.*, equally steep. I do not think so, however. I can quite understand in these experiments that the posterior side of the head, after rounding and becoming indented by the promontory, may have resisted this more, and the anterior side then rounded the symphysis slightly. Dr Champneys' remarks on Dr Duncan's paper as to this point are valuable. He falls into error, however, when he speaks of the posterior surface of the symphysis in relation to the head mechanism. The head rests on the upper margin of the pubis. The posterior surface of the pubis shelves forward, and does not come into relation with the head until the head is in the pelvis. (Fig. 29.)

The usual explanation of the onward advance of the head after the membranes are ruptured is, that the uterine force is conducted exclusively through the spine, and thus, from its articulation with the occiput, the latter is pushed down in advance. No one has yet, however, told us why the uterine force should prefer the spine to any other foetal route. The spine conduction is based on the idea that because the occiput usually descends first in ordinary pelves, therefore it is shoved down by the foetal spine articulated near it. Further, the spine theory ignores the compactness of the foetus and the close apposition of the chin

<sup>1</sup> It is doubtful if the head does "round" and is not simply driven down. At the risk of being accused of inconsistency I leave the paragraphs on this division as already written.



to the sternum, so well shown in Braune's plate. Recently, Labat has published a diagram of the uterus and foetus in a woman who died during labour from eclampsia. There the spine is so curved that the conduction of the uterine force along it to the occiput is an impossibility. The spine theory, however, utterly fails when applied to the explanation of the

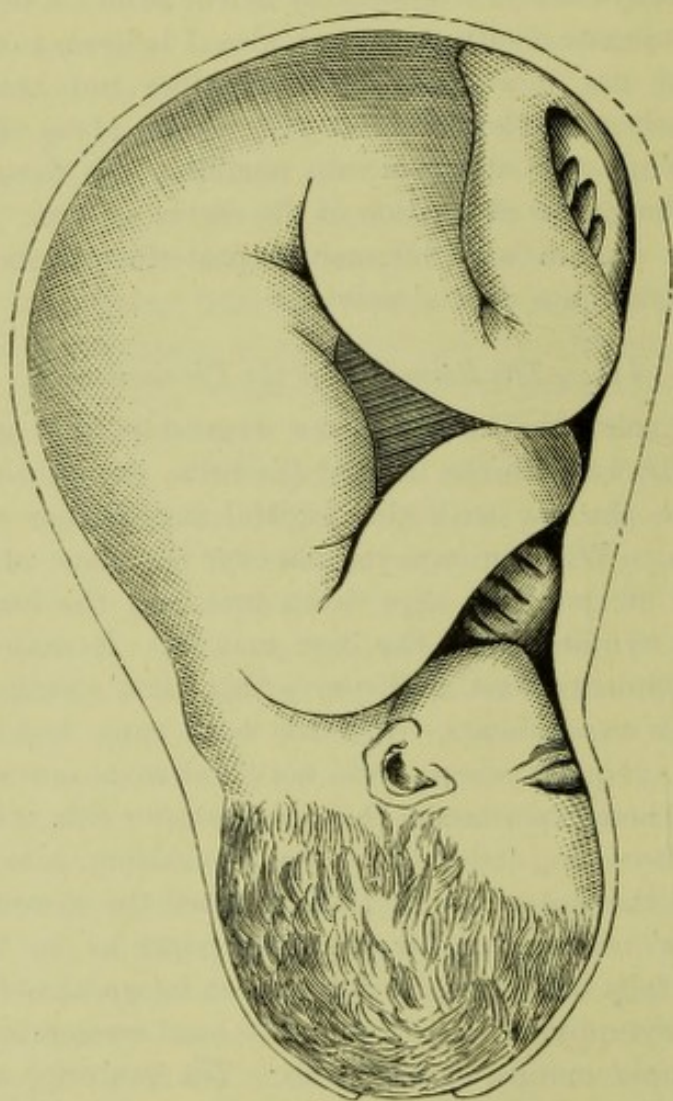


FIG. 31.

FÆTUS IN UTERO, seen from front, from a woman who died during labour (*Labat*).  
Note curve of body.

movements of the head at the brim of the rickety pelvis, so utterly that I need not waste time in refuting it. (Fig. 31.)

The cases of rickety pelvis I have seen are twelve in number (up to 1881). Two of them were in Dr A. R. Simpson's consulting practice, two were seen with Dr Ronaldson, and the rest were in dispensary practice. In all, the conjugate varied from 3 to  $3\frac{1}{4}$  inches, whilst in one it was  $2\frac{1}{2}$ . One was a face presentation, two were the rare posterior-parietal-bone presentations, and the rest were anterior-parietal presentations. In all of them turning was employed. No mother was lost: one child was still-born,



in one I had to perforate behind the ear, in another Dr Simpson perforated for prolapse of funis, whilst in the rest, living and thriving children were obtained. In two of the cases where living children were obtained, all the previous children had been delivered still-born by forceps, and in one case Dr Simpson extracted a living child by turning where a previous labour had been terminated by craniotomy. Four of the children had the vertical spoon furrow in front of the ear. In the case I had to perforate after turning, the posterior side of the head was indented just below the parietal eminence, showing transverse contraction at the brim.

In regard to the method of turning employed in such cases, it, of course, requires to be the bipolar. It is better to have skilled assistance, and to be careful as to the following points:—After the head has been pushed away from the brim, and the breech depressed, care should be taken to manipulate the head up to the fundus before any traction is made. After both legs have been secured, the traction made should be very slight. The important thing is to push the foetus down vigorously, and thus keep the arms down. This saves time, as delay in bringing down the arms may prove fatal to the child's life. In the extraction of the head the following method should be employed:—The child's head lying transverse in the brim, the body is carried over the symphysis as far as it will go, and moderate traction kept up. Then, with the woman in the dorsal posture, and the assistant kneeling on the bed at her side, pressure is made on the head with both hands, and in the axis of the brim. The pressure is not to be moderate. In all the cases I have driven the head through with all the force I could exert, and have never seen any harm ensue. When the head is thus forced into the pelvic cavity, the child should be swung to the perineum, and then the head can be rapidly extracted in the ordinary way, viz., by two fingers in the mouth and two below the occipital protuberance. The most important thing is the downward pushing of the foetus and the propulsion of the head suprapubically. I have thus followed Goodell's teaching thoroughly, except that I use suprapubic pressure earlier, and employ very little traction.

In the last place, I have now to consider and summarise the lines, based on mechanism, to be laid down as to the treatment of arrested head at the brim. In order to make this complete, and to take advantage of the important literature found, I am glad to say, in our own Transactions, I shall take up the question in its wide sense. Given a head arrested at the brim, how is the practitioner to treat his case intelligently and safely? We all know the routine advice—Put on the forceps; if that fails, try to turn; and if this fails, then perforate. Cases are recorded where all this has been followed by Cæsarean section. It is better, however, to differentiate the cases as follows:—In the first place, chloroform the patient and palpate the head suprapubically. Note the relation



of the retraction ring. By all means examine the head bimanually, *i.e.*, with two fingers in the vagina and hand above pubis. So far we learn if the head lies above the brim or is arrested while passing, if the lower uterine segment is elongating dangerously, or if the head is hydrocephalic. Then pass the hand into the vagina, and note the mechanism. If the head is transverse at the brim, note how the sagittal suture lies, and the relation of the fontanelles. If the sagittal suture is transverse and near the sacrum or symphysis, and if both fontanelles are easily touched, then there is in all probability conjugate contraction. Next measure the conjugate and feel the space between the forehead and iliac margin of the brim, and the occiput and its corresponding margin. By this we learn the relation of the head to the aperture, *viz.*, the brim, through which it has to pass.

Now, I. If the head is presenting a parietal bone, then forceps is certainly contra-indicated, and turning proper. But it may be said, How can one tell if the head will come through by turning alone? The following points will help in this:—

(1) The conjugata vera should not be less than 3 inches. A living child cannot be brought through a conjugate of  $2\frac{1}{2}$  inches.

(2) If the forehead is dipping well, or if both fontanelles are on a level, and some little space felt in the transverse diameter on the side of the forehead and occiput, and if the conjugate is above 3 inches, then turning should bring through a living child.

(3) If, however, the fontanelles are not level, *i.e.*, if the anterior fontanelle is higher than the posterior, while the parietal bone presents, then turning will probably fail, as this mechanism shows transverse diminution at the brim too; cranioclasm is indicated.

II. If the occiput dips, and the anterior fontanelle is high, and the sagittal suture in an oblique diameter, then, as the pelvis is justo-minor or obliquely contracted, *cæteris paribus*, the treatment should be forceps or cranioclasm, not turning. The limit of forceps in justo-minor pelves is not well known, but the craniotomy limit is higher than in rachitic cases.



## CHAPTER XIII.

### THE MECHANISM OF THE SEPARATION OF THE PLACENTA AND MEMBRANES DURING LABOUR (Normal and Abnormal)—ON THE EXPULSION OF THE PLACENTA BEFORE THE BIRTH OF THE CHILD.

DURING labour the membranes and placenta become separated and expelled, but while the expulsion of these takes place after the child is born, the entire separation does not occur at any one period. During the first stage of labour the membranes in the lower portion of the uterus, in the part termed the lower uterine segment, become detached. The placenta, if placed partly in this segment, a condition known as placenta prævia, becomes also separated. The rest of the membranes and the placenta do not become separated until after the child is born, and this is followed by their expulsion as a whole.

The question to be considered at present is this: How are the membranes and placenta separated? Is the mechanism in all of them the same, or Have we one for the separation of the part of the membranes and placenta when in the lower uterine segment, and another for the portions attached higher up?

I hope to be able to show that one mechanism accounts for all.

At the end of pregnancy the uterus will be found to be divided into three parts, viz., *the cervix with its canal*, the *lower uterine segment*, and the *uterine musculature* above the latter. These parts are defined as follows:—

The *cervical canal* opens by the os externum into the vagina below, and is sharply defined above by the os internum. The cervical canal has its anterior and posterior walls in apposition, and remains intact until the beginning of labour. Since Stoltz in France, and Duncan in this country, insisted that the cervical canal during pregnancy took no part in the formation of the uterine cavity proper, and was never encroached on by the foetus, many attacks have been made on their view; but all, so far as I can judge, have not shaken it. The most valuable section of a full-time pregnancy, published recently by Waldeyer of Berlin, confirms this doctrine in every particular.

The *lower uterine segment* is the segment of the uterine wall lying within 2 inches or so of the os internum, and is characterised by the



loose attachment of the peritoneum to it. Where the peritoneum becomes firmly attached, the third portion of the uterus begins. The lower uterine segment is bounded below by the os internum, while above, there is, in addition to the peritoneal limit already mentioned, a part of the uterine wall as its upper boundary where the contraction ring and circular vein develop during labour (*v.* also Chap. XIV. for more detail on this point).

The *uterine cavity* is lined by the placenta and membranes. Normally the placenta is placed above the upper limit of the lower uterine segment, although rarely part of it dips into it, constituting the dangerous condition known as placenta prævia. The membranes line the part of the uterine wall unoccupied by placenta, and in the great majority of pregnancies, therefore, the lower uterine segment is covered on its uterine aspect by membranes.

The membranes consist of amnion, chorion, decidua reflexa and decidua vera. For our present purpose, we regard them from a purely physical aspect. Near the uterine wall we find a spongy layer, made up of a minute meshwork, and this divides the membranes into a compact layer lying next the uterine cavity, and a thin layer set on the uterine wall. The spaces of this meshwork are the fundi of the uterine glands of the mucous membrane of the unimpregnated uterus, which has, as the result of conception, become the decidua vera.

The placenta, viewed in the same aspect, is made up of two portions separated by a spongy layer. Towards the uterine cavity we have the part made up of amnion, chorion, chorionic villi with intervillous spaces between, and the portion of the serotina known as the large-celled layer.

On the uterine side of the placental spongy layer we get a part of the serotina lying on the uterine wall. The spongy layer in the placenta has an origin similar to that in the membranes, as the spaces are lined by columnar epithelium.

There is thus in the membranes and placenta a spongy layer, each lying in the same plane, and therefore continuous, forming a line of cleavage, at which the membranes and placenta will be separated as the result of labour.

If we now look at the uterus after labour has gone on for some time, we find a remarkable change has taken place in its divisions. The lower uterine segment and cervix have now become canalised, and together make a tube measuring 10 cm. in all its diameters.

By the end of the first stage we get the membranes in the lower uterine segment separated by a tearing of the partitions already alluded to, and this separation is caused in the following manner:—

As the result of the uterine pains, and the deeper passage of the child's head, the area of the lower uterine segment is increased. Of the



membranes, only the amnion is driven on and expanded, a condition allowed by the loose union of the amnion to the chorion. The increase in area of the lower uterine segment is not participated in by the deciduæ, owing to the loose spongy layer, and we thus get a disproportion between the site of the attachment of the deciduæ and the deciduæ themselves, a disproportion causing tension on the partitions sufficient to tear them—*i.e.* to cause separation.

While this explains the separation of the membranes in the lower uterine segment, we have now to consider how the membranes and placenta, placed above the retraction ring, are separated during the third stage. The conditions here are different, as the lower uterine segment is passively stretched during labour, while the uterus above the retraction ring actively retracts and relaxes, and during retraction diminishes the uterine area it bounds. The changes there taking place are probably as follows:—

As the result of the uterine pains in the first and second stages of labour, and in the beginning of the third stage, we get a diminution in area of the placenta, *i.e.*, in its long axes, and an increase in its thickness. No separation of the placenta takes place until some time after the child is born. It is further known that the foetal heart is slowed during the pains, and also, as we can note when the child's head is born, that the face becomes congested during a pain, the congestion passing off as the pain dies away.

To understand all this, we must consider briefly *the blood supply of the placenta and uterus.*

The placenta has blood poured into it from two sides. On the amniotic side the umbilical artery gives it a most abundant supply, and one that rapidly pours into it. On its attached side the curling arteries pour blood into the intervillous spaces, the two blood supplies thus interdigitating with one another. The foetal blood passes in by two arteries and returns by one vein. The venous supply of the uterus is, so far as Hyrtl's injections show, much more abundant than the arterial.

The maternal blood pours by the curling arteries directly into the intervillous spaces, and returns by veins to the uterine wall. The result of a uterine pain is to compress the curling arteries, and prevent blood passing into the intervillous spaces. It does the same to the uterine veins, but as these are so abundant, the blood in the intervillous spaces drains off, and we get no congestion of them. I have examined microscopical sections of a parturient six months' uterus, and found no blood in the intervillous spaces. The abundant foetal blood supply of the placenta is well shown in them (Pl. IX. fig. 4). The same holds good in a case of Porro uterus, an inverted uterus with placenta attached, and in the separated full-time placenta; in all, the intervillous



spaces are empty (figs. 1, 2, and 6). They are indeed practically obliterated, and the villi are in close apposition (Pl. IX.). This is quite different in the pregnant and non-parturient uterus. In a four months' pregnancy examined (Pl. IX. fig. 3), the intervillous spaces are wide and the villi far apart. During a pain, therefore, the diminution in area of the placenta is compensated for by its thickening, and there is probably an actual diminution in bulk of the placenta, owing to the comparative emptiness of the intervillous spaces. But why does the placenta diminish in area with the uterus during a pain? Why does it increase in area again as the pain dies off, and Why is it not separated until after the child is born?

The reason seems to me to be that, owing to the foetal blood pressure, the placenta is pressed against the uterine wall sufficiently to make it practically act in unison with it, so far as increase and diminution of area are concerned, and the increase in the general-contents-pressure of the uterus during a pain will also tend in the same way, and both will prevent any separation. As the pain dies off, the foetal blood is at once pumped vigorously into the expanding villi, and causes the placenta to increase in area, as the corresponding part of the uterine wall to which it is attached does. The maternal blood pours into the intervillous spaces, and is also a factor in the expansion as the pain dies off. The reason why the placenta is not separated (unless *prævia*) during the first and second stages of labour, seems to me quite evident. Separation is brought about, as we shall see, by a tearing of the spongy layer. This layer lies between placenta and uterine wall, and can only be torn when the placental site and the placenta at the plane of the spongy layer are unequal. So long as the placenta responds exactly, by diminution and expansion of its area, to the diminution and expansion (brought about by the pain) in area of the muscular surface of the uterus to which it is attached, there can be no tension on the partitions, and no tear of them.

When the child's head is born, no inspiration takes place, as the placenta is not separated. When a pain comes, the face of the child becomes congested, the congestion passing off as the pain dies away. The reason of the congestion is the comparative emptying of the intervillous spaces and the slowing of the foetal heart, both tending to produce a certain amount of asphyxia. The compression of the villi is physically like a vasomotor constriction in an adult, and causes the slowing of the heart.

When the child is born, it cries vigorously, and aspirates the blood from the villi. If allowed to remain attached for some time (say an hour) it can remove the blood from the villi almost completely. But not only are the villi emptied of the foetal blood. The intervillous spaces, to our knowledge of which Sir William Turner has contributed



so much, are also empty and the villi closely pressed together. This is an anatomical fact, as I have found them empty in all the third stage uteri examined, and also in the shed placenta. This is not to be wondered at when we remember the great thickening that has taken place in the wall of the third stage uterus, and the practical obliteration of the vessels there, during a pain. The emptiness of the intervillous spaces in the shed placenta, and close apposition of the villi, is clear evidence of the entire absence of blood in them during the third stage of labour.

If the uterus be palpated during the third stage, it will be noted to harden and diminish in bulk markedly, and then to increase in bulk and become softer. During the hardening, the internal uterine surface diminishes greatly, the retraction ring barely admitting the finger, and the uterine wall thickens: during relaxation, the internal uterine area increases so that the hand passed in can be even moved about freely, and the retraction ring expands so as to allow the hand to pass. The condition of the uterine wall is not known exactly, but I believe it is thinner. Unfortunately, we do not know how the relaxing muscle increases the internal uterine surface in area, but as a matter of fact it does, and this diastole is probably active. One thinks of the relaxing uterine muscle as anything but active, but the term "relaxation," like so much of our terminology, is misleading. We know also, both by clinical and sectional evidence, that the lower part of the placenta often separates first (*v.* Chapter V.).

The mechanism of the separation seems to me therefore to be as follows:—When the child is born the placental area may diminish to 4 inches  $\times$  4 inches, as shown in a specimen in my possession. No separation takes place then, because there is no disproportion between the area of the uterine muscle to which the placenta is attached and the placenta itself. However much the area diminishes, the placenta cannot separate, because the disproportion necessary cannot take place. When the uterus contracts to the amount it does after the child is born, the placenta fills the uterine cavity, and any further diminution in uterine bulk never leads to a disproportion between placenta and the area of the uterine muscle to which it is attached, but the two are always equivalent.

After the pain has died off, the uterus relaxes, and as a matter of fact has an increase in area in its anterior and posterior surfaces. Now comes in a different phase in the behaviour of the placenta. The foetal blood has been aspirated from it; the intervillous spaces are empty, and therefore during the increase in the internal uterine area, we have cut off the two factors in bringing about the equivalent expansion in area of the placenta during the relaxation following the pains of the first and second stages, *i.e.*, we get the placenta smaller in area at the plane of



separation than the placental site. This repeated disproportion in area, *i.e.*, slight excess of area of the placental site over that of the placenta itself, tears the partitions in the spongy layer, *i.e.*, separates the placenta. This disproportion need only be slight, as we know how early the placenta, when *prævia*, begins to be separated over the expanding lower uterine segment.

During the third stage separation, blood may be effused by the relaxing muscle, and collect between uterine wall and placenta. The retro-placental clot or blood effusion is a consequence of the separation, and relieves the maternal system of some blood that might embarrass the heart's action if aspirated to the right side.

The last phenomenon in the third stage is the expulsion of the separated placenta, when it either comes edge-ways or inverted. This mechanism of Duncan and Schultze has nothing to do with separation, but belongs to expulsion.

The placenta during the third stage of labour is therefore separated after the pain dies off, when the partitions of the spongy layer are torn, owing to the increase in the placental site not being participated in by the placenta itself. We thus get the disproportion of separation which is necessary to tear these partitions.

The membranes are separated during the third stage in entirely the same way. The wrinkled and folded membranes lying above the spongy layer do not participate in the increase in area of their site after a pain, and the tension thus put on their spongy layer tears it, and separates them.

All the separation of membranes and placenta occurring in normal or abnormal labour can thus be accounted for in one way. *Separation of placenta and membranes takes place owing to a disproportion between the part to be separated and the site of its attachment.* Below the retraction ring, the increase in site is brought about chiefly by traction of the retracting muscle on the lower uterine segment; above the retraction ring the increase in area during the third stage happens after the pain, during the uterine diastole, and not being participated in by the comparatively bloodless placenta, leads to the necessary disproportion of separation. It is evident that this disproportion of separation has its necessary limits. Measurement of the trabeculæ in the spongy layer, and a knowledge of the amount of elongation necessary to tear healthy trabeculæ, should find an approximation to its value, but my work on this point is not as yet ready for publication.

An important part of the proof advanced in the present paper depends on the existence of the intervillous circulation. This circulation is denied by Hicks, and strongly contended for by Turner. Waldeyer, in a recent communication, unhesitatingly supports the view that an intervillous circulation does exist.








FIG. 1.

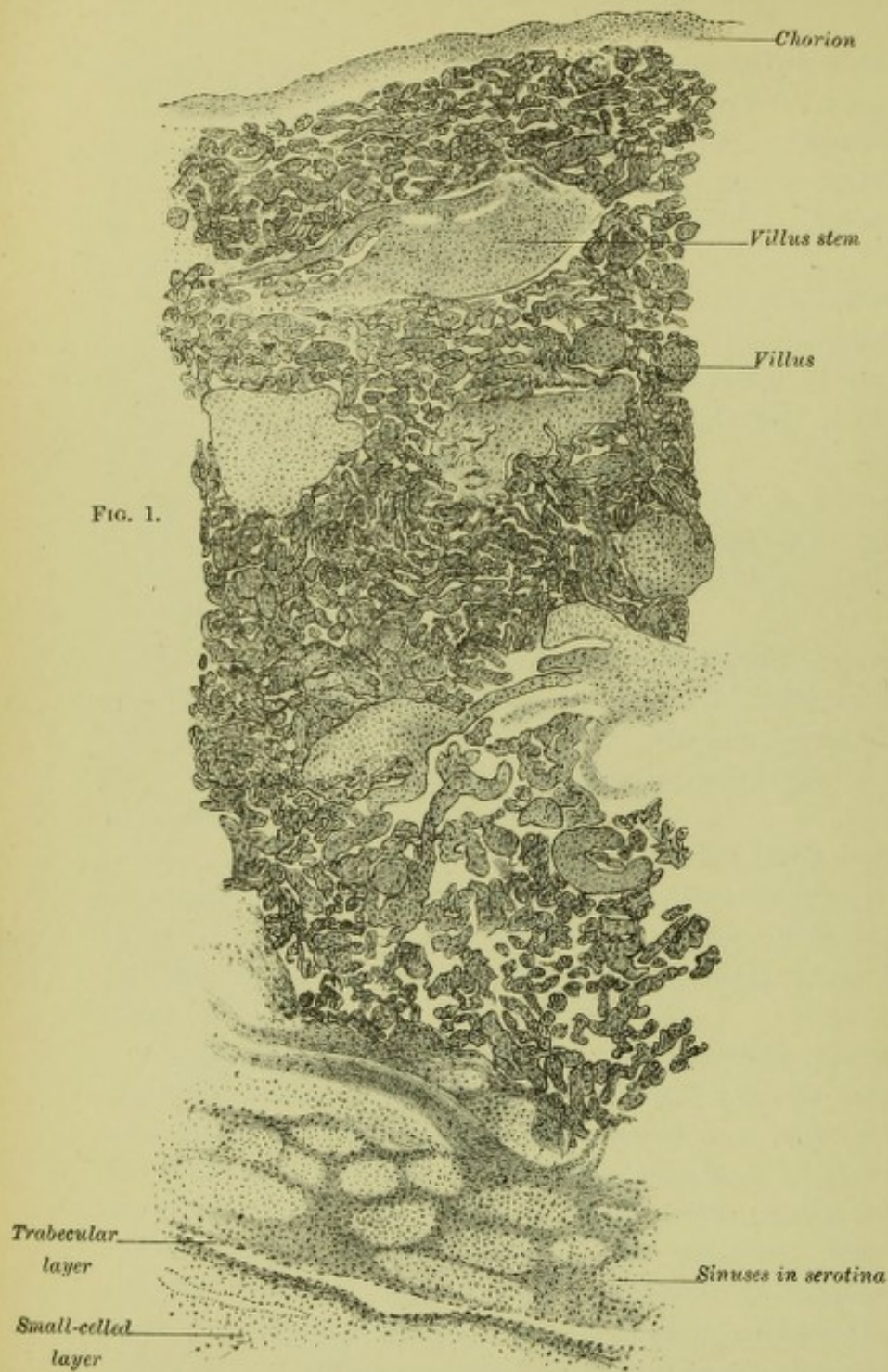


FIG. 2.

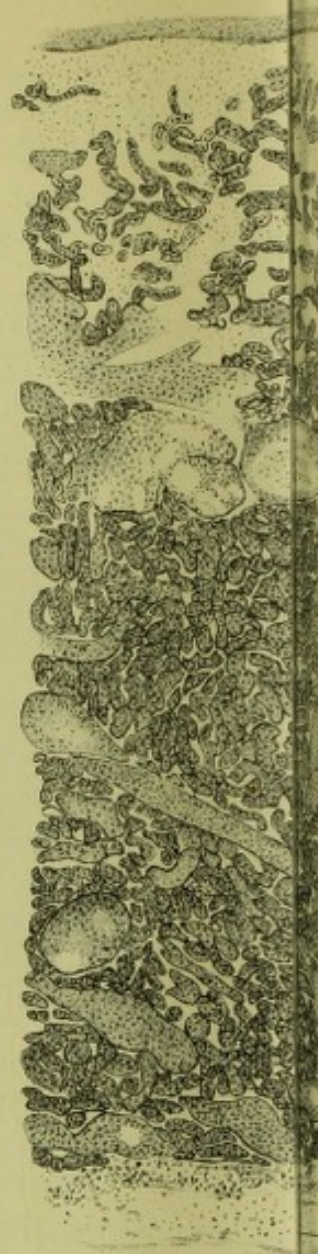

FIG. 4.

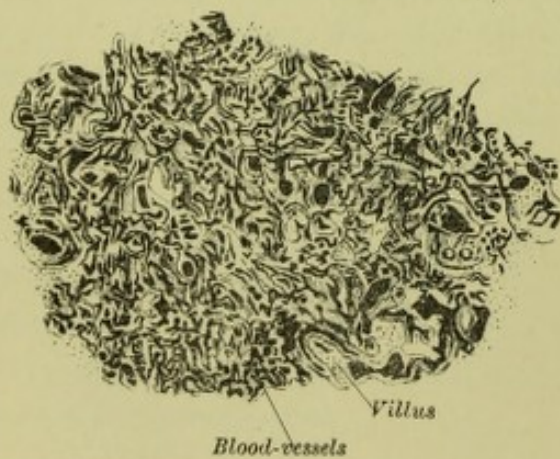
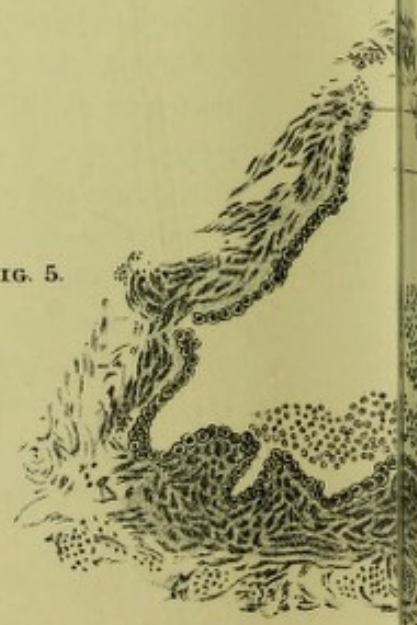

FIG. 5.





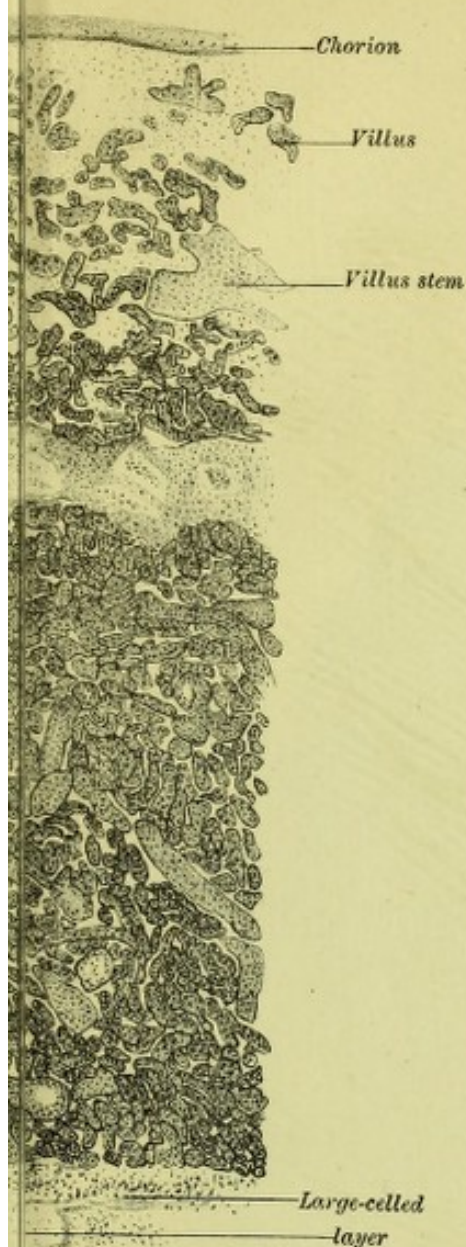


FIG. 3.

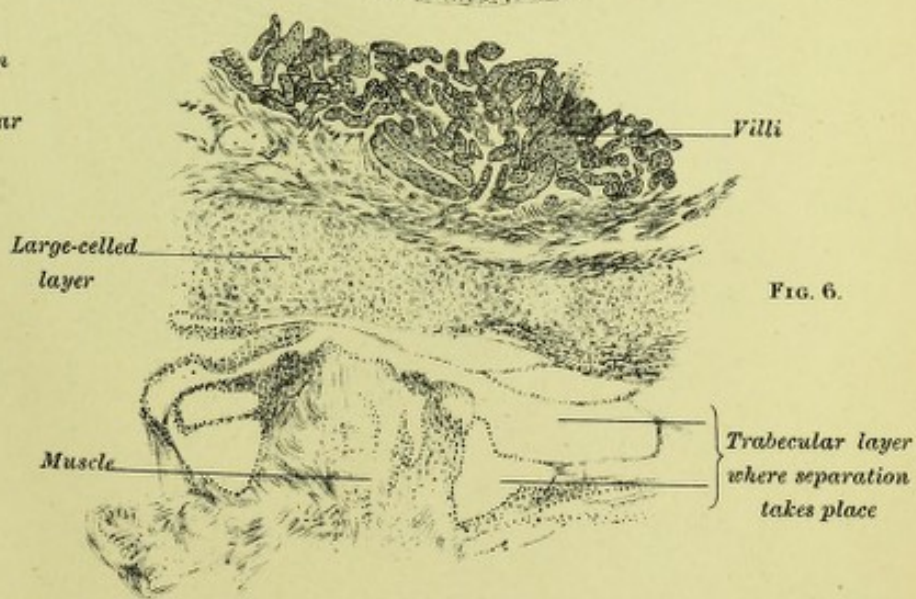
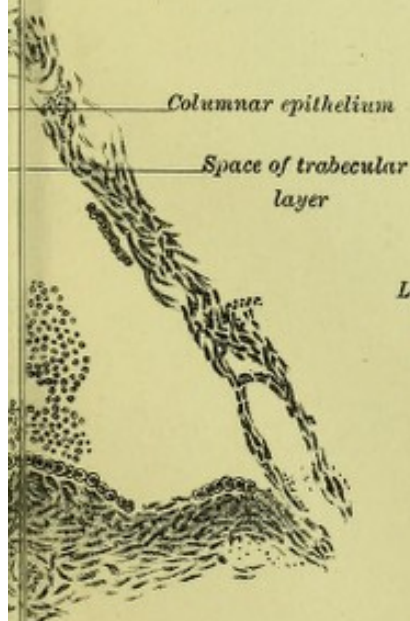
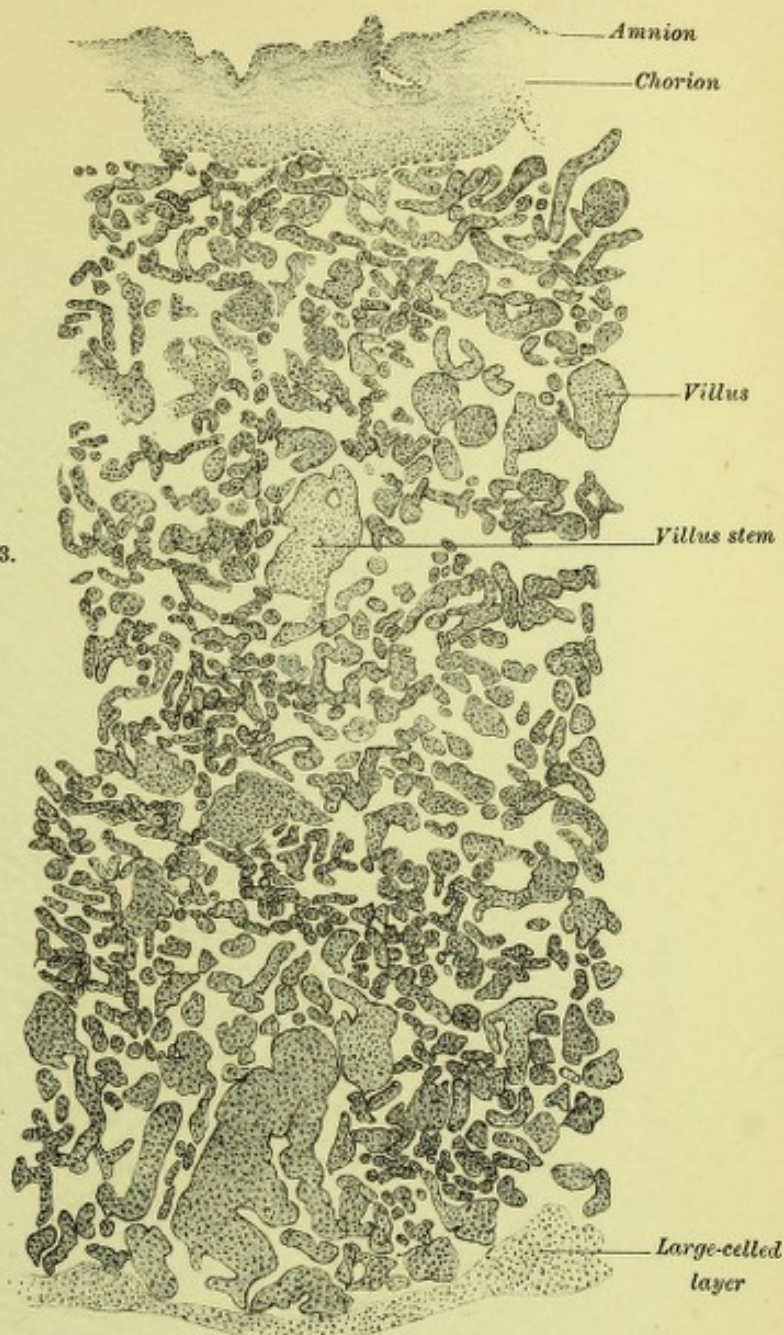

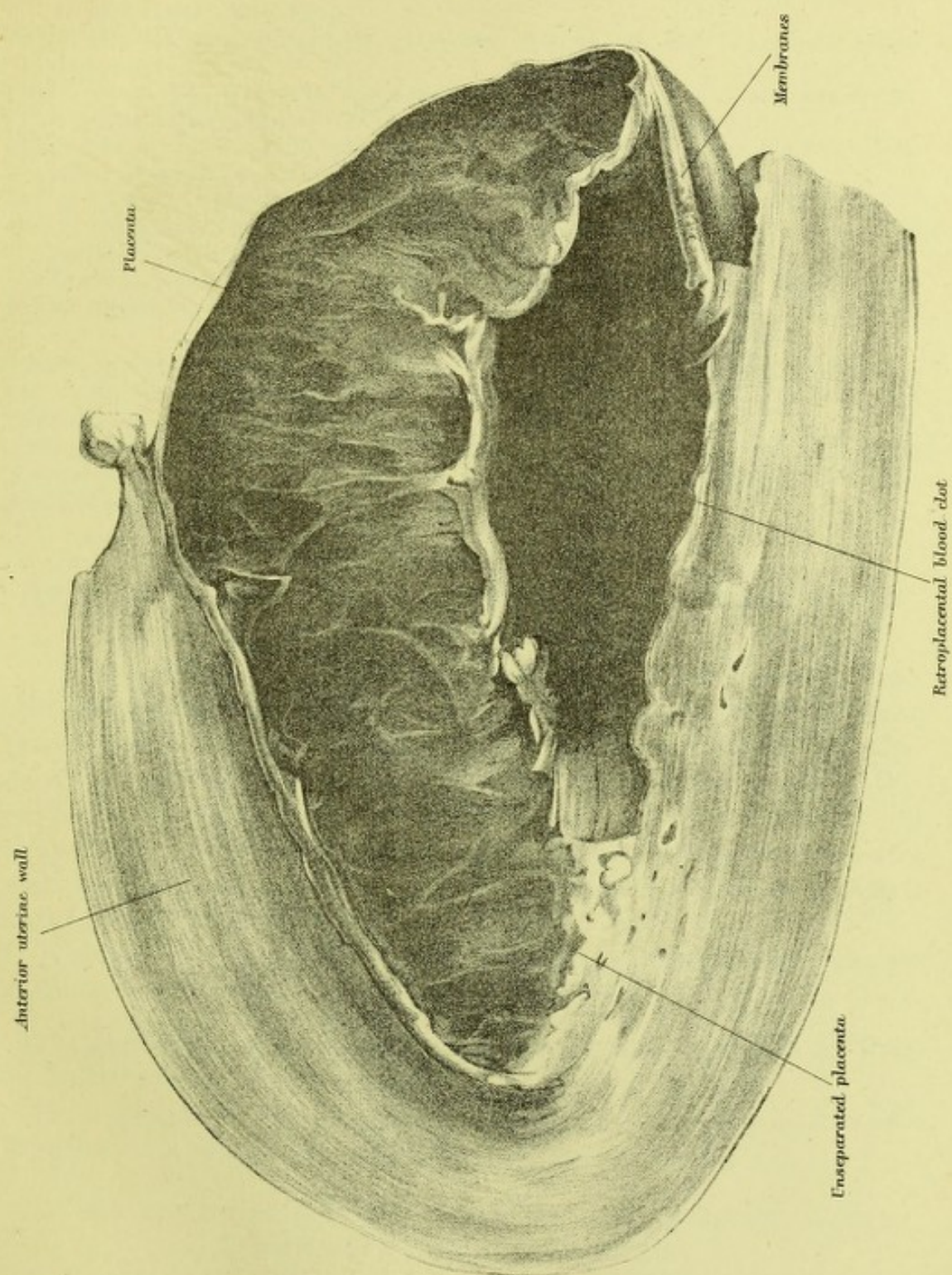


FIG. 6.
















## EXPLANATION OF PLATES.

## PLATE IX.

FIG. 1.—Section of the placenta attached to inverted third stage uterus (muscle not shown). The amnion is stripped off, and the villi so closely pressed together that we see no intervillous system.

FIG. 2.—Section of shed placenta. Amnion stripped off, and intervillous spaces obliterated.

FIG. 3.—Section of 4½ months' placenta attached to uterus, but muscle not drawn. Note that in this pregnant specimen the intervillous spaces are evident.

FIG. 4.—Section of 6 months' placenta from parturient uterus; villi injected. Note villi so closely pressed that specimen seems one mass of them.

FIG. 5.—Space of trabecular layer magnified, showing lining of columnar epithelium.

FIG. 6.—Section of 3rd stage uterus with placenta attached. The trabecular layer is well seen, as also the close appression of villi.

All specimens drawn with  $\frac{2}{3}$  inch object-glass, and reduced by one half. FIG. 5 magnified 300 diameters.

## PLATE X.

Shows a vertical mesial section of a third stage uterus, with placenta separated in part by the retroplacental blood present. This specimen was obtained from a case of Cæsarean section, Porro's modification ( $\frac{1}{2}$ ths nat. size).

The following are some of the measurements:—Length of uterine wall from which placenta separated,  $2\frac{7}{8}$  inches; length of part of membranes separated,  $1\frac{1}{4}$  inches; length of separated placental edge, 4 inches (nearly).

## EXPULSION OF THE PLACENTA BEFORE THE BIRTH OF THE CHILD.

For some time past, anomalous separations of the placenta have occupied my thoughts, but I intended to defer special investigation of these till opportunity of studying them in the living woman occurred. A recent paper by Dr Helme has induced me, however, to consider this matter, inasmuch as both in Dr Helme's paper and in the discussion on it at the Edinburgh Obstetrical Society, the opinion was unanimously expressed that the case recorded was against my view of placental separation.

The anomalous separations I purpose bringing before you to-night are as follow:—

I. CASES WHERE THE PLACENTA IS SEPARATED AND EXPELLED IN TWIN BIRTHS IN AN ANOMALOUS MANNER.

II. CASES WHERE THE NORMALLY SITUATED PLACENTA IS SEPARATED AND EXPELLED IN A SINGLE BIRTH BEFORE THE CHILD IS BORN.

I. CASES WHERE THE PLACENTA IS SEPARATED AND EXPELLED IN TWIN BIRTHS IN AN ANOMALOUS MANNER.

In a twin labour we may have the following phenomena as regards separation of the placenta:—

1. *Both placentaë may be separated and expelled after the birth of both children.*



2. *Both placentaë may be separated and expelled before the birth of the second child.*

3. *The placenta of the first born child may be separated and expelled after the birth of the first child and before the birth of the second.*

4. *The placenta of the second child may be expelled after the birth of the first, the second being still-born.*

5. *Both children being born, the placenta of the second may be born before that of the first.*

6. *Both placentaë may be expelled before the birth of the children.*

In 1 we have the normal third stage.

In 2 and 3 the difference is due to the fact that in the former there is only one placenta, in the latter two.

In 4 and 6 we have cases analogous to prolapsus placentaë.

The two forms for discussion under head I. are 3 and 5; 4 and 6 come under head II.

3. *The placenta of the first born child may be separated and expelled after the birth of the first child, and before the birth of the second.*

Denman gives two cases of this :—

(1) C. J. ; twins. The placenta of the first child was expelled immediately. The feet of the second were then found in the vagina and brought down. There was not the slightest hæmorrhage. The first was born alive, the second putrid.

(2) M. C. ; twins. The placenta of the first was expelled before the birth of the second, *without hæmorrhage*. Both children were born alive at the full period.

We have here, therefore, a remarkable phenomenon, viz., the separation of a placenta while the uterus contains a second child and has a large uterine area. After the first child is born, the area of its placenta cannot be 4 inches by 4 inches. However the placenta separates in such, it is at an area comparatively large, and also without the aid of blood effusion. It will of course be asked, Does the view propounded by me explain such cases? To this I answer, that nothing in these cases militates against my view, my caution being dictated by the circumstance that we have not all the facts of such before us. My view, put in the most general manner, does not assert that any area is required for the separation of a placenta. All that is necessary is a disproportion between placental area and placental site. When in twin cases the first child is born alive, as happened in the second case narrated, we have the two placentaë under different conditions. That of the child unborn has its foetal circulation intact and its maternal only partially obliterated; while, on the other hand, that of the born child has its foetal circulation stopped entirely and its maternal circulation as in the former. It does not, therefore, respond to the increase in site following a pain, becomes



separated, and then expelled. This, I believe, will be found to be the essential mechanism.

5. *Both children being born, the placenta of the second may be born before that of the first.*

An interesting case of this has been recently recorded by Dr Helme. It is briefly as follows: the first child was born spontaneously, while the second required its bag of membranes ruptured, and had spina bifida. The cord was not pulsating when it was born, and no respirations were made.

During the third stage the uterus contracted badly and relaxed considerably. Ultimately the lower placenta was expelled, but the upper was only partially separated, and was ultimately removed manually. Dr Helme, by passing his hand in early in the third stage, found the placenta both unseparated, even after contraction and relaxation had occurred.

Dr Helme urges—1. That the lower placenta was separated and expelled by uterine pains, *i.e.*, by diminution of area. 2. That the placenta of the still-born child had its foetal half not a bloodless structure, as it did not aspirate the blood there. 3. That the placenta of the living child was not expelled, although he believes all the conditions I demand for such expulsion were present.

Dr Helme's facts bear evidence of accuracy, but he has built upon them a superstructure of criticism which they cannot bear. Thus—1. The second child was dead; at any rate its cord was not pulsating, and it did not breathe. Yet Dr Helme makes the remarkable statement that its foetal portion was not a "bloodless structure," inasmuch as it did not breathe. Dr Helme evidently thinks that the only way the foetal portion of the placenta is rendered bloodless is by the child's aspiration. The death of the child does the same, and consequently this placenta had the conditions as to circulation my view demands.<sup>1</sup>

The placenta of the living child was removed manually, as its upper portion was unseparated. This means, of course, that it was adherent there.

Dr Helme, indeed, is in a dilemma about this upper placenta. The diminution of area was, according to him, sufficient to separate the lower placenta; then why not the upper one too? If Dr Helme wishes to criticise, he should certainly criticise the diminution in area theory.

The fact is that Dr Helme has made a perfectly simple case complicated. The explanation I would give is as follows:—During the relaxations following the pains, the lower placenta and lower part of the

<sup>1</sup> Dr Helme has further misunderstood my view. During the normal third stage I consider that the placenta does not follow up the expansion of its site following a pain; but I do not assert that the absence of blood in the foetal portion is one of the factors. It is the absence of the active foetal circulation due to the foetal heart. Every one knows that the cord may be tied immediately after birth without materially hindering the third stage, and therefore Dr Helme's criticism, besides being erroneous on this point, is unnecessary.



upper placenta became separated. As during the third stage, relaxation was so prominent and contraction so feeble, I am indeed disappointed not to have had Dr Helme's support instead of his adverse opinion. The part of the placenta not separated was the part adherent; for, whatever may be said to the contrary, a placenta separated manually is an adherent placenta, and Dr Helme knows his work too well to separate manually a non-adherent placenta. The two placentæ at a certain stage were, therefore, exactly analogous to an ordinary placenta with its lower part separated and its upper adherent. The expulsion of the lower one would not have occurred had the placenta been a single one.

## II. CASES WHERE THE PLACENTA IS SEPARATED AND EXPELLED IN A SINGLE BIRTH BEFORE THE CHILD IS BORN.

This so-called prolapsus placentæ is one of the most remarkable phenomena connected with labour. That the normally situated placenta with its membranes should be expelled entire without hæmorrhage, and before the child is born, in a full time labour, seems incredible; yet fully authenticated cases have been noted, and place the matter beyond doubt. In a recent paper, Münchmeyer gives the history of the known cases, and describes a case with valuable details occurring in the Dresden Klinik. His case, so far as it bears on the present question, is briefly as follows:—The patient had a deformed pelvis (rachitic and universally contracted: c.v., 3-3½ inches). She was in labour for some time, and at 2 A.M. the fœtal heart-sounds were not heard. Five and a half hours after this the placenta and membranes presented at the vulva, and were removed intact. The child was turned, and born with great difficulty.

The question to be settled here is whether the dead child was the result or cause of the premature separation of the placenta. That neither blood effusion nor diminution of area caused the placental separation is evident. I would urge that the placental separation and expulsion in cases like Münchmeyer's are brought about as follows:—As the result of the prolonged labour the child dies; this cuts off the fœtal circulation. The intervillous circulation is also diminished by prolonged uterine retraction, and thus we have the placenta prevented from following up the expansion of its site after the pain dies off, *i.e.*, we get a disproportion between the placental site and placental area, and separation as the result. The conditions are the same as in the normal third stage, except that the intervillous circulation is less diminished. The length of the labour after the child is dead is of importance, as this means more marked uterine retraction and greater diminution of the intervillous circulation.

It will be advisable, in conclusion, to restate my views on the subject



of the separation of placenta and membranes, so as to give definiteness to the discussion. I hold that the placenta does not separate as the result of diminution of area of the placental site. In order to get separation there must be a disproportion between placental site and placental area. In placenta prævia the expansion in area of the lower

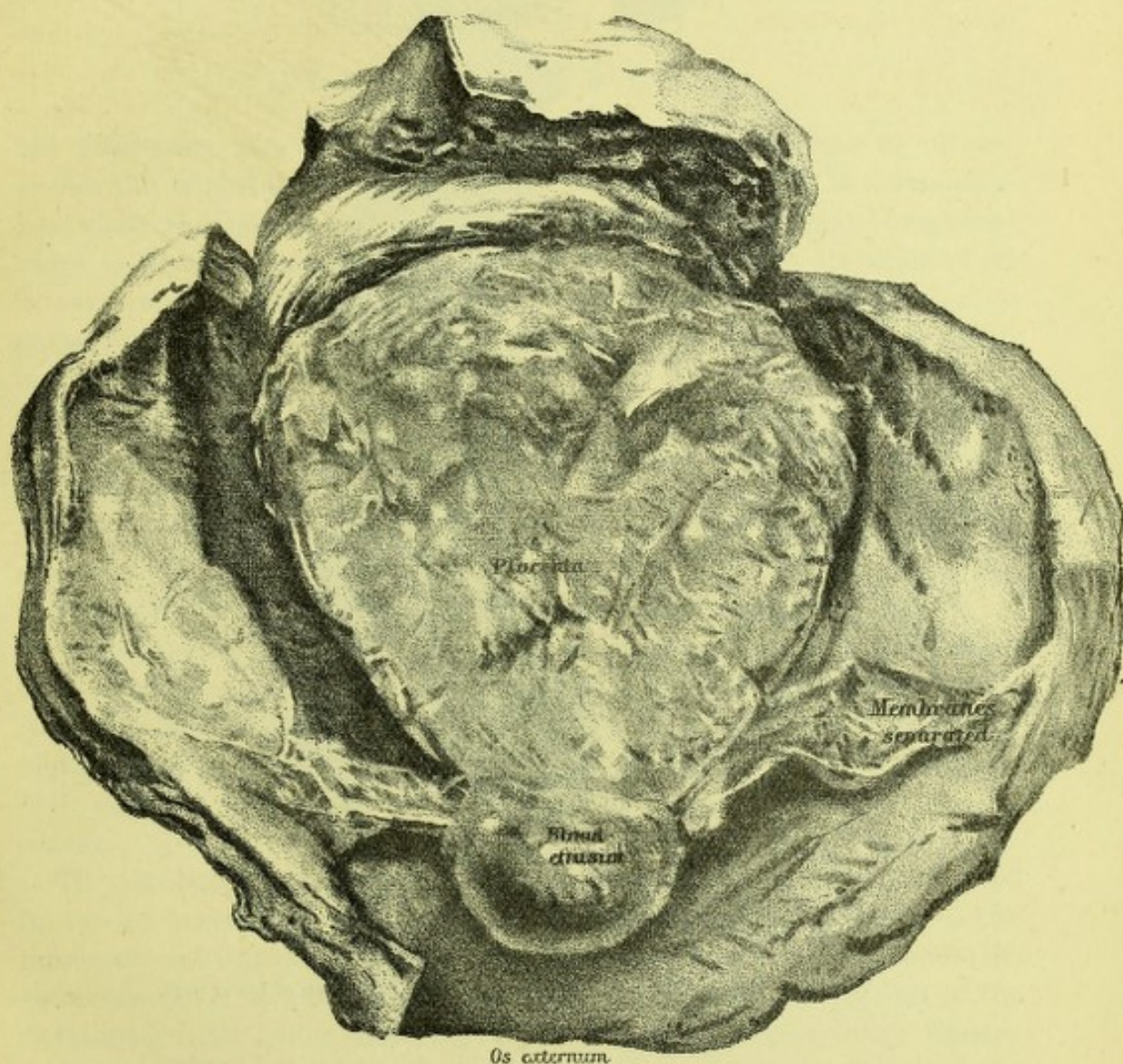


FIG. 32.

THIRD STAGE UTERUS WITH PLACENTA ATTACHED.—Note shape of placenta and uterine cavity.

uterine segment not being participated in by placenta, gives the necessary disproportion. In the third stage the disproportion is brought about as follows:—

1. The placental site increases slightly as the pain dies off.
2. The placenta does not respond to this, as its foetal and intervillous circulation are cut off.



I may add that no area of diminution is necessary for separation, but merely disproportion between the placental site and area.

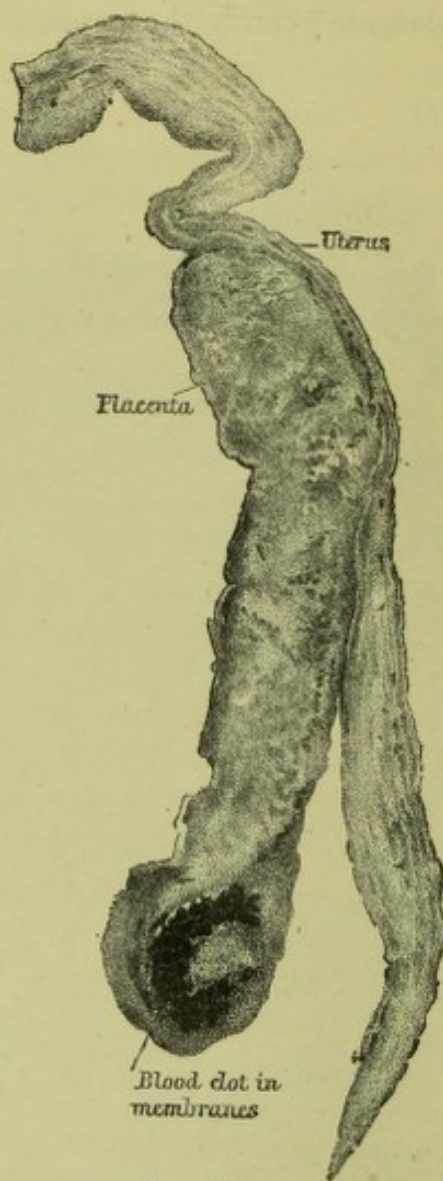

FIG. 33.

VERTICAL MESIAL SECTION OF FIG. 32.—Note separation of lower part.



## CHAPTER XIV.

### PLACENTA PRÆVIA.<sup>1</sup>

MR PRESIDENT AND GENTLEMEN ! it needs no words of mine to picture to you the importance to human life of placenta prævia. In a complication where the lives of both mother and child are so seriously threatened there is certainly occasion enough for the most serious attention of all in our branch of the profession ; and such attention and mutual comparison of our international knowledge will, I rest assured, not be wanting at our Congress to-day.

In bringing such a subject before you, my first thought is " How best to do it ? " Surely, by considering what facts we really know, and what treatment these facts indicate.

At the very threshold of our subject, then, we are met with the question—

WHAT IS PLACENTA PRÆVIA ? Placenta prævia may be defined as the attachment of part of the placenta within a certain distance from the os internum, or its attachment to that part of the uterus proper (*i.e.* the uterus excluding the cervical canal), which becomes stretched and expanded during labour. These definitions require some explanation, and we take the second or functional definition first for a special reason.

The results of the frozen sectional anatomy of women who have died in labour have shown us that the uterus proper is divided into two markedly contrasted portions by the retraction ring. All above the retraction ring is active during labour, while a certain portion of the developed canal below this ring is the passively dilated lower uterine segment. Where the lower limit of this meets the upper limit of the cervical canal it is difficult to say, although Chiari's section gives some help in settling this question by the upper limits of the arbor vitæ.

In post-partum uteri of the first 12 hours we can note distinctly that the passively stretched portion below the retraction ring is divided almost equally between lower uterine segment and cervical canal. We can thus define placenta prævia as *the attachment of part of the placenta such that it lies on a part of the uterine wall proper whose upper boundary*

<sup>1</sup> An address delivered at the opening of a discussion on Placenta Prævia at the First International Congress of Gynæcology and Obstetrics held at Brussels, Sept. 1892.



during labour is the retraction ring. As this part becomes expanded during labour, this is merely the old definition of Rigby expressed in terms of modern anatomy.

We have now, however, to face a more difficult question, viz.—“What portion of the uterus at the end of pregnancy corresponds to the part of the uterus which during labour is bounded above by the retraction ring?” The answer is “the lower uterine segment,” and I have now to define this important portion of the full-time pregnant uterus. The lower uterine segment is a hemispheroidal portion of the uterus with the os internum as its lowest point and its upper limit about  $2\frac{1}{2}$ – $3\frac{1}{2}$  inches along the walls from that. The characteristics of the lower uterine segment are usually given as (1) looseness of its peritoneal covering; (2) separability of its lamellæ; (3) presence of a vein at the upper margin; (4) greater thinness as compared with the upper portion of the uterine wall. (v. Pl. XII. fig. 4.)

None of these distinctions is satisfactory in every case. The looseness of peritoneum is best marked in front, not so well behind; the upper limit varies, and the vein is not always present behind and sometimes not in front. For practical purposes we can accept however this hemispheroidal portion of the uterus as a special segment, and thus get the shortest and best definition of placenta prævia, viz., “insertion of part of the placenta in more or less of the lower uterine segment.”

Recently Hofmeier has published an account of a four months' pregnant uterus with apparent placenta prævia, where the praeval part of the placenta was developed over the reflexa which had not yet become adherent to the vera. Kaltenbach has proposed, indeed, a definition of placenta prævia based on Hofmeier's specimen and others described by himself, viz., that the placenta is prævia when inserted over the lower pole of the reflexa. This definition has indeed been accepted by Olshausen in the last edition of Schroeder's well-known Text-book of Midwifery (eighth edition), so that the new view has the support of those whose opinion carries great weight.

This raises an important practical question, and also one of great scientific interest. No early ovum has been found without the reflexa covering it. The reflexa is practically an extension of the serotina over the ovum, and its edges in early pregnancy are thick and with many villi attached. In a specimen of a six weeks' pregnancy which I examined carefully with the help of my assistant, Dr Lovell Gulland, the reflexa is about  $\frac{1}{8}$ th inch at its junction with the serotina, and gradually thins as it passes up from this point to about  $\frac{1}{10}$ th. In many specimens of two months' pregnancy the villi have been found well developed over the lower pole of the reflexa (Hofmeier, Kaltenbach), while in a specimen of a four months pregnancy of which I show a drawing, the placenta was still quite evident over the lower end of the



reflexa. I may briefly state here the view I take of the reflexa. I consider the human ovum as an embedded one—one implanted in the decidua—the decidua serotina thus consisting of a deep portion next the uterine wall and a superficial portion—the decidua reflexa. This embedding of the pregnant ovum is found only in mammals high in the scale, *e.g.*, in the insectivora. In the hedgehog, for instance, Hubrecht has shown that the impregnated ovum when it comes in contact with

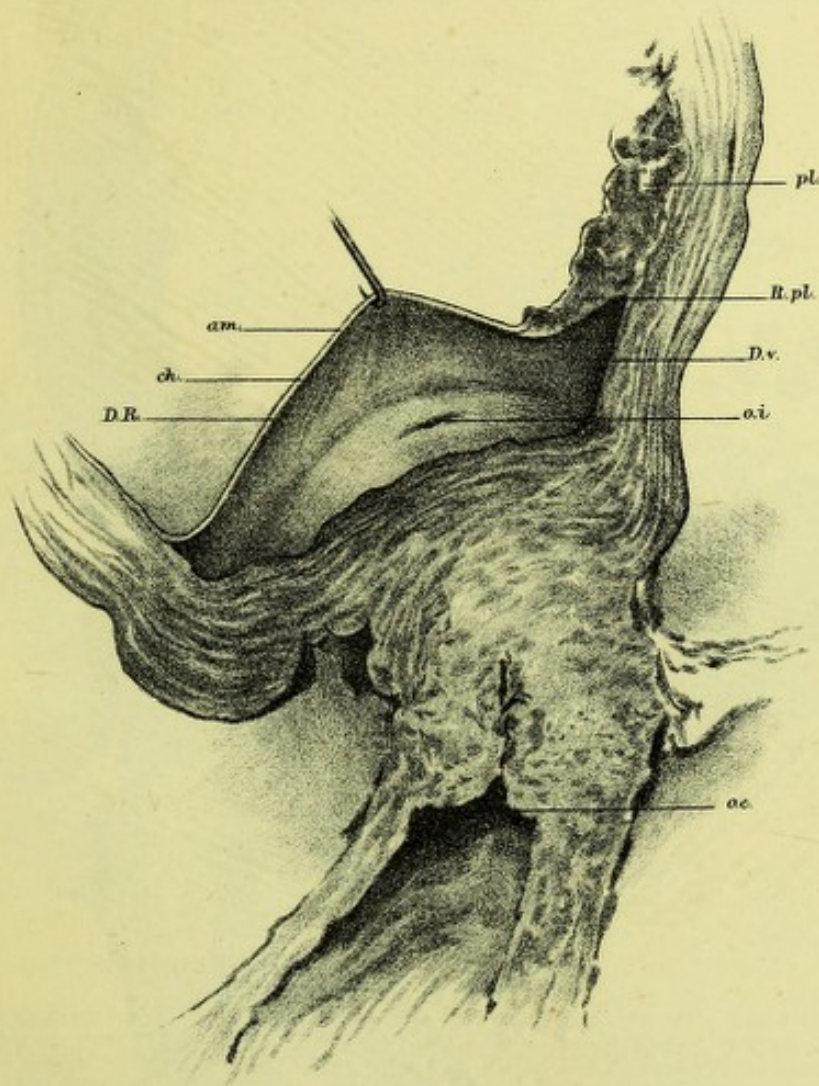


FIG. 34.

CERVIX AND LOWER PART OF UTERUS (4TH MONTH); REFLEXA AND AMNION HOOKED UP TO SHOW REFLEXAR PLACENTA.

*o.e.*, Os externum; *o.i.*, Os internum; *R.pl.*, Reflexa placenta; *pl.*, Placenta; *am.*, Amnion; *ch.*, Chorion; *D.R.*, Decidua reflexa; *D.v.*, Decidua vera.

the serotina or tropho-spongia, apparently destroys the epithelium and is soon sunk into the tropho-spongia, which then closes over it and gives it thus a reflexa. How the reflexa forms in the human female is not known, but I incline to the belief that it either occurs as in the hedgehog, or that the human ovum grafts itself on a portion of the



serotina denuded of epithelium and that the serotina completes itself over it.

Where the so-called reflexa meets the serotina proper we get the villi

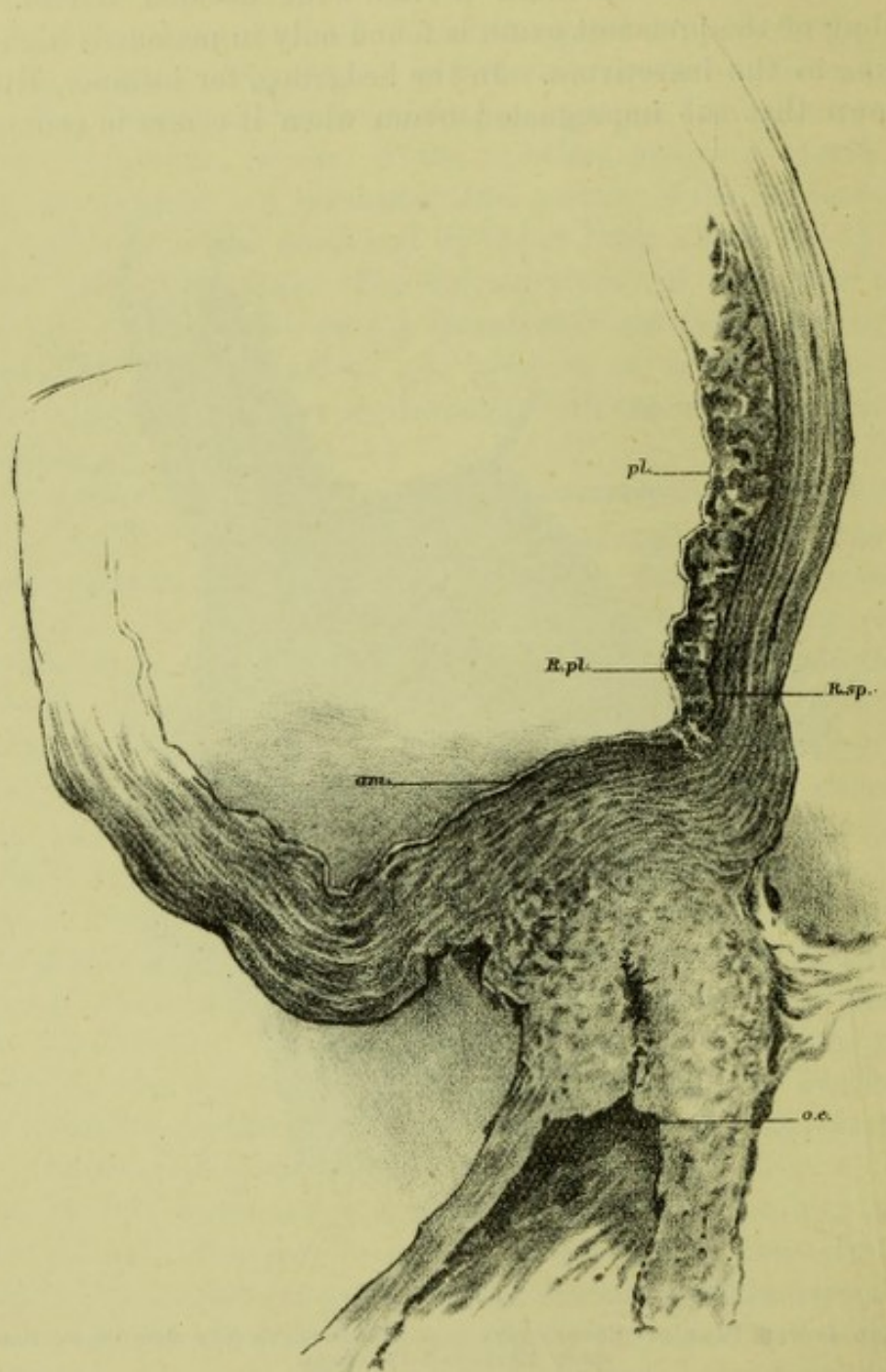


FIG. 35.

As in FIG. 34. *R.sp.*, Linear space between reflexa and vera.

at first remaining well developed, their development being less marked as we pass towards the highest point of the reflexa. The drawings I show illustrate this well, the development of villi on the reflexa being quite considerable.



This growth of villi on reflexa is not persistent and ultimately we get an atrophy of what one might term the reflexar placenta. This happens partly from the fact that the blood nourishment to the reflexa is much less than that to the serotina proper, and also to an active property of the villi recently indicated in a paper on the placenta by Dr Gulland and myself. Where the tips of the villi touch the serotina proper one can see a band of condensed and degenerated tissue due to an active and apparently phagocytic action of the villi. This enables us to under-

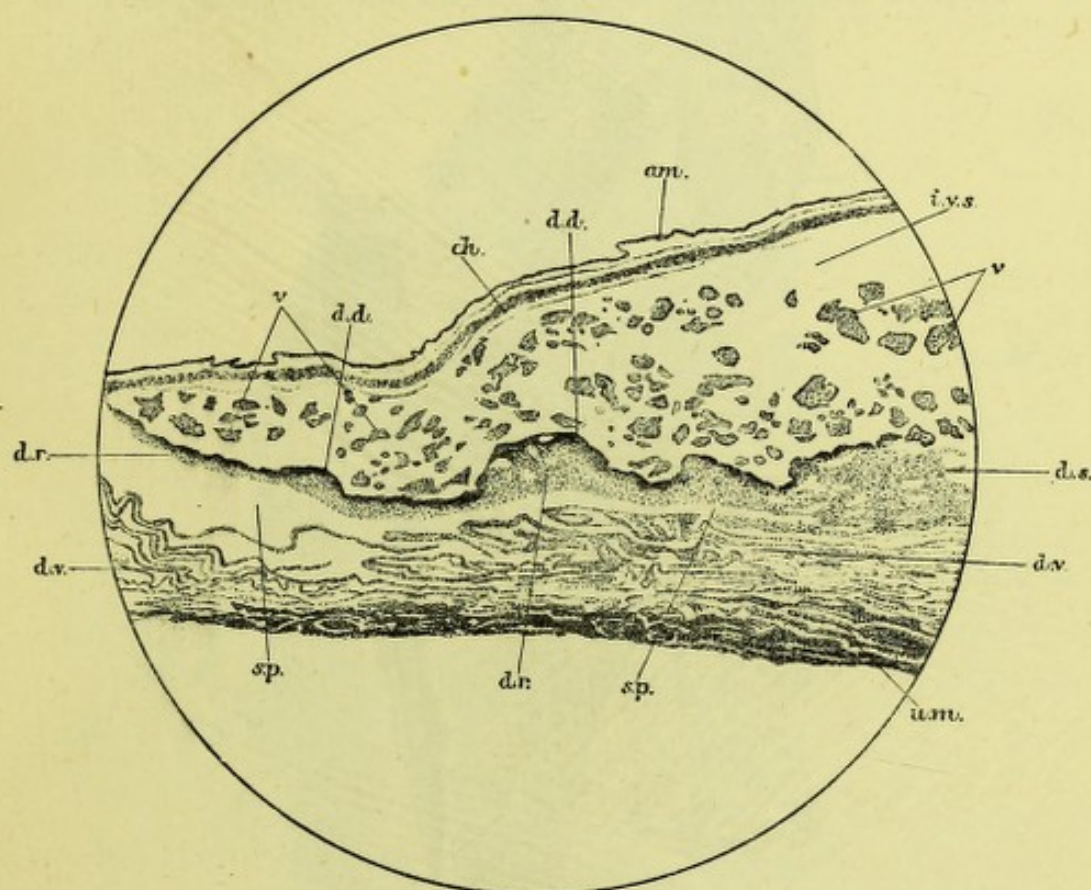


FIG. 36.

SECTION THROUGH THE PLACENTA, DECIDUA REFLEXA, AND DECIDUA VERA, AT THE LOWER MARGIN OF THE PLACENTA OF A FOUR MONTHS' HUMAN PREGNANCY, to show the degeneration, of the reflexa. *am.*, Amnion; *ch.*, Chorion; *v.*, Villus; *i.v.s.*, Intervillous space; *d.v.*, Decidua vera; *d.s.*, Decidua serotina; *d.r.*, Decidua reflexa; *d.d.*, Degenerated decidua; *u.m.*, Uterine muscle; *sp.*, Space between the decidua reflexa and decidua vera.

stand how the reflexar placenta atrophies as pregnancy goes on and ultimately the part of the reflexa over the os internum may remain only as a thick part of the membranes at the edge of the placenta proper. This process of degeneration and thinning of the reflexa placenta is well seen in my specimen of a four months' pregnancy.

I must now state the view I advocate for the occurrence of placenta prævia. It is that of primary implantation of the impregnated ovum low down or even over the os internum. The forcible objection that Kaltenbach urges against this view seems to me not quite valid. He



holds that the small ovum would pass into the cervical canal and be lost. We must remember, however, that the hypertrophied and folded decidua there will practically obliterate the os internum and thus implantation over it may happen. But why should such a low implantation happen? We only know that it is more apt to occur in cases where the mucous membrane has been unhealthy. The hypothesis I would advance, but merely as an hypothesis, is that the human ovum can only

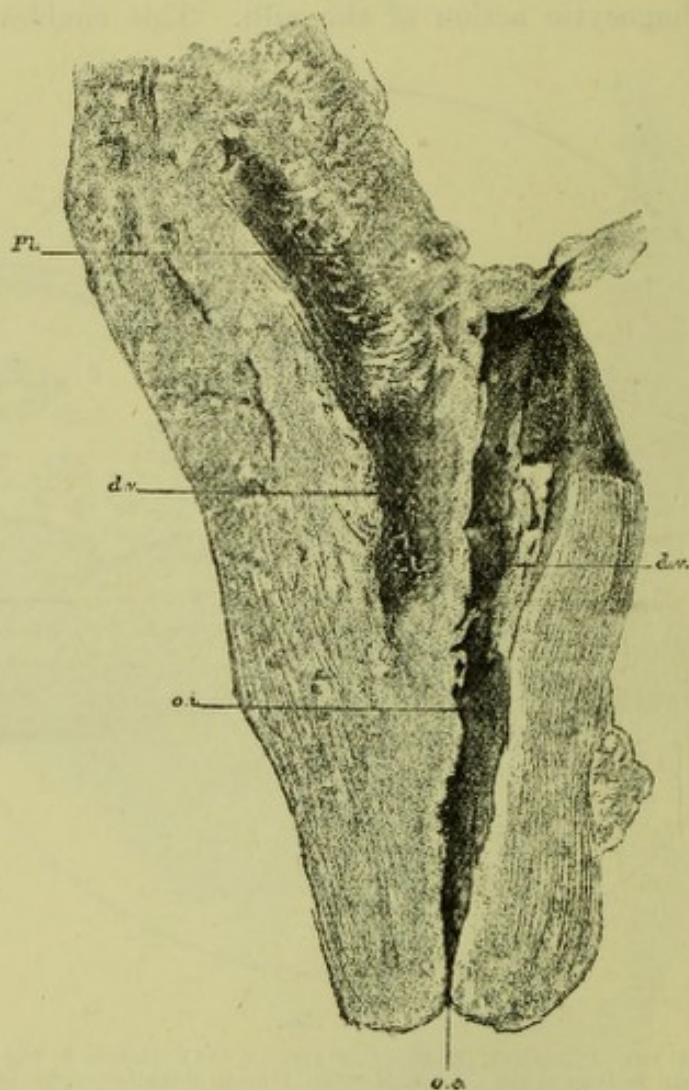


FIG 37.

VERTICAL MESIAL SECTION OF CERVIX AND LOWER UTERINE SEGMENT OF A FOUR MONTHS' PREGNANCY, with edge of placenta low down (}). *Pl.*, Placenta; *d.v.*, Decidua vera thickened; *o.i.*, Os internum.

graft on a surface denuded of epithelium and that thus it does not graft in the Fallopian tube, but in some part of the uterine cavity where the epithelium has been removed by menstruation. If then the ovum does not meet with the connective-tissue surface until it has passed low down in the uterine cavity some form of placenta prævia will happen.

Placenta prævia is thus primary implantation of the ovum in the lower uterine segment. The valuable contributions of Hofmeier and



Kaltenbach do not seem to me, as yet, to have shaken the orthodox view I have taken on me to defend, but there is no doubt that all specimens must be carefully scrutinised from their point of view.

What is it, then, that makes this condition of placenta so dangerous to mother and child? The answer of course is, the hæmorrhage, and thus I therefore take up now—

I. THE SPECIAL MICROSCOPICAL ANATOMY OF THE PLACENTA WHEN ATTACHED TO THE LOWER UTERINE SEGMENT.

II. THE CAUSE OF THE SEPARATION OF THE PRÆVIAL PORTION.

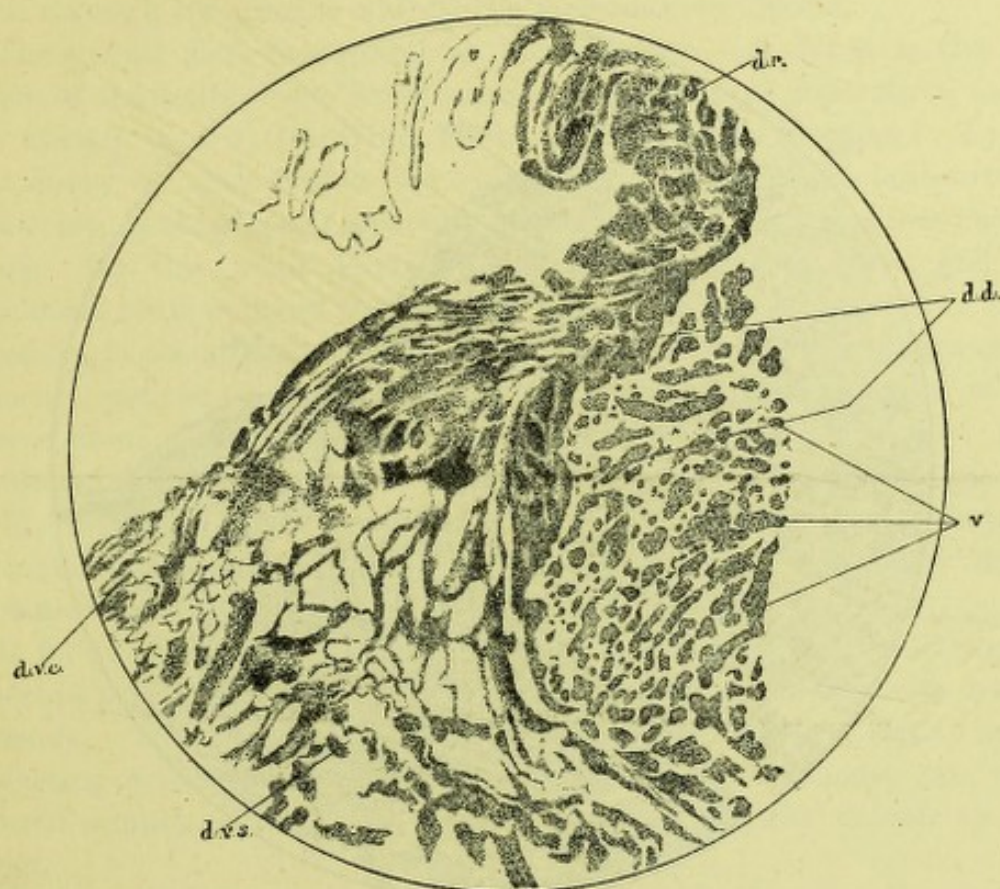


FIG. 38.

SECTION THROUGH THE EDGE OF THE PLACENTA AND DECIDUÆ IN A FOUR MONTHS' HUMAN PREGNANCY. *d.v.c.*, Compact layer of the decidua vera; *d.v.s.*, Spongy layer of the decidua vera; other letters as in Fig. 36. (Specimen from Fig. 37.)

I. THE SPECIAL MICROSCOPICAL ANATOMY OF THE PLACENTA WHEN ATTACHED TO THE LOWER UTERINE SEGMENT, SO FAR AS IT BEARS ON SEPARATION OF THE PLACENTA AND BLEEDING.—This description is based on an examination of several specimens of pregnancy, but specially on a four months' pregnancy, where the lower edge of the placenta was within an inch of the os internum. The reflexa did not take any special part in the formation of the prævial portion in this case, although the great thickening of the decidua vera between the lower placental edge



and the os internum gave a condition likely to favour the formation of a reflexar placenta.

The parts specially to be noted are—(1) *the muscular wall*; (2) *the spongy layer*; (3) *the large-celled layer with its intimate union to the tips of the villi*; (4) *the blood supply*.

(1) *The Muscular Wall of the lower Uterine Segment* is characterised anatomically by the longitudinal direction of its fibres, and functionally by its property of passive distention, and has been already sufficiently alluded to (v. p. 126).

(2) *The Spongy Layer* is very well marked in early pregnancy, but is

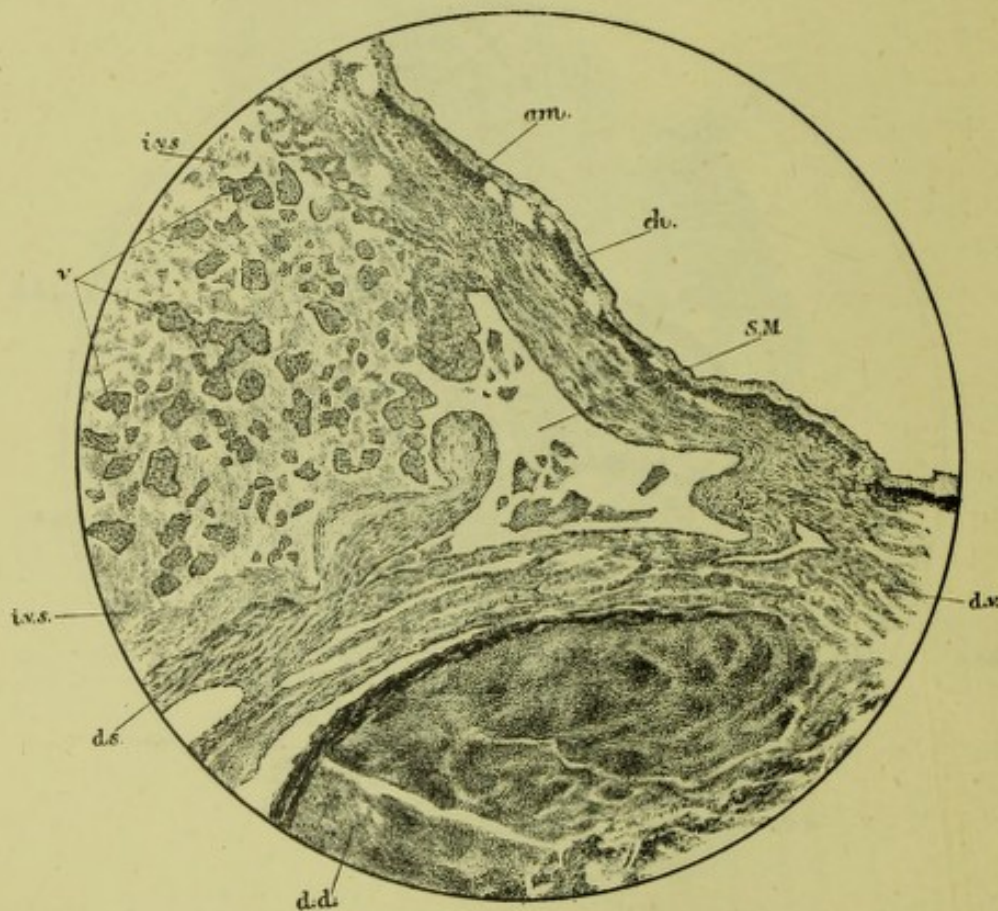


FIG. 39.

SECTION THROUGH THE EDGE OF THE PLACENTA AND DECIDUA OF A SIX MONTHS' HUMAN PREGNANCY. S.M. Sinus of Meckel into which villi project; other letters as in Fig. 36.

less broad in advanced uteri. At all stages of pregnancy it is well marked, is now known to be formed by the fundi of the dilated uterine glands, and is of the highest importance as being the layer where separation of the placenta takes place.

(3) *The large-celled Layer with its intimate Union to the Tips of the Villi.*—At this part of the placental section we note an intimate union of the villi with the large-celled serotinal layer. This has been already alluded to, but is here of importance owing to its preventing separation at this level.



(4) *The Blood-supply in the Region of the lower Uterine Segment.*—On this question of the blood-supply to the placenta we have much material; and now, thanks to the work of John Hunter, Farre, Sir William Turner, Waldeyer, Bumm, Hofmeier and others, we have accurate and valuable information on this necessary point. The blood-supply to the lower uterine segment and maternal portion of placenta when attached there, is derived from the uterine artery and mainly from a branch of it which first passes through the retracting portion of the uterus. The curling arteries pour their blood into the intervillous spaces, while by Meckel's sinus, and veins usually lying in the cotyledonary substance, it passes back through the uterine wall to the maternal circulation.

The special facts concerning us, however, are—(a) What is the condition of the walls of the blood-vessels at the line of separation, *i.e.*, at the spongy layer? (b) What is the source of the bleeding? To the first query we answer that the walls of the blood-vessels, both arteries and veins, *at the plane of separation are thin-walled, and thus tear through easily.* On this point Farre and Waldeyer are very clear, and my specimens quite support their view. One thing also to be kept in mind specially, is the abundant venous supply of the lower uterine segment in placenta prævia, and the drawing of a vertical mesial section of the uterus from a patient with central placenta prævia who died from pneumonia on the fifth day after labour illustrates this point completely.

The source of the hæmorrhage is therefore *mainly the torn thin-walled maternal vessels in the spongy layer of the serotina.* Any other source, such as Meckel's sinus, is insignificant.

It follows from all that I have said that the arrest of hæmorrhage in placenta prævia is due to collapse of the torn thin-walled vessels and to pressure. The musculature in the lower uterine segment has no active retracting power, although uterine retraction can influence the main arterial supply to the lower uterine segment for the reason already given.

II. THE CAUSE OF THE SEPARATION OF THE PRÆVIAL PORTION OF THE PLACENTA.—This was first indicated by Matthews Duncan of Edinburgh and London, and is, with some additions briefly, as follows:—The hemispheroidal lower uterine segment of the full time pregnant uterus becomes converted during labour into a tubular canal: has its superficial area increased and has special transverse stretching most marked the nearer the part is to the lower uterine segment. The portion of the placenta attached to the lower uterine segment does not equally stretch, and thus the filaments of the spongy layer become torn, *i.e.*, the prævial portion of the placenta becomes separated. From the torn blood-vessels we get what is known as unavoidable hæmorrhage. This mechanism is held by all as that occurring in labour in placenta prævia of full time.



Can we give any more exact data? What we want to know is (1) The superficial area of the lower uterine segment at full time : (2) The superficial area of the tubular canal into which it becomes converted when the lower uterine segment is fully canalised. These data unfortunately are not yet obtained, as a plaster cast of the cavity of a full-time uterus has not yet been made. We have, fortunately, casts of the eighth month's uterus and of the developed genital canal near the end of the second stage. These casts my friends Drs Barbour and Webster have placed at my disposal and I have utilised them as follows:—

On the cast of the eight months pregnant uterus, I marked off the lower uterine segment approximately as lying within  $2\frac{1}{2}$  in. or  $6\frac{2}{5}$  cm. from the os internum. This hemispheroidal portion was covered with paper and the paper flattened out, measured. The area was 15 sq. inches.

In the developed lower uterine segment (with probably part of the cervical canal) I found the area, taken in the same way to be 37.75 sq. inches.

These data are imperfect, as the pregnant uterus was an eighth month's one, and Barbour and Webster were unable to fix definitely the lower limits of the lower uterine segment in the labour one. The measurements do not however exaggerate the amount of expansion of the lower uterine segment during labour but fall short of it, inasmuch as the canalised part is considerably stretched during the pains. I hope that subsequent observers will by plaster casts give us fuller and more exact data.

Hæmorrhage, however, in placenta prævia often comes on at the seventh or eighth month, and many, especially Bayer, have attempted to explain this on the theory that the taking up of the supravaginal portion of the cervix into the uterus causes the separation of the placenta and the hæmorrhage. I am not inclined to accept this view, but the question is complex and must be considered as still *sub lite* so far as hæmorrhage at the seventh month or so is concerned. The condition of the edge of the placenta in such cases, *viz.* its somewhat atrophied condition, is still open to investigation, especially from the point of view of the persistence of the reflexa.

Placenta prævia in all its aspects is no new thing in labour. At the end of pregnancy we have, normally, the membranes lining the lower uterine segment, *i.e.* we have the prævial membranes. These in normal labour become separated up to the retraction ring and give the slight tingling hæmorrhage so indicative of first stage pains. In the first stage of abortion at the second month we get the thickened decidua vera in the lower segment also separated, and thus the more abundant bleeding of early miscarriage. In placenta prævia we get the prævial



portion of the placenta separated from the morbidly vascular lower segment, and thus a hæmorrhage tremendously exaggerated as compared with the trifling diagnostic hæmorrhage of early normal labour.

I have now finally to take up the great question of Treatment.

It would be impossible to do more than indicate the leading principles which should guide one in such cases.

It is evident from the preliminary anatomical and physiological facts I have laid before you, that the hæmorrhage can best be arrested by pressure and that one should certainly use a form of pressure which also canalises the lower uterine segment and cervical canal. These are, however, not the only principles for guidance one must rely on. In any treatment the antiseptic method must be carried out with the strictest care and thus any prolonged form of treatment will put greater risks of failure in this most important feature of all obstetric operations. A last guiding point is that we are too apt to forget that the largest number of placenta prævia cases must be treated by the general practitioner who looks to the specialist for guidance as to the simplest and safest method of treatment.

I am convinced that the plan of treatment most available in the majority of cases is the bipolar version of Braxton Hicks, performed as early as the dilatation or dilatability of the maternal passages allows, with subsequent rapid or slow delivery of the child as the case may demand. The advantages of this method of treatment are ; (1) that it can be performed even with slight dilatation of the cervical canal ; (2) that it absolutely checks hæmorrhage ; (3) that the limbs and breech drawn down dilate the mother's canals ; (4) that it does not perceptibly increase the mother's risks ; (5) that only in cases of rigidity of the maternal parts or prolapse of the cord it diminishes the chance of the child's life ; (6) that it permits of thorough antiseptics ; (7) that it leads to no delay in urgent cases and requires no special armamentarium. This treatment I advocate unless in those slight cases where rupture of the membranes is sufficient.

I do not exclude dogmatically other forms of treatment. The tamponnade of the vagina until cervical dilatation is sufficient to allow of version has given good results in the hands of many. Of the separation of the placenta from the lower uterine segment as recommended by an eminent authority, Dr Barnes, I have no personal experience, and so far as I know no sufficient basis has as yet been brought forward to recommend its employment.

Practically speaking we must always rely on early version and judicious delivery. This will give the best results in multiparæ. The difficult cases are in elderly primiparæ or in those where the placenta occupies nearly the whole of the lower uterine segment (central). In the first named one gets great help from the use of india-rubber dilators



(Keiller, Barnes, and others) passed into the cervix and followed by version as soon as possible, the labour being then left to go on as above indicated. In the so-called central placenta prævia it is best to perforate the placenta, bring down a foot, and leave the labour to go on slowly or not as may seem best.

We must not aim at too much. The mother's life is first, the child's second. One must therefore not spend too long in dilating with dilators, as that may cause great blood loss; nor extract too rapidly, as we thus get laceration of the mother and additional hæmorrhage.

After the question of version, the next most important is that of stimulation. We are often summoned when much blood has been lost, and stimulation imperative. For such stimulation, nothing is better than hypodermics of sulphuric ether and autotransfusion. I would specially recommend subcutaneous saline transfusion with the apparatus of Münchmeyer. It is simple and effective, and, above all, is no last resort. To my mind its great value is that it can be used in advance of urgent indications, can be safely trusted even to the inexperienced and young practitioner, and does not require those absolute indications necessary for venous transfusion. Above all, it is a practitioner's remedy—one that from its simplicity can be improvised readily with a simple funnel, a piece of tubing, and the ordinary hollow needle of an aspiratory case. Sterilisation of the apparatus is easy, and the salt solution at 100° F. can be readily prepared in the proportion of one teaspoonful of salt to the pint. I have repeatedly used it with great benefit, and in my maternity service it is always employed in placenta prævia cases, even where the loss of blood has not been too great.

This seems to me an important point—the fact that by it we can, in advance of serious indications as it were, increase markedly the bulk of the maternal blood.

Even when delivery is completed the obstetrician's anxiety is not finished, and careful watch must be kept against *post-partum* hæmorrhage. As this most often comes from the lacerated cervix, reliance must be made on pressure with the fingers, or when necessary the lacerated lips may be stitched. If the hæmorrhage comes from the lower uterine segment, Duhrssen's iodoform tampon should have a fair trial.



## CHAPTER XV.

### THE ANATOMY AND MECHANISM OF EARLY ABORTION.

THIS subject, especially the mechanism, has as yet attracted very little attention. Through the kindness of Dr Bruce, I have had several aborting uteri to examine, and these will form the basis of the present communication. The specimens are five in number, and comprise—

- (1) *Six to eight weeks pregnant uterus in first stage of abortion.*
- (2) *Uterus, with greater part of membranes still adherent to fundus.*
- (3) *Uterus, with incomplete abortion.*
- (4) and (5) *Uteri after abortion.*

As the first was a unique and very valuable specimen, it was examined specially, and entire sections made by means of the celloidin process, so as to keep everything *in situ*. These sections were very successful. The other specimens were utilised chiefly to show the anatomy of the lower uterine segment.

I purpose considering the subject of this paper under the following heads :—

- I. The Gross Anatomy of the Uterus of Early Pregnancy.
- II. The Descriptive Anatomy of the Early Aborting Uterus in its First Stages.
- III. The Mechanism of Abortion.

#### I. THE GROSS ANATOMY OF THE UTERUS OF EARLY PREGNANCY.

If we take the two months uterus<sup>1</sup> as our specimen, it will be found that it is made up of the cervical canal and body proper, the former being about  $1\frac{1}{2}$  inches long, the latter 3 inches in a straight line from os internum to fundus. Its antero-posterior depth, at its greatest, is nearly  $2\frac{3}{4}$  inches. Inside we have the early foetus lying in the amniotic cavity, and both domed in by the decidua reflexa, which has not, as yet, blended with the decidua vera (*v. fig. 2*).

The lower uterine segment has not as yet been sufficiently studied in

<sup>1</sup> These measurements are based on three of these specimens prepared by Braune, Hofmeier, and myself.



early pregnancy. As we shall see, it is well marked as the result of uterine action in the aborting uterus, and therefore investigation on its conditions in early pregnancy is urgently needed. In Hofmeier's specimen he notes that the part of the anterior uterine wall, with loose peritoneum, is nearly an inch in extent.

In all but one of the specimens examined, the serotina is relatively large, and the placenta has developed to a small extent on the beginning of the reflexa.<sup>1</sup>

There is thus in the early pregnant uterus a portion not entirely attached, viz., the part covered by the reflexa, its only attachment to the uterus being by the broad-based serotina.

In the deep layer of the serotina, and also in the vera, there is a well-marked spongy layer next the uterine wall, and it is here that we have the line of separation during abortion.

## II. THE DESCRIPTIVE ANATOMY OF THE EARLY ABORTING UTERUS IN ITS FIRST STAGES.

The special specimen I wish first to describe is an entire two months uterus in the first stage of abortion. Dr Bruce had laid it open by a longitudinal incision through the posterior wall; the incision had gone through the muscular wall and decidua vera, and laid open the cervical canal fully. One can see (fig. 1) a polypoid swelling in the lower uterine segment and cervical canal, with a fringe of tissue surrounding its neck. This fringe is the portion of the decidua vera separated from the lower uterine segment, by the first stage action, and its lower edge corresponds, or nearly so, to the os internum. The apparent polypus really contains foetus and liquor amnii, covered by amnion and decidua reflexa.

The whole specimen was carefully hardened, prepared in celloidin, and entire sections cut. The principal one is an entire vertical mesial section, but transverse sections were also made to ascertain the condition higher up.

The description of the vertical mesial section is as follows:—It shows the anterior uterine wall, with bladder attached, and ovum with decidua reflexa, in position. The uterine wall is divided into two parts by the peritoneal investment. Down to a point 2 ins. from the fundus the peritoneum is firmly adherent. This, therefore, marks distinctly the retracting portion of the uterus. At this point the attachment of the peritoneum to the uterus becomes markedly loose, and a distinct fold of peritoneum marks the change. The retracting portion has an average thickness of  $\frac{9}{16}$  in., while in the lower uterine segment it varies from  $\frac{4}{16}$  in. to  $\frac{6}{16}$  in. The decidua vera of the retracted portion is still unseparated; over the lower uterine segment it has become detached. This is very well shown, and is in exact agreement with what is known of

<sup>1</sup> Specimens by Hofmeier.



full time labour at the end of the first stage, viz., the membranes (or placenta, in placenta prævia) are separated from the lower uterine segment, but attached where it lies above this.

What has happened in the first stage of this abortion is, that (1) the lower uterine segment has been expanded transversely and longitudinally; (2) the decidua vera has been separated where attached to the lower uterine segment; (3) the peritoneum over the lower uterine segment has had its connective tissue union with the uterus slackened and made more evident; (4) the ovum, covered by reflexa, has been driven down into the lower uterine segment and cervical canal, and lies there like a polypus, the neck of the apparent polypus being found on microscopic examination to be placenta; (5) the bulk of the retracting portion of the uterus has greatly diminished. The measurements on this specimen are as follow:—From fundus to upper limit of lower uterine segment  $1\frac{7}{8}$  ins.; from upper limit of lower uterine segment to os externum  $2\frac{1}{2}$  ins.

There has been only slight elongation of lower uterine segment and cervical canal in a vertical direction, the chief increase being thus transversely. Cases like this have been erroneously described as cervical pregnancy, but such a form of pregnancy is an impossibility.

The difference in thickness between lower uterine segment and body proper is quite evident; whereas, in the pregnant uterus, the thickness of the wall is pretty equal, and, if anything, is greater in the lower uterine segment (fig. 2).

	Two Months Pregnant Uterus.	First Stage of Abortion.
Cervical canal and lower uterine segment . . . . .	} 2 ins. to $2\frac{1}{2}$ ins. 2 ins. $2\frac{3}{4}$ ins. $1\frac{5}{8}$ to $1\frac{7}{8}$ in. $1\frac{1}{8}$ to $1\frac{3}{8}$ in.	$2\frac{1}{2}$ ins.
Fundus to lower uterine segment . . . . .		2 ins.
Antero-posterior of body . . . . .		$1\frac{3}{8}$ ins.
Thickness of body wall . . . . .		$1\frac{3}{8}$ in.
Thickness of lower uterine segment . . . . .		$1\frac{1}{8}$ to $1\frac{5}{8}$ in.

In the specimens where the membranes were adherent on the fundus, and in one where a small portion was still adherent, the looseness of peritoneum over the anterior portion of the lower uterine segment was very apparent.

### III. THE MECHANISM OF ABORTION.

We may take this up under the head of—(a) *Normal and Complete*; (b) *Abnormal*.

(a) *Normal and Complete*.—Of this there are two varieties depending on the size of the ovum proper, covered by the reflexa. When this is small we get the deciduæ separated as follows:—In the first stage of



abortion the decidua over the lower uterine segment is separated. In the later stage all above the lower uterine segment is then separated, and the whole expelled. This mechanism of separation I do not discuss at present, as it is the same as in normal labour, and I have already considered it. The line of separation is in the spongy layer of the vera and serotina.

The second variety of normal mechanism is where, in addition to the early separation of the vera over the lower uterine segment, we get the ovum proper, covered by reflexa, driven down into the cervical canal, but remaining attached above to the decidua over the retracting muscle, by an apparent neck. The rest of the decidua is then separated, and the whole expelled.

(b) *Abnormal*.—We may get the following variations in the process, all being incomplete:—(1) The fœtus alone, or entire ovum, with its chorion may be expelled through the reflexa. The decidua vera et reflexa are retained or expelled later; (2) The ovum covered by reflexa may be expelled, the apparent polypus neck having been snapped. We thus get a part expelled that is often considered by the practitioner as the entire abortion. He sees an oval sac covered by decidua, with amnion below this, and liquor amnii and fœtus inside. It is really only the ovum proper covered by reflexa, and the decidua vera et serotina, in the shape of a sac, are still in utero.

I say nothing in regard to treatment, except one thing. When called on to interfere, as we usually are, at the end of the first stage, the finger passed into the cervical canal feels, at the top of it, A PORTION OF DECIDUA ALWAYS SEPARATED from the lower uterine segment. This indicates the line of separation, and if the finger be passed in along this plane, the entire part to be removed can be bi-manually separated and expelled.

#### EXPLANATION OF PLATES.

##### PLATES XI. AND XII.

- FIG. 1.—Early aborting uterus (end of first stage). The posterior wall has been laid open by a vertical mesial incision passing through the decidua vera ( $\frac{1}{2}$ ).
- FIG. 2.—Early pregnancy (two months). The uterus was removed for cervical cancer: *o.e.*, os externum; *o.i.*, os internum; *F.A.*, upper limit of firm attachment of peritoneum; *pl.*, placenta; *d.v.*, decidua vera; *d.r.*, decidua reflexa. (Hofmeier.)
- FIG. 3.—Vertical mesial section of early aborting uterus; posterior uterine wall not shown.
- FIG. 4.—Vertical mesial section of post-partum uterus (1st day) where placenta had been prævia. (Margonal.)



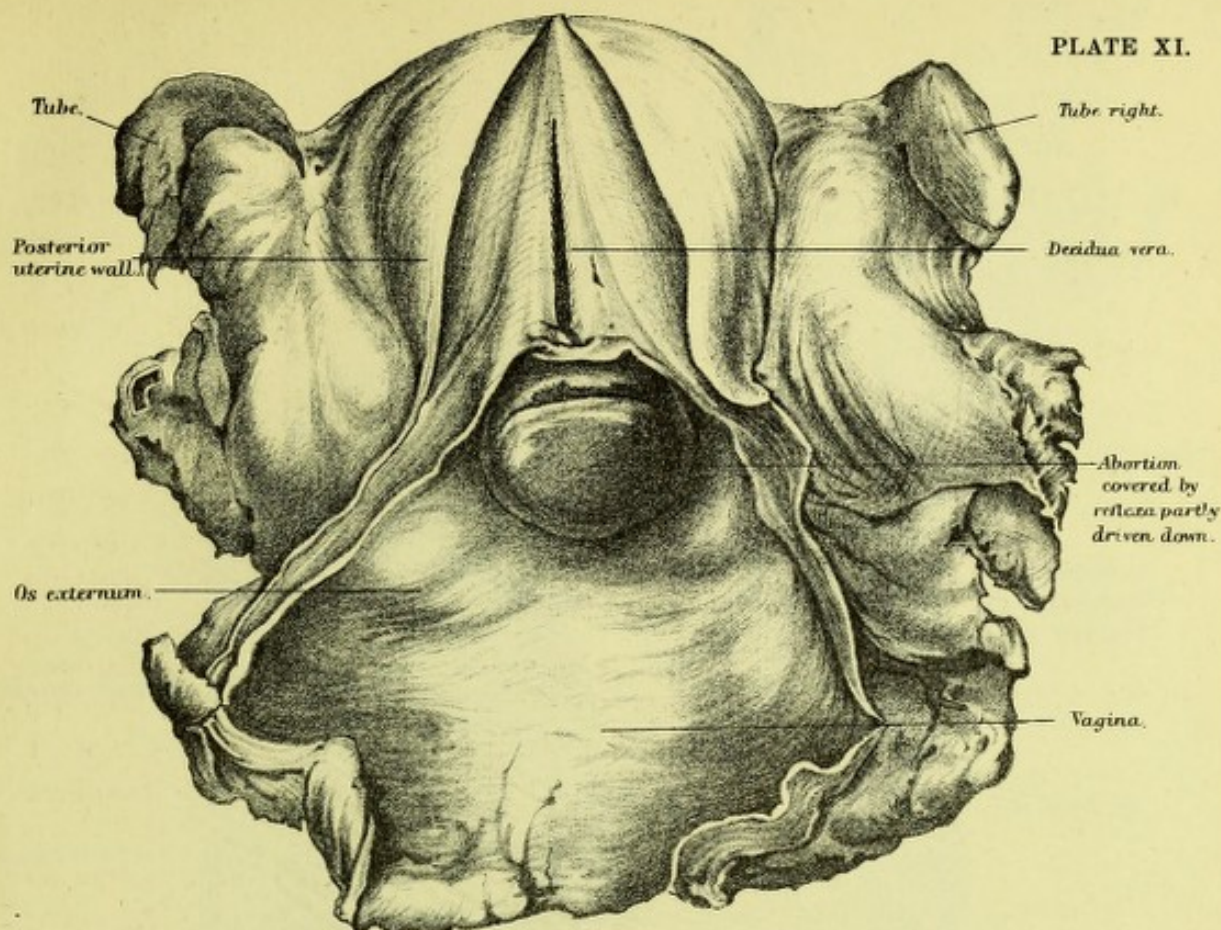


FIG. 1.

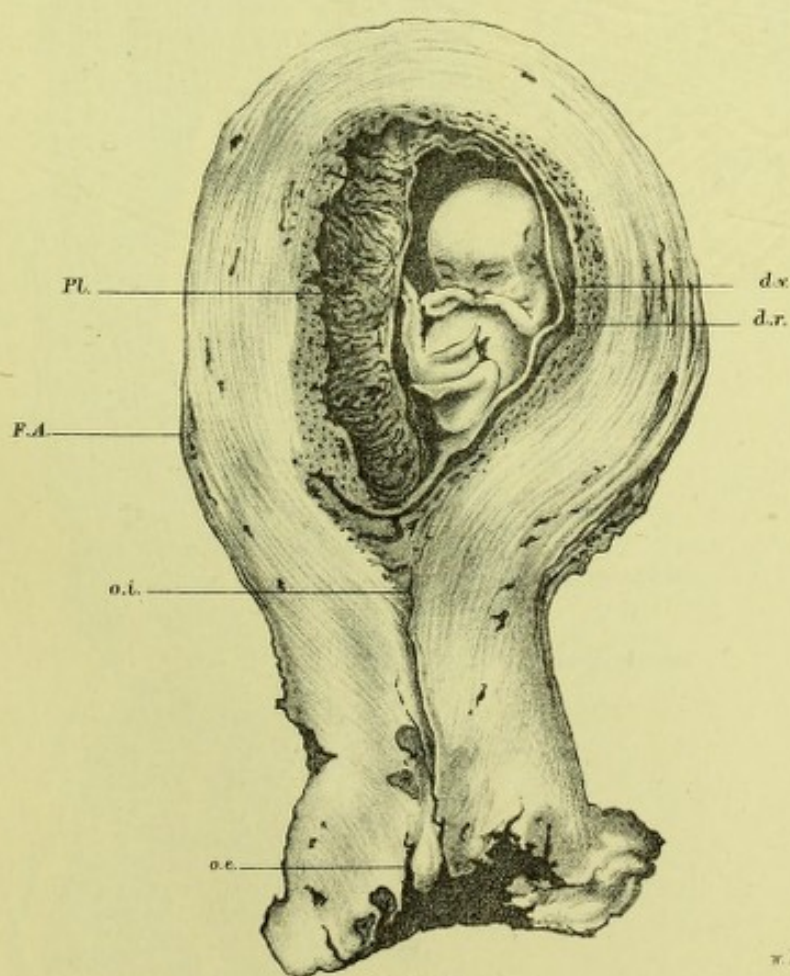



FIG. 2.







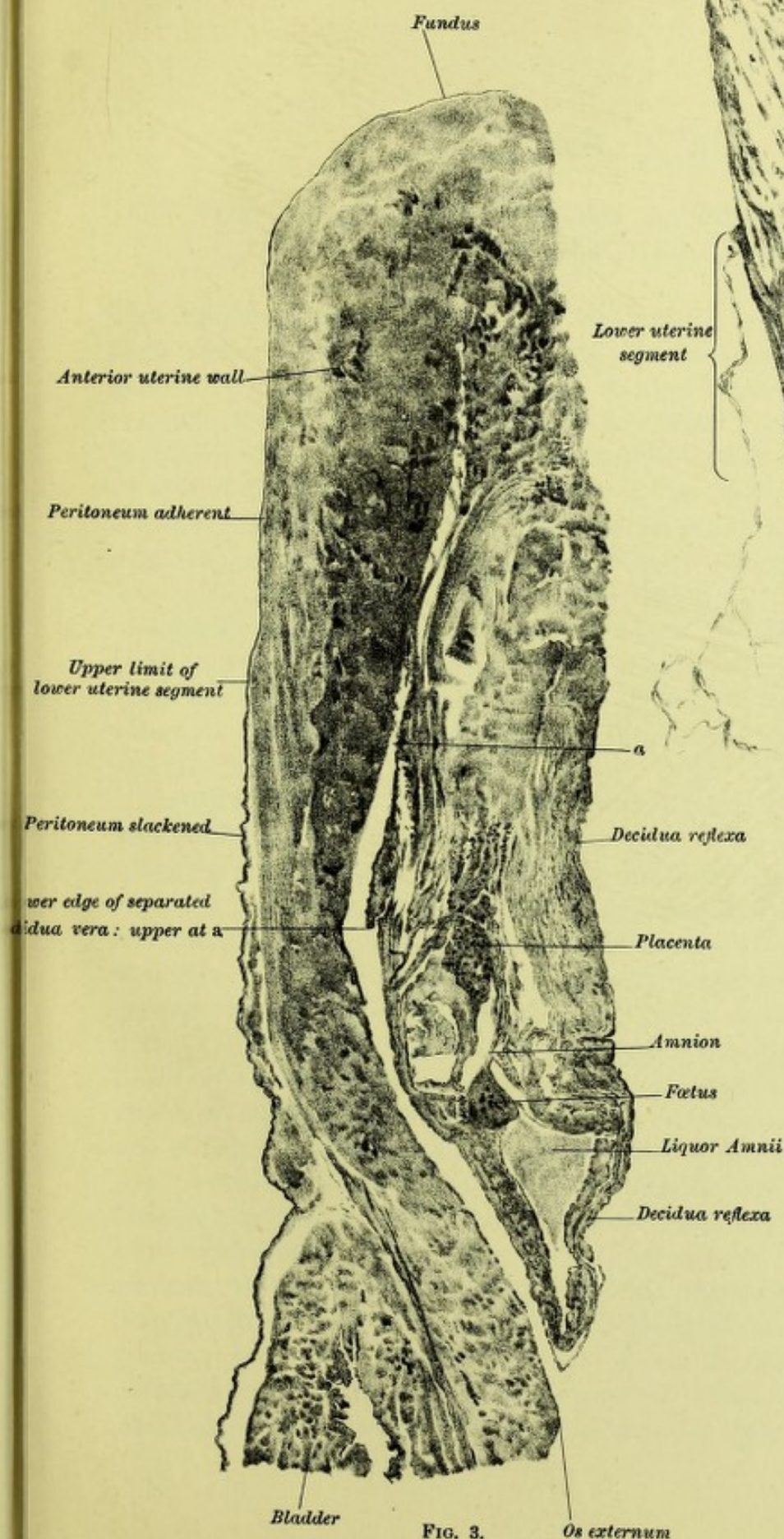


FIG. 3.

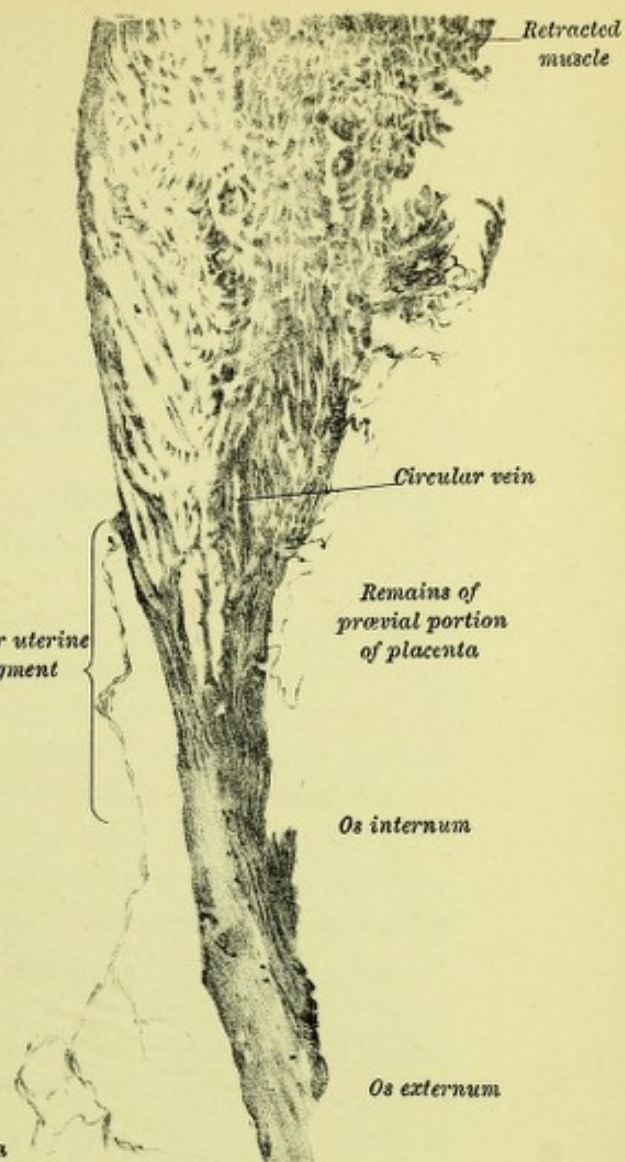



FIG. 4.







## CHAPTER XVI.

### ON THE DILATATION OF THE ANUS AND URETHRA RESULTING FROM NATURAL LABOUR.

THE brilliant and accurate results obtained in pregnancy and labour from frozen sectional anatomy have somewhat overshadowed those gained by clinical investigation. In reality, however, this anatomical research should give a greater impetus to clinical work, as it has enabled us to correct clinical data, to allow for unavoidable errors, and, finally, to extend the necessarily narrow scope of the view given by sections of a frozen cadaver. In a clinical investigation based on accurate measurement we can obtain a picture of consecutive phenomena, whereas the view given by a section is necessarily a picture of only one phase,—undeniably accurate and precise to a degree unattainable by clinical work, but yet limited in its scope. These two methods, and others based on them, must, in fact, go hand in hand. Each has its special value, its special defect, and we must supplement and correct them by careful combination.

To-night I wish to make a short clinical contribution to phenomena well known but not yet accurately described. The changes in the anus when the head is passing the perineum are well known to all, while less known is the dilatation the urethra is subjected to during labour. We have no accurate account of them, and no precise sketch. I thought it would be of value to know the maximum distension of the anus and urethra during labour as a preliminary to some more extended observations. The measurements seemed to me little open to fallacy, and likely to be easily made. In addition, I believed that photographs might be obtained of the perineum in its various degrees of distension, and in this way a permanent record obtained of some of its changes. It was necessary that all this should be carried out in the Maternity Hospital by the Residents, with a certain amount of suggestion and supervision on my part. I am strongly of opinion that much valuable clinical observation could be made by the Maternity Residents, with great profit to obstetric science, to say nothing of the valuable and exact training gained by them personally. I was fortunate in having the measurements made by my Residents of 1890, Drs Marshall and Alexander. I am specially indebted to them for their zeal and accuracy,




and take this opportunity of thanking them for the extra night-work they so cheerfully undertook. The photographic work was done by a former Resident, Dr Melville, to my entire satisfaction; and I have also to thank him for the intelligence and care he took in this matter.

The method employed was as follows:—The anus was measured, at the time of its apparent greatest distension, in two diameters—antero-posterior and transverse. Its shape was noted, photographs of typical cases taken, and the general features of the various changes noted.

The urethral measurements were more difficult to make, so as to avoid fallacy. It was evident that measurements might estimate the maximum distensibility of the urethra more than its normal dilatibility. The following plan was adopted to avoid error as much as possible, as well as because it insured against risk of sepsis to the bladder. Hegar's dilators were taken, and at the end of pregnancy that one passed which seemed to measure its ordinary stretching point. The first one tried was always a large one, not likely to pass, and then successive lower diameters employed, until the one that was chosen fitted. As Hegar's dilators are numbered according to their diameter in millimetres ( $\frac{1}{2}$ "), they were for this reason specially convenient. I am well aware that this method is not by any means accurate, but, as we shall see, it gave approximately correct results.

The same measurement was taken at the end of labour and on the tenth day of the puerperium. The last were made by our excellent staff-nurse, Mrs Hall.

The anal measurements were made on twenty-one cases, of whom sixteen were primiparæ. The average maximum antero-posterior was an inch ( $2\frac{1}{2}$  cms.) as nearly as may be, while the average maximum transverse was slightly over the inch ( $1\frac{5}{8}$ "). The shape of the distended anus was, however, not circular, but that of a reversed D, the vertical limb being forward so, .


The greatest distension is antero-posteriorly, when the head is entering on the perineum (the *Einschneidung* of the Germans), while the transverse is greatest when the head is passing (*Durchschneidung*). Some unimportant variations in shape need not be noted. In one case a photograph was obtained at the moment when the child's nose had passed, and the anus is then a transverse slit. (*Vide* first table.)

The next table gives the results of the urethral measurements. The initial calibre at end of pregnancy was that of a dilator whose diameter lay between 6 and 8 mm. After the third stage the dilatibility varied between 9 and 12 mm., the average increase being almost exactly 3 to 4 mm. On the tenth day of the puerperium the calibre was usually 1 millimetre above the one at the end of pregnancy.

I have now finally to consider the mechanism of these changes and their physiological and pathological bearings, if any. The anus is



normally a closed slit passing through the pelvic floor nearly at right angles to the long axis of the vagina, and it is so closed that we have its short lateral walls in apposition (Symington), and the external aperture a very short sagittal mesial line.

When the head is entering on the perineum we get a transverse stretching of the perineum, the well-known convex bulging, and also an elongation and driving back. The part of the sacral segment in front and inclusive of the anterior rectal wall is elongated and driven forward more markedly than that behind, and thus we get the anus converted into a flattened ring, through which the anterior rectal wall is seen. The anus is, therefore, altered into the  shape already given. The greatest distension is found when the broad occiput is passing the anus; but when the occiput has passed and is emerging, the narrower sinciput, and the fact that the occiput is now elongating the hymen and vulva, expose the anus to less tension and give a lessened transverse, and especially a smaller antero-posterior diameter.

The stretching the anus undergoes at this time sometimes causes fissure, but it is rare to find fissure remaining as a condition requiring operation. This is apparently prevented by the stretching of the sphincter, which, as we know, is the cure for fissure of the anus and its intense pain, *i.e.*, the stretching of the anus during labour will cure fissure if it causes it.

The urethra, like the anus, is a closed muscular slit. The exact relations of the walls are disputed, and need not detain us at present. That the urethra becomes distended or permeable to an instrument of larger calibre is known to many, I have no doubt, inasmuch as I have known of the finger passed into the bladder inadvertently after labour, and also the vaginal tube of the douche inserted, and the bladder distended instead of the vagina washed out.

The measurements made in the second table show a distinct increase in the capacity of the urethra for distension. This, so far as one could judge, chiefly affects its lower part; but the exact length of this portion was not ascertained, and would be difficult to estimate clinically. The cause of this increased capacity for distension is evidently the transverse stretching of the vagina by the occiput. The close blending of urethra and vagina makes the urethra participate in this vaginal distension, and explains the condition of greater dilatability after labour. The urethra is apparently not elongated in its long axis during labour, as we learn from sectional anatomy.

In conclusion, I would urge that an investigation on frozen puerperal sections as to the amount of urethral, bladder, and rectal stretching would be of value. The inquiry would be of value in relation to the retention of urine after labour. As a matter of fact, we may have paresis of the bladder in the puerperium causing retention if there is



any urethral spasm from vaginal, perineal, or vestibular lacerations. Where there is no laceration the paresis of the bladder may be counter-balanced by the diminished urethral resistance brought about by its stretching. These factors have been entirely overlooked hitherto, but evidently must be accounted for and given their right place in estimating the causation of these conditions.

No.	Para.	Antero-posteriorly.	Transversely or Laterally.	No.	Para.	Antero-posteriorly.	Transversely or Laterally.
1	i.	1 inch	1½ inch	13	i.	2 inch	1½ inch
2	i.	1 "	1½ "	14	i.	1½ "	1 "
3	i.	1 "	1 "	15	i.	1½ "	1½ "
4	i.	1 "	1½ "	16	i.	1 "	1½ "
5	i.	1 "	1½ "	17	ii.	1½ "	1½ "
6	i.	1 "	1 "	18	ii.	1½ "	1 "
7	i.	1 "	1½ "	19	v.	1½ "	1½ "
8	i.	1 "	1½ "	20	vi.	1½ "	1 "
9	i.	1 "	1½ "	21	ix.	1 "	1 "
10	i.	1 "	1½ "			20½ inches	22½ inches
11	i.	1½ "	1½ "			1 inch	
12	i.	1½ "	1½ "				

No.	Para.	Before Parturition.	After 3rd Stage.	End of Stay in Hospital.		Remarks.
				No.	Day.	
1	i.	6 <i>Hegar</i>	10	7	11th	{ In 2nd Stage when admitted.
2	i.	6 "	9	7	10th	
3	i.	?	8	8	10th	
4	i.	6 "	10	7	13th	
5	i.	7 "	10			
6	i.	7 "	10	6	16th	
7	i.	7 "	10	7	10th	
8	i.	7 "	10	8	13th	
9	i.	7 "	10	7	12th	
10	i.	7 "	9	6	9th	
11	i.	8 "	11	8	11th	
12	i.	8 "	9	6	10th	
13	i.	8 "	11			
14	i.	8 "	10			
15	i.	9 "	12			
16	ii.	7 "	10	10	20th	
17	ii.	7 "	9	8	10th	
18	ii.	8 "	11	8	10th	
19	ii.	8 "	11	8	10th	
20	ii.	8 "	10	8	10th	
21	ii.	8 "	10	7	10th	
22	ii.	8 "	10	7	10th	
23	iii.	8 "	10	7	10th	



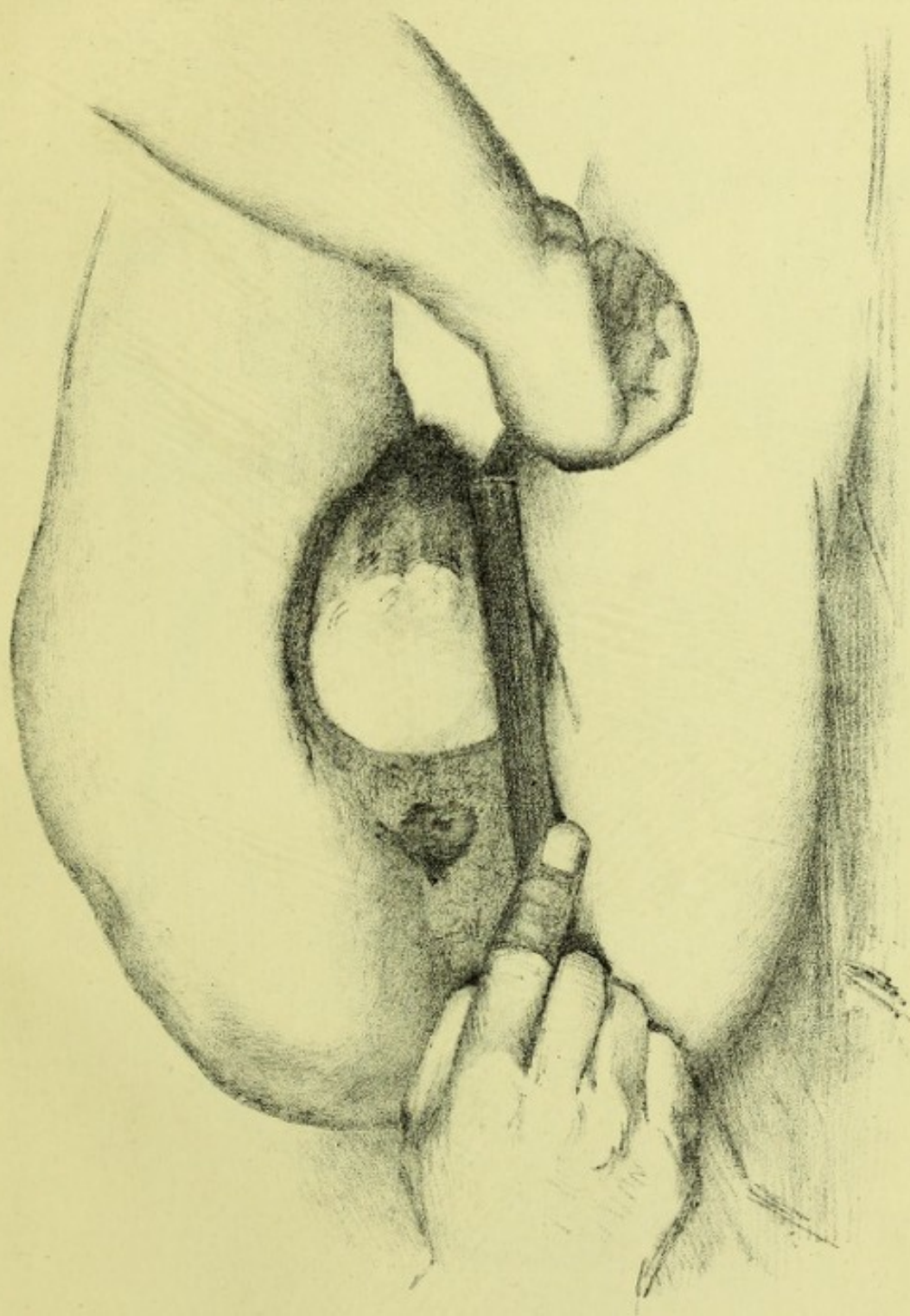



FIG. 40.—HEAD PASSING PERINEUM NORMALLY. The posterior hand holds foot-rule for measurement.







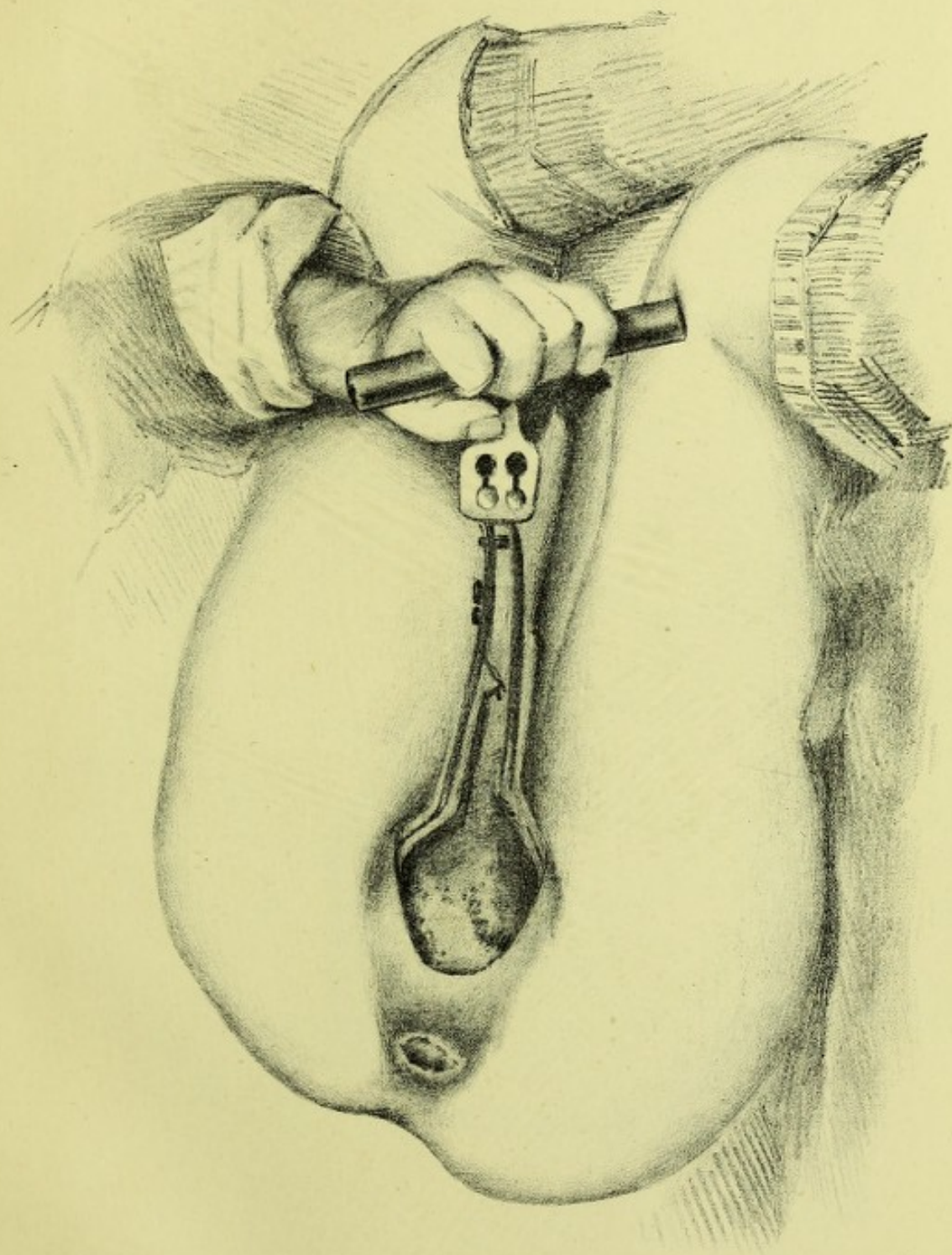



FIG. 41.—HEAD DISTENDING PERINEUM IN FORCEPS CASE.







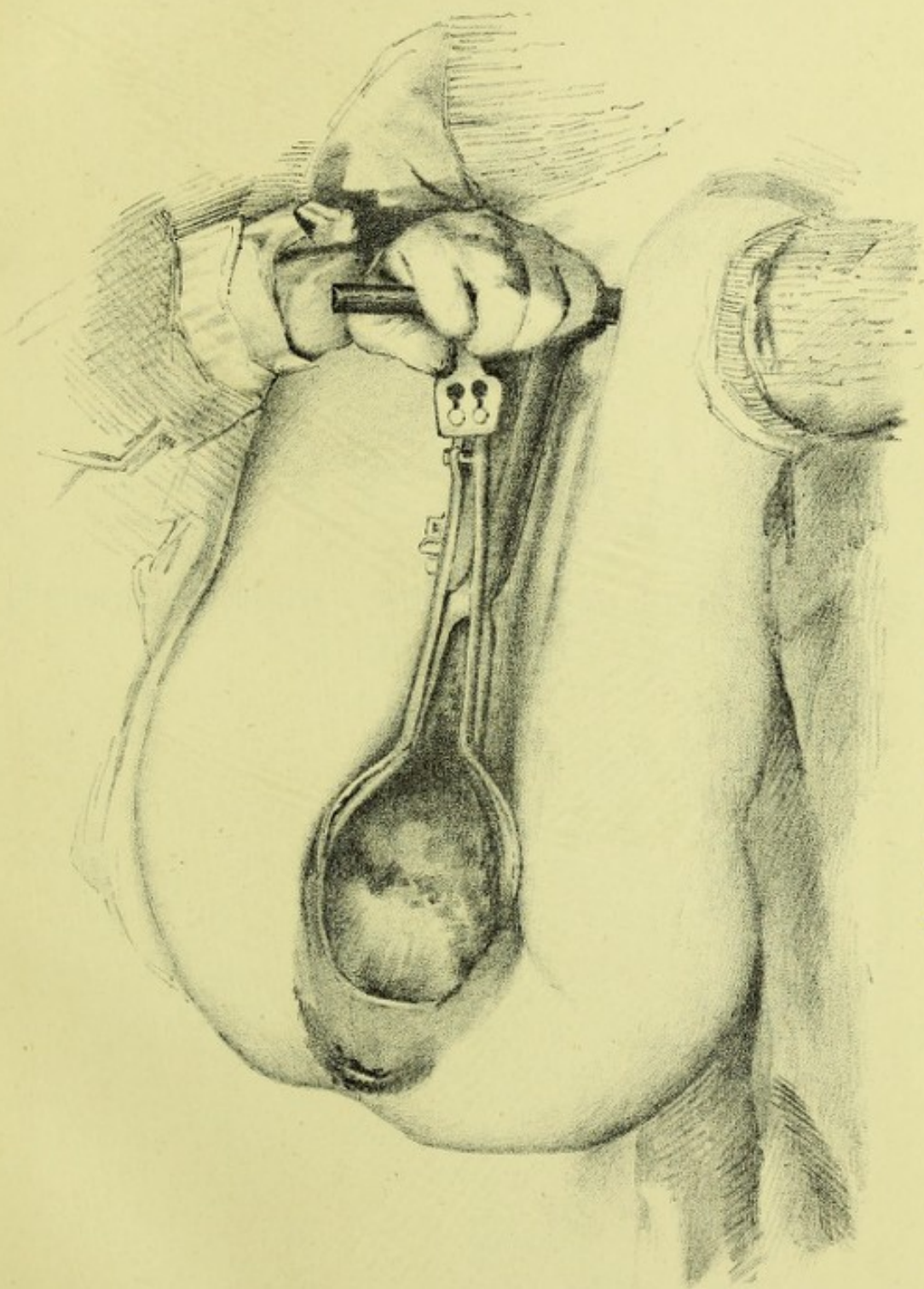



FIG. 42.—HEAD DISTENDING PERINEUM IN FORCEPS CASE.







# PART III.

CONTRIBUTIONS TO OBSTETRIC AND GYNÆCOLOGICAL  
PATHOLOGY.



PART III

CONTENTS OF PART III AND THE APPENDIX  
LISTED



## CHAPTER XVII.

### A CONTRIBUTION TO THE SECTIONAL ANATOMY OF ADVANCED EXTRAUTERINE GESTATION.

No subject presents more points of interest to the gynæcologist than Extrauterine Gestation. The remarkable nature of this deviation from normal pregnancy, the difficulty attending its diagnosis, the protean changes it may undergo during its development, as well as the marked risk both to mother and child, render it one of the most important subjects for his investigation. Although many observers have been in the field, and much has been added to our knowledge through their valuable investigations, the number of points on which even elementary information is needed is very great. Of these the most clamant is an anatomical one. We do not know to a demonstration what is the site of advanced gestation and what stages it has passed through prior to this, although some important links in the chain have been found by Dezeimeris, Lawson Tait, Werth, and Fränkel.

The authors have examined frozen sections of two specimens—the one a four and a half months' extrauterine pregnancy *in situ* in the bony pelvis; the other an entire cadaver with advanced abdominal gestation.

One important point is in regard to the method of investigation adopted. Ordinary anatomical dissection of specimens removed from the body in the ordinary way is notoriously defective and unsatisfactory, and has led to several specimens being described erroneously as ovarian when they were really in the broad ligament. The only accurate way to study such is to do so by frozen sections of the entire cadaver, or at any rate of the specimen still in relation to the bony pelvis. We thus see peritoneal relations undisturbed, and can without much displacement examine the entire sections by a method of modified dissection.

The first specimen had advanced to between the fourth and fifth month. Dr Hart saw the patient for the first time in the Buchanan Ward of the Royal Infirmary, and found her with a tumour the size of a cocoanut in the site of the right broad ligament, and reaching from the right iliac margin to the region of the recto-vaginal space, which



bulged down markedly. The uterus was displaced to the left side, as well as upwards, and was about the size of a two months' pregnancy. From the history of five months' amenorrhœa, and the occasional attacks of fainting and pain during that time, there was no difficulty in coming to the conclusion that we had here to deal with an extrauterine gestation developing between the layers of the broad ligament. Two days after, the patient collapsed markedly, evidently from rupture of the sac and loss of blood. Eight hours afterwards, when she had somewhat rallied, an exploratory abdominal incision was made to see if anything could be done. Blood poured out whenever the peritoneum was opened, and on passing the fingers in, rupture deep down through the posterior lamina of the broad ligament was found, a condition which did not admit of removal of the sac, inasmuch as it had developed down between the rectum and vagina. The incision was therefore closed, and the patient sank in about ten hours.

On post-mortem, which was performed by Dr Bruce, the bony pelvis and contents were removed and frozen, and in this way the relations were preserved—an impossibility if the parts are scooped out from the pelvis in the usual way.

The pelvis when frozen was sawn in the mesial, right sagittal lateral, and left sagittal lateral planes, so as to cut sac and uterus.

The following points are noteworthy :—

In the mesial line the foetus and placenta are contained in a space bounded above by the laminae of the broad ligament, and below by the paraproctal tissue and that at the base of the broad ligament. The placenta is attached to the inner aspect of the tube and broad ligament, the foetus lying below. The vertical measurement is 4.10 cm., the transverse 8.7 cm.

A similar section to the left of the middle line shows the enlarged uterus, and hæmatoma between the peritoneum and the rectum. The rupture had occurred through the posterior lamina, and low down.

The uterus measures 10 cm. vertically, has a well marked decidua, and the dip of the vesico-uterine pouch is only 5 cm. from the fundus. The left Fallopian tube and ovary are intact. This specimen, therefore, shows that the gestation, primarily Fallopian, had developed between the layers of the broad ligament and into the connective tissue between the peritoneum and rectum. It was thus, prior to its intra-peritoneal rupture, entirely extra-peritoneal (*v.* Plate XIII., figs. 1 and 2).

The second specimen was the unopened body of a female, aged 38, small and very emaciated, who was supposed to have gone a little beyond the term of normal pregnancy; but little information of any kind could be obtained, as she was destitute, with no friends. The usual appearances of a multiparous pregnancy were present, without any varicosity of the venous system.



On delivery into the dissecting-room the extremities were cut off; and the head and trunk, after a process of freezing by means of ice and salt, were cut into a series of sagittal mesial and lateral slabs, six in all, of about  $1\frac{1}{2}$  inches in thickness. These slabs may be for convenience mentioned as 1R, 2R, 3R and 1L, 2L, 3L—viz., the first slab on the right side, and so on.

In the sagittal mesial section the saw passed almost exactly in the mesial plane of the body. There is nothing particular to remark about the brain and head and neck, the specimen presenting the usual appearances exhibited in sections made in this manner.

In front of the spinal cord and within the dura mater there was found a thin layer of granular-looking substance, which extended as low down as the tenth dorsal vertebra; after examination, it was found to be albuminous in nature.

*Thorax.*—The mesial section was made through a part of the right lung, which projected a little to the left of the middle line; the aortic arch was cut through, exposing the semilunar valves and the origin of the innominate artery. The sagittal section shows the œsophagus in the upper part of its thoracic portion, and also its cardiac termination at the stomach.

The right auricle is seen, and the right ventricle with its tricuspid valve are cut through, both columnæ carneæ and chordæ tendineæ being well exposed. The left auricle is shown in the mesial section in front of the spinal column as a vertical slit, the greater portion lying more to the left of the plane of section. The left lateral sections also exhibit the left ventricle.

The posterior and diaphragmatic surfaces of the lungs were found to be firmly adherent to the thoracic wall, and the right side of the heart and great vessels were more or less filled with a buffy coagulum of blood, which had to be removed after the parts were hardened in spirit.

The antero-posterior diameter of the thoracic cavity at the lower end of the manubrium sterni is 6.50 cm., and at the upper level of the diaphragm, is 9 cm. These measurements are small and can be accounted for to a certain extent by the small size of the subject. Dohrn endeavours to show, by a series of chest measurements, that the antero-posterior diameter of the base of the thoracic cavity is diminished during pregnancy. This body cannot, however, be taken into account as in any way tending to prove that such is the case, or to the contrary.

The heart was small, with no fat, and the valves were in a normal condition. The upper portion of the left auricle reached up to the fifth dorsal vertebra, and the lower part of the base of the heart was on a level with the lower margin of the eighth dorsal vertebra. The thick-



ness of the apex of the left ventricle was 0.4 cm., and although the heart was small, the greatest thickness of the left ventricular wall amounted to 1.5 cm. Taking Peacock as our authority, we find the greatest average thickness of the left ventricle in a normal heart to be 1.26 cm., and at the apex 0.526 cm. Du Crest gives 1.5 cm. in pregnant females as the average thickness, supporting Larcher's view that the ventricular wall has increased during the pregnant period. The heart being small in this case, and the measurements of the left ventricle, at the same time, being above the average, it is probable that there has been an increase in the thickness of its wall. This derives additional interest from the fact that the increased vascularity of parts about the foetus is principally due, as regards the mother, to increased calibre of the vessels in the extra-peritoneal tissue, and not to a special differentiation of uterine mucous membrane. This increased thickness of the ventricular wall would not be due to any necessity for an increased driving power or an increase in the vascular fluid required for a specialised maternal placenta. The uterus is sympathetically enlarged as well as remarkably elongated in its cervical region. From the os externum to the os internum (*i.e.*, to vesico-uterine dip) is 3 inches, the body being  $4\frac{3}{4}$  inches long. It is remarkable that the cervix is elongated, as in prolapsus uteri.

The diaphragm reaches as high as the lower border of the eighth dorsal vertebra, and is higher than those exhibited in Braune's illustrations of sections of pregnant females. The cause of this is due to the greater upward growth of the tumour and the small abdominal distension in an antero-posterior direction. The abdominal wall in front derives great support from the position of the uterus which lies immediately behind it.

The kidneys are enlarged, and the calibre of the ureters and pelvis of the left kidney greatly increased, the ureter being irregularly dilated in its course towards the bladder (hydronephrosis).

The stomach was almost empty, containing only a small quantity of fluid food. In the mesial section its pyloric end was cut through (Pl. XIV.), being bent backwards and to the right. The duodenum is seen embracing the head of the pancreas opposite the twelfth dorsal and first lumbar vertebræ. The small intestines were matted together and pushed over to the left in the abdominal cavity. The transverse colon, which was distended with gas and contained very little faecal matter, together with the great omentum, was adherent to the abdominal wall in front. Its under surface was greatly thickened and firmly adherent to the foetal tumour, Pl. XIV. The sigmoid flexure is seen in the left lateral section as a vertical slit.

In describing the gestation sac and its contents we shall try to avoid too minute detail. The first great point to settle is the relations of the



peritoneum to the sac, and it will simplify matters if we state the one broad fact brought out in the sections—viz., that the *gestation is entirely extra-peritoneal, and that foetus and placenta lie in extra-peritoneal connective tissue.*

The foetal capsule and its contents, which occupy a great portion of the abdominal cavity, rise up to the upper margin of the second lumbar vertebra and extend well into the right half of the sections, pushing the intestines up and to the left. In front the tumour is separated above from the abdominal wall by the great omentum, while below, its wall is formed by the uterus; behind, it is separated from the posterior abdominal wall by a double layer of peritoneum. The uterus is much enlarged, the upper surface of the fundus being on a level with the upper border of the first sacral vertebra. It was pushed over to the left side, none being found in the right outer lateral section. The peritoneum has been entirely stripped away from its posterior and the upper part of its anterior surfaces; and from the fundus bands of tissue connect it with the upper and inner surface of the foetal sac. On the left side of the fundus a small fold of peritoneum enclosed the left Fallopian tube and left ovary.

The left Fallopian tube passed obliquely downwards from the left side of the fundus to the left iliac fossa, its fimbriated end being attached to the tumour.

The left ovary was found below the Fallopian tube and left under surface of the capsule, and is seen in the left lateral section 3 from the median line in the angle between the abdominal wall and left iliac fossa (*v.* Plate XV., fig. 6). It measured  $1'' \times 1\frac{3}{8} \times \frac{3}{4}$  in thickness, and was enclosed in the same fold of peritoneum with the Fallopian tube. The ovarian vessels were greatly increased in calibre. The right Fallopian tube and ovary cannot be identified, being taken up with the sac.

*Peritoneum.*—Owing to the surfaces of the peritoneum being more or less adherent, it required great care to trace its general relation. In the mesial section it will be seen to be reflected from the inner surface of the anterior abdominal wall on to the front of the uterus at the upper level of the pubes; the bladder lies below the lines of reflection, and is deficient of a serous covering. The front of the enlarged uterus is covered for a short distance, and the peritoneum is there reflected on the foetal capsule. The uterus for about 4 cm., projects into the cavity of the capsule, this portion of its surface being rough and deficient of any serous investment. The foetal capsule is seen to be enveloped in front and above, and behind the membrane is reflected on to the rectum at about the level of the fourth sacral vertebra. On the left side the peritoneum passes from the left iliac fossa and covers a small portion of the upper part of the body of the uterus, and from this is reflected on to the capsule, forming a fold in which the left Fallopian tube and ovary



are enclosed. The relations of the peritoneum to the other organs do not require any special remark.

On the right side the peritoneum is lifted up. The foetus has thus developed beneath the peritoneum, elevating the folds of the broad ligament after distending them, and in its upward growth stripping the peritoneum up from the right side of the anterior abdominal wall for a distance of  $7\frac{5}{8}$  in. above the pelvic brim. Posteriorly the deepest portions of the pouch of Douglas lie at the level of the fourth and fifth sacral vertebræ.

The foetal capsule and its contents are found to extend into the hypogastric, umbilical, lumbar, and right inguinal regions.

The *Sac* can be studied in all its relations in the sections. Microscopical examination of its walls were made at various points—viz., at its uppermost portion, and also at the anterior abdominal wall below the peritoneal reflection (Plate XIV., fig. 4).

In the former part there was peritoneum and unstriped muscle, showing the Fallopian tube origin; in the latter connective tissue. The capsule was thus formed by connective tissue, bounded outside by the special structures displaced—viz., either by muscular abdominal wall or by peritoneum.

On the right side of the body a deep dissection was made from the skin, and the cæcum and peritoneum found displaced up.

Further details and drawings on this point will be given when an account of the minute structure of the placenta is published.

*The Uterus.*—The cervix contained a plug of mucus, and in the flattened cavity of the uterus was found a small amount of disintegrated tissue.

*The Foetus* is situated below the placenta and between the uterus in front and the abdominal wall behind. Together with the placenta, it is seen to be enclosed in a distinct capsule.

The placenta consists of an oval-shaped and flattened mass of tissue situated in the abdominal cavity and extra-peritoneally, and lying above the foetus. Its long axis is directed up and down, and in the mesial section is seen to extend from the upper margin of the second lumbar vertebra to a little below the upper border of the first sacral vertebra. It is attached to the posterior aspect of the anterior abdominal wall and outer surface of peritoneum. Where attached to the anterior abdominal wall, the veins there are enlarged.

The diameter of its long axis is 13.5 cm., and its average antero-posterior measurement is 7.5 cm. Around it is a thin investment of connective tissue, and it is firmly attached at points, especially in front and above, to the surrounding capsule by bands of vascularised tissue. In the right sections a cavity is seen between the capsule and the placenta, which was filled with a mass of grumous blood and gases of



decomposition, the position of which corresponds to a well-defined darkening of the skin of the anterior abdominal wall, as if the patient had suffered from a severe blow or fall.

The fœtus weighed 2 lbs. 4 oz. without the umbilical cord. It was fairly well nourished, but decomposition had commenced, especially at the lower part of the abdomen. Around the body and flexed extremities it measured  $13\frac{1}{2}$  inches in circumference, and around its long axis  $18\frac{3}{4}$  inches. The head was covered with hair, and the nails were well developed. The position of the fœtus was peculiar—the face looked directly upwards, the head was bent abruptly backwards, and both thoracic and abdominal cavities were greatly flattened antero-posteriorly. The right arm and forearm were bent backwards, and rested along the right side of the head, the wrist and hand being flexed. The left arm was rotated inwards, and rested along the left side of the body, and the hand was flexed in the concavity formed by the extended back of the fœtus. The right thigh was twisted round, and the knee flexed so that the anterior surface of the leg looked backwards, the foot being turned outwards and abducted. The left thigh and left ankle were extended, the knee was flexed, the sole of the foot looking upwards. The general arrangement of the body and limbs will be better understood by shortly stating that the head being sharply bent backwards and the trunk flattened and extended, a concavity was formed behind, in which the extremities were more or less situated. The internal antero-posterior measurement of the thoracic and abdominal cavities had an average measurement of only 3 mm. No examination of the internal organs of the fœtus was possible from the decomposition which had set in, and the saw having passed through the body three times while making the sections. From the umbilicus the cord passed upwards to the placenta between the latter and the posterior surface of the capsule. Development of fœtus corresponded to about the seventh or eighth month.

The consideration of these two sections shows, therefore, a special phase in the development of extrauterine gestation. They demonstrate that a Fallopian tube pregnancy may develop between the layers of the broad ligament, and may continue this extra-peritoneal mode of growth, stripping off the peritoneum from the uterus, bladder, and pelvic floor, until it becomes in great part surrounded by a peritoneal capsule derived from these organs. All this is done without any actual intra-peritoneal invasion. The placenta in the advanced gestation case is attached in front to the extra-peritoneal connective tissue, the veins there enlarging and acting like uterine veins.

In this special cadaver, therefore, the gestation began probably in the right Fallopian tube, developed into the layers of the broad ligament, and grew extra-peritoneally, lifting up the peritoneum on the



right side of the middle line both anteriorly and posteriorly, and also stripping the posterior uterine wall and upper part of the anterior uterine wall. The extra-peritoneal tissue, with its blood-vessels, is therefore not only capable of forming anastomoses in abdominal aneurism, as Turner and Chiene have shown, but may attempt to carry on the functions of the maternal portion of the placenta.

We have here what may be termed a slow displacement of the placenta. At first it lay in the Fallopian tube, but the growing ovum has slowly pushed it up (a process attended with blood extravasation) from pelvis to abdominal cavity, until at last its upper edge is about 10 inches from its original site. Part of this is due to growth, of course. The uterus also has had its cervical portions elongated in the same way to 3 inches.

These sections have an important bearing on the *Classification* of extrauterine gestation. Much has been written, and little really demonstrated, on this point. The Tubal variety is undoubted; the Tubo-ovarian has also been demonstrated; but the Ovarian is a very doubtful form. The Subperitoneo-pelvic or Intra-ligamentous variety of Dezeimeris, Tait, and Werth, is demonstrated in the second specimen, which also shows the ovary thinned out on the posterior lamina of the broad ligament. The presence of the ovarian structure in the cyst wall of an extrauterine gestation has been brought forward as evidence of its being the Ovarian variety; it more probably shows that it is Subperitoneo-pelvic.

The chief interest centres on the anatomical nature of abdominal gestation. The second case shows that this can be extra-peritoneal, a fact never hitherto demonstrated, although strongly contended for by Tait. We do not deny that we may have either a partial extra-peritoneal and intra-peritoneal variety, or an entirely intra-peritoneal variety, but we ask for actual proof of such. If it be urged that a purely intra-peritoneal form must exist because placenta has been found attached to the uterus and intestine, we answer that in the cadaver shown (Plate XIV.) the placenta has been attached to the portion of uterine wall where the peritoneum is stripped off; or it might have been attached to the other abdominal viscera, but yet carrying a layer of peritoneum before it, be still extra-peritoneal.

We therefore hold that the following varieties have been demonstrated, viz.,—Tubal, Tubo-ovarian, Subperitoneo-pelvic, Subperitoneo-abdominal. An Abdominal variety, partly intra-peritoneal and partly extra-peritoneal, is probable; a purely Intra-peritoneal variety has yet to be accurately demonstrated, and the same holds good as to the Ovarian variety.

Hitherto we have always regarded the peritoneal cavity as the site



specially chosen by extrauterine gestation for its development, but we must now more closely scrutinise such in the light of this and similar cases.

We defer at present full consideration of the changes on the placenta, but give a brief account of the results so far.

It has often been thought that the moot points in the structure of the placenta might be cleared up by an examination of the placenta in advanced extrauterine gestation. Here, it is argued, we have the peritoneum taking the position of the serotina of the uterus, and therefore a comparison of the placental structure in normal and abnormal implantation should throw light on, for instance, the origin of the intervillous spaces, whether really maternal and filled with blood. The results in the specimens are as follow:—In a Fallopian-tube pregnancy at the second month, the villi were seen embedded in many and large cells analogous to the decidual cells of normal pregnancy. No sinus system was evident, except enlargement of the veins in the muscular coat. The normal Fallopian tube near was also markedly infiltrated with cells, and wherever villi were the columnar epithelium of the mucous membrane had disappeared.

In the advanced gestation the placental structure had been evidently undergoing a destructive process. The villi lie in organised blood-clot, with abundant blood-crystals, and are atrophied and irregular in outline. There is nothing comparable to the intervillous system of the normal placenta, nor to the beautiful and large cells found in the serotina near the villi. The growth of the placenta in the advanced extrauterine gestation has evidently been attended with much blood extravasation, and, as a consequence, destruction of the part analogous to the ordinary maternal portion.

The placenta in the  $4\frac{1}{2}$  months' gestation is unfortunately not yet hard enough for section.

The following seem to us fair deductions from the specimens we have examined, and we arrange these for convenience, in a series of propositions:—

1. Fallopian-tube pregnancy may develop into the broad ligament (Intra-ligamentous, Werth), and continue this development beneath the peritoneum of the pelvic floor (Subperitoneo-pelvic of Dezeimeris).

2. An advanced gestation may be derived from a Fallopian-tube pregnancy which develops as given in 1, and further lifts up the peritoneum until we get—

3. An Abdominal case entirely extra-peritoneal. For this form we suggest the term—Extraperitoneo-abdominal.

4. The placental changes in the Extraperitoneo-abdominal form are destructive to placental tissue and function, and inimical therefore to vigorous foetal life.



5. In treatment one great principle is to interfere where safest for the mother, without regard to foetal life.

6. The placenta should be left after operation, unless it can be ligatured, as separation causes uncontrollable hæmorrhage. This is the usual reason for leaving it untouched, and one that cannot be gainsaid.\* The extra-peritoneal position of the placenta, and the great chance of its organising, as is shown in our specimen, forms another powerful argument for leaving it alone. In operations for advanced gestation the foetus only should be removed, the cord tied, returned, and the wound closed, unless a septic condition requires drainage.

We are indebted to Dr Bruce for verifying the microscopical structure of the cyst wall, to Dr R. Stewart for his valuable aid in the microscopical part, and to Mr Wm. Keiller, who made careful tracings and drawings of the sections.

#### DESCRIPTION OF PLATES.

##### PLATE XIII.

FIG. 1.—Sagittal lateral section (right) of pelvis with extrauterine gestation in right broad ligament.

FIG. 2.—Sagittal mesial section of same pelvis, showing uterus with decidua. This section demonstrates, *inter alia*, that what is termed clinically retro-uterine hæmatocele may be hæmatoma.

##### PLATE XIV.

FIG. 3.—Sagittal mesial section of cadaver with advanced extrauterine gestation subperitoneo-abdominal (1R).

FIG. 4.—Sagittal lateral section of same (2R).

##### PLATE XV.

FIG. 5.—Sagittal lateral (2L) of same.

FIG. 6.—Sagittal lateral (3L) of same.

FIG. 7.—Fränkel's diagram of his case.

FIG. 8.—Schuchardt's diagram of his case.

\* See, however, Chap. XXIV., Case 2.



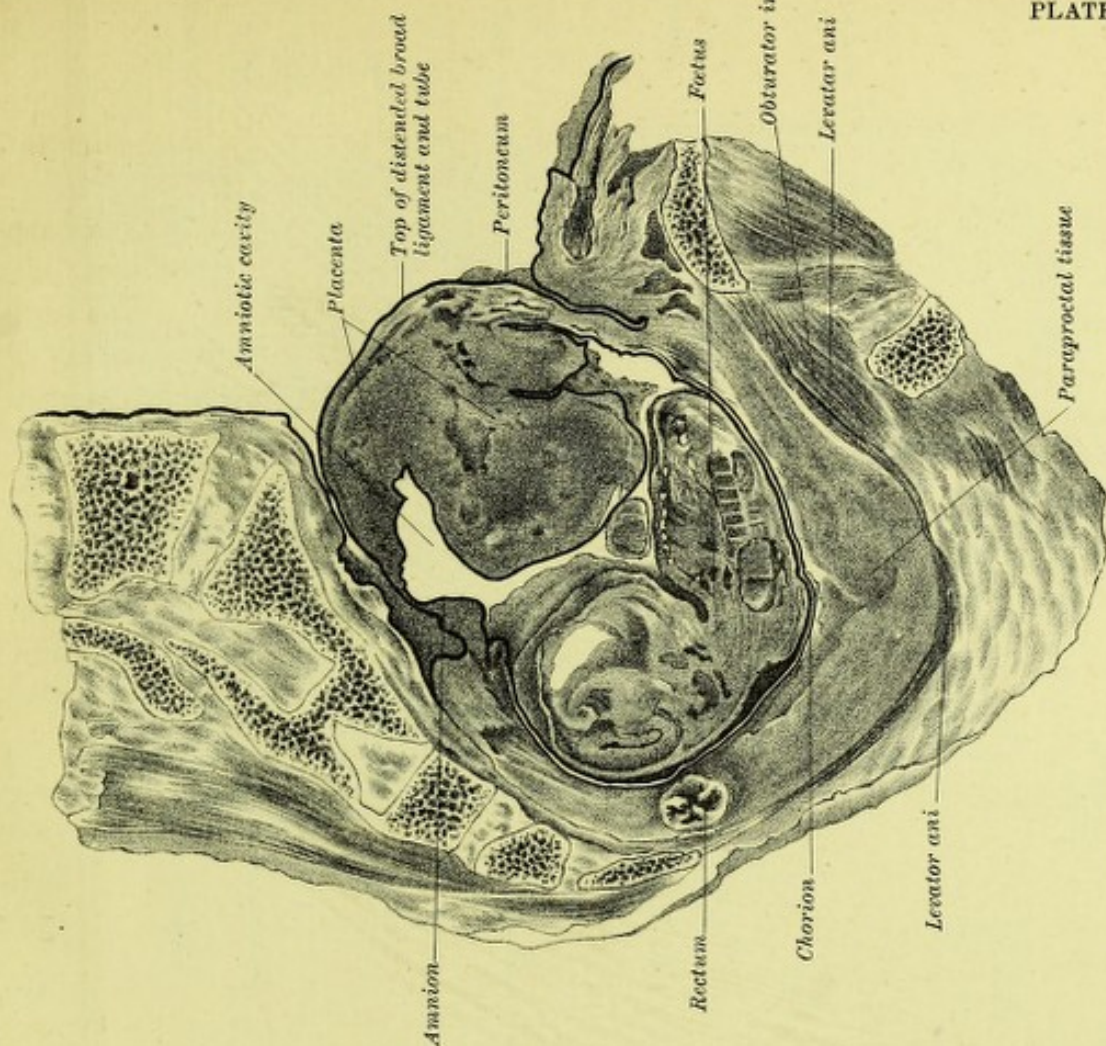


FIG. 1.

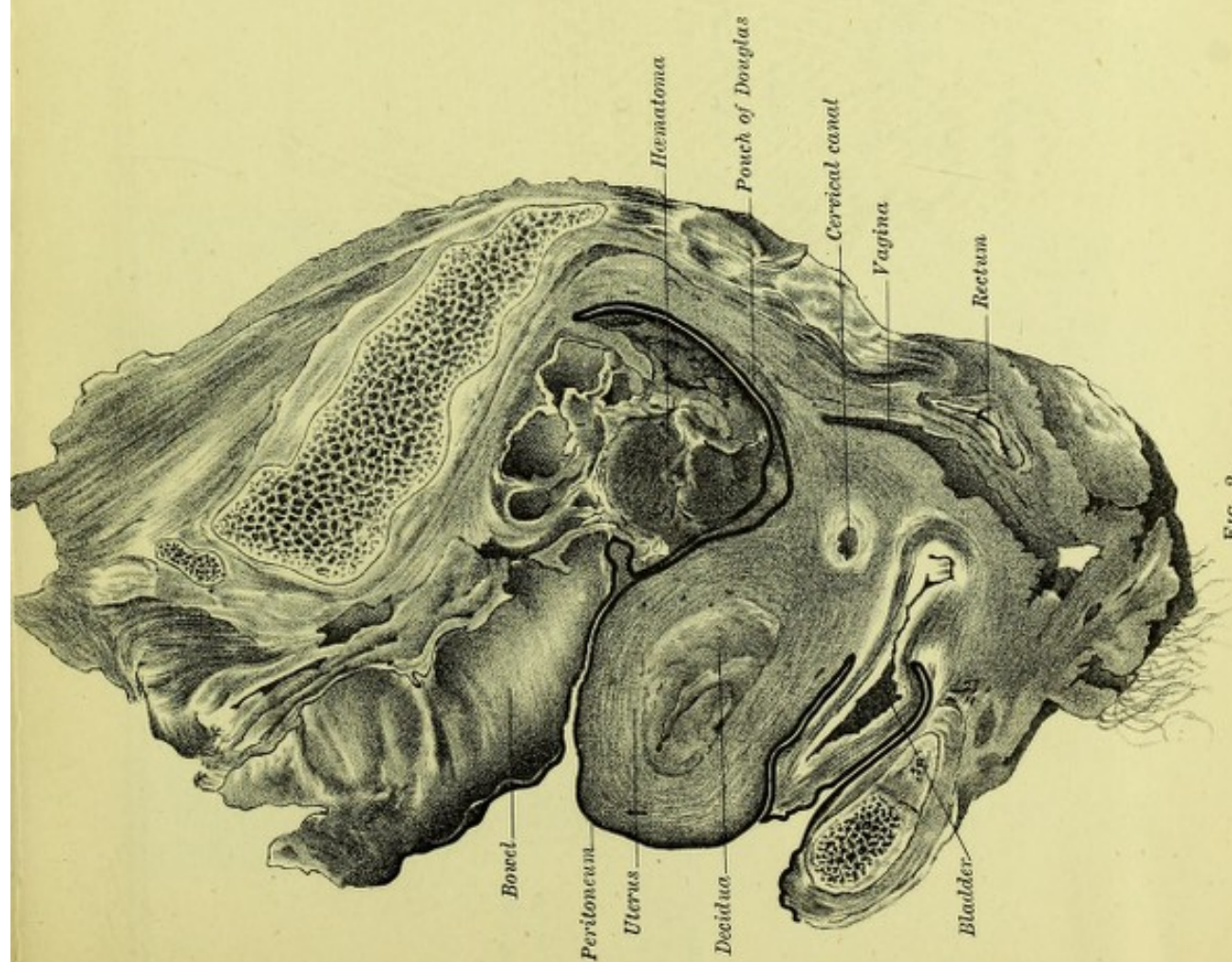

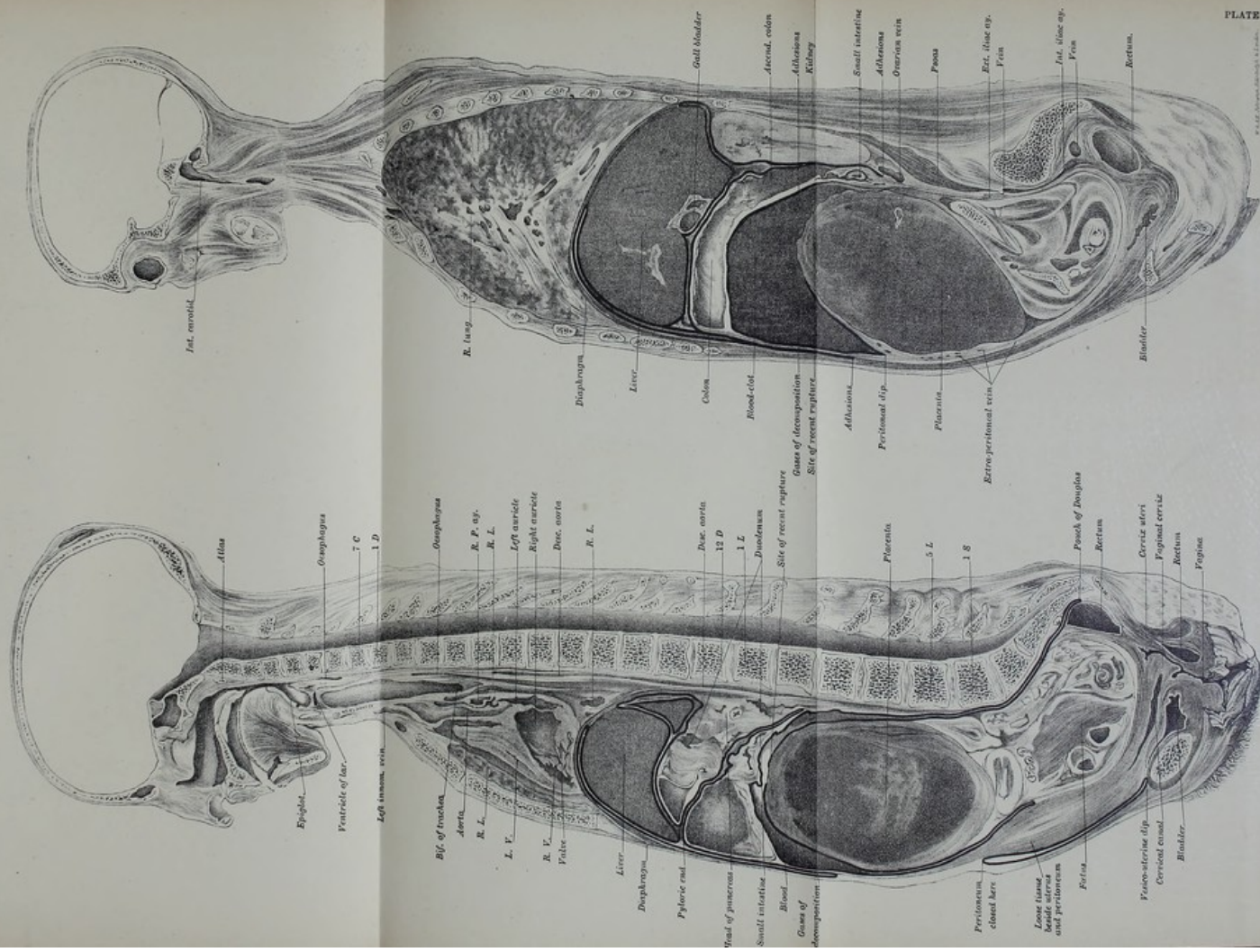


FIG. 2.
















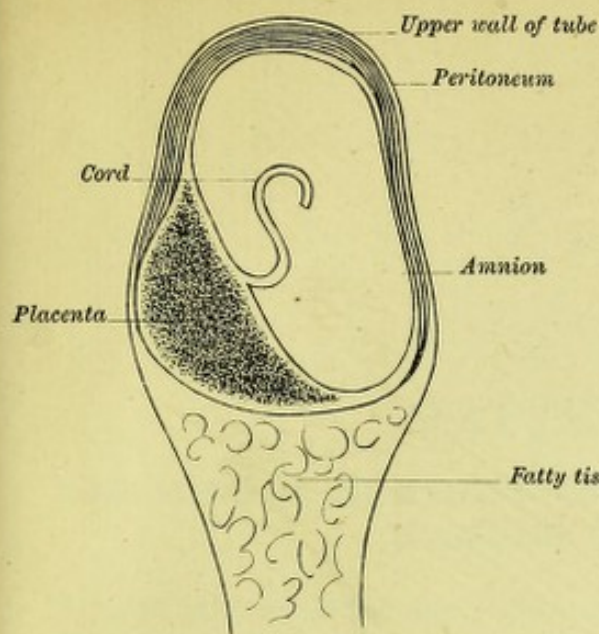


FIG. 7. (DIAGRAMMATIC.)

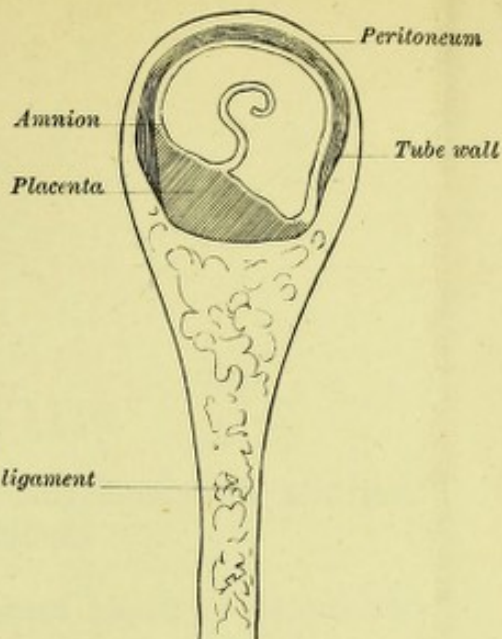


FIG. 8. (DIAGRAMMATIC.)

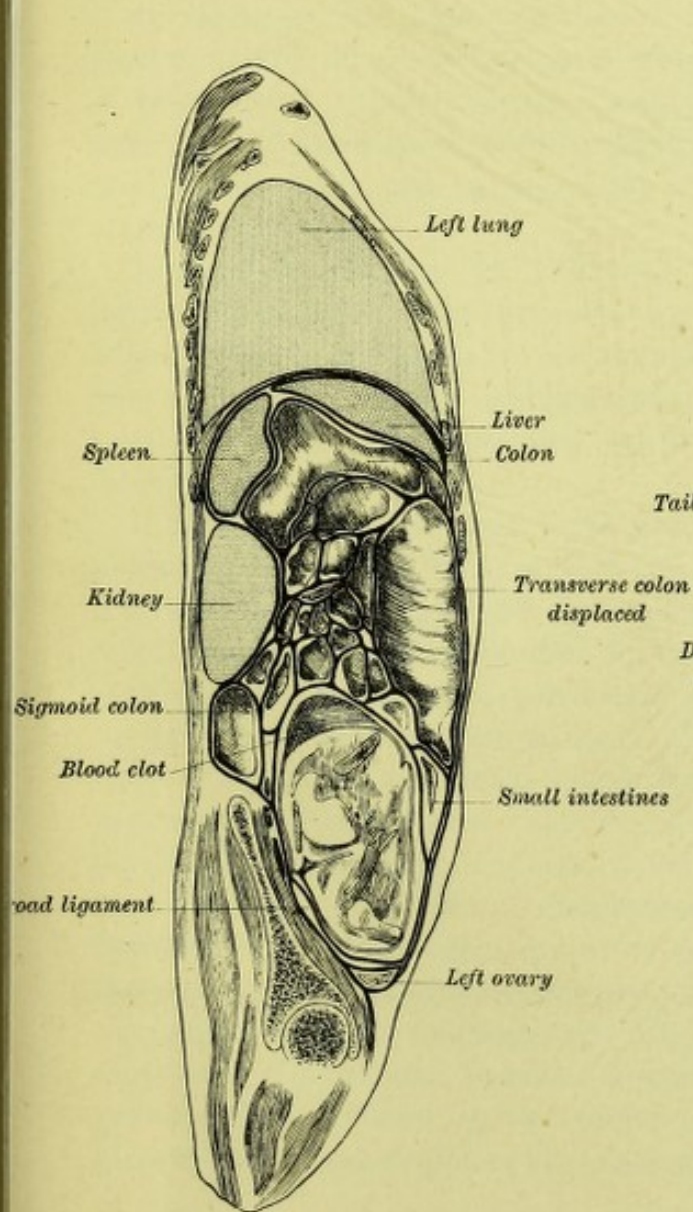


FIG. 6. (3 L.)

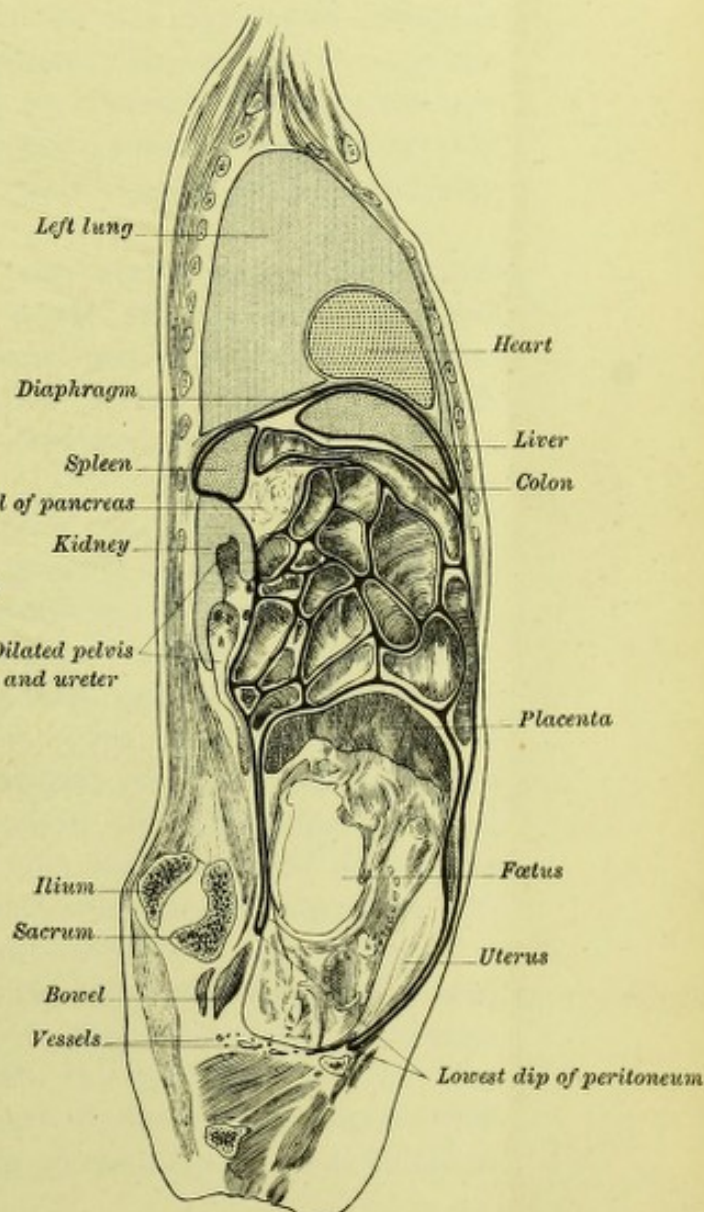



FIG. 5. (2 L.)







## CHAPTER XVIII.

### THE MINUTE ANATOMY OF THE PLACENTA IN EXTRA-UTERINE GESTATION.

I HAVE first to define the limits of the present paper. I do not take up the anatomy of the extrauterine placenta in the various varieties of this condition, but consider merely its development in what I have termed the extra-peritoneal form. I must, therefore, briefly explain what is meant by this.

As all know, the Fallopian tube is, in the vast majority of cases, the starting point of an extrauterine gestation. The most common result of this is that rupture occurs, usually at the second month, through some part of the tube covered by peritoneum, a result almost invariably fatal if left alone, and as invariably curable if operated on in time by abdominal section.

A rarer termination in Fallopian tube gestation is, that further development takes place between the layers of the broad ligament, which become separated to accommodate fœtus and placenta. Even here rupture into the peritoneum may occur; but if the peritoneum remain intact we may get a continuance of development as follows:—

If in the early Fallopian tube gestation the fœtus lies above the placenta, we may get both it and the placenta developing between the layers of the broad ligament. The placenta in its growth has its downward displacement soon limited by the pelvic muscles, while the fœtus may rupture through the peritoneal lamina and lie in the peritoneal cavity free among the intestines. This gives us, therefore, a mixed form of gestation, the fœtus being intra-peritoneal, the placenta extra-peritoneal. The placenta thus develops in the broad ligament and pelvic connective tissue, and has in addition been displaced downwards by the fœtus, the amount of displacement being necessarily small. If, however, in an early tubal gestation the fœtus lies lower in the tube, the placenta thus occupying the part of the tube covered by peritoneum, we may then get a development between the layers of the broad ligament as in the previous instance, but with this special difference. The growing fœtus pushes up the upper part of the broad ligament with placenta, and thus displaces the placenta up until it may lie attached to



anterior abdominal wall opposite the level of the lumbar vertebræ. The fœtus and placenta too, lie, therefore, in extra-peritoneal tissue, the peritoneum being lifted up as the pregnancy goes on. This extra-peritoneal development of extrauterine gestation is remarkable, but is not unique in pathology, being analogous to the development of a burrowing pelvic abscess or of a papillomatous ovarian cyst. (Fig. 1, Pl. XVI.)

We may sum up the stages, therefore, as, (*a*) Fallopian tube; (*b*) broad ligament in the first place; then (*c*) either placenta extra-peritoneal, fœtus intra-peritoneal; or (*d*) both extra-peritoneal.

If we now take up specially what is more properly the subject of the present communication, the minute anatomy of the extra-uterine placenta in its extra-peritoneal development, we must keep in mind the following points. While the placenta begins its development in the mucous membrane of the Fallopian tube, it soon develops in connective tissue; and during its development here undergoes a slow displacement. In the case where both fœtus and placenta are extra-peritoneal, the fœtus lying below, the placenta must have been displaced upwards for at least 10 inches. Inasmuch as this amount of displacement was accomplished in about as many months there was never any gross separation, but a slow microscopic progress which, as we shall see, causes slow blood effusion and organisation.

In investigating the minute structure of the extrauterine placenta I had the following material:—

1. Tube with placenta attached from a ruptured tubal gestation at the second month.
2. Broad ligament gestation at fourth month.
3. Abdominal gestation, entirely extra-peritoneal, and at nearly full time.
4. Abdominal gestation, with fœtus probably intra-peritoneal, and placenta certainly extra-peritoneal.

The last preparation I owe to the great kindness of Dr Barbour, and no one appreciates more than I do the self-denial which gave me such a valuable specimen.

The tubal gestation was cut in paraffin, the others in celloidin and the investigation was carried on in the laboratory of the Royal College of Physicians.

The following is a brief summary of the results:—

In the Fallopian tube gestation the villi lie embedded in decidual cells, and no intervillous sinus system seems to exist. Large sinuses, however, have formed in the muscular wall. The villi are well formed, and are covered with perfect epithelium. The decidual cells are large, and have large nucleus and nucleoli. (Figs. 2, 3, and 4, in Pl. XVI. and XVII.)



In the broad ligament placenta we begin to see the serious damage caused to placental structure by its development in connective tissue. The villi are less perfect in contour, blood extravasation is present, blood crystals are in abundance, while the decidual cells are few and less perfect.

In the advanced abdominal gestation where the placenta is in the pelvic connective tissue, and therefore less displaced, we see fairly perfect villi, decidual cells, blood crystals with large areas of extravasated blood, which may be the remains of an attempt at a placental sinus system.

The most remarkable alteration in placental structure is found, however, in the abdominal gestation with the extreme displacement of the placenta. Here the placenta is converted into a mass of organising blood clot, with large areas of blood crystals, great compression and distortion of the villi, entire absence of decidual cells, and no recognisable intervillous sinus system; although the enlargement of the veins in the abdominal wall at the placental site points to some such arrangement existing. (Figs. 5, 6, and 7, Pl. XVIII. and XIX.)

We may, therefore, say broadly that the development of the placenta in the extra-peritoneal form of extrauterine gestation is a destructive one, reduces the placenta practically to compressed villi, where the serotina is destroyed and replaced by blood crystals and organising blood clot. The least damage is done to the placenta, which from its more favourable position in the lower part of the tube with the foetus above, is, as I have already explained, displaced least.

In the last place, I have to point out the important bearing of these facts on the life of the foetus. One of the most common terminations of an extrauterine gestation is to have the foetal bones discharged per rectum, or in fact to terminate as a pelvic abscess. Such are evidently extra-peritoneal developments of a Fallopian tube gestation, where the destructive process going on in the placenta has killed the foetus, and where the proximity of the whole gestation to bowel unprotected by peritoneum has led to an endosmosis of intestinal gases, or passage of micro-organisms such as to determine putrid suppuration.

A more favourable termination is where, from the higher position of the foetus, we get its escape into the peritoneal cavity, less displacement of the placenta, and thus less interference with its functions. These are the cases where a full time foetus can be removed, and where the placenta, from its extra-peritoneal position, is not recognised at the time and is left undisturbed for ultimate absorption if away from bowel. Proximity to bowel may lead to its putrefaction and breaking down. (*v.* Chap. XIX.)



## DESCRIPTION OF PLATES.

## PLATES XVI., XVII., XVIII., AND XIX.

- FIG. 1.—Sagittal lateral section of advanced extra-peritoneal extrauterine gestation (Hart and Carter).  
FIG. 2.—Villi and serotina of two months' Fallopian tube gestation.  
FIG. 3.—Enlarged veins in muscular wall of Fallopian tube gestation.  
FIG. 4.—Villi and serotina of two months' Fallopian tube gestation.  
FIG. 5.—Placenta in advanced extra-peritoneal extrauterine gestation.  
FIG. 6.—Villus in organised blood-clot of advanced extrauterine gestation (extra-peritoneal).  
FIG. 7.—Villi and blood crystals of advanced extra-peritoneal extrauterine gestation.  
FIG. 8.—Decidual cells from uterine decidua of broad ligament gestation ( $4\frac{1}{2}$  months).



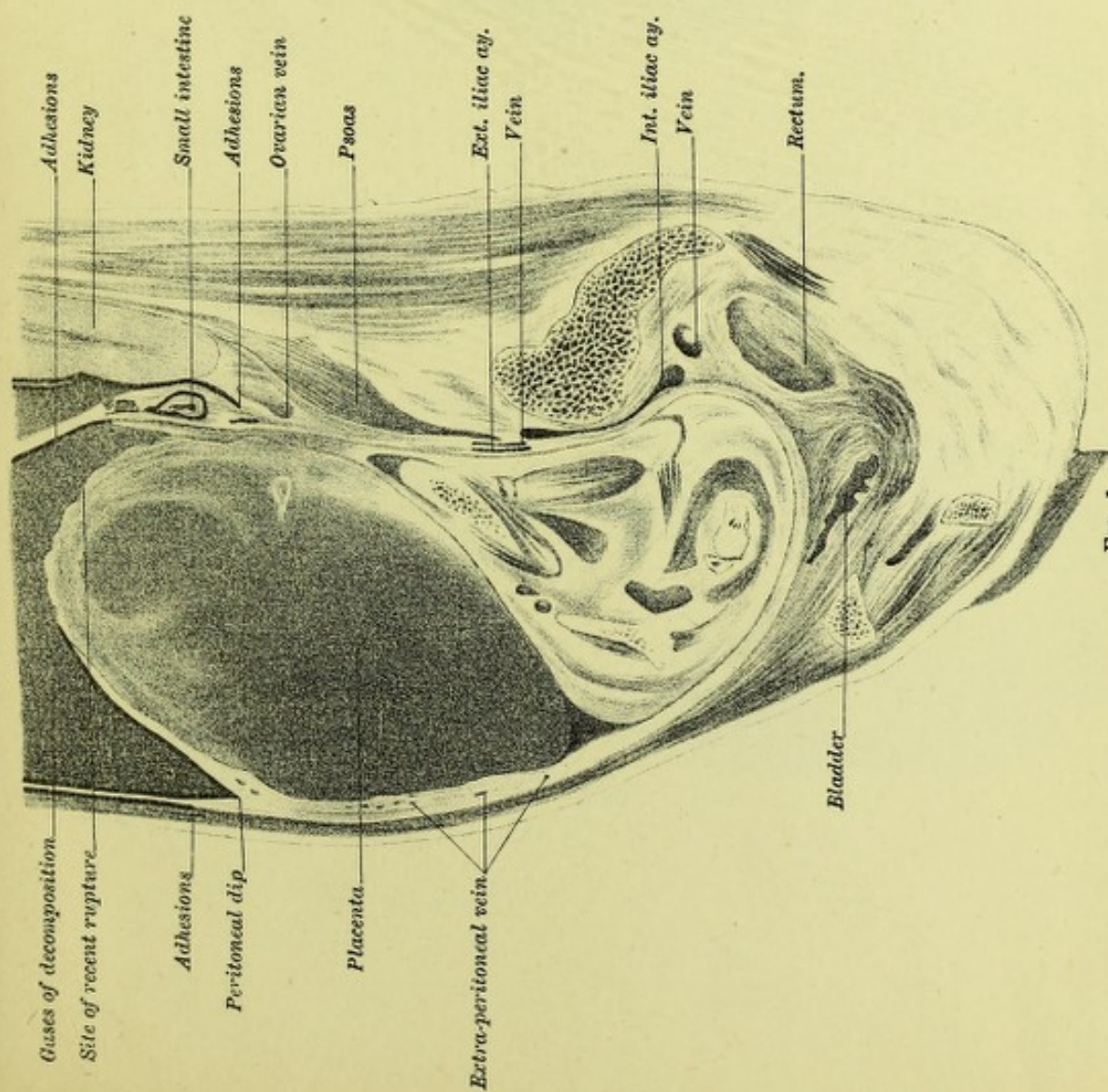


FIG. 1.

Sagittal lateral section of advanced extra-peritoneal extra-uterine gestation (Hart and Carter).

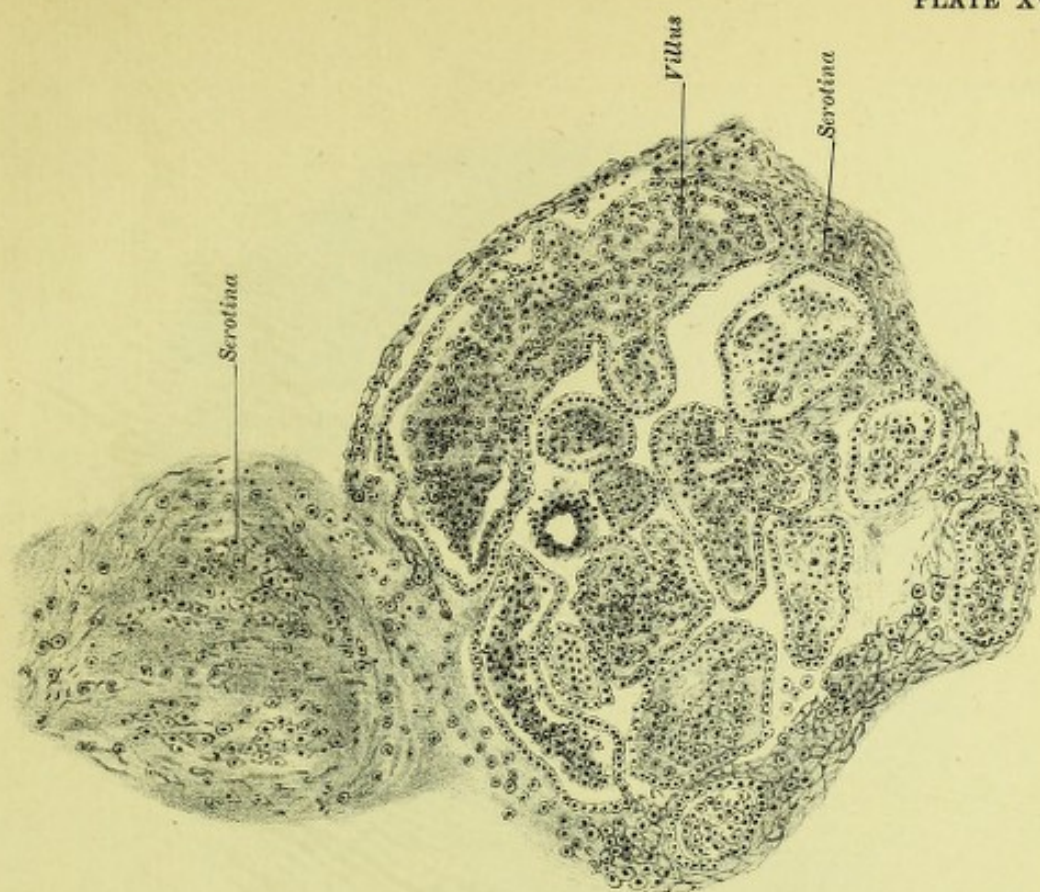



FIG. 2.

Villi and serotina of two months' Fallopian tube gestation ( $\times 75$ ).







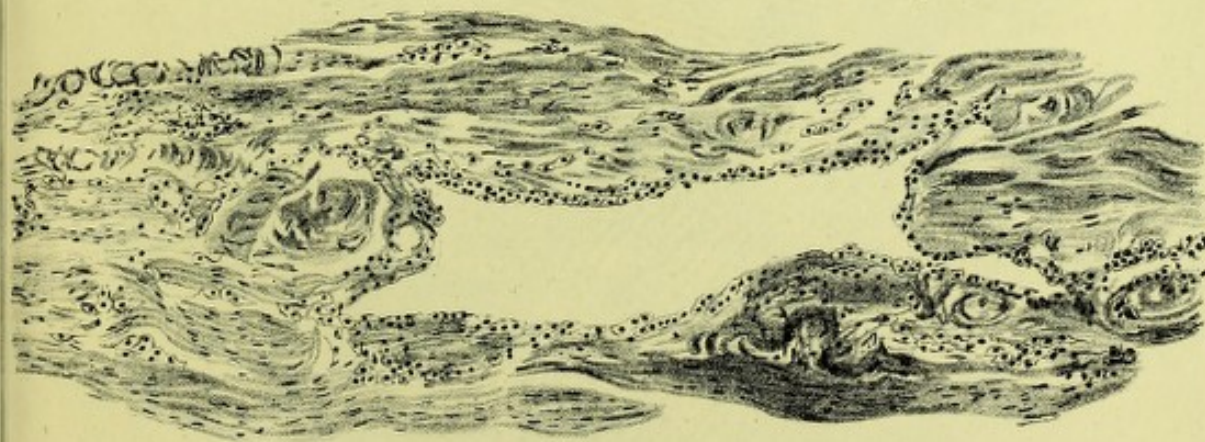


FIG. 3.


Enlarged vein in muscular wall of Fallopian tube gestation ( $\times 75$ ).

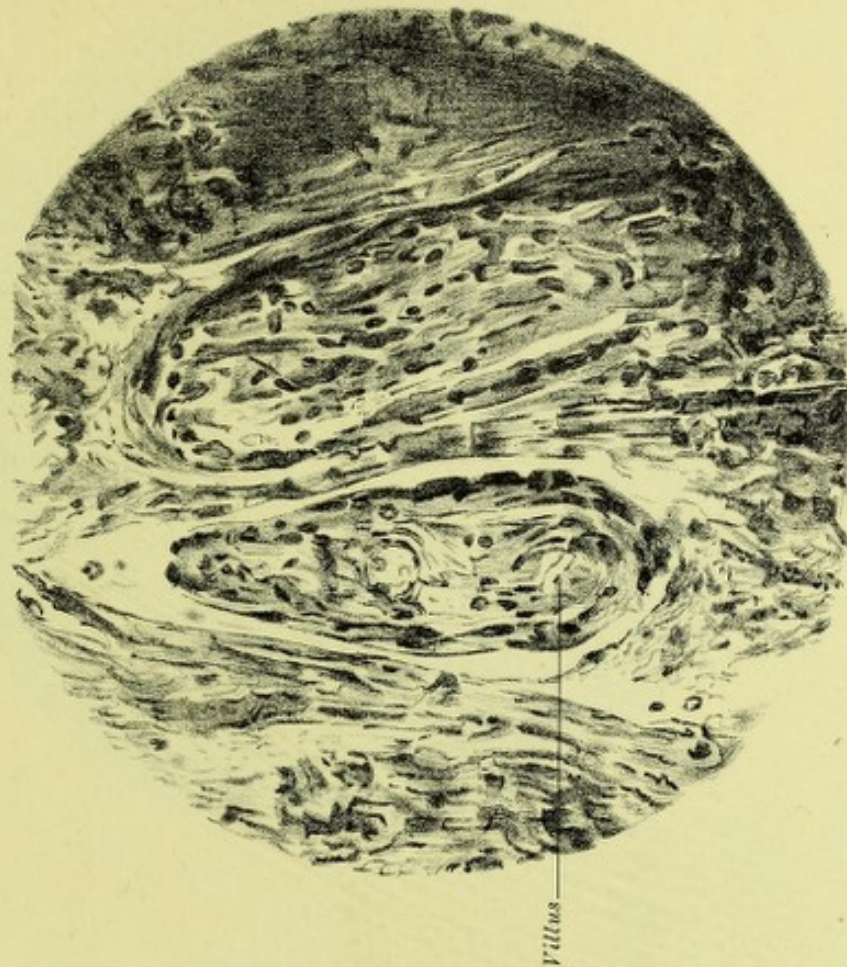

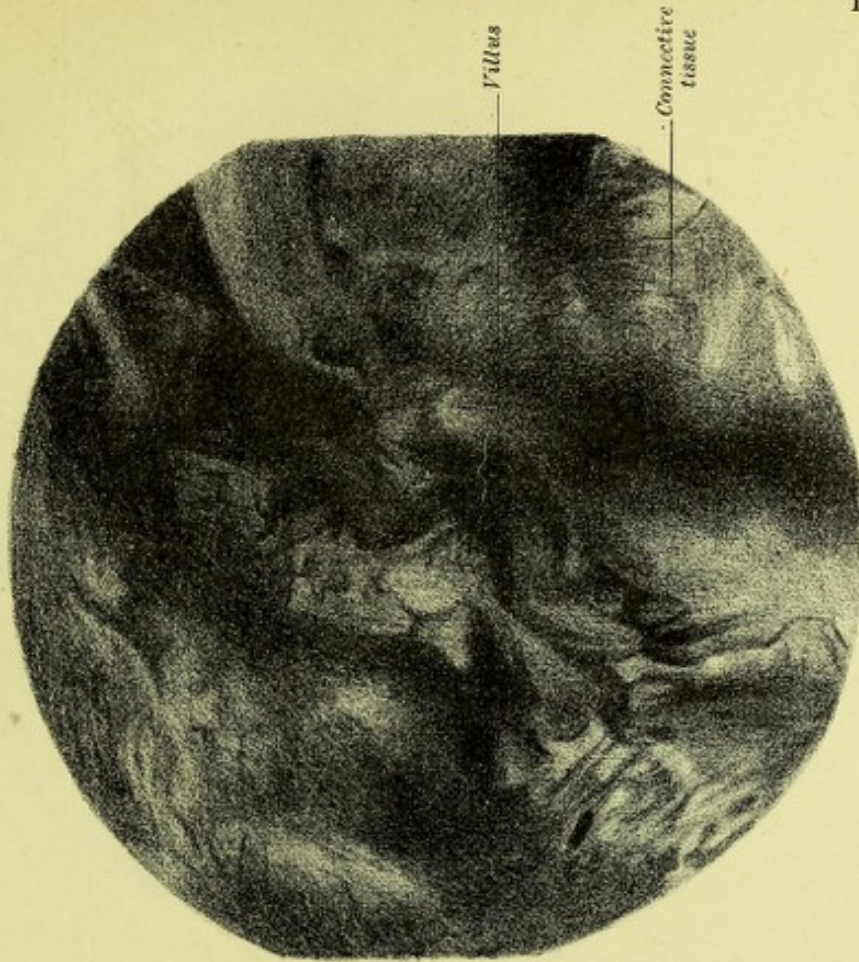
FIG. 4.

Villi and serotina of two months' Fallopian tube gestation ( $\times 300$ ).









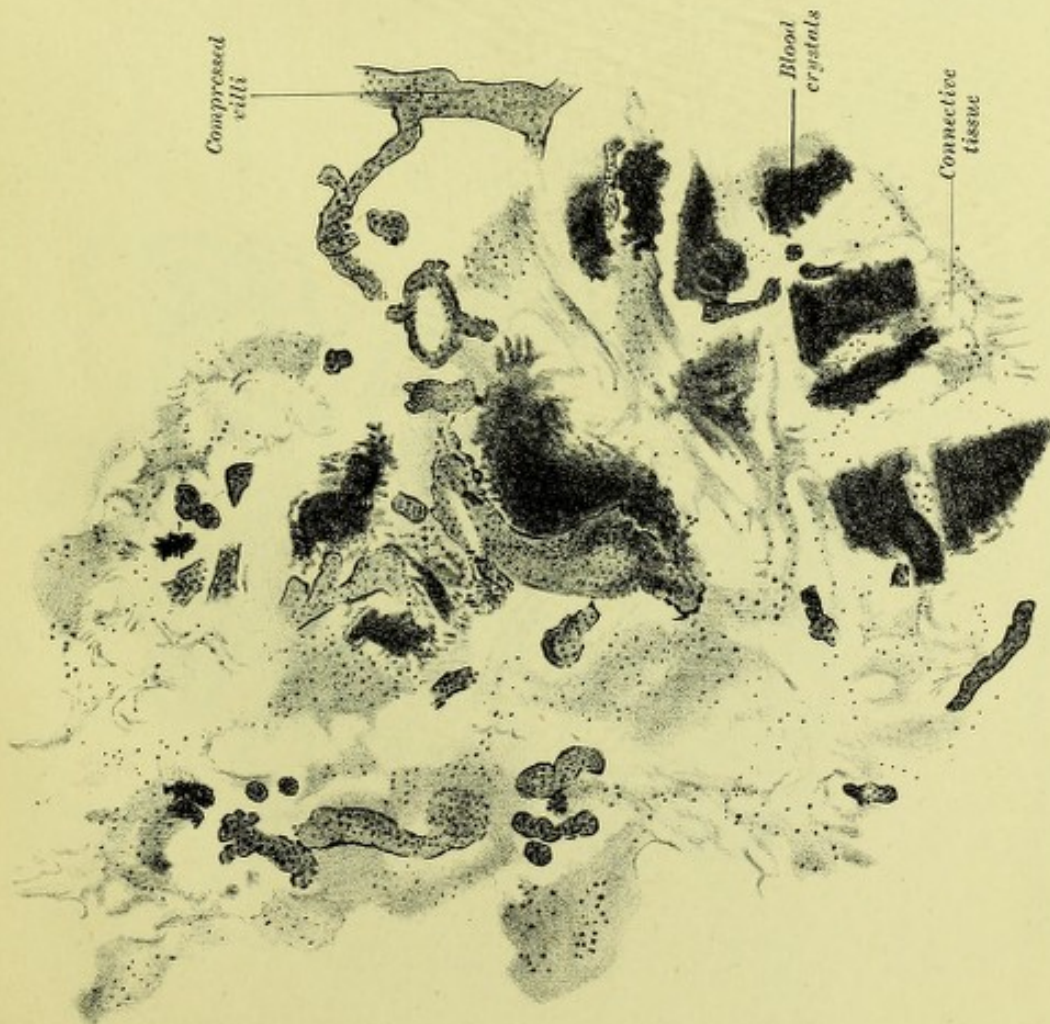Villus

Connective  
tissue

FIG. 6.

Villi in organised blood clot of advanced extra-uterine gestation (extra-peritoneal) showing compression and distortion ( $\times 300$ ).

W. & A. T. Johnson, Edinburgh & London.



Compressed  
villi


Blood  
crystals

Connective  
tissue

FIG. 5.

Placenta in advanced extra-peritoneal extra-uterine gestation ( $\times 25$ ).







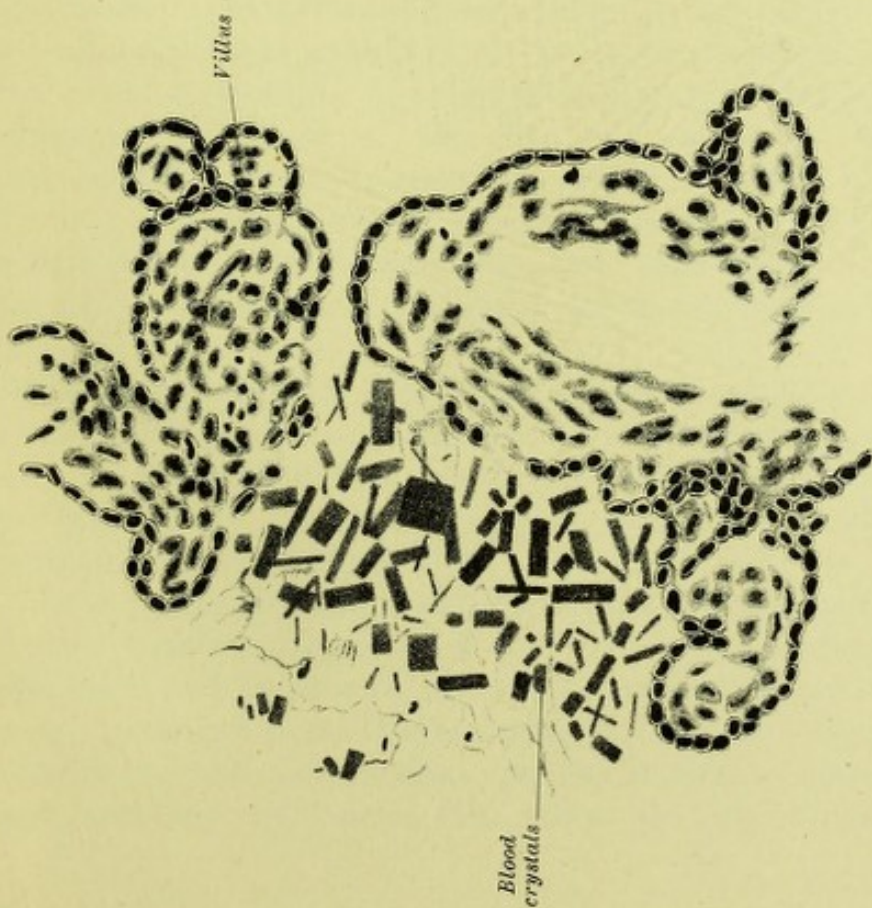


FIG. 7.  
Villi and blood crystals of advanced extra-peritoneal extra-uterine  
gestation ( $\times 280$ ).

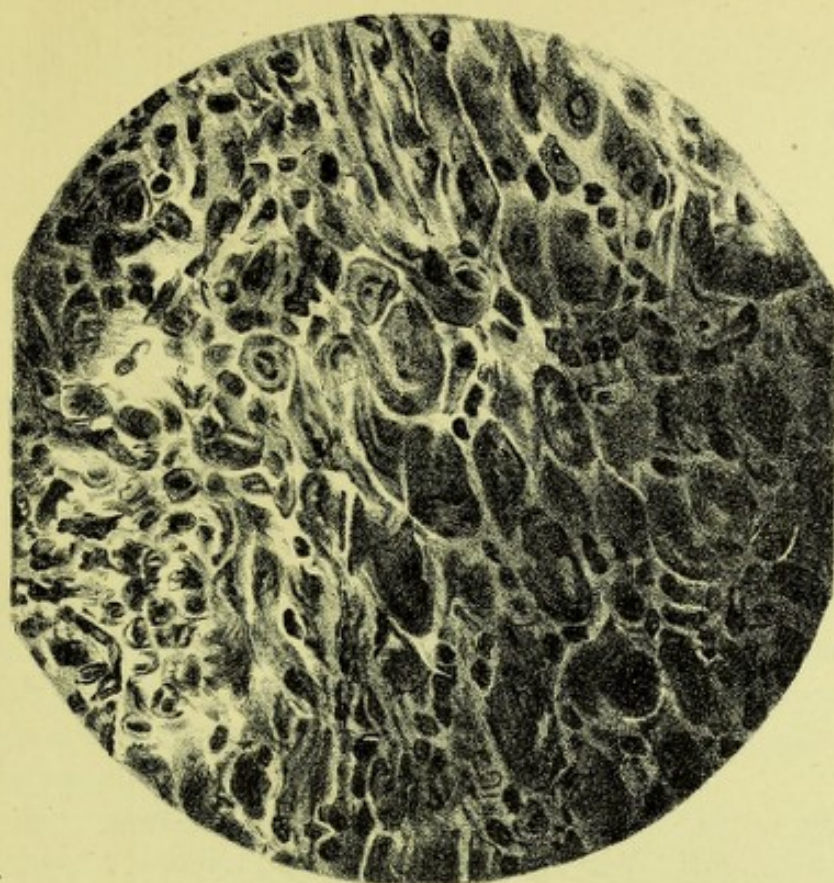



FIG. 8.  
Decidual cells from uterine decidua of broad ligament gestation ( $4\frac{1}{2}$  months)  
( $\times 375$ ).







## CHAPTER XIX.

### ON THE DISPLACEMENT OF THE PLACENTA IN EXTRA-UTERINE GESTATION AND ITS RELATION TO THOSE CASES ENDING IN PELVIC ABSCESS.

ONE of the most frequent terminations of an advanced extrauterine gestation is its discharge like a pelvic abscess. Authors such as Parry speak of the suppuration of the sac, but this is too general a term, and leads one to suppose that any extrauterine sac may suppurate; whereas, as a matter of fact, I hope to show that a certain definite case is most likely to do so.

Many authors hold that the peritoneum is the placental site in advanced extrauterine gestation; indeed, Matthews Duncan says, "Every author on this subject recognises the peritoneal insertion of the placenta, and in every such case I believe it is the original insertion." I do not understand how such an eminently careful and judicious author as Duncan undoubtedly was could make such a statement, as the placenta in extrauterine gestation has as yet never been proved to be peritoneal, and at present all real proof is against even its probability. The usual explanation, however, of the suppurating sac and viscus perforation was death of the child and consequent formation and discharge of pus from the peritoneal cavity. It would be a mere waste of time, however, to refute this view, as it is based on erroneous pathology, does not explain why only some cases suppurate, and contradicts well-known facts about the peritoneum as an absorbing sac.

The first glimpse of light on this subject came from Dezeimeris' recognition of what we now know to be broad ligament pregnancy, and now from the work of Tait, Werth, Hart and Carter, Olshausen, Croom and Webster, we are in a position to make a great advance in the explanation of suppurating cases.

In two papers previously published I have demonstrated the existence of broad ligament pregnancy, and also the extra-peritoneal position of both fœtus and placenta in an advanced abdominal gestation. In the latter especially I found the placenta displaced up and greatly altered in structure. All these points, especially those as to placental displacement, were only briefly given then, and as they are of great importance



in the special suppurating cases we are considering to-night, I purpose considering them more in detail.

Cases of extrauterine gestation, ending as abscess, have the following characteristic clinical points:—The fœtus is discharged usually by the rectum; escape by the vaginal fornix is rarer; and most rare of all is discharge by the bladder. In a table of 29 cases published by Lusk, 16 discharged fœtal bones and debris by the rectum, 4 by the vagina, 6 by the abdominal walls below the level of the umbilicus; 3 are indefinitely described. The cases usually end so about mid-term; never in this way within the first two or three months; and rarely so at full time. The cases when so discharging, are chronic, do not have peritonitis, and very often recover.

What, then, is the nature of the extra-peritoneal gestation ending as pelvic abscess? I believe the two great factors producing it are—(1) *extra-peritoneal development*, (2) *displacement of the placenta*.

(1) *Extra-peritoneal Development*.—By this is meant that the gestation begins in the Fallopian tube, develops into the broad ligament, and, if it continue its development, goes on growing extra-peritoneally. This development explains why we get the discharge through the rectum, bladder, or vagina, and also why we do not get discharge of contents much above the level of the navel. The doubled-up fœtus measures about nine inches at the most, while from pelvic floor to navel is about six inches, and this accordingly limits the peritoneal elevation. The extra-peritoneal development of placenta and fœtus does not explain, however, the death of the fœtus. There is no reason why, as the result of this extra-peritoneal attachment of the placenta, the fœtus should die, as the normal placenta, I hold, develops in connective tissue. We need another factor, viz. :—

(2) *Displacement of the Placenta*.—This has, as yet, been found only in the specimen of advanced gestation examined by Dr Carter and myself. Here the placenta is attached to the extra-peritoneal tissue of the anterior abdominal wall, its upper edge being 10 inches above the pubis. In its minute structure the villi were found compressed, with large areas of blood crystals and cicatricial connective tissue. The slow displacement had caused blood effusion, and the organisation of this gave rise to the remarkable changes I have mentioned.

*I therefore urge, as an explanation of cases of extrauterine gestation ending as abscess, that such began in the Fallopian tube and developed into the broad ligament.* The relative position of fœtus and placenta is of the greatest importance. *In this special class of case the fœtus lies below, and as it grows, displaces up the placenta.* This causes the serious changes in the placenta, death of the fœtus, and its subsequent discharge. The dead fœtus lies next bowel unprotected by peritoneum, and we get fœtid infection, as in ischio-rectal abscess. An extrauterine



gestation in the left broad ligament early touches the rectum, whereas, on the right side, considerable development must take place before colon or rectum is reached. A statistical inquiry on broad ligament cases in relation to this point would be of great interest.

It may be urged, however, that this displacement of the placenta has only been noted by myself, and that it may be exceptional. Undoubtedly we must get further confirmation; but there are many facts indirectly supporting it. In the first place, in cases perforating in the rectum, the fœtus is felt low down and close to vagina or rectum. In the next place, in several trustworthy cases where the fœtus has been living at the end of pregnancy and where *post-mortem* examination was made, the placenta was found lower and extra-peritoneal, and the fœtus above it in the peritoneum. Barbour, Croom, and Webster have brought forward instances of this in our own Society. Indeed, we may say that a *sine quâ non* for the safe development of the fœtus in broad ligament gestation is "*the position of the fœtus above the placenta, so that in its subsequent extra-peritoneal (partial or complete) development it does not displace the placenta.*"

In conclusion, I wish to summarise my present opinions on the gross pathological anatomy of extrauterine gestation, and add some cautions which I think may be of use to future investigators.

1. In the great majority of cases, extrauterine gestation begins in some part of the Fallopian tube. It very rarely develops to an advanced period in the intact tube. A good sectional and accurate demonstration of a tubo-ovarian pregnancy is still a desideratum.

2. Ovarian pregnancy is one of the rarest occurrences possible.

3. From the tubal pregnancies we get the starting-point of most of the sequelæ of extrauterine pregnancies, as Tait first suggested:—(a) Rupture up to the third month through the peritoneal part of the tube. (b) Development in tube and broad ligament, with fœtus above and placenta below. This development may go on extra-peritoneally with child alive and placenta not displaced. Another possibility is that the fœtus may escape through the peritoneal lamina into the peritoneal cavity, the placenta remaining extra-peritoneal or in the Fallopian tube (Croom and Webster).

When the child is low and the placenta displaced, we get the suppurative termination described more particularly in the present paper. This may be put in the following tabular form:—

*Scheme of Classification of Extrauterine Pregnancy.*

1. Ovarian (extremely rare).
2. Primary intra-peritoneal (not proved as yet, and improbable).
3. Fallopian tube: interstitial; in isthmus; in ampulla usually; tubo-ovarian not well demonstrated. From Fallopian tube form we may get—



- (a) Rupture and intra-peritoneal hæmatocele (first to third month).
- (b) Development in tube to nearly full time (excessively rare).
- (c) Development into broad ligament (intra-ligamentous; subperitoneo-pelvic).
  - (1) Continued extra-peritoneal development, with placenta below; may get living child.
  - (2) Development with placenta displaced; death of child; suppuration and discharge by bowel.
  - (3) Development with placenta below, extra-peritoneal and not displaced; child may escape with or without amnion into peritoneum.

What we term "abdominal pregnancies,"—*i.e.*, advanced extrauterine gestation—may arise as follows:—

(a) From an early rupture (up to third month) of a Fallopian tube gestation, the fœtus only escaping, the cord remaining unruptured, and the placenta remaining and developing in the tube (Croom and Webster).

(b) Development from Fallopian tube into broad ligament; fœtus escaping into peritoneum; placenta remaining behind in extra-peritoneal tissue (Barbour).

(c) Development of fœtus and placenta entirely extra-peritoneally (Hart and Carter).

The exact nature of Lithopædion is unknown.

I have now to conclude with some general considerations on this subject. It may seem a strong statement to make, but it is at the same time true that there is hardly any subject in obstetrics on which there has been so much error as in extrauterine gestation. For this there have been two great reasons. The first is the belief so long accepted, and, as yet tenaciously held by many, that advanced gestations are not derived from the Fallopian tube *viâ* the extra-peritoneal tissue, but are primarily peritoneal. By this they mean that the placenta is primarily implanted on peritoneum. Now, this has never been demonstrated, but has, unfortunately, dominated and misled investigators. It is remarkable that the other great dogma as to the peritoneum, *viz.*, the old error of the danger of operating on it, retarded the progress of abdominal section for years. I believe the doctrine of the primary peritoneal gestation is responsible for much of the confusion in extrauterine gestation, and the sooner this Jonah is cast overboard the better.

No case of primary or secondary implantation of the placenta on peritoneum has been proved. One of the best recorded cases by Walker, quoted in *Müller's Handbuch* by Küstner, is not by any means proved to be such. Not only is the evidence defective, but the record makes it very probable that the case was originally extra-peritoneal, and that the



fœtus ruptured into the peritoneal cavity, leaving the placenta behind in the connective tissue. Then the drawing of the minute structure of the placenta shows a condition exactly the same as I have found in a case where the placenta developed without displacement in the extra-peritoneal tissue.

I do not deny that primary peritoneal implantation of the placenta may take place, but, at present, evidence of its occurrence in woman is quite wanting.

The second cause of retardation has been the method of investigation usually adopted in advanced cases. Until pathologists examine the entire cadaver by freezing and section cutting, or at least remove the gestation with the bony pelvis in connection and investigate it in a similar manner, they had better bury the preparation than inflict on us the results of their work.



## CHAPTER XX.

### ALLEGED GROWTH OF THE PLACENTA IN EXTRA-UTERINE GESTATION AFTER THE DEATH OF THE FÆTUS.

WITHIN recent years the statement has been confidently made by several eminent gynæcologists that the placenta in extrauterine gestation may grow after the fœtus has died. Up till recently I was of the same opinion, but fresh consideration of this belief in the light of new material has seriously shaken me in it, and I therefore wish to reopen this question.

Mr Lawson Tait says: "As I am responsible for having made a statement that I had seen the placenta growing after the fœtus had clearly been dead for some time, let me here draw the attention of Dr Buckmaster and others to the evidence upon which the statement is based. In Case No. VI. the rupture had occurred apparently in the tenth or eleventh week of a gestation, and the placenta was lying in the midst of a quantity of clots as a round mass the size of a cricket ball, for the most part in the wall of the tube, for when the tumour was removed the placenta was still adherent to part of its inner surface and the pelvic mass was intact. On slitting it open the ovum cavity was found to contain about a dessert-spoonful of liquor amnii, but there was no trace of fœtus at all.

"As we have very frequent experience of this kind of incident—the growth of a huge placenta, embracing a small ovum cavity without any, or with only a slight, trace of a fœtus in the so-called uterine 'moles' we have no reason to do other than expect that it will occasionally occur in tubal pregnancy. As a matter of fact such was the state of matters in this case.

"In Case XIX., when the fœtus was found it was only about two and one-half inches long, and had evidently been dead for some considerable time, for it was partly digested, whereas the placenta had grown to be quite as large as that of an intrauterine fœtation of four months, and it had been forming adhesions to intestine and omentum, giving rise to recurrent hemorrhages, for which the operation had ultimately to be performed.

"Similar appearances occurred also in Cases XXIV., XXX., XXXII., and XXXVII.



"In looking over the records of cases which have gone beyond the full period of gestation, I find numerous illustrations which cannot be other than the growth of the placenta after the death of the child. No emphasis in any case is laid upon this fact, but the descriptions completely establish it. In a case mentioned by the first Mr Samuel Hey, of Leeds, the patient went over the nine months with a false labour, and the child died. Three months after the mother succumbed from the sufferings involved in the carriage of the ectopic gestation. The child was found to be fully developed and showed no marks of decomposition. As the child had attained a size so unusual as to weigh nearly two pounds and a half, the cyst was supposed to be the right Fallopian tube, but the description makes it perfectly clear that it was the right broad ligament together with the tube. The placenta in this case must have grown greatly after the death of the child."

The following opinions were given at a discussion in the London Obstetrical Society in 1887 :

"Another point in which Mr Tait was greatly interested was that indicated by Mr Knowsley Thornton when he gave evidence to the effect that the placenta grew after the death of the fœtus. When evidence on this point was first brought forward, it was one of the observations to which he (Mr Tait) had listened with great hesitation, and he had several times written to this effect, for he could not believe it. But there could be no question now that it was so, that after the fœtus died the placenta went on growing in at least a fairly large number of these cases."

In the same debate Dr G. E. Herman said : "There were two kinds of placenta met with in extrauterine gestation : one kind was thin and spread out, having very extensive attachments, and this kind would evidently be very difficult of complete removal, and much more difficult at term than at the fourth month, as in the case related by Mr Tait. There were other cases in which the placenta formed a thick, solid lump, thicker than a normal placenta, and closer in texture, looking not unlike a piece of hepatised lung. In this kind the vascular connection between the placenta and the maternal structures was much less extensive and the placenta could be removed without great difficulty.

"He had exhibited to the Society at its meeting on 2nd June 1886, an extrauterine fœtus and placenta which he had successfully removed. In that case the placenta was of this kind and its removal was easy. The placenta now shown of Dr Champneys' case presented the same characters, and he gathered from the paper that it was so loose that it might have been easily removed.

"Mr Knowsley Thornton had exhibited to the Society a fœtus and placenta which he had removed with success, and the condition of this placenta was similar.



"So was the one exhibited this evening by Mr Doran, and there was another in the museum of the Royal College of Surgeons which was like those already mentioned. Judging from the cases at present known to him, he thought this transformation of the placenta into a fleshy mass easy of removal took place after the death of the fœtus. It would help greatly in treatment if we knew upon what these differences in the placenta depended, and could diagnose the condition of the placenta before operation."

Mr Knowsley Thornton, in a case which he believed to be tubal (the tumour reached nearly to the umbilicus), stated that "the fœtus would appear to have died about the beginning of the fourth month, while the placenta continued to grow, and hence at the time of operation presented that peculiar solid mass which simulated a solid ovarian or uterine tumour."

Freeland Barbour, in describing a frozen section of an extrauterine gestation which had advanced to the middle of the fifth month, speaks of death having been caused by hæmorrhage from "the continued growth of the placenta after the fœtus had died."

In his recent most valuable work on the *Surgical Diseases of the Ovaries and Fallopian Tubes*, Mr Bland Sutton expresses himself guardedly, saying: "In the majority of cases the fœtus dies. When this event occurs at the fourth or fifth month there is reason to believe that the placenta may in some instances continue to grow, instead of undergoing atrophy."

It is evident from these quotations that, among several observers well qualified to judge, it is held that the placenta undeniably large as compared with that of normal pregnancy, found in cases of extrauterine gestation where the fœtus has died, is due to a growth of the placenta continuing after the death.

Yet for this statement there seems to me no adequate proof.

Before one could make such a deduction it must be shown:

1. That the placenta in cases where the fœtus is alive is distinctly smaller than in those where for some time previous to examination the fœtus has died.

2. The part that so grows should be demonstrated microscopically by an examination of such cases as are indicated under 1.

This proof, however, has not been given, and it may simplify this part of the paper if I say that, so far as I have read, no proof has ever been brought forward.

It is an undoubted fact that the extrauterine placenta is, to the naked eye, markedly different from the normal one. If we take the placenta as displayed in the more recent literature, we find that on section it is a dense, liver-like substance, resembling closely a blood-clot



hardened in spirit. So unlike normal placenta is it that one's first thought on looking at it is that it is some solid tumour.

I have personally examined, *post-mortem*, four cases of extrauterine gestation in regard to the question of this alleged growth of the placenta after the death of the fœtus. One of these was a broad-ligament gestation, the others were advanced abdominal gestations. All were examined by means of frozen sections, and microscopical examination of the placenta was also made. These cases are now to be considered so far as they bear on our present inquiry.

I. BROAD-LIGAMENT GESTATION.—This was a pregnancy which had developed between the layers of the broad ligament, and was about the fourth and a half month. The fœtus lay below in the sac, while the placenta was at the roof of the sac. This specimen is figured in

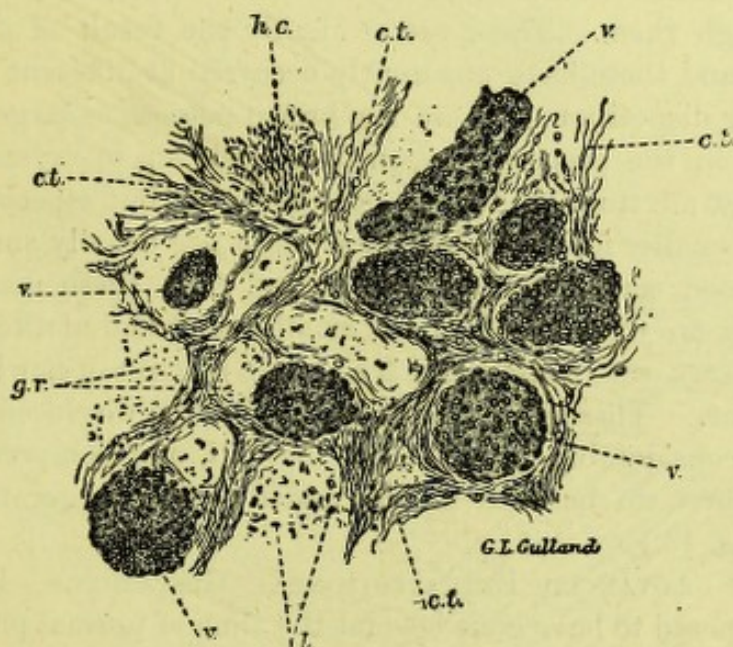


FIG. 43.

PLACENTA OF EXTRAUTERINE GESTATION AT 4½ MONTHS.  $\times 200$ . v., Villus, c.t., Connective tissue; h.c., Hematoidin crystals; l., Leucocytes; g.r., Granular debris.

the original paper by Dr Carter and myself, and copied in Tait's *Ectopic Gestation* and Bland Sutton's *Surgical Diseases of the Ovaries and Fallopian Tubes*. The fœtus was quite fresh and not macerated, and seemed less advanced than one would have expected.

The placenta formed a firm mass attached to the extraperitoneal surface of the top of the broad ligament, and measured two and three-quarter inches (vert.) by two inches (breadth) by three inches (antero-posteriorly).

On microscopical examination it is found to be made up of villi which in structure and arrangement differ considerably from the normal (fig. 47). They are disposed very irregularly and are not nearly so numerous as in



an ordinary placenta. The individual villi are compressed, so that the connective tissue of which they are formed is much denser than usual and the nuclei crowded very closely together. Only here and there are vessels to be found in the villi. A covering of a single layer of flattened epithelium can usually be traced round them, but sometimes this seems to have disappeared. These villi are embedded, not in blood spaces as in the normal placenta, but in connective tissue of the ordinary areolar variety, in which are a certain number of fat cells, and which is here and there traversed by bands of unstriped muscular fibres. This connective tissue is sometimes compressed in the neighbourhood of the villi, and in the same situation its meshes are often full of leucocytes. The blood vessels of this connective tissue are fairly numerous, but stand in no very traceable relation to the villi. But the most striking feature in the sections is the enormous number of hematoidin crystals scattered through them. These are evidently the result of old blood extravasations, and these have apparently occurred at different dates, to judge from their disposition. There are brown masses, as large as peas, here and there in the preparations, entirely made up of crystals, large and small, whilst all through the connective tissue, but especially close to the villi, are smaller foci in which the crystals are usually small. All trace of red blood corpuscles has disappeared from these masses, but many leucocytes are to be found in the smaller ones and at the margins of the larger masses, where also there is a certain amount of newly formed connective tissue. These extravasations have often displaced the connective tissue considerably from around the villi, and compressed villi are here and there to be seen in the midst of the larger masses of crystals.<sup>1</sup> (Fig. 43.)

II. CASE OF ADVANCED EXTRAPERITONEAL GESTATION. — Here the woman was supposed to have gone beyond the time of normal pregnancy. The foetus had begun to decompose, but was fairly well nourished and not macerated. It weighed two pounds four ounces.

The placenta was attached to the anterior abdominal wall and inner surface of the peritoneum as follows: It measured five and two-fifth inches vertically, three and one-fourth inches from side to side, and three and one-fourth inches antero-posteriorly (thirteen and one-half by eight by eight centimetres), *i.e.*, was somewhat cocoanut-shaped. To the naked eye and touch it had a firm, spirit-hardened, liver-like aspect. On microscopical examination it was found practically to be connective tissue, with large areas of extravasated blood crystals and tortuous, distorted villi, with more or less degenerated epithelium. More particularly it may be described as follows: In this case the placenta is formed almost entirely of the foetal villi and blood-clot more or less

<sup>1</sup> The description of the microscopical conditions is that of my assistant, Dr Lovell Gulland, who is an expert in this matter.



organised; the maternal connective tissue takes little or no part in its structure. The villi are greatly altered, and are much more compressed than those in Case I., the alteration in them consisting rather in an extreme tortuosity and distortion of the villus as a whole than in any very marked pathological change in its individual elements. The villus stems are generally isolated, and often widely separated from one another. They are embedded in connective tissue of a very low type, apparently the result of organisation of blood clot, as numerous masses of hematoidin crystals are found scattered through it. Some of the crystals are very large, others very small; but they are not so numerous

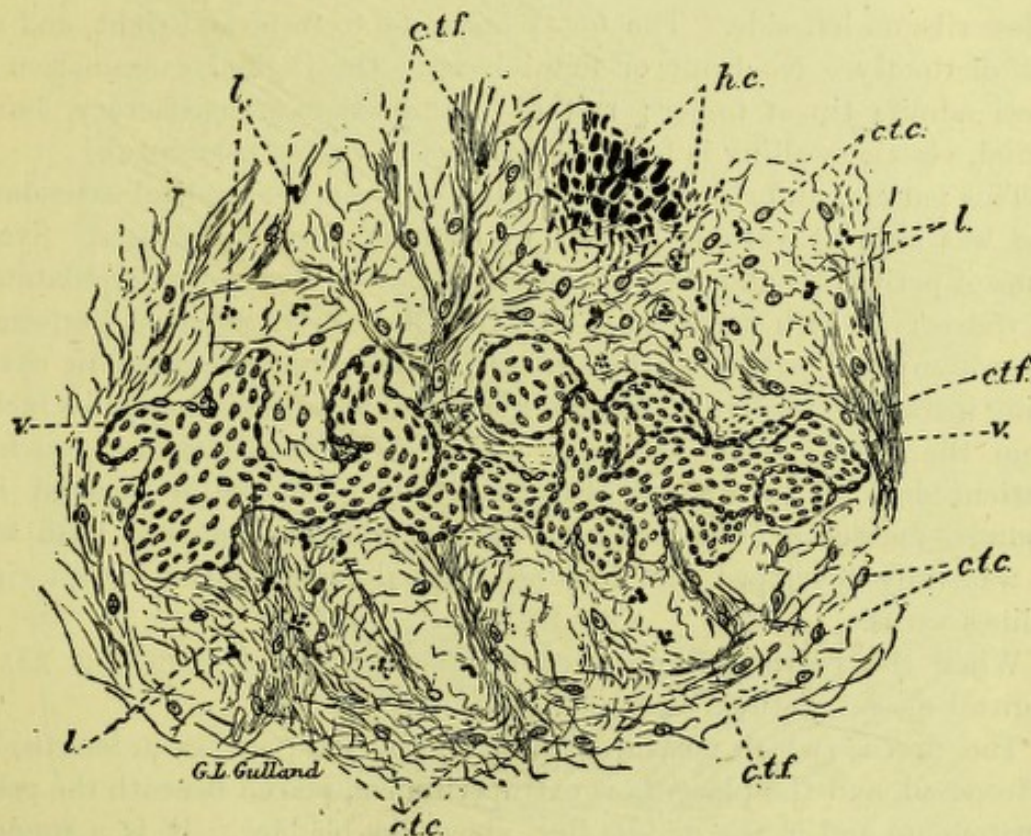


FIG. 44.

PLACENTA OF EXTRAUTERINE GESTATION AT FULL TERM.  $\times 250$ . *v.*, Villus; *h.c.*, Hematoidin crystals; *c.t.c.*, Connective-tissue corpuscles; *ctf.*, Connective-tissue fibres; *l.*, Leucocytes.

as a whole as in Case I., and the organisation of the extravasations has gone on to greater perfection. Many capillaries are to be found in the more fully organised parts of the intervillous tissue, few in the less perfectly organised areas. Leucocytes are numerous, but they have not the same marked relation to the villi as in Case I., nor are the capillaries arranged with any relation to the villi. (Fig. 44.)

III. ABDOMINAL GESTATION: FÆTUS AT FULL TIME IN PERITONEAL CAVITY, WITH PLACENTA LYING BENEATH PELVIC PERITONEUM AND IN PART ABOVE BLADDER.—This specimen has not been specially described before. Abdominal section was performed by Prof. Simpson and a



dead foetus extracted. On *post-mortem* the pelvis was removed by Dr Freeland Barbour, to whose great kindness I owe the specimen.

The points of interest in the clinical history are as follows: Last menstruation, beginning of July, 1886; severe vomiting in September, with bloody discharge and apparent abortion (evidently a decidua); then a great deal of pain, persisting for weeks, beginning usually at 10 P.M. and lasting till 4 or 5 A.M.; in beginning of April foetal movements ceased, pain passed off, and abdomen diminished in size.

On physical examination a tumour is felt reaching from pelvis and right iliac fossa up to below left ribs; vertical measurement, eight inches. Head of foetus can be felt between examining hands immediately below ribs on left side. The foetal limbs lie to front and right, and are felt distinctly. No bruit or foetal heart. On vaginal examination os uteri admits tip of finger; rest of examination unsatisfactory, but a round, elastic swelling is felt through roof of vagina (placenta).<sup>1</sup>

This patient unfortunately vacillated between her medical attendants and was seen at various periods by at least three specialists. Symptoms of peritonitis and obstruction of the bowels came on after dilatation of the cervix with tents, and on 22nd May Prof. Simpson performed laparotomy and extracted the child, now dead, from the amniotic cavity lying intraperitoneally. The cord was found separated about two inches from the navel. The placenta, which lay below, was not touched. Patient died at 10 A.M. on May 24, 1887. The child weighed five pounds, measured twenty inches; skin peeling and bones of head soft. It was fully developed, and had no external malformation except right talipes varus.

When the pelvis was removed it was frozen and sawn (fig. 45) in sagittal mesial section.

The uterus (which measures three and one-half inches in length) lies retroposed, and the placenta is extraperitoneal, placed beneath the pelvic peritoneum and in the middle line, above the bladder. It is a rounded mass, measuring four inches in all its diameters. It has the ordinary liver-like aspect and is firm to the touch. Large veins are seen lying at its anterior and posterior edges. (Fig. 45.)

The placenta here, on microscopical examination, presents a much more nearly normal appearance than in either of the foregoing cases. In some places the villi are as closely packed together as in the normal placenta, and they are in most situations identical in appearance with normal villi, but here and there they are widely separated from one another. In this placenta also blood extravasation has occurred; the villi are embedded, not in connective tissue, but in blood-clot. In this the outlines of the red blood corpuscles are still recognisable in places, though there are many fibrin threads running through it, and in some

<sup>1</sup> Report by Dr J. Hutchison, Dr Keiller's resident physician, Royal Maternity Hospital.



places, especially round some of the villi, dense layers have been deposited. There are many hematoidin crystals also, all of large size, and found almost exclusively near the villi. There is little or no

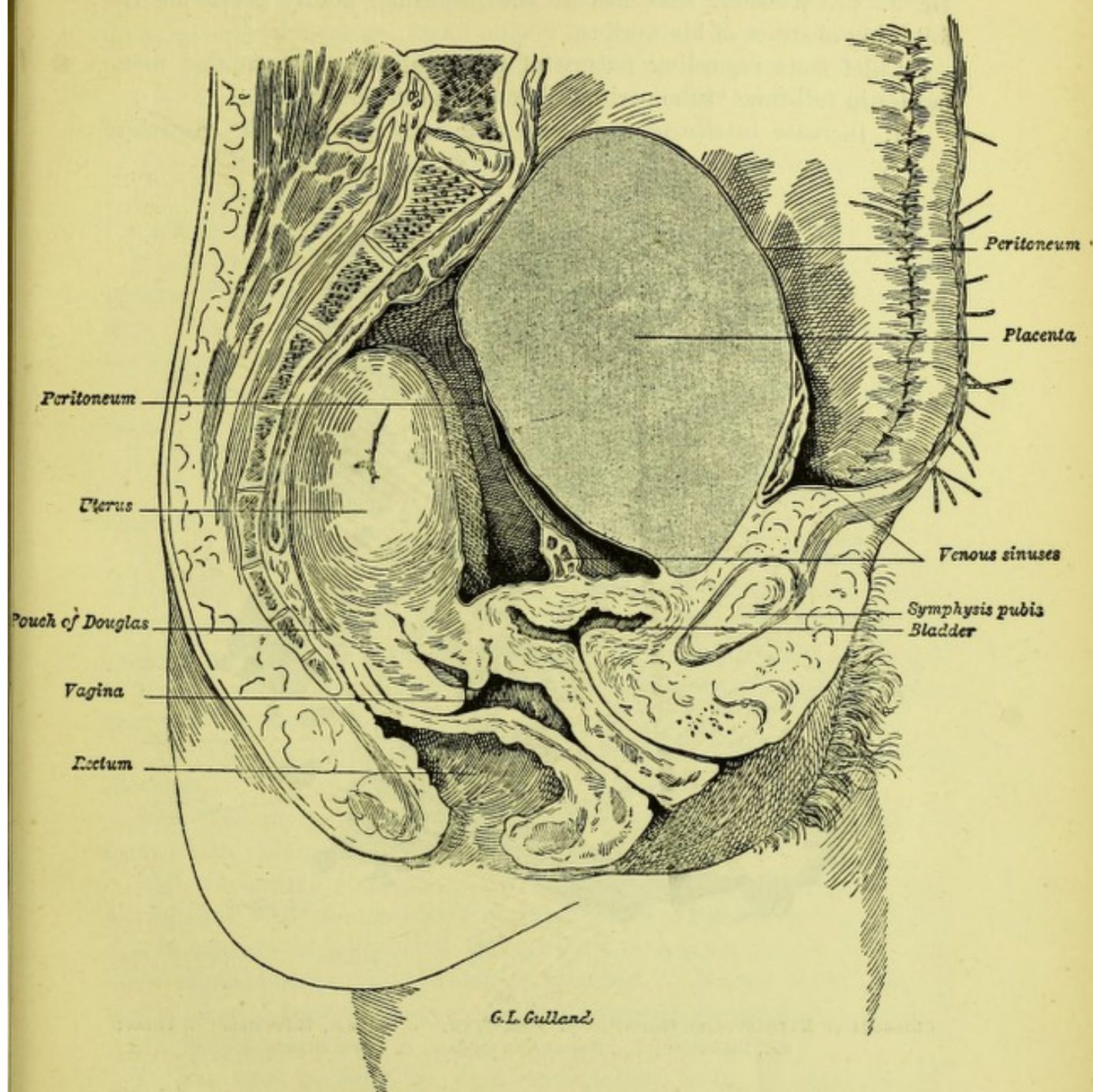


FIG. 45.

SAGITTAL MESIAL SECTION OF PELVIS, showing extraperitoneal placenta (4).

maternal connective tissue, except near the margin of the placenta, and in the specimens examined the blood-clot had nowhere as yet become organised. (Fig. 46.)

#### IV. CASE OF FULL-TIME INTRAPERITONEAL EXTRAUTERINE PREGNANCY;



PLACENTA IN TUBE, FŒTUS AND AMNIOTIC SAC IN PERITONEAL CAVITY ; LAPAROTOMY BY DR HALLIDAY CROOM AND DEAD CHILD EXTRACTED ; MOTHER DIED.—This case will shortly be published *in extenso* by Dr J. C. Webster, who has in the meantime kindly given me the following abstract of his work :

“Chief facts regarding nature of placental sac, placenta, and membranes in full-time ‘tubo-peritoneal ectopic gestation’ :

“1. Increase in size of Fallopian tube accompanying the growth of

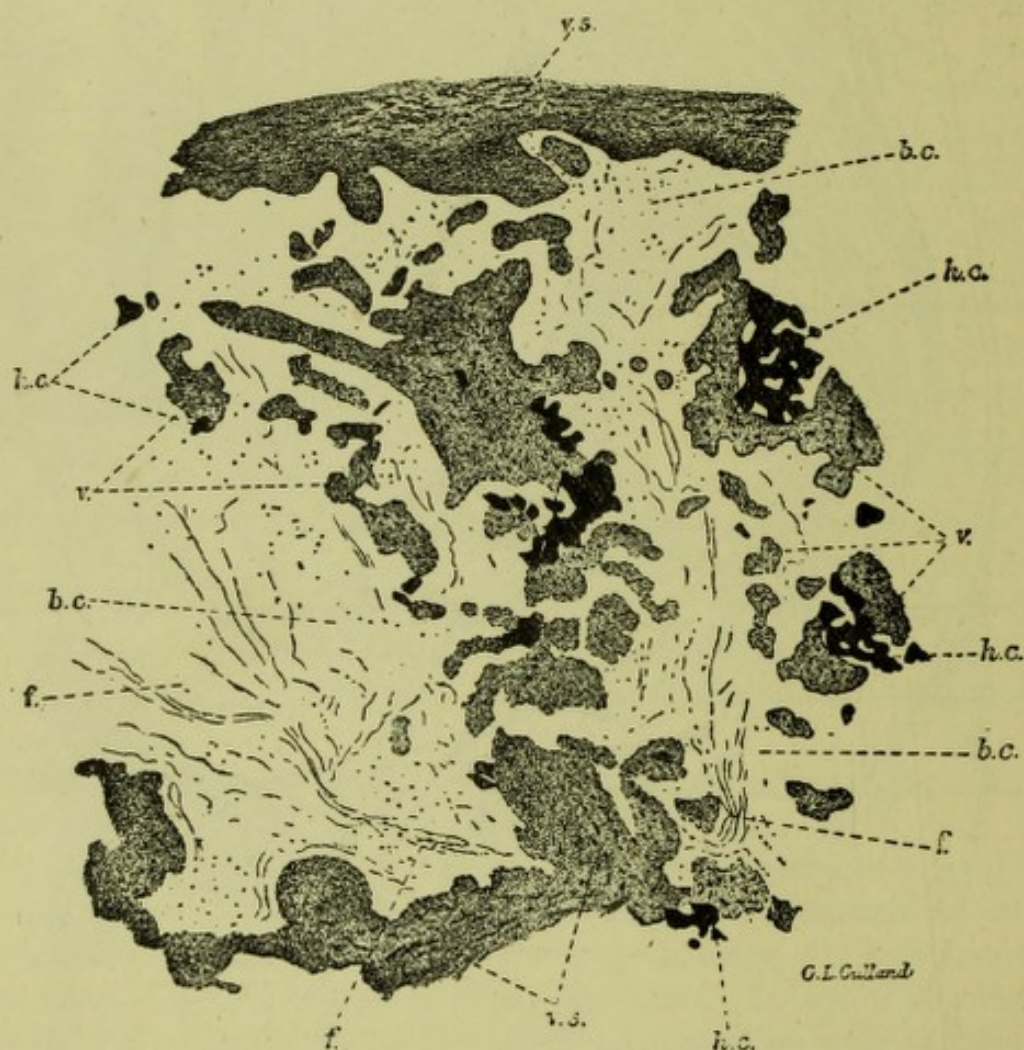


FIG. 46.

PLACENTA OF EXTRAUTERINE GESTATION AT FULL TERM.  $\times 50$ . *v.s.*, Villus stem ; *v.*, Villus ; *b.c.*, Blood-clot ; *h.c.*, Hematoidin crystals ; *f.*, Fibrin strands.

placenta, due to increase in connective tissue and muscle, chiefly in former.

“2. The proportion of these two elements to each other is the reverse of what is found in the normal tube, the connective tissue now being greatly in excess.

“3. The connective tissue is more compact for most part and the fibres in many places larger than in normal tube.



"4. The normal arrangement of the muscle in two layers is completely altered, the fibres being found in groups, which run in various directions.

"5. There is enormous enlargement of vessels opposite placental site, and the large sinuses are found chiefly in deep layers of the wall.

"6. Trabeculæ containing vessels extend into placenta from the wall.

"7. The epithelium normally lining tube no longer exists, no glandular layer like that found in uterine pregnancy being seen.

"8. No decidual cells are found anywhere in placental sac wall.

"9. Placenta, at time of operation in its sac, was a discoid mass in left side of pelvis, extending above brim for about three inches.

"10. After death (thirty-eight hours after operation) the shape became changed owing to blood extravasation into its substance, so that it was found as an irregular rounded mass, the greater portion of the placenta being destroyed.

"11. Sections of unaltered placental tissue resemble closely those of normal placenta in uterine pregnancy.

"12. Villi are seen attached to sac wall.

"13. Trabecular bands of various sizes pass from sac wall into placental substance.

"14. In several places the placental structure is much altered by old hæmorrhages, the villi being compressed and having lost their covering epithelium, in some cases having a sort of hyaline degeneration, but in most cases having become very fibrous, their vessels being obliterated and indicated by lines of blood crystals. Blood-clots are seen in various stages of degeneration.

"15. The amniotic covering resembles that seen in an ordinary placenta.

"16. The chorionic layer under the amnion is of dense fibrous tissue, from which villous stems project.

"17. Secondary (peritoneal) sac which contained the fœtus is lined throughout with amnion which in many places is considerably wrinkled.

"It consists of a layer of cubical epithelial cells resting on a thin layer of connective tissue, which is attached to fibrous layer—altered and thickened peritoneal covering of the various structures to which it was attached."

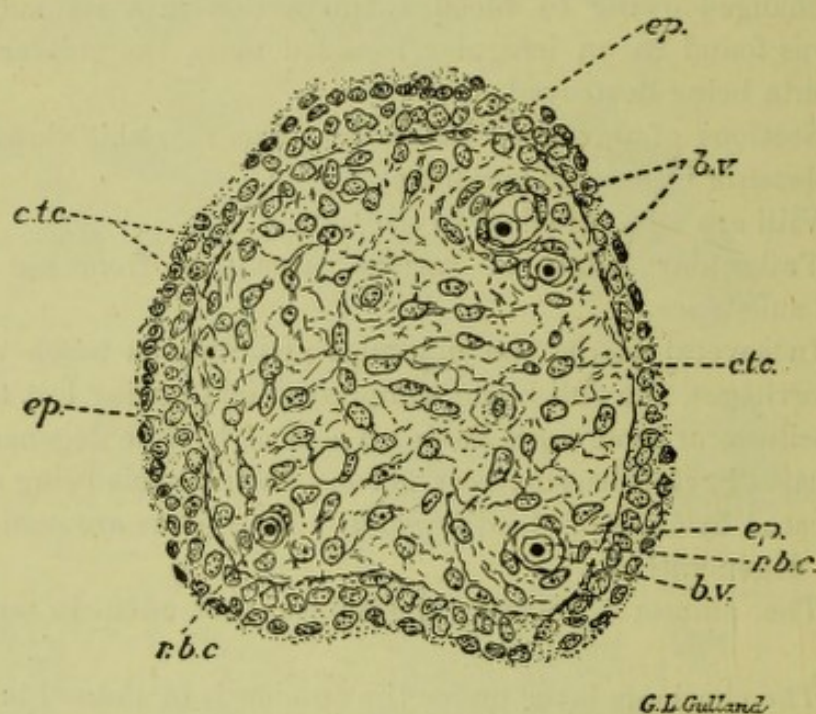
I have now to consider what explanation is to be given of the undeniably altered conditions of the placenta, especially in the first three cases, to which the present remarks apply.

*The ordinary belief is that the placenta has grown after the death of the fœtus.*

Now, no statement has been made as to what part of the placenta grows. It cannot be the fœtal portion, as the fœtus is alleged to be dead, and there is no special maternal portion in advanced cases except



the ordinary connective tissue, and no reason why this should grow when the active villi are dead. The increase in bulk of the placenta is brought about by organised blood-clot, and we see no reason why the death of the fœtus should cause this blood effusion. The apparent reason for this belief seems to be that the alleged primary extrauterine gestation, where the villi were supposed to graft themselves on the peritoneum and where the placenta was necessarily stationary, seemed to call for this alleged growth of placental tissue after the death of the fœtus as the only explanation of the unusual placental bulk. The primary grafting of villi on the free surface of the peritoneum is, however, a myth, and so with its discredit the dependent myth of the placental growth after fœtal death must disappear.



G.L. Gulland

FIG. 47.

TRANSVERSE SECTION OF VILLUS FROM PLACENTA OF A NORMAL SIX WEEKS' PREGNANCY.  $\times 400$ .  
*ep.*, Double epithelial layer; *c.t.c.*, Connective-tissue corpuscle; *b.v.*, Blood vessels; *r.b.c.*, Red blood corpuscle.

*I believe that the increased bulk of the placenta is produced only during the life of the fœtus and not after its death.*

In none of the four cases I record can one trace any special relation between the bulk of the placenta and fœtal death. In Cases II. and III. the fœtuses were well developed and near full time, and in Case I. the fœtus was evidently not long dead. The real explanation of the increased size and altered structure is much more probably as follows: We now know that there is no primary peritoneal pregnancy—*i.e.*, no case known where the placenta has had the free peritoneal surface as its maternal portion. Advanced abdominal gestation has arisen primarily from a Fallopian-tube pregnancy where the placenta remains in the



extraperitoneal tissue or, more rarely, in the tube. The fœtus may be also extraperitoneal, or by secondary rupture may lie, with or without its amnion, in the peritoneal cavity.

In this extraperitoneal development of the placenta we have two things happening which do not occur in normal pregnancy. The extraperitoneal placenta (1) develops below a serous membrane which it separates from the subjacent tissues; (2) it is displaced usually either down and not extensively if the growing fœtus lies above it, or up and extensively if the fœtus lies below. *It is this extraperitoneal burrowing and displacement that causes the blood effusion and connective-tissue formation leading to the larger bulk of placenta, and it can only happen during active fœtal life. The alterations in the structure of the placenta, when extensive, cause the death of the fœtus, and in proportion as these are less profound are the children healthy.* (Fig. 47).

In the last case (Webster's, No. IV.) the placenta developed in the tube, was not subject to displacement as in the first three, and thus had no great alteration in the structure of its fœtal portion. Unfortunately its size could not be accurately estimated, owing to blood extravasation the result of operation.



## CHAPTER XXI.

### A CONTRIBUTION TO THE PATHOLOGY, SYMPTOMS, AND TREATMENT OF ADHERENT PLACENTA.

FEW complications of the third stage are more disliked by the obstetrician than adherent placenta. While not now the bugbear it was in former times, yet the risks of hæmorrhage and septic mischief make it still formidable, although, fortunately, the latter complication is rare and thoroughly preventible. We are not yet in a position to explain the pathology of this complication. Indeed, to do so in any instance would require such an extended knowledge of the case before conception and after labour as must necessarily be rare. I believe that obstetricians are to blame in not more thoroughly examining the shed placenta in adherent cases, although it may be urged that the mischief is probably in the spongy layer and next the external wall. Granting even this, we do not as yet know the microscopic anatomy of such cases as we ought.

My attention has been directed to this subject from my very good fortune in obtaining a remarkable specimen of an inverted third stage uterus with the placenta adherent. As the microscopical anatomy of the specimen is interesting, and seems to me to partially explain such a complication, I have thought it well to describe it along with some remarks on its clinical aspects.

In examining this specimen, I did so by making microscopical sections of the entire thickness of the uterine wall and placenta by the celloidin process, so as to ascertain the difference of structure and arrangement in the serotinal layer as compared with a normal third stage uterus also with the placenta attached.

In the normal specimen we can recognise the following parts between villi and uterine wall :—

1. Where the serotina and villi meet we have a band of dense tissue, which stains more deeply, and is apparently formed by a blending of villi and serotinal tissue.<sup>1</sup> Owing to its density its exact structure is difficult to make out accurately, but it is probably connective tissue, and processes from it pass up between the villi forming the partitions

<sup>1</sup> Drawings of the placenta in adherent and normal third stage cases are shown at Plate IX. For the nature of this layer see Chapter VI., where it is shown to be due to the phagocytic action of the villi.



between the lobes. Occasionally one sees in it some of the cells of the large-celled layer.

2. *The large-celled layer*, sharply differentiated from the former, and made up of large endothelial-like cells, with nucleus and nucleolus. Scattered through this layer are many nuclei which stain deeply with logwood.

3. *The spongy layer*.—This is a broad, well-defined layer, with large spaces lined by perfect columnar epithelium.

4. A much less meshy layer lying on the uterine muscle.

The contour of the muscle is not flat but toothed.

In the sections of the adherent placenta the same structures can be made out, but *the mesh-work or spongy layer is much less marked, the spaces are markedly smaller, and in none of them can epithelium be detected.* There is no evidence, however, of chronic inflammatory affection—a point on which I had the valuable advice of Dr Woodhead. The cause of the non-separation here depended apparently on the defective development or pathological condition of the mesh-work or spongy layer, where the normal plane of separation for the placenta lies. How this has happened I am unable to explain, but the way in which it prevents separation is too evident to require special remark.

Cases of adherent placenta vary much in their degree, and range from those where no hæmorrhage accompanies the third stage, and where the separation of the placenta is easily performed by the hand, up to those where there is profuse hæmorrhage, sometimes proving rapidly fatal, as well as those where separation is effected manually with the greatest difficulty even by the most skilled, and where the patient runs grave risk of septicaemia. A clinical classification of adherent placenta, therefore, seems to me a requisite, and I submit the following as one based on the gravity of the case, and thus giving an idea of the prognosis.

1. *Cases of total adhesion, unaccompanied by hæmorrhage, where the separation of the placenta manually is easy, and is accomplished in the normal plane of separation.*

2. *Cases of partial adhesion, high up in the uterus where the placenta is separated in its lower part; often accompanied by serious hæmorrhage. The upper adhesion is extensive.*

3. *Cases of adhesion low down, the placenta being separated above; not usually accompanied with hæmorrhage.*

4. *Cases of very perfect adhesion, usually accompanied with little hæmorrhage, but where separation is effected manually with great difficulty. The placenta may be separated where the villi and serotina meet, and thus the uterus is left with the usual deciduous layer of the serotina still adherent, and often with portions of the foetal placenta attached.*

This classification is of course a sharp one, and combinations of the varieties often occur. The first class is the typical and easy one. The



patient has probably had a previous endometritis, has a slow second stage, and then a third stage where the placenta is not separated and expelled in the usual time. I have noticed this slow second stage occasionally, and usually set it down to ineffective uterine pains owing to the adhesion preventing proper uterine retraction. During the third stage the uterus may contract irregularly, developing nodules, as it were, in its contour. As the placenta is not expelled within three quarters of an hour, and is still in the uterus and unseparated, the obstetrician makes up his mind to separate manually, a procedure easily accomplished. I need not give the details of this, but remark that the patient must be chloroformed and the vagina douched with corrosive sublimate (1 in 3000). The dorsal posture is the best, and both hands are employed, the outer one to steady and depress the uterus as required. The separation of the placenta is best effected from below up, the entire separation being finished before expulsion is brought about. Sometimes confusion to the inexperienced operator is caused by his passing his hand within the membranes instead of keeping outside them. That an antiseptic uterine douche be used after full expulsion, goes without saying.

The second class of case gives by far the most serious complication at the time. Blood pours from the relaxed uterine wall where the lower part of the placenta is separated, while the attachment above hinders uterine retraction. The attendant, despite all care to secure retraction by legitimate grasping and friction of the uterus, by hypodermics of ergotine, and the use of the hot douche, fails, and unless the placenta is properly separated manually, so as to remove the cause of inefficient uterine action, the case may speedily become serious. Cases of ordinary flooding so readily, as a rule, yield to the usual means given above, that manual removal of the placenta is quite unnecessary interference. I think, however, that we err in waiting in this class of adherent placenta before resorting to separation by the use of the hand. No doubt the advice given here may be abused by the inexperienced, but the mistake can be rendered harmless by antiseptics, and further experience will correct the error of undue meddling. I wish, therefore, to urge caution in this instance, viz., the attendant must always, in a flooding that looks threatening, remember the possibility of this dangerous upper adhesion of the placenta with the lower part separated. The greater the adhesion above the greater the risk.

The fourth class is not accompanied by flooding, but the union of uterus and placenta is so dense that separation is a matter of immense difficulty. The placenta in such cases is separated where the villi and serotina blend, and the separated placenta is practically the foetal portion with amnion and chorion. This is the case where septicæmia is to be feared. The uterus is left lined by a layer of dead tissue, affording a nidus for infection, and exposing the patient to the gravest septic



risks. Such require most stringent antisepsis during the puerperium, and the immediate use of the intra-uterine douche if any threatening of mischief arise.

Separation of the placenta when adherent may occur, therefore, in the following planes: (*a*) Where villi and serotina blend; (*b*) in normal spongy layer; (*c*) even at a superficial distance below muscle, usually only partial.

In conclusion, I would urge a more systematic microscopical examination in all cases of adherent placenta, especially where any superficial muscle is removed.



## CHAPTER XXII.

### MITRAL STENOSIS AND THE THIRD STAGE OF LABOUR.

PREGNANCY with stenosis of the mitral valve forms one of the most serious cases in Obstetrics. Not only does the pregnancy exercise the most unfavourable effect on the heart, bringing the patient in a few months to the most advanced stage of cardiac disease, but we find also, on the completion of the third stage of labour, a most alarming condition often supervening, a condition that may speedily be fatal.

This important complication has been most ably brought before our Society by one whose death we all so much deplore—Dr Angus Macdonald—in his work on *Chronic Heart Disease in Pregnancy and Parturition*. I have no intention of taking up the question of mitral stenosis in all the aspects considered by him, but merely wish to direct your attention to its connection with the third stage of labour. Since studying Dr Macdonald's monograph, I have seen several instances of the complication, about eight in all. Three of these I purpose bringing briefly before you to-night, the more especially as in one of them a *post-mortem* was obtained and an important condition of the heart found. Of these eight, seven died; this shows how serious this condition is. The cases are briefly as follow:—

#### *Case of Abortion complicated with Mitral Stenosis.* (Report by Dr Mackness.)

Mrs S., age 27; fourth pregnancy.

*Previous History.*—Her first child died when 9 months old. Some years ago she consulted Dr Angus Macdonald, who told her that if she became pregnant again she would probably die as a result; since then she has had two children, one of which is dead, and the other alive, being 3 years old. No trouble with any of the labours, except that she stated that, as a result of mismanagement of the last one, she has always had some uterine trouble, the nature of which was not ascertained.

*Present Condition.*—She is about four months pregnant; has been perfectly well; she has had a troublesome sore throat and some falling out of the hair, but no other signs of syphilis, and the living child is



quite healthy. On 2nd September she went to the theatre, and got rather severely crushed in the crowd, causing some faintness. On 3rd September she became suddenly faint, and felt some pain in the abdomen. On 4th September she had several fainting attacks during the day, during which her husband states that her lips became very blue; a medical man was called in, and prescribed some mixture (nature unknown); he saw her again next day, and told her that she was going to abort, advising her to send to the Maternity for assistance. On the afternoon of 5th September Mr Booth saw her, and states that she had had some hæmorrhage about two hours before, losing about  $\bar{3}$ ij. or  $\bar{3}$ ij. of blood; this had then ceased, however; there was some slight pain on pressure in the right side of the hypogastric region, extending into the right iliac region; there were no pains; during the morning she had been vomiting and was very weak. The case was treated as one of threatened abortion; gr. xx. of chloral hydrate given, and she was told to keep in bed; at 10 P.M. she was found to have slept a little; there had been no further hæmorrhage or pains, but she complained of flatulence; pulv. glycyrrhizæ co. was ordered. On 6th September she was in much the same condition; she had taken castor oil in the morning, but had vomited it again; the abdomen was a good deal distended, the percussion note being tympanitic all over nearly; liver dulness about  $5\frac{1}{2}$  inches below costal margin; urine was high-coloured and scanty; tongue flabby, and covered with fur. During the night she was extremely restless, and suffered from vomiting and a great desire to go to stool. On 7th September she was a good deal better when the husband went to his work at 8 A.M.; at about 8.20 she became very faint, and an old woman who was called in is stated to have passed her finger into the womb and removed something; she became much worse, and I saw her for the first time at about 12.15 P.M. At this time she was apparently moribund, lying on the bed almost unconscious; she could not be roused to answer any questions; pulse about 140, very irregular, and almost imperceptible at the wrist; on auscultation the heart's beat was very feeble, and no murmur could be detected; her face was livid and lips extremely blue; extremities cold and clammy; respiration rapid and shallow; extremely restless; pupils equal and moderately dilated; when told to put out her tongue she did so, and it was found to be coated with fur, and protruded slightly to the right side; there was no hæmorrhage and no pains. About  $\bar{3}$ ij. of high-coloured urine were drawn off; it contained no albumen. Hot bottles were put round her, and  $\bar{3}$ ij. of brandy given every twenty minutes. On examining per vaginam the os admitted one finger, and the fœtus was felt in utero; there was some dulness over the right iliac region. At 1.30 the pulse had improved slightly, but the lips were still extremely blue and the extremities cold; a hot vaginal douche was given to try



and set up uterine action. At 2.30 the condition was still the same; the pulse was only kept up by the frequent administration of brandy with hypodermics of ether; milk was also given every few minutes in small quantities; she was continually asking for something to drink. It was then decided to empty the uterus as far as possible; the fœtus was found in the vagina, and the os easily admitted two fingers; half the placenta was then removed, but her condition became so serious that it was decided to proceed no further; there was hardly any hæmorrhage; a uterine douche was then given. At 3 P.M. she became much worse, the breathing became more rapid, and the pulse weaker; the face was completely blue and livid. At 3.8 P.M. the breathing ceased, and she had a convulsion of a tonic character, the face being drawn and the arms extended, with the fingers also extended, while at the same time she became black in the face. This then passed off, and at 3.10 P.M. the heart stopped beating.

*Post-mortem* was performed by Dr Bruce. As the body was considerably decomposed, and lying in a small room of a large tenement, only necessary examination was performed.

*Abdomen.*—No peritonitis; uterine appendages normal; uterus about size of a three months' pregnancy, and containing blood-clot.

*Thorax.*—Right side of heart completely engorged, and lungs œdematous. Heart found with marked mitral stenosis; recent ulceration on aortic cusps.

*Comment on Case I.*—This case was, unfortunately, seen too late by Dr Mackness. There was, however, mitral stenosis with some fresh endocarditis and sudden severe symptoms arising on the 7th, when the abortion was going on. Little blood seems to have been lost, and while the fit was probably due to fresh ulcerative endocarditis, as no albuminuria was present, the death seems to have been caused by the slow engorgement of the right heart and lungs. I regret now that venesection was not performed; but the fresh endocarditic lesion rendered the prognosis, if not hopeless, at least excessively grave. The effects of the engorgement seem to have been prolonged, a fact due probably to its not being a full-time labour, and thus the bulk of blood less.

CASE II. occurred in the Royal Maternity Hospital, and a careful record has been prepared by Dr J. W. Ballantyne, then Resident. This account he will lay before the Society, with careful sphygmograms made at the time. I may state, however, that on the completion of the third stage the pulse suddenly flickered, becoming almost imperceptible.

CASE III.—*Labour complicated with Mitral Stenosis, Justo-minor Pelvis, and Prolapse of the Cord.* (Report by Dr Mackness.)

Mrs W., age 26, iii.-para. Her two former labours had been instru-



mental ones, and at the first one she suffered from convulsions, the child being still-born; the second child died eighteen months after birth. She had never had rheumatic fever, and did not know that she had any cardiac lesion; she had been perfectly well during the whole pregnancy, except that for a fortnight before delivery she had noticed that on climbing the stairs she became rather breathless. Labour pains commenced a little before midnight on 3rd October, and she at once found difficulty in breathing, and soon was unable to lie down. About 3.45 A.M. a considerable quantity of liquor amnii escaped. At about 4.30 A.M. I saw her, and found a small woman of about 5 feet 3 inches sitting up in bed gasping for breath; pulse 120, fairly full, but very irregular; respirations 60 per minute; pains severe. Chloroform was at once administered, the patient half-sitting up at first; the os was found fully dilated, the head free at the brim, and a large bag of waters; the diagonal conjugate was rather under  $4\frac{1}{4}$  inches; the anterior lip of the cervix was considerably thickened; the membranes were then ruptured, and the sagittal suture found in the right oblique diameter, the small fontanelle just within reach anteriorly, while the anterior fontanelle could not be reached. High forceps were then applied with some difficulty, on account of the small size of the pelvis; as soon as the forceps were applied the cord was found to have prolapsed, and could not be kept up, but on account of the critical condition of the mother it was decided to proceed with the delivery. The child was delivered at 5.15 A.M. still-born, and could not be revived; the child was a small one. The placenta was delivered ten minutes after; very little blood was lost. After delivery the condition of the patient improved slightly; the pulse was fairly full, but still very rapid and irregular; the breathing was harsh, with numerous fine crepitations; the heart sounds were obscured by the breathing. The case was looked on as one of bronchitis, and treated accordingly with poultices and steaming, while some beef-tea was ordered and  $\bar{3}$ ss. of brandy every three hours. 7 P.M.—Condition much the same; breathing easier, but she could not lie down in bed: she had passed no urine; discharge very slight. Heart sounds impure, but the murmur could be timed. 10 P.M.—A distinct precordial thrill was noticed, and it was suspected that it was a case of mitral stenosis. Ordered 10 minims of tr. strophanthi every four hours; brandy to be continued also. Considerable œdema of hands and feet.

5th October, 10.30 A.M.—Breathing very much easier, and had improved with the first dose of strophanthus; had had no sleep; pulse 120, moderately strong, and rather irregular; distinct presystolic murmur to be made out now over mitral area. 3 P.M.—Since last seen she had had a fainting fit, during which the lips became perfectly blue. Pulse fairly strong, but irregular; heart was thumping considerably.



Owing to a mistake of the friends, 80 minims of tr. of strophanthus had been given in twelve hours. She was now ordered 5 minims of tr. strophanthi every four hours, and  $\bar{z}$ ss. of brandy every three hours.

6th October.—Very much better; lying down in bed and breathing comfortably; œdema gone; passing plenty of urine. She remained in this condition until 8th October, when she was sent to Professor Fraser's Ward in the Royal Infirmary.

In review it will be seen that in all these instances the serious complications began on completion of labour. In Case I., death resulted speedily; in the third there was temporary but great embarrassment; and in the second we had in a few hours pulmonary œdema and ultimately death. How are we to read these records? Briefly, the matter may be put as follows:—During pregnancy we have imposed on the heart the task of driving a larger bulk of blood through the ordinary circulation and an additional area formed by the enlarging uterus and placenta. For this extra task the left ventricle of the heart normally hypertrophies. Mitral stenosis is in itself a serious cardiac disease apart from any pregnancy, inasmuch as the weak left auricle soon fails in its increased duty, the lungs become engorged, and the right side of the heart dilated. If the work of pregnancy, however, be added, then we get compressed into a few months, what otherwise might have taken years; so that at the beginning of labour we may get such failure of compensation that we have a dilated and weak left auricle, congested lungs, and a dilated right heart. When the labour is finished and free hæmorrhage does not occur, we get returned to the right side of the heart the extra amount of blood before accommodated in the uterine and placental sinuses. The right heart more or less speedily becomes distended and the lungs engorged, so that we may get death with over-distension of the heart, as in Case I.; great dyspnœa and threatened death, as in Case III.; or sudden pulmonary œdema, as in Case II. I am well aware that this view of the over-distension of the heart after the third stage has been disputed, and that it has been alleged that the abdominal veins can accommodate the extra amount of blood. This objection has always seemed to me absurd, inasmuch as it could also be made to prove that in a normal body the blood should not return to the right side of the heart at all. In this respect it resembles the Traube-Rosenstein theory of eclampsia, which, as we know, when logically pursued, made eclampsia one of the normal phenomena of parturition. The *post-mortem* in Case I. clearly demonstrates that even in an abortion, where there is little hæmorrhage, the right heart may become paralysed from over-distension. How much more, then, may this happen in a full-time case!

The considerations I have already advanced have no mere theoretical interest, but are of the highest practical value. They lead us to the



discussion of the important question of—How can we best treat such cases, especially in the third stage of labour?

Of course it is our duty to discountenance marriage most strenuously in all cases of women with mitral stenosis. This goes without saying. Unfortunately, our advice is seldom asked, and when given, not very often followed; so that we get the problem before us of mitral stenosis and pregnancy—What is best now?

The only thing I do during pregnancy is to keep the patient at rest as much as possible, and administer tincture of strophanthus steadily when circulatory disturbance begins. I prefer it to digitalis, as it is a pure cardiac stimulant, and does not contract the small arteries as digitalis does. Digitalis, from its action on the arteries, tends to throw more blood into the venous system, and thus more to the right side of the heart. Strophanthus, on the other hand, gives us heart stimulus, and does not increase the work of the heart by contracting the arterioles. I am aware, however, that I am treading on debatable ground here, and ground foreign to me. I can only say that strophanthus has given me distinctly better results than digitalis. During labour one must keep up the action of the strophanthus, and deliver as soon as possible, using chloroform as usual. But now comes the worst period, viz., the third stage, and the one that demands our greatest vigilance. The plan I advocate at that time is as follows:—

1. Give no ergotin.
2. Feel no alarm at even free hæmorrhage.
3. Be specially on the outlook if hæmorrhage is scanty.
4. If the circulation becomes embarrassed, as evidenced by irregular heart action or dyspnœa, then push strophanthus and drycup over the heart, as suggested by Dr Connel. Bleed the patient from the arm if the latter fail.
5. Even if all seem right, have the patient constantly watched for the first day.

This treatment is diametrically opposed to that of many. Spiegelberg, for instance, says that loss of blood is highly dangerous, even when it is lost *guttatim*. This is quite true in part. The *guttatim* loss is dangerous, but only because it is not a free one. To conserve blood in such cases is to overload, and perhaps paralyse the heart. My experience on this point is quite the opposite of Spiegelberg's. The worst case I ever had lost blood profusely and recovered. In those cases under my own full care I have acted on these principles, and lost only one case—the case where hæmorrhage was not marked, where all seemed well, and yet death occurred suddenly a few hours after I left her.<sup>1</sup>

The views advanced seem to me to place the retro-placental blood-clot

<sup>1</sup> The administration of ergotin seems to me dangerous, as tending to prevent hæmorrhage, and therefore should not be employed unless the hæmorrhage is too profuse, while undue conservation of blood adds to the heart's work.



and the gush of blood one so often has in a multipara when the placenta is separating, in a new light. I have no doubt many of us have felt that these two occurrences have been due perhaps to want of vigilance or skill in the management of the third stage. The retro-placental clot has no function in separating the placenta, but it and the occasional gush should be regarded as salutary, as getting rid of that extra bulk of blood which, if returned to the systemic circulation, might embarrass cardiac action even in a healthy woman. I do not wish to seem to think lightly of hæmorrhage, or to even hint that one is not to be most careful in attending to the third stage; I only state what I feel now, that in a normal case the blood-clot in the placenta and membranes, or the teacupful of blood lost in a single gush, is really better out of the patient's systemic circulation and heart.

I am specially indebted to Dr Bruce for examining the heart in Case I., and to Dr Mackness for his careful and unbiassed clinical records.

Since the above was written, I have met with three additional cases. In two of these I obtained *post-mortem* examinations, with results confirming my previous conclusions, and demonstrating effectively the main cause of sudden death at the end of labour.

THE FIRST PATIENT was admitted to the Maternity in a dying condition. The history of her case, for which I am indebted to Dr Eden, one of the residents, is as follows:—

“Mrs J., age 34, was admitted to Royal Maternity Hospital on 5th January at 4 P.M., on the recommendation of Dr Simpson of Leith.

“When first seen after admission, patient was sitting propped up in bed, in the attitude of complete orthopnoea, and labouring painfully for breath. The lips were markedly cyanotic, the hands cold, and the patient seemed restless and excited. The pulse at the wrist was rapid and feeble; respiration between 40 to 50 per minute; and so great was the dyspnoea that she could only with difficulty reply to questions put to her. She stated, however, that she was seven months pregnant with her first child, and had been married seven years. Three years ago she had rheumatic fever. Since the occurrence of pregnancy she had suffered from breathlessness, cough, swelling of feet, and increasing inability for all exertion. Latterly she had become rapidly worse.

“On examination of the heart a loud systolic murmur was heard at the aortic area, and a rough murmur was indistinctly heard in the mitral area. In the axilla the first sound was pure. The lungs presented loud crepitations everywhere, and some dulness was made out at the bases posteriorly. The abdomen showed a uterine tumour a little above the umbilicus. From the attitude of the patient the foetal heart could not be heard.



"On vaginal examination the os was found to be undilated, and there had been no labour pains. The rectum was loaded, as also was the lower part of the colon; the bowels had not been moved for several days. The urine was very scanty, highly concentrated, and contained albumen. There was considerable œdema of feet and legs.

"An enema was given at once, and afterwards  $\bar{z}$ ss. of Henry's solution with 15 m tinct. belladonnæ. Every hour, ether and strophanthus were given by the mouth.

"The patient grew quieter after an hour or two of rest, and through the following day continued in much the same condition. On the evening of 6th January she became worse, and the lungs appeared to be more choked. She was therefore dry cupped in six places over the back. This produced some relief. About midnight, however, the nurse in charge became alarmed and summoned the house physician, who found her *in articulo mortis*."

On *post-mortem* great œdema of the lungs with pleural and pericardial effusion was found, and the following was found to be the condition of the heart. For its examination I am indebted to the kindness of Dr Woodhead:—

"The *right auricle* was normal, and contained a large well-formed ante-mortem clot, which extended from the auricular appendage through the tricuspid valve and blocked the inferior vena-cava opening. Similarly the *right ventricle* was filled with a firm, decolorised clot, continuous with the one lying in the right auricle, as well as filling for a short distance the pulmonary artery. This clot had different degrees of consistency, and was exceptionally firm near the septum. There were only slight changes in the right ventricle, and these were confined to the muscular walls, the chamber being slightly dilated, and the muscular fibres only showing slight fatty changes.

"The *left auricle* was to a slight extent dilated and hypertrophied, but the *left ventricle* was markedly hypertrophied, and in it, lying next the septum, was a considerable quantity of firm, decolorised clot, and small recent clots in the rest of the cavity. At the inner angle of the mitral valve were a few small recent vegetations, and one or two at the opposite angle. The outer angle of the mitral valve was much thickened, and at the point where the papillary muscle joins the chordæ tendineæ, and again where the chordæ tendineæ join the margin of the cusps, was marked thickening. The angles of the valves were quite adherent, and the auriculo-ventricular opening slightly stenosed. The cusps of the *aortic opening* were bound together at each margin with quite recent vegetations, which almost filled the lumen of the aortic opening, and gave it, on looking from above, an irregular, egg-shaped appearance. The sinuses were well defined, but the valves were thickened and calcareous. In the aorta were some small ante-mortem clots. The



cavity measured  $4\frac{1}{4}$  inches vertically; the thickness of the wall was  $\frac{3}{4}$ — $\frac{1}{4}$  inch at the extreme apex.

"*Lungs*.—The lungs were congested and œdematous, the bronchial mucous membrane congested, and the glands at the root of the lungs congested and slightly pigmented. There was also a slight pleurisy.

"*Liver*.—The morbid changes in the liver were venous congestion, fatty infiltration and degeneration, with clots in the veins.

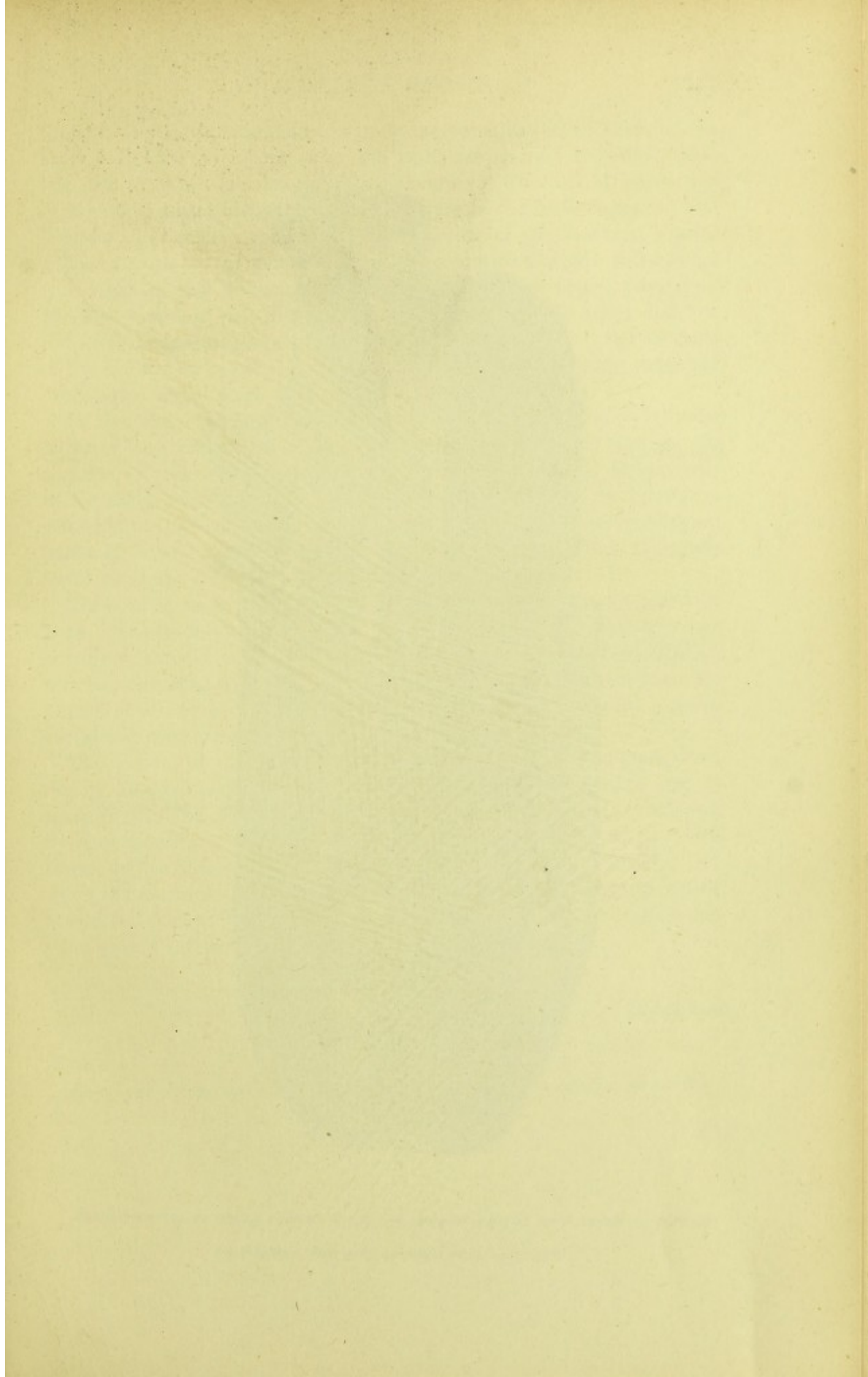
"*Kidneys*.—In the kidney were cicatrices from old infarcts. The capsule was slightly adherent; the cortex was thin and irregular; the epithelium in the tubules was full and apparently fatty, and the Malpighian tufts large and the organ congested. The iodine reactions were negative." Microscopical examination of the mitral valve showed ulcerative endocarditis (simple) with no micro-organisms. In this case it is evident that the strain of pregnancy aggravated the heart condition, setting up fresh left-sided endocarditis, especially in the aortic segments. The aortic stenosis thus produced was of the most marked type, and as a result, we had an obstruction to the circulation causing failure of compensation, with pulmonary, pleural, and pericardial effusion. The result was exactly analogous to that of mitral stenosis, except that the resistance of the strong left ventricle had first to be overcome.

THE SECOND FATAL case has been already mentioned, regarding her second labour, in my previous paper, as "the worst case I ever had." During the puerperium of her second child she had free hæmoptysis, showing pulmonary congestion. In this, her third pregnancy, there was great œdema of the lower limbs and dyspnœa on exertion. The presystolic murmur was well marked and the heart's action irregular. Under the use of digitalis, which she had taken for several years intermittently and with great benefit, the œdema disappeared.

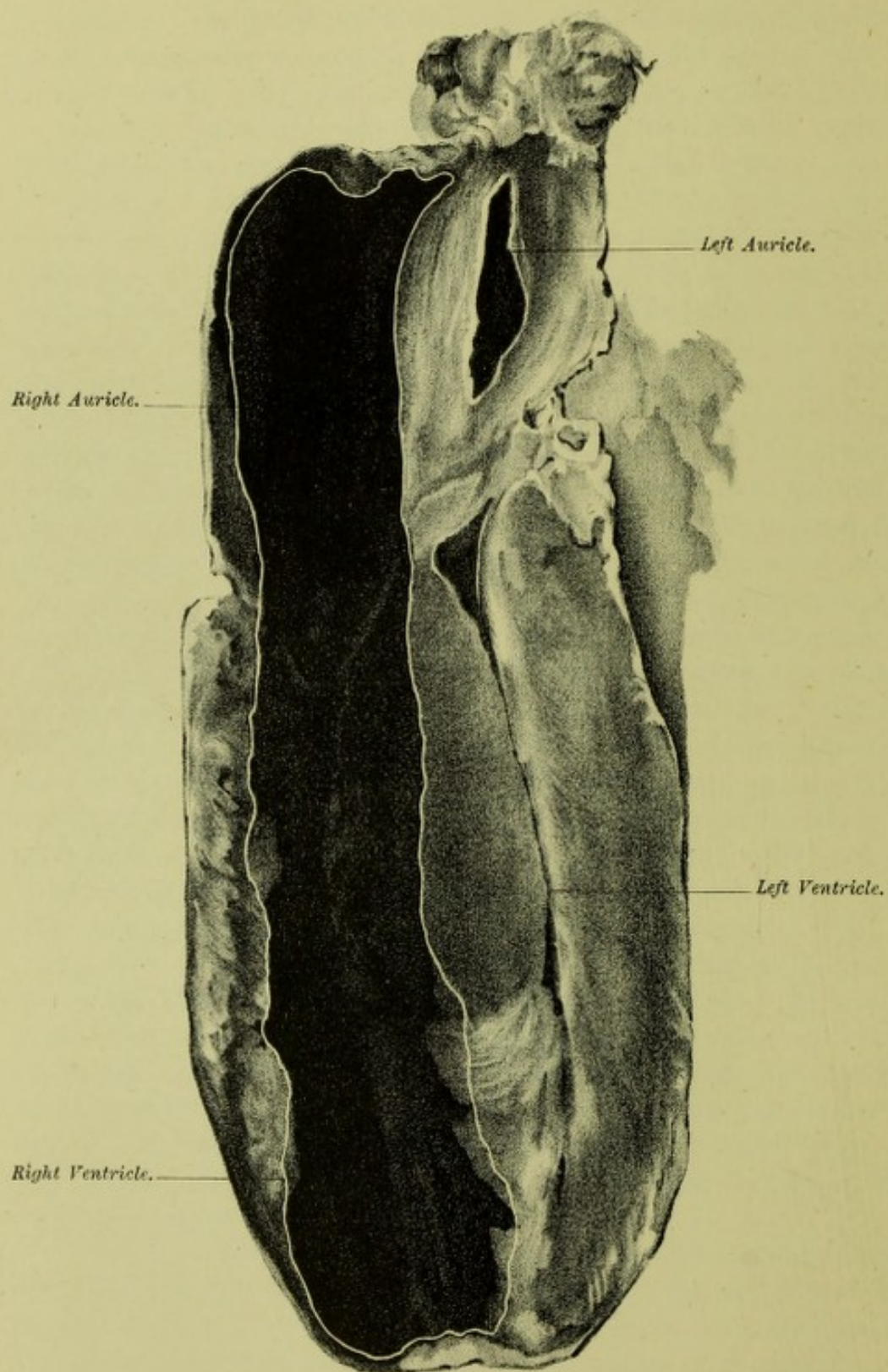
She fell in labour on the 2nd March, and I saw her at 9 A.M. The first stage was completed, and I delivered with forceps. In the third stage there was a fair amount of hæmorrhage with adherent placenta, as in her last confinement. I removed the placenta manually, but immediately on the completion of the separation she turned her head slightly to the left side, became unconscious, breathed with great rapidity, and died before I had time to do anything further than give a stimulant hypodermically.

Dr Bruce performed the *post-mortem*. On the thorax being examined after opening the chest, it could be seen that the right auricle was greatly distended. The bloodvessels of the heart were then tied, and the heart removed so as to ascertain the condition of the cavities so far as blood distension was concerned. The right auricle, as already said, was over-distended. The heart was frozen in the vertical position, with the result that the auricular distension diminished markedly. It was therefore thawed and refrozen with its left-sided aspect lower. It was









SECTION OF HEART WITH MITRAL STENOSIS IN CASE OF SUDDEN DEATH AT END OF LABOUR.

White line marks inner aspect of right wall of heart.



then divided by a vertical saw-cut so as to expose both sides of the heart. Blood-clot was found in the right auricle and ventricle. The left side of the heart was completely empty. The mitral valve was extremely stenosed, admitting merely the tip of the little finger.

From what I have said as to the condition of the heart, it is quite a fair account to say that— (1) On the completion of the third stage the right auricle became over-distended and the heart paralysed. (2) The dyspnœa was due to absence of blood in the lung, and the unconsciousness to anæmia of the brain from emptiness of the left side of the heart. It is possible that the right side became partly engorged during the second stage.

In the THIRD CASE seen by me the patient had a marked presystolic murmur, and was pregnant for the second time. During the last six months of pregnancy she took tincture of strophanthus, three drops thrice daily, with no intermission. During all the time no symptoms referable to the heart appeared. She had an easy labour and recovered perfectly, except that on the second day of the puerperium there was facial paralysis, left-sided, for a few hours.

These cases seem to me to require little comment. The prognosis in such depends on two things, viz., the extent to which dilatation has advanced, and the endocarditis set up. When the failure in compensation has extended to the right side of the heart, weakening it, then the sudden strain from the excess of blood entering when the third stage is completed may prove fatal.

The extent of the dilatation of the right side may be judged of, during life, by percussion, the existence of venous pulsation and of hæmoptysis, and also, as Broadbent has more especially pointed out, by the nature of the murmur. When the first sound is not well heard, or has disappeared, this shows weakness of the left auricle; and when the murmur loses its intensity, this means, within certain limits, a weakening of the heart's action by dilatation of the left auricle and right side of the heart that bodes ill for labour.

---

#### DESCRIPTION OF PLATE.

##### PLATE XX.

Shows heart of fatal case of mitral stenosis cut, when frozen, so as to expose cavities.



the heart is a vertical muscle, it is to a large extent in the  
front. The heart is found in the right ventricle and the  
left side of the heart are completely separate. The right ventricle  
is situated anteriorly and the left ventricle is situated posteriorly.

From what I have said, it is evident that the heart is a  
vertical muscle. The heart is a vertical muscle, it is to a large extent  
in the front. The heart is found in the right ventricle and the  
left side of the heart are completely separate. The right ventricle  
is situated anteriorly and the left ventricle is situated posteriorly.

During the normal state, the heart is a vertical muscle, it is to a large extent  
in the front. The heart is found in the right ventricle and the  
left side of the heart are completely separate. The right ventricle  
is situated anteriorly and the left ventricle is situated posteriorly.

There are some points to be noted in the study of the heart. The heart is a  
vertical muscle, it is to a large extent in the front. The heart is found in the  
right ventricle and the left side of the heart are completely separate.

The effect of the heart is to pump the blood. The heart is a vertical muscle, it is to a large extent  
in the front. The heart is found in the right ventricle and the  
left side of the heart are completely separate. The right ventricle  
is situated anteriorly and the left ventricle is situated posteriorly.

THE JOURNAL OF THE AMERICAN MEDICAL ASSOCIATION

CHICAGO, ILL., MAY 1, 1919

Vol. 26, No. 19

Published by the American Medical Association, 535 North Dearborn Street, Chicago, Ill.

Subscription price, \$5.00 per annum in advance. Single copies, 15 cents.

Entered as second-class matter, May 2, 1912, under post office number 384, at Chicago, Ill., under special agreement of post office and postmaster.

Acceptance for mailing at special rate of postage provided for in Act of October 3, 1917, authorized on May 1, 1919.

Postage paid at Chicago, Ill.



# PART IV.

PRACTICAL PAPERS IN OBSTETRICS AND GYNÆCOLOGY.



PART IV

REMARKS ON THE HISTORY OF THE



## CHAPTER XXIII.

### IMPROVED METHOD OF MANAGING THE THIRD STAGE OF LABOUR—HOW CAN THE ACCOUCHEUR BEST GUARD THE PERINEUM WHILE THE FÆTAL HEAD IS PASSING?

IN the present communication I wish to describe a method of managing the third stage of labour which I have practised for some time. It is based on a new view as to the separation of the placenta, given in Chap. XIII. For the sake of clearness, however, I give a brief summary of the views there advanced. I wish also to criticise the hitherto accepted, but in my opinion erroneous view, that the placenta is separated by diminution in area of the placental site. My only reason for doing so, however, is that my views have been criticised by my friend Dr Freeland Barbour, to whom I wish to reply. I should otherwise have contented myself with a mere statement of what I believe to be the correct opinion on this much debated point.

#### SUMMARY OF THE CAUSE OF THE SEPARATION OF THE PLACENTA DURING THE THIRD STAGE OF LABOUR.

1. At the beginning of labour the placenta and uterus are together to be considered as made up of the following parts, so far as the question of separation is concerned:—

(a) *The part to be separated*, comprising—

Amnion,  
Chorion,  
Chorionic villi,  
Intervillous spaces,  
Large-celled layer of serotina.

(b) *The line of separation*, lying between the large-celled and small-celled layers of the placenta, and termed the spongy layer. It is formed chiefly by the persistent fundi of the uterine glands.

(c.) *The part left behind* after the placenta is separated, and consisting of the small-celled layer with remains of uterine glands, smaller in lumen, lies on the uterine muscle.



2. The chorionic villi get their blood supply from the umbilical arteries of the foetus. The intervillous spaces have blood poured into them from the maternal circulation, the blood passing by the curling arteries into the spaces, and from these into the uterine sinuses by the slanting veins. The venous supply of the uterus is much more abundant than the arterial.

3. At the spongy layer we may regard the placental area (*i.e.*, uterine surface of separated placenta) and placental site as coinciding during pregnancy, with the spongy layer joining them.

4. Separation of the placenta can only take place when there is disproportion between placental area and placental site.

5. The placenta does not separate during the first and second stages of labour, because all changes in the placental site (diminution during pains and expansion when pain dies off) are accurately responded to by the placenta, owing to the activity of the foetal and maternal blood supplies.

6. During the third stage of labour the foetal circulation is cut off and the villi are closely pressed together, showing obliteration of intervillous spaces. The increase in placental site following a third stage pain is not followed up by the placental area, as the placenta is now practically a bloodless structure.

7. The placenta does not separate on diminution of placental site to  $4'' \times 4''$ .

8. Any diminution of site below this introduces no relative change at the plane of separation. The area of the placental site and the placenta still correspond.

9. A disproportion in area between the placental site and the placenta brings about tension on the trabeculae of the spongy layer, *i.e.*, tears them.

10. This disproportion happens during the third stage in the elastic recoil following a pain, and therefore separation occurs after the pain. During the recoil the placental site increases slightly, but the placenta, now bloodless or nearly so, does not respond: hence disproportion of area.

11. The placenta, when separated, is expelled by the pains either as Duncan or Schultze has figured.

12. All separations of placenta or membranes follow one mechanism—*“Placenta and membranes separate when there is a disproportion at the plane of separation between their area and their site of attachment. This disproportion is only slight, as the trabeculae are microscopic.”*

The gist of the view advocated is that the placenta separates in the third stage after the pains, and is expelled, when separated, by the pains. The important practical point is that manipulation cannot separate the placenta, but can only aid expulsion.



*The Management of the Third Stage deducible from the view expressed.*

At the beginning of my practice I adopted Credé's method of expression of the placenta. The Credé method is intended to separate and expel the placenta. I had not tried it long when I found it most unsatisfactory. Not only did it cause bleeding by forcing blood into the lacerated tissues below the placental site, but on two occasions I expelled the placenta *minus* the entire membranes, and had to chloroform my patient and remove these manually. The error of this lay in the Credé method, which I consider the most dangerous plan possible for separation of the placenta.

I came to the conclusion, therefore, that the uterus would manage the separation of the placenta better than I could, and accordingly for some years I merely kept my hand on the uterus, employed manipulation of it if bleeding came on, and limited the Credé method to helping the expulsion, never employing it to separate the placenta. My guide to the period of separation was the marked decrease in the size of the uterus.

This method gave good results; why, I did not know, and I fell back for comfort on the fact, unfortunately not well enough known, that non-interference with a natural process gives better results than ignorant, though well-meant meddling. I do not at all depreciate thorough manipulation of the uterus when hæmorrhage is taking place. I hold this to be imperative. What I condemn is quite another matter, viz., forcible compression of the uterus to expel the unseparated placenta.

The method I have now adopted gives me excellent results, and is based entirely on the view I have summarised. For convenience I shall arrange my description in the form of brief rules.

1. When the child is born, note that the fundus uteri stands at or below the level of the umbilicus, and that the uterus does not contain a second child. Give an ergotine injection in a multipara, at any rate, if labour has been slow.

2. Do not tie the cord until the child has cried freely, and then tie only one ligature.

3. Cut the cord on the placental side of the ligature, and let the placental part of the cord drain thoroughly into any small dish; then tie it, to prevent any staining of the bed linen. Tie a second ligature at once, however, if a second child be present.

4. Before applying the first ligature it should be thoroughly ascertained by abdominal palpation that the uterus is not so relaxed as to bleed.

5. Continue with the hand on the uterus; do nothing when a good contraction comes on, and allow the uterus its normal relaxation after the pain is over.



6. Should bleeding from the uterus come on, or should the pains be feeble, then grasp the uterus so as to bring on a contraction to arrest hæmorrhage.

7. Do nothing further in a normal case until the lessening of the bulk of the uterus shows that the placenta is separated and being expelled; the expulsion may then be aided by "expression."

8. One can tell when the placenta is separated and not driven down by noting that gentle expression drives it down.

The reasons for the above treatment are as follow:—Ergotine and manipulation are used to ensure good marked retraction and to empty the intervillous spaces well. The foetal circulation is aspirated thoroughly by allowing the child to cry well, and by draining the cord. These two measures give the necessary disproportion sooner, as the placenta cannot now follow up the increase in the placental area during relaxation, is made as small in area as possible, and relaxation thus sooner tears the spongy layer.

Since practising this procedure I have had no difficulty in the normal third stage of labour. Interference is reduced to a minimum, and the membranes expelled intact.

I now wish, in conclusion, to answer Dr Barbour's objections to my view, and to criticise his.

1. "*Berry Hart* in his paper<sup>1</sup> brings forward a very novel theory of the mode of separation of the placenta. He makes several statements which are open to criticism. He says that we know that diminution in the placental site does not separate the placenta—a fact which (he says) my preparations demonstrate; but we cannot let this pass without qualification. These preparations show only that diminution up to a certain point (4 in. by  $4\frac{1}{2}$  in.) takes place without separation. It is quite evident that there must be a theoretical limit beyond which diminution cannot go without separation; and it is quite possible, though not yet proved, that 4 in. by  $4\frac{1}{2}$  in. comes near this limit. We might go a step further and say that diminution up to 4 in. by  $4\frac{1}{2}$  in. may prepare the way for separation, but of this in another paper."

I still adhere to this opinion, for the following additional reasons: When the placental area is diminished to 4 in. by  $4\frac{1}{2}$  in. it does not separate, and will not separate at any less area, because this smaller area introduces no further change in the relations of uterus to placenta. At the 4 in. by  $4\frac{1}{2}$  in. area the placenta is firmly grasped all round, and at a less area it is only more firmly grasped, and the other relations are unaltered. When Dr Barbour says that "there must be a theoretical limit beyond which diminution cannot go without separation," he begs the whole question. This, indeed, is the fatal error in Dr Barbour's view—his predetermined idea that diminution of area causes separation. My reason for writing the short note on placental separation already alluded to was simply to protest against this assumption which is made by all investigators.

<sup>1</sup> "Note on the Mechanism of the Separation of the Placenta, etc," *Edinburgh Medical Journal*, July 1887.



"2. If this theory were correct, the placenta should be separated by the relaxations after the contractions of the First and Second Stages. To this objection he answers, that in these stages the foetal circulation allows the placenta to re-expand, but that during the Third, the cessation of this changes the conditions. To this I reply—

"3. That the placenta remains attached where the foetus has died before labour, and where consequently the foetal circulation has ceased, as is seen in the frozen sections by Schroeder and myself."

The answer to this is evident—the maternal circulation in the intervillous spaces is quite sufficient to make the placenta respond to all changes in its site.

"1. The question of separation of the placenta must be kept quite distinct from its expulsion.

"2. Evidence is accumulating that, at the commencement of the third stage, the placenta is still as a whole or in great part attached.

"3. Diminution in area of its site to 4 in. by  $4\frac{1}{2}$  in. does not mean separation of the placenta.

"4. Diminution in area beyond that + the action of the uterus as a whole on the placental mass, I regard as the formal cause; the pains of the third stage as the efficient cause of separation. Blood effusion is an accident, i.e., not essential.

"5. During the contractions of the third stage the surface of the placenta is thrown into heights and hollows; the heights do not necessarily mean effusion below.

"6. The placenta descends usually with its edge or a point near its edge first, as Duncan described; sometimes foetal surface first, as Baudelocque and Schultze described.

"The third stage I regard as a second labour in miniature. After the pain that expels the child comes a pause, during which the placenta is still as a whole or in great part attached; then labour comes on again, and the placenta is first detached and then expelled. This second labour is not always marked off by a distinct interval from the first, sometimes one long pain expels the child and then detaches and expels the placenta."

Conclusion 4 is the one on which Dr Barbour's view stands or falls. It is very remarkable that he should have come to this conclusion, as it does not follow from his paper, and he gives neither proof nor mechanism for it. He says that the placenta separates when the placental site is below 4 in. by  $4\frac{1}{2}$  in., but of this there is not a tittle of evidence. No section demonstrates this, and no clinical observations can, as these are evidently misleading. Why Dr Barbour, who believes that a diminution of placental area below 4 in. by  $4\frac{1}{2}$  in. is necessary to separate the placenta, should have attempted to ascertain the mechanism of separation by passing his hand into the uterus is to me incomprehensible. It would lead me too far on this subject to point out the error of such a method, but its untrustworthiness and disturbance of natural mechanism are apparent.

In addition, Dr Barbour has attempted to solve the question of separation without taking the minute anatomy of the spongy layer into account, and omitting all consideration of the blood supply of the placenta. He regards the placenta as "spongy," and thinks that this physical property allows expansion and diminution of the placenta when necessary. This is too vague an explanation, and gives us no definite ground.



The terms contraction and retraction are not yet well defined or understood. By Contraction I understand that the uterine muscle diminishes in bulk, that the uterine area that the muscle subtends diminishes, and that the muscle and area resume their condition prior to contraction when the contraction ceases. In Retraction the greater part of the diminution in bulk and area is retained, but not all. Dr Barbour's definition does not coincide with clinical evidence, and would make labour "tonic," which it is not. Consequently I hold that a certain amount of relaxation after retraction takes place normally.

Dr Barbour's papers have seemed to me most valuable in many respects, but his conclusions only demonstrate the futility of the attempt to explain separation as the result of diminution of placental site. As to the third stage being a "labour in miniature," I see no advantage in the comparison, more especially as in the third stage we have separation and expulsion, whereas in the first and second stages it is merely a question of expulsion if we leave out of account the separation of the membranes over the lower uterine segment.

The view I advocate is a consistent one, explains all separations by one law, and gives clear indications for management. The management based on Dr Barbour's view should be to get the uterus to retract as much and as quickly as possible, so as to diminish the placental site and separate the placenta. Such a method would be in every way dangerous, would tend to partial expulsion of placenta and membranes, with all the dangers attendant on such a course. On this ground alone I would strongly condemn his view.

#### HOW CAN THE ACCOUCHEUR BEST GUARD THE PERINEUM WHILE THE FETAL HEAD IS PASSING?

I have no intention of considering the various methods of so-called support of the perineum. I purpose merely describing the plan I have taught for some years, as I find among many students and practitioners conflicting ideas of what is best done in an ordinary labour case. I take up, therefore, shortly—

1. *The relations of the uterus and its contents when the normally rotated foetal head is beginning to distend the perineum.*

2. *A consideration of how the foetal head should pass the perineum so as to leave a minimum of tear.*

3. *A description of how the medical attendant can best guard the perineum so as to avoid undue rupture.*

1. *The relations of the uterus and its contents when the normally rotated foetal head is beginning to distend the perineum.*

At this period of the labour, the lower uterine segment, cervical canal,



and pelvic floor have been canalised by the retracting uterus elongating and pushing the foetal contents downwards, the occiput leading. The perineum or sacral segment is being driven back, its lower end elongated and thinned, and the vulvar cleft, chiefly in its lower part, *i.e.*, below the level of the vestibule, greatly distended. Uterine retraction sets up in the foetus and retained liquor amnii a general-contents-pressure, which is distributed over that part of the skull periphery lying below the girdle of resistance. The diameters of the girdle of resistance will vary greatly, according to whether the occiput or sinciput dips. In the latter case the antero-posterior diameters will be increased, and the risk of tear augmented in like proportion. The demonstration of this belongs to elementary obstetrics.

In taking (2) *the consideration of how the foetal head should pass the perineum so as to have a minimum of tear*, I have first to point out that the term extension of the head, as the fourth consecutive movement of the labour mechanism, is a most misleading one. It implies that the chin leaves the sternum while passing the perineum; and that during the anterior fixation of the occiput under the pubic arch, antero-posterior and increasing diameters of the foetal head form the antero-posterior diameters of the girdle of resistance. I deny *in toto* that the chin leaves the sternum, and hold that this fixation of the occiput and descent of the sinciput is not the best or normal mechanism. The best mechanism to avoid tear is for the occiput to lead, for the head to be driven on by a steady movement of translation, any rotation on a bi-parietal axis so taking place as to favour occipital dipping and never dipping of the sinciput. It is easy to see how the erroneous idea of extension arose. The attendant, while the patient lay on her left side, watched the passage of the foetal head from behind, saw more of the anterior portions of the head appear, and accounted for it by extension.

We now pass on to (3) *a description of how the medical attendant can best guard the perineum, so as to avoid undue tear.*

All the attendant can do, apart from the familiar means of relaxing perineal spasm by chloroform and hot applications, is to prevent the sinciput being forced down in advance of, or faster than the occiput. He restrains the foetal head from passing too rapidly. He thus has always to get the occiput to lead, and to get it fully born first if possible. So far as I can judge, the best way of doing this is as follows:—

With the patient lying, of course, on her left side, the attendant places the thumb of his right hand, guarded by a napkin soaked in hot sublimate, in front of the anus and presses it gently there. The pressure is not in the direction of a line joining his thumb and the pubic arch, but nearly in that of the axis of the pelvic outlet. By this, descent of the sinciput is hindered, and that of the occiput favoured. When the latter is beginning to pass under the pubic arch, the fingers of the same hand



are placed between it and the apex of the arch, so that when the occiput has cleared the arch the fingers are passed towards the nape of the neck, and the head thus grasped in the hand, the thumb lying over the sagittal suture. This gives one complete command over the head which is now engaging in the diameters between the nape of the neck and forehead and face, and allows the whole passage with as little tear as possible.



## CHAPTER XXIV.

### CASES ILLUSTRATING THE RARER FORMS OF OPERATIONS IN GYNÆCOLOGY AND OBSTETRICS.

#### 1. CASE OF SUCCESSFUL ABDOMINAL SECTION FOR RUPTURED FALLOPIAN-TUBE GESTATION.

CASES of ruptured Fallopian-tube gestation, ending fatally, are comparatively frequent, so that it seems advisable to record this case as emphasising the value and safety of abdominal section in properly selected instances. The credit of strenuously practising and advocating this treatment as early as 1881 is due to Mr Lawson Tait, but so far as I am aware, very few operators have followed his example.

My case is briefly as follows: Mrs F., from Glasgow, was seen by me at the Buchanan Ward, Royal Infirmary, Edinburgh, on April 8, 1886. She complained then of attacks of pain in the lower part of the abdomen, coming on every two or three days, of some slight bloody discharge, and stated that her menstruation had ceased for about three months. On abdominal palpation, a rounded tumour, the size of an egg, could be felt in the left iliac fossa. On bimanual examination, the uterus enlarged to the size of a two-months' pregnancy, and lying to the front and right, could be made out, as well as an elongated tumour on the left side, running between the uterus and the body which was felt in the left iliac region on abdominal palpation. The history and physical signs left no doubt in my mind that we had to deal with a Fallopian-tube gestation, and one suitable for abdominal section. The patient agreed to remain in hospital, but her friends refused permission to operate. A few days after admission a decidua was discharged, and on the evening of the 16th April, Dr Helm telephoned to me that the patient had become suddenly collapsed, and almost pulseless. I saw her shortly afterwards, when she had somewhat rallied under stimulation, and I urged her friends to allow operative interference, as the sac had no doubt ruptured, and the patient's life was in great danger. They ultimately consented, and on the 19th I opened the abdomen.

The patient was chloroformed, and all antiseptic precautions, except the use of the spray, were followed.

After making an incision two inches in length, I came upon a very congested omentum, and found abundant blood welling up from beneath



its lower edge whenever a sponge was pressed in. This looked alarming, but the blood was tarry-like and stained the sponges a chocolate colour; it had evidently been effused some time. I enlarged the abdominal incision with scissors to three inches, lifted up the omentum and found the pelvis filled with this blood, a small fœtus (six weeks) among the coils of intestines, the left Fallopian tube enlarged and the rupture about as large as the tip of the index finger, in the posterior aspect of the ampulla. I clamped the uterine end of the tube with a pair of locking forceps, and was proceeding to do the same on the other side of the rupture, but desisted, as I felt I could as quickly loop up and tie the portion of the tube with the rupture in it. I accordingly did so, using silk and tying the Staffordshire knot. This occupied only a few seconds, and I now sponged out the pelvis thoroughly, washing it out with water at 100° Fahr. The remarkable effect of water at a temperature of 110° to 120° Fahr. in causing uterine retraction, and thus checking hæmorrhage, is now well known. In a recent very able communication on the method of action of warm water, read by Dr R. Milne Murray, before the Edinburgh Obstetrical Society, the power of the warm water in causing contraction on unstriated muscle, was well shown. It seemed to me then, that equally hot water might be of use in hæmorrhage from the pelvic peritoneum. In this case there was some oozing, and I therefore poured in water at 120° Fahr. for a few seconds and then sponged it out. It blanched the omentum markedly and seemed to check the oozing, although, of course, this may have stopped spontaneously. It certainly did no harm, and I beg to recommend further trial in suitable cases. The patient made an uninterrupted recovery, and six weeks afterwards left the hospital well, with only some thickening in the pouch of Douglas on the left side.

In regard to ruptured Fallopian-tube gestation, the question arises as to whether one should operate, or trust to rest, the use of the ice-bag, stimulants, and the hypodermic use of morphine. I have seen two cases of rupture, at the fifth or sixth week, recover perfectly under this treatment; while a third rallied, the pregnancy becoming abdominal, and ultimately discharging through the rectum. If, then, it were objected that, in this case, the same expectant treatment might have succeeded, I would urge that the conditions found on abdominal section closely resemble those discovered on *post-mortem* examination in fatal cases. The number of women who die from rupture of a Fallopian-tube gestation, at the second or third month, is considerable; and the question arises as to whether a false impression has not got out among the profession, and even among specialists, that such cases are beyond treatment, and, of necessity, fatal. What is urged against operative treatment is, that diagnosis in such cases is difficult, the collapse too profound to admit of section, and the operation in itself very difficult.



The diagnosis is, however, fairly easy. We have arrest of menstruation for some weeks, irregular discharges, pain, and then a sudden attack characterised by pallor, sickness, or vomiting, pain, collapse, and lateral or posterior effusions in the pelvis, with some enlargement of the uterus. The practitioner sometimes regards the condition as brought about by irritant poisoning, but will be kept right by noting the unusual pallor of the woman, indicating internal hæmorrhage. The collapse, in some cases, is very profound, but not, as a rule. The patients may live some hours, or even days, as I shall show presently, and may be operated on much oftener than is at present held. While the operation may be difficult, I am inclined to think this has been greatly exaggerated. If the operator makes his abdominal incision, and passes in his finger to touch the uterus, he can readily make out the relations, clamp the tube on either side of the rupture, and ligature the portion ruptured. Of Mr Tait's twenty-one cases, only one, the first, died. A doubtful case has been recorded by Hunter of New York,

Name or Author.	Where Case Recorded.	How Far Advanced.	Fallopian Tube Affected.	How long Patient Lived.
Harley	<i>L. O. T.</i> , i, 101	5 months	Left tube	11 hours
Grace	" ii, 49	6-7 weeks	" "	13 days
Marshall and Hewitt	" v, 154	8 "	" "	12 hours.
Greenhalgh	" "	—	Interstitial	A few hours
Haydon	" "	3 months	Right tube	24 hours
Truman	" vii, 164	12 weeks	" "	2 "
Brown	" xi, 7	16-20 weeks	" "	13 "
Worship	" xi, 211	—	" "	48 "
Meadows	" xiii, 268	6 months	" "	40 "
M'Callum	" xv, 248	4 "	—	3-6 "
Turner	" xvi, 31	2 "	" "	15 "
Meadows	" xviii, 259	4-5 "	—	52 "
Routh	" xxi, 93	3 "	" "	8 "
Doran	" xxi, 169	4 "	Left "	10 minutes
Godson	" xxii, 186	6 weeks (?)	Right "	8 hours
Burton	" xxii, 34	6 "	" "	9 "
Godson	" xxiii, 109	6 "	" "	Dying when admitted to workhouse
Duncan, J. M.	" xxiii, 263	5 weeks	" "	36 hours
Daly	" xxiv, 155	2 months	" "	4 days
Doran	" xxiv, 228	2 "	" tubo-interstitial	24 hours

with a fatal result, and also one, with a like ending, by Bozeman, where the operation was evidently too long delayed. This, at the worst, gives three deaths in twenty-four cases, or about 12 per cent.; while, if we exclude Hunter's and Bozeman's cases, we get a mortality of less than 4 per cent.

In order, however, to investigate these points more fully, I collected the cases of ruptured Fallopian-tube gestation shown to the Obstetrical



Society of London, and described in their valuable *Transactions*. The table appended shows that there have been exhibited twenty cases, that of these only five died rapidly, that all the others lived for periods varying from eight to twenty-four hours, and some for several days.

In most of the cases there was no matting of parts, and little to render the operation very difficult. In the discussions on these specimens, abdominal section was urged as a means of treatment, by Playfair, Wells, Meadows, Wiltshire, and others. Perhaps the most striking point in the whole matter is, that there have been so few deaths in the operative cases. This shows that there is very little risk in operative treatment, and as there is really no clearer case for abdominal section than such, I hope it will become more generally employed.

## 2. CASE OF EXTRAUTERINE EXTRAPERITONEAL PREGNANCY OPERATED ON AT THE FOURTH MONTH.

My reason for narrating this case is not only its comparative rarity but also the encouragement it gives to operative treatment in such.

During the night of the 11th January 1893 I was called to see Mrs. A. who had been seized with sudden pain, faintness, and collapse. As I was aware she had passed two periods, I fully expected that a Fallopian-tube pregnancy had ruptured intraperitoneally, but did not find on my arrival the collapse one would have expected. Internal examination was negative and I therefore administered a sedative and postponed examination under chloroform till next day.

I then found the uterus retroverted, enlarged, and lying to the left. There was no appreciable intraperitoneal effusion nor hæmatoma and I therefore abandoned all idea of ruptured gestation. I may mention here that the patient had one child six years old and that during the pregnancy there was a subperitoneal fibroid about the size of an egg on the left side of the fundus. Any thickening I felt during this examination I attributed to this, and the stoutness of the patient also hindered investigation. Ten days afterwards there was some uterine hæmorrhage with dilated cervix and I curetted away decidual shreds but this I attributed to ordinary abortion.

The patient's condition did not improve after this. Spasmodic and severe pains came on which I could only vaguely ascribe to renal or hepatic colic. During March however a tumour developed at the right iliac margin, gradually increased towards the middle line so as to drive me to a reconsideration of the whole case.

The condition at the end of March was thus as follows:—There was amenorrhœa for about four and a half months; a history of collapse with shreddy discharge at the second month and occasional subsequent attacks of spasmodic pain; a tumour spreading from the right iliac fossa and over mesial, with its top two finger breadths below the navel. Over



the lower part of this tumour a bruit could be heard and milk was present in the breasts. I was therefore driven to the conclusion that I had here an extrauterine gestation developing extraperitoneally. This diagnosis explained all the facts. The rupture at the second month had been into the right broad ligament and the gestation had then developed between its layers until it attained the condition and relations given above. For a month I had been completely at fault and only saw land after much puzzling. What misled me most was the negative result of my examination on the day subsequent to the rupture. During this time I had the valuable help and advice of Drs G. W. Balfour and C. E. Underhill.

Such being the diagnosis, the question of treatment had to be faced at once. The patient was in excellent health and had an amount of energy and pluck that made me feel certain she would stand operative treatment well.

There was no doubt in my mind that delay was dangerous. Hæmorrhage was going on in the sac, as it had increased in size latterly very rapidly and it might rupture soon. Even if that did not happen there was the risk of the death of the fœtus and its discharge by rectum or bladder. I accordingly advised operation strongly and it was agreed to.

I must now state what I believed to be the relations of the organs. The uterus was retroverted and to the left. The gestation was developing partly in the broad ligament and pelvic connective tissue and lay mesially behind the bladder. The fundus of the sac was free from placenta; this was of importance as it gave me access without risk of hæmorrhage so far as the incision was concerned. What I thought I might do was to incise the abdomen, ascertain the relations of the sac; if extraperitoneal I would cut into it, remove fœtus and placenta and plug with iodoform gauze. If found pediculated, which I did not anticipate, I would ligature and remove entire if possible.

Accordingly on 30th March I operated as follows with the assistance of Drs J. C. Webster, Gulland, and Lawson Dick. I made a mesial incision in the abdominal wall ending 2 inches above the pubes and about 4 inches in length. When the abdomen was opened I came on the top of the sac, covered with peritoneum and with the abdominal reflexion high. I incised the peritoneum over the sac, stripped it to the sides and thus exposed the upper connective tissue environment of the gestation *i.e.*, the top of the sac. I had thus opened into the abdominal cavity at the upper part of the incision and also exposed the extraperitoneal gestation. I next tapped the sac with an aspiratory needle but got neither fluid nor blood. I therefore laid the sac open, cutting through a friable pigmented half inch thick wall, and found blood clot occupying a sac about the size of a large orange, placenta on the anterior wall and no fœtus so far as I could make out. I cleared



out the clots and separated the placenta hoping to feel the foetus then. Bleeding, however, was somewhat profuse and so after separating an apparently perfectly fresh piece of placenta about the size of the palm of my hand, I had to tampon the sac with gauze, close off the peritoneal cavity and stitch the gestation sac opening to the abdominal wound. This latter stitching was really unnecessary.

The patient was in no way disturbed by all this but I myself had some puzzling points to settle. In the first place the sac was not so large and did not dip so deeply as I knew it must: then secondly, where was the foetus? The placenta was fresh and normal in appearance. Had I believed that the placenta could grow after the early foetus had died all would have been clear but this was in my opinion an untenable theory.

On the 6th day after (4th April) I removed the gauze in part and on 6th April I removed it all and then felt at the bottom an opening about the size of a crown piece with the membranes and liquor amnii bulging. I ruptured them and came on the head of the foetus. Pushing a pair of ovariectomy forceps through it I then extracted a fresh  $4\frac{1}{2}$  months' foetus and found a lower cavity with placenta on the anterior wall.

I washed out the cavity, plugged it with gauze and next day on removing the plug, cleared out the rest of the placenta, the main piece being the size of the palm. I could then explore the sac digitally and found it to be hourglass shaped, the cavities being upper and lower with a circular opening between. The foetus and membranes lay in the lower and the placenta lined the anterior wall of both compartments. The deepest part of the sac touched the sacrum. The gestation had thus begun in the Fallopian tube, developed in the broad ligament lifting up the anterior lamina mainly and burrowing more deeply towards the sacrum. The placenta was in a favourable position and had not been displaced much by the growing foetus.

The after progress of the case was slow but good. Drainage was kept up for a month and irrigation freely used. In this way placental debris was washed out and occasionally small pieces of placenta. On one or two occasions, prior to the separation of a small piece of placenta the patient had a slight rigor but this passed off whenever the sac was washed out. I should mention that in the second week there was some phlegmasia of the left leg.

The patient was completely well in about seven weeks after operation. It was remarkable how the sac slowly contracted and ultimately completely closed. As the contraction went on the vertical position of the tube slowly changed into a right sided and oblique one indicating how in natural healing the original position of the organs is resumed.

In this case both foetus and placenta developed extraperitoneally. In all cases of extrauterine gestation the site of the placenta determines the



nature of the gestation. The fœtus may become intraperitoneal after being tubal or extraperitoneal, but, as a rule, which as yet knows no exception, the placenta while arising in the tube and developing in the connective tissue of the pelvis does not become intraperitoneal in the sense of ever grafting itself on the free surface of the peritoneum.

I wish to emphasise in conclusion my belief that the treatment of extrauterine gestation in such cases must be operative, and that the operation should be undertaken as soon as possible. In early nonpediculated cases such as this the fear of hæmorrhage from the necessary separation of the placenta is irrational. One can separate and plug the sac with gauze and if entire separation is impossible at first, it can be completed in a few days afterwards. The opening into the sac should be left large and it will be found that drainage goes on perfectly by means of the gauze until a glass tube can be substituted.

The following is Dr Gulland's report of the structure of the placenta :—

"I received from Dr Hart two pieces of the placenta of this case,—one of which was removed at the time of the operation, the other removed seven days afterwards. These were both fixed in saturated sublimate solution immediately after removal, and pieces of them were hardened, cut in paraffin, and mounted in the usual way.

"The piece of placenta removed at the operation was perfectly normal, as far as the fœtal structures were concerned (*see fig. 48*). The villi were exactly like those of a normal  $4\frac{1}{2}$  months' placenta, which is in my possession, both as to their arrangement and their microscopical structure. They were covered by a single layer of well preserved cubical epithelium; the connective tissue core of the villi consisted of retiform tissue—connective tissue corpuscles lying on fine fibrils; and the vessels in the villi were filled with fœtal blood-corpuscles. The intervillous spaces were not so near the normal. Most of the maternal blood had of course drained out of them as the placenta was being removed piecemeal, but a certain amount was still to be seen in the sections. In addition, however, there were a few delicate threads of fibrin, which might have been recently formed, and here and there through the placenta were larger masses of fibrin, some almost as large as a pea. These were evidently the result of an old clotting of the maternal blood; the masses of fibrin sometimes surrounded a villus or two, and had compressed them, and the fibrin was riddled with leucocytes.

"The pieces of placenta removed during the after-treatment were very different in appearance. They were firm, dark brown masses, evidently composed largely of blood-clot, and when sectioned it was found that the greater amount of the tissue consisted of this material. The villi had been crushed and distorted, and in many cases widely separated by the hæmorrhage. The epithelial covering of the villi was not so distinct as



in the former specimens, and both its nuclei and those of the connective tissue of the villi were markedly degenerated. The fibrils of the connective tissue, instead of the delicate network which they normally present, were in a state of hyaline degeneration, and greatly swollen; the bloodvessels could not be distinguished. The intervillous spaces were filled with dense masses of fibrin, in the meshes of which the outlines of degenerated red blood corpuscles could be made out; there were a fair number of leucocytes also to be seen.

"These specimens are instructive as showing the perfectly normal way

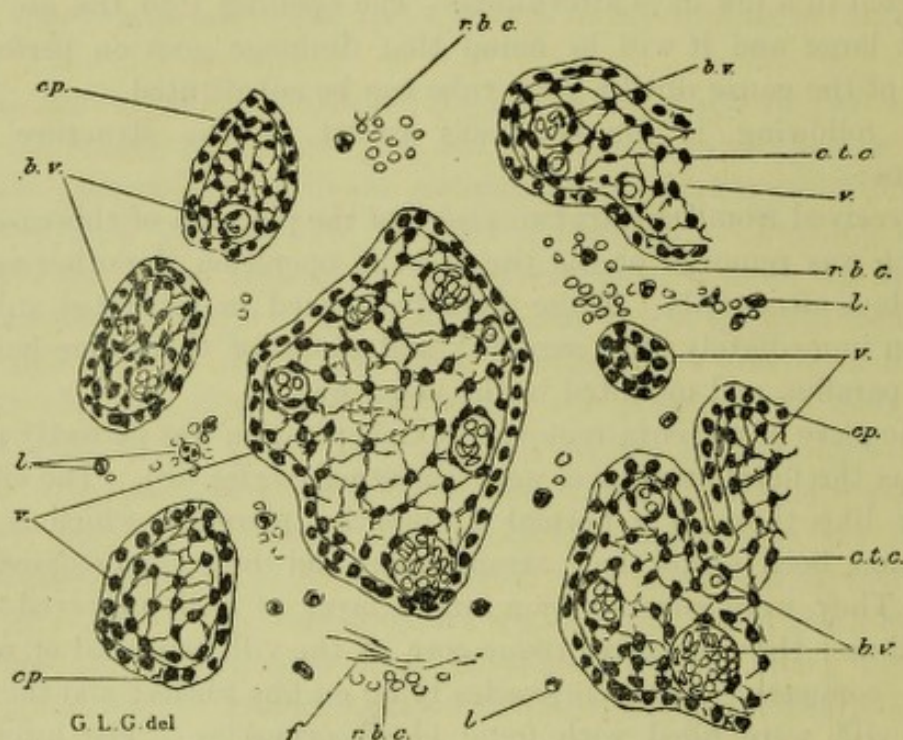


FIG. 48.

PART OF THE PLACENTA OF AN EXTRAUTERINE PREGNANCY (4½ months) removed at the operation.

v., Villus; b.v., Blood-vessel (foetal); ep., Epithelium covering the villus; c.t.c., Connective tissue corpuscle; l., Leucocyte; r.b.c., Red blood corpuscles (maternal) in intervillous spaces; f., Fibrin. Obj. Zeiss DD, Oc. 4.

in which the villi develop in extrauterine gestation, and also the way in which they are altered by the death or removal of the fœtus and by hæmorrhage.

### 3. CASE OF SUCCESSFUL CÆSAREAN SECTION (PORRO'S MODIFICATION).

The propriety of Cæsarean section in suitable cases is not now questioned, but much requires to be done to settle its indications and to perfect its *technique*. Thanks to the work of Porro and Sãnger, we are now in possession of vastly improved methods and results, so that



what is now chiefly necessary is the publication of all cases where such operations are performed, as a basis that shall be sufficient, in time, for generalisation. My case is briefly as follows.

Mrs C., aged 25, had been five times pregnant. On two occasions craniotomy had been performed; once abortion was induced at the fifth month, and once premature labour between the sixth and seventh. The child was stillborn in the last instance and with difficulty. After the fourth pregnancy she was advised by Dr Angus Macdonald to have Battey's operation performed, and was sent to me, after Dr Macdonald's death, by Dr Stewart Stirling for advice in the matter. I thought it better to advise Porro's operation, should pregnancy occur again, as this would give her a living child and ensure future sterility. The patient was specially anxious to undergo the risks labour brought her as seldom as possible. Her pelvis, when measured, had a conjugate diameter of 3 inches, and therefore a true conjugate of about  $2\frac{1}{4}$  inches. The transverse at the brim was also narrowed. The pelvis was a rickety one, with a narrow transverse.

She soon became pregnant, and I therefore agreed to perform Porro's operation a few days before labour began. On 25th March last, I operated in a private nursing home, in the following manner. The ordinary details and preparations as for abdominal section I, of course, omit.

Chloroform having been administered by my assistant, Dr Stewart, I made a six-inch incision through the abdominal walls, and opened the peritoneal cavity. The uterus was incised *in situ* to the same extent, Dr Barbour keeping up steady pressure all the time. I speedily came down on the membranes in the lower third of the incision, and completed the incision with a probe-pointed bistoury, guided on the index finger. After rupturing the membranes with Péan's forceps, I passed my hand into the uterine cavity, brought out the child head first, and handed it to Dr Stirling. While this was being done, Dr Barbour had turned the uterus out of the abdominal cavity, and held it so, grasping the isthmus firmly and pressing the abdominal wall round it. I passed an elastic tourniquet, held ready by Mr Caird, round the isthmus immediately above Dr Barbour's grasp, and tightened it. The opening of the uterus, and the procedure up to the application of the tourniquet, occupied only a few seconds, and the blood lost was trifling. The child was vigorous, and continues to thrive. I now passed Lawson Tait's modification of Koeberlé's *serre-nœud* round the uterus above the elastic tube, and tightened it. The uterus and placenta were amputated, the handle of the *serre-nœud* brought over the pubes, and thus the stump was pulled down accurately to the lower angle of the wound. The abdominal incision was closed in the ordinary way with silk sutures, after the peritoneal toilette, care being taken to close it firmly round the stump,



which was dusted with persulphate of iron and iodoform. There was no shock, the patient made an uninterrupted recovery, and is now, along with her baby (a girl), in excellent health.

I have to thank the gentlemen already mentioned for their valuable aid, as well as Professor Simpson and Dr Helm, who were present.

I now wish to make a few remarks based on this case, and four others I have seen or assisted at. I performed Porro's modification in my case, as it was the patient's desire to have no further risk. The weak point in Porro's operation is the extraperitoneal treatment of the pedicle. In certain cases, however, notably in malacosteon, dead children with putrefaction, and in pregnancy with fibroids, it is the best operation. It is by no means formidable, if performed as I have described, and gives a good rate of recovery. The improved Cæsarean section according to Säger and Leopold will, however, I am of opinion, be the cutting operation of the future, should it be ultimately shown that the uterine incision does not stretch and cause risk in future pregnancies.

Porro's operation should be performed before labour sets in. The advantages of this are great. The operator can make his arrangements and have skilled assistance at a definite hour. The idea that one should wait for labour, so as to have uterine retraction and less hæmorrhage, is an erroneous one, and leads the operator into difficulties. The waiting causes risk to the child's life, undue delay while assistants are being summoned, and should, therefore, not be deliberately chosen. A further point is that the development of the lower uterine segment, abdominal position of the bladder, and formation of the circular vein, force one to make the abdominal incision higher up, interfere with the formation of the pedicle, and may lead to serious hæmorrhage if the circular vein be wounded. There is little risk of hæmorrhage when the operation is performed before labour sets in, provided one operates quickly, uses the elastic tourniquet, has an efficient assistant, and, in fact, regards the whole operation as one analogous to a rapid surgical amputation.

Three points of scientific interest come up specially now, namely, the condition of the uterus and placenta in relation to the third stage of labour, the primitive shape of the child's head, and the condition of the patient's urine so far as any peptonuria was concerned.

On the second and third points I wish to make a few remarks, as I have considered the uterus and placenta in another paper. Before operation the child was found by palpation lying dorso-anterior, with head in the left iliac fossa. A few hours after birth a plaster cast of the upper part of the head was taken. This was found almost perfectly symmetrical, with no shear present.

The urine was tested daily during the puerperium for peptones, and none found. Fehling's solution in the cold was the reagent used.



It is remarkable that this case is, so far as I am aware, the first successful Cæsarean operation of any kind in Scotland.

#### 4. CASE OF VAGINAL HYSTERECTOMY FOR CARCINOMA CERVICIS IN EARLY PREGNANCY.

The rarity of this combination has induced me to contribute this short note. So far as I am aware, only one similar case treated by radical operation has been recorded in this country, although Hofmeier and Landau have published cases abroad.

The patient whose case I wish briefly to narrate was sent to the Infirmary on 25th August 1891, by Dr Wilson of Mid Calder. She was a married woman, aged 33, and had three months before admission a flooding at a menstrual period, with a bloody discharge for two months afterwards, and an offensive one during the month prior to admission. The rest of her history is of no special moment. On physical examination under chloroform the cervix was found enlarged, fungating, and breaking down; parametrium quite free; uterus enlarged somewhat, softened, and perfectly mobile.

There was no doubt about the cervical condition; almost none about the pregnancy; and as it was evident that it was a favourable case for radical treatment, I had no hesitation in recommending total extirpation strongly. Supra-vaginal amputation of the cervix was, in my opinion, contraindicated by the pregnancy, as the probability of bringing on immediate abortion seemed to me to render it inadvisable in this instance. Winter of Berlin has, however, in a recent paper on Schroeder's supra-vaginal amputation for cancer of the portio, given a case where the entire cervix was amputated in the second month of pregnancy, abortion following at the fourth month. The patient recovered, and was delivered of a living, full-time child three years afterwards, and six years after operation had no return of disease.

On 3rd September I performed vaginal hysterectomy with the aid of my friend Dr J. C. Webster. I need only sketch the method I adopted, as the operative details are now well known. After careful local disinfection, the cervix was grasped with a volsella and brought well down and forwards. I then made a transverse incision in the posterior fornix a little above the cervical junction, opened the pouch of Douglas, and sutured the peritoneum and cut vaginal edge with juniper catgut. The cervix was then brought well back, the vesico-uterine pouch cut into, and the peritoneum and vaginal wall also sutured with catgut. The lateral attachments were then severed from below up as follows:—With a curved handled needle a stout silk ligature was passed and tied, so as to command the lower portion of the parametric tissue. This ligatured portion was then cut with scissors on the uterine side, the separation of course stopping short of the uppermost part commanded by the ligature.



Another ligature was then passed higher up, and the tissue similarly severed until the parametrium and lower half of the left broad ligament were freed from the uterus. I then began on the right side, and in a similar way ligatured and separated the parametric tissue and broad ligament. This allowed the uterus to be drawn outside entirely, and the upper portion of the left broad ligament to be easily ligatured and cut. The uterus now being removed, traction on the ligatures, which had been left long, enabled me to draw down the broad ligaments and carefully inspect them. All the ligatures had held perfectly, but one oozing point at the base of the right broad ligament required an additional ligature. The inner aspects of the broad ligaments were then brought together with a catgut suture, and the vagina lightly packed with iodoform gauze. Less than a tablespoonful of blood was lost.

The patient made a good recovery, the pulse never rising above 100. When the ligatures were separating, the temperature ran up to  $104^{\circ}$  and even  $105^{\circ}$ , but fell whenever Dr Webster removed them. As yet the patient is well but one can say nothing, of course, as to the prognosis.

I have thought it of advantage to record this case owing to its rarity. Unfortunately cancer cases come to the specialist late in this country, but I hope that, with increased knowledge on the part of the profession as well as of women themselves, we may see them early enough for operative interference.

Dr Gulland, who examined the specimen, reported as follows:—"The uterus was opened in the middle line posteriorly, and fixed in saturated solution of corrosive sublimate. The measurements were: longitudinally, from fundus to the normal os externum,  $3\frac{1}{2}$  inches; cavity of uterus and cervix, 3 inches; external circumference about  $1\frac{1}{2}$  inches below the fundus, 8 inches; the amniotic cavity was about  $1\frac{1}{2} \times \frac{3}{4} \times \frac{3}{4}$  inches, and the cervix was about  $1\frac{1}{4}$  inches long. The placenta was situated at the fundus and on the posterior wall of the uterus.

"Growing from about  $\frac{2}{3}$  of the circumference of the vaginal aspect of the cervix, and springing mainly from the anterior lip, was a tumour of about the size of a hen's egg, of the 'cauliflower excrescence' variety. This joined the normal part of the cervix all round at an acute angle, and was separated from it by a deep groove, except in the cervical canal, where the transition was not marked in this way. In the canal about  $\frac{2}{3}$  of an inch of the cervix seemed free from the tumour, but the amount of normal tissue varied considerably at different points, and was less in the fornix than in the cervical canal. After hardening, the tumour could pretty easily be distinguished from the normal tissue of the cervix, and as far as could be made out from the specimen, all the diseased tissue seemed to be removed. Microscopically the tumour presents the characters of a carcinoma derived from the vaginal aspect



of the cervix; and it is found to correspond in its distribution pretty nearly to what one expects from examining the specimen with the naked eye. It is more of an outgrowth from the cervix than an ingrowth into it, though the epithelial tubes or processes forming it do, of course, pass for some distance up into the cervical tissue proper, and on the mucous surface the tumour growth overlaps to some extent the normal mucous membrane.

"The tumour proper consists of large epithelial cells, resembling those normally seen on the vaginal aspect of the cervix, but larger. The outlines of the cells are very distinct, but there are no such processes as in the 'prickle-cells' of the vaginal epithelium. Towards the vaginal surface the cells are polygonal on section, but they never become flattened into squames except at the very surface, whilst at the inner end of the processes invading the cervical tissue the basal cells are somewhat more cubical. Some of these invading processes are hollow, and in their lumen lie masses of leucocytes which have wandered thither between the cancer cells; others are solid, but there is no attempt to form cell-nests. The nuclei of the cancer cells are large, rounded, and contain little chromoplasm. Large numbers of the cells are multiplying by mitosis, and I have in several cases noted the irregular triple mitotic forms which Hansemann has described in cancer cells. One rarely meets degenerated nuclei except where the tumour has ulcerated. The stroma of the cancer consists of a very vascular connective tissue, whose arrangement is like that of the reticulum of adenoid tissue, and whose meshes are packed with leucocytes in all stages of growth, of reproduction by mitosis, and of decay. These are most numerous near the tumour processes, and are there almost exclusively of the variety whose granules stain with eosin. I examined a section stained by Dr W. Russell's method, and found that the basophile leucocytes, which that method demonstrates, were only present in small number. Through the normal cervical tissue are also scattered an unusually large number of leucocytes, many of which are eosinophiles. At many points on the vaginal aspect the tumour has ulcerated, and the appearances produced vary to a certain extent. Either the stroma, which, of course, closely resembles granulation tissue, and which here contains occasional large macrophages, becomes superficial, or the tumour is riddled by leucocytes which separate and destroy the cancer cells, so that appearances are produced very like those seen in the epithelium of the tonsil.

"The blood-vessels of the cervix are unusually large and numerous, and the supply to the stroma of the growth exceedingly free, though mainly effected by capillaries. There are few lymphatics in the stroma, and in the large lymphatic vessels running alongside of the cervical vessels, which contain numbers of leucocytes, mostly degenerated, I was



not able to detect a single cancer cell with certainty. Nor could I see in the parts of the cervix and uterus which were examined any metastatic nodules."

[The patient some months afterwards took influenza, and then ulcerative endocarditis, from which she died. There was then return of cancerous disease in the iliac region.]

#### A CONTRIBUTION TO THE PATHOLOGY OF THE LYMPHATICS OF THE FEMALE PELVIS.

In this communication I wish to draw attention to one or two points in the pathology of the lymphatic system of the female pelvis, as illustrated in two cases to be briefly narrated.

Case I.—A. B., *æt.* 27, consulted me in May 1882 as to her state of health. She was an under-sized, wretchedly thin girl, who had felt unable for her usual occupation of a domestic servant; but the medical men whom she had consulted had been unable to find anything tangible to account for her condition. When I saw her, however, the inguinal glands of the left groin (those parallel to Poupart's ligament) had begun to be enlarged, and the left leg was painful and somewhat swollen. In the vast majority of cases, enlargement of the inguinal glands parallel to Poupart's ligament, means some irritation in the external genitals or lower fourth of the vagina, an irritation either syphilitic, gonorrhœal, or cancerous. The external genitals and vagina were in this girl, however, perfectly healthy, and the condition of part was, further, virginal. Deep palpation of the left iliac region gave a sense of resistance at the left margin of the true pelvis; and on bimanual examination of the pelvic organs I found the following condition:—The normal-sized uterus was lying close to the right margin of the true pelvis. At the left side of the true pelvis could be felt a firm resisting mass, about the size of half a cocoa-nut. It seemed firmly fixed to the pelvic wall, and gave no feeling of fluctuation.

The diagnosis I gave was that of a malignant tumour in the sub-peritoneal tissue in the true pelvis, having the situation already described, and spreading through the lymphatics. The other possibilities were—

1. An inflammatory condition.
2. Malignant peritoneal disease.

1. The absence of fluctuation, the density of the swelling, and the want of any history as to blood effusion, abortion, or any inflammatory reaction, put this out of the question.

2. Malignant peritoneal disease usually begins in the ovary, involves the pelvic peritoneum soon, does not displace the uterus, and soon sets up ascites.



The next question that comes up is of course, Did the diagnosis given explain all the symptoms and physical signs? The chief symptoms were pain and œdema of the leg. The pressure of the mass on the pelvic nerves and blood-vessels was sufficient explanation of this. But how as to the enlargement of the inguinal glands when there was no primary affection of the external genitals and lower fourth of vagina whose lymphatics pour into these glands? This was at once explained by the knowledge of the anatomical fact that at the obturator foramen, on its pelvic aspect, there lies a gland or collection of glands—the

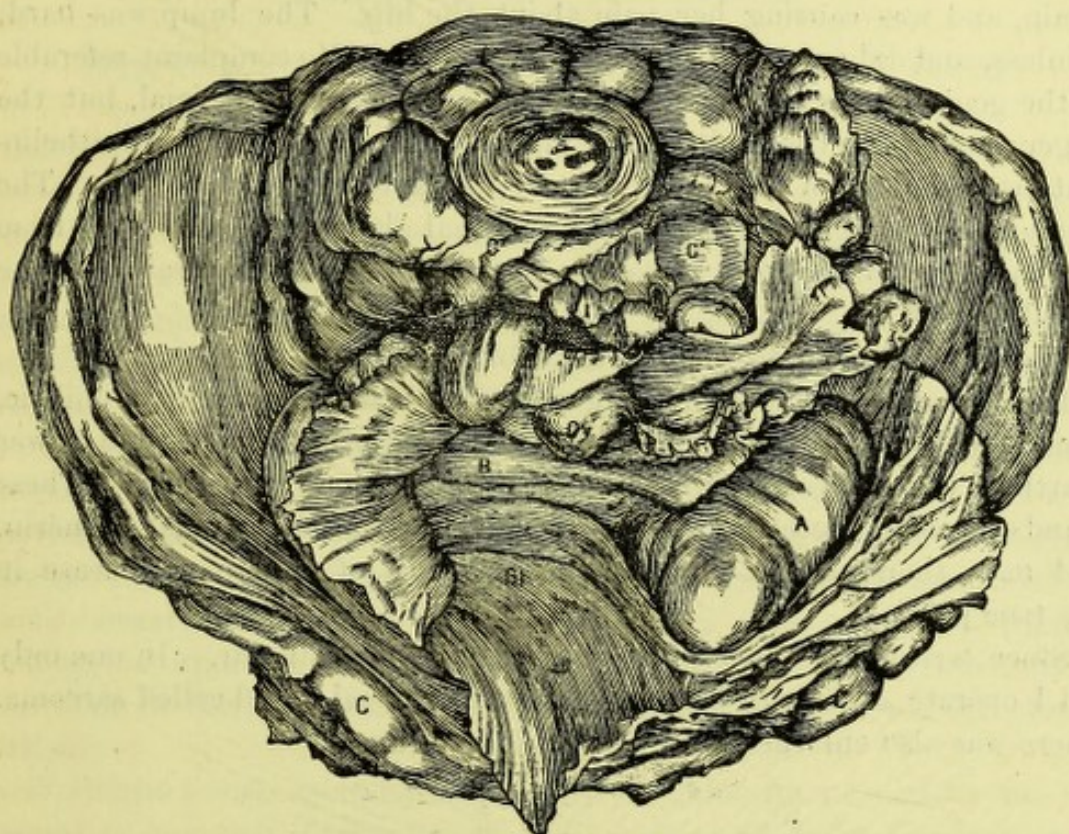


FIG. 49.

SARCOMATOUS TUMOUR OF THE PELVIC CONNECTIVE TISSUE.

A, Tumour; B, Uterus; Bl., Bladder; Ov., Ovary; C C, Inguinal; and C' , Sacral Lymphatic Glands.

obturator glands of M. Guérin—which communicate with the inguinal glands.

The after progress of the case need not be detailed. Any operation was hopeless, and one could only palliate the pain by large doses of morphia given hypodermically. The girl died miserably about six months afterwards.

On *post-mortem* the pelvis was removed, and Fig. 49 gives a view of the parts as seen through the brim. The displaced uterus (B), subperitoneal malignant mass (A), enlarged inguinal glands on both sides, and the large mass of the sacral glands (C) are well seen.



On more minute examination, I found the enlarged obturator glands, as well as the sacral ones, in front of the sacrum. The primary tumour (A) did not communicate directly with the enlarged left inguinal glands. Microscopical examination showed it to be a round-celled sarcoma. This case illustrates, therefore, not only a rare form of pelvic disease, but will draw attention to the lymphatic communication between the obturator glands and those of the inguinal glands parallel to Poupart's ligament.

Case II.—I was asked by Mr Chiene to see an old woman who had a lump in the groin, which she said had come down suddenly after a strain, and was causing her pain about the hip. The lump was hard, painless, and did not seem hernial in its nature. No complaint referable to the genitals was made. The external genitals were normal, but the finger passed into the vagina came on a bleeding and evidently epitheliomatous condition of the lower part of the anterior vaginal wall. The whole case was perfectly clear; the inguinal glands were enlarging from vaginal infection, and the radiating pains were due to implication of the sacral glands.

We may recapitulate, therefore, as follows:—

Enlargement of the oblique inguinal glands may be due to syphilitic, gonorrhœal, or malignant affections of the external genitals and lower fourth of vaginal wall, the lymphatics of which pour into these. These glands, however, receive branches from the obturator glands of Guérin, and may, therefore, be enlarged as the result of malignant disease in the true pelvis.

Since writing the above I have seen four cases similar. In one only did I operate, and there I found an extraperitoneal round-celled sarcoma. There was also enlargement of the inguinal glands.



## APPENDIX.

### PRESIDENTIAL ADDRESSES

#### INTRODUCTORY ADDRESS TO EDINBURGH OBSTETRICAL SOCIETY.

GENTLEMEN,—In opening the session I have first to thank you for the very great and unexpected honour you did me in electing me your President. To have been one in your Presidential roll, where so many famous men have preceded me, I shall always count the greatest honour of my life, and my earnest hope is that I may so discharge its duties as to merit your approval and favourable regard.

This year we have to mourn the loss of Dr Matthews Duncan, who has been so long and intimately connected with our Society, and who, by his writings, conferred on it a reputation second only to that given by the illustrious Sir James Simpson. Dr Duncan's clearness of intellect and honesty of purpose gained him many most attached friends, while his kindness to the younger Fellows, and the great interest he took in their scientific work, make his unexpected death the greater blow.

To-night I wish specially to consider Dr Duncan's scientific work. It seems to me only fitting to do this, as most of his papers were read before our Society, and although time only can try all men's work, it will be of value to consider his just now, even at the risk of such an estimate being deemed premature. I do so, however, not in the spirit of a critic—that would be presumption—but as one who, like many others, derived the greatest benefit from the study of his writings.

Duncan's scientific work arranges itself naturally under the divisions of *Obstetrical, Statistical, and Gynæcological*.

In his *Obstetrical and Statistical* work Duncan is seen at his best. His mind was essentially exact, one that needed facts before it could arrive at a conclusion, and one that could not, as a rule, speculate on insufficient data. His was the mind of the accurate physicist, and it is his great merit that he imported physical conceptions into Midwifery, and scorned with loathing the guess-work that blew up a frothy deduc-



tion only to disappear under the first whiff of common-sense. The "Researches in Obstetrics," and the "Contributions to the Mechanism of Natural and Morbid Parturition," fully establish his claims to stand in the first rank of scientific observers. The papers on "Uterine Statics" are admirable, and specially good is that on the function of the sacrum in relation to body weight. This matter is put with a clearness to which little has been added. In his other papers, especially in regard to the development of the female pelvis and the production of deformed pelves, he is less successful in his application of purely mechanical principles, but they are nevertheless full of interest and value. I may remark, indeed, on this point, that pure mechanics will not account entirely for such a thing as the shape of the female pelvis. There is something vital in addition, a type of growth whose factors we are not in a position as yet to define.

It is to Duncan, especially in this country, that we are indebted for correct views on the condition of the cervical canal during and at the end of pregnancy. He clearly demonstrated that it remained intact till the beginning of labour. His views on the behaviour, during labour, of the cervix and what we now term the lower uterine segment, were very correct, so that, as the result of these clear anatomical conceptions, his work on Placenta Prævia, especially his contributions "On the spontaneous Separation of the Placenta when Prævia," and "On the Source of Hæmorrhage," then, are in my opinion the best he ever wrote. His paper on "The alleged Synclitism of the Fœtal Head during Labour," and against the alleged Nægele obliquity at the beginning of normal labour, are models of terseness, accuracy, and scientific criticism. I know no papers on the mechanism of labour from which the young specialist can learn more, and none more worthy of his careful study. It is, indeed, impossible to do justice to Duncan's work on this head without unduly trespassing on your time, and I therefore, pass over his papers, on the "Production of Face Cases," on the "Efficient Powers of Parturition," "The Expulsion of the Placenta," "Production of Inverted Uterus," with the remark that alone they would have thoroughly established his claim to rank as one of our best investigators. His monograph on "Fecundity, Fertility, and allied Topics," in which he had the valuable assistance of Professor P. G. Tait, is a monument of most valuable work, and gives facts and data of the greatest importance.

In all these papers we see pictured the bent of Duncan's mind—accuracy in facts, caution in defining the object and limits of his paper, carefulness in deduction, a determination to exclude all sources of fallacy, with careful criticism of previous observers. Yet he evidently had a speculative tendency, which not only crops up in his papers occasionally (*v. Papers on the Perineum*, p. 7), but entirely dominated



a famous paper "On the Retentive Power of the Abdomen." Here his speculations and theories are beyond all bounds, and show Duncan in a rôle one would never, from his other works, have deemed him capable of assuming. The conceptions usually held of the physics of the abdomen are erroneous, and often grotesquely so, but Duncan gave in his consideration of this subject not the certain sound one would have expected from him, and no accurate physical ideas. Yet I know that he valued this paper highly.

As a gynæcologist Dr Duncan shone chiefly as a critic. I have no doubt his work on this subject will be severely criticised by some, and I admit that much of it is negative. In many respects, however, it has been most valuable. While there is very much in Gynæcology that we can regard with pride and admiration, there is a great deal which we can now only look on with a feeling of humiliation. The utter want of common-sense, to say nothing of the entire absence of pathological or anatomical basis, for much of the treatment of minor Gynæcology, is a matter of notoriety. As a critic of this, Duncan did most notable service. Undoubtedly he pushed his negative policy too far, as is well seen in his early opposition to ovariectomy, and the grudging he displayed to major operative treatment. Yet such conservatism is of the greatest use even in this; and Duncan's spirit, in a modified form, should be in our thoughts always in considering the question of treatment of disease.

His treatise on Perimetritis and Parametritis is a clear and accurate account of this matter at the time it was written, and was the product of much careful thought and clinical observation. His account of serous peritonitis is specially good and original, and not well enough known, as one sees even yet, when we read records of cases where evidently it was not diagnosed. In glancing over this work once more, what struck me most was the absence of all reference to sepsis as a cause of pelvic inflammatory conditions. Prophylaxis on this basis is not even mentioned, and consequently it is of historic interest, that in 1869, the most philosophical treatise on these subjects has no hint of what we now consider the great etiological factor in pelvic inflammatory conditions. In his after writings Duncan enthusiastically accepted Lister's great work. Our advance in treatment can be gauged by the fact that the only operative treatment recommended in long-standing pelvic abscess, and as a last resort, is tapping with a trocar.

In the clinical lectures on Diseases of Women there is much that is interesting, but little that is helpful in treatment. Duncan had lived through the time when much of minor Gynæcology was meddlesome and bad, and when major Gynæcology was fighting for its existence. This seems to have engendered in him a suspiciousness of most of our alleged advances. There is little of the spirit of modern Gynæcology in the



lectures, and he had evidently little faith in its future. In his fourth edition he says, "I believe the time will come when nearly all the diseases of women will be explained by a transcendental physics, including chemistry." That day is far off at present, and future generations must judge. Will the President of our Society in the 25th century be an expert in Quaternions and ether vibrations? Will it ever be possible to treat diseases of women by subcutaneous injection of antidotes to bacteriological products?

From what I have said it can be seen that I would place Duncan in the very highest rank as a scientific and clinical observer in Obstetrics, but I would at present rate his gynæcological work as most valuable for its engendering the spirit of caution, and even of suspicion to our alleged advances. This latter may seem scant praise, but I do not put it forward as such. The student of Gynæcology is heir to many facts and theories of whose value he is ignorant. What a misfortune if he has been so taught that he considers a stem pessary as natural and fit a treatment for an alleged flexion as a plastic operation is for a ruptured sphincter ani! A teacher must appraise and criticise facts and remedies, just as a sound lawyer would tell his client that the shares in some vaunted bubble company were worthless, and that his real monetary strength lay in some apparently sober investments. This is what one chiefly learns from Duncan's Gynæcology and Obstetrics—appreciation of a scientific method of investigation, a power of considering plausible statements critically, a reverence for natural processes as the real teachers of scientific treatment.

The record of Duncan's life and commanding personality is inspiring to all. What a record of steady, strenuous work! What an example of honest endeavour to get at the truth, cost what it might! How generous in his aid to younger scientific workers! We all count his connection with our Society one of its greatest glories.

I do not at present say anything about the past session's work, except that it is of a very high order, and I have every reason to believe that this standard will be maintained during the present year.

The work already published in our *Transactions* has taken a high place in scientific Obstetrics and Gynæcology, and it is for us to maintain and raise that standard. One thing that has always struck me in connection with our Society has been the kindly and generous help in scientific work and suggestion given by the senior members to the younger Fellows. Duncan had this spirit to the full, and no one has more of it than the teacher of so many of us here—Professor Simpson. Another and more recent factor in advancing our prosperity has been the establishment of the Royal College of Physicians' laboratory chiefly



by the strenuous work of Dr Batty Tuke. The Fellows of our Society have taken ample advantage of the great help it gives to anyone anxious to investigate. No one can now say that in Edinburgh little facility is afforded for scientific work, and a heavy responsibility rests on all in our city who, with material and facilities for research, let the golden opportunity slip.

VALEDICTORY ADDRESS TO THE EDINBURGH OBSTETRICAL SOCIETY.

GENTLEMEN,—In leaving the Presidential Chair, I do so with a strong appreciation of the great honour you conferred on me by electing me your President, and also one of gratitude for the very pleasant relations that have existed between us. The papers brought before us have been most valuable, and not the least gratifying feature has been the very great ability displayed by those of some of our younger Fellows,—an ability that promises great things for the future, and will, I am convinced, support and extend the high reputation our Society has already acquired.

To-night I wish to sketch briefly the history of Modern Gynæcology in its main aspects of progress, history, and present status. Such an attempt is full of difficulty—almost, indeed, of danger—as the opinions of gynæcologists on many subjects are greatly at variance. Yet a candid statement of my opinion may be valuable in eliciting the views of others, and enabling us to consider past errors, with the best way of avoiding them for the future.

Modern Gynæcology is at present near its jubilee. One has only to glance at some of the text-books on Diseases of Women, published fifty or sixty years ago, to recognise that Gynæcology did not then exist, even when one makes allowance for the time text-book writers take, as a rule, before they realise advance in science. In Gooch's *Account of some of the most Important Diseases peculiar to Women*, published in 1831, we find the greater part of the work taken up with obstetric conditions, diseases of children, and a discussion on the plague. Polypus uteri occupies forty-seven pages, and with a few on irritable uterus, the then lecturer at St. Bartholomew's, London, concludes his work.

Blundell's work (1837) is one of a very different kind. He describes uterine displacements, bladder diseases, ovarian dropsy, polypi, uterine inversion, uterine cancer, as well as functional diseases. In his treatment, he is in some respects as advanced as our most modern gynæcologists. His views on the surgery of the abdomen, based on experimental research, bear the mark of undoubted genius, and it is



hardly credible that in 1828 such a correct and far-seeing statement as the following could be published : <sup>1</sup>—

"I may be pardoned, perhaps, for endeavouring, on this occasion, to draw the notice of the profession to the following operations, all to appearance feasible, though by no means all of equal promise, stating distinctly, at the same time, that my design at present is to recommend them to *consideration* merely, and not to *practice*, except as observed above, in cases otherwise desperate.

1stly. *A division of both the Fallopian tubes, and even the removal of a small piece of them, so as to render them completely impervious, a fit addition apparently to the Cæsarean operation, the danger of which it would scarcely increase.*—The effect of this operation would be to prevent subsequent impregnation, without, however, destroying the sexual propensities, or the menstrual action of the womb; and as many, besides Mr Barlow's patient, have, on the Continent, recovered from the Cæsarean operation, the possibility of a second need for it should, I think, by all means be precluded. In those cases also of contracted pelvis, in which, notwithstanding the excitement of parturition in the seventh month, it is still necessary to destroy the children by opening the head, and reducing their size in order to bring them down through the pelvis, I think it would not be amiss to adopt this operation in order to produce sterility. An opening, two fingers broad, might be made above the symphysis pubis near the linea alba; the Fallopian tubes might be drawn up to this opening one after the other, and a piece of the tube might then be taken out. This operation, much less dangerous than a delivery by perforating the head when the pelvis is highly contracted, may, I think, be safely recommended.

2ndly. *The extirpation of the healthy ovaries.*—This operation, even granting it to be safe, can scarcely in any instance be necessary, though it may be observed, by the way, that it would probably be found an effectual remedy in the worst cases of dysmenorrhœa, and in bleeding from monthly determination of the inverted womb, where the extirpation of this organ was rejected . . . . .

3rdly. *The extirpation of the ovarian cyst in schirrus, combined with dropsy, or in simple dropsy,* will most probably be prevented by extensive adhesions, if the dropsical cyst be large and of long standing; but if the cyst be small, containing (as in Nathan Smith's case) a few pints only, the adhesions, it may be, will be found of small extent and easily separable. It remains to be ascertained, *by observation*, in what degree the abdominal adhesions may be divided, without an unjustifiable risk to the life of the patient. In the case of Janet Ireland, operated on by a very able surgeon, Mr Lizars of Edinburgh, the whole of the diseased mass could not, I believe, be removed from the abdomen; notwithstanding, the patient got well, gathered flesh, and was relieved of her central pains. These considerations are very encouraging, but we must *beware of rashness*, and, above all, we must be careful to select for the operation those cases only in which there is a reasonable hope.

5thly. *The removal of the cancerous womb when the ulceration first makes its appearance.*—To omit the operations performed upon the Continent, as well as those by Dr Weatherell and Mr Banner, the event of Mrs Moulden's case, hereafter detailed, has, it is presumed, clearly proved the possible success of this operation. Without the help of surgery this disease appears to be totally helpless; but of rashness, as before observed, it is necessary to beware.

6thly. *Extirpation of the puerperal uterus.*—When the Cæsarean operation is performed, or when a patient is evidently sinking after rupture of the womb, let it be remembered that the wound formed by the extirpation of womb, and which might probably be much reduced in extent by drawing the parts together with a ligature, would merely take the place of a more formidable wound: that, I mean, formed in the womb by the Cæsarean operation, and which, by the operation here performed, would, together with the uterus, be taken completely out of the body. No operation, perhaps, can be more unpromising—shall I say, more unjustifiable—in the present state of our knowledge, but I thought it proper to mention it. From four rabbits I removed the uterus within a few hours after delivery, after having drawn together, by means of ligatures, the parts by which they were connected to the pelvis,—I mean the vagina, broad ligaments, and Fallopian tubes. The mass removed was large enough to fill the hollow of the hand, as the rabbit is multiparous, and has two wombs of great capacity. Of these four rabbits, three, to my great surprise, recovered—the fourth dying from internal hemorrhagy, in consequence of the detachment of the ligatures, which had been insecurely tied. A practitioner of considerable acuteness, Mr Webber of Yarmouth, informs me that, being called to an inversion of the puerperal uterus, he successfully removed it on the fifteenth day after delivery."

<sup>1</sup> Blundell's works are his *Diseases of Women*, edited by Castle, London, 1837; his *Surgery of the Abdomen*, an appendix to Ashwell's treatise on Parturition, London, 1828; v. also *Lancet*, 1828.



Thus Blundell anticipated—(1) the section of the Fallopian tubes now practised by many after Cæsarean section; (2) the extirpation of the ovaries for dysmenorrhœa and inversions, now known as Battey's operation; (3) Porro's modification of the Cæsarean section. In extirpation of the cancerous uterus he stated at the same time what is exactly the modern standpoint, "The general surgeons would, I presume, of preference remove the parts by incision above the symphysis, and a facility would thus be afforded for ascertaining the state of the abdominal viscera; but I suspect it will be found at last that it is through the outlet of the pelvis that the parts may be removed with the fairest prospect of success."—(Castle's edition of Blundell's *Diseases of Women*, p. 185.)

No one can read Blundell's works without being impressed by his genius and wonderful intuition, and it is remarkable that so little general credit has been given him for his advances. This may have been due to a distrust of speculation unaccompanied by actual statistical results, as well as to an unfitness of the times for such advances. His environment was too much for him. His work on Gynæcology is also distinctly wanting in methods of investigation of disease, and this must have prevented the general acceptance of his views, and hindered the progress of the science. In some respects he reminds one of Lizars of Edinburgh, but Blundell was by far the greater man.

The greatest advance in Gynæcology was made by Sir James Simpson by his invention of the uterine sound and sponge tent. These instruments gave a means of diagnosis and treatment hitherto lacking, and opened up the realm of the pathology of the uterus. His original memoir on the uterine sound is a marvellous piece of work, and gives one a clear idea of the immense stride made by its use. He first points out the means then at the disposal of the specialist for gynæcological diagnosis, viz.,—(1) the state of the uterine functions; (2) the condition of the functions of the immediate viscera; (3) the existence of sympathetic mammary or spinal pains; (4) the condition of the patient's general health. Thus local examination was almost *nil*; but we of the present time are far too apt to forget that the four points so laid down are of very great importance in investigating a case, and are too much neglected for abundant local examination. Then follows his description of the sound and its use in the diagnosis of subinvolution, superinvolution (conditions really discovered by it) in fibroids, etc. It is also marvellous to see how clearly Simpson had grasped the idea of the modern bimanual, as he really describes its use combined with that of the sound most accurately. Indeed, one is tempted to ask, Why Simpson did not see the limitation and danger of the sound, and the much greater value in most points of the bimanual? Such a step was, however, at that time impossible, even to such a giant as Simpson was.



Genius is great, but it cannot conquer environment completely, and the time then was not ripe for this step.

This paper gave Gynæcology its first great impetus, and a perusal of it impresses one deeply with Simpson's power.

Looking back on its use from a modern standpoint, we can see that great abuses and dangers resulted from the employment of the sound, and some have urged that its limited use now shows that its original invention was a mistake, and that from its indiscriminate application more harm than good has resulted. We now know its risks, especially since our knowledge of antiseptics, and we have been able to limit its use greatly by the extension of the bimanual, especially when performed under anæsthesia. All this, however, detracts in no way from Simpson's fame. There is an evolution in Science as in Nature, and although the former works, unlike the latter, from the complicated and perhaps dangerous, to the simple and safe, it is none the less apparently a law in our mental processes. One can look at Listerism in this same light.

The perusal of Simpson's many other papers serves to increase our admiration; and his great obstetric work, to say nothing of what he did for anæsthesia, mark him as a giant in this subject—one whose name can never fade nor have its lustre dimmed. He is the only one of whom we can say in Gynæcology, *Magna pars fuit*.

To Sims in America we owe a great advance—the discovery of the Sims' speculum. It may be urged that the use of the speculum dates from the 7th century, when Paulus Ægineta wrote of the dioptra, and that I have ignored Recamier's claims. No one can deny, however, that Sims gave us the best speculum, and the only one of any use for real operative work. The reason of this is evident. Sims observed a natural fact, viz., the dilatation of the vagina in a certain posture, and attained it artificially by the simplest means. This showed his genius—the power of observing a natural phenomenon and imitating it in the simplest way possible. And so it will be of every alleged discovery: it can only live as truth so far as it is based on real fact and in its working follows the natural mechanism. This discovery and his work on vesico-vaginal fistula and prolapsus uteri are, in my opinion, Sims' real claims to be considered one of the great founders of Gynæcology. In some respects, however, he was too much under the influence of the mechanical school. We must now pass on to higher advances, those of abdominal surgery. In this, Simpson<sup>1</sup> and Sims played little or no part, while Blundell could only foresee and advise what neither he nor his contemporaries during his period of active life could practise. The terrible death of the sufferer from cystic ovarian disease stirred the compassion of Keith, Wells, and Atlee, and to the indomitable work of

<sup>1</sup> It must not be forgotten that Simpson fought most nobly and keenly for ovariectomy when most men were against it (c. Dr G. W. Balfour's Valedictory, *Ed. Med. Chir. Trans.*, 1883).



that great trio we owe one of our noblest advances. One admires the courage of these men. They operated in a hostile and even threatening profession, on cases often hopeless from long continuance and manyappings, with many errors clinging to them as their legacy from the past; and yet from their work has come a technique which leaves little to be desired. Keith's share in all this has been great. His development of an asepsis in his operations even prior to Lister's work, and his share in the development of the peritoneal toilette, give him one of the highest places among the pioneers of abdominal work.

The victory won over ovariectomy made the next advance a much easier matter. I refer to the modern operative treatment of diseased uterine appendages, known as Battey's and Tait's operations. For long, gynaecologists ignored tubal disease. They did this in spite of a fair amount of pathological evidence, as one can see from Cruveilhier's Atlas, where tubercular disease was figured (1829); from Boivin and Duges' Plates, which showed hydrosalpinx and probably distended purulent tubes (1833); and, lastly, from Hooper (1832), where pyosalpinx and hydrosalpinx were distinctly figured. In later years much of this was forgotten, and gynaecological text-book writers thought they did their duty sufficiently if they figured Hooper's plate. Inflammatory pelvic disease was classed as either pelvic peritonitis or cellulitis, and the possibility of its being a tubal condition never considered by the vast mass of specialists, if indeed by any. The relation between tubal disease and peritonitis was hardly thought of in this country, and the overwhelming preponderance of inflammatory conditions posterior to the broad ligament alleged to be due to the pouch of Douglas being the deepest part of the peritoneal cavity (in the erect posture!), so that fluid gravitated there, and not as pointing to a tubal origin. The present tendency is to class most pelvic inflammatory swellings as tubal, the usual gynaecological rebound. Despite the pathological evidence already quoted and the great work of Bernutz and Goupil, well worthy of perusal at the present time, with its careful record of tubal distension followed by peritonitis and death (*v. Meadows' Translation*, vol. ii. pp. 97-101), nothing was done in the way of rational treatment until Battey, Hegar, and Tait opened a new field of operative work, rescued numberless women from suffering and death, and took away from Gynaecology the opprobrium of hopeless and helpless minor medication of serious disease.

Battey, as is well known, attacked the problem of such cases from the standpoint of theory—wild theory. To establish an artificial menopause was his aim, not to remove pathological organs. Yet none the less should he be denied the highest credit for what he has done. Far away from the great educational centres and opportunities for pathological investigation, he yet clearly saw that certain cases in Gynaecology



were allowed to drift on to hopeless invalidism or death, often with nothing but a well-fitting pessary—the usual verbal jingle, as effective as Mrs Partington's mop in an Atlantic storm—to restore comfort and health. Battey, unlike Blundell, had the courage of his theory, and the operations he did and encouraged others to do showed that operative interference was rational and safe in such. Soon the real naked-eye pathological conditions were revealed, and Tait speedily outstripped all in his daring and ability, more especially established the importance of tubal disease, and wrung from present pathology abundant if tardy proof of its frequent existence. Hegar was also in this advance, and especially in tubercular disease has done great work.

Very much, however, remains to be accomplished under this head. Ultimate results, so difficult to get and requiring immense courage to publish, are not thoroughly known. The exact pathology of tubal and ovarian disease is too little known, and, undoubtedly, there has been much rash and crude work. As in all gynæcological advances, there has been fussy and meddlesome interference with women's appendages, and possibly many tubes and ovaries have been sacrificed that might well have been spared. Still, shrinkage in indications is going on, and no doubt we shall soon settle down to greater precision and a more thorough knowledge of this subject.

I am tempted to consider fully what has been done further in the surgery of the abdomen, especially advances in hepatic and renal surgery; but to take up these would be too great a tax on your patience. For the same reason I must also restrain myself from any remarks on extra-uterine gestation.

So far, then, I have merely touched the mountain-tops of our subject, and laid myself open to the criticism of attributing nearly all the advances in Gynæcology to Anglo-Saxon investigators. I must therefore consider now the outside workers, as well as those of Germany and France.

No one has had more influence for good in gynæcological operative work than Lister. When once the gynæcologist has grasped the idea of the "clean touch," he opens up to himself the realm of safe operative work. Bacteriology has explained what was hitherto inexplicable. Gynæcology at one time had sad experience of such cases as death from peritonitis after the use of the sound, tent, or stem pessary, or after some minor operation such as curetting. We now know what that means—Sepsis. It is Lister's immortal fame to have robbed obstetrics and surgery of their main terror.

France has done much for Gynæcology, and the names of Dupuytren, Recamier, Koeberlé, Bernutz, Goupil, and Péan are illustrious and famous. No French work has impressed me so much as that of Bernutz and Goupil, with its sound views on treatment, and one is amazed that



its influence in this country has not been greater. Yet, I think, France should have done more. Its modern school, as represented in Pozzi's most valuable text-book, shows her, however, now thoroughly abreast of the times.

German gynæcologists, especially of late years, have greatly extended our knowledge, and to their work on cervical and perineal surgery—above all, to the courage and thoroughness with which they are trying to solve the difficult problem of the treatment of uterine cancer—we are immensely indebted. It would be impossible even to enumerate the many illustrious names of which German Gynæcology can at present boast; but among those who are gone I may specially mention Schroeder, whose solid and enduring work has been of the greatest value, and who has founded a noteworthy school of observers. Finally, our German confrères take a leading position in scientific investigation, and their thoroughness and enthusiasm are an example to all.

In this brief sketch I have omitted many names deserving of mention. Ephraim M'Dowell and Nathan Smith, as the pioneers in ovariectomy, deserve all the praise America has lavished on them. To one living American investigator, Emmet, Gynæcology owes much. His observations on lacerations of the cervix are pathological contributions of high value, and although his operation has been frightfully abused by many, this has been done despite his strong protest. Emmet's scientific honesty is one of the glories of American Gynæcology.

So far I have merely taken up the questions of the progress of Gynæcology. Its actual history is quite another matter, so far as congratulation goes. The negative condition of knowledge in Gooch's time soon changed its quantity, and an amount of pernicious dogma and theory was let loose, from the evil effects of which we have not yet rallied. Probably the worst of these schools, as we might term them, was that of the ulcerationists, with their one simple cervical pathological lesion, and its one simple cure. We get the fullest information as to this ulceration of the cervix from J. H. Bennet's work on *Inflammation of the Uterus*. Here Bennet runs riot in the most woeful manner. Every pelvic symptom a woman had was due to ulceration of her cervix: almost every gynæcological patient had it, and there was no rest for her until the cervix had been scarred and cicatrised to a supposed normal condition. I know no more appalling nor ghastly book than Bennet's, nor any epoch in our history we should regard with more shame.

The doctrines of the extreme mechanical school are about as bad. The leading dogma in its faith is that a woman's pelvic health is all a question of the angle her uterus makes with the horizon, or depends on the angular relation between the uterine body and cervix. So simple and exact a matter is feminine comfort. As Bennet's work was the



result of Recamier's speculum, so uterine displacements followed the discovery of the sound. One is almost ashamed to say that we now know that ulceration of the cervix does not exist, and has never existed. As to uterine displacements, it is notorious that a fixed position of the uterus was assumed as normal, though in reality the uterus has no fixed position, but rather an extensive range: while certain conditions considered pathological are, in fact, normal. Fortunately now, the current belief as to displacements is that their significance is slight, that few require direct treatment, and that the vast majority are secondary inflammatory conditions, as Schultze and Emmet have so clearly pointed out. While most have thrown off all this pernicious error, there are still some faults to be guarded against in the magnification of the significance of slight pelvic lesions, and the ignoring of the general constitutional state or neurotic diathesis. One must never forget that certain lesions are the result of normal child-birth, may exist for years without harm, be detected when the patient is below par, and erroneously considered the cause. How many a hard-worked, run-down woman, primarily handicapped with a neurotic constitution and over-weighted with the cares of maternity, is assured that all her troubles are due to a slight displacement or a minor cervical split, and is supposed to be cured by some mechanical nostrum, or by the obliteration of a cervical laceration! But I need not enlarge on a subject so wisely treated by Clifford Allbutt, and whose cure has been clearly indicated by Weir Mitchell. By all means let us give an exact opinion of pelvic lesions when we are consulted, but let us beware of overestimating or underestimating their significance, and ignoring neurosis and neurasthenia.

We see then that Gynæcology started from such a condition as one finds in Gooch—irritable uterus: as instruments for examination were invented or revived we got diseases discovered, generally at first misunderstood, and often a system of pathology based on them alone. Bennet made most diseases secondary to ulceration of the cervix, just as the displacement school explained everything as originating in a version or flexion. What saved Gynæcology mainly was the results derived from abdominal surgery, which showed us the folly of much of the previous work, as well as gave an impetus to exact anatomical and pathological investigation. What lessons, then, are we to draw from the past? But first let us not imagine for one moment that we are above the faults and follies of our predecessors: nay, that we have not fallen into worse. Every age merely changes its craze, and many modern facts in Gynæcology and the other branches of Medicine reveal us as credulous and simple as the mediæval practitioner. We can keep before us, however, the great fact that our knowledge of the nature of any disease depends on our knowledge of the development and anatomy of the organ concerned; on our information as to its functions; and,



finally, on what we know of its pathology. How often has a system of elaborate medication been slain by a single fact in anatomy or pathology, and laid as prone and discredited as Goliath! Anatomical, physiological, and pathological research must be the basis of our future advances, and the test applied to all alleged discoveries. "Investigate" must be our motto. One thing further has struck me in Gynæcology, and that is, that our clinical history of disease is not quite crystallised out. This is a point worthy of our most careful attention, and in this respect we have much to learn from pure Surgery and Medicine.

Gynæcology has sprung from Medicine, and has long existed as one of its branches. Gradually it has emancipated itself, and now stands free, undoubtedly, as a branch of Surgery. Yet gynæcologists in our famous Infirmary are still linked with physicians, and do their operative work amongst them. This is unseemly, absolutely unscientific, and should be speedily put right. No general surgeon would tolerate phthisis and skin-disease patients in his ward, and yet to Gynæcology in the leading Medical School of the country half of a physician's ward is allotted. We must undoubtedly leave the physicians, bag and baggage, and establish ourselves as an independent surgical speciality.

Looking back on the past of Gynæcology, we can truly say that it has been a brilliant one, and that the future is still more full of promise. There has been much to be proud of: much, alas! that is humiliating. Yet we are thankful that always in our dark days there have been some faithful to truth and common sense, and who never bowed the knee to Moloch, but were contrariwise abusive to the supposed advances, and therefore helpful to Truth. Let all of us, even the youngest, have a healthy scepticism, and be most doubtful of any truth so evident that it has been accepted without proof.

Our special societies have a value that cannot be overestimated. Every such society should regard itself as a band of workers, or rather builders, whose duty it is, man by man, to contribute each his stone to the growth of its special science. We must resist the temptation to build more than our material warrants, and eschew all attempts to complete our ideas with tricked-out canvas, which must soon decay, and be torn down with reproach. It is given to few to make such gigantic contributions as Harvey, Simpson, and Lister, but most can at least add some fact, fill up some gap, and feel that their work, though humble, has been true,

"One stone the more swung to her place,  
In that dread Temple of Thy Worth."







## LIST OF PUBLISHED WORKS AND PAPERS.

## PUBLISHED WORKS.

- (1) *The Structural Anatomy of the Female Pelvic Floor* (imp. 4to): MacLachlan & Stewart, Edinburgh, 1880.
- (2) *Manual of Gynecology* (demy 8vo, 682 figs.): W. & A. K. Johnston, Edinburgh and London, 1890. 4th Edition (with Dr Freeland Barbour).
- (3) *The Relations of the Abdominal and Pelvic Organs in the Female* (large folio atlas): W. & A. K. Johnston, Edinburgh and London. Translated into French, Italian, and Spanish.
- (4) *Atlas of Female Pelvic Anatomy* (imp. 4to, 37 plates, 89 pp. typ.): W. & A. K. Johnston, Edinburgh and London.
- (5) *Contributions to the Sectional Anatomy of the Female Pelvis* (imperial 4to atlas): W. & A. K. Johnston, Edinburgh and London.

## PUBLISHED PAPERS.

- \* (1) "On Sympathetic Pain."—*Practitioner*, 1879.
- \* (2) "A Study of Two Vertical Mesial Sections of the Female Pelvic Floor in Relation to Prolapsus Uteri and the Normal Support of the Uterus."—*Edinburgh Medical Journal*, 1879.
- \* (3) "On a Source of Error in the Clinical Estimation of the Elongation of the Cervix during Labour."—*Edinburgh Medical Journal*, 1879.
- \* (4) "On the Bearings of the Shape of the Foetal Head on the Mechanism of Labour."—*Edinburgh Medical Journal*, 1879.
- (5) "On the Position and Distension of the Female Bladder."—*Edinburgh Medical Journal*, 1880.
- (6) "On the Shape of the Empty Female Bladder."—*Edinburgh Medical Journal*, 1881.
- \* (7) "On some of the Phenomena of Parturition."—*Edinburgh Medical Journal*, 1881.
- (8) "On Sacro-Pubic Hernia."—*Edinburgh Medical Journal*, 1881.
- (9) "On the alleged Synclitic Movement of the Foetal Head during Labour."—*Edinburgh Medical Journal*, 1882.
- (10) "On the Causation of the Movements of the Head at the Brim of the Ricketty Pelvis."—*Edinburgh Medical Journal*, 1882.
- (11) "The Anatomy and Etiology of the Genu-pectoral Posture."—*American Journal of Obstetrics*, 1881.
- (12) "On some Points in the Physics of the Rectum and Bladder."—*Edinburgh Medical Journal*, 1882.
- \* (13) "Note on a Unique Cause of Delay in the Third Stage of Labour."—*Medical Press and Circular*, 1882.
- (14) "Note on the Naked Eye Anatomy of the Female External Genitals."—*Edinburgh Medical Journal*, 1882.
- (15) "A Contribution to the Anatomy and Etiology of Rupture of the Peritoneal Portion of the Vagina during Labour."—*Edinburgh Medical Journal*, 1883.
- (16) "A Contribution to the Pathology of the Lymphatics of the Female Pelvis."—*Edinburgh Clinical and Pathological Journal*, 1883.
- \* (17) "A Further Contribution to the Structural Anatomy of the Female Pelvic Floor."—*Edinburgh Clinical and Pathological Journal*, 1883.
- (18) "A Critical Consideration of the Methods of Anatomical Research."—*Edinburgh Medical Journal*, 1885.

\* Those papers marked with an asterisk are not printed in the present volume.



- (19) "On the Nature and Cause of the Movement of Internal Rotation."—*Edinburgh Medical Journal*, May 1886.
- (20) "Case of Successful Abdominal Section for Ruptured Fallopian Tube Gestation."—*British Medical Journal*, 1886.
- \*(21) "A Contribution to the Anatomy of the Post-partum Uterus with Special Reference to Placenta Prævia."—*Edinburgh Medical Journal*, 1887.
- \*(22) "Note on the Mechanism of the Separation of the Placenta."—*Edinburgh Medical Journal*, 1887.
- (23) "The Mechanism of the Separation of the Placenta and Membranes during Labour."—*Proceedings of the Royal Society*, Vol. xv., pp. 427-435.
- (24) "Mitral Stenosis and the Third Stage of Labour."—*Edinburgh Medical Journal*, 1888.
- (25) "Case of Successful Cæsarean Section."—*British Medical Journal*, 1889.
- (26) "A Contribution to the Sectional Anatomy of Advanced Extrauterine Gestation" (with Dr Carter of Glasgow).—*Edinburgh Medical Journal*, October 1887.
- (27) "The Nature and Aim of Investigations on the Structural Anatomy of the Female Pelvic Floor."—*Edinburgh Medical Journal*, 1889.
- (28) "Improved Method of Managing the Third Stage of Labour."—*Edinburgh Medical Journal*, October 1888.
- (29) "A Contribution to the Pathology, Symptoms, and Treatment of Adherent Placenta."—*Edinburgh Medical Journal*, 1889.
- (30) "Note on some Anomalous Cases of Separation and Expulsion of Placenta before the Birth of the Child."—*Edinburgh Medical Journal*, 1889.
- (31) "The Minute Anatomy of the Placenta in Extrauterine Gestation."—*Edinburgh Medical Journal*, October 1889.
- (32) "Mitral Stenosis and Labour."—*Edinburgh Medical Journal*, August 1889.
- (33) "On the Displacement of the Placenta in Extrauterine Gestation and its Relation to these Cases ending in Pelvic Abscess."—*Edinburgh Medical Journal*, April 1891.
- (34) "The Anatomy and Mechanism of Early Abortion."—*Edinburgh Obstetrical Transactions*, Vol. xvi.; also *Report of Laboratory of Royal College of Physicians*, *Edinburgh*, Vol. iii.
- (35) "The Inconsistencies of the Present Nomenclature for Positions."—*Edinburgh Medical Journal*, 1891.
- (36) "On the Dilatation of the Anus and Urethra resulting from Natural Labour."—*Edinburgh Medical Journal*, 1891.
- \*(37) "A First Series of Twenty Completed Abdominal Sections."—*Edinburgh Medical Journal*, 1891.
- (38) "Introductory Presidential Address."—*Edinburgh Medical Journal*, 1891.
- (39) "On the Alleged Growth of the Placenta in Extrauterine Gestation after the Death of the Fœtus."—*American Journal of Obstetrics*, Vol. xxv., 1892.
- (40) "On the Structure of the Human Placenta with Special Reference to the Origin of the Decidua Reflexa."—*Transactions of Edinburgh Obstetrical Society*, Vol. xvii., and *Laboratory Reports of Royal College of Physicians*, *Edinburgh*, Vol. iv.
- (41) "Valedictory Presidential Address."—*Edinburgh Medical Journal*, 1892.
- (42) "Note of a Case of Vaginal Hysterectomy for Carcinoma Cervicis in Early Pregnancy."—*Edinburgh Medical Journal*, 1892.
- (43) "The Anatomy of Advanced Pregnancy in *Macacus Rhesus* Studied by Casts, Frozen Sections, and Microscopically."—*Journal of Anatomy and Physiology*, 1893.
- \*(44) "On Typical Abortion."—*International Clinics*, Vol. iii., Series ii.: Lippincott, Philadelphia, 1892.

\* Those papers marked with an asterisk are not printed in the present volume.



- (45) "On the Mechanism of the Expulsion of the Fœtus during Labour."—*Transactions of Edinburgh Obstetrical Society*, 1893-94.
- (46) "Placenta Prævia." Opening Address at Brussels International Congress, 1892. *In Course of Publication.*
- \*(47) "On Placental Classification in Mammals." *In Preparation.*
- \*(48) "The Extraperitoneal Variety of Extrauterine Gestation." *In Course of Publication.*

## LITERATURE.

## CHAPTER II.

*Braune*—Topographisch Anatomischer Atlas: Leipzig, Veit & Co., 1872. *Campbell, H. F.*—Résumé of a Report on Position, Pneumatic Pressure, and Mechanical Appliances in Uterine Displacements: Atlanta, Georgia, 1875. *Campbell, H. F.*—Pneumatic Self-Replacement of the Gravid and Non-Gravid Uterus: *Amer. Gyn. Trans.*, vol. i. *Campbell, A. S.*—Pneumatic Pressure and the Genu-Pectoral Posture in Reduction of Uterine Luxation: *Amer. Jour. of Obst.*, vol. x., p. 62, 1877. *Doughty*—Atmospheric Distention of the Vagina in the Knee-Chest Posture—Is it the Real Factor?: *Amer. Jour. of Obst.*, vol. ix., p. 561, 1876. *Foster*—A Contribution to the Topographical Anatomy of the Uterus and its Surroundings: *Amer. Jour. of Obst.*, vol. xiii., p. 30, 1880. *Hart*—The Structural Anatomy of the Female Pelvic Floor: MacLachlan and Stewart, Edinburgh, 1880. *Küstner*—Untersuchungen über den Einfluss der Körperstellung auf die Lage des nicht graviden, besonders des puerperalen Uterus: *Arch. f. Gyn.*, Band xv., S. 37, 1879. *Löhlein*—Ueber die Sogenannte Garrulitas vulvæ: *Zeits. f. Geburt. u. Gyn.*, Band v., Heft 1, Seite 141, 1880. *M'Leod*, Surgeon-Major, Bengal Medical Service—The Surgical Function of the Omentum: *Edin. Med. Jour.*, vol. xxiii., p. 1, 1878. *Mundé*—The Reposition of Retro-Displacement of the Gravid Uterus by Posture and Atmospheric Pressure: *Amer. Jour. of Obst.*, p. 292, 1876. *Rüdinger*—Topographische-Chirurgische Anatomie des Menschen: Stuttgart, 1873. *Schatz*—Garrulitas Vulvæ: *Arch. f. Gyn.*, Band v., S. 159, 1873. *Hennig and Crédé* in same. *Schröder*—Noch ein Wort über die normale Lage und Lageveränderungen der Gebärmutter: *Arch. f. Gyn.*, Band ix., S. 68, 1876. *Sims*—Clinical Notes on Uterine Surgery: Hardwicke, 192 Piccadilly, London, 1866. *Simpson and Hart*—The Relations of the Abdominal and Pelvic Organs in the Female; illustrated by a full-sized chromo-lithograph of the section of a cadaver frozen in the genu-pectoral posture: W. & A. K. Johnston, London and Edinburgh. *Solger*—Ueber ein bisher nicht erkanntes Hinderniss der Reposition des retroflectirten schwangeren Uterus: *Beit. z. Geburt. u. Gyn.* heraus. von der Gesells. f. Geburt. in Berlin, Band x., Heft 1., S. 22, Berlin, 1875.

## CHAPTER IV.

Atlases of *Legendre, Braune, Rüdinger*, and *Pirogoff*. *Barbour*—Cases of Carcinoma of the Female Pelvic Organs: *Ed. Med. Journal*, July 1880. *Barkow*—Anatomische Untersuchungen über die Harnblase des Menschen: Breslau, 1858. *Crédé*—Beiträge zur Bestimmung der normalen Lage der gesunden Gebärmutter. *Foster*—A Contribution to the Topographical Anatomy of the Uterus and its Surroundings: *Am. J. of Obstetrics*, January 1880. *Hart*—The Structural Anatomy of the Female Pelvic Floor. Appendix, Note C.: Edinburgh, 1880. *His*—Ueber Präparate zum Situs Viscerum mit besonderen Bemerkungen über die Form und Lage der Leber, des Pankreas, der Nieren und Nebennieren, sowie der Weiblichen Beckenorgane: *Archiv. für Anatomie und Physiologie* (His, Braune, and Du Bois-Reymond), 1878, S. 53. *Kocks*—Die normale und Pathologische Lage und Gestalt des Uterus sowie deren Mechanik: Bonn, 1880. *Schröder*—Noch ein Wort über die normale Lage und die Lageveränderungen der Gebärmutter: *Ibid.*, Bd. ix., S. 68. *Schultze*—Ueber die pathologische Antelexion der Gebärmutter, etc.: *Archiv. für Gynäkologie*, Bd. viii., S. 134. *Turner*—Introduction to Human Anatomy. p. 797. *Winckel*—

\* Those papers marked with an asterisk are not printed in the present volume.



Die Krankheiten der weiblichen Harnröhre und Blase : Billroth's Handbuch. For other literature see Foster's paper.

## CHAPTER V.

- Chadwick*—The Function of the Anal Sphincters, so-called : Am. Gyn. Tr., vol. ii., p. 43.  
*Duncan, J. M.*—Researches in Obstetrics : A. & C. Black, Edin. *Hart*—Structural Anatomy of Pelvic Floor : Edin., 1880. *Hilton*—Rest and Pain : Smith, Elder, & Co., London. *James*—Physics of Bladder, etc. : Ed. Med. Jour., 1879.  
*Power*—Physiology of Micturition and Retention of Urine : Practitioner, 1875, p. 38.

## CHAPTER VI.

- Breschet, G.*—Recherches anatomiques et physiologiques sur la gestation des Quadrumanes : Mém. de l'Acad. d. Sciences de l'Institut de France, Tome xix., 1845.  
*Engelmann*—The Mucous Membrane of the Uterus, with especial reference to the Development and Structure of the Decidua : Amer. Journ. of Obst., vol. viii.  
*Hart and Gulland*—On the Structure of the Human Placenta, with special reference to the Origin of the Decidua Reflexa : Rep. Laborat. Roy. Coll. Phys., Edin., iv., 1892. *Hertwig, O.*—Textbook of the Embryology of Man and Mammals (English Translation) : London, 1892. *His, W.*—Anatomie Menschlicher Embryonen : 1885.  
*Hubrecht*—Studies in Mammalian Embryology : 1. The Placentation of Erinaceus Europæus, with remarks on the Phylogeny of the Placenta : Quart. Journ. of Micros. Sc., vol. xxx. p. 283. *Hunter, John*—Collected Works, by Palmer, vol. iv. p. 71. *Keibel*—Zur Entwicklungsgeschichte der menschlichen Placenta : Anatom. Anzeiger, p. 537, 1889. *Kölliker, A.*—Entwicklungsgeschichte der menschen und der höheren Tiere : 1879. *Kundrat*—Untersuchungen über die Uterusschlerinhant : Stricker's Jahrbuch, 1873. *Leopold*—Studien über die Uterusschlerinhant während Menstruation, Schwangerschaft und Wochenbett : Arch. f. Gynæk, Bd. xi. *Minot*—Uterus and Embryo : 1. Rabbit ; 2. Man : Jour. of Morph., vol. ii. p. 341.  
*Selenka, E.*—Studien über Entwicklungsgeschichte der Tiere, 5 tes Heft. Erste Hälfte, 1891 ; Zweite Hälfte, 1892 : Wiesbaden. *Bland Sutton*—Surgical Diseases of the Ovaries and Fallopian tubes : London, 1891, p. 7 et seq. *Turner, Sir W.*—Lectures on the Comparative Anatomy of the Placenta : 1876. On the Placentation of the Ape.—Phil. Trans. Roy. Soc., Part ii., 1878. *Waldeyer, W.*—Die Placenta von Inuus nemestrinus : Sitzber. d. Berlin Akad., 1889, Part ii., p. 697. Bemerkungen über den Ban der Menschen—und Affen Placenta : Arch. f. mikr. Anat., vol. xxxv., 1890, p. 1.

## CHAPTER VII.

- Dural, M.*—Le Placenta des Rongeurs : Journ. de l'Anat. et de la Physiol., vol. xxvi., et seq. *Frommel*—Ueber die Entwicklung der Placenta von Myotus murinus : Wiesbaden, Bergmann, 1888. *Goodsir, John*—The Structure of the Human Placenta : Anat. Memoirs, edited by Sir Wm. Turner, p. 445. Edinburgh, A. & C. Black, 1868. *Gottschalk*—Beitrag zur Entwicklungsgeschichte der menschlichen Placenta : Arch. für Gynäk., Bd. xxxvii., 2. Weitere Studien über die Entwicklung der menschlichen Placenta : Arch. für Gynäk., Bd. xl., 2. *Hubrecht*—Studies in Mammalian Embryology : I. The Placentation of Erinaceus Europæus, with Remarks on the Phylogeny of the Placenta : Quarterly Journ. of Micros. Science, vol. xxx., p. 283. *Kastschenko*—Das menschliche Chorionepithel und dessen Rolle bei der Histogenese der Placenta : Archiv. für Anat. und Entw. His and Braune, 1885. *Keibel*—Zur Entwicklungsgeschichte der menschlichen Placenta : Anatomischer Anzeiger, p. 537, 1889. *Langhans*—Untersuchungen über die menschliche Placenta : Arch. für Anat. und Entw. His and Braune, 1877. *Minot*—Uterus and Embryo : I. Rabbit ; II. Man : Journal of Morphology, vol. ii., p. 341. *Turner, Sir William*—Lectures on the Comparative Anatomy of the Placenta : Edinburgh, A. & C. Black, 1876. On the Placentation of the Ape : Phil. Trans. Roy. Soc., Part II., 1878.

For additional literature, see MINOT.



## CHAPTER IX.

Only necessary literature given.

*Hart, D. B.*—Structural Anatomy of Female Pelvic Floor: Edinburgh, 1880. Contributions to Topographical, etc., Anatomy; Edinburgh, 1885. *Lahs*—Die Theorie der Geburt.<sup>1</sup> *Leishman*—The Mechanism of Parturition: London, Churchill, 1864. *Lusk*—Science and Art of Midwifery: London, 1882. Lusk's description of the cause of rotation is suggestive. He says "it is always the most dependent portion of the presenting part which rotates to the front." *Martel*—De l'accommodation en Obstetrique. *Simpson, A. R.*—Contributions to Obstetrics and Gynecology: Edinburgh, 1880 (article, "Head Flexion in Labour"). *Stephenson*—On the Mechanism of Labour: Lond. Obstet. Jour., vi., p. 401. *West, Uvedale*—Cranial Presentations and Cranial Positions: Glasg. Med. Journal, 1875. This is a valuable article, and contains the following interesting statement in regard to malrotated occipito-posterior cases:—"The cases which terminate with the face or forehead at the pubes are originally positions in which the uterine efforts are so perversely directed that the forehead gets down into the pelvis during the first stage" (p. 323, conclusion 11). . . . "The anterior or frontal end of the head will frequently pass first to the floor of the pelvis and then come forward to the arch of the pubes" (p. 323, part of conclusion 15).

## CHAPTER XII.

*Barnes*—Obstetric Operations: London, Churchill. *Duncan, J. M.*—The Revolutions of the Foetal Head in passing through a brim contracted only in the Conjugate Diameter: Laboratory Note, Lond. Obst. Tr., vol. xx. See also Discussion. *Goodell*—Labour in Narrow Pelvis: Tr. of Intern. Congress. Philadelphia, 1877. This is the best paper extant on this subject. *Labat*—Recherches Cliniques Expérimentales sur la tête du Fœtus: Paris, 1881. *Litzmann*—Ueber die hintere Scheitelbeinstellung: Arch. f. Gyn., Bd. ii., S. 433. *Simpson, A. R.*—Forceps v. Turning: Contrib. to Obst. and Gyn. Edinburgh, A. C. Black, 1881. *Turner*—Case of Delivery by the Breech through a Greatly Narrowed, Flat, Rachitic Pelvis: Ed. Obst. Tr., vol. vi., p. 111. *Veit*—Di. Hinterscheitelbeinstellung: Zeitschrift für Geburtshilfe und Gynäkologie, Bd. iv., S. 229. See Duncan and Goodell's papers for other references.

## CHAPTER XIII.

*Hicks, J. B.*—Anatomy of the Human Placenta, Lond. Obst. Jour., xiv., 1873. *Turner, Sir William*—Lectures on the Anatomy of the Placenta: Edinburgh, 1876. Observations on the Structure of the Human Placenta: Jour. of Anat. and Phys., 1873. *Waldeyer*—Medianschnitt einer Hochschwangeren u.s.w.: Bonn, 1886. Über den Placentarkreislauf des Menschen: Sitzungsberichte der K. K. Akad. der Wissenschaften zu Berlin, vi., 1887.

## CHAPTER XIV.

*Ahlfeld*—Die Entstehung der Placenta prævia: Zeitschrift für Geburtshilfe, Bd. xxi. A. describes a valuable preparation of placenta prævia overlapping the os internum in part, in the formation of which the reflexa took no part. *Auvard*—De la con-

<sup>1</sup> While admitting fully the value of Lahs' work and Professor Simpson's extension of it, I wish to urge that the special wedge shape of the head is not necessary to flexion or rotation. Lahs evidently believes that the priority in movement of the occiput in flexion and rotation is due to its special shape, but this seems to me more satisfactorily explained as I have already done. Professor Simpson, as we know, has measured the angles in Braune's plate of a parturient woman, and found that the occiput is subtended by a less angle than the sinciput. This would seem conclusive, but we get the same angles at shoulder and body in Chiara's plate of an impacted cross birth. Then, again, Lahs explains the passage of the occiput over the perineum prior to the sinciput coming under the pubic arch by this special angle again. But in spontaneous expulsion the breech is driven over the perineum in the same way, showing, I think, that this happens because the occiput or trunk is so driven through because it lies over the sacral segment which yields back. I mean by this that it is the sacral segment which yields back to let the occiput or breech pass, and not any special shape of the occiput which favours it.

I hold, therefore, that Lahs has not brought forward sufficient evidence as yet in support of his theory. In saying this I merely condemn my own hasty acceptance of it in a paper read before the Edinburgh Obstetrical Society in 1879.



duite a tenir dans les cas de placenta prævia : Paris, Doin, 1886. *Auvard*—Traité pratique d'accouchements. Paris, Doin, 1890. *Barbour and Webster*—Anatomy of Advanced Pregnancy and of Labour, studied by means of Frozen Sections and Casts : Laboratory Reports, Royal College of Physicians, Edin. vol. ii. *Barnes, R. and F.*—Obstetric Medicine and Surgery ; vol. ii., pp. 243, *et seq.* *Bayer*—Über Placenta prævia : Verh. der deutsch. Gesellschaft für Gynäk. Erster Kongress. Leipzig, 1886. *Behm*—Die Combinirte Wendung bei Placenta prævia : Arch. für Gynäk., Bd. xxxv. *Bumm*—Zur Kenntniss der Uteroplacentargefässe : Arch. für Gynäk., Bd. xxxvii. *Chiari*—Ueber die Topographischen Verhältnisse des Genitales : Wien. Toeplitz, & Deuticke, 1885. *Duncan, J. Matthews*—Mechanism of Morbid and Natural Parturition : Chapters xxi.-xxv. Edin., A. & C. Black, 1875. *Farre, A.*—v. Todd's Cyclopædia. *Hart and Gulland*—On the Structure of the Human Placenta, with special reference to the origin of the Decidua Reflexa : Reports of the Royal College of Physicians, Edin., vol. iv. *Hart*—A Contribution to the Anatomy of the post partum Uterus, with special reference to Placenta Prævia : Edin. Med. Jour., July 1887. *Hicks, J. B.*—Lancet, 1860 ; and Lond. Obst. Jour., 1864. *Hofmeier*—Die menschliche Placenta ; Zur Anatomie and Aetiologie der Placenta prævia : Wiesbaden, Bergmann, 1890. *Hofmeier*—Zur Behandlung der Placenta prævia. H. advocates early bipolar version and careful and not too speedy delivery ( $\frac{1}{2}$ — $1\frac{3}{4}$  hours). In 46 cases, five died ; two from loss of blood, one from loss of blood and infection before labour. Total mortality for mothers is thus 10·8 per cent. *Hofmeier and Benckiser*—Beiträge zur Anatomie des Schwangeren und Kreissenden Uterus. *Hubrecht*—Studies in Mammalian Embryology : Quart. Jour. of Micros. Sc, xxx., p. 283. *Hunter, Wm.*—On the Anatomy of the Gravid Uterus : 1774. *Kaltenbach*—Zur Pathogenese der Placenta prævia : Zts. für Geb., Bd. xix. *Minot*—Article Placenta in Buck's reference Handbook of the Medical Science : Wood & Co., New York, 1887. *Müller, Ludwig*—Placenta prævia : Stuttgart, Enke, 1877. *Münchmeyer*—Ueber den Werth der subcutanen Kochsalzinfusion zur Behandlung schwerer Anämie : Arch. für Gyn., xxxiv. *Pinard and Varnier*—Etudes d'anatomie obstétricale : Paris, 1892. *Rigby*—Essay on Uterine Hæmorrhage : London, 1842. *Runge*—Mittheilungen aus der Göttinger Frauenklinik : Placenta prævia totalis : Arch. für Gynäk., xli. Gives some valuable drawings. The arterial blood supply to the lower uterine segment is injected. The direct vessels are a little more marked than in Hofmeier's preparations, but not more than in ordinary pregnancy. *Schroeder*—Lehrbuch der Geburtshülfe : Zehnte Auflage. (Edited by Olshausen and Veit.) Bonn, Cohn, 1888. *Spiegelberg*—Lehrbuch der Geburtshülfe. *Turner, Sir Wm.*—Lectures on the Comparative Anatomy of the Placenta : Edin. A. & C. Black, 1876. *Veit, J.*—Placenta prævia in Müller's Handbuch : (v. paragraph 46, p. 81, Bd. ii.) Stuttgart, 1889. *Waldeyer*—Bemerkungen über den Bau der Menschen und Affen Placenta : Arch. für Micros. Anat. xxxv. *Waldeyer*—Ueber der Placentarkreislauf des Menschen : Sitzungsbericht der Königl. Preuss. Akad. der Wissensch, 1887, I. S. 83. *Winter*—Zwei Medianschnitte durch Gebärende. Berlin, Fischer, 1889. This atlas gives a valuable section of a uterus with lateral placenta prævia.

The question of statistics is too wide to be considered here. Information can be obtained in the works of Trask, L. Müller, Auvard, Hofmeier, Behm. Müller gives 64 per cent. as infantile mortality : 1 in 4 as maternal. Recent statistics give maternal mortality as about 8 per cent.

#### CHAPTER XV.

*Hofmeier and Benckiser*—Beiträge zur Anatomie des schwangeren und kreissenden Uterus : Stuttgart, Enke.

#### CHAPTER XVII.

*Campbell*—Memoir on Extrauterine Gestation : Edin., A. & C. Black, 1840. This is an excellent critical treatise. *Chiene*—Contributions to Surgical and General Pathology : Edin., E. & S. Livingstone, 1870. From a consideration of four cases of



obliterated aorta, Chiene concludes that anastomosis can be satisfactorily carried on by what Sir W. Turner has described as the sub- or extra-peritoneal system of arteries (*v. Turner, Sir Wm.*). *Dezeimeris*—*Jour. des Connaiss. Med. Chir.*, Jan. 1837. We have, unfortunately, not had access to *Dezeimeris*' memoir. The references to it made by Campbell, Werth, and especially Tait, enable us to gather the scope of his paper, however. *Dezeimeris* drew attention especially to the "subperitoneo-pelvic form," and our preparations confirm his statements fully. His views on this point have, however, received scant attention, are denied by Campbell, and ignored by all English authors with the exception of Parry and Tait. For this *Dezeimeris* is partly to blame, as his minute classification of the varieties of extra-uterine gestation laid him open to criticism. *Fränkel*—*Diagnose und operative Behandlung der Extrauterinschwangerschaft. Volkmann's Sammlung*, No. 60. *Fränkel* here records a case where the gestation developed in the left Fallopian tube and broad ligament (*v. Fig. 7, Plate III.*) *Schuchardt*—*Virch. Arch.*, Bd. 89, S. 133. *Parry*—*Extrauterine Pregnancy*: Lewis. London, 1876. This is by far the best systematic treatise in any language.

## CHAPTER XX.

*Tait, Lawson*—*Diseases of Women*: vol. i., Richardson & Co., Leicester, 1889 (*vide also Ectopic Gestation*): Lond. Obst. Trans., xxix., p. 504. <sup>2</sup> *Herman, G. Ernest*—Lond. Obst. Trans., xxix., p. 506. *Thornton, J. K.*—Lond. Obst. Trans., p. 85. See also *Brit. Gyn. Jour.*, vol. iv., p. 37. <sup>4</sup> *Hart and Barbour*—*Manual of Gynecology*: first edition, p. 271. Barbour does not speak of this growth in his original paper, *Edin. Med. and Edin. Obst. Trans.*, 1882. <sup>5</sup> *Sutton, J. Bland*—*Surgical Diseases of the Ovaries and Fallopian Tubes*: Castell & Co. London, 1891. <sup>6</sup> *Hart and Carter*—*Edin. Med. Jour.*, October, 1887. <sup>7</sup> *Hart, D. Berry*—*Displacement of the Placenta in Extrauterine Gestation and its Relation to those Cases ending in Pelvic Abscess*: *Edin. Med. Jour.*, October, 1889 and 1891.

## CHAPTER XXII.

*Balfour, G. W.*—*Diseases of the Heart*; Second edition, London, 1882. *Broadbent*—*Mitral Stenosis*: *Internat. Jour. Med. Sc.*, 1886. *Hart, D. B.*—*Mitral Stenosis and the Third Stage of Labour*: *Edin. Med. Jour.*, Feb. 1888.


## CHAPTER XXIV.

*Barbour, A. H. F.*—*Sectional Anatomy of Labour*: *Edin. Med. Jour.*, 1887. *Labour: a Criticism of Papers by Cohn, Champneys, and Hart*: *Edin. Med. Jour.*, 1888. *Hart, D. B.*—*A Contribution of the Anatomy of the Post-Partum Uterus, with special reference to Placenta Prævia*: *Edin. Med. Jour.*, 1887. *Note on the Mechanism of the Separation of the Placenta during the Third Stage of Labour*: *Ibid.*











✓





Riley Dunn & Wilson Ltd  
EXPERT CONSERVATORS & BOOKBINDERS



