

## **The students guide to surgical diagnosis / by Christopher Heath.**

### **Contributors**

Heath, Christopher, 1835-1905.

### **Publication/Creation**

London : J. & A. Churchill, 1879 (London : William Clowes.)

### **Persistent URL**

<https://wellcomecollection.org/works/ajy78xyf>

### **License and attribution**


This work has been identified as being free of known restrictions under copyright law, including all related and neighbouring rights and is being made available under the Creative Commons, Public Domain Mark.

You can copy, modify, distribute and perform the work, even for commercial purposes, without asking permission.



Wellcome Collection  
183 Euston Road  
London NW1 2BE UK  
T +44 (0)20 7611 8722  
E [library@wellcomecollection.org](mailto:library@wellcomecollection.org)  
<https://wellcomecollection.org>









22900108006









Digitized by the Internet Archive  
in 2014



12-9

B<sup>2</sup>. V. 14



6/6

B. V. 1

LONDON HOSPITAL  
MEDICAL COLLEGE

---

THE STUDENT'S GUIDE  
TO  
SURGICAL DIAGNOSIS



BY THE SAME AUTHOR.

**INJURIES AND DISEASES OF THE  
JAWS.** JACKSONIAN PRIZE ESSAY. Second Edition,  
8vo, with 164 Engravings, 12s.

**A COURSE OF OPERATIVE SURGERY.**  
With 20 Plates drawn from Nature by M. LÉVEILLÉ,  
and coloured by hand under his direction. Large 8vo,  
40s.

**PRACTICAL ANATOMY.** A Manual of Dis-  
sections. Fourth Edition, crown 8vo, with 16 Coloured  
Plates and 264 Engravings, 14s.

**MINOR SURGERY AND BANDAGING.**  
A Manual for the Use of House-Surgeons, Dressers, and  
Junior Practitioners. Fifth Edition, fcap. 8vo, with  
86 Engravings, 5s. 6d.

2K

THE STUDENT'S GUIDE  
TO  
SURGICAL DIAGNOSIS

BY  
CHRISTOPHER HEATH, F.R.C.S.,

HOLME PROFESSOR OF CLINICAL SURGERY IN UNIVERSITY COLLEGE,  
LONDON, AND SURGEON TO UNIVERSITY COLLEGE HOSPITAL;  
HONORARY FELLOW OF KING'S COLLEGE, LONDON



LONDON HOSPITAL  
MEDICAL COLLEGE

LONDON  
J. & A. CHURCHILL, NEW BURLINGTON STREET  
1879

BY THE SAME AUTHOR.

**INJURIES AND DISEASES OF THE  
JAWS.** JACKSONIAN PRIZE ESSAY. Second Edition,  
8vo, with 164 Engravings, 12s.

**A COURSE OF OPERATIVE SURGERY.**  
With 20 Plates drawn from Nature by M. LÉVEILLÉ,  
and coloured by hand under his direction. Large 8vo,  
40s.

**PRACTICAL ANATOMY.** A Manual of Dis-  
sections. Fourth Edition, crown 8vo, with 16 Coloured  
Plates and 264 Engravings, 14s.

**MINOR SURGERY AND BANDAGING.**  
A Manual for the Use of House-Surgeons, Dressers, and  
Junior Practitioners. Fifth Edition, fcap. 8vo, with  
86 Engravings, 5s. 6d.

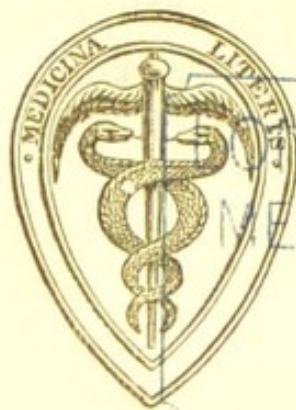

2K

THE STUDENT'S GUIDE  
TO  
SURGICAL DIAGNOSIS

BY  
CHRISTOPHER HEATH, F.R.C.S.,

HOLME PROFESSOR OF CLINICAL SURGERY IN UNIVERSITY COLLEGE,  
LONDON, AND SURGEON TO UNIVERSITY COLLEGE HOSPITAL;  
HONORARY FELLOW OF KING'S COLLEGE, LONDON



LONDON HOSPITAL  
MEDICAL COLLEGE

LONDON  
J. & A. CHURCHILL, NEW BURLINGTON STREET  
1879

95400  
9413

M19425

WELLCOME INSTITUTE LIBRARY	
Coll.	welMOmec
Call	
No.	W0141
	1879
	H43s

## PREFACE.

---

HAVING been a clinical teacher for some years, I have constantly been struck with the difficulty which even a well-read student finds in bringing his knowledge to bear promptly and efficiently upon the patient before him. The recognition of the several symptoms which the student has learnt in lectures or by reading can be best directed by the teacher at the bedside; but in his absence it is not always easy for the student to get a clue to the nature of the case before him. An attempt is made in the following pages to afford this assistance by grouping surgical affections anatomically, and by arranging the symptoms of each in the order in which they would strike a painstaking observer. No attempt is made to discuss the pathology or treatment of any of the



disorders described, and the description itself is purposely limited to the most salient points. At the same time, I have endeavoured to point out the differential diagnosis of affections likely to be confounded, and have in many cases employed the tabular method for convenience of reference.

I have to thank my colleague, Mr. Arthur Barker, for kindly reading my manuscript and making many valuable suggestions for its improvement, but I am alone responsible for all the statements contained in the work. I hope it may prove of service to those beginners in the study of surgery for whom alone it is intended, and from whom I shall gladly receive any suggestions for its future improvement.

CHRISTOPHER HEATH.

36, CAVENDISH SQUARE,

*June, 1879.*

# CONTENTS.



## CHAPTER I.

### INTRODUCTION.

	PAGE
Accurate diagnosis to be attained only by careful observation ... ..	1
Necessity for case-taking ... ..	2
Heads for reports on surgical cases ... ..	3

## CHAPTER II.

The head, affections of ... ..	13
The scalp, tumours of ... ..	13
wounds of ... ..	16
The skull, fractures of ... ..	16
The brain, concussion and compression ... ..	18

## CHAPTER III.

The face, affections of ... ..	21
The eye            „            ... ..	24
The ear            „            ... ..	29
Ulceration of face, diagnostic table of ... ..	32
The nose, affections of ... ..	33

## CHAPTER IV.

	PAGE
The mouth, affections of ... ..	36
The tongue           "       ... ..	39
The teeth             "       ... ..	42
The jaw, fracture and dislocation of ... ..	43
The gums, affections of ... ..	45
The jaw, tumours of ... ..	46
The palate ... ..	48

## CHAPTER V.

The throat, affections of ... ..	49
Dysphagia, acute and chronic ... ..	50
Dyspnœa,           "       "       ... ..	51
Valvular disease of heart, diagnostic table of ... ..	54
Aphonia and aphasia ... ..	54

## CHAPTER VI.

The neck, affections of ... ..	55
Goître       ... ..	55
Aneurisms of root of neck ... ..	56
Fractured clavicle       ... ..	58

## CHAPTER VII.

Injuries about the shoulder ... ..	60
diagnostic table of ... ..	61
Shoulder-joint, affections of ... ..	64

## CHAPTER VIII.

The upper arm ... ..	66
Humerus, fractures of ... ..	66
inflammatory diseases of ... ..	68
tumours of ... ..	69



	PAGE
Upper arm, inflammatory affections of ... ..	70
The elbow " " " " " "	74
injuries about, diagnostic table of ...	76
painful conditions of ... ..	78

CHAPTER IX.

The fore-arm and hand ... ..	79
The radius and ulna, fractures of ... ..	79
affections of ... ..	80
Teno-synovitis and ganglion ... ..	81
The wrist-joint ... ..	82
The hand, affections of ... ..	82
The fingers, injuries of ... ..	87

CHAPTER X.

The breast, affections of ... ..	88
Diagnostic table of adenoma, sarcoma, and scirrhus ...	89
Cysts of breast ... ..	90
Rapidly growing tumour of breast ... ..	91
The nipple ... ..	92

CHAPTER XI.

The thorax, affections of ... ..	93
injuries of ... ..	94

CHAPTER XII.

The abdomen, affections of ... ..	97
Abdominal tumours ... ..	99

CHAPTER XIII.

Injuries of abdomen ... ..	106
Hæmaturia ... ..	107
Intestinal obstruction ... ..	108

## CHAPTER XIV.

	PAGE
Tumours of the groin ... ..	112
Inguinal tumours ... ..	113
Femoral tumours ... ..	116
Scrotal tumours ... ..	119
Hernia, reducible ... ..	121
strangulated ... ..	122

## CHAPTER XV.

The urinary function ... ..	124
Retention of urine ... ..	124
in female ... ..	125

## CHAPTER XVI.

Morbid conditions of the urine ... ..	128
Blood in urine ... ..	128
Albumen in urine ... ..	129
Pus                   „ ... ..	130
Urinary deposits ... ..	130

## CHAPTER XVII.

The male genitals, affections of... ..	132
Urethral discharges ... ..	134
Venereal sores ... ..	135
The scrotum ... ..	135
The testicle ... ..	136

## CHAPTER XVIII.

The female genitals, affections of ... ..	139
Vaginal discharges ... ..	141

## CHAPTER XIX.

The rectum, affections of ... ..	143
Hæmorrhoids ... ..	144

*Contents.*

xi

	PAGE
Fistula in ano ... ..	145
Fissura ani ... ..	147
Difficult defæcation ... ..	147

## CHAPTER XX.

The lower limbs, affections of ... ..	149
Lameness in children ... ..	149
Hip-disease ... ..	150
Lameness in elderly people ... ..	153
Fracture of neck of thigh-bone ... ..	154
Dislocation of head of thigh-bone ... ..	156

## CHAPTER XXI.

The thigh, affections of ... ..	159
Tumours of femur ... ..	162
The buttock and back of thigh ... ..	164
Popliteal aneurism ... ..	165
Fractured thigh ... ..	166
patella ... ..	167

## CHAPTER XXII.

The knee, affections of ... ..	169
Fluid in bursa and joint ... ..	170
Inflammation about knee ... ..	171
Synovitis, acute and chronic ... ..	172
Knock-knee ... ..	174

## CHAPTER XXIII.

The leg, affections of ... ..	175
Ulcers of the leg ... ..	175
Ostitis and periostitis of tibia ... ..	178
Fracture and tumour of leg ... ..	180



## CHAPTER XXIV.

	PAGE
The foot, affections of ... ..	183
Club-foot, its varieties ... ..	183
Sprain and dislocation of ankle ... ..	184
Chronic disease of ankle ... ..	186
Gout and bunion ... ..	187
Frost-bite and senile gangrene ... ..	188

## CHAPTER XXV.

The back, affections of ... ..	190
Congenital and other tumours ... ..	190
Caries of spine and angular curvature ... ..	191
Lateral curvature of spine ... ..	192

## CHAPTER XXVI.

After amputation ... ..	196
Tension of stump, rigor ... ..	196
Osteo-myelitis, necrosis ... ..	197
Tetanus ... ..	198

## CHAPTER XXVII.

Constitutional conditions ... ..	199
Good health ... ..	199
Inflammatory fever ... ..	201
Pyæmia, hectic ... ..	202
Delirium tremens ... ..	203
INDEX ... ..	205



# GUIDE TO SURGICAL DIAGNOSIS.

---

## CHAPTER I.

### INTRODUCTION.

THE object of the following work being to assist the student of surgery in forming a diagnosis of cases coming before him, it will be convenient to describe the method of reporting a surgical case in a hospital; for though all cases need not be reported in writing, it is by the study of this method that the greatest accuracy in observing will be attained. Imperfect observation must lead to inaccurate or, at least, haphazard diagnosis; and though experience may enable the surgeon to grasp the nature of a case as it were intuitively, it would be most unsafe for the inexperienced student to omit any of the steps by which an accurate diagnosis may be secured.

The habit of note-taking is one which must be adopted early in life, if it is to become easy and serviceable, and the briefest note made at the time of seeing a patient is infinitely more valuable than an elaborate record penned hours or days afterwards. *How* to observe, is an art to be attained only by practice, but *what* to observe in any given case can be learnt to a certain extent from books, provided the clue to the nature of the case is given to the student. This, it is the object of the following pages to furnish so far as may be; for it must be remembered that though in surgical descriptions the symptoms are arranged according to their order of importance and successively, in the living patient they are more or less commingled, masking one another, and requiring care for their disentanglement.

The following are the "Heads for Reports on Surgical Cases" used in University College Hospital for some years past with great advantage. They were compiled by Mr. Rickman Godlee, M.S., F.R.C.S., when Surgical Registrar of the hospital, and have been revised by their author specially for this work.



[EXPLANATION—In taking the *history* of a case the student is expected to investigate all the points mentioned in section A. (p. 3), and then to search for the points which may refer to the particular case in section B. (pp. 4–6). The same plan is to be followed with regard to the *present condition*, of which section A. (p. 7) is required for all patients, while sections B. and C. (pp. 7–11) contain references to special diseases and injuries.]

## HISTORY.

§ A. *General. Required for all cases except paragraphs marked \*, which may be omitted in cases of simple injury.*

DATE OF ADMISSION—NAME—AGE—SEX.

OCCUPATION—How long followed—Previous occupations, if any.

\* PRESENT ILLNESS—Exact date of commencement †, and character and sequence of each successive symptom—All previous treatment—Cause assigned, if any.

PRESENT INJURY—Method of infliction, by direct or indirect violence—Immediate effect with reference to consciousness, power of walking, etc.—Hæmorrhage, amount and character—Length of time between infliction and admission.

PREVIOUS ILLNESSES—Enumerate—If a disease be doubtful (as *e. g.* Syphilis), give symptoms in detail—The most important for a surgical case are Gonorrhœa, Syphilis, Rheumatism, Gout, Phthisis, or Tumour.

PREVIOUS INJURIES—Describe carefully.

† Date to be stated in days of month, *not* days of week.

- \* **MANNER OF LIFE**—Dwelling healthy or otherwise; Clothing—Locality in which patient has lived; and, if many, enumerate them—Food and drink; if intemperate, state extent.
- \* **FAMILY HISTORY**—Married or single—Number of children; and, if any have died, cause of death—Diseases, if any, in father or mother, sisters or brothers, uncles or aunts, or grandparents.

§ B. *Special points in History of some of the most important Surgical Diseases.*

1. **GENERAL DISEASES.**

**TUMOURS**—Family history very important (to include Scrofula, Syphilis, Phthisis, etc.)—How and when first noticed—Assignable cause—Rapidity of growth—Amount and character of pain—If ulcerated, has hæmorrhage occurred?

If of Breast, special inquiry into previous condition of organ, number of children, state of genital organs, menstruation, hysteria, etc.

**ABSCESS**—Disease of Bone, Joint, Gland or Bursa. If in abdomen, disease of Liver, Intestine, Kidney, Uterus or Prostate—Struma—Syphilis—Injury—Rigors and other signs of fever.

**ACUTE FEVERS** (*Erysipelas, Phlebitis, etc.*)—Rigors—Headache—Pain in back—Loss of appetite—Vomiting—Diarrhœa. These symptoms to be detailed in their exact sequence. Particular attention to be paid to a preceding wound, however slight.

**SYPHILIS**—Date of primary infection—Description of sore, and how soon noticed after infection—Character of succeeding bubo, if any—Nature and time of occurrence of all secondary symptoms.

**SOFT CHANCER**—Date of infection—How soon noticed



— Position — Number — Character of succeeding bubo, if any.

ANEURISM—Special attention to occupation—Injury, Rheumatism, Syphilis, and Drink.

## 2. BONES AND JOINTS.

Pay particular attention to:—Previous injury—Syphilis, Struma, Phthisis, or Rheumatism in patient or relatives—Gonorrhœa—Exposure to cold or Phosphorus-poisoning.

UNUNITED FRACTURE—Previous treatment accurately—Predisposing causes, viz., Pregnancy, Lactation, Syphilis, Fevers, General Cachexy, Scurvy, and Old Age.

## 3. DEFORMITIES.

Congenital or acquired—Paralysis; and if it has occurred, when and from what cause—Injury or disease, when and of what nature—Neurotic history in family—If spasmodic, seek cause, central or peripheral.

## 4. ALIMENTARY CANAL.

TUMOURS OF MOUTH—Condition of teeth—Smoking—Syphilis.

STRICTURE OF ŒSOPHAGUS—Swallowing of irritating substances—Vomiting and power of deglutition—Hæmatemesis—Pain—History of Cancer or Hysteria.

STRICTURE OF RECTUM—Syphilis—Dysentery—Cancer—Condition of bowels, habitual and recent, viz. relaxed or confined, passage of blood or mucus—Shape and size of fæces—Pain.

HÆMORRHOIDS—Nature of occupation—Disease of Liver—Drink—If a woman, number of children—

Varicose Veins—General condition of bowels—Hæmorrhage.

HERNIA—First appearance—Cause, *i. e.* congenital, straining, change of habit of body, viz. obesity or emaciation—Reducibility—Previous strangulation.

If strangulated, exact period, *in hours*, of commencement, and nature of pain and vomiting—Cause of strangulation—Last action of bowels and passage of flatus.

INTESTINAL OBSTRUCTION—Duration and character of symptoms (gradual or sudden)—Previous condition of bowels—History of Hernia—Dysentery—Phthisis—Syphilis—Enteric fever—Blood passed with the motions—Emaciation—History of tumour in family.

#### 5. GENITO-URINARY ORGANS.

FISTULA—History of Phthisis or injury.

MICTURITION—(a) Frequency by night and by day—(b) Pain before, during, or after—(c) Passage of blood—(d) Sudden stoppage.

*Pain*—Penis, Perinæum, Pubes, or Loins.

*Rigors* or febrile attacks with vomiting.

*Urine*—Naked-eye characters.

STONE—Duration of symptoms—Rheumatism or Gout—Soil on which patient has lived, and frequency of stone in the locality—Renal colic—Gravel.

STRICTURE—Cause—Number of claps and duration and treatment of them—Nature of injury, if any; whether followed by hæmorrhage from urethra, and treatment—Previous treatment—Exact duration and progress.

VARICOCELE—Lymphatic temperament, constipation, masturbation; other varicosities, such as piles, varicose veins, etc.



## PRESENT CONDITION.

§ A. *General for all Patients.*

STATE OF HEALTH—*i. e.* Nutrition—Emaciation—Disposition—Complexion—Muscular development—Premature decay, including, if necessary, state of arteries, arcus senilis, etc.

SKIN—Moist or dry—Cool or hot—Presence or absence of eruptions.

PULSE—Number, character, compressibility—Irrregularity in force or rhythm.

RESPIRATION—Frequency and character, *i.e.* deep or shallow, abdominal or thoracic.

TONGUE—Clean or foul—Nature of fur—Moist or dry—Pale or red—Prominent papillæ—Indentations of teeth. Inquiry into general condition of circulatory, respiratory, and digestive systems.

URINE—Reaction—Specific gravity—Appearance—Deposit (microscopical and naked-eye appearance)—Presence or absence of Albumen and Sugar.

MENSTRUAL HISTORY of all females between 14 and 45 years, viz. answers to questions:—Regular? If not, How often? How much? Is there excessive pain?

§ B. *Special for some of the most important Surgical Diseases.*

1. GENERAL DISEASES.

TUMOURS—Position—Size—Shape—Consistence—Edge (defined or not)—Mobility—Condition of superjacent skin—Pain—Tenderness. And if present: Fluctuation—Pulsation—Translucency—Impulse on coughing—Glandular enlargement. Note the presence or absence of other tumours.

ABSCCESS—Acute or chronic—Superficial or deep—Extent—Character of pus—Communication, if any, with internal organ or cavity or bone.

ANEURISM—Amount of pulsation and whether expansile—Pain—Condition of pulse below—State of heart and vessels—Thrill and Bruit—Diminution in size on compression of artery above—Pressure signs.

SYPHILIS—Seek for secondary manifestations, in Skin, Mouth and Throat; Bones, especially such as are subcutaneous; Joints, Testicle, Eye, Brain, or Internal Viscera. If congenital, note stature, type of face and teeth.

## 2. BONES AND JOINTS.

Expose both limbs and compare the two sides.

Measurements:—(a) of affected part; (b) of the limb elsewhere both in length and girth—N.B. Take definite points referred to an immovable bony prominence.

Shape and size of deformity, if any.

Presence or absence of fluctuation.

Amount of mobility:—(a) Active; (b) Passive.

Amount, and character of pain:—(a) at rest; (b) in motion. Nocturnal pains.

Condition of skin.

Temperature of part.

## 3. ALIMENTARY CANAL.

STRICTURE OF ŒSOPHAGUS—Position—Size—Amount of swallowing possible—Presence or absence of tumour, or symptoms of tumour in chest—Reaction and microscopical examination of Vomited matters.

STRICTURE OF RECTUM—Shape and size of fæces—Frequency of Defæcation (Tenesmus, &c.?)—Re-



sult of digital examination—Result of palpation of abdomen.

HÆMORRHOIDS—Internal or External—Amount of Hæmorrhage—Prolapsus ani.

HERNIA—Position—Size—Shape—Impulse—Percussion note—Pain—Tenderness—Condition of bowels—Vomiting, and, if present, its nature and frequency—N.B. If scrotal, note position of testicle—Peritonitis.

INTESTINAL OBSTRUCTION—Distention of abdomen, uniform or irregular—Visible peristaltic action of Intestines—Presence or absence of tumour—Tenesmus—Character and frequency of vomiting—Peritonitis—Examine seats of unusual Herniæ, *i. e.* Obturator, Perineal, Sciatic, Diaphragmatic, Vaginal, or Rectal.

FISTULA—Length—Direction—Position of internal and external openings—State of lungs.

PERITONITIS—Position of patient—Expression and colour of face—Vomiting, nature of—Abdominal pain, tenderness or distention—Movable dulness in abdomen—Jaundice—Hiccough—Constipation.

#### 4. GENITO-URINARY ORGANS.

Frequency of micturition by night and day at time of admission—Renal tenderness—Amount and position of pain, &c., as in taking the history.

STRICTURE—Number—Position—Size on admission.

TUMOUR OF TESTICLE—Does it involve Skin, Spermatic Veins, Tunica Vaginalis, Testicle, Epididymis or Cord? Does it extend up to the external abdominal ring? Impulse on coughing—Reducibility into Abdomen—Translucency—Weight—Consistence.

## 5. SKIN.

ULCERS—Describe exactly Position—Size—Shape—Depth—Edges—Base—Condition of surrounding skin—Surface (size and colour of granulations)—Discharge—Tenderness and Pain—Tendency to bleed.

RASHES — Position — Shape — Colour—Condition of edge (elevation and definition)—Notice whether colour disappears on pressure—Does it consist of a simple erythema or of papules, vesicles, scales, pustules, or tubercles?

§ C. *Special for Special Injuries.*

SIMPLE FRACTURES—Crepitus—Unnatural mobility—Position—Nature (simple or comminuted)—Direction—Deformity (including shortening)—Amount of bruising—Amount of swelling—Vesication—Temperature of limb—Pulse below injury.

COMPOUND FRACTURES—As above and in addition:—Size and position of wound—Nature of wound—Amount of hæmorrhage—Presence or absence of local emphysema.

INJURIES OF HEAD—Pay particular attention to condition of intellect, local or general paralysis, especially condition of bowels, bladder, and pupils—Pulse very important—Note urine particularly—If a fracture, is it simple or compound, fissured, depressed or punctured?—Bleeding from nose, ear, or mouth, or escape of clear fluid, with exact periods of commencement and cessation—Ecchymosis under conjunctiva, with date of appearance—Headache, position and quality—Impairment of vision.

INJURIES OF CHEST—Number and character of respirations—Hæmoptysis—Local or general emphysema—Physical signs on admission.



INJURIES OF SPINE—Deformity or tenderness of spine—Paralysis to be noted exactly, including Bladder and Rectum—Anæsthesia and hyperæsthesia.

INJURIES OF ABDOMEN—Amount and continuance of shock—Position of pain and tenderness—Appearance of blood in urine or motions—If a wound, character of discharge—Vomiting—Hiccough—Jaundice—Be on the watch for Peritonitis.

BURNS—Extent—Depth, *i. e.* redness, vesication, exposure of tops of papillæ, destruction of whole of skin, destruction of subcutaneous fat or deeper tissues—Shock—Vomiting—Pneumonia—Diarrhœa—Head symptoms—Œdema glottidis.

### PROGRESS OF CASE.

No definite rules can be laid down for taking notes of a case in progress; the method will be the same as that indicated under 'Present Condition,' but some general principles may be of service.

1. All surgical appliances should be intelligibly described at the time of their application, and the length of time they are employed, with any modification, noted.

2. The steps of an operation are to be mentioned individually and the dressings applied afterwards, with the frequency with which they are changed. Afterwards (*e. g.* in a case of amputation) the points to be watched are:—

- a.* The condition of the flaps themselves and their edges, their respective distances, &c.
- b.* The amount of surrounding inflammation.
- c.* The character and amount of discharge.
- d.* The period of granulation and nature of the granulations.
- e.* The period of removal of sutures or ligatures.

3. All treatment and diet is to be carefully recorded.

4. In all acute cases a note should be taken at least once a day, including pulse, respiration, and temperature; and in chronic cases twice a week, or less often in proportion to their chronicity.

5. In urinary cases, when operative interference is being carried on, the urine should be examined every day. Care must be taken that it is fresh, and its reaction observed, so that the exact time in the progress of the case when decomposition occurs may be noted.



## CHAPTER II.

## THE HEAD.

1. *In infants*.—A circumscribed puffy tumour of the scalp, found immediately after birth, and probably after a tedious labour, which pits on pressure, and is more or less discoloured, is a *caput succedaneum*, or limited extravasation of blood into the scalp, due to pressure sustained in the birth. THE SCALP.  
Caput succedaneum.
2. A congenital vascular mark or growth on the skin, varying in colour from red to purple, and often raised above the general surface of the scalp or skin, is a *nævus*, or “mother’s mark.” Nævus.
3. A congenital tumour bulging out between the cranial bones, pulsating, or, if of large size, semi-translucent, is an *encephalocele*, or *meningocele*, which may be large enough to give the idea of a monstrous “double-head.” Encephalocele, or meningocele.
4. *In the adult*.—Multiple tumours of the scalp, varying in size from a pea to an orange,

Sebaceous cysts. and of very slow growth, are *sebaceous cysts*, the contents of which are commonly solid, but may be semi-liquid, or, when very large, quite liquid, with distinct fluctuation.

Congenital cysts. 5. Similar tumours occur on the face, and are freely movable with the skin, but firmly-fixed tumours about the orbits and brows, over which the skin is stretched, are *congenital cysts*, connected with the periosteum, and requiring careful dissection for their removal. Occasionally such a cyst proves to be really a small encephalocele.

Cirroid aneurism. 6. A tumour of the scalp, somewhat resembling a nævus (2) but more prominent and pulsating, being made up of tortuous arteries, is a *cirroid aneurism*, or *aneurism by anastomosis*.

Gummata ulcerated. 7. Indurated spots about the scalp and face, tending to ulcerate and heal, leaving flattened cicatrices more or less circular in shape, are *gummata* due to syphilitic infection, either acquired or congenital.

Herpes zoster. 8. A crop of vesicles with inflamed bases appearing along the line of one of the branches of the fifth nerve on the forehead, is an example of *herpes zoster*, which may seriously affect the nutrition of the eye itself. The scars left by herpes zoster of the fifth, closely resemble those of syphilitic ulceration on the face.



9. Painful swellings of the skull, soft and Nodes.  
doughy at first, but becoming harder in process  
of time, and more painful at night, are *syphilitic*  
*nodes*, and it is to be remembered that similar  
swellings may be developed on the inner  
surface of the skull, giving rise to brain-  
symptoms.

10. An extremely dense chronic outgrowth Ivory  
from one of the bones of the skull is occasion-<sup>exostosis.</sup>  
ally met with in a patient otherwise healthy,  
constituting an *ivory exostosis*.

11. A semi-fluctuating swelling occurring Cephalhæ  
shortly after the receipt of an injury must<sup>matoma.</sup>  
be caused by blood effused beneath the peri-  
cranium, forming a *hæmatoma* or *cephalhæma-*  
*matoma*. In children the blood is often effused  
beneath the periosteum of the parietal bone,  
and marks out very distinctly the shape of  
that bone. When some hours have elapsed  
more or less coagulation of the blood will have<sup>Partial co-</sup>  
taken place, and the clot being softer in the<sup>agulation.</sup>  
centre than at the circumference will give  
the finger the impression of sinking into a  
hollow, and lead to the erroneous idea of the  
existence of a depressed fracture. When some  
days have elapsed, and redness with evident  
heat of skin is present, suppuration has<sup>Suppura-</sup>  
probably occurred around the softened clot,<sup>tion.</sup>



but this can be decided positively only by a puncture.

Pott's  
"puffy  
tumour."

12. A circumscribed puffy swelling of the scalp, occurring some days after an injury, is said to indicate a collection of matter beneath the skull, but is seldom if ever seen.

Scalp-  
wounds.

13. *Hæmorrhage* from scalp-wounds, if severe, is usually arterial and will be recognized by its colour, for it is seldom in jets. Profuse venous hæmorrhage is a serious symptom, indicating injury to the sinuses of the brain.

Erysipelas  
of scalp.

14. An oedematous condition of the scalp, with redness spreading on to the face, followed by oedema of the eyelids or ears, occurring after a scalp-wound, is a symptom of erysipelas of the scalp, which is usually announced by a rigor and great rise of temperature, and often by bilious vomiting.

Depression  
or fissure.

15. A *simple fracture or depression of the skull* may be masked by extravasated blood (11), and may be unaccompanied by brain symptoms, but is, nevertheless, to be carefully watched, as inflammatory mischief may supervene.

Compound  
fracture.

16. A *compound fracture of the skull* is usually readily recognized with the finger, which feels the fissure or the depressed piece of bone with overlapping edges surrounding it.



17. A *punctured fracture*, caused by some pointed instrument, is more apt to be overlooked, from the small size of the wound, but is most serious in its nature, from the amount of injury inflicted on the inner table and dura mater. Punctured fracture.

18. A fall on the head may, without injuring the part struck, produce *fracture of the base* of the skull, with or without brain symptoms. Blood flowing from the ears in considerable quantity, followed by the continuous escape of clear watery fluid, is generally indicative of this accident, the gravity of which will depend upon the brain symptoms present at the time or supervening afterwards. Fracture of base.

19. A patient partially or completely insensible after receipt of an injury to the head must have some affection of the brain, which may be due solely to the injury, or in part to the *influence of alcohol*. The odour of the breath and the previous history of the patient will throw light upon this; and it should be noted that a drunken man is usually quarrelsome when roused, and apt to resent interference. The pupils are usually contracted, and when the patient is roused they suddenly dilate, and recontract as the patient dozes off. Alcohol.



## 20. THE BRAIN.

Concussion  
and Com-  
pression.

*Concussion.*

*Compression.*

1. Symptoms follow immediately on the injury.

1. Symptoms follow immediately if due to depressed bone, but after an interval if due to extravasated blood or suppuration.

2. Insensibility is only partial, and patient can be roused to answer questions.

2. Insensibility is complete, and patient cannot be roused by any stimulus.

3. Respiration is quiet, shallow, irregular, and sighing.

3. Respiration is deep, stertorous, and slow.

4. Pulse is quick, feeble, irregular or intermitting.

4. Pulse is slow, full, and regular.

5. Skin is cold and clammy.

5. Skin is hot and perspiring.

6. Pupils contracted but sensible.

6. Pupils dilated or unequal, and insensible.

7. No paralysis of limbs or bladder.

7. Paralysis of one side and bladder.

Shock.

21. A patient who has received any severe injury suffers, more or less, from partial insensibility, failure of the heart's action, and a cold, clammy skin, constituting what is termed *shock*.

Concussion.

22. Symptoms closely resembling these, but of an aggravated character, and depending upon some violence done to the head, indicate the occurrence of *concussion of the brain*. A patient who has lain for some hours in a state of partial collapse from concussion of the brain will, when reaction has begun, not uncommonly

Reaction.

vomit. By this the action of the heart is



stimulated, and the supply of blood to the brain increased, leading to (1) return of consciousness; or (2) to the effusion of blood from some torn vessel, and the onset of urgent symptoms of compression; or (3) to an inflammatory condition of the contents of the cranium. Secondary effects.

23. The symptoms of *return of consciousness* are obvious; but it must not be supposed that the mental condition will at once regain its complete equilibrium. Some amount of confusion of ideas, coupled with a tendency to excitement, may be present for a day or two. Return of consciousness.

24. The symptoms of *effusion of blood* will depend upon the vessel injured. If at the base of the skull or in the substance of the brain, it will be impossible to localize the mischief; but if one of the middle meningeal arteries should be torn or give way, the well-marked sudden supervention of symptoms of compression, coupled with unilateral paralysis, may indicate sufficiently the lesion on the opposite side of the head to warrant interference. Effusion of blood.

25. The symptoms of *inflammation* of the brain and its coverings are great heat of head, violent throbbing pain, a flushed face, and a hard, full pulse. Violent mental excitement, Inflammation of brain.



often almost manical, is apt to be followed by coma, and death from effusion.

Compres-  
sion.

26. Total insensibility, with stertorous breathing and dilated pupils, points to *compression of the brain* from some cause. If immediately following an injury, it is due either to depression of bone or effusion of blood; if occurring later, it is probably due to the effusion of blood; but if occurring after the onset of inflammatory symptoms, it is due, in all probability, to the formation of pus upon or in the brain, or to serous effusion into the ventricles.

Convul-  
sions.

27. Convulsive movements, sometimes of a rhythmical character, superadded to symptoms of brain mischief, are usually indicative of some laceration of brain substance. The convulsive movements generally affect the limbs of one side more than the other, and will be found chiefly on the side opposite to that on which the cerebral lesion has occurred. Some of the symptoms of compression will probably be present.

## CHAPTER III.

## THE FACE.

28. A CONGENITAL fissure of the upper lip Hare-lip. constitutes *hare-lip*, which may be single or double, and may be combined with fissure of the soft and hard palate.

29. A "port-wine stain" or other "mother's Nævus and mark" is a form of capillary *nævus*. Brown <sup>mole.</sup> marks, often covered with hairs, are moles, and these may be combined with *nævus*.

30. A scarlet, burning hot condition of the <sup>Facial ery-</sup> skin of the face, accompanied in severe cases <sup>sipelas.</sup> by œdema of the cellular tissue of the eyelids, so as to cause great deformity, and ushered in by rigors and great rise of temperature, is due to erysipelas. This may be traumatic, spreading from a wound of the face or scalp; or idiopathic, in which case it almost always begins about the nose.

31. A distortion of the face, in which the <sup>Facial</sup> mouth is drawn to one side, is due to paralysis <sup>paralysis.</sup>



Facial  
paralysis.

of the facial nerve, which may be consequent upon (1) exposure to cold, (2) disease in the temporal bone, or (3) brain affection. In a well-marked case the eye of the affected side is permanently open (the cornea being apt to suffer in consequence), and the rest of the face on the affected side hangs loosely on the bones, there being no muscular tone. The saliva is consequently apt to run out of the corner of the mouth, and the food to collect under the cheek from paralysis of the buccinator muscle. The healthy muscles, having no antagonists, draw the mouth over; and there is a marked contrast between the healthy, winking eye and the stony stare of the paralysed side.

From brain  
affection.

In facial paralysis consequent upon brain affection the nerve-fibres supplying the orbicularis palpebrarum generally escape, and consequently the eye is unaffected. The facial paralysis is on the same side as the cerebral lesion, and for the most part on the side opposite to that of the paralysed limbs.

Following  
fracture.

Facial paralysis may occur a few days after fracture of the base of the skull, from pressure on the nerve during the repair of the temporal bone, and this may be the only evidence of a fracture having occurred.

32. A swollen state of one side of the face,



coming on in twenty-four hours after some Mumps. uneasiness and pain have been felt about the jaws, is due to inflammation of the parotid gland, and constitutes *mumps*. The submaxillary glands are apt to be involved, and sometimes the testicles become enlarged and painful.

33. *Ecchymosis* or bruising of the face is usually the result of violence, but may be consequent upon the giving way of subcutaneous vessels from violent exertion, as in coughing. The colour will go through the shades of purple, green, and yellow as the effused blood undergoes absorption.

34. *Subcutaneous crepitation* is usually symptomatic of the escape of air into the cellular tissue, and may follow the act of blowing the nose after a fracture of the nasal bones. A subcutaneous clot in process of absorption will, however, occasionally give a crepitant feeling closely resembling that of air.

Crepitation.

Of air.

Of blood-clot.

Ptosis.

35. *Dropping of the upper eyelid*, with inability to raise it, may be a congenital affection; but, following an injury, is an evidence of paralysis of the third cranial nerve. The diagnosis will be confirmed if, on raising the lid with the finger, the pupil of the eye is seen to be dilated and insensible to light, and the eye turned outwards.

Mydriasis.



Divergent strabismus. 36. *Inability to turn the eye outwards* indicates some paralysis of the sixth nerve; but the patient may be the subject of ordinary convergent strabismus. squint, both eyes being more or less turned in habitually, in the effort to focus a defective eye.

Myosis. 37. A *contracted pupil*, not dependent upon disease of the iris, is often the effect of an injury of the upper part of the spinal cord propagated through the sympathetic.

Hordeolum. 38. A *minute painful abscess* at the edge of the eyelid (commonly called a sty) must not be confounded with the cyst of the eyelid; a slowly growing tumour appearing beneath the skin of the lid, but always to be opened from the conjunctival surface at a point which is discoloured and thinned.

Tarsal cyst. Ectropion. 39. A distortion, or drawing-down, of the *eyelid* by an old scar may cause great deformity and discomfort from the overflow of tears; but the common "watery eye" is due usually to some obstruction of the lachrymal apparatus, which, if acute, may cause an abscess and ulceration of the skin to the inner side of the eye in the position of the lachrymal sac.

Epiphora. Lachrymal abscess. THE EYE. 40. *Effusion of blood* beneath the ocular conjunctiva may be from the giving way of



a small vessel during violent exertion, *e.g.* in whooping-cough of children. As the result of injury, the palpebral conjunctiva may be much discoloured by blood—the common “black-eye;” but blood beneath the ocular conjunctiva is more serious, and may indicate fracture of the anterior part of the base of the skull, and escape of blood through the orbit.

Subconjunctival  
ecchymosis.

41. A reddened condition of the *conjunctiva* covering the eye may be chronic or acute. If chronic, it depends ordinarily upon some irritation due to the eyelid, there being either (1) inverted eyelashes, (2) inverted eyelid, or (3) a granular condition of the lining of the lid, which must be everted over a probe in order to bring the velvety roughened surface into view.

Trichiasis.  
Entropion.

Granular  
lids.

42. *Acute conjunctivitis* may be recognized by the bright red of the injected conjunctiva, and the heat, pain, and lachrymation complained of, coupled with the feeling of dust in the eye. The possibility of a foreign body being lodged in the conjunctiva or cornea is to be always borne in mind, and inquiry should be directed to this point, and a careful search made if necessary, by everting the lids over a probe, and by oblique illumination of the cornea with a lens. In the absence of a foreign body,

Conjunctivitis.



Catarrhal ophthalmia. Gonorrhœal ophthalmia.

the affection will probably prove to be simple conjunctivitis, unless there should be any possibility of inoculation with gonorrhœal matter having occurred. In that case prompt measures should be taken to close and protect the sound eye, and the diagnosis will be confirmed in a few hours by the occurrence of a profuse purulent discharge from between the lids of the affected eye. In infants the same disease may be present from inoculation at birth, but both eyes are affected.

Ophthalmia neonatorum.

Strumous ophthalmia.

43. In strumous children, the subjects of conjunctivitis, the leading feature is the inability to face the light, but if a glance at the eye can be obtained, one or more little superficial vesicles on the conjunctiva may be seen, which, when they break, leave little ulcers on the sclerotic, or at the margin of the cornea. These must not be confounded with the true ulcer of the cornea.

Phlyctenulæ.

Ulcer of cornea.

44. In a slightly reddened eye, a perfectly clear cornea may appear at one point to have lost a portion of its substance, there being a slight hollow left. This is the early stage of an ulcer of the cornea, but in the later stage of healing there will be more or less permanent opacity developed at the spot. Such a minute opacity is termed a *nebula*, but if of large size,

Opacity of cornea.



it is a *leucoma*, and may have resulted from injury by caustic lime, or from a small-pox pustule. A milk-white patch on the surface of the cornea may be due to the incautious use of a lead-lotion, and is sometimes capable of removal.

45. A *general opacity of the cornea*, with distinct blood vessels on its surface, and a chronically inflamed condition of the parts, is mostly due to the irritation of granular lids. A perfectly smooth cornea, looking like ground glass in some portion and clear in another, is an evidence of congenital syphilis. Confirmation should be sought in the condition of the teeth, which may be "notched and pegged," in scars at the angles of the mouth, and in depressed nasal bones, and also in the general appearance of the patient, who will usually be about the age of puberty, and may present an abnormal prominence of the forehead.

Opaque  
cornea.

Interstitial  
keratitis.

46. A *contracted and irregular pupil* is a result of inflammation of the iris, recent or old, and is accompanied by a change in the colour of the iris from blue to green, or from brown to rust-colour. Well-marked beads of lymph are usually seen on the iris in syphilitic cases, and the general signs of inflammation, viz. pain, redness around the cornea, and dimness of vision,

Iritis.



are more marked than in rheumatic or even traumatic iritis. The dilatation of the pupil following the continued use of belladonna for the treatment of iritis, must not be confounded with mydriasis.

**Cataract.** 47. An *opacity*, varying from a slight haze to a well-marked whiteness, seen behind the iris is caused by cataract of the lens, or its capsule, or both. In early, and therefore doubtful cases, the pupil should be dilated with atropine, and the eye illuminated obliquely by means of a lens, when the striæ in the cataract will appear white. If, on the contrary, direct illumination with an ophthalmoscopic mirror be employed, the striæ of early cataract will appear dark, while it will be found impossible in fully formed cataract to light up the fundus of the eye.

**Glaucoma.** 48. *Pain in the eye* and over the brow, often sudden in its onset and most acute in its character, coupled with dilatation of the pupil and greatly increased tension or hardness of the eye-ball, are the symptoms of acute *glaucoma*. The early recognition of this disease is most important, since the prompt performance of an iridectomy appears to offer the only prospect of saving the eye.

**Amaurosis.** 49. *Widely dilated pupils*, with loss of vision



in both eyes, is usually evidence of disease of the nervous apparatus of the eye or of the brain, requiring careful ophthalmoscopic examination for its determination.

50. *Blindness of one eye* may exist for a long time without the knowledge of the patient, who at last discovers the loss accidentally. A white film seen floating at the fundus of an otherwise apparently healthy eye, is an example of detached retina which may be complete or partial, with a corresponding loss of vision, and is commonly met with in adult or advanced life. A buttonlike growth, with more or less metallic lustre, seen at the fundus of a blind eye is probably a sarcoma springing from the choroid, and occurs commonly in children. Its diagnosis with the ophthalmoscope should be determined with a view to early removal of the eye-ball.

Detached  
retina.

Sarcoma of  
choroid.

51. Bleeding from the ear after a blow may be from laceration of the pinna or meatus, or from rupture of the membrana tympani. Severe bleeding from the ear is one of the symptoms of fracture of the base of the skull, and is usually followed by the escape of clear fluid in large quantity from the subarachnoid space (18).

THE EAR.  
Hæmorrhage from  
ear.

52. A circumscribed elastic swelling of the

Hæma-  
toma.



pinna, following a blow, is a *hæmatoma*, or collection of blood, which may either be absorbed or develop into an abscess.

Ruptured  
membrana  
tympani.

53. *Rupture of the membrana tympani* may be diagnosed by the consequent deafness, and by the fact that in most cases the patient, by forcibly expiring, with the mouth and nose closed, can drive air through the ear with a whistling sound. Inspection with a good light through a speculum will decide the question in doubtful cases.

Chronic  
discharge.

54. A slight *chronic discharge* from the ear may be due to irritation of the meatus from the presence of cerumen or a foreign body, which should be got rid of by careful syringing before further examination is made.

Purulent  
discharge.

55. A *profuse purulent discharge* may be due to an abscess or a polypus of the meatus, but is very frequently accompanied by perforation of the membrana tympani, and more or less deafness. It is a symptom of serious disease of the middle ear, which may end suddenly in mischief propagated to the brain.

The diagnosis between an abscess of the meatus and the more serious abscess of tympanum may be made as follows:—

*Abscess of Meatus.*

1. Patient in good health.
2. No crackling in ear.
3. Meatus swollen, and soon almost closed.
4. Pain slowly becoming intense, and referred to meatus and occiput.
5. No tinnitus.
6. Deafness only due to obstructed meatus.
7. Auricle swollen and standing out from head.
8. Membrana tympani, if seen, natural.
9. No vertigo or delirium.

*Abscess of Tympanum.*

1. Follows scarlet fever, measles, or catarrh.
2. Preceded by crackling.
3. Meatus not swollen.
4. Pain rapidly becoming intense, and referred to temporal region and angle of jaw.
5. Tinnitus very early.
6. Deafness early and extreme.
7. Auricle natural. Puffiness over mastoid process.
8. Membrana tympani bulged outwards.
9. Vertigo often, delirium frequently, present.

56. *Deafness* is often connected with ob- Deafness.  
struction of the Eustachian tube, and its patency should be ascertained by making the patient expire forcibly with the mouth and nose closed, when he will be aware of a "click" and sense of fulness in the ear, which will disappear on swallowing. The condition of the throat, and especially of the tonsils (as to chronic enlargement), should always be investigated in cases of deafness. The application of a watch to the head, on the deaf side, will determine whether the auditory nerve retains its function.





58. A red, hot, and swollen condition of the THE NOSE.  
 ala of the nose may be due to a pimple or Inflam-  
 small boil within the nostril, or may be the mation of.  
 commencement of erysipelas of the face. In  
 the case of a *pimple*, the inflammation is con-  
 fined to the ala, and there is throbbing pain,  
 and upon inspection the pustule can be seen  
 within the nostril. In *erysipelas* the skin of Erysipelas.  
 the whole nose is more or less affected, looking  
 red and glazed, and the blush extending to  
 the cheeks. The patient has a peculiar "skin-  
 bound" feeling, and some smarting, but no  
 throbbing in the early stage; and the general  
 temperature is raised three or four degrees.

59. A chronic red tuberculated condition of Acne rosa-  
 the nose and face, may be due to *acne rosacea*, cea.  
 and in no way connected with intemperate  
 habits. A generally hypertrophied condition  
 of the skin of the nose, which is red and tuber-  
 culated, constitutes *lipoma*. Lipoma.

60. *Ulceration* of the skin of the nose may Ulceration.  
 be due to lupus, rodent ulcer, epithelioma,  
 syphilis, or struma. (57)

61. A *chronic discharge* from the nostril, if Chronic  
 watery, is probably caused by polypus; if discharge.  
 purulent, is usually due either to ozaena or  
 suppuration of the antrum.

62. A constant, highly offensive discharge



**Ozæna.** from both nostrils, containing greenish crusts, which come away on blowing the nose, is characteristic of *ozæna*, and it should be noted that the patient has ordinarily lost the sense of smell, and is unaware of his offensiveness. An inspection of the cavity of the nose will detect ulceration, which can also be found at the posterior nares by the finger passed behind the soft palate.

**Necrosis.** 63. *Necrosed bone* may be detected with the probe in bad cases, particularly those of syphilitic origin, or following scarlatina. The possible presence of a foreign body, in the case of a child, should not be forgotten.

**Suppuration of the antrum.** 64. An intermittent purulent discharge from one nostril, which is slightly offensive to the patient but does not affect the bystanders, is generally due to suppuration in the *antrum*. The diagnosis will be confirmed, if it is found that the discharge is increased by the horizontal posture in bed, and especially by lying on the sound side, when the pus is apt to trickle down the throat and cause nausea. Also if the teeth are unsound, and especially if there are tender stumps; but any deformity of the jaw itself must not be expected, nor any bulging of the cheeks in ordinary cases. The mucous membrane of the nose is healthy.



65. More or less *obstruction* of one or both nostrils, with occasional watery discharge, should lead to inspection of the nose with a good light. A grey or yellowish jelly-like mass, which reflects the light from its surface, is almost certainly an ordinary gelatinous polypus. The diagnosis will be cleared up by using a probe, with which the growth can be lifted away from the septum. The finger passed behind the soft palate will commonly detect large polypi hanging down into the pharynx. The influence of the weather upon polypus nasi should be noted, damp causing them to increase largely in size; also the shape of the nose externally, one side not unfrequently being bulged out by the growth within.

66. A *vascular growth* seen from the anterior nares may be merely a prominent inferior turbinate bone or a displaced septum. The careful use of a probe will clear up the diagnosis.

67. A *vascular growth obstructing* the nares may either be a fibrous polypus growing from the nasal cavity or from the base of the skull; or, if of a softer character, may be a growth protruding from the antrum into the nostril. A careful examination of the posterior nares and pharynx, and also of the superior maxilla, will be necessary to clear up the diagnosis, which is always very obscure.



## CHAPTER IV.

## THE MOUTH.

Cleft  
palate.

68. The return of milk through the nose of an infant who is fed with a spoon because it is found impossible to suckle it, depends upon a fissure of the palate.

Cracked  
lip.

69. A crack in the centre of the lower lip occurring in cold weather is a simple matter, depending partly upon general health.

Chancre.

70. A crack or small ulcer, with an indurated base and enlargement of the submental glands, if occurring in the female or in youths, is probably a *chancre*, and inquiry should be directed as to possible infection. The early affection of the glands, and the stationary character of the sore, will serve to distinguish it from epithelioma.

Mucous  
papules.

71. Slightly raised papules, with or without ulceration, may be found on the lips of persons suffering from *constitutional syphilis*, or infants the subjects of congenital syphilis. Atten-

tion should specially be directed to these in the case of "wet-nurses" or "nurse-children."

72. A ragged ulcer, occurring mostly in the lower lip of smokers, and originating in a wart, is generally *epithelioma*. In advanced cases the skin around is hard and infiltrated, and the submaxillary lymphatic glands are enlarged and tender, or even ulcerated. Epithelioma.

73. A hot, swollen, and tender state of either lip, with a general brawny condition of the skin, coming on in twenty-four hours, in a patient out of health, is a form of *carbuncle*, which is apt to be rapidly fatal from purulent deposit in the facial veins. Carbuncle.

74. A small, semi-transparent *tumour* of either lip, but more commonly the lower, slowly increasing without pain, is a cyst due to the obstruction of a mucous follicle. Mucous cyst.

75. Rapid, unhealthy inflammation and sloughing of the lips or cheek, occurring in ill-nourished children whose surroundings are unhealthy, or who may possibly have been dosed with calomel "teething-powders," is an extension of *gangrenous stomatitis*. The gums and mucous membrane of the mouth will be found ulcerating and sloughy, and the teeth dropping out of the exposed alveoli. The breath is most offensive, and the patient in a very exhausted condition. Cancerum oris.



Ulcerative  
stomatitis.

76. Ulceration of the mucous membrane of the mouth and gums in children constitutes the disease known as *ulcerative stomatitis*; or, if the parts are covered with aphthæ, or superficial ulcers having a white exudation, it is known as "thrush." This last must not be confounded with the much more serious disorder, "diphtheria," in which thick false-membranes are formed about the tonsils and back of the throat, and extend down the air-passages.

Thrush  
and diph-  
theria.

Chronic  
ulceration.

77. Chronic ulceration of the mucous membrane of the cheek in adult life is irregular and fissured, and is usually of syphilitic origin, but in advanced life may be epitheliomatous, in which case there is more or less induration of the base of the ulcer.

Ranula.

78. A semi-transparent, bluish tumour beneath the tongue, very elastic and yielding to the finger, and giving no inconvenience except from its size and position, is a *ranula* or mucous cyst, not usually connected with the salivary ducts, which can often be traced over the wall with a fine probe. A more opaque and solid cyst is occasionally met with in the same situation, containing inspissated sebaceous matter. This is of congenital origin.



79. A difficulty in sucking may occasionally result from shortness of the *frænum linguae*, commonly known as "tongue-tie;" or, in older children, an impediment of speech is sometimes supposed to depend upon the same cause.

80. Morbid conditions of the tongue may be due to structural change in the organ, the result of disease, or may be simply evidence of general constitutional disturbance.

A *white-coated* tongue commonly accompanies any febrile disturbance.

A *brown, moist* tongue is an evidence of digestive disorder and over-loaded stomach or bowels.

A *brown, dry* tongue is generally indicative of depressed vital power, and is found in the typhoid condition of patients dying from blood-poisoning.

A *red, moist* tongue is found in many feeble patients, particularly those suffering from exhaustive discharges.

A *red, dry* tongue is usual in cases of pyrexia, or inflammatory fever of any kind, but the prominent papillæ with or without white fur (strawberry-tongue) are characteristic of scarlet fever.

A *red and glazed* tongue is found in patients



who are reduced to a debilitated state, in which they are unable to take, or at least to digest, food or stimulants.

81. The *mode of protruding* the tongue varies and is often characteristic.

Tremulous. A *tremulous*, moist and flabby tongue is seen in feeble, nervous patients, especially in drunkards on the verge of *delirium tremens*.

Slow protrusion. A *slow, hesitating* protrusion of the tongue is highly characteristic of the confusion of intellect in a case of concussion of the brain.

Unilateral paralysis. A protrusion of the tip *to one side*, in the absence of structural disease, indicates paralysis of the muscles of the side to which the organ turns.

Syphilitic tongue. 82. *Structural changes in the Tongue.* A loss of epithelium in patches, leaving a glazed bluish appearance, is highly characteristic of tertiary syphilis; and in more severe cases, there will be cracks or scars in the tongue, especially at the tip.

Psoriasis linguæ. 83. A circumscribed *white patch* on the tongue, due to thickening of the epithelium, constitutes *psoriasis*, and may depend upon local irritation from a tooth or clay-pipe. The hypertrophied epithelium is shed from time to time, and then leaves a red surface for a short period.



84. Great *hypertrophy* or thickening of the epithelium combined with cracks constitutes *ichthyosis linguae*, which is generally regarded as especially likely to pass into epithelioma.

85. Deep *irregular fissures* in the tongue, showing white cicatrices the result of ulceration, are syphilitic in their origin, and are commonly found with the following:—

86. A lump in the tongue, slowly developing and remaining stationary without pain for many months, is probably a *gumma* or syphilitic deposit, which may undergo absorption under treatment and then leave a contracted condition of the tongue, liable to be mistaken, at first sight, for unilateral atrophy from paralysis.

87. *Chronic ulceration* of the tongue is due to the local irritation of decayed teeth, and either to tertiary syphilis or epithelioma, and the diagnosis between the two diseases is often very difficult. So much so, that it may be necessary to try anti-syphilitic remedies tentatively for diagnostic purposes, or to remove a small portion of diseased tissue for microscopic examination, before a confident opinion can be formed.

88. The following table, altered from Fairlie Clarke, gives the leading features of the two principal diseases of the tongue:—



Differential  
diagnosis  
of cancer  
and syphi-  
lis of  
tongue.

## CANCER.

1. Generally over age of forty.
2. Begins at one side, generally at middle or posterior third.
3. Shape circular.
4. Pain acute and darting.
5. Ulceration primary—*i. e.* the ulcer becomes indurated.
6. Tongue tied down and immovable.
7. Speech thick and indistinct.
8. Glands soon become enlarged.
9. Frequently attended by sloughing.
10. Increases steadily ; sometimes rapidly.
11. No amendment under treatment.
12. Family history of cancer (?).

## SYPHILIS.

1. Generally under forty.
2. Frequently in central line.
3. Shape oval or oblong.
4. Pain slight or none at all.
5. Ulceration secondary—*i. e.* the induration becomes ulcerated.
6. Tongue free and movable.
7. Speech easy and distinct.
8. Glands not affected.
9. Never sloughs.
10. Increases slowly, or remains stationary.
11. Amends under treatment.
12. Syphilitic history and symptoms.

The teeth.

Premature  
loss.

Syphilitic.

Marked.

89. Badly developed teeth in childhood are an evidence of some interference with nutrition, depending upon congenital causes or improper feeding. Premature loss and decay of the temporary teeth may be an evidence of strumous diathesis. Notches in the borders of the permanent incisors, and "pegging" of the canines may be taken as collateral evidence of a congenital syphilitic taint. Mere irregularity of the borders or transverse markings upon the permanent incisor teeth are evidences of dis-



turbance of health when the teeth were in process of growth.

90. Chronic *inability to open the mouth* may depend upon old cicatrices of the cheek, which can often be felt and seen; but the more common cause of closure of the jaws is spastic contraction of the masseter from irritation of the teeth, and specially of a wisdom tooth which has not room for its proper development. Sudden closure of the jaws may be due to trismus or lock-jaw, consequent upon some injury or operation: *vide Tetanus*.

Closure of jaws.

Trismus.

91. Inability to close the mouth, if of recent occurrence, depends upon some form of *dislocation of the lower jaw*. If the mouth is widely open and the chin prominent, with a distinct hollow in front of each ear, the dislocation is double. If the mouth is only partially open, and the chin displaced to one side, the dislocation and consequent hollow in front of the ear will be found on the opposite side. But a lateral displacement of the chin may depend upon a *fracture of the neck* of the jaw on the same side as the displacement; in which case considerable bruising will probably be detected in the region of the fracture.

Dislocation of lower jaw.

Double.

Single.

Fracture of neck.

92. Inability to close the mouth and to speak articulately may depend upon a *fracture*

Fracture of lower jaw.



*of the lower jaw* from a blow or fall upon the face. The injury usually leads to laceration of the gums and consequent hæmorrhage from the mouth, and the displacement of the fragments is readily recognized by the irregularity of the teeth. Should there be no displacement, or should the fracture extend through the angle or ramus of the jaw, it will be necessary to grasp the two sides of the jaw and move them forcibly in order to determine the existence of a fracture, of which, however, the patient is usually fully conscious, from his own sensations.

Neglected  
fracture.

93. A swollen, red, and painful state of the tissues covering the lower jaw, occurring some days after the receipt of violence (even of tooth-extraction), should lead to a suspicion of fracture, which from neglect may have induced inflammation and possibly necrosis of the inferior maxilla.

Inflamma-  
tion from  
teeth.

94. A swollen, tender, and hot condition of the tissues of the face depends in the great majority of cases upon carious teeth, with a previous history of frequent attacks of face-ache. Examination of the mouth will show swollen gums, and the peccant tooth will prove exquisitely tender when struck sharply with a metallic body, and will probably feel to the patient slightly elevated from its socket.



95. An elastic fluctuating swelling in any part of the face, or for some distance down the neck, may prove to be an abscess due to diseased teeth, and the matter may have perforated the alveolus beyond the fang without having in any way involved the crown of the tooth and mouth. Formidable looking elastic swellings of the temporal region are caused by matter, due to disease of the lower jaw, passing beneath the zygoma and temporal fascia.

Alveolar  
abscess.

96. An unhealthy purulent discharge from the mouth, with great foetor of breath, will be found commonly to depend upon necrosis of the alveolus, the consequence of neglected abscess. Bare bone will be readily detected with the finger or a probe.

Necrosis of  
alveolus.

97. A hot, swollen, and tender condition of the gums in an infant depends usually upon the irritation due to uncut teeth. The condition is important, since, if not relieved by timely lancing of the gums, convulsions and other serious results may ensue.

98. A *red line* upon the edge of the gums, which are a little tender and spongy, accompanied by slight foetor of breath and a metallic taste in the mouth, are the symptoms of mild mercurialization; which may be increased to sloughing of the gums and profuse salivation

Mercurial  
gum.



by injudicious persistence in the administration of mercury.

Lead gum. A *blue line* upon the edge of the gum is characteristic of lead-poisoning, and inquiry should be made as to employment and the presence of colic and wrist-drop.

Scurvy. A general *spongy* condition of the gums, with, in severe cases, horrible fœtor and sloughing, is produced by scurvy, and is often present and unsuspected in a mild form.

Epulis. 99. Growths about the gums, whether small and pedunculated or large and sessile, are classed together under the term *epulis*. If firm in texture and slow of growth, the epulis is probably *fibrous*; if more rapid and dark in colour it will be *myeloid*, and if inclined to ulcerate and become painful, it may prove *epitheliomatous*. A general *hypertrophy of the gums*, causing them to overhang and bury the teeth, is occasionally met with in children.

Tumour of upper jaw. 100. A gradually increasing prominence of the cheek, with more or less involvement of the mouth, blocking of the nostril, and eventual double-vision from displacement of the eye-ball, points to some tumour of the superior maxilla. A careful examination with the finger both externally and from within the mouth, will



determine whether the tumour is of uniform consistence throughout, or whether it is yielding at the most prominent part, with possibly a feeling of crackling in the vicinity of the more elastic portion. In the latter case the tumour is cystic, and the crackling is due to Cyst. the thinning of the bone by absorption. If apparently solid, attention should be directed to the point of its origin, and the mode and rapidity of its growth. The nostril should be examined from the front with a good light, and the finger be carried behind the soft palate to investigate the growth from the posterior nares.

101. A chronic enlargement of the lower jaw Tumour of lower jaw. should similarly be examined from without and from within the mouth, for the detection of any elastic or crackling portion.

102. The fluid contents of a maxillary tumour Both jaws. may be *purulent*, but are more probably *cystic*. Abscess. The number of teeth which have been cut should be noted, for a cyst in either jaw may Dentigerous cyst. be due to a misplaced or inverted tooth, and in this case there will be no solid growth. But cysts may be combined with solid growth Cysts. contained in their walls, or be developed upon a solid tumour, and require tapping before the size of the growth can be accurately ascertained.



Solid  
tumours.

103. A solid tumour of either jaw may be simple or malignant, the diagnosis (which is often difficult) depending upon the rapidity of growth, and tendency to invade surrounding structures and to fungate, which characterize malignant growths about the face.

Cleft palate

104. A congenital fissure of the palate may extend through the soft palate alone, or through both hard and soft palates, and may be combined with single or double hare-lip. In the latter case, the inter-maxillary bones are frequently displaced from their normal position.

Ulceration  
of palate.

Perforation of the hard or soft palate by disease may leave an aperture with smooth edges, which cannot be confounded with the congenital fissures. As the result of ulceration, the soft palate may be adherent to the back of the pharynx, more or less completely shutting off the nose from the mouth, and leading to nasal intonation and loss of smell.

## CHAPTER V.

## THE THROAT.

105. Pain in the throat, with difficulty of swallowing and thickness of voice, coming on in a few hours with general feverish symptoms, commonly denotes acute inflammation of the tonsils. On inspection, the mucous membrane of the fauces will be found deeply congested and swollen, and the affected tonsil will be seen bulging out the soft palate, between the pillars of which it is placed. There is usually a good deal of tenderness about the angles of the jaws, and some swelling in that region. Cynanche tonsillaris.

106. Chronic discomfort in the throat in children, with a tendency to breathe with the mouth open and to snore, accompanied by deafness, is commonly due to chronic enlargement of the tonsils. Inspection will show two large pale glistening masses in the fauces, the surfaces of which are generally pitted, and often present yellow masses of inspissated mucus. Enlarged tonsils.



Ulceration  
of tonsils.

107. A uniformly injected dusky red condition of the fauces is a common symptom of *constitutional syphilis*, and is often accompanied or followed by ulceration of the tonsils, which may be considered diagnostic of that disease, if both tonsils are affected with deep, nearly circular ulcers, having a grey surface, the rest of the tonsil being healthy. (The white patches of aphthæ and the thick pellicle of diphtheria cover the whole tonsil and the fauces.)

Ulceration  
of pharynx.

Ulceration of the soft palate and of the back of the pharynx, in adults, is nearly always symptomatic of tertiary syphilis. The ulcers have a yellow sloughy surface, and exude a quantity of thin purulent discharge (104).

Dysphagia.

108. *Difficulty of swallowing*, is a common symptom of acute tonsillitis (105), but if coming on suddenly may be due to *acute inflammation of the pharynx*, which on inspection will be seen to be reddened and œdematous. This is most commonly seen in connection with acute laryngitis, the symptoms of which are much more urgent (112).

Pharyngi-  
tis.

Chronic  
dysphagia.

109. *Chronic inability to swallow* may be purely nervous or hysterical, in which case the

Hysterical.

patient (female), when induced to make the effort, never brings up the food again. If



some apparent obstruction exists to the passage of food the forefinger should be introduced into the pharynx, when, if the posterior wall is felt to be bulged forward by an elastic swelling, the case is probably one of post-pharyngeal abscess. Failing this, the finger should be passed as far as possible down the gullet, and will sometimes detect the upper margin of an epithelioma, the cause of the trouble.

Post-pharyngeal abscess.

Epithelioma.

110. A patient with *organic stricture of the œsophagus* can swallow readily, but after a minute or two the food regurgitates into the mouth. Careful palpation may detect a thickening in the neck, or enlarged glands in front of the vertebral column, in cases of cancer; and the history will show the fact if the contraction depends upon the swallowing of caustic fluids. The possible presence of a foreign body is to be borne in mind, and the cautious use of a bougie may serve to detect it.

Organic stricture.

Caustic fluids.

111. *Violent cough* following immediately upon swallowing fluids is often a symptom of perforation of the trachea by cancerous disease of the œsophagus, in which case the expectoration will contain particles of the fluid swallowed.

Perforation of trachea.

112. *Difficulty of breathing*, if acute, may be due to a foreign body in the wind-pipe or to affections of the larynx, heart, or lungs.

Dyspnœa.



Laryngeal. When the breathing has the peculiar whistling sound of laryngeal obstruction, attention should be at once directed to the throat, when a foreign body may be detected, or it will be found, more probably, that there has been for some hours pain, with difficulty in swallowing. The finger passed down the throat will then feel the epiglottis much swollen and the surrounding parts œdematous. The case is one of *acute laryngitis*; and prompt scarification of the swollen parts, or more probably laryngotomy, will be requisite to save the patient's life.

Heart-disease. 113. Acute dyspnœa may supervene upon various forms of *heart-disease*, and it will be noticed that the breathing is of a sighing, gasping character, but with none of the laryngeal stridor. An acute attack of dyspnœa may

Asthma. be due to *asthma*, of which the patient is the subject. The attack is very alarming in character, the patient's face becoming dusky and the superficial veins injected, while he seems to be struggling for his last breath. There is, however, no laryngeal breathing, and on auscultation the chest will be found free from disease. The dyspnœa caused by acute

Stitch in side. *pleurisy* or a *broken rib* is very characteristic, the patient having no difficulty in filling his chest up to a certain point, when he receives a



sharp stab in the side which makes him suddenly relax his muscles and involuntarily expire.

114. Difficulty of breathing, coming on gradually, may depend upon disease of the lungs, <sup>Chronic dyspnœa.</sup> effusion into the pleura, or aneurism, and a careful examination of the chest should be made.

Dulness on percussion beneath the clavicles <sup>Tubercle.</sup> is symptomatic of tubercle; at the base of the lung, of pneumonia. Dulness over one side of the chest, with displacement of the heart to the opposite side, is symptomatic of fluid in the pleural cavity. Dulness over the central portions of the chest may be due to aneurism of <sup>Hydrothorax.</sup> the aorta, or to some mediastinal tumour, or to effusion into the pericardium, in which case the dyspnœa will be urgent. When the dys- <sup>Aneurism.</sup> pnœa is clearly due to aneurism, but doubt exists as to whether it is owing to actual pressure on the trachea or to spasm of the laryngeal muscles consequent upon implication of the pneumogastric nerve, which might be relieved by tracheotomy, it may be advisable to administer chloroform for diagnostic purposes, and, should the breathing be relieved, to operate at once.

115. Valvular disease of the heart may be <sup>Heart-disease.</sup> diagnosed according to the following table (from Dr. Harvey):—



BRUIT, if *systolic*, and loudest at

Base = Aortic obstruction ;

Apex = Mitral insufficiency.

BRUIT, if *diastolic*, and loudest at

Base = Aortic insufficiency ;

Apex = Mitral obstruction. (*presystolic*)

PULSE, if *regular*,

Full or strong

Jerking, resilient

} = Aortic disease.

PULSE, if *irregular*,

Intermittent, unequal

Soft, small, weak

} = Mitral disease.

Aphonia.

116. *Loss of voice*, or huskiness, is a common symptom of acute or chronic disease of the larynx, for the diagnosis of which laryngoscopic examination will be necessary. It is to be noted that even in complete *aphonia* the words are formed by the mouth and larynx, but no sound is produced ; whereas in *aphasia* dependent upon brain-disease the power of forming words is wanting.

Aphasia.

## CHAPTER VI.

## THE NECK.

117. A swollen condition of the lymphatic glands beneath the jaw, or along the sternomastoid may be acute or chronic. In both cases search should be made for a source of irritation in the mouth, in the ear, or on the scalp. Chronic enlargement of the cervical glands is common in strumous children, and may be found in adults, the subjects of general lymphadenoma. Enlarged  
cervical  
glands.

The glands in the lower part of the neck immediately above the clavicle are often affected in cancer of the breast. Enlargement of the sub-occipital glands is generally held to be evidence of hereditary syphilis, if not due to irritation of the scalp from pediculi, etc. Lymphadenoma.

118. A tumour in close connection with the wind-pipe, and moving with it when the patient swallows, is an enlarged thyroid gland or *goître*. This may be unilateral or on both Goître.



sides and not equally developed; and may be solid, cystic, or pulsating. The form of goître in which great prominence of the eye-balls is the symptom which attracts attention is known as *exophthalmic goître*.

Wry-neck. 119. Distortion of the neck may be due to contraction of the sterno-mastoid muscle, in which case the head is twisted so that the face is turned towards the healthy side. Caries of the cervical vertebræ may be the cause of great stiffness and deformity of the neck, and abscesses resulting from it may point in almost any position (post-pharyngeal, 109).

Indurated sterno-mastoid. 120. A thickened condition of the sterno-mastoid muscle is not uncommon in newly-born children, and is probably due to a strain or slight tear of muscular fibres in the birth, though it is thought by some surgeons to be evidence of congenital syphilis.

Aneurism of root of neck. 121. A pulsating tumour in the position of one of the large arteries of the root of the neck will probably convey a thrill to the finger, and a *bruit*, or "bellows sound," to the ear applied to it. It may then be safely pronounced an *aneurism*, but it is by no means easy to be certain as to the vessel from which it may spring.

Carotid aneurism. 122. A *carotid aneurism* is under cover of the sterno-mastoid muscle, and on the right



side will be fairly limited below. On the left side, however, it may spring from the thoracic portion of the vessel, and is liable to be confounded with aneurism of the arch of the aorta.

123. A *subclavian aneurism* may affect one or more portions of the vessel. In the third and second portions its outline can be defined in the posterior triangle of the neck, and it will be found to make painful pressure on the brachial nerves. In the first portion the aneurism is deeply placed beneath the sterno-mastoid muscle and clavicle, and is apt to make pressure upon the great veins of the arm and neck; and to cause laryngeal symptoms by pressure upon the recurrent laryngeal branch of the pneumogastric nerve; or by pressure on the sympathetic may cause contraction of the pupil. A sphygmographic tracing of the two radial pulses will show a marked difference between them in the case both of subclavian and innominate aneurisms, the abrupt rise and fall of health being lost in a general curve. The pulse in both subclavian and innominate aneurisms is smaller than natural.

124. An *innominate aneurism* is to be felt beneath the inner border of the sterno-mastoid, and generally rises into the space between the

Subclavian  
aneurism.

Innominate  
aneurism.



two muscles of opposite sides. It bulges forward the inner end of the clavicle and upper part of the sternum, and commonly involves the aorta to a certain degree, giving rise to a varying area of dulness over the upper part of the chest, and more or less compressing the lung.

Aortic  
aneurism.

125. An *aneurism of the arch of the aorta* may simulate any one of the preceding forms. The more general bulging of the chest-wall, and more general impulse and thrill over a larger area of dulness, may help to a right conclusion, particularly if the veins of the left side are evidently obstructed by pressure on the left brachio-cephalic vein. Symptoms of pressure on the trachea or bronchus may accompany aortic aneurism, leading to deficient expansion of one or both lungs; but the absence of a *bruit* is no proof that the tumour is not aneurismal, for it may be wanting or be masked by the powerful beating of a hypertrophied heart.

Fractured  
clavicle.

126. An irregularity of the clavicle with a history of preceding violence, such as a fall on the shoulder, is probably a *fracture*, which, if recent, will be at once recognized by the crepitus and pain caused by moving the arm. But in children the accident may be overlooked at

the time, and attention be called only to the swelling due to callus developed in the process of cure. At this stage the appearances closely resemble those of a limited periostitis, but nodes on the clavicle do not occur in childhood, though they may be found in various stages in adult life. Node on clavicle.

127. A *dislocation* of the inner end of the clavicle can only be produced by extreme violence, and the deformity is obvious. A displacement of the clavicle may be found in extreme cases of lateral curvature of the spine, and great bending of the bone itself is seen in cases of rickets. Dislocation of clavicle.



## CHAPTER VII.

## INJURIES ABOUT THE SHOULDER.

- Dislocation of outer end of clavicle. 128. Deformity of the shoulder following a fall, with pain, but *without* appreciable loss of voluntary movement in the shoulder-joint, is probably due to dislocation of the outer end of the clavicle upon the acromion process.
- Fracture or dislocation. 129. Deformity of the shoulder *with loss of power* over the arm may be due to wasting of the deltoid, consequent upon an old injury; but if the injury is recent, there can be no deformity without fracture or dislocation. Investigation as to the direct or indirect nature of the violence inflicted on the shoulder will be advisable before inspection of the part is made, and then careful inspection and comparison of the injured and sound shoulders should be made before any manipulation is attempted. The following tables from Hamilton give the leading diagnostic features of four principal injuries.

130. *Differential Diagnosis of Injuries about the Shoulder.*

<i>Signs of a dislocation. (Cause, a fall upon the elbow, or sometimes a direct blow.)</i>	<i>Signs of fracture through the surgical neck. (Cause, generally direct blows, but in aged people frequently caused by falling on the elbow.)</i>	<i>Signs of separation of the epiphysis, only below age of twenty. (Cause, direct blows.)</i>	<i>Signs of a fracture of the neck of the scapula. (Cause, generally a di- rect blow.)</i>
<ol style="list-style-type: none"> <li>1. Preternatural im- mobility.</li> <li>2. Absence of crepitus.</li> <li>3. When the bone is brought to its place it will usually remain without the employment of force.</li> </ol>	<ol style="list-style-type: none"> <li>1. Preternatural mo- bility often, but not con- stantly present.</li> <li>2. Crepitus produced easily when there is no impaction, or when the displacement is not com- plete, but with difficulty when impaction exists, or the displacement is com- plete.</li> <li>3. When once the frag- ments have been displaced it is exceedingly difficult ever afterwards to main- tain them in place.</li> </ol>	<ol style="list-style-type: none"> <li>1. Preternatural im- mobility.</li> <li>2. Feeble crepitus; less rough than the crepitus produced when broken bones are rubbed against each other.</li> <li>3. Fragments when re- placed are not easily maintained in place.</li> </ol>	<ol style="list-style-type: none"> <li>1. Preternatural mo- bility.</li> <li>2. Crepitus, generally detected by placing the finger on the coracoid process, and the opposite hand upon the back of the scapula, while the head of the humerus is pushed outwards and rotated.</li> <li>3. When reduced it will not remain in place.</li> </ol>



4. Inability to place the hand upon the opposite shoulder, or to have it placed there by an assistant, while at the same time the elbow touches the breast.
5. Depression under the acromion process; always greatest underneath the outer extremity, but more or less in front or behind, according as the dislocation may be into the axilla, forwards, or backwards.
6. Round smooth head of the bone sometimes felt in its new situation, and very plainly removed from its socket; moving with the shaft. Absence of the head of the bone from the socket.
4. The hand can be easily placed upon the opposite shoulder, while the elbow rests against the front of the chest.
5. A slight depression below the acromion, not immediately underneath its extremity, but an inch or more below.
6. Head of bone in the socket, and moving with the shaft when impacted. The upper end of the lower fragment being often felt distinctly pressing upwards toward the coracoid process, its broken extremity being easily distinguished by its irregularity from the head of the bone.
4. The hand can be easily placed upon the opposite shoulder, while the elbow rests against the front of the chest.
5. The depression is not immediately under the acromion, yet higher than in most fractures of the surgical neck, perhaps one inch below the acromion process.
6. Head of the bone in its socket, and not moving with the shaft. Upper end of lower fragment projecting in front when displacement exists, and feeling less sharp and angular than in case of a broken bone; indeed, being slightly convex and rather smooth, it may easily be mistaken for the head of the bone.
4. The hand may generally, but with difficulty, be placed upon the opposite shoulder with the elbow resting upon the front of the chest.
5. Depression under the acromion process, but not so marked as in dislocation.
6. Head of the bone may be felt in the axilla, but less distinctly than in dislocation; never much forwards or backwards; head of the bone moves with the shaft. Head of the bone not to be felt under the acromion process, although it has not left its socket.

7. Elbow carried outwards, and in certain cases forwards or backwards, and not easily pressed to the side of the body.

8. Arm shortened in the sub-clavicular dislocation, slightly lengthened in the sub-glenoid, and its length not changed in the sub-coracoid dislocation.

7. Elbow hanging against the side when the fragments are not displaced, but away from the side when displacement exists.

8. Length of arm unchanged, unless the fragments are impacted or overlapped, or both fragments are much tilted inwards. If the fragments are completely displaced the arm is shortened.

7. Elbow hanging against the side when the fragments are not displaced, but away from the side when displacement exists.

8. Length of arm not changed unless the fragments are overlapped, or both fragments are tilted upon each other. When the fragments are overlapped the arm is shortened.

7. Elbow carried a little outwards, but not so much as in dislocation. Easily brought against the side of the body.

8. Arm lengthened.

9. The coracoid process carried a little toward the sternum and downwards.

10. Pressing upon the coracoid process, it is found to be movable, and it is also observed that it obeys the motions of the arm.



Acute  
inflam-  
mation.

131. A swelling of the shoulder coming on a few hours after an injury, or in the course of an inflammatory disease, such as rheumatism, or in pyæmia, with great pain increased by the slightest movement of the arm, is due to *acute inflammation* of the shoulder joint. The effusion distends the joint beneath the deltoid, and an elastic swelling can be detected with both eye and finger, filling up the natural hollow below the acromion, and to the outer side of the coracoid process. The patient will probably support the elbow with the opposite hand, keeping the arm away from the side, and in front of the body.

Chronic  
inflam-  
mation.

132. A similarly distended condition of the shoulder joint, coming on with little or no pain, is seen in *chronic synovitis*, occurring in strumous subjects. In both cases, suppuration may occur, and the matter, bursting through the capsule, may burrow under the deltoid, and point at the anterior or posterior edges of that muscle, some distance down the arm.

Sinuses.

133. *Sinuses* left after the discharge of matter from the shoulder closely resemble those leading to dead bone in the humerus, but if the joint is involved, any movement of it will give pain, and probably pressure of the head of the humerus against the glenoid cavity will give rise to grating indicative of *articular caries*.

134. A painful condition of the shoulder with *Rheumatic*. considerable loss of power, occurring in elderly people who complain of damp weather, is due to *rheumatic* affection of the ligaments. When enlargement of the head of the humerus occurs, with great limitation of movement and crackling or grating in the joint, the case may be *Rheumatoid*. considered one of *rheumatoid arthritis*.



## CHAPTER VIII.

## THE UPPER ARM.

135. Pain and loss of power in the upper arm, following an injury, may be caused by a *fracture* of the shaft of the humerus, with or without deformity due to displacement of the fragments. In very old or cancerous subjects, fracture of this bone from muscular action is not unknown. If the fragments are displaced, the fracture is obvious; but if not, the patient will probably be aware of grating on moving the limb, and the presence of *crepitus* may be easily detected by grasping, and slightly rotating the two ends of the bone. A compound fracture may be induced by one end of the bone perforating the skin, and the close proximity of the great vessels and their liability to injury is to be borne in mind.

136. A fracture of the humerus immediately above the condyles, may, if displaced, closely resemble a dislocation of the fore-arm back-

wards. However much swollen the parts may be, it will be possible to distinguish, with the finger, the prominent internal condyle, and to ascertain its relation to the ulna. With the fore-arm bent at a right angle to the humerus, the olecranon is in a straight line with the back of the condyle, and there is only room for the ulnar nerve between the two points of bone. In a dislocation of the ulna there will be a wide separation between the two bones, and if once reduced, they will maintain their proper relations; whereas in the fracture, although the deformity can be relieved with ease, it is immediately reproduced by muscular action.

Diagnosis  
from dis-  
location.

137. In a fracture of the humerus above the condyles, a *vertical split* often extends into the elbow-joint, giving rise to inflammation of the joint, and subsequent stiffness. This may be diagnosed by flexing and rotating the forearm, when the condyles may be found to move separately.

Fracture  
into joint.

138. In young persons up to the age of 16, *separation of the lower epiphysis* of the humerus may occur with symptoms closely resembling those of fracture above the condyles, but in these cases crepitus is less strongly marked, and may be absent altogether.

Separation  
of the  
lower  
epiphysis.



Acute  
periostitis.

139. A swollen and painful state of the shaft of the humerus, coming on a few hours after the receipt of a blow or exposure to wet and cold, or during an attack of scarlet or typhoid fever, is due to *acute periostitis*. In children especially, a brawny, œdematous condition of the soft parts is apt to supervene, with great heat of the part and rise in the temperature of the body; and in from twenty-four to forty-eight hours after the onset of the attack an obscure sense of fluctuation may be detected. An early and deep incision, avoiding large vessels and nerves, will probably evacuate pus, and the edge of the knife will come into contact with bare bone, the case having developed into one of *acute necrosis*.

Sub-  
periosteal  
abscess.

Acute  
necrosis.

Abscess in  
joint.

140. The foregoing condition, when overlooked or neglected in the early stage, is apt to lead to great destruction of bone, possibly of the entire shaft, with abscesses burrowing in various directions, and occasionally the formation of matter in the adjacent joints, although suppuration generally stops at the epiphysis. The occurrence of symptoms of *pyæmia* in the early, and of *hectic* in the later stages, must not be overlooked.

Pyæmia  
and hectic.

Chronic  
sinuses.

141. *Sinuses*, some of them possibly healed and others discharging, in connection with



*Tumour of humerus*

considerable thickening of the humerus, point to necrosis which has undergone repair, the *sequestrum* being enclosed in a thick shell of new bone, through which *cloacæ* allow the discharge of pus. A probe introduced into one of the sinuses will probably touch bare bone, and the question of propriety of removal must be settled with reference to the date of the acute attack rather than the apparent mobility of the sequestrum, which is probably tightly locked in new bone. From six weeks to two months is the average time for a sequestrum to separate.

Sequestrum.  
Cloacæ.

142. A chronic enlargement of the humerus, with constant gnawing pain, which becomes worse at night, is due either to *periostitis* or *osteitis*, and may be limited or general. Inquiry should be directed to the possible existence of constitutional syphilis, either acquired or hereditary.

Chronic  
periostitis  
and  
osteitis.

143. A distinct swelling or outgrowth from the humerus, and particularly at its upper or lower ends, will be a *tumour*, the nature of which, though necessarily obscure, must be determined by reference to its rapidity of growth and consistence. Rapidity of growth, with great elasticity or softness, points to malignancy; slowness of growth and hard-

Tumour of  
humerus.



ness, to non-malignant or semi-malignant tumours.

Exostosis. 144. A dense, osseous *exostosis* may be met with attached to the shaft of the humerus, but a congenitally largely developed supra-condyloid spine bridging over the ulnar nerve, which is not rare, must not be confounded with disease.

Angeioleucitis or lymphangitis. 145. Red lines running superficially up the arm, and particularly on its inner side, are *inflamed lymphatics*, and these will be traceable to some source of irritation in the hand or fore-arm. The patient will complain of a feeling of tightness, which prevents complete extension of the fore-arm, and the lymphatic glands above the inner condyle and in the axilla will be found tender and swollen.

Axillary abscess. 146. A reddened oedematous condition of the skin of the pectoral region, with distension of the axilla, so that the arm cannot be brought to the side, is found in a later stage of lymphatitis, and is due to the presence of matter in the axilla, and beneath the pectoralis major. In this stage the constitutional disturbance may be severe and the symptoms alarming, the pulse being rapid and feeble, the temperature very high, and the patient collapsed.

147. Chronic enlargement of the axillary



glands may depend upon disease of the arm or breast, or originate from constitutional causes. The glands of the lymphatics from the arm lie along the axillary vessels, but those of the breast lie along the border of the pectoralis major, the lymphatics from them joining the deeper axillary glands. Hence, in recent glandular enlargement from breast disease, the lymphatic glands are readily felt and removed; but in long-standing disease deeper glands will be involved, in perilous proximity to the axillary vessels.

Axillary  
lymph-  
adenoma.

148. Dark broad lines, with more or less hardness about them, traceable up the arm to the trunk, are *inflamed veins*, with clots or *thrombi* in them. These are generally found in combination with inflammation of a severe type, such as erysipelas or sloughing phagedæna, with great constitutional disturbance.

Phlebitis.

149. A bright red blush, from which the colour disappears on pressure to return immediately it is removed, combined with very perceptible heat of skin, is probably *erysipelas* in the early stage, spreading upwards from a wound. The upper margin is well defined, and may be noted to be rapidly extending up the arm; but the blush fades off at the sides

Erysipelas.



of the limb. In all probability there will have been a rigor and sudden rise of temperature of the body, and the discharge from the wound will have diminished.

Phlegmonous erysipelas.

The above conditions, combined with an œdematous condition of the skin, show erysipelas of a more severe character, accompanied by correspondingly severe constitutional symptoms; and if a "boggy" condition of the limb has come on, the case is one of cellulitis, combined with erysipelas.

Bursitis over the olecranon.

150. A circumscribed fluctuating swelling at the back of the elbow-joint is due to inflammation of the subcutaneous bursa, which may be chronic, as in "miner's elbow," or more frequently acute and dependent upon some injury.

Diffused.

151. An inflamed and œdematous condition of the skin and subcutaneous tissues about the elbow, and reaching for some distance above and below the joint, may be due to neglect of an inflamed and suppurating bursa, which has burst subcutaneously, and induced cellulitis of an extensive character. A similar condition may be found in any part of the hand or arm, as the consequence of a poisoned wound.

Cellulitis.

Erythema nodosum.

152. A hot, mottled pink condition of the skin over the subcutaneous surface of the ulna



of both arms, presenting at intervals indurations or knots, which are very characteristic, constitutes *erythema nodosum*. It is found in weakly children and young adults, and is always more developed over the shins than on the arms.

Circumscribed swellings of a chronic character in the same situation, but more deeply placed, are *periosteal nodes* due to syphilis. Syphilitic nodes.

153. A dilated condition of the veins of the bend of the elbow, in which a distinct pulsation and thrill can be detected with the finger, is an example of the now rare affection called *aneurismal varix*, in which, owing to a puncture of the brachial artery through the vein in the operation of venæsection, a communication between the two vessels exists. On applying a stethoscope a characteristic rasping *bruit* will be readily heard. Aneurismal varix.

154. A bent elbow may be due to cured disease leaving slight mischief in the joint, which the patient is unwilling to overcome by use; or permanent adhesions, fibrous or osseous, which render the joint useless. The mere carrying an arm in a sling for some weeks will lead to passive contraction of the biceps, or this may be due to irritation of some branch of the musculo-cutaneous nerve from a cicatrix Bent elbow.



or puncture in bleeding. The administration of chloroform will enable the diagnosis and probably the cure to be effected simultaneously.

Acute  
synovitis.

155. A hot, swollen, red, and painful condition of the elbow-joint itself, is indicative of *acute synovitis*, and the effused fluid produces a characteristic swelling behind the joint, obliterating the depressions below the two condyles. The fore-arm is placed between pronation and supination (thumb upwards) and at nearly a right angle with the upper arm.

Chronic  
synovitis.

156. A chronic swelling of the elbow-joint, painless when at rest, in which the bony prominences are obliterated and the range of motion much impaired, is due to *chronic synovitis*, with thickening of the synovial membrane. Hence in advanced cases a soft cushion is formed between the humerus and ulna, allowing of a certain amount of feeling of elasticity when the olecranon is forcibly pressed upon.

Sinuses.

157. *Sinuses* may form on the inner and outer sides of the elbow-joint, as the result of suppuration in the cavity, and if upon moving the elbow grating can be felt, it is clear that *articular caries* has occurred.

Articular  
caries.

158. A greatly swollen elbow, in which all

the bony prominences are masked, and in which fluctuation is readily perceived, may be due to *suppuration*, in which case the ordinary signs of inflammation will be present in great intensity. But when the part is cool, and the temperature and pulse of the patient normal, it is due to *chronic effusion* into the joint, which if long continued will lead to disorganization of the joint by stretching the ligaments. It is well to note that this may be met with in patients suffering from *locomotor ataxy*, an depend upon the affection of the spinal cord.

159. A distorted condition of the elbow, the result of an injury, is apt to be masked almost immediately after the accident by the swelling which rapidly supervenes. When difficulty in forming a diagnosis arises from this cause delay is advisable.

160. The leading diagnostic features of some of the principal injuries about the elbow-joint are grouped together in the following table:—



### Differential Diagnosis of Injuries about the Elbow.

<i>Dislocation of both bones backwards. (Cause, a fall on the palm.)</i>	<i>Fracture of lower end of humerus. (Cause, a fall on the elbow.)</i>	<i>Dislocation of radius forward. (Cause, a fall on the hand in supination.)</i>	<i>Fracture of olecranon (transverse). (Cause, a fall upon the elbow.)</i>
<ol style="list-style-type: none"> <li>1. Olecranon projects behind, and is on a higher level than condyles.</li> </ol>	<ol style="list-style-type: none"> <li>1. Projection behind larger and containing condyles, higher up the arm.</li> </ol>	<ol style="list-style-type: none"> <li>1. Prominence of head of radius in front of external condyle, with hollow behind it.</li> </ol>	<ol style="list-style-type: none"> <li>1. A gap in the posterior sharp border of the ulna to be felt, or a wide separation if dislocation of ulna forwards also exists.</li> </ol>
<ol style="list-style-type: none"> <li>2. Prominence increased on attempting flexion, and diminished on extension.</li> </ol>	<ol style="list-style-type: none"> <li>2. Deformity easily reduced with crepitus by extension, but at once re-produced by muscles.</li> </ol>	<ol style="list-style-type: none"> <li>2. Ulna in relation with internal condyle. Flexion to a little more than right angle easy, and then abruptly checked. Hand with thumb upward.</li> </ol>	<ol style="list-style-type: none"> <li>2. Fore-arm semi-flexed, and cannot be extended voluntarily.</li> </ol>

- |   |   |   |                             |
|---|---|---|-----------------------------|
| 3. Olecranon and head of radius retain their mutual relationship, but have lost relation to the condyles.                           | 3. Olecranon and head of radius retain relations to condyles, and move with them.                                     | 3. Slight shortening of outer border of fore-arm. | 3. Fragment freely movable. |
| 4. Fore-arm shortened in front only, and more or less fixed at right angles with upper arm; thumb upwards, fingers slightly flexed. | 4. Fore-arm of normal length, but humerus shortened. Abnormal lateral mobility on upper arm.                          |   |                             |
| 5. Tissues in front of joint tightly stretched over lower end of humerus, and coracoid process, if broken off, to be felt there.    | 5. Sharpedge of broken humerus (rounded in case of separation of epiphysis) to be felt beneath soft tissues in front. |   |                             |
| 6. Pain and numbness of little and ring fingers from stretching of ulnar nerve.   |   |   |                             |



Painful  
subcuta-  
neous  
tubercle.

161. An exquisitely tender spot about the elbow, upon which the slightest pressure produces an agony of pain, is a *painful subcutaneous tubercle* developed upon a branch of subcutaneous nerve, and must be excised.

Neuroma.

162. A firm tumour, painful on pressure, and producing numbness in one of the large nerves of the arm is a *neuroma*. This may be multiple, in which case there is usually less pain than when a single tumour exists. A neuroma is likely to follow any injury in which a large nerve has been severely wounded or divided.

Gummata.

163. Indolent indurations of the skin, subcutaneous tissue or muscles of the arm, and particularly in the neighbourhood of the elbow, are probably *gummata* due to constitutional syphilis, which, if left untreated, slowly ulcerate, causing multiple irregular openings in the skin, from which a thin purulent discharge takes place with sloughs of cellular tissue.

## CHAPTER IX.

## THE FORE-ARM AND HAND.

164. A deformity of the fore-arm following immediately upon an injury, and accompanied by loss of power, so that the limb is supported by the opposite hand, is due to a *fracture* of one or both of the bones of the fore-arm. The surgeon will easily detect irregularity in the subcutaneous surface of the ulna, but less readily in the radius; and crepitus will be felt upon reducing the deformity by extension.

Fractured  
radius and  
ulna.

165. In children, bending of the bones of the fore-arm with possibly a "green-stick fracture" of the radius may occur, but care should be taken to compare the two fore-arms, lest an old deformity due to rickets should be mistaken for a recent injury.

Bending  
and green-  
stick  
fracture.

166. A distortion of the wrist, following a fall on the hand, is in the great majority of cases due to a *Colles' fracture* of the lower end of the radius, with the following symptoms:—

Colles'  
fracture.



The hand is abducted so that the lower end of the ulna is unnaturally prominent, and there is more or less projection on the dorsal aspect of the wrist, with a corresponding hollow beneath, but as a rule there is no crepitus, owing to the impaction of the fragments.

Separation  
of radial  
epiphysis.

167. In young persons, a separation of the *lower epiphysis* of the radius will produce a deformity closely resembling a dislocation of the carpus and hand, which is a very rare accident. If the styloid process of the radius is in proper relation with the hand, and moves with it, the case must be one of fracture or separation of the epiphysis; whereas in dislocation of the carpus, the styloid processes of both radius and ulna project prominently beneath the skin.

Dislocation  
of the  
wrist.

Deformity.

168. Deformity of the arm with shortening of the radial border is apt to follow separation of the lower epiphysis of the radius, from subsequent want of growth in the bone.

Rickets.

169. An enlargement of the lower end of the radius in both arms, coming on slowly in ill-nourished children, is due to *rickets*, and is generally combined with more or less bending of the shafts of the radius and ulna, and of the bones of the lower limb, with enlargement of the ends of the ribs.



170. An enlargement of the lower end of the radius in the young adult is probably *myeloid*, and may grow to large size, pushing before it the articular cartilage, without involving the wrist joint.

171. A slightly swollen condition of the back of the wrist, with pain upon any movement of the hand or fingers, following some prolonged and unwonted exertion, is due to effusion into the sheaths of the extensor tendons beneath the annular ligament. On applying the hand to the part while movement is made, a crepitation will be felt, which might be confounded with the crepitus of fracture.

172. A circumscribed elastic tumour at the back of the wrist, giving little or no pain, but sometimes connected with a feeling of weakness in the part, is a *simple ganglion* or cyst containing jelly-like fluid.

An elastic swelling of the palm of the hand, projecting above and below the anterior annular ligament, is a *compound ganglion*. This often contains rice-like or melon-seed bodies, which can be squeezed from one part to the other of the cyst, giving a peculiar grating sensation. The disease may extend along the synovial sheaths of the thumb and fingers, causing great deformity.



Synovitis  
of wrist.

173. A swollen condition of the wrist, resembling a bracelet, with puffing of the synovial membrane between the tendons, is due to *synovitis of the wrist joint*, which will be acute if there be great heat and tenderness with general rise of temperature, but is more frequently chronic. The whole hand is then puffed, especially about the dorsum, and sinuses are apt to form, leading down to caries of the carpal bones, which may be felt to grate together.

THE  
HAND.

Poisoned  
wound.

174. A hot, scarlet, and swollen condition of the skin of a finger, spreading with smarting pain from a puncture, is an example of *erythema* depending upon an animal poison, and is therefore frequently met with in cooks and poulterers, and occasionally as the result of a post-mortem examination. Red lines spreading up the arm from such a wound are inflamed lymphatics, and the gland above the inner condyle, or those in the axilla, will probably be swollen and tender.

Lympha-  
titis.

Whitlow  
superficial.

175. A swollen and extremely painful condition of the last phalanx of a finger, following a trifling injury, is probably the commencement of a superficial *whitlow*; and at a later stage the matter may be found beneath the skin at the top of the finger, or around the nail, which will be loosened.



A more serious condition is when the tissues over the last phalanx are acutely inflamed without any evidence of superficial abscess, giving rise to deep-seated throbbing pain, which entirely deprives the patient of rest. Here the inflammation involves the periosteum of the phalanx, and a free incision will be necessary for its relief, or necrosis of the phalanx will probably ensue. Whitlow  
deep.

A swollen and inflamed condition of the tissues of any part of the finger will come under the term whitlow, but these are seldom examples of the true thecal abscess, which is a rare affection.

176. A swollen, œdematous condition of the hand affecting both palmar and dorsal surfaces, but more distinct on the dorsum because of the thin skin, is usually due to deep-seated inflammation, with formation of matter beneath the palmar fascia. A very similar condition of the back of the hand alone may be due to cellulitis, consequent upon a poisoned wound or the bite of an insect in an unhealthy subject. Palmar  
abscess,  
  
Cellulitis.

177. The possible presence of a foreign body is not to be forgotten in examining all cases of inflammation about the hand, though the search for portions of a needle which are exciting no irritation is to be deprecated. Foreign  
bodies.



Necrosis of phalanx. 178. A finger, swollen and deformed, and presenting several sinuses through which pus exudes, is an example of neglected whitlow, with more or less disorganization of the part. If the mischief is confined to the terminal phalanx, a probe will detect bare and necrosed bone, which may be easily removed; but if grating is felt between the several phalanges, as well as dead bone at various parts, it is obvious that the finger cannot be saved.

Onychia. 179. A chronic enlargement of the end of the finger, in a strumous or syphilitic child, with unhealthy ulceration and offensive discharge around the abnormally wide nail, is an example of *onychia maligna* so called, though the affection is perfectly amenable to treatment. Unhealthy granulations by the side of the nail are due to in-growing of the nail, which has probably received some injury interfering with the matrix.

In-growing nail. Chancre. 180. An intractable sore in the neighbourhood of the nail, with unhealthy surface, occurring on the hand of a surgeon or any one liable to be brought in contact with syphilis, may be regarded as a *chancre* although no induration of its base is present, if the lymphatic gland above the inner condyle is enlarged, and the sore improves under local mercurial treatment.



181. The nails of adults may be brittle and irregularly cracked so as to come away in scales, and this is generally due to syphilitic poison, the diagnosis being confirmed by the existence of *psoriasis palmaris*. In children the same thing may occur as the consequence of congenital syphilis.

Diseased  
nails.

182. A swollen, indurated, but painless condition of the first phalanx of the finger, coming on slowly and showing no tendency to suppurate, is the result of constitutional syphilis, and is apt to end in atrophy of the phalanx and consequent shortening and deformity of the finger.

Dactylitis  
syphilitica.

183. Dense, nodulated *tumours*, growing slowly to such a size as to lead to great deformity of the fingers from which they spring, are cartilaginous, but if more rapid in growth and softer are probably myeloid.

Enchondroma.

184. A swollen condition of the articulations of the fingers may be due to *gout*, which, in the acute stage, will lead to great pain and redness in the joints affected, and in the chronic form will give rise to great deformity, owing to the deposit of urate of soda in the form of "chalk-stones" within or in close connection with the articulations. Occasionally, in very severe cases, ulceration of the skin

Gout.



takes place, with discharge of a white creamy fluid. Confirmatory evidence of gouty diathesis is to be sought in chalk-stones in the great toe and pinna.

Rheumatic  
gout.

185. A deformity of the fingers, consisting in chronic enlargement of the joints, at first from effusion in, and afterwards from nodular deposits near, the articulations, is due to *rheumatoid arthritis*. In the later stages more or less ankylosis of the joints occurs, with contraction of the fingers, so as to give a claw-like appearance to the hand.

Finger  
flexed.

186. A *flexed finger* may result from division or rupture of the corresponding extensor tendon; but if all the fingers are affected, together with the wrist, there is probably paralysis and wasting of the extensor muscles from lead-poisoning, or from some injury to the musculo-spiral nerve. Confirmatory evidence of lead-poisoning (plumbism) will be found in a blue line upon the gums.

Injury of  
nerves.

187. *Over-extended fingers*, the skin of which is glistening and absolutely devoid of hair, are due to injury of one of the main nerves of the arm supplying the flexors and skin. The temperature of the part is below the normal standard, and sensation is either much diminished or altered. The nails are usually much incurved.

188. A finger may be drawn down by the contraction of a cicatrix, as in whitlow, but more frequently by a contraction of the *palmar fascia*, which gives rise to a dense ridge, running up the palm to the finger.

189. A painful and swollen condition of the metacarpus, following a blow, is probably due to fracture of one or more metacarpal bones. There may be no displacement or consequent deformity; but crepitus can usually be obtained by pulling upon the corresponding finger.

190. A deformity of a finger, resulting from an injury, will be due either to a fracture or dislocation. A fracture of a phalanx is obvious, but a dislocation may be overlooked unless care is taken to compare the two hands, and to note any limitation of movement.

191. A sinking in of the head of one of the metacarpal bones may be due to rupture of the transverse ligament of the metacarpus.



## CHAPTER X.

## THE BREAST.

The virgin breast. 192. The healthy breast varies in size in different individuals, and in the same woman at different times. At puberty the breast becomes more prominent than in childhood, and not unfrequently is somewhat "lumpy" until menstruation is thoroughly established. At each menstrual period the breast is apt to be tender and slightly swollen from sympathy with the ovaries.

Complexion. The development of the nipple, and the colour of the areola around it, vary considerably with the complexion of the woman. A blonde virgin has generally a small and slightly prominent nipple with a pink areola, while a brunette will have a large nipple and a well-marked and even dark areola, with black hairs and sebaceous follicles well developed.

Pregnancy. Enlargement of both breasts, with pigmentation of the areolæ and development of the seba-

ceous follicles, is one evidence of pregnancy, but cannot be depended on alone. Moisture of the nipples is a more reliable sign, and the presence of milky fluid almost conclusive. (See Abdominal Tumours.)

193. A small nodule in the breast may be a chronic mammary tumour (adenoma) or the commencement of sarcoma or scirrhus, and the diagnosis is often difficult.

<i>Adenoma.</i>	<i>Sarcoma.</i>	<i>Scirrhus.</i>
Patient under thirty, and single.	Patient any age.	Patient above thirty.
Tumour dense, but elastic and movable beneath skin and on deeper part of breast.	Tumour elastic and movable, but rapidly involving surrounding tissue.	Tumour hard and attached to deeper part of breast, though movable beneath skin at first.
Pain, if present, of a neuralgic character, and worse at menstrual period.	Pain not severe as a rule.	Pain severe and of a sharp lancinating character, and shooting down the arm.
Skin and lymphatics never involved.	Skin eventually involved, but no lymphatic enlargement.	Skin and lymphatics early involved.
Grows very slowly, and varies in size.	Grows very rapidly, and apt to recur locally.	Grows rapidly, except in old people.
Nipple not retracted.	Nipple often excludes fluid.	Nipple often retracted.
No family history.	No family history.	Often hereditary.

194. An unmarried woman under thirty hardly ever has scirrhus, but over forty is



Scirrhus. probably more liable to it than a mother. The tumour may have grown to some size before attention is called to it by pain, and if near the surface will dimple the skin over it or retract the nipple, but if more deeply placed may attach the breast to the pectoral muscle. The enlargement of the lymphatic glands of the axilla or neck is the most important point in the diagnosis and prognosis of a case of scirrhus.

Cysts. 195. An elastic tumour of the breast may be a cyst, abscess, or tumour. Careful palpation will, in many cases, determine whether fluid is present or not, and occasionally fluid may be squeezed out of the nipple, but in doubtful cases a puncture alone will decide the question. If the fluid proves to be—

- (1) pus, the case is one of abscess;
- (2) milky fluid, the case is one of galactoceles;
- (3) clear fluid, the case is one of simple cyst;
- (4) dark fluid, the case is one of compound cyst or cyst with sarcoma;
- (5) watery fluid containing microscopic "hooklets," the case is one of hydatid.

The most elastic tumour is the sarcoma or the medullary cancer.



196. A large rapidly growing tumour of the breast may be encephaloid cancer or sarcoma, or some benign growth probably combined with cysts. The presence of cysts negatives the idea of encephaloid cancer, and these should therefore first be looked for. Next comes the question of lymphatic enlargement, since cancer alone infiltrates the glands. Lastly, the condition of the skin, which in simple growths is merely stretched and thinned so as eventually to give way; while in medullary cancer it is infiltrated and thickened, and probably presents small flattened nodules at various points, and is traversed by large veins.

Large  
tumour of  
rapid  
growth.

197. A fungating tumour of the breast may be encephaloid cancer or a sarcomatous growth with cysts. In the latter case the disease will be of long standing, and, the skin having become thinned, one of the cysts will have burst, and a growth taken place from its wall. This growth consists of granulations, and the parts around are healthy, there being no lymphatic enlargement. In medullary disease the growth is extremely rapid, the fungus bleeds readily, and the skin and lymphatics are extensively infiltrated.

Fungating  
tumour.

198. The *skin of the breast* may be rendered hard and dense by deposit of scirrhus in and



Skin of  
breast.

beneath it, so as to produce a species of cuirass ; or, more commonly, may be retracted and ulcerated, the ulcer being irregular, with sharp-cut edges and hard base. It may be thinned by cysts so as to appear blue, or may be infiltrated by medullary cancer so as to be thick and nodulated. It may be hot and reddened in inflammation of the breast, or red and œdematous when an abscess is pointing beneath. Occasionally, in a nursing mother it presents one or more little sebaceous tumours, constituting *molluscum contagiosum*, and derived from the child.

Nipple.

199. The *nipple* may be retracted congenitally, or from the growth of a scirrhus tumour beneath. It may be sessile congenitally, or become so by infiltration of the skin from encephaloid cancer. It may be cracked and fissured from irritation of the child's mouth, or may have mucous tubercles developed around it from contact of a syphilitic child. It may have an abscess developed in or around it, from blocking of one of the lactopherous ducts.

## CHAPTER XI.

## THE THORAX.

200. Deformity of the chest wall may be congenital or acquired. A depression in the middle line of the sternum is a common congenital affection, and may extend to actual division or aperture. A prominent sternum, with depression of the ribs on each side, constituting "pigeon-breast," is common in rickety children, whose weak ribs yield to the pressure of the atmosphere. It may be induced also by imperfect filling of the chest, consequent upon enlarged tonsils in children who habitually snore and breathe with the mouth open. An unduly prominent sternum, with a more or less "barrel-shaped" chest, is commonly found in cases of angular curvature of the dorsal spine, and in these a tight string appears to be tied round the body in the position of the diaphragm, by which the abdominal wall is drawn in.

Congenital  
fissure.

Pigeon-  
breast.

Gibbous  
chest.



Flattening. Flattening of the chest wall at any part may be due to the absorption of fluid effused into the pleura, and in the upper part of the chest to the contraction of a vomica or phthisical cavity.

INJURY TO CHEST. 201. A severe crush of the thorax may kill the patient outright, by rupturing the heart or great vessels; and when less severe, may render the patient insensible for some time from shock.

Dyspnœa. 202. Pain and difficulty in drawing breath are common symptoms of injury to the chest.

Cutting pain. A sharp, cutting pain, occurring at the same spot on each inspiration, so that the lungs cannot be properly filled, is probably due to a broken rib or ribs. In a thin subject, crepitus may be felt with the hand or heard with the stethoscope, but is often imperceptible; but

Relieved by pressure. great relief will be afforded by the support of the hand to the chest wall, until a bandage or plaster is applied.

Depression of wall. 203. A distinct depression in the chest wall may be due to the fracture of several ribs, or, in children, to bending of the bones, but must not be confounded with the falling in of the ribs due to old pleurisy, or the contraction of a phthisical cavity.

204. A crackling of the subcutaneous cellular



tissue over the seat of a broken rib is due to Emphysema, and is a proof that the lung has been injured. If unchecked, the emphysema may become very extensive. Subcutaneous emphysema may or may not be accompanied by a tympanitic condition of the corresponding side of the chest, due to distension of the pleural cavity with air, and constituting *pneumothorax*.

205. A stitch in the side at each inspiration (which is shallow and catching), coming on a few hours after an injury to the chest, and accompanied by rise of temperature and pulse and inability to lie down, is due to pleurisy, the characteristic rub of which may be heard with a stethoscope during the first few hours.

206. Dyspnœa, with dulness on percussion and absence of breath-sounds over one side of the chest, following an injury, is due to the presence of fluid in the pleura, which may be blood, serum, or pus. If the pleura is much distended, the heart will be displaced towards the opposite side, and the apex will be found beating in an abnormal position. The nature of the fluid may be diagnosed by the time which has elapsed since the accident; thus, blood is effused immediately, serum is the



result of pleurisy a few hours later, and pus may occur in the later stages of pleurisy, or from decomposition of blood. The introduction of an aspirator needle is often the only method of determining the question.

## CHAPTER XII.

## THE ABDOMEN.

207. A small red tumour found in the navel of young infants, is a vascular growth connected with the stump of the umbilical cord, and is unimportant unless it should be accompanied by the discharge of urine from a pervious urachus, or of fæces from an unobliterated omphalo-mesenteric duct. Vascular  
navel.

208. A red vascular protrusion in the middle line of the abdominal wall, below the umbilicus, from which urine is constantly pouring, and around which the skin is cicatrized, is an example of extroversion of the bladder, which is usually associated with epispadias. Ectopia  
vesicæ.

209. A protrusion of the navel, or exomphalos, is important only when it contains intestine. The tumour may be of any size up to that of a child's head, and is usually tense and tympanitic, with distinct gurgling as the Exom-  
phalos.



intestine is returned into the abdomen. If vomiting is present with a large exomphalos, strangulation of the bowel should always be suspected.

Scarring. 210. White scars in the skin of the abdomen, scattered irregularly over the whole surface, are due to over-distension of the abdominal wall at some period, and in the female are pretty conclusive evidence of a previous pregnancy. More circular scars grouped together may be due to the use of croton-oil or tartar-emetic ointment; and small triangular cicatrices, to leech-bites; or groups of parallel linear cicatrices, to cupping.

Dilated veins. 211. Dilatation and tortuosity of the superficial veins of the abdomen is a symptom of obstruction to the return of blood through the deeper veins from any tumour, and especially from cirrhosis of the liver compressing the vena cava. The rarer dilatation of the epigastric arteries occurs in obstruction of the aorta or iliacs.

Dilated arteries. Paralysis. 212. A relaxed condition of the abdominal muscles, so that they flap up and down with the ascent and descent of the diaphragm, is an evidence of paralysis depending upon some lesion of the spinal cord.

213. Copper-coloured, more or less circular



spots, with a scale upon them, are commonly scattered over the abdomen in secondary syphilis. These must not be confounded with the brown patches without scale found in chloasma.

214. *Diagnosis of Abdominal Tumours.*

The following tumours are common to both sexes :—

215. *Ascites*, or dropsy of the peritoneum, gives a uniform roundness to the lower part of the belly, when the fluid is small in quantity; or a general distension of the abdominal walls, if much fluid is present. The skin is tense and shining, and the umbilicus flat or protruding, the superficial veins being enlarged. On palpation a distinct wave of fluid can be felt from one side to the other; and when the patient is recumbent the intestines float forward, giving a clearer note on percussion in front than in the loins, where the fluid collects. On turning the patient on his side the fluid gravitates to the lower part, and a clear percussion-note may be obtained on the higher side, provided the abdomen is not very tense.

In a case of moderate ascites it will be possible to map out the liver, stomach, and spleen by careful palpation and percussion;



but if a large quantity of fluid is present, this will be impossible until paracentesis has been performed.

Distended  
bladder.

216. A *distended bladder* is in the median line, and bulges out the central portion of the abdominal wall. Percussion over it is dull, unless some coils of small intestine should happen to cover it, which is not unfrequently the case, while both flanks are clear when the patient is recumbent. Pressure over the tumour causes pain and a desire to micturate, and the use of a catheter results in its gradual disappearance.

Tympanites.

217. *Tympanites*, or general distension of the intestines, is not unfrequent in hysterical women, in whom *borborygmi*, or gurglings, are commonly heard. Extreme tympanites may occur in either sex as the result of intestinal obstruction, in which case the distended coils of small intestine may be felt or seen rolling about beneath the tense abdominal wall. Or it may occur as the result of peritonitis, in which case the intestines are usually fixed. The percussion-note in all cases is tympanitic.

Solid  
tumours.

218. *Solid tumours*, dull upon percussion, and to be readily mapped out provided there is no ascites, may be connected with the liver, spleen, intestines, or kidney. A tumour



occupying the right hypochondrium, and ex- Liver.  
tending forwards to the middle line or beyond  
it, and downwards to the pelvis, dull on  
percussion and solid to the touch, or possibly  
with one fluctuating spot, will be the *liver*.  
The diagnosis will be rendered certain if the  
edge of the liver with the notch in it can be  
felt.

A tumour occupying the left hypochondrium, Spleen.  
and extending forwards and downwards, dull  
on percussion and with a notch in its border,  
must be the *spleen*.

A small hard mass, slightly changing its Faeces.  
position from time to time, will be either a  
mass of *faeces* impacted in the intestines, or  
a mass of cancer attached to its wall. Impacted  
*faeces* are most common in the large intestine,  
and give a somewhat doughy sensation to the  
fingers when steadily pressed against the mass.  
Hard *cancer* is most frequent at the pylorus Scirrhus.  
and the lower end of the small intestine, close  
to the cæcum, or in the sigmoid colon, and is  
perfectly unyielding.

219. An obscure tumour in the loin can be Kidney.  
best examined when the patient is recumbent,  
one hand being placed beneath the loin, and  
the other immediately below the false ribs,  
the abdominal muscles of the patient being



relaxed as far as possible by flexing the thighs, and supporting the head and shoulders with pillows so as to flex the trunk. If it is a mass of fæces in the ascending or descending colon, it will be readily felt; but if an enlargement of the *kidney*, it will be more deeply placed, and the resonant colon will be found in front of it. The possible existence of a movable kidney must be borne in mind.

Cystic  
kidney.

220. A *fluid tumour* in the loin <sup>may</sup> must be due either to cystic degeneration of the kidney or to psoas abscess. The kidney may, owing to obstruction of the ureter, become enormously distended with fluid, so as to form a distinctly fluctuating tumour in the loin, which never finds its way into the groin.

Psoas  
abscess.

A psoas abscess, on the other hand, tends to pass into the groin, and fluctuation may usually be traced beneath Poupart's ligament into Scarpa's triangle, where an impulse will be felt on the patient coughing. Symptoms of caries of the spine, with, probably, irregularity of the spinous processes, will be found, if carefully looked for.

Iliac  
abscess.

221. An obscurely fluctuating swelling in the *iliac region* will probably be an iliac abscess, due to disease of the pelvis or lumbar vertebrae, or of the sacro-iliac joint. The con-



dition of this joint is best tested by forcibly squeezing the innominate bones together, and then attempting to draw them asunder, by pressure on the iliac crests.

222. On the right side, a fluctuating swelling in the iliac region may be due to a perityphlitic abscess, or abscess caused by inflammation of the cellular tissue around the cæcum, the acute symptoms of which will be present; and if perforation of the cæcum has occurred, there will be crepitation of the cellular tissue from the escape of intestinal gas.

223. In the *male*, a solid tumour in the iliac region may be due to a retained testicle taking on inflammatory swelling, in which case acute symptoms of inflammation will be present; or developing medullary cancer with considerable rapidity. The presence or absence of the testicle from the scrotum, which should always be investigated, will give the clue to the case.

224. In the *female*, the possible existence of a "phantom tumour" must not be ignored, for occasionally the irregular contraction of the abdominal muscles gives rise to a tumour of such solidity as to deceive the most experienced surgeon, but disappears absolutely under the influence of chloroform. No doubt, some of these



Movable  
kidney.

phantoms have been examples of loose kidney, a condition in which the organ may be readily displaced.

Uterine.

225. A tumour in the median line, rising out of the pelvis, is probably uterine, if it is not the distended bladder. Pregnancy is first to be eliminated by inquiry as to menstruation, by examination of the breasts, and by listening for the foetal heart, which, after the fourth month, ought to be recognizable. Lastly, a vaginal examination will determine whether the *os uteri* is soft and velvety, as is the case in pregnancy. All suspicion of pregnancy being removed, the introduction of the uterine sound will determine whether the long diameter of the uterus is greater than the average two inches and a half. Supposing the uterine sound to pass four or five inches readily, and to move with the tumour, when pressed from side to side, it is obvious that the tumour is uterine, and probably a fibroid.

Ovarian.

226. A tumour occupying one side of the abdomen, having grown up from the pelvis, is probably ovarian. It is dull on percussion, and elastic to the touch, or if of large size, may fluctuate distinctly. If no ascites is present, both flanks will be resonant in whatever position the patient is placed; but if there is fluid in

the peritoneum, the most dependent part will be dull, though the dulness over the tumour will not vary.

When fluctuation is present, but it is doubtful whether it is ascitic or ovarian, an assistant's hand pressed edgeways into the median line over the tumour will serve to break the wave of ascites, and thus clear up the doubt.

227. A cyst with such thin walls that the Parovarian fluctuation closely resembles that of ascites is <sup>cyst.</sup> probably a cyst of the broad ligament (parovarium), and tapping will make its nature evident at once, the fluid being perfectly limpid, whilst that of ascites is yellow serum, and that of an ovarian cyst darker, and as a rule more viscid.



## CHAPTER XIII.

## INJURY TO ABDOMEN.

Collapse. 228. A patient, after the receipt of some injury to the abdomen, is more or less collapsed. He is faint and pallid, and lies with the knees drawn up, and on regaining consciousness complains of pain at the seat of injury.

Vomiting. 229. Vomiting, if occurring immediately after the accident, or during reaction from the shock, is not of importance, provided no blood is ejected. If blood is mixed with the vomit, and intense pain complained of over the stomach, with rapid distension of the peritoneum, the case is probably one of rupture of the stomach.

Ruptured intestine. 230. Pain in the belly, following an injury, may be due to bruise or rupture of the intestine, and is accompanied by vomiting of bile, and by constipation and distension of the intestines with gas, from paralysis of the muscular coat.

231. Great pallor and faintness, following an

injury, are symptomatic of internal hæmorrhage, Internal hæmorrhage. which may come from the liver or the spleen, or from one of the large vessels. Dulness of the most dependent parts of the peritoneal cavity will be found upon percussion, and the level of dulness will gradually rise as the blood collects.

232. *Bloody urine* is a common result of an abdominal injury, but may also arise from disease. The voluntary evacuation of bloody urine is a nearly positive evidence that the bladder is not ruptured, and if the hæmorrhage is free the bladder soon becomes distended again. Hæmaturia.

When the blood is thoroughly mixed with the urine, rendering it smoky if in minute quantity; dark red if in larger quantity; or scarlet, with rapid spontaneous coagulation when passed or drawn off, the injury is in the *kidneys*. Renal.

When the urine first passed or drawn off is lighter than the latter portion, which also contains dark clots, the seat of hæmorrhage is the *bladder* or *prostate*—the former probably in young and middle-aged patients, the latter in elderly men. Vesical and prostatic.

When the urine flows from the meatus without effort, or when, during micturition, Urethral.



the first portion of the urine is bloody, the bulk of it clear, and the last ejected portions bloody, the seat of hæmorrhage is the *urethra*.

Ruptured  
bladder.

233. A patient who has received a blow in the region of the bladder, followed by collapse, inability to make water, and burning pains in the groins, may be presumed to have his bladder ruptured. The diagnosis will be confirmed if, on passing a catheter, bloody urine and clots are evacuated, and particularly if, on the injection of warm water, it is found impossible to distend the bladder, but the patient is conscious of warm fluid in his groins. Should some hours have elapsed since the accident, the abdomen will be distended, and the catheter may, when passed into the bladder, find its way through the rent into the peritoneal cavity, and evacuate a large quantity of fluid, which will ebb and flow with the rise and fall of the diaphragm during respiration.

Ruptured  
urethra.

234. Hæmorrhage from the urethra is an evidence of injury of the canal from within by instruments, or from without by a kick or blow from falling astride some hard body.

#### INTESTINAL OBSTRUCTION.

235. In all cases of acute intestinal obstruction, careful search should be made in all the



ordinary and extraordinary situations of a hernia, so that strangulation may not be overlooked. Failing to find a hernia, the surgeon should make a careful examination of the abdomen by palpation and percussion, in order, if possible, to discover the position of the obstruction before tympanites comes on.

Palpation  
and  
percussion.

236. *In the child*, careful examination may detect a sausage-shaped mass, dull on percussion, with a history of diarrhoea or violent straining, followed by the discharge of bloody mucus from the bowel. The case is then one of intussusception.

Intussus-  
ception.

The finger introduced into the rectum may detect an intussusception of the large intestine when low down.

237. *In the adult*, careful palpation and percussion may detect the elongated tumour of an intussusception, but more commonly simply a mass dull upon percussion. If this is yielding and doughy, it is probably a (1) faecal accumulation; if quite hard, it may be a large (2) gall-stone, or a mass of (3) scirrhus. The history will show whether there has been (1) habitual constipation, or (2) jaundice, with pain about the liver, or (3) chronic difficulty in relieving the bowels, with pain and possibly bloody discharge.

Fæces.

Gall-stone.

Scirrhus.



238. More frequently nothing can be detected, or at most a little increase of dulness on percussion at one point, with no definite tumour. The case is then probably one of internal strangulation, from a twist of the bowel or some constricting band. If the obstruction is of some duration, the intestines will be fully distended with gas, and will be felt, or in a thin subject seen, moving under the abdominal walls, unless peritonitis should be present, or the patient have been brought under the influence of opium.

Twist.

Band.

Tympan-  
ites.

Vomiting.

239. Persistent vomiting is almost conclusive evidence that the obstruction is in the small intestine. If occurring early, it is evidence of tight strangulation high up; but if stercoraceous, the obstruction must be at some distance down the bowel.

Chronic  
obstruc-  
tion.

240. In cases with a history of chronic and increasing difficulty in evacuating the bowel, ending in complete obstruction, the disease is almost certainly in the large intestine, and probably in the sigmoid flexure. An examination *per rectum* may detect cancerous deposit, though frequently out of reach, which may be detected through the abdominal wall if there is not much distension. In long-continued chronic obstruction the peritoneum may

become distended with gas, so as to render the abdomen extremely tympanitic, although the distended coils of intestine may not be perceptible through the thinned abdominal walls.



## CHAPTER XIV.

## TUMOURS OF THE GROIN.

Inguinal  
or  
femoral.

241. The diagnosis of a tumour of the groin will depend mainly upon whether it is inguinal or femoral—whether it is above or below Poupart's ligament, which is sometimes obscured by the overlapping of the tumour. This is particularly the case in a large femoral hernia, where the tumour turns up over Poupart's ligament, and closely resembles an inguinal hernia. The diagnosis is best made by carefully examining the ligament itself, which can usually be made out with ease; or by putting the finger upon or into the external abdominal ring, which, even in the female, can be readily made out. In health, nothing should be in the inguinal canal but the spermatic cord in the male, or the round ligament in the female, which latter is seldom to be defined.

In all cases of inguinal tumour in the male the presence of the testicle of the corresponding side in the scrotum should be at once ascertained.

INGUINAL TUMOURS.

242. A protrusion, noticed on coughing, at the internal abdominal ring or in the inguinal canal, is probably a *hernia*, if the testicle is in the scrotum. If large enough to lodge in the inguinal canal and form an elongated tumour, the protrusion is a *bubonocoele*, and will be readily returned with a gurgle when the patient lies down, if it is intestine; or if omentum, will give the characteristic knotty feeling.

243. An elongated elastic tumour, lodged in the inguinal canal, which has an impulse on the patient coughing, and may be pushed up without being thoroughly reduced, is probably a *hydrocele of the cord*. If large enough to protrude out of the ring, it will be found closely connected with the spermatic cord, and will give a dull note on percussion. With care it may be demonstrated to be translucent.

244. An elastic swelling immediately above the outer part of Poupart's ligament, having an impulse on coughing, but dull on percus-



sion, and irreducible, is probably an *iliac abscess*. The diagnosis will be rendered easy if the swelling is large enough to fluctuate.

Lymph-  
adenoma.

245. *Enlargement of the lymphatic glands* which lie above or upon Poupart's ligament, is a common result of a sore on the penis or scrotum, but may arise from constitutional causes, in which case the glands are more apt to form one large mass. Glandular induration connected with a venereal sore is an evidence of its infecting character; but inflammation and suppuration show the local character of the sore, or may depend upon urethral irritation only.

246. *Diagnosis of Inguinal Tumours.*

HERNIA.	HYDROCELE OF CORD.	ILIAC ABSCESS.	LYMPHADENOMA.	TESTIS.
Impulse on coughing.	Impulse on coughing (slight).	Impulse on coughing.	No impulse on coughing.	No impulse on coughing.
Reducible with gurgle.	Apparently reducible.	Non-reducible.	Non-reducible.	Non-reducible.
Clear on percussion if intestinal.	Dull on percussion.	Dull on percussion.	Dull on percussion.	Dull on percussion.
Feels like intestine, or knotty if omentum.	Elastic feel, like small elongated bag of fluid.	Elastic, and possibly deep fluctuation.	Hard, well defined. Not tender unless inflamed.	Obscurely elastic and characteristic-ally painful.



## FEMORAL TUMOURS.

247. A large femoral tumour is either a hernia, a psoas abscess, or a fatty tumour; a small tumour may, in addition, be a gland or a femoral cyst.

Hernia.

248. A tumour with a distinct impulse on coughing, appearing below the inner end of Poupart's ligament, and reducible with or without a gurgle, is probably a *hernia*. A larger tumour turning up over Poupart's ligament, clear on percussion, and giving the feel of intestines, which when drawn down can be reduced beneath Poupart's ligament, is also a femoral hernia.

Psoas  
abscess.

249. A tumour with a distinct impulse on coughing, appearing beneath the outer part of Poupart's ligament, dull on percussion, elastic, and possibly fluctuating, is a *psoas abscess*. This tumour may, if large enough, be prolonged beneath the femoral vessels, and form a large fluctuating tumour on the inner side of the thigh, and may be apparently reducible when the patient lies down, the fluid it contains being forced upwards by the pressure employed; but there will be no intestinal gurgle, and the tumour will return immediately the pressure is withdrawn.

250. A lobulated tumour of the groin, dull on percussion, with no impulse, and irreducible, is probably a *fatty tumour*.

251. A small obscure tumour, deeply placed beneath the inner end of Poupart's ligament, with no impulse on coughing, may be a *lymphatic gland* or a *cyst in the femoral canal*. Lymphatic gland, or femoral cyst.

The only importance of either is, that a small strangulated femoral hernia may be mistaken for it; but if there are general symptoms of strangulation, an incision will at once clear up the case.

252. *Enlarged femoral lymphatic glands* depend upon some irritation of the skin of the foot or leg, commonly upon some trifling graze of the heel which is overlooked. A general enlargement of the femoral lymphatic glands may be a part of general lymphatic disease from constitutional causes. Chronic lymphadenitis. Lymphadenoma.



*253. Diagnosis of Femoral Tumours.*

HERNIA.	PSOAS ABSCESS.	FATTY TUMOUR.	CYST IN CANAL.
Impulse on coughing.	Impulse on coughing.	No impulse.	No impulse.
Reducible with gurgle.	Irreducible.	Irreducible.	Irreducible.
Clear on percussion if intestinal.	Dull on percussion.	Dull on percussion.	
Feels like intestine, or knotty if omentum.	Elastic or fluctuating.	Lobulated.	LYMPHADENOMA. Hard and ill-defined.

SCROTAL TUMOURS.

254. Tumours of the scrotum are conveniently divided into reducible and irreducible.

255. *Reducible Scrotal Tumours.*

HERNIA.	CONGENITAL HY- DROCELE.	VARICOCELE.
Impulse on coughing.	No impulse, unless combined with hernia.	Impulse on coughing, when large.
Percussion clear if intestinal, dull if omental.	Percussion dull.	Percussion dull.
Ring and inguinal canal occupied, spermatic cord obscured.	Ring and canal clear.	Ring occupied by enlarged spermatic cord.
Intestine to be felt, and returned with gurgle, and remains up till effort is made, when it returns from above.	Fluid to be felt, and readily returned when patient lies down, and reappears slowly when he stands up, filling from below.	Feels like a bag of worms when small, but like intestine when large; can be reduced by pressure, and fills again while pressure is made on ring.
Opaque. Testicle below tumour.	Translucent. Testicle behind tumour.	Opaque. Testicle soft or atrophied.
Any age.	Childhood.	Young adult, and on left side, mostly.



*256. Irreducible Scrotal Tumours.*

HERNIA.	HYDROCELE.	HÆMATOCELE.	SARCOCELE.
Sausage-shape.	Pyriform.	Globular.	Irregular.
Intestine clear, omentum dull on percussion.	Dull on percussion.	Dull on percussion.	Dull on percussion.
Intestinal or knotty in feel according to contents.	Elastic or fluctuating.	Tense or doughy.	Elastic, with more or less induration.
Opaque.	Translucent.	Opaque.	Opaque.
Sudden.	Chronic.	Sudden.	Chronic.

## HERNIA.

257. A tumour occurring in one of the common situations for hernial protrusion, having an impulse on coughing, and returning under manipulation with a gurgle when the patient lies down, is a *reducible hernia*, producing no general symptoms, except perhaps a dragging sensation. If dull on percussion, with a knotty or doughy feeling, and returning without a gurgle, the contents of the sac are in great part omental.

258. A hernial tumour of large size, tense and tympanitic, or dull on percussion and knotty, which resists moderate attempts at reduction, but still has an impulse on coughing; which is not painful, and does not produce marked constipation or vomiting, or retention of flatus, is an *irreducible hernia*, which may or may not yield to treatment.

259. A similar tumour of long standing, combined with obstinate constipation, retention of flatus, and hiccup, and often, but not always, some impulse on coughing, but without vomiting or rise of temperature, is probably an *incarcerated hernia*, in which the bowel is obstructed by retained matters.

260. A small recent hernial protrusion, or a



Strangu-  
lated  
hernia.

larger old hernia recently increased in size by some exertion, which is tense and painful, the pain radiating over the abdomen, accompanied by some rise of temperature, is probably a *strangulated hernia*. The diagnosis will be confirmed if all impulse in the tumour is wanting; if persistent sickness is present, the vomit being offensive, and eventually stercoraceous; if there is no passage of fæces or even flatus through the bowels, which are becoming distended; and if the patient have the drawn features constituting the *facies Hippocratica*.

261. In the case of a man who has a few hours before received an injury of the scrotum, leaving a painful condition of the parts, it is possible that a strangulated hernia may be confounded with hæmatocele or orchitis.

STRANGULATED HERNIA.	HÆMATOCELE.	ORCHITIS.
Suddenly produced, or, if present before, strangulated thus.	Suddenly produced by some external violence.	Developed a few hours after a blow, or following gonorrhœa.
Pain in groin and about abdomen, with considerable constitutional depression and anxiety of face.	Pain in scrotum and constitutional disturbance slight after the first few minutes.	Pain in scrotum and along the cord to the loins. Feverish disturbance of system.
Tumour tense, and giving the sensation of intestine when manipulated. Skin normal.	Tumour tense and heavy, globular in shape, and not translucent. Skin often bruised.	Tumour excessively tender to the touch, cord thickened. Skin reddened, veins enlarged.
Impulse on coughing to be felt along the groin, in which there is more fulness than usual, but ceases abruptly at the point of strangulation.	No impulse in groin, which is perfectly normal.	No impulse on coughing.
Percussion over tumour gives a clear sound, unless the protrusion is omental.	Percussion gives a dull note.	Percussion gives a dull note.
Vomiting probably present, continuous, and eventually stercoraceous.	Vomiting immediately following the accident, but not continued.	Nausea and faintness, but seldom vomiting.



## CHAPTER XV.

## THE URINARY FUNCTION.

Spasmodic  
retention.

262. Inability to pass water, occurring in a healthy young man, is probably due to some *spasmodic* or *inflammatory* condition of the urethra. Inquiry will elicit the existence of a recent gonorrhœa, some excess in liquor, or some exposure to damp cold. The distress is not usually great, and can be readily relieved with a catheter.

Organic  
retention.

263. Retention, with a full bladder to be felt about the pubes, the patient (usually a middle-aged man) being bowed forward to relieve the pressure, and yet unable to control the violent straining efforts of the abdominal muscles, is the result of very complete obstruction from *organic stricture*. Considerable induration will probably be found in the perinæum, and the skin will be hot and perspiring.

264. Retention occurring in elderly men

who have long been aware of some difficulty in emptying the bladder, is generally due to <sup>Prostatic retention.</sup> *congestion of the prostate*, brought on by slight excess in liquor, by venereal excitement, or by injudicious use of catheters. The finger passed into the rectum will feel the prostate to be swollen, hot, and tender, and the patient will complain of weight in the perinæum, and of the passage of blood when straining.

265. Retention occurring in a perfectly healthy man of middle age, who has from some cause been unable to take an opportunity of emptying his bladder for some hours, is due simply to temporary loss of power or *atony* of the muscular walls of the bladder. <sup>Atony of bladder.</sup>

266. Complete retention, following a paralytic seizure or an injury to the spine, is due to paralysis of the nerves supplying the bladder, and will be followed, sooner or later, by overflow. <sup>Paralysis.</sup>

267. Sudden retention, occurring in a previously healthy man, may be due to the impaction of a small renal calculus in the urethra, probably close to the meatus. In a child, retention may occur from the same cause, or more rarely from stone in the bladder. <sup>Impacted calculus.</sup>

268. Incontinence of urine in the adult male



Inconti-  
nence.

usually means overflow from a full bladder, which will probably be found dull and resistant over a considerable area in the hypogastrium. The nocturnal incontinence of children depends usually upon constitutional causes, but may result from phimosis, stone in the bladder, or ascarides.

Retention  
in female.

269. Retention of urine in the unimpregnated *female* is probably hysterical. In pregnant women the pressure of the uterus or its displacement may obstruct the urethra, and, during labour, the child's head may cause the same result.

Stricture.

270. Frequency of micturition, especially at night, with slowness in emptying the bladder, and a constant reduction in the calibre of the stream of water passed, which may be twisted or even forked, points to *organic stricture* of the urethra, which may be felt indurated in the perinæum.

Stone.

271. Frequency of micturition, worse in the daytime after exertion, with pain referred to the end of the penis, and aggravated by emptying the bladder, points to *stone* in the bladder. The diagnosis will be confirmed if the urine is thick and occasionally contains blood after carriage exercise, but can only be definitely settled by the use of the sound.

272. Gradually increasing difficulty in passing water, occurring in elderly men, is usually due to *enlargement of the prostate*, which should be examined *per rectum*. If in such a case there is irritability of the bladder, with purulent urine, the presence of a stone in the bladder should be suspected.

Enlarged prostate.

273. The frequent voidance of small quantities of scalding urine, high coloured, and perhaps containing a little blood, coupled with great pain above the pubes and in the rectum and considerable constitutional disturbance, points to acute inflammation of the bladder, the cause of which must be investigated.

Acute cystitis.

274. The voidance of thick, purulent urine, which when poured from one vessel to another hangs in strings, is symptomatic of chronic inflammation of the bladder.

Chronic cystitis.



## CHAPTER XVI.

## MORBID CONDITIONS OF THE URINE.

Stone in  
kidney.

275. *Blood in the urine*, rendering it smoky or brown, coupled with pain in the loins following active exertion, is a symptom of stone in the kidney.

Stone in  
ureter.

276. A microscopic trace of blood, sufficient to answer the tests for albumen, coupled with excruciating pain in the loin and running down into the thigh and scrotum, with retraction of the testis, faintness and vomiting, coming on suddenly and ceasing abruptly, are the symptoms of passage of a calculus down the ureter into the bladder. The transient presence of albumen serves to distinguish a case of right renal colic from one of hepatic colic from the passage of gall-stones, in which case also there is usually some jaundice.

Renal and  
hepatic  
colic.

Stone in  
bladder.

277. Blood in the urine, especially after exertion, coupled with frequency of micturi-

tion, pain above the pubes and at the end of the penis, which is aggravated by emptying the bladder, are symptoms of stone in the bladder, or ulceration of the vesical mucous membrane.

278. Blood voided in large quantities with the urine is a symptom of a morbid growth in the bladder, probably villous in early adult life, malignant in late adult life. <sup>Growth in bladder.</sup>

279. Bloody urine retained in the bladder of elderly men, associated with pain at the end of the penis, is usually a symptom of congestion of the prostate, requiring the use of the catheter for some time after the hæmorrhage has ceased. In the female, the blood mixed with urine may be due to menstruation or disease of the uterus. <sup>Congested prostate.</sup>

280. *Albumen* in the urine may result from slight hæmorrhage, from chronic disease of the kidneys, or from the presence of pus. <sup>Albumin-uria.</sup>

The presence of blood-corpuscles must be ascertained with the microscope, and, if unaccompanied by tube-casts, will probably be due to one of the causes given above. If the blood-corpuscles are entangled in tube-casts, they are due to acute nephritis. <sup>Acute nephritis.</sup>

Albuminous urine of low specific gravity, with numerous casts either transparent and



Bright's disease. waxy or granular and oily, indicates advanced Bright's disease of the kidney.

Pyelitis. 281. Acid urine, containing pus in large quantity without any tube-casts, coupled with pain about the kidney, which may be dilated, is due to pyelitis—this may be caused by obstruction to the flow of urine from any cause; to stone in the kidney, or to tubercle, and is commonly accompanied by a good deal of irritation of the bladder. Pus in small quantity in acid urine is due to gonorrhœa or abscess of the prostate, or, in the female, to leucorrhœa.

Cystitis. 282. Alkaline urine containing pus is due to disease of the bladder, chronic cystitis resulting from retention from any cause, or to the irritation of stone. Combined with chronic cystitis there may be chronic disease of the kidney, with urine of low specific gravity and tube-casts.

Diabetes. 283. Urine of the specific gravity of 1030 and upwards should be tested for sugar, which, if present, is an evidence of diabetes.

#### URINARY DEPOSITS.

284. The urine is acid and clear when passed, but becomes cloudy on cooling, and deposits a pink sediment which is readily dis-

solved by heat. The deposit is urate or lithate <sup>Urate of</sup> of soda, and the condition is compatible with <sup>soda.</sup> perfect health.

The urine is neutral or alkaline, and possibly <sup>Phos-</sup> not quite clear when passed, and deposits a <sup>phates.</sup> white sediment, not dissolved by heat but by nitric acid. The deposit consists of the triple phosphates, and the condition is probably one of debility and exhaustion.

The urine is acid, high-coloured, and clear, <sup>Uric acid.</sup> and deposits red sand which is gritty and crystalline. The deposit is uric or lithic acid, and the diathesis is either gouty or rheumatic.

A slight flocculent deposit from acid urine <sup>Mucus.</sup> is probably healthy mucus; a thick, yellow, sticky deposit from acid or alkaline urine is <sup>Pus.</sup> pus.

The microscopic examination of the urine, and the application of various reagents, will be found at length in medical treatises.



## CHAPTER XVII.

## THE MALE GENITALS.

Phimosis. 285. An orifice of the foreskin, so contracted that retraction is difficult or impossible, constitutes *phimosis*. This may be congenital, inflammatory, or cicatricial.

Balanitis. 286. A reddened, hot, and swollen state of the foreskin, with a thick, curdy, or purulent discharge from beneath it, constitutes *balanitis*. The foreskin can probably be retracted sufficiently to show the orifice of the urethra to be healthy.

Gonorrhœa. 287. A similar condition, with a purulent discharge from the urethra, occurs in *gonorrhœa*.

Sore  
beneath  
foreskin. 288. A reddened, hot, and swollen condition of the prepuce, extremely painful when touched, particularly at one spot, with a sanious offensive discharge from beneath the foreskin, but not from the urethra, is symptomatic of a *sloughing sore* on the glans penis. In a later stage, if unrelieved by a timely

incision, the upper surface of the foreskin may become dark and sloughy, and the glans protrude.

289. An œdematous foreskin, with a dense hard mass to be felt in it or through it at one point, implies an indurated chancre, and the diagnosis will be confirmed by enlargement of the lymphatic glands of the groin.

Chancre  
beneath  
foreskin.

290. An œdematous condition of the foreskin of some weeks' duration, with a scanty semi-purulent discharge from beneath it, is due probably, in a young man, to *venereal warts*; in an older man, to *epithelioma*. The diagnosis can only be made certain by laying open the prepuce, when the warts will be known by their shape and projection from a non-ulcerated surface; while epithelioma will present a ragged ulcer, with more or less surrounding induration.

Warts, or  
epitheli-  
oma.

291. A series of small vesicles, with inflamed bases on the foreskin or glans penis, or both, constitutes *herpes preputialis*, and must not be confounded with venereal sores.

Herpes pre-  
putialis.

292. An œdematous ring of tissue behind the glans penis, thereby fully exposed, is due to retraction of a tight foreskin, which, not having been brought forward, has become swollen, and will, if not relieved, ulcerate in

Paraphi-  
mosis.



the line of greatest tension. This is a *paraphimosis*; but a very similar condition may be produced by a child having tied a thread round the penis.

#### URETHRAL DISCHARGES.

- Viscid. 293. A viscid gummy discharge, found between the swollen lips of the urethra a day or two after connection, is the early symptom of gonorrhœa.
- Purulent. 294. A thick, yellow, or greenish discharge, with scalding in passing water, is characteristic of gonorrhœa or urethritis.
- Watery. 295. A thin, white, or watery discharge is a gleet, and may be the remnant of a gonorrhœa, or may be kept up by the presence of a stricture. It may be a symptom of urethral chancre, for which search should be made.
- Mucous. 296. A perfectly clear mucous discharge, during erection and sexual excitement, is perfectly compatible with health, and is not to be confounded with involuntary emissions.
- Spermatic. 297. An involuntary emission, or "wet-dream," occurring occasionally during continency, consists of greyish-white fluid, which, under the microscope, should contain large numbers of living spermatozoa.

298. Small white threads found in the urine <sup>Prostatic.</sup> when recently passed, are due to slight prostatic irritation, and are unimportant.

299. *Venereal sores* on the penis may be <sup>Venereal</sup> infecting or non-infecting, *i.e.* true chancres <sup>sores.</sup> leading to constitutional symptoms of syphilis, or simple local contagious ulcers.

*Syphilitic.*

Single sore.  
More or less circular.  
Ulceration indolent.  
Grey surface.  
Base indurated, if long standing.  
Does not inoculate readily.  
  
Glands in groin enlarged and indolent.  
Originated in a crack or pimple.  
Nothing seen for some days after connection.  
Improves under mercury.

*Non-syphilitic.*

Multiple sores.  
Irregular in shape.  
Ulceration active.  
Yellow secreting surface.  
Base not indurated.  
  
Readily inoculates surrounding skin of thigh or abdomen.  
Glands in groin inflamed, and apt to suppurate.  
Originated in a pustule or ulcer.  
Irritation and redness noticed at once.  
Gets worse under mercury.

SCROTUM.

300. A reddened condition of the scrotum <sup>Inflamed.</sup> may be due to inflammation of the testicle, or of the skin of the scrotum itself. A common cause of a reddened, oedematous condition of <sup>From</sup> the scrotum is extravasation of urine from <sup>extrava-</sup> ruptured urethra, and attention should at once be directed to the condition of the urinary <sup>sation.</sup>



organs. Apart from any history, the fact that the redness and œdema have travelled forward from the perinæum to the scrotum and then upwards towards the groins, the urinous smell, and the formation of black sloughs at various points, will sufficiently mark the case as one of extravasation of urine.

Acute  
œdema.

301. An acute inflammatory œdema of the scrotum is occasionally met with, having the above symptoms, except that the urinous smell is wanting.

Elephanti-  
asis.

302. Great hypertrophy of the scrotum, of a chronic character, is met with occasionally in Europeans, but more frequently in Asiatics, and constitutes one form of elephantiasis.

Epitheli-  
oma.

303. A warty ulcer of the scrotum, especially common in chimney-sweeps and millers, is an example of epithelioma.

#### TESTICLE.

Acute  
orchitis.

304. A swollen, painful condition of the testicle, with redness of the scrotum and slight effusion into the tunica vaginalis, is symptomatic of inflammation, or *acute orchitis*. If due to a blow or to mumps, the body of the testis will be enlarged and the epididymis and cord healthy; but in the great majority of cases the vas deferens will be found thickened and the



epididymis swollen and tender, as well as the body of the testis, the inflammation being propagated from the urethra. The disease may originate in any urethral irritation, but is commonly due to gonorrhœa, the discharge of which diminishes as the testis enlarges.

305. A chronically enlarged testis must be carefully examined to ascertain which part is most affected, and, if possible, where the affection began. (1) If the body alone is enlarged, the epididymis and cord being healthy, the disease is probably *syphilitic*, and attention should be directed to other symptoms of constitutional syphilis. (2) If the body of the testis is fairly healthy, but the epididymis enlarged and nodulated, with some thickening of the adjacent vas deferens, the disease is probably *tubercular*. (3) If the vas deferens is thickened throughout its length, the epididymis enlarged and hard, and the body of the testis thickened, the case is probably one of *chronic inflammation* following acute orchitis, or dependent upon urethral irritation.

306. The formation of an abscess in connection with the testis is generally due to *tubercle*, and under these circumstances the disease is usually extensive, and is apt to invade the vesiculæ seminales, which can be felt enlarged *per rectum*.



Hernia  
testis.

307. A ragged opening in the skin of the scrotum, through which an irregular soft mass protrudes, covered with unhealthy granulations and giving rise to a constant thin, purulent discharge, is an example of *hernia* or *fungus testis*, the result of tubercle or of chronic inflammation.

Hydro-  
sarcocele.

308. A slowly growing tumour of the testicle, which may be solid or cystic, and stretching but not involving the skin, is a *non-malignant* new-growth, often masked by the presence of fluid in the tunica vaginalis, which requires to be drawn off before a diagnosis can be made.

Malignant  
tumour.

309. A rapidly growing tumour of the testicle, solid, but soft and elastic, and rapidly becoming adherent to the scrotum, is probably *malignant*. Examination of the spermatic cord will show it to be thickened, and probably there will be pain in the loins, and possibly a tumour to be felt there.

Fungus  
hæma-  
todes.

310. A large *bleeding fungus* protruding through the scrotum is a later stage of malignant disease of the testicle.

## CHAPTER XVIII.

## FEMALE GENITAL ORGANS.

311. The commonest affection of the genital organs in female infants is adhesion of the <sup>Adherent</sup> ~~nymphæ.~~ nymphæ, often confounded with imperforate vagina, which is a much more serious affection. When the nymphæ are separated, the vagina, with the hymen, will be readily seen.

312. A rapid gangrenous ulceration of the <sup>Noma.</sup> labium, in an ill-nourished child, is analogous to *cancrum oris*, and constitutes *noma*. It is apt to be mistaken for venereal disease, or the effects of violence.

313. A small red growth, looking like a <sup>Vascular</sup> ~~urethra.~~ minute strawberry, projecting from the meatus urinarius, is a vascular papilloma, which gives rise to painful micturition. In infants a prolapse of the vesical mucous membrane is occasionally met with, and must not be confounded with this.



Labial  
hæma-  
tocele.

314. A swollen, discoloured condition of one of the labia is probably due to hæmorrhage into it, either from a kick, or from giving way of a varicose vein; but the possible occurrence of a strangulated labial hernia must not be overlooked.

Labial  
cyst.

315. The labium may be distended on its vaginal surface by a thin-walled cyst, which is often, though not always, connected with the gland of Bartholine.

Labial  
abscess.

316. A swollen, hot, and tender condition of the labium is caused by an abscess, which may have originated spontaneously, or may be due to suppuration of a cyst. The careful introduction of the finger will detect fluctuation on the vaginal surface, at which point a natural opening may have already formed in neglected cases.

Venereal  
sores.

317. Sores on the labia or nymphæ, of *venereal* origin, may be infecting or non-infecting (*vide* 299). The induration of the true chancre is seldom so well seen in the female as in the male, and the presence of a chancre in the vagina or on the cervix uteri will be overlooked unless a careful examination is made with a speculum.

318. Flattened, slightly raised, circular patches about the labia, perinæum, and anus,



are mucous tubercles, which readily infect Mucous  
neighbouring parts by their discharge, and are tubercles.  
of *sypilitic* origin.

Large warts, due to the irritation of vaginal Warts.  
discharges, may be found massed about the  
perinæum and labia, and infecting neighbour-  
ing parts, but are *non-sypilitic*.

319. Ulceration of the nymphæ and clitoris, Epitheli-  
of an intractable character, occurring in middle- oma.  
aged women, is usually *epitheliomatous*, and the  
glands of the groin will be found enlarged or  
ulcerated in the later stages of the disorder.

320. A solid enlargement of the labium, Elephan-  
in which the part is converted into a fibro- tiasis.  
cellular mass, may be considered a variety of  
*elephantiasis*.

#### VAGINAL DISCHARGES.

321. A thick white discharge, often profuse, Leucor-  
may be found in female children and adults of rhœa.  
all ages, constituting *leucorrhœa*, and depend-  
ing upon slight local irritation, ascarides, etc.  
A chronic discharge is often due to uterine  
disease, and examination of the cervix uteri  
with the finger and speculum will be necessary  
for the determination of its source of origin.

322. A thick, yellow, or greenish discharge, Gonor-  
accompanied by an inflamed condition of the rhœa.



nymphæ and labiæ and pain in micturition, is *gonorrhœal*.

Vesico-  
vaginal  
fistula.

323. The discharge of the urine by the vagina is caused by a vesico-vaginal or utero-vesical fistula, the position of which should be determined with a speculum.

Recto-  
vaginal  
fistula.

324. A discharge of fæces or flatus *per vaginam* may be due to a recto-vaginal fistula, or to carcinomatous perforation of the recto-vaginal wall. The introduction of the finger into the vagina often gives useful information in cases of obstructed rectum.

Prolapsus  
uteri.

325. A vascular body of large size, projecting from the vulva of the unimpregnated female, is either a prolapsed uterus, or an example of great hypertrophy of the cervix. The inverted vagina will be healthy if the prolapse is recent, but may be ulcerated or almost cuticular if it is of long standing. The os uteri will be found at the most dependent point, and the introduction of a uterine sound will determine whether the case is one of displacement of a normal uterus, two inches and a half in length, or of hypertrophied cervix. A catheter passed into the bladder will also determine whether the bladder is drawn down, as it usually is in a case of *procidentia uteri*.

Hypertro-  
phied  
cervix.

## CHAPTER XIX.

## THE RECTUM.

326. In a new-born child the absence of Imperforate anus. meconium should direct attention to the anus, which may be seen to be obstructed by a membrane, constituting the simplest form of imperforate anus. A well-formed anus being present, the finger, when introduced, may encounter an obstruction some short distance up the bowel, due to a septum which becomes tense when the child cries or strains. The most serious form of malformation is when there is no anus, or merely a dimple in the skin, the fæces being entirely retained, or passing in small quantity through the urethra or the vagina.

327. A congested condition of the veins of Hæmorrhoids. the anus, which can be seen to be swollen and prominent, depends upon some obstruction to the circulation in the rectum, due either to



congestion of the liver or abdominal tumour, or, in the female, to pregnancy or some uterine displacement.

External  
hæmor-  
rhoids.

328. Coincident with the above condition may be found a prominent hard mass of a dark colour, varying in size from a pea to a marble, situated at one side of the anus. This is a clot which has formed in a vein, and which may be slowly absorbed, leaving behind a loose fold of skin, the result of the distension. Occasionally inflammation takes place around the clot, and a small localized abscess results.

Blind  
internal  
hæmor-  
rhoids.

329. A sense of weight and discomfort about the rectum, giving the idea that it is never properly emptied, accompanied usually by the occasional appearance of a little dark blood with the stools, though nothing is protruded from the anus, are the symptoms of internal piles. A careful examination with the finger will probably detect internal hæmorrhoids.

Bleeding  
internal  
hæmor-  
rhoids.

330. The constant protrusion of vascular masses from the anus, with the loss of bright arterial blood, in sufficient quantity to splash the closet-pan and eventually blanch the patient, are the symptoms of bleeding internal hæmorrhoids. These can be both felt with the finger and be protruded, with the help of an enema, for examination and treatment.



331. When considerable loss of blood occurs without any protrusion, the hæmorrhage may come from a vascular surface, which can be detected and treated through a rectal speculum.

332. A uniform smooth vascular mucous protrusion from the anus is a *prolapse*, which may involve only the mucous membrane, or the entire thickness of the bowel in severe cases. It is met with in children, as the result of debility, but may be due to the straining from a stone in the bladder or a phimosis.

333. A small vascular *polypus* of the rectum, which is not uncommon in children, may be mistaken for a prolapse, if care is not taken to search for the pedicle.

334. A hot, swollen, and painful condition of the skin by the side of the anus, the natural hollow of the ischio-rectal fossa being obliterated by the swelling, is symptomatic of an ischio-rectal abscess. One finger passed into the rectum will easily detect fluctuation between it and another on the surface; and the matter will burst into the rectum, if not promptly relieved.

335. One or more fistulous openings near the anus, constantly discharging thin pus, are the common results of neglected ischio-rectal abscess. A probe carefully introduced along



the fistula will, in the great majority of cases, pass for a variable distance by the side of the rectum, and can then be easily made to touch the point of the finger introduced into the bowel, showing the fistula to be "complete." Occasionally, however, the fistula takes a tortuous or horse-shoe course, and the internal opening cannot be found until some part of the track has been laid open, constituting a "blind external fistula."

Complete  
fistula.

Blind  
external.

Blind  
internal.

A soft, semi-fluctuating, or boggy spot near the anus, with the occasional discharge of pus with the motions, is due to an internal fistula with no external aperture, or "blind internal fistula." With care it may be possible to pass a bent probe up the rectum, and to hook it into the fistula, so as to make the point prominent beneath the skin. In all cases of fistula in ano, the result of ischio-rectal abscess, the condition of the lungs should be investigated.

Fistula a  
symptom.

336. *Fistulæ* in ano may be found in combination with other diseases of the rectum, such as extensive tertiary ulceration with stricture, or with malignant disease, especially epithelioma; and a careful examination with the finger should therefore be made in all cases of fistula.

337. Pain in defæcation is a symptom of



ulceration of the rectum rather than of piles. *Fissure.*  
Extremely severe pain, lasting an hour or more after defæcation, coupled with an occasional streak of blood in the fæces, is the common symptom of *fissure*. On dilating the bowel slightly, the ulcer may be seen running up one side of the anus, or may be detected for a varying distance above it with the finger.

338. Ulcerations in the folds of skin at the *Rhagades.*  
verge of the anus are usually syphilitic, constituting *rhagades*, or being combined with mucous tubercles.

339. Painful defæcation, with a constant profuse thin discharge from the anus, is probably due to tertiary ulceration of the rectum, which can be detected with the finger, and commonly leads to stricture when it heals. *Tertiary ulceration.*

340. Painful defæcation, combined with difficulty and the occasional passage of blood and bloody pus, may be due to ulcerated *scirrhus*, which can be detected as a hard mass infiltrating the coats of the bowel. *Ulcerated scirrhus.*

341. *Difficult defæcation* may be due solely to the impaction of hardened fæces, particularly in females, or to the pressure of a retroflexed or retroverted uterus. *Difficult defæcation.*

The finger passed into the rectum may



Stricture. detect a distinct ring or fibrous stricture, or a hard mass of scirrhus. This may be on one side of the rectum, so as to be easily examined, or may surround the bowel, giving it very much the form and consistence of the os and cervix uteri.

Epithelioma.

A hard mass, more or less completely encircling the anus, and spreading for some inch or more up the bowel, with or without ulceration at some point, is probably *epithelioma*.

## CHAPTER XX.

## THE LOWER LIMBS.

342. In all cases of *lameness occurring in children*, it is advisable to strip the patient and let him walk without assistance, if possible, so as to notice the position of the body and limbs, and the mode of using them. Lameness of children.

343. A child may have one lower limb obviously smaller than the other, owing to *wasting of the muscles*, and this may be due either to want of use from joint-disease or to paralysis. In disease it will be noticed that the joint is unconsciously fixed by the muscles, and is never moved; whereas, in paralysis the joint is free, but the muscles are too weak to effect the proper movements. Wasting of limb.

344. Slight *dragging of the leg*, which is itself healthy, is a common early symptom of spinal mischief; but complete wasting of the muscles, especially of the extensors, is evidence Dragging of leg.



of old spinal mischief, and is commonly seen in "infantile paralysis." In these cases the child, when walking, throws its thigh outwards by means of the psoas and iliacus muscles in a very characteristic way, and the foot will often be found to be the subject of acquired varus or club-foot.

Early hip-disease.

345. A child walking with a slight limp, and standing with one foot a little in advance of the other, may complain of pain in the knee only, and yet will move the knee when walking, and keep the hip motionless. Pain in the hip will be produced on striking the heel or pressing upon the trochanter, and any attempt to flex the hip-joint will be resisted by the muscles. In cases in which flexion has already occurred, in order to demonstrate that the mischief is in the hip-joint, the patient should be laid upon a flat table, so that his spine is in contact with it. The healthy limb will also be in contact with the table, but the diseased limb will be found to be flexed at a variable angle. On attempting to bring the diseased limb down parallel to its fellow, pain will be produced, and it will be found that the loins are raised from the table, so that a hollow is formed beneath them; but the administration of an anæsthetic will at once allow the



limb to be brought down by relaxing the muscles.

346. Deformity of the spine, consisting in *lordosis* or exaggeration of the normal lumbar curve, is a common result of old hip-disease, but is sometimes mistaken for the original malady. A spine thus affected can always be brought straight temporarily by laying the patient down and bringing the pelvis sufficiently forward, with corresponding malposition of the limb affected. Lordosis in hip-disease.

347. An acutely painful condition of the hip-joint, which is slightly flexed and cannot be moved without causing a cry from the patient, who persistently grasps the thigh with one or both hands so as to obviate the slightest movement, is symptomatic of *acute inflammation* of the hip-joint. Under these circumstances there is considerable constitutional disturbance, the temperature being raised three or four degrees, the skin of the hip being reddened, and the patient having a flushed cheek, bright eye, and rapid pulse. Acute hip-disease.

348. A swollen buttock, of which the skin is tense and glazed, the bony prominences being masked by the general swelling, is characteristic of *acute abscess* from hip-disease. The limb will be found to be strongly flexed Abscess of hip.



and adducted, and the patient emaciated and much reduced by previous pain, but now comparatively easy. On palpation the fluctuation of matter will be readily detected beneath the thinned gluteal muscles.

Chronic  
hip-disease.

349. Sinuses, discharging thin pus, are common accompaniments of old-standing hip-disease, and are generally situated along the lower border of the glutæus maximus, near the great trochanter, in the groin, or down the thigh. The position of the limb is such as often to lead to the erroneous idea that the head of the femur is dislocated, the limb being flexed and adducted, with the trochanter major carried forward and unnaturally prominent, the buttock being much wasted and flattened. The pelvis is also considerably raised in the affected side, causing a corresponding lateral curvature of the spine and shortening of the limb, which is, however, more apparent than real, as proved by careful measurement of the two sides.

Articular  
caries.

350. Under an anæsthetic, with complete muscular relaxation, it may be possible to demonstrate the grating of *articular caries* in the hip-joint; but, even in very complete disorganization of the joint, this may not always be present. Under similar circum-



stances it will be possible to distinguish Ankylosis. between true and false ankylosis after hip-disease, the former being almost always present when healing has taken place after the disease has run to the extent of articular abscess and resulting sinuses, the scars of which are visible.

351. *Lameness in elderly people* may follow Lameness. slowly upon a fall, which produced no deformity at the time, and, on examination, the hip may present many of the symptoms of fracture of the neck of the femur (355). The symptoms are due to absorption of the neck of the femur.

352. Lameness in elderly people, combined with considerable enlargement of the hip-joint and crackling when the limb is moved, is due to *chronic rheumatoid arthritis*, which will probably be found to affect the knee and other joints. The buttock will be found to be wasted from want of use, and the limb apparently shortened by tilting of the pelvis, or really shortened by destruction of the upper part of the acetabulum. Rheumatoid arthritis.

353. A remarkable condition of disorganization of the hip-joint is occasionally met with in patients suffering from *locomotor ataxy*, and depends apparently upon the affection of the nervous system. In locomotor ataxy.



Fracture or  
dislocation.

354. A *deformity* of the hip, following directly upon an injury, must be due either to a fracture or a dislocation. A knowledge of the nature of the accident and age of the patient may assist in the diagnosis, which, however, can be safely made solely from the resulting deformity.

Fracture of  
neck of  
femur.

355. A fall upon the trochanter at any age is more likely to produce a fracture than a dislocation. A bruised hip, with loss of power, shortening of the thigh-bone, and eversion of the foot, are conclusive signs of fracture of the neck of the thigh-bone. Whether the fracture is impacted or not is the point of greatest practical importance to be ascertained, and this is to be done by careful measurements and gentle manipulations, lest the impaction should be loosened and the cure delayed or prevented.

Measure-  
ments.

356. Measurements made from the anterior superior iliac spine to the malleolus will show shortening on the affected side in almost all cases of fracture of the neck of the femur, but the amount will vary under different circumstances. A doubtful half-inch may be suddenly increased to an inch and a half by giving way of the periosteum which held the fragments of an intra-capsular fracture together. A shortening of an inch may be increased to two



inches by injudicious handling and separation of an impaction.

In all cases of fracture of the neck of the femur the trochanter is nearer the crest of the ilium than natural. The distance between these two points should therefore be carefully measured; or the same result may be more accurately gauged as follows:—The patient being recumbent, a tape is laid across the body at the level of the anterior superior spines of the ilium, when a measurement made at right angles to this line from the tops of the great trochanters will determine whether one trochanter is higher than the other, the measurement corresponding to Bryant's "test-line." The distance from the anterior superior iliac spine to the point where the two lines meet, if compared on the two sides, will also demonstrate whether any rotation of the trochanter exists.

Relation of trochanter.

Bryant's test-line.



*Fractured Neck of Thigh-bone.*

NON-IMPACTED FRACTURE.

1. In old persons, mostly women.
2. From slight indirect violence.
3. Bruising and shortening slight.
4. Foot everted.

IMPACTED FRACTURE.

1. In adult males.
2. From severe injury applied to the trochanter.
3. Bruising and shortening considerable.
4. Foot fixed, more often everted than inverted.



5. Trochanter rotates with the femur with obscure crepitus.

5. Trochanter rotates on a shortened arc, and is therefore less prominent than on opposite side. Crepitus absent unless impaction is loose.

Whether the fracture is within or without the line of insertion of the capsular ligament can only be surmised, in the great majority of cases, and is comparatively unimportant.

Dislocation of head of femur.

357. A well-marked deformity of the hip, in which the bony prominences are distinctly visible and are unobscured by bruising, is due to a dislocation of the head of the femur.

Dorsal dislocation.

If the thigh is flexed, *inverted*, and fixed; the trochanter abnormally prominent, so that the hips are widened; the limb shortened so that the knee is well above the opposite knee, and the great toe rests against the instep of the sound side, the head of the femur will be found dislocated upwards and backwards on the dorsum ilii, and moving with the femur when rotated.

Sciatic dislocation.

358. If the thigh is *inverted* and fixed, but the trochanter not abnormally prominent; if the limb is shortened so that the knee rests against the opposite knee, and the ball of the great toe touches its fellow, the head of the femur will be found dislocated backwards into the sciatic notch (below the tendon, Bigelow), where it



may produce pain and numbness down the thigh by pressure on the sciatic nerve. It is possible to feel the head of the femur in the sciatic notch with the finger introduced into the rectum or vagina.

359. If the thigh is *lengthened*, there must be a dislocation downwards into the obturator foramen. The limb will be advanced and abducted, with the toes pointed and the body thrown forward. On examining the hip the trochanter will be found less prominent than normal, and the head of the bone may be felt in the inner side of the groin. Obturator dislocation.

360. If the foot of an adult is *everted*, the case is probably one of impacted fracture of the neck of the femur; but if the head of the femur is to be felt below Poupart's ligament, it is an example of dislocation on the pubes. Pubic dislocation.

361. Nélaton's test-line for a dislocation upwards or backwards is drawn from the anterior superior iliac spine to the tuber ischii. In the normal condition this line touches the top of the trochanter major, which is quite below it. In a dislocation upwards or backwards the top of the trochanter will be considerably above this line. Test-line for dislocation.

362. Undue prominence of one or both buttocks, with very marked increase in the lumbar



Congenital  
dislocation  
of hip.

curve of the spine, first noticed when a child begins to walk, is probably due to *congenital dislocation* of the head of the femur on to the dorsum ilii, on one or both sides. The patient shambles along with a characteristic rolling gait, and the heads of the bones may be felt through the atrophied muscles. These cases are apt to be mistaken for examples of spinal curvature; but it will be found that any attempt to straighten the spine by apparatus renders the patient unable to keep his equilibrium, by shifting the centre of gravity.

## CHAPTER XXI.

## THE THIGH.

363. The femoral *lymphatic glands*, which lie in a vertical row to the inner side of the femoral vessels, may be acutely inflamed, in which case red lines may be traced up the thigh from some source of irritation below, and the glands themselves will be swollen and tender, or there may be fluctuation in or around them from the presence of matter, which will be quite superficial. Femoral abscess.

364. A more deeply seated, elastic, and fluctuating tumour may be found to the inner side of the femoral vessels, near the apex of Scarpa's triangle, in which a distinct impulse is produced on coughing. This is a *psoas abscess*, dependent upon disease of the dorsal vertebræ, the matter having found its way down the sheath of the psoas muscle. A projection of the dorsal vertebræ should be looked for. Psoas abscess.



Iliac  
abscess.

365. A deeply seated elastic tumour, in which an impulse is produced on coughing, may be found to the outer side of the femoral vessels, immediately below Poupart's ligament. This is either an *iliac abscess*, the matter being in the sheath of the iliac muscle, or a psoas abscess which has not fully descended.

Femoral  
hernia.

366. A tense tumour, with a distinct impulse on coughing, appearing beneath Poupart's ligament to the inner side of the femoral vessels, is probably a small *femoral hernia*. It may disappear so soon as the effort of coughing ceases, or may require a little gentle pressure with the finger before it slips up. A larger tumour, with a clear percussion-note, lying immediately below Poupart's ligament and returnable beneath it with a gurgle, is a reducible femoral hernia (248).

Dilated  
femoral  
artery.

367. In thin old persons the *femoral artery* may often be felt and seen so distinctly, immediately below Poupart's ligament, as to lead to the suspicion of femoral aneurism, and a *bruit* may be easily produced by the pressure of the edge of a stethoscope.

Femoral  
aneurism.

368. A pulsating tumour in the position of the femoral artery may be pronounced *aneurismal* if there is a distinct expansion of the sac at each pulsation, with a thrill which is readily



communicated to the finger, and a distinct aneurismal *bruit* or blowing sound heard at all times and in all positions of the limb. Pressure upon the artery above will cause a diminution of the tumour and cessation of the impulse and *bruit*.

369. A *rapidly growing tumour* connected with the upper part of the femur may so raise the femoral artery as to cause suspicion of aneurism, but here it will be noticed that the bulk of the tumour does not pulsate, and that the pulsation is confined to the normal line of the vessel. Tumour  
beneath  
artery.

370. A *rigid condition of the femoral artery* is often met with in old persons, the vessel feeling like a small gas-pipe. In such cases spontaneous gangrene of the foot and leg is very likely to occur. Rigid  
artery.

371. A *pulseless condition of the femoral artery* may be due to some injury inflicted upon the limb, by which the inner coats of the artery have been lacerated without complete rupture of the vessel. Or, when arising spontaneously, may be due to arteritis, or to the passage of a plug or embolon from above. In any case gangrene below the obstructed point may be anticipated. Pulseless  
artery.

372. A *tortuous and dilated condition of the internal saphenous vein* in the thigh is not un- Varicose  
saphena.



common, and the vein may be found blocked or inflamed as the consequence of phlebitis set up lower down.

Tumours of  
the thigh.

373. A *tumour of the thigh*, if subcutaneous, is probably either fatty or sebaceous. A fatty tumour may be lobulated, some of its lobules dipping between the muscles, or may be so uniformly elastic as closely to resemble an abscess, an aspirator-puncture being necessary to decide the question. A sebaceous tumour is close beneath the skin, and with care the obstructed duct may probably be discovered.

Deep  
tumours.

A deeper tumour may be connected with the muscles, and if small may be a *gumma*, in which case evidence of constitutional syphilis should be sought for. A larger, slowly growing, tumour is probably fibrous, and connected with the fascia; or if more rapid may be a sarcomatous or encephaloid tumour of muscle.

Cured  
aneurism.

The possible occurrence of an aneurism of the femoral artery in Hunter's canal, which may have undergone spontaneous cure and be diminishing in size, must not be overlooked.

Bony  
tumour.

374. Deeply seated tumours of the thigh spring mostly from the femur or its periosteum, and the question of their malignancy or semi-malignancy must be determined mainly by reference to their rapidity of growth and im-



plication of surrounding structures, the more rapid and softer the growth the more malignant as a rule being its nature.

A hot, swollen, and painful condition of the thigh occurring spontaneously, especially after or during the acute fevers, or after some slight blow in a child or young person, is probably due to acute periostitis of the femur. On deep pressure through the slightly œdematous soft parts, the bone, probably the lower half, will be found enlarged and painful; and in from twenty-four to forty-eight hours the obscure fluctuation of deeply seated matter may be detected. The temperature will be raised three or four degrees, the patient's skin will be dry and flushed, the tongue coated and the eyes bright. Acute  
necrosis

375. Deep fluctuation in the lower part of the thigh may be easily detected if care be taken to apply the fingers in the direction of the muscular fibres, and not across them. In more advanced cases, where the matter is under the fascia lata or skin, there can be no difficulty in its detection. Abscess.

376. A thickened thigh with sinuses discharging at various points, through which a probe can detect bare bone, is an example of necrosis of the femur. The amount of thicken- Chronic  
necrosis.



ing of the limb will depend upon the time which has elapsed since the original acute inflammation, and the amount of repair by new bone which has occurred.

The  
buttock.

377. A deformity of the *buttock* is generally due to old hip-disease, by which the head of the femur is either dislocated, or so completely destroyed without dislocation that the great trochanter is drawn up out of its place, and is mistaken for the head of the bone. In these cases the application of Nélaton's test-line for dislocation is deceptive, the trochanter being well above it.

Abscess  
over  
trochanter.

378. A swelling over the *great trochanter*, following a blow upon the part, with fluctuation and, later, discharging sinuses pointing some distance down the thigh, is due either to inflammation and suppuration of the *bursa* between the trochanter and the broad tendon of the glutæus maximus, or to caries and necrosis of the trochanter itself. In children especially, there may be flexion and adduction of the limb with wasting of the glutæal muscles, so as closely to resemble hip-disease.

Back of  
thigh.

379. A *tumour of the back of the thigh* may be fatty, or connected with the ham-string muscles or the femur. An elastic, fluctuating tumour, with an impulse on coughing, is a



psoas or sacro-iliac abscess which has taken the unusual course of passing through the great sacro-sciatic foramen to the back of the thigh, and may reach down to the popliteal space, or even lower. When the fluid part of the abscess has become absorbed and only a semi-solid mass is left, the diagnosis is rendered very difficult.

A small, tense, elastic tumour in connection with the insertions of the inner ham-strings or with the origins of the gastrocnemii, is a cyst containing synovial fluid, and is an exaggeration of the bursa commonly found in these situations.

380. A tumour in any part of the popliteal space having an expansile pulsation synchronous with that in the femoral artery, and arrested by pressure upon that vessel, is presumably a popliteal aneurism. A *bruit* will not be audible in all cases or at all times, and if the aneurism is small the pressure effects will be *nil*, but if the aneurism is large or increasing rapidly there will be great pain running down the leg, and the obstruction to the return of blood through the vein will cause congestion or œdema of the limb.

381. A tense, uniform swelling of the ham with flexion of the knee, producing consider-

Psoas  
abscess.

Ganglion.

Popliteal  
aneurism.

Popliteal  
abscess.



Ruptured  
popliteal  
artery.

able constitutional disturbance and occurring in a patient below middle-age, is probably due to abscess beneath the popliteal fascia connected with the lymphatic glands. A similar condition coming on rapidly in an elderly man after some unwonted exertion of the limb, and accompanied by coldness and numbness of the leg and absence of pulsation in the tibial arteries, is due to rupture of the popliteal artery or of a small aneurism arising from it. If some hours have elapsed since the accident, symptoms of gangrene of the foot and leg will probably be already apparent.

Fractured  
thigh.

382. *Deformity of the thigh*, following the application of violence, accompanied by loss of power and bruising, is due either to laceration of the muscles with extravasation of blood, or to fracture of the femur. This occurrence of shortening must be due to fracture, provided the head of the bone is in its socket, and manipulation will detect the crepitus of a broken bone. A thin layer of clot immediately beneath the skin gives sometimes a species of crepitation to the finger, but more resembling that of air in the cellular tissue than true crepitus.

Bent femur.

*In children* a femur may be bent by violence, or may have become bent previously owing to



rickets, in which case both thigh-bones will probably be deformed.

383. A deformity of the thigh may be produced by the tearing away of the quadriceps extensor from the patella in some violent effort, and the consequent gap left just above the knee-joint. The more common event is for the patella itself to break across, in which case the upper fragment will be found drawn up from the lower one, there being a variable gap between the two, with considerable effusion into the knee.

Rupture of quadriceps.

Fractured patella.

384. Considerable deformity of the *lower end* of the femur may be produced by an exostosis, a favourite situation for which is close above the internal condyle. Occasionally, owing to narrowness of the pedicle of the exostosis it becomes broken by some slight violence, and lies loose for a time beneath the soft tissues.

Exostosis.

385. Great deformity of the *lower end of the thigh*, following an injury, may be due to fracture close above the condyles; to separation of the lower epiphysis in children and young persons, or to dislocation of the tibia forwards. In all these cases the rapid super-vention of swelling of the knee-joint renders the diagnosis difficult unless the case is seen immediately after the accident. In the frac-

Injury of lower end of femur.



ture and separation of the epiphysis the condyles still hold their proper relation to the head of the tibia, which is wanting in the dislocation. In the fracture there is shortening, and crepitus is easily made out, but less so in the separation of the epiphysis. In the dislocation there is no shortening of the femur, which is extremely prominent in the popliteal space, stretching and even rupturing the popliteal vessels and nerves.

## CHAPTER XXII.

## THE KNEE.

386. A deformity of the knee, following directly on an injury or over-exertion of the joint, may be due to a *dislocation of the patella*, more frequently outwards than to the inner side. Occasionally the patella is twisted so that its edge is prominent beneath the skin, the knee being extended and fixed. Dislocation of patella.

387. In a knee-joint semi-extended and fixed by some twist of the joint, it will be found that there is a slight prominence on the head of the tibia to the inner side of the ligamentum patella, which is painful on pressure. This is a *luxated semi-lunar cartilage*, which can only be reduced by forcible flexion and extension of the joint. Displaced semi-lunar cartilage.

388. A bruised knee may be distended with blood, as can be proved at once by the aspirator, and some little time after the accident Blood in knee.



by the peculiar crepitation of the blood-clot on palpation; and hence the solid feeling of the effusion and the slowness of its absorption.

Fluid in  
bursa.

As the result of an injury, the *bursa* in front of the patella or the knee-joint may be distended with effusion. If the swelling is in front of the patella, which lies in close relation to the condyles, and forms a prominence in front of the knee-joint, in which fluid can be detected or a creaking sound can be elicited when the amount is small, the effusion is in the *bursa patellæ*. If the patella is raised from the condyles so that it floats upon the fluid, which distends the synovial pouch on each side of and above the bone, the effusion is within the joint. It must be borne in mind that, with the leg fully extended and the thigh relaxed, it is easy in non-muscular persons to push the patella from side to side without the presence of any fluid; but under such circumstances it will not "rap" upon the condyles when pressed vertically, as it will when floating on fluid.

Fluid in  
joint.

Wound of  
knee.

389. A wound of the knee-joint may be diagnosed by the direction and extent of the incision, and by the rapid escape of glairy synovial fluid. A wound of the *bursa patellæ* will give exit to a small quantity of fluid



somewhat resembling synovia, but the position of the wound immediately in front of the patella, and, if necessary, the introduction of a probe dipped in carbolic-oil into the limited cavity, will settle the diagnosis.

390. A hot, reddened condition of the skin over the knee may be due to the application of irritants to the skin, *e.g.* iodine; to acute inflammation of the bursa patellæ; or to acute synovitis of the knee-joint. (a) In the case of local irritation, the skin will be found thickened wherever the irritant has been applied, the pain will be of a stinging burning character, and there will be little constitutional disturbance, the temperature of the body being normal. (b) In the case of bursitis the swelling is confined to the front of the patella, the focus of inflammation being in the position of the bursa, and the redness fading off to the sides. Distinct localized fluctuation may be found if the sac of the bursa is entire, but frequently it has given way, and the contained matter has become diffused. (c) In the case of acute inflammation of the knee-joint, there is great effusion into and distension of the joint, which is semi-flexed, with considerable constitutional disturbance, the temperature being raised three or four degrees, the

Inflamma-  
tion about  
knee.

Local  
irritant.

Inflamed  
bursa.

Synovitis.



Suppuration.

skin dry and tongue coated, and the patient sleepless from pain in the joint. If the mischief has been going on for forty-eight hours, and the pain has become of a throbbing character, the probability is that suppuration in the joint has occurred, but this important question should be settled by the use of the aspirator before a free incision is made.

Acute inflammation of the knee.

391. Acute inflammation of the knee-joint not resulting from injury, but occurring in the course of a surgical case or one of the acute fevers, is probably a result of pyæmia, and will be accompanied by sudden variations of temperature followed by rigors and sweatings, or by a persistently high temperature with rapid pulse and great emaciation.

Chronic effusion into knee.

392. The presence of chronic effusion into the knee will give the same local symptoms as an acute effusion (388), except that there will be no redness or heat of skin. A chronically over-distended joint may be considered the subject of *hydrarthrosis*, or dropsy of the joint.

Loose body.

393. The occurrence of effusion into the knee-joint, following sudden violent pain of a sickening character during exercise, should lead to the suspicion of the existence of a loose cartilage, which may not readily be



discovered for some time. These loose bodies are usually of small size, and, even when found, readily elude the finger and disappear into the interior of the joint.

394. A uniform chronic swelling of the knee, by which the bony outlines are masked and the movements of the joint much restricted, giving to the finger an elastic feeling often closely resembling the fluctuation of fluid, and allowing the patella to be pressed down and rise again as if upon an elastic cushion, is due to a chronic thickening of the synovial tissues, generally connected with struma in children, and constitutional syphilis in adults. Strumous thickening.

395. Sinuses discharging pus in connection with the knee-joint, are often evidences of disorganisation of the articulation, and probably of articular caries, in which case grating of the bones may be felt on pressing the bones together, or bare bone may be detected with the probe. There are, however, frequently long and tortuous sinuses about strumous knees which do not communicate with bone at all, but are due to peri-articular mischief. Sinuses.

396. A tumour involving the lower end of the femur may invade the knee-joint, and at first sight closely resemble disease of the articulation. The tumour will be found, how- Tumour of lower end of femur.



ever, to involve only the upper part of the joint, the tibia and the lower part of the articulation being quite healthy, but the condyles of the femur greatly increased in circumference. In the case of a myeloid tumour the articular cartilage is pushed forward by the tumour, but in medullary disease the joint cavity is invaded by the growth, which is more rapid in its development and more elastic to the touch.

Dislocation. 397. A dislocation of the tibia from the femur can only arise from extreme violence, which will probably inflict irreparable injury upon the soft parts in the neighbourhood. The question of amputation or excision will be decided mainly by the condition of the popliteal vessels, as shown by the pulsation or otherwise of the tibial vessels.

Knock-knee.

398. A deformity of one or both knees in which the two joints are approximated or overlap one another when the patient walks, giving him a peculiar shambling gait, constitutes *genu valgum*, or *knock-knee*, which is constantly combined with, if not caused by flat foot. An opposite condition of things, in which the knees bow outwards, constitutes *genu extorsum* or *varum*. This last is often combined with a rickety condition of the bones of the leg, leading to "bow-legs."

## CHAPTER XXIII.

## THE LEG.

399. *Ulcers* are commonly found about the *Ulcers*. legs, the nearer the knee the more probably they are due to tertiary syphilis, the nearer the ankle the more probably they are simple or varicose.

400. Multiple ulcers, with sharp-cut edges of Tertiary. irregular shape, but with a more or less circular tendency; healed in one part, but breaking down in another, and occurring before the age of forty, are undoubtedly *tertiary* in origin.

401. Small ulcers with a grey surface about Irritable. the inner ankle, very painful, particularly at night, are commonly found in patients with varicose veins. These *irritable* ulcers will be found to have produced no rise of temperature in the surrounding skin if the finger is laid upon it.



Callous. 402. An ulcer with thick edges, and a glazed surface, which has probably existed for months or years, is a typical *callous* ulcer, and is often connected with varicosities.

Inflamed. 403. Any ulcer may take on *inflammation*, in which case, the surface and surrounding skin become injected and hot, the activity of the ulcerative process increased, and the pain in the part aggravated.

Phagadæna. 404. A rapidly spreading ulcer, in which, though the size increases daily, no distinct sloughs can be seen, may be considered an example of *phagadæna*.

Sloughing. 405. An inflamed ulcer in which the edges of surrounding skin are seen to die in patches which came away as sloughs, the discharge from the ulcer being profuse and offensive, is an example of *sloughing* ulcer.

Sloughing  
phagadæna 406. An ulcer suddenly putting on a peculiar white or greyish appearance, due to the rapid formation of superficial sloughs, which have a sodden macerated appearance, is attacked by "hospital gangrene," or "*sloughing phagadæna*."

Hospital  
gangrene. In the later stages an ulcer attacked by this disease rapidly spreads, by ulceration and sloughing combined, until the bones are exposed and the limb destroyed. The early recognition of "hospital gangrene" in a ward



is most important, as immediate isolation is necessary for the preservation of the patients.

407. An ulcer with a flat bluish edge, and a <sup>Healthy</sup> uniform surface of red short granulations which <sup>ulcer.</sup> bleed readily, without heat, and without pain, is a typical healthy or healing ulcer, and is the standard to which all other ulcers must be brought by treatment.

408. Enlarged, tortuous, and varicose veins <sup>Varicose</sup> are common in the leg, and interfere much <sup>veins.</sup> with its nutrition. Hence a varicose limb is apt to be congested and cold, or may present ulcers. Pregnancy or any abdominal tumour is apt to render the internal saphenous vein varicose, and under these circumstances there is often a distinct impulse in the vein upon the patient coughing, and should the vein give way at any time, fatal hæmorrhage may occur from the yielding of the valves.

409. Indurated spots scattered over the legs, <sup>Gummata.</sup> some of which are softening and evidently contain matter, while others are open ragged ulcers, with a yellow slough and thin discharge, are *gummata* in various stages, and are due to constitutional syphilis.

410. Slight swelling over the head of the <sup>Ostitis of</sup> tibia, with deep-seated pain, aggravated at night, if in an adult, is symptomatic of ostitis



Abscess. and possibly abscess in the head of the tibia. In a child or youth, the same symptoms are generally premonitory of caries, which as it develops lead to reddening of the skin, and eventually to the discharge of a small quantity of pus. A sinus is apt to form with unhealthy granulations protruding from its orifice, and through this, a probe may readily detect gritty bone.

Perforation of joint. 411. Occasionally violent and destructive inflammation of the knee-joint may suddenly supervene upon caries of the head of the tibia, showing that perforation of the articular cartilage has occurred.

Acute periostitis of tibia. 412. A hot, reddened and œdematous condition of the skin over the tibia, occurring in a young person a few hours after the receipt of a blow or exposure to damp and cold, and accompanied by a marked rise in the temperature of the body, a dry tongue, and rapid pulse, is symptomatic of *acute periostitis* of the tibia. A few hours later on there will be fluctuation, and, unless the matter is evacuated by a timely incision, acute necrosis of the shaft of the tibia, in part or whole, will supervene.

Erythema nodosum. 413. A condition liable to be confounded with the above, but quite distinct, is met with



in young persons, generally females. The skin over the tibia is reddened in patches with healthy skin intervening, each of the patches having the knotty feel which is characteristic of the disease—*erythema nodosum*. On careful examination, the skin alone will be found to be affected, and usually on *both* legs. In the early stage the redness is very faint, and when dying away, the marks somewhat resemble bruises. Throughout there is little if any constitutional disturbance, but the patient is usually feeble and out of health or overworked.

414. A *localized swelling* over the subcu- Nodes.  
taneous surface of the tibia is usually a local periostitis or node. The swelling, at first œdematous, soon gives evidence of fluctuation, owing to the effusion of fluid beneath the periosteum; but this may become entirely absorbed under treatment. The hard node, often very painful, especially at night and in damp weather, is a later stage of the same affection, which is invariably connected with tertiary syphilis.

415. A *general enlargement* of the tibia may Enlarged  
be due to chronic periostitis or ostitis, or tibia.  
follow necrosis, in which last case there will probably be found sinuses, through which a



probe will reach a sequestrum, after passing through a varying quantity of new bone thrown out around it.

Rickets.

416. A deformity of the tibia may be due to *rickets* in early life, in which case the bone will be bent, and probably flattened, and both limbs will be affected; or to old fracture, in which case the deformity will probably affect one limb only, and a sharp ridge or edge of bone will be found prominent beneath the skin.

Fractures.

417. An injured leg, in which there is recent deformity, with inability to stand and bear weight upon it, and pain, has probably sustained a *fracture* of one or both bones. A fractured tibia, being subcutaneous, is readily recognized by the displacement of the fragments and crepitus; but a fractured fibula, unless broken in its lower third, is easily overlooked without care.

Tumour.

418. A *tumour of the leg* may originate in bone or muscle, and more frequently in bone. Tumours of the head of the tibia may be myeloid or malignant; if involving the shafts of the tibia or fibula, may be fibrous or enchondromatous when of slow growth, sarcomatous or malignant if rapid in development and leading to spontaneous fracture.

Of bone.

Tumours of muscle are not unfrequently gum- Of muscle.  
matous or syphilitic, if of long standing and  
slow growth, but may be sarcomatous or  
malignant if of rapid growth.

419. A painful condition of the calf of the Rupture  
leg, coming on suddenly in a middle-aged of calf-  
or elderly patient who is making some active muscles.  
exertion at the moment, is probably due to  
rupture of some of the muscular fibres of the  
calf. The same accident may affect the  
muscles of the front of the leg.

420. Total inability to stand, following a Ruptured  
sudden sharp pain near the heel during violent tendo  
exertion, is due to *rupture of the tendo Achillis*; Achillis.  
and, upon examination, the two ends of the  
ruptured tendon will be found separated by a  
space of an inch or more.

421. A deep-seated pain in the leg, following Phlebitis.  
a bruise or coming on spontaneously in gouty  
subjects, may be due to *phlebitis* of the deep  
veins of the leg, in which case there will be  
congestion and œdema of the leg and foot, and  
a hard, knotted condition of the veins behind  
the inner mallolus. This condition, if over-  
looked, may lead to serious visceral mischief,  
by the moving onward of clots into the general  
circulation.



Aneurismal  
varix.

422. The occasional formation of an *aneurismal varix*, by a communication taking place between the tibial arteries and veins, may be diagnosed by the peculiar "rasping" *bruit* to be heard over the part.

## CHAPTER XXIV.

## THE FOOT.

423. The deformity known as *Club-foot* may be met with as a congenital malformation, or as the result of paralysis. In the congenital cases the deformity is more marked, the parts are rigid, and the muscular development of the rest of the limb is good. In the paralytic cases the deformity is less marked, and can frequently be temporarily reduced by the hand of the surgeon; the parts are limp and relaxed, and the muscles of the whole limb are wasted.

424. When the heel is drawn up by contraction of the muscles of the calf, so that the patient walks on the ball of the great toe, or sometimes, in extreme cases, on the back of the foot, the case is one of congenital *talipes equinus*. When the heel occupies its proper relation to the leg, but the front of the foot drops, so that the toes catch against the



ground when the patient attempts to walk, the case is one of paralysis of the extensors, or acquired *talipes equinus*.

Talipes  
varus.

425. When the foot is folded up, so that the patient brings the outside to the ground, and frequently has induced large flat corns on that part by the pressure of walking, the case is one of *talipes varus*. When the natural arch of the foot is lost, so that the patient brings the inner side of the foot flat on the ground, he is said to suffer from "flat foot" (*talipes planus*). An exaggeration of this condition, in which the bones of the inner side of the foot become unduly prominent and the toes are twisted outwards, constitutes *talipes valgus*.

Flat foot.

Talipes  
valgus.

Talipes  
calcaneus.

426. A condition found in infants, in which the foot can be brought up against the front of the leg, is perfectly compatible with healthy locomotion when the child grows up. When, however, there is firm contraction of the extensors of the foot, so that it is constantly held in this position, with the heel unduly prominent, it constitutes *talipes calcaneus*. This condition is frequently met with in infants the subjects of *spina bifida*. (442.)

Sprained  
ankle.

427. A painful, swollen condition of the ankle and foot, the skin of which is more or less discoloured by extravasated blood, may



be simply a *sprained ankle*, in which more or less laceration of the ligaments of the joint and fibres of the extensor brevis digitorum has occurred, or may be an example of dislocation or fracture of the malleoli. In cases rendered doubtful by swelling, a certain diagnosis cannot be made until the swelling has partially subsided.

428. A dislocation of the foot is sufficiently obvious from the deformity produced, but is less obvious if fracture of one or both malleoli is combined with the dislocation. In a case of compound dislocation, the amount of injury to the soft parts, especially the main vessels, and the age of the patient will principally determine the question of amputation.

The foot, when forcibly twisted outwards, may or may not be completely dislocated, but is apt to cause fracture of the lower third of the fibula (Pott's fracture), and either laceration of the internal lateral ligament or fracture of the internal malleolus. In this last case the skin is tightly stretched over the broken end of the shaft of the tibia, which is apt to protrude.

429. An irregular prominence on the outer side of the foot, following "sprained ankle," may be due solely to *extravasation of blood* from



rupture of muscle, in which case the swelling will pit on pressure, and the limb will be of the same length as the opposite one. If the swelling is hard and bony, and the limb shorter than natural, the swelling is due to *dislocation of the astragalus*, which bone may or may not be broken across in addition.

Dislocated  
astragalus.

Ganglion.

430. A circumscribed elastic swelling found in close relation with one of the tendons surrounding the ankle-joint is probably a *ganglion*, from which the characteristic jelly-like contents can be readily evacuated with a needle.

Puffy  
ankles.

431. A puffy and oedematous condition of the ankles towards night may be due simply to debility and long standing, but should always excite a suspicion of albuminuria, and should lead to an investigation of the urine before any surgical proceeding is undertaken.

Chronic  
disease of  
ankle.

432. A permanently enlarged condition of the ankle, with great restriction of its movements, is due to some affection of the joint, probably to a thickened condition of the synovial membrane of strumous origin. The elastic swelling is to be looked for both in front of and behind the joint, and the elasticity may be so great as to lead to a suspicion



of the presence of fluid, which can be cleared up with the aspirator.

Sinuses about the foot lead more frequently to carious tarsal bones than to a diseased ankle-joint, but the tarsal joints themselves frequently become involved with the bones. Caries of tarsus.

433. A deep circular ulcer of the sole of the foot, most commonly beginning in a suppurating corn or in the positions in which corns are most frequently found, and accompanied by more or less loss of sensation in the foot, is an example of the *perforating ulcer*, which appears to be generally connected with some affection of the nerves supplying the limb. Necrosed bone is frequently to be felt through such an ulcer, and pieces may come away spontaneously. Perforating ulcer.

434. Inflammation of the ball of the great toe may be due to *gout* or to a *bunion*. The suddenness of the attack, the general disturbance, and the spreading redness of gout, will distinguish it from the purely local inflammation of the bursa, formed over a distorted metatarso-phalangeal joint which had previously been swollen and tender. Gout and bunion.

A chronic enlargement of the head of the metatarsal bone of the great toe may be due simply to injudicious pressure of the boot, Chronic bunion.



or may be evidence of a general tendency to rheumatoid arthritis.

Ingrowing  
toe-nail.

435. A painful condition of the nail, with unhealthy granulations springing up by the side and exuding a thin discharge, is due to *in-growing toe-nail*, the ragged edge of which constantly irritates the matrix and must be removed for a cure to be effected.

Chilblain.

436. A bluish, glazed, and cold condition of the toes is not unfrequent in young persons of feeble circulation, constituting *chilblains*, which itch and tingle severely, and are apt to blister, in which case unhealthy sores result.

Frost-bite.

437. A cold, pale, and insensible condition of the toes and foot must be due to some interference with the circulation, and may be consequent upon *frost-bite*, to cutting off the supply of arterial blood by ligature of the main vessel, or to plugging of the main artery.

Senile  
gangrene.

438. A dark, shrivelled condition of the toes is a common symptom of commencing *senile gangrene*, or may be a later stage of the early bloodless condition described above.

Moist  
gangrene.

439. A <sup>re</sup>conjected, purple or black condition of the toes, between which blebs of offensive fluid are apt to form, is a condition of *active gangrene*, due to inflammation or venous obstruction. In the part immediately above the

line of actual gangrene there will be a bright red blush, fading off gradually into healthy skin.

440. A dark-coloured spot beneath the nail of the great toe, if occurring after some slight blow, is only extravasated blood, and unimportant unless painful from the tension produced. A persistent black spot about the toe should be viewed with suspicion, as it may be the commencement of *melanosis*. Blood  
beneath  
toe-nail.  
  
Melanosis.

441. *Ulceration between the toes*, causing a peculiarly offensive discharge, is always syphilitic; and so, also, a *scaly eruption* in the sole of the foot, which is frequently seen in conjunction with ulceration of the toes or alone. Ulcerated  
toes.  
  
Lepra  
plantaris.



## CHAPTER XXV.

## THE BACK.

Congenital  
Tumour.

442. A congenital tumour in the middle line is in all probability a *spina bifida*. In the infant, the tense, elastic, semi-translucent swelling, obviously connected with the spinal column, reducible in size by pressure and increasing upon the child crying, will at once distinguish the malformation; but in the adult, the remains only of the cyst, shut off from the spinal canal and more or less dried up, will be found, and may be confounded with simple tumours.

Spina  
bifida.

The probable occurrence of club-foot, and particularly of talipes calcaneus, in the subjects of spina bifida of the lumbar region is not to be overlooked. (426.)

Tumours.

443. An elastic slowly growing tumour of the back may be sebaceous, fatty, or an abscess.

Sebaceous.

A *sebaceous* tumour is clearly connected with the skin, which does not glide over it as in the

case of a fatty tumour. A *fatty* tumour may Fatty.  
be lobulated, and thus distinguishable from an  
*abscess*, but often it is not so, and nothing but Abscess.  
a puncture with an aspirator will decide the  
question. A feature common to *both* is the  
tendency to shift slowly lower down the trunk  
by gravitation.

444. A well-developed localized inflamma- Anthrax.  
tion of the skin and subcutaneous tissue, vary-  
ing in size from a crown-piece to a cheese-plate,  
red and œdematous, and probably having small  
apertures through which pus is discharged,  
constitutes a *carbuncle*, the favourite position  
of which is the nape of the neck or between  
the shoulders.

445. The deformity caused by the projection Caries of  
of the vertebræ in *angular curvature*, due to spine.  
caries of the spine, can hardly be overlooked  
in an advanced case, but may be readily missed  
when slight. A patient suffering from pain  
in the back, irritation of the spinal cord, or  
abscess supposed to be connected with the  
vertebræ, should be tested by stooping till  
the fingers touch the toes, so that the slightest  
irregularity of the spinal processes or un-  
natural fixation of the vertebræ may be ob-  
served. He should also rise on his toes and  
come sharply on to his heels, to test for pain



in the spinal column. Mere pressure upon the spinous processes with the fingers is practically useless as a test, since hysterical hyperæsthesia of the skin may cause the patient to cry out, but a hot sponge may detect tenderness before any actual projection has occurred.

Abscess.

The common occurrence of cervical, dorsal or lumbar abscess, or of psoas and iliac abscesses, in connection with angular curvature must not be overlooked.

Lateral curvature.

446. "Growing out of the shoulder," generally the right, is one of the earliest symptoms of *lateral curvature* of the spine. Careful inspection of the back will show whether the projection of the scapula is due simply to feebleness of muscles, or to displacement backwards of the angles of the ribs consequent upon the rotation of the vertebræ in lateral curvature. A more or less complete double curve may be detected in all cases of lateral curvature, the dorsal and lumbar curves being on opposite sides.

In investigating a case of lateral curvature, regard should be had (1) to the condition of the thorax and its contents; (2) to the length of the lower limbs, which may not be equal; and (3) to any employment or habits which may induce deformity.



447. An elastic circumscribed swelling over the back of the pelvis, if not a fatty tumour, is probably an abscess, connected either with disease of the pelvic bones or of the sacro-iliac joint. The condition of the joint may be tested by pressing the innominate bones together and then drawing them asunder, and by making the patient try to stand on one leg, which will induce pain in the affected joint. There is sometimes pain along the sciatic nerve, even in early and mild cases.

Sacro-iliac  
disease.

448. An irregularity of the spine following upon an injury may be due (1) to fracture of the spinous processes, which may be felt to be movable; (2) to crushing of the bodies of one or more vertebræ, so that the spinous processes project as in angular curvature; or (3) to dislocation of a vertebra.

Injury to  
spine.

The condition of the spinal cord is of the greatest moment, and this should be carefully investigated, although time alone will show whether any symptoms present may be due to blood, which may become absorbed, or to crush of the cord itself by the vertebræ, or to simple concussion.

Spinal  
cord.

449. A patient with the legs paralysed, both as regards motion and sensation, in whom no reflex contraction can be excited by tickling

Lumbar  
lesion.



the soles of the feet; but who is able to pass his water and retain his motions, has sustained some injury of the lumbar vertebræ affecting the *cauda equina*.

Dorsal  
lesion.

A patient who is paralysed in the lower limbs, but in whom reflex action can be excited after the first shock has passed off; whose abdominal muscles are paralysed, and who has retention of urine and involuntary escape of fæces, has sustained some injury of the *lower dorsal* region.

Upper  
dorsal.

A patient who, in addition to the foregoing, has complete paralysis of the intercostal muscles, so that the thorax is immovable and the abdominal muscles flap to and fro with each action of the diaphragm, has sustained some injury of the *upper dorsal* region.

Lower  
cervical.

A patient, who, in addition to the foregoing, has paralysis of the arms, has sustained an injury of the *lower cervical* region.

Upper  
cervical.

In an immediately fatal case of injury of the spine, injury of the cord above the origin of the phrenic nerve (third cervical) may be looked for, or crush of the medulla oblongata by the odontoid process.

Fracture or  
dislocation  
of the  
coccyx.

450. A painful condition of the lower part of the back, following a kick or a fall in the sitting posture, may be due solely to bruising

of the sacrum; but if pain is felt in the rectum, particularly during defæcation, the finger should be introduced into the anus to detect a fracture or dislocation of the coccyx.



## CHAPTER XXVI.

## AFTER AMPUTATION.

**Tension.** 451. The amount of action in a stump will depend very much upon the method of dressing. A continuous elevation of temperature, with pain in the stump, coming on twenty-four hours after an amputation, depends in most cases upon tension of the flaps from the presence of blood or serum, for which no proper exit has been provided. The occurrence of a well-marked rigor under such conditions would probably be coincident with the commencement of suppuration.

**Rigor.** 452. The occurrence of a rigor, with sudden rise of temperature, from forty-eight hours onwards after an amputation, is symptomatic either of the outbreak of erysipelas, or of the commencement of pyæmia.

**Erysipelas.** The discovery of a red blush, which disappears on pressure, around the wound and

for some distance above it, will confirm the diagnosis of erysipelas; the repetition of the rigors, with pain in one or more of the large joints, and a tendency to jaundice will confirm that of pyæmia (464).

453. A swollen, tense condition of a stump, in which there is no "pocketing" of matter, accompanied by great rise of temperature and a rapid feeble pulse, is apt to be followed by profuse discharge of effusive pus from the medullary canal and around the bone, which will be bare, the case being one of *osteo-myelitis*, or inflammation of the medullary membrane. Symptoms of pyæmia may at any moment arise in such a case.

454. The failure of a stump or compound fracture to heal, depends probably upon *necrosis* of the bone. A probe introduced into the unhealed sinus will touch bare bone, which may be simply a ring, the vitality of which has been destroyed by the saw, or a large sequestrum extending some inches up the limb. After six weeks or more, the necrosis will generally be thrown off, and may be removed.

455. A hard, swollen, and tender condition of the main veins of a stump, imply that they have been the subjects of *phlebitis*. Secondary



abscesses may be looked for in the course of the veins, and the occurrence of pyæmia is not improbable.

Tetanus.

456. A feeling of *malaise* coming on at any period after an amputation, and accompanied by stiffness about the jaws and throat, may be the early symptoms of *trismus* or lock-jaw, and will soon be followed by the characteristic grin, or *risus sardonicus*, due to contraction of the facial muscles. In a later stage the general spasms of tetanus may be looked for, leading to well-marked *opisthotonus*, and almost invariably, when acute, ending fatally. In tetanus the spasms never completely remit and the mental condition is unaffected, whereas in hydrophobia there are very distinct remissions, and the patient becomes delirious.

Healed stump.

457. A healed stump may be (1) conical, so that the bone is the most prominent point; or (2) have the cicatrix adherent to the end of the bone; or (3) be liable to jerking from spasm of the muscles; or (4) be painful from the entanglement of one of the nerves in the cicatrix, or from pressure upon the neuromatous end of a divided nerve.

## CHAPTER XXVII.

## CONSTITUTIONAL CONDITIONS.

458. The general condition and health of a surgical patient is of the greatest moment, and may be most conveniently considered apart from local disease or injury. General conditions.

459. A patient in *good health* may be expected to look his age but not much more, for although a young man may lose his hair early, he ought not to be grey, or to have "crow's-feet" at the corner of his eyes. A patient who looks younger than his age is apt to be fatter than is compatible with perfect health, and may have a weak heart. Women after forty are proverbially fatter than before, but this applies to married women rather than the single, who often enjoy perfect health although thin and angular. Good health.

460. The *complexion* will vary according to breed, and a sallow skin is compatible with Complexion.



perfect health, provided the eye is clear and the tongue clean. The marble-white skin of anæmia, the transparent skin of phthisis, and the tallowy-white skin of cancer are especially undesirable in patients about to be submitted to a surgical proceeding.

Functions. 461. The *functions* of the body are regularly performed in health, without any special thought on the part of the patient. The bowels act regularly once in the twenty-four hours, the motions being of healthy consistence, size, and colour. The urine is passed five or six times daily, does not disturb the patient at night, or at least, not till early morning; is clear when passed and on cooling, not offensive, moderately acid, and of specific gravity 1015-25. The digestion is good, there being no pain after food nor eructations, and no great flatulence. The heart and lungs perform their functions without the knowledge of the patient, who is able to make any ordinary exertion without distress. The temperature is normal, 98·4°, and does not vary at different times of the day.

Female. In healthy *women* the menstrual function is regular as to time and quantity, which, though varying in different individuals, should never be excessive, and is accompanied by slight *malaise* rather than pain.



In pregnancy "morning sickness" is quite compatible with good health if not excessive, and the general health should not suffer, although locomotion may be difficult in the latter months.

462. A patient who, a few hours after an operation or injury, has a hot skin, quick pulse, and rise in temperature of three or four degrees, is suffering from inflammatory or traumatic fever. Inflammatory fever. is suffering from inflammatory or traumatic fever in its early stage, which may be due solely to tension of the wound from pent-up blood or serous effusion, or to irritation from a foreign body, *e.g.* the presence of a catheter in the urethra. If unrelieved, a *rigor* or well-marked shivering fit will probably occur within twenty-four hours, and the occurrence of suppuration may be anticipated. Pyrexia. The constitutional symptoms become more marked, the pulse quickened to 120 and much fuller than natural, the temperature standing at 102° or 103°, the tongue being coated and the mouth dry. The symptoms are those of well-developed *pyrexia*.

463. The occurrence of a *rigor* a few hours after the passage of a catheter may, or may not, be a serious symptom. Rigors. A man with perfectly healthy kidneys may have a rigor after the use of an instrument, followed by a profuse



sweating and no other symptom, or at most only a little blood in the first urine passed. But in a patient with kidneys and bladder previously damaged by long-standing stricture or stone in the bladder, the occurrence of a rigor may mark the outset of an attack of *acute interstitial suppurative nephritis*. The temperature will fall during the sweating stage, but never to the normal standard, and will rise again rapidly upon the occurrence of successive rigors. The patient is apt to pass into a semi-unconscious condition, ending in coma and death from uræmia.

Pyæmia.

464. Rigors recurring at intervals of twenty-four hours or less, with a rise of temperature to  $105^{\circ}$  to  $106^{\circ}$ , followed by very profuse and exhaustive sweating, generally mark the onset of *pyæmia*. In such a case the pulse is rapid and feeble, and the patient emaciates rapidly, and complains of general tenderness of the surface, his skin having a yellowish tint, and both it and his breath giving a characteristic sweet odour. The occurrence of secondary abscesses in the large joints and internal organs may be expected, and the patient dies exhausted or occasionally makes a tedious recovery.

Hætic.

465. A patient suffering from exhaustive discharges is apt to emaciate rapidly, and to

have nocturnal exacerbations of temperature, with flushed cheeks and bright eyes, followed by profuse sweating. The pulse is feeble, the urine high-coloured and scanty, and diarrhoea is apt to carry off the patient, who is said to be in a condition of *hectic*.

466. A patient of intemperate habits, having sustained an injury, is apt to be sleepless and to see *spectra* about the bed. The tongue is moist and thickly coated, and is tremulous when protruded, and there is tremor of the hands. The patient is feeble and exhausted, with quick pulse and clammy skin, but perfectly sensible at first, though, as the disease progresses, he may become temporarily maniacal and require restraint. He is suffering from *delirium tremens*.





# INDEX.

---

## A

Abdomen, affections of the, 97  
 injuries of, 11, 106  
 tumours of the, 99  
 Abscess, 4, 8, 24, 45, 70, 83,  
 102, 137, 145, 151, 159, 163  
 Abscess of tympanum, 31  
 of meatus, 31  
 Acne rosacea, 33  
 Acute fevers, 4  
 Adenoma of breast, 89  
 Albuminuria, 129  
 Alcohol, 17  
 Alimentary canal, 5, 8  
 Alveolus, necrosis of, 45  
 Amaurosis, 28  
 Aneurism, 5, 8, 53, 56, 160,  
 165  
 Aneurismal varix, 73, 182  
 Angeioleucitis, 70, 159  
 Angular curvature, 191  
 Ankle, chronic disease of, 186  
 sprain of, 184  
 Ankylosis of hip, 153  
 Antrum, suppuration of, 34  
 Anus, imperforate, 143  
 Aortic aneurism, 58  
 Aphasia, 54  
 Aphonia, 54  
 Arm, the fore, 79  
 the upper, 66  
 Ascites, 99  
 Asthma, 52  
 Atony of bladder, 125  
 Axillary abscess, 70

## B

Back, affections of, 190  
 Balanitis, 132  
 Bent elbow, 73  
 Bladder, distended, 100  
 ruptured, 108  
 Bleeding from ear, 29  
 Blindness, 29  
 Blood effused on brain, 19  
 in knee-joint, 169  
 Bloody urine, 107, 128  
 Bone, tumours of, 69, 81, 173  
 Bones, diseases of, 5, 8  
 Brain, compression of, 18, 20  
 concussion of, 18  
 inflammation of, 19  
 Breast, affections of the, 88  
 Bubonocoele, 113  
 Bunion, 187  
 Burns, 11  
 Bursa of olecranon, 72  
 of patella, 170  
 Bursitis, 72, 170  
 Buttock, affections of the, 164

## C

Cancrum oris, 37  
 Caput succedaneum, 13  
 Carbuncle, 191  
 Caries of spine, 191  
 Carotid aneurism, 56  
 Cartilage, semi-lunar, dis-  
 placed, 169  
 Case-taking, 3



Cataract, 28  
 Cephalhæmatoma, 15  
 Chancre, 36, 84  
 Chest, injuries of, 10, 94  
 Chilblain, 188  
 Cirroid aneurism, 14  
 Clavicle, dislocated, 59, 60  
     fractured, 58  
 Cleft-palate, 36, 48  
 Closure of jaws, 43  
 Club-foot, 183, 190  
 Coccyx, injuries of, 194  
 Colles' fracture, 79  
 Compression of brain, 18, 20  
 Concussion of brain, 18  
 Congenital cysts, 14, 190  
     dislocation of femur, 158  
 Conjunctivitis, 25  
 Consciousness after head-injury, 19  
 Convulsions, 20  
 Cornea, affections of, 26  
 Cracked lip, 36  
 Crepitation of air, 23  
     of blood, 23  
 Curvature of spine, angular, 191  
     lateral, 192  
 Cynanche tonsillaris, 49  
 Cyst of breast, 90  
     jaws, 47  
     lip, 37  
 Cystitis, 127, 130

## D

Dactylitis syphilitica, 85  
 Deafness, 31  
 Deformities, 5  
     of thigh, 166  
 Delirium tremens, 203  
 Dentigerous cyst, 47  
 Diabetes, 130  
 Difficult defæcation, 147  
 Discharge from nostril, 33  
 Dislocation of clavicle, 59, 60  
     femur, 156  
     foot, 185  
     jaw, 43

Dislocation of humerus, 61  
     patella, 169  
     tibia, 174  
     wrist, 80  
 Dragging of leg, 149  
 Dysphagia, 50  
 Dyspnœa, 51, 94

## E

Ear, the, 29  
 Ecchymosis of face, 23  
     of conjunctiva, 25  
 Ectopia vesicæ, 97  
 Ectropion, 24  
 Elephantiasis scroti, 136  
 Emphysema, 95  
 Encephalocele, 13  
 Enchondroma, 85  
 Enlarged tonsils, 49  
 Entropion, 24  
 Epiphysis, separation of, 67, 80, 167  
 Epithelioma, 37, 51, 133, 136, 141, 148  
 Epulis, 46  
 Erysipelas, 4, 21, 33, 71, 196  
 Erythema nodosum, 72, 178  
 Exomphalos, 97  
 Exostosis, 70, 167  
     ivory, 15  
 Eye, the, 24  
 Eyelid, dropped, 23

## F

Face, affections of the, 21  
     ulcers of, 32  
 Facial erysipelas, 21  
     paralysis, 21  
 Fatty tumour, 117, 191  
 Female genitals, the, 139  
 Femoral abscess, 159  
     aneurism, 160  
     artery, affections of, 160  
     ring, cyst of, 117  
     tumours, 116, 159  
 Femur, dislocation of, 156

Femur, fracture of neck of, 154  
 Fibrous polypus, 35  
 Finger, affections of, 85  
 Fissure of anus, 146  
 Fistula, anal, 9, 145  
     urinary, 6  
 Foot, affections of the, 183  
 Foreskin, affections of, 132  
 Fractures, compound, 10  
     simple, 10  
     united, 5  
 Fracture of clavicle, 58  
     finger, 87  
     jaw, 43  
     humerus, 61, 66  
     neck of thigh, 154  
     patella, 167  
     radius and ulna, 79  
     scapula, 61  
     skull, 16, 17  
     thigh, 166  
     tibia, 180  
 Frost-bite, 188

## G

Ganglion, 81  
 Gangrene, 188  
 Gangrenous stomatitis, 37  
 Genitals, female, 139  
     male, 132  
 Genito-urinary organs, 6, 9  
 Gingivitis, 45  
 Glaucoma, 28  
 Goitre, 55  
 Gonorrhœa, 132  
 Gout, 85, 187  
 Granular lids, 25  
 Groin, tumours of the, 12  
 Gummata, 13, 41, 78, 177  
 Gums, diseases of the, 45

## H

Hæmatocele, 120, 123  
     labial, 140

Hæmatoma auris, 29  
 Hæmaturia, 107  
 Hæmorrhage from ear, 29  
     intracranial, 19  
     from scalp, 16  
 Hæmorrhoids, 5, 9, 143  
 Hand, affections of the, 82  
     injuries of, 10  
 Head, affections of, 13  
 Heart-disease, 52  
     sounds, 54  
 Hectic, 202  
 Hernia, 6, 9, 113, 116, 120,  
     121, 160  
     testis, 138  
 Hip, deformity of, 154  
     disease, 150  
 Herpes preputialis, 133  
     zoster, 14  
 Hordeolum, 24  
 Hydrarthrosis, 75  
 Hydrocele, 120  
     of cord, 113  
 Hydro-thorax, 53  
 Hypertrophy of gums, 46

## I

Ichthyosis linguæ, 41  
 Iliac abscess, 102, 113, 160  
 Impacted calculus, 125  
 Incarcerated hernia, 121  
 Incontinence of urine, 126  
 Ingrowing toe-nail, 187  
 Inguinal tumours, 113  
 Injuries about elbow, 76  
     about shoulder, 60  
 Innominate aneurism, 57  
 Interstitial keratitis, 27  
 Intestinal obstruction, 6, 9, 108  
 Intussusception, 109  
 Iritis, 27  
 Irreducible hernia, 121  
 Ischio-rectal abscess, 145  
 Ivory exostosis, 15



## J

- Jaw, dislocation of, 43
  - fracture of, 43
  - tumours of, 46
- Joints, diseases of, 5, 8

## K

- Keratitis, 27
- Kidney, tumour of, 101
- Knee, affections of the, 169
- Knock-knee, 174

## L

- Labium, affections of, 140
- Lachrymal abscess, 24
- Lameness in children, 149
  - in elderly people, 153
- Laryngeal dyspnœa, 52
- Leg, affections of the, 175
- Lipoma of nose, 33
- Locomotor ataxy, joint-affec-  
tion in, 75, 153
- Loose body in knee, 172
- Lordosis in hip-disease, 151
- Loss of voice, 54
- Lower limbs, the, 149
- Lymphadenoma, 55, 70, 114,  
117
- Lymphatitis, 70, 159

## M

- Male genitals, the, 132
- Melanosis, 189
- Meningocele, 13
- Menstruation, 7, 200
- Micturition, 6
- Mole, 21
- Mouth, affections of, 36
  - tumours of, 5
- Mucous cyst of lip, 37
  - tubercles, 36, 140

- Myeloid tumour, 46, 81, 174
- Myosis, 24

## N

- Nævus, 21
- Nail, affections of, 85
  - ingrowing, 84, 188
- Neck, affections of the, 55
  - of thigh-bone, fracture of,  
154
- Necrosis, 45, 68, 84, 163, 179
- Nephritis, acute, 129
- Neuroma, 78
- Nipple, the, 92
- Nodes, 15, 59, 73, 179
- Noma, 139
- Nose, affections of the, 33
- Nymphæ, adherent, 139

## O

- Œdema of scrotum, 136
- Œsophagus, stricture of, 5, 51
- Onychia, 84
- Opaque cornea, 27
- Ophthalmia, 26
- Orchitis, 123, 136
- Osteomyelitis, 197
- Otorrhœa, 30
- Ovarian tumour, 104
- Ozæna, 34

## P

- Painful defæcation, 147
- Palate, cleft, 36, 48
  - ulceration of, 48
- Palmar abscess, 83
- Paralysis, facial, 21
  - sixth nerve, 24
  - spinal, 193
  - third nerve, 23
- Paraphimosis, 133
- Parovarian cyst, 105
- Patella, dislocation of, 169
  - fracture of, 167

Perforating ulcer of foot, 187  
 Periostitis, acute, 68, 163  
     chronic, 69, 179  
 Peritonitis, 9  
 Perityphlitis, 103  
 Phantom tumour, 103  
 Pharynx, ulceration of, 50  
 Phimosis, 132  
 Phlebitis, 4, 71, 197  
 Phlyctenulæ, 26  
 Piles, 143  
 Pleurisy, 95  
 Polypus nasi, 35  
     recti, 145  
 Popliteal abscess, 165  
     aneurism, 165  
 Prolapsus recti, 145  
     uteri, 142  
 Prostate, enlarged, 127, 129  
 Psoas abscess, 102, 116, 159,  
     164  
 Psoriasis linguæ, 40  
 Ptosis, 23  
 Puffy tumour of scalp, 16  
 Pulse, 7  
 Pupil, contracted, 24, 27  
     dilated, 23, 28  
 Purulent discharge from ear,  
     30  
     from nose, 34  
 Pyæmia, 197, 202  
 Pyelitis, 130

## R

Radius, fracture of, 79  
 Ranula, 38  
 Rectum, affections of, 5, 143  
 Reducible hernia, 121  
 Respiration, 7  
 Retention of urine, 124  
 Rheumatism, 65  
 Rheumatoid arthritis, 65, 86,  
     153  
 Rickets, 80, 166, 180  
 Ruptured bladder, 108  
     gastrocnemius, 181  
     intestine, 106

Ruptured membrana tympani,  
     30  
     popliteal artery, 166  
     quadriceps, 167  
     tendo Achillis, 181  
     urethra, 108

## S

Sacro-iliac disease, 193  
 Sarcocoele, 120, 137  
 Scalp, 13  
     wounds of, 16  
     erysipelas of, 16  
 Scirrhus of breast, 89  
     of rectum, 148  
 Scrotal tumours, 119  
 Scrotum, affections of the, 135  
 Sebaceous cysts, 14  
 Secondary effects of concus-  
     sion, 19  
 Senile gangrene, 188  
 Shock, 18  
 Shoulder, injuries about, 60  
 Shoulder-joint, inflamed, 64  
     injuries near, 60  
 Skin, 7, 10  
 Skull, fracture of, 16  
     fracture of base of, 17  
 Soft chancres, 4, 135  
 Spina bifida, 190  
 Spine, injuries of, 11, 193  
 Sterno-mastoid, indurated, 56  
 Stomatitis, 37  
 Stone in bladder, 6, 126, 128  
     kidney, 128  
     urethra, 125  
     ureter, 128  
 Strangulated hernia, 122  
 Stricture of œsophagus, 5, 50  
     rectum, 5, 147  
     urethra, 6, 9, 126  
 Styte in eye, 24  
 Subclavian aneurism, 57  
 Subconjunctival ecchymosis,  
     25  
 Swallowing, difficulty of, 50  
 Synovitis, 74, 82, 171  
 Syphilitic sores, 135

## P



## T

- Tarsal cyst, 24  
 Teeth, the, 42  
     inflammation from, 44  
 Tenosynovitis, 81, 186  
 Testicle, retained, 103  
     tumours of, 9, 136  
 Tetanus, 198  
 Thigh, affections of the, 159  
 Thorax, affections of the, 93  
 Throat, the, 49  
 Tibia, periostitis of, 178  
     fracture of, 180  
 Tongue, the, 7, 39  
     affections of the, 39  
     tie, 39  
 Tonsillitis, 49  
 Tonsils, enlarged, 49  
     ulcerated, 50  
 Trichiasis, 25  
 Trochanter, abscess over, 164  
 Tubercle, 53  
 Tumours, 4, 7  
     abdomen, 99  
     breast, 89  
     groin, 112  
     jaws, 46  
     thigh, 159, 162, 164  
 Tympanites, 100, 110  
 Tympanum, abscess of, 31

## U

- Ulcer of cornea, 26  
     of face, 32

- Ulcer of leg, 175  
     mouth, 37, 38  
     nose, 33  
     rectum, 147  
     tongue, 41  
 Ulna, fracture of, 79  
 Ununited fractures, 5  
 Urethral discharges, 134  
 Urinary deposits, 130  
     function, the, 124  
 Urine, the, 7, 128  
 Uterine tumour, 104, 142

## V

- Vaginal discharges, 141  
 Varicocele, 6  
 Varicose veins, 177  
 Vascular navel, 97  
     urethra, 139  
 Venereal sores, 135, 140  
 Vertebrae, caries of, 56  
 Vomiting, 18, 110

## W

- Warts, venereal, 133, 141  
 Wasting of leg, 149  
 Whitlow, 82  
 Wound of knee, 170  
 Wry-neck, 56



# STUDENT'S GUIDE SERIES.

---

A New Series of Medical Text-Books Moderate in  
Size and Price.

---

*\* \* The following are now ready.*

**MEDICAL DIAGNOSIS.** By SAMUEL FENWICK, M.D., F.R.C.P.,  
Physician to, and Lecturer on Medicine at, the London Hospital.  
Fourth Edition. Fcap. 8vo, with 105 Engravings, 6s. 6d.

**SURGICAL ANATOMY.** By EDWARD BELLAMY, F.R.C.S.,  
Surgeon to, and Lecturer on Anatomy at, Charing Cross Hospital.  
Fcap. 8vo, with 50 Engravings, 6s. 6d.

**MATERIA MEDICA.** By JOHN C. THOROWGOOD, M.D. Lond.  
F.R.C.P., Lecturer on Materia Medica at the Middlesex Hospital.  
Fcap. 8vo, with Engravings, 6s. 6d.

**PRACTICE OF MEDICINE.** By MATTHEW CHARTERIS, M.D.,  
Professor of Medicine in Anderson's College, and Lecturer on Clinical  
Medicine in the Royal Infirmary, Glasgow. Second Edition. Fcap.  
8vo, with Engravings on copper and wood, 6s. 6d.

**PRACTICE OF MIDWIFERY.** By D. LLOYD ROBERTS, M.D.,  
F.R.C.P., Vice-President of the Obstetrical Society of London, Phy-  
sician to St. Mary's Hospital, Manchester. Second Edition. Fcap.  
8vo, with 111 Engravings, 7s.

**DENTAL ANATOMY AND SURGERY.** By HENRY E.  
SEWILL, M.R.C.S. Eng., L.D.S., late Dental Surgeon to the West  
London Hospital. Fcap. 8vo, with 77 Engravings, 5s. 6d.

**ZOOLOGY.** By ANDREW WILSON, Lecturer on Zoology, Edinburgh.  
Fcap. 8vo, with 29 Engravings, 6s. 6d.

**HUMAN OSTEOLOGY.** By W. W. WAGSTAFFE, F.R.C.S.,  
Assistant Surgeon to, and Lecturer on Anatomy at, St. Thomas's  
Hospital. Fcap. 8vo, with 23 Plates and 68 Engravings, 10s. 6d.


**DISEASES OF WOMEN.** By ALFRED L. GALABIN, M.D.,  
F.R.C.P., Assistant Obstetric Physician to Guy's Hospital. Fcap.  
8vo, with 63 Engravings. 7s. 6d.

**SURGICAL DIAGNOSIS.** By CHRISTOPHER HEATH, F.R.C.S.,  
Holme Professor of Clinical Surgery in University College, and  
Surgeon to University College Hospital. Fcap. 8vo, 6s. 6d.

---

J. & A. CHURCHILL, NEW BURLINGTON STREET.





J. & A. CHURCHILL'S  
MEDICAL CLASS BOOKS.

---

ANATOMY.

*BRAUNE*.—An Atlas of Topographical Anatomy, after Plane Sections of Frozen Bodies. By WILHELM BRAUNE, Professor of Anatomy in the University of Leipzig. Translated by EDWARD BELLAMY, F.R.C.S., and Member of the Board of Examiners; Surgeon to Charing Cross Hospital, and Lecturer on Anatomy in its School. With 34 Photo-lithographic Plates and 46 Woodcuts. Large imp. 8vo, 40s.

*FLOWER*.—Diagrams of the Nerves of the Human Body, exhibiting their Origin, Divisions, and Connexions, with their Distribution to the various Regions of the Cutaneous Surface, and to all the Muscles. By WILLIAM H. FLOWER, F.R.C.S., F.R.S., Conservator of the Museum of the Royal College of Surgeons. Second Edition, containing 6 Plates. Royal 4to, 12s.

*GODLEE*.—An Atlas of Human Anatomy: illustrating most of the ordinary Dissections; and many not usually practised by the Student. By RICKMAN J. GODLEE, M.S., F.R.C.S., Assistant-Surgeon to University College Hospital, and Senior Demonstrator of Anatomy in University College. With 48 Imp. 4to Coloured Plates, containing 112 Figures, and a Volume of Explanatory Text, with many Engravings, 8vo, £4 14s. 6d.

*HEATH*.—Practical Anatomy: a Manual of Dissections. By CHRISTOPHER HEATH, F.R.C.S., Holme Professor of Clinical Surgery in University College and Surgeon to the Hospital. Fourth Edition. With 16 Coloured Plates and 264 Engravings. Crown 8vo, 14s.



**ANATOMY**—*continued.*

**HOLDEN.**—**Human Osteology:** comprising a Description of the Bones, with Delineations of the Attachments of the Muscles, the General and Microscopical Structure of Bone and its Development. By LUTHER HOLDEN, F.R.C.S., Senior Surgeon to St. Bartholomew's and the Foundling Hospitals, and ALBAN DORAN, F.R.C.S., late Anatomical, now Pathological, Assistant to the Museum of the Royal College of Surgeons. Fifth Edition. With 61 Lithographic Plates and 89 Engravings. Royal 8vo, 16s.

*By the same Author.*

**A Manual of the Dissection of the Human Body.** Fourth Edition. Revised by the Author and JOHN LANGTON, F.R.C.S., Assistant Surgeon and Lecturer on Anatomy at St. Bartholomew's Hospital. With Engravings. 8vo, 16s.

ALSO,

**Landmarks, Medical and Surgical.** Second Edition. 8vo, 3s. 6d.

**MORRIS.**—**The Anatomy of the Joints of Man.**

By HENRY MORRIS, M.A., F.R.C.S., Surgeon to, and Lecturer on Anatomy and Practical Surgery at, the Middlesex Hospital. With 44 Plates (19 Coloured) and Engravings. 8vo, 16s.

**WAGSTAFFE.**—**The Student's Guide to Human**

**Osteology.** By WM. WARWICK WAGSTAFFE, F.R.C.S., Assistant-Surgeon to, and Lecturer on Anatomy at, St. Thomas's Hospital. With 23 Plates and 66 Engravings. Fcap. 8vo, 10s. 6d.

**WILSON — BUCHANAN — CLARK.**—**Wilson's**

**Anatomist's Vade-Mecum:** a System of Human Anatomy. Tenth Edition, by GEORGE BUCHANAN, Professor of Clinical Surgery in the University of Glasgow, and HENRY E. CLARK, M.R.C.S., Lecturer on Anatomy in the Glasgow Royal Infirmary School of Medicine. With 450 Engravings, including 26 Coloured Plates. Crown 8vo.

**Anatomical Remembrancer (the); or, Complete Pocket Anatomist.** Eighth Edition. 32mo, 3s. 6d.

---

*NEW BURLINGTON STREET.*



**BOTANY.**

**BENTLEY.**—A Manual of Botany. By Robert

BENTLEY, F.L.S., Professor of Botany in King's College and to the Pharmaceutical Society. With nearly 1200 Engravings. Fourth Edition. Crown 8vo. [In preparation.]

**BENTLEY AND TRIMEN.**—Medicinal Plants:

being descriptions, with original Figures, of the Principal Plants employed in Medicine, and an account of their Properties and Uses. By ROBERT BENTLEY, F.L.S., and HENRY TRIMEN, M.B., F.L.S. In 4 Vols., large 8vo, with 306 Coloured Plates, bound in half morocco, gilt edges, £11 11s.

---

**CHEMISTRY.**

**BERNAYS.**—Notes for Students in Chemistry;

being a Syllabus of Chemistry compiled mainly from the Manuals of Fownes-Watts, Miller, Wurz, and Schorlemmer. By ALBERT J. BERNAYS, Ph.D., Professor of Chemistry at St. Thomas's Hospital. Sixth Edition. Fcap. 8vo, 3s. 6d.

*By the same Author.*

**Skeleton Notes on Analytical Chemistry,**

for Students in Medicine. Fcap. 8vo, 2s. 6d.

**BLOXAM.**—Chemistry, Inorganic and Organic;

with Experiments. By CHARLES L. BLOXAM, Professor of Chemistry in King's College. Fourth Edition. With nearly 300 Engravings. 8vo, 16s.

*By the same Author.*

**Laboratory Teaching; or, Progressive**

Exercises in Practical Chemistry. Fourth Edition. With 83 Engravings. Crown 8vo, 5s. 6d.

**BOWMAN AND BLOXAM.**—Practical Chemistry,

including Analysis. By JOHN E. BOWMAN, formerly Professor of Practical Chemistry in King's College, and CHARLES L. BLOXAM, Professor of Chemistry in King's College. With 98 Engravings. Seventh Edition. Fcap. 8vo, 6s. 6d.

---

*NEW BURLINGTON STREET.*



**CHEMISTRY—continued.**

**CLOWES.**—Practical Chemistry and Qualitative Inorganic Analysis. An Elementary Treatise, specially adapted for use in the Laboratories of Schools and Colleges, and by Beginners. By FRANK CLOWES, D.Sc., Senior Science Master at the High School, Newcastle-under-Lyme. Third Edition. With 47 Engravings. Post 8vo, 7s. 6d.

**FOWNES AND WATTS.**—Physical and Inorganic Chemistry. Twelfth Edition. By GEORGE FOWNES, F.R.S., and HENRY WATTS, B.A., F.R.S. With 154 Engravings, and Coloured Plate of Spectra. Crown 8vo, 8s. 6d.

*By the same Authors.*

Chemistry of Carbon-Compounds, or Organic Chemistry. Twelfth Edition. With Engravings. Crown 8vo, 10s.

**LUFF.**—An Introduction to the Study of Chemistry. Specially designed for Medical and Pharmaceutical Students. By A. P. LUFF, F.I.C., F.C.S., Lecturer on Chemistry in the Central School of Chemistry and Pharmacy. Crown 8vo, 2s. 6d.

**TIDY.**—A Handbook of Modern Chemistry, Inorganic and Organic. By C. MEYMOTT TIDY, M.B., Professor of Chemistry and Medical Jurisprudence at the London Hospital. 8vo, 16s.

**VACHER.**—A Primer of Chemistry, including Analysis. By ARTHUR VACHER. 18mo, 1s.

**VALENTIN.**—Introduction to Inorganic Chemistry. By WILLIAM G. VALENTIN, F.C.S. Third Edition. With 82 Engravings. 8vo, 6s. 6d.

*By the same Author.*

A Course of Qualitative Chemical Analysis. Fifth Edition by W. R. HODGKINSON, Ph.D. (Würzburg), Demonstrator of Practical Chemistry in the Science Training Schools. With Engravings. 8vo, 7s. 6d.

ALSO,

Chemical Tables for the Lecture-room and Laboratory. In Five large Sheets, 5s. 6d.

---

NEW BURLINGTON STREET.



## CHILDREN, DISEASES OF.

**ELLIS.**—A Practical Manual of the Diseases of Children. By EDWARD ELLIS, M.D., late Senior Physician to the Victoria Hospital for Sick Children. With a Formulary. Fourth Edition. Crown 8vo. *[In preparation.]*

**SMITH.**—Clinical Studies of Disease in Children. By EUSTACE SMITH, M.D., F.R.C.P., Physician to H.M. the King of the Belgians, and to the East London Hospital for Children. Post 8vo, 7s. 6d.

*By the same Author.*

On the Wasting Diseases of Infants and Children. Third Edition. Post 8vo, 8s. 6d.

**STEINER.**—Compendium of Children's Diseases; a Handbook for Practitioners and Students. By JOHANN STEINER, M.D. Translated by LAWSON TAIT, F.R.C.S., Surgeon to the Birmingham Hospital for Women, &c., 8vo, 12s. 6d.

---

## DENTISTRY.

**SEWILL.**—The Student's Guide to Dental Anatomy and Surgery. By HENRY E. SEWILL, M.R.C.S., L.D.S., late Dental Surgeon to the West London Hospital. With 77 Engravings. Fcap. 8vo, 5s. 6d.

**SMITH.**—Handbook of Dental Anatomy and Surgery. For the Use of Students and Practitioners. By JOHN SMITH, M.D., F.R.S.E., Dental Surgeon to the Royal Infirmary, Edinburgh. Second Edition. Fcap. 8vo, 4s. 6d.

**STOCKEN.**—Elements of Dental Materia Medica and Therapeutics, with Pharmacopœia. By JAMES STOCKEN, L.D.S.R.C.S., late Lecturer on Dental Materia Medica and Therapeutics and Dental Surgeon to the National Dental Hospital. Second Edition. Fcap. 8vo, 6s. 6d.

---



**DENTISTRY—continued.**

**TAFT.**—A Practical Treatise on Operative Dentistry. By JONATHAN TAFT, D.D.S., Professor of Operative Surgery in the Ohio College of Dental Surgery. Third Edition. With 134 Engravings. 8vo, 18s.

**TOMES (C. S.).**—Manual of Dental Anatomy, Human and Comparative. By CHARLES S. TOMES, M.A., M.R.C.S., Lecturer on Anatomy and Physiology at the Dental Hospital of London. With 179 Engravings. Crown 8vo, 10s. 6d.

**TOMES (J. and C. S.).**—A Manual of Dental Surgery. By JOHN TOMES, M.R.C.S., F.R.S., and CHARLES S. TOMES, M.A., M.R.C.S. Second Edition. With 262 Engravings. Fcap. 8vo, 14s.

---

**EAR, DISEASES OF.**

**BURNETT.**—The Ear: its Anatomy, Physiology, and Diseases. A Practical Treatise for the Use of Medical Students and Practitioners. By CHARLES H. BURNETT, M.D., Aural Surgeon to the Presbyterian Hospital, Philadelphia. With 87 Engravings. 8vo, 18s.

**DALBY.**—On Diseases and Injuries of the Ear. By WILLIAM B. DALBY, F.R.C.S., Aural Surgeon to, and Lecturer on Aural Surgery at, St. George's Hospital. Second Edition. With Engravings. Fcap. 8vo, 6s. 6d.

**JONES.**—A Practical Treatise on Aural Surgery. By H. MACNAUGHTON JONES, M.D., Professor of the Queen's University in Ireland, Surgeon to the Cork Ophthalmic and Aural Hospital. With 46 Engravings. Crown 8vo, 5s.

*By the same Author.*

**Atlas of the Diseases of the Membrana Tympani.** In Coloured Plates, containing 59 Figures. With Explanatory Text. Crown 4to, 21s.

---

*NEW BURLINGTON STREET.*



## FORENSIC MEDICINE.

### *OGSTON.*—Lectures on Medical Jurisprudence.

By FRANCIS OGSTON, M.D., Professor of Medical Jurisprudence and Medical Logic in the University of Aberdeen. Edited by FRANCIS OGSTON, Jun., M.D., Assistant to the Professor of Medical Jurisprudence and Lecturer on Practical Toxicology in the University of Aberdeen. With 12 Plates. 8vo, 18s.

### *TAYLOR.*—The Principles and Practice of Medical Jurisprudence. By ALFRED S. TAYLOR, M.D., F.R.S., late Professor of Medical Jurisprudence to Guy's Hospital. Second Edition. With 189 Engravings. 2 Vols. 8vo, 31s. 6d.

*By the same Author.*

### A Manual of Medical Jurisprudence. Tenth Edition. With 55 Engravings. Crown 8vo, 14s.

ALSO,

### On Poisons, in relation to Medical Jurisprudence and Medicine. Third Edition. With 104 Engravings. Crown 8vo, 16s.

### *WOODMAN AND TIDY.*—A Handy-Book of Forensic Medicine and Toxicology. By W. BATHURST WOODMAN, M.D., F.R.C.P.; and C. MEYMOTT TIDY, M.B. With 8 Lithographic Plates and 116 Wood Engravings. 8vo, 31s. 6d.

---

## HYGIENE.

### *WILSON.*—A Handbook of Hygiene and Sanitary Science. By GEORGE WILSON, M.A., M.D., Medical Officer of Health for Mid Warwickshire. Fourth Edition. With Engravings. Crown 8vo, 10s. 6d.

---

NEW BURLINGTON STREET.



**HYGIENE**—*continued.*

**PARKES.**—A Manual of Practical Hygiene.

By EDMUND A. PARKES, M.D., F.R.S. Fifth Edition by F. DE CHAUMONT, M.D., F.R.S., Professor of Military Hygiene in the Army Medical School. With 9 Plates and 112 Engravings. 8vo, 18s.

*By the same Author.*

**Public Health:** being a Concise Sketch of

the Sanitary Considerations connected with the Land, with Cities, Villages, Houses, and Individuals. Revised by Professor WILLIAM AITKEN, M.D., F.R.S. Crown 8vo, 2s. 6d.

---

**MATERIA MEDICA AND THERAPEUTICS.**

**BINZ AND SPARKS.**—The Elements of Thera-

peutics: a Clinical Guide to the Action of Medicines. By C. BINZ, M.D., Professor of Pharmacology in the University of Bonn. Translated and Edited with Additions, in conformity with the British and American Pharmacopœias, by EDWARD I. SPARKS, M.A., M.B., F.R.C.P. Lond. Crown 8vo, 8s. 6d.

**OWEN.**—Tables of Materia Medica; com-

prising the Contents, Doses, Composition, and Manufacture of Pharmacopœial Preparations. By ISAMBARD OWEN, B.A., M.R.C.P., Medical Registrar and Lecturer on Botany to St. George's Hospital. Fourth Edition. Crown 8vo, 2s. 6d.

**ROYLE AND HARLEY.**—A Manual of Materia

Medica and Therapeutics. By J. FORBES ROYLE, M.D., F.R.S., and JOHN HARLEY, M.D., F.R.C.P., Physician to, and Joint Lecturer on Clinical Medicine at, St. Thomas's Hospital. Sixth Edition. With 139 Engravings. Crown 8vo, 15s.

**THOROWGOOD.**—The Student's Guide to

Materia Medica. By JOHN C. THOROWGOOD, M.D., F.R.C.P., Lecturer on Materia Medica at the Middlesex Hospital. With Engravings. Fcap. 8vo, 6s. 6d.

**WARING.**—A Manual of Practical Therapeu-

tics. By EDWARD J. WARING, M.D., F.R.C.P. Third Edition. Fcap. 8vo, 12s. 6d.

---

*NEW BURLINGTON STREET.*



**MEDICINE.**

**BARCLAY.**—A Manual of Medical Diagnosis.

By A. WHYTE BARCLAY, M.D., F.R.C.P., Physician to, and Lecturer on Medicine at, St. George's Hospital. Third Edition. Fcap. 8vo, 10s. 6d.

**CHARTERIS.**—The Student's Guide to the

Practice of Medicine. By MATTHEW CHARTERIS, M.D., Professor of Materia Medica, University of Glasgow; Physician to the Royal Infirmary. With Engravings on Copper and Wood. Second Edition. Fcap. 8vo, 6s. 6d.

**FENWICK.**—The Student's Guide to Medical

Diagnosis. By SAMUEL FENWICK, M.D., F.R.C.P., Physician to the London Hospital. Fourth Edition. With 106 Engravings. Fcap. 8vo, 6s. 6d.

*By the same Author.*

**The Student's Outlines of Medical Treat-**

ment. Fcap. 8vo, 7s.

**FLINT.**—Clinical Medicine : a Systematic Treatise

on the Diagnosis and Treatment of Disease. By AUSTIN FLINT, M.D., Professor of the Principles and Practice of Medicine, &c., in Bellevue Hospital Medical College. 8vo, 20s.

*By the same Author.*

**A Manual of Percussion and Auscultation ;**

of the Physical Diagnosis of Diseases of the Lungs and Heart, and of Thoracic Aneurism. Post 8vo, 6s. 6d.

**HALL.**—Synopsis of the Diseases of the Larynx,

Lungs, and Heart : comprising Dr. Edwards' Tables on the Examination of the Chest. With Alterations and Additions. By F. DE HAVILLAND HALL, M.D., Assistant-Physician to the Westminster Hospital. Royal 8vo, 2s. 6d.

**WHITTAKER.**—Students' Primer on the Urine.

By J. TRAVIS WHITTAKER, M.D., Clinical Demonstrator at the Royal Infirmary, Glasgow. With Illustrations, and 16 Plates etched on Copper. Post 8vo, 4s. 6d.



**MIDWIFERY.**

*BARNES.*—Lectures on Obstetric Operations, including the Treatment of Hæmorrhage, and forming a Guide to the Management of Difficult Labour. By ROBERT BARNES, M.D., F.R.C.P., Obstetric Physician to, and Lecturer on Diseases of Women, &c., at St. George's Hospital. Third Edition. With 124 Engravings. 8vo, 18s.

*CLAY.*—The Complete Handbook of Obstetric Surgery; or, Short Rules of Practice in every Emergency, from the Simplest to the most formidable Operations connected with the Science of Obstetricy. By CHARLES CLAY, M.D., late Senior Surgeon to, and Lecturer on Midwifery at, St. Mary's Hospital, Manchester. Third Edition. With 91 Engravings. Fcap. 8vo, 6s. 6d.

*RAMSBOTHAM.*—The Principles and Practice of Obstetric Medicine and Surgery. By FRANCIS H. RAMSBOTHAM, M.D., formerly Obstetric Physician to the London Hospital. Fifth Edition. with 120 Plates, forming one thick handsome volume. 8vo, 22s.

*ROBERTS.*—The Student's Guide to the Practice of Midwifery. By D. LLOYD ROBERTS, M.D., F.R.C.P., Physician to St. Mary's Hospital, Manchester. Second Edition. With 111 Engravings. Fcap. 8vo, 7s.

*SCHROEDER.*—A Manual of Midwifery; including the Pathology of Pregnancy and the Puerperal State. By KARL SCHROEDER, M.D., Professor of Midwifery in the University of Erlangen. Translated by CHARLES H. CARTER, M.D. With Engravings. 8vo, 12s. 6d.

*SWAYNE.*—Obstetric Aphorisms for the Use of Students commencing Midwifery Practice. By JOSEPH G. SWAYNE, M.D., Lecturer on Midwifery at the Bristol School of Medicine. Seventh Edition. With Engravings. Fcap. 8vo, 3s. 6d.

---

*NEW BURLINGTON STREET.*



## MICROSCOPY.

**CARPENTER.**—The Microscope and its Revelations. By WILLIAM B. CARPENTER, C.B., M.D., F.R.S. Sixth Edition. With more than 500 Engravings. Crown 8vo. [In preparation.]

**MARSH.**—Section-Cutting: a Practical Guide to the Preparation and Mounting of Sections for the Microscope, special prominence being given to the subject of Animal Sections. By Dr. SYLVESTER MARSH. With Engravings. Fcap. 8vo, 2s. 6d.

**MARTIN.**—A Manual of Microscopic Mounting. By JOHN H. MARTIN, Member of the Society of Public Analysts, &c. Second Edition. With several Plates and 144 Engravings. 8vo, 7s. 6d.

**WYTHE.**—The Microscopist: a Manual of Microscopy and Compendium of the Microscopic Sciences, Micro-Mineralogy, Micro-Chemistry, Biology, Histology, and Pathological Histology. By J. H. WYTHE, A.M., M.D., Professor of Microscopy and Biology in the San Francisco Medical College. Third Edition. With 205 Illustrations. Royal 8vo, 18s.

---

## OPHTHALMOLOGY.

**HIGGENS.**—Hints on Ophthalmic Out-Patient Practice. By CHARLES HIGGENS, F.R.C.S., Ophthalmic Assistant-Surgeon to, and Lecturer on Ophthalmology at, Guy's Hospital. Second Edition. Fcap. 8vo, 3s.

**JONES.**—A Manual of the Principles and Practice of Ophthalmic Medicine and Surgery. By T. WHARTON JONES, F.R.C.S., F.R.S., Ophthalmic Surgeon and Professor of Ophthalmology to University College Hospital. Third Edition. With 9 Coloured Plates and 173 Engravings. Fcap. 8vo, 12s. 6d.

**MACNAMARA.**—A Manual of the Diseases of the Eye. By CHARLES MACNAMARA, F.R.C.S., Surgeon to Westminster Hospital. Third Edition. With 7 Coloured Plates and 52 Engravings. Fcap. 8vo, 12s. 6d.



**OPHTHALMOLOGY**—*continued.*

**NETTLESHIP.**—*The Student's Guide to Diseases of the Eye.* By EDWARD NETTLESHIP, F.R.C.S., Ophthalmic Surgeon to, and Lecturer on Ophthalmic Surgery at, St. Thomas's Hospital. With 48 Engravings. Fcap. 8vo, 7s. 6d.

---

**PATHOLOGY.**

**JONES AND SIEVEKING.**—*A Manual of Pathological Anatomy.* By C. HANDFIELD JONES, M.B., F.R.S., and EDWARD H. SIEVEKING, M.D., F.R.C.P. Second Edition. Edited, with considerable enlargement, by J. F. PAYNE, M.B., Assistant-Physician and Lecturer on General Pathology at St. Thomas's Hospital. With 195 Engravings. Crown 8vo 16s.

**VIRCHOW.** — *Post-Mortem Examinations: a Description and Explanation of the Method of Performing them, with especial reference to Medico-Legal Practice.* By Professor RUDOLPH VIRCHOW, Berlin Charité Hospital. Translated by Dr. T. B. SMITH. Second Edition, with 4 Plates. Fcap. 8vo, 3s. 6d.

**WILKS AND MOXON.**—*Lectures on Pathological Anatomy.* By SAMUEL WILKS, M.D., F.R.S., Physician to, and Lecturer on Medicine at, Guy's Hospital; and WALTER MOXON, M.D., F.R.C.P., Physician to, and Lecturer on Clinical Medicine at, Guy's Hospital. Second Edition. With 7 Steel Plates. 8vo, 18s.

---

**PSYCHOLOGY.**

**BUCKNILL AND TUKE.**—*A Manual of Psychological Medicine: containing the Lunacy Laws, Nosology, Ætiology, Statistics, Description, Diagnosis, Pathology, and Treatment of Insanity, with an Appendix of Cases.* By JOHN C. BUCKNILL, M.D., F.R.S., and D. HACK TUKE, M.D., F.R.C.P. Fourth Edition, with 12 Plates (30 Figures). 8vo, 25s.

---

*NEW BURLINGTON STREET.*



**PHYSIOLOGY.**

**CARPENTER.**—Principles of Human Physiology. With Steel Plates and nearly 400 Engravings. By WILLIAM B. CARPENTER, C.B., M.D., F.R.S. Ninth Edition. Edited by Mr. Henry Power. 8vo. [Nearly ready.]

*By the same Author.*

**A Manual of Physiology.** With upwards of 250 Illustrations. Fifth Edition. Crown 8vo. [In preparation.]

**DALTON.**—A Treatise on Human Physiology : designed for the use of Students and Practitioners of Medicine. By JOHN C. DALTON, M.D., Professor of Physiology and Hygiene in the College of Physicians and Surgeons, New York. Sixth Edition. With 316 Engravings. Royal 8vo, 20s.

**FREY.**—The Histology and Histo-Chemistry of Man. A Treatise on the Elements of Composition and Structure of the Human Body. By HEINRICH FREY, Professor of Medicine in Zurich. Translated by ARTHUR E. BARKER, Assistant-Surgeon to the University College Hospital. With 608 Engavings. 8vo, 21s.

**FULTON.**—A Text-Book of Physiology, including Histology. By J. FULTON, M.D., Professor of Physiology and Sanitary Science in Trinity Medical College, Toronto ; Surgeon to the Toronto General Hospital. Second Edition, with 151 Engravings. 8vo, 15s.

**RUTHERFORD.**—Outlines of Practical Histology. By WILLIAM RUTHERFORD, M.D., F.R.S., Professor of the Institutes of Medicine in the University of Edinburgh ; Examiner in Physiology in the University of London. Second Edition. With 63 Engravings. Crown 8vo (with additional leaves for Notes), 6s.

**SANDERSON.**—Handbook for the Physiological Laboratory : containing an Exposition of the fundamental facts of the Science, with explicit Directions for their demonstration. By J. BURDON SANDERSON, M.D., F.R.S., Jodrell Professor of Physiology in University College ; E. KLEIN, M.D., F.R.S., Assistant-Professor in the Brown Institution ; MICHAEL FOSTER, M.D., F.R.S., Prælector of Physiology at Trinity College, Cambridge ; and T. LAUDER BRUNTON, M.D., F.R.S., Lecturer on Materia Medica at St. Bartholomew's Hospital Medical College. 2 Vols., with 123 Plates. 8vo, 24s.



**SURGERY.**

**BRYANT.** — *A Manual for the Practice of Surgery.* By THOMAS BRYANT, F.R.C.S., Surgeon to, and Lecturer on Surgery at, Guy's Hospital. Third Edition. With 672 Engravings (nearly all original, many being coloured). 2 vols. Crown 8vo, 28s.

**BELLAMY.** — *The Student's Guide to Surgical Anatomy; a Description of the more important Surgical Regions of the Human Body, and an Introduction to Operative Surgery.* By EDWARD BELLAMY, F.R.C.S., and Member of the Board of Examiners; Surgeon to, and Lecturer on Anatomy at, Charing Cross Hospital. Second Edition. With 76 Engravings. Fcap. 8vo, 7s.

**CLARK AND WAGSTAFFE.** — *Outlines of Surgery and Surgical Pathology.* By F. LE GROS CLARK, F.R.C.S., F.R.S., Consulting Surgeon to St. Thomas's Hospital. Second Edition. Revised and expanded by the Author, assisted by W. W. WAGSTAFFE, F.R.C.S., Assistant-Surgeon to St. Thomas's Hospital. 8vo, 10s. 6d.

**DRUITT.** — *The Surgeon's Vade-Mecum; a Manual of Modern Surgery.* By ROBERT DRUITT, F.R.C.S. Eleventh Edition. With 369 Engravings. Fcap. 8vo, 14s.

**FERGUSON.** — *A System of Practical Surgery.* By Sir WILLIAM FERGUSON, Bart., F.R.C.S., F.R.S., late Surgeon and Professor of Clinical Surgery to King's College Hospital. With 463 Engravings. Fifth Edition. 8vo, 21s.

**HEATH.** — *A Manual of Minor Surgery and Bandaging, for the use of House-Surgeons, Dressers, and Junior Practitioners.* By CHRISTOPHER HEATH, F.R.C.S., Holme Professor of Clinical Surgery in University College and Surgeon to the Hospital. Sixth Edition. With 115 Engravings. Fcap. 8vo. 5s. 6d.

*By the same Author.*

**A Course of Operative Surgery: with**  
Twenty Plates drawn from Nature by M. LÉVEILLÉ, and Coloured by hand under his direction. Large 8vo, 40s.

ALSO,

**The Student's Guide to Surgical Diag-**  
nosis. Fcap. 8vo, 6s. 6d.

---

*NEW BURLINGTON STREET.*



**SURGERY—continued.**

**MAUNDER.**—Operative Surgery. By Charles F. MAUNDER, F.R.C.S., late Surgeon to, and Lecturer on Surgery at, the London Hospital. Second Edition. With 164 Engravings. Post 8vo, 6s.

**PIRRIE.**—The Principles and Practice of Surgery. By WILLIAM PIRRIE, F.R.S.E., Professor of Surgery in the University of Aberdeen. Third Edition. With 490 Engravings. 8vo, 28s.

---

**TERMINOLOGY.**

**DUNGLISON.**—Medical Lexicon: a Dictionary of Medical Science, containing a concise Explanation of its various Subjects and Terms, with Accentuation, Etymology, Synonymes, &c. By ROBLEY DUNGLISON, M.D. New Edition, thoroughly revised by RICHARD J. DUNGLISON, M.D. Royal 8vo, 28s.

**MAYNE.**—A Medical Vocabulary: being an Explanation of all Terms and Phrases used in the various Departments of Medical Science and Practice, giving their Derivation, Meaning, Application, and Pronunciation. By ROBERT G. MAYNE, M.D., LL.D., and JOHN MAYNE, M.D., L.R.C.S.E. Fourth Edition. Fcap. 8vo, 10s.

---

**WOMEN, DISEASES OF.**

**BARNES.**—A Clinical History of the Medical and Surgical Diseases of Women. By ROBERT BARNES, M.D., F.R.C.P., Obstetric Physician to, and Lecturer on Diseases of Women, &c., at, St. George's Hospital. Second Edition. With 151 Engravings. 8vo, 28s.

**DUNCAN.**—Clinical Lectures on the Diseases of Women. By J. MATTHEWS DUNCAN, M.D., Obstetric Physician to St. Bartholomew's Hospital. 8vo, 8s.

**EMMET.**—The Principles and Practice of Gynæcology. By THOMAS ADDIS EMMET, M.D., Surgeon to the Woman's Hospital of the State of New York. With 130 Engravings. Royal 8vo, 24s.

---

*NEW BURLINGTON STREET.*



**WOMEN, DISEASES OF**—*continued.*

**GALABIN.**—The Student's Guide to the Diseases of Women. By ALFRED L. GALABIN, M.D., F.R.C.P., Assistant Obstetric Physician and Joint Lecturer on Obstetric Medicine at Guy's Hospital. With 63 Engravings. Fcap. 8vo, 7s. 6d.

**REYNOLDS.**—Notes on Diseases of Women. Specially designed for Students preparing for Examination. By J. J. REYNOLDS, M.R.C.S. Fcap. 8vo, 2s. 6d.

**SMITH.**—Practical Gynæcology: a Handbook of the Diseases of Women. By HEYWOOD SMITH, M.D., Physician to the Hospital for Women and to the British Lying-in Hospital. With Engravings. Crown 8vo, 5s. 6d.

**WEST AND DUNCAN.**—Lectures on the Diseases of Women. By CHARLES WEST, M.D., F.R.C.P. Fourth Edition. Revised and in part re-written by the Author, with numerous additions, by J. MATTHEWS DUNCAN, M.D., Obstetric Physician to St. Bartholomew's Hospital. 8vo, 16s.

---

**ZOOLOGY.**

**BRADLEY.**—Manual of Comparative Anatomy and Physiology. By S. MESSENGER BRADLEY, F.R.C.S., late Lecturer on Practical Surgery in Owen's College, Manchester. Third Edition. With 61 Engravings. Post 8vo, 6s. 6d.

**CHAUVEAU AND FLEMING.**—The Comparative Anatomy of the Domesticated Animals. By A. CHAUVEAU, Professor at the Lyons Veterinary School; and GEORGE FLEMING, Veterinary Surgeon, Royal Engineers. With 450 Engravings. 8vo, 31s. 6d.

**HUXLEY.**—Manual of the Anatomy of Invertebrated Animals. By THOMAS H. HUXLEY, LL.D., F.R.S. With 156 Engravings. Fcap. 8vo, 16s.

*By the same Author.*

Manual of the Anatomy of Vertebrated Animals. With 110 Engravings. Post 8vo, 12s.

**WILSON.**—The Student's Guide to Zoology: a Manual of the Principles of Zoological Science. By ANDREW WILSON, Lecturer on Natural History, Edinburgh. With Engravings. Fcap. 8vo, 6s. 6d.

---

NEW BURLINGTON STREET.









Riley Dunn & Wilson Ltd  
EXPERT CONSERVATORS & BOOKBINDERS



