Artistic anatomy / by Mathias Duval ; translated by Frederick E. Fenton.

Contributors

Duval, Mathias, 1844-1907.
Fenton, Frederick E.

Publication/Creation

London ; New York : Cassell, 1884.

Persistent URL

https://wellcomecollection.org/works/gthxs8pj

License and attribution

This work has been identified as being free of known restrictions under copyright law, including all related and neighbouring rights and is being made available under the Creative Commons, Public Domain Mark.

You can copy, modify, distribute and perform the work, even for commercial purposes, without asking permission.

Wellcome Collection
183 Euston Road
London NW1 2BE UK
T +44 (0)20 7611 8722
E library@wellcomecollection.org
https://wellcomecollection.org

ARTISTIC ANATOMY

MATHIAS DUVAL

22101420379

Wolf

Digitized by the Internet Archive
in 2014

https://archive.org/details/b20418449

THE FINE-ART LIBRARY.

EDITED BY JOHN C. L. SPARKES,

Principal of the National Art Training School, South Kensington Museum.

0. 1. 85
C

ARTISTIC ANATOMY.

BY

MATHIAS DUVAL,

MEMBER OF THE ACADEMY OF MEDICINE, ANATOMICAL PROFESSOR AT THE SCHOOL OF FINE ART, FELLOW OF THE FACULTY OF MEDICINE, DIRECTOR OF THE ANTHROPOLOGICAL LABORATORY AT THE SCHOOL FOR HIGHER STUDIES, PARIS.

TRANSLATED BY

FREDERICK E. FENTON, M.R.C.P.E.,

FELLOW OF THE MEDICAL SOCIETY OF LONDON, AND MEMBER OF THE WEST LONDON MEDICO-CHIRURGICAL SOCIETY.

CASSELL & COMPANY, LIMITED:

LONDON, PARIS & NEW YORK.

1884.

[ALL RIGHTS RESERVED.]

M15165

WELLCOME INSTITUTE LIBRARY

Coll.	welMOmec
Call No.	QS4
	1881
	D98p3E

AUTHOR'S PREFACE.

THIS little work is an epitome of a course of lectures which for about ten years I had the honour of delivering at the École des Beaux Arts. If during that time I have arrived at a right understanding of the teachings of anatomy, I owe it to the great interest taken in the subject by my listeners of all ages; and my first duty is to thank them for their free interchange of ideas with me, thus enabling me to understand their requirements and the mode of answering them. But if the mode of exposition I have adopted is to be rendered clear to a constantly renewed audience, I must, in publishing this work, first explain to the reader how the lectures are to be used, and the principles which guided me in their production.

This summary of anatomy is intended for those artists who, having commenced their special studies, have drawn the human form either from the antique or from the living model—who, in a word, have already what may be termed a general idea of forms, attitudes, and movements. It is intended to furnish them with a scientific notion of those forms,

attitudes, and movements. Thus it is far less a description of the forms of a particular region than the anatomical explanation of those forms, and of their modifications in a state of repose or movement, that we have in view. That is why, instead of proceeding from the superficial parts to the deeper organs of the skeleton, we take the latter as the starting-point of our studies. In this way alone can we determine the laws which govern the reciprocal movements of the segments of the members, and the movements of the members with regard to the trunk, as also the reciprocal action of these segments towards each other and in relation to the whole body.

When to these fundamental notions is added the knowledge of the muscular masses which move these bones, the artist will at once be enabled to analyse through the skin as through a transparent veil the action of the parts which produce the forms with their infinite variety of character and movement.

This method of teaching, which may be said to proceed by synthesis, differs from that followed by the generality of works on this subject—books which treat by analysis. We make special allusion to the treatise of Gerdy,* which is about the most careful

* P. N. Gerdy: "Anatomy of the Forms of the Human Body for Painting, Sculpture, and Singing." Paris, 1829.

work on plastic anatomy yet published, but which errs in a somewhat too lengthy description of the exterior form, whilst sufficient space is not devoted to explaining the anatomical reasons of those forms. On the other hand, the remaining anatomical works in the hands of the students in our art schools generally comprise a volume of text and an illustrated atlas.* Under these conditions, may I be allowed to remark, somewhat severely, it may be, that our young artists study the atlas by copying and re-copying the plates, but do not read the text. Thus it will be understood why, in this work, a different method has been pursued; and the fact of the plates being intermixed with the text, and in such a way that they cannot well be understood without the aid of the accompanying pages, will in all probability result in the student thoroughly and carefully perusing the text.

Passing on to the manner of using the present work, we must acknowledge that reading anatomical details is at first dry; it will always be so, unless proceeded with in a simple and systematic manner. In the oral courses, the lecturer, handling the objects, and aided by his improvised drawings on the black-

* It is not always thus abroad. Thus in Germany there is the work of F. Harless ("Lehrbuch der Plastischen Anatomie für Akademische Anstalten." Stuttgart, 1876; 2nd edit.)

board, can make the most complex parts interesting; and by adroit repetitions and varied illustrations, fix the attention and render the subject comprehensible, whereas it is quite different in a written description. In this case it is the reader who must animate the text for himself, by examining and manipulating the parts needful for the elucidation of the descriptions. For this purpose a skeleton and a good plastic figure will suffice. On the cast, with the aid of the plates which accompany the text, it will be easy to follow the course of the muscles; and in this way alone will the study of them become profitable, the student being enabled to examine the model on different sides. By handling the bones, by placing the articulating surfacial in contact, the dry descriptions of articulated mechanism will take a tangible form, and will henceforth remain impressed on the memory. Notwithstanding our diagrams of the movements of pronation and supination for example, it is only by handling the bones of the fore-arm that the student will be enabled to fully appreciate the marvellous mechanism by which the rotation of the radius round the ulna is effected, allowing the hand to present alternately its palmar and dorsal surface; and the same is the case as regards the skeleton of the foot and head, and the movements of the lower jaw, &c.

The artist will find in this book some pages devoted to the *facial angle*, to the forms of the head, *brachycephalic* and *dolichocephalic* heads, and to some other questions of *anthropology*, and will doubtless thank us for having considered here ideas which are daily becoming familiar to the general public.

Our only regret concerning these anthropological studies is that the limits of this volume did not permit us to go deeper into the teachings of the anthropological laboratory, the direction of which was confided to me after the loss of our illustrious master, Broca.

I take this opportunity of expressing my gratitude to my excellent master, Professor Sappey, who allowed me to borrow from his magnificent treatise on anatomy the figures on osteology and myology which constitute the chief merit of this work; and to my friend and colleague, E. Cuyer, whose skilful pencil reproduced the figures from the photographic atlas of Duchenne, as well as the two illustrations of the Gladiator, and the sundry diagramatic drawings which complete the theoretical explanations of the text.

M. DUVAL.

CONTENTS.

CHAPTER PAGE

I. INTRODUCTION.—PLASTIC ANATOMY: ITS HISTORY, IMPORTANCE, AND OBJECTS—ORDER OF THESE STUDIES—DIVISION OF SUBJECT 1

First Part.—OSTEOLOGY.

II. OSTEOLOGY AND THE SCIENCE OF JOINTS IN GENERAL —NOMENCLATURE—VERTEBRAL COLUMN . . 13

III. SKELETON OF THE TRUNK (THORAX) — STERNUM— RIBS—THORAX AS A WHOLE 30

IV. SKELETON OF SHOULDER—CLAVICLE—SCAPULA—HEAD OF HUMERUS—SHOULDER JOINT 43

V. HUMERUS AND ELBOW JOINT 55

VI. SKELETON OF FORE-ARM—RADIUS AND ULNA—MOVEMENTS OF PRONATION AND SUPINATION . . 64

VII. SKELETON OF THE HAND—WRIST (CARPUS)—HAND AND FINGERS (METACARPAL BONES AND PHALANGES) —PROPORTIONS OF THE UPPER LIMB—BRACHIAL INDEX—EGYPTIAN CANON 74

VIII. SKELETON OF THE HIPS—PELVIS (ILIAC BONES AND SACRUM)—THE PELVIS ACCORDING TO SEX . . 91

IX. THE FEMUR AND THE ARTICULATION OF THE HIPS— PROPORTIONS OF THE HIPS AND SHOULDERS . 104

X. THE FEMUR AND THE ARTICULATION OF THE KNEE JOINT; THE SHAPE OF THE REGION OF THE KNEE 122

XI. SKELETON OF THE LEG: TIBIA AND FIBULA, THE MALLEOLI OR ANKLES—GENERAL VIEW OF THE SKELETON OF THE FOOT; TIBIO TARSAL ARTICULATION 137

XII. SKELETON OF THE FOOT; TARSUS (CALCANEUM); METATARSUS; TOES AND FINGERS—PROPORTIONS OF THE INFERIOR MEMBERS—THE FOOT AS A COMMON MEASURE 146

CHAPTER PAGE

XIII. SKELETON OF THE HEAD: SKULL (OCCIPITAL, PARIETAL, FRONTAL, TEMPORAL); SHAPES OF THE SKULL (DOLICHOCEPHALIC AND BRACHYCEPHALIC HEADS) 155

XIV. SKELETON OF THE FACE: THE ORBITAL CAVITIES; LOWER JAW; TEETH—CAMPUS FACIAL ANGLE . 165

Second Part.—MYOLOGY.

XV. OF THE MUSCLES IN GENERAL—MUSCLES OF THE TRUNK: ANTERIOR REGION (PECTORALIS MAJOR; THE OBLIQUE AND RECTI MUSCLES OF THE ABDOMEN) 181

XVI. MUSCLES OF THE BACK: TRAPEZIUS, LATISSIMUS DORSI, AND TERES MAJOR MUSCLES . . . 195

XVII. MUSCLES OF THE SHOULDER: DELTOID: SERRATUS MAGNUS—THE HOLLOW AND SHAPE OF THE ARMPIT 205

XVIII. MUSCLES OF THE ARM: BICEPS; CORACO-BRACHIALIS; BRACHIALIS ANTICUS; TRICEPS—SHAPE OF THE ARM 214

XIX. MUSCLES OF THE FORE-ARM, MUSCLES ANTERIOR: EXTERNAL AND POSTERIOR SUPERFICIAL . . 222

XX. THE DEEP POSTERIOR MUSCLES OF THE FORE-ARM (ANATOMICAL SNUFF-BOX) — MUSCLES OF THE HAND 233

XXI. MUSCLES OF THE PELVIS, THE GLUTEAL MUSCLES; FASCIA LATA.—MUSCLES OF THE THIGH: SARTORIUS, TRICEPS, ADDUCTORS, &c. . . . 240

XXII. MUSCLES OF THE LEG—TENDON ACHILLES—MUSCLES OF THE FOOT 255

XXIII. MUSCLES OF THE NECK: STERNO-CLEIDO-MASTOID, INFRA-HYOID, AND SUPRA-HYOID MUSCLES . . 268

XXIV. MUSCLES OF THE HEAD—MUSCLES OF MASTICATION —MUSCLES OF EXPRESSION: HISTORY (LEONARDO DA VINCI; HUMBERT DE SUPERVILLE; DUCHENNE OF BOULOGNE, AND DARWIN) 277

XXV. MUSCLES OF EXPRESSION—POSSIBLE AND IMPOSSIBLE COMBINATIONS OF CERTAIN CONTRACTIONS OF THE MUSCLES OF THE FACE 294

ARTISTIC ANATOMY.

CHAPTER I.

INTRODUCTION.

Anatomy in general; the anatomy of the external forms of man: physiology of the same. Origin of the knowledge of the Greek artists of the anatomy of the external forms; the influence of gymnastics upon Greek art. The Renaissance and anatomical study: Mundini de Luzi (1316). — The anatomical studies of Leonardo da Vinci, Michael Angelo, and Raphael. Titian and André Vesale. The anatomical course of the School of Painting (1648). What the artist requires in the study of anatomy: proportions, forms (or contours), attitudes, movements. The order of these studies; divisions of the subject.

ANATOMY, as the derivation of the word indicates (from *ἀνὰ*, across, and *τομὴ*, section), is the study of the parts composing the body—muscles, bones, tendons, ligaments, various viscera, &c.—parts which we separate one from the other by dissection, in order to examine their shapes and their relations and connections.

This study may be accomplished in various ways: (1) from a philosophical and comparative point of view, by seeking the analogies and differences that the organs present in animals of different species—which is called *Comparative Anatomy;* (2) from a

practical point of view, by seeking out the arrangement of organs, the knowledge of which is indispensable to the physician and surgeon—this is called *Surgical* or *Topographical Anatomy;* (3) by examining the nature and arrangement of the organs which determine the external forms of the body—this is *Plastic Anatomy*, called also the *Anatomy of External Forms*, the *Anatomy of Artists*. It is the anatomy of external forms that we shall study here; but as the artist ought to know not only the form of the body in repose, or in the dead subject, but also the principal changes of form in the body when in a state of activity, of movement, and of function, and should understand the causes which determine these changes, plastic anatomy ought to be complemented by a certain amount of knowledge of the functions of the organs, *e.g.*, muscles and articulations; so that under the title of anatomy of the external forms of man we shall study at the same time the anatomy and the physiology of the organs which determine these forms. We should be contending for what has been long since conceded, were we to endeavour to show to what an extent the studies of anatomy and physiology are indispensable to the artist, who seeks to represent the human form under many and various types of action. Nevertheless, it may be useful to explain how the *chefs-d'œuvre* of ancient art have been produced with admirable anatomical exactness, by men who certainly had not gone through any anatomical studies, and to show what special conditions aided them to acquire, by constant practice, the knowledge that we

are obliged to seek day by day in the study of anatomy.

The Greek sculptors have reproduced the human form with marvellous anatomical exactness; in fact, the works of Phidias (the *Theseus* and the *Ilissus*), those of Myron (the *Discobolus*), those of Lysippus and of Praxiteles (the *Sleeping Fawn*), those of Agasias (the *Fighting Gladiator*), and other masterpieces given as models in all the schools of art, are such that it is impossible to find fault with them, or to discover in them the least inexactitude, either from an anatomical or a physiological point of view;* in fact, not only are the muscles, for example, prominent exactly in their places, but more than that, these prominences are differently accentuated in corresponding muscles on the different sides, according to the nature of the movement; one side will present the muscles swelled up in a state of contraction, or the muscles may be in repose, that is, relaxed and relatively flattened. At the time when these works of art were produced, the study of anatomy, or even the dissection of the human body, had not yet been attempted; the respect in which the dead body was held was such, that the physicians themselves, who should have been able to justify their motives for this study, had never as yet dissected a human body; in order to supply this want of direct knowledge Hippocrates had dissected animals, and

* We must look for other reasons than ignorance or indifference to explain the fixed scapulæ in pre-Phidian sculpture or the exaggerated forms given to the extensor brevis of the foot and other muscles. This qualification is necessary to this general statement.—Ed.

had arrived at certain conclusions by the analogy that exists between the organs of quadrupeds and those in man. Galen himself dissected monkeys only, seeking to confine his examination to animals, whose anatomical construction might be considered as most closely resembling that of man. Galen never possessed a human skeleton, for in a passage in his anatomical works, he states the pleasure that he found in studying at last some human bones that had been deposited in a marshy place by a river which had overflowed its banks. We seem then to have a singular contradiction between these two facts, as we know on the one hand, that the Greek artists have shown in their works a most rigorous anatomical exactitude, whilst on the other hand, neither they nor their contemporary physicians and surgeons had made a study of the anatomy of man by the practice of dissection.

But this contradiction disappears altogether when we examine the conditions which permitted those artists to have constantly before their eyes the nude human body, living and in motion, and so set them to work to analyse the forms, and thus to acquire by the observation of the mechanism of active muscular changes, an empirical knowledge, as precise as that which is now obtained by the accurate study of anatomy and physiology. It is sufficient, in fact, to recall to mind the extreme care the ancients gave to the development of strength and of physical beauty by gymnastic exercises. In Homer we see the heroes exercising themselves in

racing, in quoit throwing, and in wrestling; later we come to the exercise of the athletes who trained themselves to carry off the palm in the Olympic games; and it is evident, in spite of the ideas that we hold now respecting wrestlers and acrobats, that the profession of an athlete was considered a glorious one, as being one which not only produced a condition of physical beauty and high character, but constituted in itself a true nobility. Thus the life of the gymnast came to exercise a decisive influence on Greek art. The prize of the conqueror in the Olympic games was a palm, a crown of leaves, an artistic vase; but the chief glory of all was that the statue of the victor was sculptured by the most celebrated artist of the time. Thus Phidias produced the handsome form of Pantarces, and these athletic statues form almost the only archives of the Olympiads, upon which Emeric David was able to reconstruct his Greek chronology. From these works, which became ideals of strength and beauty, the artist had long been able to study his model, which he saw naked every day, not only before his exercises, whilst rubbing himself over with oil, but during the race, or the leaping match, which showed the muscles of the inferior extremities, or during the throwing of the quoit, which made the contractions of the muscular masses of the arm and the shoulder prominent; and during the wrestling matches, which from the infinite varieties of effort, successively brought all the muscular powers into play. Was it then surprising, that the images of the gods destitute of movement and of life, which

had so long satisfied the religious sentiment of the people, were succeeded by artistic representations of man in action in statues such as could embody the idea of strength and beauty, studies of the living statues of the gymnasium. Further we shall see the decline of art proceed side by side with the abandonment of the exercises of the gymnasium. Much later, in the Middle Ages, art awoke and embodied ideas in figures without strength and life indeed, but which nevertheless express in a marvellous manner the mysterious aspirations of the period ; but these have not anything in common with the realistic representation of the human form well developed and active, as seen in Greek art. At the time of the Renaissance, artists not having any longer a living source of study in athletic sports, recognised the necessity of seeking for more precise knowledge in the *anatomical* study of the human body, in addition to the inspiration drawn from the study of the antique, and thus we see that the revival of the plastic arts came about at the time of the introduction more or less regular of the practice of dissection. This was not brought about without some difficulty.

In the year 1230, Frederic II., Emperor of Germany and King of the Two Sicilies, passed a law prohibiting the practice of medicine without the practitioners having first studied the anatomy of the human body. In spite of two papal excommunications hurled against the author of this edict, dissections were henceforth regularly pursued in Italy ; and one century later — in the year 1316—Mundini de Luze was able to write the

first treatise on human anatomy, containing descriptions made from studies of the dead body. This treatise was printed in 1478. Artists rivalled physicians in the ardour with which they pursued their anatomical studies; and it may be said that all the painters and sculptors in the fifteenth century gave most careful attention to dissection, or at least studied demonstrations made upon the dead body, for all have left amongst their drawings studies that leaves no doubt on this head. Among the great masters it may be noted that Leonardo da Vinci (1452—1519), has left thirteen portfolios of various drawings and studies, among which are numerous anatomical studies of remarkable fidelity. The greater number of these were taken from Milan by the French in 1796, and afterwards they were in part restored to Italy, some of them, however, went to enrich the British Museum in London, and were published by

FIG. 1.

Reproduction of a drawing of an anatomical study by Leonardo de Vinci. (Choulant's work, page 8.) This design represents the minute dissection of the muscles of the lateral region of the neck and trunk.

Chamberlain.* In Fig. 1 is reproduced one of these anatomical drawings. It shows with what care—perhaps with over-scrupulous care—the illustrious master endeavoured to separate by dissection the various fasciculi of pectoral muscle, deltoid, and sterno-cleido mastoid. It may be noted also that in the *Treatise on Painting* Leonardo da Vinci devotes numerous chapters to the description of the muscles of the body, the joints of the limbs and of the "cords and small tendons which meet together when the muscles contract to produce its action," &c.; and finally, in this same *Treatise on Painting*, he makes allusion at different times to a *Treatise on Anatomy*, which he intended to publish, and for which he had gathered together numerous notes. These are fortunately preserved in the Royal Library at Windsor.

Michael Angelo also (1475—1564) made at Florence many laborious studies of dissections, and has left among his drawings beautiful illustrations of anatomy, of which several have been published in Choulant's work, and by Seroux d'Agincourt.† Finally, we have numerous drawings by Raphael himself, as proof of his anatomical researches, among which we ought to mention as particularly remarkable, a study of the skeleton intended to give him the exact indication of the direction of the limbs

* See Ludwig Choulant. *Gesichte und Bibliographie des Anatomeschen Abbildungen.* Leipzig: 1852. (A very curious work wherein is found much information respecting the connection of anatomy with the plastic arts.)

† Seroux D'Agincourt. *History of Art by its Monuments.* Paris: 1811, Vol. i., p. 177.

and the position of the joints for a figure of the swooning Virgin in his painting of the Entombment (Choulant, p. 15). We cannot end this short enumeration without quoting further the names of Titian and André Vesale, in order to show into what intimate relations artists and anatomists were brought by their common studies. Titian, in fact, is considered the real author of the admirable figures which illustrate the work—"De Humani Corporis Fabrica"—of the immortal anatomist, André Vesale, justly styled the restorer of anatomy. It is necessary, however, to add that though some of the drawings are by Titian, the greater number were executed by his pupil, Jean Calcar, as is pointed out in the preface to the edition of the work published at Bâle in 1543.

The renaissance of the plastic arts and that of anatomy were therefore simultaneous, and closely bound up one with the other; ever since that time it has been generally recognised that it is necessary to get by anatomical study that knowledge of form which the Greeks found themselves able to embody in consequence of the opportunities they had of studying the human figure in the incessant exercises of the gymnasium. Again, in 1648, when Louis XIV. founded at Paris the *Académie de Peinture et de Sculpture*, which later on took the title of the *École des beaux-arts*, two sections of study were instituted side by side with the studios properly so called, for imparting to the pupils instruction considered as fundamental, and indispensable to the

practice of art. These were the sections of perspective and anatomy.

It is not our place to plead, otherwise than by the preceding historical considerations, the cause of anatomy in its relation to painting and sculpture; but we ought at least to examine what method is likely to prove the most useful for its study. If each anatomical detail does not correspond to an artistic need we are liable in following any treatise written with other than an artistic aim, to be entangled in superfluous names and into useless descriptions; while at the same time we might neglect details which are to the artist of great importance, although considered of secondary value by authors who have written especially for students in medicine.

We ought, then, to ask ourselves, in the first place, what are the ideas that the artist should seek for in his study of anatomy? To this question all will reply that the ideas of proportion, of form, of attitudes and movements, are those in which anatomy is relied upon to furnish precise rules; and as the expression of the passions, either in painting or sculpture, cannot be reproduced except by various changes in the general attitude of the body, and in the special mechanism of the physiognomy moved by the muscles, we must conclude that our study should deal not only with proportions, form, attitudes and movements, but also with the expression of the emotions and passions. This, then, is the object to be attained. Suppose we try to accomplish it by examining in a first series of studies all that

belongs to proportions; afterwards, in a second series, all that has relation to form; in a third, attitudes, &c. Such an order of proceeding, logical though it be, will have the disadvantage of causing numerous repetitions, and the more serious inconvenience of artificially separating parts which in the structure of the body are intimately connected. Thus, form is determined sometimes by osseous prominences, sometimes by the soft parts, which may be muscular or tendinous. Attitudes are determined by the muscles; but these are subject to laws which result from the position and action of the joints; so with movements, in the expression of which it is necessary to consider, at the same time, what the conformation of the osseous levers (the direction of the bones and their articulation) allows, as well as that which the muscles accomplish, also the direction of the muscles and the differences of shape produced by their swelling and tension in action, as well as when the antagonist muscles are relaxed. Proportions themselves cannot be defined without an exact knowledge of the skeleton, for it is the bones alone which should furnish us with the marks from which to take measurements. A knowledge of the bones and of their articular mechanism is indispensable to us, that we may guard ourselves against being deceived in certain apparent changes of length in the limbs when certain movements take place.

We see, then, that all the ideas previously enumerated as proportion, form, attitude, movement, depend on the study of the skeleton and of the muscles.

It will thus be easiest and most advantageous to proceed in the following manner:—We will first of all study the skeleton, which will teach us the direction of the axis of each part of the limbs, the relative lengths and proportions of these portions, and the osseous parts which remain uncovered by the muscles, and show beneath the skin the shape and the mechanism of the articulations in their relation to movements and attitudes. We shall then study the muscles, and endeavour to know their shapes, at the same time that we complete the knowledge we shall have acquired of attitudes and movements. In the third place, we will attempt the analysis of the expression of the passions and emotions; and the study of the muscles of the face, of which the mechanism in the movements of the physiognomy is so special, that it would be inconvenient to attempt to treat it with that of the muscles of the trunk and limbs.

First Part.—THE BONES.

CHAPTER II.

THE SKELETON, ARTICULATIONS, PROPORTIONS.

Osteology and *Arthrology*.—The method of anatomical nomenclature: Parts on the median line, single and symmetrical; the lateral parts in pairs; the meaning of the terms *internal* and *external*.—Of the bones in general: the long bones (shafts and extremities); the flat bones (surfaces, borders); the short bones.—Prominences of bone (processes, spines) cavities and depressions of bone (fossæ, grooves).—Bone and cartilage.—The axis of the skeleton: the vertebral column.—The vertebræ (bodies, transverse processes, spinous processes, &c.)—Cervical region (seven vertebræ), Dorsal (twelve vertebræ), Lumbar (five vertebræ).—Articulations of the vertebræ.—Movements of the head (atlas and axis).—The curves of the vertebral column.—Outline of the posterior aspect of the column. Proportions.

In view of what we have already said it will be evident that, in studying the skeleton, we shall be examining a great number of forms and considering the mechanism of movements and attitudes, while at the same time we are acquiring a knowledge of the proportions of the body. This suffices to show the importance of *Osteology*, or the study of bones (ὀστέον, bone; λόγος, description), and of *Arthrology*, or the study of joints (ἄρθρον, a joint): we may say, in

fact, to use a formula which well expresses the physiological functions of those parts, that the bones are the levers of movement, and that the articulations represent the fixed points or fulcrums of these levers; while the powers which produce motion are represented by the muscles.

Before attempting the details of the different parts of the skeleton, it is necessary to consider the method of nomenclature, so that by the employment of proper terms, we may make the descriptions which follow more easy.

In the first place, in anatomy, in the description of the bones, as in those of other organs, we have to consider the relation of the portion under consideration with the rest of the body: and thus each bone, as well as the other organs or their parts, will be found under one or other of two different conditions: either it belongs to the median portion of the body, which is when the antero-posterior vertical plane, passing through the axis of the body, divides it into two similar segments; or else it is situated outside this median plane. As a type of the first class, we will take the *sternum* (see fig. 7, p. 31); this is a central single bone; it has no fellow, and is composed of two symmetrical portions, one part on the right and one part on the left; as a type of the second class, we will take the *humerus* (fig. 12, p. 49), which is a bone situated at the side and one of a pair, inasmuch as there are two, one on the right and one on the left of the median plane. From these two examples it is easy to understand that for the

description of each *single and symmetrical* bone, it will be necessary to speak of anterior parts or surfaces (looking at the anterior portion of the body), of the posterior parts (looking from behind), of the lateral portions (right and left), finally, of parts superior and inferior, (in the case of the sternum a *superior* and *inferior extremity*): on the other hand, in the description of a *double* and *non-symmetrical* bone, we shall also have to speak as heretofore of parts superior and inferior, anterior and posterior; but instead of two similar symmetrical portions, one on each side of an imaginary line, it has two dissimilar halves, of which one looking towards the median plane, towards the axis of the body, is called the *internal* part, and the other looking to the outer side (as away from the axis) is called the *external* part. It is necessary, for brevity and accuracy, to clearly comprehend the meaning of these terms in descriptive anatomy (anterior and posterior, internal and external, superior and inferior) which serve to show the relation of the parts to the skeleton as a whole.

After this first division of bones into single and median, and into double and lateral, if we glance at the skeleton (Fig. 2), it seems at first sight that the various bones present an infinite variety of shape, and defy classification or nomenclature; careful attention however, will show us that they may be all included in one of the following three classes—viz., the long bones, the flat, or broad bones, and the short bones.

The long bones, which usually act as the axes

of the limbs (*e.g.*, the *humerus femur tibia*, &c.) are composed of a central portion, cylindrical or prismatic in shape, called the *body*, *shaft*, or *diaphysis* (διαφύω, to be between), and of two extremities, or *epiphyses* (ἐπιφύω, to be at the end), usually marked by protuberances and articular surfaces. The flat bones (*e.g.*, the *shoulder-blade* and the *iliac bone*) are formed of osseous plates, on which are described *surfaces*, *borders*, and *angles*, all easy to understand with special explanations. Finally, the small bones, which are found all together in the median portion and centre of the skeleton in the vertebral column and in the extremities of the limbs, the hand and foot, present a form more or less wedge-shaped, of which we describe surfaces and borders.

Whether the bone be long, flat, or short, it presents prominences and depressions. The projecting portions of bone are called by various names—*tuberosities*, *protuberances*, *processes*, *apophyses*, *crests*, *spines*. To some of these names is added an adjective, which shows, more or less exactly, the form of the process or projection. Thus we speak of a *spinous process*, *mastoid process* (μαστὸς, a nipple; εἶδος, form), *styloid process*, &c. The cavities are called by various names—*fossa*, *depression*, *groove*, *foramen*, *sinus*, *canal*, &c. To these also are added names which indicate their shape, as the *digital fossa*, from its resemblance to the imprint of the tip of the finger on a soft body, the *glenoid cavity* (γλήνη, cavity), the *cotyloid cavity* (χοτύλη, a basin); but more frequently

still, the added adjective bears allusion to a connection of the cavity with certain organs, as the *bicipital groove*, that which contains the tendons of the biceps, the *canine fossa*, as corresponding to the root of the canine tooth.

In certain portions, bone, strictly so called, characterised by hardness, solidity, and whiteness of colour, is found in continuation with a substance which differs from bone in its elasticity, its want of solidity (it is soft enough to be divided by the scalpel), by its yellow colour, and by a certain degree of transparence. This substance is known by the name of cartilage. Thus the curved bones termed ribs are prolonged at their anterior extremity by a portion called the *costal cartilage*, which presents the same form as the ribs properly so called.

When comparing the skeleton of various animals, as man, the dog, the horse, the sheep, &c., we are struck by the fact that a portion—the shoulder-blade, for example—may be in one composed solely of osseous structure, as in man, while in another these parts will be formed of cartilage, as in the posterior portion of the shoulder-blade of the sheep. This is easily explained by the fact that in all animals the bones, at the commencement of their formation, are constructed solely of cartilage, which is gradually transformed into bone by the deposition of calcareous salts within its structure as the animal grows; and this transformation of primitive cartilage by lime-salts, which may spread, more or less, into any part of the primitive cartilaginous

skeleton, leaves some portions in the cartilaginous state, according to the species of animal. It will

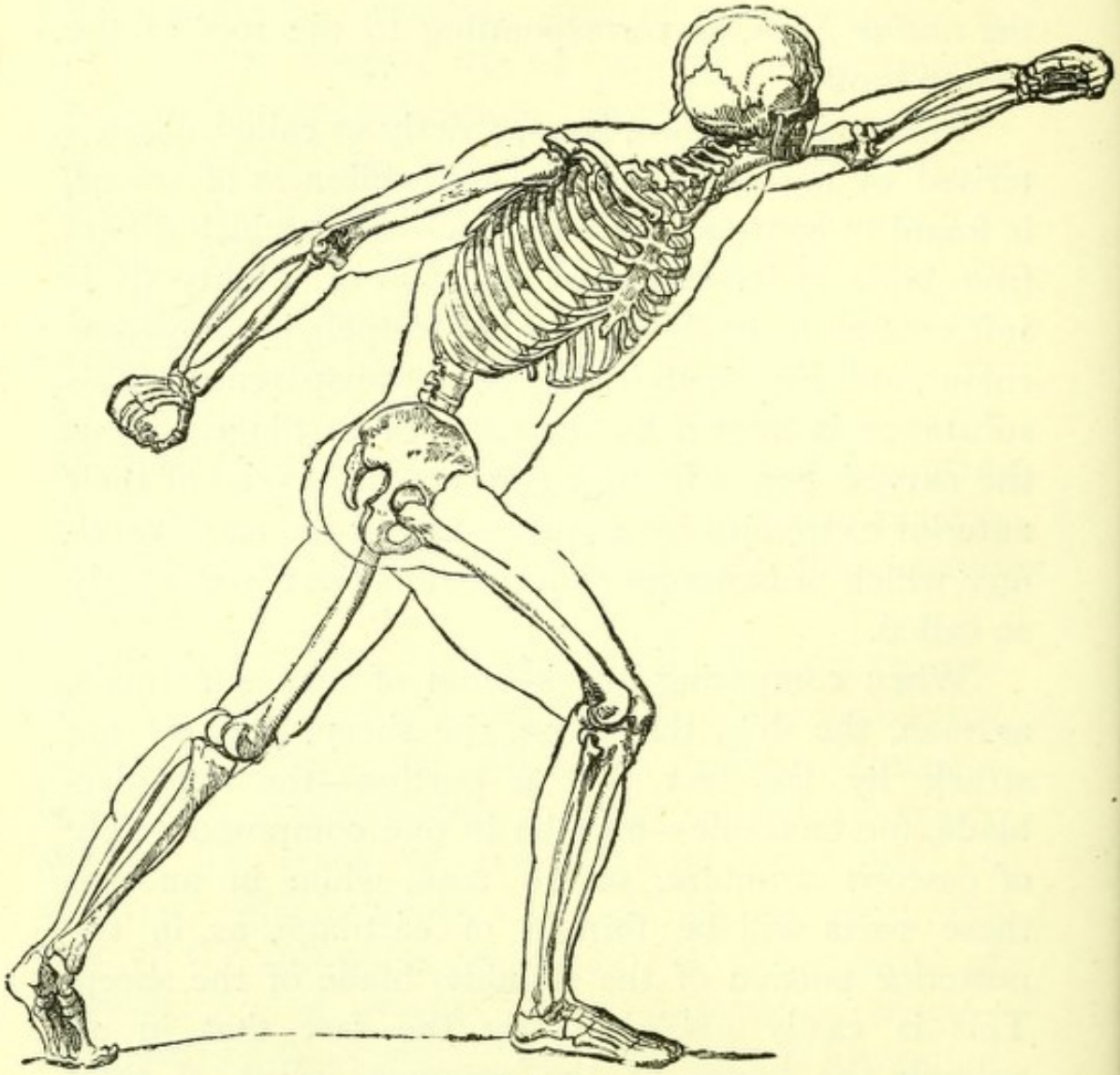

FIG. 2.

THE COMPLETE SKELETON (in the attitude of the Gladiator of Agasias).

not do, then, to attach too much importance to the fact that some parts will be found bony in one animal and cartilaginous in another. With the progress of advancing age the bones tend to become

uniform in structure. It is thus we find that in the skeletons of old people the costal cartilages are more or less ossified.

The skeleton, as a whole, has an axis, which is a column formed by pieces of bone placed one on the other, with intervening discs, the *vertebral column* formed by the *vertebræ*. At the top the column supports the head; to the sides are attached those osseous parts which surround the cavities of the *trunk*, *thorax* above, and *pelvis* below; and to the trunk are attached the structures of the limbs; those above, the *superior* or *thoracic*, those below, the *inferior* or *pelvic*. It is therefore with the vertebral column that we commence the study of the skeleton; afterwards we will take the upper portion of the trunk, or thorax, and the members which belong to it, the *shoulder*,

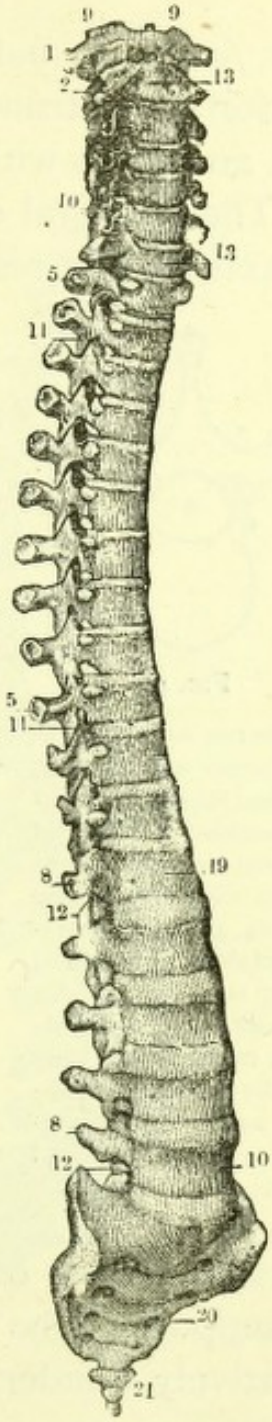

FIG. 3.

THE VERTEBRAL COLUMN (antero-lateral aspect).—1, the first cervical vertebra (atlas);—9, 9, its occipital articulating surfaces;—2, the second cervical vertebra or axis;—13, its body;—4, seventh cervical;—5, 5, transverse processes of the ten first dorsal vertebra;—8, 8, transverse processes of the lumbar vertebra;—10, 11, 12, articular processes;—19, 19, bodies of the lumbar vertebra;—20, the sacrum;—21, the coccyx.

arm, *fore-arm*, and *hand*; later, we will take the lower portion of the trunk with its members the *thigh*, *leg*, and *foot*, and finish with the study of the bones of the head.

The vertebral column is intended not only to form an axis for the rest of the skeleton, but also to serve as an attachment more or less direct for all the other bony structures; it also protects the central nervous cord or spinal nerve. It forms for this purpose a species of bony canal, within the central cavity of which the spinal marrow is contained. It is for this reason that each of the pieces which compose it, called a vertebra, is a sort of bony ring (Fig. 4). The anterior portion of the ring is very thick, representing the segment of a cylinder, and is called the body of the vertebra (2, Fig. 4), and it is the placing of these vertebral bodies one upon the other which constitutes essentially the vertebral column, considered as the median column of support. The lateral portion of the ring is comparatively slender, but it gives origin to certain projections or processes, three in number, on each side, of which one directed transversely outwards is called the *transverse process* (3, Fig. 4), the other two, directed more or less vertically—one above, the other below, being called the *articulating processes*, superior

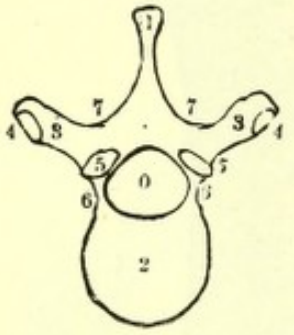

FIG. 4.

OUTLINE OF A VERTEBRA (upper surface).—*o*, vertebral foramen; 1, spinous process;—2, body of vertebra;—3, 3, transverse process with articulating facets (4, 4) for the tuberosity of the rib (see p. 38); —5, 5, superior articular processes;—6, 6, the parts which connect the body with the base of the transverse and articular processes;—7, 7, vertebral plates.

and inferior. These serve for uniting together the adjoining vertebræ (5, 5, Fig. 4). Finally, the posterior portion of the vertebral ring is prolonged backwards in a protuberance, more or less pointed, called the *spinous process* (1, Fig. 4).

Such are the most important parts which we find in each vertebra, but they present particular characters according to the region to which each vertebra belongs. In fact, we distinguish in the vertebral column three regions (Fig. 5): the region of the neck or *cervical* (*cervix*, the neck), the region of the back or *dorsal*, and that of the loins or the *lumbar* region; there are seven cervical vertebræ, twelve dorsal, and five lumbar, making a total of twenty-four; we do not

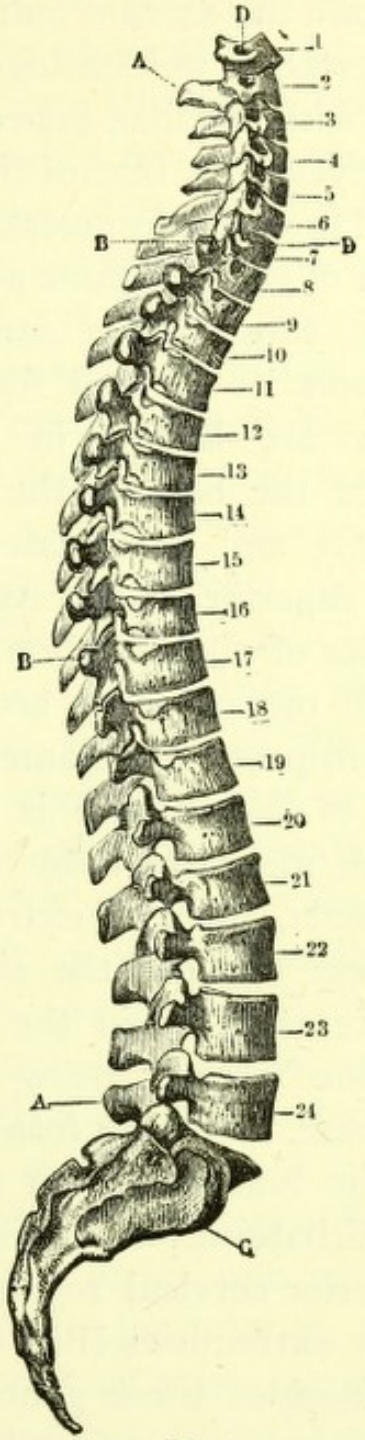

FIG. 5.

VERTEBRAL COLUMN (lateral view).—1 to 7, bodies of cervical vertebræ;—8 to 19, bodies of dorsal vertebræ;—20 to 24, bodies of lumbar vertebræ;—A A, spinous processes;—B, B, articular surfaces of transverse processes for the tuberosities of the ribs (see p. 38);—C, auricular surface of sacrum.

include the sacrum and the coccyx, which are formed of vertebræ welded together, forming a body articulative with the iliac bones, the description of which will be given with that of the pelvis.

The more important characters of the vertebræ in each of those regions are as follows—to dwell merely upon those which contribute to give to the whole column its general form:—1. The *bodies of the vertebræ* are largest in the lumbar region, this part forms the base of the column, it is here that it is largest and of greatest solidity: as we ascend to the superior dorsal vertebræ we perceive that the bodies of the vertebræ diminish in size: in the cervical region they are slightly broader, but their antero-posterior diameter is less; the superior portion of the column is characterised by its mobility much more than by its solidity. 2. The *spinous processes*, the free extremities of which project more or less beneath the skin according to the regions, are remarkable in the dorsal region for their distinct "spine" shape; being very obliquely sloped from top to base, and from front to rear; on the other hand, in the lumbar region these processes are formed of quadrilateral planes directed horizontally, and in the superior cervical region they are short and bifid at their extremities (Fig. 6, p. 28).

Besides these general characters in each region there are certain vertebræ which demand special mention owing to the peculiarities of their shape. These are the two first and the last cervical.

The *first cervical*, called the *Atlas*, because as

directly supporting the head, it has been compared to the giant Atlas, who carries the globe of the heavens, is reduced to a simple bony ring, without a body or spinous process; it is remarkable for the presence, upon each of its lateral portions, of an oval articulating surface which receives the *condyles* of the occipital at the base of the skull, and it is this occipito-atloid articulation which allows the movements of the head, of flexion in the front, and of extension behind. The *second cervical vertebra* is called the *axis*, because its body is surmounted by a process directed vertically upwards called the *odontoid* process (ὀδοὺς, a tooth; εἶδος, form), being similar in shape to a tooth; this is received into a sort of ring, partly fibrous, partly bony, on the anterior portion of the atlas (Fig. 6, 6, 12), and becomes a veritable pivot or axis, round which the movements of lateral rotation of the head are effected, the action of turning the face to the right hand or to the left; it is not therefore by the occipito-atloid articulation, but principally by the atlo-axoid that the movements of rotation of the head are accomplished, the atlas forming in that case one body with the head, and moving with it around the odontoid process whilst in the movements of flexion and extension the first vertebra forms one with the axis. These functions, of little importance as regards the external forms, for these bones are deeply situated at the base of the skull, are nevertheless too interesting with respect to the articulating mechanism, not to find a notice here. The peculiarity which distinguishes the last cervical vertebra is that it is im-

portant as regards the external form. For this reason the *seventh cervical vertebra* receives the name of *prominens*, as its spinous process presents more the characters of the spinous processes of the dorsal region, it is long, spine-shaped, terminating in a tubercle which always shows as a projection easily visible beneath the skin; and this projection is also more conspicuous as it corresponds to that part of the neck where the trapezius muscle represented only by a fibrous plane, not fleshy, forms a flat surface in the centre of which the projection in question appears placed on the level of a transverse line passing through the superior border of the shoulder (see Fig. 52, page 197). It may be observed that when the model bends the head forward the spinous process of the seventh cervical becomes very prominent.

We have been disconnecting the vertebræ in order to account for the construction of the vertebral column; we must next see how the different vertebræ are placed one upon the other, how they articulate in such a manner as to form a column not rigid but elastic and curved. The vertebræ are placed on each other so that the inferior articulating processes of one fit exactly on to the superior articulating processes of the next beneath, and thus throughout the series we see (Fig. 5) that the bodies of the vertebræ are not in contact one with the other, the space which separates them being filled in the living subject by elastic fibrous discs, which in the mounted skeleton we imitate by the interposition of plates of leather, cork, or pasteboard. These *intervertebral discs* are very thick in the

lumbar region, and become much thinner in proportion as we ascend to the superior dorsal and cervical regions; being compressible and elastic, these fibrous discs give to the column, formed by the placing one on an other of the bodies of the vertebræ, a certain degree of flexibility, whereas a column formed of bone alone would have been quite rigid.—The ligaments placed at the posterior portion of the vertebræ are very interesting as regards these movements; they are the *yellow ligaments* joining together the vertebral laminæ. By the vertebral laminæ we mean the posterior portion of the vertebral ring (7, 7, Fig. 4), which portion, continuous behind with the spinous process (1, Fig. 4), might be described as resulting from the bifurcation of the root of this spine; the yellow ligaments themselves consist of two short bands of peculiar tissue placed on each side of the root of each spinous process, and uniting the inferior border of the laminæ of one vertebra, with the superior border of the vertebra situated next below it.

The *yellow* or *elastic tissue* which composes these ligaments is similar to a piece of india-rubber; it is elastic, that is to say it is able to stretch, and to return again by its own reaction to its original size when the cause which distended it has ceased to act: so that each movement of flexion of the column in front results in moving the vertebral plates one upon the other, by means of stretching the yellow ligaments. When the anterior muscles of the trunk which accomplish this flexion cease to contract, it is not necessary, in order to straighten the

column, that the posterior muscles of the back should come into play; the elasticity of the yellow ligaments suffices for this, as they return to their original dimensions and draw together the vertebral laminæ. We may say then that there is at the posterior portion of the column within each vertebra a pair of small springs which keeps the column erect, so that the erect attitude of the trunk is maintained in a state of repose simply by the presence of the elastic ligaments; more is required when a man supports upon his back any extra weight or burden.

In the great carnivorous animals, as the lion, and in the greater number of quadrupeds, a long elastic band is superadded to the posterior surface of the column. This *posterior cervical ligament*, which supports the head, starts from the occipital, and is attached to all the cervical vertebræ; it is represented in man by a fibrous median partition placed between the muscles of the right and left side of the neck. The vertebral column is not straight, as the vertebral bodies and intervertebral discs are, in fact, slightly wedge-shaped (thicker behind than in front, or conversely), and the situation of these wedges differing according to their regions, produces throughout the column the curves peculiar to each region. These curves are three in number (Fig. 5), proceeding from above downwards. The first, or *cervical curve*, is convex anteriorly, its most prominent portion corresponding to the fourth or fifth cervical vertebra. The second, or dorsal curve, is concave anteriorly, its most concave portion corresponding to the seventh dorsal

vertebra. Finally, the third, or lumbar curvature is, like the first, convex anteriorly, its most prominent portion corresponding to the third lumbar vertebra.

In animals the vertebral column has but two curves, one the cervical convex inferiorly, the other, the dorso-lumbar concave inferiorly.

We have now to examine the influence that the vertebral column has in moulding the external form, and to see if the length of the column can be made use of for a system of proportion.

It is evident, in the first place, that the posterior portions of the vertebræ only can affect the outline of the body, the anterior portions of the bodies of the vertebræ being deeply hidden in the cavity of the thorax. Therefore, in the skeleton, the posterior surface of the vertebral column (Fig. 6) presents itself under the aspect of a median crest, formed by a series of spinous processes, the *spinal crest*, on each side of which is a groove bounded without by a series of transverse processes (the grooves of the transverse processes). In the living subject these grooves are filled up by powerful and thick muscles, which project in such a manner that the back presents a furrow in the median line bounded on each side by these muscles, at the bottom of which the bony structure of the vertebral column is shown only by a series of projections placed one beneath the other, like the beads of a necklace, each one being formed by the summit or free extremity of a spinous process. These projections are well seen in the dorsal region on examination of the curvature of the posterior

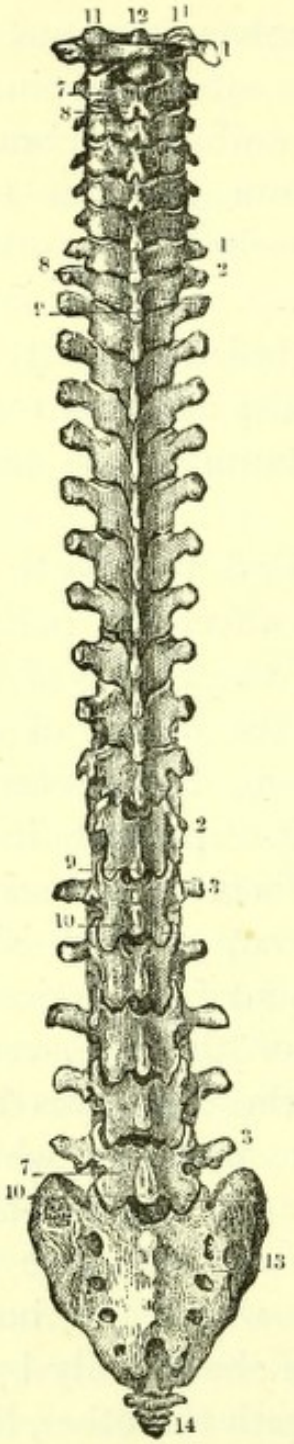

FIG. 6.

VERTEBRAL COLUMN (posterior ew).—1, 1, cervical transverse processes;—2, 2, dorsal transverse processes;—3, 3, lumbar transverse processes;—7, 8, 9, 10, spinous processes;—11, 11, articular surfaces for occipital bone of skull;—12, odontoid process of the axis;—13, 14, sacrum and coccyx.

convexity of this portion of the column, and they show themselves still more clearly when the subject bends forward, and thereby increases this curvature. They are not visible in the cervical region, where a bed of powerful muscles covers them; but we have seen that the seventh cervical, or vertebra prominens, is remarkable for the projection which its spinous process makes. Finally, in the lumbar region, these projections are but little marked, the spinous processes here being short and terminated, not by a point, but by a vertical border.

The measurements of the vertebral column are useful on the one hand, as absolute dimensions, length and height, of the column, and on the other hand, as regards the relation of its length with the stature of the subject. The height of the column in the

average adult man is from twenty-three to twenty-four inches, being five for the cervical region, eleven for the dorsal, and seven for the lumbar. But as the length of the vertebral column does not serve as a common measure for the total height of the body or for its different parts, it cannot be used as the basis of a system of proportions. A German zoologist, Carus, has advanced the idea that the length of the column forms the third of the height; but this proposition is not exact. On the other hand, it is not easy to measure the column from the atlas as far as the last lumbar, without taking account of the sacrum and coccyx. We find more frequently that the length of the trunk, from the superior limit of the thorax to the inferior limit of the pelvis, gives a measurement more easy to take, and more useful for the general proportions of the body.

It is enough to say here that the proportion of the vertebral column to the height varies according to age and sex, and according as the stature is very great or very little; the vertebral column is, in fact, in comparison with the height, longer in the infant and in the female than in the adult male; it is also much longer in proportion to the height, in subjects of short stature. The cause of difference of stature between men and women, infants and adults, long people and short, is principally due to the length of the lower extremities—a question which will be dealt with later on.

CHAPTER III.

THE TRUNK AND THORAX.

The Sternum: its three portions — manubrium, gladiolus, xiphoid appendix; its situation, its direction, the levels to which the extremities correspond; its dimensions, absolute and relative.—Of the ribs; the true ribs, the false and floating ribs; the obliquity, curvature, and bending on themselves of the ribs; the head, neck, tuberosity, angle and body of the ribs.—Of the thorax in general; its posterior aspect, the anterior aspect (the chondro-sternal and chondro-costal nodules; the base, the pit of the stomach.

THAT portion of the vertebral column which is formed by the seven cervical vertebræ, is free, and forms of itself the bony structure of the *neck*. It is the same in the lumbar region, where the five vertebræ alone form the bony structure of the abdomen; but the twelve dorsal vertebræ corresponding to the superior two-thirds of the trunk, are in connection with numerous osseous ribs, which constitute with them the frame-work of the *thorax*.

In the front part of the thorax is the sternum, a bone in the middle line, single and symmetrical. This bone is, in the early stage of existence, formed of pieces placed one upon the other in a vertical series, and may be compared to a species of small anterior vertebral column, these distinct portions alone representing a species of vertebral

bodies; it is found composed in this manner in a certain number of animals. In the adult subject these pieces are more or less joined together. There remain only three distinct portions, one superior

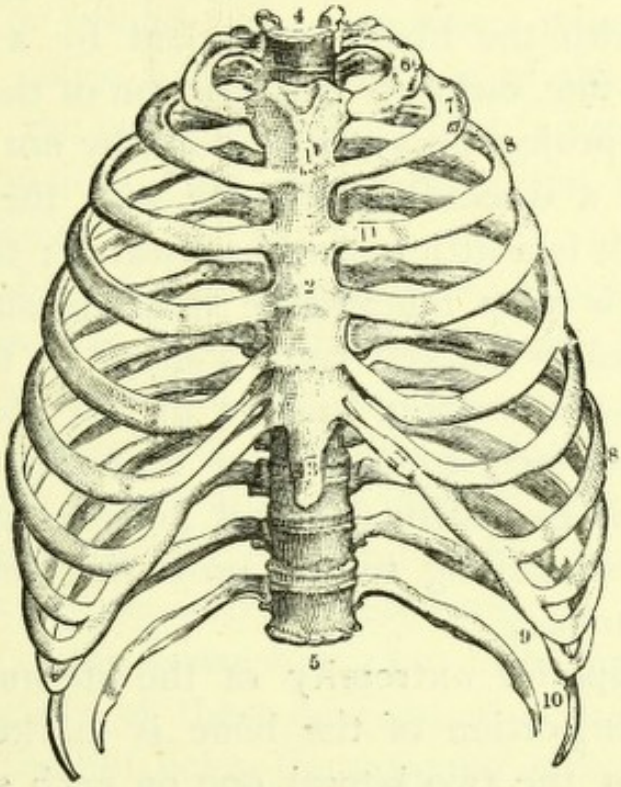

FIG. 7

THORAX (anterior view).—1, handle or manubrium of sternum;—2, its body;—3, its xiphoid appendix;—4, body of first dorsal vertebra;—5, twelfth dorsal vertebra;—6 and 7, first and second ribs;—8, 8, the true or sternal ribs;—9, 10 the floating ribs;—11, costal cartilages.

one in the middle, and one inferior; and as some have compared the sternum to a sword, they have given to the superior portion the name of the hilt (1, Fig. 7); to the central portion that of the body, or blade (2, Fig. 7), and to the inferior (3, Fig. 7),

that of the point or xiphoid appendix (ξίφος, a sword). Thus constituted, the sternum presents for our consideration an anterior surface, a posterior surface, two lateral borders, a superior and an inferior extremity.

The anterior surface is smooth ; but the union of the hilt with the blade is marked by a prominent transverse line, owing to the junction of the two parts forming a projecting angle in front, by not being continuous in a direct line the one with the other ; in fact the hilt is a little curved backwards ; this projecting angle is very remarkable in some subjects, and gives a clearly marked convex shape to the superior portion of the anterior surface of the thorax. The posterior surface, which is not necessary for artists to study, is generally flat and presents a returning angle corresponding to the projecting angle of the anterior surface.

The superior extremity of the sternum forming the broader portion of the bone is marked by three depressions, the two lateral, one on each side, articulated with the internal extremity of the corresponding clavicle, and the one in the middle called the *fourchette of the sternum*, rendered deeper still by the presence of the heads of the clavicles, which is easily discerned on the living model : this forms the inferior border of the deep depression situated at the lower part of the front of the neck, and is limited on either side by the sterno-cleido-mastoid muscles.

The inferior extremity of the sternum is formed by the piece called the xiphoid appendix, which

remains very frequently in the cartilaginous state, in the form of a plate thin and tapering; in shape and direction it is very variable; it varies in different persons, being sometimes pointed, or square, or bifurcated, and it may be situated in a plane corresponding to the body of the sternum or be turned towards one side, either before or behind: in a case where it projects in front it may cause a slight elevation of the skin of the region of the pit of the stomach or epigastrium; but it is a detail of form so irregular that it is not worth reproducing.

The lateral borders of the sternum are not vertical but form a concave line at the level of the junction of the body and the hilt, the hilt increasing in size towards its superior part, and the blade or body of the bone enlarging towards its inferior part. Each of the borders is marked by seven small depressions made to receive the anterior extremity of each of the cartilages of the seven first ribs. The first, from above downwards, of these depressions is situated on the border of the hilt, below the articular surface where the clavicle comes; the second depression is situated in the line of the junction of the hilt with the blade, those following are situated on the edge of the blade, and the spaces between the depressions become smaller as they approach the lower part of the blade, so that the last depressions for the sixth and seventh costal cartilages are almost fused into one.

It is not sufficient to know the sternum as a solitary bone, we should also be able to determine its exact direction when taken in relation with the other parts

of the thorax, in the complete skeleton. This direction is not vertical but very oblique, so that the superior part of the sternum is less removed from the vertebral column than the inferior part; we may define this direction by saying that the sternum forms an angle of fifteen to twenty degrees with the vertical passing through the inferior extremity (angle x, Fig. 8), and afterwards an angle of seventy to seventy-five degrees with a horizontal passing through this same extremity (angle y, Fig. 8). Such is the direction of the sternum in the male; in the female it is less oblique, and approaches the vertical—a disposition which artists are prone to exaggerate by giving a more rounded form to the superior portion of the thorax in the female. To compare the relations of the sternum with the rest of the thorax it is necessary further to determine the level of the parts corresponding to the two extremities by comparison with the vertebral column. The superior extremity of the sternum does not correspond to the first dorsal vertebra, but rather to the second, or the disc which separates the second and third, so that the horizontal plane passing through the superior extremity of the sternum

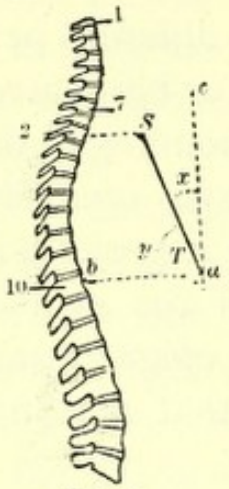

FIG. 8.

THE RELATIVE POSITIONS OF THE STERNUM (S T) AND THE VERTEBRAL COLUMN. —1, the first cervical vertebra; — 7, seventh cervical vertebra; — 2, second dorsal vertebra, on a line with the upper extremity of the sternum; —10, tenth dorsal vertebra (on a line with the inferior extremity of the sternum).—x and y, the angles which the oblique plane of the sternum (in the male) makes with the vertical and horizontal planes passing through the inferior extremity of the sternum.

strikes the second dorsal vertebra at its middle or lower part (Fig. 8); and below the horizontal plane passing through the inferior extremity strikes the tenth dorsal vertebra; viewing the thorax in profile, we see the sternum project between the second and eleventh vertebra.

The length of the sternum is on the average, in the adult man eight inches, of which there are two inches for the hilt, four and a half inches for the blade, and the remainder for the xiphoid appendix.

But what is more important to know is, that this measure of length of the sternum without the xiphoid appendix which, when present, is scarcely visible, and, so to speak, is no part of the complete subject, is found in various parts of the skeleton, which for the most part are adjacent to the sternum, and this may be taken as a common measure for constructing a correctly proportioned thorax.

As a fact, this measure of the length of the hilt and blade of the sternum is equal to the clavicle, also to the spinous border of the shoulder-blade, and to the distance which separates the two shoulder-blades in the figure when the arms are hanging by the side; finally, again the length of the sternum is equal to the length of the hand without the third phalanx of the middle finger. Vertebral

The dorsal column and the sternum being known, it is easy to understand the arrangement of the parts which complete the thorax: these parts are arranged somewhat like the hoops of a cask, proceeding from the vertebral column to the sides of the

sternum ; their posterior and central portions are bony, and take the name of *ribs ;* and their anterior portion, where it joins the sternum, is cartilaginous, and takes the name of *costal cartilage.* The ribs are twelve in number on each side. They are known as first, second, and third ribs, &c., counting from above downwards ; the first seven are classed as *true ribs,* or sternal ribs, which have the cartilages directly joined to the sternum, the five last as *false ribs* when the cartilages are not joined immediately to the sternum. Of the five false ribs, the three first, the eighth, ninth, and tenth ribs, are provided with cartilages which connect them obliquely to that of the seventh rib. The two last, the eleventh and twelfth, are remarkable for their shortness ; they are provided at their extremities with rudimentary cartilage only, which is not attached to any other portion of the skeleton ; so that these last ribs are called *floating ribs,* their extremities being free in the thickness of the walls of the abdomen.

In a general sense the ribs are long bones, which may be compared to the hoops of a cask, presenting an external surface and an internal surface, a superior border and an inferior border. These circular bands are not horizontal, but oblique, from above downwards and from behind forwards: so that the anterior extremity of a rib is always placed on a lower level than its posterior extremity.

More than that, the ribs present a double curve : they are bent like the circular hoops of a cask in order to surround the thorax, and present, therefore, a

curve similar to that of a scroll, of which the convexity is turned outwards and the concavity inwards; but, again, they are twisted upon themselves as if the anterior extremity had been forcibly carried inwards by a movement of rotation upon its own axis. This curvature of torsion makes the external surface, which is really external to the central portion of the rib, become superior at its anterior portion. In order to have a good idea of the torsion of the ribs it is necessary to take a single rib and place it on a horizontal surface, such as a table; it will be then seen that, instead of its being in contact through its entire extent with the flat surface, it touches it only at two points, as if it formed a half-hoop of a cask to which a slight spiral twist had been given.

The ribs vary much in length, in order to correspond to the shape of the thorax which is ovoid, and not cylindrical; the length of them increases from the first to the eighth, which is the longest, and corresponds to the largest part of the thorax; and it gradually diminishes from the eighth to the twelfth.

In examining a rib, beginning at its posterior extremity, will be found, taking them in order, the following portions, the indication of which is useful for the study of the shape of the thorax:—First, an extremity slightly raised, called the head of the rib, which head, shaped like a wedge, articulates with the body of the vertebra into which it is received, precisely like a wedge, into the space which separates the bodies of two vertebræ; so that it is in contact by the summit of the wedge with the intervertebral disc,

and by the surfaces of the wedge with the vertebra which is situated above and that which is situated below the disc. Beyond the head, the rib presents a portion narrow and lengthened, called the *neck* of the

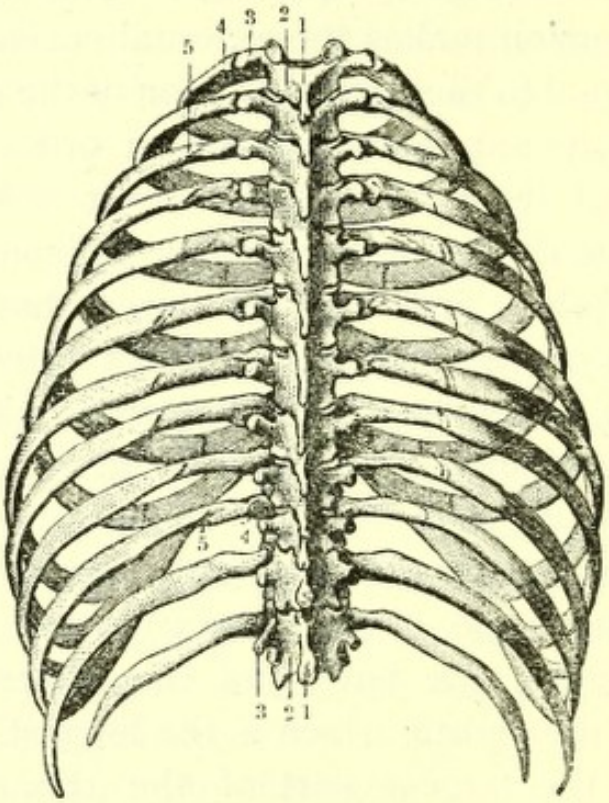

FIG. 9.

THORAX (posterior view).—1, 1, spinous processes of the dorsal vertebræ;—2, 2, vertebral laminæ;—3, 3, series of transverse processes;—4, 4, the parts of the ribs included between the tuberosities and the angles of the ribs;—5, 5, angles of the ribs, becoming more distant from the vertebral column as the rib becomes more inferior.

rib, which neck is placed in front of the transverse process of the vertebra corresponding and parallel to it.

At the external extremity of the neck is a slight enlargement called the *tuberosity*, which corresponds to the level of the external extremity of the transverse

process of the vertebræ, corresponding and articulating with the process (Fig. 4); the ribs then are fixed behind to the bodies of the vertebræ and the transverse processes (Fig. 9), and these articulations are such that the ribs move slightly, their anterior extremity rising upwards and their convexity gently projecting forwards in the action of elevation, this movement constitutes essentially the respiratory act.*

Going on from the tuberosity, the *body* of the rib is formed of osseous plate, which at first is directed directly outwards (4, 4, Fig. 9); then, after travelling some distance, it bends abruptly, so as to be directed forward, describing the characteristic curve of the rib. We give to this curve the name of the *angle* of the rib (5, Fig. 9). The series of the angles of the ribs shows, upon the posterior aspect of the thorax, a line plainly visible, curved, with its convexity outwards, the summit of this convexity corresponding to the eighth rib, which is the longest, and upon which a relatively greater distance separates the angle from the tuberosity (Fig. 9).

Such are the characters of ribs in general. For the peculiar characters of the several ribs, after we have spoken of the two last ribs, it will suffice to note the shortness of the superior ribs, and principally of the first, which is flattened downward from above—that is to say, curved along the borders, and not along the surfaces—and does not present any twist.

The ribs are continued in front by the *costal cartilages;* these cartilages, in proceeding to join

* So far as the bony structure partakes of this act.—ED.

the sternum, follow a course more or less oblique, so that the cartilage of the first rib is oblique from above downwards, and from without inwards; that of the second is horizontal; that of the third is oblique from below upwards, and from without inwards; and those following present the same obliquity (Fig. 7), which becomes more accentuated in the cartilages lower down. The spaces which separate these cartilages are wide above, especially between the cartilages of the three first ribs, and become narrowed towards the lower part.

The whole of the thorax, which we have just examined in its constituent parts, forms a species of truncated cone, with its base below and its apex above; but, from an artist's point of view as to form, it is not necessary to take this form into account, as the shape of the summit of the thorax is completely changed by the addition of the osseous girdle constituted by the clavicle and shoulder-blade.

We limit ourselves, then, to a rapid view of the posterior surface, the anterior surface, and the base of the thorax.

The posterior surface (Fig. 9) presents upon the skeleton, in the median line, the series of spinous processes, and on each side a double row, first of transverse processes, and then the angles of the ribs. As already explained (page 27), respecting these several details, the summits of the spinous processes, although just under the skin, are scarcely visible, especially in a very muscular subject.

On the anterior surface of the thorax (Fig. 7), in

a very muscular subject, the osseous details do not show on the external figure, except the sternal *fourchette* (page 32) and the heads of the clavicles, which are more or less visible. The great pectoral muscles form on each side a large fleshy plane, and the median line of separation of these muscles is marked by a narrow depression corresponding to the central portion of the sternum, the only region where this bone becomes subcutaneous ; but in less muscular subjects, in the aged and in thin children, all the details of the thoracic frame-work show beneath the skin, and reveal clearly the forms of the costal cartilages with their obliquities, the thin intervals of separation becoming narrower as we get lower down. Moreover, especially in infants, the articulation of the cartilages with the sternum, and the articulation of the cartilages with the anterior extremities of the ribs, are shown by a double row of nodules, as the points of junction of the osseous and cartilaginous portions are slightly elevated. We find again a series of *chondro-sternal* nodules (χόνδρος, cartilage) marking the borders of the sternum, and, on the outer side, a series of *chondro-costal* nodules, marking the line of junction of the ribs with the cartilages. This chondro-costal line descends obliquely from within outwards ; so that above, it is very near the sternum, owing to the shortness of the cartilage of the first rib, and below it is withdrawn from the sternum owing to the greater length of the cartilages of the ninth and tenth ribs. The *base*, or *inferior circumference* of the thorax is con-

tinuous, without distinct limits upon the living subject, with the abdominal wall behind and upon the sides; but in front this circumference presents a depression in the form of an inverted **V**, with the mouth looking downwards (Fig. 7); this depression, limited on both sides by the cartilages of the false ribs, and corresponding at its apex to the junction of the body of the sternum with its costo-xiphoid appendix, shows in the living subject a depression of the same form, called the pit of the stomach, or *epigastrium* (ἐπὶ, upon; γαστήρ, stomach). Upon the dead body, or upon a model in a state of repose, the outlines of the pit may be compared to a pointed arch; but when the model makes a violent effort, as in taking a deep inspiration, the elevation of the ribs spreads the cartilages of the false ribs from the median line, and the pointed arch in question shortens and tends to take a rounded form. On the other hand, in very muscular subjects, the great anterior muscles of the abdomen are sufficiently thick at their superior parts where they cover the cartilages of the false ribs, to add their shape to that of the cartilages, and to give to the epigastric region a more rounded form. It is this form of a rounded arch, that the Greek sculptors have adopted almost exclusively, and this choice we find justified to some extent in the fact that they had for their models very muscular athletes, whom they studied during the wrestling-matches of the gymnasium, when efforts which dilated the thorax most powerfully were to be observed.

CHAPTER IV.

THE SHOULDER.

The osseous structure of the shoulder. The clavicle : its body with its double curve : its two extremities, sternal or internal, acromial or external : its proportions.—The shoulder-blade : its situation and relations.—The spine of the scapula : acromion : coracoid process : glenoid cavity.—Proportions of the scapula : the distance which separates the right from the left.—The upper portion of the humerus : the surgical neck, the anatomical neck : the articular head : the tuberosities. — The shoulder-joint scapulo-humeral : its proper movements : the increase of mobility assured by the acromio-clavicular and sterno-clavicular articulations : the to-and-fro motion of the scapula : the importance of this mechanism with regard to the external form.

THE whole of the shoulder is formed of two bones, of which one is situated in the front, the *clavicle*, and the other behind, the *shoulder-blade* or *scapula*.

The *clavicle* (*clavicula*, diminutive of *clavis*, a key), is a long bone, placed transversely at the upper part of the thorax, one on each side of the *manubrium* or hilt of the sternum, connecting the sternum with the shoulder-blade. Its form is that of an italic *S* slightly accentuated, that is to say, it describes in a horizontal plane two curves, the internal portion being convex in front, and the outer part convex behind (Fig. 10). It consists of a body and two extremities: the *body*, flattened downward, presents a smooth superior surface, which in the model shows very clearly

beneath the skin, and a rough inferior surface internally, where it is in contact with the first rib, and externally, where it is in contact with the acromion process of the scapula (see below): a *posterior and anterior border*, both smooth, but concave and convex in an inverse sense: an *internal extremity* thickened, forming a species of head, which articulates with the corresponding lateral facet on the manubrium of the sternum: the *outer extremity* being flattened downward, and articulates with the acromion process of the scapula. These articulations increase the mobility of the shoulder-joint as we shall see in the study of that joint; we find that the clavicle, almost horizontal when the arms are hanging in an attitude of repose beside the trunk, becomes oblique in direction when the arms are moved upward and forward, or especially upward and backward, towards its outer extremity. The length of the clavicle, as we have already said (page 35), should be equal to the sternum hilt and body without the xiphoid appendix.

FIG. 10.

RIGHT CLAVICLE: UPPER SURFACE.—1, body of clavicle;—2, 3, inner or sternal extremity;—4, 5, outer or acromial extremity.

The *shoulder-blade* or *scapula* is a flat bone, and consists of a bony plate very thin at certain points, thick only on the borders, and triangular in form: this bone is placed on the lateral and posterior portion of the thorax, and corresponds above at the

base to the second rib: below, at its apex to the eighth rib: it is attached by a slight articulation called the *acromio-clavicular articulation*, to the external extremity of the clavicle; and does not possess any other ligamentous connections with the adjacent bones; it is on this account capable of great freedom of movement.

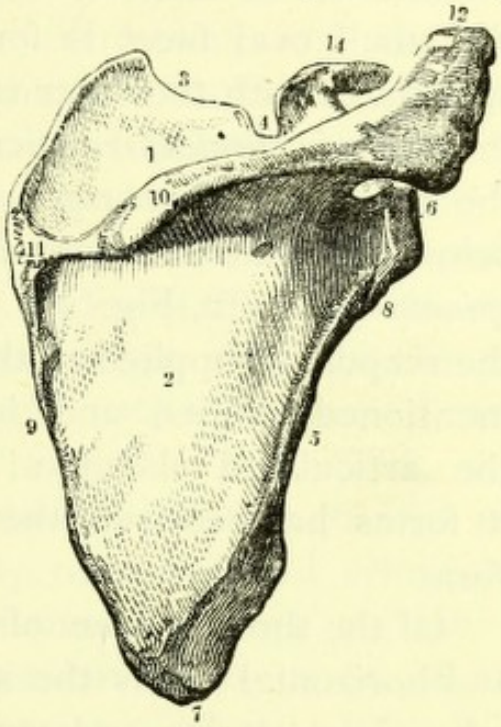

FIG. 11.

SHOULDER-BLADE: POSTERIOR SURFACE. —1, supra-spinous fossa;—2, infra-spinous fossa; — 3, superior border with coracoid notch (4);—5, external or axillary border with depression for attachment (8) of the long head of the triceps brachialis; — 6, glenoid cavity;—7, inferior angle;—9, internal or spinal border;—10 and 11, spine of shoulder-blade extending into acromion (12); —14, coracoid process.

The shoulder-blade is described as possessing two surfaces, three borders and three angles. The *posterior surface*, free and visible throughout its entire extent upon the mounted skeleton, is divided into two unequal portions, the upper one the smaller, and the lower one the larger, by a bony crest, called the spine of the scapula (10, 11, Fig. 11), which traverses the bone obliquely from within outwards, and from below upwards. It becomes more and more prominent as it approaches the outer border or shoulder properly so-called), and afterwards is prolonged into a plane which becomes free, and forms

the most elevated and external part of the skeleton of the shoulder (12, Fig. 11), under the name of the *acromion* (ἄχρος, summit; ὦμος, the shoulder). It is on the internal or anterior border of this acromion that the small oval facet is found, by which the scapula articulates with the outer extremity of the clavicle by the *acromio-clavicular* articulation; above the spine of the scapula is the *supra-spinous fossa* (1, Fig. 11), below the spine is a larger portion called the *infra-spinous fossa* (2, Fig. 11). The anterior surface of the scapula is applied to the ribs between the above-mentioned limits, and is but little visible upon the articulated skeleton; the large surface which it forms has received the name of the *subscapular fossa*.

Of the three borders of the scapula, one is *superior* and horizontal; it is the shortest of the three. The other is posterior and vertical, parallel to the crest formed by the series of spinous processes of the vertebræ; to this is given the name of the ~~*spinal*~~ Vertebral *border*. The third, or outer, is oblique, directed downwards and backwards, corresponding to the region of the arm-pit, and has received the name of the *axillary border*. It is particularly to be noticed that the spinal border is thin; the axillary border, on the contrary, is thick, and presents towards its superior limit a rough space, for the insertion of the long portion of the triceps brachialis muscle (8, Fig. 11), while the superior border is remarkable for the presence at its outer extremity of a process which projects vertically upwards, so as to

form a hook, and which, having been likened to the beak of a crow, has received the name of the *coracoid process* (κόραξ, a crow; εἶδος, form). The coracoid process (14, Fig. 11) is placed in front and on the inner side of the acromion, and the two together form an arch within the shoulder, called the *coraco-acromial arch*, the central portion of which is formed by a fibrous band proceeding from one of these osseous points to the other *the coraco-acromial ligament.* Of the three angles of the scapula, one only—the superior external angle, which is situated beneath the coraco-acromial arch—deserves a particular description; this angle is very thick, and spreads itself out into an articular surface (6, Fig. 11), which looks almost directly outwards, and articulates with the head of the humerus. This surface is slightly hollowed out, and bears the name of the *glenoid cavity;* in the recent subject, where it is covered with its fibrous parts, a fibrous band, the *glenoid ligament*, borders the circumference of this surface, and increases its depth.

As regards the relative proportion of the scapula, it may be noted that the length of the spinal border is equal to the length of the clavicle, and equal also to the distance which separates the scapulas behind, when the spinal borders are vertical; which is the case when the arms are hanging beside the body in a state of repose.

With respect to the movements of the shoulder-blade, and their results on the external form, they will be studied with the articulation of the scapula

with the humerus, the *scapulo-humeral* articulation. We must now pass on to describe the upper portion of the bone of the arm.

The bone of the arm, or *humerus*, is one of the long bones, and is composed of a shaft, prismatic in form, or, more correctly speaking, nearly cylindrical, as the edges of the prism are but slightly marked, and of two enlarged extremities, one inferior, which takes part in the articulation of the elbow; the other superior, which takes part in the articulation of the shoulder. We will only concern ourselves for the present with the superior extremity.

Voluminous and rounded into an irregular sphere, the superior extremity of the humerus is continuous with the body of this bone by a conical neck, called the *surgical neck* of the humerus. This extremity is traversed by a circular groove, oblique from above downwards, and from without inwards, called the *anatomical neck* (3, Fig. 12). This is well-marked, and divides the sphere into two parts; the one, situated above, and internal to the anatomical neck, is very regularly rounded, smooth, covered over by a layer of cartilage, and is called the head of the humerus (2, Fig. 12); it is normally in contact with the glenoid cavity of the shoulder-blade, in which it glides according to the movements of the arm; the other part of the head, situated below, and external to the anatomical neck, is rough, and divided into two tuberosities by a vertical groove, which is prolonged as far as the superior part of the body of the bone, and which, from its serving as a lodgment for

the long tendon of the biceps, has received the name of the *bicipital groove* (6, Fig. 12). The tuberosity situated on the outer side of the bicipital groove is large, and is called the *great tuberosity* (4, Fig. 12); it presents three small surfaces which receive the insertions of the deep muscles of the shoulder —supra-spinous, infra-spinous, and teres minor muscles. The tuberosity, situated internal to the bicipital groove, is smaller. It is called the *smaller tuberosity* of the humerus (5, Fig. 12), and gives attachment to one muscle only, the subscapularis. The articulation of the shoulder, or *scapulo-humeral* articulation, may serve us as a type for the study of articulations in general. It is necessary, in each articulation, to consider how the shapes of the bony surfaces in contact correspond to each other. From this we should be able to deduce the nature of the movements that the articulation permits of. It is, therefore, necessary to consider the disposition of the ligaments; that is to say, of the fibrous bands which proceed from one bone to the other, and from this we should deduce what should be the limits imposed upon those movements, of which we have previously stated the existence.



FIG. 12.

LEFT HUMERUS (anterior surface): 1, body of the bone; —2, articular head; — 3, anatomical neck;—4, great tuberosity;—5, lesser tuberosity:—6, bicipital groove;—7, deltoid impression; —11, condyle;—12, trochlea;—13, external condyloid ridge;—14, internal condyloid ridge;—17, coronoid depression.

In the scapulo-humeral articulation the articular surfaces are represented on one side by a cavity of very little depth, the glenoid cavity of the shoulder-blade, and on the other side by the head of the humerus, smooth and regularly rounded.

Such an arrangement of surfaces in contact permits the head to glide in all directions within the cavity, and consequently the upper limb can be moved in all directions, forwards, backwards, inwards, towards the axis of the body (adduction), outwards or away from the axis of the body (abduction), and upwards as in elevation.

The ligamentous covering of the joint is formed by an articular capsule, or fibrous band which is attached on one side to the margin of the glenoid cavity, and on the other side to the tuberosities of the humerus, or rough surfaces which surround the head properly so-called.

This ligament is sufficiently loose to allow the head of the humerus great freedom of movement within the glenoid cavity, without any part of the capsule being put on the stretch and thus stopping its movement. Thus the movement of the arm forwards is very extensive, as are those backwards and directly inwards, this last being checked only by the meeting of the arm with the lateral surface of the trunk. But the movement of abduction or of elevation outwards becomes difficult when the arm approaches the horizontal ; here an arrangement comes into action which is of great importance, the study of which shows us that the superior member, besides

the mobility which belongs to the shoulder-joint proper (scapulo-humeral articulation), derives an increase of mobility from the articulations of the shoulder-blade with the clavicle, and of the clavicle with the sternum.

When we apply a humerus to a scapula in such a manner as to cause the head of the former to glide in the glenoid cavity from above downwards, which corresponds to the movement of the arm in the opposite direction, that is to say, to the raising of the arm outwards, we observe that at the moment when the humerus attains the horizontal position, the tuberosities touch the acromio-coracoid arch which surmounts the glenoid cavity, and which is completed by the coraco-acromial ligament (page 47); in the complete subject, in the living man, when the arm is elevated in carrying it outwards, the same effect of meeting and, so to speak, of contact between the tuberosities of the humerus and the acromial arch is produced with this result—that the arm, once horizontal, is with difficulty raised higher by the simple play of the scapulo-humeral articulation, that is to say, by the gliding of the head of the humerus in the glenoid cavity. But now a new source of mobility is employed, a new articulation is brought into play, that of the scapulo-clavicular joint or acromio-clavicular, in other words, of the acromion with the outer extremity of the clavicle. The entire scapula moves round the extremity of the clavicle; its inferior angle is carried forward; its external angle, that is to say, the glenoid cavity with the anterior of the coraco-acromial arch, is

carried upwards, and the movement of elevation of the arm is then continued by the play of the shoulder-blade, which is moved by the muscles of the shoulder.

As the result is an important change of shape in the shoulder, we ought to particularly examine the shoulder in the region of the back, upon a model in which the arm is raised outwards above the horizontal position. The point of the shoulder is raised, and as this elevation is accompanied by a movement of the shoulder-blade, the spinal border of this bone does not remain parallel to the dorsal spine, but it approaches closer to it at its superior extremity, while it is drawn further away at its inferior, that is to say, it is obliquely directed from above downwards, from within outwards. The inferior angle becomes prominent in the lower part of the armpit, as we may observe in a subject with the arms folded, and shows in a striking manner on a dead crucified body. If the elevation of the arm approaches the vertical, the spinal border of the shoulder-blade has a tendency to become horizontal, and we observe this change of movement in the model when the bone is seen along the posterior surface of the shoulder and the back, and we should scarcely at first recognise the appearances presented as what we are accustomed to study in its ordinary situation on the skeleton.

But when the arm is elevated vertically, so that it comes in contact with the side of the head, movement takes place not only in the scapulo-humeral and in the acromio-clavicular joints, but also in the articulation of the internal extremity of the clavicle

with the sternum. In that case, in fact, the whole of the shoulder is raised upwards (by the superior fibres of the trapezius muscle), and the clavicle represents the arm of the lever by which this movement is accomplished, whilst the sterno-clavicular articulation is the hinge. Thus we see the clavicle is changed in its direction, from the horizontal, to become oblique upwards and outwards, that is, its external extremity is raised and carried a little backwards.

The clavicle plays a very important part in the movements of the superior limb. This explains why it is found specially developed in those animals whose anterior members enjoy great freedom of movement—such as man, the monkey, the bat, the cat, and lion, where these members serve not only for walking, but also for seizing and tearing their prey :—while in those which possess the power of opening the arms (projection outwards), of bringing them together and of projecting them forwards—the clavicle indeed exists, but in a very rudimentary state ; but in those animals which, like the horse, use their fore-limbs for walking and perform with them oscillating movements in a plane parallel to that of the body —there is not a trace of clavicle. The part the clavicle takes in the movement of the arm explains also why the bone presents a variable size according to the needs of various persons. It is stronger in the male than in the female ; stronger in the working man than in the student ; stronger, finally, on the right side than the left, from the habit of using the right arm for the most part in those

actions which demand strength and skill. In the left-handed, it is the left clavicle that is stronger than the right—in a word, this bone is, like all the other parts of the skeleton, stronger in proportion as it takes part in active and frequently repeated movements. Thus the breadth of the shoulders is one of the characteristics of athletes; and it is to the strength of the bony structure formed by the clavicle and shoulder-blade, sustained by the first ribs, that this superior portion of the thorax owes its characteristic aspect.

Owing to the presence of this scapulo-clavicular girdle, the thoracic cage does not present much of the form of a cone at the superior summit of the trunk; it is this region of the summit which becomes broader in a lateral direction as the clavicle is more developed. It will be enough to compare this region of the thorax in man with that of such animals as the dog or the horse, which owing to the absence of the clavicle, have a thorax transversely flattened in the region of the shoulders, and consequently the shoulder-blades more closely applied upon the sides of the thoracic cage.

We should here examine the different questions which belong to the dimensions and proportions of the shoulder; but, as this study consists entirely of a comparison in the male and female of the transverse diameters from the head of one humerus to the other, and from one acromion to the other, with the diameter of the hips, we will proceed with it after we have described the pelvis and corresponding part of the region of the thigh.

CHAPTER V.

THE ARM AND ELBOW.

The bony structure of the arm and elbow.—The body of the *humerus*.—The axis of the arm and fore-arm.—The twisted groove of the humerus; the inferior extremity of the humerus; the trochlea and condyle; the external and internal condyloid ridges.—The superior extremities of the two bones of the fore-arm; the ulna (great sigmoid cavity, olecranon, coronoid process); radius (neck, head, and cavity). — The articulation of the elbow; transverse hinge joint.—Movements of flexion and extension; impossibility of any lateral movements; the limit of extension.—The external form of the elbow; angle opening outwards: prominence of the internal condyloid ridge and olecranon.

THE *body of the humerus* is prismatic in its upper and middle parts, and flattened from front to back at its lower extremity. This body, covered over by thick muscles, presents to us but little interest as regards its outward shape; it is necessary only to note its direction to know that, when the arm is hanging down in the state of repose, the humerus is not altogether vertical, but a little oblique from above downwards and from without inwards. We shall see that the axis of the bones of the fore-arm is oblique in the opposite direction; for this reason the arm and fore-arm form at the line of the elbow a very obtuse angle, looking outwards (Fig. 16, page 67).

Among other details to be noted upon the body of the humerus, the *bicipital groove* is worthy

of remark. This vertical groove, which separates the great tuberosity from the lesser on the superior extremity of the humerus (page 49), is prolonged upon the body of the bone, and presents an internal or posterior lip slightly prominent, and an external or anterior much more marked, giving insertion to the broad tendon of the great pectoral muscle. At the line of junction of the superior with the middle third of the bone, this anterior lip expands abruptly in a rough surface shaped like the letter V (7, Fig. 12), of which the angle looks downwards, and which, giving insertion to the deltoid muscle, has received the name of the deltoid V, or groove. Immediately outside of this groove is a broad, shallow depression, which starting above on the posterior surface of the bone, terminates below, losing itself on the anterior face—that is to say, it describes a spiral round the body of the bone; and, as it gives to it the appearance of a prism twisted on its axis, it has received the name of the *groove of torsion* of the humerus.

The inferior extremity of the humerus deserves to be studied in detail, as its shape gives the key to the movements of the elbow-joint, and explains at the same time several details seen in this region in the living model. This extremity is flattened from front to back, and is enlarged into a broad surface, its inferior limit presenting three prominences, smooth and covered with cartilage. Of these three projections the two internal form by themselves a regular pulley-block (12, Fig. 12) having a groove and two lips. This articular portion is called the *trochlea* (*trochlea*—pulley).

The internal lip is most prominent, that is to say, it descends lower than the external. The third projection (11, Fig. 12) which is situated on the inner side of the trochlea is short and rounded, and receives the name of the *condyle* (κόνδυλος, a prominence in the shape of a knob or head).

The lateral portions of the inferior extremity of the humerus are each formed by a rough projection (non-articular) giving insertion to muscles and ligaments; the external projection above the condyle takes the name of the *external condyloid ridge* (13, Fig. 12); the internal above the trochlea that of the *internal condyloid ridge* (14, Fig. 12).

This inferior portion of the humerus articulates with the upper extremities of the bones of the fore-arm; and we will next proceed to study the formation of these extremities in order to understand the movements of the elbow-joint and the forms of that region.

The fore-arm is formed of two bones (Fig. 13) which, when the upper limb is hanging in a state of repose beside the body, the palmar surface of the hand being turned forwards, are placed parallel to each other, one on the outer, one on the inner side. The inner bone (1, Fig. 13) is called the *ulna* or *cubitus*, and it is that which by its upper extremity (*olecranon*) forms the bony prominence of the elbow; the outer bone (10, Fig. 13) is called the *radius* (from the Latin *radius*, a spoke of a wheel), because in certain movements (see under pronation and supination) it forms the radius of a circle round the ulna. For the present

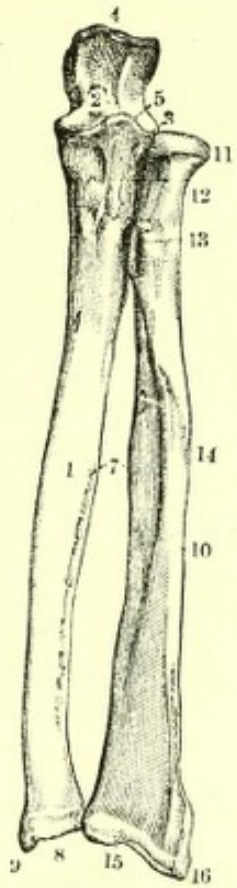

FIG. 13.

THE BONES OF THE FORE-ARM (anterior surface): 1, body of ulna; — 2, great sigmoid cavity; — 3, lesser sigmoid cavity with head of radius; — 4, olecranon; — 5, coronoid process; — 7, interosseous space; — 8, inferior extremity of ulna with styloid process (9); — 10, body of radius; — 11, its head; — 12, neck; — 13, tubercle for biceps; — 14, depression for pronator teres muscle; — 15, inferior extremity of radius with styloid process (16).

we will describe only the upper extremities of these two bones (Figs. 13 and 14).

The superior extremity of the ulna is in shape exactly like half a pulley, as if its model had been taken in wax; in fact, this bone articulates with the pulley or trochlea of the humerus, and closely embraces this trochlea by a broad depression called the *great sigmoid cavity* of the ulna. This cavity (2, Fig. 13) presents in its centre a ridge prominent from before backwards, which corresponds to the groove in the trochlea of the humerus. In front, the great sigmoid cavity is formed (5, Fig. 13) by a bony prominence called the *coronoid process* (compared to the beak of a crow; κορώνη, a crow; εἶδος, form), and as, in flexing the fore-arm upon the arm, this process is lodged in the cavity which, on the anterior surface of the lower extremity of the humerus, is situated above the trochlea, this cavity is likewise called the coronoid (17, Fig. 12). Behind, the great sigmoid cavity is formed by a process, comparatively speaking very large (4, Fig. 13), which constitute the most prominent portion of the elbow, and which accentuates in a high degree the forms

behind the fore-arm when it is flexed; to this process is given the name of the *olecranon* (ὠλένη, the elbow; κάρηνον, the head); during the extension of the fore-arm, the olecranon lodges partly in the cavity, which is situated above the trochlea, upon the posterior surface of the humerus, and is called in consequence the *depression for the olecranon* (4, Fig. 15).

The superior extremity of the radius forms a small head (11, Fig. 13) which a narrowed portion (neck of the radius—12, Fig. 13) separates from the body of the bone; this head is flattened at the top and hollowed out into a cup, into which is received the condyle of the humerus (Fig. 14).

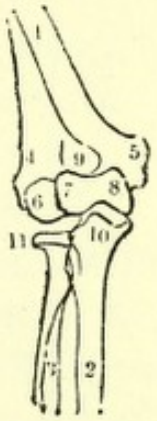

FIG. 14.

FIGURE OF THE ELBOW JOINT, RIGHT SIDE (anterior view):—1, inferior portion of shaft of humerus;—2, ulna;—3, radius;—4, external condyloid ridge;—5, internal condyloid ridge;—7 and 8, trochlea;—9, coronoid fossa;—10, coronoid process;—11, head of radius.

We see, then, that the articular surfaces of the elbow are formed, in the humerus (6, 7, 8, Fig. 14), by a transverse series of projections (the lips of the trochlea and condyle), and in the fore-arm by a series of depressions moulded on these projections, so that the whole forms a movement similar to that between two cogwheels (Fig. 14), a species of transverse hinge. Thus it is easy to understand, *a priori*, how this disposition of the parts does not permit any lateral displacement of the bones, or transverse movement; the movements forward and backward are, in fact, the only kind possible in the elbow-joint. The forward

movement—that is to say, that by which the anterior surface of the fore-arm is brought near the anterior surface of the arm constitutes *flexion* of the fore-arm. The movement in the opposite direction constitutes *extension.*

The disposition of the ligaments—that is, of the fibrous bands or articular capsule which fastens the bones together, modifies very slightly the mechanism we have just deduced from the shape of the articular surfaces; in fact, this capsule is formed on the inner and outer surfaces by ligamentous fibres, very dense and short, called the lateral ligaments, which prevent all lateral movement. On the other hand, the anterior and posterior portions of this ligament are loose, so as not to offer any opposition to the movements of flexion and extension. The only limit to these movements is that resulting from the bony projections of the ulna coming in contact with the humerus. Thus, the movement of flexion can be prolonged until the coronoid process arrives at the coronoid fossa and touches the bottom of that cavity; then the fleshy masses of the fore-arm come into contact with the anterior surface of the humerus, especially if the model is muscular, and flexion is no longer possible The movement of extension, on the contrary, has a

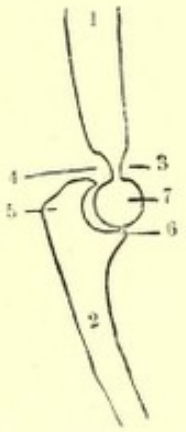

FIG. 15.

ANTERO - POSTERIOR SECTION OF THE ELBOW (through the ulna):—1, humerus;—2, ulna;—3, coronoid fossa;—4, olecranoid depression;—5, olecranon;—6, coronoid process;—7, section of trochlea.

limit which it is important to state precisely, resulting from the beak of the olecranon touching the bottom of the olecranoid fossa (Fig. 15); this is produced when the fore-arm has attained, in the movement of extension, that situation which brings its own axis in a direct line with that of the arm. The extension of the elbow cannot therefore exceed the degree which brings the humerus and fore-arm into the same plane; that is to say, the fore-arm can never make with the arm an angle facing backwards.

By comparing the particulars of the mechanism of the elbow with that which we have previously seen of the mechanism of the scapulo-humeral articulation, it will be easy to understand how we may, from the study of the articular surfaces and ligaments, learn precisely the laws of the mechanism of joints, and as, for example, the head of the humerus received into a single cavity may allow to the arm every species of movement, so the arrangement of a hinge-joint, with a series of projections and depressions, fitted one to the other in a transverse line, renders only the movements of flexion and extension possible in the elbow. As regards the external form, we learn from the knowledge of the bones which form the elbow-joint:—1st, with respect to the angle which the fore-arm makes with the arm; if we examine it either upon the skeleton or upon the living subject, the superior members lying in a state of repose beside the body, the palm of the hand being turned forward so that the humerus (page 55) is slightly oblique from above downwards and from without inwards, the two bones of the fore-

arm are directed obliquely in the opposite direction—that is, from above downwards and from within outwards—these two parts form at their point of junction—that is, at the level of the elbow—an *angle* the base of which looks outwards and the apex inwards ;—2nd, concerning the bony prominences which are seen beneath the skin at the line of the elbow.

After the previous study of these osseous structures, we should be able to recognise upon the living model those details of the figure which correspond to the four bony points, namely, the coronoid process in front, the olecranon behind, the external condyloid ridge on the outer, and the internal condyloid ridge on the inner side ; but the coronoid process, covered by muscles, is so buried in the surrounding structure that it does not show externally. It is the same with the external condyloid ridge, as this projection, not very prominent in the skeleton, disappears completely in the complete subject, since this external condyloid ridge is situated at the bottom of the angle facing outwards which the fore-arm makes with the arm, and the mouth of this angle is filled up by the external muscles of the fore-arm (especially the supinator longus), which take their origin from the external border of the humerus.

On the other hand, the internal condyloid ridge and olecranon always show clearly beneath the skin, and the olecranon forms that projection, commonly called the *tip of the elbow*, which shows so prominently behind during the flexion of the fore-arm upon the arm, and which follows the movements of the fore-arm, that is

to say, it seems to rise towards the arm during the extension of the fore-arm and to descend during flexion. As regards the internal condyloid ridge it is this projection which corresponds to the apex of the angle formed by the axis of the fore-arm with that of the arm (Fig. 16, page 67); this point placed a little above the line of the elbow is a fixed point. There is one matter of detail which we must not forget when we compare the length of the fore-arm with that of the arm, that is, if we should take the olecranon as a measure we should make a serious error, as the level of this projection changes with respect to the humerus according as the fore-arm is fixed or extended; on the other hand, the internal condyloid ridge, forming a fixed point, should rather be chosen.

CHAPTER VI.

THE FORE-ARM.

The bony structure of the fore-arm; ulna and radius, their difference in length and size. The inferior extremities of these bones; their styloid processes (prominence at the wrist); triangular ligament. Position of the hand during *supination* and *pronation*, the movements of supination and pronation. Changes of form in the fore-arm during pronation and supination; change in direction.—Prominences of the wrist (styloid processes), their levels; the angle which the axis of the hand makes with that of the fore-arm.

HAVING now examined the two bones of the fore-arm (ulna and radius) only as to their superior extremities in order to study the articulation of the elbow-joint, we will continue their description, and study their bodies and their inferior extremities, then consider the forms of the fore-arm, the movements that these two bones accomplish one with the other, and finally the articulation of their inferior extremities with the hand.

A superficial glance at the bony structure of the fore-arm (Fig. 13, p. 58) suffices to show that the two bones which compose it offer in many respects a striking contrast to each other; these two bones do not appear on the same level either above or below; above, the *ulna* (by the olecranon) extends beyond the *radius* and ascends higher than it; below, on the other hand, it is the radius (15 and 16, Fig. 13) which

extends beyond the ulna and descends below it; we should also note immediately a fact, which is of great importance, and to which we shall have often again to refer, namely, that the radius, descending below the ulna, is found to be the only bone of the fore-arm which articulates with the hand (*radio-carpal* articulation, not *radio-ulnar carpal*, see p. 76). As regards size these bones present a contrast as well; the ulna is thick and bulky at its upper part, but it becomes thinner as it descends, and its inferior extremity is comparatively small (Fig. 13); the radius, on the other hand, is small and slender at its upper part, and increases in size below; finally, its inferior extremity, articulating with the hand, forms a large bony surface.

After what we have now said of these two bones, we need not enter into minute details of the shape of the body or central portion of each of them.

Their bodies are regularly prismatic in form. We perceive on the superior portion of the body of the radius, immediately below the neck, a tuberosity (13, Fig. 13) looking forwards and inwards which gives insertion to the tendon of the biceps (*bicipital tuberosity*); from this tuberosity an oblique line passes downwards and outwards, and terminates upon the middle part of the external surface of the bone in a rough space (14, Fig. 13) called the *impression of the pronator teres*, because it gives insertion to the muscle of that name.

With regard to the ulna, we need only notice that its internal surface is subcutaneous in its lower

two-thirds, and that, like the tibia in the leg, it forms directly the outline of the internal border of the fore-arm.

The inferior extremity of the radius (15, 16, Fig. 13) is broad, and presents a facet on its lower surface, which receives the two first bones of the wrist (scaphoid and semilunar), its outer side is prolonged into a short pointed process which constitutes the external prominence of the wrist, and bears the name of the *styloid process* of the radius (16, Fig. 13). The inferior extremity of the ulna is small, forms a rounded head (8, Fig. 13), and is prolonged on its inner side into a *styloid process* which forms the internal prominence of the wrist. We have already said that the inferior extremity of the ulna does not descend as low as the corresponding portion of the radius; this difference of level between the two bones is partly filled up by a fibro-cartilaginous disc called the *radio-ulnar triangular ligament*, which proceeds from the external border of the inferior extremity of the radius to the base of the styloid process of the ulna, passing beneath the head of the latter bone (F, Fig. 18, page 75); the bones of the hand (carpus) articulate with the radius and with this triangular ligament, so that the ulna does not take part directly in the articulation of the fore-arm with the hand (Fig. 18).

Up to the present we have considered the two bones of the arm as placed parallel side by side, and separated by a comparatively broad interval, called the *interosseous space* (7, Fig. 13). In fact, they are so

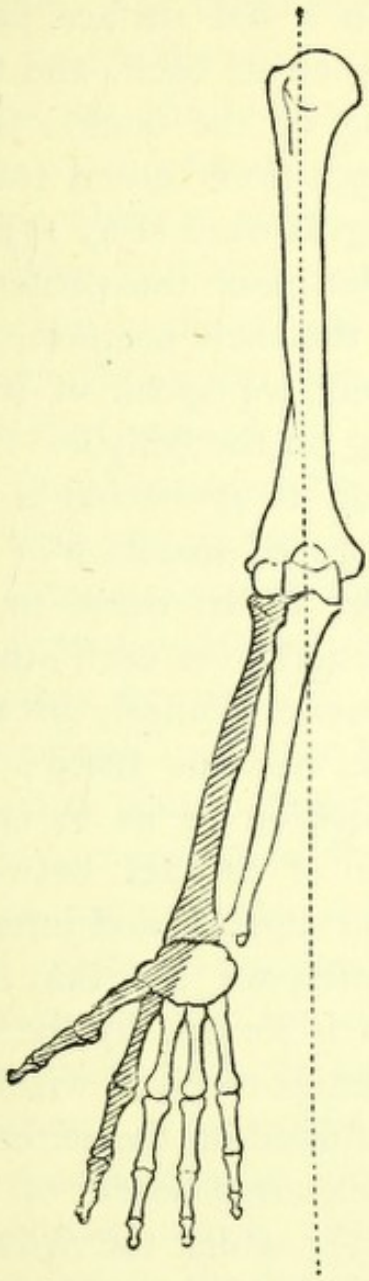

FIG. 16.

RIGHT FORE-ARM IN SUPINATION (the radius and radial half of the hand are shaded by oblique lines): the radius is parallel to the ulna.

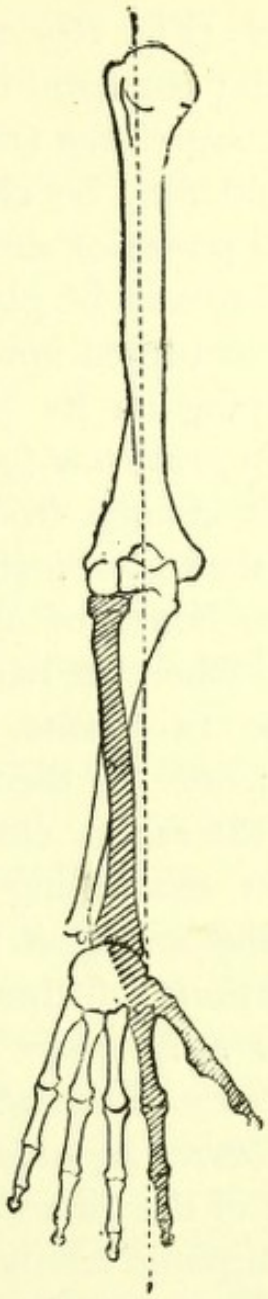

FIG. 17.

THE RIGHT FORE-ARM IN PRONATION: the radius (shaded) crosses the ulna, and the radial half of hand (shaded) is placed on the inner side.

placed, when the arm is hanging beside the body, in a state of repose, with the palm of the hand looking

forwards (Fig. 16), or placed on a flat surface, palm upwards; the hand is then lying on its back, and this we call *supination* (*supinus*, lying on the back). But the hand may be changed in position, turned round with its posterior surface looking forward (Fig. 17) or, if the fore-arm be placed on a flat plane this posterior surface is turned upwards. In this new position, the hand lying on its palmar aspect, we speak of it as being in *pronation* (*pronus*, lying on the belly).

This change from supination to pronation is accomplished by a reciprocal change of situation in the the two bones of the fore-arm, which cease to be parallel when the hand is prone, and cross each other; but the two bones do not move similarly in this action; one of them, the ulna, remains fixed; the other, the radius changes its position so as to cross it. On examining the points of contact between the radius and ulna, namely, the superior and inferior articulations of these two bones, we see that the *superior radio-ulnar articulation* is formed by the circumference of the head of the radius received within a cavity (*lesser sigmoid cavity*), situated on the external surface of the ulna (below the external border of the great sigmoid cavity, 3, Fig. 13); whilst the *inferior radio-ulnar articulation* is formed by a sigmoid cavity situated on the internal surface of the inferior extremity of the radius, receiving the circumference of the head of the ulna.

Therefore, in the superior radio-ulnar articulation, the head of the radius turns on its own axis in gliding in the sigmoid cavity of the ulna; the superior

extremity of the radius does not move from its situation beside the ulna; in the inferior radio-ulnar articulation, on the contrary, the radius moves round the axis of the head of the ulna, as a wheel round its axle; whilst a spoke of the wheel is represented by the triangular ligament (page 66), of which the summit attached to the styloid process of the ulna is a fixed point, whilst its base attached to the radius moves with that bone.

These considerations of articular mechanism may be best understood by examining a portion of the skeleton containing the bones of the fore-arm, which, as is usual in articulated preparations, are connected together by metallic bands that permit the normal movements. We see then in moving the radius round the ulna, that in causing the hand to pass from supination to pronation, it is necessary to bring the body of the radius across that of the ulna, in such a manner, that while the superior extremity of the first bone remains still on the outer side, its inferior extremity is entirely changed in its situation, and leaves the outer side to be carried to the inner (Figs. 16 and 17). In accomplishing this movement, we perceive that the hand, which articulates only with the radius, must follow the movement of this bone, so that the thumb or radial border of the hand must change from the outer to the inner side; the hand, which in supination turns its palm in front, now presents its back, and it is this which constitutes the passage from supination (Fig. 16) to pronation (Fig. 17).

The general form of the fore-arm, irrespective of

the details which we will explain later on regarding the configuration of the muscles, depends directly on the position of its bony structure, and is changed according as these two bones are parallel or crossed. When the hand is supinated (Fig. 16), the radius being then placed parallel to the ulna and separated from it by a large interosseous space, the form of the fore-arm is that of the segment of a limb presenting two borders—an external or radial, and an internal or ulnar—and two surfaces, one anterior, the other posterior. The fore-arm, in a word, is slightly flattened from front to back, by reason of these two bones being parallel to each other. But when, from the position of supination, the hand passes to that of pronation, the two bones cross and approach each other, coming in contact, and the interosseous space disappears (Fig. 17). The radius and ulna, taken as a whole, form a single mass, which may be compared to that which two rods assume, placed at first parallel at a certain distance from each other, and which afterwards cross and come into direct contact. Thus in pronation the shape of the fore-arm becomes completely changed, especially in its lower two-thirds. Instead of a segment of a limb with two surfaces and two borders, it represents a segment rounded and almost cylindrical in its middle part; only the inferior part (wrist) and the superior part (bend of the elbow) preserve the form flattened from front to back.

Artists are usually not sufficiently imbued with these important facts; thus they readily believe that if a figure has been represented with the arm in

supination, and that for some reason this attitude has been changed to that of pronation, it is enough merely to change the hand and wrist without interfering with any other portion of the model of the fore-arm. The details into which we are now about to enter show clearly that the form of the fore-arm throughout its entire extent, and particularly in the middle part, undergoes a change, and this fact will be still more evident when, in studying the muscles of that region, we see that their direction is completely changed, and contributes to modify the shape of the fore-arm, when the hand passes from supination to pronation, and the reverse. In accomplishing the movements of pronation and supination, the fore-arm changes not only in form, but also in direction. We have previously seen that when the radius and ulna are placed parallel one with the other (supination), the axis of the fore-arm makes with that of the arm an angle opening outwards. We may again express this fact by saying that if in this case we prolong the axis of the humerus downwards (see the dotted line in fig. 16), this axis falls within the head (inferior extremity) of the ulna, and consequently lies well to the inner side of the radius and interosseous space.

But in pronation, when the radius crosses the ulna at its centre, and is placed internal to it at its lower part, the result is that the two crossed bones of the fore-arm, taken as a whole, are found continuous in line with the humerus, the angle of the elbow has disappeared, and the axis of the arm and that of the fore-arm are almost in the same straight line (Fig. 17).

In order to make the best use, with respect to outward form, of the various details of the bony structures which we have been studying, we will, before commencing the study of the hand, first note once more the prominences which form the inferior extremities of the radius and ulna at the level of the wrist. Of these two projections, which are to the hand what the ankle-bones or malleoli are to the feet, one is external, formed by the styloid process of the radius (16, Fig. 13), the other is internal, and is formed by the head of the ulna and the base of its styloid process.

The first (external or radial) is situated much lower than the second (internal or ulnar).

This position of the bones we may easily verify upon ourselves, without a skeleton, by clasping with the thumb and index-finger of one hand the wrist of the other; we then perceive that the radius descends much lower than the ulna (Fig. 13). Hence, the articular line of the fore-arm with the hand is obliquely directed from above downwards, and from within outwards (the hand being supposed to be supinated), and accordingly the hand does not articulate with the fore-arm in such a manner that the axes of the two parts are in the same line. These two axes form here a very obtuse angle, similar to that formed by the junction of the arm and fore-arm with the elbow; but this angle is in the opposite direction, that is to say, with its base looking inwards (towards the axis of the body, the arm hanging in a state of repose), with its highest point outwards, corresponding to the styloid process of the radius.

We will now sum up the various folds which the superior member presents at the points of junction of its three principal parts (arm, fore-arm, and hand). The humerus is obliquely directed from above downwards, and from without inwards; the two bones of the fore-arm in supination are obliquely pointed in the opposite direction, namely, from above downwards, and from within outwards; finally, the axis of the hand is again oblique in the same direction as the humerus, namely, from above downwards, and from without inwards. The junction of the arm and the fore-arm forms an angle opening outwards; that of the fore-arm and hand forms an angle opening inwards.

CHAPTER VII.

THE HAND.

The bony structure of the hand: 1st, the wrist or carpus; eight bones in two rows, one superior (scaphoid, semi-lunar, &c.), the other inferior (trapezium, trapezoid, &c.)—The radio-carpal articulation, its movements. The medio-carpal articulation, its movements. The movements of the whole; the forms of the wrist during flexion. —2nd, Palm of the hand or metacarpus; metacarpal bones; their relative lengths (form of the shut fist).—Carpo-metacarpal articulations; the peculiarities of the articulation of the thumb; its movements of opposition.—3rd, The fingers: their phalanges, first, second, and third. Articulations of the phalanges; their movements.—Proportions of the superior member: the arms extended (the square figure of the ancients); the hand as a common measure; the middle finger and the Egyptian Canon of Charles Blanc.—Brachial index.

THE hand is composed of three parts: the wrist, the palm, and the fingers. The bony structure of the wrist is called the *carpus*, that of the palm the *metacarpus* (*μετὰ*, below; *καρπὸς*, the wrist); the fingers are formed by small bones called *phalanges*.

As the carpus is almost completely hidden by the soft parts, fibrous and tendinous, which cover it, we shall enumerate the bones which compose it and show their articulations, so as to understand the mechanism of this portion of the skeleton.

Notwithstanding its small compass, the carpus is made up of not less than eight bones, which are placed in two transverse rows, the one *superior* or *brachial*

(next the fore-arm), the other *inferior* or *metacarpal* (next the metacarpus).

We enumerate these bones starting from the radial border of the hand (side of the thumb) to the ulnar (side of the little finger). The four bones of the first series are ranged thus: the *scaphoid* (S, Fig. 18), named from the cavity on the inferior surface being compared to a boat (σκάφη, a boat; εἶδος, form); the *semi-lunar* (L, Fig. 18), and the *cuneiform*, whose names indicate their shape; and finally the *pisiform* (P, Fig. 18), which, small and rounded like a pea, is placed not on the internal, but on the anterior surface of the cuneiform (Fig. 19). The four bones of the second row, counting still from without inwards, are (Fig. 18): the *trapezium*, the *trapezoid*, the *os magnum*, and the hooked or *unciform* bone (*uncus*, a hook). In examining the bony structure of the carpus as a whole, we see that the anterior or palmar surface presents the form of a vertical groove, limited on the inner side by the projection formed by the pisiform bone on the first row, and the process of the unciform bone on the second, and on the outer by a process belonging

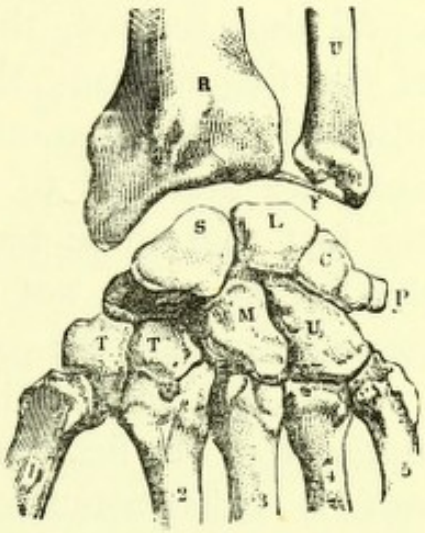

FIG. 18.

THE BONY STRUCTURE OF THE WRIST (dorsal surface) R, radius;—U, ulna;—F, triangular ligament;—S, scaphoid;—L, semi-lunar;—C, cuneiform;—P, pisiform;—T, trapezium;—T, trapezoid;—M, os magnum;—U, unciform.—Below the carpus: 1, 2, 5, 4, 5, the five metacarpal bones counting from that of thumb (1).

to the trapezium ; but this groove is formed into a canal by the presence of a broad fibrous ligament (the anterior annular ligament of the wrist), which passes like a bridge from the internal prominences to the external. Beneath this bridge, and consequently in the canal thus formed, the tendons of the flexor muscles of the fingers pass, the fleshy bodies of which are situated in the fore-arm, while the tendinous insertions are attached to the phalanges. This explains the fact that these tendons, seen at the lower part of the fore-arm, are not visible externally during their passage through the palm of the hand.

The first row of the carpus forms, by the superior surfaces of its first three bones, a concave articular surface which articulates with the fore-arm, the scaphoid and semilunar being in contact with the concave surface of the inferior extremity of the radius, the cuneiform with the inferior surface of the triangular ligament (Fig. 18). This articulation, called the *radio-carpal*, permits movement forwards (flexion of the hand), backwards (extension of the hand), and laterally (bending of the hand towards either the radial or ulnar side of the fore-arm). On the other side the first row of the carpal bones articulates with the second row, and this articulation, called the *medio-carpal*, forms a species of interlocked joint, the inferior prominence of the scaphoid projecting into the second row, to a level with the trapezoid, and the head of the os magnum being received reciprocally into the first row on a level with the semilunar (Fig. 18). The movements of flexion and extension are permitted in the medio-

carpal articulation, but the lateral movements are very limited or almost nil.

It follows from this arrangement: 1st. That the flexion and extension of the hand at the level of the wrist are very extensive, and amount almost to a right angle, both before and behind, the mobility of the radio-carpal and medio-carpal articulations aiding each other in these movements; on the contrary, the lateral motion of the wrist is very limited, as it is confined to the radio-carpal articulation, and this articulation possesses ligaments, very strong and thick, which curtail considerably the extent of these movements. 2nd. That in the flexion of the hand, when it forms a right-angle with the fore-arm, the posterior surface of the wrist does not present an abrupt curve, but rather a rounded form; the right-angle which the hand then makes with the fore-arm is made up of two articulations, that is to say, one part in the radio-carpal, the other in the medio-carpal articulations.

The *metacarpus* (Fig. 19), or skeleton of the palm of the hand, is composed of five bones placed parallel, one beside the other (metacarpal bones), and separated by spaces called interosseous (or intermetacarpal). These metacarpal bones are, notwithstanding their small size, classed as long bones, and are therefore composed of a shaft and two extremities. Their body is more or less prismatic and triangular; their superior or carpal extremity is cuboid, or wedge-shaped; their inferior or digital is rounded, and takes the name of the head. We distinguish the metacarpal bones by the names of the first, second, third metacarpal, &c.,

counting from the thumb towards the little finger; or, again, by the name of the finger to which they correspond (as the metacarpal bone of the thumb, index finger, &c.) The first metacarpal bone, or that of the thumb, is very short, and remarkable for other characteristics which we will note afterwards, when referring to its movements; the second, or metacarpal bone of the index finger, and the third, or that of the middle finger, are the longest. The third is generally longer than the rest, so that a line passing through the heads of the series of metacarpal bones describes a curve with its convexity downwards, of which the most prominent part corresponds to the head of the third metacarpal bone. When the hand is firmly closed, and the fingers bent in the palm, it is the head of the third which forms the most prominent part of the fist.

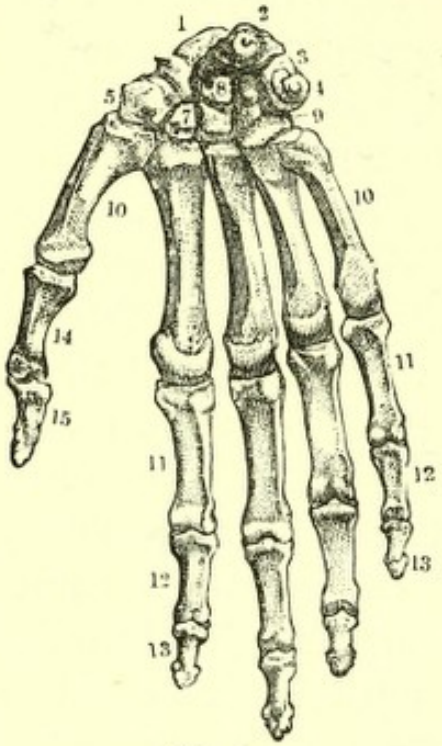

FIG. 19.

BONY STRUCTURE OF HAND (anterior or palm surface).—1, 2, 3, and 4, the four bones of superior row of carpus;—5, 7, 8, 9, the four bones of inferior row;—10, 10, the five metacarpal bones;—11, the first phalanges;—12, 12, the second phalanges;—13, 13, the third phalanges;—14 and 15, the two phalanges of the thumb.

The metacarpal bones articulate with the carpus by their superior extremities, or bases. In these articulations of the metacarpal bones we find a very different arrangement for the first (that of the thumb)

compared with that of the four last metacarpal bones.

1st. The articulation of the metacarpal bone of the thumb is formed by the trapezium, which presents a facet resembling a saddle, concave from side to side, and convex from before backwards, and the base of the first metacarpal bone, which presents a facet alternately concave and convex, corresponding to the facet on the trapezium on which it is fixed. It results, then, that as the rider can move himself on his saddle forwards and backwards, and to either side, the metacarpal bone of the thumb can equally move itself in all these directions, and accomplish the movement of circumduction by which the extremity of the thumb describes a circle. It is this mobility that permits the thumb to extend itself from the index finger, to place itself in front of the other fingers, and come in contact with them. This is called the *movement of opposition* of the thumb, and it is owing to this property that the thumb possesses, namely, of opposing itself to the fingers, that the hand of man forms such a wonderful organ for prehension and for performing all manual labour. The articulation of the trapezium and metacarpal bone, which is the source of these movements, thus deserves particular mention, which we will complete by saying that the two bones are attached to each other by an articular capsule, or fibrous band, sufficiently loose to permit all the movements which the first metacarpal bone can make, by reason of the shape of the trapezo-metacarpal articular surfaces.

2nd. On the contrary, the articulations of the

metacarpal bones of the four other fingers do not present anything like such mobility. In fact, whilst the base of the first metacarpal bone is free, without being connected with that of the second, the bases of the other metacarpal bones are in contact with each other by their lateral surfaces, and are united by their dorsal, palmar, and interosseous ligaments. Again, the tranverse line of union between the second row of the carpus and the base of these metacarpal bones (carpo-metacarpal line) is tortuous, the carpus and metacarpus being dovetailed into each other, especially at the level of the second and third metacarpals, where this line describes a figure like the letter M, by reason of a prominence of the third metacarpal bone, projecting into the carpus at the same time that the trapezoid is received into a depression at the base of the second metacarpal bone (Fig. 19). The carpus and the four last metacarpal bones therefore form a whole of which the parts are slightly movable one on the other, and are capable only of slight gliding movements giving a certain elasticity to the whole. We see that if the palm of the hand had been formed of one continuous bone, pressure or a sudden shock would produce fracture. These accidents are avoided by the presence of numerous parts united in such a manner as to glide slightly one on the other, at the same time not presenting any real mobility.

This will explain the advantage which the first row of the carpus possesses in common with the second. Each of them, instead of being formed by one single bone, is made up of a series of small bones

placed side by side, and closely joined together by the dorsal, the palmar, and the interosseous ligaments.

The fingers are formed of small long bones, placed end to end and termed *phalanges;* each finger has three phalanges, except the thumb, which has only two. We distinguish these phalanges by the names of the first, second, or third phalanx, counting from the base to the free extremity of the fingers; and we give the name of ungual phalanx to the last because it supports the nail. These phalanges, like all the long bones, are made up of a shaft and two extremities. The shaft is flattened from front to back, and presents on its anterior surface a small groove or hollow, to lodge the flexor tendons of the fingers; while the extremities present characters which we will point out when studying the articulations of the fingers.

The articulations for each finger are: 1st, the metacarpo-phalangeal articulation; 2nd, the articulation of the first with the second; and 3rd, the articulation of the second with the third; all these articulations of the phalanges being formed upon the same plan.

1st. The metacarpo-phalangeal articulations are formed by the head of the metacarpal bone being received into a glenoid cavity in the base of the first phalanx. Such an adaptation of articular surfaces will permit every kind of movement, and it is easy to understand that each finger can be flexed on the metacarpus (on the palm of the hand), extended, and also inclined to either side (the act of separating the fingers when they have been in contact); but the articular capsule or fibrous band

which surrounds each metacarpo-phalangeal joint fixes an exact limit to these movements. Thus extension cannot be prolonged much further than that position in which the axis of the fingers forms a very obtuse angle with that of the metacarpal bones behind, for just then the anterior portion of the capsule is put on the stretch, and as this part is fibrous, thick and resisting, it prevents any increase of extension. On the other hand, this capsule is strengthened on either side by a lateral ligament which, being inserted at the posterior part of the head of the metacarpal bone, is found stretched, according as flexion is produced, and when this act of flexion arrives at a right angle, the lateral ligaments do not permit it to be carried any farther. It is easy to prove this upon ourselves, as we cannot flex the first phalanx on the metacarpus beyond this point, for we cannot, in any case, bring the anterior surface of the first segment of a finger in contact with the palm of the hand, but only the other segments, as we shall see when we come to study the articulations of the first phalanges with the second, and the second with the third.

2nd. The articulations of the phalanges, that is, those of the first with the second, and those of the second with the third, are constructed on a different plan from the metacarpo-phalangeal articulations. Instead of a head received into a glenoid cavity, we find here, at the inferior extremity of the phalanx, a surface formed like a pulley, or trochlea of two prominences or lips of the pulley separated by a groove or

hollow (Fig. 19); and on the other hand, on the superior extremity of the succeeding phalanx we find two cavities corresponding to the lips of the pulley, and separated by a projection which corresponds to the groove. Therefore, given a single phalanx, it will be easy to say whether it is a first, second, or third phalanx, as the first phalanx has at its base a single articular cavity, while the second and third have two placed side by side; and again, the third, or ungual phalanx may be distinguished at the first glance from the second by the shape of its free extremity, which is expanded like a horse-shoe, in order to support the finger-nail. But we should notice especially in the articular surfaces of the phalanges, that these joints, reproducing on a smaller scale the pulley or trochlea in the elbow, present an analogous mechanism, and like all trochlean joints, permit only the movements of flexion and extension. In fact, as each of us may prove upon his own hand, while the fingers may be flexed, extended, or moved from side to side at their metacarpo-phalangeal articulations, at their phalangeal articulations they can be flexed and extended only; thus, while the finger enjoys great freedom of movement at its base, it only possesses that of flexion and extension in its component parts. The movement of extension of the phalanges is limited, because the anterior portion of the articular capsule put on the stretch by the movement is short and strong, but we find a great variety in different subjects, and with some, such elasticity that the terminal phalanges can be bent backwards. As regards

flexion, it is limited only by the soft parts on the anterior surface of a phalanx coming in contact with the corresponding portion of that upon which it is bent.

Having examined the different portions of the bony structure of the upper limb in relation to movement and form, it is necessary to study its proportions—namely, to inquire, on the one hand, what comparison the length of the limb bears to the height, and, on the other, to compare the length of the different sections of the body with each other.

The comparison between the superior members and the height may be expressed in two ways: first, by examining the two superior members raised transversely in the horizontal position—the distance which then separates the extremity of one hand from that of the other is termed the *span of the upper limbs*, and this transverse measure includes not only the length of the arms, but also the breadth of the shoulders; secondly, by examining the upper limb hanging vertically beside the body, and noting to what level on the lower limb the extremity of the hand (nail of the middle finger) reaches.

The relation of the span of the upper limbs to the height has been expressed long since by the formula known as the *square figure of the ancients* (Fig. 20); if we cause two horizontal lines to pass, one at a tangent to the soles of the feet (*c*, *d*), the other at a tangent to the summit of the head (*a*, *b*), and two vertical lines at right angles to the extremities of the two arms extended horizontally, these four lines form

by their junction a perfect square; in other words, the man having the arms horizontal is enclosed within a square. This shows that the span of the arms is equal to the height.

This statement is correct for a man of the Caucasian race of the middle height, but it is not so for the yellow and black races, in whom the span of the arm is greater than the height. If from man we pass on to the superior monkeys, called anthropoid (chimpanzee, gorilla, &c.), we find that the span of the arms in these becomes more and more extended as compared with the height, until it becomes almost double. Thus, in the gorilla, the height being 5 ft. 7¼ in., the span become s 8 ft. 9¼ in. and in the chimpanzee, to a height of 5 ft. 5¼ in., the corresponding span is 6 ft. 6 in.

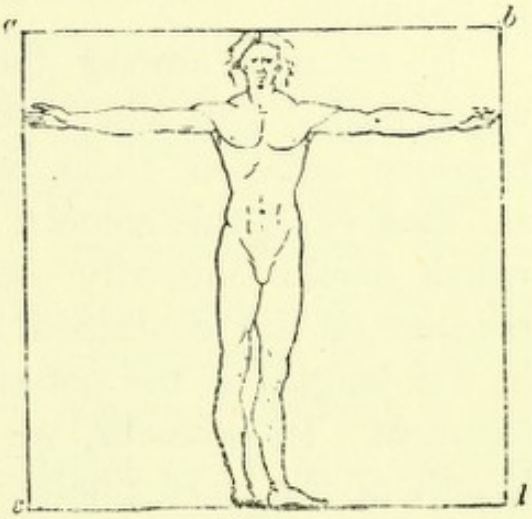

FIG. 20.

Figure in a square, ancient method.

So, when we examine the upper limbs hanging freely beside the body, we find that in the European of average height the extremity of the middle finger corresponds in general to the middle of the thigh; in subjects of short stature this extremity of the hand descends a little lower than the middle, and, on the other hand, in very tall men it rests a little higher. In the yellow and black races the extremity of the

hand descends much lower than the middle of the thigh; and if we pass on from the human species to the superior (or anthropoid) class of monkeys, we see that in the chimpanzee the extremity of the hand descends below the knee; in the gorilla it corresponds to the middle of the leg; and, finally, in the orang-outang, and especially in the gibbon, it reaches almost to the ankle.

If we seek among the various portions of the upper limb a part which would answer as a common measure between them, we cannot find anything satisfactory in this respect. The length of the hand, which would naturally seem to be indicated as a measure, is not contained an even number of times in the length of the bones of the shoulder, arm, or fore-arm. If, however, we take from the hand the length of the third phalanx of the middle finger, we have a measure equal to that of the spinal border of the shoulder-blade, and consequently to that of the clavicle. Under those conditions we may say that the length of the humerus is equal to twice that of the hand, and that of the fore-arm equal to the length of the hand plus its half; but these proportions are so variable that they cannot be insisted on. We should attach more importance to the rule that takes the hand as a common measure of the entire body in regard to height, taking the height as being equal to ten hands. This is a proportion which often answers in reality, but which presents too many exceptions to be laid down as a law.

We may here state the fact once for all, that there

is not an *absolute rule* for the anatomist, or system of proportions applicable to every class of subject, to those of small as well as those of large stature. If, on the contrary, an ideal proportion is adopted, in which a human figure has been altered, so as to correspond to the abstract conception of beauty, we say that this question of proportion belongs no longer to the domain of anatomy or observation, but that here we rather touch æsthetic doctrines ; it is for this reason that we have limited ourselves, when putting forward various ideas of proportion, to indicating within such limits as direct observation permits, whether a part of a limb might serve as a common measure for this limb, and moreover for the total length of the body. The *Egyptian canon* as demonstrated by Charles Blanc, which has a certain historical interest, is that the *length of the middle finger*, taken as a common measure, should be contained nineteen times in the length of the body. In fact, the "Selection of Funeral Monuments" by Lepsius (Leipzig, 1852) contains the drawing of a very curious Egyptian figure, divided by transverse lines into nineteen parts (not including the head-dress). Now as several passages in different ancient authors seem to indicate that the Egyptian sculptors have taken the finger as the unit of the system, Charles Blanc very ingeniously remarks this fact, that in the figure in question, one of the horizontal lines, the eighth beginning at the soles of the feet, passes exactly at the base of the middle finger in the right hand (closed holding a key), while the seventh touches the extremity of the middle

finger of the extended left hand. It seems to him, then, very probable that the distribution of these horizontal lines indicates a system of measuring the figure, and that the space between the seventh and the eight line measures the length of the middle finger, which thus becomes the standard of this system of proportion. According to the Egyptian rule, the length of the middle finger will be found nineteen times in that of the height (Fig. 21); it may be that this rule was adopted by the Greek artists, and Charles Blanc does not hesitate to think that Polycletus, who has composed (compare Pliny and Cicero) a *Treatise on Proportions*, with a model in marble known by the name of *Doryphorus*, used no other system but the Egyptian; there has been always found in a number of antique figures this same proportion of nineteen times the middle finger to the height of the body, and in the Achilles, for example, the total height does not exceed by more than $\frac{1}{20}$th of an inch the length of the middle finger multiplied by nineteen.

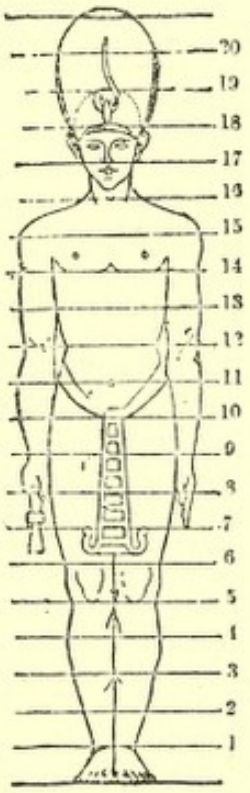

FIG. 21.
The Egyptian Canon.

An interesting proportion to note is that between the arm and fore-arm, especially as it has been with anthropologists the object of important researches, and will familiarise us with the term *index*, which we must frequently make use of, especially when com-

paring the transverse and antero-posterior diameters of the cranium. We give, in anthropology, the name *index* to the number which expresses the proportion of one dimension to some other, this last being represented by 100. Supposing, in fact, that we compare one length, A, equal to one metre, with another length, B, equal to two metres, in this case, the first length being half that of the second, we speak of the index found as 50 (because 50 is the half of 100, and we suppose the second length to be equal to 100). Now the fore-arm is shorter than the arm; it represents about three-fourths of it; if, then, we take the number 100 to represent the length of the humerus, the number 75, which is three-fourths of 100, would represent the length of the fore-arm; and then in denoting by the *brachial index* the proportion of the length (always shorter) of the fore-arm, with that of the arm (always longer) we simply say that the brachial index is represented by 75.

This method of notation which reduces any numerical proportion to the centesimal system is very valuable, as it permits us to follow without difficulty the degree in which a proportion varies according to the race or species.

Thus we come to speak of the brachial index (proportion of the fore-arm to the arm) as 75. We have chosen this particular number in order to make the example easy; in reality, in adult European subjects this index is only 74—that is to say, that the fore-arm is to the arm as 74 is to 100. If we measure the same parts in the adult negro, and reduce to the

centesimal proportion the numbers obtained, we find the brachial index here is 79—or that the fore-arm is to the arm as 79 to 100. In the negro, then, the fore-arm is longer compared with the arm, as 79 is a greater part of 100 than 74. Finally, if we pass on from the human species to the anthropoid monkeys, we see that the brachial index comes to be 80, and even 100—that is to say, that the length of the fore-arm becomes equal to that of the arm; and we know, therefore, that the great length of the superior members in the anthropoids (page 86) is principally owing to the greater length of the fore-arm. But the most interesting fact is that in the human race the brachial index is not the same at different ages—thus, in the European infant at birth, this index is 80; before the end of the first year it is only 77, and by degrees during childhood it descends until it arrives at 74 in the adult. This clearly shows that the humerus, during the growth of the body, lengthens in proportion more than the bones of the fore-arm; so that they, which were at first to the humerus as 80 is to 100, come gradually to be as 77 to 100, and finally as 75 or 74 to 100. If we were to glance at the comparative anatomy in the skeleton of a lion or horse, we should see that in those animals the fore-arm becomes longer in proportion to the humerus, so as to equal, and afterwards to surpass, the length of that bone.

CHAPTER VIII.

THE PELVIS.

The bony structure of the hips.—The pelvis; sacrum (five vertebræ welded together); *coccyx* (the caudal appendage in man and the monkeys resembling man); the *iliac bones* (ilium, pubes, ischium); the cotyloid cavity; the acetabulum and its notch directed downwards.—The articulations of the pelvis; *symphyses* (sacro-iliac and pubic); sacro-iliac ligaments; ilio-pubic or Poupart's ligament (fold of the groin).—The pelvis as a whole; its median anterior hollow (form of the abdomen).—Comparison of the pelvis in the male and female.

THE *pelvis*, or osseous girdle of the region of the *hips*, is to the inferior portion of the trunk what the thorax is to the superior part; it is the same to the inferior limbs as the scapulo-clavicular girdle is to the superior. But, whereas the girdle of the shoulders and thorax is formed of many movable and isolated pieces of bone (sternum, ribs, clavicle, shoulder-blade), the pelvis is formed only by four bones, large, with thick walls, and not movable one upon the other. Of these four pieces two are posterior and central, single and symmetrical, these are the sacrum and coccyx, which are continuous with the vertebral column; the other two are in pairs, and are placed one on each side of the pelvis —these are the *iliac bones*, distinguished as the right and left iliac. The sacrum, or *sacred bone* (Figs. 3, 5, 6, and Figs. 24 and 27), called thus because it was this

part that the ancients offered in sacrifice to their gods, is formed of five vertebræ (sacral vertebræ) closely united together, but all the portions are easily seen on a careful examination. Taken together it forms a pyramid, the base of which (2, Fig. 24) is turned upwards and forwards, corresponding to the narrow body of the first sacral vertebra. This sacral pyramid, being directed obliquely from above downwards, and from before backwards (Fig. 5), presents a surface called antero-inferior, or rather inferior, on which we recognise five united vertebral bodies (Fig. 3, page 19); a posterior surface—better called superior—on which we recognise the rudimentary spinous processes (Fig. 6, page 28) and the laminæ of these same five vertebræ, these portions being all united together; and, finally, the lateral borders, which are enlarged above into a surface intended to articulate with the corresponding iliac bone, which surface, shaped in the form of an ear, has received the name of the *auricular surface* of the *sacrum* (C, Fig. 5).

The *coccyx* (21, Fig. 3), placed below the sacrum, presents a rudimentary caudal appendage, and instead of being, as in the greater number of mammals, free and movable, is found in man curved towards the interior of the pelvis, whose inferior outlet it contributes to close. This disposition, which is found in the anthropoid apes, has relation to the vertical position, in which the weight of the abdominal viscera is borne upon the pelvis, and necessitates accordingly such arrangements of the bony structure as may strengthen the inferior outlet of the pelvis.

The coccyx is formed of a series of four vertebræ, welded one with the other, and so diminished in size that each of them is reduced to a small osseous nodule, representing a rudimentary vertebral body—thus the coccyx forms a short chain of four small bony tubercles.

The *iliac bones*, called also the bones of the hip, are two in number, one on each side, articulating behind with the sacrum, and uniting in front with each other on a level with the pubic region (Figs. 24, 27). In order to understand the order and the names of the parts of which an iliac bone consists, it is necessary to notice that this bone is made up originally, in the infant, of three distinct parts, which are afterwards joined together as age advances; of these parts, the superior is called the *ilium;* the two others are inferior, that placed in front is called the *pubis*, that behind, the *ischium*. As shown in Fig. 22, the junction of the three parts tends towards the central portion of the bone, at the level of the great articular cavity (acetabulum) of the hip, and forms a radiated figure, representing a species of star with three branches, of which the centre corresponds nearly to that of the cavity already indicated. We shall see that the names of almost all the parts of the iliac bone are derived from those of its three constituent portions, namely, the *ilium*, *pubis*, and *ischium*.

We notice, 1st, on the external surface of the iliac bone, above, a large space called the *external iliac* fossa (5 and 6, Fig. 23), marked by two curved lines limiting the insertion of the gluteal muscles (4

and 5, Fig. 23); below this space or iliac fossa is placed a circular cavity (13 and 14, Fig. 25), broad and deep, the shape of which has been compared to that of a basin, and which, in consequence, has received the name of the *cotyloid cavity;** its use is to form the hip-joint for the reception of the head of the femur. The margin of this cavity is prominent throughout its entire extent, except below where it is hollowed out into a broad groove (16, Fig. 23) called the *great notch* of the acetabulum; this notch is a valuable starting point to settle the natural position either of the iliac bone or of the entire pelvis (Fig 25). If, in fact, this bone or the pelvis is supposed to belong to a figure in the upright position this large cotyloid notch should be directed downwards, as shown in Fig. 23. Below the cotyloid cavity, the iliac bone is pierced by a large orifice, called the *obturator foramen* (22, Fig. 23) and the bony parts which surround this foramen are: behind, the *tuberosity of the ischium* (20, Fig. 23); in

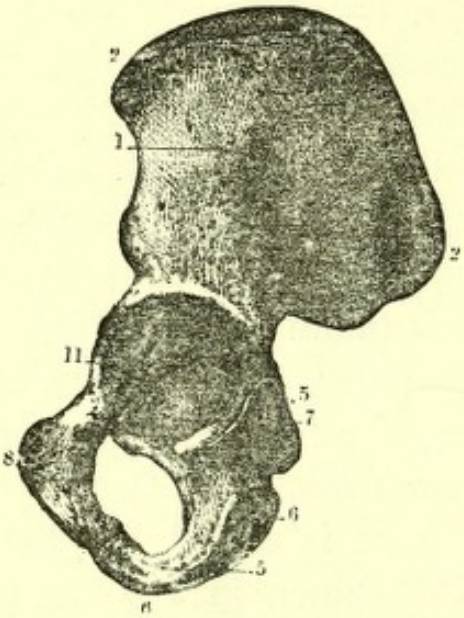

FIG. 22.

THE ILIAC BONE OF AN INFANT: its three primitive pieces:—1, ilium;—2, its superior border;—5, 6, ischium, its autabular part (in 7);—8, pubis, its autabular part (11).

* Usually, in English anatomical writings, called the acetabulum (a vinegar cup) from its resemblance.

front and above, the *horizontal ramus of the pubis* (18); below, a bony plate formed by a prolongation of the pubis (19) proceeding to join the ischium, and therefore called the *descending ramus of the pubis* and *the ascending ramus of the ischium.* 2nd. The internal surface of the iliac bone presents above, the internal iliac fossa (10, Fig. 24); below this, a flat surface corresponding to the base of the acetabulum, and, lower still, the obturator foramen bounded as we have already described. 3rd. The borders of the iliac bone are distinguished (Fig. 23) as superior, anterior, posterior, and inferior. The *superior border*, called the *crest of the ilium* (1, Fig. 23), is thick and curved like an italic *S*; it is this which marks on the living model the line of the hips—namely, the limit between the lateral part of the abdomen and the lateral part of the pelvis; it terminates in front in the anterior superior iliac spine (2, Fig. 23). The anterior border begins at the anterior superior iliac spine, and presents in succession from above downwards, a notch, then a prominence called the *anterior inferior spine of the ilium* (7, Fig. 23), below which is a groove giving passage to the psoas muscle (see later); finally, this border is continuous with the *horizontal ramus of the pubis*, of which the internal part forms the *spine of the pubis* (17, Fig. 23). The posterior border of the iliac bone forms a large notch limited above by the *posterior spine of the ilium* (9, Fig. 23), and below by the tuberosity of the ischium; this notch is divided by a spinous eminence the *sciatic spine* (11, Fig. 23) into two unequal parts,

of which the superior, the larger, is called the *great sciatic notch* (12, Fig. 23), and the inferior, the smaller, the *lesser* sciatic notch. Finally, the *inferior*

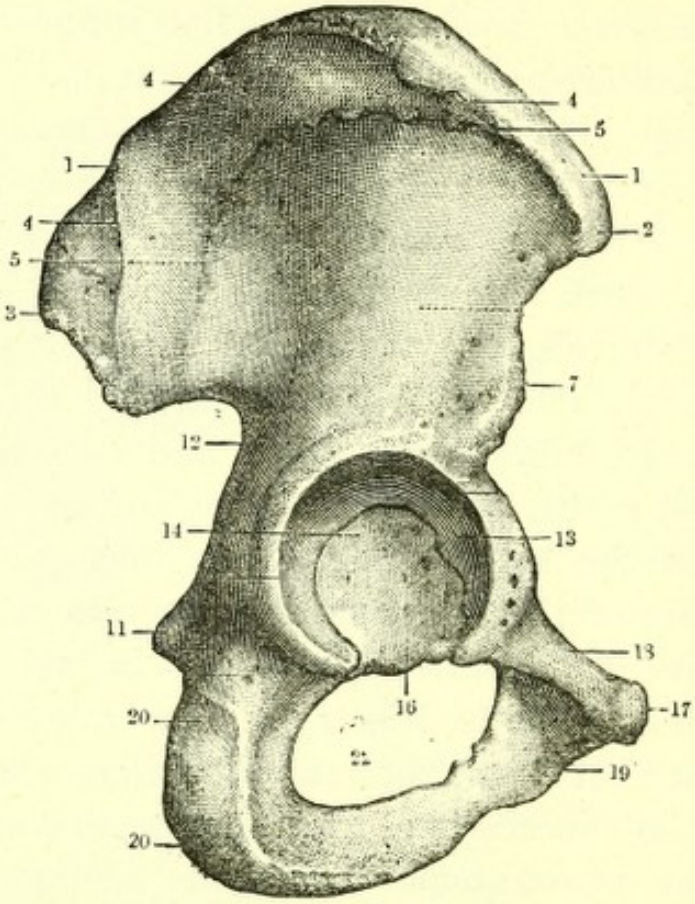

FIG. 23.

RIGHT ILIAC BONE (external surface).—1, 1, iliac crest.—Anterior superior iliac spine ;—3, posterior superior iliac spine ;—4, posterior semi-circular line ; - 5, anterior or inferior semi-circular line ;—7, anterior inferior iliac spine ;—11, sciatic spine ;—12, great sciatic notch ;—13, autabulum ; and 14, its pit (fovea) ;—16, its great notch, directed downwards ;—17, spine of pubis ;—18, horizontal ramus of pubis ;—19, body and descending ramus of pubis ;—20, 20, tuberosity of ischium ;—22, obturator foramen.

border is formed by the descending ramus of the pubis and the ascending ramus of the ischium. We will finish the description of this bone by describing its four angles: the antero-superior (2, Fig. 23) is formed by

the anterior superior iliac spine; the antero-inferior (17, Fig. 23) by the pubis presenting a rough surface which articulates with the pubis of the opposite side; the infero-posterior (20, Fig. 23) is formed by the tuberosity of the ischium; and finally, the supero-posterior, thick and flattened, presents on its inner side a large rough surface, called from its form the *auricular surface*, corresponding to the articular surface of the sacrum.

In order to construct the pelvis, the two iliac bones are joined together, and these in their turn join the sacrum by articulations which have nothing in common with those which we have already studied in the limbs—for example, the shoulder or elbow. In those articulations of the limbs the bones were in contact by smooth surfaces, which glided one upon the other without anything interposed between them; such articulations are characterised by their mobility. On the other hand, the sacrum is united on each side to the iliac bones, and they articulate in front with each other by rough surfaces, between which are placed plates, more or less thick, of fibro-cartilage (similar to the inter-vertebral discs), which, in consequence, do not allow them to glide one on the other, but closely join them together. These articulations, which bear the name of *symphyses* (σύν, together, φύομαι, to weld), are remarkable, not for mobility, but for solidity. Behind, the two *sacro-iliac symphyses* support the sacrum firmly wedged in between the two bones of the hip, and the strong ligaments placed behind the symphysis permit the sacrum to support the weight transmitted to it by the

vertebral column; in front, the *symphysis pubis* (3, Fig. 24), besides having fibro-cartilage placed between the bones and adherent to them, is also strengthened by fibrous bands passing superficially from one bone to the other.

The symphyses form the whole of the pelvis (the sacrum, with the two iliac bones) into a single part; but, at the same time, owing to the elasticity which these joints enjoy, the pelvis can resist without injury the shocks which are transmitted to it by the vertebral column and the lower members, and which would be fatal if this osseous belt were composed of a single bone continuous throughout. The sacro-iliac and pubic cartilages, from their inter-articular substance, may be compared to elastic cushions placed between the bones, which break and check the shock which is produced—when, for example, we jump from a height and alight on the soles of the feet.

Beside the articulations of the symphyses, the pelvis also possesses ligaments which proceed from one osseous prominence to another more or less distant; thus, behind, are the two *sacro-sciatic ligaments*, which, arising together from the lower border of the sacrum in the form of a broad fibrous band, proceed outwards, and, diverging, are attached, one—the *great sacro-sciatic ligament*—to the tuberosity of the ischium, the other—the *lesser sacro-sciatic ligament*—to the spine of the ischium. These ligaments form the sciatic notches into foramina, through which important muscles pass; and, but for this fact, these

ligaments would not be mentioned here, as they do not show externally, being covered by the thick layer of the gluteal muscles. But it is not so with the ligaments (or fibrous bands) which are situated in the anterior portion of the pelvis, and which proceed from the anterior superior spine of the ilium to the spine of the pubis. This ligament—called the *ilio-pubic*, *crural arch*, or *Poupart's ligament*—is immediately subcutaneous, and corresponds to the fold of the groin; in fact, at its level, the skin is slightly, if at all, covered with fat. As it is attached to the entire length of the ligament by the subcutaneous cellular tissue, it follows that it shows a depression extending from the spine of the ilium to the pubis. This depression is nothing else but the fold of the groin, marking the limit between the skin of the abdomen and that of the thigh.

The pelvis as a whole (Fig. 24) forms a pyramid, with its base upwards, its truncated summit downwards; this apex is entirely hidden in the living model. The inferior limbs are attached on each side in such a manner that they approach each other at the lower part of the pelvis, so as to leave between them a narrow interval—the perineum, which corresponds to the inferior extremity of the pelvis. But the outline of the base of the pelvis is marked clearly throughout the whole of its circumference, at least at the sides and front; on each side the iliac crests, on the superior borders of the iliac bones, form a slightly undulating line, the middle portion of which is most elevated, while its anterior extremity inclines abruptly down-

wards to terminate at the anterior superior spine of the crest of the ilium, clearly seen in the model when the skin is not loaded with fat; in front, the base of the pelvis presents an extensive hollow with its concavity upwards, the central parts correspond to the symphysis pubis, and the lateral parts are formed

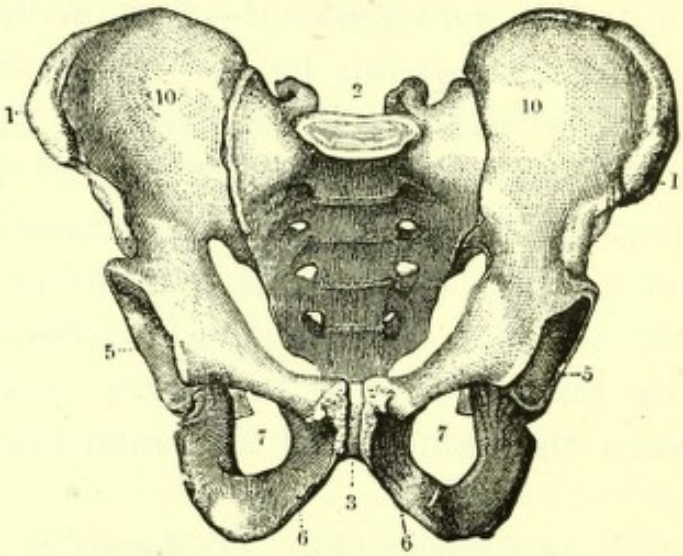

FIG. 24.

PELVIS OF THE MALE.—1, 1, Iliac crests;—2, sacrum;—3, symphysis pubis;—5, 5, cotyloid cavities acetabula;—6, 6, descending rami of pubis and ascending rami of ischium;—7, 7, obturator foramina;—10, 10, internal iliac fossa.

by Poupart's ligaments or crural arches, passing on each side from the spine of the pubes to the corresponding anterior superior spine of the crest of the ilium. This anterior median hollow of the pelvis forms the inferior limit of the abdomen, and gives to the anterior abdominal region the form of a shield rounded at both ends, a form which the ancients seem to have exaggerated in adopting for the epigastric pit a configuration rounded instead of oval, which is the shape

it presents in the skeleton. We have previously (page 42) shown how, in numerous cases, the form adapted by the ancient sculptors is sufficiently justifiable.

After having studied the pelvis with regard to its mechanism and its influence on the external form, we ought now to examine it with regard to its pro-

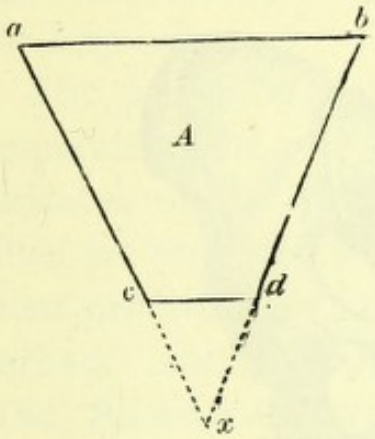

FIG. 25.

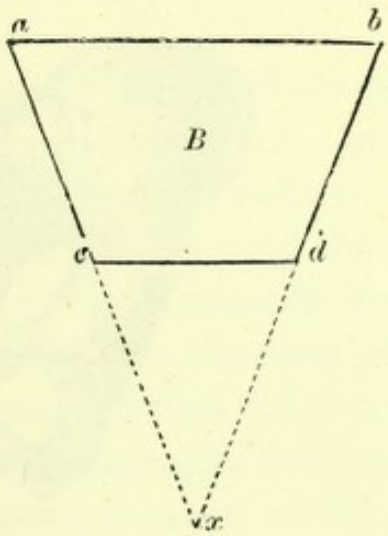

FIG. 26.

Diagrams showing that the pelvis of the male (A) represents a long segment (*a*, *b*, *c*, *d*) of a short cone, (*a*, *b*, *x*), while the pelvis of the female (B) represents a short segment (*a*, *b*, *c*, *d*) of a long cone (*a*, *b*, *x*).

portions, namely, its transverse dimensions; but as the prominence of the hips is formed not only by the superior border of the iliac bones, but also by the great trochanters (femur), we ought not to quit this examination without comparing the bones of the thigh with the pelvis; for this reason we must confine ourselves for the moment to the study of the proportions of the pelvis taken first alone and then comparatively in the male and in the female skeleton.

Generally speaking the pelvis of the female is

broader and shorter than that of the male; in the male (Fig. 24) the superior transverse diameter, which is a line that passes through the most prominent portion of the crest of the ilium of one side to the corresponding part of the other, measures from 10 to 12 inches (on the average 11 inches); whilst in the female this

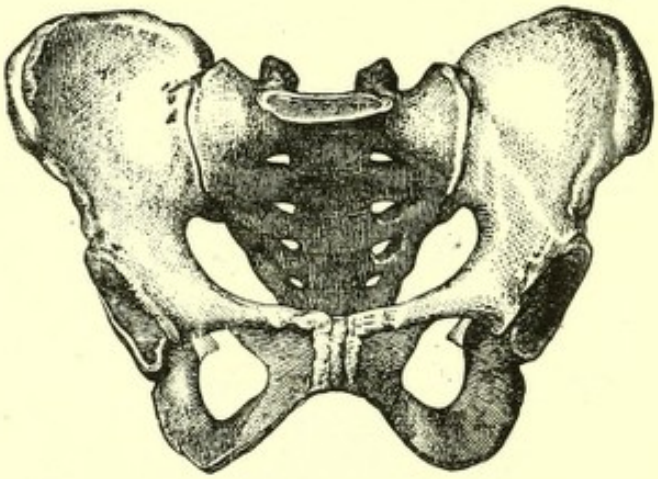

FIG. 27.

Pelvis of the female.

line measures from $10\frac{1}{4}$ to $13\frac{3}{4}$ inches (on the average 12 inches). On the contrary the height of the pelvis in man is about 8 inches, whilst it is not more than $7\frac{1}{4}$ inches in the female. Again, in comparing (Figs. 24 and 27) a male and female pelvis, we see that the first is very narrow, the second comparatively very broad inferiorly.

If we suppose a line drawn at a tangent to the sides of the pelvis we see that these lines must be prolonged downwards for a considerable distance in order to meet in the female pelvis, but in that of the male they join at a short distance from the lower part.

In order to reduce these facts to a simple formula we may say therefore on consideration of the Figs. 25 and 26, which show this arrangement by means of a diagram, and by remarking the manner in which the pelvis form segments of pyramids or cones, that the *pelvis of a male represents a long segment of a short cone*, while *that of the female represents a short segment of a long cone.*

The particular details of shape which distinguish the pelvis in the two sexes are relatively: 1st. In the thickness of the walls; in the male the walls of the pelvis are stronger, the iliac crest thicker, and the different prominences for the insertions of muscles better marked. 2nd. The *pubic arch* and the *obturator foramina.* As we have previously observed that the pelvis in the female is, at its lower part, much broader than in the male, we naturally find the various parts of which it is formed are broader than in the male. Thus the pubic arch, limited above by the symphysis, and on each side by the descending rami of the pubis, is very broad, and at the same time much more flattened in the female, in whom it assumes the form of an elliptical arch, while in the male (compare Fig. 24 and Fig. 27 at 3, 6, 6) this same arch is narrow and raised, and takes the form of a pointed arch. For the same reason the tuberosities of the ischium are wider apart in the female than in the male. The obturator foramina are wide and triangular in the female, while they are narrow and oval in the pelvis of the male.

CHAPTER IX.

THE THIGH.

The femur: its superior extremity: *neck*, *head*, and *trochanters*.—Articulation of the hips, or *coxo-femoral articulation;* movements which it allows; limits of these movements (capsular ligament and the ligament of Bertin); the definite limits of extension (ilio-femoral ligament); the narrow limits of adduction (ligamentum teres); the influence of atmospheric pressure (experiments of the brothers Weber). The transverse dimensions of the hips and shoulder in the male and female; the various formulæ (ovoid of the ancients, ovoid and elliptical of Salvage); the correct formula; the inter-humeral and inter-trochanteric diameters; the inter-acromial and inter-iliac diameters.—The external form of the region of the hips and great trochanter in particular; the osseous prominences brought into relief in the external form as flat and depressed surfaces.

THE femur (Figs. 28 and 31), or bone of the thigh, is one of the long bones—the largest in the skeleton—and composed, like all the long bones, of a shaft and two extremities (Fig. 28). We will first consider its upper extremity, then its articulations with the iliac bone.

The superior extremity of the femur is composed of a *head*, supported by a neck, and of tuberosities placed at the junction of the neck with the body of the bone. The head of the femur (5, Fig. 31) is regularly rounded, and forms three-fourths of a sphere. Its spherical surface, turned inwards, is smooth and covered with

cartilage, except at a depression (6, Fig. 31) seen a little below its centre, which gives attachment to an intra-articular ligament (*ligamentum teres:* see further on). The neck of the femur (7, Fig. 31), arising from the base of the head, is directed downwards and outwards in the form of a segment of a cylinder, flattened a little from front to back to become attached to the upper extremity of the shaft of the femur at an obtuse angle, looking downwards and inwards (Fig. 28). This angle, which the axis of the neck makes with that of the body, varies in different individuals, according to circumstances which are well known. In the adult male it is about 135 degrees; in the female it is less open—that is, it approaches nearer to a right-angle (90 degrees). It is this which contributes to increase the transverse diameter of the hips in the female. Finally, in both sexes this angle approaches gradually to a right-angle with the advance of age—a change that contributes to shorten the height in the aged. At the junction of the neck of the femur with the body of the bone we find developed two

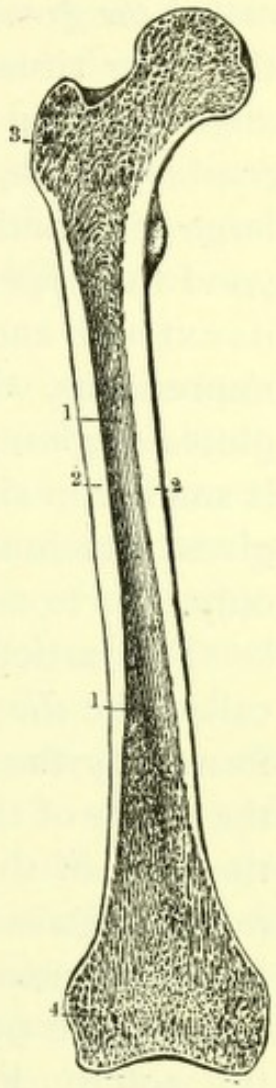

FIG. 28.

VERTICAL SECTION OF FEMUR.—1, 1, 2, 2, the body of the bone with the medullary canal hollowed out; — 3, the great trochanter, whence the neck is given off, terminating in the head; —4, inferior extremity of the bone.

tuberosities—one situated above and to the outer side, called *the great trochanter* (3, Fig. 28 and 8, Fig. 31); the other situated below and to the inner side in the angle between the neck and the shaft, called the *lesser trochanter* (10, Fig. 31). The great trochanter is of large size, and quadrilateral in shape, extending beyond the upper border of the neck, and presenting on its external and internal surfaces and borders numerous impressions, where we see inserted the muscles of the gluteal region; the lesser trochanter, on the contrary, is smaller in size, mammillated or conoid in shape, and gives attachment to the psoas and iliacus muscles only.

The articulation of the femur with the pelvis called the *ilio-femoral* or *coxo-femoral* articulation, is formed by the reception of the head of the femur into the cavity of the acetabulum into which it exactly fits; the edge of the cavity is surrounded by a ligament (*the cotyloid ligament*) which maintains its shape in passing from one extremity of the great cotyloid notch to the other (page 95), in such a manner as to bridge over this notch. From the presence of like articular surfaces, that is to say of a spherical head received within a corresponding spherical cavity, we should expect to find in this articulation every possible description of movement; and this is what actually takes place: the head of the femur can glide in all directions in the cavity in which it is received, and these gliding movements vary according as the limb is moved either by the movement of *abduction* (the inferior limb being carried outwards, away from the middle line) or by a

movement of *adduction* (towards the middle line), or by a movement of *flexion* (forwards, the anterior surface of the thigh being brought towards that of the abdomen), or lastly, by a movement of *extension* the reverse of flexion, that is backwards. But these movements are variously influenced by the disposition of the ligamentous parts, so that while some are limited, others are very extensive.

The ligamentous apparatus of the coxo-femoral joint is composed of a long capsule or fibrous band, which arises from the margin of the cotyloid cavity and surrounding the neck of the femur terminates by its other extremity in a line at the base of the neck; but the disposition of this capsule differs very much before and behind.

1st. Behind—the capsule is not inserted into the neck of the femur; it presents a free border which forms a half circle on the posterior surface of the neck, therefore, this posterior portion of the capsule attached on the one hand to the iliac bone (border of the acetabulum), and on the other not being inserted into the femur, cannot at any time become tense. It is the movement of flexion which should make tense this posterior portion of the capsule, had it been inserted into both bones; but this movement may be continued as far as it is possible without causing tension in the part. It is for this reason we speak of the flexion of the thigh as unlimited, and in fact, it may be continued until the anterior surface of the thigh comes in contact with the abdomen.

2nd. In front—the capsule is well inserted into a

rough line at the base of the neck of the femur, which proceeds from the great trochanter to the lesser; so that it is put on the stretch when the thigh is carried backwards during extension, and checks this movement when it arrives at a certain point. This is in fact what takes place; but before fixing exactly the position to which this check corresponds, we should note again that this anterior portion of the ligament is very thick and strong, composed of ligamentous fibres leading directly from the cotyloid margin to the inter-trochanteric space, and to this we give the name of the *ilio-femoral ligament*. Owing to the strength of this ligament, the movement of extension can be limited and checked at any given moment. Now if we try the experiment on ourselves, having flexed the thigh on the abdomen and then gradually extend it, we shall perceive that the movement is arrested at the moment when the axis of the thigh is in a continuous line with that of the body (or if the subject is upright, when the thigh is vertical). If we repeat this experiment on the dissected subject, with the joint prepared, we shall see that the ilio-femoral ligament is relaxed when the thigh is flexed on the pelvis, and becomes tense in proportion as the bone is extended, and that this tension arrives at its maximum when the femur is found in a line with the trunk, and presents an insurmountable obstacle to any further extension.

However, a man in the upright position can move his thigh backward; but it is necessary to observe, if for example, it is the right thigh which is carried backward, it is not in the right coxo-femoral joint

that the movement takes place, but in the left, or rather the trunk is flexed upon the left femur. We may therefore state that when the thigh has come, by extension, to be in the same continuous plane with the trunk, that the thigh and trunk form one and the same piece, and that the two parts are immovable one upon the other as regards extension, which has reached its limit, and cannot be prolonged any further; and that accordingly when one thigh is carried behind the vertical line, the trunk must be carried to an equal extent in front of the vertical, as is represented, for example, by the right thigh with the trunk moving as a single piece on the left coxo-femoral articulation.

It is also the ilio-femoral ligament formed by the antero-inferior fibres of the articular capsule which presents the obstacle in *abduction*, or the movement of the thigh outwards; in the upright position, the ligament, being tense, renders abduction difficult and limited, but when the thigh is slightly flexed on the pelvis, the ligament being relaxed, abduction (separation of the thighs) becomes comparatively easy.

The movement of *adduction*, or bringing the thighs together, presents this peculiarity, that it is almost impossible in the upright position, but it becomes very easy, if the joint is slightly bent. If we try the experiment on an articulation in which the ilio-femoral ligament is cut, we perceive that in the position of extension, the movement of abduction is just as difficult as if the ligament were intact. It is necessary, therefore, to seek elsewhere than in the

anterior portion of the capsule for the arrangement which limits and arrests the adduction of the thigh. We shall find the explanation in the existence of an intra-articular ligament, placed in the interior of the joint. This ligament, called the *ligamentum teres*, is attached by one extremity to the rough depression which the head of the femur presents a little below its centre (6, Fig. 31), and by the other extremity, bifurcated, to the ischial and pubic margins of the great cotyloid notch. We have already seen that in the pelvis of a man in the upright position, this notch looks directly downwards (page 96), the ligament in this position is also vertical, and is put on the stretch, for by it, as it were, the head of the femur is suspended from the pelvis (hence the name of *suspensory ligament* given to it by some anatomists). Now, in the upright position, the femur being vertical, the movement of adduction could be produced only by the gliding of the head of the femur from below upwards in the cotyloid cavity, but this gliding movement cannot take place, the head of the femur being held down in this position by the tense round or suspensory ligament. If, on the contrary, the femur is slightly flexed, the round ligament will be found relaxed; this permits the gliding of the head in the cavity, a movement which now takes place from before backwards in order to produce adduction, which may now be accomplished with ease. The experiment which proves these facts without giving an anatomical explanation (obtainable only from a prepared subject) is very easy to accomplish upon

oneself, and gives a striking result; in fact, holding oneself perfectly upright, rigid, and thrown backwards as far as possible, it will be seen that it is almost impossible to bring the two knees together, and to cause, by abduction of the thighs, the slight interval to disappear which separates their inferior extremities, and that frequently adduction is almost lost, and impossible in this position, so that we should be unable, by bringing the knees together, to crush a fragile body; for instance, an egg placed between them.

But if we flex the thighs a little on the pelvis, or easier still, the trunk on the thighs, adduction becomes extremely easy, and now we can knock together the inner surfaces of the knees with great force.

The coxo-femoral articulation, so remarkable for the various details of animal mechanism that we have shown, is also remarkable for the fact that upon it we can most conveniently demonstrate a law which applies also to all the other articulations, but of which we have reserved the explanation until we should arrive at the articulation of the hip; we refer to the law relative to *the influence of atmospheric pressure in maintaining articular surfaces in contact.* Up to the present, in studying the articulations, we have spoken of the form of the articular surfaces, and from their outline we have been able to deduce what should be the nature of the movements permitted in the joint under consideration; we have afterwards spoken of the ligaments which surround the joint, and from their

arrangement we have been able to infer the limits, more or less restricted, imposed upon their movements. But we have not as yet spoken of the conditions which enable one articular surface to glide upon another without separating, and which maintain the surfaces in intimate and permanent apposition. We may, perhaps, have thought that this part devolves on the ligaments, but this would be an error; it is the atmospheric pressure which keeps up this contact; this demands an explanation other than that supplied by animal mechanism, and a demonstration by an experiment made on the coxo-femoral joint.

The examples showing how atmospheric pressure can cause two bodies to adhere closely one to the other are, so to speak, innumerable; the cupping-glass, for instance, when applied to a smooth surface, adheres strongly thereto, because the air contained between is rarified, and consequently the atmospheric pressure presses down the surface, and causes it to become fixed. There is a toy called a "sucker," which we frequently see in the hands of young lads, and which affords us a still simpler example. It consists of a round piece of leather, strong and flexible, having a string fastened in its centre by one of its surfaces. When we apply the other face of the disc to a stone—a paving stone, for example—in such a manner as to compress the disc and to exclude any air which exists between it and the surface of the stone, and then pull sharply on the string, we raise the stone from its place, for the atmospheric pressure causes the disc

of leather to adhere to the stone, because there is not any air left between their surfaces.

Now, the head of the femur is received into the acetabulum in a manner identical to that which we have just described. On the one hand, the head of the femur is placed exactly against the base of the cavity; and this contact is absolutely perfect, the irregularities which the base of the cavity presents upon the skeleton being filled up by adipose tissue. On the other hand, the cotyloid ligament closely encircles the base of the head of the femur, and may be compared to the edges of the cupping-glass, which we have just mentioned. Now, as a vacuum exists between the two articular surfaces, and the air cannot penetrate between them, they adhere very closely to each other, still allowing one to glide on the other (the head moving round in the cavity); but, if by any means the air obtains access between the articular surfaces, adhesion immediately ceases, the atmospheric pressure being then experienced within as well as without the articulation.

The experiments which explain those facts have been demonstrated by the brothers Weber, and may be reproduced in the following manner:—On a subject suspended by the shoulders, we dissect away the soft parts (skin and muscles) which surround the hip-joint, and raise those parts so as to expose the articular capsule; if we then cut around this capsule through its entire thickness, we see that the inferior member does not become detached from the trunk, although there is not any ligament connecting the

femur with the pelvis (we do not now speak of the presence of the intra-articular or round ligament by which the femur is suspended from the pelvis, but which lies loosely in the acetabulum); it is therefore the atmospheric pressure which maintains the articular surfaces in contact. And if, from the interior of the pelvis, we perforate the base of the cavity, we at once hear a slight whistling noise, produced by the air entering the cavity and spreading between the articular surfaces, and the corresponding inferior member becomes detached and falls down, the head of the femur not being supported by any connecting ligament. But this is not all. We may, on the same subject, and on the same articulation, renew the experiment so as to render it still more striking. If we take the detached limb, and, having closed with a little wax the opening made at the base of the cotyloid cavity, we replace the head of the femur within the cavity, and cause it to glide about so as to make the contact of the articular surfaces perfect and exclude the air between them, we see that the head of the femur remains attached within the cavity, and that the lower limb is again suspended from the pelvis; but, when we raise the stopper of wax, and permit the air to enter again between the articular surfaces, the lower limb is immediately detached from the pelvis, and the head of the bone drops from the cavity. This experiment may be repeated any number of times.

We have felt it important to dwell here, once for all, on the important part which atmospheric pressure plays in the mechanism of joints. Analogous

experiments, but more delicately executed, show that this pressure plays comparatively the same part in the other articulations in maintaining their articular surfaces in contact.

To return to the study of the region of the hip, and especially to the great trochanter, we must see what are the *transverse dimensions* of this region, and what are the *external forms* in the figure directly resulting from the presence of the great trochanter.

The *transverse distance* which separates one great trochanter from the other should be compared with that which separates the heads of the humeri ; in other words, we must now compare the *diameter of the hips* with that of the *shoulders*.

What strikes us most in this comparison, at the first glance at a series of skeletons, is the great projection which the hips form in the female. In order to express this, various formulæ have been proposed : they consist in considering the trunk as a figure more or less regularly oval, of which one extremity corresponds to the shoulders, the other to the hips, and to see according to the sex which diameter exceeds the other. The ancients did not hesitate to express this formula in the following manner :—In the male and in the female the trunk represents an ovoid—that is to say, an oval similar to that of a figure of an egg having a greater and a lesser extremity ; but in the male this has its greater extremity superior, while in the female the greater is inferior. Therefore, in the female the diameter of the hips exceeds that of the shoulders, while in the male it is the diameter of the shoulders

which exceeds that of the hips. This formula as regards the female is evidently exaggerated, as we see in a moment by comparing the actual figures. It seems, in fact, to Salvage and Malgaigne, to be exaggerated, and in their works on anatomy, they propose substituting the following formula: Allowing that the trunk of the male is an ovoid, with the greater extremity superior, the trunk of the female forms an ellipse—that is to say, a figure in which both extremities are of the same dimensions; therefore, in the male the diameter of the shoulders exceeds that of the hips, and that in the female the diameter of the hips does not exceed that of the shoulders, but is only just equal to it.

Now this last formula also exaggerates the real proportions of the hips in the female. The correct formula is as follows:—In the male, as well as in the female, the trunk represents an ovoid with the greater extremity superior; but while in man the difference between the greater extremity and the lesser is very considerable, in the female this difference is very slight. We shall see by figures that in the female the diameter of the hips, though always less, differs very little from that of the shoulders. In the male the distance from the head of one humerus to the corresponding part on the opposite side (*inter-humeral diameter*) is on the average 15¼ inches, and the measure taken from one great trochanter to the other (*inter-trochanteric diameter*) is 12¼ inches; therefore there is between the two diameters a difference of about one-fifth. In the female the inter-humeral diameter

is on the average 14 inches; the inter-trochanteric diameter is 12½ inches; therefore there is between the two diameters a difference of only one-twelfth. These figures also serve to demonstrate that the diameter of the shoulders is much greater in the male than in the female (15 to 14), and that inversely the diameter of the hips is much greater in the female than in the male (12½ to 12¼); so that, accordingly, if a man and a woman of average stature are supposed to throw their shadow on the same portion of a screen, the shadow of the shoulders of the male would cover a much larger surface than the shadow of the shoulders of the female; and on the contrary, the shadow of the hips of the woman would exceed the shadow of the hips of the man, but only to a very small extent.

By the diameter of the hips we have, in the preceding considerations, understood the inter-trochanteric diameter. There is, however, a method of considering the subject which justifies to a certain extent the formulæ adopted by the authors previously mentioned; it consists in comparing on the skeleton in both sexes the diameter of the pelvis (the femurs being removed) with the diameter of the shoulders (the humeri being removed). Then the shoulders are represented by the *inter-acromial diameter*, and the hips by the *inter-iliac* (from one iliac crest to the other). Under these circumstances the exact measurements show that in the male the inter-acromial diameter is 12¾ inches, and the inter-iliac 11 inches; therefore, as in the preceding, the trunk, deprived of its members, still represents an ovoid, with its greater extremity superior; but we see

that in the female, the inter-acromial diameter being 11½ inches, the inter-iliac increases to 12 inches; and therefore that here the trunk, deprived of its members, represents an ellipse or an ovoid, with its greater extremity inferior, the superior extremity differing very little in size from the inferior. But this mode of mensuration does not express the subject as it exists, for the artist does not consider the trunk as otherwise than complete—that is to say, provided with its superior and inferior members—and it is necessary to take into account the part which they take in the diameters of the two extremities of the trunk by the presence of their extremities (the head of the humerus and the great trochanter). We have thought fit, however, to show here this mode of mensuration, for it explains clearly the greater diameter of the pelvis in the female, compared with that of the male, as we have previously seen.

If we arrange in a table the figures given in the preceding for the inter-humeral, inter-trochanteric, inter-acromial, and inter-iliac diameters in the male and in the female, or if, better still, we represent those figures by proportionate lines intended to express, on the profile of a man and that of a woman, the proportionate value of the diameters of the region of the shoulders compared with the diameters of the pelvis and the hips, and if we cause vertical lines to pass through the extremities of the inter-iliac and inter-trochanteric diameters, we obtain two figures which express in a striking manner all that has been pointed out (Figs. 29 and 30).

We see, in fact, that in the male subject (Fig 29) the vertical lines (*y* and *y*) passing through the extremities of the inter-trochanteric (*d d*) and the inter-iliac (*c c*) diameters, both fall within the extremity of the inter-

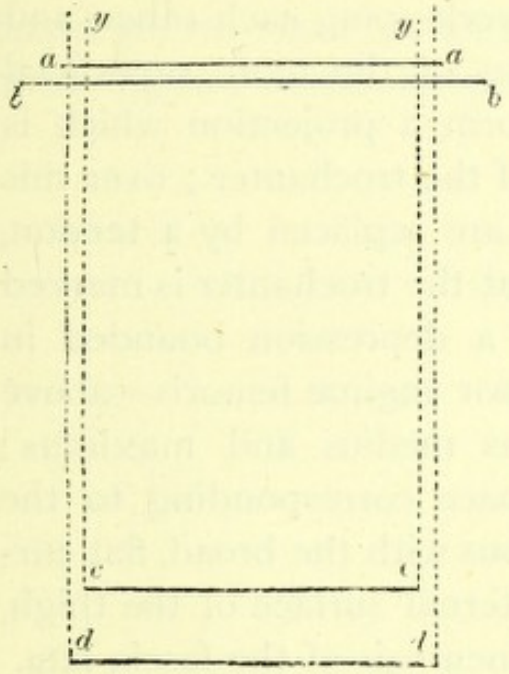

FIG. 29

Diagram comparing the diameters of the hips with the diameters of the shoulders in the male.



FIG. 30.

Diagram comparing the diameters of the hips with the diameters of the shoulders in the female.

humeral diameter (*b b*), and also the inter-acromial (*a a*); on the contrary, in the female (Fig. 30) we find that these same vertical lines both fall within the extremeties of the inter-humeral diameter, but on the outer side of the inter-acromial.

After this study of the proportions of the hips we will say a word concerning the influence of the great trochanter on the external form. In looking at the skeleton the great trochanter stands out so clearly, and

forms on the outer side a projection so considerable that we should expect to see in the external model a prominence corresponding to the shape of the great trochanter. However, it is not so. The muscles which proceed from the pelvis to be attached to the great trochanter are numerous, overlapping each other, and thick, and the fleshy bodies of the more superficial are sufficiently strong to form a projection which is slightly raised above that of the trochanter ; over this surface their fleshy bodies are replaced by a tendon, more or less flattened, so that the trochanter is marked on the external figure by a depression bounded in front by a muscle—the tensor vaginæ femoris—above and behind by the gluteus medius and maximus ; below, the flat concave space corresponding to the great trochanter is continuous with the broad, flat surface which occupies the external surface of the thigh, and corresponds to the aponeurosis of the fascia lata.

There are many analogous cases where osseous projections are frequently marked on the external figure by a depression, and the reason is always the same as that just explained, that these osseous projections give insertion to muscles, the fleshy bodies of which give place to tendinous expansions at a little distance from them, and form by their thickness a raised surface round the prominence ; in a general way, then, we may say that, with a few exceptions (such as the malleoli of the ankle joints), wherever an osseous surface is covered over only by the skin, the muscles which surround this surface arise above its level, and in consequence the bone is marked by a depression, more

or less pronounced as the subject is more or less muscular. Thus the middle portion of the sternum is marked externally by a depression limited on each side by the swelling of the great pectoral muscles, and the internal surface of the tibia forms a long and broad groove when the anterior and posterior muscles of the leg are well developed.

CHAPTER X.

THE THIGH AND KNEE.

The bony structure of the thigh and knee.—*Body* of femur: its curvature; oblique direction; linea aspera.—Inferior extremity of femur: condyles; inter-condyloid space: anterior trochlea. — *Patella:* ligament of the patella.—Inferior part of the bones of the leg. —*Tibia:* its surfaces; its anterior tuberosity.—Head of *fibula*.—Articulation of the knee; relation of the bones in flexion and extension.—Ligamentous apparatus: capsule: its laxity and extent in front, whence the facility and extent of movement in flexion: its strength and shortness behind, whence the limit of movement in extension.—Lateral ligaments of the knee, their special mechanism deduced from their eccentric insertion superiorly.—Lateral movements of the knee: crucial ligaments.—Form of the region of the knee: flat surface beneath the patella; projections of patella: tendon of patella and adipose mass which project beyond it.—Osseous projections of the external surface and the tendons inserted.—Simplicity of the form of internal surface of the knee.

HAVING studied the upper extremity of the femur with regard to the articulation, proportions, and contour of the region of the hips, we shall continue the study of this bone by examining its *shaft* and *inferior extremity*, and this latter part brings us to the *articulation of the knee.*

The shaft of the femur is not straight but slightly curved with its convexity forward. On the living model this convexity may still be recognised in the form of the anterior surface of the thigh which is

distinctly convex forwards from above downwards (bulged in front), the muscles which cover the femur in front being disposed in such a manner as to increase this appearance still more, as their fleshy bodies are grouped together in the middle line of the anterior region of the thigh. Again, the femur, in the model when standing upright, is not directed vertically but rather obliquely from above downwards, and from without inwards (Fig. 31), so that the superior extremities of the femur are placed at some distance, comparatively speaking, from each other, while the lower extremities come very near each other at the level of the knees. In the female this obliquity is more clearly marked than in the male, for the upper extremities of the two bones are in the former placed more widely apart, as we have already seen when demonstrating the relative diameter of the hips (inter-trochanteric diameter) in the female.

The form of the shaft of the femur is that of a triangular prism presenting three surfaces—one anterior, one postero-external, and one postero-internal; and three borders, two lateral and one posterior. The two lateral borders are very rounded, not sharp; the posterior, on the contrary, is very prominent, and forms a rough line, called the *linea aspera* (1, Fig. 31), which gives insertion to a number of muscles. This linea aspera divides above into two *bifurcations* slightly diverging, of which the external (2, 2, Fig. 31) proceeds towards the great trochanter and the internal towards the lesser. Below, this linea aspera bifurcates in the same manner, one of its branches going to the

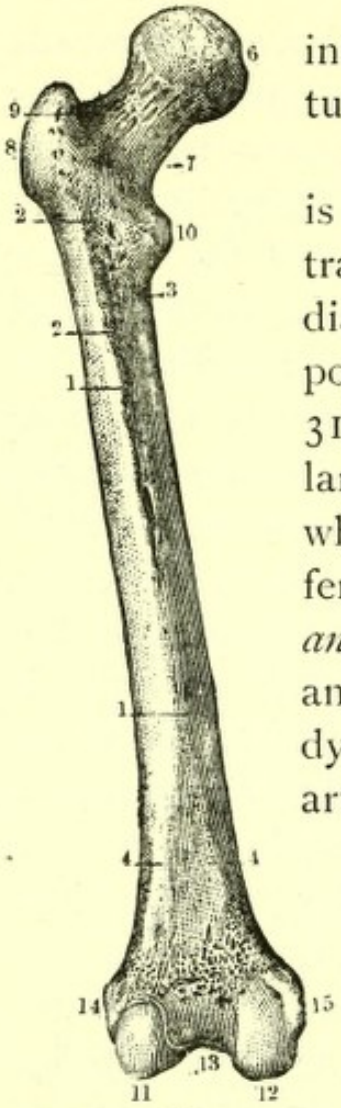

FIG. 31.

LEFT FEMUR (posterior view).—1, 1, linea aspera;—2, 2, its external superior bifurcation;—3, its internal superior bifurcation;—4, 4, its inferior bifurcations;—5, head of femur;—6, depression in the head giving insertion to ligamentum teres (see p. 110);—7, neck of femur;—8, great trochanter;—9, internal surface of great trochanter;—10, lesser trochanter;—11, external condyle;—12, internal condyle;—13, inter-condyloid notch;—14, 15, tuberosities surmounting each of these condyles.

internal, the other to the external tuberosity of the femur (4, 4, Fig. 31).

The *inferior extremity* of the femur is widely expanded, both in the transverse and in the antero-posterior diameter. When we examine the posterior aspect of this extremity (Fig. 31) we see that it is formed by two large prominences directed backwards, which are termed the *condyles* of the femur, and are known as the *external and internal condyles.* The inferior and posterior surfaces of these condyles are smooth and covered with articular cartilage; between them is a deep hollow called the *inter-condyloid space* (13, Fig. 31). When, on the contrary, we examine the anterior surface of the lower end of the femur we see that the condyles are united, and their surface becomes smooth and continuous in front in an articular surface shaped like a pulley; this is called the *trochlea of the femur.* This trochlea presents a depression in the middle line and two lips, of which the external, continuous with the external condyle, is more prominent

and rises higher than the internal, which is continuous with the condyle of the same side. These details are very important, for, as we shall see, the lips of the femoral pulley show prominently beneath the skin when the knee is strongly flexed, and we can notice their differences in prominence and height. In forming the articulation of the knee, the inferior extremity of the femur comes in direct contact with the patella and the superior extremity of the tibia, and is indirectly connected with the upper extremity of the fibula. We will now consider the patella and the upper extremities of the two bones of the leg.

The *patella*, which has been compared to a disc (whence its name), is, speaking more correctly, triangular in shape, presenting an anterior surface smooth and slightly convex, and a posterior moulded on the trochlea of the femur, and is formed by a prominence in the middle line corresponding to the groove of the pulley, and two lateral depressions, each corresponding to one of the lips. The circumference of the patella is formed by two lateral oblique borders, with a base directed upwards, giving attachment to the tendon of the triceps, and the summit directed downwards, giving attachment to a strong ligament which is inserted into the anterior tuberosity of the tibia, and is termed the *ligament of the patella*. Properly speaking, this ligament is a continuation of the triceps tendon. The patella should be considered as a sesamoid bone, which is an osseous nodule developed in the thickness of a tendon (in the thickness of the tendon of the triceps of the thigh).

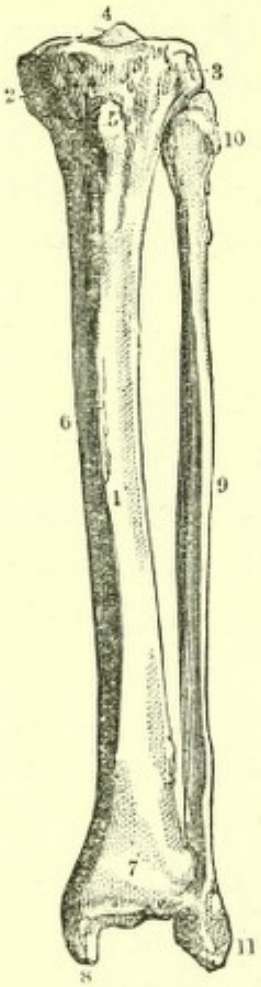

FIG. 32.

THE TWO BONES OF LEFT LEG (anterior view). — 1, body of tibia; — 2, its internal head; —3, its external head; — 4, spine of tibia; —5, anterior tuberosity of tibia; —6, crest of tibia; —7, inferior extremity of tibia with internal malleolus (8); 9, body of fibula; —10, its superior extremity; —11, its inferior extremity or external malleolus.

The leg, like the fore-arm, is composed of two bones, one, the larger of the two, placed on the inner side (1, Fig. 32)—the *tibia;* the other, much slighter, situated on the outer, and a little behind—the *fibula* (9, Fig. 32). As in the case of the two bones of the fore-arm, the two bones of the leg end at different levels above and below. Above, the tibia rises higher than the fibula, and it is for this reason that it alone takes a direct part in the articulation of the knee; below, the fibula extends lower than the tibia — so that the external malleolus descends lower than the internal. We will now for a moment examine the superior extremities of the two bones.

The superior extremity of the tibia is enlarged transversely, and presents on its upper surface two flat surfaces slightly hollowed out, called the *glenoid cavities*, the external (3, Fig. 32) and the internal (2, Fig. 33), each articulating with the femoral condyle of the same name. The space which, in the form of an antero-posterior groove, separates these two spaces, presents in its centre a projection shaped like a blunt cone, which

corresponds to the inter-condyloid space of the femur.

With regard to the circumference of the superior extremity of the tibia, all the details of interest which it presents are grouped together on its antero-external surface. First, in front, at the line of junction of the upper extremity with the body of the bone, is situated a large rounded eminence, called the anterior tuberosity of the tibia, which gives insertion to the ligament of the patella previously mentioned; secondly, on the outer side, and a little backwards, is a rounded surface, smooth and covered with cartilage, for articulation with the head of the fibula (10, Fig. 31). In the central portion of a line slightly curved, with its convexity upwards, proceeding from the anterior tuberosity of the tibia to the articular surface of the fibula, is placed a bony prominence more or less marked, according to the subject, called the tuberosity of the anterior tibial, from the name of the muscle to which it gives attachment. If we add to these the articular surface for the fibula, with the head of that bone, we have the three principal osseous prominences which are seen to the outer side of this line—namely, the anterior tuberosity of the tibia, the tuberosity for the anterior tibial, and the head of the fibula.

The superior extremity of the head of the fibula (10, Fig. 32), irregularly rounded, is placed on the outer side, and a little backwards, upon the superior extremity of the tibia, but does not reach the level of the upper surface of the latter. It presents behind a projection directed vertically upwards, called the

styloid process, but this, being surrounded by the external lateral ligament of the knee to which it gives attachment, is not perceived in the external form.

Such are the bony structures which take a direct (femur, tibia, patella) and indirect part (fibula) in the knee-joint. In the living model, in the erect posture, the condyles of the femur rest by their inferior surface on the upper surface of the tibia, and the apposition of the articular surfaces is rendered more exact by a fact which is of little importance as regards the external form —that the border of the surface of the upper extremity of the tibia is provided with a fibrous disc, called the *semi-lunar fibro-cartilage*, which increases the depth of this border (5, 5, Fig. 34), so that the corresponding condyle of the femur is received into a true articular cavity; at the same time, the patella is applied to the trochlea. When, on the other hand, the model is kneeling, or, more generally, when the leg is flexed (carried backwards), the patella, which is firmly fixed to the tibia by its ligament, glides from above downwards on the trochlea, and comes in contact with the anterior surface of the condyles at the same time that they are in contact with the upper surfaces of the tibia by their entire posterior part. After this rapid sketch of the articulation of the knee, we shall have to study in detail its ligamentous apparatus, and then consider its peculiarities of structure.

The ligamentous apparatus of the knee is composed essentially of a *capsule* or fibrous band—which, as we have already seen in the articulations previously studied, is attached to the borders of

the articular surfaces. In the femur it is inserted at the borders of the trochlea and cartilaginous surfaces of the condyles; in the tibia, at the margins of the upper surfaces; and finally, on the edges of the patella. But though these insertions are easy to understand, we must dwell upon the arrangements of this capsule, its length, and laxity, contrasted in its anterior posterior, and lateral regions; and then consider how it renders certain movements easy and very extensive, while it limits others or renders them almost impossible.

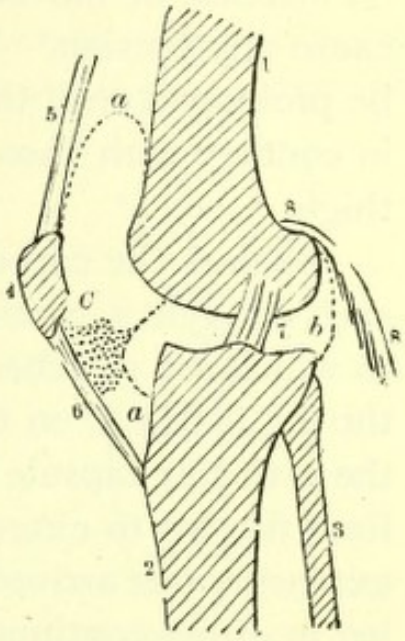

FIG. 33.

THE ARTICULAR PARTS OF THE KNEE (antero-posterior section).—1, femur;—2, tibia;—3, fibula;—4, patella;—5, triceps tendon;—6, ligament of patella or tendon;—7, one of the cruciai inter-articular ligaments;—8, 8, one of the muscles of the calf;—*a*, *a*, anterior part, and *b*, posterior part of the articular capsule;—*C*, adipose mass beneath patella.

In front (*a a*, Fig. 33) the capsule is very loose and expanded; and the part which extends from the anterior limit of the trochlea to the upper border of the patella forms a large pouch—a cul-de-sac—which ascends beneath the tendon of the triceps muscle (5, Fig. 33), and is known by the name of the *cul-de-sac beneath the triceps*. This arrangement accounts for the ease and extent of the movement of flexion. In this movement, the tibia being carried backwards, and drawing with it the patella, as we have previously mentioned, that portion of the capsule situated beneath

the patella would be put on the stretch and curtail this movement if it had been short and compact; but the capsule at this point is so expanded and lax that no increase of movement on the part of the leg can cause any tension. Thus the flexion of the knee may be prolonged until the soft parts of the leg (calf) come in contact with those of the posterior surface of the thigh.

Behind, the capsule is short and thick, forming on each condyle a species of fibrous capsule (*b*, Fig. 33), to which are attached the muscles of the calf. When the leg is flexed on the thigh, this posterior portion of the articular capsule is relaxed; but as the leg passes from flexion to extension it becomes tense, and when extension has arrived at that point which brings the leg in direct continuation with the thigh this tension of the capsule has attained a degree which prevents any further movement, and therefore fixes the limb in this position. There is, moreover, another important arrangement which acts, and more forcibly, in the same manner; this is that of the lateral portions, internal and external, of the capsule, which are each strengthened by a distinct ligament (the *lateral ligaments*).

The *internal lateral ligament* is shaped like a broad band, so that it seems united more or less with the corresponding portion of the capsule.

The *external lateral ligament*, on the contrary, is in the form of a rounded cord, very strong and quite distinct from the capsule, especially as its inferior extremity is not inserted into the tibia, but into the head of the fibula (to the *styloid process*, p. 128), close

beside the insertion of the biceps muscle (Fig. 60, page 258). But what is more remarkable in regard to those ligaments is that their superior extremities, attached to the lateral surfaces of the condyles, are not inserted at the centre of the curve of the condyles, but at a point situated behind (*a*, Figs. 34 and 35).

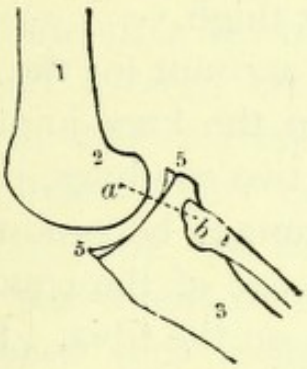

FIG. 34.

THE KNEE: state of the lateral ligaments (*a*, *b*) during flexion.—1, femur; —2, condyle of femur; —3, tibia; —4, fibula; —5, 5, section of disc or semi-lunar fibro-cartilage (p. 128).

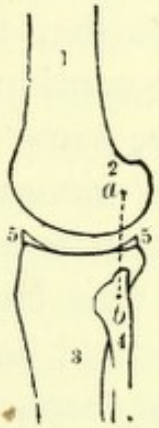

FIG. 35.

THE KNEE: lateral ligaments tense during extension of the leg on the thigh (the distance, *a b*, is greater here than in preceding figure); for the lettering, see preceding figure.

Therefore during flexion these ligaments are relaxed, but according as extension is produced, or as the tibia is carried forward on the curved surface of the condyles of the femur, these ligaments gradually become tense, their points of insertion becoming further and further apart, owing to the eccentric insertion (behind) of their superior extremities. When the leg reaches that position of extension in which it is found on the same plane with the femur, the tension of the lateral ligaments

is such as to arrest its movement and completely fix the leg on the thigh. This may be seen by comparing Figs. 34 and 35. We see, then, that owing to the position of the anterior, posterior, and lateral parts of the ligamentous apparatus of the knee, the movement of flexion in this joint is very extensive, while that of extension is limited, as it cannot be prolonged further than the position which brings the leg in direct continuation with the thigh.

These same arrangements account for the amount of *lateral movement* possible in the knee-joint. This articulation being formed by two condyles, it is very evident that lateral flexion cannot be produced, for then it would be necessary for one of the condyles to leave the corresponding space on the tibia. Here we may mention the slight gliding movements which take place between the condyle of the femur and the tibia, a movement produced by a rotatory movement, of which the other condyle forms the centre. These slight movements of rotation, which contribute to the motion by which we direct the point of the foot outwards or inwards are impossible during complete extension ; and it is easy to understand that when, in extension, the tibia is fixed on the femur by the tension of the lateral ligaments, and the posterior part of the capsule, all unilateral gliding movement is impossible ; for it would stretch in a further degree, at the side of the joint, the parts which have already arrived at their maximum of tension. But when flexion is produced, and especially when it arrives at a right angle, as in the subject when seated, slight

movements of rotation of the leg become possible; they are of small extent, it is true, especially inwards; since it is easier for the knee to take part in the movement which turns the foot outwards than that which turns it inwards. This difference between rotation inwards and outwards is due to the presence within the joint of two ligaments called the *crucial ligaments*, of which we will only mention that they arise from the spine of the tibia between the two flat surfaces (page 126), and ascend, crossing in the inter-condyloid space, to the corresponding surface of each of the condyles. This crossing of the two ligaments is increased by the rotation of the tibia inwards, as this movement tends to twist them one on the other when they contract, and fix the tibia, so as to prevent rotation inwards. On the other hand, rotation outwards unwinds these ligaments, and renders them more parallel, and, therefore, more relaxed; so that this movement could be very extensive, if the lateral ligaments did not prevent too great displacement between the condyle of the femur and the corresponding surface of the tibia.

There are still in the knee-joint several anatomical particulars which we will examine when studying this region with regard to the external forms of the living model. The posterior surface of the knee is covered by numerous muscles and tendons which form what has been termed the *popliteal space;* therefore the study of this region will be taken when we come to the description of the muscles of the leg and thigh; but,

on the external and internal lateral surfaces, and on the anterior surface of the knee all the details observed in the outward form are caused solely by the osseous and ligamentous parts, some of which we have already spoken of, and we will now point out the remainder.

The anterior surface of the knee should be examined in two different positions—in that of extension or slight flexion, and in forcible flexion. 1st, In forcible flexion we observe principally the form of the femoral trochlea (see above, page 124); 2nd, in extension we find on the anterior surface of the knee, in succession from above downwards, a *flat triangular space beneath the patella*, corresponding to the tendon of the triceps muscle of the thigh; next, the *prominence of the patella*, showing clearly beneath the skin its triangular shape, with the base above and apex below. The two superior angles of the patella are frequently very distinct in the form of two small rounded projections; below, the tendon of the patella forms a longitudinal eminence in the middle line, reaching almost to the tuberosity of the tibia, which is seen as a large projection. But, again, we frequently perceive on each side of the ligament, immediately below the patella, a slight eminence, easily depressed, which corresponds to parts which we have not yet described; we speak of the portion of the capsule situated beneath the ligament of the patella, which extends from the lower ligament of the patella to the anterior border of the flat surface of the tibia. This portion of the capsule (*c*, Fig. 33) is thick and formed almost entirely by a *large*

mass of adipose tissue, which is prolonged almost into the interior of the joint (where it forms the *fatty ligament* of some authors), and which forms outside the articulation in front of the knee, a prominence divided into two lateral parts by the ligament of the patella (*b*, Fig. 33), which depresses it in its centre. When the triceps muscle draws forcibly on the patella and its ligament, these compress this adipose mass to a much greater degree, so as to form a kind of hernia on each side, and then the bilateral prominence in question is much more clearly marked.

On the external lateral surface of the knee we note three osseous prominences. These are :—in front, the *anterior tuberosity of the tibia* (seen here in profile); behind, *the head of the fibula ;* between these two, the *tuberosity of the anterior tibial.* To each of these are attached the tendons coming from the thigh, which are marked on the external surface of the knee by three strong vertical bands ; viz. :—in front, the tendon of the patella (seen here in profile) ; behind, the tendon of the biceps femoris, proceeding to be inserted into the head of the fibula ; and in the middle, the inferior part of the aponeurosis of the fascia lata (see as follows) which becomes narrow and thickened, and forms a true tendon, which is attached to the tuberosity of the anterior tibial.

In proportion as the anterior and external surfaces of the knee are complex so is the form of the internal surface simple. Here the internal condyle of the femur and the corresponding tuberosity of the tibia,

form together a large hemisphere, perfectly regular; for it is not marked by any ligament or tendon, the internal lateral ligament forming a broad band (page 130), which does not exhibit any prominence, the tendons of this region winding round the internal tuberosity of the tibia, behind and below, to become inserted into the upper portion of its outer surface in the form of a broad and thin tendinous expansion, called the *pes anserinus* (page 246 and Fig. 61.)

CHAPTER XI.

THE LEG.

The bony structure of the leg.—*Tibia* and *fibula:* tibio-fibular articulation: absence of mobility in the fibula (differences between the leg and fore-arm: between the foot and hand, also in the quadrumanous monkeys. Inferior extremities of these bones: *tibio-fibular articulation:* malleoli or ankle-bones which limit it: comparison of the internal malleolus and the external with regard to length, situation, and form.—The whole of the skeleton of the foot: *tarsus*, *metatarsus*, and *toes*.—Importance of the bony structure of the tarsus and influence on the form of the foot: construction and arrangement of tarsus, posterior half (two bones placed one on the other: the *astragalus*, above, *calcaneum*, below): anterior half single on the outer side (the *cuboid*), double on the inner (the *scaphoid* and three *cuneiform*).—Articulation of the leg with the foot, movements which it permits.

THE two bones of the leg are placed, as we have previously seen (page 126), parallel to each other, the *tibia* on the inner side, the *fibula* on the outer side and somewhat behind (Fig. 32, page 126). The *shaft* of the *tibia* is triangular in shape, and therefore presents three surfaces and three margins (1, Fig. 32): an internal surface covered only by the skin and appearing externally as a long flat surface, broader above where it looks a little forward, and inclining directly inwards at its inferior part, where it becomes continuous with the prominence of the ankle or internal malleolus (Fig. 61, page 261). The external surface

is slightly concave in order to lodge the antero-external muscles of the leg, of which the principal is the tibialis anticus; below, this surface inclines forwards, following the course of the tibialis muscle, which, from the antero-external region of the leg, is directed towards the base of the great toe, on the internal border of the foot (Fig. 59, page 257). The posterior surface of the tibia is entirely covered by the strong and numerous muscles of the posterior region of the leg. Finally, of the three margins of the shaft of the tibia the anterior is particularly prominent, and is known by the name of the *crest of the tibia* (6, Fig. 32, page 126).

The *fibula* (9, Fig. 32) consists of a body long and slender, triangular and prismatic in form, in which it is difficult at first sight to recognise the three surfaces and three margins, because this bone appears twisted on itself from front to back, and from within outwards; but we may do so easily if we consider the real meaning of the surfaces which change their direction, and note the fact that the lateral peroneal muscles, which cover its external surface, wind round it below and behind to arrive at the foot by passing behind the malleolus of the external ankle (Fig. 60, page 258), so that the external surface of the bone becomes posterior inferiorly, and the other two surfaces follow the same course, the internal becoming anterior below, and the posterior internal.

These two bones are separated throughout their entire length by an interval called the *interosseous space* (Fig. 32, page 126), broader above than below,

which is filled up by a fibrous membrane (interosseous membrane) passing from one bone to the other, and serving as an insertion for the anterior and deep posterior muscles of the leg. Above, the fibula articulates with the postero-internal surface of the superior extremity of the tibia, and this superior *tibio-fibular articulation* possesses a very slight gliding movement. Below, the fibula articulates with the corresponding part of the tibia by a species of symphysis; and this *inferior tibio-fibular* articulation has hardly any mobility: it only gives a certain amount of elasticity to the *tibio-fibular joint*, into which the foot is received. We see, therefore, that there is, with regard to mobility, a great difference between the two bones of the leg and those of the fore-arm; in the fore-arm, one of the bones, the radius, is moveable on the other, the ulna, and can turn in such a manner as to cross the latter and produce thus the movements of pronation and supination of the hand. Between the fibula and the tibia there is nothing of the kind; the foot is not capable of any movement which may be compared to that which takes place in the hand during pronation and supination. We may say that it is the same with monkeys, in the class called quadrumana; they have not the power of pronation and supination of the foot, which, from this point of view, and also in every other respect, is properly speaking a foot and not a posterior hand, as their ancient name of *quadrumana* would lead us to suppose.

By their junction the inferior extremities of the

tibia and fibula form an articular cavity in which portion of the foot is received, namely, the superior bone of the tarsus, the *astragalus*. This cavity, which has received the name of the *tibio-fibular mortise*, comprises three walls, of which two, the superior and internal, are formed by the tibia, and one only, the external, by the fibula; the two lateral walls correspond to the two osseous parts which form the ankle-bones and which, known in anatomy by the name of *malleoli* (*from malleus*, a hammer), are distinguished as the *internal or tibial* and *external or fibular malleoli* (Fig. 32, page 126). As the internal ankle-bone or malleolus (8) is of a form and situation very different to that of the external (11), it is important to note here the configuration of the osseous parts of which the subcutaneous prominences are explained by the presence of one or the other of the ankle-bones.

The malleoli differ in their *level* with regard to a horizontal plane, in their *situation* with regard to a transverse plane, and finally in their *form*. First, with regard to their horizontal plane, we see at the first glance that the external or fibular malleolus (11) descends much lower than the internal (8); this will be found to agree with the fact previously stated (page 126)—that, if the superior extremity of the fibula does not rise to the level of the superior surface of the tibia, on the other hand, this bone descends much lower than the inferior extremity of the tibia. Second, with regard to the transverse plane of the two malleoli, if we remember that the fibula is situated behind and to the outer side of the tibia, and that the

same position is maintained by the inferior extremities of the two bones, we can easily understand that the external malleolus should be on a plane posterior to the internal ; thus the first appears to be moved backwards and the second forwards. A transverse line which passes through the centre of the internal malleolus, on the other side of the fibio-tibular articular space, passes in front of the anterior border of the external malleolus ; and, on the other hand, a transverse line, passing through the centre of the external malleolus, passes on the inner side of the posterior border of the internal malleolus. Thirdly, with regard to the differences of form, these are the direct result of the shape of the osseous parts. The malleolar portion of the tibia, or internal malleolus, is square, presenting a horizontal inferior border, and two vertical—one anterior, the other posterior. On the contrary, the malleolar portion, or inferior extremity, of the fibula is triangular in shape, or rather like the blade of a spear or the head of a serpent, separated from the shaft of the bone by a slight neck ; it terminates below in a pointed extremity, formed by the convergence of the two oblique borders—one anterior, the other posterior.

Before entering on the study of the articulation of the leg with the foot, or *tibio-tarsal joint*, we must glance at the whole of the bony structure of the foot, so as to understand the signification and relation of one of the bones (*astragalus*), which is received into the tibio-fibular joint.

As the hand is composed of three segments,

counting from the base to the free extremity—the carpus, metacarpus, and fingers, so also the foot is composed of segments similar to the preceding, counting from behind forwards—the *tarsus, metatarsus*, and *toes;* but while in the hand, where the function is principally that of prehension, the fingers are long and the carpus very short, in the foot, which serves as a base of support, the fingers (toes) are comparatively short, while the tarsus, which corresponds to the carpus, possesses considerable development; it forms, in fact, the half of the length of the foot. In order to understand the form of the foot and its mechanism it is necessary especially to study the bones which compose the tarsus.

As the carpus in the hand is formed by two rows of bones, so also the tarsus is composed of two groups or two halves—one-half *posterior* and one *anterior*. The *posterior half* comprises only two bones, which are placed one on the other; therefore one is placed below, resting on the sole by a more or less considerable portion of its inferior surface; this is the *calcaneum* (3, Fig. 36; 1 to 6, Fig. 38), which is prolonged backwards to form the projection of the heel; the other is placed above the preceding, and is called the *astragalus* (1, 2, Fig. 36; 7, 8, Fig. 38), and alone articulates with the leg by the tibio-fibular joint. The *anterior half* is divided into two parts—one external, composed of only one bone, the *cuboid* (8, Fig. 36; 13, Fig. 38); and an internal, formed by one bone posteriorly, the *scaphoid* (4, Fig. 36), and three small bones anteriorly—the *three cuneiform* bones (5, 6, 7, Fig. 36).

After this brief sketch of the tarsus, and before entering into the details of the configuration of its parts and the whole taken together, having seen the particular place occupied by the *astragalus* we must study its articulation with the bones of the leg—with the tibia and fibula. With regard to the part of the astragalus which is received into this cavity, it is formed by the posterior three-fourths (1, Fig. 36) of the superior part of the bone, separated from the anterior fourth by a narrow portion called the neck (2, Fig. 36). This articular part is in the form of a pulley, with the antero-posterior groove hardly perceptible, but the lips are prolonged on the sides of the bone, and come in contact with the corresponding parts of the internal and external malleoli. A similar configuration of articular surfaces enables us to conclude, *a priori*, that the *tibio-astragaloid articulation* permits movement only in the antero-posterior plane, namely, movement forward (flexion of the foot) and backwards (extension). The astragalus is received into the cavity as into a vice, and such an

FIG 36.

THE BONES OF THE FOOT, seen from the dorsal surface.—1, astragalus (with its head and neck, 2);—3, calcaneum;—4, scaphoid;—5, first cuneiform;—6, second cuneiform;—7, third cuneiform;—8, cuboid;—9, the metatarsus;—10, 11, the two phlanges of the great toe;—12, 13, 14, the first, second, and third phlanges of the other toes.

arrangement prevents any lateral movement, allowing only oscillation forwards and backwards in the plane, corresponding to the opening of a vice (the opening limited by the two malleoli). It is true that each one may see in his own foot lateral movements, and especially that by which we raise the interal border of the foot and depress the external, or the reverse, but on a dissected subject we see that the latter movements do not take place between the astragalus and the leg, but between the astragalus and the rest of the foot, as we shall see later on, and that the tibio-astragaloid articulation permits only the movements of *flexion* and *extension*. Of these two movements that of extension is the most extensive, as it may be continued until the axis of the foot becomes continuous with that of the leg, and here it is arrested by the meeting of the posterior border of the joint with the projections on the posterior border of the astragalus; but the movement of flexion by which the dorsal surface of the foot is brought near the anterior surface of the leg is very limited, for it is impossible to cause the foot to make with the leg an angle less than forty-five degrees, opening upwards and forwards. The form of the pulley of the astragalus accounts for this fact, for this pulley is larger in its anterior part than in the posterior (1, Fig. 36), so that it is in the form of a wedge with its base anteriorly. Now, in proportion as flexion is produced, this base, this large part of the wedge, is placed in the joint, and the astralagus is found to be in the same condition as a wedge with a base too large to

penetrate into a given cavity; thus the movement is arrested, and tibio-astragaloid articulation is fixed. We cannot carry flexion further without bursting asunder the tibio-fibular joint, just as we should split a piece of wood by driving violently into it a wedge larger than the cavity to be filled.

CHAPTER XII.

THE FOOT.

Bony structure of the foot.—Union of bones of tarsus; astragalus and calcaneum (canalis tarsi, or tunnel of the tarsus); sub-astragalar articulations as a whole; special functions of astragalus in the mechanism of the foot.—The other articulations of tarsus, allowing of only slight gliding movements.—*Metatarsus* and *Metatarsal* bones; importance of fifth metatarsal with regard to form.—The *toes* and their *phalanges*.—Skeleton of the foot as a whole, or forms of foot.—Plantar arch.—*Proportions of foot:* the foot as a common measure of the lower limb and the height.

WE will now examine briefly the bones of the *tarsus*, especially with regard to the details which mark their articulations. The inferior surface of the *astragalus* presents two articular facets, separated by a groove transversely oblique. These two facets correspond with two, similarly situated on the superior surface of the calcaneum, but placed to the inner side of the superior surface, because the astragalus is not placed directly on the calcaneum, but overlaps it a little on the inner side, so that it projects beyond on this side, while the other projects on the external side (Fig. 36, page 143). The two facets of the calcaneum are also separated by a groove transversely oblique. It follows, therefore, that when the astragalus is in its place, the groove of the astragalus and the calcaneum meet as a concavity, forming a species of tunnel, which

may be seen opening outwards upon the skeleton of the foot (9, Fig. 88), and which is called the *cavity of the tarsus*, or *canalis tarsi*. In this cavity are situated the principal ligamentous bands which attach the astragalus to the calcaneum; therefore these ligaments, placed between the two calcaneo-astragaloid articulations, of which one is placed before, the other behind, form a sort of pivot, around which the movements between the astragalus and the calcaneum take place, and since, as we shall see, the rest of the tarsus and the whole of the foot forms one with the calcaneum; it is round the calcaneo-astragaloid ligaments as a centre that the movements take place by which, apart from the mobility derived from the articulation of the knee, the point of the foot is turned inwards or outwards, and also those movements by which the external or internal borders of the foot are elevated.

The two articulations by which the posterior half of the tarsus is united to the anterior half (Fig. 36, page 143), the *calcaneo-cuboid* on the outer side, and the *calcaneo-scaphoid* on the inner, are formed on types entirely different to each other, and such that all the rest of the foot forms one with the calcaneum and moves easily with it upon the astragalus. The articulation on the anterior extremity of the calcaneum with the posterior surface of the cuboid presents an interlocked arrangement little marked, but surrounded by thick and solid ligaments, especially at its inferior part (the *inferior calcaneo-cuboid ligament*, or *great ligament of the sole*), so that between the calcaneum and the cuboid only an insensible gliding movement

takes place, and these two bones form in reality, from a mechanical point of view, one elastic piece.

On the contrary, the *astragalo-scaphoid* articulation is formed by the anterior extremity of the astragalus, by the part which is situated in front of the neck (page 143), and has therefore received the name of *head* (9, Fig. 37), a name it well deserves from its prominent rounded shape. This head of the astragalus is continuous below by its cartilaginous surface with the anterior surface of the anterior articulation of the calcaneous with the astragalus. Therefore the astragalus forms an intermediate piece between the leg and the rest of the skeleton of the foot ; and by the calaneo-astragaloid articulations and the astragalo-scaphoid forming a complete articulation which may for shortness be called a *sub-astragaloid articulation*, the foot possesses the lateral movements by which the point is carried inwards or outwards, and its external border elevated on one edge, and the internal depressed on the reverse. On the other hand, the movements of flexion and extension take place only in the *super-astragaloid articulation*, the articulation, previously explained, of the astragalus with the tibia and fibula.

The bones of the anterior half of the tarsus, namely, the *cuboid* on the outer side, the *scaphoid* with the three *cuneiform* on the inner side, articulate with each other by facets which are flat, but present rough surfaces towards their inferior or plantar portions intended for the interosseous ligaments. It is sufficient to say that in all these articulations a slight gliding

movement takes place, not sufficient to give true mobility to these bones, but only a certain elasticity to the plantar arch which they form by their arrangement. We will point out the peculiarities that are to be noted in each of these bones: in the *scaphoid* its form is flattened before and behind, and lengthened from within outwards; in the *cuboid* is an oblique groove (14, Fig. 38) which it presents on its inferior or plantar surface, which is intended for the tendon of the *long peroneal* muscle (see below); finally, of the three *cuneiform* which are distinguished, counting from within outwards, as the first, second, and third cuneiform (Fig. 36, page 143), the second (6) is smaller than the rest, therefore it does not descend as far forward as the first (5), and third (7, Fig. 36), between which it is placed so that at its level, the tarso-metatarsal line forms a notch opening into the tarsus, into which the posterior extremity of the second metatarsal is received.

In front of the tarsus is found the *metatarsus* corresponding to the metacarpus, while the toes correspond to the fingers of the hand. We have only a few words to say about those portions of the skeleton which resemble the corresponding parts of the hand.

The metatarsal bones, five in number, are long bones composed of a prismatic body and two extremities, one posterior or tarsal shaped exactly like the cuneiform bones, so that they resemble the arrangement of the stones of an arch; the other anterior or digital formed by a head which articulates with the

base of the first phalanges. These bones are placed parallel side by side, but that of the great toe is not shorter than its fellows like the metacarpal bone of the thumb; the great toe does not possess anything like the same amount of mobility as the thumb in the hand. Finally, with regard to particular details, it is

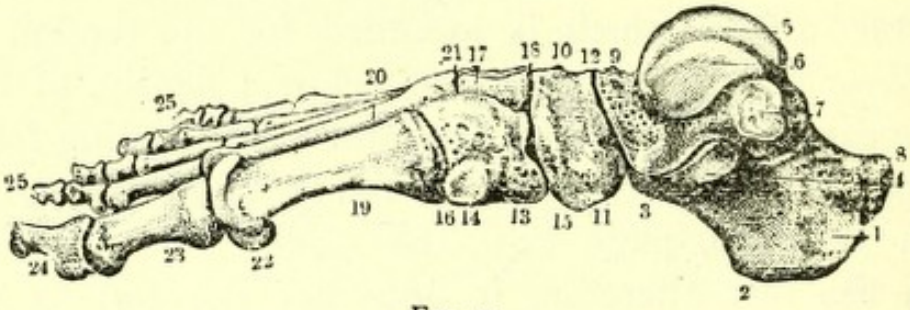

FIG. 37.

RIGHT FOOT (internal border).—1, 2, 3, 4, calcaneum;—5, 6, 7, astragalus;—8, posterior calcaneo-astragaloid articulation;—9, head and neck of the astragalus;—10, 11, scaphoid;—12, astragalo-scaphoid articulation;—13, 14, first cuneiform;—15, articulation of the first cuneiform with the scaphoid;—16, the articulation of the first cuneiform with the metatarsal bone of the left toe;—17, the second cuneiform;—18, its articulation with the scaphoid;—19, the first metatarsal bone;—20, the second metatarsal bone;—21, the articulation of the second metatarsal bone with the cuneiform bones;—23, 24, the phalanges of the great toe;—25, 25, phalanges of the other toes.

necessary to note in the first metatarsal (19, Fig. 37) its large size, in the second (20, Fig. 38), its greater length, for it passes behind the others (in entering into the notch which corresponds to the second cuneiform), and it also exceeds them in length, so that the second toe is much longer than the rest.

In the fifth we must note the form of its tarsal extremity, which is prolonged behind into a process (19, Fig. 38) which constitutes the external part of the prominence of the foot; this process of the

fifth metatarsal bone give insertion to the short peroneal muscle.

The phalanges of the toes (Fig. 37 and 38) resemble in number and arrangement the corresponding bones of the hand, only they are much shorter, especially those of the little toe, the two last of which

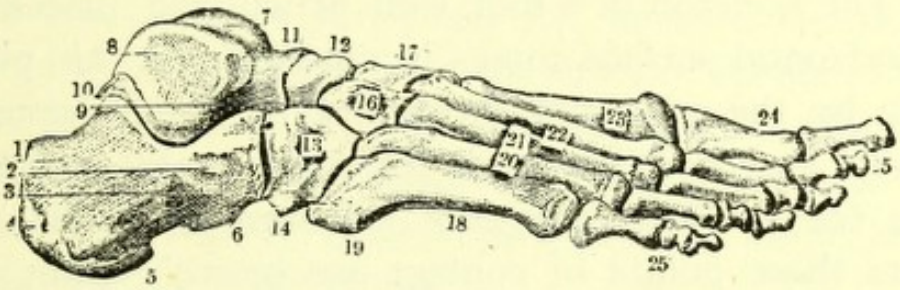

FIG. 38.

RIGHT FOOT (external border).—1 to 6, the calcaneum ;—7, the pulley-like surface of the astragalus ;—8, the lateral facet of the astragalus for the external malleolus ;—9, the tunnel of the tarsus (canalis tarsi) ;—10, the posterior calcaneo-astragaloid articulations ;—11, head and neck of the astragalus ;—12, the scaphoid ;—13, cuboid ; 14, commencement of the groove on the inferior surface of the cuboid (for the tendon, of the long peroneus muscle) ;—16, third cuneiform ;—17, second cuneiform ;—18, the five metatarsal bones with their posterior processes (19) ; 20, 21, 22, 23, fourth third, second, and first metatarsal bones ;—24, to 25, phalanges of the toes.

are reduced to small osseous nodules, therefore the fifth toe is always much shorter than the rest. The names of the phalanges are the same as in the hand (page 81).

The whole of the skeleton of the foot forms a true *arch* which presents two curves or concavities, one antro-posterior, the other transverse. The *sole* of the foot forms a hallow which extends from the posterior extremity of the calcaneum to the anterior extremity of the metatarsal bones ; but this plantar hallow is much more elevated on the inner side (Fig. 37), while

it is elliptically arched in the outer (Fig. 38). It is necessary then, in order to understand the general form of the foot, to consider that its *back* looks upwards and outwards, and the sole downwards and inwards, the *external border* is thin, and comes almost in contact with the ground, its *internal border* is thick and so is much elevated from the ground.

The skeleton of a foot well articulated placed on a horizontal surface comes in contact with this plane only by the posterior extremity of the calcaneum (heel), and by the heads of the metatarsal bones (the toes). When the foot is covered with its soft parts these points of contact are scarcely changed; for, besides the heel and the anterior extremity of the foot, we see that the greater part of the external border (especially in the part which corresponds to the fifth metatarsal) touches the ground but lightly, unless the subject is carrying a heavy load, which, pressing upon the palmar arch, brings its elasticity into play and slightly flattens it. We shall see later on that it is the muscles (especially the long peroneal) which act as the cord which bends the bow and maintains the plantar arch.

As we have already inquired into the relation of the hand and upper limb, we shall now see if the foot can furnish anything relative to the *proportions of the body*. Here no more than in the hand can we make the foot a common measure for the body in general and for the inferior limb in particular. It is necessary to confine ourselves to such indications as are exact only in the average subject. Thus it is easy to perceive

upon the skeleton that the distance from the superior extremity of the head of the femur to the inferior border of the internal condyle is equal to two feet; but this has no practical value—it cannot be used on the living body, as it is difficult to recognise the level of the superior part of the head of the femur. If, instead of the head of this bone, we take the superior border of the great trochanter (a part easily felt beneath the skin), we find that the length from the superior border of the great trochanter to the inferior border of the external condyle scarcely ever measures two feet; in fact, the great trochanter is upon a considerably lower level than the head of the femur.

The leg, including the thickness of the foot, does not contain the length of the foot an even number of times; in fact the distance from the inferior border of the internal condyle of the femur to the ground (or the sole of the foot) is not equal to twice the length of the foot; but it is interesting to observe in general that the length of the leg, plus the thickness of the foot, is equal to the distance from the great trochanter to the inferior border of the external condyle; therefore the middle of the lower limb (starting from the great trochanter) corresponds exactly to the line of the knee.

When we compare the length of the foot with the leg, beginning from below upwards, we find a regular proportion, and one of practical interest—viz., that from the ground to the middle of the patella usually measures twice the length of the foot.

As a common measure of the height of the body,

the foot does not give us a result that can be expressed by an even number. From the numerous researches of Leger on this question, the length of the foot is generally contained $6\frac{1}{3}$ times in the height. However, this number presents an interesting fact when we express this proportion by taking the third part of the foot for a unit; $6\frac{1}{3}$ feet forming nineteen thirds of the foot, we see that the height of the body contains nineteen thirds of the foot. Now the number 19 is precisely the same that, in the Egyptian canon, according to Charles Blanc, expresses the proportion that the middle finger bears to the height.

With regard to the foot itself, we will only say that the tarso-metatarsal line offers, on the skeleton, a simple means of dividing the foot. This line is oblique from before front to back and from within outwards; therefore its internal extremity at the base of the first metatarsal bone divides the foot into an anterior and posterior half, while its external extremity, at the base of the fifth metatarsal (process) divides it into a posterior and two anterior thirds.

CHAPTER XIII.

THE HEAD.

The bony structure of the *head;* division into *skull* and *face.* Study of the vault, or skull-cap. *Occipital* bone: its surface.—*Parietal* bone (parietal eminence and curved temporal line).—*Frontal* bone (frontal prominences, superciliary arches: orbital arches and processes).—*Temporal* bone: mastoid process of temporal; its surface; its zygomatic process.—Sutures of the bones of the vault of skull: their articulation; its characteristic aspect; sagittal suture; lambdoid suture; sphenoidal sutures.—General form of skull: long heads; square heads.—Cephalic indices: dolichocephalic, brachycephalic, and mesaticephalic skulls.

THE *skeleton of the head* is formed of two parts intimately united to each other: one superior and posterior, formed of flat bones, simple in form, and called the *cranium* or *skull*, containing the encephalon (the cerebrum and cerebellum), the organs of intelligence and volition; and an anterior and inferior part, formed of numerous bones, very complex in shape, called the bony structure of the *face*, surrounding numerous cavities which lodge the principal organs of sense and the apparatus of mastication.

The *skull.*—The cranium is ovoid in form with its greater diameter antero-posterior; the walls which form it can be distinguished as a *base*, which we need not study here, and *skull-cap* (lateral and superior walls) which we will now examine. The bones which

enter into the structure of this skull-cap, or vault of the skull, are the *occipital* behind, the *frontal* in front, the two *parietal* above, and the *temporal* on the sides.

The *occipital* (3, Fig. 39) forms the whole posterior

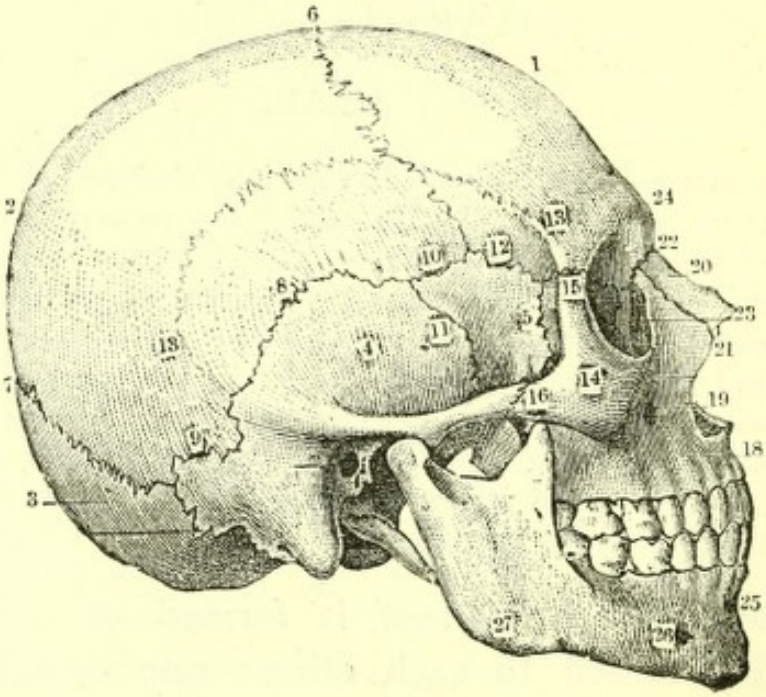

FIG. 39.

THE SKULL (lateral surface).—1, frontal bone;—2, parietal;—3, occipital;—4, temporal;—5, the great wing of the sphenoid (see page 162);—6, coronal suture;—7, lambdoid suture;—8, 9, parieto-temporal suture;—10, spheno-parietal suture;—11, spheno-temporal suture;—12, fronto-sphenoidal suture;—13, curved line limiting the temporal fossa;—14, 15, 16, malar bone;—18, the superior maxillary bone, with the infra-orbital foramen (19);—20, 21, 22, the bones proper of the nose;—23, the lachrymal groove;—24, the nasal eminence;—25, the inferior maxillary bone;—26 the mental foramen;—27, the angle of the jaw.

part of the base and vault of the skull. We distinguish in it two portions: 1st, an inferior part, which is horizontal, pierced by a large foramen (*occipital foramen*), through which the cavity of the cranium communicates with that of the vertebral canal. In

front of this foramen is the *basilar process* of the occipital; upon each side are the *condyles* by which the head articulates with the vertebral column—namely, with the lateral masses of the atlas (page 23).

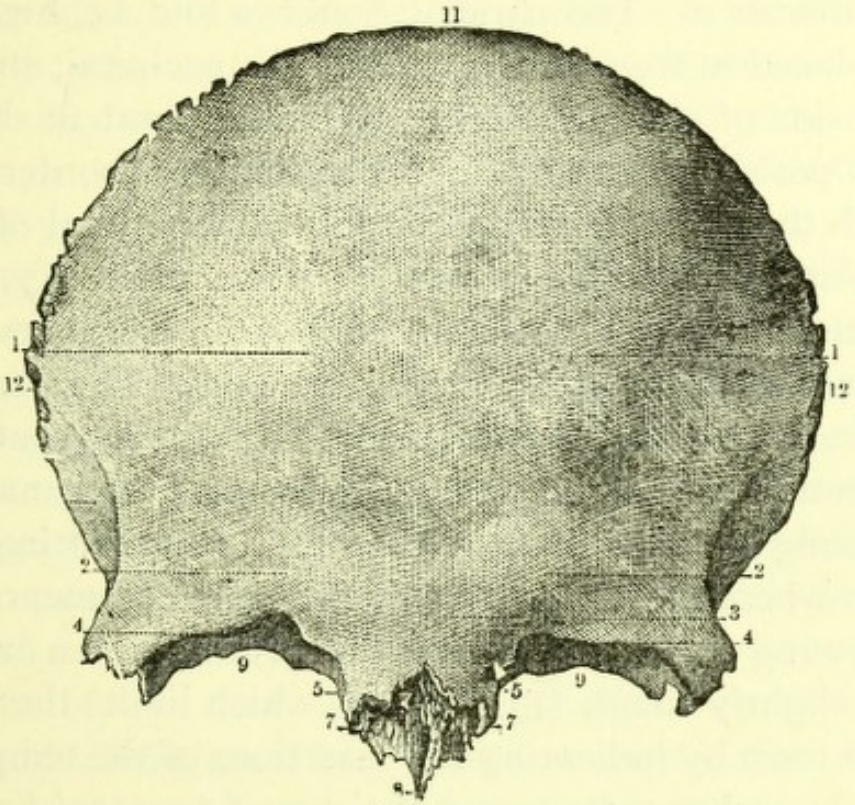

FIG. 40.

FRONTAL BONE (anterior surface).—1, the frontal prominences;—2, 2, superciliary ridges;—3, nasal eminences;—4, 4, supra orbital notches;—5, 5, the internal orbital processes;—7, 7, nasal notches;—8, nasal spine;—9, 9, fossa or arches of the orbits;—11, the superior border;—12, the lateral parts of the border.

2nd, a posterior part (3, Fig. 29) called the *shell-shaped portion* of the occipital, triangular in form, with the apex directed upwards. The borders of this shell are hollowed out into numerous and irregular denticulations, which work in with similar denticulations on the posterior border of the parietal bones (7, Fig. 39);

the external or posterior surface of this shell is crossed towards its central part by a *semicircular* crest, which gives insertion to the superficial muscles of the neck (see trapezius and sterno-mastoid), and of which the centre forms a prominence called the external occipital protuberance. The parietal bones (2 and 13, Fig. 39) are placed in front of the shell of the occipital, one on each side of the middle line. Quadrilateral in shape, each parietal presents four denticulated borders, of which the superior articulates with the parietal of the opposite side, the posterior with the occipital (7, Fig. 89), the anterior with the frontal (6), the inferior, which is concave (8, Fig. 89), with the temporal. The parietal presents on its external surface—1st, at its centre a projection called the *parietal eminence*, better marked in young subjects than in the adult, representing the place where the ossification of the bone commences in the young child ; 2nd, below this prominence a curved line, slightly rough (13, Fig. 89), which limits the temporal fossa by indicating the insertions of the temporal muscle—whence its name, the *curved temporal line*.

The *frontal* (1, Fig. 39), like the occipital, presents a part which belongs to the base of the skull and to the face (9, 9, Fig. 40), for it forms the vault of the orbit (see below), and a part called the *shell*, which forms the anterior and superior wall of the cranium. This shell has a rounded superior border (11, Fig. 40) which articulates by its denticulation with the parietal bones (6, Fig. 49) ; beginning from this border and descending towards the face we find parts important with regard to form, and which are :—1, the *frontal*

prominences (1, 1, Fig. 40) better marked in young subjects and in females than in the adult male ; 2, the *superciliary prominences or arches* (2, 2, Fig. 40) which are directed obliquely upwards and outwards, these prominences being, on the other hand, better marked in the adult, and owing their prominence to the fact that the thickness of the frontal is hollowed out at their level into cavities called the frontal sinuses, which become more developed as the subject advances in age ; 3, finally, the *orbital arches* (4, 4, Fig. 40) which form the superior border of the orbit. Curved with the concavity downwards, each of these orbital arches forms on the outer side an *external orbital process* (6, 6, Fig. 40), which articulates with the malar or cheek-bone (15, Fig. 39), and on the inner side an *internal orbital process* (5, 5, Fig. 40) which, with its fellow of the opposite side, bounds a median part called the *nasal notch* (7, Fig. 40) into which are received the bones of the nose (22, Fig. 39), and the ascending process of the maxillary bone (see page 166). Again, each arch presents, towards its internal part, a small notch called the *supra orbital notch* (Fig. 40).

The *temporal bones*, one on each side of the skull (11, 4, and 31, Fig. 39), are very complex in shape, but we shall study here only one portion. Each temporal is composed of two parts, one belonging to the base, and another belonging to the lateral wall of the skull ; the part belonging to the base forming a pyramidal mass of bony substance very hard, called the *petrous bone*, which contains the delicate organs of the internal ear, while the part belonging to the lateral wall of the

skull (4, Fig. 39), forms an irregular osseous disc resting upon the base of the petrous portion of the bone. An orifice, the *auditory canal* which leads into the petrous portion, is found towards its centre (31, Fig. 39). Taking this orifice of the auditory canal as a centre, we find on the external surface of the temporal—1, behind the auditory canal the *mastoid portion* of the temporal (33, Fig. 39), which is prolonged downwards in a cone in the shape of a nipple (μαστός, a nipple) called the *mastoid process;* 2, above the auditory canal the *shell of the temporal* (4, Fig. 39), a broad portion, with rounded borders articulating with the inferior border of the parietal (8, Fig. 39). In front is a process (20, Fig. 41) which is given off and directed horizontally towards the face and joins the malar bone (16, Fig. 39), this process, connecting the skull with the face, is called the *zygomatic process* (ζυγός, a yoke which joins), and forms with the corresponding part of the malar bone the *zygomatic arch.* The zygomatic process rises from the temporal by two roots (Fig. 39), one longitudinal, antero-posteriorly passing above the orifice of the external auditory canal, the other transverse, situated at the base of the skull, and limiting in front the auditory canal, a cavity into which is received the condyle of the lower jaw. Finally, below the auditory canal, the temporal gives origin to a *styloid process* (32, Fig. 39), long and slender with the summit very sharp, giving insertion to some small muscles of the neck (see supra-hyoid muscle.)

The whole of the bones that we have taken in

review articulate by denticulated borders, and the name of *sutures* is given to these lines of union. As the skull must be studied by the artist, not only with regard to its external forms, but also as an *object* which figures frequently as an accessory in still life compositions, and as the representation of these sutures contributes to give to the skull its exact physiognomy, we must not leave the subject without carefully pointing them out. It is necessary for this purpose to consider the skull from its upper and its lateral surface.

Examined as to its upper surface, the skull presents a suture in the middle line, antero-posterior and inter-parietal, called the *sagittal suture.* Behind, on a level with the superior angle of the shell of the occipital (7, Fig. 39), this median suture bifurcates and becomes continuous with the two occipito-parietal sutures, and we give to the whole the name of the *lambdoid suture*, because it resembles the form of a Greek lambda (more exactly that of V reversed, Λ). In front, the inter-parietal suture (or sagittal) is met by the two parieto-frontal sutures (6, Fig. 39) which form a transverse line, to which has been given the name of the *coronal suture.*

On examining the skull on one of its lateral surfaces, we see that the sutures form here a more complex design, because, besides the bones already described, there is a new osseous plate placed at the level of the temporal fossa (5, 10, 11, 12, Fig. 39) which takes part in the construction of the lateral wall of the skull. This quadrilateral plate belongs to

the *sphenoid*, a very complex bone situated at the base of the skull, into which it is fitted like a wedge (σφήν, a wedge) extending laterally in the form of a wing; it is the great wing of the sphenoid which is placed in the lateral surface of the skull, in front of the shell of the temporal, and below that of the frontal. We see then, following from above downwards, the *coronal suture* (6, Fig. 39); this suture bifurcates below into an anterior suture called the *spheno-frontal* (12), and a posterior (10) called the *spheno-parietal*. This last, which is very short, divides also at its inferior extremity into an inferior suture vertical, called the *spheno-temporal* (11), and a superior, curved, called the *temporo-parietal* (8), which bounds the shell of the temporal and proceeds backwards to the level of the mastoid portion of this bone, to join the inferior extremity of the *lambdoid* or *occipito-parietal* suture.

We have said that the general form of the skull is that of an ovoid with its greater extremity posterior, but it is a common observation that this ovoid may present, in different subjects, very different proportions—*e.g.*, certain skulls show a great predominance of length in the antero-posterior diameter over that of the transverse, and it is then commonly said that the skull is long; it is said, on the contrary, that the skull is square when the transverse diameter almost equals the antero-posterior. Anthropologists have endeavoured to measure exactly the proportion between the transverse and antero-posterior diameters of the skull, and they have described it by the name of the *cephalic index*. As we have previously

explained respecting the proportion of the arm and fore-arm (*brachial index*, page 89), we understand by the name of index the number which indicates the proportion between a short and a greater length, the latter being considered as equal to 100—that is to say, the figures obtained by direct measurement being reduced to a centesimal proportion. We find that in certain skulls the transverse diameter is relatively very short, seeing that it is represented by 75; the antero-posterior being 100, we say that the cephalic index of these skulls is 75, and we give to them the name of *dolichocephalic* (δολιχός, lengthened; κεφαλή, head). Others present a transverse diameter which approaches the antero-posterior, since it is represented by 83 or 84, the antero-posterior being 100. This cephalic index of 83 is that of heads called *brachycephalic* (βραχύς, short). Between these two types are the heads of average or intermediate form called *mesaticephalic*, and of which the cephalic index is from 77 to 80. The importance of dolichocephalic and brachycephalic types with regard to race has been exaggerated, a Swedish anatomist, Retzens, having advanced the theory that the aboriginal races of Europe are brachycephalic, while the races coming afterwards are dolichocephalic; but the fact recently shown that the Basques are dolichocephalic, and that dolichocephalic skulls have been found among the fossil skulls of ancient Europe has destroyed the value of this theory. We can only say with regard to the cephalic index, considered as relating to the different races, that the dolichocephalic

type is best marked in the Australians, Hottentots, Caffres, Negroes, and Nubians; the brachycephalic in the Indo-Chinese, Lapps, and people of Auvergne; and that the Norman and, in general, the Parisian skulls (from the twelfth to the nineteenth century) present principally the mesaticephalic type.

CHAPTER XIV.

THE FACE.

The bony structure of the ace.—*Orbital cavities:* their margins; their depth.—Nasal fossæ (anterior orifice).—Prominence of the cheek (malar bone and its branches).—Superior maxillary.—Inferior maxillary body, vertical branch (sigmoid notch, coronoid process, and condyle): lower jaw at various ages.—The teeth: their parts; their names (incisors, canines, molars); their number; relative dimensions of incisors.—Articulation of the lower jaw.—The face and skull as a whole with regard to form.—*Facial angle of Camper:* its measure; its proper value according to race; its exaggeration in the antique heads.—The head as a common measure: law of eight heads; variations according to the height of the individual; point which corresponds to the middle of the body.

THE *FACE.*—Instead of describing the bones of the face separately we will group them together around the cavities which they circumscribe and the prominences which they form; therefore we will study successively the *cavity of the orbit*, the orifice of the *nasal fossæ*, the prominence of the *cheek-bone*, and, lastly, the region of the *mouth*, along with which we will describe the *teeth*, the *lower jaw*, and its articulation with the base of the skull.

The *orbits.*—The orbits are two cavities situated symmetrically one on each side of the upper portion of the face below the forehead. Each of these cavities is formed like a pyramid with four faces, of which the

summit penetrates from before backwards towards the cranial cavity, and of which the base, turned forwards, forms the orbital opening. This opening, or *orbital brim*, is quadrilateral (Fig. 41), limited by an internal border (7) and an external border, both almost vertical, by a superior border (3) and an inferior border, both oblique, from above downwards and from within outwards.

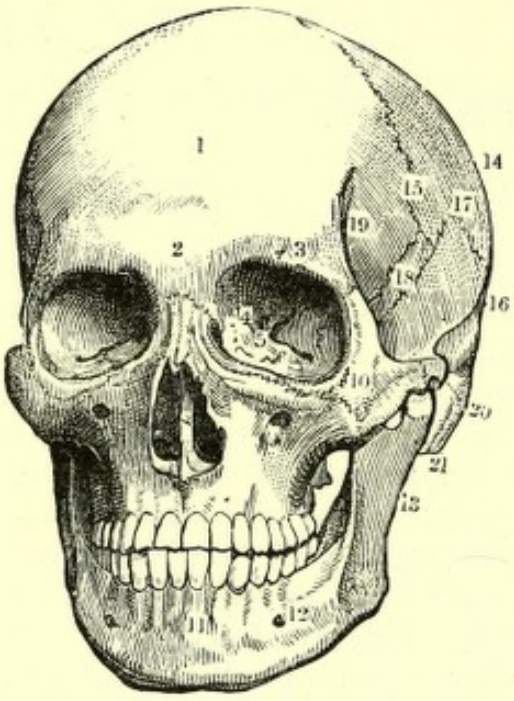

FIG. 41.

THE BONY STRUCTURE OF THE FACE.—1, the frontal bone ;—2, the nasal eminence ;—3, supra-orbital notch;—4, the optic foramen ;—5, the sphenoidal fissure ;—6, the spheno-maxillary fissure ;—7, the lachrymal groove ;—8, the partition and opening of the nasal fossæ ;—9, the infra-orbital foramen ;—10, the malar bone ;—11, the symphysis of the chin ;—12, the mental foramen ;—13, the ascending ramus of the lower jaw ;—14, —the parietal bone ;—15, the coronal suture ;—16, the temporal bone ;—17, the temporo-parietal sature ;—18, the great wing of the sphenoid ;—19, the origin of the line which bounds the temporal fossa ;—20, the zygomatic arch ;—21, the mastoid process.

The superior border is formed by the orbital arch of the frontal bone (3, Fig. 41) previously described ; the inferior border is formed by the *superior maxillary* bone, and a little below its centre a hole, called the *infra-orbital* foramen, is perceived (9, Fig. 41), which is placed almost in the same vertical line as the supra-orbital notch previously described (page 159). The internal border is formed by the junction of the internal orbital process of the frontal with the ascending process of the superior

maxillary (Figs. 39 and 41). At its inferior part this border presents a depression called the *lachrymal groove* (7, Fig. 41), which is the commencement of a canal connecting the orbit with the corresponding nasal fossa. Finally, the external border is formed by the junction of the external orbital process of the frontal with the superior process of the *malar bone*, or bone of the cheek (10, Fig. 41; 14 and 15, Fig. 39).

The cavity of the orbit has for its walls the osseous plates belonging to the frontal (superior wall) and to the several bones of the face we have previously mentioned when describing the orbital opening. We need not enter here into the description of these surfaces and of the several special bones which compose them. We shall only say that the internal wall is directed from before backwards, while the external is oblique, from behind forwards and from without inwards. We note, lastly, at the deepest part (towards the summit) of the cavity, several apertures, by which the orbit communicates with the deep cavities, which appear as dark spots; first, a circular orifice called the *optic foramen* (4, Fig. 41); then, on the outer side of these, two fissures directed outwards, one obliquely upwards (*sphenoidal fissure*, 5, Fig. 41), and the other obliquely downwards (*spheno-maxillary fissure*, 6, Fig. 41).

The orifice of the nasal fossæ (8, Fig. 41) is situated in the middle of the face below the level of the orbits. It is in the form of a heart inverted (with its base turned downwards); it is bounded below by the two

superior maxillary bones which unite in the middle line, upon the sides by the same bones, and above by two small bones placed on each side of the median line the *nasal bones* (Fig. 39, page 156) which articulate above with the frontal and on each side with the ascending process of the corresponding maxillary.

Below, and to the outer side of the orbit, is the prominence of the cheek formed by the *malar bone* (10, Fig 41). This bone is formed like a star with four branches—the *superior branch* (15, Fig. 39) joins the external orbital process of the frontal; the *anterior branch* (17, Fig. 39), or internal, forms with the superior maxillary; the inferior boundary of the orbit, the *external branch* (16, Fig. 39) or posterior, joins the zygomatic process of the temporal to form the *zygomatic arch;* the inferior branch is reduced to a prominent margin which joins with the body of the bone to form the *prominence of the cheek.*

There remain now only two bones to examine on the skeleton of the face, namely, the two bones which bound the cavity of the mouth and support the teeth: these are the superior and inferior maxillary or jaw-bones. The *superior maxillary* (18, Fig. 39) has been in a great measure described since we have noted its principal borders and its ascending process with respect to the orbital and nasal openings. All that remain to be noticed are: 1, the slightly hollowed form of its anterior surface (Fig. 41); 2, its inferior or *alveolar* border, so named because it presents a series of cavities intended to lodge the roots of the upper teeth. The presence of these cavities is marked on

the anterior surface of the alveolar border by a series of corresponding prominences separated by depressions corresponding to the intervals of the alveoli.

The *inferior maxillary* or *jaw-bone* (Fig. 42) deserves a longer consideration than the other bones of the face, for it takes so direct a part in the external form that we may say that all the details of its shape are marked in the configuration of the chin and the lower parts of the cheeks. It is originally composed of two distinct halves, one right and one left, which are joined together in early life in the median line forming the symphysis of the chin (11, Fig. 41). It is sufficient to describe one of these halves, such as we see it when looking at a skull in profile (Fig. 39).

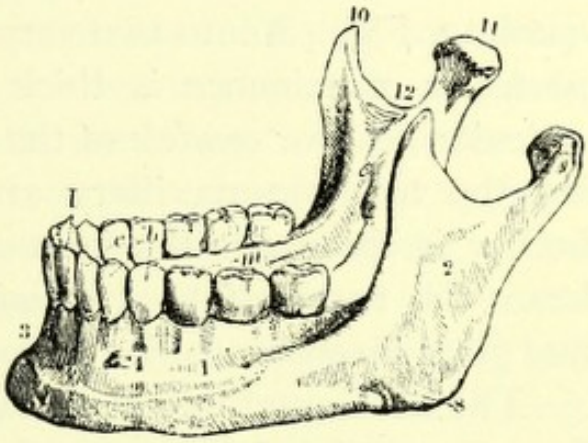

FIG. 42.

THE INFERIOR MAXILLARY BONE (side view).—1, the body of the inferior maxillary bone and its external oblique line;—2, the ascending ramus;—3, the symphysis of the chin;—4, the mental foramen;—8, the angle of the jaw;—10, coronoid process;—11, the condyle;—12, sigmoid notch. *c*, canine tooth;—*b*, bicuspid;—*m*, molar.

We see that this half is formed of two strong osseous plates called the *branches* of the jaw-bone, one *horizontal* called the body (1, Fig. 42), the other *vertical*, both joined together at an angle more or less approaching a right angle, of which the prominence directed downwards and backwards is called the *angle of the jaw* (27, Fig. 39, and 8, Fig. 42).

The *vertical branch* consists of a flat external surface (2, Fig. 42), a thick posterior border and a thin anterior border which is continuous below with the external surface of the horizontal branch or body in the form of a slightly prominent line called the *external oblique line* (1, Fig. 42), and finally, a superior border which is divided by a deep notch (*sigmoid notch* 12, Fig. 42) into two very prominent parts. The posterior prominence is thick and terminates by an articular head or *condyle* of the jaw (11, Fig. 42), forming the temporo-maxillary articulation, the anterior border is thinner in the form of a triangular plate, it bears the name of the *coronoid process* (10, Fig. 42), and gives insertion to the temporal muscle.

The horizontal branch or *body* of the jaw extends from the angle of the jaw to the *symphysis* of the chin (3, Fig. 42) ; it has an external surface on which we remark an orifice (12, Fig. 41, and 5, Fig. 42) called the *mental foramen*, which is placed in the same vertical line as the supra-orbital notch and the infra-orbital foramen. Its inferior border is sometimes slightly undulated, its superior border is alveolar—presenting the prominences and depressions corresponding to the alveoli of the teeth and their interstices.

The lower jaw changes its characters according to age : in the infant, the angle is very obtuse and but slightly prominent ; in the adult it becomes almost a right angle ; in the aged, the form of the jaw is changed by the loss of the teeth and by the absorption of the alveolar border, and consequently a loss

of height in the horizontal branch. Therefore, in order to bring the lower jaw in contact with the upper the lower jaw has to move strongly forwards and upwards, whence a characteristic prominence of the symphysis of the chin which seems to project upwards and forwards to meet the prominence of the nose in the aged.

The teeth which furnish each of the maxillary bones are thirty-two in number in the adult—eight in each lateral half of each maxillary. We divide the teeth into a part fixed in the alveolar cavity, and called the *root*, and a free part called the *crown*. The form of the crown permits the division of the teeth into four distinct classes, which in each half of the jaw are arranged in the following manner, beginning from the median line:—Two *incisors* (I, Fig. 42), one *canine* (*c*, Fig. 42), two *bicuspids* (*b*, Fig. 42), and three *molars* (*m*, Fig. 42)—total, eight. Situated at the most external and posterior portion of the dental arch, the molars and bicuspids are hidden by the cheeks, and we will only mention that they are characterised by a crown formed of numerous tubercles (four for the molars, two for the bicuspids). On the other hand, the canines and the incisors are easily seen when the lips are separated. The *canines* are characterised by a conical crown with a sharp extremity, which presents great development in the carnivores—*e.g.*, in the dog (whence the name of canines). The *incisors* present a crown flattened from before backwards, rectangular in form (square), with a free border cut off like a chisel. Their relative volume is subject to a law so constant

that it should be here stated. The two largest incisors are the median superior, next in order of decrease the lateral superior, then the lateral inferior, and finally the median inferior, which are the smallest.

The articulation of the jaw-bone with the skull, or *temporo-maxillary articulation*, is formed by the condyle of the jaw (11, Fig. 42, and 29, Fig. 39), which is secured in the cavity which the temporal presents in front of the auditory canal and behind the transverse root of the zygomatic process (page 160). This *glenoid cavity* of the temporal is lined with cartilage, together with the transverse root in question, which in certain moments is in contact with the condyle of the jaw. This is the fibrous capsule which surrounds the articulation, and it is strengthened on the outer side by an external lateral ligament, which proceeds obliquely from the point of junction of the two roots of the zygomatic process downwards and backwards to become attached to the neck of the condyle of the jaw. Therefore, when the jaw is depressed by a movement of rotation of the maxillary condyle upon its axis, this external lateral ligament is made tense, and draws the condyle forward, causing it to leave the glenoid cavity and come in contact with the transverse root of the zygomatic process. There is, then, when the mouth is widely opened (the lower jaw being greatly depressed), a displacement of the condyle of the jaw forwards, which is easily seen in very thin subjects, and which should be noted here with its own particular mechanism.

The face, as a whole, presents a special interest

when we take various individuals and races and compare its development with that of the skull. In general, the more prominent the skeleton of the face the less the skull (the forehead) is developed. This is the idea of Camper, a Dutch artist about the middle of the eighteenth century.

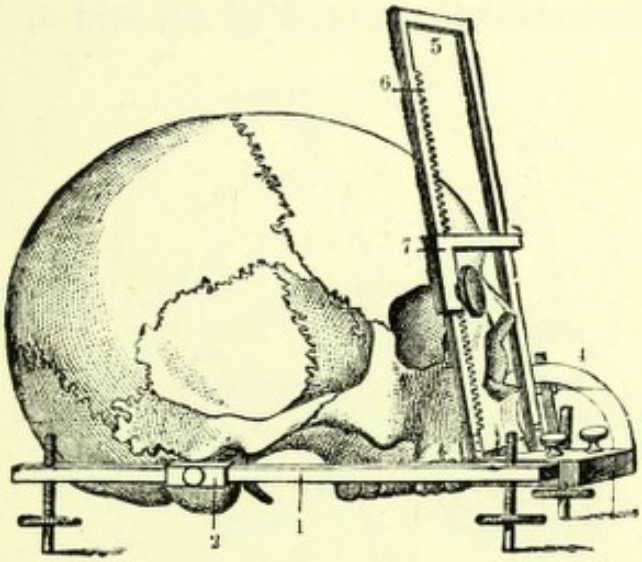

FIG. 43.

THE MEASUREMENT OF THE FACIAL ANGLE (goniometer applied to a skull) — 1, the inferior horizontal plane of the goniometer;—2, movable piece with a pin introduced into the auditory meatus;—4, graduated circle;—5, the oblique plane attached below by a hinge to the horizontal;—6, the rack for placing the bar (7) on the prominent part of the forehead.

Camper proposed to measure the relative development of the skull and face by the angle which the geometrical plane of the profile of the face makes with that of the anterior part of the skull. This facial angle has always been the subject of much study on the part of anatomists and anthropologists, who have modified and perfected the process of measurement. It will be sufficient here to show the idea that Camper had, and that he made it a study, as he said, to furnish

artists with a means of giving character to the different physiognomies of men and animals. This angle is determined by two planes (upon a head seen in profile, by two lines): one, which we may call horizontal, proceeds from the external auditory canal to the nasal spine, and is situated at the inferior border of the orifice of the nasal fossa (1, Fig. 43, and *a*, *b*, Fig. 44);

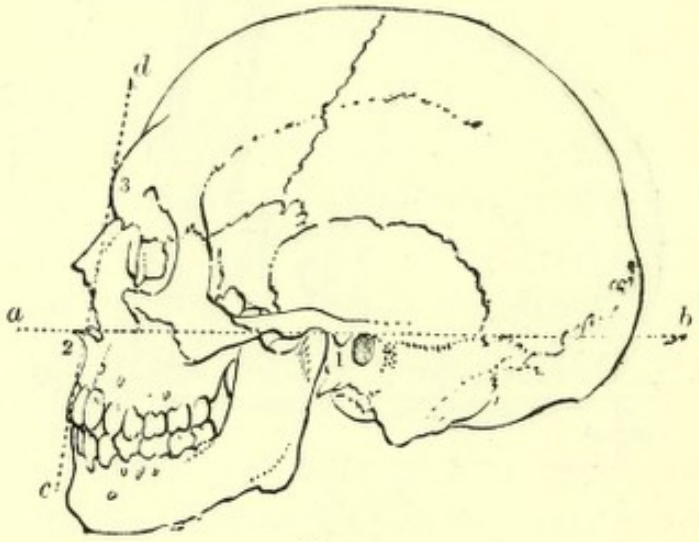

FIG. 44.

THE FACIAL ANGLE OF A SKULL OF THE CAUCASIAN RACE (after Camper).—*a b* and *c d*, the lines which mark this angle (see the text);—1, the anditory foramen;—2, nasal spine;—3, the most prominent part of the forehead.

the other, more or less oblique from below upwards and backwards, is at a tangent below to the prominence of the incisor teeth, and above to the most prominent part of the forehead (*c*, *d*, Fig. 44). Figure 43 gives an idea of the apparatus with which we measure the facial angle at the present day. It represents the facial goniometer of Jacquart. The mode of measurement here differs from that employed by Camper, in that the inferior or horizontal plane

passes forward not by the nasal spine, but by the prominence of the incisors.

Figures 44 and 45, which are reproduced from those of Camper, show on the one hand that the facial angle is never equal to a right-angle, but that it approaches it in the best types of the white race. The ancients sought by an exaggeration to idealise

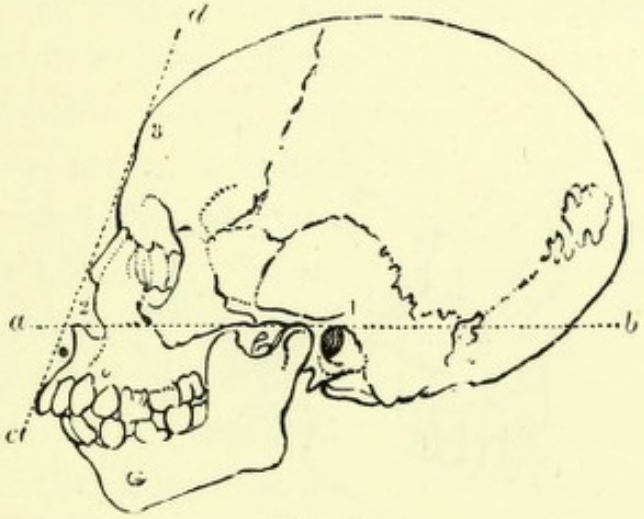

FIG. 45.

THE FACIAL ANGLE OF A NEGRO (after Camper). The figures are the same as in the preceding.

the profile of the human face, and by increasing the fulness of the forehead they have given to heads of gods and heroes a facial angle larger than ninety degrees (Fig. 46). These figures show, also, the decrease of the facial angle in proportion as we pass from the white to the yellow and black races:— "The angle which the facial line or characteristic line of the visage makes," said Camper, "varies from seventy to eighty degrees in the human species. All who raise it higher disobey the rules of art (from imitation of the antique); all who bring it lower fall into the like-

ness of the monkeys. If I cause the facial line to fall in front I have an antique head; if I incline it backwards I have the head of a negro; if I cause it to incline still further I have the head of a monkey; inclined still more I have that of a dog, and, lastly, that of a goose."* The figures which explain these

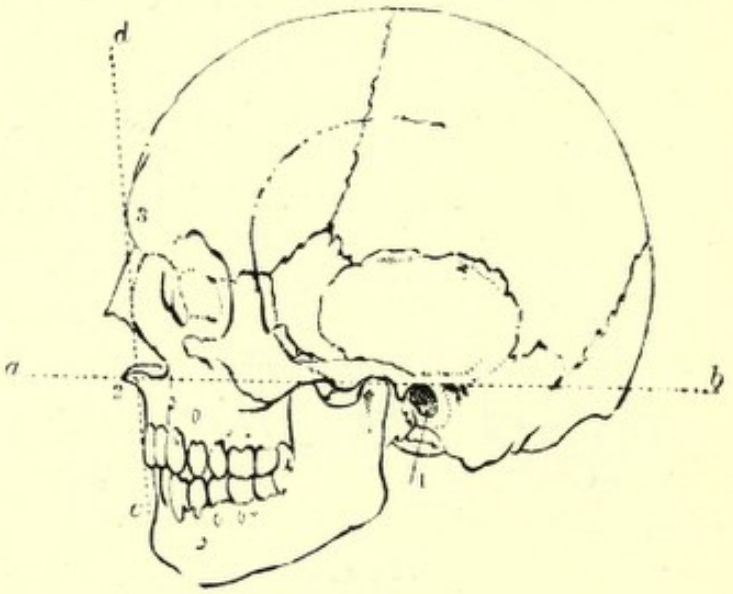

FIG. 46.

THE FACIAL ANGLE OF AN ANTIQUE HEAD (Apollo Belvedere)—(Camper).

ideas are as follows:—The facial angle of Camper averages 80 degrees in the Caucasian race; 75 degrees in the yellow, or Mongol; 60 to 70 degrees in the Negro; 31 degrees in the great monkeys (gorilla); lastly, 25 degrees in the head of a Newfoundland dog.

According as we have studied the various segments of the limbs, we have seen that some of them

* Pierre Camper. "Dissertations sur les differences rúlles que présentent les traits du visage chez les hommes de différents pays et de différent âges." (Œuvres posthumes. Paris, 1786.)

have been chosen, according to the various systems, to serve as a common measure for these limbs, and for the entire body. Thus we have spoken of the canons having for a unit the *hand* (contained about ten times in the height of the body), the *foot* (contained a little more than six times in the total height), the *middle finger* (contained nineteen times), &c., &c. It is true, also, that the head—*i.e.*, the vertical distance from its summit to the base of the chin — should have been taken also as a common measure ; and this has been done long ago, since Vitruvius, speaking of the proportions of the human body, states this fact—that the height of the head should be the eighth part of the whole body. Leonardo da Vinci, Dürer, and J. Cousin, have followed the rule of the Latin author ; and the law which makes the head the eighth of the total height, has for a long time past become classic in all the schools. The choice of the head as a unit seems sufficiently justified by the two facts that on the one hand, in every representation of the human body, the head is always visible, and forms a part distinct from the rest of the body, and that, admitting that it makes the eighth part of the height, this number is particularly convenient, not being too high ; and, moreover, even that is to say divisible by two (and by four). In this respect it offers, for example,

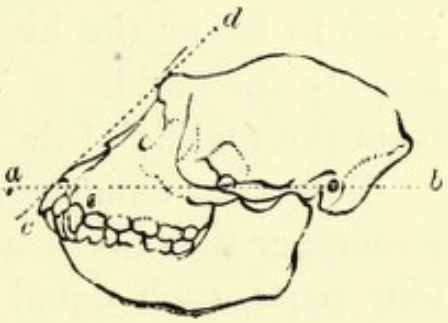

FIG. 47.

THE FACIAL ANGLE OF A MONKEY. (Camper).

a great advantage over that of nineteen, which represents the proportion of the middle finger to the height.

Gerdy, who has adopted the law of eight heads, distributes them thus in the height of the body: the first division comprises the head itself; the second extends from the chin to the level of the nipples; the third from the nipples to the umbilicus; the fourth from the umbilicus to the os pubis; the fifth from the last point to the middle of the thigh; the sixth from the thigh to below the knee; the seventh from below the knee to the middle of the leg; and, lastly, the eighth, from the middle of the leg to the sole of the foot.

Before we examine the value of this law, we must remember that the head itself has been divided into four parts, each equal to the length of the nose: the first part proceeds from the top of the head to the beginning of the hair; the second from the beginning of the hair almost to the root of the nose; the third from the root almost to the base of the nose; and the fourth from the base of the nose to the chin.

Now, if we submit to experiment the system of the law of eight heads, we see that it is accurate only in subjects of great height, for those who attain seventy-four inches and over; below seventy-two inches the subjects do not measure more than seven and a half, or only seven times the height of their head. In fact, the height of the head is a quantity which varies very little according to the subject; it is on the average, as an absolute value, from $8\frac{2}{3}$ to 9 inches, and the variations which this value may present do not vary lower than $8\frac{1}{4}$ inches, nor rise above 9 inches. A

subject who measures eight heads is very tall ($9 \times 8 = 72$, equal, or superior, to 72 inches); and a subject who only measures seven heads is of short stature ($8\frac{2}{3} \times 7 = 61$, equal, or more frequently exceeding, 61 inches).

This difference in the number of heads that the body measures in relation to the absolute height of subjects seems more interesting than the narrow theory which would assign strictly the length of eight heads to each human figure. This absolute system does not agree with that which observation proves correct. Besides, it would be an error to suppose that the ancient sculptors would be slaves to such a system of proportions, since we find in their works precisely the same variations that we do in nature. The *Gladiator*, it is true, measures eight heads; but at the first glance at this *chef d'œuvre*, we have the impression of a subject of great stature—of a man tall and spare. The *Apollo* measures only $7\frac{2}{3}$ heads, the *Laocoon* the same, and the *Antinous* only $7\frac{1}{2}$.

These several variations are owing almost solely to the greater or lesser length of the lower limbs. Whether the subject be tall or short, the trunk (with the head and neck) varies comparatively little; but the thighs and legs make the differences of length. Regarding the diversity that we meet with in this question, we see that Gerdy himself has not been exact in indicating the points where the lengths of the head begin and terminate which divide the lower limb, the middle of the thigh, and the lower part of the knee; those points are badly defined, especially as he does not indicate precisely the superior extremity

of the thigh. But the looseness and contradiction becomes still more evident when we come to seek, according to the various authors, the intersection between the fourth and fifth head; that is to say, the middle of the body. Without speaking of the singular inconsistency of Vitruvius, who places the middle of the body at the level of the navel, we will note only this fact, that for the passage from the fourth head to the fifth some take the pubis, others some other point. This centre of the height falls lower as the stature of the subject is increased.

Professor Sappey has proved that in subjects of small stature the centre of height corresponds to the symphysis of the pubis; for those of middle height, and over it falls about half an inch before the pubis. But it may be situated at a still lower level, and the artists of antiquity have frequently placed it much lower. In fact, as Professor Sappey says, the taller the stature is, the more the centre of the body tends to fall below the symphysis, and the figures of heroes and gods are of tall stature.

We will say, then, in conclusion: 1, that the head, compared with the height, is shorter as the height increases; 2, that to produce a human figure, the absolute dimensions of which would give the impression of a subject of short stature, it would be necessary to give it about $7\frac{1}{2}$ heads, and to cause the centre of the body to fall on the symphysis pubis, while to produce a figure to give the impression of tall stature it would be necessary to give it 8 heads, and to place the centre of the body more or less below the symphysis pubis.

Second Part.

MUSCLES AND MOVEMENTS.

CHAPTER XV.

PECTORAL AND ABDOMINAL MUSCLES.

Of *muscles* in general.—*Muscular contraction:* changes of form which result; movements produced. Composition of muscles; fleshy body and tendon; aponeurosis. Nomenclature of muscles, their classification into long, broad, and short muscles; their distribution into superficial and deep. Muscles of the trunk, anterior region.—*Great pectoral*, its relation with the armpit, its action, it is doubled by the lesser pectoral.—The *external oblique muscle of the the abdomen*, its fleshy part, its abdominal aponeurosis, linea alba of abdomen.—Groove and inferior space bounded by the prominence of the external oblique and rectus.—Internal oblique and transversalis muscles—*Rectus abdominis* muscle, its aponeurotic sheath, its aponeurotic intersections.

THE form of the body is produced by the muscles disposed upon the skeleton, their function being to move its several parts upon each other. The muscles are formed by peculiar tissue called *muscular tissue* or *muscular fibre*, which has the property of changing its form, namely, of *contracting* under the influence of nervous action in most cases controlled by the will. In contracting the biceps muscle situated on the anterior surface of the arm, we see that this muscle which, in a state of repose, is fusiform and long

becomes in action (in contraction) short, thick, and rounded, and as it is attached below to one of the bones of the fore-arm it draws the anterior surface of the fore-arm towards the anterior surface of the upper arm and produces flexion in the elbow-joint. This simple experiment, which is easy to repeat at any moment, gives a clear idea of the part which muscles play in the animal economy, and of the part that they take in producing the external forms of man, for it shows that they are the *active agents* of movements in which the bones are the *passive levers*, and at the same time that a muscle in action presents a very different shape to that which it has n a state of repose, a change which may be stated in a more general manner by saying that in action a muscle becomes shorter and more prominent.

In general, besides their *fleshy body*, the only part which contracts and changes its form, the muscles have extremities more or less slender called *tendons*, formed of a white tissue, which are, as it were, actual cords by which the muscle is attached to the bones; during the contraction of muscle these tendons do not change in form but, as with all tight cords when in a state of tension, only become more visible and clearly marked beneath the skin, which they raise up.

The muscles are enveloped by a fibrous membrane called the *aponeurosis*, which keeps their fleshy bodies in place, but frequently the tendons instead of being rounded in the form of a cord are flattened and thin in the form of a membrane, and the term aponeurosis is also applied to these membraniform tendons.

The muscles have been variously named according to various orders of ideas ; sometimes from the region they occupy (*pectoral, gluteal, anterior brachial muscles, &c.*) or from their direction (*oblique of the abdomen*), or from their dimensions (*gluteus maximus, gluteus medius, and peroneus longus, &c.*), or again from their form (*trapezius, rhomboid, serratus*), or from their structure (*semi-membranosus, semi-tendinosus*). Another mode of nomenclature which Chaussier attempted to make general, forms the name of a muscle by the association of the names of the bones to which it is attached ; in this way we get the *sterno-cleido-mastoid muscle*, and most of the muscles of the neck ; this nomenclature cannot be easily applied to all muscles, for it would make some names of an inconvenient length, owing to the complexity of the bony insertions.

Before we terminate this rapid sketch, it may be useful, with regard to plastic anatomy, to point out how the muscles are classed, according to their form and situation. 1st. With regard to their form we distinguish the muscles as *long*, *broad*, and *short*, the *long muscles* consisting in general of a fleshy body fusiform in shape, with cord-like tendons, are principally distributed among the great segments of the limbs (arm, fore-arm, thigh, leg) ; the *broad muscles*, constructed of a fleshy body, broad and thin, with tendons membranous and aponeurotic, are almost exclusively placed on the trunk (pectorals, trapezius, latissimus dorsi, &c.). Lastly, the *short muscles*, frequently wanting tendons, formed by a body that is very

slightly expanded, and inserted directly into the bone, are found principally in the extremities of the limbs (hand and foot) and in the face.

2nd. With regard to their situation we distinguish the muscles as *superficial* and *deep*. The *superficial muscles* (Fig. 48), are those which are entirely visible when the subject is stripped of its skin, and of which, accordingly, the fleshy body and tendons are marked in their principal details on the external form. These superficial muscles should be carefully studied here with regard to their insertions, forms, and actions. The *deep muscles*, situated below the preceding, form fleshy masses, which are shown externally by the manner in which they fill up the external depressions of the skeleton, and raise up the superficial muscles. The general indications of these muscular masses are sufficient for the artist without studying the insertions and forms of each of the muscles composing any given mass.

MUSCLES OF THE TRUNK.

Under the title of the anterior muscles of the trunk we will study *(pectoral and abdominal)* the muscles of the back and posterior surface of the neck (*trapezius* and *latissimus dorsi*). With regard to the muscle which covers the lateral wall of the trunk (*serratus magnus*) its study will be considered after that of the muscles of the shoulder and arm-pit.

Great pectoral muscle.—The great pectoral muscle forms a large fleshy mass (1, Fig. 49) which covers the anterior surface of the thorax, on each side

of the middle line of the sternum, and extends outwards almost to the superior part of the arm. This muscle is attached (1st) to the internal half of the

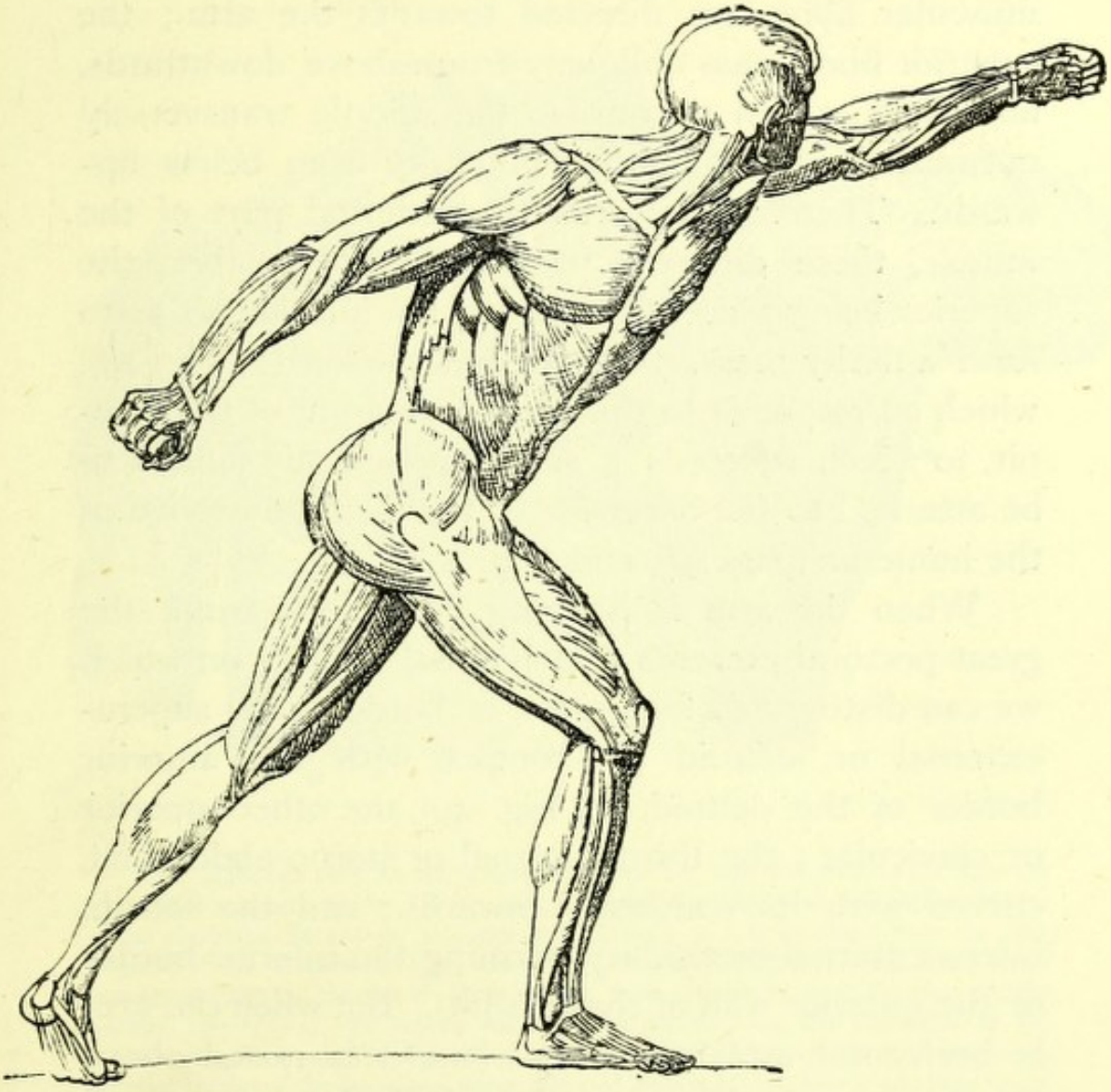

FIG. 48.

GENERAL VIEW OF THE SUPERFICIAL MUSCLE (the *Gladiator* of Agasias with the skin removed. Compare with Figure 2, page 18).

anterior border of the clavicle (2, Fig. 49); (2nd), to the whole extent of the anterior surface of the sternum (3, Fig. 49); and (3rd), to the aponeurosis

of the rectus muscle of the abdomen. It presents, also, a deep fascia arising from the seven first ribs (9, 9, 9, Fig. 49). From these thoracic insertions the muscular fibres are directed towards the arm; the superior fibres pass obliquely from above downwards, and from within outwards; the middle transversely outwards, and the inferior obliquity from below upwards. Therefore, towards the external part of the muscle, these different parts cross each other, the superior being placed in front of the inferior, so as to form a fleshy mass, narrower, but thicker (7, Fig. 49), which corresponds to the anterior margin of the arm-pit, to which succeeds a short aponeurotic tendon to be attached to the outer lip of the bicipital groove of the humerus (page 56, and Fig. 12).

When the arm is hanging beside the trunk the great pectoral presents a polygonal surface on which we can distinguish four sides, or borders, one supero-external or deltoid (in contact with the anterior border of the deltoid, 12, Fig. 49), the other superior or clavicular; the third, internal or sterno-abdominal, curved with its convexity inwards; and the fourth, infero-external or axillary (forming the inferior border of the anterior wall of the arm-pit). But when the arm is horizontal, and especially when it is raised above the horizontal (Fig. 50), the clavicular border and the deltoid are found in the same line continuous with each other, so that the figure of the muscle is then represented by a triangle with the base inwards (sterno-abdominal border).

Essentially the action of the great pectoral is to

bring the arm near to the trunk; its shape becomes prominent when we carry the arms forwards and bring them near each other, as in the attitude of

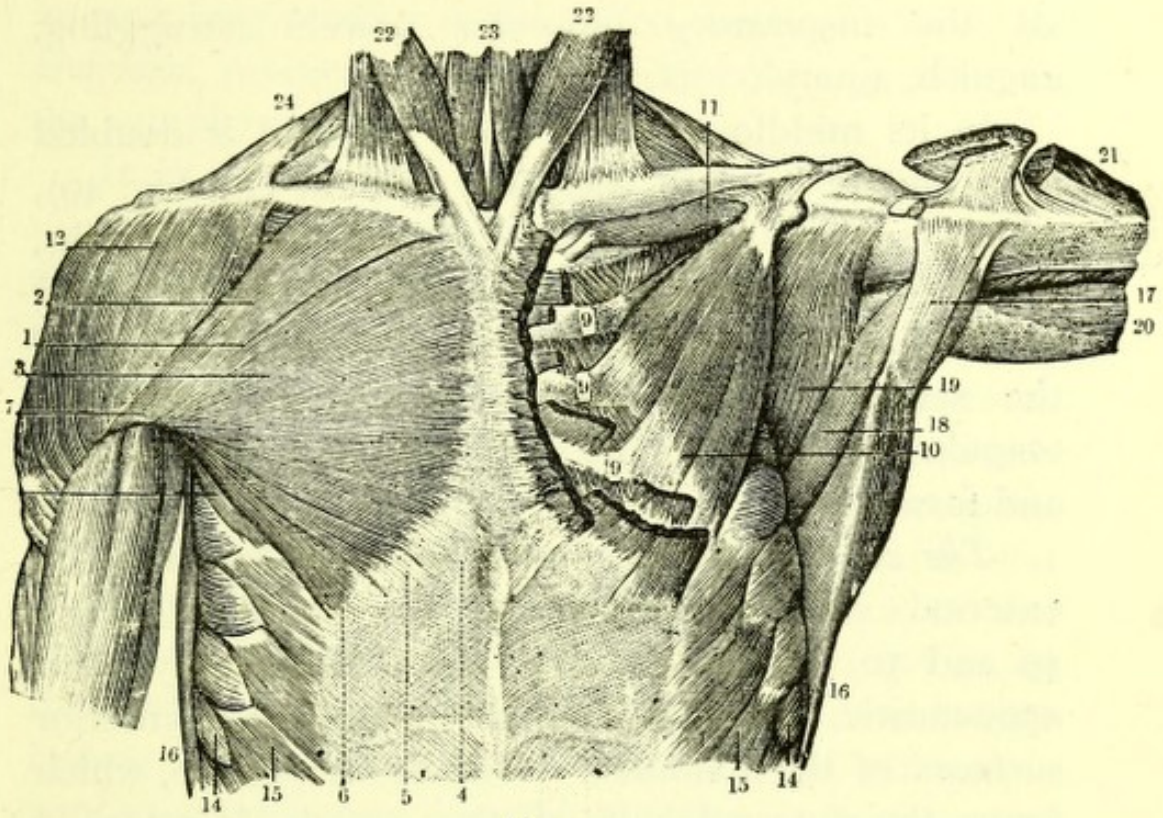

FIG. 49

THE MUSCLES OF THE ANTERIOR SURFACE OF THE THORAX (to the right the superficial muscles; to the left the deep muscles).—1, the great pectoral muscle;—2, its clavicular fibres;—3, its costo-sterno fibres;—4, 5, 6, its origin from the aponeurosis of the abdomen;—7, its external portion formed by the superposition of the preceding fibres (9, bundles of fibres arising from the cartilages of the ribs; 10, the pectoral minor);—11, the sub-clavius;—12, the deltoid;—14, the digitation of the serratus magnus;—15, the digitations of the external oblique of the abdomen;—16, anterior border of the latissimus dorsi, and (17) tendon of the same;—18, teres major muscle;—19, the sub-scapularis;—20, the long head of the triceps brachialis;—21, the humeral extremity of the deltoid;—22, 22, the sterno-cleido-mastoid;—23, the sterno-hyoid;—24, the trapezeus muscle.

prayer. It also becomes well marked in climbing, for then the muscle takes its fixed point at the humerus and draws the trunk towards it. Acting in a similar

manner upon the thorax, with the humerus as a fixed point, this muscle elevates the ribs, and consequently expands the thorax (respiration). Thus we see that it contracts when the subject brings into action all the inspiratory muscular powers (struggling, anguish, agony).

In its middle part the great pectoral is doubled by a muscle beneath, the *lesser pectoral* (10, Fig. 49), which, arising from the third, fourth, and fifth ribs, is directed upwards and outwards, to be attached to the internal border of the coracoid process of the scapula. This muscle serves to move the scapula by drawing its superior part downwards and forwards.

The external oblique muscle of the abdomen.—The external oblique muscle of the abdomen (Figs. 49 and 50) forms a large sheet half fleshy, half aponeurotic, which covers the lateral and anterior surfaces of the abdomen. The fleshy portion, which forms the external half of the muscle, is attached to the external surface of the seven last ribs, into which it is inserted by triangular slips or digitations, interlacing with those of the latissimus dorsi and serratus magnus (15, Fig. 49 and Fig. 53). From these costal insertions the fibres are carried downwards, the posterior vertically, to be attached to the iliac crest (Fig. 53), the others obliquely downwards and forwards, to give origin to a broad membraniform tendon (9, Fig. 50) called the *aponeurosis of the external oblique muscle.* The fibres of this aponeurosis, continuing in the original direction

of the muscular fibres, pass in front of the rectus muscle of the abdomen (12 and 15, Fig. 50) almost to the median line, where, interlacing with the aponeurotic fibres of its fellow on the opposite side, it forms a long median raphé, called the *linea alba of the abdomen*, proceeding from the xiphoid appendix to the symphysis pubis (10, Fig. 50).

It is important, with regard to the external form, to define the direction of the line at which the aponeurotic fibres of the external oblique succeed to the fleshy (Fig. 50). This line descends vertically from its origin at the inferior angle of the great pectoral, but at its lower part inclines abruptly outwards (4, Fig. 50) to join the anterior superior iliac spine, describing a curve with its convexity downwards and inwards. This line marks the prominence of the anterior or internal border of the muscle; and as, on the other hand, the rectus forms, by its external border raising the aponeurosis of the external oblique, a similar prominence, describing a line at first vertical but inclining inwards below (15, Fig. 50), it follows that this, the region of the anterior surface of the abdomen, is traversed by a narrow vertical groove which opens out below into a large triangular space. This triangular space, bounded above and on the outer side by the external oblique, and on the inner side by the rectus, is limited below by the fold of the groin, the line at which the aponeurosis of the external oblique becomes attached to the crural arch (page 100). In the male this part of the aponeurosis of the external oblique is perforated exactly over the inner

third of the crural arch (13, Fig. 50) in order to give passage to certain vessels—an anatomical detail which is shown when the subject is stripped of the skin, but which is not of any importance with regard to form.

The external oblique muscle draws the ribs downwards and forwards. If the two muscles of that name (that of the right and that of the left side) contract at the same time they bend the body forward; but when one muscle only—*e.g.*, that of the right side—contracts it imparts to the trunk a movement of rotation to the left or opposite side. Generally speaking, whenever we make any effort the oblique muscles of the abdomen contract, and their prominence, especially that of their costal indigitations and their anterior borders, become clearly marked.

The external oblique muscle is lined by two muscular layers placed beneath it, and which are, passing from superficial to deep, the *internal oblique* (15, Fig. 51) and *transversalis* muscles. The internal oblique is formed by fibres which arise from the lumbar vertebra and the crest of the ilium, and radiate forwards (Fig. 51) to become attached, the superior set to the three last ribs, while the middle and inferior mass of fibres are continued in front by an aponeurosis, or broad flat tendon. This aponeurosis soon becomes united, partly with that of the external oblique and that of the transversalis beneath. The *transversalis* muscle is formed by fibres directed horizontally, and terminates in front by an aponeurosis which passes behind the *rectus abdominis*.

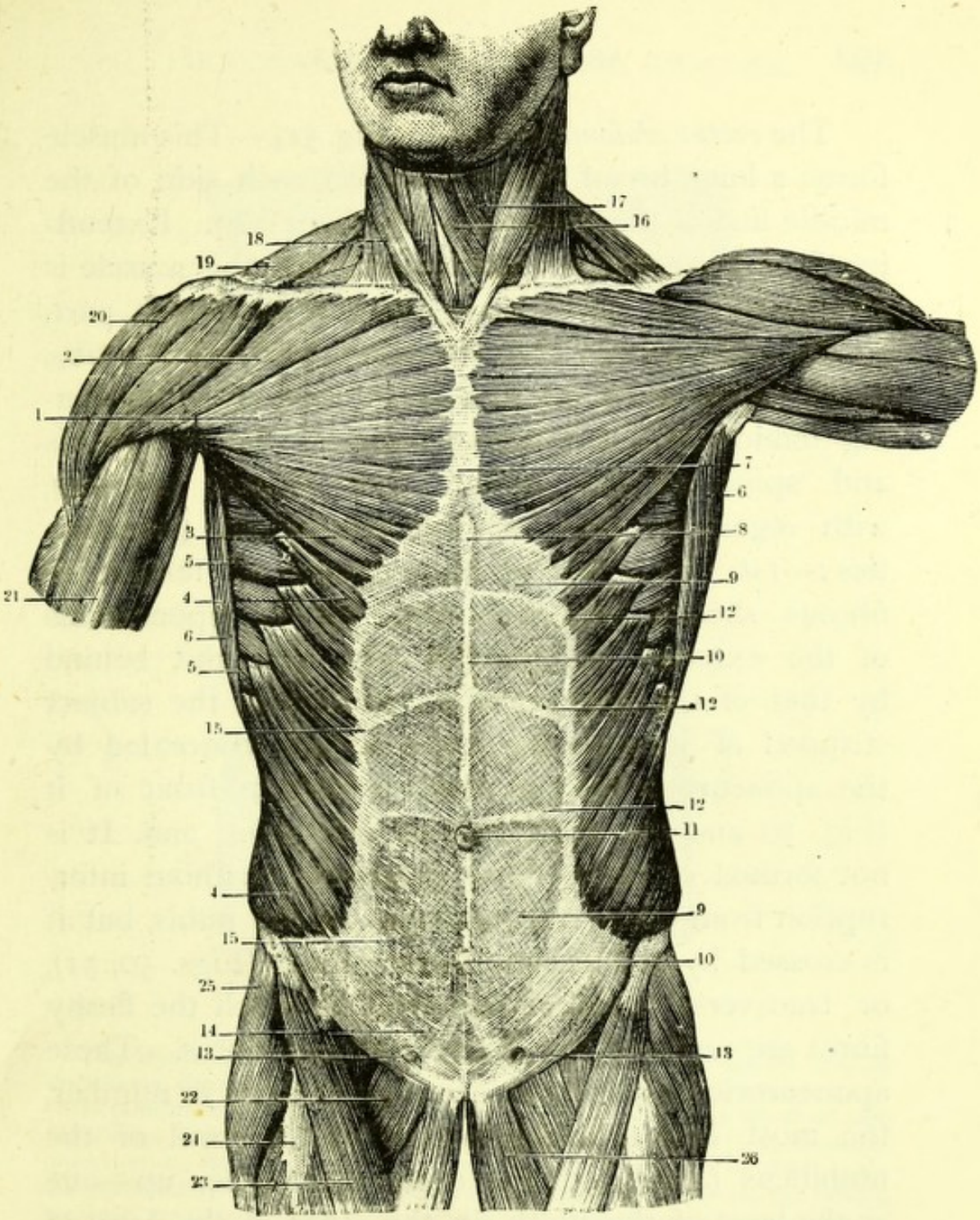

FIG. 50.

THE MUSCLES OF THE ANTERIOR WALL OF THE TRUNK.—1, 2, 3, the great pectoral ;—4, 4, the external oblique of the abdomen ;—5, 5, the serratus magnus ;—6, 6, the anterior border of the latissimus dorsi ;—7, 8, the inferior portion of the sternum ;—9, the aponeurosis of the external oblique ;—10, linea alba ;—11, umbilicus ;—12, 12, 12, the tendinous intersections of the rectus abdominis ;—13, the inguinal ring—14, the pyramidalis of the abdomen ;—15, the external border of the rectus abdominis ;—16, the sterno-hyoid ;—17, the omo-hyoid ;—18, sterno-cleido-mastoid ;—19, the trapezius; —20, the deltoid ;—21, the biceps brachialis ;—22, the pectineus ;—23, the sartorius ; —24, the rectus femoris ;—25, the tensor of the *fascia lata* ;—26, the adductors.

The *rectus abdominis* (11, 11, Fig. 51).—This muscle forms a long, broad, fleshy band on each side of the middle line of the abdomen—the *linea alba.* Extending from the epigastric pit to the pubis, this muscle is attached above by its base, which is its widest part, to the cartilages of the fifth, sixth, and seventh ribs, below at its apex, its narrowest part, by a glistening tendon to the interval between the symphysis and spine of the pubis. This muscle presents, with regard to form, several remarkable peculiarities:—1st. It is placed in a species of furrow, or fibrous sheath, formed in front by the aponeurosis of the external oblique (16, Fig. 51), and behind by that of the transversalis; so that in the subject stripped of its skin its shape is half concealed by the aponeurotic lamina which passes in front of it (Fig. 50 and the right half of Fig. 51). 2nd. It is not formed of fleshy fibres proceeding without interruption from the costal cartilages to the pubis, but it is crossed by aponeurotic intersections (Figs. 50, 51), or transverse lines, at the level of which the fleshy fibres are replaced by short tendinous fibres. These aponeurotic intersections are usually three in number, the most inferior being placed at the level of the umbilicus (4, Fig. 50), the other two higher up—one at the level of the ninth rib, the other at the level of the seventh. These intersections adhere to the anterior wall of the sheath of the muscle, and as the muscle is thinner at their level each of them is marked by a transverse groove more or less regular. 3rd. That portion of the muscle below the umbilicus does not

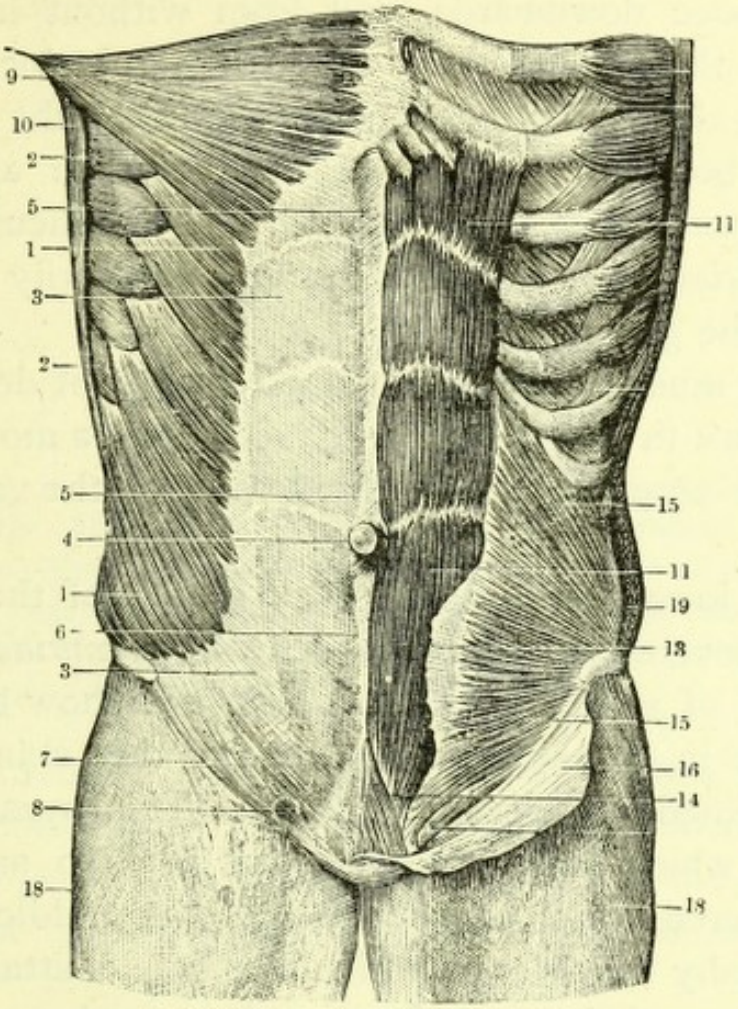

FIG. 51.

THE MUSCLES OF THE ABDOMEN (the superficial on the right side, the deep on the left).—1, the external oblique ;—2, 2, the serratus magnus ;—3, 3, the aponeurosis of the external oblique ;—4, the umbilicus ;—5, 6, the linea alba ;—7, the crural arch or fallopian ligament ;—8, the inguinal ring ;—9, pectoralis major ;—10, latissimus dorsi ;—11, 11, the rectus abdominis ;—13, the anterior portion of its sheath ;—14, the pyramidalis ;—15, 15, the internal oblique of the abdomen ;—16, the inferior portion of the aponeurosis of the external oblique turned downwards ;—18, the upper part of the thigh covered by its aponeurotic envelope ;—19, a section of the external oblique of the abdomen.

present any aponeurotic intersection, but it rapidly diminishes in breadth from the umbilicus to the pubis, so that the external border of the muscle is oblique

from above downwards, and from without inwards. It is to this arrangement that the fact is due, which we have already dwelt on (page 189), that the narrow groove bounded by the external oblique and the rectus spreads out at the level of the umbilicus into a broad, triangular surface, bounded inferiorily by the fold of the groin.

This muscle flexes the trunk; that is, it depresses the thorax in bringing it near the pubis—a movement which it accomplishes by the flexion of the vertebral column.

The lower part of the rectus muscle of the abdomen is covered by a small muscle, the *pyramidalis* (14, Fig. 51), of which the contour does not show beneath the skin in the supra-pubic region, this skin being always lined by a cushion of fat. This pyramidalis muscle, which is just pointed out here so as to be remembered, forms on each side of the middle line a small fleshy triangle, of which the base is attached to the pubis, and the apex forms a short tendon which is continuous with the linea alba, the median fibrous raphé resulting from the interlacing of the aponeurosis of the external oblique and transversalis muscles of the abdomen.

CHAPTER XVI.

MUSCLES OF THE BACK.

Trapezius, its insertions, its aponeurotic parts; figure of a hood formed by the whole of the lower parts of both muscles.—*Latissimus dorsi*—Deep muscles partly visible in the spaces of the trapezius and latissimus dorsi—1, lateral region of neck (splenius and great complexus muscles); 2, region of the scapula (rhomboid, infraspinatus, teres major and teres minor muscles).

Trapezius muscle.—This muscle forms, with the latissimus dorsi, two broad muscular sheets which cover over all the region of the back and the posterior part of the neck, and extend to the shoulder and arm.

The *trapezius* muscle is inserted as follows:—1. On the one hand to the inner third of the curved line of the occipital (13, Fig. 52) to a fibrous plane which proceeds from the occipital protuberance to the spinous process of the seventh cervical vertebra (posterior cervical ligament, page 26); then to the spinous process of the seventh cervical vertebra, and lastly, to the spinous processes of the twelve dorsal. 2. From these insertions which all correspond to the middle line of the back, the muscular fibres are carried outward towards the shoulder, the middle transversely, the superior obliquely downwards (9, Fig. 53), the

inferior ascending obliquely, and become attached to the osseous girdle of the shoulder, to the superior border of the spine of the scapula (Fig. 52), and the external third of the posterior border of the clavicle (19, Fig. 50).

With regard to the external shape, this muscle presents this remarkable fact, that in certain regions the muscular fibres are replaced by aponeurotic, so that in these regions the muscle is thinner and shows slightly depressed surfaces. These regions are three in number: 1. At the inferior part of the neck and the superior part of the back (10, Fig. 52), at which level the fibres of origin of the muscle are aponeurotic, and form with those of the opposite side an elliptical surface with its greater diameter vertical, towards the centre of which the spinous processes of the sixth and seventh cervical vertebra form a well-marked projection (*vertebra prominens*, page 24). 2. At the lower part of the back, at the level of the last dorsal vertebræ, the fibres of origin of the trapezius are also aponeurotic, in a small triangular space, very short; but in the living model, when the trapezius is strongly contracted, its inferior extremity seems hollowed out, because at that level the muscular fibres are wanting, and in consequence do not swell up when the muscle is in action. 3. At the level of the root of the spine of the scapula, the inferior fibres of the trapezius form a small triangular aponeurosis which glides on the corresponding bony part; then is seen the commencement of the series of insertions of the muscle into the posterior border of the scapular spine.

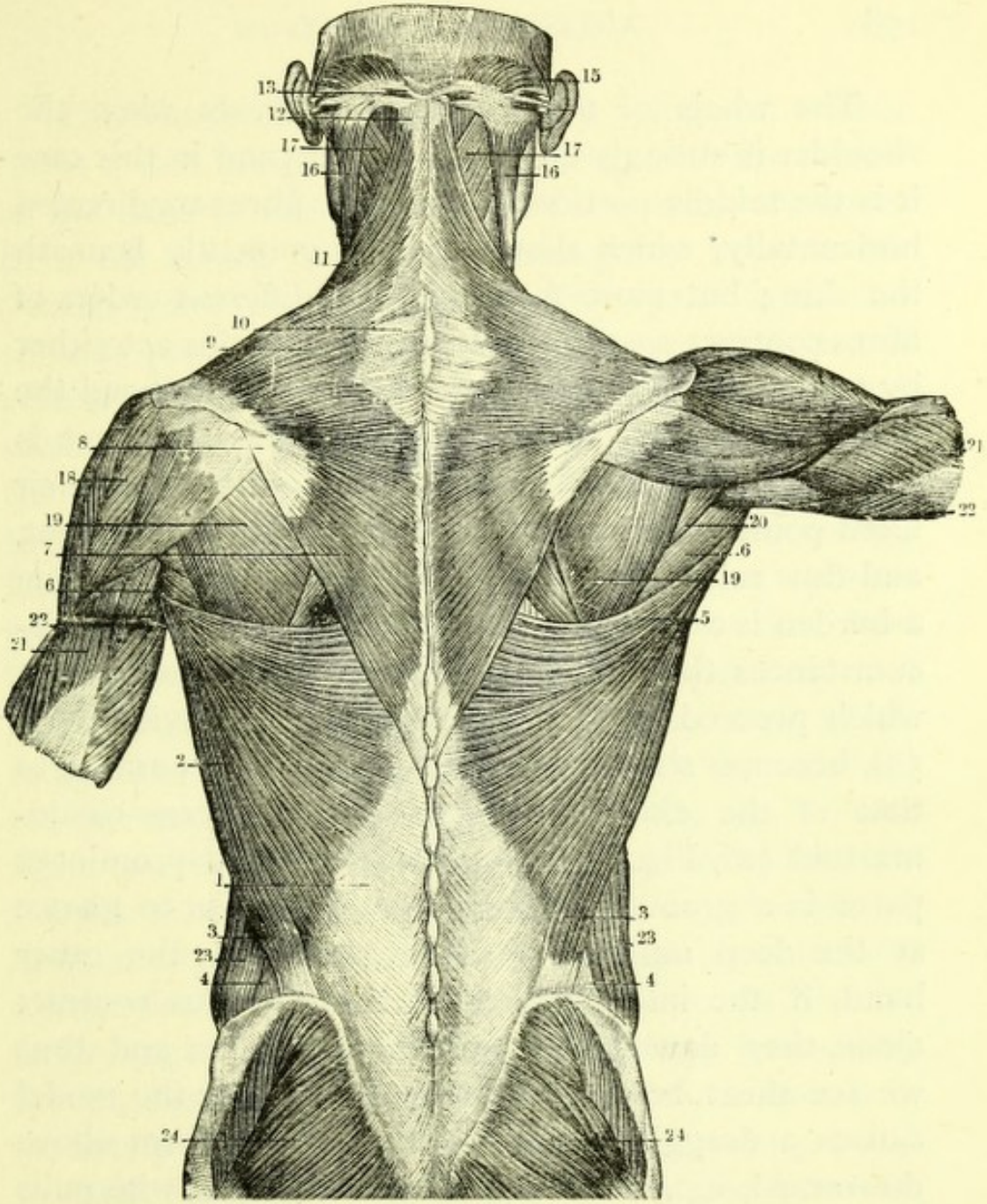

FIG. 52.

THE SUPERFICIAL MUSCLES OF THE BACK.—1, the lumbo-sacral aponeurosis; —2, the latissimus dorsi ;—3, its iliac fasciculus ;—4, the space which separates it from the external oblique ;—5, the upper portion of the latissimus dorsi ;—6, 6, the teres major muscle ;—7, the lower portion of the trapezius, with its aponeurotic portion (8) on a level with the spine of the scapula ;—9, the central portion of the trapezius, with its aponeurosis (10) ;—11, 12, 13, the upper portion of the trapezius ;—15, the occipito-frontalis muscle ;—16, the sterno-cleido-mastoid ;—17, the splenius capitis ;—18, the deltoid ;—19, the infra-spinatus ;—20, the teres-minor ;—21, 21, the external head, and 22, 22, internal head of the triceps brachialis ;—23, the posterior portion of the external oblique of the abdomen ,—24, 24, the gluteus maximus.

The whole of the trapezius contracts when the shoulder is strongly drawn backwards, and in this case it is the middle portion, of which the fibres are directed horizontally, which shows most prominently beneath the skin; but more frequently its different orders of fibres contract separately; thus the superior act either by taking the shoulder as a fixed point, to bend the head to the corresponding side (as when the face is slightly turned to the opposite side); or by taking their fixed point at the occipital and the cervical ligament, and thus raising and supporting the scapula, as when a burden is carried on the shoulder. Under those circumstances the cervical border of the trapezius, that which proceeds from the occipital to the clavicle (Fig. 53), becomes strongly prominent in a line parallel to that of the external border of the sterno-cleido-mastoid (26, Fig. 53); between these two prominent parts is a groove to which we will return to glance at the deep muscles of this region. On the other hand, if the inferior fibres of the trapezius contract alone, they draw the shoulder downwards, and thus we see them become prominent whenever the model causes a dragging with his upper limbs from above downward, *e.g.*, in the case of a bell-ringer who pulls violently and with all his weight on a rope.

The whole of the two trapezius muscles (right and left), form on the back (Fig. 52) a triangular figure with its apex below, which resembles the contour of a monk's hood. Hence the trapezius has been called the *cucullury muscle* (*cucullus*, a hood); and artists commonly call it the *hood* of the back.

Latissimus dorsi muscle (1, 2, 3, 5, Fig. 52).—This forms a vast muscular sheet extending from the region of the loins to the upper part of the arm. It arises from the centre of a broad triangular aponeurosis (lumbo-sacral aponeurosis, 1, Fig. 52), from the spinous processes of the six or seven last dorsal vertebræ, from the spinous processes of the lumbar and sacral vertebræ and the posterior third of the crest of the ilium (3, Fig. 52); the muscular fibres succeed to this aponeurosis along an oblique line proceeding from the iliac crest towards the last dorsal spinous processes, and at the same time three or four new fleshy bands join the muscle arising from the external surfaces of the three or four last ribs by slips which indigitate with the most inferior of the external oblique muscle of the abdomen (4, 4, Fig. 53). From these insertions the muscular fibres are directed; the inferior almost vertically upwards, the superior almost horizontally outwards, and all converge so as to form a large fleshy band (5, Fig. 52) which covers the inferior angle of the scapula, passes along its axillary border, beside the *teres major muscle* (see later), to mount up into the posterior wall of the arm-pit and to reach the upper part of the shaft of the humerus, into which it is inserted by a broad tendon, in the external or posterior lip of the bicipital groove (page 56).

This muscle acts in a manner similar to the lower part of the trapezius, but with more energy, since it depresses not only the scapula but also the humerus. It is the contraction of the latissimus

dorsi which enables us to bring the arm with force to the side, carrying the upper limb slightly backwards, so that if the contraction is carried very far the arms become crossed behind the back. But the prominence formed by the external border of the latissimus dorsi during contraction (Fig. 53) is principally shown when the muscle accomplishes a powerful effort, that of violent dragging, or pulling from above downwards, as in pulling on a rope hanging vertically (ringing a bell), or in hanging by the arms from a horizontal bar. If in this situation—the exercise of the trapeze, for example—the model raises himself, and brings the trunk near the bar, the latissimi dorsi muscles become very prominent, for then they take their fixed points in the arms, and act on the trunk by carrying it upwards and forwards.

The trapezius and latissimus dorsi form by themselves the superficial layer of the back (Fig. 52). Among the numerous deep muscles of the dorsal region there are not any which are visible throughout their entire extent on the external model, but there are many which partly appear in the spaces which limit the borders of the trapezius, latissimus dorsi, and superficial muscles of the shoulder and neck. These spaces are two in number, one in the side of the neck, the other at the level of the lower half of the scapula.

The space on the lateral surface of the neck is bounded (Figs. 52 and 53) behind by the supero-anterior border of the trapezius; in front by the postero-external border of the sterno-cleido-mastoid.

This space, which represents a groove, long and very superficial, extending from the occipital region to the middle of the clavicle, has an inferior part (25, Fig. 53) covered over by the platysma muscle of the neck (to which we will return when considering the anterior region of the neck), and a superior part, in which we perceive a small part of two powerful muscles of the neck. 1st. The muscular fibres which we see (17, Fig. 52) directed obliquely from below upwards, and from within outwards towards the mastoid process, belong to the *splenius* muscle, which arises from the spinous processes of the last cervical, and four or five first dorsal, and ascends obliquely outwards to be attached partly to the transverse processes of the atlas and axis (splenius of the neck), and partly (splenius of the head) to the mastoid process of the temporal bone passing beneath the sterno-cleido-mastoid (16, Fig. 52). 2nd. The small fleshy triangle, which appears beneath the splenius, between that muscle and the superior part of the trapezius, belongs to a powerful muscle of the neck, called the *great complexus*, on account of the complicated arrangement of its fibres, a muscle concerning which we will only mention that it arises from the occipital, and descends obliquely outwards, to be attached by a series of digitations to the transverse processes of the five or six first dorsal vertebræ.

The space situated at the level of the lower part of the scapula is triangular in form (Figs. 52 and 53). When the arm is hanging beside the trunk of the three sides which bound it, the superior and internal border

is formed by the trapezius, the superior and external by the deltoid ; lastly, the inferior is formed by the superior border of the latissimus dorsi. The spinal border of the scapula appears towards the inner part of the triangular space, and divides it into two unequal parts, one internal, smaller, where a small part of the rhomboid muscle is seen ; the other external, more extended, where the prominence of the muscles of the infra-spinous fossa are marked, *the infra-spinatus teres minor*, and *teres major* muscles. We will only devote a few lines to the description of these muscles.

The *rhomboid muscle* arises from the spinous processes of the two last cervical, and four or five upper dorsal vertebræ ; the fibres are directed obliquely downwards and outwards, to be inserted into the spinal border of the scapula. It is only the lower fibres which appear on the model, at the internal part of the triangular space.

The *infra-spinatus muscle* (19, Fig. 52) rises from the whole of the infra-spinous fossa of the scapula, except the thick part of its axillary border. From this origin its fibres ascend and, converging, pass beneath the deltoid (Fig. 53), and are inserted by a short tendon into the great tuberosity of the humerus (the middle facet of this tuberosity).

The *teres minor muscle* (20, Fig. 52) rises from the upper part of the thick border of the infra-spinous fossa towards the axillary border of the scapula, then ascends parallel to the fibres of the infra-spinatus, passing with that muscle beneath the deltoid, to be inserted also into the great tuberosity of the humerus

(to the most inferior of the three facets on this tuberosity).

The *teres major* (6, Fig. 52 and 8, Fig. 53) arises from the lower part of the thick border of the infra-spinous fossa; it ascends upwards and outwards like the preceding muscles; but it soon leaves the teres minor (5, Fig. 54). Instead of remaining at the posterior part of the skeleton of the shoulder by passing beneath the deltoid, it joins the latissimus dorsi (Figs. 17, 18 and 49), and passes with it in front of the long portion of the triceps, finally blending with the latissimus dorsi, it is inserted into the internal lip of the bicipital groove of the humerus. The long portion of the triceps brachial is found, therefore, to pass between the teres minor, behind, and the superior part of the teres major, in front (Fig. 52, between 20 and 6).

The different muscles which we have seen, either entirely or in part, in the triangular space bounded by the trapezius, latissimus dorsi and deltoid, when the arm is hanging beside the trunk, become more visible when the arm is raised and arrives at the horizontal position (see the right side of the Fig. 52). The space in question becomes much lengthened from within outwards, and the deltoid leaves uncovered a greater extent of the infra-spinatus, teres major and minor; at the same time the scapula, by the elevation of the arm (page 51) being moved so that its inferior angle is drawn away from the vertebral column, the rhomboid muscle allows us to perceive a greater extent of its fibres, between the external border of the

trapezius and the superior border of the latissimus dorsi.

Although the other deep muscles of the back are not visible on the subject stripped of its skin, we must not leave the dorsal region without giving a few of the names of the powerful fleshy masses which occupy the lumbar region, on each side of the spinous processes, and which form two powerful muscular columns, causing a prominence beneath the aponeurosis of the latissimus dorsi (Fig. 52). This mass is formed by two muscles which are closely blended together at their inferior part (at the level of the loins), but become distinct at the last rib; they form an external muscle called the *sacro-lumbalis*, which is attached by a series of tendons to the angles of the ribs, and an internal muscle called the *longissimus dorsi* which, by a triple series of tendons, is attached to the sides, and to the transverse and spinous processes of the dorsal vertebræ. The action of the sacro-lumbalis and longissimus dorsi is to straighten the trunk, and maintain it when a burden is borne on the shoulders or back. It is for this reason that their common mass in the lower part of the back is so developed in men who usually carry heavy loads on the shoulders, and forms that powerful muscular mass of the loins, of which the prominence is visible beneath the skin and the aponeurosis of the latissimus dorsi (1, Fig. 52).

CHAPTER XVII.

MUSCLES OF THE SHOULDER AND ARM-PIT.

The *deltoid:* its form, thickness, different actions according to the fibres which contract; this muscle has not any *momentum.*—Muscular forms of the shoulder as a whole.—The muscles beneath (supra-spinatus and sub-scapularis).—*Serratus magnus muscle:* its relation with the arm-pit, its nine costal digitations, three only visible on the model; its action, it becomes very visible with each effort of the arm.—Forms of the region of the arm-pit, prominence of the coraco-brachialis muscle, peculiarities presented by the skin relations of the biceps and triceps with the arm-pit.

THE superior and external surface of the prominent part of the shoulder is formed by a single and powerful muscle, the *deltoid.* Beneath this are several deep muscles which fill up the corresponding fossæ of the scapula (supra-spinous and sub-scapularis). But, when the arm is raised and maintained in the horizontal position, the surface dips, at the inner part of the root of the arm, into a cavity, which is the pit corresponding to the external prominence of the shoulder; this cavity, called the *arm-pit* or *axillary space,* has for a roof the skeleton of the shoulder covered by the deltoid, and for its walls—in front, the great pectoral of which the plane joins the anterior border of the deltoid, and behind, the latissimus dorsi, of which the plane partly joins the posterior

border of the deltoid; lastly, on the inner side, a muscle applied to the wall of the thorax, the *serratus magnus*. Of the muscles which we have named, some have already been studied with regard to the muscular structure of the trunk (great pectoral and latissimus dorsi); the others, the *deltoid* and *serratus magnus*, we will study with the region of the shoulder and axillary space.

Deltoid muscle.—So called because it resembles a Greek delta in form, which is that of a triangle (of which the base is above and the apex below); this muscle is short, broad, thick, and shaped like half a cone to embrace the shoulder joint. It arises above from the external third of the anterior border of the clavicle (12, Fig. 49), from the acromio-clavicular articulation, from the convex border of the acromion, and from the entire extent of the posterior border of the spine of the scapula (18, Fig. 52). From this origin its fibres are directed downwards, the middle vertically, the anterior or clavicular downwards, and a little backwards, and the posterior a little obliquely forwards to be inserted by a short tendon into the external surface of the humerus on a rough V shaped groove, called the deltoid (page 56).

This muscle is very thick and forms coarse fibrous bands, which may be seen to contract separately beneath the skin, like distinct muscles, according as the movement effected requires specially the contraction of this or that portion of the muscle. The action of the deltoid is the elevation of the arm, separating it from the trunk and supporting it in the

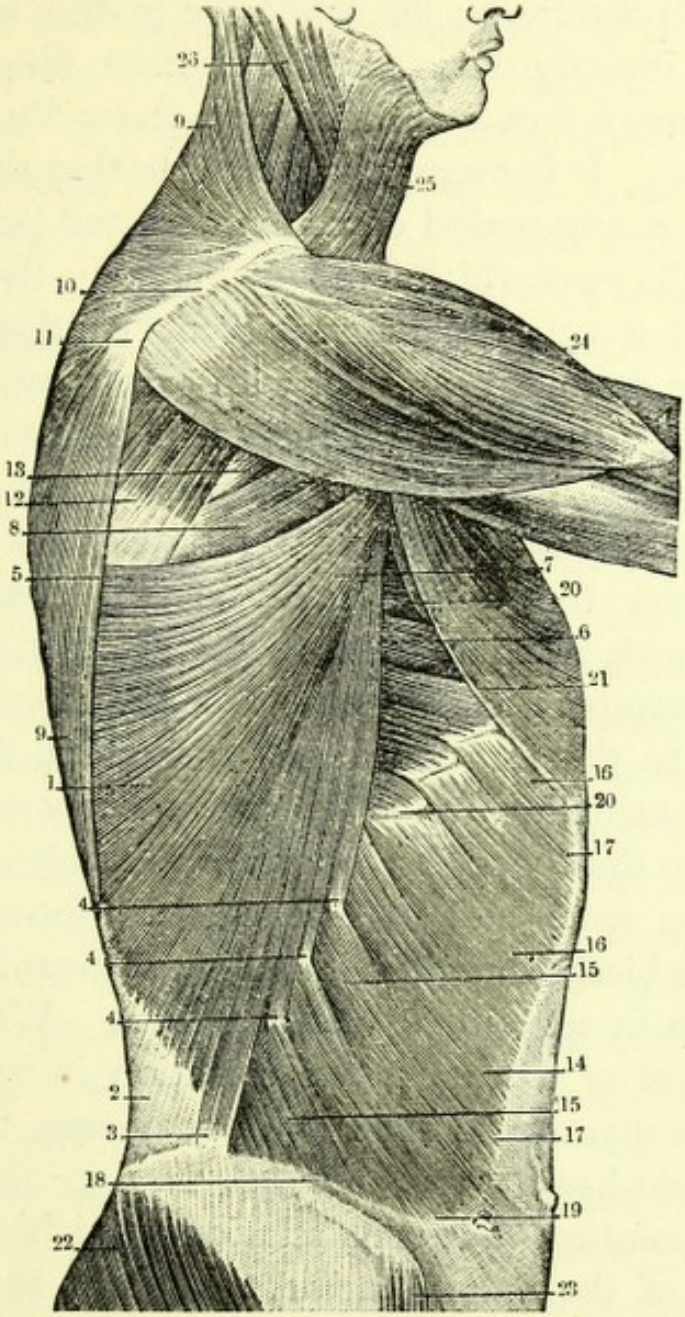

FIG. 53.

THE SUPERFICIAL MUSCLES OF THE SHOULDER AND THE LATERAL PORTION OF THE TRUNK.—1, the latissimus dorsi;—2, the lumbo-sacral aponeurosis;—3, 4, 4, the iliac and costal origins of the latissimus dorsi;—5, 6, 7, the upper portion of the latissimus dorsi;—8, the teres major;—9, 10, 11, the trapezius;—12, the infra-spinatus;—13, the teres minor;—14, 15, 16, the external oblique of the abdomen;—17, 18, the anterior and interior border of the same muscle;—19, its inferior internal angle rounded (see page 191);—20, 20, serratus magnus;—21, the pectoralis major;—22, the gluteus maximus;—23, the tensor of the *fascia lata*;—24, the deltoid;—25, the platysma myoides;—26 the sterno-cleido-mastoid.

horizontal direction; but while the middle fibres raise the arm directly outwards, the anterior fibres elevate it and carry it forwards, and the posterior fibres carry it backwards. It is necessary to remark that this muscle is never, at any period of action, directed perpendicularly on the lever which it moves—namely, the humerus on which it acts obliquely. Hence, although very thick, the deltoid cannot act with great power; therefore the attitude which consists in maintaining the arms raised horizontally, is one which requires great effort and quickly produces fatigue. In order to understand the unfavourable arrangement of the deltoid with relation to its humeral lever, it is sufficient to compare it with that which the biceps presents relative to the fore-arm, and to see that the biceps, which acts obliquely on the radius, becomes perpendicular to that bone in proportion as flexion is carried on in the arm; and when the elbow forms a right-angle the biceps muscle is found in the most favourable condition to act with all possible force. We term the *momentum* of a muscle the situation in which it is perpendicular to its lever; we may say, then, that the deltoid has not any momentum.

In pointing out the relations which the three borders of the deltoid present, we will sum up the various details of the muscular contour of the shoulder:—1st. The *superior border* of the deltoid, by its origin from the anterior border of the clavicle and the posterior border of the spine of the scapula, doubles the insertions of the trapezius which is attached to the other lip and border of the same bony parts (Fig.

53). The clavicle, acromion, and spine of the scapula form a species of bony intersection between the trapezius and deltoid; and in animals which have no clavicle, and in which the spine of the scapula is not well developed, the fibres of the deltoid and trapezius are directly continuous. We observe an arrangement of this nature in the horse. 2nd. The *anterior border* of the deltoid is separated from the corresponding border of the great pectoral by a linear interval, very narrow below, but a little broader above, where it forms a small triangle, of which the base corresponds to the middle of the clavicle (Fig. 50). This interval, which becomes visible during the contraction of the two muscles when we endeavour to raise the arm upwards and forwards while it is held behind, as in the act of drawing a load, gives passage to a vein called the *cephalic*, which under those circumstances becomes prominent and swollen. 3rd. The *posterior border* of the deltoid forms one of the sides of the triangular space which we have studied in the region of the back, at the level of the infra-spinous fossa (Figs. 52 and 53); therefore, under the posterior border, pass successively on the one hand the infra-spinatus and teres minor, which pass directly beneath the deltoid, and on the other the teres major and latissimus dorsi, which pass more deeply, separated from the deltoid by the long portion of the biceps (Fig. 54).

Two muscles of the shoulder remain to be mentioned which are not visible on the model, but we must at least name them in order to explain how

the fossæ of the skeleton of the shoulder are filled up. These are:—1st. The *supra-spinatus muscle* (11, Fig. 54), which occupies the supra-spinal fossa of the scapula, passes beneath the coraco-acromial arch, and is inserted into the great tuberosity of the humerus (to the upper facet on this great tuberosity). 2nd. The *subscapularis* muscle (19, Fig. 49), which occupies the subscapular fossa and is inserted into the lesser tuberosity of the humerus.

The *serratus magnus muscle* (14, Fig. 49; 5, Fig. 50; 2, Fig. 51; 20, Fig. 53).—This muscle, applied to the lateral part of the thorax, is hidden throughout the greater part of its extent by the scapula and muscular structures of the shoulder; but it becomes superficial at its lower part, in prominent indigitations —a series of details very characteristic in the contour of the lateral region of the thorax—and as, at the same time, it constitutes the internal wall of the armpit, we must describe it here in detail.

The serratus magnus arises from the whole of the spinal border of the scapula. From this origin its fibres radiate upwards, forwards, and downwards, and divide into nine interdigitations, which are inserted into the external surfaces of the nine first ribs. The body of the muscle, with the five or six upper digitations, is hidden by the great pectoral muscle (21, Fig. 53), and only its three or four last digitations (the most inferior) are visible on the inferior lateral part of the thorax between the borders of the great pectoral and the latissimus dorsi; they interlace with the superior digitations of the external oblique muscle of

the abdomen (20 and 16, Fig. 53). When the arm is hanging loosely, or slightly raised, we see at this level only three digitations of the serratus magnus; but when the arm is strongly elevated the great pectoral frequently leaves another uncovered.

The action of this muscle is to fix the scapula, drawing this bone downwards and forwards, while the rhomboid, on the other hand, draws it upwards and backwards. The fixing of the scapula being necessary to afford a fixed point to the muscles of the arm (particularly the biceps) whenever the upper limb accomplishes a powerful effort, explains why the inferior digitations of the serratus magnus become so clearly visible in the living model while contracting the muscles of the arm, as in wrestling, or lifting from the ground a heavy body, or in pushing back an adversary, &c.

The serratus magnus muscle forms the inner wall of the arm-pit, a cavity of which the anterior wall is represented by the great pectoral, and the posterior by the latissimus dorsi. This cavity forms a triangular pyramid; its summit, directed upwards, corresponds to the coracoid process of the scapula. On a dissected subject this cavity is open inferiorly, but in the living model it is closed by the skin which forms the base of the pyramid, and which, in passing from the inferior border of the great pectoral to the corresponding border of the latissimus dorsi, is depressed so as to ascend in the axillary space, into which it is drawn by the fibrous band forming what Gerdy has termed the *suspensory ligament* of the skin

of the arm-pit, and which is attached to the coracoid process, being continuous with the aponeurosis of the lesser pectoral.

In order to finish the description of this cavity we must say a few words concerning its borders, the folds which correspond to the lines of junction of its three walls; there is not anything particular to point out with regard to its anterior border (connecting the great pectoral with the external surface of the latissimus dorsi), nor of its posterior border (the attachment of the serratus magnus to the spinal border of the shoulder-blade); we need only speak of the external border which corresponds to the root of the arm. This border is comparatively thick, and corresponds to the upper part of the shaft of the humerus. It is formed by two muscles which descend from the scapula towards the anterior surface of the arm, the *biceps* and *coraco-brachialis*, which we will notice briefly. We will say, first of all, that the form of the coraco-brachialis is clearly visible beneath the skin of the base of the arm-pit, when the arm is strongly raised, as for example in a subject crucified, when it is the only muscle which raises the depressed skin in the arm-pit. We see that this skin is covered with hair more or less abundant, according to the individual, and it is a classic habit to omit this part of the hairy system in every representation of an elevated character; but the artist should be convinced by the study of anatomy that he should never conform to the habit of tracing on the skin of the hollow of the arm-pit a fanciful contour, since this skin is smooth

and regularly depressed, and that on its external part only is a fusiform muscular prominence, that of the coraco-brachialis, forming the origin of the plane of the anterior surface of the arm.

The triceps brachialis muscle, which, by its long portion, ascends to take its origin from the scapula, does not pass, like the biceps and coraco-brachialis, through the arm-pit, but proceeds through the middle of the posterior wall, since, as we have already said, it passes between the teres minor on the one hand, and the teres minor and latissimus dorsi on the other (Figs. 52 and 54).

CHAPTER XVIII.

MUSCLES OF THE ARM.

1st Anterior muscles: *Biceps*, its two heads; its fusiform body, its bifurcation below (aponeurotic expansion and tendon); its action (supinator and flexor of fore-arm); influence of its aponeurotic expansion on the contour of the fore-arm. — *Coraco-brachialis*, *brachialis anticus*. 2nd. Posterior muscle: *Triceps brachialis*, its three portions, flat surface formed by its inferior tendon; general contour of the posterior surface of the arm, action of triceps.— External forms of the arm, external and internal intermuscular grooves.

THE muscles of the arm form two distinct fleshy masses, one anterior formed by the *biceps*, which occupies the entire length of the arm, by the *coraco-brachialis* which occupies only the superior part; and lastly, by the *brachialis anticus*, which occupies the inferior part; and one posterior, formed by one muscle only, the *triceps brachialis*.

The *biceps* (12, Fig. 54, and 21, Fig. 50) is so called because it is double at its upper part, formed by two portions which are known by the names of the *long* and *short heads*. The long head of the biceps presents the form of a long tendon, which ascending in the bicipital groove of the humerus (page 56) arrives in the scapulo-humeral joint, and is inserted into the raised border of the glenoid cavity

of the scapula. The short head of the biceps has a less complex course, and proceeds to the summit of the coracoid process, where it is inserted beside the coraco-brachialis.

These two tendons (long and short head) descend in the external angle of the arm-pit, covered by the great pectoral (Fig. 50, page 191); a little above the lower border of this muscle the fleshy fibres succeed the tendinous and form two cylindrical bodies which descend and soon become united, at the level of the middle of the anterior surface of the arm, in one large muscular body, very marked in muscular subjects (12, Fig. 54). To this fleshy body succeeds, a little above the elbow joint, a flat tendon, at first broad, which

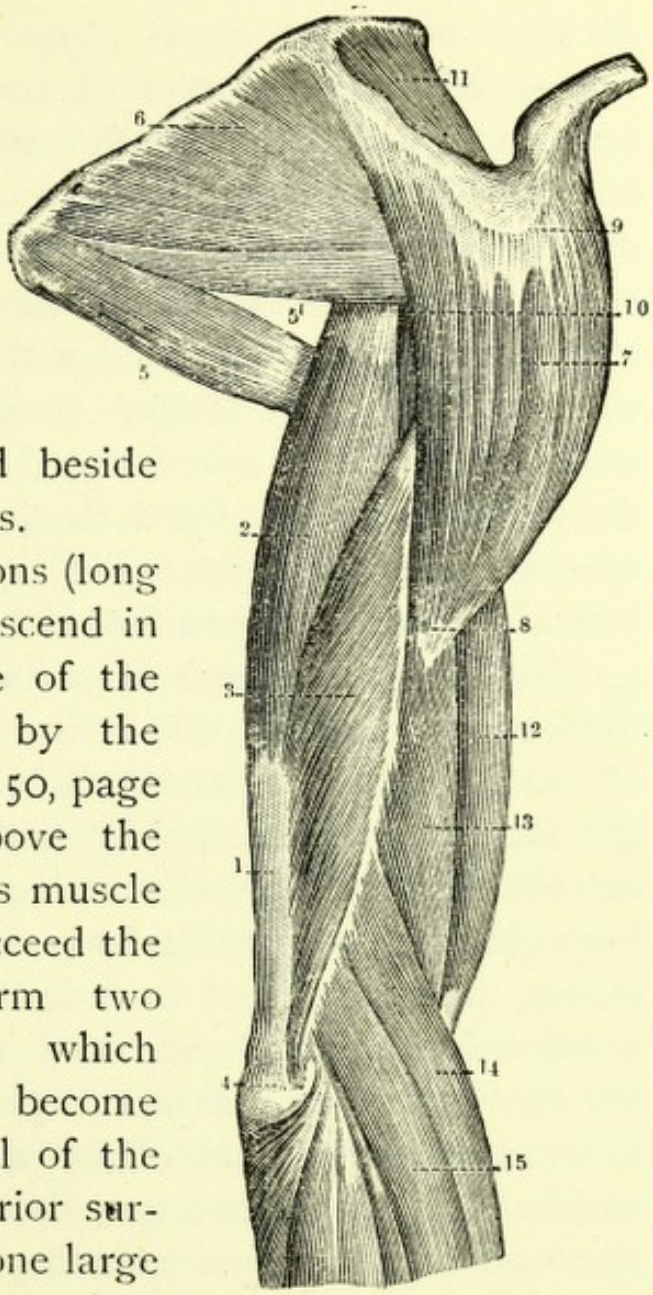

FIG. 54.

THE MUSCLES OF THE SHOULDER AND ARM (seen from the external side).—1, the triceps brachialis;—2, its long head;—3, its external head;—4, its attachment to the olecranon;—5, the teres major;—5', the teres minor;—6, the infra-spinatus;—7, 8, 9, 10, the deltoid;—11, the supra-spinatus;—12, the biceps brachialis;—13, the brachialis anticus;—14, the supinator longus;—15, extensor carpi radialis longior.

divides into two parts, one aponeurotic, called the *aponeurotic expansion* of the biceps; the other tendonous, called the inferior proper tendon of the biceps. The aponeurotic expansion (2, Fig. 55) is directed downwards and inwards, passes over the common mass of the flexor muscles of the fore-arm, and soon becomes blended with the aponeurosis of these muscles; the tendon proper (3, Fig. 53) dips down between the anterior and external muscles of the fore-arm, and is fixed to the bicipital tuberosity of the radius (page 65, and Fig. 13), upon which it turns to be inserted into the posterior part.

The biceps muscle is essentially the flexor of the fore-arm on the arm, this action is evident, known to all, and it is useless to dwell on it, except to recall the fact, as we have already said with regard to the deltoid, that the biceps, in acting on the fore-arm is found inserted perpendicularly on the lever which it moves, and that it is then in the most favourable position for the development of all its strength. But the contraction of the biceps produces at the same time, with the flexion of the elbow, two effects to which it is important to direct attention—1st. If the fore-arm is in pronation the tendon of the biceps is clearly twisted round the upper part of the radius, since it is inserted into the posterior part of this tuberosity; therefore, the first effect produced by its contraction is a rotation of the radius outwards, a movement of supination; the biceps is, therefore, a supinator, and one of the most powerful. 2nd. During the contraction of the biceps, its aponeurotic expan-

sion is tense, and strongly binds down the mass of the flexor muscles of the fore-arm; hence it marks on the inner fleshy part of this portion of the limb, two fingers' breadth below the internal condyloid ridge, a distinct furrow; the contraction of the biceps produces, therefore, in the fore-arm, some very remarkable changes of form.

The changes of form, which at the level of the arm, accompany the contraction of the biceps, are well known, and it is sufficient to recall the fact, that the fleshy body of this fusiform muscle is lengthened in the state of repose, becoming short and globular during the contraction. Nothing is more striking, nor gives a better idea of the change of form in a muscle during contraction, than to examine the biceps in a model, who brings it gradually into action flexing the fore-arm on the arm. We see, then, on the anterior surface of the arm a species of fleshy ball becoming more and more clearly marked, which swells up and contracts at the same time, so that it seems to mount up towards the upper part of the arm, towards the inferior border of the great pectoral.

The *coraco-brachialis muscle* forms a small fusiform fleshy mass, occupying the upper part of the inner surface of the arm. It arises on the one hand from the coracoid process of the scapula (beside the short head of the biceps), and is inserted into the middle of the internal border of the humerus. When the arm is hanging loosely the lower half only of this muscle is visible on the subject, and its prominence is blended with that of the biceps, while its superior half is

hidden within the axillary space, covered by the great pectoral, but becomes visible beneath the skin of the arm-pit when the arms are raised, as in the position on the cross, and we have already dwelt upon the contour which the fusiform muscular body of this muscle presents at the external part of axillary space. When the coraco-brachialis contracts, its form becomes more prominent, like that of every muscle in contraction; but it is not more visible on this account, for this muscle, which draws the arm to the thorax against which it is applied, conceals by this movement the region in which its prominence is marked.

The *brachialis anticus muscle* (13, Fig. 54, and 4, 4, Fig. 55).—Situated beneath the lower half of the biceps, which overlaps it on each side, this muscle covers the corresponding part of the anterior surface of the humerus, to which it is attached. Arising at the level of the deltoid impression, the fleshy fibres descend almost to the level of the elbow where they are replaced by a flat tendon, which is inserted into the base of the coronoid process of the ulna. As the ulna does not present any of the lateral movements which constitute supination and pronation, the brachialis anticus is simply a flexor of the fore-arm, and we see it, when this movement is forcibly accomplished, swell up on each side of the lower part of the biceps.

Triceps brachialis.—This muscle (21, 22, Fig. 52, 1, 2, 3, Fig. 54), which forms alone the entire muscular structure of the posterior surface of the arm, has been called the *triceps*, because it is composed of three

portions, separated above, united below ; one central or median called the *long portion or head*, and two lateral distinguished as the *external* and *internal portions* or *heads*. The *long head* (2, Fig. 54) forming a fleshy body thick and fusiform, arises by a short tendon from the upper part of axillary border of the scapula immediately below the glenoid cavity, and passes between the teres major and minor muscles (page 213). At the level of the junction of the middle with the lower third of the arm, this fleshy body terminates at its upper part in a flat tendon (1, Figs. 54 and 56) broad and triangular, which receives the other two portions of the muscle on each of its borders. The *external head* (3, Fig. 54) arises from the upper part of the posterior surface of the humerus (above and to the outer side of the groove of torsion), and is directed obliquely downwards and inwards to be attached to the external border of the flat tendon, accompanying this muscle almost to the elbow. Lastly, the *internal head* (22, Fig 52) arises from the lower part of the posterior surface of the humerus (below and to the inner side of the groove of torsion), and is attached to the internal border of the inferior common tendon. This tendon is inserted (4, Fig. 54) into the posterior surface of the olecranon (of the ulna).

The form of the triceps, or posterior surface of the arm, is caused by the presence of the inferior common tendon which, forming a large flat surface below, becomes narrow and pointed towards its upper part. This tendon or the flat surface which it forms is overlapped

on each side by the prominence of the inner and outer heads. Above, on the upper two-thirds of the posterior surface of the arm, two fleshy bodies are seen side by side, the external formed by the outer head, the internal by the long portion (the inner head not ascending upwards except by a few fibres, which at this level unite their forms with that of the long portion). These various details, viz., the tendinous flat surface above the olecranon, the muscular prominences which bound it on each side, and the two fleshy bodies which ascend above it—become visible in a marked degree when the subject forcibly extends the fore-arm on the arm, as in struggling against any resistance which causes the position of flexion to be maintained. It is hardly necessary to say that the triceps is essentially the extensor muscle of the fore-arm on the arm. It is not only for the purpose of a regular enumeration, but also with regard to the anatomical interpretation of their external forms, that we have classed the muscles of the arm as anterior and posterior, as on each side of the arm, both its internal and external borders, a groove runs which separates the anterior from the posterior muscles. In each of these grooves is a fibrous partition called the internal and external intermuscular aponeurosis, which is inserted by the corresponding borders to the humerus, and on the other side to the general aponeurotic covering of the limb ; therefore this aponeurosis is slightly drawn towards the humerus, along two vertical lines corresponding to the intermuscular partition, and on the external form two grooves clearly exist, each

corresponding to one of the intervals between the anterior and posterior muscles.

The internal groove commences at the inferior extremity of the coraco-brachialis, and descends almost to the inner condyle. Above it is faintly marked, because the numerous nerves and vessels surrounded by cellular tissue fill up the intermuscular space at this level ; below it spreads out, and tends to be confounded with the form of the internal part of the brachialis anticus.

The external groove (Fig. 54) is short. It begins at the level of the lower extremity of the deltoid and does not descend to the external condyle, because the first muscles of the external region of the fore-arm arise (the *supinator longus*, 14, Fig. 54) almost from the lower part of the external border of the humerus, so that this groove is filled up by these muscles where they curve forwards towards the bend of the elbow.

CHAPTER XIX.

MUSCLES OF THE FORE-ARM.

Division into four groups:—1st. The *superficial anterior muscles,* or *those arising from the inner condyle:* pronator teres, flexor carp radialis, palmaris longus, and flexor carpi ulnaris. 2nd. The *anterior deep muscles* (flexors of the fingers and pronator quadratus). 3rd. *External muscles:* supinator longus (importance with regard to the forms of the external region of elbow); the extensor carpi radialis, longior, and brevior; the supinator brevis. 4th. The *posterior superficial muscles:* the extensor communis, extensor minimi digiti, extensor carpi ulnaris, and the anconeus.

Muscles of the fore-arm.—The two bones of the fore-arm are covered by a series of muscles with fleshy bodies, generally fusiform, terminating inferiorily in tendons frequently very long, which become prominent in the region of the wrist. Some of these muscles move the fore-arm on the arm, or the radius on the ulna, but the action of the greater number is to move the hand on the fore-arm and the different segments of the fingers on each other. These muscles are divided into five regions, each composed of four muscles, making the total number of muscles in the arm twenty. But we must dwell upon the superficial muscles, a short mention being sufficient for the deeper ones. We distinguish:—1st. An anterior superficial layer, of which each muscle will be studied; 2nd. An anterior deep layer, which we will rapidly

glance at; 3rd. An external layer; 4th. A superficial posterior layer, which we must view in detail; and 5th. A posterior deep layer, respecting which we shall only say sufficient to enable the reader to understand the shape of the wrist formed by the corresponding tendons.

I. The *anterior superficial muscles.*—All these muscles arise by a common muscular mass from the *internal condyle*, into which they are inserted without exceeding the level, so that at the inner side of the elbow, contrary to what takes place on the outer side, the muscular structure of the fore-arm does not ascend on the corresponding side of the arm. If from the inner condyle we draw four lines, of which the first goes towards the middle of the radius, the second towards the outer side of the hand, the third towards the middle, and the fourth towards the inner border of the hand; these four lines, of which the first is very oblique and the others gradually approach the vertical, will give us the direction of each of these four anterior superficial muscles of the fore-arm, which are, in the order of the lines, from the most external to the internal, the *pronator teres*, the *flexor carpi radialis*, the *palmaris longus*, and the *flexor carpi ulnaris.*

The *pronator teres* (6, Fig. 55) is fleshy throughout the entire extent in which it is visible on the model; arising from the internal condyle, it is directed obliquely downwards and outwards, and disappears beneath the external muscles of the fore-arm (beneath the supinator longus) and arrives on

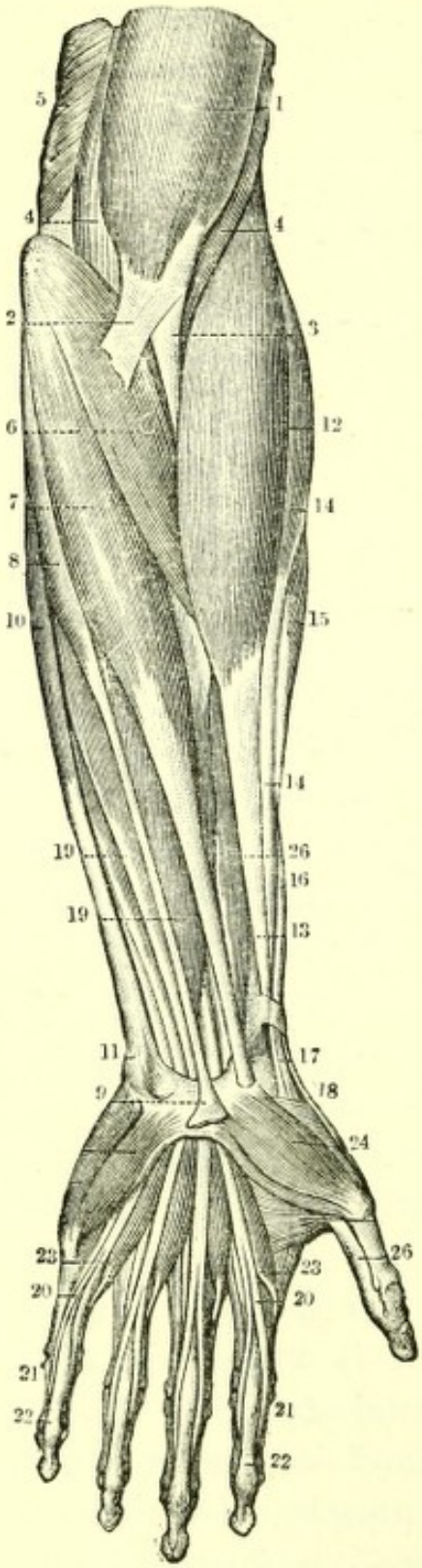

the radius around which it is slightly twisted, to be inserted into the middle of its external surface (impression for the pronator teres (page 65). Its contraction turns the radius forward and inwards, producing pronation. This muscle forms the external side, very oblique, of a triangular pit, of which the outer side is formed by the supinator longus (12, Fig. 55). In this pit (pit of the elbow) the biceps dips down (3, Fig. 55) with the brachialis anticus (4, 4, Fig. 55) to be inserted into the bones of the fore-arm. The upper part of the pronator teres is crossed by the aponeurotic expansion of the biceps (2, Fig. 55), and we have already

FIG. 55.—THE ANTERIOR MUSCLES OF THE LEFT FORE-ARM.—1, the biceps brachialis;—2, its aponeurotic expansion;—3, its tendon;—4, 4, brachialis anticus;—5, the internal head of the triceps;—6, pronator radii teres;—7, flexor carpi radialis;—8, 9, palmaris longus;—10, flexor carpi ulnaris;—11, its attachment to the pisiform bone;—12, 13, supinator longus;—14 and 15, the extensor carpi radialis, longior, and brevior;—16 the abductor longus pollicis;—17, its tendon;—18, tendon of extensor longus pollicis;—19, 20, 21, the superficial flexor of the fingers and its tendons;—22, tendons of the deep flexors;—23, 23, the lumbricales;—24, abductor brevis pollicis;—26, flexor longus pollicis.

dwelt on the particulars of the form which is the result of this arrangement.

The *flexor carpi radialis* (7, Fig. 55) arises from the inner condyle, forms a fusiform fleshy body, descending obliquely, which at the level of the middle of the fore-arm is replaced by a tendon which gradually becomes narrower, gains the external part of the wrist (on a level with the base of the eminence at the base of the thumb), and then disappears beneath the annular ligament of the carpus, lying in a groove on the anterior surface of the trapezium, to be inserted into the base of the metacarpal bone of the index finger. This muscle flexes the hand on the fore-arm ; when it contracts, its tendon becomes very prominent and raises the skin at the lower part of the anterior surface of the fore-arm ; it forms the first tendinous prominence that we meet in this level in passing from the radial to the ulnar border.

The *palmaris longus* (8, 9, Fig. 55) is a miniature reproduction of the preceding muscle ; arising from the internal condyle, it presents at first a short fusiform fleshy body (8) to which soon succeeds a long slender tendon descending almost vertically towards the middle of the wrist, where it terminates by being inserted into the annular ligament of the carpus (9, Fig. 55) ; it flexes the hand on the fore-arm, and, like the preceding, its tendon forms below a well-marked prominence situated in the middle line on the inner side of the tendon of the preceding muscle. In some subjects this muscle is absent, and it is frequently subject to important variations of form.

The *flexor ulnaris* (10, 11, Fig. 55) arises not only from the inner condyle like the three preceding muscles, but also (18, Fig. 56) from the corresponding border of the olecranon and the internal border of the ulna ; it descends vertically beside the ulna, and presents this remarkable peculiarity that the fleshy fibres accompany the tendon to its point of insertion, which is the pisiform bone of the carpus (11, Fig. 55). Hence its form is not marked by a prominence such as those produced by the tendons of the preceding muscles, and this muscle helps to give a rounded form to the whole extent of the internal border of the fore-arm. It is a flexor of the hand, which it at the same time inclines towards the internal border of the fore-arm.

II. *Anterior deep muscles.*—With regard to form these muscles constitute a fleshy mass lying beneath the preceding, and terminate below in numerous tendons, which the muscular fibres accompany low down ; the tendons and lower part of the muscular fibres appear on the model in the bottom of the grooves between the tendon of the flexor radialis and that of the palmaris longus, and between the tendons of the palmaris and the flexor ulnaris (19, 19, Fig. 55). Lower down in the hand the tendons of these muscles lie in the anterior groove of the carpus, formed into a canal by the corresponding annular ligament, and are inserted into the phalanges of the fingers, presenting peculiar features which we will rapidly point out in enumerating these muscles.

These are, 1st, the *flexor digitorum sublimis* (19, Fig.

55), which divides below into four tendons, one for each finger (except the thumb); 2nd, the *flexor digitorum profundus*, which also divides into four tendons, one for each finger (except the thumb); therefore, at the base of the anterior surface of each finger we see two tendons—one superficial (23, Fig. 55), and the other deep. The first presents at the level of the first phalanx (20, Fig. 55) a slit or button-hole, through which the second passes; owing to this arrangement the tendon of the deep flexor is inserted into base of the third phalanx (22, Fig. 55); while the superficial flexor is inserted into the base of the second (21, Fig. 55). There is a flexor muscle for each of these phalanges (the first phalanges of the fingers have special flexors, the small *lumbricales muscles* of the palm of the hand).

3rd. The *flexor longus pollicis* (26, Fig. 55), the tendon of which is inserted into the base of the second or last phalanx of the thumb; and 4th, the *pronator quadratus muscle*, a deep fleshy mass, disposed in a different manner to the preceding muscles, which must be raised in order to see it. This muscle is formed by transverse fibres placed in the whole of the lower part of the fore-arm, and passing from the external border of the radius to the internal border of the ulna; its contraction brings these two bones closer to each other, and consequently produces pronation, since the radius cannot be brought near the ulna without turning round it, from the position of supination to that of pronation.

III. *External muscles.*—These form a fleshy mass

which ascends on the inferior third of the external border of the humerus (Fig. 54, page 215) and descends along the external border of the radius.

Of these four muscles, one only is visible on the model throughout its entire extent—viz., 1st, the *supinator longus* (14, Fig. 54; 12, 13, Fig. 55), which arises from the external border of the humerus, between the brachialis anticus and the outer head of the triceps, so that on this side the muscular structures of the fore-arm ascend on the arm almost midway to the insertion of the deltoid. The supinator longus enlarges as it descends, so that it presents its greatest size at the level of the external condyle, the prominence of which it completely conceals. It forms the external vertical boundary (page 224) of the triangular pit of the bend of the elbow; then, a little below the point where it passes the pronator teres, the fleshy fibres are replaced by a long tendon which lies on the radius, and (13, Fig. 55) is inserted into the base of the styloid process of that bone. Notwithstanding its name, this muscle is not essentially a supinator; it acts thus only when the fore-arm is in a position of forced pronation, and it keeps it in a position between supination and pronation. Its principal action is the flexion of the fore-arm on the arm, and in this movement its form is clearly shown externally in the form of a prominent band, which rises from the arm, and forms, on the antero-external part of the elbow, a strong fleshy mass, filling up on this side the hollow of the angle produced by the flexion of the fore-arm on the arm. The supinator longus is the most

important of the muscles of the fore-arm with regard to the part it takes in the form of this region.

The two next muscles (14 and 15, Fig. 55) are partly hidden by the preceding; they are the *radialis* muscles (2 and 3), distinguished as the *extensor carpi radialis longior* and *brevior* (15, Fig. 54), which arise from the internal condyle and the lower part of the external border of the humerus, and present a thick fleshy body (3 and 5, Fig. 56), which increases the prominence of the supinator longus, and helps to conceal the inner condyle. At about the same level as in the supinator longus, a tendon succeeds the fleshy body of each of these muscles, inclines a little backward (Fig. 56), and, having been crossed by the *extensor ossis metacarpi pollicis* and the *extensor primi internodii pollicis* muscles (7 and 8, Fig. 56, and the posterior deep muscles of the fore-arm), arrives at the dorsal surface of the wrist, and is inserted, in the case of the radialis longior, into the base of the metacarpal bone of the index finger (dorsal surface), and in that of the radialis brevior into the base of the metacarpal bone of the middle finger (6, Fig. 56).

4th. On the upper part of the radius is a small deep muscle, which does not show on the model, and which we mention here only to point out that its presence increases the prominence of the muscular mass on the outer side of the elbow; this is the *supinator brevis*, formed by fibres which are rolled round the radius, so as to turn this bone from without inwards, thus producing supination.

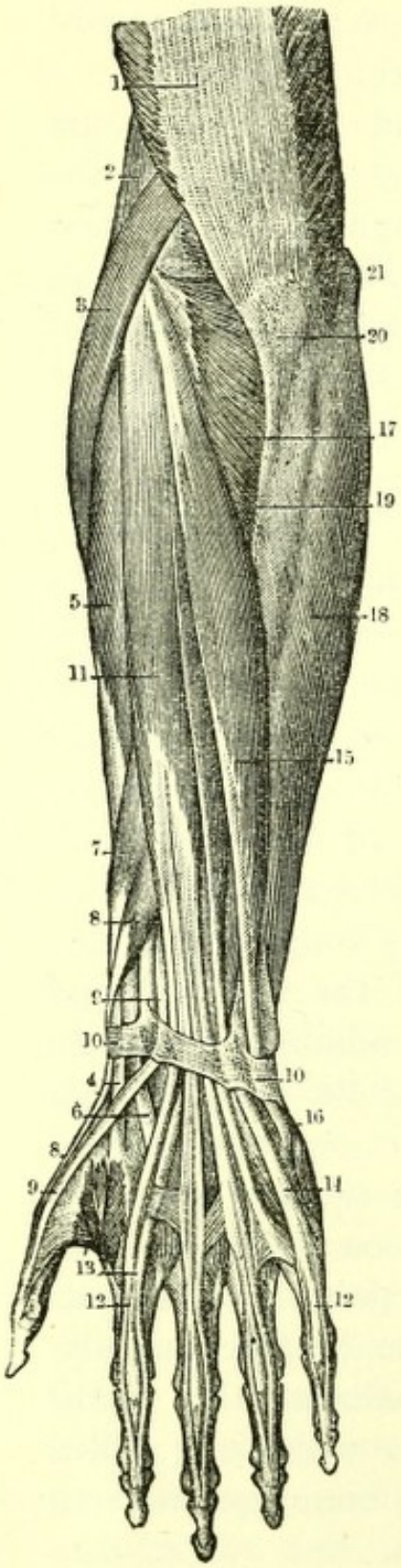

IV. The *posterior superficial muscles* (Fig. 56).—These four muscles arise from the external condyle, to which they are attached by a common tendon; from this origin they are directed downwards, the first almost vertically, the last (*anconeus*) very obliquely backwards and inwards. They are the *extensor communis digitorum*, the *extensor minimi digiti*, the *extensor carpi ulnaris*, and the *anconeus*.

1st. The *extensor communis digitorum* (11, Fig 56), arising from the external condyle, forms a long fusiform fleshy body, to which succeeds, at the inferior third of the posterior surface of the fore-arm, a tendon which soon sub-divides into four ten-

FIG. 56.—THE POSTERIOR MUSCLES OF THE LEFT FORE-ARM.—1, the tendon of triceps brachialis;—2, supinator longus;—3 and 4, extensor carpi radialis longior;—5 and 6, extensor carpi radialis brevior;—7 and 8, abductor longus pollicis and extensor brevis pollicis;—9, 9, the extensor longus pollicis;—10, 10, the angular ligament of the wrist dorsal aspect;—11, 12, the extensor communis digitorum and its tendons;—13, the tendon of the extensor in dicis;—14, the tendon of the extensor minimi digiti;—15, 16, extensor carpi ulnaris;—17, anconeus;—18, the flexor carpi ulnaris;—19, the posterior border of the ulna;—20, olecranon;—21, the inner condyle.

dinous cords, which remain together until they have passed a groove situated in the centre of the inferior extremity of the radius, but which separate when they reach the dorsal surface of the wrist, diverging so as to be attached to each of the four fingers. On the dorsal surface of the first phalanx of each finger (12, Fig. 56) the extensor tendon divides into three slips, the central one inserted into the base of the second phalanx, while the two lateral join again to be inserted into the base of the third phalanx.

2nd. The *extensor minimi digiti* is merely a small bundle of fleshy fibres from the preceding muscle, more or less distinctly detached from its inner border, but continued by a distinct tendon, which passes through a fibrous groove in the posterior part of the radio-ulnar articulation, and from the wrist is directed towards the posterior surface of the little finger (14, Fig. 56), at which point, becoming united with the tendinous fasciculi from the common tendon furnished to the same finger, it presents the arrangement in three slips (12) already described.

3rd. The *extensor carpi ulnaris* (15, Fig. 56).—Its fusiform fleshy body arises from the external condyle and is directed obliquely downwards and inwards, reaching the posterior surface of the ulna, into which it is inserted, and is replaced by a tendon at the inferior fourth of that bone (15, Fig. 56). This tendon passes in a groove on the posterior surface of the ulna (10, Fig. 56) and at the inner part of the dorsal surface of the carpus, it terminates almost immediately

by being inserted into the base of the metacarpal bone of the little finger (16, Fig. 56).

These three muscles are extensors of the fingers and hand. If we examine a living model which has the arm folded on the trunk, the dorsal surface of the fore-arm being turned forwards, and which quickly moves the fingers and hand, we see clearly the movements of the fingers marked by muscular movements in the upper two-thirds of the posterior surface of the fore-arm. We can, by following the prominences of these muscles in contraction, clearly recognise their fusiform bodies.

4th. The *anconeus* occupies the superior part of the posterior surface of the fore-arm, as its name indicates (*ἀγκών*, olecranon, elbow), it is a muscle of the region of the elbow; it forms (17, Fig. 56) a triangular fleshy mass, of which the apex is attached to the external condyle, and the base is inserted into the external surface of the olecranon, and corresponding part of the ulna (19, Fig. 56). As the ulna does not possess the movements of rotation, or from side to side, but only flexion and extension of the humerus, the anconeus situated behind the elbow joint has no other action than that of extending the fore-arm on the arm. When this movement is forcibly produced, we see the anconeus clearly marked by a triangular prominence, of which the upper border, the shortest, is united with the prominence of the outer head of the triceps; and we have already mentioned the anatomical fact that the inferior portion of the triceps is directly continuous in the fore-arm with the anconeus.

CHAPTER XX.

MUSCLES OF THE FORE-ARM.

The posterior deep muscles of the fore-arm, their tendons at the level of the wrist (*anatomical snuff-box*).—Muscles of the hand :—1st. Muscles of the thumb, or *thenar eminence* (abductor brevis of thumb). 2nd. Muscles of the little finger, or *hypothenar eminence* (palmaris brevis, abductor minimi digiti). 3rd. Muscles of the middle palmar region (lumbricales and interossei).

THE deep posterior muscles of the fore-arm are important only, with regard to external forms, in the arrangement of their tendons in the wrist and hand; for this reason we will describe them with the muscular structures of the hand and fingers.

As in the other regions of the fore-arm, we find in the deep posterior layer, four muscles. The fleshy bodies of these four small muscles are completely hidden beneath the posterior superficial muscles; but their tendons, at least those of the first three, emerge beneath the external border of the common extensor of the fingers, and their form is shown (7 and 8, Fig. 56) by details of great importance on the outer side of the dorsal aspect of the wrist. These four muscles, proceeding from the most external to the internal are—the *extensor ossis metacarpi pollicis*, the *extensor primi internodii pollicis*, the *extensor secundi internodii pollicis*, and the *extensor indicis*.

The two first (7 and 8, Fig. 56), the *extensor ossis metacarpis* (7), and the *extensor primi internodii pollicis* (8), must be described together, as their fleshy bodies and tendons are placed together and are almost united throughout the greater extent of their course. These two muscles emerge at about the commencement of the inferior third of the outer border of the common extensor of the fingers; and their fleshy bodies form at this point (namely, the junction of the posterior surface with the external border of the fore-arm) an oblong prominence, which is soon succeeded by a double tendon, crossing the radial tendons to be directed towards the external surface of the styloid process of the radius, where it passes through a groove which the dorsal annular ligament of the carpus (10) forms into a canal. At the external border of the carpus these two tendons form a prominence, well marked beneath the skin which they elevate when we strongly separate the thumb from the other fingers. Finally, at the base of the metacarpal bone of the thumb these tendons separate, one—that of the *extensor ossis metacarpi pollicis* to be inserted into the base of the metacarpal bone, while the other—that of the *extensor primi internodii pollicis*, is inserted into the base of the first phalanx of the thumb (8, at the level of the thumb, Fig. 56).

The *extensor primi internodii pollicis* (9, Fig. 56), emerges like the preceding on the outer side of the common extensor, but lower down; its tendon only appears at this point, and is divided almost vertically

downwards to pass, on the posterior surface of the inferior extremity of the radius, into a small groove. From the dorsal surface of the wrist it is directed obliquely outwards, crossing only the tendons of the radial muscles, and reaches the base of the metacarpal bone of the thumb, where it is placed beside the tendon of the extensor primi internodii, and, descending lower than this tendon, is inserted into the second or last phalanx of the thumb (9, Fig. 56).

The two tendons of the extensor ossis metacarpis and the primi internodii pollicis on the one side, and the extensor secundi internodii on the other, form on the outer part of the dorsal region of the wrist a triangular figure, of which the apex corresponds to the superior extremity of the thumb, and the base to the inferior extremity of the radius. When we separate the thumb strongly from the index finger, that is to say, when we contract the three small muscles which we have been studying, the corresponding tendons mark the borders of this triangle in the form of prominent cords, between which is a deep triangular depression; to this depression we give the name of the *anatomical snuff-box* (4, Fig. 56).

The *extensor indicis* is not visible on the model; it is deeply situated beneath the common extensor of the fingers, and terminates in a tendon (13, Fig. 56) which unites with the tendinous fibres from the common extensor to the index finger. It is to this muscle that the second finger of the hand owes its power of extension independent of the other fingers, and of

performing the functions which have given it the name of the index or indicating finger.

Muscles of the hand.—The numerous muscles belonging to the hand form an interesting study with regard to the mechanism of the multiple and delicate movements of the fingers, but as the various details of their complex arrangement do not show very plainly on the external form of the model we will confine our study of them to an enumeration of their principal points.

The dorsal region of the hand (Fig. 56) does not possess any muscular fleshy bodies, but only presents the tendons belonging to the muscles of the fore-arm. On the other hand, the anterior or palmar region of the hand possesses, beside the tendons which transmit the action of the muscular bodies of the fore-arm, numerous small muscles, which are divided into three groups :—1st, an external group, belonging to the thumb, forming at the level of the first metacarpal bone, the fleshy prominence known as the *thenar eminence;* 2nd, an internal group, belonging to the little finger, forming the *hypothenar eminence;* 3rd, a middle group or palmar proper, formed by small muscles belonging to the other fingers.

1st. *The thenar eminence* (24, 25, Fig. 55) is in the form of a long ovoid, with the large superior extremity corresponding to the bones of the carpus, and the smaller inferior extremity corresponding to the base of the first phalanx of the thumb. It is formed by four muscles, namely, the *abductor pollicis* (24, Fig. 55), which proceeds from the scaphoid to the outer side of the first phalanx of the thumb; the *opponens*

pollicis, which arises from the trapezium, and is inserted into the entire length of the outer border of the metacarpal bone, so that its contraction draws all the thumb (phalanges and metacarpal bone) towards the palm of the hand, and thus opposes it to the other fingers; the *flexor brevis pollicis*, which proceeds from the trapezium to the base of the first phalanx; and finally, the *abductor pollicis* (25, Fig. 55), a muscle remarkable for its arrangement, for it arises from the middle of the palm of the hand, from the anterior surface of the third metacarpal bone, and forming a comparatively broad fleshy body, which fills up the space between the first and second metacarpal bones, is inserted into the inner side of the base of the first phalanx of the thumb.

2nd. The *hypothenar eminence* is long and elliptical in form; it is at first covered by a small muscle which is not shown by any external prominence but only by the folds which it marks in the skin during its contraction; this is the *palmaris brevis*, and is formed of transverse fibres, which, arising from the anterior ligament of the carpus, are inserted into the deep surface of the skin on the internal border of the hand; the contraction of these fibres draws the skin of this part inwards, so that it forms an irregular vertical furrow, while the prominence of the skin of the upper part of the hypothenar eminence becomes more clearly marked. The hypothenar eminence itself is formed by three small muscles vertically arranged beside the fifth metacarpal bone, and which are, 1, the *abductor minimi digiti* (28,

Fig. 55), passing from the pisiform bone to the outer side of the first phalanx of the little finger; 2, the *flexor brevis* (27, Fig. 55) of the little finger, passing from the prominence of the unciform bone to the inner side of the same phalanx; and lastly, 3, the *opponens minimi digiti*, arising from the unciform bone and inserted into the entire length of the fifth metacarpal bone, so that its contraction slightly draws on the whole of the little finger, and opposes it to a certain degree to the thumb.

3rd. The muscles of the middle region of the palm of the hand are of two sorts. Some are arranged between the tendons of the flexor muscles (see anterior deep muscles of the fore-arm, page 227) and form small fleshy bodies, which have been compared to the form of a worm—hence their name of *lumbricales*. The others are arranged in the spaces between the metacarpal bones—hence their name of interosseous muscles.

The *lumbricales muscles*, as the Figure 55 shows (23, 23), are four in number—one for each of the four fingers. Their superior extremity is attached to the corresponding deep flexor tendon; from this origin they descend obliquely to reach the external border of the first phalanx of each finger; at this level the tendon of the muscle is inserted, consequently it is a flexor, so that we find a flexor muscle for each of the three phalanxes (page 227). The tendon of the lumbricalis is prolonged on the back of the finger, where it unites with one of the lateral slips of the corresponding extensor tendon, with which it

proceeds to the dorsal surface of the third phalanx, to the extension of which it contributes.

The *interosseous muscles* are two in number in each metacarpal space; one, the stronger of the two, occupies principally the dorsal part of the space—hence its name of the *dorsal interosseous;* the other, smaller, called the *palmer interosseous,* because it occupies only the palmar part of the metacarpal space. These muscles are attached to the sides of the first phalanxes of the fingers by their inferior extremities. Their arrangement, into the details of which we will not enter here, is such that the dorsal interossei serve to separate the fingers from each other, while the palmar serve to bring them together.

CHAPTER XXI.

MUSCLES OF THE PELVIS AND THIGH.

Gluteus maximus, its thickness, its form (four borders, of which the inferior is thick and free), its relations with the great trochanter *gluteus medius*. — The subjacent muscles as a whole (gluteus minimus, pyriformis, &c.).—Muscles of the thigh: 1st, External region, *tensor fascia lata* (*vagina femoris*), its importance with regard to external forms, aponeurosis of *fascia lata*; 2nd, Anterior region, *sartorious*, peculiarities of this muscle during contraction, *triceps cruralis* (rectus, vastus internus, vastus externus); 3rd, Internal region, mass of the *adductors*; 4th, Posterior region (biceps, semi-tendinosus, and semi-membranosus).

Muscles of the pelvis.—The muscles of the pelvis visible on the model are all situated on the posterior surface of that part of the skeleton, and form the *gluteal region.* In front the anterior wall of the abdomen, descending to the crural arch and pubis (Fig. 50, page 191), conceals the muscles which proceed from the interior of the pelvis towards the thigh —muscles of which a short sketch will be given, with the fleshy masses of the anterior crural region.

Of the muscles of the gluteal region two only are superficial and well marked on the model—viz., the *gluteus maximus* and *gluteus medius.*

The *gluteus maximus muscle* (Fig. 52, page 197) is the largest and thickest of all the muscles of the body. It is composed of large fleshy fibres obliquely directed

from the sacro-iliac region towards the upper part of the femur. Its fibres arise from the posterior extremity of the crest of the ilium (4, Fig. 23, page 96), and, by an aponeurosis from the crest of the sacrum, and with the fleshy fibres which arise from the sacro-sciatic ligament, are directed downwards and outwards (Fig. 48). At the level of the great trochanter these fibres are replaced by a broad, thick, tendinous lamina, which is continuous superficially with the outer aponeurosis of the thigh (*fascia lata*, see later), and which is inserted deeply into the external branch of the bifurcation of the linea aspera of the femur (page 123). This muscle presents four borders, which are parallel in the shape of a diamond ; (1) an *internal border*, presenting a slight convexity on the inner side, and (2) an *external border*, slightly convex. This border corresponds to the line along which the fleshy fibres are replaced by tendinous ones ; it forms a prominence, which encircles the region of the great trochanter behind. When we have enumerated the muscles lying beneath the gluteus maximus it will be easy to understand that this muscular structure as a whole is so prominent that we find the great trochanter, forming on the model a slightly depressed region bounded behind and above by the prominence of the glutei, and in front by the tensor muscle of the fascia lata (see *Muscles of the thigh*). (3) The *inferior border* of the gluteus maximus is thick, and forms an oblique prominence, beneath which emerge the posterior muscles of the thigh ; it is this which forms the inferior prominence of the region of the buttock. (4) The

superior border, on the contrary, is thin (Fig. 53, page 207), and is continuous with an aponeurosis which covers the gluteus medius, so that at this level its prominence is little marked on the model, being lost more or less in the plane corresponding to the gluteus medius.

The gluteus maximus is an extensor of the thigh on the pelvis. In the upright position it supports the pelvis behind and prevents it from inclining forwards. It is by its action that the trunk is raised so as to be in the same line as the upright lower limb. The gluteus maximus is therefore the muscle of the upright position, and we observe the large size which it presents in the human species compared with its small proportions in the animals which have not the biped attitude.

The *gluteus medius muscle* is situated both beneath and above that of the gluteus maximus, that is to say, the postero-inferior part is covered by the preceding muscle, but its antero-superior part is uncovered on the model. This latter part (Fig. 53, between 22 and 23) is, however, covered by a thick aponeurosis, which conceals the prominence of the fibres of the muscle, not allowing the whole of their mass to appear. Arising from the anterior three-fourths of the crest of the ilium (as far as the level of the anterior superior spine), the fibres of the gluteus medius descend, converging towards the great trochanter, into the external surface of which they are inserted by a thick aponeurotic tendon. The fleshy fibres cease a little above the great trochanter so as to form a prominence along a curved

line with its concavity downwards, which forms the superior boundary of the depression corresponding to the region of the great trochanter, as we have stated above. The gluteus medius, by its posterior fibres, acts like the gluteus maximus which covers them; by its anterior fibres it draws the thigh outwards, causing it to turn on its axis from without inwards.

These muscles (gluteus maximus and medius) are lined by a series of deep muscles filling up the large space which we observe on the skeleton between the great trochanter and the external iliac fossa. These muscles, which we will only enumerate so as to understand the importance of the prominence of the buttock, are, taking them from above downwards and from before backwards, as follows—the *gluteus minimus*, which almost exactly lines the gluteus medius, proceeding from the external iliac fossa to the anterior border of the great trochanter; the *pyriformis*, of which the fleshy body is situated within the pelvis, on the sides of the anterior surface of the sacrum, escapes from the pelvis through the great sciatic notch, and from this is directed almost horizontally towards the great trochanter, into the upper border of which its tendon is inserted; the *obturator internus*, which proceeds from the anterior surface of the pelvis, is reflected on the lesser sciatic notch and inserted into the internal surface of the great trochanter; and finally, the *quadratus femoris*, formed by short horizontal fibres, which proceed from the external part of the tuberosity of the ischium to the posterior border of the great trochanter.

Muscles of the thigh.—The muscles of the thigh are arranged around the femur, and frequently in a direction so oblique that they belong by one portion, for example, to the anterior region, and by their other portion to the internal. We can, however, class them into four regions—the external, comprising the *tensor vagina femoris* (*fascia lata*); the anterior, comprising the *sartorius* and *triceps crural;* the internal, comprising the *adductors;* and finally, the posterior region, comprising the *biceps*, the *semi-membranosus*, and the *semi-tendinosus.*

The *tensor vagina femoris muscle* (3, Fig. 57).—This is continuous in front with the plane of the gluteus medius (23, Fig. 53, page 207), but forms a prominence better marked and more distinct than that muscle. It arises from the anterior superior spine of the ilium, and its fleshy body is directed downwards and backwards on the external surface of the thigh, to terminate shortly by being inserted into the broad and thick aponeurosis (the *fascia lata*) which covers this region (4, Fig. 57). In this aponeurosis we can distinguish the vertical fibres, which proceed directly from the muscle and descend to the external surface of the knee, where they form a distinct prominent tendon, to be inserted into the tuberosity of the anterior tibial (see page 127). This muscle is a rotator inwards of the thigh and all the lower limb, and contributes also to the flexion of the thigh on the pelvis; therefore, when the thigh is extended and not turned inwards, the tensor muscle forms beneath the iliac spine a long muscular model, but when

it is in action, this model becomes short, as broad as it is long, and forms a characteristic globular mass. This contrast in the form of the tensor muscle in repose and in action has been beautifully shown on the Gladiator, in which there is contraction of the tensor of the right thigh and relaxation of that of the left.

The aponeurosis of the *fascia lata* covers a large fleshy mass, the *vastus externus* of the triceps, which belongs to the anterior muscles. This muscle, thus covered in, is shown throughout its entire extent in the external form, but the details of its configuration, at least in its upper two-thirds, are not revealed.

The *sartorius muscle* (5, Figs. 57 and 23; Fig. 50, page 191). — This is the longest muscle in the human

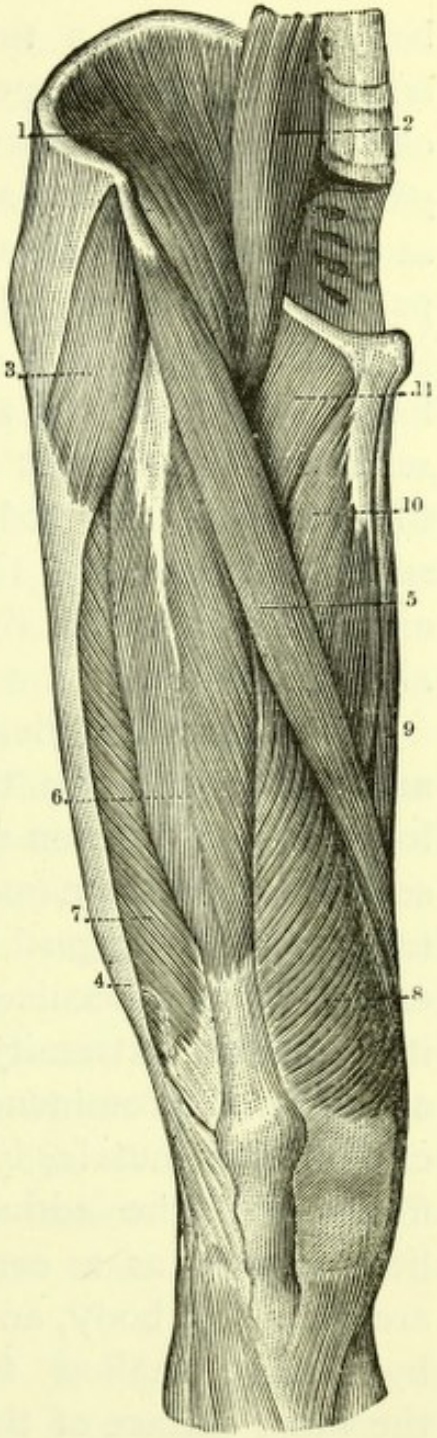

FIG. 57.

THE MUSCLES OF THE ANTERIOR SURFACE OF THE RIGHT THIGH.—1, the iliacus;—2, the psoas;—3, the tensor vagina femoris;—4, its tendon (fascia lata);—5, the sartorius;—6, the rectus (long head of triceps);—7, vastus externus, the external head);—8, vastus internus, the internal head;—9, the gracilis;—10, the adductor longus;—11, the pectineus.

body; it forms a thin fleshy band, which arises from the anterior superior iliac spine, and is directed obliquely downwards and inwards; crossing the upper part of the anterior surface of the thigh, it arrives at the internal surface, then descending to the knee passes behind the inner condyle of the femur (Fig. 61), describing a curve with the concavity forward, to terminate at the upper part of the internal surface of the tibia in a flat tendon (19 and 20, Fig. 61) which is inserted into that bone, forming the superficial layer of the *pes anserinus* (a tendinous expansion in which the gracilis and semi-tendinosus also take part).

The sartorius flexes the thigh on the pelvis, and the leg on the thigh; so that it gives to the lower limb a position similar to that of a tailor when seated, hence the name of this muscle (Lat., *sartor*, a tailor). With regard to form this muscle is shown externally in a peculiar manner. When it contracts, its superior extremity only shows its swelling by an external prominence; throughout the rest of its extent, this muscle, lying on a thick compressible fleshy bed (the adductors) depresses it, sinking a little into it, as a cord must when twisted tightly around a soft body, and therefore marks its presence by a large shallow furrow, felt especially towards the inner surface of the thigh, at the junction of the upper two-thirds with the lower third.

Triceps cruralis (6, 7, 8, Fig. 57).—The triceps crural belongs both to the external and internal regions of the thigh as well as to the anterior;

but the portion of most importance with regard to form—the *rectus femoris*—is situated in front. The triceps, as its name indicates, is composed, like its fellow in the arm, of three portions: one, the middle, called the *rectus*, and two lateral, the vastus internus, and the vastus externus.

The *rectus* (24, Fig. 50, and 6, Fig. 57) is long and fusiform in shape, that is to say, larger in its centre than at its extremities. Its superior extremity, the more slender of the two, arises by a short tendon from the anterior inferior iliac spine, passing between the tensor vagina femoris and the sartorius. The rectus emerges from the triangular space which separates these two muscles (Fig. 57), descends vertically on the anterior surface of the thigh, and about four inches above the patella forms a broad triangular tendon (Figs. 57 and 59), the borders of which give insertion to the vastus internus and externus muscles, and whose base is inserted into the patella. From the lower part of the patella arises a broad ligament (page 136), which is inserted into the tuberosity of the tibia; therefore, we see that by means of this ligament, or tendon of the patella, the triceps is inserted into the tibia (Fig. 33, page 129).

The *vastus internus muscle* (8, Fig. 57) is a very large fleshy mass, which quite surrounds the femur, for, arising from the internal lip of the linea aspera of the femur, it covers the internal surface, the anterior, and also the external surface of the bone, forming a fleshy body, which is carried vertically downwards

to be inserted by its antero-external fibres into the deep surface, and by the others into the internal border of the triangular ligament above the patella. These last fibres (the internal), easily seen on the subject, are obliquely directed, and form a fleshy mass, which descends to the level of the patella (8, Fig. 57, and 17, Fig. 61). Again, the line along which they are inserted into the tendon is vertical, continuous almost at a right angle with the lower border of the muscle, directed horizontally from the level of the patella. These details are of great importance with regard to the contour of the region above the patella, and are all the more perceptible when they are contrasted, as we shall see, with the arrangement presented at the same level by the lower part of the vastus externus.

The *vastus externus* (7, Fig. 57), of which the name is less justified than that of the preceding muscle, covers the external part of the vastus internus, and extends vertically from the base of the great trochanter to the external border of the triangular tendon; but the line along which it is inserted into this tendon, describes a curve of which the concavity looks towards the supero-external angle of the patella, from which it is separated by a considerable interval (Figs. 57 and 60). Therefore, on the external form the flat surface above the patella forms a species of triangle, of which the borders are very different, the internal being vertical, the external oblique, curved, and situated high up; the base of the triangle corresponds to the patella, and the lateral

parts of the capsule of the knee; its truncated summit corresponds to the inferior extremity of the fleshy body of the rectus; the borders of this flat surface, formed by the muscular parts of the triceps, become very prominent when this muscle contracts, when the leg is brought forcibly in extension on the thigh. It is hardly necessary to point out, since it is clear from its anatomical arrangement that the triceps, passing by the patella and its ligament to the anterior tuberosity of the tibia, is essentially the extensor muscle of the leg.

The *mass of the adductor muscles.*—We understand by the name of the *mass of the adductors* the numerous muscles that are arranged in the inner part of the thigh, and which, passing from the pubis and ischium along the entire length of the femur, fill up the triangular space which the skeleton presents between the internal surface of the femur and the corresponding half of the pelvis. Some of the muscles of this mass take especially the name of adductors. We will study in succession three muscles clearly visible on the model, viz., the *pectineus*, the *adductor medius* or *longus*, and the *gracilis;* then we will mention briefly the muscles almost hidden by the preceding, namely, the *adductor brevis* and the *adductor magnus.*

The *pectineus muscle* (22, Fig. 50, and 11, Fig. 57) —the first and shortest of the muscles of this region is in appearance a broad fleshy band which extends from the horizontal ramus of the pubis to the upper part of the shaft of the femur (a rough line passing from the linea aspera to the lesser trochanter). The lower

part of this muscle is hidden by the sartorius, and the upper part itself does not show clearly beneath the skin, which is always more or less loaded with fat in this region. The pectineus and the upper part of the sartorius bound a triangular space with its apex below, known in surgical anatomy as *Scarpa's triangle*, in which terminates a large muscle, of which the fleshy body is for the most part situated in the cavity of the pelvis and abdomen. This is the *psoas iliacus* muscle (1 and 2, Fig. 57) which arises from the lateral parts of the lumbar vertebræ (*psoas*) and from the internal iliac fossa (*iliacus*), passes beneath the crural arch (page 100) and arrives at the bottom of the triangular space to be inserted into the lesser trochanter. This muscle is not visible on the external form, as the triangular space of which it forms the floor is filled up by the blood vessels and lymphatic glands which give to this region an irregular contour, varying considerably in different individuals (Fig. 51).

The adductor longus is triangular in shape (10, Fig. 57); its tendinous apex arises from the spine of the pubis, and its base, hidden by the sartorius, is inserted into the middle portion of the linea aspera of the femur.

The *gracilis* is visible throughout its entire length on the inner surface of the thigh (9, Fig. 57); it forms a long slender fleshy band, broad above and narrow below; it arises from the internal border of the descending ramus of the pubis, from which origin it descends vertically; a little above the inner condyle of the femur it is replaced by narrow tendon (15, Fig.

58), which passes behind the condyle, describing a slight curve like the sartorius, and with the tendon of this last muscle forms the pes anserinus (pages 246 and 252, being inserted into the upper part of the internal surface of the tibia.

Covered by the preceding muscles and placed more deeply, are the adductors brevis and magnus, which fill up the space between the gracilis and the femur. The *adductor brevis* extends from the pubis to the upper part of the linea aspera ; the adductor magnus is a large muscle which arises from the tuberosity and ascending ramus of the ischium, and is inserted into the entire length of the linea aspera of the femur, so that it presents its superior fibres horizontal and its inferior almost vertical ; among these last the most internal, called the *long portion* of the *adductor magnus*, presents below a distinct tendon which projects above the internal surface of the knee, and is inserted into a tubercle which is placed above the inner condyle of the femur.

The action of all these muscles which we have just studied, except the pectineus, is to draw the thigh inwards towards the axis of the body ; they also bring the knees close to each other, hence they are called the adductors of the thigh.

The *posterior muscles of the thigh.*—These muscles, three in number, arise from the tuberosity of the ischium, and thus their superior extremities are hidden beneath the gluteus maximus. They emerge beneath the inferior border of that muscle and thence descend vertically ; above the posterior surface of the

knee they divide into two masses, one, the external, formed by a single muscle, the *biceps femoris*, the other internal, formed by two muscles placed one on the other, the *semi-membranosus* and the *semi-tendinosus*.

The *biceps femoris* (12, Fig. 58) is so called because, like the biceps in the arm, it is formed above by two heads, a long head which arises from the tuberosity of the ischium, and a short head, more deeply placed, which arises from the lower half of the linea aspera of the femur. These two heads unite in a tendon (12, Fig. 58) which the muscular fibres accompany for the greater part of its length, and which, inclining towards the external lateral part of the knee, is inserted in the form of a strong cord into the summit of the superior extremity of the head of the fibula. This muscle flexes the leg on the thigh, and when it accomplishes this action its tendon becomes very prominent, forming the external boundary of the pit of the ham or popliteal space.

The *semi-tendinosus* (13, Fig. 58), visible throughout its entire extent (except that part that is hidden beneath the gluteus maximus), has been so called because in a great part of its length, almost equal to its lower half, it is represented only by its tendon. Its fleshy body arises above from the ischium, and descends parallel to the long portion of the biceps, to the inner side of which it is situated; towards the junction of the middle with the lower third of the posterior surface of the thigh, this fleshy body becomes narrower, and is immediately replaced by a tendon (13, Fig. 58) which inclines inwards, passes behind

the internal condyle of the femur, describing a slight curve with its concavity forwards like the tendons of the sartorius and gracilis, with them (pages 246 and 250) it forms the pes anserinus, and is inserted into the upper part of the internal surface of the tibia (24, Fig. 61). This muscle flexes the leg, and marks in this movement the prominence of its tendon as the internal boundary of the pit of the ham.

The *semi-membranosus*, situated beneath the preceding, which overlaps it below and on both sides, is so called because its upper half is formed by a broad membranous tendon arising from the tuberosity of the ischium. The muscular fibres commence below the middle of the thigh and form a large fleshy body, thick, broad, and short, which passes into a strong tendon (14, Fig. 58) inserted into the posterior surface of the internal tuberosity of the tibia.

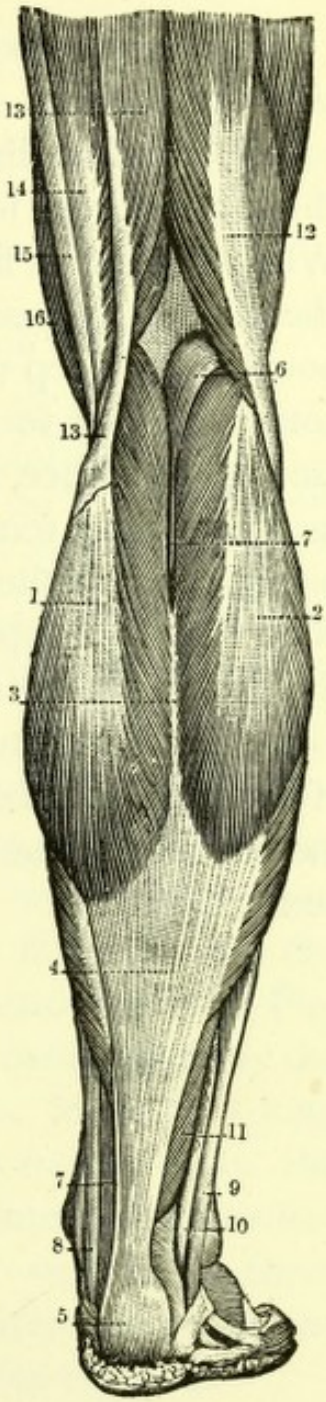

FIG. 58.
THE POPLITEAL REGION AND POSTERIOR SURFACE OF THE RIGHT LEG.—1, internal gastrocnemius;—2, external gastrocnemius;—3, space between gastrocnemii;—4, 5, tendon Achilles;—6, 7, 7, plantaris muscle and its tendon;—8, tendons of deep muscles (common flexor and posterior tibial);—9, peroneus longus;—10, peroneus brevis;—11, soleus;—12, biceps femoris;—13, semi-tendinosus;—14, semi-membranosus;—15, gracilis;—16, sartorius.

The fleshy body of this muscle overlaps on each side the tendon of the semi-tendinosus, and passing to the median line of the posterior surface of the thigh and knee, forms a large muscular prominence. When the leg is flexed on the thigh, the tendons of the biceps and semi-tendinosus become prominent, bounding a deep pit (pit of the ham or popliteal space) corresponding to the upper part of the posterior surface of the knee, and the fleshy body of the semi-membranosus remains hidden in the bottom of this pit; but when the leg is extended on the thigh there is no longer a popliteal space, the posterior surface of the knee presenting, on the contrary, a prominent form, produced in the upper part by the fleshy mass of the semi-membranosus, and in the lower part by the median masses of the calf, as we shall see in the next chapter.

CHAPTER XXII.

MUSCLES OF THE LEG.

General arrangement of the muscles with regard to the skeleton.—Anterior muscles of the leg (tibialis anticus and extensors).—External or peroneal muscles; relations of the long peroneal with the sole of the foot, its influence on the form of the foot—Posterior muscles; gastrocnemii muscles (details of their composition and form). Soleus muscle, plantaris, *tendon Achilles*.—Muscles of the foot; 1st, back of foot (extensor brevis muscle); 2nd, muscles of the sole of the foot.

Muscles of the leg.—The arrangement of the skeleton of the leg (tibia and fibula) is such that we should expect *à priori* to find four muscular masses, one on each of the surfaces of the skeleton, but the internal surface of the tibia is subcutaneous (2, Fig. 59) not covered by any muscle, and, overlapped by the anterior and posterior fleshy masses, it forms a long flat surface, slightly hollowed, proceeding from the internal surface of the knee to the internal malleolus. The leg, therefore, presents for our study only three groups of muscles, the anterior or antero-external, the external or peroneal, and the posterior regions.

Anterior muscles (Fig. 59).—Arranged in the space which separates the fibula from the tibia, they are three in number, which are called, proceeding from the tibia to the fibula, the *tibialis anticus*, the *extensor proprius pollicis*, and the *extensor longus digitorum*.

The *tibialis anticus* (or *anterior tibial*, 3, Fig. 56) arises from the external surface of the tibia, and from the anterior tibial tuberosity (page 127), and descends inclining obliquely inwards in the form of a prismatic or fusiform fleshy body, of which the inferior extremity gradually becomes narrower, to be replaced by a strong tendon at the commencement of the lower third of the leg. This tendon, inclining more and more to the inner side (2, Fig. 61), passes obliquely over the anterior surface of the tibia, arrives in front of the internal malleolus, where it glides beneath the anterior annular ligament and reaches the inner part of the dorsum of the foot (3, Fig. 61), where it is inserted into the first cuneiform and base of the first metatarsal bone. It is a flexor of the foot, since it draws the dorsal surface of the foot towards the anterior surface of the leg, at the same time that it turns the point of the foot inwards, and slightly raises its internal border. This muscle, during contraction, shows externally all the details of its shape, namely, at the level of the leg a fleshy body which slightly overlaps the anterior crest of the tibia, and in front of the ankle an oblique cord marking clearly the direction of the tendon.

The *extensor proprius pollicis* (5, Fig. 59), as regards its fleshy body, is hidden between the preceding muscle and the following one. Its tendon only, accompanied still by some of the muscular fibres, appears (2, Fig. 60) at the lower third of the anterior surface of the leg, on the outer side of the tendon of the tibialis anticus, and passes with it, but a

little more obliquely, beneath the annular ligament of the ankle, along the inner part of the dorsal surface of the foot (4, Fig. 61), to be inserted into the base of the second phalanx of the great toe. When the great toe is forcibly turned up during extension this tendon is clearly shown throughout its entire course.

The *extensor longus digitorum* (*common extensor of the toes*, 4, Fig. 54,) arises from the external tuberosity of the tibia, to the outer side of the tubercle of the tibialis anticus, and from the upper three-fourths of the internal surface of the fibula; it descends vertically, and presents below a tendon divided into numerous slips, which remain together (3, Fig. 60) to pass beneath the annular ligament. Immediately after, these slips spread out like a fan (4, Fig. 60) in the form of five tendons, of which the first four reach the toes (from the second to the fifth toe), into the last phalanges of which they are

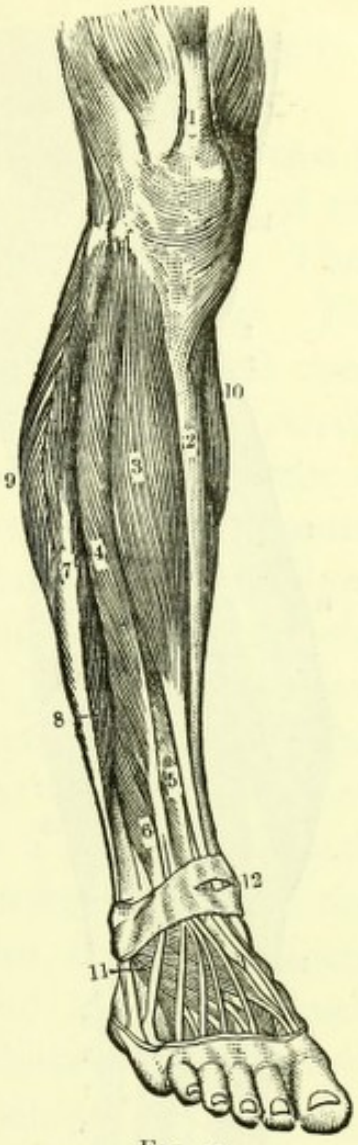

FIG. 59.

MUSCLES OF THE ANTERIOR REGION OF THE LEG.—1, tendon of the rectus femoris;—2, tibi ;—3, the anterior tibial muscle;—4, the common extensor of the toes;—5, the proper extensor of the great toe;—6 the peroneus tertius;—7 and 8, the peroneus longus and brevis;—9, the external head of the gastrocnemius,—10, the internal head of the gastrocnemius;—11, extensor brevis digitorum;—12, the superior annular ligament of the dorsum of the foot.

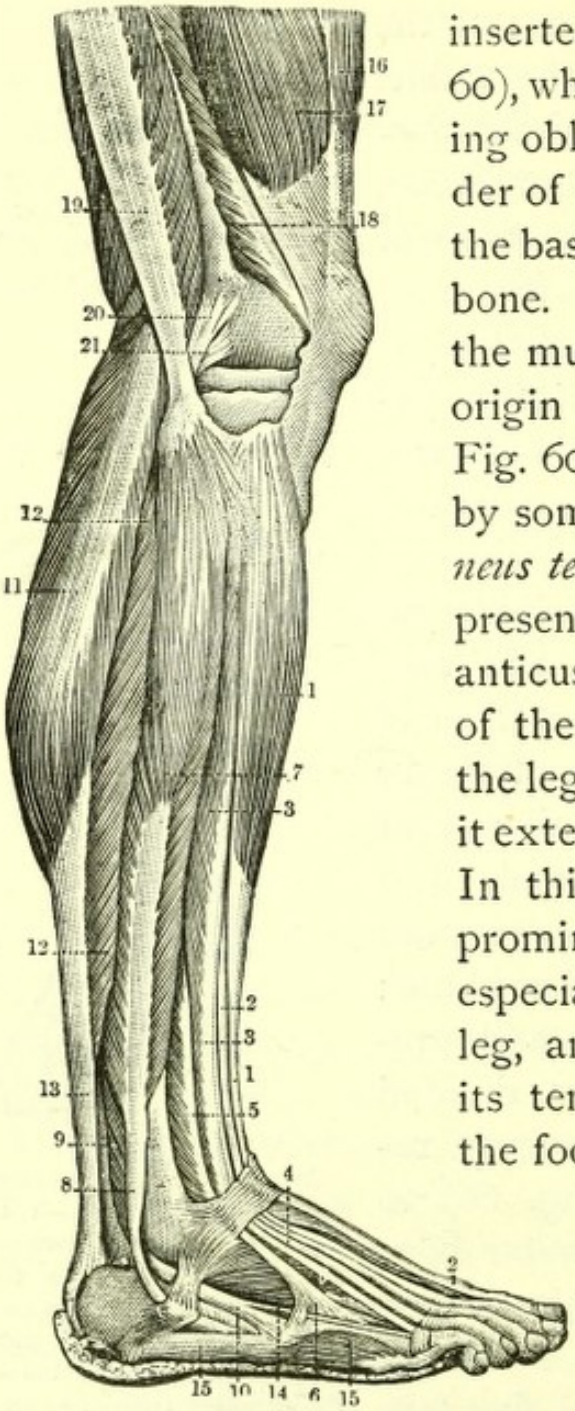

FIG. 60.

MUSCLES OF THE LEG (external surface).—1, 1, the anterior tibial muscle;—2, 2, the tendon of the extensor proprius pollicis;—3, 3, the extensor longus digitorum with its tendons (4, 5, and 6);—7, the peroneus longus and its tendon (8);—9, peroneus brevis and its tendon (10);—11, the external head of the gastrocnemius; 12, 12, the soleus;—13, tendo Achillis;—14, extensor brevis digitorum;—15, abductor minimi digiti;—16, the rectus femoris;—17, 18, vastus externus;—19, tendon of the biceps femoris;—20, external lateral ligament of the knee.

inserted, while the last (6, Fig. 60), which is shorter, descending obliquely on the outer border of the foot, is inserted into the base of the fifth metatarsal bone. (This last tendon and the muscular part which gives origin to it (6, Fig. 59, and 5, Fig. 60) have been described by some authors as the *peroneus tertius*. It is not always present.) With the tibialis anticus the common extensor of the toes flexes the foot on the leg, while at the same time it extends the toes on the foot. In this action it shows the prominence of its fleshy body especially at the middle of the leg, and the prominences of its tendons on the back of the foot like diverging cords; the tendon which goes to the fifth metatarsal raises the outer border of the foot, and it is only at that time that

its prominence shows beneath the skin. Usually it is but little marked.

The *external muscles* (Fig. 60).—These are two in number, placed on the external lateral surface of the fibula, and are called the *lateral peroneal muscles.* They are distinguished as the *long* and *short peroneal.* The *long peroneal* is formed by a fleshy body which commences at the head of the fibula, and which, relatively broad and thick, descends almost to the middle of the leg, where a tendon appears which the muscular fibres accompany for some distance. At this level exactly, that is, the middle third of the external surface of the fibula (7, Fig. 60), the *short peroneal* arises, which is thus placed beneath the tendon of the preceding muscle, so that as regards form these two muscles are united in a long fleshy body occupying the superior three-fourths of the external surface of the fibula. Their two tendons descend also united in one single mass, and incline obliquely from the external surface of the fibula on the posterior (8, 9, Fig. 60), so as to pass behind the external malleolus (9, 10, Fig. 58), around which they are bent as on a pulley and directed on to the outer border of the foot. Then only the tendons separate from each other, to be inserted into two points diametrically opposite on the foot. One (that of the short peroneal) is directed horizontally from behind forwards, on the outer surface of the foot (10, Fig. 60), to be inserted into the base or posterior extremity of the fifth metatarsal bone; while the other, that of the long peroneus, is directed obliquely forwards and

downwards so as to reach the sole of the foot, beneath which it passes, lying in the groove of the cuboid bone; it then runs obliquely across the sole of the foot, from the outer towards the inner border, deeply hidden by the plantar muscles and ligaments, and arrives at the posterior extremity of the first metatarsal bone, into which it is inserted.

These two muscles, but especially the short peroneal, extend the foot and carry its point to the outer side, while at the same time they raise its external border; we see, therefore, that this action is the reverse of that of the tibialis anticus. But the long peroneal has another important function which explains why the muscle becomes prominent whenever a particular effort is demanded of the foot, as for example, when it is carried forward in dancing, or in the act of imparting motion to an object; this muscle, owing to the arrangement of its tendon, which passes like the string of a bow across the hollow of the sole of the foot, acts by increasing this hollow, and therefore raises the plantar arch, and this is marked on the dorsal surface by an increase of the curve of the foot.

Posterior muscles (Fig. 58).—The posterior region of the leg is very fleshy, and is formed by numerous and powerful muscles which are divided into two groups:—the superficial group, which we shall describe in detail, and the deep group, for which a few words will be sufficient. The superficial group is formed by the two *gastrocnemii*, the *plantaris* and *soleus* muscles.

The *gastrocnemii* (γαστήρ, belly; κνήμη, leg) or *twin muscles*, which form essentially the prominence of the calf, are two in number, one on each side of the middle line of the calf, and are distinguished (by their relation to the axis of the body) as the *internal* and *external gastrocnemius*. The internal (1, Fig. 58) arises from the upper part of the internal condyle of the femur; the external (2, Fig. 58) from the same point on the external condyle. Both descend together, each forming a long ovoid fleshy body; these two bodies, separated at first by a small triangular space, come almost immediately in contact with each other, and are then only separated by an interval very narrow and vertical (3, Fig. 58). Finally, they terminate by a rounded inferior

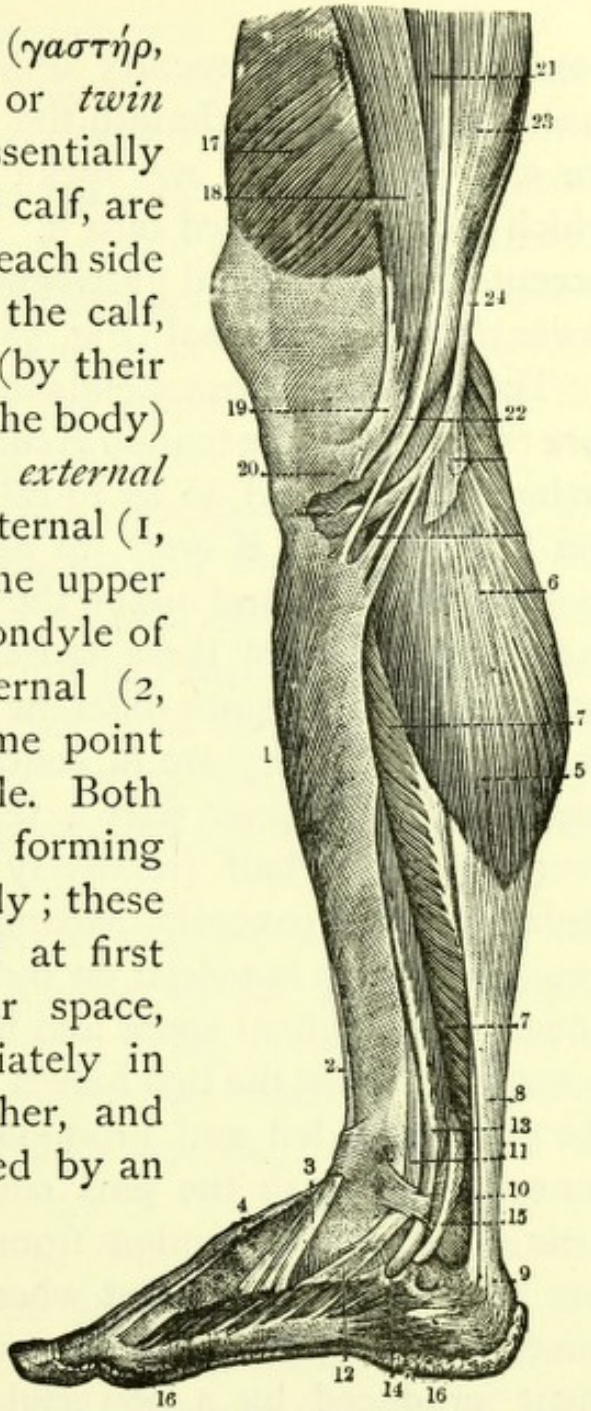

FIG. 61.

MUSCLES OF THE LEG (internal surface).—1, tibialis anticus;—2 and 3, its tendon;—4, tendon of the extensor proprius pollicis;—5 and 6, internal head of the gastrocnemius;—7, soleus;—8, tendo Achillis;—9, its attachment to the ossecalcis;—10, tendon of the plantaris muscle;—11 and 12, tendon of the tibialis posticus;—13 and 14, tendon of the flexor longus digitorum;—15, tendon of the flexor longus pollicis;—16, 16, abductor pollicis;—17, vastus internus;—18, 19, 20, sartorius;—21, 22, gracilis;—23, semi-membranosus;—24, semi-tendinosus.

border with its convexity downwards, showing the insertion of the muscle into the *tendon Achilles*, which we will study when we speak of the soleus muscle, which is also inserted into it. Except in some rare exceptions the internal gastrocnemius descends a little lower than the external (Fig. 58).

These two muscles extends the foot on the leg, therefore they act (by the tendon Achilles) on the calcaneum or bone of the heel so as to raise the heel and cause the living model, if erect, to rest on the point of the foot (on the toes) and not on the sole of the foot. Now the constitution of these muscles is such that their external form is quite different when they are in repose and when they are in contraction. Each muscle presents at its upper part a tendon, which expands over the outer half (relatively to the axis of the limb), which it conceals, leaving the inner half quite free (that which is placed on the inner side the middle line of the popliteal space and the calf, page 50). In a state of repose the two halves of the muscle unite in the same rounded and prominent shape, so that we cannot distinguish the part covered by the aponeurotic expansion of tendon from the part formed by free muscular fibres. But when the living model is raised on the points of the feet or in any other movement produced by a powerful contraction of these muscles, we see in each of the muscles the free fleshy part swell up much more strongly than the part covered and tied down by the aponeurosis. Therefore, at that moment, the whole convex form of the calf presents a slight ovoid flat surface on each side,

and a long vertical prominence in the middle line. This prominence is produced by the free muscular parts of the two muscles, which approach each other, remaining together during contraction, and uniting their double mass in a single median prominence. The Fig. 58, by the differences in shading, enables us to distinguish the aponeurotic from the muscular parts, and to observe the important details of the shape into the study of which we have entered. The clear or aponeurotic parts correspond to the two flat surfaces already mentioned, and the shaded or fleshy parts correspond to the median prominence, with this difference, that in the calf in contraction, this median prominence is smoother than in Fig. 58, the two halves which compose it being merged into a single mass, except at the triangular space in their superior part.

We will now return to what we have already said (pages 257 and 258) relative to the posterior region of the knee examined on a living model when the leg is extended. If the model raises himself on the points of the feet it is no longer possible to speak of the *popliteal space* as a hollow in the posterior surface of the knee. Under these conditions, the prominence already studied of the semi-membranosus and that of the median fleshy bodies of the gastrocnemii almost join each other, and the plantaris muscle, of which we will speak immediately, help to fill up the space; the region of the popliteal space forms in reality a prominent part, and the posterior surface of the knee is marked in its central portion by a strong

muscular form of which it is not possible to understand the cause, except by an attentive study of the gastrocnemii and semi-membranosus muscles.

The *soleus muscle*, so called because its form has been compared to that of a *sole* (Latin—*solea*), is placed beneath the gastrocnemii, which overlap it more on the internal (7, Fig. 61) than on the external border (12, Fig. 60) of the calf. Arising from the head of the fibula and from the tibia, it gives origin below to a broad triangular tendon with its base above, into the outer surface of which are inserted the grastrocnemii muscles. This tendon, accompanied still on its deep surface and on each of its borders by the fibres of the soleus (Fig. 58), descends, becoming narrower and thicker, and about two inches above the calcaneum it becomes free, entirely wanting in muscular fibres. This is the *tendon Achilles*, transmitting the action of the gastrocnemii and soleus, which arrives at the calcaneum, at which point it expands slightly to be inserted into the posterior surface of that bone (5, Fig. 58).

The soleus has the same action as the gastrocnemii, therefore when the foot is strongly extended we see the prominence of its fibres marked on each side of the upper part, or triangular base of the tendon Achilles.

The *plantaris* is a small, insignificant muscle, of which the fleshy body (6, Fig. 58), very short, arising from the outer condyle of the femur, is united with the external gastrocnemius. To this small fleshy body succeeds a long, thin tendon (7, Fig. 58), which descends obliquely between the gastrocnemii and the

soleus to reach the inner border of the tendon Achilles, which it follows in descending (10, Fig. 61). Sometimes it is united with this tendon early in its course, and sometimes it reaches the calcaneum, or it may be lost in the fatty cellular tissue which surrounds the tendon Achilles near the calcaneum.

The posterior deep muscles are not visible on the model except at the lower part of the inner border of the leg. At this point they present on the inner side of the tendon Achilles (8, Fig. 58) a series of tendons which resemble the tendons of the peroneal muscles, arranged in the same manner on the other side at the moment when they reach the posterior surface of the fibula, and are reflected on the external malleolus (9, 10, Fig. 58). These muscles are the *tibialis posticus*, the *flexor communis digitorum*, and the *flexor proprius pollicis*. The fleshy bodies of these muscles, deeply hidden beneath the superficial muscles, arise from the posterior surface of the tibia from the fibula and interosseus membrane. Their tendons descend obliquely towards the posterior surface of the internal malleolus, where those of the tibialis posticus and the common flexor alone are visible (the tendon of the flexor pollicis being almost entirely hidden beneath the tendon Achilles). From this they are reflected on the internal malleolus and pass into the sole of the foot, following the internal groove of the calcaneum. The tibialis posticus is almost immediately inserted into the scaphoid bone (12, Fig. 61), and the other two tendons reach the toes, where they are arranged in the same manner as we have described

in the hand for the tendons of flexor pollicis and deep flexor of the fingers.

Muscles of the foot.—The foot presents not only the muscles of the plantar region, like the hand in its palmar part, but also possesses a fleshy body developed on its dorsal region and called the *extensor digitorum brevis* muscle.

This muscle (11, Fig. 59, and 14, Fig. 60) is formed by a short, flat, fleshy body, arranged crosswise on the back of the foot; so that it proceeds obliquely from without inwards and from behind forwards. Its postero-external extremity is rounded and attached to the supero-external surface of the calcaneum in the calcaneo-astragaloid or *anfractuose cavity of the tarsus* (page 147). From this origin it is directed forwards and inwards; becoming broader, it passes beneath the tendons of the common extensor and immediately divides into four muscular slips, each of which soon changes into a tendon. These tendons cross those of the common extensor, so as to form with them a figure with lozenge-shaped spaces, and proceed to the first four toes to be inserted into the base of their first phalanges uniting with the extensor tendons. This muscle aids in the extension of the toes, and by its obliquity counteracts the tendency of the long extensor in the other direction. When it contracts, the portion of its fleshy body situated to the outer side and behind the tendons of the long extensor become very prominent, not being tied down by anything, and this prominence is still clearer when behind it is found a depression, more or less evident, corres-

ponding to the anfractuose or calcaneo-astragaloid cavity of the tarsus.

We will not stay to describe the muscles of the sole of the foot with regard to form. The foot owes all the peculiarities of its form to its bony structure; the muscles of the sole round off by their presence the angle of the skeleton and fill up the cavities, but do not modify essentially the bony forms. On the other hand, these numerous muscles are in general but little developed. United into common masses, also, it is frequently difficult, except for the minute anatomist, to isolate and recognise distinctly each fleshy body. It is therefore useless for an artist to enter into a study in detail of these muscles, which reproduce in their general arrangement the distribution of the muscles of the hand. We will content ourselves, then, by saying that the sole of the foot, like the palm of the hand, possesses three muscular masses—1st. One internal (16, Fig. 61), belonging to the great toe, formed by the *abductor pollicis*, which arises from the calcaneum, and by the *flexor brevis*, the *adductor pollicis* and *transversus pedis*, which arise from the anterior bones of the tarsus and from the metatarsus; 2nd. The other external (15, Fig. 60), belonging to the fifth toe, formed by the *abductor*, which arises from the calcaneum, and the *flexor brevis* from the cuboid; 3rd. Finally, a central mass, formed by the *flexor brevis digitorum*, the *lumbricales*, and *interossei*—which repeat what we have said regarding the muscles of the same name, but less developed and more easily studied, in the hand.

CHAPTER XXIII.

MUSCLES OF THE NECK.

Lateral and anterior regions of the neck.—Sterno-mastoid muscles. They bound, on the anterior surface of the neck, a triangle containing the infra-hyoid and supra-hyoid regions.—Organs comprised in the neck (vertebral column, œsophagus, and trachea).—Infra-hyoid muscles, omo-hyoid, sterno-hyoid, sterno-thyroid, and thyro-hyoid. — Supra-hyoid muscles, digastric, stylo-hyoid and mylo-hyoid.

Muscles of the neck.—We have already, in treating of the trapezius, studied the muscular structure and form of the posterior region of the neck, and various details have been given relative to the upper part of the lateral surfaces of the neck, or the oblique longitudinal groove between the anterior border of the trapezius and the external border of the sterno-cleido-mastoid (pages 200 and 201). It now remains to examine the inferior part of this groove and all the anterior region of the neck. This study should begin with that of the sterno-cleido-mastoid muscles, which form the most important forms of these regions, and which by their direction map out on the anterior surface of the neck a muscular interval or space in which it will be easy to study the deeply-placed muscles.

The *sterno-cleido-mastoid muscles* are two in number, one on each side of the neck, extending from

the upper part of the thorax, obliquely upwards and backwards, to the base of the head (19, Fig. 62). Their inferior part is formed by two heads — one

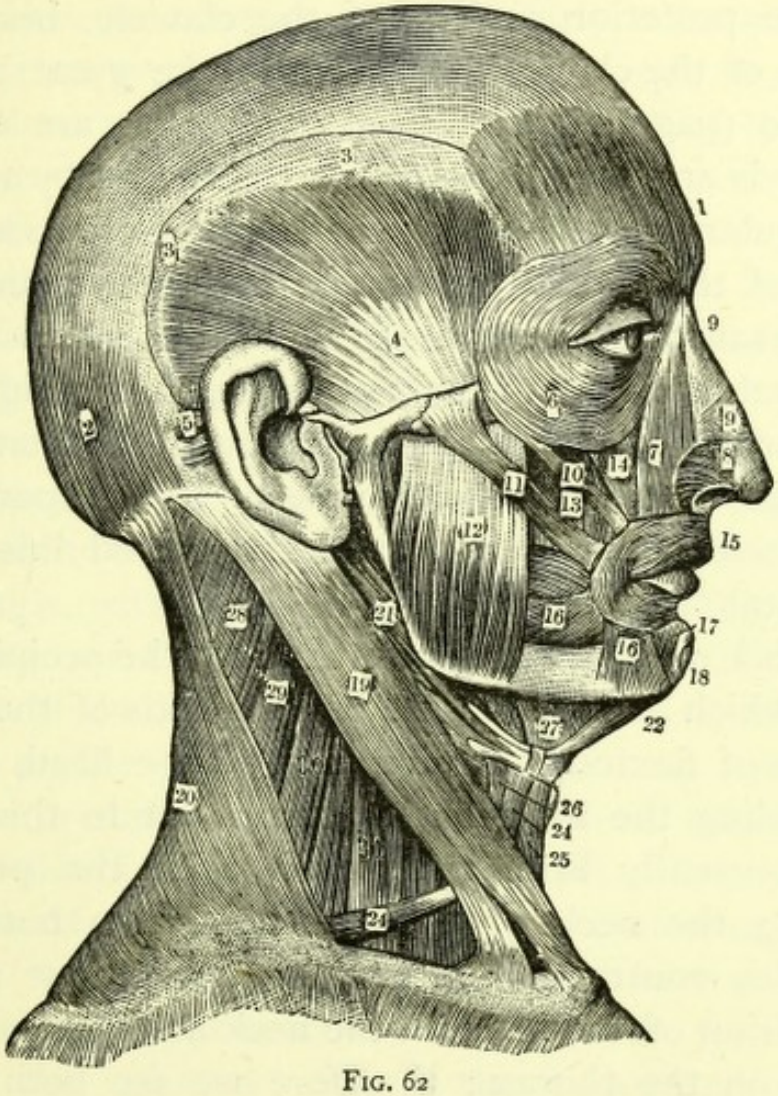

FIG. 62

MUSCLES OF THE NECK AND FACE.—1, frontal;—2, occipital;—3, aponeurosis of the occipital frontalis;—4, temporal;—6, orbicularis palpebrarum;—7, levator labii superioris et alæ nasi;—8, dilator naris anterior and posterior;—9, compressor naris;—9′, pyramidalis nasi;—10, zygomaticus minor;—11, zygomaticus major;—12, masseter;—13, caninus;—14, levator labii superioris;—15, orbicularis oris;—16, buccinator;—16′, depressor anguli oris, or triangularis oris;—17, depressor labii inferioris, or quadratus menti;—19, sterno-cleido-mastoid;—20, trapezius;—21, digastric and stylo-hyoid;—22, anterior belly of the digastric;—24, omo-hyoid;—25, sterno-hyoid;—26, thyro-hyoid;—27, mylo-hyoid;—28, 29, splenius.

internal or sternal, which arises by a strong tendon from the first piece of the sternum (18, Fig. 50, page 191), the other external or clavicular, which arises in the form of a thin fleshy band from the internal fourth of the posterior surface of the clavicle, beside the origin of the clavicular portion of the great pectoral muscle (page 185). These two heads are directed upwards and backwards, separated at first by a narrow triangular space, of which the base corresponds to the head of the clavicle (Fig. 49); they then unite into a single muscular body, broad and thick, which ascends obliquely towards the base of the head, passing behind the vertical border of the lower jaw to be inserted into the base of the mastoid process of the temporal bone and the corresponding part of the curved line of the occipital (16, Fig. 52).

This muscle, being inserted into the occipital at a part which is situated behind the axis of the movements of flexion and extension of the head, acts by extending the head on the neck, but to this movement, usually little marked, it adds the power of flexing the neck on the trunk. When both these muscles contract at the same time, they produce extension of the head on the neck and flexion of the neck on the thorax; therefore we see both clearly marked beneath the skin in a person lying down who raises his head (by flexion of the neck). But more frequently one muscle only contracts, and it acts by turning the face to the opposite side; therefore in the living model who looks to the right the face turns to this side by the contraction of the left sterno-cleido-

mastoid muscle, of which the prominence is well shown beneath the skin as a broad cord, passing from the sternum to the region of the ear (mastoid process of the temporal). There are various attitudes in which this prominence is particularly remarkable, as when we carry the head quickly to one side to answer a question or give an order; or in the act of listening intently, when we concentrate our attention to one side and extend the head a little, turning the region of the ear upwards and forwards, an attitude in which the sterno-mastoid becomes particularly prominent beneath the skin of the neck.

From their insertions and direction we see that these two muscles are very close to each other below and wide apart above. They thus form the borders of a triangle, with its apex below corresponding to the fourchette of the sternum and its base to the whole breadth of the lower jaw. This triangle is the anterior region of the neck, which is divided into two parts by the presence of the os hyoides—a small bone without direct connection with the rest of the skeleton and placed transversely above the prominence of the larynx (23, Fig. 62). The inferior part forms a vertical plane, oblique downwards and backwards, for it sinks behind the sternum; this is the infra-hyoid region, containing the infra-hyoid muscles. The superior part forms a plane approaching more or less the horizontal, proceeding from the hyoid bone to the chin and the circumference of the lower jaw; this is the supra-hyoid region, or that of the chin, containing the supra-hyoid muscles.

Before entering into the description of these regions we must point out the presence of organs which, placed on the anterior surface of the cervical vertebral column, fill up the space between it and the muscles in question. These organs are represented by two canals which descend from the posterior region of the cavity of the mouth into the cavity of the thorax. One of these canals is soft and fleshy with a cavity effaced during repose; this is the *œsophagus*, or alimentary canal, applied in front of the vertebral column. The other, placed in front of the preceding, forms the respiratory canal, or *trachea*, which on account of its functions is always open. To secure this condition it is formed by cartilaginous rings which give it an almost cylindrical form and render it prominent below or in the middle space of the infra-hyoid muscles. The upper rings of the trachea form strong cartilaginous pieces, constituting the cartilages of the larynx, placed below the hyoid bone, of which the largest, called the thyroid cartilage, forms by its anterior and superior part the prominence commonly known as the *pomum Adami* (Fig. 62).

The *infra-hyoid muscles* arise from the superior circumference of the thorax, and ascend towards the inferior border of the hyoid bone. They are four in number—two superficial (the omo-hyoid and sterno-hyoid) and two deep (the sterno-thyroid and thyro-hyoid).

The omo-hyoid (24, Fig. 62) is a small muscle, long and slender, with a very remarkable course. It arises from the upper border of the scapula (behind

the coracoid notch), and is directed at first horizontally forwards and inwards along the posterior border of the clavicle; at the centre of this bone it turns on itself and is directed upwards beneath the sterno-mastoid to be inserted into the lateral part of the lower border of the hyoid bone. This muscle, covered at first by the trapezius and then by the sterno-mastoid, is visible on the model in two parts of its course only—at the point where it terminates anteriorly, in front of the sterno-mastoid, and again at its middle part, in the lower portion of the groove which separates the trapezius from the sterno-mastoid. Although deeply placed, this muscle becomes visible beneath the skin, for it raises itself sharply during certain actions. Evidently, from its slender form, we cannot expect to see in this muscle an elevator of the scapula; perhaps it serves to depress the hyoid bone. But the most important fact is that when it contracts, especially during spasmodic efforts in respiration, as in the strong inspiration in sighing or sobbing, it acts by preventing the skin and loose aponeurotic tissue from being too strongly depressed in the supra-clavicular fossa by atmospheric pressure (the vacuum in the thorax being caused by the inspiratory effort). Therefore, if the neck is thin and the fossa well marked, as in an aged female, we see clearly shown in the supra-clavicular fossa, during the movements of sobbing or abrupt respiration, the cord corresponding to the central portion of the omo-hyoid muscle.

The *sterno-hyoid* (23, Fig. 49, and 25, Fig. 62) forms a long, thin, fleshy band, extending from the

posterior surface of the head of the clavicle to the lower border of the hyoid bone. Both these muscles are contiguous to each other by their internal borders above, but below, at the deep median fossa corresponding to the fourchette of the sternum, they are separated by a triangular space, in which appear the trachea and the inner border of the following muscle.

The two deep muscles of this region form in reality a single muscle, lining the sterno-hyoid beneath which it is placed, but divided into two unequal parts. This muscle arises from the posterior part of the first piece of the sternum, and ascends vertically projecting beneath the sterno-hyoid (Fig. 49); arrived at the thyroid cartilage it is inserted into its external surface; this lower part, the longer of the two, is called the *sterno-thyroid;* but it is continuous with the second portion, the shorter, which, arising from the thyroid cartilage, ascends to be inserted into the hyoid bone and has received the name of the *thyro-hyoid.*

The *supra-hyoid muscles* proceed from the hyoid bone to the base of the skull and jaw-bone, and by their contraction elevate this bone, as can be easily observed in those who bring into action the pharynx or larynx, as in the act of singing or swallowing. The type of these supra-hyoid muscles is afforded by the *digastric muscle* composed of two fleshy bodies or *bellies,* one anterior, the other posterior, connecting by one of its bodies the hyoid bone with the base of the skull, and by the other connecting that bone with the chin region of the jaw. Next come two other muscles, one posterior, placed beside the posterior belly of the

digastric and called the *stylo-hyoid*, and the other beside the anterior belly, called the mylo-hyoid.

The *digastric muscle* arises from the internal surface of the mastoid process of the temporal; from this origin it descends obliquely downwards and forwards (posterior belly, 21, Fig. 62) forming a fusiform fleshy body, which near the hyoid bone is replaced by a round tendon. This tendon is attached by a fibrous expansion to the hyoid bone, and taking a fixed point at this expansion it turns abruptly, so that from a direction oblique downwards and forwards it is directed obliquely upwards towards the chin; at the same time this tendon is soon replaced by a new fusiform fleshy body (anterior belly, 22, Fig. 62) which is inserted, on the posterior surface of the symphysis of the chin, into a small depression called the digastric fossa. We see that this muscle, with its two bodies, is admirably arranged to raise the hyoid bone, and consequently the whole of the larynx, for one of its bodies carries the hyoid bone upwards and forwards, the other upwards and backwards, and if the two bodies contract at the same time they raise the hyoid bone directly upwards.

The *stylo-hyoid* is a small muscular fasciculus which lines the posterior belly of the digastric beneath which it is situated (21, Fig. 62). Arising from the styloid process of the temporal, this muscle descends downwards and forwards forming a species of groove which receives the posterior belly of the digastric, with which it is closely connected, as at the level of the hyoid bone the tendon of the digastric pierces the stylo-

hyoid; the latter terminates by an aponeurotic slip which is inserted into the lateral parts of the hyoid bone. On the model the stylo-hyoid and digastric are united in one cylindrical form (Fig. 62).

The *mylo-hyoid muscle* (27, Fig. 62) forms the floor of the cavity of the mouth. It constitutes a quadrilateral fleshy plane, of which the superior border is attached to the internal surface of the horizontal branch of the lower jaw in a prominent oblique line, and of which the inferior border is inserted into the hyoid bone. The anterior border of this plane is continuous with the corresponding border of the muscle of the opposite side, so that the two muscles, that of the right and left side, form in reality a single fleshy layer constituting the inferior or mental wall of the mouth. This muscle is lined on its deep surface by the fleshy fibres of muscles which are not visible externally, and which, arising from the small tubercles developed on the posterior surface of the symphysis of the chin, are inserted either into the hyoid bone (genio-hyoid, *genial tubercles*) or into the tongue (*genio-glossus*).

CHAPTER XXIV.

MUSCLES OF THE HEAD.

1st. Muscles of *mastication; masseter*, its form, its part in the physiognomy (character of firmness, of violence); *temporal*. 2nd. Muscles of expression; nature and special mechanism of the muscles of the *skin;* object of their study (expression of an actual passion, momentary and not characteristic of the subject).—History of the question.—Leonardo da Vinci, Le Brun, Camper, Charles Bell, Lavater, Sue, Humbert de Superville.—Particular interest of the drawings given by Humbert de Superville (Unknown Signs of Art). —Duchenne of Boulogne and the experimental method applied to the study of the physiognomy.—Darwin (the physiognomy from the philosophical point of view of transformation and evolution).

THE muscles of the head are with few exceptions placed in the anterior region, on the level of the *face*, and are divided into two very distinct classes—1st, the muscles which serve for mastication and move the lower jaw; and 2nd, the muscles which, under the influence of the emotions, modify the traits of the countenance and serve for the expression of the passions. We call these the *muscles of expression.*

The muscles of mastication reproduce the general arrangement that we have already met with in the various muscles of the trunk and limbs. They are attached to the bones, and they have a fleshy body more or less thick, which swells up when beginning to contract, and is marked by its prominence, as the

biceps shows its contraction by becoming prominent on the anterior region of the arm. The muscles of expression, on the contrary, present a new type. These are the muscles of the *skin*, which move the skin and not the parts of the skeleton; therefore their fleshy bodies are in general very slender, and their contraction is not marked by any local swelling corresponding to the fleshy body, but only by change in place and form of the folds and membranous structures of the face (eyelids, lips, &c.). We will first study the muscles of mastication.

Muscles of mastication, masseter.—The muscles which move the lower jaw are inserted into the vertical branch; those on the inner side are the *pterygoid* (so called because they arise from the pterygoid process of the sphenoid bone). We need not dwell on those here for they are deeply hidden in the lateral fossa of the head and face and are not visible in any part in the external form; the others on the outer side are inserted either into the angle of the jaw (masseter muscle) or into the coronoid process (temporal muscle).

The masseter muscle is a quadrilateral fleshy mass (12, Fig. 62) of which the superior border arises from the zygomatic arch (Fig. 39), and the inferior border is inserted into the angle of the jaw. The anterior border of this muscle is thick, and in thin subjects forms a prominence in front of which the cheeks form a depression more or less marked. In contraction the masseter raises the lower jaw and brings it into contact with the upper, against which it presses strongly.

It would be superfluous to dwell here on the part this muscle plays in mastication. It is more important to remark that during violent emotions, or even when we accomplish a powerful effort, we involuntarily close the jaws. Contracting the masseter, therefore, in anger, menace, and in the strong expression which we characterise commonly by saying that the subject grinds his teeth, we see the masseter shown in the form of a quadrilateral prominence on the side of the face. Therefore the accentuation of the form of the masseter contributes to give to the physiognomy an energetic expression, but generally that of brute force.

The *temporal muscle* (4, Fig. 62) occupies the entire extent of the temporal fossa of the skull (Fig. 39); it arises from the bones that form that fossa and from an aponeurosis which, arising from the borders of that fossa, is attached to the other part of the zygomatic arch, so as to form a species of cover (temporal aponeurosis) to the fossa in question. From these multiple points of origin the fleshy fibres converge below and form a strong tendon which embraces the coronoid process of the inferior maxillary (25, Fig. 39), into which it is inserted. This muscle raises the lower jaw, but as it is shut up, so to speak, in a close space (temporal fossa and aponeurotic cover) it does not show during its contraction a remarkable prominence in the temporal region; nevertheless, in a subject who accomplishes the movements of mastication we see the skin of the temple, in front of the zygomatic arch, slightly raised in a series of rythmical

movements; these movements alone show externally the contractions of this muscle during mastication.

Muscles of expression.—From what we have already said respecting the peculiar arrangement of these muscles of the skin, it is easy to understand that their study must be made in a totally different manner to that of the muscles of the skeleton. Therefore we must not seek to define the form of the fleshy body, but rather trace the direction it takes, along which the muscle exercises traction on the skin; then, given the bony and cutaneous insertions of the muscle, we must know the direction in which it acts, and we can define the form of the folds it causes to appear on the skin, and ascertain what expression the physiognomy acquires by these changes. Before we enter into these details, it is necessary to glance rapidly at the history of this special question of human physiognomy, then to note in what spirit and by what method this study should be undertaken.

First we must remark that we study here, with regard to the muscles of the face, *physiognomy in an active state,* namely, the characters that affect the traits of the face at a given moment, under the influence of a passionate movement which causes the involuntary contraction of one of the numerous muscles of the skin, thus we see that the muscles deserve the name of those of *attention, pain, menace, laughter, sorrow, contempt, disgust,* &c. But we do not pretend to study the physiognomy in a state of repose, nor to learn by the normal and permanent

accentuation of certain of these traits, the character of the subject and the passions that most frequently disturb him. Doubtless, these two studies have numerous points in common; it is easy to admit that, in a subject who frequently abandons himself to transports or anger and menace, the contraction frequently repeated of the muscles which correspond to these passions, can at length modify the character of the face, so as to leave imprinted thereon the violent sentiments that have frequently agitated him.

But this analysis of the character of a subject is a very delicate study, always very uncertain and admitting of philosophical developments which would carry us far from the domain of anatomy. On the other hand, the determination of expressive character that impresses on the face the contraction of this or that muscle has become, from the researches of Duchenne (of Boulogne), a study which presents all the precision and certainty that we can claim from considerations strictly deduced from anatomy.

Before the researches of Duchenne, the majority of books written on expression dwelt almost entirely on the *physiognomy*, or the means of recognising the character by the study of the habitual state of the traits of the countenance. We must specially note the works of Le Brun, Camper, Lavater, C. Bell, Humbert de Superville, Gratiolet, and then we will dwell on the labours of Duchenne and Darwin.

Already, in the works of Leonardo da Vinci, we find some valuable indications of the state of the countenance and neck in the expression of the

passions, and this great master has, for example, clearly perceived the part that the platysma muscle of the neck takes in the expression of violent passions, and the transverse folds which then mark it beneath the chin. But we must pause at the name of Le Brun in order to find the studies of this nature arranged in a species of doctrinal whole; the publications, in which the teaching of Le Brun on this subject has been preserved, are numerous.* The artist will find there a number of interesting observations, curious comparisons, and ingenious explanations; Le Brun occupied himself principally with the resemblance of certain types of human physiognomies to the heads of animals, he studied particularly physiognomy which deals with the relations of the countenance to the character.

Camper, whose works we have already quoted respecting the facial angle (page 173) entered principally into the study of anatomy and physiology. He analysed the action of muscles, and it was he who first laid down this general rule, viz., that the contraction of each muscle of the face produced in the skin one or more folds, of which the direction is always perpendicular to that of the muscle, a precept that we shall find to be true with regard to almost every muscle of the face, and especially for the frontal, the great zygomatic, &c. Besides the exact observations that the artist will meet in the works of Camper,

* See especially. *Conférences sur l'expression des differents charactères des passions*, Paris, 1667. (These conferences have been reprinted in the edition of Lavater, by Moreau. Vol. ix., 1820.)

he will find in addition an interesting historical account of the question.

An English physiologist, Sir Charles Bell, celebrated for his studies of the nervous system, has also analysed the expressions of the face.* But though his work affords picturesque descriptions and admirable illustrations, it is, excepting these, more interesting to the physiologist than the artist, for the author applies himself principally to investigating the nature of the nerves that give motion to the muscles, and the intimate relations that exist between the movements of expression and those of respiration, questions which have not a direct interest for the plastic arts.

The title of the work of Lavater (*The Art of Knowing the Man by his Countenance*)† indicates the object sought by the author. We find in this work good illustrations, and curious observations, especially applicable to the study of physiognomy, but frequently without order, without method, and accompanied by dissertations on whimsical subjects, such as the chapters devoted to *imaginations* and *envies*, to *warts* and *beards*, and to *lines of animality*, &c.

In order to have an idea of the manner in which, at this epoch, authors attempted the study of the physiognomy, making this delicate analysis a pure affair of sentiment, it is sufficient to mention the work

* *The Anatomy and Physiology of Expression.* 1844. (3rd edition, published after the death of Sir Charles Bell, and containing his last corrections.)

† The edition to consult is that issued in 1820, in ten volumes by Moreau.

of Sue (*Physiognomie des Corps Vivants, Considére depuis l'Homme jusqú a la Plante.* Paris, 1797.) In the middle of a long affected treatise on the physiognomy and its relation to the passions, this is, for example, how he expresses himself concerning the mouth :— "A mouth delicate and pure is perhaps one of the best recommendations. The beauty of the portal proclaims the dignity of that which passes through. Here also is the voice, the interpreter of the heart and mind, the expression of truth, friendship, and the most tender sentiments." With regard to the incessant comparison of human physiognomy with that of animals, the author stops at nothing in this singular course, and speaks dogmatically on the physiognomy of fishes, serpents, grasshoppers, and intestinal worms (!), as well as that of man. "Many fishes," said he, "are wanting in that which gives a character of amenity, kindness, and tenderness." "The intestinal worms have a very decided physiognomy . . . . the character of their physiognomy inspires in man sorrow and awe."

Amidst the works of a more serious, though still empirical character, we must mention in particular one which, although speaking of the countenance in a secondary degree, yet presents on this subject several valuable observations, we have endeavoured to utilise in the representation by diagram of the action of the muscles of the skin in the face. We speak of the treatise of Humbert de Superville (*Des Signes Inconscients de l'Art*, 1827). The author gives three drawings of the human face, in which the lines repre-

sent the eyes, the lower boundary of the nose, and the lips. In one of these drawings (Fig. 63) the lines are all horizontal, in the other (Fig. 64) they are all inclined downwards and outwards (from the median line), and in the third (Fig. 65) they are all inclined upwards and outwards. The author remarks that the first figure (with the lines horizontal) produces an impression of calmness, greatness, and constancy; and

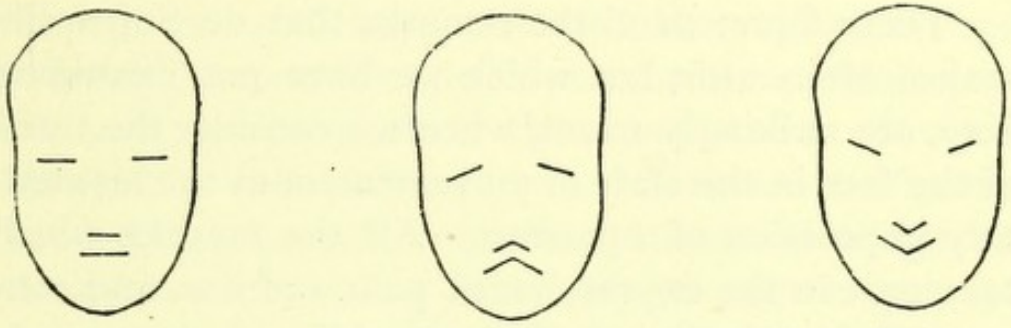

Fig. 63. Fig. 64. Fig. 65.

The Three Figures of Humbert de Superville—(Fig. 63, calmness; Fig. 64, sadness; Fig. 65, gaiety).

he adds that likewise in nature and architecture horizontal lines give rise to the idea of calmness, stability, and grandeur: the cedar, with its horizontal branches, is of all the trees the one that realises this impression in the highest degree. On the contrary, the second figure (with the lines oblique downwards) gives an impression of sadness, pain, and grief; and the author does not fail to compare the direction of the features of such a countenance with the direction of the architectural lines in tombs and funeral monuments, and that of the branches of the trees which everywhere are planted in preference to others in cemeteries, and

whose branches always hang obliquely. Lastly, the third figure (with the lines obliquely upwards) gives rise to the impression of gaiety, laughter, levity, inconstancy; and, to continue the preceding comparison, everyone must acknowledge that Chinese architecture, with its lines oblique and diverging upwards and outwards, can never—at least, in the eyes of a European—produce an impression of greatness and majesty.

These figures, and the remarks that de Superville makes afterwards, but which we have not examined here, are strikingly exact, when we consider the traits of the face in the state of movement, or in the momentary expression of a passion. All the muscles which take part in the expression of pain, sadness, and contempt help to incline the features obliquely downwards and outwards, some by acting on the line of the eyes, others on that of the mouth, &c. On the contrary, the muscle of laughter, raising the angles of the mouth, renders that feature oblique upwards and outwards, and—for certain reasons that we will analyse further on—seems to give a similar direction to the line of the eyes. In a word, features, starting from the state of repose, represented by the first figure of Humbert de Superville (Fig. 63), oscillate in two opposite directions, either ascending, to express the scale of gaiety and laughter (traits oblique upwards and outwards, Fig. 65), or descending, sadness, pain, and tears (traits oblique downwards and outwards, Fig. 64). The exactness of the drawings furnished by Humbert de Superville for the general expression

of the physiognomy induces us to try, by similar drawings, to represent the action of each muscle separately. Knowing the action of a muscle, and knowing from the photographs of Duchenne the direction that it imparts to a certain feature of the face, either to the line of the eyebrows, the opening of the eyelids, or that of the nostrils, or to that of the lips, we have indicated by a simple stroke or line these changes, either in direction or in the form of one of those lines, and have obtained theoretical figures sufficiently expressive to characterise the passion geometrically, so to speak, in the manifestation of which this or that muscle is affected. Such are the figures 67, 69, 71, 73, 74, 75, 77 (page 296 and following), by which we will explain the study of each muscle of expression. We may say that these drawings, without any pretension, are, so to speak, the primer of the language of physiognomy.

We now arrive at the history of the work of Duchenne, to which we owe all that follows. While all his predecessors had been taken up with observation, Duchenne introduced the experimental method into the study of physiognomy. His process, simple in conception, was very delicate in application. He proceeded by causing the contraction of each muscle singly, and that the expression that resulted might be appreciated not only at the moment of the experiment, but again at any time, and submitted to the judgment of all, he photographed the subject at the moment when the muscle was contracted. This last operation was easily accomplished, but the excitation

of a single muscle was a more delicate operation. Everyone knows that by electricity, in placing the two electric excitors (the two poles of the current) on the course of a muscle, we can cause the contraction of the muscle beneath the skin. But no subject would lend himself to this experiment. At first he tried on the dead body of a criminal executed, a short time after death; for the muscles of the face lose their excitability two hours after death, and then it is only by laying it open (raising the skin) that we can obtain contraction by the application of electricity. On the other hand, if we attempt it on any living subject, we can, it is true, cause a muscle to contract by applying electricity over its site; but the electric current, traversing the skin to reach the muscle, at the same time that it excites the motor nerves of the muscle, excites also the sensory nerves of the skin and produces acute pain. From this fact we see that we produce on the face of the subject, not a simple and characteristic expression, but a true grimace, or an irregular contraction of all the muscles under the influence of the pain.

Duchenne had the good fortune to be able to experiment on a subject in whom a particular infirmity rendered impossible the last inconvenience we have noted. This was an old pensioner of the hospital who had *anesthesia* of the face (*ἀ* (*ν*), absence of; *αἴσθησις*, sensibility), or in whom the skin of the countenance was insensible to the most painful excitation; electricity could be applied to the skin of this unfortunate man and traverse it without producing

painful reaction, and then excite the muscles beneath, which had perfectly preserved their contractility and performed their functions as in a normal subject. He could, therefore, cause this or that muscle alone to contract, and excite, for example, the action of the great zygomatic, giving to the face the expression of laughter, without the subject having any idea of what his physiognomy reflected ; his face, by the action of the electricity, was laughing, while his thoughts might be indifferent or fixed on sad recollections ; on the other hand, for example, by the contraction of the superciliary muscle, his countenance might express the most acute pain, while his thoughts might be quite indifferent or borne away by gay and pleasant ideas. In a word, Duchenne was able to realise, under the most precise conditions of experiment, an experimental study of the physiology of the muscles of expression.

The work in which Duchenne has given the result of his labours is remarkable, particularly for the magnificent atlas of photographs that accompany it, and which have been obtained by the above process. From these photographs have been reproduced as exactly as possible the several figures that accompany the descriptions which follow (Figs. 66, 68, 70, 72, page 296 and following). We cannot enter here into a complete statement of the results obtained by Duchenne, but we will seek at least to show the serious and scientific value of these studies, and to inspire the wish to refer to the original work.

These studies have for the artist this important

result, namely, to prove to him that frequently the contraction of a single muscle is sufficient to express a passion, and that it is not necessary to change all the features in order to give to the face the stamp of pain, attention, menace, contempt, disgust, &c., each of these sentiments being expressed by a slight modification, either of the eye alone, or of the lip alone. Each expression has, so to speak, its own exact, precise and single mark, produced by a single local modification, but this local modification seems to be reflected throughout the physiognomy, and therefore, from unaided observation, artists had for a long time believed that, for example, attention and pain were shown by the combined action of a number of facial muscles. Now experiment proves that pain is expressed solely by a muscle which raises and wrinkles the brows, and on a face (Fig. 70) where this muscle alone is contracted (*superciliary muscle*, page 302) the expression of pain is complete. We naturally believe that the mouth also takes part in it, but if we cover the upper part of the countenance, we perceive that the lower part of the face is in a state of complete repose.

To bring to a close this history, which is not the least interesting part of the subject, we must say that the labours of Duchenne were not at first received with great favour in France. Physiologists as well as artists showed a certain distrust of a work which pretended to give precise rules and scientific laws to a subject about which it had been the custom to imagine fanciful and sentimental

comparisons. Few persons understood the nature of the physiological exigency which forced Duchenne to choose as a subject for these experiments, a poor man with a physiognomy almost imbecile in repose, and they did not consider that if this face was old, wrinkled, thin, and vulgar, there was the greater reason to be struck with the precision with which the electric excitation enabled the most opposite and characteristic expressions to be taken.

As has been too often the fate of scientific discoveries, the work of Duchenne was neglected in France, and was not appreciated until it had been adopted by a foreign country, and the Englishman Darwin had made the results of the French physiologist the basis of his interesting studies.

Is it necessary to call to mind the extent and immense repute of the works of Darwin on the *origin of the species*, on the *evolution of animals and plants*, and on the *descent* of man? What this great naturalist has done for the general morphology of plants and animals he wished to do for the physiology of the human face. Seeking in the logical chain of natural facts the cause of all biological phenomena, he endeavoured to discover in the attentive study of the movements of expression, and in the pursuit of their mode of origin and development, a series of new arguments in favour of the theory of evolution. In a word, Darwin, by invoking the association of certain useful movements and comparing the functions with the expressions with which they are associated, sought to explain why one muscle in particular rather than

another is affected by the expression of this or that passion. We cannot here enter further into the analysis of this philosophical work. It is sufficient to remark (having commended the perusal of it as most interesting to the artist*) that before we explain anything it is necessary that it should be firmly established. Therefore the explanation of the part that each muscle takes in the expression must be impossible until the fact of the action and the expression of muscle has been scientifically demonstrated. The philosophical work of Darwin could not have been undertaken if it had not been preceded by the experimental work of Duchenne.

The figures which illustrate the work of Darwin are in a great measure only reproductions of the photographs published by Duchenne about ten years previous. However, as we have already mentioned, attention has been recalled in France to the works of Duchenne, a more favourable judgment has been passed, and justice rendered to him who had opened the way to the experimental study of physiognomy. In 1874 the French began to devote, in the course of anatomy in the School of Fine Arts, several lectures to the account of what we must call the primer or grammar of the expression of physiognomy. Happy in seeing his works included in this classical course of instruction, Duchenne, whom death carried off a few years later, gave to the School of Fine Arts the complete

* Charles Darwin. *The Expression of the Emotions in Man and in Animals.* Translated into French by MM. S. Pozzi and R. Renolt. Paris, 1874.

series of large original photographs from which these publications are reduced, and this beautiful collection is to-day one of the most valuable in the French museum of anatomy (Museum Hugnier).

Although this history must appear long it is nevertheless very incomplete, being given only with a particular object—that of comparing the works of Duchenne with those preceding him. Those of Duchenne will be made the basis of the studies which follow. We will finish by noting, as agreeable and instructive for the purpose, the works that treat in a more general manner of the expression and the physiognomy, such as those of Lemoine, Gratiolet, and Piderit.*

* Albert Lemoine: *De la Physionomie et de la Parole.* Paris, 1865. Pierre Gratiolet: *De la Physionomie et des Mouvements d'Expression.* Paris, 1865. Piderit: *Wissenschaftliches System der Mimik und Physiognomik.* 1867.

CHAPTER XXV.

MUSCLES OF THE FACE.

Muscles of the upper part of the face: *Frontal* (attention); *orbicular* of the eyelids, superior *orbital* portion (reflection); *pyramidalis* (menace); *superciliary* (pain).—Muscles of the middle region of the face: *Great zygomatic* (laughter); *lesser zygomatic* and *external common elevator* (tenderness, sorrow); *internal common elevator* (weeping bitterly); *transverse* of nose (lewdness).—Muscles of the lower region of the face: *Orbicular* of lips; *buccinator; triangular* of lips (contempt); *square muscle* of the lip (disgust); *platysma* muscle of the neck.—Classification into muscles completely expressive and expressive by complement.—Of associations possible and impossible with regard to mechanism and with regard to the nature of the passions.—Conclusion.

THE platysma muscles of the face which are attached by one extremity to the skeleton and by the other to the skin, move and change the folds and the membranous curtains formed by the latter. These different cutaneous parts are very complex, but at the same time known to persons who are the greatest strangers to anatomy. For them it is useless to describe here the eyebrows, the eyelids, the palpebral fissure, the wing of the nose and the lips. We will only point out, with regard to these parts, the signification of their various anatomical terms, the employment of which will be useful in abridging the descriptions that follow.

On the *eyebrow* we distinguish a broad internal part (towards the median axis of the face) called the *head* of the eyebrow, and an external part called the *tail* of the eyebrow which becomes thinner as it is removed from the middle line.

Each of the two extremities of a palpebral fissure bears the name of the *commissure* or *angle*. We distinguish, therefore, on the eyelids an *external commissure* or *angle* characterised by its pointed form, and an *internal* characterised by its rounded form, bounding a small oval space called the *lachrymal lake*, at the bottom of which a rose-coloured fleshy tubercle projects (the *caruncula lachrymalis*). We also give the name of *commissure* (or angle) to each extremity of the buccal aperture (*commissure of the lips*).

Lastly, we must note a normal fold which exists more or less marked in every subject, and the changes of which take a great part in the expression produced by the various muscles of the cheeks. This is the *naso-labial fold*, so named because, arising from the region bounded by the cheek and the side of the nose, it is directed obliquely downwards and outwards, passes at a short distance from the posterior border of the wing of the nose, and terminates towards the commissure of the lips. In the subject who served for the experiments of Duchenne (Fig. 70, page 302) this fold was strongly marked, as it is also in all old people.

The muscles of expression are arranged, some around the eyes and eyebrows, occupying the upper region of the face; the others grouped about the wings of the nose and the mouth, so that they occupy

the middle and especially the lower region of the face. The first are the *occipito-frontalis*, the *pyramidalis nasi*, the *corrugator supercilii*, and the *orbicularis palpebrarum;* the second are the *zygomaticus major* and *minor*, the *levator anguli oris*, the *levator labii et alæ nasi*, the *compressor nasi*, the *orbicularis oris* (to which we may add the *buccinator*), the *triangularis* and *quadratus menti;* finally, in the neck and extending to the lower lip is the *platysma myoides*, which takes a considerable part in certain powerful expressions.



Fig. 66.

Contraction of the Frontal Muscles (expressions of *attention* and *astonishment.*)

In the study of each of these muscles we will enter but little into anatomical details: to point out the situation of the muscle, its fixed insertion into the bones of the face, its direction, and, lastly, the point of the skin where it takes its movable insertion will be sufficient. On the other hand, we will carefully inquire into its mechanism and the manner in which its contraction changes the skin of the face, and the nature and the direction of the folds which it marks thereon. On a figure realising

these changes we should ask ourselves what expression results. And lastly, we will endeavour to give a drawing of this expression after a mode of representation copied from that employed by Humbert de Superville (page 285).

A.—MUSCLES OF THE UPPER PART OF THE FACE (FOREHEAD, EYEBROWS, EYELIDS, AND ROOT OF NOSE).

1st. *Occipito-frontalis muscle* (muscle of *attention*).—This muscle (1, Fig. 62, page 269) extends as a fleshy sheet, quadrilateral in form, on each lateral half of the forehead. Its lower border is attached to the skin of the eyebrow. From this origin its fibres ascend vertically and parallel to each other towards the region of the roots of the hair, and becomes continuous, at this level, with the tendinous fibres of the epicranial aponeurosis. This aponeurosis, which lines the hairy scalp and is adherent to it, is prolonged to the occipital region where it terminates in a fleshy layer, the occipital muscle, which is attached to the superior curved line of the occipital bone.

FIG. 67.

Diagram of the *frontal muscles* (*attention*).

In order to understand the mechanism of the frontal muscle it is necessary to consider it as taking its fixed insertion at the posterior part of the skull, through the medium of the epicranial aponeurosis and

the occipital muscle; its free insertion is that which it takes in the deep surface of the skin of the eyebrow. The frontal, therefore, in contracting draws this skin from below upwards, and consequently raises the eyebrow, and causes the transverse folds to appear in the skin of the forehead.

In examining (Fig. 66) a face in which this muscle is contracted we perceive that it expresses *attention;* if the contraction of the muscle is very great this expression of attention changes to that of *astonishment.* In entering into the detail of the changes that the face then presents we see that the eyebrow is raised and its superior convexity is very marked, that the eye is widely opened, clear and brilliant, and that the forehead is furrowed on each lateral half by curved folds concentric with the curve of the eyebrow folds, which are continued more or less from one side to the other, and describing curves in the middle line with the concavity upwards. In a child or young woman, in whom the skin is supple and elastic, it does not give rise to the formation of folds, and the skin of the forehead remains quite smooth during the contraction of the frontal muscle, and then the elevation of the eyebrow, the exaggeration of its curve and the state of the eyes, open and bright, are sufficient to give the expression of attention.

Figure 67 is the representation of *attention,* characterised here solely by the form of the eyebrows and the frontal folds.

2nd. *The orbicular muscles of the eyelids* (6, Fig. 62).—The orbicular muscle of the eyes is a very

extensive muscle which encircles the palpebral orifice. It is composed of numerous portions which can act more or less independently, and which have not all an equal importance in the expression of the face.

a. One part of this orbicular muscle, called the *palpebral part* (*orbicularis palpebrarum*), is contained in the thickness of the eyelids and produces by its contraction the closing of the eyes. If this contraction is moderate it produces only a certain drawing together of the eyelids and reduces the opening of the eyes to the form of a linear slit. This state of the palpebral opening does not constitute by itself an expression, properly speaking, but it may be complementary to various expressions—thus, associated with a slight contraction of the triangular muscle of the lips, which is the muscle of disgust and discontent (page 312), it gives to the countenance the expression of disdain and contempt.

b. A second part of the orbicular muscle is arranged in a circular manner on the outer side of the eyelids and corresponds exactly to the contour of the orbital orifice of the skeleton (Fig. 41, page 166, and Fig. 62, page 269). This portion, which we may call the *orbital orbicular*, is divided itself into two parts: one, the *inferior orbital orbicular*, the contraction of which moves the lower eyelid slightly upwards and causes a furrow at its junction with the cheek, and without being expressive by itself, completes the expression of laughter by giving to it a character of frankness and truth; and a *superior orbital orbicular*, which merits a study in detail, for it produces by

itself a characteristic expression, that of reflection, meditation, and contemplation.

This *superior orbital orbicular* (muscle of *reflection*) is placed beneath the skin of the eyebrow, and its fibres, like it, describe an arc with the concavity downwards, of which each extremity is adherent to the corresponding part (internal or external border) of the orbital opening. The mechanism therefore of this muscle is easily foreseen, for like all curved muscles, more or less fixed at their extremities, it must in contraction straighten its curve. It accordingly changes in the same manner the eyebrow to the skin of which it is adherent, and effaces its curve, rendering it straight transversely; it depresses, and consequently makes tense, the skin of the forehead, causing its wrinkles to disappear.



FIG. 68.

THE UPPER PART OF THE ORBICULARIS PALPETRARUM (*reflection*).

In examining (Fig. 68) a face in which this muscle is contracted we perceive that it expresses reflection. In Figure 68, owing to the great development of the eyebrow, which is greatly lowered, its hairs

descend into the eyes, and the expression is rather that of painful reflection of intense application of the mind preoccupied with sadness; but we see in every case that this expression is obtained essentially by the lowering and straight direction of the eyebrow, which veils the eye and effaces all wrinkles on the forehead. This change of the features is precisely the reverse of that produced by the frontal muscle, as is shown by the comparison of Figures 66 and 68, and in fact the two states of the mind corresponding to the expression given by each of the muscles are precisely the reverse of each other. We cannot be at the same time attentive to an external object and meditating in reflection. Usually the succession of these states of the mind and of the physiognomy is as follows:—We are attentive to that on which we are looking, the eye open, brilliant, the eyebrow raised, and the forehead wrinkled (contraction of the frontal muscle); afterwards we reflect on what we have seen and are, so to speak, away from the external world—the eyebrow lowered, the forehead smooth, and the eye veiled (contraction of the superior orbital orbicular), or the eyes may be closed (contraction of the whole of the orbicular of the eyelids).

FIG. 69.

Diagram representation of *reflection, meditation.*

Figure 69 is the representation of *reflection*, characterised by the absence of the frontal folds, the depression of the eyebrows and the presence of two

small vertical folds in the space between the eyebrows, to which the depression of the eyelid gives rise (Fig. 68). This representation of reflection (Fig. 69) does not acquire its full demonstrative signification until we compare it with that of attention (Fig. 67).

Fig. 70.

Superciliary Muscle (*sorrow*).

3rd. *Pyramidalis muscle* (or *muscle of menace*).—This small muscle, situated in the space between the eyebrows on a level with the root of the nose (9, Fig. 62, page 269), is formed by short vertical fibres, of which the inferior extremity is attached to the nasal bones (Fig. 41, page 166) and the superior to the deep surface of the skin of the space between the eyebrows.

The mechanism of this muscle therefore produces this essential result:—Taking its fixed insertion at the nasal bones, it draws downward the skin of the space between the eyebrows, forming there short transverse folds, and depresses slightly the head of the eyebrow.

In a face where this muscle is contracted (see

the atlas of Duchenne, page 289) the expression is that of harshness, menace, and aggression. With regard to the physiognomies which Duchenne produced with this contraction, we can readily believe that if the subject was represented in full its attitude should be that of menace; that, for example, it would shake its fist or brandish a weapon. Moreover, anything which throws a shadow or a dark look between the eyebrows gives to the physiognomy a character of harshness, as when the contraction of the pyramidalis produces the transverse folds in this region. Therefore, in those persons in whom the eyebrows seem to meet, owing to an exaggerated development of hair in the space between, the physiognomy always presents at first sight the stamp of severity and harshness, which may not agree in the least with the true moral character of the subject. The expression of the pyramidalis is too delicate, and due to a change of the features too local and slight for us to express it by a drawing, as we have done in the case of the preceding muscles.

FIG. 71.

Diagram representation of *sorrow.*

4th. *Superciliary muscle* (or muscle of pain).—This short muscle is deeply hidden beneath the skin of the region of the head of the eyebrow. Its fixed insertion is into the frontal bone, above the superciliary arch; from this origin its fibres are directed

outwards and slightly downwards to be inserted into the deep surface of the skin at the middle of the eyebrow (page 295).

Its mechanism consists therefore in drawing the eyebrow inwards and slightly upwards, and as it is attached to the middle of the eyebrow it draws it together at this point, namely, towards its inner part. The eyebrow is therefore, so to speak, abruptly hooked upwards and inwards, like a curtain that has been tucked up and attached to a fixed point. It therefore produces on the skin of the forehead folds concentric to this gathering together of the eyebrow and situated in the middle of the forehead.



FIG. 72.
GREAT ZYGOMATIC MUSCLE (expression of *gaiety* of *laughter*).

Figure 70 represents, after a photograph of Duchenne, the state of the physiognomy caused by the contraction of the superciliary muscle. This physiognomy has an expression characteristic of suffering, and with a greater accentuation of the action of the muscle shows in the highest degree the expression of physical or mental agony.

We see that the only parts changed in this physiognomy (compare Fig. 66, page 296) are the head of the eyebrow and the region between the eyebrows on the forehead, therefore pain is expressed by the raising of the head of the eyebrow and its gathering together abruptly at the middle, and by the presence of the short folds immediately above this and the more extended folds occupying the middle region of the forehead.

Figure 71 is the representation of pain, expressed by the changes only of the region of the head of the eyebrow (compare for contrast with Fig. 73 following).

B.—Muscles of the middle region of the face.

5th. The *great zygomatic muscle* (or muscle of *laughter*).—This muscle (11, Fig. 62), called also the *external oblique elevator of the commissure of the lips*, has its fixed attachment on the cheek-bone; from this origin it is directed obliquely downwards and inwards (in front) to be inserted into the deep surface of the skin of the commissure of the lips.

Its mechanism consists in drawing this commissure upwards and outwards, and from this action there follow in the expression of the countenance some complex changes easy to foresee *à priori;* at first the orifice of the mouth is enlarged transversely; its direction ceases to be straight since its external extremity is raised, so that each lateral half of the mouth is directed obliquely upwards and outwards.

As the naso-labial line (Fig. 66) ends, by its inferior extremity, near the commissure of the lips, this inferior extremity of the naso-labial line is also carried upwards, describing a slight curve concentric to the commissure of the lips, at the same time that the rest (the whole) of the naso-labial line ceases to be straight and describes a curve with its convexity downwards. The skin of the cheek gathered up towards the cheek-bone becomes more prominent, and forms, towards the external angle of the eye, several radiated folds (commonly called crows'-feet) which throw a slight shadow beneath the external angle of the eye; this causes us to imagine that the line of the eyelids is a little raised on the outer side (becomes slightly oblique upwards).

FIG. 73.

Diagram representation of *laughter.*

Figure 72, representing the contraction of the great zygomatic muscle, affords us the frank expression of gaiety and laughter, and we see that the changes of the physiognomy take place only, as we have already said, in the line of the lips, the naso-labial line, and the external angle of the eyes.

Figure 73, giving the representation of laughter, according to the preceding description of the great zygomatic muscle, is very similar to the corresponding figure of Humbert de Superville (Fig. 65, page 285), only, in order to express the reality without having

regard here to appearances, we have drawn the lines of the eyes horizontal ; and again, the naso-labial furrow has been represented with its form convex downwards and inwards for the upper two-thirds, and with the slight hook which its inferior extremity describes. This naso-labial furrow is of the utmost importance as regards the expressions produced by all the muscles of the region of the lips, as we shall see in all the following muscles.

FIG. 74.

Diagram representation of the *external common elevator* (muscle of *grief*).

6th. The *lesser zygomatic and common external elevator* (muscle of *grief*). — On the inner side of the great zygomatic there exists frequently (10, Fig. 62, page 269), but not constantly, a small muscular fasciculus which arises from the anterior part of the cheek-bone and descends to be inserted into the thickness of the upper lip. This muscle, called the *lesser zygomatic*, does not take part in the expression of laughter ; in fact it changes the naso-labial furrow in the same manner as the following muscle (the external common elevator), and so expresses, as we shall see, emotion, sadness, and grief.

The *common external elevator* (of the lip and the wing of the nose) arises (14, Fig. 62, page 269) from the inferior border of the orbit and descends to the upper, giving off sometimes, but not constantly, a small fasciculus to the wing of the nose.

Its contraction raises the upper lip itself, but not the labial commissure, so that each half of the line of the lips, raised within and remaining depressed at its outer extremity, becomes slightly oblique from above downwards and from within outwards (the reverse of the obliquity produced by the great zygomatic muscle), at the same time the centre of the naso-labial furrow is raised and the furrow becomes curved with its concavity downwards and inwards (the reverse of the curve produced by the great zygomatic).

FIG. 75.

Diagram representation of the *internal common elevator* (muscle of *grief* with tears).

By means of these changes the physiognomy takes the expression of discontent, emotion, and grief (see the atlas of Duchenne).

We give here only one drawing (Fig. 74) in which are shown the two essential changes produced by this muscle (obliquity of the line of the lips and curve of the naso-labial furrow), which seems to us to show in a satisfactory manner the expression of grief in tears. We comprehend the value of this drawing better by comparing it with the Figure 73. We see that the changes produced by the muscle of grief (lip and naso-labial furrow) are precisely the reverse of those produced by the muscle of laughter, as the two corresponding emotions are the reverse of each other. We remark also how slight is the distance which separates these two muscles, and how delicate

in anatomical arrangement are the shades which separate them, so delicate that authors do not agree as to whether the muscle found between them, the lesser zygomatic muscle, when it exists, should be considered as associated with the great zygomatic or, as we think, with the common external elevator. Beyond doubt their anatomical relations should remind us, in the nature of the passions and their expression, how small a distance exists between laughter and tears.

7th. The *common internal elevator* (muscle of *sobbing*, of *weeping bitterly*).—This muscle (7, Fig. 62) arises above from the internal border of the orbit; it descends almost vertically to be inserted by some of its fibres into the wing of the nose, and by the majority into the upper lip, not far from its central portion.

It therefore raises the middle of the lip, the labial commissure remaining fixed, and gives accordingly to each half of the line of the lips an oblique direction downwards and outwards (like the preceding muscle, but in a more characteristic manner); at the same time it dilates the nostril by raising the wing of the nose; lastly, by the pulling that it exercises vertically on the skin of the naso-labial furrow, it raises *en masse* the inner and upper part of this furrow and renders it straight, causing it to form a species of groove wherein the tears flow when they pour abundantly from the inner angle of the eyelids. These changes (see the atlas of Duchenne) give to the physiognomy the expression of grief with abundant tears, or of weeping bitterly.

The drawing of Figure 75 renders this expression to a certain degree difficult to realise with the simple elements we use in these formulæ. We see that all the folds of the face converge towards the inner angle of the eye, or towards the point of attachment of this muscle.

8th. *Transverse muscle of the nose* (muscle of *lewdness*).—This muscle (9, Fig. 62) is attached to the skin of the cheek on a level with the lateral parts of the nose, from this origin it is directed transversely on the lateral surface of the nose to reach the back of that organ where a thin aponeurosis establishes the continuity between that of one side and that of the other.

This aponeurosis, which embraces the back of the nose, forms the fixed point towards which these muscles draw the skin of the cheek and nose so as to mark on the lateral surface of the nose a series of vertical folds (perpendicular to the direction of the muscle).

Duchenne considered the change produced by these muscles to be characteristic of the expression of lewdness. Perhaps this muscle by itself is not sufficiently expressive, but when its contraction accompanies that of certain other muscles, we find very clearly in the physiognomy the element of lewdness pointed out by Duchenne. In his atlas this author gives the photograph of a countenance in which he had produced contraction of the frontal, the great zygomatic, and the transverse; a countenance of which the expression may be directly interpreted as

that of an old man in whom the *attention* (frontal) is *agreeably* excited (great zygomatic) by a spectacle arousing *lewd* ideas (transverse); the face produced by Duchenne would be, for example, a study of the physiognomy for a head of the old man in the classic subject of Susanna in the bath.

We have not attempted to represent by a drawing an unsatisfactory and perhaps doubtful idea of the expression of this muscle.

C.—Muscles of the lower part of the face.

9th. *Orbicularis muscle of the lips.*—In the thickness of the lips as in that of the eyelids, is arranged a muscle, the fibres of which surround the orifice of the mouth, this orbicular of the lips (15, Fig. 62) possessing principally functions not pertaining to expression but to the duties devolved on the lips (prehension of food, mastication, suction, &c.); if it takes any part in the play of the physiognomy, it is only by imparting to it those changes which constitute a slight grimace rather than a real expression. As in the orbicular of the eyes we distinguish in it the internal fibres corresponding to the free border of the lips and the external more eccentrically placed. If the first alone contract (internal orbicular) they tightly close the orifice of the mouth, pressing against the teeth the free border of the lips, from which they cause the rosy and fleshy aspect to disappear. We have then the movement commonly known as *biting the lips.* If the second (external orbicular) contract

solely, they project the lips forwards and render their orifice prominent and rounded, this is the action called *pouting*.

We will not dwell at length on the muscle which constitutes the fleshy layer of the cheeks and forms the lateral walls of the cavity of the mouth. This muscle called the *buccinator* (*buccinare*, to play the trumpet) takes part only in those functions, of which the opening and the cavity of the mouth are the seat; it plays an important part in mastication by bringing beneath the crown of the teeth the food which falls outside the alveolar arches. Lastly, it aids in the articulation of sounds and the playing of wind instruments (whence its name of *buccinator*), for it is the contraction of this muscle that expels from the mouth the air which inflates the cheeks.

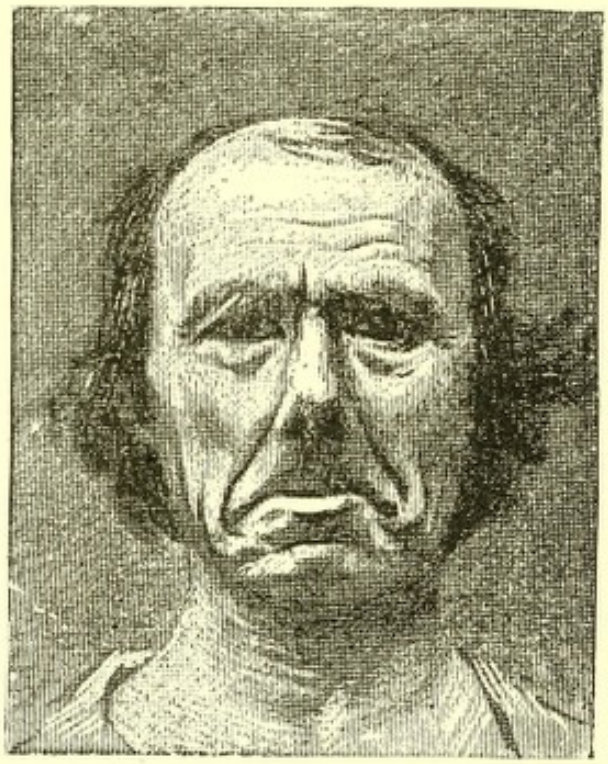

FIG. 76.

TRIANGULAR MUSCLE OF THE LIPS (expression of *discontent*, of *contempt*).

10th. *The triangular muscle of the lips* (muscle of *contempt*).—This muscle belongs to the lower lip. It forms (16, Fig. 62) a small fleshy triangle of which

the base is attached to the lower jaw, to the outer side of the symphysis of the chin, and from this origin its fibres converge towards the commissure of the lips where, by the apex of the triangle, it is inserted into the deep surface of the skin.

This muscle depresses the labial commissure and therefore renders the line of the lips oblique downwards and outwards; again, it draws downwards the inferior extremity of the naso-labial furrow so as to render this furrow almost straight, except at its inferior extremity which describes a slight curve embracing the labial commissure.

FIG. 77.

Diagram representation of the expression of *discontent*, of *contempt*.

The expression produced by this change, if they are slightly marked, is that of *sadness;* if they are very much so, that of *contempt.* We have already seen (page 300) that the partial closing of the eyelids usually helps to complete the expression of contempt.

Figure 76, copied from Duchenne, renders well, by the contraction only of the two triangular muscles of the lips, the expression of discontent and scorn. The depression of the commissure of the lips is characteristic, and the naso-labial furrow, very marked in the subject under experiment, is greatly changed in its direction and in the form of its inferior extremity, according to the mechanism that we have explained.

Lastly, the drawing of Figure 77 gives, so to speak, the graphic formula of contempt in marking, after the preceding figure, the inferior part of the naso-labial furrow, and the concentric folds which it forms below this extremity.

11th. The *square* muscle of the *lower* lip (muscle of *disgust*).—This muscle (17, Fig. 62), partly hidden by the base of the preceding, arises like it from the anterior part of the horizontal branch of the inferior maxillary, from this origin the fibres ascend obliquely upwards and inwards to be inserted into the whole length of the lower lip.

It depresses the lower lip, turning it outwards more or less strongly, so as to produce the grimace characteristic of a person who, having introduced into the cavity of the mouth a morsel of food which he does not find to his taste, rejects it forcibly, forming a species of groove with the lower lip turned outwards; if the contraction is less energetic the physiognomy expresses disgust.

We must refer to the atlas of Duchenne for the reproduction of this expression, always more or less rude, and have not attempted a drawing with a simple line as the indication of the labial fissure.

12th. *Platysma muscle of the neck.*—On each lateral half of the anterior surface of the neck is extended a thin muscular sheet lining the skin (25, Fig. 53, page 207). This platysma muscle is attached below to the upper parts of the chest, from which origin its fibres are directed obliquely upwards and forwards

towards the lower jaw, to be inserted into the skin of the chin, of the lower lip, of the commissure of the lips and of the cheek; the more superior fibres are almost horizontal extending from the skin of the region of the ear towards that of the labial commissure; to these superior fibres we sometimes give the name, but little justified, of the *risorius of Santorini.*

The platysma, which is not expressive by itself, adds its contraction to that of various muscles of the face, so as to give to the corresponding expression a character of terrible energy; the *risorius of Santorini* does not therefore produce the expression of laughter (of gaiety), but only that of *grinning*, of forced laughter, threatening, or sneering. The platysma in all these cases acts by depressing the lower jaw, slightly opening the mouth, and drawing the labial commissure downwards; it marks at the same time a series of transverse folds on the skin of the neck. These elements are capable of giving to the physiognomy a terrible character, which Leonardo da Vinci has so well observed when, in his chapter on the mode of representing a person in a state of violent anger, he says, "make the sides of the mouth in a bow, the neck thick and swollen, and marked with wrinkles in front."

If the characteristic changes of the contraction of the platysma of the neck accompany those produced by the frontal muscle, the physiognomy, as the series of photographs of Duchenne shows, takes the expression of attention and astonishment produced by a terrible spectacle. Associated with that of the

superciliary, the expression becomes that of acute pain, as, for example, in a wretch under torture, or a victim torn by a beast of prey. If the contraction of the pyramidalis is accompanied by that of the platysma we have the expression of a savage and barbarous threat, &c.

General considerations.—Associations and combinations.—From the enumeration we have made of the facial muscles from the forehead to the neck, we must perceive that, among these muscles, there are some which are by themselves completely expressive (*e.g.*, the frontal, superciliary and great zygomatic) and others which are expressive only in a complementary sense, or intended only to complete or change an expression produced by another muscle (such are the palpebral portion of the orbicular of the eyelids, the transversalis of the nose and the platysma of the neck), and lastly, others which are almost non-expressive, but yet associated with the true muscles of the expression (*e.g.* the buccinator). But we have not space here to dwell on these classifications.

A more important question is that of the association of the action of various muscles, and especially of the muscles which are completely expressive by themselves. The expression peculiar to each of these muscles is, so to speak, one of the syllables or words of the language of physiognomy, but like every other language physiognomy associates these syllables and words to arrive at its expressions. Now experience shows that usually these associations and combinations are composed of four elements, usually two

suffice, three muscles are sometimes in play simultaneously, hardly ever four.

Again, if we endeavour to realise these combinations theoretically, by supposing the contractions of two muscles associated at random, we soon perceive that among the combinations some are easy and ordinary, and this is on account of the nature of the passions which we suppose associated and the mechanism of the corresponding muscles, while others are impossible for the same reason.

The following is an example of easy combination concordant both to the passions and also to the muscular mechanism, viz., the combination of the contraction of the frontal and of the great zygomatic, or of attention and laughter. On the one hand attention (frontal) might be excited by a spectacle which provokes laughter (zygomatic); on the other hand the frontal muscle and the great zygomatic being situated, the one in the forehead and the other in the cheek, acting, one on the eyebrow, the other on the lips, the mechanism of one is independent of that of the other; this however, from an anatomical point of view, does not prevent the two contracting simultaneously, exactly as the biceps might contract in order to flex the fore-arm, at the same time that the common extensor of the fingers extends the digital phalanges.

On the other hand, as impossible combinations discordant both to the sentiments and muscular mechanism, we may, for example, consider the simultaneous contraction of the frontal and the superior

orbital portion of the orbicular of the eyelids. The first muscle expresses attention, the second reflection, or two states of the mind opposed to each other, which cannot be at the same time open to external phenomena and meditating in internal analysis. Again, the first muscle raises, the second depresses the eyebrow, which cannot be at the same time drawn in two opposite directions; just as, to take an example from the muscles of the limbs, the fore-arm cannot be at the same time flexed by the action of the biceps and extended by that of the triceps.

By submitting them to the same analysis we see that nothing is easier or more concordant to their mechanism and to the passions than the simultaneous contraction of the frontal and the triangular of the lips (attention and contempt), of the superciliary and the square muscle of the lips (pain and disgust), the pyramidalis and the internal common elevator (menace and sorrow), &c. On the contrary, for the same double series of reasons we find impossible and discordant associations, such as those of the great zygomatic and the square muscle of the chin (gaiety and disgust), the pyramidalis and the superciliary (menace and pain), and of the internal common elevator and the great zygomatic (sorrow and laughter).

There are, however, combinations which at first sight appear discordant to the nature of the passions, but which are found notwithstanding not to have any obstacle to their realisation in the mechanism of the countenance. We take, for example, the superciliary

and the great zygomatic: one expresses pain, the other laughter—two expressions of an opposite nature; however, as these muscles correspond, one belonging to the head of the eyebrow, the other to the labial commissure, they can act without one counteracting the other, and we may well understand their simultaneous contraction. Now on reflection we find that this association, anatomically possible, is often realised, notwithstanding the apparent incompatibility of the corresponding passions. In the midst of violent physical pain, which causes the involuntary and irresistible contraction of the superciliary, a serene and powerful will finds still the energy to smile. In order to find the realisation in a work of art it is sufficient to study the expression of the countenance of Seneca in the painting by Giordano. A similar example is offered by that of a young woman who has become a mother, and who, though still quivering with the pain of childbirth (superciliary muscle), is divided betwixt the physical pain and the mental joy of seeing the infant to whom she has given birth and at whom she smiles (great zygomatic muscle).

These latter examples show that the anatomical conditions take the lead up to a certain point of those which result from the nature of the passions, and that a combination of expressions is possible only when it can be realised with regard to the facial muscles.

We will finish here these short instructions on the physiology of the face, happy if we have been

successful in showing the artist that in the play of the face there is neither fancy, caprice, nor inspiration, but that all is subject to exact and precise rules which are the orthography of the language of physiognomy, and that the possible combinations are both large and varied, so that the artist can preserve his liberty of action while conforming to these rules, as the poet observes those of grammar without being on that account embarrassed in the scope of his genius.

INDEX.

	PAGE
Abdomen, Forms of	189
Abdomen, Muscles of	188
Abduction and Adduction	109
Achilles, Tendon of	264
Acromion	44
Adductors of the Thigh Muscles	249
Adipose, Ligament	135
Alveoli, Dental	168
Anatomy, Definition and History	1
Anatomical Neck	48
Anatomical Snuff-box	235
Anconeus Muscle	232
Anterior Tibial Muscle	256
Arm	55
Armpit, Hollow of	205
Arthrology	13
Association of Expressions	295
Astragalus Bone	146
Athletes	5
Atlas, Vertebræ	23
Attention, Expression of	298
Auditory Canal	160
Axis, Vertebra	23
Back, Muscles of	195
Bertin, Ligament of	108
Biceps Brachialis	214
Biceps Cruralis	252
Bicipital Groove	56
Bicipital Tuberosity	65
Brachialis Anticus Muscle	218
Brachycephalics	163
Buccinator, Muscle	312
Calcaneum	146
Camper	173
Canine Teeth	171
Canons	87
Caruncula Lachrymalis	295
Carpo-Metacarpal Articulation	80
Carpus	74
Cartilages	17
Caucasian Race	174
Cervical Ligament	26
Cheek, Prominence of	168
Chin	169
Chondro-costal Articulation	41
Chondro-sternal Articulation	41
Clavical	43
Coccyx	92
Combination of Expressions	316
Commissure of Lips	295
Commissure of Eyelids	295
Complexus Muscle	201
Condyle	57
Condyles of Femur	124
Contempt, Expression of	217
Coraco-Brachialis Muscle	312
Coracoid Process	47
Coronal Suture	162
Coronoid Process	58
Cotyloid Cavity	94
Coxo-Femoral Articulation	106
Cranium	155
Crucial Ligaments	133
Crural Arch	99
Cuboid Bone	148
Cuneiform Bone	75
Deltoid Muscle	206
Deltoid Expression	54
Diaphyses	16
Digastric Muscle	275

PAGE

Discs, Intervertebral . . . 25
Disgust, Impression of . . 314
Dissections 4
Dolichocephalics 163
Duchenne of Boulogne . . 292

Egyptian Canon 87
Elbow, Articulation of . . 57
Elevators of Lips, Muscles . 296
Epicondyle 57
Epigastric Pit 42
Epiphyses 16
Epitrochlea 57
Extensor brevis digitorum . 266
Extensors of Fingers, Muscles 229
Extensors of Toes, Muscles . 257
Eyebrow 295
Eyelids 298

Face, Skeleton of the . . . 165
Facial Angle 173
Fascia Lata 244
Femur Bone 104
Fibula Bone 138
Flexor carpi radialis . . . 225
Flexors of Fingers, Muscles . 223
Flexors of Toes, Muscles . . 265
Foot 143
Fore-arm 64
Fourchette of Sternum . . 32
Frontal Bone 158
Frontal Muscle 297

Gastrocnemii, Muscle . . . 261
Gerdy 178
Gladiator 179
Glenoid, Cavity 47
Gluteal, Muscles 240
Gracilis 250
Gratiolet 293
Groove, Bicipital . . . 49, 56
Gymnasium 6

Hand 74
Head, as a Canon 178
Head, Movements of . . . 277
Head, Muscles of 277
Head, Bones of 154

PAGE

Hips 91
Humerus 48, 54
Hypothenar Eminence . . . 237

Iliac Bones 93
Incisors, Teeth 171
Index Finger 78, 233
Index, Brachial 89
Index, Cephalic 163
Infra-spinatus Muscle . . . 202
Infra-hyoid Muscle 272
Interosseous Spaces. . . . 66
Interosseous Muscles . . . 239
Ischium 95

Jaw, Articulation of the . . 172

Knee, Articulation of . . . 128
Knee, Form of 133

Lambdoid, Suture 161
Latissimus Dorsi Muscle . . 199
Laughter 306
Le Brun, Studies of Expression 281
Leg 126, 137, 255
Linea Alba 189
Lips 295
Lumbricoides Muscles . . . 238

Malar Bone 168
Malleoli 140
Masseter Muscle 278
Mastoid Process 160
Maxillary Bone, Inferior . . 169
Maxillary Bone, Superior . 168
Medio-carpal Articulation . 76
Menace, Expression of . . 302
Mesaticephalics 163
Metacarpus 77
Metatarsus 149
Michael Angelo 8
Middle Finger 78, 177
Molar Teeth 171
Monkeys 176
Mortise, Tibio-fibular . . . 140
Movement of Muscles . . . 181
Muscles in general 181
Muscular Contraction . . . 181

PAGE
Nasal Fossa 167
Naso-Labial Fold 295
Neck, Movements of 270
Neck, Muscles of 268
Neck, Region of 268
Negro, Facial Angle of . . 176

Oblique Muscles of the Abdomen 188
Obturator Foramen 94
Obturator Muscle 243
Occipital Bone 156
Occipital Muscle 207
Odontoid Process 23
Œsophagus 272
Olecranon 59
Omo-hyoid Muscle 272
Opponens Muscles . . 237, 238
Opposition, Movements of . 79
Orbicular Muscle of Eyelids . 298
Orbicular Muscle of Lips . . 311
Orbicularis Palpebrarum . . 299
Orbital Processes 159
Orbits 165
Osteology 13

Palpebral Muscle 299
Parietal Bones 158
Patella 125
Patella, Ligament of 125
Pectineus Muscle 249
Pectoral Muscles 184
Pelvis 91
Peroneal Muscles . . . 149, 259
Pes Anserinus 246
Phalanges of Fingers 81
Phalanges of Toes 151
Physiology 4
Pisiform Bone 75
Plantaris Muscle 264
Platysma Muscles 314
Platysma of Neck 314
Pomum Adami 272
Popliteal Space 133
Poupart's Ligament 99
Pronation 68
Pronator Quadratus 227
Pronator Teres 223

PAGE
Proportion of Arm 85
,, Clavicle 35
,, Foot 152
,, Leg 153
,, Lower Limb . . 152
,, Pelvis 116
,, Sternum 35
,, Upper Limb . . 84
,, Vertebral Column 28
Psoas Muscle 250
Pterygoid Muscle 278
Pubis 93
Pyramidalis Abdominis Muscle 194
Pyramidalis Muscle of Face . 302
Pyriformis Muscle 243

Quadratus Femoris 243
Quadratus Menti 296

Radial Muscles 229
Radio-carpal Articulation . . 65
Radio-ulnar Articulation . . 68
Radius 57
Rectus Abdominis 192
Rectus Femoris 247
Reflection, Expression of . . 300
Rhomboid Muscles 202

Sacro-lumbalis Muscle . . . 204
Sacro-sciatic Ligament . . 98
Sacrum 91
Sartorius Muscle 245
Scaphoid Bone 75
Scapulo-humeral Articulation 49
Sciatic Notch 96
Semi-lunar Bone 75
Semi-lunar Ligaments . . . 128
Semi-membranosus Muscle . 253
Semi-tendinosus Muscle . . 252
Serratus Magnus Muscle . . 210
Shoulder 43
Shoulder Blade 44
Sigmoid Cavities 68
Soleus Muscle 264
Sorrow, Expression of . . . 313
Sphenoid Bone 162
Splenius Muscle 201
Sterno-cleido-mastoid Muscle 268

PAGE
Sterno-thyroid Muscle . . . 274
Sternum 30
Stylo-hyoid Muscle 275
Styloid Process 6
Subastragaloid Articulation . 148
Sue on Physiognomy . . . 284
Superciliary Muscle . . . 303
Superville, Humbert de . . 284
Supination 68
Supinator Muscles . . 221, 229
Supra-hyoid Muscles . . . 274
Supra-Spinous Muscles . . 210
Sutures of Skull 161
Symphysis of Pubis 98
Symphysis, Sacro-iliac . . . 97

Tarsus 147
Temporal Bone 159
Temporal Muscle 279
Temporo-maxillary Articulation 172
Teeth 171
Tendo Achillis 264
Tendon in general 182
Tensor of Fascia Lata . . . 244
Teres Major Muscle . . . 203
Thenar Eminence 236
Thigh 244
Thorax 30
Thyro-hyoid Muscle . . . 274
Thyroid Cartilage 272
Thumb 78
Tibia 137
Tibialis Anticus 256
Tibio-fibular Articulation . . 139

PAGE
Tibio-tarsal Articulation . . 141
Titian and André Vesale . . 9
Toes 149
Trachea 272
Transversalis 190
Transversalis Nasi 310
Trapezium 75
Trapezius Muscle 195
Trapezoid Bone 75
Triangular Muscle of Lips . 312
Triceps Brachialis 218
Triceps Femoris 246
Trochanters 106
Trochlea 57
Trochlea Humeral 60
Trochlea Femoral 124
Trunk, Muscles of 184

Ulna 65
Unciform Bone 75

Vertebra 21
Vertebra Prominens . . . 24
Vertebral Column 19
Vinci, Leonardo de . . . 8

Weeping, Muscle of . . . 309
Wrist 74

Xiphoid Appendix 32

Yellow Ligaments 25

Zygomatic Muscles 305
Zygomatic Process 160

CASSELL & COMPANY, LIMITED, BELLE SAUVAGE WORKS, LONDON, E.C.

WELLCOME LIBRARY INSTITUTE

The Fine Art Library.

Edited by JOHN SPARKES,

Principal of the South Kensington Art Schools.

WITH AN INTRODUCTION BY PROFESSOR RUSKIN.

The English School of Painting. By M. ERNEST CHESNEAU, late Inspector of Fine Arts. Translated by L. N. ETHERINGTON. Illustrated with upwards of 100 Engravings. Crown 8vo, cloth gilt, 5s.

The Flemish School of Painting. By A. J. WAUTERS. Translated by Mrs. HENRY ROSSEL. With about 100 Illustrations. Crown 8vo, cloth gilt, 5s.

Artistic Anatomy. By M. MATTHIAS DUVAL, Membre de l'Académie de Médicine, Professeur d'Anatomie à l'École des Beaux-Arts. Translated by F. E. FENTON, M.R.C.P., F.R.C.S., &c. With about 100 Illustrations. 5s.

The Dutch School of Painting. By M. HENRY HAVARD. Translated by G. POWELL. With about 100 Illustrations. 5s.

CASSELL & COMPANY, LIMITED, *Ludgate Hill, London.*

MONTHLY, price **1s.**

The MAGAZINE of ART.

"*A very storehouse of Art. Every year the* MAGAZINE OF ART *more surely justifies its name.*"—TIMES.

"*The only Art magazine which at all keeps pace with the moving current of Art.*"—ACADEMY.

"*Its exquisite beauty should carry it into every home.*"—STANDARD.

"*Contains better literature than any of the other Art periodicals.*"—PALL MALL GAZETTE.

The Magazine of Art Yearly Volume. With nearly 500 choice Engravings from famous Paintings, and from Original Drawings by the First Artists of the day, and Original Etching is published at 16s.

CASSELL & COMPANY, LIMITED, *Ludgate Hill, London.*

Practical Guides to the Study of Water Colour Oil, and China Painting.

EACH CONTAINING FULL INSTRUCTIONS TO THE STUDENT.

ANIMAL PAINTING IN WATER COLOURS. With 18 Coloured Plates by FREDERICK TAYLER, late President of the Royal Society of Painters in Water Colours. *Crown 4to, cloth.* 5s.

CHINA PAINTING. By FLORENCE LEWIS, of the Lambeth School of Art. With 16 Coloured Plates. 5s.*

"This is the best and most practical work we have seen on the subject."—*Decoration.*

TREE PAINTING IN WATER COLOURS. With 18 Coloured Plates by W. H. J. BOOT. 5s.

"This useful volume will supply a want often felt by the learners of water-colour painting."—*Bazaar.*

WATER-COLOUR PAINTING, A COURSE OF. Eighth and Enlarged Edition. With 24 Coloured Plates from Designs by R. P. LEITCH. 5s.*

"The water-colour illustrations alone are worth treble the cost of the volume."—*Birmingham Post.*

FLOWER PAINTING IN WATER COLOURS. First and Second Series. With 20 Coloured Plates by F. E. HULME, F.L.S., F.S.A., in each. 5s. each.

"The coloured plates are very beautifully drawn and printed."—*Queen.*

FIGURE PAINTING IN WATER COLOURS. With 16 Coloured Plates from Original Designs by BLANCHE MACARTHUR and JENNIE MOORE. 7s. 6d.

"A remarkable book. . . . No lessons can be more complete."—*Court Journal.*

PAINTING IN NEUTRAL TINT, A COURSE OF. With 24 Plates by R. P. LEITCH. 5s.

"The directions to the students are ample, and the twenty-four plates are admirably varied."—*Daily News.*

SEPIA PAINTING, A COURSE OF. With 24 Plates from Designs by R. P. LEITCH. 5s.

"Sepia painting thoroughly well treated with respect to form, colour, light, and shade."—*Standard.*

SKETCHING FROM NATURE IN WATER COLOURS. By AARON PENLEY. With Illustrations in Chromo-Lithography after Original Water-Colour Drawings. 15s.

"A very attractive and useful volume, indispensable to all learners, and of much service to advanced practitioners in the art."—*Art Journal.*

LANDSCAPE PAINTING IN ILS, A COURSE OF LESSONS IN. By A. F. GRACE, Turner Medallist, Royal Academy. With Nine Reproductions in Colour after TURNER, CONSTABLE, DE WINT F. WALKER, MASON, MÜLLER, and A. F. GRACE; and numerous examples engraved on wood from well-known Pictures. *Extra demy folio.* 42s.

"This large and splendid volume is one which will render good service to students."—*Queen.*

* *An Edition of these Works in the French Language is published, price 10fr. each.*

CASSELL & COMPANY, LIMITED, *Ludgate Hill, London; and all Booksellers.*

SELECTIONS FROM VOLUMES

Published by Cassell & Company, Limited.

A History of British Fossil Reptiles. By SIR RICHARD OWEN, K.C.B., F.R.S., &c. With 268 Plates. Complete in Four Volumes. Price £12 12s. the set.

Italy: from the Fall of Napoleon I., in 1815, to the Death of Victor Emmanuel in 1878. By JOHN WEBB PROBYN. 7s. 6d.

London's Roll of Fame. With Portraits and Illustrations. 12s. 6d.

Humphry Sandwith. A Memoir by his Nephew, THOMAS HUMPHRY WARD. With Portrait. 7s. 6d.

Oliver Cromwell: the Man and his Mission. By J. ALLANSON PICTON, M.P. With Steel Portrait. Price 7s. 6d.

English Poetesses. By E. S. ROBERTSON, M.A. 5s.

The Life of the Right Hon. W. E. Gladstone. By GEORGE BARNETT SMITH. *Eleventh and Cheap Edition.* With Portrait. 3s. 6d. *Jubilee Edition*, 1s.

Life and Times of the Rt. Hon. John Bright. By W. ROBERTSON. With Portrait. 7s. 6d.

India: the Land and the People. By SIR JAMES CAIRD, K.C.B., F.R.S. Revised and Enlarged. 10s. 6d.

Constitutional History and Political Development of the United States. By SIMON STERNE, of the New York Bar. 5s.

Russia. By D. MACKENZIE WALLACE, M.A. *Cheap Edition*, in One Vol., with Two Maps, 10s. 6d.

Burnaby's Ride to Khiva. *Cheap Edition*, crown 8vo, cloth, 1s. 6d. *People's Edition*, 6d.

A History of Modern Europe. By C. A. FYFFE, M.A., *New and Revised Edition.* Vol. I. Demy 8vo, 12s.

Four Years of Irish History, 1845—1849. A Sequel to "Young Ireland." By SIR C. GAVAN DUFFY, K.C.M.G. Cloth, 21s.

Wood Magic: A Fable. By RICHARD JEFFERIES, Author of "The Gamekeeper at Home," &c. *Cheap Edition*, cloth, 6s.

A Police Code, and Manual of the Criminal Law. By C. E. HOWARD VINCENT, late Director of Criminal Investigations. *Pocket Edition* (Abridged), for Policemen and Householders, 2s.

Cassell & Company, Limited: Ludgate Hill, London; Paris; and New York.

5R—11.84

The Magazine of Art. Yearly Volume. With about 500 Illustrations by the first Artists of the day, and beautifully-executed Etching, for Frontispiece. Cloth gilt, gilt edges, 16s.

Some Modern Artists. With highly-finished Engravings of their most popular Masterpieces and Portraits. 12s. 6d.

The Forging of the Anchor. With 20 Illustrations specially executed for the Work, by the first Artists of the day. Small 4to, cloth, gilt edges, 5s., or Japanese morocco, padded (in box), 6s.

Picturesque Europe. *Popular Edition.* Vols. I., II., & III., with 13 exquisite Steel Plates, and about 200 Original Engravings in each by the best Artists. Cloth gilt, 18s. each; or Vols. I. & II. bound in one, 31s. 6d. N.B.—The *Original Edition*, in Five magnificent Volumes, royal 4to size, can still be obtained, price £10 10s.

Egypt: Descriptive, Historical, and Picturesque. By Prof. G. EBERS. Translated by CLARA BELL, with Notes by SAMUEL BIRCH, LL.D., D.C.L., F.S.A. With Original magnificent Engravings. Cloth bevelled, gilt edges. Vol. I., £2 5s.; Vol. II., £2 12s. 6d., or the Two Vols. in box, £4 17s. 6d.

Picturesque America. Complete in Four Vols. with 12 exquisite Steel Plates and about 200 Original Wood Engravings in each. Royal 4to, £2 2s. each.

Landscape Painting in Oils, A Course of Lessons in. By A. F. GRACE, Turner Medallist, Royal Academy. With Nine Reproductions in Colour. Extra demy folio, cloth, gilt edges, 42s.

Illustrated British Ballads. With Several Hundred Original Illustrations. Complete in Two Vols. Cloth, 7s. 6d. each; cloth, gilt edges, 10s. 6d. each; morocco, Two Vols., 25s.

Sunlight and Shade. Original and Selected Poems. With exquisite Engravings by the best Artists of the day. 7s. 6d.

Choice Poems by H. W. LONGFELLOW. Illustrated from Paintings by his Son ERNEST W. LONGFELLOW. Small 4to, cloth, 6s.

The Doré Fine Art Volumes comprise—

	£ s. d.		£ s. d.
Milton's Paradise Lost	1 1 0	**Munchausen**	0 5 0
The Doré Bible	2 10 0	**Fairy Tales Told Again**	0 5 0
Don Quixote	0 15 0		

Cassell's New Natural History. Edited by Prof. DUNCAN, M.B., F.R.S., assisted by Eminent Writers. With nearly 2,000 Illustrations. Complete in 6 Vols., 9s. each.

European Butterflies and Moths. By W. F. KIRBY. With 61 Coloured Plates. Demy 4to, cloth gilt, 35s.

The Book of the Horse. By the late S. SIDNEY. With Twenty-five Coloured Plates, and 100 Wood Engravings. *New and Revised Edition.* Demy 4to, cloth, 31s. 6d.; half-morocco, £2 2s.

The Illustrated Book of Poultry. By L. WRIGHT. With 50 Coloured Plates and numerous Wood Engravings. Demy 4to, cloth, 31s. 6d.; half-morocco, £2 2s.

The Illustrated Book of Pigeons. By R. FULTON. Edited by L. WRIGHT. With Fifty Coloured Plates and numerous Engravings. Demy 4to, cloth, 31s. 6d.; half-morocco, £2 2s.

Canaries and Cage-Birds, The Illustrated Book of. With Fifty-six Coloured Plates and numerous Illustrations. Demy 4to, cloth, 35s.; half-morocco, £2 5s.

Dairy Farming. By Professor SHELDON, assisted by eminent Authorities. With Twenty-five Fac-simile Coloured Plates, and numerous Wood Engravings. Cloth, 1s. 6d.; half-morocco, £2 2s.

Dog, The Illustrated Book of the. By VERO SHAW, B.A. Cantab. With Twenty-eight Fac-simile Coloured Plates, drawn from Life expressly for the Work, and numerous Wood Engravings. Demy 4to, cloth bevelled, 35s.; half-morocco, 45s.

European Ferns: their Form, Habit, and Culture. By JAMES BRITTEN, F.L.S. With Thirty Fac-simile Coloured Plates, Painted from Nature by D. BLAIR, F.L.S. Demy 4to, cloth gilt, gilt edges, 21s.

Familiar Wild Birds. By W. SWAYSLAND. FIRST SERIES. With 40 full-page exquisite Coloured Illustrations and numerous Original Wood Engravings. 12s. 6d.

Familiar Garden Flowers. FIRST, SECOND, and THIRD SERIES. By SHIRLEY HIBBERD. With Forty Full-page Coloured Plates by F. E. HULME, F.L.S., in each. 12s. 6d. each.

Familiar Wild Flowers. Complete in Five Series. By F. E. HULME, F.L.S., F.S.A. With Forty Coloured Plates and Descriptive Text in each. 12s. 6d. each.

Vignettes from Invisible Life. By JOHN BADCOCK. With numerous Illustrations specially executed for the Work. Crown 8vo, 3s. 6d.

Universal History, Cassell's Illustrated. Vol. I., Early and Greek History; Vol. II., the Roman Period; Vol. III., the Middle Ages. With numerous high-class Engravings. Price 9s. each.

England, Cassell's History of. With about 2,000 Illustrations. Nine Vols., cloth, 9s. each; or in library binding, £4 10s.

United States, Cassell's History of the. With 600 Illustrations and Maps. 1,950 pages, extra crown 4to. Complete in Three Vols., cloth, £1 7s.; or in library binding, £1 10s.

The History of Protestantism. By the Rev. J. A. WYLIE, LL.D. With 600 Original Illustrations. Three Vols., 4to, cloth, £1 7s.; or in library binding, £1 10s.

Old and New London. A Narrative of its History, its People, and its Places. With 1,200 Illustrations. Complete in Six Vols., 9s. each; or in library binding, £3.

Greater London. Uniform with "Old and New London." Vol. I. By EDWARD WALFORD. With about 200 Original Illustrations. Extra crown 4to, cloth gilt, 9s.

Our Own Country. An Illustrated Geographical and Historical Description of the Chief Places of Interest in Great Britain. Complete in 6 Vols., with upwards of 200 Illustrations in each. 7s. 6d. each.

Old and New Edinburgh, Cassell's. Complete in Three Volumes. With 600 Original Illustrations, specially executed for the Work. Extra crown 4to, cloth, 9s. each.

Krilof and His Fables. By W. R. S. RALSTON, M.A. *Third Edition, Enlarged*, 3s. 6d.

The Adventures and Discourses of Captain John Smith. By JOHN ASHTON. With Fac-similes of the Original Illustrations. Cloth or parchment, 5s.

Treasure Island. By R. L. STEVENSON. 304 pages. Crown 8vo, cloth, 5s.

Technology, Manuals of. Edited by Prof. AYRTON, F.R.S., and RICHARD WORMELL, D.Sc., M.A.

A Prospectus sent post free on application.

Cassell & Company, Limited: Ludgate Hill, London; Paris; and New York.

Cassell's Concise Cyclopædia, containing 12,000 subjects and about 600 Illustrations. Complete in One Volume. 15s.

A First Sketch of English Literature. By Professor HENRY MORLEY. Crown 8vo, 912 pages, cloth, 7s. 6d.

Popular Educator, Cassell's. *New and thoroughly Revised Edition.* Complete in Six Vols. Price 5s. each.

Science for All. Complete in Five Vols. Edited by Dr. ROBERT BROWN, M.A., F.L.S., &c., assisted by Eminent Scientific Writers. Each containing about 350 Illustrations. Cloth, 9s. each.

The Practical Dictionary of Mechanics. Containing 15,000 Drawings, with Comprehensive and TECHNICAL DESCRIPTION of each Subject. Four Vols., cloth, £4 4s.

The Countries of the World. By ROBERT BROWN, M.A., Ph.D., F.L.S., F.R.G.S. Complete in Six Vols., with 750 Illustrations, 7s. 6d. each. Library binding, Three Vols., 37s. 6d.

Peoples of the World. Vols. I., II., III., & IV. By Dr. ROBERT BROWN. With numerous Illustrations. Price 7s. 6d. each.

Cities of the World. Complete in Three Vols. Illustrated throughout with fine Illustrations and Portraits. Cloth gilt, 7s. 6d.

Gleanings from Popular Authors. Complete in Two Vols. With Original Illustrations. Price 9s. each.

Heroes of Britain in Peace and War. By E. HODDER. With 300 Illustrations. Two Vols., 7s. 6d. each; or in Library binding, One Vol., 12s. 6d. *Popular Edition*, Vol. I., cloth, 5s.

The Sea: its Stirring Story of Adventure, Peril, and Heroism. By F. WHYMPER. Complete in Four Vols., each containing 100 Original Illustrations. 4to, 7s. 6d. each. Library binding, Two Vols., 25s.

Morocco: its People and Places. By EDMONDO DE AMICIS. Translated by C. ROLLIN TILTON. With nearly 200 Original Illustrations. Extra crown 4to, *Cheap Edition*, cloth, 7s. 6d.

Energy and Motion. A Text-book of Elementary Mechanics. By W. PAICE, M.A. Cloth, 1s. 6d.

Energy in Nature. By WM. LANT CARPENTER, B.A., B.Sc. With 80 Illustrations. 3s. 6d.

The Field Naturalist's Handbook. By the Rev. J. G. WOOD and THEODORE WOOD. Cloth, 5s.

The Encyclopædic Dictionary. A New and Original Work of Reference to all the Words in the English Language, with a Full Account of their Origin, Meaning, Pronunciation, and Use. Seven Divisional Volumes now ready, price 10s. 6d. each; or bound in Double Volumes, in half-morocco, 21s. each.

Library of English Literature. Edited by Professor HENRY MORLEY. With Illustrations taken from Original MSS., &c. Each Vol. complete in itself.

VOL. I. SHORTER ENGLISH POEMS. 12s. 6d.
VOL. II. ILLUSTRATIONS OF ENGLISH RELIGION. 11s. 6d.
VOL. III. ENGLISH PLAYS. 11s. 6d.
VOL. IV. SHORTER WORKS IN ENGLISH PROSE. 11s. 6d.
VOL. V. LONGER WORKS IN ENGLISH VERSE AND PROSE. 11s. 6d.

*** Vol. I., *Popular Edition*, now ready, 7s. 6d.

Dictionary of English Literature. Being a Comprehensive Guide to English Authors and their Works. By W. DAVENPORT ADAMS. 720 pages, extra fcap. 4to, cloth, 10s. 6d.

Dictionary of Phrase and Fable. Giving the Derivation, Source, or Origin of 20,000 Words that have a Tale to Tell. By Rev. Dr. BREWER. *Enlarged and Cheaper Edition*, cloth, 3s. 6d.; superior binding, leather back, 4s. 6d.

The Royal Shakspere. A Handsome Fine-Art Edition of the Poet's Works. Vols. I. & II., containing Exquisite Steel Plates and Wood Engravings. The Text is that of Prof. Delius, and the Work contains Mr. FURNIVALL's Life of Shakspere. Price 15s. each.

Cassell's Illustrated Shakespeare. Edited by CHARLES and MARY COWDEN CLARKE. With 600 Illustrations by H. C. SELOUS. Three Vols., royal 4to, cloth gilt, £3 3s.

The Leopold Shakspere. The Poet's Works in Chronological Order, and an Introduction by F. J. FURNIVALL. With about 400 Illustrations. Small 4to, cloth, 6s.; cloth gilt, 7s. 6d.; half-morocco, 10s. 6d.; morocco, or tree calf, 21s.

PRACTICAL GUIDES to PAINTING, with numerous Coloured Plates, and full Instructions by the Artists:—

Animal Painting in Water Colours. With 18 Coloured Plates by FRED. TAYLER. 5s.

Flower Painting in Water Colours. 1ST & 2ND SERIES. By F. E. HULME, F.L.S. 5s. each.

Figure-Painting in Water Colours. By BLANCHE MACARTHUR and JENNIE MOORE. 7s. 6d.

China Painting. By FLORENCE LEWIS. 5s.

Tree Painting in Water Colours. By W. H. J. BOOT. 5s.

Water-Colour Painting, A Course of. By R. P. LEITCH. 5s.

Neutral Tint, A Course of Painting in. By R. P. LEITCH. 5s.

Sepia Painting, A Course of. By R. P. LEITCH. Cloth, 5s.

The Early Days of Christianity. By the Ven. Archdeacon FARRAR, D.D., F.R.S. *Popular Edition,* 1 Vol., cloth, 6s.; Persian morocco, 10s. 6d. *Library Edition, Ninth Thousand,* Two Vols., demy 8vo, cloth, 24s. (*Can also be had in morocco binding.*)

The Life of Christ. By the Ven. Archdeacon FARRAR, D.D., F.R.S.

Bijou Edition, complete in Five Vols., in case, 10s. 6d. the set.
Popular Edition, in One Vol., cloth, 6s.; cloth gilt, gilt edges, 7s. 6d.; Persian morocco, 10s. 6d.; tree calf, 15s.
Library Edition. 31*st Edition.* Two Vols., cloth, 24s.; morocco, £2 2s.
Illustrated Edition. With about 300 Illustrations. Extra crown 4to, cloth, gilt edges, 21s.; calf or morocco, £2 2s.

The Life and Work of St. Paul. By the Ven. Archdeacon FARRAR, D.D., F.R.S. *Popular Edition,* One Vol., cloth, 6s.; Persian morocco, 10s. 6d. *Library Edition.* (19*th Thousand.*) Two Vols., demy 8vo, cloth, 24s.; morocco, £2 2s. *Illustrated Edition,* cloth, gilt edges, 21s.

An Old Testament Commentary for English Readers. By various Writers. Edited by the Right Rev. C. J. ELLICOTT, D.D. Lord Bishop of Gloucester and Bristol. Complete in Five Vols., price 21s. each.

VOL. I. contains GENESIS to NUMBERS.
VOL. II. contains DEUTERONOMY to SAMUEL II.
VOL. III. contains KINGS I. to ESTHER.
VOL. IV. contains JOB to ISAIAH.
VOL. V. contains JEREMIAH to MALACHI.

A New Testament Commentary for English Readers. Edited by the Right Rev. C. J. ELLICOTT, D.D., Lord Bishop of Gloucester and Bristol. Three Vols., cloth, £3 3s.; or in half-morocco, £4 14s. 6d.

VOL. I. contains the FOUR GOSPELS. £1 1s.
VOL. II. contains the ACTS to GALATIANS. £1 1s.
VOL. III. contains the EPHESIANS to the REVELATION. £1 1s.

Sermons Preached at Westminster Abbey. By ALFRED BARRY, D.D., D.C.L., Bishop of Sydney, Metropolitan of New South Wales, and Primate of Australia. Cloth, 5s.

Martin Luther the Reformer. By Prof. KOESTLIN. With Portrait. 1s.; cloth gilt, 2s.

The Bible Educator. Edited by the Very Rev. E. H. PLUMPTRE, D.D. Illustrated. Four Vols., 6s. each; or Two Vols., 21s.

The Book of Health. A Systematic Treatise for the Professional and General Reader upon the Science and the Preservation of Health. Edited by MALCOLM MORRIS. With Contributions by eminent Medical Authorities. Price 21s. ; half-morocco, 25s.

Our Homes and How to make them Healthy. Edited by SHIRLEY FORSTER MURPHY, assisted by eminent Contributors. Royal 8vo, cloth, Illustrated, 15s. ; half-morocco, 21s.

The Family Physician. A Modern Manual of Domestic Medicine. By PHYSICIANS and SURGEONS of the Principal London Hospitals. Royal 8vo, cloth, 21s.

Medicine, Manuals for Students of.

Elements of Histology. By E. KLEIN, M.D., F.R.S. 6s.
Surgical Pathology. By A. J. PEPPER, M.B., M.S. 7s. 6d.
The Dissector's Manual. By W. BRUCE CLARKE, F.R.C.S., and C. B. LOCKWOOD, F.R.C.S. 6s.
Physiological Physics. By J. MCGREGOR ROBERTSON. 7s. 6d.
Surgical Applied Anatomy. By F. TREVES, F.R.C.S. 7s. 6d.
Human Physiology. By HENRY POWER, F.R.C.S. 6s.
Clinical Chemistry. By CHAS. H. RALFE, M.D., F.R.C.P. 5s.
Materia Medica and Therapeutics. By J. MITCHELL BRUCE, M.D., F.R.C.P. 7s. 6d.

Prospectus will be sent post free on application.

Clinical Manuals for Practitioners and Students of Medicine. *A List sent post free on application.*

The Domestic Dictionary. An Encyclopædia for the Household. Illustrated throughout. 1,280 pages, royal 8vo. *Cheap Edition*, price 7s. 6d. ; half-roan, 9s.

Cassell's Dictionary of Cookery. The Largest, Cheapest, and Best Book of Cookery. With 9,000 Recipes, and numerous Illustrations. *Cheap Edition*, price 7s. 6d. ; half-roan, 9s.

Choice Dishes at Small Cost. Containing Practical Directions to Success in Cookery, and Original Recipes for Appetising and Economical Dishes. By A. G. PAYNE. 3s. 6d.

A Year's Cookery. Giving Dishes for Breakfast, Luncheon, and Dinner for Every Day in the Year, with Practical Instructions for their Preparation. By PHYLLIS BROWNE. 3s. 6d.

What Girls Can Do. A Book for Mothers and Daughters. By PHYLLIS BROWNE. *Cheap Edition.* 3s. 6d.

☞ **Cassell & Company's Complete Catalogue,** *containing a List of Several Hundred Volumes, including Bibles and Religious Works, Fine-Art Volumes, Children's Books, Dictionaries, Educational Works, Handbooks and Guides, History, Natural History, Household and Domestic Treatises, Science, Serials, Travels, &c. &c., sent post free on application.*

Cassell & Company, Limited: Ludgate Hill, London; Paris; and New York.

71