

## **Quain's elements of anatomy / [Jones Quain].**

### **Contributors**

Quain, Jones, 1796-1865.  
Sharpey, William, 1802-1880.  
Thomson, Allen, 1809-1884.  
Cleland, John, 1835-1925.

### **Publication/Creation**

London : James Walton, 1867.

### **Persistent URL**

<https://wellcomecollection.org/works/jfbfgt2j>

### **License and attribution**


This work has been identified as being free of known restrictions under copyright law, including all related and neighbouring rights and is being made available under the Creative Commons, Public Domain Mark.

You can copy, modify, distribute and perform the work, even for commercial purposes, without asking permission.



Wellcome Collection  
183 Euston Road  
London NW1 2BE UK  
T +44 (0)20 7611 8722  
E [library@wellcomecollection.org](mailto:library@wellcomecollection.org)  
<https://wellcomecollection.org>





JONES,  
12, Eversholt St.,  
LONDON TOWN.  
BOOKS BOUGHT.



22101445584





D. IV.

19/9

Re 41  
519

18298

QUAIN'S ANATOMY.

H. 951  
15/3/67

GEORGE WATSON

# QUAIN'S ELEMENTS OF ANATOMY

Seventh Edition

EDITED BY

WILLIAM SHARPEY, M.D., F.R.S.

PROFESSOR OF ANATOMY AND PHYSIOLOGY IN UNIVERSITY COLLEGE, LONDON

ALLEN THOMSON, M.D., F.R.S.

PROFESSOR OF ANATOMY IN THE UNIVERSITY OF GLASGOW

AND

JOHN CLELAND, M.D.

PROFESSOR OF ANATOMY IN QUEEN'S COLLEGE, GALWAY

IN TWO VOLUMES

ILLUSTRATED BY UPWARDS OF 800 ENGRAVINGS ON WOOD.

VOL. I.

LONDON

JAMES WALTON

BOOKSELLER AND PUBLISHER TO UNIVERSITY COLLEGE

137, GOWER STREET.

1867.



16853

QUALITY

ELEMENTS OF ANATOMY

Second Edition

THE AUTHOR

WILLIAM KEMMEL, M.D., F.R.S.

ALBANY, N.Y., 1867

LONDON:

BRADBURY, EVANS, AND CO., PRINTERS, WHITEFRIARS.

M15119

WELLCOME INSTITUTE	
LIBRARY	
Coll.	waMOmec
Call	
No.	Q54
	1867
	Q19
	V



## ADVERTISEMENT.

---

THE successive Editions of Dr. Jones Quain's "Elements of Anatomy" were, up to the fourth inclusive, published under the superintendence of the Author. The duty of editing the fifth edition was undertaken by Mr. Richard Quain, then Professor of Anatomy in University College, and Dr. Sharpey; the several parts being apportioned between them, as follows, viz.:—The General Anatomy to Dr. Sharpey, with the Descriptive Anatomy of the Brain, the Heart, and of the Organs of Respiration, Voice, Digestion, Urine, and Generation; and to Mr. Quain the remaining portion of the Descriptive Anatomy, comprehending the Bones, Muscles, Articulations, Fasciæ, Vessels, Nerves, and the Organs of the Senses, together with the Surgical Anatomy of the different regions. On that occasion extensive changes were made throughout the work, and a great part was entirely re-written.

The increasing claims of professional duty having prevented Mr. Quain from continuing his services in preparing the Sixth Edition, his place was taken by Mr. Ellis, his successor in the Chair of Anatomy at University College, who was accordingly associated with Dr. Sharpey, and edited that portion of the work which had previously fallen to the share of his predecessor.

In the present edition the General Anatomy, entirely re-written by Dr. Sharpey for the fifth edition, has been again revised by him, and has undergone extensive changes, adapting it to the present state of the science. The whole of the Descriptive Anatomy has been edited by Dr. Thomson and Dr. Cleland. The text of this part has been thoroughly revised, and in great measure recast by Dr. Cleland, with the assistance and supervision of Dr. Thomson. New figures have in most cases been substituted for those of former editions, drawn on a larger scale, or deemed otherwise more



illustrative of the objects, and many additional figures have been introduced. The duty of selecting these figures and superintending their execution has been performed by Dr. Thomson. All those of the bones, and most of those of the joints have been drawn from the natural objects. Many of the figures of the muscles were also drawn from nature, and most of the others, though founded on approved published prints, have been modified and finished from actual dissections. When figures are not original, the sources whence they have been taken are faithfully indicated. Of those borrowed from the works of Kölliker, Sappey, and Frey, a certain number are impressions from electro-type copies, obtained through the courtesy of the authors and publishers of these works. The new cuts have been executed chiefly by Messrs. Robert Tennant and Stephen Miller, of Glasgow; the former as draughtsman, the latter as engraver. Several of those new to the General Anatomy are by Mr. W. H. Wesley, of London.

The Section on Surgical Anatomy has been reprinted as originally written by Professor R. Quain, with only a few verbal alterations.

Instead of the paragraphs headed "dissection," distributed through the work in former editions, it has been thought preferable to supply a systematic but concise set of directions for dissection at the end of the book. Whilst it is hoped that this chapter will add to the utility of the work, it is by no means intended that it should supersede the use of special Manuals of Practical Anatomy.

# CONTENTS OF THE FIRST VOLUME.

## ELEMENTS OF ANATOMY.

	PAGE
INTRODUCTION . . . . .	i

### GENERAL ANATOMY.

	PAGE		PAGE
GENERAL CONSIDERATIONS ON THE		CONNECTIVE TISSUE . . . . .	lxix
TEXTURES . . . . .	iii	Areolar Tissue . . . . .	lxix
Physical Properties . . . . .	iv	Fibrous Tissue . . . . .	lxxiv
Chemical Composition . . . . .	v	Yellow or Elastic Tissue . . . . .	lxxvi
Vital Properties . . . . .	vii	Special Varieties of Connective	
DEVELOPMENT OF THE TEXTURES . . . . .	ix	Tissue . . . . .	lxxviii
Structure of Cells . . . . .	xiii	CARTILAGE . . . . .	lxxx
Production of Cells . . . . .	xv	Hyaline Cartilage . . . . .	lxxxix
Motion of the Protoplasm in		Elastic or Yellow Cartilage . . . . .	lxxxv
Cells . . . . .	xix	Fibro-Cartilage . . . . .	lxxxvi
Relation of Cells to the formation		BONE OR OSSEOUS TISSUE . . . . .	lxxxvii
of textures . . . . .	xxi	External Configuration . . . . .	lxxxvii
Intercellular substance . . . . .	xxiii	Physical Properties . . . . .	lxxxviii
NUTRITION and Regeneration of		Chemical Composition . . . . .	lxxxix
the Textures . . . . .	xxiv	Structure . . . . .	xc
THE BLOOD . . . . .	xxvii	Periosteum . . . . .	c
Physical and Organic Constitu-		Marrow . . . . .	c
tion . . . . .	xxvii	Blood-vessels, &c. . . . .	ci
Chemical Composition . . . . .	xxxiii	Formation and Growth of Bone . . . . .	cii
Red Corpuscles . . . . .	xxxiii	Ossification in Membrane . . . . .	ciii
Liquor Sanguinis . . . . .	xxxvii	Ossification in Cartilage . . . . .	cvi
Origin of Fibrin . . . . .	xxxviii	MUSCULAR TISSUE . . . . .	cxv
Serum . . . . .	xxxix	General Structure of Voluntary	
Mean Composition of the Blood . . . . .	xli	Muscles . . . . .	cxv
Different kinds of Blood . . . . .	xlii	Structure of the Fibres . . . . .	cxviii
Coagulation of the Blood . . . . .	xliv	Connection with Tendons . . . . .	cxxi
THE LYMPH AND CHYLE . . . . .	xlvi	Blood-vessels and Lymphatics . . . . .	cxixiii
Lymph . . . . .	xlvi	Nerves . . . . .	cxvix
Chyle . . . . .	xlvi	Involuntary Muscles . . . . .	cxvix
Formation of the Corpuscles of the		Development of Muscle . . . . .	cxvix
Lymph and Chyle . . . . .	1	Growth of Muscles . . . . .	cxvix
Formation of the Blood-Cor-		Chemical Composition of Muscle . . . . .	cxvix
puscles . . . . .	1	Physical and Vital Properties of	
EPIDERMIC, EPITHELIAL, OR CUTI-		Muscle . . . . .	cxvix
CULAR TISSUE . . . . .	lii	NERVOUS SYSTEM . . . . .	cxvix
General nature . . . . .	lii	Chemical Composition . . . . .	cxvix
Scaly Epithelium . . . . .	lii	Structural Elements . . . . .	cxvix
Columnar Epithelium . . . . .	lvi	Ganglia . . . . .	cxli
Spheroidal Epithelium . . . . .	lviii	Cerebro-Spinal Nerves . . . . .	cxliv
Ciliated Epithelium . . . . .	lviii	The Sympathetic or Ganglionic	
Motion of Cilia . . . . .	lxi	Nerve . . . . .	clviii
PIGMENT . . . . .	lxiii	Vital Properties of the Nervous	
ADIPOSE TISSUE . . . . .	lxv	System . . . . .	clxii
		Development of Nerves . . . . .	clxiii



	PAGE		PAGE
BLOOD-VESSELS . . . . .	clxv	Glands of Mucous Membrane . . . . .	cc
Arteries . . . . .	clxvii	Nerves . . . . .	cci
Veins . . . . .	clxxii	Secretion . . . . .	cci
Capillary Vessels . . . . .	clxxv	SKIN . . . . .	cci
Development of Blood-Vessels . . . . .	clxxx	The Epidermis or Cuticle . . . . .	cci
ABSORBENT OR LYMPHATIC SYS- . . . . .		The True Skin, its Structure . . . . .	cciii
TEM . . . . .	clxxxii	Papillæ . . . . .	cciv
Distribution and Origin . . . . .	clxxxii	Blood-vessels and Lymphatics . . . . .	ccv
Structure . . . . .	clxxxiv	Nerves . . . . .	ccvi
Absorbent Glands . . . . .	clxxxvi	Nails . . . . .	ccvi
SEROUS MEMBRANES . . . . .	cxci	Hairs . . . . .	ccviii
SYNOVIAL MEMBRANES . . . . .	cxci	Glands of the Skin . . . . .	ccxv
MUCOUS MEMBRANES . . . . .	cxcev	SECRETING GLANDS . . . . .	ccxviii
Structure . . . . .	cxcevii	DUCTLESS OR VASCULAR GLANDS . . . . .	ccxxvi

## SPECIAL ANATOMY.

### DIVISION I.—SYSTEMATIC OR DESCRIPTIVE ANATOMY.

	PAGE		PAGE
SECTION I.—OSTEOLOGY . . . . .	2	Malar Bone . . . . .	49
The Skeleton . . . . .	2	Nasal Bone . . . . .	49
I. THE VERTEBRAL COLUMN . . . . .	3	Lachrymal Bone . . . . .	50
Moveable Vertebrae . . . . .	4	Inferior Turbinate Bone . . . . .	50
General Characters . . . . .	4	Inferior Maxillary Bone . . . . .	51
Characters Peculiar to . . . . .		Hyoid Bone . . . . .	52
Groups of Vertebrae . . . . .	5	THE SKULL AS A WHOLE . . . . .	53
Dorsal Vertebrae . . . . .	5	The Sutures . . . . .	53
Lumbar Vertebrae . . . . .	6	General Conformation of the . . . . .	
Cervical Vertebrae . . . . .	7	Skull . . . . .	55
The First and Second Cer- . . . . .		Exterior . . . . .	55
vical Vertebrae . . . . .	8	Interior . . . . .	60
Fixed or United Vertebrae . . . . .	10	Development of the Skull . . . . .	64
Sacrum . . . . .	10	Periods of Ossification of the . . . . .	
Coccyx . . . . .	12	Bones of the Skull . . . . .	70
The Vertebral Column as a . . . . .		The Vertebral Theory of the . . . . .	
whole . . . . .	13	Skull . . . . .	71
Development of the Ver- . . . . .		The Various Forms of the . . . . .	
tebrae . . . . .	15	Skull . . . . .	72
Periods of Ossification . . . . .	20	IV. BONES OF THE UPPER LIMB . . . . .	74
Theoretical Comparison of . . . . .		Scapula . . . . .	74
the Vertebrae . . . . .	21	Clavicle . . . . .	77
II. THE THORAX . . . . .	23	Humerus . . . . .	78
The Sternum or Breast- . . . . .		Radius . . . . .	80
Bone . . . . .	23	Ulna . . . . .	81
The Ribs . . . . .	24	Carpus . . . . .	83
The Thorax as a whole . . . . .	27	Scaphoid Bone . . . . .	84
Development of the Ribs and . . . . .		Semilunar Bone . . . . .	84
Sternum . . . . .	27	Cuneiform Bone . . . . .	84
Periods of Ossification of the . . . . .		Pisiform Bone . . . . .	85
Ribs and Sternum . . . . .	29	Trapezium . . . . .	85
III. THE BONES OF THE SKULL . . . . .	29	Trapezoid Bone . . . . .	85
Occipital Bone . . . . .	29	Os Magnum . . . . .	85
Frontal Bone . . . . .	33	Unciform Bone . . . . .	86
Temporal Bone . . . . .	35	Metacarpus . . . . .	86
Sphenoid Bone . . . . .	38	Digital Phalanges . . . . .	87
Ethmoid Bone . . . . .	42	Development of the Upper . . . . .	
Superior Maxillary Bone . . . . .	44	Limb . . . . .	88
Palate Bone . . . . .	46	Periods of Ossification of the . . . . .	
Vomer . . . . .	48	Bones of the Upper Limb . . . . .	90



	PAGE		PAGE
V. THE PELVIS AND LOWER LIMB	93	SECTION III.—MYOLOGY	167
Innominate Bone . . . . .	93	MUSCLES OF THE HEAD AND	
The Pelvis . . . . .	97	NECK . . . . .	169
Femur . . . . .	100	Superficial Muscles . . . . .	169
Patella . . . . .	103	Epicranial Muscles . . . . .	169
Tibia . . . . .	103	Muscles of the Eyelids . . . . .	171
Fibula . . . . .	105	Muscles of the Nose . . . . .	173
Tarsus . . . . .	106	Muscles of the Lips and	
Calcaneum . . . . .	107	Mouth . . . . .	175
Astragalus . . . . .	107	Muscles of the Orbit . . . . .	179
Cuboid Bone . . . . .	108	Action of . . . . .	179, 501*
Scaphoid Bone . . . . .	108	Muscles of the Jaw . . . . .	181
Cuneiform Bones . . . . .	109	Submaxillary Muscles . . . . .	183
Metatarsus . . . . .	109	A.—Muscles connecting	
Digital Phalanges . . . . .	110	the Hyoid Bone with	
The Bones of the Foot as a		the Skull . . . . .	183
whole . . . . .	110	B.—Muscles of the Tongue	185
Development of the Lower		Muscles of the Pharynx and	
Limb . . . . .	110	Soft Palate . . . . .	187
Periods of Ossification of the		Muscles depressing the Hyoid	
Bones of the Lower Limb	112	Bone . . . . .	191
Comparison of the Upper		Flexor Muscles of the Neck .	193
with the Lower Limb . . . . .	115	Fasciæ of the Head and Neck	196
Relation of the Limbs to the		MUSCLES OF THE UPPER LIMB	198
Segments of the Trunk . . . . .	117	Muscles attaching the Upper	
The Skeleton adapted to the		Limb to the Trunk pos-	
Erect Posture . . . . .	117	teriorly . . . . .	200
SECTION II.—ARTHROLOGY . . . . .	118	Muscles attaching the Upper	
Modes of Articulation . . . . .	118	Limb to the Trunk an-	
Motions of the Bones in the		teriorly . . . . .	203
joints . . . . .	120	Muscles of the Shoulder . . . . .	208
ARTICULATIONS OF THE TRUNK		Muscles of the Arm . . . . .	212
AND HEAD . . . . .	121	Muscles of the Fore-Arm . . . . .	215
Articulations of the Verte-		a. Anterior and Inner	
bral Column . . . . .	121	Regions (Flexors and	
Articulations of the Atlas,		Pronators . . . . .	215
Axis, and Occipital Bone . . . . .	125	b. Posterior and Outer	
Articulations of the Ribs . . . . .	128	Regions (Extensors and	
Temporo-Maxillary Articula-		Supinators) . . . . .	220
tion . . . . .	132	Muscles of the Hand . . . . .	225
ARTICULATIONS OF THE UPPER		Muscles of the Thumb . . . . .	225
LIMB . . . . .	134	Muscles of the Little Finger	227
The Scapulo-Clavicular Arch . . . . .	134	Action of the Muscles of the	
The Shoulder-Joint . . . . .	136	Fore-Arm and Hand . . . . .	228
Articulations of the Fore-		Fasciæ of the Upper Limb . . . . .	229
arm and Elbow . . . . .	138	MUSCLES OF THE TRUNK . . . . .	232
The Wrist-Joint and Articula-		Dorsal Muscles of the Trunk	
tion of the Hand . . . . .	142	(Muscles of the Back) . . . . .	232
Connection of the Metacarpal		Dorsal and Lumbar Fasciæ . . . . .	240
Bones with the Carpus,		Muscles of the Thorax . . . . .	240
and with each other . . . . .	144	Diaphragm . . . . .	243
Articulations of the Metacar-		Movements of Respiration . . . . .	246
pal Bones with the Pha-		MUSCLES OF THE ABDOMEN . . . . .	248
langes, and of the Pha-		Fasciæ of the Abdomen . . . . .	257
langes with each other . . . . .	145	Fasciæ of the Perinæum . . . . .	259
ARTICULATIONS OF THE PELVIS	147	Fasciæ of the Pelvis . . . . .	260
ARTICULATIONS OF THE LOWER		Muscles of the Perinæum . . . . .	261
LIMB . . . . .	151	A.—In the Male . . . . .	261
The Hip-Joint . . . . .	151	B.—In the Female . . . . .	265
The Knee-Joint . . . . .	153	MUSCLES OF THE LOWER LIMB	266
Articulations of the Leg and		Muscles of the Hip and Thigh	266
Ankle . . . . .	158	Gluteal Region . . . . .	266
Articulations of the Foot . . . . .	160	Posterior Femoral Region	
VOL. I.		(Hamstring Muscles) . . . . .	270
		b *	



	PAGE		PAGE
Iliac Region . . . . .	271	Branches of the Internal Carotid Artery . . . . .	360
Anterior Femoral Region . . . . .	273	Ophthalmic Artery . . . . .	360
Internal Femoral Region (Adductor Muscles) . . . . .	276	Anterior and Middle Cerebral Arteries . . . . .	363
Action of the Muscles of the Hip and Thigh . . . . .	279	Circle of Willis . . . . .	363
Muscles of the Leg and Foot . . . . .	279	Subclavian Arteries . . . . .	364
Anterior Region of the Leg . . . . .	279	Branches . . . . .	367
External Region . . . . .	282	Vertebral Artery . . . . .	367
Posterior Region . . . . .	282	Thyroid Axis . . . . .	371
Short Plantar Muscles . . . . .	289	Inferior Thyroid . . . . .	371
Muscles of the Great Toe . . . . .	289	Suprascapular . . . . .	371
Muscles of the Little Toe . . . . .	290	Transverse Cervical . . . . .	373
Action of the Muscles of the Leg and Foot . . . . .	291	Internal Mammary Artery . . . . .	374
Fasciæ of the Lower Limb . . . . .	292	Superior Intercostal and Deep Cervical Arteries . . . . .	376
SECTION IV.—ANGEIOLOGY . . . . .	297	Axillary Artery . . . . .	377
THE HEART . . . . .	297	Branches . . . . .	377
Relation to Surrounding Parts . . . . .	297	External Thoracic Branches . . . . .	379
The Mediastinum . . . . .	297	Subscapular Artery . . . . .	379
Pericardium . . . . .	300	Circumflex Arteries . . . . .	380
External Form of the Heart . . . . .	302	Brachial Artery . . . . .	381
Interior of the Heart . . . . .	304	Branches . . . . .	383
General Description . . . . .	304	Ulnar Artery . . . . .	388
Special Description . . . . .	308	Branches . . . . .	389
Position of the Parts of the Heart with Relation to the Wall of the Thorax . . . . .	313	Recurrent Branches . . . . .	389
Fibrous and Muscular Structure of the Heart . . . . .	316	Interosseous Artery . . . . .	390
Vessels and Nerves . . . . .	321	Muscular Branches . . . . .	391
Weight and Dimensions . . . . .	321	Carpal Branches . . . . .	391
Development of the Heart and Great Blood-Vessels . . . . .	323	Superficial Palmar Arch . . . . .	393
Peculiarities of the Fœtal Heart and Great Vessels. —Fœtal Circulation . . . . .	327	Radial Artery . . . . .	394
PULMONARY VESSELS . . . . .	331	Branches . . . . .	397
Pulmonary Artery and Veins . . . . .	331	Deep Palmar Arch . . . . .	400
SYSTEMIC VESSELS . . . . .	332	Various Conditions of the Arteries of the Hand . . . . .	400
ARTERIES . . . . .	332	THORACIC AORTA . . . . .	401
AORTA . . . . .	332	Branches . . . . .	402
Arch of the Aorta . . . . .	332	Bronchial Arteries . . . . .	402
Peculiarities of the Arch of the Aorta . . . . .	336	(Esophageal Arteries) . . . . .	402
BRANCHES OF THE ARCH OF THE AORTA . . . . .	338	Intercostal Arteries . . . . .	402
Coronary Arteries . . . . .	338	ABDOMINAL AORTA . . . . .	404
Innominate Artery . . . . .	340	A.—Visceral Branches . . . . .	406
Common Carotid Arteries . . . . .	341	Cœliac Artery or Axis . . . . .	406
External Carotid Artery . . . . .	345	Coronary Artery of the Stomach . . . . .	407
Branches of the External Carotid Artery . . . . .	346	Hepatic Artery . . . . .	408
Superior Thyroid Artery . . . . .	346	Splenic Artery . . . . .	408
Lingual Artery . . . . .	348	Superior Mesenteric Artery . . . . .	410
Facial Artery . . . . .	349	Branches . . . . .	410
Occipital Artery . . . . .	351	Inferior Mesenteric Artery . . . . .	412
Posterior Auricular Artery . . . . .	353	Branches . . . . .	412
Temporal Artery . . . . .	353	Anastomoses on the Intestinal Tube . . . . .	412
Internal Maxillary Artery . . . . .	354	Capsular or Suprarenal Arteries . . . . .	413
Ascending Pharyngeal Artery . . . . .	357	Renal or Emulgent Arteries . . . . .	414
Internal Carotid Artery . . . . .	359	Peculiarities . . . . .	414
		Spermatic and Ovarian Arteries . . . . .	414
		B.—Parietal Branches of the Abdominal Aorta . . . . .	416
		Inferior Phrenic Arteries . . . . .	416
		Branches . . . . .	416
		Lumbar Arteries . . . . .	417



	PAGE
Branches . . . . .	417
Minute Anastomoses of the	
Visceral and Parietal	
Branches of the Abdo-	
minal Aorta . . . . .	417
Middle Sacral Artery . . . . .	418
Common Iliac Arteries . . . . .	418
Internal Iliac Artery . . . . .	420
Hypogastric Artery . . . . .	420
Branches of the Internal	
Iliac Artery . . . . .	421
Vesical Arteries . . . . .	421
Uterine and Vaginal Arte-	
ries . . . . .	422
Obturator Artery . . . . .	423
Branches . . . . .	424
Pudic Artery . . . . .	425
Branches . . . . .	426
Sciatic Artery . . . . .	429
Gluteal Artery . . . . .	429
Ilio-Lumbar Artery . . . . .	429
Lateral Sacral Arteries . . . . .	430
External Iliac Artery . . . . .	431
Epigastric Artery . . . . .	432
Circumflex Iliac Artery . . . . .	433
Femoral Artery . . . . .	434
Superficial Inguinal	
Branches . . . . .	437
Deep Femoral Artery . . . . .	437
Muscular Branches . . . . .	439
Anastomotic Artery . . . . .	440
Popliteal Artery . . . . .	441
Branches . . . . .	442
Posterior Tibial Artery . . . . .	444
Small Branches . . . . .	444
Peroneal Artery . . . . .	444
Plantar Arteries . . . . .	446
Branches . . . . .	447
Anterior Tibial Artery . . . . .	448
Branches . . . . .	449
Dorsal Artery of the Foot . . . . .	450
VEINS . . . . .	452
UPPER VENA CAVA . . . . .	453
Innominate or Brachio-	
Cephalic Veins . . . . .	453
Lateral Tributaries . . . . .	453
Veins of the Face, Neck	
and Head . . . . .	455
Facial Vein . . . . .	455
Temporal Vein . . . . .	457
Internal Maxillary Vein . . . . .	457
Facial Communicating	
Vein . . . . .	457

	PAGE
External Jugular Vein . . . . .	459
Internal Jugular Vein . . . . .	459
Venous Circulation within	
the Cranium . . . . .	460
Cerebral Veins . . . . .	460
Cranial Sinuses . . . . .	461
Ophthalmic Vein . . . . .	464
Veins of the Diploë . . . . .	465
Superficial Veins of the	
Upper Limb . . . . .	466
Deep Veins of the Upper	
Limb . . . . .	467
Axillary Vein . . . . .	468
Subclavian Vein . . . . .	469
Azygos Veins . . . . .	469
Veins of the Spine . . . . .	471
LOWER VENA CAVA . . . . .	473
Veins of the Lower Limb and	
Pelvis . . . . .	475
Superficial Veins of the	
Lower Limb . . . . .	475
Deep Veins of the Lower	
Limb . . . . .	476
Femoral Vein . . . . .	476
External Iliac Vein . . . . .	477
Internal Iliac Vein . . . . .	477
Common Iliac Vein . . . . .	479
PORTAL SYSTEM OF VEINS . . . . .	479
Portal Vein or Vena Portæ . . . . .	479
Coronary Vein of Stomach . . . . .	480
Splenic Vein . . . . .	480
Mesenteric Veins . . . . .	481
VEINS OF THE HEART . . . . .	482
Development of the Great	
Veins . . . . .	483
ABSORBENTS . . . . .	486
Thoracic Duct . . . . .	487
Right Lymphatic Duct . . . . .	488
Lymphatics of the Lower	
Limb, and Surface of the	
Lower Half of the Trunk . . . . .	488
Absorbents of the Abdomen	
and Pelvis . . . . .	490
Lymphatics of the Thorax . . . . .	495
Lymphatics of the Upper	
Limb, and of the Breast	
and Back . . . . .	497
Lymphatics of the Head and	
Neck . . . . .	499

NOTE.—On Action of Muscles of  
the Eye . . . . . 501\*





# ELEMENTS OF ANATOMY.

---

## INTRODUCTION.

*Division of natural Bodies.*—The material objects which exist in nature belong to two great divisions ; those which are living or which have lived, and those which neither are nor have ever been endowed with life. The first division comprehends animals and plants, the other mineral substances.

In a living animal or plant, changes take place, and processes are carried on, which are necessary for the maintenance of its living state, or for the fulfilment of the ends of its being ; these are termed its functions, and certain of these functions being common to all living beings serve among other characters to distinguish them from inert or mineral substances. Such are the function of *nutrition*, by which living beings take extraneous matter into their bodies, and convert it into their own substance, and the function of generation or *reproduction*, by which they give rise to new individuals of the same kind, and thus provide for the continuance of their species after their own limited existence shall have ceased.

But in order that such processes may be carried on, the body of a living being is constructed with a view to their accomplishment, and its several parts are adapted to the performance of determinate offices. Such a constitution of body is termed organisation, and those natural objects which possess it are named *organised bodies*. Animals and plants, being so constituted, are organised bodies, while minerals, not possessing such a structure, are *inorganic*.

*Object of Anatomy.*—The object of anatomy, in its most extended sense, is to ascertain and make known the structure of organised bodies. But the science is divided according to its subjects ; the investigation of the structure of plants forms a distinct study under the name of Vegetable Anatomy, and the anatomy of the lower animals is distinguished from that of man or human anatomy under the name of Comparative Anatomy.

*Organs and Textures.*—On examining the structure of an organised body, we find that it is made up of members or organs, through means of which its functions are executed, such as the root, stem, and leaves of a plant, and the heart, brain, stomach, and limbs of an animal ; and further, that these organs are themselves made up of certain constituent materials named tissues or textures, as the cellular, woody, and vascular tissues of the vegetable, or the osseous, muscular, connective, vascular, and various others, which form the animal organs.

Most of the textures occur in more than one organ, and some of them indeed, as the connective and vascular, in nearly all, so that a multitude of organs, and these greatly diversified, are constructed out of a small number of constituent tissues, just as many different words are formed by the varied combinations of a few letters; and parts of the body, differing widely in form, construction, and uses, may agree in the nature of their component materials. Again, as the same texture possesses the same essential characters in whatever organ or region it is found, it is obvious that the structure and properties of each tissue may be made the subject of investigation apart from the organs into whose formation it enters.

*General and Descriptive Anatomy.*—These considerations naturally point out to the Anatomist a twofold line of study, and have led to the subdivision of Anatomy into two branches, the one of which treats of the nature and general properties of the component textures of the body: the other treats of its several organs, members, and regions, describing the outward form and internal structure of the parts, their relative situation and mutual connection, and the successive conditions which they present in the progress of their formation or development. The former is usually named “General” Anatomy, or “Histology;” \* the latter “Descriptive” Anatomy.

\* From *ιστός*, a web.



# GENERAL ANATOMY.

---

## GENERAL CONSIDERATIONS ON THE TEXTURES.

*Enumeration of the Textures.*—The human body consists of solids and fluids. Only the solid parts can be reckoned as textures, properly so called; still, as some of the fluids, viz. the blood, chyle, and lymph, contain in suspension solid organised corpuscles of determinate form and organic properties, and are not mere products or secretions of a particular organ, or confined to a particular part, the corpuscles of these fluids, though not coherent textures, are to be looked upon as organised constituents of the body, and as such may not improperly be considered along with the solid tissues. In conformity with this view the textures and other organised constituents of the frame may be enumerated as follows :—

The blood, chyle, and lymph.

Epidermic tissue, including epithelium, cuticle, nails, and hairs.

Pigment.

Adipose tissue.

Connective tissue, viz.

Areolar tissue.

Fibrous tissue.

Elastic tissue.

Cartilage and its varieties.

Bone or osseous tissue.

Muscle.

Nerve.

Blood-vessels.

Absorbent vessels and glands.

Serous and synovial membranes.

Mucous membrane.

Skin.

Secreting glands.

Vascular or ductless glands.

*Organic Systems.*—Every texture taken as a whole was viewed by Bichat as constituting a peculiar system, presenting throughout its whole extent in the body characters either the same, or modified only so far as its local connections and uses render necessary; he accordingly used the term



“organic systems” to designate the textures taken in this point of view, and the term has been very generally employed by succeeding writers. Of the tissues or organic systems enumerated, some are found in nearly every organ; such is the case with the connective tissue, which serves as a binding material to hold together the other tissues which go to form an organ; the vessels, which convey fluids for the nutrition of the other textures, and the nerves, which establish a mutual dependence among different organs, imparting to them sensibility, and governing their movements. These were named by Bichat the “general systems.” Others again, as the cartilaginous and osseous, being confined to a limited number or to a particular class of organs, he named “particular systems.” Lastly, there are some tissues of such limited occurrence that it has appeared more convenient to leave them out of the general enumeration altogether, and to defer the consideration of them until the particular organs in which they are found come to be treated of. Accordingly, the tissues peculiar to the crystalline lens, the teeth, and some other parts, though equally independent textures with those above enumerated, are for the reason assigned not to be described in this part of the work.

*Structural Elements.*—It is further to be observed, that the tissues above enumerated are by no means to be regarded as simple structural elements; on the contrary, many of them are complex in constitution, being made up of several more simple tissues. The blood-vessels, for instance, are composed of several coats of different structure, and some of these coats consist of more than one tissue. They are properly rather organs than textures, although they are here included with the latter in order that their general structure and properties may be considered apart from their local distribution; but indeed it may be remarked, that the distinction between textures and organs has not in general been strictly attended to by anatomists. The same remark applies to mucous membrane and the tissue of the glands, which structures, as commonly understood, are highly complex. Were we to separate every tissue into the simplest parts which possessed assignable form, we should resolve the whole into a very few constructive elements; and, having regard to form merely, and not to difference of chemical constitution, we might reduce these elements to the following, viz.—1. *simple fibre*; 2. *homogeneous membrane*, either spread out or forming the walls of tubes or cells; and 3. *globules or granules*, varying in diameter from the  $\frac{1}{12000}$ th to the  $\frac{1}{6000}$ th of an inch. These, with a quantity of *amorphous matter*, homogeneous or molecular, might be said, by their varied combinations, to make up the different kinds of structure which we recognise in the tissues; and if we take into account that the chemical nature of these formative elements and of the amorphous matter may vary, it will be readily conceived that extremely diversified combinations may be produced.

#### PHYSICAL PROPERTIES.

The animal tissues like other forms of matter are endowed with various physical properties, such as consistency, density, colour, and the like. Of these the most interesting to the Physiologist is the property of imbibing fluids, and of permitting fluids to pass through their substance, which is essentially connected with some of the most important phenomena that



occur in the living body, and seems indeed to be indispensable for the maintenance and manifestation of life.

All the soft tissues contain water, some of them more than four-fifths of their weight; this they lose by drying, and with it their softness and flexibility, and so shrink up into smaller bulk and become hard, brittle, and transparent; but when the dried tissue is placed in contact with water, it greedily imbibes the fluid again, and recovers its former size, weight, and mechanical properties. The imbibed water is no doubt partly contained mechanically in the interstices of the tissue, and retained there by capillary attraction, like water in moist sandstone or other inorganic porous substances; but the essential part of the process of imbibition by an animal tissue is not to be ascribed to mere porosity, for the fluid is not merely lodged between the fibres or laminae, or in the cavities of the texture; a part, probably the chief part, is incorporated with the matter which forms the tissue, and is in a state of union with it, more intimate than could well be ascribed to the mere inclusion of a fluid in the pores of another substance. Be this as it may, it is clear that the tissues, even in their inmost substance, are permeable to fluids, and this property is indeed necessary, not only to maintain their due softness, pliancy, elasticity, and other mechanical qualities, but also to allow matters to be conveyed into and out of their substance in the process of nutrition.

#### CHEMICAL COMPOSITION.

*Ultimate Constituents.*—The human body is capable of being resolved by ultimate analysis into chemical elements, or simple constituents, not differing in nature from those which compose mineral substances. Of the chemical elements known to exist in nature, the following have been discovered in the human body, though it must be remarked, that some of them occur only in exceedingly minute quantity, if indeed they are constant: oxygen, hydrogen, carbon, nitrogen, phosphorus, sulphur, chlorine, fluorine, potassium, sodium, calcium, magnesium, iron, silicon, manganese, aluminium, copper.

*Proximate Constituents.*—The ultimate elements do not directly form the textures or fluids of the body; they first combine to form certain compounds, and these appear as the more immediate constituents of the animal substance; at least the animal tissue or fluid yields these compounds, and they in their turn are decomposed into the ultimate elements. Of the immediate constituents some are found also in the mineral kingdom, as for example, water, chloride of sodium or common salt, and carbonate of lime; others, such as albumen, fibrin, and fat, are peculiar to organic bodies, and are accordingly named the proximate organic principles.

The animal proximate principles have the following leading characters: They all contain carbon, oxygen, and hydrogen, and the greater number also nitrogen; they are all decomposed by a red heat; and excepting the fatty and acid principles, they are, for the most part, extremely prone to putrefaction, or spontaneous decomposition, at least, when in a moist state; the chief products to which their putrefaction gives rise being water, carbonic acid, ammonia, and sulphuretted, phosphuretted, and carburetted hydrogen gases. The immediate compounds found in the solids and fluids of the human body are the following:

I. *Azotised Substances*, or such as contain nitrogen, viz., albumen, blood-fibrin, muscle-fibrin (or syntonin), casein, globulin, gelatin, chondrin, extractive soluble in alcohol, extractive soluble in water, salivin, kreatin, kreatinine, pepsin, mucus, horny matter or keratin, pigment, hæmatin, pyin,



urea, uric acid, hippuric acid, inosinic acid, sarkin (or hypoxanthin), leucin, tyrosin, azotised biliary compounds.

II. *Substances destitute of Nitrogen*, viz., fatty matters (except cerebrie acid), glycogen (or animal starch), animal glucose, sugar of milk, inosit, lactic, formic, and oxalic acids, certain principles of the bile.

Some of the substances now enumerated require no further notice in a work devoted to anatomy. Of the rest, the greater number will be explained, as far as may be necessary for our purpose, in treating of the particular solids or fluids in which they are chiefly found; but there are a few of more general occurrence, the leading characters of which it will be advisable here to state very briefly, viz.:—

A. *Albuminoid Principles*, albumen, fibrin, and casein. Coagulable—fibrin spontaneously, albumen by heat, casein by rennet. Precipitated by mineral acids, tannic acid, alcohol, corrosive sublimate, subacetate of lead, and several other metallic salts. *When coagulated*, not soluble in water, cold or hot, unless after being altered by long boiling; insoluble in alcohol; soluble in alkalies; soluble in very dilute and also in concentrated acids; the solutions precipitated by red and yellow prussiates of potash.

B. *Gelatinous Principles*, gelatin and chondrin. Not dissolved by cold water; easily soluble in hot water; the solution (at least that of gelatin) congealing when cold. Precipitated by tannic acid, alcohol, ether, and corrosive sublimate, and not by the prussiates of potash. *Chondrin* precipitated by acids, alum, sulphate of alumina, persulphate of iron, and acetate of lead, which do not precipitate gelatin.

C. *Extractive Matters*, associated with lactic acid and lactates. All soluble in water, both cold and hot; some in water only; some in water and rectified spirit; some in water, rectified spirit, and pure alcohol.

D. *Fatty Matters*. Not soluble in water, cold or hot; soluble in ether and in hot alcohol.

It has been shown by Mr. Graham,\* that chemical substances may be distinguished into two classes—the *crystalloid* and the *colloid*—which differ in several important characters. Crystalloid bodies, of which water, most salts and acids, and sugar, may be taken as examples, have a disposition to assume a crystalline state; their solutions are usually sapid, diffuent, and free from viscosity; they readily diffuse in liquids, and pass through moist organic membranes or artificial septa of organic matter, such as parchment-paper. Colloids, on the other hand, are characterised by low diffusibility and great indisposition to permeate organic septa, so that when they are associated with crystalloids, the latter may be easily separated by diffusion through a septum into another fluid; i.e. by “dialysis.” Colloids are, moreover, generally tasteless; they have little or no tendency to crystallize, and their solution, when concentrated, is always, in a certain degree, viscous or gummy. Among the colloids may be reckoned hydrated silicic acid, and various hydrated metallic peroxides, also albumen, fibrin, gelatin, starch, gum, and vegetable and animal extractive matters. Several substances may exist either in the colloid or the crystalloid condition. In point of *chemical* activity the crystalloid appears to be the more energetic, and the colloidal the more inert form of matter; but the colloids possess an activity of their own, arising out of their physical properties, and especially their penetrability, by which they become a medium for liquid diffusion, like water itself. Another characteristic is their tendency to change; the solution of hydrated silicic acid, for instance, cannot be preserved; after a time it congeals. In this respect a liquid colloid might be compared to liquid water at a temperature below freezing, or to a supersaturated saline solution. This dominant tendency of the particles of a colloid to cohere, aggregate, and contract, is obvious in the gradual

\* Liquid Diffusion applied to Analysis,—Phil. Trans., 1861.



thickening of the liquid and its conversion into a jelly; and in the jelly itself the contraction still proceeds, causing separation of water, and division into a clot and serum. Their permeability to fluids, their ready capability of physical changes, and their comparative chemical inertness, are properties by which colloid bodies seem fitted to form organised structures, and to take part in the processes of the living economy. In a recent research,\* Mr. Graham has found that silicic acid may combine both in a dissolved and in a gelatinous state with a variety of very different fluids without undergoing alteration; and presuming that the organic colloids are invested with similar wide powers of combination, he remarks that the capacity of a mass of gelatinous silicic acid to assume alcohol, or even olein, without disintegration or alteration of form, and to yield it up again in favour of some other substituted fluid, may perhaps afford a clue to the penetration of the colloid matter of animal membrane by fatty and other bodies insoluble in water; and moreover, that the existence of *fluid* compounds of silicic acid of a like nature, suggests the possibility of the formation of a compound of colloid albumen with olein, soluble also and capable of circulating with the blood.

The important relation which this new chemical doctrine bears to the constitution and organic processes of the animal body, has appeared to justify the introduction of the present notice of it; for further information the reader is referred to the sources already cited.

#### VITAL PROPERTIES OF THE TEXTURES.

Of the phenomena exhibited by living bodies, there are many which, in the present state of knowledge, cannot be referred to the operation of any of the forces which manifest themselves in inorganic nature; they are therefore ascribed to certain powers, endowments, or properties, which so far as known, are peculiar to living bodies, and are accordingly named "vital properties." These vital properties are called into play by various stimuli, external and internal, physical, chemical, and mental; and the assemblage of actions thence resulting has been designated by the term "life." The words "life" and "vitality" are often also employed to signify a single principle, force, or agent, which has been regarded as the common source of all vital properties, and the common cause of all vital actions.

As ordinary physical forces, such as mechanical motion, heat, electricity, chemical action, and the like, although differing from each other in specific character and mode of operation, are nevertheless shown to be mutually convertible and equivalent, and are held to be but different modifications of one and the same common force or energy, so it may in like manner come to be shown that vital action is similarly related to the physical forces as they are related to each other, and is also a manifestation, under conditions special to the living economy, of the same common energy.

1. *Assimilative Force*.—Of the vital properties, there is one which is universal in its existence among organised beings, namely, the property, with which all such beings are endowed, of converting into their own substance, or "assimilating," alimentary matter. The operation of this power is seen in the continual renovation of the materials of the body by nutrition, and in the increase and extension of the organised substance, which necessarily takes place in growth and reproduction; it manifests itself, moreover, in individual textures as well as in the entire organism. It has been called the "assimilative force or property," "organising force,"

\* On the Properties of Silicic Acid and other Analogous Colloidal Substances,—Proceedings of the Royal Society, June 16th, 1864.



“plastic force,” and is known also by various other names. But in reality the process of assimilation produces two different effects on the matter assimilated : first, the nutrient material, previously in a liquid or amorphous condition, acquires determinate form ; and secondly, it may, and commonly does, undergo more or less change in its chemical qualities. Such being the case, it seems reasonable, in the mean time, to refer these two changes to the operation of two distinct agencies, and, with Schwann, to reserve the name of “plastic” force for that which gives to matter a definite organic form ; the other, which he proposes to call “metabolic,” being already generally named “vital affinity.” Respecting the last-named agency, however, it has been long since remarked, that although the products of chemical changes in living bodies for the most part differ from those appearing in the inorganic world, the difference is nevertheless to be ascribed, not to a peculiar or exclusively vital affinity different from ordinary chemical affinity, but to common chemical affinity operating in circumstances or conditions which present themselves in living bodies only.

2. *Vital Contractility*.—When a muscle, or a tissue containing muscular fibres, is exposed in an animal during life, or soon after death, and scratched with the point of a knife, it contracts or shortens itself ; and the property of thus visibly contracting on the application of a stimulus is named “vital contractility,” or “irritability,” in the restricted sense of this latter term. The property in question may be called into play by various other stimuli besides that of mechanical irritation—especially by electricity, the sudden application of heat or cold, salt, and various other chemical agents of an acrid character, and, in a large class of muscles, by the exercise of the will, or by involuntary mental stimuli.

The evidence that a tissue possesses vital contractility is derived, of course, from the fact of its contracting on the application of a stimulus. Mechanical irritation, as scratching with a sharp point, or slightly pinching with the forceps, electricity obtained from a piece of copper and a piece of zinc, or from a larger apparatus if necessary, and the sudden application of cold, are the stimuli most commonly applied. Heat, when of certain intensity, is apt to cause permanent shrinking of the tissue, or “crispation,” as it has been called, which, though quite different in nature from vital contraction, might yet be mistaken for it ; and the same may happen with acids and some other chemical agents, when employed in a concentrated state ; in using such stimulants, therefore, care should be taken to avoid this source of deception.

3. *Vis Nervosa*.—The stimulus which excites contraction may be applied either directly to the muscle, or to the nerves entering it, which then communicate the effect to the muscular fibre, and it is in the latter mode that the voluntary or other mental stimuli are transmitted to muscles from the brain. Moreover, a muscle may be excited to contract by irritation of a nerve not directly connected with it. The stimulus, in this case, is first conducted by the nerve irritated, to the brain or spinal cord ; it is then, without participation of the will, and even without consciousness, transferred to another nerve, by which it is conveyed to the muscle, and thus at length excites muscular contraction. The property of nerves by which they convey stimuli to muscles, whether directly, as in the case of muscular nerves, or circuitously, as in the case last instanced, is named the “vis nervosa.”

4. *Sensibility*.—We become conscious of impressions made on various parts of the body, both external and internal, by the faculty of sensation ;



and the parts or textures, impressions on which are felt, are said to be sensible, or to possess the vital property of "sensibility."

This property manifests itself in very different degrees in different parts ; from the hairs and nails, which indeed are absolutely insensible, to the skin of the points of the fingers, the exquisite sensibility of which is well known. But sensibility is a property which really depends on the brain and nerves, and the different tissues owe what sensibility they possess to the sentient nerves which are distributed to them. Hence it is lost in parts severed from the body, and it may be immediately extinguished in a part, by dividing or tying the nerves so as to cut off its connection with the brain.

It thus appears that the nerves serve to conduct impressions to the brain, which give rise to sensation, and also to convey stimuli to the muscles, which excite motion ; and it is not improbable that, in both these cases, the conductive property exercised by the nervous cords may be the same, the difference of effect depending on this, that in the one case the impression is carried upwards to the sensorial part of the brain, and in the other downwards to an irritable tissue, which it causes to contract ; the stimulus in the latter case either having originated in the brain, as in the instance of voluntary motion, or having been first conducted upwards, by an afferent nerve, to the part of the cerebro-spinal centre devoted to excitation, and then transferred to an efferent or muscular nerve, along which it travels to the muscle. If this view be correct, the power by which the nerves conduct sensorial impressions and the before-mentioned "*vis nervosa*" are one and the same vital property ; the difference of the effects resulting from its exercise, and, consequently, the difference in function of sensorial and motorial nerves, being due partly to the different nature of the stimuli applied, but especially to a difference in the susceptibility and mode of reaction of the organs to which the stimuli are conveyed.

## DEVELOPMENT OF THE TEXTURES.

The tissues of organised bodies, however diversified they may ultimately become, show a wonderful uniformity in their primordial condition. From researches which have been made with the microscope, especially during the last few years, it has been ascertained that the different organised structures found in plants, and to a certain extent, also those of animals, originate by means of minute corpuscles, which, having for the most part a vesicular structure, have been named cells. These so-called cells, remaining as separate corpuscles in the fluids, and grouped together in the solids, persisting in some cases with but little change, in others undergoing a partial or thorough transformation, produce the varieties of form and structure met with in the animal and vegetable textures. Nay, the germ from which an animal originally springs, so far at least as it has been recognised under a distinct form, appears as a cell ; and the embryo, in its earliest stages, is but a cluster of cells produced apparently from that primordial one ; no distinction of texture being seen till the process of transformation of the cells has begun.

No branch of knowledge can be said to be complete ; but, even now that a quarter of a century has elapsed since the promulgation of the cell-doctrine, there is, perhaps, none which can be more justly regarded as in a state of progress than that which relates to the origin and development of the textures, and much of the current opinion on the subject is uncertain, and must be received with caution. In these circumstances, in order both to facilitate the exposition, and to explain to the reader more fully the groundwork of the doctrines in question, we shall begin with a short



account of the development of the tissues of vegetables ; for it was in consequence of the discoveries made in the vegetable kingdom that the happy idea arose of applying the principle of cell-development to explain the formation of animal structures, and they still afford important aid in the study of that, as yet, more obscure process.

#### OUTLINE OF THE FORMATION OF VEGETABLE STRUCTURE.

When a thin slice from the succulent part of a plant is viewed under the microscope, it is seen to consist chiefly or entirely of a multitude of vesicles adhering together, of a rounded or angular form, and containing various

Fig. I.

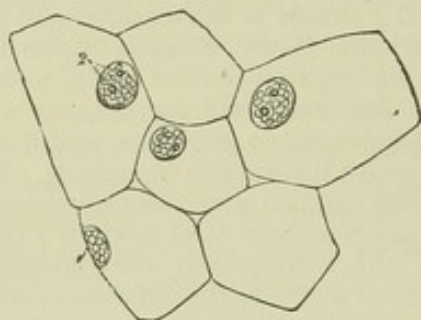


Fig. I.—NUCLEATED CELLS FROM A BULBOUS ROOT ; MAGNIFIED 290 DIAMETERS (Schwann).

coloured or colourless matters in their interior ; these are the elementary cells (fig. I. ; fig. II.,<sup>1 2</sup>). These cells are so constructed that their walls are in close apposition, or are separated only by an intercellular substance, which, according to Hugo von Mohl,\* has so great a similarity to the substance of the cell-walls that it is often impossible, even with the aid of chemical re-agents, to discover a line of demarcation between them. That eminent phytologist supposes that within what is commonly called the cell-wall there exists an extremely delicate membrane, constituting an interior vesicle, which he names the "Primordial utricle." This is in most cases so closely applied to the exterior wall as to be undistinguishable ; but in young cells, and in those of strictly cellular plants, such as the Algæ, &c., during the whole of their existence it may, according to Mohl, be separated by treating the tissue with alcohol, or hydrochloric or nitric acid, and then the interior vesicle appears shrivelled up and separated from the wall of the cavity. But the reality of the alleged primordial utricle has been called in question, and the supposed internal membrane is held to be merely the limiting surface of the cell-contents shrunk away from the inside of the containing cavity, and perhaps somewhat consolidated and defined by the re-agents employed. Still, whether the cell-contents have a vesicular limiting membrane or not, they originally present a marked contrast in chemical nature to the containing cell-wall and inter-cellular substance, and would appear to fulfil a different purpose in the process of tissue development.†

Besides such cells, phænogamous or flowering plants contain tubes, vessels, and other forms of tissue (fig. II.,<sup>4 6</sup>) ; but a great many plants of the class cryptogamia are composed entirely of cells, variously modified, it is true, to suit their several destinations, but fundamentally the same throughout ; nay, there are certain very simple modes of vegetable existence, in which a single cell may constitute an entire plant, as in the well-known green powdery crust which coats over the trunks of trees, damp walls, and

\* Die vegetabilische Zelle ; or English translation by Henfrey.

† See an interesting discussion of this subject by Mr. Huxley in the British and Foreign Medical Review for 1853.



other moist surfaces. In this last case, a simple detached cell exercises the functions of an entire independent organism, imbibing and elaborating extraneous matter, extending itself by the process of growth, and continuing its species by generating other cells of the same kind. Even in the aggregated state in which the cells exist in vegetables of a higher order, each cell still, to a certain extent, exercises its functions as a distinct individual; but it is now subject to conditions arising from its connection with the other parts of the plant to which it belongs, and is made to act in harmony with the other cells with which it is associated, in ministering to the necessities of the greater organism of which they are joint members. These elementary parts are therefore not simply congregated into a mass, but combined to produce a regularly organised structure; just as men in an army are not gathered promiscuously, as in a mere crowd, but are regularly combined for a joint object, and made to work in concert for the attainment of it; living and acting as individuals, but subject to mutual and general control.

Now the varied forms of tissue found in the higher orders of plants do not exist in them from the beginning; they are derived from cells. The embryo plant, like the embryo animal, is in its early stages entirely formed of cells, and these of a very simple and uniform character; and it is by a transformation of some of these cells in the further progress of development that the other tissues, as well as the several varieties of cellular tissue itself, are produced. The principal modes, as far as yet known, in which vegetable cells are changed, are the following.

1. The cells may increase in size; simply, or along with some of the other changes to be immediately described.

2. They alter in shape. Cells have originally a spheroidal or rounded figure; and when in the progress of growth they increase equally, or nearly so, in every direction, and meet with no obstacle, they retain their rounded form. When they meet with other cells extending themselves in like

Fig. II.

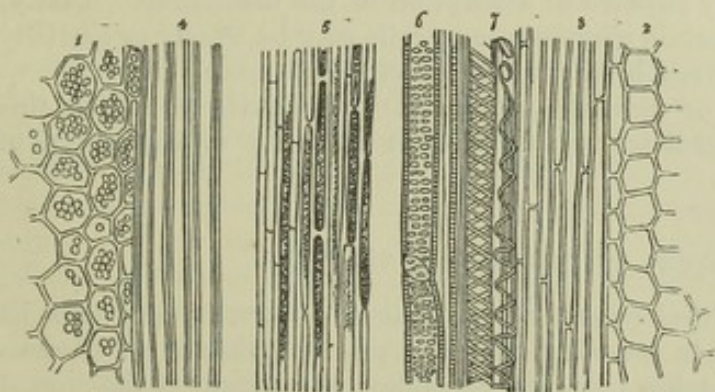


Fig. III.

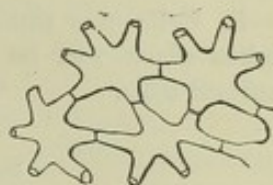

Fig. II.—TEXTURES SEEN IN A LONGITUDINAL SECTION OF THE LEAF-STALK OF A FLOWERING PLANT.

Fig. III.—STELLATE VEGETABLE CELLS.

manner, they acquire a polyhedral figure (fig. II.,<sup>1 2</sup>), by mutual pressure of their sides. When the growth takes place more in one direction than in another, they become flattened, or they elongate and acquire a prismatic, fusiform, or tubular shape (fig. II.,<sup>3 4 5</sup>). Sometimes, as in the common rush, they assume a starlike figure, by mutual adhesion of their walls at



certain points, whilst they retire from each other elsewhere, so as to leave radiating branches connected with the points of similar rays from adjacent cells (fig. III.).

3. The cells coalesce with adjoining cells, and open into them. In this way a series of elongated cells placed end to end may open into one another by absorption of their cohering membranes, and give rise to a tubular vessel.

4. Changes take place in the substance and in the contents of the cells. These changes may be chemical, as in the conversion of starch into gum, sugar, and jelly, and in the production of various coloured matters, essential oils, and the like. Or they may affect the form and arrangement of the contained substances; thus, the contents of the cell very frequently assume the form of granules, or spherules, of various sizes; at other times the contained matter, suffering at the same time a change in its chemical nature and in consistency, is deposited on the inner surface of the cell-wall, so as to thicken and strengthen it. Such "secondary deposits," as they are termed by botanists, usually occur in successive strata, and the deposition may go on till the cavity of the cell is nearly or completely filled up (fig. IV.). It is in this way that the woody fibre and other hard tissues of the plant are formed. It farther appears that the particles of each layer are disposed in lines, running spirally round the cell. In place of forming a continuous layer, these secondary deposits may leave little spots of the cell-wall uncovered, or less thickly covered, and thus give rise to what is named pitted

Fig. IV.

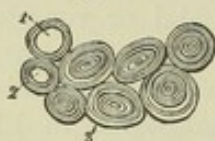

Fig. IV. — CROSS SECTION OF LIGNEOUS CELLS CONTAINING STRATIFIED DEPOSIT.

tissue (fig. II.,<sup>6</sup>); or they may assume the form of a slender fibre or band, single, double, or multiple, running in a spiral manner along the inside of the cavity, or forming a series of separate rings or hoops, as in spiral and annular vessels (fig. II.,<sup>7</sup>). New matter may be absorbed or imbibed into the cells; or a portion of their altered and elaborated contents may escape as a secretion, either by transudation through the cell-wall, or by rupture or absorption of the membrane. Lastly, in certain circumstances, cells may be wholly or partially removed by absorption of their substance.

5. Cells may produce or generate new cells. The mode in which this takes place will be immediately considered, in speaking of the origin of animal cells.

#### FORMATION OF THE ANIMAL TEXTURES.

Passing now to the development of the animal tissues, it may first be remarked generally, that in some instances the process exhibits an obvious analogy with that which takes place in vegetables; for certain of the animal tissues, in their earlier conditions, appear in form of a congeries of cells, almost entirely resembling the vegetable cells, and, in their subsequent transformations, pass through a series of changes in many respects parallel to some of those which occur in the progress of vegetable development. Cartilage affords a good example of this. Figures v. and VI., A, are magnified representations of cartilage in its early condition; and whoever compares them with the appearance of vegetable cells, shown in figures I. and II., must at once be struck with the resemblance. Fig. VI., B and C, shows the subsequent changes on the primary cells of cartilage; the parietes are seen to have become thickened by deposit of fresh material, and the mass



between the cavities is increased. Now, although in certain cases it would seem that this increase is in part due to deposit of intermediate substance independently of the coalescence of thickened cell-walls, yet the process on the whole may be not unaptly compared with the formation of the hard tissues of plants from the thickened sides of vegetable cells. Again, during the growth of most cartilages the cells increase in number, new ones being formed within the old, as happens in many vegetable structures.

The instance now given, and others to the same effect, which will be mentioned as we proceed, tend to show a certain fundamental resemblance in the process of textural development in the two kingdoms; but, when we come to inquire into the various modifications which that process exhibits in the formation of particular textures, we encounter serious difficulties. The phenomena are sometimes difficult to observe, and, when recognised, are perhaps susceptible of more than one interpretation; hence have arisen con-

Fig. V.

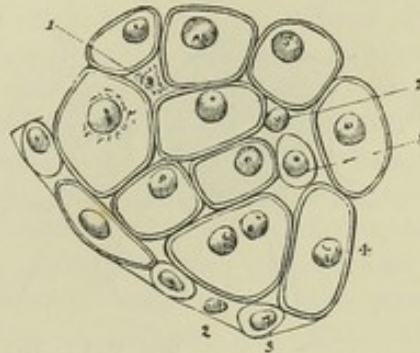
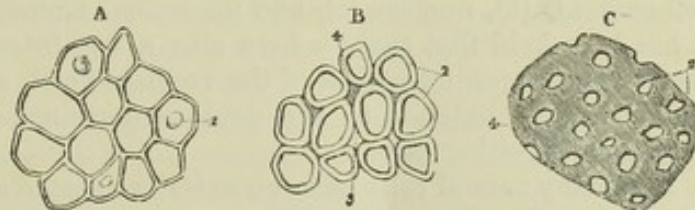


Fig. V. — SECTION OF A BRANCHIAL CARTILAGE OF A TADPOLE, SHOWING THE EARLY CONDITION OF THE CELLS; MAGNIFIED 450 DIAMETERS (Schwann).

Fig. VI. — CARTILAGE OF THE BRANCHIAL RAY OF A FISH (*Cyprinus erythrophthalmus*) IN DIFFERENT STAGES OF ADVANCEMENT; MAGNIFIED 450 DIAMETERS (Schwann).



flicting statements of fact, and differences of opinion, at present irreconcilable, which future inquiry alone can rectify, and which in the mean time offer serious obstacles to an attempt at generalisation. In what follows, nothing more is intended than to bring together, under a few heads, the more general facts as yet made known respecting the formation of the animal textures, in so far as this may be done without too much anticipating details, which can only be suitably and intelligibly given in the special history of each texture.

*Structure of Cells.*—A vegetable cell consists of, 1. a containing wall or envelope, surrounding and enclosing the other parts, and named, from the nature of the substance of which it is composed, the *cellulose wall* (fig. VII., a, a'); 2. the *cell contents*—fluid, slimy, or of mixed nature (b); 3. the *nucleus* (c), a rounded corpuscle situated somewhere in the interior, which however disappears from many vegetable cells when they have reached maturity. In the nucleus are commonly to be seen one (c) or two (c'), rarely more, minute spots named *nucleoli*. Further, some phytologists maintain that within the cell-wall, and distinct from it, there is a delicate membrane or film immediately inclosing the cell-contents, the *primordial utricle*; but although the semblance of such an interior enveloping film may be brought into view by the application of certain re-agents (as at d), its



existence as a natural structure is (as already remarked, p. x) at best but doubtful.

Fig. VII.

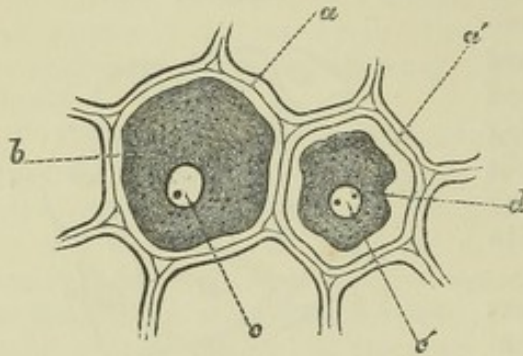


Fig. VIII.

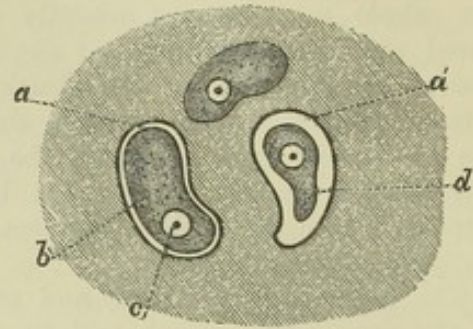


Fig. VII.—DIAGRAM OF VEGETABLE CELLS.

*a, a'*, cellulose wall; *b*, cell-contents; *c, c'*, nucleus; *d*, contents shrunk away from cell-wall.

Fig. VIII.—DIAGRAM OF ANIMAL CELLS (OF CARTILAGE).

*a, a'*, capsule; *b*, cell-contents; *c*, nucleus; *d*, cell-contents shrunk away from the capsule.

Certain animal cells have a structure conformable throughout with that just indicated as belonging to vegetable cells. Thus, the cartilage cell has an outer envelope or *capsule* (fig. VIII., *a, a'*), not indeed composed of cellulose but of animal matter, comparable nevertheless with the vegetable cellulose-wall, and in like manner continuous with the intercellular substance. The cell-contents (*b*), nucleus (*c*), and nucleolus or nucleoli, correspond. Finally, it has been held that there is here also a fine interior envelope corresponding to the primordial utricle of the vegetable cell, and it may be added that the agreement extends to the doubt entertained of the reality of such a membrane in either case.

But many animal cells have no exterior capsule answering to the cellulose vegetable cell-wall, and accordingly represent only the parts of the vegetable cell which are within that enclosure; that is, the nucleus and the mass of cell-contents. The chyle-lymph- and pale blood-corpuscles, the mucus- and salivary corpuscles, and the cells that first appear in the embryo, may be adduced as examples. Some cells of this description have or acquire a fine membranous envelope closely investing their surface, and corresponding to the supposed primordial utricle; but many of them appear to be naked, and to consist of a nucleus surrounded by a mass of soft matter—the so-called cell-contents—often containing solid granules which are held together by a tenacious substance. In these cases the matter at the surface is more condensed than in the interior, where not unfrequently it is more or less fluid. There is moreover a well-defined superficial outline, but there is wanting an internal contour-line marking off an envelope distinct from the contained substance. Such bodies, it is true, may sometimes show appearances indicating the presence of an envelope, when they are treated with certain chemical re-agents; but in such cases the apparent envelope may be produced by the action of the substances employed. At the same time it must be borne in mind that various cells which in their young state have no envelope, distinctly acquire one at a later stage of their existence; and this occurrence is especially to be observed in cells which are destined to form consistent structures, such as epidermis and epithelium. In these



cases the younger and more deeply-seated cells have no envelope, but acquire one before taking their place in the more superficial firm layers.\*

The envelope, when present, is thin, transparent, homogeneous, flexible, and permeable to fluids. The contents differ greatly in different cells; but in those that form the first foundation of the tissues and organs in the embryo, in young cells generally, and in some cells throughout their whole existence, the contained matter is a peculiar semifluid substance, named *protoplasm*, and granular particles, mostly of a fatty nature, densely or sparingly mixed with it. The protoplasm is transparent, colourless, not diffuent, but tenacious and slimy, and under high magnifying powers is seen to contain very fine molecules. In chemical properties it agrees generally with albuminoid bodies, but in many animal cells it doubtless also includes other organic principles, especially fat and glycogenous or amyloid matter. The protoplasm is endowed with remarkable powers of contraction and motion, to be afterwards referred to. But, while certain cells, as already said, retain their primary constitution, others acquire very different matters: many contain mucus; the fat-cells are filled with oil; the cells of glands include the characteristic ingredients of the secretions; the substance of the red blood-cells is coloured, and certain cells are filled with particles of pigment. Very commonly in vegetable cells the protoplasm occupies but a small part of the space within, while the remainder is filled with watery fluid with which the protoplasm does not mingle.

*Free Nuclei.*—Besides the bodies which have been called cells, corpuscles having all the characters of cell-nuclei exist abundantly in various tissues, such as the membranous walls of the capillaries, the sheaths of nerve-fibres, muscular fibres, &c. But in some of these cases it is obvious, in others highly probable, that the nuclei are associated with a certain amount of protoplasm, although not in the usual mass and form of a cell.

*Production of Cells.*—Consistently with the present state of knowledge on this subject, the following may be assigned as the several modes in which cells and nuclei are observed to be produced in the animal system; but while the process varies in outward conditions in each of these cases, it can scarcely be doubted that it will prove to be intrinsically and fundamentally the same in all.

*a. In the Ovum.*—The ovum may be regarded as a cell derived from the parent. In mammalia (fig. IX., A), it has a transparent but stout external membrane (a); within this is the yelk (b), corresponding to the cell-contents; in the yelk is the germinal vesicle (c), including the germinal spot (*macula germinativa*), which are comparable, respectively, to the nucleus and nucleolus. The yelk consists originally of fine molecular particles held together in a transparent tenacious matrix of protoplasm; and when once fertilisation has taken place, the yelk-mass undergoes a process of subdivision or "segmentation," whereby it is fashioned into

\* The existence of animal cells destitute of envelope, although more insisted on of late years, has been all along recognised in the study of cell-development, and was expressly pointed out by Schwann himself (*Microscopische Untersuchungen*, &c., p. 209). It has appeared to some that another name should be used to designate bodies which thus exist in a naked non-vesicular form. Brücke proposes to call them "elementary organisms," a term too cumbersome for use; as the first "shaped" products of organisation which appear in the development of all but the lowest organised beings, they might be named "protoplasts," or, as that name has been already used in a widely different sense—"monoplasts;" but, after all, seeing the universal currency of the term "cell," it is probably most convenient and best to adhere to it, with the understanding that in many cases it is used in a conventional sense.



cells, progressively increasing in number, which combine to form the first material substratum of the tissues and organs of the embryo, and are hence termed "embryonic cells."

The outline of the process is this. The germinal vesicle disappears; the yelk shrinks somewhat together, then separates into two halves (B); the first two segments divide each again into two (C), and the binary

Fig. IX.

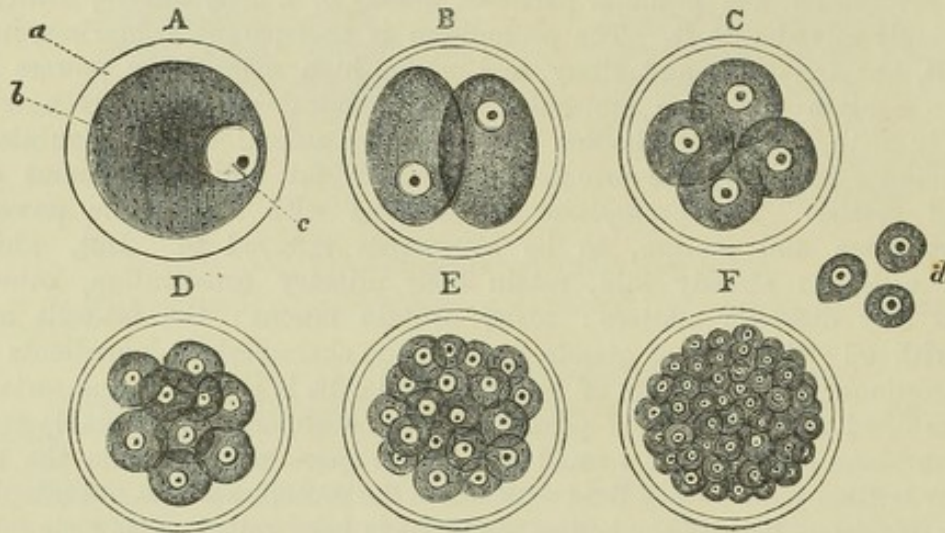


Fig. IX.—DIAGRAMMATIC FIGURES TO ILLUSTRATE THE FORMATION OF CELLS WITHIN THE MAMMALIAN OVUM BY SEGMENTATION OF THE YELK; MAGNIFIED.

a, external membrane; b, yelk; c, germinal vesicle containing the germinal spot; d, embryonic cells further magnified.

division thus goes on (D, E,) pretty regularly, until a large group of small segments is produced (F). These final segments are the embryonic cells (d); they probably have no distinct, separable envelope; but, like other naked cells, they are formed of a nucleus and body of protoplasmic matter. The nucleus is a globule of soft pellucid substance; it may not be always discoverable in the earlier segments, being hidden by the opaque granular mass; but it soon comes into view, and it seems to play an important part in the formation of the cells. The nucleus in fact appears to initiate the process of division, by itself dividing into two halves, which, speedily acquiring full size, serve as two centres of attraction, round each of which separately the yelk-substance is gathered, and thus parted into two new segments. Possibly the substance of the vanishing germinal vesicle and spot may give rise to the first nucleus.

Fig. X.

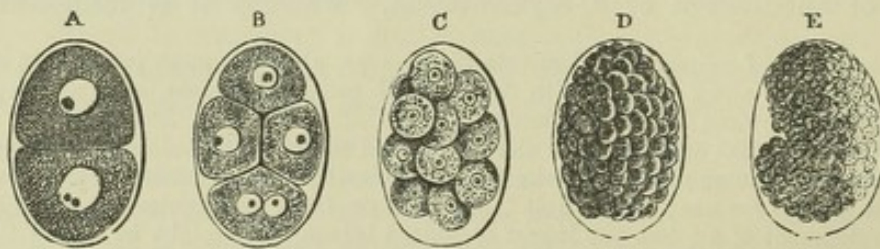


Fig. X.—DIVISION OF THE YELK OF ASCARIS.

A, B, C (from Kölliker), ovum of *Ascaris nigrovenosa*; D and E, that of *Ascaris acuminata* (from Bagge).



The formation of cells by segmentation of the yelk may be traced with comparative ease in the ova of many invertebrata. The accompanying figures represent the several stages of the process in small species of the ascaris worm. Figures A, B and C are from the *Ascaris nigrovenosa*, as observed by Kölliker. He found that, after the germinal vesicle had disappeared, a new nucleus with nucleolus was formed in its place. The segmentation then goes on as in the mammalian ovum, but the nuclei are visible from the first; and from appearances, such as those seen in the lowermost segments of A and B, it seems probable that the division of the nucleus is preceded by that of the nucleolus.

I may remark that I once observed the ovum of the ascaris under the microscope whilst one of the large segments was actually undergoing division. There was first a very obvious heaving motion among the granules throughout the whole mass; then ensued a constriction at the circumference, which, proceeding inwards, soon completed the division; but all this time the nuclei were quite hidden by the enveloping granular matter.

In some animals the segmentation process affects only a part of the yelk.

*b. Division of free Cells.*—Essentially the same process of fissiparous propagation by which the cells are multiplied within the ovum continues to take place in the embryonic cells at future stages, and in their descendants in the organs and fluids of the body throughout life. The steps of the operation have been best observed and proved in the colourless blood-corpuscles, but it takes place in various other cells (fig. XI.).

1. *Into two.*—The body of the cell is observed to be somewhat lengthened, and its nucleus divided into two; a constriction then begins in the middle and proceeds until the substance of the cell is parted into two halves, each of which contains a nucleus. There can be little doubt that here also the division begins with the nucleus. The colourless blood-corpuscle we presume to have no proper cell-wall, but if, as some believe, an envelope or primordial utricle is present, it is also involved in the division.

2. *Into more than two.*—The division is usually into two, as above described, but Remak has observed instances in the frog-larva of cells dividing into as many as five or six new cells; that is, after the nucleus had divided in a corresponding way. The difference in this modification of the process may simply be that whilst in the preceding case the two halves of the divided cell part from each other, and the resulting new cells undergo fresh subdivision solitarily, they in the present case remain associated in a group. Perhaps the formation of pus-corpuscles from connective tissue-corpuscles, as described by Virchow, may be an instance of this kind. Where the swollen primitive corpuscle acquires a distinct cell-membrane or capsule which incloses its progeny, the case comes to resemble the so-called "endogenous" propagation, as in cartilage, to be next described.

*c. Division of inclosed Cells.*—An example of this is afforded by cartilage. The cells in that tissue are surrounded by an outer capsule, which is continuous, or at least coherent, with the substance of the matrix. (Fig. XII., A). Here, as in the previous cases, there is first a division of the nucleus into two; this is followed by cleaving of the cell-body likewise into two, and thus two young cells are formed from a parent one.

Fig. XI.

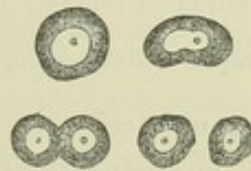


Fig. XI.—COMMENCEMENT, PROGRESS, AND RESULT, OF DIVISION OF A FREE CELL.



So far the process is the same as before ; but now a species of capsule is formed round each of the young cells (E), whilst the old one inclosing them becomes blended with the intercellular matrix, and is no longer traceable (C).

Fig. XII.

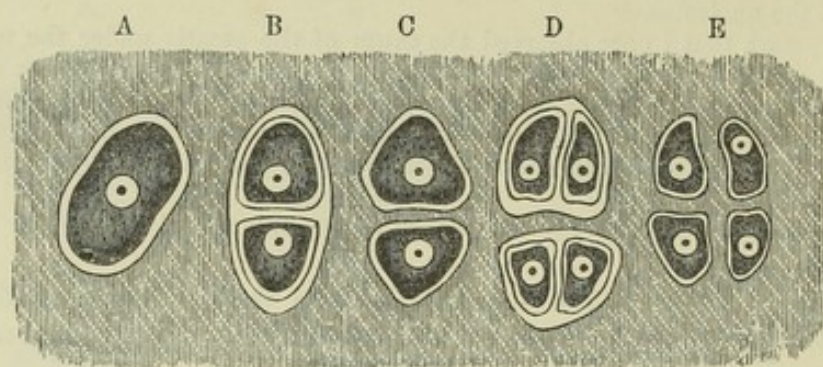


Fig. XII.—IDEAL PLAN OF THE MULTIPLICATION OF CELLS OF CARTILAGE.

A, cell in its capsule ; B, divided into two, each with a capsule ; C, primary capsule disappeared, secondary capsules coherent with matrix ; D, tertiary division ; E, secondary capsules disappeared, tertiary coherent with matrix.

The new cells, in turn, divide in the same way, so as to make a group of four, each of which is surrounded by its own capsule (D), whilst the capsules of the first descent (secondary) blend with the matrix (E) like their predecessor. In certain cases the whole series of capsules may remain visible ; in others, and especially in morbid conditions, the young capsules may not be formed, or may all disappear, leaving the young cells surrounded by the still conspicuous original capsule, like the yolk-segments in the ovum.

The multiplication of cells in the ovum and in cartilage, seeing that it takes place within an enclosing envelope, has been named "endogenous ;" but it will be perceived that the difference between this and the division of a free cell is unimportant.

*d. Multiplication of Nuclei in Cells.*—Irregularly shaped cells have been found in the medullary cavities of bone (Robin and Kölliker), containing many nuclei, and such cells afford an example of the multiplication of nuclei within a cell without separation into new cells. Other multinucleated cells are formed in the spleen and pass into the blood of the splenic vein (Kölliker) ; but if these eventually divide into uninucleated cells, as seems most probable, the case falls under *b*, 2.

*e. Multiplication of free Nuclei.*—Bodies having the characters of nuclei and designated as such, commonly make their appearance in large numbers where growth or new formation of tissue is going on. There can be little doubt that these are produced by division of previously existing nuclei, uninclosed in cells but yet originally descended from cells, and probably associated with an inconspicuous amount of shapeless protoplasm. The new nuclei may continue in the same condition as those from which they immediately sprung, or it may happen that the protoplasm grows and accumulates round the groups of multiplying nuclei, each of which assumes its distinct share, and there thus results a group of new cells. The nuclei lying on the

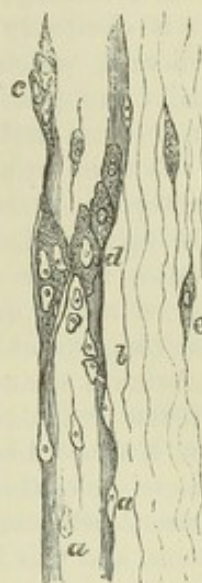


walls of the capillary vessels have been observed to multiply in this way in the formation of new (morbid) growths, as is shown in fig. XIII.

Fig. XIII.—CAPILLARY VESSEL FROM A FIBROID TUMOUR; MAGNIFIED (adapted from C. O. Weber, Virch. Arch. 1864).

*a, a*, nuclei on the wall of the capillary; *b*, nucleus after division into two; *c*, group of nuclei surrounded by protoplasm; *d*, new cells; *e*, cells of connective tissue.

Fig. XIII.



Seeing the successive generations of cells which proceed from a single one in the ovum, and the propagation of cells in a similar manner which occurs at after-periods, physiologists have been naturally led to look to the ovum for the original source to which all succeeding cells in the economy might be traced back; and, as that body is itself derived from the parent organism, it is conceived that a peculiar germinative matter is handed down from parent to offspring, and, receiving an impulse by fecundation, begins in the ovum the series of assimilative and reproductive actions which is afterwards continued throughout life. Seeing, moreover, that throughout all these operations the nucleus takes the first apparent step in the propagation of cells, and by itself increases and multiplies, that body may not unreasonably be regarded as the original depositary and subsequent representative of the germinative matter in its most characteristic type, although, no doubt, the protoplasm of the primary cell-contents is, in its degree, endowed with the same property. According to this view, all cells in the animal economy are derived from pre-existing cells, and all are to be referred back through preceding generations to the ovum. Schwann, on the other hand, maintained that cells may arise altogether independently of pre-existing cells, and that in animals this was actually the most prevalent mode of cell-production. He conceived that cells are formed out of a soft or liquid organisable matter, which he named "cyto-blastema," or simply "blastema," and which in animals that have a circulating blood is derived from that source. The blastema might be contained in cells, lodged in the interstices of cells and tissues, or deposited on the surface of growing parts; and cells might arise in any of these situations, viz., in previously existing cells, or in the interstitial and free blastema. As to the steps of the process of formation, Schwann adopted and applied to animal cells the account given by Schleiden of cell-genesis in vegetables. According to Schleiden, nuclei are first formed by aggregation of matter round nucleoli which appear in the cyto-blastema, and a cell-wall is produced by deposition and condensation of fresh matter on the nucleus, which he regarded as the generator of the cell, and therefore named the "cytoblast." Among later observers who deny the uninterrupted descent of all cells from the ovum, may be mentioned M. Robin, who believes that the embryonic cells derived from the ovum do not generate secondary cells, but suffer complete dissolution, at the same time that fresh nuclei are independently formed in their interstices from the dissolved substance.

The doctrine of independent cell-formation, which, in contradistinction to derivation from previously existing parent-cells, it has been proposed to call "equivocal cell-generation," has greatly lost ground since it was first promulgated; and perhaps it must be abandoned as regards cell-formation in the higher animals. At the same time, undue weight must not be allowed to the natural *à priori* argument against it as a case of spontaneous generation. It must further be borne in mind that in certain lichens, algæ and fungi, spores entirely constituted as cells arise, not indeed independently of a parent organism, but to all appearance not immediately from pre-existing cells or nuclei.

*Motion of the Protoplasm in Cells.*—In the cells of the *Vallisneria*, *Chara*, and various other plants, when exposed under the microscope, the green



coloured grains (of chlorophyll) and other small masses and corpuscles contained in the cavity, are seen to be moved along the inside of the cell-wall in a constant and determinate direction. This phenomenon appears to be of very general occurrence in the vegetable kingdom, although the movement does not always go on with the same regularity as in the instances cited. It is obviously due to a layer of protoplasm on the inner surface of the cell-wall, which enters into a peculiar flowing or undulating motion and trails the passive corpuscles along with it; but how the motion of the protoplasm itself is produced is not at all understood.

Motions are also observed in animal protoplasm; cells in form of nucleated protoplasm-masses of irregularly stellate or jagged outline, which lie in the areolar tissue and are called connective tissue-corpuscles, and similar bodies in the substance of the cornea, have been noticed slowly to change figure whilst under observation (in the tissues of the recently killed frog), shrinking in at one part of their uneven contour and extending their soft substance at another. The effect seems to be due to a contractile property of the protoplasm comparable to the contractility of muscular substance; for Kühne\* has found that the substance of these protoplasm bodies contracts under the electric stimulus, and contractions may be excited in the corneal cells through the medium of fine nerves which are distributed to them, and this both by mechanical and electrical stimulation. Now the soft transparent matter named "sarcode" which constitutes the bodies of the *amoeba* and *actinophrys*, and the animal part of the foraminifera and other allied organisms of simple nature exhibits similar retractile and extensile movements, and may also be made to contract by electrical excitement; and accordingly it is reckoned as an example of protoplasm by some recent observers of authority and designated by that name. It is further to be noted, however, that the varied movements of these amoebine animals are very generally accompanied by a flowing of fine particles to and fro in their pellucid substance, as if there were a thinner and more diffuent portion confined within the more firm exterior part. The movement of the fluid matter, and consequent flow of the particles carried by it, have been ascribed by some observers to an impulse caused by the contractions of the firmer portion, but there are cases in which this explanation is hardly sufficient, and the point remains in doubt.

To the same class of phenomena are probably to be referred the remarkable movements observed in the pigment-cells of the frog's skin, which have been so lucidly investigated by Professor Lister.† In these ramified cells the dark particles of pigment are at one time dispersed through the whole cell and its branches, but at another time they gather into a heap in the central part, leaving the rest of the branched cell vacant, but without alteration of its figure. In the former case the skin is of a dusky hue; in the latter, pale. The phenomenon is probably due to some kind of motion of the protoplasm, although it must be admitted that Mr. Lister has adduced arguments of considerable weight to prove that there is some impulse operating directly on the particles, and that they move independently of the surrounding matter, which he considers to be fluid. Like the movements of the protoplasm, the aggregation of the pigment molecules can be excited through the nerves, both mechanically and electrically.

Lastly, the pale blood-corpuscles and other similarly constituted cells of

\* Untersuchungen über das Protoplasma und die Contractilität. 1864.

† Phil. Trans. 1858.



common occurrence exhibit changes of figure and movements of an amoebine character which seem naturally to be referred to the present head.

The fact above mentioned that these movements of cells may be excited by stimulation of the nerves is especially worthy of note, in as much as it proves that operations effected in and by cells are more or less under the governance of the nervous system. Moreover the well-known influence of mental states over the secretions, and the effects resulting from experimental stimulation of the nerves of secreting glands, although doubtless due in part to changes in the blood-vessels, seem to show that this subjection to the nervous system extends even to the chemical and physical operations which take place in secreting cells. A curious and interesting observation in proof of this is adduced by Kölliker. He found that the light of the fire-fly, *lampyrus*, is emitted from cells in which albuminoid matter is decomposed with production of urate of ammonia, and that the emission of light could be brought on or rendered more vivid by electrical and other stimuli operating through the nerves.

The well-known tremulous movement which so often affects minute particles of matter, is not unfrequently observed in the molecular contents of cells; but this phenomenon depends simply upon physical conditions, and is of a totally different character from the motions of the protoplasm above referred to.

*Of Cells in Relation to the Formation of Textures.*—In a certain sense it might be said that the foundation of all the textures and organs of the body is formed of cells; for in the early embryo all the different parts of the body, so far as they are characterised by form and position, are made up of embryonic cells; but how the different and special characters of the fully organised textures are produced is still a matter of no little uncertainty. No doubt certain textures in their mature condition are composed of cells, which, on the supposition of continuous cell-generation, must be the progeny of the embryonic cells, although modified in character to suit them to their special destination. The epidermis, the several varieties of epithelium, and the plain or non-striated muscular tissue are examples of this. Other textures or textural elements are not made up of cells or formed immediately from cells, as, for example, the fibres of connective tissue, which are produced in intercellular substance. But there remain cases of tissue-formation in which, whilst it is generally admitted that cells or nuclei take part, it is not agreed to what extent or in what precise mode these bodies share in the process: the development of the fibres of voluntary muscles and nerves afford an illustration of this, as will be afterwards shown in its proper place. Accordingly the reasonableness of certain limitations and qualifications of the doctrine of tissue-development from cells has been recognised by judicious histologists even from its first promulgation.

Of the changes which cells or their elements undergo in the formation of tissues, or afterwards in the exercise of their functions when constituting part of the living organism, the following are what may be considered as best ascertained; and it is to be observed that the same cell may undergo more than one of the changes indicated.

1. Cells may increase in size and change their figure. When a cell grows equally or nearly so in all directions, it preserves its globular shape; but more commonly the growth is greater in one dimension than in another, and then the cell becomes flattened, in which case it may remain as a round disk or change into an oval, fusiform, or strap-shaped figure. When



growing cells meet one another, they generally become angular or polyhedral; and this change may be combined with elongation into the prismatic or flattening into the tabular form, as exemplified in the columnar and scaly varieties of epithelium. A more remarkable change of figure occurs in those instances where a cell sends out branches at various

Fig. XIV.

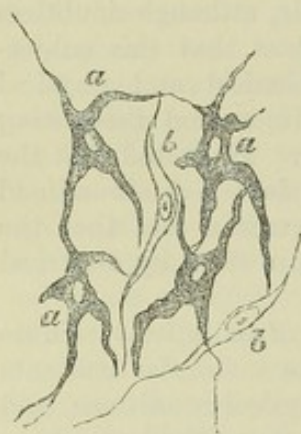


Fig. XIV.—RAMIFIED AND FUSIFORM CELLS, FROM THE TISSUE OF THE CHOROID COAT OF THE EYE; MAGNIFIED 350 DIAMETERS (after Kölliker).

*a*, cells with pigment;  
*b*, colourless fusiform cells.

points of its circumference, as happens with certain varieties of pigment-cells (fig. XIV.), connective tissue-corpuses, and nerve-cells. Of course when the changes of figure are accompanied by an absolute increase in size, there must be assumption of new matter by the cell. The nucleus seems to be less subject to alteration in size and shape. It may grow somewhat larger as the cell increases, especially at first; thus it enlarges and flattens in epithelium cells. In the cells of non-striated muscle it becomes oblong or rod-shaped. Sometimes it disappears, as in the flattened cells of the cuticle.

2. Whilst the above-described changes of figure are going on, the cell wall may acquire increased density and strength; and in a flattened cell, when much extended, the opposite sides may cohere so as to convert it into a scale. The thickening of the cell-membrane may take place by deposition of new matter on its inner surface, as in vegetable cells, or on the outside, as is probably the case in the partial thickening of the cell-wall in certain forms of intestinal epithelium; but there are cases in which it is difficult to

determine in what way the change is affected. The substance of a cell thus condensed may have changed more or less in chemical nature, as in the cuticle, where the cells, while deep-seated and recently formed, are soluble in acetic acid, but as they rise to the surface lose this property and acquire a horny character.

3. Changes may take place in the cell-contents. Granular matter in cells may be dissolved and consumed, as is well seen in the formation of blood-corpuses from granular cells in the oviparous vertebrata. On the other hand, new matters may appear, as fat and pigment within the adipose and pigmentous cells, and the peculiar constituents of certain secretions in the cells of secreting organs, in which last case the cells may burst and discharge their contents. Lastly, the process may take on more of a plastic and organising character, as in the generation of young cells, already described, and the formation of the spontaneously moving bodies named spermatozoa, which are produced from the nuclei of cells.

These plastic changes are equally unexplained with the other alterations of form and structure which accompany the production and metamorphoses of cells. As regards the changes in the quantity and chemical nature of the contained matter, it may be remarked, that the introduction of new matter into a cell is so far a phenomenon of imbibition, and, as such, must be to a certain extent dependent on the endosmotic effect produced by the substance already within the cell, and on the comparative facility with which the matter to be introduced is imbibed and transmitted by the permeable cell-wall. Some substances, moreover, being more readily imbibed than others, the quality as well as the quantity of the imbibed material will be so far



determined by the same circumstances. Thus, uric acid, known to be present in minute quantity in the blood, is gathered up by the cells of the kidneys, and other chemical compounds existing in the circulating fluid may be segregated in like manner by cells, to be discharged by excretion. Also in the converse operation of absorption of aliment, the cells of the intestinal epithelium become charged with particles of fat. But, while an alteration in the contents of a cell may be thus brought about by the imbibition of one kind of matter in preference to another, the contained substance may be also changed in its qualities by a process of conversion taking place within the cell.

4. Cells ultimately present differences in their relations to each other.

a. They may remain isolated, as in the instance of the corpuscles of blood, chyle, and lymph, and those formed in certain secretions.

b. They may be united into a continuous tissue, by means of a cementing intercellular substance; the epithelium and cuticle, the nails and hairs, afford instances of this. In cartilage, where this occurs, the capsules of the cells may become more or less blended with the intercellular substance.

c. The parietes of neighbouring cells meet at particular points, and, absorption taking place, their cavities become united. It is supposed that ramified cells may thus open into one another; and Schwann conceives that the networks of capillary vessels originate in this way.

*Intercellular Substance.*—Of the matter which lies between cells—the intercellular substance—and its relation to them, it may be observed that sometimes it is in very small quantity, and seems merely to cement the cells together, as in epidermis and epithelium; at other times it is more abundant, and forms a sort of matrix in which the cells are imbedded, as in cartilage. It is homogeneous, translucent, and firm in most cartilages, and pervaded by fibres in yellow cartilage. In connective tissue it consists of fibres, with soft interstitial matter, which is scanty in the denser varieties, but abundant in the lax tissue of the umbilical cord; in bone the intercellular substance is calcified and mostly fibrous. As to the production of the intercellular substance, there can be little doubt that in cartilage it is derived from the cells. Formed as capsules round the cells by excretion from their surface, or by conversion of their proper substance, and being blended into a uniform mass, it accumulates while the cells multiply, and while fresh material is supplied to them from the blood, which they convert into chondrinous substance. Kölliker supposes that, in like manner, simple membrane, such as the *membrana propria* of gland-ducts, may be produced by excretion from a series of cells; in which case such membranes would come under the same description as intercellular substance. The source of the intercellular substance is in other cases not so apparent, but it may be presumed that the cells have some influence in its nutrition and maintenance.

From what has been said it will be obvious that cells and nuclei play an important part in the growth of textures, and probably in nutrition. The former process is usually accompanied by a great multiplication of cells or nuclei, the peculiar constituent of which—the protoplasm—seems to be specially endowed with the faculty of propagation by division, and of increase by appropriating and converting new matter. It is conceivable that in this way it may serve for the extension of growing tissue and the development of structural elements from the crude materials of growth. Again, in the nutrition of a mass of tissue the crude material may undergo preparation by the cells or nuclei that lie in the interstices of the structure.

The existence of this protoplasmic germinative substance is very general, perhaps indeed universal, in the animal and vegetable kingdoms. But whilst in the great



majority of organic beings it assumes the form of a nucleated cell (protoplast, or monoplast), as the first condition of their organised structure, in simpler modes of life and organisation it is not subject to the same limitation of form and mass. In the *mycetozoa* (*myxomycetes*), a curious tribe, heretofore mostly reckoned among the fungi, but standing as it were in the debateable ground between the animal and vegetable kingdoms, the protoplasm is extended into reticular masses, or irregularly anastomosing trains, spread over the surface of bark and other bodies to which it parasitically clings; whilst in vibrios and some other infusorial animalcules of the simplest kind, it appears as fine molecular particles; but it is most probably derived from parents in all instances, however minute and apparently insignificant these may be.

Professor Beale proposes to distinguish the matter of organised bodies into two kinds, viz., "germinal matter"—which comprehends the active matter of cells and nuclei, and appears to correspond with what has been already described as protoplasm—and "formed material," under which term he includes all the structural elements and intercellular substances lying outside and between cells, the cell-wall itself when present, and certain products, not germinative, which may be included in the cell-contents. "Germinal matter" grows and increases, and is converted into "formed material;" and all "formed material" has passed through the condition of "germinal matter." In nutrition, according to Dr. Beale, "pabulum does not pass through the cell-wall to become altered by the action of the cell, but certain of its constituents are converted into germinal matter,—the living substance, which becomes tissue, or is changed into substances which form the constituents of the secretions." Formed material may be endowed with peculiar and important properties, but is destitute of the power of producing matter like itself,—"it has no power to *produce* structure or to alter itself."\* I presume it is not meant by this to imply that "formed material" is incapable of undergoing further organisation; for otherwise the proposition would be in contradiction to well-known facts, such as the formation of fibres in the matrix of cartilage, &c.

Professor Bennett considers that organisation begins with molecules or granules of various composition and endowments. These are of two kinds—*histogenetic*, formed by precipitation from fluids, and *histolytic*, derived from the disintegration of previously formed tissues. Molecules of disintegration may in peculiar circumstances become the basis of matter which undergoes development, so that histolytic, or disintegration particles of one period become the histogenetic or formation molecules of another. Certain molecules are endowed with the power of active movement, and the motions in cells and tissues depend upon them; they are mutually attracted by a molecular force, and thus unite to produce cells and higher forms of tissue.†

Molecules and granules are, no doubt, more elementary forms of organisable substance than cells; still it is matter of observation that in the early embryo and in the production of certain tissues, these particles in the first instance unite to form cells. This, Dr. Bennett by no means denies, only he regards the formation of cells as of subordinate moment in the general process of organisation. For my own part I am disposed to think that in the process of organisation, as distinguished from its result, the cognisable form and mass of the organisable material, whether as cell or molecule, are of altogether subordinate consideration to the nature of its substance.

#### NUTRITION AND REGENERATION OF THE TEXTURES.

*Nutrition.*—The tissues and organs of the animal body, when once employed in the exercise of their functions, are subject to continual loss of material, which is restored by nutrition. This waste or consumption of matter, with which, so to speak, the use of a part is attended, takes place in different modes and degrees in different structures. In the cuticular

\* On the Structure of the Simple Tissues of the Human Body, &c., 1861; and Archives of Medicine for 1862.

† For a brief but lucid exposition of his views on this subject, see Dr. Bennett's paper On the Molecular Theory of Organisation, as given in abstract in the Proceedings of the Royal Society of Edinburgh for the 1st of April, 1861.



textures the old substance simply wears away, or is thrown off at the surface, whilst fresh material is added from below. In muscular texture, on the other hand, the process is a chemical or chemico-vital one; the functional action of muscle is attended with an expenditure of moving force, and a portion of matter is consumed in the production of that force; that is, it undergoes a chemical change, and being by this alteration rendered unfit to serve again is removed by absorption. The amount of matter changed in a given time, or, in other words, the rapidity of the nutritive process, is much greater in those instances where there is a production and expenditure of force, than where the tissue serves merely passive mechanical purposes. Hence, the bones, tendons, and ligaments are much less wasted in exhausting diseases than the muscles, or than the fat, which is consumed in respiration, and generates heat. Up to a certain period, the addition of new matter exceeds the amount of waste, and the whole body, as well as its several parts, augments in size and weight: this is "growth." When maturity is attained, the supply of material merely balances the consumption; and, after this, no steady increase takes place, although the quantity of some matters in the body, especially the fat, is subject to considerable fluctuation at all periods of life.

It would be foreign to our purpose to enter on the subject of nutrition in general; we may, however, briefly consider the mode in which the renovation of substance is conceived to be carried on in the tissues.

The material of nutrition is immediately derived from the plasma of the blood, or liquor sanguinis, which is conveyed by the blood-vessels, and transudes through the coats of their capillary branches; and it is in all cases a necessary condition that this matter should be brought within reach of the spot where nutrition goes on, although, as will immediately be explained, it is not essential for this purpose that the vessels should actually pass into the tissue.

In cuticle and epithelium, the nutritive change is effected by a continuance of the process to which these textures owe their origin. The tissues in question being devoid of vessels, nutrient matter, or blastema, is furnished by the vessels of the true skin, or subjacent vascular membrane; this matter is appropriated by young cells derived most probably from pre-existing ones. These new cells enlarge, alter in figure, often also in chemical nature, and, after serving for a time as part of the tissue, are thrown off at its free surface.

But it cannot in all cases be so clearly shown that nutrition takes place by a continual formation and decay of the structural elements of the tissue; and it must not be forgotten, that there is another conceivable mode in which the renovation of matter might be brought about, namely, by a molecular change which renews the substance, particle by particle, without affecting the form or structure; by a process, in short, which might be termed "molecular renovation." Still, although conclusive evidence is wanting on the point, it seems probable that the crude material of nutrition first undergoes a certain elaboration or preparation through the agency of cells and nuclei disseminated in the tissue; which may serve as centres of assimilation and increase, as already explained.

*Office of the Vessels.*—In the instance of cuticle and epithelium, no vessels enter the tissue, but the nutrient fluid which the subjacent vessels afford penetrates a certain way into the growing mass, and the cells continue to assimilate this fluid, and pass through their changes at a distance from, and independently of, the blood-vessels. Whether, in such cases, the whole of the



residuary blastema remains as intercellular substance, or whether a part is again absorbed into the vessels, is not known. In other non-vascular tissues, such as articular cartilage, the nutrient fluid is doubtless, in like manner, conveyed by imbibition through their mass, where it is then attracted and assimilated. The mode of nutrition of these and other non-vascular masses of tissue may be compared, indeed, to that which takes place throughout the entire organism in cellular plants, as well as in polypes and some other simple kinds of animals, in which no vessels have been detected. But even in the vascular tissues the case is not absolutely different; in these, it is true, the vessels traverse the tissue, but they do not penetrate into its structural elements. Thus the capillary vessels of muscle pass between and around its fibres, but do not penetrate their inclosing sheaths; still less do they penetrate the fibrillæ within the fibre; these, indeed, are much smaller than the finest vessel. The nutrient fluid, on exuding from the vessels, has here, therefore, as well as in the non-vascular tissues, to permeate the adjoining mass by transudation, in order to reach these elements, and yield new substance at every point where renovation is going on. The vessels of a tissue have, indeed, been not unaptly compared to the artificial channels of irrigation which distribute water over a field; just as the water penetrates and pervades the soil which lies between the intersecting streamlets, and thus reaches the growing plants, so the nutritious fluid, escaping through the coats of the blood-vessels, must permeate the intermediate mass of tissue which lies in the meshes of even the finest vascular network. The quantity of fluid supplied, and the distance it has to penetrate beyond the vessels, will vary according to the proportion which the latter bear to the mass requiring to be nourished.

We have seen that in the cuticle the decayed parts are thrown off at the free surface; in the vascular tissues, on the other hand, the old or effete matter must be first reduced to a liquid state, then find its way into the blood-vessels, or lymphatics, along with the residual part of the nutritive plasma, and be by them carried off. But, in certain cases, the mode of removal of the old matter is not clear; as, for example, in the crystalline lens, which is destitute of vessels, and grows by deposition of blastema and formation of cells at its surface; here we should infer that the oldest parts were nearest the centre, and if we suppose them to be changed in nutrition, it is puzzling to account for their removal.

From what has been said, it is clear that the vessels are not proved to perform any other part, in the series of changes above described, beyond that of conveying matter to and from the scene of nutrition; and that this, though a necessary condition, is not the essential part of the process. The several acts of assuming and assimilating new matter, of conferring on it organic structure and form, and of disorganising again that which is to be removed, which are so many manifestations of the metabolic and plastic properties already spoken of, are performed beyond the blood-vessels. It is plain, also, that a tissue, though devoid of vessels, and the elements of a vascular tissue, though placed at an appreciable distance from the vessels, may still be organised and living structures, and within the dominion of the nutritive process. How far the sphere of nutrition may, in certain cases, be limited, is a question that still needs further investigation; in the cuticle, for example, and its appendages, the nails and hairs, which are placed on the surface of the body, we must suppose that the old and dry part, which is about to be thrown off or worn away, has passed out of the limits of nutritive influence; but to what distance beyond the vascular surface of the skin the province of nutrition extends, has not been determined.

*Regeneration.*—When part of a texture has been lost or removed, the



loss may be repaired by regeneration of a new portion of tissue of the same kind ; but the extent to which this restoration is possible is very different in different textures. Thus, in muscle, a breach of continuity may be repaired by a new growth of connective tissue ; but the lost muscular substance is not restored. Regeneration occurs in nerve ; in bone it takes place readily and extensively, and still more so in fibrous, areolar, and epithelial tissue. The special circumstances of the regenerative process in each tissue will be considered hereafter ; but we may here state generally, that, as far as is known, the reproduction of a texture is effected in the same manner as its original formation.

In experimental inquiries respecting regeneration, we must bear in mind, that the extent to which reparation is possible, as well as the readiness with which it occurs, is much greater in many of the lower animals than in man. In newts, and some other cold-blooded vertebrata, indeed (not to mention still more wonderful instances of regeneration in animals lower in the scale), an entire organ, a limb, for example, is readily restored, complete in all its parts, and perfect in all its tissues.

In concluding what it has been deemed advisable in the foregoing pages to state respecting the development of the textures, we may remark, that, besides what is due to its intrinsic importance, the study of this subject derives great interest from the aid it promises to afford in its application to pathological inquiries. Researches which have been made within the last few years, and which are still zealously carried on, tend to show that the structures which constitute morbid growths are formed by a process analogous to that by which the natural or sound tissues are developed : some of these morbid productions, indeed, are in no way to be distinguished from areolar, fibrous, cartilaginous, and other natural structures, and have, doubtless, a similar mode of origin ; others, again, as far as yet appears, are peculiar in structure and composition, but still their production is with much probability to be referred to the same general process. The prosecution of this subject, however, does not fall within the scope of the present work.

## THE BLOOD.

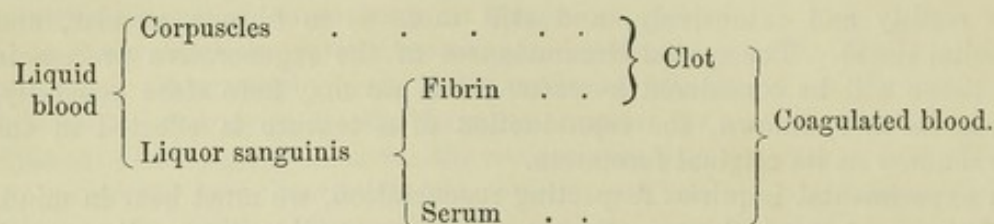
### PHYSICAL AND ORGANIC CONSTITUTION.

The most striking external character of the blood is its well-known colour, which is florid red in the arteries, but of a dark purple or modena tint in the veins. It is a somewhat clammy and consistent liquid, a little heavier than water, its specific gravity being 1052 to 1057 ; it has a saltish taste, a slight alkaline reaction, and a peculiar faint odour.

To the naked eye the blood appears homogeneous ; but when examined with the microscope, either while within the minute vessels, or when spread out into a thin layer upon a piece of glass, it is seen to consist of a transparent colourless fluid, named the "lymph of the blood," "liquor sanguinis," or "plasma," and minute solid particles or corpuscles immersed in it. These corpuscles are of two kinds, the red and the colourless : the former are by far the most abundant and have been long known as "the red particles," or "globules," of the blood ; the "colourless," "white," or "pale corpuscles," on the other hand, being fewer in number and less conspicuous, were later in being generally recognised. When blood is drawn from the vessels, the liquor sanguinis separates into two parts ;—into fibrin, which becomes solid, and a pale yellowish liquid named *serum*. The fibrin in solidifying involves the corpuscles and forms a red consistent



mass, named the clot or *crassamentum* of the blood, from which the serum gradually separates. The relation between the above-mentioned constituents of the blood in the liquid and the coagulated states may be represented by the subjoined scheme :—



*Red Corpuscles.*—These are not spherical, as the name “globules,” by which they have been so generally designated, would seem to imply, but flattened or disk-shaped. Those of the human blood (fig. xv., <sup>1, 2</sup>) have a nearly circular outline, like a piece of coin, and most of them also present a shallow cup-like depression or dimple on both surfaces; their usual figure is, therefore, that of biconcave disks. Their magnitude differs somewhat even in the same drop of blood, and it has been variously assigned by authors; but the prevalent size may be stated at from  $\frac{1}{3500}$ th to  $\frac{1}{3200}$ th of an inch in diameter, and about one-fourth of that in thickness.

Fig. XV.

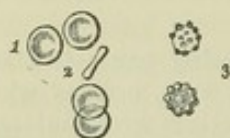

Fig. XV.—RED CORPUSCLES OF HUMAN BLOOD; MAGNIFIED ABOUT 500 DIAMETERS (Wagner).

1, shows depression on the surface; 2, a corpuscle seen edgewise; 3, red corpuscles altered by exposure.

In mammiferous animals generally, the red corpuscles are shaped as in man, except in the camel tribe, in which they have an elliptical outline. In birds, reptiles, and most fishes, they are oval disks with a central elevation on both surfaces (fig. xvi., from the frog), the height and extent of which, as well as the proportionate length and breadth of the oval, vary in different instances, so that in some osseous fishes the elliptical form is almost shortened into a circle. The blood corpuscles of invertebrata, although they (except in some of the red-blooded annelides) want the red colour, are also, for the most part, flattened or disk-shaped; being in some cases circular, in others oblong, as in the larvæ of aquatic insects. Sometimes they appear granulated on the surface like a raspberry, but this is probably due to some alteration occurring in them.

Fig. XVI.

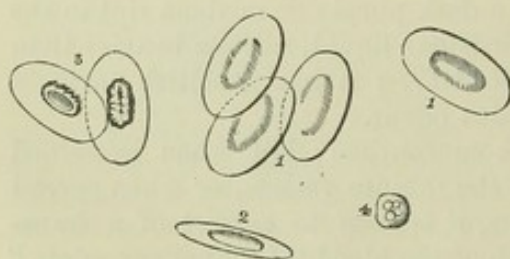


Fig. XVI.—BLOOD CORPUSCLES OF THE FROG; MAGNIFIED ABOUT 500 DIAMETERS.

1, shows their broad surface; 2, one seen edgewise; 3, shows the effect of weak acetic acid; the nucleus has become distinct; 4, a colourless or lymph corpuscle (from Wagner).

The size of the corpuscles differs greatly in different kinds of animals; it is greater in birds than in mammalia, and largest of all in the naked amphibia. They are for the most part smaller in quadrupeds than in man; in the elephant, however, they are larger, being  $\frac{1}{2700}$ th of an inch, which is the largest size yet observed in the blood-corpuscles of any mammiferous



animal: the goat was long supposed to have the smallest, viz., about  $\frac{1}{6400}$ th of an inch; but Mr. Gulliver has found that they are much smaller in the Meminna and Napu musk deer, in which animals they are less than  $\frac{1}{12000}$ th of an inch. In birds they do not vary in size so much; from Mr. Gulliver's very elaborate tables of measurement it appears that they range in length from about  $\frac{1}{1700}$ th to  $\frac{1}{2600}$ th of an inch; he states that their breadth is usually a little more than half the length, and their thickness about a third of the breadth or rather more. He found a remarkable exception in the corpuscles of the snowy owl, which measure  $\frac{1}{1330}$ th of an inch in length; and are only about a third of this in breadth. In scaly reptiles they are from  $\frac{1}{1500}$ th to  $\frac{1}{1200}$ th of an inch in length; in the naked amphibia they are much larger: thus, in the frog they are  $\frac{1}{1000}$ th of an inch long, and  $\frac{1}{1700}$ th broad; in the salamander they are larger still; but the largest yet known in any animal are those of the proteus, which are  $\frac{1}{400}$ th of an inch in length, and  $\frac{1}{727}$ th in breadth; the siren, which is so much allied to the proteus in other respects, agrees with it also in the very large size of its blood-corpuscles; they measure  $\frac{1}{420}$ th of an inch in length, and  $\frac{1}{760}$ th in breadth. In the skate and shark tribe the corpuscles resemble those of the frog, in other fishes they are smaller.

From what has been stated, it will be seen that the size of the blood-corpuscles in animals generally is not proportionate to the size of the body; at the same time Mr. Gulliver remarks, that "if we compare the measurements made from a great number of different species of the same order, it will be found that there is a closer connection between the size of the animal and that of its blood-corpuscles than has been generally supposed;" and he has pointed out at least one example of a very natural group of quadrupeds, the ruminants, in which there is a gradation of the size of the corpuscles in relation to that of the body.

C. Schmidt, on account of the varying size which the corpuscles present, in dependence upon the density of the liquor sanguinis, has subjected them to repeated measurements when *dried*, in a very thin layer upon slips of glass. It has been thus found that from 95 to 98 per cent. present the same magnitude.

*Structure.*—The large corpuscles of the frog and salamander, when drawn from the vessels and placed under the microscope, appear to consist of a thin, transparent, vesicular *envelope*, enclosing a solid oval *nucleus* in the centre, with a quantity of softer *red-coloured matter* disposed round the nucleus and filling up the space between it and the envelope. When exposed to the action of weak acetic acid, (fig. XVI.,<sup>3</sup>) the colouring matter is speedily extracted, and the nucleus becomes distinct, whilst the envelope is rendered so faint as to be scarcely visible; but its outline may be still brought into view by adding solution of iodine, which gives it colour and opacity. Pure water extracts the colour and distends the corpuscle by imbibition, altering its shape from oval to round, and making the nucleus more conspicuous. Often in these circumstances the nucleus is displaced from its central position, and it may even be extruded altogether, as if by bursting of the corpuscle, which then appears flattened and colourless, and in this condition is generally supposed to represent only the ruptured and empty envelope; but even with the help of iodine, no rent can be perceived in it. For this and also for other reasons some think that what remains behind after escape of the nucleus is really the soft and now colourless substance of the corpuscle, and that it has no distinct envelope. On the opposite view it is suggested that the absence of apparent laceration in the envelope is owing



in venous than arterial blood ; and it is much greater in the blood of the splenic and hepatic veins than in venous blood generally. They are destitute of colour, finely granulated on the surface, and specifically lighter than the red corpuscles. The large corpuscles are less distinctly granular than the small. Water has little effect on them ; acetic acid brings speedily into view a nucleus, which frequently presents a reddish tint (Virchow and Kölliker), consisting sometimes of one, but more commonly of two, three,

Fig. XVIII.

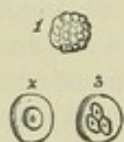


Fig. XVIII. — PALE CORPUSCLES OF HUMAN BLOOD ; MAGNIFIED ABOUT 500 DIAMETERS.

1, natural aspect ; 2 and 3, acted on by weak acetic acid, which brings into view the single or composite nucleus.

or four, large clear granules (fig. XVIII., <sup>2, 3</sup>). The number of apparent nuclei is said by Mr. Wharton Jones to depend upon the strength of the acetic acid employed ; if the acid is much diluted, only one is seen ; if strong acid is used, the nucleus breaks up into three or four nuclear-looking particles. Under the action of the acid the circumferential part of the corpuscle becomes clear of granules and pellucid, and swells up by imbibition with a regular and well-defined outline, which has been taken for the indication of a fine envelope, but conclusive evidence on this point is wanting. The clear substance is eventually dissolved, the nucleus remaining.

The pale corpuscles frequently undergo curious changes of shape, sending out processes into which the granules enter, and retracting them again ; in short, exhibiting phenomena which have been aptly

compared to the movements of an amœba.

Albuminous granules and molecules of a fatty nature occur in the blood in varying numbers ; sometimes very scantily, or not at all, but the latter sometimes in vast numbers so as to give the serum a turbid, milky appearance. These are probably derived directly from the chyle (its "molecular base"), and they are especially seen in the blood of herbivora, in sucking animals, and in pregnant women.

*Occasional Elements.*—Besides the foregoing, the blood occasionally presents the following constituents :—(1) bodies like cells, enclosing blood-corpuscles, noticed by Ecker and Kölliker in the blood of the spleen and hepatic vessels, and elsewhere. (2) Pigmentous granule-cells. (3) Pale, fine-granular, roundish aggregations, in the splenic blood. (4) Peculiar bodies, three or four times larger than the pale corpuscles, but in other respects resembling them. (5) Caudate, pale, or pigmentous cells. (6) Fibrinous coagula.

*Liquor Sanguinis, or Plasma.*—This is the pale clear fluid in which the corpuscles are naturally immersed. Its great character is its strong tendency to coagulate when the blood is withdrawn from the circulating current, and on this account it is difficult to procure it free from the corpuscles. Nevertheless, by filtering the slowly coagulable blood of the frog, as was first practised by Müller, the large corpuscles are retained by the filter, while the liquor sanguinis comes through in perfectly clear and colourless drops, which, while yet clinging to the funnel, or after they have fallen into the recipient, separate into a pellucid glassy film of fibrin, and an equally transparent diffuent serum. When human blood is drawn in inflammatory diseases, as well as in some other conditions of the system, the red particles separate from the liquor sanguinis before coagulation, and leave the upper part of the liquid clear. In this case, however, the plasma is still mixed with the pale corpuscles, which, being light, accumulate at the top. On coagulation taking place in these circumstances, the upper part of



the clot remains free from redness, and forms the well-known "buffy coat" so apt to appear in inflammatory blood. Now, in such cases, a portion of the clear liquor may be taken up with a spoon, and allowed to separate by coagulation into its fibrin and serum, so as to demonstrate its nature. Professor Andrew Buchanan has pointed out another method of separating the liquor sanguinis from the red corpuscles, which I have repeatedly tried with success; it consists in mixing fresh-drawn blood with six or eight times its bulk of serum, allowing the red particles to subside, and then decanting the supernatant fluid, and filtering it through blotting-paper; the admixture of serum delays coagulation, and a great part of the liquor sanguinis, of course diluted, and usually more or less coloured, passes through the filter, and subsequently coagulates.

Coagulated plasma, whether obtained from buffy blood, or exuded on inflamed surfaces, presents, under the microscope, a multitude of fine filaments confusedly interwoven, as in a piece of felt; but these are more or less obscured by the intermixture of corpuscles and fine granules, the former having all the characters of the pale corpuscles of the blood. The filaments are no doubt formed by the fibrin, as it solidifies in the coagulation of the liquor sanguinis.

Blood may be freed from fibrin by stirring it with a bundle of twigs, which entangle the fibrin as it concretes.

## CHEMICAL COMPOSITION OF THE BLOOD.

The blood is slightly alkaline in reaction. Carbonic acid, oxygen, and nitrogen gases may be extracted from it, by exhaustion (Magnus), by heating after dilution with water (L. Meyer), or by both these means combined (Setschenow). Carbonic acid is yielded in largest proportion, oxygen next, and nitrogen least. The nitrogen appears to be simply retained by absorption, the other two partly by absorption and partly by weak chemical combination. The combined oxygen is probably in great part held by some component of the red corpuscles; the carbonic acid, which is obtained in larger measure from serum, seems to be combined partly with carbonate of soda in a bicarbonate, and partly with phosphate of soda, from both of which combinations it can be set loose by heat and reduction of pressure. Arterial blood yields more oxygen and less carbonic acid than venous blood.

On being evaporated, 1000 parts of blood yield, on an average, about 790 of water and 210 of solid residue. This residue has nearly the same ultimate composition as flesh. A comparative examination of dried ox-blood and dried flesh (beef), by Playfair and Boeckmann, gave the following mean result:—

	<i>Flesh.</i>	<i>Blood.</i>
Carbon . . . . .	51.86	51.96
Hydrogen . . . . .	7.58	7.25
Nitrogen . . . . .	15.03	15.07
Oxygen . . . . .	21.30	21.30
Ashes . . . . .	4.23	4.42

*Red Corpuscles.*—The specific gravity of the red corpuscles, in a moist



state, is calculated at 1.088. They consist, as already stated, of an insoluble, colourless tegumentary substance (envelope) and an included red matter, which is soluble and separable by water. The former doubtless belongs to the group of albuminoids or protein-bodies, and some have regarded it as a species of fibrin, but in truth it cannot be specifically characterised. In numerical statements of blood-analyses it is reckoned along with the globulin. The soluble coloured ingredient, for which it is convenient to retain the old name of *cruur*, is separable into two substances,—one named *globulin*, of itself colourless, and very nearly allied to albumen in its nature; the other a colouring principle, named *hæmatin* or *hæmatosin*, which imparts redness to the first; and hence the *cruur* is often also designated as *hæmato-globulin*. These may be separated by the following process:—

Blood deprived of fibrin by stirring is mixed with at least four times its bulk of saturated solution of sulphate of soda, and thrown upon a filter; a few of the corpuscles pass through with the liquid, but the greater part remain on the filter in form of a moist red mass. This is boiled with alcohol slightly acidulated with sulphuric acid; the hæmatin is thereby dissolved, while the colourless globulin remains behind. Carbonate of ammonia is then added to the acid solution of hæmatin while it is yet hot, to remove sulphuric acid, and, after being cleared by filtration from sulphate of ammonia, and a little globulin which is precipitated, the liquor is evaporated to a twelfth of its bulk; it then deposits the hæmatin in form of a dark brown or almost black powder, from which a minute proportion of fat may be extracted by means of ether.

*Hæmatin* thus obtained appears to be altered by the process of separation, for it is no longer soluble in water. It is insoluble also in alcohol and ether; but it readily dissolves in any of these liquids after being mixed with potash, soda, or ammonia, forming deep red solutions. It likewise dissolves in alcohol to which an acid has been added, but its acid combinations are insoluble in water. When burned, it yields nearly ten per cent. of peroxide of iron, representing nearly seven per cent. of iron. The quantity of iron is estimated by Schmidt as 1 to 230 parts of red corpuscles. According to Mulder, hæmatin is composed of carbon 65.84, hydrogen 5.37, nitrogen 10.40, oxygen 11.75, and iron 6.64; or  $C_{44}, H_{22}, N_3, O_6, Fe$ .

That hæmatin is an altered product is further shown by an observation of Hoppe, confirmed by Stokes, both of whom have found that the solution of *cruur* (obtained by diffusing the red clot in water) is speedily decomposed by acids, and that the coloured product of decomposition, which has all the characters of hæmatin, agrees with hæmatin in its effects on the prismatic spectrum, but differs in this respect from the natural or unaltered colouring matter of the *cruur*, which Mr. Stokes distinguishes by the name of *cruurin*.\*

There has been much question as to the condition in which the iron exists in hæmatin, and especially whether it be in the state of oxide and in special combination with some part of the constituent oxygen, or associated in an elementary form with the organic matter, as sulphur is in albumen. The latter view seems to be the more probable, for the whole of the iron may be removed from hæmatin, without abstracting oxygen or disturbing the relative proportions of the other elements. When thus

\* For an account of the examination of the colouring matter of the blood by the prism, and of the differences in its absorptive effect on light, according to its oxidated or deoxidated condition, the reader is referred to an important paper by Professor G. G. Stokes, in the Proceedings of the Royal Society for June 16, 1864, vol. xiii. p. 355.



deprived of iron the hæmatin retains its colour, and has suffered no appreciable change in character. It would seem therefore that iron, although a constant ingredient in the red corpuscle, is not an essential constituent of hæmatin, and it is, at any rate, clear that the red colour of the blood is not caused by iron.

*Globulin.*—When the hæmatin has been extracted from the blood-corpuscles by the foregoing method, the globulin and envelopes remain in combination or mixture with sulphuric acid. Globulin is a protein compound, agreeing very nearly with albumen and casein in elementary composition, so far as this has been ascertained, but most resembling the latter substance in its general characters. Globulin is nearly insoluble in pure water, but readily dissolves on a very slight addition of either an alkali or an acid. Weak acids throw it down from its solution in alkali, but when added in slight excess re-dissolve it. In like manner it is precipitated by alkalies from its solutions in acids and re-dissolved by excess. From neither of these solutions is it thrown down by heat. It is dissolved by neutral salts, and from this solution heat throws it down in an insoluble precipitate. From its slightly alkaline solution in water it is thrown down by a stream of carbonic acid, and may be re-dissolved by passing air or oxygen through the liquid. Its precipitate is distinguished from that of other albuminoids by being always in form of fine granules or molecules. But the most important and distinctive character of globulin is its fibrino-plastic property, to be afterwards further referred to, by which it co-operates with another protein-substance in producing solid fibrin; this property is destroyed by exposure of the solution to a boiling heat.

Globulin forms the greater part of the crystalline lens, and it is no doubt present in the pale blood-corpuscles; it exists also in the chyle and lymph, the cornea, the aqueous humour, and various other tissues and fluids, if its presence is to be inferred from the manifestation of the fibrino-plastic property. The globulin of the red corpuscles is crystallisable, as will be presently explained.

The *cruor*, or the soluble matter of the red corpuscles, which consists of the globulin and colouring principle (the cruorin of Stokes) together, forms in water a solution (maintained probably by soda and salts) which in its effects with re-agents agrees with solution of globulin. Berzelius reckons the relative proportions of globulin and hæmatin as 94.5 of the former, and 5.5 of the latter. Schmidt makes them 87.59, and 12.41 respectively. The corpuscles also contain a solid phosphuretted fat in small quantity, which may be stated at rather more than 2 parts in the 100 of dried corpuscles. 100 parts of dried cruor yield by calcination about 1.3 of brown alkaline ashes, which consist of carbonate of alkali with traces of phosphate 0.3, phosphate of lime 0.1, lime 0.2, subphosphate of iron 0.1, peroxide of iron 0.5, carbonic acid and loss 0.1.

*Blood-crystals.*—In the blood of man and various animals, when drawn from the vessels and set aside for a time, red crystals occasionally appear, consisting of globulin tinted by the colouring matter: and their formation may be promoted by adding water to defibrinated blood so as to set free the cruor from the corpuscles, and exposing the watered blood first to a stream of oxygen and then to carbonic acid. Or a drop of blood, defibrinated or not, is to be mixed with a little water on a slip of glass, exposed for a little to the air, then breathed upon, and finally covered with thin glass and placed in a bright light, which seems to favour the crystallisation. The



crystals are said readily to appear in both cases ; but I must confess that the second method has generally failed in my hands with human or bullock's blood. The addition of alcohol, ether, and especially chloroform, greatly promotes the operation.

From human blood, and that of most mammals, the crystals are prismatic in form (fig. XIX.<sup>1</sup>), but tetrahedral in the guineapig, rat, and mouse (<sup>2</sup>), hexagonal plates in the squirrel (<sup>3</sup>), and rhombohedrons in the hamster (<sup>4</sup>).\*

Fig. XIX.

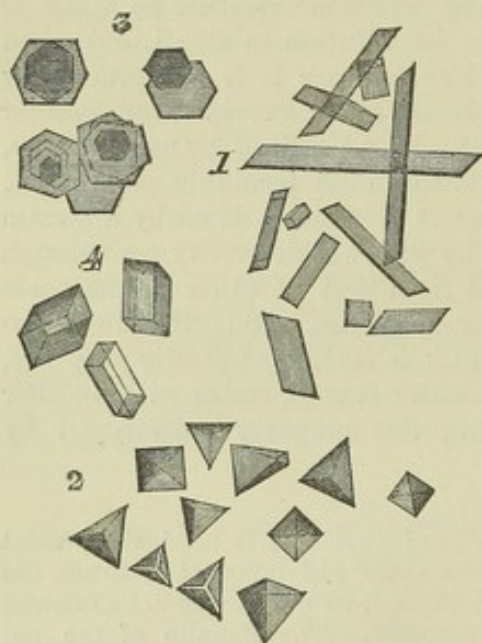


Fig. XIX.—BLOOD CRYSTALS MAGNIFIED.

1, from human blood ; 2, from the guineapig ; 3, squirrel ; 4, hamster.

by Teichmann by treating blood with concentrated acetic acid, are considered to be of this nature. Crystals, moreover, of a substance (also occurring amorphously) which has been named "hæmatoidin," and is probably derived from modified hæmatin, are often found in old coagula and effusions of blood within the body. These occur in form of rhombic plates or prisms, of a yellow or red colour ; they are insoluble in water, alcohol, ether, and acetic acid, and contain no iron.

The crystallising matter is perhaps modified in its properties under these different forms ; at least, it has been found that all are not equally soluble in water. The red colouring principle (hæmatin) is not essential to the crystals, for Lehmann has, by recrystallisation, obtained them free from colour, and apparently unchanged in other respects ; neither does the undissolved envelope or tegumentary frame of the corpuscle take any share in the crystallisation. The crystallising matter, therefore, must be the colourless protein-substance of the cruor, namely, globulin. It has been proposed to call this substance "blood-crystalline," on account of its property of crystallising, which does not belong to the globulin of the crystalline lens, so far as is yet known. The change of name, however, is confusing, and appears inexpedient, especially as we know that all forms of globulin agree in the much more characteristic property of being fibrino-plastic.

The hæmatin itself, or some chemical modification of it, can also, it is supposed, be crystallised ; and the rhombic prisms and acicular crystals (*hæmin crystals*), obtained

*Proportion of red Corpuscles.*—The red corpuscles form by far the largest part of the organic matter in the blood : their proportion may be ascertained by filtering defibrinated blood mixed with solution of Glauber's salt, as already mentioned ; or by weighing the dried clot, and making allowance for the fibrin it contains. The latter method, however, will serve only to give a rough estimate, as the very uncertain amount of serum remaining in the clot and affecting its weight cannot be determined. Prevost and Dumas made too large a deduction for the solid matter supposed to belong to the retained serum, and this reduced the estimate of

\* A late writer, Bojanowski, represents them as rectangular tables in man and hexagonal plates in the mouse. *Zeitsch. f. Wissensch. Zool.* 1862.



the dried corpuscles too much, viz. to 129 parts per 1000 of blood. Lecanu also gives it at from 120 to 130. Becquerel and Rodier at from 131 to 152. Schmidt, from three modes of calculation, which it is needless here to explain, arrived at the conclusion that the proportion of moist red corpuscles in 1000 parts of blood is from 480 to 520; but there are reasons for regarding this as too high an estimate. He considers that in the moist state they consist of 31 per cent. of solid matter and 69 per cent. of water: on this understanding, of course, much of the water estimated by the loss in drying blood must be assigned to the corpuscles.\*

Different observers agree that, as a general rule, the proportion of red particles is greater in the blood of the male sex than in that of the female. Lecanu gives the following mean result, derived from numerous analyses, exhibiting the proportion of dry crassamentum and water in the blood of the two sexes. No deduction is made for the fibrin; but, considering its small relative quantity, any possible variation in it cannot materially affect the general conclusion.

	Male.		Female.
Crassamentum, from	115·8 to 148	.	68·3 to 129·9
Water	778 to 805	.	790 to 853

Becquerel and Rodier state the crassamentum in the female at from 113 to 137.

Lecanu found the following differences in the crassamentum according to temperament:—

	Male.		Female.
Sanguine temperament	136·4	.	126·1
Lymphatic temperament	116·6	.	117·3

As regards age, Denis found the proportion of crassamentum greatest between the ages of 30 and 40. Sudden loss of blood rapidly diminishes it. In two women who had suffered from uterine hæmorrhage, the crassamentum amounted to only 70 parts in 1000. The same effect may be observed to follow ordinary venesection. In a person bled three times in one day, Lecanu found in the first drawn blood 139, and in the last only 76 parts of crassamentum in the 1000. This effect may be produced very suddenly after a bleeding. Prevost and Dumas bled a cat from the jugular vein, and found 116 parts of crassamentum in 1000, but in blood drawn five minutes afterwards, it was reduced to 93. The sudden loss of blood probably causes a rapid absorption of serous and watery fluid into the vessels, and thus diminishes the relative amount of the red particles. It is found that the blood of warm-blooded animals is richer in crassamentum than that of the cold-blooded; and, among the former, the proportion is highest in the class of birds.

*Liquor Sanguinis.*—The fluid part of the blood, as already described, separates spontaneously into fibrin and serum. The fibrin may be obtained by stirring the blood as soon as possible after it is drawn, or by washing the crassamentum with water, to free it from cruor. Procured in either of these ways, the fibrin contains pale corpuscles and a small portion of fat. From dried fibrin of healthy human blood, Nasse obtained near 5 per cent. of fat, and still more from the fibrin of buffy blood. The proportion of fibrin in the blood does not exceed  $2\frac{1}{2}$  parts in 1000; indeed, according to the greater number of observers, it is not more than  $2\frac{1}{2}$ . As a general rule, the quantity is somewhat greater in arterial than in venous blood, and it is increased in certain states of the body, especially in inflammatory diseases and in pregnancy. Nasse thinks that the whole fibrin

\* For an account of Schmidt's method, see Lehmann's *Physiological Chemistry* (Cavendish Society's Translation), vol. ii.



cannot be separated from the blood by the processes employed, for he believes that a portion remains suspended in the liquid in form of minute microscopic scales or films.

Denis pointed out, that fibrin obtained from the coagulum of venous blood, if quite recent, and not previously much exposed to the air, is capable of being slowly dissolved in a slightly-heated solution of nitre. Scherer and Nasse have confirmed this statement, and the latter finds that fibrin got by stirring may also be dissolved in the same way, provided it is quite fresh. On the other hand, nitre does not dissolve fibrin of arterial blood, nor fibrin that has been some time exposed to the air, from whatever source it may be derived; nor, according to Scherer, the fibrin of the buffy coat.

*Origin of Fibrin.*—It is now ascertained that the fibrin is not present, as such, in a liquid form, in the plasma, but is produced at the moment of consolidation by the co-operation or combination of two previously distinct substances. About twenty years ago, Professor Andrew Buchanan\* discovered that the fluid of hydrocele, which might in an unmixed state be kept for an indefinite time without coagulating, very speedily congealed and separated into clot and serum when mixed with a little blood. Ordinary blood-serum, blood-clot, especially washed clot, and buffy coat, even after being dried and long kept, when added in small proportion to the hydrocele-fluid, produced the same effect. From these facts Dr. Buchanan concluded that fibrin exists as a liquid both in hydrocele-fluid and in the liquor sanguinis, that liquid fibrin does not coagulate spontaneously, but requires for that end the influence of some "suitable re-agents," that such a re-agent is naturally present in the blood, and brings about the solidification of its fibrin in the natural process of coagulation, and that it is absent from the hydrocele fluid, but when supplied by the addition of blood, causes the fluid fibrin to solidify. On further reasoning on the facts he had observed, Dr. Buchanan was led to believe that "coagulant power" was mainly seated in the pale corpuscles, which abound in the washed clot and the buffy coat, and are present in the serum; and that their efficacy depended on their organisation as elementary cells. In harmony with this latter view, he found on trial that the organised tissues, such as muscle, skin, and spinal marrow, possessed the same power, though in a less degree than the pale corpuscles, in which, as primary cells, the metabolic power is more energetic.

The remarkable phenomenon described by Dr. Buchanan did not obtain the consideration it deserved, and the coagulation of hydrocele-fluid under the conditions stated, was commonly ascribed to some catalytic action of the substance added, which induced liquid fibrin present in the fluid to solidify. In 1861, however, Dr. A. Schmidt, of Dorpat, apparently unaware of Dr. Buchanan's observations, fell upon facts of the same kind, and pursuing the investigation by an elaborate series of experiments not only with hydrocele-fluid, but with pericardial, peritoneal, and other serous fluids and effusions, which give a like result, has satisfactorily shown that fibrin has no existence in a liquid state, but that when it appears as a coagulum in a fluid, it is actually produced then and there by the union of two constituents present in solution, and forthwith shed out as a solid matter. One of these constituents which contributes in largest

\* Proceedings of the Glasgow Philosophical Society, Feb. 19, 1845.



measure to the product, he names *fibrinogenous substance*, the other *fibrinoplastic substance*. In the coagulation of hydrocele-fluid, the former, or *fibrinogen*, is already there, while the *fibrinoplastin* is supplied from the blood. It is not that the latter converts albumen into fibrin, for after a certain amount of fibrin has been coagulated from the serous fluid no further addition will generate more, although abundance of albumen remains; and again, a given quantity of fibrinoplastin will not coagulate with equal rapidity and intensity any amount of fluid containing fibrinogen. In short, the fibrinoplastic substance seems not to operate as a ferment or by catalysis, but by combining with the other necessary ingredient. Now Schmidt has shown that the fibrinoplastic matter presents all the chemical characters of globulin, and is in fact nothing else than that substance. Accordingly he finds, as already stated, that blood-crystals are highly fibrinoplastic. This globulin is not restricted to the red corpuscles; it exudes from them into the plasma in the coagulation of the blood, and a residual portion remains in the serum when the process is over; globulin doubtless exists also in the pale corpuscles. Nor is it confined to the blood. From chyle and lymph, from the aqueous humour of the eye and watery extract of the cornea, from the vitreous humour and crystalline lens, from connective tissue, and from saliva and synovia, a substance may be obtained having the same re-actions and the same fibrinoplastic power. Fibrinogen may be thrown down from hydrocele-fluid by a mixture of alcohol and ether; it very closely resembles globulin in its chemical relations, only it is less soluble in acids and alkalies, and less energetic in all its re-actions. Of course, it exists in blood-plasma, and in the process of coagulation of the blood combines with globulin, transuded from the corpuscles, to form the fibrin of the clot.\*

*Serum*.—This is a thin and usually transparent liquid, of a pale yellowish hue; it is, however, sometimes turbid, or milky, and this turbidity may depend upon different conditions, but most commonly on excess of fatty molecules. The specific gravity of serum ranges from 1025 to 1030, but is most commonly between 1027 and 1028 (Nasse), and is more constant than that of the blood. The solid contents of the serum are not more than 8 or 9 in 100 parts; the proportion of water being, for males 90·88, and for females 91·71. It is always more or less alkaline. When heated, it coagulates, in consequence of the large quantity of albumen it contains; and after separation of the albumen, a thin saline liquid remains, sometimes named "serosity." The following ingredients are found in the serum:—

*Albumen*.—This principle is considered to be combined with soda as an albuminate; its quantity may be determined by precipitating it in the solid form by means of heat or alcohol, washing with distilled water, drying, and weighing the mass. Its proportion is about 80 in 1000 of serum, or nearly 40 in 1000 of blood.

*Globulin*.—When serum is diluted with about ten times its bulk of distilled water, and subjected to a stream of carbonic acid, the liquid becomes turbid, and globulin is precipitated. It may also be obtained from the diluted serum by the cautious addition of acetic acid, but the least

\* Schmidt, Alex., in Reichert & Du Bois Reymond's *Archiv. für Anat. u. Physiol.*, 1861 and 1862. For a lucid account of the progress and present state of this question, founded on a confirmatory repetition of Buchanan's and of Schmidt's fundamental experiments, see an article on "the Coagulation of the Blood," [by Dr. Michael Foster,] in the *Natural History Review* for 1864, p. 157.



excess of acid will re-dissolve the precipitate. This globulin is probably the *casein* of the serum described by various authorities.

*Fatty Compounds.*—It has been already stated that the red corpuscles and the fibrin yield a certain quantity of fat; but a portion of the fat of the blood remains in the serum, partly dissolved, and partly diffused in the liquid. It may be separated by gently agitating the serum with about a third of its bulk of ether, or by evaporating the serum and digesting the dry residue in ether, or in boiling alcohol. The turbid milky aspect which serum often exhibits, is in most cases due to a redundancy of fat, and may accordingly be removed by agitation with ether.

The fatty matters of the blood are of various kinds, viz., *cholesterin*, *serolin*, and the ordinary saponifiable fats of the body (*margarates* and *oleates*); also, according to Berzelius and Lecanu, a *phosphuretted fat*, similar to that found in the brain. Berzelius, indeed, is disposed to think that the blood contains every variety of fat that is found in other parts of the body. Lecanu could not obtain the phosphuretted fat from either the serum or the fibrin, and Berzelius therefore supposes that it is associated with the red corpuscles; he also states that the fat extracted from the fibrin is different from ordinary fat. The usual quantity of fat of all kinds in 1000 parts of blood is stated by Lecanu to be 5·15, by Simon 2·3, and by Nasse 2·0.

*Extractive Matters.*—When the serum has been freed from albuminous matter by coagulation, and from fat by ether, and is evaporated to dryness, a yellowish or brown mass remains, consisting of organic matters mixed with salts; the former belonging principally to the ill-defined class of substances denominated “extractive matters.” These have now been more carefully sifted, and have yielded several definite and recognisable bodies, generated in the natural process of decomposition of the tissues, or residual matters of nutrition formed in the blood itself, and on their way to be excreted by the kidneys. Several of the substances to be next mentioned belong to this class, and as they are obviously excrementitious and transitory ingredients, they are not allowed to gather in any notable quantity in the healthy state of the economy.

*Creatin and Creatinin.*—Products of the natural “wear” of the muscles, or derived from fleshy food. These compounds, which are found in muscular substance and in the urine, together with *hypoxanthin* (also named *sarkin*), obtainable from the same sources, have been stated to exist in excessively small quantities in the blood.

*Urea.*—This substance, which accumulates in the blood of animals after extirpation of the kidneys or ligature of the renal arteries, as well as in certain diseases, has been found in very minute quantity in the healthy blood of the ox and of the calf, by Marchand and Simon, and in that of man, by Lehmann, Garrod, and others. It is, however, in such excessively small quantity, that its estimation is attended with great difficulty.

*Uric Acid* has been shown to exist in healthy blood by Dr. Garrod, and in that of persons suffering from gout it is in such considerable quantity as to be readily detected. In health its proportion is extremely small.

*Hippuric Acid* is found in the blood of herbivora, and according to some observers in that of man. There is, however, much doubt upon this point.

*Leucin and Tyrosin*, which exist in almost all secretions and excretions, probably are present in minute quantity in the blood; but as yet they have only been detected in it in disease of the liver.

*Sugar* has been found in the blood of dogs, oxen, and cats, also in that



of diseased and healthy persons. The quantity is very small. The form of sugar is that known as glucose or grape sugar.

*Colouring Principles.*—A yellow or greenish-yellow colouring principle, supposed to be the same as that of the bile, has been found by various chemists in the blood of persons affected with jaundice, and, according to Lecanu and Denis, a certain amount of it may be detected even in healthy blood. The colouring matter which gives a pale yellowish tint to ordinary serum does not, however, exhibit the reactions of bile-pigments.

*Odoriferous Matters.* Denis describes three. 1. One combined with fat, smelling like garlick. 2. One supposed to depend on a volatile oil, with an odour said to be of peculiar character in each species of animal, and to be heightened by adding sulphuric acid to the blood. 3. One of a variable character, derived from the food. Schmidt found that the blood of only three animals yielded an odour distinctive of the species.

*Salts.*—1. Having soda and potash as bases, combined with lactic, carbonic, phosphoric, sulphuric, and fatty acids. Also chlorides of sodium and potassium, the former in large proportion. Schmidt has pointed out that the potash salts exist almost exclusively in the blood-corpuscles and the soda salts principally in the serum. In the corpuscles there are principally chloride of potassium and phosphate of potass: in the serum, chloride of sodium, and phosphate of soda. The following table (giving the mean of eight experiments) exhibits the relative quantities of potassium and sodium, and of phosphoric acid and chlorine, in the blood corpuscles and plasma.

100 parts of Inorganic Matters.

<i>Blood-Corpuscles.</i>		<i>Plasma.</i>		<i>Blood-Corpuscles.</i>		<i>Plasma.</i>	
K.	Na.	K.	Na.	PO <sub>5</sub> .	Cl.	PO <sub>5</sub> .	Cl.
40.89	9.71	5.19	37.74	17.64	21.00	6.08	40.68

The Table shows that the chlorides are, relatively to the phosphates, in much larger quantity in the plasma than in the blood-corpuscles; and that the phosphates are, relatively to the chlorides, in much larger proportion in the blood-corpuscles than in the plasma.

2. Lactate of ammonia. 3. Salts with earthy bases, viz., lime and magnesia with phosphoric, carbonic, and sulphuric acids.

The earthy salts are for the most part associated with the albumen, but partly with the crassamentum. As they are obtained by calcination, it has been suspected that the phosphoric and sulphuric acids may be in part formed by oxidation of the phosphorus and sulphur of the organic compounds. Nasse found in 1000 parts of blood 4 to 7 of alkaline, and 0.53 of earthy salts.

*Mean Composition.*—The following statement of the mean composition of human venous blood is from Lecanu. (*Etudes chimiques sur le sang humain*, Paris, 1837.)



Free oxygen, nitrogen, and carbonic acid	}	10·98	}	Serum . . . 869·15
Extractive matters				
Fatty matters, viz.				
Phosphuretted fat				
Cholesterin				
Serolin				
Oleic and margaric acids (free)				
Ditto combined with soda				
Volatile odoriferous oily acid (combined with a base).				
Salts, viz.				
Chloride of sodium				
„ potassium				
„ ammonium				
Carbonate of soda				
„ lime				
„ magnesia				
Phosphate of soda				
„ lime				
„ magnesia				
Lactate of soda				
Yellow colouring matter				
Albumen . . . . .		67·80		
Water . . . . .		790·37		
Fibrin . . . . .		2·95		
Hæmatin . . . . .	2·27	} Corpuscles 127·90	}	Crassamentum 130·85
Albumen (globulin)	125·63			
				1000·

Lecanu's statement refers all the water of the blood to the serum, and thus exaggerates the quantity of albumen. The following statement (from Lehmann) may be taken as a more correct account of the distribution of the several constituents; but the proportion assigned of albumen is probably somewhat too low.

In 1000 parts of Blood.

	<i>Corpuscles.</i>	<i>Plasma.</i>	<i>Total.</i>
Water . . . . .	344	451·45	795·450
Hæmatin . . . . .	8·375	...	8·375
Globulin and Envelopes . . . . .	141·110	...	141·110
Fat . . . . .	1·155	0·860	2·015
Extractive matters . . . . .	1·300	1·970	3·270
Saline " . . . . .	4·060	4·275	8·335
Fibrin . . . . .	...	2·025	2·025
Albumen . . . . .	...	39·420	39·420
			1000·

*Difference between Arterial and Venous Blood.*—By arterial blood is meant that which is contained in the aorta and its branches (systemic arteries), the pulmonary veins and left cavities of the heart; the venous blood is that of the veins generally, the pulmonary arteries, and right cavities of the heart. Their differences, apart from their functional effects in the living body, come under the heads of colour and composition.

1. Colour. Arterial blood, as already stated, is scarlet, venous blood dark, or purple. Venous blood assumes the scarlet colour on exposure to air, *i. e.*, to oxygen. This change is greatly promoted by the saline matter of the serum, and may be accelerated by adding salts or sugar to blood, especially by carbonate of potash, or of soda, and by nitre. Salts added to dark blood, without exposure to oxygen or air, cause it to assume a red colour, but not equal in brightness to that of arterial blood. On



the other hand, the addition of a little water darkens the blood. According to Professor Stokes, the corpuscles in the former case "lose water by exosmosis, and become thereby highly refractive, in consequence of which a more copious reflexion takes place at the common surface of the corpuscles and surrounding fluid. In the latter case they gain water by endosmosis, which makes their refractive power more nearly equal to that of the fluid in which they are contained, and the reflexion is consequently diminished."\* But the presence of serum or of saline matter is not indispensable to the brightening, for although the clot when washed free from serum scarcely if at all reddens on exposure to oxygen, yet it is found that the red matter when squeezed out of the clot and dissolved in water, still becomes brighter and clearer on exposure to oxygen, whilst the colour is darkened (and the solution becomes turbid from deposition of globulin), on being shaken with carbonic acid. As in this case the colouring matter is extracted from the corpuscles and is reddened by oxygen without the presence of salts, it is plain that the difference of colour of arterial and venous blood essentially depends, not on a difference in the figure or density of the corpuscles, but on an alteration produced in their colouring substance by oxidation and deoxidation, which alters its absorptive effect on the light.

2. Composition. The arterial blood, so far as is known, is uniform in nature throughout; but in passing through the capillary vessels into the veins, whilst it generally acquires the common characters of venous blood, it undergoes special changes in its passage through particular organs, so that the blood of all veins is not alike in quality. Thus the blood of the hepatic veins differs from that of the portal vein, and both are in various respects different from what might be regarded as the common venous blood, which is conveyed by the veins of the limbs, and of the muscular and cutaneous parts of the body generally. Moreover, Bernard has shown that the blood of veins returning from secreting glands differs according to the state of functional activity of the organs. Whilst their function is in abeyance the blood in their veins is dark, as usual, but when secretion is active, the blood, which then also flows much more freely and abundantly, comes through from the arteries to the veins with very little, if any, reduction of its arterial brightness; it also retains nearly the whole of its separable oxygen.

Compared with blood from a cutaneous vein, arterial blood is found to contain a very little more water (about five parts in 1000), and to have a somewhat lower specific gravity. The arterial plasma yields more fibrin and coagulates more quickly; the serum is said by Lehmann to contain less albumen and less fat, but more extractive and a little more saline matter. According to the same authority, the corpuscles also contain less fat, but relatively more hæmatin and salts. Arterial blood yields more oxygen gas, and less of, both free and combined, carbonic acid.

*Blood of the portal vein*, compared with that of the jugular vein, is stated by Lehmann to contain more water in proportion to solid matter, less fibrin and albumen, more fat, extractive matter and salts. Its corpuscles are said to be richer in hæmatin.

*In the blood of the splenic vein*, as compared with that of the corresponding artery, according to the observations of Funke, the red corpuscles are smaller, more spheroidal in form, and more resistant to the destructive effects of water; and when they run together it is in rounded heaps, not in regular piles. Their cruor has a marked tendency to form crystals. The pale corpuscles are vastly more numerous than in the arterial blood, and some of them have a yellowish tint (as if in transition to red disks). *Granule-cells* occur occasionally and sparingly, twice as large as the pale corpuscles, but otherwise resembling them. The plasma is distinguished by its poverty in fibrin.

*The blood of the hepatic veins* shows, according to Lehmann's statement, the following differences from that of the portal vein. It is richer in both red and pale corpuscles, possibly from loss of water. The red corpuscles present the same peculiarities of size, form, resistance to water, and mode of aggregation, as in the splenic venous blood. They contain less fat and salts than in portal blood, less hæmatin, at least less iron, but somewhat more extractive matter; the proportion of pale corpuscles to the red is increased. The plasma is more concentrated, but is deficient in

\* Proc. Royal Soc., vol. xiii. p. 362.



fibrin (or spontaneously coagulating matter), and does not form a true clot. The serum contains less albumen and fat, and much less saline, but more extractive matter. The hepatic venous blood, moreover, yields sugar, derived from glycogen, formed in the liver.

The blood of the *renal veins* is said by Bernard and Brown Séquard not to coagulate in the normal state of the kidney and its function, from which they infer that it contains little or no fibrin; but it may be that there is something present which prevents the two constituents of the fibrin from reacting on each other.

#### COAGULATION OF THE BLOOD.

In explaining the constitution of the plasma, we have been obliged so far to anticipate the account of the coagulation of the blood. The following are the phenomena which usher in and which accompany this remarkable change. Immediately after it is drawn, the blood emits a sort of exhalation, the "halitus" having a faint smell; in about three or four minutes a film appears on the surface, quickly spreading from the circumference to the middle; a minute or two later the part of the blood in contact with the inside of the vessel becomes solid, then speedily the whole mass; so that, in about eight or nine minutes after being drawn, the blood is completely gelatinised. At about fifteen or twenty minutes, or it may be much later, the jelly-like mass begins to shrink away from the sides of the vessel, and the serum to exude from it. The clot continues to contract, and the serum to escape for several hours, the rapidity and degree of the contraction varying exceedingly in different cases; and, if the serum be poured off, more will usually continue to drain slowly from the clot for two or three days.

The nature of the change which takes place in the coagulation of the blood has been already spoken of; it is essentially owing to the coagulation of the liquor sanguinis, the fibrin being generated in that liquid by the concurrence of its two constituents in the way already explained, and separating in form of a solid mass, which involves the corpuscles but allows the serum to escape from it in greater or less quantity. But although the solidification of the fibrin and formation of a red clot would undoubtedly take place independently of any mechanical co-operation on the part of the corpuscles, still it must not be forgotten that the red disks are not altogether indifferent while coagulation goes on; for they run together into rolls, as already described, and the circumstance of their doing so with greater or with less promptitude materially affects the result of the coagulating process. Thus there seems good reason to believe that, as H. Nasse has pointed out, one of the causes—and in inflammatory blood probably the chief cause—of the production of the buffy coat, is an exaltation of the natural tendency of the red disks to run together, whereby being more promptly and more closely aggregated into compact masses, they more speedily subside through the liquid plasma, leaving the upper part of it colourless by the time coagulation sets in; and Mr. Jones has drawn attention to another influential circumstance depending likewise on the corpuscles, in inflammatory blood, namely, the more rapid and close contraction of the network, or spongework as he terms it, into which the little rolls of corpuscles unite, and the consequent expulsion of the great part of the liquor sanguinis from its meshes before the fibrin solidifies, in which case the mass of aggregated corpuscles naturally tends to the lower part of the vessel, whilst the expressed plasma, being lighter, accumulates at the top. Of course it is not meant to deny that more tardy coagulation of the plasma would produce the same result as more



speedy aggregation of the corpuscles ; it is well known, indeed, that blood may be made to show a buffy coat by delaying its coagulation, but buffed inflammatory blood is not necessarily slow in coagulating.

*Circumstances affecting Coagulation.*—Various causes accelerate, retard, or entirely prevent the coagulation of the blood ; of these it will here suffice to indicate the more important and best ascertained.

1. Temperature.—Cold delays, and at or below 40 degrees Fahr. wholly suspends, coagulation ; but even frozen blood, when thawed and heated again, will coagulate. Moderate elevation of temperature above that of the body promotes coagulation.

2. Coagulation is accelerated by contact of the blood with foreign matter, such as the sides of the basin or other vessel into which it is drawn. On the other hand, the maintenance of its fluidity is favoured by retention within its vessels or natural receptacles where it is in contact with the natural tissues of the body ; but when the coats of the vessels or other tissues, with which the blood is contiguous, lose their vitality and are altered in their properties, they become as foreign bodies, and coagulation is promoted. The usual exposure of drawn blood to the air promotes coagulation, but according to Lister, by no means so powerfully as has been heretofore generally understood. The effect of other gases is the same. Coagulation speedily takes place when blood is subjected to the air-pump, and has therefore been said to occur readily in vacuo, but Lister finds that this is owing to the agitation caused by the bubbling of the blood from the escape of liberated gas, whereby more and more of it is successively brought into contact with the sides of the vessel.

3. Arrest of the blood's motion *within the body* favours coagulation, probably by arresting those perpetual changes of material, both destructive and renovative, to which it is naturally subject in its rapid course through the system. The coagulation of the stagnant blood after death is also largely to be ascribed to the alteration then ensuing in the coats of the containing vessels. Lister found that, after death, blood remains longer fluid in the small veins than in the heart and great vessels ; and even in these the coagulation is usually slow. Agitation of *exposed* blood accelerates coagulation by increasing its exposure to foreign contact.

4. Water, in a proportion not exceeding twice the bulk of the blood, hastens coagulation ; a larger quantity retards it. Blood also coagulates more speedily when the serum is of low specific gravity, indicative of much water in proportion to the saline ingredients.

5. Almost every substance that has been tried, except the caustic alkalies, when added to the blood *in minute proportion*, hastens its coagulation ; although many of the same substances, when mixed with it in somewhat larger quantity, have an opposite effect. The salts of the alkalies and earths, added in the proportion of two or three per cent. and upwards, retard, and, when above a certain quantity, suspend or prevent coagulation ; but, though the process be thus suspended, it speedily ensues on diluting the mixture with water. Caustic potash and soda permanently destroy the coagulability of the blood. Acids delay or prevent coagulation. Opium, extract of belladonna, and many other medicinal agents from the vegetable kingdom, are said to have a similar effect when mixed with the blood ; but the statements of experimenters by no means entirely agree respecting them.

6. Certain states of the system.—Faintness occasioned by loss of blood favours coagulation ; states of excitement are said to have, though not



invariably, the opposite effect. Impeded aëration of the blood in disease, or in suffocative modes of death, makes it slow to coagulate ; probably from retention of carbonic acid. In cold-blooded animals, with slow circulation and low respiration, the blood coagulates less rapidly than in the warm-blooded ; and, among the latter, the tendency of the blood to coagulate is strongest in birds, which have the greatest amount of respiration, and highest temperature.

7. Coagulation commences earlier, and is sooner completed, in arterial than in venous blood. Dr. Nasse finds that women's blood begins to coagulate nearly two minutes sooner than that of the male sex.

In general, when blood coagulates quickly, the clot is more bulky and less firm, and the serum is less effectually expressed from it ; so that causes which affect the rapidity of coagulation will also occasion differences in the proportion of the moist clot to the exuded serum.

There is no sufficient evidence of evolution of heat or of disengagement of carbonic acid from blood during its coagulation, which some have supposed to occur.

*Theory of Coagulation.*—Although it is certain that the coagulation of the blood consists in solidification of fibrin, and although it seems tolerably well established that this is the result of the combination of two primarily separate animal principles, it is by no means clearly understood how such combination and solidification do not naturally take place within the living body, and how the several conditions already mentioned as influencing the process operate in promoting or opposing coagulation.

According to the explanation proposed a few years ago by Dr. B. W. Richardson,\* the blood is kept liquid within the vessels by ammonia, which maintains the fibrin in solution (or, as it may be now expressed, hinders the union of fibrinogen and globulin), and drawn blood coagulates in consequence of the loss of ammonia which escapes from it on exposure. Drawn blood placed in an atmosphere of ammonia remains fluid ; and, according to Dr. Richardson, the natural presence of ammonia in blood may be demonstrated, as well as its extrication from blood on exposure to air or in a vacuum. The more extensive and thorough the exposure, the more speedy is the escape of ammonia, and the quicker is the coagulation. Heat hastens coagulation by hastening the extrication of ammonia, whilst, by retaining it, cold delays or suspends the change. Moreover Dr. R. found that air which had become charged with the volatile element by passing through one portion of blood delayed the coagulation of another portion through which it was sent.

Nothing could at first sight appear more natural and consistent than this explanation ; but of the facts on which it mainly rests, some have since been disputed, and others differently interpreted. Thus after a most elaborate research, a late inquirer (Thiry) has been unable to find evidence of free ammonia in fresh blood. Again, Lister finds that blood may be poured from one piece of a vein into another, in a small stream through the air several times, so as to give ample opportunity for the escape of ammonia, and yet remain fluid for hours after. Lastly, the different effects of heat and cold may be ascribed to their influence in promoting or hindering the mutual reaction of the two constituents of the fibrin.

According to another view, which is fundamentally the same as that entertained by John Hunter and some other British physiologists, and which has recently been advocated by Professor Brücke of Vienna,† the blood has a natural tendency to coagulate ; or, if we may use the language suggested by later researches, the globulin and fibrinogen naturally tend to combine ; within the body this tendency is held in check by some inhibitory or restraining influence exercised by the coats of the vessels and the living tissues in contact with the blood ; but when blood is withdrawn from its natural receptacles, or if these lose their vitality, its intrinsic disposition to

\* The Cause of the Coagulation of the Blood. 1857.

† British and Foreign Medico-Chirurgical Review, vol. xix. 1857.



coagulate being no longer opposed, is allowed to prevail. At the same time it is not inconsistent with this theory to admit the positive efficacy of contact with foreign or dead matter in promoting coagulation. Mr. Lister,\* on the other hand, considers that the blood has no spontaneous tendency to coagulate, either within or without the vessels, but that the coagulation is brought about in drawn blood by contact with foreign matter. Accepting the conclusion of Schmidt, that globulin and fibrinogen are necessary to the evolution of fibrin, he thinks that if these bodies unite in ordinary chemical combination, the action of foreign matter may determine their union, as spongy platinum promotes the combination of oxygen and hydrogen. He considers that the living vessels do not exert any action to prevent coagulation, but that their peculiarity, as distinguished from an ordinary solid, consists in the remarkable circumstance that their lining membrane, in a state of health, is wholly negative in its relation to coagulation, and does not cause that molecular disturbance, so to speak, which is produced in the blood by all ordinary matter. When the vessels lose their peculiar property by death, or become seriously altered by disease or injury, their contact with the blood induces coagulation like that of an extraneous body. Finally, it may be observed, that in any attempted explanation of the coagulation of the blood, it is well to bear in mind that there is a purely physical or chemical phenomenon, which, as suggested by Mr. Graham, has a certain analogy to it, namely, the change from the liquid to the insoluble state so easily induced in colloidal matter by slight external causes.

## THE LYMPH AND CHYLE.

A transparent and nearly colourless fluid, named "lymph," is conveyed into the blood by a set of vessels distinct from those of the sanguiferous system. These vessels, which are named "lymphatics," from the nature of their contents, and "absorbents," on account of their reputed office, take their rise in nearly all parts of the body, and, after a longer or shorter course, discharge themselves into the great veins of the neck; the greater number of them previously joining into a main trunk, named the thoracic duct,—a long narrow vessel which rises up in front of the vertebræ, and opens into the veins on the left side of the neck, at the angle of union of the subclavian and internal jugular; whilst the remaining lymphatics terminate in the corresponding veins of the right side. The absorbents of the small intestine carry an opaque white liquid, named "chyle," which they absorb from the food as it passes along the alimentary canal; and, on account of the milky aspect of their contents, they have been called the "lacteal vessels." But in thus distinguishing these vessels by name, it must be remembered, that they differ from the rest of the absorbents only in the nature of the matters which they convey; and that this difference holds good only while digestion is going on; for at other times the lacteals contain a clear fluid, not to be distinguished from lymph. The lacteals enter the commencement of the thoracic duct, and the chyle, mingling with the lymph derived from the lower part of the body, is conveyed along that canal into the blood.

*Glands.*—Both lacteals and lymphatics, in proceeding to their destination, pass into and out of certain small, solid, and vascular bodies, named lymphatic glands, which have a special structure and internal arrangement, as will be afterwards described; so that both the chyle and lymph are sent through these glands before being mixed with the blood.

This much having been explained to render intelligible what follows, we

\* On the Coagulation of the Blood; the Croonian Lecture for 1863,—Proceedings of the Royal Society, vol. xii. p. 580.



may now consider the lymph and the chyle, which, as will be seen, are intimately related to the blood.

#### LYMPH.

The lymph may be procured free from admixture of chyle, and in quantity sufficient for examination, from the larger lymphatic vessels of the horse or ass. It may also be obtained by opening the thoracic duct of an animal that has fasted for some time before being killed. It is a thin fluid, transparent and colourless, or occasionally of a pale yellow hue; its taste is saline, its smell faint and scarcely perceptible, and its reaction alkaline. Sometimes the lymph has a decided red tint, of greater or less depth, which becomes brighter on exposure to the air. This redness is due to the presence of coloured corpuscles, like those of the blood: and it has been sometimes supposed, that such corpuscles exist naturally in the lymph, in greater or less quantity; but they are more probably introduced into the lymphatic vessels accidentally. It can, in fact, be shown that when an incision is made into a part, the blood very readily enters the lymphatics which are laid open, and passes along into larger trunks; and in this way blood is conveyed into the thoracic duct, or any other large vessel, exposed as usual by incision immediately after the animal is killed. Indeed, mere rough handling of some organs, such as the liver and spleen, will rupture the fine vessels and cause the contents of the issuing lymphatics speedily to become red from admixture of blood.

The lymph, when examined with the microscope, is seen to consist of a clear liquid, with corpuscles floating in it. These "lymph corpuscles," or lymph globules, agree entirely in their characters with the pale corpuscles of the blood, which have been already described (page xxxi.). It is alleged that some of the lymph corpuscles have a yellowish tint. Occasionally, smaller particles are found in the lymph; also, but more rarely, a few oil globules of various sizes, as well as red blood-corpuscles, the presence of which has just been referred to.

The liquid part (lymph-plasma) bears a strong resemblance in its physical and chemical constitution to the plasma of the blood; and accordingly, lymph fresh-drawn from the vessels coagulates after a few minutes' exposure, and separates after a time into clot and serum. This change is owing to the combination of the constituents of the fibrin contained in the lymph-plasma, and in this process most of the corpuscles are entangled in the coagulum. The serum, like the corresponding part of the blood, consists of water, albumen, extractive matters, fatty matters in very sparing quantity, and salts. Sugar exists in small quantity in the lymph, and urea, in the proportion of from 0.01 to 0.02 per cent.; leucin has also been found, at least in the lymphatic glands.

Human lymph has been obtained fresh from the living body in several instances, from lymphatic vessels opened by wounds or other causes. It has been found to agree in all material points with the lymph of quadrupeds.

#### CHYLE.

The chyle of man and mammiferous animals is an opaque, white fluid, like milk, with a faint odour and saltish taste, slightly alkaline or altogether neutral in its reaction. It has often a decided red tint, especially when taken from the thoracic duct. This colour, which is heightened by



exposure to air, is doubtless generally due to the presence of blood-corpuscles, and may be explained in the same way as the occasional red colour of lymph.

Like blood and lymph, both of which fluids it greatly resembles in constitution, the chyle consists of a liquid holding small particles in suspension. These particles are, 1. *Chyle corpuscles*, or chyle globules, precisely like the lymph globules and pale blood corpuscles already described. 2. *Molecules*, of almost immeasurably minute but remarkably uniform size. These abound in the fluid, and form an opaque white molecular matter diffused in it, which Mr. Gulliver has named the *molecular base* of the chyle. The addition of ether instantly dissolves this matter, and renders the chyle nearly, but not quite, transparent; whence it may be inferred that the molecules are minute particles of fatty matter, and no doubt the chief cause of the opacity and whiteness of the chyle. According to the late Prof. H. Müller, they are each coated with a fine film of albuminoid matter. They exhibit the usual tremulous movements common to the molecules of many other substances. 3. *Oil globules*; these are of various sizes, but much larger than the molecules above described, and are often found in the chyle in considerable numbers. 4. *Minute spherules* (Gulliver), from  $\frac{1}{24000}$  to  $\frac{1}{8000}$  of an inch in diameter; probably of an albuminous nature, and distinguished from the fatty molecules by their varying magnitude and their insolubility in ether. The *Free nuclei* described in the chyle by Kölliker he now considers to be derived from corpuscles accidentally ruptured in the examination.

The plasma, or liquid part of the chyle, contains fibrin, so that chyle coagulates on being drawn from the vessels, and nearly all the chyle corpuscles, with part of the molecular base, are involved in the clot. The serum which remains, resembles in composition the serum of lymph; the most notable difference between them being the larger proportion of fatty matter contained in the chyle-serum.

The following analyses of lymph and chyle exhibit the proportions of the different ingredients; but it must be explained that the amount of the corpuscles cannot be separately given, the greater part of them being included in the clot and reckoned as fibrin. No. 1 is the mean of two analyses, by Gubler and Quevenne, of human lymph taken during life from the lymphatics of the thigh; No. 2, the mean of three analyses by Gmelin of lymph from the thoracic duct of horses after privation of food; No. 3, by Dr. O. Rees, of chyle from the lacteals of an ass, after passing the mesenteric glands.

	I.	II.	III.
Water . . . . .	937.32	939.70	902.37
Fibrin . . . . .	0.595	10.60	3.70
Albumen . . . . .	42.775	38.83	35.16
Fat . . . . .	6.51	a little	36.01
Extractive matter . . . . .	5.05	10.87	22.76
Salts . . . . .	7.75		
	1000.	1000.	1000.

The extractive matters of the chyle and lymph probably vary with the nature of the food: they generally contain sugar and urea in appreciable quantities.

The chyle, when taken from the lacteal vessels before it has reached the glands, is generally found to coagulate less firmly than in a more advanced stage of its progress. In like manner the lymph, before passing the lymphatic glands, occasionally exhibits the same weak coagulation; but Mr. Lane justly remarks, that the lymph does not differ in coagulability in the different stages of its progress so



decidedly and so generally as has been sometimes alleged; and this observation accords with the statement of Mr. Hewson on the same point.

Dr. Rees has examined the fluid contained in the thoracic duct of the human subject. It was obtained from the body of a criminal an hour and a half after execution, and, from the small quantity of food taken for some hours before death, it must have consisted principally of lymph. It had a milky hue with a slight tinge of buff; part of it coagulated feebly on cooling: its specific gravity was 1024. Its analysis, compared with that of chyle from the ass, showed less water, more albumen, less aqueous extractive, and a great deal less fat.

#### FORMATION OF THE CORPUSCLES OF THE LYMPH AND CHYLE.

The lymph-plasma appears to consist fundamentally of blood-plasma, which, having exuded from the capillary blood-vessels and yielded nutritive material to the tissues, is, with more or less admixture of waste products, returned by the lymphatics. As to the origin of the lymph and chyle corpuscles, it may, in the first place, be observed that the greatly increased proportion of these bodies in the vessels which issue from the lymphatic glands, and the vast store of corpuscles having the same characters contained in the interior recesses of these glands, are unmistakeable indications that the glands are at least a principal seat of their production. They are, most probably, produced by division of parent corpuscles or cells contained in the glands, and in some measure also by further division of corpuscles thus produced, after they have made their way into the lymphatic vessels. The corpuscles found sparingly both in chyle and lymph before passing the mesenteric glands may be in part formed in the agminated and solitary follicular glands of the intestine—which, though differing so much in form, yet in essential structure have much in common with the lymphatic glands—and may come partly also from the irregular deposits of pale corpuscles, which have recently been recognised in the intestinal mucous membrane. Lymph-corpuscles are supposed also to be produced in the spleen, and in the thymus and thyroid glands; but corpuscles, although few in number, and not invariably present, have been found in the lymph of various regions of the body before it has reached the glands, and they are present in the lymph of cold-blooded vertebrata, whose lymphatic vessels, although forming a well developed system, do not pass through glands. It, therefore, seems necessary to admit some further source of the corpuscles; but what this may be is very much a matter of conjecture. It has been suggested that lymph corpuscles are produced by multiplication of cells in the epithelium which lines the lymphatic vessels, in the same way as mucous corpuscles are supposed to be formed from the epithelium of mucous membranes.

#### FORMATION OF THE BLOOD CORPUSCLES.

*In the embryo of batrachians.*—In the early embryo of the frog and newt (in which, perhaps, the steps of the process are best ascertained), at the time when the circulation of the blood commences, the corpuscles in that fluid appear as rounded cells, filled with granular matter, and of larger average size than the future blood corpuscles. The bodies in question, although spoken of as cells and presenting a regularly-defined outline, have no separable envelope. They contain, concealed in the midst of the granular mass, a pellucid globular nucleus, which usually presents one or two small clear specks, situated eccentrically. The granular contents consist partly of fine molecules, exhibiting the usual molecular movements; and partly of little angular plates, or tablets, of a solid substance, probably of a fatty nature. After a few days, most of the cells have assumed an oval figure, and are somewhat reduced in size; and the granular matter is greatly diminished in quantity, so that the nucleus is conspicuous. Now, also, the blood corpuscles, previously colourless, have acquired a yellowish or faintly red colour. In a further stage, the already oval cell is flattened, the granules entirely disappear, the colour is more decided, and, in short, the blood corpuscle acquires its permanent characters. From this description it will be seen that the blood-cells which first appear agree in nature with the embryonic cells (described at page xvi), and they are, in all probability, produced by the process of segmentation, which is known to take place in the frog's ovum. The different parts of the embryo in its early condition, the heart, for example, are for a time entirely composed of cells of the same kind, and all have probably a common origin.



*In the bird.*—In the egg of the bird, the first appearance of blood corpuscles, as well as of blood-vessels, is seen in the blastoderma, or germinal membrane, a structure formed by the extension of the cicatrix in the early stages of incubation. The commencing embryo, with its simple tubular heart, is seen in the middle of this circular membrane, and blood-vessels, containing blood corpuscles, appear over a great part of its area. These first vessels, therefore, though connected with the heart, and intended to convey nutriment to the embryo, are formed in an exterior structure; but in a somewhat later stage, blood-vessels and corpuscles are developed in various textures and organs within the body. The formation of blood corpuscles in the vascular area of the blastoderma has been sedulously investigated by various inquirers; and from their concurrent statements, we learn that these corpuscles, at a certain stage of their progress, are rounded bodies, larger than the blood-disks of the adult. They contain a granular nucleus, and are quite devoid of colour. These spheroidal colourless corpuscles in their further advancement become flattened, and assume an oval figure. While undergoing these changes of form, they acquire a red colour, which is at first faint and yellowish, but gradually deepens.

As to the earlier part of the process—the production of the above-mentioned round cells, whose subsequent conversion into coloured oval disks has just been described—it has been held that the cells which form the substance of the blastoderma and embryo partly pass directly into blood corpuscles, and partly generate the latter by fissiparous multiplication.

*In man and mammalia.*—In the embryo of man and mammalia the primitive blood corpuscles are round, nucleated, colourless bodies, as in the cases above described. Their substance, originally granular, speedily clears up and acquires colour, and thus they appear as nucleated red corpuscles, of spheroidal shape, and of much larger size than the future red disks. They are embryonic cells, most probably loosened from each other and set free in the excavation of the originally solid vessels in the blastoderma and embryo-body; and, both in their primitive state and after acquiring colour, they increase in number by fissiparous multiplication, as represented in fig. XI., p. xvii. These large nucleated red and colourless corpuscles, continuing to increase in number, constitute the earliest and, for a time, the only corpuscles in the embryo-vessels. But their multiplication is soon arrested, and a new epoch in blood-formation begins with the development of the liver. The blood which returns to the embryo charged with fresh material of nutrition from the maternal system, has then to pass, at first entirely, afterwards in great part, through the vessels of the liver, and it would seem that henceforth colourless nucleated corpuscles are produced in that organ and poured abundantly into the general mass of blood by the hepatic veins. It is probable that the liver continues its hæmopoietic or blood-forming function throughout foetal life; but, in the meanwhile, the spleen and lymphatic system have also begun to produce pale corpuscles, and in after periods supersede the liver in that office. These corpuscles, either immediately or after fissiparous multiplication, acquire colour like the first—those from the liver and spleen probably in great part before they leave these organs—and are converted into nucleated red corpuscles. The nucleated red corpuscles thus produced are gradually converted into, or at least succeeded by, smaller disk-shaped red corpuscles without nuclei, having all the characters of the blood-disks of the adult. This transition or substitution begins early, and proceeds gradually, until at length, long before the end of intrauterine life, the *nucleated* red corpuscles have altogether vanished.

Throughout life the mass of blood is subject to continual change; a portion of it is constantly expended, and its place taken by a fresh supply. It is certain that the corpuscles are not exempted from this general change, but it is not known in what manner they are consumed, nor has the process been fully traced by which new ones are continually formed to supply the place of the old. With regard to the latter question, it may be stated, that the explanation which has hitherto found most favour with physiologists is, that the corpuscles of the chyle and lymph passing into the sanguiferous system, become the pale corpuscles of the blood; and that these last are converted into red disks. Pale corpuscles are also generated in the spleen, and, after part of them have changed into red disks, pass directly into the blood, independently of those derived from the chyle and lymph. As to the manner in which the pale corpuscles are transformed into the red, there is considerable difference of opinion.



According to one view (adopted by Paget, Kölliker, Funke, and others), the pale corpuscles gradually become flattened, acquire coloured contents, lose their nuclei, and shrink somewhat in size, and thus acquire the characters of the red disks. But Mr. Wharton Jones has, from an extended series of observations, arrived at the conclusion that, whilst in birds, reptiles, and fishes, the pale or lymph corpuscle, suffering merely some alteration of form and contents, becomes the red disk, its nucleus alone is developed into the red disk of mammalian blood. According to this view (supported by Busk, Huxley, and Gulliver), while the red corpuscle of oviparous vertebrata is the transformed pale corpuscle—its development not proceeding beyond this stage—the non-nucleated red disk of man and mammalia is, on the other hand, considered to be, not the homologue of the oval nucleated red disk of the oviparous vertebrata, but that of its nucleus. It is not within the scope of this work to enter upon a discussion of the relative merits of these opinions, and the reader is referred to physiological works for a consideration of these and other views adopted by various authors upon the point at issue.

### EPIDERMIC, EPITHELIAL, OR CUTICULAR TISSUE.

*General nature and situation.*—It is well known, that when the skin is blistered, a thin, and nearly transparent membrane, named the cuticle or epidermis, is raised from its surface. In like manner, a transparent film may be raised from the lining membrane of the mouth, similar in nature to the epidermis, although it has in this situation received the name of "epithelium;" and under the latter appellation, a coating of the same kind exists on nearly all free surfaces of the body. It is true that in many situations the epithelium cannot be actually raised from the subjacent surface as a coherent membrane, still its existence as a continuous coating can be demonstrated; and, although in different parts it presents important differences, it has in all cases the same fundamental structure, and its several varieties are connected by certain common characters.

The existence of a cuticular covering in one form or other, has been demonstrated in the following situations: viz. 1. On the surface of the skin. 2. On mucous membranes; a class of membranes to be afterwards described, which line those internal cavities and passages of the body that open exteriorly, viz., the alimentary canal, the lachrymal, nasal, tympanic, respiratory, urinary, and genital passages; as well as the various glandular recesses and ducts of glands, which open into these passages or upon the surface of the skin. 3. On the inner or free surface of serous membranes, which line the walls of closed cavities in the head, chest, abdomen, and other parts. 4. On the membranes termed synovial within the joints. 5. On the inner surface of the blood-vessels and lymphatics.

*Structure in general.*—This tissue has no vessels, and, except in certain parts of the organs of the senses, is devoid of nerves, and of sensibility; it, nevertheless, possesses a decidedly organised structure. Wherever it may exist, it is formed essentially of nucleated cells united together by cohesive matter, often in too small quantity to be apparent. The cells, in whatever way they may be produced, make their appearance first in the deepest part of the structure, where they receive material for growth from the blood-vessels of the subjacent tissue; then, usually undergoing considerable changes in size, figure, and consistency, they gradually rise to the surface, where, as shown at least in various important examples, they are thrown off and succeeded by others from beneath. In many situations the cells form several layers, in which they may be seen in different stages of progress, from their first appearance to their final desquamation. The layer or layers thus formed, take the shape of the surface to which they are



applied, following accurately all its eminences, depressions and inequalities. Epithelium when destroyed or cast off, is, for the most part, very readily regenerated.

In accordance with the varied purposes which the epithelium is destined to fulfil, the cells of which it is composed come to differ in different situations, in figure and size, in their position in respect of each other, their degree of mutual cohesion, and in the nature of the matter they contain, as well as in the vital endowments which they manifest; and founded on these modifications of its constituent cells, or, at any rate, those forming the superficial layer, four principal varieties of epithelium have been recognised, namely, the *scaly*, the *columnar*, the *spheroidal*, and the *ciliated*, each of which will now be described in particular.

It may first be remarked, however, that amidst these changes the nucleus of the cell undergoes little alteration, and its characters are accordingly remarkably uniform throughout. It is round or oval, and more or less flattened; its diameter measures from  $\frac{1}{6000}$ th to  $\frac{1}{4000}$ th of an inch, or more. Its substance is insoluble in acetic acid, and colourless, or but slightly tinted. It usually contains one or two nucleoli, distinguished by their strong dark outline; and a variable number of more faintly-marked granules irregularly scattered. For the most part, the nucleus is persistent, but in some cases it disappears from the cell.

*Scaly Epithelium.*—The *scaly*, *lamellar*, *tabular*, or *flattened* epithelium (comprehending, in part, the pavement or tessellated epithelium of the German anatomists). In this variety the epithelium particles have the form of small angular plates, or thin scales; in some situations forming a single thin layer, in others accumulating in many super-imposed strata, so as to afford to the parts they cover a defensive coating of considerable strength and thickness.

As a *simple layer*, it is found on the serous, and some synovial membranes, the inner surface of the heart, blood-vessels and absorbents; also partly lining the cerebral ventricles and covering the choroid plexuses; on certain parts within the eye and ear, and in some gland ducts.

If the surface of the peritoneum, pleura, pericardium, or other serous membrane be gently scraped with the edge of a knife, a small quantity of soft matter will be brought away, which, when examined with the microscope, will be found to contain little shred-like fragments of epithelium, in which a few of its constituent particles still hold together, like the pieces composing a mosaic work (fig. xx.). These particles, which are flattened cells, have for the most part a polygonal figure, and are united to each other by their edges. Each has a nucleus, apparently in or near the centre. The addition of weak acetic acid renders the angular outline of the cells as well as the nucleus more distinct. The cells differ somewhat in size on different parts of the serous membrane; and those which cover the plexus choroides send downwards short, pointed, transparent processes towards the subjacent tissue.

The epithelium of the vascular system resembles in many parts that of

Fig. XX.

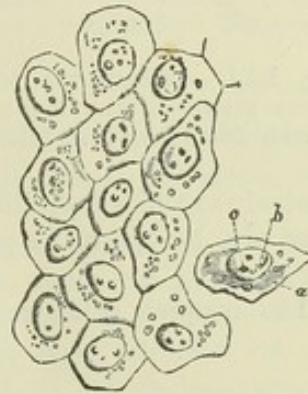


Fig. XX.—FRAGMENT OF EPI-  
THELIUM FROM A SEROUS  
MEMBRANE (PERITONEUM);  
MAGNIFIED 410 DIAMETERS.

a, cell; b, nucleus; c, nu-  
cleoli (Henle).



the serous membranes ; but in some situations, and especially in the arteries, the flattened cells, together with their nuclei, assume an oblong fusiform figure, and sometimes their outline becomes indistinct from blending of neighbouring cells.

A scaly epithelium, in which the cells form several layers, (thence named *stratified*) covers the skin, where it constitutes the scarf-skin or epidermis, which, together with the hairs and nails, will be afterwards more fully described. In this form it exists, also, on the conjunctival covering of the eyeball ; on the membrane of the nose for a short distance inwardly ; on the tongue and the inside of the mouth, throat and gullet ; on the vulva and vagina, extending some way into the cervix of the uterus ; also (in both sexes), on a very small extent of the membrane of the urethra, adjoining the external orifice. It is found, also, on the synovial membranes which line the joints. Its principal use, no doubt,

is to afford a protective covering to these surfaces, which are almost all more or less exposed to friction.

The cells in this sort of epithelium become converted into broad thin scales, from  $\frac{1}{850}$  to  $\frac{1}{500}$  of an inch in diameter, which are loosened and cast off at the free surface. Such scales, both single and connected in little patches, may be at all times seen with the microscope in mucus scraped from the inside of the mouth, as shown in fig. XXI. ; but to trace the progressive changes of the cells, they must be suc-

cessively examined at different depths from the surface, and the epithelium must also be viewed in profile, or in a perpendicular section, as exhibited in fig. XXII.

The deepest cells, or those next the subjacent tissue, are sometimes

Fig. XXI.

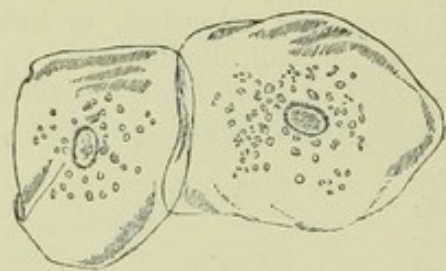


Fig. XXI.—EPITHELIUM SCALES FROM THE INSIDE OF THE MOUTH ; MAGNIFIED 260 DIAMETERS (Henle).

Fig. XXII.

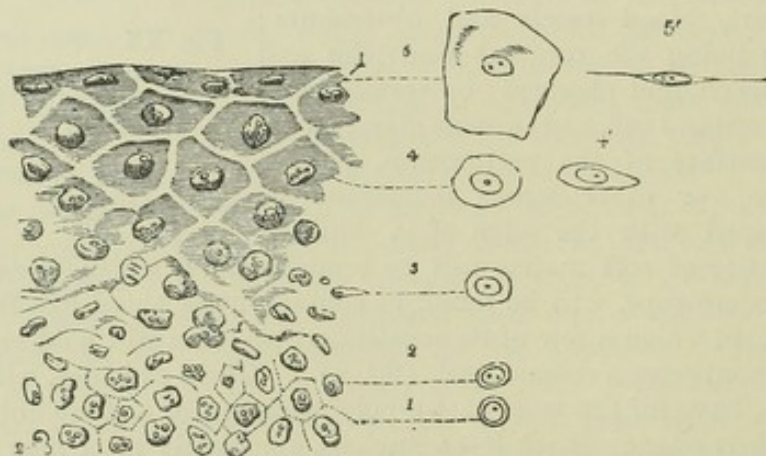


Fig. XXII.—EPITHELIUM FROM THE CONJUNCTIVA OF THE CALF, FOLDED SO THAT THE FREE SURFACE FORMS THE UPPER BORDER OF THE FIGURE, AND RENDERED TRANSPARENT BY ACETIC ACID.

1, 2, 3, 4, 5, progressive flattening of the cells as they rise to the surface. The outline figures represent single cells from different depths, viewed on their surface ; and at 4' and 5', edgewise. Magnified 410 diameters (chiefly after Henle).



rounded or spheroidal in shape (fig. XXII, <sup>1</sup>), and but little larger than their nucleus; but more commonly the undermost layer is formed (as shown in fig. XXIII.) of oblong cells, which are placed vertically, and may be larger in size than the round cells which lie immediately over them. Such oblong vertical cells occur in the undermost layer of the epidermis, and similarly in the epithelium of the cornea and of various parts of the mucous membranes. Sometimes they form two or three successive rows. Higher up in the mass the cells are enlarged; they have a globular or oval figure, and are filled with soft matter; they next become flattened, but still retain their round or oval outline; then the continued flattening causes their opposite sides to meet and cohere, except where separated by the nucleus, and they are at length converted into thin scales, which form the uppermost layers. While they are undergoing this change of figure, their substance becomes more firm and solid, and their chemical nature is more or less altered; for the cell-membrane of the softer and more deep-seated cells may be dissolved by acetic acid, which is not the case with those nearer the surface. The nucleus at first enlarges, as well as the cell, but in a much less degree. The scales near the surface overlap a little at their edges, and their figure is very various; somewhat deeper it is mostly polygonal, and more uniform.

In various parts, the more superficial and denser layers of the scaly epithelium can be readily separated from the deeper, more recently formed, softer and more opaque part which lies underneath; so that the latter is often distinguished as the Malpighian or mucous layer (*stratum* or *rete mucosum*), although it is now well understood not to be an independent membrane. This point will be again noticed in treating of the skin.

*Furrowed and spinous cells of epithelium.*—It was long since noticed by Henle that the flattened cells sometimes present a striated appearance, and quite recently Max Schultze and Virchow have described cells marked on the surface with parallel ridges and furrows (*Riffzellen*), and others (*Stachelzellen*) covered with spines, and therefore presenting a fringed or denticulate border (fig. XXIV.). Both varieties have been found in the epithelium of the tongue, lips, and conjunctiva, and in the epidermis; and in all cases are confined to the deeper or Malpighian layers. Similar cells have been found in epithelial cancer and in canceroid tumours; and flattened cells, beset with minute spines on their free surface, have recently been noticed (by Broueff and Eberth) in the epithelium covering the inner surface of the cat's amnion.

In thin vertical sections of the epidermis of the fingers I have seen what appeared to be cells with a deeply serrated outline, in the Malpighian layer, but I have not been able to separate them so as to examine them singly.

*Growth.*—It must be admitted that the continued production of new cells by which this and other kinds of epithelium are maintained, is not yet thoroughly understood. It was at one time commonly believed that the cells which go through the changes of form and position already described, are formed from nuclei arising by independent formation in a blastema supplied by the subjacent vascular membrane; but it is now

Fig. XXIII.

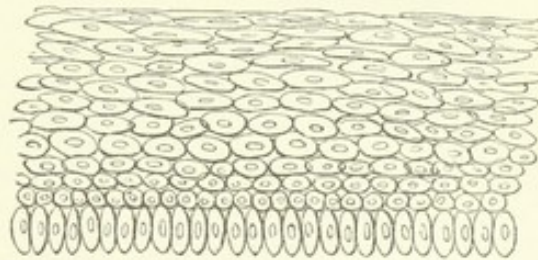


Fig. XXIII.—DIAGRAM OF SECTION OF EPITHELIUM, IN WHICH THE UNDERMOST CELLS ARE OBLONG AND VERTICAL.



more generally held that the new epithelium-cells are produced by division of pre-existing cells in the lowermost stratum. In the earliest condition of the embryo there are special layers of cells, derived from the primitive embryonic cells, set aside for the production of the epidermis and of the intestinal and glandular epithelium; and it is quite conceivable, and by some histologists considered most probable, that

Fig. XXIV.

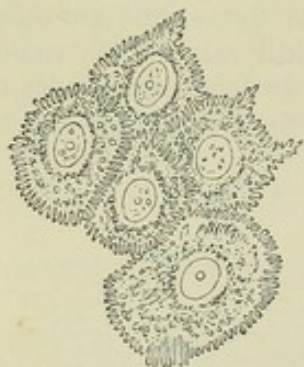


Fig. XXIV.—SPINOUS CELLS FROM THE MALPIGHIAN LAYER OF THE HUMAN EPI-  
DERMIS; ABOUT  $\frac{1}{1000}$  INCH  
IN DIAMETER (after M.  
Schultze, Virch. Arch. vol.  
30).

the subsequent generations of epidermic and epithelial cells by which the tissue is throughout life maintained, are derived by unbroken descent from the original embryonic stratum. At the same time the reproduction of epidermis in cicatrices after wide and deep destruction of the subjacent skin, implies some other source of new cells; unless indeed it be supposed that the new cuticle grows exclusively from the old at the circumference of the sore. Setting aside this supposition, we might conceive the new cells to come from the connective-tissue corpuscles of the granulating surface of the new-growing skin; and a recent writer (Dr. Otto Weber) describes such mode of reproduction of epidermis as actually observed by him in the healing of wounds; moreover, it may be questioned whether, in certain situations, this may not be the regular process by which the growth of epithelium is maintained.

When the lowermost cells are elongated and vertical, it is difficult to conceive that they rise up as such, and take their place in the upper strata; for the cells next above them are spheroidal in shape and smaller in size. It seems more likely that they divide into or produce the smaller cells. It might be supposed that an oblong vertical cell, by division of its nucleus and separation of the upper portion of the cell-body, produces a new and smaller cell, which rises up, while the parent cell maintains its place, and lengthens out again for a repetition of the process. Dr. Schneider\* describes appearances actually observed by him in the epithelium covering the front of the cornea, which seem to indicate a process of this kind; but much more extended observations are required to settle the point. I have seen cells with double or divided nuclei in the epithelium of the bladder, but not confined to the deep strata; on

Fig. XXV.

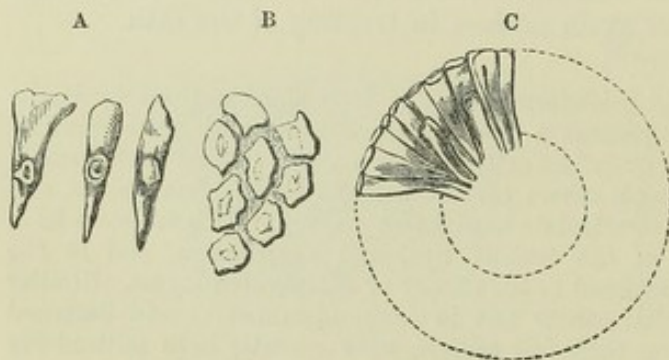


Fig. XXV.—A, COLUMNS OF EPITHELIUM FROM THE  
INTESTINE MAGNIFIED; B, VIEWED BY THEIR BROAD  
FREE EXTREMITY; C, SEEN IN A TRANSVERSE SECTION  
OF AN INTESTINAL VILLUS (from Henle).

the other hand, I have never been able to perceive indications of division in the deep vertical cells of the epidermis; at the same time it is plain that the latter are not mere nuclei imbedded in a blastema;—the nucleus is surrounded by a tolerably well-marked cell-body, which has a deeply denticulate or fringed border at the part turned towards the corium.

*Columnar Epithelium*  
(Cylinderepithelium of  
Germ. Anat.).—In this  
variety (figs. XXV. and  
XXVI.), the constituent

cells are elongated in a direction perpendicular to the surface of the membrane, so as to form short upright columns, which may be of the same thickness

\* Würzb. Naturwiss : Zeitschrift, vol. iii. 1862.



throughout, but are, more frequently, smaller or even pointed at their lower or attached extremity, and broader at the upper (fig. xxv. A). They are mostly flattened on their sides, by which they are in mutual apposition, at least in their upper and broadened part, and have, therefore, so far a prismatic figure, their broad flat ends appearing at the surface of the epithelium in form of little polygonal areas (fig. xxv. B). The nucleus, usually oval, and containing a nucleolus, is placed near the middle of the column, and is often so large in proportion to the cell, as to cause a bulging at that part; in which case the height of the nucleus differs in contiguous columns, the better to allow of mutual adaptation.

This variety of epithelium is confined to mucous membranes. It is found in the stomach; on the mucous membrane of the intestines in its whole extent; in the whole length of the urethra, except a small part at the orifice. It extends along the ducts of the greater number of glands, whether large or small, which open on the mucous membrane, but not through their entire length; for, at their extremities, these ducts have for the most part an epithelium of a different character. It covers also the inner membrane of the gall-bladder.

In these different situations the cells form but a single layer. On the proper olfactory region of the nasal mucous membrane there is a modification of the columnar epithelium, in which the cells, tinged with brownish yellow pigment, are associated with the terminations of the olfactory nerves, and present other peculiarities, which will be noticed in the special description of the organ of smelling.

The substance ordinarily contained in the columnar cells has a faintly granular aspect, and consists chiefly of mucus, which is no doubt produced in the cell. Under exposure to water this mucus swells up and escapes in form of a pellucid drop (fig. xxvii., *a*, *b*). During digestion of food containing oil or fat, the cells of the intestinal epithelium are often found to be filled with minute fat-molecules; as if they had some part to perform in the absorption of that aliment. The wall of the cell forming the basis or free end is comparatively thick (fig. xxvi., *a*), and is marked by fine parallel lines running perpendicular to the surface (fig. xxvii., 1, 2). The thick, striated border is superadded, as it were, to the thin proper wall forming the base of the cell, and is regarded by Kölliker, who first pointed out its striated character, as an excreted product of the cell, deposited upon its outer surface, as occurs in the cuticular structures of many of the inferior animals. As to the striation, it might no doubt be produced by a fine columnar or fibrous structure, but most observers agree with Kölliker in ascribing it to fine tubular passages perforating the cell-wall; and it is further supposed that such porous structure would account for the assumption of fat-molecules or other minutely divided matters into the cell, and may be subservient to an absorptive function in cells so constituted. It must be stated, however, that a thickened striated border has been since observed in various other epithelium cells which are not so obviously connected with the function of absorption, such as those lining the biliary and urinary passages, and the parotid and pancreatic ducts.

As fat, in a state of minute division, is undoubtedly taken into the epithelium cells of the intestinal villi and disappears from them again, it was natural to look for some

Fig. XXVI.

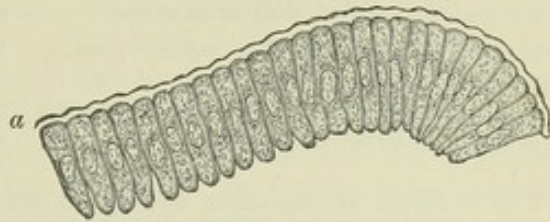


Fig. XXVI. — EPITHELIUM FROM INTESTINAL VILLUS OF A RABBIT; MAGNIFIED 300 DIAMETERS.

*a*, Thick border (from Kölliker).



way by which it might be conveyed from hitherto the search has not been successful.

Fig. XXVII.

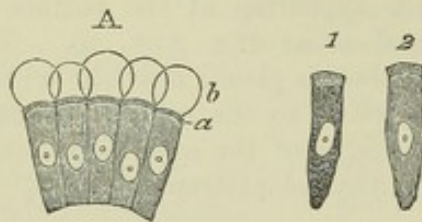


Fig. XXVII.—CELLS OF INTESTINAL EPITHELIUM OF RABBIT, TREATED WITH WATER; MAGNIFIED 350 DIAMETERS.

1 and 2 show striated or porous border, somewhat swollen by imbibition; *a*, *b*, pellucid drops of mucus which have escaped from the cells (from Kölliker).

the cells into the lacteal vessels; but The alleged communication of the cells in question with lacteal vessels, through the intermedium of connective-tissue corpuscles, rests on no sufficient evidence. It is true that processes, like roots, have in some cases been observed running down from columnar cells into the subjacent tissue, and in the epithelium of the olfactory membrane these radical processes are long and ramified; but the connection of these prolongations with connective-tissue corpuscles is as yet a matter of presumption only; although there is proof of such connection in the case of some ciliated epithelium cells; and it is material to observe that the *intestinal* epithelium, when examined fresh and without the aid of condensing reagents, shows no such processes.

The particles of columnar epithelium are undoubtedly subject to shedding and renovation; but although various suppositions have been hazarded as to the mode in which this is effected, it must be admitted that no satisfactory account has been given of the process. According to Donders and Kölliker, the columnar cells on the villi appear occasionally to cast off a part from their upper end, with subsequent reparation of the loss. That is, a cell enlarges and a second nucleus appears; the upper and broader part, with one nucleus and much of the cell contents, separates, and the lower remaining portion, with its nucleus, grows again to the natural size. The extruded portion is supposed to become a mucus-corpuscle.

*Spheroidal Epithelium.*—In this variety, the cells for the most part retain their primitive roundness, or, being flattened where they touch, acquire a polyhedral figure, in which no one dimension remarkably predominates. Hence the above term was applied to this form of epithelium by Mr. Bowman. But in some places the cells show a tendency to lengthen into columns and in others to flatten into tables, especially when this epithelium approaches the confines of one or other of the preceding varieties; in such cases it has been named *transitional*; moreover, when the scaly and columnar varieties border upon one another, the figure of their particles is gradually

Fig. XXVIII.

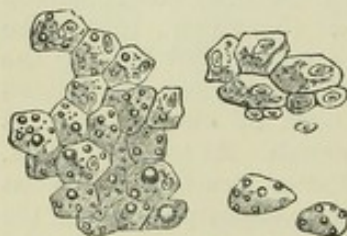


Fig. XXVIII.—CELLS FROM THE LIVER MAGNIFIED (Dr. Baly).

changed, presenting various intermediate forms; in other words, the epithelium there puts on the transitional character, though it may be only for a very small space.

The spheroidal epithelium is found in the excretory ducts of the mammary, perspiratory, and of many mucous glands, and a modification of the spheroidal epithelium lines the inmost secreting cavities, or commencing ducts of glands generally (fig. XXVIII.). In this last-mentioned situation, where it is sometimes distinguished by the name of *glandular epithelium*, the nucleated cells contain a large proportion of

fine granular matter; in some cases even, the peculiar ingredients of the secretion may be recognised in them; and it is conceived, that they have a considerable share in preparing or separating these matters from the blood.

*Ciliated Epithelium.*—In this form of epithelium, the particles, which are



generally columnar, bear at their free extremities little hair-like processes, which are agitated incessantly during life, and for some time after death, with a lashing or vibrating motion. These minute and delicate moving organs are named *cilia*. They have now been discovered to exist very extensively throughout the animal kingdom; and the movements they produce are subservient to very varied purposes in the animal economy.

In the human body the ciliated epithelium occurs in the following parts, viz.:—1. On the mucous membrane of the air passages and its prolongations. It commences at a little distance within the nostrils, covers the membrane of the nose and of the adjoining bony sinuses, extends up into the nasal duct and lachrymal sac. From the nose it spreads backwards a certain way on the upper surface of the soft palate, and over the upper or nasal region of the pharynx; thence along the Eustachian tube and lining membrane of the tympanum, of which it covers the greater part. The lower part of the pharynx is covered by scaly epithelium as already mentioned; but the ciliated epithelium begins again in the larynx a little above the glottis, and continues throughout the trachea and the bronchial tubes in the lungs to their smallest ramifications. 2. On the mucous lining of the uterus, commencing at the middle of the cervix and extending along the Fallopian tubes, even to the peritoneal surface of the latter at their fimbriated extremities. 3. Lining the *vasa efferentia*, *coni vasculosi*, and first part of the excretory duct of the testicle. 4. To a large extent on the pareties of the ventricles of the brain, and throughout the central canal of the spinal cord.

In other mammiferous animals, as far as examined, cilia have been found in nearly the same parts. To see them in motion a portion of ciliated mucous membrane may be taken from the body of a recently killed quadruped. The piece of membrane is to be folded with its free or ciliated surface outwards, placed on a slip of glass, with a little weak salt water or serum of blood, and covered with a bit of thin glass or mica. When it is now viewed with a magnifying power of 200 diameters, or upwards, a very obvious agitation will be perceived on the edge of the fold, and this appearance is caused by the moving cilia with which the surface of the membrane is covered. Being set close together, and moving simultaneously or in quick succession, the cilia, when in brisk action, give rise to the appearance of a bright transparent fringe along the fold of the membrane, agitated by such a rapid and incessant motion, that the single threads which compose it cannot be perceived. The motion here meant, is that of the cilia themselves; but they also set in motion the adjoining fluid, driving it along the ciliated surface, as is indicated by the agitation of any little particles that may accidentally float in it. The fact of the conveyance of fluids and other matters along the ciliated surface, as well as the direction in which they are impelled, may also be made manifest by immersing the membrane in fluid, and dropping on it some finely pulverised substance (such as charcoal in fine powder), which will be slowly but steadily carried along in a constant and determinate direction; and this may be seen with the naked eye, or with the aid of a lens of low power.

The ciliary motion of the human mucous membrane is beautifully seen on the surface of recently extracted nasal polypi; and single ciliated particles, with their cilia still in motion, are sometimes separated accidentally from mucous surfaces in the living body, and may be discovered in the discharged mucus; or they may even be purposely detached by gentle abrasion.



But the extent and limits of the ciliated epithelium of the human body have been determined chiefly from its anatomical characters.

Cilia have now been shown to exist in almost every class of animals, from the highest to the lowest. The immediate purpose which they serve is, to impel matter, generally more or less fluid, along the surfaces on which they are attached; or, to propel through a liquid medium the ciliated bodies of minute animals, or other small objects on the surface of which cilia are present; as is the case with many infusorial animalcules, in which the cilia serve as organs of locomotion like the fins of larger aquatic animals, and as happens, too, in the ova of many vertebrate as well as invertebrate animals, where the yolk revolves in its surrounding fluid by the aid of cilia on its surface. In many of the lower tribes of aquatic animals, the cilia acquire a high degree of importance: producing the flow of water over the surface of their organs of respiration, indispensable to the exercise of that function; enabling the animals to seize their prey, or to swallow their food, and performing various other offices of greater or less importance in their economy. In man, and the warm-blooded animals, their use is apparently to

impel secreted fluids or other matters along the ciliated surface, as, for example, the mucus of the windpipe and nasal sinuses, which they carry towards the outlet of these cavities.

The cells of the ciliated epithelium contain nuclei, as usual; they have most generally an elongated or prismatic form (fig. XXIX.), like the particles of the columnar epithelium, which they resemble too in arrangement but are often of greater length and more slender and pointed at their lower end. The cilia are attached to their broad or superficial end, each columnar particle bearing a tuft of these minute hair-like processes. In some cases, the cells are spheroidal in figure, the cilia being still, of course, confined to that portion of the cell which forms part of the general surface of

the epithelial layer, as shown in fig. XXX., which represents such cells from the epithelium of the frog's mouth. In man this form occurs in the ciliated

epithelium of the cerebral ventricles and tympanum, where the cells form but a single stratum. The columnar ciliated epithelium also may exist as a simple layer, as in the uterus and Fallopian tubes, the finest ramifications of the bronchia, and the central canal of the spinal cord; but in various other parts—as the nose, pharynx, Eustachian tube, the trachea and its larger divisions—there is a layer of elongated cells beneath the superficial ciliated range, filling up the spaces between the pointed extremities of the latter, and beneath this is an undermost layer formed of small rounded cells (fig. XXXI.). Probably the sub-jacent cells acquire cilia, and take the place of ciliated cells which are cast off; but the mode of

renovation of ciliated epithelium is not yet fully understood.

The relation of the ciliated, as well as other epithelium cells, to the connective-tissue

Fig. XXIX.

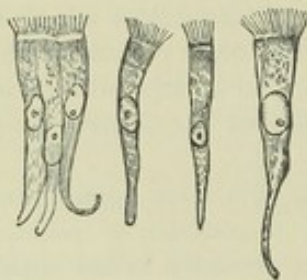


Fig. XXIX. — COLUMNAR CILIATED EPITHELIUM CELLS FROM THE HUMAN NASAL MEMBRANE; MAGNIFIED 300 DIAMETERS.

Fig. XXX.

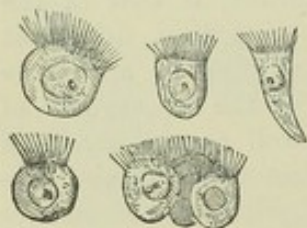


Fig. XXX.—SPHEROIDAL CILIATED CELLS FROM THE MOUTH OF THE FROG; MAGNIFIED 300 DIAMETERS.



of the subjacent membrane, has much engaged attention since the importance of the connective-tissue corpuscles has come to be recognised; and a strong impression or belief prevails that such epithelium cells are structurally connected by prolongations from their lower ends with these corpuscles, and genetically related to them. As a matter of observation such anatomical connection is affirmed on excellent authority (Lockhart Clarke, Gerlach and others) in reference to the columnar ciliated epithelium of the central canal of the spinal cord and the Sylvian aqueduct, but the evidence in other cases is not so satisfactory.

Fig. XXXI.

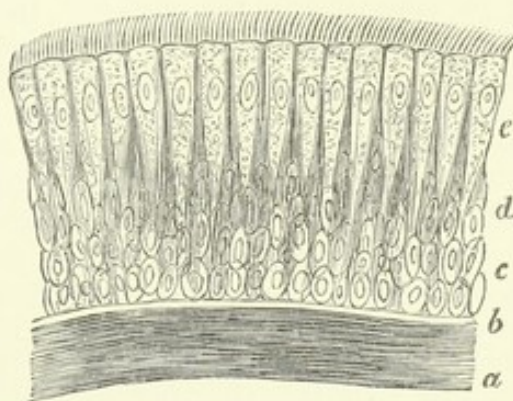


Fig. XXXI.—CILIATED EPITHELIUM FROM THE HUMAN WINDPIPE; MAGNIFIED 350 DIAMETERS.

*a, b*, subjacent membrane; *c*, lowermost or round cells; *d*, middle layer of oval cells; *e*, superficial or ciliated cells (from Kölliker).

The cilia themselves differ widely in size in different animals, and they are not equal in all parts of the same animal. In the human windpipe they measure  $\frac{1}{4000}$ th to  $\frac{1}{2500}$ th of an inch in length; but in many invertebrate animals, especially such as live in salt water, they are a great deal larger. In figure they have the aspect of slender, conical, or slightly flattened filaments; broader at the base and usually pointed at their free extremity. Their substance is transparent, soft, and flexible. It is to all appearance homogeneous, and no fibres, granules, or other indications of definite internal structure, have been satisfactorily demonstrated in it.

*Motion of the cilia.*—The manner in which the cilia move, is best seen when they are not acting very briskly. Most generally they seem to execute a sort of fanning or lashing movement; and when a number of them perform this motion in regular succession, as is generally the case, they give rise to the appearance of a series of waves travelling along the range of cilia, like the waves caused by the wind in a field of corn. When they are in very rapid action the undulation is less obvious, and, as Henle remarks, their motion then conveys the idea of swiftly running water. The undulating movement may be beautifully seen on the gills of a mussel, and on the arms of many polypes. The undulations, with some exceptions, seem always to travel in the same direction on the same parts. The impulsion, also, which the cilia communicate to the fluids or other matters in contact with them, maintains a constant direction; unless in certain of the infusoria, in which the motion is often variable and arbitrary in direction, and has even been supposed to be voluntary. Thus in the windpipe of mammalia, the mucus is conveyed upwards towards the larynx, and if a portion of the membrane be detached, matters will still be conveyed along the surface of the separated fragment in the same direction relatively to that surface, as before its separation.

The persistence of the ciliary motion for some time after death, and the regularity with which it goes on in parts separated from the rest of the body, sufficiently prove that, with the possible exceptions alluded to, it is not under the influence of the will of the animal nor dependent for its production on the nervous centres, and it does not appear to be influenced in any



way by stimulation or sudden destruction of these centres. The time which it continues after death or separation differs in different kinds of animals, and is also materially influenced by temperature and by the nature of the fluid in contact with the surface. In warm-blooded animals the period varies from two or three hours to two days, or even more ; being longer in summer than in the cold of winter. In frogs the motion may continue four or five days after the destruction of the brain ; and it has been seen in the gullet of the tortoise fifteen days after decapitation, continuing seven days after the muscles had ceased to be irritable.

With the view of throwing further light on the nature of this remarkable kind of motion, experiments have been made to ascertain the effect produced on it by different physical chemical and medicinal agents ; but, so far as these experiments have gone, it would seem that, with the exception of moderate heat and cold, alkaline solutions, chloroform vapour, and perhaps some other narcotics, these agents affect the action of the cilia only in so far as they act destructively on their tissue.

The effect of change of temperature is different in warm and cold-blooded animals. In the former the motion is stopped by a cold of  $43^{\circ}$  F., whereas in the frog and river mussel it goes on unimpaired at  $32^{\circ}$  F. E. H. Weber has made the interesting observation that in ciliated epithelium particles detached from the human nasal membrane, the motion which has become languid or quiescent from the cold, may be revived by warmth, such as that of the breath, and this several times in succession. A moderately elevated temperature, say  $100^{\circ}$  F., does not affect the motion in cold-blooded animals ; but, of course, a heat considerably higher than this, and such as to alter the tissue, would put an end to it in all cases. Electric shocks, unless they cause abrasion of the ciliated surface (which is sometimes the case), produce no visible effect ; and the same is true of galvanic currents. Fresh water, I find, arrests the motion in marine mollusca and in other salt-water animals in which I have tried its effect ; but it evidently acts by destroying both the form and substance of the cilia, which in these cases are adapted to a different medium. Most of the common acid and saline solutions, when concentrated, arrest the action of the cilia instantaneously in all animals ; but dilution delays this effect, and when carried farther, prevents it altogether ; and hence it is, probably, due to a chemical alteration of the tissue. Virchow has observed that a solution of either potash or soda will revive the movement of cilia after it has ceased. Narcotic substances, such as hydrocyanic acid, salts of morphia and strychnia, opium and belladonna, are said by Purkinje and Valentin to have no effect, though the first-named agent has certainly appeared to me to arrest the motion in the river-mussel. In confirmation of an observation of Professor Lister,\* I find that exposure for a few moments to the vapour of chloroform arrests ciliary action, and that the motion revives again if the application of the vapour is discontinued.

Bile stops the action of the cilia, while blood prolongs it, in vertebrated animals ; but the blood or serum of the vertebrata has quite an opposite effect on the cilia of invertebrate animals, arresting their motion almost instantaneously.

It must be confessed that the nature and source of the power by which the cilia act are as yet unknown ; but whatever doubt may hang over this question, it is plain that each ciliated cell is individually endowed with the faculty of producing motion, and that it possesses in itself whatever organic apparatus and whatever physical or vital property may be necessary for that end ; for single epithelium cells are seen to exhibit the phenomenon long after they have been completely insulated.

Without professing to offer a satisfactory solution of a question beset with so much difficulty, it seems, nevertheless, not unreasonable to consider the ciliary motion as

\* Phil. Trans. 1858, p. 690, where will be found other valuable observations on the effect of external agents on ciliary action.



being probably a manifestation of that property on which the more conspicuous motions of animals are known to depend, namely, vital contractility; and this view has at least the advantage of referring the phenomenon to the operation of a vital property already recognised as a source of moving power in the animal body. But, assuming this view to be sound, so far as regards the nature of the motile property brought into play, it affords no explanation of the cause by which the contractility is excited and the cilia maintained in constant action.

It is true that nothing resembling a muscular apparatus in the ordinary sense of the term, has been shown to be connected with the cilia, nor is it necessary to suppose the existence of any such; for it must be remembered that while the organic substance on which vital contractility depends is probably uniformly the same in composition, it does not everywhere assume the same form and texture. The anatomical characters of human voluntary muscle differ widely from those of most involuntary muscular structures, and still more from the contractile tissues of some of the lowest invertebrate animals, although the movements must in all these cases be referred to the same principle. The heart of the embryo beats while yet but a mass of cells, united, to all appearance, by amorphous matter, in which no fibres are seen; yet no one would doubt that its motions depend then on the same property as at a later period, when its structure is fully developed.

In its persistence after systemic death and in parts separated from the rest of the body, the ciliary motion agrees with the motion of certain muscular organs, as the heart, for example; and the agreement extends even to the regular or rhythmic character of the motion in these circumstances. It is true, the one endures much longer than the other; but the difference appears to be one only of degree, for differences of the same kind are known to prevail among muscles themselves. No one, for instance, doubts that the auricle of the heart is muscular, because it beats longer after death than the ventricle; nor, because a frog's heart continues to act a much longer time than a quadruped's, is it inferred that its motion depends on a power of a different nature. And the view here taken of the nature of the ciliary motion derives strength from the consideration that the phenomenon lasts longest in cold-blooded animals, in which vital contractility also is of longest endurance. In the effects of heat and cold, as far as observed, there is also an agreement between the movement of cilia and that of muscular parts; while, on the other hand, it must be allowed that electricity does not appear to excite their activity. The effects of narcotics afford little room for inference, seeing that our knowledge of their local action on muscular irritability is by no means exact; but in one instance, at least, an agent, chloroform vapour, which stops the action of the freshly excised heart of a frog, arrests also the ciliary motion. Something, moreover, may depend on the facility or difficulty with which the tissues permit the narcotic fluid to penetrate, which circumstance must needs affect the rapidity and extent of its operation. Again, we see differences in the mode in which the cilia themselves are affected by the same agent; thus fresh water instantly arrests their motion in certain cases, while it has no such effect in others.

The discovery of vibrating cilia on the spores and other parts of certain cryptogamic vegetables may perhaps be deemed a strong argument on the opposite side; but it is by no means proved that the sensible motions of plants (such, at least, as are not purely physical), and those of animals, do not depend on one common vital property.

## PIGMENT.

The cells of the cuticle, and of other textures which more or less resemble it in structure, sometimes contain a black or brown matter, which gives a dark colour to the parts over which the cells are spread. A well-marked example of such pigment-cells in the human body is afforded by the black coating which lines the choroid membrane of the eye and covers the posterior surface of the iris. They are found in the epidermis of the Negro and other dark races of mankind, and in the more dusky parts of the



cuticle of the European. In different forms also they exist on certain parts of the investing membrane (pia mater) of the spinal cord, in the membranous labyrinth of the ear, and (with brownish yellow pigment) on the olfactory region of the nose.

The pigment cells of the choroid membrane (fig. XXXII.) are for the most part polyhedral in figure, most generally six-sided, and connected together like the pieces of a mosaic pavement; others are spheroidal, and most of

Fig. XXXII.

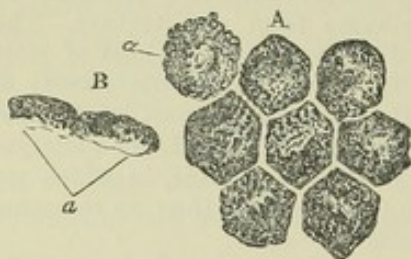


Fig. XXXII.—PIGMENT-CELLS FROM THE CHOROID; MAGNIFIED 370 DIAMETERS (Henle).

A, cells still cohering, seen on their surface; *a*, nucleus indistinctly seen. In the other cells the nucleus is concealed by the pigment granules.

B, two cells seen in profile; *a*, the outer or posterior part containing scarcely any pigment.

those on the back of the iris are of that shape. The cells contain the pigment, strictly so called, which consists of black or brown granules or molecules of a round or oblong shape, and almost too small for exact measurement. These molecules are densely packed together in some cells; in others they are more scattered, and then it may be seen that there is a certain amount of colourless matter included along with them. When they escape from the ruptured cells, they exhibit very strikingly the molecular movement; and in consequence of this movement the apparent figure of the particles is subject to change. It is worthy of remark, that when viewed singly with a very high magnifying power they look transparent and almost

colourless, and it is only when they are heaped together that their blackness distinctly appears. The cells have a colourless nucleus, which is very generally hidden from view by the black particles. It contains a central nucleolus.

Examined chemically, the black matter is found to be insoluble in cold and hot water, alcohol, ether, fixed and volatile oils, acetic and diluted mineral acids. Its colour is discharged by chlorine. The pigment of the bullock's eye, when purified by boiling in alcohol and ether, was found by Scherer to consist of 58.672 carbon, 5.962 hydrogen, 13.768 nitrogen, and 21.598 oxygen; its proportion of carbon is thus very large. Preceding chemists had obtained from its ashes oxide of iron, chloride of sodium, lime, and phosphate of lime.

The dark colour of the Negro is known to have its seat in the cuticle, and chiefly in the deeper and softer part named the rete mucosum. It is caused by cells containing dark-brown colouring matter, either diffused through their substance or in form of granules—usually more densely aggregated round the nucleus. These cells are found along with ordinary, colourless cells, which in other respects they entirely resemble: and the depth of tint depends on the proportion of each. It is affirmed, on good authority, that the nuclei of these epidermic pigment-cells are coloured, but of this I have not been able to satisfy myself in examinations of the Negro skin. The dark parts of the European skin owe their colour and its different shades to intermixture in the cuticle of similar cells in different proportions. Lastly, it cannot be doubted, that in both the coloured and white races, the colouring matter of the skin is the same in its essential nature as that of the choroid. In Albino individuals, both Negro and European,



in whom the black matter of the choroid is wanting, the cuticle and the hair are colourless also.

In some situations the pigment-cells become irregular and jagged at their edges, or even branch out into long irregular processes. Such ramified cells are very common in many animals. In the human body pigment-cells of this description are found in the dark tissue on the outer surface of the choroid coat, *lamina fusca* (fig. XXXIII., *a a*), and on the pia mater covering the upper part of the spinal cord. The condition of the pigment in the hairs will be afterwards described.

When the cuticle of the Negro is removed by means of a blister, it is renewed again of its original dark hue; but if the skin be destroyed to any considerable depth, as by a severe burn, the resulting scar remains long white, though it at length acquires a dark colour.

*Uses.*—In the eye the black matter seems obviously intended to absorb redundant light, and accordingly its absence in Albinos is attended with a difficulty of bearing a light of considerable brightness. Its uses in other situations are not so apparent. The pigment of the cuticle, it has been supposed, may screen the subjacent cutis from the pungency of the sun's rays, but in many animals the pigment is not only employed to variegate the surface of the body, but attaches itself to deep-seated parts. Thus, in the frog the branches and twigs of the blood-vessels are speckled over with it, and in many fish it imparts a black colour to the peritoneum and other internal membranes.

Fig. XXXIII.

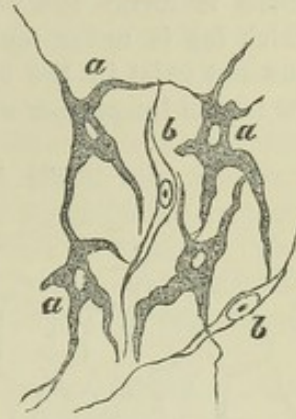


Fig. XXXIII.—RAMIFIED PIGMENT CELLS, FROM THE TISSUE OF THE CHOROID COAT OF THE EYE; MAGNIFIED 350 DIAMETERS (after Kölliker).

*a*, cells with pigment; *b*, colourless fusiform cells.

## ADIPOSE TISSUE.

The human body in the healthy state contains a considerable amount of fatty matter of different kinds. Fat, as has been already stated, is found in the blood and chyle, and in the lymph, but much more sparingly. It exists, too, in several of the secretions, in some constituting the chief ingredient; and in one or other of its modifications it enters into the composition of certain solid textures. But by far the greater part of the fat of the body is inclosed in small cells or vesicles, which, together with their contained matter, constitute the adipose tissue.

This tissue is not confined to any one region or organ, but exists very generally throughout the body, accompanying the still more widely distributed cellular or areolar tissue in most though not in all parts in which the latter is found. Still its distribution is not uniform, and there are certain situations in which it is collected more abundantly. It forms a considerable layer underneath the skin, and, together with the subcutaneous areolar tissue in which it is lodged, constitutes in this situation what has been called the *panniculus adiposus*. It is collected in large quantity round certain internal parts, especially the kidneys. It is seen filling up the furrows on the surface of the heart, and imbedding the vessels of that organ underneath its serous covering; and in various other situations it is depo-



sited beneath the serous membranes, or is collected between their folds, as in the mesentery and omentum, at first generally gathering along the course of the blood-vessels, and at length accumulating very copiously. Collections of fat are also common round the joints, lying on the outer surface of the synovial membrane, and filling up inequalities; in many cases, lodged, like the fat of the omentum, in folds of the membrane, which project into the articular cavity. Lastly, the fat exists in large quantity within the bones, where it forms the marrow. On the other hand there are some parts in which fat is never found in the healthy condition of the body. Thus it does not exist in the subcutaneous areolar tissue of the eyelids and penis, nor in the lungs, nor within the cavity of the cranium.

Fig. XXXIV.

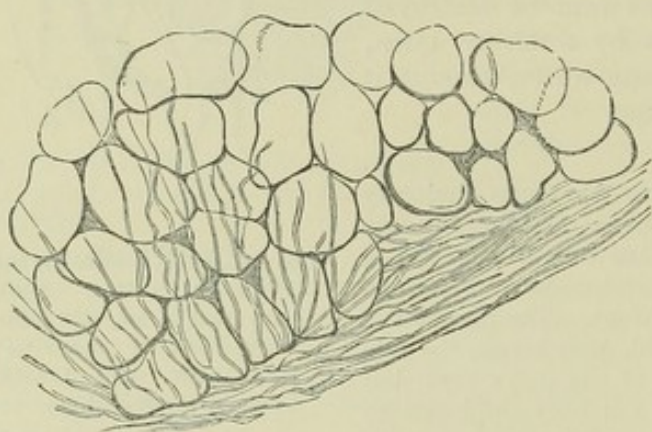


Fig. XXXIV.—A SMALL CLUSTER OF FAT-CELLS; MAGNIFIED 150 DIAMETERS.

When subjected to the microscope, the adipose tissue (fig. XXXIV.) is seen to consist of small vesicles, filled with an oily matter, and for the most part lodged in the meshes of the areolar tissue. The vesicles are most commonly collected into little lobular clusters, and these again into the little lumps of fat which we see with the naked eye, and which in some parts are aggregated into round or irregular masses of

considerable magnitude. Sometimes the vesicles, though grouped together, have less of a clustered arrangement; as when they collect alongside of the minute blood-vessels of thin membranous parts.

In well-nourished bodies the vesicles or fat-cells are round or oval, unless where packed closely together, in which case they acquire an angular figure, and bear a striking resemblance to the cells of vegetable tissues. The greater number of them are from  $\frac{1}{300}$ th to  $\frac{1}{600}$ th of an inch in diameter, but many exceed or fall short of this measurement. Each one consists of a very delicate envelope, inclosing the oily matter, which, completely filling the envelope, appears as a single drop. The envelope is generally quite transparent, and apparently homogeneous in structure. In ill-nourished bodies, and especially in those presenting serous infiltration of the tissues (as in dropsy), different forms of fat-cells are observed. (1.) Granular, yellowish-white vesicles, containing numerous small fat globules. (2.) Yellow, or yellowish-red cells, filled with serum and globules of brownish-yellow fat. The relative proportion of the serum and fat varies; but in all cases of this description Kölliker states that he has discovered a nucleus and nucleolus. The nucleus may be seen without re-agents, but is rendered more apparent by acetic acid. The vesicular envelope is found in different conditions. Sometimes it is normal; but it has been seen finer and also thicker than usual. When thickened it may present the appearance of either a single or a double contour. (3.) Fatless cells, with normal or thickened walls. (4.) Fat-cells containing crystals (probably of margaric acid), either yellow or white in colour. At first sight these cells appear filled



with opaque and granular contents, but upon minute examination are seen to contain stelliform acicular crystals, though in some cases their aspect is very faintly granular. It is not improbable that the crystals are formed after death.

Schwann discovered a nucleus in the fat-cells of the embryo ; the nucleus contains one or two nucleoli, and is attached to the inside of the cell-wall or imbedded in its substance. Although nuclei have rarely been seen in the cells of well-nourished adipose tissue in after-life, they are readily found when the fat has partially disappeared, and hence it may be inferred that they are always present. This is corroborated by an observation of Bruch, that the endosmose of water always renders a nucleus apparent.

The common fat of the human body has been represented as a mixture of a solid fatty substance named "margarin," and a liquid oily substance, "olein ;" the suet or fat of oxen and sheep, on the other hand, consisting chiefly of a second solid principle, "stearin," associated with olein. These substances, margarin, olein, and stearin, are neutral bodies, and themselves compounded of a base named "glycerine" with three fatty acids respectively, the margarin, oleic, and stearic.

To the above reckoned neutral fats of the animal body a fourth, namely, "palmitin," has now been added ; and they are all considered to be compounds of three equivalents of acid,—oleic, margarin, stearic, or palmitic,—with one equivalent of glycerine, minus six equivalents of water. They have accordingly been named, "triolein," "trimargarin," "tristearin," and "tripalmitin." The triolein, or liquid fat, holds the other three in solution ; and the varying consistency of animal fats depends on the relative proportion of the solid and liquid ingredients.

During life the oily matter contained in the cells is liquid ; but the acicular crystalline spots which are sometimes seen after death indicate a partial solidification of one of its constituents. This has been supposed to be the margarin ; but it appears from its chemical relations to be most probably margarinic acid.

The fat being thus contained in closed cells, it will be readily understood why, though liquid or nearly so in the living body, it does not shift its place in obedience to pressure or gravitation, as happens with the water of dropsy and other fluids effused into the interstices of the areolar tissue ; such fluids, being unconfined, of course readily pass from one place to another through the open meshes.

The areolar tissue connects and surrounds the larger lumps of fat, but forms no special envelope to the smaller clusters ; and although fine fasciculi and filaments of that tissue pass irregularly over and through the clusters, yet it is probable that the vesicles are held together in these groups mainly by the fine network of capillary vessels distributed to them. In the marrow the connective tissue is very scanty ; indeed the fat cells in some parts of the bones are said to be altogether unaccompanied by connective filaments.

The adipose tissue is copiously supplied with blood-vessels. The larger branches of these pass into the fat lumps, where they run between the lobules and subdivide, till at length a little artery and vein are sent to each small lobule, dividing into a network of capillary vessels, which not only surrounds the cluster externally, but passes through between the vesicles in all directions, supporting and connecting them. The lymphatics of the fat, if it really possess any, are unknown. Nor have nerves been seen to terminate in it, though nerves destined for other textures may pass through it



Accordingly it has been observed that, unless when such traversing nervous twigs happen to be encountered, a puncturing instrument may be carried through the adipose tissue without occasioning pain.

As to the uses of the fatty tissue, it may be observed, in the first place, that it serves the merely mechanical purpose of a light, soft, and elastic packing material to fill vacuities in the body. Being thus deposited between and around different organs, it affords them support, facilitates motion, and protects them from the injurious effects of pressure. In this way, too, it gives to the exterior of the body its smooth, rounded contour. Further, being a bad conductor of heat, the subcutaneous fat must so far serve as a means of retaining the warmth of the body, especially in warm-blooded creatures exposed to great external cold, as the whale and other cetaceous animals, in which it forms a very thick stratum, and must prove a much more effectual protection than a covering of fur in a watery element.

But the most important use of the fat is in the process of nutrition. Composed chiefly of carbon and hydrogen, it is absorbed into the blood and consumed in respiration, combining with oxygen to form carbonic acid and water, and thus contributing with other hydrocarbonous matters to maintain the heat of the body; and it is supposed that when the digestive process introduces into the system more carbon and hydrogen than is required for immediate consumption, the excess of those elements is stored up in the form of fat, to become available for use when the expenditure exceeds the immediate supply. According to this view, active muscular exercise, which increases the respiration, tends to prevent the accumulation of fat by increasing the consumption of the hydrocarbonous matter introduced into the body. Again, when the direct supply of calorific matter for respiration is diminished or cut off by withholding food, or by interruption of the digestive process, nature has recourse to that which has been reserved in the form of fat; and in the wasting of the body caused by starvation, the fat is the part first consumed.

The use of the fat in nutrition is well illustrated by what occurs in the hedgehog and some other hybernating animals. In these the function of alimentation is suspended during their winter sleep, and though their respiration is reduced to the lowest amount compatible with life, and their temperature falls, there is yet a considerable amount of hydrocarbonous material provided in the shape of fat before their hybernation commences, to be slowly consumed during that period, or perhaps to afford an immediate supply on their respiration becoming again active in spring.

It has been estimated that the mean quantity of fat in the human subject is about one-twentieth of the weight of the body, but from what has been said, it is plain that the amount must be subject to great fluctuation. The proportion is usually largest about the middle period of life, and greatly diminishes in old age. High feeding, repose of mind and body, and much sleep, favour the production of fat. To these causes must be added individual and perhaps hereditary predisposition. There is a greater tendency to fatness in females than males; also, it is said, in eunuchs. The effect of castration in promoting the fattening of domestic animals is well known.

In infancy and childhood the fat is confined chiefly to the subcutaneous tissue. In after-life it is more equally distributed through the body, and in proportionately greater quantity about the viscera. In Hottentot females fat accumulates over the gluteal muscles, forming a considerable prominence; and, in a less degree, over the deltoid. A tendency to local accumulations of the subcutaneous fat is known to exist also in particular races of quadrupeds.

*Development.*—According to Valentin, the fat first appears in the human embryo about the fourteenth week of intra-uterine life. At this period fat is deposited in cells already formed in the tissues. The cells first seen are for the most part insulated, but by the end of the fifth month they are collected into small groups. They are also at first of comparatively small size. As already stated, the foetal fat-cells contain a nucleus in their early condition which is afterwards hidden from view.



It has been a question whether, when the fat undergoes absorption, the vesicles are themselves consumed along with their contents. Dr. W. Hunter believed that they still remained after being emptied; he was led to this opinion by observing the condition of the areolar tissue in dropsical bodies from which the fat had disappeared, there being in such cases a marked difference in aspect between the parts of that tissue which had originally contained fat and those which had not, which difference he attributed to the persistence of the empty fat vesicles. Gurlt states that the fat-cells in emaciated animals are filled with serum, and this statement is fully confirmed by the observations of Kölliker, Todd and Bowman, myself, and others.

## CONNECTIVE TISSUE.

This substance consists of fibres of two kinds, more or less amorphous matter, and peculiar corpuscles. By means of its fibres it serves in the animal body as a bond of connection of different parts; also as a covering or investment to different organs, not only protecting them outwardly, but, in many cases entering into their structure and connecting and supporting their component parts. The corpuscles, on the other hand, are destined for other than mechanical purposes; they appear to be essentially concerned in the nutrition and reparation of tissues.

Three principal modifications or varieties of connective tissue have long been recognized, consisting of the same structural elements but in widely different proportions, and thereby exhibiting a difference in their grosser or more obvious characters and physical properties. They are known as the *areolar*, the *fibrous*, and the *elastic* tissues, and will be now severally treated of. Without disregarding the alliance of cartilage and bone to the connective tissues, we shall not, in imitation of some respected authorities, include them in the same group; but there remain certain forms of tissue, occurring locally, or met with as constituents of other textures, which properly belong to this head, and will be briefly considered in a separate section as subordinate varieties of connective tissue.

Cartilage and bone are included in the group of connective tissues or connective substances by several eminent German histologists, and present undoubted points of relationship with these tissues, both in their nature and the general purpose which they serve in the animal frame. Thus, yellow cartilage shows an unmistakable transition to elastic connective tissue, as fibro-cartilage does, even more decidedly, to white fibrous tissue. Moreover, the animal basis of bone agrees entirely in chemical composition, and in many points of structure, with the last named tissue. Still, when it is considered that cartilage, in its typical form, consists of a quite different chemical substance, chondrin, and that bone is characterized by an impregnation of earthy salts, it seems more consistent with the purpose of histological description to recognise cartilage and bone as independent tissues. As to their community of origin, little stress need be laid on it as a basis of classification, seeing that the origin of blood-vessels, nerves and muscles, may be traced up to protoplasm-cells, to all appearance similar to those that give rise to the connective tissues, and belonging to the same embryonic layer.

## THE AREOLAR TISSUE.

If we make a cut through the skin and proceed to raise it from the subjacent parts, we observe that it is loosely connected to them by a soft filamentous substance, of considerable tenacity and elasticity, and having, when free from fat, a white fleecy aspect; this is the substance known by the names of "cellular," "areolar," "filamentous," "connective," and



"reticular" tissue ; it used formerly to be commonly called "cellular membrane." In like manner the areolar tissue is found underneath the serous and mucous membranes which are spread over various internal surfaces, and serves to attach those membranes to the parts which they line or invest ; and as under the skin it is named "subcutaneous," so in the last-mentioned situations it is called "subserous" and "submucous" areolar tissue. But on proceeding further we find this substance lying between the muscles, the blood-vessels, and other deep-seated parts, occupying, in short, the intervals between the different organs of the body where they are not otherwise insulated, and thence named "intermediate ;" very generally, also, it becomes more consistent and membranous immediately around these organs, and, under the name of the "investing" areolar tissue, affords each of them a special sheath. It thus forms inclosing sheaths for the muscles, the nerves, the blood-vessels, and other parts. Whilst the areolar tissue might thus be said in some sense both to connect and to insulate entire organs, it also performs the same office in regard to the finer parts of which these organs are made up ; for this end it enters between the fibres of the muscles, uniting them into bundles ; it connects the several membranous layers of the hollow viscera, and binds together the lobes and lobules of many compound glands ; it also accompanies the vessels and nerves within these organs, following their branches nearly to their finest divisions, and affording them support and protection. This portion of the areolar tissue has been named the "penetrating," "constituent," or "parenchymal."

It thus appears that the areolar is one of the most general and most extensively distributed of the tissues. It is, moreover, continuous throughout the body, and from one region it may be traced without interruption into any other, however distant ; a fact not without interest in practical medicine, seeing that in this way dropsical waters, air, blood, and urine, effused into the areolar tissue, and even the matter of suppuration, when not confined in an abscess, may spread far from the spot where they were first introduced or deposited.

On stretching out a portion of areolar tissue by drawing gently asunder the parts between which it lies, it presents an appearance to the naked eye of a multitude of fine soft elastic threads, quite transparent and colourless, like spun glass ; these are intermixed with fine transparent films, or delicate membranous laminæ, and both threads and laminæ cross one another irregularly and in all imaginable directions, leaving open interstices or areolæ between them. These meshes are, of course, more apparent when the tissue is thus stretched out ; it is plain also that they are not closed cells, as the term "cellular tissue" might seem to imply, but merely interspaces which open freely into one another : many of them are occupied by the fat, which, however, as already explained, does not lie loose in the areolar spaces, but is enclosed in its own vesicles. A small quantity of colourless transparent fluid is also present in the areolar tissue, but, in health, not more than is sufficient to moisten it. This fluid is generally said to be of the nature of serum ; but it is not improbable that, unless when unduly increased in quantity or altered in nature by disease, it may resemble more the liquor sanguinis, as is the case with the fluid of most of the serous membranes.

On comparing the areolar tissue of different parts, it is observed in some to be more loose and open in texture, in others more dense and close, according as free movement or firm connection between parts is to be provided for. In some situations, too, the laminæ are more numerous ; in



others the filamentous structure predominates, or even prevails exclusively ; but it does not seem necessary to designate these varieties by particular names, as is sometimes done.

When examined under the microscope, the areolar tissue is seen to be principally made up of exceedingly fine, transparent, and apparently homogeneous filaments, from about  $\frac{1}{30000}$ th to  $\frac{1}{25000}$ th of an inch in thickness, or even less (fig. XXXV.). These are seldom single, being mostly united by means of a small and usually imperceptible quantity of a homogeneous connecting substance into bundles and filamentous laminæ of various sizes, which to the naked eye, appear as simple threads and films. Though the bundles may intersect in every direction, the filaments of the same bundle run nearly parallel to each other, and no one filament is ever seen to divide into branches or to unite with another. The associated filaments take an alternate bending or waving course as they proceed along the bundle, but still maintain their general parallelism. This wavy aspect, which is very characteristic of these filaments, disappears on stretching the bundle, but returns again when it is relaxed.

The filaments just described, though transparent when seen with transmitted light under the microscope, have a white colour when collected in considerable quantity and seen with reflected light ; and they not only occur in the areolar tissue strictly so called, but form the chief part of the tendons, ligaments, and other white fibrous connective tissues. They were long supposed to be the only fibrous constituent existing in the areolar tissue, but it has been shown (and chiefly through the inquiries of Eulenberg, Henle, and Bowman) that fibres of

another kind are intermixed with them ; these agree in all characters and are obviously identical with the fibres of the yellow elastic tissue, and have accordingly been named the yellow or elastic fibres, to distinguish them from the white or waved filaments above described. They were at one time termed nuclear fibres (Kernfasern), on account of their supposed origin from nuclei ; but as it now appears that they have no connection either with nuclei or cells, the latter appellation must be abandoned. Moreover, they differ

in chemical nature from cells and nuclei, in as much as they resist the action of boiling alkaline solutions of potash and soda, of moderate strength, which very speedily destroy the cells and nuclei.

Fig. XXXV.

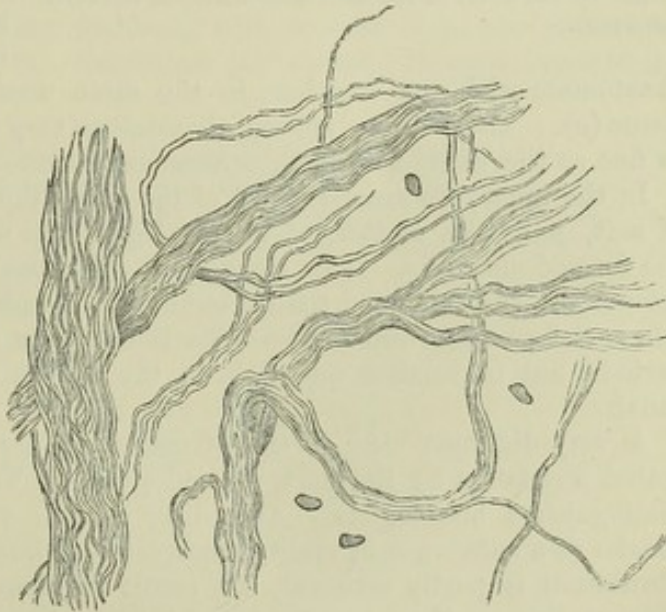


Fig. XXXV.—FILAMENTS OF AREOLAR TISSUE, IN LARGER AND SMALLER BUNDLES, AS SEEN UNDER A MAGNIFYING POWER OF 400 DIAMETERS.

Two or three corpuscles are represented among them.



In certain portions of the areolar tissue, as for instance in that which lies under the serous and mucous membranes of particular regions, the yellow or elastic fibres are abundant and large, so that they cannot well be overlooked; but in other parts they are few in number, and small, and are then in a

Fig. XXXVI.

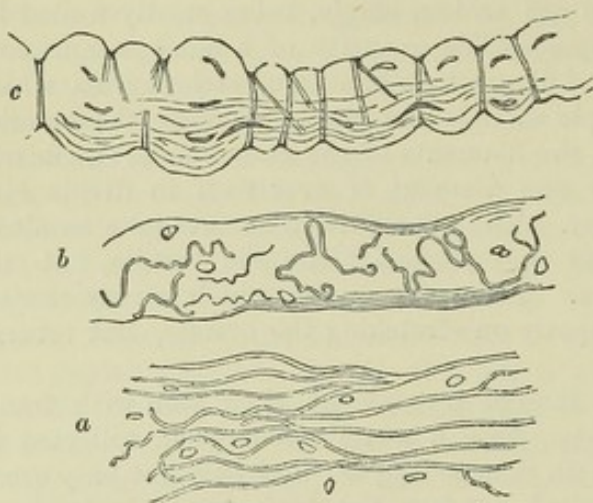


Fig. XXXVI.—MAGNIFIED VIEW OF AREOLAR TISSUE (FROM DIFFERENT PARTS) TREATED WITH ACETIC ACID.

The white filaments are no longer seen, and the yellow or elastic fibres with the nuclei come into view. At *c*, elastic fibres wind round a bundle of white fibres, which by the effect of the acid is swollen out between the turns.

anastomose with one another, in the same manner as in the pure elastic tissue (*a*). They differ among themselves very widely in size, some being as fine as the white filaments, others many times larger.

In the immature areolar tissue of the foetus there is a considerable amount of soft, jelly-like matter, of muco-albuminous nature, in the interstices of the formed elements. This amorphous substance is for the most part inconspicuous in the perfected tissue, but exists abundantly in the umbilical cord, where it forms the well-known Whartonian jelly; it may also be seen, at all periods, but in smaller quantity, in the areolar tissue within the vertebral canal.

A very different view of the structure of areolar tissue from that here stated was taken by Reichert, and adopted by Virchow, Donders, and other distinguished histologists. According to this view the apparent bundles consist of a substance in reality amorphous or homogeneous, and its seeming fibrillation is partly artificial, the result of cleavage, and partly an optical illusion, arising from creasing or folding. In point of fact, however, the bundles readily separate into fibrils after exposure to dilute solutions of chromic acid, or to lime-water, or to baryta-water, by which the uniting matter is dissolved; so that there can be no doubt of their truly fibrillar structure. At the same time it is not denied that immature fasciculi may probably occur, in which the fibrillation is incomplete. Moreover, a homogeneous substance, not to be confounded with the soft, jelly-like matter previously noticed, but of firm consistence and agreeing in chemical nature with the fibrils, envelopes the fasciculi in some situations in form of a fine

great measure hidden by the white filaments; in such cases, however, they can always be rendered conspicuous under the microscope by means of acetic acid, which causes the white filaments to swell up and become indistinct, whilst the elastic fibres, not being affected by that reagent, come then more clearly into view (fig. XXXVI.). Under the microscope the elastic fibres appear transparent and colourless, with a strong, well-defined, dark outline. They are, moreover, remarkable for their tendency to curl up, especially at their broken ends, which gives them a very peculiar aspect, and in many parts of the areolar tissue they divide into branches and join or



sheath (Kölliker) ; and it will be afterwards noticed as constituting a special form or variety of connective tissue occurring elsewhere.

The elastic fibres lie, for the most part, without order, among the bundles of white filaments; but here and there we see an elastic fibre winding round one of these bundles, and encircling it with several spiral turns. When acetic acid is applied, the fasciculus swells out between the constricting turns of the winding fibre, and presents a highly characteristic appearance (c). This remarkable disposition of the elastic fibres, which was pointed out by Henle, is not uncommon in certain parts of the areolar tissue; it may be always seen in that which accompanies the arteries at the base of the brain. It must be observed, however, that the encircling fibre sometimes forms not a continuous spiral, but several separate rings; moreover, the whole appearance is explained by some histologists on the supposition that the bundles in question are naturally invested with a delicate sheath, which, like the elastic tissue, resists acetic acid, but, on the swelling up of the bundle under the operation of that agent, is rent into shreds or segments, mostly annular or spiral, which cause the constrictions. Kölliker, who admits that some fasciculi have a sheath, yet supposes that in these, as well as in naked bundles, the encircling fibres are produced by prolongations from the corpuscles (to be immediately noticed), uniting in form of a thread, or of a network wrapped round the bundle.

Bodies, mostly with nuclei, and of the nature of cells, although not shown to possess a distinct cell-wall, are found in the areolar tissue. These are the *connective-tissue corpuscles*. Some lie in the meshes of the tissue, others are included within the fasciculi. The former are of no very regular shape, rounded or oval (as in fig. XXXIV.), or, as described in the frog by Kühne, having a stellate or jagged outline with processes or offsets of unequal size and length, here and there connected with processes from neighbouring corpuscles:—in short, misshapen little masses of protoplasm, but containing usually a well-formed oval nucleus and conspicuous nucleolus. Those within the fasciculi are fusiform, with pointed ends, and lie lengthwise in the direction of the fasciculus (as shown, though imperfectly, in fig. XXXVI. c.).

These bodies were imagined to be hollow, and by the intercommunication of their supposed tubular offsets, it was conceived that they formed a system of reticulating canals destined to distribute nutritive fluid to the connective tissue and other parts into which that tissue enters. But, though soft, they are evidently solid objects, and though they probably effect some chemical change, or exert some other influence on the interstitial nutritive plasma, or in some other way minister to nutrition, it is clearly not as a system of channels for the conveyance of fluid. In the frog they exhibit slow but distinct movements and changes of shape, like the pale blood-corpuscles; and they may be regarded as cells retaining their primitive protoplasmic condition, and subservient not only to the nutrition, but to the extension and repair of tissues. There can be little doubt, moreover, that they are largely concerned in pathological and degenerative, as well as in reparative processes.

The areolar tissue contains a considerable quantity of water, and consequently loses much of its weight by drying. It is almost wholly resolved into gelatine by boiling in water. Acetic acid causes it, that is, the bundles of white fibrils, to swell up into a soft, transparent, jelly-like mass.

Numerous blood-vessels are seen in the areolar tissue after a minute injection. These for the most part only pass through it on their way to other more vascular textures, but a few seem to end in capillaries destined for the tissue itself, and dense clusters of vessels are distributed to the fat lobules. Large lymphatic vessels proceeding to distant parts also pass along this texture, and abundant lymphatic networks may be discovered in many parts of the subcutaneous, subserous, and submucous areolar tissue, having



evident relation to the function of the membranes under which they lie. Absorption readily takes place from the interstices of the texture, but that process may be effected through the agency of blood-vessels as well as of lymphatics.

Larger and smaller branches of nerves also traverse this tissue on their way to other parts ; but it has not been shown that any remain in it, and accordingly it may be cut in a living animal apparently without giving pain, except when the instrument meets with any of these traversing branches. It is not improbable, however, that nerves end in those parts of the areolar tissue which, like that of the scrotum, contain contractile fibres ; but, if present in such cases, the nerves, like the vessels of the fat, are, after all, destined not to the areolar tissue but to another mixed with it.

The physical properties of this texture have been sufficiently indicated in the foregoing description ; also its want of sensibility. The vital contractility ascribed to certain portions of it is most probably due to the presence of muscular tissue.

With the exception of the epithelium, no tissue is so readily regenerated as the areolar. It is formed in the healing of wounds and in the adhesion of inflamed surfaces. It is produced also in many morbid growths.

#### FIBROUS TISSUE.

This substance is one of those which are serviceable in the body chiefly on account of their mechanical properties, being employed to connect together or to support and protect other parts. It is met with in the form of ligaments, connecting the bones together at the joints ; it forms the tendons of muscles, into which their fleshy fibres are inserted, and which serve to attach these fibres to the bones. In its investing and protecting character it assumes the membranous form, and constitutes a class of membranes termed "fibrous." Examples of these are seen in the periosteum and perichondrium which cover the bones and cartilages, in the dura mater which lines the skull and protects the brain, and the fibrous layer which strengthens the pericardium, also in the albugineous coat of the testicle, and the sclerotic coat of the eye, which inclose the tender internal parts of these organs. Fibrous membranes, named "aponeuroses" or "fasciae," are also employed to envelope and bind down the muscles of different regions, of which the great fascia inclosing the muscles of the thigh and leg is a well-known example. The tendons of muscles, too, may assume the expanded form of aponeuroses, as those of the broad muscles of the abdomen, which form strong fibrous layers in the walls of that cavity and add to their strength. It thus appears that the fibrous tissue presents itself under two principal forms, the *fascicular* and the *membranous*.

*Physical Properties.*—The fibrous tissue is white or yellowish white, with a shining, silvery, or nacreous aspect. It is exceedingly strong and tough, yet perfectly pliant ; but it is almost devoid of extensibility. By these qualities it is admirably suited to the purposes to which it is applied in the animal frame. By its inextensible character it maintains in apposition the parts which it connects against any severing force short of that sufficient to cause actual rupture, and this is resisted by its great strength, whilst its flexibility permits of easy motion. Accordingly the ligaments and tendons do not sensibly yield to extension in the strongest muscular efforts ; and though they sometimes snap asunder, it is well-known that bones will break more readily than tendons of equal thickness. The fibrous membranes are proportionally strong and alike inextensible ; they will gradually yield, it is



true, when the extending force acts slowly and for a long time, as when tumours or fluids slowly gather beneath them ; but perhaps this gradual extension is accompanied with some nutritive change affecting the properties of the tissue.

*Structure.*—The fibrous tissue is made up of fine filaments, agreeing in all respects with the white filaments of the areolar tissue already described. Like these they are collected into bundles, in which they run parallel and exhibit the same wavy character, cohering very intimately. The bundles appear to the naked eye as fine shining threads or narrow flattened bands, for they vary greatly in thickness. They either run all in one direction as in long tendons, or intersect each other in different planes as in some aponeuroses, or they take various directions and decussate irregularly with each other as in the dura mater. And when they run parallel to each other, as in tendon, they do not keep separate throughout their length, but send off slips to join neighbouring bundles and receive the like in turn ; so that successive cross sections of a tendon or ligament present different figures of the sectional areas of the bundles. A sheath of dense areolar tissue covers the tendons and ligaments on the outside, and a variable amount of the same tissue lies between the larger fasciculi ; little in tendons, more in some fibrous membranes.

The filaments swell up and become indistinct when acted on by acetic acid, like those of areolar tissue, and here also the acid discloses the existence of corpuscles and of elastic fibres, intermixed in small proportion with the rest of the tissue. The elastic fibres are fine and generally branched and connected together. The corpuscles, which have no real connection with the elastic fibres, are for the most part lodged where the angles of the fasciculi (which are usually prismatic in form) meet. They are fusiform or lanceolate in figure, pointed at the ends, and lie lengthwise among the bundles. In cross sections there is an appearance of radiating pointed processes, diverging from the spots where the corpuscles are situated, and these have been taken for branches or offsets extending laterally from these bodies ; but it seems to be satisfactorily shown that the apparent branches are merely the crevices between the fasciculi, diverging from the point where their angles meet. But although these fissures do not contain branches radiating from the corpuscles, flat membranous shreds can here and there be extracted from them, which are by some supposed to be part of a membrane by which each several bundle is ensheathed and separated from its neighbours.

The surface of a tendon or of any other part consisting of this texture, appears marked across the direction of the fasciculi with alternate light and dark streaks, which give it a peculiar aspect, not unlike that of a watered ribbon. This appearance is owing to the wavy course of the filaments, for when the light falls on them their bendings naturally give rise to alternate lights and shadows.

The fibrous and areolar tissues thus agreeing in their ultimate structure, it is not to be wondered at that sometimes the limits between the two should be but ill defined, and that the one should pass by inconspicuous gradations into the other. Instances of such a transition may be seen in many of the fasciæ ; these at certain parts consist of dense areolar tissue, but on being traced farther are seen gradually to take on the fibrous character ; and fasciæ, which in one body consist of areolar tissue, may be decidedly fibrous in another.

In chemical constitution also the fibrous tissue is similar to the areolar. It contains about two-thirds of its weight of water ; it becomes transparent,



hard, and brittle, when dried, but readily imbibes water again and regains its original properties. It is resolved into gelatin by boiling.

The fibrous tissue receives blood-vessels, but in general they are inconsiderable both in number and size compared with the mass of tissue to which they belong. In tendons and ligaments with longitudinal fasciculi, the chief branches of the vessels run parallel with and between the larger fasciculi, and, sending communicating branches across them, eventually form a very open network with large oblong meshes. Some fibrous membranes, as the periosteum and dura mater, are much more vascular; but the vessels seen in these membranes do not strictly belong to them, being destined for the bones which they cover. The lymphatics of fibrous tissue, are not sufficiently known to be spoken of with certainty.

As to nerves, their general existence in this texture has not been satisfactorily demonstrated by anatomical investigation. Recent inquiries into this subject have shown that the smaller tendons contain no nerves, and the larger only such nervous filaments as accompany and belong to the vessels; and the same is true of the ligaments. The fasciæ and the sheaths of tendons are also destitute of nerves. On the other hand, fine nerves have been traced in the interosseous membrane of the leg, and nervous filaments are even abundant in the periosteum, but the majority of them do not belong to the membrane itself, but are destined for the subjacent bone. Nerves have also been traced in the dura mater; some accompany the vessels, others appear destined for the membrane itself, and others again for the bones.

It has been proved by numerous observations and experiments, that the tendons, ligaments, and other structures composed of fibrous tissue, are, in the healthy state, quite insensible; but then it is known, on the other hand, that they occasion severe pain when inflamed, which cannot well be accounted for on the supposition that they are entirely destitute of nerves. Bichat, while he admitted their insensibility to cutting, burning, and most other kinds of stimuli which cause pain in sensible textures, ascribed to them a peculiar sensibility to twisting or to violent extension, and this opinion has been supported by other authorities of weight, but the proofs of it are not clear.

It readily heals and unites when divided, as is seen in cases of broken tendo Achillis. Fibrous tissue is very generally produced as a uniting medium of broken bones when osseous union fails to take place; it is common as a diseased production in various kinds of tumours.

#### YELLOW OR ELASTIC TISSUE.

Whilst the fibrous tissue is remarkable for its want of extensibility, and owes its usefulness as a constituent of the frame in a great measure to that character, the substance we have now to consider possesses this property in a very high degree, and is employed wherever an extensible and highly elastic material is required in the animal structure.

Examples of this texture on a large scale are seen in the horse, ox, elephant, and other large quadrupeds, in which it forms the great elastic ligament, called *ligamentum nuchæ*, that extends from the spines of the vertebræ to the occiput, and aids in sustaining the head; in the same animals it also forms an elastic subcutaneous fascia, which is spread over the muscles of the abdomen and assists in supporting the contents of that cavity. In the human body it is met with chiefly in the following situations, viz. :—



1. Forming the *ligamenta subflava*, which extend between the arches of adjacent vertebrae; these ligaments, while they permit the bones to be drawn apart in flexion of the body, aid in restoring and maintaining their habitual approximation in the erect posture—so far, therefore, relieving the constant effort of the erector muscles. 2. Constituting the chief part of the stylohyoid, thyrohyoid, and cricothyroid ligaments, and those named the vocal cords. Also extending, in form of longitudinal bands, underneath the mucous membrane of the windpipe and its ramifications. 3. Entering, along with other textures, into the formation of the coats of the blood-vessels, especially the arteries, and conferring elasticity on these tubes. 4. Beneath the mucous membrane of the gullet and lower part of the rectum, also in the tissue which surrounds the muscular coat of the gullet externally. 5. In the tissue which lies under the serous membranes in certain parts. 6. In many of the fasciæ, where it is mixed with much areolar tissue. 7. Largely in the suspensory ligament and subcutaneous tissue of the penis. 8. In considerable quantity in the tissue of the skin.

The elastic tissue in its purest and most typical condition, such as is seen in the ligamentum nuchæ of quadrupeds and the ligamenta subflava of the human spine, has a yellow colour more or less decided; it is extensible and elastic in the highest degree, but is not so strong as ordinary fibrous ligament, and it breaks across the direction of its fibres when forcibly stretched. Its fibres may be easily torn separate in a longitudinal direction; they are often gathered into irregular fasciculi which run side by side but join at short distances by slips with one another, and are further connected by areolar tissue, which is always intermixed with them in greater or less quantity. Elastic ligaments are also covered outwardly with a sheath of areolar tissue.

When the elastic fibres are mixed up with a large proportion of some other kind of tissue, their yellow colour may not appear, but they can always be recognised by their microscopic characters. When viewed under a tolerably high magnifying power, they appear quite transparent, with a remarkably well-defined dark outline (fig. XXXVII.). They run side by side, following a somewhat bending course, but with bold and wide curves, unlike the undulations of the white connective filaments. As they proceed they divide into branches, and join or anastomose together in a reticular manner. Elastic networks may be composed of fine fibres with wide meshes, and this is the character of all at first; but while some continue in this state, in others the elastic fibres grow larger and broader and the intervening spaces narrower, so that the tissue may acquire a lamellar character and present the appearance of a homogeneous membrane, which may be either entire, or with gaps or perforations at short intervals, in which case it constitutes the fenestrated membrane of Henle, found in the coats of the blood-vessels. A remarkable character which elastic fibres exhibit in many specimens, is their singular tendency to curl up at their broken ends; and these

Fig. XXXVII.

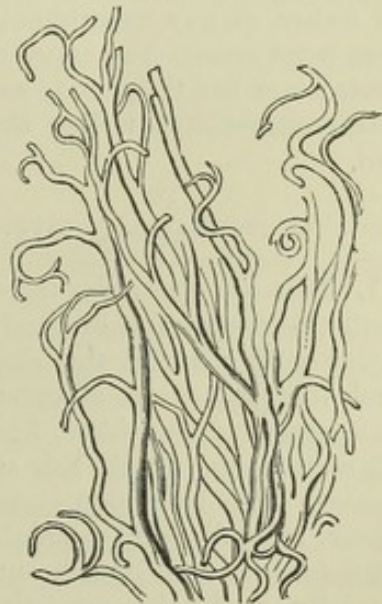

Fig. XXXVII.—ELASTIC FIBRES  
FROM THE LIGAMENTA SUBFLAVA,  
MAGNIFIED ABOUT 200 DIAMETERS.



ends are not pointed, but abruptly broken across. Their size is very various; the largest in man are nearly  $\frac{1}{4000}$ th of an inch in diameter, the smallest perhaps not more than  $\frac{1}{24000}$ th. In some varieties of the tissue the larger sized fibres prevail; this is the case with the ligamenta subflava, where their general diameter is about  $\frac{1}{7500}$ th of an inch; in other instances, as in the chordæ vocales, they are exceedingly fine. In some animals elastic fibres are met with  $\frac{1}{1500}$ th of an inch in thickness. Acetic acid produces no change on the elastic fibres, while it speedily alters the wavy areolar fibres that are usually intermixed with them in greater or less number. They also withstand boiling for a short time in solutions containing ten to fifteen per cent. of caustic potash or soda, by which the white fibres and the corpuscles of connective tissue are speedily destroyed.

The elastic tissue, of course, contains water, and loses much of its weight by drying; but the proportion is said not to be so great as in most other soft tissues. By very long boiling it yields a substance in some points resembling gelatin, while a portion, equal to rather more than the half, remains undissolved.

The gelatin, no doubt, comes from the intermixed areolar tissue; but the dissolved matter is not pure gelatin, for it is precipitated by acetic acid, and by some other reagents which do not disturb a solution of pure gelatin. The nature of the substance which remains undissolved has not been determined. Caustic potash and soda have little effect on elastic tissue in the cold, and in weak solutions even when hot, unless the application is long continued; boiling in concentrated solutions speedily dissolves it. It is soluble with the aid of heat in dilute hydrochloric acid.

Little is known respecting the blood-vessels and nerves of this texture. The yellow ligaments which contain it in its purest form, are but scantily supplied with vessels; and no nerves have been traced into them. I am not aware of any experiments or observations as to their sensibility, but there is no reason for supposing it to be greater than that of ordinary ligaments; nor has it been shown that structures containing this tissue possess vital contractility, unless they also contain contractile fibres of another kind.

#### SPECIAL VARIETIES OF CONNECTIVE TISSUE.

1. *Jelly-like connective tissue, or mucous tissue.* In the early embryo the areolar tissue consists of a pellucid jelly and nucleated corpuscles. The soft, watery jelly contains the chemical principle of mucus, or *mucin*, and, in much less proportion, albumen, but no gelatin. In the general course of development of the tissue, fibres, both white and elastic, are formed in the soft matrix, and finally this substance entirely or in a great measure disappears. But in certain cases the course is different. The cells may disappear, only the jelly remaining, as in the vitreous humour of the eye; or the corpuscles may branch out and join together in form of a network in the jelly, with the persisting nuclei at the spots whence the threads diverge. Such a condition is seen in the enamel-organ of growing teeth. The areolar tissue surrounding and imbedding the vessels in the umbilical cord consists of fusiform and ramified corpuscles associated with white fibrillar bundles and elastic fibres, along with much of the soft matrix, which is persistent at the time of birth and constitutes the jelly of Wharton.



2. *Retiform*\* *connective tissue*; *Reticular tissue*, and *Cytogenous tissue* (Kölliker); *Adenoid tissue* (His). In this case the matrix disappears; neither white nor elastic fibres are developed, but the ramified corpuscles unite together into a reticular or fine trabecular structure (fig. XXXVIII.); either retaining their nuclei as at *a*, or losing them and then forming a fine network of simple fibres without nuclei, as at *b*.

That in both forms the tissue is constructed of ramified corpuscles is shown by its withstanding boiling in water, whilst it readily dissolves in hot alkaline solutions. This form of connective tissue enters into the construction of certain organs and textures, where it serves as a supporting framework to their peculiar elements and their nourishing blood-vessels, and thus becomes a "sustentacular" tissue (*Stützgewebe*, Germ.). In this way it forms a trabecular network within the lymphatic glands, containing the lymph or chyle corpuscles in its meshes (as

at *c*). So also it is found in the solitary and agminated follicular glands of the intestine, the tongue and tonsils; in the thymus gland; in the pulp and Malpighian bodies of the spleen, and in the tissue of the intestinal mucous membrane at certain parts; in all which situations the meshes contain corpuscles of similar external character with those in the lymphatic glands. But although thus related to glands and thence named "adenoid" tissue, it exists also as a sustaining structure in the brain and spinal cord, where, with finer branches and closer meshes, it forms an extremely delicate framework supporting the proper nervous substance, and has been called the *reticulum* (Kölliker).

3. *Homogeneous connective tissue*. More consistent than the mucous or jelly-like tissue, and differing also in chemical nature, inasmuch as it appears to be collagenous (*i. e.*, yielding gelatin), and thus more nearly related in substance to the white fibrillar tissue. It contains no fibres or fibrils, and may be quite transparent and uniform in character, or faintly granular and striated. For the most part this substance occurs in the form of *homogeneous membranes*; examples of which are found in the external coat of fine vessels, the hyaloid membrane in the eye, the capsules of the Malpighian bodies in the kidney and spleen, the capsules of the solitary and agminated intestinal glands and the lingual and tonsillar follicular glands, in the Graafian follicles, and in certain gland-ducts. It must be noted, however, that some homogeneous membranes, as, for example, the posterior elastic lamina of the cornea, are of a different nature.

\* I use the term "retiform," not because it signifies more or less than "reticular," but because the latter term is not unfrequently applied to areolar tissue.

Fig. XXXVIII.

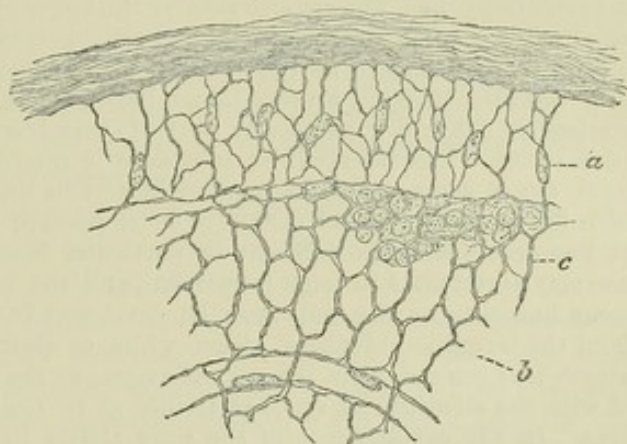


Fig. XXXVIII. —THIN SECTION FROM THE CORTICAL PART OF A LYMPHATIC GLAND, MAGNIFIED.

A network of fine trabeculae formed by retiform or adenoid tissue, from the meshes of which the lymph-corpuscles have been washed out, except at *c*, where they are left (after His, slightly altered).



## DEVELOPMENT OF CONNECTIVE TISSUE.

In those parts of the embryo where connective tissue is to be developed, there is at first a deposit of nucleated corpuscles, having the characters common to the cells of which the early embryo-body throughout consists. Between the cells is a small amount of soft amorphous intercellular substance, which increases in quantity. This is at first of a muco-albuminous nature, but is in great part changed into a gelatinous substance, which assumes a fibrillar character, and becomes converted into the bundles of white wavy filaments that constitute the chief part of the areolar and fibrous tissues. These bundles, after their first appearance, increase in size, and continue to grow larger after birth. Amongst these white fasciculi, elastic fibres, in varying proportion, appear at a somewhat later period. These are also produced from the intercellular substance, which in this case undergoes a different chemical change. They appear from the first in form of networks pervading the intercellular mass throughout, and not as single shorter fibres gradually lengthening out and joining together; nor do they appear to be formed by the linear coalescence of granules, but by immediate differentiation in the intercellular substance. The elastic fibres are at first exceedingly fine, but acquire greater thickness as development advances, and in some situations what was originally a network may become an elastic membrane. The cells in part remain as the connective-tissue corpuscles already described; irregularly ramified in open areolar tissue, but fusiform within the bundles and in the interstices of dense fibrous tissue; part of them become filled with fat, and form the adipose tissue. The intercellular substance is usually reduced to an inconspicuous amount, but in some situations remains in notable quantity.

Such is the most general course of development; but, as will be understood from what has preceded, it is different in particular cases. Thus, the intercellular substance may accumulate in large proportion, and the cells finally disappear, as in the vitreous humour; or the cells may be developed into retiform or cytogenous tissue, without the formation of fibres, either white or elastic, in which case the jelly-like substance may remain, as in the enamel-organ; or the reticular interstices may become filled with the elements of another tissue, as in the lymphatic glands and nervous centres. In the development of the pure elastic ligaments the cells shrink as the elastic fibres grow larger, and at length disappear altogether.

The intercellular substance may be excreted by the cells, but there is no clear proof of this; it may be an independent deposit between them; and the disappearance of the cells from pure elastic ligament would seem to show that, whatever be the influence they exert in the original formation, they are not needed for carrying on the nutrition, or even for the further growth of the tissue.

The foregoing account of the formation of connective tissue is derived from Kölliker's latest observations; \* but Max Schultze considers that the intercellular substance, or matrix, is neither excreted by the cells, nor deposited *ab extra*, but is in reality formed by conversion of part of the protoplasm which forms the bodies of the cells (nucleated protoplasm masses): the matrix thus increases and becomes fibrillated at the expense of the cells, which, now reduced to the nuclei surrounded with a small portion of protoplasm, remain as the connective-tissue corpuscles.

## CARTILAGE.

This is the well-known substance commonly called "gristle." The following are its more obvious characters. When in mass, it is opaque and of a pearly or bluish white colour, in some varieties yellow; but in thin slices it is translucent. Although it can be easily cut with a sharp knife, it is nevertheless of very firm consistence, but at the same time highly elastic, so that it readily yields to pressure or torsion, and immediately recovers its original shape when the constraining force is withdrawn. By reason of

\* Neue Untersuchungen über die Entwicklung des Bindegewebes. Würzb. naturwiss. Zeitschr., vol. ii. Also Handbuch der Gewebelehre, 4th edit. 1863.



these mechanical properties, it is rather extensively used in the construction of the body. Its specific gravity is 1.15.

In the early embryo the skeleton is, in great part, cartilaginous; but the cartilage forming its different pieces, which have the outward form of the future bones, in due time undergoes ossification or gives place to bone, in the greater part of its extent at least, and hence this variety of cartilage is named "temporary."

Of the permanent cartilages a great many are in immediate connection with bone, and may be still said to form part of the skeleton. The chief of these are the articular and the costal cartilages; the former cover the ends or surfaces of bones in the joints, and afford these harder parts a thick springy coating, which breaks the force of concussion and gives ease to their motions; the costal or rib-cartilages form a considerable part of the solid framework of the thorax, and impart elasticity to its walls. Other permanent cartilages enter into the formation of the external ear, the nose, the eyelids, the Eustachian tube, the larynx, and the windpipe. They strengthen the substance of these parts without undue rigidity; maintaining their shape, keeping open the passages through them where such exist, and giving attachment to moving muscles and connecting ligaments.

Cartilages, except those of the joints, are covered externally with a fibrous membrane named the *perichondrium*.

When a very thin slice of cartilage is examined with the microscope, it is seen to consist of nucleated cells, also named cartilage corpuscles, disseminated in a solid mass or matrix. (Figs. XXXIX., XL., and XLI.)

The matrix is sometimes transparent, and to all appearance homogeneous; sometimes dim and very faintly granular, like ground glass: both these conditions occur in *hyaline cartilage*, which may be regarded as the most typical form of the tissue. Two varieties exist in which the matrix is pervaded to a greater or less extent by fibres. In the one, named *elastic* or *yellow cartilage*, the fibres are similar to those of elastic tissue; in the other, named *fibro-cartilage*, they are of the white kind as in ordinary ligament.

#### HYALINE CARTILAGE.

In hyaline cartilage the matrix, as just stated, is uniform and, in the normal state, free from fibres. The cells consist of a rounded, oval, or bluntly angular *cell-body* of translucent, but sometimes finely granular-looking substance, with a clear round *nucleus* and one or more *nucleoli*. The cell-body lies in a cavity of the matrix, which, in its natural condition, it entirely fills. This cavity is bounded and inclosed by a transparent *capsule*, which is seldom obvious to the eye, for it coheres intimately with the surrounding matrix, with which it agrees in nature, and cannot usually be distinguished without the aid of re-agents. The capsule has been regarded as a secondary cell-wall and compared to the cellulose wall of vegetable cells; while the body it contains is, on the same view, considered to be homologous with the primordial utricle and its contents. But the same doubt prevails here as in the case of vegetables, as to the existence of a proper membrane (the utricle) immediately investing the substance of the cell. (See page xiv, and figures VIII. and IX.)

In thin slices of young cartilage the capsules may be freed from the matrix by means of concentrated mineral acids, and can then be shown as distinct vesicles



having the cell-bodies within. The effect of acids is promoted by previous boiling of the cartilage in water. By exposure to water and some other liquids the cell-body shrinks away from the inside of the capsule, and assumes a jagged or otherwise irregular figure, and then may hide the nucleus. It often contains larger or smaller fat globules.

The cells are rarely dispersed singly in the matrix; they usually form groups of different shapes and sizes. Towards the surface of the cartilage the groups are generally flattened conformably with the surface (fig. XL), appearing narrow and almost linear when seen edgewise, as in a perpendicular section. (Fig. XXXIX., *a*.) The cells in a group have a straight outline where they adjoin or approach one another, but at the circumference of the group their outline is rounded.

Such is the structure of hyaline cartilage in general, but it is more or less modified in different situations.

Fig. XXXIX.

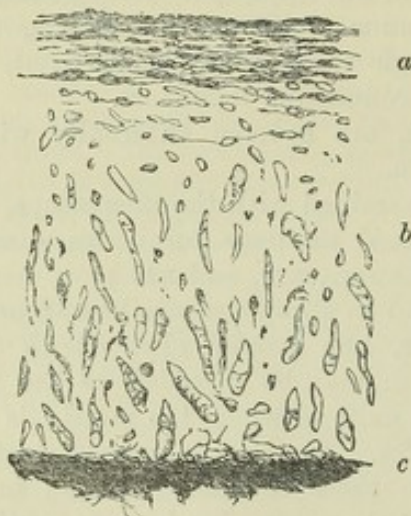


Fig. XL.

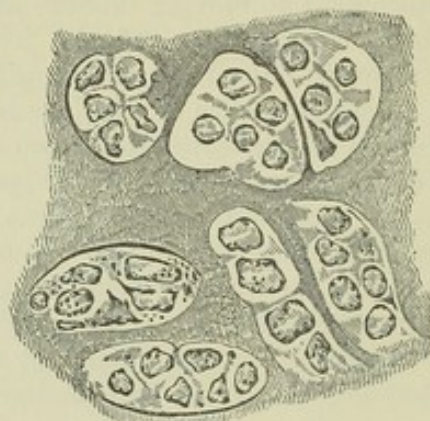


Fig. XXXIX.—DIAGRAM REPRESENTING A VERTICAL SECTION OF ARTICULAR CARTILAGE, SEEN WITH A LOW MAGNIFYING POWER.

*a*, Flattened groups of cells near the surface; *b*, oblong groups, for the most part directed vertically; *c*, part of the bone.

Fig. XL.—A THIN LAYER PEELED OFF FROM THE SURFACE OF THE CARTILAGE OF THE HEAD OF THE HUMERUS, SHOWING FLATTENED GROUPS OF CELLS.

The shrunken cell-bodies are distinctly seen, but the limits of the capsular cavities where they adjoin one another are but faintly indicated. Magnified 400 diameters.

In *articular cartilage*, the matrix in a thin section appears dim, like ground glass, and has an almost granular aspect. The cells and nuclei are small. The groups which they form are flattened at and near to the surface, and lie parallel with it (fig. XXXIX., *a*, and fig. XL.); deeper and nearer the bone, on the other hand, they are narrow and oblong, like short strings of beads, and are mostly directed vertically. (Fig. XXXIX., *b*, fig. XL.) It is well known that articular cartilages readily break in a direction perpendicular to their surface, and the surface of the fracture appears to the naked eye to be striated in the same direction, as if they had a columnar structure; this has been ascribed to the vertical arrangement of the rows of cells, or to a latent fibrous or columnar disposition of the substance of the matrix (Leidy). It was formerly held that the free surface of articular cartilage is covered with epithelium continued



from that of the synovial membrane, a thin stratum of areolar tissue being interposed; but the existence of such a covering is certainly not general, at least in the adult. It is easy, no doubt, to peel off a thin film from the surface of the cartilage of the head of the humerus or femur; but this superficial layer is really part of the cartilage, and its broad patches of cells with the intermediate matrix are not to be mistaken. (See fig. XL.) At the same time, it is true that near the margin of these cartilages a layer of fine filamentous tissue, covered with epithelium, is prolonged a certain way over their surface from the synovial membrane. The matrix of articular cartilage rarely, or perhaps never, becomes pervaded by fibres like those so often seen in rib-cartilage, nor is it prone to ossify.

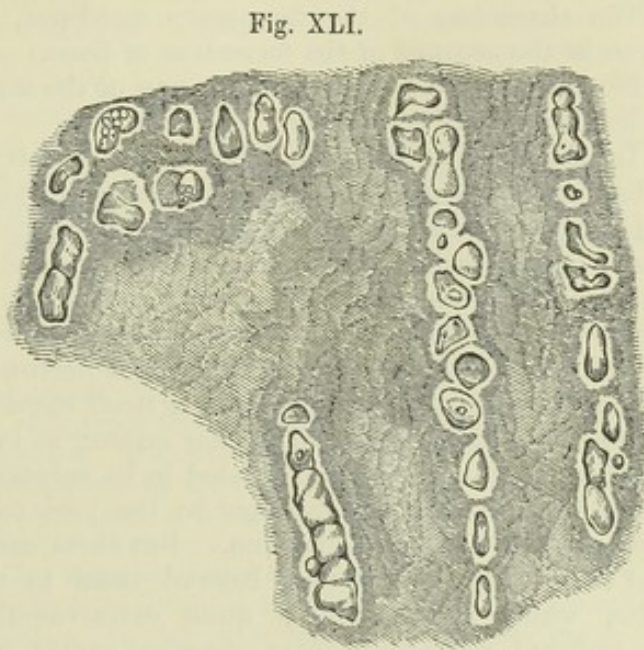


Fig. XLI.—VERTICAL SECTION OF ARTICULAR CARTILAGE OF THE HEAD OF THE HUMERUS.

A deep portion near the bone. Magnified 400 diameters. Each cell-cavity contains a mass shaped like itself, the shrunken cell body, in the midst of which a round nucleus is probably concealed.

In the *cartilages of the ribs*, the corpuscles or cells, which are of large size, are also collected in groups. Near the exterior of the cartilage they are flattened, and lie parallel with the surface, forming a superficial stratum from  $\frac{1}{200}$  to  $\frac{1}{300}$  of an inch thick. As to those situated more inwardly, we can sometimes observe, in a transverse slice, that they form oblong groups disposed in lines radiating to the circumference; but this arrangement is not constant, and they often appear quite irregular. The cells, with the exception of those lying upon the surface, commonly contain larger or smaller drops of oil; and the nucleus being generally undiscoverable, is concealed by the fat or may itself have undergone a fatty metamorphosis. The matrix is tolerably clear, except where fibres have been developed in it, in which parts it is opaque and yellowish. Such fibrous patches are very frequent; the fibres are fine, straight, and parallel, appearing transparent when few together; they withstand the action of acetic acid. It is not uncommon to find the rib cartilages extensively ossified.

It was observed by Herissant\* that the costal cartilages, after many months' maceration in putrid water, would sometimes break up into thin plates, directed across the axis of the cartilage; from which he inferred that these cartilages were naturally made up of such transverse lamellæ: but the point does not appear to have been further investigated.

The description given of the microscopic characters of the costal cartilages will apply with little variation to the ensiform cartilage of the sternum, to

\* Mém. de l'Acad. des Sc. de Paris, 1748.



the cartilages of the larynx and windpipe, except the epiglottis and cornicula laryngis, and to the cartilages of the nose. With the exception of the last, these resemble the rib-cartilages also in their tendency to ossify.

The characters of the temporary cartilages, which are hyaline, will be given in the account of the formation of bone.

No nerves have been traced into any of the cartilages, and they are known to be destitute of sensibility.

In the healthy state, no bloodvessels penetrate the articular cartilages. Whatever nutrient fluid they require seems to be derived from the vessels of adjoining textures, especially the bone, and to be conveyed through the tissue by imbibition. In the embryo, a layer of vessels is prolonged some way over the surface, underneath the synovial membrane; but, as development proceeds, these sub-synovial vessels retire towards the circumference of the cartilage, and eventually form a narrow vascular border round it, which has been named the *circulus articuli vasculosus*.

When the tissue exists in thicker masses, as in the cartilages of the ribs, canals are here and there excavated in its substance, along which vessels are conducted to supply nourishment to the part too distant to receive it from the vessels of the perichondrium. But these canals are few and wide apart, and the vessels do not pass beyond them to ramify in the intermediate mass, which is accordingly quite extra-vascular. It must be further remembered respecting these vascular canals, that many of them lead to spots where the cartilage is undergoing ossification, and convey vessels to supply the bony deposits.

Ordinary permanent hyaline cartilage contains about three-fifths of its weight of water, and becomes transparent by drying. By boiling it in water for fifteen or twenty hours it is resolved into chondrin. This is a substance said to gelatinise on cooling, although it may be doubted whether the congelation is not in reality owing to an admixture of gelatin derived from fibrous tissue not duly separated from the cartilage. Like gelatine, chondrin is thrown down from its solutions by tannic acid, alcohol, ether, creosote, and corrosive sublimate, and not by prussiate of potash. It differs from gelatin in being precipitated by the mineral and other acids, the acetic not excepted; also by alum, sulphate of alumina, persulphate of iron, and acetate of lead; the precipitates being soluble in an excess of the respective precipitants. The temporary cartilages are resolved into a matter which has the chemical reactions of chondrin, but does not gelatinise. Cartilage affords by incineration a certain amount of mineral ingredients; 3·4 per cent. of ashes were obtained from costal cartilages by Frommherz and Gugert, and 100 parts of these ashes were found to consist of

Carbonate of soda	35·07
Sulphate of soda	24·24
Chloride of sodium	8·23
Phosphate of soda	0·92
Sulphate of potash	1·20
Carbonate of lime	18·37
Phosphate of lime	4·06
Phosphate of magnesia	6·91
Oxide of iron, and loss	1·00

Von Bibra found the amount of carbonates very small, and that of the other salts very variable. Soda-salts greatly preponderate over those of potash, which may even be absent altogether.



*Development of hyaline cartilage.*—The parts of the embryo which are about to become cartilages are made up at first of the common embryonic cells from which the tissues generally originate. The cell-contents clear up, the nucleus becomes more visible, and the cells, mostly of polygonal outline, appear surrounded by clear lines of pellucid substance, forming as it were a network of bright meshes inclosing them, but in reality consisting of the cohering capsules of the contiguous cells, and constituting all that exists of the matrix at this time. Amyloid matter appears at an early period in the protoplasm of cartilage cells. Rouget found it in the sheep's embryo of two months, both in ossifying cartilage and in the cartilages of the trachea. The subsequent changes consist in enlargement and multiplication of the cells and development of the intermediate matrix. The cells multiply by division. The process is described at page xvii, although all the successive steps there described and represented in the figure (xii.) have not been actually traced. In growing cartilage from the frog-larva, Heidenhain\* observed a double (*i. e.* divided) nucleus in some cells, and in certain of these a straight linear partition running across the cell between the two nuclei. This partition was recognised to be double, and doubtless formed by the contiguous thin capsules of two new cells formed by division of the previously single one. It is doubtful how the capsule or secondary cell-wall is produced; whether excreted by the cell which it afterwards incloses, as held by Kölliker, or formed by conversion of a superficial layer of the protoplasm of the cell-body, as taught by Max Schultze, or a primarily independent deposit round the cells. However this may be, there is at first no matrix but what is made up of the simple capsules. In further growth there is a difference according as the cells do or do not undergo frequent division. In the latter case a cell becomes surrounded by many concentric capsules formed in succession; that is, the first capsule is expanded, and the others formed each within its expanding predecessor, so that the cartilage comes to consist of scattered cells, each with a concentric system of capsules, which by means of re-agents may be rendered visible in the neighbourhood of the cells, but further off are inseparably blended into a uniform substance. When, on the other hand, the cells have a tendency to frequent subdivision, the new capsules are produced by the new cells, and are included in and finally blend with those which had belonged to the previous cells, as shown by fig. xii.

The matrix, although thus formed of the capsules, becomes to all appearance homogeneous; but in sections of cartilage that have been exposed to acids and other re-agents, the contour lines of the capsules round cells and cell-groups may be more or less distinctly brought into view. But whilst admitting that the capsules have a share in the production of the matrix, Kölliker and some other histologists incline to the opinion that part of it is an independent deposit. Heidenhain, however, has found that when thin sections of cartilage are digested for twenty-four hours in water, at from 112° to 122° F., or in diluted nitric acid with chlorate of potash for a greater or less time according to the degree of dilution, the matrix becomes parted or marked off into polygonal areas corresponding to the larger groups of cells, and these again into smaller groups, or single cells, without any intervening substance; the whole matrix thus appearing to be portioned out into segments, each appertaining to a larger or smaller group of cells, and in all probability representing the aggregated capsules belonging to them.

The vital changes which occur in cartilage take place very slowly. Its mode of nutrition has been already referred to; it is subject to absorption, and when a portion is absorbed in disease or removed by the knife, it is not regenerated. Also, when fractured, as sometimes happens with the rib-cartilages, there is no re-union by cartilaginous matter, but the broken surfaces become connected, especially at their circumference, by fibrous or dense areolar tissue, often by a bony clasp. But notwithstanding that normally it is not regenerated, hyaline cartilage occurs in perfectly characteristic form as a morbid product in certain tumours.

## ELASTIC OR YELLOW CARTILAGE.

The epiglottis and cornicula of the larynx, the cartilages of the ear and of the Eustachian tube, differ so much from the foregoing, both in intimate

\* Studien des Physiologischen Instituts zu Breslau, 2ter Heft, 1863.



structure and outward characters, that they have been included in a class apart, under the name of the "elastic," "yellow," or "spongy" cartilages. These are opaque and somewhat yellow, are more flexible and

Fig. XLII.

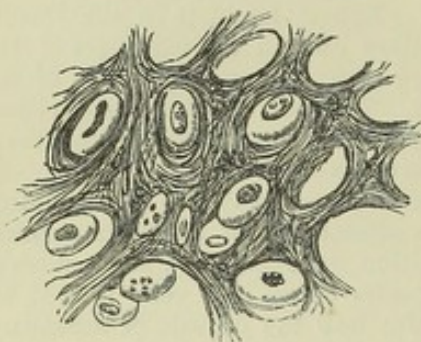


Fig. XLII.—SECTION OF THE EPI-  
GLOTTIS, MAGNIFIED 380 DIAMETERS  
(Dr. Baly).

tough than the ordinary cartilages, and have little tendency to ossify. They are made up of cells and a matrix, but the latter is everywhere pervaded with fibres (fig. XLII.), except sometimes in a little area or narrow zone left round each of the cells. These fibres resist the action of acetic acid; they are in most parts short, straight, and confusedly intersecting each other in all directions, like the filaments in a piece of felt; in such parts the matrix has a rough indistinctly granular look. Here and there the fibres are longer and more fasciculated, but still interlace at short distances. In thin sections the cells readily drop out from the matrix, leaving empty the cavities which they occupied.

In the foetus the matrix of elastic cartilage is at first homogeneous and hyaline, and the elastic fibres are then produced in it, quite independently of the cells, and in the same way as in the intercellular substance of growing elastic ligaments.

#### FIBRO-CARTILAGE.

This is a substance consisting of a mixture of the fibrous and cartilaginous tissues, and so far partaking of the qualities of both. Like hyaline cartilage, it possesses firmness and elasticity, but these properties are united with a much greater degree of flexibility and toughness. It presents itself under various forms, which may be enumerated under the following heads:—

1. *Inter-articular* fibro-cartilages. These are interposed between the moving surfaces of bones, or rather of articular cartilages, in several of the joints. They serve to maintain the apposition of the opposed surfaces in their various motions, to give ease to the gliding movement, and to moderate the effects of great pressure. In the joint of the lower jaw and in that of the clavicle they have the form of round or oval plates, growing thinner towards their centre; in the knee-joint they are curved in form of a sickle, and thinned away towards their concave free edge. In all cases their surfaces are free, while they are fixed by synovial or fibrous membrane at their circumference or extremities. The synovial membrane of the joint, or at least its epithelial coat, is prolonged for a short distance upon these fibro-cartilages, from their attached margin.

2. The articular cavities of bones are sometimes deepened and extended by means of a rim or border of fibro-cartilage. A good example of one of these *circumferential* or *marginal* fibro-cartilages is seen in the hip-joint, attached round the lip of the cotyloid cavity.

3. *Connecting* fibro-cartilages are such as pass between the adjacent surfaces of bones in joints which do not admit of gliding motion, as at the symphysis of the pubes and between the bodies of the vertebræ. They have the general form of disks, and are composed of concentric rings of fibrous tissue with cartilage interposed; the former predominating at the



circumference, the latter increasing towards the centre. The bony surfaces between which they pass are usually encrusted with true cartilage. The modifications which they present in particular instances are described in the special anatomy of the joints.

4. The bony grooves in which tendons of muscles glide are lined with a thin layer of fibro-cartilage. Small nodules of this tissue (*sesamoid fibro-cartilages*) may also be developed in the substance of tendons, of which there is an example in the tendon of the *tibialis posticus*, where it passes beneath the head of the *astragalus*. Lastly, fibro-cartilage is sometimes connected with muscular tissue, and gives attachment to muscular fibres, like that which is known to exist at the orifices of the heart.

Fibro-cartilage appears under the microscope to be made up of bundles of fibres, like those of ordinary ligament, with cartilage-cells intermixed; but the proportion of the two elements differs much in the different instances above enumerated. In general the fibrous tissue very greatly predominates, and in some cases, as in the inter-articular laminae of the knee-joint, it constitutes almost the entire structure. In the intervertebral disks the cartilage-corpuscles are abundant towards the centre of the mass where the cartilaginous tissue prevails, and the substance is softer.

In chemical composition this texture agrees most with ligament, yielding gelatin when boiled.

Its bloodvessels are very few, and, according to Mr. Toynbee,\* are confined to the parts that are fibrous. Its vital changes are slow; it is subject to absorption, but much less readily so than bone; hence it is no uncommon thing to find the intervertebral disks entire when the adjacent bodies of the vertebrae have been destroyed by disease. It has not much tendency to ossify.

Little is known concerning the mode of development of fibro-cartilage. Mr. Toynbee concludes from his researches that the cartilaginous element is relatively more abundant at early periods.

## BONE, OR OSSEOUS TISSUE.

The bones are the principal organs of support, and the passive instruments of locomotion. Connected together in the skeleton, they form a framework of hard material, which affords attachment to the soft parts, maintains them in their due position, and shelters such as are of delicate structure, giving stability to the whole fabric, and preserving its shape; and the different pieces of the skeleton, being jointed moveably together, serve also as levers for executing the movements of the body.

While substantially consisting of hard matter, bones in the living body are covered with periosteum and filled with marrow; they are also pervaded by vessels for their nutrition.

*External configuration.*—In their outward forms the bones present much diversity, but have been reduced by anatomists to the following classes:—

1. Long or cylindrical, such as the chief bones of the limbs. These consist of a body or shaft, cylindrical or more frequently angular in shape, and two ends or heads, as they are often called, which are usually much thicker than the shaft. The heads, or ends, have smooth surfaces for articulation with neighbouring bones. The shaft is hollow and filled with marrow, by which

\* Phil. Trans. 1841.



sufficient magnitude and strength are attained without undue increase of weight. 2. Tabular or flat bones, like the scapula, the ilium, the ribs, the lower jaw, and the bones forming the roof and sides of the skull. Many of these contribute to form the walls of cavities. 3. Short bones, often also called round bones, though most of them rather are angular; the wrist and tarsus afford examples of these. 4. Irregular or mixed bones, which would, perhaps, be better named "complex:" such as cannot be entirely referred to any of the foregoing classes. These are mostly situated in the median plane, and have a complex but symmetrical figure; the vertebræ may be taken as instances of them.

The surfaces of bones present various eminences, depressions, and other marks; and, to designate these in descriptive osteology, certain general terms are employed, of which the following are those most commonly in use.

1. Eminences. To any prominent elevation jutting out from the surface of a bone the term "process" or "apophysis" is applied. It often happens that such a process is originally ossified separately from the rest of the bone, and remains long unconnected with the main body (by osseous union at least); in this condition it is named an "epiphysis." In many bones, considerable portions at the extremities or most prominent parts are originally ossified separately as epiphyses. This is the case with the ends of the long bones, and in this instance the shaft is named the "diaphysis."

Processes or apophyses are further designated according to their different forms. A slender, sharp, or pointed eminence is named a "spine" or "spinous process;" a tubercle, on the other hand, is a blunt prominence; a "tuberosity" (tuber) is broader in proportion to its elevation, and has a rough uneven surface. The term "crest" is usually applied to the prominent border of a bone, or to an elevation running some way along its surface; but the latter is more commonly denominated a "line" or "ridge." A "head" (caput, capitulum, or capitellum) is a rounded process, supported on a narrower part named its neck (cervix). A "condyle" has been defined to be an eminence bearing a flattened articular surface; but this term has been very variously applied by anatomists both ancient and modern.

2. Cavities and depressions of bones. An aperture or perforation in the substance of a bone is named a "foramen." A passage or perforation often runs for some way in the bone, and then it is termed a "canal" or "meatus." On the other hand, it may assume the form of a "fissure," and is named accordingly. A "fossa" is an open excavation or depression on the surface of a bone, or of a part of the skeleton formed by several bones. A fossa may form part of a joint, and be adapted to receive the prominent part of a neighbouring bone; it is then said to be "glenoid," when shallow; but a deep excavation, of which the socket for the head of the thigh-bone is an example, is named a "cotyloid" cavity. The meaning of the terms "notch" (incisura), and "groove," or "furrow" (sulcus), is sufficiently plain. "Sinus" and "antrum" are names applied to certain large cavities situated within the bones of the head and opening into the nose.

*Physical properties of bone.*—Bone has a white colour, with a pink and slightly bluish tint in the living body. Its hardness is well known, but it also possesses a certain degree of toughness and elasticity; the last property is peculiarly well marked in the ribs. Its specific gravity is from 1.87 to 1.97.



*Chemical Composition.*—It consists of an earthy and an animal part, intimately combined together; the former gives hardness and rigidity, the latter tenacity, to the osseous tissue.

The earthy part may be obtained separate by calcination. When bones are burned in an open fire, they first become quite black, like a piece of burnt wood, from the charring of their animal matter; but if the fire be continued with free access of air, this matter is entirely consumed, and they are reduced to a white, brittle, chalk-like substance, still preserving their original shape, but with the loss of about a third of their weight. The earthy constituent, therefore, amounts to about two-thirds of the weight of the bone. It consists principally of phosphate of lime, with about a fifth part of carbonate of lime, and much smaller proportions of fluoride of calcium, chloride of sodium, and magnesian salts.

The animal constituent may be freed from the earth, by steeping a bone in diluted hydrochloric acid. By this process the salts of lime are dissolved out, and a tough, flexible substance remains, which, like the earthy part, retains the perfect figure of the original bone in its minutest details; so that the two are evidently combined in the most intimate manner. The animal part is often named the cartilage of bone, but improperly, for it differs entirely from cartilage in structure, as well as in physical properties and chemical nature. It is much softer and much more flexible, and by boiling it is almost wholly resolved into gelatin. It may accordingly be extracted from bones, in form of a jelly, by boiling them for a considerable time, especially under high pressure.

The earthy or saline matter of bone, as already stated, constitutes about two-thirds or 66·7 per cent., and the animal part one-third, or 33·3 per cent.; but from observations made on animals, it appears that the proportion of the several constituents may differ somewhat in different individuals of the same species under apparently similar conditions. The proportion of earthy matter appears to increase for some time after birth, and is considerably greater in adults than in infants; but from the varying conditions of individuals as to health and nutrition in after life, there is as yet no thoroughly comparable series of experiments to determine whether any constant difference exists in old age. Moreover, it is not clearly established that the differences observed depend on the composition of the proper osseous substance; for the larger proportion of animal matter in infancy may be due to the greater vascularity of infantile bones and the difficulty of thoroughly removing the vessels from their pores. The spongy osseous tissue, carefully freed from fat and adhering membranous matter, has been found to contain rather less earth than the compact substance, and in accordance with this result, differences, although on the whole insignificant, have been found in different bones of the skeleton, apparently depending on the relative amount of their compact and spongy tissue. (Rees, Von Bibra, Alphonse Milne-Edwards.) Here again it remains to be shown that the result is not due to differences in the proportion of minute pores and lacunæ, which contain soft matter scarcely separable in such experiments.

Subjoined are the statements of two analyses. The one, by Berzelius, is well known; the other, which nearly agrees with it, was performed by Mr. Middleton, in the laboratory of University College.\*

	Berzelius. Middleton.	
Animal matter . . . . .	33·30	— 33·43
Phosphate of lime . . . . .	51·04	— 51·11
Carbonate of lime . . . . .	11·30	— 10·31
Fluoride of calcium . . . . .	2·00	— 1·99
Magnesia, wholly or partially in the state of phosphate . . . . .	1·16	— 1·67
Soda and chloride of sodium . . . . .	1·20	— 1·68

\* Philosophical Magazine, vol. xxv. p. 18.



The phosphate of lime is peculiar, and passes in chemistry under the name of the "bone-earth phosphate." It is a tribasic phosphate, consisting probably of 8 equivalents of lime and 1 of water, with 3 eq. of phosphoric acid. Von Bibra and A. Milne-Edwards,\* found the proportion of the carbonate of lime to the phosphate, greater in spongy than in compact tissue, and less in infantile bones generally than in those of adults. M. Edwards considers that carbonate is formed from decomposition of the basic phosphate by the carbonic acid of the blood, and that the proportion must necessarily vary with the state of nutrition; in infancy there is less decomposition and also more rapid elimination of the products of decomposition, hence proportionally less carbonate of lime. The fluoride of calcium is found in larger quantity in fossil than in recent bones—indeed, its presence in the latter was lately denied altogether; but since then, the original statements of Morichini and of Berzelius, to the effect that it exists in recent as well as fossil bones, have been satisfactorily confirmed.

*Structure.*—On sawing up a bone, it will be seen that it is in some parts dense and close in texture, appearing like ivory; in others open and reticular: and anatomists accordingly distinguish two forms of osseous tissue, viz., the *compact*, and the *spongy* or *cancellated*. On closer examination, however, especially with the aid of a magnifying glass, it will be found that the bony matter is everywhere porous in a greater or less degree, and that the difference between the two varieties of tissue depends on the different amount of solid matter compared with the size and number of the open spaces in each; the cavities being very small in the compact parts of the bone, with much dense matter between them; whilst in the cancellated texture the spaces are large, and the intervening bony partitions thin and slender. There is, accordingly, no abrupt limit between the two,—they pass into one another by degrees, the cavities of the compact tissue widening out, and the reticulations of the cancellated becoming closer as they approach the parts where the transition takes place.

In all bones, the part next the surface consists of compact substance, which forms an outer shell or crust, whilst the spongy texture is contained within. In a long bone, the large round ends are made up of spongy tissue, with only a thin coating of compact substance; in the hollow shaft, on the other hand, the spongy texture is scanty, and the sides are chiefly formed of compact bone, which increases in thickness from the extremities towards the middle, at which point the girth of the bone is least, and the strain on it greatest. In tabular bones, such as those of the skull, the compact tissue forms two plates, or tables as they are called, inclosing between them the spongy texture, which in such bones is usually named *diploe*. The short bones, like the ends of the long, are spongy throughout, save at their surface, where there is a thin crust of compact substance. In the complex or mixed bones, the two substances have the same general relation to each other; but the relative amount of each in different parts, as well as their special arrangement in particular instances, is very various.

On close inspection, the cancellated texture is seen to be formed of slender bars or spicula of bone and thin lamellæ, which meet together and join in a reticular manner, producing an open structure which has been compared to lattice-work (*cancelli*), and hence the name usually applied to it. In this way considerable strength is attained without undue weight, and it may usually be observed that the strongest laminae run through the structure in those directions in which the bone has naturally to sustain the greatest pressure. The open spaces or areolæ of the bony network com-

\* Ann. des Sc. Nat. 4me Série, vol. xiii. 1860.



municate freely together ; in the fresh state they contain marrow or blood-vessels, and give support to these soft parts.

Fig. XLIII.

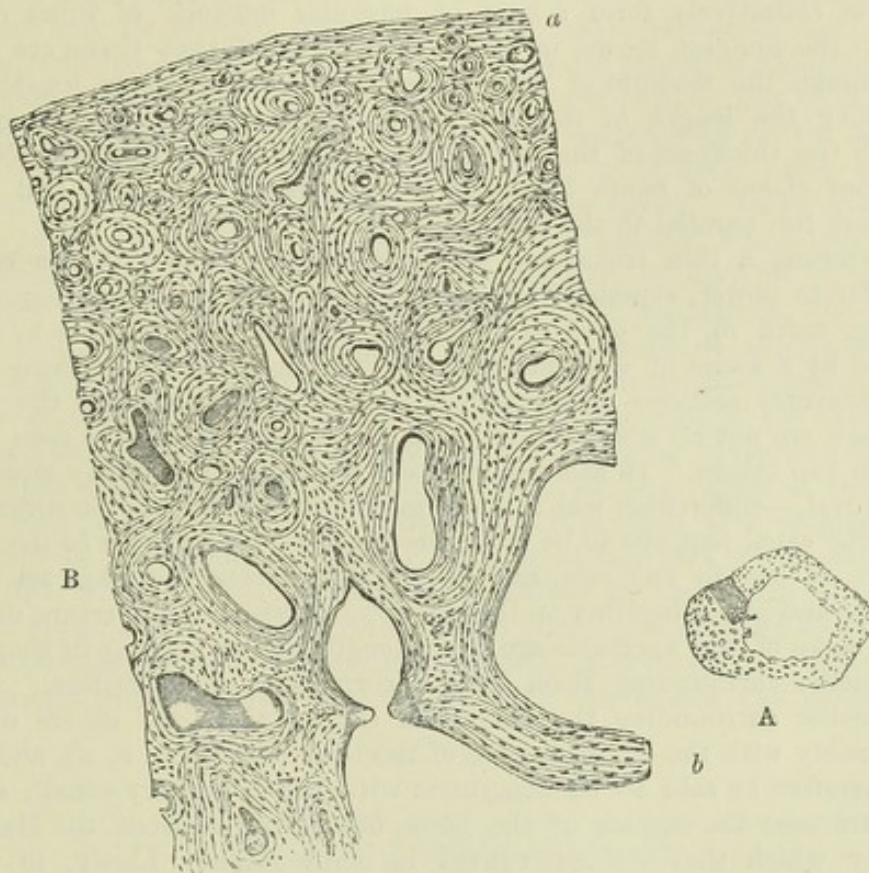


Fig. XLIII.—A, TRANSVERSE SECTION OF A BONE (ULNA) DEPRIVED OF ITS EARTH BY ACID.

The openings of the Haversian canals seen. Natural size. A small portion is shaded to indicate the part magnified in Fig. B.

B, PART OF THE SECTION A, MAGNIFIED 20 DIAMETERS.

The lines indicating the concentric lamellæ are seen, and among them the corpuscles or lacunæ appear as little dark specks.

The compact tissue is also full of holes ; these, which are very small, are best seen by breaking across the shaft of a long bone near its middle, and examining it with a common magnifying glass. Numerous little round apertures (fig. XLIII. A) may then be seen on the broken surface, which are the openings of short longitudinal passages running in the compact substance, and named the Haversian canals, after Clopton Havers, an English physician and writer of the seventeenth century, who more especially called attention to them. Bloodvessels run in these canals, and the widest of them also contain marrow. They are from  $\frac{1}{1000}$ th to  $\frac{1}{200}$ th of an inch in diameter : I have measured some which were no more than  $\frac{1}{2000}$ th, but these are rare ; the medium size is about  $\frac{1}{300}$ th. The widest are those nearest the medullary cavity, and they are much smaller towards the circumference of the bone. They are quite short, as may be seen in a longitudinal section, and somewhat crooked or oblique at their ends, where they



freely open into one another, their oblique communications connecting them both longitudinally and laterally. Those also which are next the circumference of the bone, open by minute pores on its external surface, and the innermost ones open widely into the medullary cavity ; so that these short channels collectively form a sort of irregular network of tubes running through the compact tissue, in which the vessels of that tissue are lodged, and through the medium of which these vessels communicate together, not only along the length of the bone, but from its surface to the interior, through the thickness of the shaft. The canals of the compact tissue in the other classes of bones have the same general characters, and for the most part run parallel to the surface.

On viewing a thin transverse section of a long bone with a microscope of moderate power, especially after the earthy part has been removed by acid (fig. XLIII. B), the opening of each Haversian canal appears to be surrounded by a series of concentric rings. This appearance is occasioned by the transverse sections of concentric lamellæ which surround the canals. The rings are not all complete, for here and there one may be seen ending between two others. In some of the sets the rings are nearly circular, in others oval,—differences which seem mostly to depend on the direction in which the canal happens to be cut : the aperture, too, may be in the centre, or more or less to one side, and in the latter case the rings are usually narrower and closer together on the side towards which the aperture deviates. Again, some of the apertures are much lengthened or angular in shape, and the lamellæ surrounding them have a corresponding disposition. Besides the lamellæ surrounding the Haversian canals, there are others disposed conformably with the circumference of the bone (fig. XLIII. B, *a*), and which may therefore be said to be concentric with the medullary canal ; some of these are near the surface of the bone, others run between the Haversian sets, by which they are interrupted in many places. Lastly, in various parts of the section, lines are seen which indicate lamellæ, differing in direction from both of the above-mentioned orders. As to the circumferential laminæ, Messrs. Tomes and De Morgan state that they are by no means so common as is generally supposed ; further, that they are most conspicuous in bones of full growth, in which, consequently, nutritive changes proceed slowly ; and that their presence may be made the means of determining, within certain limits, the age at which a bone has arrived. These authors observe, that in young and rapidly-growing bones the laminæ are frequently seen to have an undulating direction, which they consider as a sign that the tissue is undergoing rapid nutritive changes.

The appearance in a longitudinal section of the bone is in harmony with the account above given : the sections of the lamellæ are seen as straight and parallel lines, running in the longitudinal direction of the bone, except when the section happens to have passed directly or slantingly across a canal ; for wherever this occurs there is seen, as in a transverse section, a series of rings, generally oval and much lengthened on account of the obliquity of the section.

The cancellated texture has essentially the same lamellar structure. The slender bony walls of its little cavities or areolæ are made up of superimposed lamellæ, like those of the Haversian canals (fig. XLIII. B, *b*), only they have fewer lamellæ in proportion to the width of the cavities which they surround ; and, indeed, the relative amount of solid matter and open space constitutes, as already said, the only difference between the two forms of bony tissue ; the intimate structure of the solid substance and the



manner of its disposition round the cavities being essentially the same in both.

Besides the openings of Haversian canals as above described, a transverse section of the compact bone now and then presents vacuities or spaces formed by absorption of the tissue. These are named "Haversian spaces" by Tomes and De Morgan, who first showed that they occur not only in growing bone but at all periods of life. In their primitive condition these cavities are characterised by an irregular or jagged outline, and their formation by absorption is further indicated by their encroaching on the adjacent groups of concentric lamellæ, which have been, as it were, eaten away to a greater or less extent to give place to the new cavity. In another stage the spaces in question are lined by new formed lamellæ, which may as yet be confined to the peripheral part of the vacuity, or may fill it up in a concentric series, leaving a Haversian aperture in the middle, and in fact constituting a system of concentric Haversian lamellæ, interpolated or intruded among those previously existing. The concentric lamellæ, which thus come to occupy a greater or less extent of the area of the cavity, are of course bounded exteriorly by segments of adjoining Haversian lamellæ, which have been more or less cut in upon in the excavation of the space. It has been further observed by Tomes and De Morgan, that vacuities may sometimes be seen which are being filled up at one part by the deposition of lamellæ, whilst they are extending themselves by absorption at another. The Haversian spaces are most numerous in young and growing bones; but, as already stated, they occur also after growth is completed. Their origin and changes will be better understood after the reader has perused the

Fig. XLIV.

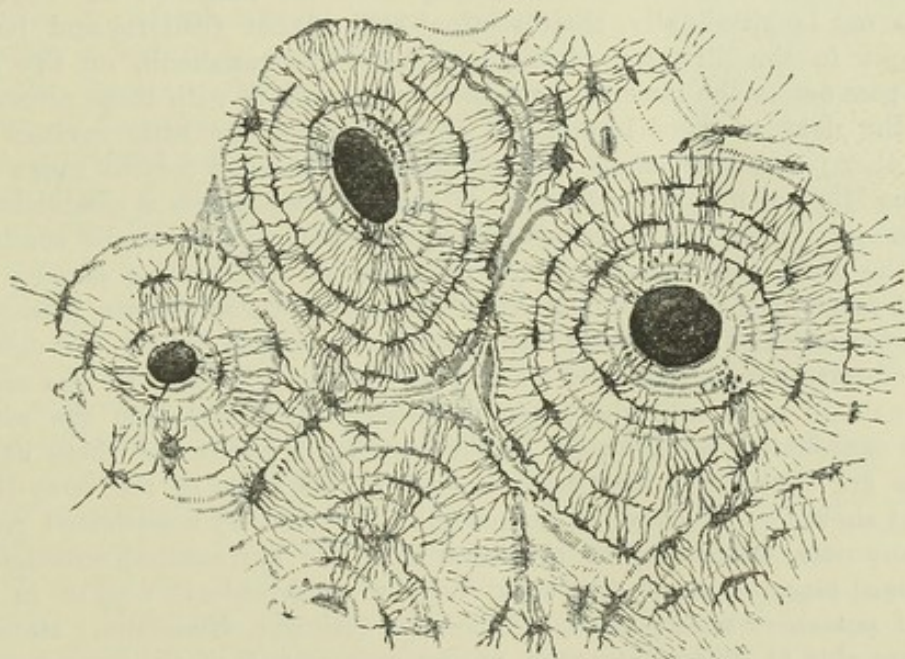


Fig. XLIV.—TRANSVERSE SECTION OF COMPACT TISSUE (OF HUMERUS) MAGNIFIED ABOUT 150 DIAMETERS.

Three of the Haversian canals are seen, with their concentric rings; also the corpuscles or lacunæ, with the canaliculi extending from them across the direction of the lamellæ. The Haversian apertures had got filled with débris in grinding down the section, and therefore appear black in the figure, which represents the object as viewed with transmitted light.



account of the growth and development of bone, to which head, indeed, the subject more properly belongs, although it has seemed expedient to introduce it here.

All over the section numerous little dark specks are seen among the lamellæ. These were named the "osseous corpuscles;" but as it is now known that they are in reality minute cavities existing in the bony substance, the name of "lacunæ" has since been more fittingly applied to them. To see the lacunæ properly, however, sections of unsoftened bones must be prepared and ground very thin, and a magnifying power of from 200 to 300 must be employed. Such a section, viewed with transmitted light, has the appearance represented in fig. XLIV. The openings of the Haversian canals are seen with their encircling lamellæ, and among these the corpuscles or lacunæ, which are mostly ranged in a corresponding order, appear as black or dark brown and nearly opaque, oblong spots, with fine dark lines extending from them and causing them to look not unlike little black insects; but when the same section is seen against a dark ground, with the light falling on it (as we usually view an opaque object), the little bodies and lines appear quite white, like figures drawn with chalk on a slate, and the intermediate substance, being transparent, now appears dark.

The lacunæ, as already stated, are minute recesses in the bone, and the lines extending from them are fine pores or tubes named "canaliculi," which issue from their cavity. They present some variety of figure, but in such a section as that represented for the most part appear irregularly fusiform, and lie nearly in the same direction as the lamellæ between which they are situated; or, to speak more correctly, the little cavities are flattened and extended conformably with the lamellæ; for when the bone is cut longitudinally, their sections still appear fusiform and lengthened out in the direction of the lamellæ. The canaliculi, on the other hand, pass across the lamellæ, and they communicate with those proceeding from the next range of lacunæ, so as to connect the little cavities with each other; and thus, since the canaliculi of the most central range open into the Haversian canal, a system of continuous passages is established by these minute tubes and their lacunæ, along which fluids may be conducted from the Haversian canal through its series of surrounding lamellæ; indeed it seems probable that the chief purpose of these minute passages is to convey nutrient fluid from the vascular Haversian canals through the mass of hard bone which lies around and between them. In like manner the canaliculi open into the great medullary canal, and into the cavities of the cancellated texture; for in the thin bony parietes of these cavities lacunæ are contained; they exist, indeed, in all parts of the bony tissue. As first shown by Virchow, each lacuna is occupied by a nucleated cell, or soft corpuscle, which may be separated from the surrounding substance by prolonged maceration of decalcified bone in hydrochloric acid or in solution of potash or soda; and later observers (Rouget, Neumann,) state that they are able to detach also the proper osseous wall of the lacuna and its appertaining canaliculi after decalcification, and to obtain it separate with its included corpuscle. The soft corpuscle or cell has an angular outline corresponding to the shape of the lacuna, but it is not proved that it sends branches along the canaliculi, as Virchow supposed, or that it has a membranous envelope. Nevertheless it can scarcely be doubted that the protoplasm of the nucleated corpuscle takes an important share in the nutritive process in bone, and very probably serves both to modify the nutritive



fluid supplied from the blood and to further its distribution through the lacunar and canalicular system of the bony tissue. Virchow considers that the corpuscles of bone are homologous with those of connective tissue.

To return to the lamellæ. With a little pains thin films may be peeled off in a longitudinal direction from a piece of bone that has been softened in acid. These for the most part consist of several laminæ, as may be seen at the edge, where the different layers are usually torn unequally, and some extend farther than others. Examined in this way, under the microscope, the lamellæ are seen to be perforated with fine apertures placed at very short distances apart. These apertures were described by Deutsch,\* but they have not much attracted the notice of succeeding observers; they appear to me to be the transverse sections of the canaliculi already described, and their relative distance and position accord sufficiently with this explanation. According to this view, therefore, the canaliculi might (in a certain sense) be conceived to result from the apposition of a series of perforated plates, the apertures of each plate corresponding to those of the plates contiguous with it; in short, they might be compared to holes bored to some depth in a straight or crooked direction through the leaves of a book, in which case it is plain that the perforations of the adjoining leaves would correspond; it being always understood, however, that the passages thus formed are bounded by proper parietes. The apertures now referred to must be distinguished from larger holes seen in some lamellæ which give passage to the perforating fibres to be mentioned further on.

But the lamellæ have a further structure. To see this the thinnest part of a detached shred or film must be examined, as shown in figs. XLV. and XLVII.; it will then appear plainly that they are made up of transparent fibres, decussating each other in form of an exceedingly fine network. The fibres intersect obliquely, and they seem to coalesce at the points of intersection, for they cannot be teased out from one another; but at the torn edge of the lamella they may often be seen separate for a little way, standing out like the threads of a fringe. Most generally they are straight, as represented in the figure; but they are not always so, for in some parts they assume a curvilinear direction. Acetic or hydrochloric acid causes these fibres to swell up and become indistinct, like the white fibres of connective tissue; care must therefore be taken in their examination that the remains of the decalcifying acid be removed from the tissue, by maceration in water or in solution of an alkaline carbonate. Moreover, the fibro-reticular structure is not equally distinct in all parts where its presence is recognisable; for in some places it is less decidedly marked, as if the fibrillation were incompletely developed—resembling in this respect the areolar and fibrous tissues.

In many instances the lamellæ are perforated by fibres, or rather bundles

Fig. XLV.




Fig. XLV.—THIN LAYER  
PEELED OFF FROM A SOFT-  
ENED BONE, AS IT APPEARS  
UNDER A MAGNIFYING  
POWER OF 400.

This figure, which is intended to represent the reticular structure of a lamella, gives a better idea of the object when held rather farther off than usual from the eye.

\* De Penitiori Ossium Structura. Wratisl. 1834, p. 17, Fig. 6.



of fibres, which pass through them in a perpendicular, or more or less oblique direction, and, as it were, bolt them together. These *perforating fibres* may be seen, with the aid of the microscope, in a thin transverse slice of a decalcified cylindrical or cranial bone, on pulling asunder the sections of the lamellæ (as in fig. XLVI.). In this way some lamellæ will generally be observed with fibrous processes attached to them (fig. XLVI. *b*) of various lengths, and usually tapering and pointed at their free extremities, but sometimes truncated—probably from having come in the way of the knife. These fibres have obviously been drawn out from the adjacent lamellæ, through several of which they must have penetrated. Sometimes, indeed, indications of perforations may be recognised in the part of the section of bone from which the fibres have been pulled out (fig. XLVI. *c*). The processes in question are thus, so to speak, viewed in profile; but they may frequently also be seen on the flat surface of detached lamellæ, projecting like nails driven perpendicularly or slantingly through a board (fig. XLVII. *a*); whilst the lamellæ at other parts present obvious apertures of considerable size, through which the perforating fibres had passed (fig. XLVII. *b, b*).

Fig. XLVI.

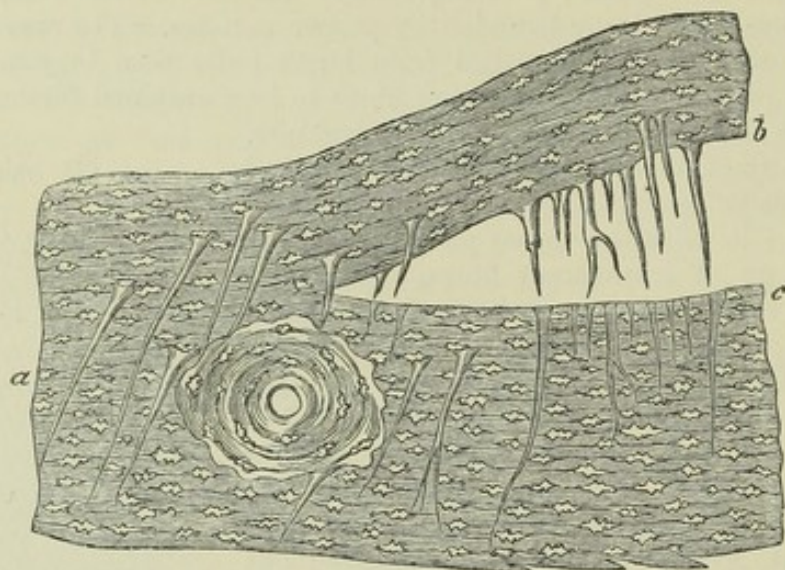


Fig. XLVI.—MAGNIFIED VIEW OF A PERPENDICULAR SECTION THROUGH THE EXTERNAL TABLE OF A HUMAN PARIETAL BONE, DECALCIFIED.

At *a*, perforating fibres in their natural situation; at *b*, others drawn out by separation of the lamellæ; at *c*, the holes or sockets out of which they have been drawn (H. Müller).

These perforating fibres, since first noticed by me, have been shown by Kölliker to exist very generally in the bones of fishes, and to a certain extent in those of amphibia.\* I had myself found them abundant in the turtle, and had no doubt of their general existence in vertebrata. The late lamented Henry Müller, of Würzburg, has supplied many details respecting their arrangement in man and mammalia.† Kölliker considers them to be connected with the periosteum, and this, no doubt, is the case with some of them—some of those, for example, which penetrate the external table of the cranial bones; but in cross sections of cylindrical bones they often appear to spring, with their broad ends, from the deeper lamellæ, and taper outwards into fine points, which do not reach the periosteum; although without doubt they must, like the bony layers in which they occur, have been formed by subperiosteal ossification. They are

\* Würzburger Naturw. Zeitschr. vol. i. p. 306.

† Ibid., vol. i. p. 296.



rarely found, and when present are smaller, in the concentric systems of Haversian lamellæ; in this case they must of course have been formed from the vascular tissue (similar in nature to that under the periosteum) which occupied the Haversian spaces and produced the concentric laminae. Perforating fibres exist abundantly in the *crusta petrosa* of the teeth.

Fig. XLVII.

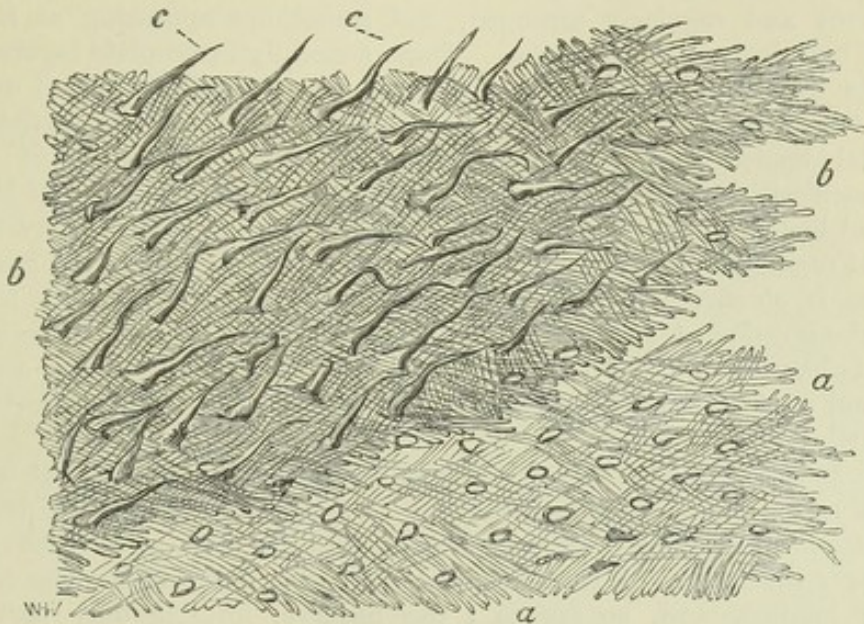


Fig. XLVII.—LAMELLE TORN OFF FROM A DECALCIFIED HUMAN PARIETAL BONE AT SOME DEPTH FROM THE SURFACE.

*a*, a lamella, showing reticular fibres; *b*, *b*, darker part, where several lamellæ are superposed; *c*, *c*, perforating fibres. Apertures through which perforating fibres had passed, are seen especially in the lower part, *a*, *a*, of the figure. Magnitude as seen under a power of 200, but not drawn to a scale (from a drawing by Dr. Allen Thomson).

The perforating fibres, or rather bundles of fibres, for the most part agree in character with the white fibrous tissue, but some, according to H. Müller, are of the nature of elastic tissue. H. Müller has shown that in some parts the fibres escape calcification, and thus, as they shrink in drying, leave tubes or channels in the dry bone, generally leading from the surface inwardly. In this way he explains the nature and mode of production of the "tubes" described by Tomes and De Morgan as penetrating the bone in certain situations, and conjectured by them to be modified lacunæ.\* I at one time believed that these tubes had no relation to the perforating fibres, but I have no doubt of the correctness of Müller's explanation; at the same time I am satisfied that uncalcified fibres, though numerous at particular spots, are by no means so frequent as might be inferred from Müller's account of them, and that the perforating fibres may be said to be generally calcified. Finally, these fibres seem to have no physiological significance: they may be regarded as merely a modification of the mechanical structure of the tissue.

In a thin transverse section of hard bone, the curved lines, or rather bands which represent the cut edges of the lamellæ, generally present, with transmitted light, a dark, granular-like, and a light, transparent, and usually narrower zone. Under a high power of the microscope the former appears thickly dotted over with fine dark points. In a decalcified section the dark part shows a multitude of short bright lines running radially across it, with dark angular particles between them. The lines are probably caused by pores and fine clefts passing through the lamella; the appearance of dark particles seems to me to be produced by the cut ends of the reticulating fibres of which it is made up. A longitudinal section of a cylindrical bone carried across the

\* Phil. Trans. 1853, p. 116.



lamellæ presents a corresponding appearance, for as the fibres run more or less obliquely to the axis of the bone, they present cut ends in a longitudinal section also.

It thus appears that the animal basis of bone is made up of lamellæ composed of fine reticular fibres ; but interposed among these lamellæ, layers are here and there met with of a different character, viz. :—

1. Strata of amorphous or granular aspect, in which the lacunæ are very conspicuous and regularly arranged, and sometimes appearing as if surrounded by faintly-defined areolæ. These generally incomplete layers often terminate by a scalloped border as if made up of confluent round or oval bodies ; this is indicated also by the occasional occurrence of oval or flattened spheroidal bodies singly or in small groups near the border of these layers, each with a cavity, apparently a lacuna, in the centre. In fact, if the round bodies shown in figure XLVIII. had a central vacuity, they would very well represent the objects here referred to. In some parts the granular substance is obscurely fibrous, and transitions may be observed to the well-marked reticular laminae. The layers described principally occur, so far as I have been able to observe, near the surface of the compact tissue, and at the circumference of many of the systems of concentric Haversian lamellæ.

2. Irregular layers of rounded bodies, apparently solid and without central cavity or mark, well represented in figure XLVIII., which is after a drawing from nature by Dr. A. Thomson. I have hitherto met with these layers chiefly near the surface of the shaft of long bones, lying among the circumferential laminae, and, so far as I can observe, forming only part of a circuit. They can occasionally be recognised in a transverse section as short curvilinear bands of peculiar aspect, broader in the middle and thinning away at the ends, appearing here and there between the cut edges of two ordinary circumferential laminae.

The appearances described under 1 and 2, and especially the last, as represented in fig. XLVIII., suggest the notion of irregular layers of spheroidal bodies, some single, but mostly confluent in groups, adherent to the subjacent surface ; and one is especially tempted to this belief by the account given by Gegenbaur \* of the deposition of osseous matter in growing bone at certain points in the form of oval or spheroidal globules, which in size and aspect would sufficiently answer to the objects above described. Nevertheless I incline rather to the explanation offered by Professor C. Lovén, of Stockholm, to whom I showed the figure and specimens ; viz., that the surface covered apparently with globular bodies, single or in botryoidal groups, is really a cast in relief from a contiguous surface of bone that has been excavated by absorption. It is known that in the growth of a bone absorption occurs at various parts, and is often followed by fresh ossific deposition ; as, for example, in the excavation and subsequent filling up of the Haversian spaces. The absorption in such cases is a healthy process, but the absorbed surface is, as in absorption from disease, eroded or scooped out into sinuous hollows, the larger of which are again carved on the inside into smaller rounded pits. New osseous matter deposited on such a surface fills up its hollows, and when the new layer is detached, it exhibits a raised impression corresponding with them.†

\* *Jenaische Zeitschrift für Medizin und Naturwissenschaft.* Vol. 1. p. 353.

† Two observations which I have had occasion to make favour this explanation. A cross section of a (large) serpent's rib shows an outer and an inner series of concentric lamellæ surrounding the medullary canal, and the inner trenches on the outer by a festooned border such as often bounds a series of Haversian rings. Now, in the decalcified rib, it is easy to peel off the inner from the outer layers, and the detached surface of the former shows a number of oval eminences, some with one, others with two, three, or more lacunæ in their substance ; whilst what was the contiguous surface of the outer layers has excavations that correspond. Again, in the grinding tooth of the horse, the surface of the



*Ossified cartilage* is found on the articular ends of adult bones, lying underneath the natural cartilage of the joint, both in the moveable articu-

Fig. XLVIII.

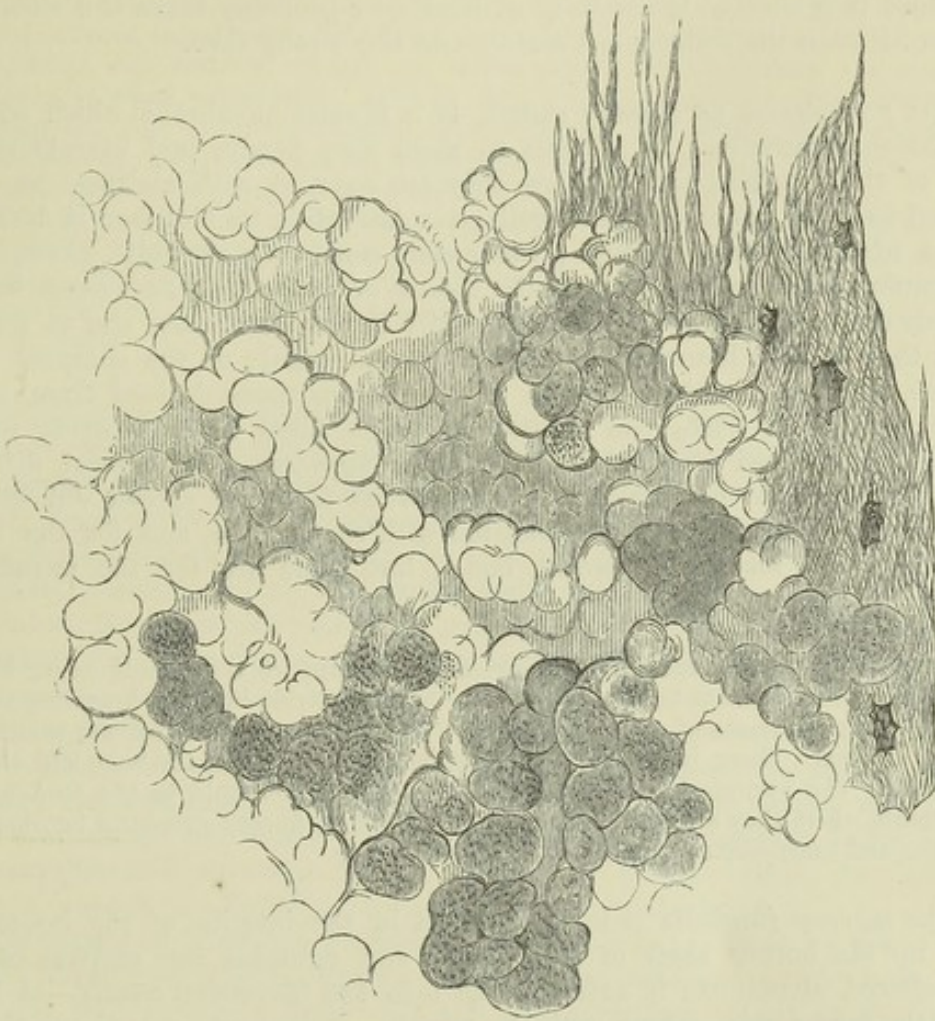


Fig. XLVIII.—PORTION OF A NODULATED LAYER OF BONE-TISSUE FROM NEAR THE SURFACE OF THE SHAFT OF A DECALCIFIED HUMERUS.

At one side shreds of fibrous lamellæ are seen in the figure. Magnified 300 diameters.

lations and in symphyses, and is in fact the deeper part of the cartilage which has been encroached upon by the calcifying process. The animal basis is here, however, of a totally different nature from that of the bone

crusta petrosa which is contiguous to the dentine or to the enamel, is marked over with spheroidal bodies having, in decalcified specimens, very much the appearance represented in Fig. XLVIII., but most of them with one or more lacuna-like cavities within. They look very like distinct globules, and have been described by Czermak as calcified cells containing lacunæ; but on carefully viewing the decalcified layer in profile-sections and otherwise, I am led to the conclusion that they are mammillary elevations of the surface, continuous by their (sometimes contracted) bases with the general substance. The enamel is destroyed in the decalcification, but the surface of the dentine of the cervix and root from which the mammillated layer of crusta petrosa has been detached, is found to be excavated in a manner to correspond with it; an arrangement well calculated to secure their mutual connection.



beneath ; for, when the earthy matter is extracted by means of an acid, the tissue which remains has all the characters of cartilage.

As to the mode in which the earthy matter is connected with the animal substance, we know that the combination is very intimate, but the manner in which it is effected is not fully understood ; probably there is a chemical union between the collagenous matter and the earthy salts.

*The periosteum*, as already stated, is a fibrous membrane which covers the bones externally. It adheres to them very firmly, and invests every part of their surface, except where they are covered with cartilage or connected to other bones by fibro-cartilage. According to Kölliker it is composed of two different layers ; the outer, consisting of white fibres, and containing occasional fat-cells, is the means of supporting numerous blood-vessels destined for the bone, which ramify in the membrane, and at length send their minute branches into the Haversian canals of the compact substance, accompanied by processes of filamentous tissue derived from, or at least continuous with, the periosteum. The inner layer is made up of elastic fibres ; and frequently presents the appearance of several distinct strata of "elastic membrane." Fine nervous filaments spread out in the periosteum ; they are chiefly associated with the arteries, and for the most part destined for the subjacent bone ; but some are for the membrane itself.

The chief use of this membrane is evidently to support the vessels going to the bone, and afford them a bed in which they may subdivide into fine branches, and so enter the dense tissue at numerous points. Hence, when the periosteum is stripped off at any part, there is great risk that the denuded portion of the bone will die and exfoliate. The periosteum also contributes to give firmer hold to the tendons and ligaments where they are fixed to bones ; indeed, these fibrous structures become continuous and incorporated with it at their attachment.

The *marrow* (*medulla ossium*) is lodged in the interior of the bones ; it fills up the hollow shaft of long bones and occupies the cavities of the cancellated structure ; it extends also into the Haversian canals—at least into the larger ones—along with the vessels. Like ordinary adipose tissue, it consists of vesicles containing fat, with blood-vessels distributed to them. A fine layer of a highly vascular areolar tissue lines the medullary canal, as well as the smaller cavities which contain marrow ; this has been named the medullary membrane, internal periosteum, or endosteum ; but it cannot be detached as a continuous membrane. Its vessels partly supply the contiguous osseous substance, and partly proceed to the clusters of adipose vesicles, among which there is but very little connective tissue, in consequence perhaps of their being contained and supported by bone.

The marrow differs considerably in different situations. Within the shaft of the long bones it is of a yellow colour, and contains, in 100 parts, 96 of fat, 1 of connective tissue, and 3 of water. In short bones, and in the cancellated ends of long bones, but especially in the cranial diploe, the bodies of the vertebræ, the sternum, and the ribs, it is red or reddish in colour, of more fluid consistence, and with very few fat cells. That from the diploe consists of 75 parts of water and 25 of solid matters, which are chiefly albumen, fibrin, extractive and salts, with mere traces of fat. While, however, the fat cells are scanty in the red-coloured marrow, it contains minute, roundish nucleated cells—the proper marrow-cells of Kölliker. These, which include no fat, correspond in character with the cells found in the articular ends of long bones affected with hyperæmia ; they occur normally in the cranial bones, ver-



tebræ, and sternum, and in variable number in the scapula, the innominate, and facial bones.

The marrow serves the same general purposes in the economy as ordinary fat. Placed within the bones, which are made hollow for the sake of lightness, it serves as a light and soft material to fill up their cavities and support their vessels. In birds, for the sake of still further lightening their skeleton, the larger bones, instead of being filled with marrow, contain air, which passes into them from the lungs by openings at their extremities. Even in man there are certain hollow bones of the cranium and face which are naturally filled with air. The cavities of these bones are named sinuses; they open into the adjoining air-passages, and are lined with a prolongation of the mucous membrane, underneath which is a thin periosteum.

The bones do not at first contain fatty marrow; in the foetus their cavities are filled with a transparent reddish fluid, like bloody serum, only more consistent and tenacious, with granular marrow cells. In dropsical subjects also, the marrow, like the rest of the fat, is consumed to a greater or less extent, its place being occupied by a serous fluid.

*Blood-vessels.*—The bones are well supplied with blood-vessels. A network of periosteal vessels covers their outward surface, others penetrate to the cavities of the spongy part and the medullary canal, on the sides of which they ramify, and fine vessels, deprived of their muscular coat, run through all parts of the compact tissue in the Haversian canals. The sides of these internal cavities and canals make up together a large extent of inward surface on which vessels are spread. The nutritious fluid conveyed by these vessels no doubt escapes through their coats and permeates the surrounding dense bone interposed between the vascular canals; and it seems highly probable that the system of lacunæ and communicating canaliculi, already described, is a provision for conducting the exuded fluid through the hard mass. When a bone is macerated, its vessels and membranes are destroyed, whilst the intermediate true bony matter, being of an incorruptible and persistent nature, remains; a process which, for obvious reasons, cannot be effected with the soft tissues of the body.

The vessels of bone may be recognised while it is yet fresh by the colour of the blood contained in them; but they are rendered much more conspicuous by injecting a limb with size and vermilion, depriving the bones of their earth by means of an acid, and then drying them and putting them into oil of turpentine, by which process the osseous tissue is rendered transparent whilst the injected matter in the vessels retains its red colour and opacity. Numberless small vessels derived from the periosteum, as already mentioned, pass along the Haversian canals in the compact substance. These are both arterial and venous, but, according to Todd and Bowman, the two kinds of vessels occupy distinct passages; and the veins, which are the larger, present, at irregular intervals, pouch-like dilatations calculated to serve as reservoirs for the blood, and to delay its escape from the tissue. Arteries, of larger size but fewer in number, proceed to the cancellated texture. In the long bones numerous apertures may be seen at the ends, near the articular surfaces; some of these give passage to the arteries referred to, but the greater number, as well as the larger of them, are for the veins of the cancellated texture, which run separately from the arteries. Lastly, a considerable artery goes to the marrow in the central part of the bone; in the long bones this medullary artery, often, but improperly, called "the nutritious artery," passes into the medullary canal, near the middle of the shaft, by a hole running obliquely through the compact substance. The vessel, which is accompanied by one or two veins, then sends branches upwards and downwards to the marrow and medullary membrane in the



central cavity and the adjoining Haversian canals. Its ramifications anastomose with the arteries of the compact and cancellated structure ; indeed, there is a free communication between the finest branches of all the vessels which proceed to the bone, and there is no strictly defined limit between the parts supplied by each. In the thigh-bone there are two medullary arteries entering at different points.

The veins of the cancellated texture are peculiar and deserve special notice. They are large and numerous, and run separately from the arteries. Their arrangement is best known in the bones of the skull, where, being lodged in the diploe or spongy texture between the outer and inner compact tables, they have received the name of the diploic veins. They run in canals formed in the cancellated structure, the sides of which are constructed of a thin lamella of bone, perforated here and there for the admission of branches from among the adjoining cancelli. The veins, being thus inclosed and supported by the hard structure, have exceedingly thin coats. They issue from the bone by special apertures of large size. A similar arrangement is seen in the bodies of the vertebræ, from whence the veins come out by large openings on the posterior surface.

*The lymphatics of the bones* are but little known ; still, there is evidence of their existence, for, independently of the authority of Mascagni (which is of less value in this particular instance, inasmuch as he does not state expressly that he injected the vessels which he took for the lymphatics of bone), we have the testimony of Cruikshank, who injected lymphatics coming out of the body of one of the dorsal vertebræ, in the substance of which he also saw them ramifying.\*

*Fine nerves* have been seen passing into the medullary canal of some of the long bones along with the artery, and following its ramifications, but their ultimate distribution is doubtful ; and Kölliker describes fine nervous filaments as entering with the other arteries of the bone to the spongy and compact tissue. As far, however, as can be judged from observations on man and experiments on the lower animals, the bones, as well as their investing periosteum, are scarcely if at all sensible in the healthy condition, although they are painfully so when inflamed.

Some hold that the same is true of the marrow, or rather the medullary membrane ; others, among whom are Duverney and Bichat, affirm, on the contrary, that the medullary tissue is sensible. They state that, on sawing through the bone of a living animal, and irritating the medullary membrane by passing a probe up the cavity, or by injecting an acrid fluid, very unequivocal signs of pain will be manifested. Beclard, who affirms the same fact, points out a circumstance which may so far account for the result occasionally turning out differently,—namely, that when the bone happens to be sawn through above the entrance of the medullary artery, the nerves going along with that vessel are divided, and the marrow consequently rendered insensible, as happens with any other sensible part when its nerves are cut.

*Formation and growth of bone.*—The foundation of the skeleton is laid at a very early period, for among the parts that appear soonest in the embryo, we distinguish the rudiments of the vertebræ and base of the skull, which afterwards form the great median column to which the other parts of the bony fabric are appended. But it is by their outward form and situation only, that the parts representing the future bones are then to be recognised ; for at that early period they do not differ materially in substance from the other structures of the embryo, being, like these, made up of granular

\* Anatomy of the Absorbing Vessels, 1790, p. 198.



corpuscles or elementary cells, united together by a soft amorphous matter. Very soon, however, they become cartilaginous, and ossification in due time beginning in the cartilage and continuing to spread from one or from several points, the bone is at length completed.

But while it is true with respect to the bones generally that their ossification commences in cartilage, it is not so in every instance. The tabular bones, forming the roof of the skull, may be adduced as a decided example to the contrary; in these the ossification goes on in a membranous tissue quite different in its nature from cartilage;\* and even in the long bones, in which ossification undoubtedly commences and to a certain extent proceeds in cartilage, it will be afterwards shown that there is much less of the increment of the bone really owing to that mode of ossification than has, till lately, been generally believed. It is necessary, therefore, to distinguish two species or modes of ossification, which for the sake of brevity may be called the *intramembranous* and the *intracartilaginous*.

*Ossification in membrane.*

—The tabular bones of the cranium, as already said, afford an example of this mode of ossification. The base of the skull in the embryo is cartilaginous; but in the roof, that is to say, the part comprehending the parietal, the upper and greater part of the frontal, and a certain portion of the occipital bones, we find (except where there happen to be commencing muscular fibres) only the integuments, the dura mater, and an intermediate membranous layer, which differs from cartilage in its intimate structure as well as in its more obvious characters, and in which the ossification proceeds.

The commencing ossification of the parietal bone, which may be selected as an example, appears to the naked eye in form of a net-work in which the little bars or spicula of bone run in various directions, and meet each other at short distances. By and by the ossified part, becoming

Fig. XLIX.

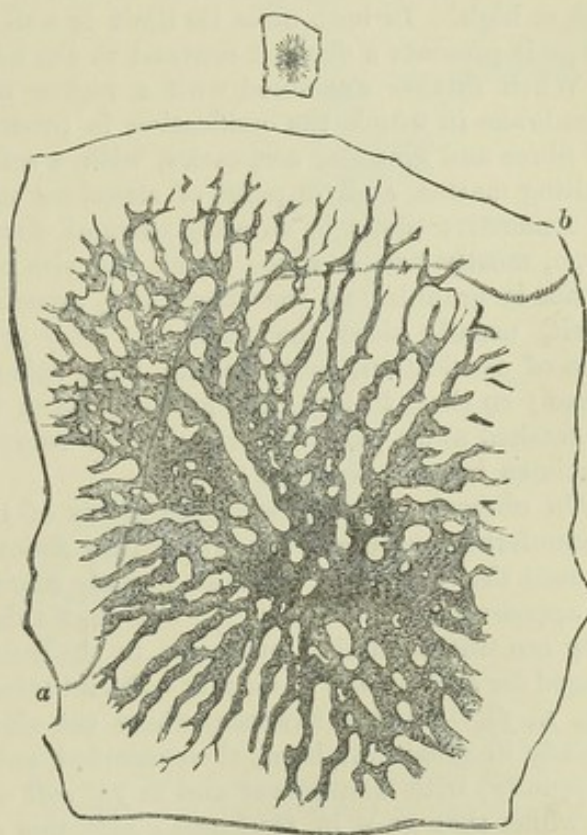


Fig. XLIX.—PARIETAL BONE OF AN EMBRYO SHEEP. SIZE OF THE EMBRYO,  $2\frac{1}{2}$  INCHES.

The small upper figure represents the bone of the natural size, the larger figure is magnified about 12 diameters. The curved line, *a, b*, marks the height to which the subjacent cartilaginous lamella extended. A few insulated particles of bone are seen near the circumference, an appearance which is quite common at this stage.

\* This fact was pointed out and insisted on by Dr. Nesbitt, who distinguishes the two different modes of ossification, and so far his views are quite correct.—See his *human Osteogeny*, Lond. 1736.



extended, gets thicker and closer in texture, especially towards the centre, and the larger bony spicula which now appear, run out in radiating lines to the circumference. The ossification continues thus to spread and consolidate until the parietal meets the neighbouring bones, with which it is at length united by suture.

The figure (XLIX.) represents the parietal bone of an embryo sheep about two inches and a half long, and shows the character of the ossification as it appears when the object is magnified about twelve diameters. The bone is formed in membrane as in the human foetus, but a thin plate of cartilage rises up on its inside from the base of the skull. The ossification, however, is decidedly unconnected with the cartilage, and goes on in a membrane lying outside of it. The cartilaginous plate is not represented in the figure, but a dotted curve-line, *a, b*, near the top, marks the height to which it reached, and from this it will be seen that the ossification extended beyond the cartilage. In the region of the frontal bone the cartilage does not even rise so high. In both cases its limit is well defined, and under the microscope it presents a decided contrast to the adjacent membrane.

When further examined with a higher magnifying power, the tissue or membrane in which the ossification is proceeding, appears to be made up of fibres and granular corpuscles, with a soft amorphous or faintly granular uniting matter, and, in point of structure might not unaptly be compared to connective tissue in an early stage of development. The corpuscles are large, mostly two or three times the size of blood corpuscles; their substance is granular in character, and, especially in specimens preserved in spirit, usually hides the nucleus. They are densely packed all over the area of ossification, covering the bony spicula, and filling up their interstices; so that, to bring the growing parts into view, the corpuscles must be washed away with a hair pencil, or removed by short immersion of the specimen in weak solution of soda.

On observing more closely the points of the growing osseous rays at the circumference of the bone, where they shoot out into the soft tissue, it will be seen that the portion of them already calcified is granular and rather dark in appearance (fig. L., *a, b, c*), but that this character is gradually lost as they are traced further outwards in the membrane, in which they are prolonged for a little way in form of soft and pliant bundles of transparent fibres (fig. L., *f*). Further inwards, where the slender rods or bars of bone are already in great part hard, their calcified substance is coated over (although unequally) with transparent and as yet soft and imperfectly calcified matter, by which they grow in thickness; and this ossifying substance spreads out at their sides, and encroaches on the intervening space, in form of a bright trellis-work (fig. L., *d*), thin towards its outer limit, and there composed of fine fasciculi, but denser and coarser nearer the bone, where the trabeculae are thick and round, and already granular from commencing earthy impregnation.\* The interstices of this mesh-work are in some parts occupied by one or more of the corpuscles, but at other parts they are reduced to short narrow clefts or mere pores. The appearance which I have endeavoured to describe is especially well seen at those places where a cross bridge of bone is being formed between two long spicula (as at *e*); we may there distinguish the clear

\* A notion of this appearance may also be obtained from Fig. LVIII., page cxiii., which represents intramembranous ossification advancing under the periosteum of a long bone. From *a* to *c* is the ossifying trellis-work, but coarser than in the early cranial bone. From *a* to *b* is the part already impregnated with earthy deposit, which is encroaching on the part *b, c*, as yet soft and pellucid.



soft fibres or trabeculae which have already stretched across the interval ; and the darkish granular opacity indicating the earthy deposit (*a, a'*) may be perceived advancing into them and shading off gradually into their pellucid substance without a precise limit. This soft transparent matter, which becomes ossified, may, wherever it occurs, be distinguished by the name of "osteogenic substance," as proposed by H. Müller, or simply of "osteogen." It is or becomes fibrous in intimate structure, and for the most part finely reticular, like the decalcified bone itself, but must not be confounded with fibres which may pre-exist in the membranous tissue in which the bone is growing.

The granular corpuscles or cells everywhere cover in a dense layer the osteogenic substance, and lie in its meshes ; most probably they yield or excrete that substance, and hence it has been proposed to call them "osteoblasts." On this view the process might be compared to the production, by cells, of the matrix of cartilage and the intercellular fibrillating substance in growing connective tissue ; also to the excretion of membranous, cuticular, and other deposits by cells, and layers of cells, long since pointed out by Kölliker.

But some of the granular cells are involved in the ossifying matrix, and eventually inclosed in lacunae. Single cells may accordingly be seen partially sunk in the recent osteogenic deposit, which then gradually grows over them and buries them in its substance ; and the cavity in which the corpuscle is thus inclosed becomes a lacuna.

Some observers state that when such a corpuscle is as yet but half sunk in the growing substance, processes may be seen passing from the imbedded side into fine clefts of the matrix, which close in around them and become the canaliculi ; and that as the inclosure of the corpuscle is completed, canaliculi are in like manner formed in the rest of its circumference. It is also supposed that the canaliculi are afterwards extended by absorption, so as to anastomose with those of neighbouring lacunae. But from all I can see of the process, it seems more probable that whilst the ossific matter closes in around the corpuscle

Fig. L.

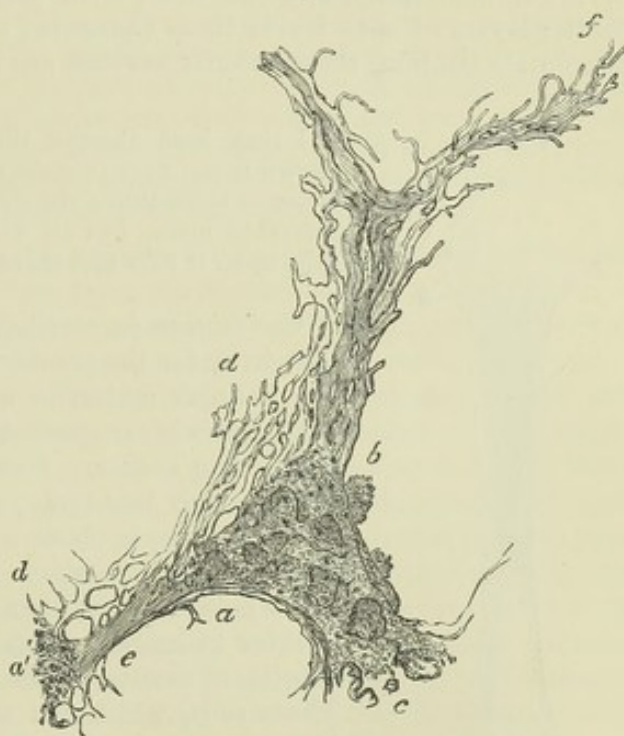


Fig. L.—THE GROWING END OF A SPICULUM FROM THE PARIETAL BONE OF AN EMBRYO SHEEP at about the same period of advancement as in Fig. XLIX. ; magnified 150 diameters, but drawn under a power of 350 diameters.

*a, b, c,* and *a'*, parts already calcified ; *d, d*, irregular network of soft and pellucid osteogenic substance, on which the calcification is encroaching ; *a, e, a'*, a connecting bar or bridge still soft at *e*, but calcified at *a* and *a'* ; *f*, extremity formed of bundles of soft osteogenic fibres. N.B. The structure represented was covered over and hidden by granular corpuscles which have been removed. In the calcified part, *a, b, c*, superficial excavations are seen which are probably commencing or incomplete lacunae, from which the corpuscles have been washed out. From a drawing by Mr. J. Marshall, F.R.S.



and forms the lacuna, the canaliculi and their communications may be merely channels left as vacuities in the osseous deposit, into which the processes of the now stellate corpuscle pass but a short way.

As the bone extends in circumference, it also increases in thickness; the vacuities between the bony spicula become narrowed or disappear, and at a more advanced period the tabular bones of the cranium are tolerably compact towards the centre, although their edges are still formed of slender radiating processes. At this time also numerous furrows are grooved on the surface of the bone in a similar radiating manner, and towards the centre these are continued into complete tubes or canals in the older and denser part, which run in the same direction. The canals, as well as the grooves, which become converted into canals, contain blood-vessels supported by processes of the investing membrane, and are lined with granular cells, which deposit concentric layers of bone inside these channels; and when thus surrounded with concentric laminæ, these tubular cavities are in fact the Haversian canals.

Fig. LI.

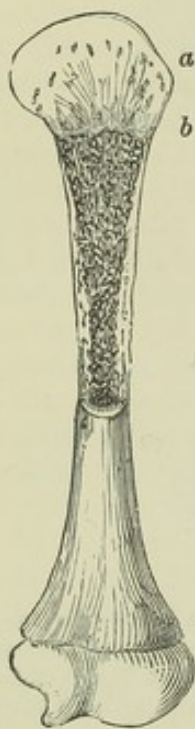

Fig. LI.—HUMERUS OF A FÆTUS, NATURAL SIZE.

The upper half is divided longitudinally. *a*, cartilage, *b*, bone, which terminates towards the cartilage by a slightly convex surface.

length separate points of ossification appear in them, and form epiphyses, which at last are joined to the body of the bone.

The new-formed osseous tissue is red and obviously vascular, and blood-vessels extend a little way beyond it into the adjoining part of the cartilage.

I may here observe that in earlier stages, such as that shown in fig. XLIX., vessels may be seen in the soft tissue, some twice or three times the size of a blood-capillary, others considerably more, but all with only a homogeneous coat with cells upon it here and there, and without a muscular layer.

*Ossification in cartilage.*—It has already been stated that in by far the greater number of bones, the primitive soft cellular matter of which they originally consist is very quickly succeeded by cartilage, in which the ossification begins. One of the long bones taken from a very small embryo, just before ossification has commenced in it, is observed to be distinctly cartilaginous. In the tibia of a sheep, for example, at a time when the whole embryo is not more than an inch and a quarter in length, we can plainly see that the substance consists of cartilage-cells imbedded in a pellucid matrix. These cells, which can scarcely be said to be collected into groups, are much larger in the middle part of the shaft where ossification afterwards commences, and there also they are mostly placed with their long diameter across the direction of the bone: towards the ends they are much smaller and closer together, and the cartilage there is less transparent. As it enlarges the cartilage acquires firmer consistence; it represents in figure the future bone, though of course much smaller in size, and it is surrounded with a fibrous membrane or perichondrium, the future periosteum. Vessels ramify in this membrane, but none are seen in the cartilage until ossification begins.

In a long bone the ossification commences in the middle and proceeds towards the ends, which remain long cartilaginous, as represented in fig. LI. At



In a long bone these precursory vessels are seen at either end of the ossified portion of the shaft, forming a red zone in that part of the cartilage into which the ossification is advancing. The vessels are lodged in excavations or branching canals in the cartilage, (fig. LI. *a*,) which also contain granular corpuscles and soft matter. Other vascular canals enter the cartilage from its outer surface, and conduct vessels into it directly from the perichondrium; at least, this may be seen when the ossification approaches near to the ends of the bones.

Dr. Baly has observed that in a transverse section of the ossifying cartilage, its cells appear arranged in radiating lines round the sections of the vascular canals; \* and I may also remark that in many of these radiating groups the cells successively diminish in size towards the centre, that is, as they approach the canal. The canals which enter from the surface of the cartilage are probably formed by processes from the vascular subperichondrial tissue, which, excavating the canals by absorption, thus extend themselves through the mass of cartilage; and as the perichondrium affords material for the growth of the cartilage at the surface, so these vascular processes probably yield matter for the multiplication of the cells in the interior of the mass. The canals which pass into the cartilage from the ossified part are, in like manner, most probably formed by processes of the subperiosteal tissue which pierce the bone and extend through the medullary cavities within it to the cartilage, into which they penetrate for a short way beyond the advancing limit of ossification.

To examine the process more minutely, let an ossifying bone be divided lengthwise, as in fig. LI., and then from the surface of the section (as at *a*, *b*) take off a thin slice of cartilage, including a very little of the ossified part, and examine it with the microscope. Such a view, seen with a low power, is shown in fig. LII. The cartilage at a distance from the surface of the ossified part has its cells uniformly disseminated in the matrix, (as at *a*, where it appears in the figure as if granular,) but at and near to the limit where the ossification is encroaching upon it, the cells are gathered into rows or oblong groups, between which the transparent matrix appears in form of clear longitudinal lines (often obscurely striated) obliquely intersecting each other (*b*). *Tomes* and *De Morgan* state that these rows are formed by segmentation of the cartilage cells transversely to the line of ossific advance. Turning now to the newly-formed bone (*c*), which from its dark opaque aspect contrasts strongly with the cartilage, and tracing it towards their mutual boundary, we see plainly the dark lines of ossification shooting up into the clear spaces of the cartilage between the groups of corpuscles. The earthy deposit, in fact, proceeds through the matrix, and affects also those parts of the cartilage-capsules which form the circumference of a group, so that the new osseous substance forms in the first instance oblong areolæ or loculi, which inclose the groups of cells. This is further illustrated by a thin transverse section, carried nearly parallel to the ossifying surface, and partly encroaching on it, so as to take off a little of the bone along with the cartilage, as represented in fig. LIII. In this view we see, at one part, the dark and nearly circular sections of the newly-formed osseous areolæ; at another, sections of the rows of cartilage cells with the clear matrix between and around them, and into this the dark ossification is advancing.

On using a higher power, as in figs. LIV. and LV., it will be seen that the cells forming the groups are placed with their long diameter transversely, as if they had been flattened and piled upon one another; but in the immediate vicinity of the bone they become greatly enlarged and more rounded. In most of them the outline of the capsule is distinct from that of the mass within. As to the matter they

\* *Müller's Physiology*, plate I., fig. 16.



contain, in some it is a pellucid substance strongly refracting the light, and nearly filling the capsule; in others it is faintly granular and light like ground glass, and has a well-defined outline, and in these there is a very distinct nucleus, varying much in size in different cells, but always most regularly circular, and inclosing one or more nucleoli; lastly, a good many cells may be seen, in which the contained mass or cell-body has shrunk and does not nearly fill the capsule, and then it is usually coarsely granular or grumous, with an uneven, and in some, a jagged outline.

Fig. LII.

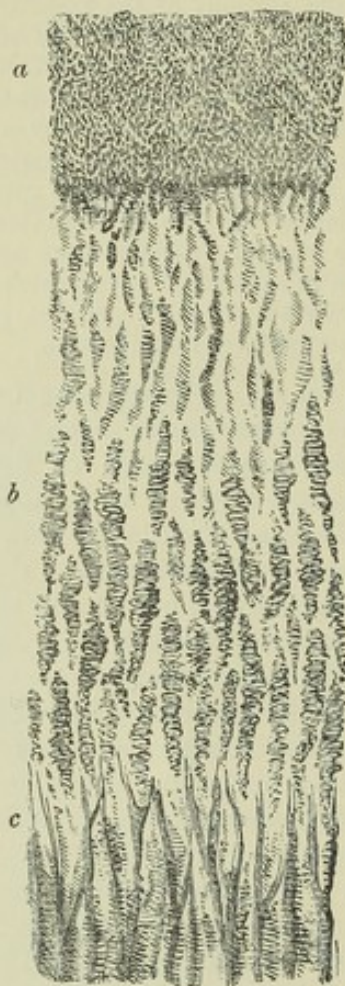

Fig. LIII.

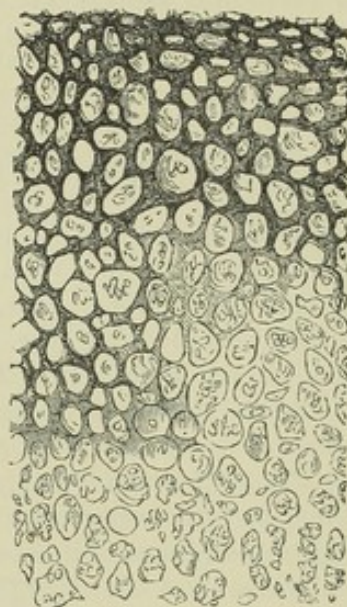


Fig. LII.—THIN LONGITUDINAL SECTION OF OSSIFYING CARTILAGE FROM THE HUMERUS OF A FETAL SHEEP.

*a*, cartilage cells uniformly diffused; *b*, cells nearer the boundary of the ossification, collected into piles and inclosed in oblong areolæ of the clear matrix; *c*, dark lines of ossification extending into the matrix and forming the primary bony areolæ. Magnified about 70 diameters.

Fig. LIII.—TRANSVERSE SECTION OF THE OSSIFYING CARTILAGE REPRESENTED IN FIG. LII.,

Made a little above *c*, along the surface of ossification, and including part of the new bone, magnified 70 diameters. The circular sections of the groups of cells and of the osseous areolæ are seen; and the dark bone extending into the clear intercellular matrix.

It thus appears that the bony tissue, as it advances into the cartilage, has at first a sort of alveolar structure, made up of fusiform *areolæ* or short tubular cavities, with thin parietes, which are formed by calcifi-



cation of the matrix and partial calcification of the capsules of the cartilage-cells. But this condition, which differs from that of perfect bone, is only transitory, and at a short distance below the ossifying surface we see a change taking place in the newly-formed tissue; the structure becomes more open, the original cartilage cells disappear from its interstices, and the medullary spaces, with their lamellated parietes, as in the permanent cancellated tissue, begin to be formed. This, which is the next step of the process, takes place in the following manner:—The *primary areolæ* of the bone above described open into one another both laterally and longitudinally by absorption of their intermediate walls, and by their confluence give rise to the larger or *secondary cavities*, the *medullary spaces* of H. Müller, which succeed them lower down. This is shown in a longitudinal section in fig. LV., and in transverse section in fig. LVI., A, which represents a thin section made almost immediately below the surface of ossification, and in which the primary cavities are seen to have coalesced into larger ones. A transverse section somewhat lower down, (fig. LVI., B,) shows that they go on enlarging by further absorption and coalescence, and that their sides are thickened by layers of new bone; this soon begins to be deposited, (fig. LV., *b, b*, in longitudinal, and LVI., A, in cross section) and goes on increasing, (fig. LVI., B). In the meantime the cartilage cells have disappeared, and the bony cavities are filled with soft matter, in which there are a few fibres and numerous granular corpuscles resembling those seen in the intramembranous ossification (*d*, fig. LV.); there are also many blood-vessels. In the end, some of the enlarged cavities and open structure remain to form the cancellated tissue, but much of this structure is afterwards removed by absorption, to give place to the medullary canal of the shaft. In many of these cavities the walls of the coalesced primary areolæ may long be distinguished, like little arches, forming by their union a sort of festooned outline, within which the new bony laminae are situated.

The primary osseous matter forming the original thin walls of the areolæ, and produced by calcification of the cartilaginous matrix, is decidedly granular, and has a dark appearance; the subsequent or *secondary deposit* on the other hand is quite transparent, and of an uniform, homogeneous aspect. This secondary deposit begins to cover the granular bone a very short distance (about  $\frac{1}{80}$ th of an inch) below the surface of ossification, and, as already stated, increases in thickness further down. The lacunæ first appear in this deposit; there are none in the primary granular bone. The cartilage cells do not become calcified. According to H. Müller the capsules

Fig. LIV.

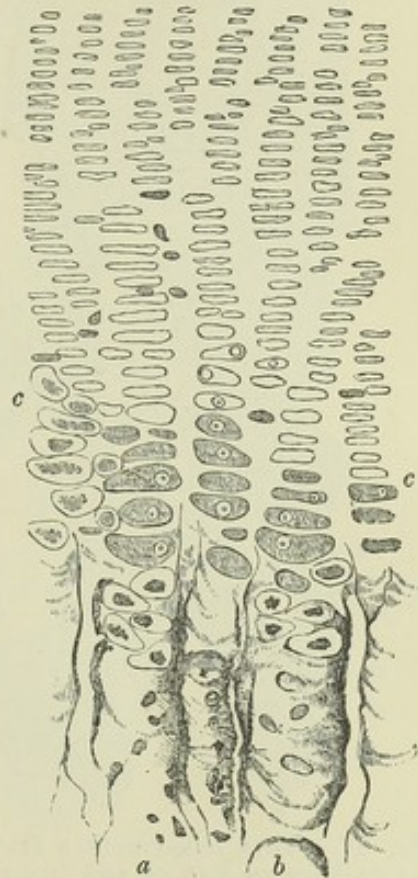


Fig. LIV.—SMALL PORTION OF A SECTION SIMILAR TO THAT IN FIG. LII., MORE HIGHLY MAGNIFIED (ABOUT 140 DIAMETERS).

*a, b*, two of the new-formed osseous tubes or areolæ, with a few cartilage cells and granular corpuscles lying in them; *c, c*, cartilage cells near the ossifying surface, exhibiting the appearances described in the text.



are opened by absorption, and the granular bodies contained within them (*i. e.*

Fig. LV.

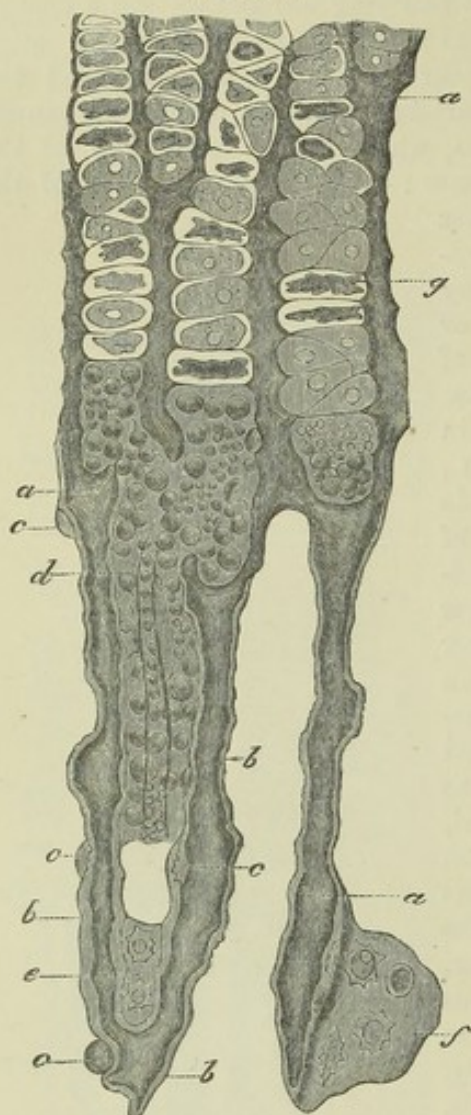


Fig. LV.—THIN LONGITUDINAL SECTION OF THE GROWING END OF THE SHAFT OF THE METATARSAL BONE OF A SLINK CALF, MAGNIFIED.

The upper part of the figure shows four groups of cartilage cells, with calcified matrix between them forming the walls of four primary areolæ filled as yet by the original cartilage cells, except at the lower part where these are replaced by granular corpuscles. Lower down are two oblong spaces (secondary or medullary cavities); one, indicated by *d*, is nearly filled by granular corpuscles and vessels, the other is vacant. The walls of these spaces are beginning to be lined with secondary osseous deposit, shown in the figure as a lighter layer, *b*, *b*, and *b*; *c*, *c*, and *c*, are corpuscles about to be imbedded in the ossifying substance and inclosed in laminae; *g*, a cartilage cell of which the body has shrunk from the inside of the capsule. After H. Müller and Kölliker.

the proper cell-bodies) produce by fissiparous multiplication the granular osteoblastic cells which succeed them. On the other hand, Lovén\* has suggested, and, as I think, with more probability, that the osteoblastic corpuscles properly belong to the vascular processes of the subperiosteal tissue, which, as already stated, penetrate the new-formed bone and spread throughout its cavernulated structure. The excavation and removal of the cartilage, as well as the partial absorption of the walls of the bony cavities, is no doubt effected by this tissue, and the abundant osteoblastic cells which appear in it are most probably derived by descent from similar cells equally abundant beneath the periosteum. The cells or corpuscles in question, in whatever way produced, are disposed in a layer or layers upon the walls of the secondary or medullary spaces, in immediate contact with the new osteogenic deposit, which here, as in the intra-membranous ossification, they probably secrete. Here too the osteogenic substance is finely reticular, and retains that character when calcified; for the secondary bony deposit is formed in layers made up of finely reticulating fibres, like the lamellæ of perfect bone shown in fig. XLV. On a careful inspection, and with a certain adjustment of the light, fine striæ may be seen in many parts indicating the obliquely decussating fibres of the new-formed laminae. The structure in some measure reminds us of the secondary deposit inside the oblong cells of the wood of coniferous trees, in which the ligneous matter is arranged in fibres, or rather in fine lines, running obliquely round the wall of the cell and crossing one another in alternate layers.

The lacunæ are formed, as described in the intra-membranous ossification, by some of the granular corpuscles becoming imbedded in the osteogenic substance, and inclosed in a cavity formed round them by its further deposit. Lacunæ formed from cartilage cells exist but very scantily. Examples occur in articular cartilage, and in that of the pubic symphysis, when, as commonly happens in mature life, the part of these tissues adjoining the bone is encroached on by a species of ossification, as noticed at page xcix. The ossifying process in this case is mere calcification of the cartilage, and stellate lacunæ, not

\* Studier och Undersökningar öfver Benväfnaden. Stockholm. 1863.



intercommunicating by canaliculi, remain in the partially ossified cells. When this hard tissue is decalcified by an acid, the original cells and cartilaginous matrix become apparent.

Fig. LVI., A.

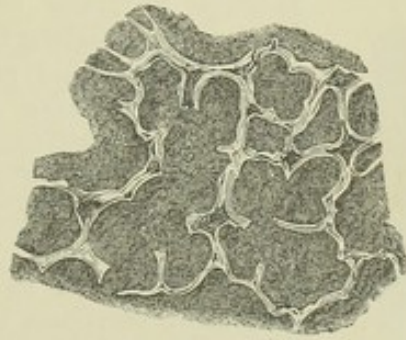


Fig. LVI., B.

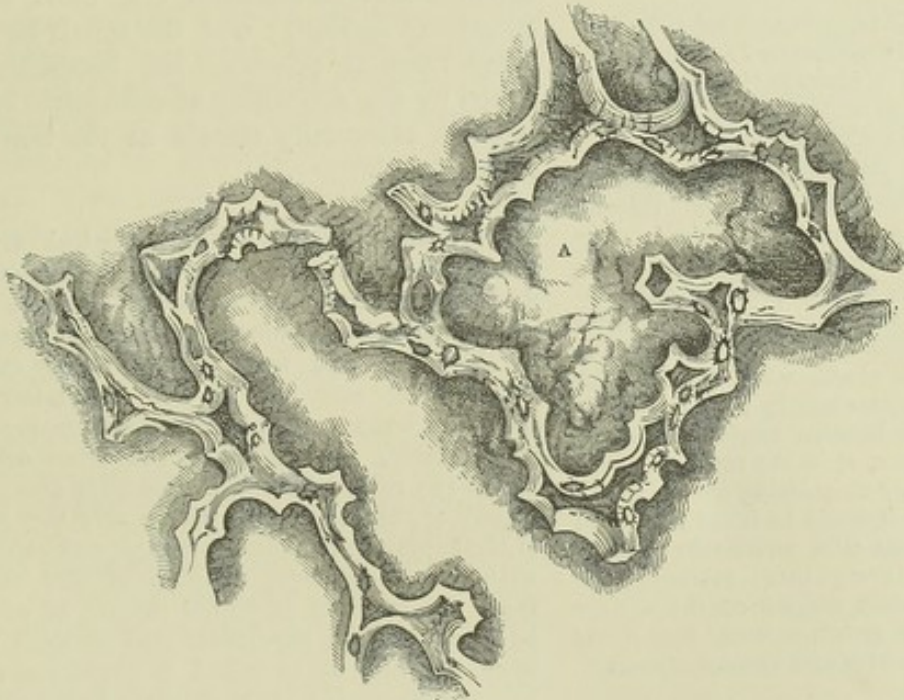


Fig. LVI.—A AND B REPRESENT TWO TRANSVERSE SECTIONS OF GROWING BONE, AS IN FIG. LIII., BUT MUCH MORE MAGNIFIED (ABOUT 120 DIAMETERS).

They show the lateral coalescence of the primary bony areolæ and the thickening of the sides of the enlarged cavities by new osseous deposit. The section A is made almost immediately below the surface of ossification ; B, is somewhat lower, and shows the cavities still more enlarged and their sides more thickened than in A. The new osseous lining is transparent, and appears light in the figures ; the dark ground within the areolæ is owing to opaque *débris*, which collected there in grinding the sections. It must be further noticed that the letter A within the larger figure marks a place where a bony partition had been accidentally broken away, for the large space was naturally divided into two.

As ossification advances towards the ends of the bone, the portion as yet cartilaginous continues to grow at the same time, and increases in every dimension. The part already osseous increases also in circumference ; the medullary canal, of which for some time there is no appearance, begins to be excavated in the interior by absorption, and the sides of the shaft acquire



compactness and solidity. The increase in girth is brought about by deposition of bone at the surface underneath the periosteum. It has been sometimes supposed that a formation of cartilage precedes the bone also in

Fig. LVII.

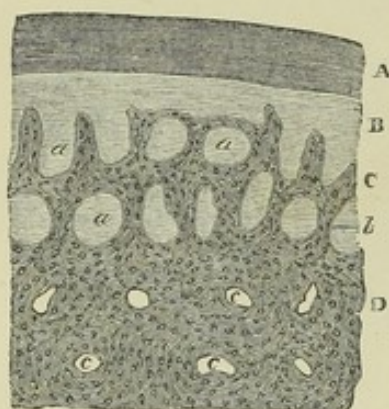


Fig. LVII.—TRANSVERSE SECTION OF SUPERFICIAL PART OF GROWING METATARSAL BONE OF A CALF, MAGNIFIED 45 DIAMETERS (from Kölliker).

A, periosteum; B, vascular soft tissue (sub-periosteal blastema of some writers); C, new bony growth with wide spaces, *a, a, a*, some being open grooves, others tubular, seen in cross section; D, more advanced and now compact tissue of the shaft, with the tubular spaces now nearly filled with concentric lamellae leaving Haversian canals, *c, c*, in the centre. With a higher magnifying power, in the tissue B would be found fibres and granular cells, and layers of these cells everywhere covering the osteogenic deposit on the surface of the growing bone, and lining the grooves and tubular spaces.

lucid, coarsely reticulated fibres of soft tissue (fig. LVIII. *b, c*) into which the earthy deposit is advancing. These osteogenic fibres are intermixed with granular corpuscles or cells, but form no part of the cartilage, and they are no doubt of the same nature as those seen in the intramembranous ossification of the skull. Their reticulations are in most cases directed transversely, and sometimes they are little, if at all, in advance of the limit between the bone and cartilage. I have observed the structure here described in several bones of the (well advanced) foetal sheep, also in the human scapula, humerus, femur, tibia and fibula, metacarpus and metatarsus, and, as was to be anticipated, it has since been found in all the long bones.

Ossification having thus proceeded for some time in the shaft, at length begins in the extremities of the bone from one or more independent centres, and extends through the cartilage, leaving, however, a thick superficial layer of it unossified, which permanently covers the articular end of the bone. The epiphyses thus formed continue long separated from the shaft or diaphysis by an intervening portion of cartilage, which is at last ossified, and the bone is then consolidated. The time of final junction of the

this situation; but such is not the case, for the vascular soft tissue in immediate contact with the surface of the growing bone is not cartilage, but a blastema containing fibres and granular corpuscles; in fact, the increase takes place by intramembranous ossification, and accordingly the Haversian canals of the shaft are formed in the same way as those of the tabular bones of the skull,—that is, the osseous matter is not only laid on in strata parallel to the surface of the bone, but is deposited around processes of the vascular membranous tissue which extend from the surface obliquely into the substance of the shaft, (fig. LVII., *a, a*, in transverse section); and the canals in which these vascular processes lie, becoming narrowed by the deposition of concentric osseous laminae, eventually remain as the Haversian canals (*c, c*).

That the ossification at the periosteal surface of the bone does not take place in cartilage, may be made apparent in the following manner. Strip off the periosteum from a growing bone at the end of the shaft, and from the adjoining cartilage also, taking care not to pull the latter away from the bone. A thin membranous layer will still remain, passing from the bone over the cartilage; now, take a thin slice from the surface, including this membrane with a very thin portion of the subjacent bone and cartilage, and examine it with the microscope, scraping off the cartilage from the inside if it be too thick. It will then be seen that the superficial part or shell of the bone, if it may be so called, is prolonged a little way over the surface of the cartilage by means of pel-



epiphyses is different in different bones ; in many it does not arrive until the body has reached its full stature. Meanwhile the bone increases in length by the ossification continuing to extend into the intervening cartilage, which goes on growing at the same time ; and it appears that in the part of the shaft already ossified little or no elongation takes place by interstitial growth. This is shown by an experiment first made by Dr. Hales and afterwards by Duhamel and by John Hunter, in which two or more holes being bored in the growing bone of a young animal at a certain measured distance from each other, they are found after a time not to be farther asunder, although the bone has in the mean while considerably increased in length.\* In like manner the shaft also increases in circumference by deposition of new bone on its external surface, while at the same time its medullary canal is enlarged by absorption from within. A ring of silver or platinum put round the wing-bone of a growing pigeon, becomes covered with new bone from without, and the original bone included within it gets thinner, or, according to Duhamel, who first made the experiment, is entirely removed, so that the ring comes to lie within the enlarged medullary canal.

Madder given to an animal along with its food, tinges the earth of bone, which, acting as a sort of mordant, unites with and fixes the colouring matter. Now, that part of the bone which is most recently formed, and especially that part which is actually deposited during the administration of the madder, is tinged both more speedily and more deeply than the older part ; and, as in this way the new osseous growth can be readily distinguished from the old, advantage was taken of the fact by Duhamel, and afterwards by Hunter, in their inquiries as to the manner in which bones increase in size. By their experiments it was shown that when madder is given to a young pig for some weeks, the external part of its bones is deeply reddened, proving that the new osseous matter is laid on at the surface of that previously formed. Again, it was found that when the madder was discontinued for some time before the animal was killed, an exterior white stratum (the last formed) appeared above the red one, whilst the internal white part, which was situated within the red,

Fig. LVIII.

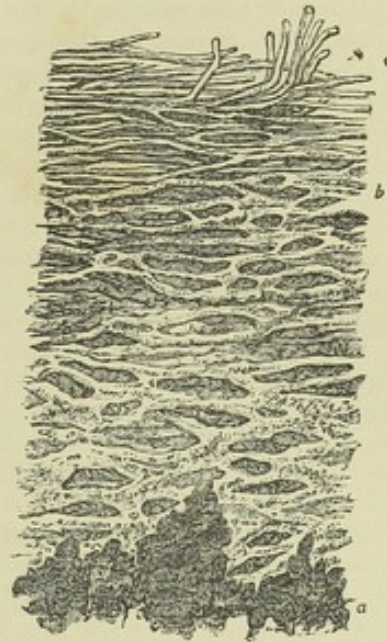


Fig. LVIII. — SUBPERIOSTEAL LAYER FROM THE EXTREMITY OF THE BONY SHAFT OF THE OSSIFYING TIBIA, AS DESCRIBED IN THE TEXT.

The cartilage and more open bony tissue have been scraped off from the inside of the crust, except at *a*, where a dark shade indicates a few vertical osseous areolæ out of focus and indistinctly seen. The part *a*, *b*, of the crust is ossified, and of granular aspect ; between *b* and *c* are the clear reticulated fibres into which the earthy deposit is advancing. \* Magnified 150 diameters.

\* Hales *Veget. Statics.*, 4th edit. p. 340 ; Duhamel *Mem. de l'Acad. des Sc.* 1743 et seq. Hunter (reported by Home) in *Trans. of Soc. for Imp. of Med. and Chir. Knowledge*, vol. ii. ; also *Catalogue of Hunterian Museum*, vol. i. p. 249. Duhamel was led from some of his experiments to infer that an interstitial elongation took place near the ends ; but there is some doubt left as to the precise circumstances of the experiments in these cases. Both Hales and Duhamel, in experimenting on the growing tibia of a chicken, observed that the addition of new bone was much greater at the upper end. Dr. Humphry has found that in the femur the elongation is greater at the *lower*, and in the humerus at the *upper* end of the shaft (*Med. Chir. Trans.* vol. xlv.).



and had been formed before any madder was given, had become much thinner; showing that absorption takes place from within. In this last modification of the experiment also, as noted by Mr. Hunter, a transverse red mark is observed near the ends of the bone, beyond which they are white; the red part, indicating the growth in length during the use of the madder, and the white beyond, that which has taken place subsequently,—thus showing that the increase in length is caused by the addition of new matter to the extremities.\* But other changes take place in the bone. The spaces in the cancellated structure become enlarged, as well as the medullary canal, by absorption; whilst in other parts the tissue becomes more compact by farther deposit on the inner surface of the vascular cavities. The sides of the shaft in particular acquire greater solidity by the narrowing of the Haversian canals, within which the vascular membrane continues to deposit fresh layers of bone; and madder administered while this process is going on, colours the interior and recently-formed laminae, so that in a cross section the Haversian apertures appear surrounded with a red ring. Lastly, Tomes and De Morgan have shown that in bones which have acquired their full size, a production of new systems of Haversian lamellae continues throughout life, as described at page xciii.

From the foregoing account it is evident that a great portion of a long bone is formed independently of cartilage. Those physiologists, therefore, appear to have reason on their side, who consider the pre-existence of that tissue as not being a necessary condition of the ossific process, and who regard the precursory cartilage of the foetal skeleton in the light of a temporary substitute for bone, and also as affording as it were a mould of definite figure and of soft but yet sufficiently consistent material in which the osseous tissue may be at first deposited and assume a suitable form. In fact the cartilage-cells are not ossified, and, as to the slender walls of the primary areolae formed by calcification of the intercellular cartilaginous matrix, most of them are, in a long bone, swept away by absorption, in the excavation of the medullary canal; so that they can only remain—coated, however, and obscured by secondary laminated deposit—in the cancellar structure of bones which begin to ossify in cartilage.†

The time of commencement of ossification in the different bones, as well as the number and mode of conjunction of their bony nuclei, are subjects that belong to special anatomy. It may, however, be here remarked in general, that the commencement of ossification does not in all cases follow the order in which the bones appear in their soft or cartilaginous state. The vertebrae, for instance, appear as cartilages before there is any trace of the clavicle, yet ossification begins in the latter sooner than in any other bone of the skeleton. The time when it commences in the clavicle, and consequently the date of the first ossification in the skeleton, is referred by some to the seventh week of intra-uterine life; others assign a considerably earlier period; but owing to the uncertainty that prevails as to the age of early embryos, the dates of commencing ossification in the earliest bones cannot be given with precision.

In regard to the number and arrangement of the nuclei, the following general facts may be stated:—1. In the long bones there is one centre of ossification in the middle, and the ends are for the most part ossified from separate nuclei; whilst a layer of cartilage remains interposed until the bone has nearly attained its full length. By this means the bone is indurated in the parts where strength is most required, whilst its longitudinal growth is facilitated. 2. The larger foramina and cavities of the

\* M. Flourens has repeated and varied these experiments, and represented the results in beautiful delineations. *Recherches sur le Développement des Os et des Dents*. Paris, 1842.

† Nesbitt, in 1736, maintained that the cartilage is “entirely destroyed;” he therefore considered it to be a mere temporary substitute; but the steps of the process of infracartilaginous ossification as now traced with the aid of the microscope were unknown to him. The view stated in the text, together with most of the facts adduced in support of it, was published in the fifth edition of this work in 1846, but, notwithstanding the comprehensive researches of Bruch, by which he was led to the same opinion (*Denks. d. Schweiz. naturf. Gesells.* 1852), it met with little notice, and probably less assent, until the subject was treated of in a special memoir by the late H. Müller (*Zeits. für wissensch. Zool.*, vol. ix., 1858), to whom the doctrine in its modern shape is now commonly ascribed.



skeleton are for the most part formed by the junction of two, but more generally of three or more nuclei round the aperture or included space. The vertebral rings, the acetabulum, the occipital foramen, and the cranium itself, are illustrations of this. It is easy to conceive that in this way the ready and equable enlargement of such cavities and apertures is provided for. 3. Bones of a complex figure, like the vertebræ, have usually many nuclei; but the converse is not always true. 4. We can frequently connect the number of nuclei with the principle of uniformity of type on which the skeleton of vertebrated animals is constructed. Thus the typical form of the sternum seems to be that of a series of distinct bones, one placed between each pair of ribs in front, as the vertebræ are behind, and this is its permanent condition in many quadrupeds. In man it conforms to the archetype in its mode of formation, in so far as it is ossified from several centres, and for some time consists of several pieces; but, to suit the fabric of the human thorax, these at last coalesce one with another, and are reduced in number to three.

In the reunion of fractured bones, osseous matter is formed between and around the broken ends, connecting them firmly together; and when a portion of bone dies, as happens in necrosis, a growth of new bone very generally takes place to a greater or less extent, and the dead part is thrown off. The several steps of the process of restoration in these instances are so fully described in works on Surgical Pathology, that it is unnecessary to add to the length of this chapter by introducing an account of them here.

## MUSCULAR TISSUE.

The muscular tissue is that by means of which the active movements of the body are produced. It consists of fine fibres, which are for the most part collected into distinct organs called muscles, and in this form it is familiarly known as the flesh of animals. These fibres are also disposed round the sides of cavities and between the coats of hollow viscera, forming strata of greater or less thickness. The muscular fibres are endowed with *contractility*, a remarkable and characteristic property, by virtue of which they shrink or contract more or less rapidly under the influence of certain causes which are capable of exciting or calling into play the property in question, and which are therefore named *stimuli*. A large class of muscles, comprehending those of locomotion, respiration, expression, and some others, are excited by the stimulus of the will, or volition, acting on them through the nerves; these are therefore named "voluntary muscles," although some of them habitually, and all occasionally, act also in obedience to other stimuli. There are other muscles or muscular fibres which are entirely withdrawn from the control of the will, such as those of the heart and intestinal canal, and these are accordingly named "involuntary." These two classes of muscles differ not only in the mode in which they are excited to act, but also to a certain extent in their anatomical characters; and on this account we shall consider the structure of each class separately.

*Of the structure of voluntary muscles.*—The voluntary muscular fibres are for the most part gathered into distinct masses or muscles of various sizes and shapes, but most generally of an oblong form, and furnished with tendons at either extremity, by which they are fixed to the bones.

The two attached extremities of a muscle are named, in anatomical descriptions, its origin and insertion,—the former term being usually applied to the attachment which is considered to be most fixed, although the rule cannot be always applied strictly. The fleshy part is named the belly, which in some cases is interrupted in the middle or divided into two by a tendon, and then the muscle is said to be biventral or digastric; on



the other hand it may be cleft at one end into two or three portions, in which case it is named bicipital or tricipital.

Fig. LIX.

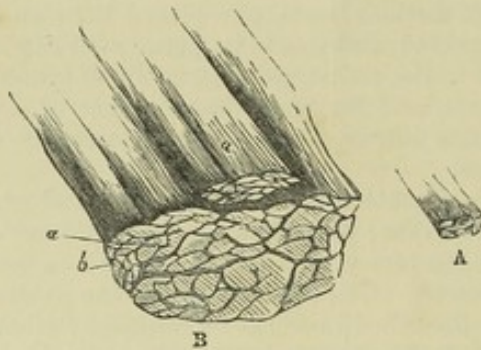


Fig. LX.

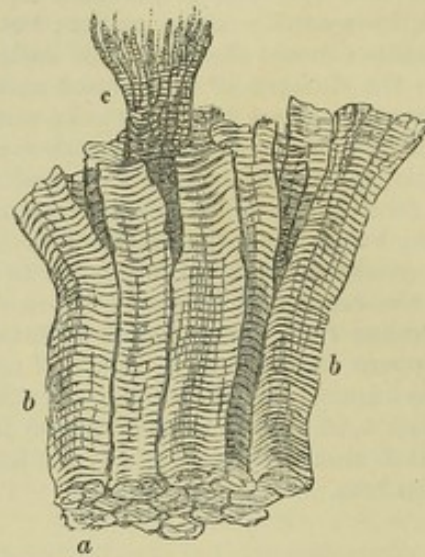


Fig. LIX.—A, SMALL PORTION OF MUSCLE, NATURAL SIZE; B, THE SAME MAGNIFIED 5 DIAMETERS, CONSISTING OF LARGER AND SMALLER FASCICULI, SEEN IN A TRANSVERSE SECTION.

Fig. LX.—A FEW MUSCULAR FIBRES, BEING PART OF A SMALL FASCICULUS, HIGHLY MAGNIFIED, SHOWING THE TRANSVERSE STRIÆ.

*a*, end view of *b*, *b*, fibres; *c*, a fibre split into its fibrils.

The muscular fibres are collected into packets or bundles, of greater or less thickness, named fasciculi or lacerti (fig. LIX.), and the fibres themselves consist of much finer threads, visible by the aid of the microscope, which are termed muscular filaments, fibrillæ or fibrils (fig. LX., *c*). The fibrils run parallel with each other in the fibres, and the fibres are parallel in the fasciculi and the fasciculi extend continuously from one terminal tendon to the other, unless in those instances, like the rectus muscle of the abdomen and the digastric of the inferior maxilla, in which the fleshy part is interrupted by interposed tendinous tissue. The fasciculi also very generally run parallel, and although in many instances they converge towards their tendinous attachment with various degrees of inclination, yet in the voluntary muscles they do not interlace with one another.

*Sheath.*—An outward investment or sheath of areolar tissue (sometimes named *perimysium*) surrounds the entire muscle, and sends partitions inwards between the fasciculi; furnishing to each of them a special sheath. The areolar tissue extends also between the fibres, but does not afford to each a continuous investment, and therefore cannot be said to form sheaths for them. Every fibre, it is true, has a tubular sheath; but this, as will be afterwards explained, is not derived from the areolar tissue. The tissue of the sheath is composed of elastic (yellow) as well as of white fibres; but the elastic element is found principally in its investing (as distinguished from its penetrating) portion. The chief uses of the areolar tissue are to connect the fibres and fasciculi together, and to conduct and support the bloodvessels and nerves in their ramifications between these parts. The relation of these different subdivisions of a muscle to each other, as well as the shape of the fasciculi and fibres, is well shown by a transverse section (figs. LIX. and LX.).



*Fasciculi.*—The fasciculi are of a prismatic figure, and their sections have therefore an angular outline. The number of fibres of which they consist varies, so that they differ in thickness, and a large fasciculus may be divisible into two or three orders of successively smaller bundles, but of no regularly diminishing magnitude. Some muscles have large, others only small fasciculi; and the coarse or fine texture of a muscle, as recognized by the dissector, depends on this circumstance. The length of the fasciculi is not always proportioned to the length of the muscle, but depends on the arrangement of the tendons to which their extremities are attached. When the tendons are limited to the ends of a long muscle, as in the sartorius, the fasciculi, having to pass from one extremity to the other, are of great length; but a long muscle may be made up of a series of short fasciculi attached obliquely to one or both sides of a tendon, which advances some way upon the surface or into the midst of the fleshy part, as in the instance of the rectus muscle of the thigh, and the tibialis posticus. Muscles of the kind last referred to are named “penniform,” from their resemblance to the plume of a feather, and other modifications of the arrangement, which can be readily conceived, are named “semi-penniform” and “compound penniform.” Many short fasciculi connected thus to a long tendon, produce by their combined operation a more powerful effect than a few fasciculi running nearly the whole length of the muscle; but by the latter arrangement the extent of motion is greater, for the points of attachment are moved through a longer space.

*Fibres; their figure and measurement.*—In shape the fibres are cylindrical, or prismatic, and in the latter case often with some rounded surfaces and angles. Their size is tolerably uniform, although fibres occur here and there in a muscle which differ greatly in size from the prevailing standard. Mr. Bowman gave the average diameter in the male at  $\frac{1}{332}$  and in the female at  $\frac{1}{434}$  of an inch. According to later measurements by Kölliker in different regions of the body, the prevailing size of the fibres in the muscles of the trunk and limbs is from  $\frac{1}{750}$  to  $\frac{1}{400}$  of an inch, but is less in those of the head, especially in the facial muscles, in which he found the diameter to range from  $\frac{1}{750}$  down to  $\frac{1}{2400}$  of an inch.

*Cross stripes.*—When viewed by transmitted light with a sufficiently high power of the microscope, the fibres, which are then clear and pellucid in aspect, appear marked with fine parallel stripes or bands passing across them directly or somewhat obliquely with great regularity (figs. LX. and LXI. A). The stripes are commonly said to be dark, with light intervals; but it is probably more correct to speak of both light and dark stripes which alternately cross the fibre. It must, however, be remembered that the substance of the fibre is quite translucent, and, by changing the focus, the stripes which at first appeared dark become light, and the previously light ones are now dark. In what may be considered the definite or true focus, the dark and light stripes are nearly of equal breadth, and then also may be seen, very generally but not in all cases, a fine dark line passing along the middle of the light stripe and dividing it into two (fig. LXI. A). This intermediate line when closely examined appears to be a row of dark points. About eight or nine dark and as many light stripes may be counted in the length of  $\frac{1}{1000}$  of an inch, which would give about  $\frac{1}{17000}$  inch as the breadth of each. But whilst this may be assigned as their usual breadth, they are in different parts found to be much narrower, so that not unfrequently they are double the above number in an equal space. This closer approximation may generally be noticed in thicker and apparently contracted parts



of the fibre, but it is by no means confined to such parts. This cross-striped appearance, which is most beautiful and characteristic, is found in all the voluntary muscles; but it is not altogether confined to them, for it is seen in the fibres of the heart, which is a strictly involuntary organ: striped fibres are also found in the pharynx and upper part of the gullet, in the muscles of the internal ear, and those of the urethra, parts which are not under the direct control of the will.

*Structure of the fibres.*—A muscular fibre may be said to consist of a large number of extremely fine filaments or fibrils inclosed in a tubular sheath. This, the proper sheath of the fibre, is named *sarcolemma* or *myolemma*. It consists of transparent and apparently homogeneous membrane agreeing

Fig. LXI.

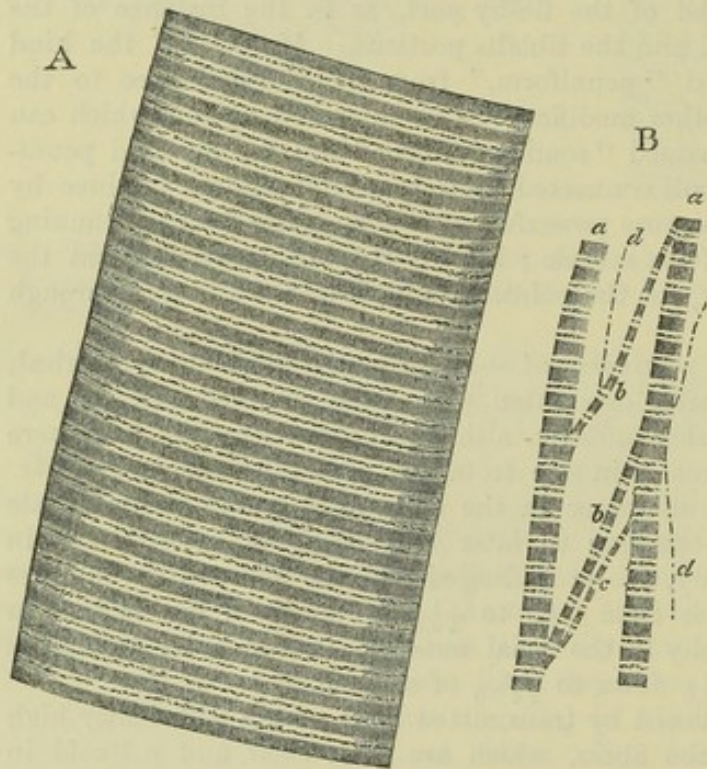


Fig. LXI. A. PORTION OF A MEDIUM-SIZED HUMAN MUSCULAR FIBRE, MAGNIFIED NEARLY 800 DIAMETERS.

B, *Separated bundles of Fibrils*, equally magnified. *a, a*, larger, and *b, b*, smaller collections; *c*, still smaller; *d, d*, the smallest which could be detached, possibly representing a single series of sarcous elements.

in chemical characters with elastic tissue, and, being comparatively tough, will sometimes remain entire when the included fibrils are ruptured by stretching the fibre, as represented in fig. LXII. In this way its existence may be demonstrated; and it is especially well seen in fish and other animals which have large fibres, for in these it is thicker and stronger. It may also be well shown in fresh muscular fibres from the frog, by exposing them to water under the microscope. The fluid is imbibed and then collects between the substance of the fibre and its sheath so as to separate the membrane and make it apparent. At the same time, as regards mammalian muscles, it must

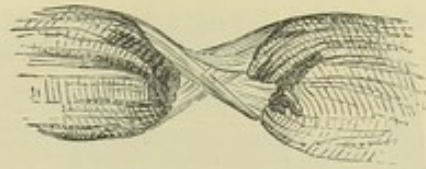
be admitted that it is not always easy to bring the sarcolemma distinctly into view.

*Fibrils.*—Lines and fissures are sometimes seen running lengthwise in the substance of the fibres, and indicating their fibrillar structure, as in some of those represented in fig. LX.; and when these longitudinal lines are well marked, the transverse striæ are comparatively indistinct. In a thin transverse section the ends of the fibrils may be seen, when highly magnified, as small dots or points, which occupy the whole sectional area of the fibre, showing plainly that the latter is not hollow, as has sometimes been maintained, but possesses the same fibrillar structure throughout its whole thickness. The fibrils are closely connected together in the fibre by an inter-



mediate pellucid substance in very sparing quantity ; they may be partially separated and spread out by breaking across a fibre, and gently bruising the broken end, as at *c* (fig. LX.), or by splitting up its substance with fine needles ; and the separation is facilitated by previous immersion of the muscle for some time in alcohol or in a weak solution of chromic acid, which either strengthens the fibrils, or, by acting on the uniting substance, weakens their lateral cohesion. But whilst in this way the fibrillar structure is made apparent, and the fibre may be split up into fine bundles or skeins of fibrils (fig. LXI. B), and threads apparently single may be detached, yet it is by no means easy to say when we thus arrive at an insulated ultimate fibril. A thread so separated (fig. LXI. B, *c*) when viewed in proper focus with a magnifying power of 400 or 600, appears to consist of a row of dark quadrangular particles, named *sarcous elements* by Mr. Bowman, with bright intervals between them, as if they were connected by some pellucid substance of less refractive power. For the most part also a dark line may be discovered passing across the middle of each bright space. I am disposed, however, to think that the filaments thus described consist of more than one ultimate fibril ; for I have now and then seen in specimens of human muscle treated with chromic acid, a finer filament (as at *d*, fig. LXI.) lying alongside one or more of those above described, and, whether itself an ultimate fibril or not, showing at least that those with the quadrangular particles are composite. In such a fine fibril the dark sarcous elements, whilst agreeing in length with those alongside, are slender, rod-shaped, or linear in figure ; and in the middle of the bright intervals between them there is a dark point. In short the fibril looks like a line regularly broken at short distances, with a dot in each of the breaks. From this it may be inferred that the greater breadth of the quadrangular particles is caused by the lateral apposition of several rod-shaped particles ; and it is plain that the appearance of a dark line in the bright interval is produced by a transverse range of the intervening dots.

Fig. LXII.



This account corresponds very much with what is seen on a larger scale in the muscular fibres of insects, by which I do not mean the fine, naturally separated, fibres of the thoracic muscles, sometimes taken for fibrils, but the larger fibres, in which fibrils answering to the above description are readily separable. In these, the rather long rod-shaped sarcous elements, of which the fibrils consist, give a fluted character to the broad cross stripes or bands which, by mutual apposition, they produce in the fibre (fig. LXIII).

The intermediate dotted line was long since noticed by Busk and Huxley, and was considered by them to be produced, most probably, by the interposition of a row of minute sarcous elements ; but, as they justly observe, it is not invariably present.

*Cause of the stripes, and cleavage into disks.*—When the fibrillæ lie undisturbed in the fibre, the elementary particles of collateral fibrils are situated in the same transverse plane, and it is to this lateral coaptation of the particles that the transverse striping of the fibre is due. (See fig. LXIV.) Accordingly, the cross stripes are not confined to the surface of the fibre, but may be seen throughout its entire thickness on successively deepening the focus of the microscope. The fibres, moreover, when treated with certain reagents (such as very dilute hydrochloric acid), show a tendency to



cleave across in a direction parallel to these stripes, and even break up into transverse plates or disks, which are formed by the lateral cohesion of the particles of adjacent fibrils. To make up such a disk, therefore, every fibril contributes a particle, which separates from those of its own fibril, but co-

heres with its neighbours on either side, and this with perfect regularity. Indeed, Mr. Bowman conceives that the subdivision of a fibre into fibrillæ is merely a phenomenon of the same kind, only of more common occurrence, the cleavage in the latter case taking place longitudinally instead of trans-

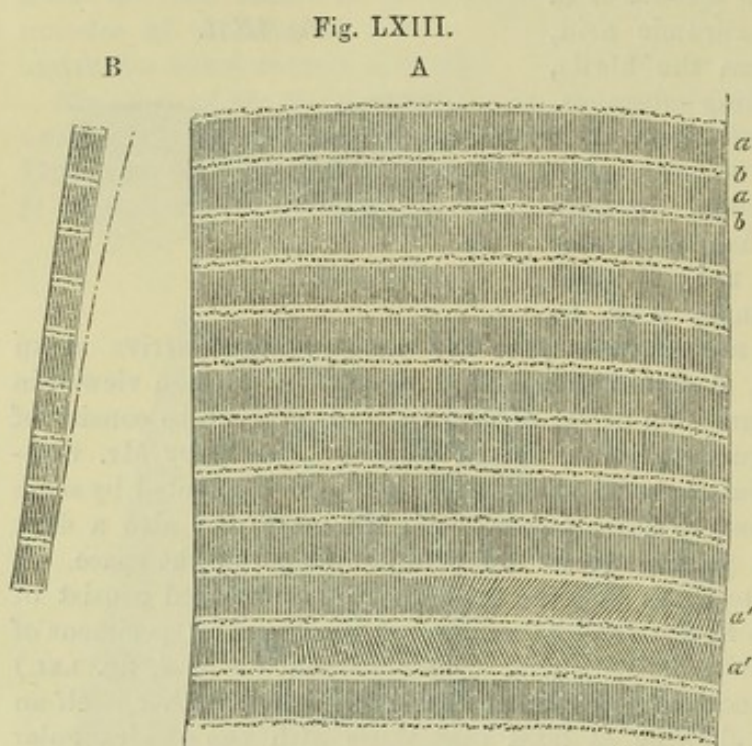


Fig. LXIII. A.—PORTION OF A (RATHER SMALL SIZED) MUSCULAR FIBRE, FROM A WATER BEETLE, MAGNIFIED 730 DIAMETERS.

*a, a*, dark cross bands formed by the apposition of slender rod-shaped sarcois elements; *b, b*, light stripes with intermediate line of dark specks; at *a', a'*, inclined position of rods, as here and there seen. B, a detached bundle of fibrils equally magnified. On one side an apparently single series of elongated sarcois elements, with intermediate dots, possibly a single fibril.

existence as such in the fibre, any more than the disks; but that both the one and the other owe their origin to the regular arrangement of the particles of the fibre longitudinally and transversely, whereby, on the application of a severing force, it cleaves in the one or in the other direction into regular segments.

While some consider that the fibrils are composed throughout of the same substance, and that the alternation of dark and light portions is due to unimportant modifications of it, others believe that the light and dark parts differ essentially in nature. In proof of this Brücke adduces observations to show that the dark parts, or sarcois elements, doubly refract the light (or are "anisotropic"), whilst the intermediate light substance is singly refractive ("isotropic"). Moreover, as the sarcois elements and the dark stripes formed by them are variable in size and position—the stripes being sometimes broad and widely apart, at other times narrow and closer together—Brücke infers that the dark, doubly-refracting, or anisotropic substance consists of an aggregation of undistinguishably minute, doubly-refracting molecules, named by him *disdiaclasses*, imbedded in the isotropic matter; which, by grouping together in various numbers and modes, give rise to the variations in the size, figure, and arrangement of the sarcois elements. In reference to this view I may observe that while it

Fig. LXIV.



Fig. LXIV.—DIAGRAM TO SHOW HOW THE STRIPES OF MUSCULAR FIBRE ARE PRODUCED.

versely: accordingly, he considers that the fibrillæ have no



is easy to see that the muscular fibres are doubly refractive, and while the light and dark parts most probably differ in certain physical and chemical properties, it is not so clearly made out that the doubly refracting property is confined to the one of them.

*Nuclei, or muscle-corpuscles.*—A number of pale, finely granular, oval corpuscles, resembling cell-nuclei, are found in the fibres. In mammalian muscles they lie upon the inner surface of the sarcolemma, but in frogs they are distributed through the substance of the fibre (fig. LXV.). These have been supposed to be connected with the growth and nutrition of the muscle. They are obvious in the foetus some time before birth, but afterwards the addition of acetic acid is usually required in order to render them visible. They are probably nuclei pertaining to the elongated cells in which the substance of the fibres is originally developed; and a small amount of granular matter which is not uncommonly collected around them has been regarded as a remnant of the formative protoplasm. Other corpuscles, mostly fusiform, but varying in shape, and having the character of connective-tissue corpuscles, lie here and there outside the sarcolemma, and doubtless belong to the interposed connective tissue.

*Interstitial granules.*—Different observers, and especially Kölliker, have described fine granules disposed in rows between the fibrils or smaller bundles of fibrils, as of frequent occurrence in the muscular fibres of man and animals (fig. LXVI.). They have been especially noted in the heart, and although they do not naturally show the characters of fat, it has been presumed that they may by conversion give rise to the fatty degeneration of muscular tissue. I must confess that I have not been able to perceive these granules in healthy human voluntary muscle.

*Length and ending of the fibres.*—The fibres composing a muscle are of limited length, not exceeding one inch and a half; and accordingly in a long fasciculus a fibre does not reach from one tendinous attachment to the other, but ends with a tapering pointed extremity, invested with its sarcolemma, and cohering with neighbouring fibres. Unless when either is fixed to a tendon, both extremities of the fibre terminate in the way described, so that it has a long fusiform shape.

*Branched fibres.*—Generally speaking, the fibres neither divide nor anastomose; but this rule is not without exception. Branched and anastomosing fibres are common in the heart (fig. LXXII.); in the tongue of the frog the muscular fibres (fig. LXVII.) as they approach the surface divide into numerous but not anastomosing branches, by which they are attached to the under surface of the mucous membrane. The same thing has also been seen in the tongue of man and many other animals; and the fibres of the facial muscles of mammals have been shown by Busk and Huxley to divide in a similar manner where they fix themselves to the skin.

*Connection with tendons.*—According to Professor Kölliker the mode of

Fig. LXV.



Fig. LXV.—A FROG'S MUSCULAR FIBRE TREATED WITH ACETIC ACID, MAGNIFIED 350 DIAM. (from Kölliker).

The nuclei are somewhat shrunk. Interstitial granules in longitudinal rows, here and there, but these are mostly indistinct from compression, and appear as mere lines.



connection differs when the muscular fibres are continuous in a direct line with those of the tendon from that which is observed when the former join the latter at a more or less acute angle. In the first case, the two are directly continuous, the muscular fibre being distinguishable from that of the fibrous tissue by its striation alone. In the second case, the muscular fibres terminate in conical processes, which are received in corresponding

Fig. LXVI.



Fig. LXVII.

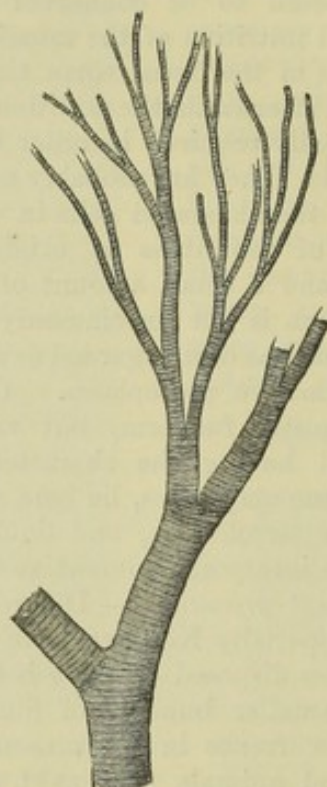


Fig. LXVI.—FROG'S MUSCULAR FIBRE, SHOWING INTERSTITIAL GRANULES, MAGNIFIED 350 DIAM. (from Kölliker).

Fig. LXVII.—A BRANCHED MUSCULAR FIBRE FROM THE FROG'S TONGUE, MAGNIFIED 350 DIAM. (from Kölliker).

depressions of the tendinous structure, to which they cling; the connective tissue of the one being continuous with that of the other. Weismann, who adopts this view on later observations of his own, states that the sarcolemma surrounds the ends of the fibres, which are not continuous with but rather, as it were, cemented to the tendon. Mr. Ellis, on the other hand, describes the connection of striated muscle with tendon as taking place in all cases in the following manner. When a muscular fibre is about to end in a tendon, its component fibrils are collected into bundles of different lengths and sizes like the roots of a tree. Around each bundle tendinous tissue is collected, forming a sheath which appears gradually to cease as it is continued backwards on the undivided fibre. The muscular fibrils of a bundle in approaching the tendon gradually cease, each having probably its own tendinous thread to fix it. The central bundles of fibrils reach further than the circumferential, and thus when the latter are broken off by attempts made to detach a fibre from its neighbours, the fibre appears to have a pointed ending. In this case also Weismann maintains that the sarcolemma intervenes between the muscular substance and the tendon.



Mr. Ellis does not confirm Professor Kölliker's account of the oblique mode of attachment. He states that in such instances as the gastrocnemius and soleus, every fibre is provided with its separate tendon and is continuous with it as above described, and that the increasing thickness of the main tendon from above downwards is due to successive additions, in form of strata, of the contributing tendons from the lower placed layers of muscular fibres; and this explanation is supported by subsequent observations of Fick, Margo, and Frey. In attaching themselves to the skin and mucous membranes, the muscular fibres, according to the careful description of Dr. Salter, divide into pointed processes or fine filaments which are continuous with those of the connective tissue.

*Blood-vessels.*—The blood-vessels of the muscular tissue are extremely abundant, so that, when they are successfully filled with coloured injection, the fleshy part of the muscle contrasts strongly with its tendons. The arteries, accompanied by their

Fig. LXVIII.

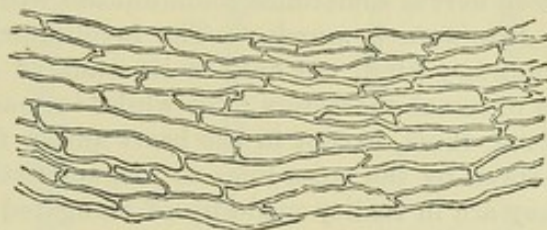


Fig. LXVIII.—CAPILLARY VESSELS OF MUSCLE, FROM AN INJECTION BY LIEBERKÜHN, SEEN WITH A LOW MAGNIFYING POWER.

The specimen was preserved in spirits; when the muscle is dried, the vessels appear much closer.

The capillaries destined for the proper tissue of the muscle are extremely small (fig. LXVIII.), they form among the fibres a fine network, with narrow oblong meshes, which are stretched out in the direction of the fibres: in other words, they consist of longitudinal and transverse vessels, the former running parallel with the muscular fibres, and lying in the angular intervals between them,—the latter, which are much shorter, crossing between the longitudinal ones, and passing over or under the intervening fibres.

None of the capillary vessels enter the sarcolemma or proper sheath of the fibre, and the nutritious fluid which they convey must therefore reach the finer elements of the muscle by imbibition. Moreover, as the capillaries do not penetrate the fibres, but lie between them, their number in a given space, or their degree of closeness, will in some measure be regulated by the number and consequently by the size of the fibres; and accordingly in the muscles of different animals it is found that when the fibres are small, the vessels are numerous and form a close network, and *vice versa*: in other words, the smaller the fibres, the greater is the quantity of blood supplied to the same bulk of muscle. In conformity with this, we see that in birds and mammalia, in which the process of nutrition is active, and where the rapid change requires a copious supply of material, the muscular fibres are much smaller and the vessels more numerous than in cold-blooded animals, in which the opposite conditions prevail.

*Lymphatics.*—Of lymphatic vessels in the muscular tissue nothing certain is known. From an examination of the lymphatics which appear to proceed



from different muscles, Kölliker infers that small muscles are destitute of such vessels, and that the few which apparently issue from some of the larger muscles, belong to the sheath and its larger subdivisions, and not to the proper muscular tissue.

*Nerves.*—The nerves of a voluntary muscle are of considerable size. Their branches pass between the fasciculi, and repeatedly unite with each other in form of a plexus, which is for the most part confined to a small part of the length of the muscle or muscular division in which it lies. From one or more of such *primary* plexuses, nervous twigs proceed and form finer plexuses composed of slender bundles, containing not more than two or three dark-bordered nerve fibres each, whence single fibres pass off between the muscular fibres and divide into branches which are finally distributed to the tissue. The mode of final distribution will be described with the general anatomy of the nerves.

Nerves of small size accompany the branches of blood-vessels within muscles, but do not reach the capillaries; though destined for the vessels these nerves sometimes communicate with the proper muscular plexuses.

*Involuntary muscles.*—The involuntary muscular tissue differs from the voluntary kind, not only in its want of subjection to the will, but also in its external characters; for whilst in many parts it appears in the form of fibres, these, except in the heart and a few instances of less note, are unmarked by the cross lines so characteristic of the striped fibres; moreover, they are in reality made up of elongated contractile cells cemented together by some kind of uniting medium.

*Plain or unstriped muscular tissue* (fig. LXIX.).—This is generally of a pale colour. The fibres are for the most part roundish or prismatic, but are readily flattened in examination. Some are not above  $\frac{1}{7000}$  of an inch in diameter; but the larger measure from  $\frac{1}{4300}$  to  $\frac{1}{3500}$  (Ellis). Under the microscope they have a peculiar soft aspect, without a strongly-shaded border; and they are marked at short intervals with oblong corpuscles, which give them a very characteristic appearance, especially after the application of acetic acid, which renders the corpuscles much more conspicuous. The substance of the fibres is translucent, but clouded or finely granular; and in the latter case the granules are sometimes arranged in longitudinal lines. There is no sarcolemma. These fibres, as already said, are made up of cells, named *contractile fibre-cells*, which were first distinguished as the true elements of the tissue by Kölliker. The cells may form fibres, bundles, and strata, or may be less regularly arranged, or mixed with other tissues in greater or less proportion. They are of an oblong flattened shape (figs. LXX. and LXXI), usually pointed at the ends, but sometimes abruptly truncated, and varying greatly in length according to the part or organ in which they are found. Some occur which are cleft or forked at one end. They measure for the most part from  $\frac{1}{600}$  to  $\frac{1}{300}$  of an inch or more in length. Their substance is finely granular and sometimes faintly striated, and, with few exceptions, no distinction is visible between envelope and contents. Each has a nucleus (*a, a*), rarely more than one, which is always elongated and either oval or rod-shaped. Accordingly the nuclei of the fibres above described belong to the constituent cells. By macerating the tissue in nitric acid diluted with four times its weight of water, the separation of the cells is greatly facilitated.

It is proper to state that a different view of the structure of the plain muscular tissue is entertained by some authorities. Mr. Ellis, after a very extended inquiry,



has arrived at the conclusion that it consists of fibres, which are not made up of the cells described, but agree in essential structure with those of voluntary muscle; and he considers the so-called nuclei as corpuscles belonging to the investing tissue of the

Fig. LXX.

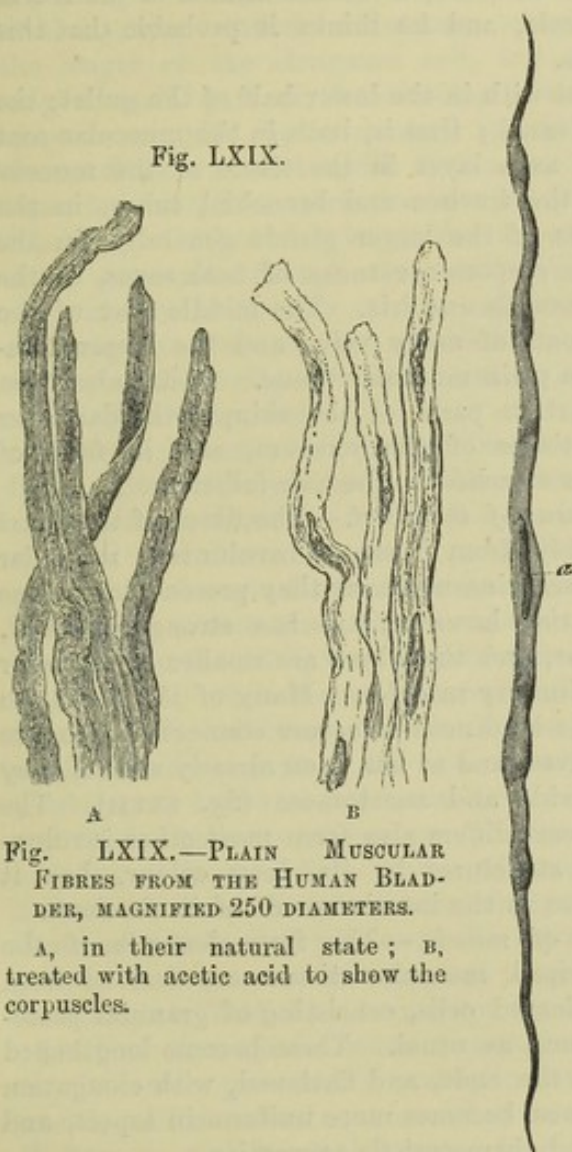


Fig. LXIX.—PLAIN MUSCULAR FIBRES FROM THE HUMAN BLADDER, MAGNIFIED 250 DIAMETERS.

A, in their natural state; B, treated with acetic acid to show the corpuscles.

Fig. LXXI.

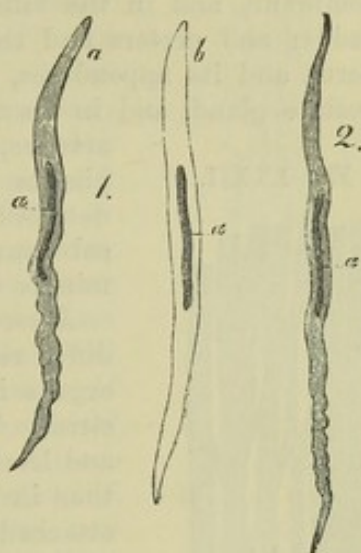


Fig. LXXI.—MUSCULAR FIBRE-CELLS FROM HUMAN ARTERIES, MAGNIFIED 350 DIAMETERS (Kölliker).

*a*, natural state; *b*, treated with acetic acid.

Fig. LXX.—MUSCULAR FIBRE-CELL FROM THE MUSCULAR COAT OF THE SMALL INTESTINE, MAGNIFIED (Kölliker).

muscular fibres. Without denying that there may be a modification or variety of the non-striated muscular fibres not divisible into singly nucleated cells, I nevertheless think that the existence of such contractile cells must now be admitted as fully established, and that the fibres and bundles of the plain muscular tissue are commonly made up of these cells.

The plain muscular tissue is for the most part disposed between the coats of the membranous viscera, as the stomach, intestines, and bladder, in the parietes of the air tubes, excretory ducts of glands, and the like. It is generally collected into larger and smaller fasciculi, which in many cases cross one another and interlace. The fasciculi are connected at their ends with tendinous tissue, and are thus inserted into the membranous and



firmer parts in the neighbourhood. Small tendons are also fixed by blending with the fibrous sheaths investing contiguous muscular bundles. In the gullet Mr. Ellis has found that the longitudinal muscular fasciculi are intersected wholly or partially, at intervals of from  $\frac{1}{20}$  to  $\frac{1}{10}$  of an inch, by small tendons into which they are inserted, after the fashion of the rectus abdominis, only on a miniature scale, and he thinks it probable that this disposition may exist in other parts.

The plain muscular tissue is met with in the lower half of the gullet, the stomach, and the whole intestinal canal; that is, both in the muscular coat of the alimentary canal, and also as a layer in the tissue of the mucous membrane, and in the villi; in the trachea and bronchial tubes, in the bladder and ureters and the ducts of the larger glands generally, in the uterus and its appendages, in the corpora cavernosa of both sexes, in the prostate gland, and in the ciliary muscle and iris. The middle coat of the

arteries, the coats of many veins and the larger lymphatics contain plain muscular tissue. It has also been detected in certain parts of the skin, in the dartos or subcutaneous tissue of the scrotum, and in form of minute muscles attached to the hair-follicles.

*Muscular tissue of the heart.*—The fibres of the heart differ remarkably from those of involuntary muscular organs in general, inasmuch as they present transverse striæ. The striæ, however, are less strongly marked, and less regular, and the fibres are smaller in diameter than in the voluntary muscles. Many of the fibres are attached to the tendinous structure connected with the orifices and valves, and as has been already stated, they are seen to divide and anastomose (fig. LXXII). The tissue of the heart differs also from most other involuntary muscular structures by its deep colour, but it agrees with them in the interlacement of its fasciculi.

*Development of muscle.*—The form-elements of the plain or unstriated muscular tissue are derived from embryonic nucleated cells, consisting of granular protoplasmic substance, as usual. These become lengthened out, pointed at the ends, and flattened, with elongation

of the nucleus, whilst their substance becomes more uniform in aspect, and acquires its permanent condition and characteristic properties.

The striated muscular tissue is also developed in the embryo from cells. Schwann considered each fibre to be formed by the linear coalescence of several cells; and this opinion is still maintained by some authorities. Recent researches, however, for the most part, tend to establish the view originally, I believe, promulgated by Remak, viz., that the fibres are produced by the elongation of single cells, with differentiation of their contents and multiplication of their nuclei; and Dr. Wilson Fox, who has quite lately investigated the process in the tadpole, the chick, and the mammalian embryo, at very early stages, has arrived at the same conclusion.\* Dr. Fox finds that the first elements of the muscular fibres are rounded or oval cells, with a clear nucleus and granular contents, agreeing in all respects with the cells of which the parts of the embryo body originally consist. To form a muscular fibre, a cell elongates, often with pointed ends; the nucleus

Fig. LXXII.

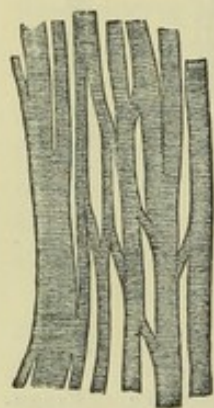


Fig. LXXII.—MUSCULAR FIBRES FROM THE HEART, MAGNIFIED, SHOWING THEIR CROSS-STRIÆ, DIVISIONS AND JUNCTIONS (from Kölliker).

\* Phil. Trans. 1866, p. 101.



generally divides into two, and by further division these are multiplied ; a fine membrane, at first absent or invisible, is soon discovered, bounding the cell and inclosing its contents. In the mean time the substance becomes striated longitudinally at one part, and more transparent, the granules disappearing. The striation, which is the first indication of the proper muscular substance, extends throughout the length of the elongated cell, but at first affects only a small part of its breadth, and the remaining space is occupied by unchanged granular matter and the nucleus or nuclei which lie on one side. In due time, however, this conversion into the proper muscular substance, further shown by the appearance of cross striæ, proceeds through the whole thickness of the cell, or fibre as it may now be called ; the inclosing cell-membrane becomes the sarcolemma, and the nuclei, with a small residue of the granular protoplasm still adhering to them, remain.

*Growth of muscles.*—The muscular fibres of the growing foetus, after having acquired their characteristic form and structure, continue to increase in size till the time of birth, and thenceforward up to adult age. In a full grown foetus most of them measure twice, and some of them three or four times their size at the middle of foetal life ; and in the adult they are about five times as large as at birth. This increase in bulk of the individual fibres would, of course, so far account for the concomitant enlargement of the entire muscles. But there would seem to be also a multiplication of the fibres ; and Budge believes he has proved this as regards the muscles of frogs. Two modes of production of new fibres have been described—viz. first, from connective tissue corpuscles lying between the existing fibres, by a process analogous to the original development of the muscle (von Wittich) ; secondly, by the splitting up of a fibre through its whole length into two or more smaller ones ; preceded by multiplication of its included nuclei. This second process has been observed by Weismann and by Kölliker in frogs, in the winter season, and appears to serve for the replacement of fibres destroyed by fatty degeneration, which is said to be not uncommon in these creatures. Dr. Beale, however, denies that the new and slender fibres are derived from an old and larger one by splitting of its substance ; he believes that they are produced from cells, as in the first mode, and that the old fibre is removed. The great increase in the muscular tissue of the uterus during gestation takes place both by elongation and thickening of the pre-existing fibre-cells of which that non-striated tissue consists, and by the development of new muscular fibre-cells from small, nucleated, granular cells lying in the tissue. In the shrinking of the uterus after parturition the fibre-cells also shrink to their previous size ; many of them become filled with fat granules (fig. LXXIII.), and many are doubtless removed by absorption.

Fig. LXXIII.

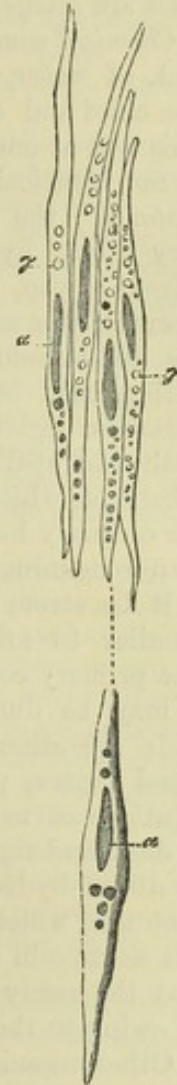


Fig. LXXIII.—MUSCULAR FIBRE-CELLS FROM THE UTERUS, THREE WEEKS AFTER DELIVERY. THE UPPER FOUR TREATED WITH ACETIC ACID, MAGNIFIED 350 DIAMETERS (from Kölliker).

a, nuclei ; γ, fat granules.



As far as can be concluded from the observations and experiments that have hitherto been made on the subject, the striated muscular tissue is not regenerated in warm-blooded animals. It is true, that when a muscle is cut across, or a portion removed, the breach will heal, but the loss of substance is not repaired by new-formed muscular tissue. Striated muscular fibres have been found in certain tumours of the ovary and testicle, but these cases are altogether peculiar and abnormal.

*Chemical composition of muscle.*—Muscular tissue contains nearly 80 per cent. of water, so that in being dried it loses about four-fifths of its weight. The chief and characteristic constituent of the fibre is an albuminoid body. This was at one time regarded as fibrin; but, as it was afterwards shown to be not identical with that substance, it was distinguished by the name of *syntonin*; the grounds of distinction being, that syntonin is soluble in very dilute hydrochloric acid, and can be extracted from muscle by that solvent; also, that its solution is precipitated by neutral salts. More recently, the subject has been investigated by Kühne, who maintains that the albuminoid matter of muscle exists in the fibres in a liquid form during life, but coagulates after death, and thereby gives rise to the cadaveric rigidity which then invades the muscles. When extracted from fresh and still irritable frogs' muscles at a temperature of freezing, this substance, which Kühne names *myosin*, is liquid; but if it be then exposed to the ordinary heat of the atmosphere it partially coagulates, and the portion then remaining liquid (the *muscle serum*) when heated to 112° F., or less if it be strongly acid, yields a further coagulum, which Kühne considers peculiar to muscle; and finally, at 167°, ordinary coagulated albumen. The primary coagulation is hastened by the presence of blood, and possibly it may be due to the mutual reaction of two albuminoids analogous in their operation to the fibrinogen and fibrinoplastin (or globulin) of the blood (antea, p. xxxviii.). The coagulum of myosin is soluble in strong solutions of neutral salts, and accordingly it may thereby be dissolved out of dead and rigid muscles; but it loses this property if previously dissolved in dilute hydrochloric acid. It then, in fact, agrees with the so-called syntonin, which Kühne regards, not as an original albuminoid of muscle, but as myosin altered by the process of extraction. It has been suggested that the ready solution of muscular fibre in dilute hydrochloric acid may be owing to the presence of pepsine in minute quantity.

Other organic compounds also exist in muscle, but in very small proportion in comparison with the albuminoid matter. Most of them probably result from the process of wear of the original muscular substance. Among the most notable are,—1. Kreatin and Kreatinine, both of them nitrogenized and crystalline, the former neutral, the latter (derived from it), alkaline; both are also found in the urine. 2. Sarkin (or Hypoxanthin). 3. Non-nitrogenized substances, viz.: grape sugar; inosit—an unfermentable sugar from the tissue of the heart; glycogen, at least in embryos and young animals. 4. Various organic acids, viz., lactic, inosinic, butyric, acetic, formic and uric. 5. Salts, in which potash predominates over soda, magnesia over lime, and phosphoric acid over chlorine,—muscle, in this respect, resembling blood-corpuscles as contrasted with serum. Lastly, a variable amount of fat may be extracted from muscle, and also gelatin; the latter no doubt from connective tissue; for it must be remembered that a piece of muscle subjected to analysis comprehends, along with the proper muscular fibres, more or less of connective tissue, blood-vessels and nerves. The account here given of the chemical constitution of muscle applies



especially to the striped variety, but, so far as is known, it is essentially the same in the non-striated tissue.

The juice expressed from a muscle after death, and especially after rigidity has set in, is acid, from the presence of lactic acid; so that the cut surface of a dead muscle reddens litmus-paper. On the other hand, a perfectly fresh section of muscle in the living body, or while it retains its irritability, is alkaline or neutral. But while this is true of a living muscle in its usual state, it gives a decided acid reaction after it has been strongly exerted, as, for instance, after tetanic spasm excited by electricity or by strychnia poisoning. The acid is probably generated by a change in the saccharine matter of the muscle. Ultimately the tissue in all cases becomes alkaline from putrefaction and the evolution of ammonia.

*Physical properties of muscle.*—A dead muscle has little strength, and may be torn asunder by a force of no great amount. A living muscle readily yields to extension, and shrinks exactly to its original length when the extending force ceases. Its elasticity is therefore said to be small in degree, but very perfect or complete in operation. A dead muscle, especially after cadaveric rigidity has come on, resists extension more powerfully, but does not afterwards return to its original length; hence its elasticity is said to be greater than that of the living muscle, but less perfect.

The red colour of muscle is well known, but it differs greatly in degree in different cases. It is usually paler in the involuntary muscles; but here the heart again is a striking exception. In most fish the chief muscles of the body are nearly colourless, and in the breast of wild fowl we see a difference in the depth of colour in different strata of the same muscles. The redness is no doubt partly due to blood contained in the vessels, but not entirely so, for a red colouring matter, apparently of the same nature as that of the blood, is obviously incorporated with the fibres.

Under this head must also be mentioned the manifestation of electricity by a quiescent but living muscle. When a muscle taken from a living or recently killed animal (a frog is commonly used) is brought into connection with the ends of a very delicate galvanometer, so that one extremity of the latter touches the outer surface of the muscle, and the other a cross section made through its fibres, the needle will deviate so as to indicate an electric current passing along the wire from the surface of the muscle to its cross section. If both ends of the galvanometer touch points in the length of the muscle equidistant from its middle, no effect ensues, but if one point of contact be farther than the other from the middle, a current will pass along the wire from the nearer to the more distant point. The same results are obtained with a small shred or fasciculus of the muscle. The phenomenon described is called "the muscular current," and is supposed to indicate a state of electric polarity in the particles of the muscle, probably caused by chemical changes going on in its substance.

*Vital properties of muscle.*—The muscular tissue possesses a considerable degree of *sensibility*, but its characteristic vital endowment, as already said, is *irritability* or *contractility*, by which it serves as a moving agent in the animal body.

*Sensibility.*—This property is manifested by the pain which is felt when a muscle is cut, lacerated, or otherwise violently injured, or when it is seized with spasm. Here, as in other instances, the sensibility belongs, properly speaking, to the nerves which are distributed through the tissue, and accordingly when the nerves going to a muscle are cut, it forthwith becomes insensible. It is by means of this property, which is sometimes called the "muscular sense," that we become conscious of the existing state of the muscles which are subject to the will, or rather of the position and direction of the limbs and other parts which are moved through means of the voluntary muscles, and we are thereby guided in directing our voluntary movements towards the end in view. Accordingly, when this muscular sense is lost, while the power of motion remains,—a case which, though rare, yet sometimes occurs,—the person cannot direct the movements of the affected limbs without the guidance of the eye.

*Irritability or Contractility.*—The merit of distinguishing this property of the animal body from sensibility on the one hand, and from mere mechanical phenomena on the other, is due to Dr. Francis Glisson, a celebrated English physician of the seventeenth century; but irritability, according to the view which he took of it, was supposed to give rise to various other phenomena in the animal economy besides the visible contraction of muscle, and his comprehensive acceptance of the term has



been adopted by many succeeding authorities, especially by writers on pathology. Haller, in his use of the term irritability, restricted it to the peculiar property of muscle.

*Stimuli.*—In order to cause contraction, the muscle must be excited by a stimulus. The stimulus may be applied immediately to the muscular tissue, as when the fibres are irritated with a sharp point; or it may be applied to the nerve or nerves which belong to the muscle: in the former case, the stimulus is said to be “immediate,” in the latter, “remote.” The nerve does not contract, but it has the property, when stimulated, of exciting contractions in the muscular fibres to which it is distributed, and this property, named the “vis nervosa,” is distinguished from contractility, which is confined to the muscle. Again, a stimulus may be either directly applied to the nerve of the muscle, as when that nerve is itself mechanically irritated or galvanised; or it may be first made to act on certain other nerves, by which its influence is, so to speak, conducted in the first instance to the brain or spinal cord, and then transferred or reflected to the muscular nerve.

The stimuli to which muscles are obedient are of various kinds; those best ascertained are the following, viz.: 1. Mechanical irritation of almost any sort, under which head is to be included sudden extension of the muscular fibres. 2. Chemical stimuli, as by the application of salt or acrid substances. 3. Electrical; usually by means of a galvanic current made to pass through the muscular fibres or along the nerve. 4. Sudden heat or cold; these four may be classed together as *physical stimuli*. Next, *mental stimuli*, viz.: 1. The operation of the will, or volition. 2. Emotions, and some other involuntary states of the mind. Lastly, there still remain exciting causes of muscular motions in the economy, which, although they may probably turn out to be physical, are as yet of doubtful nature, and these until better known may perhaps without impropriety be called *organic stimuli*; to this head may be also referred, at least provisionally, some of the stimuli which excite convulsions and other involuntary motions which occur in disease.

*Duration of irritability after death.*—It is known that if the supply of nutrient material be cut off from a muscle by arresting the flow of blood into it, its contractility will be impaired, and soon extinguished altogether, but will, after a time, be recovered again if the supply of blood be restored. The influence of the blood supplied to muscles in maintaining their contractility has been strikingly shown by Dr. Brown-Séquard, who has succeeded in restoring muscular contractility in the bodies both of man and animals some time after death, and after it had become to all appearance extinct, by injecting into the vessels arterial blood deprived of its fibrin, or defibrinated venous blood previously reddened by exposure to the air. In warm-blooded animals in which the nutritive process is more active, and the expenditure of force more rapid, the maintenance of irritability is more closely dependent on the supply of blood and the influence of oxygen, so that it sooner fails after these are cut off. In accordance with this statement it is known that while the muscles of man and quadrupeds cease to be irritable within a few hours after death, and those of birds still sooner, the muscular irritability will remain in many reptiles and fish, even for days after the extinction of sensation and volition, and the final cessation of the respiration and circulation,—that is, after systemic death. A difference of the same kind is observed among warm-blooded animals in different conditions; thus irritability endures longer in new-born animals than in those which have enjoyed respiration for some time and are more dependent on that function; and in like manner, it is very lasting in hibernating animals killed during their winter sleep.

But the duration of this property differs also in different muscles of the same animal. From numerous careful observations Nysten concluded that in the human body its extinction takes place in the following order, viz.: 1, the left ventricle of the heart; 2, the intestines and stomach; 3, the urinary bladder; 4, the right ventricle; in these generally within an hour; 5, the gullet; 6, the iris; 7, the voluntary muscles, *a*, of the trunk, *b*, of the lower, and *c*, the upper extremities; 8, the left auricle, and, 9, the right auricle of the heart, which last was on this account styled by Galen the “ultimum moriens.” In one case Nysten observed the right auricle to continue irritable for sixteen hours and a half after death. But it has been recently found that a voluntary muscle will give signs of a certain degree of



irritability even later than this, if it is struck a smart blow with a blunt edge, such as the back of a knife, across the direction of the fibres. The contraction then produced is quite local, and confined to the part struck. Funke states that he and the brothers Weber obtained this result in the body of a decapitated criminal twenty-four hours after death.

The time of duration is affected by the mode of death. Thus the irritability is said to be almost wholly and immediately extinguished by a fatal stroke of lightning, and to disappear very speedily in the bodies of persons stifled by noxious vapours, such as carbonic acid, and especially sulphuretted hydrogen. In like manner certain causes acting locally on muscles accelerate the extinction of their irritability.

*Rigor mortis.*—The “cadaveric rigidity,” or stiffness of the body, which ensues shortly after death, is a phenomenon depending on the muscles, which become fixed or set in a rigid state, so as to resist flexion of the joints. The rigidity almost invariably begins in the muscles of the lower jaw and neck, then invades those of the trunk, and afterwards those of the limbs,—the arms usually before the legs. After persisting for a time, it goes off in the same order. It usually comes on within a few hours after death, rarely later than seven hours. In some cases it has been observed to begin within ten minutes (Sommer), and in others not till sixteen or eighteen hours; and the later its access, the longer is its endurance. The rigidity comes on latest, attains its greatest intensity, and lasts longest in the bodies of robust persons, cut off by a rapidly fatal disease, or suddenly perishing by a violent death; in such cases it may last six or seven days. On the other hand, it sets in speedily, is comparatively feeble, and soon goes off in cases where the body has been much weakened and emaciated by lingering or exhausting diseases; also in newborn infants, and in the muscles of animals that have been hunted to death. It seems thus to be affected by the previous state of nutrition of the muscles. Destruction of the nervous centres does not prevent the occurrence of rigidity, nor are the muscles of paralysed limbs exempted from it, provided their nutrition has not been too deeply affected. The fibres of stiffened muscles are less translucent than before, but no other change is discovered by the microscope. They no longer show the muscular electric current.

The immediate cause of the muscular rigidity is doubtful: some conceive it to be an effect of vital contraction,—the last effort of life as it were; others, with more probability, ascribe it to a solidification of the tissue caused by chemical changes occurring after death. Kühne adduces various arguments, some of them, it must be admitted, of a cogent character, to show that the stiffening is due to post-mortem coagulation of the myosine. He thinks that the substance of the fibre is liquid during life; but it is difficult to reconcile this notion of actual fluidity of substance with some of the most obvious properties of a living muscle. At the same time, it is conceivable that liquid myosin may be present in the interstices of more consistent elements of the living fibre, and may give rise to rigidity by coagulating after death. Free lactic acid is developed in the substance of rigid muscle, and some regard it as the cause of the coagulation of the myosin, but although an acid condition very generally accompanies rigidity, the concurrence is not invariable or essential. Dr. Brown-Séquard, in opposition to the chemical theory, maintained that he could remove rigidity by injecting blood into the vessels of the muscle; but Kühne holds this to be impossible after rigor has decidedly set in. The general accession of rigidity is an unequivocal sign of death.\*

## NERVOUS SYSTEM.

OF the functions performed through the agency of the nervous system, some are entirely corporeal, whilst others involve phenomena of a mental or psychical nature. In the latter and higher class of such functions are first to be reckoned those purely *intellectual operations*, carried on through the instrumentality of the brain, which do not immediately arise from an

\* The subject of muscular contraction and other questions relating to the functional activity of muscle, treated of in former editions of this work, have outgrown the space that could be allotted to their consideration here, and as, moreover, they properly belong to a treatise on physiology, they have now been omitted.



external stimulus, and do not manifest themselves in outward acts. To this class also belong *sensation* and *volition*. In the exercise of sensation the mind becomes conscious, through the medium of the brain, of impressions conducted or propagated to that organ along the nerves from distant parts; and in voluntary motion a stimulus to action arises in the brain, and is carried outwards by the nerves from the central organ to the voluntary muscles. Lastly, *emotion*, which gives rise to gestures and movements varying with the different mental affections which they express, is an involuntary state of the mind, connected with some part of the brain, and influencing the muscles through the medium of the nerves.

The remaining functions of the nervous system do not imply necessary participation of the mind. In the production of those movements, termed *reflex*, *excited*, or *excito-motory*, a stimulus is carried along afferent nerve-fibres to the brain or spinal cord, and is then transferred to efferent or motor-nerve-fibres, through which the muscles are excited to action; and this takes place quite independently of the will, and may occur without consciousness. The motions of the heart, and of other internal organs, the contraction of the coats of the blood-vessels, as well as the invisible changes which occur in secretion and nutrition, are in a certain degree subject to the influence of the nervous system, and are undoubtedly capable of being modified through its agency, though, with regard to some of these phenomena, it is doubtful how far the direct intervention of the nervous system is necessary for their production. These actions, which are all strictly involuntary, are, no doubt, readily influenced by mental emotions; but they may also be affected through the nerves in circumstances which entirely preclude the participation of the mind.

The nervous system consists of a *central part*, or rather a series of connected *central organs*, named the *cerebro-spinal axis*, or *cerebro-spinal centre*; and of the *nerves*, which have the form of cords connected by one extremity with the cerebro-spinal centre, and extending from thence through the body to the muscles, sensible parts, and other organs placed under their control. The nerves form the medium of communication between these distant parts and the centre. One class of nervous fibres, termed *afferent* or *centripetal*, conduct impressions towards the centre,—another, the *efferent* or *centrifugal*, carry motorial stimuli from the centre to the moving organs. The nerves are, therefore, said to be internuncial in their office, whilst the central organ receives the impressions conducted to it by the one class of nerves, and imparts stimuli to the other,—rendering certain of these impressions cognisable to the mind, and combining in due association, and towards a definite end, movements, whether voluntary or involuntary, of different and often of distant parts.

Besides the cerebro-spinal centre and the nervous cords, the nervous system comprehends also certain bodies named *ganglia*, which are connected with the nerves in various situations. These bodies, though of much smaller size and less complex nature than the brain, agree, nevertheless, with that organ in their elementary structure, and to a certain extent also in their relation to the nervous fibres with which they are connected; and this correspondence becomes even more apparent in the nervous system of the lower members of the animal series. For these reasons, as well as from evidence derived from experiment, but which is of a less cogent character, the ganglia are regarded by many as nervous centres, to which impressions may be referred, and from which motorial stimuli may be reflected or emitted; but of local and limited influence as compared with the cerebro-spinal centre, and



operating without our consciousness and without the intervention of the will.\*

The nerves are divided into the *cerebro-spinal*, and the *sympathetic* or *ganglionic* nerves. The former are distributed principally to the skin, the organs of the senses, and other parts endowed with manifest sensibility, and to muscles placed more or less under the control of the will. They are attached in pairs to the cerebro-spinal axis, and like the parts which they supply are, with few exceptions, remarkably symmetrical on the two sides of the body. The sympathetic or ganglionic nerves, on the other hand, are destined chiefly for the viscera and blood-vessels, of which the motions are involuntary, and the natural sensibility is obtuse. They differ also from the cerebro-spinal nerves in having generally a greyish or reddish colour, in their less symmetrical arrangement, and especially in the circumstance that the ganglia connected with them are much more numerous and more generally distributed. Branches of communication pass from the spinal and several of the cerebral nerves at a short distance from their roots, to join the sympathetic, and in these communications the two systems of nerves mutually give and receive nervous fibres; so that parts supplied by the sympathetic may be also in nervous connection with the cerebro-spinal centre.

The nervous system is made up of a substance proper and peculiar to it, with inclosing membranes, nutrient blood-vessels, and supporting connective tissue. The *nervous substance* has been long distinguished into two kinds, obviously differing from each other in colour, and therefore named the *white*, and the *grey* or *cineritious*.

#### CHEMICAL COMPOSITION.

The information we possess respecting the chemical composition of nervous matter is for the most part founded on analyses of portions of the brain and spinal cord; but the substance contained in the nerves, which is continuous with that of the brain and cord, and similar in physical characters, appears also, as far as it has been examined, to be of the same general chemical constitution. No very careful comparative analysis has yet been made of the grey and white matter, to say nothing of the different structural elements of the nervous substance; and indeed it must be remembered, that, in portions of brain subjected to chemical examination, capillary blood-vessels, connective, and perhaps other accessory tissues, as well as interstitial fluid, are mixed up in greater or less quantity with the true nervous matter, and must so far affect the result.

The nervous matter may be said to consist of an albuminoid body, in part liquid, with fatty principles, extractive matters, salts, and much water. The water, which forms from three-fourths to four-fifths or more of the whole cerebral substance, may be removed by immersion in alcohol and evaporation. When the solid matter which remains after removal of the water is treated with ether and hot alcohol, the fatty compounds are extracted from it by these menstrua, and there remains a mixture of coagulated albuminous matter and salts, with a small remnant due to accessory tissues, chiefly vessels.

The *albuminoid constituent* is not sufficiently known to be characterised specifically. It no doubt belongs, in some small proportion, to the interstitial fluid. Of that which

\* From the researches of Dr. Augustus Waller it appears probable that ganglions exert some influence over the nutrition of the nerve-fibres connected with them, and serve to maintain the structural integrity of these fibres; for it has been found that when a ganglionic nerve is cut across in a living animal, the part beyond the section after a time becomes atrophied, while the part connected with the ganglion retains its integrity.



is contained in the proper nervous substance, a portion—forming the central part of the nerve fibres (axis cylinder)—appears in microscopic observations to be solid; whilst in the surrounding part (medullary sheath) the albuminoid is liquid and incorporated with fatty matter, also liquid, being probably combined as a colloid with the fat, in the way pointed out by Mr. Graham (see ante, page vii). The fats are—

1. The *cerebric acid* of Fremy, called *cerebrin* by Gobley, because he considers it a neutral body, acid only from contamination with phosphoric acid, but containing phosphorus, which also is regarded as an impurity by W. Müller.

2. *Oleo-phosphoric acid* of Fremy, a very unstable compound, held by Gobley to be a mixture of oleic acid and his glycero-phosphoric acid, which, it may be remarked, he has found also in the yolk of the egg.

3. *Olein*, *margarin*, and *palmitin*, with their acids.

4. *Cholesterin*—although this is no longer considered a true fat, and may, moreover, be a product of tissue change.

The extractive matters probably belong chiefly to the interstitial fluid; but, however this may be, they may be held to represent the products of decomposition of the nervous substance. The following have been recognised:—

1. *Lactic*, *formic*, *acetic*, and (traces of) *uric acid*.

2. *Inosit*.

3. *Kreatin*.

4. *Hypoxanthin* (or *sarkin*).

5. *Leucin* (in the ox).

In regard to free acid, Funke has found the same law to prevail in nerve as in muscle—namely, that the substance of nerves in the living but quiescent state is neutral, but becomes acid after death or prolonged excitement. The saline or inorganic matters found by incineration are—*phosphoric acid*, *phosphates of alkalis*, which, as in muscle, largely predominate over other salts, *potash*, as a base largely exceeding *soda*; *earthy phosphates*, in smaller proportion, *magnesia* prevailing over *lime*; *phosphate of iron*; *chloride of sodium*, *sulphate of potash*, and a trace of *silica*. From fresh brain-substance Breed obtained 0.027 per cent. of ashes, which per 100 parts yielded 55.24 phosphate of potash, 22.93 phosphate of soda, 1.23 phosphate of iron, 1.62 phosphate of lime, 3.4 phosphate of magnesia, 4.74 chloride of sodium, 1.64 sulphate of potash (the sulphuric acid doubtless from combustion of principles containing sulphur), 9.15 free phosphoric acid (from combustion of phosphorus), and 0.42 silicic acid.

The white substance contains nearly 75 per cent. of water; the grey about 85; the proportion of water is less in the spinal cord, and still less in the nerves. The fat amounts in the grey matter to nearly 5 and in the white to nearly 15 per cent.; in the nerves the proportion fluctuates largely. It is worthy of note that the brain during embryo and infantile life contains much less fat and more water; moreover, the grey and the white matter do not present the same differences as in after life in the proportions of water and fat which they respectively contain. The brain of embryos of from ten to twenty-two weeks has been found to yield only from 0.99 to 1.5 per cent. of fat; that of the full grown foetus from 3 to 4 per cent. The water in the foetal brain at birth is about 85 per cent., both in the white and the grey substance.

#### STRUCTURAL ELEMENTS.

When subjected to the microscope, the nervous substance is seen to consist of two different structural elements, viz., *fibres* and *cells*. The fibres are found universally in the nervous cords, and they also constitute the greater part of the nervous centres: the cells on the other hand are confined in a great measure to the cerebro-spinal centre and the ganglia, and do not exist generally in the nerves properly so called, although they have been found at the terminations of some of the nerves of special sense, and also interposed here and there among the fibres of particular nerves; they are contained in the grey portion of the brain, spinal cord, and ganglia, which grey substance is in fact made up of these cells intermixed in many parts with fibres, and with a variable quantity of supporting connective substance.



In further pursuing the subject, we shall first examine the fibres and cells by themselves, and afterwards consider the structure of the parts which they contribute to form, viz., the cerebro-spinal organs, the ganglia, and the nerves.

The fibres are of two kinds: 1, the *white, tubular, medullated*, or *dark bordered*, and 2, the *grey, pale, non-medullated*, or *gelatinous*. The former are by far the most abundant; the latter are found principally in the sympathetic nerve, but are known to exist also in many of the cerebro-spinal nerves.

The *White or Tubular Fibres* (fig. LXXIV).—These form the white part of the brain, spinal cord, and nerves. When collected in considerable numbers and seen with reflected light, the mass which they form is white and

Fig. LXXIV.

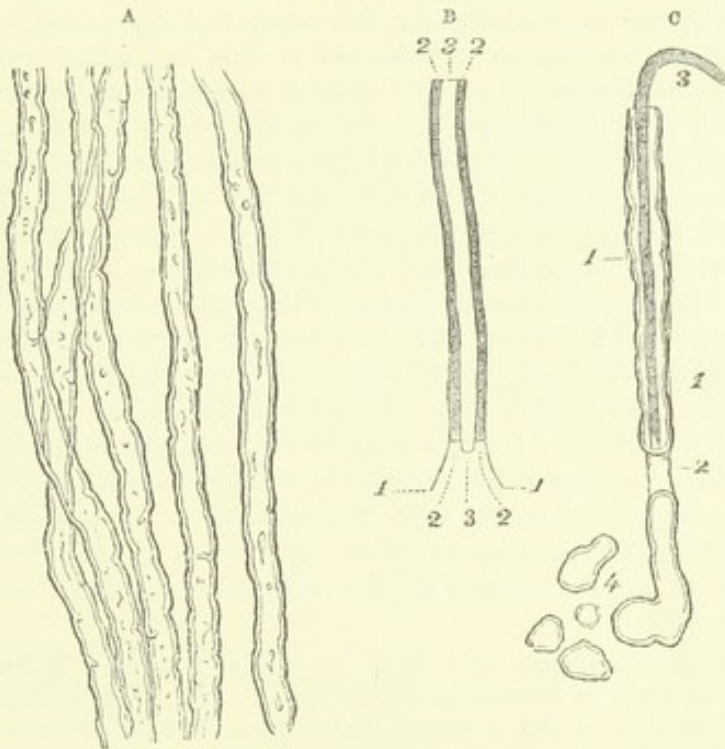


Fig. LXXIV.—A. WHITE OR TUBULAR NERVE-FIBRES, showing the sinuous outline and double contours.

B. DIAGRAM to show the parts of a tubular fibre, viz. 1, 1, *membranous tube*. 2, 2, *white substance or medullary sheath*. 3, *axis or primitive band*.

C. DIAGRAM intended to represent the appearances occasionally seen in the tubular fibres. 1, 1, *membrane of the tube* seen at parts where the white substance has separated from it. 2, a part where the white substance is interrupted. 3, *axis projecting beyond the broken end of the tube*. 4, *part of the contents of the tube escaped*.

opaque. Viewed singly, or few together, under the microscope, with transmitted light, they are transparent; and if quite fresh from a newly-killed animal, and unchanged by cold or exposure, they appear as if entirely homogeneous in substance, like threads of glass, and are bounded on each side by a simple and usually gently sinuous outline. Their size differs considerably even in the same nerve, but much more in different parts of the nervous system; some being as small as the  $\frac{1}{12000}$ th and others upwards of the  $\frac{1}{1300}$ th of an inch in diameter; moreover, the same fibre may change its size in different parts of its course, and it is generally smaller at its central and peripheral ends. Very speedily after death, and especially on exposure to the action of water, these seemingly homogeneous fibres become altered:



and it is when so altered that they are commonly subjected to examination, as represented in fig. LXXIV A. In particular instances, and in favourable circumstances, it may be discovered that the fibre is composed of a fine membranous tube, inclosing a peculiar soft substance, and that this contained substance itself is distinguishable into a central part placed like a sort of axis in the middle of the tube, and a peripheral portion surrounding the axis, and occupying the space between it and the tubular inclosing membrane. In the annexed ideal plan (fig. LXXIV B), the *membranous tube*, or *primitive sheath*, is marked 1, 1 : the central part, marked 3, was named *cylinder axis* by Purkinje, who considered it to be identical with the structure previously described by Remak under the name of the *primitive band* (*fibra primitiva*) ; the matter surrounding it, marked 2, 2, is supposed to be the chief cause of the whiteness of the brain and nerves, and it was accordingly named the *white substance* by Schwann, and by others, though less appropriately, the *medullary sheath*. It is this last-mentioned substance which undergoes the most marked change on exposure ; it then seems to suffer a sort of coagulation or congelation, and when this has taken place, it very strongly refracts the light, and gives rise to the appearance of a dark border on each side of the nerve-tube (fig. LXXIV, A and C). This border, though darker than the rest of the tube, is nevertheless translucent, and is either colourless, or appears of a slightly yellowish or brownish tint ; it is bounded by two nearly parallel lines, so that the nerve-fibre has then a double contour, and the inner line, less regular than the outer, gradually advances further inwards as the change in the white substance extends to a greater depth. The dark contours pursue a sinuous course, often with deep and irregular indentations ; while straight or curved lines of the same character, occasioned no doubt by wrinkles or creases occurring in the layer of white substance, are frequently seen crossing the tube. By continued exposure, round and irregular spots appear at various points, and at length the contents of the nerve-tube acquire a confusedly curdled or granulated aspect.

The double contour appears only in fibres of a certain size ; in very fine tubes, which become varicose or dilated at intervals, the double line is seen only in the enlargements, and not in the narrow parts between. It often happens that the soft contents of the tube are pressed out at the ruptured extremities, as in fig. LXXIV. c, 4, and then the round or irregular masses of the effused matter are still surrounded by the double line, which proves that this appearance is produced independently of the membranous tube. So long as this tube is accurately filled by the contained matter, its outline cannot be distinguished ; but sometimes, when the white substance separates at various points from the inside of the tube, the contour of the fibre becomes indented and irregular, and then the membrane of the tube may, in favourable circumstances, be discerned as an extremely faint line, running outside the deeply-shaded border formed by the white substance, and taking no part in its irregular sinuosities (fig. LXXIV., c, 1, 1). The membranous tube may also be distinguished at parts where the continuity of the contained matter is broken in consequence of traction, squeezing, or like injury of the fibre ; in such parts the double line produced by the white substance is wanting, and the faint outline of the membranous tube may be perceived passing over the interruption (2). The fine transparent membrane which forms this tube, named also the *primitive sheath*, appears to be quite simple and homogeneous in structure ; so far as can be judged, it agrees in chemical nature with elastic tissue. Treatment with weak chromic acid, or iodine, or, still better, staining with carmine or aniline-red (magenta), brings into view nuclei attached along the sheath. They are found on the fibres of the nerves generally, but not in the optic and auditory nerves, nor in the brain and spinal cord ; and, indeed, it is still a question whether the fibres of these last-named nerves and nervous centres are provided with a membranous sheath.



The *axis cylinder*, *axis band*, or *axial fibre* is situated in, or near, the middle of the nerve-tube, where it may occasionally be seen, on a careful inspection, as a greyish stripe or band, bounded on either side by a very faint, even outline, having no share in the sinuosities of the white substance (fig. LXXIV, c).

The axis is of a more tenacious consistence than the white substance, and may accordingly be sometimes seen projecting beyond it at the end of a broken nerve-tube, either quite denuded, or covered only by the tubular membrane, the intervening white substance having escaped. Although the name of axis-cylinder would seem to imply that it had actually a cylindrical figure, yet this is by no means certain; and whether naturally cylindrical or not, it certainly very generally appears more or less flattened when subjected to examination. To all outward appearance, usually, it is solid and homogeneous, but sometimes it is striated longitudinally, and towards its termination at the peripheral extremity of the nerve, it very commonly divides into finer filaments. The axis-cylinder consists of a solid albuminoid substance, whereas the medullary sheath or white substance consists mainly of fat and a certain proportion of albuminous matter, combined with it as a colloid into an oleo-albuminous liquid. Accordingly, whilst water, especially when cold, rapidly produces congelation of the white substance, ether, on the other hand, causes it speedily to disappear as if by solution, and globules of oil then make their appearance both within and without the tube, the remaining contents becoming granular from precipitation of albumen.

The existence of an axial fibre is probably universal in nerve-fibres, though it is not generally visible without preparation. To bring it into view, a solution of carmine or aniline-red (magenta) may be used, which stains it red—first colouring the denuded and projecting ends, but finally also the part still surrounded with the medullary sheath. Glacial acetic acid, chromic acid, iodine, alcohol, chloroform, collodium, and other reagents, are also employed with greater or less advantage.

Many of the tubular nerve-fibres, when subjected to the microscope, appear dilated or swollen out at short distances along their length, and contracted in the intervals between the dilated parts. Such fibres have been named *varicose* (fig. LXXV). They occur principally in the brain and spinal cord, and in the intracranial part of the olfactory, in the optic, and acoustic nerves; they are occasionally met with also in the other nerves, especially in young animals. These fibres, however, are naturally cylindrical like the rest, and continue so while they remain undisturbed in their place; and the varicose character is occasioned by pressure or traction during the manipulation, which causes the soft matter contained in the nerve-tube to accumulate at certain points, whilst it is drawn out and attenuated at others. Most probably the change takes place before the white substance has coagulated. The fibres in which it is most apt to occur are usually of small size, ranging from  $\frac{1}{12000}$ th to  $\frac{1}{3600}$ th of an inch in diameter; and when a very small fibre is thus affected, the varicosities appear like a string of

Fig. LXXV.

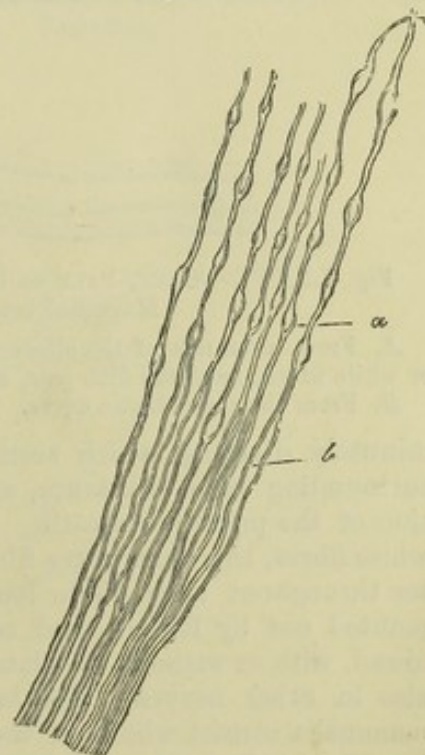


Fig. LXXV.—FIBRES FROM THE ROOT OF A SPINAL NERVE.

At *a*, where they join the spinal cord, they are varicose; lower down at *b*, they are uniform and larger (from Valentin).



globules held together by a fine transparent thread. As already remarked, the double contour caused by congelation of the white substance does not appear in the highly-constricted parts. The axis takes no part in this change, indeed it may sometimes be seen running through the varicosities and undergoing no corresponding dilatation.

Neither in their course along the nervous cords, nor in the white part of the nervous centres, have these tubular fibres ever been observed to unite or anastomose together, nor are they seen to divide into branches; it is therefore fair to conclude that, though bound up in numbers in the same nervous cords, they merely run side by side like the threads in a skein of silk, and that they maintain their individual distinctness throughout the trunk and branches of a nerve; but in many cases the fibres divide in approaching the peripheral termination of the nerve, as will be again noticed.

*Grey, Pale, Non-medullated, or Gelatinous Fibres* (fig. LXXVI).—The white fibres, at the peripheral extremities of many nerves, lay aside their medullary sheath and dark borders, and are prolonged into pale fibres, often

Fig. LXXVI.

A



B

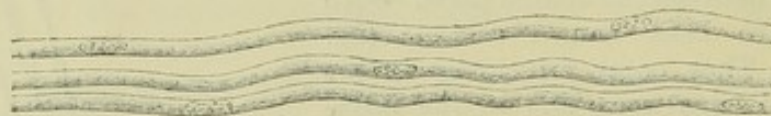

Fig. LXXVI.—GREY, PALE OR GELATINOUS NERVE-FIBRES (from Max Schultze. Magnified between 400 and 500 diameters).

A. From a branch of the olfactory nerve of the sheep; at *a, a*, two dark bordered or white fibres, from the fifth pair, associated with the pale olfactory fibres.

B. From the sympathetic nerve.

minutely dividing, which seem to represent the axis-cylinder deprived of surrounding white substance, and either naked or covered with a prolongation of the primitive sheath. But, apart from these pale continuations of white fibres, there are nerve-fibres which exhibit the non-medullated character throughout their whole length. These are the pale, grey fibres first pointed out by Remak, and commonly designated by his name, which are found, with or without associated white fibres, chiefly in the sympathetic but also in other nerves. The branches of the olfactory nerve of man and mammalia consist wholly of these pale fibres. They were named gelatinous (by Henle) from their aspect, not their chemical nature. They measure from  $\frac{1}{8000}$ th to  $\frac{1}{6000}$ th of an inch in diameter, appear flattened, translucent, homogeneous, or very faintly granular, and sometimes finely striated longitudinally. At short distances they bear oblong nuclei, which have been supposed to belong to a sheath (Max. Schultze). As these fibres generally end peripherally—and some (olfactory) are known to begin centrally—by a



number of fine fibrils, it has been by some anatomists suggested, by others maintained, that they are really bundles of immeasurably fine filaments; moreover, it is asserted that the fibrillar structure may be actually observed in pale sympathetic fibres; but this view, however probable, stands in need of confirmation.

Pale fibres are also met with (in the sympathetic nerve especially) which appear as fine simple filaments with fusiform enlargements, often finely granular in substance, and possibly of the nature of nuclei, but placed in the continuity of the fibre, and not merely attached to a sheath.

*Nerve-cells*, sometimes called *Nerve-vesicles*.

—These, as already mentioned, constitute the second kind of structural elements proper to the nervous system. They are found in the grey matter of the cerebro-spinal centre and ganglions, constituting a principal part of the last-mentioned bodies, and thence often named *ganglionic corpuscles* or *ganglion globules*; they exist also in some of the nerves of special sense at their peripheral expansions, and, here and there, in the course of certain other nerves. The nerve-cells may have a spheroidal, oval, or pyriform shape (fig. LXXVII); and such for the most part is their form in the ganglions; but many, and especially those from the grey matter of the spinal cord and brain, are of an angular or irregular figure, and send out processes,

Fig. LXXVII.

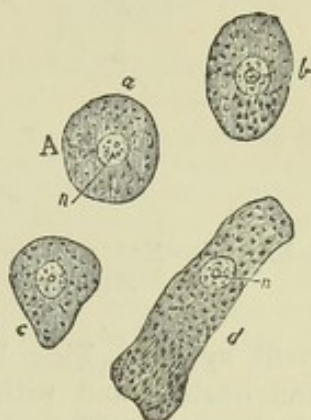


Fig. LXXVII. — GANGLIONIC NERVE-CELLS, MAGNIFIED (from Valentin).

Fig. LXXVIII.

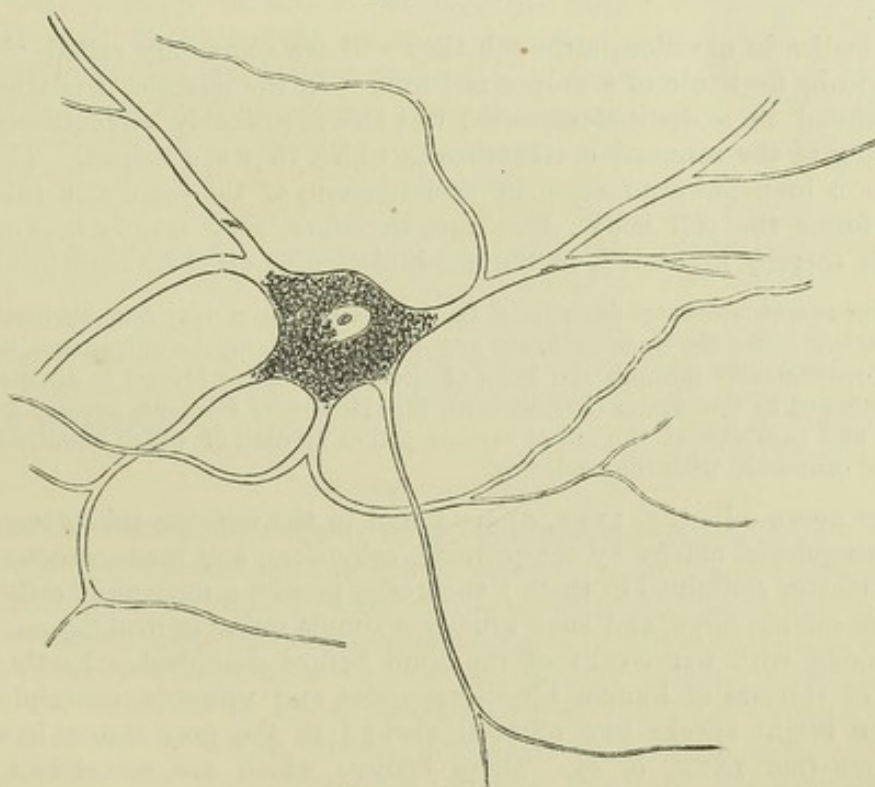


Fig. LXXVIII. — RAMIFIED NERVE-CELL, FROM THE GREY MATTER OF THE HUMAN MEDULLA OBLONGATA. MAGNIFIED 350 DIAMETERS (from Kölliker).



often finely branched, from their circumference (figs. LXXVIII and LXXIX); and then they are often named, according to the number of processes they present, uni-, bi-, and multipolar; terms obviously ill chosen, but rendered

Fig. LXXIX.

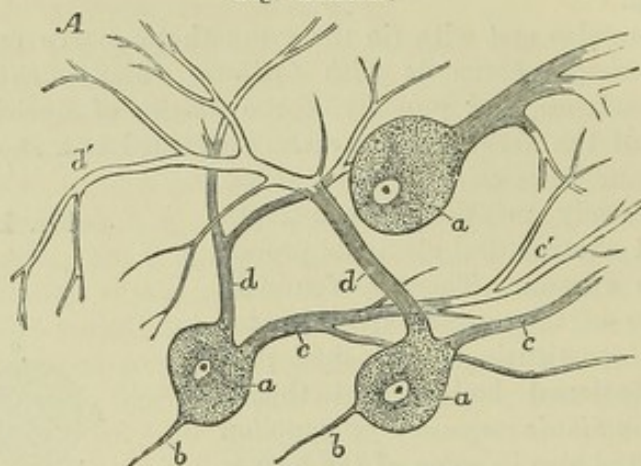


Fig. LXXIX.—NERVE-CELLS FROM THE CORTICAL GREY MATTER OF THE CEREBELLUM. MAGNIFIED 260 DIAMETERS (from Kölliker, reduced).

current by use. They have each, as a rule, a large, well-defined, clear, round nucleus, and within this an equally distinct nucleolus, or sometimes more than one. The substance of the cell is soft and translucent, but finely granular or punctuated, and slightly tinged throughout with a brownish red colour; and cells are often seen, especially those of the large ramified kind, with one, or sometimes two, much deeper coloured brown patches, caused by groups of pigment granules; the colour is deeper in adult age than in infancy.

The bodies in question, although they still are commonly called “cells,” appear to be destitute of a proper cell-wall. In the ganglia, it is true, they are enclosed in a distinct capsule; but this is probably adventitious, and pertaining to the connective structure in which they are lodged. The outrunners or branches are formed by prolongations of the same soft substance which forms the cell body; they are, therefore, very readily broken, and the cells thereby mutilated, in the manipulation required for their insulation.

Various recent observers describe a faint striation, or a very fine fibrillation, in the branched cells; the lines or fibrils are said to run along the outrunners, and also to pass continuously through the body of the cell from one branch to another; it is further alleged by one writer (Frommann), that bundles of filaments proceed from the nucleus and pass out of the cell at various points, in each of which bundles there is one fibril connected with the nucleolus.

Other nerve-cells (fig. LXXX, *a*) are found in the nervous substance, which are distinguished chiefly by the pellucid, colourless, and homogeneous aspect of the matter contained in them; such cells possess a nucleus like the rest; they are seldom large, and have usually a simple round or oval figure. They occur along with nerve-cells of the kind before described. Lastly, small bodies of the size of human blood-corpuscles and upwards, containing one or more bright specks like nucleoli, abound in the grey matter in certain situations (fig. LXXX, *b*, *c*). These bodies, which are sometimes called “granules” (*Körner* in German), resemble the nuclei of nerve-cells; and it may be a question whether they are not the nuclei of cells in which the



cell-matter or protoplasm is very scanty, and accidentally detached in examination. These nucleus-like bodies are very abundant in the superficial grey matter of the cerebellum.

In the grey matter of the cerebro-spinal centre, the nerve-cells appear as if imbedded in a sort of matrix of granular substance, interposed between them in greater or less quantity, and very generally traversed by nerve-fibres. But it is very probable that the appearance of granular or molecular matter results from a confused interlacement of very fine fibrils, and especially of the fine ramifications of nerve-cells; or from the crushing and breaking down of such fibres in the process of examination. In the ganglia properly so called, the cells are packed up among nerve-fibres, but each cell is also immediately surrounded by an inclosing capsule (fig. LXXXII. and LXXXIII.).

The proper nervous substance of the brain and spinal cord is described by Kölliker as being traversed in all directions and supported by a framework of connective tissue—the “retiform” connective tissue described at page lxxix. This is formed of an inter-union of ramified connective-tissue corpuscles, or of a network of fine fibres alone, originally proceeding from such corpuscles. Kölliker names this supporting structure the *reticulum* of the nervous centres (fig. LXXXI.). Virchow proposes the term *neuroglia*. It is not merely an open mesh-work, but consists also of fine laminae formed of a close interlacement of the finest fibrils, disposed as membranous partitions and tubular compartments for separating and inclosing the nervous bundles.

Such being the structural elements of the nervous substance, we have next to consider the arrangement of these cells and fibres in the ganglia and nerves which they contribute to form; the intimate structure of the encephalon and spinal cord being treated of in the part of this work which is devoted to special or descriptive anatomy.

#### OF THE GANGLIA.

The bodies so named are found in the following situations—viz. : 1. On the posterior root of each of the spinal nerves, on one, and probably the corresponding root of the fifth nerve of the encephalon, and on the seventh pair, glosso-pharyngeal and pneumogastric nerves, involving a greater or less amount of their fibres; also on the branches of certain cerebro-spinal nerves. 2. Belonging to the sympathetic nerve. (a)—In a series along each side of the vertebral column, connected by nervous cords, and constituting what was once considered as the trunk of the sympathetic. (b)—On branches of the sympathetic; occurring numerously in the abdomen, thorax, neck, and head; generally in the midst of plexuses, or at the point

Fig. LXXX.

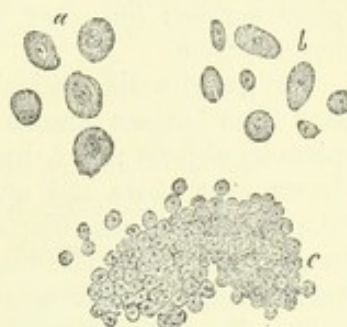


Fig. LXXX.—SMALL NERVE-CELLS.

a, from the (cortical) grey matter of the brain. b and c are from the cortical substance of the cerebellum; b resemble detached cell-nuclei. c are smaller bodies, also like cell-nuclei, densely aggregated (from Hannover, magnified 340 diameters).

Fig. LXXXI.

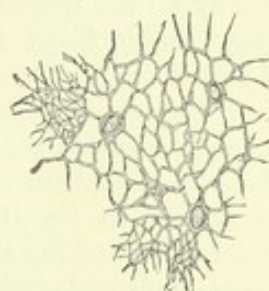


Fig. LXXXI.—PART OF THE RETICULUM FROM THE SPINAL CORD.

Open meshes are seen generally, but at two places the close lamelliform interlacements are shown. Magnified 350 diameters (from Kölliker).



of union of two or more branches. Those which are found in several of the fossæ of the cranium and face are for the most part placed at the junction of fine branches of the sympathetic with branches, usually larger, of the cerebro-spinal nerves; but they are generally reckoned as belonging to the sympathetic system.

The ganglia differ widely from each other in figure and size: those which have been longest known to anatomists are most of them large and conspicuous objects; but, by the researches of Remak and others, it has been shown that there are numerous small, or what might be almost termed microscopic ganglia, disposed along the branches of nerves distributed to the tongue, the heart, the lungs, and some other viscera; also connected with fine plexuses of nerves between the coats of the intestines.

Ganglions are invested externally with a thin but firm and closely adherent envelope, continuous with the fibrous sheath of the nerves, and composed of connective tissue; this outward covering sends processes inwards through the interior mass, dividing it, as it were, into lobules, and supporting the numerous fine vessels which pervade it. A section carried through a ganglion, in the direction of the nervous cords connected with it, discloses to the naked eye merely a collection of reddish-grey matter traversed by the white fibres of the nerves. The nervous cords on entering lay aside their investing sheath and spread out into smaller bundles, between which the grey ganglionic substance is interposed; and their fibres are gathered up again into cords, furnished with sheaths, on issuing from the ganglion. The microscope shows that this grey substance consists of nerve-cells and fibres with supporting connective tissue. The nerve-cells, or ganglion globules, have mostly a round, oval, or pyriform figure (figs. LXXVII., LXXXII. and LXXXIII.). They are inclosed in capsules formed of a transparent membrane with attached or imbedded nuclei.

Of the relation between the nerve fibres in a ganglion and the ganglion cells, it may be stated that many fibres pass through without being connected with the cells, but that every nerve-cell is connected with a fibre or with fibres. According to Dr. Beale, each cell is connected with, at least, two fibres, which, on reaching the nervous bundle in which they are distributed, run in opposite directions (fig. LXXXII.). One of the fibres is straight, usually of tolerable size, and connected with the cell at one spot like a stalk—in pyriform cells at the small end. The other, usually smaller, begins or is attached at some distance from the insertion of the first, and makes several turns on the surface of the cell, but within its capsule, which are continued as spiral coils round the straight fibre, and then the two part company and, apparently, run in opposite directions in the nervous bundle in which they mingle.

The spiral fibre bears large oblong nuclei along its course. These are seen on its spiral turns upon the surface of the cell, and some, at the commencement of the fibre, seem to be beneath the surface. It may be single from the first, or begin by two or more filaments which join at some distance from the cell. Both fibres increase in size as they proceed. They have at first the character of pale fibres (or axis cylinders), then one of them—generally the straight one, but it may be the other—at a short distance from the cell acquires a medullary sheath and becomes a dark bordered fibre. At the same time it cannot be positively said that both fibres may not become dark bordered, or both continue as pale fibres. The spiral fibre may make more or fewer coils, and Dr. Beale thinks they are more numerous in older cells—for in some cases the smaller fibre (answering to the spiral one elsewhere) is not coiled; and the cells in such cases he considers to be young or recently formed.



Dr. Beale's observations have been made chiefly on the ganglia of frogs, the cells of which have very commonly a pyriform shape like the one represented in the figure. In mammalia they are more spheroidal, and the observation of their connection with fibres is more difficult; but from examinations in mammalia, so far as they have gone, Dr. Beale infers that the relation of the cells and fibres is essentially the same as in frogs.

Fig. LXXXII.

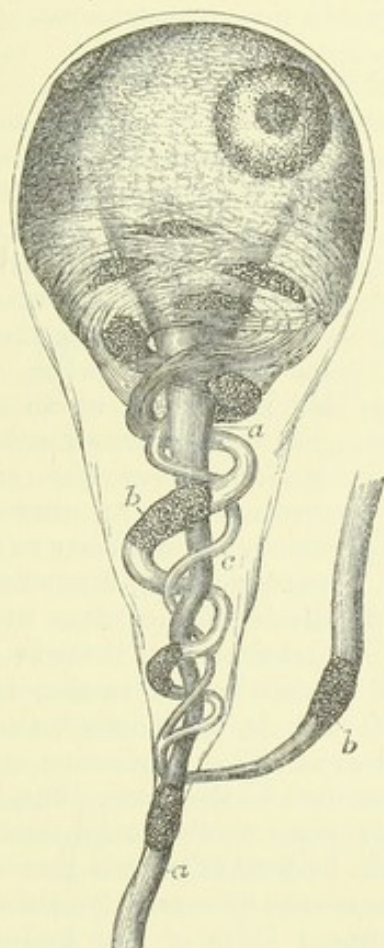


Fig. LXXXIII.

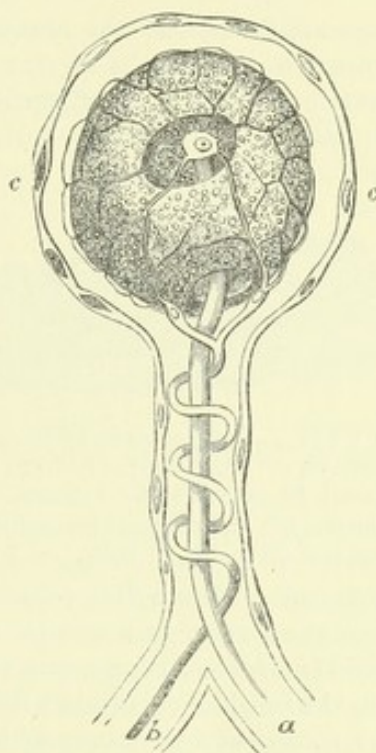


Fig. LXXXII.—GANGLION-CELL OF A FROG, MAGNIFIED; ACCORDING TO BEALE.

Reduced and adapted from one of his figures. *a, a*, straight fibre; *b, b*, coiled fibre; *c*, smaller one joining it.

Fig. LXXXIII.—MAGNIFIED GANGLION-CELL, FROM THE SYMPATHETIC OF THE FROG, ACCORDING TO J. ARNOLD. Virch. Arch. 1865.

*a*, straight fibre; *b*, coiled fibre, arising by a superficial net connected with nucleolus of the cell; *c, c*, capsule with nuclei.

Two subsequent writers, Julius Arnold and L. G. Courvoisier, have confirmed Dr. Beale's original observation in almost every point; but whilst Beale describes the two fibres as connected with the substance of the cell and at its surface only—or, at least, could not obtain satisfactory evidence of its passing into the interior—Arnold, and (after him) Courvoisier describe (as had previously been done by Harless and others) the straight fibre as traceable into the nucleus, with which Arnold thinks its medullary sheath, here altogether inconsiderable, is continuous, whilst the axial part ends in the nucleolus, which he regards as the knobbed end of the axis cylinder. Then both describe a network of exquisitely fine fibrils, which, springing from the nucleolus as a centre, traverses the substance of the cell and comes to the surface between the cell-body and its sheath, and finally unites into the spiral fibre. According to this account, the nucleolus is, as it were, the end of the straight fibre and beginning of the spiral one, or *vice versa*; or, at least, the point of organic connection between them in the cell.



Courvoisier describes both fibres as acquiring a medullary sheath, the straight one first. He has found the above described structure in the ganglia of fish, birds, and mammals; but whilst in the frog the cell has never, or scarcely ever, more than one straight and very rarely more than one spiral fibre, he finds that in other vertebrates a cell may give off such twin fibres from two or more parts of its circumference.

In the spinal ganglia of the skate, torpedo, and dog-fish, there is a different arrangement. In these, as first pointed out by R. Wagner, two fibres are connected with each ganglion-cell, at opposite sides or opposite poles,—one directed centrally toward the root of the nerve, and the other outwardly towards its branches.

#### CEREBRO-SPINAL NERVES.

These are formed of the nerve-fibres already described, collected together and bound up in sheaths of connective tissue. A larger or smaller number of fibres inclosed in a tubular sheath form a slender round cord of no determinate size, usually named a *funiculus*; if a nerve be very small it may consist of but one such cord, but in larger nerves several funiculi are united together into one or more bundles, which, being wrapped up in a common membranous covering constitute the nerve (fig. LXXXIV.).

Fig. LXXXIV.

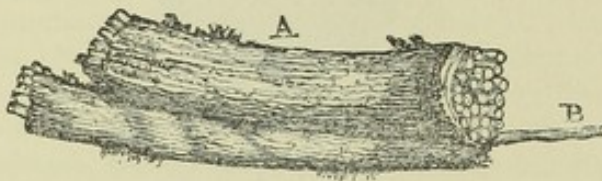

Fig. LXXXIV.—PORTION OF THE TRUNK OF A NERVE, CONSISTING OF MANY SMALLER CORDS OR FUNICULI WRAPPED UP IN A COMMON SHEATH.

A, the nerve; B, a single funiculus drawn out from the rest (from Sir C. Bell).

Accordingly, in dissecting a nerve, we first come to an outward covering, formed of connective tissue, often so strong and dense that it might well be called fibrous. From this common sheath we trace laminæ passing inwards between the larger and smaller bundles of funiculi, and finally between the funiculi themselves, connecting them together as well as conducting and supporting the fine blood-vessels which are distributed to the nerve. But, besides the interposed areolar tissue which connects these smallest cords, each funiculus has a special sheath of its own, as will be further noticed presently.

The common sheath and its subdivisions consist of connective tissue, presenting the usual white and yellow constituent fibres of that texture, the latter being present in considerable proportion. The special sheaths of the funiculi, on the other hand, appear to be formed essentially of a fine transparent membrane, which may without difficulty be stripped off in form of a tube from the little bundle of nerve-fibres of which the funiculus consists. When examined with a high power of the microscope, this membrane presents the aspect of a thin transparent film, which in some parts appears to be quite simple and homogeneous, but is more generally marked with extremely fine reticulated fibres. Corpuscles resembling elongated cell-nuclei may also be seen upon it when acetic acid is applied. The tissue investing a nerve and inclosing its proper fibres, as now described, is named the *neurilemma*, and the term is for the most part applied indiscriminately to the whole of the enveloping structure, though some anatomists use it to denote only the sheaths of the funiculi and smaller fasciculi, whilst they name the general external covering of the nerve its “cellular sheath” (*vagina cellulosa*).

Some recent writers, believing that the primitive sheath or membranous tube of the nerve-fibre corresponds to the sarcolemma of muscle, have proposed to designate it as the *neurilemma*, and to use the term *perineurium* for the coarser sheathing of the nerves and nervous cords, to which the term



neurilemma has been heretofore applied. The use of the term *perineurium* is unobjectionable and may sometimes be convenient, but the proposed new and restricted application of the term *neurilemma* will, I think, lead to ambiguity, and is of doubtful propriety.

The funiculi of a nerve are not all of one size, but all are sufficiently large to be readily seen with the naked eye, and easily dissected out from each other. In a nerve so dissected into its component funiculi, it is seen that these do not run along the nerve as parallel insulated cords, but join together obliquely at short distances as they proceed in their course, the cords resulting from such union dividing in their further progress to form junctions again with collateral cords; so that in fact the funiculi composing a single nervous trunk have an arrangement with respect to each other similar to that which we shall presently find to hold in a plexus formed by the branches of different nerves. It must be distinctly understood, however, that in these communications the proper nerve-fibres do not join together or coalesce. They pass off from one nervous cord to enter another, with whose fibres they become intermixed, and part of them thus intermixed may again pass off to a third funiculus, or go through a series of funiculi and undergo still further intermixture; but throughout all these successive associations (until near the termination of the nerve) the fibres remain, as far as known, individually distinct, like the threads in a rope.

The fibres of the cerebro-spinal nerves are chiefly, in some cases perhaps exclusively, of the white or medullated kind, but in most instances there are also grey fibres in greater or less number. Moreover, it has often appeared to me as if there were filaments of extreme tenuity, like the white filaments of connective tissue, but of doubtful nature, mixed up with well-characterised nerve-fibres within the sheaths of the funiculi. Lying alongside each other, the fibres of a funiculus form a little skein or bundle, which runs in a waving or serpentine manner within its sheath; and the alternate lights and shadows caused by the successive bendings being seen through the sheath, give rise to the appearance of alternate light and dark cross stripes on the funiculi, or even on larger cords consisting of several funiculi. On stretching the nerve, the fibres are straightened and the striped appearance is lost.

*Vessels.*—The blood-vessels of a nerve supported by the sheath divide into very fine capillaries, said by Henle to measure in the empty state not more than  $\frac{1}{6000}$ th of an inch in diameter. These, which are numerous, run parallel with the fibres, many of them within the funicular sheaths, but are connected at intervals by short transverse branches, so as in fact to form a network with long narrow meshes.

*Branching and conjunction of Nerves.*—Nerves in their progress very commonly divide into branches, and the branches of different nerves not unfrequently join with each other. As regards the arrangement of the fibres in these cases, it is to be observed, that, in the branching of a nerve, collections of its fibres successively leave the trunk and form branches; and that, when different nerves or their branches intercommunicate, fibres pass from one nerve to become associated with those of the other in their further progress; but in neither case (unless towards their peripheral terminations) is there any such thing as a division or splitting of an elementary nerve-fibre into two, or an actual junction or coalescence of two such fibres together.

A communication between two nerves is sometimes effected by one or two connecting branches. In such comparatively simple modes of connec-



tion, which are not unusual, both nerves commonly give and receive fibres ; so that, after the junction, each contains a mixture of fibres derived from two originally distinct sources. More rarely the fibres pass only from one of the nerves to the other, and the contribution is not reciprocal. In the former case the communicating branch or branches will of course contain fibres of both nerves, in the latter of one only.

In other cases the branches of a nerve, or branches derived from two or from several different nerves, are connected in a more complicated manner, and form what is termed a plexus. In plexuses—of which the one named “brachial” or “axillary,” formed by the great nerves of the arm, and the “lumbar” and “sacral,” formed by those of the lower limb and pelvis, are appropriate examples—the nerves or their branches join and divide again and again, interchanging and intermixing their fibres so thoroughly, that, by the time a branch leaves the plexus, it may contain fibres from all the nerves entering the plexus. Still, as in the more simple communications already spoken of, the fibres, so far as is known, remain individually distinct throughout.

Some farther circumstances remain to be noticed as to the course of the fibres in nerves and nervous plexuses.

Gerber has described and figured nerve-fibres, which, after running a certain way in a nerve, apparently join in form of loops with neighbouring fibres of the same bundle, and proceed no further. Such loops might of course be represented as formed by fibres which bend back and return to the nervous centre ; and so Gerber considers them. He regards them as looped terminations of sentient fibres appropriated to the nerve itself—as the *nervi nervorum*, in short, on which depends the sensibility of the nerve to impressions, painful or otherwise, applied to it elsewhere than at its extremities. The whole matter is, however, involved in doubt : for, admitting the existence of the loops referred to, which yet requires confirmation, it is not impossible that they may be produced by fibres which run back only a certain way, and then, entering another bundle, proceed onwards to the termination of the nerve. Again, it has been supposed, that, in some instances, of nervous conjunctions, certain collections of fibres, after passing from one nerve to another, take a retrograde course in that second nerve, and, in place of being distributed peripherally with its branches, turn back to its root and rejoin the cerebro-spinal centre. An apparent example of such nervous arches without peripheral distribution is afforded by the optic nerves, in which various anatomists admit the existence of arched fibres that seem to pass across the commissure between these nerves from one optic tract to the other, and to return again to the brain. These, however, are perhaps to be compared with the commissural fibres of the brain itself, of which there is a great system connecting the symmetrical halves of that organ. But instances of a similar kind occurring in other nerves have been pointed out by Volkmann ; as in the connection between the second and third cervical nerves of the cat, also in that of the fourth cranial nerve with the first branch of the fifth in other quadrupeds, and in the communications of the cervical nerves with the spinal accessory and the descendens noni. But certain fibres of the optic nerves take a course deviating still more from that followed generally, for they appear to be continued across the commissure from the eyeball and optic nerve of one side to the opposite nerve and eye, without being connected with the brain at all, and thus to form arches with peripheral terminations, but no central connection. In looking, however, for an explanation of this arrangement, it must be borne in mind that the retina contains nerve-cells, like those of the nervous centres, and perhaps the fibres referred to may be intended merely to bring the collections of nerve-cells of the two sides into relation independently of the brain. Julius Arnold has found an arrangement of fibres at the junctions of the nerve-plexus of the iris similar to that in the optic commissure.\*

The disposition of the fibres at the points of division and junction of the branches

\* Virchow's Archiv. 1863.



of nerves still requires further investigation. For some interesting observations on the subject the reader is referred to a paper by Dr. Beale.\*

*Origins or Roots of the Nerves.*—The cerebro-spinal nerves, as already said, are connected by one extremity to the brain or to the spinal cord, and this central extremity of a nerve is, in the language of anatomy, named its origin or root. In some cases the root is single, that is, the funiculi or fibres by which the nerve arises are all attached at one spot or along one line or tract; in other nerves, on the contrary, they form two or more separate collections, which arise apart from each other and are connected with different parts of the nervous centre, and such nerves are accordingly said to have two or more origins or roots. In the latter case, moreover, the different roots of a nerve may differ not only in their anatomical characters and connections, but also in function, as is well exemplified in the spinal nerves, each of which arises by two roots, an anterior and a posterior—the former containing the motory fibres of the nerve, the latter the sensory.

The fibres of a nerve, or at least a considerable share of them, may be traced to some depth in the substance of the brain or spinal cord, and hence the term “apparent or superficial origin” has been employed to denote the place where the root of a nerve is attached to the surface, in order to distinguish it from the “real or deep origin” which is beneath the surface and concealed from view.

To trace the different nerves back to their real origin, and to determine the points where, and the modes in which their fibres are connected with the nervous centre, is a matter of great difficulty and uncertainty; and, accordingly, the statements of anatomists respecting the origin of particular nerves are in many cases conflicting and unsatisfactory. Confining ourselves here to what applies to the nerves generally, it may be stated, that their roots, or part of their roots, can usually be followed for some way beneath the surface, in form of white tracts or bands distinguishable from the surrounding substance; and very generally these tracts of origin may be traced towards deposits of grey nervous matter situated in the neighbourhood; such, for instance, as the central grey matter of the spinal cord, the grey centres of the pneumo-gastric and glosso-pharyngeal nerves, the corpora geniculata and other larger grey masses connected with the origin of the optic nerve. It would further seem probable that certain fibres of the nerve roots take their origin in these local deposits of grey matter, whilst others become continuous with the white fibres of the spinal cord or encephalon, which are themselves connected with the larger and more general collections of grey matter situated in the interior or on the surface of the cerebro-spinal centre.

There is still much uncertainty as to the precise mode in which the nerve-fibres originating or terminating in the grey matter are related to its elements, and for the most part, indeed, individual fibres on being traced into the grey matter, become so hidden in the mass as to elude further scrutiny. Nevertheless, as a continuity between the nerve-fibres and nerve-cells in the grey matter has now been traced in individual examples by many different observers, and as such connections may be held to be general in the ganglions, it is not unfair to infer that, but for the obstacles to successful investigation, the cells in the grey matter of the cerebro-spinal centre would by this time also have been shown to be generally connected with the nerve-fibres.

\* On the Branching of Nerve Trunks, &c., Archives of Medicine, vol. iv. p. 127.



Three modes of connection of cells with fibres are described. 1. From a cell, which may have several branched outrunners, one stout unbranched process is continued into a nerve-fibre, at first naked, and probably representing only the axis cylinder, then acquiring a medullary sheath and dark borders, and finally a membranous tube or primitive sheath. 2. From one or more finely divided branches of a cell, or of more than one cell, equally fine fibrils are prolonged, which coalesce into a pale fibre, having the characters of an axis cylinder, which then, as in the former case, may in its progress become a dark-bordered medullated fibre. 3. The extreme ramifications of a cell or cells become connected, as in the last case, with fibrils, which join into a nerve-fibre; but the connection takes place by the intervention of small bipolar cells, which are by one pole continuous with the branches of the larger cell or cells, and by the other with fine fibrils which join into a pale fibre, or into an axis cylinder of a dark bordered fibre. Gerlach, and after him Waldeyer and others, have described this last mode of connection, as seen by them in the cerebellum. In the cortical grey matter of the cerebellum there are well known large cells generally with one undivided process directed centrally, and two or three finely divided branches towards the surface (fig. LXXIX.). Scattered in the neighbourhood of these large cells, and also collected in a layer named the *stratum ferrugineum*, or rust-coloured layer, are numerous small cells, often called granules (fig. LXXX. c); and it is alleged by the above named authorities that fine ramifications of the large cells join neighbouring small cells or pass inwards to join those of the stratum ferrugineum, and that the small or intermediate cells are, on the other hand, connected with filaments which coalesce into nerve-fibres as above described. This statement derives support from the important observations of Mr. Lockhart Clarke, on the structure of the olfactory bulb. Along with this indirect connection through small intervening cells, Gerlach supposes that a process or processes of the large cells pass directly into nerve-fibres; and should such direct connection take place by the prolongation of an unbranched cell-process into a nerve-fibre, the arrangement would be analogous to that in the ganglia; the simple origin, representing that of the straight fibre from the ganglion-cell, whilst the ramified origin, with the intervening small cells, might be compared to that of the superficial or spiral fibre, with its interposed nuclei.

The fibres of origin of a nerve, whether deeply implanted or not, on quitting the surface of the brain or spinal cord to form the apparent origin or free part of the root, are in most cases collected into funiculi, which are each invested with a sheath of neurilemma. This investment is generally regarded as a prolongation of the pia mater, and in fact its continuity with that membrane may be seen very plainly at the roots of several of the nerves, especially those of the cervical and dorsal nerves within the vertebral canal, for in that situation the neurilemma, like the pia mater itself, is much stronger than in the cranium. The funiculi, approaching each other if originally scattered, advance towards the foramen of the skull or spine which gives issue to the nerve, and pass through the dura mater, either in one bundle and by a single aperture, or in two or more fasciculi, for which there are two or more openings in the membrane. The nerve roots in their course run beneath the arachnoid membrane, and do not perforate it on issuing from the cranio-vertebral cavity; for the loose or visceral layer of the arachnoid is prolonged on the nerve and loosely surrounds it as far as the aperture of egress in the dura mater, where, quitting the nerve, it is reflected upon the inner surface of the latter membrane, and becomes continuous with the parietal or adherent layer of the arachnoid. The nerve, on escaping from the skull or spine, acquires its external, stout, fibrous sheath, which connects all its funiculi into a firm cord, and then, too, the nerve appears much thicker than before its exit. The dura mater accompanies the nerves through the bony foramina, and becomes continuous with their external sheath and (at the cranial foramina) with the pericranium;



but the sheath does not long retain the densely fibrous character of the membrane with which it is thus connected at its commencement.

The arrangement of the membranes on the roots of certain of the cranial nerves requires to be specially noticed.

The numerous fasciculi of the olfactory nerve pass through their foramina almost immediately after springing from the olfactory bulb, and then also receive their neurilemma. The bulb itself, and intracranial part of the nerve, which are to be regarded as being really a prolongation or lobe of the brain, are invested externally by the pia mater, but are not fasciculated. The arachnoid membrane passes over the furrow of the brain in which this part of the nerve lies, without affording it a special investment.

The optic nerve becomes subdivided internally into longitudinal fasciculi by neurilemma a little way in front of the commissure: on passing through the optic foramen it receives a sheath of dura mater, which accompanies it as far as the eyeball. The acoustic nerve becomes fasciculated, receives its neurilemma, and acquires a firm structure on entering the meatus auditorus internus in the temporal bone, towards the bottom of which it presents one or more small ganglionic swellings containing the characteristic cells. Up to this point it is destitute of neurilemma, and of soft consistence, whence the name "*portio mollis*" applied to it.

The larger root of the fifth pair acquires its neurilemma and its fasciculated character sooner at its circumference than in the centre, so that, in the round bunch of cords of which it consists, those placed more outwardly are longer than those within, and, when all are pulled away, the non-fascicular part of the nerve remains in form of a small conical eminence of comparatively soft nervous substance.

Most of the nerves have ganglia connected with their roots. Thus, the spinal nerves have each a ganglion on the posterior of the two roots by which they arise; and in like manner several of the cranial, viz., the fifth, seventh, glosso-pharyngeal, and pneumo-gastric, are furnished at their roots, or at least within a short distance of their origin, with ganglia which involve a greater or less number of their fibres, as described elsewhere in the special anatomy of those nerves.

*Termination, or peripheral distribution, of nerves.*—It may be stated, generally, and apart from what may apply to special modes of termination, that, in approaching their final distribution, the *fibres* of nerves, medullated and non-medullated, commonly divide into branches (fig. LXXXV); and the former, either before or after division, generally lose their medullary sheath, and consequently their dark borders, and take on the characters of pale fibres. The axis-cylinder participates in the division, and it might be said that the white fibres are represented in their further progress, by the axis-cylinder and its ramifications; still, the primitive sheath or membranous tube continues some way along these pale branches after the medullary sheath has ceased, but may finally too desert them. By repeated division the fibres become smaller and smaller; but whilst some of the resulting small fibres may be simple, many are really bundles of exquisitely fine pale fibrils, straight, sinuous, or somewhat tortuous in their course. They bear nuclei, some of which, no doubt, may appertain to the prolongation of the primitive sheath; but others, generally fusiform and granular, are interposed, as it were, in the course of the fibres, and are continuous with them at either end; nuclei, moreover, of a triangular or irregular shape, are common at the bifurcations of the fibres. These pale fibres often join into networks; but their further disposition in different parts will be treated of below. In the meantime it must be explained that the original dark-bordered fibres which thus undergo division and change, or which may proceed singly to end in a different and special manner, are commonly provided with a tolerably strong sheath with nuclei, which, as it stands well apart from



the dark borders of the fibre, is very conspicuous. This is sometimes considered to be only the primitive sheath of the fibre modified in character,

Fig. LXXXV.

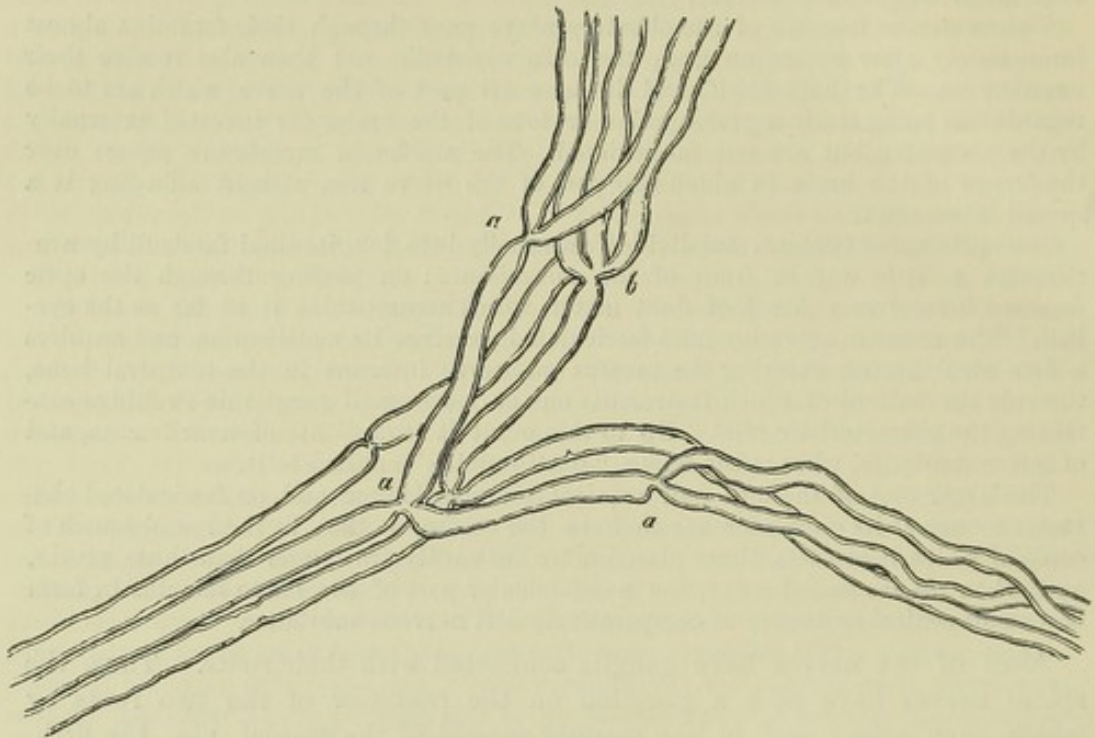


Fig. LXXXV.—SMALL BRANCH OF A MUSCULAR NERVE OF THE FROG, NEAR ITS TERMINATION, SHOWING DIVISIONS OF THE FIBRES.

*a*, into two; *b*, into three; magnified 350 diameters.—(From Kölliker.)

but it seems more probable that it is derived from the neurilemma or perineurium which incloses the fine bundles or funiculi, and, as these part into smaller collections and single fibres, undergoes a corresponding division, and finally sends sheaths along single fibres.

In further treating of the terminations of nerves it will be convenient to consider the sensory and motor nerves separately.

Of the *sensory*, or, at least, *non-muscular* nerves, the following modes of final distribution have been recognised.

A. By *networks*, or *terminal plexuses*. These are formed by the branching and interjunction of the pale fibres above described. The meshes of the net may be at first wider, and the threads, or bundles of threads, larger, but from these, finer filaments forming closer reticulations proceed, and then sometimes the nuclei become less frequent, or disappear. Such networks are found in the skin of the frog, rat, and mouse; in various parts of the mucous membranes, in the cornea, and also in the connective tissue beneath serous membranes or between their layers in different parts—of which the mesentery of the frog affords a good example. In some of these cases the nerve-fibres come into the vicinity of connective-tissue-corpuscles, but, so far as I have been able to see, are not connected with them.

B. *Sensory terminal organs*. Three varieties of these are now recognised, viz., *a*., *end-bulbs*—*b*., *touch-corpuscles*, and *c*., *Pacinian bodies*. These have so far a common structure, that in all of them there is an inward part or *core* (*Innenkolben* Germ.) of soft, translucent, finely granular matter; an outer capsule of ordinary connective tissue with its pertaining corpuscles; and, finally, one or sometimes more nerve-fibres, pale and without dark contours, which pass into the core and apparently end with a free, usually somewhat swollen, or knobbed extremity. Thus agreeing in their internal and probably essential structure, the terminal organs differ chiefly, or at least most obviously, in their capsule, which, simple in the end-bulbs, becomes



highly complicated in the Pacinian bodies; and therefore in the further account of them it will be convenient to begin with the former, although the Pacinian bodies have been much longer known.

*a. End-bulbs.* Noticed incidentally by Kölliker, but first investigated and recognised as distinct organs by W. Krause, who named them *Endkolben*. Their figure in man and apes is usually spheroidal (fig. LXXXVI), but oblong in some quadrupeds. They measure about  $\frac{1}{400}$ th of an inch in diameter, but may exceed this in length with a less breadth, when of an oval shape. They have a simple outer capsule of connective tissue, bearing nuclei, and within this a core of clear soft matter, in which specks resembling fat-granules become visible after exposure to a solution of soda. To an end-bulb there proceeds usually one, but sometimes two, or even three dark-bordered nerve-fibres; and sometimes an originally single fibre divides into two or three immediately before entering the corpuscle; or several branches of one fibre may each run into a separate end-bulb. The fibre or fibres pass into the core, lose their dark borders, and appear to end, when their ends can be traced, in a bulbous extremity or knob. The nerve-fibre, when about to enter the corpuscle, is often much coiled, and this may be the case too with its pale continuation within, which contributes greatly to obscure its actual termination. End-bulbs have been hitherto found in the conjunctiva over the sclerotic coat of the eye, and in the mucous membrane on the floor of the mouth, the lips, soft palate, and tongue, being in these last-mentioned situations lodged in papillæ, or at their roots; also, more deeply, in the skin of the glans of the penis and clitoris.\*

Fig. LXXXVI.

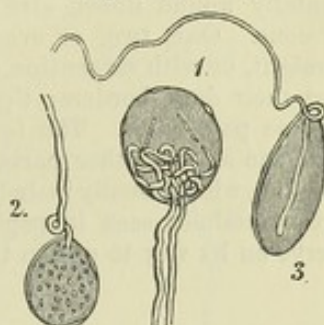


Fig. LXXXVI. — THREE NERVE-END-BULBS FROM THE HUMAN CONJUNCTIVA, TREATED WITH ACETIC ACID, MAGNIFIED 300 DIAMETERS.

1. With two nerve-fibres forming coils within. 2. With one nerve-fibre and fat-granules in the core. 3. Of an oval figure; termination of nerve distinct. Nuclei on the capsules of 1 and 2.—(From Kölliker, after a drawing by Lüdden).

A

Fig. LXXXVII.

B

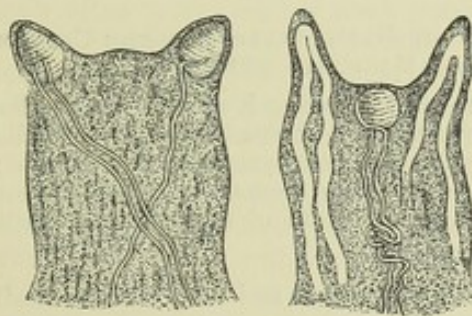


Fig. LXXXVII.—END-BULBS IN PAPILLÆ, MAGNIFIED, TREATED WITH ACETIC ACID.

A, from the lips; the white loops in one of them are capillaries. B, from the tongue. Two end-bulbs seen in the midst of the simple papillæ. *a, a*, nerves.—(From Kölliker).

*b. Touch-bodies, or tactile corpuscles (corpuscula tactûs).* Discovered by R. Wagner and Meissner. These are mostly of an oval shape, nearly  $\frac{1}{300}$  of an inch long, and

\* W. Krause has lately described peculiar organs in the skin of the penis and clitoris, allied to the end-bulbs, which he proposes to call *genital nerve-corpuscles*. They are various in form, but present a mulberry-like surface. One, or two, rarely three or four, dark-bordered nerve-fibres enter each of them. They have a delicate sheath of connective tissue, with many nuclei, and soft finely granular contents allied to the core of the end-bulbs.



$\frac{1}{800}$  of an inch thick. Within is a core of soft, transparent, homogeneous substance, with sparsely imbedded granules; outside, a capsule of connective tissue, with oblong nuclei directed transversely to the axis (and rendered more conspicuous by acetic acid or coloration with carmine), which, together perhaps with some horizontally wound fibres, give the corpuscle somewhat the appearance of a miniature fir-cone. One, two, or even more nerve-fibres, run to the corpuscle, and proceeding straight, or with serpentine windings, approach the summit, up to this point retaining their dark borders; they then pass into the core, and, so far as can be seen, end as fine pale fibres. The touch-corpuscles are found in the skin of the hand and foot, and one or two other parts, where they are inclosed in certain of the cutaneous papillæ, which usually include no vessels. It may be here observed that loops of nerves are sometimes seen in papillæ without touch-bodies, but probably they belong to a nerve on its way to end in the corpuscle of a neighbouring papilla.

Fig. LXXXVIII.

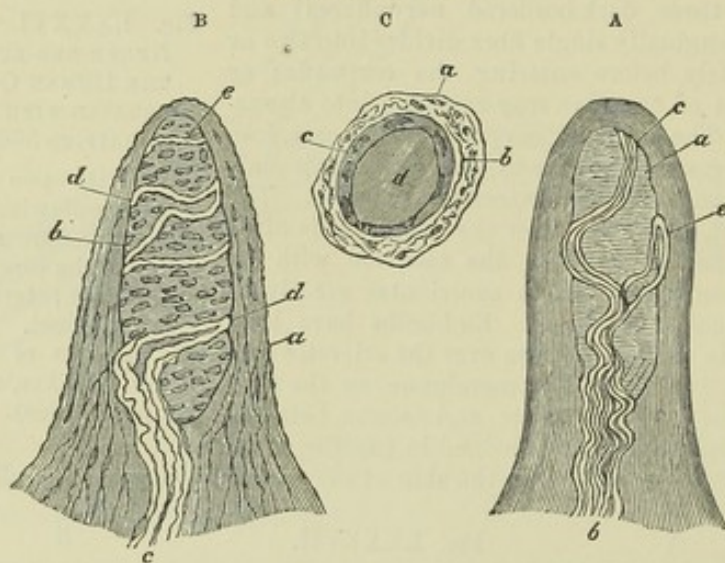


Fig. LXXXVIII.—PAPILLÆ FROM THE SKIN OF THE HAND, FREED FROM THE CUTICLE AND EXHIBITING THE TACTILE CORPUSCLES. MAGNIFIED 350 DIAMETERS.

A. Simple papilla with four nerve-fibres. *a*, Tactile corpuscle; *b*, nerves. B. Papilla treated with acetic acid; *a*, cortical layer with cells and fine elastic filaments; *b*, tactile corpuscle with transverse nuclei; *c*, entering nerve with neurilemma or perineurium; *d*, nerve-fibres winding round the corpuscle. C. Papilla viewed from above so as to appear as a cross section. *a*, cortical layer; *b*, nerve-fibre; *c*, sheath of the tactile corpuscle containing nuclei; *d*, core (after Kölliker).

*c. Pacinian bodies.* In dissecting the nerves of the hand and foot, certain small oval bodies like little seeds, are found attached to their branches as they pass through the subcutaneous fat on their way to the skin; and it has been ascertained that each of these bodies receives a nervous fibre which terminates within it. The objects referred to were more than a century ago described and figured by Vater,\* as attached to the digital nerves, but he did not examine into their structure, and his account of them seems not to have attracted much notice. Within the last few years, their existence has been again pointed out by Cruveilhier and other French anatomists, as well as by Professor Pacini of Pisa, who appears to be the first writer that has given an account of the internal structure of these curious bodies, and clearly demonstrated their essential connection with the nervous fibres. The researches of Pacini have been followed up by Henle and Kölliker,† who named the corpuscles after the Italian savant; and to their memoir, as well as to the article "Pacinian Bodies," by Mr. Bowman, in the "Cyclopædia of Anatomy," and to more recent

\* Abr. Vater, Diss. de Consensu Partium Corp. hum.; Vitemb. 1741, (recus. in Halleri Disp. Anat. Select. tom. ii.) Ejusd. Museum Anatomicum; Helmst. 1750.

† Ueber die Pacinischen Körperchen; Zurich, 1814.



papers by W. Krause\* and Engelmann,† the reader is referred for details that cannot be conveniently introduced here.

The little bodies in question (fig. LXXXIX) are, as already said, attached in great numbers to the branches of the nerves of the hand and foot, and here and there one or two are found on other cutaneous nerves. They have been discovered also within the abdomen on the nerves of the solar plexus, and they are nowhere more distinctly seen or more conveniently obtained for examination, than in the mesentery and omentum of the cat, between the layers of which they exist abundantly. They have been found on the pudic nerves on the glans penis and bulb of the urethra, on the intercostal nerves, sacral plexus, cutaneous nerves of the upper arm and neck, and on the infraorbital nerve. Lately they have been recognised on the periosteal nerves, and, in considerable numbers, on the nerves of the joints. They are found in the foetus, and in individuals of all ages. The figure of these corpuscles is oval, somewhat like that of a grain of wheat,—regularly oval in the cat, but mostly curved or reniform in man, and sometimes a good deal distorted. Their mean size in the adult is from  $\frac{1}{15}$  to  $\frac{1}{10}$  of an inch long, and from  $\frac{1}{26}$  to  $\frac{1}{20}$  of an inch broad. They have a whitish, opaline aspect: in the cat's mesentery they are usually more transparent, and then a white line may be distinguished in the centre. A slender stalk or peduncle attaches the corpuscle to the branch of nerve with which it is connected. The peduncle contains a single tubular nerve-fibre ensheathed in filamentous connective tissue, with one or more fine blood-vessels; and it joins the corpuscle at or near one end, and conducts the nerve-fibre into it. The little body itself, examined under the microscope, is found to have a beautiful lamellar structure (fig. xc, A). It consists, in fact, of numerous concentric membranous capsules incasing each other like the coats of an onion, with a small quantity of pellucid fluid included between them. Surrounded by these capsules, and occupying a cylindrical cavity in the middle of the corpuscle, is the core, formed of transparent and homogeneous soft substance, in the midst of which the prolongation of the nerve-fibre is contained. The number of capsules is various; from forty to sixty may be counted in large corpuscles. The series immediately following the central or median cavity, and comprehending about half of the entire number, are closer together than the more exterior ones, seeming to form a system by themselves, which gives rise to a white streak often distinguishable by the eye along the middle of the corpuscles when seen on a dark ground. Outside of all, the corpuscle has a coating of ordinary connective tissue. The capsules, at least the more superficial ones, consist each of an internal layer of longitudinal and an external of circular fibres, which resemble the white fibres of areolar and fibrous tissue, with cell-nuclei attached here and there on the inner layer, and a few branched fibres of the yellow or elastic kind running on the outer. The nerve-fibre, conducted along the centre of the stalk, enters the corpuscle, and passes straight into the central cavity, at the further end of which it terminates.

The fibrous neurilemma surrounding the nerve-fibre in the peduncle accompanies it also in its passage through the series of capsules, gradually decreasing in thickness as it proceeds, and ceasing altogether when the nerve has reached the central cavity. According to Pacini, with whom Reichert agrees in this particular, the neurilemma forms a series of concentric cylindrical layers, which successively become continuous with, or rather expand into the capsules, the innermost, of course, advancing farthest. Others suppose that the capsules are all successively perforated by a conical channel which gives passage to the nerve with its neuro-

Fig. LXXXIX.

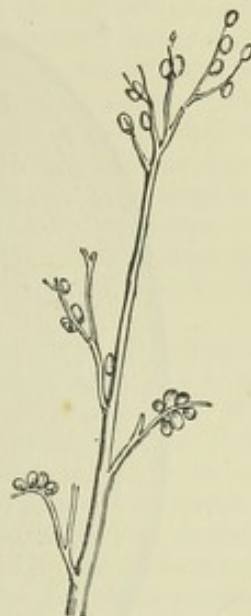

Fig. LXXXIX. — A NERVE OF THE MIDDLE FINGER, WITH PACINIAN BODIES ATTACHED. NATURAL SIZE (after Henle and Kölliker).

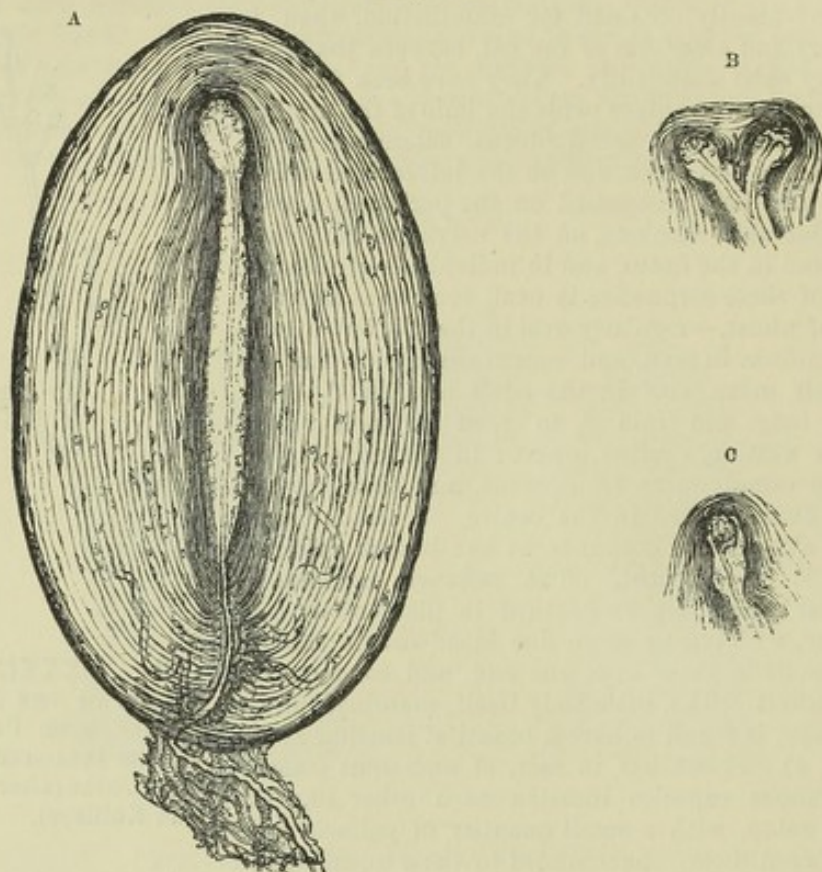
\* Anat. Untersuchungen; Hanover, 1861, and Zeits. f. rat. Med. xvii. 1865.

† Zeits. f. Wiss. Zool. xiii. 1863.



lemma, but at the same time has its own proper wall, round which, on the outside, the capsules are attached. Whichever view may be correct, the capsules are, as it were, strung together where the nerve passes through them, and each intercapsular space, with its contained matter, is shut off from the neighbouring ones. The nerve-fibre, the disposition of which must now be noticed, is single as it runs along

Fig. XC.



A, MAGNIFIED VIEW OF A PACINIAN BODY FROM THE MESENTERY OF A CAT, showing the lamellar structure, the capsules with their nuclei, the inner and closer series of capsules appearing darker in the figure, the nerve-fibre passing along the peduncle, and penetrating the capsules to reach the core in the central cavity, where it loses its strong, dark outline, and terminates by an irregular knob at the distal and here dilated end of the cavity. Connective tissue (neurilemma or perineurium) and blood-vessels are represented in the peduncle, and tortuous capillaries are seen running up among the capsules. B and C represent the termination of the nerve with the distal end of the central cavity and adjoining capsules, to illustrate varieties of arrangement. In B the fibre, as well as the core and adjoining capsules, is bifurcated.

the peduncle, unless when the latter supports two corpuscles; it retains its dark double contour until it reaches the central cavity, where, diminished in size, and freed from its perineurium, it becomes somewhat flattened, and presents the appearance either of a pale, finely granular, and very faintly-outlined band or stripe, little narrower than the previous part of the fibre, or of a darker and more sharply defined narrow line; differing thus in appearance according as its flat side or its edge is turned towards the eye. The pale aspect which the fibre presents in the centre of the corpuscle has with some probability been ascribed to its losing the white substance or medullary sheath on entering the cavity. Ilenle and Kölliker, however, think that it is more likely the result merely of a diminution in size, together with a certain degree of flattening. It sometimes happens that the fibre regains its original magnitude and double contour for a short space, and changes again before it terminates; this is especially liable to occur while it passes through a sharp flexure in a crooked central cavity. The fibre ends by a sort of knob at the further extremity of the median cavity, which is often itself somewhat dilated. In



many cases, the fibre, before terminating, divides into two branches, as represented in figure B: a division into three has been observed, but this is very rare. In case of division of the fibre, the cavity is generally, but not invariably, divided in a corresponding measure, and the inner set of capsules present a figure in keeping with it. It is worthy of remark, that the nerve-fibre in its course along the cavity runs almost exactly in the axis of the channel, and it maintains this position even when passing through the abrupt flexures of an irregularly-shaped cavity. It sometimes happens that a fibre passes quite through one corpuscle and terminates in a second, resuming its original size and dark outline while passing from the one to the other. Pappenheim states that he has seen a nerve-fibre going through two Pacinian bodies without terminating in either, but returning again to the parent nerve in form of a loop. Other varieties occur, for an account of which the reader is referred to the several authorities already mentioned. A little artery enters the Pacinian bodies along with the nerve, and soon divides into capillary branches, which pierce the parietes of the passage and run up between the capsules. Mr. Bowman finds that they then form loops, and return by a similar route into a vein corresponding to the artery: he states also that a single capillary usually accompanies the nerve as far as the central capsule, and passes some way on its wall, sometimes in a spiral direction.

There is considerable difference of opinion as to the condition of the nerve-fibre in the Pacinian body. Kölliker thinks that it retains its primitive sheath, and is not wholly deprived of its medulla; and that the surrounding core is composed of a nearly homogeneous connective tissue, in which he has seen faintly-marked nuclei and faint longitudinal striation. Engelmann, on the other hand, considers the core to be an expansion of the medullary sheath of the nerve, and ascribes the appearances noticed by Kölliker to changes occurring in the originally homogeneous medulla, as in the case of a white nerve-fibre. The pale fibre within he considers to be simply the axis-cylinder. The core and pale fibre of the end-bulbs he regards in precisely the same way, and thinks it not improbable that the touch-corpuscles will be found to conform. He looks upon the simple capsule of the end-bulb as a development of the primitive nerve-sheath, to which, in the Pacinian bodies, is superadded a series of concentric coats of connective tissue. Engelmann, besides adducing other arguments, refers especially to the structure of the Pacinian bodies of birds, as affording material evidence in support of his view.

Nothing positive is known concerning the special purpose in the animal economy which these curious appendages of the nerves are destined to fulfil. In an anatomical sense a Pacinian body might be viewed as a more complex development of an end-bulb, from which it differs chiefly in the multiplied layers of the capsule. W. Krause endeavours to show that the series of concentric capsules with interposed fluid is an arrangement for converting the effect of mechanical traction into fluid pressure upon the nerve, so that tension and traction of the tissue in which the corpuscle is placed, may be felt and appreciated as ordinary pressure. Their presence in the mesentery of the cat seems, at first sight, against their importance as sentient organs, but it turns out upon trial, that the part in question is remarkably sensitive.

#### C. Other terminations of sensory nerves.

*a. In hair-follicles.* By far the majority of the nerves of the skin end in hair-follicles. Up to their entrance, at least, they retain their dark borders, but their arrangement within and actual mode of termination are unknown.

*b. In the teeth.* Dark bordered nerve-fibres, in fine bundles, enter the teeth and pass into the tooth-pulp; but their mode of termination has not been clearly made out.

*c. In organs of special sense.* For the peripheral distribution of the optic and acoustic nerves, and the elaborate apparatus in the eye and ear with which they are connected, the reader is referred to the details given in the special anatomy of these organs. Respecting the more simple termination of the olfactory nerve, it has been shown by Max Schultze, that on the olfactory membrane, alongside columnar epithelium cells, there are special nucleated cells of a fusiform shape, and probably of a nervous nature (*olfactory cells*), from which proceed a superficial and a deep process, often presenting a beaded appearance like varicose nerve-fibres. The superficial processes end abruptly at the surface of the epithelium between the columnar cells; the deep and more slender processes pass vertically inwards. They are probably continued from terminal fibres of the olfactory nerve, but the continuity has not been actually traced.



An analogous arrangement is described by Axel Key as discoverable in the fungiform papillæ of the frog's tongue. Among non-ciliated columnar epithelium cells are fusiform *gustatory cells*, having, like the olfactory cells, fine rod-like processes reaching to the surface, and slender, varicose, central filaments, which seem to be continuous with pale fibrils, into which the axis-cylinder of the gustatory nerve-fibres finally divides; and in such way that one axis cylinder may be connected with several cells.

*d. In epithelium.*—Hoyer believes he has seen fine, pale filaments continued from the plexus of the cornea into the epithelium covering its anterior surface, where they appeared to pass between the cells. Von Heusen describes and figures exquisitely fine filaments connected with the nucleoli of epithelium cells on the tadpole's tail. He finds evidence to satisfy him that their filaments are continued from the cutaneous nerves, which he therefore conceives to run out into epithelium cells as their terminal organs, and end in the nucleoli.

*e. In glands.*—The termination of nerves in secreting glands will be most conveniently given in the account of the structure of these organs. In the meantime it may be stated that Pflüger has traced nerve fibres to the nuclei of the cells which line the terminal saccules of the salivary glands.

Termination of nerves in muscles:—

*A. In plain or unstriped muscle.*—Dr. Beale, and, after him, Dr. Klebs, have described the nerves of the muscular coat of the frog's bladder as finally distributed in networks of pale fibres, with nuclei. The networks are at first coarser, with larger grey fibres made up of coalesced fibrils (fibrillar fibres), and from these proceed finer bundles and single fibrils, forming closer reticulations, constituting the intra-muscular plexus, which is disposed among the muscular fasciculi and fibre-cells. A more intimate relation to the latter could not be traced with certainty, although Klebs met with a single instance of a nerve-fibril entering a muscular fibre-cell. The nerves distributed to the middle or muscular coat of the arteries are, according to Beale, disposed in a similar plexiform manner; and Julius Arnold has since found a terminal pale nervous network of the same kind in the iris of the rabbit.

*B. In voluntary muscle. a. By Plexuses.*—As mentioned in the account of the muscular tissue, the nerves in the voluntary muscles form plexuses, of which the branches grow finer and the meshes closer as they advance further into the tissue. The individual fibres, while still associated in small bundles, undergo division (fig. LXXXV.), and at length single dark-bordered fibres pass off to the muscular fibres. These nerve-fibres on approaching or reaching a muscular fibre divide still further. As to their ulterior and final distribution, there is great divergence in the statements of very able observers. Beale and Kölliker agree in opinion that the fibres lose their dark borders and run further on as pale fibres, which do not penetrate the sarcolemma. Dr. Beale describes these pale fibres, in the mouse and frog, as distributed in a fine network, bearing nuclei, adhering to, but outside, the sarcolemma, and extending over a great length of the muscular fibre. Kölliker, whose observations were made on the frog, found the fibres apparently to terminate by free ends; at the same time, having seen, here and there, indications, although imperfect, of a fine network, such as he had observed in the electric organ of the torpedo, he is not disposed to exclude the possibility of such mode of termination.

*b. By terminal organs.*—Since the publication of Beale and Kölliker's observations, a very different account has been given by Rouget—namely, that the muscular nerves end in peculiar terminal organs, which have been named the *motorial end-plates*, to be seen on the muscular fibres, and his account has been in the main confirmed by various contemporary observers, although some important authorities still hold to a different view. The end-plates are described as small lamelliform objects, of an oval or irregular, and often deeply indented outline; their size varies from  $\frac{1}{1500}$  to  $\frac{1}{350}$  of an inch, according to the size of the muscular fibre, of which the plate may embrace one-third, or more, of the circumference. There is a question whether these organs are situated without or within the sarcolemma. W. Krause, who adopts the former view, describes the end plate as consisting of a thin lamina of connective tissue, attached by its oval or irregular border to the sarcolemma, with clear non-granular nuclei in it, and a finely granular matter underneath, between it and the sarcolemma, in which the axis-cylinder of the nerve-fibre ends, in form of one, or sometimes more, short pale fibres, with free and swollen extremities; whilst the medullary sheath ceases, and the primitive sheath



is continued into the covering lamina of connective tissue. On the other hand, Rouget, Kühne, and most of those who have given descriptions of the organs in question, maintain that the end plate is within the sarcolemma, interposed between it and the proper muscular substance. According to their descriptions, the ultimate nerve-fibre, on reaching the muscular fibre, either immediately or after running but a short way on the surface, sends its axis-cylinder through the sarcolemma to spread out into the plate, whilst the primitive (or perhaps perineural) sheath joins the sarcolemma, and the medullary sheath, which continues on the still dark bordered fibre up to this point, here abruptly ceases. The proper substance of the plate, usually lobed at its circumference (Kühne), is continuous with the axis-cylinder, and is mostly held to be an expansion of it, for it is said to have the same homogeneous or, at most, faintly granular aspect, and to agree with it in optical and micro-chemical characters. Around and beneath this lamina is a bed of granular matter, with large imbedded nuclei having one or more bright nucleoli. The sarcolemma over the seat of the end-plate, and the plate itself, are slightly raised above the general surface, so that the whole structure has been designated by Kühne as the *nerve-eminence* (Nerven-hügel). It would appear that a muscular fibre has but one terminal organ, and receives consequently but one nerve-fibre, so that, allowing the muscular fibre to be one inch and a half long, a considerable length must be governed by one terminal nerve-fibre. As, moreover, the fibres of a nerve undergo division, probably repeated division, before ending, it follows that one fibre in a nerve-root or trunk may supply several muscular fibres. The motorial end-plates have now been recognised in mammalia, birds, and scaly reptiles, and, in a modified form, in various invertebrata.\*

*Differences of cerebro spinal Nerves.*—It remains to notice the differences which have been observed among the cerebro-spinal nerves in regard to the size of their fibres, and the proportionate amount of the different kinds of fibres which they respectively contain.

As already stated, both white and grey fibres exist in cerebro-spinal nerves, and those of the former kind differ greatly from each other in size. Volkmann and Bidder, who have bestowed much pains in endeavouring to arrive at an approximate estimate of the relative amount of the large and the small fibres in different nerves, give the following as the more important results of their researches:—

1. The nerves of voluntary muscles have very few small fibres, usually in not larger proportion than about one to ten.
2. In the nerves of involuntary muscles, whether derived immediately from the cerebro-spinal system or from the sympathetic, the small fibres eminently preponderate, being about a hundred to one.
3. The nerves going to the integuments have always many small fibres, at least as many small as large.
4. Nerves of sentient parts of mucous membranes have from five to twenty times more small fibres than large: in mucous membranes possessing little sensibility, the nerves are made up chiefly of small fibres. The nerves distributed in the pulp of the teeth consist principally of large fibres.

It is plain, however, that Volkmann and Bidder must have reckoned in with their small fibres more or fewer of the non-medullated sort, so that the proportion assigned to the small fibres in their estimate must be taken as including some grey, as well as white fibres; and this agrees with the observation previously made by Remak, that many more grey fibres are contained in the cutaneous than in the muscular nerves. The roots of the spinal nerves contain fine fibres, but according to Remak only in very small proportion: Volkmann and Bidder state that in man the anterior roots contain proportionally more large fibres than the posterior. In almost all nerves the fibres diminish in size as they approach their termination.

The fibres of the optic nerve for the most part resemble the white fibres of the brain, and readily become varicose. The same is true of the acoustic nerve, from its

\* For further information on the termination of the nerves, see the Croonian Lectures, by Professor Kölliker, Proceedings of the Royal Society, 1862, and by Dr. Beale, *ibid.*, 1865; also a discussion of the question by Dr. B. in his "Archives of Medicine" for 1865.



origin to its entrance into the internal auditory foramen, where it becomes fasciculated; also of the intra-cranial part of the olfactory, which, however, contains in addition grey matter and nerve-cells, and may, indeed, be reckoned as part of the brain. The branches of the olfactory in the nose are almost wholly made up of fibres bearing nuclei, and having all the outward characters of the grey fibres, like which, also, they cohere or cling fast together in the bundles which they form. Some branches seem to consist entirely of such fibres; others contain a few white fibres intermixed, which, however, may be derived from the nasal branches of the fifth pair.

#### OF THE SYMPATHETIC OR GANGLIONIC NERVE.

This name is commonly applied to a nerve or system of nerves present on both sides of the body, and consisting of the following parts, viz.:—1. A series of ganglia, placed along the spinal column by the side of the vertebræ, connected with each other by an intermediate nerve-cord, and extending upwards to the base of the skull and downwards as far as the coccyx. This principal chain of ganglia, with the cord connecting them, forms what is often named the trunk of the sympathetic. 2. Communicating branches, which connect these ganglia or the intermediate cord with all the spinal and several of the cranial nerves. 3. Primary branches passing off from the ganglionic chain or trunk of the nerve, and either bestowing themselves at once, and generally in form of plexuses, on the neighbouring blood-vessels, glands, and other organs, or, as is the case with the greater number, proceeding in the first instance to other ganglia of greater or less size (sometimes named præ-vertebral) situated in the thorax, abdomen, and pelvis, and usually collected into groups or coalescing into larger ganglionic masses near the roots of the great arteries of the viscera. 4. Numerous plexuses of nerves, sent off from these visceral or prævertebral ganglia to the viscera, usually creeping along the branches of arteries, and containing in various parts little ganglia disseminated among them. Some of these plexuses also receive contributions from spinal or cerebral nerves, by means of branches which immediately proceed to them without previously joining the main series of ganglia.

*Structure of the sympathetic nerve.*—The nervous cords of the sympathetic consist of white fibres, and of pale or grey fibres mixed with a greater or less amount of filamentous connective tissue, and inclosed in a common external fibro-areolar sheath. The white fibres differ greatly from each other in thickness. A few are of large size, ranging from  $\frac{1}{2500}$  to  $\frac{1}{1500}$  of an inch; but the greater number are of much smaller dimensions, measuring from about  $\frac{1}{8300}$  to  $\frac{1}{4500}$  of an inch in diameter, and, though having a well-defined sharp outline, for the most part fail to present the distinct double contour seen in the larger and more typical examples of the tubular fibre. The pale, non-medullated fibres, have partly the characters of Remak's grey fibres, already described, and often look as if they were really made up of exquisitely fine fibrils; but there are also pale fibres of much less thickness, which, at short distances, are interrupted by, or might be said to swell out into, fusiform nuclei.

The more grey-looking branches or bundles of the sympathetic consist of a large number of the pale fibres mixed with a few of the dark-bordered kind; the whiter cords, on the other hand, contain a proportionally large amount of white fibres, and fewer of the grey; and in some parts of the nerve grey fasciculi and white fasciculi, respectively constituted as above described, run alongside of each other in the same cords for a considerable space without mixing. This arrangement may be seen in some of the branches of communication with the spinal nerves, in the trunk or cord



which connects together the principal chain of ganglia, and in the primary branches proceeding from thence to the viscera. In the last-mentioned case the different fasciculi get more mixed as they advance, but generally it is only after the white fasciculi have passed through one or more ganglia that they become thoroughly blended with the grey; and then, too, the nervous cords receive a large accession of grey fibres (apparently derived from the ganglia), which are mixed up with the rest, and take off more and more from their whiteness.

*Relation of the sympathetic to the cerebro-spinal nerves.*—We have next shortly to consider the relation between the sympathetic and the cerebro-spinal system of nerves. On this important question two very different opinions have long existed, in one modification or another, amongst anatomists. 1. According to one, which is of old date, but which has lately been revived and ably advocated by Valentin, the sympathetic nerve is a mere dependency, offset, or embranchment of the cerebro-spinal system of nerves, containing no fibres but such as centre in the brain and cord, although it is held that these fibres are modified in their motor and sensory properties in passing through the ganglia in their way to and from the viscera and involuntary organs. 2. According to the other view, the sympathetic nerve (commonly so called) not only contains fibres derived from the brain and cord, but also proper or intrinsic fibres which take their rise in the ganglia; and in its communications with the spinal and cranial nerves, not only receives from these nerves cerebro-spinal fibres, but imparts to them a share of its own proper ganglionic fibres, to be incorporated in their branches and distributed peripherally with them. Therefore, according to this latter view, the sympathetic nerve, commonly so called, though not a mere offset of the cerebro-spinal nerves, yet, receiving as it does a share of their fibres, is not wholly independent, and for a like reason the cerebro-spinal nerves (as commonly understood) cannot be considered as constituted independently of the sympathetic; in short, both the cerebro-spinal and the sympathetic are mixed nerves, that is, the branches of either system consist of two sets of fibres of different and independent origin, one connected centrally with the brain and cord, the other with the ganglia. Hence, if we look to the central connection of their fibres as the essential ground of distinction among nerves, the cerebro-spinal system of nerves might, strictly speaking, be considered as consisting of and comprehending all the fibres having their centre in the cerebro-spinal axis, whether these fibres run in the nerves usually denominated cerebral and spinal, or are distributed to the viscera in the branches of the nerve usually named the sympathetic; and, on the same ground, the sympathetic or ganglionic system, strictly and properly so called, would consist of and comprehend all the fibres connected centrally with the ganglia, wherever such fibres exist and into whatever combinations they enter, whether proceeding to the viscera or distributed peripherally with the nerves of the body generally; the nerve-fibres which emanate from the ganglia on the roots of the spinal and cerebral nerves being reckoned into the system, as well as those from ganglia, usually denominated sympathetic. While ready, however, to acquiesce in the justice of the above distinction, we do not mean to employ the terms already in use in a sense different from that which is currently received.

In endeavouring to decide between the two views above stated, it may be first observed that the existence in the sympathetic nerve of fibres connected centrally with the cerebro-spinal axis, is proved not only by tracing bundles of fibres from the roots of the spinal nerves along the communicating branches and into the sympathetic, but



by the pain or uneasy sensations which arise from disease or disturbance of organs, such as the intestines, supplied exclusively by what are considered branches of the sympathetic; by experiments on living or recently killed animals, in which artificial irritation of the roots of the spinal nerves, or of various parts of the cerebro-spinal centre, caused movements of the viscera; and by experiments on the sympathetic nerve in the neck, by which it is shown that the dilatation of the pupil and the tonicity of the cutaneous vessels of the head are dependent on fibres which pass along the sympathetic nerve but are centrally connected with the upper part of the spinal cord.

These facts, it is evident, accord with both of the above-mentioned opinions respecting the constitution of the sympathetic; but it may be further shown that this nerve contains fibres which arise from the ganglia and take a peripheral course, so that the second of the two opinions approaches nearer to the truth. In support of this assertion we may adduce the actual observation of nerve-fibres proceeding from the nerve-cells of the ganglia in a peripheral direction only; and there are also other grounds for believing that more fibres pass out of the sympathetic ganglia than can possibly be derived from the brain and cord. This seems to follow from a comparison of the aggregate size of the branches issuing from these ganglia with that of all the branches which can be supposed to enter them. To explain this, however, we must first consider the mode of communication between the sympathetic and spinal nerves.

The branches of communication which pass between the ganglia or gangliated cord of the sympathetic and the spinal nerves, are connected with the anterior and greater branch of each of the latter nerves, a little in advance of the spinal ganglion; and at the point of connection the communicating branch in most cases divides into two portions, one central, running towards the roots of the spinal nerve and the spinal cord, the other, peripheral, taking an outward course along with the anterior branch of the spinal nerve, with which it becomes incorporated and distributed. It can scarcely be doubted that the central portion, whilst it may contain fibres sent by the sympathetic to the spinal nerves or to the spinal cord, must necessarily contain all those which proceed from the cord to the sympathetic, and that, on the other hand, the peripheral division must consist of fibres immediately proceeding from the sympathetic and distributed peripherally with the spinal nerve. It is further observed, that in some of the junctions with the spinal nerves, the central and peripheral divisions of the communicating branch are about equal in size, and that in others the central part is greater than the peripheral, whilst in others, again, the peripheral prevails over the central. Now, in an animal such as the frog, in which the spinal nerves are of small size and few in number, it is possible, with the aid of the microscope, to compare by measurement the central and peripheral divisions of the communicating branch in all the communications between the sympathetic and the spinal nerves, or even to count the fibres when the branches are very fine; and by such a comparison Volkmann and Bidder have shown, that, after making all reasonable deductions and allowances, the whole amount of the fibres, or at least the aggregate bulk of the fasciculi, which obviously pass from the sympathetic and run outwards with the spinal nerves, considerably exceeds that of the central fasciculi which must contain the fibres contributed to the sympathetic from the cerebro-spinal system: and if to these peripheral fibres we add the branches distributed to the viscera, it seems plain that more fibres must proceed from the ganglia than can possibly be supposed to enter them from the spinal nerves or spinal cord, and that consequently the ganglia must themselves be centres in which nerve-fibres take their rise. It is worthy of remark, that in the frog, according to the observations of the anatomists just named, the central division of the communicating cord greatly exceeds the peripheral in the connections with the upper spinal nerves, but that lower down it gradually diminishes, absolutely as well as in comparison with the peripheral, and at length disappears altogether, so that the fasciculi connected with the eighth and ninth spinal nerves are entirely peripheral in their course.

Another circumstance still remains to be noticed respecting the communications of the sympathetic and spinal nerves. It has been long known that in most of these communications there are usually two connecting cords passing between the sympathetic and the spinal nerve; and it has been remarked also by various observers, that these cords contain grey as well as white fasciculi. More recently, however, Todd and Bowman have called attention to the fact that one of the two connecting cords is



altogether of the grey kind, consisting of gelatinous fibres, with, as usual, a very few white or tubular fibres mixed with them; and this observation has since been confirmed by Beck. The other cord either is entirely white, or more commonly, as appears to me, is made up of a white and grey portion running alongside each other. It seems highly probable that the white cords and the white fasciculi of the mixed cords contain the cerebro-spinal fibres which the spinal nerves contribute to the sympathetic, and that the grey cords and fasciculi are contributions from the sympathetic to the spinal nerves. In corroboration of this view, Mr. Beck observes that the grey cords on leaving the ganglia give small branches to the neighbouring vessels, and are reduced in size before joining the spinal nerves. Another interesting fact respecting these communications has been pointed out by the last-named observer somewhat similar to that previously noticed in the frog, namely, that whilst the grey and white connecting cords are in the thorax of nearly equal size, the grey one relatively increases lower down, and in the pelvis constitutes the sole communication between the sacral ganglia of the sympathetic and the spinal nerves, the white branches from the latter to the sympathetic passing over the sacral ganglia without joining them, to enter the sympathetic plexuses sent to the pelvic viscera.

The tubular fibres of each white communicating fasciculus can be traced back to both the anterior and the posterior root of the spinal nerve, and pale fibres from the grey fasciculus may be traced up into the anterior root, and as far as the ganglion of the posterior root, which root has also pale fibres above the ganglion. Whether these central pale fibres proceed from the sympathetic to the spinal cord (possibly to be distributed to its vessels), or are sent from the cord and spinal ganglia to the sympathetic, or pass both ways, is as yet uncertain.

As to the further progress of the cerebro-spinal fibres conveyed to the sympathetic by the communicating branches, Valentin has endeavoured to show that after joining the main gangliated cord or trunk of the sympathetic, they all take a downward direction, and after running through two or more of the ganglia, pass off in the branches of distribution, leaving the trunk considerably lower down than the point where they joined it. He conceives that this arrangement, which he calls "*lex progressus*," is proved by experiments on animals, in which he found, that on irritating different parts of the cerebro-spinal axis, as well as different branches of nerves, the visceral movements which followed bore a relation to the point irritated, which corresponded with the notion of such an arrangement. Volkmann and Bidder, on the other hand, show that this opinion cannot be reconciled with the observed anatomical disposition of the fibres, for there are fasciculi from the communicating branches which obviously pass upwards; nor will the experimental evidence in its favour apply to the upper part of the sympathetic, where, as Valentin himself admits, motorial fibres must be supposed to run in an upward direction to account for the contraction of the pupil which follows section of the cervical part of the sympathetic.

From what has been stated it seems reasonable to conclude that nerve-fibres take their rise in the ganglia both of the cerebro-spinal and sympathetic nerves, and are in both kinds of nerves mixed with fibres of cerebral or spinal origin; that the ganglia are nervous centres which may probably receive through afferent fibres impressions of which we are unconscious and reflect these impressional stimuli upon efferent or motor fibres: that perhaps, even, certain motorial stimuli emanate from them, the movements excited by or through the ganglia being always involuntary, and affecting chiefly the muscular parts of the viscera, the sanguiferous, and perhaps the absorbent vessels; and that, in fine, the chief purpose served in the animal economy by the ganglia and the ganglionic nerve-fibres, whether existing in acknowledged branches of the sympathetic, or contained in other nerves, is to govern the involuntary, and, for the most part, imperceptible movements of nutrition, in so far at least as these movements are not dependent on the brain and spinal cord; for it must not be forgotten that there is unquestionable evidence to prove that the visceral and vascular motions are influenced by nerve-fibres connected with the cerebro-spinal centre.



Among various physiologists of consideration, who adopt this view in a more or less modified shape, some have been further of opinion that the fibres of ganglionic origin differ in structure, size, and other physical characters from those which arise in the cerebro-spinal axis. As regards this question, I must confess, that there does not seem to me to be conclusive evidence to show that peculiar anatomical characters are distinctive of the fibres of different origin. It has been already stated that both dark-bordered and pale fibres may be connected with ganglion-cells, and for aught that has been proved to the contrary, all three varieties of fibres spoken of, large tubular, small tubular, and grey, may arise both in the cerebro-spinal axis and in the ganglia; although it is certainly true that the two latter kinds largely predominate in the sympathetic, and abound in other nerves, or branches of nerves, which appear to receive large contributions from ganglia.

#### VITAL PROPERTIES OF THE NERVOUS SYSTEM.

The fibres of nerves are endowed with the property of transmitting impressions, or the effect of impressions, from the point stimulated towards their central or their peripheral extremities. One class of fibres conduct towards the nervous centres and are named "afferent," their impressions being "centripetal;" another class of fibres conduct towards their distal extremities, which are distributed in moving parts, and these fibres are named "efferent," whilst their impressions are "centrifugal." Impressions propagated centripetally along the nerves to the brain give rise to sensations, varying according to the nerve impressed, and the objective cause of the impression; stimuli transmitted outwardly, on the other hand, are conveyed to muscles, and excite movements. Motorial stimuli thus passing along efferent nervous fibres may emanate from the cerebrum as in voluntary and emotional movements, or possibly from some other central part, as in the case of certain involuntary motions; or such stimuli may be applied in the first instance to afferent fibres, by these conducted to the brain or some other central organ, and then "reflected" by the central organ to efferent fibres, along which they are propagated to the muscle or muscles to be moved; and in this case the intervention of the central organ may give rise to sensation or not, the difference in this respect probably depending on the part of the nervous centre where the reflection takes place.

The property of conducting a stimulus or propagating its effects in a determinate direction, belongs to the fibres of the nerves, and in all probability also to the fibrous part of the nervous centre, while it is probable that to the cells or corpuscles of the grey matter of the central organs, is assigned the office of receiving impressions conveyed from without, and presenting them to the conscious mind, of mediating between the mind and the efferent fibres in excitation of the latter by mental stimuli (as in voluntary and emotional acts), of transferring to efferent fibres stimuli conducted to the centre by afferent fibres in the production of reflex movements, and, possibly, of originating purely corporeal stimuli in certain involuntary motions. In addition to these endowments, the nerves are concerned in controlling and regulating the molecular changes and chemical actions which occur in nutrition, secretion, and other allied processes. It may no doubt be fairly questioned, whether the effect justly attributable to the nerves in such cases is not produced merely through the influence which they exert over the motions of the minute vessels and contractile tissues concerned; but the tendency of late observations on the nerves of secreting glands, and the experiments on the luminiferous organ of the fire-fly, referred to in a



former chapter, is towards the recognition of some more direct operation.

The properties above mentioned, of the nerves and nervous centres, have been commonly ascribed to a peculiar force developed in the nervous system, which has received the names of "nervous force," "nervous principle," "nervous influence," and "vis nervosa" (in the largest sense of that term); and whilst some physiologists consider that force as a species of agency altogether peculiar to living bodies, others have striven to identify it with some of the forces known to be in operation in inanimate nature, or to show its fundamental relationship to them.

The greater number of nerves possess both afferent and efferent fibres, and are named compound or moto-sensory, inasmuch as they minister both to sensation and motion. In such compound nerves the two kinds of fibres are mixed together and bound up in the same sheaths; but in the most numerous and best-known examples of this class, the afferent and efferent fibres, though mixed in the trunk and branches of the nerves, are separated at their roots. This is the case in the spinal nerves: these have two roots, an anterior and posterior, both for the most part consisting of many funiculi, and the posterior passing through a ganglion with which the fibres of the anterior root have no connection. Now it has been ascertained by appropriate experiments on animals, that the anterior root is efferent and contains the motor fibres, and that the posterior is afferent and contains the sensory fibres. The fifth pair of cranial nerves has a sensory root furnished with a ganglion, and a motor root, like the spinal nerves. The glossopharyngeal and pneumo-gastric nerves are also decidedly compound in nature; they are also provided with ganglia at their roots, which involve a greater or less number of their fasciculi; but it has not yet been satisfactorily determined whether in these nerves the fibres which have different properties are collected at the roots into separate bundles, nor how they are respectively related to the ganglia. The sympathetic, as already stated, contains both afferent and efferent fibres.

Simple nerves are such as contain either afferent or efferent fibres only. The olfactory, auditory, and optic are simple afferent and sensory nerves. The third, fourth, and sixth, the facial, the spinal accessory and hypoglossal nerves are generally regarded as examples of simple motor nerves; there is reason to believe, at least, that they are simple and motor in their origin, or as far as their proper fibres are concerned, and that the sensibility evinced by some of them in their branches is owing to sensory fibres derived from other nerves which join them in their progress.

The nerves governing the motions of the blood-vessels are commonly spoken of as the "vaso-motorial nerves;" but although this term is often of convenient application, there seems no sufficient reason for reckoning these nerves as a distinct system, any more than motorial nerves distributed to other parts or organs whose motions are independent of the will.

#### DEVELOPMENT OF NERVES.

The knowledge as yet acquired respecting this process is not very positive or consistent, so that much room is left for speculation and conjecture. The *nerve-cells* are generally said to be derived from the common embryo-cells, which, undergoing modification in their substance, send out branches from their circumference and acquire the character of nerve-cells. As they are sometimes found with double or divided nuclei, it is inferred that they increase in number by division, after the manner of cells generally. According to the most generally current descriptions, the *fibres* are stated to be formed by the linear coalescence of fusiform cells, and to



be at first pale and grey, but afterwards to acquire medulla and become white. This change of aspect is apparent in the human embryo of the fourth or fifth month. Harting considers that the fibres represent at first only naked axis-cylinders, and suggests that the enclosing membranous tube and white substance are produced as an excretion from the axial fibre. According to Kölliker's account of the growth of nerve-fibres at their peripheral ends, as observed in the tail of batrachian larvæ, the existing fibres are prolonged by rows of fusiform cells which coalesce into pale fibres. These send out fine offshoots, which may join with neighbouring fibres, or with branched or stellate cells, which change into branched fibres, and in both of these ways the branching and conjunction of the nerves go on. The first fibres thus generated (embryonal fibres, Köll.) virtually represent bundles of two, three, or more tubular dark-bordered fibres, into which they are speedily converted; the formation of the medullary sheath proceeding outwards along the branches.

Dr. Beale has studied the formation of cells and fibres both in embryo and adult animals, and the following are the principal results of his observations. In both, cells are formed from nuclei imbedded in granular matter; the new-formed cells are connected one to another, and two cells thus connected withdraw from each other, whilst the connecting isthmus lengthens out and becomes a fibre. The fibres accordingly do not sprout out from a previously insulated simple cell, but are spun out of the substance of the cell, or nucleus, with which they are connected from the beginning. Ganglion-cells also increase in number by division into two or more, and in this case the multiplied fibres belonging to the new cells form a bundle corresponding to the nervous stem or peduncle of the original cell. A ganglion cell may also arise from (apparently) a nucleus placed in the course of a fibre, viz., a little oblong granular mass (of germinal matter, Beale) connected at each end with a fibre. This body first clears up at its circumference, then deviates from the straight line, so that the two portions of the fibre originally prolonged from its extremities, come to be connected with it at one side, and finally, by further change in its figure, at one end of it, as two fibres, whilst their continuations in the bundle from which they have been, as it were, looped out, run in opposite directions. The two fibres at first proceed straight from the cell, but afterwards one becomes twisted round the other, and the coils increase with the age of the cell, but the cell-body dwindles as it grows older. A nerve-fibre in a fasciculus may also be formed from two nuclei connected at their ends which withdraw from each other, the connecting thread then lengthening out into a fibre. For further details, Dr. Beale's original memoir may be consulted.\*

To the foregoing may be added the chief conclusions arrived at by von Hensen from recent observations on the growing nerves in the tadpole's tail. According to his account, fine nervous branches are seen running out, on the tail-fin, into almost imperceptibly fine filaments. The nerves are at first pale, smooth, without nuclei, and represent the naked axis-cylinders, though much finer. Then nuclei appear upon them, but these belong to very long-drawn fusiform cells which now really *inclose* these axis-cylinders, and form the primitive sheath of the nerve-fibres; but this ensheathment stops before reaching the finest branches, *i.e.*, until they grow larger. Afterwards the medulla appears. According to von Hensen, nerves do not grow from cells—such as cells of a nervous centre—outwards in the direction of their branches. He thinks the mode is thus:—Two nerve-cells are connected by a fibre, or what may be the rudiment of many fibres; of the cells, the one is central, the other eventually becomes a peripheral terminal organ; (as already stated, he believes the cutaneous nerve-fibres to be connected with epithelium cells); the latter, in the progress of growth and development, is withdrawn from the former, and the nerve thus lengthened. Moreover, both cells may divide, and the nerve or fibre splits in correspondence, so that a nerve comes to be connected with several central and several peripheral cells. The peripheral cell or cells may divide more extensively than the central, but as corresponding divisions take place in the nerve-fibres, every peripheral cell or terminal organ maintains its connection with the nervous centre. Von Hensen remarks that the foundation of the nervous centres and of the nerves of special sense, as well as those of the skin, is laid in the corneous layer of the blastoderm, from which both the central and peripheral cells are derived originally. It will be seen that

\* Phil. Trans. 1863.



the principle of formation of nerve-fibres advanced by von Hensen is substantially the same as that previously published by Dr. Beale.

*Re-union and regeneration of nerves.*—The divided ends of a nerve that has been cut across readily reunite, and in process of time true nerve fibres are formed in the cicatrix, and restore the continuity of the nervous structure. The conducting property of the nerve, as regards both motion and sensation, is eventually re-established through the re-united part. But immediately after the section, a process of degeneration begins in the peripheral or severed portion of the nerve. The medulla of the white fibres degenerates into a granular mass consisting, apparently, of fatty molecules, and is then totally removed, while the axial fibre, with the primitive sheath and nuclei, remains; but, according to some authorities, the latter also suffer more or less. After reunion takes place, and usually not till then, the medulla is gradually restored, the restoration proceeding from the point of reunion outwards along the nerve, which is then restored to its primitive integrity both in structure and function. From experiments of Philipeaux and Vulpian, it would seem that in very young animals restoration of the severed portion may take place without previous reunion.

The degeneration above referred to does not affect the part of the nerve remaining in connection with the nervous centre, which seems to exert an influence in maintaining the nutrition of the nerve. The ganglia, as well as the brain and spinal cord, have been shown by Dr. Waller to be centres of this influence. He found that in the central and undegenerated portion of a divided spinal nerve, while the fibres belonging to the anterior root owe their integrity to their connection with the spinal cord, those of the posterior root are similarly dependent on the ganglion; and that if the posterior root be cut between the ganglion and the spinal cord, not only will the fibres which belong to it in the trunk of the nerve beyond the ganglion remain unchanged, but also those above the ganglion, in the portion of the root left in connection with it; whereas the segment of the same root which remains connected with the cord but severed from the ganglion degenerates. Section of the sympathetic nerve in the neck is followed by degeneration of the cephalic segment as high as the superior cervical ganglion, but no farther.

### BLOOD-VESSELS.

The blood, from which the solid textures immediately derive material for their nourishment, is conveyed through the body by branched tubes named blood-vessels. It is driven along these channels by the action of the heart, which is a hollow muscular organ placed in the centre of the sanguiferous system. One set of vessels, named *arteries*, conduct the blood out from the heart and distribute it to the different regions of the body, whilst other vessels named *veins* bring it back to the heart again. From the extreme branches of the arteries the blood gets into the commencing branches of the veins or revehent vessels, by passing through a set of very fine tubes which connect the two, and which, though not abruptly or very definitely marked off from either, are generally spoken of as an intermediate set of vessels, and by reason of their smallness are called the *capillary* (i.e., hair-like) *vessels*, or, simply, *the capillaries*.

The conical hollow muscular heart is divided internally into four cavities, two placed at its base, and named auricles, and two occupying the body and apex, named ventricles. The auricles are destined to receive the returning blood from the great veins, which accordingly open into them, and to pass it on into the ventricles; whilst it is the office of the latter to propel the blood through the body. The ventricles have therefore much thicker and stronger sides than the auricles, and the great arterial trunks lead off from them. Each auricle opens into the ventricle of the same side, but the right auricle and ventricle are entirely shut off from those of the left side by an imperious partition placed lengthwise in the heart.

The blood is sent out by the left ventricle into the main artery of the body, named the aorta, and passes through the numerous subordinate



arteries, which are branches of that great trunk, to the different parts of the system, then, traversing the capillaries, it enters the veins, and is returned by two great venous trunks, named the superior and inferior venæ cavæ, to the right auricle. In passing from the arteries to the veins the blood changes in colour from red to dark and is otherwise altered in quality; in this condition it is unfit to be again immediately circulated through the body. On returning, therefore, to the right side of the heart, the blood, now dark and venous, must re-acquire the florid hue and other though less obvious qualities of arterial blood before it is permitted to resume its course. For this purpose, being discharged by the right auricle into the right ventricle, it is driven, by the contraction of that ventricle, along the pulmonary artery and its branches to the lungs, where, passing through the capillary vessels of these organs, it is exposed to the influence of the air, and undergoes the requisite change, and having now become florid again, it enters the commencing branches of the pulmonary veins, which, ending by four trunks in the left auricle convey it into that cavity, whence it is immediately discharged into the left ventricle to be sent again along the aorta and through the system as before.

The blood may thus be considered as setting out from any given point of the sanguiferous system and returning to the same place again after performing a circuit, and this motion is what is properly termed the *circulation* of the blood. Its course from the left ventricle along the aorta, throughout the body, and back by the venæ cavæ to the right ventricle, is named the *greater* or *systemic circulation*, and its passage through the lungs by the pulmonary artery and pulmonary veins from the right to the left side of the heart, is termed the *lesser* or *pulmonary circulation*; but the blood must go through both the greater and the lesser circulation in order to perform a complete circuit, or to return to the point from which it started. As the vessels employed in the circulation through the lungs have been named pulmonary, so the aorta which conveys the blood to the system at large is named the systemic artery, and the venæ cavæ the systemic veins, whilst the two sets of capillaries interposed between the arteries and veins, the one in the lungs, the other in the body generally, are respectively termed the pulmonary and the systemic capillaries.

The blood flows in the arteries from trunk to branches, and from larger to smaller but more numerous tubes; it is the reverse in the veins, except in the case of the *vena portæ*, a vein which carries blood into the liver. This advehent vein, though constituted like other veins in the first part of its course, divides on entering the liver into numerous branches, after the manner of an artery, sending its blood through these branches and through the capillary vessels of the liver into the efferent hepatic veins to be by them conducted into the inferior vena cava and the heart.

The different parts of the sanguiferous system above enumerated may be contemplated in another point of view, namely, according to the kind of blood which they contain or convey. Thus the left cavities of the heart, the pulmonary veins, and the aorta or systemic artery, contain red or florid blood fit to circulate through the body; on the other hand, the right cavities of the heart with the venæ cavæ, or systemic veins, and pulmonary artery, contain dark blood requiring to be transmitted through the lungs for renovation. The former or red-blooded division of the sanguiferous system, commencing by the capillaries of the lungs, ends in the capillaries of the body at large; the latter or dark-blooded part commences in the systemic capillaries and terminates in those of the lungs. The heart



occupies an intermediate position between the origin and termination of each, and the capillaries connect the dark and the red set of vessels together at their extremities, and serve as the channels through which the blood passes from the one part of the sanguiferous system to the other, and in which it undergoes its alternate changes of colour, since it becomes dark as it traverses the systemic capillaries and red again in passing through those of the lungs.

## ARTERIES.

These vessels were so named from the notion that they naturally contain air. This error which had long prevailed in the schools of medicine was refuted by Galen, who showed that the vessels called arteries, though for the most part found empty after death, really contain blood in the living body.

*Mode of Distribution.*—The arteries usually occupy protected situations ; thus after coming out of the great visceral cavities of the body they run along the limbs on the aspect of flexion, and not upon that of extension where they would be more exposed to accidental injury.

As they proceed in their course the arteries divide into branches, and the division may take place in different modes. An artery may at once resolve itself into two or more branches, no one of which greatly exceeds the rest in magnitude, or it may give off several branches in succession and still maintain its character as a trunk. The branches come off at different angles, most commonly so as to form an acute angle with the further part of the trunk, but sometimes a right or an obtuse angle, of which there are examples in the origin of the intercostal arteries. The degree of deviation of a branch from the direction of the trunk was supposed to affect the force of the stream of blood, but Weber maintains, that it can produce little or no effect in a system of elastic tubes maintained, like the arteries, in a state of distension.

An artery, after a branch has gone off from it, is smaller than before, but usually continues uniform in diameter or cylindrical until the next secession ; thus it was found by Mr. Hunter that the long carotid artery of the camel does not diminish in calibre throughout its length. A branch of an artery is less than the trunk from which it springs, but the combined area or collective capacity of all the branches into which an artery divides, is greater than the calibre of the parent vessel immediately above the point of division. The increase in the joint capacity of the branches over that of the trunk is not in the same proportion in every instance of division, and there is at least one case known in which there is no enlargement, namely, the division of the aorta into the common iliac and sacral arteries ; still, notwithstanding this and other possible exceptions, it must be admitted as a general rule that an enlargement of area takes place. From this it is plain, that as the area of the arterial system increases as its vessels divide, the capacity of the smallest vessels and capillaries will be greatest, and as the same rule applies to the veins, it follows that the arterial and venous systems may be represented, as regards capacity, by two cones whose apices (truncated it is true) are at the heart, and whose bases are united in the capillary system. The effect of this must be to make the blood move more slowly as it advances along the arteries to the capillaries, like the current of a river when it flows in a wider and deeper channel, and to accelerate its speed as it returns from the capillaries to the venous trunks.

When arteries unite they are said to anastomose or inosculate. Anasto-



moses may occur in tolerably large arteries, as those of the brain, the hand and foot, and the mesentery, but they are much more frequent in the smaller vessels. Such inosculations admit of a free communication between the currents of blood, and must tend to promote equability of distribution and of pressure and to obviate the effects of local interruption.

Arteries commonly pursue a tolerably straight course, but in some parts they are tortuous. Examples of this in the human body are afforded by the arteries of the lips and of the uterus, but more striking instances may be seen in some of the lower animals, as in the well-known case of the long and tortuous spermatic arteries of the ram and bull. In very moveable parts like the lips this tortuosity will allow the vessel to follow their motions without undue stretching; but in other cases its purpose is not clear. The physical effect of such a condition of the vessel on the blood flowing along it must be to reduce the velocity, by increasing the extent of surface over which the blood moves, and consequently the amount of impediment from friction; still it does not satisfactorily appear why such an end should be provided for in the several cases in which arteries are known to follow a tortuous course. The same remark applies to the peculiar arrangement of vessels named a "*rete mirabile*," where an artery suddenly divides into small anastomosing branches, which in many cases unite again to reconstruct and continue the trunk. Of such *retia mirabilia* there are many examples in the lower animals, but, as already remarked, the purpose which they serve is not apparent. The best known instance is that named the *rete mirabile* of Galen, which is formed by the intracranial part of the internal carotid artery of the sheep and several other quadrupeds.

*Physical Properties.*—Arteries possess considerable strength and a very high degree of elasticity, being extensible and retractile both in their length and width. When cut across, they present, although empty, an open orifice; the veins, on the other hand, collapse, unless when prevented by connection with surrounding rigid parts.

*Structure.*—In most parts of the body the arteries are inclosed in a sheath formed of connective tissue, and their outer coat is connected to the sheath by filaments of the same tissue, but so loosely that when the vessel is cut across its ends readily shrink some way within the sheath. The sheath may inclose other parts along with the artery, as in the case of that enveloping the carotid artery, which also includes the internal jugular vein and pneumo-gastric nerve. Some arteries want sheaths, as those for example which are situated within the cavity of the cranium.

Independently of this sheath, arteries (except those of minute size whose structure will be afterwards described with that of the capillaries) have been usually described as formed of three coats, named, from their relative position, internal, middle, and external; and as this nomenclature is so generally followed in medical and surgical works, and also correctly applies to the structure of arteries so far as it is discernible by the naked eye, it seems best to adhere to it as the basis of our description, although it will be seen, as we proceed, that some of these coats are found by microscopic examination really to consist of two or more strata differing from each other in texture, and therefore reckoned as so many distinct coats by some authorities.

*Internal coat.* This may be raised from the inner surface of the arteries as a fine transparent colourless membrane, elastic but very easily broken, especially in the circular or transverse direction, so that it cannot



be stripped off in large pieces. It is very commonly corrugated with very fine and close longitudinal wrinkles, caused most probably by a contracted state of the artery after death. Such is the appearance presented by the internal coat to the naked eye, but by the aid of the microscope it is found to consist of two different structures, namely: 1. An *epithelium*, forming the innermost part or lining. This is a simple layer of thin elliptical or irregularly polygonal scales, which are often elongated into a lanceolate shape. These epithelial elements have round or oval nuclei, which, however, may disappear; indeed, the whole structure sometimes becomes indistinct, especially in the larger arteries. 2. *Elastic layers*. These form the chief substance of the inner coat. The elastic tissue appears for the most part in form of the "perforated" or "fenestrated" membrane of Henle. This consists of a thin and brittle transparent film, and may exist in one or several layers; and in that case it may be stripped off in small shreds, which have a remarkable tendency to curl in at their upper and lower borders, and roll themselves up as represented in the figure (fig. XCI.). The films of membrane are marked by very fine pale streaks, following principally a longitudinal direction, and joining each other obliquely in a sort of network. Henle considers these lines to be reticulating fibres formed upon the membranous layer. This membrane is further remarkable by being perforated with numerous round, oval, or irregularly-shaped apertures of different sizes. In some parts of the arteries the perforated membrane is very thin, and therefore difficult to strip off; in other situations it is of considerable thickness, consisting of several layers; but it often happens that the deeper layers of the elastic structure, i. e., those farther from the inner surface, lose their membranous character, and pass into a mere network of longitudinal anastomosing fibres of elastic tissue. These longitudinal reticulating fibres are, however, sometimes spoken of as constituting a distinct coat.

The inner coat may thus be said to be formed of *epithelium* and *elastic layers*; the latter consisting of elastic tissue under two principal forms, namely, the fenestrated membrane and the longitudinal elastic networks: and these two forms may coexist in equal amount, or one may predominate, the other diminishing or even disappearing altogether.

It is further to be observed, that in the inner coat of the aorta and the larger arteries, in addition to the elements described, lamellæ are found of a clear, homogeneous, often striated or sometimes even fibrillated substance, mostly of the nature of connective tissue, and pervaded by longitudinal elastic networks of varying fineness. Immediately beneath the epithelium these transparent layers, the *striated layers* (Kölliker), may contain imbedded nuclei, which have been found by Langhans to belong to branched or irregularly stellate cells; or they may be more uniform and destitute of nuclei, in which case they more resemble elastic membranes.

Fig. XCI.

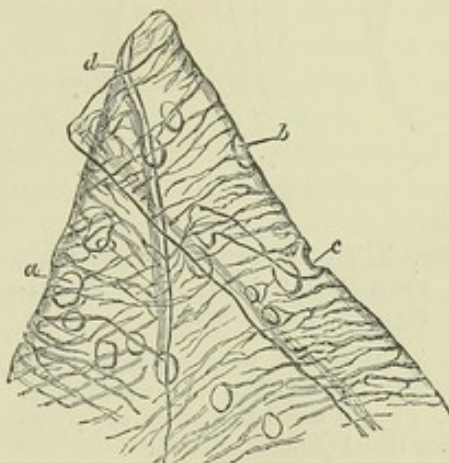


Fig. XCI.—PORTION OF FENESTRATED MEMBRANE FROM THE CRURAL ARTERY, MAGNIFIED 200 DIAMETERS (from Henle).

a, b, c, perforations.



**Middle coat.** This consists of plain muscular tissue, in fine bundles, disposed circularly round the vessel, and consequently tearing off in a circular direction, although the individual bundles do not form complete rings. The considerable thickness of the walls of the larger arteries is due chiefly to this coat; and in the smaller ones, it is said to be thicker in comparison with the calibre of the vessel. In the largest vessels it is made up of many layers; and

Fig. XCII.

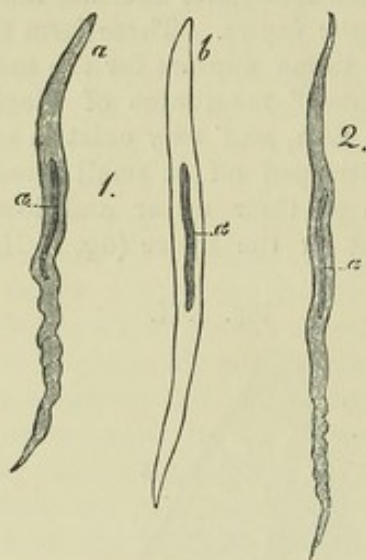


Fig. XCII.—MUSCULAR FIBRE-CELLS FROM HUMAN ARTERIES. MAGNIFIED 350 DIAMETERS.

1. From the popliteal artery; *a*, natural; *b*, treated with acetic acid.  
2. From a small branch of the posterior tibial (from Kölliker).

shreds of elastic membrane, homogeneous, finely reticular, or quite similar to the fenestrated membrane of the inner coat, are often found between the layers. The middle coat is of a tawny or reddish-yellow colour, not unlike that of the elastic tissue, but when quite fresh, it has a softer and more translucent aspect. Its more internal part is often described as redder than the rest, but the deeper tint is probably due to staining by the blood after death. This coat is highly elastic, and was at one time regarded by many, especially among the French anatomists, as being identical in nature with the yellow elastic tissue: but it consists in reality of two constituents, namely, 1st, muscular fibre-cells, seldom more than from  $\frac{1}{300}$  to  $\frac{1}{200}$  of an inch long, collected in bundles, as already stated. 2ndly, fine elastic fibres mixed with the muscular bundles and traversing the muscular layers in form of elastic networks, which, in the larger arteries, pass into the elastic laminæ already mentioned. The elastic fibres are accompanied by white fibres of areolar tissue in small quan-

tity, the proportion of which increases with the size of the artery. It is important further to note that the muscular tissue of the middle coat is more pure in the smaller arteries, and that the admixture of other tissues increases in the larger sized vessels; in these, moreover, the muscular cells are smaller. Accordingly, the vital contractility of the arteries, which depends on their middle coat, is very little marked in those of large size, but becomes much more conspicuous in the smaller branches.

**External coat.** This consists of two layers of different texture, viz., 1st, an internal stratum of genuine elastic tissue, most obvious in arteries of medium calibre, and becoming thinner, and at length disappearing in those of small size; 2ndly, an outer layer, consisting of fine, and closely felted bundles of white connective tissue, mixed with elastic fibres. The bundles and fibres in large and middle-sized arteries chiefly run diagonally or obliquely round the vessel, and their interlacement becomes much more open and lax towards the surface of the artery, where they connect the vessel with its sheath, or with other surrounding parts. This white fibrous layer is usually of great proportionate thickness in the smaller arteries.

Some arteries have much thinner coats than the rest, in proportion to their calibre. This is strikingly the case with those contained within the



cavity of the cranium, and in the vertebral canal ; the difference depends on the external and middle coats, which in the vessels referred to are thinner than elsewhere.

The coats of arteries receive small vessels, both arterial and venous, named *vasa vasorum*, which serve for their nutrition. The little nutrient arteries do not pass immediately from the cavity of the main vessel into its coats, but are derived from branches which arise from the artery (or sometimes from a neighbouring artery), at some distance from the point where they are ultimately distributed, and divide into smaller branches within the sheath, and upon the surface of the vessel, before entering its coats. They form a network in the tissue of the external coat, from which a few penetrate into the middle coat, and follow the circular course of its fibres ; none have been discovered in the internal coat, unless the observations of Jäsche and Arnold are to be trusted, who affirm that they have seen vessels in that situation. Minute venules return the blood from these nutrient arteries, which, however, they do not closely accompany, and discharge it into the vein or pair of veins which usually run alongside the artery.

Arteries are generally accompanied by larger or smaller nerves ; and when in the operation of tying an artery, these happen to be included along with it in the ligature, great pain is experienced, but the vessel itself, when in a healthy condition, is insensible. Nerves are, nevertheless, distributed to the coats of arteries, probably for governing their contractile movements. The nerves come chiefly from the sympathetic, but also from the cerebro-spinal system. They form plexuses round the larger arteries, and run along the smaller branches in form of fine bundles of fibres, which here and there twist round the vessel, and single nerve fibres have been seen closely accompanying minute arteries. The fine branches destined for the artery penetrate to the middle coat, in which they are chiefly distributed. They lay aside their medullary sheath and form a plexus of pale fibres, the finest of which are without nuclei.

*Vital properties.—Contractility.* Besides the merely mechanical property of elasticity, arteries are endowed in a greater or less degree with vital contractility, by means of which they can narrow their calibre. This vital contractility, which has doubtless its seat in the plain muscular tissue of the middle coat, does not cause rapid contractions following in rhythmic succession like those of the heart ; its operation is, on the contrary, slow, and the contraction produced is of long endurance. Its effect, or its tendency, is to contract the area of the arterial tube, and to offer a certain amount of resistance to the distending force of the blood ; and as the contracting vessel will shrink the more, the less the amount of fluid contained in it, the vital contractility would thus seem to adjust the capacity of the arterial system to the quantity and force of the blood passing through it, bracing up the vessels, as it were, and maintaining them in a constant state of tension. In producing this effect, it co-operates with the elasticity of the arterial tubes, but it can be shown that after that property has reached its limit of operation the vital contraction can go further in narrowing the artery. The vital or muscular contractility of the arteries, then, counteracts the distending force of the heart and seems to be in constant operation. Hence it is often named "tonicity," and so far, justly, but at the same time, like the contractility of other muscular structures, it can, by the application of various stimuli, be artificially excited to more vivid action than is displayed in this natural tonic or balanced state ; and, on the other hand, it sometimes relaxes more than the habitual degree, and then the vessels yielding to the distending force of the heart become unusually dilated. Such a remission in their contractile force (taking place rather suddenly) is probably the cause of the turgescence of the small vessels of the skin which occurs in blushing, and the arteries of erectile organs are probably affected in the same manner, so as to permit of an augmented flow of blood into the veins or venous cavities when erection begins.



The vital contractility of small-sized arteries is easily demonstrated in the transparent parts of cold-blooded animals. If the point of a needle be two or three times drawn quickly across one of the little arteries (not capillaries) in the web of a frog's foot placed under the microscope, the vessel will be seen slowly to contract, and the stream of blood passing through it becomes smaller and smaller, and, by a repetition of the process, may be made almost entirely to disappear. After persisting in this contracted state for some minutes, the vessel will gradually dilate again to its original size. The same effect may be produced by the application of ice-cold water, and also by electricity, especially the interrupted electric current. Moreover, if one of the small arteries in the mesentery of a frog or of a small warm-blooded animal, such as a mouse (Poiseuille), be compressed so as to take off the distending force of the blood from the part beyond the point where the pressure is applied, that part will diminish in calibre, at first no doubt from its elasticity, and therefore suddenly, but afterwards slowly. This gradual shrinking of an emptying artery after its elasticity has ceased to operate, may be shown also by cutting out the frog's heart or dividing the main trunks of the vessels: it is obviously due to vital contraction. The contractility of the smaller arteries, as well as its subjection to the influence of the nervous system, is beautifully shown in the experiment of cutting and afterwards stimulating the cervical sympathetic nerve in a cat or rabbit. Immediately after the section, the vessels of the ear become distended with blood from failure of their tonic contraction; but on applying the galvanic stimulus to the upper portion of the nerve, they immediately shrink again, and on interrupting the stimulation they relax as before. The tonic contraction of these vessels appears to be maintained by the spinal cord operating through the branches of the cervical part of the sympathetic nerve; it has been found, moreover, that direct stimulation of the spinal cord causes contraction of other arteries, and probably through branches of spinal nerves.

The contractility of the middle-sized and larger arteries is not so conspicuous, and many excellent observers have failed to elicit any satisfactory manifestation of such property on the application of stimuli to these vessels. Others, however, have observed a sufficiently decided, though by no means a striking degree of contraction slowly to follow mechanical irritation or electric stimulation of these arteries in recently-killed animals. To render this effect more evident, my former colleague, Dr. C. J. B. Williams, adopted a method of experimenting which he had successfully employed to test the irritability of the bronchial tubes. He tied a bent glass tube into the cut end of an artery, and filled the vessel, as well as the bend of the tube with water; the application of galvanism caused a narrowing of the artery, the reality of which was made manifest by a rise of the fluid in the tube. Contraction is said also to follow the application of chemical stimulants, but as these may directly corrugate the tissue by their chemical action, the evidence they afford is less satisfactory. Cold causes contraction of the larger arteries, according to the testimony of various inquirers; and, as in the smaller arteries, a gradual shrinking in calibre ensues in these vessels, when the distending pressure of the blood is taken off, by the extinction or impairment of the force of the heart on the approach of death. From the experiments of Dr. Parry, it would appear that the contraction thus ensuing, proceeds considerably beyond what would be produced by elasticity alone, and that it relaxes after death, when vitality is completely extinct, so that the artery widens again to a certain point, at which it is finally maintained by its elasticity.

#### VEINS.

*Mode of distribution.*—The veins are ramified throughout the body, like the arteries, but there are some differences in their proportionate number and size, as well as in their arrangement, which require to be noticed.

In most regions and organs of the body the veins are more numerous and also larger than the arteries, so that the venous system is altogether more capacious than the arterial, but the proportionate capacity of the two cannot be assigned with exactness. The pulmonary veins form an exception to this rule, for they do not exceed in capacity the pulmonary arteries.

The veins are arranged in a superficial and deep set, the former running



immediately beneath the skin, and thence named subcutaneous, the latter commonly accompanying the arteries, and named *venæ comites vel satellites arteriarum*. The large arteries have usually one accompanying vein, and the medium-sized and smaller arteries two; but there are exceptions to this rule; thus, the veins within the skull and spinal canal, the hepatic veins, and the most considerable of those belonging to the bones, run apart from the arteries.

The communications or anastomoses between veins of considerable size, are more frequent than those of arteries of equal magnitude.

*Structure.*—The veins have much thinner coats than the arteries, and collapse when cut across or emptied; whereas, a cut artery presents a patent orifice. Notwithstanding their comparative thinness, however, the veins possess considerable strength, more even, according to some authorities, than arteries of the same calibre. The number of their coats has been differently reckoned, and the tissues composing them differently described by different writers, and this discrepancy of statement is perhaps partly due to the circumstance that all veins are not perfectly alike in structure. In most veins of tolerable size, three coats may be distinguished, which, as in the arteries, have been named external, middle, and internal.

The *internal coat* is less brittle than that of the arteries, and therefore admits of being more readily peeled off without tearing; but, in other respects, the two are much alike. It consists of an epithelium, a striated lamella containing nuclei, and the usual elastic layers; these occur as dense lamelliform networks of longitudinal elastic fibres, and but seldom as fenestrated membranes.

The *middle coat* is much thinner than that of the arteries, and its muscular tissue has a much larger admixture of white connective tissue. Its fibres are both longitudinal and circular, the one set alternating with the other in layers. The former are well-developed elastic fibres, longitudinally reticulating; the circular layers consist of bundles of muscular fibre-cells and white connective tissue, mixed with a smaller proportion of fine elastic fibres. In medium-sized veins the middle coat contains several successions of the circular and longitudinal layers, but the latter are all more or less connected together by elastic fibres passing through the intervening circular layers. In the larger veins the middle coat is less developed, especially as regards its muscular fibres, but in such cases the deficiency may be supplied by muscularity of the outer coat. Kölliker states that the middle coat is wanting altogether in most of the hepatic part of the vena cava, and in the great hepatic veins; and even where its thickness is considerable, it is less regularly or not at all disposed in layers, and its muscular fibres are more scanty. The muscularity of the *middle coat* is best marked in the splenic and portal veins; it is apparently wanting in certain parts of the abdominal cava and in the subclavian veins.

The *external coat* is usually thicker than the middle coat; it consists of connective tissue and longitudinal elastic fibres. In certain large veins, as pointed out by Remak, this coat contains a considerable amount of plain or non-striated muscular tissue. The muscular elements are well marked in the whole extent of the abdominal cava, in which they form a longitudinal network, occupying the inner part of the external coat; and they may be traced into the renal, azygos, and external iliac veins. The muscular tissue of the *external coat* is also well developed in the trunks of the hepatic veins and in that of the vena portæ, whence it extends into the splenic and superior mesenteric.



Other veins present peculiarities of structure, especially in respect of muscularity. 1. The striated muscular fibres of the auricles of the heart are prolonged for some way on the adjoining part of the venæ cavæ and pulmonary veins. 2. The plain muscular tissue is largely developed in the veins of the gravid uterus, and is described as being present in all three coats. 3. On the other hand, muscular tissue is wanting in the following veins, viz., *a*, those of the maternal part of the placenta; *b*, most of the veins of the brain and pia mater; *c*, the veins of the retina; *d*, the venous sinuses of the dura mater; *e*, the cancellar veins of the bones; *f*, the venous spaces of the corpora cavernosa. In most of these cases the veins consist merely of an epithelium and a layer or layers of connective tissue more or less developed; in the corpora cavernosa the epithelium is applied to the trabecular tissue. It may be added that in the thickness of their coats the superficial veins surpass the deep, and the veins of the lower limbs those of the upper.

The coats of the veins are supplied with nutrient vessels, *vasa vasorum*, in the same manner as those of the arteries. Nerves have not been demonstrated in the coats of veins generally, but small branches have been traced on some of the larger veins.

*Vital properties.*—Veins, when in a healthy condition, appear to be almost devoid of sensibility. They possess vital contractility, which shows itself in the same manner as that of the arteries, but is greatly inferior in degree, and much less manifest. The muscular parts of the great veins, near the auricles of the heart, on being stimulated, in recently killed quadrupeds, exhibit quick and decided contractions, somewhat resembling those of the auricles themselves. Mr. Wharton Jones has discovered a rhythmic pulsation in the veins of the bat's wing, the pulsation occurring from ten to twelve times in a minute; and it is worthy of note that the muscular tissue of these veins appears to be of the plain or unstriped variety.

*Valves.*—Most of the veins are provided with valves, a mechanical contrivance beautifully adapted to prevent the reflux of the blood. The valves

are formed of semilunar folds of the lining membrane, strengthened by included connective tissue, which project obliquely into the vein. Most commonly two such folds or flaps are placed opposite each other (fig. XCIII. A); the convex border of each, which, according to Haller, forms a parabolical curve, is connected with the side of the vein; the other edge is free, and points towards the heart, or at least in the natural direction of the current of the blood along the vessel, and the two flaps obliquely incline towards each other in this direction. Moreover, the wall of the vein immediately above (or nearer the heart than) the curved line of attachment of the valves, is dilated into a pouch or sinus on either side (fig. XCIII. B *a*), so that when distended with blood or by artificial injection, the vessel bulges out on

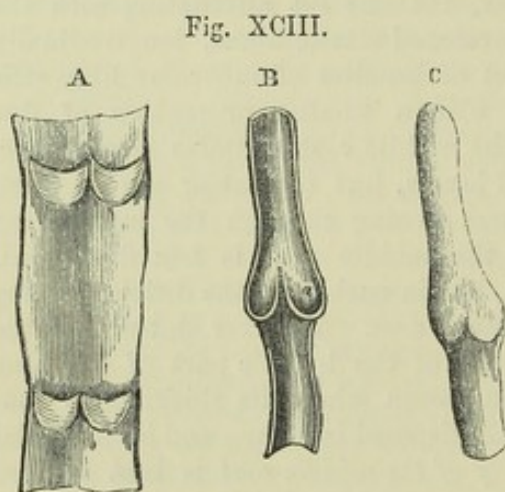


Fig. XCIII.—DIAGRAMS SHOWING VALVES OF VEINS.

A. Part of a vein laid open and spread out, with two pairs of valves. B. Longitudinal section of a vein, showing the apposition of the edges of the valves in their closed state. C. Portion of a distended vein, exhibiting a swelling in the situation of a pair of valves.

each side, and thus gives rise to the appearance of a knot or swelling wherever a valve is placed (as in fig. c). From the above description, it is plain that the valves are so directed as to offer no obstacle to the blood in its



onward flow, but that when from pressure or any other cause it is driven backwards, the reflux blood, getting between the dilated wall of the vein and the flaps of the valve, will press them inwards until their edges meet in the middle of the channel and close it up.

The valvular folds are usually placed in pairs as above described; in the veins of the horse and other large quadrupeds three are often found ranged round the inside of the vessel; but this rarely occurs in the human body. On the other hand, the valves are placed singly in some of the smaller veins, and in large veins single valves are not unfrequently placed over the openings of smaller entering branches; also in the right auricular sinus of the heart there is a single crescentic fold at the orifice of the vena cava inferior, and another more completely covering the opening of the principal coronary vein.

Many veins are destitute of valves. Those which measure less than a line in diameter rarely, if ever, have them. In man, valves are wanting in the trunks of the superior and inferior venæ cavæ, in the trunk and branches of the portal vein, in the hepatic, renal and uterine veins; also in the spermatic veins of the female. In the male, these last mentioned veins have valves in their course, and in either sex a little valve is occasionally found in the renal vein, placed over the entrance of the spermatic. The pulmonary veins, those within the cranium and vertebral canal, and those of the cancellated texture of bone, as well as the trunk and branches of the umbilical vein, are without valves. Valves are not generally found, and when present are few in number, in the azygos and intercostal veins. On the other hand, they are numerous in the veins of the limbs (and especially of the lower limbs), which are much exposed to pressure in the muscular movements or from other causes, and have often to support the blood against the direction of gravity. No valves are met with in the veins of reptiles and fishes, and not many in those of birds.

#### CAPILLARY VESSELS.

That the blood passes from the arteries into the veins was of course a necessary part of the doctrine of the circulation, as demonstrated by Harvey; but the mode in which the passage takes place was not ascertained until some time after the date of his great discovery. The discovery of the capillary vessels, and of the course of the blood through them, was destined to be one of the first-fruits of the use of the microscope in anatomy and physiology, and was reserved for Malpighi (in 1661).

When the web of a frog's foot is viewed through a microscope of moderate power (as in fig. xciv.), the blood is seen passing rapidly along the small arteries, and thence more slowly through a net-work of finer channels, by which it is conducted into the veins. These small vessels, interposed between the finest branches of the arteries and the commencing veins, are the capillary vessels. They may be seen also in the lungs or mesentery of the frog and other batrachians, and in the tail and gills of their larvæ: also in the tail of small fishes; in the mesentery of mice or other small quadrupeds; and generally, in short, in the transparent vascular parts of animals which can readily be brought under the microscope. These vessels can also be demonstrated by means of fine injections of coloured material, not only in membranous parts, such as those above-mentioned, but also in more thick and opaque tissues, which can be rendered transparent by drying.

The capillary vessels of a part are most commonly arranged in a network, the branches of which are of tolerably uniform size, though not all strictly equal; and thus they do not divide into smaller branches like the arteries, or unite into larger ones like the veins; but the diameter of the tubes, as well as the shape and size of the reticular meshes which they form, differs in



different textures. Their prevalent size in the human body may, speaking generally, be stated at from  $\frac{1}{3500}$  to  $\frac{1}{2000}$  of an inch, as measured when naturally filled with blood. But they are said to be in some parts considerably smaller, and in others larger than this standard: thus, Weber has measured injected capillaries in the brain, which he found to be not wider

Fig. XCIV.

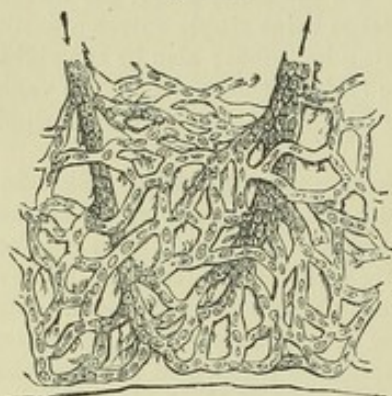

Fig. XCIV. — CAPILLARY BLOOD-VESSELS IN THE WEB OF A FROG'S FOOT, AS SEEN WITH THE MICROSCOPE (after Dr. Allen Thomson).

The arrows indicate the course of the blood.

than  $\frac{1}{4700}$  of an inch, and Henle has observed some still smaller,—in both cases apparently smaller than the natural diameter of the blood corpuscles. The capillaries, however, when deprived of blood, probably shrink in calibre immediately after death; and this consideration, together with the fact that their distension by artificial injection may exceed or fall short of what is natural, should make us hesitate on such evidence to admit the existence of vessels incapable of receiving the red particles of the blood. The diameter of the capillaries of the marrow, or of the medullary membrane, is stated as high as  $\frac{1}{1200}$  of an inch. In other parts, their size varies between these extremes: it is small in the lungs, small also in muscle; larger in the skin and mucous membranes. According to Mr. Toynebee, the extreme branches of the arteries and the com-

mencing veins in certain parts of the synovial membranes are connected by loops of vessels, which are dilated at their point of flexure to a greater size even than the vessels which they immediately connect.

There are differences also in the size or width of the meshes of the capillary network in different parts, and consequently in the number of vessels distributed in a given space, and the amount of blood supplied to the tissue. The network is very close in the lungs and in the choroid coat of the eye, close also in muscle, in the skin, and in most parts of the mucous membrane, in glands and secreting structures, and in the grey part of the brain and spinal cord. On the other hand, it has wide meshes and comparatively few vessels in the ligaments, tendons, and other allied textures. In infants and young persons, the tissues are more vascular than in after-life; growing parts, too, are more abundantly supplied with vessels than those which are stationary.

The figure of the capillary network is not the same in all textures. In many cases the shape of the meshes seems accommodated to the arrangement of the elements of the tissue in which they lie. Thus in muscle, nerve, and tendon, the meshes are long and comparatively narrow, and run conformably with the fibres and fasciculi of these textures (fig. xcv.). In other parts the meshes are rounded or polygonal, with no one dimension greatly predominating (fig. xcvi.). In the smaller-sized papillæ of the skin and mucous membranes, the vessels of the network are often drawn out into prominent loops.

*Structure of the small-sized vessels and capillaries.*—The capillary vessels have real coats, and are not mere channels drilled in the tissue which they pervade, as has sometimes been maintained. In various parts they are readily separable from the surrounding substance, as in the brain and



retina, and in such cases it is easy to display their independent membra-

nous parietes. The number as well as the structure of the coats of the capillaries differs according to the size of the vessels. Capillaries of a diameter less than  $\frac{1}{2400}$  of an inch, were until lately believed to have but a single coat, formed of simple homogeneous transparent membrane, with nucleiform corpuscles attached to it or inclosed in its substance; but from recent researches (by Auerbach, Eberth, and Chrzonszczewsky,) it has been ascertained that they are furnished with an epithelium, to which the nuclei of the capillary

Fig. XCV.

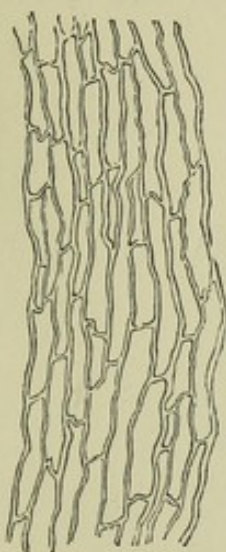

Fig. XCV.—INJECTED CAPILLARY VESSELS OF MUSCLE, SEEN WITH A LOW MAGNIFYING POWER.

Fig. XCVI.

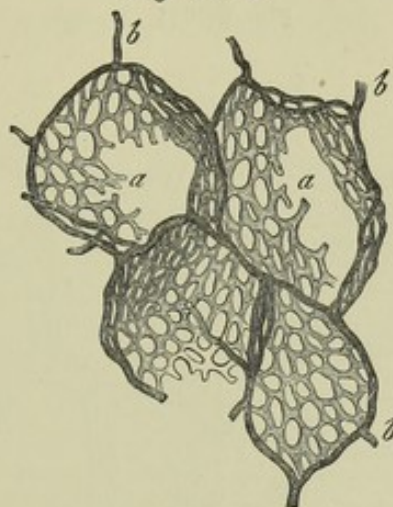


Fig. XCVI.—NET-WORK OF CAPILLARY VESSELS OF THE AIR CELLS OF THE HORSE'S LUNG, MAGNIFIED.

*a, a*, capillaries proceeding from *b, b*, terminal branches of the pulmonary artery (after Frey).

coat really belong. The cells of the epithelium are, as in the larger vessels, flattened into scales and form but a single layer, in which the outline of the scales, or their lines of junction one with another, may be made apparent by nitrate of silver injection; after which the nuclei may be brought into view by acetic acid or carmine (fig. XCVII.). The epithelium scales, which are polygonal in the small arteries and veins (*A, v*), gradually become oblong or spindle-shaped as they pass into the capillaries, and throughout these vessels the epithelium presents the same characters, only the flattened cells or scales become longer and narrower in the smaller capillaries, and fewer in number in the circumference of the tube. In the brain usually only two cells are to be seen in the cross section of a capillary, but in the large capillaries of the kidney and bladder the number may rise to four or five, and in this case the scales are shorter and broader. At the points of junction of the capillaries the cells are much broader and not spindle-shaped but radiate, with three or four pointed branches fitting in between the cells of the three or four adjoining vessels which meet at the spot (fig. XCVII., *c c'*).

Auerbach describes the capillary wall as formed entirely of flattened epithelium cells fitted together at their edges into a continuous and coherent membrane, without any further supporting structure; but Chrzonszczewsky discovered portions of the capillaries in which the epithelium cells had been displaced, and where spaces of some extent were left entirely devoid of nuclei and of the outline markings of the cells; and in these parts the outline of the capillary wall was still entire and continuous, and its substance quite structureless. He concludes, therefore, that there is a homogeneous coat and within this an epithelium, to which the nuclei belong.



In vessels one or two degrees larger, there is added on the primitive homogeneous membrane a layer of plain muscular tissue, in form of the usual

Fig. XCVII.

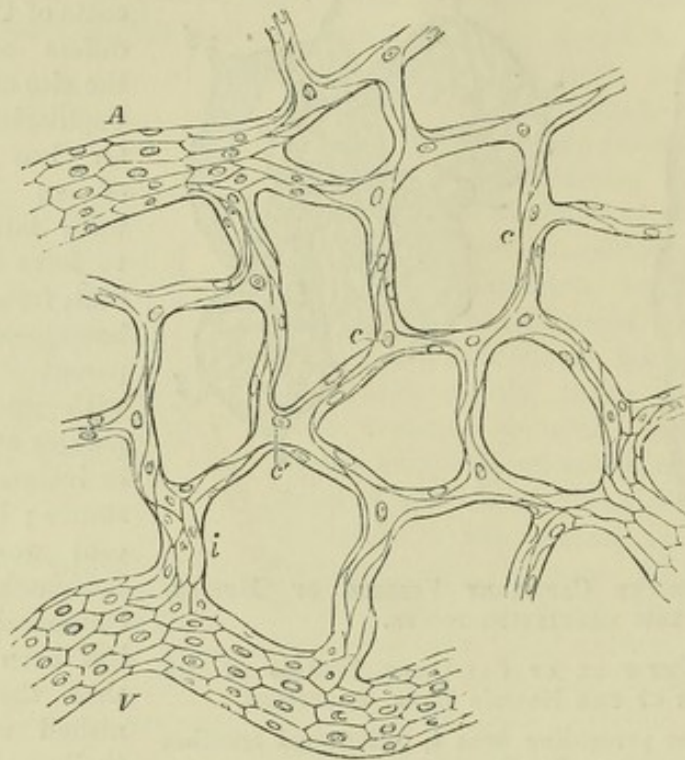


Fig. XCVII.—MAGNIFIED VIEW OF CAPILLARY VESSELS FROM THE BLADDER OF THE CAT.

A, V, an artery and a vein; *i*, transitional vessel between them and *c c*, the capillaries. The muscular coat of the larger vessels is left out in the figure to allow the epithelium to be seen; at *c'*, a radiate epithelium scale with four pointed processes, running out upon the four adjoining capillaries (after Chrzonszczewsky, Virch. Arch. 1866).

oblong contractile fibre-cells, which are directed across the diameter of the vessel. The elongated nuclei of these cells may be brought into view by means of acetic acid, as shown in the figure (xcviii.). This layer corresponds with the middle or muscular coat of the arteries. In the smallest vessels in which it appears the muscular cells are few and apart, and a single long cell may turn spirally round the tube; in larger vessels, especially those of the arterial system, they are of course more densely laid on. Outside the muscular coat is the areolar or connective tissue coat, containing fibres and connective tissue corpuscles, with longitudinally-placed nuclei.

In vessels of  $\frac{1}{60}$  of an inch in diameter, or even less, the elastic layers of the inner coat may be discovered (fig. xcvi., *A*,  $\delta$ ), in form generally of fenestrated membrane, more rarely of longitudinal reticulating elastic fibres; while the primitive membrane disappears. The small veins, but two or three removes from the capillaries, differ from arteries of corresponding size, chiefly in the inferior development of their muscular tissue.

In reference to the structure of capillaries, it is to be further observed that in parts which are pervaded by a supporting network of retiform connective tissue, such as the substance of the lymphatic glands, the solitary



and agminated intestinal glands and adjacent mucous membrane, etc., the small blood-vessels and capillaries commonly receive a coating of connective tissue corpuscles, which are similar to those of the retiform tissue and connected with the fine trabeculæ of the network, by which the vessels are

Fig. XCVIII.

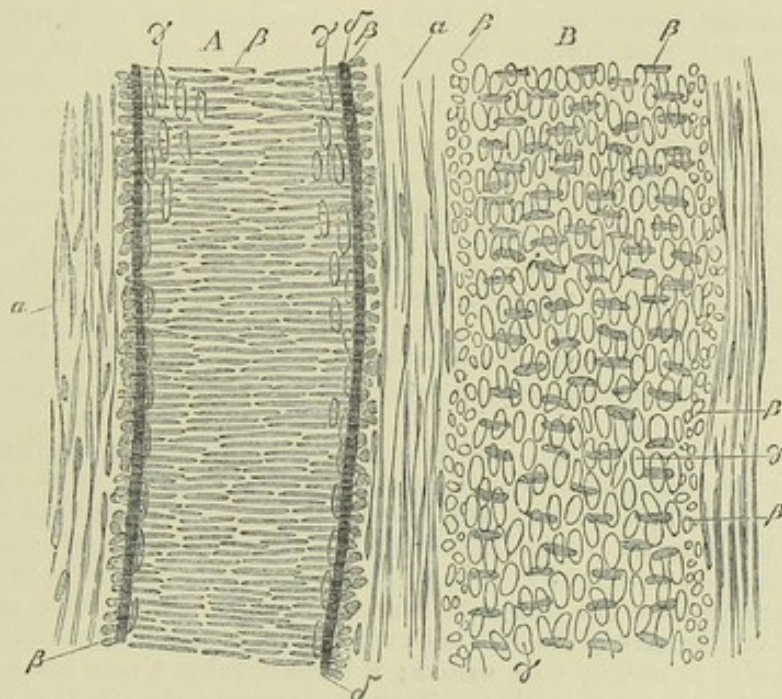


Fig. XCVIII.—A SMALL ARTERY A, WITH A CORRESPONDING VEIN B, TREATED WITH ACETIC ACID, AND MAGNIFIED 350 DIAMETERS (after Kölliker).

α, external coat with oblong nuclei ; β, nuclei of the transverse muscular tissue of the middle coat (when seen endwise, as at the sides of the vessel, their outline is circular) ; γ, nuclei of the epithelium-cells ; δ, elastic layers of the inner coat.

thus supported. On the smallest capillaries the corpuscles are but sparingly distributed, but nevertheless afford a continuous covering to the vessel by their finely reticulating outrunners. This coating is named by His, who has most fully described and figured it, the *adventitia capillaris*.

*Vital properties.*—From the share which the capillaries take in many vital actions, both healthy and diseased, and especially from the part they have been supposed to play in the process of inflammation, much pains has naturally been bestowed to find out whether they are endowed with vital contractility. There is still, however, a difference of opinion on this question ; and, while this property evidently exists in vessels, however small, provided with a muscular coat, it has not been shown by equally direct evidence, to belong to the more simply constructed capillaries ; and it must be confessed, that the proofs commonly adduced of the existence of vital contractility in these vessels, are ambiguous and inconclusive. These proofs are chiefly the two following : viz., 1st, That stimulants, such as alcohol, oil of turpentine, pepper, and ice or ice-cold water, applied to the frog's foot or mesentery, cause the capillary vessels to shrink in diameter, and that this contraction is speedily followed by their dilatation beyond their natural capacity ; the shrinking of the vessels being attributed to the direct operation of the stimuli on their contractility, and their subsequent dilatation to the temporary exhaustion of that property, consequent on its previous undue excitation. 2ndly, That when the vessels are preternaturally dilated, in the way above-described, or by the action of ammonia or common salt, they



may, after a time, be made to contract to their usual size by the reapplication of stimuli.

*Termination of arteries.*—The only known termination of arteries is in veins, and this takes place by means of capillary vessels of some of the forms above described, unless in the maternal part of the placenta, and in the interior of erectile organs, in which it has been supposed that small arteries open into wide venous cavities, without the intervention of capillaries. Additional modes of termination have, however, been assumed to exist. Thus, it was believed that branches of arteries ended in exhalant vessels, which, in their turn, terminated by open orifices on the skin, on the surface of different internal cavities, or in the areolar tissue; other arterial branches were supposed to be continued into the ducts of secreting glands, and it was, moreover, imagined that, besides the red capillaries, there existed finer vessels, which passed between the arteries and the veins, and from their smallness were able to convey only the colourless part of the blood. The existence of these colourless or "serous" vessels, as they were called (*vasa serosa*, *vasa non rubra*), was held, by most authorities, to be universal; by others it was assumed as necessary, at least, in the colourless textures; but these views have now been generally abandoned, although they long prevailed almost without question, and were made the basis of not a few influential doctrines in pathology and practical medicine. Of course it is not denied, that in growing parts there may be capillaries in an incomplete state of development, which admit only the plasma of the blood.

*Erectile, or cavernous tissue.*—By this term is understood a peculiar structure, forming the principal part of certain organs which are capable of being rendered turgid, or erected, by distension with blood. It consists of dilated and freely intercommunicating branches of veins, into which arteries pour their blood, occupying the areolæ of a network formed by fibrous, elastic, and probably contractile bands, named trabeculæ, and inclosed in a distensible fibrous envelope. This peculiar arrangement of the blood-vessels scarcely deserves to be regarded as constituting a distinct texture, though reckoned as such by some writers; it is restricted to a very few parts of the body, and in these is not altogether uniform in character; the details of its structure will, therefore, be considered with the special description of the organs in which it occurs.

#### DEVELOPMENT OF BLOOD-VESSELS.

The first vessels which appear are formed within the ovum, in the germinal membrane; and the process subsequently goes on in growing parts of the animal body. New vessels, also, are formed in the healing of wounds and sores, in the organisation of effused lymph, in the restoration of lost parts, and in the production of adventitious growths. The following may serve as an outline of the process.

The network of vessels which form the vascular area in the germinal membrane of the egg at an early stage of incubation (see page li.), consists of arteries and veins communicating, without capillaries. These vessels are at first solid cylinders of larger or smaller diameter, made up of formative cells cohering together. By liquefaction of their substance in the interior, these cylinders become tubes, and their central cells thus set free are the primitive blood-corpuscles. The uniformly cellular substance forming the wall of the primitive vessels is then converted into the different coats. It is probable that a similar mode of formation of arteries and veins goes on within the body of the embryo as its organs and members are progressively developed; but arteries and veins may also begin as capillaries, which grow into larger vessels, as will presently be explained.

The small vessels and capillaries originate from nucleated cells similar to those which at first constitute the different parts of the embryo. The cell-wall, or envelope, of these cells, shoots out into slender pointed processes, tending in different directions, so that they acquire an irregularly star-shaped or radiated figure. The prolongations from neighbouring cells encounter one another, and join together by their ends, and the irregularly ramified or reticular cavities thus produced are the channels of rudimentary capillaries. In growing parts, such as the tail of batrachian larvæ, where new vessels are formed in the vicinity of those already existing, as represented in the adjoining figure (xcix.) by Kölliker, not only do the processes of the stellate cells join those of neighbouring cells, but some of them meet and join with similar



pointed processes which shoot out from the sides of neighbouring capillary vessels, and in this manner the new vessels are adopted into the existing system. The junctions of the cells with each other or with capillary vessels are, at first, of great tenuity, and contrast strongly with the central and wider parts of the cells; they appear then to be solid, but they afterwards become pervious and gradually widen, blood begins to pass through them, and the capillary network acquires a tolerably uniform calibre. The original vascular network may become closer by the formation of new vessels in its interstices, and this is effected by similarly metamorphosed cells, arising in the areolæ and joining at various points with the surrounding vessels, and also simply by pointed offshoots from the existing capillaries stretching across the intervals and meeting from opposite sides, so as when enlarged to form new connecting arches. From observations made on the foetal membranes of sheep, Mr. Paget has found that the mode of formation of capillaries described by Kölliker in batrachians, holds good also in mammiferous animals.\* The simple homogeneous coat of the capillaries is thus formed out of the walls of the coalescing cells; the lining epithelium must be a subsequent formation. Whilst the finest capillaries retain this simple structure, those that are larger acquire the additional coats already described; and arteries and veins, as already stated, especially the smaller ones, appear to be formed in the same manner; indeed, it would seem not unreasonable to presume, that the several gradations of structure seen as permanent conditions in vessels of successively larger calibre, may represent the successive steps by which a vessel, having originally the small size and the simple membrane of a fine capillary, increases in width and acquires the complex tunics of a vein or artery. Further observations, however, are required on this point. Kölliker states, that many vessels which eventually attain a medium size, are originally derived from round cells, which unite in single or double rows and form the primitive simple membranous tube of such vessels, by coalescence of their cavities and walls.

The blood-vessels may be said to increase in size and capacity in proportion to the demands made on their service. Thus, as the uterus enlarges in pregnancy, its vessels become enlarged, and when the main artery of a limb is tied, or otherwise permanently obstructed, collateral branches, originally small and insignificant,

Fig. XCIX.

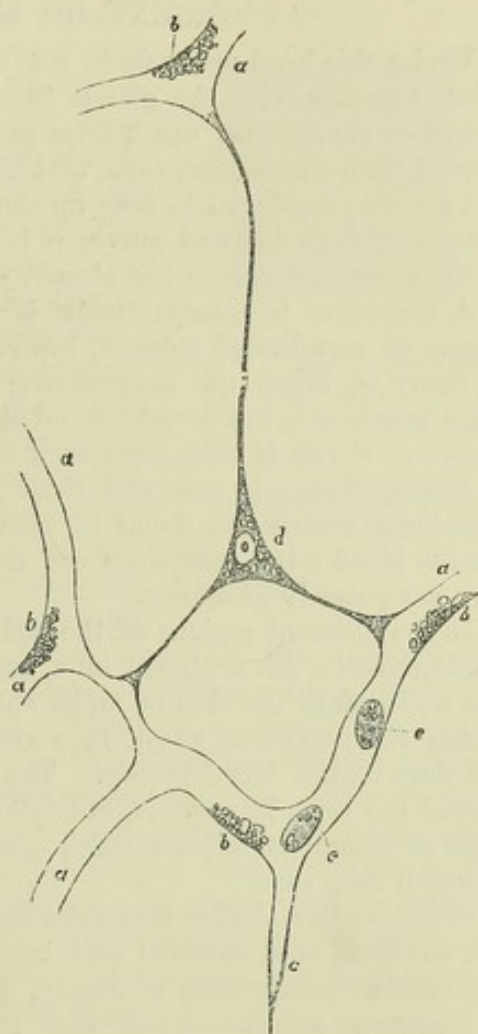


Fig. XCIX.—CAPILLARY BLOOD VESSELS OF THE TAIL OF A VERY YOUNG FROG LARVA. MAGNIFIED 350 DIAMETERS (after Kölliker).

*a*, capillaries permeable to blood; *b*, granules, attached to the walls of the vessels and concealing nuclei; *c*, hollow prolongation of a capillary, ending in a point; *d*, a branched cell, containing a nucleus and granules, and communicating by three branches with prolongations of capillaries already formed; *e*, blood corpuscles.

\* Supplement to Müller's Physiology, by Baly and Kirkes, 1848, p. 104.



augment greatly in size, to afford passage to the increased share of blood which they are required to transmit, and by this admirable adaptation of them to the exigency, the circulation is restored. In such cases, an increase takes place in length, as well as in diameter, and accordingly the vessels very commonly become tortuous.

### ABSORBENT OR LYMPHATIC SYSTEM.

Under this head we include not only the vessels specially called lymphatics, together with the glands belonging to them, but also those named lacteal or chyliferous, which form part of the same system, and differ in no respect from the former, save that they not only carry lymph like the rest, but are also employed to take up the chyle from the intestines during the process of digestion and convey it into the blood. An introductory outline of the absorbent system has already been given at page xlvii.

A system of lymphatic vessels is superadded to the sanguiferous in all classes of vertebrated animals, but such is not the case in the invertebrata; in many of these, the sanguiferous vessels convey a colourless or nearly colourless blood, but no additional class of vessels is provided for conveying lymph or chyle, at least none such has hitherto been detected.

*Distribution.*—In man and those animals in which they are present, the lymphatic vessels are found in nearly all the textures and organs which receive blood; the exceptions are few, and with the progress of discovery may yet possibly disappear.

In the different regions of the body, and in the several internal viscera, the lymphatics are arranged in a superficial and a deep set. The former run underneath the skin or under the membranous coats immediately enveloping the organs in which they are found; the latter usually accompany the deep-seated blood-vessels. The principal lymphatic vessels of a part exceed the veins in number, but fall short of them in size; they also anastomose or intercommunicate much more frequently than the veins alongside of which they run.

*Origin.*—Lymphatics may arise superficially, *i.e.* immediately underneath free surfaces, both external and internal, as for example those of the skin and mucous membranes, or deeply, in the substance of organs.

*Plexiform origin.*—When they arise superficially, the lymphatics most generally begin in form of networks or plexuses, out of which single vessels emerge at various points and proceed to enter lymphatic glands or to join larger lymphatic trunks. Such mode of commencement may be termed the *plexiform*. The plexuses for the most part consist of several strata, becoming finer as they approach the surface, in respect both of the calibre of the vessels and the closeness of their reticulation. This is shown in figure c., which is meant to represent the lymphatic plexuses of the skin. But even the most superficial and finest network is composed of vessels which are larger than the sanguiferous capillaries.

The short anastomosing branches of these plexuses are often of very unequal size, even in the same stratum, some being dilated and almost saccular whilst others immediately communicating with these are narrow, so that the network may assume a varicose character. In some situations the plexuses have much the appearance of strata of intercommunicating cellular cavities, and a characteristic example of this appearance is afforded by the intestine of the turtle after its lymphatics have been injected with mercury; these vessels are then seen to emerge from what has all the appearance of a dense stratum of small rounded cells filled with mercury and lying beneath the surface of the mucous coat. This appearance, however, may be regarded as



produced by the short distended branches of a very close lymphatic network, and transitions are accordingly met with between this and the more usual and regular forms.

But whilst the superficial commencement of lymphatics is generally plexiform, the rule is not without exception. The lacteals of the intestinal villi, for example, although they form networks in the larger and broader villi, arise in others by a single vessel beginning with a blind or closed extremity at the free end of the villus, whence it sinks down to join the general plexus of the intestinal membrane.

*Lacunar origin.*—When lymphatics arise deeply, their origin may be hidden from view, and the precise mode in which it takes place unknown. There may be cases in which it is still plexiform; but another and doubtless more general mode of origin from the interior of organs, long suspected and often upheld on imperfect evidence, has now been satisfactorily ascertained, which may not inappropriately be termed *lacunar*. In this case the lymphatic vessels proceed from irregular or shapeless spaces in the internal parts of organs; the spaces, that is, which intervene between the several structures of which the organ is composed. Thus, in a gland, they are the spaces which lie between or surround the blood-vessels, secreting tubes or saccules, partitioning or inclosing membranes, and the like. Though shapeless, or at least of no regular form, these anfractuous cavities are limited and defined by a lining of epithelium, agreeing in character with that of the lymphatic vessels. It may be presumed that their opposite sides are in apposition or in near proximity, as in serous membranes, for the lymph deposited in these recesses is not suffered to accumulate, but is drained off by the lymphatic vessels which lead out of them.

The lacunar condition of the lymphatic system at its commencement was shown to exist in the testicle by Ludwig and Tomsa, and has since then been found in the kidney by Ludwig and Zwarykin, in the thymus gland by Frey, in the spleen by Tomsa, in the liver (forming canals which inclose the blood-capillaries) by MacGillivray, and in the salivary glands by Giannuzzi. His has also discovered that the blood-vessels of the brain and spinal cord are surrounded and inclosed by lymph-channels—*perivascular canals*—which follow their course and eventually terminate in ordinary lymphatic vessels; an arrangement that brings to mind an earlier observation of Rusconi, who found that the aorta and mesenteric arteries of the frog and salamander are inclosed in large lymphatic canals. The spaces which so extensively separate the frog's skin from the subjacent muscles, were recognised by the late Professor Johannes Müller as belonging to the lymphatic system, and von Recklinghausen has shown that the subcutaneous lymph spaces of the frog's leg communicate with lymphatic vessels which envelope the blood-vessels of the foot; also that milk injected into these spaces finds its way into the blood. The lymphatic system of man and the higher animals in being thus partly constituted by lacunæ or interstitial receptacles, so far agrees with the sanguiferous system of crustaceans and insects.

It has been sometimes maintained that the lymphatics of glandular organs communicate at their origin with the ducts; but, although it is no uncommon thing for matters artificially injected into the ducts of glands, as, for instance, those of the liver and testicle, to pass into the lymphatics, a careful examination of such cases

Fig. C.

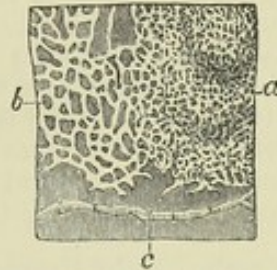


Fig. C.—LYMPHATIC VESSELS OF THE SKIN OF THE BREAST INJECTED (after Breschet).

*a*, superficial, and *b*, deeper plexus; *c*, a lymphatic vessel, which proceeded to the axillary glands.



leads to the conclusion that the injected material does not find its way from the ducts into the lymphatics by any naturally-existing communication, but by accidental rupture of contiguous branches of the two classes of vessels. It seems probable, also, that the communications often held to exist between the commencing lymphatics, both superficial and deep, and capillary blood vessels, have no better foundation, and that the passage of injection, here also relied on as evidence, is to be accounted for in the same way. A fact mentioned by Kölliker throws light on these alleged communications with sanguiferous capillaries. In investigating the lymphatics of the tadpole's tail with the microscope, that observer not unfrequently noticed that blood corpuscles got into the lymphatics from the small blood-vessels, and he was able to recognise in the living animal the communications by which they passed. At first he looked on these communications as natural, but after repeated and careful investigations, he satisfied himself that they were produced accidentally by contusion or some other injury inflicted on the parts.

*Structure.*—In structure the lymphatic vessels much resemble the veins, only their coats are thinner, so thin and transparent indeed that the contained fluid can be readily seen through them. When lymphatics have passed out from the commencing plexuses and lacunæ they are found to have three coats. The internal coat is covered with a lining of epithelium, consisting of a single layer of flattened nucleated cells, which in the larger lymphatics have mostly an oblong figure, but in small or commencing vessels are more rounded, with an indented, bluntly serrated, or wavy border, by which the adjacent cells fit to each other, like the epidermic cells of grasses and some other plants (fig. CI.). Beneath the epithelium

Fig. CI.

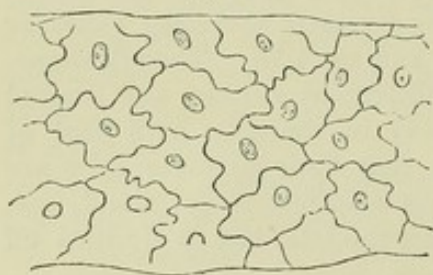

Fig. CI.—PORTION OF A LYMPHATIC VESSEL SHOWING ITS PECULIAR EPITHELIUM. TREATED WITH NITRATE OF SILVER. FROM THE INTER-MUSCULAR LAYER OF THE INTESTINE OF THE GUINEA PIG (after Auerbach). MAGNIFIED 240 DIAMETERS.

the inner coat is formed of a layer or layers of longitudinal elastic fibres. The middle coat consists of plain muscular tissue disposed circularly, mixed with finely reticulating elastic fibres taking the same direction. The external coat is composed mainly of white connective tissue with a sparing intermixture of longitudinal elastic fibres, and some longitudinal and oblique bundles of plain muscular tissue. In the thoracic duct there are striated white layers (as in the aorta) beneath the epithelium, between it and the elastic layers of the inner coat; and in the middle coat there is a longitudinal layer of white connective tissue with elastic fibres, immediately within the muscular layer.

The commencing lymphatics, whether in plexuses or single (as in the villi), for the most part look like mere channels excavated in the surrounding tissue, without independent coats, and they were regarded as such by various eminent authorities. It has now, however, been ascertained that they invariably have a lining of epithelium formed of the characteristic indented scales (fig. CI.), as in other small lymphatics. This is made apparent by injection of solution of nitrate of silver, which blackens and brings into view the serrated lines of juncture of the flattened cells, whilst the nuclei may be made to appear by means of acetic acid or carmine. But it is not clearly determined whether there is any other coat outside the epithelium, even in cases where the vessels are separable from the adjoining tissue. By the same method of preparation an epithelial lining of similarly



marked character has been shown to exist on the walls of the interstitial lymph spaces or lacunæ of origin.

The lymphatics receive vasa vasorum, which ramify in their outer and middle coats : nerves distributed to them have not yet been discovered, although their probable existence has been inferred on physiological grounds.

*Vital properties.*—That the lymphatics are endowed with vital contractility is shown by the effect of mechanical irritation applied to the thoracic duct, as well as by the general shrinking and emptying of the lacteal and lymphatic vessels on their exposure to the contact of cold air, in the bodies of animals opened immediately after death.

*Valves.*—The lymphatic and lacteal vessels are furnished with valves serving the same office as those of the veins, and for the most part constructed after the same fashion. They generally consist of two semi-lunar folds arranged in the same way as in the valves of veins already described, but deviations from the usual structure here and there occur. Thus Mr. Lane has observed some valves in which the planes of the semi-lunar flaps were directed not obliquely but transversely across the vessel, an arrangement calculated to impede the flow of fluid in both directions, but not completely to intercept it in either. In others, described by the same authority, the two folds, placed transversely as before, were coalesced at one end, so as to represent a transverse septum with an incomplete transverse slit. In a third variety, he found the valve formed of a circular fold corresponding with a constriction outside, and probably containing circular contractile fibres capable of completely closing the tube.

Valves are not present in all lymphatics, but where they exist they follow one another at much shorter intervals than those of the veins, and give to the lymphatics, when much distended, a beaded or jointed appearance. Valves are placed at the entrance of the lymphatic trunks into the great veins of the neck. They are wanting in the reticularly-arranged vessels which compose the plexuses of origin already spoken of ; so that mercury injected into one of these vessels runs in all directions so as to fill a greater or less extent of the plexus, and passes along the separate vessels which issue from it.

The lymphatics of fish and naked amphibia are, generally speaking, destitute of valves, and may therefore be injected from the trunks ; in the turtle a few valves are seen on the larger lacteals which pass along the mesentery, but none on those upon the coats of the intestine ; and valves are much less numerous in the lymphatics and lacteals of birds than in those of mammiferous animals.

*Orifices.*—It was at one time a prevalent opinion among anatomists that the lymphatic and lacteal vessels begin on various surfaces by open mouths, through which extraneous matters are absorbed. This was especially insisted on as regards the commencing lacteals in the intestinal villi. That opinion has been since given up ; but quite recently von Recklinghausen has obtained what he considers satisfactory evidence of openings in the lymphatics on the surface of the peritoneum. He stretched the tendinous centre of the diaphragm, excised from a rabbit, over a ring of cork, covered it with a film of milk, and then, watching it with the microscope, saw the milk globules at various points drawn down as if in a vortex, and disappearing. He then found they had passed into the lymphatics of the peritoneal covering of the diaphragm, by small openings, not more than twice the diameter of a blood-corpuscle, over which the peritoneal epithelium was similarly perforated. Observations in confirmation of these have since been made in the Physiological Institute of Leipsic, under the direction of Professor Ludwig, by Dr. Dybkowski, who has found epithe-



lial apertures (answering very nearly to those described by von Recklinghausen) on the dog's pleura, by which the superficial lymphatics open on the surface of the membrane; he also found that fine particles of colouring matter could, under certain conditions, be made to pass from the cavity of the pleura into the lymphatics, and apparently by the openings in question.\*

Respecting these observations, however, it must be remarked, that the apertures described do not open upon a surface in contact with extraneous matters, as that of the skin or a mucous membrane, but into a serous cavity; and perhaps they may be explained on the supposition that the peritoneum, pleura, and other serous sacs, are really large lymph-lacunæ, from which lymphatic vessels lead out as emissaries, as in the case of the subcutaneous lymph-spaces of the frog, and the testicular and other lymph-lacunæ constructed on a smaller scale.

*Absorbent* or *lymphatic glands*, named also *conglobate glands*, and by modern French writers *lymphatic ganglions*, are small solid bodies placed in the course of the lymphatics and lacteals, through which the contents of these vessels have to pass in their progress towards the thoracic or the right lymphatic duct. These bodies are collected in numbers along the course of the great vessels of the neck, also in the thorax and abdomen, especially in the mesentery and alongside the aorta, vena cava inferior, and iliac vessels. A few, usually of small size, are found on the external parts of the head, and considerable groups are situated in the axilla and groin. Some three or four lie on the popliteal vessels, and usually one is placed a little below the knee, but none farther down. In the arm they are found as low as the elbow joint.

Lymphatic vessels may pass through two, three, or even more lymphatic glands in their course, whilst, on the other hand, there are lymphatics which reach the thoracic duct without encountering any gland in their way.

The size of these bodies is very various, some being not much bigger than a hempseed, and others as large or larger than an almond or a kidney-bean. In shape, too, they present differences, but most of them are round or oval.

The lymphatics or lacteals which enter a gland are named *afferent* or *afferent vessels* (*vasa inferentia seu afferentia*), and those which issue from it *efferent vessels* (*vasa efferentia*). The afferent vessels, on approaching a gland, divide into many small branches, which enter the gland; the efferent vessels commonly leave the gland in form of small branches, and at a little distance beyond it, or sometimes even before issuing from it, unite into one or more trunks, usually larger in size but fewer in number than those of the afferent vessels.

The internal structure of lymphatic glands has been long a subject of inquiry. Hewson considered that a lymphatic gland essentially consists of a network of finely-divided lymphatic vessels on and between which capillary blood-vessels are ramified; the whole being gathered up and compacted into a comparatively dense mass by connective tissue, which at the surface of the gland forms for it an inclosing capsule. The afferent and efferent vessels are, according to Hewson, continuous with each other within the gland, and the cellular cavities described as intervening between them and serving as the medium of their communication, were held by him to be nothing more than partial dilatations of some branches of the common connecting plexus.

Hewson's view of the constitution of the lymphatic glands was, till

\* Berichte der K. Sächs: Gesellsch: der Wissensch: July, 1866, p. 191. In the same publication, p. 247, is an account, by F. Schweigger-Seidel and J. Dogiel, of open communications between the frog's peritoneum and the great lymph-sac (*cisterna magna*) behind it; also founded on observations made in the Physiological Institute of Leipsic.



lately, accepted by most anatomists; but recent researches have shown that the structure of these bodies is more complex. The following account is founded on the descriptions of His and Kölliker.

A lymphatic gland is covered externally with a coat composed of connective tissue, mixed in certain animals, with muscular fibre-cells. This coat or capsule is complete, except at the part where it gives passage to the efferent lymphatics and the larger blood vessels; and this part of the gland, which often presents a depression or fissure, may be named the *hilus* (fig. CII. *a*). The proper substance of the gland consists of two parts, the *cortical*, and within this the *medullary*. The cortical part occupies all the superficial part of the gland, except the hilus, and in the larger glands may attain a thickness of from two to three lines. The medullary portion occupies the centre, and extends to the surface at the hilus. It is best marked in the inwardly seated glands, such as the lumbar and mesenteric, whilst in the subcutaneous glands it is more or less encroached upon by a core of connective tissue, *hilus-stroma* (His), which enters with the larger blood-vessels at the hilus, and surrounds them together with the lymph-vessels, in the centre of the gland, so that the medullary part is reduced to a layer of no great thickness bounding inwardly the cortical part.

Throughout both its cortical and medullary part the gland is pervaded by a trabecular frame-work which incloses and supports the proper glandular substance. The trabeculae pass inwards from the capsule. They consist, in the ox, chiefly of plain muscular tissue; in man, of connective tissue, sparingly intermixed with muscular fibre-cells. In the cortical part they are mostly lamellar in form, and divide the space into small compartments, *alveoli*, from  $\frac{1}{60}$  to  $\frac{1}{24}$  of an inch wide, which communicate laterally with each other through openings in the imperfect partitions between them (fig. CIII. *A*). On reaching the medullary part the trabeculae take the form of flattened bands or cords, and by their conjunction and reticulation form a freely intercommunicating meshwork throughout the interior. (In the figures they are represented mostly as cut across.) In these alveoles and meshes is included the proper *glandular substance*, which appears as a tolerably firm pulp, or *parenchyma*. In the alveoli of the cortical part this forms rounded nodules (fig. CIII. *A d*); in the trabecular meshes of the medullary part it takes the shape of rounded cords joining in a corresponding network (figs. CIII. *B d*; CIV. *a a*); and as the containing meshes communicate, so the contained gland-pulp is continuous throughout. But both in the cortical alveoles and the medullary trabecular meshes, a narrow space (left white in the figs. CIII. *l*; CIV., CV. *b*) is left all round the gland-pulp, between it and the alveolar partitions and trabecular bands, like what would be left had the pulp shrunk away from the inside of a mould in which it had been cast. This space is both a receptacle and a channel of passage for the lymph that goes through the gland; it is the *lymph-sinus*

Fig. CII.

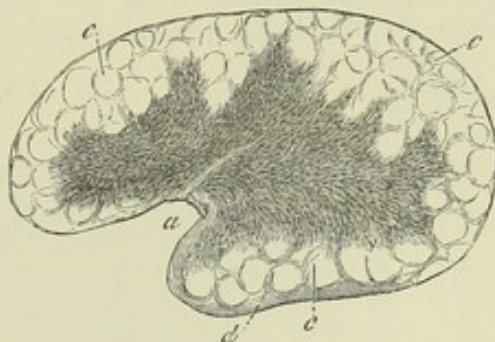


Fig. CII.—SECTION OF A MESENTERIC GLAND FROM THE OX, SLIGHTLY MAGNIFIED.

*a*, hilus; *b*, medullary substance; *c*, cortical substance with indistinct alveoli; *d*, capsule (after Kölliker).



(His), or the *lymph-channel*. It is traversed by retiform connective tissue (fig. cv. *c c*), in which the nuclei of the spindle-shaped or ramified cells are mostly apparent, and is filled with fluid lymph, containing many lymph-corpuscles, which may be washed out from sections of the gland with a hair pencil, so as to show the sinus, while the firmer gland-pulp, which the sinus surrounds, keeps its place. The latter, the proper glandular substance, is also pervaded and supported by retiform tissue, mostly non-nucleated (fig. cv. *a*), communicating with that of the surrounding lymph-sinus, but marked off from it by somewhat closer reticulation at their mutual boundary, not so close, however, as to prevent fluids, or even solid corpuscles, from passing from the one to the other. This glandular pulp is made up of densely-packed lymph-corpuscles, occupying the interstices of

Fig. CIII.

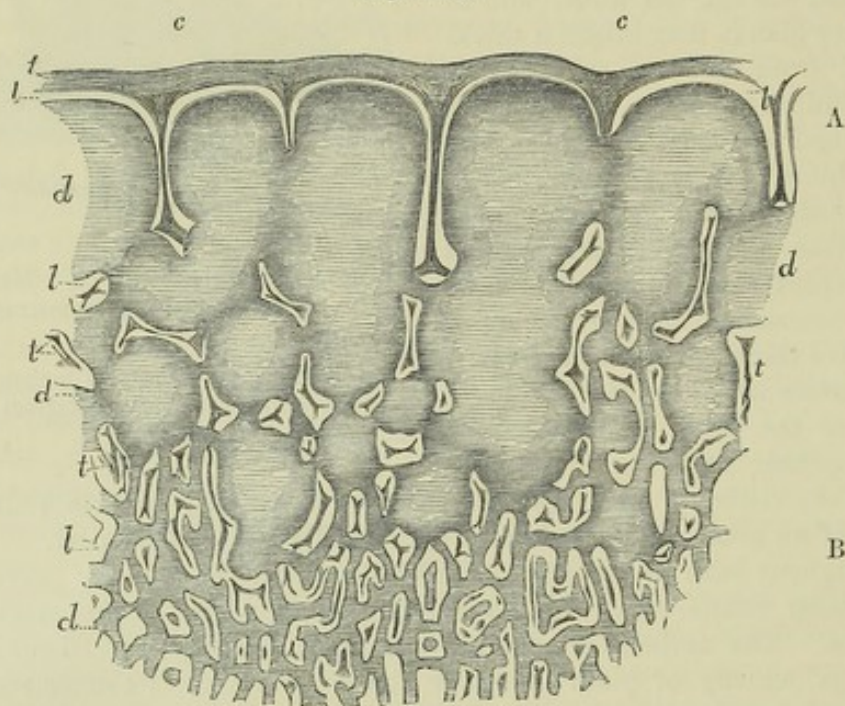


Fig. CIII.—SECTION OF A MESENTERIC GLAND OF THE OX (magnified 12 diameters).

The section includes a portion of the cortical part, A, in its whole depth, and a smaller portion of the adjoining medullary part, B; *c, c*, outer coat or capsule sending partitions into the cortical part to form alveoli, and trabeculae, *tt*, which are seen mostly cut across; *dd*, the glandular substance forming nodules in the cortical part, A, and reticulating cords in the medullary part, B; *l, l*, lymph-sinus or lymph channel, left white (after His).

its supporting retiform tissue, and is traversed by an abundant network of capillary blood-vessels, which runs throughout the proper glandular pulp, both cortical and medullary, but does not pass into the surrounding lymph-sinus. Arteries enter and veins leave the gland at the hilus, surrounded, in some glands, as already said, with a dense inclosure of connective tissue. The arterial branches go in great part directly to the glandular substance, but partly also to the trabeculae. The former end in the glandular capillary network above-mentioned, from which the veins begin, and tend to the hilus alongside the arteries. The branches to the trabeculae run upon these bands, and are in part conducted to the coat of the gland to be there distributed; some of them in an indirect way reach the glandular substance. The blood-vessels of the gland-pulp are supported by its pervading retiform tissue, which is not only connected to them, but forms an additional or



adventitious coat round their small branches, and even on some of the capillaries (page clxxxix).

Fig. CIV.

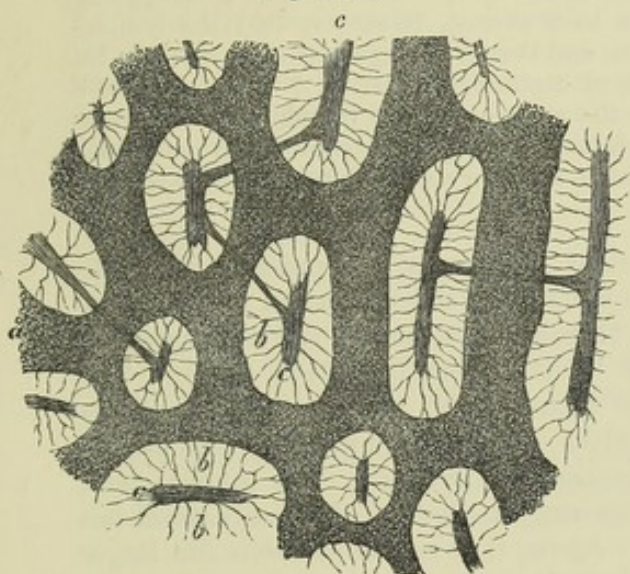


Fig. CV.

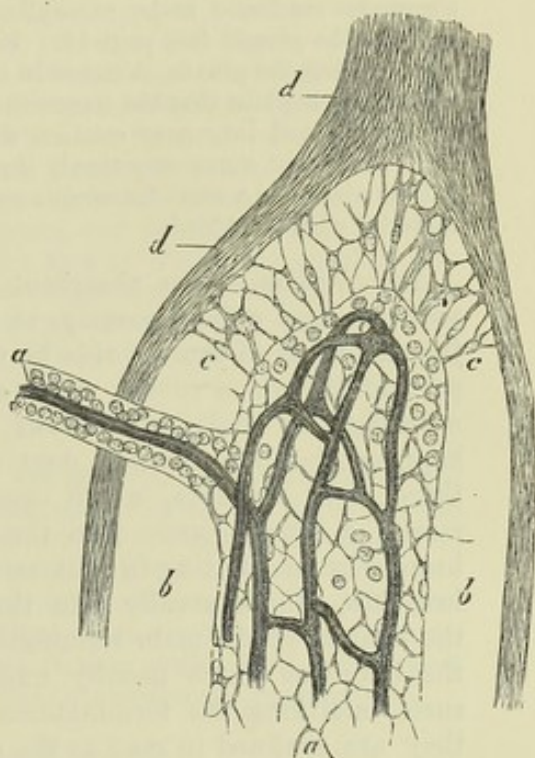


Fig. CIV.—SECTION OF MEDULLARY SUBSTANCE OF AN INGUINAL GLAND OF THE OX (magnified 90 diameters.)

*a, a*, glandular substance or pulp forming rounded cords joining in a continuous net (dark in the figure); *c, c*, trabeculae; the space, *b, b*, between these and the glandular substance is the lymph-sinus, washed clear of corpuscles and traversed by filaments of retiform connective tissue (after Kölliker).

Fig. CV.—A VERY SMALL PORTION OF THE MEDULLARY SUBSTANCE FROM A MESENTERIC GLAND OF THE OX (magnified 300 diameters).

*d, d*, trabeculae; *a*, part of a cord of glandular substance from which all but a few of the lymph corpuscles have been washed out to show its supporting meshwork of retiform tissue and its capillary bloodvessels (which have been injected, and are dark in the figure); *b, b*, lymph-sinus, of which the retiform tissue is represented only at *c, c* (after Kölliker).

As to the lymphatics of the gland, it seems now to be tolerably well made out, that the afferent vessels, after branching out upon and in the tissue of the capsule, send their finer branches through it to open into the lymph-sinuses of the cortical alveoli, and that the efferent lymphatics begin by fine branches leading from the lymph-sinuses of the medullary part, and forming at the hilus a dense plexus of tortuous and varicose-looking vessels, from which branches proceed to join the larger efferent trunks. The lymph-sinus, therefore, forms a channel for the passage of the lymph, interposed between the afferent and efferent lymphatics, communicating with both, and maintaining the continuity of the lymph stream. The afferent and efferent vessels, where they open into the lymph-sinus, lay aside all their coats, except the epithelium, and the sinus is lined throughout its whole extent with a similar epithelium, consisting, as in the commencing lymph-lacunae, of a single layer of flattened cells.



It is not unreasonable to presume that in the proper glandular substance, there is a continual production of lymph-corpuscles, most probably by fissiparous multiplication, which pass into the lymph sinus, and that fresh corpuscles are thus added to the lymph as it passes through a gland; and this view is supported by the fact, that the corpuscles are found to be more abundant in the lymph or chyle after it has passed through the glands (see page l.). It has been alleged, moreover, that the lymph, after passing the glands, is richer in fibrin, and therefore coagulates more firmly. In any case it is plain that the numerous blood capillaries distributed in a gland, must bring the blood into near relation with the elements of the lymph, and the latter fluid, as it must move very slowly through the relatively wide space within the gland, is thus placed in a most favourable condition for some not improbable interchange of material with the blood.

*Termination.*—The absorbent system discharges its contents into the veins at two points, namely, at the junction of the subclavian and internal jugular veins of the left side by the thoracic duct, and in the corresponding part of the veins of the right side by the right lymphatic trunk. The openings, as already remarked, are guarded by valves. It sometimes happens that the thoracic duct divides, near its termination, into two or three short branches, which open separately, but near each other; more rarely, a branch opens into the vena azygos—indeed the main vessel has been seen terminating in that vein. Again, it is not uncommon for larger branches, which usually join the thoracic duct, to open independently in the vicinity of the main termination; and this is more apt to happen with the branches which usually unite to form the right lymphatic trunk. By such variations the terminations in the great veins are multiplied, but still they are confined in man to the region of the neck; in birds, reptiles, and fish, on the other hand, communications take place between the lymphatics of the pelvis, posterior extremities and tail, and the sciatic or other considerable veins of the abdomen or pelvis.

The alleged terminations of lymphatics in various veins of the abdomen, described by Lippi as occurring in man and mammalia, have not been met with by those who have since been most engaged in the prosecution of this department of anatomical research, and accordingly his observations have generally been either rejected as erroneous, or held to refer to deviations from the normal condition.\* But, while such (extra-glandular) terminations in other veins than those of the neck have not been generally admitted, several anatomists of much authority have maintained that the lacteals and lymphatics open naturally into veins within the lymphatic glands. This latter opinion which has been strenuously advocated by Fohmann in particular, is based on a fact well known to every one conversant with the injection of the vessels in question, namely, that the quicksilver usually employed for that purpose, when it has entered a gland by the inferent lymphatics, is apt to pass into branches of veins within the gland, and thus finds its way into the large venous trunks in the neighbourhood, in place of issuing by the efferent lymphatic vessels. But, although it, of course, cannot be doubted that, in such cases, the mercury gets from the lymphatics into the veins, no one has yet been able to perceive the precise mode in which the transmission takes place, and, looking to the circumstances in which it chiefly occurs, it seems to be more probably owing to rupture of contiguous lymphatics and veins within the glands, than to a natural communication between the two classes of vessels in that situation.

*Lymphatic hearts.*—Müller and Panizza, nearly about the same time, but independently of each other, discovered that the lymphatic system of reptiles is furnished, at its principal terminations in the venous system, with pulsatile muscular sacs,

\* In a communication inserted in Müller's Archiv. for 1848, p. 173, Dr. Nuhn, of Heidelberg, affirms the regular existence of these abdominal terminations, and refers to three instances which he met with himself. In two of these, the lymphatics opened into the renal veins, and in the other into the vena cava.



which serve to discharge the lymph into the veins. These organs, which are named lymph-hearts, have now been found in all the different orders of reptiles. In frogs and toads two pairs have been discovered, a posterior pair, situated in the sciatic region, which pour their lymph into a branch of the sciatic or of some other neighbouring vein, and an anterior more deeply-seated pair, placed over the transverse process of the third vertebra, and opening into a branch of the jugular vein. The parietes of these sacs are thin and transparent, but contain muscular fibres of the striated kind, freely ramifying, decussating in different layers, as in the blood-heart. In their pulsations they are quite independent of the latter organ, and are not even synchronous with each other. In salamanders, lizards, serpents, tortoises, and turtles, only a posterior pair have been discovered, which, however, agree in all essential points with those of the frog. In the goose, and in other species of birds belonging to different orders, Panizza discovered a pair of lymph-sacs opening into the sacral veins, and Stannius has since found that these sacs have striated muscular fibres in their parietes; but, although this observer, in some cases, exposed them in the living bird, he was not able to discover any pulsation or spontaneous movement in them. Nerve-fibres, both dark bordered and pale, have been observed in the lymph-hearts of the frog, and also nerve-cells in those of the common tortoise. (Waldeyer.)

*Development of lymphatic vessels.*—Kölliker has observed the formation of lymphatics from ramified cells in the tails of young salamander-larvæ. He states that the process takes place nearly in the same manner as in the case of sanguiferous capillaries; the only notable difference being, that whilst the growing lymphatics join the ramified cells, and thus extend themselves, their branches very rarely anastomose or become connected by communicating arches. The soundness of his conclusions has, however, been called in question and the subject requires further elucidation. New-formed lymphatics have been injected in adhesions between inflamed serous membranes.

## SEROUS MEMBRANES.

The serous membranes are so named from the apparent nature of the fluid with which their surface is moistened. They line cavities of the body which have no outlet, and the chief examples of them are, the peritonæum, the largest of all, lining the cavity of the abdomen; the two pleuræ and pericardium in the chest; the arachnoid membrane in the cranium and vertebral canal; and the tunica vaginalis surrounding each of the testicles within the scrotum.

*Form and arrangement.*—In all these cases the serous membrane has the form of a closed sac, one part of which is applied to the walls of the cavity which it lines, the *parietal* portion; whilst the other is reflected over the surface of the organ or organs contained in the cavity, and is therefore named the *reflected* or *visceral* portion of the membrane. Hence the viscera in such cavities are not contained within the sac of the serous membrane, but are really placed behind or outside of it; merely pushing inwards, as it were, the part of the membrane which immediately covers them, some organs receiving in this way a complete, and others but a partial and sometimes very scanty investment.

In passing from one part to another, the membrane frequently forms folds which in general receive the appellation of ligaments, as, for example, the folds of peritonæum passing between the liver and the parietes of the abdomen, but which are sometimes designated by special names, as in the instances of the mesentery, meso-colon, and omentum.

The peritonæum, in the female sex, is an exception to the rule that serous membranes are perfectly closed sacs, inasmuch as it has two openings by which the Fallopian tubes communicate with its cavity.

A serous membrane sometimes lines a fibrous membrane, as where the arachnoid lines the dura mater, or where the serous layer of the peri-



cardium adheres to its outer or fibrous part. Such a combination is often named a *fibro-serous* membrane.

The inner surface of a serous membrane is free, smooth, and polished ; and, as would occur with an empty bladder, the inner surface of one part of the sac is applied to the corresponding surface of some other part ; a small quantity of fluid, usually not more than merely moistens the contiguous surfaces, being interposed. The parts situated in a cavity lined by serous membrane can thus glide easily against its parietes or upon each other, and their motion is rendered smoother by the lubricating fluid.

The outer surface most commonly adheres to the parts which it lines or covers, the connection being effected by means of areolar tissue, named therefore “subserous,” which, when the membrane is detached, gives to its outer and previously adherent surface a flocculent aspect. The degree of firmness of the connection is very various : in some parts, the membrane can scarce be separated ; in others, its attachment is so lax as to permit of easy displacement. The latter is the case in the neighbourhood of the openings through which abdominal herniæ pass, and accordingly when such protrusions of the viscera happen to take place, they usually push the peritonæum before them in form of a hernial sac.

The visceral portion of the arachnoid membrane is in some measure an exception to the rule of the outer surface being everywhere adherent ; for in the greater part of its extent, it is thrown loosely round the parts which it covers, a few fine fibrous bands being the sole bond of connection ; and a quantity of pellucid fluid is interposed, especially in the vertebral canal and base of the cranium, between the arachnoid and the pia mater, which is the membrane immediately investing the brain and spinal cord.

*Structure and properties.*—Serous membranes are thin and transparent, so that the colour of subjacent parts shines through them. They are tolerably strong, with a moderate degree of extensibility and elasticity. They consist of, 1st, a simple layer of scaly *epithelium* already described and figured (fig. xx.), which, however, is in part ciliated on the serous membrane lining the ventricles of the brain and central canal of the spinal cord. 2ndly, the *fibrous layer*. This consists of fine but dense areolar connective tissue, which is, as usual, made up of bundles of white filaments mixed with fine elastic fibres ; the former, when there are two or more strata, take a different direction in the different planes ; the latter unite into a network, and, in many serous membranes, as remarked by Henle, are principally collected into a reticular layer at the surface, immediately beneath the epithelium. The constituent connective tissue of the serous membrane is of course continuous with the usually more lax *subserous areolar tissue* connecting the membrane to the subjacent parts. Where the arachnoid membrane lines the dura mater, and possibly also in some other cases, the fibrous layer usually belonging to the serous membrane is wanting, its place being supplied by the fibrous membrane beneath, on which the epithelium is immediately applied.

Blood-vessels ending in a capillary network with comparatively wide meshes pervade the subserous tissue and the tissue of the serous membrane. Plexuses of lymphatics also exist in the subserous tissue, but not under every part of the membrane ; in the costal pleura, for example, the lymphatics are confined to the parts which cover the intercostal and sterno-costal muscles. When present the lymphatics extend in form of fine superficial plexuses through the fibrous layer of the membrane to its surface, immediately beneath the epithelium (Dybkowski), and may then open into the serous



cavity by cognizable apertures, as already stated. Fine nervous fibres, with nerve-cells in some places, have been described by several anatomists, in or immediately beneath the serous membranes of various regions; nevertheless it would seem, that when in a healthy condition these membranes possess little or no sensibility; they are altogether devoid of vital contractility.

*Fluid.*—The internal surface of serous cavities is moistened and lubricated with a transparent and nearly colourless fluid, which in health exists only in a very small quantity. This fluid, which is doubtless derived from the blood-vessels of the membrane, has been commonly represented as similar in constitution to the serum of the blood. But it was long since remarked by Hewson (and a similar opinion seems to have been held by Haller and Monro), that the fluid obtained from the serous cavities of recently-killed animals coagulates spontaneously, and thus resembles the lymph of the lymphatic vessels, and, we may add, the liquor sanguinis or plasma of the blood, the coagulation being, of course, due to the presence of fibrin, or of its two constituents fibrinogen and globulin. Hewson, who regarded the fluid as lymph, found that the coagulability diminished as the quantity increased. In confirmation of Hewson's statement, I may mention that I have always found the fluid obtained from the peritoneal cavity of rabbits to coagulate spontaneously in a greater or less degree. Hewson made his observations on the fluid of the peritonæum, pleura, and pericardium, in various animals, viz., bullocks, dogs, geese, and rabbits.\*

When the fluid gathers in unusual quantity as in dropsies, it rarely coagulates spontaneously on being let out; but will often yield a coagulum on the addition of globulin as already stated (page xxxviii.). From this it may be inferred that fibrinogen is present, but not the globulin (fibrino-plastin) requisite to generate fibrin.

The identity in character of the fluid of serous cavities and the lymph plasma is, it need scarcely be remarked, in keeping with the notion of their being great lymph-spaces in open connection with lymphatic vessels. But this view is quite reconcilable with the mechanical purpose commonly ascribed to these membranes, of lubricating and facilitating the movement of mutually opposed surfaces.

When a serous membrane is inflamed, it has a great tendency to throw out coagulable lymph (or fibrin) and serum, the two constituents of the blood-plasma, the former chiefly adhering to the inner surface of the membrane, whilst the latter gathers in its cavity. The coagulable lymph spread over the surface, in form of a "false membrane," as it is called, or agglutinating the opposed surfaces of the serous sac and causing adhesion, becomes pervaded by blood-vessels, and in process of time converted into areolar tissue.

Breaches of continuity in these membranes are readily repaired, and the new-formed portion acquires all the characters of the original tissue.

## SYNOVIAL MEMBRANES.

Resembling serous membranes in general form and structure, the synovial membranes are distinguished by the nature of the secretion which lubricates their surface, for this is a viscid glairy fluid resembling the white of an egg, and thence named *synovia*.

These membranes line the cavities of joints, and are interposed between moving parts in certain other situations; being in all cases intended to lessen friction, and thereby facilitate motion. They are composed of a scaly epithelium, which may consist of several strata, and a layer of dense areolar tissue pervaded by vessels and attached by tissue of the same kind to the parts beneath.

The different synovial membranes of the body are referred to three classes, viz., *articular*, *vesicular*, and *vaginal*.

1. *Articular synovial membranes*, or *Synovial capsules of joints*. These

\* See Hewson's Works, published by the Sydenham Society, p. 157, with some important remarks in notes xviii. and lxviii., by the editor, Mr. Gulliver.



line and by their synovial secretion lubricate the cavities of the diarthrodial articulations, that is, those articulations in which the opposed surfaces glide on each other. In these cases the membrane may be readily seen covering internally the surface of the capsular or other ligaments which bound the cavity of the joint, and affording also an investment to the tendons or ligaments which happen to pass through the articular cavity, as in the instance of the long tendon of the biceps muscle in the shoulder-joint. On approaching the articular cartilages the membrane passes over their margins, and becoming much more firmly adherent, terminates after advancing but a little way on their surface. This, as already explained (page lxxxiii.), is the condition in the adult, but in the foetus the membrane, closely adhering, is continued over the whole surface of the cartilage, so that it would seem to become obliterated or absorbed in consequence of pressure or friction when the joint comes to be exercised. The blood-vessels in and immediately underneath the membrane are sufficiently manifest in most parts of the joint. They advance but a little way upon the cartilages, forming a vascular zone round the margin of each, named "*circulus articuli vasculosus*," in which they end by loops of vessels dilated at the bent part greatly beyond the diameter of ordinary capillaries. In the foetus, according to Mr. Toynbee, these vessels, like the membrane itself, advance further upon the surface of the cartilage.

In several of the joints, folds of the synovial membrane, often containing more or less fat, pass across the cavity; these have been called synovial or mucous ligaments. Other processes of the membrane simply project into the cavity at various points. These are very generally cleft into fringes at their free border, upon which their blood-vessels, which are numerous, are densely distributed. They often contain fat, and then, when of tolerable size, are sufficiently obvious; but many of them are very small and inconspicuous. The fringed vascular folds of the synovial membrane were described, by Dr. Clopton Havers (1691), under the name of the *mucilaginous glands*, and he regarded them as an apparatus for secreting synovia. Subsequent anatomists, while admitting that, as so many extensions of the secreting membrane, these folds must contribute to increase the secretion, have, for the most part, denied them the special character of glands, considering them rather in the light of a mechanical provision for occupying spaces which would otherwise be left void in the motion of the joints, and this view is no doubt right as regards the larger, fat-inclosing folds. The smaller and less obvious fringes have, however, been found, on investigation by Mr. Rainey, to be most probably secreting organs as originally supposed by Havers. Mr. Rainey\* has found that the processes in question exist in the bursal and vaginal synovial membranes as well as in those of joints, wherever, in short, synovia is secreted. He states that their blood-vessels have a peculiar convoluted arrangement, differing from that of the vessels of fat, and that the epithelium covering them, "besides inclosing separately each packet of convoluted vessels, sends off from each tubular sheath secondary processes of various shapes, into which no blood-vessels enter." Kölliker, who has since taken up the inquiry, also finds that fringed membranes exist in all joints and synovial sheaths, as well as in most synovial bursæ, and that they consist of vascular tufts of the synovial membrane, covered by epithelium, and now and then containing fat-cells and more rarely isolated cartilage cells. He also observed the curious "non-vascular secondary processes," described by Mr. Rainey, the larger of which, he says, consist of fibres of areolar tissue in the centre, sometimes containing cartilage cells, and a covering of irregularly thickened epithelium.

2. *Vesicular or Bursal synovial membranes, Synovial bursæ, Bursæ mucosæ.*—In these the membrane has the form of a simple sac, interposed, so as to prevent friction, between two surfaces which move upon each other. The sy-

\* Proceedings of the Royal Society; May 7th, 1846.



novial sac in such cases is flattened and has its two opposite sides in apposition by their inner surface which is free and lubricated with synovia, whilst the outer surface is attached by areolar tissue to the moving parts between which the sac is placed. As in the case of articular synovial membranes, the bursal membrane on the rubbing surfaces may be, at parts, obliterated.

In point of situation the bursæ may be either deep-seated or subcutaneous. The former are for the most part placed between a muscle or its tendon and a bone or the exterior of a joint, less commonly between two muscles or tendons: certain of the bursæ situated in the neighbourhood of joints not unfrequently open into them. The subcutaneous bursæ lie immediately under the skin, and are found in various regions of the body interposed between the skin and some firm prominence beneath it. The large bursa situated over the patella is a well-known example of this class, but similar, though smaller bursæ are found also over the olecranon, the malleoli, the knuckles, and various other prominent parts. It must, however, be observed, that, among these subcutaneous bursæ, some are reckoned which do not always present the characters of true synovial sacs, but look more like mere recesses in the subcutaneous areolar tissue, larger and more defined than the neighbouring areolæ, but still not bounded by an evident synovial membrane. These have been looked on as examples of less developed structure, forming a transition between the areolar tissue and perfect synovial membrane.

3. *Vaginal Synovial membranes or Synovial sheaths.*—These are intended to facilitate the motion of tendons as they glide in the fibrous sheaths which bind them down against the bones in various situations. The best-marked examples of such fibrous sheaths are to be seen in the hand and foot, and especially on the palmar aspect of the digital phalanges, where they confine the long tendons of the flexor muscles. In such instances one part of the synovial membrane forms a lining to the osseo-fibrous tube in which the tendon runs, and another part is reflected at each end upon the tendon, and affords it a close investment. The space between the parietal and reflected portions of the membrane is lubricated with synovia and crossed obliquely by one or more folds or duplications of the membrane, in some parts inclosing elastic tissue. These are named “fræna,” and pass from one part of the membrane to the other.

*Synovia.*—As already stated, this is a viscid transparent fluid; it has a yellowish or faintly reddish tint, and a slightly saline taste. According to Frerichs, the synovia of the ox consists of 94·85 water, 0·56 mucous and epithelium, 0·07 fat, 3·51 albumen and extractive matter, and 0·99 salts. If a drop of synovial fluid is examined microscopically, it is found to contain (in addition to fat-molecules and epithelium cells) small, granular corpuscles, bearing a close resemblance to the pale corpuscles of the blood. It is doubtful whether these bodies have a special nature and purpose, or whether they are merely transitory forms of epithelium particles.

## MUCOUS MEMBRANES.

These membranes, unlike the serous, line internal passages, and other cavities which open on the surface of the body, as well as various recesses, sinuses, gland-ducts and receptacles of secretion, which open into such passages. They are habitually subject to the contact of foreign substances introduced into the body, such as air and aliment, or of various secreted or excreted matters, and hence their surface is coated over and protected by mucus, a fluid of a more consistent and tenacious character than that which moistens the serous membranes.



The mucous membranes of several different or even distant parts are continuous, and, with certain unimportant reservations, to be afterwards explained, they may all be reduced to two great divisions, namely, the *gastro-pulmonary* and *genito-urinary*. The former covers the inside of the alimentary and air passages as well as the less considerable cavities communicating with them. It may be described as commencing at the edges of the lips and nostrils where it is continuous with the skin, and proceeding through the nose and mouth to the throat, whence it is continued throughout the whole length of the alimentary canal to the termination of the intestine, there again meeting the skin, and also along the windpipe and its numerous divisions as far as the air cells of the lungs, to which it affords a lining. From the nose the membrane may be said to be prolonged into the lachrymal passages, extending up the nasal duct into the lachrymal sac and along the lachrymal canals until, under the name of the conjunctival membrane, it spreads over the fore part of the eyeball and inside of the eyelids, on the edges of which it encounters the skin. Other offsets from the nasal part of the membrane line the frontal, ethmoidal, sphenoidal and maxillary sinuses, and from the upper part of the pharynx a prolongation extends on each side along the Eustachian tube to line that passage and the tympanum of the ear. Besides these there are offsets from the alimentary membranes to line the lachrymal, salivary, pancreatic, and biliary ducts, and the gall-bladder. The *genito-urinary* membrane invests the inside of the urinary bladder and the whole tract of the urine in both sexes, from the interior of the kidneys to the orifice of the urethra, also the seminal ducts and vesicles in the male, and the vagina, uterus, and Fallopian tubes in the female.

The mucous membranes lining the ducts of the mammary glands, being unconnected with either of the above-mentioned great tracts, have sometimes been enumerated as a third division, and the number might of course be multiplied, were we separately to reckon the membranes prolonged from the skin into the ducts of the numerous little glands which open on the surface of the body.

The mucous membranes are attached by one surface to the parts which they line or cover by means of areolar tissue, named "submucous," which differs greatly in quantity as well as in consistency in different parts. The connection is in some cases close and firm, as in the cavity of the nose and its adjoining sinuses; in other instances, especially in cavities subject to frequent variation in capacity, like the gullet and stomach, it is lax and allows of some degree of shifting of the connected surfaces. In such cases as the last-mentioned the mucous membrane is accordingly thrown into folds when the cavity is narrowed by contraction of the exterior coats of the organ, and of course these folds, or *rugæ*, as they are named, are effaced by distension. But in certain parts the mucous membrane forms permanent folds, not capable of being thus effaced, which project conspicuously into the cavity which it lines. The best-marked example of these is presented by the *valvule conniventes* seen in the small intestine. These, as is more fully described in the special anatomy of the intestines, are crescent-shaped duplicatures of the membrane, with connecting areolar tissue between their laminae, which are placed transversely and follow one another at very short intervals along a great part of the intestinal tract. The chief purpose of the *valvule conniventes* is doubtless to increase the surface of the absorbing mucous membrane within the cavity, and it has also been supposed that they serve mechanically to delay the alimentary mass in its progress downwards. A mechanical office has also been as-



signed to a series of oblique folds of a similar permanent kind, though on a smaller scale, which exist within the cystic duct.

*Physical properties.*—In most situations the mucous membranes are nearly opaque or but slightly translucent. They possess no great degree of tenacity and but little elasticity, and hence are readily torn by a moderate force. As to colour, they cannot be said intrinsically to have any, and when perfectly deprived of blood they accordingly appear white or at most somewhat grey. The redness which they commonly exhibit during life, and retain in greater or less degree in various parts after death, is due to the blood contained in their vessels, although it is true that after decomposition has set in, the red matter of the blood, becoming dissolved, transudes through the coats of the vessels, and gives a general red tinge to the rest of the tissue. The degree of redness exhibited by the mucous membranes after death is greater in the foetus and infant than in the adult. It is greater too in certain situations; thus, of the different parts of the alimentary canal, it is most marked in the stomach, pharynx, and rectum. Again, the intensity of the tint, as well as its extent, is influenced by circumstances accompanying or immediately preceding death. Thus the state of inflammation, or the local application of stimuli to the membrane, such as irritant poisons, or even food in the stomach, is apt to produce increased redness; and all the mucous membranes are liable to be congested with blood and suffused with redness when death is immediately preceded by obstruction to the circulation, as in cases of asphyxia, and in many diseases of the heart.

*Structure.*—A mucous membrane is composed of the *corium* and *epithelium*. The *epithelium* covers the surface, and has already been described (p. iii., et seq.). The membrane which remains after removal of the epithelium is named the *corium*, as in the analogous instance of the true skin. The corium may be said to consist of a *fibro-vascular layer*, of variable thickness, bounded superficially or next the epithelium by an extremely fine transparent lamella, named *basement membrane* by Bowman, and *primary membrane*, *limitary membrane*, and *membrana propria* by others who have described it. It must be explained, however, that these two constituents of the corium cannot in all situations be separated from each other, nor indeed can the presence of both be proved by actual demonstration in all parts of the mucous membranes.

The *basement membrane* is best seen in parts where the mucous membrane is raised into villous processes or where it forms secreting crypts or minute glandular recesses, such as those which abound in the stomach and intestinal canal. On teasing out a portion of the gastric or intestinal mucous membrane under the microscope, some of the tubular glands are here and there discovered which are tolerably well cleared from the surrounding tissue, and their parietes are seen to be formed of a thin pellucid film, which is detached from the adjoining fibro-vascular layer, the epithelium perhaps still remaining in the inside of the tube or having escaped, as the case may be. The fine film referred to is the basement membrane. It may by careful search be seen too on the part of the corium situated between the orifices of the glands, and on the villi, when the epithelium is detached, although it cannot be there separated from the vascular layer. In these parts it manifestly forms a superficial boundary to the corium, passing continuously over its eminences and into its recesses, defining its surface, and supporting the epithelium. In other parts where villi and tubular glands are wanting, and especially where the mucous membrane, more



simply arranged, presents an even surface, as in the tympanum and nasal sinuses, the basement membrane is absent, at least not demonstrated. In such situations it may possibly have originally existed as a constituent of the corium, and have been obliterated or rendered inconspicuous in consequence of subsequent modifications.

The basement membrane, as already said, forms the peripheral boundary of the corium; it is in immediate connection with the epithelium. By its under surface it more or less closely adjoins the fibro-vascular layer. The vessels of the latter advance close up to the basement membrane, but nowhere penetrate it; the delicate film of which it consists is indeed wholly extra-vascular. In structure the membrane in question seems perfectly homogeneous, but marks resembling the nuclei of epithelium cells are sometimes seen disposed evenly over its surface, and some observers, considering these as forming an integrant part of the membrane, have looked on them as so many reproductive centres from which new epithelium particles are generated. Mr. Bowman, on the other hand, considers these objects as nuclei belonging to the undermost and as it were nascent epithelium cells, which have remained adherent to the really simple basement membrane.

The *fibro-vascular layer* of the corium is composed of vessels both sanguiferous and lymphatic, with fibres of connective tissue, and, in many parts, of non-striated muscular tissue, variously disposed. The nerves also which belong to the mucous membrane are distributed in this part of its structure.

The vessels exist universally in mucous membranes, except in that which covers the anterior surface of the cornea; there the epithelium and basement membrane are present, but, in the adult, no vessels except at the border. Elsewhere the branches of the arteries and veins, dividing in the submucous tissue, send smaller branches into the corium, which at length form a network of capillaries in the fibro-vascular layer. This capillary network lies immediately beneath the epithelium, or the basement membrane when this is present, advancing with that membrane into the villi and papillæ to be presently described, and surrounding the tubes and other glandular recesses, into which it is hollowed. The lymphatics also form networks, which communicate with plexuses of larger vessels in the submucous tissue; their arrangement generally, as well as in the villi, has been already noticed.

The fibres of connective tissue which enter into the formation of the corium are both the white and the elastic. The former are arranged in interlacing bundles, the elastic commonly in networks; but the amount of both is very different in different parts. In some situations, as in the gullet, windpipe, bladder, and vagina, the connective tissue is abundant, and extends throughout the whole thickness of the fibro-vascular layer, forming a continuous and tolerably compact web, and rendering the mucous membrane of those parts comparatively stout and tough. In the stomach and intestines, on the other hand, where the membrane is more complex, and at the same time weaker in structure, the elastic fibres are wanting and the white connective tissue is in small proportion; its principal bundles follow and support the blood-vessels, deserting, however, their finer and finest branches which lie next the basement membrane; and accordingly there exists, for some depth below this membrane, a stratum of the corium in which very few if any filaments of the common areolar tissue are seen. In this stratum of the gastro-enteric mucous membrane, the tubular glands with their lining epithelium are set, and between and around them the numerous sanguiferous capillaries and lymphatic vessels are distributed; but the sub-



stance of the membrane in which these parts lie is constructed of the variety of connective tissue known as cytogenous or retiform (p. lxxix, fig. XXXVIII.), which is formed of ramified and reticularly connected corpuscles, with or without nuclei persistent at the points whence the branches divaricate; and in the meshes of this tissue is contained a profusion of granular bodies having all the characters of pale blood- or lymph-corpuscles. This structure (fig. CVI.), which prevails in the mucous membrane of the stomach and intestines, both large and small, is sometimes named *lymphoid tissue* from its resemblance to the interior tissue of the lymphatic glands and of other bodies belonging to or supposed to belong to the lymphatic system, and especially those known as the solitary and agminated glands of the alimentary mucous membrane. The tissue forming the last-named bodies, indeed, is often continuous with the lymphoid tissue in their vicinity. The deepest layer of the alimentary mucous membrane, from the commencement of the oesophagus downwards, is formed throughout by non-striated muscular tissue, and is named *muscularis mucosæ*. This lies next to the submucous tissue, and consists of bundles running in many parts both longitudinally and circularly, in others in one of these directions only. Prolongations from it pass up between the glands to be distributed in the villi.

The free surface of the mucous membranes is in some parts plain, but in others is beset with little eminences named papillæ and villi. The *papillæ* are best seen on the tongue; they are small processes of the corium, mostly of a conical or cylindrical figure, containing blood-vessels and nerves, and covered with epithelium. Some are small and simple, others larger and compound or cleft into secondary papillæ. They serve various purposes; some of them no doubt minister to the senses of taste and touch, many appear to have chiefly a mechanical office, while others would seem intended to give greater extension to the surface of the corium for the production of a thick coating of epithelium. The *villi* are most fully developed on the mucous coat of the small intestines. Being set close together like the pile or nap of cloth, they give to the parts of the membrane which they cover the aspect usually denominated "villous." They are in reality little elevations or processes of the superficial part of the corium, covered with epithelium, and containing blood-vessels and lacteals, which are thus favourably disposed for absorbing nutrient matters from the intestine. The more detailed description of the papillæ and villi belongs to the special anatomy of the parts where they occur.

In some few portions of the mucous membrane the surface is marked with fine ridges which intersect each other in a reticular manner, and thus

Fig. CVI.

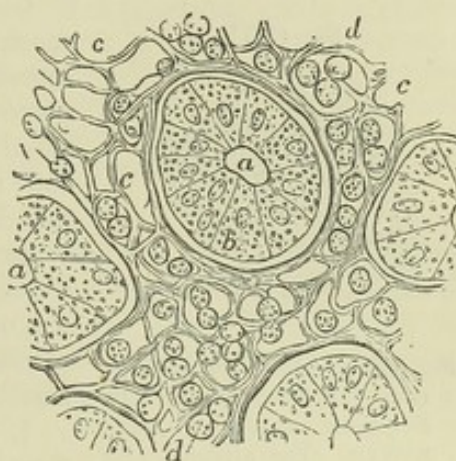


Fig. CVI. — LYMPHOID OR RETIFORM TISSUE OF THE INTESTINAL MUCOUS MEMBRANE OF THE SHEEP (from Frey). MAGNIFIED 400 DIAMETERS.

Cross section of a small fragment of the mucous membrane, including one entire crypt of Lieberkühn and parts of several others: *a*, cavity of the tubular glands or crypts; *b*, one of the lining epithelial cells; *c*, the lymphoid or retiform spaces, of which some are empty, and others occupied by lymph-cells as at *d*.



inclose larger and smaller polygonal pits or recesses. This peculiar character of the surface of the membrane, which might be called "alveolar," is seen very distinctly in the gall-bladder, and on a finer scale in the vesiculæ seminales; still more minute alveolar recesses with intervening ridges may be discovered with a lens on the mucous membrane of the stomach (fig. CVII.).

Fig. CVII.

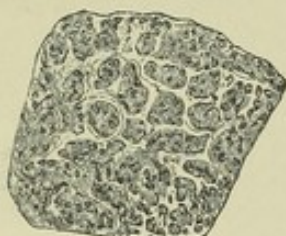

Fig. CVII.—PORTION OF MUCOUS MEMBRANE OF THE STOMACH, SLIGHTLY MAGNIFIED. The alveolar pits and small orifices of the tubular glands are seen (after Ecker).

*Glands of mucous membranes.*—Many, indeed most, of the glands of the body pour their secretions into the great passages lined by mucous membranes; but there are certain small glands which may be said to belong to the membrane itself, inasmuch as they are found in numbers over large tracts of that membrane, and yield mucus, or special secretions known to be derived from particular portions of the membrane. Omitting local peculiarities the glands referred to may be described as of three kinds, viz. :—

1. *Tubular glands.*—These are minute tubes formed by recesses or inversions of the basement membrane, and lined with epithelium. They are usually placed perpendicularly to the surface, and often very close together, and

they constitute the chief substance of the mucous membrane in those parts where they abound, its apparent thickness depending on the length of the tubes, which differs considerably in different regions. The tubes open by one end on the surface; the other end is closed, and is either simple or loculated, or even cleft into two or more branches. The tubular glands are abundant in the stomach, and in the small and large intestines, where they are comparatively short and known as the crypts of Lieberkühn. They exist also in considerable numbers in the mucous membrane of the uterus.

2. *Small compound glands.*—Under this head are here comprehended minute but still true compound glands of the racemose kind, with single branched ducts of various lengths, which open on different parts of the membrane. Numbers of these, yielding a mucous secretion, open into the mouth and windpipe. They have the appearance of small solid bodies, often of a flattened lenticular form, but varying much both in shape and size, and placed at different depths below the mucous membrane on which their ducts open. The glands of Brunner, which form a dense layer in the commencing part of the duodenum, are of this kind.

3. *Solitary and agminated glands, conglobate glands* (Henle), *follicular glands* (Kölliker).—Found in various parts of the alimentary mucous membrane, also in the palpebral conjunctiva. They may be single (*solitary glands*), or in patches (*agminated glands*). Their structure is well known, but, although they are called glands, their function is still enigmatical. They are small sacs reaching down into the submucous tissue, closed and covered above by the mucous membrane. Within is fine retiform tissue, supporting radiating blood-capillaries, with bodies like lymph-corpuscles in the meshes, and communicating with a similar tissue (lymphoid tissue) diffused in the adjacent part of the membrane; for, although they do not open on the surface, their reticular capsule rarely forms a perfect inclosure. Several of these saccules are sometimes placed round a recess of



the mucous membrane which opens on the surface, and which may be simple, as in certain glands at the root of the tongue and in the pharynx, or complex and multilocular, as in the tonsils.

On the hypothesis that these bodies are really secreting glands, it has been presumed that they are occasionally opened by dehiscence for the discharge of their contents. According to another view they are dependencies of the lymphatic system, and there are various analogies and indications of relationship which might be adduced in favour of this opinion. On the other hand, it is not easy to see what special connection there can be between the lymphatic system and the collections of these bodies at the root of the tongue and in the tonsils, where, indeed, their presence is more reconcilable with the notion of their being secreting organs; in short, it must be confessed that the question as to their function has still to be answered.

*Nerves.*—The mucous membranes are supplied with nerves, and endowed with sensibility; but the proportion of nerves which they receive, as well as the degree of sensibility which they possess, differs very greatly in different parts. As to the mode of distribution and termination of their nerves, there is nothing to be said beyond what has been already stated in treating of the nerves in general.

*Secretion.*—Mucus is a more or less viscid, transparent, or slightly turbid fluid, of variable consistency. It is somewhat heavier than water, though expectorated mucus is generally prevented from sinking in that liquid by entangled air-bubbles. Examined with the microscope, it is found to consist of a fluid, containing solid particles of various kinds, viz., 1. Epithelium-particles detached by desquamation; 2. Mucus-corpuscles, which are bodies resembling much the pale corpuscles of the blood; 3. Granules and molecules occasionally. The viscosity of mucus depends on the liquid part, which contains a peculiar substance, named by the chemists *mucin*. This ingredient is precipitated and the mucus rendered turbid by the addition of water or a weak acid, but it may be partly redissolved in an excess of water, and completely so in a strong acid. This mucin is soluble in alkalies, and its acid solutions are not precipitated by ferrocyanide of potassium. Little can, of course, be expected from a chemical analysis of a heterogeneous and inseparable mixture of solid particles with a liquid solution, such as we find in mucus, which is, moreover, subject to differences of quality according to the part of the mucous membrane whence it is derived. Examined thus in the gross, however, the nasal mucus has been found to yield water, mucin, alcohol-extract with alkaline lactates, water-extract with traces of albumen and a phosphate, chlorides of sodium and potassium, and soda. Fat has been obtained by analysis of pulmonary mucus, reputed healthy.

*Regeneration.*—The reparatory process is active in the mucous membranes. Breaches of continuity occasioned by sloughing, ulceration, or other causes, readily heal. The steps of the process have been examined with most care in the healing of ulcers of the large intestine, and in such cases it has been found that the resulting cicatrix becomes covered with epithelium, but that the tubular follicles are not reproduced.

## THE SKIN.

The skin consists of the cutis vera or corium, and the cuticle or epidermis.

The *epidermis*, *cuticle*, or *scarf-skin*, belongs to the class of epithelial structures, the general nature of which has been already considered. It forms a protective covering over every part of the true skin, and is itself quite insensible and non-vascular. The thickness of the cuticle varies in different parts of the surface, measuring in some not more than  $\frac{1}{240}$ th, and in others from  $\frac{1}{24}$ th to  $\frac{1}{12}$ th of an inch. It is thickest in the palms of the hands and soles of the feet, where the skin is much exposed to pressure, and it is not



improbable that this may serve to stimulate the subjacent true skin to a more active formation of epidermis; but the difference does not depend solely on external causes, for it is well marked, even in the foetus.

*Structure.*—The cuticle is made up of flattened cells agglutinated together in many irregular layers. They at first contain nuclei with soft and moist contents, and, by successive formations beneath them, are gradually pushed to the free surface, become flattened in their progress into thin irregular scales, for the most part lose their nuclei, and are at last thrown off by desquamation. The deepest cells are elongated in figure, and placed perpendicularly on the

Fig. CVIII.

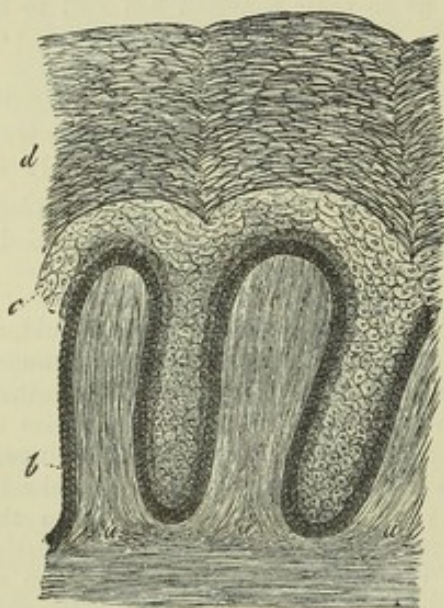


Fig. CVIII.—SKIN OF THE NEGRO, IN A VERTICAL SECTION, MAGNIFIED 250 DIAMETERS.

*a, a*, cutaneous papillæ; *b*, undermost and dark-coloured layer of oblong vertical epidermis-cells; *c*, mucous or Malpighian layer; *d*, horny layer.

surface of the corium (fig. CVIII. *b*), like the particles of columnar epithelium; they are denticulate at their lower ends, and fit into corresponding fine denticulations of the corium. These perpendicular cells generally form one, but in some places two or three strata; above them are cells of a more rounded shape, *c*. As the cells change their form, they undergo chemical and physical changes in the nature of their contents; for those in the deeper layers contain a soft, opaque, granular matter, soluble, as well as their envelope, in acetic acid, whilst the superficial ones are transparent, dry, and firm, and are not affected by that acid. It would seem as if their contents were converted into a horny matter, and that a portion of this substance is employed to cement them together. These dry, hard scales may be made to reassume their cellular form, by exposure for a few minutes to a solution of caustic potash or soda, and then to water. Under this treatment they are softened by the alkali and distended by imbibition of water.

The more firm and transparent superficial part of the epidermis, *d*, may be separated from the deeper, softer, more opaque, and recently-formed part, which constitutes what is called the Malpighian layer, or *rete mucosum*, *c*.

Many of the cells of the cuticle contain pigment, and often give the membrane more or less of a tawny colour, even in the white races of mankind; the blackness of the skin in the negro depends entirely on the cuticle. The pigment is contained principally in the cells of the deep layer or *rete mucosum*, and appears to fade as they approach the surface, but even the superficial part possesses a certain degree of colour. More special details respecting the pigment have been already given (page lxiii).

The under or attached surface of the cuticle is moulded on the adjoining surface of the corium, and, when separated by maceration or putrefaction, presents impressions corresponding exactly with the papillary or other eminences, and the furrows or depressions of the true skin; the more prominent inequalities of the latter are marked also on the outer surface of the cuticle, but less accurately. Fine tubular prolongations of the cuticle sink down into the ducts of the sweat glands, and are often partially drawn out



from their recesses when the cuticle is detached, appearing then like threads proceeding from its under surface.

*Chemical composition.*—The cuticle consists principally of a substance peculiar to the epithelial and horny tissues, and named *keratin*. This horny matter is insoluble in water at ordinary temperatures, and insoluble in alcohol. It is soluble in the caustic alkalies. In composition, it is analogous to the albuminoid principles, but with a somewhat larger proportion of oxygen; like these, it contains sulphur. Besides keratin, the epidermis yields, on analysis, a small amount of fat, with salts, and traces of the oxides of iron and manganese. The tissue of the cuticle readily imbibes water, by which it is rendered soft, thick, and opaque, but it speedily dries again, and recovers its usual characters.

The *true skin*, *cutis vera*, *derma*, or *corium*, is a sentient and vascular texture. It is covered and defended, as already explained, by the insensible and non-vascular cuticle, and is attached to the parts beneath by a layer of areolar tissue, named “subcutaneous,” which, excepting in a few parts, contains fat, and has therefore been called also the “*panniculus adiposus*” (fig. CXXIII. d.). The connection is in many parts loose and moveable, in others close and firm, as on the palmar surface of the hand and the sole of the foot, where the skin is fixed to the subjacent fascia by numerous stout fibrous bands, the space between being filled with a firm padding of fat. In some regions of the body the skin is moved by striated muscular fibres, which may be unconnected to fixed parts, as in the case of the orbicular muscle of the mouth, or may be attached beneath to bones or fasciæ, like the other cutaneous muscles of the face and neck, and the short palmar muscle of the hand.

*Structure.*—The corium consists of a *fibro-vascular layer*, which is supposed to be bounded at the surface next the cuticle, by a fine homogeneous *basement membrane* or *membrana propria*, like the corresponding part of the mucous membrane. No such superficial film can, it is true, be raised from the corium, but from its distinct presence in small gland ducts, which are continuous with the corium, and from the fact that a thin homogeneous membrane lies between the commencing cutis and cuticle in the embryo, it is presumed that a limitary membrane of this sort ought to be reckoned as an element of the corium, although, as in the analogous case of the mucous membrane, it cannot be shown to exist generally over the surface. The *fibro-vascular* part is made up of an exceedingly strong and tough framework of interlaced fibres, with blood-vessels and lymphatics. The fibres are chiefly of the white variety, such as constitute the chief part of the fibrous and areolar tissues, and are arranged in stout interlacing bundles, except at and near the surface, where the texture of the corium becomes very fine. With these are mixed yellow or elastic fibres, which vary in amount in different parts, but in all cases are present in smaller proportion than the former kind; also connective-tissue corpuscles, fusiform or ramified, and for the most part reticularly anastomosing. The interlacement becomes much closer and finer towards the free surface of the corium, and there the fibres can be discovered only by teasing out the tissue, which often acquires an almost homogeneous aspect. Towards the attached surface, on the other hand, the texture becomes much more open, with larger and larger meshes, in which lumps of fat and the small sudatory glands are lodged, and thus the fibrous part of the skin, becoming more and more lax and more mixed with fat, blends gradually with the subcutaneous areolar tissue to which it is allied in elementary constitution. Bundles of plain muscular tissue are distributed in the



substance of the corium wherever hairs occur ; and their connection with the latter will be afterwards explained. Muscular bundles of the same kind are found in the subcutaneous tissue of the scrotum, penis, perineum, and areola of the nipple, as well as in the nipple itself. They join to form reticular superimposed layers, which are separated from the parts beneath by a stratum of simple lax areolar tissue, but towards the surface they are immediately applied to the corium. In the areola they are disposed circularly.

In consequence of this gradual transition of the corium into the subjacent tissue, its thickness cannot be assigned with perfect precision. It is generally said to measure from a quarter of a line or less to nearly a line and a half. As a general rule, it is thicker on the posterior aspect of the head, neck, and trunk, than in front ; and thicker on the outer than on the inner side of the limbs. The corium, as well as the cuticle, is remarkably thick on the soles of the feet and palms of the hands. The skin of the female is thinner than that of the male.

For convenience of description it is not unusual to speak of the corium as consisting of two layers, the "reticular" and "papillary." The former, the more deeply-seated, takes no part in the construction of the papillæ, but contains in its meshes hair-follicles, cutaneous glands, and fat. The latter is divided into papillæ, and receives only the upper portion of the hair-follicles and glands, together with the terminal expansion of the vessels and nerves.

The free surface of the corium is marked in various places with larger or smaller furrows, which also affect the superjacent cuticle. The larger of them are seen opposite the flexures of the joints, as those so well known in the palm of the hand and at the joints of the fingers. The finer furrows intersect each other at various angles, and may be seen almost all over the surface ; they are very conspicuous on the back of the hands. These furrows are not merely the consequence of the frequent folding of the skin by the action of muscles or the bending of joints, for they exist in the foetus. The wrinkles of old persons are of a different nature, and are caused by the wasting of the soft parts which the skin covers. Fine curvilinear ridges, with intervening furrows, mark the skin of the palm and sole ; these are caused by ranges of the papillæ, to be immediately described.

*Papillæ.*—The free surface of the corium is beset with small eminences

Fig. CIX.

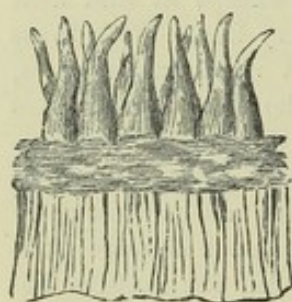


Fig. CIX.—PAPILLÆ, AS SEEN WITH A MICROSCOPE, ON A PORTION OF THE TRUE SKIN, FROM WHICH THE CUTICLE HAS BEEN REMOVED (after Breschet).

Fig. CX.

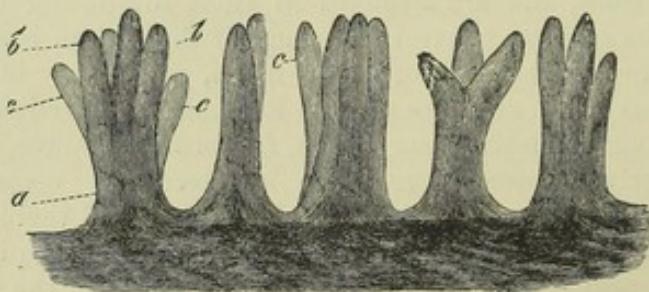


Fig. CX.—COMPOUND PAPILLÆ FROM THE PALM OF THE HAND, MAGNIFIED 60 DIAMETERS.

*a*, basis of a papilla ; *b, b*, divisions or branches of the same ; *c, c*, branches belonging to papillæ of which the bases are hidden from view (after Kölliker).



thus named, which seem chiefly intended to contribute to the perfection of the skin as an organ of touch, seeing that they are highly developed where the sense of touch is exquisite, and *vice versa*. They serve also to extend the surface for the production of the cuticular tissue, and hence are large-sized and numerous under the nail. The papillæ are large, and in close array on the palm and palmar surface of the fingers, and on the corresponding parts of the foot (fig. cx.). There they are ranged in lines forming the curvilinear ridges seen when the skin is still covered with its thick epidermis. They are of a conical figure, rounded or blunt at the top, and sometimes cleft into two or more points, when they are named compound papillæ. They are received into corresponding pits on the under surface of the cuticle. In structure they resemble the superficial layer of the corium generally, and consist of a homogeneous tissue, presenting only faint traces of fibrillation, together with a few fine elastic fibres. On the palm, sole, and nipple, where they are mostly of the compound variety, they measure from  $\frac{1}{200}$  to  $\frac{1}{100}$  of an inch in height. In the ridges, the larger papillæ are placed sometimes in single but more commonly in double rows, with smaller ones between them (fig. cxxiii.), that is, also on the ridges, for there are none in the intervening grooves. These ridges are marked at short and tolerably regular intervals with notches, or short transverse furrows, in each of which, about its middle, is the minute funnel-shaped orifice of the duct of a sweat gland (fig. cxi.). In other parts of the skin endowed with less sensibility, the papillæ are smaller, shorter, fewer in number, and irregularly scattered. On the face they are reduced to from  $\frac{1}{800}$  to  $\frac{1}{300}$  of an inch; and here they at parts disappear altogether, or are replaced by slightly elevated reticular ridges. In parts where they are naturally small, they often become enlarged by chronic inflammation round the margin of sores and ulcers of long standing, and are then much more conspicuous. Fine blood-vessels enter most of the papillæ, forming either simple capillary loops in each, or dividing into two or more capillary branches, according to the size of the papilla and its simple or composite form, which turn round in form of loops and return to the veins. Other papillæ receive nerves, to be presently noticed.

*Blood-vessels and lymphatics.*—The blood-vessels divide into branches in the subcutaneous tissue, and, as they enter the skin, supply capillary plexuses to the fat clusters, sweat glands, and hair follicles. They divide and anastomose still further as they approach the surface, and at length, on reaching it, form a dense network of capillaries, with rounded polygonal meshes. Fine branches are sent into the papillæ, as already mentioned. The lymphatics are abundant in some parts of the skin, as on the scrotum and round the nipple; whether they are equally so in all parts may be doubted. They form networks, which become finer as they approach the surface, and communicate underneath with straight vessels, and these, after a longer or a shorter course, join larger ones or enter lymphatic glands. The finest and most superficial network, although close to the surface of the corium, is

Fig. CXI.

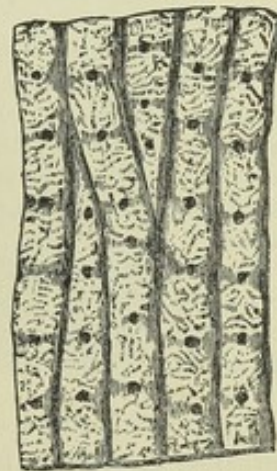

Fig. CXI.—MAGNIFIED VIEW OF FOUR OF THE RIDGES OF THE EPIDERMIS, CAUSED BY ROWS OF PAPILLÆ BENEATH, WITH SHORT FURROWS OR NOTCHES ACROSS THEM; ALSO THE OPENINGS OF THE SUDORIFEROUS DUCTS (after Breschet).



beneath the net of superficial blood-capillaries; in certain parts on the palm and sole, lymphatics pass into the papillæ, but do not reach their summits.

*Nerves.*—Nerves are supplied in very different proportions to different regions of the skin, and according to the degree of sensibility. They pass upwards towards the papillary surface, where they form plexuses, of which the meshes become closer as they approach the surface, and the constituent branches finer, so that the latter come at last to consist of only one or two primitive fibres. The fibres also become more attenuated the further they proceed towards their final destination. In the finest and most superficial part of the plexus, the ultimate fibres, or at least some of them, undergo actual division. Little more can be said of the termination of nerves on the general cutaneous surface. A large share of the cutaneous nerves is distributed to the hair-follicles, whilst some end in special terminal organs, namely, *end-bulbs*, *tactile corpuscles*, and *Pacinian bodies*. The last-named bodies are seated in the subcutaneous tissue. End-bulbs are found on the glans penis and glans clitoridis, and in some of the papillæ on the red border of the lips. The tactile corpuscles of the skin are more numerous; they are found in certain papillæ of the palm and sole, more sparingly in those of the back of the hand and foot, the palmar surface of the fore-arm and the nipple. Such papillæ commonly contain no blood-vessels, and are named "tactile," as distinguished from the "vascular" papillæ which receive no nerves. Sometimes, however, a tactile and a vascular papilla may spring from the same stem. The structure of these different terminal corpuscles has been already described (pages cl to clv).

*Chemical composition.*—The corium being composed chiefly of white fibrous tissue, has a corresponding chemical composition. It is, accordingly, in a great measure, resolved into gelatin by boiling, and hence, also, its conversion into leather by the tanning process.

*Development of the cutis.*—The cutis consists at first of cells which may in animals be traced back to the first formative cells of the embryo. Many of them give rise to connective tissue; others to vessels and nerves; and a third portion is converted into fat-cells. No doubt the muscular tissue also originates from cells. The mode of formation of these several elementary tissues has been already described. Progressive development takes place from within outwards, so that the papillæ are formed latest.

The *cuticle* at first differs in no point from the cutis, but consists of the earliest formative cells. Their subsequent metamorphoses and the mode of production of new cells have not been accurately determined; the question has been already considered at page lv.

*Nails and hairs.*—The nails and hairs are growths of the epidermis, agreeing essentially in nature with that membrane; their epidermic tissue is destitute of vessels and nerves, and separable from the cutis.

*Nails.*—The posterior part of the nail which is concealed in a groove of the skin is named its "root," the uncovered part is the "body," which terminates in front by the "free edge." A small portion of the nail near the root, named from its shape the *lunula*, is whiter than the rest. This appearance is due partly to some degree of opacity of the substance of the nail at this point, and partly to the skin beneath being less vascular than in front.

The part of the corium to which the nail is attached, and by which in fact it is secreted or generated, is named the *matrix*. This portion of the skin is highly vascular and thickly covered with large vascular papillæ.



Posteriorly the matrix forms a crescentic groove or fold, deep in the middle but getting shallower at the sides, which lodges the root of the nail; the rest of the matrix, before the groove, is usually named the *bed* of the nail. The small lighter-coloured part of the matrix next the groove and corresponding with the lunula of the nail, is covered with papillæ having no regular arrangement, but the whole remaining surface of the matrix situated in front of this, and supporting the body of the nail, is marked with longitudinal and very slightly diverging ridges cleft at their summits into rows of papillæ. These ridges, or *laminae*, as they are sometimes, and perhaps more suitably, named, fit into corresponding furrows on the under surface of the nail. The cuticle, advancing from the back of the finger, becomes attached to the upper surface of the nail near its posterior edge, that is, all round the margin of the groove in which the nail is lodged; in front the cuticle of the point of the finger becomes continuous with the under surface of the nail a little way behind its free edge.

The nail, like the cuticle, is made up of scales derived from flattened cells. The oldest and most superficial of these are the broadest and hardest, but at the same time very thin and irregular, and so intimately and confusedly connected together that their respective limits are scarcely discernible. They form the exterior, horny part of the nail, and cohere together in irregular layers, so as to give this part a lamellar structure. On the other hand, the youngest cells, which are those situated at the root and under surface, are softer and of a rounded or polygonal shape. The deepest layer differs somewhat from the others, in having its cells elongated, and arranged perpendicularly, as in the case of the epidermis. Thus the under part of the nail (fig. CXII. B) corresponds in nature with the Malpighian or mucous layer of the epidermis, and the upper part (c) with the horny layer. As in the case of the epidermis, the hardened scales may be made to reassume their cellular character by treatment with caustic alkali, and afterwards with water; and then it is seen that they still retain their nuclei. In chemical composition the nails resemble epidermis; but, according to Mulder, they contain a somewhat larger proportion of carbon and sulphur.

The growth of the nail is effected by a constant generation of cells at the

Fig. CXII.

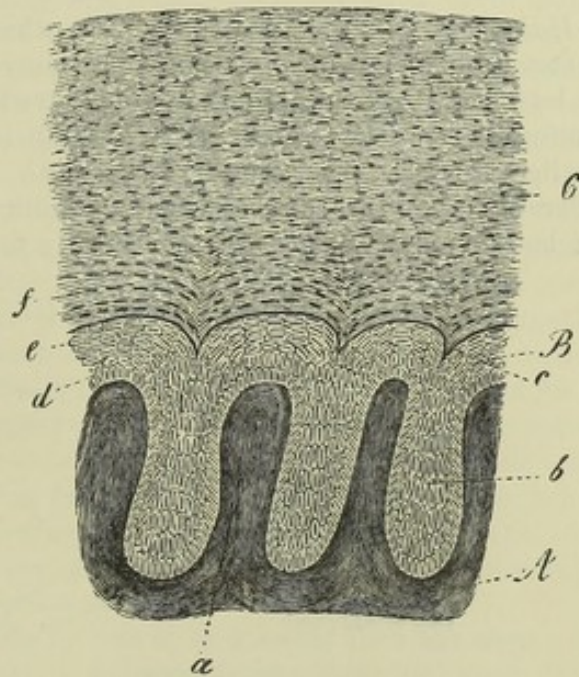


Fig. CXII.—VERTICAL TRANSVERSE SECTION THROUGH A SMALL PORTION OF THE NAIL AND MATRIX, LARGELY MAGNIFIED (after Kölliker).

A, corium of the nail-bed, raised into ridges or laminae, *a*, fitting in between corresponding laminae, *b*, of the nail; B, Malpighian, and C, horny layer; *d*, deepest and vertical cells; *e*, upper flattened cells of Malpighian layer.



root and under surface. Each successive series of these cells being followed and pushed from their original place by others, become flattened into dry, hard, and inseparably coherent scales. By the addition of new cells at the posterior edge the nail is made to advance, and by the apposition of similar particles to its under surface it grows in thickness; so that it is thicker at the free border than at the root. The nail being thus merely an exuberant part of the epidermis, the question at one time raised, whether that membrane is continued underneath it, loses its significance. When a nail is thrown off by suppuration, or pulled away by violence, a new one is produced in its place, provided the matrix remains.

*Development in the fetus.*—In the third month of intra-uterine life the part of the embryonic corium which becomes the matrix of the nail is marked off by the commencing curvilinear groove, which limits it posteriorly and laterally. The epidermis on the matrix then begins to assume, in its under part, the characters of a nail, which might, therefore, be said to be at first covered over by the embryonic cuticle. After the end of the fifth month it becomes free at the anterior border, and in the seventh month decidedly begins and thenceforth continues to grow in length. At birth the free end is long and thin, being manifestly the earlier-formed part which has been pushed forward. This breaks or is pared off after birth, and, as the infantile nail continues to grow, its flattened cells, at first easily separable, become harder and more coherent, as in after life.

*Hairs.*—A hair consists of the root, which is fixed in the skin, the shaft or stem, and the point. The *stem* is generally cylindrical, but often more or less flattened; sometimes it is grooved along one side, and therefore reniform in a cross section: when the hair is entire it becomes gradually smaller towards the point. The length and thickness vary greatly in different individuals and races of mankind as well as in different regions of the body. Light-coloured hair is usually finer than black.

Fig. CXIII.

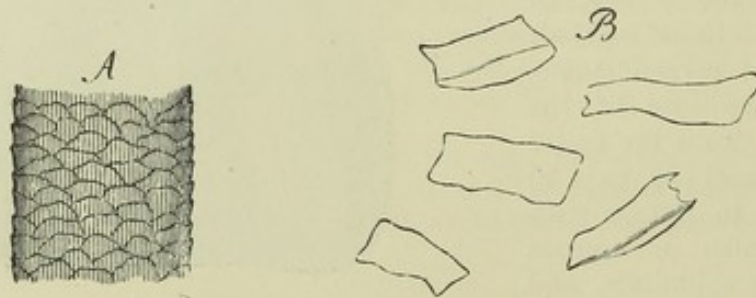


Fig. CXIII.—A, SURFACE OF A WHITE HAIR, MAGNIFIED 160 DIAMETERS. THE WAVED LINES MARK THE UPPER OR FREE EDGES OF THE CORTICAL SCALES. B, SEPARATED SCALES, MAGNIFIED 350 DIAMETERS (after Kölliker).

The stem is covered with a coating of finely-imbricated scales, the upwardly projecting serrated edges of which give rise to a series of fine waved transverse lines, which may be seen with the microscope on the surface of the hair (fig. CXIII. A). Within this scaly covering, by some called the *hair-cuticle*, is a *fibrous substance* which in all cases constitutes the chief part and often the whole of the stem; but in many hairs the axis is occupied by a substance of a different nature, called the *medulla* or *pith*, for which reason the surrounding fibrous part is often named “cortical,”



although this term is more properly applied to the superficial coating of scales above mentioned. The *fibrous substance* is translucent, with short longitudinal opaque streaks of darker colour intermixed. It may be broken up into straight, rigid, longitudinal fibres, which, when separated, are found to be flattened, broad in the middle, where they measure  $\frac{1}{4400}$  of an inch in breadth, and pointed at each end, with dark and rough edges. The fibres may be resolved into flattened cells of a fusiform outline; these are mostly transparent, or marked with only a few dark specks. The colour of the fibrous substance is caused by oblong patches of pigment-granules, and generally diffused colouring matter of less intensity. Very slender elongated nuclei are also discovered by means of reagents, whilst specks or marks of another description in the fibrous substance are occasioned by minute irregularly-shaped cavities containing air. These air-lacunules are abundant in white hairs, and in very dark hairs may be altogether wanting; they are best seen too in the former, in which there is no risk of deception from pigment-specks. Viewed by transmitted light they are dark, but brilliantly white by reflected light. When a white hair has been boiled in water, ether, or oil of turpentine, these cavities become filled with fluid, and are then quite pellucid; but when a hair which has been thus treated is dried, the air quickly finds its way again into the lacunæ, and they resume their original aspect.

The medulla or pith, as already remarked, does not exist in all hairs. It is wanting in the fine hairs over the general surface of the body, and is not commonly met with in those of the head; nor in the hairs of children under five years. When present it occupies the centre of the shaft and ceases towards the point. It is more opaque and deep-coloured than the fibrous part; in the white hairs of quadrupeds it is white, but opaque and dark when seen by transmitted light. It seems to be composed of little clusters of cells, differing in shape, but generally angular, and containing minute particles, some resembling pigment-granules, and others like very fine fat granules, but really for the most part air-particles, apparently included in some solidified tenaceous substance. The whole forms a continuous dark mass along the middle of the stem, interrupted at parts for a greater or less extent. In the latter case, the axis of the stem at the interruptions may be fibrous like the surrounding parts, or these intervals may be occupied by a clear, colourless matter; and, according to Henle, some hairs present the appearance of a sort of canal running along the axis and filled in certain parts with opaque granular matter, and in others with a homogeneous transparent substance.

The root of the hair is lighter in colour and softer than the stem; it swells out at its lower end into a bulbous enlargement or knob (fig. CXIV. c), and is received into a recess of the skin named the *hair-follicle*, which, when the hair is of considerable size, reaches down into the subcutaneous fat. The follicle, which receives near its mouth the opening ducts of one or more sebaceous glands (*k, k*), is somewhat dilated at the bottom, to correspond with the bulging of the root; it consists of an outer coat continuous with the corium (fig. CXIV. g, h; CXV. d, d), and an epidermic lining (fig. CXIV. e, f; CXV. b, c), continuous with the cuticle. The outer or *dermic* coat is thin but firm, and consists of three layers. The most external is formed of connective tissue in longitudinal bundles, without any elastic fibres, but with numerous long fusiform corpuscles. It is highly vascular, and possesses nervous fibrils. It is intimately connected above with the corium, and determines the form of the follicle. The most







mucous or Malpighian layer of the epidermis in general, and contains soft growing cells, including pigment in the coloured races, which at the lower part form a much thinner stratum and pass continuously into those of the hair-knob; the internal layer or *inner root-sheath* represents the superficial or horny layer of the epidermis according to some authorities; but others maintain that it is not continuous with that part of the skin, but ceases abruptly a little below the orifices of the sebaceous ducts. When detached from the hair it is found to be covered internally with imbricated downwardly-projecting scales, forming the *cuticle of the root-sheath*, which is applied to the cortical scaly cuticle of the hair proper, to whose upwardly-directed scales it fits like a mould. Its scales, as well as those of the hair-cuticle, pass, at the bottom of the follicle, into the round cells of the hair-knob. Now, after reckoning off this cuticular lining, the inner root-sheath still consists of two layers, which towards the bottom of the follicle become blended into one. The innermost (that next the cuticula) is known as *Huxley's layer*; it consists of flattened polygonal nucleated cells, two or even three deep. The outer layer is composed of oblong, somewhat flattened cells without nuclei, in which fissures and holes are liable to occur from accidental laceration, so as to give it the aspect of a perforated or fenestrated membrane. At the lower part both layers pass into a single layer of large polygonal nucleated cells without openings between them.

The soft bulbous enlargement of the root of the hair is attached by its base to the bottom of the follicle, and at the circumference of this attached part it is continuous with the epidermic lining. At the bottom of the follicle it, in fact, takes the place of the epidermis, of which it is a growth or extension, and this part of the follicle is the true matrix of the hair, being, in reality, a part of the corium (though sunk below the general surface), which supplies material for the production of the hair. This productive part of the follicle is, accordingly, remarkably vascular; in the large tactile hairs on the snout of the seal and some other animals it is raised in form of a conical vascular papilla or pulp, which fits into a corresponding excavation of the hair root, and Kölliker states that a vascular eminence of similar structure exists in the hairs generally, both small and large, of man as well as quadrupeds. As the follicle, in short, is a recess of the corium, so the hair-papilla is a cutaneous papilla sunk in the bottom of it. The papilla is described as being commonly of an ovoid shape and attached to the bottom of the follicle by a narrow base, or a sort of pedicle (fig. CXIV., i). Nervous branches of considerable size enter the follicles of the large tactile hairs referred to, but their final distribution has not been traced; the pain occasioned by pulling the hair seems to indicate that the human hair-follicles are not unprovided with nerves.

Fine muscles, each formed of a slender bundle of plain muscular tissue, are connected with the hair-follicles (fig. CXVI.). Their mode of attachment is described by Kölliker and Lister to be the following: they arise from the most superficial part of the corium, and pass down obliquely to be inserted into the outside of the follicle below the sebaceous glands. They are placed on the side to which the hair slopes, so that their action in elevating the hair is evident. Some anatomists have also recently described a layer of circularly-disposed muscular cells as applied immediately to the outside of the follicle.

*Growth of hair.*—On the surface of the papilla or vascular matrix, at the bottom of the follicle, there is a growth of nucleated cells. The cells for the most part lengthen out and unite into the flattened fibres which compose



the fibrous part of the hair, and certain of them, previously getting filled with pigment, give rise to the coloured streaks and patches in that tissue; their nuclei, at first, also lengthen in the same manner, but, at last, partly become indistinct. The cells next the circumference expand into the scales which form the imbricated cuticular layer (fig. CXV., e, e). The medulla, where it exists, is formed by the cells nearest the centre; these retain their primitive figure longer than the rest; they become coherent, and their cavities may coalesce together by destruction of their mutually adherent parietes, whilst collections of pigment granules make their appearance in them and around their nuclei, forming an opaque mass, which occupies the axis of the hair.

Fig. CXVI.

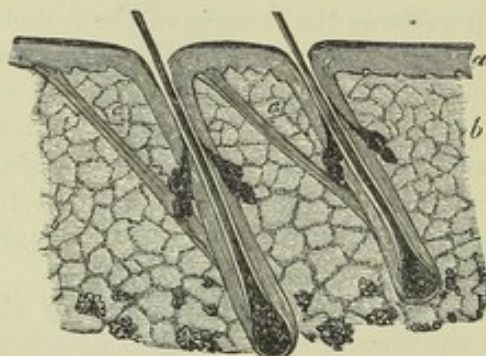


Fig. CXVII.

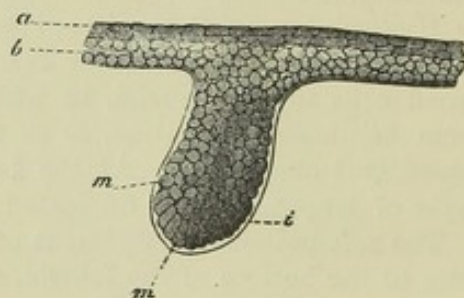


Fig. CXVI.—SECTION OF THE SKIN OF THE HEAD, WITH TWO HAIR FOLLICLES, SLIGHTLY MAGNIFIED (from Kölliker).

a, epidermis; b, corium; c, muscles of the hair-follicles.

Fig. CXVII.—HAIR RUDIMENT FROM AN EMBRYO OF SIX WEEKS, MAGNIFIED 350 DIAMETERS (after Kölliker).

a, horny, and b, mucous or Malpighian layer of cuticle; i, limiting membrane; m, cells, some of which are assuming an oblong figure, which chiefly form the future hair.

The substance of the hair, of epidermic nature, is, like the epidermis itself, quite extravascular, but, like that structure also, it is organised and subject to internal organic changes. Thus, in the progress of its growth, the cells change their figure, and acquire greater consistency. In consequence of their elongation, the hair, bulbous at the commencement, becomes reduced in diameter and cylindrical above. But it cannot be said to what precise distance from the root organic changes may extend. Some have imagined that the hairs are slowly permeated by a fluid, from the root to the point, but this has not been proved. The sudden change of the colour of the hair from dark to grey, which sometimes happens, has never been satisfactorily explained.

*Development of the hair in the fœtus.*—The rudiments of the hairs may be discerned at the end of the third or beginning of the fourth month of intra-uterine life, as little black specks beneath the cuticle. They at first appear as little pits in the corium (fig. CXVII.), filled with cells of precisely the same nature as those of the Malpighian or mucous layer of the cuticle, with which they are continuous; so it might correctly be said that the hair rudiments are formed of down growths of the mucous layer, which sink into the corium. A homogeneous limiting membrane next appears (i), inclosing the collection of cells, and continuous above with a similar simple film which at this time lies between the cuticle and the corium; it becomes the innermost or hyaline layer of the dermic coat of the follicle. The hair rudiments next lengthen and swell out at the bottom, so as to assume a flask-shape (fig. CXVIII).



Cells are deposited outside the liminary membrane, which eventually give rise to fibres, corpuscles, and other constituents of the dermic coat. While this is going on outside, the cells within the follicle undergo changes. Those in the middle lengthen out conformably with the axis of the follicle, and give rise to the appearance of a short conical miniature hair, faintly distinguishable by difference of shade from the surrounding mass of cells, which are also slightly elongated, but across the direction of the follicle. The papilla (figs. cxviii., &c., *h*) makes its appearance at the swollen root of the little hair; and the residuary cells contained within the rudimentary follicle form the root sheath, the inner layer of which, or inner root-sheath, lying next to the hair (fig. cxix., *d*), is soon distinguished by its translucency from the more opaque outer part that fills up the rest of the cavity. The young hair continuing to grow, at last perforates the cuticle (fig. cxx., *g*), either directly, or after first slanting up for some way between the mucous and horny strata. The young hair is often bent like a whip, and then the double part protrudes.

Fig. CXVIII.

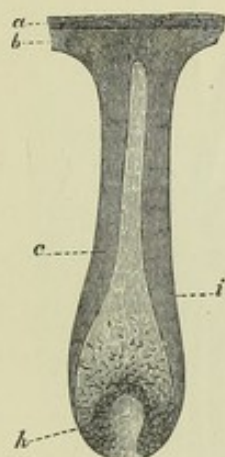


Fig. CXIX.

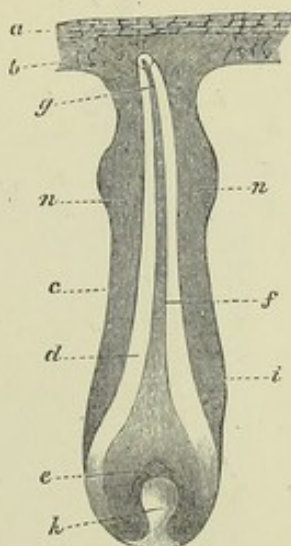


Fig. CXX.

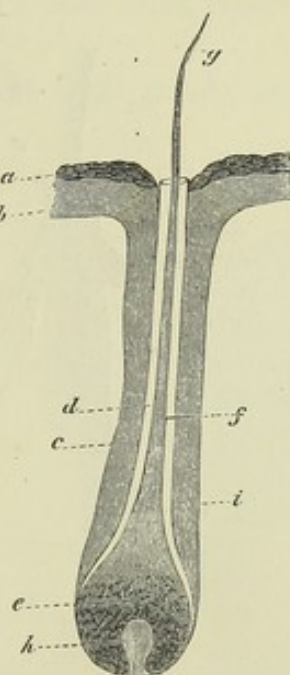


Fig. CXVIII.—RUDIMENT OF A HAIR OF THE EYEBROW, MAGNIFIED 50 DIAMETERS (after Kölliker).

The cells form an internal cone indicating the position of the future hair. *a*, horny layer of cuticle; *b*, mucous layer; *c*, external layer of root sheath; *i*, liminary membrane; *h*, papilla.

Fig. CXIX.—HAIR RUDIMENT MEASURING 0.22 OF A LINE, FROM THE EYEBROW, WITH THE YOUNG HAIR NOT YET RISEN THROUGH THE CUTICLE (after Kölliker).

*a*, *b*, *c*, *h*, *i*, as in fig. cxviii.; *e*, hair knob; *f*, stem, and *g*, point of the hair; *d*, internal layer of the root sheath, still inclosing the hair; *n*, *n*, commencing sebaceous follicles.

Fig. CXX.—HAIR FOLLICLE FROM THE EYEBROW WITH THE HAIR JUST ERUPTED; THE INNER LAYER OF THE ROOT-SHEATH RISES TO THE MOUTH OF THE HAIR FOLLICLE (after Kölliker.)

The letters denote the same parts as in Fig. CXIX.

The first hairs produced constitute the *lanugo*; their eruption takes place about the fifth month of intra-uterine life, but part of them are shed before birth, and are found floating in the liquor amnii. Kölliker affirms that the infantile hairs are entirely shed and renewed within a few months after birth; those of the general sur-



face first, and afterwards the hairs of the eyelashes and head, which he finds in process of change in infants about a year old.

The new hairs are generated in the follicles of the old (figs. CXXI. and CXXII.). An increased growth of cells takes place in the soft hair-knob, and in the adjoining part of the root-sheath (the outer layer); the growing mass pushes up the hair-knob, and detaches it from its generative papilla. The newly-formed mass of cells, occupying the lower part of the follicle, and resting on the papilla, is gradually converted into a new hair with its root-sheath, just as in the primitive process of formation in the embryo; and as the new hair lengthens and emerges from the follicle, the old one, separated from its matrix by the interposition of the new growth, is gradually pushed towards the opening, and at last falls out, its root-sheath having previously undergone partial absorption. When a hair is pulled out, a new one grows in its place, provided the follicle (from which the growth proceeds) remains entire. Heusinger, who experimentally studied the process in the large hairs situated on the lips of the dog, found that a new hair appeared above the surface in a few days after the evulsion of the old one, and attained its full size in about three weeks.

Fig. CXXI.

Fig. CXXII.

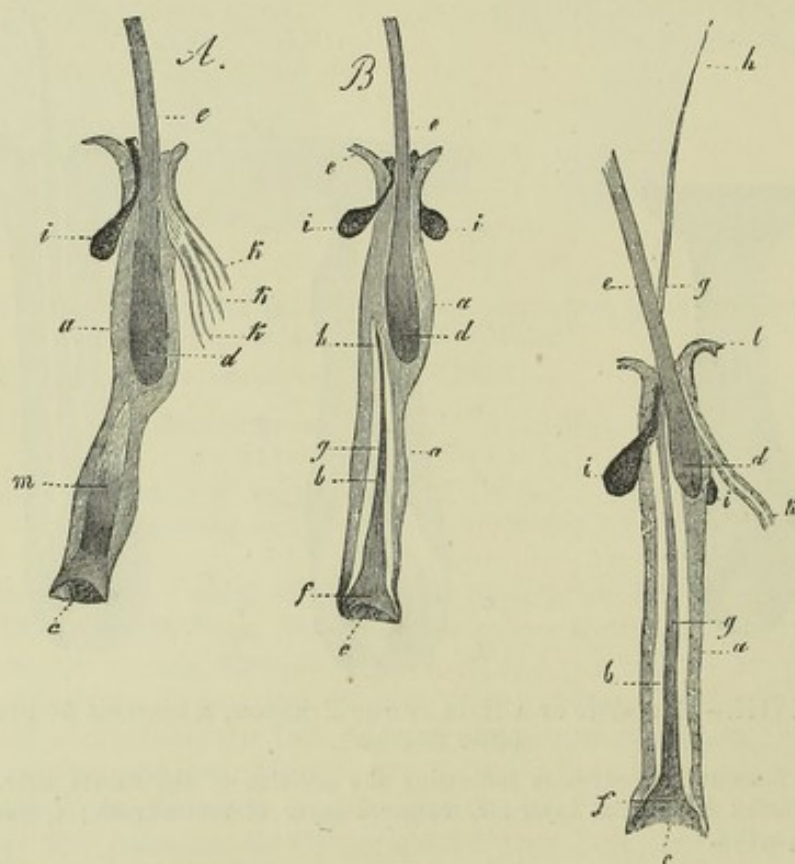


Fig. CXXI.—TWO EYELASHES OF AN INFANT, PULLED OUT FROM THEIR FOLLICLES, MAGNIFIED 20 DIAMETERS (from Kölliker).

A, the new cell-growth forming a cone, *m*, in the interior (as in fig. CXVIII.). In B, the cone has separated into the new hair, *f*, *g*, and its inner root-sheath, *b*; *a*, outer, and *b*, inner root-sheath of new hair; *c*, pit for papilla; *d* and *e*, the knob and stem of old hair; *f*, knob; *g*, stem; and *h*, the point of new hair; *i*, sebaceous glands; *k*, sweat-glands here opening into mouth of hair-follicle.

Fig. CXXII.—EYELASH OF AN INFANT, WITH YOUNG HAIR COME FORTH, MAGNIFIED 20 DIAMETERS (from Kölliker).

*l*, epidermis continuous with outer root-sheath; other letters as in preceding figures.

*Distribution and arrangement.*—Hairs are found on all parts of the skin except the palms of the hands and soles of the feet, the dorsal surface of the third phalanges of the fingers and toes, the upper eyelids, the glans, and the inner surface of the prepuce.



On the head they are set in groups, on the rest of the skin for the most part singly. Except those of the eyelashes, which are implanted perpendicularly to the surface, they have usually a slanting direction, which is wonderfully constant in the same parts.

*Chemical nature.*—The chemical composition of hair has been investigated principally by Vauquelin, Scherer, and Van Laer. When treated with boiling alcohol, and with ether, it yields a certain amount of oily fat, consisting of margaric acid, and olein, which is red or dark coloured, according to the tint of the hair. The animal matter of the hair thus freed from fat, is supposed to consist of a substance yielding gelatin, and a protein compound containing a large proportion of sulphur. It is insoluble in water, unless by long boiling under pressure, by which it is reduced into a viscid mass. It readily and completely dissolves in caustic alkalies. By calcination, hair yields from 1 to 1½ per cent. of ashes, which consist of the following ingredients—viz., peroxide of iron, and according to Vauquelin, traces of manganese, silica, chlorides of sodium and potassium, sulphates of lime and magnesia, and phosphate of lime. With the exception of the bones and teeth, no tissue of the body withstands decay after death so long as the hair, and hence it is often found preserved in sepulchres, when nothing else remains but the skeleton.

*Glands of the skin.*—These are of two kinds, the sweat glands, and the sebaceous, which yield a fatty secretion.

Fig. CXXIII.

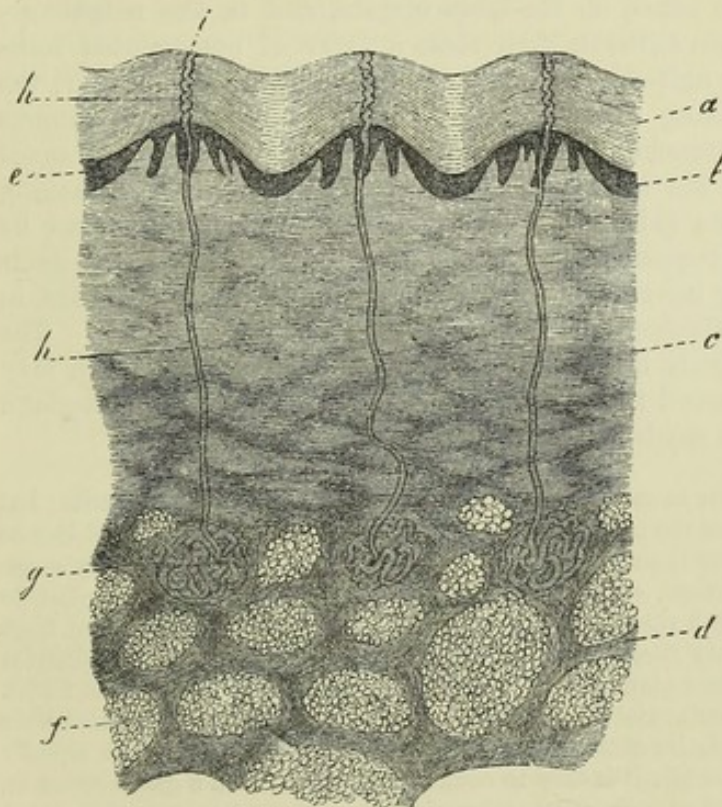


Fig. CXXIV.

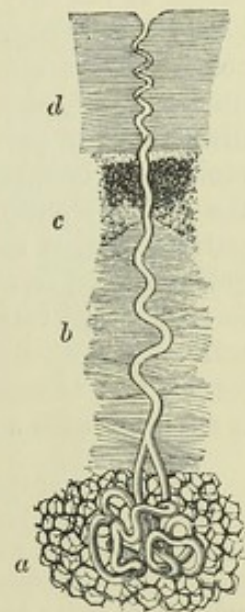


Fig. CXXIII.—VERTICAL SECTION OF THE SKIN AND SUBCUTANEOUS TISSUE, FROM END OF THE THUMB, ACROSS THE RIDGES AND FURROWS, MAGNIFIED 20 DIAMETERS (from Kölliker).

a, horny, and b, mucous layer of the epidermis; c, corium; d, *panniculus adiposus*; e, papillae on the ridges; f, fat clusters; g, sweat-glands; h, sweat-ducts; i, their openings on the surface.

Fig. CXXIV.—MAGNIFIED VIEW OF A SWEAT-GLAND WITH ITS DUCT (after Wagner).

a, the gland surrounded by vesicles of adipose tissue; b, the duct passing through the corium; c, its continuation through the lower, and d, through the upper part of the epidermis.



*The sudoriferous glands or sweat-glands* (figs. CXXIII. and CXXIV.).—These are seated on the under surface of the corium, and at variable depths in the subcutaneous adipose tissue. They have the appearance of small round reddish bodies, each of which, when examined with the microscope, is found to consist of a fine tube, coiled up into a ball (though sometimes forming an irregular or flattened figure), from which the tube is continued, as the duct of the gland, upwards through the true skin and cuticle, and opens on the surface by a slightly widened orifice. The duct, as it passes through the epidermis, is twisted like a corkscrew, that is, in parts where the epidermis is sufficiently thick to give room for this; lower down it is but slightly curved. Sometimes the duct is formed of two coiled-up branches, which join at a short distance from the gland, as happens to be the case in the specimen represented in figure CXXIV. The tube, both in the gland and where it forms the excretory duct, consists of an outer coat, continuous with the corium, and reaching no higher than the surface of the true skin, a thin homogeneous membrana propria, and an epithelial lining, consisting of one or more strata of cells (often containing brownish pigment), and continuous with the epidermis, which alone forms the twisted part of the duct. The outer, dermic or fibrous, coat is formed of homogeneous or finely fibrous connective tissue with corpuscles. The larger gland-ducts in the axilla, at the root of the penis, on the labia majora, and in the neighbourhood of the anus, contain between their coats a layer of non-striated muscular fibres, arranged longitudinally. In the larger glands, moreover, the duct is rarely simple, being more usually parted by repeated dichotomous division into several branches, which before ending give off short caecal processes; in rare cases the branches anastomose. On carefully detaching the cuticle from the true skin, after its connection has been loosened by putrefaction, it usually happens that the cuticular linings of the sweat-ducts get separated from their interior to a certain depth, and are drawn out in form of short threads attached to the under surface of the epidermis. The coils of the duct are loosely held together by connective tissue, which may form a sort of capsule round the body of the gland. Each little sweat-gland is supplied with a dense cluster of capillary blood-vessels.

The *contents* of the smaller sweat-glands are fluid, without any formed elements; but in the larger sweat-glands of the axilla the contents are semi-fluid, and abound in fine pale granules and nuclei; or their secretion is extremely viscid, with a varying quantity of large, opaque, colourless, or yellow granules, with nuclei and cells, similar to epithelium cells; and in both cases it may also contain fat. Kölliker states that from the nature of their contents these larger glands might be separated into a distinct group from the ordinary sweat-glands, were it not for the presence of transitional forms.

*Distribution.*—Sweat-glands exist in all regions of the skin, and attempts have been made to determine their relative amount in different parts, for they are not equally abundant everywhere; but while it is easy to count their numbers in a given space on the palm and sole, the numerical proportion assigned to them in most other regions must be taken with considerable allowance. According to Krause, nearly 2,800 open on a square inch of the palm of the hand, and somewhat fewer on an equal extent of the sole of the foot. He assigns rather more than half this number to a square inch on the back of the hand, and not quite so many to an equal portion of surface on the forehead, and the front and sides of the neck; then come the breast, abdomen, and fore arm, where he reckons about 1100 to the inch, and lastly, the lower limbs and the back part of the neck and trunk, on which the number in the same space is not more than from 400 to 600.

The *size* of the sweat-glands also varies. According to the observer last named, the average diameter of the round-shaped ones is about one-sixth of a line; but in some parts they are larger than this—as, for example, in the groin, but especially in



the axilla. In this last situation, Krause found the greater number to measure from one-third of a line to a line, and some nearly two lines in diameter.

The *development* of the sweat-glands has been carefully studied by Kölliker. He states that their rudiments, when first discoverable in the embryo, have much the same appearance as those of the hairs, and, in like manner, consist of processes of the mucous layer of the epidermis, which pass down and are received into corresponding recesses of the corium. They are formed throughout of cells collected into a solid mass of an elongated-pyriform, or rather club shape, continuous by its small end with the soft layer of the cuticle, and elsewhere surrounded by a homogeneous limiting membrane, which is prolonged above between the corium and cuticle. The subsequent changes consist in the elongation of the rudimentary gland, the formation of a cavity along its axis—at first without an outlet—the prolongation of its canal through the epidermis to open on the surface, and, in the mean time, the coiling up of the gradually lengthening gland-tube into a compact ball, and the twisting of the excretory duct as it proceeds to the orifice. The original homogeneous membrane of the duct becomes thickened and is continuous with the surface of the corium, whilst an epithelium appears within, consisting of several layers of polygonal or rounded cells. The ceruminous glands in the auditory passage are known to consist of a tube coiled into a rounded or oval ball, like the sweat-glands; and the investigations of Professor Kölliker show such a further correspondence between the two, in structure and mode of development, as to lead him to regard the ceruminous glands as a mere local variety of the sudoriferous, which, as above noticed, present specialities both of structure and secretion in particular regions of the body.

The *sebaceous glands* (fig. CXXV.), pour out their secretion at the roots of the hairs, for, with very few exceptions, they open into the hair follicles, and are found wherever there are hairs. Each has a small duct, which opens at a short distance within the mouth of the hair follicle, and, by its other end, leads to a cluster of small rounded secreting saccules, which, as well as the duct, are lined by epithelium, and usually charged with the fatty secretion, mixed with detached epithelium particles. The number of saccular recesses connected with the duct usually varies from four or five to twenty; it may be reduced to two or three, in very small glands, or even to one, but this is rare. These glands are lodged in the substance of the corium. Several may open into the same hair follicle, surrounding it on all sides, and their size is not regulated by the magnitude of the hair. Thus, some of the largest are connected with the fine downy hairs on the *alæ* of the nose and other parts of the face, and there they often become unduly charged with pent-up secretion.\*

Fig. CXXV.

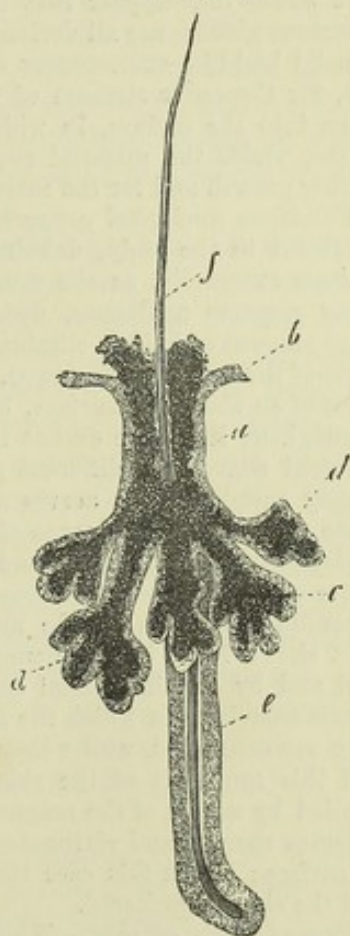


Fig. CXXV.—SEBACEOUS GLAND FROM THE FACE WITH BRANCHED DUCT, OPENING INTO A HAIR-FOLLICLE, MAGNIFIED 50 DIAMETERS (from Kölliker).

a, epithelium continuous with  
b, the mucous layer of epidermis;  
c, contents of gland; d, d, the  
groups of saccules on the branches  
of the duct; e, hair-follicle; f,  
hair.

\* A few years ago it was discovered by Dr. Gustavus Simon, that the sebaceous and



*Development of the sebaceous glands.*—The rudiments of the sebaceous glands sprout like little buds from the sides of the hair follicles; they are at first, in fact, excrescences of the external or mucous layer of the root-sheath (fig. cxix., n, n), and are composed entirely of nucleated cells. Each little process soon assumes a flask shape and is at first solid; but in due time a group of cells containing fat particles appears in its centre, and gradually extends itself along the axis of the pedicle until it penetrates through the root-sheath, and the fat cells thus escape into the cavity of the hair follicle, and constitute the first secretion of the sebaceous gland. They are soon succeeded by others of the same kind, and the little gland is established in its office. Additional saccules and recesses, by which the originally simple cavity of the gland is complicated, are formed by budding-out of its epithelium, as the first was produced from the epithelial root-sheath, and are excavated in a similar manner.

It would thus appear that the rudiments of the hair follicles, sweat-glands and sebaceous glands, are all derived from the same source. They all originally appear as solid bud-like excrescences of the soft Malpighian or mucous layer of the epidermis, for the outer stratum of the root-sheath must be regarded as such; these grow down into the corium, in which recesses are formed to receive them, and which, of course, yields the material required both for the production of new cells for their further growth and for the maintenance of their secreting function.

*Functions and vital properties of the skin.*—The skin forms a general external tegument to the body, defining the surface, and coming into relation with foreign matters externally, as the mucous membrane, with which it is continuous and in many respects analogous, does internally. It is also a vast emunctory, by which a large amount of fluid is eliminated from the system, in this also resembling certain parts of the mucous membrane. Under certain conditions, moreover, it performs the office of an absorbing surface, but this function is greatly restricted by the epidermis. Throughout its whole extent the skin is endowed with *tactile sensibility*, but in very different degrees in different parts. On the skin of the palm and fingers, which is largely supplied with nerves and furnished with numerous prominent papillæ, the sense attains a high degree of acuteness; and this endowment, together with other conformable arrangements and adaptations, invests the human hand with the character of a special organ of touch. A certain though low degree of vital contractility, depending doubtless on the muscular fibres in its tissue, also belongs to the skin. This shows itself in the general shrinking of the skin caused by naked exposure to cold and by certain mental emotions, and producing the state of the surface named "*cutis anserina*," in which the muscular bundles protrude the hair follicles with which they are connected, whilst they retract or depress the intermediate cutaneous tissue; and this condition of the skin may be produced locally by the electric stimulus applied by means of the magneto-electric apparatus. The scrotum, as is well known, becomes shrunk and corrugated by the application of cold or mechanical irritation to its surface; but in this case the contraction takes place in the subcutaneous tissue, and the skin is puckered.

*Reproduction of skin.*—When a considerable portion of the skin is lost, the breach is repaired partly by a drawing inwards of the adjoining skin, and partly by the formation of a dense tissue, less vascular than the natural corium, and in which, so far as I know, hairs and glands are not reproduced, so that some deny that the cutaneous tissue is regenerated. Still the new part becomes covered with epidermis, and its substance sufficiently resembles that of the corium to warrant its being considered as cutaneous tissue regenerated in a simple form. I may add, that in small breaches of continuity from cuts inflicted in early life, the uniting part sometimes acquires furrows similar to those of the adjoining surface.

### SECRETING GLANDS.

The term gland has been applied to various objects, differing widely from

hair follicles were infested by a worm, which he has described and delineated in Müller's Archiv. for 1842. Since then, further interesting details respecting this curious parasite, with observations on its development, have been contributed by Mr. E. Wilson. Phil. Trans. 1844.



each other in nature and office, but the organs of which it is proposed to consider generally the structure in the present chapter, are those devoted to the function of secretion.

By secretion is meant a process in an organised body, by which various matters, derived from the organism, are collected and discharged at particular parts, in order to be further employed for special purposes in the economy, or to be simply eliminated as redundant material or waste products. Of the former case, the saliva and gastric juice, and of the latter, which by way of distinction is often called "excretion," the urine and sweat may be taken as examples.

Secretion is very closely allied to nutrition. In the one process, as in the other, materials are selected from the general mass of blood and appropriated by textures and organs; but in the function of nutrition or assimilation, the appropriated matter is destined, for a time, to constitute part of the texture or organ, whereas in secretion it is immediately discharged at a free surface. The resemblance is most striking in those cases in which the waste particles of the texture nourished are shed or cast off at its surface, as in the cuticle and other epithelial tissues.

In man, and in animals which possess a circulating blood, that fluid is the source whence the constituents of the secretions are proximately derived; and it is further ascertained, that some secreted matters exist ready formed in the blood, and require only to be *selected* and separated from the general mass, whilst others would seem to be *prepared* from the materials of the blood, by the agency of the secreting organ. Among the secreted substances belonging to the former category, several, such as water, common salt, and albumen, are primary constituents of the blood, but others, as urea, uric acid, and certain salts, are the result of changes, both formative and destructive, which take place in the solid textures and in the blood itself, in the general process of nutrition. Again, as regards those ingredients of the secretions which are prepared or elaborated in the secretory apparatus, it is to be observed, that the crude material may undergo changes in organic form, as well as in chemical composition. Evidence of this is afforded by the solid corpuscles found in many secretions, as well as by the seminal cells and spermatozoa produced in the testicle.

In the structural adaptations of a secreting apparatus, it is in the first place provided that the blood-vessels approach some free surface from which the secretion is poured out. The vessels, however, do not open upon the secreting surface, for their coats, as well as the tissue covering them, are permeable to liquids; and the most favourable conditions for the discharge of fluid are ensured by the division of the vessels into their finest or capillary branches, and by the arrangement of these capillaries in close order, as near as possible to the surface. In this way, their coats are reduced to the greatest degree of tenuity and simplicity, and the blood, being divided into minute streams, is extensively and thoroughly brought into contact with the permeable parietes of its containing channels, as well as effectually and, by reason of its slow motion, for a long time exposed to those influences, whether operating from within or without the vessels, which promote transudation.

Such a simple arrangement as that just indicated is sufficient for the separation of certain substances from the general mass of the blood; for the coats of the vessels and tissue superjacent to them are not permeated with equal facility by all its constituents; and in certain cases the elimination of



fluid in the animal body is effected without the necessary aid of any more complicated apparatus. Thus, the exhalation of carbonic acid and watery vapour from the interior of the lungs and air passages, is probably produced in this simple manner, although the structure of the exhaling membrane is, for other reasons, complex; and the discharge of fluid into cavities lined by serous membranes, which is known to be preternaturally increased by artificial or morbid obstruction in the veins, may be a case of the same kind.

But another element is almost always introduced into the secreting structure, and plays an important part in the secretory process; this is the nucleated cell. A series of these cells, which are usually of a spheroidal or polyhedral figure, is spread over the secreting surface, in form of an epithelium, which rests on a simple membrane, named the basement membrane, or *membrana propria*. This membrane, itself extravascular, limits and defines the vascular secreting surface; it supports and connects the cells by one of its surfaces, whilst the other is in contact with the blood-vessels, and it may very possibly, also, minister, in a certain degree, to the process of secretion, by allowing some constituents of the blood to pass through it more readily than others. But the cells are the great agents in selecting and preparing the special ingredients of the secretions. They attract and imbibe into their interior those substances which, already existing in the blood, require merely to be segregated from the common store and concentrated in the secretion, and they, in certain cases, convert the matters which they have selected into new chemical compounds, or lead them to assume organic structure. A cell thus charged with its selected or converted contents yields them up to be poured out with the rest of the secretion, the contained substance escaping from it either by exudation or, as is probably more common, by dehiscence of the cell-wall, which, of course, involves the destruction of the cell itself. Cells filled with secreted matter may also be detached, and carried out entire with the fluid part of the secretion; and, in all cases, new cells speedily take the place of those which have served their office. The fluid effused from the blood-vessels, no doubt, supplies matter for the nutrition of the secreting structure, besides affording the materials of the secretion, the residue, when there is any, being absorbed.

Examples, illustrative of the secreting agency of cells, are afforded both by plants and animals. Thus, cells, are found in the liver of various animals, and especially of crustaceans and mollusks, some of which contain a substance resembling coloured biliary matter, and others particles of fat. Also, in the urinary organ of mollusks, cells are seen which inclose little opaque masses of uric acid. The secretion of the sebaceous follicles in man often contains detached cells filled with fat; and, according to Mr. Goodsir's observation, the ink-bag of the cuttle-fish is lined with an epithelium, the constituent cells of which are charged with pigment, similar to that which imparts the dark colour to the inky secretion. This last instance, as well as the production of spermatozoa, is an example of the formation of new products within secreting cells, a process further illustrated in plants, which afford abundant and decided evidence of the production of young cells, spermatie filaments, starch-granules, oil, various colouring matters, and other new compounds, in the interior of cells.

Both in animals and plants, the individual cells which are associated together on the same secreting surface may differ from each other in the nature of their contents. Thus, in the liver of mollusca some cells con-



tain biliary matter, and others contain fat; and in the recent soft part of the epidermis and its appendages, it is quite common to see cells filled with pigment mixed with others which are colourless.

A secreting apparatus, effectual for the purpose which it is essentially destined to fulfil, may thus be said substantially to consist of a simple membrane, named the *membrana propria* or basement membrane (marked *a* in the plan, fig. CXXVI.), supporting a layer of secreting cells on one of its surfaces (indicated by the dotted line *b*, in the figure), whilst finely-ramified blood-vessels are spread over the other (*c*). But whilst the structure may remain essentially the same, the configuration of the secreting surface, or (what amounts to the same thing) of the supporting basement membrane, presents various modifications in different secreting organs. In some cases, the secreting surface is plain, or, at least, expanded, as in various parts of the serous, synovial, and mucous membranes, which may be looked on as

Fig. CXXVI.

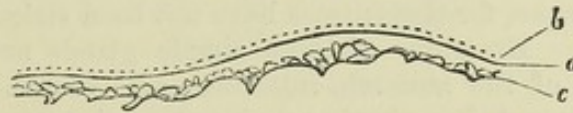

Fig. CXXVI.—PLAN OF A SECRETING MEMBRANE.

*a*, membrana propria or basement membrane; *b*, epithelium, composed of secreting nucleated cells; *c*, layer of capillary blood-vessels.

examples of comparatively simple forms of secreting apparatus; but, in other instances, and particularly in the special secretory organs named glands, the surface of the secreting membrane is variously involved and complicated. An obvious, and no doubt a principal, purpose of this complication is to increase the extent of the secreting surface in a secreting organ, and thus augment the quantity of secretion yielded by it. No connection has been clearly shown to exist between the *quality* of the secretion and the particular configuration, either internal or external, of the organ; on the other hand, we know that the same kind of secretion that is derived from a complex organ in one animal, may be produced by an apparatus of most simple form in another.

The more immediate purpose of the complication of the secreting membrane being to augment its surface within a comparatively circumscribed space, two principal modes are found by which the membrane is so increased in extent, namely, by rising or protruding, in form of a prominent fold or some otherwise shaped projection (fig. CXXVII., *d*, *e*), or by retiring, in form of a recess (fig. CXXVIII., *g*, *h*).

The first-mentioned mode of increase, or that by *protrusion*, is not what is most generally followed in nature, still it is not without example, and, as instances, we may cite the Haversian fringes of the synovial membranes, the urinary organ of the snail, which is formed of membranous lamellæ, and perhaps, also, the choroid plexuses in the brain, and the ciliary processes in the eye-ball, although secretion may not be the primary office of the last-mentioned structures. In most of these cases, the membrane assumes the form of projecting folds, which, for the sake of further increase of surface, may be again plaited and complicated, or cleft and fringed, at their borders (fig. CXXVII., *e*, *f*).

The plan of augmenting the secreting surface by *recession* or *inversion* of the membrane, in form of a cavity, is, with few exceptions, that generally



adopted in the construction of secreting glands. The first degree is represented by a simple recess (fig. CXXVIII., *g, h*), and such a recess, formed of

Fig. CXXVII.

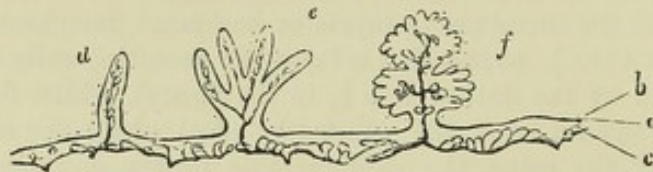

Fig. CXXVII.—PLAN TO SHOW AUGMENTATION OF SURFACE BY FORMATION OF PROCESSES.

*a, b, c*, as in preceding figure; *d*, simple, and *e f*, branched or subdivided processes.

secreting membrane, constitutes a *simple* gland. The shape of the cavity may be tubular (*g*) or saccular (*h*), and, in either case, it is called indifferently a *crypt*, *follicle*, or *lacuna*, for these names have not been strictly distinguished in their application. Examples of these simple glands are found in the mucous membrane of the stomach, intestines, and uterus. The secreting surface may be increased, in a simple tubular gland, by mere lengthening of the tube, in which case, however, when it acquires considerable length, the tube is coiled up into a ball (fig. CXXVIII., *i*), so as to take up less room, and adapt itself to receive compactly ramified blood-vessels. The sweat-glands, already described, and the ceruminous glands of the ear are instances of simple glands formed of a long convoluted tube. But the great means adopted for further increasing the secreting surface is by the subdivision, as well as extension, of the cavity, and when this occurs the gland is said to be *compound*. There is, however, a condition which might be looked on as a step between the simple and compound glands, in which the sides or extremity of a simple tube or sac become pouched or loculated (fig. CXXVIII., *k, l*). This form might be named the *multilocular crypt*.

In the compound glands, the divisions of the secreting cavity may assume a tubular or a saccular form, and this leads to the distinction of these glands into the "tubular," and the "saccular," or "racemose."

The *racemose* compound glands (fig. CXXVIII. *c*) contain a multitude of saccules, opening in clusters, into the extremities of a branched tube, named the excretory duct. The saccules are rounded, pyriform or thimble shaped, and then often named "cæcal." They are, as usual, formed by a proper or basement membrane, and lined, or often rather filled, with secreting cells; they are arranged in groups, round the commencing branches of the duct, into which they open both terminally and laterally (fig. CXXVIII. *c, n*); or it might with equal truth be said that the branches of the duct are distended into clusters of saccular dilatations. The ultimate branches of the duct open into larger branches (*o*), these into larger again, till they eventually terminate in one or more principal excretory ducts (*m*), by which the secretion is poured out of the gland. It is from the clustered arrangement of their ultimate vesicular recesses that these glands are named "racemose" (in German "traubenförmige Drüsen"); and they, for the most part, have a distinctly lobular structure. The lobules are held together by the branches of the duct to which they are appended, and by interlobular connective tissue which also supports the blood-vessels in their ramifications. The larger lobules are made up of smaller ones, these of still smaller, and so on, for several successions. The



smallest lobules (*n*) consist of two or three groups of saccules, with a like number of ducts, joining into an immediately larger ramusculæ (*o*), which issues from the lobule ; and a collection of the smallest lobules, united by

Fig. CXXVIII.

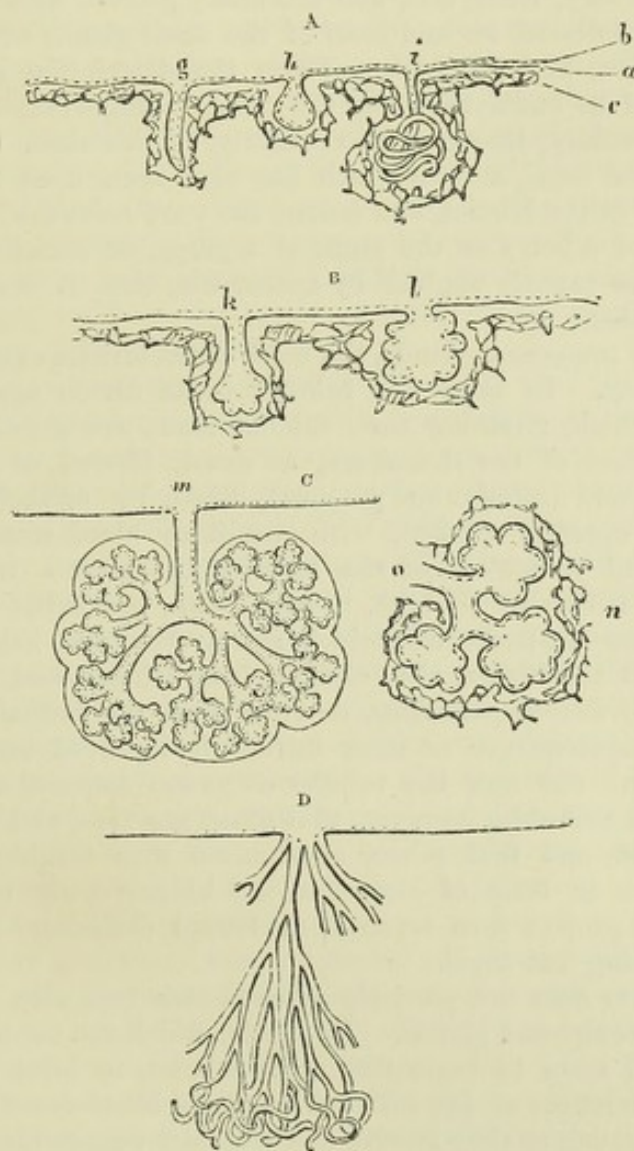


Fig. CXXVIII.—PLANS OF EXTENSION OF SECRETING MEMBRANE, BY INVERSION OR RECESSION IN FORM OF CAVITIES.

A, simple glands, viz., *g*, straight tube ; *h*, sac ; *i*, coiled tube. B, multilocular crypts ; *k*, of tubular form ; *l*, saccular. C, racemose, or saccular compound gland ; *m*, entire gland, showing branched duct and lobular structure ; *n*, a lobule, detached with *o*, branch of duct proceeding from it. D, compound tubular gland.

connective tissue and vessels, forms one of the next size, which, too, has its larger branch of the duct, formed by the junction of the ramuli belonging to the ultimate lobules. In this way, the whole gland is successively made up, the number of its lobules and of the branches of its duct depending on its size ; for whilst some glands of this kind, like the parotid and pancreas, consist of innumerable lobules, connected by a large and many-branched duct, others, such as the duodenal glands of Brunner and many mucous glands, are formed of but two or three ultimate lobules, or



even of a single one, with a duct, minute in size and sparingly branched, to correspond. In fact, a small racemose gland resembles a fragment of a larger one.

A great many compound glands, yielding very different secretions, belong to the racemose class. As examples, it will be sufficient to mention the pancreas, the salivary, lachrymal, and mammary glands, with the glands of Brunner already referred to, and most of the small glands which open into the mouth, fauces, and windpipe. From the description given of their structure, it will be understood why the term "conglomerate glands" has been applied especially, though not exclusively, to this class. Their smallest lobules were called *acini*, a term which has also been used to denote the saccular recesses in the lobules, and indeed the word *acinus*, which originally meant the seed of a berry or the stone of a grape, or sometimes the grape itself, has been so vaguely applied by anatomists, that it seems better to discard it altogether.

Of the *tubular* compound glands, the most characteristic examples are the testicle and kidney. In these the tubular ducts divide again and again into branches, which, retaining their tubular form, are greatly lengthened out. The branches of the ducts are, as usual, formed of a limiting or basement membrane (*membrana propria*), lined by epithelium, and in contact, by its opposite surface, with capillary blood-vessels. By the multiplication and elongation of the tubular branches a vast extent of secreting surface is obtained, whilst, to save room, the tubes are coiled up into a more or less compact mass, which is traversed and held together by blood-vessels, and sometimes, also, divided into lobules and supported, as in the testicle, by fibrous partitions, derived from the inclosing capsule of the gland. In consequence of their intricately involved arrangement, it is difficult to find out how the tubular ducts are disposed at their extremities. It seems probable, however, that some are free, and simply closed without dilatation, and that others anastomose with neighbouring tubes, joining with them in form of loops; in the kidney, little round tufts of fine blood-vessels project into terminal or lateral dilatations of the ducts, but without opening into them.

The human liver does not precisely agree in structure with either of the above classes of compound glands. Its ducts, which are neither coiled nor sacculated, would seem to begin within its lobules, in form of a network occupying the interstices of the reticular capillary blood-vessels, which also are peculiar, inasmuch as they receive and transmit venous blood.

Lastly, there are certain little bodies of doubtful nature, connected with the mucous membrane of the intestines, and known as the solitary and the agminated glands, which differ from all those hitherto spoken of, inasmuch as they are small saccules without an opening. Some anatomists are of opinion that they discharge their contents, from time to time, by bursting; whilst others, without denying the possibility of this, are disposed to take a different view of these glandular bodies, and (as, at any rate there are no ducts) refer them to the class of "ductless glands," under which head they will be again adverted to. The full description of these glands, as well as of the peculiarities in the structure of the liver and kidney above referred to, belongs to the details of special anatomy.

Besides blood-vessels, the glands are furnished with lymphatics, which in the compound glands proceed from lacunar lymphatic spaces within, as already stated (p. clxxxiii.). Branches of nerves have also been followed, for some way, into these organs, and the well-known fact, that the flow of



secretion in several glands is affected by mental emotions, shows that an influence is exerted on secreting organs through the medium of the nervous system ; and this is further shown by the fact, now ascertained, that an increased flow may be brought on by direct or reflex stimulation of their nerves. The distribution of these nerves in the salivary glands has been recently traced by Pflüger. He finds that dark-bordered nerve-fibres proceed to the cæcal grandular saccules ; that the membranous tube of the nerve-fibre becomes continuous with the membrana propria of the saccule, whilst the fibre, retaining its dark borders, passes into the saccule and divides into fine branches, which run between the nucleated gland-cells lining it, and finally penetrate the walls of these cells and become connected with their nuclei. Other nerve fibres proceeding to the saccules come from ganglionic or nerve-cells ; these fibres are chiefly pale or non-medullated, though not without admixture of the dark bordered kind, and are supposed to belong to the sympathetic system. These ganglionic fibres have also been traced to the gland-cells.

From what has been stated, it will be apparent that the substance of a gland consists of the ducts, blood-vessels, lymph-lacunæ, and a few nerves, in some cases connected by an intervening tissue. In the testicle there is a very small amount of intermediate connective tissue, which, with the aid of the blood-vessels, holds the tubules but feebly together, so that the structure is comparatively loose, and readily admits of being teased out ; but then it is sufficiently protected and supported by a fibrous capsule on the outside, and fibrous septa within the gland. In the racemose glands there is a good deal of uniting connective tissue, which surrounds collectively each group of saccules, binds together the lobules, and supports the vessels in their ramifications. The substance of the kidney contains scarcely any well characterised fibrous connective tissue, except bundles which here and there accompany the larger branches of vessels, but there is an abundant, though very delicate, network of retiform tissue in a soft, amorphous matter between the tubules and blood-vessels, which binds them together.

*Parenchyma* is a term sometimes employed in describing glandular organs, though it is less in use now than formerly. It is used sometimes to denote the solid part of a gland composed of the various tissues already mentioned ; at other times to signify any substance, of whatever nature, lying between the ducts, vessels, and nerves. In this last sense, the parenchyma is in certain glands represented by connective tissue, in others by corpuscles and amorphous matter, whilst in some it can scarcely be said to exist.

Some glands have a special envelope, as in the case of the kidney and testicle ; others, as the pancreas, have none.

The ducts of glands ultimately open into cavities lined by mucous membrane, or upon the surface of the skin. They are sometimes provided with a reservoir, in which the secretion is collected, to be discharged when the purposes of the economy so demand. The reservoir of the urine receives the whole of the secreted fluid ; in the gall-bladder, on the other hand, only a part of the bile is collected. The vesiculæ seminales afford another example of these laterally appended reservoirs. The ducts are constructed of a basement membrane and lining of epithelium, and in their smaller divisions there is nothing more ; but in the larger branches and trunks a fibro-vascular layer is added, as in the ordinary mucous membrane, with which many of them are continuous, and with which they all agree in nature. A more or less firm outer coat, composed of connective tissue, comes, in many cases, to surround the mucous lining, and between the two,



or, at any rate, outside the mucous coat, there is in some ducts a deposit of non-striated muscular tissue. The epithelium is usually composed of spheroidal or polyhedral cells at the commencement of the ducts, and is columnar in the rest of their length, though sometimes flattened or scaly, as in the mammary gland.

### DUCTLESS OR VASCULAR GLANDS.

There are certain bodies which have received the name of glands on account of their resemblance in general appearance and structure to the ordinary secreting organs. They differ, however, from the latter in the fact of their possessing no ducts for the discharge of secretion ; so that the products of secretive action, if finding any outlet, are compelled to do so by rupture, by filtration through the tissues, or by re-absorption into the circulating current. The bodies in question have been termed "ductless" for this obvious anatomical reason : and "vascular," on certain physiological or theoretic grounds, as they are supposed to effect some change in the blood which is transmitted through them.

To this class belong the following bodies :—the spleen, the thyroid body, thymus gland, supra-renal capsules, pituitary body ; and, according to various authorities, we ought to place in the same category the solitary closed follicles of the stomach and intestines, the Peyerian glands, the follicular glands at the root of the tongue, and also the lymphatic glands. The peculiar structure of each of these organs (except the lymphatic glands, already treated of) will be considered in its proper place in that portion of this work which is devoted to special anatomy ; and we have here to give only a general outline of those structural provisions which are, with more or less modification, common to them all.

The following may be taken as a general account of the mode in which their constituent elements are arranged. The form of the gland is determined by a fibrous, and in some instances dense and firm, investing membrane, which in the larger organs is furnished with prolongations projecting inwards as septa, giving considerable firmness to the texture, and either forming loculi or rounded cavities within them, or merely leaving spaces between the septa, in which the peculiar substance of the gland is placed. The investing membrane consists of both white and elastic fibres, in varying proportion, and, in many instances in the lower animals, of non-striated muscular fibres. Each gland is abundantly supplied with blood-vessels, both arterial and venous ; the former commonly dividing frequently, but entering into no anastomosis until they have arrived at their ultimate ramification in a capillary plexus ; the latter (the veins) are usually large, valveless, and in some situations appear dilated into sacs ; but this appearance has been questioned. Lymphatic vessels, proceeding from lacunæ within the gland, and nerves exist in very varying proportions.

The blood-vessels as they pass through these glands are in some cases closely surrounded by a peculiar pulpy substance, varying in amount and colour at different periods, but generally existing in considerable quantity. This pulp consists of corpuscles, granular matter, and fat-molecules. The corpuscles are of very different kinds and vary widely in size ; some, and those are the best established, resemble lymph, chyle, or pale blood-corpuscles ; others, free nuclei ; some, of more questionable existence, are said to be large compound cells, containing in their interior globules closely



resembling those of the blood ; others are described as containing many nuclei, and much granular matter.

These being the general characters of the ductless glands, the varieties met with in the human body may be arranged as follows :—

*a.* Rounded and closed capsules filled with nucleated cells, nuclei, and intercellular fluid, and traversed by blood-capillaries ; the capsules placed singly or in flat patches under a mucous membrane (solitary and agminated intestinal glands), or surrounding a simple or complex recess lined by and opening on the surface of a mucous membrane (certain lingual and pharyngeal glands, and tonsils) ; it being uncertain whether the contents of the capsules are discharged by rupture or transudation, or taken up by absorption.

*b.* A lobulated organ inclosing a sinuous internal cavity, with no outlet, filled with a liquid secretion containing corpuscles ; the cavity branching into the lobules, and ending in the smallest of them, according to one opinion, by groups of saccular dilatations of its membrana propria, covered outwardly by capillary blood-vessels, as in the racemose secreting glands. According to another view the walls of the cavity in an ultimate lobule are not set round with saccules, but with small solid pellets, formed of aggregated corpuscles similar to those of the fluid, and bounded towards the outer surface of the lobule by a membrana propria, *within* which is a group of blood-vessels pervading the corpuscular matter, as in *a*, (thymus).

*c.* A glandular body containing different-sized locular spaces formed by a stroma of fibrous or more or less homogeneous connective tissue : the loculi containing granules, nuclei, and nucleated cells of various sizes, with intercellular fluid (anterior lobe of the pituitary body and supra-renal capsules), or lined by a membrana propria and epithelium, and filled with clear tenacious fluid (thyroid body).

*d.* An organ containing a peculiar pulp lodged in the interstices of a trabecular and highly vascular structure ; also capsules with contents as in *a*, attached to the vessels, and surrounded by the pulp, which, while containing collections of red blood-corpuscles in various conditions, resembles generally in nature the matter within the capsules, and is likewise traversed by fine blood-vessels (spleen).

*e.* Rounded or oval bodies having in their interior intercommunicating loculi and intertrabecular spaces, further subdivided by retiform tissue, and partially occupied by a corpuscular gland-pulp traversed by blood-capillaries ; everywhere round the pulp a space left for the passage of lymph, communicating with the afferent and efferent lymphatics (lymphatic glands).

The purposes fulfilled by most of the organs referred to are still involved in great obscurity, and very different opinions are held on the subject by eminent authorities in Physiology.







## DIVISION I.

---

### SYSTEMATIC OR DESCRIPTIVE ANATOMY.

---

SYSTEMATIC or Descriptive Anatomy embraces the consideration of the organs of the body in an order arranged according to their nature and connections. It is called Systematic in opposition to Topographic or Demonstrative Anatomy, in which the various dissimilar organs found in each region are described together, and which is particularly adapted for the study of the relative position of parts.

The organs and parts of the body may be regarded from two distinct points of view, the Physiological and the Morphological.

Viewed in their physiological aspect, they form a series of instruments fitted for the accomplishment of particular purposes. Thus, for example, the bones form levers, which are moved by the muscles; and the combinations of these in the hand are fitted for grasping, while those of the foot are adapted for walking.

But considered apart from the functions of its organs, the human body, as well as all other organisms, exhibits a regular plan in its construction, to investigate the nature of which is the object of Morphological Anatomy. That plan cannot be competently examined except with the aids furnished by the study of Development and Comparative Anatomy. One of the most general facts connected with the plan of construction of the human body is its segmented nature, similar sets of parts being placed in succession, so that the line of their series forms the long axis of the body, and parts found in one segment or member of the series correspond, often very distinctly, to parts in other segments.

The segmented plan is that on which are constructed not only vertebrate animals, or all those which are possessed of a vertebral column, but also the higher invertebrate classes. It is most manifestly displayed in the class *articulata*, in some of which nearly the whole body is composed of a chain of precisely similar segments; while in others the segments are fused together in groups, so as to form more complicated structures. In the human body the appearance of segmentation is seen most conspicuously in the osseous system; it likewise pervades the nervous system, and is observable in some other structures. The trunk of the body is formed by a series of segments, indistinguishably blended together in some of the systems, but distinct in others; while the limbs are rather to be regarded as lateral outgrowths connected with a certain number of segments. Such segments of the body may be named *vertebral segments*, or, as Goodsir has suggested, *somatomes*; and to distinguish sections of the skeleton, the nervous, muscular, or other systems, the terms *sclerotome*, *neurotome*, *myotome*, &c., proposed by the same author, may sometimes be conveniently employed.



Correspondence of structural elements in different animals, or in different segments of the same animal, constitutes what is now generally called *homology*. Thus the wings of birds and the forelimbs of quadrupeds are homologous with the upper limbs of man, and vertebræ are homologous one with another. To distinguish the correspondence of parts which lie in series from that which exists between structures in different animals, Owen has suggested for the former the term *homotypy*, and the phrase *serial homology* is likewise employed. Thus the bones of the foot are serially homologous, or homotypic, with those of the hand.

To express resemblance of a general nature, arising from similarity of function, the term *analogy* has been adopted by recent authors. While structures fundamentally similar are regarded as homologous, although the progress of their development and the purposes for which they are adapted may be different, organs adapted for similar purposes are said to be analogous, however different in their original anatomical relations may be the parts of which they are composed. Thus the gills, being the respiratory organs of fishes, are analogous to the lungs of the air-breathing vertebrata; but they are not homologous parts.

DESCRIPTIVE TERMS.—As it is the office of descriptive anatomy to indicate with precision not only the form and structure, but also the position in relation to other parts of objects which are often irregular and complicated, it is important that it should have a generally recognised system of nomenclature: hence many words expressive of relative position, have acquired a restricted technical sense in which they are generally used by anatomists. It may be proper to mention here the most important of those terms. The *mesial plane* is that in which the body might be divided into a right and left lateral half; the *middle line* being the line before and behind, in which that plane meets the surface of the body. *Internal* and *external* denote relative nearness to and distance from the mesial plane towards either side. *Superficial* and *deep* indicate distance from the surface; and in the expression of this relation it is well to avoid the use of the terms *external* and *internal*, *inner* and *outer*, *above* and *below*, or to employ them with the utmost caution, lest they become a source of confusion. Nevertheless, an exception to this rule is still very generally made in the instances of some phrases which have been long in use. Thus the superficial and deep oblique muscles of the abdomen are commonly called external and internal, and so also with the superficial and deep inguinal rings. *Superior*, *inferior*, *above*, *below*, *anterior*, and *posterior* have reference to the position of parts in the erect posture of the body. As, however, the employment of those terms, though unobjectionable in human anatomy, is liable to give rise to ambiguity in general or comparative descriptions of structure in man and animals, it is frequently preferable to substitute others which express position by reference to a region or structure towards which the part is directed. Thus *ventral* and *dorsal* may be often employed instead of anterior and posterior, and, in the limbs, *proximal* and *distal* instead of superior and inferior. The inferior aspect of the lung may be called diaphragmatic, the posterior aspect of the gullet vertebral, and so on.

## SECTION I.—OSTEOLOGY.

The osseous system forms the *skeleton* or solid framework of the body. It supports the soft parts, protects delicate organs, and furnishes places of attachment to the muscles, by which the different movements are executed. The osseous parts of the skeleton are bound together by ligaments; and in some parts the framework is completed by the addition of cartilages. A *natural skeleton* is one in which the connecting parts have been preserved; while, in an *artificial skeleton*, the ligaments and cartilages having been removed by complete maceration, the bones are united by artificial mechanical contrivances, and the cartilages are replaced by some other substance.

The number of bones in the skeleton varies at different ages of life, some which are originally distinct becoming united together as the process of

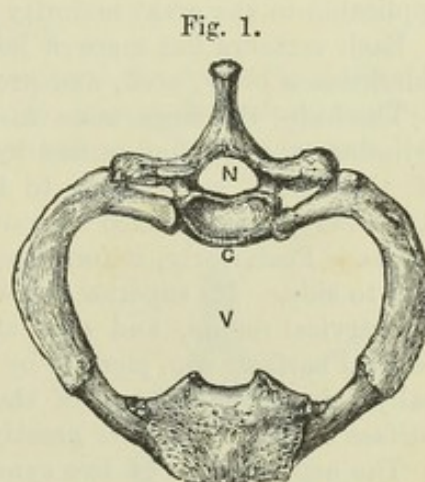


ossification proceeds. The following is an enumeration of those usually reckoned as distinct in middle life :—

	Single Bones.	Pairs of Bones.	Total.
The spinal column consists of twenty-four free vertebræ, the sacrum, and the coccyx . . . . .	26		26
The skull consists of twenty-two bones : of these eight are cranial, viz., four single bones, the occipital, frontal, ethmoid and sphenoid ; and two pairs, the parietal and temporal. Fourteen are facial, viz., two single bones, the vomer and inferior maxillary bone ; and six pairs, the nasal, lacrymal, superior maxillary, malar, palatal, and turbinated . . . . .	6	8	22
There are twelve pairs of ribs, a sternum, and a hyoid bone . . . . .	2	12	26
The superior extremities consist each of a clavicle and scapula, humerus, radius, ulna, eight carpal bones, five metacarpal, and fourteen digital . . . . .		32	64
The inferior extremities consist each of a pelvic bone, femur, patella, tibia, fibula, seven tarsal bones, five metatarsal, and fourteen digital . . . . .		31	62
	34	83	200

Besides the bones above enumerated, there exist, likewise, three pairs of auditory ossicles, and, in addition to the patella, various smaller bones called sesamoid. The auditory ossicles, though enclosed within the temporal bones, may be considered as belonging to the skeleton. The sesamoid bones are only accessories to the tendons in which they are developed.

Fig. 1.—FIRST DORSAL VERTEBRA, FIRST RIB AND CARTILAGE, AND UPPER PART OF THE STERNUM, SEEN FROM ABOVE, GIVING A VIEW OF A SEGMENT OF THE VERTEBRATE SKELETON.  $\frac{1}{2}$  C, body or centre ; N, vertebral ring or neural arch ; V, cavity of the chest enclosed by the ribs or visceral arch.



The segments of the skeleton are so disposed as to surround or partially enclose two cavities of unequal size—the neural and visceral. The neural cavity, comprehending the cranium and vertebral canal, is of great width in the head, and comparatively small in the rest of its length : it is nearly completely bounded by bony walls in its whole extent. The visceral cavity, placed in front of the vertebral column throughout its length, is only imperfectly represented in the head by spaces enclosed by the bones of the face : its walls, which are very incomplete, are most perfect in the thorax and pelvis, and leave large open spaces in the regions of the neck and abdomen. In these several regions, the relative position of the walls of the neural and visceral cavities and of their contained viscera remains the same.

## 1.—THE VERTEBRAL COLUMN.

The vertebral column may be considered as the foundation of the whole skeleton, not only because it exists in all animals which possess an osseous system, but because it is the centre round which the other parts are developed



and arranged. Superiorly, it supports the skull; laterally, the ribs are attached to it, through which it receives the weight of the upper limbs; and near its inferior extremity it rests upon the pelvic bones, which communicate the weight of the body to the lower limbs. Besides being a pillar of support to the rest of the skeleton, it furnishes protection to the spinal cord by enclosing it in an osseous canal. It is composed of a series of bones, called *vertebræ*, the most of which are united together by joints and elastic substance, and a few by bony connection, in such a manner that, although the amount of motion allowed between each pair is slight, the aggregate of that in the whole is sufficient to give the column very considerable flexibility.

The twenty-four upper *vertebræ* remain separate in the adult, and retain their mobility: they increase in size from above downwards. They are succeeded by five others, which rapidly diminish in size from above downwards, and which are united into one mass, called the *sacrum*; beyond the *sacrum* are four dwindled terminal members of the series, which as age advances become likewise united, and form the *coccyx*. Thus the column may be said to consist of two irregular pyramids, the common base of which is at the superior extremity of the *sacrum*.

### THE MOVEABLE VERTEBRÆ.

#### GENERAL CHARACTERS.

The general characters of the *vertebræ* are best exhibited in those which are placed near the middle of the column. Those at the extremities present a greater number of distinctive peculiarities. The following description is applicable to the great majority of moveable *vertebræ*.

Each *vertebra* has more or less the form of a ring, and presents for consideration a body, arch, and processes.

The *body*, the large mass in the anterior part of the *vertebra*, is a short cylinder, which, when united by elastic intervertebral plates with the others of the series, contributes to form a firm but flexible pillar of support. Anteriorly, it is rounded forwards, and slightly hollowed from above downwards. Posteriorly, it forms part of the ring, and is slightly hollowed from side to side. Its superior and inferior surfaces are nearly flat, excepting in the cervical region, and give attachment to the intervertebral plates. The vertical surfaces are pierced by numerous foramina for blood-vessels, principally veins: one or more of these, situated near the middle of the posterior surface exceeds the other greatly in size.

The *arch* consists of two symmetrical halves which spring from the body, towards its back part, and meet in the middle line behind. The anterior part of each lateral half, rounded and narrow, is called the *pedicle*; the posterior part is broad and flat, and is called the *lamina* or *plate*.

The *spinous process* or *spine* projects backwards from the arch in the middle line. The appearance presented by the linear series of spinous processes has led to the application of the name *spine* to the whole column. The *transverse processes*, placed one at each side, project outwards from the arch. The *articulating processes*, two superior and two inferior, project upwards and downwards from the *laminae*. They are furnished with articular surfaces, coated with cartilage, which in the superior processes look backwards, and in the inferior look forwards, so that the former face the latter in adjoining *vertebræ*.

The concavities on the upper and lower borders of the *pedicles* are named *notches*, and constitute by the apposition of those of contiguous *vertebræ* the



*intervertebral foramina*, a series of rounded apertures which communicate with the vertebral canal, and transmit the spinal nerves and blood-vessels.

The *foramen*, enclosed by the vertebral *ring*, is bounded anteriorly by the body, and posteriorly and laterally by the arch. The series of rings united by ligaments constitutes the *vertebral canal*, in which the spinal cord is contained.

*Texture*.—The bodies of the vertebræ are almost entirely composed of spongy substance, the surface being covered with only a thin layer of compact tissue. Venous canals, commencing at the larger foramina behind, traverse the cancellated structure. The arch and processes contain a much smaller proportion of spongy substance, being covered with compact tissue of considerable density in some places.

#### CHARACTERS PECULIAR TO GROUPS OF VERTEBRÆ.

The moveable vertebræ are divided into three groups, named from the regions which they occupy, *cervical*, *dorsal*, and *lumbar*.

Each of those groups is marked by distinctive characters. The central vertebræ of each group differ so much in all their parts from those of other groups, that any portion, such as the body, ring, or one of the processes, is alone sufficient to indicate to which they belong. On the other hand, the vertebræ at the extremities of each group are assimilated in their characters to those of the neighbouring group.

In the following description the characteristics of each group, as existing in its central members, will first be given, and then the slighter differences of other members will be stated.

#### DORSAL VERTEBRÆ.

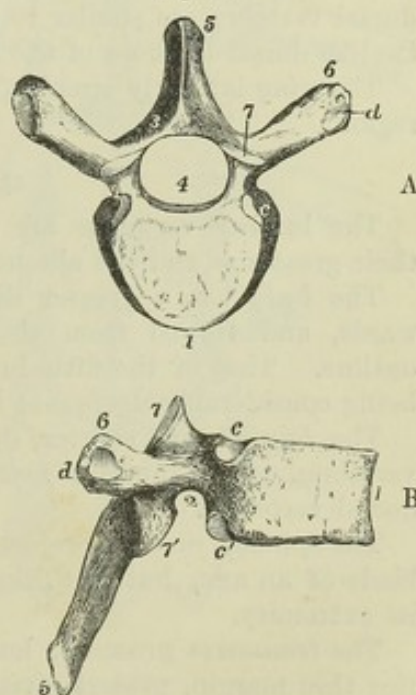
The dorsal vertebræ, twelve in number, support the ribs. They are the simplest in form, and ought to be the first to engage the attention of the student. Their position is between the cervical and lumbar groups, and they are also of intermediate size.

Fig. 2.—THE SIXTH DORSAL VERTEBRA.  $\frac{1}{2}$

A, viewed from above; B, viewed from the right side. 1, the body; 2, the pedicle; 3, the lamina; 4, vertebral ring, nearly circular; 5, spinous process; 6, transverse process; 7, 7', superior and inferior articulating processes; c, c', superior and inferior facets on the body for the articulation of the head of the rib; d, facet on the transverse process for the articulation of the tubercle of the rib.

The *body* is somewhat narrower in front than behind: its antero-posterior and transverse diameters are nearly equal, and it is somewhat heart-shaped, as seen from above or below. It is specially characterized by the presence, at the place where it joins the arch, of depressed articular surfaces for the heads of ribs. In the greater number of instances, there are two costal surfaces on each side,—one on the superior, the other on the inferior border,—so placed that each completes with that of the adjacent vertebra a cavity for the head of one

Fig. 2.





rib. The body of the first dorsal vertebra is, however, distinguished by having on each side a complete articular surface for the head of the first rib, besides a smaller surface on the lower border for one facet of the second rib; the costal surface on the tenth vertebra is usually complete for the tenth rib; and on the eleventh and twelfth there is only one articular surface on each side for the corresponding ribs.

The *laminae*, shorter and deeper than in the cervical vertebræ, are imbricated or sloped one pair over another like tiles on a roof. The *pedicles* are nearly on a level superiorly with the upper surface of the body; and hence the superior notches are very shallow, while the inferior notches are comparatively deep.

The *spinous process*, described as bayonet-shaped, is three-sided, elongated, and sloped, and terminates in a slight tubercle. It is longest and has the greatest downward inclination in those towards the centre of the series; and in them the terminal tubercles are slender, while those of the upper and lower vertebræ are thickened.

The *transverse processes* are directed outwards and backwards, and present in front of the extremity, which is enlarged into a rough tubercle, a small surface for articulation with the tubercle of the rib. There is, however, no such surface in the case of the eleventh or twelfth dorsal vertebræ. In several of the lowest dorsal vertebræ there may readily be recognized on the extremity of the transverse process, when looked at from behind, three tubercular elevations, varying somewhat in form and size, and which are named the external, internal, and inferior tubercles of the transverse process. In the twelfth vertebra, in which the transverse process is extremely short, those three tubercles are most fully developed. They correspond respectively to the transverse, mammillary, and accessory tubercles afterwards noticed in the lumbar vertebræ. (See Fig. 4, e, f, 6.)

The *articulating processes* have their cartilaginous surfaces nearly vertical. Those of the superior processes look backwards and slightly upwards and outwards, those of the inferior processes look forwards and slightly downwards and inwards. But the superior articular processes of the first dorsal vertebra are similar to those of the cervical, and the inferior of the twelfth dorsal to those of the lumbar vertebræ.

The *ring* is nearly circular, and is smaller than in the cervical or lumbar region.

#### LUMBAR VERTEBRÆ.

The lumbar vertebræ are five in number. They are distinguished by their great size and the absence of costal articulating surfaces.

The *body* has a greater diameter transversely than from before backwards, and viewed from above or below its surface presents a reniform outline. That of the fifth lumbar vertebra has the distinctive character of being considerably deeper at its anterior than at its posterior margin.

The *laminae* are shorter, deeper, and thicker than those of the dorsal vertebræ. The superior *notches* are shallow, the inferior deep, as in the dorsal vertebræ.

The *spinous process*, projecting horizontally backwards, is shaped like the blade of an axe, but is thickened and rough along the edge which forms its extremity.

The *transverse processes*, long and compressed, with a superior and inferior thin margin, project directly outwards. Their extremities lie in series with the external tubercles of the lower dorsal transverse processes and



with the ribs. Behind each, at its base, is a small process pointing downwards, which corresponds with the inferior tubercles of the dorsal transverse processes, and is also called the *accessory process*. The transverse processes of the fifth lumbar vertebra are shorter and thicker than those above, and are usually slanted a little upwards.

Fig. 3.—THIRD LUMBAR VERTEBRÆ.  $\frac{1}{2}$

A, from above; B, from the right side. 1, the body; 2, the pedicle and intervertebral notch; 3, the lamina; 4, the vertebral ring, somewhat triangular; 5, the spinous process; 6, transverse process; 7, 7', superior and inferior articulating processes; *e*, the mammillary tubercle, apparently on the superior articulating process; *f*, the accessory tubercle, between the articulating and transverse processes.

The *articulating processes* are thick and strong. Their articular surfaces are placed vertically and curved so as to lie in the arc of a circle. Those of the superior pair, concave, look backwards and inwards; those of the inferior, convex, look forwards and outwards. The superior pair are further apart than the inferior, and embrace the inferior pair of the vertebra above them. From each superior articular process a tubercle projects backwards, which corresponds with the internal tubercles of the dorsal transverse processes, and is also called the *mammillary process*.

The *ring* is large and triangular, or widely lozenge-shaped.

Fig. 4.—TWO LOWER DORSAL AND TWO UPPER LUMBAR VERTEBRÆ.  $\frac{1}{2}$

with portions of the eleventh and twelfth ribs of the right side: viewed from behind, chiefly to show the relations of the transverse processes and adjacent tubercles. 1, body of the eleventh dorsal vertebra; 5, spinous process of the second lumbar; 6, the transverse process; 7, 7', superior and inferior articulating processes; *e*, mammillary, and *f*, accessory tubercle. These indications are placed only on the alternate vertebrae to avoid crowding the figure.

#### CERVICAL VERTEBRÆ.

The cervical vertebrae are seven in number. The first and second are so peculiar in form that they require a separate description. The following characters belong to the five lower vertebrae:—

The *body* is small, and broader from side to side than from before back-

Fig. 3.

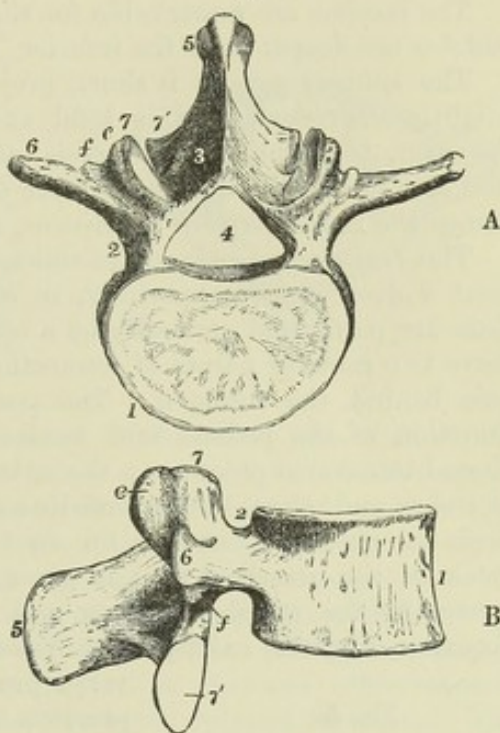
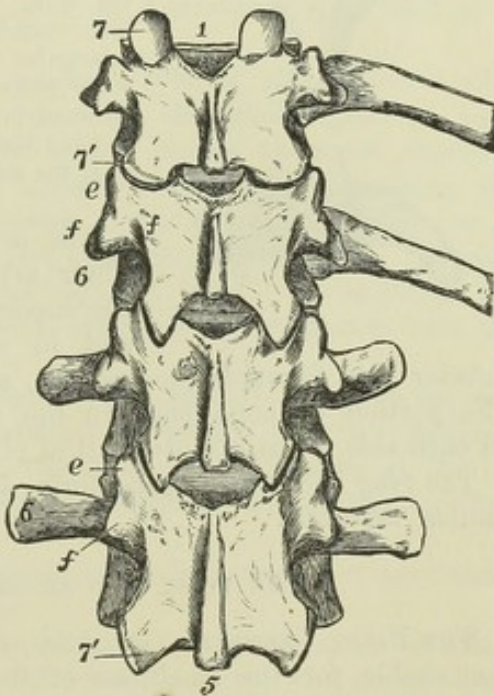


Fig. 4.





wards. Its superior surface is rendered transversely concave by the upward projection of its lateral margins, and is sloped down anteriorly. The under surface, on the contrary, is rounded off at the sides, while its anterior margin forms a marked projection downwards.

The *laminae* are remarkable for their length and flatness. The superior notches are deeper than the inferior.

The *spinous process* is short, projects horizontally backwards, or is only slightly depressed, and is bifid at its extremity. That of the seventh, however, terminates in a tubercle, and is so long as to be readily felt below the skin, while the others lie more deeply, and are covered with muscles: hence the name *vertebra prominens*, applied to the seventh.

The *transverse processes* are short, and bifid at the extremity. They present a deep groove superiorly, in which the spinal nerves lie; and at the base are perforated vertically by a round foramen of considerable size. They have two roots or points of connection with the vertebra, one in front and one behind the foramen. The posterior root springs from the place of junction of the pedicle and lamina, and in so far corresponds with the dorsal transverse processes; the anterior root is attached to the body of the vertebra and ranges in the same line with the ribs. The foramen corresponds with the space left between the root of a dorsal transverse process and the neck of the attached rib: it gives passage usually in the upper six vertebræ to the vertebral artery and vein, but in the seventh, though the foramen likewise exists, those vessels rarely pass through it. The trans-

verse process of the seventh cervical vertebra presents only a slight appearance of a groove on its upper surface, and is widened rather than bifid at its extremity.

Fig. 5.

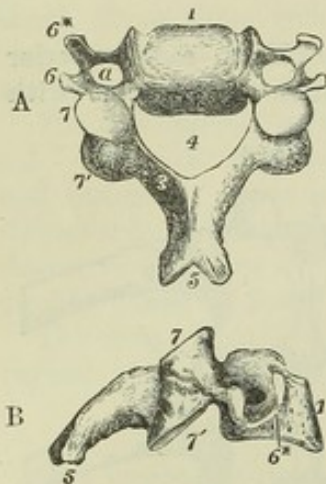


Fig. 5.—THIRD CERVICAL VERTEBRA.  $\frac{1}{2}$

A, from above and slightly from behind; B, from the side. 1, the body; 2 (omitted), the pedicle and inter-vertebral notch; 3, lamina; 4, vertebral ring, of a triangular form; 5, bifid spinous process; 6, 6\*, transverse process—6, posterior, 6\*, anterior tubercle; a, foramen in the root of the transverse process transmitting the vertebral artery; 7, 7', articulating processes—7, the superior, 7', the inferior.

The *articulating processes* are large and flat. Their articular surfaces are situated obliquely, the superior pair looking backwards, upwards, and in most of them slightly inwards; the inferior pair forwards, downwards, and in most of them slightly outwards. The portion of bone between the superior and inferior articular surface on each side forms a short vertical pillar.

The *ring* is of a triangular form, and larger than in either the dorsal or lumbar vertebræ.

#### THE FIRST AND SECOND CERVICAL VERTEBRÆ.

THE FIRST VERTEBRA, or *Atlas*, so called from supporting the head, is remarkable for the smallness of the parts occupying the position of the body and spinous process.

The *ring*, which is large from before backwards, is wider in the posterior than the anterior part of its extent. The wide posterior part corresponds to

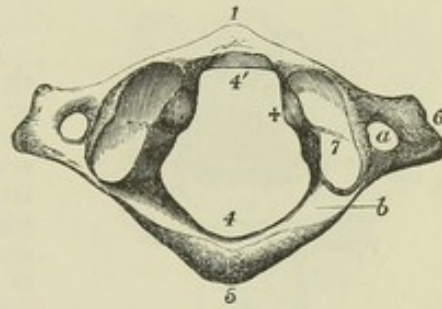


the rings of the succeeding vertebræ; the narrower anterior part is occupied by the odontoid process of the axis, and in the recent state is separated

Fig. 6.—THE ATLAS VERTEBRÆ, FROM ABOVE.  $\frac{1}{2}$

1, the anterior arch, with a tubercle in front; 4, the posterior part of the ring, with 5, an indication of a spinous tubercle; 4', the anterior part of the ring, containing the odontoid process, and indicating in front of 4' the smooth surface on which the process moves in rotation; 6, the transverse process with a slight indication of division into two tubercles; 7, the condyloid articulating process; + inside it indicates the rounded tubercle to which the transverse ligament is attached;  $\alpha$ , the foramen in the transverse process;  $b$ , the groove on the posterior arch for the vertebral artery.

Fig. 6.



from the posterior by the transverse ligament of the atlas. In front of the ring is the *anterior arch*, sometimes called the body, from which projects forwards the *anterior tubercle*, while its posterior aspect presents an articular surface which glides in rotation of the head upon the odontoid process of the axis. At the sides of the ring are the *lateral masses*—two stout portions of bone which receive the weight of the head, and present large articular surfaces on their superior and inferior aspects. They are situated in front of the places of exit of the nerves, and in this and other respects differ from the articular processes of the five lower cervical vertebræ. The superior articular surfaces, which receive the condyles of the occipital bone, are of oval form, converging in front, concave from before backwards, and looking inwards as well as upwards. At the internal margin of each is a rounded smooth tubercle with a rough depression, which gives attachment to the transverse ligament. The inferior articular surfaces are smaller than the superior pair, flat, nearly circular, looking downwards and inclined a little inwards.

The *laminae* unite behind to form a *posterior tubercle*, the rudiment of a spinous process. They are thick and round in the greater part of their extent, but at their junction with the lateral masses they are flattened by a smooth transverse groove on the upper border of each, marking the course of the vertebral artery as it passes inwards from the foramen of the transverse process before entering the cranium. This groove is sometimes converted into a foramen by a small arch of bone. It transmits the sub-occipital nerve as well as the vertebral artery, and corresponds with the notches of the other vertebræ.

The *transverse processes* project considerably further outwards on each side than those of the vertebræ immediately following; they are flattened from above downwards and somewhat rough, they are rounded at the extremity, and at the root of each is the foramen which transmits the vertebral artery.

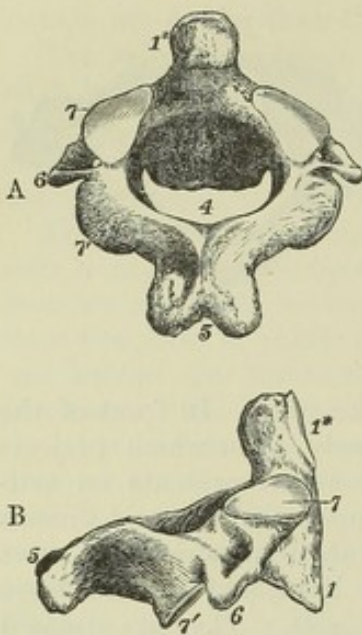
The *SECOND VERTEBRÆ*, *Vertebra dentata*, or *Axis*, forms a pivot on which the head with the first vertebra rotates.

The *body* is surmounted superiorly by the odontoid process, and is somewhat narrowed and prolonged below to fit into the depression of the body of the third vertebra. In front it presents a low vertical ridge, with a depression on each side, to which the upper part of the longus colli muscle is attached. The *odontoid process* (*p. dentatus*) consists of an enlarged



extremity termed the *head*, and a narrower lower part or *neck*. It presents in front a smooth surface for articulation with the atlas, and behind, a smooth groove to receive the transverse ligament of the atlas. The study

Fig. 7.

Fig. 7.—THE AXIS VERTEBRA.  $\frac{1}{2}$ 

A, seen from above and behind; B, seen from the right side. 1, the body; 4, the vertebral ring or foramen; 5, the spinous process, bifid and very large; 6, the transverse process; 7, the superior articulating process; 7', the inferior oblique articulating process; 1\* in A, is placed at the side of the odontoid process; in B, in front of it, marking the smooth surface of articulation with the anterior arch of the atlas.

of development appears to show that the odontoid process is in reality the body of the atlas anomalously connected with the vertebra dentata. The superior articular surfaces, placed, like those of the atlas, in front of the intervertebral groove, lie on the sides of the base of the odontoid process, partly on the body and partly on the arch of the vertebra. These surfaces look upwards and slightly outwards, and are of considerable

size; they receive the weight of the head transmitted through the lateral masses of the atlas. The inferior articulating processes, separated by a notch from the body, are similar in form and position to those of the succeeding vertebræ.

The *spinous* process is very large, rough, and deeply bifid, affording attachment to several muscles, and is grooved on its inferior surface. The plates which support it are of proportionate size and strength.

The *transverse* processes are short, and are scarcely grooved or bifurcated. The foramen at the root of each is inclined obliquely downwards and inwards.

### THE FIXED OR UNITED VERTEBRÆ.

#### THE SACRUM.

The sacrum (os sacrum) is placed below the last lumbar vertebra, above the coccyx, and between the ossa innominata, and forms the upper and back part of the pelvis. It consists in early life of five vertebræ, which in the adult are united into one bone. The first of the five is the largest vertebra in the column; those which follow become rapidly smaller, and the fifth is rudimentary. Hence the sacrum is massive above and slender below, and is triangular in general form, with its base directed upwards. It is concave and smooth in front, convex and uneven behind. The direction of its surfaces is very oblique, its pelvic aspect looking downwards and forwards, and forming at the place where it meets with the last lumbar vertebra the projection termed *promontory*. It presents for consideration a pelvic, a dorsal, and two lateral surfaces, a base and an apex, together with the sacral portion of the spinal canal.

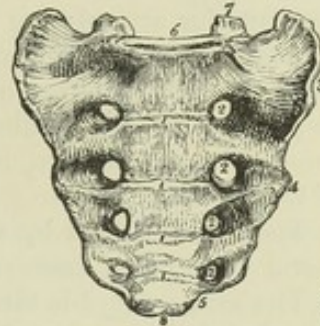
The *pelvic surface* is concave from above downwards, and slightly so from side to side. It is marked across the middle by four transverse lines or



ridges, which indicate the places of union of the bodies of the five vertebræ; and at the extremities of these ridges are situated on each side four *foramina* called *anterior sacral*, which transmit the anterior divisions of the sacral nerves. These foramina are sloped externally into grooves, and diminish gradually in size from above downwards.

Fig. 8.—SACRUM OF THE MALE, VIEWED FROM BEFORE.  $\frac{1}{4}$

1, 1, four transverse ridges, indicating the place of original separation of the bodies of the five sacral vertebræ; 2, anterior sacral foramina; 3, 4, lateral surface; 5, a notch which, with the coccyx, forms a passage for the fifth sacral nerve; 6, oval surface of the upper part of the sacrum for articulation with the body of the last lumbar vertebra; 7, superior articular processes; 8, inferior oval surface for articulation with the coccyx.

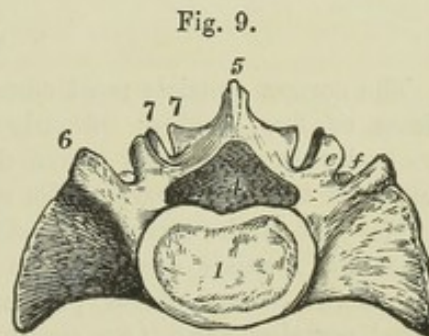


The *dorsal surface* is convex, very uneven, and somewhat narrower than the pelvic surface. It presents along the median line four small eminences, the spinous processes, usually more or less connected, so as to form a ridge. Below the last spinous process is a triangular opening, the termination of the spinal canal, the lateral margins of which are formed by the imperfect laminae of the fifth sacral vertebra, and present a pair of tubercles, the *sacral cornua*, which project downwards, and articulate with the cornua or horns of the coccyx. On each side of the ridge of spines the surface is smooth and hollowed in the position of the united laminae, and beyond this surface are two rows of eminences, the inner of which corresponds with the articular and mammillary processes of the lumbar vertebræ, while the outer ranges with the transverse processes. In the groove between the two rows are placed the four *posterior sacral foramina*, which are smaller than the anterior, and transmit the posterior divisions of the sacral nerves.

The lateral aspect or border presents anteriorly a large uneven surface, covered in the recent state with cartilage, which articulates with the ilium, and is called from its shape the *auricular surface*: behind this it is rough and very uneven for the attachment of the posterior sacro-iliac ligaments. Lower down, the margin of the sacrum is thin and sinuous, giving attachment to the sacro-sciatic ligaments, and terminates in the *inferior lateral angle*; below which the breadth of the bone is suddenly contracted, so that with the adjacent part of the coccyx a notch is formed for the transmission of the fifth sacral nerve.

Fig. 9.—UPPER SURFACE OR BASE OF THE SACRUM OF A MALE, TO COMPARE WITH FIG. 3, A, OF THE LUMBAR VERTEBRA.  $\frac{1}{4}$

1, the body; 4, the foramen, ring, or sacral canal; 5, the spinous process of the first sacral vertebra; 6, the part corresponding to a transverse process, in front of which is the large lateral mass; 7, the superior articulating process; 7', the inferior articulating process; e, the mammillary tubercle; f, the accessory tubercle, slightly seen.



The *base*, looking upwards and forwards, presents in the middle an oval



surface which articulates with the body of the last lumbar vertebra, and behind this, a triangular aperture, which leads into the sacral canal, and is bounded behind by the sharp depressed border of the laminae of the first sacral vertebra. On each side of the aperture is an articulating process with a vertical articular surface looking backwards and inwards like the superior articulating processes of the lumbar vertebrae. In front of this is a groove which forms part of the last lumbar intervertebral foramen. The external portion of the base presents posteriorly an eminence corresponding to the lumbar transverse process, and in front of that a large smooth convex surface, inclined forwards and continuous with the iliac fossa of the pelvis.

The *apex*, formed by the small inferior surface of the body of the fifth sacral vertebra, is transversely oval, and articulates with the coccyx.

The *sacral canal* is three-sided, curved with the bone, and gradually narrowed as it descends. It opens below on the posterior surface of the bone, between the sacral cornua, where the laminae of the last sacral vertebra do not unite. From this canal there pass outwards in the substance of the bone four pairs of intervertebral foramina, or short canals, each of which divides externally into an anterior and posterior sacral foramen.

*Curvature.*—The curve of the sacrum varies greatly in different skeletons: in some it is slight and confined to the lower end, while in others it is observable in the whole length, but especially about the middle.

*Differences in the sexes.*—The sacrum of the female body is broader in proportion to its length than that of the male, so as to approach the form of an equilateral triangle, and is seldom curved greatly, or in its whole extent. The sacrum of the female also usually inclines backwards from the direction of the lumbar vertebrae to a greater extent than that of the male.

*Varieties.*—The sacrum is subject to numerous and considerable variations. It not unfrequently consists of six pieces, and it has been found, but much more rarely, reduced to four. (Soemmerring, "Lehre von den Knochen und Bändern, &c., herausgegeben von Rudolph Wagner," 1839, p. 128.) It is not fully determined whether these differences depend on increased development of the first coccygeal vertebra and on diminished development of the fifth sacral, or whether there may not be an interposition of a new vertebra in one instance, and the loss of one of the ordinary series in the other. Occasionally the bodies of the first and second sacral vertebrae are not joined, although complete union has taken place in every other part; and in like manner sometimes a space is left between their arches. The lower end of the sacral canal may be open to a greater extent than usual, in consequence of some of the vertebral laminae not having reached the middle line posteriorly: it has even been found open in its whole extent. (Thomson.) Instances occur in which the first sacral vertebra has on one side the usual sacral form, while on the other it has the appearance of a lumbar vertebra, and occasionally it presents characters on both sides, intermediate between those of the sacrum and lumbar vertebrae.

#### THE COCCYX.

The coccyx consists most commonly of four rudimentary vertebrae; sometimes of five, seldom of only three. The coccygeal vertebrae diminish gradually in size from above downwards, and are placed in a continuous line with the lower part of the sacrum.

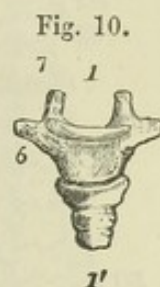
The *first* of the series is considerably broader than the others. It presents superiorly a small oval concave surface which articulates with the apex of the sacrum, two lateral projections corresponding with those of the last sacral vertebra, and two small processes, termed *cornua*, corresponding to a certain extent with articulating processes, which project upwards from its posterior aspect and rest upon the sacral cornua. The lateral parts project



outwards, usually forming with the sacrum the notch for the fifth sacral nerve, and in some instances uniting with the sacrum so as to form a fifth sacral foramen.

Fig. 10.—FOUR COCCYGEAL VERTEBRÆ, SEEN FROM BEFORE.—FROM A MALE SUBJECT OF MIDDLE AGE.  $\frac{1}{3}$

The upper piece is separate from the second; the three lower are united together in one piece, and separated only by grooves. 1 is placed above the middle or body of the first coccygeal vertebra; 1' is below the fourth piece; 6 indicates the transverse portion; 7, the superior articulating tubercle.



The remaining three coccygeal vertebræ are much smaller than the first, and correspond solely to vertebral bodies. When separate, the second piece presents an upper and lower flattened surface. The third and fourth pieces are mere rounded nodules. In middle life, the first piece is usually separate, while the three lower pieces are most frequently united into one, the original separation being indicated only by transverse grooves.

In advanced life, the coccygeal vertebræ, having been previously joined into one bone, become also united to the sacrum. This union occurs at an earlier age and more frequently in the male than in the female, but it is subject to much variation.

#### THE VERTEBRAL COLUMN AS A WHOLE.

The *average length* of the vertebral column is about twenty-eight inches. Its length varies to a considerable extent in different persons, but not so much as might be anticipated from a comparison of their stature; the relative height of individuals depending more frequently on a difference in the length of their lower limbs than of the vertebral column.

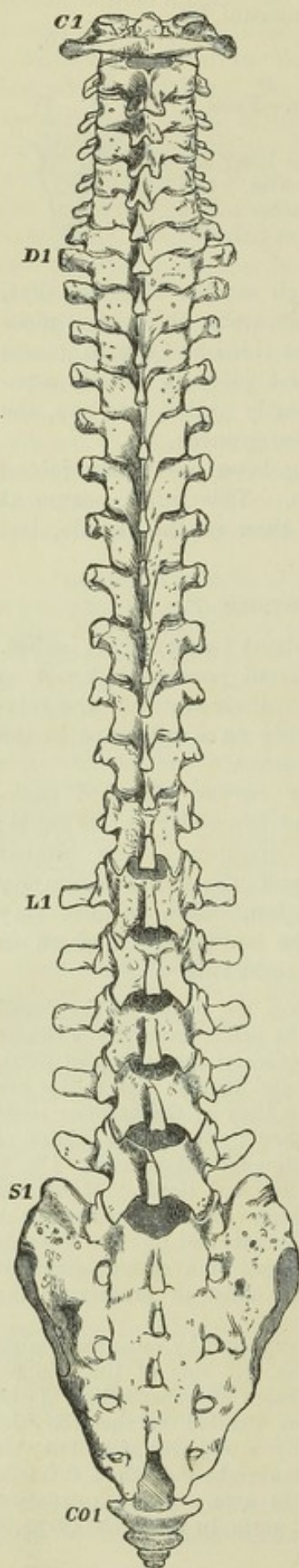
**CURVES.**—The vertebral column presents four curves, directed backwards and forwards. In the neck and loins the convexity is forwards; in the back and pelvis it is in the opposite direction. The lumbar convexity is much greater than the cervical; and the sacral concavity is greater than the thoracic. In the dorsal region, there is also very frequently a slight degree of lateral curvature, the convexity of which in the great majority of cases is directed towards the right side.

In connection with the thoracic concavity of the column, the bodies of the dorsal vertebræ are somewhat thinner in front than behind. The pelvic concavity is chiefly dependent on the diminished vertical diameter of the bodies of the sacrum in front, and the bending forward of the coccyx. The cervical and lumbar convexities are attended with a slightly greater thickness of the posterior than of the anterior parts of the intervertebral discs, and they are in part maintained by the elastic tension of the ligamenta subflava acting upon the most flexible portions of the column. (W. & E. Weber, "*Mechanik der Mensch. Gewerkezeuge*," p. 91; and Henle, "*Handbuch der Syst. Anat. des Menschen*," vol. i., p. 32.) These curves are connected with the maintenance of the erect posture. They are absent in infants and increase towards adult age. They confer upon the column the advantages of a spring, giving it greater strength and elasticity, and at the same time assist in preserving the equilibrium of the body.

The lateral curvature in the dorsal region has been supposed by some anatomists to be connected with the position of the aorta on the left side of the column. Cruveilhier mentions, in support of this opinion, three cases of transposition of the aorta, in which the convexity of the lateral curve was directed to the left side. (Cruveilhier, "*Traité d'Anatomie*," 4th edit., p. 65.) By a majority of writers this curve is imputed to the greater muscular action on the right side than the left, occasioned by the preference usually given to the right arm. This explanation originated with Bichat. Otto describes a case of right aorta, in which the curve of



Fig. 11.



the column had the usual direction, and in which the right arm was more muscular than the left. ("Seltene Beobachtungen," part 2, p. 61; see also R. Quain, "Anatomy of the Arteries," p. 19.)

Fig. 11.—VERTEBRAL COLUMN OF AN ADULT MALE, SEEN FROM BEHIND.  $\frac{1}{4}$

C 1 to above D 1, the seven cervical vertebrae; D 1 to above L 1, the twelve dorsal vertebrae; L 1 to above S 1, the five lumbar vertebrae; S 1 to above CO 1, the sacrum; CO 1, and below, the four coccygeal vertebrae. The attention of the reader is called to the transition in the form of the transverse processes and tubercles indicated in this specimen, which is well marked.

FORM.—On the *anterior* aspect of the column, the pillar formed by the bodies of the vertebrae is seen to become broader from the axis to the first dorsal vertebra. At this place it ceases to widen, and even becomes slightly narrower from the first to about the fourth dorsal vertebra; from that level it then becomes gradually wider down to the base of the sacrum. The width between the extremities of the transverse processes is considerable in the atlas; it is small in the axis, becomes greater as far as the first dorsal vertebra, thence it is again gradually contracted as far as the last dorsal, and becomes suddenly much greater in the lumbar region.

On the *lateral* aspect, the diameter of the bodies from before backwards is seen to increase most rapidly in the dorsal region. The tips of the transverse processes of the dorsal vertebrae, being directed backwards, describe a greater curvature than the bodies; while the spinous processes exhibit a smaller curvature, on account of the middle dorsal set being most sloped downwards, while those above and below project backwards.

On the *posterior* aspect, the spines occupy the middle line. Those of the dorsal region are in many instances inclined a little, some to one side and some to the other. At the sides of the row of spines are the vertebral grooves, corresponding to the laminae, and bounded externally in the cervical and dorsal regions by the transverse processes, and in the lumbar by the mammillary processes. They are broad but shallow in the neck, and become deep and narrow lower down; the narrowest part being at the last dorsal vertebra. Along the grooves is a series of spaces between the laminae, which, in the natural condition, are filled up by the yellow ligaments. The extent



of these intervals is very trifling in the neck and in the greater part of the back, it increases in the lower third of the dorsal, and still more in the lumbar region. The interval between the occipital bone and the arch of the atlas is considerable, and so is that between the last lumbar vertebra and the sacrum.

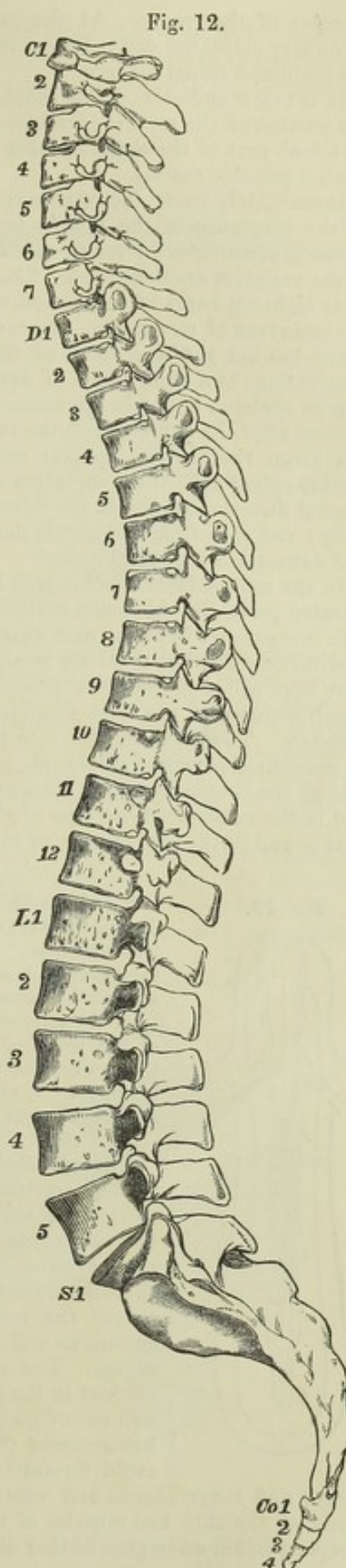
Fig. 12.—THE SAME VERTEBRAL COLUMN AS IN FIG. 11, VIEWED FROM THE LEFT SIDE.  $\frac{1}{2}$

The letters and figures indicate the several vertebræ. The attention of the reader is called to the different curvatures of the column here shown, the shape and size of the bodies and intervertebral spaces, the form and transitions of the transverse and spinous processes, and the differences in the costal articulating surfaces.

#### DEVELOPMENT OF THE VERTEBRÆ.

*Earliest steps of foetal development as related to the first formation of the Vertebral Column and Skeleton.*—The first step in the formative process within the ova of vertebrate animals is the production on the surface of the yolk of a superficial layer of organised cells, termed *blastoderm*, or *germinal membrane*. In the progress of development, this substance very soon comes to be divided into three strata or layers, which may be distinguished from each other by their structural differences, and have been named from their position the upper, middle, and lower layers of the germinal membrane. The upper and lower layers retain throughout their simple cellular structure, and take no share in the formation of the skeleton. From a part of the upper layer the medullary rudiments of the brain and spinal marrow are derived; while the rest of its extent is the source of the cuticular covering of the body. The whole of the deeper layer is taken up in the formation of the epithelium of the mucous membranes of the alimentary canal and its dependencies. But the middle layer has a far more complex and important destination, as it furnishes the formative material from which are developed the rudiments of the osseous, muscular and vascular systems, together with the peripheral nerves, the fibrous coats of the alimentary canal, and many other parts of the body.

The earliest indication of embryo-form consists in the production of the *primitive trace* and groove, which takes place in the part of the upper and middle layers to be occupied by the embryo. The deepening of this groove by the elevation of its sides lays the foundation of the cerebro-spinal canal or cavity, and this is finally closed in superiorly by the meeting and union of the elevated and approximated





margins of the groove. At the same time there is enclosed within the cavity the medullary substance derived from the upper layer, which constitutes the rudiment of the brain and spinal marrow.

It is below and around this tubular cerebro-spinal cavity, and in the substance of the portion of the middle germinal layer immediately adjacent to it, that the cranio-vertebral part of the skeleton takes its origin by steps of which the following is the briefest possible outline.

Immediately below the cerebro-spinal groove, previous to its closure, there appears in the substance of the middle layer a linear condensed structure, termed *chorda dorsalis* or *notochord*; round this at a later period the base of the skull and bodies of the vertebrae are developed. The *chorda dorsalis* may be seen in the embryo-chick after eighteen hours of incubation, and at corresponding periods of advancement in the embryos of mammalia. In the human embryo, although the first origin of this chord has not yet been observed, there is no reason to doubt its existence; and from observations at a later period of development it is certain that the foundation of the human skeleton is laid in a manner essentially the same as in animals.

Soon after the extension of the two upper germinal layers in the dorsal direction has given rise, in the manner mentioned, to the neural cavity and its contained cerebro-spinal axis, the incurvation of all the three germinal layers in a downward or ventral direction results in the formation of the walls of the visceral cavities of the body; and thus from the *chorda dorsalis* as a centre there proceeds upwards a neural and downwards a visceral arch.

In the middle layer itself, which is destined for the production of the most complicated parts, the thickened portion which is next to the *chorda dorsalis* on either side is separated from the part which is more remote, and it is in the inner portion now mentioned that there are produced at a very early period those structures which have been called *primitive* or *primordial vertebrae* by embryologists, the formation of which constitutes the next stage in the progress of the earliest development of the skeleton. These rudimental structures consist of small dark quadrilateral patches of condensed germinal substance, to the number of three or four, situated on each side of the *chorda dorsalis*. The anterior of them corresponds to the atlas vertebra, and in the subsequent increase of their number, the new ones make their appearance farther and farther backwards, or towards the caudal extremity.

Fig. 13.

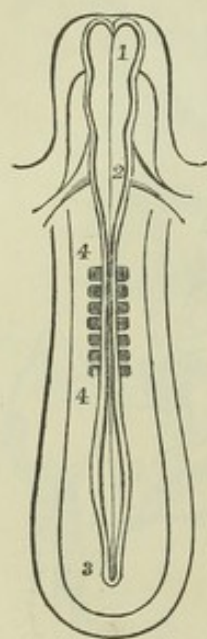


Fig. 13.—This and the three following figures are intended to illustrate the first formation of the vertebral segments, or "primitive vertebrae," and some of the changes by which the permanent vertebral and costal arches are produced. Fig. 13 gives in outline a magnified view of the embryo of the chick about twenty-six hours after the commencement of incubation, as it lies prone in the centre of the germinal membrane. 1, 2, 3, cerebro-spinal canal; 1—2, the cerebral part; 2—3, the spinal part, not yet closed in the caudal region; 4—4, seven primitive vertebrae, proto-vertebrae, or vertebral segments; near 2, the rudiments of the heart.

The so-called primordial vertebrae have, however, a more extended destination than to serve as the basis of formation of the elements of the vertebral column; for each pair of them contains the rudiments, not only of the osseous and cartilaginous parts of a vertebra which cross the middle plane, but also in the thoracic region a portion of a rib, and throughout the whole extent the central parts of a spinal pair of nerves and the cutaneous and muscular parts which cover the whole vertebral region. The process by which these several parts come to be distinct in the progress of development is somewhat intricate. It will be sufficient to mention here that, after a considerable change has occurred in each of the primordial vertebral masses by the rapid formation of cells within them, each becomes cleft into an

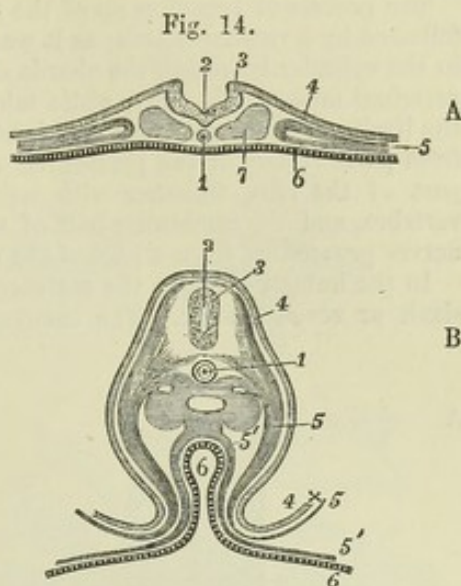
upper and lower (dorsal and ventral) division or plate. The upper constitutes the basis of the skin and muscles of the vertebral part of the trunk, while the lower or deeper portion undergoes further division in connection with the development of very



dissimilar elements from its substance. In the first place, the outer half of each is divided by a transverse fissure into two parts, of which the anterior, or that towards the head, is afterwards converted into the root and ganglion of a spinal nerve;

Fig. 14, A.—Transverse section through the spinal part of the embryo represented in fig. 13, at the place where the spinal canal is still open, or is only a groove. 1, chorda dorsalis; 2, spinal canal or primitive groove; 2 to 3, medullary plates, continuous with 4, the corneous layer of the blastoderm; 5, the middle layer; its outer part divided into two laminae, the upper being the volunt-motory, in which osseous and muscular plates afterwards make their appearance, and the lower being the involunt-motory or intestino-fibrous lamina; 6, the epithelial, or lowest layer of the blastoderm; 7, the inner part of the middle layer, in which the primitive vertebral segments are developed.

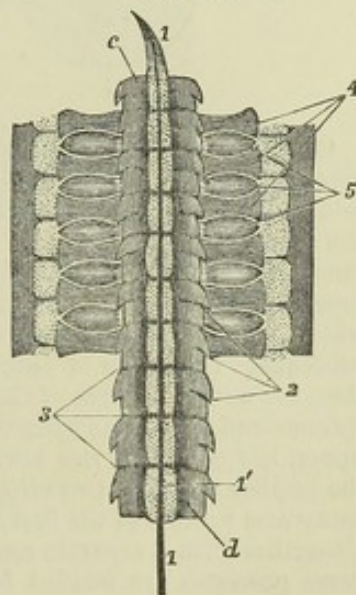
Fig. 14, B (adapted from Remak and Kölliker).—Transverse section of the lumbar part of an embryo more advanced, or towards the fifth day, showing the spinal canal and spinal marrow closed, the visceral plates and intestine formed, &c. 1, chorda dorsalis in its sheath; 2, canal of the spinal marrow; 3, medullary substance of the spinal marrow; 4, corneous layer; 5, outer lamina of the middle layer forming the visceral plates, and along with the corneous layer the amnion  $4 \times 5$ ; 5', inner lamina of the middle layer or intestino-fibrous; the figure 5' is placed in the peritoneal cavity; immediately above it are seen the rudiments of the Wolffian bodies, the aorta in the middle between them, and on each side the Wolffian duct; 6, the intestinal cavity and epithelial layer, extending at 5', 6, into the blastoderm of the yolk sac.



and the posterior is the source of the transverse process of a vertebra and adjacent portion of a rib. The inner part of the primordial vertebral mass passes inwards in two modes: 1st, by its deepest part it passes above and below the chorda dorsalis, and joining with the corresponding structures from the opposite side, surrounds

Fig. 15.

Fig. 15 (from Remak and Kölliker).—The cervical part of the primitive vertebral column and adjacent parts of an embryo of the sixth day, showing the division of the primitive vertebral segments into permanent vertebral arches, rudiments of the spinal nerves, &c. 1, 1, chorda dorsalis in its sheath, pointed at its upper end; 2, points by three lines to the original intervals of the primitive vertebrae; 3, in a similar manner indicates the places of new division into permanent bodies of vertebrae; *c* indicates the body of the first cervical vertebra; in this and the next the primitive division has disappeared, as also in the two lowest represented, viz., *d* and the one above; in those intermediate the line of division is shown: 4, points in three places the vertebral arches; and 5, similarly three commencing ganglia of the spinal nerves: the dotted segments outside these parts are the muscular plates.



the chorda; 2nd, its more superficial part completes the formation of a ring, or a part of a cylinder, round the spinal cord. This may be considered as the



membranous stage in the development of the vertebral column. It may be proper to remark that there is no similar original division in the cephalic portion of the primordial skeleton, but the chorda dorsalis is prolonged for a short distance into the middle of the basilar part.

The process of breaking up of the primordial vertebral masses above referred to is followed by a reconstruction, as it were, of the vertebræ, which consists in this—that in the cylinder investing the chorda dorsalis the lines of separation of the primordial vertebral masses fade away, while midway between them new lines appear, marking the limits of the permanent vertebræ; and thus each permanent vertebra is formed from parts of two of the primordial masses; the arch, the transverse processes and part of the ribs, together with half the body, being derived from one primitive vertebra, and the remaining half of the body together with the corresponding pair of nerves proceeding from a part of the next primordial mass in succession.

In the human embryo, the vertebral column begins to become cartilaginous in the sixth or seventh week. The cartilage spreads rapidly over the bodies, but much

more slowly into the arches, in which the union of the cartilages of opposite sides is not completed till during the fourth month (Kölliker). At the period of the first appearance of the cartilaginous bodies, the chorda dorsalis consists of a solid column of large thin-walled cells, surrounded by a transparent sheath; but it becomes constricted, and gradually dwindles within each vertebral body, while it remains more fully developed in the intervertebral spaces, and enters into the formation of the intervertebral discs.

Fig. 16.

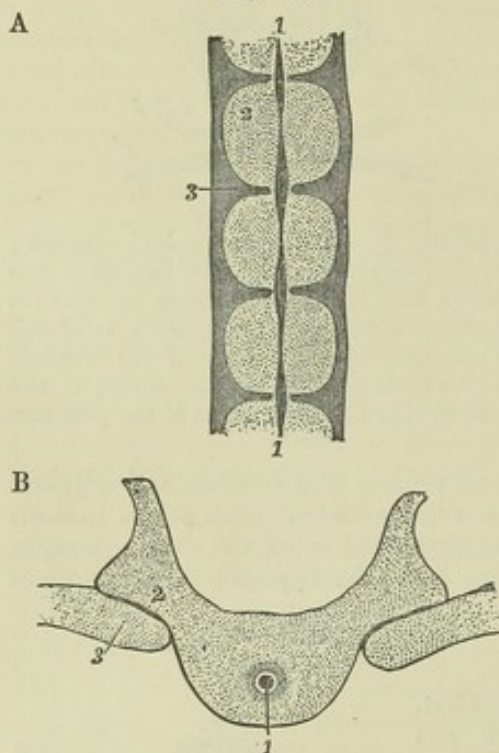


Fig. 16, A & B (from Kölliker, figs. 80 & 81).  
—SECTIONS OF THE VERTEBRAL COLUMN  
OF A HUMAN FŒTUS OF EIGHT WEEKS.

A, transverse longitudinal section of several vertebræ. 1, 1, chorda dorsalis, its remains thicker opposite the intervertebral discs; 2 is placed on one of the bodies of the permanent vertebræ; 3, on one of the intervertebral discs.

B, transverse horizontal section through a part of one dorsal vertebra. 1, remains of the chorda dorsalis in the middle of the body; 2, arch of the vertebra; 3, head of a rib.

**OSSIFICATION.**—The ossification of each typical vertebra proceeds from three principal nuclei. One of these, which is occasionally double at first, appears in the middle of the cartilage, and is afterwards converted into the main part of the body; the other two, placed one on each side, appear opposite the roots of the transverse processes, usually a little earlier than the nucleus of the body; and form the arch and processes, together with an angular part on each side of the body, namely, that part which in the dorsal region supports the heads of the ribs. At different periods subsequent to the age of puberty, five epiphyses, or supplementary centres of ossification, are added. Three of these are small portions of bone, placed on the tips of the spinous and transverse processes: the other two are thin circular plates, one on the upper, the other on the lower surface of the body, chiefly at its circumference. In the lumbar vertebræ two other epiphyses surmount the mammillary processes. The transverse process of the first lumbar vertebra is sometimes observed to be developed altogether from a separate centre. Most of the anterior divisions of the cervical transverse processes are ossified by the extension into them of osseous substance from the neighbouring posterior part of the process and from the arch; but that of the seventh usually presents a separate osseous nucleus, and small nuclei have also been observed by Meckel in those of the second, fifth, and sixth vertebræ.



In the atlas, the lateral masses and posterior arches are ossified from a pair of centres corresponding to those in the arches of the succeeding vertebræ. In the anterior arch one or two separate nuclei appear soon after birth; and even three have been observed. There is frequently a small epiphysis on the posterior tubercle.

Fig. 17. — ILLUSTRATES THE OSSIFICATION OF THE VERTEBRÆ.

A, foetal vertebra, showing the three primary centres of ossification; 1, 2, for the pedicles, laminae, and processes; 3, for the body.

B, dorsal vertebra from a child of two years, as seen from above; 1 & 2 are seen to have encroached upon the body at \*, and into the articular and transverse processes, and to have united behind in the spinous process, leaving cartilaginous ends.

C, dorsal vertebra at about sixteen or seventeen years, showing the epiphyses on the transverse processes, 4 & 5, and spinous process, 6, and the upper epiphysal plate of the body, 7.

D & E, parts of a lumbar vertebra of about the same age, showing, in addition to the foregoing, 8, the lower epiphysal plate of the body; 9 & 10, the epiphyses of the superior articular processes (mammillary tubercles).

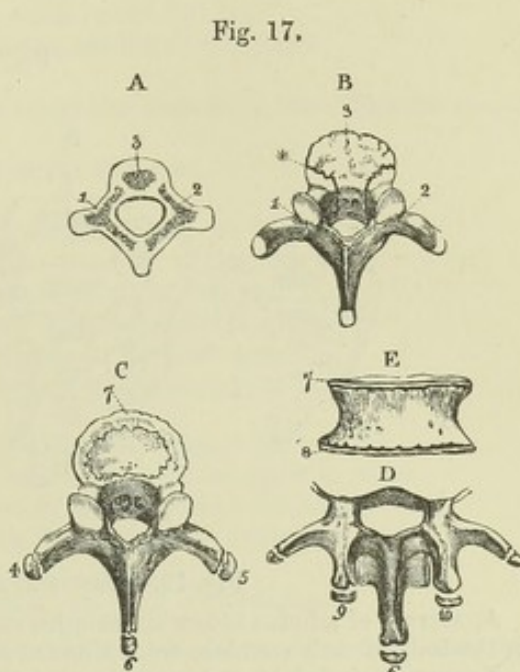


Fig. 17.

In the axis there appear, about the same time as in the other vertebræ, a pair of osseous centres in the arch, one or two in the body (Cruveilhier), and shortly afterwards a pair in the odontoid process which very soon unite together. At birth, the odontoid process is of larger size than the body, from which it is still distinct; and its general appearance confirms the evidence of comparative anatomy, that it is to be regarded as the displaced body of the atlas.

Fig. 18.—OSSIFICATION OF THE ATLAS AS SEEN FROM ABOVE.

A, the atlas before birth; 1 & 2 ossified deposits in the posterior parts of the arch; the anterior part is cartilaginous.

B, the atlas of a child in the first year; 1 & 2, as before; 3, the point of ossification in the anterior arch.

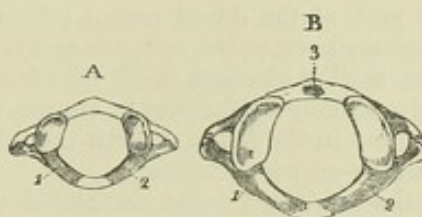


Fig. 18.

Fig. 18.\*—OSSIFICATION OF THE AXIS AS SEEN FROM THE FRONT.

A, the axis of the foetus of seven months, showing at 3 the centre for the body, and at 4 & 5 two centres for the base of the odontoid process.

B, the axis shortly after birth, showing at 1 & 2 the centres for the arch; 3, the centre for the body; 6, the two centres of the odontoid process united into one.

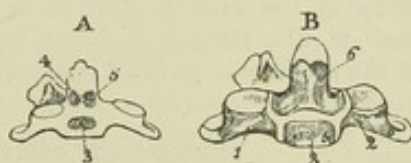


Fig. 18.\*

The sacral vertebræ present the three ordinary great centres of ossification, viz., one in the body, and a pair in the arch; but in each of the first three or sometimes four sacral vertebræ the anterior part of the lateral masses on each side is formed



from an additional centre. On the body of each sacral vertebra, epiphysial plates are formed at a later period, as in other vertebræ. To complete the ossification of the sacrum, there are also formed on each side of it two flat and irregular plates, of which one extends over the first three vertebræ, while the other connects the last two.

Fig. 19.

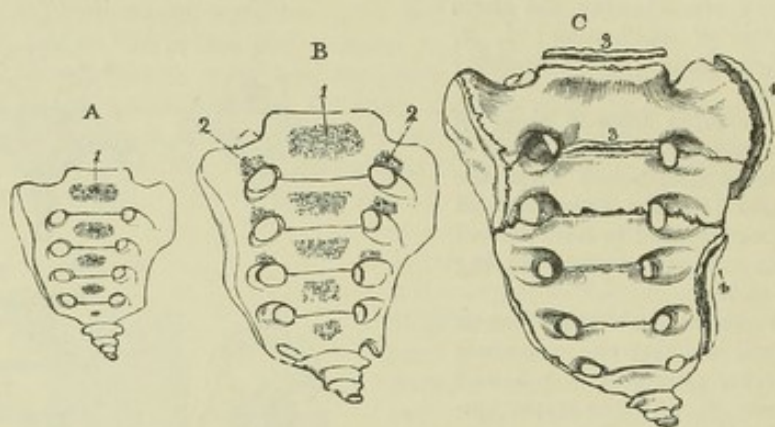


Fig. 19.—OSSIFICATION OF THE SACRUM.

A, sacrum of a fœtus before six months, seen from the front, showing the ossific nucleus in the body of each vertebra, from 1 downwards.

B, sacrum of a child at birth, showing three pairs of additional nuclei for the lateral masses, 2, 2, close above the sacral foramina.

C, sacrum of a person of about twenty-five years of age. At 3 & 3, epiphysial plates are still visible above and below the first vertebral piece, and the fissures still remain between the first and second and the second and third lateral pieces; at 4 & 4' are shown the lateral epiphysial plates.

Each of the coccygeal vertebræ is usually ossified from a single centre; but occasionally one of the first three contains two granules placed side by side.

*Progress of Ossification in the Vertebral Column.*—The deposit of bone in the arches of the vertebræ takes place first in those belonging to the upper end of the column, and gradually proceeds downwards. In the bodies, it first occurs in the lower part of the dorsal region (about the ninth dorsal vertebra); and from that the process is extended upwards and downwards, reaching last of all the atlas and the coccyx, neither of which ossify till after birth. But though the nuclei of the lower dorsal vertebræ are the first to appear, they are soon surpassed in size by those below them; and in the fœtus at birth the relative size of the nuclei corresponds with that of the fully-grown vertebræ.

In the subjoined table are stated the ages at which the osseous centres of the vertebral column appear and the steps of union take place. But it is to be observed that it is only attempted to state these ages approximately, both because of the great difficulty, in most instances, of determining the age of the human fœtus with accuracy, and because of a certain amount of variety which probably exists in the rapidity of the growth of bone in different cases. (See Albinus, "*Icones Ossium fœtus*," p. 68; Meckel, in his "*Archiv*" vol. i. 1815, p. 648, tab. vi.; Humphry, "*On the Skeleton*," p. 132; Aitken, "*Growth of the Recruit*," 1862.)

#### PERIODS OF OSSIFICATION OF THE VERTEBRÆ.

In the vertebræ generally—

The three primary centres appear in the 7th or 8th week (fœtal life).

The epiphyses of the processes appear in the 18th year or later.

The epiphysial plates of the body appear in the 18th or 20th year.

The two centres of the arch unite in the first year.



## In the vertebræ generally—

The arch and the body unite in the 3rd year.

The vertebra and its epiphyses unite in the 25th year or later.

## In the atlas—

Ossification of the anterior arch appears in the 1st year.

The two centres of the posterior arch unite in the 3rd year.

The anterior and posterior arches unite in the 5th or 6th year.

## In the axis—

The centre of the body and (a little later) the centres of the odontoid process appear in the 6th month.

The body and odontoid process unite in the 3rd year.

## In the sacrum—

The additional lateral centres appear from the 6th to the 8th month.

The lateral epiphysal plates appear from the 18th to the 20th year.

The body and arch unite in the 5th vertebra in the 2nd year.

The body and arch unite in the 1st vertebra in the 5th or 6th year.

The lower vertebræ unite with one another in the 18th year.

The upper vertebræ unite with one another in the 25th year or later.

## In the coccyx—

Ossification of the 1st vertebra appears about the time of birth.

Ossification of the 2nd vertebra appears from the 5th to the 10th year.

Ossification of the 3rd vertebra appears from the 10th to the 15th year.

Ossification of the 4th vertebra appears from the 15th to the 20th year.

## THEORETICAL COMPARISON OF THE VERTEBRÆ.

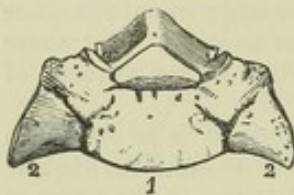
The study of the correspondence of parts in different vertebræ, or of their homology, involves complicated questions, which cannot be competently discussed without reference to the various forms found throughout the vertebrate classes of animals. But there are some points connected with this subject to which the attention of the student of human anatomy may here be briefly directed.

In considering the serial relations of the bodies of the vertebræ, it is necessary to distinguish the masses formed round the chorda dorsalis—the *centra*—from the angular portions derived by ossification from the arch. The only peculiarities in the series of centra are to be found at or near the extremities of the column. One of these, of less note, is presented by the first coccygeal vertebra, the cornua and lateral projections of which, although ranged in series with parts which in the preceding vertebræ are derived from the osseous nuclei of the arch, are, nevertheless, ossified from the centrum. The other peculiarity presented by the atlas and axis is of a more remarkable kind. The odontoid process of the axis is the true centrum of the atlas, disguised by remaining distinct from the rest of the vertebra to which it belongs, and becoming adherent to the centrum of the succeeding vertebra. The main proofs that this view is correct are, 1st, that the odontoid process originates in cartilage distinct from the proper centrum of the axis; 2nd, that the remains of the chorda dorsalis have been traced through the odontoid process to the occipital bone; and 3rd, that in early life, and in certain animals (especially turtles), the odontoid process is similar in appearance to the succeeding centra. The anterior nucleus of the atlas must, therefore, be regarded as a pre-central or sub-central structure. (Rathke, "Entwicklungsgeschichte der Natter," p. 120; and "Entwickl. der Schildkröten," p. 77.) It is proper to observe that both sets of the articular surfaces of the atlas and the superior pair belonging to the axis are placed upon those parts which in succeeding vertebræ form the angles of the bodies; these articular surfaces, therefore, correspond in position, not with the smooth facets of the articulating processes, but rather with those for the heads of the ribs in the dorsal vertebræ. This is seen not only from their position in front of the trunks of the spinal nerves, and from the superior articular surfaces of the axis actually abutting on the centrum, but also from the condition of parts in many animals. Thus, in birds and reptiles the lateral masses and anterior nucleus of the atlas unite to form a mesial disc, which articulates with the body of the axis in front of the odontoid process and with a single condyle on the occipital bone, while at the same time the axis and atlas are likewise connected by articulating processes placed behind the nerves and in series with those which follow.



On examination of the series of transverse processes, a certain amount of correspondence cannot fail to be noticed between the anterior divisions of those of the cervical vertebræ and ribs; especially when it is considered that in certain instances those of the seventh cervical vertebra are replaced by ribs which are articulated in two places with the vertebra; and that in the neck of saurian reptiles short ribs are found very similar in appearance to the anterior divisions of the transverse processes in the human subject. On the other hand, these processes differ from ribs in being for the most part ossified in continuity with the arch; and on that account some anatomists prefer to compare them with the costal facets on the dorsal vertebræ, and with processes on which in birds and reptiles those facets are elevated. The transverse, mammillary, and accessory processes of the lumbar vertebræ lie in series, as has been seen, with the three sets of tubercles on the transverse processes of the twelfth and other dorsal vertebræ, whence it may be argued, as has been done by Retzius, that the whole transverse process of a dorsal vertebra corresponds to three processes of a lumbar vertebra. At the same time, the mammillary processes are not mere subsidiary parts developed on the transverse processes, for in some animals, as the hedgehog and the armadillo, they are of much greater size than the transverse processes themselves, continue distinct from them in nearly the whole length of the thoracic region, and may be seen to lie in series with prominences on the articulating processes of the cervical vertebræ. The lumbar transverse processes are not without a certain degree of correspondence with ribs, which is illustrated by the first of the series being sometimes replaced by a short thirteenth rib on one or both sides, and is also indicated by the existence on the upper borders of the lumbar transverse processes of grooves, sometimes pretty distinct, which lie in series with the intervals between

Fig. 20.

Fig. 20.—OSSEOUS PART OF THE FIRST VERTEBRA OF THE SACRUM OF A PERSON OF FOUR OR FIVE YEARS OLD.  $\frac{1}{3}$ 

1, the body; 2, 2, the large lateral masses between which and the body and the transverse processes deep fissures are seen running backwards.

the necks of the ribs and the dorsal transverse processes. In the sacrum, the special lateral centres of ossification in the three upper vertebræ may, very probably, be regarded as costal elements. (Retzius, "Müller's Archiv," 1849; J. Müller, "Vergl. Anat. der Myxinoiden;" August Müller, "Müller's Archiv," 1853; Humphry, "Treatise on the Human Skeleton;" Cleland, in "Nat. Hist. Review," 1861 and 1863.)

It is not to be wondered at that the vertebral column, from its being the most regularly segmented structure in the body, as well as from its forming the basis of the osseous system, should have held a prominent place in the various schemes, according to which it has been attempted to resolve the skeleton into a certain number of elements, repeated in modified forms in the different segments. Among the various schemes of this description may be mentioned those of Oken, Carus, Geoffroy St. Hilaire, Owen, MacIise, and Goodsir. (Oken, "Physiophilosophie," and in "Isis," 1817, 1819, 1820; C. G. Carus, "Lehrbuch der Zootomie," 2nd edit.; Geoffroy St. Hilaire, "Philosophie Anatomique;" Owen, "On the Archetype and Homologies of the Vertebrate Skeleton;" MacIise, "Comparative Osteology," and the Article "Skeleton" in "Todd's Cyclopæd. of Anat. and Physiol.;" Goodsir, "Edinburgh New Philosophical Journal," 1857, p. 118.)

Based upon morphological views, there has likewise been introduced by Owen a system of nomenclature, which being adhered to in his descriptive writings, and adopted more or less by various English writers, demands attention. In that system the word *vertebra* is employed to signify a segment of the skeleton, the term *centrum* is preserved in its usual signification, the laminæ are called *neurapophyses*, the spine the *neural spine*, the articulating processes *zygapophyses*, the ribs *pleurapophyses*, the mammillary processes *metapophyses*, and the accessory processes *anapophyses*. Two descriptions of transverse processes are distinguished, viz., the *diapophyses* and the *parapophyses*; the dorsal transverse processes and the posterior parts of the cervical transverse processes being examples of the first, while the anterior parts of the cervical transverse processes are referred to the second. The ideal



arrangement named by Owen the "typical vertebra" is completed by the addition to the parts now mentioned of a pair of *hæmapophyses* and a *hæmal spine*, situated in front of the centrum, as the neurapophyses and neural spine are placed behind; but in the thorax, according to his views, the hæmapophyses are supposed to be transplanted to the extremities of the pleurapophyses, and form the costal cartilages, carrying with them the sternum or series of hæmal spines.

However interesting these views may be, and however expedient the adoption in Comparative Anatomy of some such words, expressive of anatomical relations, more especially when it shall appear that the doctrines suggesting the terminology are sufficiently established; yet, as these are still imperfect, and as the names by which most parts of the human body are commonly designated have been long in use, and are very generally understood, it seems premature for the present to attempt a theoretical reformation of the nomenclature of human descriptive anatomy.

## THE THORAX.

The parts which enter into the construction of the thoracic part of the skeleton are the dorsal vertebræ already described, the sternum, the ribs, and the costal cartilages.

### THE STERNUM OR BREAST-BONE.

The sternum (*os pectoris*, *os xiphoides*) is situated in the median line at the fore part of the thorax, in a sloping position, inclined downwards and forwards. It is connected with the rest of the trunk by the costal cartilages

Fig. 21.—THE STERNUM OF A MIDDLE-AGED MAN.  $\frac{1}{2}$

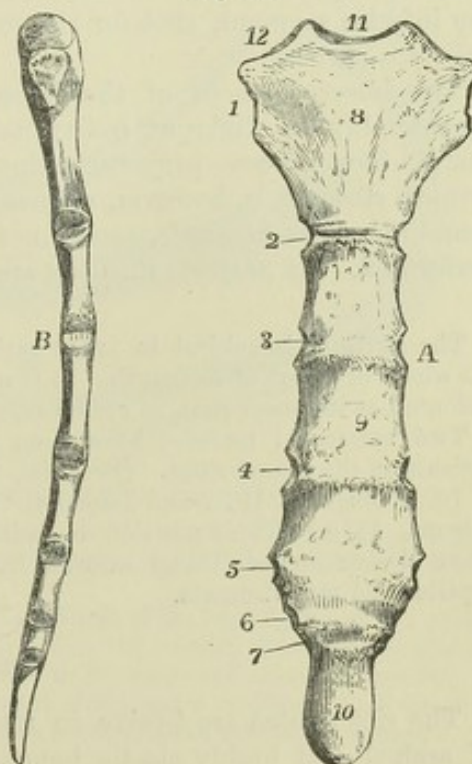
A, from before, 1, 2, 3, 4, 5, 6, & 7, the articular surfaces for the corresponding costal cartilages; 8, manubrium or upper piece, still slightly separate from the body; 9, middle of the body; 10, ensiform portion, osseous, and united to the body; 11, inter-clavicular notch; articular notch for the clavicle.

B, the same sternum viewed from the right side, showing the general convexity of the bone forwards. The different facets of articulation of the clavicle and costal cartilages will be distinguished by their position in comparing the figure B with A.

of the seven highest pairs of ribs, and gives attachment to the clavicles. It consists originally of six segments. The first of these usually remains distinct up to middle life, and is called the *manubrium*; the succeeding four are united into one in the adult, and form the *body*; the sixth generally remains cartilaginous up to the period of puberty, and sometimes partially so even to advanced age, and is called the *xiphoid*, or *ensiform process*, or *cartilage*.

The sternum is flattened from before backwards, and presents a slight vertical curve with the convexity in front. It is of unequal width, being

Fig. 21.





broad at the upper part of the manubrium, considerably narrower at the lower end of that portion and in the following segment, somewhat wider near the lower than at the upper end of the body, and finally compressed and narrowed where the body joins the ensiform cartilage. It consists of light cancellated texture, with a thin covering of compact bone, so as to be liable to crushing from violence.

The *manubrium* is the thickest part of the sternum. Its superior border is divided into three deep notches; the middle one is named the *incisura*, *furcula*, or *interclavicular notch*; the lateral ones form two depressed articular surfaces directed upwards and outwards, for articulation with the clavicles. Each lateral border presents superiorly a rough depression close to the clavicular surface, but looking directly outwards, which receives the cartilage of the first rib; and, at its inferior angle, a small surface which, with a similar one on the second segment, forms a notch for the cartilage of the second rib. The inferior margin is straight, and united by intervening cartilage to the upper margin of the second segment.

The *body* is marked on its anterior surface by three slight transverse elevations, which mark the lines of junction of its four component parts. Its posterior or thoracic surface, together with that of the manubrium, is of more uniform smoothness. The lateral margins present each five notches for the reception of costal cartilages, and a small surface superiorly, which, with the similar depression on the manubrium, forms the notch for the second costal cartilage.

The notches for the third, fourth, and fifth costal cartilages are opposite the lines of junction of the four segments of the body of the sternum; those of the sixth and seventh are placed close together on the sides of the inferior segment, that for the seventh being frequently completed by the ensiform cartilage.

The lower segment of the bone, often called ensiform cartilage, varies considerably in different individuals. In its simplest form it is a thin spatula-like process projecting downwards between the cartilages of the seventh ribs. It is, however, subject to very frequent varieties of form; being sometimes bent forwards, sometimes backwards, often forked, and sometimes perforated. It projects into the aponeurosis of the abdominal muscles.

The sternum is subject to many varieties. It is sometimes divided vertically in the whole or a part of its length. It is not unfrequently much shorter than usual, and indented at its lower part, as occurs especially from the pressure of the cobbler's last.

Two episternal nodules have been found in some rare cases surmounting the incisura of the manubrium. (Breschet, "Annales des Sciences Naturelles," 2d series, v. 10, Zoologie, p. 191; and Luschka, "Die Halsrippen und die Ossa supra-sternalia," Vienna, 1859.) Their position is indicated by the asterisks (\*\*) in figure 24, E. They derive an additional interest from the occurrence of suprasternal bones in reptiles and monotremata.

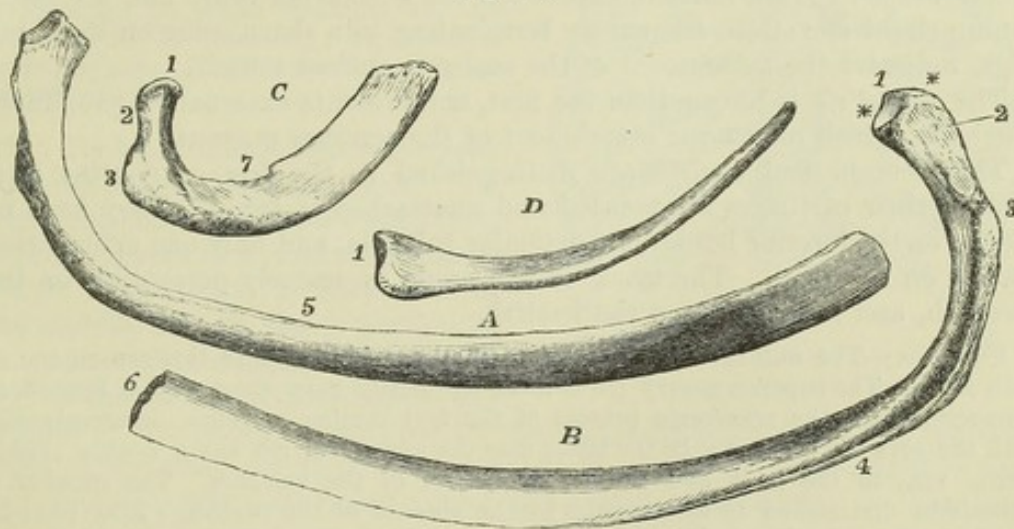
#### THE RIBS.

The ribs (*costæ*) are twelve in number on each side. They form a series of arched and highly elastic bones, which extend outwards and forwards from the vertebral column, and form the lateral walls of the thorax. Their anterior extremities give attachment to cartilaginous prolongations—the costal cartilages, the first seven pairs of which pass forward to the sternum. On this account the first seven pairs of ribs are called *sternal*, or *true ribs*, while the remaining five pairs are called *asternal*, or *false ribs*.



**CHARACTERS COMMON TO MOST OF THE RIBS.**—These are best marked in the ribs near the middle of the series. The posterior extremity is thickened, and is termed the *head* or *capitulum*; it presents a superior and an inferior oblique articular surface for articulation with the bodies of two vertebræ, and, between them, a slight ridge, to which the interarticular ligament is attached. At a little distance from the head, and separated from it by the neck, is the *tubercle*, which is directed backwards, and presents a smooth surface for articulation with the transverse process of the inferior of the two vertebræ with which the head is connected, and, outside that, a roughness marking the insertion of the posterior costo-transverse ligament. The part termed the *neck*, between the head and the tubercle, is slenderer than the rest of the rib. The whole extent beyond the tubercle constitutes the *body*. It becomes laterally compressed, and wider from above downwards, towards the anterior extremity. Outside the tubercle, between it and the most convex part of the body, is a rough line, which corresponds to the outer border of the erector spinæ muscle, and which is termed the *angle*, because at this point the curve of the rib is more sudden, and changes from an outward and backward to a forward direction. The inferior border presents on its inner aspect a *groove*, in which lie the intercostal vessels and nerve, and which is best marked opposite the angle, and disappears in front. The anterior extremity is hollowed at its tip into an oval pit, into which the costal cartilage is implanted.

Fig. 22.

Fig. 22.—THE FIRST, SIXTH, AND TWELFTH RIBS OF THE RIGHT SIDE.  $\frac{1}{3}$ 

A, the sixth seen from above and the outer side; B, the same rib viewed from below and within; C, the first rib viewed from above and without; D, the twelfth rib viewed from above and within.

1, the head in C & D, the ridge between the two facets of the head in B; 2, the neck; 3, the tubercle, in B presenting the rough tubercle and the smooth facet for articulation with the transverse process; 4, the lower border with the ridge and subcostal groove; 5, the upper border; 6, the oval pit for the attachment of the costal cartilage; 7, in the first rib, C, the scalene tubercle, and near it the smooth groove for the subclavian artery.

**Inclination and Curves.**—There is a general inclination of the ribs downwards from the head to the anterior extremity. This slope is greatest between the head and angle; beyond that point it is diminished, and it is again increased further forwards, and diminished at the anterior extremity. The curve of the ribs is much more marked towards the back part than in



front, and is most so in the neighbourhood of the angle. At first the rib is directed backwards as well as outwards. Besides the main curves now mentioned the rib is somewhat twisted on itself, so that the two extreme portions cannot be made to rest at the same time on a flat surface. It follows, from the same twisting in the majority of the ribs, that while their surfaces are vertical posteriorly, they are sloped upwards and inwards at the anterior part.

**CHARACTERS PECULIAR TO CERTAIN RIBS.**—The ribs increase in length from the first to the eighth, and decrease from the ninth to the twelfth, so that the last is little longer, often even shorter, than the first. The first rib is the broadest, and after it the middle ones; the twelfth is the narrowest. The distance of the angle from the tubercle increases gradually from the second to the eleventh; in the first the angle coincides with the tubercle, in the last it is not perceptible.

The *first* rib is shorter and broader than any of the others. Its direction is slightly inclined, and its surfaces lie nearly in the same flat plane. Its superficial and thoracic surfaces look respectively upwards and downwards. The head is small, and presents a single articular surface. The neck is round and slender. It articulates with the body and transverse process of the first dorsal vertebra alone. On the superior or superficial surface are two very slight smooth depressions with an intervening rough mark, and a considerable rough surface behind. The rough surface marks the attachment of the scalenus medius muscle, the posterior depression the position of the subclavian artery, the anterior depression the subclavian vein; and the intervening slight elevation, frequently terminating in a sharp spine on the inner edge, indicates the attachment of the scalenus anticus muscle.

The *second* rib is longer than the first, and presents externally a prominent roughness which marks the attachment of the serratus magnus.

The *eleventh* and *twelfth* are distinguished as the *free* or *floating* ribs, because their cartilages are pointed and unattached in front. They have no groove on the inferior border, no articular tubercle, and only one articulating surface on the head. The mark of the angle is scarcely perceptible on the eleventh, and is absent from the twelfth.

**Varieties.**—The number of the ribs is sometimes increased to thirteen on one or both sides. The supernumerary rib is most frequently very short, and is formed in connection with the transverse process of the first lumbar vertebra, or occasionally with the seventh cervical: in the latter case the additional rib has a double attachment, viz., to the body and transverse process of the vertebra. The number is sometimes diminished to eleven pairs by the absence of the twelfth. Ribs likewise occur greatly expanded or forked at their anterior extremities; and occasionally two or more ribs are united together in a part of their extent by their margins.

The **COSTAL CARTILAGES** are continuations of the ribs. Their breadth diminishes gradually from the first to the last, whilst the length increases as far as the seventh, after which it becomes gradually less. Their line of direction varies considerably. The first descends a little, the second is horizontal, and all the rest, except the last two, ascend more and more from the rib towards the sternum as they are situated lower down. The external or costal extremity, convex and uneven, is implanted into and united with the end of the corresponding rib. The internal extremities of the upper seven (except the first), are smaller than the external and somewhat pointed, and fit into the corresponding angular surfaces on the side of the sternum, with which they are articulated in synovial cavities. Each of the cartilages of the first three asternal ribs becomes slender towards its ex-



tremity, and is attached to the lower border of that which is next above it. The last two are pointed and unattached.

The first cartilage, which is directly united to the sternum without articular cavity, usually becomes more or less ossified in the adult male; and the others likewise exhibit a considerable tendency to ossify in advanced life. This tendency is not so great in the female, in whom costal respiration is generally more extended than in the male.

#### THE THORAX AS A WHOLE.

The thorax is of a somewhat conical shape, with convex walls. Its upper inlet is contracted, and bounded by the first dorsal vertebra, the first pair of ribs, and the manubrium of the sternum. Its inferior margin curves downwards and backwards on each side from the ensiform process to the twelfth

Fig. 23.—FRONT VIEW OF THE THORAX, SHOWING THE STERNUM COSTAL CARTILAGES, RIBS, AND DORSAL VERTEBRÆ.  $\frac{1}{2}$

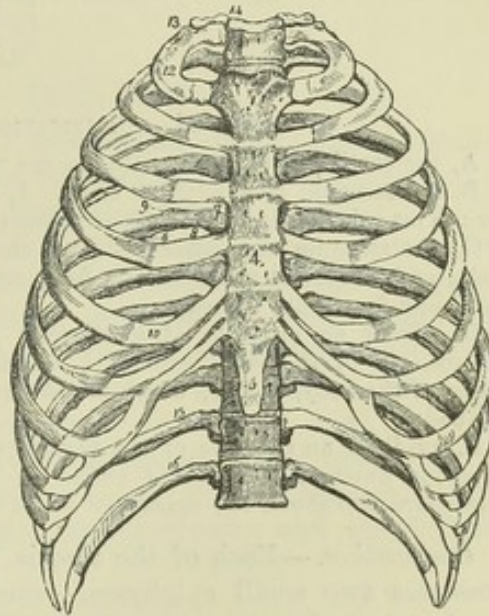
1, the manubrium, or first piece of the sternum; 2, is close to the place of union of the first costal cartilage; 3, the clavicular notch; 4, the middle of the body of the sternum; 5, the ensiform piece; 6, the groove on the lower border of the ribs; 7, the vertebral end of the ribs; 8, the neck; 9, tubercle; 10, costal cartilage; 12, the first rib; 13, its tuberosity; 14, the first dorsal vertebra; 15, the eleventh; 16, the twelfth rib.

rib. Its longitudinal axis is directed upwards and slightly backwards. Its transverse diameter, at its widest part, greatly exceeds that from before backwards. The latter is shortened in the middle line by the projection of the vertebral column, but on each side of the column a considerable extension of the cavity is produced by the backward direction of the posterior parts of the ribs, and thus the weight of the body is thrown further back and more equally distributed round the vertebral column. At the same time a broad furrow is produced between the spines of the vertebræ and the angles of the ribs, in which are placed the *erectores spinæ* muscles.

#### DEVELOPMENT OF THE RIBS AND STERNUM.

The first origin of the posterior parts of the ribs in connection with the primordial vertebræ has been already mentioned. In the second month cartilage appears in them, deposited independently of the vertebræ. Different opinions have been held as to whether the tubercle or the head of the rib is the primary point of its connection with the vertebra: it appears probable that the whole extent from head to tubercle is an expansion of the original connection. (Kölliker, "*Entwicklungsgeschichte*," fig. 81; Rathke, "*Entwick. der Natter*;" Huxley, "*On the Theory of the Vertebrate Skull*," p. 74.) After becoming cartilaginous, the ribs pass round in the visceral wall, and, according to Rathke, before reaching the front, the first seven on

Fig. 23.





each side are united together at their anterior extremities in two longitudinal strips of cartilage, which afterwards join together in the middle line to form the sternum.

Fig. 24.

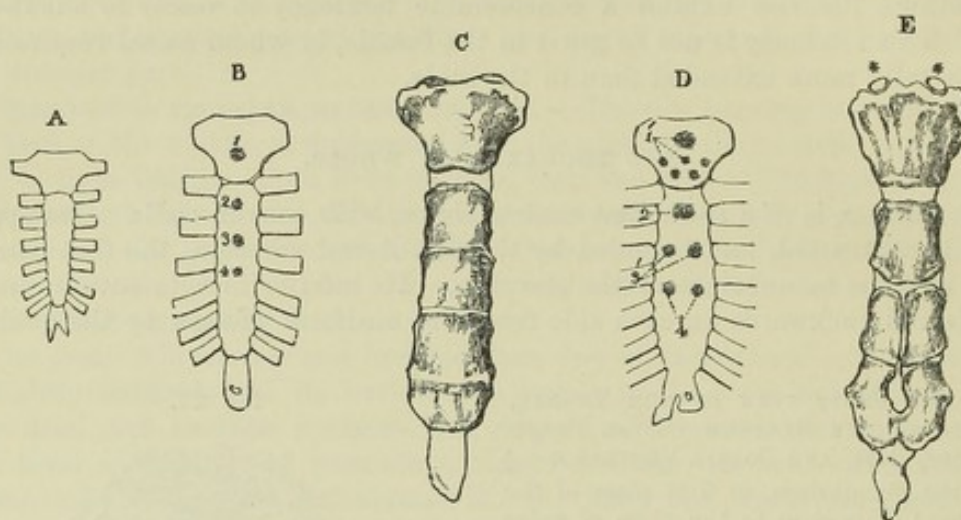


Fig. 24.—OSSIFICATION OF THE STERNUM.

A, the cartilaginous sternum before the middle of foetal life.

B, the sternum of a child at birth. 1, 2, 3, & 4, mark the commencing ossific nuclei for the manubrium and three upper pieces of the body.

C, the sternum soon after puberty, showing cartilage between the manubrium and body, and imperfect union of the first, second, and third pieces of the body, while the third and fourth are united.

D, shows an example of a sternum at birth with an unusual number of ossific centres, six in the manubrium, 1', which is very uncommon; two pairs in the lower pieces of the body, 3' & 4', which is not unusual; 2, the single centre of the first piece of the body.

E, exhibits an example of the perforated sternum which probably depends upon the imperfect union of the pairs of ossific nuclei shown in D in the lower part of the body; this figure also shows two episternal bones or granules, \* \*.

*Ossification.*—Each of the ribs is ossified from one principal centre, and possesses two small epiphyses,—one belonging to the head, and, except in the last two ribs, another belonging to the tubercle.

The sternum is ossified in a number of separate pieces, one, at least, for each segment; the manubrium sometimes possesses two, placed one above

Fig. 25.

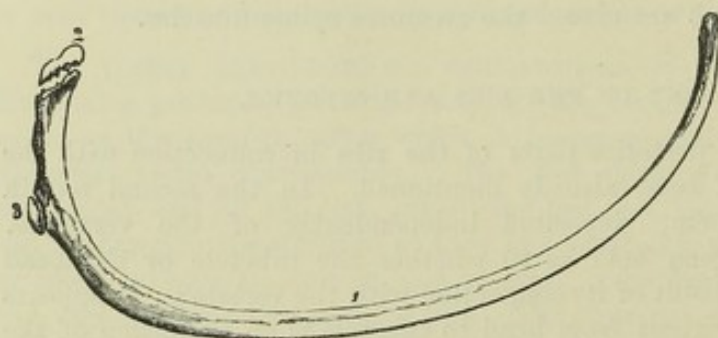


Fig. 25.—ONE OF THE MIDDLE RIBS OF A PERSON ABOUT EIGHTEEN OR TWENTY YEARS OF AGE.

Showing, at 1, the principal piece or body; 2, the epiphysis of the head; 3, that of the tubercle.

the other, and has been found with a greater number. The third, fourth, and

fifth segments, as well as the ensiform portion, are frequently formed each from two nuclei placed side by side, which may remain distinct for



a considerable time ; the second segment has rarely more than one nucleus. Additional nuclei occasionally appear between some of the segments.

#### PERIODS OF OSSIFICATION OF THE RIBS AND STERNUM.

In the ribs—

The principal centres appear in the 7th or 8th week (foetal life).

The epiphyses appear from the 16th to the 20th year.

The shaft and epiphyses unite about the 25th year.

In the sternum—

Ossification in the first segment appears in the 6th or 7th month (foetal life).

Ossification in the second segment appears in the 7th or 8th month (foetal life).

Ossification in the third and fourth segments appears shortly before birth.

Ossification in the fifth segments appears in the 1st year or later.

Ossification in the sixth or ensiform segment appears very variously from the 6th to the 15th year, or later.

The lower segments of the body unite after puberty.

The upper segments of the body unite from the 25th to the 30th year.

The body and ensiform segment generally unite in middle age.

The manubrium and body unite in old age.

#### THE BONES OF THE SKULL.

The skull is of a spheroidal figure, compressed on the sides, broader behind than before, and supported on the vertebral column. It is formed of a number of bones, all of which, with the exception of the lower jaw, are almost immovably united together by lines and narrow surfaces, more or less uneven, termed *sutures*. The skull is divided by anatomists into two parts, the cranium and the face. The cranium protects the brain ; the face surrounds the mouth and nasal passages, and completes with the cranium the cavities for the eyes. The cranium is composed of eight bones, viz. : the *occipital*, two *parietal*, the *frontal*, two *temporal*, the *sphenoid*, and the *ethmoid*. The face is composed of fourteen bones, of which twelve are in pairs, viz. : the *superior maxillary*, *malar*, *nasal*, *palate*, *lachrymal*, and *inferior turbinated bones* ; and two single, viz., the *vomer*, and the *inferior maxilla*.

#### THE OCCIPITAL BONE.

The occipital bone is situated at the lower and back part of the cranium. Its general form is that of a curved lozenge concave superiorly, through which, in its lower and anterior part, passes a large oval foramen, forming the communication between the cranium and spinal canal. The bone thus presents four borders and four angles, which receive names according to their position. The portion of the bone behind the foramen is *tabular*, that in front of the foramen forms a thick mass named *basilar process*, and the parts on the sides of the foramen, bearing the condyles or articulating processes by which the head is supported on the first vertebra, are distinguished as the *condyloid portions*.

The occipital bone articulates by its two superior borders with the parietal bones, and by its two inferior borders with the temporal bones, while the extremity of its basilar process is united to the body of the sphenoid, in the young condition by cartilage, but after the age of twenty years by continuous osseous\* substance.

\* Hence Sæmmerring described the occipital and sphenoid as a single bone under the name *spheno-occipital*, or *basilar*.



The TABULAR PORTION on its *posterior surface* presents a rough prominence, the *external occipital protuberance*, arching outwards from which, on each

Fig. 26.

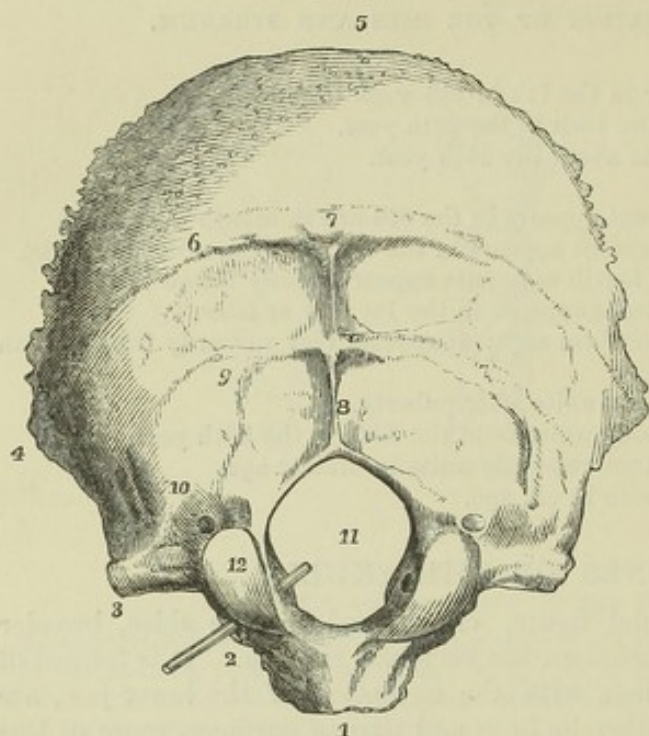


Fig. 26. — OCCIPITAL BONE FROM BELOW AND BEHIND, SHOWING THE EXTERNAL SURFACE.  $\frac{1}{2}$

1, basilar process; 2, condyloid portion, the probe marks the anterior condyloid foramen; 3, jugular or transverse process; 4, external or lateral angle; 5, superior angle; 6, superior curved line; 7, external or posterior occipital protuberance; 8, external occipital crest; 9, inferior curved line; 10, groove and ridge connected with the attachment of the superior oblique muscle; 11, foramen magnum; 12, articular condyle; immediately above it the posterior condyloid foramen.

covered by the hairy scalp, convex and uniform; the lower, uneven and marked by the impressions of the muscles of the neck which are attached

side, is the *superior occipital ridge or curved line*, which divides the surface into two parts, the upper,

Fig. 27.

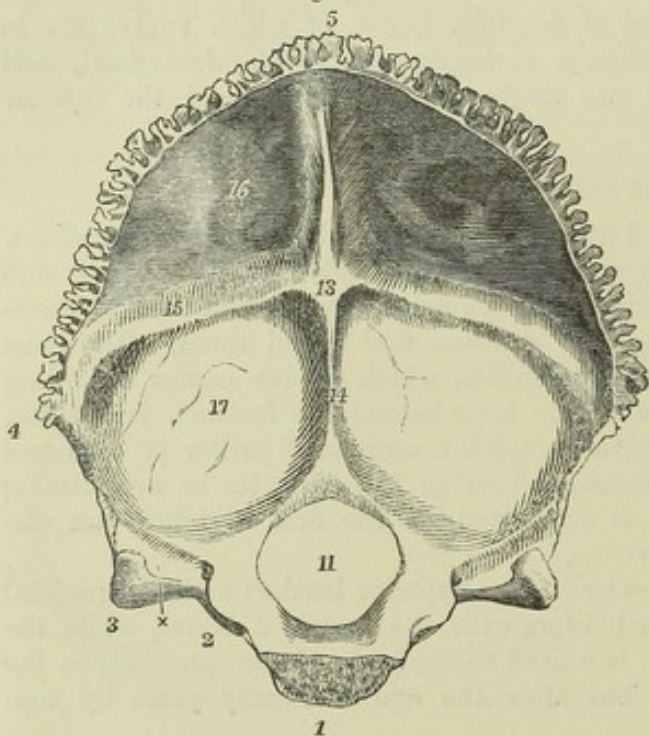


Fig. 27. — OCCIPITAL BONE FROM BEFORE, SHOWING THE INTERNAL SURFACE.  $\frac{1}{2}$

1, basilar process sawn through at the place of union with the sphenoid bone; 2, condyloid portion; 3, jugular or transverse process; x, between 2 & 3, the sigmoid groove of the lateral sinus and jugular notch; 4, external or lateral angle; 5, superior angle; 1 to 3, the edge of articulation with the petrous bone; 3 to 4, with the mastoid bone; 4 to 5, with the parietal bone; 11, foramen magnum; 13, internal occipital protuberance and groove of the torcular Herophili; 14, inferior spine; 15, groove of the lateral sinus; from 5 to 13, groove of the superior longitudinal sinus; 16, cerebral fossa; 17, cerebellar fossa.

to it. This lower surface is divided into two lateral portions by a median ridge called the *external occipital crest or spine*, and each of these portions is again divided into



an upper and a lower surface by the *inferior curved line* or *ridge*, which, after extending some distance outwards, is met by a ridge and groove passing from before backwards. These surfaces mark the attachments of the rectus capitis major and minor, and of the obliquus capitis superior muscles.

The *deep surface* of the bone is marked by two crucial smooth ridges, one extending from the upper angle to the great foramen, and the other transversely from one lateral angle to the other, and at the point of intersection of these ridges is the *internal occipital protuberance*. Separated by these ridges are four hollows, the *superior* and *inferior occipital fossæ*, which lodge respectively the posterior cerebral and the cerebellar lobes. The superior and transverse ridges are grooved in the course of the longitudinal and lateral venous sinuses respectively. The space where those grooves meet at the internal occipital protuberance receives the torcular Herophili. The inferior ridge is single, and is named the internal occipital crest or spine. The margins of the tabular portion are deeply serrated above the lateral angles for articulation with the parietal bones, and, below that level, with the mastoid portions of the temporal bones.

The CONDYLOID PORTIONS bear the articulating condyles on their inferior surface, close to the margin of the foramen magnum. The condyles are so placed, that a line touching their posterior extremities would cross the middle of the foramen magnum. They are elliptical and placed obliquely so as to converge in front; their surfaces are convex from behind forwards and from side to side, and slightly everted. Their inner borders are rough, and receive the insertion of the odontoid ligaments of the axis. In front and to the inside of the condyles are the anterior condyloid foramina, which pass forwards and outwards from the interior of the cranium, and transmit the hypoglossal nerves. Behind the condyles are two pits, containing usually the posterior condyloid foramina; each of these gives passage to a vein; but they are often absent on one or both sides. Externally to the condyle, on each side, is a portion of bone, which is placed over the transverse process of the atlas, continuous posteriorly with the tabular part, and anteriorly having a free excavated margin, the *jugular notch*, which contributes with a fossa in the temporal bone to form the *foramen lacerum jugulare*; its external extremity projects into the angle between the mastoid and petrous portions of the temporal bone, and is called the *jugular eminence*. This process presents inferiorly a rough elevation, which gives attachment to the rectus capitis lateralis muscle; and superiorly a deep groove for the lateral sinus before it terminates in the jugular notch.

The BASILAR PROCESS projects forwards and upwards into the middle of the base of the skull. It increases in thickness and diminishes in breadth towards its extremity. Inferiorly it gives attachment to the rectus capitis anticus major and minor muscles and the fibrous band of the pharynx. Its superior surface presents a smooth depression, the basilar groove, which supports the medulla oblongata, and close to each lateral margin a slight grooved mark, which indicates the place of the inferior petrosal sinus.

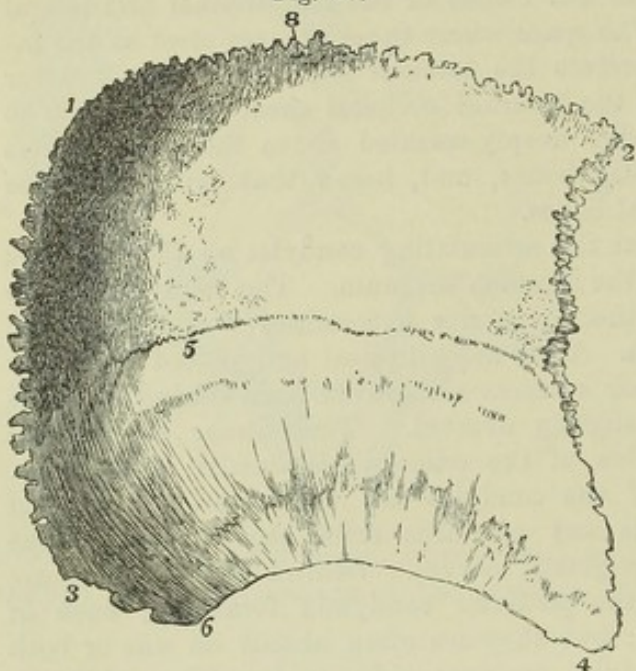
*Varieties.*—The upper and lateral angles vary greatly in the degree of their acuteness. The upper borders are subject to considerable variation, from the presence of ossa triquetra. The condyles vary greatly in size, prominence, and convexity, and are often somewhat unsymmetrical. In some old subjects there is a mark at the back of the foramen magnum, where the occiput rests on the posterior arch of the atlas. Occasionally there is a projection downwards from the jugular process, resembling the descending lateral process found in most mammals.



## THE PARIETAL BONE.

The parietal bones form a principal part of the roof of the skull. They have the shape of quadrilateral plates, convex externally, concave internally. They are a little broader above than below, and the anterior inferior angle is the most acute. They articulate with one another in the middle line, with the frontal bone anteriorly, the occipital posteriorly, and the temporal and sphenoid below.

Fig. 28.

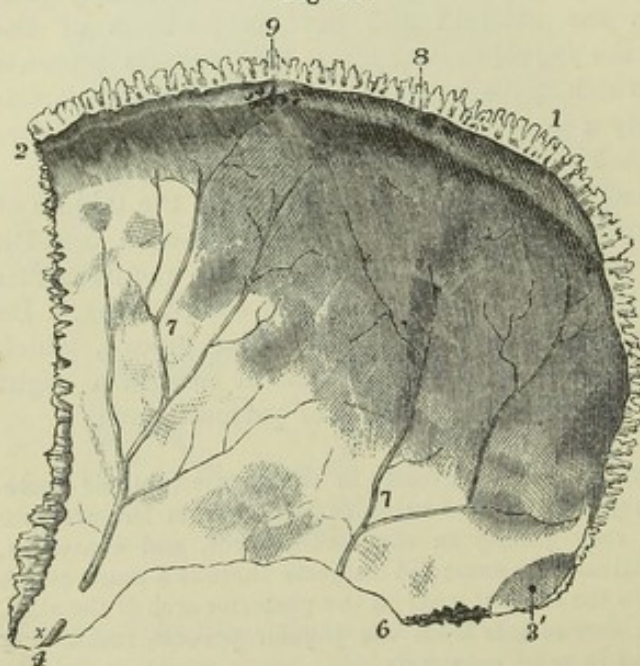
Fig. 28.—EXTERNAL SURFACE OF THE RIGHT PARIETAL BONE.  $\frac{1}{2}$ 

1. Posterior superior angle; 2, anterior superior angle; 3, posterior inferior angle; 4, anterior inferior angle; from 1 to 2, superior border in the sagittal suture; from 2 to 4, anterior border in the coronal suture; from 1 to 3, posterior border in the lambdoidal suture; from 4 to 6, the part of the inferior border in the squamous suture; from 3 to 6, the part in the additamentum suturae squamosae; 5, the temporal or semicircular line above which is the parietal eminence.

anterior to the lower part of the posterior margin; it is the parietal part of the temporal ridge, and bounds a surface somewhat flatter than the rest,

On the *outer surface*, the point of greatest convexity is called the *parietal eminence*. Below this a curved line is directed from the anterior to the lower part of the posterior margin; it is the parietal part of the temporal ridge, and bounds a surface somewhat flatter than the rest, *planum temporale*, which forms part of the temporal fossa. Near the posterior and upper angle, close to the middle line, there is often a small perforation of variable dimensions, the *parietal foramen*, which transmits a communicating vein.

Fig. 29.

Fig. 29.—THE PARIETAL BONE FROM THE INSIDE.  $\frac{1}{2}$ 

1, 2, 3, 4, & 6 indicate the same parts as in the last figure: between 1 & 2 the half-groove of the superior longitudinal sinus; 7, the ramified grooves of the meningeal vessels; at x this groove is converted into a



canal, and throughout the inner surface the dimpling of the convolutions of the cerebrum ; 8, the parietal foramen ; 9, the irregular pits for the glandulæ Pacchionii.

On the *inner surface*, the hollow corresponding to the eminence is called the parietal fossa. This surface is marked by grooves branching upwards and backwards, corresponding with the course of the middle meningeal vessels, and by depressions corresponding with the convolutions of the brain. A slight depression along the superior border completes with the one of the opposite side a groove marking the course of the longitudinal sinus ; and a depression at the posterior inferior angle forms a small part of the groove of the lateral sinus. Near the upper border there are in most skulls, but particularly in those of old persons, small irregular pits, *foveæ glandulares*, the result of absorption produced by the so-named glandulæ Pacchionii.

*Borders.*—The anterior, superior, and posterior borders are serrated. The inferior border presents in the greater part of its extent a sharp or squamous edge, with a slightly fluted surface directed outwards and overlapped at its anterior extremity by the great wing of the sphenoid, and behind that by the squamous part of the temporal bone ; but at its posterior part it is serrated, and articulates with the mastoid portion of the temporal. The posterior border is the most deeply serrated. The anterior border is slightly overlapped by the frontal bone above, but overlaps the edge of that bone inferiorly.

## THE FRONTAL BONE.

The frontal bone, arching upwards and backwards from above the orbits, forms the fore part of the vault of the skull. It likewise presents inferiorly two thin horizontal laminae, the *orbital plates*, which form the roofs of the orbits and are separated by a mesial excavation, the *incisura ethmoidalis*.

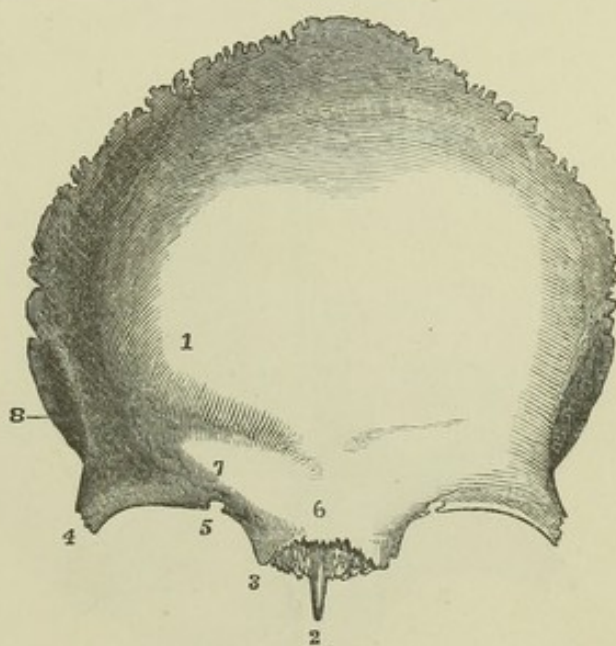
Fig. 30.—FRONTAL BONE FROM BEFORE, SHOWING ITS EXTERNAL SURFACE.  $\frac{1}{2}$

1, frontal protuberance ; 2, nasal spine, and above this the serrated surface for articulation of the nasal and superior maxillary bones ; 3 to 4, supra-orbital edge—3, internal, and 4, external angular process ; 5, supra-orbital notch or foramen ; 6, glabella ; 7, superciliary eminence and ridge ; 8, temporal ridge, and behind this a part of the temporal fossa.

The frontal is articulated with twelve bones, viz., posteriorly with the parietals and sphenoid ; outside the orbits with the malars ; and between the orbits, from before backwards, with the nasal, superior maxillary, lachrymal and ethmoid bones.

*Anterior Surface.*—The part forming the greatest convexity of the forehead on each side is called the *frontal eminence*. It is separated by a slight depression below from the *superciliary ridge*, a curved elevation of

Fig. 30.





varying prominence immediately above the margin of the orbit. Between the superciliary ridges is the *nasal eminence* or *glabella*. The margin of the orbit, the *orbital arch*, is most defined towards its outer part; it presents towards its inner third the *supra-orbital notch*, sometimes converted into a foramen, which transmits the supra-orbital nerve and artery. The extremities of the orbital arch point downwards, and form the *internal* and *external angular processes*. The internal angular process is slender; the external is thick and strong, and articulates with the malar bone. The temporal ridge springs from the external aspect of this process, and arches upwards and backwards to be continued on the parietal bone: it separates the temporal from the frontal part of the outer surface of the bone.

*Inferior Surface.*—The orbital surfaces are somewhat triangular, their internal margins being parallel, while the external are directed backwards and inwards. Close to the external angular process is the *fossa lachrymalis*, which lodges the lachrymal gland; and close to the internal angular process is the *fovea trochlearis*, a small depression to which the pulley of the trochlearis muscle is attached. Between the orbits in front is the serrated surface which articulates with the superior maxillary and nasal bones, and in the middle line a sharp process of variable length, the *nasal spine*, descends between the latter bones and the central plate of the ethmoid. On the sides of the incisura ethmoidalis, the inner table of the bone extends nearer the middle line than the outer, and the intervening margin is thrown into shallow spaces, which form the roofs of cells in the ethmoid bone. Traversing this margin are two grooves, which complete, with the ethmoid, the *anterior* and *posterior internal orbital foramina*. The anterior groove transmits the nasal twig of the ophthalmic nerve and the anterior ethmoidal vessels; the other, the posterior ethmoidal vessels. Further forward, on each side of the nasal spine, is a larger hollow,

the opening of the *frontal sinus*, which extends for a variable distance behind the superciliary ridges, and which communicates with the cavity of the nose. Outside the orbital surface behind the serrated border for the malar bone, there is a large serrated triangular area which articulates with the great wing of the sphenoid.

Fig. 31.

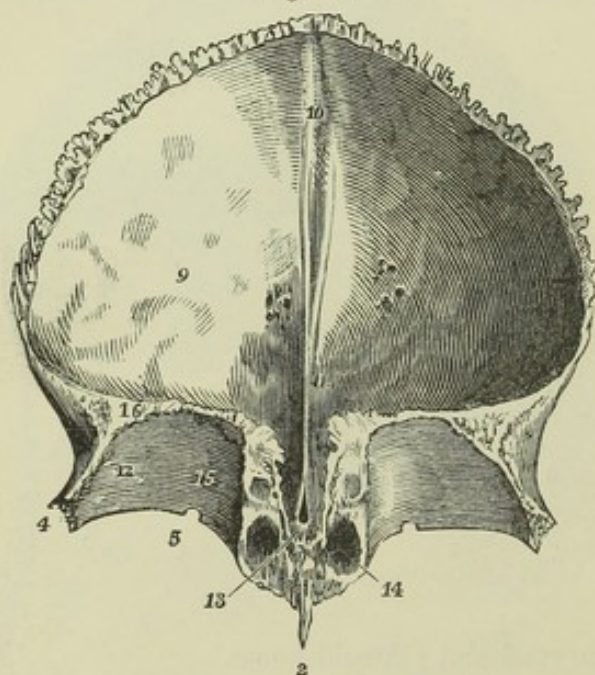


Fig. 31.—THE FRONTAL BONE FROM BEHIND AND BELOW, SHOWING THE INTERNAL CEREBRAL SURFACE AND THE ROOF OF THE ORBITS.  $\frac{1}{2}$

2, 4, and 5, as in the preceding figure; 9, internal or cerebral surface, slightly marked by cerebral convolutions and glandular pits; 10, groove of the superior longitudinal sinus, ending below in,

11, the internal frontal crest, which leads down to, 13, the foramen cæcum; 12, the orbital plate, the number is placed in the depression for the lachrymal gland; 14, the



opening of the frontal sinus; 15, placed near the inside of the roof of the orbit indicates the inner ends of the ethmoidal or internal orbital foramina.

*Cerebral Surface.*—This surface forms a large concavity, but the roofs of the orbital plates, which form its floor, are convex from side to side. It is covered with digitate impressions, which, with the intervening ridges, are strongly marked over the orbits. A groove, the *sulcus frontalis*, which lodges the commencement of the longitudinal sinus, ascends in the middle of the upper part of the bone; its margins approach inferiorly, and are elevated into a ridge, the *crista frontalis*. A small foramen, usually formed in part by the central plate of the ethmoid, is situated at its base; it is known as the *foramen cæcum*, but transmits a minute vein from the nasal fossæ. This surface is bounded posteriorly by a thin linear border, which articulates with the lesser wings of the sphenoid, and superiorly and laterally by a serrated border, which articulates with the parietals, and which, as has before been mentioned, slightly overlaps those bones above, and is overlapped by them at the sides.

## THE TEMPORAL BONE.

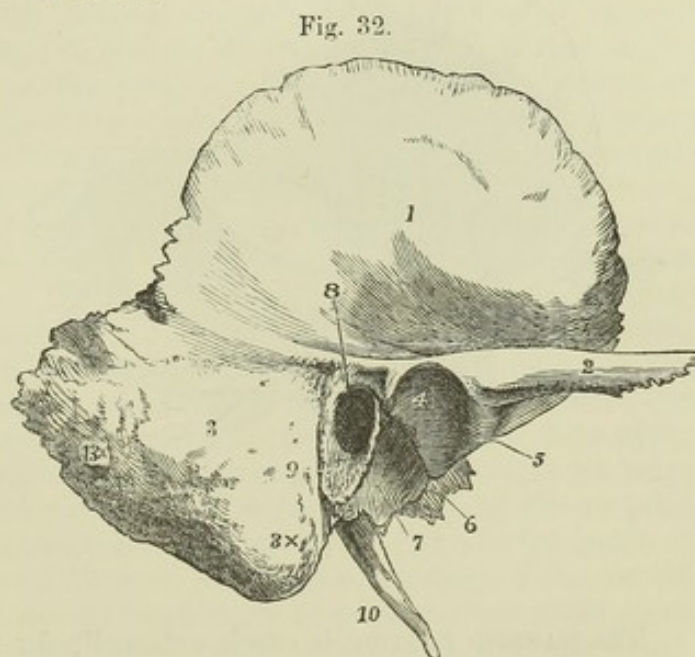
The temporal bone (*os temporis*) takes part in the construction of the side and base of the skull, and contains in its interior the organ of hearing. It is usually described in three parts, viz., an expanded anterior and superior part the *squamous* portion, a much thicker posterior portion the *mastoid*, and below and between these the *petrous* portion, a three-sided pyramid exhibiting at its base externally the aperture of the ear and projecting forwards and inwards into the base of the skull.

It articulates posteriorly and internally with the occipital bone, superiorly with the parietal, anteriorly with the sphenoid and, by the zygomatic process, with the malar.

The *SQUAMOUS PORTION* extends forwards and upwards from its connection with the other portions, and presents superiorly an arched border which describes about two-thirds of a circle.

Fig. 32.—RIGHT TEMPORAL BONE FROM THE OUTSIDE.  $\frac{2}{3}$

1, the external surface of the squamous part; 2, the zygoma; 3, the mastoid part; 3x, the mastoid process; 4, the articular part of the glenoid fossa; 5, the articular eminence at the root of the zygoma, and above it the tubercle; 6, fissure of Glaser; 7, the tympanic plate forming the posterior non-articular part of the glenoid fossa, terminating behind in the vaginal process; 8, the meatus auditorius externus; 9, the auditory process; 10, the styloid process; 13x, the mastoid foramen.



The *inner surface* is marked by cerebral impressions, and by meningeal grooves. At its upper border, the outer table is prolonged considerably

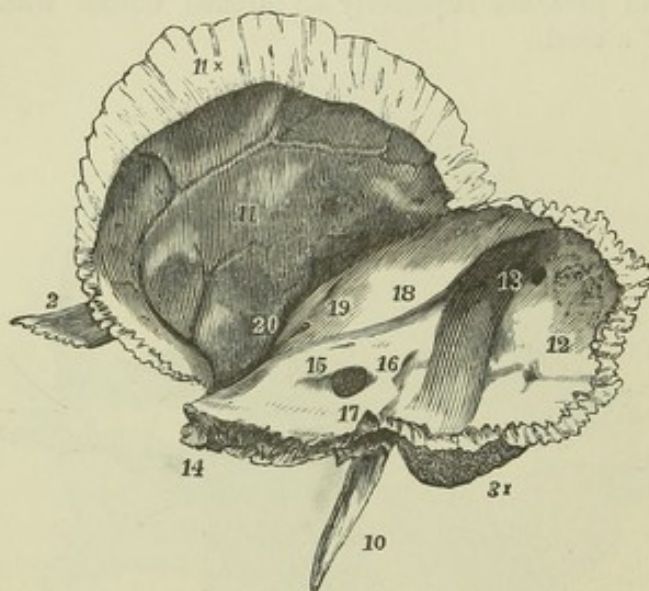


beyond the inner, forming a thin scale with the rough surface looking inwards and overlapping the corresponding bevelled edge of the parietal bone. But in front the border is thicker, looks directly forwards, and is serrated for articulation with the great wing of the sphenoid bone.

The *outer surface* is in its greatest extent vertical, with a slight convexity, and forms part of the temporal fossa. From its lowest part a long process, the *zygoma*, takes origin.

The *zygoma*, or *zygomatic process*, is at its base of considerable breadth, and projects outwards. It then becomes narrower, and is twisted on itself so as to present an outer and inner surface, and a sharp upper and lower border. The superior margin is the thinnest, and is prolonged furthest forwards. The bevelled extremity is serrated, and articulates with the malar bone. At its base the zygomatic process presents two roots. The *anterior* root is a broad convex ridge, directed inwards. The *posterior* root passes backwards, and is divided into two parts, of which one turns inwards in front of the meatus externus, while the other, gradually subsiding, is continued backwards over that opening, and marks behind it the line of union of the squamous and mastoid portions of the bone. At the point of division of the two roots is a slight *tubercle*, which gives attachment to the external lateral ligament of the lower jaw. Between them is the *glenoid fossa*, a depression elongated from without inwards, and which, together with a cylindrical elevation on the anterior root of the zygoma in front of it, is coated with cartilage, and forms the articular surface for the joint with the lower jaw. The fissure of Glaser separates this articular part of the glenoid fossa from the remaining part behind, which is formed by the tympanic plate of the petrous division of the temporal bone and lodges a portion of the parotid gland.

Fig. 33.

Fig. 33.—THE RIGHT TEMPORAL BONE FROM THE INNER SIDE.  $\frac{2}{3}$ 

The indications where marked are the same as in the preceding figure. 11, the inner or cerebral surface of the squamous portion; 11x, the squamous edge; 12, inner surface of the mastoid portion; 13, the sigmoid groove of the lateral sinus—the figure is placed at its upper part, and close to the mastoid foramen; 14, the apex of the petrous bone; 15, the meatus auditorius internus; 16, the shelf of bone covering the aqueduct of the vestibule; 17, is above the aqueduct of the cochlea; 18, the superior petrosal groove; 19, the eminence of the superior semicircular canal; 20, the hiatus Fallopii.

The **MASTOID PORTION** is rough externally for the attachment of muscles, and is prolonged downwards behind the aperture of the ear into a nipple-shaped projection—the *mastoid process*. This process forms the outer wall of a deep groove on its inner side, the *digastric fossa*, which gives attachment to the

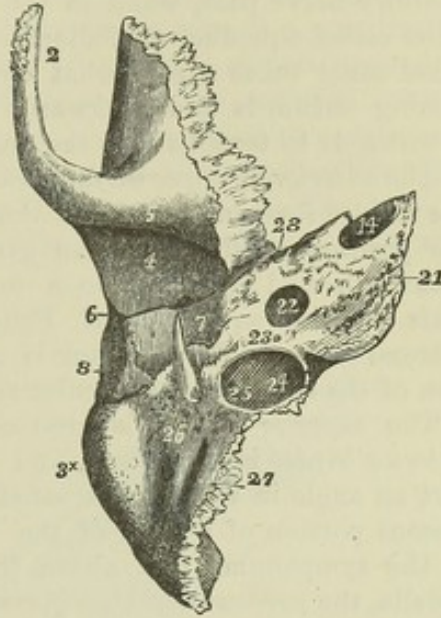


digastric muscle; and internal to that is the slight *occipital groove*, for the occipital artery. The internal surface of the mastoid portion is marked by a deep sigmoid depression, descending in the angle between it and the petrous portion, which is part of the groove of the lateral sinus. A passage for a vein, of very variable size, the *mastoid foramen*, usually pierces the bone near its posterior margin, and opens into the groove.

Fig. 34.

Fig. 34.—THE RIGHT TEMPORAL BONE FROM BELOW.  $\frac{2}{3}$

The indications where marked are the same as in the preceding figures. 14, is at the apex of the petrous bone in the upper opening of the carotid canal; 21, lower rough surface of the petrous bone; 22, the lower opening of the carotid canal; 23, the small foramen of Jacobson's nerve; 24, the jugular depression, and within it, 25, the foramen of Arnold's nerve; 26, stylo-mastoid foramen—the figure is placed in the anterior part of the digastric groove; 27, groove of the occipital artery; 28, place of the anterior opening of the osseous Eustachian canal.



The PETROUS PORTION is named from its hardness. It contains the organ of hearing. It forms a three-sided pyramid, with its base directed outwards, one surface looking downwards, and the other two turned towards the interior of the skull.

*Inferior surface, base and apex.*—At the base is the aperture of the ear. It forms a short canal, the *meatus auditorius externus*, directed inwards and a little forwards, narrower in the middle than at its extremities, and leading into the cavity of the *tympanum*. It is bounded superiorly by the posterior root of the zygoma, and posteriorly in the remainder of its circumference chiefly by the *external auditory process*, a curved uneven border, to which the cartilage of the ear is attached. This process is the thickened outer extremity of the *tympanic plate*, a lamina one surface of which forms the anterior wall of the external auditory meatus and the *tympanum*, while the other looks forwards and downwards. The anterior margin of the tympanic plate is separated from the glenoid fossa by the *fissure of Glaser*, which communicates with the tympanum, while its posterior margin descends as a sharp edge, the *vaginal process*, which partly surrounds the front of the styloid process at its base. The *styloid process* is long and tapering, and is directed downwards and forwards. It is placed in front of the digastric fossa, and has immediately behind it the foramen which forms the outlet of the canal of the facial nerve, named *stylo-mastoid* from its position between the styloid and mastoid processes. A smooth rounded and deep depression, the *jugular fossa*, lies internal to the styloid process; it is close to the posterior margin of the bone, and completes with the jugular notch of the occipital bone the foramen lacerum posterius. In front and a little to the inside of the jugular fossa is the *carotid foramen*, the inferior extremity of the carotid canal; and internal to the carotid foramen is a rough surface which gives attachment to the levator palati muscle, and is continued into the rough inner extremity, or *apex* of the petrous bone. The *carotid canal* ascends at first perpendicularly, then turns horizontally forwards and inwards, and



emerges at the apex, close to the anterior margin. It transmits the internal carotid artery.

The *posterior surface* looks backwards and inwards, and forms part of the posterior fossa in the base of the skull. It presents a large orifice leading into a short canal which is directed outwards, the *meatus auditorius internus*. This canal is terminated by a lamella of bone, the *lamina cribrosa*, presenting in the lower part small apertures through which the fibrils of the auditory nerve pass, while in its upper part is the commencement of the canal called aqueduct of Fallopius, which transmits the facial nerve. The facial canal takes a somewhat circuitous course through the petrous bone, passing outwards and backwards over the labyrinth of the ear, and then downwards to terminate at the stylo-mastoid foramen.

The *anterior or upper surface*, looks upwards and forwards, and forms part of the middle fossa in the base of the skull. A depression over the apex marks the position of the Gasserian ganglion. A narrow groove runs obliquely backwards and outwards to a foramen named the *hiatus Fallopii*, which leads to the aqueduct of Fallopius; and lodges the large superficial petrosal nerve. Farther back is a rounded eminence, indicating the situation of the superior semicircular canal.

The *superior border* is grooved for the superior petrosal sinus. The *anterior border* is very short, and forms at its junction with the squamous part an angle in which is situated the orifice of the *Eustachian canal*, the osseous portion of a tube of the same name, which leads from the pharynx to the tympanum; and above this, partially separated from it by a thin lamella, the *processus cochleariformis*, a small passage which lodges the tensor tympani muscle. The *posterior border* articulates with the basilar process of the occipital bone, and bounds the foramen lacerum posterius.

*Small foramina.*—The opening of the *aqueductus vestibuli* is a narrow fissure covered by a depressed scale of bone, and situated on the posterior surface of the petrous bone, about three lines behind the internal auditory meatus; that of the *aqueductus cochleæ* is a small foramen, beginning in a three-sided wider depression in the posterior margin, directly below the internal auditory meatus. In the plate between the jugular fossa and the carotid canal is the foramen by which the nerve of Jacobson passes to the tympanum. In the ascending part of the carotid canal is the minute foramen for the tympanic branch of the carotid plexus. In the jugular fossa are a groove and foramen for the auricular branch of the vagus nerve; and parallel to the hiatus Fallopii, close to the canal for the tensor tympani muscle, are a groove and foramen for the small superficial petrosal nerve.

#### THE SPHENOID BONE.

The sphenoid, or wedge-shaped bone, is placed across the base of the skull, near its middle. It enters into the formation of the cavity of the cranium, the orbits, and the posterior nares. It is of very irregular shape, and consists of a central part or *body*, a pair of lateral expansions called the *great wings*, which form the largest part of the bone, a pair of much smaller horizontal processes in front, called the *small wings*, and a pair which project downwards, the *pterygoid processes*.

The sphenoid is articulated with all the seven other bones of the cranium and with five of those of the face, viz., posteriorly with the occipital and with the petrous portions of the temporals, anteriorly with the ethmoid frontal and malars, laterally with the squamous portion of the temporals, the parietals and frontals, and inferiorly with the vomer and palate bones.



The BODY.—The superior surface presents in the middle a deep pit, the *pituitary fossa*, *sella turcica*, or *ephippium*, which lodges the pituitary body. In front of the fossa, separated from it by a shallow transverse groove, is a narrow portion of bone on a level with the optic foramina, the *olivary process*, on which rests the commissure of the optic nerves; and in front of this is a surface on a slightly higher level, continuous with the superior surfaces of the small wings, and having a slight projection forwards of its anterior border, which articulates with the cribriform plate of the ethmoid, and is called the *ethmoidal spine*. Behind the pituitary fossa is a prominent lamella, the *dorsum sellæ*, the posterior surface of which is sloped upwards and forwards in continuation of the basilar groove of the occipital bone. The angles of this lamella project over the fossa, and are called the *posterior clinoid processes*. On each side of the body the surface descends obliquely to a considerably lower level than the fossa; it presents close to the margin of the fossa a superficial curved groove directed from behind forwards, marking the course of the internal carotid artery.

Fig. 35.

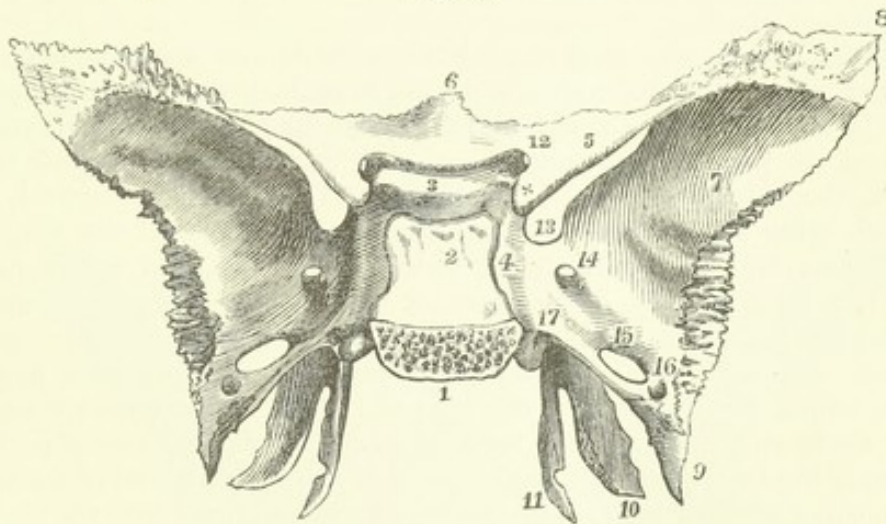


Fig. 35.—THE SPHENOID BONE FROM ABOVE AND BEHIND. 3

1, the basilar surface, sawn separate from the occipital bone; 2, inclined surface of the body terminating superiorly in the two posterior clinoid processes; 3, is placed on the olivary eminence or process, and between it and 2 is the sella turcica, or pituitary fossa; in front of 3 is the transverse groove of the optic commissure; 4, the side of the body with the sigmoid groove of the internal carotid artery and cavernous sinus; 5, the lesser wings; ×, the anterior clinoid process; 6, the ethmoid spine; 7, the cerebral surface of the greater wings; 8, the upper angle of the great wings, which articulates with the parietal bone; 9, the spinous process; 10, the external, and 11, the internal pterygoid process; 11, is placed opposite the hamular process and groove for the tendon of the tensor palati muscle; 12, the optic foramen; 13, the sphenoidal fissure or foramen lacerum orbitale; 14, the foramen rotundum; 15, the foramen ovale; 16, the foramen spinosum; 17, is placed above the posterior opening of the pterygoid or Vidian foramen.

The *posterior surface* is flat, and united to the basilar process of the occipital bone, in early life by cartilage, but in adult age by continuous bony substance.

*Anterior and inferior surfaces.*—Posteriorly, the body of the sphenoid is solid, but anteriorly and inferiorly it contains two large cavities, the *sphenoidal sinuses*, separated by a thin mesial lamina, the *sphenoidal septum*, and covered in front and below by the *sphenoidal spongy bones*. A prominent spine, called the *rostrum*, formed partly by the septum, partly by the



spongy bones, dips forwards and downwards, and is connected with the vomer. A thin edge, the *sphenoidal crest*, extends from the rostrum to the ethmoidal spine, and articulates with the central plate of the ethmoid.

The *sphenoidal spongy bones*, *cornua sphenoidalia*, or *bones of Bertin*, are a pair of thin curved plates, whose closest anatomical relationship in the adult is with the sphenoid bone, but which are originally distinct, and are frequently united by earlier or stronger ankylosis with the ethmoid or palate bones, so as to adhere, at least in part, to either of these in disarticulation of the skull, and thus to lay open the sinuses of the sphenoid. The anterior part of each looks forwards, and leaves a considerable round opening by which the sinus communicates with the nasal cavity; the lower and posterior part is of a triangular form, with the apex directed backwards.

At the anterior and outer angle of the sphenoidal spongy bone is a small part which enters into the formation of the inner wall of the orbit, articulating in front with the ethmoid, behind with the sphenoid, above by a small angle with the frontal, and below with the orbital process of the palate bone. It is most frequently fused in the adult with the sphenoid or ethmoid, often, however, with the palate bone only, and sometimes it remains free. (See Cleland in Trans. of Roy. Soc. for 1862.)

The GREAT WINGS, *alæ majores*, project outwards and upwards from the sides of the body. The lower and back part of each, horizontal in direction, occupies the angle between the petrous and squamous portions of the temporal bone; from its pointed extremity it sends downwards a short and sharp projection, the *spinous process*. The upper and fore part is vertical, and three-sided, lying between the cranial cavity, the orbit, and the temporal fossa. The *cerebral surface* of the great wing is concave, and forms part of the middle fossa of the base of the cranium. The *external surface* (temporo-zygomatic) is divided by a ridge into an inferior part, which looks downwards into the zygomatic fossa, and an elongated superior part, looking outwards, which forms a part of the temporal fossa. The *anterior surface* looks forwards and inwards, and consists of a quadrilateral *orbital* portion, which forms the back part of the external wall of the orbit, and of a smaller inferior portion which overhangs the pterygoid process, looks into the sphenomaxillary fossa, and is perforated by the foramen rotundum. Posteriorly, the cerebral and external surfaces are separated by the margins which articulate with the temporal and parietal bones; anteriorly, the superior divisions of the external and anterior surfaces are separated by the margin which articulates with the malar bone, while their inferior divisions come into contact with each other, and form the upper part of the posterior boundary of the pterygo-maxillary fissure; internally, the cerebral and orbital surfaces come into contact at the outer border of the sphenoidal fissure; and superiorly, all three surfaces abut against the triangular area which articulates with the frontal bone.

The SMALL WINGS, *alæ minores*, or *wings of Ingrassias*, extend nearly horizontally outwards from the fore part of the superior surface of the body. The extremity of each is slender and pointed, and comes very close to, but not into actual contact with the great wing. The superior surface forms part of the anterior fossa of the base of the cranium, the inferior overhangs the sphenoidal fissure and the back of the orbit. The anterior border, thin and serrated, passes directly outwards, and articulates with the orbital plate of the frontal bone. The posterior border is prominent and free, and forms the boundary between the anterior and middle cranial fossæ: it is pierced at its base by the optic foramen, and immediately beyond that projects



backwards, making a smooth rounded knob, the *anterior clinoid process*, which inclines towards the posterior process of the same name, and is grooved on its inner margin for the internal carotid artery.

The *PTERYGOID PROCESSES* project downwards and slightly forwards, between the body and the great wings. Each consists of two plates united in front and diverging behind, so as to enclose between them the *pterygoid fossa*. The *external pterygoid plate* lies in a plane extending backwards and outwards; its outer surface bounds the zygomatic fossa, and gives attachment to the external pterygoid muscle. The *internal pterygoid plate* is longer and narrower than the external, and is prolonged into a slender process turned outwards and named the hook-like or *hamular process*, round which in a groove plays the tendon of the tensor palati muscle. At its base, the internal plate turns inwards beneath the body, from which its extremity remains distinct as a slightly raised edge, which articulates with the margin of the vomer; and external to this it is marked by a small groove, which contributes with the palate bone to form the *pterygo-palatine canal*. The walls of the pterygoid fossa are incomplete at the lower part in the disarticulated sphenoid bone, an angular interstice existing between the plates, which, in the articulated skull, is occupied by the pyramidal process of the palate bone. In this fossa arises the internal pterygoid muscle, and at its base is a slight depression, distinguished as the *navicular fossa*, which gives attachment to the tensor palati muscle.

Fig. 36.

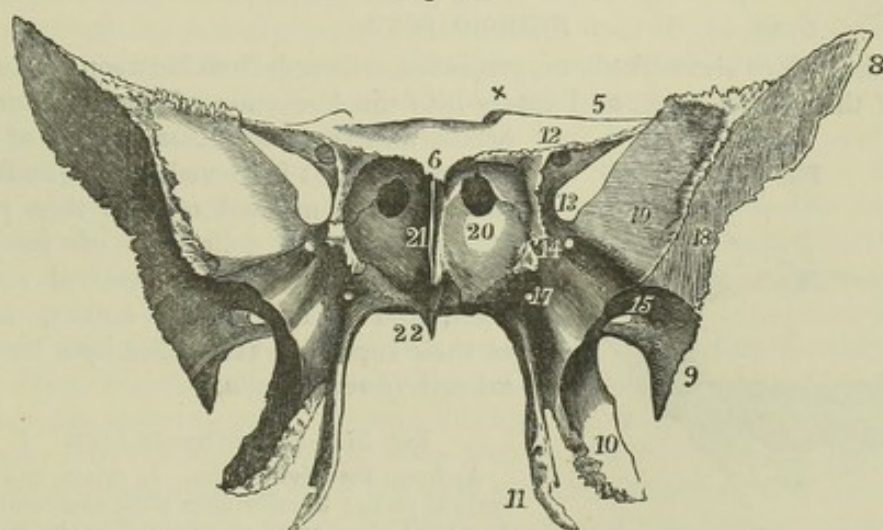


Fig. 36.—THE SPHENOID BONE FROM BEFORE. 3

The indications where marked are the same as in the preceding figure. 17, marks the anterior opening of the Vidian foramen or canal; 18, the external or temporal surface of the great wing; 19, its orbital surface; 20, the sphenoidal turbinated or spongy bone; above 20, the opening into the sphenoidal sinus; 21, the sphenoidal spine; 22, the rostrum, and above 22, the inverted laminae, which fit with the edges of the vomer.

**FISSURES and FORAMINA.**—Each lateral half of the bone presents a fissure, four foramina, and a canal. The *sphenoidal fissure* is the obliquely placed elongated interval between the great and small wing; it is closed externally by the frontal bone, so as to form the *foramen lacerum orbitale*; it opens into the orbit, and transmits the third, fourth and sixth nerves, the ophthalmic division of the fifth nerve, and the ophthalmic vein. Above and to the inside of it is the *optic foramen*, which is inclined outwards and forwards from the side of the olivary process, pierces the base of the small



wing, and transmits the optic nerve and the ophthalmic artery. The *foramen rotundum* is directed forwards through the great wing, below the sphenoidal fissure; it opens immediately below the level of the orbit, and transmits the superior maxillary division of the fifth nerve. The *foramen ovale* is a large foramen, external and posterior to the foramen rotundum, situated near the posterior margin of the great wing, and directed downwards; it transmits the inferior maxillary division of the fifth nerve. The *foramen spinosum* is a small foramen immediately external and posterior to the foramen ovale; it pierces the posterior angle of the great wing, and transmits the middle meningeal vessels.

The *Vidian*, or *Pterygoid canal*, passes through the bone horizontally from before backwards at the base of the internal pterygoid plate; it opens anteriorly into the sphenomaxillary fossa, and posteriorly into the foramen lacerum medium, and transmits the Vidian nerve and vessels.

*Varieties.*—The groove of the internal carotid artery on the inner aspect of the anterior clinoid process is frequently converted into a foramen by a spiculum of bone stretching outwards to that process from the side of the pituitary fossa, and forming what has been called the *middle clinoid process*; and in cases where this occurs another spiculum is sometimes found, uniting the anterior and posterior clinoid processes. In many cases a third spiculum, the *lingula* (Henle), projects backwards from the posterior extremity of the carotid groove outside the artery. A bridge of bone, or of ligament, sometimes passes from the margin, and sometimes from the extremity of the external pterygoid plate to the spinous process. The foramen ovale and foramen spinosum are frequently open behind.

#### ETHMOID BONE.

The ethmoid, or sieve-like bone, projects downwards from between the orbital plates of the frontal bone, and enters into the formation of the cranium, the orbits, and the nasal fossæ. It is of a cuboid figure. It is exceedingly light for its size, being composed of very thin plates of bone and a collection of irregular cells. It consists of a *central vertical plate*, and of *two lateral masses*, united at their superior extremities by a horizontal *cribriform lamella*.

Fig. 37.

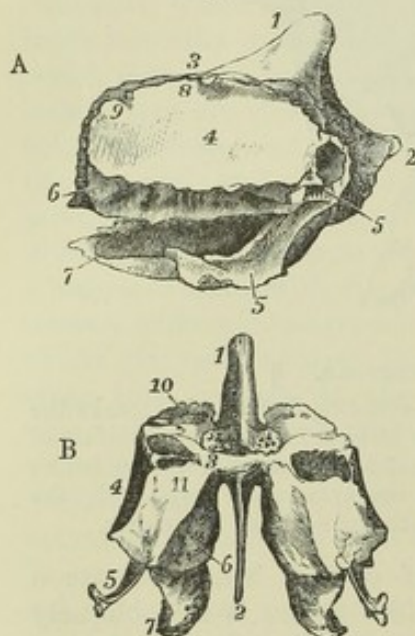


Fig. 37.—THE ETHMOID BONE.  $\frac{2}{3}$

A, from the right side. 1, crista galli; 2, vertical plate; 3, cribriform plate and foramina; 4, orbital plate or os planum; 5 5, the uncinate process; 6, the superior, and 7, the inferior turbinated bone; 8, the anterior, and 9, the posterior ethmoidal groove or foramen.

B, the ethmoid bone from behind. The indications where marked are the same as in A. 10, the lateral or cellular part of the bone; 11, its posterior surface of union with the sphenoidal turbinated and palate bones.

It articulates with thirteen bones: the frontal, sphenoid and vomer, the nasal, lachrymal, superior maxillary, palatal, and inferior turbinated bones.

The *CENTRAL PLATE* lies in the mesial plane, and forms the upper part of the septum of the nose. Its superior margin appears in the cranial cavity, above the cribriform lamella, in the form of a ridge which rises anteriorly into a thick process, the *crista galli*, to which the falx cerebri is attached.



The anterior margin of the crista galli is vertical and broad, usually presenting a groove, which completes the foramen cæcum of the frontal bone. Below the level of the cribriform lamella, the anterior margin of the central plate articulates with the nasal process of the frontal and with the nasal bones. The inferior margin articulates in front, and sometimes even in its whole extent, with the septal cartilage of the nose; and in its posterior half, in the adult, is more or less completely joined by osseous union on one or both sides to the two plates or alæ of the vomer. The posterior margin is very thin, and is united to the sphenoidal crest of the sphenoid. This plate presents a number of grooves and minute canals leading from the foramina of the cribriform lamella, for the transmission of the olfactory nerves.

The LATERAL MASSES enclose a number of spaces of irregular form, the *ethmoidal cells*, which in the recent state are lined with prolongations of the mucous membrane of the nose. On the *external aspect* of each lateral mass is a thin, smooth lamina, of a quadrilateral form, the *orbital plate* or *os planum*, which closes in the ethmoidal cells, and forms a considerable part of the inner wall of the orbit. The orbital plate articulates in front with the lachrymal, behind with the sphenoid, above with the frontal, and below with the orbital surfaces of the superior maxillary and palate bones. In front of the orbital plate the lateral mass extends forwards, under cover of the lachrymal bone; and from this part descends the *uncinate* or *cuneiform* process, a long thin lamella which curves downwards, outwards, and backwards, forming part of the inner wall of the maxillary antrum, and articulating at its extremity with the inferior turbinated bone. (See fig. 50.)

The *internal aspect* forms part of the external wall of the nasal fossa, and consists of a thin, uneven, osseous plate, connected above with the cribriform lamella, and exhibiting a number of canals and grooves for branches of the olfactory nerve. It is divided at its back part by a channel, directed upwards and forwards from its posterior margin to about its middle. This is called the *superior meatus of the nose*, and communicates with the posterior ethmoidal cells. The short margin which overhangs this channel constitutes the *superior turbinated process* or *spongy bone*. Below this is a slightly folded margin of much greater extent, and free in front, the *inferior turbinated process* or *middle spongy bone*, which overhangs the *middle meatus of the nose*. From the front of the middle meatus a passage, the *infundibulum*, is prolonged upwards and forwards through the anterior ethmoidal cells, and opens into the frontal sinus. (See also fig. 54.)

In the separate ethmoid bone the cells are open posteriorly and superiorly, but when the bone is in connection with the rest of the cranium these cells are closed, above by the frontal bone, and behind by the sphenoidal spongy bones. In the superior margin are two grooves, which complete with the frontal bone the internal orbital foramina.

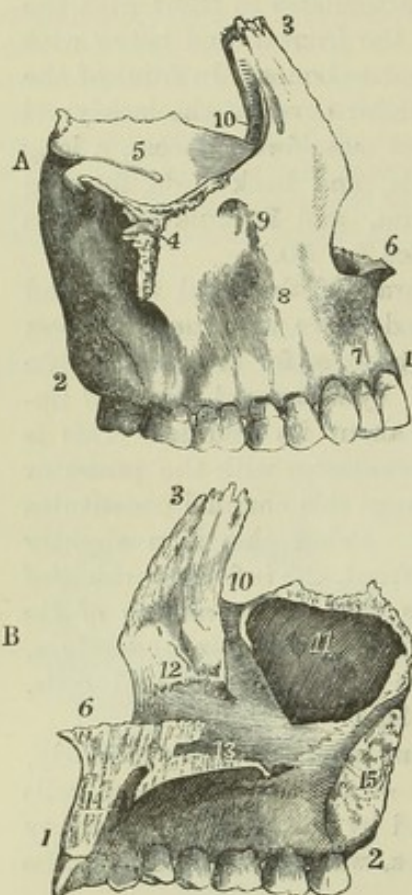
The CRIBRIFORM LAMELLA corresponds in size to the incisura ethmoidalis of the frontal bone which it occupies. At the sides of the crista it is depressed into two grooves which lodge the olfactory bulbs; and it is pierced by numerous foramina for transmission of the filaments of the olfactory nerves. The foramina, which lie along the middle of each groove, are simple perforations; the internal and external sets are longer, and are the orifices of small canals which subdivide as they descend on the central plate and lateral masses. At the anterior extremity is a small fissure at each side of the crista galli, close to its base, and external to this a foramen, connected usually by a slight groove with the anterior internal orbital foramen, which transmits the nasal branch of the ophthalmic nerve.



## THE SUPERIOR MAXILLARY BONE.

This, the upper jaw, is one of the principal bones of the face; it supports all the teeth of the upper range, and takes part in the formation of the hard palate, the floor of the orbit, and the floor and lateral wall of the nasal cavity. It presents inferiorly a thick ridge, the alveolar process perforated with the sockets for the roots of the teeth, and a horizontal palate plate; externally, a convex surface corresponding with the anterior and lateral parts of the face; superiorly, an ascending or nasal process and an orbital plate; and internally, a nasal surface, opening from which is a large cavity or sinus, hollowed out beneath the orbital plate in the body of the bone. The superior maxillary bone articulates with its fellow, with the nasal, frontal, lachrymal, ethmoid, palate, malar, vomer, and inferior turbinated bones, and with the nasal cartilages.

Fig. 38.

Fig. 38.—SUPERIOR MAXILLARY BONE OF THE RIGHT SIDE.  $\frac{1}{2}$ 

A, from the outside; B, from the inside.

1 to 2, alveolar process or arch—1 at the middle incisor tooth, 2 marks the tuberosity, and above it, in A, the posterior dental foramina; 3, the nasal or ascending process; 4, malar tuberosity or process; 5, orbital plate or process; 6, placed in the nasal notch marks the nasal crest terminating in the nasal spine; 7, the incisor or myrtiform fossa; 8, is in front of the canine fossa; 9, the infra-orbital foramen, and below 5, the infra-orbital groove and canal; 10, groove of the nasal or lachrymal duct; 11, antrum maxillare, or maxillary sinus; 12, on the inner surface of the nasal process, marks the oblique ridge for the attachment of the inferior turbinated bone; 13, is placed above the palate-plate; from 13 to 6, the vomeric and septal crest; from 13 to 14, the incisor foramen; 15, placed on the surface of articulation of the body with the palate-bone, points to the posterior palatine or palato-maxillary canal. These figures also exhibit a full set of the upper teeth of one side as they occur in middle life, little worn by use.

The *alveolar border* or process, thick and arched, is hollowed out into sockets or *alveoli*, corresponding in number, form, and depth to the roots of the teeth, which are fixed in them.

The *palate plate*, along with that of the opposite side, forms about three-fourths of the hard palate. Its superior surface is smooth and concave from side to side; its inferior surface is vaulted and rough, and is marked laterally with grooves for nerves and vessels, which reach the palate through the posterior palatine canal. Its posterior extremity falls short of that of the alveolar arch and body of the bone, and articulates with the horizontal process of the palate bone, which completes the hard palate. The mesial border rises into a serrated vertical ridge, upon which the vomer rests. This border, or ridge, is interrupted at its anterior part by a canal, the *incisor foramen*, which is completed on its mesial side by a slender lamina



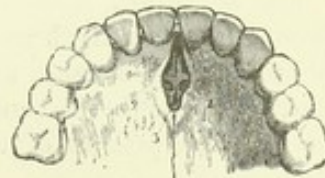directed backwards from the anterior to the posterior border, from the latter of which, however, in young bones the lamina remains disconnected. In front of this canal the mesial border of the bone rises to a considerably greater height than behind it, forming, with its neighbour, the *nasal crest*—a grooved elevation which supports the extremity of the vomer and the septal cartilage, and is prolonged forwards into the *nasal spine*. Each incisor foramen widens out below into a larger hollow, which, when placed in apposition with its fellow, completes a mesial aperture, the *anterior palatine foramen*. Viewed from below, this aperture may be seen to be divided into four smaller foramina, two of which placed laterally are the incisor foramina, called also *foramina of Stenson*, while the other two, placed in the middle line, one before the other, are distinguished as the *foramina of Scarpa*. The whole communication between the nose and the palate may be designated collectively as the *anterior palatine canal*.

The terms *incisor foramen* and *anterior palatine canal* are often used convertibly and vaguely to express what has been above defined as the anterior palatine canal, or its inferior opening. According to the definitions here given, *incisor foramen* has the same meaning in human as in comparative anatomy, while *anterior palatine canal* is restricted to an appearance which presents itself only in man and a few animals. The lamina passing backwards from before each incisor foramen corresponds to the mesial palatine process of the intermaxillary bone in other animals, *e. g.*, the carnivora: while the incisor foramina are those which are seen largely developed in those animals, and are the remains of a primitive communication between the nose and mouth. The foramina of Scarpa lie in the suture between the laminae referred to. They transmit the naso-palatine nerves; the nerve of the right side occupying, according to Scarpa, the posterior one, which is usually largest, and that of the left side the anterior: but they are very inconstant. (Scarpa, *Annot. Anatom.*, lib. ii. cap. 5.)

Fig. 39.—FRONT PART OF THE PALATE AND ALVEOLAR ARCH OF AN ADULT,  $\frac{2}{3}$

Showing the lower opening of the anterior palatine or incisor foramen. 1, 2, are placed on the palate plates of the two superior maxillary bones; 4, anterior palatine foramen, in which is seen a partial division into four openings—the two lateral, with lines pointing to them from 1 and 2, are the incisor foramina (*foramina of Stenson*); the anterior and posterior, indicated by 3 and 4, are the naso-palatine, or *foramina of Scarpa*.

Fig. 39.



The *external surface* is divided into an anterior and a posterior part by the *malar process*, a prominence presenting a large triangular roughness for articulation with the malar bone, which abuts by its upper border against the edge of the orbital surface, and at its inferior angle projects outwards and downwards above the first molar tooth. The anterior portion is excavated in a smooth curved notch at its internal margin for the opening of the anterior nares. It is marked by a prominence corresponding to the position of the fang of the canine tooth; and internal to this is a slight depression, the *incisor* or *myrtiform fossa*; while between it and the malar process is the much deeper *canine fossa*, in which arise the levator anguli oris and compressor nasi muscles. Above the canine fossa, immediately below the margin of the orbit, is the *infra-orbital foramen*, which transmits the superior maxillary nerve. The posterior portion looks partly into the zygomatic, partly into the pterygo-maxillary fossa. It exhibits a convexity, the *tuberosity*, which projects backwards, and is perforated by a number of foramina transmitting the superior dental nerves and arteries.



The *ascending* or *nasal process* projects upwards from the anterior and internal part of the bone. Its surfaces are continuous with the external and internal surfaces of the bone ; its internal surface, towards its summit, is rough for articulation with the lateral mass of the ethmoid ; its anterior border is rough for articulation with the nasal bone, and its summit serrated for articulation with the frontal. Posteriorly, it articulates by a linear edge with the lachrymal bone ; and external to this it presents a well-marked groove for the lachrymal sac, the *lachrymal groove*, which is continued downwards on the inner surface of the bone, between this process and the orbital plate, and is converted into a canal by the lachrymal and inferior turbinated bones.

The *orbital surface* passes forwards to the margin of the orbit, and backwards to the speno-maxillary fissure, and is bounded externally by the surface for the malar bone, and internally by the lachrymal groove and a rough edge which articulates with the lachrymal, ethmoid, and palate bones. It is interrupted by a groove which commences in its posterior border, and leads forwards into a complete canal, the *infra-orbital*, of which the infra-orbital foramen is the anterior termination. At the inner and fore-part of the orbital surface is a minute depression, which gives origin to the inferior oblique muscle of the eye.

The *nasal surface* presents an oblique rough line beneath the ascending process, for articulation with the inferior turbinated bone, and behind that process the lachrymal groove. Behind the lachrymal groove is the large opening into the sinus ; below and behind the sinus the surface is rough for articulation with the palate bone ; and traversing the lower part of this roughness is a smoother groove, passing downwards and forwards from the posterior margin, and completing with the palate bone the posterior palatine canal.

The *maxillary sinus*, or *antrum of Highmore*, is a large cavity lying above the molar teeth and below the orbital plate, lined in the fresh state by mucous membrane, and communicating with the middle meatus of the nose. Its orifice is considerably diminished by contiguous bones, viz., by the uncinate process of the ethmoid, the inferior turbinated bone, and the palate bone.

#### THE PALATE BONE.

The palatal or palate bone forms the back part of the palate, and the lateral wall of the nose between the superior maxillary bone and the internal pterygoid process. In form it has a general resemblance to the letter L, consisting of a horizontal and a vertical plate and three processes, viz., the pyramidal process, extending outwards and backwards from the junction of the horizontal and vertical plates, and the orbital and sphenoidal processes, surmounting the vertical plate.

The palate bone articulates with its fellow, and with the superior maxillary, ethmoid, sphenoid, vomer, and inferior turbinated bone.

The *horizontal* or *palate plate* presents posteriorly a thin free border, forming the limit of the hard palate, and giving attachment to the soft palate or velum ; anteriorly it articulates with the palate plate of the superior maxillary bone, and internally by a thick serrated border with its fellow of the opposite side, forming with it a ridge for articulation with the vomer, continuous with that of the superior maxillaries ; externally, at its junction with the vertical plate, it is grooved by the extremity of the posterior palatine canal. Its superior surface is smooth, and forms the back



part of the floor of the nasal cavity ; its inferior surface is rough, and is marked near its posterior border by a transverse ridge passing inwards from the base of the pyramidal process, giving attachment to the tendinous fibres of the tensor palati muscle.

Fig. 40.—THE PALATE BONE OF THE RIGHT SIDE.  $\frac{2}{3}$

A, from the outside and behind ; B, from the inside.

1, the upper surface of the palatine plate ; 2, its posterior curved border or palatine arch ; 3, posterior nasal or palatine spine ; 4, the rough surface of adjacent articulation rising superiorly into the vomeric crest, as in A ; 5 5, the nasal process ; 6, the ridge or shelf supporting the inferior turbinated bone ; 7, the sphenoidal process ; 8, in B, the orbital process, showing a cellular cavity ; 8', in A, its orbital surface ; 9, the sphenopalatine notch ; 10, 11, 12, the pyramidal process—10, rough surface of union with the external pterygoid plate, 11, with the internal ditto, and 12, the inter-ptyergoid smooth surface ; 13 13, palato-maxillary or posterior palatine canal.

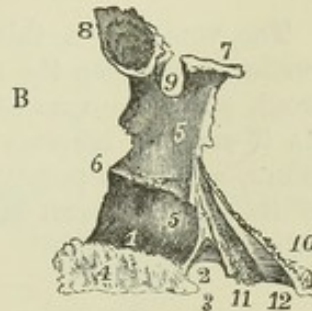
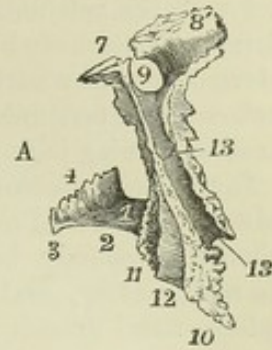
The *vertical plate* is very thin. Its *internal surface* looks towards the nasal cavity, and is divided into two parts, corresponding to the middle and inferior meatus of the nose, by a nearly horizontal ridge which articulates with the inferior turbinated bone. The *external surface* is traversed by a smooth impression, directed downwards and slightly forwards, the upper part of which forms the internal wall of the spheno-maxillary fossa, while the lower part is hollowed into a deep groove, completing with the superior maxillary the *posterior palatine canal*, which transmits the large descending palatine nerve and accompanying vessels. In front of this canal the external surface is in contact with the internal surface of the maxillary bone and the side of the antrum ; behind the canal it articulates inferiorly with the hinder border of the maxillary, superiorly with the inner surface of the pterygoid process.

The *pyramidal process* or *tuberosity* fits into the cleft between the pterygoid plates. It presents posteriorly a triangular surface which is smooth and grooved, and completes the pterygoid fossa on its sides ; it is rough for articulation with the borders of the pterygoid plates. Inferiorly, close to its connection with the horizontal plate, are two small foramina, the *posterior* and *external small palatine* foramina, the extremities of two minute canals which transmit the smaller palatine nerves ; the external one is smallest and inconstant.

The *orbital process* surmounts the anterior margin of the vertical plate. It has the general appearance of an inverted pyramid, and has five surfaces, two of which, the superior and external, are free, and the rest articulated. The superior surface forms the posterior angle of the floor of the orbit ; the external looks into the spheno-maxillary fossa, the anterior articulates with the maxillary, the internal with the ethmoid, and the posterior, which is small and only exists towards the extremity of the process, articulates with the sphenoidal spongy bone.

The orbital surface is frequently found enlarged, extending upwards between the

Fig. 40.





ethmoid and sphenoid as far as the frontal bone. This condition results from the union with the palate bone of a separate centre of ossification, more usually united with the ethmoid or sphenoid, and already described with the sphenoidal spongy bone (p. 40).

The *sphenoidal process* curves upwards, inwards, and backwards from the posterior part of the vertical plate. Its superior or external surface is in contact with the sphenoidal spongy bone and the base of the internal pterygoid plate, and is grooved for the completion of the pterygo-palatine canal; its internal or under surface looks to the posterior nares; and at its base a third surface looks forwards and outwards into the spheno-maxillary fossa. Its inner extremity is in contact with the wing of the vomer.

The *spheno-palatine* foramen is formed in greatest part by the deep notch between the orbital and sphenoidal processes, and is completed above by the sphenoidal spongy bone. It leads from the spheno-maxillary fossa into the nasal cavity, and transmits the internal nerves from Meckel's ganglion and the nasal branch of the internal maxillary artery.

#### THE VOMER.

The vomer is a thin mesial bone, irregularly quadrilateral, and placed vertically between the nasal fossæ. It articulates with the sphenoid, ethmoid, palate, and maxillary bones, and with the septal cartilage of the nose. As it usually becomes united by ankylosis, at an early age, to other bones, and is frequently more or less absorbed and even distorted in some of its parts, it can be studied as a separate bone in certain specimens only.

Fig. 41.

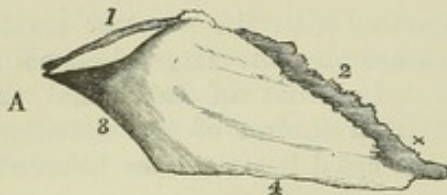
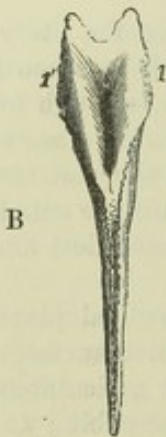


Fig. 41.—THE VOMER.  $\frac{2}{3}$

A, from the right side; B, from above.

1 1', the upper everted edges on each side of the hollow which receives the rostrum of the sphenoid; 2, the anterior or ethmoid border, grooved to receive the septal cartilage of the nose, and prolonged at x into a process which rests upon the nasal crest; 3, the posterior or free border; 4, the inferior or maxillary and palatine border.



The part of the vomer which lies below the diagonal line extending from its posterior to its anterior extremity is a thin *mesial plate*, that which lies above this line consists of two *alæ*, rising on each side of a mesial groove, in which lies the septal cartilage of the nose. The *alæ* posteriorly are thick and expanded, and form the bifid posterior extremity of the bone, which rests beneath the sphenoid. The superior border of each *alæ*, extending forwards from that point, articulates edge to edge with the lamella projecting at the base of the internal pterygoid plate, the sphenoidal process of the palate bone, and the extremity of the rostrum of the sphenoid; the anterior border, sloping downwards and forwards, in contact with the septal cartilage, is free in the inferior part, and is united superiorly by ankylosis on one or both sides with the central plate of the ethmoid. The anterior extremity of the vomer forms a short vertical line which fits in behind the nasal crest of the maxillaries, and from the upper end of which a process projects forwards in the groove



of the crest, while from its lower end a point projects downwards between the incisor foramina. The inferior border articulates with the ridge or crest which rises from the palate plates of the maxillary and palate bones. The posterior border, thin, smooth, and unattached, separates the posterior nares.

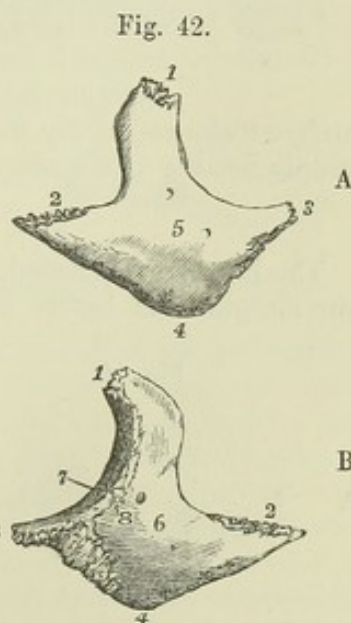
THE MALAR BONE.

The malar bone forms the most prominent part of the cheek, and, by a deep plate, divides the orbit from the temporal fossa. It articulates by a broad serrated surface near its anterior inferior angle with the malar process of the superior maxillary bone, by a slenderer posterior process with the zygoma, by a superior process with the frontal, and, continuously with that, by the margin of its deep plate with the great wing of the sphenoid bone. Between its sphenoidal and maxillary articulations a small portion of free margin generally intervenes, which closes the anterior extremity of the sphenomaxillary fissure. The facial surface is convex, and pierced by one or more *malar foramina*, which pass through from the orbital surface and transmit a small nerve and vessels. The orbital surface is concave from above downwards, and enters into the formation of the outer wall and floor of the orbit. The posterior surface is concave from side to side, and looks into the temporal and zygomatic fossæ; it is also pierced by a small foramen.

Fig. 42.—RIGHT MALAR BONE.  $\frac{2}{3}$

A, from the outside; B, from the inside.

1, superior or frontal angle and serrated edge; 2, posterior or external angle and serrated surface for the zygoma; 3, anterior or internal angle; 4, inferior angle; from 1 to 2, the temporal border; from 1 to 3, the orbital border; from 1 to 8, edge of articulation with the frontal and sphenoid bones; at 8, the notch terminating generally the sphenomaxillary fissure; from 2 to 4, the masseteric rough border; between 8, 3, and 4, the triangular serrated surface for articulation of the superior maxillary bone; 5, the external surface; 6, the deep or posterior surface; 5 and 6, near the foramina for the temporo-malar nerves; 7, the orbital surface, with the orbito-malar foramen.



THE NASAL BONE.

The nasal bones form the bridge of the nose. They are thick and

Fig. 43.

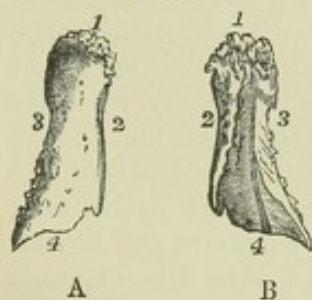

Fig. 43.—RIGHT NASAL BONE.  $\frac{2}{3}$

A, from the front; B, from behind.

1, upper or frontal serrated border; 2, internal border for adjacent articulation; 3, external or superior maxillary border; 4, lower free border; in B, 4 is placed at the lower end of the groove for the nasal nerve.

narrow above, but gradually become wider and thinner below. The superior border of each is serrated, and articulates with the frontal bone; the inferior unites with the nasal cartilage; the external edge articulates with the ascending process of the superior maxillary bone; and the internal with its fellow

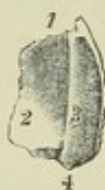

and with the nasal spine of the frontal bone and the perpendicular plate of the ethmoid. The anterior surface, concave at its upper part, convex in the rest of its extent, presents a minute vascular foramen; the posterior or nasal surface is marked by a groove for the passage of the nasal nerve.

#### THE LACHRYMAL BONE.

The lachrymal bone, or *os unguis*, is a thin scale of bone placed at the anterior and inner part of the orbit. It articulates superiorly with the frontal bone, posteriorly with the orbital plates of the ethmoid; anteriorly it presents a longitudinal or vertical groove, and articulates with the ascending process of the superior maxillary bone, completing with it the groove for the lachrymal sac; inferiorly it articulates in its greatest extent with the orbital plate of the superior maxillary bone, while its anterior

Fig. 44.

Fig. 44.—RIGHT LACHRYMAL BONE, FROM THE OUTSIDE.  $\frac{2}{3}$ 

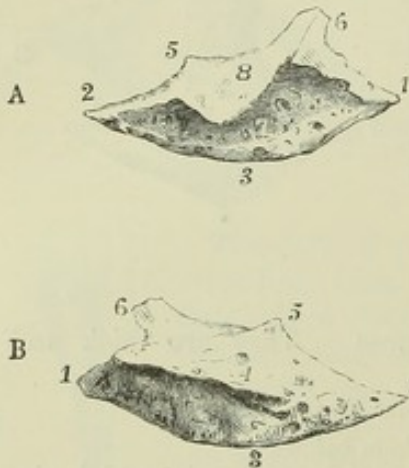
1, upper or frontal border; 2, the orbital surface; 3, lachrymal groove; 4, the process which meets the inferior turbinate bone.

grooved part projects downwards, taking part in the formation of the lachrymal canal, and terminates in a pointed extremity, *hamulus lachrymalis*, which fits into an angle between the superior maxillary and inferior turbinate bone. The inner surface looks superiorly to the anterior ethmoidal cells, and inferiorly to the middle meatus of the nose.

#### THE INFERIOR TURBINATED BONE.

The inferior turbinated, or spongy bone, is a slender lamina, attached by one margin from before backwards along the lateral wall of the nose, and

Fig. 45.

Fig. 45.—THE INFERIOR TURBINATED BONE OF THE RIGHT SIDE.  $\frac{2}{3}$ 

A, from the outside; B, from the inside.

1, anterior angle; 2, posterior angle; 1, 3, 2, inferior free border; 4, internal convex surface; 5, part of the bone articulating with the uncinate process of the ethmoid; 6, portion articulating with the lachrymal; 7, the outer concave surface; 8, the deflected scale of bone from the upper border, which, by union with the superior maxillary, forms a part of the inner wall of the maxillary sinus.

projecting into the nasal cavity, so as to divide the middle from the inferior meatus. It is slightly convoluted, its convexity looking upwards and inwards, and its free margin being dependent, slightly thickened, and rolled upon itself. The attached margin articulates anteriorly with the oblique ridge below the ascending process of the superior maxillary bone, and ascends abruptly to complete the lachrymal canal and articulate with the lachrymal bone; behind this it bends downwards, forming part of the inner wall of the antrum below the entrance into that cavity; above and behind this, it presents a small projection which articulates with the uncinate process of the ethmoid, and posteriorly it is attached to the horizontal line on the vertical plate of the palate bone.



This bone is marked by horizontal grooves and canals for vessels and nerves, but not, as the turbinations of the ethmoid are, with vertical grooves for the olfactory nerve.

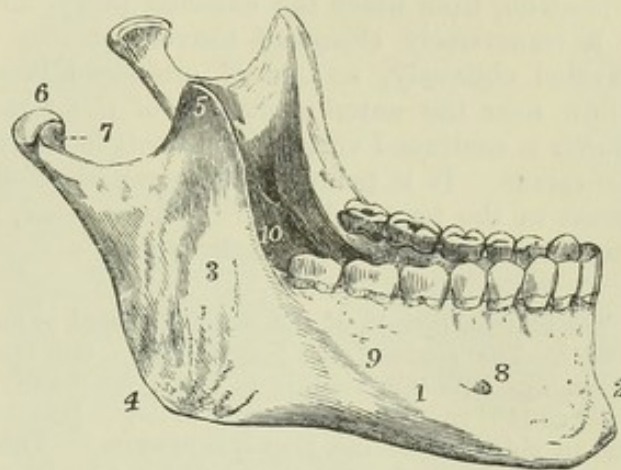
THE INFERIOR MAXILLARY BONE.

The inferior maxilla, or lower jaw, is the thickest and strongest bone of the face, and moves on the rest of the skull by means of a pair of articular surfaces or condyles. It has the shape of an inverted arch bent forwards upon itself, and consists of a middle larger and horizontal part—the body, and of two rami or ascending branches.

Fig. 46.—THE INFERIOR MAXILLARY BONE, FROM THE RIGHT SIDE AND ABOVE.  $\frac{1}{2}$

1, the body; 2, the symphysis; 3, the ramus; 4, the angle, near it the oblique ridges marked by the attachment of the masseter muscle; 5, the coronoid process; 6, the condyle or articular head; 7, placed in the sigmoid notch, points to the front of the neck; 8, the mental foramen; 9, the external oblique ridge; 10, the inferior dental foramen and mylohyoid groove of the left side. This figure represents a full set of the teeth of the lower jaw in middle life. (See also, for the view of the inner surface of the lower jaw, figure 53, the vertical section of the skull.)

Fig. 46.



The body is marked in the middle by a vertical ridge, indicating the original division of the bone into two lateral parts, and thence named the *symphysis*. The superior or *alveolar* border is hollowed out into sockets for the teeth. The inferior border, thicker anteriorly than beneath the ramus, is slightly everted in front, constituting the chin, or *mentum*, a prominence peculiar to the human skull. On the outer surface, on each side of the symphysis, below the incisor teeth, is a shallow depression, the *incisor fossa*, which gives origin to the levator menti muscle, and, more externally, the *labial* or *mental foramen*, which transmits the facial branches of the inferior dental nerve and artery. From beneath the mental foramen an elevation, the *external oblique line*, extends upwards and outwards to the anterior border of the ramus. The deep surface is marked, on each side of the symphysis, along the inferior margin, by a depression, indicating the anterior attachment of the digastric muscles, and above them by two pairs of prominent tubercles, *spinæ mentales*, placed closely together, giving attachment, the upper pair to the genio-hyo-glossi, and the lower to the genio-hyoidei muscles. An oblique prominent line, the *mylo-hyoidean ridge*, leading from beneath the *spinæ mentales*, upwards and outwards to the ramus, gives attachment to the mylo-hyoideus muscle. Above this line is a smooth depression for the sublingual gland, and beneath and external to it another for the submaxillary gland.

The *ramus* is thinner than the body of the bone, and its border forms, posteriorly and inferiorly with that of the body, an angle, called the angle of the jaw. The external surface is flat and marked by slight unevenness, and towards the angle by ridges at the place of attachment of the masseter



muscle. The internal surface presents at its middle the *inferior dental foramen*, leading into the *dental canal*, which lodges the dental nerve and vessels. Passing down from the sharp inferior margin of this foramen is the *mylo-hyoid groove* (occasionally a canal for a short space), marking the passage of the mylo-hyoid nerve with an accompanying artery and vein. Behind this, inside the angle, is a marked roughness for the internal pterygoid muscle.

Each ramus is surmounted by two processes, the condyle and the coronoid, which are separated by a deep excavation, the *sigmoid notch*. The *condyle* is continued upwards from the posterior part of the ramus. It is supported by a constricted portion, the *neck*, which presents anteriorly a depression, from which the external pterygoid muscle arises. The condyle is a transversely elongated convex articular process, whose major axis is directed obliquely, so that if prolonged it would meet with that of its fellow near the anterior margin of the foramen magnum. The *coronoid process* is continued vertically upwards in front, from the anterior margin of the ramus. It is pointed, and gives attachment by its margin and inner aspect to the temporal muscle. At its base, in front, is a groove, to which the buccinator muscle is attached.

The anterior margin of the ramus is placed at nearly a right angle to the alveolar border. The angle of the jaw, which is the meeting of the posterior border of the ramus with the base, is in the adult usually about  $120^\circ$ ; in infancy it is as great as  $140^\circ$  or more; in strongly developed jaws it may be diminished to  $110^\circ$  or less; and in old and toothless jaws it is increased. These changes are connected with a variety of circumstances, among which may be noticed,—the development of the temporary and permanent teeth, the absorption of the alveolar arch in advanced age, the elongation of the face and upper jaw towards adult life, and the varying state of development of the masseter muscles at different periods.

#### THE HYOID BONE.

The hyoid bone, or *os linguae*, is situated at the base of the tongue, and may be felt between the chin and the thyroid cartilage. It is suspended from the tips of the styloid processes of the temporal bones by a pair of slender bands, the *stylo-hyoid ligaments*, which are osseous in most animals. Hence, though not strictly a bone of the cranium or face, it properly falls to be considered in this place. It is shaped like the letter U, and consists of a body and two pairs of cornua.

Fig. 47.

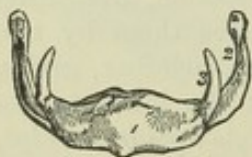

Fig. 47.—THE HYOID BONE, FROM BEFORE.  $\frac{2}{3}$

- 1, the prominent part of the body; 2, the great cornu;  
3, the lesser cornu.

The *body*, or central piece, is compressed from before backwards, and lies in a plane, directed downwards and forwards. Its anterior surface is convex, and marked in the middle by a vertical ridge, on each side of which are depressions for the attachment of muscles. Its posterior surface is concave, and is directed towards the epiglottis.

The *great cornua* project backwards from the sides of the body, and end in rounded extremities.

The *small cornua*, or *cornicula*, short and conical, project upwards and backwards from the place of junction of the body with the great cornua,



and give attachment at their extremities to the stylo-hyoid ligaments. They continue for a long time movable, as the cartilage which connects them remains unossified till an advanced period of life.

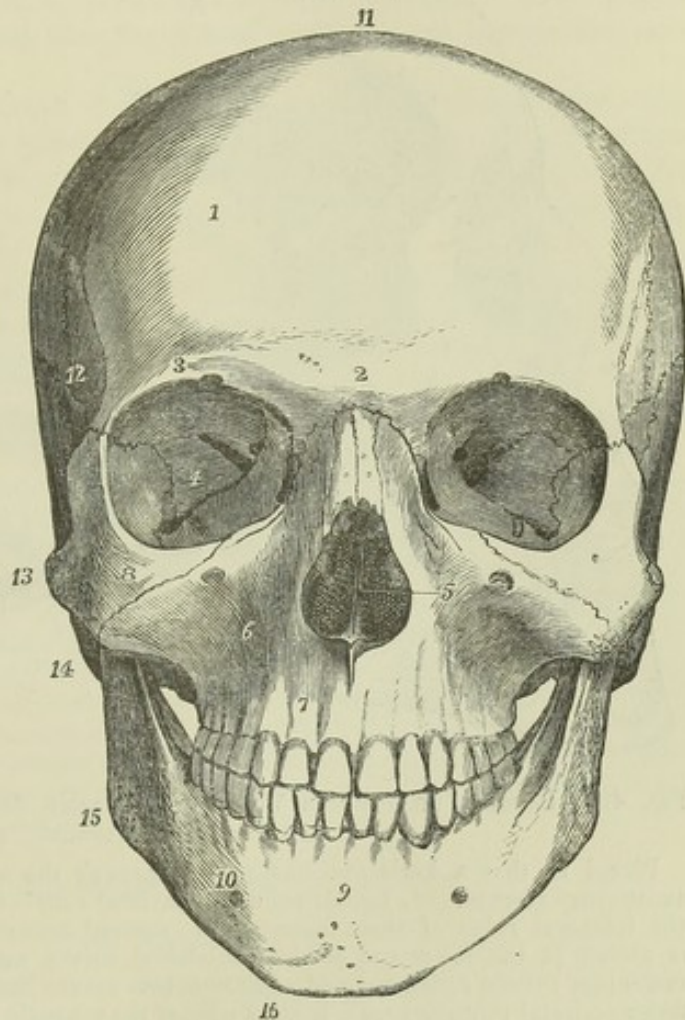
## THE SKULL AS A WHOLE.

Fig. 48.—FRONT VIEW OF THE SKULL OF A YOUNG MAN OF ABOUT TWENTY YEARS OF AGE.  $\frac{1}{2}$

Placed with the anterior nasal spine and the middle of the meatus auditorius externus in the horizontal plane. (In this, as in most other figures, the figures and letters of indication are placed only on one side.) 1, frontal eminence; 2, middle of the lower part of the frontal bone, or glabella, between the superciliary eminences, and above the transverse suture of union with the nasal and superior maxillary bones; 3, supra-orbital ridge at its middle—to the inside of the figure is the supra-orbital notch; 4, the orbit—the figure is placed on the orbital plate of the sphenoid bone, between the foramen lacerum orbitale and the spheno-maxillary fissure; 5, the anterior opening of the nares, within which are seen in shadow the nasal crest of the superior maxillary bones, the vertical plate of the ethmoid bone, and on each side the turbinated bones; 6, superior maxillary bone at the canine fossa—above the figure is the infra-orbital foramen;

7, myrtiform, or incisor foramen; 8, malar bone; 9, symphysis menti and median ridge; 10, body of the lower jaw, above the outer oblique ridge and the mental foramen; 11, vertex, immediately over the coronal suture; 12, temporal fossa, at the meeting of the frontal, parietal, temporal, and sphenoid bones; 13, zygoma; 14, mastoid process; 15, angle of the jaw; 16, mental angle. In this skull there are fourteen teeth in each jaw, the wisdom teeth having not yet appeared.

Fig. 48.



## THE SUTURES.

The sutures of the skull are best distinguished when named from the bones between which they lie, as, for example, occipito-parietal, occipito-mastoid, fronto-ethmoid, parieto-sphenoid, &c. Those which occur in the arch of the skull require more particular notice. The cranium is intersected superiorly by three great serrated sutures, two of which, placed transversely, correspond to the anterior and posterior margins of the parietal bones, while the third lies in the middle line and passes between them. On each side also there runs an irregular longitudinal line of suture from the malar to the



occipital bone, bounded by the frontal and parietal bones above, and the malar, sphenoid, and temporal bones below.

Fig. 49.

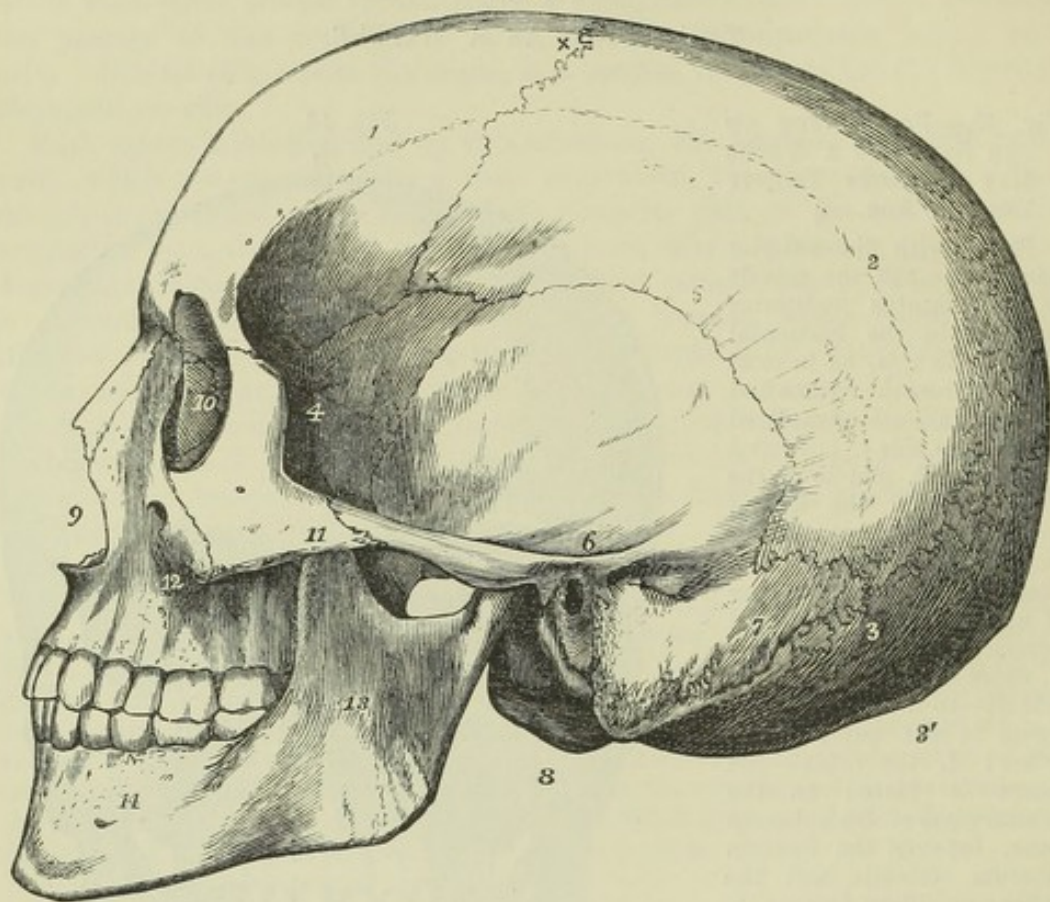


Fig. 49.—LATERAL OR PROFILE VIEW OF THE SAME SKULL AS THAT REPRESENTED IN THE PRECEDING FIGURE.  $\frac{1}{2}$

Placed so that a horizontal line passes through the anterior nasal spine and meatus auditorius externus. 1, frontal bone; 2, parietal bone—figures 1 and 2 are placed above the temporal ridge of these bones; x x, coronal suture; 3, occipital bone—the figure is placed at the lower end of the lambdoidal suture, and at its meeting with the additamentum suturæ squamosæ and additamentum suturæ lambdoidalis; 3', external or posterior occipital protuberance; 4, great wing of the sphenoid bone, between the frontal, anterior inferior angle of the parietal and squamous part of the temporal bones; 5, the summit of the squamous part of the temporal bone; 6, at the lower part of the same and at the root of the zygoma immediately over the meatus auditorius externus; 7, mastoid portion of the temporal bone, in front of which is the mastoid process—the figure is close to the mastoid foramen; 8, the left condyloid process of the occipital bone; 9, the anterior opening of the nares or nasal notch; 10, the inner wall of the orbit, on the lachrymal bone; 11, the malar bone, close to its junction with the zygoma; 12, superior maxillary bone—the figure is placed on the body behind the canine fossa; 13, ramus of the lower jaw, at its middle; 14, body of the lower jaw, near the mental foramen.

The *fronto-parietal*, or *coronal suture*, connects the frontal and the two parietal bones. It commences at each side, about an inch behind the external orbital process of the frontal bone, above the great wing of the sphenoid, and mounts upwards and backwards to the vertex. It presents the most marked dentations in the middle of each lateral half; at the summit the serrated surface is oblique, the frontal bone overlapping the parietal, while similarly at the lower part the parietal overlaps the frontal.

The *occipito-parietal*, or *lambdoidal suture*, situated between the occipital



and parietal bones, inclines downwards and outwards on each side and has somewhat of the form of the Greek letter  $\Lambda$ . The *occipito-mastoid suture* (*additamentum suturæ lambdoidalis*) is in continuation with it.

The *parietal*, or *sagittal suture*, connects the two parietal bones: it is continued in children, and not unfrequently in adults, by a suture between the two halves of the frontal bone, the *frontal suture*.

The *spheno-parietal suture*, the line of contact of the parietal bone and great wing of the sphenoid, is about half an inch in extent. It is absent only in very rare cases, and then the frontal and temporal bones come into contact.

The *temporo-parietal suture* consists of two very distinct parts, the *squamous suture*, arched in direction, in which the scale-like margin of the squamous portion of the temporal bone overlays the similar margin of the parietal, and the *parieto-mastoid suture* (*additamentum suturæ squamosæ*), which is thick and serrated.

From the nature of the squamous suture, the inferior margins of the parietal bones cannot be pressed outwards by forces acting either from above or from within, without at the same time pushing before them the squamous margins of the temporals. When the *pars squamosa* is thus acted on, it may either bulge outwards alone, or may press downwards the base of the *pars petrosa*. Both phenomena are observable in broad skulls.

**OSSA TRIQUETRA.**—Supernumerary ossicles are found in a great number of skulls, interposed between the cranial bones, like islets in the sutures. They are called *ossa triquetra*, *ossa Wormii*, *ossa suturarum*, &c. They are of irregular form, with margins adapted to the character of the sutures in which they are situated. They are most frequently found in the occipito-parietal suture, where they occur sometimes in great numbers, more or less symmetrically arranged; in other instances, one or several bones of considerable size may occupy the place of the superior part of the occipital. They are less frequent in the parietal suture and at the anterior fontanelle, are found only in small numbers in the fronto-parietal suture, and rarely occur in the squamous. A single triquetrous bone intervenes sometimes between the parietal and sphenoid; and still more frequently between the parietal and the place of meeting of the squamous and mastoid portions of the temporal.

#### GENERAL CONFORMATION OF THE SKULL.

##### THE EXTERIOR.

The surface of the skull may be conveniently divided into superior, inferior, anterior, and lateral regions.

The **SUPERIOR REGION**, extending from the supra-orbital ridges in front to the superior curved line of the occipital bone behind, and bounded laterally by the temporal ridges, is smooth and convex, covered only by the muscular fibres and fascia of the occipito-frontalis muscle and the integument. It is of an oval form, broader in the parietal than the frontal region, flattened in front, and projecting somewhat in the middle behind.

The **ANTERIOR REGION** of the skull, below the forehead, presents the openings into the orbits, bounded by the frontal, malar, and superior maxillary bones; and between the orbits, the bridge of the nose, formed by the nasal bones and ascending processes of the superior maxillaries. Below the nasal bones is the nasal aperture, of an inverted heart shape: its thin margin gives attachment to the nasal cartilages, and projects forwards in the middle line below as the nasal spine. Below the nasal aperture are the incisor fossæ of the upper jaw; below the orbits are the canine fossæ; and external to the canine fossæ are the prominences of the cheeks, formed by the anterior inferior parts of the malar bones. The lower jaw completes the



skeleton of the face below. The foramina in this region, on each side, are the supra-orbital foramen or notch in the superior margin of the orbit, the infra-orbital foramen below the inferior margin of the orbit, the mental foramen of the lower jaw, and the small irregular foramina of the malar bone.

The orbits are pyramidal fossæ, irregularly quadrilateral, with their bases

Fig. 50.

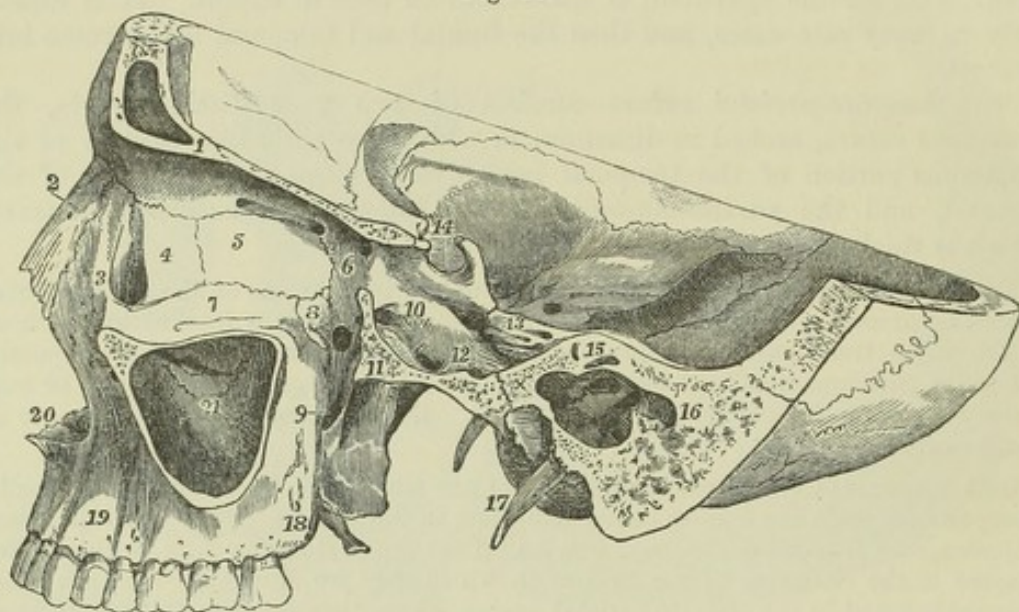


Fig. 50.—SECTION OF THE SKULL OF A MAN OF MIDDLE AGE, IN TWO PLANES, ONE OF WHICH PASSES VERTICALLY THROUGH THE LEFT ORBIT TO THE INNER SIDE OF ITS MIDDLE, AND THE OTHER OBLIQUELY FROM BEHIND THE ORBIT, BACKWARDS AND OUTWARDS, THROUGH THE TYMPANUM AND MASTOID PROCESS, AND TO THE OUTSIDE OF THE FORAMEN ROTUNDUM AND FORAMEN OVALE.  $\frac{1}{2}$

1, section of the frontal bone in the roof of the orbit; 2, left nasal bone; 3, nasal process of the superior maxillary bone; 4, left lachrymal bone, and in front the groove of the nasal duct; 5, placed on the os planum of the ethmoid bone, below the anterior of the ethmoid foramina; 6, is placed below the root of the lesser wing of the sphenoid bone, between the optic foramen and the posterior internal orbital or ethmoid foramen, and close to the foramen lacerum orbitale; 7, floor of the orbit, formed by orbital plate of the superior maxillary bone—the figure is placed close to the inside of the infra-orbital groove; 8, is placed on the orbital plate of the palate bone, in front of and above the sphenopalatine foramen and sphenomaxillary fossa; 9, marks the upper extremity of the posterior palatine (or palato-maxillary) canal; towards 11 in the fossa is the opening backwards of the Vidian canal; 10, the cranial opening of the foramen rotundum—its anterior opening is seen in the sphenomaxillary fossa; 11, section of the great wing of the sphenoid bone outside the round and oval foramina; 12, is placed close to and between the spinous and oval foramina; 13, is placed on the anterior surface of the petrous bone, near the apex, or in the fossa of the Gasserian ganglion; towards the orbit are seen the foramen lacerum anterius, sigmoid groove of the internal carotid artery, and pituitary fossa, below the figure and externally the hiatus Fallopii; 14, the pituitary fossa, with the anterior and posterior clinoid processes; 15, section of the petrous bone above the labyrinth; two of the semicircular canals are opened; immediately below is the tympanum. The inner wall is seen with the promontory, fenestra ovalis and pyramid in shadow; forwards, at x, the opening of the tympanum towards the Eustachian canal, and backwards, below 16, the opening into the mastoid cells; 17, left styloid process—that of the right side is seen in perspective below the skull, close by the occipital condyle; 18, tuberosity of the superior maxilla; 19, canine fossa; 20, nasal notch and anterior nasal spine; 21, inner wall of the antrum seen by the removal of its outer wall; above the figure is an irregular opening, viz., the opening of the antrum into the middle meatus of the nose, and above that the uncinat process of the ethmoid bone. The figure 21 is placed below the deflected plate of the inferior turbinated bone, where it completes a part of the inner wall of the antrum.



directed forwards and outwards, their inner walls being nearly parallel, and their outer walls diverging so much as to be at right angles one to the other. The roof of each orbit is formed by the orbital process of the frontal and the small wing of the sphenoid bone; the floor consists of the orbital processes of the malar and superior maxillary bones, and of the small orbital surface of the palate bone at the back part; the inner wall consists of the ascending process of the superior maxillary, the lachrymal, the ethmoid, and the sphenoid bone; and the outer wall of the orbital surfaces of the malar bone and great wing of the sphenoid. The *sphenoidal fissure* (foramen lacerum orbitale), at its inner extremity, occupies the apex of the orbit, while its outer and narrower part lies between the roof and the external wall. The foramen opticum is internal and superior to the sphenoidal fissure. In the angle between the external wall and the floor is the *spheno-maxillary fissure*, bounded by the sphenoid, palate, superior maxillary, and malar bones, and leading into the spheno-maxillary fossa at its back part, and the zygomatic fossa at its fore part. Passing forwards from the margin of the spheno-maxillary fissure is the commencement of the infra-orbital canal, grooving the posterior part of the floor of the orbit. At the fore part of the inner wall is the lachrymal groove, formed by the superior maxillary and lachrymal bones, and leading into the nasal duct: further back, between the ethmoid and frontal bones are the anterior and posterior internal orbital foramina; in the anterior margin of the roof is the supra-orbital foramen or notch; and in the outer wall are the minute foramina which perforate the malar bone.

The LATERAL REGION of the skull presents in a horizontal line from behind forwards the mastoid process, the external auditory meatus, the glenoid fossa, with the condyle of the lower jaw, and the *zygomatic* or *malar arch*, formed by the zygomatic process of the temporal bone and the posterior part of the malar. When the head of the lower jaw is in the glenoid cavity, the coronoid process lies internal to the malar arch. The upper part of the space bridged over by this arch is called the *temporal fossa*, the lower part the *zygomatic fossa*, the line of division being the rough ridge which divides the external surface of the great wing of the sphenoid bone into an upper and lower portion. The temporal fossa is occupied by the temporal muscle; it is bounded superiorly by the temporal ridge; and the frontal, parietal, sphenoid and malar bones take part in its formation. The zygomatic fossa is occupied in part by the external pterygoid muscle; its wall is formed internally by the external pterygoid plate, superiorly by the lower part of the great wing of the sphenoid bone, and anteriorly by the superior maxillary. Inferiorly the external pterygoid plate comes nearly into contact with the superior maxillary bone, but is usually separated from it, though not always, by a thin portion of the pyramidal process of the palate bone; superiorly, it is divided from it by the *pterygo-maxillary fissure*, a vertical opening, which leads into the spheno-maxillary fossa, and which is continued above into the outer extremity of the horizontal spheno-maxillary fissure opening into the orbit.

The *spheno-maxillary fossa* is the space which lies in the angle between the pterygo-maxillary fissure and the inner or posterior half of the spheno-maxillary fissure. It is bounded posteriorly by the external pterygoid process and inferior division of the anterior surface of the great wing of the sphenoid bone, anteriorly by the tuberosity of the superior maxillary bone, and internally by the vertical plate of the palate bone. Into this narrow space five foramina open, viz., on the posterior wall, the foramen rotundum, the Vidian canal, and, between the sphenoidal process of the



palate bone and the root of the internal pterygoid plate, the pterygo-palatine canal; on the inner wall, the spheno-palatine foramen formed by the palate bone and a small part of the sphenoidal spongy bone, and opening into the nasal cavity; and inferiorly, the posterior palatine canal, which leads down to the palate between the palatal and superior maxillary bones.

Fig. 51.

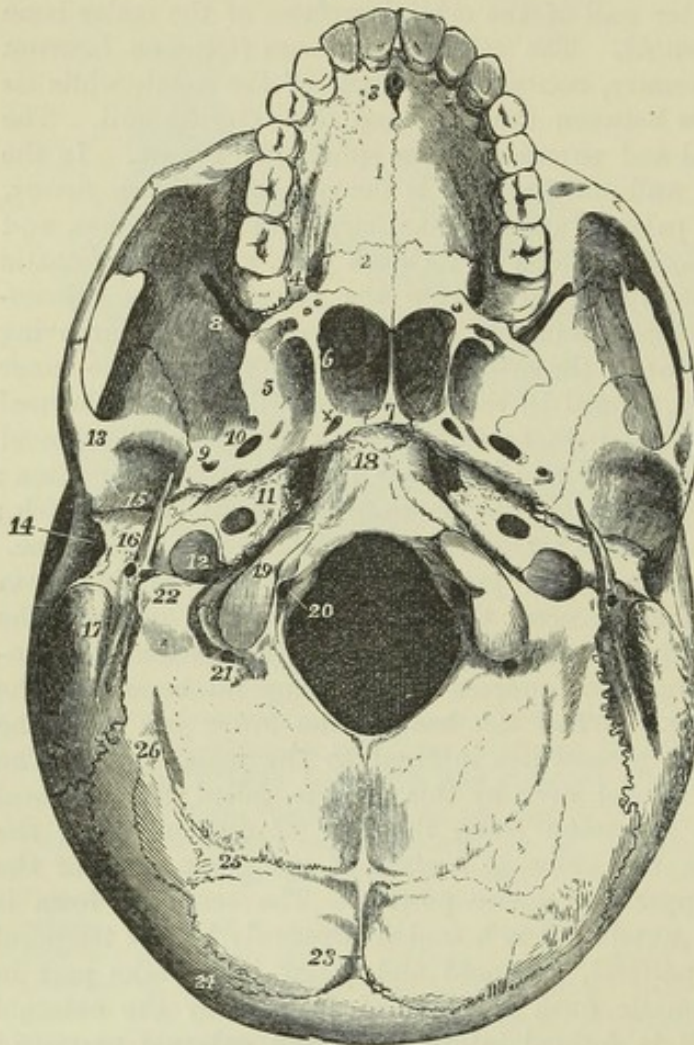


Fig. 51.—BASIS OF THE SKULL, VIEWED FROM BELOW, WITHOUT THE INFERIOR MAXILLARY BONE.  $\frac{1}{2}$

1, palatine plate of the superior maxillary bone—the figure is placed near the mesial suture; 2, palatine plate of the palate bone—the figure is placed below the transverse suture between the palate and superior maxillary bones; 3, the anterior palatine foramen, showing four smaller foramina within; 4, is placed outside the posterior palatine foramen, inside the tuberosity of the superior maxilla, and in front of the smaller posterior palatine foramina in the pyramidal process of the palate bone; 5, inner surface of the external pterygoid plate of the sphenoid bone; 6, is placed within the posterior opening of the nares on the inner surface of the internal pterygoid plate; 7, is upon the upper part of the posterior edge of the vomer; x marks the posterior opening of the pterygo-palatine canal, and is placed

above or in front of the posterior opening of the Vidian canal in the foramen lacerum anterius; 8, spheno-maxillary fissure leading into the orbit; 9, foramen spinosum; 10, foramen ovale; 11, is placed on the apex of the petrous bone, between the foramen lacerum anterius and the inferior opening of the carotid canal; 12, is placed in the jugular (or digital) fossa of the temporal bone, and indicates the foramen lacerum posterius; 13, on the articular eminence of the inner root of the zygoma in front of the glenoid cavity of the temporal bone; 14, meatus auditorius externus; 15, glenoid cavity in front of the fissure of Glaser; 16, tympanic plate or posterior part of the glenoid cavity, close to the styloid process, below which is seen the stylo-mastoid foramen; 17, mastoid process, and to its inside the digastric and occipital grooves; 18, basilar process of the occipital bone, and in front the mark of the still incomplete union with the body of the sphenoid bone; 19, condyloid articular process of the occipital bone; 20, is placed in the foramen magnum, and points to the lower opening of the anterior condyloid foramen; 21, posterior opening of the posterior condyloid foramen; 22, jugular process of the occipital bone, to its inner side the jugular notch, to its outer and above, the stylo-mastoid foramen; 23, is placed on one side, in front (above in the figure) of the external occipital protuberance, and the line indicates the upper part of the external occipital spine; 24, superior curved line of the occipital bone; 25, inferior curved line; 26, groove and ridge of insertion of obliquus capitis superior muscle.



The *INFERIOR REGION*, or *external base of the skull*, extending from the incisor teeth to the occipital protuberance, and transversely from the mastoid process and dental arch on one side to the corresponding points on the other, is divisible, on removal of the lower jaw, into an anterior, middle, and posterior part.

The *anterior part* consists of the palate and the alveolar arch. It is traversed longitudinally by a mesial suture, and transversely by that between the maxillary and palate bones. Anteriorly, in the middle line, is the anterior palatine foramen, with the four smaller foramina contained within it; posteriorly, on each side, at the base of the alveolar border, is the posterior palatine foramen, and external and posterior to that, the posterior and external small palatine foramina. The palate is surrounded in front and on the sides by the alveolar arch and teeth of the upper jaw.

The *middle part*, extending back to the front of the foramen magnum, is the most complicated. Its central portion has been called the *guttural fossa*. In the middle line is the basilar process of the occipital bone, and in front of that the body of the sphenoid bone, concealed anteriorly by the extremity of the vomer. On each side, the petrous portion of the temporal bone reaches as far forwards as the extremity of the basilar process; and between the petrous and squamous portions of the temporal is the back part of the great wing of the sphenoid bone. Between this division of the base of the skull and the palate are the *posterior nares*, separated by the vomer, and bounded above by the body of the sphenoid bone, below by the horizontal plates of the palate bones, and on the sides by the internal pterygoid processes. Between the pterygoid plates is the pterygoid fossa; and placed in an oblique line backwards and outwards from this are the foramen ovale, foramen spinosum, and processus spinosus; while behind and parallel to these is a *groove for the Eustachian tube*, formed by the margins of the sphenoid bone and pars petrosa, leading into the Eustachian orifice, and in a line with the fissure of Glaser. Between the apex of the pars petrosa, the basilar process, and the sphenoid bone, is the *foramen lacerum anterius basis cranii*, called also *foramen lacerum medium*, on the external wall of which opens the carotid canal, and on the anterior the Vidian canal; it is closed inferiorly by a plate of cartilage, but its area is crossed by the internal carotid artery and by the Vidian nerve. Behind the pars petrosa, and bounded posteriorly by the jugular fossa of the occipital bone, is the *foramen jugulare*, or *foramen lacerum posterius*: it is divided into a large external and posterior part, bounded anteriorly by the jugular fossa of the temporal bone, and occupied by the jugular vein; and a small anterior and inner part, bounded by a portion of the pars petrosa distinct from the jugular fossa, and transmitting the glosso-pharyngeal, vagus, and spinal accessory nerves. The two parts of the foramen lacerum posterius are sometimes completely separated by a spiculum of bone. Anterior to this opening is the carotid foramen, external to it is the stylo-mastoid foramen and styloid process, and internal to it is the anterior condyloid foramen.

The *posterior part* of the inferior region presents on each side of the fore part of the foramen magnum, in a transverse line outwards, the occipital condyle, the rough surface for the rectus capitis lateralis muscle, the occipital groove of the temporal bone, the digastric fossa, and the mastoid process. Behind is the inferior division of the expanded part of the occipital bone, with its ridges and muscular impressions.



## THE INTERIOR OF THE SKULL.

1. THE CRANIAL CAVITY.—The walls of the cranium present two layers of compact tissue, the *outer* and *inner tables*, and between these, in the greater part of their extent, cancellated substance, called *diploe*. The inner

Fig. 52.

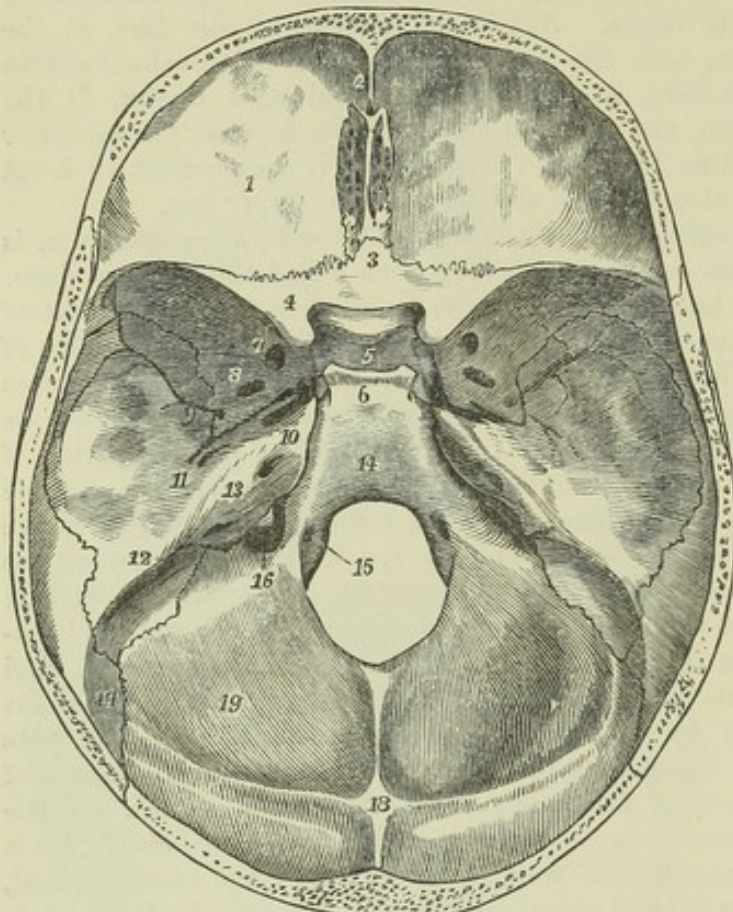


Fig. 52. — INTERNAL BASIS OF THE SKULL, OPENED BY A HORIZONTAL INCISION ONE INCH ABOVE THE SUPRA-ORBITAL ARCHES AND EXTERNAL OCCIPITAL PROTUBERANCE.  $\frac{1}{2}$

1, anterior fossa and roof of the orbit, as formed by the frontal bone, marked by impressions of cerebral convolutions; 2, is close to the foramen cecum and in front of the crista galli and cribriform plate of ethmoid; 3, is close behind the ethmoidal spine of the sphenoid and behind the cribriform plate; 4, lesser wing of Ingrassias, terminating posteriorly in the anterior clinoid process, inside which the inner opening of the optic foramen is seen; 5, the pituitary fossa, in front of it the olivary eminence and transverse groove of the optic

commissure; 6, the inclined plate of the body of the sphenoid, or dorsum sellæ, terminating in the posterior clinoid processes, and to the side of these the sigmoid groove of the internal carotid artery; 7, foramen rotundum, to the inner side of which anteriorly, but not seen, is the foramen lacerum orbitale; 8, foramen ovale; 9, foramen spinosum; 10, is placed on the ridge of the petrous bone, near its apex, and to the inside of the hollow occupied by the Gasserian ganglion; in front of this is the foramen lacerum anterius; 11, is placed internal to the eminence of the superior semicircular canal of the labyrinth, and behind the hiatus Fallopii; 12, is upon the prominent ridge of the petrous bone, in which (on the opposite side) the superior petrosal groove is marked; 13, is upon the posterior surface of the petrous bone—to the inside, the meatus auditorius internus, behind, the scale of bone covering the aqueduct of the vestibule; 14, basilar groove; 15, inner or upper opening of the anterior condyloid foramen; 16, jugular part of the foramen lacerum posterius; 17, outer part of the groove of the lateral sinus, where it crosses the lower angle of the parietal bone; 18, internal occipital protuberance, and between it and the foramen magnum, the internal occipital spine; between 17 and 18, the upper part of the groove of the lateral sinus, between 17 and 16 the lower part; 19, cerebellar fossa.

or *vitreous* table has a smooth, close-grained, shining appearance, is hard and brittle, and is thrown into irregular digitate impressions corresponding to the convolutions of the brain. The thinnest portions of the cranial wall are the cribriform plate of the ethmoid and the orbital plates of the frontal bone, in both of which the *diploe* is entirely absent; in the middle part of the inferior occipital fossæ, and in the squama and glenoid fossa of the temporal, the bone is also very thin and compact.



The upper part of the cranial cavity forms an unbroken arch ; the lower part is divisible into three parts or fossæ having different levels.

The *anterior fossa*, formed by the orbital plates of the frontal bone, the small wing of the sphenoid, and the cribriform plate of the ethmoid, supports the anterior lobes of the brain. It is deepest opposite the ethmoid bone, and convex over the orbits. It is pierced by the foramina of the cribriform plate, and by the foramen cœcum in front of the crista galli of the ethmoid bone.

The *middle fossa* presents a mesial and two lateral parts. The mesial part is small, being formed by the olivary process and sella turcica of the sphenoid bone, and limited behind by the dorsum sellæ. The lateral part on each side, formed by the great wing of the sphenoid, the squamous part of the temporal, and the anterior surface of the petrous part, lodges the middle lobe of the brain. The foramina of the middle fossa are the foramen opticum, the sphenoidal fissure, foramen rotundum, foramen ovale, foramen spinosum, foramen lacerum medium, and hiatus Fallopii.

The *posterior fossa*, deeper and larger than the others, extends back to the occipital protuberance, and lodges the cerebellum and medulla oblongata. The occipital bone and the petrous and mastoid portions of the temporal bone take part in its formation. In the posterior surface of the pars petrosa, which limits this fossa anteriorly on each side, is the internal auditory meatus, below it is the foramen lacerum posterius, below and internal to that is the anterior condyloid foramen, and in the middle line is the foramen magnum.

*Grooves for Bloodvessels.*—The groove of the middle meningeal artery commences at the foramen spinosum of the sphenoid bone, and ramifies principally on the squamous portion of the temporal bone and on the parietal. The groove of the internal carotid artery lies on the side of the body of the sphenoid bone, and terminates on the internal margin of the anterior clinoid process. The groove of the superior longitudinal sinus, commencing at the foramen cœcum in front of the crista galli of the ethmoid bone, enlarges as it passes backwards in the middle line of the roof of the skull, and terminates at the internal occipital protuberance. At that point commence the grooves of the lateral sinuses, which pass outwards on the occipital bone, cross the posterior inferior angles of the parietal bones, descend on the mastoid portions of the temporal bones, run inwards again on the occipital, and turn forwards to terminate at the jugular foramen. The groove of the inferior petrosal sinus lies between the petrous portion of the temporal bone and the basilar process ; that of the superior petrosal sinus extends along the superior angular edge of the petrous portion.

**THE NASAL CAVITIES AND COMMUNICATING SINUSES.**—The nasal cavities are placed one at each side of the middle line, being separated by a vertical septum. They open in front and behind by the anterior and posterior nares already described, and communicate by foramina with the sinuses of the frontal, ethmoid, sphenoid, and superior maxillary bones. Their vertical extent, as well as that from before backwards, is considerable, but the transverse width of each is very limited, especially in the upper part.

The *internal wall*, or *septum narium*, is formed principally by the central plate of the ethmoid bone and the vomer ; but the frontal spine, the rostrum of the sphenoid bone, and the crests of the maxillary and palate bones likewise enter into its composition. It presents a great angular deficiency in front, which in the recent state is filled up by the septal cartilage. In



very many cases it deviates from the middle line, and more frequently to the left than to the right side. The concave side is that on which the ala of the vomer is most intimately connected with the ethmoid.

Fig. 53.

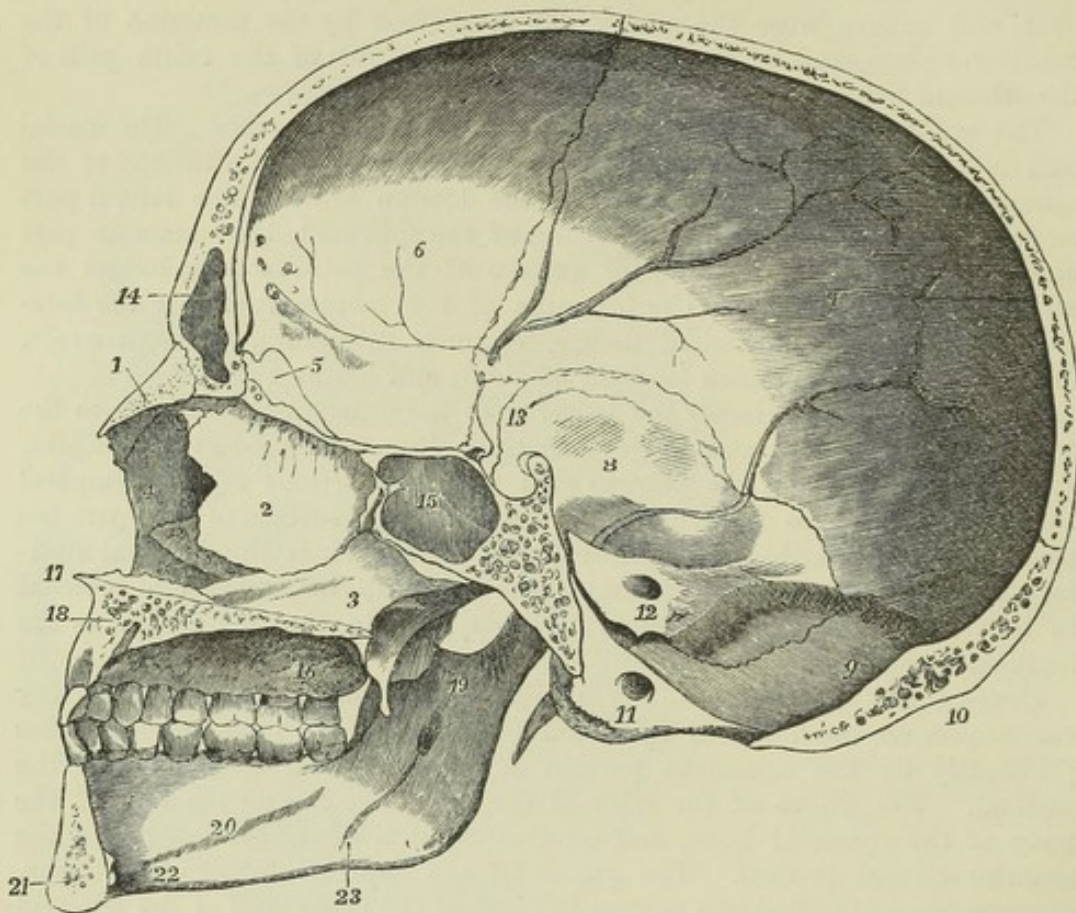


Fig. 53.—VERTICAL SECTION OF THE ADULT SKULL IN AN ANTERO-POSTERIOR PLANE, PASSING A LITTLE TO THE LEFT OF THE MIDDLE, SHOWING THE SEPTUM NARIUM, &c.  $\frac{1}{2}$

1, nasal bone; 2, perpendicular plate of the ethmoid bone, with olfactory foramina and grooves at its upper part; 3, vomer; 4, nasal process of the right superior maxillary bone, forming part of the wall of the right nasal fossa; below this the anterior extremity of the right inferior turbinate bone, and below that, at  $\times$ , the fore part of the right inferior meatus of the nose; 5, crista galli; 6, inner surface of the frontal bone; 7, of the parietal bone; 8, squamous part of the temporal,—all these being marked by grooves of cerebral convolutions and meningeal vessels; 9, placed on the occipital bone below the internal or anterior occipital protuberance; 10, the posterior or external occipital protuberance; 11, placed on the condyloid process below the anterior condyloid foramen; 12, placed on the posterior surface of the petrous bone below the meatus auditorius internus; between 9 and 12 the groove of the right lateral sinus, crossing also the mastoid bone; 13, placed above the sella turcica and between the anterior and posterior clinoid processes; 14, part of the left frontal sinus, the figure being placed on the left side of the septum, between the left and the right sinus; 15, part of the left sphenoidal sinus, the figure being placed on the septum of the sinuses; 16, hard palate and alveolar arch—the figure is placed near the lower opening of the posterior palatine canal, and the grooves which extend forwards from it; 17, anterior nasal spine; 18, section of the left superior maxillary bone, and near the place to which the line points, the section of the lower part of the anterior palatine canal; 19, placed on the inner surface of the ramus of the lower jaw, below the sigmoid notch, and above the inferior maxillary foramen; 20, inner surface of the body of the jaw on the oblique or mylo-hyoid ridge; 21, section of the lower jaw, near the symphysis; behind the symphysis, and between 21 and 22, the mental or genioid spines; 23, groove for the mylo-hyoid nerve.

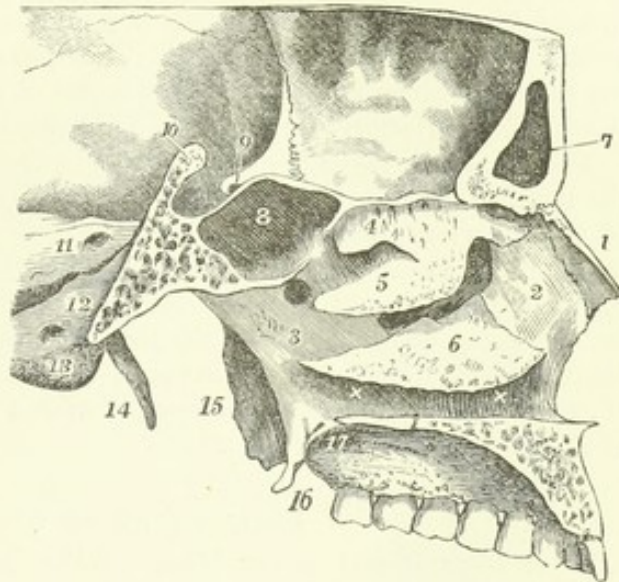


The *roof* is horizontal in its middle part, but sloped downwards before and behind. The middle part is formed by the cribriform plate of the ethmoid bone, the fore part by the frontal and nasal bones, and the back part by the sphenoidal spongy bone.

The *floor*, formed of the palate plates of the maxillary and palate bones, is smooth, and concave from side to side. Towards its anterior extremity is the superior orifice of the incisor canal.

Fig. 54.—VERTICAL ANTERO-POSTERIOR SECTION OF A PART OF THE CRANIUM, TO THE LEFT OF THE MIDDLE, VIEWED FROM THE INNER SIDE, TO SHOW THE OUTER WALL OF THE LEFT NASAL FOSSA, &c.  $\frac{1}{2}$

Fig. 54.



1, nasal bone; 2, nasal process of the superior maxillary bone; 3, ascending plate of the palate bone; 4, superior turbinate bone of the ethmoid—below it the superior meatus, behind it the opening into the left sphenoidal sinus; 5, the middle turbinate bone—below it the middle meatus, in which are seen the uncinate process of the ethmoid, and between it and the inferior turbinate bone the opening into the maxillary sinus, superiorly and anteriorly, the opening of the infundibulum and anterior ethmoidal cells; behind it, and above 3, the sphenopalatine foramen; 6, the inferior turbinate bone—below it the inferior meatus  $\times \times$ , below these marks the section of the palatine plates of the left palate and superior maxillary bones; 7, the left frontal sinus; 8, the left sphenoidal sinus; 9, the left optic foramen in the root of the lesser wing of the sphenoid and anterior clinoid process; 10, the ridge of the dorsum sellae divided; and between 9 and 10, the sella turcica; 11, is placed on the posterior surface of the petrous bone, close to the internal auditory meatus; 12, is placed on the basilar process of the occipital bone, close to the foramen lacerum posterius; 13, is placed below the anterior condyloid foramen; 14, left styloid process; 15, external, and 16, internal pterygoid processes; 17, posterior palatine canal and grooves.

The *external wall* is the most extensive. The bones which take part in its formation are the nasal, superior maxillary, ethmoid, lachrymal, inferior spongy, and palate bones, and the internal pterygoid plates. The superior and inferior turbinated processes of the ethmoid bone (superior and middle turbinated bones), and the inferior spongy bone, projecting inwards, overhang three galleries or *meatus*. The *superior meatus*, very short, is directed downwards and forwards between the superior and inferior turbinated processes of the ethmoid bone; into it open anteriorly the posterior ethmoidal cells, and posteriorly the sphenopalatine foramen. The *middle meatus*, the space between the inferior turbinate process of the ethmoid and the inferior spongy bone, communicates at its fore part with the anterior ethmoidal cells, and, by means of the infundibulum, with the frontal sinus, while in its middle is the opening of the maxillary sinus. The *inferior meatus*, longer than the others, lies below the inferior spongy bone, between it and the floor of the nasal cavity; in its fore part is the orifice of the nasal duct.



The *SINUSES* are hollows within certain cranial bones, which communicate with the nasal cavities by narrow orifices, and are named *ethmoidal*, *frontal*, *sphenoidal*, and *maxillary*. The maxillary sinus begins to be formed about the fourth month of foetal life; the frontal, ethmoidal, and sphenoidal first appear during childhood, but remain of small size up to the time of puberty, when they undergo a great enlargement. In advanced life they all increase in size by absorption of the cancellated tissue in their vicinity. The *ethmoidal sinuses* are numerous smaller spaces in the lateral masses of the ethmoid bone. The *frontal sinuses*, formed in the substance of the frontal bone, communicate with the middle meatus narium through the infundibula of the ethmoid bone. The *sphenoidal sinuses*, hollowed out in the sphenoid bone, and limited below and in front by the sphenoidal spongy bones, open anteriorly opposite the posterior ethmoidal cells.

The *maxillary sinus* is of an irregular pyramidal form; its apex points to the malar tuberosity; its sides are formed by the orbital and lateral plates of the superior maxillary bone; its base, or internal wall, which separates it from the nasal cavity, is formed by the maxillary, palate, and inferior turbinated bones, and the uncinate process of the ethmoid; an irregular gap or deficiency being left between the uncinate process and the inferior turbinated bone, by which the sinus opens into the middle meatus. The alveolus of one of the molar teeth generally forms a marked projection in the floor of the sinus, at its outer part.

#### DEVELOPMENT OF THE SKULL.

EARLY DEVELOPMENT OF THE HEAD.—When the head of the embryo has become so far developed as to rise completely out from the plane of the germinal mem-

Fig. 55.

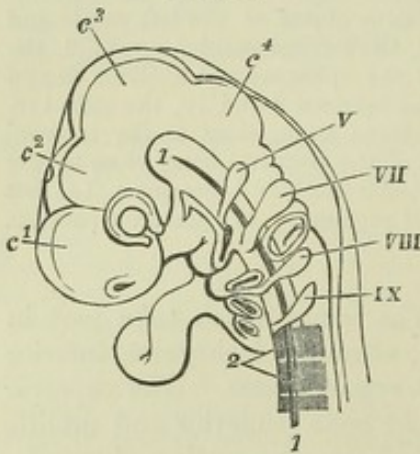


Fig. 55.—MAGNIFIED SIDE VIEW OF THE HEAD AND UPPER PART OF THE BODY OF AN EMBRYO-CHICK OF THE FOURTH DAY (adapted from Remak and Huxley).

1, chorda dorsalis; 2, three of the upper primitive cervical vertebræ; C¹, first cerebral vesicle, with the nasal fossa below; C², second part of the first cerebral vesicle, or thalamus opticus, with the eye below it; C³, the middle cerebral vesicle; C⁴, the cerebellum, between which and the cervical vertebræ is the medulla oblongata, these two constituting the first and second parts of the third cerebral vesicle. At the upper part of the chorda dorsalis, where it afterwards reaches the post-sphenoid, is seen the rectangular bend of the middle of the cranium, which takes place at the sella turcica; and in front of this, towards the eye, the pointed infun-

dibulum; V, the rudiment of the trigeminus nerve; VII, the facial; VIII, the vagus; IX, the hypoglossal; in front and below these numbers respectively, first the upper and lower jaw, or first branchial arch, with the first cleft, which becomes the meatus auditorius externus; and lower down the second, third, and fourth branchial arches and clefts in succession; in front of these the aortic bulb attaches the heart; between VII and VIII, the auditory vesicle.

brane, two curvatures forwards are observed, the posterior of which is at the junction of the head with the spinal column, while the anterior is opposite the second cerebral vesicle, and is so placed that the fore part of the skull is bent at right angles to the back part. Behind the anterior curvature, the ventral margins of the dorsal plates are thrown on each side into four processes, the *branchial* or *visceral arches*, behind each of which is a fissure or *branchial cleft* in which the epithelial layer of



the gullet passes out and becomes continuous with that of the integument. In a human embryo of three weeks of age all the arches are visible (Thomson). The first or highest visceral arch is the first to appear, and it is likewise the first to unite with its fellow of the opposite side: it forms by its lower part the outline of the lower jaw. The posterior or upper part of the first branchial cleft remains as the external aperture of the ear, the tympanic cavity and the Eustachian tube, while its anterior part together with the whole of the other branchial clefts are filled up. Connected with the upper edge of the first visceral arch, at its origin, a process is developed, the *maxillary lobe*, which passes forwards beneath the eye, forming the side part of the face. The eyes are formed in connection with the sides of the anterior cerebral vesicle, and, in front of them, a quadrilateral mesial lobe, the *middle frontal process*, passes down and forms the nose and middle part of the upper lip. At the angles of the extremity of the middle frontal process are two slight lobes, the *internal nasal processes* of Kölliker; above these are two notches, the rudimentary nostrils, and between the nostrils and eyes another pair of lobes, the *external nasal processes* of Kölliker, or *lateral frontal processes* of Reichert. The maxillary lobe becomes united to the internal and external nasal processes; but between it and the latter there is left the nasal duct. About the ninth week the inferior parts of the maxillary lobes, having sent projections inwards, are united in the middle line and form the palate.

Fig. 56.—A. MAGNIFIED VIEW FROM BEFORE OF THE HEAD AND NECK OF A HUMAN EMBRYO OF ABOUT THREE WEEKS (from Ecker, *Icones Physiol. Tab. xxix. fig. I.*).

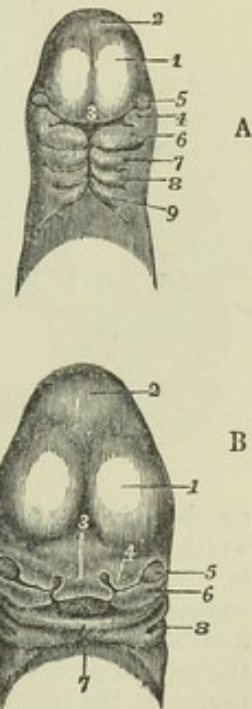
1, anterior cerebral vesicle or cerebrum; 2, middle ditto; 3, middle or naso-frontal process; 4, superior maxillary process; 5, eye; 6, inferior maxillary process or first visceral arch, and below it the first cleft; 7, 8, 9, second, third, and fourth arches and clefts.

B. ANTERIOR VIEW OF THE HEAD OF A HUMAN FŒTUS OF ABOUT THE FIFTH WEEK (from Ecker, as before, fig. IV.).

1, 2, 3, 5, the same parts as in A; 4, the external nasal or lateral frontal process; 6, the superior maxillary process; 7, the lower jaw; x, the tongue; 8, first branchial cleft becoming the meatus auditorius externus.

*Formation of the cranium.*—The chorda dorsalis passes into the base of the skull, as far forwards as the sphenoidal region. According to the observations of H. Müller on the calf (Ueber das Vorkommen von Chordaresten, &c., in *Zeitschr. für Rat. Med.* 3rd series, vol. ii.), it extends from the odontoid process of the axis through the basilar process of the occipital bone to the back of the dorsum sellæ, which it pierces, and is lost behind the pituitary body. Before attaining the osseous state, the cranium passes through a membranous and cartilaginous condition, in which it is termed the *primordial cranium*. In the membranous cranium, the blastema, immediately beyond the extremity of the chorda dorsalis, presents two thick bars, the *lateral trabeculæ* of Rathke, with a very thin part in the middle line between them, corresponding to the position of the pituitary body (see fig. 57, 4). These trabeculæ unite in front in the ethmoidal region, and it is to be remarked that in the cartilaginous stage the ethmo-vomerine cartilage or mesial septum of the nose is continued directly forwards from the region containing the chorda dorsalis. In the cartilaginous stage of the cranium the cartilage can only be traced in the basilar parts, and corresponds in extent to the occipital bone below the level of its protuberance, the petrous and mastoid portions of the temporal bone, the sphenoid and the ethmoid, while the part of the wall in which the frontal and parietal bones, the upper part of the occipital, and the squamous portions of the temporals appear, remains membranous. The extent, however, over which the cartilage of the primordial cranium extends differs in different animals, and is greater in many mammals than in man (Kölliker). The nasal bones are derived from the middle

Fig. 56.





frontal process, the superior maxillaries from the maxillary lobes, and the lachrymals probably from the lateral frontal lobes.

Fig. 57.

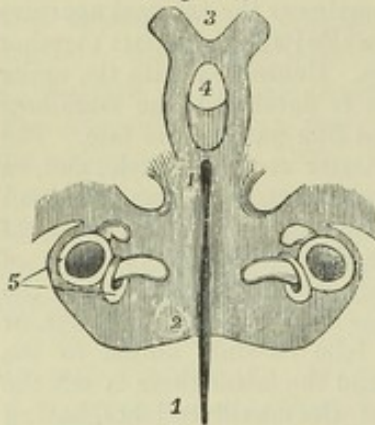


Fig. 57.—THE LOWER OR CARTILAGINOUS PART OF THE CRANIUM OF A CHICK ON THE SIXTH DAY (from Huxley, Elements of Compar. Anat. Fig. 57, F').

1, 1, chorda dorsalis; 2, the shaded portion here and forwards is the cartilage of the base of the skull; at 2 the occipital part; at 3 the prolongations of cartilage into the anterior part of the skull called *trabeculae cranii*; 4, the pituitary space; 5, parts of the labyrinth.

*Formation of the face.*—In studying the early development of the bones of the face it is necessary likewise to take into consideration the ossicles of the ear, viz., the malleus, incus, and stapes; for although in the adult these ossicles are so minute, and

Fig. 58.

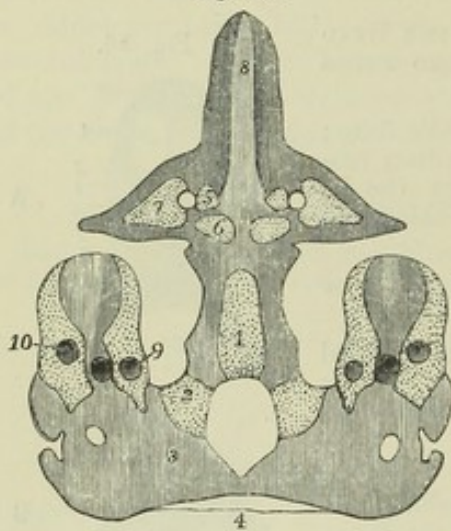


Fig. 58.—VIEW FROM BELOW OF THE CARTILAGINOUS BASE OF THE CRANIUM WITH ITS OSSIFIC CENTRES OF A HUMAN FŒTUS EIGHT INCHES LONG (about five months, from Huxley, as before, Fig. 59, slightly altered, the bone being dotted to distinguish it from the cartilage, which is shaded with lines).

1, the basilar part, 2, the condyloid or lateral parts, and 3, 4, the tabular or superior part of the occipital surrounding the foramen magnum; 5, centres of the pre-sphenoid on the inside of the optic foramen; 6, centres of the post-sphenoid; 7, centres of the lesser wings or orbito-sphenoid; 8, septal cartilage of the nose; 9 & 10 parts of the labyrinth.

so entirely contained within the cavity of the tympanum that they have not been included in the description of the skull, they are importantly connected in their origin with a

number of other bones. In each of the three first visceral arches a strip of firm tissue, which becomes cartilaginous, appears. That of the first arch is the most perfect, and is divided into three parts: the proximal part passes forwards some distance in contact with the basis cranii, it becomes ossified without passing through a cartilaginous stage, and from it are developed the palate bone and internal pterygoid plate; the middle part, which is very small, forms the body of the incus, and gives off two processes, the long and short processes of that ossicle; the remaining part, much the largest of the three, is prolonged downwards to meet its fellow of the opposite side at the extremity of the arch, and is named *Meckel's cartilage* after its first describer. (Meckel, "Handbuch der Mensch. Anat.") The upper extremity of Meckel's cartilage forms the malleus, the handle of which is developed as a process directed backwards. The lower portion is destined ultimately to dwindle away, but in the first instance increases in size, and forms a rod, on the external surface of which the lower jaw is formed. It can be detected on the internal aspect of the ramus of the jaw, up to the eighth month of foetal life, but its only permanent vestige is the processus gracilis of the malleus, which, when the tympanic cavity becomes closed inferiorly by the growth of the tympanic plate, remains with its extremity fixed in the fissure of Glaser. The proximal extremity of the cartilage of the second visceral arch forms the stapes, and in succession downwards from this are found the stapedius muscle, the styloid process of the temporal bone, the stylo-hyoid ligament, and the small cornu of the hyoid bone. The only permanent portions of the cartilage of the third visceral arch are the great cornu and the body of the hyoid bone. (Reichert "Ueber



die Visceralbogen," Müller's Archiv, 1837. See for a figure of Meckel's cartilage the description of the ossicles of the ear.)

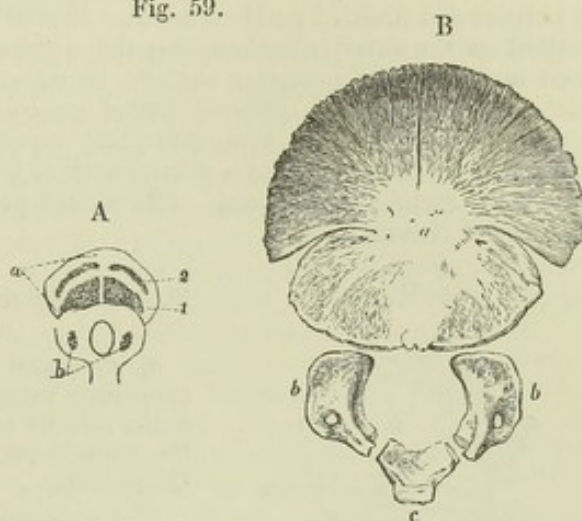
**OSSIFICATION.**—The *occipital* bone, for some time after birth, consists of four separate pieces, a basilar, a tabular, and two condyloid parts. The lines of junction of the

Fig. 59.—OSSIFICATION OF THE OCCIPITAL BONE.

A, in a foetus of 10 weeks (from Meckel, Archiv, vol. i. tab. vi.); *a*, upper or tabular part; 1 & 2, lower and upper pairs of ossific centres in it; *b*, lower part or basilar and condyloid portions: ossific centres are seen in the condyloid portions.

B, occipital bone of a child at birth; *a*, upper or tabular part, in which the four centres have become united into one, leaving fissures between them; *b, b*, the ossified condyloid portions; *c*, the basilar portion.

Fig. 59.



basilar and condyloid parts pass through the condyles near their anterior extremities; those of the condyloid and tabular parts extend outwards from the posterior extremity of the foramen magnum. The basilar and condyloid parts arise each from one osseous nucleus. In the tabular part there are probably in most cases four nuclei, placed in pairs above and below the occipital protuberance: Meckel mentions four additional nuclei, placed two at the superior and one at each lateral angle ("Handbuch der Mensch. Anat." ii. § 543); the different nuclei speedily unite to form a single thin tabular mass.

The *parietal* bones are ossified each from one nucleus which is placed near the centre of the bone or at the parietal eminence.

The *frontal* bone consists for a year, or from one to two years after birth, of two lateral portions, which not unfrequently remain separate during life (as happens also

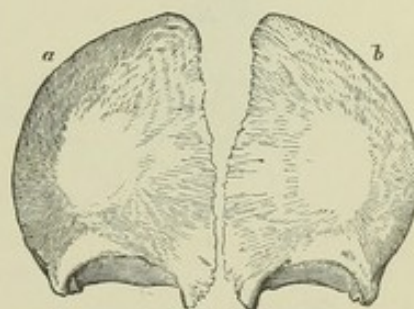
Fig. 60.—FRONTAL BONE OF A FŒTUS SHORTLY BEFORE BIRTH.

*a* & *b* indicate the two separate portions of the bone, in each of which the radiation of bony spicula from the frontal eminence is seen.

in the majority of animals), with a vertical suture between them, the *frontal suture*. Ossification begins on each side from a single nucleus above the orbit, or in the place of the frontal eminence.

The *Fontanelles*. Opposite the angles of the parietal bones, there are spaces which remain unoccupied by bone, after the osseous wall of the skull is elsewhere completed. Two of these, the *anterior* and *posterior fontanelles*, are in the middle line; the *lateral fontanelles*, two on each side, are opposite the inferior angles of the parietal bones, and are less important. The anterior fontanelle, situated between the adjacent angles of the parietal bones and the ununited halves of the frontal bone, is quadrangular in form, and remains open for some time after birth. The posterior fontanelle, situated between the parietal bones and the superior angle of the occipital bone, is triangular; it is filled up before birth, but during parturition the compression of the child's head forces the angle of the occipital bone beneath the edges of the parietals,

Fig. 60.





and produces a triangular depression at the site of the posterior fontanelle, which is easily recognised by the finger of the accoucheur.

The *temporal* bone, considered in respect of its development, consists of the squamous and petro-mastoid parts, the tympanic plate, and the styloid process. The squamous part, inclusive of the zygomatic process, is ossified from a single nucleus. The petrous and mastoid portions are also formed from only one centre: bone is first deposited on the anterior surface, over the cochlea, and there afterwards appear one or two nuclei on the posterior surface, in connection with the formation of the semicircular canals; the different nuclei soon unite, and ossification extends into the mastoid process. The tympanic plate appears in the membranous wall of the tympanum and external ear as a slender arch of bone forming three-fourths of a ring, inclosing the *membrana tympani*. The styloid process is formed, as already stated, in the second visceral arch.

Fig. 61.

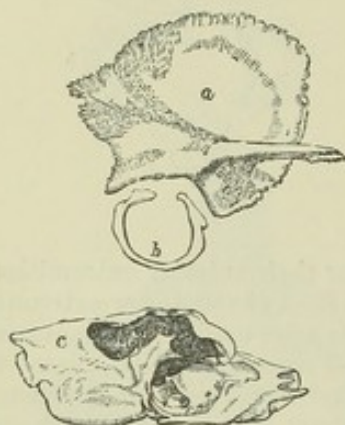


Fig. 61.—SEPARATE PARTS OF THE TEMPORAL BONE OF A CHILD AT BIRTH.

*a*, squamous part with the zygoma; *b*, the tympanic bone forming an imperfect ring open superiorly; *c*, the petrous and mastoid part; *c* being placed on the mastoid part: part of the cavity shown is the tympanum.

The *sphenoid* bone presents in infancy traces of a natural division into a posterior or *post-sphenoid* part, to which the *sella turcica* and great wings belong, and an anterior or *pre-sphenoid* part, to which belong the body in front of the olivary process and the small wings,—a division which is found in many animals complete and persistent through life. The first osseous nuclei of the post-sphenoid division occur in the great wings, one on each side, between the foramen rotundum and foramen ovale, and spread thence outwards into the wing and downwards into the external pterygoid process. The internal pterygoid processes arise from distinct nuclei, and, although in the human subject they soon unite with the external pterygoid, in other animals they remain separate, and are named by comparative anatomists the *pterygoid bones*.

Fig. 62.

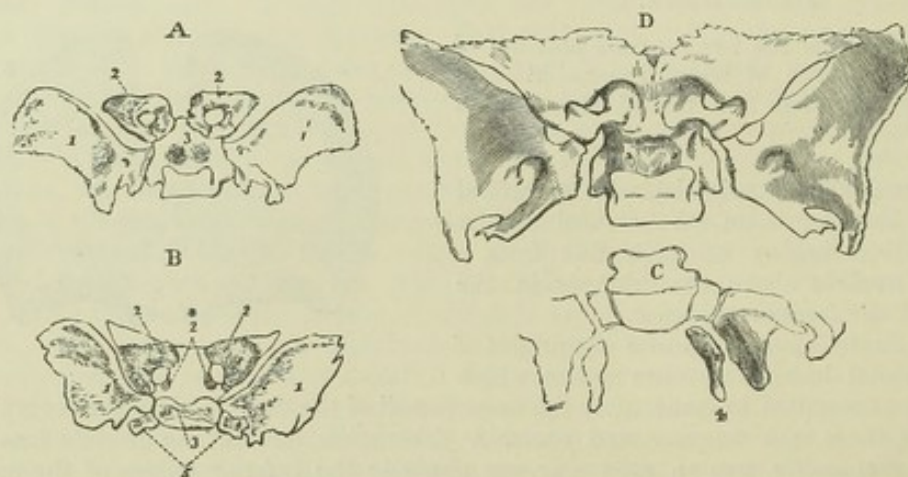


Fig. 62.—OSSIFICATION OF THE SPHENOID BONE.

A, sphenoid bone from a foetus of three months, seen from above; 1, 1', the greater wings ossified; 2, 2', the lesser wings, in which the ossification has encircled the optic foramen, and a small suture is distinguishable at its posterior and inner side; 3, two round granules of bones in the body below the *sella turcica*, the rest being cartilaginous.

B, copied from Meckel (Archiv, vol. i. tab. vi. fig. 23), and stated to be from a foetus



of six months; 2\*, additional nuclei for the lesser wings; 5, separate lateral processes of the body: the other indications are the same as in A.

C, sketch of the back part of the bone shown in A; 4, the internal pterygoid processes still separate.

D, the sphenoid at the usual period of birth. The great wings are still separate. The anterior sphenoid is now joined to the body, and the internal pterygoid processes (not seen in the figure) are united to the external.

In the post-sphenoid part of the body two granules appear, placed side by side in the sella turcica, and after their union two others appear, from which are formed the parts on which are placed the carotid grooves. In the pre-sphenoid division the first pair of nuclei appear outside the optic foramina, and extend by their growth into the small wings: another pair of granules appear on the inner sides of the foramina, and the pre-sphenoid portion of the body either results from the union of these, or is an independent growth. The pre-sphenoid is united to the body of the post-sphenoid long before the latter is united to the great wings. Their line of union is indicated for some time by a hole filled with cartilage, round above, and opening inferiorly into a wide notch, which is recognisable for several years after birth. The body of the pre-sphenoid is for a year or two broad and rounded inferiorly, but becomes gradually narrower and more prominent: it is separated at first by a layer of fibro-cartilage from the sphenoidal spongy bones. The *sphenoidal spongy bones* seldom appear till after birth: each is in early life a hollow pyramid formed by the union of three separate laminae, viz., an inferior, an external, and a superior: the inferior lamina forms the greater part of what can be distinguished in the adult; the external is that to which the orbital portion belongs; while the superior lamina, forming the inner wall and roof of the original sphenoidal sinus, becomes, as the sinus expands, partly absorbed and partly united to the attenuated body of the pre-sphenoid, which is ultimately reduced to the thin septum sphenoidale and the rostrum.

The *ethmoid* bone exhibits osseous deposit first in the orbital plates, whence it spreads into the turbinated portions; in its mesial part ossification begins above and passes down into the nasal septum, and outwards into the cribriform plate.

The *superior maxillary* bone commences to ossify at a very early period—immediately after the lower maxilla and the clavicle, and before the vertebrae. Its early growth has not yet been sufficiently studied. Béclard (Meckel's Archiv., vi. p. 432)

Fig. 63.

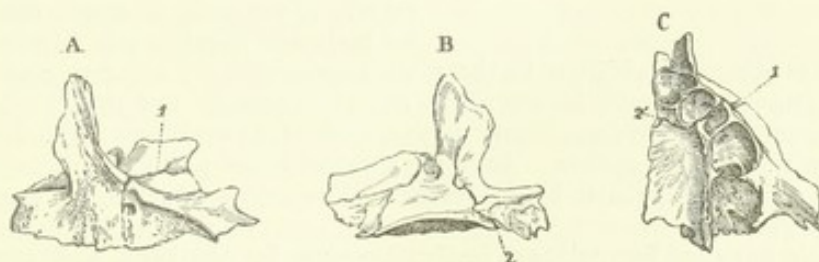


Fig. 63.—DIFFERENT VIEWS OF THE SUPERIOR MAXILLARY BONE OF A FETUS OF FOUR OR FIVE MONTHS.

A, external surface; a fissure, 1, is seen extending through the orbit into the infra-orbital foramen.

B, the internal surface; the incisor fissure, 2, extends from the foramen upwards through the horizontal plate and some way into the nasal process.

C, the bone from below, showing the imperfect alveoli and the incisor fissure, 2', 1, which crosses the palatine plate, between the second and third alveolus, and passes through the outer part of the bone.

states that it consists at first of five pieces, viz., 1, an alveolar arch; 2, a palatal part; 3, an orbital and malar; 4, a nasal and facial; 5, an incisor part. This, however, does not appear to be a constant arrangement. In all young subjects, and sometimes even in the adult, there is a fissure, the *incisor fissure*, passing outwards from the incisor foramen to the alveolar border, in front of the canine socket. The part in



front of this fissure—namely, that which bears the incisor teeth—forms in all mammals except man a separate bone, the *intermaxillary* or *premaxillary*; and anatomists have therefore sought with great care for proofs of its original independence in the human subject, but it does not appear that even in the earliest stages of development it has been seen by any one entirely unattached to the rest of the bone, or that its line of suture has been traced upon the facial surface. On the other hand, in cases of completely cleft palate, the bones supporting the incisor teeth are placed on a projecting portion of bone, which is articulated to the fore part of the vomer, and is entirely detached from the superior maxillary bones.

The *palate* bone is formed from a single centre, which is deposited at the angle between its horizontal and ascending parts.

Fig. 64.



Fig. 64.—THE FŒTAL VOMER NEAR THE TIME OF BIRTH.

1 & 2 show the two plates of which the bone consists, and which are united behind and below.

The *vomer* begins to ossify posteriorly near the upper part. It consists at first of two laminae united posteriorly and inferiorly. The inferior border afterwards exhibits a flat surface marked by a mesial line, which articulates with the maxillary and palate bones and ends abruptly behind the crista nasalis. The margins of this surface become gradually absorbed. The appearance of a mesial plate does not take place for a little time after birth.

The *malar*, *nasal*, *lacrimal*, and *inferior turbinated bones* are each ossified from a single centre.

Fig 65.

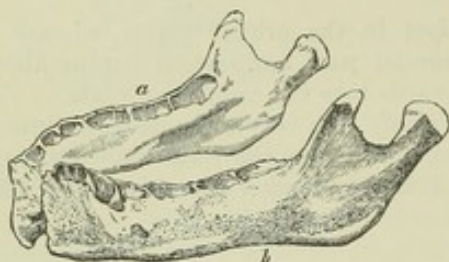


Fig. 65.—THE INFERIOR MAXILLA OF A CHILD AT BIRTH.

*a* & *b* indicate the two portions separate at the symphysis.

The *inferior maxilla* begins to ossify before any other bone except the clavicle. It consists of two equal lateral parts, which are still separate at the time of birth. The ossific matter is at first deposited in fibrous tissue, and later in cartilage. Some observers admit only a single ossific centre for each side (Nesbitt and Meckel); while,

according to others, in addition to the main piece there are separate nuclei for the coronoid process, the condyle, the angle, and the inner side of the alveolus (Spix), or only for some of these parts (Kerckringius, Béclard, Cruveilhier). The dental canal is at first a simple open groove. As in the superior maxilla the alveoli are gradually developed from the groove by its division into compartments by partitions of subsequent growth.

The *hyoid* bone has five points of ossification—one for the body, and one for each of its great and small cornua. The ossification begins in the great cornua, and soon follows in the body in the last month of foetal life.

#### PERIODS OF OSSIFICATION OF THE BONES OF THE SKULL.

In the occipital bone—

Ossification of the tabular part appears in the 7th week (foetal life).

Ossification of the basilar part appears in the 7th or 8th week.

Ossification of the condyloid part appears in the 7th or 8th week.

The condyloid and tabular parts unite in the 4th year.

The basilar and condyloid parts unite in the 5th or 6th year.

In the parietal bone ossification appears in the 7th or 8th week.

In the frontal bone ossification appears in the 7th week.

The parts of the frontal bone unite in the course of the 2nd year.



## In the temporal bones—

- Ossification of the squamous part appears in the 7th or 8th week.
- Ossification of the petro-mastoid part appears in the 4th month.
- Ossification of the ossicula auditus appears in the 4th month.
- Ossification of the tympanic ring appears in the 3rd month.
- Ossification of the styloid process appears after puberty.
- The squamous, petro-mastoid, and tympanic parts unite in the 1st year.

## In the sphenoid bone—

- Ossification of the great wings appears in the 8th week.
- Ossification of the posterior part of the body appears in the 8th or 9th week.
- Ossification of the internal pterygoid processes appears in the 4th month.
- Ossification of the anterior part of the body, including the small wings, appears in the 8th or 9th week.
- Ossification of the sphenoidal spongy bones appears about the time of birth.
- The centres of the posterior part of the body unite in the 4th month.
- The internal and external pterygoid processes unite in the 5th or 6th month.
- The anterior and posterior parts of the body unite in the 8th month.
- The body and great wings unite in the 1st year.
- The sphenoidal spongy bones and the body unite about the age of puberty.

## In the ethmoid bone—

- Ossification of the lateral masses appears in the 4th or 5th month.
- Ossification of the vertical and cribriform plates appears in the 1st year.

## In the superior maxillary bones ossification appears in the 6th or 7th week.

## In the palate, vomer, nasal, and malar bones ossification appears in the 7th or 8th week.

## In the lachrymal bones ossification appears in the 8th week.

## In the inferior turbinated bones ossification appears in the 5th month.

## In the inferior maxillary bone ossification appears in the 6th week.

- The two parts of the inferior maxillary bone unite in the 1st year.

## In the hyoid bone—

- Ossification of the body and great cornua appears before birth.
- Ossification of the small cornua appears in the 1st year.

## THE VERTEBRAL THEORY OF THE SKULL.

The idea that the skull is composed of a series of vertebræ, whose arches are expanded and united to enclose and protect the encephalon, appears to have originated with Goethe in 1791, but occurred independently to Oken, and was first published by him in 1807. Since then many conflicting theories have been brought forward on the subject by different anatomists, who have estimated the cranial vertebræ at numbers varying from three to seven; while by others the idea has been entirely rejected, and even the possibility of referring the bones of the skull to distinct segments denied. Some of the facts in favour of the vertebral theory are sufficiently manifest. Thus, the basilar process of the occipital bone, and the mesial parts of the post-sphenoid and pre-sphenoid bones, lie in series with and bear considerable resemblance to the centra or bodies of vertebræ, as is seen particularly in those animals in which the pre-sphenoid and post-sphenoid bones remain distinct: the visceral arches of the embryo likewise form a series: in the roof of the skull a certain degree of repetition of parts from behind forwards is also visible, especially in some of the lower animals: the mode of formation of the head and of the trunk is almost the same up to the time when the primordial vertebræ appear in the latter: and lastly, the general resemblance of the occipital bone to a vertebra is admitted by all. On the other hand, as it must be allowed that there is no original division of the cartilaginous basis of the cranium, in that part of it which lies in front of the sphenoid bone, and to which the chorda dorsalis does not penetrate, it is not easy to trace a resemblance to vertebral form; and in the face it is still more difficult to demonstrate in the several parts a definite arrangement of visceral or costal arches. Deterred by the differences of opinion with respect to the number of cranial segments and the bones which belong to each, some may be inclined to set aside the discussion entirely, but we must not too rashly decide against the existence of such segmentation, nor forget that some correspondence



between several bones of the skull and vertebræ in man and animals is generally admitted by scientific anatomists, and that the difficulties which oppose the enunciation of clearer views on the serial relations of the cranial elements arise in great measure from deficient information and want of agreement among anatomists as to individual points in the correspondence of those elements throughout the animal series. (See, in addition to the works previously referred to, Huxley, "Elements of Comparative Anatomy," 1864; Cleland, "On the Relations of the Vomer," &c., Trans. Roy. Soc. 1862; Spix, "Cephalogenesis," 1815; Von Baer, "Entwicklungsgesch. der Thiere," 1828-37; Hallman, "Die Vergleich. Anat. des Schläfenbeins," 1837; Bojanus in Isis, 1818-1819.)

#### THE VARIOUS FORMS OF THE SKULL.

I. *Differences according to Age.*—In the earlier stages of its development the posterior part of the skull bears a very large proportion to the anterior part; so much so, that in the second month of foetal life the line of the tentorium cerebelli is vertical to the basis cranii, and divides the cranial cavity almost equally into two parts. At the time of birth the parietal region has reached its largest development in proportion to the occipital and frontal regions. The greatest frontal breadth is then smaller in proportion to that between the parietal eminences than afterwards. In the first years of childhood the superior parts of the skull grow more rapidly than the base. Thus, in the frontal region, the upper part of the frontal bone grows more rapidly than its orbital processes, giving the prominent appearance of the frontal eminences peculiar to children. The face at birth is calculated as being scarcely an eighth of the bulk of the rest of the head, while in the adult it is at least a half (Froriep, "Charakteristik des Kopfes nach dem Entwicklungsgesetz desselben"). In harmony with the growth of the face the lower part of the forehead is brought forward by elongation of the anterior cranial fossa, and on the approach of adult age it becomes in the male still more prominent by the expansion of the frontal sinuses. The face becomes elongated in the progress of growth, partly by increased height of the nasal fossæ, partly by the growth of the teeth and the enlargement of the alveolar arches of the jaws. In old age the proportion of the face to the cranium is diminished by the loss of the teeth and absorption of the alveolar portions of the jaws. In consequence of this the upper jaw retreats, while in the lower jaw the same cause gives, especially when the mouth is closed, a greater seeming prominence to the chin.

II. *Sexual Differences.*—The female skull is, in general, smaller, lighter, and smoother than that of the male; it is less marked by muscular prominences, and has also the frontal sinus less developed. The face is smaller in proportion to the cranium, the jaws narrower, and the frontal and occipital regions less capacious in proportion to the parietal. (Huschke.) The female skull resembles the formed skull of the boy more than that of the adult male; but it must also be admitted that it is often impossible to determine the sex by the appearance or form of a skull.

III. *National Differences.*—That characteristic forms of skull are presented by the various races of men has probably been long known, but was first distinctly pointed out by Camper. Subsequently the investigations of Blumenbach raised the study of those different forms to a recognised position in ethnology. The extent and constancy of the ethnical differences of skulls are matters open to discussion; but it must be allowed, that although many skulls are to be met with which fail to exhibit the characteristics of the race to which they belong, or which present peculiarities similar to those of nations considerably removed from them, yet not only are there certain forms of skull highly distinctive of the principal varieties of mankind, but the prevailing form in one nation is often very distinguishable from those found in nations inhabiting neighbouring countries. Great differences occur with respect to size in the skulls of different nations. Among the smallest skulls may be mentioned those of the Hindoo and ancient Peruvian; among the most massive those of the Scandinavian, the Caffre, and the Maori. Various characters are found belonging to the skulls of rude tribes, which serve to distinguish them from those of civilised nations. Among those characters may be mentioned,—a depressed appearance between the middle line of the calvarium and the temporal ridge, both of which stand out prominently, making the roof of the skull seem like a house top; a greater width of the zygomatic arches, and of the anterior nares; greater strength of the jaws and teeth,



and especially projection forwards of the incisors, so that those of the upper meet those of the lower jaw at an angle, instead of both sets being nearly perpendicular as in cultivated nations. Elongation of the face downwards may be regarded as a specially human characteristic connected with the use of voice and speech, but projection of the jaws forwards is only advantageous for the seizure of food, and gives an appearance of approach to the still further projected form of the jaws in the lower animals, particularly when accompanied, as it often is, by deficient development of the chin.

The degree of projection of the face in different races of men, and its prominence and increased proportion to the cranium in the lower animals, Camper proposed to express by the angle contained between two lines, one of them descending from the most prominent part of the forehead to the incisor margin of the upper jaw, the other passing through the meatus auditorius externus and the nasal spine: this he termed the *facial angle*. He estimated its maximum in the European adult at  $80^\circ$ , and in the skull of a young negro he found it diminished to  $70^\circ$ ; while in antique works of art he pointed out that it was increased for artistic effect to  $90^\circ$  or more, an extent never realised in nature. In animals, the facial angle is always much lower than in man. According to Camper and Lawrence, it reaches in the young orang as high a point as  $56^\circ$  or  $60^\circ$ ; but in the adult orang they found it attaining only to  $47^\circ$ , while Owen finds it to be as low as  $30^\circ$ . (Owen, "Zoolog. Trans.," vol. i. p. 373.) Several modifications of Camper's angle have been suggested; but, like it, they all labour under the disadvantage of being subject to modification from other peculiarities besides the relations proposed to be estimated.

A convenient method of comparing the skulls of different races was introduced by Blumenbach, and has been much employed,—the *norma verticalis*, or examination of the skull by looking perpendicularly down upon it, which exhibits in one view the proportionate length and breadth of the cranium, the projection of the jaw beyond the forehead, and the lateral prominence of the zygomatic arches. In addition to the *norma verticalis* and profile view, Prichard has likewise employed the front view in examining skulls, showing that, whereas in well-formed European heads, lines drawn from the zygomatic arch and touching the temples are parallel, the same lines in the skulls of Esquimaux and others meet over the forehead, and form with the basis a triangular figure.

More recently, a classification of skulls has been made by Retzius, which has met with considerable acceptance. According to his arrangement, they may be primarily divided into the *dolichocephalic*, or those which are elongated from before backwards, and the *brachycephalic*, or those which have nearly as great breadth as they have length. In each of those divisions are distinguished the *prognathous* skulls, or those in which the upper jaw is visible when they are examined by the *norma verticalis*, and the *orthognathous*, in which the jaw is overhung by the forehead. The nations of Western Europe present the orthognathous dolichocephalic type of skull; the African negro the prognathous dolichocephalic type; the Slavonic nations exhibit the orthognathous brachycephalic type; the Mongolians the prognathous brachycephalic. (Camper, "On the Connection between Anatomy, Drawing, &c.," transl. by Cogan, 1794; Blumenbach, "Institutions of Physiology," by Elliotson, 1820; and "De Generis Humani Varietate Nativâ," 1795; Prichard, "Researches into the Physical History of Mankind," and "Natural History of Man;" Morton, "Crania Americana;" Thurnam and Davies, "Crana Britannica;" Huschke, "Schädel, Hirn, und Seele des Menschen und der Thiere, &c.," 1854; Meigs, "Cranial Characteristics of the Races of Men," Philad. 1857; Retzius, "On the present State of Ethnology with reference to the Form of the Skull," translated in Brit. and For. Medico-Chir. Review, April & July, 1860; Carpenter, in "Cyclop. of Anat. and Physiol.")

IV. *Irregularities of Form*.—The most frequent irregularity in the form of the skull is want of symmetry. This sometimes occurs in a marked degree, and there is probably no skull perfectly symmetrical. The condition which has been observed to co-exist most frequently with irregular forms of skull is *synostosis*, or premature obliteration of certain of the sutures. The cranial bones increase in size principally at their margins; and when a suture is prematurely obliterated, the growth of the skull in the direction at right angles to the line of suture may be supposed to be checked, and increased growth in other directions may take place to supply the defect.



(For an account of the varieties of form thus produced, see Virchow, "Gesammelte Abhandlungen," 1856.) Another series of irregular forms of skull is that produced by pressure artificially applied in early life, and is best exemplified from among those American tribes who compress the heads of their children by means of an apparatus of boards and bandages: it is also illustrated in a slighter degree by individual instances in which undue pressure has been employed unintentionally. (Gosse, "Essai sur les Déformations artificielles du Crane," 1855.) Posthumous distortions likewise occur in long-buried skulls, subjected to the combined influence of pressure and moisture. (Wilson, "Prehistoric Annals of Scotland.")

#### IV.—BONES OF THE UPPER LIMB.

The superior extremity, or upper limb, consists of the shoulder, the arm, the fore arm, and the hand. The bones of the shoulder are the scapula and clavicle; in the arm is the humerus; in the fore arm are the radius and ulna; and in the hand three groups of bones, the carpus, metacarpus, and digital phalanges.

##### SCAPULA.

This bone is placed upon the upper and back part of the thorax, occupies the space from the second to the seventh rib, and forms the posterior part of the shoulder.

It is attached directly to the trunk only by the clavicle, and from it is suspended the humerus.

It is of an irregular triangular form, flat in the greater part of its extent, and elongated downwards; and is so placed, that its internal border is likewise posterior. Its angles may be termed superior, inferior, and external.

It has an anterior and posterior surface, and presents at its external angle the *head* with its *glenoid* cavity or articular surface for the humerus, supported on a short thick *neck* of bone, and surmounted by the *coracoid* process; also, springing from its posterior surface, the *spine* terminating in the *acromion* process.

The *anterior surface* exhibits in the greater part of its extent a shallow concavity, the *fossa subscapularis* or *venter*, occupied by the subscapularis muscle, and marked by irregular prominent lines converging upwards and outwards, which give attachment to the tendinous intersections of that muscle. Separated, however, from this concavity, there are several smaller flat spaces: one is a triangular surface in front of the superior angle, another is a smaller surface at the inferior angle, and these, together with a rough line running close to the posterior border and uniting them, give attachment to the serratus magnus muscle: there is also a grooved area occupied by the lower border of the subscapularis muscle, close to the external border, and separated from the fossa subscapularis by a prominent ridge descending from the neck of the bone.

The *posterior surface* or *dorsum* is divided by the spine into two unequal parts, the superior and smaller of which is called *fossa supra-spinata*, the inferior *fossa infra-spinata*. The supra-spinous fossa has its greatest vertical extent at its internal extremity, but is deepest externally: it is occupied by the supra-spinatus muscle. The infra-spinous fossa, much larger than the preceding, presents in the middle a convexity corresponding to the concavity of the venter, and outside this a concavity bounded by the prominent external border. It is marked near the inner border by short lines, corresponding to tendinous septa of the infra-spinatus muscle, and is occupied by that muscle in the greater part of its extent. Adjacent to the external border, in its middle third, is a narrow interval giving attachment to the



teres minor muscle ; and beneath this, extending over the inferior angle, is a raised oval surface, from which the teres major arises. These spaces are separated from that of the infra-spinatus muscle by a rough line, which gives attachment to an aponeurotic septum.

The *spine* of the scapula is a massive plate of bone projecting backwards from the dorsum, and curving slightly upwards. It extends outwards and

Fig. 66.

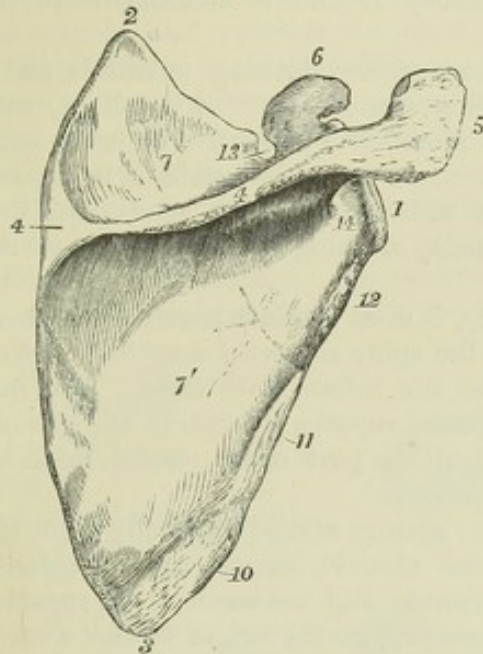
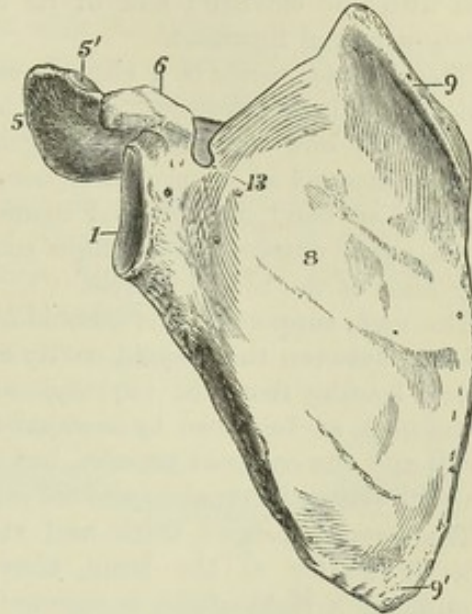


Fig. 67.

Fig. 66.—RIGHT SCAPULA FROM BEHIND.  $\frac{1}{3}$ 

1, glenoid head ; 2, superior angle ; 3, inferior angle ; 4, spine ; 4, at the base, points by a line to the triangular smooth surface of the spine ; 5, acromion ; 6, coracoid process ; 7, supraspinous fossa ; 7', infraspinous fossa ; 1 to 2, superior border ; 2 to 3, posterior border or base ; 1 to 3, external or inferior border ; 10, is opposite the oval surface of origin of the teres major muscle ; 11, the oblique groove where the teres minor muscle rises ; 12, the rough ridge where the long head of the triceps rises ; 13, supra-scapular notch ; 14, is below the great scapular notch.

Fig. 67.—RIGHT SCAPULA FROM BEFORE.  $\frac{1}{3}$ 

1, 5, 6, & 13, as in fig. 66 ; 5', articular facet on the acromion for the clavicle ; 8, subscapular fossa ; 9, long, narrow surface, and 9', triangular rough surface, separated from the subscapular fossa and giving attachment to the upper and lower parts of the serratus magnus muscle.

a little upwards from the internal border near its upper fourth, towards the middle of the neck, and becoming gradually elevated towards its external extremity, it turns forwards and is continued into the acromion process. The upper and lower surfaces are smooth, of a triangular form, concave, and form part respectively of the supraspinous and infraspinous fossæ. It presents two unattached borders, the most prominent of which arises from the internal border of the bone by a smooth, flat, triangular surface, on which the tendon of the inferior part of the trapezius muscle glides, as it passes to be inserted into a rough thickening beyond, which projects slightly downwards. In the rest of its extent this border is rough, broad, and subcutaneous, giving attachment by its superior margin to the trapezius, and by its inferior to the deltoid muscle. The other, the external border, short, smooth, and concave, arises near the neck of the scapula, and is continuous with the under surface of the acromion, surrounding thus the *great scapular notch* between the spine and the neck of the bone.



The *acromion process*, projecting outwards and forwards from the extremity of the spine, is situated above and behind the glenoid cavity, and forms the summit of the shoulder. It is an expanded process, compressed from above downwards. Its superior surface, rough and subcutaneous, is continuous with the prominent border of the spine; its inferior surface, smooth and concave, is continuous with the superior surface and external border of the spine. On its internal border anteriorly is a narrow oval surface for articulation with the clavicle; and at its extremity it affords attachment to the coraco-acromial ligament.

The *glenoid cavity* is a slightly concave surface, looking outwards and a little upwards and forwards. It is ovoid or rather pyriform in shape, with the narrow end uppermost, and gently incurved in front. It is in some degree flattened at its circumference, where, in the recent state, it is covered by a fibrous band, the glenoid ligament, which deepens its concavity; and at its upper extremity is a slight roughness, marking the attachment of the long head of the biceps muscle.

The *neck*, supporting the glenoid cavity, is most distinct posteriorly, where it forms between the glenoid cavity and the spine the *great scapular notch* or *groove*, leading from the supraspinous to the infraspinous fossa. The line of the neck, as described by anatomists, passes superiorly between the glenoid cavity and the coracoid process, but that of the part often named neck by surgeons passes internal to the coracoid process.

The *coracoid process*, thick and strong, springs almost vertically from the superior border of the bone, above the glenoid cavity, but, suddenly bending at a right angle, is directed forwards and outwards. Its superior surface, towards the base, is rough and uneven, giving origin to the coraco-clavicular ligaments; on its outer border is attached the coraco-acromial ligament, at its extremity the coraco-brachialis muscle and short head of the biceps, and on the inner edge the pectoralis minor.

The *borders* or *costæ* of the scapula are three in number. The *superior* border is the shortest; it extends from the superior angle outwards and downwards towards the coracoid process, at the base of which it presents a rounded *suprascapular notch* (*incisura semilunaris*), which is converted into a foramen by a ligament or occasionally a spiculum of bone, and is traversed by the suprascapular nerve, and sometimes also by the accompanying vessels. The *external, axillary, or inferior* border presents at its upper part, beneath the glenoid cavity, a rough tuberculated ridge, above an inch long, to which the long head of the triceps muscle is attached: a little below this there is usually a slight groove, where the dorsal branch of the subscapular artery passes backwards: and at its lower extremity the border is thick, and rounded over into the space from which the teres major muscle arises. The *internal, vertebral, or posterior* border, called also the base, is the longest of the three, and is divisible into three parts, viz., a short one opposite the triangular surface of origin of the prominent border of the spine, and the portions above and below that space, both of which incline outwards as they recede from the spine. The upper part gives attachment to the levator anguli scapulæ muscle, the middle one to the rhomboideus minor, and the lower to the rhomboideus major muscle.

*Texture.*—The triangular part of the scapula is in great part thin and translucent, and contains little cancellated tissue. The neck, the coracoid and acromion processes, the prominent border of the spine, and the part near the inferior angle, derive their greater thickness and strength from increased thickness of the compact bony substance in some parts, and



from cancellated tissue in others. A vascular foramen usually pierces the inferior surface of the spine, and others are to be found on the anterior surface of the bone, near the neck.

## THE CLAVICLE.

The clavicle or collar bone extends transversely outwards, with an inclination backwards, from the summit of the sternum to the acromion process of the scapula, and connects the upper limb with the trunk.

It is curved somewhat like an italic *f*: the convexity of the internal curve is directed forwards, and extends over two-thirds of the length of the bone; that of the outer curve looks backwards, and is most marked near the outer fourth of the bone.

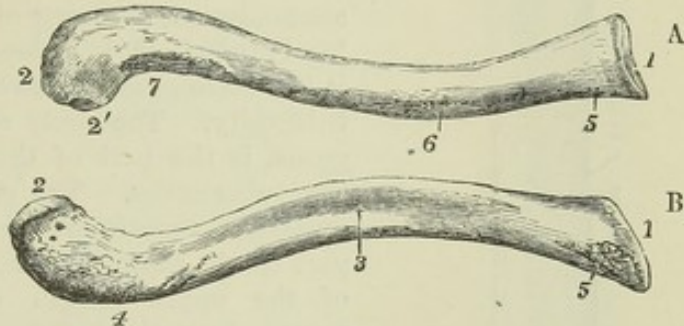
The clavicle, towards its scapular end, is compressed and broad from above downwards, but in the extent of its inner curve it is more or less prismatic or cylindrical. In its description, four surfaces of the shaft may be distinguished, together with the two extremities.

Fig. 68.—THE RIGHT CLAVICLE.  $\frac{1}{2}$

A, from above; B, from below.

1, sternal end; 2, acromial end; 2', small facet for articulation with the acromion; 3, groove on the lower surface for the subclavius muscle; 4, rough elevation at the place of attachment of the coraco-clavicular ligaments; 5, rough depression at the place of attachment of the costo-clavicular or rhomboid ligament; 6, in front, the mark of the attachment of the pectoralis major; 7, that of the deltoid muscle.

Fig. 68.



The *superior surface* is broadest in its outer part; it is principally subcutaneous, but near the inner extremity presents a slight roughness, marking the clavicular attachment of the sterno-cleido-mastoid muscle. The *anterior surface* opposite the outer curve is a mere rough border, from which the deltoid muscle takes origin, but in the inner half of its extent is broadened out into an uneven space more or less distinctly separated from the inferior surface, and giving attachment to the pectoralis major muscle. The *posterior surface* is broadest at the inner extremity, and smooth in the whole extent of the internal curvature; but towards its outer extremity it forms a narrow rough border which separates it from the superior surface, and gives attachment to the trapezius muscle. On the *inferior surface* an elongated roughness near the scapular extremity marks the attachment of the coraco-clavicular ligaments; extending inwards from this, over the middle third of the bone, is a groove in which the subclavius muscle is inserted; and near the sternal end is a smaller rough depression, to which the costo-clavicular ligament is attached.

The *internal extremity* is the thickest part of the clavicle. It presents a somewhat variably concavo-convex surface, somewhat triangular in form, with its most prominent angle directed downwards and backwards. The compressed *external extremity* is convex from before backwards, and articulates by a small oval surface with the acromion.



*Texture.*—The interior of the clavicle contains coarse cancellated tissue in its whole extent. It almost always presents a foramen for a medullary artery on its posterior surface, and sometimes others.

#### THE HUMERUS.

The humerus or arm bone extends from the scapula to the bones of the forearm, with each of which it is articulated. It hangs nearly vertically from the shoulder, with an inclination inwards towards the lower end. It is divisible into a superior extremity, including the head, neck, and greater and smaller tuberosities; the shaft; and the inferior extremity, including the external and internal supracondyloid eminences, and the inferior articular surface. In general form it is subcylindrical and slightly twisted.

The *superior extremity* is the thickest part of the bone. The *head* is a large hemispherical articular elevation, directed inwards, upwards, and somewhat backwards. The *neck*, as described by anatomists, is the ring of bone which supports the head; inferiorly, it passes into the shaft; superiorly, it is a mere groove between the head and the great tuberosity. The *neck*, as often described by surgeons, is the part of the shaft immediately below the tuberosities. The *great tuberosity* is a thick projection, continued upwards from the external part of the shaft, and reaching nearly to the level of the upper margin of the head; it is surmounted by three flat surfaces, the uppermost of which gives attachment to the supra-spinatus muscle, the lowest to the teres minor, and the intermediate one to the infra-spinatus muscle. Separated from the great tuberosity by the commencement of the bicipital groove, the *small tuberosity*, rounded and prominent, looks directly forwards and gives attachment to the subscapularis muscle.

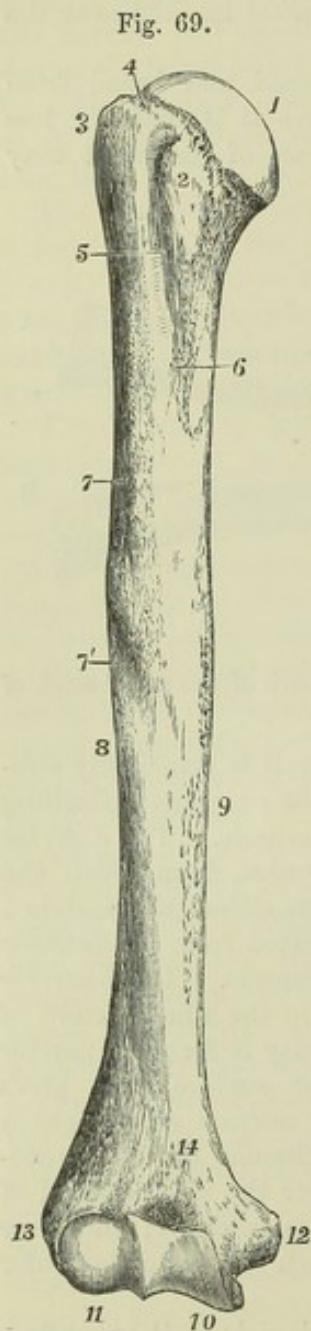


Fig. 69.—RIGHT HUMERUS FROM BEFORE.  $\frac{1}{2}$

1, the articular head; 2, lesser tuberosity; 3, greater tuberosity; 4, neck of anatomists; 5, bicipital groove; 6, inner bicipital ridge, and mark of the attachment of the latissimus dorsi and teres major muscles; 7, outer bicipital ridge, and rough surface of insertion of the pectoralis major, running down into 7', the triangular mark of the insertion of the deltoid; 8, spiral groove; 9, inner ridge of the humerus; 10, trochlear articular surface; 11, capitellum, or radial condyle; 12, epitrochlear or internal supracondyloid eminence; 13, capitellar or external supracondyloid eminence; 14, coronoid depression or fossa.

The *shaft* or *body*, thick and cylindrical superiorly, becomes somewhat thinner as it descends, and in the lower third is expanded transversely and becomes somewhat three-sided. Superiorly on its anterior aspect is the bicipital groove, so named from lodging the long



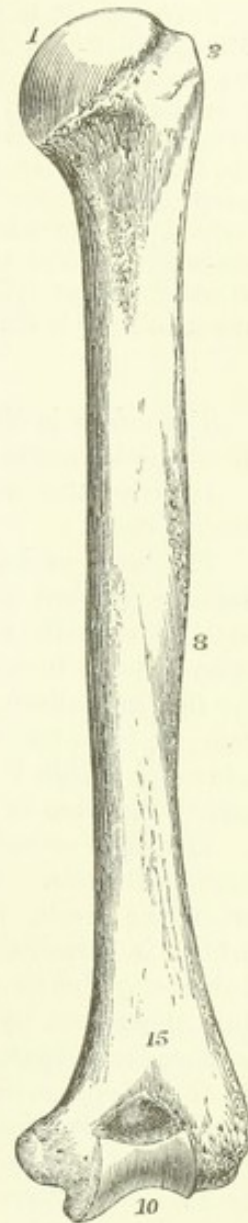tendon of the biceps muscle: this groove, commencing between the tuberosities, descends with an inclination inwards, and is bounded by two rough ridges, the external and most prominent of which gives attachment to the pectoralis major muscle, the internal or posterior to the latissimus dorsi and teres major. Towards the middle of the shaft, on the inner lateral line, is a rough linear mark where the coraco-brachialis muscle is inserted, and lower down there is a medullary foramen directed downwards into the interior of the bone. On the external part of the shaft, near its middle, in a line anteriorly with the external bicipital ridge, is a large, rough, and uneven surface, of a triangular shape, the *impression of the deltoid muscle*. Below this the external bicipital ridge is continued into a smooth elevation which, descending on the front of the shaft to the inferior extremity, separates an external from an internal surface, while at the sides two sharp edges, the *external and internal supracondyloid ridges* spring from the eminences of the same name and ascend for some distance, separating the anterior from the flat posterior surface. About the middle of the shaft externally, a broad depression, the *musculo-spinal groove*, passes downwards and forwards in a spiral direction, limited above by the deltoid impression and below by the external supracondyloid ridge, and lodges the musculo-spiral nerve and the accompanying artery.

Fig. 70.—RIGHT HUMERUS FROM BEHIND.

1, 3, 8, & 10, the same as in Fig. 69; 15, is placed above the olecranon fossa.

The *inferior extremity* is much enlarged laterally, flattened from before backwards, and is curved slightly forwards. Projecting on either side are the *external and internal supracondyloid eminences* (the *condyles* of most authors, *epicondyle* and *epitrochlea* of Chaussier), the internal of which is much more prominent than the external, and is slightly inclined backwards. The *inferior articular surface*, fitting by peculiar curved grooves and eminences to the corresponding surfaces of the radius and ulna, is divided by a ridge into an external and an internal part. The external part, articulated with the radius, consists of a rounded eminence directed forwards, called the *capitellum*, and a groove internal to it; it does not extend to the posterior surface. The internal part, the *trochlea*, articulates with the ulna, and extends completely round from the anterior to the posterior surface of the bone; it is grooved down the middle like the surface of a pulley, and is somewhat broader behind than in front; anteriorly, its margins are inclined downwards and inwards; posteriorly, upwards and outwards, and so that seen from behind, it lies in the middle part of the bone. Anteriorly, the internal margin of the trochlea is the most prominent, and widens below into a convexity parallel to the groove; posteriorly, the external margin is most

Fig. 70.





prominent. Above the trochlea posteriorly is a large and deep pit, the *olecranon fossa*, which receives the olecranon process of the ulna in extension of the forearm; and above it anteriorly, separated from the olecranon fossa only by a thin lamina of bone, is the much smaller *coronoid fossa* which receives the coronoid process in flexion. Above the capitellum is a shallow depression, into which the head of the radius is pressed in complete flexion.

*Varieties.*—It is not uncommon to find a small hooklike process, with its point directed downwards, placed in front of the internal supracondyloid ridge, the *supracondyloid process*. From its extremity, a fibrous band, giving origin to the pronator radii teres muscle, passes to the internal supracondyloid eminence, and through the arch thus formed passes the median nerve, accompanied frequently by the brachial artery, or by a large branch rising from it. This process represents a portion of the bone completing a foramen in carnivorous animals. Much has been written on the subject. (Struthers' Edin. Med. Journ. 1848. Gruber, "Canalis supracondyloideus humeri," Mem. de l'Acad. Imp. de St. Petersburg, 1859, p. 57. Hyrtl, "Topogr. Anat." v. ii. p. 283.) The thin plate between the olecranon and coronoid fossæ is sometimes perforated.

#### THE RADIUS.\*

The radius is the external of the two bones of the forearm, and extends from the humerus to the carpus. It is thickest at its lower extremity.

It articulates with the humerus, the ulna, the scaphoid, and the semi-lunar bones.

The *head*, or superior articular extremity, is of the form of a disc, with a smooth vertical margin. It presents on its summit a depression, which articulates with the capitellum of the humerus, and is surrounded by a convex part, broadest internally where it glides upon the groove internal to the capitellum. The smooth, short, cylindrical surface of the vertical margin, likewise broadest internally, rolls on the small sigmoid cavity of the ulna and within the orbicular ligament. The head is supported on a constricted portion of a cylindrical form, named the *neck*.

The *shaft* or *body* is slightly curved, with the convexity directed outwards and backwards. On its internal aspect superiorly, where it is continuous with the neck, is the *bicipital tuberosity*, to the posterior border of which is attached the tendon of the biceps muscle. Below the bicipital tuberosity the shaft presents three sides, the external of which is rounded into the others by smooth convex margins, while the anterior and posterior surfaces are separated by an acute internal margin, which gives attachment to the interosseous ligament. The *external surface* is convex transversely as well as longitudinally; it is marked near the middle by an oval rough part, about one inch and a half long, which gives insertion to the pronator radii teres. The *anterior surface* is marked in its upper part by a shallow longitudinal groove for the flexor longus pollicis; inferiorly it is expanded, and presents a flat impression corresponding with the pronator quadratus; and above the middle is the foramen for the medullary vessels, directed upwards into the bone. The *posterior surface* presents slight oblique impressions of the extensor muscles of the thumb.

The *lower extremity* of the radius, broad and thick, and somewhat quadrilateral, presents inferiorly a large surface, which articulates with the carpus, and internally a small one, which articulates with the ulna. The carpal

\* When the arm is at rest it hangs naturally with the thumb directed forwards and inwards, as in partial pronation; but in anatomical description the forearm is placed as in supination, with the thumb directed outwards and the palm of the hand looking forwards.



articular surface, which is slightly concave, is somewhat five-sided and divided by a line into a quadrilateral internal part, which articulates with the semi-lunar bone, and a triangular external part, which articulates with the scaphoid bone. The ulnar articular surface is vertical, and forms a right

Fig. 71.—RIGHT RADIUS FROM BEFORE.

Fig. 72.—RIGHT RADIUS FROM BEHIND.  $\frac{1}{3}$

1, head, showing the hollow above for the humerus, and the short cylindrical surface surrounding it for the ulnar articulation; 2, the neck; 3, the tubercle; 4, is opposite to the oblique line; 5, internal border or interosseous ridge; the shaded part near 5 marks the slight hollow in which the flexor longus pollicis muscle lies; 6, carpal articular surface; 7, styloid process; 8, the articular hollow for the lower end of the ulna; 9, impression at the middle of the outer border of the attachment of the pronator radii teres; 10 and 11, oblique depressions marking the places of the extensor longus digitorum and extensor ossis metacarpi pollicis; between 7 and 8, the dorsal grooves for the tendons of the extensor muscles.

angle with the inferior surface; it is concave from before backwards, forming a *semilunar cavity*, in which the rounded lower end of the ulna plays. At the external angle of the inferior surface a part projecting downwards, called the *styloid process*, gives attachment to the external lateral ligament of the wrist joint, while the anterior and posterior margins are likewise rough and prominent for other ligaments. On its external and posterior aspects the inferior extremity of the radius is marked by grooves, which transmit the extensor tendons. Thus, on the external border, is a flat groove directed downwards and forwards which lodges the extensor ossis metacarpi and extensor primi internodii pollicis; and on the posterior surface are three grooves, the middle one of which, oblique and narrow, and with prominent borders, lodges the extensor secundi internodii pollicis; while of the two others, which are broad and shallower, the external, subdivided by a slight mark, gives passage to the extensores carpi radiales longior and brevior, and the internal transmits the extensor communis digitorum and extensor indicis.

Fig. 71.





Fig. 72.



#### THE ULNA.

The ulna is the internal of the two bones of the forearm. It is longer than the radius by the extent of the olecranon process. It is largest at its upper extremity, and is curved and three-sided elsewhere, except for a short distance at the lower end, where it is straight and cylindrical. It is inclined downwards and outwards from the humerus in such a direction that a straight line passing from the great tuberosity of the humerus downwards through the capitellum would touch the lower end of the ulna.

The ulna articulates with the humerus and the radius: in the natural skeleton it is not in contact with the carpal bones, being separated from the cuneiform bone by an inter-articular fibro-cartilage.



The *superior extremity* of the ulna presents for articulation with the humerus a large articular surface, the *great sigmoid cavity*, which looks forwards and is bounded in its posterior and upper part by the olecranon, a thick process continued upwards from the shaft, and in its lower part by the coronoid process, which projects forwards. The great sigmoid cavity is concave from above downwards, with its inferior wall deeper than its superior, and is convex from side to side, being traversed by a vertical ridge. The part external to this ridge is broad and convex above, while the part internal to the ridge is broad and concave below: a slight constriction, and sometimes a notch of division, occurs across the middle of the cavity. Continuous

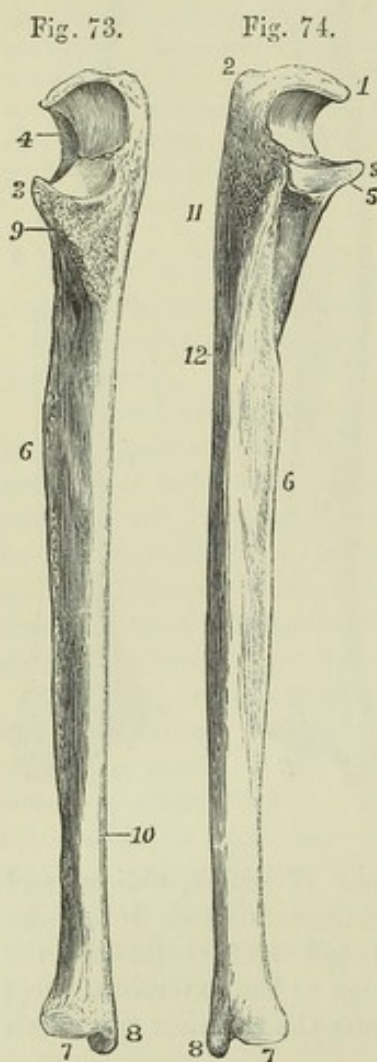


Fig. 73.—RIGHT ULNA FROM BEFORE.

Fig. 74.—RIGHT ULNA FROM BEHIND AND WITHOUT.  $\frac{1}{2}$

1, point or beak of the olecranon; 2, tuberosity of the olecranon; 3, end of the coronoid process; 4, greater sigmoid articular surface, 4 points to the upper division of this surface; 5, lesser sigmoid cavity, and below it the ridge for the supinator brevis muscle; 6, external border or interosseous ridge; 7, lower extremity or head; 8, styloid process; 9, rough surface of insertion of the brachialis anticus muscle on the front of the coronoid process; below 10, the oblique line marking the attachment of the pronator quadratus muscle; 11, triangular surface for the anconeus muscle; 12, upper part of the posterior border, to the right of which the depressions for the long extensor muscles of the fingers occupy the posterior surface.

with the great is the *small sigmoid cavity*, a small articular surface on the outer side of the base of the coronoid process, slightly concave from before backwards, and articulating with the cylindrical part of the head of the radius. The *olecranon* forms by its anterior surface a part of the articular surface of the great sigmoid cavity; superiorly, broad and uneven, it gives attachment to the triceps extensor muscle, and posteriorly it presents a subcutaneous surface which is continuous with the posterior margin of the shaft. Between its anterior and superior surfaces is an acute projection which fits, in extension of the elbow, into the olecranon fossa of the humerus, and between the superior and posterior surface is a rectangular prominence

which forms the point of the elbow. The *coronoid process* terminates in a sharp ridge, the prominent anterior extremity of which is received during flexion into the coronoid fossa of the humerus: its superior surface forms part of the surface of the great sigmoid cavity; the inferior surface rises gradually from the anterior surface of the bone, and is covered by a large triangular roughness which gives insertion to the brachialis anticus muscle.

The *body or shaft* in the upper three-fourths of its extent is three-sided, and presents a slight curve with the convexity backwards, but near the lower extremity is slender, straight and cylindrical. The *anterior surface* is grooved in the upper half, where the flexor profundus muscle takes origin; and at its lower end has an oblique line to which the pronator quadratus



is attached. Placed near the upper third is a foramen for vessels, directed upwards into the medullary cavity. The *internal surface* is smooth, and somewhat excavated superiorly on the side of the olecranon, where it gives attachment to the flexor profundus muscle, while inferiorly it is subcutaneous. The *posterior surface*, more uneven, looks outwards and backwards; an oblique ridge, descending from behind the small sigmoid cavity, limits a superior triangular area, which extends over the outer side of the olecranon and gives attachment to the anconeus muscle; immediately below the small sigmoid cavity is a short space looking directly outwards, to which the supinator brevis is attached; while the remaining and largest part of this surface is slightly impressed by the extensor muscles. Of the three *margins*, the anterior and posterior are rounded, and for the most part smooth; the external is sharp, and gives attachment to the interosseous ligament.

The *inferior extremity* presents a rounded articular head; and on the internal aspect of the head a short cylindrical projection, the *styloid process*, which descends in a line with the inner and posterior surface of the shaft, and gives attachment to the internal lateral ligament of the wrist joint. The *head* presents two aspects, of which one, flattened and circular in form, looks towards the wrist joint; whilst the other, narrow and cylindrical, looks outwards, and is received into the semilunar cavity in the contiguous border of the radius. The head and the styloid process are separated posteriorly by a groove, which is traversed by the tendon of the extensor carpi ulnaris; and inferiorly by a depression, into which the triangular fibro-cartilage which intervenes between the ulna and the carpus is inserted.

#### THE CARPUS.

The carpus is composed of eight short bones, which are disposed in two ranges, four in each range. Enumerated from the radial to the ulnar side, the bones which constitute the first or superior range are named scaphoid, semilunar, cuneiform, and pisiform; those of the second or inferior range, trapezium, trapezoid, os magnum, and unciform.

Fig. 75. — HALF-DIAGRAMMATIC VIEW OF THE CARPUS AND PROXIMAL PARTS OF THE METACARPAL BONES, FROM BEFORE, WITH THE CARPAL BONES SLIGHTLY SEPARATED TO SHOW THE FORM OF THEIR SURFACES OF CONTACT WITH EACH OTHER.  $\frac{2}{3}$

1, scaphoid bone; 2, semilunar, presenting in this instance, as often occurs, a small surface of articulation with the unciform bone; 3, cuneiform or pyramidal; 4, pisiform, laid upon the last; 5, trapezium, the figure is placed upon the ridge, to the inside of which is the groove for the tendon of flexor carpi radialis; 6, trapezoid bone; 7, os magnum, the figure is placed on the tuberosity; 8, unciform bone, the figure is placed on the unciform process. The metacarpal bones will be distinguished by the first being articulated separately with the trapezium. The articulation of the os magnum with the fourth metacarpal bone is represented somewhat too large.

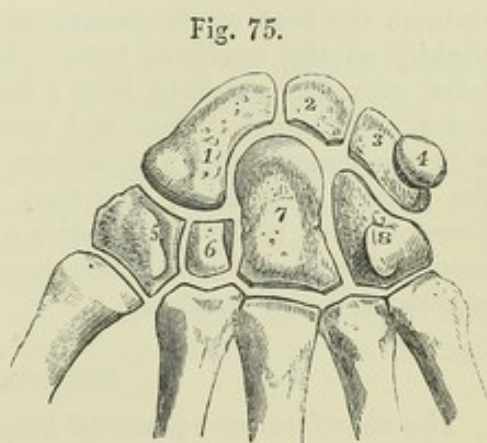


Fig. 75.

The dorsal surface of the carpus is convex, the palmar is concave from side to side, the concavity being bounded by four prominences, one at the outer and one at the inner extremity of each range. The anterior annular



ligament is stretched across the carpus between these prominences, so as to form a canal for the transmission of the flexor tendons.

The superior surfaces of the scaphoid, semilunar and cuneiform bones form, when in apposition, a continuous convexity which corresponds with the concavity presented by the radius and the interarticular cartilage, while the pisiform bone is attached in front of the cuneiform, with which alone it articulates. The line of articulation between the superior and inferior ranges is concavo-convex from side to side, the trapezium, trapezoid and os magnum bounding a cavity which lodges the external part of the scaphoid, and the os magnum and unciform rising up in a convexity, which is received into a hollow formed by the scaphoid, semilunar, and cuneiform bones.

#### THE SCAPHOID BONE.

The scaphoid, or *navicular* bone, the largest and most external of the first row of carpal bones, is of a curved form, and lies with its longest axis directed outwards and downwards. Its superior surface, convex and smooth for articulation with the radius, is inclined backwards, so that the posterior surface of the bone is not so deep as the anterior. The internal surface, narrow from above downwards, articulates with the semilunar bone. The outer extremity, rough superiorly for the attachment of ligaments, presents inferiorly an articular convexity, which occupies the hollow formed by the upper surfaces of the trapezium and trapezoid bones, and is continuous with a large concave surface extending over the rest of the inferior aspect of the bone, and articulating with the os magnum. The fore part of the outer extremity of the scaphoid bone projects forwards, forming one of the tubercles to which the anterior annular ligament is attached. The scaphoid articulates with five bones, viz., the radius, the semilunar, trapezium, trapezoid, and os magnum.

#### THE SEMILUNAR BONE.

The semilunar, or *lunate* bone, irregularly cubic, is named from the crescentic concavity from before backwards of its inferior surface, which rests on the head of the os magnum, and frequently also by a bevelled edge slightly on the unciform bone. Its external surface is vertical, and articulates with the scaphoid bone; its internal surface looks downwards and inwards, is much deeper and narrower than the external, and articulates with the cuneiform. The convex superior surface, which articulates with the radius, is inclined, like that of the scaphoid, more backwards than forwards, and hence the anterior surface is deeper than the posterior. The semilunar articulates with five bones, viz., the radius, scaphoid, cuneiform, os magnum, and unciform.

#### THE CUNEIFORM BONE.

The cuneiform or *pyramidal* bone, is somewhat wedge-shaped, its internal extremity, rough for ligaments, forming the blunt narrow end of the wedge. Superiorly it presents an articular surface, which glides upon the triangular cartilage interposed between it and the ulna; externally it articulates with the semilunar bone, and inferiorly with the unciform, by means of a surface which is concavo-convex from without inwards. Its anterior surface is distinguished from the posterior by a smooth circular facet on its outer half, which articulates with the pisiform bone. The cuneiform articulates with three bones, viz., the semilunar, pisiform, and unciform.



## THE PISIFORM BONE.

The pisiform bone, or *os rotundum*, so called from its resemblance to a pea, lies on a plane anterior to the other bones of the carpus. Posteriorly it possesses an articular surface, which rests on the cuneiform bone. The mass of the bone is so inclined from this surface downwards and outwards, that the pisiform bone of one hand is distinguishable from that of the other.

Fig. 76.—DORSAL VIEW OF THE CARPUS, WITH A PORTION OF EACH OF THE METACARPAL BONES.  $\frac{1}{2}$

1, scaphoid ; 2, semilunar ; 3, cuneiform ; 4, pisiform ; 5, trapezium ; 7, trapezoid ; 8, os magnum ; 9, unciform.

## THE TRAPEZIUM.

The trapezium, or *os multangulum majus*, is the most external of the second row of carpal bones. It presents a rhombic form when seen from its dorsal or palmar aspect, and has its most prominent angle directed downwards. Its anterior surface is marked by a vertical groove traversed by the tendon of the flexor carpi radialis muscle, and external to the groove by a ridge, or tubercle, one of the four prominences which give attachment to the anterior annular ligament. Of the internal sides of the rhomb, the superior articulates with the scaphoid bone, the inferior with the trapezoid bone, and by a small facet close to the inferior angle also with the second metacarpal bone. Of the external sides the superior is rough, and the inferior presents a smooth surface convex from behind forwards, and concave from without inwards, which articulates with the metacarpal bone of the thumb, and is separated by a rough line at the inferior angle from the surface for the second metacarpal bone. The trapezium articulates with four bones, viz., the scaphoid, trapezoid, and first and second metacarpals.

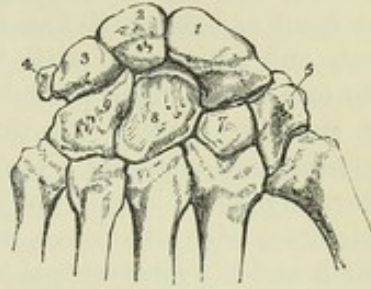


Fig. 76.

## THE TRAPEZOID BONE.

The trapezoid bone, or *os multangulum minus*, is considerably smaller than the trapezium. Its longest diameter is from before backwards. Its posterior surface, which is pentagonal, is much larger than the anterior. The external inferior angle of the anterior surface is distinguished by being prolonged a little backwards between the trapezium and second metacarpal bone. The superior surface articulates with the scaphoid bone ; the external with the trapezium ; the internal with the os magnum ; and the inferior by a large surface convex from side to side with the second metacarpal bone. The trapezoid articulates with four bones, viz., the scaphoid, trapezium, os magnum, and second metacarpal bone.

## THE OS MAGNUM.

The os magnum, or *os capitatum*, is the largest of the carpal bones. In form it is elongated vertically, rectangular inferiorly, rounded superiorly. The articular surface of the superior extremity or *head* is prolonged on the outer, but not on the inner side, and is continued further down behind than in front. A *neck* is formed beneath by depressions on the anterior and posterior surfaces. The anterior surface of the bone is much narrower than the posterior. The posterior surface projects downwards at its



internal inferior angle. On the external side beneath the surface for the scaphoid is a short surface for the trapezoid bone; and on the internal surface is a vertically elongated surface which articulates with the unciform bone. Inferiorly this bone articulates by three distinct surfaces, of which the middle is much the largest, with the second, third, and fourth metacarpal bones. The os magnum articulates with seven bones, viz., the scaphoid, semilunar, trapezoid, unciform, and second, third, and fourth metacarpal bones.

#### THE UNCIFORM BONE.

The unciform bone is readily distinguished by the large process projecting forwards and curved slightly outwards on its anterior surface. Seen from the front or behind, it has a triangular form. Its external surface is vertical, and articulates with the os magnum; its inferior surface is divided into two facets which articulate with the fourth and fifth metacarpal bones; its superior surface, meeting the cuneiform, is concavo-convex, inclines upwards and outwards towards the head of the os magnum, and is separated internally by a rough border from the inferior surface. The unciform articulates with five bones, viz., the os magnum, semilunar, cuneiform, and fourth and fifth metacarpal bones.

#### THE METACARPUS.

The metacarpus, the part of the hand which supports the fingers, consists of five shafted bones, which are numbered from without inwards. These bones are placed in a slightly arched plane, and are nearly parallel one with the other, with the exception of the first, which diverges from the second.

Fig. 77.

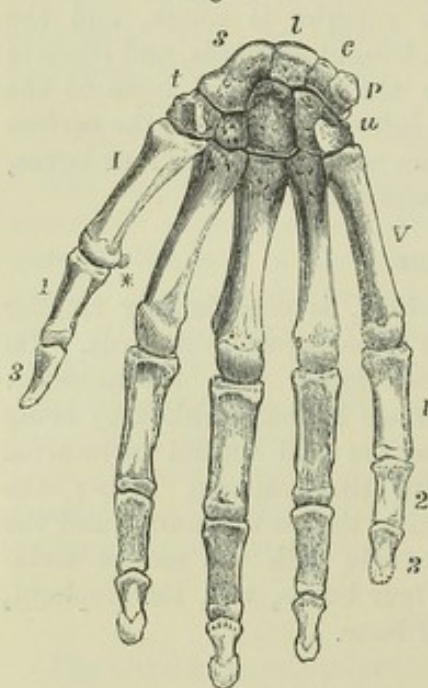


Fig. 77.—THE RIGHT HAND FROM BEFORE.  $\frac{1}{2}$

s, scaphoid bone; l, semilunar; c, cuneiform; p, pisiform; t, trapezium; next it the trapezoid, not lettered; next the os magnum, also not lettered; u, unciform.

I to V, the metacarpal bones; 1, 3, first and second phalanges of the thumb; 1, 2, 3, the first, second, and third phalanges of the little finger, and similarly for the other three fingers, not marked; \*, one of the sesamoid bones of the thumb seen sidewise.

The metacarpal bones are slightly curved, so as to present a concavity directed forwards. They are terminated at their carpal extremities by expanded portions of different forms, and at the digital ends by large rounded heads. The first metacarpal bone is thicker and shorter than the others. The remaining four decrease regularly in length, according to their position from without inwards, and the second and third are thicker than the fourth and fifth.

The *shaft* of the first metacarpal bone is somewhat compressed from before backwards, flat behind, and transversely convex in front. The shafts of the others are prismatic, presenting a broad surface towards the back of the hand, and towards the palm a rounded margin between the two lateral surfaces. They are most slender immediately beyond the carpal extremity, and become gradually thicker towards the head. They present on their dorsal surfaces each a triangular subcutaneous area, bounded



by lines which, proceeding from the sides of the head, pass upwards and converge in the second, third, and fourth metacarpal bones opposite the middle of the carpal extremity, and in the fifth towards its inner side.

The *heads* or *digital extremities* articulate with the proximal phalanges. Their smooth rounded surfaces are broader, and extend further on the palmar than on the dorsal aspect of the bones; and on the sides present hollows and elevations for the attachment of ligaments.

The *carpal extremity* presents distinctive peculiarities in each metacarpal bone. That of the first has only one articular surface, concave from before backwards, and convex from side to side, which articulates with the trapezium; and posteriorly a rough prominence, to which the extensor metacarpi pollicis is attached. The second presents a transversely concave surface which receives the trapezoid bone; on the radial side it articulates by a small facet on its posterior part with the trapezium, on the ulnar side with the third metacarpal bone, and by a narrow facet wedged between the third metacarpal and trapezoid bones, with the os magnum. The third bone articulates superiorly with the os magnum, and on the sides with the contiguous metacarpal bones: at its posterior and outer angle it forms a projection upwards. The fourth articulates principally with the unciform bone above, but also by a narrow facet with the os magnum; on its radial side are two small surfaces, and on the ulnar side one, for articulation with the adjacent metacarpal bones. The fifth articulates superiorly with the unciform bone by means of a concave surface inclined slightly outwards, and externally with the fourth metacarpal bone, while on its ulnar side it presents a rough and prominent tuberosity.

From the proximal position of its epiphysis, the metacarpal bone of the thumb has been considered by Winslow and some other anatomists, as a phalanx of the first row, and the bone which it supports a phalanx of the middle row.

#### THE DIGITAL PHALANGES.

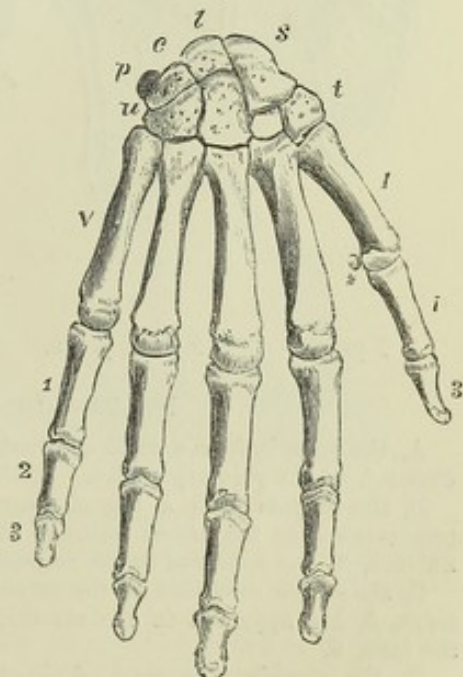
Fig. 78.—RIGHT HAND SEEN FROM BEHIND.  $\frac{1}{2}$

The indications are the same as in the preceding figure.

The digital phalanges, or *internodia*, are fourteen in number; three for each finger, except the thumb, which has only two. In each instance the first or proximal phalanx is longer than the second, and the second longer than the third.

Those of the *first row* are slightly curved like the metacarpal bones. Their dorsal surfaces are smooth and transversely convex; the palmar are flat from side to side, and bounded by rough margins, which give insertion to the fibrous sheaths of the flexor tendons. Their proximal extremities are thick, and articulate each by a transversely oval concave surface with the corresponding metacarpal bone. Their distal extremities, smaller and more

Fig. 78.





compressed antero-posteriorly, are each divided by a shallow groove into two condyles.

Those of the *middle row* are four in number. Smaller than those of the preceding set, they resemble them in form, with this difference, that their proximal extremities present on the articular surface a slight middle elevation and two lateral depressions, adapted to articulate with the condyles of the first phalanges.

The *terminal* or *ungual* phalanges, five in number, have proximal extremities similar to those of the middle row, but with a rough depression in front, where the flexor tendons are inserted. They taper towards their somewhat flattened and expanded free extremities, which are rough and raised round the margins and upon the palmar aspect in the ungual process.

**SESAMOID BONES.**—A pair of sesamoid bones is placed in the palmar wall of the metacarpo-phalangeal articulation of the thumb; and similar nodules, single or double, are sometimes found in the corresponding joint of one or more of the other fingers, most frequently of the index and little fingers.

#### DEVELOPMENT OF THE UPPER LIMB.

**FIRST APPEARANCE OF THE LIMBS.**—The earliest traces of limbs in the human embryo are observed in the fourth or fifth week as elevations of the ventral plates on the sides of the body, tipped with a thickening of the cuticle. In the fifth or sixth week there is distinguishable in each a laterally compressed expansion, the rudimentary hand or foot, and a more cylindrical pedicle, the arm or leg. About the eighth week the division into fingers and toes takes place, the pollex of each

Fig. 79.

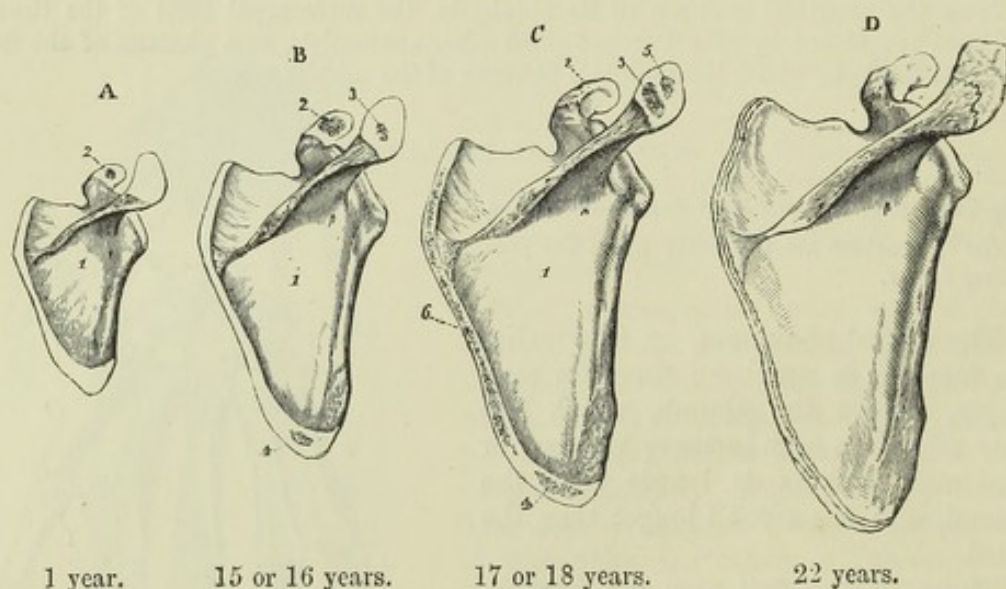


Fig. 79.—OSSIFICATION OF THE SCAPULA.

A, the scapula from a child of about one year old. 1, shows the large spreading ossification from the primary centre. 2, the commencing nucleus in the coracoid process.

B, the scapula from a boy of about fifteen or sixteen years. The coracoid process, (represented as too much separate in the figure), is now partially united at its base; a nucleus, 3, has appeared in the acromion, and another, 4, at the lower angle.

C, shows the condition of the scapula at seventeen or eighteen years of age; a second point, 5, has appeared in the acromion, and ossification has advanced into the ridge of the base, 6.

D, the scapula of a man of about twenty-two years of age; the acromion and the ridge of the base are still separate. A thin scale on the coracoid process and an epiphysis of the glenoid head, which sometimes occur, have been omitted.



limb being developed on the superior margin. The upper limb appears before the lower, and sooner exhibits a separation of digits. The division into arm and forearm, thigh and leg, is observable about the eighth week (Kölliker, loc. cit.). The nerves are seen extending directly into the limbs soon after their first appearance; but it is not determined whether the bones and muscles are derived from extensions of the dorsal plates, or have an independent origin in the ventral plates.

**OSSIFICATION OF THE UPPER LIMB.**—With the exception of the clavicle, all the bones of the upper limb begin to ossify from cartilage. The *Scapula* is developed in the greater part of its extent from a single osseous nucleus, but possesses also supplementary nuclei in the coracoid process and acromion, and along the base. The nucleus of the coracoid process is especially worthy of attention, both because it appears in the first year, while the other supplementary nuclei are formed only after puberty, and because, although reduced to a mere epiphysis in mammals, it forms a distinct and sometimes large bone in other vertebrate animals. The acromion is ossified from two or more nuclei. Along the base of the young scapula a strip of cartilage extends, corresponding with a much more largely developed permanent cartilage found in many animals; and in this there first appears a nucleus of bone at the inferior angle, then a prolonged ossification throughout its length. Occasionally a separate epiphysal lamina occurs, in the border of the glenoid cavity.

Fig. 80.—OSSIFICATION OF THE CLAVICLE.

*a*, the clavicle of a foetus at birth, osseous in the shaft, 1, and cartilaginous at both ends.  
*b*, clavicle of a man of about twenty-three years of age; the shaft, 1, fully ossified to the acromial end; the sternal epiphysis, 2, is represented rather thicker than natural.

Fig. 80.



The *Clavicle* begins to ossify before any other bone in the body. Its ossification commences before the deposition of cartilage in connection with it, but afterwards progresses in cartilage as well as in fibrous substance. It is formed from one principal piece, and has a thin epiphysis at its sternal end.

Fig. 81.

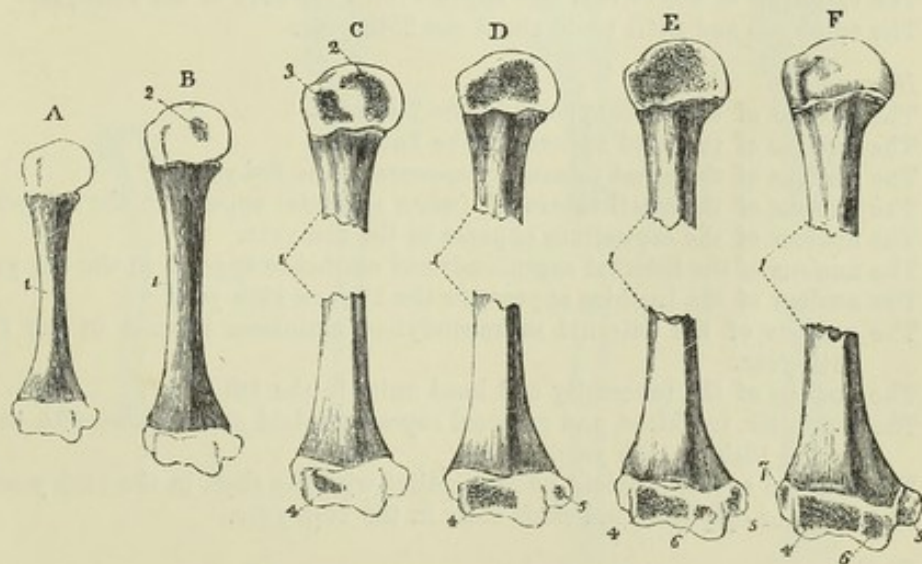


Fig. 81.—OSSIFICATION OF THE HUMERUS.

A, humerus of a full-grown foetus; B, humerus at two years of age; C, in the third year; D, at the beginning of the fifth year; E, at about the twelfth year; F, at the age of puberty.

1, the primary piece for the shaft; 2, nucleus for the articular head; 3, that for the tuberosity; 4, for the radial condyle and adjacent part of the trochlea; 5, for the inner or trochlear eminence; 6, for the inner part of the trochlea; 7, for the external or capitellar eminence.



The *Humerus* is formed, like most of the long bones, from a principal centre for the shaft, and from a superior and an inferior terminal epiphysis. The superior epiphysis is formed by the union of two original nuclei—one in the head, the other in the great tuberosity, to which is added, according to Bécclard and Humphry, a nucleus belonging to the small tuberosity. The inferior epiphysis has four original nuclei, the largest of which extends inwards from the capitellum, while a small one appears at the inner part of the trochlea, and one in each supracondyloid eminence; the internal supracondyloid epiphysis remains distinct from the other three nuclei, which become fused into one mass previous to their union with the shaft.

The *Radius* and *Ulna* are each developed from an osseous centre in the middle of the shaft and from an epiphysial nucleus in each extremity. The epiphyses of the ulna are very small; the upper one involves only the extremity of the olecranon.

The *Carpus* is entirely cartilaginous at birth. Each *Carpal bone* is ossified from a single nucleus.

The *Metacarpal bones* and *Phalanges* are formed each from a principal piece and one epiphysis. The ossification of the principal pieces begins at an early period. In the four inner metacarpal bones the epiphysis is at the distal extremity, while in the metacarpal bone of the thumb and in the phalanges it is placed at the proximal extremity.

#### PERIODS OF OSSIFICATION OF THE BONES OF THE UPPER LIMB.

##### I. *Scapula.*

The principal nucleus appears in the 7th or 8th week.

The nucleus of the coracoid process appears in the 1st or 2nd year.

The two nuclei of the acromion appear from the 14th to the 16th year.

The nuclei of the inferior angle, base, and glenoid cavity, appear from the 16th to the 18th year.

The coracoid process and body unite about the time of puberty.

The other parts unite from the 22nd to the 25th year.

##### II. *Clavicle.*

The principal nucleus (earliest of all bones) appears about the 6th week.

The epiphysis of the sternal end appears from the 18th to the 20th year.

The epiphysis and shaft unite about the 25th year.

##### III. *Humerus.*

The nucleus of the shaft appears in the 7th week.

The nucleus of the head appears in the 2nd year.

The nucleus of the great tuberosity appears in the 3rd year.

The nucleus of the small tuberosity (when separate) appears in the 5th year.

The nucleus of the capitellum appears in the 3rd year.

The nucleus of the internal supracondyloid eminence appears in the 5th year.

The nucleus of the trochlea appears in the 11th or 12th year.

The nucleus of the external supracondyloid eminence appears in the 13th or 14th year.

The nucleus of the tuberosity and head unite in the 5th year.

The capitellar, trochlear, and external supracondyloid nuclei unite with the shaft in the 16th or 17th year.

The internal supracondyloid nucleus unites with the shaft in the 18th year.

The superior epiphysis and shaft unite in the 20th year.

##### IV. *Radius.*

The nucleus of the shaft appears in the 7th or 8th week.

The nucleus of the carpal extremity appears at the end of the 2nd year.

The nucleus of the head appears in the 5th year.

The superior epiphysis and shaft unite about the 17th or 18th year.

The inferior epiphysis and shaft unite about the 20th year.

##### V. *Ulna.*

The nucleus of the shaft appears in the 8th week.



Fig. 82.

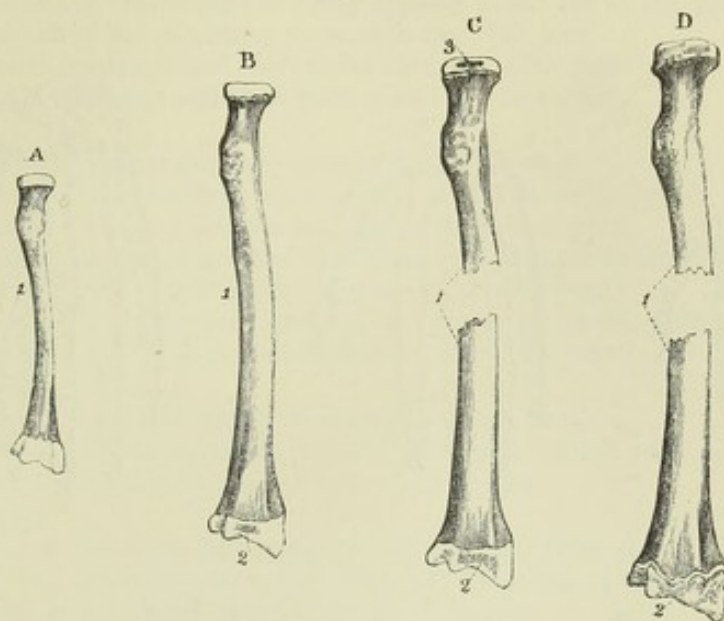


Fig. 82.—OSSIFICATION OF THE RADIUS.

A, the radius of a full-grown fetus ; B, the radius at about two years of age ; C, at five years ; D, at about eighteen years.

1, the primary piece or shaft ; 2, the ossific point of the lower or carpal epiphysis ; 3, that of the upper end. In D, the upper epiphysis is already united to the shaft, while the lower epiphysis is still separate.

Fig. 83.

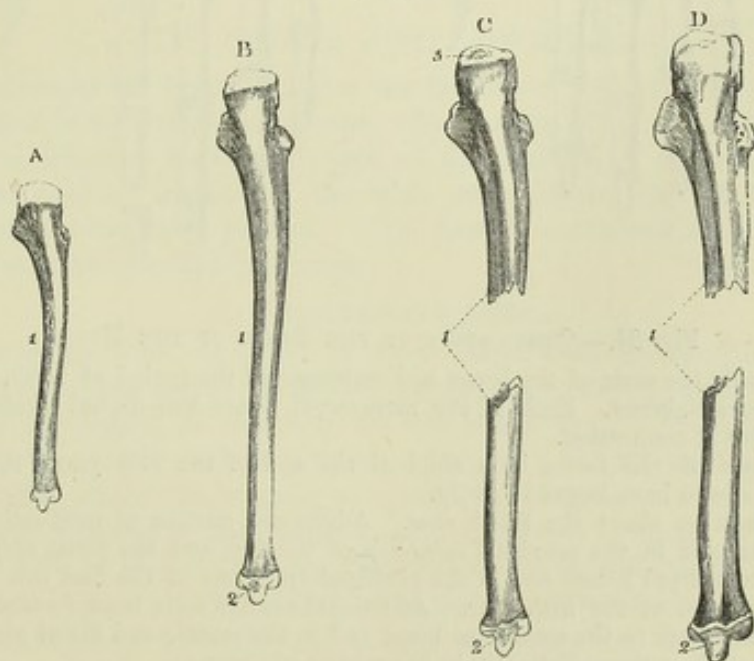


Fig. 83.—OSSIFICATION OF THE ULNA.

A, the ulna of a child at birth ; B, the ulna of a child at the end of the fourth year ; C, of a boy of about twelve years of age ; D, the ulna of a male of about nineteen or twenty years.

1, the primary piece of the shaft ; 2, the nucleus of the lower epiphysis ; 3, the nucleus of the upper epiphysis. In D, the upper epiphysis is united to the shaft, while the lower one is still separate.



Fig. 84.

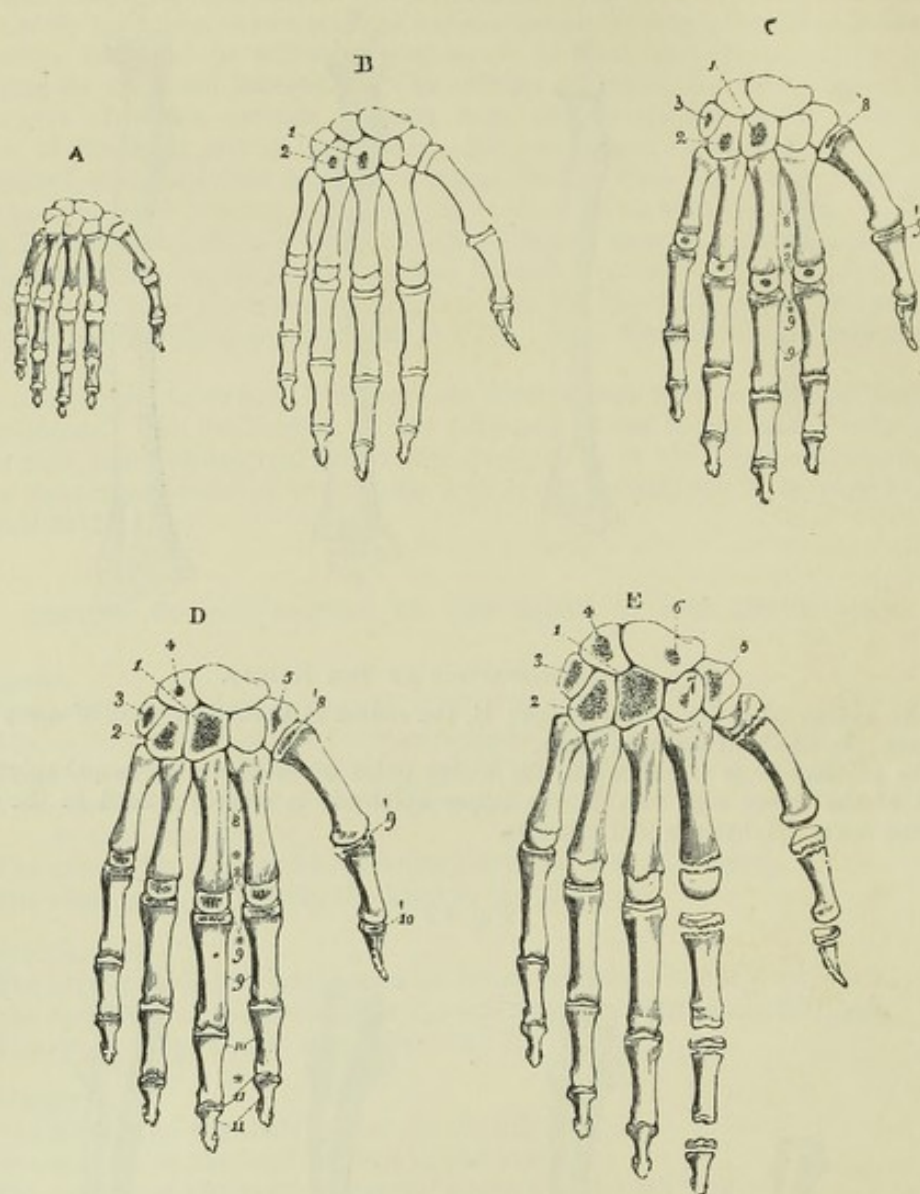


Fig. 84.—OSSIFICATION OF THE BONES OF THE HAND.

A, represents the state of the bones and cartilages at the period of birth. The carpus is entirely cartilaginous. Each of the metacarpal bones and digital phalanges has its primary centre of ossification.

B, the state of the bones in a child at the end of the first year; the os magnum and unciform bone have begun to ossify.

C, the condition about the third year. Additional centres of ossification are seen in the cuneiform and in the proximal epiphysis of the first and the distal epiphyses of the other four metacarpal bones, and in the proximal epiphyses of the first row of phalanges.

D, the condition at the fifth year. Additional centres have been formed, first in the trapezium, and later in the semilunar bone, and in the middle and distal phalanges: (the figure does not show them distinctly in the middle phalanges).

E, the condition at about the ninth year. Additional centres have been formed in the scaphoid and trapezoid bones, and the more developed epiphyses of the metacarpal bones and phalanges are shown, in the first and second separately.

1, os magnum; 2, unciform; 3, cuneiform; 4, semilunar; 5, trapezium; 6, scaphoid; 7, trapezoid; 8, metacarpal bones, the principal piece; 8\*, four metacarpal epiphyses; 8', that of the thumb; 9, the first range of phalanges; 9\*, their epiphyses; 9', that of the thumb; 10, second range of phalanges; 10', epiphysis of terminal phalanx of thumb; 11, terminal range of phalanges of the fingers; 11\*, their epiphyses.



*Ulna*—continued.

The epiphysis of the carpal extremity appears in the 4th or 5th year.

The epiphysis of the olecranon appears in the 10th year.

The superior epiphysis and shaft unite about the 17th year.

The inferior epiphysis and shaft unite about the 20th year.

VI. *Carpus*.

The nucleus of the os magnum appears in the 1st year.

The nucleus of the unciform bone appears in the 1st or 2nd year.

The nucleus of the cuneiform bone appears in the 3rd year.

The nuclei of the trapezium and semilunar bones appear in the 5th year.

The nucleus of the scaphoid bone appears in the 8th year.

The nucleus of the trapezoid bone appears in the 8th or 9th year.

The nucleus of the pisiform bone appears in the 12th year.

VII. *Metacarpus*.

The nuclei of the shafts appear in the 8th and 9th week.

The nuclei of the epiphyses appear from the 3rd to the 5th year.

The epiphyses and shafts unite about the 20th year.

VIII. *Phalanges*.

The nuclei of the shafts appear in the 8th, 9th, and 10th weeks.

The nuclei of the epiphyses appear from the 3rd or 4th to the 5th or 6th years.

The epiphyses and shafts unite before the 20th year.

NOTE. From what is stated above it appears that in the bones of the arm and forearm the epiphyses which meet at the elbow-joint begin to ossify later and unite with their shafts earlier than those at the opposite ends of the bones, while in the bones of the thigh and leg the epiphyses distant from the knee-joint are the latest to ossify (excepting the fibula) and the first to unite with their shafts. In the bones of the arm and forearm the nutrient foramina are directed towards the elbow; in those of the thigh and leg they are directed away from the knee. Thus in each bone the epiphysis of the extremity towards which the nutrient foramen is directed is the first to be united to the shaft.

## V.—THE PELVIS AND LOWER LIMB.

The divisions of the lower limb are the haunch or hip, thigh, leg, and foot. In the haunch is the innominate bone, which, as entering into the formation of the pelvis, likewise constitutes part of the skeleton of the trunk; in the thigh is the femur; in the leg the tibia and fibula; and at the knee a large sesamoid bone, the patella. The foot is composed of three parts; the tarsus, metatarsus, and phalanges.

## THE INNOMINATE BONE.

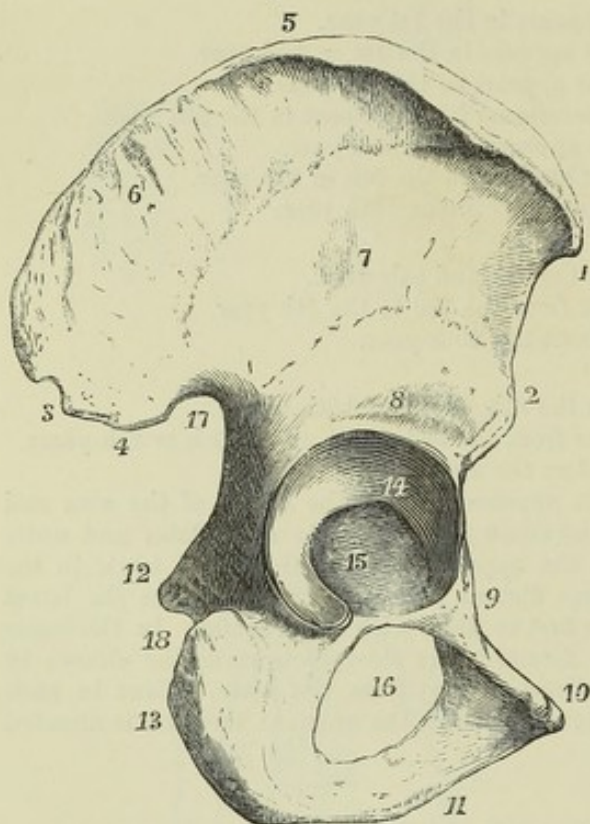
The innominate bone, *os coxae*, or *pelvic bone*, with its neighbour of the opposite side and the addition of the sacrum and coccyx, forms the pelvis; it transmits the weight of the body to the lower limb. In form it is constricted in the middle and expanded above and below, and is so curved upon itself that while the superior expansion is directed inwards posteriorly and outwards anteriorly, the inferior part is curved inwards so as to reach the middle line in front. On the external aspect of the constricted portion is the *acetabulum*, a cavity which articulates with the femur, and perforating the inferior expansion is a large opening, the *obturator foramen*. The superior wider part of the bone forms part of the abdominal wall: the inferior enters into the formation of the true pelvis. The innominate bone articulates with its fellow of the opposite side, with the sacrum and with the femur.

In the description of this bone it is convenient to recognise as distinct the three parts of it which are separate in early life, viz., the *ilium*, *os pubis*, and *ischium*. These three portions meet at the acetabulum, in the



formation of which they all take part; and the os pubis and ischium also meet on the inner side of the obturator foramen.

Fig. 85.

Fig. 85.—RIGHT OS INNOMINATUM FROM THE DORSAL ASPECT.  $\frac{1}{3}$ 

1, anterior superior spinous process; 2, anterior inferior ditto; 3, posterior superior; 4, posterior inferior spinous process; 5, crest of the ilium; 6, surface occupied by the gluteus medius muscle above the superior curved line above 3, is a rough surface to which the gluteus maximus is attached; 7, surface between the superior and inferior curved lines occupied by the gluteus minimus; 8, groove above the acetabulum, occupied by the posterior tendon of the rectus femoris; 9, superior ramus of the pubis and pectineal eminence; 10, crest and spinous process of the pubis; 11, place of meeting of the descending or inferior ramus of the pubis with the ascending ramus of the ischium; 12, tuberosity of the ischium; 13, cartilaginous surface of the acetabulum; and 15, synovial depression and pit for the round ligament; 16, thyroid, or obturator foramen; 17, greater, and 18, lesser sciatic notches; between the acetabulum and the ischial tuberosity is seen the groove occupied by the obturator externus muscle.

The *ilium* constitutes the superior expanded portion of the bone, and forms a part of the wall of the acetabulum by its inferior extremity. Above the acetabulum it is limited anteriorly and posteriorly by margins which diverge at right angles one from the other, and superiorly by an arched thick and extensive border, the *crista ilii*. The *crest* is curved like the letter *f*, the anterior extremity pointing slightly inwards and the posterior outwards; its surface is broadest in its anterior and posterior thirds, it is rough for the attachment of muscles, and on it may be distinguished an external and internal lip and an intermediate space. The anterior extremity of the crest forms a projection forwards called the *anterior superior spine of the ilium*, and, separated from it by a concave border, and placed immediately above the acetabulum, is another eminence called the *anterior inferior spine*: the projecting posterior extremity of the crest forms the *posterior superior spine*, and separated from it by a notch is the *posterior inferior spine*, below which the posterior border of the bone is hollowed out into the *great sciatic notch*. The external surface, or *dorsum* of the ilium, concavo-convex from behind forwards, presents, close to the posterior extremity of the crest, a roughness of some extent, to which the gluteus maximus muscle is attached, and is traversed by two rough arched lines, one of which, the *superior curved line*, beginning in front at the upper border of the bone, about an inch and a half from its anterior extremity, arches backwards to the upper part of the great sciatic notch, while the other, the *inferior curved line*, shorter



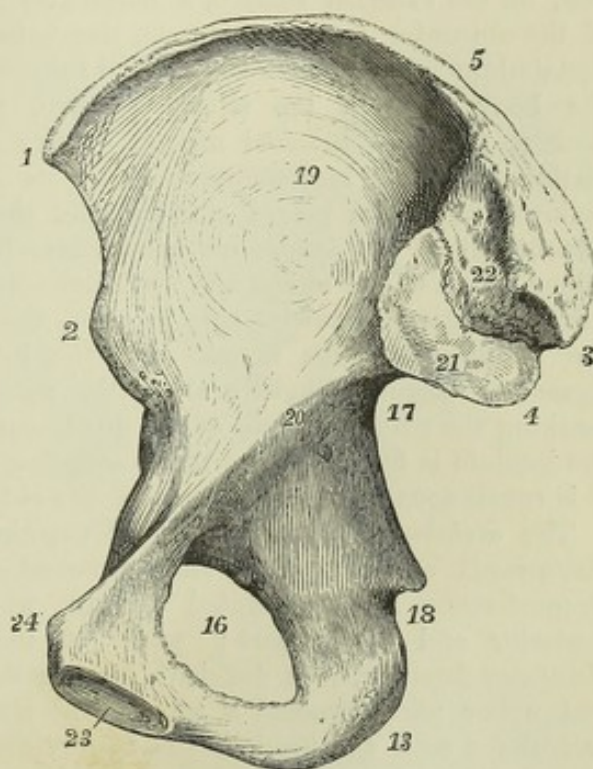
and less strongly marked, extends from the space between the anterior spinous processes to the middle of the great sciatic notch. The space between the crest and the superior curved line has the form of a curved triangle, broad behind and pointed in front, and gives attachment to the gluteus medius muscle, while that between the two curved lines gives attachment to the gluteus minimus. The internal surface of the ilium is divided into three parts. The anterior of these, the largest, is called the *iliac fossa*; it is concave and smooth, and towards the middle of it the bone is very thin. The posterior part is subdivided; presenting inferiorly for cartilaginous articulation with the sacrum the smooth but uneven *auricular surface*, broad in front and extending to the posterior inferior spine behind; and superiorly a more uneven and rough surface for the attachment of ligaments. The third part, entering into the formation of the true pelvis, is not distinguished by any mark in the adult from the ischium and os pubis; it is separated from the iliac fossa by a smooth border, the *ilio-pectineal line*, which extends from the auricular surface to the pubic spine.

Fig. 86.—RIGHT OS INNOMINATUM,  
FROM THE INNER OR PELVIC  
SURFACE.  $\frac{1}{2}$

2, 3, 4, 5, 13, 16, 17, and 18, indicate the same parts as in the preceding figure; 19, iliac fossa; 20, ilio-pectineal line or brim of the true pelvis, ending at 24; 21, auricular cartilaginous sacro-iliac surface; 22, rough tuberculated surface for the posterior sacro-iliac ligaments; 23, oval surface of the symphysis pubis; 24, spinous process of the pubis, terminating the crest of the pubis and the ilio-pectineal line; between 17 and 20, the pelvic surface of the ilium.

The *os pubis* or *os pectinis* forms the anterior wall of the pelvis, and bounds the obturator foramen in the upper half of its extent. At its outer and upper extremity it forms a part of the acetabulum; at its inner extremity it presents an elongated oval surface, articulating by fibro-cartilage with the bone of the opposite side, its junction with which is called the *symphysis pubis*. The part which passes downwards and outwards below the symphysis is called the *inferior* or *descending ramus*, the upper part is called the *superior* (or *horizontal*) *ramus*, and the flat portion between the rami may be distinguished as the *body*. The deep or pelvic surface of the os pubis is smooth; the outer surface is roughened near the symphysis by the attachments of muscles. At the superior extremity of the symphysis is the *angle* of the pubis, and extending outwards from this on the superior border is the rough *crest*, terminating in the projecting *spine*. The descending ramus is flat from before backwards; the superior or ascending ramus becomes prismatic, and increases in thickness as it passes upwards and out-

Fig. 86.





wards, and between its posterior and superior surfaces there is prolonged outwards from the spine a ridge called the *pectineal line*, which is the pubic portion of the *ilio-pectineal line*. The surface in front of the pectineal line is covered by the pectineus muscle; the inferior surface of the superior ramus presents a deep groove for the obturator vessels and nerve, directed from behind forwards and inwards. Above the acetabulum the concavity of the border extending from the anterior inferior spine of the ilium to the spine of the pubis is interrupted by a slight elevation, the *ilio-pectineal eminence*, situated at the junction of the os pubis and ilium.

The *ischium* is the posterior and lowest part of the os innominatum, and bounds the obturator foramen in the lower half of its extent. Superiorly it forms about two-fifths of the acetabulum, inferiorly it is enlarged in a thick projection, the *tuberosity*, and this part, diminishing in size, is continued forwards into the *ramus*. On its posterior border, behind the acetabulum, a sharp process, the *spine*, projecting with an inclination inwards, forms the inferior limit of the *great sciatic notch*, and is separated from the tuberosity by a short interval, the *small sciatic notch*, against the smooth margin of which glides the tendon of the obturator internus muscle. In front of this, on the external surface, a horizontal groove, occupied by the tendon of the obturator externus muscle, lies between the inferior margin of the acetabulum and the tuberosity. The tuberosity, which is the part on which the body rests in the sitting posture, presents a rough surface continuous with the internal margin of the ramus, and on which may be distinguished four impressions, viz., on its upper and broad part two slight hollows, which are placed side by side, the external corresponding to the attachment of the semimembranosus muscle, and the internal to the conjoined origin of the biceps and semitendinosus; and inferiorly two elongated rough elevations, likewise side by side, the external giving attachment to the adductor magnus muscle, and the internal to the great sacro-sciatic ligament: there is likewise along the outer margin a rough elevated line, marking the place of origin of the quadratus femoris muscle. The ramus of the ischium is flattened like the descending ramus of the pubis, with which it is continuous on the inner side of the obturator foramen.

The *acetabulum* is a *cotylod* or cup-shaped cavity, looking outwards, downwards and forwards, and surrounded in the greater part of its circumference by an elevated margin, which is most prominent at the posterior and upper part; while at the opposite side, close to the obturator foramen, it is deficient, leaving the *notch* or *incisura*. Its lateral and upper parts present a broad bent riband-like smooth surface, which articulates with the head of the femur, and in the recent state is coated with cartilage, but the lower part of the cup and the region of the notch are depressed below the level of the articular surface, lodge a mass of fat, and have no cartilaginous coating. Rather more than two-fifths of the acetabulum are formed from the ischium, less than two-fifths from the ilium, and the remainder from the os pubis. The iliac portion of the articular surface is the largest, the pubic the smallest: the non-articular surface belongs chiefly to the ischium.

The *obturator* or *thyroid* foramen, also called *foramen ovale*, is internal and inferior to the acetabulum. In the male it is nearly oval, with the long diameter directed downwards and outwards; in the female it is more triangular, or narrowed at its lower part. In the recent state it is closed by a fibrous membrane, except in the neighbourhood of the groove in its upper margin.



## THE PELVIS.

The ossa innominata with the sacrum and coccyx form the osseous walls of the pelvis.

This part of the skeleton may be considered as divided into two parts at the level of the upper border of the symphysis pubis, the sacral promontory and the ilio-pectineal lines. The circle thus completed constitutes the *brim* or *inlet* of the lower or *true pelvis*; the space above it, between the iliac fossæ, belongs really to the abdomen, but has been called the upper or *false pelvis*. The inferior circumference, or *outlet* of the pelvis, presents three bony eminences, the coccyx and the tuberosities of the ischium. Between the tuberosities of the ischium in front is the *pubic* or *sub-pubic arch*, which bounds an angular space extending forwards to the symphysis, and is formed by the descending rami of the ossa pubis and the ascending rami of the ischia. The interval between the sacrum and coccyx and the ischium on each side is bridged over in the recent state by the sacro-sciatic ligaments, which therefore assist in bounding the outlet of the pelvis.

Fig. 87.

VIEW OF THE PELVIS OF A MIDDLE-AGED MAN, AS SEEN FROM BEFORE, IN THE ERECT ATTITUDE OF THE BODY.  $\frac{1}{4}$

1, 2, anterior extremities of the crest of the ilium in front of the widest transverse diameter of the upper or false pelvis; 3, 4, acetabula; 5, 5, thyroid or obturator foramina; 6, sub-pubic angle or arch.

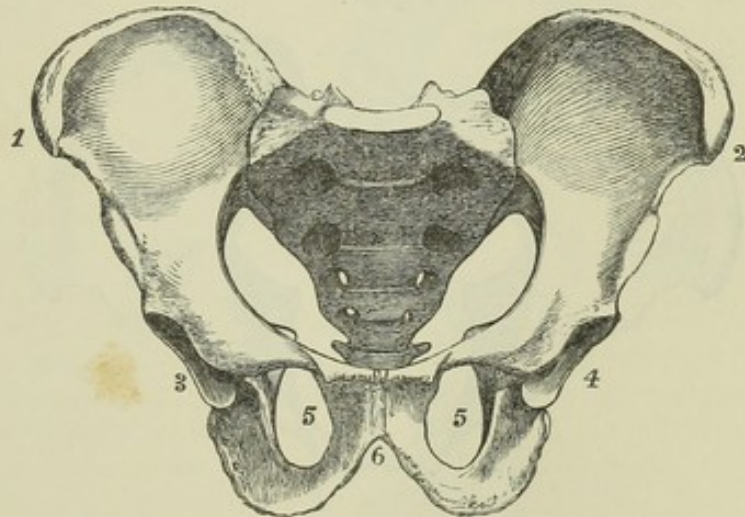


Fig. 87.

Fig. 88.

VIEW OF THE PELVIS OF A MIDDLE-AGED WOMAN.  $\frac{1}{4}$

Similarly placed with that shown in the preceding figure, and designed to illustrate, by comparison with it, the principal differences between the male and female pelvis, *viz.*, the greater distance in the female between the acetabula, the wider and shallower true pelvis, the triangular form of the obturator foramen, the greater width between the tuberosities of the ischium, and the greater width of the sub-pubic arch. The numbers indicate the same parts as in the preceding figure.

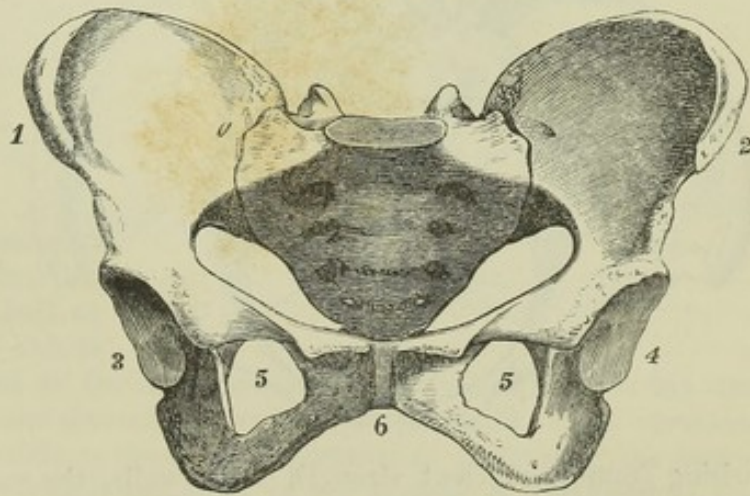


Fig. 88.



*Position of the Pelvis.*—In the erect attitude of the body, the pelvis is so inclined that the plane of the brim of the true pelvis forms an angle with the horizontal, varying in different individuals from  $60^{\circ}$  to  $65^{\circ}$ . The base of the sacrum was found by Nägele in a large number of well-formed female bodies to be about  $3\frac{1}{4}$  inches above the upper margin of the symphysis pubis; the level of the top of the coccyx he found varying from 22 lines above the apex of the pubic arch to 9 lines below the same point, and on an average to be 7 or 8 lines above it (Nägele, "Das weibliche Becken," &c., Carlsruhe, 1825; Wood, article "Pelvis" in the Cyclopædia of Anatomy and Physiology). The pelvic aspect of the sacrum, near its base, looks much more downwards than forwards, hence the sacrum appears at first sight to occupy the position of the keystone of an arch; but being in reality broader at its pelvic than on its dorsal aspect, it is a key-stone inverted or having its broad end lowest, and is only supported in its place by cartilage and ligaments. The line of pressure of the weight of the body on the sacrum is directed downwards towards the symphysis pubis, and the resistance of the head of the thighbone on each side is directed upwards and inwards: hence in the most frequent deformities of the pelvis,

Fig. 89.

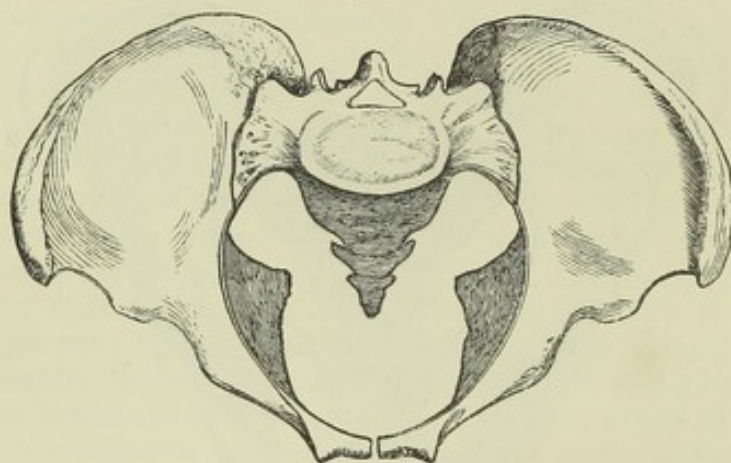
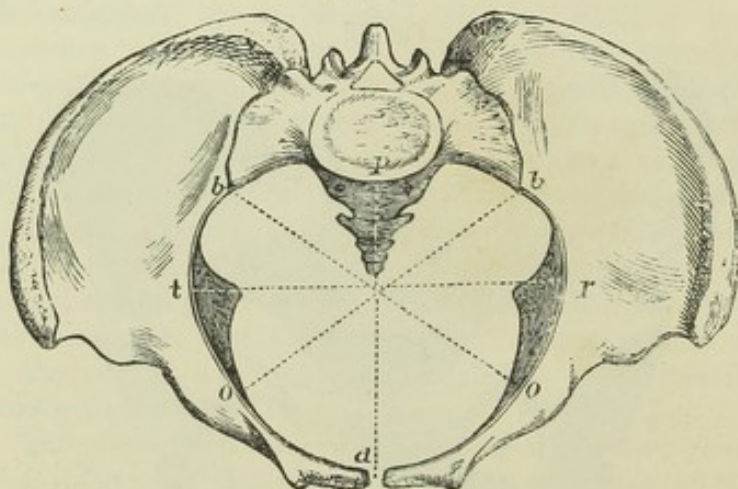


Fig. 90.



Figs. 89 and 90.

SKETCHES OF THE MALE AND FEMALE PELVIS.  $\frac{1}{4}$

As seen from above and in front, or at right angles to the brim of the true pelvis: designed farther to illustrate the differences of the male and female form, and showing in the lower figure of the female pelvis the lines in which the dimensions of the pelvis are usually measured; (these lines are only marked on the brim of the pelvis).

*a, p*, antero-posterior or conjugate diameter; *t, r*, transverse or widest diameter; *o, b*, oblique diameters.

In the original specimens, which were selected as giving the full average dimensions, the following were the measurements in inches:—

Antero-posterior or conjugate diameter—female,  $4\frac{1}{2}$ ; male, 4. Transverse diameter—female,  $5\frac{1}{4}$ ; male,  $4\frac{1}{2}$ . Oblique diameter—female, 5; male,  $4\frac{1}{4}$ .

arising from insufficient strength of its walls, the sacrum is projected into the inlet of the pelvis, and the acetabula approach the middle line, while the pubic bones are pressed forwards and downwards between them.



The *axis of the pelvis* is the name given to a line drawn in the middle at right angles to the planes of the brim, cavity and outlet. The posterior wall, formed by the sacrum and coccyx, being about five inches long and

Fig. 91.—VERTICAL ANTERO-POSTERIOR SECTION OF A FEMALE PELVIS, MADE THROUGH THE SYMPHYSIS PUBIS AND MIDDLE OF THE SACRUM AND COCCYX, SHOWING THE LEFT LATERAL HALF (reduced from Nägele's figure).  $\frac{1}{3}$

1, symphysis pubis; 2, base of the sacrum and promontory; 3, coccygeal bones; 4, anterior superior spine of ilium; 5, tuberosity of ischium; 6, spine of ischium (the obturator foramen is not represented so pointed below as it generally is in females). The vertical and horizontal lines in the lower part of the figure serve as standards of comparison for the degree of inclination of the pelvis, as illustrated by the next figure.

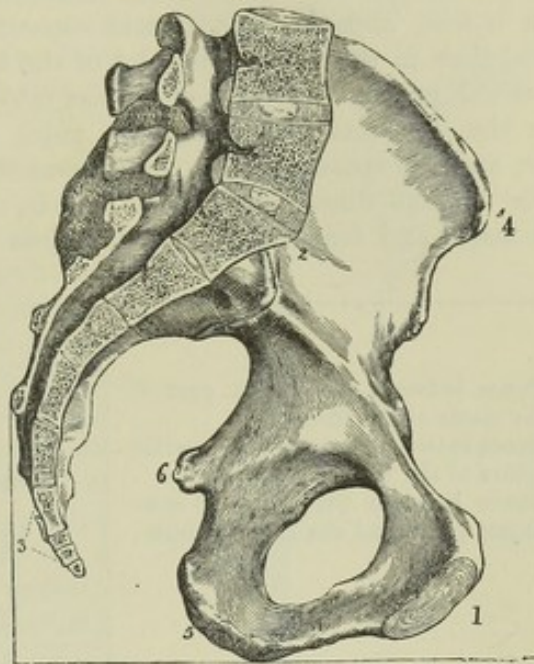


Fig. 91.

Fig. 92.—SKETCH OF PART OF THE PRECEDING FIGURE, SHOWING THE INCLINATION OF THE BRIM OF THE PELVIS AND ITS AXIS IN THE ERECT POSTURE.  $\frac{1}{3}$

a, b, line of inclination of the brim of the true pelvis from above the symphysis pubis to the promontory of the sacrum; c, f, a line inclining backwards and upwards, touching the lower edge of the symphysis pubis and point of the coccyx; c, d, axis of the brim at right angles to the plane of the brim; from d to the dotted line at right angles to e f, curved axis of the cavity continued into that of the outlet of the osseous pelvis; h, g, axis of the outlet of the pelvis when the soft parts are combined.

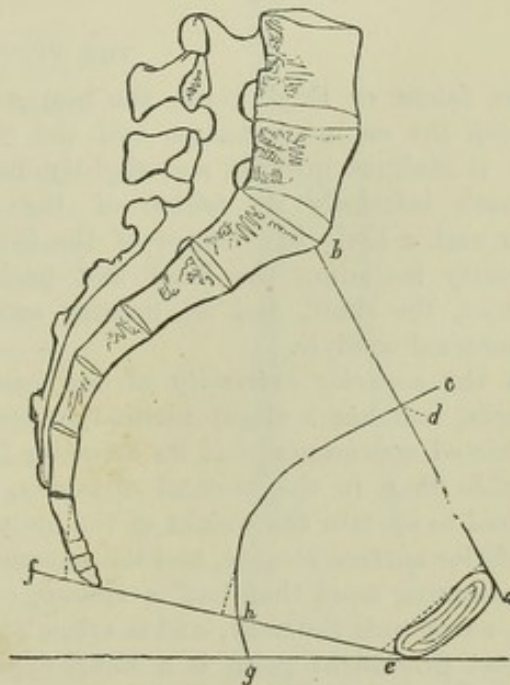


Fig. 92.

concave, while the anterior wall at the symphysis pubis is only one and a half or two inches long; the axis is

curved: it is directed at the inlet upwards and forwards towards the umbilicus, and at the outlet downwards and a little forwards. The curvature of the axis of the pelvis is specially important as indicating the course in which the child's head is propelled in the process of parturition; and it may be mentioned that in the female pelvis with the soft parts entire, the axis of the outlet is curved much more forwards than in the skeleton, the



posterior wall being prolonged in that direction by the integuments of the perinæum.

*Differences according to Sex.*—The size and form of the pelvis differ remarkably in the two sexes. In the female the constituent bones are more slender and less marked with muscular impressions; the perpendicular depth is less, and the breadth and capacity greater: the ilia are more expanded than in the male; the inlet of the true pelvis is more nearly circular, the sacral promontory projecting less into it, and is broader from side to side; the depth of the symphysis pubis is less, the pubic arch is much wider, and the space between the tuberosities of the ischia greater.

The average dimensions of the pelvis, as measured in a number of full-sized males and females, may be stated as follows, in inches :—

	MALE.			FEMALE.		
Distance between the widest part of the crests of the ilium . . . .	10	to	11	10½	to	11
Distance between the anterior superior spines of the ilium . . . .	9½	—	10	10	—	10½
Distance between the front of symphysis pubis and the sacral spines .	6½	—	7	6½	—	7½
<b>TRUE PELVIS.</b>						
	Brim.	Cavity.	Outlet.	Brim.	Cavity.	Outlet.
Transverse diameter . . . .	4½	4½	3½	5¼	5	4¾
Oblique diameter . . . .	4¼	4½	4	5	5¼	4¾
Antero-posterior diameter . . . .	4	4½	3¼	4½	5¼	5

#### THE FEMUR.

The femur or thigh bone, the largest bone of the skeleton, is situated between the os innominatum and the tibia. In the erect position of the body it inclines inwards and slightly backwards as it descends, so as to approach inferiorly its fellow of the opposite side, and to have its upper end a little in advance of the lower. It is divisible into a superior extremity including the head and neck and two eminences called trochanters, the shaft, and an inferior extremity expanded into an external and internal condyle.

At the *superior extremity* of the bone, the *neck* extends inwards and upwards, and has a slight inclination forwards from the shaft. It has a constricted appearance, and its diameter from before backwards is less considerable than in the vertical direction, in which last greater strength is required to sustain the weight of the body. Its superior surface is shortest; its inferior surface longest, and the anterior shorter than the posterior. The *head*, forming more than half a sphere, covered with cartilage in the fresh state, surmounts the neck, and is articulated with the acetabulum. Beneath its most prominent point is a small depression or pit, which gives attachment to the round ligament of the hip joint.

The *trochanter major* is a thick truncated process prolonged upwards in a line with the external surface of the shaft. In front it is marked by the insertion of the gluteus minimus; externally an oblique line directed downwards and forwards indicates the inferior border of the insertion of the gluteus medius muscle, and lower down a horizontal line, continued upwards in front of the trochanter, marks the upper limit of the vastus externus.



Internally at its base, and rather behind the neck, is the *trochanteric* or *digital*

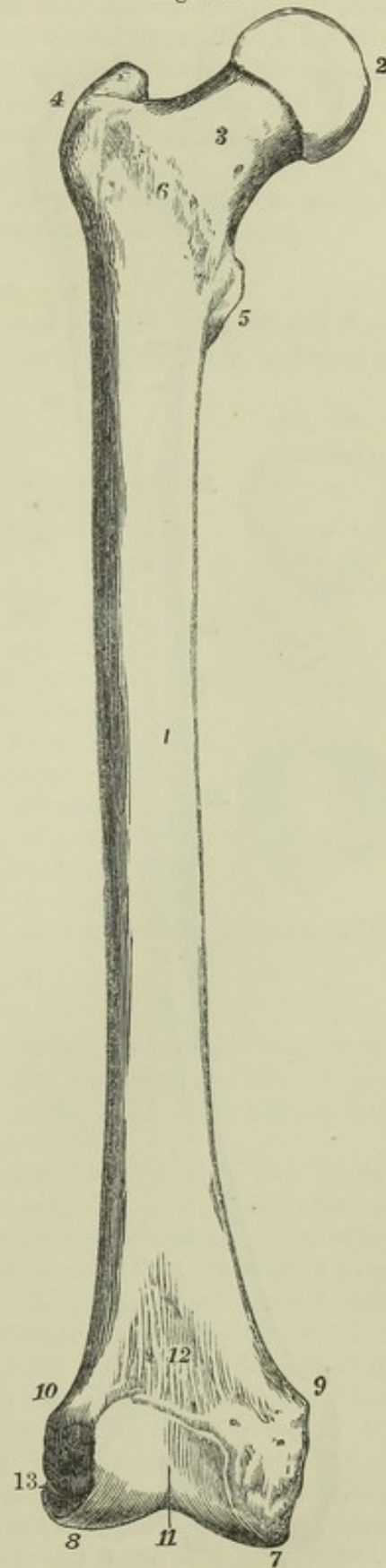
Fig. 93.—FEMUR OF A MALE FROM BEFORE.  $\frac{1}{3}$

1, shaft; 2, head; 3, neck; 4, great trochanter; 5, small trochanter; 6, anterior inter-trochanteric line; 7, internal articular condyle; 8, external articular condyle; 9, internal tuberosity; 10, external tuberosity; 11, the patellar articular surface; above it 12, the flat part of the femur sometimes called the suprapatellar surface; 13, the depression for the tendon of the popliteus muscle.

*fossa*, which gives attachment to the ob-turator externus muscle. The posterior border of the great trochanter is prominent, and continued into a smooth elevation, the *posterior inter-trochanteric line*, which passes downwards and inwards to the small trochanter, and limits the neck posteriorly. The *small trochanter*, a conical rounded eminence, projects from the posterior and inner aspect of the bone, and gives attachment to the tendon of the psoas and iliacus muscles. The *anterior trochanteric line* is a rough ridge limiting the neck in front between the two trochanters; it indicates the superior border of the crureus and vastus internus muscles, and is continuous beneath the great trochanter with the line which limits the vastus externus.

The *shaft* is slightly arched from above downwards, with the convexity forwards. It is expanded at its upper and lower ends. Towards the centre it is nearly cylindrical, but with an inclination to the prismatic form. Its anterior and lateral surfaces, smooth and uniform, are covered by the crureus and vasti muscles. The elevation which separates the anterior from the internal surface is at the upper part strongly marked and inclined forwards, giving the appearance to the bone as if the forward inclination of the neck were produced by a twisting outwards of the upper end of the shaft. The lateral surfaces in the middle of their extent approach one another behind, being only separated by the *linea aspera*. The *linea aspera* is a prominent ridge, extending along the central third of the shaft posteriorly, and bifurcating above and below. It inclines slightly inwards in the middle, so as to make the external

Fig. 93.





surface of the shaft seem concave in that part. It presents two sharp

Fig. 94.

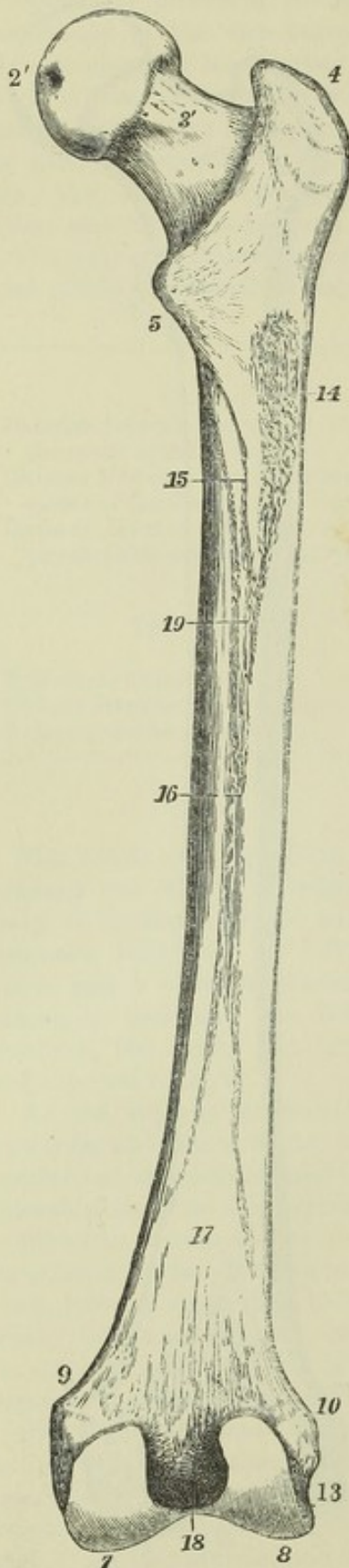


Fig. 94.—FEMUR OF A MALE FROM BEHIND.  $\frac{1}{2}$

4, 5, 7, 8, 9, 10 and 13, the same as in the preceding figure; 2', pit on the head for the round ligament of the hip-joint; 3', the back of the neck, showing a slight groove of the obturator externus muscle as it passes over the capsular ligament and neck; 14, rough impression of the attachment of the gluteus maximus muscle in the upper and outer continuation of the linea aspera; 15, two lines running up towards the lesser trochanter from the linea aspera, marking the attachments of the adductor brevis and pectineus muscles; 16, flat elevated surface of the linea aspera; 17, flat triangular popliteal surface between the lower divisions of the linea aspera; 18, intercondyloid or crucial notch; 19, foramen for the nutritious or medullary vessels.

margins and a flat interval. The external division of its superior bifurcation passes up to the great trochanter, and in its course is strongly marked where the gluteus maximus is attached; the internal division terminates in front of the small trochanter. The inferior divisions terminate at the tuberosities of the condyles, and enclose between them a flat triangular surface of bone, which is free from muscular attachments, and forms the floor of the upper part of the popliteal space. Towards the superior part of the linea aspera is the foramen for the medullary vessels directed upwards into the bone.

The *inferior extremity* presents two rounded eminences, the *condyles*, united anteriorly, but separated posteriorly by a deep *inter-condyloid fossa*. Their greatest prominence is directed backwards, and their curve, as it increases towards that part, may be compared to that of a partially uncoiled piece of watch-spring. The external condyle is the broadest and most prominent in front; the internal is the longest and most prominent inferiorly. One large articular surface, coated continuously with cartilage, extends over both condyles, but opposite the front of the inter-condyloid fossa it is divided by two slight linear depressions into three parts, an elevated surface on each side of the fossa for articulation with the tibia; and a grooved anterior surface for the patella. The patellar surface is of a trochlear form, being marked by a vertical hollow; the

external portion of this surface is the most prominent, and rises highest.



The tibial surfaces are nearly parallel, except in front, where the internal turns obliquely outwards to reach the patellar surface. Above the condyles are two rough tuberosities, one on each side of the bone, which give attachment to the external and internal lateral ligaments of the knee joint. Between the external tuberosity and the back part of the external condyle is a smooth groove directed downwards and forwards, and ending anteriorly in a pit, in which the popliteus muscle takes origin.

In the female the angle made by the neck of the femur with the shaft is less obtuse than in the male; and from the greater width of the pelvis, and the shortness of the limbs, the convergence of the thigh bones inferiorly is more apparent.

#### THE PATELLA.

The patella, *rotula*, or knee-pan, is situated at the front of the knee joint, is attached inferiorly by a ligament or tendon to the tibia, and may be

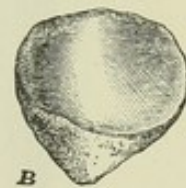
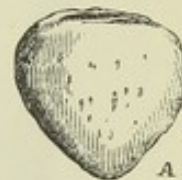
Fig 95.—RIGHT PATELLA.  $\frac{1}{2}$

A from before; B from behind.

Both views show the lower extremity pointing slightly inwards; the posterior view shows the articular cartilaginous surface, divided by an elevated ridge into a smaller internal and a larger external part.

considered as a sesamoid bone developed in the tendon of the quadriceps extensor cruris. It is compressed from before backwards, and has the form of a triangle with the apex below. Its anterior surface is subcutaneous; its superior border is broad, and gives attachment to the extensor muscles; its inferior angle, together with a rough depression on its deep aspect, gives attachment to the ligamentum patellæ. The deep surface, except at the inferior angle, is coated with cartilage for articulation with the femur, and is divided by a vertical elevation into two parts, the external of which is largest and is transversely concave, while the internal is convex.

Fig. 95.



#### THE TIBIA.

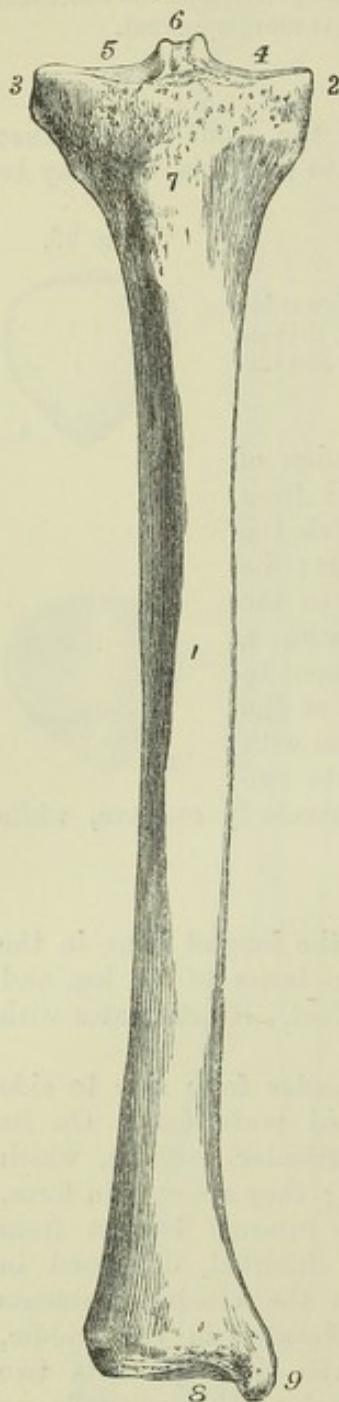
The tibia, or shin bone, is, next to the femur, the longest bone in the skeleton. It is the anterior and inner of the two bones of the leg, and alone communicates the weight of the trunk to the foot. It articulates with the femur, fibula, and astragalus.

The superior extremity is thick and expanded, broader from side to side than from before backwards, and slightly hollowed posteriorly. On its superior aspect are placed two slightly concave articular surfaces, which sustain the femur. These are the *condyloid surfaces*; they are oval in form, the external being widest transversely, and the internal longest from before backwards. Between them is an irregular interval, depressed in front and behind, where it gives attachment to the crucial ligaments and semilunar cartilages of the knee joint, and elevated in the middle, where is formed the *spine*. The summit of the spine presents two prominent tubercles, which are formed by the prolongation upwards on its sides of the margins of the condyles; that of the outer condyle being turned slightly forwards, and that of the inner more slightly backwards. On the sides of the upper extremity of the bone are two rounded eminences, the *external* and *internal tuberosities*; the outer one of these,



somewhat smaller than the other, is marked posteriorly by a flat surface which articulates with the fibula, while the inner presents a groove for the insertion of the semi-membranosus muscle. Lower down, in front, is situated the *anterior tuberosity* or *tubercle*, rough inferiorly, where it gives attachment to the ligamentum patellæ, and smooth above, where it is covered by a synovial bursa.

Fig. 96.

Fig. 96.—RIGHT TIBIA FROM BEFORE.  $\frac{1}{3}$ 

1, shaft, and shin or anterior border; 2, inner tuberosity; 3, outer tuberosity; 4, inner, and 5, outer, condyloid articular surface; 6, crucial spine, with fossa at its root in front; 7, anterior tuberosity or tubercle; 8, lower articular surface for astragalus; 9, malleolus internus.

The *shaft* of the tibia is three-sided, and diminishes in size as it descends for about two-thirds of its length, but increases somewhat towards its lower extremity. The *internal surface* is convex and subcutaneous, except at the upper part, where it is crossed by the tendons of the sartorius, gracilis, and semitendinosus muscles. It is separated from the external surface by a sharp subcutaneous, slightly sinuous *crest*, the *shin ridge*, which descends from the anterior tuberosity, and is smoothed away in the inferior third of the bone. The *external surface* is slightly hollowed in the larger part of its extent, where it gives origin to the tibialis anticus muscle; but beneath the point where the crest disappears it turns forwards, becomes convex, and is covered by the extensor tendons. The *posterior surface* is traversed obliquely in its upper third by the *popliteal line*—a rough mark which extends upwards and outwards to the external tuberosity, giving attachment to the soleus muscle, and separating a triangular area, in which the popliteus muscle lies, from the space below, which gives origin to the flexor longus digitorum and tibialis posticus. Internally, the posterior surface is separated from the internal by a smooth rounded border; while on its external side is a sharp ridge, inclined forwards above, to which the interosseous membrane is attached. Near the popliteal line is a large medullary foramen, directed downwards into the interior of the bone.

The *inferior extremity*, much smaller than the superior, is expanded transversely, and projects downwards on its inner side, so as to form a thick process, the *internal malleolus*. Inferiorly it presents for articulation with the astragalus a cartilaginous surface, which is quadrilateral, concave from before backwards, and having its posterior border narrower and projecting



farther downwards than the anterior ; internally the cartilaginous surface is continued down in a vertical direction upon the internal malleolus, clothing its outer surface somewhat more deeply in front than behind. The

Fig. 97.—RIGHT TIBIA FROM BEHIND.  $\frac{1}{2}$

6, and 9, as in the preceding figure ; 2', groove behind the internal tuberosity for the tendon of the semi-membranosus muscle ; 10, inclined articular facet below and behind the outer tuberosity for the head of the fibula ; 11, oblique line of tibia, above which is the triangular popliteal surface ; 12, foramen directed downwards for the nutritious or medullary vessels ; 13, triangular rough surface for the lower interosseous ligament and small cartilaginous surface below it for articulation with the fibula ; 14, below a slight groove marking the place of the flexor longus pollicis muscle ; 15, below the groove of the tendons of the flexor communis digitorum and tibialis posticus muscles, behind the malleolus internus.

external surface, slightly concave, is rough superiorly for ligament, and smooth below for articulation with the fibula. The posterior surface is marked by a double groove on the internal malleolus for the tendons of the tibialis posticus and flexor longus digitorum, and more externally by a slight depression where the flexor longus pollicis lies ; the inner surface of the internal malleolus is subcutaneous.

The tibia is slightly twisted, so that when the internal malleolus is directed inwards, the internal tuberosity is inclined backwards—a conformation which deserves attention in the diagnosis and adjustment of fractures.

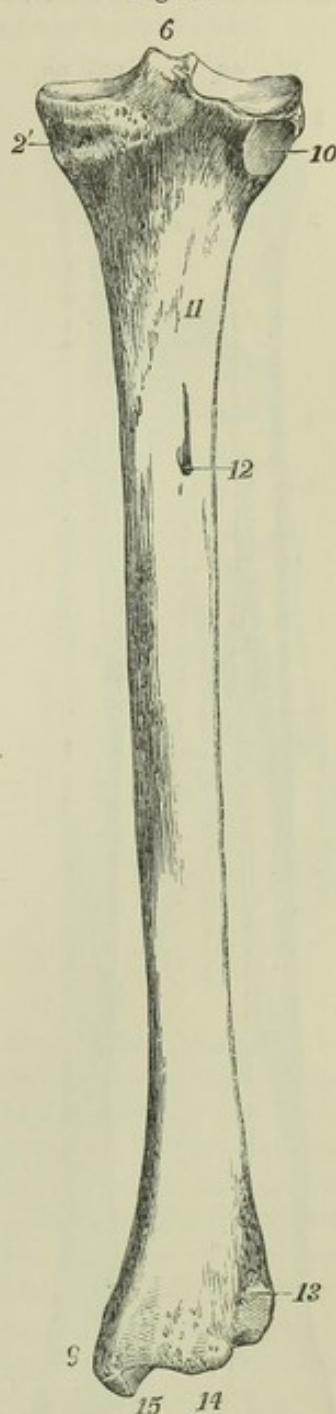
#### THE FIBULA.

The fibula, or *peroneal bone*, is situated at the external side of the leg : it is nearly equal to the tibia in length, but is much more slender. Its inferior extremity is placed a little in advance of the upper ; and its shaft is slightly curved, so as to have the convexity directed backwards, and, in the lower half, slightly inwards towards the tibia.

The *superior extremity*, or *head*, somewhat expanded, presents a small oval cartilaginous surface looking upwards and inwards, which articulates with the external tuberosity of the tibia, and externally to this a rough prominence directed upwards, to which the tendon of the biceps muscle is attached : its external surface is subcutaneous ; the rest is rough for ligaments.

The *inferior extremity*, or *external malleolus*, is larger than the head of the bone, and longer and more prominent than the internal malleolus ; internally it forms the outer limit of the ankle-joint, and presents a triangular smooth surface for articulation with the astragalus, bounded posteriorly by a rough depression where the transverse ligament is attached : its anterior

Fig. 97.





border, after projecting rather abruptly forwards, slopes downwards and backwards; its posterior border presents a shallow groove traversed by the tendons of the peronei muscles; while externally it is convex and subcutaneous, and a triangular subcutaneous surface is continued up from it for an inch or two on the shaft.

Fig. 98.



Fig. 99.



Fig. 98.—RIGHT FIBULA FROM THE OUTSIDE AND BEFORE.  $\frac{1}{3}$

1, shaft, outer and anterior surface, showing the oblique grooves of the peronei muscles; 2, head; 3, its projection, giving insertion to the tendon of the biceps femoris; 4, malleolus externus or lower end, the figure is placed opposite its anterior or oblique edge; above this is seen the triangular subcutaneous surface of the bone.

Fig. 99.—RIGHT FIBULA FROM THE INSIDE AND BEHIND.  $\frac{1}{3}$

5, the oblique surface of articulation with the tibia superiorly; 6, points to the internal or interosseous ridge; 7, the triangular rough surface for the lower interosseous ligament; 8, the external malleolar surface for articulation with the astragalus; 9, groove behind the malleolus externus for the tendons of the peronei muscles.

The *shaft* is irregularly four-sided and twisted. One surface, from which the peronei muscles take origin, looks forwards at the commencement, then turning outwards and backwards is continued behind the subcutaneous space of the lower end to the groove behind the malleolus. Another surface looking backwards in the upper half of its extent, winds inwards and terminates above the articular surface of the malleolus; near its upper end this surface is rough, giving attachment to the soleus muscle, and in the rest of its extent it is occupied by the flexor longus pollicis. The remaining part of the surface of the bone, internal, turns forwards inferiorly, and terminates on the anterior margin of the malleolus: it is divided by a longitudinal line to which the interosseous ligament is attached, into a posterior and upper part, which gives origin to the tibialis posticus, and an anterior and lower part, from which arise the long extensors of the toes and the peroneus tertius, the interosseous membrane being attached to the line between these surfaces. About the middle of the posterior surface is the medullary foramen directed downwards into the bone.

#### THE TARSUS.

The tarsus is composed of seven bones, viz., the os calcis, astragalus, cuboid, scaphoid, and three cuneiform.



## THE CALCANEUM.

The calcaneum, or *os calcis*, is the largest bone of the foot. Projecting downwards and backwards it forms the heel. Above it articulates with the astragalus, and in front with the cuboid bone. Its principal axis extends forwards and outwards from its posterior extremity to the cuboid bone.

Fig. 100.—RIGHT FOOT VIEWED FROM ABOVE, SHOWING ITS DORSAL ASPECT.  $\frac{1}{3}$

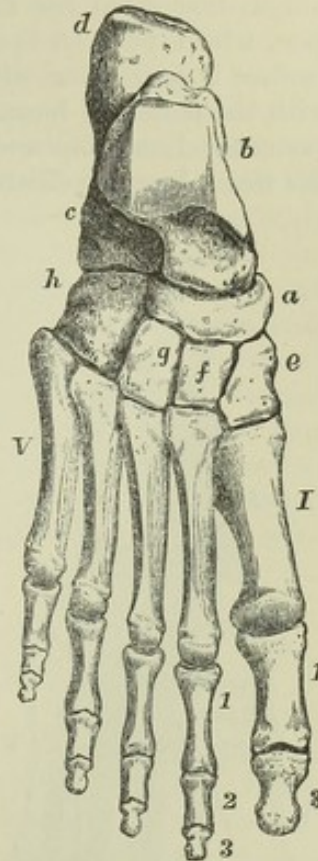
*a*, scaphoid bone; *b*, astragalus; *c*, *os calcis*; *d*, its great tuberosity; *e*, internal or first cuneiform; *f*, middle cuneiform; *g*, external cuneiform; *h*, cuboid bone. I to V, the series of metatarsal bones; 1, 3, first and terminal phalanges of the great toe; 1, 2, 3, are placed opposite to the first, second, and terminal phalanges of the second toe.

The large posterior extremity, or *tuber calcis*, presents inferiorly two *tubercles*, which rest upon the ground, and the internal of which is largest: the rest of its surface, looking backwards, is divided into a lower part, which receives the attachment of the tendo Achillis, and an upper part, smooth and less prominent, separated from that tendon by a synovial bursa. The part in front of the tuber forms a slightly constricted *neck*. The internal surface of the bone, traversed by the plantar vessels and nerves and the flexor tendons, is deeply concave, and its concavity is surmounted in front by a flattened process, the *sustentaculum tali*, which projects inwards near the anterior extremity of the bone, in a line with its upper surface, and presents inferiorly a groove occupied by the tendon of the flexor longus pollicis. The superior surface presents two articular facets for the astragalus: the anterior of these is placed over the sustentaculum, and is flat; the other, external and posterior to this, and larger, is separated from it by a rough furrow, giving attachment to the interosseous ligament, and is convex from without inwards and backwards. In front of this latter facet is a rough depression, from which the extensor brevis digitorum takes origin. The anterior extremity articulates, by a surface slightly concave in the vertical and convex in the transverse direction, with the cuboid bone; and internal to this, in front of the sustentaculum tali, it gives attachment to the inferior calcaneo-scaphoid ligament. The inferior surface, projecting in a rough anterior tubercle, gives attachment to the calcaneo-cuboid ligaments. The external surface is subcutaneous, and on the whole smooth, but presents in its fore-part superficial grooves traversed by the tendons of the peronei muscles.

## THE ASTRAGALUS.

The astragalus or *talus*, irregular in form, receives the weight of the body from the leg. It articulates with the tibia and fibula above, the *os calcis* below, and the scaphoid in front. Its longest axis is directed forwards and inwards. Its convex anterior extremity is called the *head*, and the circular groove behind it the *neck*. The superior articular surface, placed behind

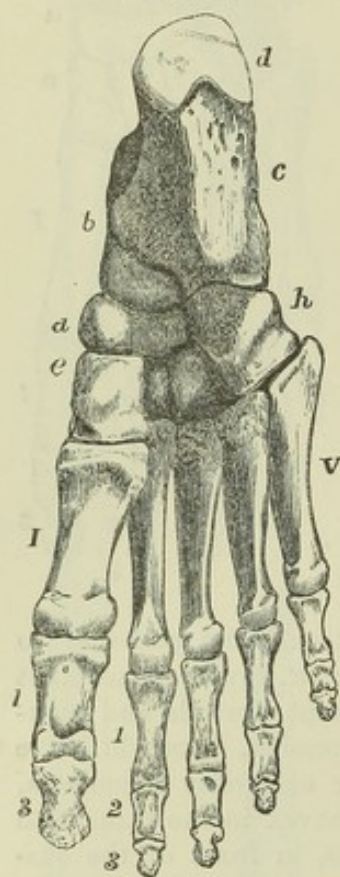
Fig. 100.





the neck, consists of a middle and two lateral parts. The middle part, looking upwards to the tibia, is convex from before backwards, broader in front than behind, with its outer margin higher and longer than the inner, and curved, while the inner is straight. The inner lateral part is narrow, and articulates with the internal malleolus; the outer lateral part, much deeper, articulates with the external malleolus. Inferiorly, there are two smooth surfaces, which articulate with the calcaneum. The posterior of these, the largest, concave from within outwards and forwards, is separated by a rough depression for the interosseous ligament from the flat anterior surface, which rests on the sustentaculum tali. The anterior margin of this surface is continuous with the rounded surface of the head, which articulates with the scaphoid bone. The posterior border of the bone lies behind the sustentaculum tali, and, like that process, is grooved by the tendon of the flexor longus pollicis.

Fig. 101.

Fig. 101.—RIGHT FOOT VIEWED FROM BELOW, SHOWING THE PLANTAR ASPECT.  $\frac{1}{3}$ 

The indications are the same as in the preceding figure; the middle and external cuneiform bones are not lettered; the sesamoid bones are not represented; they will be seen in the view of the articulations of the foot.

#### THE CUBOID BONE.

This bone is situated at the outer side of the foot, between the calcaneum and the fourth and fifth metatarsal bones. It deviates from the cuboid form and becomes rather pyramidal by the sloping of four of its surfaces towards the smaller external border. The posterior surface articulates with the os calcis, the anterior surface, also covered with cartilage, is divided into an internal quadrilateral and an external triangular facet, articulating with the fourth and fifth metatarsal bones. On the internal surface, in the middle, and touching its superior border, is a smooth surface, which articulates with the external cuneiform bone, and behind this, in some instances, a smaller surface articulating with the scaphoid, while the remainder is rough for ligaments. The external border presents a vertical groove, in which the tendon of the peroneus longus lies; and the inferior surface is traversed obliquely near its anterior margin by

a continuation of the same groove; behind this there is a thick ridge, which, with the rest of the inferior surface, gives attachment to the calcaneo-cuboid ligaments. The superior surface looking outwards and upwards, is on the whole even, but rather rough.

#### THE SCAPHOID BONE.

The scaphoid or *navicular* bone is placed at the inner side of the foot, between the astragalus and cuneiform bones. It is short from behind forwards, and broad from side to side. It presents posteriorly an articular concavity for the head of the astragalus, and anteriorly a convex surface divided, by two lines converging below, into three facets which articulate



respectively with the three cuneiform bones. On its outer side, in some instances, is a small smooth surface, by which it is articulated to the cuboid bone. Its superior and inferior surfaces are rough, and on its inner border, directed downwards, is a prominent *tubercle* to which the tendon of the *tibialis posticus* muscle is attached.

#### THE CUNEIFORM BONES.

These wedge-shaped bones, three in number, are distinguished numerically according to their order from within outwards. They intervene between the scaphoid bone and the three inner metatarsal bones, and present anteriorly and posteriorly smooth surfaces for articulation with those bones. The first or internal cuneiform bone is the largest; it is narrow above, and thick and rough towards the sole; its dorsal surface looks inwards and upwards, and is marked by an oblique descending groove, in which the tendon of the *tibialis anticus* lies; its external surface, concave and rough inferiorly, is smooth and articular above. The second and third, or middle and external, cuneiform bones each present a quadrangular surface superiorly, and a narrower rough edge below, contributing thus to form the transverse arch of the foot. The proximal ends of the three bones are in the same transverse line; but as the middle bone is the shortest, the internal and external project forwards, so as to articulate laterally not only with the sides of that bone, but also with the base of the second metatarsal bone, which is inserted between them. The outer side of the third cuneiform articulates by a smooth flat surface with the cuboid, and by a small narrow facet (sometimes absent) with the fourth metatarsal bone.

#### THE METATARSUS.

The five metatarsal bones are distinguished by numbers, according to their position from within outwards.

They resemble the metacarpal bones of the hand in being shafted bones, slightly convex from behind forwards on the dorsal aspect, and having irregularly shaped proximal extremities, three-sided shafts, and rounded *heads* which articulate with the phalanges. The first metatarsal bone is much thicker and more massive, though shorter than any of the rest. The others diminish in length from the second to the fifth.

The *proximal extremities* resemble those of the metacarpal bones exactly as regards the number of bones with which each articulates. The first articulates with one bone, the internal cuneiform; the second with four bones, viz. the three cuneiform and the third metatarsal; the third with three bones, viz. the external cuneiform and the adjacent metatarsals; the fourth with four bones, viz. the cuboid, external cuneiform, and the adjacent metatarsals; the fifth with two bones, viz. the cuboid and the fourth metatarsal. The fourth, however, is sometimes connected with only three bones, its facet for articulation with the external cuneiform being absent. The tarsal extremity of the first metatarsal bone presents a slightly concave articular surface, and is broad below and narrow above. That of the fifth presents externally a large rough tuberosity which projects beyond the other bones at the outer side of the foot; and the line of its articulation with the cuboid bone is so oblique that, if prolonged inwards, it would reach the digital end of the first metatarsal bone. The tarsal ends of the remaining three bones are broad and flat above, rough and narrower below, and by their wedge-like form assist in producing the transverse arch of the foot.

The *shafts* present in the greater part of their extent a prominent border



looking upwards, which in the middle three projects between the dorsal interosseous muscles on each side.

The *heads*, smaller than the tarsal extremities, are marked on their sides by depressions and tubercles. Their articular surfaces, smooth and convex, are prolonged on the inferior aspect, where they terminate in bifid margins. That of the first metatarsal bone presents inferiorly a ridge in the middle, with grooved depressions placed one on each side and corresponding to the position of the sesamoid bones.

#### THE PHALANGES.

The phalanges of the toes so closely correspond in general conformation with those of the fingers that it will only be necessary in this place to state the points in which they differ from the latter.

The phalanges of the four outer toes are much smaller than the corresponding phalanges of the hand; but those of the great toe are larger than those of the thumb. The shafts of the first row of phalanges in the four outer toes are compressed laterally and narrowed in the middle; those of the second row, more especially the fourth and fifth, are very short, and consist of little beyond what is necessary to unite their articular extremities. The last two phalanges of the little toe are in adults not unfrequently connected by bone into one piece.

**SESAMOID BONES.**—Two sesamoid bones lie side by side in the plantar wall of the first metatarso-phalangeal joint, and glide in the grooves on the head of the first metatarsal bone. Small sesamoid bones sometimes occur in the corresponding joints of the other toes.

#### THE BONES OF THE FOOT AS A WHOLE.

The foot is narrowest at the heel, and as it passes forwards becomes broader as far as the heads of the metatarsal bones. The posterior extremity of the calcaneum is inclined inwards and backwards. The astragalus, overhanging the sustentaculum tali, inclines inwards from the calcaneum so much that its external superior angle is directly over the middle line of the calcaneum, and hence the internal malleolus appears more prominent than the external. The foot is arched from behind forwards, the posterior pier of the arch being formed by the heel, the anterior by the balls of the toes. The arch, indeed, may be considered as double in front, with a common support behind. The internal division of the arch is that which bears the greater part of the weight of the body, and is most raised from the ground; it consists of the calcaneum in its posterior two thirds, the scaphoid and cuneiform bones, and the three inner toes; the outer arch is formed by the calcaneum in its whole length, the cuboid bone, and the fourth and fifth toes, a great part of which rests upon the ground in standing. Besides being arched longitudinally, the foot presents likewise a transverse arch formed by the cuboid and three cuneiform bones and the metatarsal bones.

#### DEVELOPMENT OF THE LOWER LIMB.

The early stages of development in the lower limbs are similar to those which have been already described in connexion with the upper.

**OSSIFICATION.**—The *innominate bone* is formed from the three principal pieces previously mentioned, viz., the ilium, ischium, and os pubis, and various others of an epiphysal nature. The deposit of bone commences in the cartilaginous piece of the ilium a little later than in other large bones; it is followed by that in the ischium, and still later by that in the pubis. One epiphysis extends over the whole length of the crest of the ilium; a second covers the tuberosity of the ischium, passing forwards



over the greater part of the ramus ; a third, inconstant, is placed on the anterior inferior spine of the ilium ; and a fourth, likewise inconstant, at the symphysis pubis. Moreover, between the extremities of the three principal osseous pieces, where they meet in the acetabulum, there is situated in early life a thin stratum of cartilage, which becomes ossified from one or more centres, and presents the shape of the letter Y.

Fig. 102.

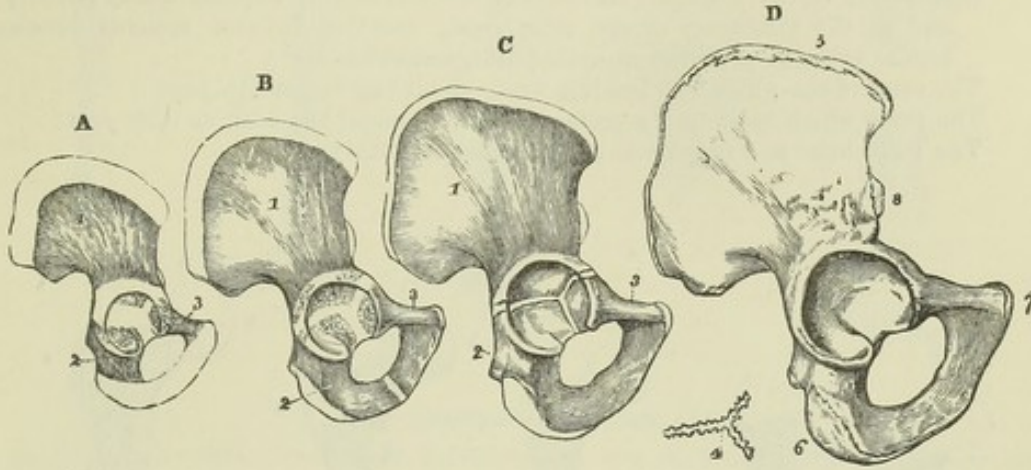


Fig. 102.—OSSIFICATION OF THE OS INNOMINATUM.

A, the condition of the bone at birth. Bone has spread from three nuclei into the ilium, ischium, and pubis, which meet in the cartilage of the acetabulum.

B, the bone of a child under six years of age. The rami of the ischium and pubis are farther ossified, but still separate.

C, a bone of two or three years later, in which the rami are united.

D, the bone of the right side from a person of about twenty years. Union has taken place in the acetabulum, and the additional epiphyses are seen on the crest of the ilium, the anterior inferior spine, the ischial tuberosity, and the margin of the symphysis pubis.

In A, B and C, 1, ilium ; 2, ischium ; 3, pubis ; under D, 4, Y-shaped piece formed of several fragments which begin to ossify about the 14th year, and often unite into this form before the completion of the acetabulum ; 5, epiphysis of the crest ; 6, that of the tuberosity of the ischium ; 7, that of the symphysis pubis ; 8, that of the anterior inferior spine of the ilium.

The *pelvis* of the foetus and young child is of very small capacity proportionally to the size of the body, and those viscera which are afterwards contained for the most part in the true pelvis occupy a part of the abdominal cavity. The obliquity of the pelvis is considerably greater in early life than in the adult.

The *femur* is developed from one principal ossific centre for the shaft and from four epiphyses, which appear in the following order :—a single nucleus for the lower extremity, one for the head, one for the great trochanter, and one for the small ; these epiphyses become united to the main part of the bone in an order of time the reverse of that in which they appear.

The *tibia* and *fibula* each present, besides the principal centre of ossification for the shaft, a superior and an inferior epiphysis. In the tibia the superior epiphysis appears first, and it not only includes the lateral tuberosities, but sends down a process in front, extending into the anterior tuberosity. In the fibula the inferior epiphysis is the first to appear, and in both bones the inferior epiphyses are first united to the shaft.

The *tarsal bones* are ossified each from a single nucleus, with the exception of the os calcis, which, in addition to its principal osseous centre, has an epiphysis incrusting the upper part of its posterior extremity.

The *metatarsal bones* and *phalanges* agree respectively with the corresponding bones in the hand, in the mode of their development. Each bone is formed from a principal piece and one epiphysis ; and while in the four outer metatarsal bones the epiphysis is at the distal extremity, in the metatarsal bone of the great toe and in the phalanges it is placed at the proximal extremity.



## PERIODS OF OSSIFICATION OF THE BONES OF THE LOWER LIMB.

I. *Os Innominatum.*

The chief nucleus of the ilium appears in the 8th or 9th week.

The chief nucleus of the ischium appears in the 3rd month.

The chief nucleus of the pubis appears from the 4th to the 5th month.

Ossification in the Y-shaped cartilage of the acetabulum appears about puberty ; and in the epiphyses of the iliac crest, anterior inferior spinous process, ischial tuberosity, and symphysis pubis, somewhat later.

The rami of the pubis and ischium unite about the 7th or 8th year.

The parts which meet in the acetabulum unite about the 16th or 17th year.

The main bone and epiphyses unite about the 25th year.

Fig. 103.

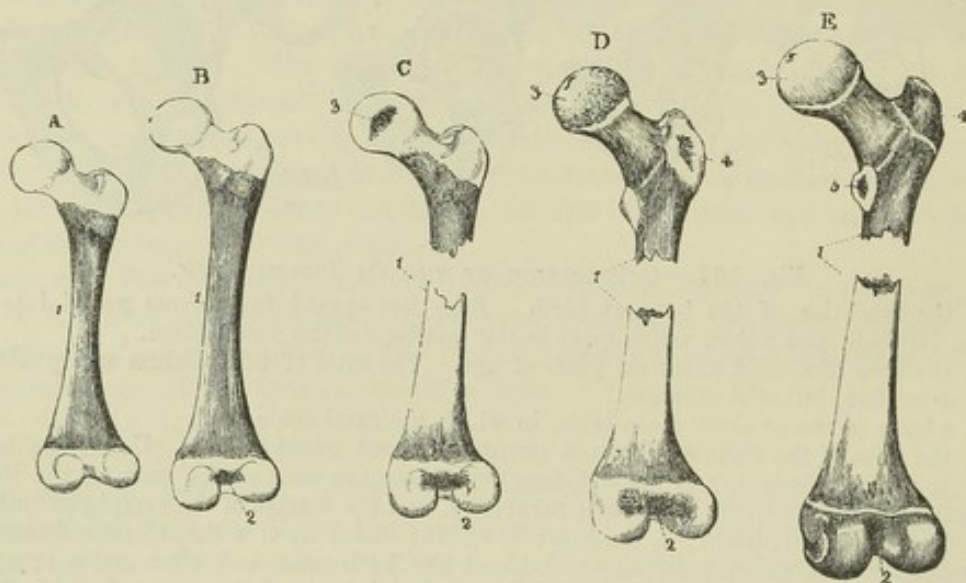


Fig. 103.—OSSIFICATION OF THE FEMUR.

A, femur of a foetus of about eight months ; the body is osseous ; both ends are cartilaginous.

B, femur of a child at birth, showing a nucleus in the lower epiphysis.

C, femur of a child of about a year old, showing a nucleus in the articular head.

D, femur of the fifth or sixth year. Ossification has extended from the shaft into the neck, and a nucleus has appeared in the great trochanter.

E, femur of about the age of puberty, showing more complete ossification and a nucleus in the lesser trochanter.

1, shaft ; 2, lower extremity ; 3, head ; 4, great trochanter ; 5, small trochanter.

II. *Femur.*

The nucleus of the shaft appears in the 7th week.

The nucleus of the lower epiphysis appears in the 9th month.

The nucleus of the head appears at the end of the 1st year.

The nucleus of the great trochanter appears in the 4th year.

The nucleus of the small trochanter appears in the 13th or 14th year.

The small trochanter and shaft unite about the 17th or 18th year.

The great trochanter and shaft unite about the 18th year.

The head and shaft unite about the 18th or 19th year.

The lower epiphysis and shaft unite after the 20th year.

III. *Tibia.*

The nucleus of the shaft appears in the 7th week.

The upper epiphysis appears sometimes before, sometimes after birth.



Fig. 104.

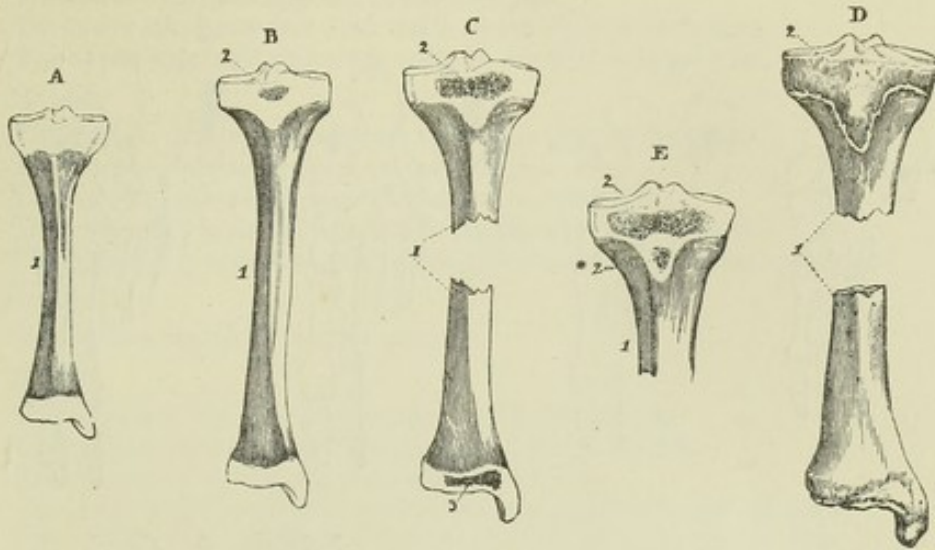


Fig. 104.—OSSIFICATION OF THE TIBIA.

A, tibia of a foetus some weeks before birth ; the shaft is ossified ; the ends are cartilaginous.

B, tibia of a child at birth, showing the commencement of a nucleus in the upper epiphysis.

C, tibia of the third year, showing the nucleus of the lower epiphysis.

D, tibia of about eighteen or twenty years, showing the united condition of the lower epiphysis, while the upper remains separate. The upper epiphysis is seen to include the anterior tuberosity.

E shows an example of a separate centre for the anterior tuberosity.

1, shaft ; 2, superior epiphysis ; 2\*, separate centre for the anterior tuberosity ; 3, inferior epiphysis.

Fig. 105.

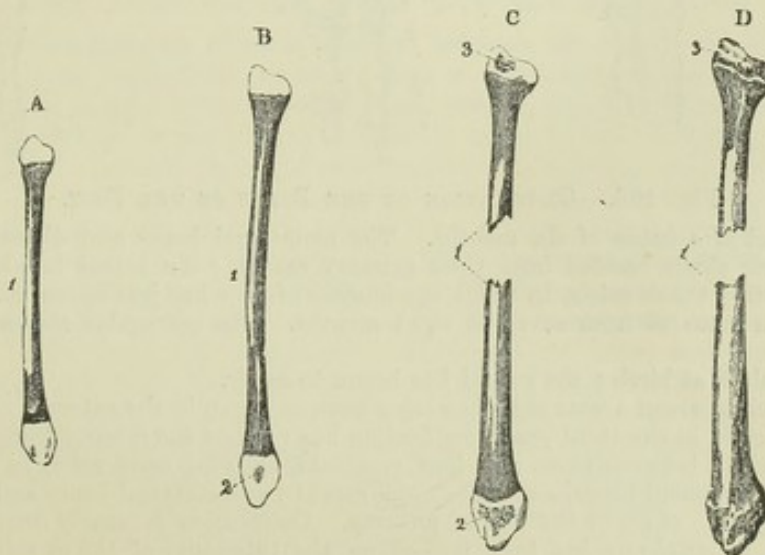


Fig. 105.—OSSIFICATION OF THE FIBULA.

A, fibula from a child at birth. The shaft ossified ; the ends cartilaginous.

B, fibula from a child of two years, showing a nucleus in the lower epiphysis.

C, the bone of a child of about four years, showing the nucleus of the upper epiphysis ; the lower ought to have been shown as more advanced.

D, fibula of a person of about twenty years, in which the lower end is complete, but the upper epiphysis is still separate.

1, shaft ; 2, lower epiphysis ; 3, upper epiphysis.



Fig. 106.

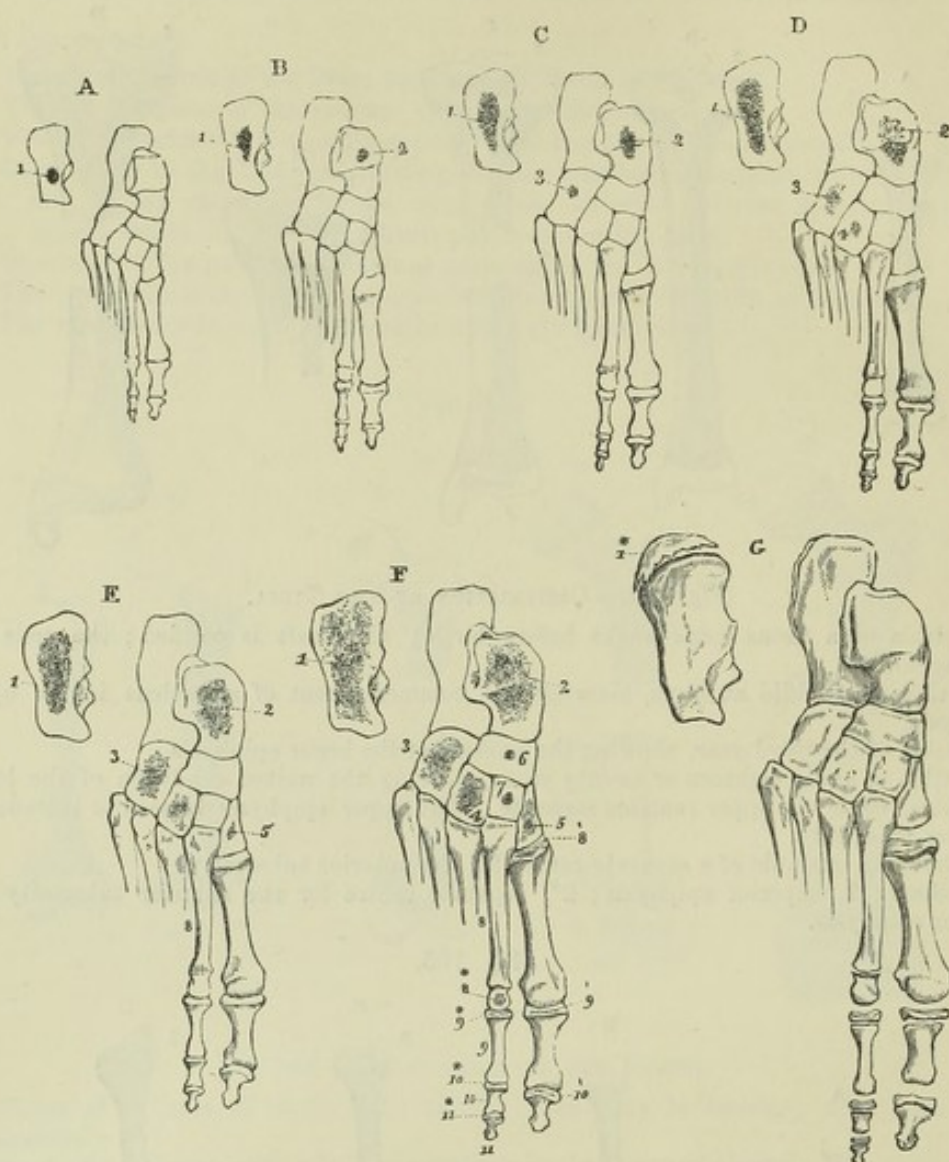


Fig. 106.—OSSIFICATION OF THE BONES OF THE FOOT.

A, right foot of a fetus of six months. The metatarsal bones and digital phalanges have each their shafts ossified from their primary centres; the tarsus is wholly cartilaginous, excepting the os calcis, in which the nucleus of bone has just appeared.

B, foot of a fetus of from seven to eight months. The astragalus shows an osseous nucleus.

C, from a child at birth; the cuboid has begun to ossify.

D, from a child about a year old, showing a nucleus begun in the external cuneiform.

E, from a child in the third year; ossification has reached the internal cuneiform.

F, from a child between three and four years old, showing ossification in the middle cuneiform and scaphoid bones, and in the epiphyses of the metatarsal bones and phalanges.

G, from a person of about the age of puberty. Ossification is nearly complete in the tarsal bones; an epiphysis has been formed on the tuberosity of the os calcis, and the epiphyses of the metatarsal bones and phalanges are shown separate.

1, nucleus of the os calcis; 1\* in G, the epiphysis of the os calcis; 2, nucleus of the astragalus; 3, of the cuboid; 4, of the external cuneiform; 5, of the internal cuneiform; 6, of the scaphoid; 7, of the middle cuneiform; 8, metatarsal bones; 8\*, distal epiphyses of the four metatarsal bones; 8', proximal epiphysis of the first; 9, first range of digital phalanges; 9\*, proximal epiphyses of the four outer of these phalanges; 9', that of the first phalanx of the great toe; 10, second range of phalanges; 10\*, the epiphyses of these phalanges; 10', epiphysis of the terminal phalanx of the great toe; 11, four terminal phalanges; 11\*, their epiphyses.



*Tibia* (continued)—

- The lower epiphysis appears in the 2nd year.
- The lower epiphysis and shaft unite in the 18th or 19th year.
- The upper epiphysis and shaft unite in the 21st or 22nd year.

IV. *Fibula*.

- The nucleus of the shaft appears soon after that of the tibia.
- The lower epiphysis appears in the 2nd year.
- The upper epiphysis appears in the 3rd or 4th year.
- The lower epiphysis and shaft unite in the 21st year or later.
- The upper epiphysis and shaft unite after union of the lower epiphysis.

V. *Patella*.

- Ossification begins in the 3rd year.

VI. *Tarsus*.

- The nucleus of the os calcis appears in the 6th month.
- The nucleus of the astragalus appears in the 7th month.
- The nucleus of the cuboid bone appears at birth.
- The nucleus of the external cuneiform bone appears in the 1st year.
- The nucleus of the internal cuneiform bone appears in the 3rd year.
- The nucleus of the middle cuneiform bone appears in the 4th year.
- The nucleus of the scaphoid bone appears in the 4th or 5th year.
- The epiphysis of the os calcis appears in the 10th year.
- The epiphysis of the os calcis is united in the 15th or 16th year.

VII. *Metatarsus*.

- The nuclei of the shafts appear in the 8th or 9th week.
- The epiphyses appear in the 3rd to the 8th year.
- The shafts and epiphyses unite from the 18th to the 20th year.

VIII. *Phalanges*.

- The nuclei of the shafts appear in the 9th or 10th week.
- The epiphyses appear from the 8th to the 10th year.
- The shafts and epiphyses unite from the 19th to the 21st year.

## COMPARISON OF THE UPPER WITH THE LOWER LIMB.

The general resemblance which is manifest between the upper and lower limbs is found, on a closer inspection, to result from a community of plan, which can be traced even into certain comparatively minute details, and is not confined to any one system. The details of the correspondence in many points, however, are still undetermined, and even with regard to some parts of the skeleton, variety of opinion still exists. In the hand and foot the correspondence of the bones is very plain. The palmar and plantar aspects being regarded as similar, the great toe corresponds obviously to the thumb; the four anterior tarsal bones bear a close resemblance to the four inferior carpal bones in the particulars of their metatarsal articulations; and of the remaining tarsal bones the scaphoid obviously corresponds to the bone of the same name in the hand, the astragalus to the semilunar bone, and the os calcis to the cuneiform and pisiform bones united. The great difference in the appearance of the tarsus from that of the carpus depends principally on the large development of the os calcis and astragalus, by means of which the scaphoid is thrown forward and inwards, and the aspect of the tarsus morphologically posterior, that on which the flexor tendons pass to the sole, is turned towards the inner side. If this be the correct comparison of the bones of the hand and foot, with regard to which there cannot be any doubt, it naturally follows that the tibia, lying as it does on the same side of the limb as the great toe, corresponds with the radius: a doctrine which, first laid down by De Blainville and then by Barclay, has been subsequently enunciated by Flourens and Owen. Some anatomists, however, struck by the resemblance of the patella to the olecranon, in position and in giving attachment to an extensor muscle similar in appearance to the triceps extensor brachii, have taken a different view; thus, according to Vicq D'Azyr, the tibia corresponds with the ulna, while, according to Bourguery, Cruveilhier, and Martins, its upper end corresponds with the ulna and its lower end with the radius. This latter hypothesis must be regarded as



particularly unhappy, as it is difficult to conceive how any substantial homology, or a resemblance other than fanciful, can be traced by imagining half of a bone to correspond with one structure, and the other half with a structure totally different. Equally artificial is the proposition of Vicq D'Azyr to compare the upper limb of one side with the lower limb of the other side of the body. The assumed correspondence of the olecranon and patella, which has led to those theories, is not borne out by a comparison of the development of the two structures. The patella is formed, distinct from the tibia, as a sesamoid bone in a tendon, while the olecranon is mainly derived from the principal centre of ossification of the ulna, and is formed only in part by the superior epiphysis of that bone. In support of the more probable view, that the ulna corresponds with the fibula, it is to be noticed that in the echidna the head of the fibula is prolonged upwards into a process which much more closely corresponds with the olecranon than does the patella. It may also be observed that in certain mammals, such as the bear or other plantigrades, in which there is a power of partial pronation, the radius crosses the forearm obliquely, and its upper end is brought somewhat in front of the ulna; while in the greater number of mammals, in which there is no power of pronation or supination, the radius is placed entirely to the front and internally, and the ulna is thrown to the outside and behind, in the same manner as the fibula is to the outside of and behind the tibia; and the resemblance between the respective bones in the fore and hind limbs is made the more striking that the radius and tibia are in these animals generally the principal bones, while the ulna and fibula are in many species only partially developed. An examination of the fore limb in a series of animals shows that the articulation of the radius with a separate portion of the humerus external to that with which the ulna articulates is quite exceptional, the most common arrangement being that the ulna forms the posterior and the radius the anterior part of one great sigmoid cavity similar to that formed by the ulna in the human subject. In comparing the humeral with the femoral region it may be well to have regard to the apparent twist inwards which is seen in both femur and humerus, but especially in the latter bone. This appearance of twisting is given to the humerus by the direction of the musculo-spiral groove, and by the obliquity in the direction of all the ridges of the bone. In the femur the twisted appearance is very slight, and is most obvious below and in front of the small trochanter. In the humerus the appearance of twisting is much more marked, and is more especially obvious at the spiral groove. If, while the forearm remains unmoved, the lower end of the humerus were turned outwards a quarter of a circle, so as to undo the twist of the bone, the inner condyle would then overhang the flexor aspect of the forearm, and the outer condyle the extensor aspect, and the flexor and extensor muscles would pass directly downwards from the condyles to their terminations. Assuming this mode of viewing the position of the humerus to be correct, we may proceed to compare the limbs by considering the hand and foot, and also the forearm and leg, as having their flexor surfaces directed towards the mesial plane of the body (the position in which they are developed), while the condyles of the humerus and femur continue to be external and internal in position, and the anterior or flexor surface of the humerus corresponds with the anterior or extensor surface of the femur. From this it follows that one of the propositions maintained by those who regard the tibia and ulna as homologous, viz., that the quadriceps extensor femoris obviously corresponds with the triceps brachialis, must be erroneous, and that the biceps femoris may more justly be viewed as corresponding with the triceps brachialis, while the rectus femoris is homologous with the biceps of the arm, and the vasti and crureus with the brachialis anticus muscle, which in some animals extends up to the neck of the humerus; so also the space between the lips of the linea aspera of the femur (which in most animals is much broader than in man) will correspond with the posterior surface of the humerus below the musculo-spiral groove.

The detailed comparison of the bones of the shoulder and pelvis is beset with many difficulties, and it must therefore suffice here to remark that it requires further investigation than has been brought to bear upon it, and simply to state that while the scapula obviously corresponds with the ilium, the clavicle is generally regarded as corresponding with the os pubis, and the coracoid process (or coracoid bone of birds and reptiles) with the ischium. Humphry, indeed, has put forward the idea that the upper and lower limbs ought to be regarded not as lying in series but as facing one another,—that is to say, as being related to one another symmetrically,



one at the upper and the other at the lower end of the trunk, in the same way that the limbs of opposite sides are arranged symmetrically on either side of the mesial plane. Thus, in the skeleton of a quadruped, the scapula and humerus slope backwards from the shoulder-joint, and the ilium and femur slope forwards from the hip-joint; the prominence of the elbow looks backwards, and that of the knee looks forwards; and hence, according to Humphry, the coracoid and pubis and the clavicle and ischium respectively correspond. It will, however, suggest itself to the reader from the remarks already made, that there are serious difficulties in the way of attributing to those appearances, which are only the result of later development, more than a mere secondary importance. (Copious reference to the literature of this subject is made in the paper by Ch. Martins in the "*Annales des Sciences Naturelles, Zoologie*," vol. viii. 1857, p. 45. See also Humphry, "*On the Limbs of Vertebrate Animals*," &c. Cambridge, 1860.)

#### RELATION OF THE LIMBS TO THE SEGMENTS OF THE TRUNK.

The various anatomists who have written on this subject agree in considering that the limbs, in their extent beyond the shoulder and hip, are radiations from or appendages of one or more segments of the trunk. Opinions, however, are much divided with regard to the nature of the pelvic and shoulder girdles, and, in particular, it has been warmly debated whether or not they are costal arches. Owen holds the opinion that they are costal, and further considers that the scapula and coracoid process form the costal arch of the occipital vertebra, with the free part of the limb as its appendage, while the clavicle is derived from another segment; and that in like manner the ilium and ischium form the costal arch of one segment supporting the lower limb, and that the pubic bone belongs to another. The circumstance which has specially led to the supposition that the upper limb and the occipital bone are connected is, that the shoulder girdle is attached to the skull in most osseous fishes; but it may be objected to this hypothesis that in the higher vertebrata the anterior extremities are developed from a portion of the embryo considerably removed from the skull; and Goodsir fairly argues, from the nervous supply to the limbs, and from the limbs first appearing with the digits arranged in series in the plane of the lateral plates of the embryo, that a limb is not an appendage to a single segment of the trunk, but belongs to several segments. (Owen, "*On the Nature of Limbs*;" Goodsir, "*On the Morphological Constitution of Limbs*," *Edinb. New. Phil. Journ.*, Jan., 1857.)

#### THE SKELETON ADAPTED TO THE ERECT POSTURE.

Throughout the whole of the human frame numerous peculiarities in the form and proportion of parts exist, connected with the assumption of the erect posture. The most striking of the structural peculiarities related to this circumstance are seen in the skeleton, and they are equally apparent in the head, trunk, and limbs. The body of man, unlike that of animals, is, for the purposes of station and progression, balanced on one or both pelvic limbs, which are extended to a straight line at the knee-joint. The lower limb is remarkable for its length and strength. The foot of man alone has an arched instep, and it likewise presents a great breadth of sole. The great toe is distinguished by its large development, and especially from that of the quadrumana, by its want of opposability, being formed not for grasping but for supporting the weight of the body and giving spring to the step. The femur is greatly elongated, its length exceeding considerably that of the tibia. This length of femur is not only requisite in order to give a sufficient extent of stride, but also to enable the body to be balanced in different degrees and varieties of stooping. Thus, for example, in a crouching attitude, with the feet placed side by side, it is necessary in order to balance the fore part of the body that the pelvis should be brought back behind the perpendicular rising from the balls of the toes on which the weight is rested: and in order to accomplish this, if there be a long tibia directed forwards from the ankle, there must be a femur of still greater length directed backwards from the knee. The breadth of the pelvis, in like manner, in lateral movements of the body, enables the balance to be more easily maintained by compensating inclinations of different parts to opposite sides of the base of support, and the long neck of the femur gives an advantageous insertion to the muscles by which the balance of the body on the thigh is principally preserved (*viz.*, the adductor and gluteal muscles), placing them more nearly at



right angles to the bones on which they act. The *os innominatum* is principally distinguished from the same bone in animals by the breadth of the iliac portion, which gives support to the viscera and attachment to the greatly developed gluteal muscles, by the shortness and strength of the pillar of bone extending from the auricular surface to the acetabulum, and by the marked nature of the angle which the pubic part forms with the iliac, as it passes inwards from the acetabulum to the symphysis, and thus completes the peculiarly broad pelvis. The strong and expanded sacrum supports the spinal column, while the short coccyx is bent forwards and aids in forming the floor of the pelvic cavity. The spinal column, by its pyramidal form, is fitted to sustain the weight which bears down upon its lower part, and by means of its different curvatures gives elasticity and strength, and allows considerable range of motion to the trunk without removal of the centre of gravity from within its base. The thorax is so formed as to bring the weight of its contents very much over and to the sides of the bodies of the vertebræ rather than in front. Thus, the thorax is broad from side to side, and compressed from before backwards; the transverse processes and proximal parts of the ribs are inclined backwards, so as to enlarge the chest behind the transverse plane of the bodies of the vertebræ, and the axis of the cavity is directed upwards and backwards, so that its contents may thus be supported on the column in the erect posture. The upper limbs are also thrown outwards and backwards by the long clavicles which support them and form the fulcrum of their free movements. The blades of the scapulæ are thus made to lie more nearly in one transverse plane, with the glenoid fossæ looking outwards, a position manifestly unsuited to the support of the weight of the body on the limb. In those animals which habitually use their fore limbs for support, the glenoid fossæ look downwards, and rest on the humeri; but if the human body be placed so as to be rested on the hands, the glenoid cavity lies on the inside of the head of the humerus, and the scapula is supported upon the humerus by the acromion process. While stability and strength have been provided in the lower limb, mobility and lightness have been secured in the upper. This is apparent on comparison of the shoulder, elbow, and wrist, with the hip, knee, and ankle. In the hand also, the movable phalanges are as long as the carpal and metacarpal bones taken together, whereas in the foot they are not a third of the length of the tarsal and metatarsal bones. The skull of man differs from that of animals in being nearly balanced on the vertebral column, the condyles of the occipital bone being brought forwards towards the middle of the base, by the comparative shortness of that part of the skull which lies in front of the foramen magnum, and the projection backwards of that which lies behind it. In animals the skull hangs forwards, as it were, from the extremity of the column, and is sustained by an elastic substance (*ligamentum nuchæ*), which is attached on the one hand to the spinous processes of the vertebræ, and on the other to the occipital protuberance.

## SECTION II.—ARTHROLOGY.

### MODES OF ARTICULATION.

THE name of articulation, synonymous with joint, is given in descriptive anatomy to the connection subsisting in the recent skeleton between any of its denser component parts, whether bones or cartilages. In all instances, excepting the bones of the head, which are so closely set together in the sutures as to have no more than the fibrous periosteum between them, some softer intervening substance lies between the bones, uniting them together, or clothing the surfaces which are opposed; but the manner in which the several pieces of the skeleton are thus connected, or the modes of articulation, vary to a great degree both in the form and nature of the uniting substances and in the extent of motion which they allow between the bones. In some instances, as in that of the cranial bones already referred to, the closeness of the apposition, the unevenness of the fitting surfaces or edges, and the small amount and dense nature of the



intervening substance, are such as to admit of little or no perceptible motion. In other instances the extremities of the bones are placed at such a distance, and the intervening substance (ligament or cartilage) possesses so much of a yielding quality, that bending or other motions may take place, even while the bones are thus mediately but continuously united. But in the greater number of the connections between the bones, and in those which may be regarded as more properly deserving the name of joints, the apposed surfaces of bone are not united either directly or mediately with each other, but are free by solution of continuity, and are covered with plates of smooth cartilage, the surfaces of which fit accurately together, and the bones are held together by ligamentous structures placed in the vicinity of the joints. In such articulations the bones are capable of gliding or moving upon each other in various extent and directions, according to the shape of the opposed cartilaginous surfaces, and the form and attachments of the ligamentous and other bands which unite them. It is upon distinctions such as those now adverted to that the various kinds of joints or articulations have been brought under the three classes of *SYNARTHROSIS*, *AMPHIARTHROSIS*, and *DIARTHROSIS*.

*Synarthrosis* means direct or immediate union, and comprehends the joints with little or no motion. It is found chiefly in various forms of suture by which the bones of the head, excepting the lower jaw, are united. The suture, properly so called, is *serrated* or *dentated* when the contiguous margins of the bones are subdivided or broken up into projecting points and recesses by which they fit very closely to one another, as in the borders of most of the tabular bones of the cranium. The *squamous* or scaly suture is that in which, as in the union of the temporal with the parietal bone, the edges are thinned and bevelled, so that one overlaps the other to a considerable extent.

The term *harmonia* has been employed to denote simple apposition of comparatively smooth surfaces or edges, as in the case of the two superior maxillary bones; and the term *schindylesis* has been used to express that kind of union in which one bone is received into a groove in another, as occurs between the rostrum of the sphenoid bone and the vomer. The impaction of the roots of the teeth in their sockets has likewise been reckoned among the articulations, though with doubtful propriety, and has been designated by the term *gomphosis*.

*Amphiarthrosis* means the mixed articulation, or that in which there is mediate union by some intervening substance, with partial mobility. The articulations between the bodies of the vertebræ, that between the two ossa pubis at the symphysis, and that between the two first pieces of the sternum, may be taken as examples of this mode of connection. Some of the joints of this kind pass on the one hand into *synarthrosis*, and on the other into *diarthrosis*.

*Diarthrosis* includes the complete joints with separate surfaces of the bones and synovial cavities, and is attended with considerable yet varying degrees of mobility. In this form of joint, plates of cartilage cover the articular parts of the bones and present within the joint free surfaces of remarkable smoothness, and these surfaces are further lubricated by the synovial fluid secreted from the delicate membrane which lines the fibrous coverings and all other parts of the articulating cavity except the cartilage. This membrane is continuous with the margin of the articular cartilages, and along with the cartilages completely encloses the joint cavity. The bones are further held together by fibrous tissue in the various forms of ligaments, such as membranous capsules, flat bands, or rounded cords. These ligaments, it is true,



are not so tight as to maintain the bones in close contact in all positions of the joint, but are rather tightened in some positions and relaxed in others, so that they may be looked upon chiefly as controllers of the motions. The bones are likewise held together in diarthrodial joints, by atmospheric pressure, and by the surrounding muscles.

#### MOTIONS OF THE BONES IN THE JOINTS.

The various movements of the bones on one another in the joints are distinguished by different terms according to their directions, viz., angular movement, circumduction, rotation, and shifting; but it is proper to remark that although different kinds of motion, answering to these several terms, may readily be recognised, yet there are few of the motions which occur in the joints which are of one sort only, but rather several kinds of movement are frequently combined in one, and they also run into one another in great variety.

*Angular movement*, or *opposition*, is movement in such a manner as to increase or diminish the angle between two bones, so that they shall lie more or less nearly in a straight line. The different kinds of angular movement are designated by different terms according to the directions in which they take place with reference to the limb or body: thus, *flexion* and *extension* indicate angular movements, which have the effect of bending or straightening parts upon one another or upon the trunk of the body; *adduction* and *abduction* indicate angular movement to and from the mesial plane of the body, or, when fingers and toes are referred to, these terms may be used to denote movement to and from the middle line of the hand or foot.

*Circumduction* is the movement performed when the shaft of a long bone or a part of a limb describes a cone, the apex of which is placed in the joint at or near one extremity of the bone, while the sides and base of the cone are described by the rest of the moving part.

*Rotation* signifies movement of a bone round its axis without any great change of situation.

*Shifting* is a term which may be applied to that kind of movement in which the surfaces of adjacent bones are displaced without any accompanying angular or rotatory motion, as in the sliding of flat surfaces over each other, such as in some of the carpal and tarsal articulations, or in the movement of advance and retreat of the lower jaw.

The term *ginglymus* is used to distinguish a hinge joint, or one which admits only of flexion and extension. *Enarthrosis* (Cruveilhier) is the ball-and-socket form of joint, like the shoulder and hip, allowing motion in every direction. *Arthrodia* is employed by Winslow and Cruveilhier to signify a joint admitting of very little movement.

In the preceding paragraphs attention has been called only to the directions of the movements of the parts united in the joints, but the movements of opposed articular surfaces relatively one to another are likewise worthy of notice.

In the movements of the joints, when occurring between separate opposed surfaces, there is generally more or less of a *gliding* motion of one surface on the other; but it is to be observed that in some joints a small amount of motion may be produced without gliding, by the alternate contact and separation of different parts of the opposed surfaces, to which the name of *coaptation* (Goodsir) has been applied; and that in other joints the articular surface of one bone may travel over that of another, so as to bring different parts of the surfaces successively into contact, in the manner of a wheel rolling on the ground, with or without this change of place being accompanied by gliding motion.

In the various joints provided with synovial cavities, the cartilaginous surface of the bones are so formed as usually to be in close apposition or contact; but it would



appear that in certain positions they are not entirely so, and it can scarcely be doubted that when the surfaces are separated to any extent, doublings of the synovial membrane, or fatty processes connected with it and placed in the immediate vicinity of the joint, contribute to fill up the vacuity. There are even instances in which it would appear that the separation of the surfaces must be considerable, as in the case of the patella, more especially in complete extension of the knee.

## ARTICULATIONS OF THE TRUNK AND HEAD.

### ARTICULATIONS OF THE VERTEBRAL COLUMN.

The movable vertebræ are connected together by elastic discs interposed between the bodies; by synovial joints between the articulating processes; and by ligaments.

Fig. 107.—A LUMBAR VERTEBRA, SEEN FROM ABOVE, WITH PART OF THE INTERVERTEBRAL DISC ADHERING TO THE BODY.  $\frac{1}{2}$

1, 1, the concentric arrangement of the fibrous laminae; 2, the central soft cartilaginous or gelatinous substance.

The *intervertebral discs* are plates of composite structure placed one between the bodies of each pair of vertebræ from the axis to the base of the sacrum. Each is composed of a laminar part externally, and of a pulpy substance in the centre.

The laminar part forms more than half of the mass, and consists of concentric laminae of fibro-cartilage and fibrous tissue alternating one with another. These laminae are not quite vertical, for if a vertical section of a disc be made, a certain number of the layers nearest to the circumference of the disc will be seen bulging outwards, while others situated more deeply and less closely compacted together are convex towards the centre; and

Fig. 107.

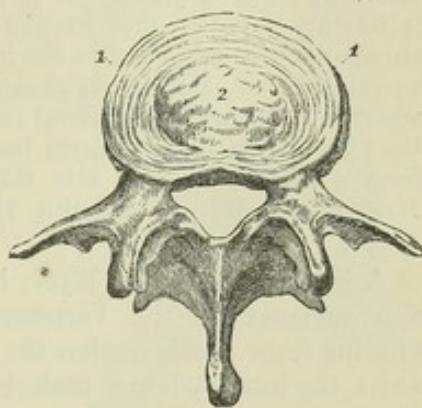
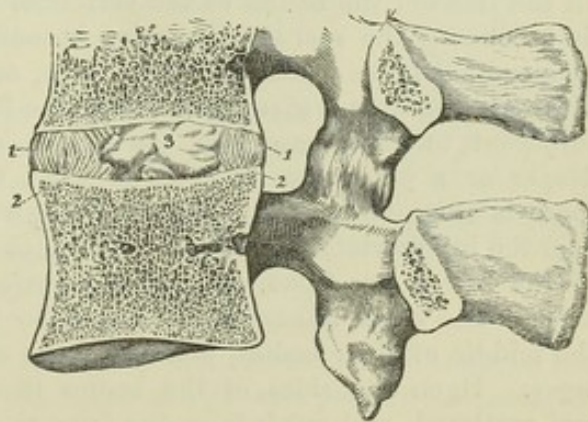


Fig. 108.—VERTICAL ANTERO-POSTERIOR SECTION THROUGH TWO LUMBAR VERTEBRÆ, SHOWING THE ARRANGEMENT OF THE INTERVERTEBRAL DISC.  $\frac{2}{3}$

1, 1, the fibrous oblique bands, which are curved outwards; 2, those which are curved inwards; 3, the central soft cartilaginous or gelatinous substance: the capsule of the joint between the articular processes is represented.

Fig. 108.



when the spine is bent in any direction, the curves of the different layers are augmented on the side towards which the column is inclined. The individual layers consist chiefly of fibres extending obliquely between the



vertebræ and firmly attached to both; the direction of the obliquity being reversed in each successive layer, in one stretching downwards from right to left, and in the next from left to right. Some of the fibres also are nearly horizontal. The central part of the fibro-cartilage is a pulpy and elastic material which, when the pressure which confines it is taken off by cutting through the intervertebral substance, rises up so as to assume a conical form. It is then seen to be of a lobate structure, and, examined under the microscope, exhibits a finely fibrous and homogeneous matrix, with numerous spherical and elliptical cells, some of them resembling cartilage-corpuscles, others larger and of various appearance.

It is now generally admitted that the pulp of the intervertebral disc is a persistent part of the chorda dorsalis; homologous, therefore, with those larger vestiges of the chorda dorsalis which occupy the biconical cavities between the bodies of the vertebræ in fishes. According to Luschka, there is present in each disc a synovial cavity, and the lobes of the pulp are synovial villi, similar to those which are to be found in the knee and shoulder joints, but of larger size, and occupying the whole cavity; and it is worthy of notice that in like manner secondary cavities, developed within the chorda dorsalis, are found in the intervertebral substance in many fishes. The same writer describes small synovial sacs, in the cervical region, in those parts of the discs which are attached to the lateral elevations of the bodies of the vertebræ. Occasionally the pulp of the discs projects backwards, through the surrounding laminæ, so as to form a slight projection into the spinal canal. (Luschka, "Die Halbgelenke des Menschlichen Körpers," Berlin, 1858, p. 84.)

A thin cartilaginous layer, incomplete towards the circumference, covers the surfaces of the vertebræ and gives attachment to the discs. Excluding from consideration the first two vertebræ, between which it does not exist, the intervertebral material forms in length about a fourth of the movable part of the column. The dorsal part of the column has, comparatively with the length, a much smaller proportion than the cervical or lumbar parts.

The discs in the cervical and lumbar regions are thicker in front than behind, and it has been determined that the convexity of those portions of the column is due to them much more than to the bodies of the vertebræ, while the arching of the dorsal portion, on the contrary, is rather owing to the shape of the bones. (W. and E. Weber, "Mechanik der menschl. Gehwerkzeuge," p. 90, et seq., Göttingen, 1836.)

The *anterior common ligament* is a strong band of fibres, which is placed on the front of the bodies of the vertebræ, and reaches from the atlas to the first bone of the sacrum, becoming broader as it descends. It consists of longitudinal fibres which are dense, firm, and well marked. The superficial fibres extend from a given vertebra to the fourth or fifth below it; the fibres subjacent to these pass over the bodies of several vertebræ; whilst the deeper ones pass only between adjacent vertebræ. The band is thicker towards the middle of the bodies of the vertebræ than at their margins, or over the intervertebral cartilages; by which means the transverse depressions of the bodies are filled up, and the surface of the column rendered more even. The fibres adhere more closely to the margins of the bones than to the middle of their bodies, and still more closely to the intervertebral cartilages. Upon the sides of the bodies there are some fibres which are thin and scattered, and reach from one bone to another.

The *posterior common ligament* is situated within the spinal canal, and is attached to the posterior surface of the bodies of the vertebræ; it extends from the occiput to the sacrum. It is smooth, shining, and broader at the



upper than at the lower part of the spine. In the neck it extends quite across the bodies, but in the back and loins it is broader opposite the inter-

Fig. 109.—VIEW OF A PART OF THE VERTEBRAL COLUMN, INCLUDING THE 5TH, 6TH, 7TH, 8TH, AND 9TH DORSAL VERTEBRÆ, WITH A PART OF THE 6TH, 7TH, AND 8TH RIBS, FROM THE RIGHT SIDE AND FRONT.  $\frac{1}{3}$

The 5th and 9th ribs have been removed so as to show the articular surfaces of the vertebræ corresponding to them; 1 to 2, the anterior common ligament of the bodies of the vertebræ; at  $\times \times$ , a portion of the ligament is removed so as to expose the intervertebral plate between the 8th and 9th vertebræ, in which the diagonal fibres of the external ligamentous plates are represented. (The further description of this figure will be found at p. 129.)

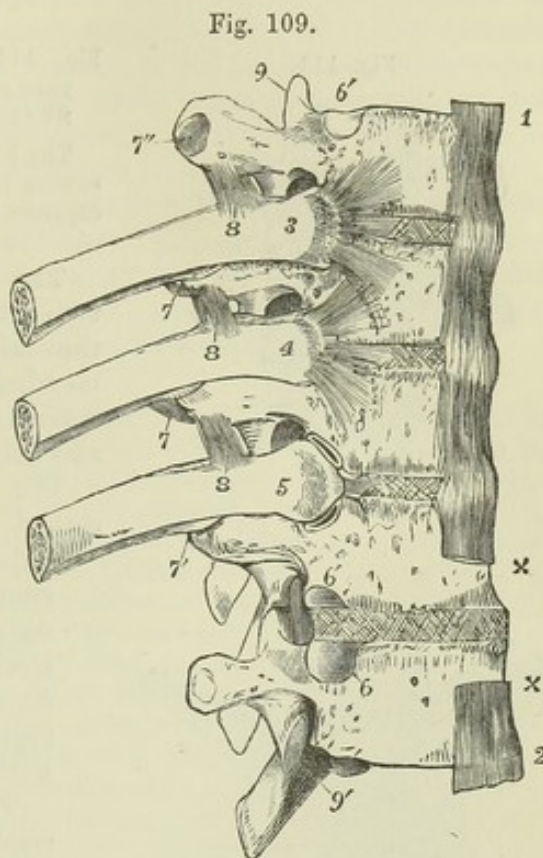


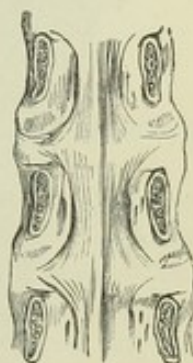Fig. 109.

vertebral cartilages than at the middle bodies, so that its margins present a series of points or dentations with intervening concave spaces. It adheres firmly to the fibro-cartilages and to the contiguous margins of the bodies of the vertebræ, but it is separated from the middle of the bodies by the transverse parts of the large venous plexus, which is in contact with the bones. Between the ligament and the prolongation of the dura mater which lines the canal, some loose connective tissue is interposed.

Fig. 110.—THE BODIES OF THREE LUMBAR VERTEBRÆ, SEEN FROM BEHIND, WITH THE POSTERIOR COMMON LIGAMENT.  $\frac{1}{3}$

The arches have been removed by cutting through the pedicles. The contraction of the posterior common ligament opposite the middle of each body, and its greater width and attachments opposite the intervertebral discs, are represented.

Fig. 110.



The joints of the articulating processes present each a synovial cavity surrounded by an irregular fibrous capsule. The fibrous bands of these capsules are longer and looser in the cervical than in the dorsal and lumbar regions.

The *ligamenta subflava* are ligaments consisting of yellow elastic tissue, which connect the laminae of the vertebræ. Their fibres are nearly vertical, and are attached superiorly to the anterior surface of the lamina, a little above the inferior margin, and inferiorly to the upper margin and part of the posterior surface of the lamina beneath. They are most distinctly seen when the arches are detached from the bodies of the vertebræ, and they are viewed from the front. Posteriorly they appear short, or in the dorsal region are concealed, being overlaid by the prominent inferior margins of the laminae



and the roots of the spines. Their outer margins are close to the articulating processes; their inner margins lie in contact in the middle line, and in that situation the ligaments are thickest.

Fig. 111.

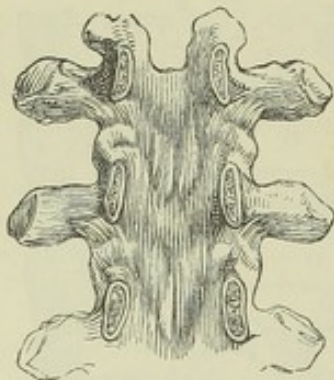


Fig. 111.—THE ARCHES OF THREE DORSAL VERTEBRÆ, SEEN FROM BEFORE, TO SHOW THE LIGAMENTA SUBFLAVA.  $\frac{1}{3}$

The bodies of the vertebræ have been removed by sawing through the pedicles, showing the articular capsules and the ligamenta subflava.

The ligamenta subflava do not exist between the occiput and the atlas, nor between the latter and the axis; common fibrous membrane supplies their place in these two spaces, constituting posterior occipito-atlantal and atlanto-axial ligaments.

The *interspinous ligaments*, thin and rather membranous, have an attachment extending from the root to near the summit of each spinous process, and connect the inferior border of one with the superior border of that next below it. They are best seen in the lumbar region, and are least developed in the neck.

The *supraspinous ligaments* consist of small compressed bundles of longitudinal fibres, which connect the summits of the

Fig. 112.

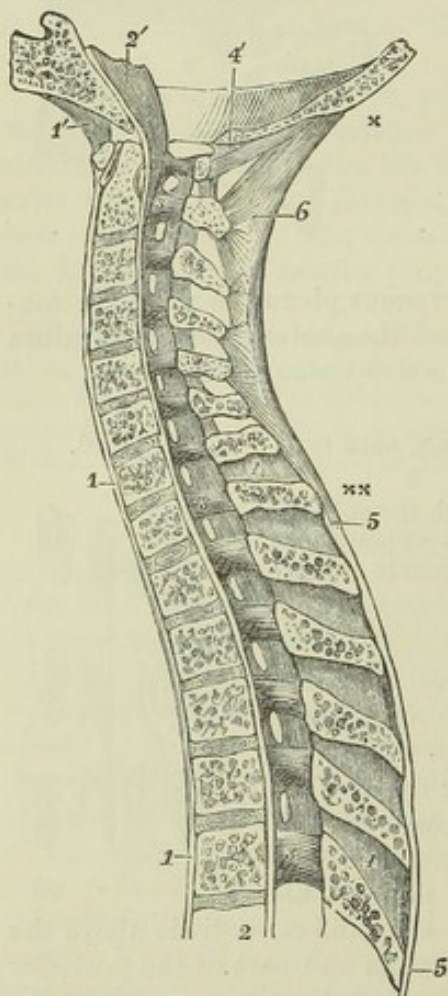


Fig. 112.—ANTERO-POSTERIOR VERTICAL SECTION OF THE UPPER PART OF THE VERTEBRAL COLUMN, AND PART OF THE OCCIPITAL BONE, SHOWING THE ARTICULATIONS (after Arnold).

1, 1, anterior common ligament of the bodies of the vertebræ; 1', anterior atlanto-occipital ligament; 2, from this figure upwards the posterior common ligament of the bodies; 2', the continuation of the preceding and the apparatus ligamentosus lying on the basilar process of the occipital bone; 3, 3, 3, these figures are placed on the inside of the arches of the 2nd and 7th cervical and 6th dorsal vertebræ; the ligamenta subflava are to be seen stretching between the laminae; 4, 4, placed upon two of the interspinous ligaments; 4', divided edge of the occipital bone behind the foramen magnum, and below it, the posterior occipito-atlantal ligament and ligaments of the arches; 5, 5, supraspinous ligaments; 6, ligamentum nuchæ; x, its upper extremity at the occipital tuberosity; x x, its lower extremity terminating in the supraspinous ligaments of the upper dorsal vertebræ.

spinous processes, and form a continuous chain from the seventh cervical vertebra to the spine of the sacrum. The posterior fibres pass down from a given vertebra to the third or fourth



below it ; those more deeply seated reach only from one to the next, or the second below it.

The *ligamentum nuchæ* is the continuation upwards of the supraspinous ligament. It is, in the human subject, a thin intermuscular septum of elastic and white fibrous tissue, the most superficial part of which extends from the spine of the seventh cervical vertebra to the occipital protuberance, while the deeper fibres, springing from the same origin, pass to the occipital spine, and the spines of the six upper vertebræ. It derives importance as the representative of a strong elastic structure in other animals.

The *intertransverse ligaments* are unimportant bands extending between the transverse processes. In the lumbar region they are membranous, in the dorsal region they are rounded bundles intimately connected with the muscles of the back ; and in the neck they are usually reduced to a few irregular fibres, which may in some instances be wanting.

**MOVEMENTS.**—The movement of flexion and extension of the vertebral column is freely allowed in the cervical and lumbar regions, but in the dorsal is limited by the small amount of intervertebral substance and the imbrication of the laminae. The greatest bending backwards is permitted in the cervical, the greatest bending forwards in the lumbar region, especially between the fourth and fifth lumbar vertebræ. Movements in other directions are limited chiefly by the articulating processes. In the dorsal region the articulating surfaces of each vertebra lie in the arc of a circle whose centre is in front of the vertebra, and round this centre a considerable degree of rotation is permitted. In the lumbar region, the centre of the circle in which the articular surfaces lie being placed behind, rotation would involve an amount of motion between the bodies of the vertebræ that is impossible ; the articulating processes, however, fit sufficiently loosely to permit of lateral flexion, and by combination of this with antero-posterior flexion, some degree of circumduction is produced. The articulating surfaces of the cervical vertebræ, being oblique and placed in nearly the same transverse plane, allow neither pure rotation nor pure lateral flexion. They permit, besides forward and backward motion, only one other, which is rotatory round an oblique axis—the inferior articulating process of one side gliding upwards and forwards on the opposing surface, and that of the other side gliding downwards and backwards, by which a combination of lateral flexion and rotation is obtained. The reader who may wish to pursue more minutely the study of the movements of the joints may consult the work of W. and E. Weber already cited ; H. Meyer, “*Handbuch der Physiol. Anat.* ;” and Henke, “*Handbuch der Anat. und Mech. der Gelenke*,” 1864.

#### ARTICULATIONS OF THE ATLAS, AXIS, AND OCCIPITAL BONE.

The atlas, axis, and occipital bone are connected by articular surfaces and ligaments, without the presence of intervertebral discs.

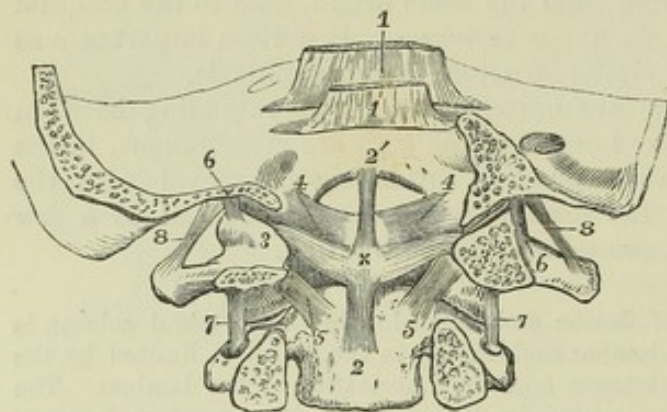
*Two pairs of synovial articulations* surrounded by capsular ligaments connect the lateral masses of the atlas with the superior articular surfaces of the axis and with the condyles of the occipital bone. The capsule of the atlanto-axial joint is strengthened behind by an accessory ligament, directed downwards and inwards to the body of the axis near the base of the odontoid process.

The *transverse ligament of the atlas* is a strong and thick band, which extends across the ring of the atlas, and retains the odontoid process in its place. It is attached on each side to the impression below the inner border of the superior articulating process. It is arched backwards behind the odontoid process, and is broadened out in the middle line. From the middle of its posterior surface a short thin bundle of fibres passes down to be attached to the body of the axis, whilst another passes up to the basilar



process. These form the figure of a cross with the transverse ligament, and serve to bind the occiput to the first two vertebræ; from this arrangement is derived the term *cruciform*, which is sometimes applied to the transverse ligament and its appendages together.

Fig. 113.



the odontoid process; 4, 4, the alar, lateral, check, or occipito-odontoid ligaments; 5, 5, the accessory ligaments of the atlanto-axial capsules, or the lower lateral ligaments of the odontoid process; 6, 6, part of the capsular ligaments of the condyloid articulations; 7, 7, capsular ligaments of the atlanto-axial articulations; 8, 8, intertransverse ligaments between the occiput and atlas.

Two *synovial membranes* are placed one in front and another behind the odontoid process; the first of these is situated between the process and the anterior arch of the atlas, the other between the process and the transverse ligament.

Fig. 114.

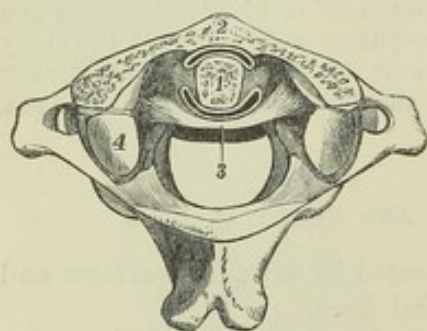


Fig. 114.—VIEW OF THE ARTICULATION OF THE ODONTOID PROCESS OF THE AXIS WITH THE ATLAS, THE UPPER PART OF THE ANTERIOR ARCH OF THE ATLAS AND THE HEAD OF THE ODONTOID PROCESS HAVING BEEN REMOVED BY A HORIZONTAL SECTION.  $\frac{1}{2}$

1, cut surface of the odontoid process; 2, cut surface of the anterior arch of the atlas; 3, transverse ligament; between 1 and 2, the anterior synovial cavity; between 1 and 3, the posterior synovial cavity of the articulation; at the sides of the odontoid process, between the anterior and posterior synovial sacs, are seen loose ligamentous fibres; 4, is placed on

the back part of the left superior articular process of the atlas: the anterior part of this process, and that of the other side, have been partly removed by the section. For the sake of distinctness, the synovial spaces are represented somewhat wider than natural.

The *odontoid* or *check ligaments* are two thick and very strong bundles of fibres, which extend from the sides of the summit of the odontoid process outwards and a little upwards to be implanted into the rough depression on the inner side of the condyles of the occipital bone, and into a small part of the margin of the foramen magnum. Some of the fibres of the two ligaments are continuous across the middle line.



Fig. 115.—TRANSVERSE SECTION SIMILAR TO THAT REPRESENTED IN FIG. 113, WITH A SMALLER PORTION OF THE OCCIPITAL BONE, THE CRUCIAL LIGAMENTS BEING REMOVED.

4, alar or odontoid ligament; 5, accessory atlanto-axial ligament; 6, 7, capsular ligaments of the occipito-atlantal and the atlanto-axial articulations; 9, placed on the head of the odontoid process; 9, 9', superior or median occipito-odontoid ligament.

The *ligamentum suspensorium dentis* or *middle odontoid ligament* consists of fibres which pass directly upwards from the summit of the odontoid process to the margin of the foramen magnum.

Fig. 115.

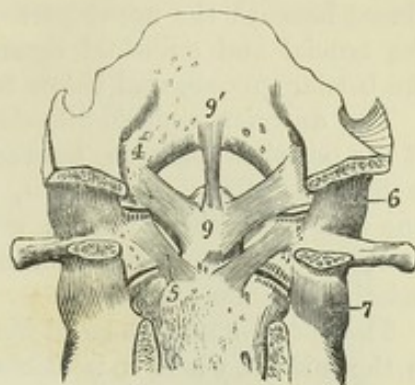


Fig. 116.

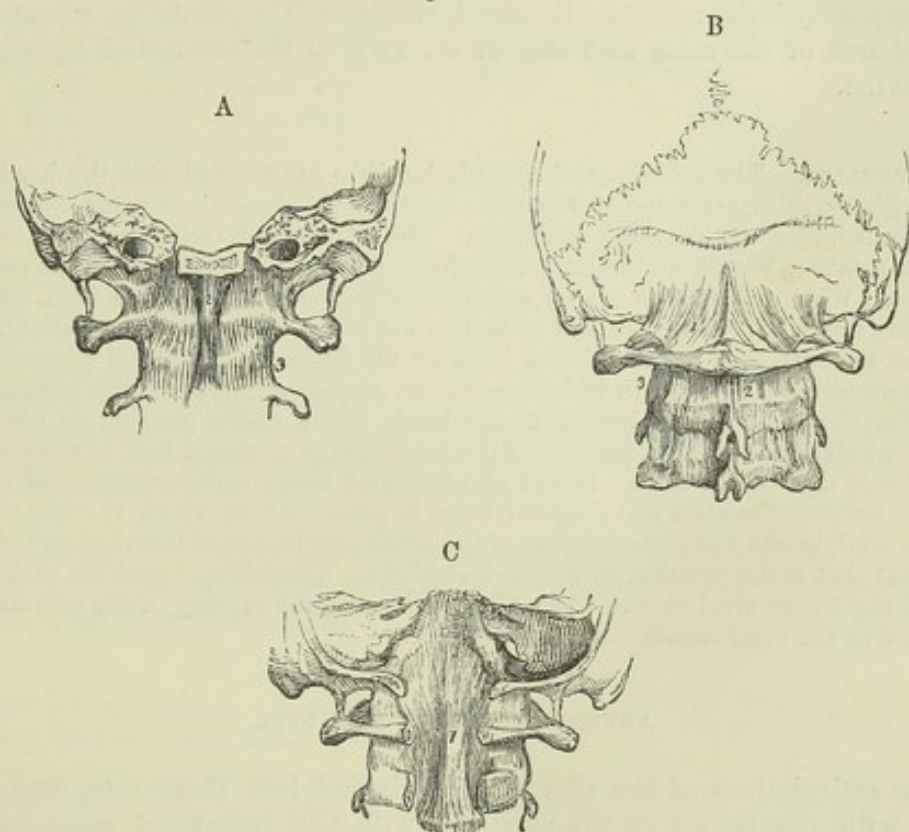


Fig. 116.—THE LIGAMENOUS STRUCTURES WHICH SURROUND THE ARTICULATIONS OF THE OCCIPUT AND TWO UPPER VERTEBRÆ.  $\frac{1}{3}$

A, the lower part of the skull sawn transversely through the basilar process, with the atlas and axis, viewed from before. 1, the anterior occipito-atlantal ligament; 2, the middle thickened part or accessory occipito-atlantal ligament; 3, the anterior atlanto-axial ligament.

B, the lower part of the skull, with three adjacent vertebrae, viewed from behind. 1, the posterior occipito-atlantal ligament; 2, the posterior atlanto-axial ligament.

C, the occipital bone sawn transversely through the foramen magnum, and a part of the arches of the atlas and axis removed posteriorly, so as to show the thickened prolongation of the posterior common ligament of the bodies of the vertebrae with the apparatus ligamentosus.



The *occipito-axial* ligament, sometimes called *apparatus ligamentosus*, is placed beneath the upper part of the posterior common ligament, and covers the crucial and odontoid ligaments. It is a broad band attached above in the basilar groove, and below to the body of the axis.

The *anterior occipito-atlantal ligament* extends from the anterior border of the occipital foramen, between the condyles, to the margin of the anterior arch of the atlas. It is thin, broad, and membranous; but in the median line it is strengthened by an *accessory* ligament, thick and round, placed in front of it, which is sometimes described as the commencement of the anterior common ligament.

The *anterior atlanto-axial ligament*, likewise thin and membranous, except in the middle, where it is thickened, extends from the border of the anterior arch of the atlas to the body of the axis.

The *posterior occipito-atlantal ligament*, thin and membranous, is attached superiorly to all that part of the margin of the occipital foramen which is behind the condyles, and inferiorly to the adjacent border of the arch of the atlas. It is partly blended with the dura mater.

The *posterior atlanto-axial ligament*, similar to the preceding, connects the neural arch of the atlas with that of the axis, in the absence of *ligamentum subflavum*.

**MOVEMENTS.**—The atlanto-axial articulation is so constructed that the head, together with the atlas, is rotated on the axis; the odontoid process serving as a pivot. The rotation is limited by the check ligaments. The atlanto-occipital articulation takes no part in rotation, but allows the head to be freely raised or depressed upon the vertebral column. When the atlas is placed symmetrically over the axis, it is seen that the opposing articular surfaces, instead of fitting one to the other, come very slightly into contact, the surface of the axis being inclined too little outwards, and presenting an antero-posterior convexity, to which there is no corresponding concavity presented by the atlas; but a slight rotation brings the bones into a stable position, in which the anterior half of one articular surface of the axis and the posterior half of the other are laid closely against the atlas. It will also be found that a certain amount of oblique motion between the atlas and occipital bone is permitted, by which the anterior half of one condyle and the posterior part of the other may be rested together on the atlas, and that that is the position of greatest stability. This oblique position is that into which the bones are brought when there is any lateral curving of the column, as is the case in the most natural and easy attitudes.

#### ARTICULATIONS OF THE RIBS.

The articulations of the ribs may be divided into three sets, connecting them with the bodies of the vertebræ, with the transverse processes, and with the sternum.

The *costo-vertebral articulation* unites the head of the rib, in most instances, with the bodies of two vertebræ by two distinct synovial joints, supported by ligaments as follows:—

The *anterior costo-vertebral, costo-central, or stellate ligament* is divided into three bundles, of which the middle one passes horizontally forwards upon the corresponding intervertebral fibro-cartilage, whilst the superior ascends to the body of the vertebra above it, and the inferior descends to that below. In the first, eleventh, and twelfth ribs, this ligament is inserted into only one vertebral body, and into no fibro-cartilage.

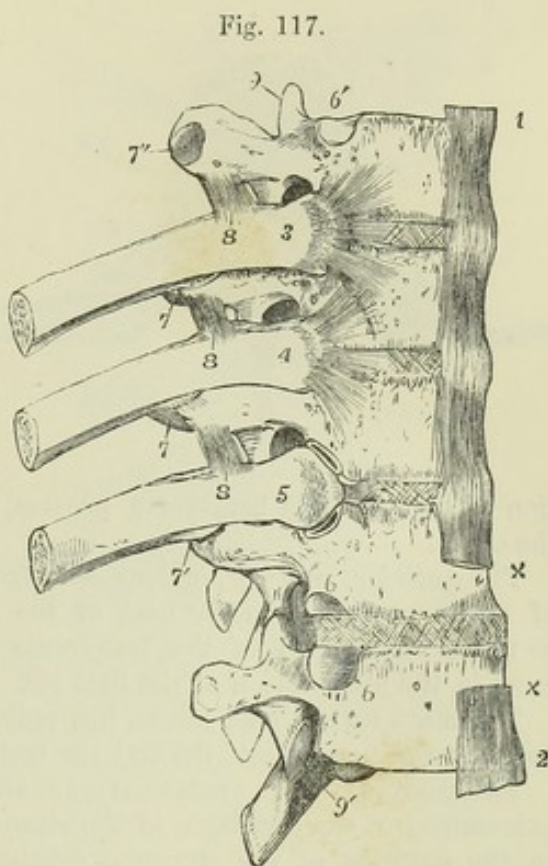
The *inter-articular ligament* is a thin and short band of fibres, which passes transversely from the ridge separating the two articular surfaces on



the head of the rib to the intervertebral substance, and divides the articulation into two parts, each lined by a separate synovial membrane. The

Fig. 117.—VIEW OF A PART OF THE VERTEBRAL COLUMN, INCLUDING THE 5TH, 6TH, 7TH, 8TH, AND 9TH DORSAL VERTEBRÆ, WITH A PART OF THE 6TH, 7TH, AND 8TH RIBS, FROM THE RIGHT SIDE AND FRONT.  $\frac{1}{3}$

The 5th and 9th ribs have been removed so as to show the articular surfaces of the vertebræ corresponding to them; 1 to 2, the anterior common ligament of the bodies of the vertebræ; at  $\times \times$ , a portion of the ligament is removed, so as to expose the intervertebral plate between the 8th and 9th vertebræ, in which the diagonal fibres of the outermost ligamentous plates are represented; 3 and 4, the heads of the 6th and 7th ribs, from which the stellate or anterior costo-central ligaments are seen spreading over the two adjacent vertebral bodies and intervertebral substance; 5, the head of the 8th rib, from which the stellate ligament has been removed, so as to expose the upper and lower synovial cavities, and between them the intervertebral or deep costo-central ligament; 6, lower, and 6', upper facet of the costo-central articulation; 7, posterior costo-transverse ligament; 7', the costo-transverse synovial cavity; 7'', the costo-transverse articular facet of the 5th vertebra; 8, the anterior or superior costo-transverse ligament; 9, superior articular process of the 5th vertebra; 9', inferior of the 9th.



ligament does not exist in the articulations of the first, eleventh, or twelfth ribs, in consequence of those ribs being each attached to only one vertebral body by a single synovial joint.

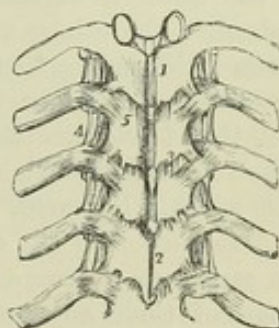
Fig. 118.—FIVE DORSAL VERTEBRÆ, WITH PORTIONS OF THE CORRESPONDING RIBS.  $\frac{1}{4}$

1 and 2 are placed on the laminae of the vertebræ, close to the interspinous ligaments; 3, one of the ligamenta subflava, which are only in part seen, being covered to some extent by the laminae of the vertebræ; 4, anterior costo-transverse ligament; 5, posterior costo-transverse ligament.

The COSTO-TRANSVERSE ARTICULATION unites the tubercle and neck of the rib to the corresponding transverse process by a synovial joint and ligaments, and by a longer ligament to the transverse process above.

The *posterior costo-transverse ligament* is a distinct band extending outwards from the posterior part of the summit of the transverse process to the rough external part of the tubercle of the rib.

Fig. 118.





The *middle* or *inter-osseous costo-transverse ligament*, or *ligamentum colli costæ*, consists of a series of very short parallel fibres, which unite the neck of the rib to the anterior surface of the contiguous

Fig. 119.

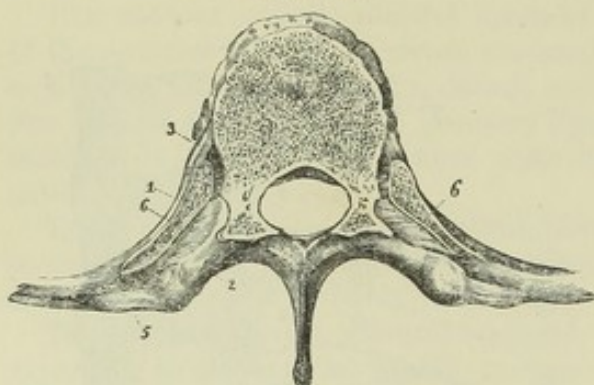


Fig. 119.—HORIZONTAL SECTION OF A DORSAL VERTEBRA, WITH THE ADJACENT PORTIONS OF TWO RIBS.  $\frac{2}{3}$

1, the rib; 2, transverse process; 3, anterior costo-central ligament; 5, posterior costo-transverse ligament; 6, interosseous or middle costo-transverse ligament.

transverse process. These fibres are seen on removing by horizontal section a por-

tion of the rib and transverse process, and forcibly drawing the one from the other.

The *anterior, superior, or long costo-transverse ligament* consists of fasciculi of fibres, passing from the neck of the rib obliquely upwards and outwards to the lower margin of the transverse process next above it. It does not exist in the articulation of the first rib.

There are no synovial joints, but only posterior costo-transverse ligaments, between the two lowest ribs and the transverse processes.

The *COSTO-STERNAL ARTICULATIONS*, situated between the anterior angular extremities of the cartilages of the sternal ribs, and the corresponding fossæ in the margins of the sternum, consist of small synovial capsules covered and supported by anterior, posterior, upper and lower ligaments; the anterior ligamentous fibres are thin, scattered, and radiated, passing from the extremity of the cartilage to the anterior surface of the sternum, where they interlace with those of the opposite side, and are blended with the aponeurosis of the pectoralis major muscle; the posterior fibres are similarly disposed, but not so thick or numerous, and connect the thoracic surfaces of the same parts; the upper and lower ligamentous fibres are inconsiderable, and are placed above and below the joint; the *synovial membranes* are interposed between the end of the cartilage of each true rib (excepting the first) and the sternum, and may best be demonstrated by slicing off a little of the anterior surface of the sternum and cartilage; that of the seventh is single; the others are usually divided into an upper and lower cavity, between which interarticular fibres are attached to the end of the cartilage and to the sternum. The cartilage of the first rib is directly united to the sternum.

A thin fasciculus of fibres connecting the cartilage of the seventh rib, and sometimes likewise that of the sixth, with the xiphoid cartilage, is called the *costo-xiphoid ligament*.

*Articulation of the cartilages one with another.*—The contiguous edges of the cartilages of some of the ribs, viz., from the sixth to the ninth, have a part of their adjacent borders smoothed into articular surfaces, which are lined by synovial membranes, and are held in connection by ligamentous fibres. Some of the articular surfaces are occasionally found to be wanting.

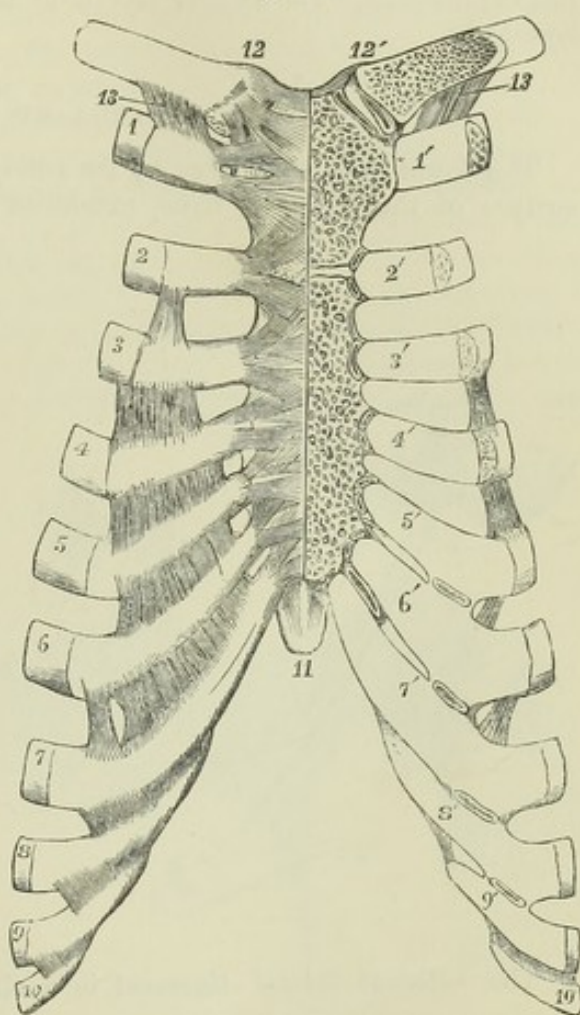
*Connection of the ribs with their cartilages.*—The external extremities of the cartilages are fixed into the oval depressions on the ends of the ribs, and the union receives support from the periosteum.



Fig. 120.—ARTICULATIONS OF THE STERNUM, CLAVICLE AND RIBS, AS SEEN FROM BEFORE (after Arnold).  $\frac{1}{3}$

On the right of the middle line the anterior ligaments are shown; on the left side, the front parts of the clavicle, sternum and costal cartilages have been removed so as to display the articular cavities. 1 to 10, the anterior extremities of the ribs from the first to the tenth inclusive, on the right side; 1' to 10', the costal cartilages of the left side from the first to the tenth inclusive; at 1', the direct union of the first costal cartilage with the sternum is shown; at the sternal ends of the cartilages marked 2' to 6', the small double synovial cavities are shown opened; between the costal cartilages on the right side, ligamentous bands are shown stretching over the intercostal spaces; and on the left side, by a section, small synovial cavities are shown between the adjacent edges of the intercostal cartilages from the 5th to the 9th; on the front of the right half of the sternum the radiating anterior costo-sternal ligaments are shown; 11, the ensiform process; 12, 12', the interclavicular ligament; and below 12, the anterior sterno-clavicular ligament; below 12', the sterno-clavicular articulation is opened, showing the interarticular fibro-cartilage and double synovial cavity; 13, the costo-clavicular or rhomboid ligament.

Fig. 120.



*Ligaments of the sternum.*—The manubrium, body and xiphoid process of the sternum, so long as they are not united by bone, are connected by intervening cartilage, and by anterior and posterior ligaments; and the whole sternum is much strengthened by thick periosteum and by the crossing and longitudinal bands of the costo-sternal ligaments already mentioned.

*Movements of the ribs.*—Each rib is capable of a certain amount of elevation and depression at its vertebral articulation, and of rotation on an axis passing between its vertebral and sternal ends. The heads of the ribs are, however, bound down by the inter-articular ligaments so tightly as to prevent any gliding motion at the attachments of those ligaments, which may therefore be regarded as the fixed points round which the ribs are moved. When the vertebral column is bent forwards, the ribs are depressed; and in the same manner, when the column is rotated, the ribs of that side towards which the upper part of the trunk is turned are raised, and those of the other side correspondingly depressed. The movement of the tubercle of the rib on the transverse process is of a gliding description, in the circumference of a circle of which the head of the rib is the centre; and as the plane in which the opposed surfaces of the costo-transverse articulation in most instances lies looks upwards and backwards, the ribs are moved backwards as well as upwards in inspiration, and forwards and downwards in expiration. The combined movements of the thoracic walls in respiration will be described along with the actions of the intercostal



muscles. It is sufficient at present to state that the elevation and rotation of the ribs in inspiration are the main causes of the antero-posterior and transverse enlargement of the chest. The angular movement is greatest in the upper and least in the lowest ribs.

#### TEMPORO-MAXILLARY ARTICULATION.

The lower jaw articulates by its condyle on each side with the smooth surface of the temporal bone, extending over the part of the glenoid fossa

Fig. 121.

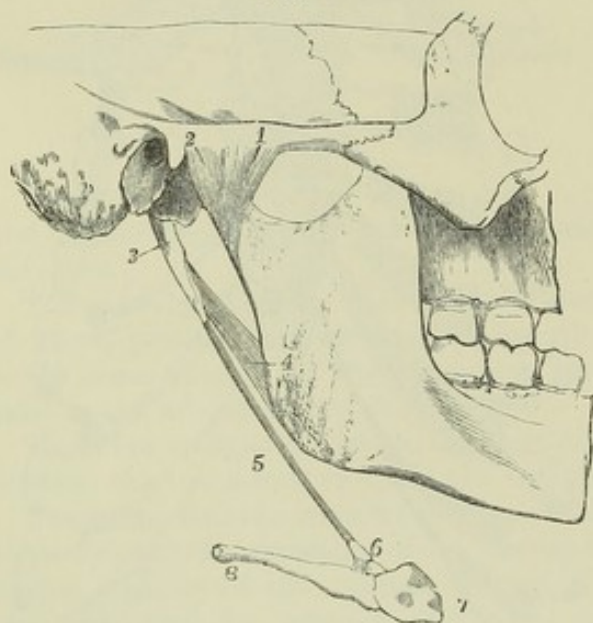


Fig. 121.—A PORTION OF THE SKULL AND LOWER JAW WITH HALF THE HYOID BONE, SEEN FROM THE RIGHT AND OUTER SIDE (after Arnold).  $\frac{1}{3}$

1, the external lateral ligament of the temporo-maxillary articulation; 2, a part of the capsular ligament of the joint; 3, styloid process; 4, stylo-maxillary ligament; 5, stylo-hyoid ligament; 6, the lesser cornu of the hyoid bone with some short ligaments attaching it to the body and great cornu; 7, the body; 8, the extremity of the great cornu.

in front of the Glaserian fissure and the anterior root of the zygoma. The joint is divided by an interarticular fibro-cartilage into an upper and lower synovial cavity.

The *external lateral ligament* is a short fasciculus of fibres, attached

Fig. 122.

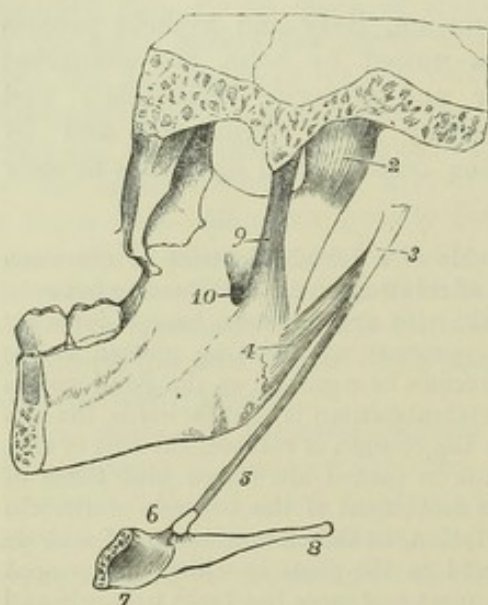


Fig. 122.—A PORTION OF THE SKULL AND LOWER JAW WITH HALF THE HYOID BONE, SEEN FROM THE INSIDE.  $\frac{1}{3}$

The indications where marked are the same as in Fig. 121; the styloid process, 3, is detached from the skull; the body of the hyoid bone, 7, is represented as cut through in the middle, so that the posterior and inner surface of the right half of the bone is seen; 9, the internal lateral ligament of the temporo-maxillary joint; 10, the upper opening of the inferior maxillary canal.

above to the external surface and the tubercle of the zygoma; and below, to the external surface and posterior border of the neck of the lower jaw, its fibres being directed downwards and backwards. Thin and short additional ligamentous fibres cover the synovial membrane

and form an irregular capsule round the joint.



The *internal lateral ligament*, thin, loose, and elongated, lies at some distance from the joint. It extends from the spinous process of the sphenoid bone downwards and a little forwards, to be attached to the inner border of the dental foramen in the inferior maxillary bone. Between it and the lower jaw are placed the external pterygoid muscle, the internal maxillary artery, and the inferior dental nerve. It has no immediate connection with the joint, and by some anatomists is not recognised as a ligament.

The *inter-articular fibro-cartilage* is a thin plate, placed between the articular surfaces of the bones. It is of an oval form, broadest transversely, thickest posteriorly, and thinnest at its centre, where it is sometimes perforated. The inferior surface, which is in contact with the condyle, is concave; the superior is concavo-convex from before backwards, conforming with the articular surface of the temporal bone. Its circumference is connected at the outside with the external lateral ligament, and anteriorly with the external pterygoid muscle.

Fig. 123.—ANTERO-POSTERIOR SECTION OF THE TEMPORO-MAXILLARY ARTICULATION OF THE RIGHT SIDE.  $\frac{1}{3}$

1, is placed close to the articular eminence, and points to the superior synovial cavity of the joint; 2, is placed close to the articular surface of the head of the lower jaw, and points to the inferior synovial cavity of the joint; x, is placed on the thicker posterior portion of the inter-articular fibro-cartilage.

*Synovial Membranes.*—The synovial membrane which lies between the inter-articular fibro-cartilage and the glenoid

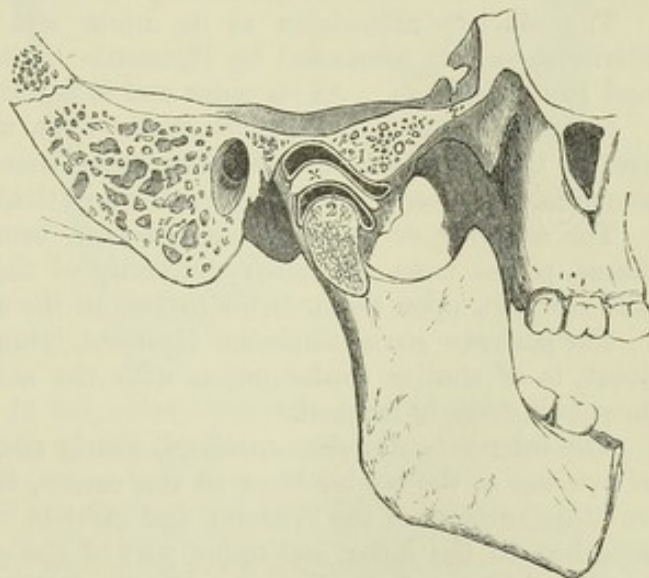
cavity is larger and looser than that which is interposed between the fibro-cartilage and the condyle of the jaw. When the fibro-cartilage is perforated the upper and lower synovial cavities necessarily communicate one with the other.

The *stylo-maxillary ligament* is the name given to a strong or thickened band of fibres connected with the cervical fascia extending from near the point of the styloid process to the posterior border of the ramus of the jaw, where it is inserted between the masseter and internal pterygoid muscles. It separates the parotid from the submaxillary gland.

It may be proper also to mention in this place the *stylo-hyoid ligament*, a thin fibrous cord, which extends from the point of the styloid process to the lesser cornu of the hyoid bone, and serves to suspend that bone from the styloid process. A considerable portion of the stylo-hyoid ligament is sometimes converted into bone in the human subject, and in animals it is naturally osseous, and constitutes the epi-hyal bone.

*MOVEMENTS.*—The jaw is capable of movements of elevation and depression, of some degree of lateral displacement, and of protraction and retraction; but it is to be observed that when the jaw is depressed, as in opening the mouth, the condyle advances from the glenoid cavity so as to be placed on the articular eminence in front

Fig. 123.





of it. The movements which take place in the superior and inferior compartments of the joint are of different kinds. In the upper the fibro-cartilage glides backwards and forwards on the temporal bone; in the lower compartment the condyle rotates on a transverse axis against the fibro-cartilage. In opening the mouth the two movements are combined: the jaw and fibro-cartilage together move forwards and rest on the convex root of the zygoma, while at the same time the condyle revolves on the fibro-cartilage. When the lower incisors are protruded beyond those of the upper jaw, the movement is confined chiefly to the upper articulation; and when the same movement is alternately performed in the joints of opposite sides a horizontal or grinding motion is produced. The fibres of the external lateral ligament remain tight both in shutting and opening the mouth, and it is owing to their direction that in opening the mouth the condyle is driven forwards.

## ARTICULATIONS OF THE UPPER LIMB.

### THE SCAPULO-CLAVICULAR ARCH.

The supporting arch of the upper limb has only one point of attachment to the trunk, namely, that at the sterno-clavicular articulation; the scapula being connected with the trunk only by muscles.

The clavicle articulates at its inner end with the first bone of the sternum, and is connected by ligaments to its fellow of the opposite side and to the first rib. At its outer end it is united to the scapula.

**STERNO-CLAVICULAR ARTICULATION.**—The articular surface of the inner end of the clavicle is considerably larger than the opposing surface of the sternum. Between the two bones an inter-articular fibro-cartilage is interposed.

The *anterior sterno-clavicular ligament*, broad and consisting of parallel fibres, passes from the inner extremity of the clavicle in front downwards and inwards, upon the anterior surface of the sternum.

The *posterior sterno-clavicular ligament*, lying on the thoracic aspect of the joint, is of similar conformation with the anterior ligament, but is not so broad or strongly marked.

The *inter-articular fibro-cartilage*, nearly circular in its form, and thicker above and at the border than at the centre, is interposed between the articulating surfaces of the sternum and clavicle. Towards its upper part it is attached to the inner and upper part of the clavicle, and at its lower edge to the cartilage of the first rib. In the latter situation it is thin and somewhat prolonged, so that the inferior border of the clavicle rests upon it.

*Synovial membranes.*—In this articulation, as in that of the lower jaw, there are two cavities lined by synovial membrane, one on each side of the inter-articular fibro-cartilage.

The *inter-clavicular ligament* is a dense fasciculus of fibres, between the contiguous extremities of the clavicles. It dips downwards in the middle, and is connected with the upper margin of the sternum, filling up a part of its interclavicular notch.

The *costo-clavicular ligament* (ligamentum rhomboides,—Weitbrecht) does not properly form part of the sterno-clavicular articulation; yet it contributes materially to retain the clavicle in its situation. It is attached inferiorly to the cartilage of the first rib near its sternal end, and passes obliquely backwards and upwards, to be fixed to a rough depression at the under surface of the clavicle near the sternal end.

**SCAPULO-CLAVICULAR CONNECTIONS.**—At its outer end the clavicle articulates with the acromion, and is connected by ligamentous fibres with the coracoid process.

The *acromio-clavicular articulation* is a synovial joint uniting the outer extremity of the clavicle with the inner edge of the acromion. It is sup-



ported above by a thick and broad *superior ligament*, and below by an *inferior ligament* which is not so strong. An *inter-articular fibro-cartilage* is frequently present, but is sometimes wanting. It is usually wedge-shaped, attached by its base to the upper part of the joint, and only partially separating the small oval articular surfaces.

Fig. 124.

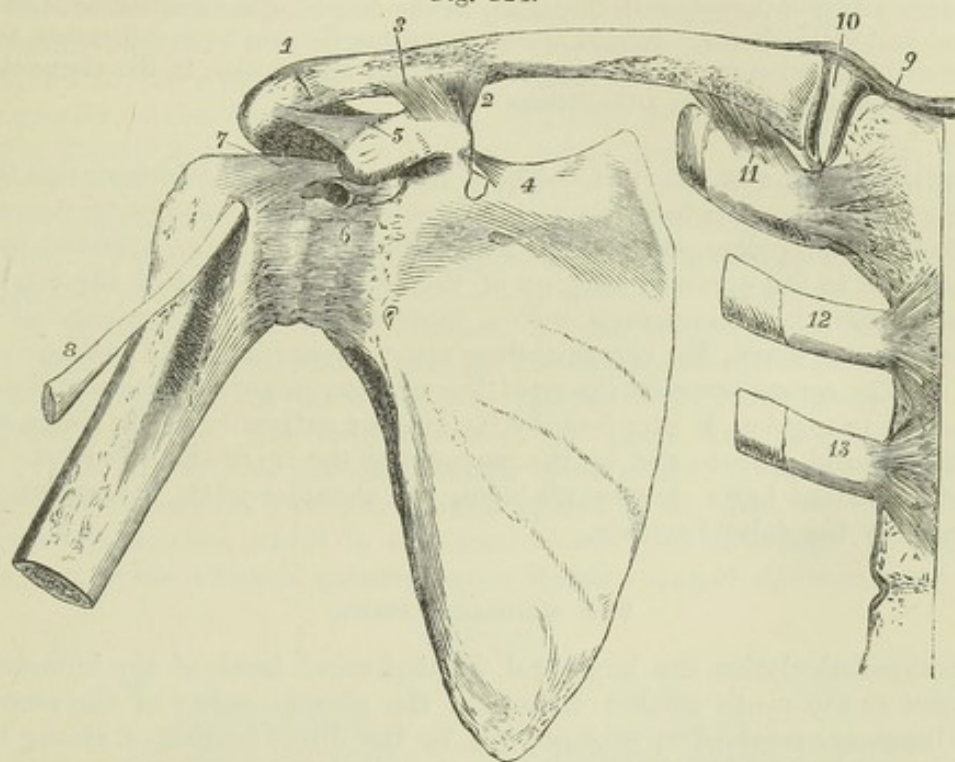


Fig. 124.—VIEW FROM BEFORE OF THE ARTICULATIONS OF THE SHOULDER BONES.  $\frac{1}{2}$

1, acromio-clavicular articulation; 2, conoid, and 3, trapezoid part of the coraco-clavicular ligament; 4, is near the supra-scapular or coracoid ligament; 5, placed on the coracoid process, points to the coraco-acromial or deltoid ligament; 6, is placed on the front of the capsular ligament of the shoulder-joint; 7, the coraco-humeral ligament or accessory part of the capsular; above 6, an aperture in the capsular ligament at the place where a part of the tendon of the subscapularis muscle pierces the capsular ligament, and is sometimes connected with a synovial bursa; 8, tendon of the glenoid head of the biceps muscle issuing between the tuberosities; 9, right half of the interclavicular ligament; 10, interarticular fibro-cartilage of the sterno-clavicular articulation, shown by removing the anterior sterno-clavicular ligament and synovial membrane; 11, the costo-clavicular or rhomboid ligament; 12 and 13, the cartilage and small part of the second and third ribs attached by their anterior costo-sternal ligaments. (See also Fig. 120.)

The *coraco-clavicular ligament*, which connects the clavicle with the coracoid process of the scapula, is divisible into two parts, each known by a particular name. The *conoid ligament*, which is the posterior or internal fasciculus, broad above, narrow below, is attached inferiorly to the inner part of the root of the coracoid process, and superiorly to a tubercle on the inferior surface of the clavicle below the convex margin of its outer curve: its fibres are directed backwards and upwards. The *trapezoid ligament*, the anterior or external fasciculus, slopes upwards, backwards, and outwards from the inner border of the coracoid process to an oblique line extending outwards from the tubercle to which the conoid ligament is attached, and is inserted at right angles to the line of attachment of that ligament to the clavicle. In the angle between the conoid and trapezoid ligaments there is frequently present a synovial bursa.



**MOVEMENTS.**—The movements allowed at the clavicular articulations are limited, not so much by the forms of the articular surfaces, as by the costo-clavicular and coraco-clavicular ligaments and the position of the thoracic wall. When the clavicle is forcibly depressed, as in lifting a heavy weight, it presses upon the first rib, the upper border of its inner end rises above the sternum, and the interarticular cartilage and inter-clavicular ligament are put upon the stretch. When the shoulders are drawn backwards and downwards, the angle between the clavicle and the upper border of the scapula is increased, by the descent of the scapular arch on the conical wall of the thorax. In raising and depressing the arm to its full extent, there is not only vertical motion at the shoulder joint, but also motion at the sterno-clavicular and acromio-clavicular articulations.

**LIGAMENTS OF THE SCAPULA.**—There are two ligaments which stretch from one part of the scapula to another. 1. The *coracoid* or *supra-scapular ligament* (*ligamentum proprium posterius*), is a thin flat band of fibres, attached by its extremities to the opposite margins of the notch at the root of the coracoid process, which it thus converts into a foramen for the transmission of the supra-scapular nerve, the corresponding artery most commonly passing above it. 2. The *coraco-acromial ligament* (*ligamentum proprium anterius*), broad, firm, and triangular, is attached by its broader extremity to the outer edge of the coracoid process, and by the narrower to the tip of the acromion. Its inferior surface looks downwards upon the shoulder-joint, the superior is covered by the deltoid muscle.

#### THE SHOULDER JOINT.

In this articulation the large and hemispherical head of the humerus is opposed to the much smaller surface of the glenoid cavity of the scapula. The bones are retained in position, not by the direct tension of strong ligaments, which would have restricted too much the movements of the joint, but by surrounding muscles and atmospheric pressure.

The *capsular ligament* is attached to the scapula round the margin of the glenoid cavity, and to the humerus at the place where the neck springs from the tuberosities and shaft. It extends furthest down the humerus on the internal or inferior aspect, and is strongest on the superior aspect. The laxity of the capsule is such that the humerus drops away from the glenoid cavity

Fig. 125.

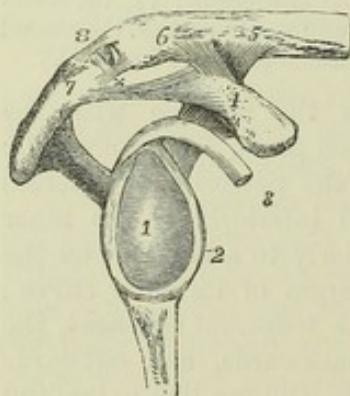


Fig. 125.—VIEW OF THE GLENOID CAVITY AND LIGAMENTS BETWEEN THE SCAPULA AND CLAVICLE OF THE RIGHT SIDE.  $\frac{1}{3}$

1, glenoid fossa, its cartilaginous surface; 2, the glenoid ligament or fibrous border; 3, the tendon of the biceps muscle seen in connection with the upper part of the glenoid fossa and ligament; 4, is placed on the upper surface of the coracoid process; 5 and 6, on the adjacent part of the clavicle; 4 to 5, the conoid; 4 to 6, the trapezoid portion of the coraco-clavicular ligament; 7, is placed on the apex of the acromion process; 4 to 7, the coraco-acromial ligament; 8, is above the acromio-clavicular articulation, which is represented as open anteriorly, showing a wedge-shaped inter-articular cartilage attached above to the superior acromio-clavicular ligament; x, the inferior acromio-clavicular ligament.

as soon as its muscular connections are detached. Superiorly and posteriorly the capsule is strengthened by the tendons of the supra spinatus, infra-spinatus,



and *teres minor* muscles, which are intimately connected with it, as they pass over it to reach the great tuberosity of the humerus. Anteriorly the tendon of the *subscapularis* muscle comes into direct contact with the synovial membrane, which is prolonged upon it through an oval opening. The insertion of the capsule is likewise interrupted opposite the bicipital groove, to give passage to the long tendon of the *biceps* muscle.

The *coraco-humeral*, or accessory ligament, is a broad bundle of fibres extending obliquely over the upper and outer part of the articulation ; it is attached to the root of the coracoid process, and thence descends towards the greater tuberosity of the humerus, intimately connected with the capsule.

The *glenoid ligament* is a firm fibrous band, about two lines deep, which is fixed to the edge of the glenoid fossa, and, by elevating the border of the cavity, renders it a little deeper. The upper part of it is connected with the tendon of the long head of the *biceps* muscle, which is also fixed into the upper part of the glenoid fossa, within the capsule of the joint.

The *synovial membrane* is reflected uninterruptedly from the glenoid cavity on the inner surface of the fibrous capsule to the humerus, but its form is complicated by its relation to the tendons of the *biceps* and *subscapularis* muscle. The long tendon of the *biceps* muscle, traversing the joint in its course from the upper border of the glenoid cavity to the bicipital groove, is enclosed in a tubular sheath, formed by an offset or process of the synovial membrane, which is continued down upon it beyond the fibrous capsule into the bicipital groove, and is thence reflected upwards upon it to

Fig. 126.

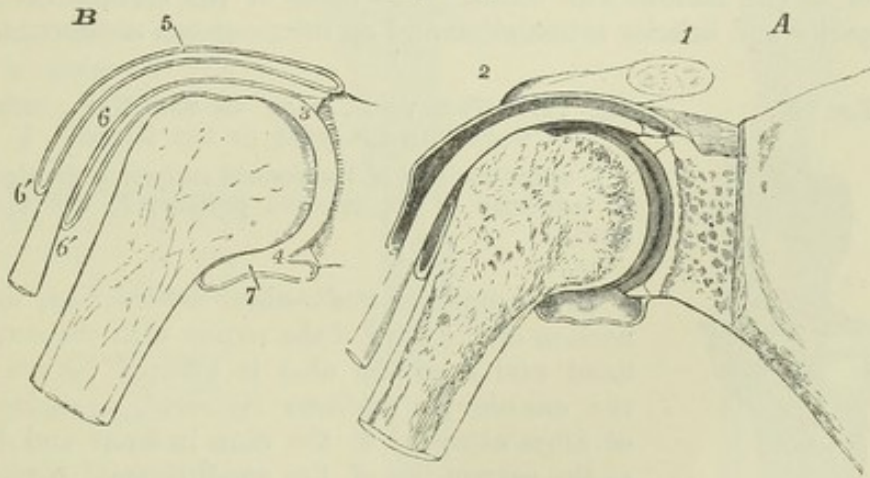


Fig. 126.—A, SECTION THROUGH THE SHOULDER JOINT, PASSING FROM WITHIN OUTWARDS THROUGH THE TENDON OF THE BICEPS AND BICIPITAL GROOVE, SOMEWHAT DIAGRAMMATIC, TO SHOW THE SYNOVIAL CAVITY OF THE JOINT, &c.  $\frac{1}{3}$

B, OUTLINE OF THE SAME, TO SHOW THE INFLECTION OF THE SYNOVIAL MEMBRANE OVER THE TENDON.

1, placed above the sawn end of the outer part of the clavicle ; 2, is near the acromial end ; 3, the cavity of the shoulder joint close to the upper part of the glenoid head, where there are seen the section of the cartilages on the head of the humerus and in the glenoid cavity of the scapula, the glenoid ligament, and the origin of the tendon of the *biceps* muscle ; 4, is in the lower part of the cavity of the joint, indicating the section of the glenoid ligament in that situation ; 5, the upper part of the capsular ligament and synovial membrane ; 6, the tendon of the *biceps* as it passes out of the joint into the bicipital groove ; 6', 6', the tubular prolongation of the synovial membrane round the tendon ; 7, the reflection of the synovial membrane on the humerus within the lower part of the capsular ligament.



its origin, where it again becomes continuous with the synovial membrane of the capsule in such a manner as to preserve the integrity of the membrane. The bursal prolongation of the synovial membrane on the tendon of the subscapularis muscle is of variable extent, sometimes scarcely existing, sometimes forming a considerable pouch on the venter of the scapula.

*Subacromial Bursa.*—Superficial to the muscles covering the top of the joint is a considerable bursa mucosa, by means of which the contiguous surfaces of the coracoid and acromion processes, and of the coraco-acromial ligament and deltoid muscle are lubricated, so as to facilitate the movements of the subjacent head of the humerus.

**MOVEMENTS.**—Great freedom of movement of the humerus in every direction is admitted at the shoulder-joint; but superiorly and posteriorly the extent of the movement is somewhat limited by the margin of the acromion. When the arm is raised, the great tuberosity of the humerus becomes locked against the acromion as soon as the position is reached in which the limb lies at right angles to the trunk, and all further elevation is accomplished by movements in the sterno-clavicular and acromio-clavicular articulations. The arch formed by the acromion, the coracoid process and the deltoid ligament, lined by the subacromial bursa, forms a sort of secondary socket, in which the extremity of the humerus, covered by the tendons inserted into the great tuberosity, revolves, and against which it is pressed when the weight of the body is made to rest upon the arms: in quadrupeds, the weight of the body is transmitted through the glenoid fossa to the humerus.

#### ARTICULATIONS OF THE FOREARM AND ELBOW.

**UNION OF THE RADIUS AND ULNA.**—The bones of the forearm are united by a superior and inferior articulation and an inter-osseous membrane.

Fig. 127.

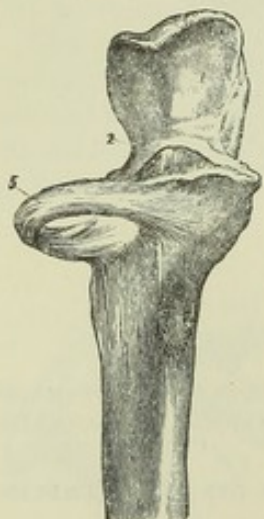

Fig. 127.—THE UPPER PART OF THE ULNA, WITH THE ORBICULAR LIGAMENT OF THE RADIUS.  $\frac{1}{2}$

1, upper division of the sigmoid surface on the olecranon; 2, extremity of the coronoid process; 5, orbicular ligament.

In the *superior radio-ulnar articulation*, the connection of the head of the radius with the small sigmoid cavity of the ulna is effected by means of the *annular* or *orbicular ligament*, a strong band of fibres attached to the ulna in front and behind at the extremities of the small sigmoid cavity, and forming four-fifths of a ring which encircles the head of the radius and binds it firmly in its situation. The outer surface is connected with the external lateral ligament of the elbow, whose fibres are inserted into it; the deep surface is smooth, and is lined by the synovial membrane of the elbow joint.

**The inferior radio-ulnar articulation.**—The connection between the semi-lunar surface of the radius and the lower end of the ulna is effected by means of a fibro-cartilage, a synovial membrane, and some scattered ligamentous fibres in front and behind. The *triangular fibro-cartilage* is a thick plate attached by its base to a ridge separating the carpal from the ulnar articulating surface of the radius; and by its apex to a depression at the root of the styloid process of the ulna, and to the side of that process. Its upper surface looks towards the ulna, its lower towards the cuneiform bone,



and it separates the inferior radio-ulnar articulation from the wrist joint. The *synovial membrane*, sometimes called from its looseness *membrana saciformis*, extends partly upwards between the radius and ulna, partly horizontally inwards between the ulna and triangular fibro-cartilage. When the fibro-cartilage is perforated, as is occasionally the case, this synovial membrane is continuous with that of the wrist joint.

Fig. 128.—THE LOWER PARTS OF THE RADIUS AND ULNA, WITH THE TRIANGULAR FIBRO-CARTILAGE CONNECTING THEM.  $\frac{2}{3}$

1, ulna; 2, its styloid process; 3, radius; 4, the part of the articular surface for the scaphoid bone; 5, that for the semilunar bone; 6, lower surface of the triangular fibro-cartilage; \* \*, a piece of whalebone passed between the fibro-cartilage and the ulna.

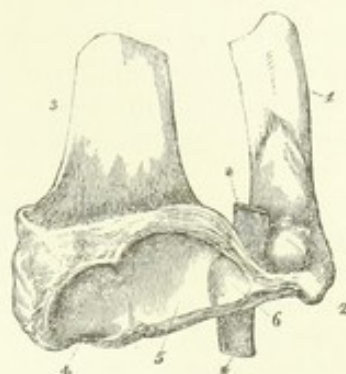


Fig. 128.

The *interosseous membrane* or *ligament* of the forearm is a thin, flat, fibrous membrane, the direction of whose fibres is for the most part obliquely downwards and inwards, and which extends between the contiguous borders of

Fig. 129.

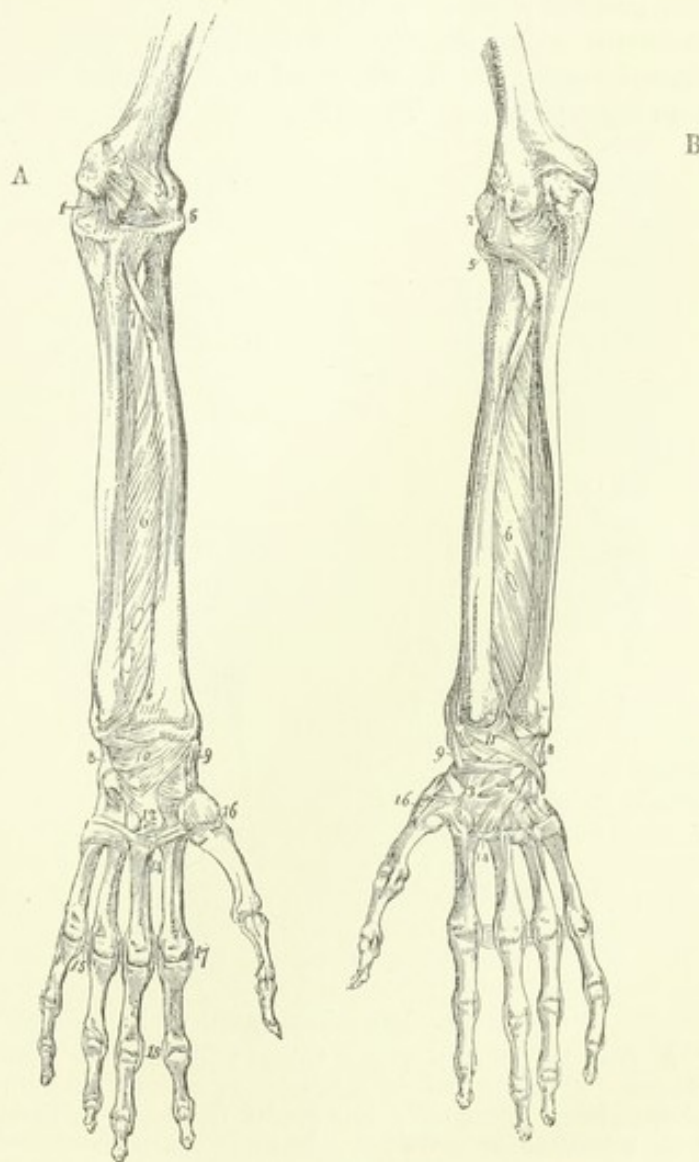


Fig. 129.—A, FRONT, AND B, BACK VIEW OF THE ARTICULATIONS OF THE FOREARM, WRIST AND HAND.  $\frac{1}{2}$

1, the internal lateral ligament of the elbow joint; 2, the external lateral; 3, the anterior; 4, points to the posterior; 5, orbicular ligament of the radius; 6, interosseous membrane; 7, oblique or round ligament; 8, internal lateral ligament of the wrist; 9, external; 10, anterior; 11, posterior; 12, palmar, and 13, dorsal carpo - metacarpal ligaments; 14, ligaments connecting metacarpal bones; 15, transverse metacarpal ligament; 16, carpo-metacarpal ligament of the thumb; 17, lateral ligaments connecting the phalangeal with the metacarpal bones; 18, lateral ligaments of the phalanges.

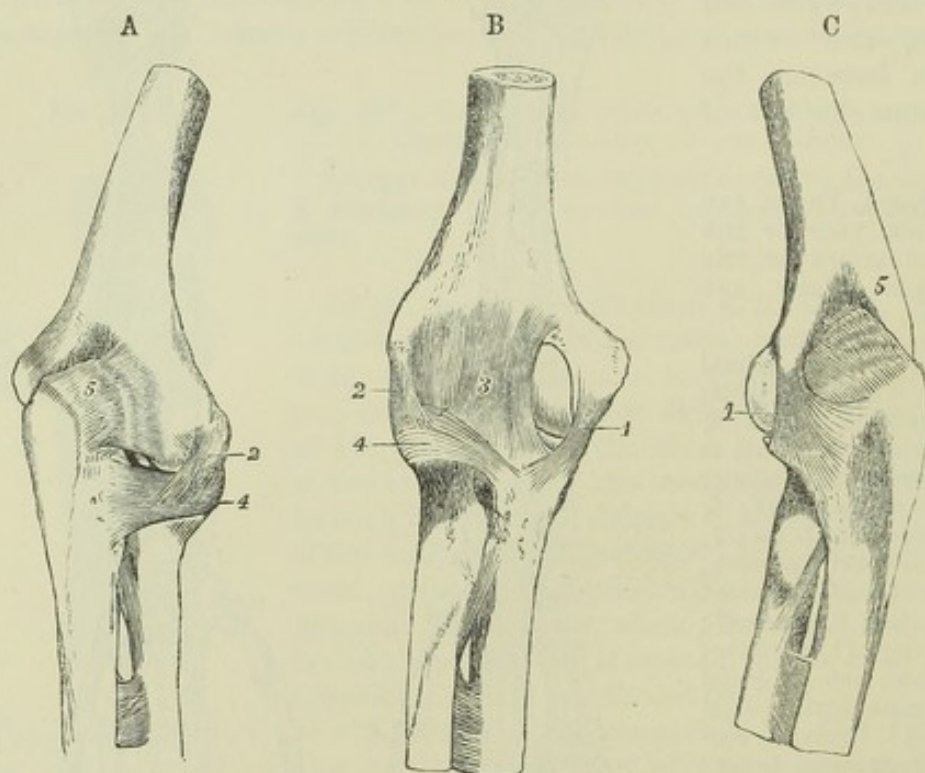


the radius and ulna. Its superior border is placed about an inch below the tubercle of the radius, leaving a space (*hiatus inter-osseus*) through which the posterior inter-osseous vessels pass. This space is diminished in size by the *round or oblique ligament*, a thin, narrow fasciculus of fibres extending obliquely downwards and outwards from the coronoid process, to be attached to the radius about half an inch below the tubercle. Other small bundles of fibres, having the same direction as the round ligament, are often to be found at intervals, decussating with the fibres of the inter-osseous ligament on its posterior surface.

**MOVEMENT OF THE RADIUS ON THE ULNA.**—The disposition of the annular ligament allows the head of the radius to rotate freely within it, while the lower end of the radius, bound by the triangular fibro-cartilage to the styloid process of the ulna, has a freedom of circumduction round that point, by which the hand is brought into the prone or supine position. Thus in pronation and supination the movement of the radius describes a part of a cone, the axis of which extends from the centre of the head of the radius to the styloid process of the ulna.

**THE ELBOW JOINT.**—The lower extremity of the humerus is in contact with the ulna and radius at the elbow, and forms with them a hinge-joint. The greater sigmoid cavity of the ulna articulates with the trochlea of the humerus, so as to admit of flexion and extension only; while the cup-shaped depression on the head of the radius is fitted to turn freely on the rounded capitulum. These bones are united principally by lateral ligaments.

Fig. 130.

Fig. 130.—LIGAMENTS OF THE ELBOW-JOINT.  $\frac{1}{2}$ 

A, from the outer side and behind; B, from the front; C, from the inner side and behind. 1, internal lateral ligament; 2, external lateral; 3, the middle strongest part of the anterior ligament; 4, orbicular ligament; 5, posterior, represented as wrinkled from relaxation in extension. In these figures the round ligament and upper part of the inter-osseous membrane are also represented below the elbow-joint.



The *internal lateral ligament*, composed of diverging and radiating fibres, is divisible into an anterior and a posterior part. The anterior part radiates from the front of the internal condyloid eminence of the humerus, and is inserted into the coronoid process, along the inner margin of the sigmoid cavity. The posterior part, of the same triangular form, passes from the under and back part of the condyloid eminence downwards to the inner border of the olecranon; and some fibres are connected with a small transverse band over the notch between the olecranon and the coronoid process.

The *external lateral ligament*, intimately connected with the tendinous attachment of the extensor muscles, is shorter and much narrower than the internal. It is attached superiorly to the external condyloid eminence of the humerus, and inferiorly becomes blended with the annular ligament of the radius; some of its hinder fibres are prolonged to the external margin of the ulna.

The *anterior ligament* consists of a thin sheet of fibres extending downwards from above the coronoid pit of the humerus, and protecting the anterior part of the synovial membrane; it is strongest in its middle part.

The *posterior ligament* is comparatively thin and weak, and consists of loose and irregular fibres passing transversely across the olecranon fossa of the humerus, and from the sides of that fossa to the olecranon process, thus completing the capsule of the joint behind.

Fig. 131.

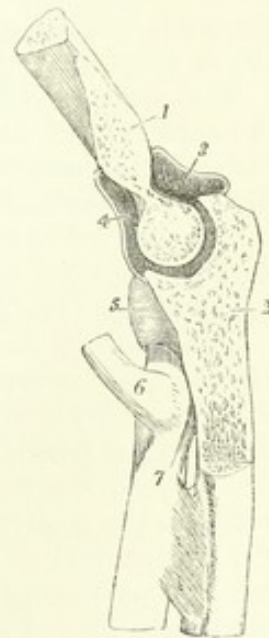

Fig. 131.—VERTICAL ANTERO-POSTERIOR SECTION OF THE ELBOW-JOINT THROUGH THE GREATER SIGMOID CAVITY OF THE ULNA AND CORRESPONDING TROCHLEAR SURFACE OF THE HUMERUS.  $\frac{1}{3}$

1, cut surface of the humerus; 2, that of the ulna; 3, posterior part, and 4, anterior part of the synovial cavity of the joint; 5, orbicular ligament enclosing the head of the radius; 6, tendon of the biceps muscle at its insertion into the tuberosity; 7, is at the lower end of the round ligament.

The *synovial membrane* extends upwards on the humerus so far as to line the fossæ for the coronoid and olecranon processes, and is loose and vascular in the latter positions. It is prolonged round the head and neck of the radius, which it separates from the smaller sigmoid cavity and annular ligament.

**MOVEMENTS.**—Flexion and extension are the only movements which can take place between the humerus and ulna, and these are limited by the locking of the coronoid and olecranon processes in the respective fossæ of the humerus which receive them. The path of motion is in a nearly vertical plane, with a direction slightly outwards. The inner lip of the trochlea being prominent below, forms an expansion which corresponds to an inward projection of the coronoid part of the ulnar surface, and is only brought into use in flexion; and the outer lip of the trochlea being everted at the upper and back part, forms a surface which is only in use in complete extension, and which then corresponds to a surface on the outer aspect of the olecranon, which comes in contact with no other part of the humerus. In flexion and extension the radius moves by its cup-shaped head upon the capitulum, and on the groove between that process and the trochlea, by a ridge internal to the cup. It is most completely in contact with the humerus in the position of semi-flexion and semi-pronation. In full extension and supination, the anterior margin of the head of the radius is barely in contact with the inferior surface of the capitulum. In full flexion, the margin of the head of the radius rests against the pit above the capitulum.



## THE WRIST-JOINT AND ARTICULATIONS OF THE HAND.

THE RADIO-CARPAL ARTICULATION, or wrist-joint, is formed between the radius and triangular fibro-cartilage above, and the scaphoid, semi-lunar and cuneiform bones below. The superior surface, concave both transversely and from before backwards, is subdivided by linear elevations into three parts corresponding to the three bones below, the innermost part being formed by the fibro-cartilage. The inferior surface, convex in both directions, is prolonged further down upon the carpal bones behind than in front.

The *internal lateral ligament* is a rounded cord passing directly downwards from the extremity of the styloid process of the ulna, to be attached to the cuneiform bone; it also sends some fibres to the anterior annular ligament and the pisiform bone.

The *external lateral ligament* extends from the styloid process of the radius to a rough surface on the outer side of the scaphoid bone, some of its fibres being prolonged to the trapezium, and also to the anterior annular ligament of the wrist.

The *anterior ligament* (radio-carpal), broad and membranous, consists partly of fibres which have a nearly transverse direction, partly of others, which diverge as they descend from the anterior border of the radius to the scaphoid, semi-lunar, and cuneiform bones: some of them are continued to the os magnum.

The *posterior ligament* extends obliquely downwards and inwards, from the extremity of the radius, to the posterior surface of the first row of the carpal bones, especially the cuneiform bone; its fibres are prolonged some distance on the surface of the carpal bones.

The *synovial membrane* is reflected from the radius and the triangular fibro-cartilage, on the surrounding ligaments, and after lining these, passes to the opposed surface of the carpal bones.

THE CARPAL ARTICULATIONS.—The bones of the carpus, the pisiform excepted, are so arranged in two rows, that while only slight movement can take place between the members of each row, a considerable amount of movement is possible between the two rows. The surface presented by the first row to the second is concave both transversely and from before backwards in the greater part of its extent, but at its outer side it is bounded by the convex part of the scaphoid bone. The opposing surface of the second row is concavo-convex from without inwards, the concavity being formed by the trapezium and trapezoid, the convexity by the os magnum and unciform bone.

The *two rows of carpal bones* are united by dorsal, palmar, and lateral ligaments. The *lateral ligaments* are placed one at the radial, the other at the ulnar border of the carpus; the former connects the scaphoid bone with the trapezium, the latter the cuneiform with the unciform. The *dorsal ligaments* consist of fibres passing in various directions; the *palmar ligaments* are chiefly composed of fibres converging towards the os magnum.

The *bones of the first row*, the pisiform bone excepted, are united by inter-osseous, and by dorsal and palmar ligaments. The *inter-osseous ligaments*, placed on the sides of the semi-lunar bone on a level with its superior surface, connect it with the scaphoid and cuneiform bones, thus completing the inferior wall of the radio-carpal joint. The *dorsal and palmar ligaments*, each two in number, extend transversely on the dorsal and palmar surfaces from the scaphoid bone to the semi-lunar, and from the semi-lunar to the cuneiform.



The bones of the second row are connected by similar means. The dorsal and palmar ligaments, each three in number, pass transversely between the contiguous bones. The inter-osseous ligaments are generally three (but

Fig. 132.

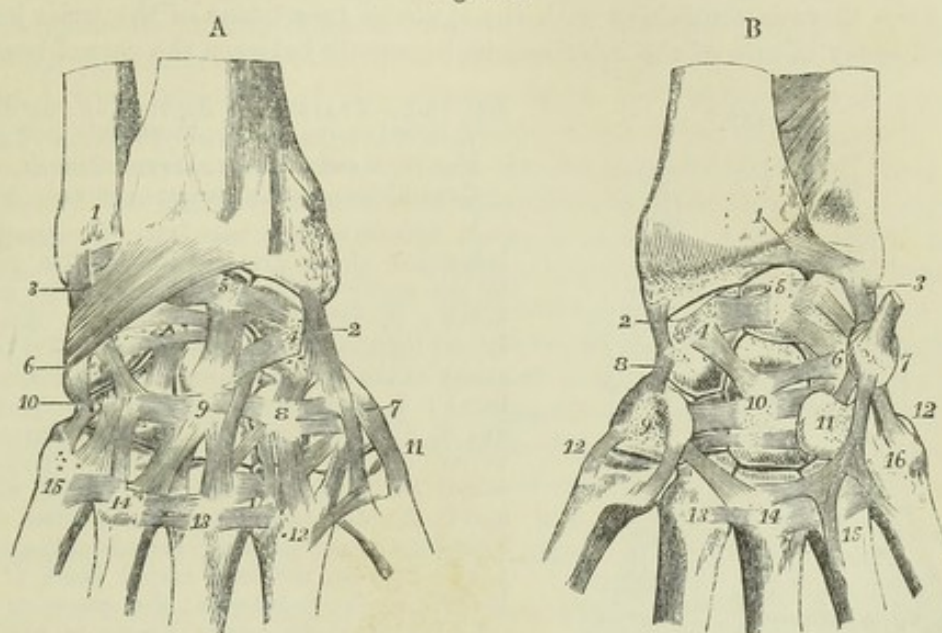


Fig. 132, A.—DORSAL VIEW OF THE DEEPER LIGAMENTS OF THE WRIST-JOINT, AND OF THE CARPAL AND CARPO-METACARPAL ARTICULATIONS (after Arnold).  $\frac{1}{2}$

1, lower part of the ulna; 2, external lateral ligament of the wrist-joint; 3, internal; near it, descending obliquely to 6, from the radius, the dorsal radio-carpal ligament; 4 to 5, transverse dorsal ligaments of the first row: 4, is on the scaphoid; 5, on the semi-lunar bone; 6, cuneiform bone, with the attachment of the dorsal radio-carpal ligament; 7, trapezium; 8, trapezoid; 9, os magnum; 10, unciform; 11 to 15, first to fifth metacarpal bones; 7 to 8, 8 to 9, and 9 to 10, transverse dorsal ligaments of the second row of carpal bones; 4 to 8, 4 to 9, 5 to 9, and others, dorsal ligaments between the first and second row; 8 to 12, 9 to 13, and others, dorsal ligaments from the second row to the metacarpal bones; between the metacarpal bones, from 11 to 15, the dorsal inter-metacarpal ligaments.

Fig. 132, B.—PALMAR VIEW OF THE LIGAMENTS OF THE WRIST-JOINT, AND OF THE CARPAL AND CARPO-METACARPAL ARTICULATIONS.  $\frac{1}{2}$

The anterior radio-carpal ligament has been removed: 1, anterior ligament of the lower radio-ulnar articulation; 2, external, and 3, internal lateral ligament of the wrist-joint; 4, scaphoid bone; 5, semilunar; 6, cuneiform; 7, pisiform, with the tendon of flexor carpi ulnaris attached; 4 to 5, and 5 to 6, palmar transverse ligaments of the first row; 8, external lateral ligament between the first and second row of carpal bones; 9, trapezium (the trapezoid is not numbered); 10, os magnum; 11, hooked process of the unciform bone; 9 to 10, 10 to 11, and others, transverse palmar ligaments of the second row; 4 to 10, and 6 to 10, some of the palmar ligaments uniting the two rows, converging on the os magnum; 7 to 11, ligament from the pisiform bone to the unciform process; 7 to 16, ligament from the pisiform to the fifth metacarpal bone; 12, external ligament of the first carpo-metacarpal articulation, the internal of which is also shown; 13, 14, 15, 16, the proximal ends of the second to the fifth metacarpal bones, on which the palmar transverse, and on three of them, a set of piso-metacarpal ligaments are shown.

sometimes only two) in number, a strong ligament being placed between the os magnum and unciform bones, another between the trapezoid and trapezium, and a slender ligament between the os magnum and trapezoid. A small inter-osseous ligament is also sometimes found between the os magnum and the scaphoid. (Fig. 133.)



The *synovial cavity* of the carpal articulations is extensive and complicated. Passing between the two rows of carpal bones, it sends likewise two processes between the three bones of the first row, and three between the four bones of the second. It is further continued downwards into the four lower carpo-metacarpal and three intermetacarpal articulations of the ulnar side. In some rare cases there is continuity with the synovial membrane of the wrist-joint, by deficiency of one of the interosseous ligaments between the carpal bones.

Fig. 133.

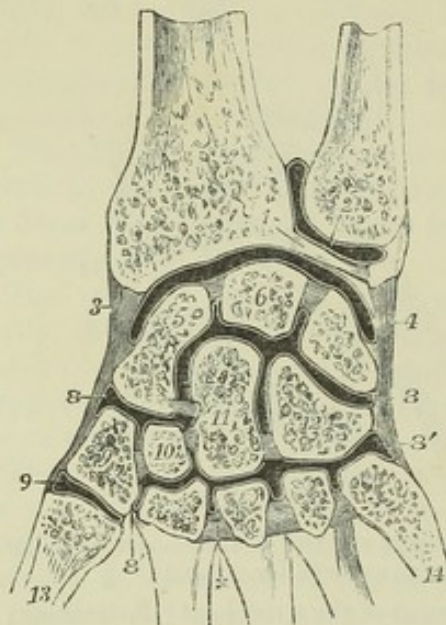


Fig. 133.—TRANSVERSE SECTION OF THE SYNOVIAL CAVITIES OF THE INFERIOR RADIO-ULNAR, RADIO-CARPAL, INTER-CARPAL, AND CARPO-METACARPAL ARTICULATIONS.  $\frac{1}{2}$

1, points to the triangular fibro-cartilage below the ulna; 2, placed on the ulna, points to the cavity of the sacciform synovial membrane; 3, external lateral, and 4, internal lateral ligament, and between them the synovial cavity of the wrist; 5, scaphoid bone; 6, semi-lunar; 7, cuneiform; 8, 8, upper portion, and 8', 8', lower portion of the general synovial cavity of the intercarpal and carpo-metacarpal articulations; between 5 and 6, and 6 and 7, the interosseous ligaments are seen separating the carpal articular cavity from the wrist-joint; between the four carpal bones of the lower row, and between the magnum and scaphoid the interosseous ligaments are also shown; the upper division of the synovial cavity communicates with the lower between 10 and 11, and between 11 and 12; x, marks one of the three interosseous metacarpal ligaments; 9', separate synovial cavity of the first carpo-

metacarpal articulation; 13, first, and 14, fifth, metacarpal bone.

NOTE. It is to be observed that in this figure, and in others of a like kind which represent the joint cavities, the white or black lines indicating the synovial membranes are, for the sake of clearness, generally represented as passing over the surfaces of the articular cartilages, although this is not the case in nature. These lines therefore must be held to represent merely the whole continuity of the articular, or, as they are often called, the synovial surfaces.

The *pisiform bone* is articulated by a fibrous capsule and synovial membrane with the cuneiform bone. Inferiorly it is united by two strong ligaments with the unciform and fifth metacarpal bones, and is sometimes also connected with other metacarpal bones; superiorly it receives the tendon of the flexor carpi ulnaris muscle. The synovial membrane is usually distinct, but sometimes communicates with that of the radio-carpal articulation.

The *anterior annular ligament* of the wrist is a strong and thick band, which extends from the prominences made by the trapezium and scaphoid bone on the radial side of the carpus, directly across to the pisiform bone and unciform process, and converts the transverse arch of the carpus into a ring through which the flexor tendons of the digits pass into the hand.

The *posterior annular ligament*, placed at the back of the wrist, is only a thickened part of the aponeurosis of the forearm. It extends from the lower part of the radius, at its outer border, to the inner part of the cuneiform and pisiform bones, and serves to bind down the extensor tendons.

#### CONNECTION OF THE METACARPAL BONES WITH THE CARPUS, AND WITH EACH OTHER.

The four inner metacarpal bones are bound together at their distal extremities by thin fibres passing between them, and constituting on their palmar



aspect, the *transverse ligament*. At their proximal extremities they are united to one another and to the carpal bones in articulations, the common synovial lining of which is derived from that of the carpal joint. In these articulations the four metacarpal bones are bound together by three *dorsal*, and three *palmar*, and by strong *interosseous* ligaments. There are also *dorsal* ligaments uniting these metacarpal bones with the carpus, each having two such ligaments except the fifth. Thus to the second, or that of the forefinger, a thin fasciculus of fibres passes from the trapezium, and another from the trapezoid bone; the third receives one from the trapezoid, and from the os magnum; the fourth from the os magnum and also from the unciform; but the fifth is connected with the unciform only. The *palmar* ligaments are not so well defined; there is a single band to each bone, except that of the little finger. There is likewise an interosseous band in one part of the carpo-metacarpal articulation, connecting the lower and contiguous angles of the os magnum and unciform to the adjacent angle of the third metacarpal bone. This ligament is usually surrounded by a part of the general synovial membrane, but sometimes it separates the cavity between the unciform and two inner metacarpal bones from the rest of the joint.

The *first metacarpal bone* is unconnected with the others, and is articulated with the trapezium by an external and internal ligament, a capsular investment, and a distinct synovial membrane.

ARTICULATIONS OF THE METACARPAL BONES WITH THE PHALANGES, AND OF THE PHALANGES WITH EACH OTHER.

The rounded head of each of the last four metacarpal bones, being received into the slight concavity in the extremity of the first phalanx, is maintained in its position by two lateral ligaments, an anterior ligament, and a synovial membrane.

The *lateral ligaments* consist of dense and thick fasciculi of fibres, placed one at each side of the joint; they are attached each by one extremity to the side of the

Fig. 134.

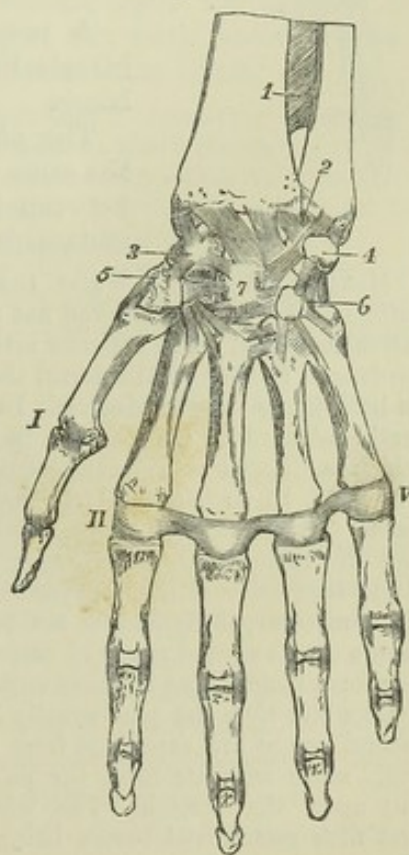


Fig. 134.—GENERAL VIEW OF THE ARTICULATIONS OF THE WRIST AND HAND FROM BEFORE.  $\frac{1}{2}$

1, lower part of the interosseous membrane; 2, and from that point across the lower end of the radius, the palmar radio-carpal ligaments; 3, scaphoid bone; 4, pisiform; 5, trapezium; 6, unciform; 7, os magnum, with most of the deeper ligaments uniting these bones; I, first metacarpo-phalangeal articulation with its external lateral ligament; II to V, transverse metacarpal ligament: in the several phalangeal articulations the lateral ligaments are shown; in the first the external only is visible.

metacarpal bone, and by the other to the anterior ligament and the contiguous extremity of the phalanx. The direction of the fibres is downwards and forwards.

The *anterior* or *palmar ligament* or rather *fibrous plate*, occupies the interval between the lateral ligaments on the palmar aspect of each joint; it



is a thick and dense fibro-cartilaginous structure, which is firmly united to the first phalangeal bone, and but loosely adherent to the metacarpal. It is

Fig. 135.

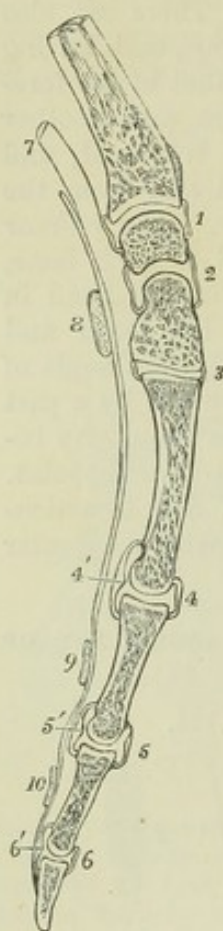


Fig. 135.—LONGITUDINAL ANTERO-POSTERIOR SECTION THROUGH THE LOWER PART OF THE RADIUS, THE CARPUS, SEMILUNAR BONE, OS MAGNUM, METACARPAL BONE, AND PHALANGES OF THE MIDDLE FINGER, TO SHOW THE SHAPE OF THE ARTICULAR SURFACES AND SYNOVIAL CAVITIES BETWEEN THESE SEVERAL BONES.  $\frac{1}{3}$

1, synovial cavity of the wrist-joint; 2, intercarpal cavity; 3, carpo-metacarpal cavity; 4, metacarpo-phalangeal cavity; 5 and 6, phalangeal cavities; 4', 5', and 6', the palmar fibro-cartilaginous plates which are attached to the base of the several phalanges; 7, indicates the place of the tendons of the long flexor muscles; 8, a transverse section of the anterior annular ligament; 9 and 10, transverse retinacula or vaginal ligaments of the flexor tendons on the first and second phalanges.

A *synovial membrane* is present in each joint, and invests the surface of the ligaments which connect the bones.

The *phalanges* are articulated with one another, on the same plan as that which obtains in the articulations between the bases of the proximal phalanges with the metacarpal bones.

**MOVEMENTS OF THE WRIST AND FINGERS.**—In the radio-carpal and common carpal articulations, there is allowed not only flexion and extension, but a certain amount of lateral bending. The superior articular surfaces of both ranges of carpal bones being prolonged further on the dorsal than on the palmar aspect, over-extension is allowed in both joints to some degree. In over-extension the opposing surfaces are most perfectly adapted to each other; in flexion, they are least so. The kind of movement which is allowed between the carpal and metacarpal bones is best illustrated by placing the hand in such a position that the weight of the body is rested upon the open palm. The metacarpal range, which naturally is concave towards the palm, is flattened; and the metacarpal, interosseous, and palmar ligaments are thus tightened, while a slight separation of the opposed surfaces of the bones takes place; so also the palmar carpo-metacarpal ligaments are tightened, and both palmar and interosseous ligaments of the second range of carpal bones. The convex part of the os magnum and unciform bone, fitted in those circumstances into the concavity of the first range, is a little wider than the part usually in contact with it; and thus, while the bones of the second range are separated from the distal side, those of the first range are pressed still more separate from the palmar aspect, and their interosseous ligaments are put upon the stretch. The whole arrangement secures elasticity. The fourth and fifth metacarpal bones, being more moveable at their carpal articulation than the second and third, bend forward very distinctly in shutting the hand, thus rendering the palm more hollow, and bringing the tips of the fingers more closely together: the movement is one of coaptation. At the phalangeal articulations the only movement allowed is that of flexion and extension, and over-extension is pre-



vented by the ligamentous structures in front of the joints. At the metacarpophalangeal articulations there is allowed, in addition, a movement of abduction and adduction, but that chiefly in the extended position. In the articulation of the metacarpal bone of the thumb with the trapezium every movement is allowed except rotation, which is prevented by the shape of the articular surfaces.

#### ARTICULATIONS OF THE PELVIS.

**ARTICULATION OF THE PELVIS WITH THE LAST LUMBAR VERTEBRA.**—The fifth lumbar is united to the first sacral vertebra by anterior and posterior ligaments of the body, ligamenta subflava of the arch and interspinous ligaments, and by an intervertebral plate, all of which are similar to those between the vertebræ above. It is also attached to the pelvis by two other ligaments, as follows :—

The *sacro-vertebral ligament* extends obliquely from the tip of the transverse process of the last lumbar vertebra downwards to the depressed lateral part of the base of the sacrum ; its form is triangular, and its fibres diverge as they descend, some of them joining the anterior sacro-iliac ligament.

The *ilio-lumbar ligament* is extended horizontally between the summit of the transverse process of the last lumbar vertebra and the iliac crest of the innominate bone ; it is inserted into the latter at the back part of the iliac fossa, where its fibres expand somewhat, so as to give it a triangular form.

**ARTICULATION OF THE SACRUM AND COCCYX, AND OF THE PIECES OF THE COCCYX.**—These articulations are effected by an *anterior ligament*, consisting of irregular fibres placed in front of the bones, a prolongation of the anterior common ligament of the vertebræ ; by a *posterior ligament* more strongly marked, composed of fibres which descend upon the bones of the coccyx from the margin of the inferior orifice of the sacral canal ; and by *intervertebral discs* between the contiguous surfaces of the bones.

A synovial membrane has been stated by Cruveilhier ("Anatomie descriptive," tom. i. p. 356. Paris, 1834), to be present in those cases in which the coccyx is freely moveable. This is in conformity with the more recent observations of Luschka on the other intervertebral discs. In the male, after middle life, the union between the sacrum and coccyx, and that between the pieces of the latter, is usually ossific. In the female this change does not generally occur till a more advanced age ; the pieces of the coccyx uniting one to another in the first place, and the joint between the sacrum and coccyx not ossifying till old age. The mobility seems to increase during pregnancy.

**THE SACRO-ILIAC ARTICULATION**, often named the *sacro-iliac symphysis*, or *synchondrosis*, is formed between the adjacent portions of the sacrum and ilium, the auricular surfaces of which are coated with cartilage, and the remaining parts are united by strong ligaments (see fig. 139).

The auricular cartilaginous plate unites the bones with great firmness. When the ilium and sacrum are forcibly torn asunder, this plate usually separates into two layers, one of which adheres to the surface of each bone. In some instances a small cavity naturally exists between these two plates of cartilage. Even when separated in part, however, these plates are very closely applied, and admit only a limited amount of movement. They are then sometimes slightly united by delicate tissue, and in advanced life, small spaces containing glairy fluid are liable to be formed between them. The cavity of this articulation becomes more apparent, and the ligaments somewhat looser before parturition.

The *posterior sacro-iliac ligament*, much the thicker, consists of a large number of strong irregular fibres extending across the interval between the posterior rough portion of the lateral surface of the sacrum and that part of



the ilium which projects beyond the dorsum of the sacrum. A superficial band extending downwards from the posterior superior iliac spine to the third or fourth piece of the sacrum, in a direction different from the other fibres, is distinguished as the *oblique sacro-iliac ligament*.

The *anterior sacro-iliac ligament* consists of thin irregular fibres passing between the sacrum and os innominatum on their pelvic surfaces.

Fig. 136.

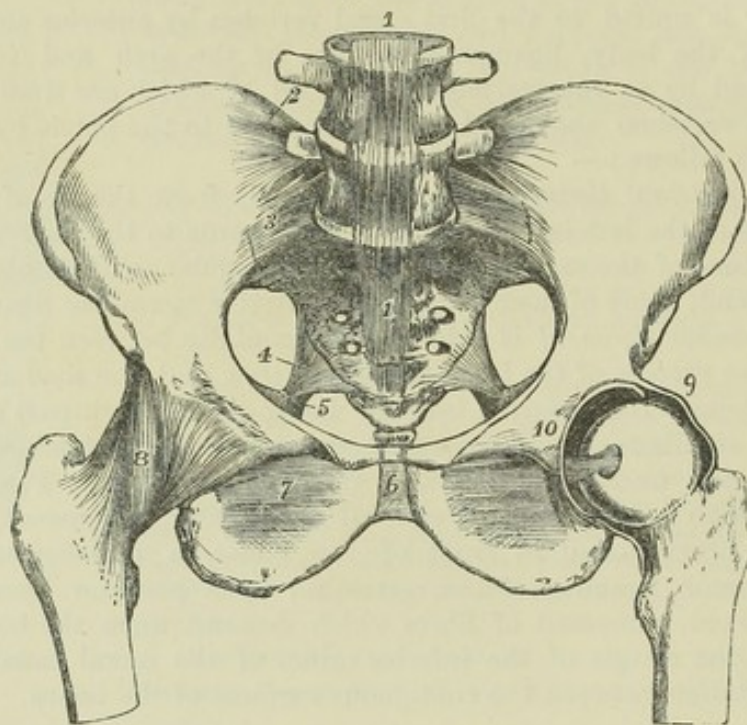


Fig. 136.—ARTICULATIONS OF THE PELVIS AND HIP-JOINT, SEEN FROM BEFORE. THE ANTERIOR HALF OF THE CAPSULAR LIGAMENT OF THE LEFT HIP-JOINT HAS BEEN REMOVED, AND THE FEMUR ROTATED OUTWARDS.  $\frac{1}{4}$

1, 1, anterior common ligament of the bodies of the vertebræ passing down over the two lowest lumbar vertebræ to the front of the sacrum and coccyx ; 2, ilio-lumbar ligament ; 3, anterior sacro-iliac ligament ; between 2 and 3, on the right side, the sacro-vertebral ligament is shown, but not with sufficient distinctness ; 4, placed in the great sacro-sciatic foramen, points to the lesser sacro-sciatic ligament ; 5, a portion of the great sacro-sciatic ligament ; 6, the anterior ligament of the symphysis pubis ; 7, the obturator membrane or ligament ; 8, the capsular ligament of the right hip-joint : the figure is placed on its ilio-femoral band ; 9, the upper part of the divided capsular ligament of the left hip-joint near the place of its attachment to the border of the acetabulum ; 10, placed on the os pubis of the left side above the transverse ligament of the acetabular notch. The head of the femur is withdrawn partially from the socket, so as to show the round ligament stretched from the transverse ligament.

**THE SACRO-SCIATIC LIGAMENTS.**—The *posterior*, or *great sacro-sciatic ligament*, elongated, broad, and triangular, is placed at the inferior and posterior part of the pelvis, whose lower aperture it assists in closing. Its base or broader part is attached to the postero-inferior iliac spine and to the side of the sacrum and coccyx ; whilst its other extremity is fixed along the inner surface of the ischial tuberosity, where it expands somewhat, and sends upwards and forwards along the margin of the ischial ramus a falciform process, the border of which is continuous with the obturator fascia, forming the inferior attachment of that structure.

The *anterior*, or *small sacro-sciatic ligament*, much shorter and thinner than the preceding one, in front of which it lies, is attached by its base to the side of the sacrum and coccyx, where its fibres are blended with



those of the great ligament ; and, by its apex, to the spine of the ischium. Its form is triangular, and the direction of its fibres is forwards and outwards.

Fig. 137.

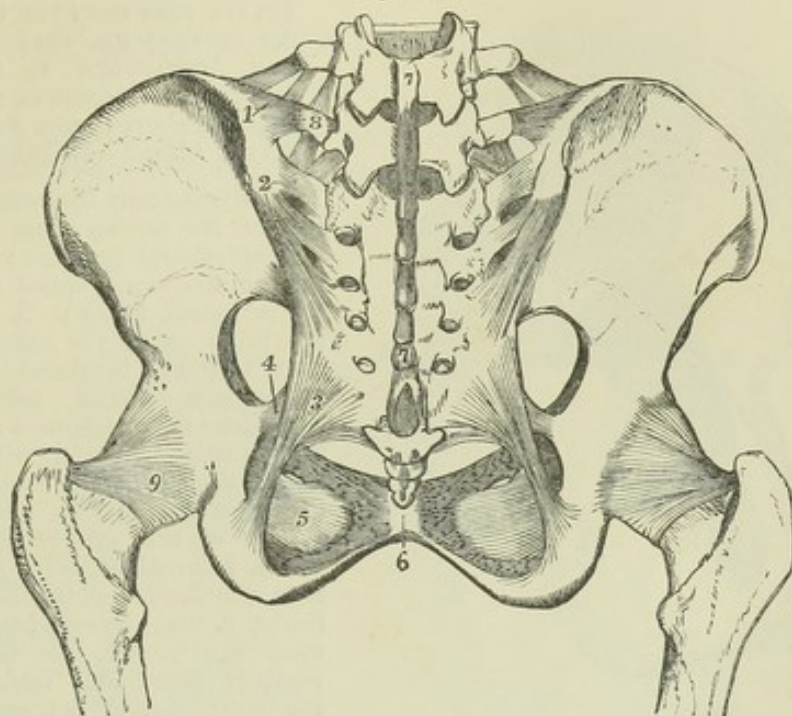


Fig. 137.—LIGAMENTS OF THE PELVIS AND HIP-JOINT, AS SEEN FROM BEHIND IN THE ERECT ATTITUDE OF THE BODY, FROM A FEMALE SUBJECT.  $\frac{1}{4}$

1, ilio-lumbar ligament : above it the last lumbar intertransverse ligament ; 2, posterior sacro-iliac ligaments, the short and the oblique ; 3, great sacro-sciatic ligament ; 4, attachment of the lesser sacro-sciatic ligament to the spinous process ; 5, obturator foramen or ligament ; 6, posterior ligament of symphysis pubis ; 7, 7, continuation of supraspinous ligaments from the lower lumbar vertebrae over the sacral spines ; 8, transverse process of last lumbar vertebra, to which from above is seen descending the last intertransverse ligament, and from below ascending the sacro-vertebral ligament ; 9, posterior surface of the capsular ligament of the hip-joint. The posterior ligaments passing between the sacrum and coccyx are also partially shown.

*Foramina.* Between the upper border of the great sacro-sciatic ligament and the innominate bone is a large space subdivided by the small sacro-sciatic ligament. The part which lies above this ligament is a large oval opening, named the *great sacro-sciatic foramen*. It transmits the pyramidal muscle, the great sciatic nerve, and the gluteal and ischiatic vessels and nerves. The part between the greater and lesser sacro-sciatic ligaments, much smaller in size, and bounded in front by the smooth surface between the spine and tuberosity of the ischium, is the *small sacro-sciatic foramen*, through which pass the obturator internus muscle and the internal pudic vessels and nerve.

The PUBIC ARTICULATION, or *symphysis pubis*, is the connection of the pubic bones in front, and is effected by fibro-cartilaginous plates and ligaments. The adjacent surfaces of bone are each coated with cartilage, and to this is attached the fibro-cartilage which unites them. The *fibro-cartilage* is thicker and stronger in front than behind, and generally contains a synovial cavity towards the back part of the joint. The ligaments are named *anterior*, *posterior*, *superior*, and *inferior*. The anterior pubic ligament consists of irregular fibres passing obliquely across from bone to bone in front of the symphysis. The superior and posterior ligaments consist of only a few fibres



on the upper and back part of the articulation. The inferior or sub-pubic ligament, thick and triangular, is attached to the rami of the pubic bones, gives

Fig. 138.

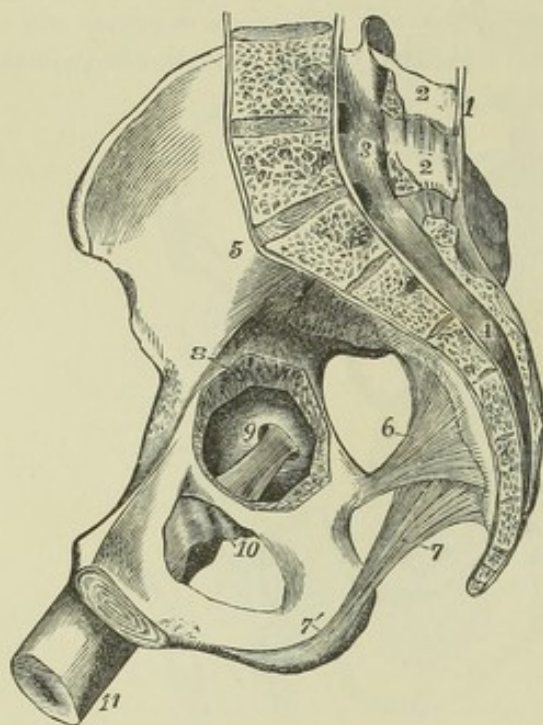


Fig. 138.—RIGHT HALF OF A FEMALE PELVIS, SEEN FROM THE INNER SIDE. AN OPENING HAS BEEN MADE INTO THE ACETABULUM TO SHOW THE TIGHTENED CONDITION OF THE ROUND LIGAMENT WITH THE FEMUR PARTIALLY FLEXED AND ADDUCTED.  $\frac{2}{3}$

1, supraspinous ligaments descending to the sacrum from 2, 2, the lumbar spinous processes; 3, 4, the lumbar and sacral spinal canal, with its periosteal lining; 5, placed on the ilium above the anterior sacro-iliac ligament; 6, placed in the great sacro-sciatic foramen, points to the lesser sacro-sciatic ligament; 7, greater sacro-sciatic ligament, with 7', its continuation over the inner border of the tuberosity of the ischium; 8, a portion of the wall of the cotyloid cavity, removed so as to give a view from the inside of the head of the femur, 9, with the round ligament put upon the stretch, the femur being partially flexed and adducted; 10, the inner part of the capsular ligament relaxed; 11, the shaft of the femur.

smoothness and roundness to the upper part of the sub-pubic arch, and forms part of the outlet of the pelvis.

The *obturator membrane* or *ligament* is a fibrous septum attached to the border of the thyroid foramen, which it closes in its entire extent, except at the upper and outer part of its circumference, where a small oval canal is left for the obturator vessels and nerve. The membrane is fixed accurately to the bony margin at the upper and outer sides of the foramen, and to the posterior surface at the inner side. The obturator muscles are attached to its surfaces.

**MOVEMENTS.**—In ordinary circumstances there is very little movement allowed between the bones of the pelvis. In the erect posture the sacrum is thrown so much backwards that none of the advantage of the key-stone of an arch is obtained by the tapering of its form from base to apex. It is only by the sinuosities of its auricular surfaces that it directly presses on the hip-bones; and as the width of the bone rather diminishes at the upper or ligamentous part, the principal strain is borne by the posterior sacro-iliac ligaments, from which the sacrum is in great measure suspended (see fig. 139) as is well illustrated by the giving way and bending inwards and downwards of their iliac points of attachment in rickety deformities of the pelvis. Thus the structure of the sacro-iliac articulation gives elasticity. The small amount of movement which is allowed between the bones of the pelvis in the ordinary state is increased during parturition in this way, that the lower part of the sacrum being pressed backwards, the wider part of the edge formed by this bone is forced farther between the ossa innominata, so as to separate them to a greater degree, and thus to increase the capacity of the pelvis. In some subjects it would appear that in pregnant women a slight amount of separation may occasionally occur at the symphysis from the extreme looseness of the connecting parts; but in general it is more probable that the only motion at the symphysis is the hinge-like movement of the ossa innominata just described, and that the cavity of the pelvis owes the principal increase of its dimensions in parturition to the same cause. (See



Wood, article "Pelvis" in "Cyclopæd. of Anat. and Physiol.;" Zaglas, in "Monthly Journ. of Med. Science," 1851; J. M. Duncan, in "Dublin Quart. Journ. of Med. Science," 1854, and "Edin. Med. Journ.," 1855.)

## ARTICULATIONS OF THE LOWER LIMB.

## THE HIP-JOINT.

This is a large ball-and-socket joint, in which the globular head of the femur is received into the acetabulum or cotyloid cavity of the innominate

Fig. 139.

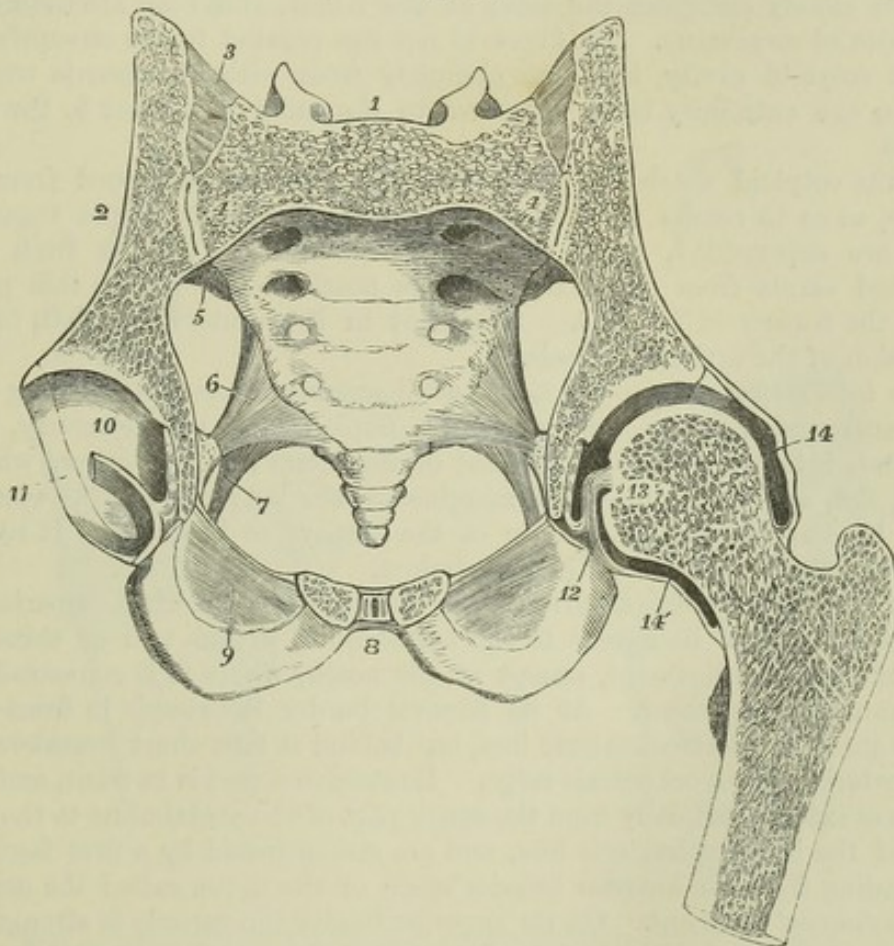


Fig. 139.—TRANSVERSE OBLIQUE SECTION OF THE PELVIS AND HIP-JOINT, CUTTING THE FIRST SACRAL VERTEBRA AND THE SYMPHYSIS PUBIS IN THEIR MIDDLE, FROM A MALE SUBJECT OF ABOUT NINETEEN YEARS OF AGE.  $\frac{1}{3}$

1, placed above the middle of the cut surface of the first sacral vertebra, and between the divided superior articular processes; 2, the divided ilium; 3, the posterior sacro-iliac ligaments also divided; 4, 4, the sacro-iliac synchondrosis, with a slight separation between the two plates of cartilage; 5, the anterior sacro-iliac ligament; 6, the anterior or short sacro-sciatic ligament; 7, a portion of the posterior or long sacro-sciatic ligament; 8, placed in front of the symphysis pubis, in the cut surface of which the small median cavity, the adjacent fibro-cartilaginous plates and the anterior and posterior ligamentous fibres are shown; 9, the lower part of the obturator membrane; 10, placed on the cartilaginous surface of the cotyloid cavity of the right side, through the middle of which the incision passes transversely and divides the round ligament and the synovial fat of the depression; 11, the cotyloid ligament or fibrous border; 12, the round ligament of the left side, where it is connected with the transverse part of the cotyloid ligament; 13, placed on the cut surface of the head of the left femur near the depression where the round ligament is attached; 14, 14', the upper and lower parts of the capsular ligament and synovial capsule.



bone. The articulating surface of the acetabulum is formed by a broad ribband-shaped cartilage occupying the upper and outer part, and folded round a depression which, extending from the notch, is hollowed out in the bottom of the cavity, and is occupied by delicate adipose tissue covered with synovial membrane, the so-called synovial or Haversian gland. The articulating surface of the femur presents a little beneath its centre a pit in which the round ligament is attached.

The *cotyloid ligament* forms a thick ring round the margin of the acetabulum, increasing the depth of its cavity, and bridging over the deficiency in its border. Its external surface is in contact with the capsular ligament, the internal closely embraces the head of the femur, and both are covered by the synovial membrane. Its fibres do not run parallel to the circumference of the cotyloid cavity, but pass obliquely from without inwards over its margin, one extremity being attached to the outer, the other to the inner surface.

At the cotyloid notch the fibres of the ligament are continued from side to side, so as to render the circumference complete, and deeper transverse fibres are superadded, from which circumstance, as well as from being stretched across from one margin of the notch to the other, this part is called the *transverse ligament*. Subjacent to it an interval is left for the admission of the articular vessels.

The *interarticular* or *round ligament* (*ligamentum teres*) is a strong fasciculus surrounded by synovial membrane, implanted by one extremity, which is round, into the fossa in the head of the femur; by the other, which is broad, flat, and bifid, into the margins of the cotyloid notch, where its fibres become blended with those of the transverse ligament. It rests on the fat in the depression of the acetabulum.

The *capsular ligament*, surrounding the joint, is attached superiorly in the greater part of its extent to the acetabulum, within two or three lines from the cotyloid ligament, except at the notch, where it is connected with the transverse ligament. At its femoral border it extends in front as far as the anterior intertrochanteric line, but behind it falls short considerably of the posterior intertrochanteric ridge. Its strongest part is in front, and there its fibres extend vertically from the upper part of the acetabulum to the lower part of the intertrochanteric line, and are strengthened by a firm fasciculus, descending from the anterior inferior spine of the ilium, called the *accessory* or *ilio-femoral ligament*. On its superior border the capsule is strengthened by fibres connected with the insertion of the gluteus minimus muscle. The fibres which arise in front of the notch of the acetabulum pass down in front of the small trochanter; those which arise behind the notch pass towards the trochanteric fossa; and between those two fasciculi, the capsule is extremely weak, and its fibres pass in a circular direction, so that opposite the posterior intertrochanteric ridge no fibres are inserted into the neck of the femur, and the reflection of the synovial membrane from the bone to the capsule can be laid bare behind the neck without cutting any part of the capsule.

The *synovial membrane* lining the joint and ligament is reflected from the neck of the femur to the inner surface of the capsule; passing over the inner surface of the capsule to the margin of the acetabulum, it is reflected from that and from the synovial fat as a tubular investment of the round ligament to the head of the femur.

**MOVEMENTS.**—In the hip-joint movement is allowed in every direction. Extension is limited by the capsular ligament, the anterior fibres of which become tense in that

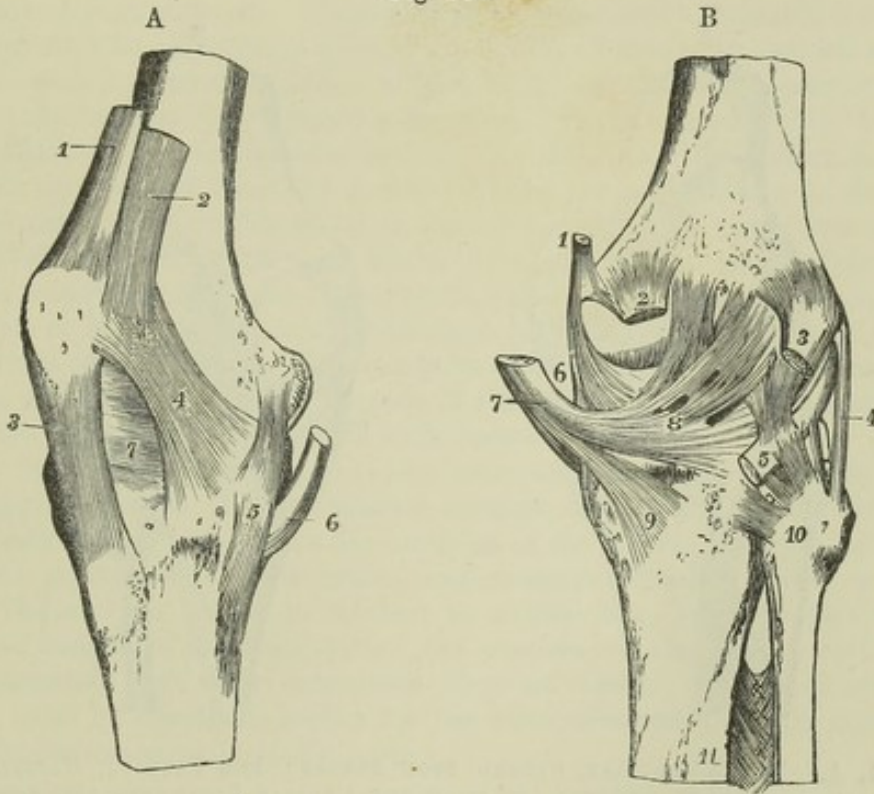


position: flexion is limited only by the contact of the neck of the femur with the acetabulum. The round ligament is put upon the stretch when the thigh is partially flexed and adducted; it therefore resists dislocation upwards and backwards on the dorsum ilii, which is, notwithstanding its presence, the most frequent kind of displacement. The round ligament is also put upon the stretch in the position of flexion and external rotation.

## THE KNEE-JOINT.

The articular surfaces of this complicated joint are the condyles of the femur and tibia, with fibro-cartilages interposed, the articulating surface of the patella, and the patellar surface of the femur. The action is mainly that of a hinge-joint. The joint is strengthened superficially by fibrous coverings

Fig. 140.

Fig. 140, A.—RIGHT KNEE-JOINT, FROM THE INSIDE AND ANTERIORLY.  $\frac{1}{2}$ 

1, tendon of the rectus muscle near its insertion into the patella; 2, insertion of the vastus internus into the rectus tendon and side of the patella; 3, ligamentum patellæ descending to the anterior tuberosity of the tibia; 4, capsular fibres forming a lateral ligament of the patella prolonged in part from the insertion of the vastus internus downwards towards the inner tuberosity of the tibia; 5, internal lateral ligament of the knee-joint seen spreading on the internal semilunar cartilage; 6, tendon of the semimembranosus muscle (after Arnold).

Fig. 140, B.—KNEE-JOINT FROM BEHIND.

1, insertion of the tendon of adductor magnus; 2, origin of the inner head of the gastrocnemius muscle; 3, outer head of the same; 4, cord-like external lateral ligament; 5, tendon of the popliteus muscle: a ligament descending from behind the outer condyle of the femur is seen attached to this tendon below, and another descending from the tendon is attached to the head of the fibula, constituting the short external lateral ligament; 6, part of internal lateral ligament; 7, tendon of the semimembranosus muscle; 8, posterior ligament of Winslow, spreading outwards from the tendon; 9, expansion of the popliteal fascia downwards from the same, represented as cut short; 10, on the head of fibula, marks the posterior superior tibio-fibular ligament; 11, upper part of the interosseous ligament, with the foramen above it for the anterior tibial artery.



derived from the muscular tendons and aponeuroses. The ligaments which have received special names are the following :—

The *internal lateral ligament*, long and flat, connects the internal tuberosity of the femur with the inner tuberosity and the hinder border of the tibia, on the shaft of which it descends for some distance. Superiorly its deep surface rests on the articular synovial membrane; below the head of the tibia the anterior slip of insertion of the semimembranosus muscle passes between the ligament and the bone.

The *external lateral ligament* is a rounded cord, which extends from the external tuberosity of the femur to the head of the fibula. Its internal surface corresponds with the tendon of the popliteus muscle and the inferior external articular vessels. The tendon of the biceps flexor cruris muscle

Fig. 141.

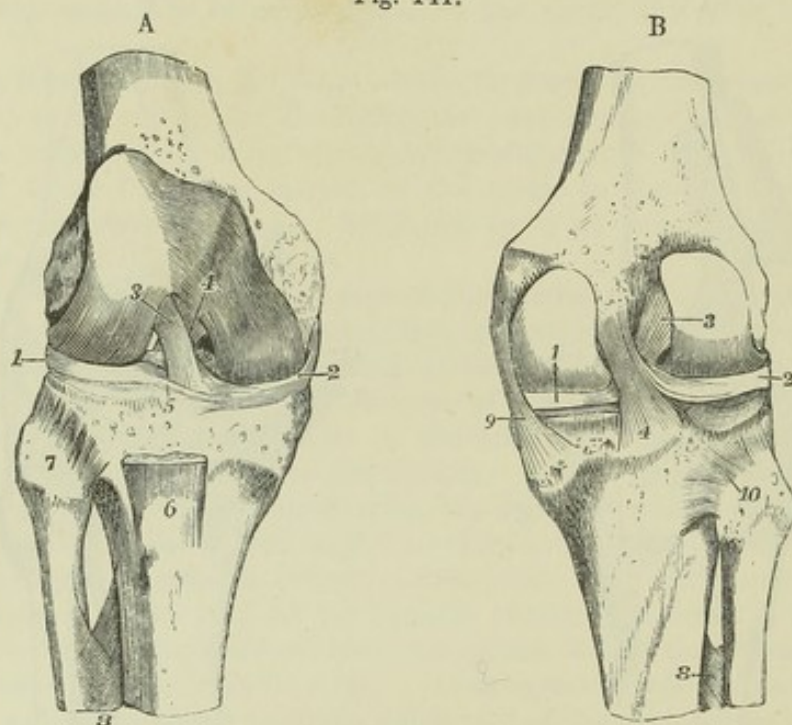


Fig. 141, A.—THE KNEE-JOINT, OPENED FROM BEFORE; THE PATELLA, CAPSULE, AND SYNOVIAL STRUCTURES REMOVED, TO SHOW THE CRUCIAL LIGAMENTS AND SEMILUNAR CARTILAGES.  $\frac{1}{3}$

1, external, and 2, internal semilunar cartilage; 3, on the outer condyloid surface of the femur, points to the anterior external crucial ligament; 4, placed on the elevated line separating the patellar from the inner condyloid surface of the femur, points to the posterior or internal crucial ligament; 5, transverse ligament of the semilunar cartilages; 6, part of the ligamentum patellæ; 7, on the head of the fibula, points to the superior anterior tibio-fibular ligament; 8, upper part of the interosseous membrane, showing the perforation for the anterior tibial artery.

Fig. 141, B.—THE KNEE-JOINT, OPENED FROM BEHIND, AND ITS STRUCTURES REMOVED, SO AS TO EXPOSE THE CRUCIAL LIGAMENTS AND SEMILUNAR CARTILAGES.  $\frac{1}{3}$

1, posterior part of the internal semilunar cartilage; 2, external semilunar cartilage; 3, upper part of the external or anterior crucial ligament; 4, lower part of the internal or posterior crucial ligament: farther up is seen its accessory band joining the external semilunar cartilage; 8, upper part of the interosseous membrane; 9, back part of the internal lateral ligament; 10, placed on the head of the fibula, points to the posterior superior tibio-fibular ligament: between the head of the fibula and the external semilunar cartilage (2) is seen the synovial surface of the tibia, upon which the semilunar cartilage descends in flexion, and where a communication sometimes takes place between the synovial cavities of the knee-joint and the tibio-fibular articulation.



is frequently divided into two by this ligament, and between the ligament and the tendon there is a synovial bursa. Further back is another band, the *short external lateral ligament*, the arrangement of which is more variable, often connected with the tendon of the popliteus muscle, and occasionally terminating in the capsular membrane.

The *posterior ligament* is a flat fasciculus of fibres passing from behind the inner tuberosity of the tibia upwards and outwards to the external condyle of the femur, and is in part continuous at its inner end with the tendon of the semi-membranosus muscle.

The *ligamentum patellæ* is a strong flat band, of a tendinous nature, attached superiorly to the lower extremity of the patella, and the depression beneath its articular surface, and inferiorly to the anterior tubercle of the tibia. Between the tibia and the ligament, near its insertion, is placed a synovial bursa. If the patella be considered a sesamoid bone, this ligament may be regarded as part of the tendon of the rectus femoris muscle.

The *crucial ligaments*, placed in the centre of the joint, pass from the sides of the intercondyloid fossa to the spaces in front of and behind the spine of the tibia. They decussate somewhat like the lines of the letter X. The *anterior or external ligament* is fixed by its lower extremity to the inner part of the pit before the spine of the tibia, and by its upper extremity it is inserted into the inner and hinder part of the external condyle of the femur; hence its direction is upwards, backwards, and outwards. The *posterior or internal ligament* is attached inferiorly to the back of the pit behind the tibial spine, and superiorly to the fore part of the intercondyloid hollow, as well as slightly to the side of the inner condyle of the femur; its fibres are directed upwards and a little forwards.

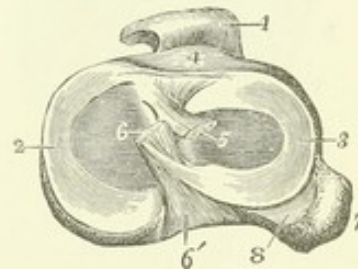
The *semilunar cartilages* are two crescent-shaped inter-articular fibro-cartilages, placed on the articulating surfaces of the head of the tibia, and interposed between these and the condyles of the femur. They have each a synovial surface above and below, and a convex border, which is thick, while the concave border is thinned to a fine edge, and the part of the articular surface of the tibia within the concave border of each cartilage is left uncovered. At their extremities they are fibrous, and are firmly fixed to the head of the tibia, whilst by the circumference they are connected with the fibrous capsule of the joint.

Fig. 142.—VIEW OF THE INTERARTICULAR FIBRO-CARTILAGES OF THE RIGHT KNEE-JOINT, FROM ABOVE, AS THEY LIE ON THE UPPER SURFACE OF THE TIBIA, WITH THE CRUCIAL LIGAMENTS DIVIDED, AND THE LIGAMENTUM PATELLÆ TURNED FORWARDS.  $\frac{1}{2}$

1, ligamentum patellæ; 2, the inner, or semicircular fibro-cartilage; 3, the outer, or nearly circular one; 4, is placed above the anterior tuberosity of the tibia in front of the transverse ligament; 5, the cut end of the anterior crucial ligament directed obliquely towards the outer side and backwards; 6, the cut end of the posterior crucial ligament, from which fibres are seen descending to the outer fibro-cartilage; 6', tibial attachment of the posterior crucial ligament; 7, the head of the fibula; 8, the synovial surface of the tibia, which extends for some way downwards towards the tibio-fibular synovial sac, with which it is sometimes continuous.

The *internal semilunar cartilage*, elongated from before backwards, is nearly of a semicircular form: its anterior cornu is small and pointed, and is inserted into an impression at the fore and outer part of the internal articular surface of the tibia; its posterior end is attached to the inner

Fig. 142.





edge of the hollow behind the spine, and is in relation with the posterior crucial ligament.

The *external semilunar cartilage* forms nearly a complete circle ; its two cornua, fixed, one before, the other between the points of the spine of the tibia, are so close at their insertion that they may be said to be interposed between the attachments of the internal semilunar plate. Its external border is in contact behind with the tendon of the popliteus muscle, and is therefore separated by this from the fibrous capsule. From this fibro-cartilage a ligamentous band ascends, to be attached to the inner condyle of the femur in connection either in front or behind with the posterior crucial ligament (*accessory band of the posterior crucial ligament*).

*Transverse ligament.*—Towards the front of the joint the convex borders of the inter-articular fibro-cartilages are connected by a slight transverse band, which receives this name. Its thickness varies much in different bodies.

*Capsular membrane.*—Under this name is described the fibrous tissue which invests the joint in the intervals between the stronger bands which have been named ligaments. It is incomplete, not extending underneath the tendons of the extensor muscles. Between the sides of the patella and the femur it consists of fibres connected with the insertion of the vasti muscles and with the fascia lata, and thus forms the structures, uniting the patella to the tibia, which have been called *lateral patellar ligaments* ;

posteriorly it covers the condyles of the femur beneath the gastrocnemius muscle. In this last situation it is thin, and a sesamoid bone is often found in connection with it in the outer, less frequently in the inner head of the muscle.

Fig. 143.

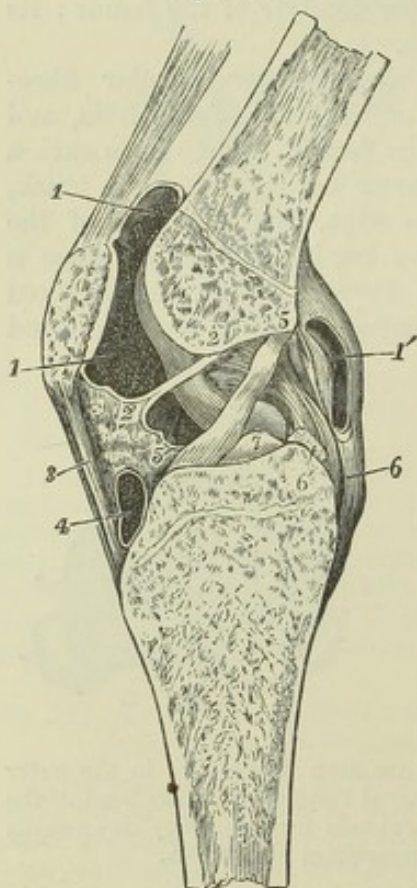


Fig. 143.—VERTICAL ANTERO-POSTERIOR SECTION OF THE LEFT KNEE-JOINT, SEEN FROM THE OUTER OR LEFT SIDE.  $\frac{1}{3}$

The section is made somewhat obliquely a little to the outside of the middle, so as to preserve entire the crucial ligaments with their attachments: it is from a young subject of eighteen or nineteen years. 1, 1, the upper portion of the synovial cavity of the joint, showing in the part above the patella the synovial pouch which extends upwards between the extensor tendons and the femur ; 1', an aperture made into the posterior portion of the synovial cavity ; 2, 2', ligamentum mucosum ; 3, ligamentum patellae ; 2', 3, the subpatellar synovial fatty cushion ; 4, bursa above the insertion of the ligamentum patellae into the anterior tibial tuberosity ; 5, 5', the anterior crucial ligament ; 5', points also to the internal semilunar cartilage within the joint ; 6, lower part of the posterior crucial ligament, the upper part of which is towards 2 ; 6', the accessory band joining the external semilunar cartilage, which is cut short ; 7, the spine of the tibia.

The *synovial membrane* is the largest in the body. Traced downwards from the femur on either side of the joint, it may be followed from the capsule to the upper surface of the semi-lunar cartilages, round the free borders of those structures to their inferior surfaces



and thence to the tibia. The crucial ligaments are invested in front by a reflected portion of the membrane continued forwards from the posterior wall of the joint. Between the tibia and patella the synovial membrane lies upon a large pad or cushion of fat, on the surface of which it forms two lateral folds (*alar ligaments*) which fit into the space between the tibia, patella and femur, while from the middle of the pad it sends backwards a cylindrical process, the *ligamentum mucosum*, through the joint to the front of the intercondyloid fossa. Above the patella the synovial membrane extends upwards some distance, forming a large pouch between the extensor tendons and the femur.

**MOVEMENTS, &c.**—In order to explain the nature of these movements, it is necessary to state some considerations with regard to the relations of the several parts of the knee-joint to each other. The knee-joint may be regarded as consisting of three articulations conjoined, viz., that between the patella and femur, and two others, one between each condyle of the femur and the tibia. In most mammals the synovial membranes of those three joints are either completely distinct or communicate with each other by only small openings. In the human subject the *ligamentum mucosum* is an indication of the original distinctness of the synovial membranes of the inner and outer joint, and the crucial ligaments may be looked upon as the external and internal lateral ligaments of those two joints respectively. Each portion of the articular surface of the femur belongs either to one or other of the three component joints of the knee, and no part is common to any two of them. On a well-marked

Fig. 144.

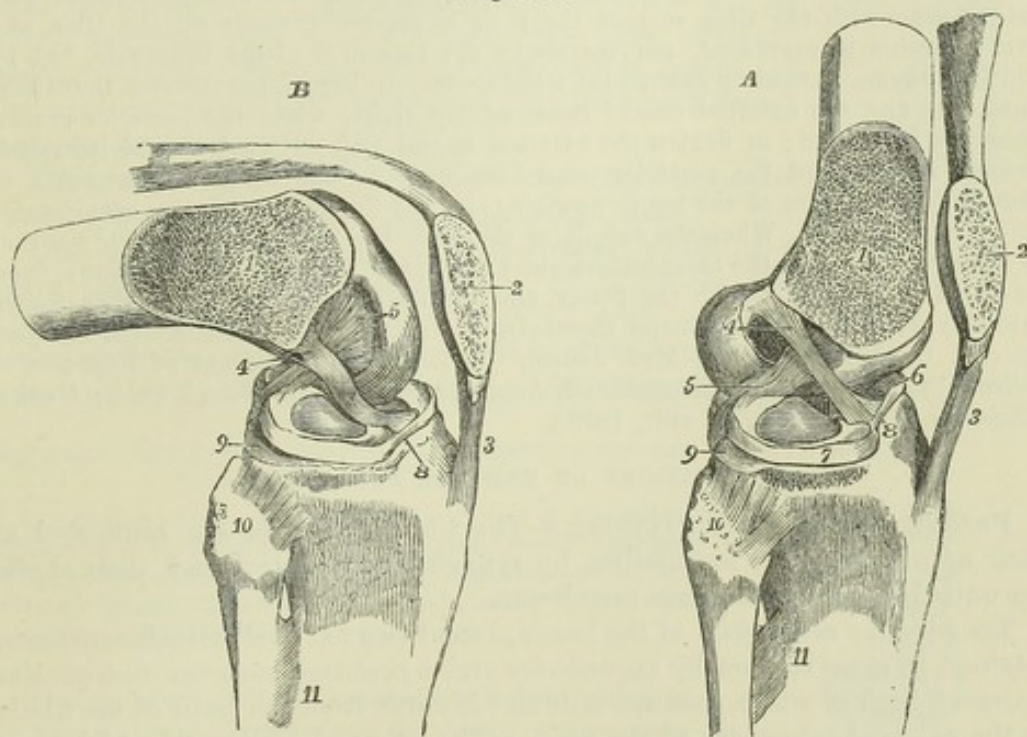


Fig. 144.—THE SUPERFICIAL PARTS OF THE KNEE-JOINT REMOVED, AND THE EXTERNAL CONDYLE OF THE FEMUR SAWN OFF OBLIQUELY, TOGETHER WITH HALF THE PATELLA, SO AS TO EXPOSE BOTH THE CRUCIAL LIGAMENTS TOGETHER.  $\frac{1}{2}$

In A, the parts are in the position of extension, in B, that of flexion, the figures being designed to show the different state of tension of the crucial ligaments in these positions. 1, sawn surface of the femur; 2, sawn surface of the patella; 3, ligamentum patellæ; 4, anterior or external crucial ligament, tense in A, and relaxed in B; 5, posterior or internal crucial ligament, relaxed in A, tense in B; 6, internal, and 7, external semilunar cartilage; 8, transverse ligament; 9, articular surface of the tibia, extending behind the external semilunar cartilage; 10, on the head of the fibula, points to the anterior superior tibio-peroneal ligament; 11, upper part of the interosseous membrane.



femur, the inferior limits of the patellar surface are quite distinguishable; the line which separates this surface from the outer tibial joint passing directly between it and the condyle, and that which separates it from the inner joint being continued backwards, so as to cut off from the rest of the inner condyle a narrow tract at the side of the inter-condyloid fossa.

The movement of the patella on the femur is one partly of gliding, partly of coaptation. This is illustrated by a careful examination of the articular surface of the patella, which is not uniformly curved from above downwards, as it would be, were the movement one of gliding only, but exhibits on each side of the vertical ridge three very slightly depressed surfaces, separated by two slight transverse elevations, and along the inner margin a seventh area, upon which the transverse lines do not encroach (Goodsir). When the knee is extended, and the patella drawn upwards by the extensor muscles, the two inferior facets of the patella are in contact with the upper margin of the femoral surface; in semiflexion the middle facets only are in contact with the femur; in greater flexion, the superior parts of the patella are in contact with the lower part of the femoral surface; and in extreme flexion the patella, which has been gradually turned outwards by the increasing prominence of the inner condyle, rests by its innermost facet on the inter-condyloid margin of that condyle. If the condyles of the femur be examined as they rest upon the tibia in the flexed position of the joint, it will be seen that the inner condyle is more elongated than the outer, and that the portion of the inner condyle which lies in front of the anterior limit of the external condyle inclines obliquely outwards, to reach the patellar surface. In the movement of extension the condyles move parallel to one another, until complete extension is nearly reached, and then, the anterior part of the rolling surface of the external condyle having already come in contact with the tibia, the inner condyle continues to glide backwards, and brings its oblique anterior part into contact with the tibia, so that the bone is rotated inwards on the tibia, and over-extension is prevented, not merely by the tightness of the ligaments, but by the femur being pressed up against the tibial spine. In complete extension the lateral ligaments and the external crucial ligament are tight, while the posterior crucial ligament is relaxed; in flexion the external lateral and external crucial ligaments become relaxed, and the posterior crucial ligament is tightened. In extension of the joint no rotation of the leg is possible; in the flexed condition a considerable amount is allowed. When the weight of the body keeps the bones in their position in the extended knee, the extensor muscles are relaxed, the patella drops down from its position in contact with the femur, and the ligamentum mucosum then comes into play, supporting the synovial membrane and fat below the patella. (See Meyer, *op. cit.*; Goodsir, in "Edin. Med. Journ.," 1855, and "Proceedings of Roy. Soc. of Edin.," 1858; Langer, "Sitzungsber. d. Acad. der Wissensch. Wien," 1858; Henke, "Zeitschr. für rat. Med.," v. viii., 1859.)

#### ARTICULATIONS OF THE LEG AND ANKLE.

**PERONEO-TIBIAL ARTICULATIONS.**—The tibia and fibula are connected at their upper and lower extremities by synovial articulation, and their shafts are united by an interosseous membrane.

The *superior extremities* of the bones present two flat oval articular surfaces, retained in close contact by an *anterior* and a *posterior superior tibio-fibular ligament*, both of which pass upwards and inwards from the head of the fibula to the external tuberosity of the tibia. The synovial membrane which lines this joint not unfrequently communicates posteriorly with that of the knee.

The *interosseous membrane* or *ligament*, which connects the shafts of the tibia and fibula, passes between the external ridge of the tibia and the ridge on the inner surface of the fibula, and is composed for the most part of parallel fibres running outwards and downwards, only a few fibres crossing them in a different direction. The membrane is broader above than below, and presents superiorly an elongated opening for the transmission of the anterior tibial vessels, and inferiorly a small aperture for the passage of the anterior branches of the peroneal vessels.



The *inferior extremities* of the tibia and fibula are in contact by surfaces which for the most part are rough and bound together by ligament, but near

Fig. 145.—ARTICULATIONS OF THE KNEE, LEG AND ANKLE, SEEN FROM BEFORE.  $\frac{1}{2}$

1, superior anterior tibio-fibular ligament; 2, interosseous membrane; 3, points to the anterior inferior tibio-fibular ligament; 4, internal lateral ligament of the ankle-joint; 5, middle vertical part (calcaneo-fibular) of the external lateral ligament of the ankle-joint; 6, anterior part (talo-fibular) of the same; 7, anterior ligament of the ankle-joint.

their lower edges are smooth and covered by cartilage. The tibial surface is concave, the fibular convex; but the lower edges of both surfaces are straight. The strong short fibres which pass directly between the opposing surfaces form the *inferior interosseous ligament*. The *anterior ligament* is a flat band of fibres, extended obliquely over the lower part of the bones, the direction of its fibres being downwards from the tibia to the fibula. The *posterior ligament*, somewhat triangular, is similarly disposed behind the articulation; its outer surface is covered by the peronei muscles. The *transverse ligament*, longer and narrower than the preceding, is placed immediately below it; its fibres are horizontal, and extend from the external malleolus to the contiguous part and hinder border of the articular surface of the tibia; it closes the interval between the bones.

The *synovial cavity* lying between the small articular surfaces is an extension of that of the ankle-joint.

**THE ANKLE-JOINT.**—In this articulation, which is a hinge joint, the inferior extremities of the tibia and fibula, united so as to form a kind of arch, embrace transversely the superior articular surface of the astragalus, so as to render lateral movement impossible when the ligaments are tense.

Fig. 146.—THE LOWER TIBIO-FIBULAR ARTICULATION AND ANKLE-JOINT, FROM BEHIND.

1, inferior posterior tibio-fibular ligament; 2, transverse ligament; 3, posterior fibres of the internal lateral ligament of the ankle-joint; 4, middle, and 5, posterior part of the external lateral ligament of the ankle-joint; 6, posterior talo-calcaneal ligament.

The *internal lateral ligament* is a flat fasciculus of fibres, much broader at the lower than at the upper part. One extremity is attached to the inferior border of the internal malleolus; the other, to the inner side of the astragalus, the os calcis, and the scaphoid bone, as well as to the inferior calcaneo-scaphoid ligament.

The *external lateral ligament* consists of three distinct bands, separated by intervals and disposed in different directions. 1. The middle band descends from the extremity of the fibula, and is inserted into the middle of the external surface of the os calcis. 2. The anterior band passes obliquely

Fig. 145.

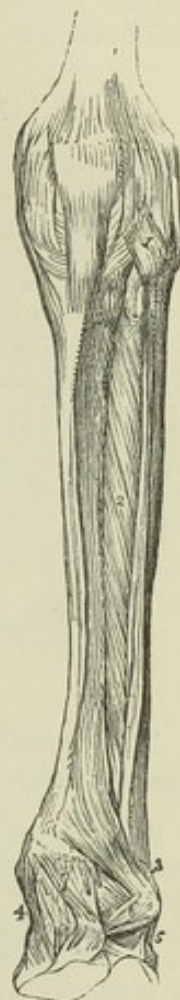
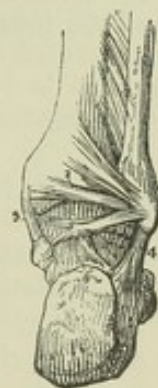

Fig. 146.





forwards and inwards from the fore part of the outer malleolus to a part of the astragalus in front of its external malleolar surface ; it is the shortest of the three. 3. The posterior band, the strongest of the three, passes almost horizontally inwards from the pit on the inner and back part of the malleolus to the posterior surface of the astragalus.

Fig. 147.

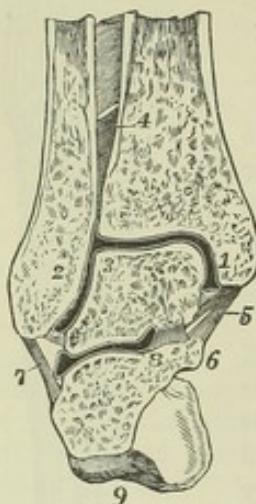


Fig. 147.—TRANSVERSE-VERTICAL SECTION OF THE RIGHT ANKLE JOINT NEAR ITS MIDDLE, AND OF THE POSTERIOR TALO-CALCANEAL ARTICULATION, SO AS TO SHOW THE SHAPE OF THE ARTICULAR SURFACES AND CAVITIES, VIEWED FROM BEFORE.  $\frac{1}{3}$

1, internal, 2, external malleolus ; 3, placed on the astragalus at the angle between its superior and its external malleolar surfaces ; 4, points to the interosseous tibio-fibular ligament ; 5, internal lateral ligament of the ankle-joint ; 6, sustentaculum tali ; 7, calcaneo-fibular or middle part of the external lateral ligament ; 8, inner part of the interosseous calcaneo-talar ligament ; 9, great tuberosity of the calcaneum : between the tibia, fibula and astragalus, the synovial cavity is indicated by the dark space enclosed by a white line ; between the astragalus and os calcis a section of the posterior calcaneo-talar synovial cavity is shown.

The *anterior* and *posterior ligaments* are merely scattered fibres in front of and behind the joint ; those of the posterior ligament are weak and principally transverse.

The *synovial membrane* of the ankle-joint extends upwards by a small process which lines the inferior peroneo-tibial articulation.

**MOVEMENTS.**—The movements at the ankle-joint are mainly those of flexion and extension of the foot, and the directions of those movements are principally determined by the shape of the articular surfaces. The external border of the superior cartilaginous surface of the astragalus is curved, and longer than the internal border, and hence extension of the ankle-joint is accompanied with a slight inward movement of the toes. The horizontal surfaces of both the tibia and astragalus are broader in front than behind ; hence in complete extension of the ankle the narrow part of the astragalus is brought into the widest part of the space between the malleoli, and a certain amount of lateral motion is allowed, whereas in complete flexion, as when the weight of the body, with completely bended knees, is supported on the toes, the broad part of the surface of the astragalus is pushed back into the narrowest part of the space, and the inferior extremity of the fibula is pressed upon, so as to stretch the ligaments between it and the tibia, and give a certain amount of spring to the joint. There appears to be no other movement between the tibia and fibula ; these bones being bound together at their lower ends with remarkable firmness.

#### ARTICULATIONS OF THE FOOT.

**ARTICULATIONS OF THE CALCANEUM, ASTRAGALUS, AND SCAPHOID BONES ONE WITH ANOTHER.**—The astragalus is connected with the calcaneum by two synovial articulations, viz., by a posterior one peculiar to those two bones, and by an anterior one common to them with the scaphoid bone. The following are the principal parts requiring description :—

*Astragalo-calcaneal ligaments.*—The *interosseous ligament*, broad and strong, passes vertically downwards from the groove between the anterior and posterior articular surfaces of the astragalus to the similar groove between the corresponding articular surfaces of the calcaneum. A membranous *posterior ligament* connects the posterior border of the astragalus with the upper surface of the calcaneum ; its fibres are oblique and very short.



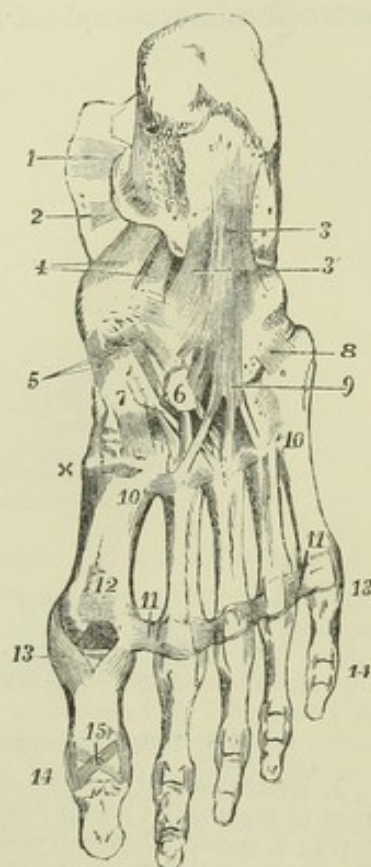
There is also an *external ligament*, consisting of a slight fasciculus of fibres, which descends perpendicularly from the outer surface of the astragalus to the external side of the calcaneum, parallel with the middle division of the external lateral ligament of the ankle-joint. It may be farther observed, that those portions of the lateral ligaments of the ankle-joint which pass down over the astragalus to the os calcis assist in uniting these two bones.

*Calcaneo-scaphoid ligaments.*—The calcaneum and scaphoid bone are not in contact, but they are connected by two ligaments. The *inferior* or *plantar* ligament, much the larger of the two, is a broad band which passes forwards and inwards from the fore-part of the calcaneum (*sustentaculum tali*) to the inferior surface of the scaphoid bone. It is in contact inferiorly with the tendon of the *tibialis posticus* muscle, while superiorly it forms the floor of the articular cavity which receives the head of the astragalus, and is lined by synovial membrane. The *external, dorsal, or inter-osseous ligament*, forms the external boundary of the cavity just mentioned, and lies deeply at the anterior part of the fossa (*sinus pedis*), between the astragalus and os calcis. Its fibres, very short, are directed from behind forwards between the contiguous extremities of the bones. They are attached posteriorly to a ridge of the os calcis that separates the articular surfaces for the astragalus and os cuboides, and anteriorly to the outer side of the scaphoid bone.

Fig. 148.

Fig. 148.—LIGAMENTS OF THE FOOT, SEEN FROM BELOW.  $\frac{1}{3}$

1 and 2, portions of the internal lateral ligament of the ankle joint descending upon the calcaneum ; 3, calcaneo-cuboid or long plantar ligament ; 3', deep or short part of the same ; 4, plantar calcaneo-scaphoid ligament ; 5, three scaphoido-cuneiform ligaments of the internal, middle and external cuneiform bones ; 6, is placed upon the external cuneiform bone towards which is seen coming from behind a cuboido-cuneiform ligament ; 7, is placed upon the internal cuneiform bone ; from 6 and 7, are seen passing downwards the plantar cuneo-metatarsal ligaments ; x, part of the first dorsal cuneo-metatarsal ligament ; 8 and 9, ligamentous fibres prolonged from the cuboid bone and sheath of the *peroneus longus* muscle upon the outer metatarsal bones ; 10, 10, between these figures the posterior intermetatarsal (or transverse) ligaments ; 11, 11, anterior transverse metatarsal ligament, continued across the four metatarsal spaces ; 12, inter-sesamoid ligament ; 13, 13, between these figures are seen the five pairs of internal and external lateral metatarso-digital ligaments ; 14, 14, between these figures are seen the five pairs of internal and external lateral digital (phalangeal) ligaments of the first series : those of the second series have no figure placed to mark them ; 15, inferior ligament of the phalangeal articulation of the great toe.



The *talo-scaphoid* or *astragalo-scaphoid ligament*, a membranous band of fibres situated on the dorsum of the foot, extends obliquely forwards from the anterior extremity of the astragalus to the superior surface of the scaphoid bone, and completes the capsule of the calcaneo-talo-scaphoid joint, formed in the rest of its extent by the plantar and external calcaneo-scaphoid ligaments.



One *synovial membrane* lines the calcaneo-talar joint, and another the calcaneo-talo-scaphoid articulation.

**CALCANEO-CUBOID ARTICULATION.** — The calcaneum is united to the cuboid bone by a synovial joint and ligaments.

The *inferior ligament* consists of two distinct fasciculi of fibres, differing in form and attachments ; of which one is superficial the other deep-seated. The superficial part, called the *long plantar ligament*, is the longest of the tarsal ligaments. Its fibres, attached behind to the inferior surface of the calcaneum as far as the anterior tubercle, pass forwards, and are attached in greater part to the tuberosity on the under surface of the cuboid bone ; some of them are continued onwards, and terminate at the bases of the third and fourth metatarsal bones, after covering the tendon of the peroneus longus muscle. The *short or deep-seated plantar calcaneo-cuboid ligament* lies close to the bones, being separated from the superficial part by some cellular tissue. Its breadth is considerable, its length scarcely an inch. One extremity is attached to the calcaneum in front of the long ligament, the other (somewhat expanded) to the under surface of the cuboid bone, internal to the tuberosity.

The *dorsal or superior ligament* is a flat band of fibres which connects the anterior and upper surface of the calcaneum with the adjacent part of the cuboid bone.

The *internal or interosseous ligament* is placed deeply in the hollow between the astragalus and os calcis, and is closely connected with the external calcaneo-scaphoid ligament.

Fig. 149.

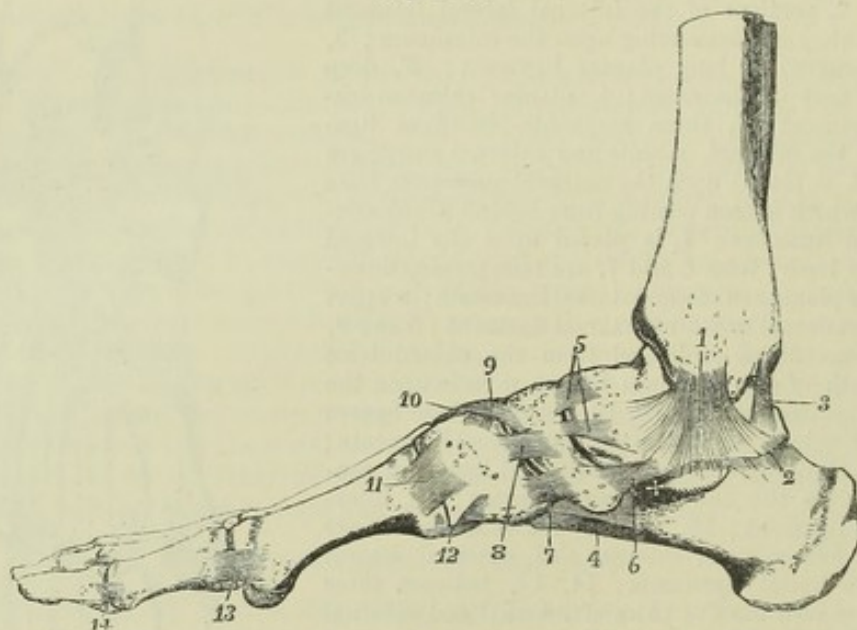


Fig. 149.—LIGAMENTS OF THE FOOT, FROM THE INNER SIDE.  $\frac{1}{2}$

1, internal lateral ligament of the ankle ; x, in front of the sustentaculum tali, showing part of the internal lateral ligament descending upon it ; 2, posterior talo-calcaneal ligament ; 3, posterior ligament of the ankle joint ; 4, part of the long and short calcaneo-cuboid ligaments seen from the inside ; 5, two superior astragalo-scaphoid or talo-scaphoid ligaments ; 6, internal talo-scaphoid ligament ; 7, internal scaphoido-cuneiform (first) ; 8, dorsal or superior cuneiform ; 9, scaphoido-cuneiform (second) ; 10, intercuneiform, or transverse dorsal cuneiform, between the first and second cuneiform bones ; 11, internal or first tarso-metatarsal ligament ; 12, inferior first tarso-metatarsal ; 13, internal lateral metatarso-digital : the internal sesamoid bone is seen below ; 14, internal lateral digital ligament (of the first toe) : those of the second toe are also seen beyond.



A separate *synovial membrane* lines this joint.

**ARTICULATIONS OF THE SCAPHOID, CUBOID, AND CUNEIFORM BONES, ONE WITH ANOTHER.**—The *scaphoid* and *cuboid* bones are connected by a *dorsal ligament*, composed of short thin fibres, extended obliquely between the two bones; a *plantar*, situated in the sole of the foot, and consisting of transverse fibres; and an *interosseous ligament*, which intervenes between the bones, and is attached to their contiguous surfaces. When the bones touch, which is not always the case, they present two small articulating surfaces, which are covered with cartilage, and have between them an offset of the adjacent *synovial membrane*.

The *scaphoid* and the *cuneiform bones* are held together by dorsal ligaments. It will be recollected that the *scaphoid* bone articulates with the three *cuneiform* by the smooth faces on its anterior surface. The *dorsal ligaments*, three in number, pass from the upper surface of the *scaphoid* to the first, second, and third *cuneiform* bones, into which they are inserted. *Plantar bands* are similarly disposed on the under surface of the bones, but these are continuous with, or offsets from, the tendon of the *tibialis posticus* muscle.

The *cuboid* and the *external cuneiform bones* are connected by a *dorsal*

Fig. 150.

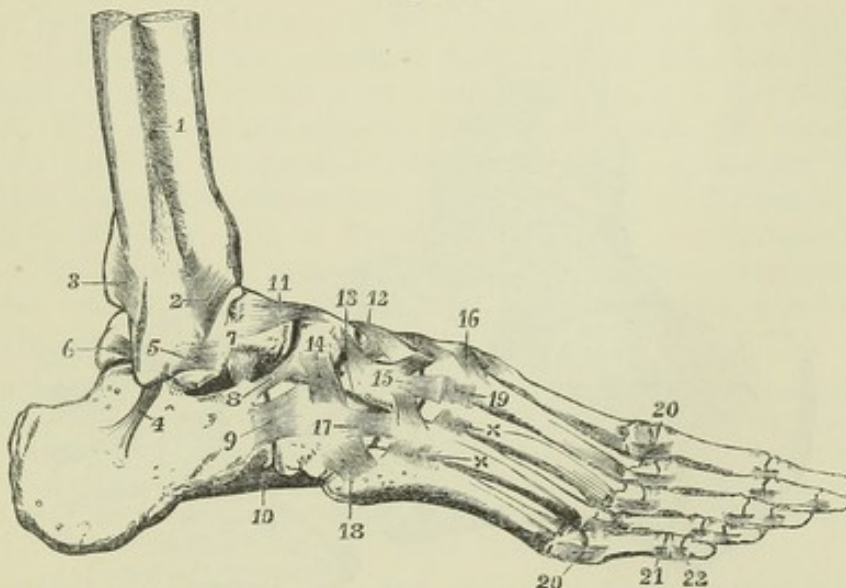


Fig. 150.—LIGAMENTS OF THE FOOT, FROM THE OUTSIDE AND DORSAL ASPECT.  $\frac{1}{2}$

1, lower part of the *interosseous membrane*; 2, lower anterior *tibio-peroneal* ligament; 3, lower posterior *tibio-peroneal* ligament; 4, middle part of the *external lateral* ligament of the ankle-joint, passing to the *calcaneum*; 5, anterior part of the *external lateral* ligament of the ankle-joint, passing to the *astragalus*; below the last ligament the *external calcaneo-talar* ligament has not been represented in this figure; 6, posterior part of the *external lateral* ligament of the ankle-joint, passing to the *astragalus*; 7, is placed above the *interosseous calcaneo-talar* ligament; 8, *dorsal calcaneo-scaphoid*; 9, *dorsal calcaneo-cuboid*; 10, part of the long *plantar* or *calcaneo-cuboid*; 11, *superior talo-scaphoid*; 12 and 13, second and third *scaphoido-cuneiform*, and between them one of the *intercuneiform* ligaments; 14, *superior scaphoido-cuboid*; 15, placed on the *external cuneiform* bone, points to the *cuneo-metatarsal* ligament of the third bone; above and below 15, are corresponding ligaments from the *external cuneiform* to the second and fourth *metatarsal* bones; 16, *cuneo-metatarsal* ligament, from the first *cuneiform* to the second *metatarsal* bone; between 12, and 16, are seen the *cuneo-metatarsal* ligaments which converge from the three *cuneiform* bones on the second *metatarsal*; 17, *cuboido-metatarsal* ligament passing to the fourth *metatarsal* bone; 18, that to the fifth; 19 and x x, *dorsal intermetatarsal* ligaments; 20, *lateral metatarso-digital*; 21, 22, *lateral digital*.



*ligament*, which is a thin fasciculus of fibres extended between them ; a *plantar ligament*, whose fibres are transverse and rather indistinct ; and a bundle of *interosseous* fibres attached to their neighbouring sides. Between the two bones a distinct articulation is formed by cartilaginous surfaces ; it is provided sometimes with a separate synovial membrane, at others with an offset from that which belongs to the scaphoid and cuneiform bones.

The *three cuneiform bones* are connected by transverse *dorsal ligaments* and strong *interosseous* fibres ; but the latter are their most efficient uniting structures. A transverse plantar ligament exists only between the two innermost bones. The articulations between these bones are lined by offsets from the synovial membrane of the joint between them and the scaphoid bone.

**ARTICULATION OF THE TARSUS WITH THE METATARSUS.**—The four anterior bones of the tarsus, viz., the three cuneiform and the cuboid, articulate with the metatarsal bones ; and as the first and third cuneiform bones project beyond the middle one, and the third cuneiform beyond the cuboid bone, the anterior surface of the tarsus is very irregular. The first metatarsal bone articulates with the internal cuneiform ; the second is wedged in between the first and third cuneiform, and rests against the second ; the third metatarsal bone articulates with the extremity of the external cunei-

Fig. 151.

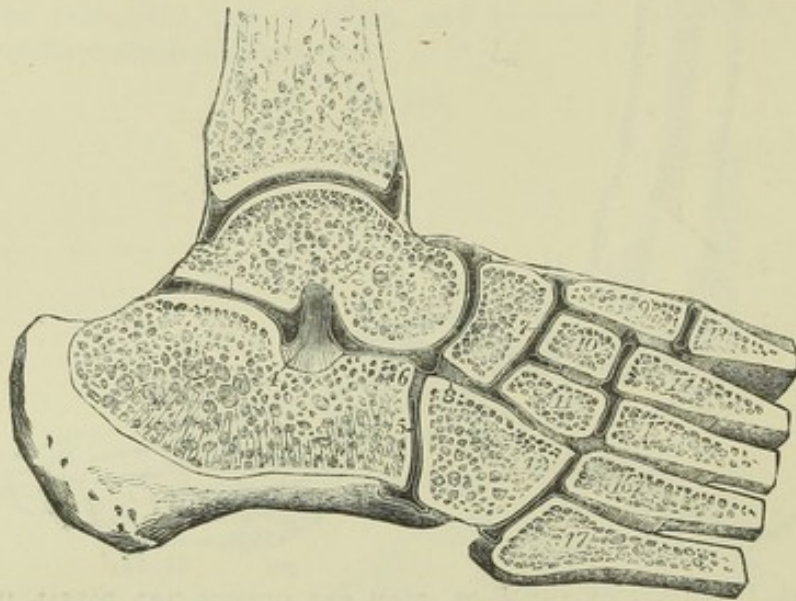


Fig. 151.—THE SYNOVIAL CAVITIES OF THE ANKLE-JOINT AND THE TARSAL AND TARSO-METATARSAL ARTICULATIONS, IN SECTION.  $\frac{1}{2}$

The section has been carried obliquely upwards and inwards across the foot, and vertically through the upper part of the astragalus and the tibia. 1, cut surface of the tibia above the ankle-joint ; 2, placed on the astragalus above the posterior calcaneo-talar synovial cavity ; 3, on the head of the astragalus close to the common calcaneo-talo-scaphoid synovial cavity ; 4, interosseous calcaneo-talar ligament ; 5, on the anterior edge of the calcaneum, points to the calcaneo-cuboid synovial cavity ; 6, interosseous calcaneo-cuboid ligament ; 7, on the scaphoid bone, marks the common scaphoido-cuneiform and intercuneiform synovial cavity ; 8, on the cuboid bone, points to the interosseous scaphoido-cuboid ligament ; 9, internal, 10, middle, 11, external cuneiform bones ; 12, cuboid : between these several bones the interosseous ligaments are shown ; from 13 to 17, are the metatarsal bones, with the interosseous ligaments between them ; 9 to 14, the interosseous ligament from the internal cuneiform to the second metatarsal bone ; 11 to 16, the interosseous ligament from the external cuneiform to the fourth metatarsal bone : there are also shown in this figure, the synovial cavity of the first tarso-metatarsal articulation, that between the middle and external cuneiform bones and the second and third metatarsal ; and that between the cuboid and the fourth and fifth metatarsal bones.



form ; and the last two with the cuboid bone. The articulations are furnished with synovial membranes, and the bones are held in contact by dorsal, plantar, and interosseous ligaments.

The *dorsal tarso-metatarsal* ligaments are flat, thin bands of parallel fibres, which pass from behind forwards, connecting the contiguous extremities of the bones before mentioned. Thus the first metatarsal bone receives a broad thin band from the corresponding cuneiform bone ; the second receives three, which converge to its upper surface, one passing from each cuneiform bone ; the third has one from the external cuneiform bone ; and, finally, the last two are bound by a fasciculus to each from the cuboid bone, and by fibres from the external cuneiform to the fourth metatarsal bone. The *plantar* ligaments are less regular ; the bands of the first and second toes are more strongly marked than the corresponding ligaments on the dorsal surface ; and those of the fourth and fifth toes, which are merely a few scattered fibres passing to the cuboid, receive support from the sheath of the peroneus longus muscle. Ligamentous bands stretch in an oblique or transverse direction from the internal cuneiform to the second and third metatarsal bones, and from the external cuneiform to the fifth metatarsal.

The *interosseous* ligaments are longitudinal in direction, and have especial interest, because of the resistance which they oppose to the surgeon in separating the metatarsus from the tarsus, in consequence of their deep position between the bones. *a.* The *internal* and largest of these lies to the outer side of the first cuneiform bone, and extends from this bone to the neighbouring side of the second metatarsal, close to the articular surface. *b.* The *external* interosseous ligament separates the articulation of the fourth and fifth metatarsal bones from the rest. It connects the outer side of the external cuneiform bone to the same side of the third, and very strongly to the inner side of the fourth metatarsal. *c.* Occasionally some fibres, of less strength and importance than the preceding, are observable on the outer side of the second metatarsal bone, connecting it to the middle cuneiform.

The interosseous ligaments are found to vary somewhat in their connections from those here stated, being sometimes attached at once to the contiguous sides of two tarsal and two metatarsal bones. Attention was first particularly directed to these ligaments by M. Lisfranc, in connection with the amputation of the foot through the tarso-metatarsal articulation. See "*Manuel des Opérations Chirurgicales*, &c. Par J. Coster." 3rd edit. Paris, 1829.

*Synovial membranes.*—There are three synovial membranes in this irregular series of articulations. *a.* One belongs to the internal cuneiform and the first metatarsal bone : the joint formed between these two bones is altogether separate and out of the range of the rest. *b.* A second synovial membrane is placed between the cuboid and the fourth and fifth metatarsal bones ; this is isolated on the inner side by the external interosseous ligament. *c.* The third or middle one is placed between the middle and external cuneiform and the second and third metatarsal bones, and is prolonged between the two last-named bones, as well as sometimes between the third and fourth metatarsal bones. The disposition of this last synovial membrane is subject to variation.

**CONNECTION OF THE METATARSAL BONES WITH ONE ANOTHER.**—The metatarsal bones are bound together at their tarsal and digital ends ; very firmly in the former, and loosely in the latter situation.

The tarsal ends or bases of the four outer bones articulate with each other, having lateral cartilaginous surfaces provided with synovial membrane, and



are connected by dorsal, plantar, and interosseous ligaments. The *dorsal* and *plantar* ligaments are short transverse bands stretching across the five metatarsal bones from one to another. The *interosseous* fibres, lying deeply between the bones, occupy the rough parts of their lateral surfaces :

Fig. 152.

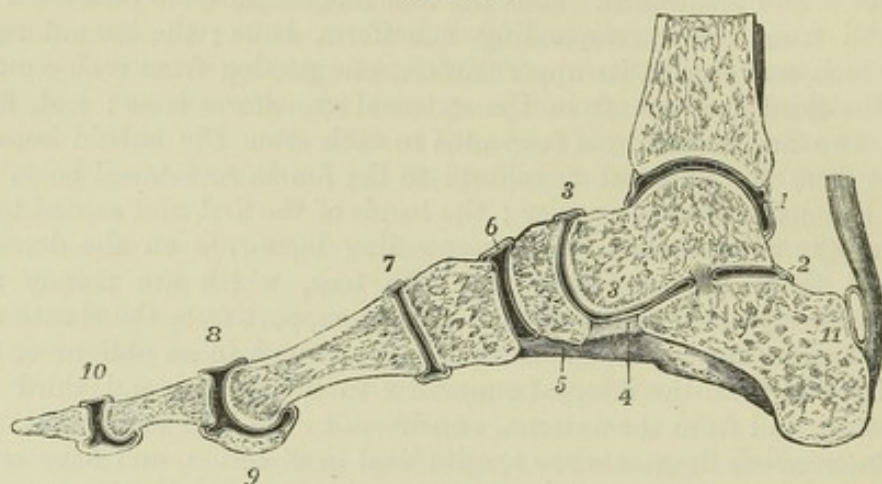


Fig. 152.—VERTICAL ANTERO-POSTERIOR SECTION OF THE ANKLE-JOINT AND ARTICULATIONS OF THE FOOT, A LITTLE TO THE INSIDE OF THE MIDDLE OF THE GREAT TOE OF THE RIGHT FOOT.  $\frac{1}{3}$

1, the synovial cavity of the ankle-joint; 2, the posterior talo-calcaneal articulation; 3, placed above the talo-scaphoid articulation; 3', on the astragalus above the anterior talo-calcaneal articulation, which is continuous with the preceding: the interosseous ligament is seen separating 2 from 3'; 4, the inferior calcaneo-scaphoid ligament; 5, part of the calcaneo-cuboid or long plantar ligament; 6, the scaphoido-cuneiform articulation; 7, the first metatarso-cuneiform articulation; 8, the first metatarso-phalangeal articulation; 9, section of the inner sesamoid bone; 10, the phalangeal articulation; 11, placed on the calcaneum, indicates the bursa between the upper part of the tuberosity of that bone and the tendo Achillis.

they are of considerable strength and firmness. The intermetatarsal articular cavities are lined with *synovial membrane*, which in each is continued forwards from that lining the joints formed between the bases of these bones and the tarsus. The first and second metatarsal bones do not articulate laterally with each other.

*Transverse metatarsal ligament.*—The digital extremities or heads of the metatarsal bones are loosely connected by a transverse band, which is identical in its arrangement with the corresponding structure in the hand, with this exception, that it is attached to the great toe, whereas in the hand the transverse metatarsal ligament does not reach the thumb.

ARTICULATIONS OF THE METATARSAL BONES WITH THE DIGITAL PHALANGES, AND OF THE LATTER ONE WITH ANOTHER.—The heads of the metatarsal bones are connected with the small concave articular surfaces of the first phalanges by two lateral ligaments, an inferior ligament, and a synovial membrane, which are closely similar to those which belong to the corresponding parts of the hand.

The articulations of the phalanges with one another are also constructed on the same plan as those of the superior extremity. In each, the bones are held in contact by two lateral ligaments and an inferior ligament or fibrous plate; and each of the cavities is lined by a synovial membrane.

MOVEMENTS, &c.—In the mechanism of the foot three arches are distinguishable, two of them longitudinal and one transverse; all of them capable of being flattened somewhat by pressure from above, and combining to secure elasticity of the parts at rest or in motion. The inner arch is formed by the os calcis, astragalus, scaphoid, and



three cuneiform bones, together with the three inner toes; the head of the astragalus being the key stone, and being supported in its position, not by immoveable piers, as would be the case in an arch of mason-work, but by them in connection with the inferior calcaneo-scapoid ligament. The outer arch is formed by the os calcis, cuboid bone, and two outer toes, and is supported by the strong inferior calcaneo-cuboid ligaments. Thus the calcaneo-scapoid and calcaneo-cuboid ligaments are stretched by the whole weight of the body bearing down upon the arch, and prevent the too great flattening of the instep; an action in which they are assisted, however, by the plantar aponeurosis. The transverse arching of the foot is most marked along the line of tarso-metatarsal articulations, and is maintained by the wedge-shape of the bones and by inferior ligaments. The weight of the body, falling upon the balls of the toes when the heel is raised, tends to spread out the metatarsal bones at their distal extremities, and to flatten the transverse arch, which recovers its position when the pressure is removed. Between the astragalus and the calcaneum only one kind of motion is possible, the centre of which is the interosseous astragalo-calcaneal ligament, and is of such a nature, that when the posterior part of the os calcis slides inwards and upwards beneath the astragalus, its cuboid extremity moves downwards and outwards. A certain amount of gliding movement is also allowed between the tarsal and metatarsal bones, and that most considerably between the cuboid bone and outer toes. Thus it happens that if the foot is flexed against the leg, and then is gradually extended by force applied to the toes, as by the action of the flexores digitorum muscles, the first part of the movement is accomplished at the ankle, and consists of extension, with only a slight inward turning of the toes; further extension is accomplished by movement between the calcaneum and astragalus, and is accompanied by depression of the outer edge of the foot; and after that a little more extension, accompanied by more considerable depression of the outer edge of the foot, is effected at the tarso-metatarsal articulations. The direction of the movement of extension of the toes at the metatarso-phalangeal articulations is upwards and outwards, so that although the great toe is in a line with the inner edge of the foot when resting on the ground, it is no longer so when over-extended, as, for instance, when supported by a shoe.

### SECTION III.—MYOLOGY.

UNDER the title MYOLOGY will be brought the systematic description of the form, position, and relations of the muscles of the body with their tendons, and in the same section it will be convenient to include that of the fasciæ and aponeuroses.

As many of the muscles consist of tendinous as well as muscular parts, the description of the tendons and their sheaths necessarily forms a part of that of the muscles; and farther, as it is impossible to separate the examination of the attachments of a muscle, or of groups of muscles, from the study of the motions produced by them, the statement of the action of the muscles will accompany their anatomical description.

In the description of the muscles, it is customary to state the attachments of their opposite ends under the names of *origin* and *insertion*; the first term being usually applied to the more fixed or proximal, and the second to the more movable or remote attachment: but it is to be observed, that it is sometimes difficult to lay down a rule for the correct use of these terms, and that in almost all instances it is of importance to consider the action of a muscle as it may affect the motions of the parts attached to both of its extremities.

As the muscles belong to the double symmetrical parts, it will be understood that it is sufficient, as in the bones and joints, to describe those occupying one side of the body.



The description of the involuntary and unstriated muscles connected with internal organs is excluded from the present section, as is also that of some small striped muscles situated in certain complicated organs, such as the larynx and ear, as it is more expedient that those muscles should be treated of under the several organs to which they belong. In the arrangement to be adopted in the anatomical description of the external and voluntary muscles, it is almost impossible to follow a strictly systematic order founded exclusively, either upon their position in the several regions of the body, or upon their actions : in the following section, therefore, an arrangement is adopted which is based in part on both of these considerations, and which seems to be the most simple and advantageous to the student.

**FASCIÆ.**—The term *Fascia* includes all the membranous dispositions of reticulated or felted fibrous tissue. These structures have usually been distinguished as the *superficial* and the *deep* ; the former consisting of looser and finer substances, and passing by their slenderer kinds into the finer varieties of connective tissue ; while the latter, denser in character, frequently exhibit more or less regular arrangements of strong white fibres, giving them a shining appearance, and are often termed *aponeuroses*.

The connective tissue of the body being that in which all others are embedded, may be considered as forming a continuous meshwork of *fasciæ* of various degrees of firmness arranged so as to enclose shut spaces, within which the other parts are contained. Thus each *fasciculus* of muscle is surrounded by connective tissue ; the larger *fasciculi* are separated by stronger partitions, and the whole muscle is invested with a layer of such distinctness, that it may appropriately be styled a *fascia*. So also the sheaths of vessels are formed of this substance ; and in certain parts stronger *septa*, having attachment to bone, and continuous with the periosteum, which likewise belongs to the series of white fibrous membranes, form partitions between dissimilar structures.

**Superficial Fascia.**—Under this name, or as *subcutaneous fascia*, is described the layer of loose tissue of varying density, which is placed immediately below the skin, all over the body. It is the web which contains the subcutaneous fat, the *panniculus adiposus*, and in some regions superficial muscles, as the *panniculus carnosus*. From the subcutaneous tissue of the eyelids, however, as well as from that of the penis and scrotum, adipose matter is entirely absent. It is to be noticed also that between the muscles and the subcutaneous fat there is always a certain amount of fascia devoid of adipose matter, and that it is in this stratum that the trunks of the subcutaneous vessels and nerves are found. But when the fat becomes absorbed, the stroma in which it was deposited is still left, and its meshes approach one another, so that in lean subjects a more fibrous condition of the subcutaneous fascia is often found than in others.

**Deep Fasciæ and Aponeuroses.**—Under the name of deep fascia is comprehended that stronger layer of fibrous or connective tissue which, lying more close to the muscles, gives them a general investment or dips between them, and forms a nearly continuous covering of the body beneath the superficial fascia. It is chiefly to the stronger parts of this fascia that the name of *aponeuroses* has been given. Those covering the muscles have been named *aponeuroses of investment* (Bichat), to distinguish them from proper tendinous expansions, or *aponeuroses of insertion*, of muscles. This distinction, however, is far from being universally applicable : *aponeuroses of insertion* are often continued into *aponeuroses of investment*, as in the instance of the *gluteus maximus*, or into mere fascia, as at the lateral parts



of the occipito-frontal aponeuroses, or the cranial origin of the trapezius muscle. The principal aponeuroses of investment are those which incase the muscles of the limbs, binding them down in a common sheath, and connected in various places by septa with the bones. They are characteristic of the limbs, there being no structure entirely corresponding to them in the rest of the body.

## MUSCLES OF THE HEAD AND NECK.

### SUPERFICIAL MUSCLES.

**EPICRANIAL MUSCLES.**—Under the title of *occipito-frontalis* muscle are comprehended a pair of occipital and a pair of frontal muscles, together with a thin aponeurosis extending over the cranium, and uniting the anterior and posterior muscles together.

*a.* The *occipitalis* muscle, thin and subcutaneous, is attached inferiorly by short tendinous fibres to the external two-thirds, sometimes much less, of the superior curved line of the occipital bone, and to the mastoid portion of the temporal bone, immediately above the attachment of the sternomastoid muscle. Its fleshy fibres, from one to two inches in length, are directed upwards, and terminate in distinct tendinous fibres, continuous with the epicranial aponeurosis. Between the muscles of opposite sides is an interval of variable size occupied by a part of that aponeurosis.

*b.* The *frontalis* muscle, longer and broader and of a paler colour than the *occipitalis*, arises superiorly in a convex line from the epicranial aponeurosis, while inferiorly its innermost fibres are continuous with the *pyramidalis nasi* muscle, and the others are blended with the *corrugator supercilii* and with the *orbicularis palpebrarum*, as far outwards as the external orbital process of the frontal bone. The fibres are nearly vertical, running slightly inwards; the margins of the right and left muscle are united for a short distance above the root of the nose, but are separated by an angular interval superiorly.

*c.* The *epicranial* or *occipito-frontal aponeurosis* extends over the upper surface of the cranium uniformly from side to side, without division. Posteriorly it is attached to the occipital muscles, and to the protuberance and superior curved lines of the occipital bone, and anteriorly it terminates in the frontal muscles, while laterally it presents no distinct margin, but below the temporal ridge becomes thinner and less aponeurotic, and gives attachment to the superior and anterior auricular muscles. Its fibres are chiefly longitudinal, and are most distinctly tendinous where they give attachment to the occipital muscles. Its outer surface is firmly bound to the skin by an abundant network of fibrous tissue, constituting the so-called superficial fascia, by the meshes of which the subcutaneous fat is divided into granules; while its deep surface glides upon the subjacent pericranium, to which it is loosely adherent through the medium of a delicate connective tissue devoid of fat.

**ACTIONS.**—By the contraction of the whole *occipito-frontalis* muscle, the scalp is drawn backwards, and the eyebrows elevated; by the contraction of the frontales muscles alone, the eyebrows are elevated, the scalp pulled forwards, and the skin of the forehead thrown into transverse wrinkles; by the contraction of the occipital muscles alone, the scalp is drawn backwards; and by the alternate action of the occipital and frontales muscles, the scalp is moved backwards and forwards. In



many persons, however, there is only a partial control over the action of these muscles, limited to the elevation of the eyebrows and horizontal wrinkling of the forehead.

**AURICULAR MUSCLES.**—Besides minute bundles of muscular fibres which pass from one part of the pinna of the auricle to another, and which will be

Fig. 153.

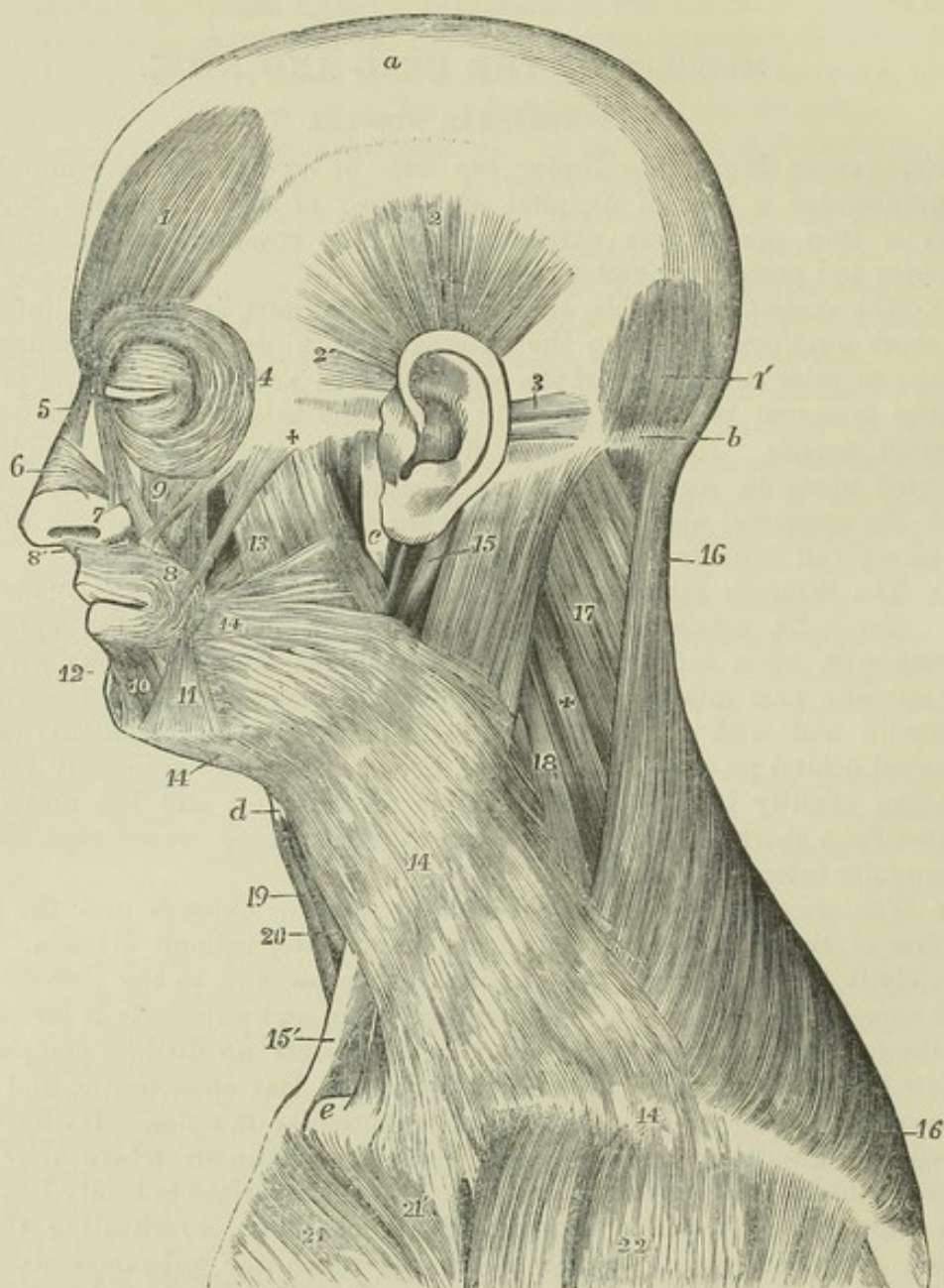


Fig. 153.—SUPERFICIAL VIEW OF THE MUSCLES ON THE LEFT SIDE OF THE HEAD AND NECK (slightly altered from Bourguery).  $\frac{1}{3}$

*a*, cranial aponeurosis; *b*, superior curved line of the occipital bone; *c*, ramus of the lower jaw; *d*, lower edge of the hyoid bone; *e*, head of the clavicle. 1, anterior or frontal, and 1', posterior or occipital part of the occipito-frontalis muscle; *a*, the aponeurotic covering of the cranium extending between the two portions of the muscle; 2, superior auricular; 2', anterior auricular; 3, posterior auricular in two fasciculi; 4, is placed in front of the temple close to the outer part of the orbicularis palpebrarum; 5, pyramidalis nasi; 6, triangularis nasi or compressor narium; 7, levator labii superioris alæque nasi; 8, orbicularis oris;



8', its attachment to the columella nasi, or depressor nasi; 9, levator labii superioris, and close by it zygomaticus minor; farther back passing from the + obliquely down towards 8, zygomaticus major; and between the zygomatici, in shadow, is seen a portion of the levator anguli oris; 10, quadratus menti or depressor labii inferioris; 11, triangularis oris or depressor anguli oris; 12, points to the situation of levator menti; 13, is placed on the masseter, it is immediately above the risorius or upper horizontal fibres of the platysma myoides, and a line points from it to the buccinator; 14, platysma myoides; 15, placed on the upper part of the sterno-mastoid, points by a line to the posterior belly of the digastric muscle; 15', the sternal tendon of the sterno-mastoid, a part of its clavicular portion is seen near e: 16, trapezius; 17, splenius capitis; +, splenius colli; 18, levator scapulæ; 19, sterno-hyoid; 20, omo-hyoid; 21, pectoralis major, its pectoral part; 21', its clavicular part; 22, deltoid.

most conveniently described along with that structure, there are attached to the external ear three larger, but still very slightly developed, muscles, which serve to move it as a whole.

The *auricularis superior* or *attollens auriculam*, the largest of the three, arises in the temporal region of the head from the epicranial aponeurosis. Its fibres are extremely delicate, and radiated in arrangement, and are inserted by a compressed tendon into the cartilage of the ear at the upper and anterior part of the helix and upper part of the concha.

The *auricularis anterior* or *attrahens auriculam*, scarcely separated from the preceding muscle, is pale and indistinct, and is attached to the thin lateral prolongation of the epicranial aponeurosis, from which it passes backwards to be inserted into the fore part of the helix.

The *auricularis posterior* or *retrahens auriculam* muscle, consists of two or three thin fasciculi, which arise from the mastoid process by short aponeurotic fibres, and are inserted into the back part of the concha. The fibres are much deeper in colour and more distinctly marked than in either of the other auricular muscles.

**ACTIONS.**—The three auriculares muscles respectively draw the pinna of the ear upwards, backwards, and forwards. In the majority of persons their action is not directly under voluntary control.

**MUSCLES OF THE EYELIDS.**—These are four in number—namely, the orbicularis palpebrarum and tensor tarsi, the corrugator supercilii, and the levator palpebræ superioris.

The *orbicularis palpebrarum* is a thin elliptical muscle closely adherent to the skin, surrounding the fissure between the eyelids and covering their surface, and spreading for some distance outwards on the temple, upwards on the forehead, and downwards on the cheek. The fibres forming concentric curves are attached by their extremities at the inner angle of the orbit: 1st, to the edges and anterior surface of the tendon afterwards described; 2nd, to the surface of the nasal process of the superior-maxilla, near the anterior margin of the lachrymal groove; and 3rd, to the internal angular process of the frontal bone.

The fibres situated in the eyelids are thin, pale and little curved, and conceal the tarsal cartilages: they are sometimes distinguished by the name "ciliaris." The peripheral fibres, "*orbicularis latus*," more largely developed, rest on the cheek and margin of the orbit. Superiorly this muscle conceals the corrugator supercilii, with which and the occipito-frontalis it is intimately connected; inferiorly it covers the origin of the elevators of the upper lip, part of the common elevator of the lip and nose, and the lachrymal sac; and externally it lies upon a part of the temporal fascia.

The *tendon* of the orbicularis muscle (*tendo palpebrarum*).—At the inner commissure of the eyelids is a small tendon, which is often obscured by the



fibres of the muscle, but is rendered apparent by drawing the lids outwards. This tendon is about two lines in length, and less than one in breadth, and is attached to the anterior margin of the lachrymal groove ; thence it runs

Fig. 154.

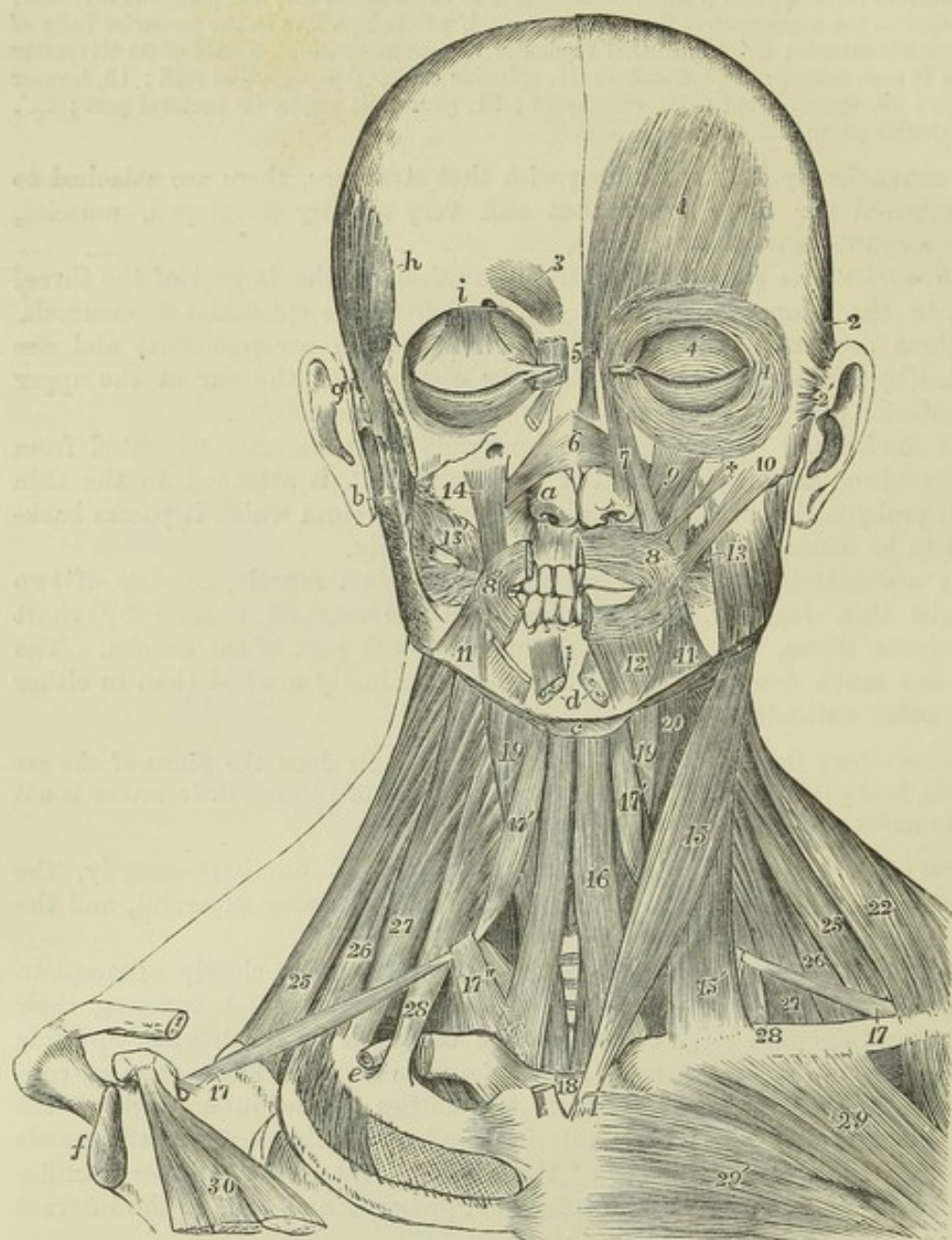


Fig. 154.—SUPERFICIAL AND DEEP VIEW OF THE MUSCLES OF THE HEAD AND NECK, FROM BEFORE (altered from Bourguery).  $\frac{1}{3}$

On the left side, the platysma alone has been removed ; on the right side, portions of the zygomatic arch and clavicle, the superficial muscles of the cranium and face, the masseter, trapezius, sterno-mastoid and pectoralis major muscles have been removed ; *a*, right alar cartilage of the nose ; *b*, upon the lobe of the right ear, points to the coronoid process of the lower jaw ; *c*, the body of the hyoid bone ; *d*, symphysis of the lower jaw ; *e*, upon the subclavian groove of the first rib, lying in which is the cut end of the subclavian artery ; *f*, the glenoid cavity of the scapula ; *g*, the right zygomatic arch separated from the malar bone ; *h*, upon the temporal ridge of the frontal bone ; *i*, above the supra-orbital ridge ; 1, frontalis muscle ; 2, superior auricular ; 2', insertion of the anterior



auricular ; 3, corrugator supercilii ; 4, malar portion of the orbicularis palpebrarum ; 4', palpebral portion ; below *i*, the expanded insertion of levator palpebræ superioris in the eyelid ; 5, pyramidalis nasi ; 6, insertion of the triangulares nasi on the dorsum of the nose ; 7, levator labii superioris alæque nasi ; 8, orbicularis oris of the left side ; 8', outer part of the same on the right side, the inner part being removed ; 9, levator labii superioris ; +, zygomaticus minor ; 10, zygomaticus major ; 11, depressor anguli oris ; 12, depressor labii inferioris ; *d*, points to the cut ends of the levatores menti ; 13, placed on the left masseter, points to the buccinator ; 13', buccinator, of the right side, a portion of the parotid duct passing through the muscle ; 14, levator anguli oris, seen also on the left side behind the zygomaticus minor. The remaining references which apply to the muscles of the neck will be found described at page 194.

horizontally outwards to the inner commissure of the eyelids, where it divides into two thin fibrous lamellæ, which diverge as they pass outwards in the substance of the eyelids, and terminate in the tarsal cartilages. One surface of the tendon is subcutaneous ; the other crosses the lachrymal sac a little above the centre, and from it a thin but firm fascia is given off, which spreads over the lachrymal sac, and adheres to the margins of the groove which lodges it.

The *tensor tarsi*—Horner, (*musculus sacci lachrymalis*,)—consists of very thin fibres resting on the fascia just mentioned. It is only a deep portion of the insertion of the marginal fibres of the ciliary part of the orbicularis muscle : two slips, one from each eyelid, passing behind the lachrymal canals, unite on the surface of the lachrymal sac before reaching their attachment on the posterior part of the lachrymal bone.

The *corrugator supercilii* is a small muscle narrower below than above, placed at the inner side of the eyebrow. It arises from the inner extremity of the superciliary ridge of the frontal bone ; thence its fibres proceed outwards and a little upwards, and end, at the middle of the orbital arch, by becoming blended with those of the orbicularis and occipito-frontalis muscles, by which it is concealed.

This muscle crosses the supra-trochlear branch of the ophthalmic nerve and the accompanying artery as they emerge from the orbit.

The *levator palpebræ superioris* is a muscle occupying the upper part of the orbit, but the insertion of which is seen in the dissection of the upper eyelid, in which it forms a broad fibrous expansion which curves downwards towards its margin, and is inserted under cover of the orbicularis muscle into the forepart of the tarsal cartilage. It will be described along with the muscles of the orbit.

**ACTIONS.**—The orbicularis palpebrarum closes the eyelids. In the ordinary closure of the eye, it is chiefly the upper lid which moves, being depressed by the superior half of the ciliary part of the muscle ; but in forcible closure both eyelids move, and not only come together, but are drawn towards the nose at the same time that the eyebrows are drawn downwards and inwards, the whole fibres of the orbicularis being thus contracted and approached towards the tendo palpebrarum. In those circumstances the fibres which form the tensor tarsi, being contracted like the others, compress the lachrymal sac, and prevent the introduction into it of the lachrymal secretion from the conjunctiva. The corrugator muscles draw the skin of the forehead downwards and inwards, raising longitudinal furrows, as in frowning. The upper eyelid is supported by the levator palpebræ, and droops when that muscle is paralysed. On the other hand, paralysis of the orbicularis is attended by an inability to close the eyelids.

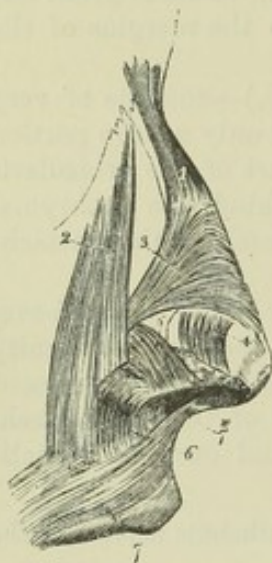**MUSCLES OF THE NOSE.**—Under this head may be conveniently grouped not only the compressor naris and smaller muscles which act upon the nose alone, but also the pyramidalis nasi which acts on the forehead, and the levator labii superioris alæque nasi whose action is common to the nose and lip.



The *pyramidalis nasi*, continuous with the innermost fibres of the frontalis muscle, extends downwards from the root of the nose, over the upper part of it, and terminates by a tendinous expansion in connection with the compressor naris muscle. The muscles of opposite sides, united superiorly, diverge slightly as they descend.

The *compressor naris*, a thin triangular muscle, arises narrow and fleshy from the canine fossa in the superior maxillary bone, and proceeding inwards, gradually expands into a thin aponeurosis, which is partly blended with that of the corresponding muscle of the opposite side, and with the pyramidalis nasi, and is partly attached to the cartilage of the nose. It is concealed at its origin by the proper elevator of the lip, and is crossed by the common elevator.

Fig. 155.

Fig. 155.—MUSCLES OF THE SIDE OF THE NOSE AND UPPER LIP.  $\frac{2}{3}$ 

1, pyramidalis nasi; 2, levator labii superioris alaeque nasi; 3, compressor naris or triangularis; 4, levator proprius alae nasi anterior; 5, levator proprius alae nasi posterior or dilatator; 6, depressor alae nasi; 7, orbicularis oris; 7\*, naso-labialis.

The *levator labii superioris alaeque nasi*, the common elevator of the lip and nose, lies along the side of the nose, extending from the inner margin of the orbit to the upper lip. It arises by a pointed process from the upper extremity of the nasal process of the superior maxillary bone, and, as it descends, separates into two fasciculi; one of these, much smaller than the other, becomes attached to the wing of the nose, whilst the other is prolonged to the upper lip, where it is blended with the orbicularis and the

special elevator muscle. It is subcutaneous, except at its origin, where the orbicularis palpebrarum overlaps it a little.

*Anomalous Fibres.*—Beneath the common elevator of the lip and ala of the nose, and connected by the lower end with the origin of the compressor naris, will be found a longitudinal muscular slip, more than an inch in length, attached exclusively to the superior maxillary bone. It was named "rhomboideus" by Santorini, and (in consequence of being attached only to one bone, and producing therefore no motion) "anomalus" by Albinus.

The *depressor alae nasi* is a small flat muscle which arises from the superior incisor fossa, and is inserted into the septum and posterior part of the ala of the nose. The external fibres curve forwards and downwards to the ala.

Besides the muscles above described there are other irregular and often indistinct fibres which cover the small alar cartilages of the nose. Of these the following may be distinguished.

The *levator proprius alae nasi posterior*, or *dilatator naris posterior*, is attached to the margin of the ascending process of the superior maxillary bone and the smaller (sesamoid) cartilages of the ala nasi on the one hand, and to the skin on the other. Another set of fibres, the *levator proprius alae nasi anterior*, or *dilatator naris anterior*, is interposed between the cartilage of the aperture of the nose and the skin, to both of which it is attached.

*ACTIONS.*—The pyramidalis muscle, being continuous with the occipito-frontalis, is the means of giving that muscle a more fixed attachment to the dorsum of the nose,



and must aid it in drawing down the integument of the forehead; but it probably acts also as an opponent to the compressor naris muscle. The compressor naris, acting along with its fellow of the other side, depresses the cartilaginous part of the nose, and to some extent also compresses the alæ together. The actions of the other muscles are sufficiently indicated by their names; the dilatation of the alæ is perceptible in natural inspiration, and is well marked in dyspnoea.

**MUSCLES OF THE LIPS AND MOUTH.**—Around the orifice of the mouth are situated an orbicular muscle with concentric fibres, and numerous other muscles, whose fibres converge towards the aperture, viz., superiorly the common elevator of the lip and nose already described, the proper elevator of the upper lip, the elevator of the angle of the mouth and the zygomatic muscles, laterally the risorius and buccinator muscles, and, inferiorly, the depressor of the angle of the mouth and that of the lower lip; and lastly, acting indirectly on the lower lip, the levator menti.

The *orbicularis oris*, or *sphincter oris*, consists of a labial or inner, and a facial or peripheral part. The *labial* or *marginal portion* reaches outwards from the oral aperture as far as the red part of the lip, and forms a slightly convex fasciculus of pale fine fibres closely applied to each other. Its fibres are free from bony attachment, and are traceable from one lip to another round the corner of the mouth. The *facial portion*, thinner and wider than the other, blends by its outer border with the several muscles that converge to the mouth from the contiguous parts of the face, and is more particularly stretched outwards by its attachment to the buccinator muscle, the fibres of which seem almost to be continuous with the deeper part of the orbicularis. Besides those fibres it has others that are attached to the subjacent cartilage and bone; viz., in the upper lip two bundles for each half; and in the lower lip one for each. In the upper lip one of the fleshy slips (*accessorius orbicularis superioris*) is thin and weak, and is attached opposite the incisor teeth, close to the alveolar edge of the upper jaw-bone; and the other, thicker and pointed, is fixed to the septum of the nose. In the lower lip the reinforcing fasciculus (*accessorius orbicularis inferioris*) arises from the surface of the lower jaw, near the root of the canine tooth, and external to the levator labii inferioris. From these points of attachment the fibres are directed outwards towards the angle of the mouth and blend with the rest.

To the inner part of the orbicularis oris muscle the skin of the lips is closely connected, whilst over the outer part fatty tissue is interposed between them. The deep surface is in contact with the mucous membrane and the labial glands, as well as with the coronary arterial arch in each lip.

The *levator labii superioris* arises immediately above the infra-orbital foramen, close to the lower border of the orbit, from the superior maxillary and malar bones, and passes downwards and a little inwards to be blended with the orbicularis and other muscular fibres in the upper lip.

At its origin this muscle is overlapped by the orbicularis palpebrarum, but its lower part is subcutaneous; it partly conceals the levator anguli oris, and the compressor naris, and beneath it the infra-orbital vessels and nerve emerge from the canal of that name.

The *levator anguli oris*, or *musculus caninus*, arises in the canine fossa immediately below the infra-orbital foramen, inclines downwards and slightly outwards, and is inserted into the angle of the mouth.

At its origin this muscle is concealed by the elevator of the upper lip; its anterior



surface supports the infra-orbital nerve and artery, which separate it from the preceding muscle; the posterior surface lies on the superior maxilla and the orbicularis and buccinator muscles, with which and the depressor anguli oris the fibres are blended.

The *zygomatici* are two narrow and subcutaneous fasciculi of muscular fibres, extending obliquely from the most prominent part of the cheek to the angle of the mouth, one being thicker and longer than the other.

a. The *zygomaticus minor*, a very small muscle, arises from the anterior and inferior part of the malar bone, and inclines downwards and forwards to terminate by joining the outer margin of the levator labii superioris; sometimes near the origin of that muscle. It lies internal to the *zygomaticus major*, but distinct from it in the whole length, and is sometimes joined by some fibres of the orbicularis palpebrarum: in some instances it is replaced by a fleshy slip from that muscle; in others it is altogether wanting.

b. The *zygomaticus major*, placed externally to the smaller muscle of the same name, arises from the malar bone near the zygomatic suture, from which it descends to the angle of the mouth, where it is continued into the orbicularis and depressor anguli oris.

The *risorius* or smiling muscle (Santorini), consisting of some very thin fasciculi, commences in the fascia over the masseter, or on the parotid gland, and extending transversely inwards in the fat of the cheek, joins the orbicularis and depressor anguli oris at the angle of the mouth. It is united with the fibres of the platysma close to their termination, and is by many regarded as a part of that muscle.

The *buccinator* muscle consists of a flat and thin but strong set of fibres in contact with the mucous membrane, and forming a considerable part of the wall of the mouth. It is attached by its upper and lower margins to the outer surface of the alveolar parts of the maxillary bones, outside the molar teeth, and between these bones it is fixed behind to a narrow band of tendinous fibres, the *pterygo-maxillary ligament*, a structure which extends from the internal pterygoid plate to the posterior extremity of the mylohyoid ridge of the lower jaw close to the last molar tooth, and separates the buccinator muscle from the superior constrictor of the pharynx. From these points the fibres of the muscle are directed forwards, approaching each other, so that the muscle is narrowed and proportionally thickened near the angle of the mouth, where it becomes incorporated with the orbicularis. The fibres near the middle of the muscle cross each other, those from above entering into the lower lip, and those from below into the upper one; but the higher and lower fibres are directed into the corresponding lip without decussation.

The buccinator is covered and supported by a thin fascia, which is closely adherent to the muscular fibres; and is overlapped by the triangularis oris, the terminal fibres of the platysma myoides, and by the facial artery and vein; it is also covered by the masseter and *zygomatici*, from which it is separated by a quantity of soft adipose tissue of a peculiar character. Opposite the second molar tooth of the upper jaw, its fibres give passage to the duct of the parotid gland.

The *depressor anguli oris*, or *triangularis oris*, is broad at its origin from a line on the external surface of the lower jaw near its base; passing upwards it is collected into a narrower bundle which is inserted into the orbicularis at the angle of the mouth.

This muscle is covered by the skin, and, at its insertion, by the *zygomaticus major*, under which its fibres pass; it conceals part of the buccinator and of the depressor of the lower lip.



Fig. 156.

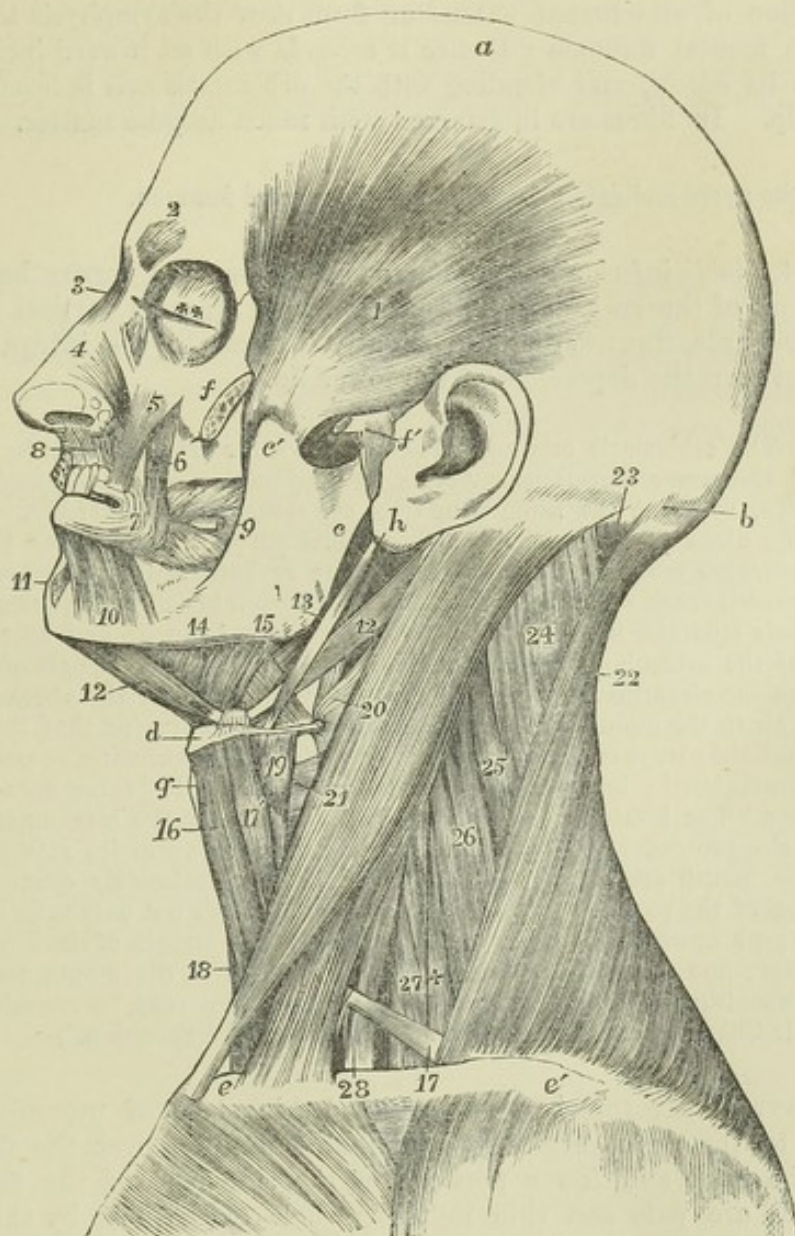


Fig. 156.—DEEP VIEW OF THE MUSCLES OF THE LEFT SIDE OF THE HEAD AND NECK (modified from Bourguery).  $\frac{1}{2}$

*a*, vertex of the head; *b*, superior curved line of the occipital bone; *c*, ramus of the lower jaw; *c'*, its coronoid process; *d*, body of the hyoid bone; *e*, sternal end of the clavicle; *e'*, acromial end; *f*, malar bone divided to show the insertion of the temporal muscle; *f'*, zygoma divided, and external lateral ligament of the jaw; *g*, thyroid cartilage; *h*, placed on the lobe of the auricle, points to the styloid process; 1, temporal muscle; 2, corrugator supercilii; 3, pyramidalis nasi; 4, lateral cartilage of the nose covered by the triangularis nasi; 5, levator labii superioris proprius; 6, levator anguli oris; 7, outer part of the orbicularis oris, the part below the nose has been removed to show more deeply 8, depressor alae nasi; 9, placed on the ramus of the jaw, points to the buccinator muscle, through which the parotid duct is seen passing; 10, quadratus menti; 11, levator menti; 12, 12, anterior and posterior bellies of the digastric; 13, placed on the angle of the jaw, points to the stylo-hyoid muscle; 14, points to the mylo-hyoid; 15, to the hyoglossus, between which and 13, is seen a part of the stylo-glossus; 16, sterno-hyoid; 17, on the clavicle, indicates the lower, and 17', the upper belly of the omo-hyoid; 18, a small part of the sterno-thyroid; 19, thyro-hyoid; 20, 21, on the sterno-mastoid muscle, point, the first to the middle, the second to the lower constrictor of the pharynx; 22, trapezius; 23, upper part of the complexus; 24, splenius capitis; 25, splenius colli; 26, levator scapulae; 27, middle scalenus; +, posterior scalenus; 28, anterior scalenus.



The *depressor labii inferioris*, or *quadratus menti*, arises from the lower jaw by a line of attachment extending from near the symphysis to a little beyond the mental foramen; thence it ascends with an inward inclination, unites with its fellow, and blending with the orbicularis oris is inserted into the lower lip. Its fibres are intermixed with much adipose matter.

It covers the nerve and artery issuing from the mental foramen.

The *levator labii inferioris* or *levator menti* arises by a narrow head from the incisor pit of the lower jaw, and expanding in a nearly vertical plane, is directed forwards, downwards, and slightly inwards to the integument of the chin between the depressors of the lower lip.

**ACTIONS.**—The orbicularis oris acting alone draws the lips together in both the vertical and transverse directions. Acting in conjunction with the buccinators it closes the lips, while at the same time they are elongated transversely. Its facial portion acting alone projects the lips. The labial portion, when acting in concert with the converging muscles, tightens the lips, one or both, against the teeth. The convergent muscles each draw their oral points of insertion in a direction corresponding to that of their muscular fibres. The common elevator of the lip and nose and the upper part of the orbicularis oris act on both the upper lip and the ala of the nose together—the one elevating, the other depressing them. When the cheeks are distended with air in the mouth, it is by the action of the buccinator that the rush of the air through the narrowed oral aperture is regulated, as in whistling, or performance on a wind instrument; hence the name “trumpeter’s muscle” sometimes given to the buccinator. The levator menti not only draws upwards the integument of the chin, but it also protrudes the lower lip, as in pouting. The muscles attached to the angles of the mouth are, along with others of the face, intimately connected with the expression of the passions: those which pass downwards not only raise the upper lip, but also push upwards the cheek, and thus elevate the margin of the lower eyelid, as in laughter; and those which descend from the angle of the mouth depress that part, as in weeping. (On the action of the facial muscles may be consulted, more especially, Sir Charles Bell, “Anatomy and Philosophy of Expression.”)

**THE PLATYSMA MYOIDES** is a pale coloured thin sheet of muscular fibres, superficial to the deep cervical fascia, and extending over the front and sides of the neck and lower portions of the side part of the face. Its fibres, which are pale and thin in their whole extent, rise by thin bands from the clavicle and acromion, and from the fascia covering the upper part of the deltoid, pectoral, and trapezius muscles; thence they proceed upwards and inwards over the clavicle and the side of the neck, gradually narrowing and approaching the muscle of the opposite side. At the lower jaw the greater number of the fibres are inserted into the side of that bone from the symphysis to the attachment of the masseter; the inner fibres mingle with those of the opposite platysma in front of the symphysis, and even cross from the one side to the other below the chin, for about an inch, those of the right side overlapping those of the left; and the posterior fibres are prolonged upon the side of the face as far as the angle of the mouth, where they become blended with the muscles in that situation, or in some instances they reach the fascia over the parotid gland, and the cheek-bone. The uppermost fibres pass into those receiving the name of risorius.

**ACTION.**—The platysma, being much less developed in man than in animals, has a comparatively limited action in the human subject; it assists in drawing the angle of the jaw downwards and outwards, and protects parts more deeply situated in the



neck. It is the only representative of a subcutaneous group of muscles largely developed in most mammals, by which very varied movements of the skin and some superficial parts may be given, as, for example, when the horse communicates a rapid motion to the skin to free itself from insects, or the dog shakes off the water after swimming, or the hedgehog elevates its spines; and which is known collectively as the *panniculus carnosus*.

## MUSCLES OF THE ORBIT.

In this group will be described seven muscles, namely, the elevator of the upper eyelid already alluded to, and six muscles of the eyeball, viz., the four straight and the two oblique muscles. Of these muscles the inferior oblique alone is confined to the fore part of the orbit, all the rest take their origin at its back part, and pass longitudinally forwards to their insertions in front.

The *levator palpebræ superioris* is a slender muscle, which arises, pointed and tendinous, above and in front of the margin of the optic foramen, and passing forwards over the eyeball, ends in a fibrous expansion inserted into the anterior surface of the tarsal cartilage of the upper eyelid.

Between this muscle and the roof of the orbit are situated the fourth and frontal nerves, and beneath it are the superior rectus muscle and the globe of the eye. In the lid, it is placed behind the palpebral ligament, close to the *membrana conjunctiva*.

The four straight muscles of the eye surround at their origin the optic nerve, and passing forwards from that point, are inserted into the front of the globe of the eye at four opposite equi-distant parts, by delicate expanded tendons which become blended into one at their termination.

The *superior rectus* arises close in front of the foramen opticum, and beneath the *levator palpebræ*; the *inferior rectus*, *internal rectus*, and *external rectus* are united in a common tendinous attachment around the circumference of the optic foramen, except above. But the external rectus differs from the others in having two heads of origin; the upper head unites with that of the superior rectus, the second head arises from a bony point on the lower margin of the sphenoidal fissure close to its wider inner end; and other fibres are implanted into a fibrous band between the heads of origin. The four recti thus attached posteriorly, pass forwards, one above, one below, and one on each side of the eyeball, becoming flattened as they lie in contact with it, and are inserted by short membranous tendons into the fore part of the sclerotic coat, at an average distance of four lines from the margin of the cornea.

In length and breadth there are some differences among these muscles. The external rectus exceeds the internal one in length. On the other hand, the internal rectus has some advantage in width, being broader than any; and the superior appears rather the narrowest of all. Between the heads of the external rectus is a narrow interval, which gives transmission to the third and sixth nerves and the nasal branch of the fifth nerve, with the ophthalmic vein.

The *superior oblique* or *trochlearis* is a narrow elongated muscle, placed at the upper and inner part of the orbit, internally to the *levator palpebræ*. It arises about a line in front of the inner part of the optic foramen; thence it proceeds towards the internal angle of the orbit, and terminates in a round tendon, which passes through a fibro-cartilaginous ring or pulley



(trochlea) attached to the fovea trochlearis of the frontal bone; it is there reflected outwards and backwards, and passes between the eye and the superior rectus, to be inserted into the sclerotic coat midway between the superior and external recti muscles, nearly equi-distant from the cornea and the entrance of the optic nerve. A synovial sheath lines the contiguous surfaces of the tendon and pulley.

This muscle is covered by the roof of the orbit, the fourth nerve entering its upper surface; and beneath it lie the nasal nerve and the internal rectus muscle.

Fig. 157.

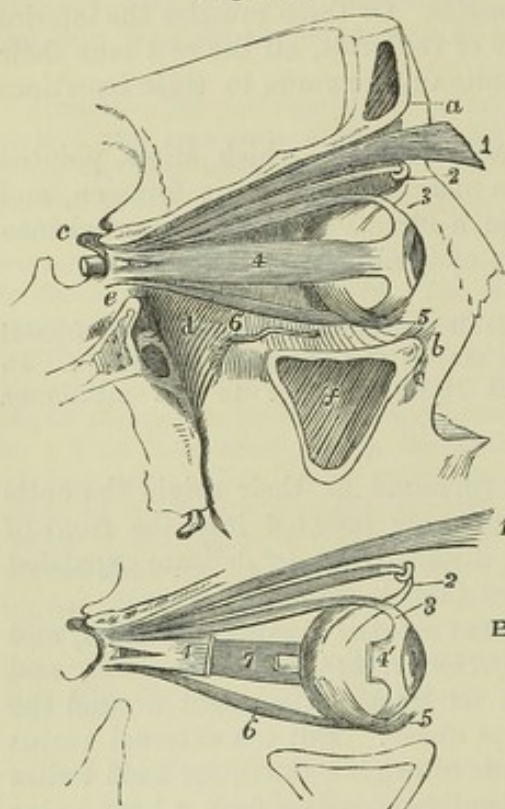


Fig. 157.—A, VIEW OF THE MUSCLES OF THE RIGHT ORBIT, FROM THE OUTSIDE, THE OUTER WALL HAVING BEEN REMOVED.  $\frac{1}{2}$

B, EXPLANATORY SKETCH OF THE SAME MUSCLES.

*a*, supraorbital ridge; *b*, lower margin of the orbit formed by the superior maxillary bone; *c*, anterior clinoid process; *d*, posterior part of the floor of the orbit above the speno-maxillary fossa; *e*, side of the body of the sphenoid bone below the optic foramen and sphenoidal fissure; *f*, sinus maxillaris; 1, anterior part of levator palpebræ superioris, where it is inserted into the eyelid; 2, pulley and tendon of the superior oblique muscle; 3, tendon of the superior rectus muscle at its insertion upon the eyeball; 4, in A, outer surface of the external rectus; 4', in B, the anterior or inserted tendon of the same muscle, a part of which has been removed; the double origin of the muscle is shown at the apex of the orbit; 5, the inferior oblique muscle crossing the eyeball below the inferior rectus; 6, the inferior rectus; 7, in B, the inside of the internal rectus, seen in consequence of the removal of a part of the external

rectus, and near it, the end of the optic nerve cut short close to the place of its entrance into the eyeball.

The *inferior oblique* is the only muscle of the eye which does not take origin at the apex of the orbit. It arises from a minute depression in the orbital plate of the superior maxillary bone, just within the anterior margin of the orbit, and close to the external border of the lachrymal groove. The muscle inclines outwards and backwards between the inferior rectus and the floor of the orbit, and ends in a tendinous expansion, which passes between the external rectus and the eyeball, to be inserted on the external and posterior aspect of the globe.

**ACTIONS.**—The recti muscles turn the eye upwards, downwards and from side to side, thus placing the axis of the eye in these or any intermediate directions. Evidence is against the supposition that the recti muscles are capable of altering the position of the eyeball in an antero-posterior direction, nor is it probable that they can in any perceptible degree change its form. (Jacob, "On Paralytic, Neuralgic, and other Nervous Diseases of the Eye," in "Dublin Med. Press," 1841; G. Johnson, the article "Orbit," in "Todd's Cyclopaedia of Anatomy and Physiology.")



## MUSCLES OF THE JAW.

The masseter, temporal, and two pterygoid muscles form a group of muscles of mastication, which may be properly considered together.

The *masseter* is a thick quadrate muscle, whose fibres are arranged so as to form two portions differing in size and direction. The *superficial* part arises from the anterior two-thirds of the lower border of the zygomatic arch, chiefly by thick tendons projecting down between the muscular fasciculi, to which they afford an extensive surface of origin: its fibres proceed downwards and a little backwards to be inserted into the lower half of the ramus of the jaw, extending as far as the angle. The fibres of the *deep* part of the muscle, much shorter than those of the superficial part, and directed downwards and forwards, arise from the posterior third of the lower border and from all the deep surface of the arch, and becoming united with the superficial part, are inserted into the upper half of the ramus of the jaw, including the coronoid process: only the upper and back part of this portion of the muscle is left uncovered by the superficial portion.

The external surface of the masseter muscle is covered for the most part only by the skin and fascia; it is, however, overlapped behind by the parotid gland, and crossed by its duct; the branches of the facial nerve and the transverse facial artery also rest upon it. Its inner surface is towards the buccinator, from which it is separated by some soft adipose tissue; it is in intimate contact with the ramus of the jaw, and covers a nerve and vessels which enter it over the sigmoid notch of that bone.

The *temporal* muscle (*crotaphite*—Winslow) is fan-shaped, occupies the temporal fossa, and arises from the whole surface of that fossa, with the exception of the anterior or malar wall; it likewise takes origin from the deep surface of the temporal fascia, which passes down over it to the zygoma, and some of its posterior fibres arising from this fascia are blended with the deep fibres of the masseter muscle. The direction of the anterior fibres is nearly vertical, that of the middle fibres oblique, and that of the posterior fibres at first horizontal. The fasciculi from this extensive origin converge as they descend, and all terminate in a tendon, which, emerging from the interior of the muscle, is implanted into all the inner surface as well as the anterior border of the coronoid process of the lower jaw-bone, as far down as the union of the body and ramus of the jaw, where they are blended with the origin of the buccinator muscle.

The upper part of the muscle is in contact with the temporal fascia; the lower and anterior part is imbedded in fat continuous with that which lies between the masseter and buccinator muscles; the insertion of the tendon is mainly concealed by the lower jaw. Between the muscle and the temporal fossa are the deep temporal arteries and the temporal nerves, which penetrate its substance. In contact with the deep surface of the muscle near its insertion the buccal nerve descends, and at the posterior border of the insertion the masseteric nerve and artery emerge.

The *internal pterygoid* muscle is related to the inner surface of the ramus of the jaw, somewhat in the same manner as the masseter is to the outer. It arises from the pterygoid fossa; its fibres, tendinous and fleshy, being attached mostly to the inner surface of the external pterygoid plate, and that portion of the tuberosity of the palate-bone which is situated between the pterygoid plates. Thence it is inclined downwards, with a direction



backwards and outwards, and is inserted into the angle and the inner surface of the ramus of the jaw as high as the dental foramen.

Between the external surface of the muscle and the ramus of the maxilla are the internal lateral ligament and the internal maxillary vessels, with the dental artery and nerve; and at its upper part the muscle is crossed by the external pterygoid muscle. Its inner surface, whilst in the pterygoid groove, is in contact with the tensor palati muscle; and lower down it corresponds with the superior constrictor of the pharynx.

Fig. 158.

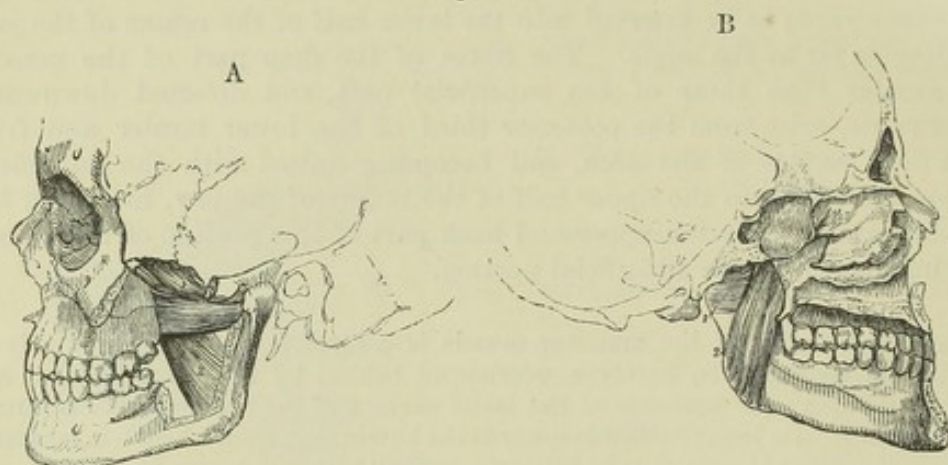


Fig. 158.—VIEWS OF THE PTERYGOID MUSCLES—A, FROM THE OUTER SIDE; B, FROM THE INNER SIDE.  $\frac{1}{4}$

1, external pterygoid, placed on the upper head in A, on the lower head in B; 2, internal pterygoid—the outer surface in A, the inner surface in B.

Fig. 159.

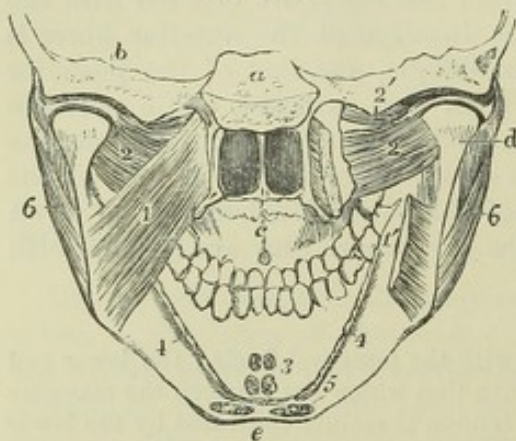


Fig. 159.—VIEW OF A DISSECTION OF THE LOWER PART OF THE SKULL AND FACE, FROM BEHIND, DESIGNED TO SHOW THE ATTACHMENTS OF THE PTERYGOID AND SOME OTHER MUSCLES (modified from Bourgery).  $\frac{1}{3}$

*a*, placed above the transverse section of the basilar part of the occipital bone, below which are seen the posterior nares and palate; *b*, transverse section through the temporal bone; *c*, roof of the mouth; *d*, back of the head and neck of the lower jaw, above which are seen the synovial cavities of the joint divided by the interarticular fibro-cartilage; *e*, placed below the symphysis menti; 1, on the left side the internal pterygoid muscle entire; 1', on the right side the lower part

of the same muscle, of which the middle portion has been removed to show the external pterygoid; 2, the lower thick portion of the external pterygoid; 2', on the right side, points to the upper smaller portion of the muscle, attached in part to the interarticular plate; 3, is placed at the side of small portions of the genio-hyoid and genio-hyo-glossus muscles cut short at their attachment to the lower and upper genial tubercles; 4, the attachment of the mylo-hyoid muscle cut short; 5, indicates the attachment at the side of the symphysis of the anterior belly of the digastric muscle; 6, the masseter muscle descending to the angle of the jaw.

The *external pterygoid* muscle, occupying the zygomatic fossa, arises by two fleshy heads placed close together, the superior of which is attached to



that part of the external surface of the great wing of the sphenoid bone which looks downwards, and to the ridge which separates that surface from the temporal fossa; while the inferior, which is larger, is attached to the outer surface of the external pterygoid plate, and to the tuberosities of the palate and upper maxillary bones. The fibres from both heads pass backwards, and being mixed with tendon, converge to be inserted into the fore part of the neck of the condyle of the lower jaw, and into the inter-articular fibro-cartilage of the temporo-maxillary articulation.

The internal maxillary artery is placed on the outer surface of this muscle, passing thence between the heads of origin; while the buccal nerve issues from between those heads. The deep surface rests against the upper part of the internal pterygoid muscle, whose direction it crosses, also the internal lateral ligament of the lower jaw, the inferior maxillary nerve, and the middle meningeal artery. The upper border is in contact with the great wing of the sphenoid bone, and is crossed by the deep temporal nerve and arteries.

**ACTIONS.**—The masseter, temporal, and internal pterygoid muscles are elevators of the lower jaw, and generally act in concert, bringing the lower in contact with the upper teeth. The opposite movement of depressing the jaw, not being opposed by any resisting obstacle, requires less force, and is effected by muscles of much smaller size, the principal of which is the digastric muscle hereafter described. The external pterygoid muscle, having the great body of its fibres nearly horizontal, draws forwards the condyle of the jaw, and when the muscles of both sides act together, the lower jaw is protracted so as to make the inferior incisor teeth project beyond the upper incisors; but their more usual mode of action is alternately on the two sides, as in the grinding movement of the molar teeth, in which a variety of muscular actions are combined. The external pterygoid muscles also, though chiefly horizontal movers of the jaw, likewise contract in opening the mouth, the condyles of the jaw being drawn forward in that movement. The masseter and internal pterygoid muscles assist in protracting the jaw; the temporal alone is a retractor. The two pterygoid muscles of one side, in advancing one condyle of the jaw, necessarily throw the teeth towards the opposite side.

#### SUBMAXILLARY MUSCLES.

##### A. MUSCLES CONNECTING THE HYOID BONE WITH THE SKULL.

The *digastric* muscle, extending from the temporal bone to the lower jaw, consists of two elongated muscular bellies united by an intervening rounded tendon, which is connected with the hyoid bone. The posterior belly, which is longer than the anterior, arises from the digastric groove of the temporal bone, and tapers downwards, forwards, and inwards: the anterior is attached to a rough depression situated on the lower border of the jaw-bone, close to the symphysis; it is less tapering than the posterior belly, and is directed downwards and backwards. The intervening tendon is connected with the body and great cornu of the os hyoides by aponeurotic fibres at right angles to its own, and by the fleshy fibres of the stylo-hyoid muscle, through which the tendon passes.

The anterior belly, placed immediately beneath the deep cervical fascia, rests on the mylo-hyoid muscle; it is connected with its fellow of the opposite side by dense fascia, and occasionally is united by muscular fibres to it or to the mylo-hyoid muscle. The posterior belly is covered by the mastoid process and the muscles arising from that bone, and crosses both carotid arteries and the jugular vein.



The *stylo-hyoid* muscle lies close to the posterior belly of the digastric muscle, being a little behind and beneath it. It arises from the base of the styloid process of the temporal bone at the external surface; and from this place it inclines downwards and forwards, to be inserted into the os hyoides at the union of the great cornu with the body. Its fibres are usually divided into two fasciculi near its insertion, for the transmission of the tendon of the digastric muscle.

The upper part of the stylo-hyoid muscle lies deeply, being covered by the sternomastoid and digastric muscles, and by part of the parotid gland; the middle crosses the carotid arteries; the insertion is comparatively superficial.

This muscle is sometimes wanting; occasionally a second is present (*stylo-hyoideus alter*,—Alb.). The position too may be varied—it has been found to the inner side of the external carotid artery instead of over that vessel. ("The Anatomy and Operative Surgery of the Arteries," by R. Quain, plate 12, fig. 5.)

Fig. 160.

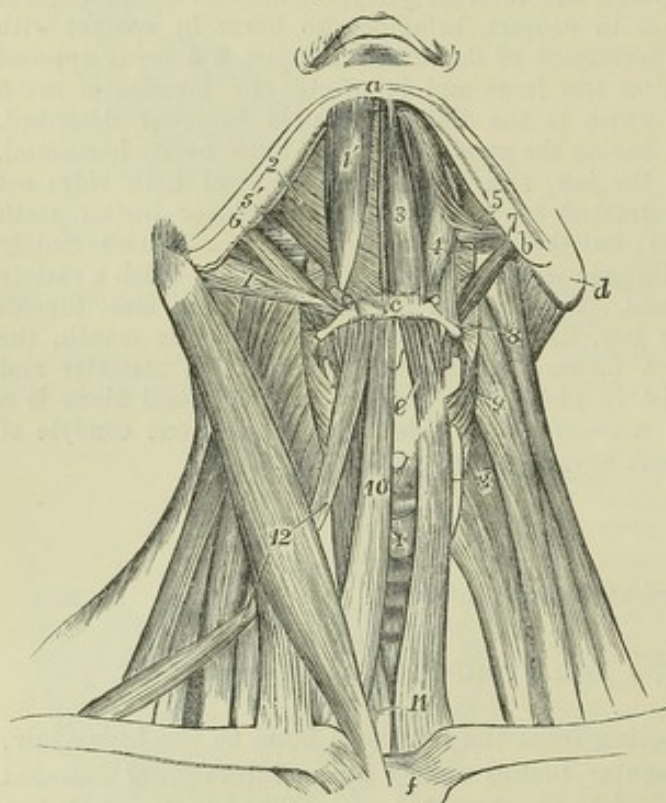


Fig. 160.—VIEW OF THE SUB-MAXILLARY MUSCLES AND THE DEPRESSORS OF THE HYOID BONE AND LARYNX, FROM BEFORE.  $\frac{1}{3}$

On the right side, the platysma alone has been removed; on the left side both the bellies of the digastric, the stylo-hyoid, the mylo-hyoid, the sterno-hyoid, and omo-hyoid muscles have been removed: *a*, symphysis; *b*, angle of the lower jaw; *c*, middle of the body of the hyoid bone; *d*, mastoid process; *e*, thyroid cartilage; *f*, upper part of the sternum; *g*, lateral lobe, and +, isthmus of the thyroid gland; above +, the front of the cricoid cartilage covered by the crico-thyroid muscle; 1, posterior belly; 1', anterior belly of right digastric muscle; 2, right mylo-hyoid; 3, left genio-hyoid; 4, hyo-glossus; 5, stylo-glossus; 5', a portion of it seen on right side; 6,

stylo-hyoid of the right side; 7, stylo-pharyngeus of the left side; 8, placed on the levator scapulae, points to the left middle constrictor of the pharynx; 9, placed on the middle scalenus, points to the left inferior constrictor; 10, right sterno-hyoid; 11, placed on the left sterno-thyroid, points also to the lower part of the right muscle; 12, placed on the right sterno-mastoid, points to the upper and lower bellies of the right omo-hyoid (*e*, points to the thyro-hyoid muscle).

The *mylo-hyoid* muscle arises from the mylo-hyoid ridge along the inner surface of the lower jaw, extending from the last molar tooth to the symphysis. The posterior fibres are inserted into the body of the os hyoides; the rest, proceeding parallel to the fibres behind, join at an angle with those of the corresponding muscle, forming with them a sort of raphé along the middle line, from the symphysis of the jaw to the os hyoides. Thus the two muscles together form a floor below the anterior part of the mouth (*diaphragma oris* of Meyer).



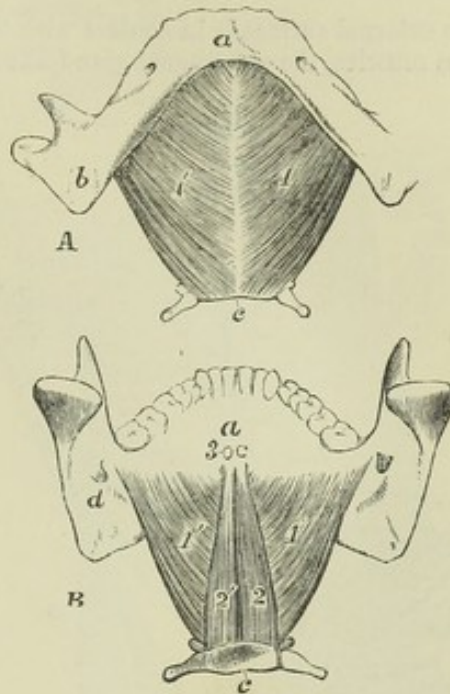
The lower surface of the mylo-hyoid muscle is covered by the digastric muscle, the sub-maxillary gland, and the sub-mental vessels and nerve. The deep surface which looks upwards and inwards to the mouth, is in contact with the genio-hyoideus and part of the hyo-glossus and stylo-glossus muscles, the ninth and gustatory nerves, the sub-lingual gland, and the duct of the sub-maxillary gland. The posterior border alone is free and unattached, and behind it the duct of the sub-maxillary gland turns in passing to the mouth.

Fig. 161.

Fig. 161.—A, THE LOWER JAW AND HYOID BONE, FROM BELOW, WITH THE MYLO-HYOID MUSCLES ATTACHED.

B, THE SAME, FROM BEHIND, WITH THE MYLO-HYOID AND GENIO-HYOID MUSCLES ATTACHED.  $\frac{1}{3}$

*a*, the symphysis; *b*, the angle of the lower jaw; *c*, the lower border of the body of the hyoid bone; *d*, in B, the inferior dental foramen and upper end of the mylo-hyoid ridge: in A, 1, the left, 1', the right mylo-hyoid muscle from below: in B, 1, the right, 1', the left mylo-hyoid muscle from above; 2, the right, 2', the left genio-hyoid muscle from above; 3, the cut ends of the attachment of the genio-glossi muscles to the superior genial spines.



The *genio-hyoid* muscle, a narrow muscle resting on the mylo-hyoid, and in contact with its fellow in the middle line, arises from the inferior of the two genial tubercles behind the symphysis of the jaw, and is inserted into the body of the hyoid bone.

It is in contact above with the lower border of the genio-glossus muscle.

**ACTIONS.**—The genio-hyoid and mylo-hyoid muscles draw the hyoid bone upwards and forwards, as happens in the first stage of deglutition. The stylo-hyoid muscle draws it upwards and backwards, and comes into action in raising the pitch of the voice. The anterior belly of the digastric muscle acts by itself like the genio-hyoid, and the posterior half like the stylo-hyoid; but when both bellies act together, they are capable of producing two movements, in one of which, when the lower jaw is fixed, the hyoid bone is elevated, and in the other, when the hyoid bone is held downwards by the depressing muscles, the digastric muscle opens the mouth by depressing the lower jaw.

#### B. MUSCLES OF THE TONGUE.

The tongue is a muscular organ attached posteriorly to the hyoid bone, and inferiorly to the lower jaw. It is composed partly of fibres peculiar to itself—the *intrinsic* muscles, which will be noticed in another place; partly of muscles arising from neighbouring parts—the *extrinsic* muscles about to be described.

The *genio-glossus* or *genio-hyo-glossus* muscle is fan-shaped, and is placed vertically in contact with its fellow close to the mesial plane. It arises by



a short tendon from the superior genial tubercle behind the symphysis of the jaw : from this its fibres diverge and are inserted in an extensive range, viz., those which are most inferior into the body of the hyoid bone, and a few into the side of the pharynx; those which are most superior into the tip of the tongue; and the intermediate fibres into its whole length, diverging transversely in its substance.

The external surface is in contact with the lingualis inferior, hyo-glossus and stylo-glossus muscles, the sub-lingual gland, the ranine vessels, and the nerves of the tongue.

Fig. 162.

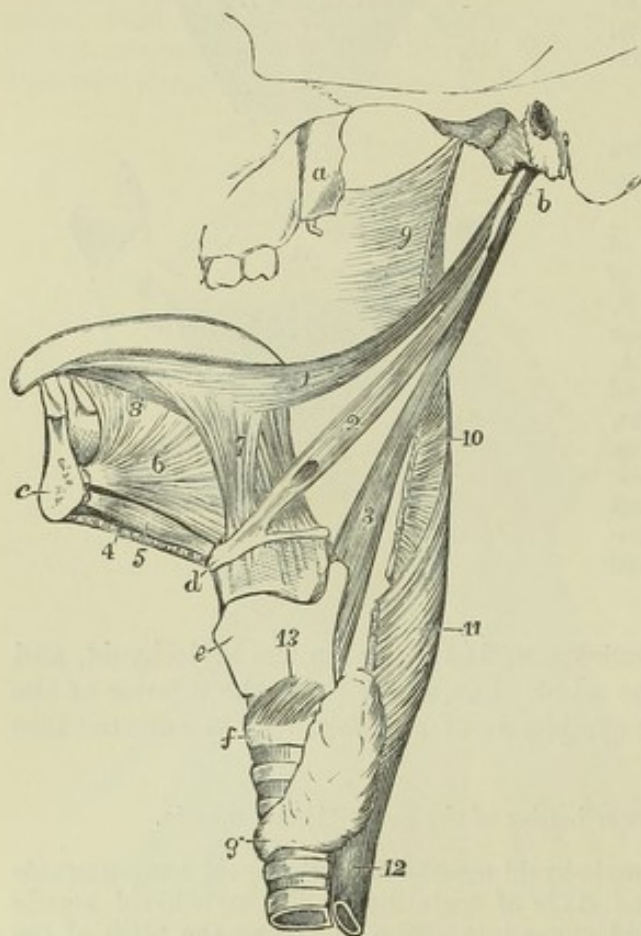


Fig. 162.—SKETCH OF A PART OF THE LEFT SIDE OF THE SKULL, THE RIGHT SIDE OF THE BODY OF THE LOWER JAW, AND THE TONGUE, HYOID BONE, LARYNX, AND TRACHEA, SHOWING THE EXTRINSIC MUSCLES OF THE TONGUE, &c.  $\frac{1}{2}$

*a*, external pterygoid process; *b*, styloid process; *c*, section of the symphysis of the lower jaw; *d*, front of the body of the hyoid bone; *e*, thyroid cartilage; *f*, front of the cricoid cartilage; between *d* and *e*, the thyro-hyoid membrane and ligament; *g*, isthmus of the thyroid gland in front of the trachea; 1, left stylo-glossus muscle; 2, stylo-hyoid; 3, stylo-pharyngeus; 4, cut edge of the mylo-hyoid; 5, genio hyoid; 6, genio-hyo-glossus; 7, hyo-glossus; 8, lingualis inferior; 9, part of the superior constrictor of the pharynx; 10, back part of the middle constrictor; 11, inferior constrictor; 12, upper part of the oesophagus; 13, crico-thyroid muscle.

The *hyo-glossus* is a flat quadrate muscle, arising from the whole length of

the great cornu of the hyoid bone, from the lateral part of the body of that bone, and from the small cornu; the fibres arising from those three sources (formerly distinguished as *cerato-glossus*, *basio-glossus*, and *chondro-glossus* respectively—Albinus) pass upwards to be inserted into the side of the tongue, blended with the *stylo-glossus* and *palato-glossus* muscles.

The *hyo-glossus* is concealed by the *digastric* and *mylo-hyoid* muscles, except at its posterior inferior angle; the deep part of the sub-maxillary gland rests on its surface, and it is crossed from below upwards by the *hypo-glossal* nerve, the *Whartonian* duct, and the *gustatory* nerve. It covers the *genio-glossus* and the origin of the middle constrictor of the pharynx, together with the *lingual* artery and *glosso-pharyngeal* nerve.

The *stylo-glossus*, the shortest of the three muscles which spring from the styloid process, arises from that process not far from its point, and from the



stylo-maxillary ligament, to which in some cases the greater number of its fibres are attached by a thin aponeurosis: passing forwards slightly downwards, it is inserted along the side and under part of the tongue as far as the tip, its fibres decussating, and becoming blended with those of the hyo-glossus and palato-glossus muscles.

This muscle lies deeply beneath the parotid gland, and is crossed by the gustatory nerve. It arises occasionally from the inner side of the angle of the lower jaw; and cases have been observed in which it was altogether absent.

Fig. 163.—VIEW OF PART OF THE LEFT SIDE OF THE HEAD AND THROAT, TO SHOW THE DEEP MUSCLES OF THE CHEEK, PHARYNX, &c. (modified from Cloquet).  $\frac{1}{3}$

The pharynx has been distended by stuffing. *a*, external pterygoid process; *b*, styloid process, with short portions of the three styloid muscles attached; *c*, body of the lower jaw, which has been divided at the place where the pterygo-maxillary ligament + is attached; *d*, body of the hyoid bone; *e*, thyroid cartilage; *f*, cricoid cartilage; *g*, interval between the first and second ring of the trachea; 1, outer part of the orbicularis oris muscle; 2, buccinator; 3, superior constrictor of the pharynx; 4, middle constrictor; 5, inferior constrictor; 6, œsophagus; 7, points by three lines to the lower parts of the stylo-glossus, stylo-hyoid, and stylo-pharyngeus muscles respectively; 8, mylo-hyoid; 9, hyo-glossus, of which a small part is removed posteriorly to show the attachment of the middle constrictor; 10, thyro-hyoid.

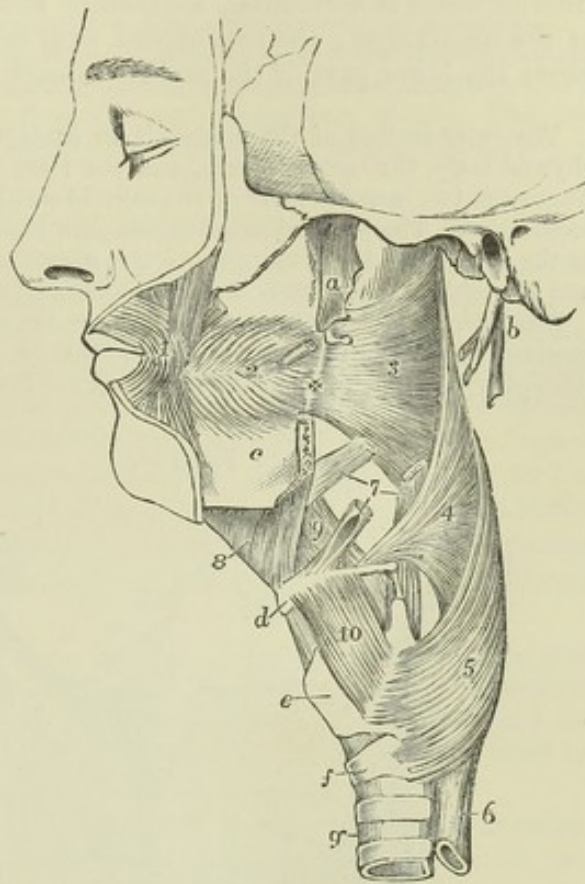
**ACTIONS.**—The genio-glossus muscle has a complicated action, one part protruding and another retracting the tongue, while a third depresses the middle portion of the organ. Protrusion is effected by contraction chiefly of its posterior, and retraction by contraction of its anterior fibres, and the middle part, or nearly the whole muscle, acts as the depressor. In deglutition the stylo-glossus muscle raises the sides of the tongue spasmodically backwards and upwards, while the hyo-glossus opposes that action. In other circumstances the first muscle assists in forming a hollow, while the second tends to producing a convexity in the dorsum of the tongue.

#### MUSCLES OF THE PHARYNX AND SOFT PALATE.

**THE PHARYNX**, the dilated superior part of the alimentary tube, extending from the base of the skull to the œsophagus, presents at the sides and posteriorly a continuous wall, in great part formed and supported by distinct muscles resting in front of the vertebral column, and is open in front towards the nasal cavity, the mouth, and larynx.

The *constrictors of the pharynx* are three thin expanded muscles which invest the pharyngeal wall, overlapping one another upwards, so that the lowest is most superficial.

Fig. 163.





The *inferior constrictor* arises from the side of the cricoid cartilage, and from the oblique lateral ridge and upper and lower borders of the thyroid cartilage, and curves backwards, expanding as it proceeds, and unites with its fellow in the middle line behind the pharynx. The direction of the inferior fibres is horizontal, concealing and overlapping the commencement of the œsophagus; the rest ascend with increasing degrees of obliquity, and cover the lower part of the middle constrictor.

The outer surface of the muscle is in contact at the side of the larynx with the thyroid body, the carotid artery, and the sterno-thyroid muscle; and from this last, where the two muscles meet on the thyroid cartilage, some fibres are continued into the constrictor. The two laryngeal nerves pass inwards to the larynx, close respectively to the upper and lower margins of this constrictor—one being interposed between it and the middle constrictor, the other between it and the œsophagus.

The inferior constrictor was described by the older anatomists as two muscles which received various names, the most appropriate of these being thyro-pharyngeus and crico-pharyngeus. In some animals they are found quite distinct from one another.

Fig. 164.

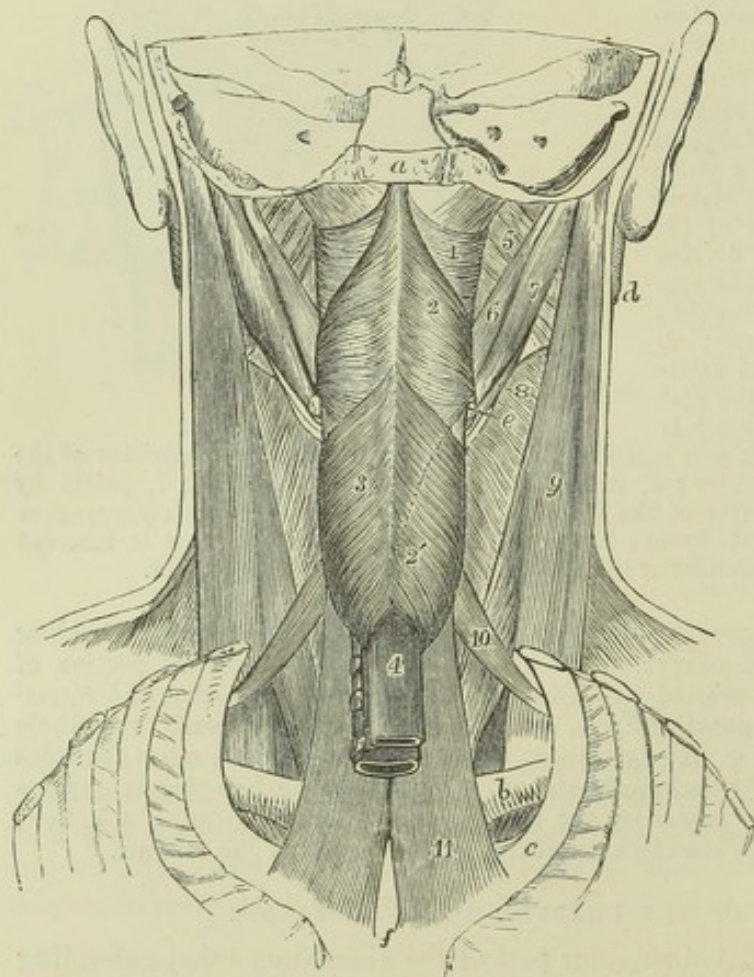


Fig. 164.—VIEW OF THE MUSCLES OF THE PHARYNX, &c. FROM BEHIND (after Bourguery).  $\frac{1}{3}$

The back part of the skull, the vertebral column and back parts of the ribs are removed. *a*, cut surface of the basilar process; *b*, the clavicle; *c*, the first rib; *d*, the ramus of the lower jaw; *e*, posterior extremity of the great cornu of the hyoid bone; *f*, posterior surface of the manubrium of the sternum; 1, superior constrictor muscle of the pharynx; above it the fibrous membrane which closes the pharynx; 2, middle constrictor; 2', a dotted line, indicating the direction of the lower part of the muscle; 3, the inferior constrictor; 4, œsophagus; 5, internal pterygoid; 6, stylo-glossus; 7, posterior belly of the

digastric; 8, a portion of the stylo-hyoid surrounding the tendon of the digastric; 9, sterno-mastoid; 10, upper belly of the omo-hyoid; 11, sterno-thyroid.

The *middle constrictor*, smaller than the preceding, arises from the upper part of the great cornu of the os hyoides, from the smaller cornu, and from the stylo-hyoid ligament: its fibres diverging greatly pass back to the middle



line of the pharynx behind, the lower fibres inclining downwards beneath the inferior constrictor, the highest ascending and overlapping the superior constrictor, and the intermediate fibres running transversely.

This muscle is separated from the superior constrictor by the stylo-pharyngeus muscle and the glosso-pharyngeal nerve, while between its origin and that of the inferior constrictor the superior laryngeal nerve pierces the thyro-hyoid membrane.

Fibres of the middle constrictor have been observed to arise from the body of the os hyoides, and the thyro-hyoid ligament (syndesmo-pharyngeus of Douglas), and a few are frequently continued into it from the genio-hyo-glossus muscle. The two middle constrictors have been found connected behind to the base of the skull by a fibrous band (Albinus).

The *superior constrictor* arises by fibres attached in series from below upwards, a few to the side of the tongue, and others to the mucous membrane of the mouth, to the extremity of the mylo-hyoid ridge of the jaw, to the pterygo-maxillary ligament which separates this muscle from the buccinator, and to the lower third of the internal pterygoid plate. From these different points the fibres of the muscle curve backwards, and are mostly blended with those of the corresponding muscle along the middle line, a few ending posteriorly in the aponeurosis which fixes the pharynx to the base of the skull. The upper margin curves round the levator palati mollis and the Eustachian tube; and the space intervening between this concave margin of the constrictor and the base of the skull is closed by fibrous membrane.

In contact with the outer surface of this muscle are the internal carotid artery, with the eighth and other large nerves; the middle constrictor, which overlaps a considerable portion; and the stylo-pharyngeus, which descends to the pharynx between the two constrictors. It conceals the palato-pharyngeus and the tonsil, and is lined by mucous membrane.

The *stylo-pharyngeus*, larger and longer than the other styloid muscles, arises from the inner surface of the styloid process, near the root, and proceeding downwards and inwards to the side of the pharynx, passes under cover of the middle constrictor muscle, where it detaches some fibres to the constrictors, and gradually expanding, is connected with the palato-pharyngeus muscle, and ends in the superior and posterior borders of the thyroid cartilage.

The external surface of this muscle is, in the upper part of its extent, in contact with the styloid process, the stylo-hyoideus muscle, and the external carotid artery; in the lower, with the middle constrictor of the pharynx. Internally it rests on the internal carotid artery and jugular vein; but more inferiorly it is in contact with the mucous membrane of the pharynx. The glosso-pharyngeal nerve is close to the muscle, and crosses over it in turning forwards to the tongue.

The *salpingo-pharyngeus* (Santorini) is a small muscle, which, arising from the Eustachian tube, descends in the interior of the pharynx towards its back part, and, after joining with the palato-pharyngeus, is lost in the muscular structure of the cavity. It is often indistinct, and is frequently absent.

THE SOFT PALATE (*velum pendulum palati*) is a movable curtain, continued backwards from the hard palate. It presents posteriorly a free pendulous margin, prolonged in the middle into a conical process, the *uvula*, and at each side into two prominent curved lines, the anterior of which, the *anterior pillar* of the fauces, descends to the side of the tongue, while the posterior line, the *posterior pillar* of the fauces, extends into the pharynx: between the two is lodged the tonsil. The constricted passage between the anterior pillars,



leading from the mouth to the pharynx, is called the *isthmus* of the fauces. The soft palate is acted on by five pairs of elongated muscles, two superior, one in the middle, and two inferior. Of the two inferior pairs of muscles, one is common to the palate and tongue, the other to the palate and pharynx.

The *palato-glossus* or *constrictor isthmi faucium* occupies the anterior pillar of the fauces. Superiorly it is anterior to all the other muscles of the velum, and its fibres are continuous with those of its fellow of the opposite side; inferiorly, it is lost on the side of the tongue.

Fig. 165.

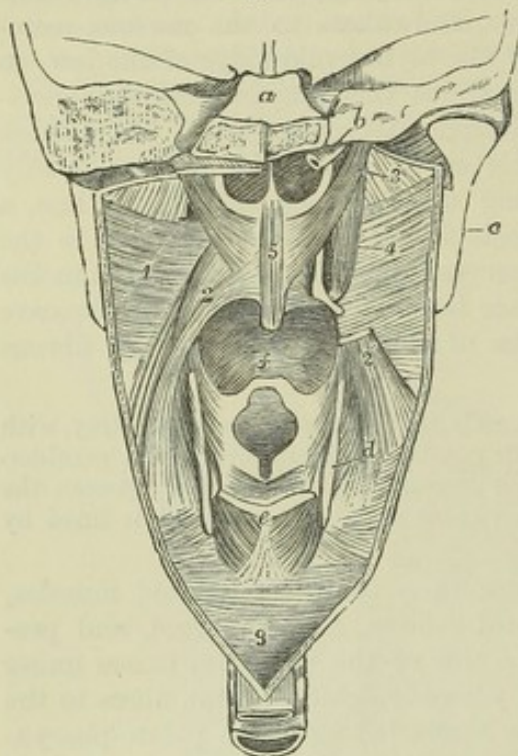


Fig. 165.—DIAGRAMMATIC VIEW OF THE MUSCLES IN THE ANTERIOR WALL AND SIDES OF THE PHARYNX, FROM BEHIND.  $\frac{1}{2}$

The posterior wall of the pharynx has been divided by a vertical incision in the middle line, and the cut edges drawn to the side so as to expose the nasal, buccal, and laryngeal openings into the pharynx. *a*, is above the cut surface of the basilar part of the occipital bone, and below that are the posterior nares; *b*, upon the cut petrous bone, points by a line to the cartilage of the Eustachian tube of the right side; *c*, the back of the ramus of the lower jaw; *d*, the posterior border of the thyroid cartilage; *e*, middle of the upper part of the cricoid cartilage; *f*, base of the tongue in the buccal aperture above the epiglottis; *g*, lower end of the cavity of the pharynx leading down into the gullet; 1, superior constrictor of the pharynx seen from within, and part of the middle constrictor; 2, palato-pharyngeus descending to its insertion in the pharynx and thyroid cartilage; 2', the lower part of the same muscle, on the right side, the upper having been removed; 3, placed on the internal pterygoid muscle,

points to the levator palati; 4, the circumflexus palati muscle on the right side descending from the navicular fossa, and winding round the pulley-like groove of the hamular process into the palate; 5, the retractor or azygos uvulae muscles; above *e*, the transverse arytenoid muscle, and below it on each side the posterior crico-arytenoid muscle.

The *palato-pharyngeus*, occupying the posterior pillar of the pharynx, arises in the soft palate by fibres connected with those of the opposite side, and passing partly above and partly below the levator palati and azygos muscles. As the muscle descends it becomes greatly expanded, and its fibres are found extended from the posterior cornu of the thyroid cartilage, back to the middle line of the pharynx posteriorly.

The *azygos uvulae* (Morgagni), so called from having been supposed to be a single muscle, consists of two slips arising, one on each side of the middle line, from the tendinous structure of the soft palate, and, sometimes, from the spine of the palate-plate, and descending into the uvula. The two slips are separated by a slight interval above, and unite as they descend.

The *levator palati* arises from the extremity of the petrous portion of the temporal bone, in front of the orifice of the carotid canal, and from the cartilaginous part of the Eustachian tube. Approaching the middle line as it



passes downwards and forwards, it is inserted aponeurotically into the posterior part of the soft palate, and meets its neighbour of the opposite side. In its upper part it is placed above the concave margin of the superior constrictor.

The *circumflexus* or *tensor palati* arises from the navicular fossa at the root of the internal pterygoid plate, from the outer side of the Eustachian tube, from the spine of the sphenoid, and the edge of the tympanic plate of the temporal bone. It descends perpendicularly, resting on the internal pterygoid plate, between it and the internal pterygoid muscle, and ends in a tendon which, winding round the hamular process, lubricated by a bursa, extends horizontally inwards, and terminates in the forepart of the aponeurosis of the soft palate and the posterior border of the palate bone.

**ACTIONS.**—The muscles of the pharynx and soft palate are so arranged as to accomplish, in conjunction with those of the tongue and hyoid bone, the action of deglutition—that is to say, the propulsion of food into the œsophagus without any portion being permitted to pass into the nasal cavity or larynx. While the tongue near the fauces is thrown upwards and backwards by the stylo-glossi muscles, and the larynx is drawn upwards and forwards under it by muscles attached to the hyoid-bone, and by the stylo-pharyngeus muscle, so as to be both closed by the epiglottis and overlapped by the tongue, the palato-glossi muscles constrict the fauces and shut off the bolus from the mouth. The soft palate is raised and made tense by its superior muscles; the palato-pharyngei, being approximated, nearly touch one another (the uvula lying in the small interval between them), and prevent the passage of the food towards the upper part of the pharynx or the posterior nares, while at the same time they form an inclined surface for its guidance into the lower part of the pharynx. The food being thus thrown into the grasp of the constrictors of the pharynx, those muscles contract from above downwards and force it into the tube of the gullet below.

#### MUSCLES DEPRESSING THE HYOID BONE.

The *sterno-hyoid* muscle, a flat band of longitudinal fibres, arises variously, from the sternum and the posterior sterno-clavicular ligament, from the clavicle and that ligament, or from the clavicle only, and occasionally, to a small extent, from the cartilage of the first rib. It is inserted into the lower border of the body of the hyoid bone.

The muscle is concealed below by the sternum and the sterno-mastoid, higher up by the skin and fascia only; it lies on the sterno-thyroid and thyro-hyoid muscles, which it partly covers. The inner border approaches that of the corresponding muscle towards the middle of its extent, but is separated from it by a slight interval superiorly, and by a larger interval near the sternum; the outer margin is in contact with the omo-hyoid near the os hyoides. The muscular fibres are, in many cases, interrupted by a transverse tendinous intersection.

The *sterno-thyroid*, broader and shorter than the preceding muscle, behind which it lies, arises from the thoracic surface of the first bone of the sternum, lower down and more internally than the sterno-hyoid muscle, and ascends, diverging a little from its fellow, to be inserted into the oblique line on the ala of the thyroid cartilage.

The greater part of its anterior surface is concealed by the sternum and the sterno-hyoid muscle, as well as by the sterno-mastoid. By its deep surface it rests on the innominate vein, the lower part of the common carotid artery, the trachea, and the thyroid body. The inner margin is contiguous to the muscle of the other side in the lower part of the neck. The median incision in the operation of tracheotomy is made between the two muscles.

This muscle is often partly crossed by transverse or oblique tendinous lines. At



the upper extremity a few fibres are often found to blend with the thyro-hyoid muscle and the inferior constrictor of the pharynx.

Fig. 166.

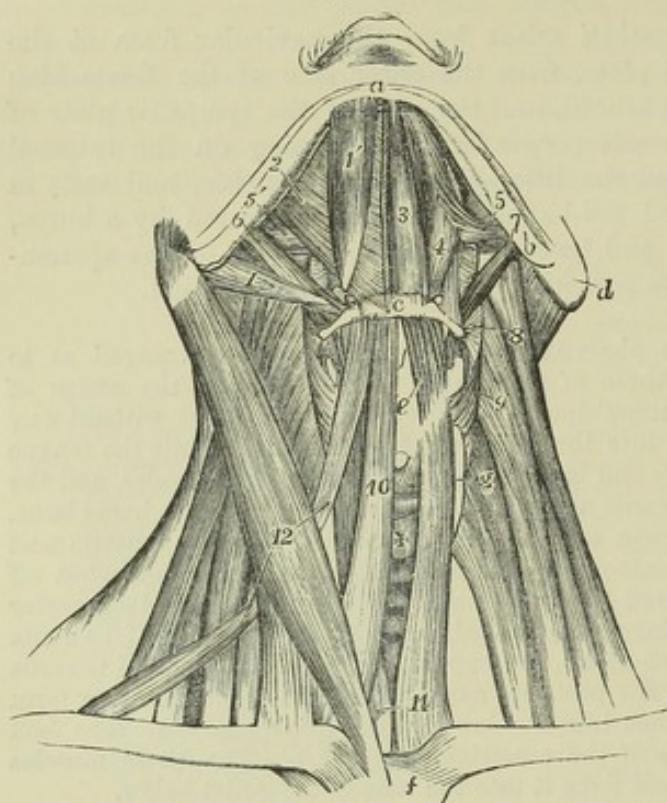


Fig. 166.—VIEW OF THE SUBMAXILLARY MUSCLES AND THE DEPRESSORS OF THE HYOID BONE AND LARYNX, FROM BEFORE.  $\frac{1}{2}$

The explanation of the references to the upper parts of the figure is given at p. 184. *c*, middle of the body of the hyoid bone; *d*, mastoid process; *e*, front of the thyroid cartilage; *f*, upper part of the sternum; *g*, lateral lobe of the thyroid gland; +, its isthmus, above which is the cricoid cartilage covered by the crico-thyroid muscle; 8, placed on the levator scapulæ, points to the left middle constrictor of the pharynx; 9, placed on the middle scalenus, points to the left inferior constrictor; 10, right sterno-hyoid; 11, placed on the left sterno-thyroid, points also to the

lower part of the right muscle; 12, placed on the right sterno-mastoid, points to the upper and lower bellies of the right omo-hyoid.

The *thyro-hyoid* muscle is continued upwards from the preceding; it arises from the oblique line on the ala of the thyroid cartilage, and is inserted into the lower border of the body and great cornu of the hyoid bone, near the place where these unite.

This muscle is concealed by the sterno-hyoid and omo-hyoid, and rests on the ala of the thyroid cartilage, and on the thyro-hyoid membrane. Between that membrane and the muscle, the superior laryngeal nerve and artery are placed before entering the larynx.

The *omo-hyoid* is a long ribbon-shaped muscle, consisting of two bellies united by an intervening tendon. It arises from the upper border of the scapula, near the suprascapular notch, and occasionally from the ligament which crosses the notch. Thence it extends forwards and only slightly upwards, across the root of the neck, till it enters beneath the sterno-mastoid muscle, and then, curving rapidly, it ascends nearly vertically, to be inserted into the lower border of the body of the hyoid bone. The tendon which divides the muscle is placed beneath the sterno-mastoid muscle, and varies much in length and form in different bodies. The tendon is enclosed within the deep cervical fascia, which after forming a sort of sheath for it, is prolonged downwards and becomes attached to the sternum and the cartilage of the first rib; and by this means, as also by fascia investing the posterior belly and descending to the clavicle, the muscle is maintained in its curved position.



At its scapular origin the muscle is covered by the trapezius, in the middle of its course by the sterno-mastoid, and at its upper part by the platysma; it crosses the scaleni muscles, the cervical nerves, the sheath of the common carotid artery and jugular vein, and the sterno-thyroid and thyro-hyoid muscles.

The muscle occasionally is attached to the clavicle instead of the scapula, arising from the former bone about its middle, and in such a case the posterior belly is absent. One instance has been recorded (R. Quain) in which the posterior belly alone was present, and was connected to the hyoid bone by a band of fascia. The muscle has likewise been observed double, one slip being attached to the clavicle and the other to the normal place of origin on the scapula.

**ACTIONS.**—While the sterno-hyoid and omo-hyoid muscles act only as depressors of the hyoid bone, and the sterno-thyroid as a depressor of the larynx, the sterno-thyroid muscle, being a direct depressor of the thyroid cartilage, may draw down the hyoid bone when it acts in conjunction with the thyro-hyoid: the latter muscle elevates the larynx when the hyoid bone is fixed. In the act of swallowing, the hyoid bone and thyroid cartilage pass suddenly upwards and forwards, and their natural position is restored by the action of the muscles under consideration, the bone moving in the direction of the omo-hyoid muscles. In the utterance of low notes the larynx and hyoid bone descend below the natural level, in the direction in which the sternal muscles pull; while in the utterance of high notes there is little elevation of the hyoid bone, but the larynx is raised by the action of the thyro-hyoid muscles.

#### FLEXOR MUSCLES OF THE NECK.

The *sterno-cleido-mastoid* or *sterno-mastoid* muscle is attached inferiorly in two parts to the anterior surface of the sternum and the inner third of the clavicle. The sternal attachment is thick and rounded, tendinous in front and fleshy behind. The clavicular portion, separated from the sternal by a narrow interval, is flat, and is composed of fleshy and tendinous fibres. Those two portions become blended together about the middle of the neck into a thick and prominent muscle, which, extending upwards and backwards, is attached superiorly to the anterior border and external surface of the mastoid process, and from thence backwards into a rough ridge of the temporal, and by a thin aponeurosis into the outer part of the superior curved line of the occipital bone.

This muscle is covered for more than the middle three-fifths of its extent by the platysma. It is also crossed by the external jugular vein, and by the ascending superficial branches of the cervical plexus of nerves. It rests on part of the sterno-hyoid and sterno-thyroid muscles, and crosses the omo-hyoid muscle; in the middle part of the neck it covers the cervical plexus and the great cervical vessels, and in the upper part, the digastric and stylo-hyoid muscles: it is pierced by the spinal accessory nerve.

The sterno-cleido-mastoid is occasionally described as two muscles, under the names sterno-mastoid and cleido-mastoid. Normally, the fibres of the clavicular part run upwards for some distance internally to those of the sternal part before finally blending with them. The muscle varies much in breadth at the lower end, the variation being due altogether to the clavicular part, which is sometimes as narrow as the sternal tendon, while in other instances it extends for three inches along the clavicle. This part of the muscle may likewise, when broader than usual, be divided into several slips separated by intervals near the clavicle. A band of muscular fibres has, in a few instances, been found reaching from the trapezius to this muscle over the subclavian artery; and the margins of the two muscles have been observed in contact. In animals without a clavicle the cleido-mastoid muscle is continued into the clavicular part of the great pectoral muscle, thus forming a mastoido-humeral muscle.

The *scalenus anticus* muscle is attached superiorly to the anterior



tubercles of the transverse processes of the third, fourth, fifth, and sixth cervical vertebræ, and inferiorly by a thick flattened tendon to a rough part of the inner border and upper surface of the first rib.

Fig. 167.

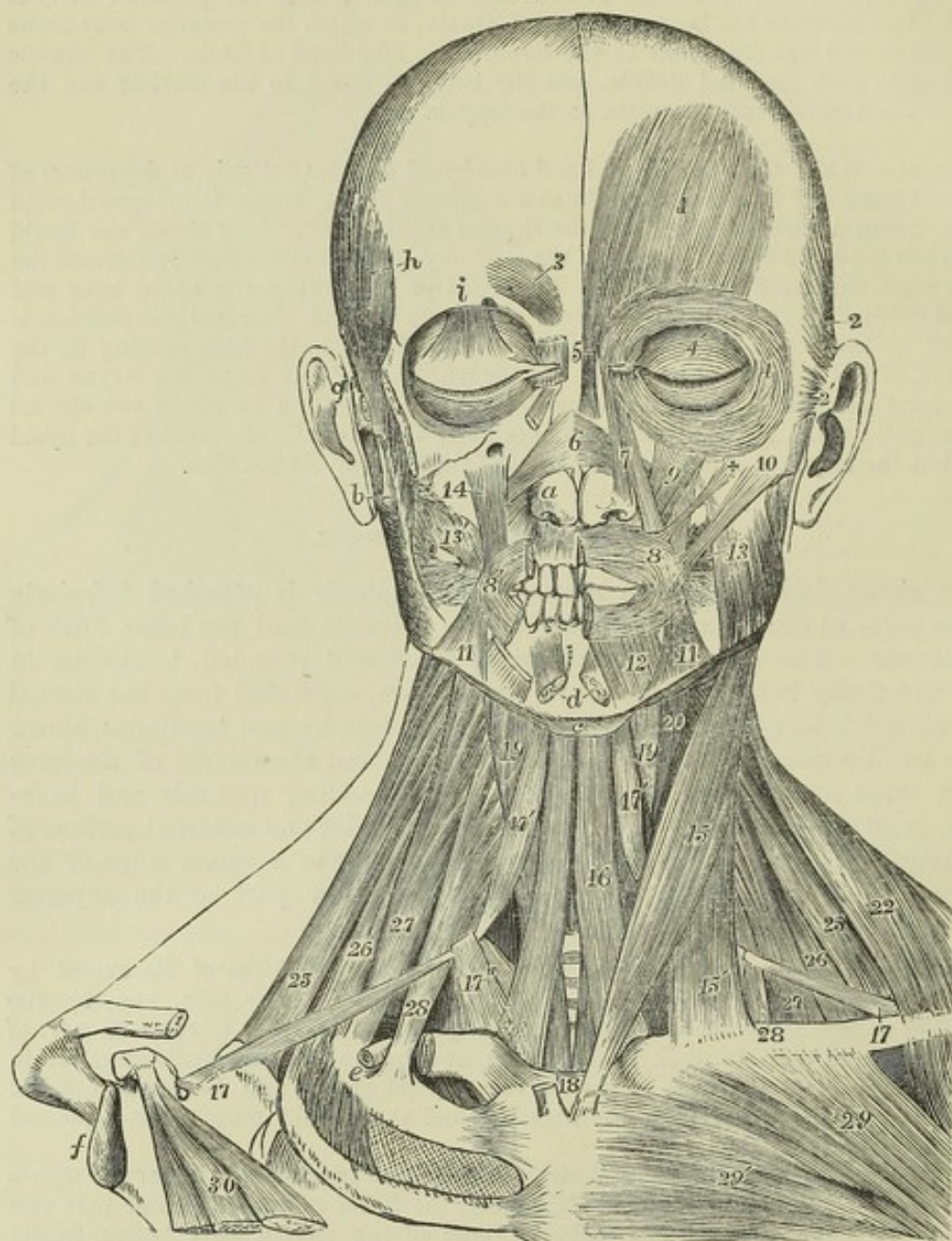


Fig. 167.—SUPERFICIAL AND DEEP VIEW OF THE MUSCLES OF THE HEAD AND NECK, FROM BEFORE.  $\frac{1}{3}$

The explanation of the references to the cranium and face will be found at page 172 : *c*, body of the hyoid bone ; *e*, subclavian groove of the first rib, above which the cut end of the subclavian artery is shown ; *f*, glenoid head of the scapula ; 15, sterno-mastoid muscle, its clavicular portion ; 16, sterno-hyoid ; 17, posterior, and 17', anterior belly of the omo-hyoid ; 17'', portion of the deep fascia, which forms a loop holding down the muscle by its central tendon ; 18, on the sternum at the interclavicular notch, points by lines upwards to the lower part of the sterno-thyroid muscles ; 19, thyro-hyoid ; 20, part of the constrictors of the pharynx ; 22, clavicular part of the trapezius ; 25, levator scapulæ ; 26, scalenus posticus ; 27, scalenus medius ; 28, scalenus anticus ; 29, clavicular, and 29', pectoral portion of the pectoralis major ; 30, pectoralis minor.



This muscle is placed deeply : in its lower part it is crossed by the posterior belly of the omo-hyoid muscle, and in its whole length it is traversed by the phrenic nerve passing obliquely from above downwards and inwards. The subclavian vein and artery pass respectively in front and behind its inferior attachment. The nerves of the brachial plexus emerge from behind its outer border above the subclavian artery. The rectus capitis anticus major arises on its inner side, the ascending cervical branch of the inferior thyroid artery lies in the groove between that muscle and the scalenus, and in front is the internal jugular vein.

The *scalenus medius* is attached superiorly to the posterior tubercles of the transverse processes of the last six cervical vertebræ; and inferiorly to a rough elevation on the first rib, extending for an inch and a half forwards from the tubercle.

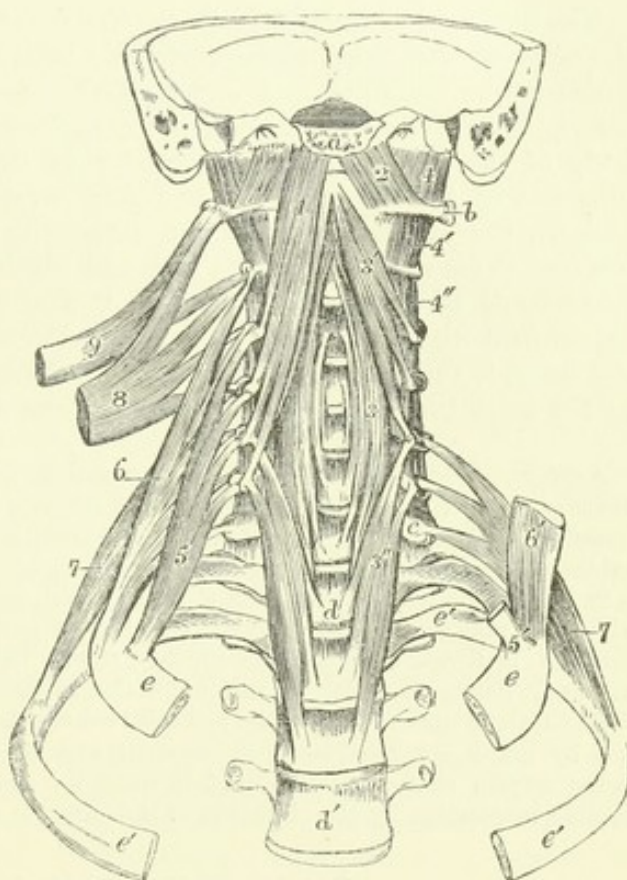
In front of this muscle, between it and the anterior scalenus, are the cervical nerves and the subclavian artery; behind it are the posterior scalenus and levator anguli scapulæ muscles. It is sometimes attached to the transverse process of the atlas.

The *scalenus posticus*, smaller than the other scaleni muscles, is attached above by two or three small tendons to the transverse processes of as many of the lowest cervical vertebræ, and inferiorly by an aponeurotic tendon to the second rib, in front of the attachment of the levator costæ.

Fig. 168.—VIEW OF THE DEEP MUSCLES CONNECTED WITH THE UPPER PART OF THE VERTEBRAL COLUMN IN FRONT.  $\frac{1}{3}$

The skull has been removed in front of the basilar and mastoid processes, together with the sternum and anterior parts of the first and second ribs. *a*, cut surface of the basilar process; *b*, transverse process of the atlas; *c*, transverse process of the seventh cervical vertebra; *d*, body of the first, *d'*, of the fourth dorsal vertebra; *e*, first, and *e'*, second rib; 1, rectus capitis anticus major muscle; 2, rectus capitis anticus minor; 3, middle part, 3', upper part, and 3'', lower part of the longus colli; 4, rectus lateralis; 4', first pair, and 4'', second pair of intertransversales; 5, scalenus anticus of the right side; 5', the tendon of attachment to the first rib on the left side, the rest of the muscle having been removed; 6, scalenus medius of the right side; 6', lower portion of the corresponding muscle of the left side; 7, scalenus posticus, its superior attachments shown upon the left side; 8, upper part of the levator scapulæ drawn out from its vertebral attachments; 9, splenius colli, shown in the same manner.

Fig. 168.





The scaleni muscles are subject to some amount of variation, both in the number of their points of attachment, and in the arrangement of their fibres. A slip from the scalenus anticus sometimes passes behind the subclavian artery.

The *rectus capitis anticus major* arises from the tubercles of the transverse processes of the third, fourth, fifth, and sixth vertebræ by tendinous slips, its origin corresponding in extent to the superior attachment of the anterior scalenus muscle: it is inserted into the basilar process of the occipital bone, a little in front of the foramen magnum. The muscles of opposite sides converge as they ascend, and their mesial fibres are longest.

The anterior surface of the *rectus capitis anticus major* supports the pharynx, the sympathetic and vagus nerves, and the great cervical vessels. The posterior surface rests upon part of the longus colli and the *rectus anticus minor*.

The *rectus capitis anticus minor*, under cover of the preceding, arises from the anterior arch of the atlas, and slightly from the root of its transverse process; it is inserted into the basilar process, between the margin of the foramen magnum and the preceding muscle, half an inch from its fellow.

The *rectus capitis lateralis* is a short thick muscle arising from the upper surface of the anterior division of the transverse process of the atlas, and inserted into the rough surface beneath the jugular eminence of the occipital bone. It completes the series of intertransversales muscles.

The anterior surface of this muscle is in contact with the internal jugular vein, the posterior with the vertebral artery.

The *longus colli* muscle rests on the front of the vertebral column from the atlas to the third dorsal vertebra: it consists of three sets of fibres, of which two are oblique, and one vertical. *a.* The superior oblique portion arises, by a narrow tendinous process, from the anterior tubercle of the body of the atlas, and is inserted into the fore part of the transverse processes of the third, fourth, and fifth cervical vertebræ. *b.* The inferior oblique, the smallest part of the muscle, extends obliquely inwards from the transverse processes of the fifth and sixth cervical to the bodies of the first two or three dorsal vertebræ. *c.* The vertical part, connected by its extremities with the other divisions, is attached superiorly to the bodies of the second, third, and fourth cervical vertebræ, and inferiorly to the bodies of the three lower cervical and two or three upper dorsal vertebræ.

**ACTIONS.**—The sterno-cleido-mastoid muscles, and in a less degree the scaleni muscles, bend forwards the head and neck towards the sternum. The sterno-mastoid muscles, when acting in concert with the extensor muscles of the head, assist in the extension, and project the chin. When the sterno-mastoid muscle of one side only is in action, the head, while it is slightly flexed, is inclined laterally to the side on which the muscle contracts, and rotation is produced, by which the face, and especially the chin, is directed towards the opposite side. This is the position which occurs in wry-neck, depending upon an unequal action of the opposite sterno-mastoid muscles.

The scalene muscles, when the vertebral column is fixed, act as elevators of the ribs, and by many are considered as constant aids in the movement of inspiration. It seems certain that when the head is fixed the sterno-mastoid muscles also assist in forcible inspiration by the elevation of the sternum and clavicles.

#### FASCIÆ OF THE HEAD AND NECK.

The SUPERFICIAL FASCIA is little developed on the head and neck, and is in great measure blended with structures described under other names. A



layer of considerable firmness intervenes between the aponeurosis of the occipito-frontalis muscle and the skin, uniting them together: from the surface of the occipital part of the muscle it becomes continuous with a superficial covering of the posterior muscles of the neck, and on either side of the epicranial aponeurosis it descends over the temporal fascia, and contains between its laminae the external muscles of the ear, with the superficial temporal vessels and nerves.

In the face, the fibres of the superficial muscles are frequently so much incorporated with the skin, that in many parts there is no distinct intervening layer of superficial fascia; and over most of the face the subcutaneous fat breaks up the fascia to a great extent. On the side of the neck, where a representative of the superficial fascia is found in the tissue containing the platysma myoides muscle, it is thin, and has embedded in it the external jugular vein and some superficial nerves.

The DEEP FASCIAE of the head and neck deserve special attention, as they give investments of considerable strength, and serve to mark the separation between several important organs.

The *temporal fascia* is a structure of an aponeurotic nature, which covers the temporal muscle above the zygoma, and gives extensive attachment to its fibres of origin. It springs inferiorly from the upper border of the zygomatic arch, and is attached in the rest of its circumference to the posterior border of the malar bone and to the temporal ridge on the frontal, parietal, and temporal bones. It is divided below into two layers, one of which is attached to the outer and the other to the inner surface of the zygoma; and in this situation there is deposited between its layers a quantity of fat, the absorption of which is one cause of the hollowness of the temples in emaciated persons. This dense fascia is separated from the integuments by the layer of thin membrane descending from the epicranial aponeurosis, and by the auricular muscles; and from the temporal muscle below, by a deeper layer of fat.

The *cervical fascia* (named also proper or deep cervical) passes forwards from the anterior border of the trapezius muscle over the sides and front of the neck beneath the platysma myoides. Posteriorly it is continuous with the layers of connective tissue with which the trapezius and deeper muscles are invested; it extends over the posterior triangle of the neck, viz., the space bounded by the trapezius and sterno-mastoid muscles and the clavicle: at the posterior border of the sterno-mastoid it divides into two layers, which form an investment for that muscle; these unite again at the anterior border into a membrane which passes forwards across the middle line, and covers the area bounded by the middle line, the border of the jaw, and the sterno-mastoid muscle, and called the anterior triangle. In the posterior triangle the fascia is attached inferiorly to the clavicle, and near that bone is perforated by the external jugular vein, which in the previous part of its course lies superficial to the membrane. In the anterior triangle it is bound superiorly to the border of the jaw in front, and further back is continued over the masseter muscle (*masseteric fascia*), and the parotid gland, which it closely invests (*parotid fascia*); it likewise sends upwards a process on the posterior and deep surfaces of the parotid gland; and a strong band of this process, known under the name of the *stylo-maxillary ligament*, extends from the styloid process to the angle of the jaw, so as to keep the parotid and submaxillary glands distinct, even although one or both of them may be greatly enlarged.

In the front of the neck the fascia is attached to the hyoid bone, and, becom-



ing stronger as it descends, it splits, a little below the level of the thyroid body, into two distinct layers. Of these the more superficial and weaker, guided by the sterno-mastoid muscles, is fixed to the sternum and the interclavicular ligament; whilst the stronger layer, lying under the former, and closely covering the sterno-hyoid and sterno-thyroid muscles, is attached to the deeper surface of that bone. These layers materially assist in closing the cavity of the chest, above the sternum: between them there exists a quantity of loose connective tissue and fat, and sometimes a small lymphatic gland.

Continuous with the deeper of those two layers, a deep layer is found likewise in the posterior triangle, investing the posterior belly of the omohyoid muscle, and binding it down to the clavicle and first rib. Still deeper than the processes now described is a layer which lies behind the depressor muscles of the larynx, investing the thyroid body, and extending thence on the trachea and large vessels at the root of the neck down to the fibrous layer of the pericardium.

Continuous with the deep processes of the cervical fascia is the *common sheath of the large cervical bloodvessels*, an envelope of fascia enclosing the carotid artery and jugular vein with the pneumogastric nerve. A thin fibrous septum intervenes between the artery and vein, thus completing a separate sheath for each.

The layer of fascia descending on the prevertebral muscles, and intervening between them and the pharynx and œsophagus, is called the *pre-vertebral fascia*.

## MUSCLES OF THE UPPER LIMB.

Between different parts of the head and trunk on the one hand, and the shoulder and humerus on the other, certain muscles pass which attach the upper limb to the body, and which, though situated mainly on the trunk, and often described along with its muscles, have so intimate a connection, both in their structure and uses, with the limb, that they may with greater propriety be treated of along with the muscles of that part. The muscles referred to are, posteriorly, the trapezius, latissimus dorsi, levator anguli scapulæ, and the rhomboidei; and, anteriorly, the two pectoral muscles, the subclavius, and the serratus magnus. Along with these might also be mentioned the clavicular part of the sterno-cleido-mastoid muscle and the omohyoid; but as these last have important relations with parts situated in the neck, they are more conveniently described among the muscles of that region.

Fig. 169.—SUPERFICIAL MUSCLES OF THE TRUNK, SHOULDER AND HIP, VIEWED FROM BEHIND.  $\frac{1}{2}$

*a*, external occipital protuberance; *b*, acromion of the scapula; *c*, crest of the ilium; 1, trapezius; 1', oval tendon of the two muscles in the upper dorsal and lower cervical region; 1'', triangular tendon of insertion; 2, latissimus dorsi; 2', 2'', its costal origins and its direct origin from the crest of the ilium; 1, 2', *c*, the superficial layer of the lumbar aponeurosis; 3, sterno-mastoid; 4, deltoid; 5, infraspinatus; 6, teres minor; 7, teres major; 8, rhomboideus major; below this on the left side is seen a triangular space bounded by the rhomboid, trapezius, and latissimus dorsi muscles, in which, when the arm is depressed, as on the right side, a part of the seventh rib is usually felt; on the left side, the arm and shoulder being elevated, the space is enlarged so as to show a part of the sixth and seventh ribs; 9, back part of the external oblique muscle of the abdomen; between 9 and 2', a small part of the internal oblique; 10, part of the gluteus medius covered by the fascia lata; 11, gluteus maximus; 12, gracilis; 13, small part of the adductor magnus; 14, semitendinosus; 15, biceps; 16, fascia lata covering the vastus externus.



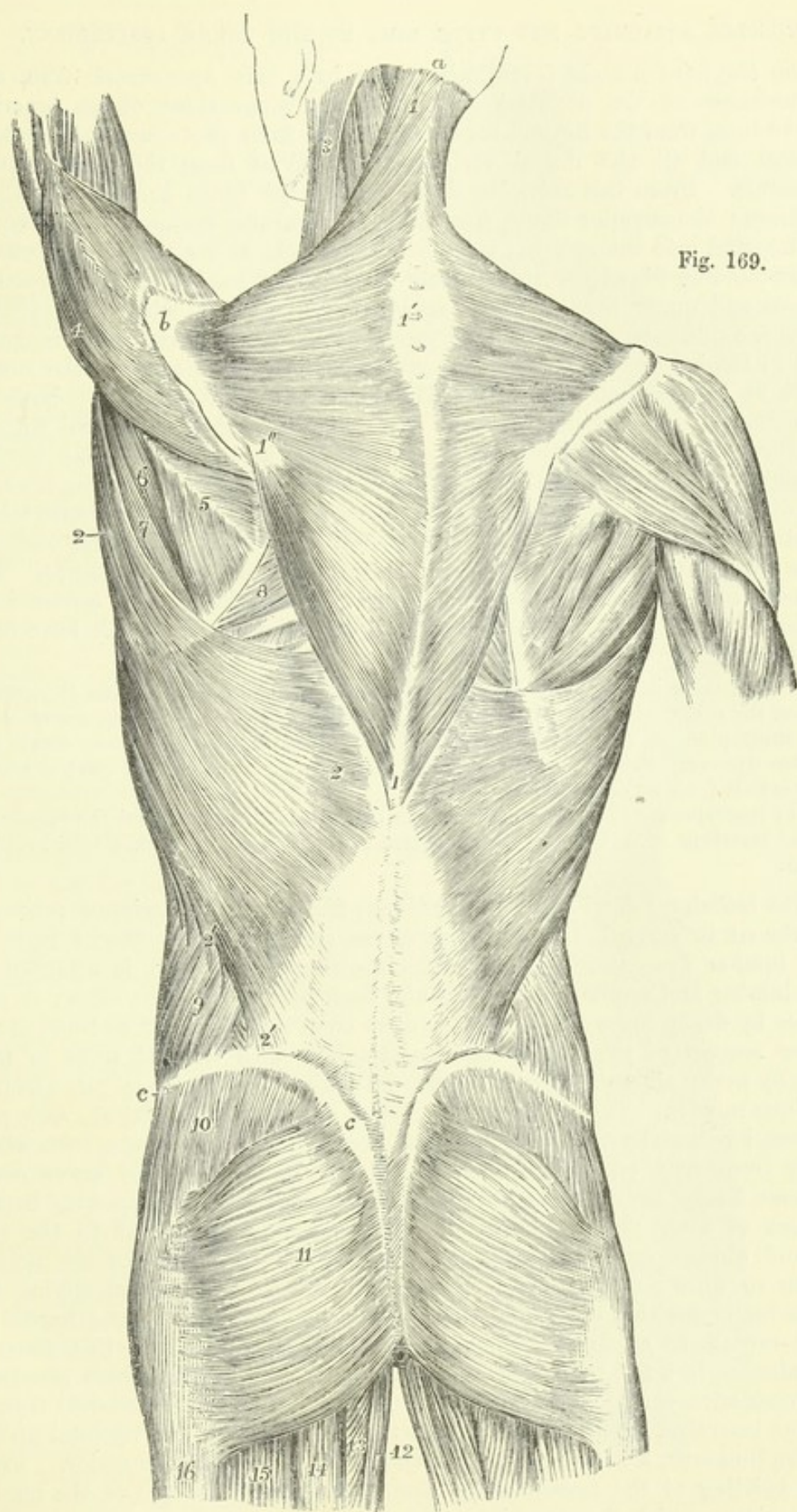


Fig. 169.



## MUSCLES ATTACHING THE UPPER LIMB TO THE TRUNK POSTERIORLY.

The *trapezius* muscle (*cucullaris*) arises by a thin aponeurosis from the protuberance of the occipital bone, and the inner third of its superior curved line, from the ligamentum nuchæ, and from the spines of the last cervical and all the dorsal vertebræ, as well as from the supraspinous ligaments. From this extended line of origin the fibres converge to their insertion: the superior fibres, descending and turning forwards in the neck, are inserted into the external third of the clavicle at its posterior border; the succeeding fibres pass transversely to the inner border of the acromion process and upper border of the spine of the scapula, while the inferior fibres ascending terminate in a flat tendon which glides over the triangular area at the base of the spine of the scapula, and is inserted into the rough mark at the root of the spine. The greater part of the origin becomes immediately muscular, but opposite the seventh cervical spine, and for the distance of several vertebræ above and below that point, a flat tendon extends outwards, widest at the middle of the space, and narrowing towards the upper and lower ends, so that the aponeuroses of the two muscles taken together have an elliptical form. The fibres of origin from the occipital bone have no tendinous lustre, and resemble rather a strong fascia. The muscles of the two sides, regarded together, have the form of a four-sided figure, or shawl, pointing downwards: hence the names which have been given to it.

The trapezius is superficial in its whole extent: it covers the splenius, the greater part of the complexus above the splenius, the levator anguli scapulæ, the rhomboidei, the supraspinatus, and small portions of the infraspinatus, latissimus dorsi, and lumbar aponeurosis. The spinal accessory nerve, and the superficial cervical artery, pass into it from its deep surface.

The trapezius is not unfrequently shorter than above described, and the number of dorsal vertebræ with which it is connected is sometimes diminished even to six or seven.

The *latissimus dorsi* arises by tendinous fibres from the spinous processes of the six or seven lowest dorsal vertebræ, and from the posterior layer of the lumbar aponeurosis, through the medium of which it is attached to the lumbar and upper sacral spines and back part of the iliac crest; it also arises by fleshy fibres for an inch or more from the iliac crest in front of the outer margin of the lumbar aponeurosis, and from the last three or four ribs by fleshy slips which interdigitate with the attachments of the external oblique muscle. The fibres at the upper part are the shortest, and pass almost horizontally outwards over the lower angle of the scapula, from which they frequently receive a fasciculus of fleshy fibres; those lower down become longer and incline from below upwards, gradually increasing in the degree of their obliquity; finally, those which are attached to the ribs ascend almost vertically. By this convergence the fibres of the muscle come to form a narrow band of some thickness, which, accompanying the *teres major* towards the axilla, winds round the lower and outer border of that muscle so as finally to be placed in front of it. At this place it terminates in a flat tendon of about two inches in length, which generally becomes adherent to that of the *teres major*, but is again detached from it at the insertion. The tendon is inserted in the floor of the bicipital groove of the humerus, a little higher than the insertion of the *teres major*. From this twisting of the muscle upon itself the anterior surface of the tendon is continuous with the posterior surface of the rest of the muscle.



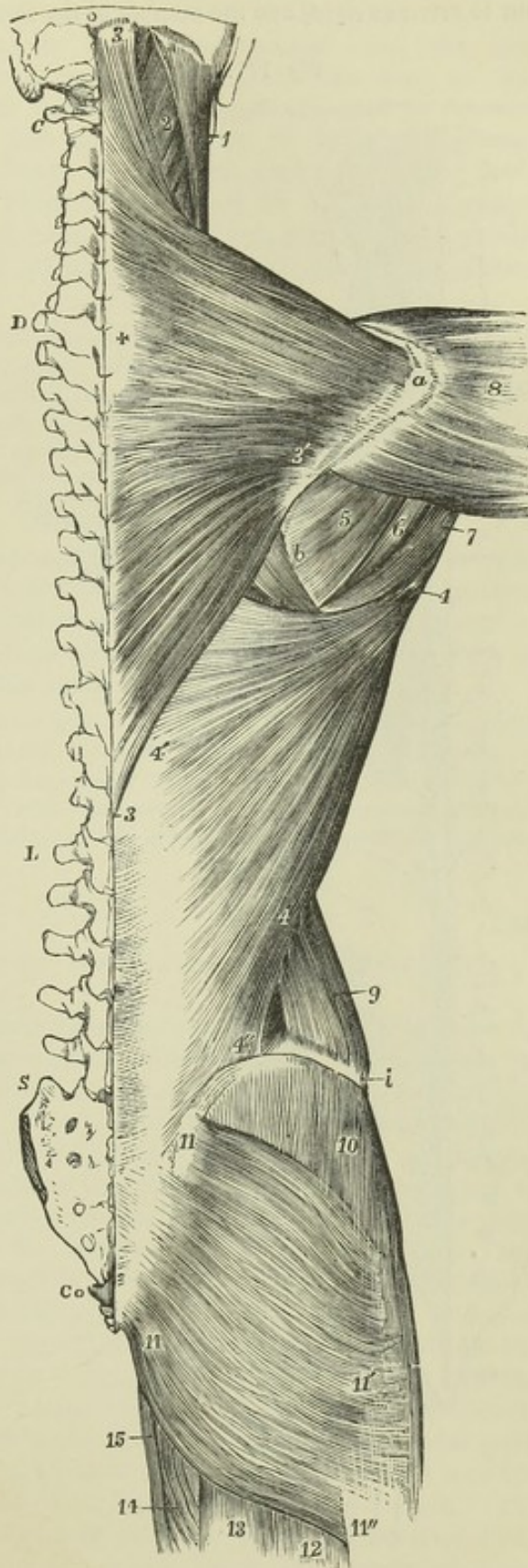
Fig. 170.—SUPERFICIAL VIEW OF THE MUSCLES OF THE TRUNK, SHOULDER AND HIP (after Bourguery).  $\frac{1}{2}$

o, occipital protuberance; C, transverse process of the atlas; D, first dorsal vertebra; L, first lumbar vertebra; S, upper piece of the sacrum; Co, first piece of the coccyx; a, acromion; b, base of the scapula; i, crest of the ilium; 1, upper and back part of the sternomastoid muscle, spreading from the mastoid process to the superior curved line of the occipital bone; 2, splenius, levator anguli scapulæ, and other deep muscles; 3, 3', upper and lower ends of the trapezius muscle; 3', triangular tendon attached to the base of the spine of the scapula; +, half of the oval tendon belonging to the two trapezius muscles in the lower cervical and upper dorsal region; 4, 4', latissimus dorsi; 4', 4'' line along which the latissimus dorsi takes origin from the lumbar fascia; 5, infraspinatus; 6, teres minor; 7, teres major; 8, middle or acromial part of the deltoid; 9, hinder part of the external oblique muscle of the abdomen; 10, gluteus medius, covered by the aponeurosis of the fascia lata; 11, 11', line of origin of the gluteus maximus from the posterior part of the ilium to the coccyx; 11', its insertion into the fascia lata over the trochanter major; 11'', a part of its insertion into the femur; 12, biceps; 13, semitendinosus; 14, adductor magnus; 15, gracilis.

The latissimus dorsi is superficial, except at its origin from the dorsal vertebræ, where it is covered by the trapezius, and at its insertion, where it dips into the axilla. It rests on part of the rhomboideus major and infraspinatus, on the teres major, serratus posticus inferior, vertebral aponeurosis, external intercostal muscles, and the posterior borders of the external and internal oblique muscles.

Between the adjacent borders of the latissimus dorsi, trapezius, and rhomboideus major, there is left, when the scapula is drawn forward, a triangular area, in which a portion of one or two ribs and an intercostal space becomes superficial; this is taken advantage of for the purpose of auscultation.

Fig. 170.





The number of dorsal vertebræ to which the latissimus dorsi is attached varies from four to seven or eight, and the number of the costal attachments is also inconstant. A

Fig. 171.

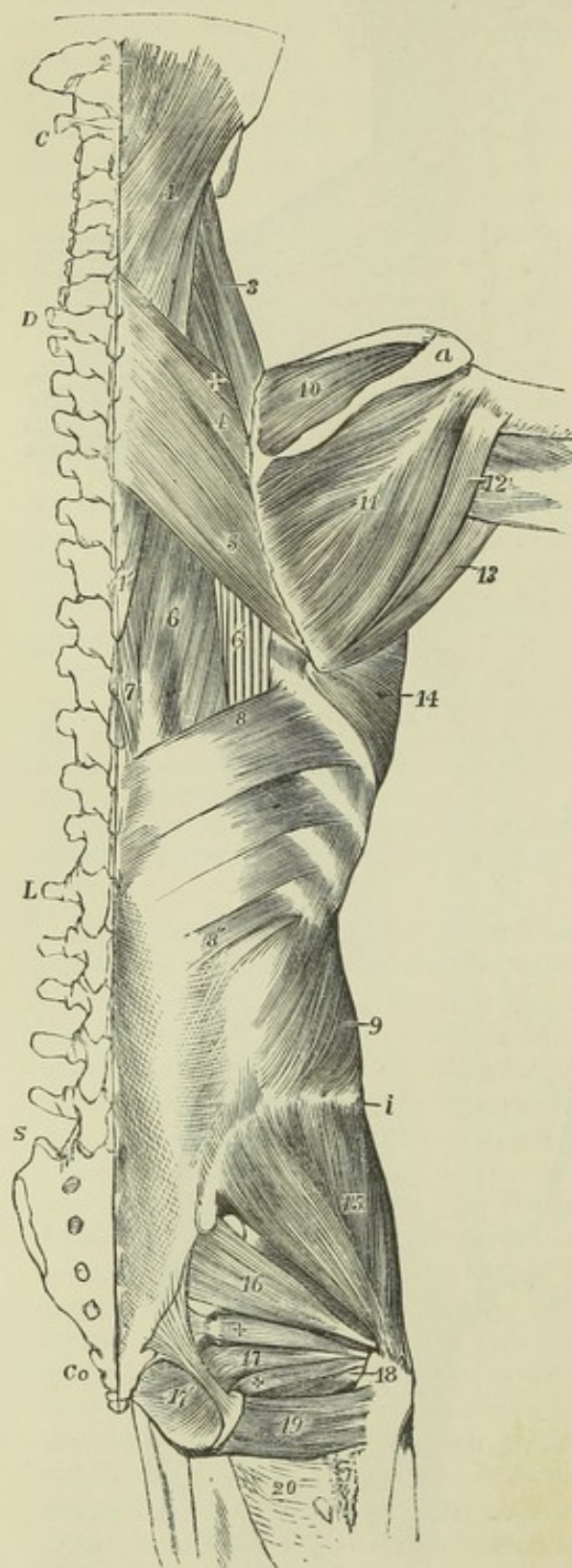


Fig. 171.—DEEPER VIEW OF THE MUSCLES OF THE TRUNK, SHOULDER AND HIP (after Boursurgery).  $\frac{1}{2}$

The trapezius, latissimus dorsi, deltoid, gluteus maximus and external oblique muscles have been removed. The bones are lettered as in the preceding figure.

1, splenius capitis and splenius colli; 1', its lower end; 2, upper part of the complexus near its insertion; 3, levator anguli scapulæ; 4, rhomboideus minor; above it +, a part of the serratus posticus superior; 5, rhomboideus major; 6, part of the longissimus dorsi; 6', part of the tendons of insertion of the sacro-lumbalis; 7, part of the spinalis dorsi; 8, upper, and 8', lower part of the serratus posticus inferior; 9, obliquus abdominis internus; 10, supraspinatus; 11, infraspinatus; 12, placed upon the long head of the triceps, points to the teres minor; 13, teres major; 14, serratus magnus; 15, gluteus medius; 16, pyriformis; 17, portion of the obturator internus; + and +, superior and inferior gemelli; 17', the pelvic portion of obturator internus; 18, the tendon of the obturator externus passing to its insertion; 19, quadratus femoris; 20, upper part of the adductor magnus.

The *rhomboidei* muscles are placed parallel to one another, and are separated only by a slight interval. They are extended obliquely from the spinous processes of the lower cervical and upper dorsal vertebræ to the base of the scapula.

The *rhomboideus minor*, a comparatively narrow muscle, arises from the spinous processes of the seventh cervical

and first dorsal vertebræ and from the ligamentum nuchæ. It inclines



downwards and outwards, and is inserted into the base of the scapula opposite the triangular surface at the commencement of the spine.

The *rhomboideus major*, three or four times broader than the preceding muscle, arises from the spinous processes of the four or five upper dorsal vertebræ, and their interspinous ligaments, and is inserted into that part of the base of the scapula which is included between the spine and inferior angle. Some of the fibres, instead of being fixed to the bone, end in a tendon which is connected to the scapula above the lower angle; and, in consequence of this arrangement, the muscle may, in part, be separated from the bone without division of its muscular or tendinous fibres.

The greater part of the rhomboidei muscles is covered by the trapezius, a small angular portion of the rhomboideus major only lying superficially in the interval between the trapezius and latissimus dorsi; the extent of this portion varies with the position of the scapula, being increased when the arm and shoulder are raised from the side. The rhomboidei cover the greater part of the serratus posticus superior, and the posterior scapular artery descends on their deep surface.

The *levator anguli scapulæ* arises by slightly tendinous slips from the posterior tubercles of the transverse processes of the first three or four cervical vertebræ, between the splenius and scaleni muscles, and forms an elongated fleshy mass which is inserted into the portion of the base of the scapula intervening between the spine and superior angle.

The number of vertebral attachments of the levator anguli scapulæ is subject to some variation. A slip has been observed to extend to it from the mastoid process of the temporal bone (Theile), and from the second rib (Meckel). It often appears as a divided muscle, the parts connected with the several vertebræ remaining separate, even to the place of insertion. In quadrupeds it is united with the serratus magnus, so as to form a single muscle.

#### MUSCLES ATTACHING THE UPPER LIMB TO THE TRUNK ANTERIORLY.

The *pectoralis major* muscle arises from the sternal half, or a little more, of the clavicle; from the anterior surface of the sternum, extending as far down as the insertion of the cartilage of the sixth rib; from the cartilages of the first six ribs, and also the bony part of the sixth rib; and from the aponeurosis of the external oblique muscle of the abdomen. Springing from this extensive origin its fibres form a thick mass, and, converging to some extent, are inserted by a tendon of considerable breadth into the ridge which forms the outer margin of the bicipital groove of the humerus, and thence downwards as far as the deltoid impression. The muscular fasciculi converge towards the axilla, and the muscle with its tendon is folded at the axillary border, so that the clavicular part remains in front, while the pectoral part passes behind. The arrangement is such that at last the folded tendon of the muscle is inserted into the humerus in two nearly parallel lines which are connected below. The fibres of the clavicular part, in the order of their origin from without inwards, are prolonged into the anterior or outer line of insertion in order from above downwards. The pectoral part of the muscle is inserted into the inner or posterior line; the fibres which have the highest origin being the lowest at their insertion, and those which arise lower in succession from the chest passing higher and higher to their insertion on the humerus. Further



Fig. 172.

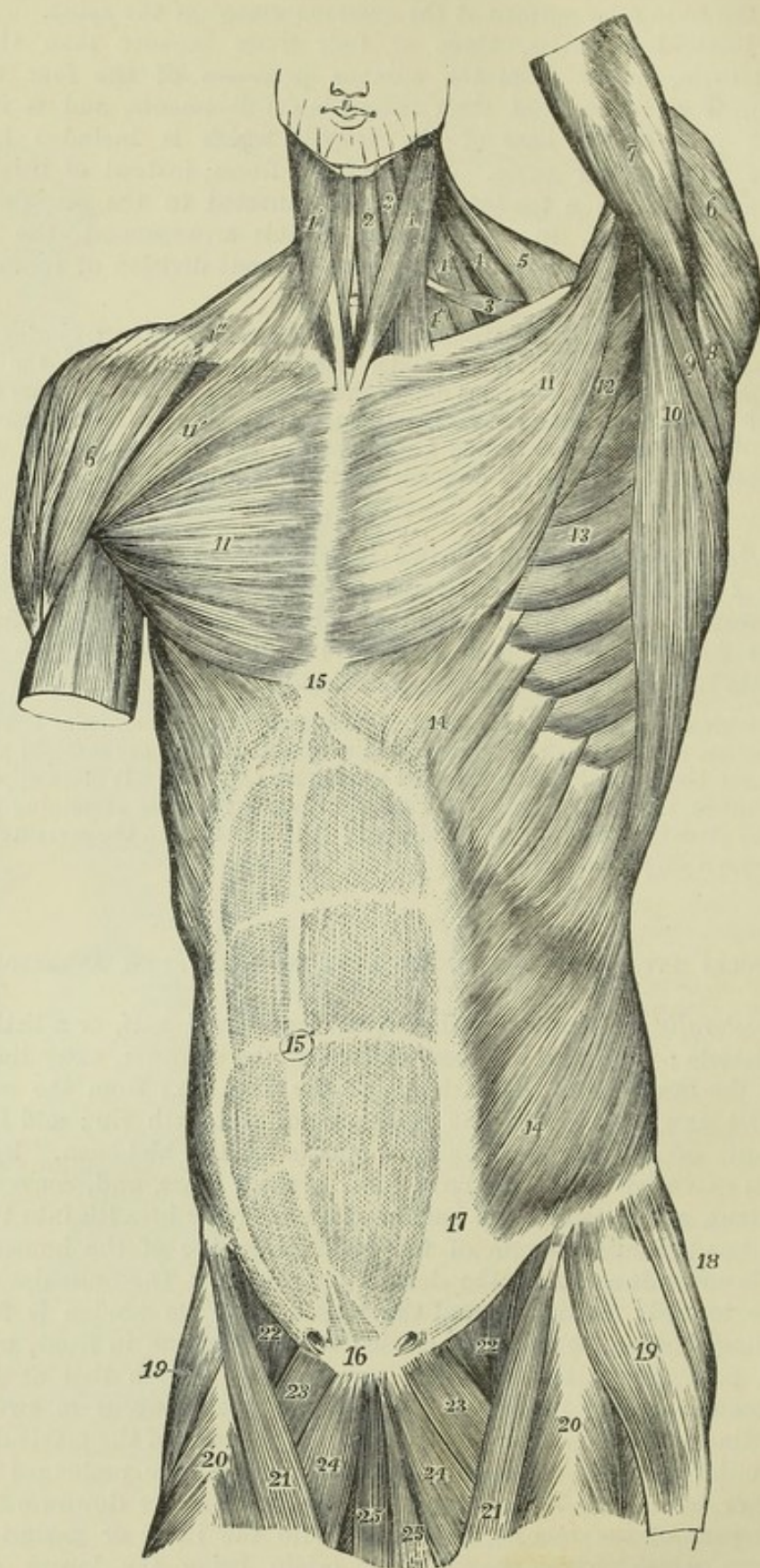


Fig. 172.—SUPERFICIAL VIEW OF THE MUSCLES OF THE TRUNK, FROM BEFORE.  $\frac{1}{2}$   
 1, sterno-mastoid of the left side ; 1', 1'', platysma myoides of the right side ; 2, sterno-



hyoid; 3, upper, 3', lower belly of the omo-hyoid; 4, levator anguli scapulæ; 4', 4'', scalene muscles; 5, anterior part of the trapezius; 6, deltoid; 7, upper part of the triceps brachii in the left arm; 8, teres minor; 9, teres major; 10, latissimus dorsi; 11, pectoralis major; 11', on the right side its clavicular portion; 12, part of the pectoralis minor; 13, serratus magnus; 14, external oblique muscle of the abdomen; 15, placed on the xiphoid cartilage at the upper end of the linea alba; 15', is placed on the umbilicus; 16, is placed over the symphysis pubis, and at the lower end of the linea alba, above 16, the pyramidal muscles are seen shining through the abdominal aponeurosis; 15 to 17, the linea semilunaris at the outside of the rectus muscle, the transverse tendinous lines of which are seen through the abdominal aponeurosis; 18, part of the gluteus medius; 19, tensor vaginæ femoris; 20, rectus femoris; 21, sartorius; 22, femoral part of the iliacus and psoas; 23, pectineus; 24, adductor longus; 25, gracilis. On either side of 16, the external adominal ring is indicated.

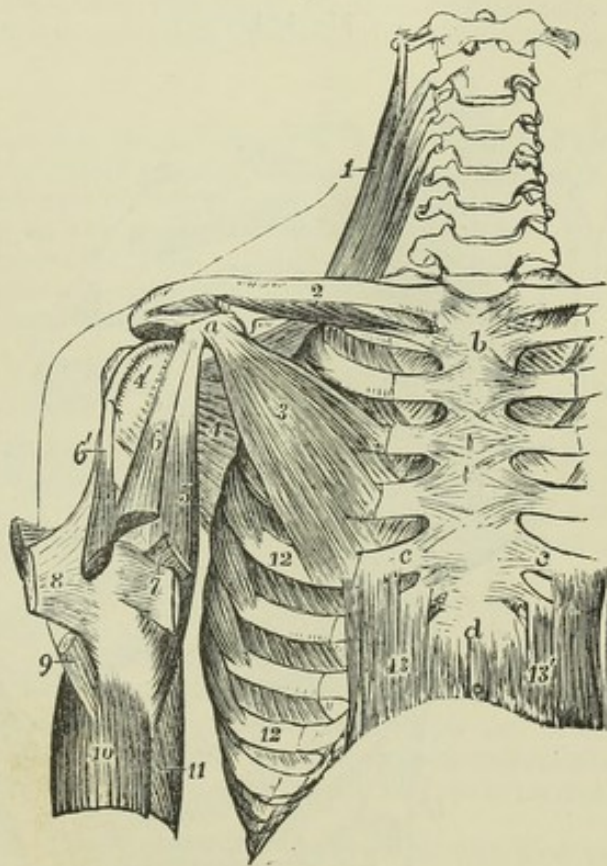
it is to be observed that the tendon of insertion of the pectoral part of the muscle passes higher than that of the clavicular part, extending as far as the base of the great tuberosity, where it sends a thin prolongation across the bicipital groove, and an offset to the head of the humerus. The lowest inserted portion of the muscle is closely united with the insertion of the deltoid. From its inferior margin an offset is prolonged to the fascia of the arm.

The folded inferior border of the pectoralis major forms the anterior margin of the axilla; the superior runs parallel with that of the deltoid muscle, from which it is separated only by a slight interval which becomes wider towards the clavicle, and in which

Fig. 173.—VIEW OF SOME OF THE DEEPER MUSCLES OF THE SHOULDER AND TRUNK, FROM BEFORE.  $\frac{1}{2}$

On the right side the pectoralis major and external oblique muscles have been removed. *a*, coracoid process of scapula; *b*, manubrium of sternum; *c*, *c*, cartilage of the fifth ribs; *d*, ensiform portion of the sternum; 1, upper part of the levator scapulæ muscle; 2, on the middle of the clavicle, points to the subclavius muscle; 3, pectoralis minor; 4, subscapularis; 4', its insertion into the lesser tuberosity of the humerus; 5, coraco-brachialis; 6, coracoid, and 6', glenoid head of the biceps brachii, both cut short near the place where they unite into one muscle; 7, on the tendon of the latissimus dorsi, points by a line to the tendon of the teres major, both passing to their insertion inside the bicipital groove, both cut short; 8, folded tendon of the pectoralis major, cut short; 9, inserted portion of the deltoid; 10, upper part of the brachialis anticus at its origin, embracing the insertion of the deltoid; 11, part of the middle and inner head of biceps; 12, on the fifth and eighth ribs, points to the insertion of the serratus magnus; 13, 13', recti abdominis.

Fig. 173.





run the cephalic vein and the humeral branch of the acromio-thoracic artery. The anterior surface is subcutaneous in the greater part of its extent, being covered only by some of the fibres of the platysma myoides and by the mamma. The posterior surface rests chiefly on the pectoralis minor, and externally and internally to that muscle forms the anterior wall of the axilla.

The tendinous fibres of origin of opposite sides sometimes decussate in front of the sternum, and occasionally the fleshy fibres also of opposite sides come into contact. In some instances additional muscular slips take origin from the aponeurosis of the external oblique muscle, and in others the lower part of the muscle presents considerable deficiency.

The *pectoralis minor* arises from the upper margins and external surfaces of three ribs near their cartilages—usually the third, fourth and fifth—and from the neighbouring parts of the intercostal aponeurosis. Its fibres converge to a narrow tendon, which is inserted into the anterior half of the inner border and upper surface of the coracoid process, in contact with the conjoined origin of the coraco-brachialis and biceps muscles.

This muscle is covered by the pectoralis major, and forms a part of the anterior wall of the axilla. When the arm is much raised a portion of the muscle is seen below the outer margin of the pectoralis major.

The *subclavius* muscle arises by a short thick tendon from the first costal arch at the junction of the rib and cartilage, close to the costo-clavicular ligament. From this tendon its fibres pass outwards and upwards, forming

Fig. 174.

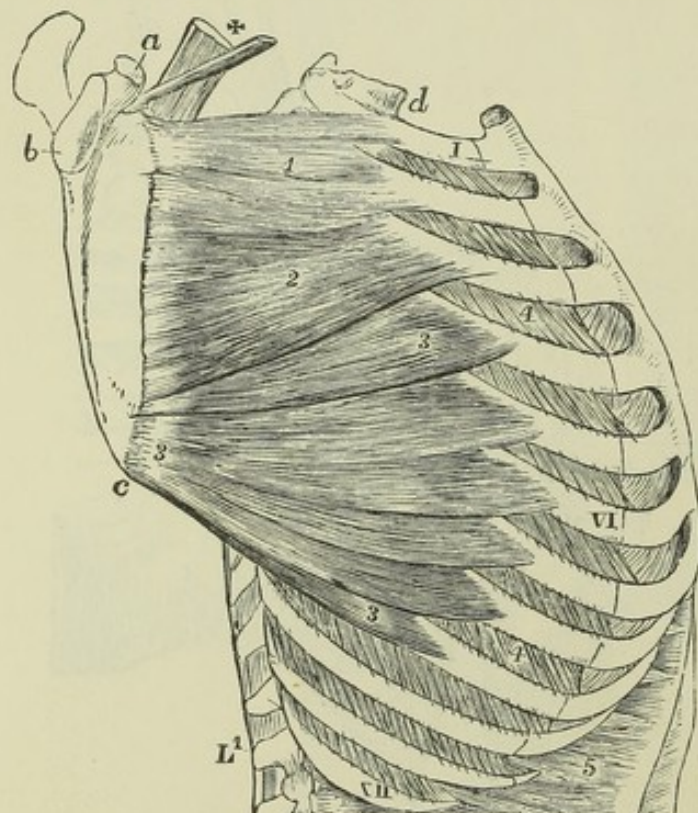


Fig. 174.—LATERAL VIEW OF THE TRUNK, SHOWING IN A DEEP DISSECTION A VIEW OF THE SERRATUS MAGNUS MUSCLE.  $\frac{1}{2}$

a, coracoid process of the scapula; b, glenoid cavity; c, lower angle; d, first dorsal vertebra; 1, VI, XII, the first, sixth, and twelfth ribs; 2, upper portion of the serratus magnus attached to the first and second ribs; 3, second or middle portion attached chiefly to the third rib; 4, lower or fan-shaped portion attached to the ribs from the fourth to the ninth; 5, external intercostal muscles marked in the third and ninth spaces; 6, upper costal origins of the transversalis abdominis; x, scapular extremities of the levator scapulae and omohyoid muscles.

a rounded belly, which is inserted into the groove along the inferior surface of the clavicle, extending as far as the recess between the conoid and



trapezoid parts of the coraco-clavicular ligament. It is covered in front by the costo-coracoid membrane or fascia.

The *serratus magnus* muscle, placed upon the upper and lateral part of the thorax, between the ribs and the scapula, is attached anteriorly by nine fleshy angular slips to the first eight ribs, two of these being connected with the second rib; it also derives some fibres from the aponeurosis covering the upper intercostal spaces. Posteriorly, the muscle, considerably narrowed, is attached to the line in front of the base of the scapula, and at the upper and lower angles of the bone into the flat surfaces which are excluded from the fossa of the subscapular muscle. The fibres are arranged in three sets, thus—*a.* Those from the first and second digitations form a thick bundle which terminates on the flat area in front of the upper angle of the scapula; *b.* those of the third and fourth digitations, but especially the first of these, which is the inferior digitation of the second rib, spread out into a triangular layer, the thinnest part of the muscle, and are attached along the line in front of the base of the scapula, extending from the place of insertion of the preceding part nearly to the lower angle of the bone; *c.* the remaining five or six digitations converge in the form of a fan, and terminate in a thick mass, which is attached posteriorly to the flat surface in front of the lower angle of the scapula.

By its deep surface, the *serratus magnus* rests on the upper ribs, the intercostal muscles, and part of the *serratus posticus superior*. Its outer surface is in contact posteriorly with the subscapular muscle, and forms anteriorly the internal wall of the axilla, being subcutaneous in the lower part of its extent.

Not unfrequently the number of digitations, and the number of the ribs with which the muscle is connected, are greater than above described. Occasionally the attachment to the first rib is wanting; and examples are recorded of the absence of the middle part of the muscle.

**ACTIONS.**—Considered with reference to the movements of the limb upon the trunk, the upper part of the trapezius, the levator scapulæ, and the rhomboid muscles are elevators of the shoulder; the lower part of the trapezius, the pectoralis minor and the subclavius are depressors; the *serratus magnus* as a whole carries forward the base of the scapula, and the rhomboidei draw it back; the latissimus dorsi and pectoralis major depress the humerus and carry it towards the middle line, behind or in front, according as the one or other muscle is in action.

More particularly, the superior fibres of the *trapezius* elevate the clavicle; the succeeding fibres acting on the acromion have also some elevating action, but tend rather to carry back the scapula towards the spine; the inferior part of the muscle acting upon the spine of the scapula would of itself depress that bone while it carried it inwards towards the dorsal spines, but acting in concert with the upper two-thirds of the muscle, a rotation is produced in the scapula round a central point in such a manner that while the whole bone, and more especially the acromion, is raised and carried towards the dorsal spines, the upper angle of the scapula is somewhat depressed and carried inwards, while the lower angle is carried outwards and elevated.

The *levator scapulæ*, in elevating the superior angle of the scapula, counteracts in some degree the rotating action of the trapezius, and this is further effected by the rhomboid muscles, more especially the greater, which, as its main attachment is near the inferior angle of the scapula, necessarily tends to raise that part and bring it nearer to the dorsal spines. In this manner when the trapezius, levator, and rhomboid muscles act together, the scapula is raised without rotation, and its base is carried at the same time inwards towards the dorsal spines.

The *subclavius*, by depressing the clavicle, diminishes the space between that bone and the first rib, and may probably act principally as a support to the sterno-clavicular articulation.

The *pectoralis minor*, in bringing the coracoid process downwards and forwards, tends to throw the lower angle of the scapula backwards.



The *serratus magnus* muscle, by withdrawing the scapula from the spinal column, enables the arm when raised from the shoulder to be still farther outstretched, as in the movement termed extension in fencing. It comes powerfully into action in all movements of pushing; it likewise combines with the trapezius in rotating the scapula.

The *latissimus dorsi* carries the elevated arm downwards and backwards, rotating it at the same time inwards, so as to make the palm look backwards, thus accomplishing such a movement as is made by the arm in swimming. By passing over the angle of the scapula it binds that process to the trunk, preventing its projection backwards; and by being folded round the outer border of the scapula, it limits the projection outwards of the same angle when the arm is raised.

The *pectoralis major* muscle, while it combines with the *latissimus dorsi* in depressing the humerus from the raised position, opposes that muscle by drawing the limb forwards. It is placed upon the stretch when the arms are thrown backwards, and is most shortened when they are folded across the chest.

Considered as acting on the trunk from the upper limb in a fixed condition, these muscles have chiefly the following effect:—They all tend to draw the trunk of the body towards the limb, as in climbing, or other like efforts. The *latissimus dorsi*, if acting on both sides, carries the body upwards and forwards, as in the use of crutches, or in throwing a somersault from the hands backwards. The pectoral and *latissimus dorsi* muscles are also muscles of forced inspiration, tending to raise and dilate the ribs, more especially when the arms are elevated. The upper parts of both trapezii muscles acting on the occipital bone aid the sterno-mastoid muscle in throwing forward the chin; and if one muscle only acts, it aids in rotating the head.

#### MUSCLES OF THE SHOULDER.

The *deltoid* is a coarsely fasciculated muscle, extending from the most prominent part of the shoulder down a third of the upper arm. It arises by a broad margin in three portions, an anterior from the external third of the clavicle, a middle from the outer edge of the acromion, and a posterior from the lower border of the spine of the scapula as far back as the triangular surface at the inner end of that portion of the bone, and the fasciculi from the extended origin, converging as they descend, are inserted by a comparatively narrow but thick extremity into the triangular rough surface above the middle of the humerus, on its outer side. This rough surface receives the name of the deltoid impression.

At its posterior part the origin of the deltoid is thin and tendinous, and in the rest of its extent fibrous septa dip down between the coarse muscular fasciculi. At the insertion it is tendinous on the deep surface, and fibrous septa also project upwards from thence into the substance of the muscle. The muscular fibres are arranged pennately round those septa with such regularity as to have suggested to Albinus the subdivision of the muscles into seven parts, four of them broad above and narrow below, and three intercalated between those parts, which are broad below and narrow above. (Albinus, *Histor. Muscul. Hom.*, p. 423.)

At the posterior border of the deltoid, the aponeurosis covering the *infraspinatus* muscle divides into two thin layers, of which one covers the muscle superficially, and the other lines its deep surface. At its anterior border this muscle is in contact with the *pectoralis major*, the cephalic vein lying between them. In immediate contact with the deep surface is the large bursa, which separates this muscle and the acromion from the shoulder joint and the muscles supporting it. The deltoid muscle covers the origins of the biceps, coraco-brachialis, and long head of the triceps, and the insertions of the subscapularis, supraspinatus, *infraspinatus* and *teres minor* muscles, as also the circumflex vessels and nerve.

The *subscapularis* muscle arises from all the venter of the scapula, with the exception of the neck of the bone and the spaces occupied by the *serratus*



magnus; it is inserted tendinously into the small tuberosity of the humerus, and by fleshy fibres into the bone for a short distance lower down. Tendinous septa, attached to the ridges of the subscapular fossa, pass outwards in the origin of the muscle, and others are prolonged inwards from the tendon of insertion.

Fig. 175.—SUPERFICIAL MUSCLES OF THE SHOULDER AND UPPER LIMB, SEEN FROM BEHIND.  $\frac{1}{2}$

a, acromion; b, base of the scapula; c, tendon of the trapezius muscle over the triangular surface of the spine of the scapula; d, olecranon of the ulna; e, external condyloid eminence; f, lower end of the ulna; 1, trapezius; 2, acromial part of deltoid; 2', the part of the same muscle rising from the spine of the scapula; 3, rhomboideus major; 4, infraspinatus; 5, teres minor; 6, teres major; 7, latissimus dorsi; +, triangular space between the trapezius, rhomboid and latissimus; 8, triceps extensor cubiti; 8', its outer head; 8'', part of its inner head; 9, anconeus; 10, part of the brachialis anticus; 11, supinator longus; 12, extensor carpi radialis longior. The explanation of the remaining references will be found in the description of fig. 182.

The tendon of this muscle is incorporated with the capsule of the shoulder-joint, and between its upper margin and the coracoid process is a bursa usually communicating with that joint. Anteriorly it is in contact at its origin with the serratus magnus, and is covered at its insertion by the coraco-brachialis and biceps, while, in the interval between, it forms part of the posterior wall of the axilla.

The *supraspinatus* muscle arises from the whole surface of the supraspinous fossa of the scapula as far forward as the outer extremity of the spine, and from an aponeurosis, by which it is covered. It

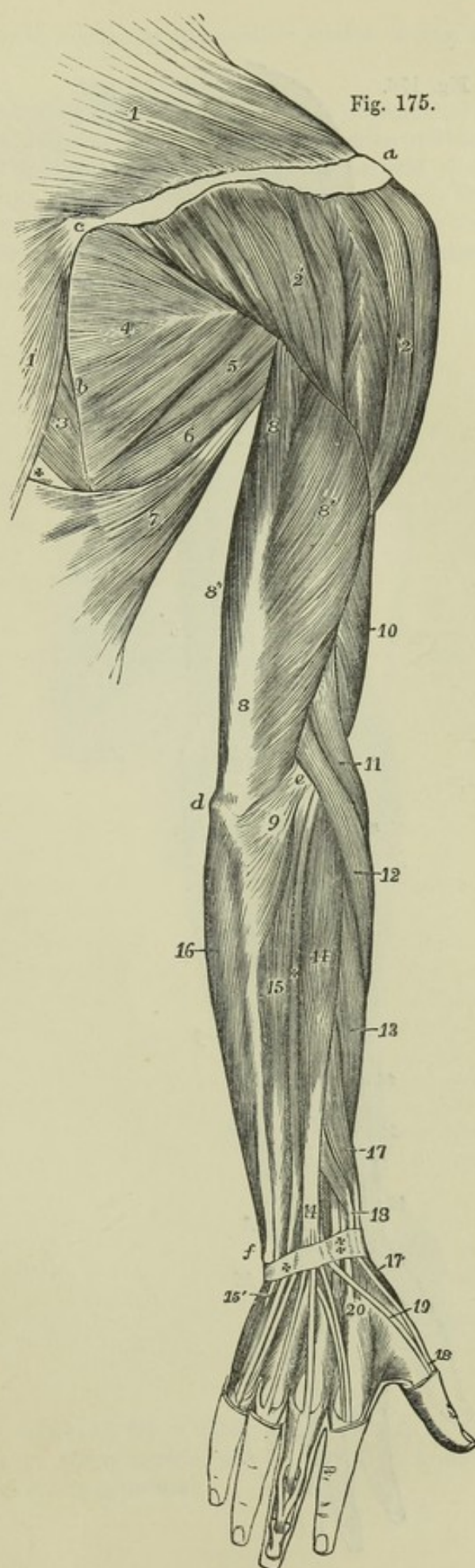
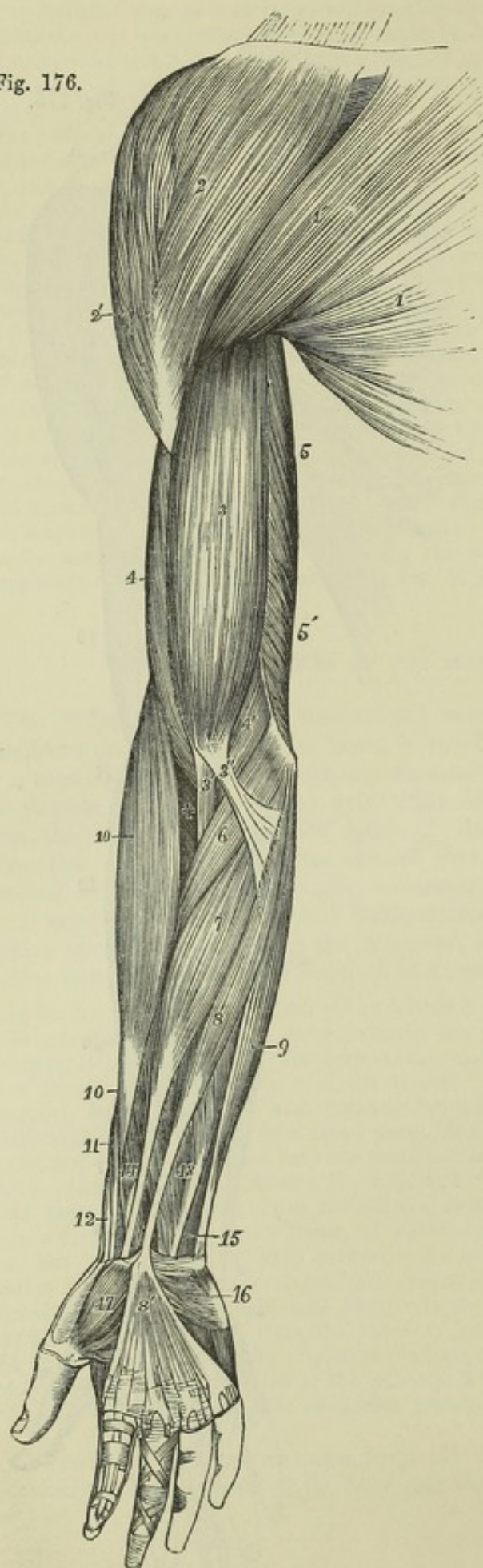




Fig. 176.



completely fills the fossa, and its fibres converge beneath the acromion to a tendon, which adheres to the capsule of the shoulder-joint, and is inserted into the upper of the three facets on the great tuberosity of the humerus.

Fig. 176.—SUPERFICIAL MUSCLES OF THE SHOULDER AND UPPER LIMB, FROM BEFORE.  $\frac{1}{2}$

1, pectoralis major; 1', its clavicular portion; 2, deltoid; 3, biceps brachii; 3', its tendon of insertion; 3'', its aponeurotic slip; 4, brachialis anticus; 4', its inner and lower portion; 5, inner head of the triceps; 5', lower part of the same, seen rising from behind the intermuscular septum. The explanation of the remaining references will be found in the description of fig. 179.

The *infraspinatus* muscle, occupying the greater part of the infraspinous fossa, arises from the under surface of the spine and from the whole surface of the blade of the scapula below the spine, except those parts at the lower angle and along the external border, to which the *teres* muscles are attached. The fibres converge to a tendon, which is concealed at first within the substance of the muscle, and is inserted into the middle facet of the great tuberosity of the humerus.

The *supraspinatus* muscle is covered by the trapezius and the acromion process.

The *infraspinatus* muscle is bound down by an aponeurosis, which superiorly and externally divides so as to enclose the deltoid muscle. It is covered by the deltoid at its upper and outer part, and by the trapezius at its upper and inner part, by



the latissimus dorsi at its lower angle, and in the intermediate portion it remains superficial.

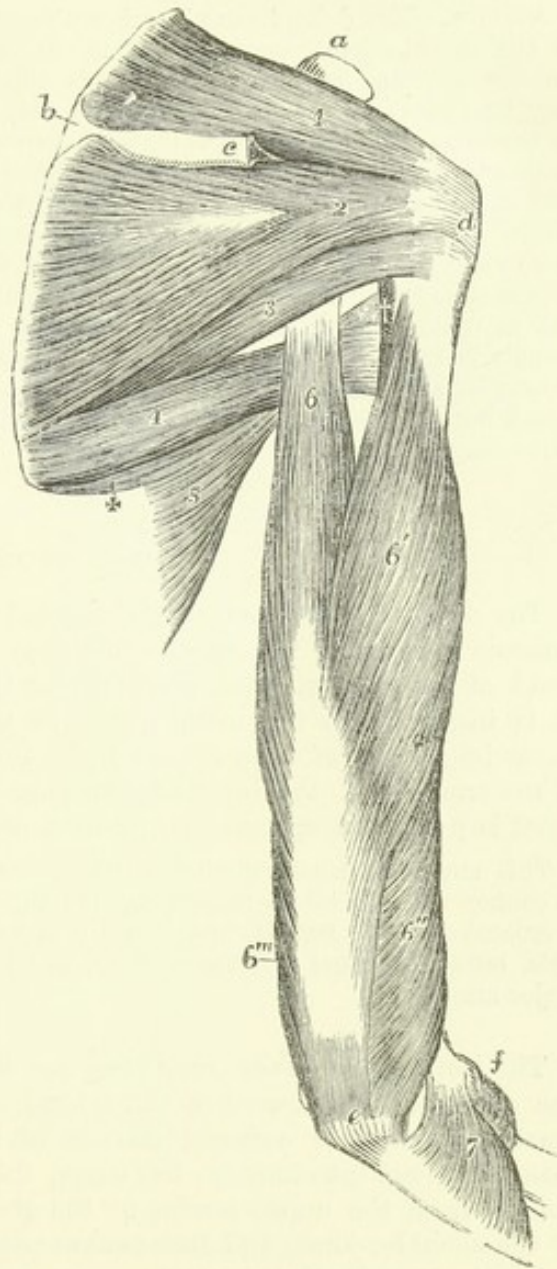
The *teres minor* muscle, is placed along the outer border of the infraspinatus, and is intimately connected with that muscle. It arises by a series of fibres from a narrow obliquely grooved surface on the dorsum of the scapula close to the axillary border, and from aponeurotic septa between it and the infraspinatus and *teres major* muscles, and is inserted by tendon into the greater tuberosity of the humerus, immediately below the infraspinatus, and by fleshy fibres into the bone for a short distance lower down.

Fig. 177.—MUSCLES OF THE RIGHT SHOULDER AND ARM, SEEN FROM BEHIND.  $\frac{1}{2}$

The acromion process and a part of the spine of the scapula, with the deltoid muscle, have been removed. *a*, coracoid process; *b*, triangular surface at the commencement of the spine; *c*, is close to the cut portion of the spine; *d*, greater tuberosity; *e*, olecranon of the ulna; *f*, is close to the external condyloid eminence and head of the radius; 1, supraspinatus muscle; 2, infraspinatus; 3, *teres minor*, placed over the triangular interval; 4, *teres major*; 5, part of latissimus dorsi; +, slip from the inferior angle of the scapula; †, on the edge of the humerus, points to the tendon of the latissimus dorsi and the quadrangular interval; 6, scapular head of the triceps, passing above between the *teres major* and *minor*; 6', outer head; 6'', lower part of the same, below the spiral groove, continued from the inner head; 6''', part of the inner head; 7, anconeus.

The *teres major* muscle arises from the flat oval surface on the dorsum of the scapula near its inferior angle, slightly from the axillary border of the bone, and from the septa interposed between it and the *teres minor* and *infraspinatus*. It is inserted by a flat tendon about two inches wide, into the inner or posterior border of the bicipital groove of the humerus, behind and in contact with the tendon of the latissimus dorsi, to which it is adherent for a short space. Close to the insertion, however, the tendons of these muscles are separated by a small bursa. The fibres of the muscle are longitudinal.

Fig. 177.





Posteriorly this muscle is covered at its lower part by the latissimus dorsi, and at its upper part it is crossed by the long head of the triceps. The outer side is surrounded by the latissimus dorsi; and the anterior surface is concealed in the upper part of its extent by the tendon of that muscle. The inner border of the muscle forms the outer margin of a triangular space, of which the other sides are the upper part of the humerus, and the axillary border of the scapula covered before and behind by the subscapular and teres minor muscles; this triangle is divided by the long head of the triceps into a superior or external quadrilateral, and an inferior or internal triangular compartment. Through the quadrilateral space pass backwards the posterior circumflex vessels and the circumflex nerve; and in the triangular subdivision the dorsal branch of the subscapular artery passes round the margin of the scapula into the infraspinous fossa. The scapular slip of the latissimus dorsi arises in connection with the teres major.

**ACTIONS.**—The deltoid muscle raises the arm from the side as far as the structure of the shoulder-joint permits: that is, till it is at right angles with the trunk. Further elevation of the upper limb is effected chiefly by the trapezius; and it may be remarked, that the insertion of that muscle corresponds exactly in extent to the origin of the deltoid, so that the two muscles may be considered continuous in structure and in action. The anterior fibres of the deltoid combine with the pectoralis major to draw the humerus forwards; the posterior assist in drawing it backwards. The supraspinatus, infraspinatus and subscapularis muscles being placed more closely round the joint, when acting in concert with the deltoid probably give steadiness and precision, while the deltoid gives the main elevating force to the movement. The supraspinatus simply elevates: the infraspinatus and subscapularis carry the arm backwards or forwards when it is raised, and rotate it outwards or inwards when hanging by the side. The teres major rotates the raised humerus inwards, the teres minor outwards: acting together they assist in depressing the arm.

#### MUSCLES OF THE ARM.

The *coraco-brachialis* muscle, elongated in form, arises from the tip of the coracoid process of the scapula, between the pectoralis minor and the short head of the biceps, with which latter it is for a short distance conjoined. It is inserted into the inner border of the humerus near its middle, in a linear impression of from two to three inches in length, between the origin of the triceps and the brachialis anticus. From its insertion a tendinous offset is prolonged upwards to the head of the humerus.

This muscle is usually pierced by the musculo-cutaneous nerve; its outer border is in contact with the biceps muscle, and its inner with the brachial artery, by which it is crossed obliquely near its insertion. It lies in front of the tendons of the subscapularis, latissimus dorsi and teres major, and is covered by the deltoid and pectoralis major muscles.

The *biceps flexor cubiti* muscle has two heads of origin of unequal length: one of these, the internal or short head, arises conjointly with the coraco-brachialis from the coracoid process of the scapula by a tendon which is soon continued into muscle; the other, the long head, arises by a cylindrical tendon from the upper border of the glenoid ligament, within the capsule of the shoulder-joint, and this tendon passing over the head of the humerus leaves the joint by the bicipital groove, and gradually enlarges into the fleshy head as it descends. The muscular fibres from those two heads, lying side by side, unite to form an elongated and thick belly, occupying the middle and lower part of the arm: the muscle then suddenly becoming narrower a little above the bend of the elbow, is continued into the flat rounded

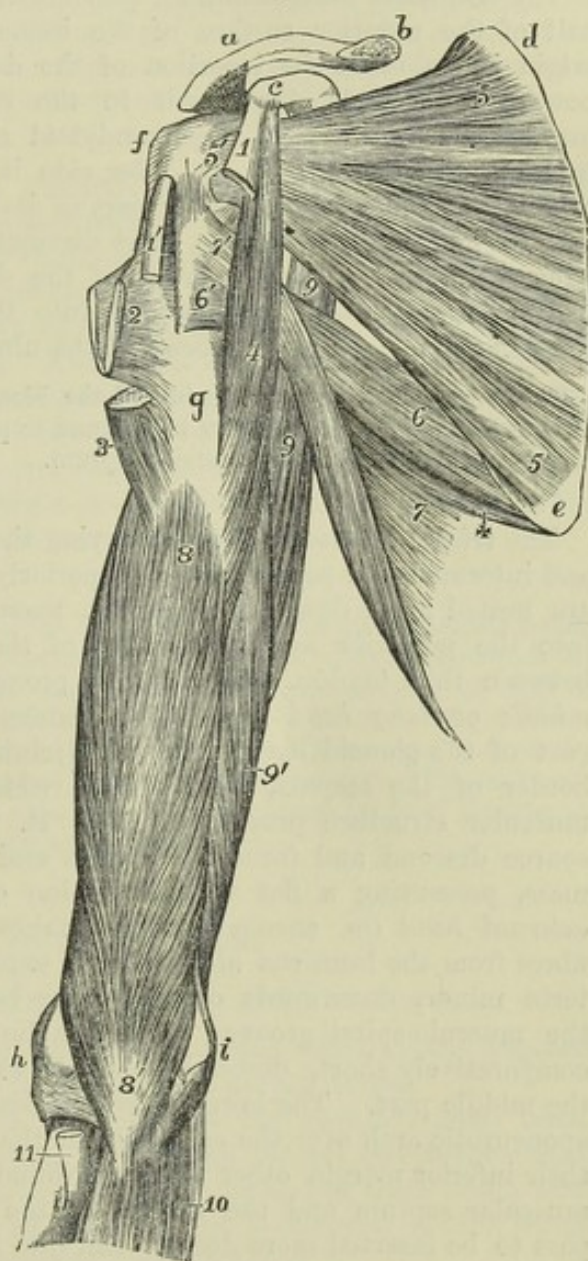


tendon of insertion. This tendon, slightly twisted upon itself as it descends, is inserted into the rough posterior margin of the tuberosity of the radius, and glides on the anterior smooth surface of that process by the intervention of a synovial bursa. From the front of the lower part of the muscle, and from the tendon at its inner side, there proceeds a fibrous expansion of an aponeurotic nature, which passing downwards and inwards becomes blended with the fascia of the forearm over the pronator radii teres.

Fig. 178.—DEEP VIEW OF THE MUSCLES OF THE RIGHT SHOULDER AND ARM, FROM BEFORE.  $\frac{1}{4}$

The clavicle is divided near its middle; the pectoralis minor is entirely removed, and portions of the biceps, pectoralis major, deltoid, and latissimus dorsi, are left near their attachments. *a*, acromion; *b*, cut part of the clavicle; *c*, coracoid process; *d*, upper, and *e*, lower triangular space left at the upper and lower angles of the scapula on its anterior surface when the serratus magnus is removed; *f*, great tuberosity of the humerus; *g*, surface of the humerus below the bicipital groove, near the ridge of attachment of the pectoralis major and deltoid muscles; *h*, outer, and *i*, inner condyloid eminence of the humerus; *1*, cut coracoid head, and *1'*, cut glenoid tendon, of the biceps muscle; *2*, folded tendon of insertion of the pectoralis major, of which one portion is seen running up to the bicipital groove; *3*, lower cut end of the deltoid; *4*, coraco-brachialis muscle; *5*, subscapularis; *5'*, its insertion into the lesser tuberosity; *6*, teres major; *6'*, its insertion behind and below the latissimus dorsi; *7*, part of the latissimus dorsi; *+*, slip proceeding from the inferior angle of the scapula; *7'*, insertion of the tendon after winding round the teres major in front of and higher than that muscle; *8*, *8'*, brachialis anticus; *9*, long or scapular head of the triceps, at the upper part seen between the teres major and subscapularis muscles, the teres minor not represented; *9'*, inner humeral head of the triceps; *10*, flexor communis digitorum profundus, taking origin round the insertion of brachialis anticus; *11*, tendon of insertion of the biceps.

Fig. 178.



Concealed above by the deltoid and pectoralis major muscles, the biceps forms in the rest of its extent the prominence of the front of the arm. It rests in its upper half on the humerus, and in its lower on the brachialis anticus, and by its inner margin is in contact in its upper half with the coraco-brachialis, in its lower with the



brachial artery. Its inferior tendon is in contact with the supinator brevis, and the fibrous expansion is stretched across the brachial artery and median nerve.

Occasionally a third head, arising from the humerus in more or less close connection with the brachialis anticus and the insertion of the coraco-brachialis, is added to the biceps muscle: this head lies generally on the outer side of the brachial artery, and has sometimes been found covering it. A muscular band has also been observed extending downwards from the biceps to the intermuscular septum over the inner condyle of the humerus, and passing over the brachial artery. (R. Quain, "The Anatomy of the Arteries," &c., p. 270, pl. 57.)

The *brachialis anticus* muscle (*brachæus internus*) arises from the lower half of the anterior surface of the humerus. At the upper part of its origin it embraces the insertion of the deltoid by two angular fleshy processes; it extends downwards to the capsule of the elbow-joint, and inwards to the internal supracondyloid ridge and intermuscular septum in its whole extent; on its outer side it is separated from the external ridge and septum in the greater part of its length by the supinator longus, and only arises from it for a short distance at its upper end. It is closely adherent to the ligament in front of the elbow-joint, and terminates below in a thick mass which is inserted into the rough triangular surface on the front of the coronoid process of the ulna.

This muscle projects at each side of the biceps, and supports the brachial artery and median nerve. Fibres have been found to pass inwards from it, over the brachial artery, to the internal intermuscular septum.

The *triceps extensor cubiti*, occupying the whole space behind the humerus and intermuscular septa, consists superiorly of three portions or heads which are united lower down in a common mass, the tendon of which is inserted into the posterior and upper part of the olecranon, a bursa intervening between that tendon and the most prominent part of this process. The *middle* or *long* head (*musculus anconeus longus*) arises from the lower part of the glenoid cavity and an adjoining rough portion of the inferior border of the scapula, by a tendon which spreads over the sides of the muscular structure proceeding from it. The muscular fibres from this source descend and form the middle and superficial part of the common mass, presenting a flat vertical tendon on their surface inferiorly. The *external* head (*m. anconeus brevis*) takes origin by tendinous and fleshy fibres from the humerus along a line extending from the insertion of the *teres minor*, downwards on the outer border of the humerus as low as the musculo-spiral groove; from this line of origin its fibres, which are comparatively short, descend obliquely to be inserted into the tendon of the middle part. The lowest fibres of this head are bound down by a slight aponeurotic arch over the extremity of the musculo-spiral groove, and below their inferior margin other fibres are found arising from the external intermuscular septum and the surface of the humerus behind; but these last pass to be inserted more deeply than into the tendon of the middle part of the muscle, and are rather to be considered as belonging to the muscular mass which forms the internal head. The *internal* or *deep* head (*m. anconeus internus*), the shortest of the three, commences in a narrow pointed part behind and below the tendon of insertion of the *teres major*, and arises from the whole posterior surface of the humerus below the musculo-spiral groove, from the internal intermuscular septum in all its length, and from the inferior portion of the external septum; some of its lower



fibres are inserted immediately into the olecranon, and the greater part of them join the deep surface of the common tendon. No muscular fibres arise from the musculo-spiral groove itself.

The method of description above followed, in which all the fibres arising below the musculo-spiral groove are assigned to the internal head, originated with Theile. (Müller's "Archiv." &c. 1839, p. 420, and "Sœmmerring v. Baue," &c.) The long head of the triceps lies between the two teres muscles above, and is in contact with the capsule of the shoulder-joint. The musculo-spiral nerve, and the superior profunda artery, pass between the inner and outer heads as they lie in the musculo-spiral groove.

*Sub-anconeus*.—On removing the triceps from the lower part of the humerus, some muscular fibres will be found passing from that part of the bone to the capsule of the elbow-joint. These fibres, which are analogous to the sub-crureus in the lower limb, have been described as distinct from the triceps under the name sub-anconeus.

The *anconeus* muscle (*anconeus quartus*) although placed below the elbow and in that respect belonging to the forearm, is in its structure, function and nervous supply, so intimately connected with the triceps, that it is most appropriately associated in description with that muscle. It arises by a narrow tendon from the extremity of the outer condyloid eminence of the humerus, at the posterior aspect. From this the fibres diverge from one another, the upper being horizontal, the rest passing downwards with increasing degrees of obliquity, and are inserted into the olecranon on its radial aspect, and into the adjacent impression on the upper third of the shaft of the ulna. Its superior fibres are parallel to the lowest fibres of the internal head of the triceps, and are generally in contact with them.

**ACTIONS.**—The biceps muscle raises the arm at the shoulder and flexes the elbow-joint; the long head of the triceps depresses the arm at the shoulder, and extends the elbow-joint. The short head of the biceps draws the arm inwards as well as upwards, as does also the coraco-brachialis. If the biceps be called into action when the hand is in pronation, its first effect, in virtue of its insertion into the back part of the tuberosity of the radius, is to produce supination of the forearm. The brachialis anticus is a simple flexor of the elbow; the external and internal heads of the triceps, and the anconeus muscle, are simple extensors of that joint.

#### MUSCLES OF THE FOREARM.

##### *a. Anterior and Inner Regions (Flexors and Pronators).*

The muscles on the front and inner part of the forearm are disposed in two sets, one being superficial, the other more deeply seated.

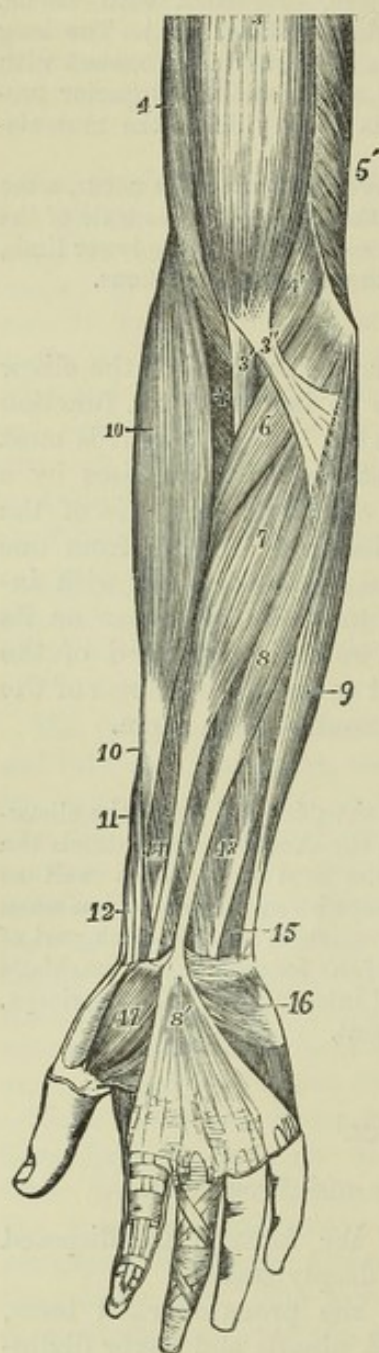
The *superficial layer* of muscles comprehends the pronator radii teres, flexor carpi radialis, palmaris longus, flexor carpi ulnaris and flexor digitorum sublimis. These five muscles are intimately united at their origin from the inner condyle, to which they are attached by a common tendon which gives fibres to each, and also sends septa between them.

The *pronator radii teres*, the most external of the group, arises by two distinct heads; one, large and superficial, is derived from the upper part of the inner condyloid eminence of the humerus, and from the common tendon above mentioned; also from the fascia and the intermuscular septum of the forearm. The second head, a thin fasciculus deeply placed, comes from the inner margin of the coronoid process, and joins the other at an acute angle. The fleshy belly thus formed proceeds outwards and down-



wards, and ends in a flat tendon which turns over the radius, and is inserted into a rough surface at the middle of the outer side of that bone.

Fig. 179.

Fig. 179.—SUPERFICIAL MUSCLES OF THE FOREARM AND HAND, SEEN FROM THE FRONT.  $\frac{1}{2}$ 

3, biceps flexor cubiti; 3', its tendon of insertion; 3'', its aponeurotic slip; 4, brachialis anticus; 4', its inner and lower portion; 5', lower part of the triceps, seen rising from behind the intermuscular septum; 6, pronator radii teres; 7, flexor carpi radialis; 8, palmaris longus, passing at 8' into the palmar aponeurosis; 9, flexor carpi ulnaris; 10, supinator longus; between 10 and 3, + marks a part of the supinator brevis; 11, extensor ossis metacarpi pollicis; 12, extensor primi internodii; 13, lower part of the flexor digitorum sublimis; 14, flexor longus pollicis; 15, small part of the flexor digitorum profundus; 16, palmaris brevis, lying on the muscles of the little finger; 17, abductor pollicis.

The pronator teres is placed superficially in the greater part of its extent; but towards its insertion it is crossed by the radial artery and nerve, and the supinator longus muscle. The ulnar border is in contact with the flexor carpi radialis and palmaris longus: the radial border forms the inner boundary of the angular space at the bend of the arm, in which are placed the brachial artery, the median nerve, and the tendon of the biceps muscle. The pronator teres covers the flexor sublimis digitorum; the ulnar artery passes behind the whole muscle, and the median nerve between its two heads.

Additional fibres frequently arise from the intermuscular septum above the inner condyloid eminence of the humerus, or from the supracondyloid process when that is present. This peculiarity is sometimes associated with a change in the direction of the brachial artery.

The *flexor carpi radialis* arises from the inner condyle by the common tendon, from the fascia of the forearm, and from the intermuscular septa placed between it and the pronator teres on one side, the palmaris longus on the other, and the flexor sublimis posteriorly. The fleshy fibres end in a flat tendon, a little below the middle of the forearm. Arrived at the carpus, the tendon

occupies a special fibrous compartment situated in the outer part of the anterior annular ligament of the wrist, and runs through a groove in the os trapezium, to which it is bound by a thin fibrous sheath lined by a synovial membrane, and is inserted into the extremity of the second metacarpal bone.

A fasciculus from the inserted tendon sometimes passes to the third and even to the fourth metacarpal bone.

In the lower half of the forearm the radial artery is placed to the outer side of the tendon.



The *palmaris longus*, the smallest muscle of this group, is placed between the flexores carpi radialis and ulnaris, resting on the flexor sublimis: it arises from the inner condyle and the intermuscular septa; forming a small muscular belly, which soon ends in a long slender tendon, inserted into the palmar fascia, near the middle of the wrist, and sometimes sending a slip to the short muscles of the thumb.

The *palmaris longus* is frequently wanting. It is subject to many variations of form, *e. g.* the muscular fibres may occupy the middle of the muscle, which then commences and ends by an elongated tendon; or the muscular structure may be placed towards the lower end, the upper part being tendinous. Occasionally there are two long palmar muscles, one having the ordinary shape, while the other has one of the forms above referred to. The most remarkable peculiarity is that in which a small muscle, a second *palmaris longus*, placed nearer to the inner border of the forearm than the usual muscle, covers the ulnar artery for some space above the carpus, and terminates partly in the annular ligament or in the fascia, and partly in the short muscles of the little finger.

The *flexor carpi ulnaris*, the innermost muscle of the superficial group, arises by two heads, one of which is attached tendinously to the inner condyloid eminence of the humerus, the other to the inner side of the olecranon, and to the posterior border of the ulna for three-fourths of its length, by an aponeurosis which is inseparably connected with the investing aponeurosis of the limb. The fibres from the humeral head descend vertically, those from the ulna pass obliquely forwards, and terminate in a tendon, which, emerging from the first head, descends along the anterior margin of the muscle, and is ultimately inserted into the pisiform bone: this tendon is prolonged, by means of ligamentous structures, to the fifth metacarpal and unciform bones, as well as to the annular ligament and muscles of the little finger.

This muscle rests on the flexor profundus digitorum. The ulnar nerve passes down into the forearm, in the interval between the two heads, and is then covered by the muscle: for the middle part of its course the ulnar artery is also covered by it, and in the lower part of the forearm, the nerve and artery, emerging from behind the muscle, lie on its radial side.

The *flexor digitorum sublimis vel perforatus*, the superficial flexor of the fingers, is a broad flat muscle placed behind the preceding muscles, along with which it takes its principal origin. It is divided inferiorly into four tendons, which pass to be inserted into the second phalanx of each of the four inner digits. More particularly, it arises from the inner condyle by the common tendon, and the fibrous septa common to it and the other muscles; from the internal lateral ligament; from the anterior surface of the coronoid process at the inner side; and by a thin flat portion from the oblique line and part of the anterior border of the radius. The fleshy belly enlarges towards the middle of the forearm, and again diminishes somewhat before its division. The four tendons pass under the annular ligament of the wrist in pairs, one in front of the other; the anterior pair consisting of those for the middle and ring fingers, the posterior of those for the index and little fingers. That for the little finger is smaller than the others.

In the palm of the hand the tendons diverge, and each accompanied by a tendon of the flexor profundus, enters a fibrous sheath which binds both tendons down to the palmar surface of the phalanges. Opposite the first phalanx the tendon of the flexor sublimis divides into two parts, which fold



closely round the tendon of the deep flexor, and are reunited by their margins behind it: the two portions of the tendon thereafter separating, pass to be inserted one on each side into a ridge at the middle of the lateral border of the second phalanx. A large *synovial bursa* loosely invests the tendons of both the superficial and deep flexors of the fingers behind the annular ligament, extending downwards into the palm of the hand. In the little finger it approaches the synovial lining of the sheath, and in the thumb it usually communicates with it.

Fig. 180.

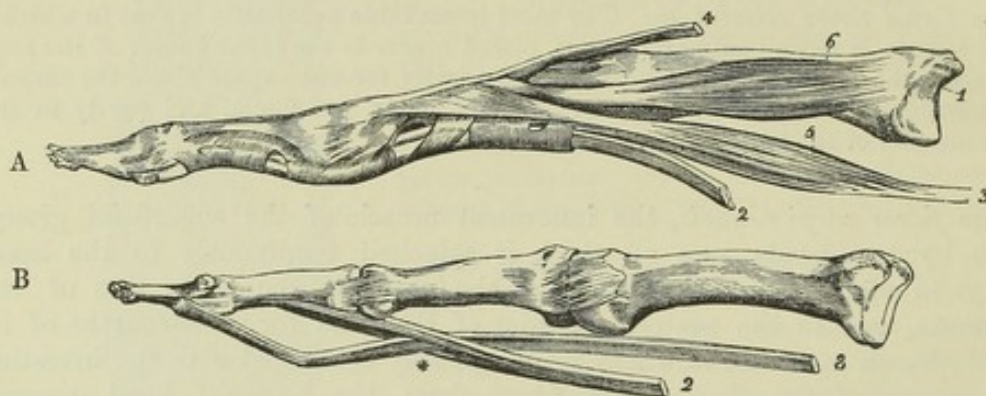


Fig. 180.—METACARPAL AND PHALANGEAL BONES OF TWO FINGERS, WITH THE TENDONS AND THEIR ACCESSORY STRUCTURES.  $\frac{1}{2}$

In A, the tendons of the flexor muscles are bound to the finger by the fibrous bands or retinacula. In B, these bands have been removed, as well as the synovial capsules and vincula accessoria: 1, metacarpal bone; 2, tendon of the flexor sublimis; 3, tendon of the flexor profundus; \*, perforation of the sublimis by the profundus tendon; 4, tendon of the extensor digitorum communis; 5, one of the lumbricales muscles; 6, one of the interosseous muscles.

The *sheaths of the flexor tendons*, by which they are bound down to the fingers, are formed opposite the first and second phalanges by strong tendinous bands of transverse fibres (*ligamenta vaginalia*) attached to the rough margins of the palmar surfaces of the phalanges. Opposite the joints, flexion is secured by the substitution for those bands of a thin membrane, strengthened by oblique decussating fibres. The tendinous sheath has a synovial lining, which is simple in front, but posteriorly dips between the tendons. A few slender and loose bands (*vincula accessoria tendinum*, *vincula vasculosa*) extend from the floor of the sheath to the deep surface of both tendons. Behind each tendon, near its insertion, is a short membranous structure (*ligamentum breve*), which fixes the tendon to the front of the phalanx situated above that into which it is inserted.

Superiorly, the flexor sublimis is concealed by the other muscles of the superficial set, and is crossed near the radius by the radial artery; it rests on the flexor pollicis longus and flexor profundus, separated from the latter by the median nerve and the ulnar artery. In the palm of the hand, its tendons are covered by the palmar fascia, the superficial palmar arterial arch, and the branches of the median nerve; and they lie in front of the accompanying tendons of the flexor profundus.

A muscular slip is frequently given from this muscle to the flexor profundus, or to the flexor longus pollicis. The tendon for the little finger is sometimes wanting.

The *deep-seated* muscles, on the anterior surface of the forearm, are the flexor profundus, flexor pollicis longus and pronator quadratus.



The *flexor profundus digitorum*, or *flexor perforans*, a large and thick muscle, arises from the hollow at the inner side of the olecranon; from the inner and anterior surfaces of the ulna for three-fourths of its length; from the ulnar half of the interosseous ligament for the same distance; and from the aponeurosis attaching the flexor carpi ulnaris to the ulna. It divides inferiorly into four tendons, only one of which, that for the index finger, is distinct from the others above the wrist—the rest being connected together as far as the palm. In the palm the tendons, as they diverge, give origin to the lumbricales muscles. Opposite the first phalanx, the tendon of each finger passes through the opening formed for its transmission in the tendon of the flexor sublimis, and is inserted into the base of the last phalanx.

Fig. 181.

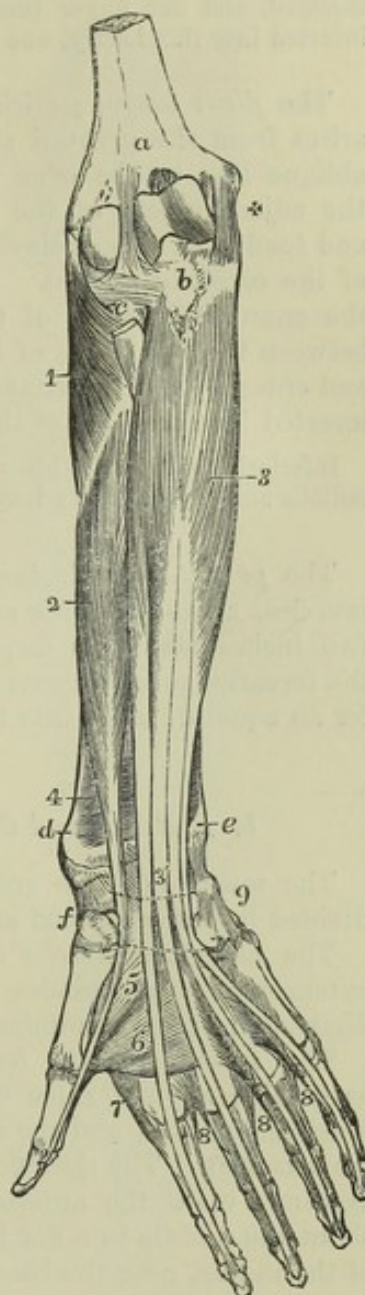


Fig. 181.—DEEP ANTERIOR MUSCLES OF THE FOREARM.  $\frac{1}{2}$

The humeral muscles and the superficial muscles of the forearm and hand, together with the lumbricales, have been removed, and the place of the anterior annular ligament of the carpus is marked by two dotted lines. *a*, surface of the humerus above the coronoid fossa; *b*, rough surface of the ulna, into which the brachialis anticus is inserted; *c*, head of the radius covered by the orbicular ligament, and between this and *a*, the anterior ligament of the elbow-joint; +, the internal lateral ligament; *d*, the lower end of the radius; *e*, that of the ulna; *f*, the scaphoid and trapezium bones; *g*, the pisiform bone; 1, supinator radii brevis; 2, flexor longus pollicis; 3, flexor digitorum profundus; 3', its four tendons, where they are about to pass into the hand under the annular ligament; 4, pronator quadratus on the lower part of the radius; 5, deep head of flexor brevis pollicis; 6, adductor pollicis; 7, first dorsal interosseous muscle; 8, in the second space, is placed between the first palmar and the second dorsal interosseous muscles; in the third space, between the third dorsal and the second palmar; in the fourth space, between the fourth dorsal and the third palmar. (For the lumbricales muscles, see Figs. 180 and 186.)

The upper extremity of this muscle embraces the insertion of the brachialis anticus. On its surface lie the median nerve and the ulnar artery and nerve. The external border is parallel with the flexor longus pollicis, from which it is separated, on the interosseous membrane, by the anterior interosseous vessels and nerve. The tendons are covered by the synovial sacs, which have been mentioned in connection with the flexor sublimis.

The *lumbricales* are four tapering fleshy fasciculi, passing from the tendons of the flexor profundus to the first digital phalanges. They arise by fleshy fibres from the outer or radial borders of the deep flexor tendons, and proceed forwards to the radial sides of the fingers, where each is inserted into an expansion of the extensor tendon on the dorsal aspect



of the metacarpal phalanx of the finger. The two inner lumbricales muscles take origin likewise from the ulnar margins of the second and third tendons.

The number of these muscles is not unfrequently diminished to three, and in rare instances is increased to five or six. The destination of one or two of them is often changed, and one finger (most frequently the third or fourth) has sometimes two inserted into it. Lastly, one muscle may be inserted into two fingers.

The *flexor longus pollicis*, placed side by side with the flexor profundus, arises from the grooved surface, on the fore part of the radius from the oblique line to the edge of the pronator quadratus; it arises also from the adjacent part of the interosseous ligament, and by a rounded fleshy and tendinous slip distinct from the rest of the muscle, from the inner part of the coronoid process. The muscle ends in a tendon which passes behind the annular ligament of the wrist close to the trapezium, turns outwards between the two heads of the flexor brevis and between the sesamoid bones, and entering a canal similar to those of the other flexor tendons, is finally inserted into the base of the second phalanx of the thumb.

Inferiorly, a part of this muscle is placed superficially between the flexor carpi radialis and the supinator longus, where it supports the radial vessels.

The *pronator quadratus*, placed close to the bones behind the last two muscles, arises from the anterior and inner surfaces of the ulna for about two inches above its carpal extremity; its fibres cross the lower part of the forearm, some transversely and others obliquely, and they are inserted for an equal distance into the fore part of the radius.

#### b. Posterior and Outer Regions (Extensors and Supinators).

The muscles of this group are, like those of the front of the forearm, divided into a superficial and a deep layer.

The *superficial muscles* are six in number, viz., the supinator longus, the extensores carpi radiales longior and brevior, the extensor communis digitorum, extensor minimi digiti, and extensor carpi ulnaris.

The *supinator radii longus* arises from the upper two-thirds of the external condyloid ridge of the humerus, and is interposed between the brachialis anticus and the external intermuscular septum, to which its fibres are attached. The thin fleshy mass proceeding from this elongated origin descends upon the anterior and outer border of the forearm, and ends about the middle in a flat tendon, which is inserted into the external border of the radius, near the base of the styloid process.

This muscle is covered only by skin and fascia, except at its insertion, where two of the extensor tendons of the thumb lie superficial to it.

The *extensor carpi radialis longior*, partly covered by the supinator longus, arises from the lower part of the external condyloid ridge of the humerus, and from the intermuscular septum. Its muscular belly ends at the meeting of the upper and middle thirds of the forearm in a flat tendon, which passes conjointly with that of the following muscle over the lower end of the radius in the outermost of the two broad grooves on the posterior surface of that bone, and is inserted into the base of the second metacarpal bone. A small bursa lies beneath the tendon at its insertion.



The *extensor carpi radialis brevis* arises from the outer condyloid eminence of the humerus by a tendon common to it and the other extensor muscles, from the intervening fibrous septa, from a superficial tendinous expansion, and from the external lateral ligament of the elbow-joint. Its muscular belly ends in a flat tendon, which descends with that of the *extensor longior*, passes through the same groove of the radius with it, and is inserted into the base of the metacarpal bone of the middle finger. A bursa is placed between this muscle and the *supinator brevis*, and a smaller one between the tendon and the metacarpal bone.

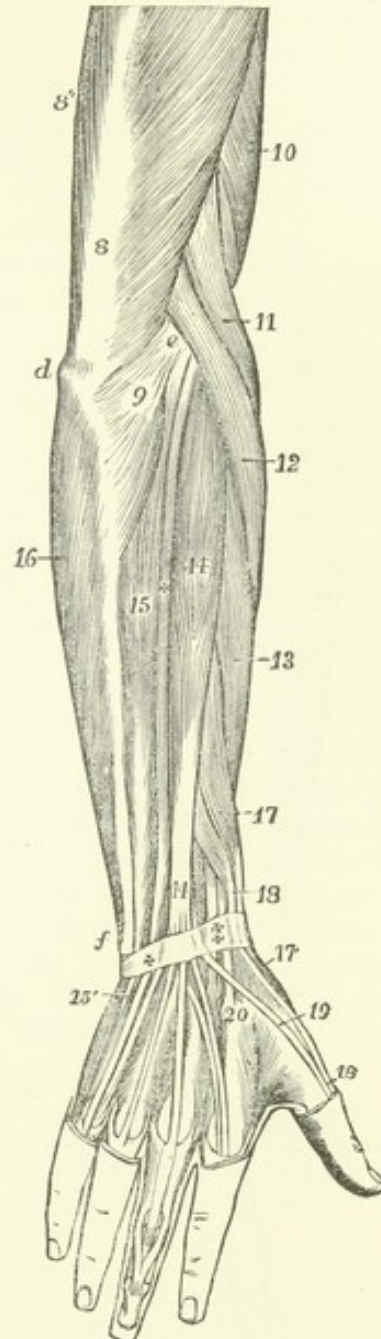
Fig. 182.—SUPERFICIAL MUSCLES OF THE FOREARM AND HAND, SEEN FROM BEHIND.  $\frac{1}{2}$

*d*, olecranon; *e*, external condyloid eminence; *f*, lower end of the ulna; 8, main tendon of the triceps extensor cubiti; 8", its inner head; 9, anconeus; 10, part of brachialis anticus; 11, supinator longus; 12, extensor carpi radialis longior; 13, — brevis; 14, extensor communis digitorum; 15, extensor carpi ulnaris; +, between 14 and 15, extensor minimi digiti; 16, origin of the flexor carpi ulnaris by an aponeurosis from the back of the ulna; 17, extensor ossis metacarpi pollicis; 17', its insertion into the first metacarpal bone; 18, extensor primi internodii pollicis; 18', its insertion into the first phalanx; + and ‡, posterior annular ligament of the carpus or retinaculum of the extensor tendons; at ‡, the tendons of the long and short radial extensors; at +, the tendon of the extensor minimi digiti; 19, tendon of the extensor secundi internodii; 20, is placed on the proximal end of the second metacarpal bone, close to the insertion of the radial extensors of the carpus: in the hand, the dorsal interossei muscles are shown, and on the middle finger the insertion of the extensor tendons.

This muscle is covered by the supinator longus and extensor carpi radialis longior, and conceals the supinator brevis and the insertion of the pronator radii teres. The tendon of this muscle and that of the extensor carpi radialis longior are crossed obliquely by the extensors of the metacarpal bone and first phalanx of the thumb.

The *extensor communis digitorum*, placed between the extensor carpi radialis brevis and the extensor minimi digiti, arises by a tendon common to it and the other superficial extensor muscles, also from the fascia of the forearm, and the septa between it and the adjoining muscles. Somewhat below the middle of the forearm the muscular part ends in four tendons, which pass between the posterior annular ligament of the wrist and the innermost broad groove on the back of the radius, and diverge as they proceed along the carpus and metacarpus to reach the fingers. Here each is increased by tendinous fibres derived from the lumbricales and interosseous muscles,

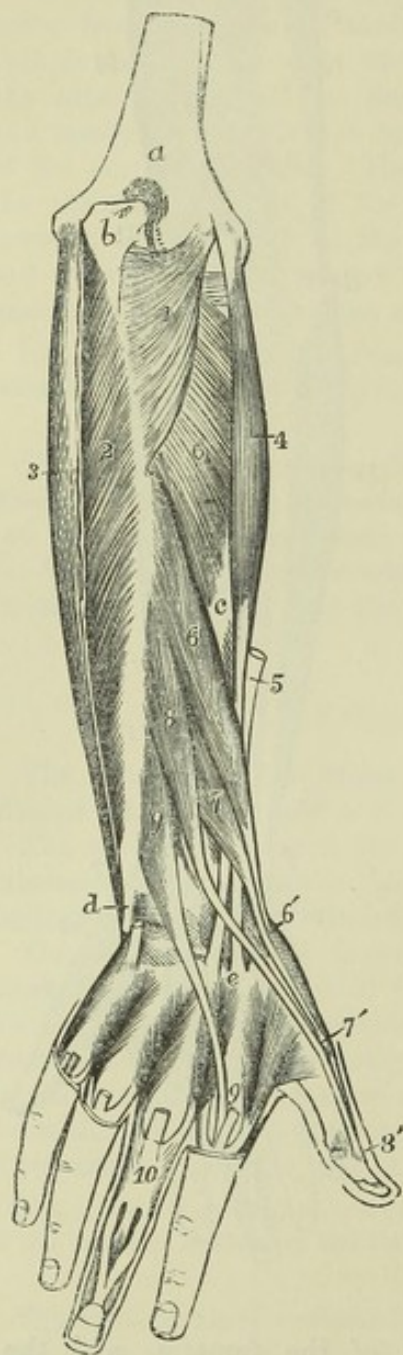
Fig. 182.





forming a fibrous expansion, which covers the back of the first and second digital phalanges, and terminates upon the third phalanx. It is attached to the second and third phalanges in the following manner:—Opposite the first bone the tendon divides into three fasciculi; the central one is much thinner than the others, and is inserted into the base of the second phalanx; the two lateral parts, continuing onwards, are joined together towards the middle or fore part of the second phalanx, and having passed beyond this, are inserted into the last phalanx. On the index and little fingers the tendons are joined before their division, by the special extensor tendons of those digits.

Fig. 183.

Fig. 183.—DEEP POSTERIOR MUSCLES OF THE FOREARM.  $\frac{1}{4}$ 

*a*, posterior surface of the humerus above the olecranon fossa; *b*, upper and back part of the olecranon; *c*, outer and back part of the middle of the radius; *d*, lower part of the ulna, grooved for the tendon of the extensor carpi ulnaris; *e*, base of the second metacarpal bone; 1, anconeus muscle; 2, surface of the flexor digitorum profundus, exposed by the removal of the aponeurotic tendon of the flexor; 3, carpi ulnaris; 4, extensor carpi radialis brevis, and 5, the cut tendon of the extensor carpi radialis longior, both descending to their insertion at *e*, into the second and third metacarpal bones; 6, extensor ossis metacarpi pollicis; 6', its insertion into the first metacarpal bone; 7, extensor primi internodii pollicis; 7', its insertion into the base of the first phalanx; 8, extensor secundi internodii pollicis; 8', its insertion into the base of the last phalanx; 9, extensor indicis; 9', its junction with the tendon of the common extensor, which is cut short: in the metatarsal spaces the four dorsal interossei muscles are represented, the tendons of the common extensor having been removed; and at 10, the insertion of the second and third dorsal interossei, by a triangular expansion, into the tendon of the extensor communis, as well as the mode of insertion of that tendon into the middle and last phalanges, are shown.

On the back of the hand the tendon of the ring-finger gives off two processes, one on each side, which pass obliquely downwards to join the tendons of the middle and little fingers: in consequence of this arrangement it follows that if those two fingers be flexed, the tendon to the ring-finger is held downwards, and it becomes impossible to extend that finger by the action of the muscle.

The tendon of the index finger is only united to that of the middle finger by a loose, transverse, semitransparent band of fibres, and is free in its action. A synovial membrane invests the tendons of this muscle as they pass under the annular ligament.

The *extensor minimi digiti* is a slender muscle which is placed between the *extensor communis digitorum* and the *extensor carpi ulnaris*, and arises by



means of a thin tendon in common with the extensor communis. The tendon in which it ends occupies a groove between the radius and ulna, passing through a ring in the annular ligament appropriated to itself, and joins the fourth digital tendon of the common extensor.

The *extensor carpi ulnaris*, the most internal of the muscles descending on the back of the forearm, arises from the external condyloid eminence of the humerus by the common tendon and from a prolongation of that structure; from the posterior border of the ulna, below the anconeus, for about the middle third; and from the fascia of the forearm. The muscular fibres derived from these sources incline somewhat inwards, and end in a tendon, which runs through a special groove in the carpal end of the ulna and a separate sheath in the annular ligament, and is inserted into the base of the metacarpal bone of the little finger on its posterior aspect.

The *deep-seated muscles* on the back of the forearm are five in number, the supinator brevis, the three extensors of the thumb and the extensor of the index finger.

The *supinator brevis* arises from the external lateral ligament of the elbow-joint, and from the annular ligament of the radius; also from a rough depression below the sigmoid cavity of the ulna, and from the outer border of that bone for two inches. The fibres of the muscle, derived from these points of attachment, as well as from a tendinous expansion on the surface, pass obliquely round the upper part of the radius, covering it closely except at the inner side, and are inserted into that bone for rather more than a third of its length, passing down to the upper margin of the insertion of the pronator teres.

The posterior interosseous nerve passes through the fibres of this muscle.

The *extensor ossis metacarpi pollicis* (abductor longus pollicis,—Alb.) arises from an elongated depression on the radial side of the posterior surface of the ulna below the origin of the supinator brevis, from a similar extent of surface of the radius below the insertion of the same muscle, and from the interosseous membrane between. Thence descending obliquely outwards it ends in a tendon, which passes in company with the extensor primi internodii pollicis through the groove on the outer border of the lower extremity of the radius, and is inserted into the base of the metacarpal bone of the thumb.

The upper part of this muscle is concealed by the common extensor, but it becomes superficial beneath, and together with the next muscle crosses the tendons of the radial extensors of the carpus, conceals the insertion of the supinator longus, and, beneath the extremity of the radius, crosses the radial artery.

The *extensor primi internodii pollicis* (extensor minor pollicis,—Alb.) lies close to the lower border of the extensor ossis metacarpi, and is much smaller than that muscle; it arises from the interosseous ligament and the radius near the middle of the forearm; its tendon accompanies that of the extensor ossis metacarpi through the same compartment of the annular ligament, and passes on to be inserted into the proximal end of the first phalanx.

The *extensor secundi internodii pollicis* (extensor major pollicis,—Alb.), much larger than the extensor primi internodii, which it overlaps, arises immediately below that muscle from the lower half of the shaft of the ulna, and from the interosseous ligament at its lower end for about an inch. Its



fibres end in a tendon, which occupies the narrow oblique groove in the middle of the posterior surface of the carpal end of the radius, and is bound down in a separate compartment of the annular ligament; it is inserted into the base of the terminal phalanx of the thumb.

The groove which lodges the radial extensors of the carpus intervenes between those which lodge the tendon of this muscle and the tendons of the other extensors of the thumb.

A part of the tendon of the extensor ossis metacarpi is often found to terminate in the upper end of the abductor pollicis. The extensor primi internodii is not unfrequently united with the extensor of the metacarpal bone, only a slender tendinous filament reaching the first phalanx. A portion of the extensor secundi internodii has been found attached to the first phalanx.

Fig. 184.

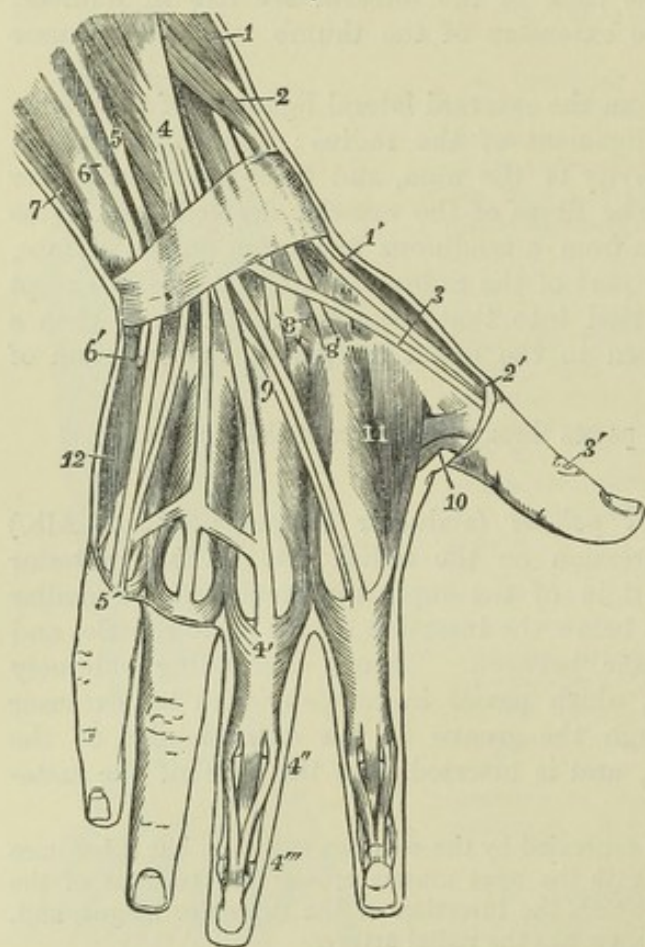


Fig. 184.—SUPERFICIAL MUSCLES AND TENDONS ON THE BACK OF THE WRIST AND HAND (After Bourguery).  $\frac{1}{2}$

The posterior annular ligament of the wrist is represented. 1, lower part of the extensor ossis metacarpi pollicis; 1', its insertion; 2, extensor primi internodii pollicis; 2', its insertion; 3, 3', tendon of the extensor secundi internodii pollicis; 4, lower part of the extensor communis digitorum, before passing below the posterior annular ligament; 4', slip of this tendon descending on the dorsum of the middle finger, where it receives the insertion of the second and third dorsal interossei; 4'', division of the tendon into three portions, of which the median is inserted into the second phalanx, the two lateral passing on to be inserted into the terminal phalanx; the union of the tendons of the third, fourth, and fifth fingers is shown; the slighter union which frequently exists between the tendons of the second and third fingers is not represented in the figure; 5, extensor minimi digiti; 5', its junction with the slip of the common extensor;

6, placed on the lower end of the ulna, points to the extensor carpi ulnaris; 6', insertion of this muscle into the base of the fifth metacarpal bone; 7, part of the flexor carpi ulnaris; 8, placed on the os magnum, points to the insertion of the extensor carpi radialis brevis; 8', placed on the base of the second metacarpal bone, points to the insertion of the extensor carpi radialis longus; 9, tendon of the extensor indicis, emerging from below the annular ligament, to pass towards the index finger; 10, small part of the adductor pollicis, and deep head of the flexor brevis pollicis; 11, first dorsal interosseous or abductor indicis: in the other three interosseous spaces are seen in succession from the radial side inwards the insertion of the first palmar, second dorsal, third dorsal, second palmar, fourth dorsal, and third palmar interossei muscles; 12, abductor minimi digiti.

The *extensor indicis* (indicator) arises from the posterior surface of the ulna for three or four inches below the middle. The tendon passes with

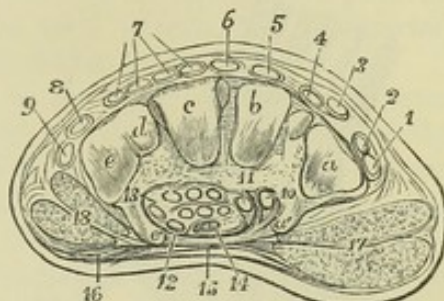


the common extensor through a compartment of the annular ligament, comes in contact with the tendon from that muscle destined for the index finger, and unites with it to form the expansion already described.

Fig. 185.—TRANSVERSE SECTION OF THE RIGHT HAND BETWEEN THE CARPUS AND METACARPUS, SHOWING THE ANTERIOR ANNULAR LIGAMENT OF THE CARPUS, AND THE PLACES OF THE VARIOUS EXTENSOR AND FLEXOR TENDONS, SEEN FROM THE DISTAL SIDE.  $\frac{1}{2}$

This figure is also designed to show the transverse arch formed by the second row of carpal bones. *a*, metacarpal articular surface of the trapezium for the metacarpal bone of the thumb; *a'*, palmar ridge of the trapezium; *b*, articular surface of the trapezoid bone for the second metacarpal bone; *c*, the surface of the os magnum for the middle metacarpal; *d*, the surface of the unciform for the fourth, and *e*, that for the fifth metacarpal bone; *e'*, unciform process; between *a'* and *e'*, the cut edge of the annular ligament is represented, the ends attached to the projecting parts of these bones, and sending another process towards the trapezium at 11, by which the tendon of the flexor carpi radialis is enclosed in the groove of the trapezium; 1, tendon of extensor ossis metacarpi pollicis; 2, extensor primi internodii; 3, extensor secundi internodii; 4, extensor indicis; 5 and 6, long and short radial extensors of the carpus; 7, the four divisions of the tendon of the common extensor of the fingers, the middle two belong to the third and fourth fingers; 8, extensor minimi digiti; 9, extensor carpi ulnaris; 10, flexor carpi radialis; 11, flexor longus pollicis; 12, the first on the ulnar side of the tendons of the flexor superficialis digitorum; 13, the same of the flexor profundus; 14, the median nerve; 15, points to the middle of the cut margin of the palmar aponeurosis stretched across the annular ligament; 16, the fibres of the palmaris brevis muscle; 17, cut surface of the muscles of the ball of the thumb; 18, muscles of the little finger.

Fig. 185.



#### MUSCLES OF THE HAND.

Besides the tendons of the long muscles and the lumbricales already described, there are placed in the hand one superficial muscle called *palmaris brevis*, the short muscles of the thumb and little finger, and the *interossei* muscles.

The *palmaris brevis* is a thin flat subcutaneous muscle, which arises from the inner margin of the palmar fascia and annular ligament; its fibres proceed transversely inwards, and are inserted into the skin along the inner border of the palm.

The *palmaris brevis* crosses the muscles of the little finger and covers the ulnar artery and nerve. It is subject to considerable variation in its breadth and thickness, consisting sometimes of only a few scattered fibres.

**MUSCLES OF THE THUMB.**—The fleshy mass which forms the *thenar prominence*, or ball of the thumb, consists of four muscles.

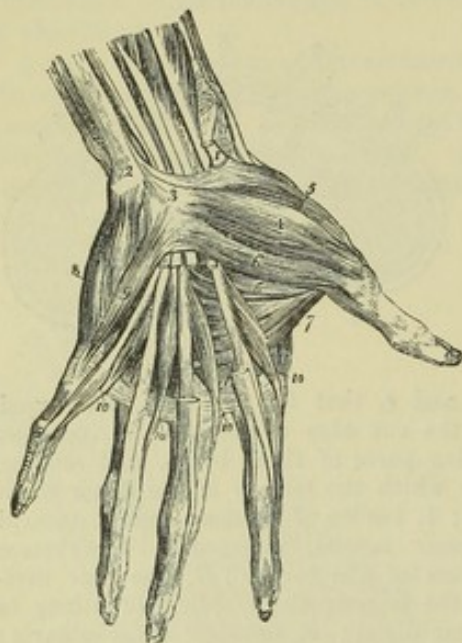
The *abductor pollicis* (*abductor brevis pollicis*, —Alb.), superficial and flat, arises from the annular ligament and from the ridge of the os trapezium, and, proceeding outwards and forwards, is inserted by a tendon into the radial border of the first phalanx of the thumb at its base.

The *opponens pollicis*, placed behind the abductor, arises from the annular ligament and from the os trapezium and its ridge, and is inserted into the whole length of the metacarpal bone of the thumb at the radial border.



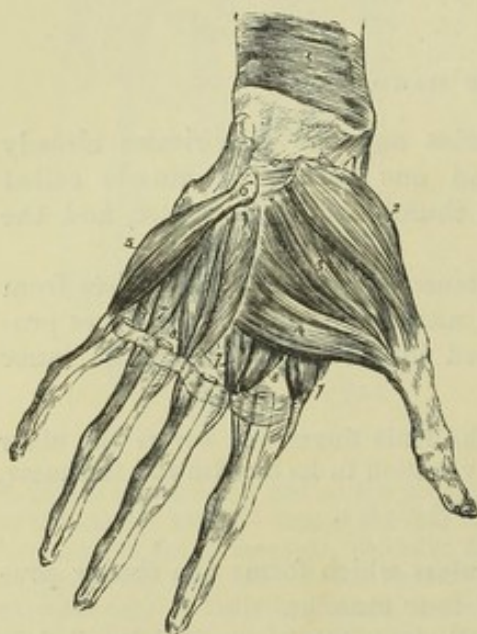
The *flexor brevis pollicis* arises by two heads, a superficial and a deep. The superficial head is attached to the outer two-thirds of the annular

Fig. 186.

Fig. 186.—MUSCLES AND TENDONS OF THE PALMAR ASPECT OF THE HAND.  $\frac{1}{2}$ 

A portion of the tendons of the superficial flexor has been cut away to show those of the deep flexor and the lumbricales. 1, tendon of the flexor carpi radialis, cut short near the place where it enters the canal in the outer attachment of the annular ligament of the carpus; 2, tendon of the flexor carpi ulnaris, inserted into the pisiform bone; 3, anterior annular ligament of the carpus; 4, abductor pollicis; 5, opponens pollicis; 6, 6, flexor brevis; 7, adductor pollicis; 8, abductor minimi digiti; 9, flexor brevis minimi digiti; 10, lumbricales, passing to their insertion on the radial side of the four fingers.

Fig. 187.

Fig. 187.—DEEP MUSCLES OF THE PALM OF THE HAND.  $\frac{1}{2}$ 

The abductor pollicis and abductor minimi digiti, together with the anterior annular ligament and the long flexor tendons in the palm, have been removed; in the forefinger the tendons of both the superficial and deep flexors remain; in the other fingers the tendons of the superficial flexor have been removed. 1, pronator quadratus muscle; 2, opponens pollicis; 3, flexor brevis pollicis; 4, adductor pollicis; 5, opponens minimi digiti; 6, unciform bone; 7, 8, interosseous muscles.

moid bones, play over the grooved surfaces of the first metacarpal bone. The tendon of the long flexor lies between the heads of origin, and grooves the surface of the muscle as it passes between the tendons of insertion.

The *adductor pollicis* arises from the anterior two-thirds of the palmar surface of the metacarpal bone of the middle finger, and is inserted into the



base of the first phalanx of the thumb along with the inner tendon of the short flexor.

**MUSCLES OF THE LITTLE FINGER.**—The fleshy mass at the inner border of the hand (*hypothenar prominence*) consists of three muscles passing to the little finger.

The *abductor minimi digiti* arises by tendinous fibres from the pisiform bone and the inserted tendon of the flexor carpi ulnaris, and is inserted into the base of the first phalanx of the little finger on the ulnar border.

The *flexor brevis minimi digiti*, separated at its origin from the abductor muscle by a small interval through which pass the deep palmar branch of the ulnar nerve and the communicating branch of the ulnar artery, arises from the front of the annular ligament, and from the tip of the hooked process of the unciform bone, and is inserted into the base of the first phalanx of the little finger, in connection with the preceding muscle. This muscle is sometimes absent, or becomes incorporated with the abductor.

The *opponens minimi digiti* (adductor ossis metacarpi digiti minimi,—Alb.) arises from the annular ligament and the unciform process, and is inserted into the ulnar border of the fifth metacarpal bone in all its length.

Fig. 188.

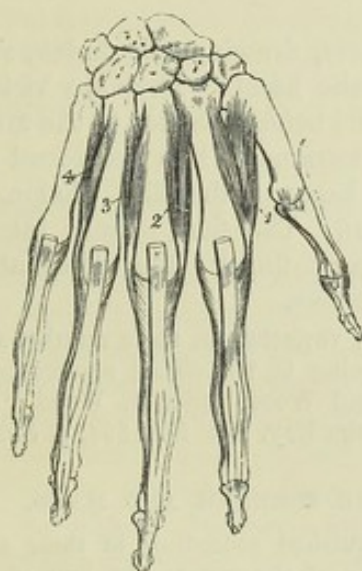


Fig. 189.

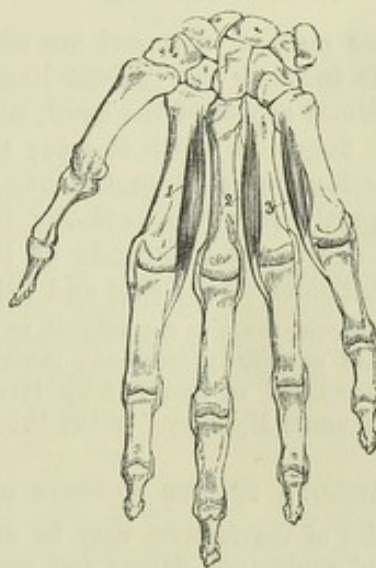


Fig. 188.—THE RIGHT HAND FROM BEHIND, SHOWING THE DORSAL INTEROSSEOUS MUSCLES.  $\frac{2}{3}$

The tendons of the extensor muscles have been removed as far as the distal ends of the metacarpal bones. 1, 2, 3, and 4, the interossei muscles, in order from the radial side inwards; their expanded insertion in connection with the extensor tendons, is shown upon the first phalanges.

Fig. 189.—THE RIGHT HAND FROM BEFORE, SHOWING THE PALMAR INTEROSSEI MUSCLES.  $\frac{2}{3}$

1, 2, and 3, refer to the first, second, and third palmar interosseous muscles.

THE INTEROSSEOUS MUSCLES occupy the intervals between the metacarpal bones. They are seven in number, all of them more or less visible from the palmar aspect, and they are divided into two sets, viz., those which are best seen on the dorsal aspect of the metacarpus, and those which are seen only in the palm. Their disposition is most easily understood by reference to their action.



The *dorsal interossei* muscles separate the fingers from the middle line of the hand; they are four in number, each occupying one of the spaces between the metacarpal bones. They are named numerically from without inwards. Each muscle arises from both the metacarpal bones between which it is placed, but most extensively from that supporting the finger upon which it acts, and the fibres converge pennately to a common tendon in the middle. Each terminates in a tendon, which is inserted partly into the base of the first phalanx, and partly into the tendon of the common extensor muscle on the dorsum of the same part of the finger. Two dorsal interossei are inserted into the middle finger and draw it to either side; of the remaining muscles one passes to the radial side of the index-finger, and the other to the ulnar side of the ring-finger; they withdraw those fingers from the middle line of the hand.

The *first dorsal interosseous* muscle or *abductor-indicis* is larger than the others; its outer and larger head of origin arises from the proximal half of the ulnar border of the first metacarpal bone, the inner is attached to the whole length of the second metacarpal bone, and between these heads there is left superiorly an interval wider than in the other dorsal interosseous muscles.

Between the heads of the abductor indicis the radial artery passes forwards to the palm of the hand; between those of the other dorsal interossei small perforating arterial branches are transmitted.

The three *palmar interossei* are adductors, drawing the index, ring, and little fingers towards the middle line of the hand. They are visible only from the palmar aspect of the hand, each one being attached to the metacarpal bone of the finger on which it acts: they terminate, like the dorsal muscles, in small tendons inserted partly into the base of the first phalanx at the side, and partly into the extensor tendon. The first palmar interosseous muscle belongs to the ulnar side of the index-finger; the others are placed on the radial sides of the ring and little fingers.

The interosseous muscles are subject to some variation in their number and form. An additional palmar interosseous muscle, going to the dorsal aponeurosis of the thumb, is described as frequent by Henle and Wood. (See J. Wood, "On some varieties in Human Myology," in the Proc. of the Roy. Soc. for 1864, p. 302.)

#### ACTIONS OF THE MUSCLES OF THE FOREARM AND HAND.

The muscles of the forearm may be distinguished according to their actions as pronators and supinators, flexors and extensors of the wrist, and long flexors and extensors of the fingers: those of the hand are flexors, adductors, abductors, opposers, and partially also extensors of the fingers.

*Pronation* is effected by the pronator quadratus and pronator teres: the flexor carpi radialis also contributes slightly to this movement. The pronator teres is fitted to flex the elbow when pronation has been completed, or when it is prevented by antagonistic muscles.

*Supination* is effected principally by the supinator brevis. The supinator longus is not so advantageously situated to accomplish this action; it is principally a *flexor of the elbow*, acting, however, only after that movement has been begun by the instrumentality of other muscles: in the extended and supinated condition of the forearm it assists in binding the radius more firmly to the humerus.

*Flexion of the wrist* is produced by the radial and ulnar flexors of the carpus, and is aided by the flexors of the fingers when the action of those muscles on the fingers is either completed, or is opposed by any resistance, as when the over-extended hand is pressed against a surface in pushing, or in the support of the body.

*Extension of the wrist*, in a similar manner, is accomplished not only by the three muscles specially devoted to that function, but also by the extensors of the fingers.

The flexors arising from the inner condyloid eminence of the humerus, and the



extensors arising from the outer condyloid eminence, are most advantageously situated for acting on the other joints over which they pass, when the position of the elbow joint is such as to keep them most on the stretch; but when flexion of those other joints is either completed or opposed, they have also some effect, though not great upon the elbow joint itself.

The *flexores sublimis* and *profundus* and the *lumbricales* muscles are the flexors respectively of the second, third, and first phalanges. The *lumbricales*, while they flex the first phalanx, at the same time, by virtue of their connection with the extensor tendons, extend the other phalanges, thus causing the fingers to pass through the movement which they undergo in making the hair-stroke in writing. They are assisted in this action by the *interossei*.

When the *thumb* is opposed to the other fingers, the metacarpal bone is drawn forwards, not only by the *opponens* muscle, but also by the *abductor*, and by the *flexor brevis*, acting when the first phalanx is flexed, or when it is fixed by the *extensor primi internodii*. The precise action of the *abductor* is to draw the thumb forwards and outwards. The *extensor ossis metacarpi* is entirely an *abductor*, as indicated by the name given to it by Albinus. The *extensor primi internodii* likewise is an *abductor* as well as an *extensor* of the first phalanx. The *extensor secundi internodii* extends both phalanges and draws the metacarpal bone directly backwards. The *adductor* and the inner fibres of the *flexor brevis* adduct the thumb. A combination of the actions of the different muscles in succession produces *circumduction*.

The *little finger* is withdrawn from the others by its *abductor*, as the *ring-finger* is withdrawn from the middle finger by the fourth dorsal *interosseous* muscle; and the *abductor* acting with the long flexors likewise assists the *flexor brevis* in keeping the first phalanx firmly down in grasping.

The *palmaris longus* has but little action, and that is exerted in tightening the palmar fascia. The *palmaris brevis* increases the hollow of the hand by pulling on the integument on the inner side, so as to increase the *hypothenar* prominence.

#### FASCLE OF THE UPPER LIMB.

The *superficial fascia* covering the muscles which pass from the trunk to the shoulder and upper limb, forms a complete investment of the upper part of the trunk, being continuous with that of the neck superiorly, and with those of the abdomen and hip inferiorly, and extending from the shoulder and over the arm, forearm and hand, so as to cover the whole limb. In the subcutaneous tissue of the upper limb bursæ are usually found placed over the *acromion*, the *olecranon*, and the knuckles.

The *superficial fascia of the pectoral region* encloses the *mammary gland*, covering it both in front and behind, and sending strong septa in between its lobes. Processes likewise extend from the investment of the gland between the masses of fat forwards to the skin and nipple, and these, from the support which they afford to the gland, have been named by Sir Astley Cooper *ligamenta suspensoria*. ("On the Anatomy of the Breast." London, 1840.)

The *superficial fascia of the arm* is most distinct opposite the bend of the elbow, where the superficial veins contained within its laminae are numerous and large. In the palm of the hand, on the contrary, the subcutaneous tissue forms a firm connecting medium between the skin and a strong aponeurosis named the *palmar fascia*: it consists of a network of fibres passing between those two structures, dividing the subcutaneous fat into small granules, so as to prevent the skin from shifting to any considerable extent.

Of the *deep fascia* the following parts require special notice. The *costo-coracoid membrane* is a distinct layer of firm fascia whose strongest fibres, distinguished sometimes as the *costo-coracoid ligament*, extend from the coracoid process to the first rib at the origin of the *subclavius* muscle, and which conceals that muscle from view. Superiorly it is attached to the



clavicle ; inferiorly it is narrowed like a funnel, and becomes thinner as it descends upon the surface of the axillary vessels, forming the anterior part of the sheath of those vessels, while the posterior part is formed by a deep process of the cervical fascia.

The *axillary fascia* is a strong membrane stretched across the axilla, and so disposed as to maintain the skin in position across that hollow. Beneath the pectoralis major muscle is a layer of fascia attached to the chest in front of the costo-coracoid membrane : it divides into two layers to inclose the pectoralis minor, and these reuniting, it continues to pass outwards, forming a strong membrane in the angle between the pectoralis minor and short head of the biceps muscle ; lower down it is joined by the superficial investment of the pectoralis major, which is folded round the margin of that muscle, and thus strengthened, it slopes outwards and backwards to the inferior border of the scapula, where it is joined by the sheaths of the latissimus dorsi and teres major muscles. The deepest hollow of the axillary fascia is formed where the layer from the surface of the pectoralis major joins that from the pectoralis minor ; and in that part especially it is perforated by numerous lymphatics. At the angle occupied by the large vessels and nerves of the limb, it is continuous with the sheath of the vessels and with the aponeurosis of the arm. The density of this fascia offers a considerable obstacle to the progress outwards of axillary abscesses.

The *aponeurosis of the upper limb* is a strong sheath which binds together all the muscles of the arm and forearm. A strong and somewhat isolated portion, bound down to the vertebral and axillary margins and to the lower border of the spine of the scapula, covers the infraspinatus and teres minor muscles as far as they are left uncovered by the deltoid muscle. On reaching the posterior border of the deltoid muscle, this aponeurosis divides into two layers, of which the deeper is continued beneath the deltoid to the shoulder-joint, and the more superficial forms a thin aponeurosis covering of that muscle, becoming more and more slender as it passes forwards.

The *aponeurosis of the arm* is composed chiefly of transverse fibres, held together by others having an oblique or longitudinal direction ; it is thin over the biceps muscle, stronger where it covers the triceps, and particularly dense as it approaches the outer and inner condyloid eminences of the humerus. It is pierced on the inner side of the limb by the basilic vein, at some distance below the axilla. It is attached to the shaft and condyloid eminences of the humerus by the two processes next to be described.

The *external and internal intermuscular septa* are two fibrous partitions which bind the aponeurosis of the arm to the humerus, and with which the neighbouring muscles of the arm are intimately connected. The external intermuscular septum extends upwards from the outer condyloid eminence along the outer lateral ridge to the insertion of the deltoid, from which it receives tendinous fibres. It is pierced from behind forwards by the musculo-spiral nerve and superior profunda artery. The internal septum, much stronger, extends along the ridge from the inner condyloid eminence to the insertion of the coraco-brachialis muscle. It is traversed from before backwards by the ulnar nerve and by the inferior profunda and anastomotic arteries.

At the bend of the elbow the aponeurosis is closely connected with the periosteum covering the condyloid eminences of the humerus and the olecranon process of the ulna ; and it is strengthened by tendinous fibres sent from the triceps and biceps muscles.

The *aponeurosis of the forearm*, like that of the arm, is composed principally of circular fibres, strengthened, however, by longitudinal and oblique fibres



descending from the condyloid eminences of the humerus, from the olecranon, and from the superficial insertion of the biceps muscle. It is attached along the subcutaneous margin of the ulna, and may be conveniently divided into an anterior and posterior part.

The *anterior part* of the aponeurosis of the forearm is much weaker than the membrane on the posterior aspect of the limb. It is continued below into the anterior annular ligament. In the hollow immediately below the bend of the elbow, it presents a small oval aperture for the transmission of a short communicating branch between the superficial and the deep veins of the forearm. It increases in density towards the hand; and a little above the wrist affords a sheath to the tendon of the long palmar muscle, which passes over the annular ligament to be inserted into the narrow end of the palmar fascia. Several white lines seen on the surface of the fascia mark the positions of the septa between the origins of the muscles descending from the inner condyloid eminence, which are continuous with it. Between the superficial and the deep flexor muscles, another layer of fascia is stretched from side to side; it is stronger below than above, where it generally consists of little more than thin connective tissue.

The *anterior annular ligament* of the carpus, previously described at p. 144, is continuous at its upper margin with the fascia of the forearm, and receives some fibres from the tendon of the flexor carpi ulnaris: the lower margin is connected with a deep part of the palmar fascia, and gives origin in part to most of the short muscles of the thumb and little finger. This structure may be considered in some measure as a developed portion of the fascia of the wrist, and also as a ligament.

The *posterior portion* of the aponeurosis of the forearm, much thicker than the anterior, is intimately connected with the strong septa between the several superficial muscles, and sends off transversely a thin membrane to separate the superficial from the deeper group of muscles. Approaching the back of the wrist, the transverse fibres increase in number and strength, and these being stretched from the outer margin of the radius on one side, to the cuneiform and pisiform bones and the palmar fascia on the other, constitute the *posterior annular ligament* of the carpus (see p. 144). This structure is attached not only to the points now indicated, but is likewise connected to the several longitudinal ridges on the posterior surface of the radius, and thus converts the intermediate grooves into fibro-osseous canals to lodge the tendons of the extensor muscles. There are six separate spaces so enclosed, and each is lined by a distinct synovial sac. The outermost space corresponds with the groove on the outer side of the radius, and gives passage to the extensores ossis metacarpi and primi internodii pollicis; the next three, placed on the back of the radius, give passage respectively to the two radial carpal extensors, the extensor secundi internodii pollicis and the common extensor of the fingers, with the extensor indicis accompanying it; between the radius and ulna is the compartment for the extensor minimi digiti, and resting in the groove on the back of the ulna is that for the extensor carpi ulnaris.

On the *back of the hand* there is only a thin layer of fascia prolonged from the posterior annular ligament over the extensor tendons, and separating them from the superficial veins and nerves. Beneath this are special fibrous membranes stretched over the interossei muscles.

On the *palm of the hand* is the *palmar fascia*, a strong aponeurosis, consisting of a central and two lateral portions. The lateral parts are very thin; they afford a delicate but firm covering to the muscles of the thumb



and little finger respectively. The central portion is one of the strongest fasciæ of the body. Occupying the interval between the thenar and hypothenar eminences and expanding towards the fingers, it has a somewhat triangular or fan-like form. The narrow end of the fascia, thicker than any other part, and composed of close parallel fibres, is connected by its deep surface with the anterior annular ligament, and is continuous superiorly with the tendon of the palmaris longus, when that muscle is present; the broader portion, becoming thinner and flatter as it advances towards the fingers, has a much more irregular and interlaced texture, and adheres more closely to the skin of the palm. Near the lower part of the palm it separates into four processes, each of which again subdivides into two slips next the root of a corresponding finger; and the bundles of fibres thus separated, dipping one on each side of the flexor tendons belonging to the finger, are attached to the margins of the metacarpal bone and to the transverse ligament which binds the metacarpal bones to each other. From the centre of each process longitudinal fibres are continued to the skin as far forward as the root of the finger. These digital processes of the palmar fascia are held together by irregular transverse fibres, which lie immediately under the skin, and serve to give great additional strength at the points of divergence.

### MUSCLES OF THE TRUNK.

The muscles passing between the trunk and the upper limb having been already described, those which belong exclusively to the trunk itself will now be treated of under the three divisions of, 1. Dorsal muscles, extending throughout the whole length; 2. Thoracic muscles, including the diaphragm; and 3. Abdominal and Perineal muscles.

#### DORSAL MUSCLES OF THE TRUNK (MUSCLES OF THE BACK).

The muscles to be described under the above head, taken as a whole, occupy more or less deeply the hollow between the entire middle line of the vertebral spines and the prominences formed towards the sides by the mastoid processes, the transverse cervical processes, the most projecting parts of the ribs, and the crest of the ilium, and they extend from the superior curved line of the occipital bone to the lower part of the sacrum. Some consist of comparatively limited portions of muscular substance, and occupy only certain parts of the extensive region now referred to; others extend either continuously or by the serial repetition of similar fasciculi, throughout the greater part of it. These muscles, together with those in the same region which belong more properly to the upper limb, have been frequently described as constituting six successive layers; but the limits of several of these layers do not present very marked natural planes of separation, and it will be sufficient for the purpose of description to arrange those which fall properly within the present section, according to the main characteristics of their form and position, into the following groups: viz., *a*, the posterior serrati muscles; *b*, the splenius and long erectors of the spine; *c*, the complexus and transverso-spinales; *d*, the interspinales and intertransversales; *e*, the short cranio-vertebral muscles. Of these muscles those included in the first two groups may be considered as having their fibres passing outwards from the middle; those in the third group as having their fibres passing inwards; those of the fourth group as having their fibres passing in a nearly vertical direction; and those of the fifth group confined



to the upper part of the vertebral column and to the head, may be looked upon as combining some examples of the others.

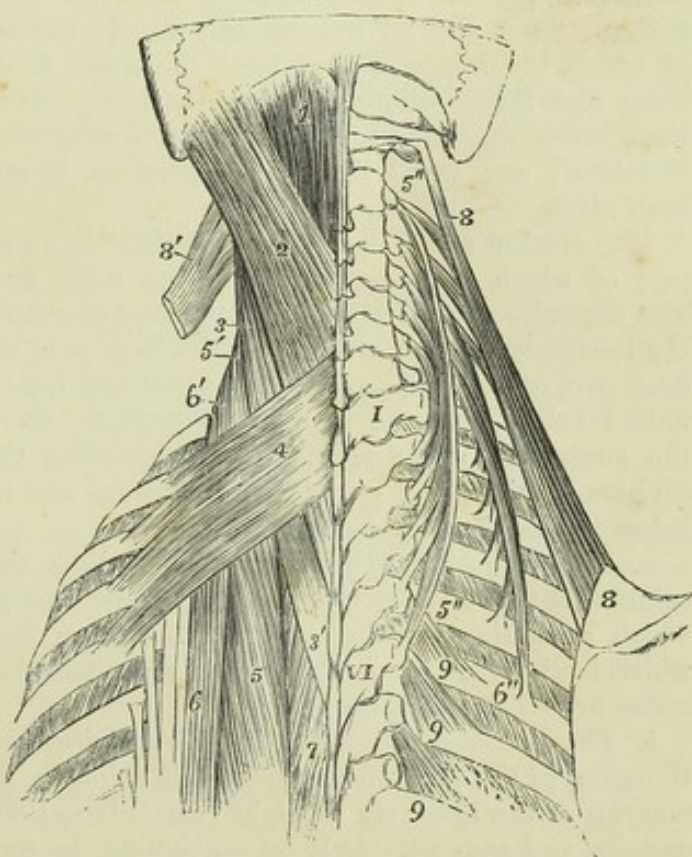
**SERRATI MUSCLES.**—The *serratus posticus superior* is a thin flat muscle, which arises from the lower part of the ligamentum nuchæ and from the spines of the last cervical and two or three upper dorsal vertebræ by a flat tendon inclining downwards and outwards, and forming about a third of the length of the muscle; it is inserted by four fleshy digitations into the second, third, fourth, and fifth ribs, a little beyond their angles. It is directed obliquely downwards and outwards, resting on the deep muscles and the angles of the ribs. The muscle is covered, excepting at its superior border, by the rhomboid and levator anguli scapulæ muscles.

The *serratus posticus inferior*, broader and stronger than the preceding muscle, passes outwards and upwards to the four lowest ribs; it arises, by a thin aponeurotic membrane, which forms part of the posterior layer of the lumbar aponeurosis, from the spinous processes and interspinous ligaments of the two last dorsal and two or three upper lumbar vertebræ. The outer part of the muscle forms a fleshy lamella inserted by four digitations into the lower border of the last four ribs. The uppermost of those digitations is very broad, and covers in part the second; the last, varying in size with the length of the twelfth rib, is entirely concealed by the rest of the muscle. The *serratus inferior* is covered by the *latissimus dorsi*, and its aponeurotic part is firmly united for some distance with the tendon of that muscle.

Fig. 190.—DORSAL MUSCLES OF THE UPPER PART OF THE TRUNK.  $\frac{1}{2}$

I, first; VI, sixth dorsal vertebra; 1, upper part of the *complexus major* muscle; 2, *splenius capitis*; 3, 3', *splenius colli*; 4, *serratus posticus superior*; 5, upper part of the *longissimus dorsi*; 5', the same continued up on the left side into the *transversalis cervicis*; 5'', 5''', on the right side the *transversalis cervicis* spread out from its attachments; 6, upper insertions of the *sacro-lumbalis* and *accessorius*; 6' the same continued up on the left side into the *ascendens cervicis*; 5'', upper, 6'', lower end of the *ascendens cervicis* of the right side spread out from its attachments; 7, small part of the *spinalis dorsi*; 8, right *levator anguli scapulæ*, dissected out from its attachments; 8', on the left side, the upper part of the *levator scapulæ*, shown in its relation to the *splenius colli*; 9, three of the *levatores costarum* shown on the right side.

Fig. 190.





**ACTIONS.**—The serratus posticus superior elevates the upper ribs, and is therefore to be regarded as a muscle of inspiration. The serratus inferior acts directly as a depressor of the lower ribs, and may aid either in expiration or inspiration; in expiration by acting in concert with the muscles which depress the higher ribs; in inspiration by fixing the lower ribs and giving firmness to the origin of the diaphragm.

**SPLenius.**—The *splenius* muscle is so named from its having the form of a strap, which binds down the parts lying under it. It is attached superiorly in part to the cervical vertebræ, in part to the skull, and is described accordingly under two names.

a. The *splenius colli* is attached inferiorly to the spinous processes of the third, fourth, fifth, and sixth dorsal vertebræ, and superiorly along with the slips of the levator anguli scapulæ to the transverse processes of the first two or three cervical vertebræ.

b. The *splenius capitis*, broader and thicker than the preceding, arises from the spines of the seventh cervical and two upper dorsal vertebræ, and from the ligamentum nuchæ as high as the third cervical vertebra. It is inserted into the lower and back part of the mastoid process, and into the outer part of the superior curved line of the occipital bone.

The splenius is covered by the trapezius, the rhomboid, and the serratus posticus superior; and on the cranium by the sterno-mastoid. It conceals, in part, the complexus and trachelo-mastoid.

**ERECTOR SPINÆ.**—The *erector spinæ* may either be regarded as one large composite muscle, or as consisting of seven distinct muscles. Viewed as one muscle it may be conveniently considered as formed of three columns, of which the inner, or that next the spine, is comparatively slender; the outer and inner columns of the remaining thicker mass consist each of a large lower muscle and of two successive slender continuations in an upward direction; and to all these seven portions, or muscles, distinct names have been given.

The erector spinæ takes origin inferiorly as a common mass, the outer part of which is muscular, while the inner and larger part is tendinous. The muscular portion arises from the posterior fifth of the crest of the ilium; the tendinous portion arises from the back part of the ilium, the lower and back part of the sacrum, and the sacral and lumbar spines; it is inseparably united below with the lumbar aponeurosis, and is prolonged upwards on the surface of the muscular part, concealing the multifidus spinæ. The division of the larger part into an external and internal column takes place below the level of the last rib.

a. The *ilio-costalis* (Theile) or *sacro-lumbalis*, the main muscle of the outer column, is fleshy inferiorly, springing from that part of the common origin which proceeds from the crest of the ilium; it ends in a series of tendons which incline slightly outwards, and are inserted one into each of the six or seven lowest ribs at their angles.

b. The *musculus accessorius ad ilio-costalem* (*ad sacro-lumbalem*) is a continuation of the preceding muscle. It arises by flat tendons from the upper margins of the lower six or eight ribs, internal to the tendons of the ilio-costalis, and ends superiorly by continuing the series of those tendons to the upper ribs.

c. The *cervicalis ascendens* consists of slips in serial continuation with those of the *musculus accessorius*, taking origin from four or five of the



highest ribs, and inserted into the transverse processes of three cervical vertebræ, usually the fourth, fifth, and sixth. Its insertions are intimately connected with those of the transversalis cervicis.

d. The *longissimus dorsi*, the main muscle of the inner column of the erector spinæ, is both larger and longer than the ilio-costalis, its original fibres passing as high as the first dorsal vertebra. Internally it is closely connected on the surface with the spinalis dorsi, from the lower part of which it generally receives one or more tendinous slips. When those slips, and the tendons of origin from the lumbar spines are cut through, the inner surface of the muscle can be brought into view. The longissimus dorsi presents two series of insertions. The inner row of insertions is a series of rounded tendons attached to the inferior tubercles of all the transverse processes of the dorsal, and the accessory processes of the lumbar vertebræ. The outer insertions form in the dorsal region a series of thin processes attached to the nine or ten lowest ribs, sometimes more or fewer, and in the lumbar region are attached by fleshy slips to the whole length of the transverse processes, and beyond these to the lumbar fascia arising from them.

e. The *transversalis cervicis* prolongs upwards the column of fibres of the longissimus dorsi. It arises from the internal tubercles of the transverse processes of the four or five highest dorsal vertebræ, and occasionally the last cervical, and is inserted into the transverse processes of five cervical vertebræ from the second to the sixth inclusive. It always receives a slip of the original fibres of the longissimus dorsi.

f. The *trachelo-mastoid* muscle, which may be regarded as the continuation of the longissimus dorsi to the head, arises in close connection with the transversalis cervicis from the upper dorsal transverse processes, and also from behind the articular processes of the three or four lowest cervical vertebræ, and forming a thin flat muscle, passes to be inserted into the posterior margin of the mastoid process, under cover of the splenius and sterno-mastoid muscles. It is the only muscle which lies between the splenius and complexus, and the only portion of the erector-spinæ concealed by the former.

g. The *spinalis dorsi* is a long narrow muscle placed at the inner side of the longissimus dorsi, and closely connected with it. It arises by numerous tendons from the spines of the first two lumbar, and the two lowest dorsal vertebræ, and is inserted into from four to eight of the higher dorsal spines. It adheres closely to the semispinalis muscle upon which it lies.

**ACTIONS.**—The splenii and trachelo-mastoid muscles of both sides acting together draw backwards the head and upper cervical vertebræ: when the muscles of one side only act the extension is accompanied by lateral flexion and rotation, especially of the head on the axis.

The greater part of the erector muscles of the spine, when those of both sides are in action, bends backwards the vertebral column and trunk; and these muscles co-operate powerfully in almost every great muscular effort of the body or limbs. It is the power of these muscles to straighten the back from the bent condition, of which a measure is obtained by the muscular dynamometer; the amount of this varies in adults of medium strength from 300 lbs. to 400 lbs. By the action of the erector muscles of one side a certain amount of lateral flexion and of rotation, which is greatest in the chest, accompanies the extension. These muscles also, by their costal attachments, if the spine be fixed, depress the ribs, and thus assist in expiration; but it is likewise conceivable that the cervicalis ascendens and musculus accessorius, in acting from fixed points above, may have the effect of elevating the ribs.



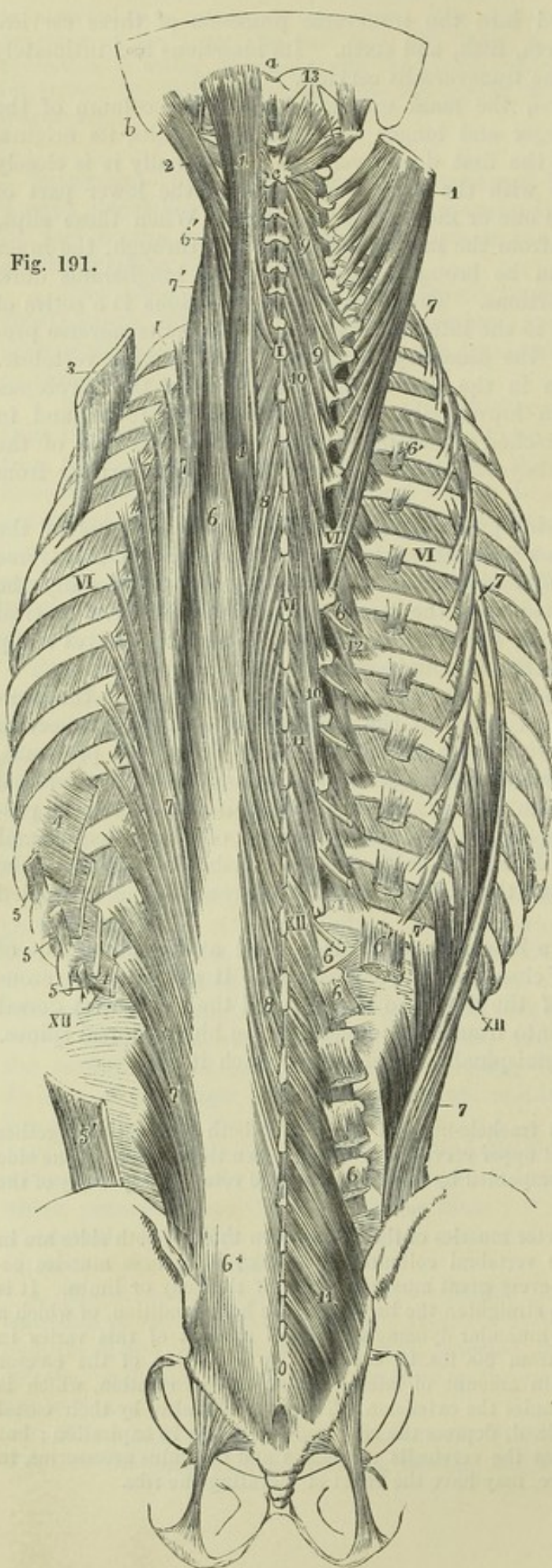


Fig. 191.

Fig. 191.—VIEW OF THE DEEP MUSCLES OF THE BACK, DESIGNED TO SHOW SOMEWHAT DIAGRAMMATICALLY THEIR ATTACHMENTS TO THE VERTEBRAL COLUMN AND RIBS.  $\frac{1}{4}$

On the left side the several parts of the erector spinae are nearly in their natural position, with the exception of the spinalis dorsi, which is drawn out laterally from the spines of the vertebrae; on the right side the spinalis dorsi has been entirely removed, the iliocostalis drawn to the outer side so as to expose its accessory muscle, and the longissimus removed excepting small portions at its insertions. Superiorly on the left side, the trachelomastoid and complexus major are left nearly in their natural positions, while on the right side, the trachelomastoid has been entirely removed, and the complexus major, separated from its occipital attachment, has been spread out to the side so as to stretch its vertebral attachments. *a*, occipital protuberance; *b*, mastoid process; *c*, bifid spinous process of the axis vertebra; *I*, spinous process of the first dorsal vertebra and first rib; *VI*, sixth dorsal spine and transverse process and sixth rib; *XII*, twelfth dorsal spine and twelfth rib. On the left side of the figure, 1, complexus major muscle; 2, trachelomastoid; 3, serratus posticus superior, detached from the vertebral column and drawn upwards from the ribs; 4, 4, the slips of attachment of the serratus posticus inferior to the four lower ribs; 5, three slips of origin of the latissimus dorsi from the lower ribs; 5', iliac origin of the same muscle; 6, common origin of the longissimus dorsi and iliocostalis from the ilium and sacrum, &c.; 6, upper part of the longissimus dorsi; 6',



transversalis cervicis continued up from the longissimus; 7, ilio-costalis (sacro-lumbalis), drawn slightly inwards to show the slips of insertion into the lumbar fascia and the various ribs; inside the costal insertions are seen the origins of the accessorius; 7', the ascendens cervicis continued upwards from the accessorius; 8, spinalis dorsi. On the right side 6 marks, in the lumbar region, the insertions of the longissimus dorsi into the upper four transverse processes (the insertion into the accessory processes not being shown), in the dorsal region the narrower tendons of insertion into the lower part of the dorsal transverse processes (the six lower only are represented); 6', the series of insertions into nine ribs; 7, the ilio-costalis drawn outwards; 7', placed between the lowest costal insertion of the ilio-costalis and the lowest origin of the accessorius; 7'', extension of the ascendens cervicis from the fifth rib towards the neck; 9, 9, semispinalis colli; 10, 10, semispinalis dorsi; 11, 11, lower dorsal and lumbar parts of the multifidus spinæ, which appears again above the semispinalis colli, above the upper 9; 12, placed upon the eighth rib, levatores costarum, long and short; 13, in the upper part of the figure points by four lines to the rectus capitis posticus, rectus major, obliquus superior and obliquus inferior muscles.

**COMPLEXUS AND TRANSVERSO-SPINALES.**—The muscles of the complicated group comprising the *complexus*, *semispinalis*, and *multifidus spinæ*, present the feature in common of ascending with an inward inclination, and are thus distinguished from those last described. The most superficial, the *complexus*, not usually included in this group, but obviously resembling the others, has the longest and most vertical fibres, but is the shortest as a whole, being limited to the upper dorsal and the cervical region; the muscle beneath it, the *semispinalis*, occupies the greater part of both these regions; while the *multifidus spinæ*, extending from the sacrum to the axis, has the shortest and most oblique fibres.

The *complexus* (*complexus major*) arises by tendinous points from the transverse processes of the seven highest dorsal and seventh cervical vertebræ, and from the articular processes of three other cervical vertebræ, together with the capsular ligament uniting them; and it is inserted into the large internal impression between the two curved lines of the occipital bone. It is narrower above than below, and its inner margin in the neck is in contact with the ligamentum nuchæ. Above the middle the muscle is partly crossed by a tendinous intersection. One interrupting tendon in particular, on the inner side, is so constant that the fibres connected with it, viz., those ascending from the three or four lowest points of origin, are often described separately, under the name of *biventer cervicis*: this portion of the muscle is also frequently connected by a tendinous slip with one or two of the spinous processes belonging to the last cervical or first dorsal vertebra.

The *complexus* muscle is covered by the splenius, except at its lowest origins from the dorsal vertebræ and at the internal portion of its upper extremity; the transversalis cervicis and trachelo-mastoid rest upon its series of origins, and the semispinalis colli, the posterior recti, and the obliqui capitis, together with the deep cervical artery, are concealed by it.

The *semispinalis* muscle consists of fibres extending from transverse processes to spines, each bundle crossing over about five vertebræ. It arises from the internal tubercles of the transverse processes of numerous dorsal vertebræ, usually the ten highest, and is inserted into spines from the axis to the fourth dorsal vertebra inclusive. It is described in two parts:—

a. The *semispinalis colli* is the part under cover of the *complexus*. It arises from the upper five or six dorsal transverse processes, and is inserted into spines of cervical vertebræ from the second to the fifth inclusive, being thickest at its insertion into the second vertebra.



b. The *semispinalis dorsi*, not covered by the complexus, consists of small muscular bundles interposed between tendons of considerable length, and forms an elongated thin stratum, especially towards its lower border. It arises from transverse processes of dorsal vertebræ from the tenth to the fifth inclusive, and is inserted into the spines of the last two cervical and first four dorsal vertebræ.

The *multifidus spinæ* reaches from the sacrum to the axis vertebra, passing up under cover of the *semispinalis*, and is much more largely developed towards the lower than the upper end of the column. In the sacral region the fibres arise from the deep surface of the tendinous origin of the erector spinæ, from the groove on the back of the sacrum as low as the fourth foramen, from the inner part of the posterior extremity of the iliac crest, and from the ligaments between that bone and the sacrum; in the lumbar region they take origin from the mammillary processes; in the dorsal region from the transverse processes; and in the neck from the articular processes of the four lower cervical vertebræ. From these several points the muscular bundles ascend obliquely, to be inserted into the laminae of the vertebræ, and into the spines from their bases nearly to their extremities. The fibres from each point of origin are fixed to several vertebræ, some being inserted into the side of the spinous process next above, and others ascending more and more vertically as high as the fourth from the place of origin; the longer fibres from one origin overlapping those from the origin next above.

The *rotatores spinæ* are eleven pairs of small muscles, which may be regarded as the deepest fibres of the *multifidus spinæ* in the dorsal region, and are distinguished by being more nearly horizontal than the rest. Each arises from the upper and back part of the transverse process, and is inserted into the vertebra next above, at the inferior margin and on part of the surface of the lamina, as far as the root of the spinous process.

**INTER-TRANSVERSALES.**—The *inter-transversales* are short muscles passing nearly vertically from vertebra to vertebra between the transverse processes. They are most developed in the cervical, and least in the dorsal region. Beneath each cervical transverse process there are two such muscles, one descending from the anterior, and another from the posterior part of the process. In the lumbar region there are likewise two sets: one set, the *inter-transversales laterales* lie between the transverse processes, and are in series with the *levator costarum*; the other set, *inter-transversales mediales* or *inter-accessorii*, pass from the accessory process of one vertebra to the mammillary process of the next, and are in series with the *inter-transversales* of the dorsal region.

**INTERSPINALES.**—The *inter-spinales* are short vertical fasciculi of fleshy fibres, placed in pairs between the spinous processes of the contiguous vertebræ. They are best marked in the neck, where they are connected one to each of the two parts into which the spinous process is divided. In the dorsal part of the column only a few are met with, and these are not constant.

The *spinalis cervicis* consists of a few irregular bundles of fibres, of greater length than the preceding muscles, placed close to the ligamentum nuchæ: they arise by two or more heads from the spines of the fifth and sixth cervical and sometimes other neighbouring vertebræ, and are inserted into the spine of the axis, and occasionally into the two vertebræ next below it. This muscle is sometimes wanting. (See Henle & Heilenbeck, in "Müller's Archiv," 1837.)

The name *sacro-coccygeus posticus*, or *extensor coccygis*, has been given to slender fibres occasionally found extending from the lower end of the sacrum to the coccyx,



and representing the extensor of the caudal vertebræ of other animals. (Günther and Milde, "Chirurgische Muskellehre," quoted in Theile, "Sömmerring von Baue," &c.)

**SHORT POSTERIOR CRANIO-VERTEBRAL MUSCLES.**—The *rectus capitis posticus major* arises by a narrow tendon from the spinous process of the axis, and expanding as it passes upwards and outwards, is inserted into and beneath the outer part of the inferior curved line of the occipital bone. Its insertion is inside and below that of the superior oblique muscle.

Fig. 192. — VIEW OF THE DEEP POSTERIOR MUSCLES OF THE UPPER PART OF THE VERTEBRAL COLUMN.  $\frac{1}{2}$

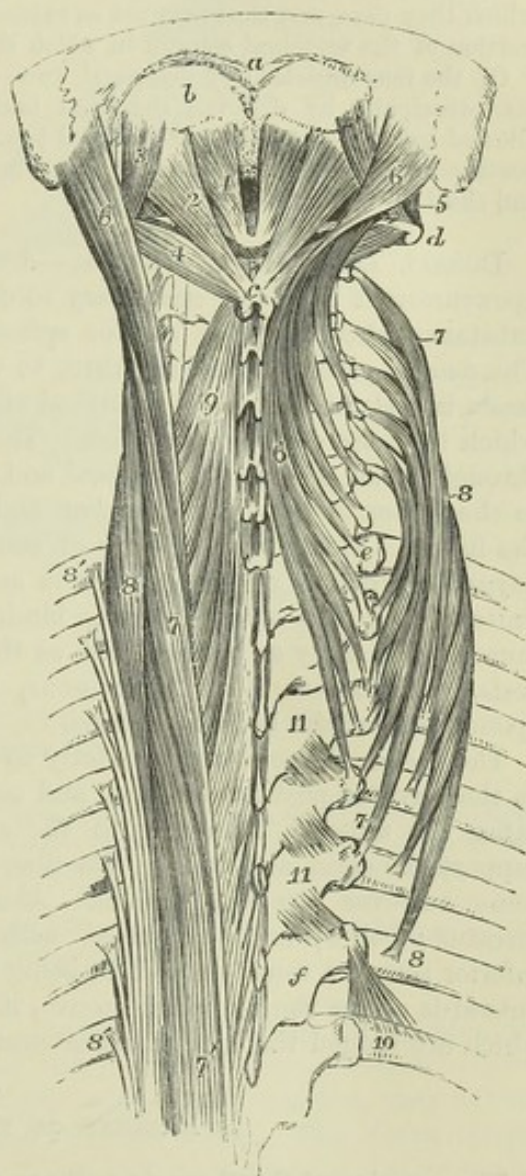
*a*, posterior occipital protuberance; *b*, surface between the superior and inferior curved lines on which the complexus is inserted; *c*, spinous process of the axis vertebra; *d*, transverse process of the atlas; *e*, transverse process of the first dorsal vertebra; *f*, lamina of the sixth dorsal vertebra; 1, rectus capitis posticus minor muscle; 2, rectus capitis posticus major; 3, obliquus superior; 4, obliquus inferior; 5, rectus capitis lateralis; 6, trachelo-mastoid, the muscle of the right side turned inwards and its slips of attachment to the dorsal and cervical transverse processes separated from each other; 7, transversalis cervicis, the figures are placed near the extreme ends of the muscle on the right side; 7', on the left side, upper part of the longissimus dorsi continued into the transversalis cervicis; 8, ascendens cervicis, the muscle of the right side is spread out; 8', on the left side, the seven upper tendinous insertions of the ilio-costalis and accessorius muscles; 9, upper part of the semispinalis colli of the left side; 10, placed on the seventh rib of the right side, close to the insertion of its levator costæ muscle; 11, 11, three rotatores vertebrarum between the third and seventh dorsal vertebræ.

The *rectus capitis posticus minor* arises from the posterior arch of the atlas by the side of the tubercle, and expands as it passes to be inserted into the inferior curved line of the occipital bone, and the rough surface between that and the foramen magnum.

The *obliquus capitis inferior*, the strongest of the muscles now under consideration, arises from the spinous process of the axis, between the origin of the rectus posticus major and the insertion of the semispinalis colli, and is inserted into the extremity of the transverse process of the atlas.

The *obliquus capitis superior*, smaller than the preceding muscle, arises from the upper surface of the transverse process of the atlas, inclines from

Fig. 192.





thence obliquely upwards and backwards, increasing somewhat as it ascends, and is inserted into a groove situated externally to the inferior curved line of the occipital bone.

The two oblique muscles, with the rectus major, form the sides of a small triangular space, in the area of which the posterior primary branch of the sub-occipital nerve and the vertebral artery will be found.

**ACTIONS.**—The transverso-spinales muscles, including the complexus, are essentially extensors of the head and vertebral column; and the movements produced by them vary according as the muscles of one side or both are in action, in a manner similar to that already pointed out in regard to the erector muscles.

The interspinales and intertransversales muscles approximate the vertebræ between which they pass, and thus may act as extensors and lateral flexors respectively of the portion of the vertebral column in which they are situated.

Of the four muscles last described, two—the rectus minor and superior oblique—act principally by drawing the head backwards, that being the chief movement allowed between the atlas and occipital bone; while the principal action of the rectus posticus major and the inferior oblique, when acting on one side, is to rotate the atlas and skull upon the axis.

**DORSAL AND LUMBAR FASCIÆ.**—Under the name of *lumbar fascia* or *aponeurosis* it has been customary to describe three layers of strong fibrous substance sheathing the erector spinæ and quadratus lumborum muscles. The deeper parts of this structure, to which by some the name of lumbar fascia is restricted, will be described along with the abdominal muscles, with which they are chiefly connected. The *superficial* or *posterior* layer is that through which the latissimus dorsi and serratus posticus inferior are attached to the spines of the dorsal, lumbar and sacral vertebræ and to the crest of the ilium. This layer, which is of considerable strength, extends outwards beyond the origin of the latissimus and serratus inferior, and being closely united with the middle layer, binds down firmly the erectores spinæ muscles: it is by some described as the lower part of the vertebral aponeurosis, with which it is continuous, by others it has been named the aponeurosis of the latissimus dorsi.

The *vertebral aponeurosis*, strictly so called, is situated on the same plane as the serratus posticus inferior, and consists of a thin lamella which separates the muscles belonging to the shoulder and arm from those which support the spine and head. Its fibres are for the most part transverse; some however are longitudinal. Above, it passes beneath the superior serratus; below, it is connected with the tendons of the latissimus and inferior serratus muscles, and in being stretched from the spinous processes outwards across the vertebral groove, it helps to enclose the angular canal in which are lodged the long extensor muscles.

#### MUSCLES OF THE THORAX.

The muscles of the thoracic wall are the inter-costales, levatores costarum, subcostales and triangularis sterni, and along with these the diaphragm intervening between the thorax and abdomen may conveniently be grouped.

The *intercostal muscles* consist of two thin layers of oblique short muscular fibres filling up the inter-costal spaces: these layers are named respectively the external and internal muscles.

The *external intercostal* muscles are formed of muscular fibres, with some tendinous fibres intermixed, directed obliquely downwards and forwards from one rib to another. Their extent for the most part is from the



tubercles of the ribs nearly to the outer end of the cartilages; but in the two lowest intervals they reach forwards to the ends of the spaces. Thin tendinous fibres having the same direction as the external intercostal muscles are continued forwards between the costal cartilages from the points where the muscles cease to the sternum, and there cover the internal intercostals.

Fig. 193

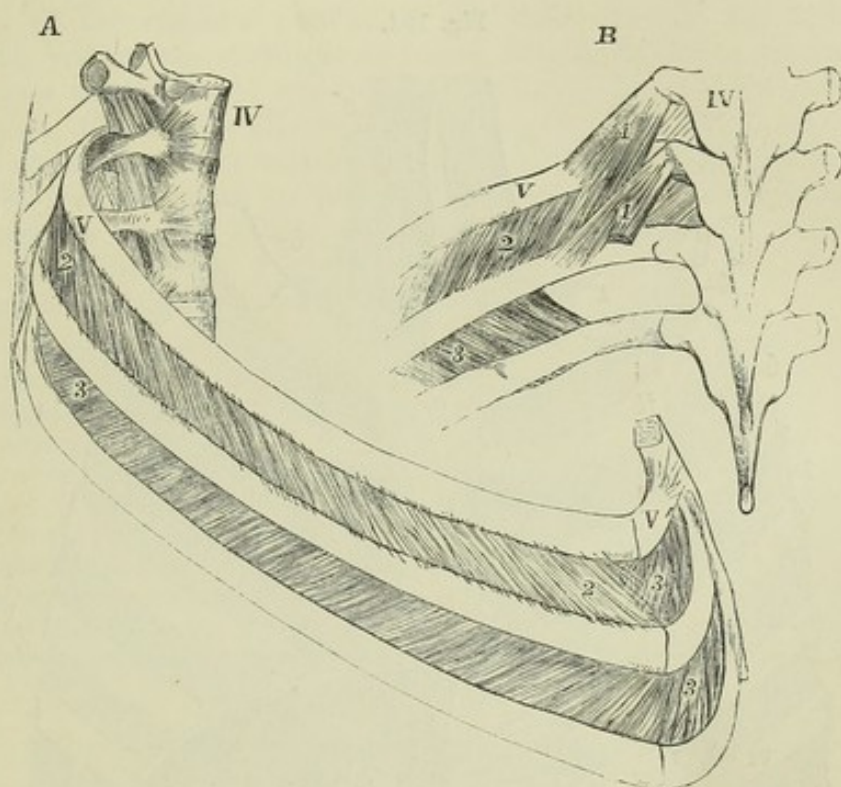


Fig. 193.—VIEW OF SEVERAL OF THE MIDDLE DORSAL VERTEBRÆ AND RIBS, TO SHOW THE INTERCOSTAL MUSCLES (after Cloquet).  $\frac{1}{3}$

A, from the side; B, from behind.

IV, the fourth dorsal vertebra; V, V, the fifth rib and its cartilage; 1, 1, the levatores costarum muscles, short and long; 2, the external intercostal muscles in the upper of the two intercostal spaces represented; 3, the internal intercostal layer shown in the lower of the two spaces represented by the removal of the external layer, and seen in A in the upper space, where the external layer terminates in front: the deficiency of the internal layer towards the vertebral column is shown in B.

The *internal intercostal* muscles, placed deeper than the preceding, are attached to the inner margins of the ribs and their cartilages. Commencing at the anterior extremities of the cartilages of the ribs, they extend as far back as a point within the angles of those bones. The fibres incline downwards and backwards, crossing those of the external intercostals; they are, however, somewhat shorter and less oblique in their direction.

The internal are separated from the external intercostal muscles at the back of the spaces by the intercostal vessels and nerves; they are lined internally by the pleura.

The *levatores costarum*, twelve on each side, arise from the tips of the transverse processes of the seventh cervical and eleven highest dorsal vertebrae. Corresponding in direction with the external intercostal muscles, on which they lie, they pass downwards and outwards, spreading as they



descend, and each is inserted into the outer surface of the rib belonging to the vertebra below that from which it springs. The levator muscles belonging to the lower ribs present some longer additional fibres which, passing over one rib, are inserted into the next one below; these fibres are sometimes distinguished as *levatores longiores costarum*.

The levatores costarum lie in series superiorly with the scalenus medius and posterior, and inferiorly with the external range of lumbar inter-transverse muscles.

Fig. 194.

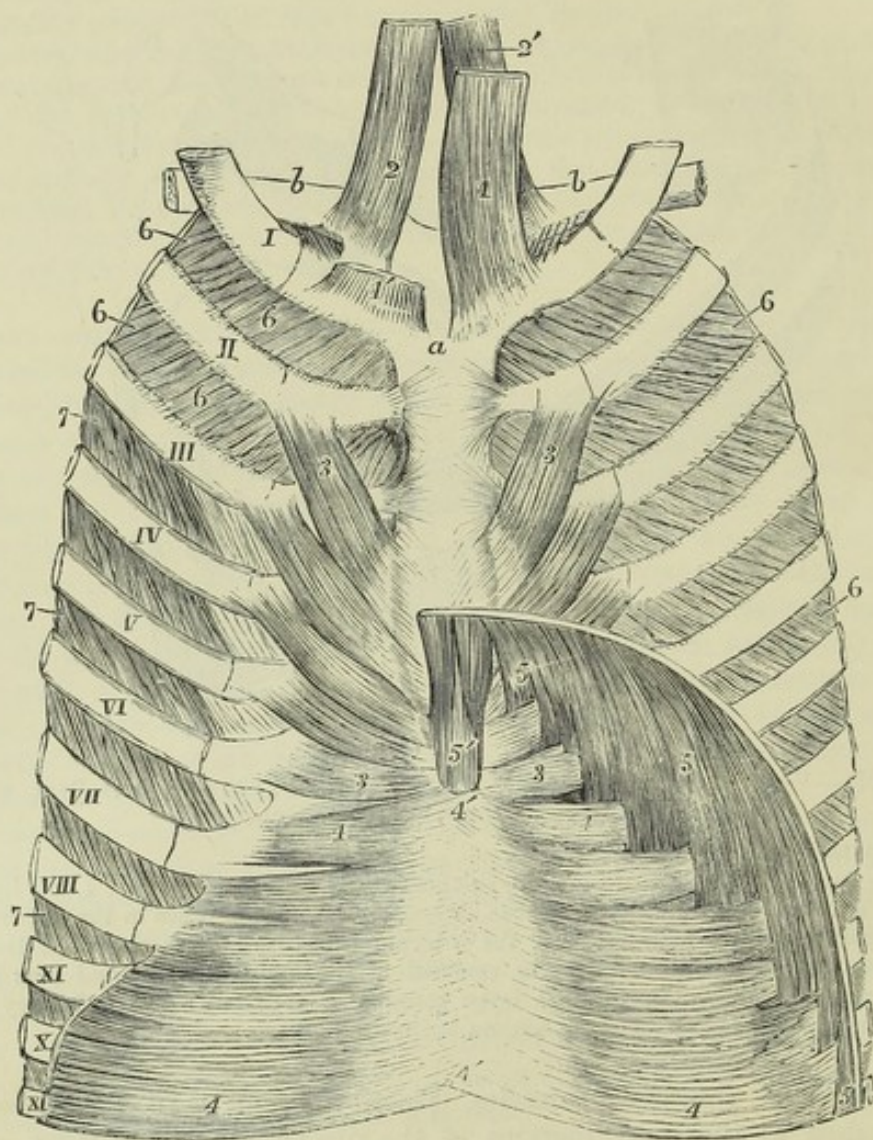


Fig. 194.—VIEW OF THE DEEP MUSCLES OF THE ANTERIOR WALL OF THE THORAX, SEEN FROM BEHIND (modified from Luschka).  $\frac{1}{4}$

*a*, back of the manubrium of the sternum; *b*, clavicles; I to XI, the anterior parts of eleven ribs and costal cartilages; 1, 1', sterno-thyroid muscle, that of the right side being cut short to show more fully the next muscle; 2, 2', the sterno-hyoid; 3, triangularis sterni; 4, upper part of transversalis abdominis united in 4', 4', the back of the linea alba; 5, attachments of the diaphragm to the lower ribs (the twelfth not represented in the figure), indigitating with those of the transversalis; 5', the two slips to the ensiform process; 6, internal layer of intercostal muscles extending to the sternum, shown in all the spaces on the right side, but only in the two uppermost of the left side; 7, in the lower spaces of the left side, indicates the external layer of intercostal muscles exposed by removing the internal layer.



The *subcostal* or *infracostal* muscles are small bundles lying on the inner aspect of the thoracic wall, close to the surface of the internal intercostals, and chiefly in the neighbourhood of the angles of the ribs. They follow the same direction as the internal intercostal muscles, but their fibres extend over two or three intercostal spaces. They are most constant on the lower ribs (see fig. 195).

The *triangularis sterni*, a thin stratum of muscular and tendinous fibres placed within the thorax, behind the costal cartilages, arises from the deep surface of the ensiform process of the lower part of the body of the sternum, and of the cartilages of one or two of the lower true ribs. Its fibres pass outwards and upwards in a diverging manner, the lowest being horizontal, the middle oblique, and the upper becoming more and more nearly vertical; and are inserted by separate slips into the cartilages of the true ribs from the sixth to the second inclusive, on the lower border and inner surface of each, at the junction with the bony part. At the lower margin the fibres are in the same plane with those of the *transversalis abdominis*, of which this muscle is a continuation upwards.

The *triangularis sterni* is subject to much variation as to its extent and points of attachment in different bodies, and even on the opposite sides of the same body. The internal mammary artery and veins pass between its anterior surface and the costal cartilages.

*Occasional Muscle.*—The *rectus sternalis*, or *sternalis brutorum*, is an elongated muscle, of nearly the same length as the sternum, frequently seen lying in front and parallel to the outer margin of that bone, and over the inner part of the pectoral muscle. It is fleshy in the middle and tendinous at both ends; it is attached superiorly to the sternum in connection with the tendon of the sterno-mastoid, and inferiorly it is connected with the *rectus abdominis* muscle. It is rarely present on both sides. It represents a muscle which is constant in some animals.

#### THE DIAPHRAGM.

The *diaphragm*, *phren*, *septum transversum*, or *midriff*, forms a musculo-tendinous partition between the abdominal and thoracic cavities. It consists of muscular fibres which arch upwards as they converge from the circumference of the visceral cavity to a tendinous structure in the centre, and it is perforated by the various structures which pass from the thorax to the abdomen.

The fibres arise from the bodies of several of the upper lumbar vertebræ by two thick *crura*; from two arches on each side external to the bodies of the vertebræ, called *ligamenta arcuata*; and from the ensiform cartilage and the cartilages of the six lower ribs.

a. The *crura* arise by tendinous fibres more or less distinctly aggregated into two bundles which are attached over a varying extent of surface. On the right side they are connected with the first, second, and third lumbar vertebræ, and the interposed fibro-cartilages, or sometimes with the second, third, and fourth; on the left side, the attachment is shorter by the breadth of one vertebra. The tendons of both *crura* curve forwards and upwards so as to enclose the aorta in an arch between them and the bodies of the vertebræ; their inner margins are united behind, so that they form a nearly complete fibrous ring round that vessel. The muscular fibres of the *crura*, springing from those tendons in thick bundles, on each side of the aorta, diverge as they pass upwards to the central aponeurosis. The innermost fibres on each side decussate with those of the side opposite, those



of the right usually lying anterior to those of the left, and, curving upwards, limit an opening for the transmission of the oesophagus, before ending in the central aponeurosis.

Fig. 195.

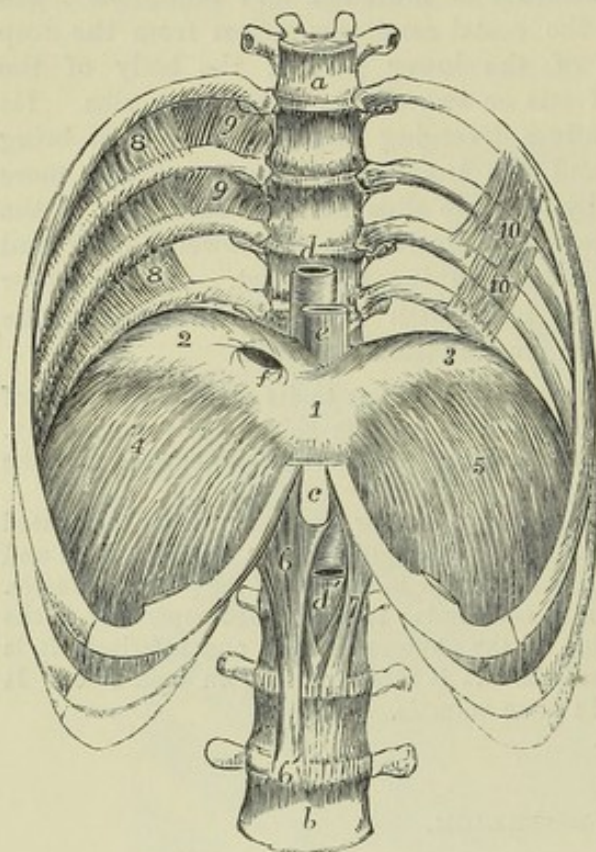


Fig. 195.—THE LOWER HALF OF THE THORAX, WITH FOUR LUMBAR VERTEBRÆ, OPENED SO AS TO SHOW THE DIAPHRAGM FROM BEFORE (modified from Luschka).  $\frac{1}{2}$

a, sixth dorsal vertebra; b, fourth lumbar vertebra; c, ensiform process of the sternum; d, the aorta descending in front of the lower dorsal vertebræ; d', the aorta emerging in the abdomen below the arch formed by the meeting of the pillars of the diaphragm; e, the oesophagus descending through its aperture in the diaphragm; f, opening in the tendon of the diaphragm for the inferior vena cava; 1, central, 2, right, and 3, left division of the trefoil tendon of the diaphragm; 4, right, and 5, left muscular part, descending from the margins of the tendon to be attached to the ribs; 6, the right, and 7, the left crus or pillar of the muscle; 8 to 8', in the three upper intercostal spaces of the right side the internal layer of intercostal muscles interrupted towards the vertebral column, where in the two upper spaces the external layer, 9, 9', is seen; in the lowest space shown

the external layer is not represented; 10, 10, on the left side, indicate the form and position of a part of the subcostal or innermost layer of intercostal muscles.

b. The *ligamentum arcuatum internum* is a fibrous band which extends from the body to the transverse process of the first lumbar vertebra, and sometimes also to that of the second, and arches over the upper part of the psoas muscle. The *ligamentum arcuatum externum* extends outwards from the transverse process of the first lumbar vertebra to the last rib, arching over the front of the quadratus lumborum: it is the upper part of the fascia covering that muscle, somewhat increased in thickness. From both ligamenta arcuata diaphragmatic muscular fibres take their origin, and are directed upwards to the posterior part of the tendinous centre.

c. The fibres arising from the cartilages of the six lower ribs form a series of serrated slips interdigitating with the attachments of the transversalis abdominis muscle. They sometimes arise also in part from the osseous ribs. The fibres proceeding from the ensiform cartilage form a narrow slip, sometimes divided, on each side of which there occurs an interval, in which the lining membranes of the thorax and abdomen are separated only by a small quantity of loose connective tissue. The anterior fibres of the diaphragm are much the shortest. The fibres of the sternal and costal slips, after being united into the general plane of the muscle, rise in an



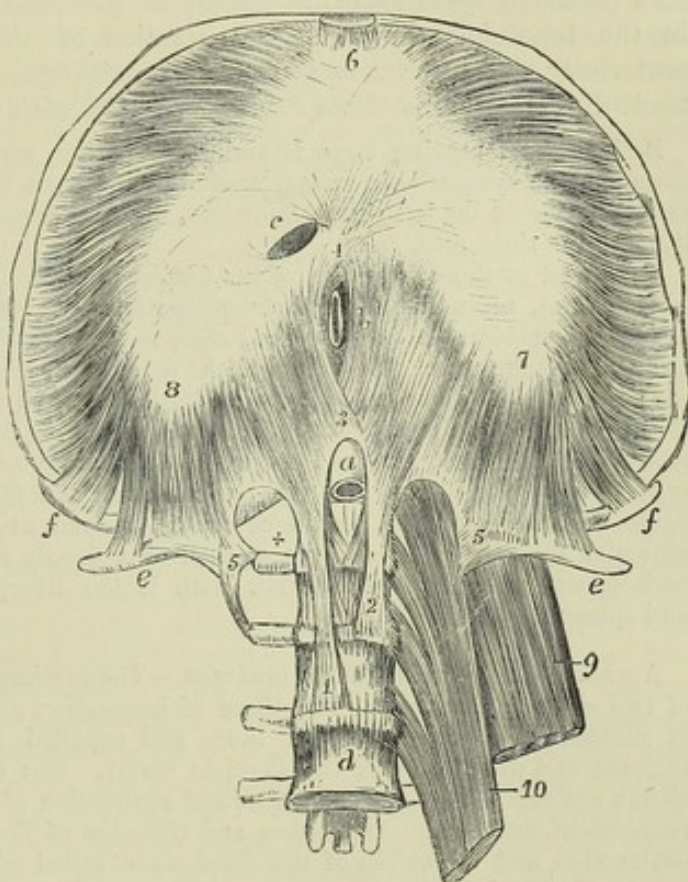
arched and converging manner to be inserted into the anterior and external margins of the central tendon.

d. The *central tendon*—*trefoil*, or *cordiform*, *tendon*, or *phrenic centre*, is a strong aponeurosis, forming the central and highest part of the diaphragm. It is elongated from side to side, and consists of three *lobes* or *alæ*, partly separated by indentations. The right lobe is the largest; and the left, which is elongated and narrow, is the smallest of the three. The central tendon is surrounded on every side by the muscular portion of the diaphragm, the fibres of which are directly continuous with those of the tendon. The tendinous fibres cross one another, and are interwoven in various directions.

Fig. 196.—VIEW OF THE  
DIAPHRAGM, FROM BE-  
LOW.  $\frac{1}{2}$

In the preparation from which this figure is drawn, the lower ribs and sternum are thrown upwards so as to expose and stretch the lower surface of the diaphragm, and the four upper lumbar vertebræ have been exposed by the removal of all the muscles on the right side, and the dissection of the *psoas magnus* and *quadratus lumborum* on the left side. *a*, the aorta emerging in the abdomen below the tendinous arch formed by the union of the pillars of the diaphragm on the first lumbar vertebra; *b*, the œsophagus seen entering the abdomen through the aperture in the united muscular crura (this aperture should have been represented a little to the left of the middle line); *c*, the aperture for the vena cava inferior situated at the place of union of the middle and right divisions of the trefoil tendon; *d*, the body of the fourth lumbar vertebra; *e, e*, the twelfth ribs near their extremities; *f, f*, the ends of the eleventh ribs; 1, the tendinous part of the right crus; 2, the left; 3, the tendinous arch formed by their union over the aorta, above which the decussation of muscular fibres is seen; 4, second decussation of muscular fibres in front of the œsophageal opening; 5, on the right side, placed near the end of the transverse process of the first lumbar vertebra, towards which, arching from above and from within, over the +, is seen the *ligamentum arcuatum internum*; and from which, passing towards *e*, is seen the *ligamentum arcuatum externum*; 5', on the left side, is in a similar position, but here the *quadratus lumborum* muscle is seen descending from the twelfth rib behind the *ligamentum arcuatum externum*, and the upper part of the *psoas* muscle is within the *ligamentum arcuatum internum*; 6, the middle division of the trefoil tendon, from which in front pass the slips of attachment of the diaphragm to the ensiform process; 7, the left, and 8, the right divisions of the trefoil tendon; from the outer and anterior margins of these the costal slips of the muscle are seen diverging, and from the posterior border of the tendon the slips of origin proceeding from the *ligamenta arcuata* and the tendinous arch of the crura; 9, part of the *quadratus lumborum*; 10, part of the *psoas magnus*.

Fig. 196.





*Foramina.*—There are in the diaphragm three large perforations for the passage respectively of the aorta, the œsophagus, and the vena cava, besides some smaller holes or fissures which are less regular.—*a.* The foramen for the aorta (hiatus aorticus), placed in front of the vertebræ, is bounded by tendinous fibres of the crura as already described. Besides the aorta, this opening transmits the thoracic duct, and generally also the vena azygos.—*b.* The foramen for the œsophagus, higher and farther forward than the preceding, as well as a little to its left, is separated from that opening by the decussating fibres of the crura. It is oval in form, and is generally entirely surrounded by muscular fibres; in some rare cases, however, a small part, the anterior margin, is found to be tendinous, being formed by the margin of the central tendon.—*c.* The opening for the vena cava (foramen quadratum) is placed in the highest part of the diaphragm, in the tendinous centre at the junction of the right and middle alæ, posteriorly. Its form is somewhat quadrangular; and it is bounded by fasciculi of tendinous fibres running parallel with its sides.

Besides the foregoing large foramina, there are small perforations through the crura for the sympathetic and splanchnic nerves on both sides, and for the vena azygos minor on the left side. Moreover, the larger azygos vein often takes its course through the right crus.

The upper or thoracic surface of the diaphragm is highly arched. Its posterior and lateral fibres, ascending from their connection with the lower margin of the thorax, are for a considerable extent placed close to the ribs, the lungs not descending so far as their attachments. The vault of the diaphragm rises higher on the right than on the left side. On the right side in the dead body it rises to the level of the fifth rib at the sternum, and on the left side only as high as the sixth. This difference has relation to the great size and firmness of the liver on the right side. It is covered superiorly by the pleura and the pericardium; the fibrous layer of the latter membrane blending with the tendinous centre, as well as with the fascia covering its muscular substance. The lower surface, of a deeply concave form, is lined by the peritoneum, and has in apposition with it the liver, the stomach, the pancreas and spleen, and the kidneys.

*ACTIONS.—MOVEMENTS OF RESPIRATION.*—The mechanical act of respiration consists of two sets of movements, viz., those of inspiration and of expiration, in which air is successively drawn into the lungs and expelled from them by the alternate increase and diminution of the thoracic cavity. The changes in the capacity of the thorax are effected by the expansion and contraction of its lateral walls, called *costal respiration*, and by the depression and elevation of the floor of the cavity, through contraction and relaxation of the diaphragm, called *abdominal respiration*. These two methods of respiration are normally combined, but in different circumstances one method is resorted to more than another. Thus, abdominal respiration is most employed in the male, costal respiration most in the female.

*Inspiration.*—The study of the movements of the thoracic walls in respiration presents the difficulty that those movements cannot be perfectly imitated on the prepared skeleton, because the force cannot on it be applied between one rib and another as during life, and because the resistance to expansion is no longer of the same description. On the prepared skeleton, by raising and depressing the sternum the ribs may be moved upwards and downwards, parallel to one another; the first rib moving as freely as the others. But during life several causes combine to make the first rib more fixed than those which follow: as for example, the weight of the upper extremity, and the strain of the intercostal muscles and ribs beneath. The movements of the thoracic walls in respiration are these:—1st. The antero-posterior diameter is increased by a forward movement of the sternum; the lower end of that bone is raised and advanced, while the upper end, which in easy respiration is at rest, or nearly so, is only raised in full inspiration. 2nd. The lateral diameter of the thorax is increased, both by the elevation and the rotation of the ribs; the first of these movements bringing larger costal arches to a level occupied in expiration by



smaller arches above them; and the second, by the movement or rotation of the ribs round an axis extending from their heads to the sternum, which everts the lower edge of the ribs, and increases the width of their arch outwards. 3rd. The capacity of the thorax, transversely and posteriorly, is increased by the elastic bending of the ribs, as well as the opening of the angle between the ribs and their cartilages, produced by the resistance of the sternum and weight of the limbs to the forward and upward motion of the extremities of the cartilages, and by the inclination backwards given to the middle ribs in their upward movement by the oblique direction of the plane of the costo-transverse articular surfaces. It is further to be noticed, that any considerable elevation of the lowest ribs, instead of increasing, would diminish the capacity of the thorax by raising the diaphragm, and accordingly in inspiration those ribs are drawn backwards and outwards rather than raised. Lastly, it may be remarked, that extension of the vertebral column is an important agent in respiration, for when the column is bent forwards, the ribs are pressed together in the concavity of the curve, and, conversely, when the column is extended the ribs are separated.

*The Intercostal Muscles.*—The manner in which these muscles act has been a subject of controversy from an early time, and cannot be said to be yet thoroughly understood. Among those who look upon the intercostal muscles as active in respiration, all are agreed that the external muscles are elevators of the ribs, and therefore muscles of inspiration. According to one view, defended by Haller, the external and internal layers have a common action, the decussating fibres acting in the direction of the diagonal between them; while according to another view, that of Hamberger, while the external intercostal muscles are admitted to be elevators, the internal are held to be depressors of the ribs. A more recent modification of these views, which is at present most generally adopted, is that maintained by Hutchison, viz., that the external intercostal muscles, and the parts of the internal intercostals placed between the costal cartilages, elevate the ribs, and that the lateral portions of the internal intercostals act as depressors. This view is founded upon a mathematical demonstration, and may be illustrated mechanically by an apparatus showing, that if two parallel bars, free at one end and attached by joints to a fixed perpendicular at the other, be united by oblique elastic bands, one set of which is directed downwards and away from the fixed upright, while another is directed downwards and towards the upright, the first set of bands will be shortened by the elevation of the bars from an oblique to a horizontal position, and the second set lengthened; whereas the first set will be lengthened and the second shortened by depression of the bars below the horizontal position. It may be objected, however, to this view, that the ribs differ from the supposed bars in respect that they are not rigid, and are not free at either end, but have the greatest extent of motion, at least in some instances, in the middle of their arch, and in the living subject, the ribs, in their elevation, both rotate upon their axis and bend upon themselves, instead of describing a simple upward and downward movement like the bars. The deficiency of the external intercostal muscles in front and of the internal behind, in which situations they would have acted as depressors, seems to point to some sort of combined action of the muscles as elevators of the ribs.

Among the more recent anatomical writers, Henle inclines to Haller's view; Luschka refers to Budge's experiments on the muscles of living animals, as proving that the internal intercostal muscles elevate the ribs (Budge, "*Lehrbuch der Physiologie des Menschen*," Weimar, 1860, p. 79); and Cruveilhier, founding on the experiments of Beau and Massiat, supports the very different but scarcely tenable view, that the intercostal muscles are not essential agents either in elevating or depressing the ribs, but only act as tensors of the intercostal spaces (op. cit. p. 575).

The levatores costarum have a similar action with the posterior fibres of the external intercostal muscles, and ought therefore to be ranked among the agents of inspiration. The scalene muscles also are usually believed to contribute, even in normal and quiet inspiration, to the support and elevation of the first and second ribs; and it is obvious that the serratus posticus superior must have a similar effect on those upper ribs to which it is attached.

*The action of the diaphragm* is more easily understood than that of the intercostal muscles. By its contraction and descent its convexity is diminished, the abdominal viscera are pressed downwards, and the thorax expanded vertically. The fibres



arising from the lowest ribs, being directed nearly vertically upwards from their costal attachments, must tend to pull those ribs upwards. The serratus posticus inferior and quadratus lumborum muscles, by opposing the diaphragm, and thus giving it a fixed point on which to descend, become assistant muscles of inspiration. The anterior fibres of the diaphragm being directed more horizontally towards the central tendon, oppose the forward motion of the sternum; hence the sternum becomes arched in patients long subject to asthma. (Hutchison, Article "*Thorax*," in Todd's "Cyclopædia of Anatomy and Physiology;" Meyer, "Physiologische Anatomie.")

In more forcible inspiration, and more especially in severe attacks of dyspnoea, there are called into play other powerful muscles, to secure the inspiratory action of which a fixed attachment must be provided by the support and elevation of the shoulder and arm; among these may be enumerated the serratus magnus and pectoralis minor, acting from the shoulder, and the pectoralis major and latissimus dorsi, acting from the raised arm, which together produce expansion and elevation of the ribs.

*Expiration.*—In normal and quiet expiration the diminution of the capacity of the chest is mainly, if not wholly, due to the return of the walls of the chest to the condition of rest, in consequence of their own elastic re-action, and of the elasticity and weight of the viscera and other parts displaced by inspiration; the lungs themselves, after distension by air, exert considerable elastic force, and no doubt the ribs and their cartilages re-act strongly by their elastic return from the elevated and bent condition into which they had been thrown by the inspiratory forces. In more forcible acts of expiration, in muscular efforts of the limbs and trunk, and in efforts of expulsion from the thoracic and abdominal cavities, all the muscles which tend to depress the ribs, and those which compress the abdominal cavity, concur in powerful action to empty the lungs, to fix the trunk, and to expel the contents of the abdominal viscera. (See further "Action of the Abdominal Muscles.")

## MUSCLES OF THE ABDOMEN.

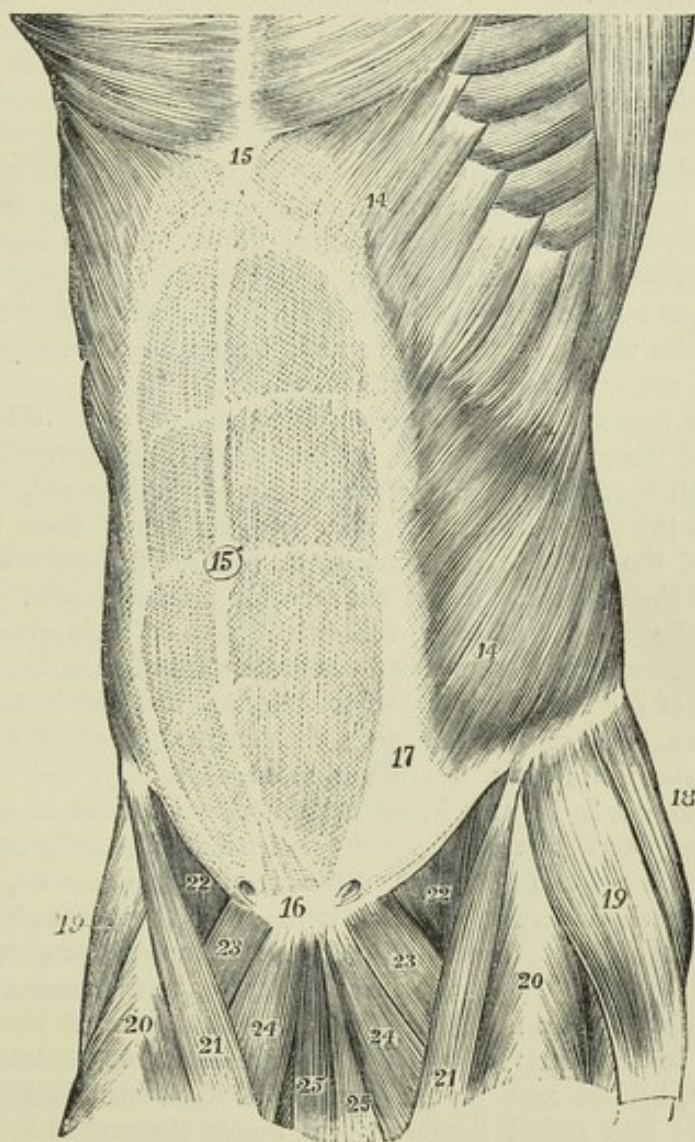
The muscular wall of the abdomen is formed, in great part of its extent on each side, of three layers of muscle, the fibres of which run in different directions; those of the two most superficial layers lying obliquely, and those of the innermost layer being transverse. In front those three layers of muscle are absent, and are replaced by tendinous expansions, which meet in the middle line, and on either side of that line the fibres of the recti muscles extend in a vertical direction between the tendinous layers, supported usually at the lower end by the pyramidales muscles. Posteriorly the wall is formed in part by aponeurosis, and in part by muscles of which the fibres are chiefly vertical, viz., the muscles of the back, and in front of them the quadratus lumborum.

The *superficial or external oblique muscle* (*descending or great oblique*) arises from the outer surface of the eight inferior ribs, by slips arranged in a serrated series, five of them meeting with origins of the serratus magnus, and three with origins of the latissimus dorsi. The slips of these two sets of muscles alternate with each other, as the tips of the fingers of one hand may be made to fit in between those of the other, and hence they are said to interdigitate, and are termed digitations. The lower and the upper digitations of the external oblique are connected with the ribs near their cartilages, the others are attached to the ribs at some distance from their extremities; the lowest digitation generally embraces the point of the twelfth rib. The fleshy fibres from the last ribs pass down in nearly a vertical direction to be inserted into the external margin of the crest of the ilium for about the anterior half of its length; all the rest incline downwards and forwards, and terminate in tendinous fibres, which form the broad aponeurosis by which the muscle is inserted.



The *aponeurosis* of the external oblique, wider at the lower than at the upper part, and larger than that of either of the subjacent abdominal muscles, extends inwards towards the middle line in front; at some distance from this, but farther out above than below, it becomes inseparably united with the aponeurosis beneath, and forms a part of the sheath of the rectus muscle in the whole extent of the space from the ensiform cartilage to the symphysis pubis. The upper part of the aponeurosis is connected externally with the larger pectoral muscle. Its lower fibres are closely aggregated together, and extend across from the anterior superior iliac spine to the spine of the pubes, in the form of a broad band, which is called the *ligament of Fallopius*, or more commonly of *Poupart*. This band is curved at the middle and outer parts, the convexity of the curve being directed towards

Fig. 197.

Fig. 197.—SUPERFICIAL VIEW OF THE MUSCLES OF THE ABDOMEN, FROM BEFORE.  $\frac{1}{5}$ 

14, external oblique muscle; 15, is placed on the ensiform cartilage at the upper end of the linea alba; 15', umbilicus; 16, symphysis pubis at the lower end of the linea alba; above 16, the pyramidales muscles are seen shining through the abdominal aponeurosis; from 14 to 17, the linea semilunaris; between this line and the linea alba are seen the transverse lines of the rectus muscle; above 22, the curved margin of Poupart's ligament; on either side of 16, the external abdominal ring is indicated.



the thigh, a form which is given to it by its connection with the fascia lata of the limb.

Above the crest of the pubes the fibres of the aponeurosis, separating from the inner part of Poupart's ligament, leave between them an oblique opening, the *superficial or external abdominal ring*, through which passes the spermatic cord in the male, and the round ligament in the female. The direction of this opening is upwards and outwards, its base being formed by the pubic crest, and its sides by the two sets of diverging fibres called the *pillars*. The upper or internal pillar is attached to the anterior surface of the symphysis pubis, interlacing with the corresponding fibres of the opposite side; the lower or external pillar is formed by Poupart's ligament, near its attachment to the spine of the pubic bone.

A portion of the aponeurosis, which is reflected backwards and outwards along the pectineal line from the attachment of Poupart's ligament to the spine of the pubes, constitutes a small triangular process with a curved external border, not far distant from the femoral ring. This receives the name of *Gimbernat's ligament*. Some curved fibres, directed across the diverging pillars and uniting them together, are named *intercolumnar*. A few of these, descending upon the spermatic cord from the margin of the opening, are prolonged upon that structure as a delicate fascia, named *intercolumnar fascia*. The intercolumnar fibres may be regarded as the lowest of a series of tendinous fibres, which cross the aponeurosis of the external oblique muscle somewhat obliquely over a considerable extent of its surface, and the strongest of which proceed from near the superior spine of the ilium and upper part of Poupart's ligament.

The *deep or internal oblique muscle* (*ascending or small oblique*), placed under cover of the external oblique, arises by fleshy fibres from the external half or two-thirds of the inner surface of Poupart's ligament, from the iliac crest for two-thirds of its length, and by some fibres from the posterior aponeurosis of the transversalis muscle, in the angle between the crest of the ilium and the outer margin of the erector spinæ muscle. From those attachments the fibres, spreading somewhat, pass to be inserted as follows: the most posterior fibres pass upwards and forwards to the lower margins of the cartilages of the last four ribs, where they are inserted in the same plane with the internal intercostal muscles; those arising further forwards from the crest of the ilium pass, the upper more obliquely, and the rest more horizontally, forwards to end in an aponeurosis in front of the abdomen; those from the front part of the crest extend horizontally inwards to the same aponeurosis; while the fibres from Poupart's ligament, usually paler than the rest, arch downwards and inwards over the spermatic cord, or the round ligament of the uterus, and end in tendinous fibres common to them and the lower part of the transversalis muscle, and hence known as the *conjoined tendon* of these muscles; through the medium of this tendon they are attached to the front of the pubes, and for some distance along the pectineal line, behind and to the outside of Gimbernat's ligament. The spermatic cord and round ligament pass under the arched lower border of the internal oblique and transversalis muscles through the internal or deep abdominal ring.

The *aponeurosis* may be regarded as the expanded tendon of the muscle continued inwards in front; it extends from the margin of the thorax to the pubes, and is wider at the upper than at the lower end. At the outer border of the rectus muscle this structure divides into two layers, one passing before, the other behind, that muscle; and the two reunite at its



inner border, so as to enclose it in a sheath. The anterior layer, as already mentioned, becomes inseparably united with the aponeurosis of the external oblique muscle, and the posterior layer is similarly incorporated with that of the transversalis. The upper border of the posterior lamina is attached to the margins of the seventh and eighth ribs, as well as to the ensiform cartilage. This division, however, of the aponeurosis into layers stops short a little above the middle distance between the umbilicus and the pubis, the aponeurosis below that level remaining undivided, and along with

Fig. 198.—LATERAL VIEW OF THE MUSCLES OF THE ABDOMEN AND TRUNK, THE INTERNAL OBLIQUE MUSCLE HAVING BEEN EXPOSED BY THE REMOVAL OF THE EXTERNAL OBLIQUE (modified from Henle).  $\frac{1}{2}$

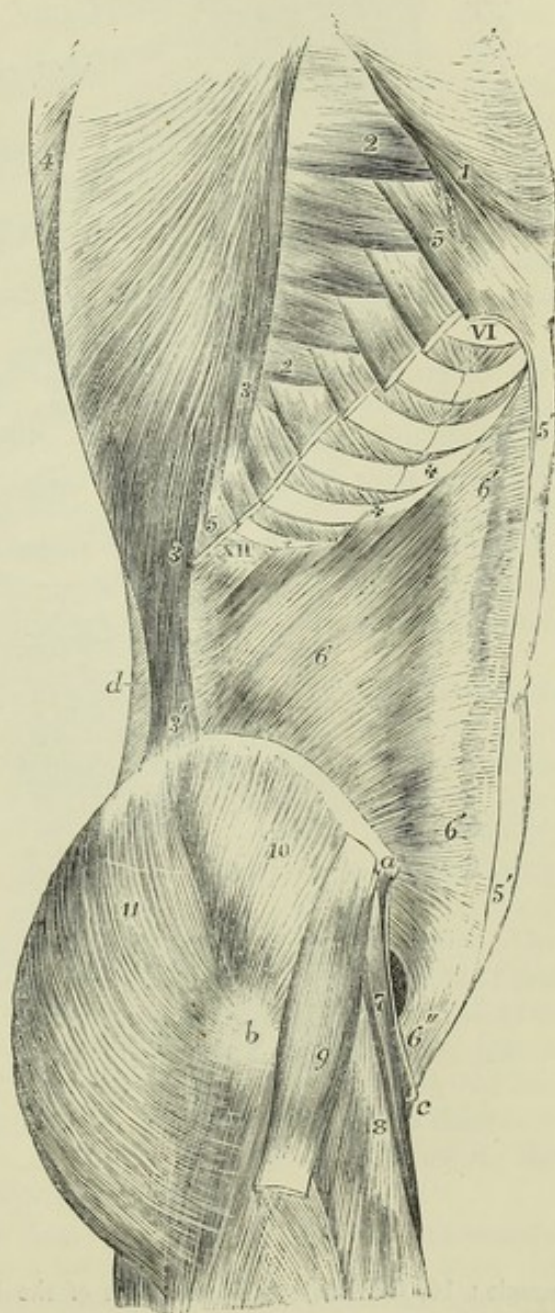
*a*, anterior superior spinous process of the ilium; *b*, trochanter major; *c*, spine of pubes; *d*, lumbar fascia; VI to XII, the sixth to the twelfth ribs; 1, lower part of the great pectoral muscle, where it is attached to the external oblique muscle; 2, 2, lower digitations of the serratus magnus from the fourth to the eighth ribs; 3, lower costal attachments of the latissimus dorsi; 3', its iliac attachment; 4, trapezius; 5, divided attachments of the external oblique, left in connection with the ribs; 5', aponeurosis of the external oblique divided in front of the rectus, where it joins the sheath; 6, internal oblique at its middle; 6', 6, line where it divides to form the sheath of the rectus; + + + XII, its attachments to the four lowest ribs; 6'', the conjoined tendon, and above, and to the outside, the internal inguinal aperture; 7, sartorius; 8, rectus femoris; 9, tensor vaginæ femoris; 10, gluteus medius; 11, gluteus maximus.

that of the transversalis muscle to which it is united, passing wholly in front of the rectus muscle. The deficiency thus resulting in the posterior wall of the sheath of the rectus muscle is marked superiorly by a well-defined lunated edge, whose concavity looks downwards towards the pubes—the *semilunar fold of Douglas*.

The internal oblique muscle is almost entirely covered by the external oblique. A small angular portion only near the place where its posterior fibres take their origin, under cover of the latissimus dorsi, is exposed between that muscle and the external oblique, and even this is not constantly found.

The *cremaster*, a muscle peculiar to the male, consists of fibres lying in

Fig. 198.





series with those of the lower border of the internal oblique muscle. It presents an external and an internal attachment. The external attachment is to Poupart's ligament near its lower part, and there its fibres are continuous with those of the internal oblique muscle; the internal attachment, smaller

Fig. 199.

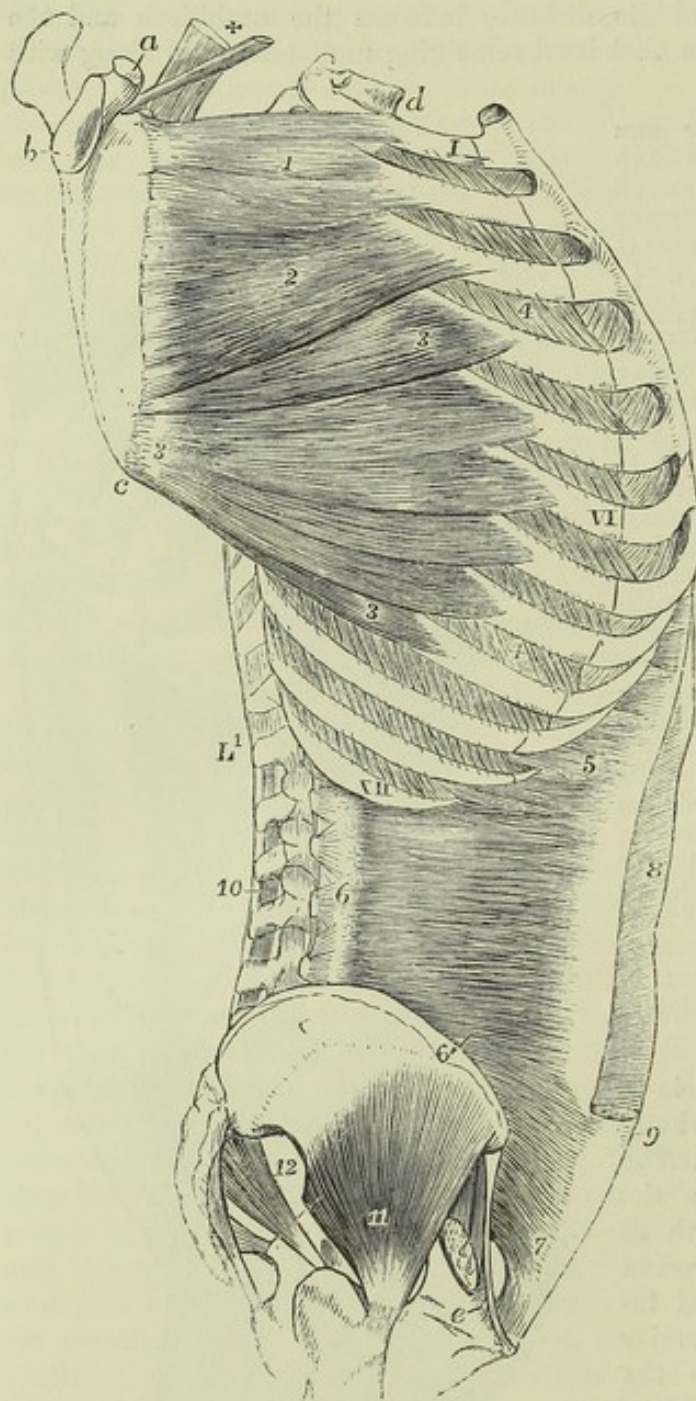


Fig. 199.—LATERAL VIEW OF THE TRUNK, GIVING A DEEP VIEW OF THE SERRATUS MAGNUS AND TRANSVERSALIS ABDOMINIS MUSCLES.  $\frac{1}{2}$

The serratus magnus is stretched out by the scapula being drawn away from the ribs. *a*, coracoid process of the scapula; *b*, glenoid cavity; *c*, lower angle; *d*, first dorsal vertebra; *e*, placed on the os pubis, points to the insertion of Gimbernat's ligament; I, VI, XII, the first, sixth, and twelfth ribs; L, first lumbar vertebra; 1, upper portion of the serratus magnus attached to the first and second ribs; 2, second or middle portion attached to the second and third ribs; 3, lower or fan-shaped portion attached to the ribs from the fourth to the ninth; 4, the external intercostal muscles; 5, upper costal origins of the transversalis abdominis; 6, origins of the muscle from the transverse processes of the lumbar vertebrae by the lumbar aponeurosis; 6', part rising from the crest of the ilium; 7, lower portion rising from the upper half of Poupart's ligament, and passing over the internal inguinal aperture; 8, sheath of the rectus muscle opened in its upper part by removing the aponeuroses of the oblique muscles; 9, the same in its lower part left entire at the place where the tendons pass entirely in front of the rectus

muscle; 10, the interspinales muscles of the lumbar vertebrae; 11, gluteus minimus; 12, pyriformis.

and less constant, is by means of a tendinous band to the spine and crest of the pubes, close to the insertion of the internal oblique muscle. The superior fibres of the muscle extend between those attachments in a series



of successively longer loops, descending in front of the spermatic cord, a few of them reaching as low as the level of the testicle: the remaining fibres, the greatest number of which descend from the outer attachment, and a few from the inner, spread out inferiorly and are embedded in the substance of a fascia, termed *cremasteric*, which adheres to the fascia propria of the testicle. Sometimes the only fibres developed are a bundle descending from the outer attachment.

In the female there may be almost constantly detected a small bundle of fibres descending on the round ligament of the uterus, which corresponds with the last-mentioned fibres of the cremaster muscle of the male.

The *transversalis abdominis* muscle, subjacent to the internal oblique, arises from the inner surface of the cartilages of the six lower ribs; from a strong aponeurosis attached to the lumbar vertebræ; from the inner margin of the crest of the ilium in the anterior two-thirds of its extent, and from the iliac third of Poupart's ligament. The greater part of the fibres have a horizontal direction, and extend forwards to a broad aponeurosis in front; the lowest fibres curve downwards like those of the internal oblique, and are inserted into the front of the pubes and into the pectineal line, through the medium of the conjoined tendon already described as common to this muscle and the internal oblique.

The *anterior aponeurosis* of the transversalis muscle commences in the greater part of its extent at the distance of about an inch from the outer border of the rectus muscle; but at its upper extremity this aponeurosis is much narrower, and there the muscular fibres of opposite sides approach nearly to the middle line behind the recti muscles. In the greater part of its extent it becomes united with the posterior layer of the aponeurosis of the internal oblique forming the rectus sheath, and inferiorly, where that aponeurosis passes entirely in front of the rectus muscle, it remains blended with it, and passes likewise in front of that muscle.

The *posterior aponeurosis* of the transversalis muscle extends backwards between the last rib and the iliac crest, and opposite the outer border of the erector spinæ muscle, is continuous with the aponeurotic structure which passes to the vertebral column in three layers, commonly named the posterior, middle, and anterior layers of the lumbar aponeurosis. The posterior, or most superficial, of these layers is that previously referred to as being connected with the tendons of the latissimus dorsi and serratus inferior muscles, and which is attached to the spinous processes of the vertebræ. The middle layer, which is the strongest, is attached to the tips and margins of the lumbar transverse processes, and lies between the erector spinæ and quadratus lumborum muscles. The remaining deepest layer, comparatively thin, passes in front of the quadratus lumborum muscle to the roots of the lumbar transverse processes, and at its upper part, where it increases in thickness and is connected with the last rib, it forms, as already mentioned, the *ligamentum arcuatum externum* of the diaphragm.

The *triangularis sterni*, when viewed from behind, along with the transversalis abdominis, has the appearance of being a continuation of that muscle upon the wall of the chest, above the diaphragm: hence the name of *transversalis thoracis*, which has sometimes been given to it.

The *rectus abdominis* is a long flat muscle, consisting of vertical fibres, situated at the forepart of the abdomen, within a tendinous sheath formed in the manner already described in the account of the aponeurosis of the



internal oblique muscle; it is separated from the muscle of the other side by a narrow interval, which is occupied by a dense fibrous structure, the *linea alba* afterwards described. It arises from the upper margin of the pubes by a flat tendon consisting of two parts, of which the internal is much

Fig. 200.

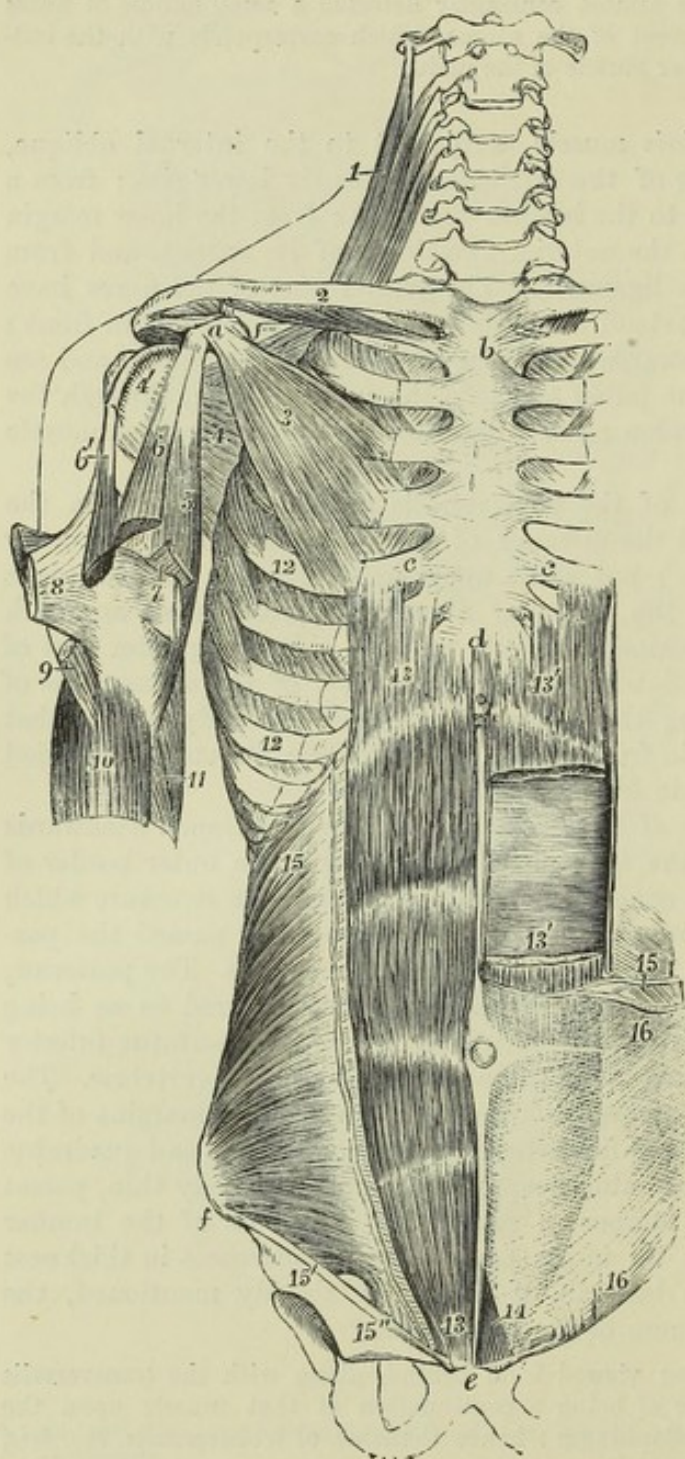


Fig. 200.—DEEP MUSCLES OF THE FOREPART OF THE TRUNK AND SHOULDER.  $\frac{1}{2}$

The explanation of the references from 1 to 11 has already been given, in the description of fig. 173.

*a*, coracoid process; *b*, sternum; *c*, *c*, cartilages of the fifth ribs; *d*, ensiform portion of the sternum; *e*, symphysis pubis; *f*, anterior superior iliac spine; 12, on the fifth and eighth ribs, near the insertion of the serratus magnus; 13, on the right side, the rectus abdominis completely exposed; on the left side 13', 13', the divided ends of the same muscle, a portion being removed; 14, points to the pyramidalis muscle exposed on the left side; 15, on the right side, the internal oblique muscle; 15', origin of its lower fibres from the deep surface of Poupart's ligament; 15'', conjoint tendon of the internal oblique and transversalis, descending to the pectineal line; between 15' and 15'', the internal or deep inguinal aperture, arched over by the muscular fibres; 15, on the left side, cut edge of the internal oblique, shown diagrammatically, to indicate the manner in which its tendon splits to form the sheath of the rectus muscle; 16, the tendon or aponeurosis of the external oblique muscle uniting in front with the sheath of the rectus.

the smaller, and is connected with the ligaments covering the

pubic symphysis, while the external one is fixed to the pubic crest. Expanding and becoming thinner at the upper end, the muscle is inserted into the cartilages of three ribs, the fifth, sixth, and seventh, usually by



three distinct parts of unequal size. Some fibres also are generally found attached to the ensiform cartilage.

The fibres of the rectus muscle are interrupted by three or more irregular tendinous intersections, named *lineæ transversæ*. The three which are most constant are placed, one opposite the umbilicus, another on a level with the ensiform cartilage, and the third intermediately between them: and these generally run across the whole muscle. When one or two additional transverse lines occur, they are usually incomplete; one of them is very generally placed below the umbilicus, the position of the other is variable. The intersections do not usually penetrate the whole thickness of the muscle, but are confined chiefly to its anterior fibres, and are firmly united to the anterior wall of the sheath of the muscle, while the posterior surface of the muscle has no attachment to the sheath.

The *lineæ transversæ* may be regarded as indications of the abdominal ribs of some of the lower animals; they sometimes extend outwards from the rectus, and penetrate partially into the internal oblique.

The *pyramidalis* is a small muscle resting on the lower part of the rectus. It arises from the front of the pubes and the ligaments of the symphysis, and becoming narrow as it ascends over the lower third of the interval between the umbilicus and pubes, is inserted into the *linea alba*.

The *pyramidalis* is covered in front by the aponeurosis of the other muscles, and rests posteriorly on the rectus, the size of the lower part of which is augmented when the *pyramidalis* is wanting.

This muscle is often absent on one or both sides: in some instances it has been found to be double. It occasionally exceeds the length above stated.

The *linea alba* is a white fibrous structure, extended perpendicularly downwards in the middle line from the ensiform cartilage to the pubes. This tendinous band is formed by the union of the aponeuroses of the two oblique and the transverse muscles, the tendinous fibres being continued in a decussating manner from one side to the other. Some longitudinal fibres are distinguishable towards its lower end. It is broader superiorly than inferiorly, and a little below the middle is widened out into a circular flat space, in the centre of which is situated the cicatrix of the *umbilicus*.

The *lineæ semilunares* are the two curved linear spaces on the surface of the abdomen, placed externally to the outer margins of the recti muscles. They are produced by the absence of muscular fibres behind that part of the aponeurotic tendons; they correspond on their inner side to the outer margin of the sheath of the rectus, and on their outer side mainly to the line of termination of the fibres of the oblique muscles in their aponeuroses.

The *quadratus lumborum* is an irregularly quadrilateral muscle, slightly broader below than above, placed between the last rib and the crest of the ilium, close to the vertebral column. It is divisible into two parts. One of these, arising by fleshy and tendinous fibres from the ilio-lumbar ligament, and from the iliac crest for several inches near the place where that ligament is attached, is inserted into the inferior border of the last rib for about half its length, and by four tendinous slips into the transverse processes of the four superior lumbar vertebræ. Another series of fibres, arising by two or three tendinous slips from as many of the inferior transverse processes at their upper margins, passes in front of those inserted into the same processes, and joins with the part of the muscle attached to the rib.



The number of the points of insertion of this muscle to the vertebræ, and the extent of its connection with the last rib, vary in different instances. It is sometimes attached to the body or transverse process of the last dorsal vertebra.

This muscle is placed between the middle and deepest layer of the lumbar aponeurosis, and its inner part is covered in front by the psoas muscle.

Fig. 201.

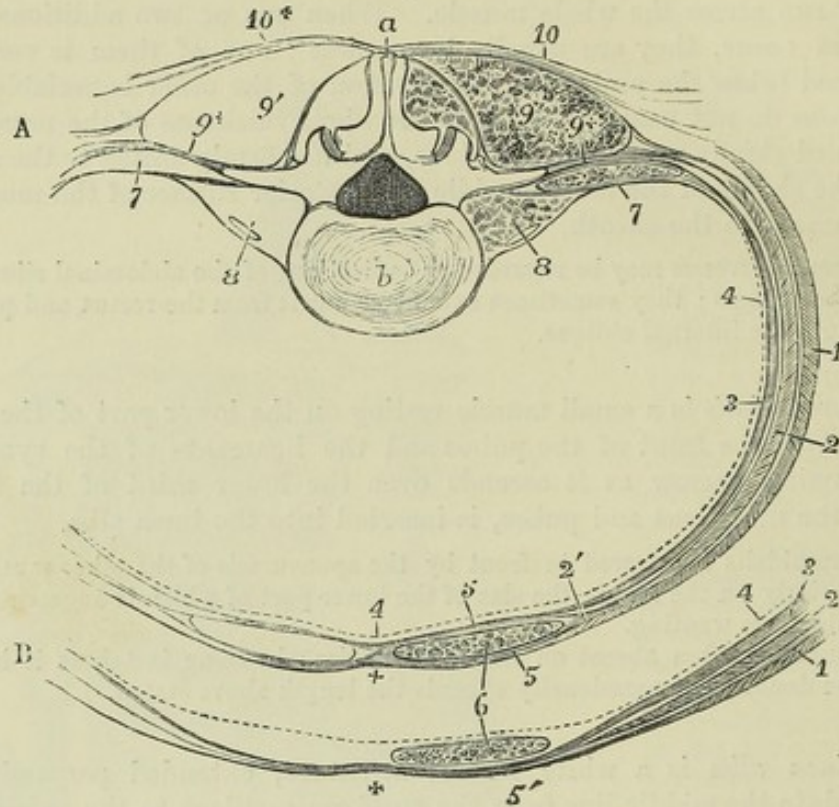


Fig. 201.—DIAGRAM OF A TRANSVERSE SECTION OF THE WALL OF THE ABDOMEN, TO SHOW THE CONNECTIONS OF THE LUMBAR AND ABDOMINAL APONEUROSES, AND THE SHEATH OF THE RECTUS MUSCLE.

A, at the level of the third lumbar vertebra; B, the fore part, at a few inches above the pubes.

a, spinous process of the third lumbar vertebra; b, body; 1, section of the external oblique muscle; 2, internal oblique; 3, transversalis; 4, a dotted line to mark the position of the fascia lining the abdomen; 5, 5, in A, the anterior and posterior parts of the sheath of the rectus, formed by the aponeurosis of the internal oblique splitting at its outer edge 2'; 6, points by two lines to the section of the rectus muscle in A and B; 7, innermost layer of the lumbar aponeurosis, covering in front the quadratus lumborum, and passing to the root of the transverse process; 8, points to the section of the psoas magnus and parvus muscles; 9, the section of the erectores spinæ muscles; 9+, the middle layer of the lumbar aponeurosis passing to the extremity of the transverse process; 10, 10+, the posterior layer of the lumbar aponeurosis, connected with the latissimus and serratus inferior: in A, at the sheath of the rectus, the aponeurosis of the external oblique is seen to unite in front with the sheath, while that of the transversalis is seen uniting with it behind: in B, the section is taken below the semilunar fold of Douglas, where all the tendons pass in front of the rectus as at 5'; the + near this, and in a similar place in A, marks the middle line and the place of the union of the several aponeuroses in the linea alba.

**ACTIONS.**—The abdominal muscles not only form a great part of the wall to enclose and support the abdominal viscera, but by their contractions are capable of acting successively on those viscera, on the thorax, and on the pelvis. When the pelvis and thorax are fixed, the abdominal muscles constrict the cavity and compress the viscera, particularly if the diaphragm be fixed or be made to descend at the same time, as occurs in vomiting and in the expulsion of the foetus, the fæces, and the urine.



If the vertebral column be fixed, these muscles press up the diaphragm, draw down the ribs, and contract the lower border of the thorax, and so contribute to expiration; but if the vertebral column be not fixed, the thorax will be bent directly forwards, when the muscles of both sides act, or rotated to either side, should they act alternately. Thus, if the external oblique of the right side be made to act on the thorax, the first effect appears to be that of drawing its margin down towards the pelvis; but, if the effort be continued, the trunk will be rotated towards the opposite side. The left internal oblique may co-operate in this action, for the direction of its fibres coincides with that of the right external oblique.

If the thorax be fixed, the abdominal muscles may be made to act on the pelvis; thus, in the action of climbing, the trunk and arms being elevated and fixed, the pelvis is drawn upwards, either directly or to one side, as a preparatory step to the elevation of the lower limbs.

The attachment of the tendinous intersections of the rectus muscle to the anterior wall of its sheath, causes the formation of corresponding transverse folds during its contraction, and may enable the separate parts of the muscle to act on different portions of the abdominal wall. By the same arrangement, when the oblique and transverse muscles contract, the breadth of the recti will be maintained and even increased; and these muscles will thus be enabled, both in the straight and in the incurved position of the abdominal wall, more effectually to compress the abdominal viscera. The pyramidalis muscle assists the inferior part of the rectus.

#### FASCLE OF THE ABDOMEN.

The *superficial fascia* of the abdomen is usually described as consisting of two layers. One of these, the *subcutaneous layer*, corresponds in its general features with the areolar subcutaneous tissue of other parts of the body, and contains embedded in it a very variable and often large quantity of fat. The other, or *deeper layer*, is of a denser and more membranous structure, contains a considerable amount of yellow elastic tissue in its substance, and is united by intervening fibres, in some places very closely, to the aponeurosis of the external oblique muscle. These two layers are both continuous with the superficial fascia on other parts of the trunk: they can be dissected as distinct layers only on the fore part of the abdomen, and are separated in a more marked manner in the lower part of its wall, where subcutaneous vessels, such as the superficial epigastric and circumflex iliac lie between them. The deep or elastic layer of the superficial fascia is bound down by a thin but dense intervening layer of fibrous tissue to the aponeurosis of the external oblique muscle in two places more particularly, viz., along the linea alba from the umbilicus to the pubes, and in the whole length of Poupart's ligament. At the lower part of the linea alba it sends fibrous and elastic processes towards the dorsum of the penis, which form its so-called suspensory ligaments. By its close union to Poupart's ligament, it comes into relation with the fascia lata of the thigh which is also united to that structure: but in the neighbourhood of the external inguinal aperture it remains free, and is prolonged downwards over the spermatic cord to the scrotum. The subcutaneous layer, losing its fat, is combined with the deeper layer as they both pass to the scrotum, and here the layer which they form acquires a reddish brown colour, and undergoes a modification in structure by being mingled largely with involuntary muscular fibres, and thus forms the *dartos tunic* of the scrotum. Some involuntary muscular fibres also exist in the altered superficial fascia which covers the penis. This covering, on leaving the scrotum posteriorly, becomes continuous with the superficial fascia of the perineum.



The parts of the superficial fascia here described have received minute attention from surgical anatomists, because of their close relation to the seat of hernial tumours: the adhesion of the fascia to Poupart's ligament, and its disposition over the inguinal aperture, spermatic cord, and scrotum, while they prevent the descent upon the thigh of matter which has been effused beneath the fascia, cause it rather to spread upwards upon the abdomen or to take its course downwards upon the scrotum.

The deep layer of the abdominal fascia is also interesting, as corresponding with the *tunica abdominalis*, a strong membrane consisting almost entirely of yellow elastic tissue, which exists in animals, as may be well seen in the horse or ox, and which contributes to the support of the viscera.

*Living membrane of the abdomen.*—On the inner surface of the wall of the abdomen is a membranous structure which lines the visceral aspect of the deepest stratum of muscles: it is divisible into two principal parts, the fascia transversalis and fascia iliaca.

The *fascia transversalis* is named from its position on the deep surface of the transversalis muscle. It is strongest and most clearly demonstrable in the lower part, where the muscular and tendinous support is somewhat weaker; and here also it is of particular interest, on account of its forming one of the coverings for inguinal hernia. Followed upwards from this situation the transversalis fascia becomes gradually less strong, and beyond the margin of the ribs it degenerates into a thin covering for the under surface of the diaphragm. Along the inner surface of the iliac crest, between the iliacus and transversalis muscles, the fascia is attached to the periosteum. For about two inches inwards from the anterior superior iliac spine, it is closely connected with the posterior surface of Poupart's ligament, and is there directly continuous with the fascia iliaca, a white line sometimes marking the place of continuity. At this place also, and to the same extent, the fascia lata is closely united with both the fascia transversalis and Poupart's ligament, which thus serves as a line of union of several layers of fascia. About midway between the iliac spine and the pubes, the external iliac artery and vein, as they pass out into the thigh, intervene between the fascia transversalis and the fascia iliaca, and from this point to the edge of Gimbernat's ligament the fascia transversalis is prolonged downwards under the crural arch, and over the artery and vein, forming the anterior portion of the funnel-shaped femoral sheath. This prolongation of the fascia transversalis passes under Poupart's ligament, and is not very closely united with it: it is strengthened by a dense band of fibres which arches over the vessels, and is inserted into the pubic crest and pectineal line behind the conjoined tendon of the transversalis and internal oblique. This band is sometimes called the *deep crural arch*. It includes beneath it, internal to the vessels, a space between Gimbernat's ligament and the vein, sufficiently large to admit the point of the little finger; this is called the *crural ring*, and is the space through which femoral hernia descends. About half way between the anterior superior iliac spine and the symphysis pubis, and about half an inch above Poupart's ligament, the spermatic cord in the male, or the round ligament in the female, pierces the fascia transversalis. The opening thus made is called the *internal* or *deep abdominal ring*, to distinguish it from the external or superficial ring in the aponeurosis of the external oblique muscle; the fascia above and internal to it is thin, but below and external to it is firm and thick, and forms a distinct crescentic margin, over which the cord or round ligament passes; from the borders of the opening a delicate funnel-shaped covering, the *infundibuliform fascia*, is prolonged downwards on the emerging struc-



ture, and forms in cases of oblique hernia one of the coverings of the tumour.

The *fascia iliaca*, more limited in extent, but stronger than the *fascia transversalis*, lines the back part of the abdominal cavity, and covers not only the muscle from which it derives its name, but also the *psoas*. The densest portion of its fibres is stretched transversely from the iliac crest, over the margin of the *psoas* muscle to the brim of the pelvis, where it is intimately blended with the periosteum. Superiorly, this membrane, becoming much weaker, is connected internally with the sacrum, and by small and distinct processes with the intervertebral substances and the neighbouring margins of the lumbar vertebræ; and finally it becomes blended with the fascia which covers the diaphragm and forms the *ligamentum arcuatum externum*. The external iliac vessels lie in front of this part of the iliac fascia. To the outer side of those vessels, the fascia turns forwards to be connected with Poupart's ligament and the *fascia transversalis*, as already described; to the inner side of the femoral vein it is attached to the ilio-pectineal line, where also the *fascia lata*, being traced upwards, is found to terminate; and between these two points, namely, behind the femoral vessels, it continues downwards over the margin of the pelvis, forming the back part of the sheath of those vessels, in the same manner as its fore part is formed by the *fascia transversalis*.

The *psoas parvus* is closely connected with the iliac fascia, by means of an expansion of its tendon.

At the back part of the abdomen is the aponeurosis of the *quadratus lumborum* muscle, forming the anterior layer of the lumbar aponeurosis; this, together with the posterior and middle layers, has been already described along with the *transversalis* muscle, with the aponeurotic origin of which they are all connected.

#### FASCIAE OF THE PERINÆUM.

As a knowledge of the disposition of the fasciæ of the perinæum and pelvis assists the comprehension of the attachments and relations of the muscles of those regions, the fasciæ will here be first described.

*Superficial Fascia.*—In the posterior half of the perinæum the subcutaneous fat is continued deeply into the ischio-rectal fossa, the pyramidal space intervening between the obturator fascia and the levator ani muscle. In the anterior half of the perinæum, beneath the subcutaneous fat, is placed a special layer of fascia, continuous with the dartos, the *proper superficial perinæal fascia*, sometimes called *fascia of Colles*. This fascia is bound down on each side to the margin of the pubic arch as far back as the ischial tuberosity; posteriorly, along a line from the ischial tuberosity to the central point of the perinæum, it turns round the posterior margin of the *transversus perinæi* muscle to join the sub-pubic fascia, to be presently described. From its deep surface likewise, an incomplete septum in the middle line dips down to the urethra and passes forwards into the scrotum. It thus happens that air blown in beneath the proper perinæal fascia on one side passes forwards and distends the scrotum to a certain extent on that side; it may then penetrate to the other also, and if injected with sufficient force may reach the front of the abdomen and travel upwards beneath the superficial fascia; but it neither passes backwards to the posterior half of the perinæum nor down upon the thighs. The same course is followed by urine or matter extravasated beneath the proper perinæal fascia.



The *deep perinæal* or *sub-pubic fascia* is stretched across the pubic arch on the deep surface of the crura of the penis and the bulb of the urethra. It consists of two distinct layers of strong fibrous membrane, separated by intervening structures. The *anterior layer*, or *triangular ligament of the urethra*, attached to the inferior margin of the symphysis pubis and to the rami of the pubic and ischial bones, and extending in the middle line back to the central point of the perinæum, is perforated about an inch from the symphysis by the urethra, immediately before its expansion into the bulb, and above and in front of this by the dorsal vein of the penis in the middle line, and by the pudic arteries and nerves on each side. At its posterior and inferior extremity it is connected with the deep layer, and with the recurved margin of the perinæal fascia. Between the two layers of the subpubic fascia are placed the membranous portion of the urethra, the deep transverse and constrictor muscles of the urethra, and Cowper's glands, together with the pudic arteries and nerves and the arteries of the bulb. The deep layer consists of a right and left lateral half, which are separated in the middle line by the urethra, close to the neck of the prostate, and are continued into the capsule of that gland. This layer of fascia is superficial to the anterior fibres of the levator ani muscle, which lie between it and the pelvic fascia, and is connected, not only with the superficial layer, but likewise with a thin web of areolar tissue which lies on the surface of the levator ani muscle, and is distinguished as the *anal fascia*.

In the female the sub-pubic fascia is divided in the middle by the vagina.

#### FASCIAE OF THE PELVIS.

The fascia lining the pelvis is described in three parts, viz., the upper part, or *undivided pelvic fascia*, and the two lower—the recto-vesical fascia, and the obturator fascia. The first of these is divided into the other two at the level of a white band of fibres, stretched from the lower part of the symphysis pubis to the spine of the ischium. The space between those two fasciæ is occupied by the levator ani and the fat and other contents of the ischio-rectal fossa.

a. The *pelvic fascia* is attached at the side superiorly for a short space to the brim of the pelvis, but in front of the line of its osseous attachment it inclines downwards towards the lower part of the symphysis pubis, following the margin of the obturator internus muscle. Anterior to the spine of the ischium, it lies between the obturator internus and the peritoneum, and at the back part of the pelvis is continued as a thin membrane over the pyriformis muscle and the sacral nerves, and is perforated by branches of the internal iliac artery and vein.

b. The *recto-vesical fascia* is the direct continuation of the pelvic fascia downwards and inwards to the viscera, below the level of the white line previously mentioned; it descends, immediately in contact with the inner surface of the levator ani muscle, to the prostate gland, the urinary bladder, and the rectum. On reaching those organs it spreads over them, and to some extent encases them. Close to the symphysis pubis, a short band is directed backwards above the prostate gland, to the bladder, with which it is intimately connected. A similar band exists at the opposite side of the symphysis pubis, and the two are separated by a narrow depression, in which the dorsal veins of the penis lie, after entering the pelvis. The bands in question are named the *anterior true ligaments of the urinary*



*bladder.* At the place where it is reflected inwards to the side of the bladder, it forms the *lateral true vesical ligament*. At the side of the bladder and prostate, the recto-vesical fascia gives a prolongation forwards on the veins (prostatic) which cover the prostate, and is firmly adherent to the capsule of that organ, except at its base, where an angular furrow, occupied by large veins, exists between the prostate and bladder. Into this furrow the incision for lithotomy ought not to extend, on account of the danger from wounding the veins and from the infiltration of urine. A portion of the recto-vesical fascia invests the vesiculæ seminales, and is extended across between the bladder and the rectum; continuing into the membrane of the opposite side, it supports the bladder, and separates that organ from the intestine. On the rectum the fascia is also reflected upwards and downwards, gradually degenerating into a thin membrane over the surface of the bowel, as it likewise does on the bladder.

c. The *obturator fascia* is a membrane stretched over the lower part of the surface of the obturator internus muscle within the pelvis. It is connected superiorly with the white band before referred to, which consists indeed of its superior fibres, and it is attached in the rest of its circumference to the rami of the pubis and ischium, the ischial tuberosity, and the greater and lesser sacro-sciatic ligaments. It lies between the obturator internus muscle and the ischio-rectal fossa, and presents in its substance towards the muscle a canal, which contains the internal pudic artery and nerve in their course to the perinæum.

The obturator fascia is sometimes included in the description of the pelvic fascia while the recto-vesical is considered as an offset from it. It will be found, however, on dissection, that the recto-vesical fascia is always most directly continuous with the pelvic fascia, and that the obturator fascia is only loosely connected with it. Indeed, the fibres of the levator ani muscle in most cases pass upwards to some extent beyond the white line, and thus separate the obturator from the pelvic fascia.

The *ischio-rectal fossa* is a pyramidal space occupied by subcutaneous fat. It is bounded externally by the obturator fascia, posteriorly by the gluteus maximus muscle and great sacro-sciatic ligament, and internally by the recto-vesical fascia; anteriorly, its base is limited by the margin of the perinæal and the sub-pubic fasciæ.

In the female the pelvic fascia is connected with the vagina in the same manner as with the other pelvic organs.

#### MUSCLES OF THE PERINÆUM.

The muscles of the perinæum differ somewhat in the two sexes, and must therefore be separately described in each. In both sexes they may be divided into two groups according as they are more immediately connected with the lower orifice of the alimentary canal or with the genito-urinary outlet. In both groups superficial and deep muscles are to be distinguished.

##### A.—IN THE MALE.

a. *ANAL GROUP.*—The *internal or circular sphincter* is a thick ring of unstriped muscle connected with the lowest circular fibres of the rectum, which will fall more naturally to be considered along with the anatomy of that organ.



The *superficial* or *external sphincter* is a thin layer of fibres placed immediately beneath the skin surrounding the margin of the anus. It is elliptical in form, about half an inch in breadth on each side of the anus, and is attached posteriorly by slight tendon to the tip and back of the coccyx; passing forwards on each side of the anus, it becomes blended anteriorly with the transverse and the bulbo-cavernosus muscles at the *central point of the perinæum*, a name given to the depressed spot situated in the male between the anus and the bulb of the urethra, and in the female between the anus and vulva.

Fig. 202.

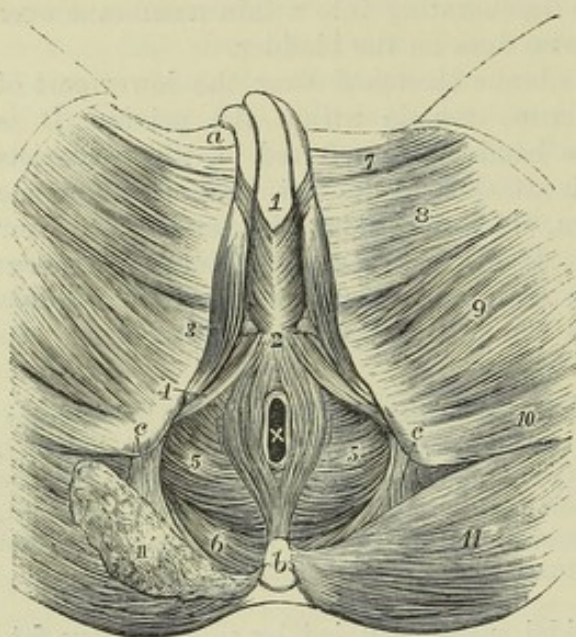


Fig. 202.—SUPERFICIAL VIEW OF THE MUSCLES OF THE PERINÆUM IN THE MALE (modified from Bourguery).  $\frac{1}{4}$

*a*, crest of the pubis; the penis cut short at this place; *b*, coccyx; *c*, placed on the tuberosity of the ischium, points by the line to the greater sacro-sciatic ligament;  $\times$ , placed within the anus; 1, placed on the spongy body of the urethra, in front of the bulbo-cavernosus muscles; 2, placed on the central point or tendon of the perinæum, marks the posterior extremity of the same muscles; 3, ischio-cavernosus; 4, transversus perinæi; 5, levator ani; from 2 to *b*, elliptical sphincter of the anus; surrounding  $\times$ , the circular sphincter is indicated; 6, coccygeus muscle; 7, adductor longus; 8, gracilis; 9, adductor magnus; 10, semitendinosus and biceps; 11, on the left side, the gluteus maximus entire; 11', the same cut on the

right side, so as to expose a part of the coccygeus muscle.

The *levatores ani* and *coccygei* are two expanded muscles continuous one with the other, which together form a floor of support for the pelvic viscera, and close in a great measure the lower orifice of the pelvis.

The *levator ani* arises in front from the posterior surface of the pubes, near the symphysis and midway between its upper and lower borders; behind from the spine of the ischium, and between those points from the pelvic fascia along the line of attachment of the obturator fascia. Some of its fibres are also traceable upwards in the substance of the pelvic fascia above the level of the obturator.

From this extensive origin the fibres of the levator proceed downwards and inwards towards the middle line of the floor of the pelvis. Its posterior fasciculi are inserted upon the side of the lower end of the coccyx; the bundles immediately in front of the coccyx unite in a median raphé with those of the opposite sides as far forward as the margin of the anus; the middle and larger portion of the muscle is prolonged upon the lower part of the rectum, where it is connected with the fibres of the external sphincter, and slightly with those of the internal; and lastly, the anterior muscular bundles pass between the rectum and the genito-urinary passages, and descending upon the side of the prostate, unite beneath the neck of the



bladder, the prostate, and the neighbouring part of the urethra, with corresponding fibres from the muscle of the opposite side, and blend also with those of the external sphincter and deep transverse perinæal muscles.

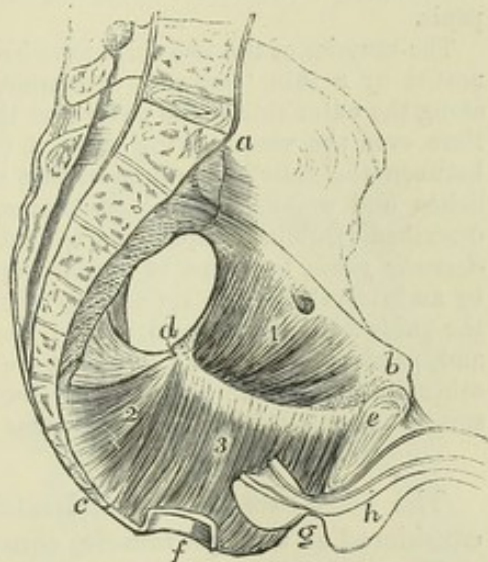
The anterior portion of the levator ani, which arises from the ramus of the pubes, close to the symphysis and above the pubic arch, and also from the adjacent fasciæ, is sometimes separated at its origin by areolar tissue from the rest of the muscle. From this circumstance, and from its connection with the prostate gland, it was described by Santorini, and since by Albinus and Soemmerring, as a distinct muscle, under the name of the *levator prostatee*. Its fibres pass backwards parallel with the middle line.

The upper or pelvic surface of the levator ani is in contact with the recto-vesical fascia, the capsule of the prostate, and the lower end of the rectum. The under, or perinæal surface, invested by the thin anal fascia, is covered by the fat which occupies the ischio-rectal fossa. The posterior border is continuous with the coccygeus.

Fig. 203.—LEFT HALF OF THE MALE PELVIS, TO SHOW THE LEVATOR ANI AND COCCYGEUS MUSCLES (after Cloquet).  $\frac{1}{2}$

*a*, the promontory of the sacrum; *b*, the crest of the pubis; *c*, the last bone of the coccyx; *d*, the spine of the ischium; *e*, the symphysis pubis; *f*, a small portion of the anal part of the rectum; *g*, half the prostate gland; *h*, half the bulb and a portion of the penis with the urethra, &c.; 1, upper part of the obturator internus muscle exposed by removing from within it the pelvic fascia; 2, coccygeus muscle, and above it and between it and *d*, the sacro-sciatic ligaments; 3, inner surface of the levator ani; the white line extending between *d* and *e*, shows the place of its origin from the fascia of the pelvis; below is shown the descent of its fibres to the anus and to the portions of the perinæum before and behind it.

Fig. 203.



The *coccygeus* muscle is composed of fleshy and tendinous fibres, forming a thin, flat, and triangular sheet, which arises by its apex from the spine of the ischium and the lesser sciatic ligament, and is attached along its base to the border of the coccyx and the lower part of the sacrum. The fibres of this muscle diverge as they approach the middle line, while those of the levator ani rather converge as they descend.

The internal or pelvic surface of this muscle assists in supporting the rectum; its external or under surface rests on the front of the sacro-sciatic ligaments, and on the gluteus maximus muscle.

The levatores ani and coccygei muscles together have been named somewhat appropriately by Meyer, the pelvic diaphragm.

*b*. GENITO-URINARY GROUP.—Covered by the special fascia of the perinæum are three muscles, placed superficially—the transverse (superficial transverse), the ischio-cavernosus, and the bulbo-cavernosus; while situated more deeply between the superficial and deep layers of the sub-pubic fascia, are the deep transverse muscle and the constrictor of the urethra, sometimes described as one muscle under the name of compressor of the urethra.



The *transversus perinæi* muscle arises from the inner surface of the pubic arch, near the ischial tuberosity, and is directed obliquely forwards and inwards to unite with the muscle of the opposite side, as well as with the sphincter ani and bulbo-cavernosus at the central point of the perinæum. It lies immediately in front of the line where the perinæal dips back to join the sub-pubic fascia. It is sometimes absent, and at other times one or more small muscular slips are found lying on the same plane with it, in front or behind.

The *ischio-cavernosus*, or erector penis muscle, embracing the crus penis, arises from the inner part of the tuber ischii, behind the extremity of the crus penis, and from the pubic arch along the inner and outer sides of the crus. From this origin the fleshy fibres are directed forwards to a tendinous expansion which is spread over the lower surface of the crus penis, and is inserted into the under and outer surfaces of that body towards the fore part.

This muscle serves to compress the crus penis, with which its tendinous fibres are blended, and thus it contributes to produce, or at least to maintain, the erection of the penis.

The muscles of the two sides have been described by Krause as in some cases connected by a thin tendinous expansion, which, according to that anatomist, extends along the outer side of the penis over the dorsal surface of the organ, and at the same time over the vessels lying upon it (Müller's Archiv, 1832): but this connection between the muscles has been in vain sought for by Theile and by Kobelt (Die männlichen und weiblichen Wollust-Organ, 1844). By Houston there have also been described (Dublin Hosp. Reports, vol. v.), under the name of *compressores venæ dorsalis penis*, two slips of muscle, separated from the erectores penis on each side by an interval, though apparently belonging to them. They are said to arise from the pubic arch, above the origin of the erector muscles and the crura of the penis, and, passing upwards and forwards, are inserted above the dorsal vein, by joining each other in the middle line. These muscles, which are well developed in the dog and several other animals, are by no means constant in the human subject.

The *bulbo-cavernosus*, accelerator urinæ, or ejaculator seminis, may be considered as a single muscle, consisting of two symmetrical parts.

The fleshy fibres of the muscle take origin behind from the central tendon of the perinæum, and from a median tendinous raphé interposed between the two halves of the muscle. The larger number of the fibres are directed round the bulb and the adjoining part of the corpus spongiosum urethræ, and join above that body with those from the opposite side by a strong aponeurosis. At the fore part, a portion of the muscle passes over the sides of the corpus cavernosum, and is attached to that body in front of the erector penis: from its insertion a tendinous offset is said to be prolonged over the dorsal vessels of the penis (Kobelt). The posterior fibres, shorter than the anterior, are inserted into the front of the triangular ligament.

The fibres which invest the most prominent part of the bulb are more or less distinct from those contiguous to them, and have been described by Kobelt as forming a separate muscle, to which he has given the name *compressor hemisphæricum bulbi*. The fibres of this muscular slip are connected by a small tendon, above the urethra, with the corresponding part of the opposite side.

This muscle compresses the bulb and the adjoining part of the corpus spongiosum of the urethra, so as to evacuate fluid lodged in the canal, as well as to increase the turgescence of the glans during erection.

The *deep transversus perinæi* muscle is a thin rather inconstant fasciculus, which, arising from the margin of the pubic arch, is directed inwards and



meets with its fellow of the opposite side behind the bulb, at the central point of the perinæum. Its fibres conceal Cowper's gland.

The *constrictor urethræ* muscle consists of a number of transverse fibres extending across the arch of the pubis, some of them above and others below the membranous portion of the urethra, and closely embracing it. In some bodies a tendinous raphé, placed over the middle of the urinary canal, separates each stratum into lateral halves.

This muscle rests in contact with the deep layer of the triangular ligament, which separates it from the anterior fibres of the levator ani.

The transverse constrictor of the urethra was known to Santorini. One of the representations of it, contained in his posthumous work, has been copied for the woodcut (Fig. 204). Indistinctly or partially noticed by other anatomists, the muscle was first fully described by Guthrie; and the whole of the muscular structure connected with the membranous part of the urethra was examined about the same time by Müller, but the results were not published till a later period. (Guthrie, "Anatomy and Diseases of the Neck of the Bladder," &c., 1834; Joannes Müller, "Ueber die organischen Nerven der erectilen männlichen Geschlechts-Organen," &c., 1836.)

Fig. 204.—POSTERIOR VIEW OF THE PUBES, WITH PART OF THE BLADDER AND URETHRA ATTACHED (from Santorini).  $\frac{1}{2}$

1, body; 2, rami of the pubes; 3, obturator internus muscle; 5, portion of the fundus and neck of the bladder laid open; 6, the prostate gland; 7, transverse fibres of the compressor urethræ muscle, passing above the urethra; 8, similar fibres passing beneath that canal.

*Circular fibres of Santorini* (stratum internum circulare, Müller).—Beneath the transverse muscle just described is a series of circular involuntary muscular fibres, entirely surrounding the membranous part of the urethra: these are continuous behind with the circular fibres of the prostate, and are referred to in the description of that body. (See Structure of the Prostate.)

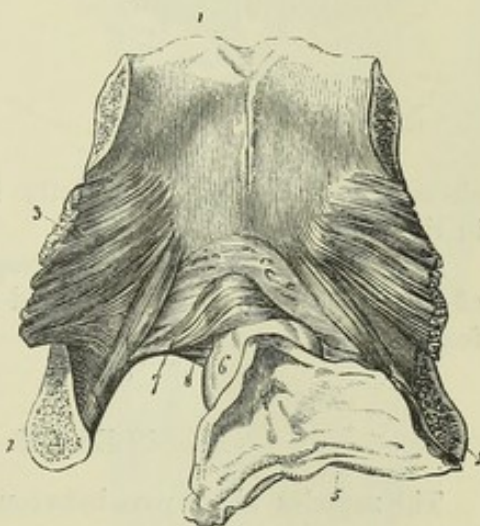
A pubo-urethral muscle was described by James Wilson (Medico-Chirurgical Trans., London, vol. i. p. 176), and is sometimes referred to as Wilson's muscle, but has not been recognised as a separate muscle by succeeding anatomists who have given special attention to the subject of the muscular structures round the urethra. An unstriped pubo-vesical band has been described, descending from the back of the symphysis to the neck of the bladder (Luschka).

#### B.—IN THE FEMALE.

In the female the anterior fibres of the *levator ani* embrace the vagina as they do the prostate in the male.

The *transversus perinæi* and the *sphincter ani* are arranged nearly in the same manner as in the male.

Fig. 204.

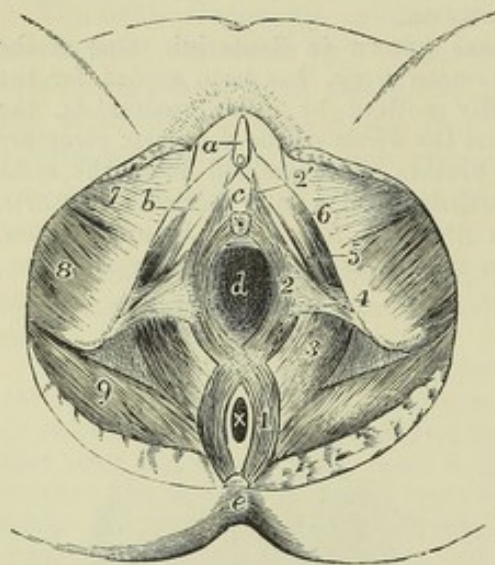




The *erector clitoridis* differs from the erector penis of the male by its smaller size alone.

The *sphincter vaginae* is attached behind to the central point of the perinæum, in common with the sphincter ani and transversus perinæi muscles; its fibres open out to surround the vaginal orifice and vestibule, closely embracing on the outer side the two bulbs of the vestibule; again

Fig. 205.

Fig. 205.—MUSCLES OF THE PERINÆUM IN THE FEMALE.  $\frac{1}{4}$ 

a, clitoris; b, crus clitoridis; c, is placed in the vestibule above the orifice of the urethra; d, vagina; x, anus; e, coccyx; 1, external sphincter ani muscle; 2, sphincter vaginae; 2', a few of its fibres prolonged to the clitoris; 3, levator ani; 4, on the left ischial tuberosity, points to the transversus perinei (the inner fibres of this muscle are represented too far forwards in the figure); 5, 6, ischio-cavernosus; 7, gracilis; 8, adductor magnus and semitendinosus, &c.; 9, gluteus maximus.

approaching each other in front, they become narrow, and are inserted upon the corpora cavernosa of the clitoris, a fasciculus crossing over these and including the vena dorsalis.

The two halves of this elliptical mus-

cle appear to correspond strictly to those of the bulbo-cavernosus muscle in the male.

A deep transverse muscle, corresponding to part of the constrictor urethræ of the male, has been described as resting on the pubic surface of the female urethra.

## MUSCLES OF THE LOWER LIMB.

The muscles which pass between the trunk and the lower limb, viz., the psoas, piriformis and coccygeus, are so few in number and so intimately connected with others, that it is inexpedient to describe them as a distinct group, as has been done in the case of the more numerous and considerable muscles which attach the upper limb to the trunk.

### MUSCLES OF THE HIP AND THIGH.

**GLUTEAL REGION.**—The muscles of this region are the three glutei, the piriformis, the obturator externus, the obturator internus with the gemelli, and the quadratus femoris.

The *gluteus maximus* is a very large and coarsely fasciculated muscle, somewhat quadrilateral in shape, which forms the greatest prominence of the gluteal region posteriorly. It arises from the posterior fifth of the iliac crest, and the irregular rough surface of the ilium subjacent to that part; from the posterior surface of the last piece of the sacrum; from the great sacro-sciatic ligament and the side of the coccyx; and between the sacrum and the ilium, from the aponeurosis of the muscles of the back. Thence it passes downwards and outwards; the fibres of its lower third are inserted



into an elongated rough impression, extending between the base of the great trochanter and the linea aspera; and those of the upper two-thirds into a thick tendinous structure, which covers the great trochanter, and joins the fascia lata of the thigh: a few of the lowest fibres terminate also in the fascia.

Fig. 206.—SUPERFICIAL MUSCLES OF THE HIP AND THIGH, SEEN FROM BEHIND.  $\frac{1}{2}$

1, gluteus medius, covered by the strong fascia lata; 2, middle of the gluteus maximus; 2', placed on the fascia lata below the place where the gluteus maximus is inserted into it, and above the insertion of the muscle into the femur; 3, vastus externus; 4, biceps flexor cruris; 4', tendon of the biceps, receiving on its outer side the oblique fibres of the short part; 5, semitendinosus; 5', its tendon near the insertion; 6, semimembranosus, its tendon of insertion is seen between 5' and 7'; 7, gracilis; 7', tendon of the gracilis near its insertion; 8, small part of the sartorius; 9, small portion of the adductor magnus; 10, outer, and 11, inner head of the gastrocnemius; 12, placed in the popliteal space, points to the origin of the plantaris.

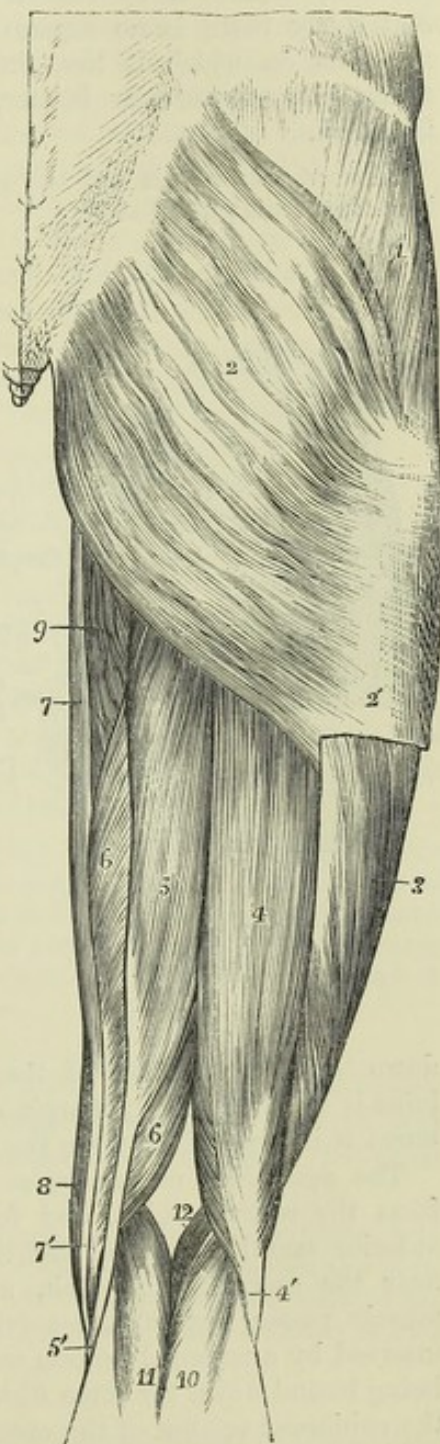
At the upper and lower borders of this muscle, the fascia lata, or aponeurosis of the limb, splits into two thin layers, which are continued, one on the deep, and the other on the outer surface, so as to enclose the muscle. A few fibres on the upper border of the muscle arise from the deeper of those two layers: the lower border, longer and looser, lies in the fold of the nates. The deep surface rests on the gluteus medius and pyriformis muscles, the tendon of the obturator internus, with the two gemelli, the quadratus femoris, a small portion of the adductor magnus, the great trochanter, the ischial tuberosity, and the origins of the hamstring muscles; it covers also the sciatic artery and nerves as they emerge from the pelvis below the pyriformis, the superficial branch of the gluteal artery passing out above that muscle, and the pudic artery and nerve lying behind the spine of the ischium.

Between the tendon of the muscle and the great trochanter of the femur, are placed two or three synovial bursæ, or a single multilocular bursa of large size. A bursa is also situated between the muscle and the tendon of the vastus externus, and another separates it from the tuber ischii.

The great size of the gluteus maximus, and the consequent prominence of the buttock, is a characteristic of man as compared with those animals which most nearly approach him in general structure.

The *gluteus medius*, covered partly by the gluteus maximus, partly by the fascia lata, arises from the surface of the dorsum ilii above the superior

Fig. 206.





curved line, and in front of the gluteus maximus, from the strong fibres of the fascia lata covering its outer surface. The muscular fibres converge as they descend, the anterior fibres passing obliquely backwards, the posterior fibres obliquely forwards, and terminate in a fan-shaped tendon, which, becoming narrowed and thick, is inserted into the oblique line directed downwards and forwards on the outer surface of the great trochanter. The tendon is separated by a small bursa from the upper part of the trochanter. Anteriorly there is no separation between this muscle and the gluteus minimus on which it lies, the two muscles running into one another at their common anterior border, and separating only at their tendons of insertion.

Between this muscle and the gluteus minimus are the gluteal nerve and deep branches of the gluteal artery.

Fig. 207.

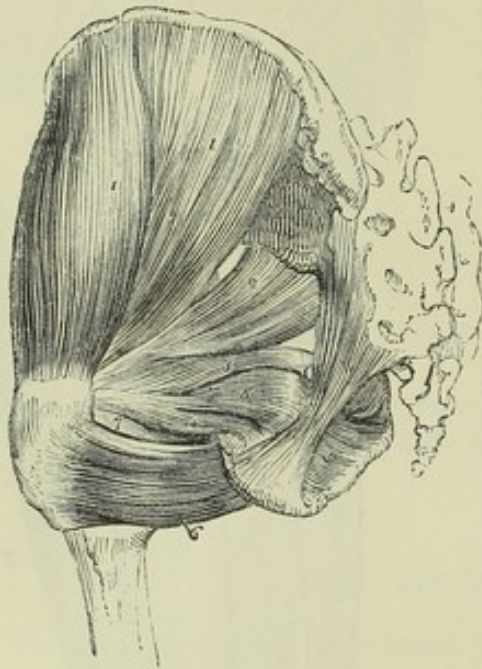

Fig. 207.—DEEP MUSCLES OF THE HIP AND PELVIS ON THE LEFT SIDE, FROM BEHIND.  $\frac{1}{4}$

The gluteus maximus and the muscles of the thigh have been removed. 1, gluteus medius; 2, piriformis; 3, gemellus superior; 4, gemellus inferior; 5, obturator internus, seen partially within the pelvis, and, after issuing by the lesser sciatic notch, between the gemelli muscles; 6, quadratus femoris; 7, tendon of the obturator externus between the gemellus inferior and quadratus.

The *gluteus minimus*, covered by the preceding muscle, arises from the whole space on the dorsum ilii between the superior and inferior curved lines. The fibres, converging as they descend, terminate in an aponeurotic expansion, superficial to the muscle, and become narrowed into a tendon which is inserted into an impression on the anterior border of the great trochanter. The tendon is bound

down to the prominence of the trochanter by a strong fibrous band which joins it from the upper margin of the capsule of the hip-joint. A synovial bursa is interposed between the tendon and the trochanter.

The *piriformis* muscle arises within the pelvis by three fleshy digitations from the second, third, and fourth divisions of the sacrum, between the anterior sacral foramina, slightly from the deep surface of the iliac bone, near the sacro-sciatic notch, and from the sacro-sciatic ligament. The muscle passes out of the pelvis by the great sacro-sciatic notch, and is inserted by a rounded tendon into the upper border of the great trochanter, being bound down for some distance from the point of its final insertion to the subjacent tendon of the obturator internus and gemelli muscles.

The *piriformis* muscle, after escaping from the pelvis, is in contact by its upper border with the gluteus medius and minimus, the gluteal vessels and nerve intervening; and by its lower border with the superior gemellus muscle, the sciatic vessels and nerves, which emerge beneath it, lying between. The muscle is frequently pierced by part of the great sciatic nerve, and is thus divided more or less completely into two parts.



The *obturator internus* muscle, in great part lodged within the pelvis, arises from the deep surface of the obturator membrane ; from the fibrous arch which completes the canal for the obturator vessels and nerves ; from a narrow strip of the bone internal to the obturator foramen ; from the posterior surface of the membrane occupying that aperture, extending on the bone downwards to the outlet, backwards as far as the sciatic notch, and upwards to the brim of the pelvis ; it also arises to some extent from the obturator fascia, which is in contact with the deep surface of the muscle. Its fibres converging as they proceed backwards from this origin, the muscle emerges from the pelvis by the small sacro-sciatic foramen, turns over on the trochlear surface of the ischium, and is directed outwards, to be inserted, in connection with the gemelli, into the upper part of the digital fossa of the great trochanter. The tendon of the muscle is formed by the union of four or five bands, occupying the surface of the muscle which is towards the bone, and lying side by side as they turn over the trochlear groove : their motion in that groove is facilitated by a synovial bursa, which sends in processes between them, and by a thin coating of cartilage on the trochlear surface of the bone. Another bursa, of much smaller size, elongated and narrow, is placed between the tendon and the fibrous capsule of the hip-joint. These bursæ are sometimes continuous with one another.

The *gemelli* (gemini) are two small narrow muscles, consisting chiefly of fleshy fibres extended horizontally at each side of the tendon of the obturator internus ; and they are named from their position above and below that tendon. The *gemellus superior*, which is usually the smaller muscle, arises from the ischial spine ; the *gemellus inferior* takes origin from the upper and back part of the tuberosity of the ischium. Passing outwards, they join the tendon of the internal obturator muscle, which is placed between them, covering and concealing it more or less, and along with it are inserted into the digital fossa of the trochanter. Some of their fibres, especially from the superior gemellus, run obliquely into the tendon of the obturator.

The superior gemellus is placed immediately below the pyriformis ; the inferior gemellus is above the quadratus femoris, and at its insertion is close to the tendon of the obturator externus muscle ; both muscles are in contact with the synovial bursæ of that tendon. These muscles may be regarded as portions of the obturator internus arising external to the pelvis. The gemellus superior is often very small, and in some cases is altogether absent.

The *quadratus femoris*, of an oblong figure, arises from the external border of the tuber ischii, and proceeding horizontally outwards, is inserted into the greater part of the linea quadrati on the posterior surface of the great trochanter of the femur.

Superiorly this muscle is close to the inferior gemellus. Its inferior border is in contact, at its origin, with the descending fibres of the adductor magnus, and at its insertion with the superior or horizontal fibres. It conceals the outer part of the obturator externus, and also the lesser trochanter, which is separated from it by a small bursa.

The *obturator externus*, arising from the anterior two-thirds of the surface of the obturator membrane, and from the outer surface of the rami of the pubes and ischium as far as the margin of the thyroid foramen, encroaching also a little upon the body of the pubes, and spreading towards the tuberosity of the ischium, extends horizontally outwards and backwards, converging to a tendon which is directed along the under and hinder surface of the neck

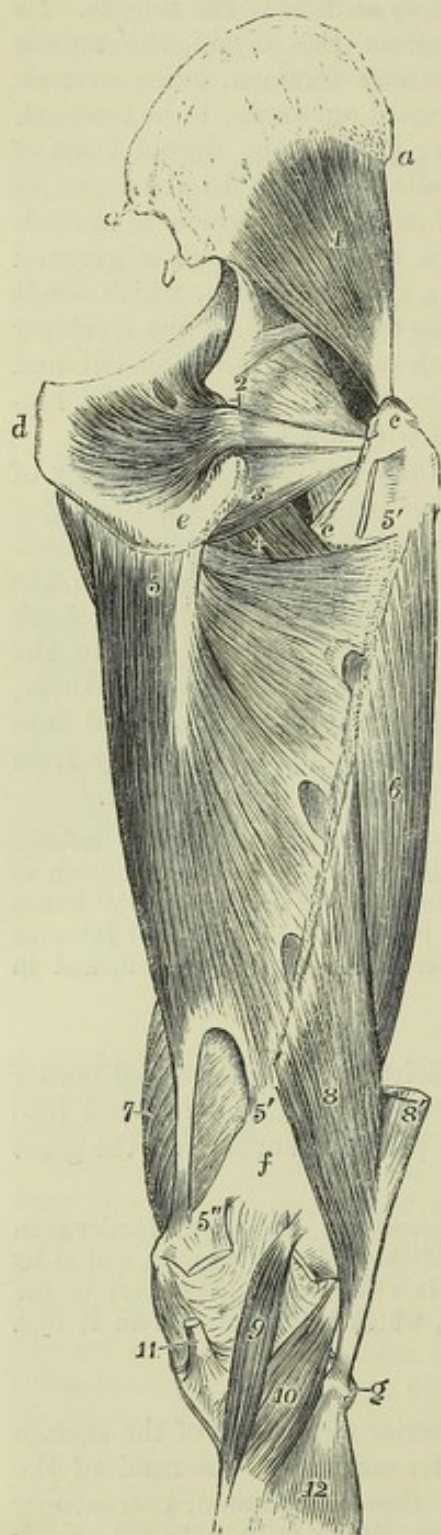


of the femur to be inserted into the trochanteric fossa below the obturator internus and gemelli.

POSTERIOR FEMORAL REGION.

(The Hamstring Muscles).

Fig. 208.



At the back of the thigh are three long flexor muscles of the knee-joint, viz., the biceps, semitendinosus, and semimembranosus.

The *biceps flexor cruris* consists of two parts, arising one from the hip-bone, the other from the femur, and uniting inferiorly to terminate on the fibula. The *long head* arises by a tendon common to it and the semitendinosus from the most prominent part of the ischial tuberosity, and the muscular fibres terminate below the middle of the thigh in an aponeurosis which is continued down into the tendon of insertion. The *short head* arises from the rough surface of the linea aspera in its whole extent, from a part of the line leading from thence to

Fig. 208.—DEEP MUSCLES OF THE RIGHT HIP AND THIGH, FROM BEHIND.  $\frac{1}{2}$

*a*, anterior, *a'*, posterior superior spine of the ilium; *b'*, posterior inferior spine; *c*, *c'*, great and small trochanter; *d*, symphysis pubis; *e*, tuberosity of the ischium; *f*, flat or popliteal surface of the femur; *g*, head of the fibula; 1, gluteus minimus; 2, obturator internus passing out of the pelvis by the lesser sciatic notch to the digital fossa of the trochanter: the gemelli muscles have been removed; 3, obturator externus; 4, small part of the back of the pectineus and adductor brevis; 5, origin of the adductor magnus from the lower part of the ischial tuberosity; 5', 5'', line of insertion of this muscle on the linea aspera, in which are seen three arched tendinous intervals for the passage of the perforating vessels; 5'', tendon of insertion into the inner tuberosity of the femur; between the lower 5' and 5'', the interval through which the femoral vessels pass into the popliteal space; the upper 5' is placed upon the cut end of quadratus femoris; 6, vastus externus; 7, vastus internus; 8, femoral head of the biceps femoris: the lower part is represented as passing too far inwards; 8', its ischial head, cut short; 9, plantaris muscle; at its upper end the outer head of the gastrocnemius; the figure 5'' is upon the cut inner head; 10, popliteus, cut short below; 11, tendon of the semimembranosus; 12, upper part of the soleus.

the outer condyle, and from a part of the adjacent flat surface of the femur



also from the external intermuscular septum between it and the vastus externus muscle, and terminates on the same aponeurosis as the long head. The inferior tendon is inserted into the head of the fibula by two portions, between which is attached the external lateral ligament of the knee-joint, being separated from them by a synovial bursa. Some of the fibres of the tendon, passing forwards and downwards, are inserted into the front of the tibia, and others passing backwards strengthen the fascia of the leg.

The *semitendinosus* muscle, arising from the tuberosity of the ischium by the tendon common to it and the biceps, for a distance of about three inches, descends on the back of the thigh, and terminates below the middle in a long, rounded, and slender tendon, which passes along the inner side of the popliteal space, resting on the semimembranosus, and curves forwards to be inserted in an expanded form into the upper part of the tibia at its inner side. There the tendon is on the same plane, but below that of the gracilis, both being under cover of the sartorius. A narrow oblique tendinous intersection traverses the muscle about the middle.

The *semimembranosus* muscle arises from the tuberosity of the ischium, above and to the outside of the origin of the biceps and semitendinosus, by a strong flattened tendon, two or three inches long, which as it descends in front of the common tendon of those two muscles, passes to their inner side. It terminates inferiorly in a thick tendon, which is inserted in three parts: the principal part turns forwards and is inserted into a well marked groove on the inner tuberosity of the tibia, beneath the internal lateral ligament of the knee-joint, some of its fibres joining that ligament; a second part, passing downwards and outwards, expands in the aponeurosis over the popliteus muscle; and the remaining fibres are directed upwards and outwards, and blend with the posterior ligament of the knee-joint, of which they may be said to form a considerable portion. The muscle consists of numerous short fibres extending obliquely between two aponeurotic expansions, which are continued upwards and downwards on the opposite sides of the muscle for three fourths of its length from the superior and inferior tendons.

The inferior tendon of the semimembranosus muscle is separated from the tendon of the inner head of the gastrocnemius by a large bursa. The muscle rests on the adductor magnus.

The hamstring muscles descend in contact with one another, being bound down by the fascia lata; but inferiorly they diverge, the biceps passing to the outside, and the semimembranosus and semitendinosus to the inner side of the knee, forming the superior borders of a diamond-shaped hollow at the back of the knee—the popliteal space. The great sciatic nerve is concealed by them while they are in contact, and its principal division, the internal popliteal, lies in contact with the semimembranosus muscle in the popliteal space.

#### ILIAC REGION.

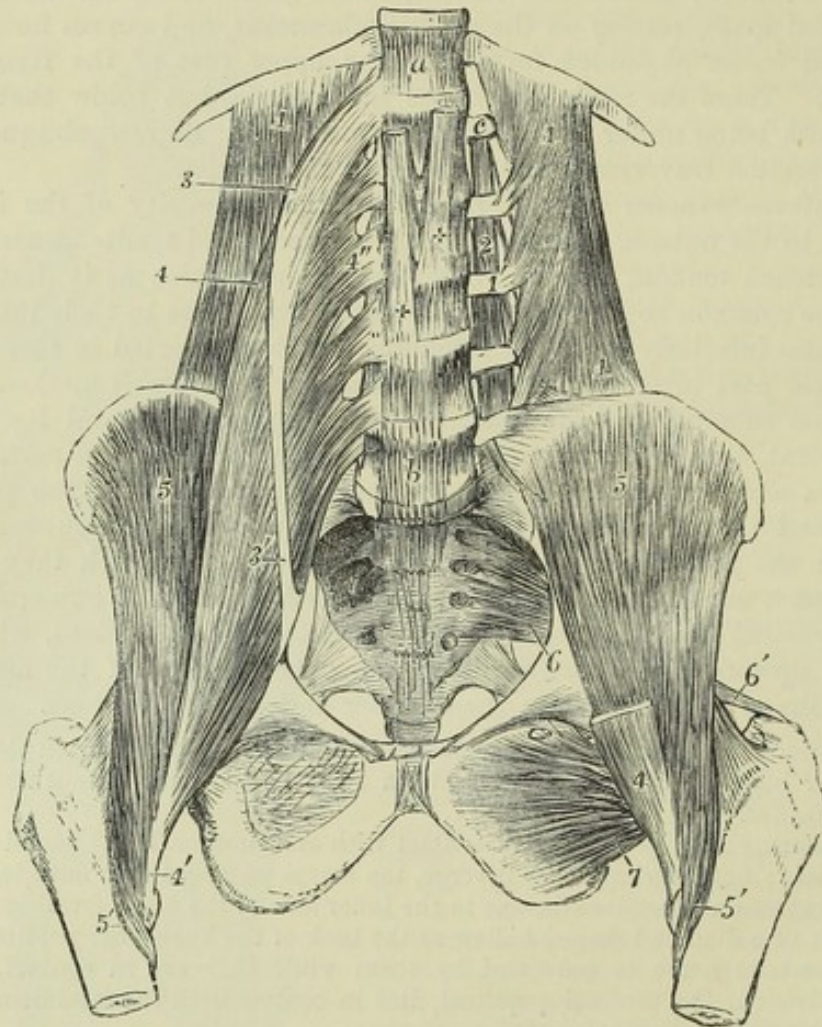
The *ilio-psoas* muscle, the great flexor of the hip-joint, is divisible into two parts, a broad outer part, the iliacus, and an elongated inner part, the psoas magnus, which are inserted together into the small trochanter.

The *iliacus* muscle arises from the iliac fossa of the innominate bone, and from the anterior border of the same, likewise from the base of the sacrum, the ilio-lumbar ligament, and the capsule of the hip-joint. Its fibres converging, as they pass downwards and inwards, are inserted for the most part into a tendon continuous with the psoas muscle; while some are prolonged to a special triangular impression on the upper part of the femur, in front of and below the small trochanter.



The *psoas magnus* arises from the upper and lower lateral parts of the bodies of the last dorsal and of all the lumbar vertebræ, from the interposed fibro-cartilages, and from the anterior surface and lower margin of the transverse processes of the lumbar vertebræ near their bases. It forms a thick elongated muscle, and is inserted into the small trochanter of the femur by means of a tendon, which is placed at first within the substance of the muscle, and afterwards at its outer side, receiving in this manner the fibres of the iliacus as well as those of the *psoas*.

Fig. 209.

Fig. 209.—DEEP DISSECTION OF THE MUSCLES OF THE ABDOMEN AND PELVIS.  $\frac{1}{4}$ 

*a*, twelfth dorsal vertebra; *b*, fifth lumbar vertebra; *c*, transverse process of the first lumbar vertebra; 1, quadratus lumborum muscle; on the left side, its fibres of origin from the transverse processes of the lumbar vertebræ are shown by the removal of the *psoas* muscles; 2, placed upon one of the intertransversales muscles of the left side; 3, marks the upper part of the *psoas parvus*, drawn somewhat to the outer side; 3', the insertion of its tendon into the brim of the pelvis; 4, points to the upper part of the *psoas magnus*; 4'', one of the origins of the muscle; 4'', the insertion of the muscle into the lesser trochanter of the femur; 5, *iliacus internus*, shown fully on the left side by the removal of the *psoas* muscles; 5', insertion of the *iliacus* muscle into a line below the trochanter minor; 6, *piriformis* muscle of the left side rising within the pelvis from the sacrum; 6', insertion of its tendon into the summit of the great trochanter; 7, the *obturator externus* seen from before on the left side; ++, the right and left tendinous pillars of the diaphragm on the front of the upper lumbar vertebræ.



The connection of the psoas with the bodies of the bones is effected by means of five distinct parts, each of which is attached to the upper and lower margins of two vertebræ and the interposed fibro-cartilage; the highest to the neighbouring margins of the last dorsal vertebra and the first lumbar, and the lowest to the edges of the fourth and fifth lumbar vertebræ with the intervertebral substance. These attachments are connected by thin tendinous arches, extending over the middle of each vertebra, covering the lumbar vessels and communicating branches of the sympathetic nerve, and giving origin to other muscular fibres. The psoas muscle, at its superior extremity, passes behind the diaphragm, below the arch of the ligamentum arcuatum internum. Resting on its inner border, along the margin of the pelvis, is the external iliac artery, and deeply in the substance of the muscle is the lumbar plexus of nerves. The ilio-inguinal and external cutaneous nerves cross the iliacus muscle, and the anterior crural nerve descends on the tendon of the psoas. The iliac fascia extends over the surface of the whole ilio-psoas muscle in the abdomen. The muscle emerges from the abdomen beneath Poupart's ligament, and turning over the brim of the pelvis rests on the capsule of the hip-joint, on which it glides by means of a large synovial bursa, which occasionally communicates with the interior of the joint; its outer margin is in contact with the rectus muscle, and its inner margin is separated from the pectineus by the internal circumflex artery.

The *psoas parvus*, an occasional muscle, placed on the surface of the psoas magnus, arises from the bodies of the last dorsal and first lumbar vertebræ, and from the fibro-cartilage between them, and soon ends in a flat tendon, which passes along the front and the inner side of the psoas magnus, to be inserted into the ilio-pectineal line and eminence.

This muscle, although it is well developed and constant in animals, is most frequently absent in the human subject. It was found in only one of twenty bodies examined by Theile with special reference to its existence. When present, it is liable to many changes in the place of origin; thus, it may be connected only with the first lumbar vertebra, or with the second and the intervertebral substance above it, and it has been observed to commence by two parts or heads separated by an interval.

#### ANTERIOR FEMORAL REGION.

The *tensor vaginæ femoris*, or ilio-aponeurotic muscle of the thigh, arises by muscular and tendinous fibres from the external surface of the iliac crest close to its fore-part, and from part of the notch between the two anterior iliac spines, external to the attachment of the sartorius; and passing downwards and a little outwards it is inserted between two laminæ of the fascia lata, about three inches below the great trochanter of the femur. The outer of these laminæ is continued upwards on the muscle in its whole extent, being part of the general investment of the limb, the deeper is connected above with the origin of the rectus muscle, and with the fibres attaching the gluteus minimus to the hip-joint. The part of the fascia, made tense by the action of the muscle, forms a strong tendinous band, which descends to the outer and back part of the knee-joint.

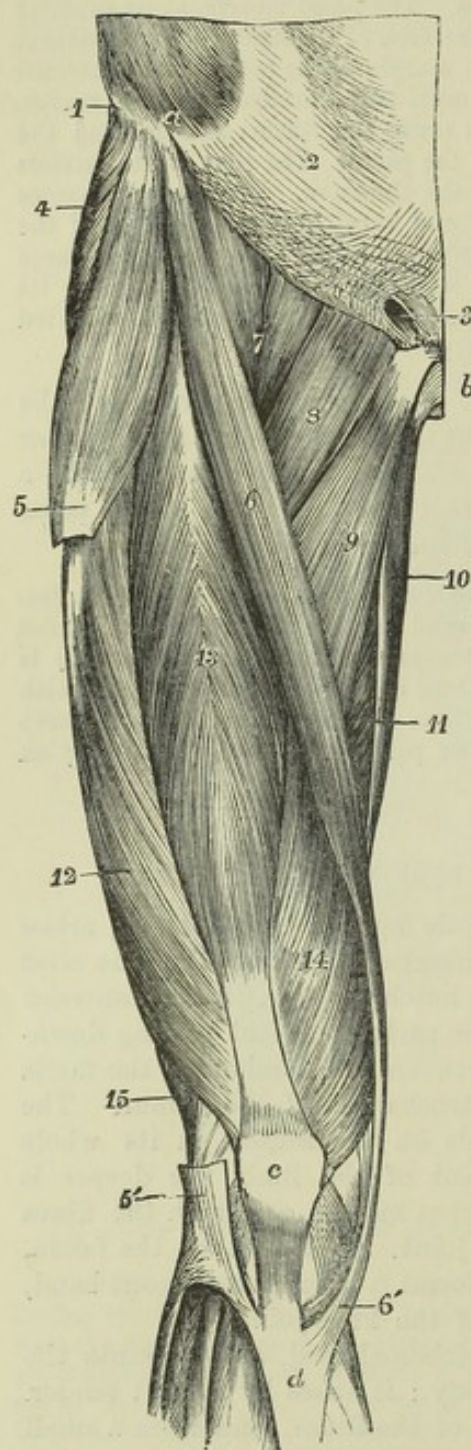
The *sartorius* is very long, narrow, and ribbon-shaped, and presents the longest fibres of all the muscles in the body: it arises by a short tendon from the anterior superior spinous process of the ilium, and from a small part of the anterior margin of that bone immediately below, and, passing downwards and inwards across the front of the thigh, is inserted by an expanded aponeurosis into the upper and inner side of the tibia, near to the tubercle, and for about an inch below it.

In this long course the muscle is directed over the anterior part of the thigh, obliquely inwards in the upper third, and vertically at the inner aspect of the limb



as far as the knee; below this it turns obliquely forwards to its place of attachment. The tendon of insertion, broad and expanded, covers the tendons of the gracilis and semitendinosus (a synovial bursa being interposed), and gives off one expansion which strengthens the capsule of the knee-joint by becoming incorporated with it, and another which blends with the fascia of the leg.

Fig. 210.

Fig. 210.—SUPERFICIAL MUSCLES OF THE FRONT OF THE THIGH.  $\frac{1}{2}$ 

a, anterior part of the crest of the ilium; b, symphysis pubis; c, patella; d, is below the anterior tuberosity of the tibia; 1, points to the insertion of the external oblique muscle into the iliac crest; 2, its aponeurosis at the linea semilunaris; 3, the external abdominal ring; 4, part of the gluteus medius; 5, tensor vaginae femoris at the place of its insertion into a portion of the fascia lata, which has been removed between 5 and 5', which latter part is seen descending to be attached to the tibia and fibula; 6, the sartorius; 6', the insertion of the sartorius; 7, psoas and iliacus conjoined; 8, pectineus; 9, adductor longus; 10, gracilis; 11, part of the adductor magnus; 12, vastus externus; 13, rectus femoris; 14, vastus internus; 15, small part of the biceps flexor cruris.

The sartorius is covered only by the fascia lata and the integument. It passes over the iliacus and rectus femoris muscles, the femoral vessels, the pectineus, the adductor longus, adductor magnus, vastus internus, gracilis, and semitendinosus muscles. The inner border of this muscle and the most projecting part of the adductor longus form the sides, and Poupart's ligament forms the base of a triangular space in the upper third of the thigh, through the middle of which the femoral artery passes. This frequently receives the name of Scarpa's triangle.

The *quadriceps extensor cruris*, the extensor muscle of the knee, is divisible into four parts, one of which, the rectus femoris, descends from the hip bone and remains distinct, while the other three, distinguished one from the other only by the arrangement of their fibres, cover the whole of the anterior and lateral surfaces of the thigh bone, from which they arise.

a. The *rectus femoris*, extended in a straight line from the pelvis to the patella, arises by two tendons, one of which is attached to the anterior inferior

spinous process of the ilium, and the other, united to the first within an inch of that point, is attached horizontally in the groove above the upper part of the brim of the acetabulum. From the prolongation of the tendon so formed the muscular fibres arise pennately, and turning outwards and



backwards as they descend, are inserted in a similar manner into the tendon below, the superior tendon being prolonged on the anterior, the inferior tendon on the posterior surface of the muscle. The inferior tendon forms a broad band inserted into the upper surface of the patella.

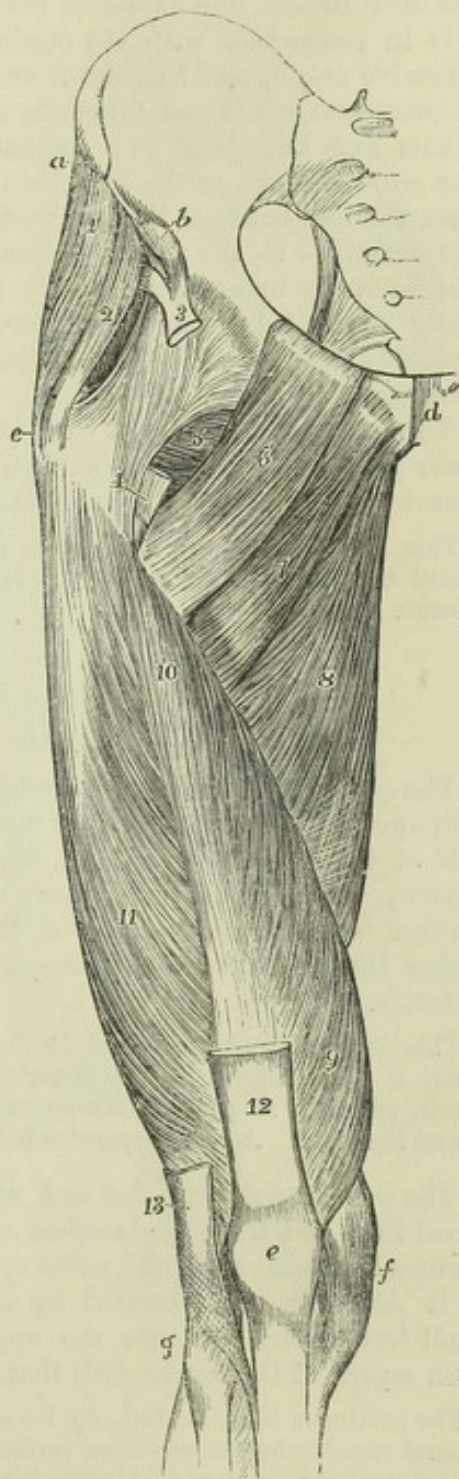
Fig. 211.—DEEP MUSCLES OF THE RIGHT THIGH IN FRONT.  $\frac{1}{2}$

*a*, anterior superior, and *b*, anterior inferior spinous process of the ilium; *c*, outer and upper part of the great trochanter; *d*, symphysis pubis; *e*, patella; *f*, inner side of the knee-joint and internal lateral ligament; *g*, head of the fibula and outer side of the knee-joint; 1, front of the gluteus medius; 2, front of the gluteus minimus, separate in this case from the medius; 3, tendon of the rectus, dividing above into its two portions, one proceeding from the inferior spine of the ilium, the other passing back over the upper border of the acetabulum; 4, on the lower part of the anterior inter-trochanteric line and at the lower end of the ilio-femoral part of the capsular ligament, points by a line to the cut tendon of insertion of the ilio-psoas muscle; 5, part of the obturator externus and quadratus femoris; 6, pectineus; 7, part of the adductor brevis; 8, adductor magnus; 9, vastus internus; 10, crureus; 11, vastus externus; 12, tendon of the rectus; 13, lower part of the slip of the fascia lata by which the tensor vaginæ femoris is inserted into the tibia and fibula.

Superiorly this muscle is overlaid by the tensor vaginæ femoris, iliacus, and sartorius muscles; further down it is covered only by fascia. The acetabular tendon lies beneath the gluteus minimus.

*b*. The *vastus externus* arises by an extensive aponeurosis attached to the base of the great trochanter in front, and to a ridge on its outer side, also to the line extending from that process to the linea aspera, and to the outer border of the linea aspera itself; the aponeurosis is prolonged on the surface of the muscle and gives origin to numerous muscular fibres: further it arises along the line which passes from the linea aspera to the external condyle in its upper two-thirds, by means of muscular fibres attached to the inter-muscular septum lying between it and the short head of the biceps. The superior fibres descend perpendicularly, the lowest are nearly horizontal, and the muscle, forming an expanded sheet applied to the surface of the crureus, is inserted by a broad flat tendon into the tendon of the rectus muscle, the patella, and the fascia lata on the front and side of the knee-joint.

Fig. 211.





*c, d.* The *vastus internus* and *crureus* consist of different sets of fibres, which are very closely united. The *vastus internus* arises from a line which descends upon the femur at some distance in front of the small trochanter, and which unites the anterior inter-trochanteric line to the inner line diverging from the *linea aspera*; from the lower half of that inner line, and from the inner lip of the *linea aspera*; as well as from the fibrous partition attached to the line extended between the *linea aspera* and the inner condyle in connection with the tendon of the adductor magnus. From this extensive origin, and likewise from the inner surface of the bone, the fibres proceed downwards and forwards, and terminate on the inner surface of the patella and knee-joint in a manner similar to those of the *vastus externus*. The *crureus* arises on the anterior and outer surfaces of the femur, reaching from the line between the trochanters to within a few inches of the patella, and outwards to the *vastus externus*. Its fibres are vertical, and are overlaid inferiorly by an aponeurosis; and the muscle is inserted by tendon and fleshy fibres into the upper border and sides of the patella, being inseparably blended with the insertions of the other parts of the quadriceps extensor.

The *subcrureus* is a small band of muscular fibres, which extends from the lower part of the anterior surface of the femur to the upper part of the synovial membrane of the knee-joint, on which it ends in scattered fibres.

This little muscle is placed beneath the *crureus* muscle, and in some cases it is united with that muscular mass. It is not unfrequently double, or consists of two separate bundles.

#### INTERNAL FEMORAL REGION.

##### (Adductor Muscles.)

The *gracilis* or *adductor gracilis* muscle, long and slender, arises by a thin aponeurosis from the inner margin of the pubic bone, along the lower half of the symphysis and the upper part of the pubic arch. The lower tendon, which is at first round, is inserted by a flattened and expanded portion into the inner side of the tibia, on the same plane with, but higher than the semitendinosus, and under the expanded tendon of the *sartorius*.

This slender muscle is covered by the fascia lata, except in a small part inferiorly, where it is overlapped by the *sartorius*; the deep surface rests against the adductor brevis, adductor magnus, semimembranosus, and the knee-joint with the internal lateral ligament. A bursa separates it from that ligament.

The *pectineus* muscle, flat and nearly quadrangular, arises from the pectineal line, and from the surface of bone in front of it, between the ilio-pectineal eminence and the pubic spine. Inclining outwards and backwards as it descends, it is inserted by a flat tendon into the femur behind the small trochanter, and into the upper part of the line which connects the *linea aspera* of the femur with that prominence.

The *pectineus* is in contact, by its anterior surface, with the fascia lata and the femoral vessels; by the posterior surface, with the obturator vessels and nerve, and the external obturator and adductor brevis muscles. By the outer border it touches the *psoas magnus*; by the inner border, the adductor longus.

The *adductor longus*, a flat triangular muscle, internal to the *pectineus*, and lying in the same plane, arises by a short tendon from the body of the pubes below the crest and near the angle, and is inserted into the inner



margin of the linea aspera in its whole length, between the vastus internus and the adductor magnus.

Fig. 212.—SUPERFICIAL MUSCLES OF THE INNER SIDE OF THE THIGH, AND MUSCLES ON THE INNER WALL OF THE PELVIS.  $\frac{1}{2}$

1, iliacus muscle; 2, part of the psoas magnus muscle; 3, obturator internus, with its fibres converging towards the lesser sciatic foramen; 4, piriformis, with three heads of origin, and its fibres converging towards the great sciatic foramen; 5, a part of the lumbar aponeurosis covering the erector spinæ muscle; 6, gluteus maximus; 7, sartorius, 7', its tendon inserted below the tuberosity of the tibia; 8, a part of the adductor longus; 9, gracilis, 9', its insertion passing below that of the sartorius; 10, part of the adductor magnus; 11, semimembranosus; 12, semitendinosus, 12', its insertion, and between 9' and 12' the tendon of the semimembranosus passing to its insertion in the inner tuberosity of the tibia.

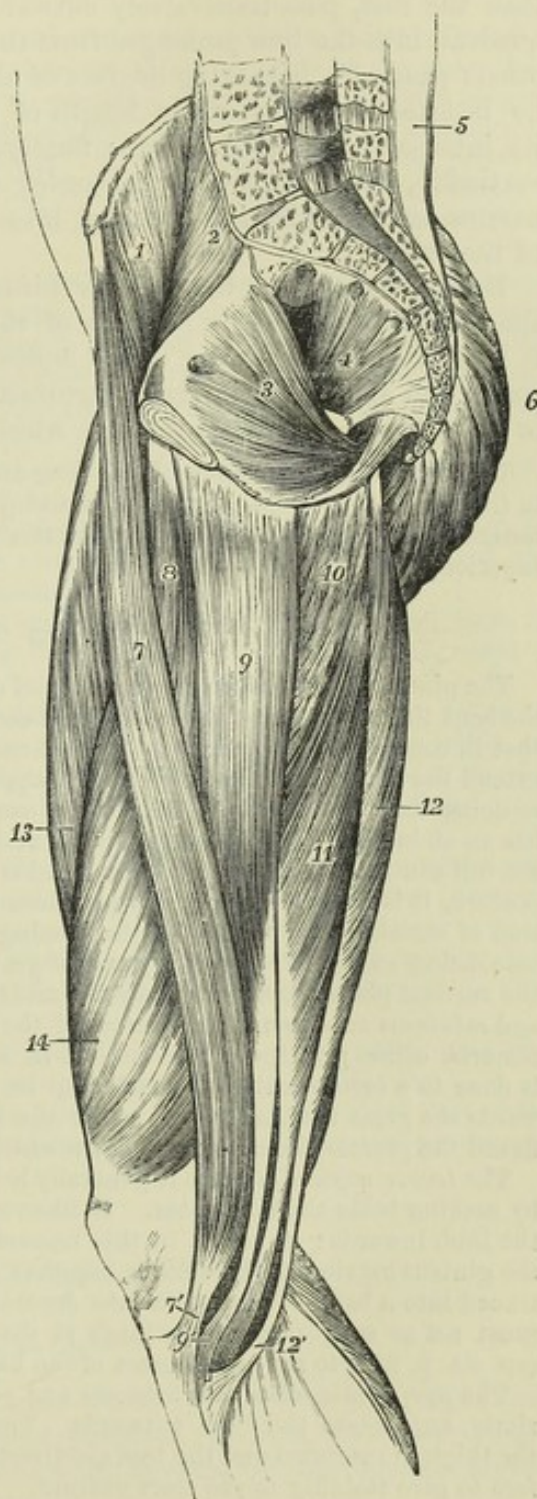This muscle is covered by the fascia lata, the sartorius, and the femoral vessels; the posterior surface rests superiorly on the adductor brevis, and inferiorly on the adductor magnus. Externally it is separated by a small interval from the pectineus, and internally it is in apposition with the gracilis.

The *adductor brevis*, thick above and broad below, arises by a narrow origin, about two inches deep, in contact with that of the gracilis, from the anterior surface of the body, and the descending ramus of the pubes; directed obliquely backwards and outwards it is inserted by a flat tendon into the whole of the oblique line leading from the small trochanter of the femur to the linea aspera, immediately behind the insertion of the pectineus.

The adductor brevis is concealed at its origin by the adductor longus and at its insertion in part by the pectineus; it rests on the adductor magnus, and by its deep surface is in contact superiorly with the obturator externus.

The *adductor magnus* muscle arises from a part of the body of the pubes

Fig. 212.





external to the lower part of the origin of the adductor brevis, from the rami of the pubes and ischium, and from the tuberosity of the ischium near the pubic arch. The muscular fibres diverge from their origin, somewhat like the ribs of a fan from their central pivot; those from the pubes, shorter than the rest, pass transversely outwards, and are inserted below the linea quadrati into the line prolonged from the linea aspera to the great trochanter; others pass with increasing degrees of obliquity downwards and outwards, to be inserted into the whole length of the linea aspera, and into a part of its internal bifurcation below; finally, some of the fibres descend almost vertically, forming the inner border of the muscle, and terminate in a narrow tendon, which is inserted into the tuberosity of the inner condyle of the femur.

Below the level of the inferior bifurcation of the linea aspera, between the tendinous and fleshy portions of the insertion of the muscle, an interval is left for the transmission of the femoral vessels backwards into the popliteal space, and along the femoral attachment the insertion is interrupted by three or more tendinous arches through which pass the perforating arteries.

This muscle is in contact with the long and short adductors and the vastus internus in front, with the hamstring muscles and gluteus maximus behind, with the gracilis muscle internally, and with the obturator externus and quadratus femoris muscles superiorly.

#### ACTIONS OF THE MUSCLES OF THE HIP AND THIGH.

The *gluteus maximus* muscle is the chief extensor of the hip-joint. By means of it the bent thigh is brought into a line with the body; but its most important action, and that in connection with which it is so largely developed in the human subject, is to extend the trunk upon the thigh when supported on the ground by the limbs, and in so doing the muscles of both sides act in combination. The upper part of the muscle has an abducting, and the lower part an adducting power upon the limb. Although the full contraction of the *glutei maximi* is required to bring the body into the erect posture, it is not necessary for its maintenance, that being effected chiefly by the tension of certain ligaments and fasciæ passing over the joints, and the body in that posture being so poised that the centre of gravity of the trunk is placed slightly behind the vertical plane passing through the middle of the hip-joints. The *gluteus medius* and *minimus* are powerful abductors of the thigh, and along with the tensor vaginae femoris, come principally into action in supporting the body on one limb, which is done to a certain extent in each step in walking. Their anterior fibres draw forwards the great trochanter, and rotate the limb inwards, and the more the thigh is flexed the greater the number of fibres which will exercise this action.

The *tensor vaginae femoris* is generally held to assist the action of the other muscles by making tense the fascia lata. It likewise aids the preceding muscles in rotating the limb inwards: its action in this respect is exactly opposed by the upper fibres of the *gluteus maximus*, which fibres, together with the tensor vaginae femoris, being continued into a band of the fascia lata descending to the outer tuberosity of the tibia, must act as supporters of the thigh at the knee-joint, and are considered by Meyer (op. cit. p. 222) to act as extensors of the knee.

The *pyriformis*, *obturator internus* and *gemelli* muscles support the hip-joint posteriorly, and rotate the limb outwards. Their greatest contraction is admitted when the thigh is extended and the toes are directed outwards; they may be supposed therefore to give stability to the erect posture.

The *quadratus femoris* is partly an adductor and partly a rotator outwards. This muscle, as well as the *pyriformis*, *obturator internus* and *gemelli*, and *obturator externus*, come to be extensors when the thigh is strongly flexed.

The *obturator externus* has its origin and insertion most approximated when the thigh is flexed, adducted, and rotated outwards, as is the case in the uppermost of the two limbs when we cross the knees in sitting. It supports the hip-joint posteriorly and inferiorly, and is a rotator outwards.



The *ilio-psoas* muscle, the flexor of the hip-joint, flexes the thigh on the body, or the body on the thigh, according as either of these is the most fixed.

The *pectineus* is partly a flexor and partly an adductor.

The *adductores magnus, longus* and *brevis* adduct the thigh, and along with their opponents the *gluteus medius* and *minimus*, and with the *gluteus maximus*, balance the body on the femur in walking.

The *adductor* muscles and *ilio-psoas*, together with the *pectineus*, being all inserted at the back part of the femur, tend to rotate the thigh outwards at the same time that they produce their adducting and flexing actions. The advantage of this preponderance of rotators outwards over rotators inwards becomes apparent by reference to the movements which take place in walking. When a step is taken, the pelvis is drawn forwards on that side on which the foot has been advanced, which involves a considerable rotation of the pelvis outwards at the other hip-joint, by the action of the muscles of the opposite limb.

The *quadriceps extensor femoris* extends the knee-joint, but, as already mentioned with regard to the *gluteus maximus*, its action is not requisite for the maintenance of the erect attitude, the knee-joint remaining in complete extension without muscular aid while the foot is firmly planted on the ground. This may be tested by the fact that the patella of a person standing with the knee extended will be found to lie quite loosely, but will become at once fixed when it is attempted to lift the foot.

The *rectus femoris*, *sartorius*, *gracilis*, *semitendinosus*, *semimembranosus*, and long head of the *biceps* act on both the hip and knee-joints.

The *sartorius* produces the flexion of the hip and knee-joints, accompanied by abduction, which occurs in the posture assumed by the tailor in sitting, and the muscle derives its name from this circumstance.

The *rectus femoris* flexes the hip and extends the knee; it acts wholly from its anterior head of origin when the thigh is fully extended, and the posterior head is alone tense when the thigh is bent.

The *hamstring muscles* extend the hip and flex the knee. It is to be observed, however, that in the ordinary movements of the body, the hip and knee-joints are flexed and extended together, and that therefore the joint on which those long muscles act must be determined by the other muscles which pass over either of those joints separately.

The *gracilis* acts as an adductor on the hip-joint. The *gracilis*, *semitendinosus*, and *sartorius* muscles form the group of rotators inwards at the knee-joint; they act along with the *popliteus* in this respect to greatest advantage in the flexed state of the knee; but they likewise favour the commencement of flexion by undoing that rotation inwards of the femoral condyles on the tibia by which extension of the knee is completed.

The short head of the *biceps* is the only flexor of the knee, which passes over that joint alone. The whole of this muscle produces external rotation of the leg.

The *subcrureus* in extension of the knee-joint probably raises the upper part of the synovial membrane, and prevents it from being pressed between the patella and femur.

## MUSCLES OF THE LEG AND FOOT.

### ANTERIOR REGION.

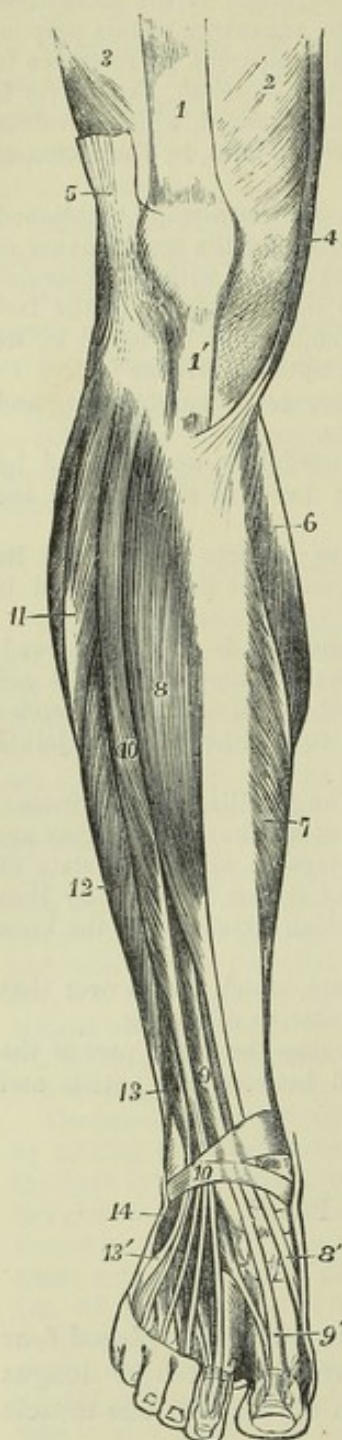
Between the tibia and fibula, on the front of the leg, are placed four muscles—the *tibialis anticus*, *extensor proprius pollicis*, *extensor longus digitorum*, and *peroneus tertius*; and on the dorsum of the foot one muscle only arises,—the *extensor brevis digitorum*.

The *tibialis anticus* arises from the external tuberosity of the tibia, and about two-thirds of the outer surface of that bone; from a small portion of the adjoining interosseous ligament; from the strong fascia of the leg; and from an aponeurotic septum placed between it and the *extensor longus digitorum*. The tendon in which all the muscular fibres terminate before



it reaches the bend of the ankle, glides in a synovial sheath beneath the anterior annular ligament, and is inserted into the inner and lower part of the internal cuneiform and the contiguous extremity of the first metatarsal bone, dividing slightly into two slips as it descends.

Fig. 213.

Fig. 213.—MUSCLES OF THE LOWER LEG AND FOOT FROM BEFORE.  $\frac{1}{2}$ 

1, tendon of the rectus femoris; 1', ligamentum patellæ; 2, the lower part of the vastus internus; 3, lower part of the vastus externus; 4, lower part of the sartorius; 5, small portion of the fascia lata cut near the place of its insertion at the knee; 6, inner head of the gastrocnemius; 7, inner part of the soleus; 8, tibialis anticus; 8', its tendon near the insertion; 9, part of the extensor longus pollicis; 9', its tendon; 10, extensor communis digitorum longus; 10', placed on the anterior annular ligament over the place of passage of the four tendons of the extensor communis; 11, peroneus longus; 12, peroneus brevis; 13, peroneus tertius; 13', tendon of the peroneus tertius at its insertion; 14, origin of the extensor communis digitorum brevis, the first head of which is seen passing to the great toe near the line from 9'.

The *extensor proprius pollicis*, placed between the tibialis anticus and the extensor longus digitorum, arises from the middle three-fifths of the anterior narrow part of the inner surface of the fibula, and from the contiguous portion of the interosseous ligament for the same extent. The fleshy fibres run obliquely forwards into a tendon placed at the anterior border of the muscle; and the tendon, after passing beneath the upper, and through the lower portion of the annular ligament in a distinct compartment, and along the dorsum of the foot, is inserted into the base of the terminal phalanx of the great toe. A delicate expansion given off from the tendon on each side spreads over the joint between the metatarsal bone and the first phalanx.

This muscle is partly concealed by those between which it is placed. It lies external to the anterior tibial artery in the leg, but crosses in front of that vessel at the bend of the ankle, and is internal to it on the foot.

The *extensor longus digitorum pedis*, is situated in contact with the tibialis anticus above, and between the extensor proprius pollicis and peroneus tertius below; it arises from the external tuberosity of the tibia;

from the head and the anterior narrowed part of the inner surface of the fibula in front of the interosseous membrane, for about three-fourths of its length; from a small part of the interosseous ligament at its upper part; also from the aponeurotic septa intervening between it and the muscles on



each side, and from the fascia of the leg. The fleshy fibres from this extensive origin pass obliquely into a tendon placed on the anterior part of the muscle. This subsequently divides into four slips, which descend through the lower part of the annular ligament, in the same sheath as the peroneus tertius, and on the dorsum of the foot pass respectively to the four outer toes. Not unfrequently the slip belonging to the fifth toe is separated with that of the peroneus tertius from the rest considerably higher up. The three inner tendons are each joined at the outer side, on the first phalanx, by a tendon from the extensor brevis digitorum: all the four tendons are continued into expansions, which are joined on the first phalanx by tendinous processes from the lumbricales and interossei muscles, and have their middle fibres inserted into the second phalanx; while their lateral parts unite together and are inserted on the third, in a manner exactly similar to the arrangement of the extensor tendons on the fingers.

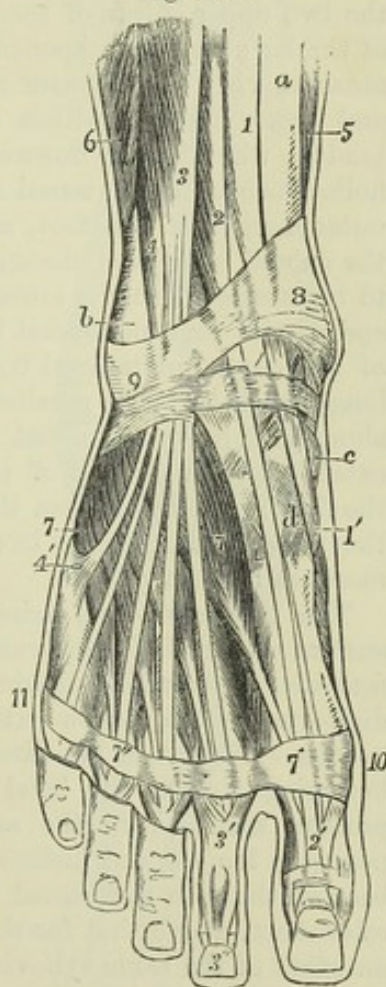
Fig. 214.—SUPERFICIAL MUSCLES AND TENDONS ON THE DORSUM OF THE FOOT AND LOWER PART OF THE LEG ANTERIORLY (after Bourguery).  $\frac{1}{3}$

*a*, lower part of the tibia; *b*, lower part of the fibula above the malleolus externus; *c*, inner side of the scaphoid bone; *d*, internal cuneiform bone; 1, lower part of the tibialis anticus muscle; 1', its tendon descending in the groove of the internal cuneiform bone; 2, extensor longus pollicis; 2', its expansion on the dorsum of the great toe; 3, extensor communis digitorum dividing into its four tendons for the toes; 3', the expansion, and 3'', the final insertion of the same upon the second toe; 4, peroneus tertius; 4', its expanded insertion on the base of the fifth metatarsal bone; 5, small part of the fibres of the soleus on the inner side of the tibia; 6, small part of the peroneus brevis; 7, extensor brevis digitorum, seen below the tendons of the extensor longus and peroneus tertius; 7', 7'', on a band of aponeurosis crossing the toes, the first and fourth tendons of the extensor brevis muscle passing to join those of the long extensor; 8, 9, anterior annular ligament, chiefly in its lower part, or ligamentum cruciatum; between 8 and *c*, the inner and lower band enclosing the extensor longus pollicis and tibialis anticus; below 9, the outer part of the same enclosing the tendons of the extensor communis and peroneus tertius; 10, 11, dorsal transverse band of the aponeurosis of the foot, uniting the heads of the metatarsal bones.

The *peroneus tertius* arises, in continuity with the lower part of the extensor longus digitorum, from the lower fourth of the inner surface of the fibula, from the lower part of the interosseous membrane, and from an aponeurosis which connects it on the outer side with the peroneus brevis. The muscular fibres end in a tendon, which, after passing through the annular ligament with the long extensor of the toes, is inserted into the upper surface of the base of the fifth metatarsal bone, and likewise in some instances into the fourth.

There is often scarcely any line of demarcation between the two preceding muscles. The peroneus tertius is sometimes as large as the extensor longus digitorum, sometimes its tendon is as large as those of that muscle combined; it has been observed to terminate on the fourth metatarsal bone; and it is sometimes altogether wanting.

Fig. 214.





Five tendons are ascribed to the extensor longus digitorum by Cowper (Myot. Reform., c. 36, p. 111), the peroneus tertius having been considered by him as part of that muscle, a view which is in some degree warranted by the form which it usually presents.

The *extensor brevis digitorum pedis* arises from the outer surface of the os calcis in front of the groove for the peroneus brevis muscle, and from the lower band of the anterior annular ligament. It divides into four tapering slips each of which terminates in a tendon; the first or most internal of these, sometimes reckoned as a distinct muscle, is inserted separately into the dorsal surface of the first phalanx of the great toe near its tarsal extremity; and the other three become severally united to the outer border of the extensor tendons proceeding to the three next toes.

#### EXTERNAL REGION.

The *peroneus longus* arises from the head of the fibula, and from more than the two upper thirds of the external surface of that bone; from the fascia of the leg; and from aponeuroses interposed between it and the contiguous muscles, viz., the extensor communis digitorum on one side, and the soleus and flexor longus pollicis on the other. It ends above the ankle in a tendon, which passes downwards behind that of the peroneus brevis in the hollow behind the external malleolus, and inclining forwards, turns over the outer margin of the foot, and enters the excavation on the lower surface of the cuboid bone, and changing its direction, proceeds inwards and forwards to be inserted into the lower part of the internal cuneiform and the tarsal end of the first metatarsal bone: an offset is continued from it to the base of the second metatarsal bone. In this course the tendon of the peroneus longus muscle, lying parallel with that of the peroneus brevis, is invested along with it by a synovial membrane, and bound down by a fibrous band extended from the end of the fibula to the calcaneum; on the outer side of the foot it separates from the peroneus brevis, and in the sole of the foot the peroneus longus lies in a synovial sheath formed by fibres of the ligamentum longum plantæ.

The *peroneus brevis* arises from the two lower thirds of the external surface of the fibula, internal to the peroneus longus, and from the intermuscular septa which dip down in front between it and the extensor longus digitorum and peroneus tertius, and behind between it and the flexor longus pollicis. The fibres are directed to a tendon on their outer surface, which becoming free at the level of the external malleolus, passes behind that process, sheathed in the same synovial membrane as the tendon of the peroneus longus, and inclining forwards is inserted into the projection at the base of the fifth metatarsal bone, having traversed a separate sheath on the calcaneum, above that for the tendon of the peroneus longus, but lined by an offset of the same synovial membrane.

#### POSTERIOR REGION.

The muscles at the back of the leg consist of a superficial group inserted into the extremity of the calcaneum, and a deeper group covered in by a deep fascia and descending to the sole.

The *superficial group* consists of three muscles; two of them, placed one on the surface of the other, are of large size, the *gastrocnemius* and *soleus* (extensor tarsi suralis vel extensor magnus,—Douglas; musculus suræ,



Scemmering), form the bulk of the calf of the leg, and are inserted into the heel by a common tendon—the tendo Achillis; the third, a small muscle, the *plantaris*, descends between the other two.

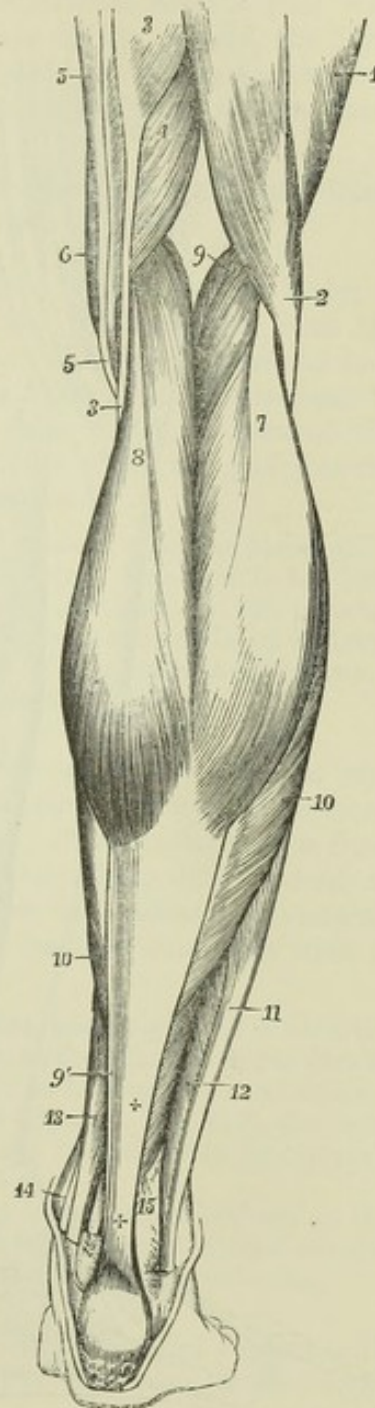
The *gastrocnemius* muscle arises by two thick tendinous heads from the condyles of the femur, and ends below in the tendo Achillis. The

Fig. 215.—SUPERFICIAL MUSCLES OF THE LOWER LEG, SEEN FROM BEHIND (after Bourguery).  $\frac{1}{2}$ .

1, lower part of the vastus externus; 2, tendon of the biceps flexor cruris, passing to its insertion in the fibula; 3, lower part and tendon of the semitendinosus; 4, lower part of the semimembranosus: its tendon is seen between 3 and 5 passing to its insertion in the tibia; 5, gracilis; 6, small part of the sartorius; 7, outer, and 8, inner head of the gastrocnemius on the tendinous part of the calf of the leg; 9, placed in the popliteal space, points to the muscular part of the plantaris; 9', its thin tendon inside the tendo Achillis; 10, the fibres of the soleus descending to the flat tendon, which, joining with that of the gastrocnemius, forms + + the tendo Achillis; 11, lower part and tendon of the peroneus longus; 12, lower fibres of the peroneus brevis, both passing behind the malleolus externus below; 13, lower part of the flexor longus digitorum; 14, small part of the tendon of the tibialis posticus, which, along with 13, descends behind the malleolus internus; 15, is placed near the lower part of the fibula, and points to the lower fibres of the flexor longus pollicis, the tendon of which is seen descending over the tibia at 15'.

outer tendon of origin is attached in an oblique line to a depression on the outer side of the external condyle, above the groove for the popliteus muscle. The inner tendon is attached in a horizontal line to an impression above the back part of the internal condyle, and along with it are fleshy fibres connected for a short distance with the ridge running to the linea aspera. The muscular fibres descending from the two heads remain separated by a vertical groove on the surface, but those next the middle meet at an angle on a tendinous structure below. The fibres of the superior tendons spread out upon the surface of the muscle; the inferior tendon lies on the deep surface of the muscular mass, and is continued upwards in a thin aponeurosis with parallel fibres, which glide against the soleus: between the superficial tendon of each head and the deep common tendon, the greater number of the muscular fibres run obliquely downwards and forwards. The lower edge of each muscular part presents a convexity downwards; the inner descending furthest. A synovial membrane, usually communicating with the knee-joint, lies beneath the inner head of origin, and separates it from

Fig. 215.





the tendon of the semimembranosus muscle. A sesamoid fibro-cartilage is sometimes met with over the outer condyle of the femur, and occasionally over the inner: it is rarely ossified.

The heads of the gastrocnemius muscle form the inferior boundaries of the popliteal space, and are placed between the hamstring muscles: the peroneal nerve is lodged between the external head and the biceps. The gastrocnemius conceals the

popliteus muscle, with the popliteal vessels and internal popliteal nerve lying on its surface; the plantaris and soleus are also covered by it. The short saphenous vein is placed on its surface, in the interval between its two parts.

Fig. 216.

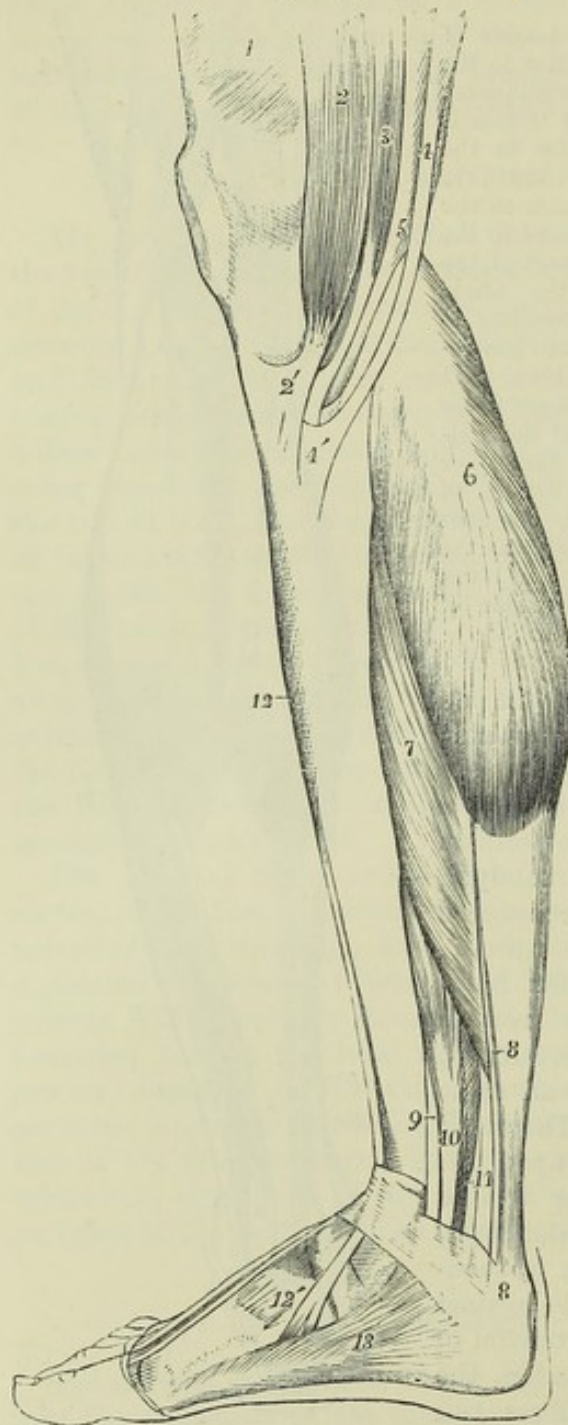


Fig. 216.—SUPERFICIAL MUSCLES OF THE LEG, SEEN FROM THE INNER SIDE (after Bourguery).  $\frac{1}{2}$

1, part of the vastus internus; 2, sartorius; 2', its flat tendon, spreading on the inner upper part of the tibia; 3, gracilis; 4, semitendinosus; 4', its insertion; and between 2' and 4', that of the gracilis; 5, semimembranosus; 6, inner head of the gastrocnemius; 7, soleus; 8, 8', placed upon the tendo Achillis, point to the small tendon of the plantaris descending on the inner side; 9, small part of the tendon of the tibialis posticus; 10, flexor communis digitorum; 11, points to a portion of the flexor longus pollicis, sunk in shadow; 12, a narrow part of the tibialis anticus; 12', on the internal cuneiform bone, above the divided tendon of insertion of the tibialis anticus; 13, abductor pollicis; there are also shown in this part of the figure the connection of the abductor posteriorly with the internal annular ligament and os calcis, and the manner in which the internal annular ligament forms a retinaculum for the tendons of the muscles of the leg as they descend.

The *soleus* muscle arises externally from the posterior part of the head of the fibula, and from the surface beneath it for a third of the length of the bone; internally from the oblique line which gives insertion to the popliteus, and from the posterior edge of the tibia about three inches below that line;

also in the space intermediate between the tibia and fibula, from a tendinous band extended from one bone to the other over the posterior tibial vessels and nerve. Inferiorly the muscular fibres descend upon the tendo



Achillis considerably further than those of the gastrocnemius. The posterior surface presents a thin covering of longitudinal aponeurotic fibres continued up from the tendon below, and gliding on the similar tendinous surface of the gastrocnemius muscle. On the deep surface the edges of two membranous tendons, the other edges of which look towards the middle line of the muscle, imbedded in its substance, are seen descending from the tibial and fibular origins: the fibres from the deep aspects of those tendons are directed obliquely inwards to a tendinous septum which divides the muscle into lateral halves; while those from their superficial aspects pass with similar obliquity to the flat tendon on the surface of the muscle, the fibres placed at the sides forming the lateral borders and part of the deep surface of the muscle. Thus the soleus is composed entirely of short oblique fibres of from one to two inches in length.

The soleus rests upon the flexor longus pollicis, flexor longus digitorum and tibialis posticus muscles, together with the posterior tibial vessels and nerve.

The *tendo Achillis*, the thickest and strongest tendon in the body, is formed by the union of the flat tendon of the gastrocnemius with the thicker and more rounded tendon of the soleus. It is from three to four inches long below the point where the muscular fibres of the soleus cease to be attached to it. It is inserted inferiorly into the back part of the tuberosity of the os calcis. Between the upper part of the tuberosity of the os calcis and the tendon a synovial bursa is interposed.

The gastrocnemius is, in some cases, joined by a bundle of muscular fibres, which arises separately from the femur above one of the condyles. This bundle has been observed passing between the popliteal artery and vein (R. Quain, op. cit. plate 80, figs. 4 and 5). To the soleus an accessory portion is occasionally added at its lower and inner part; this usually ends on the inner side of the *tendo Achillis*, but it sometimes forms a tendon, attached separately to the os calcis.

The *plantaris* arises from the femur immediately above the external condyle, and from the posterior ligament of the knee-joint, where this is covered by the corresponding head of the gastrocnemius; its muscular part is from three to four inches in length, and terminates in a long delicate tendon, which inclines inwards between the gastrocnemius and soleus, and running along the inner border of the *tendo Achillis* is inserted conjointly with it into the posterior part of the calcaneum.

The designation by which this little muscle is known was assigned to it when the tendon was believed to terminate in the plantar fascia, as the palmaris longus does in the fascia of the hand. It was so described by Galen; and, though the real manner of termination was correctly pointed out by Vesalius (Oper. 1, 2, p. 419), the error was continued through many succeeding works, and is to be found even in Cowper's "Myotomia Reformata" (p. 105).

The *plantaris* varies in its mode of termination; it is sometimes enclosed in the lower part of the *tendo Achillis*; and, in other cases, it ends in the internal annular ligament, which binds down the tendons and vessels behind the inner malleolus.

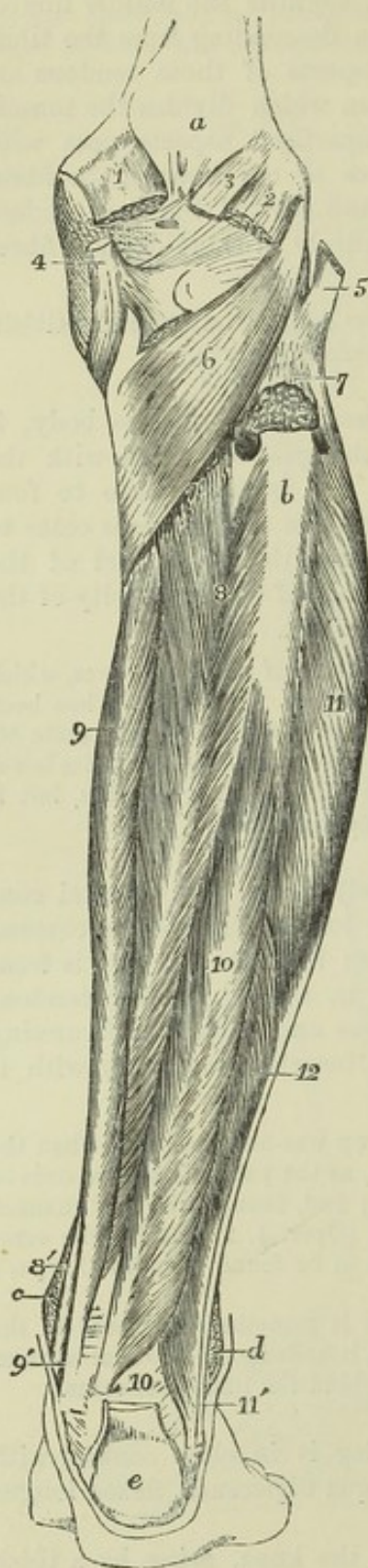The *deep group* of posterior muscles of the leg is in close contact with the bones; it consists of the popliteus, flexor longus digitorum, flexor longus pollicis and tibialis posticus.

The *popliteus*, an oblique muscle placed below the knee, arises by a thick tendon, about an inch in length, from the fore part of the popliteal groove on the outer side of the external condyle of the femur, within the external lateral ligament and capsule of the knee-joint; it is in contact with the



external semilunar cartilage, and receives additional fibres from the posterior ligament of the joint. The muscular fibres diverge as they pass downwards,

Fig. 217.

Fig. 217.—DEEP POSTERIOR MUSCLES OF THE LEG.  $\frac{1}{4}$ 

*a*, popliteal surface of the femur; *b*, bare surface of the upper fourth of the fibula, from which the soleus muscle has been removed; *c*, malleolus internus; *d*, malleolus externus; *e*, tuberosity of the os calcis, with the tendo Achillis inserted into it, and the plantaris on its inner side; 1, inner head of the gastrocnemius cut short at its origin; 2, outer head; 3, plantaris; 4, tendon of the semimembranosus muscle near its insertion, seen spreading in three portions, viz., to the inside of the tibia, towards the popliteal fascia, and towards the ligamentum posticum; 5, tendon of the biceps inserted into the head of the fibula; 6, popliteus muscle; 7, upper part of the origin of the soleus from the fibula, cut short; 7', line of its tibial origin; between these figures is seen the perforation in the upper part of the interosseous membrane; 8, tibialis posticus; 8', its tendon, passing between the flexor digitorum communis and the tibia; 9, flexor digitorum communis; 9', its tendon, with that of the tibialis posticus, passing behind the malleolus internus; 10, flexor longus pollicis; 10', placed beside its tendon, where it passes over the tibia and astragalus; 11, peroneus longus; 11', its tendon behind that of the peroneus brevis, passing down behind the malleolus externus; 12, peroneus brevis.

and are inserted into all that triangular surface of the tibia which is above the posterior oblique line.

The tendon of the popliteus muscle occupies the groove on the femur in flexion only.

The popliteus is bound down by an aponeurosis, principally derived from the tendon of the semimembranosus muscle. The popliteal vessels and internal popliteal nerve lie upon its posterior surface, and it is covered by the gastrocnemius muscle.

The three remaining muscles of this group are bound down together by a deep fascia, which extends between the tibia and fibula, and separates them from the soleus.

The *flexor longus digitorum pedis*, or *flexor perforans*, arises from the posterior surface of the tibia, in the space below the oblique line, and as far down as within three inches of the inner ankle; it likewise arises by aponeurotic fibres connected with the flexor longus pollicis, which pass over the surface of the

tibialis posticus. The fleshy fibres pass obliquely backwards into a tendon



at the posterior aspect of the muscle. The tendon descends in the groove behind the internal malleolus, superficial to the *tibialis posticus*, and invested by a distinct fibrous and synovial sheath; it is then directed under the arch of the *os calcis*, obliquely forwards and outwards, into the sole of the foot, where it crosses below the tendon of the *flexor longus pollicis*, and is connected with it by a tendinous slip; it then divides into four parts, which pass forwards to be inserted into the terminal phalanges of the four smaller toes. Each digital tendon enters a fibrous sheath on the toe for which it is destined, perforates the corresponding tendon of the *flexor brevis digitorum*, and is invested with synovial membrane, and connected by *vincula accessoria* to the phalanges; the whole arrangement being exactly similar to that which has been already described as occurring in the fingers.

The posterior tibial vessels lie upon the surface of the *flexor longus digitorum*.

Intimately connected with the tendon of the *flexor longus digitorum* are the *flexor accessorius* and the *lumbricales* muscles, which, although they occupy the foot, may be most conveniently described in this place.

The *flexor accessorius* (*moles carnea*—Sylvius) arises by two heads, the internal and larger of which is fleshy, and is attached to the inner surface of the *calcaneum*, while the external, flat, narrow and tendinous, is attached to the plantar surface of the *calcaneum* a little in front of the external tubercle, and to the *ligamentum longum plantæ*. Those origins united form a muscular mass which is inserted into the external border and upper and lower surfaces of the tendon of the *flexor longus digitorum*.

Fig. 218.—MIDDLE LAYER OF THE PLANTAR MUSCLES OF THE FOOT, TOGETHER WITH THE TENDONS OF THE LONG FLEXORS AND THE ACCESSORIUS AND LUMBRICALES MUSCLES.  $\frac{1}{4}$

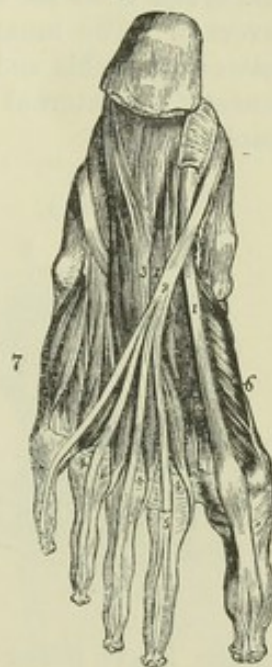1, tendon of the *flexor longus pollicis* muscle, emerging behind from its sheath below the *sustentaculum tali*, and passing deeper than, 2, the tendons of the deep common flexor; 3, two heads of the *flexor accessorius*; 4, the four *lumbricales*; 5, tendon of the *flexor brevis* cut short and left on the second toe, seen splitting to allow the passage through it of the tendon of the long flexor; 6, *flexor brevis pollicis*; 7, *flexor brevis minimi digiti*; there is also represented on the outer side of the foot the tendon of the *peroneus longus* winding round the cuboid bone, to pass across the foot in its groove, where it is concealed by the *accessorius* and other muscles.

The *lumbricales* muscles, four in number, arise from the tendons of the *flexor longus digitorum* at their point of division, each being, with the exception of the most internal, attached to two tendons, and pass forward to the inner sides of the four outer toes; each muscle ends in a tendon, which is united with the base of the first phalanx, and is inserted into the expansion of the *extensor* tendon on the dorsum of the toe.

The *lumbricales* of the foot are less fully developed than those of the hand. They are liable to the same variations.

In the sole of the foot the tendon of the *flexor longus digitorum*, together with the *flexor accessorius* and *lumbricales*, is covered below by the *flexor brevis digitorum*; the plantar nerves and hinder part of the external plantar artery being placed

Fig. 218.





between them. This divided tendon, with its additional muscles, conceals the adductor pollicis, the tendon of the flexor longus pollicis, the transversus pedis, the interossei muscles, and the plantar arterial arch.

The *flexor longus pollicis pedis* arises from the two inferior thirds of the posterior surface of the fibula, except for an inch at its lowest part; from the intermuscular septum interposed between it and the peronei; and from the aponeurosis common to it and the flexor longus digitorum, and which covers the tibialis posticus.

The muscular fibres, passing obliquely backwards and downwards, end in a tendon on their posterior surface. This tendon traverses a groove behind the tibia, and another at the back of the astragalus, being bound down to those bones by fibrous and synovial sheaths. Thence passing forwards below the sustentaculum tali, it is connected, in the sole of the foot, by a tendinous slip, with the tendon of the flexor longus digitorum, by which it is crossed, and proceeds in a fibrous sheath over the first phalanx of the great toe to be inserted into the base of the terminal phalanx.

Below the ankle the tendon of this muscle is separated from those of the tibialis posticus and flexor longus digitorum by an interval of more than half an inch, in which are placed the posterior tibial vessels and nerves.

The *tibialis posticus* muscle, placed between the two long flexor muscles, arises from the whole interosseous membrane except for two inches at the lower end, and from the adjacent surfaces of the tibia and fibula, the tibial attachment extending from the superior tibio-fibular articulation to a point at a lower level than that of the flexor longus digitorum, and the attachment to the fibula extending along the three middle fifths of that bone; it also arises from the aponeurosis derived from the adjacent muscles, which covers it. The muscular fibres end in a strong flat tendon, which, passing between the tibia and the long flexor of the toes, turns forwards in a groove beneath the internal malleolus, and is inserted into the tuberosity of the scaphoid bone.

Fig. 219.

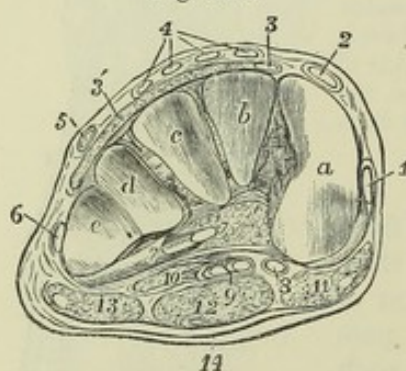


Fig. 219.—TRANSVERSE SECTION OF THE RIGHT FOOT BETWEEN THE TARSUS AND METATARSUS, SHOWING THE TENDINOUS AND APONEUROTIC STRUCTURES FROM THE FRONT.  $\frac{1}{2}$

This figure is also designed to show the transverse arch formed by the three cuneiform and the cuboid bones. *a*, articular surface of the internal cuneiform bone for the first metatarsal; *b*, the middle cuneiform; *c*, the external cuneiform; *d* and *e*, the surfaces of the cuboid bone for the fourth and fifth metatarsal bones; between these bones are seen the strong interosseous and plantar ligaments which bind them together; 1, slip of the tendon of the tibialis anticus, which passes on to its insertion in the first metatarsal bone; 2, tendon of the

extensor longus pollicis; 3, slip of the extensor brevis digitorum to the great toe; 3', remainder of the extensor brevis digitorum; 4, four slips of the extensor communis digitorum longus; 5, peroneus tertius; 6, peroneus brevis; 7, peroneus longus cut obliquely where it is emerging from the sheath below the cuboid bone; beside 7, the space between the cuneiform bones and the subjacent fasciæ and tendons is occupied by loose fatty tissue; 8, tendon of the flexor longus pollicis; 9, tendon of the flexor communis digitorum longus, with the slip of union from the flexor pollicis; 10, flexor accessorius; 11, fleshy part of the abductor pollicis; 12, flexor brevis digitorum; 13, abductor minimi digiti.



From the insertion, offsets of the tendon are prolonged forwards to all the cuneiform bones, to the os cuboides, and to the bases of the second, third, and fourth metatarsal bones; and one thin process is directed back to the sustentaculum tali. The tendon is covered by a synovial membrane behind the malleolus. Close to its insertion, where it lies against the astragalus, it contains a sesamoid fibro-cartilage, which is occasionally converted into bone.

The tibialis posticus is concealed in great part by the aponeurosis prolonged over it from the muscles on either side. Superiorly it is not covered by these muscles, and supports the posterior tibial and peroneal vessels.

#### SHORT PLANTAR MUSCLES.

**COMMON FLEXOR OF THE TOES.**—The *flexor brevis digitorum*, or *flexor perforatus*, arises by a small pointed and tendinous attachment from the inner part of the greater tuberosity of the calcaneum, from the deep surface of the plantar fascia for about two inches forwards, and from the intermuscular septum on each side. The muscle terminates in four slender tendons, inserted into the second phalanx of each of the four outer toes. Each tendon prior to its insertion divides and gives passage between its parts to the tendon of the long flexor, in a manner precisely similar to the arrangement of the tendons of the flexor sublimis and flexor profundus muscles of the hand.

This muscle lies between the abductor pollicis and abductor minimi digiti, and is covered by the plantar fascia, which adheres very closely to the posterior part of its surface, and gives origin there to some of its fibres; it conceals the flexor accessorius, with the tendons of the flexor longus digitorum, the lumbricales, and the plantar vessels and nerves.

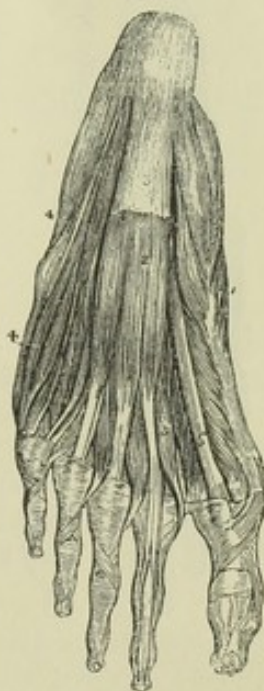Fig. 220.—SUPERFICIAL PLANTAR MUSCLES, AS SEEN ON THE REMOVAL OF THE PLANTAR FASCIA.  $\frac{1}{4}$

1, abductor pollicis; 2, flexor brevis digitorum dividing into four slips for the lesser toes: in the second, the sheath is opened so as to show the tendon of the flexor brevis perforated by that of the flexor longus; in the other three toes the transverse and oblique crossing fibres of the sheath are shown; 3, strongest portion of the plantar aponeurosis left upon the surface of the flexor brevis, near the os calcis; 4, abductor minimi digiti: the lumbricales muscles are also in part shown.

**MUSCLES OF THE GREAT TOE.**—The *abductor pollicis pedis* arises from the inner part of the larger protuberance of the calcaneum, from the internal annular ligament and the tendinous and fibrous structures on the inner border of the foot as far forwards as the internal cuneiform bone, from the septum between it and the flexor brevis digitorum, and from the plantar fascia covering it. The fleshy fibres end in a tendon, which, after uniting with the internal head of the flexor brevis pollicis, is inserted into the inner border of the base of the first phalanx of the great toe.

The *flexor brevis pollicis pedis*, single and pointed behind, but divided into

Fig. 220.





two parts or heads in front, arises by a flat tendinous process, which extends along a great part of its upper surface, from the inner border of the cuboid bone, and from the tendinous band sent to the cuneiform bones from the tendon of the *tibialis posticus*. The heads into which the muscular mass divides are intimately connected each with one of the sesamoid bones of the first metatarso-phalangeal articulation, and are inserted, one into the inner border of the base of the first phalanx in union with the *abductor pollicis*, the other into the outer border in union with the *adductor*.

The tendon of the *flexor longus pollicis* runs in the interval between the heads of the short flexor.

The *adductor pollicis pedis*, placed obliquely in the sole of the foot, and forming a thick fleshy mass, arises from the tarsal extremity of the third and fourth metatarsal bones, and from the sheath of the *peroneus longus* muscle; narrowing as it passes forwards, it is inserted, conjointly with the external head of the *flexor brevis pollicis*, into the base of the first phalanx of the great toe.

The *transversus pedis* consists of a series of narrow fasciculi of fleshy fibres, placed transversely under cover of the flexor tendons, and arising, beneath the heads of the second, third, and fourth metatarsal bones, from the ligaments connecting those bones with the phalanges. Its outer extremity is attached usually to the lateral ligament connecting the fifth metatarsal bone with the first phalanx of the little toe; but it often commences only at the fourth. The fibres of the muscle pass transversely inwards, and are inserted in union with the *adductor pollicis* into the first phalanx of the great toe.

Fig. 221.

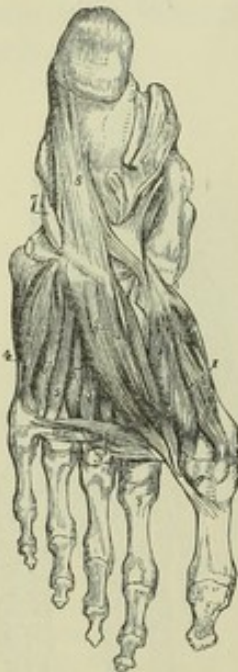

Fig. 221.—DEEPER PLANTAR MUSCLES, AS SEEN AFTER THE REMOVAL OF THE LONG FLEXOR TENDONS AND THE ACCESSORY AND LUMBRICALES MUSCLES.  $\frac{1}{4}$

1, flexor brevis pollicis; 2, adductor pollicis; 3, transversus pedis; 4, flexor brevis minimi digiti; 5, 5, part of the third and fourth dorsal interossei; 6, 6, the second and third plantar interossei; 7, tendon of the *peroneus longus* passing round the cuboid bone to enter its groove; 8, long plantar ligament passing forwards to the ridge of the cuboid bones and spreading over the groove of the *peroneus* tendon: in the upper part of the figure, on the inner side, the opened sheaths of the *flexor longus pollicis* and *flexor longus digitorum* are shown.

**MUSCLES OF THE LITTLE TOE.**—The *abductor minimi digiti* has a wide origin behind, from the front of both tubercles on the under surface of the *os calcis*, from the external intermuscular septum, and from the upper surface of the process of the plantar fascia which extends from the external tubercle to the base of the fifth metatarsal bone. The fleshy fibres end in a tendon, which, after sliding along a smooth impression on the inferior surface of the base of the fifth metatarsal bone, is inserted into the external surface of the base of the first phalanx of the little toe.

This muscle is covered by the plantar fascia. Its deep surface is in contact with



the external head of the flexor accessorius, the ligamentum longum plantæ, the peroneus longus, and the flexor brevis minimi digiti.

The *flexor brevis minimi digiti* arises by tendinous fibres from the base of the fifth metatarsal bone, and from the sheath of the peroneus longus, and terminates in a tendon which is inserted into the base and external border of the first phalanx of the little toe. It is covered partly by the abductor minimi digiti, partly by the plantar fascia.

THE INTEROSSEOUS MUSCLES of the foot, like those of the hand, are seven in number, three plantar and four dorsal; the plantar interossei, visible only from the under side, arise each from only one metatarsal bone, and their action is to approximate the toes; the dorsal muscles, visible both from above and below, arise each from two metatarsal bones, and in their action separate the toes. The arrangement of the second dorsal and first plantar interosseous muscles of the foot, in relation to the toes, is somewhat different from that of the corresponding muscles of the hand.

Fig. 222, A.—DEEP DISSECTION OF THE DORSUM OF THE FOOT, TO SHOW THE DORSAL INTEROSSEOUS MUSCLES.  $\frac{1}{4}$

1, 2, 3, 4, the several dorsal interosseous muscles: the final insertion of the extensor tendons into the phalanges of the toes is also shown in this figure, more particularly in the great toe, and the separate insertion of the tendons of the short and the long extensor.

B.—DEEP DISSECTION OF THE SOLE OF THE FOOT, TO SHOW THE PLANTAR INTEROSSEOUS MUSCLES.  $\frac{1}{4}$

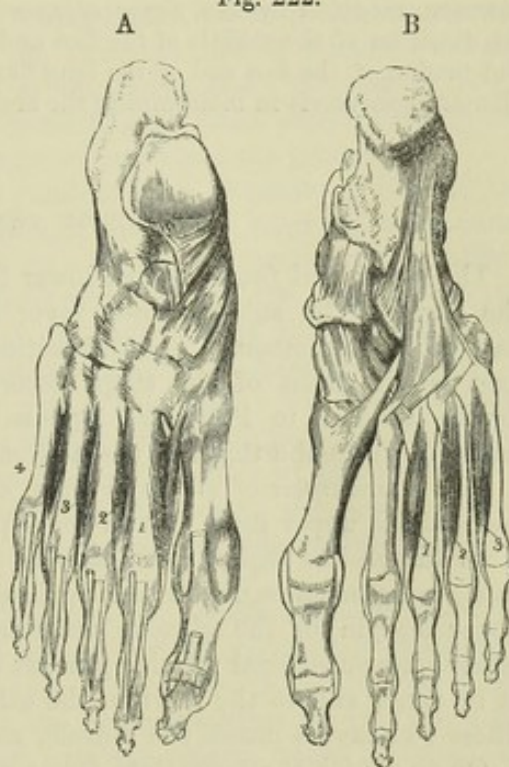
1, 2, 3, the three plantar interossei; this figure also shows the long and short plantar ligaments, and the insertion of the tendon of the peroneus longus muscle into the first metatarsal bone.

The *dorsal* interossei are arranged so as to separate the toes from the line in which the second toe rests; they lie one in each interspace, their fibres radiating pennately from a central tendon; and they terminate partly in the first phalanx and partly in the extensor aponeurosis of the toe to which each belongs. The first two are inserted one on each side of the second toe; the third and fourth are inserted on the outer sides of the third and fourth toes.

The *plantar* interossei, arranged so as to approximate the three outer toes to the second, arise from the inner and under surfaces of the third, fourth, and fifth metatarsal bones, and are inserted in a manner similar to the dorsal interossei into the inner sides of the first phalanges of the third, fourth, and fifth toes.

ACTIONS OF THE MUSCLES OF THE LEG AND FOOT.—There is only one muscle of the leg, viz., the *popliteus*, which acts on the knee-joint alone. Its principal action is that of a rotator inwards of the lower leg; and it is interesting to observe that while rotation of the leg at the knee-joint occurs only in flexion, it is in that position only that the tendon of the popliteus lies in its groove on the femur.

Fig. 222.





The *gastrocnemius* muscle acts both as a flexor of the knee and as an extensor of the foot. When the anterior muscles of the leg fix the ankle-joint, it is fitted to act as a flexor of the knee; when the knee is fixed either by being placed in complete extension or by the sustained action of the extensor muscles, the *gastrocnemius* acts entirely on the foot, and combines with the *soleus* in extending the ankle and astragalo-calcaneal joints. By the complete contraction of these muscles the heel is lifted from the ground and the body is raised on the toes. In leaping, as the limb is suddenly straightened by extension both at the knee and ankle joints, the *gastrocnemius* acts in the most advantageous manner possible on the foot, seeing that by the movement of the knee its fibres are kept stretched.

The *tibialis anticus* muscle flexes the foot upon the leg and raises its inner side: the *peroneus tertius* flexes the foot and raises its outer side: the *tibialis posticus* extends the foot and gives it an inward direction: the *peroneus longus* and *brevis* extend the foot and give it an outward direction. The *peroneus longus*, in crossing the foot inferiorly, strengthens the transverse arch formed by the metatarsal bones and anterior range of tarsal bones; especially when that arch is pressed upon by the weight of the body falling on the balls of the toes, as in stooping with bended knees.

The *flexor* and *extensor muscles* of the toes, including the *lumbricales*, act like the corresponding muscles in the hand. The direction of the *flexor longus digitorum* is, however, modified by the *flexor accessorius*, so as to bring its line of action into the direction of the middle of the foot and of the short flexor. The *flexor accessorius* and tendon of the foot and of the long flexor likewise assist the short flexor and the plantar aponeurosis in maintaining the arch of the foot.

#### FASCIAE OF THE LOWER LIMB.

The *superficial fascia* of the lower limb is similar to that of other parts of the body. The subcutaneous layer is continuous with that of the lower part of the abdomen. The disposition of the deeper and more membranous part on the front of the thigh deserves attention in respect that it is so firmly attached to Poupart's ligament as to prevent the passage of fluids under it, from the thigh to the abdomen.

The *aponeurosis of the lower limb*, or *fascia lata*, is similar to the aponeurosis of the upper limb, but in some parts much stronger.

In the *gluteal* region it is attached to the crest of the ilium, and descends as a strong membrane on the surface of the *gluteus medius*, as far as the upper margin of the *gluteus maximus* muscle; it there divides into two layers, one superficial to the *gluteus maximus*, a continuous sheet, attached at its inner end to the sacrum, the other on the deep surface of that muscle. These two layers incase the muscle, and again unite at its inferior margin.

On the *thigh* the *fascia lata* forms a continuous sheath, varying in thickness in different parts. It is strongest on the outer aspect of the limb, where its dense and glistening parallel fibres give it much the appearance of a tendinous aponeurosis, and where it serves the purpose of a tendon to the *tensor vaginae femoris*, and to a large part of the *gluteus maximus*. It is thinnest in the upper and inner part of the thigh, where it covers the adductor muscles. Near the knee, it is considerably strengthened by tendinous expansions given off from the lower termination of the extensor and flexor muscles of the knee-joint.

In front of the thigh, a little below and external to the inner end of Poupart's ligament, is placed the *saphenous opening*, an aperture in the *fascia lata* through which the internal saphenous vein passes to join the femoral vein, and which receives special attention from its being the place of exit of femoral hernia. The outer part of this opening extends to the femoral artery, and is bounded externally by a crescentic margin, the *fal-*



*ciform process*, which crosses the surface of the infundibuliform sheath of the femoral vessels. This margin in the middle of its extent is continued into looser tissue, but superiorly and inferiorly it ends in two more distinct incurved extremities, the *superior* and *inferior cornua*. The inferior cornu, the most completely defined part of the margin, lies in the angle between the internal saphenous and the femoral vein, below their junction; while the superior cornu forms a larger curve, and is bound down to the fascia of the thigh a little below and in front of Gimbernat's ligament.

It is customary to call the parts of the fascia lata which are placed external and internal to the saphenous opening the *iliac* and *pubic portions*. The iliac portion is intimately connected above with Poupart's ligament, as well as with the fascia transversalis and deep layer of the superficial fascia of the abdomen, and internally forms the falciform margin of the saphenous opening; the pubic portion, attached superiorly to the pectineal line, passes on its outer side deeply behind the sheath of the vessels, with which it is connected, and is continued into the fasciæ between the muscles.

In the natural state, the saphenous opening is filled up by the *cribriform fascia*, a thin and somewhat irregular membrane which is continuous externally with the falciform margin of the opening, and is attached internally to the surface of the pubic portion of the fascia lata: it receives its name from being perforated by numerous small blood-vessels and by the superficial lymphatics of the thigh as they pass in to join the deep group.

The fascia lata of the thigh has various deep processes. One of these, leaving the main fascia at the insertion of the tensor vaginæ femoris muscle, passes upwards within that muscle as a strong flat band on the surface of the vastus externus, and is attached superiorly round the origin of the rectus femoris, and to the tendinous arch at the insertion of the gluteus minimus muscle. Two processes, the *external* and *internal intermuscular septa*, bind the fascia to the femur in the lower part of the thigh: the external septum, situated between the vastus externus muscle and the short head of the biceps, is inserted into the linea aspera from the lower border of the tendon of the gluteus maximus to the outer condyle of the bone: the internal septum, much thinner, is inserted into the femur between the vastus internus and the adductor muscles.

*Sheaths of the Femoral Vessels.*—The femoral vessels are surrounded by an investment of fascia, which in its upper part is particularly distinct, and receives the name of the *crural sheath*. This sheath, commencing at the deep crural arch, is continuous with the fascia transversalis and fascia iliaca. Its outer border descends in contact with the artery, while its inner border is inclined outwards from the margin of Gimbernat's ligament, and comes in contact with the vein at the distance of less than an inch lower down: the sheath is therefore funnel-shaped. It is divided into three compartments, separated by thin septa: the outermost contains the artery, the middle one the vein, and the innermost forms a space the upper end of which corresponds to the crural ring, and which is occupied by a lymphatic gland and some fat; this compartment is interesting to the surgeon as being the passage by which femoral hernia descends, and on this account has been named the *crural canal*.

Extending upwards from the opening for the femoral vessels in the adductor magnus muscle, is an aponeurotic membrane which consists of transverse fibres passing from the surface of the vastus internus to the adductor magnus and adductor longus muscles. It becomes thinner as it ascends, and it encloses between the muscles named a passage sometimes called



*Hunter's canal*, which contains the femoral artery and vein, together with the internal saphenous nerve.

The *aponeurosis of the leg* is particularly dense in the upper and fore part, and is strengthened by fibres from the tendons of the biceps externally, and the sartorius, gracilis, and semimembranosus internally. Behind, over the popliteal space, it consists of strong transverse fibres, which bind together the muscles of the outer and inner sides, and is perforated at the lower part of the space by the external saphenous vein; lower down it becomes much thinner over the gastrocnemius muscle. This fascia is adherent to the periosteum covering the head, the spine and the posterior margin of the tibia, the head of the fibula, and the outer and inner malleoli; and it invests the leg completely except at the inner surface of the tibia. From its deep surface intermuscular septa are prolonged inwards. The situation of these septa is marked on the surface of the fascia by several white lines in front and on the outer side of the leg. One, parallel to the spine of the tibia, runs between the tibialis anticus and the extensor longus digitorum, and is attached deeply to the interosseous membrane; and another extending

Fig. 223.

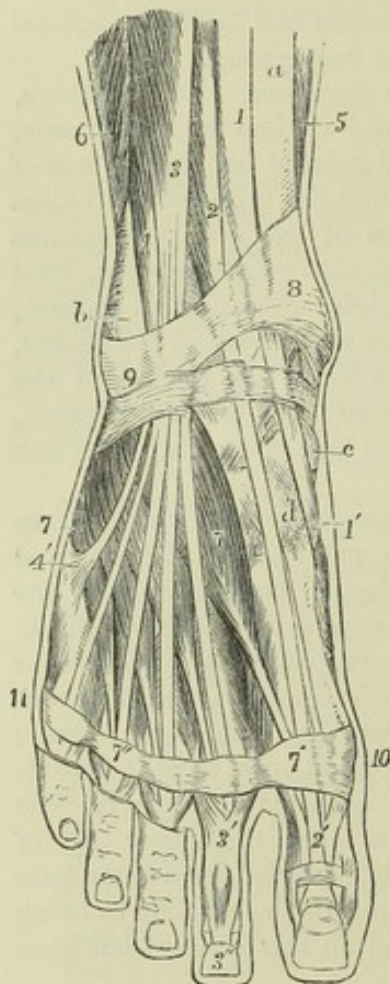


Fig. 223.—SUPERFICIAL MUSCLES AND TENDONS ON THE DORSUM OF THE FOOT AND LOWER PART OF THE LEG ANTERIORLY (after Bourguery).  $\frac{1}{2}$

a, lower part of the tibia; b, lower part of the fibula above the malleolus externus; c, inner side of the scaphoid bone; d, internal cuneiform bone; 1, lower part of the tibialis anticus muscle; 1', its tendon descending in the groove of the internal cuneiform bone; 2, extensor longus pollicis; 2', its expansion on the dorsum of the great toe; 3, extensor communis digitorum dividing into its four tendons for the toes; 3', the expansion, and 3'', the final insertion of the same upon the second toe; 4, peroneus tertius; 4', its expanded insertion on the base of the fifth metatarsal bone; 5, small part of the fibres of the soleus on the inner side of the tibia; 6, small part of the peroneus brevis; 7, extensor brevis digitorum, seen below the tendons of the extensor longus and peroneus tertius; 7', 7'', on a band of aponeurosis crossing the toes, the first and fourth tendons of the extensor brevis muscle passing to join those of the long extensor; 8, 9, anterior annular ligament, chiefly in its lower part or ligamentum cruciatum; between 8 and c, the inner and lower band enclosing the extensor longus pollicis and tibialis anticus; below 9, the outer part of the same enclosing the tendons of the extensor communis and peroneus tertius; 10, 11, dorsal transverse band of the aponeurosis of the foot, uniting the heads of the metatarsal bones.

between the long extensor and peroneus tertius in front, and the peroneus longus and brevis behind, is inserted along the anterior margin of the shaft of the fibula.

These septa, as well as the upper and anterior portion of the fascia itself, afford attachment to the muscular fibres, and thus increase greatly the extent of the surfaces from which the muscles derive their origin.

Between the superficial and the deep muscles on the back of the leg, a



layer of fascia is stretched from side to side across the limb known as the *deep fascia of the leg*. Where covered by the soleus and gastrocnemius, this fascia is weak, but it becomes stronger as it escapes from under cover of those muscles and approaches the malleoli.

Below the *ankle* the fascia of the leg becomes continuous with that of the foot. In front, and on the sides of that joint, it is strengthened by broad bands of fibres, which are called annular ligaments. These bands being merely stronger portions of the ordinary fascia, it is often difficult in dissection to mark satisfactorily the exact line of their upper and lower margins. They serve as retinacula, confining the tendons in their natural positions.

The *anterior annular ligament* includes two structures, one placed on the lower part of the leg, the other opposite the bend of the ankle. The *upper band*, *ligamentum transversum cruris* (Henle), of considerable breadth, stretches from the lower end of the fibula to the lower end of the tibia, and binds down the vertical portion of the extensor tendons as they turn forwards to the foot: the sheath for the tendon of the tibialis anticus is distinct from the others. The *lower band*, *ligamentum cruciatum cruris* (Henle), presents superficially the appearance of the letter Y placed upon its side, being single in its outer half, and usually divided into two branches internally. The outer portion consists of a strong loop of fibres arising from the fore part of the os calcis, completely surrounding the peroneus tertius and extensor longus digitorum muscles, and inserted into the fore part of the os calcis, deep in the hollow between that bone and the astragalus. Less regular is the arrangement of the bands which pass from the extremity of the loop to the inside of the foot: the strongest and most constant band passes superficial to the extensor pollicis and on the deep surface of the tibialis anticus muscle, only a few fibres passing superficial to the latter; while another band, lower down, is inserted into the inner side of the foot, in front of the ankle, after crossing both those tendons.

The loop formed by the outer part of this ligament derives additional interest from being present in the lower animals, as may be well seen in the dog or cat, and in the horse.

The *internal annular ligament* crosses the space between the inner ankle and the heel, through which the tendons of the flexor muscles run. Its upper border, continuous with the fascia of the leg (more especially the deep layer), is very imperfectly defined; and its lower border, giving origin to many fibres of the abductor pollicis, is but little more distinct. Its anterior extremity is attached to the inner malleolus, and its posterior termination is inserted into the inner margin of the calcaneum; but between these two points it arches over several osseous grooves so as to form canals for the passage of tendons. The first canal (next the malleolus) contains the tendon of the tibialis posticus, and the second that of the flexor longus digitorum, each being provided with a synovial lining. Then follows a wider space for the passage of the posterior tibial vessels and nerve. Lastly, a fourth canal upon the astragalus, lined like the two first by a synovial bursa, transmits the tendon of the flexor longus pollicis.

The *external annular ligament* extends from the point of the outer malleolus to the outer surface of the calcaneum, and keeps in place the tendons of the long and short peronei muscles. The tendons are close together, and are surrounded by one synovial sac.



The *fascia on the dorsum of the foot* is reduced to a thin membrane prolonged from the anterior annular ligament over the extensor tendons. Beneath it, deep fasciæ are placed over the short extensor of the toes and the interossei muscles.

The *plantar fascia* is stronger and thicker than any other of the fibrous membranes. It is composed of dense, white, glistening fibres, the greater number of which are ranged in a longitudinal direction, and extend from the under surface of the os calcis forwards to the heads of the metatarsal bones. It presents a central and two lateral portions, clearly marked off from each other by two strong intermuscular septa, indicated on the surface by grooves. The *inner* portion, very thin and unlike the others, invests the abductor pollicis, and is often partly removed with the skin in dissection. It is continuous round the inner border of the foot with the dorsal fascia and with the internal annular ligament. The *outer* part covers the abductor minimi digiti, and is much stronger, particularly between the outer tubercle of the calcaneum and the base of the fifth metatarsal bone, between which points it forms a strong ligament. It is continuous round the outer border of the foot with the dorsal fascia, and sends a thin prolongation forwards over the insertion of the abductor and the short flexor of the little toe. The *central portion*, like the corresponding part of the palmar fascia, is narrow behind, and becomes wider and thinner towards the toes. At the back, where it is thickest, the fascia is attached to the inner tubercle on the under surface of the calcaneum immediately behind the origin of the flexor brevis digitorum, with which muscle it is closely connected. Nearly opposite the middle of the metatarsal bones, this fascia, becoming broader and thinner as it advances, begins to divide into five processes, one for each of the toes; and from this point forwards to the base of the toes, numerous strong transverse fibres are superadded, which bind the processes together, and connect them closely with the skin. Near the articulation of the toes with the metatarsal bones, each of the five processes divides, to permit the passage of the flexor tendons; and the two bundles of fibres resulting from the division of each process, after strengthening the sheath of the tendons over which they pass, are attached to the sides of the metatarsal bone, and are blended with the transverse ligament uniting those bones. From the point of splitting of each process, as in the hand, fibrous bands are continued forwards to the skin in the division between the toes.

The two *intermuscular septa* which lie between the middle and lateral portions of the plantar fascia are prolonged deeply upwards into the sole of the foot; they separate the flexor brevis digitorum from the abductor pollicis on the inner side, and from the abductor minimi digiti on the outer side, and give partial origin to each of these muscles.

In both the foot and the hand there is a band of transverse fibres across the roots of the digits, placed immediately beneath the skin, and connected with the subjacent sheaths of the tendons. The digital nerves and vessels are covered by this structure, which receives the name of *transverse ligament* of the toes or fingers. In the foot a somewhat similar band, but consisting merely of a stronger part of the dorsal aponeurosis, crosses the place of the metatarso-phalangeal articulations.



## SECTION IV.—ANGEIOLOGY.

UNDER the name of Angeiology is included the descriptive anatomy of the vascular system, consisting of the heart, blood-vessels and absorbents. The *heart* is the central organ of the circulation, and although presenting a complex structure and mechanism, may be regarded, when viewed with reference to its development, as a curved and greatly altered blood-vessel. The *blood-vessels* are of three kinds—viz., the *arteries*, or ramifying vessels which distribute the blood from the heart; the *capillaries*, or network of simple walled microscopic vessels, in which the blood is diffused through the tissues; and the *veins*, or vessels by which the blood is returned to the heart. The *absorbents* are the small and delicate vessels which convey into the circulation fluid material capable of being converted into blood, whether derived directly from the food digested in the alimentary canal, or returned from the tissues in which it has already played some part in the nutritive processes.

*The double circulation.*—In the *systemic circulation* the blood is conveyed from the left ventricle of the heart by the arteries to every part of the body, and having parted in the capillaries with a portion of its ingredients, and undergone changes which render its purification necessary, it is returned by the veins to the right side of the heart, which is distinct from that from which it set out. The dark-coloured blood thus brought back to the right side of the heart is conducted through the *pulmonary circulation*, being propelled through the pulmonary artery by the right ventricle, undergoing in the lungs a process of purification, in which it receives oxygen from the air and parts with carbonic acid, and returning thence to the heart by the pulmonary veins, again to enter the systemic circulation.

## THE HEART.

## RELATION TO SURROUNDING PARTS.

The heart is situated in the thorax, between the two lungs, and, together with the adjacent parts of the great vessels which convey blood to and from it, is enclosed by a membranous covering, the pericardium. It is placed behind the sternum and the costal cartilages, occupying a region of about four inches in width, extending from the second intercostal space on the right side to the fifth space on the left, and reaching considerably farther on the left than on the right of the middle line.

## THE MEDIASTINUM.

The greater part of the thorax is occupied by the lungs, each of which is invested with a serous membrane, the pleura, which presents a parietal and a visceral portion, and is continued from the one portion to the other by passing on the surface of the pericardium from the anterior and posterior parts of the walls of the chest to the root of the lung. Thus the heart, enclosed in the pericardium, is situated between the right and left pleural sacs, and between the layers of an antero-posterior septum formed by the united portions of the right and left pleuræ, and known as the mediastinum.



Fig. 221.

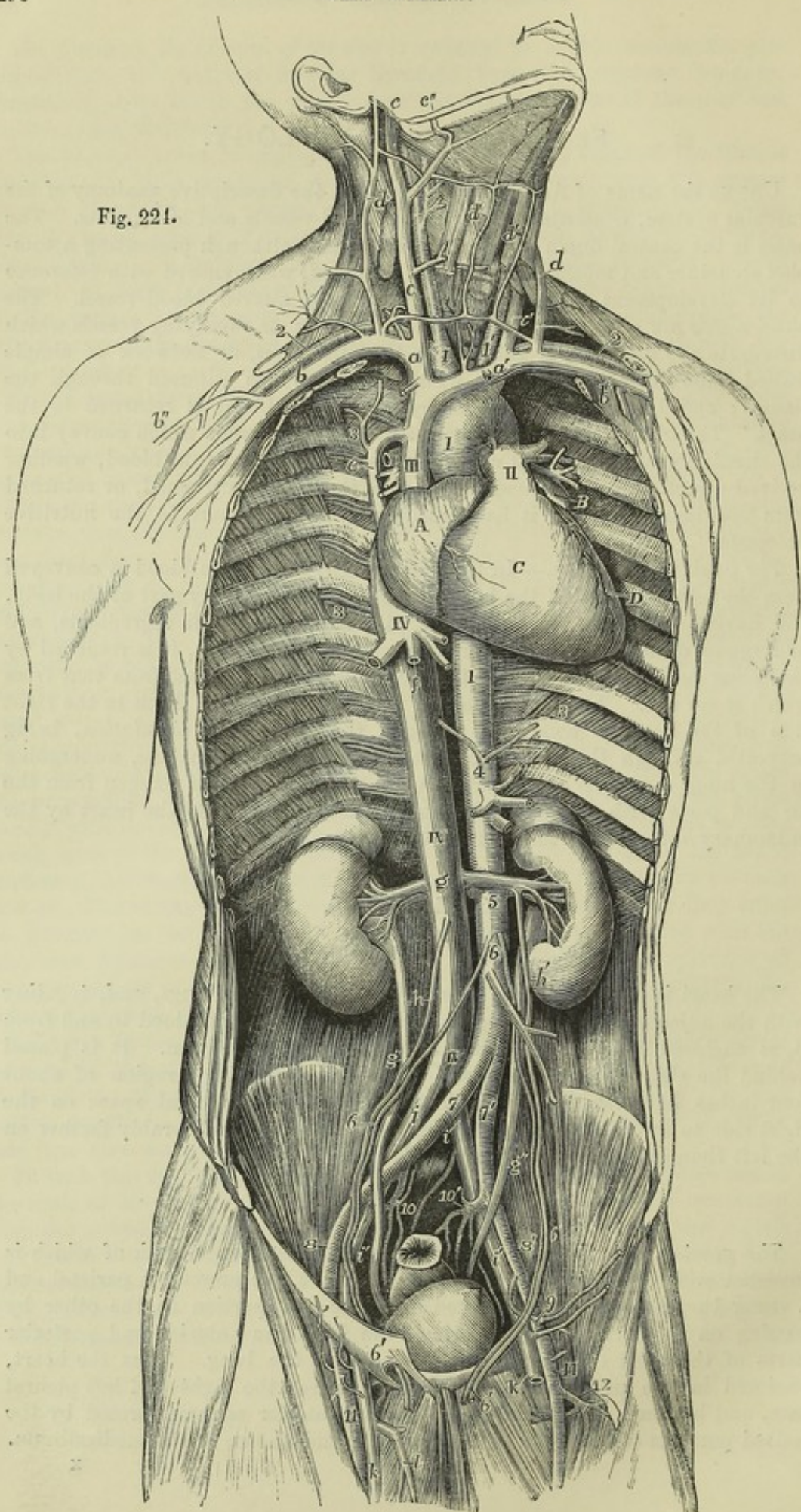




Fig. 224.—GENERAL VIEW OF THE PRINCIPAL ORGANS OF CIRCULATION, FROM BEFORE AND FROM THE RIGHT SIDE IN A MALE ADULT.  $\frac{1}{2}$

A, Right auricle; B, left auricular appendix; C, right ventricle; D, small part of the left ventricle; I, placed on the first part of the aortic arch; and on the descending aorta; II, trunk of the pulmonary artery dividing into its right and left branches, and connected to the aorta by the cord of the ductus arteriosus; III, vena cava superior; IV, vena cava inferior.

1, innominate artery and right carotid; 1', left carotid; 2, right and left subclavian arteries; 3, intercostal vessels marked only in three spaces; 4, above this figure the inferior diaphragmatic arteries, below it the coeliac axis and superior mesenteric artery; 5, renal arteries; 6, above this figure the spermatic arteries, and below it the inferior mesenteric; 6', the farther course of the spermatic vessels, on the right side they are seen to pass through the outer abdominal ring before descending to the testis; 7, 7', right and left common iliac arteries; 8, 8', external iliac arteries; 9, epigastric and circumflex iliac arteries of the left side; 10, 10', internal iliac arteries; and between these two figures the middle sacral artery; 11, femoral arteries; 12, some branches of the profunda femoris artery of the left side.

a, right innominate or brachio-cephalic vein; a', the left; b, b', right and left subclavian veins; b'', the cephalic vein of the right arm; c, c', internal jugular veins; c'', right facial vein joining the internal jugular; d, external jugular veins formed by the posterior auricular and temporal veins; d', anterior jugular veins with the transverse joining the external jugular; e, azygos vein passing over the root of the right lung; f, one of the hepatic veins; g, placed on the vena cava inferior at the origin of the renal veins; to the sides are seen the kidneys and the suprarenal bodies; g', right, g'', left ureter; h, right spermatic vein; h', the left, joining the left renal vein; i, i, common iliac veins; i', i'', external iliac veins; k, femoral veins; l, saphenous vein of the right side.

The part of this septum behind the pericardium is distinguished as the *posterior mediastinum*; it is in front of the bodies of the vertebræ, and within its cavity are the trachea, the œsophagus, the thoracic duct, the descending aorta, the vena azygos, and the pneumogastric nerves, with lymphatic vessels and areolar tissue. The *middle mediastinum* is the name given to the larger space, which is occupied by the pericardium and its contents. The *anterior mediastinum*, in front of the pericardium, is narrow and of little depth; but a knowledge of its situation is important to the phy-

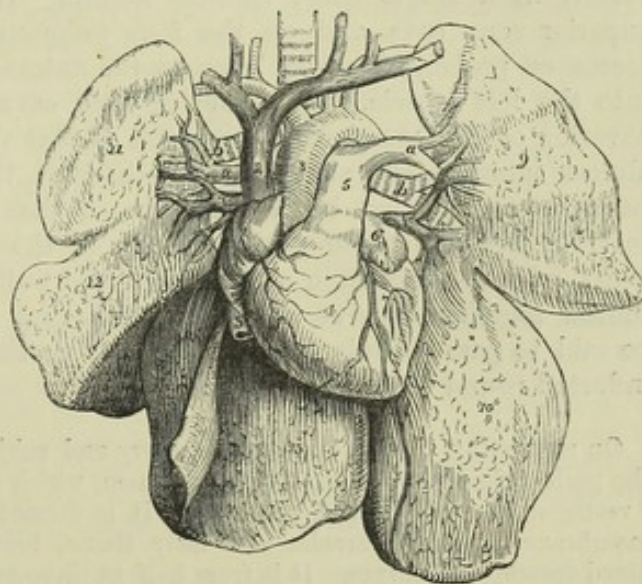
Fig. 225.—A DIAGRAMMATIC REPRESENTATION OF THE HEART AND GREAT VESSELS IN CONNECTION WITH THE LUNGS.  $\frac{1}{2}$

The pericardium has been removed, and the lungs are turned aside. 1, right auricle; 2, vena cava superior; 3, vena cava inferior; 4, right ventricle; 5, stem of the pulmonary artery; a, a, its right and left branches; 6, left auricular appendage; 7, left ventricle; 8, aorta; 9, 10, two lobes of the left lung; 11, 12, 13, three lobes of the right lung; b, b, right and left bronchi; v, v, right and left upper pulmonary veins.

sician, as it is connected with the position of the anterior margins of the

lungs relatively to the heart: at its superior part a small interval is left

Fig. 225.





between the two layers of pleura which bound it, and in this are contained the vestiges of the thymus gland; behind the second piece of the sternum the pleuræ of opposite sides come into contact, and the anterior mediastinum is reduced to a thin septum; while lower down it is inclined to the left, and widened out into an angular space of some breadth, by the margin of the left pleura receding from the sternum: opposite the lower part of this space the apex of the heart is situated, and in front of it is placed the *triangularis sterni* muscle.

#### THE PERICARDIUM.

This membranous bag, in which the heart is contained, is of a somewhat conical shape, its base being attached below to the upper surface of the diaphragm, whilst the apex, or narrower part, surrounds the great vessels which spring from the cavities of the heart, as far as their first subdivisions. It consists of two layers, one external and fibrous, the other internal and serous.

The *fibrous* layer is a dense, thick and unyielding membrane, consisting of fibres which interlace in every direction. At the base of the pericardium these fibres are firmly attached to those of the central aponeurosis of the diaphragm; and above, where the pericardium embraces the large blood-vessels, the fibrous layer is continued on their surface in the form of tubular prolongations, which become gradually lost upon their external coats. The superior vena cava, the four pulmonary veins, the aorta, and the right and left divisions of the pulmonary artery, in all eight vessels, receive prolongations of this kind.

The *serous* layer not only lines the fibrous layer of the pericardium and the part of the diaphragm to which that layer is attached, but like other serous membranes, is reflected on the surface of the viscus which it invests. It has, therefore, a visceral and a parietal portion. The parietal portion adheres firmly by its outer surface to the fibrous membrane, and becomes continuous with the visceral portion upon the arch of the aorta and other great vessels, about two or two and a half inches from the base of the heart. In passing round the aorta and pulmonary artery, it encloses both those vessels in a single short tubular sheath. It is reflected also upon the superior vena cava and on the four pulmonary veins, and forms a deep recess or prolonged cavity between the entrance of the right and left veins into the left auricle. The inferior vena cava receives only a very scanty covering of this membrane, inasmuch as that vessel enters the right auricle almost immediately after passing through the diaphragm, and is only partially surrounded by a reflection of the pericardium in the narrow interval between these parts. None of the vessels, indeed, joining the heart, with the exception of the aorta and pulmonary artery where they are united together, receive a complete covering from the pericardium, or can be said to pass entirely through the sac: portions only of the membrane are inflected round them more or less fully.

On separating the left pulmonary artery and subjacent pulmonary vein, a fold of the pericardium will be seen between them, which has been termed by Marshall the "vestigial fold of the pericardium." It is formed by a duplicature of the serous membrane, including areolar and fatty tissue, together with some fibrous bands, blood-vessels, and nerves. It is from half to three-quarters of an inch in length, and from a half to one inch deep. Above the pulmonary artery it blends with the pericardium, and passes onwards to the left superior intercostal vein. Below, it is lost, on the side of the left auricle, in a narrow streak which crosses round the lower left



Fig. 226.

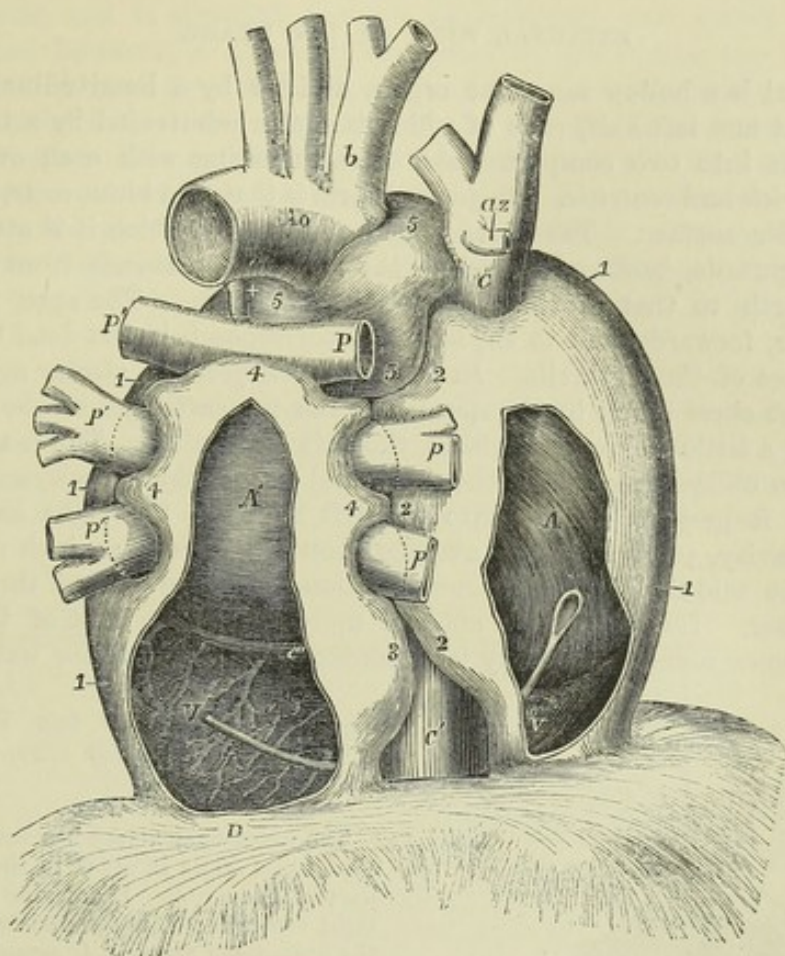


Fig. 226.—SEMI-DIAGRAMMATIC VIEW OF THE PERICARDIUM FROM BEHIND, DESIGNED TO SHOW THE PRINCIPAL INFLEXIONS OF THE SEROUS SAC ROUND THE GREAT VESSELS.  $\frac{1}{2}$

The drawing is taken from a preparation in which the heart and vessels had been partially filled by injection, the pericardium inflated and dried in the distended state, and the fibrous continuation on the vessels removed. By the removal of a portion of the pericardium from behind the right and left cavities of the heart, the position of that organ is made apparent. A bent probe is passed within the pericardium from behind the right auricle in front of the vena cava inferior to the back of the left ventricle, which may indicate the place where the large undivided sac of the pericardium is folded round that vein. A, posterior surface of the right auricle; A', the same of the left; V, right ventricle; V', left ventricle; Ao, the upper and back part of the aortic arch; b, innominate artery; C, vena cava superior; az, azygos vein; C', vena cava inferior between the diaphragm and its union with the right auricle; c', great coronary vein; +, cord of the ductus arteriosus; P, the right, P', the left pulmonary artery; p, the right, p', the left pulmonary veins; D, the back of the central tendon of the diaphragm; 1, the great undivided sac of the pericardium proceeding from before backwards towards its inflexions round the vessels; 2, portion of this on the right side which partially surrounds the vena cava superior, the upper and lower right pulmonary veins, and the vena cava inferior; 3, the portion of the left side which partially surrounds the vena cava inferior; 4, the portion which is extended upwards behind the left auricle, and partially folds over the pulmonary arteries and veins, and which meets between these different vessels the extensions of the main sac from the right and left; 5, tubular portion of the pericardium which completely surrounds the aortic and pulmonary arterial trunks.

pulmonary vein. This is shown, by Marshall, to be a vestige of the cardiac termination of the great left anterior vein existing in early embryonic life. (Marshall, "On the development of the great anterior Veins in Man and Mammalia," *Philosoph. Trans.* 1850. Part I. See hereafter the figures of the coronary vein.)



## EXTERNAL FORM OF THE HEART.

The heart is a hollow muscular organ, divided by a longitudinal septum into a right and left half, each of which is again subdivided by a transverse constriction into two compartments, communicating with each other, and named *auricle* and *ventricle*. Its general form is that of a blunt cone, flattened on its under surface. The broader end or base, by which it is attached, is directed upwards, backwards, and to the right, and extends from the level of the fourth to that of the eighth dorsal vertebra. The apex is turned downwards, forwards, and to the left, and corresponds in the dead body with the cartilage of the sixth rib. In the living subject its stroke against the walls of the chest is felt in the space between the cartilages of the fifth and sixth ribs, a little below and within the left mammilla. The heart, therefore, has an oblique position in the chest, and besides this is nonsymmetrically placed, as it projects farther into the left than into the right half of the thoracic cavity, passing on an average about an inch or an inch and a half beyond the middle line in the one direction, and upwards of three inches in the other. Its position is affected more or less by that of the body; thus it comes more extensively into contact with the anterior walls of the

Fig. 227.

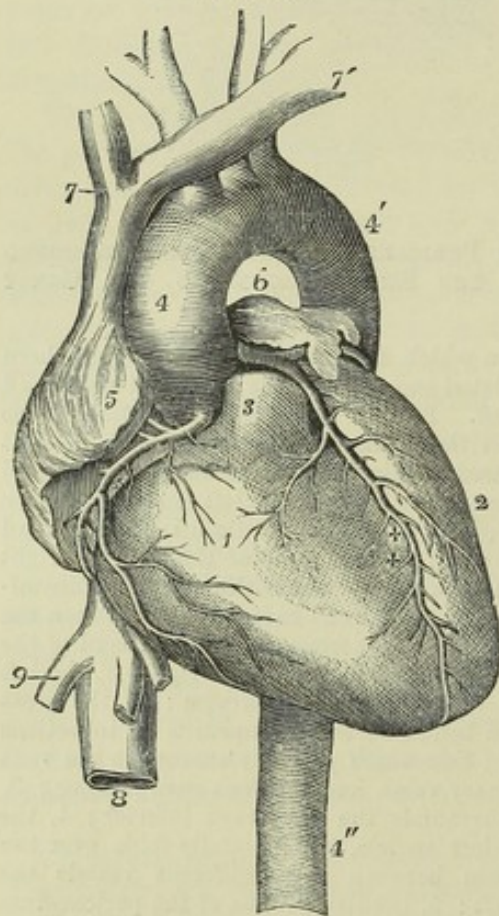


Fig. 227. — VIEW OF THE HEART AND GREAT VESSELS FROM BEFORE (from R. Quain).  $\frac{1}{2}$

The pulmonary artery has been cut short close to its origin in order to show the first part of the aorta. 1, anterior part of the right ventricle; 2, left ventricle; 3, root of the pulmonary artery; 4, ascending part of the arch of the aorta; 4', the posterior or descending part of the arch; between these is seen the transverse or middle part from which the brachio-cephalic arteries take their origin; 4'', the descending thoracic aorta; 5, the appendix and anterior part of the right auricle; 6, those of the left auricle; 7, the right, and 7', left innominate or brachio-cephalic veins joining to form the vena cava superior; 8, the inferior vena cava below the diaphragm; 9, one of the large hepatic veins; +, placed in the right auriculo-ventricular groove, points to the right or posterior coronary artery; ++, placed in the anterior inter-ventricular groove, points to the left or anterior coronary artery.

chest when the body is in the prone posture or lying on the left side. In inspiration, on the other hand, when the diaphragm sinks and the lungs expand, its apex is withdrawn from the thoracic parietes.

At its base the heart is directly attached to the great blood-vessels, and it is also connected with them by the serous layer of the pericardium, which passes from the one to the other. In the remainder of its extent the heart is entirely free, and movable within the sac of the pericardium. The



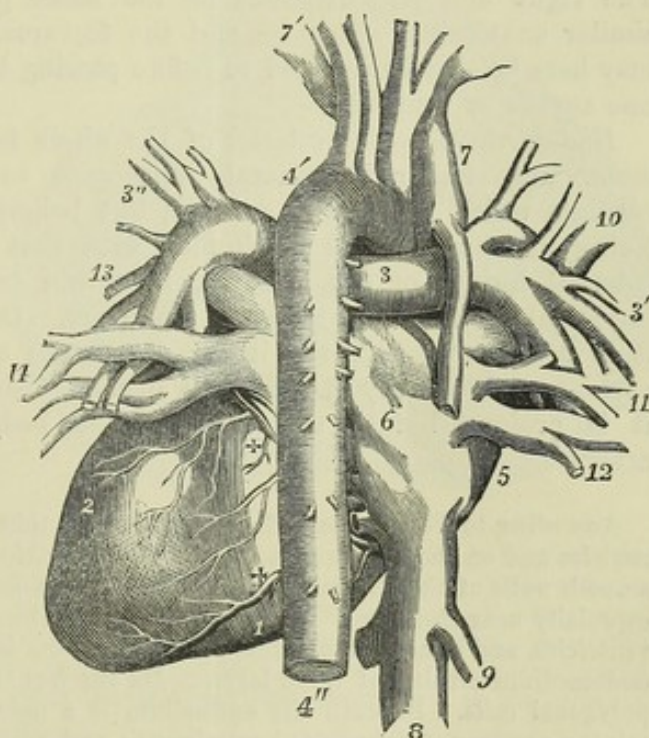
anterior surface is convex in its general form ; it is turned upwards as well as forwards, and is directed towards the sternum and costal cartilages : from these, however, it is partly separated by the lungs, the forepart of these organs advancing over it to some extent, and encroaching still farther during inspiration, so as in that condition to leave usually not more than two inches square uncovered. The posterior, which is also the under surface, is flattened, and rests on the diaphragm. Of the two borders or margins formed by the meeting of the anterior and posterior surfaces, the right or lower border, called *margo acutus*, is comparatively thin, and is longer than the upper or left border, which is more rounded and is named *margo obtusus*.

A deep transverse groove, the *auriculo-ventricular furrow*, interrupted in front by the root of the pulmonary artery, divides the heart into the auricular and the ventricular portions ; and on the ventricular portion two *longitudinal furrows* indicate the position of the anterior and posterior borders of the septum which divides one chamber from the other.

Fig. 228. — VIEW OF THE  
HEART AND GREAT VESSELS  
FROM BEHIND (from R. Quain).

1, posterior surface of the right ventricle ; 2, the same of the left ; 3, placed on the back of the right pulmonary artery near the division of the primary trunk ; 3', branches of the right pulmonary artery passing into the root of the right lung ; 3'', the same of the left ; 4', back part of the arch of the aorta ; 4'', descending thoracic aorta ; 5, part of the right auricle ; 6, is placed on the division between the right and left auricles ; 7, superior vena cava ; 7', left vena innominata ; 8, trunk of the inferior vena cava ; 9, right large hepatic vein ; 10, 11, 12, right pulmonary veins ; 13, 14, left pulmonary veins ; +, +, posterior branches of the right and left coronary arteries.

Fig. 228.



The auricular portion, situated above and behind the transverse furrow, is thin and flaccid, and is immediately connected with the great veins ; it is divided by an internal septum into two distinct cavities, which have received the names of the right and left *auricles*, from the circumstance that each is provided with an appendage somewhat resembling the ear of a dog. The ventricular portion, placed below and in front of the transverse groove, is somewhat conical, flattened on its posterior or under surface, has very thick walls, and is connected with the great arterial trunks. The two longitudinal furrows, which mark its division into a right and left chamber, situated one on the anterior, the other on the posterior surface, extend from the base of the ventricular portion, in a direct course, and are continuous one with the other a little to the right of the apex, which is thus formed entirely by the wall of the left ventricle. The anterior longitudinal furrow is nearer to



the left border, whilst the posterior furrow approaches nearer to the right border of the heart, the right ventricle forming more of the anterior, and the left more of the posterior surface of the organ. Within the transverse and longitudinal furrows are placed the proper nutrient vessels of the heart, the coronary or cardiac arteries and veins, with the lymphatic vessels and nerves imbedded in fatty and connective tissue.

#### INTERIOR OF THE HEART.

**GENERAL DESCRIPTION.**—Considered in respect of function, the heart is a double organ, composed of a right and a left part, each consisting of an auricle and a ventricle. The right portion receives into its auricle from the two venæ cavæ and coronary veins the dark venous blood returning from the various parts of the body and from the heart itself, and, by means of its ventricle, propels that blood through the pulmonary artery into the lungs. The red blood returning from the lungs by the pulmonary veins, reaches the left auricle of the heart, and is forced onwards by the left ventricle, through the aorta and its branches into every part of the body. The right and left divisions of the heart present in various respects a similar anatomical structure, and the features which are common to both may here be shortly referred to before passing to those which are peculiar to one auricle or ventricle.

**Endocardium.**—The interior of the whole heart is invested with a lining membrane, similar in general appearance to the visceral layer of pericardium which covers the exterior, but belonging to the class of vascular lining membranes, and continuous with that of the blood-vessels. This internal lining, or *endocardium*, is a thin transparent membrane, differing slightly on the two sides of the heart. On the left side of the heart it is continuous with the lining membrane of the pulmonary veins and aorta, and is usually found more opaque than on the right side, whence it is prolonged into the veins of the body and into the pulmonary artery.

According to Theile, the endocardium is very thin on the muscoli pectinati of the auricles and on the columnæ carneæ of the ventricles. It is thicker, however, on the smooth walls of the auricular and ventricular cavities, and on the muscoli papillares, especially near their tips. It is, on the whole, thicker in the auricles than in the ventricles, and attains its greatest strength in the left auricle. In both auricles the endocardium consists of three layers. On the free surface is an epithelial stratum of polygonal cells. Beneath the epithelium is a network of elastic fibres, often containing portions of fenestrated membrane; and connecting the latter to the muscular substance of the heart, is a layer of areolar tissue. Purkinje and Ræuschel (*De Arteriarum et Venarum Structura*. Breslau, 1836.) found elastic fibres beneath the endocardium in both auricles, and in the corpora Arantii, but not in the ventricles.

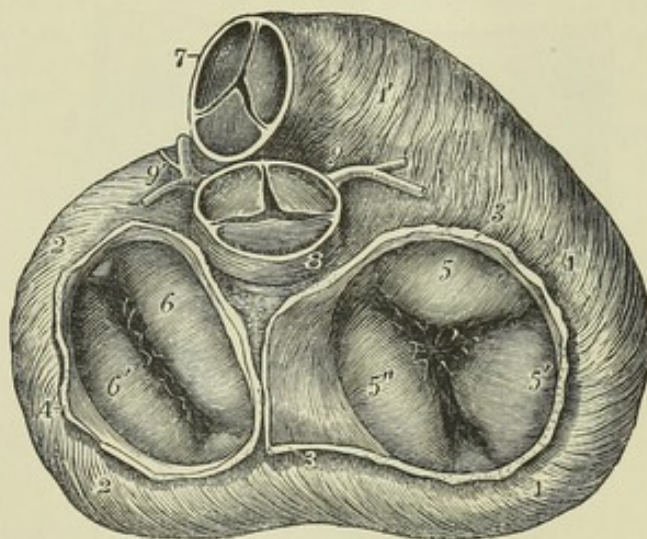
The *auricles* are both of them divisible into a large cavity, called the *atrium*, or *sinus venosus*, and a much smaller part in front, the *auricular appendage*, *auricula*, or *auricle proper*. The interior of the atrium presents smooth walls in the greater part of its extent, but the walls of the auricular appendages are thrown into closely-set reticulated bands, which in the right extend also into the sinus, and are named *muscoli pectinati*. The auricle, both on the right and the left side, receives the blood from the veins, and transmits it into the corresponding ventricle by the auriculo-ventricular opening.



The *ventricles*, on a great part of their inner surfaces, are covered with a number of irregular rounded muscular bands, named *columnæ carneæ*, which form quite a network in some parts of the ventricle, and may be classified into three kinds. The *first* kind form merely slightly prominent ridges on the walls of the ventricle, being attached by one of their sides as well as by the two extremities; the *second* are adherent by their two ends only, and are free in the rest of their extent; whilst the third kind form a few bundles, named *musculi papillares*, which are directed in general from the apex towards the base of the ventricle, in which they are attached to the muscular wall by their broader bases, and tapering more or less at their free extremities give rise to small tendinous cords, *chordæ tendineæ*, through which they are connected with the segments of the auriculo-ventricular valve. Each ventricle has two orifices, an auriculo-ventricular and an arterial opening.

Fig. 229.—VIEW OF THE BASE OF THE VENTRICULAR PART OF THE HEART, SHOWING THE RELATIVE POSITION OF THE ARTERIAL AND AURICULO-VENTRICULAR ORIFICES.

Fig. 229.



The muscular fibres of the ventricles are exposed by the removal of the pericardium, fat, bloodvessels, &c.; the pulmonary artery and aorta have been removed by a section made immediately beyond the attachment of the semi-lunar valves, and the auricles have been removed immediately above the auriculo-ventricular orifices. The semilunar and auriculo-ventricular valves are in the closed condition. 1, 1,

the base of the right ventricle; 1', the conus arteriosus; 2, 2, the base of the left ventricle; 3, 3, the divided wall of the right auricle; 4, 4, that of the left; 5, the anterior, 5', the posterior, and 5'', the left or septal segment of the tricuspid valve; 6, the anterior or aortic, and 6' the left and posterior segment of the mitral valve. In the angles between these segments are seen the smaller fringes frequently observed; 7, the anterior part of the pulmonary artery; 8, placed upon the posterior part of the root of the aorta; 9, the right, 9', the left coronary artery.

*Valves.*—In order to give to the blood propelled by the contraction of the ventricles its due direction through the arteries, two sets of valves are provided, one of which prevents the regurgitation of blood through the auriculo-ventricular openings into the auricles during the contraction of the ventricles, while the other prevents regurgitation from the arteries back into the ventricles when the contraction has ceased. These valves are mainly formed of folds of the endocardium with some fibrous tissue contained within them.

The *auriculo-ventricular* valves are composed of membranous flaps or segments, which are three in number in the valve of the right side, and two in that of the left. At their bases, the several segments are continuous with one another, so as to form an annular membrane attached round the margin of the auricular opening: they are directed downwards,



and are retained in position within the ventricle by the chordæ tendineæ, which are attached to their ventricular surfaces and free margins.

Fig. 230.

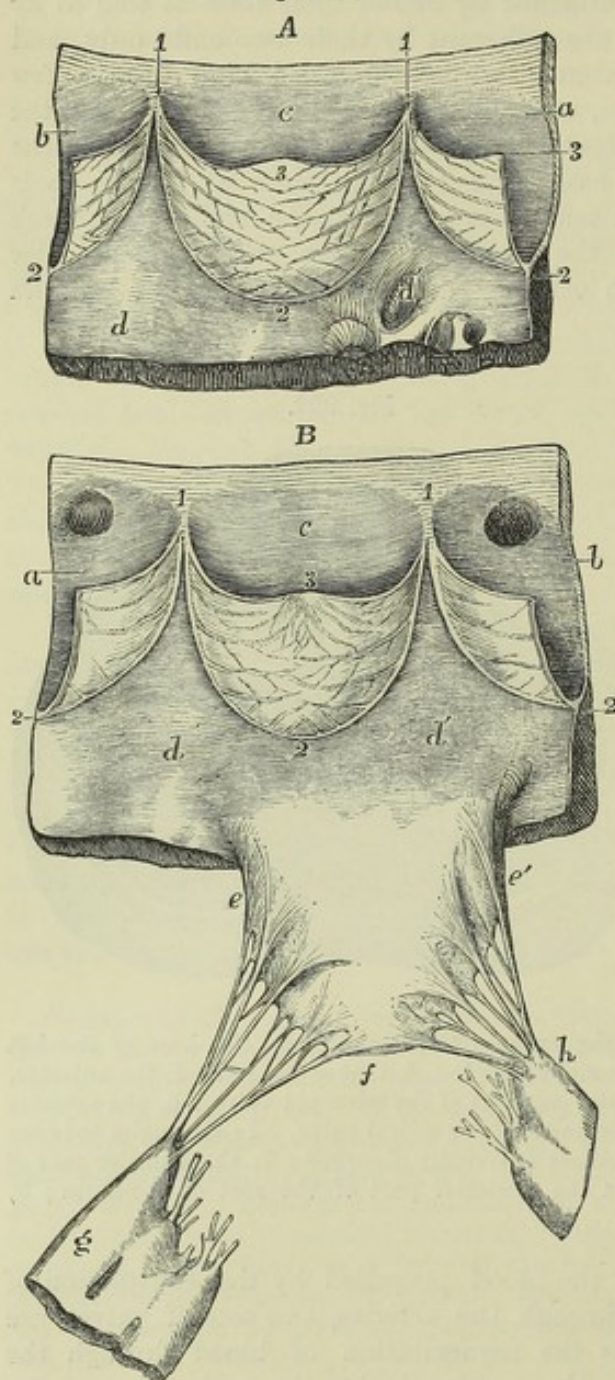


Fig. 230.—VIEWS OF PARTS OF THE SEMILUNAR AND MITRAL VALVES, AS SEEN FROM WITHIN THE VENTRICLE.

A, portion of the pulmonary artery and wall of the right ventricle with one entire segment and two half segments of the semilunar valves; *a*, half the sinus of Valsalva of the anterior segment; *b*, the same of the left posterior segment; *c*, the entire right posterior segment (see Fig. 231, A, in which the lettering is the same as in the present figure); *d*, *d'*, inner surface of the ventricle; 1, the attachment of the extremities of the segments to the inner wall of the artery; 2, the middle of the attached border of the segments; 3, the middle of the free border marked in two of the segments; upon the middle segment especially the direction of the bands of fibres strengthening the valve, as represented by Pettigrew, is shown.

B, portion of the aorta and wall of the left ventricle with one entire segment and two half segments of the semilunar valve, and the right or anterior segment of the mitral valve; *a*, half the right anterior sinus of Valsalva and segment (marked *b* in B, fig. 231); *b*, the same of the left side; *c*, the posterior sinus of Valsalva and segment entire; in *a*, and *b*, the apertures of the coronary arteries are seen; *d*, *d'*, the inner surface of the wall of the ventricle to the right of the auriculo-ventricular orifice; 1, 1, the attachments of the extremities of the segments; 2, the middle of the attached borders; 3, the middle of the free border with the corpus Arantii shown in the middle segment; *e*, *e'*, the base of the right or anterior segment of the mitral valve; *f*, its apex; between *e*, and *e'*, and *f*,

the attachment of the branched chordæ tendineæ to the margin and outer surface of the valve segment; *g*, the posterior principal musculus papillaris; *h*, the anterior principal musculus papillaris: the cut chordæ tendineæ are those which belong to the left or posterior segment and the small or intermediate segments.

During the contraction of the ventricles, the segments of the valves are applied to the openings leading from the auricles, and prevent the blood from rushing back into those cavities. Being retained by the chordæ tendineæ, the expanded flaps of the valve resist the pressure of the blood, which



would otherwise force them back through the auricular orifice; the papillary muscles, shortening as the cavity of the ventricle itself is contracted during its systole, are supposed thus to prevent the valves from yielding too much towards the auricle, which might have been the case had the chordæ tendineæ been longer, or fixed directly into the wall of the ventricle. The middle part of each segment is thicker than the rest, whilst the marginal part is thinner, more transparent, and jagged at the edges. In the angles between each pair of the principal segments of the auriculo-ventricular valves there may be found, but not constantly, as many small intermediate lobes. The muscoli papillares are arranged in groups as many as there are segments of the valve, and the chordæ tendineæ from each are distributed to the adjacent sides of two different valves, so as to draw their margins together.

According to Kürschner (Wagner's Handwörterbuch, art. "Herzthätigkeit"), three kinds of cords belong to each segment: *a*, the first set, generally two to four in number and proceeding from two different sets of papillæ, or from one of these and the wall of the ventricle, run to the base or attached margin of the segment, and are there connected also with the tendinous ring round the auriculo-ventricular opening; *b*, the second set, more numerous, and smaller than the first, proceed also from two adjacent papillary muscular groups, and are attached to the back or ventricular surface of each segment at intervals along two or more lines extending from the points of attachment of the tendons of the first order at the base of the valve to near its free extremity; *c*, the third set, which are still more numerous and much finer, branch off from the preceding ones, and are attached to the back and edges of the thinner marginal portions of the valves. A few muscular fibres prolonged from the neighbouring walls penetrate into the segments of the auriculo-ventricular valves.

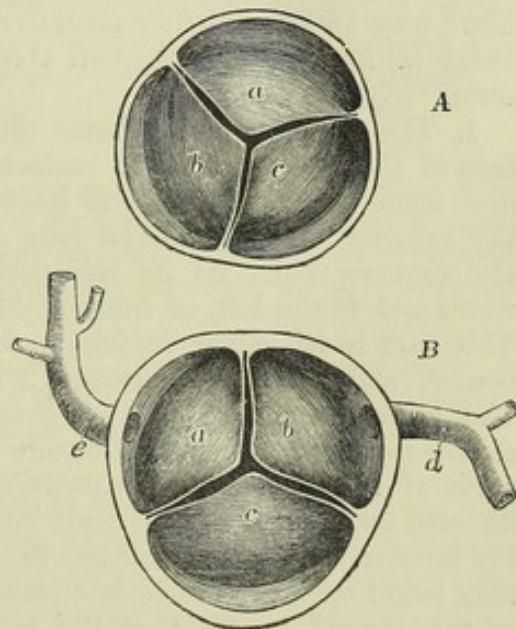
Fig. 231.—THE SEMILUNAR VALVES OF THE AORTA AND PULMONARY ARTERY, SEEN FROM THEIR DISTAL SIDE.

A, transverse section of the pulmonary artery immediately above the attachment of the semilunar valves: *a*, the anterior segment; *b*, the left, and *c*, the right posterior segments: in each the sinus of Valsalva is seen, and between them the attachment of the ends of the valve-segments to the inner wall of the artery.

B, a similar section of the aorta, showing the semilunar valves from their distal side: *a*, the left, *b*, the right anterior segments, with the sinuses of Valsalva, from which the corresponding coronary arteries are seen to take their origin; *c*, the posterior segment; *d*, the right, or posterior; *e*, the left, or anterior coronary arteries.

The *semilunar* or *sigmoid* valves, placed at the mouths of the aorta and pulmonary artery, consist of three semicircular folds, each of which is attached by its convex border to the side of the artery at the place where it joins with the ventricle, whilst its other border, nearly straight, is free, and projects into the interior of the vessel. They are composed of dupli-

Fig. 231.





captures of the endocardium, and of enclosed fibrous structure, which varies in thickness at different parts. A tendinous band strengthens the free margin of the valve, and is attached at the middle of that margin to a slight fibro-cartilaginous thickening, the *nodulus* or *corpus Arantii*. Other tendinous fibres, spreading out from the attached border of the valve, run into the valve and towards the nodule, occupying its whole extent, except two narrow lunated portions, one on each side, adjoining the free margin of the valve. These parts, which are named *lunulae*, are therefore thinner than the rest. There is also a strengthening fibrous cord surrounding the attached border of each valve. (For further information regarding the structure of the valves, consult Pettigrew, in Trans. Roy. Soc. Edin. 1864.)

During the contraction of the ventricle the valves lie against the sides of the artery, and allow the blood to flow freely past them; but during the ventricular diastole, when the column of fluid in the artery is partially thrown back by the elasticity of the coats of that vessel, the sigmoid valves are distended by the regurgitating blood, and completely close the arterial orifice. When the valves are thus closed, the whole free border and the thin lunated parts are closely applied to each other, and are held together as well as exempted from strain by the opposite and equal pressure of the blood on either side, so that the greater the pressure the more accurate must be the closure. The force of the reflux is sustained by the stouter and more tendinous part of the valve. (Retzius, in Müller's Archiv., 1843, p. 14.)

Opposite the pouches formed by the sigmoid valves, the commencing aorta and pulmonary artery present dilatations or recesses in their walls, called *sinuses of Valsalva*, which give to the transverse section of the vessel a trilobate form, and as one of these is placed behind each segment of the valve, it thus forms along with it a cup-shaped cavity.

**SPECIAL DESCRIPTION.**—The detailed anatomy of the four cavities of the heart may be conveniently considered in the order of the course of the blood in its double circulation through them from the *venæ cavæ* to the aorta.

1. The **RIGHT AURICLE** forms the right anterior and lower part of the base of the heart, and is in contact below with the pericardium where it lies upon the diaphragm: it receives blood in two large streams, from the superior and the inferior vena cava, besides the smaller quantity from the coronary vein. At its fore part its auricular appendage projects forwards and to the left, in front of the aorta, as far as the pulmonary artery. This part is triangular in form, compressed and slightly dentated at its border, and has more strongly muscular walls than the sinus venosus. The auricular appendage and anterior wall of the sinus venosus are closely ridged in a vertical direction with *musculi pectinati*; the remaining parts of the walls are comparatively smooth. The superior vena cava is directed downwards and forwards into the upper part of the auricle, while the inferior vena cava terminates in the lower and back part by a considerably larger opening, which is directed upwards and inwards. In the floor of the auricle, in front of the inferior vena cava, is the auriculo-ventricular opening, leading into the right ventricle; it is oval in form, and about an inch and a quarter in diameter, admitting three fingers easily. The other foramina opening into the right auricle are, the orifice of the large coronary vein of the heart, situated between the opening of the inferior vena cava and the auriculo-ventricular opening, and a number of small pits,



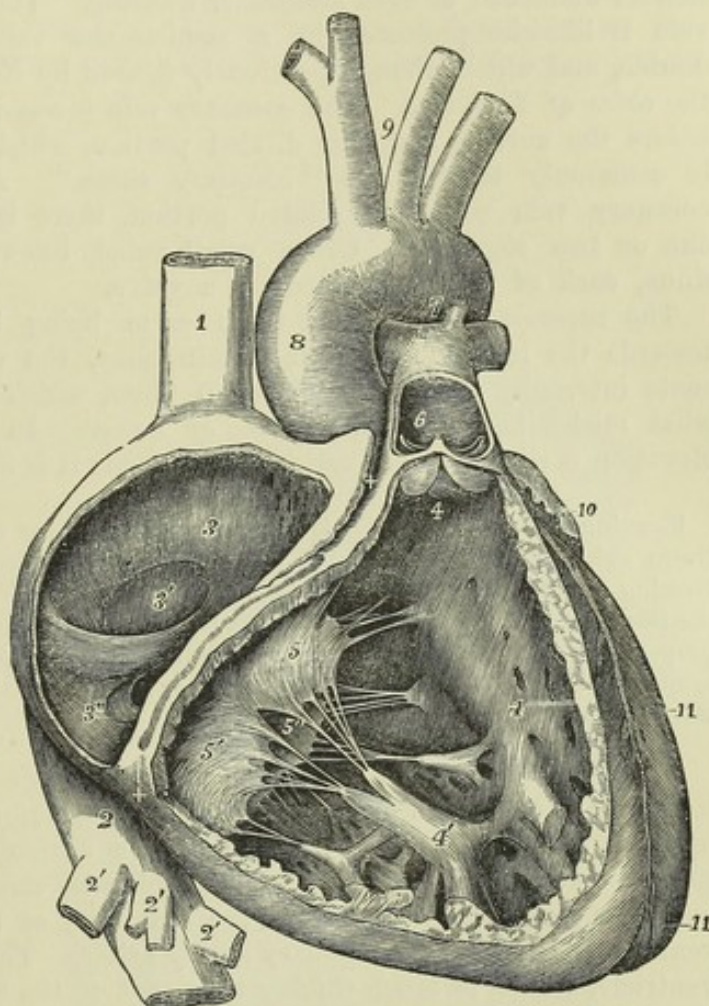
*foramina Thebesii*, some of which are recesses closed at the bottom, whilst others are the mouths of minute veins (*venæ minimæ cordis*).

The left and posterior side of the auricle is formed by the *septum auricu-*

Fig. 232.—THE RIGHT AURICLE AND VENTRICLE OPENED AND A PART OF THEIR RIGHT AND ANTERIOR WALLS REMOVED SO AS TO SHOW THEIR INTERIOR.  $\frac{1}{2}$

Fig. 232.

1, the superior vena cava; 2, the inferior vena cava at the place where it passes through the diaphragm, and below the hepatic veins; 2', the hepatic veins cut short; 3, placed upon the tubercle of Lower within the cavity of the right auricle; 3', placed in the fossa ovalis, below which is the Eustachian valve; 3'', is placed close to the aperture of the great coronary vein and the valve of Thebesius; +, +, placed in the auriculo-ventricular groove, where a narrow portion of the adjacent walls of the auricle and ventricle has been preserved; 4, 4, the cavity of the right ventricle on the right side of the septum, the upper figure is immediately below the semilunar valves; 4', large right columna carnea; 5, the anterior, 5', the posterior, and 5'', the left or septal segment of the tricuspid valve; 6, placed in the interior of the pulmonary artery, a part of the anterior wall of that vessel having been removed, and a narrow portion of it preserved at its commencement where the semilunar valves are attached. The valves are represented as in a half-closed position; two of the segments are seen fore-shortened, the third sideways; 7, concavity of the aortic arch close to the cord of the ductus arteriosus; 8, ascending part or sinus of the arch covered at its commencement by the auricular appendix and pulmonary artery; 9, placed between the innominate and left carotid arteries; 10, appendix of the left auricle; 11, 11, the outside of the left ventricle, the lower figure near the apex.



*larum*, a partition which separates it from the left auricle. At the lower part of this septum, and just above the orifice of the inferior vena cava, is situated an oval depression named *fossa* or *fovea ovalis*, which is the vestige of the foramen ovale of the foetal heart (*vestigium foraminis ovalis*), and indicates the original place of communication between the two auricles. It is bounded above and at the sides by a prominent border, which is deficient below, the *annulus ovalis* or *isthmus Vieussensii*. Continuous with the anterior inferior extremity of the annulus ovalis is a crescentic fold of endocardium, the *Eustachian valve*, springing from the anterior



margin of the inferior vena cava. This valve, which in the foetus is proportionally large, and serves, in conjunction with the annulus ovalis, to direct the blood from the inferior vena cava through the foramen ovale, is in the adult comparatively small, and very variably developed, being often cribriform or perforated by numerous foramina, and sometimes reduced to a few slender filaments, or even altogether wanting. The mouth of the coronary vein is likewise protected by a semicircular valve, which is sometimes double, and which, though previously figured by Eustachius, is often named the *valve of Thebesius*. The coronary vein is considerably dilated before it enters the auricle, and this dilated portion, which has muscular parietes, is commonly termed the "coronary sinus." At the junction of the coronary vein with this dilated portion, there is a valve consisting of one or two segments. Other small veins likewise enter the coronary sinus, each of them protected by a valve.

The superior and inferior venæ cavæ being both directed somewhat towards the left side at their terminations, the wall of the auricle presents internally a convexity between them, which has received the somewhat misleading name of *tubercle of Lower*. In the human subject this elevation is slight, but in certain quadrupeds it is more strongly marked.

Running upwards from the fossa ovalis, under cover of the annulus, there sometimes exists a small slit, which leads beneath the annulus into the left auricle, forming thus an oblique and valved aperture between the two cavities. More rarely the foramen ovale of the foetus remains so patent after birth as to interfere with the proper course of the circulation, and produce the pathological condition known as cyanosis—by the mixture of some dark or venous blood with the bright red or arterial blood of the left auricle.

2. The RIGHT OR ANTERIOR VENTRICLE extends from the right auricle towards the apex, and from the upper and anterior part of its base sends upwards, in front and to the left of the auriculo-ventricular opening, a smooth conical prolongation, free from columnæ carneæ, and named *infundibulum* or *conus arteriosus*: from the extremity of this prolongation of the ventricular cavity the pulmonary artery arises. The superficial wall of this ventricle, which is much thicker than that of the auricle, but thinner than that of the left ventricle, is formed by the part of the heart situated to the right of the anterior longitudinal groove, viz., the right border, the larger part of the anterior surface, and a part of the posterior. The internal or left wall is formed by the *septum ventriculorum*, and is convex, bulging to the right into the ventricle, so that a transverse section of the cavity presents a crescentic figure.

The *valve* guarding the right auriculo-ventricular opening is named the tricuspid valve, from the number of its segments. One of the segments, the smallest, is placed towards the left and rests upon the septum of the ventricles; the other two are placed more to the right,—one posteriorly against the right wall of the cavity, while the other, the largest of all, lying anteriorly, is interposed between the auricular and arterial openings, and has its ventricular surface directed forwards and upwards. The chordæ tendinæ arise chiefly from the muscoli papillares, but some also from the walls of the ventricle and especially from the septum. Those arising from one papillary muscle or group of muscles run up in the angular interval between two adjacent segments of the valve, and, diverging from each other, are attached to both segments.

The semilunar valves at the root of the pulmonary artery are more



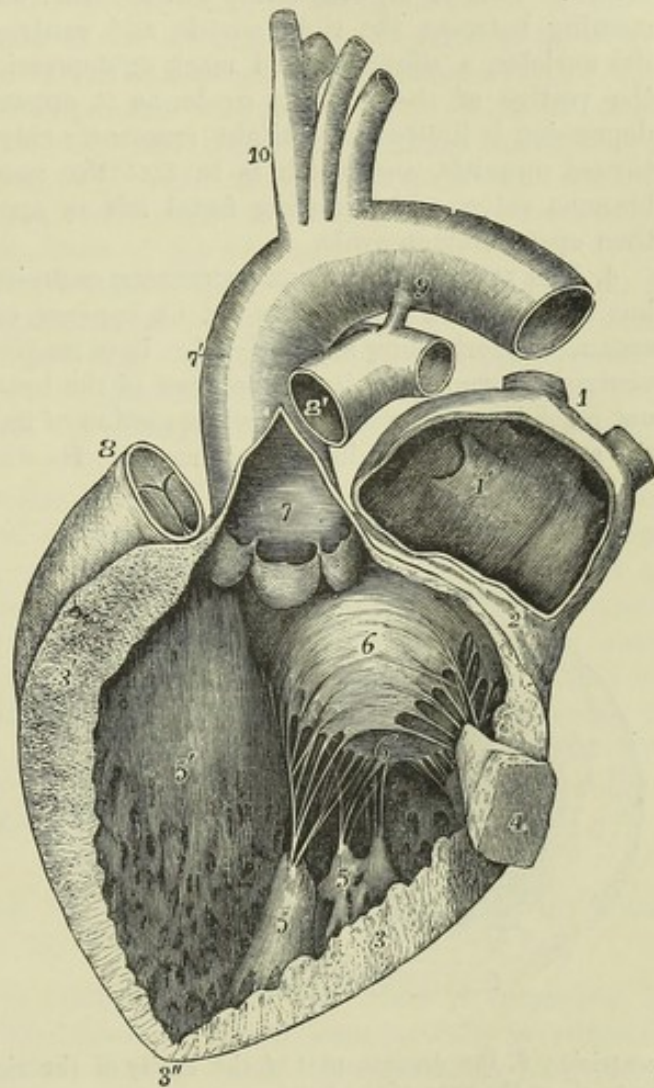
delicate than those which guard the aorta ; and the sinuses of Valsalva are less strongly marked.

3. The LEFT AURICLE occupies the left and posterior part of the base of the heart. When distended, the atrium presents from behind, where it is best seen, a quadrilateral appearance. In front it rests against the aorta and pulmonary artery ; behind, on each side, it receives two pulmonary veins, those from the left lung entering very close together ; and on the right it is in contact with the other auricle. The *auricular appendage* is

Fig. 233.—THE LEFT AURICLE AND VENTRICLE OPENED AND A PART OF THEIR ANTERIOR AND LEFT WALLS REMOVED SO AS TO SHOW THEIR INTERIOR.  $\frac{1}{2}$

The pulmonary artery has been divided at its commencement so as to show the aorta : the opening into the left ventricle has been carried a short distance into the aorta between two of the segments of the semi-lunar valves ; the left part of the auricle with its appendix has been removed. The right auricle has been thrown out of view. 1, the two right pulmonary veins cut short : their openings are seen within the auricle ; 1', placed within the cavity of the auricle on the left side of the septum and on the part which forms the remains of the valve of the foramen ovale, of which the crescentic fold is seen towards the left hand of 1' ; 2, a narrow portion of the wall of the auricle and ventricle preserved round the auriculo-ventricular orifice ; 3, the left part, 3', the right part towards the septum of the cut surface of the wall of the ventricle, seen to become very much thinner towards 3", at the apex ; 4, a small part of the anterior wall of the left ventricle which has been preserved with the principal anterior columnæ carneæ attached to it ; 5, 5, the large posterior columnæ carneæ ; 5', the left side of the septum within the cavity of the left ventricle ; 6, the right or aortic segment, and 6', the left or parietal segment of the mitral valve ; 7, placed in the interior of the aorta near its commencement and above the three segments of its semilunar valve which are hanging loosely together ; 7', the exterior of the great aortic sinus ; 8, the upper part of the conus arteriosus with the root of the pulmonary artery and its semilunar valves ; 8', the separated portion of the pulmonary artery remaining attached to the aorta by 9, the cord of the ductus arteriosus ; 10, the arteries rising from the summit of the aortic arch.

Fig. 233.



the only part of the left auricle seen from the front : it extends forwards from the left side of the atrium, and curves towards the right side, resting



on the pulmonary artery. It is more curved than that of the right auricle, and its margins are more deeply indented.

The interior of the appendix presents *musculi pectinati* somewhat similar to those in the right side of the heart, but the walls of the sinus venosus are altogether smooth, and are also thicker than those of the right auricle. Posteriorly are the openings of the pulmonary veins, usually two on each side, and entirely without valves. The two veins of either or both sides sometimes unite into one before entering the auricle, whilst in other cases there is found an additional opening, most frequently on the right side. In the lower and fore part of the auricle is situated the left *auriculo-ventricular* orifice. It is of an oval form, and is rather smaller than the corresponding opening between the right auricle and ventricle. On the septum between the auricles, a slight lunated mark or depression may be observed, which is the vestige of the *foramen ovale*, as it appears upon the left side. The depression is limited by a slight crescentic ridge, the concavity of which is turned upwards, and which is in fact the now adherent border of a membranous valve, which during foetal life is applied to the left side of the then open *foramen ovale*.

4. The LEFT OR POSTERIOR VENTRICLE occupies the left border of the heart, but only about a third of its extent appears on the anterior surface of the organ, the rest being seen behind. It is longer and narrower than the right ventricle, forming by itself the apex of the heart, as the right ventricle does not reach into that part. The cross section of its cavity is oval, not crescentic, the septum on this side being concave. Its walls, which, excepting near the

Fig. 234.

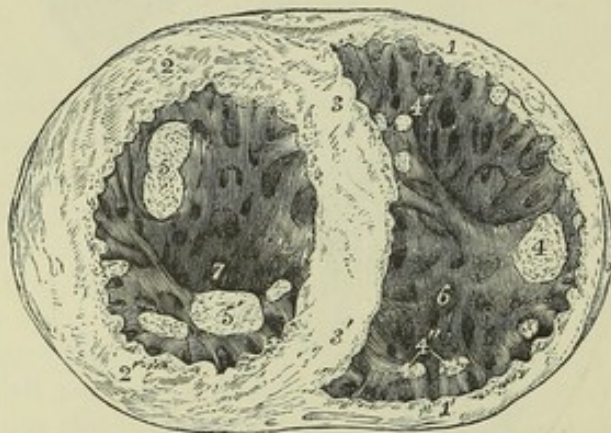


Fig. 234.—CROSS SECTION OF THE VENTRICULAR PART OF THE HEART AT TWO-THIRDS FROM THE APEX, LOOKING INTO THE CAVITIES.  $\frac{2}{3}$

1, 1', cut surface of the wall of the right ventricle; 2, 2', the same of the left; 3, 3', the same of the septum; 4, the principal columna carnea of the right ventricle on its right border; 4', some of those on the septum near the front; 4'', some of those on the posterior wall near the septum; 5, the principal anterior columna carnea of the left ventricle; 5', the largest of those situated posteriorly in the left

ventricle; 6, the deepest part of the cavity of the right ventricle; 7, that of the left ventricle at the apex of the heart.

apex, are three times as thick as those of the right ventricle, are thickest at the part where the ventricle is widest, about one-fourth of its length from the base; from this point they become thinner towards the auricular opening, but they are still thinner towards the apex which is the weakest part. The lining membrane, which is continuous with that of the left auricle and the aorta, is usually less transparent than that of the right ventricle, especially in later life. In the interior of the cavity are noticed *columnæ carneæ*, *musculi papillares* with *chordæ tendineæ*, and two orifices guarded with valves. The *columnæ carneæ* are, on the whole, smaller than those of the right ventricle, but are more numerous and more densely reticulated.



Their intersections are very numerous near the apex of the cavity, and also along its posterior wall, but the upper part of the anterior wall and septum is comparatively smooth. The *musculi papillares* are collected into two bundles, which are larger than those of the right ventricle, and are formed one from the anterior, the other from the posterior surface of the ventricle. The two orifices of this ventricle are situated very close together, with one of the segments of the auriculo-ventricular valve between; the auriculo-ventricular opening being placed at the left and posterior part of the base of the ventricle, behind and to the left of that which leads into the aorta.

The *bicuspid* or *mitral* valve, which guards the auriculo-ventricular opening, resembles in structure the tricuspid valve of the right ventricle, but it is much thicker and stronger in all its parts, and consists of only two pointed divisions or segments, continuous at their attached bases. The larger of the two segments is suspended obliquely to the right and in front of the other, between the auricular and the aortic orifices: the smaller is situated to the left and posteriorly, and close to the wall of the ventricle. There is usually a smaller lobe at each angle of junction of the two principal segments, more apparent than those of the tricuspid valve.

One portion of the chordæ tendinæ from each *musculus papillaris* is distributed to half of one segment, and the other portion to the neighbouring side of the other segment, so that when the *musculi papillares* contract, and make the segments tense, they also cause their margins to approach each other. The chordæ tendinæ are stronger and less numerous than in the right ventricle.

The arterial or aortic orifice, circular in form, and smaller than the auriculo-ventricular, is placed in front and to the right of that opening, and very close to it, being separated from it only by the attachment of the anterior segment of the mitral valve. The semilunar valves which guard it are thicker and stronger than those of the right side of the heart, the lunulæ are more strongly marked off, and the central nodules, or *corpora Arantii*, are larger. The sinuses of Valsalva are more strongly marked at the mouth of the aorta than at the commencement of the pulmonary artery, and from the two anterior of them arise the right and left coronary arteries for the supply of blood to the substance of the heart.

#### POSITION OF THE PARTS OF THE HEART WITH RELATION TO THE WALL OF THE THORAX.

The exact position of the various parts of the heart is important in reference to auscultation. This subject has of late been carefully investigated by several anatomists; but there is still some discordance in their statements on some points, caused probably by the difficulty of marking with precision the situation of non-symmetrical viscera in artificially opened bodies, and in part perhaps by differences naturally existing among individuals. The following statement derived from Luschka is in general accordance with the results of others, with the exception, as remarked by Walshe, that most of the positions are fixed a little too high. Nearly two-thirds of the bulk of the heart lie to the left of the middle line. The upper edge of the auricles corresponds with a line extending across the sternum from the second right into the first left intercostal space. The auriculo-ventricular sulcus corresponds with a line which unites the sternal end of the fifth right costal cartilage with the second left intercostal space beneath the middle of the second costal cartilage. The rounded margin formed by the wall of the



left ventricle extends from the second left intercostal space to a point in the fifth space placed two inches vertically below the nipple. The sharp margin formed by the right ventricle passes from the sternal end of the fifth right costal cartilage, and crosses behind the end of the body of the sternum and the sixth left costal cartilage, to meet the other margin at the apex.

Fig. 235.

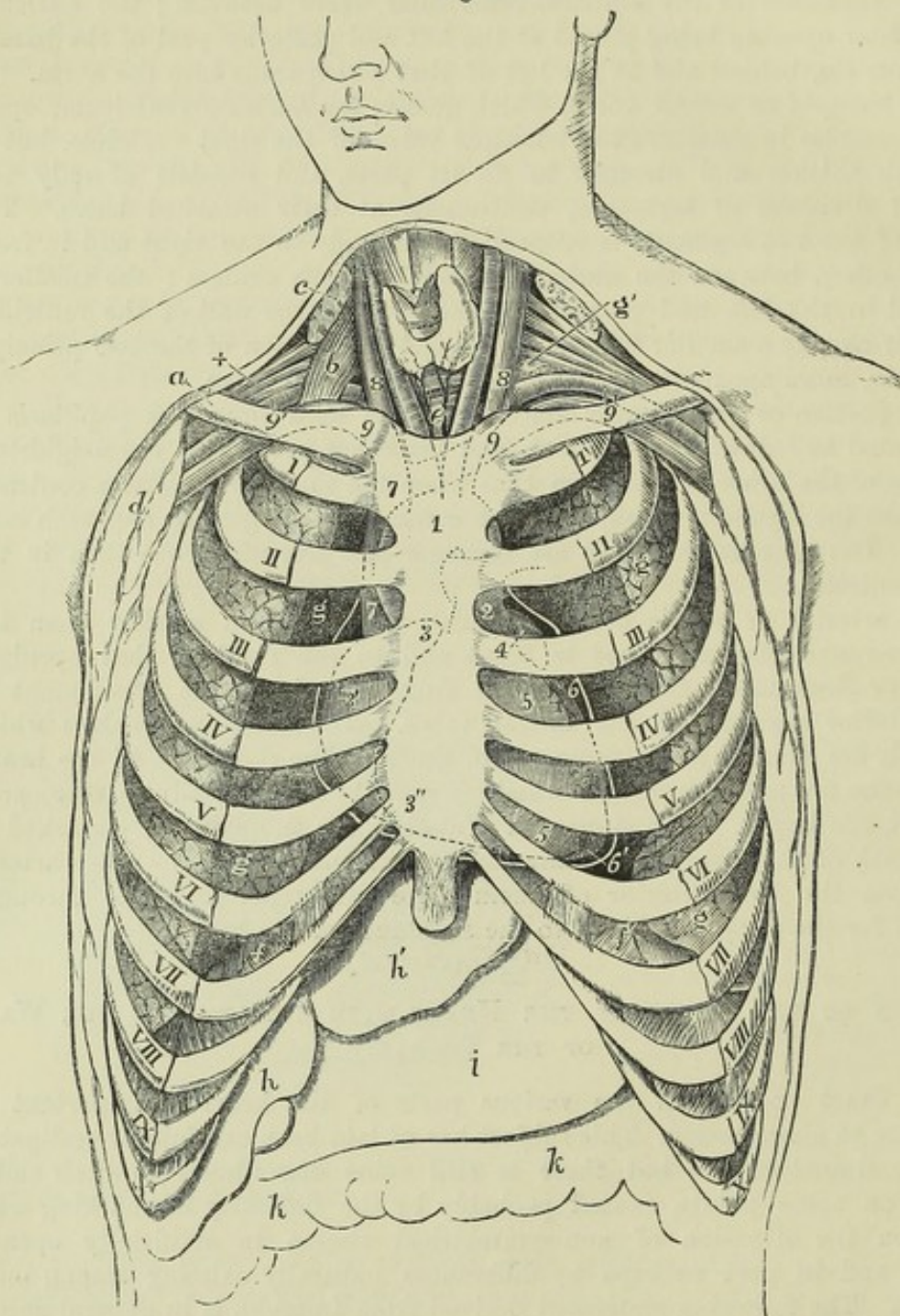


Fig. 235.—SEMI-DIAGRAMMATIC REPRESENTATION OF THE CHEST, WITH THE INTERCOSTAL SPACES DISSECTED IN FRONT TO SHOW THE POSITION OF THE HEART AND GREAT VESSELS, AS SEEN BEHIND THE STERNUM AND COSTAL CARTILAGES (from Luschka and A. Thomson).

*a*, right clavicle ; *b*, scalenus anticus muscle ; *c*, sterno-mastoid muscle divided ; *d*, pectoral muscles divided ; +, axillary nerves above the subclavian artery ; *e*, trachea below the isthmus of the thyroid body ; *f*, *f*, upper surface of the diaphragm ; *g*, *g*, surface of the lungs ; *g'*, on the left side, apex of the lung or pleura appearing in the neck ; *h*, right, *h'*, left lobe of the liver ; *i*, stomach ; *k*, *k*, transverse colon ; I, to X, first to tenth ribs near



their cartilages; 1, placed on the lower part of the manubrium of the sternum, and on the place of the arch of the aorta indicated by dotted lines; 2, placed in the second left intercostal space, on the stem of the pulmonary artery; 3, apex of the right auricle; 3', its most prominent part, behind the third space; 3'', its lower part at the junction of the sixth and seventh right costal cartilages with the sternum; 4, left auricular appendix; 5, 5, right ventricle; 6, left ventricle; 6', apex of the heart: the white line outside the heart is intended to indicate the external pericardium, as if the anterior half were removed by a transverse incision; 7, 7, vena cava superior; 8, 8, internal jugular veins; 9, 9, subclavian veins, joining the jugular; 9, 7, 9, innominate veins; the right rising behind the sterno-clavicular articulation, the left crossing obliquely behind the upper half of the manubrium. The position of the first parts of the innominate artery, left carotid and left subclavian arteries, is indicated behind and below this vein; 9', 9', outer part of the subclavian arteries. It is to be observed that in this figure the attachment of the sixth costal cartilage to the sternum is represented a little too high.

The auriculo-ventricular openings lie in the line of the auriculo-ventricular sulcus. The middle of that of the right side lies behind the sternum, between the fourth costal cartilages, and the anterior cusp of the tricuspid valve, and extends to the fifth left costal cartilage. The middle of the left auriculo-ventricular opening is in the second intercostal space, less than an inch to the left of the sternum; but as it is placed deeply, and overlaid by the arterial openings, the part immediately over it is unfavourable for auscultation, which is therefore best conducted at the point of impulse. The orifice of the pulmonary artery, according to Luschka, is placed immediately to the left of the sternum, opposite the second intercostal space, the free margin of the anterior valve reaching up to the lower border of the second rib. The aortic orifice, behind the insertion of the third left costal cartilage and the sternum, is on a slightly lower level than the orifice of the pulmonary artery, and is covered by it in two-thirds of its breadth. The aortic orifice being thus concealed, the sounds produced within it are best heard at the spot where the aorta approaches nearest to the surface, viz., opposite to the first and second intercostal spaces at the right margin of the sternum. (Luschka, *Die Brustorgane*, 1857; and *Anatomie des Menschen*, &c., 1863; Walshe, *Diseases of the Heart and Great Vessels*; Sibson, *On the Normal and Abnormal Situation and Structure of the Viscera of the Chest*, in *Trans. of the Provinc. Med. and Surg. Assoc.*, vol. xii., year 1842, and in his *Work on Medical Anatomy*; Allen Thomson, *Notice of the case of E. Groux*, &c., with *Observations on the Position and Actions of the Heart*, in *Glasgow Med. Journ.* April, 1858.)

The following additional particulars are taken from the observations of Allen Thomson. The summit of the aortic arch is on a level with the middle of the manubrium sterni; and the left border of the innominate artery at its origin from the arch is slightly to the left side of the middle line. The middle of the commencement of the aorta, where it springs from the left ventricle, is behind the left border of the sternum, on a level with the lower edge of the third costal cartilage. The ascending part of the aorta bulges beyond the right border of the sternum to the extent of at least a quarter of an inch; and the vena cava superior extends about half an inch farther in the same direction. The trunk of the pulmonary artery is wholly to the left of the middle line, and its left border is about three quarters of an inch beyond the left border of the sternum. The concavity of the aortic arch is on a level with the junction of the manubrium with the body of the sternum.

The right auricular appendage covers the lower part of the ascending aorta to the right of the pulmonary semilunar valves, and its point is exactly behind the middle line on a level with the upper border of the third costal cartilages.

The most projecting part of the right ventricle with the conus arteriosus lies behind the sternum, between the lower end of the body and the inner part of the left third intercostal space.

The right auricle extends to fully an inch beyond the right border of the sternum.



The apex of the heart is situated about three and a-half inches to the left of the middle line, and in the fifth intercostal space. The apex of the left auricular appendage is in the lower part of the second intercostal space or behind the third costal cartilage, about an inch and a quarter from the left of the sternum.

#### FIBROUS AND MUSCULAR STRUCTURE OF THE HEART.

The heart consists chiefly of muscular tissue; but besides this and the thin membranes investing its surface and lining its cavities, there enter into the formation of its wall, numerous blood-vessels, absorbents, and nerves, together with more or less fat and some areolar tissue.

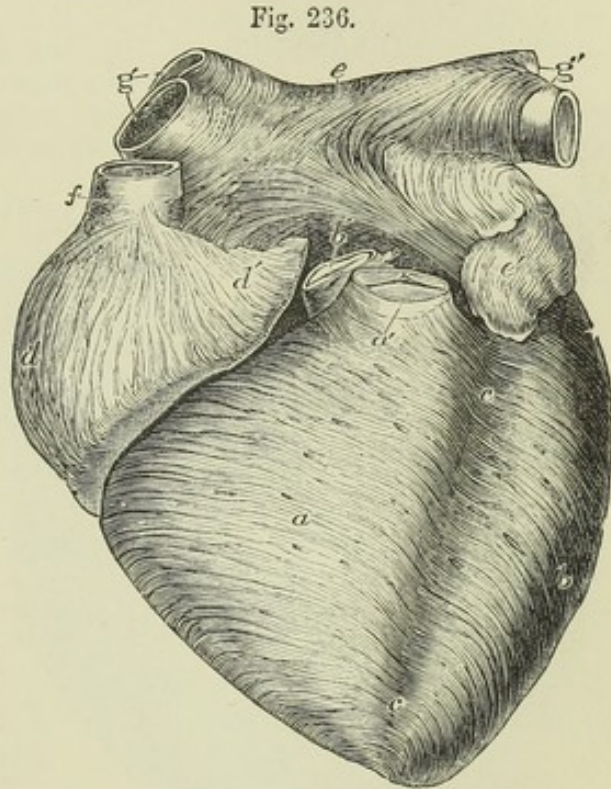
THE FIBROUS TISSUE belonging to the heart, besides what enters into the structure of the different valves and the chordæ tendineæ, is found principally surrounding the auriculo-ventricular and great arterial orifices. When we view the base of the heart so placed that the two auriculo-ventricular orifices, which are separated only by the upper edge of the septum ventriculorum are side by side, instead of the right being somewhat in front of the left, as is the case during life, the aortic opening is seen to occupy a position between and in front of them, and to have the opening of the pulmonary artery immediately in front of it. The wall of the aortic opening is firmly blended opposite one of the semilunar valves with the forepart of the right margin of the left auriculo-ventricular opening; and opposite the angle between the other two valves it is in close contact with the margin of the right auriculo-ventricular opening. In the angle between the aortic and two auriculo-ventricular openings there is found a small fibro-cartilaginous mass, which in some large animals, as the ox and elephant, is replaced by a piece of bone. From this nodule a thick process extends backwards between the two auriculo-ventricular orifices beneath the septum auricularum, and others pass forwards forming bands, one on each side of the aortic opening. These processes form the bases of what have been elaborately described by authors as the *fibrous* or *tendinous rings* of the auriculo-ventricular openings. These rings, and others which are described as bounding the arterial orifices, have had a great importance imputed to them as being the tendons of origin of the ventricular muscular fibres, a view which, however, from recent investigations to be presently noticed, appears to be incorrect. The rings around the auriculo-ventricular orifices consist of only a small quantity of loose, white, fibrous tissue, continuous with that which is found in the segments of the valves, strengthened on the sides next the septum by the processes from the fibro-cartilaginous nodule. The rings of the arterial orifices have been described by authors, and also in the previous editions of this work, as each formed by a fibrous band or zone, one edge of which is even, and gives attachment to the muscular fasciculi of the ventricle, whilst the other is scalloped into three deep semilunar notches, and is firmly fixed to the middle coat of the large artery. This scalloped margin is simply the line of junction of the endocardium with the festooned line of attachment of the semilunar valves and termination of the artery, strengthened however by areolar tissue. The fibres of the middle coat of the artery also, opposite the sinuses of Valsalva, are not arranged annularly as in other parts of the vessel, but diverge from between the sinuses, and spread upwards and laterally on the walls of the vessel; and the attachment of the artery to the ventricle is principally effected by fibrous tissue continuous with the middle coat of the artery and with the fibrous tissue in the valves, which spreads out between the small fasciculi of the muscular substance, and is firmly connected with it.



THE MUSCULAR FIBRES of the heart in their mode of action belong to the involuntary class, but are of a deep red colour, and possess the transversely striated structure. They are smaller than the ordinary voluntary muscular fibres: their striation is frequently as distinct in a longitudinal as in a transverse direction: and not only is there an exceedingly intricate interlacement of both fasciculi and fibres, but the latter appear to divide and unite frequently with each other so as to produce a finely reticulated structure.

Fig. 236.—HEART OF A YOUNG SUBJECT DISSECTED AFTER BOILING TO SHOW THE SUPERFICIAL MUSCULAR FIBRES, SEEN ANTERIORLY.  $\frac{2}{3}$

This figure is planned after one of Luschka's, but its details have been chiefly taken from an original preparation. The aorta and pulmonary arteries have been cut short close to the semilunar valves, so as to show the anterior fibres of the auricles. *a*, superficial layer of the fibres of the right ventricle; *b*, that of the left; *c, c*, anterior interventricular groove from which the coronary vessels have been removed, showing at the upper and lower part most of the fibres passing across from the right to the left ventricle, while in the middle part some dip into the septum; *a'*, pulmonary artery; *b'*, aorta; *d*, right auricle; *d'*, its appendix, both showing chiefly perpendicular fibres; *e*, upper part of the left auricle; between *e*, and *b'*, the transverse fibres which behind the aorta pass across both auricles; *e'*, appendix of the left auricle; *f*, superior vena cava, round which, near the auricle, circular fibres are seen; *g, g'*, right and left pulmonary veins with circular bands of fibres surrounding them.



The fibres of the auricles are not continuous with those of the ventricles, the two sets being connected together only by the intervention of the thin fibrous rings round the auriculo-ventricular orifices; so that when these rings are destroyed by boiling a heart for some hours, the auricles may be easily separated from the ventricles.

*Fibres of the auricles.*—These consist of a superficial set, common to both cavities, and of deeper fibres proper to each. 1. The *superficial* common or *transverse* fibres run transversely over both sinuses, near the base, and are most numerous on the anterior surface: some of them pass into the inter-auricular septum. The deeper fibres, which are *proper* to each auricle, consist of two sets, viz. the looped and the annular fibres. 2. The *looped* fibres pass over the auricle and seem to be attached by both extremities to the corresponding auriculo-ventricular rings. 3. The *annular* fibres encircle the auricular appendages from end to end, some longitudinal fibres running within them. These annular fibres also surround the entrances of the venæ cavæ on the right, and of the coronary vein and the pulmonary veins on the left side of the heart,—the muscular fibres extending for some distance



from the auricle upon the veins, especially upon the superior vena cava and the pulmonary veins.

*Fibres of the ventricles.*—The muscular fibres of the ventricles have a very intricate disposition, which has received great attention from various anatomists, such as Wolff, Gerdy, Reid, Searle, and most recently Pettigrew, the last of whom has done much to elucidate the nature of the arrangement in animals, although perhaps the whole subject cannot yet be considered as fully understood.

Fig. 237.

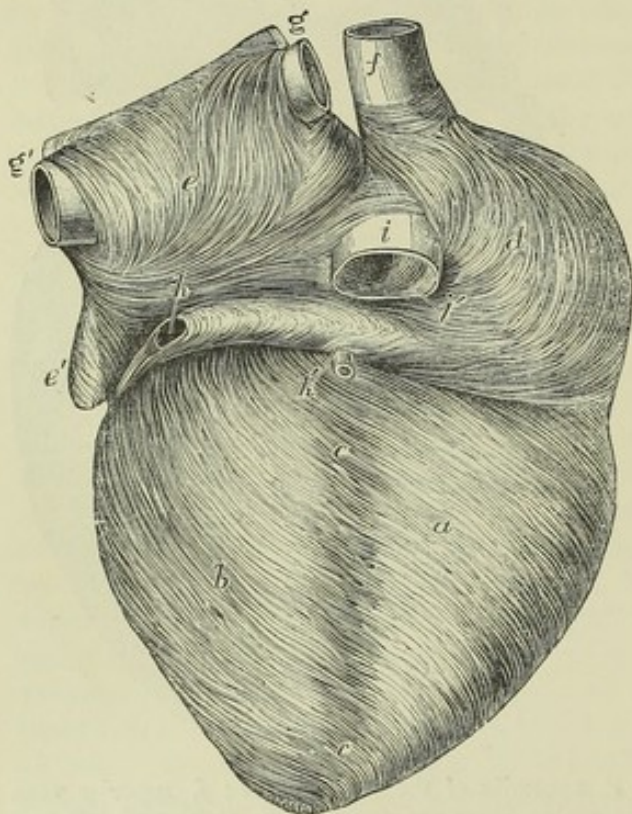


Fig. 237.—POSTERIOR VIEW OF THE SAME PREPARATION AS IS REPRESENTED IN THE PRECEDING FIGURE.  $\frac{3}{4}$

*a*, posterior surface of the right ventricle with its superficial muscular fibres dissected; *b*, the same of the left ventricle; *c*, posterior interventricular groove, from which the coronary vessels have been removed; *d*, right auricle; *e*, the left, showing some transverse fibres common to both auricles, and some belonging to each one; *f*, superior vena cava; *g, g'*, pulmonary veins cut short; *h*, sinus of the great coronary vein covered by muscular fibres; *h'*, posterior coronary vein joining the principal one; *i*, inferior vena cava; *i'*, Eustachian valve as seen from behind.

It is chiefly the reticulated structure or continual union of the greater part of the muscular fibres with each other which renders difficult the investigation

of the course and disposition of these fibres. In order to unravel them with any degree of success, it is best to boil the slightly distended heart for five or six hours, so as to destroy the connective tissue, and then carefully to dissect the heart in part by cutting and in part by tearing asunder the fibres with blunt instruments.

According to Pettigrew's observations, made principally upon the hearts of ruminating animals, as many as seven layers of fibres may be distinguished in the walls of both ventricles; \* three of these being external, three internal, and one situated immediately between them: but it may be remarked that, although some of these layers, such as the external, may be readily separated from the next, others of them run so much into those with which they are in contact, that we must regard the distinction of layers as applying more strictly to the difference of the direction of the majority of the fibres at different depths, than to a real and constant separation of determinate layers, in each of which the fibres are alike in direction. At the same time, for the convenience of description, it may be well to recognise provisionally the seven layers of Pettigrew.

One of the most important facts which has been established by Pettigrew's

\* Wolff conceived that five or six layers might be made out.

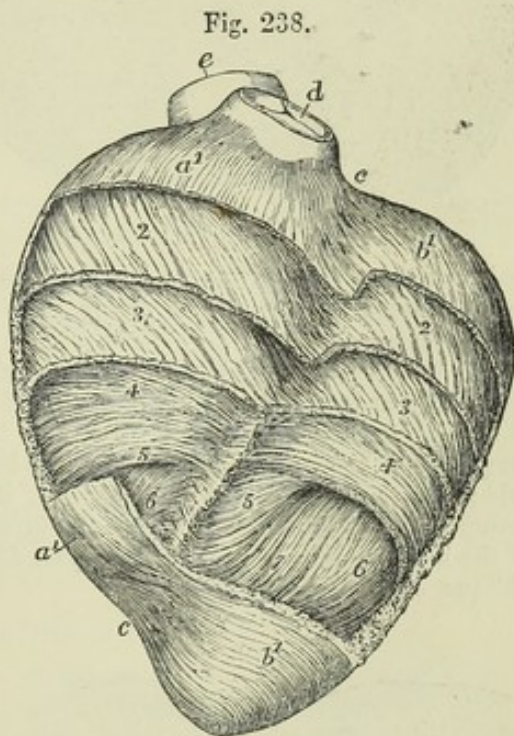


researches, is that of the continuity of the fibres of certain external layers with those of corresponding internal layers. This continuity takes place at the base of the heart round the auriculo-ventricular orifices and upon the septum, and at the apex of the left ventricle in that peculiar spiral concentration of the fibres known to previous observers as the vortex or whorl. Thus the fibres of the first or external layer are continuous with those of the deepest or innermost, in part by folding over the margin of the auriculo-ventricular orifice, and in part by penetration through the apex. In the same manner the fibres of a second or deeper external layer are continuous with those of a layer named the sixth by Pettigrew, and the fibres of the third external layer with those of the fifth; while the fibres of the middle or fourth layer of Pettigrew may be considered to return upon others of the same set. In this manner the first and seventh layers enclose all the others, the second and sixth enclose those within them, and the third and fifth enclose the fourth.

The fibres of the ventricles, therefore, do not take their origin, as was in general previously held, from the fibrous rings surrounding the auriculo-ventricular orifices

Fig. 238.—VIEW OF A PARTIAL DISSECTION OF THE LAYERS OF FIBRES OF THE VENTRICLES IN A SHEEP'S HEART IN FRONT (after the manner of Pettigrew).  $\frac{3}{4}$

At the base and apex the pericardium and connective tissue and fat alone have been removed, and the superficial layer of fibres is displayed on these parts of both ventricles. In the intervening space, layer after layer of the fibres has been removed from above downwards, reaching to a greater depth on the left than on the right side.  $a^1, a^1$ , the superficial layer of the right ventricle;  $b^1, b^1$ , the same of the left ventricle; 2, the second layer of both ventricles; 3, the third; 4, the fourth or central, with fibres nearly transverse; 5 and 6, two of the deeper layers coming next; and 7, a small part of the fibres of the deepest layer on the front of the left ventricle, passing into one of the larger papillary muscles, and derived from the posterior superficial fibres, which have entered the whorl of the apex anteriorly; the different degree of obliquity and other changes of direction of the fibres is shown in these several layers;  $c, c$ , between these letters and numbers is the anterior coronary or inter-ventricular groove, in which superiorly the greater part of the fibres of the superficial layer is seen to cross from right to left; in the remaining part of the groove, which is dissected, part of the fibres from both ventricles is seen to turn backwards towards the septum;  $d$ , the pulmonary artery cut short;  $e$ , the first part of the aorta.



and the roots of the great arteries. The only fibres which come in contact with those structures are the fibres of the superficial layer, where they dip in to be continuous with those of the deepest layer; and even these for the most part exhibit, on careful dissection, no breach of continuity of muscular fibres, but are merely bound down by white tissue penetrating between the fasciculi; a small portion, however, of the muscular fibres which surround the auriculo-ventricular orifices become continuous with the segments of the valves and with chordæ tendineæ, and through them with the muscoli papillares, the fibres of which belong chiefly to the innermost layer.

Some fibres, especially those belonging to the superficial layers, and more especially upon the posterior surface of the heart, pass round and enclose both ventricles; others, especially in front, may be considered to belong to one ventricle only. Thus the anterior superficial fibres of the right ventricle in descending from the right to the



left of the heart, pass in part across the anterior longitudinal groove, covering partially the coronary vessels, and in part dip into the groove and ascend obliquely upon the right side of the septum. The anterior fibres of the left ventricle are derived in part from those arising from the roots of the great vessels, in part from those crossing the coronary groove from the right, and in part they come out from the left surface of the septum, into which they dip in front like those of the right ventricle: those of the anterior fibres of the left ventricle which are near the apex pass spirally round this part to enter the whorl posteriorly, while the posterior set of superficial fibres, turning round the apex with a similar spiral, arrive in front and there enter the vortex. These fibres thus carried into the interior ascend upon the posterior and anterior

Fig. 239.

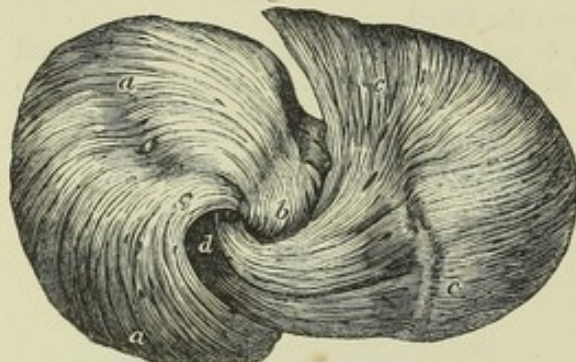

Fig. 239.—VIEW OF THE FIBRES OF THE SHEEP'S HEART, DISSECTED AT THE APEX TO SHOW THE "VORTEX" IN WHICH THE FIBRES ENTER THE APEX IN TWO SETS FROM THE EXTERNAL LAYER (from Pettigrew).

*a, a*, anterior fibres entering the apex of the left ventricle posteriorly at *b*; *c, c*, posterior fibres entering the apex anteriorly at *d*.

internal surfaces of the left ventricle, forming the almost longitudinal innermost layer of fibres,

and contribute to form the columnæ carneæ and muscoli papillares. Their direction, as they ascend internally, is nearly the opposite of that in which they made their descent externally.

The direction of the fibres in the successive layers gradually changes as we proceed from without inwards; for example on the front of the right or left ventricle it is at first very oblique from right to left of the heart, or indeed in some parts almost longitudinal from base to apex,\* it then becomes less and less oblique, until in the middle layer, which is also the thickest, it is transverse; the obliquity, being now resumed and gradually increasing, the direction is changed to that from right to left of the heart and from apex to base upwards, until at last in the interior it is extremely oblique, or nearly longitudinal.

Fig. 240.

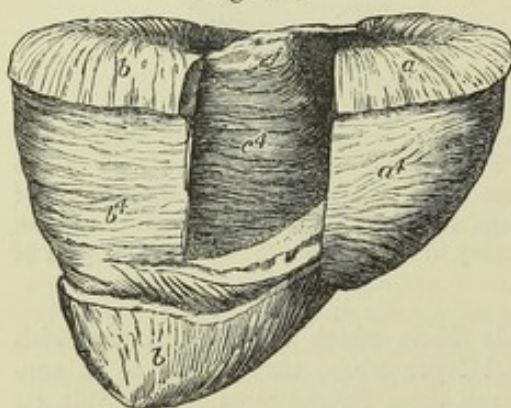


Fig. 240.—DISSECTION OF THE VENTRICLES OF THE SHEEP'S HEART, VIEWED FROM BEHIND, A PART OF THE POSTERIOR WALL BEING REMOVED TO SHOW A DISSECTION OF THE FIBRES OF THE SEPTUM AT A SIMILAR DEPTH (from Pettigrew). 3

*a*, the superficial layer of fibres of the right ventricle; *b*, the same of the left ventricle at the base and apex posteriorly; *a'*, the fourth or middle layer of fibres of the right ventricle exposed; *b'*, the same layer of the left ventricle; *c'*, the same of the septum, showing the fibres of that layer continued forward from those of the left ventricle.

It is only the three outer layers and part of the fourth layer which are distributed round both ventricles, the three internal layers belong solely to each ventricle.

The septum consists of three sets of fibres, viz., 1, those belonging to the right ventricle; 2, those belonging to the left; and 3, those common to both ventricles.

The difference of thickness of the walls of the right and left ventricles, which is so

\* The direction is less longitudinal in the human heart than in that of the sheep.



remarkable in the adult, does not exist at an early period in the foetus. An examination of the foetal heart, therefore, shows a much greater similarity in the mode of arrangement of the layers of fibres in the walls of the two ventricles than might be supposed from the examination of the adult.

It is to be observed, in conclusion, that Pettigrew's observations were made almost exclusively upon the hearts of animals. No doubt many circumstances are nearly similar in the human heart, but it is still desirable that a fuller examination of the structure of the human heart should be made, and more especially that this subject should be investigated in connection with its development.

(C. F. Wolff, *De ordine fibrarum Muscularium Cordis*; Act. Acad. Petropol. 1780—1792. Gerdy, *Rech. &c. d'Anatomie*, Paris, 1823. J. Reid, Art. "Heart," in *Cyclop. of Anat. and Physiol.* Searle, Art. "Fibres of the Heart," in the same. J. Pettigrew, in *Philos. Trans.* 1864.)

#### VESSELS AND NERVES.

The bloodvessels and nerves of the heart will only be shortly noticed in this place, as a fuller description of them will be given along with those parts of the vascular and nervous systems from which they respectively take their origin.

*Vessels.*—The substance of the heart receives its blood through the two *coronary arteries*, which arise respectively from the two anterior aortic sinuses of Valsalva. The *coronary veins* terminate in the right auricle. Besides the great cardiac or coronary vein, and another principal branch, there are two smaller orders of veins opening separately into the right auricle. The stems and larger divisions of these vessels run principally in the great transverse and longitudinal grooves of the heart; from these grooves and other parts of the external surface the smaller branches penetrate into every part of the muscular substance.

*Nerves.*—The nerves given off by the cardiac plexuses, appear rather small in comparison with the bulk of the heart; they are derived partly from the cerebro-spinal and partly from the sympathetic system, more especially from the pneumogastric nerve, and from the cervical and superior dorsal ganglia of the sympathetic nerve. Besides the larger ganglia in the cardiac plexuses at the base of the heart, the nerves present minute ganglia at different points along their course in its substance, which have been figured and described by Remak. The nerves course obliquely downwards on the ventricles of the heart, decussating with the superficial fibres, between which and the pericardium are situated their main branches and the ganglia of Remak. (Remak; *Froriep's Notizen*, 1838, p. 137; and *Müller's Archiv.* 1844, p. 463, taf. xii.)

#### WEIGHT AND DIMENSIONS OF THE HEART.

The size and weight of the heart, the thickness of its walls, the capacity of its several cavities, and the width of its great orifices, have been made the subject of extensive observation, more especially with the view to determine some standard dimensions with which to compare the deviations occurring in disease.

*Size.*—It was stated by Laennec, as the result of his experience, that the heart in its natural condition was about equal in size to the closed hand of the individual. It is about five inches long, three and a half in its greatest width, and two and a half in its extreme thickness from the anterior to the posterior surface; but linear measurements of a flaccid organ like the heart must be subject to so many accidental variations as to render them of little value.

*Weight.*—The average weight of the heart in the adult is also subject to considerable variation, ranging between rather wide limits, which depend on the general weight of the body and on the sex.

Its mean weight has been variously stated by different authors, as from 7 oz. up to 10 oz.; but according to tables published by Reid, the average weight in the adult male is as high as 11 oz., and in the female as 9 oz.; while according to Peacock the average of the male is  $9\frac{3}{4}$  oz., and that of the female 9 oz.

The weight of the heart maintains some general proportion to that of the body. According to Tiedemann this is about 1 to 160; by Clendinning it was found to be 1 to 158 in males, and 1 to 149 in females; and by Reid to be 1 to 169 in a series of thirty-seven males, and 1 to 176 in twelve females; but in the healthy males dying suddenly the ratio was as 1 to 173.



It was shown by Clendinning that the heart continued to increase in weight up to an advanced period of life, but at a comparatively slower rate subsequently to the age of twenty-nine years. Subjoined is a tabular statement of some of the average results derived from the observations of these authors.

CLENDINNING.			REID.			PEACOCK.		
Age in years.	Weight in oz.		Age in years.	Males.	Females.	Weight in oz. and drachms.		
	Males.	Females.				Males.	Females.	
15 to 29 ...	8½	8½	16 to 20 ..	8 10	6 13	8 2½	8 13	
30—50 ...	9½	8½	20—30 ...	10 4	8 0	9 0½	8 10½	
50—60 ...	10½	8	30—40 ...	10 8	9 3	9 7	8 13½	
60—+ ...	10½	8	40—50 ...	11 7	9 8	8 11	9 3	
			50—60 ...	11 10	9 14	9 12	9 7½	
			60—70 ...	12 6	9 5	10 13½	7 0	
			70—+ ...	12 6	9 6			

Entirely in accordance with these observations upon the increase of the heart's weight according to age, it has been found by Bizot that this organ continues to enlarge in all its dimensions as life advances, viz., in the length, breadth, and thickness of its walls. The greatest increase was detected in the substance of the left ventricle and the ventricular septum. (Reid, in the Lond. and Edin. Monthly Journal of Med. Science, April, 1843; T. B. Peacock, in the same journal, in 1846, and reprinted separately, with additional observations, in 1854; Clendinning, in the Medic. Chir. Transact., 1838; Bizot, Mém. de la Soc. Médic. d'Observation de Paris, tom. i. p. 262. 1836.)

*Capacity of the auricles and ventricles.*—To determine with precision the absolute and relative capacities of the four cavities of the heart, as they exist during life, is impossible; and their capacity is so much influenced by their different states of distension, and also by the different degrees of contraction of their muscular walls at the moment of death, that no constant numerical relation in this respect can be looked for between them. Hence the most opposite statements prevail, especially with regard to the size of the ventricular cavities.

The auricles are generally admitted to be rather less capacious than the ventricles. The right auricle is also said to be larger than the left, in the proportion of 5 to 4. (Cruveilhier.)

The capacity of the left ventricle has been stated by different anatomists as variously as at 1½ fluid ounces and 4 oz.; it probably does not exceed 2 oz.

The right ventricle is asserted by some to be larger than the left; by others (Lower, Sabatier, Andral) the two are stated to have an equal capacity; Cruveilhier, judging from the effect of injections, has found the left to be the larger of the two. In the ordinary modes of death, the right ventricle is always found more capacious than the left, which is probably owing to its being distended with blood, in consequence of the cessation of the circulation through the lungs: the left ventricle, on the other hand, is found nearly empty, and thus becomes more fully contracted. There are reasons for believing, however, that during life scarcely any difference of capacity exists between the two cavities.

*Size of the ventricular openings.*—The right auriculo-ventricular opening, and the orifice of the pulmonary artery, are both found to be somewhat larger after death than the corresponding openings on the left side of the heart. Their circumference is thus stated by Bouillaud. (Traité des Malad. du Cœur, tom. i. p. 52. Paris, 1835.)

		Inches and Lines.		
		Max.	Med.	Min.
Auriculo-ventricular orifices	{ Right .....	4 0	3 10	3 9
	{ Left.....	3 10	3 6	3 3
Arterial orifices . . . .	{ Right (Pulmonary)	2 10	2 7	2 6
	{ Left (Aortic) .....	2 8	2 8	2 4

According to Peacock's most recent observations, the following (omitting the



fractions of lines) are the average dimensions of these orifices in adult males and females, between the ages of 20 and 60 years :—

		Males.		Females.	
		Inches and Lines.			
Auriculo-ventricular orifices	Right . . . . .	4	6	4	0
	Left . . . . .	3	7	3	10
Arterial orifices . . . .	Right (Pulmonary) . . .	3	4	3	3
	Left (Aortic) . . . . .	3	0	2	10

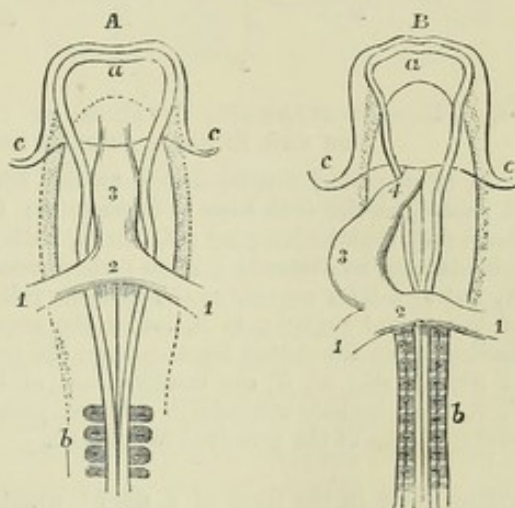
#### DEVELOPMENT OF THE HEART AND GREAT BLOOD-VESSELS.

*The Heart.*—The heart first appears as an elongated sac or dilated tube lying at the fore part of the embryo, having two veins connected with it behind, and a large arterial trunk proceeding from it in front. This tube exhibits rhythmic contractions of its walls from a very early period. Its form is at first symmetrical, but soon it becomes curved or bent upon itself like a horse-shoe, and projects on the ventral aspect of the body towards the right side.

Fig. 241.—VIEWS OF THE ANTERIOR OR CEPHALIC HALF OF THE EMBRYO-CHICK FROM THE ABDOMINAL SURFACE, SHOWING THE HEART IN THE EARLIEST STAGES OF ITS FORMATION (after Remak). Magnified about twenty times.

A, embryo after about twenty-eight or thirty hours of incubation; B, after about thirty-six hours of incubation; *a*, placed on the anterior cerebral vesicle; *b*, the primitive cervical vertebrae; *c, c*, the cephalic fold of the germinal membrane; 1, 1, primitive veins entering the auricle; 2, 3, in A, the primitive and simple sac or short tube of the heart; in B, 2, the auricular part; 3, the ventricular part beginning to bulge or be bent to the side and dilate; 4, the anterior part of the tube which becomes the aortic bulb.

Fig. 241.



As this bending increases the venous end approaches the arterial, and at the same time the tube, which progressively increases in size and in the thickness of its walls, becomes divided by two slight constrictions into three compartments, opening successively into each other. The first, next to the veins, is the *auricular* portion, the middle one is the *ventricular*, and the last, which is the primitive arterial trunk, is named the *bulbus arteriosus*.

The auricular portion becomes placed behind the ventricular compartment, and relatively to that cavity considerably enlarged. Moreover, two little pouches appear upon it, one at each side, which form the future auricular appendages. The walls of the ventricular portion are already thicker than the rest.

The next series of changes consists in the gradual subdivision of the single auricle, ventricle, and arterial bulb, each into two compartments, to form the right and left auricles, the right and left ventricles, and the pulmonary artery and aorta: and these changes are accompanied by an alteration in the position of the parts with relation to the body, the ventricular portion now lying transversely, so as to bring that portion which is afterwards to form the apex towards the left side.

This subdivision commences first in the single *ventricular* portion of the heart. A small notch appears externally to the right of the apex, which goes on increasing in depth for some weeks, and then is again gradually obliterated. In the meantime, about the fourth or fifth week, a septum begins to rise up internally from the right side of the heart, at a little distance from the apex and from the anterior wall of the cavity, and proceeds in the direction of the base, towards the arterial bulb, and about the eighth week is complete. Traces of the subdivision of the *auricular* portion com-



Fig. 242.

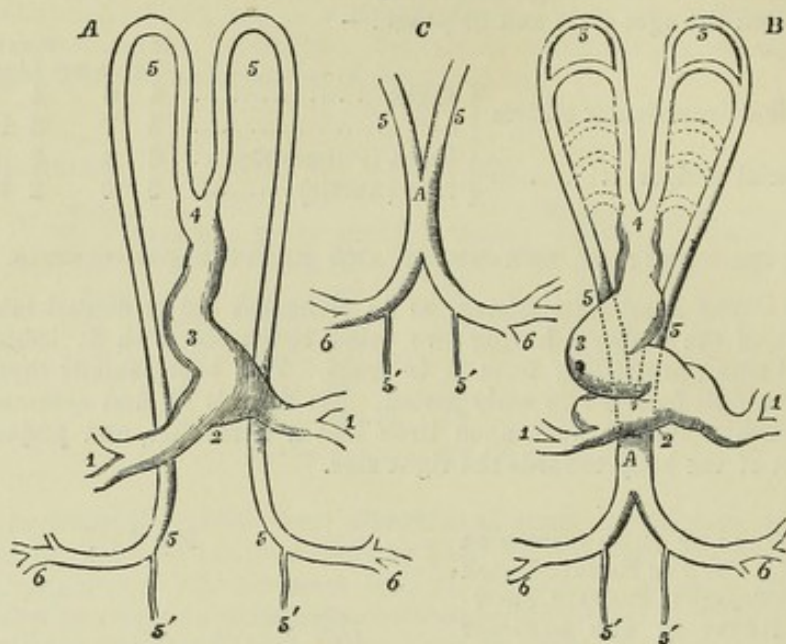


Fig. 242.—DIAGRAMMATIC OUTLINES OF THE HEART AND FIRST ARTERIAL VESSELS OF THE EMBRYO, AS SEEN FROM THE ABDOMINAL SURFACE.

A, at a period corresponding to the 36th or 38th hour of incubation in the chick ; B, and C, at the 48th hour of incubation ; 1, 1, primitive veins ; 2, auricular part of the heart ; 3, ventricular part ; 4, aortic bulb ; 5, 5, the primitive aortic arches, and their continuation as descending aorta ; these vessels are still separate in their whole extent in A, but at a later period, as shown more fully in C, have coalesced into one tube in a part of the dorsal region ; in B, below the upper 5, the second aortic arch is formed, and farther down the dotted lines indicate the position of the succeeding arches to the number of five in all ; 5', 5', the continuation of the main vessels in the body of the embryo ; 6, 6, the omphalo-mesenteric arteries passing out of the body of the embryo into the vascular area of the germinal membrane.

mence early in the form of a slight constriction on the outer surface, which marks off the future auricles, the left being at first the smaller of the two ; but the auricular septum is not begun until after that of the ventricles is completed. About

Fig. 243.

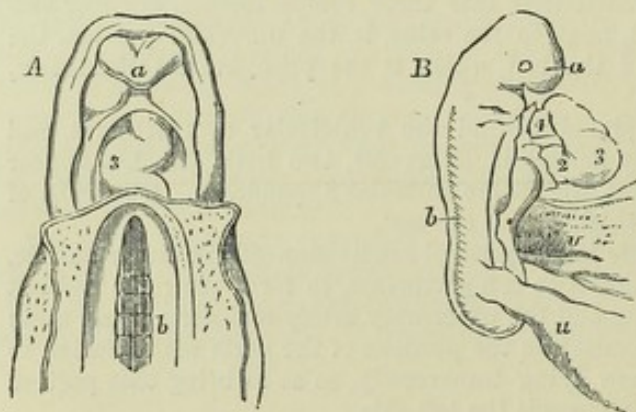


Fig. 243.—HUMAN EMBRYOES AT DIFFERENT EARLY STAGES OF DEVELOPMENT, SHOWING THE HEART IN ITS TUBULAR CONDITION.

A, upper half of the body of a human embryo of three weeks, viewed from the abdominal side (from Coste) ; a, frontal plate ; b, vertebræ, on which the primitive aortæ are lying ; 3, the middle of the tube of the heart, below it the place of entrance of the great veins, above it the aortic bulb.

B, lateral view of a human embryo more advanced than that

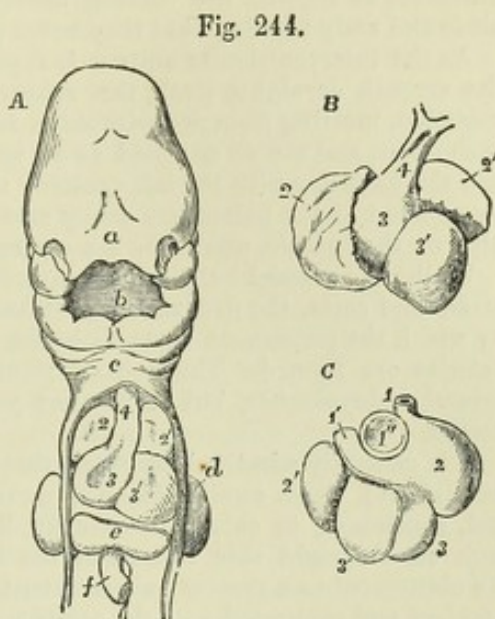
last referred to, and somewhat imperfectly developed (from A. Thomson) ; a, the frontal part of the head ; b, the vertebral column ; v, the wide communication of the umbilical vesicle or yolk sac with the intestine ; u, communication with the allantois or urachus ; 2, auricular part of the heart connected with the veins posteriorly ; 3, ventricular part of the bent tube ; 4, the aortic bulb ; near the extremities of the tube the divided pericardium is seen.



the ninth week it appears, growing from above and behind downwards and forwards, and at length comes to meet and coalesce below with the rising edge of the inter-

Fig. 244.—SHOWS THE POSITION AND FORM OF THE HEART IN THE HUMAN EMBRYO FROM THE FOURTH TO THE SIXTH WEEK.

A, upper half of the body of a human embryo said to be four weeks old (from Kölliker after Coste); B and C, anterior and posterior views of the heart of a human embryo of six weeks (from Kölliker after Ecker); *a*, frontal lappet; *b*, mouth; *c*, below the lower jaw and in front of the second and third branchial arches; *d*, upper limb; *e*, liver; *f*, intestine cut short; 1, superior vena cava; 1', left superior cava or brachio-cephalic connected with the coronary vein; 1'', opening of the inferior vena cava; 2, 2', right and left auricles; 3, 3', right and left ventricles; 4, aortic bulb.



ventricular septum. The interauricular septum, however, remains incomplete during intrauterine life, and leaves an opening in the middle, which forms the *foramen ovale*. The farther steps in the separation of the auricles are connected with the changes which take place at the entrances of the great veins. There are now three large vessels terminating in the auricular extremity of the heart; of these two correspond with the superior and the inferior vena cava, and the third is the great coronary vein. At first, after the interauricular septum is partly formed above, the inferior cava opens directly into the left auricle, which is the smaller of the two; but about the twelfth week a septum, the *valve of the foramen ovale*, which afterwards forms the floor of the fossa ovalis, rises up on the left side of the entrance of the vein, which thus comes to open into the right auricle; whilst at the same time the separation of the two auricles is also rendered more complete by the gradual advance of the valve over the foramen ovale, leaving, however, the passage open until after birth.

Another valvular fold is developed at an early period on the right and anterior border of the orifice of the inferior cava, between it and the auriculo-ventricular orifice; this is the Eustachian valve. It appears to continue the opening of the inferior cava towards the upper margin of the foramen ovale, and directs the blood of the vein through that passage.

The left auricle has at first no connection with the pulmonary veins. The manner in which this connection is afterwards established has not yet been ascertained.

Originally the heart is composed of a mass of nucleated cells, similar in character to those which primarily constitute the other organs of the body. Muscular tissue is subsequently formed from these cells; but the rhythmic contractions commence and proceed for some time, whilst the heart is yet composed of cells, and before the muscular fibres have been developed.

*The great vessels.*—At first the bulbus arteriosus is divided into two arches, which pass upwards and outwards one on each side, then turn downwards and form a right and left root of the aorta, which are at first separate, but afterwards unite behind the heart and in front of the vertebral column to form the single stem of the descending aorta. The distance soon elongates between those arches and the arterial bulb, and four other pairs of arches appear in series from above downwards, passing outwards from the vessel which ascends to the first arch, and opening into that which descends from it. Thus there are on each side *five arches*, an *internal* or *anterior* trunk uniting the origins of the arches, and an *external* or *posterior* trunk uniting their terminations, and continued into one of the *roots of the aorta*. These vascular arches are placed each in one of the branchial processes of the dorsal plates (p. 64), but it is to be noted that the whole five arches do not co-exist; for the highest



disappear before the last are developed. This arrangement of blood-vessels, together with the originally single condition of the heart, corresponds to a certain extent with the permanent condition of the heart and branchial arteries in fishes; with this difference as regards the vascular arches in the human foetus and that of mammals, birds and scaly reptiles, that they never present any farther branchial subdivision.

As the interventricular septum is approaching the base of the heart, that is, about the seventh or eighth week, the arterial bulb becomes also divided by an internal partition, meeting from opposite sides, into two vessels, which are slightly twisted on each other, and are so adjusted as to become connected, the anterior with the right and the posterior with the left ventricle: these vessels afterwards constitute the commencement of the pulmonary artery and of the aorta. A furrow subsequently, beginning on the outside, completes the separation into two vessels.

Whilst the arterial bulb is thus converted into the commencement of the pulmonary artery and aorta, the five vascular arches arising from it undergo a metamorphosis, by which the permanent aorta with the brachio-cephalic vessels and the pulmonary arteries are formed. The general results of this change have been observed by several embryologists, but it has not yet been made out with certainty in all its details.

It is generally admitted, however, that the fourth arch on the left side (counting from above), which receives blood from the aortic division of the bulb, is persistent, and, continuing to enlarge, eventually becomes the arch of the aorta. The fourth arch on the right side, as well as the first, second, and third arches on both sides, are obliterated to a greater or less extent, while certain portions of them, remaining pervious and connected with the aortic arch, appear to form the commencement of the great vessels rising from it.

Both the arches of the fifth pair were held by Baer to be connected with the

Fig. 245.

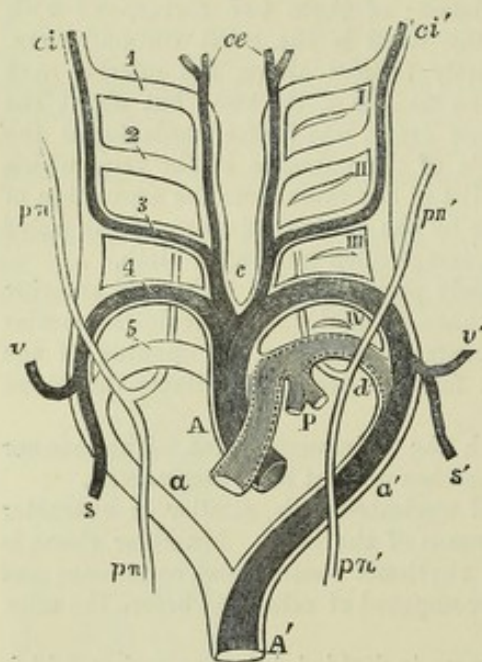


Fig. 245.—DIAGRAM OF THE AORTIC OR BRANCHIAL VASCULAR ARCHES OF THE MAMMAL, WITH THEIR TRANSFORMATIONS GIVING RISE TO THE PERMANENT ARTERIAL VESSELS (according to Rathke).

A, P, primitive arterial stem or aortic bulb, now divided into A the ascending part of the aortic arch, and P the pulmonary; *a*, the right; *a'*, the left aortic root; *A'*, the descending aorta. On the right side 1, 2, 3, 4, 5, indicate the five branchial primitive arterial arches; on the left side, I, II, III, IV, the four branchial clefts, which, for the sake of clearness, have been omitted on the right side. It will be observed, that while the fourth and fifth pairs of arches rise from the part of the aortic bulb or stem, which is at first undivided, the first, second, and third pairs are branches above *c*, of a secondary stem on each side. The permanent systemic vessels are represented in deep shade, the pulmonary arteries lighter; the parts of the primitive arches, which have only a temporary existence, are drawn in outline

only. *c*, placed between the permanent common carotid arteries; *ce*, the external carotid arteries; *ci*, *ci'*, the right and left internal carotid arteries; *s*, the right subclavian rising from the right aortic root beyond the fifth arch; *v*, the right vertebral from the same opposite the fourth arch; *v'*, *s'*, the left vertebral and subclavian arteries rising together from the left or permanent aortic root opposite the fourth arch; *P*, the pulmonary arteries rising together from the left fifth arch; *d*, the outer or back part of the left fifth arch, forming the ductus arteriosus; *pn*, *pn'*, the right and left pneumogastric nerves, descending in front of the aortic arches, with their recurrent branches represented diagrammatically as passing behind, with a view to illustrate the relations of these nerves respectively to the right subclavian artery and the arch of the aorta and ductus arteriosus.



pulmonary division of the bulb, and to send ramifications into the lungs, so as to form the right and left branches of the pulmonary artery respectively: the farther or distal portion of the right arch being obliterated, while the corresponding part of the left side continued open, as the *ductus arteriosus*, until birth. According to this view, the third arch on each side is persistent as the subclavian artery, and the external trunk above this remains as the vertebral artery, and the internal as the carotid; while the internal trunk between the third and fourth arches of the right side becomes the innominate artery. In so far as it applies to birds and some reptiles this view may be correct. But a different view of the metamorphosis, as it occurs in mammalia and man, has more recently been presented by Rathke, which has been adopted by Kölliker and others, and probably is more consistent with truth. According to Rathke, in man and mammalia one arch only, viz., the left fifth, is concerned in the formation of the pulmonary arteries; and the fifth arch of the right side is entirely obliterated. From the fifth left arch a branch is given off, which, together with the proximal part of the arch, forms the pulmonary artery, and which divides into the primary branches for the right and left lung, the distal part of the arch being converted, as according to Baer's theory, into the *ductus arteriosus*. The fourth arch of the right side, according to Rathke, forms the commencement of the right subclavian artery; a branch is given off opposite the external extremity of the fourth arch on both sides, which forms on the right side the remainder of the right subclavian, and on the left the whole of that artery; the vertebral arteries are derived from the subclavians external to the system of arterial arches; the internal trunks in their extent between the third and fourth arches remain as the common carotids, and in the remainder of their extent form the external carotids, while the third arches and the external trunks above them are converted into the internal carotid arteries. (Baer, *Entwicklungsgeschichte*, 1839; Rathke, *Untersuchungen über die Aortenwurzeln*, &c. Vienna, 1857, and Müller's *Archiv*, 1843, p. 276; A. Thomson, *Edin. New Philos. Journal*, 1830-31, and *Edin. Med. and Surg. Journ.*, No. 140; Ecker, *Icones Physiologicæ*; Bischoff's works; Kölliker, *Entwicklungsgeschichte*. 1861).

#### PECULIARITIES OF THE FŒTAL HEART AND GREAT VESSELS.—FŒTAL CIRCULATION.

*Position.*—The foetal heart, even after all its parts are formed, continues to be placed vertically in the thorax until about the fourth month, when the apex begins

Fig. 246.—VIEW OF THE FRONT AND RIGHT SIDE OF THE FŒTAL HEART, AT FOUR MONTHS, THE RIGHT AURICLE BEING LAID OPEN (from Kilian).

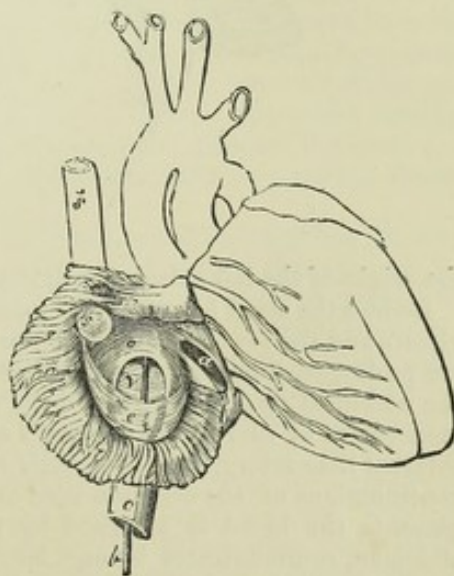
*a*, the right auriculo-ventricular opening; *b*, a probe passed up the vena cava inferior and through the foramen ovale into the left auricle; *c*, vena cava inferior; *e*, Eustachian valve; *v*, valve of the foramen ovale; *s*, *s'*, vena cava superior.

to turn towards the left side, so as to give it an oblique position.

*Size.*—As compared with the body, the heart is very much larger in the early foetus than at later periods or subsequently to birth. At one time, indeed, it occupies nearly the whole thoracic cavity. At the second month the proportion of its weight to that of the body is said by Meckel to be 1 to 50; but the ratio becomes gradually reduced to that of 1 to 120 at birth. In the adult the average is about 1 to 160.

For a long period the auricular portion is larger than the ventricular, and the right auricle is more capacious than the left; but towards birth these peculiarities disappear,

Fig. 246.





and the ventricular portion becomes the larger part of the heart. As to the ventricles themselves, the right is at first the smaller; afterwards it becomes the larger of the two, and at birth their size is about equal. In the right ventricle the infundibulum is at first less marked than afterwards.

*Structure.*—For a time the walls of the ventricles are, comparatively speaking, very thick, and the thickness of both is nearly the same. In approaching the full period, however, the left begins to be the thicker of the two. But the two chief differences in the internal structure of the foetal heart from that of the adult are the communication which exists between the two auricles by the foramen ovale, and the large size of the Eustachian valve.

The large oval orifice named the *foramen ovale* is placed at the lower and back part of the auricular septum, and is said to attain its greatest size at the sixth month. It becomes gradually occluded by a valvular fold already alluded to, which ascends from below and behind, and rises up on the left side of the rim of the foramen ovale. This rim becomes continuous at the sides with the valve, but above its free margin, which is concave and turned upwards, the foramen is left open. At length the valve passes for some distance beyond the upper part of the foramen; and still, owing to its position on the left side of the opening, it permits the passage of blood from the right to the left auricle. In the reverse direction, however, it closes the opening and no blood can pass.

Fig. 247.

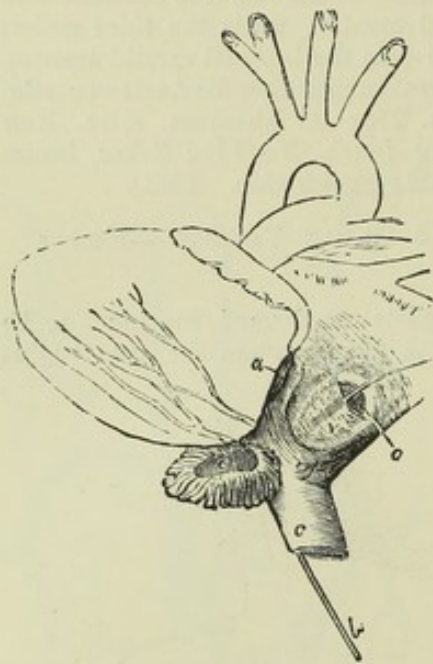


Fig. 247.—VIEW OF THE POSTERIOR AND LEFT SURFACE OF THE HEART OF A FŒTUS OF FOUR MONTHS, THE LEFT AURICLE BEING OPENED (from Kilian).

*a*, left auriculo-ventricular orifice; *c*, inferior vena cava, through which a probe *b*, is passed from below, and thence by the foramen ovale into the left auricle; *e*, left auricular appendage laid open; *o*, valve of the foramen ovale seen to be attached to the left side of the annulus ovalis of the septum.

The pulmonary artery of the foetus, in leaving the right ventricle, first gives off the branch to the right lung, and then appears to divide into its left branch and the short but wide tube named *ductus arteriosus*. This vessel, which is nearly as wide as the pulmonary artery itself, is of the thickness of a goose-quill at the time of birth, and about half an inch long. It conducts the chief part of the blood of the right ventricle into the aorta, which it joins obliquely within the termination of the arch, a little beyond

the origin of the left subclavian artery.

Besides the usual branches of the descending aorta intended to supply the abdominal viscera and the lower limbs, two large vessels, named hypogastric or *umbilical arteries*, are prolonged from the common iliacs, and passing out of the abdomen, proceed along the umbilical cord, coiling round the umbilical vein, to reach the placenta. The commencement of each of these vessels afterwards forms the trunk of the corresponding internal iliac artery, and, from their size, they might be regarded in the foetus as the continuations of the common iliac arteries into which the aorta divides. From the placenta the blood is returned by the umbilical vein, which, after entering the abdomen, communicates by one branch with the portal vein of the liver, and sends another, named *ductus venosus*, to join the vena cava inferior, as will be more fully described in the account of the vessels of the liver.

*Course of the blood in the foetus.*—The right auricle of the foetal heart receives its blood from the two venæ cavæ and the coronary vein. The blood brought by the superior cava is simply the venous blood returned from the head and upper half of



the body; whilst the inferior cava, which is considerably larger than the superior, conveys not only the blood from the lower half of the body, but also that which is sent back in a purified state from the placenta through the umbilical vein. This latter stream of blood reaches the vena cava inferior, partly by a direct passage—the ductus venosus, and partly by the hepatic veins after circulating through the liver in the *venæ portæ*.

The blood of the superior vena cava, descending in front of the Eustachian valve, and mixed with a small portion of that from the inferior cava, passes on into the right ventricle, and is thence propelled into the trunk of the pulmonary artery. A small part of it is then distributed through the branches of that vessel to the lungs, and returns by the pulmonary veins to the left auricle; but by far the larger part passes through the ductus arteriosus into the aorta, entering that vessel beyond the place of origin of the arteries of the head and upper limbs, and, mixed probably with a small quantity of the blood flowing along the aorta from the left ventricle, descends partly to supply the lower half of the body and the viscera, but principally to be conveyed along the umbilical arteries to the placenta. From all these parts it is returned by the vena cava inferior, the *venæ portæ*, and the umbilical vein; and, as already noticed, reaches the right auricle through the trunk of the inferior cava.

The blood of the inferior vena cava is only in small part distributed with that of the superior cava; by far the larger portion, directed by the Eustachian valve through the foramen ovale, flows from the right into the left auricle, and thence, together with the small quantity of blood returned from the lungs by the pulmonary veins, passes into the left ventricle, from whence it is sent into the arch of the aorta, to be distributed almost entirely to the head and upper limbs. A small portion of it, however, probably flows on into the descending aorta and joins the large stream of blood from the ductus arteriosus. From the upper half of the body the blood is returned by the branches of the superior cava to the right auricle, from which its course has been already traced.

Sabatier was of opinion that no mixture of the two streams of blood from the two *venæ cavæ* took place in the right auricle, but that all the blood of the inferior cava passed into the left auricle and ventricle, whilst that of the superior cava reached the right ventricle. He thought, however, that the two kinds of blood were intermixed at the junction of the ductus arteriosus with the aorta. The entire separation of the two streams of blood of the *venæ cavæ*, as supposed by Sabatier, is not generally admitted in the mature fœtus; but there is reason to believe that it does take place in earlier stages. In fact, the inferior cava, as already mentioned, at first opens into the left auricle, and must therefore convey its blood immediately into that cavity. As the fœtus approaches maturity, more and more of the blood of the inferior cava joins the stream from the superior cava; and, indeed, the course of the blood, and the relative position of the veins, as well as other original peculiarities of the fœtal heart, become gradually altered, to prepare the way as it were for the more important changes which take place at birth. It seems also probable that very little of the blood propelled from the left ventricle passes into the descending aorta beyond the ductus arteriosus.

From the preceding account of the course of the blood in the fœtus, it will be seen, that, whilst the renovated blood from the placenta is principally conveyed to the upper or cephalic half of the fœtus, the lower half of the body is chiefly supplied with the blood which has already circulated through the head and upper limbs, exhibiting in this a certain analogy with the mode of circulation in the turtle and various other reptiles. The larger portion of this latter stream of blood, however, is again sent out of the body to be changed in the placenta. This duty is principally performed by the right ventricle, which after birth is charged with an office somewhat analogous, in having to propel the blood through the lungs. But the passage of the placental blood is longer than that of the pulmonary, and the right ventricle of the fœtus, although probably aided by the left in the placental circulation, also takes a large share in the systemic circulation through the lower half of the body; and this, perhaps, may be the reason why the right differs less in thickness from the left ventricle in the fœtus than in the adult.

*Changes after birth.*—The immediate changes which take place at birth consist of the sudden stoppage of the placental circulation and the simultaneous commence-



Fig. 248.

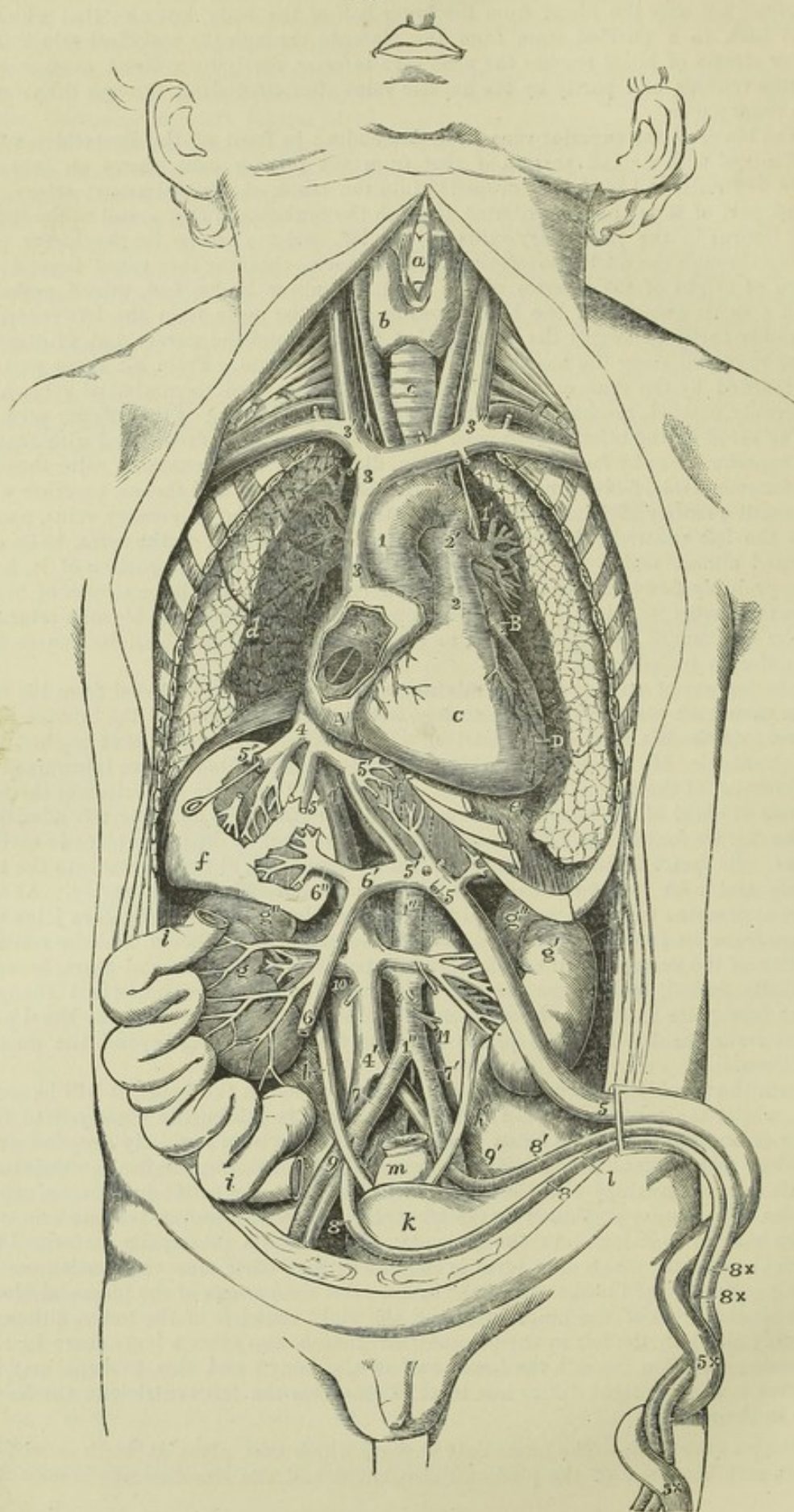




Fig. 248.—SEMI-DIAGRAMMATIC VIEW OF THE ORGANS OF CIRCULATION IN THE FŒTUS FROM BEFORE, (modified from Luschka and from Nature).  $\frac{2}{3}$

*a*, front of the thyroid cartilage; *b*, right side of the thyroid body; *c*, trachea; *d*, surface of the right lung turned outwards from the heart; *e*, diaphragm below the apex of the heart; *f*, right lobe of the liver, dissected to show ramifications of the portal and hepatic veins; *f'*, the middle part and left lobe of the liver in the same manner, showing branches of the umbilical veins and ductus venosus; *g*, right, *g'*, left kidney; *g''*, supra renal bodies; *h*, right, *h'*, left ureter; *i*, portion of the small intestine turned towards the side, to show the veins from it going to the portal vein; *k*, urinary bladder; *l*, is placed below the umbilicus, which is turned towards the left of the fœtus, and points by a line to the urachus; *m*, rectum, divided and tied at its upper part.

*A*, *A*, right auricle of the heart opened to show the foramen ovale: a probe, introduced through the large divided right hepatic vein and vena cava inferior, is seen passing through the fossa ovalis into the left auricle: at the lower part of the fossa ovalis is seen the Eustachian valve, to the right and inferiorly the auriculo-ventricular orifice; *B*, the left auricular appendix; *C*, the surface of the right ventricle; *D*, placed on the inner surface of the left lung, points to the left ventricle.

1, ascending part of the arch of the aorta; 1', back part beyond the ductus arteriosus; 2, stem of the pulmonary artery; 2', the place of division into right and left pulmonary arteries and root of the ductus arteriosus: the left pneumo-gastric nerve is seen descending over the arch of the aorta; 3, superior vena cava; 3', right, 3'', left innominate vein; 4, stem of the inferior vena cava, between the junction of the hepatic vein and the right auricle; 4', continuation of the vena cava inferior below; 5, umbilical vein within the body of the fœtus; 5 ×, without the body, in the umbilical cord; 5', 5'', ductus venosus; between 5 and 5', the direct branches of the umbilical vein to the liver; 6, vena portæ; 6', its left branch joining the umbilical vein; 6'', its right branch; 7, placed on the right iliac vein, points to the right common iliac artery; 7', left common iliac artery; 8, right, 8', left umbilical arteries coming from the internal iliac arteries; 9, 9', external iliac arteries; 10, placed below the right renal vessels; 11, inferior mesenteric artery, above the root of which are seen the two spermatic arteries.

ment of an increased flow of blood through the lungs, which then perform their office as respiratory organs. The foramen ovale, the ductus arteriosus, the ductus venosus, and the umbilical vessels, all parts peculiar to the fœtus, are gradually closed, and the right and left cavities of the heart thenceforth cease to communicate directly with each other. According to Bernt, the ductus arteriosus begins to contract immediately after several inspirations have taken place: in three or four days he sometimes found it closed; on the eighth day it was obliterated in one half the cases examined, and on the tenth day in all. The foramen ovale appears to continue open a little longer, and it sometimes remains more or less so throughout life, as already stated. The umbilical arteries, the umbilical vein and the ductus venosus shrink and begin to be obliterated from the second to the fourth day after birth, and are generally completely closed by the fourth or fifth day.

## PULMONARY VESSELS.

### PULMONARY ARTERY AND VEINS.

The *pulmonary artery* is a short wide vessel, which carries the dark blood from the right side of the heart to the lungs. It arises from the infundibulum or conus arteriosus of the right ventricle, and passes for the space of nearly two inches upwards, and at the same time backwards and to the left side, to reach the concavity of the aortic arch, where it divides into its right and left branches. The mode of attachment of the pulmonary artery to the base of the ventricle has already been fully noticed. At each side of its commencement is the corresponding coronary artery springing from the aorta, and close to its sides are the two auricular appendages. It is at first in front of the aorta, and conceals the origin of that vessel; but higher up, where it lies in front of the left auricle, it crosses to the left side of the ascending aorta, and is finally placed beneath the transverse part of the arch. The pulmonary artery and the aorta are united together



by connective tissue and by the serous layer of the pericardium, which for the space of about two inches forms a single tube around both vessels. Rather to the left of its point of bifurcation it is connected to the under side of the aortic arch by means of a short fibrous cord, which passes obliquely upwards, backwards, and to the left. This is the remains of the ductus arteriosus, a large vessel peculiar to the foetus, which has been already described.

The *two branches* of the *pulmonary artery*.—The *right branch*, longer and somewhat larger than the left, runs almost transversely outwards behind the ascending aorta and the superior vena cava into the root of the right lung, where it immediately begins to divide in the usual manner of arteries. The *left branch*, shorter than the right, passes horizontally in front of the descending aorta and left bronchus into the root of the left lung, to undergo its ramification.

The right and left pulmonary arteries, at the root of the lung, both lie in front of the bronchus and behind the veins. On the right side the bronchus is highest and the veins lowest, while on the left side the bronchus sinks to a level between the artery and veins.

*Pulmonary Veins*.—The *pulmonary veins*, which convey the red blood back from the lungs to the left side of the heart, ultimately converge into *four* short venous trunks, which are found, two on each side, in the root of the corresponding lung. The two veins of the *right* side, which are longer than those of the left, pass below the right pulmonary artery, and behind the superior vena cava, the right auricle, and the aorta, to enter the left auricle. Not unfrequently a third smaller vein exists on the right side. The two *left* pulmonary veins run a shorter course to reach the auricle, passing in front of the descending aorta.

## SYSTEMIC VESSELS.

### ARTERIES.

#### THE AORTA.

The aorta, the large main trunk of the systemic arteries, is situated partly within the thorax and partly in the abdomen. It commences at the left ventricle of the heart, and after arching over the root of the left lung, descends in front of the vertebral column, and passing through the diaphragm into the abdominal cavity, ends opposite the fourth lumbar vertebra, by dividing into the right and left common iliac arteries. In this course the aorta forms a continuous undivided trunk, which gradually diminishes in size from its commencement to its termination, and gives off larger or smaller branches at various points. Different parts of the vessel have received particular names, derived from their position or direction:—the following are generally recognized, viz., the *arch of the aorta*, the *thoracic aorta*, and the *abdominal aorta*. The short curved part, which reaches from the ventricle of the heart to the side of the third dorsal vertebra, is named the *arch*; the straight part, which extends from that vertebra to the diaphragm, is called the *thoracic aorta*; and the remainder of the vessel, down to its bifurcation, is designated the *abdominal aorta*.

#### *Arch of the Aorta.*

The arch of the aorta commences at the upper part or base of the left ventricle of the heart, behind the pulmonary artery. At first it passes upwards and to the right side, somewhat in the direction of the heart



itself, and crosses obliquely behind the sternum, approaching at the same time more nearly to that bone. Having gained the level of the upper

Fig. 249.—VIEW OF THE AORTA FROM BEFORE, WITH THE FIRST PART OF ITS PRINCIPAL BRANCHES DISSECTED OUT OF THE BODY (from R. Quain).  $\frac{1}{4}$

1, commencement of the aorta at the place where it has been separated from the left ventricle, showing below the semilunar valves closed, in front and at the sides the dilatations corresponding to these valves, or sinuses of Valsalva, and above these the origin of the right and left coronary arteries; 2, the ascending part of the arch, with the dilatation termed sinus of the arch; 3, the back of the arch, or termination of its descending portion; 4, innominate artery; 5, left carotid; 6, left subclavian; 7, hollow of the arch, and farther down the aorta, 7, 7, indicate two out of the series of intercostal arteries: the œsophageal arteries are also seen rising from the front of the thoracic aorta; 8, 8, right and left renal arteries; 9, 9, right and left common iliac arteries; 10, middle sacral artery; 11, marks one of the inferior diaphragmatic arteries; +, the coeliac axis; 12, the gastric artery; 13, the hepatic; 14, the splenic; 15, superior mesenteric; 16, inferior mesenteric; 17, right and left spermatic arteries.

Fig. 250.—VIEW OF THE AORTA FROM BEHIND, WITH ITS PRINCIPAL BRANCHES (from R. Quain).  $\frac{1}{4}$

The numbers have the same signification as in Fig. 249. The origin of the right and left intercostal arteries close to each other and near the middle of the aorta posteriorly is shown.

Fig. 249.

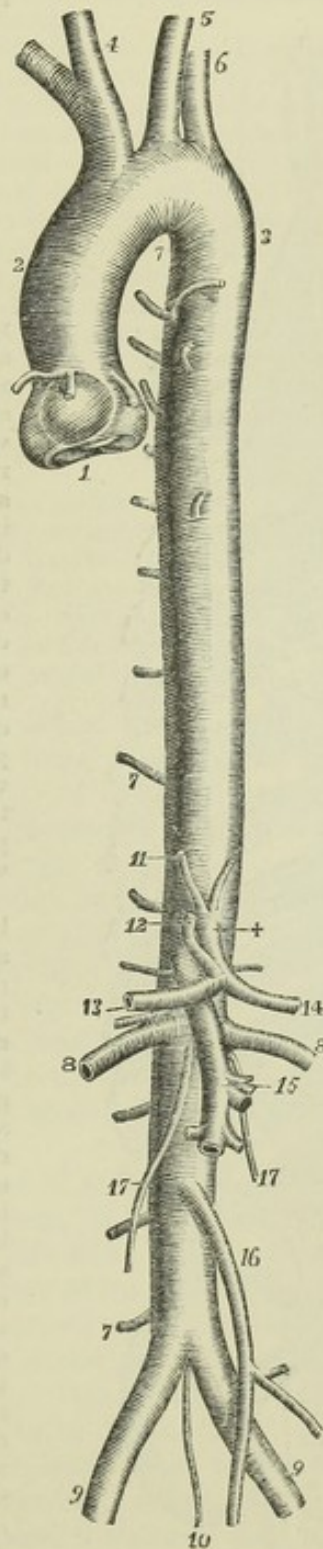
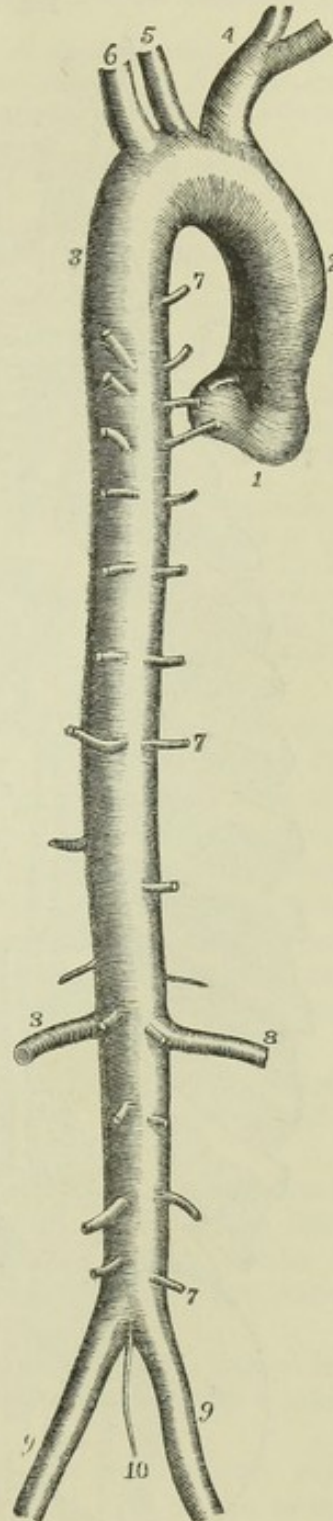


Fig. 250.





border of the second costal cartilage of the right side, the vessel alters its course, and is directed upwards, backwards, and to the left side, then directly backwards, in contact with the trachea, to the left side of the body

Fig. 251.

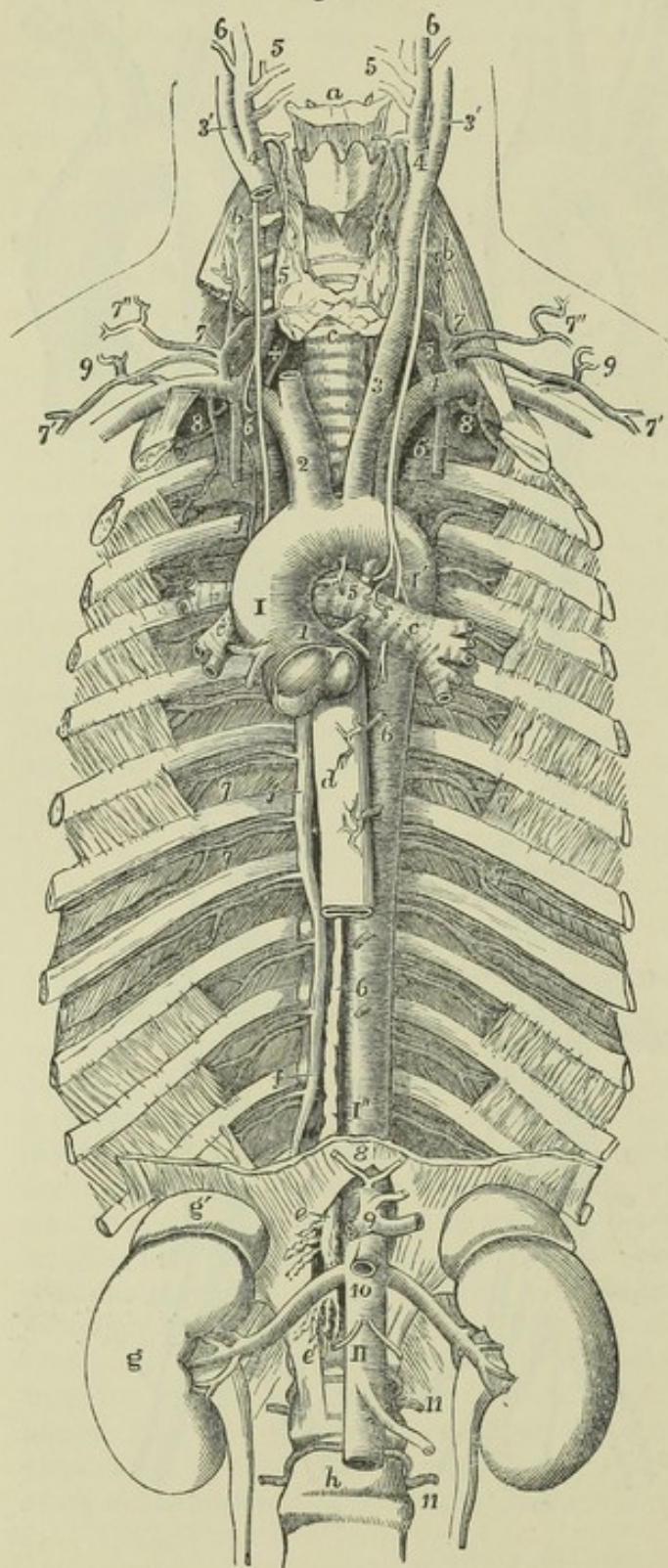


Fig. 251.—VIEW OF THE THORACIC AND UPPER PART OF THE ABDOMINAL AORTA, SHOWING THEIR RELATIONS AND PRINCIPAL BRANCHES; TOGETHER WITH A SKETCH OF THE FIRST PARTS OF THE CAROTID AND SUBCLAVIAN ARTERIES.  $\frac{1}{4}$

The first ribs have been removed in front of the attachment of the scalenus anticus muscles, and are supposed to be drawn somewhat apart; the rest of the ribs down to the eleventh are divided, along with the intercostal muscles, at some distance outside their angles; the internal intercostal muscles are left in all the spaces excepting the seventh and eighth, in which they are removed so as to expose the external layer. The diaphragm has been cut transversely near its crura, and the part left behind is supposed to be stretched upwards and to the sides.

*a*, the front of the hyoid bone; *b*, placed on the anterior scalene muscles, points to the upper part of the pneumogastric nerves; *c*, the trachea below the isthmus of the thyroid gland, and lower down the same letter is on the left bronchus; *c'*, one of the divisions of the right bronchus emerging from behind the aorta; in the hollow of the aortic arch, above 5, are seen the cord of the ductus arteriosus cut short, and the left recurrent nerve passing below the arch; +, is placed on the right side between the recurrent nerve and the vertebral artery as they pass upwards; *d*, the oesophagus; *e*, upon the right crus of the diaphragm, and farther down *e'*, mark the receptaculum chyli of the thoracic duct, and its commencement

by the lumbar plexus of lymphatic vessels and efferent mesenteric lacteal vessels; *f*, on the third, seventh, and eleventh ribs, points to the vena azygos and superior intercostal



veins of the right side ; *g*, kidney, *g'*, suprarenal body ; *h*, body of the fourth lumbar vertebra.

*I*, sinus of the aortic arch or ascending part of the arch : below this the semilunar valves are seen closed and distended by injection ; *I'*, posterior part of the arch, upon which the left pneumo-gastric nerve is seen descending ; *I''*, descending thoracic part of the aorta ; *II*, abdominal aorta emerging from between the crura of the diaphragm and descending to near its termination.

Branches of the arch and thoracic aorta ; 1, right and left coronary arteries ; 2, innominate ; 3, left carotid ; 4, left subclavian ; 5, bronchial arteries ; 6, 6, cesophageal arteries : the lower figure points by a line to the thoracic duct ; 7, intercostal arteries, marked in the sixth and seventh intercostal spaces.

Branches of the abdominal aorta ; 8, inferior diaphragmatic arteries cut short ; 9, coeliac axis with the gastric, splenic, and hepatic arteries cut short ; 10, placed on the aorta below the superior mesenteric artery (cut short) and the origin of the renal arteries ; a little below this the origin of the spermatic arteries ; below *II*, the inferior mesenteric artery, 11, 11, two of the lumbar arteries.

Branches of the carotid arteries ; the greater part of the right carotid artery has been removed to show the ascent of the vertebral artery in the canal of the transverse processes ; + is placed between the vertebral artery and the recurrent laryngeal nerve ; 3', internal carotid artery ; 4, commencement of the external carotid artery ; close to this the superior thyroid artery is given off, which is seen descending to the larynx and thyroid body ; 5, the lingual and facial arteries ; 6, continuation of the external carotid, &c.

Branches of the subclavian arteries ; on the right side the middle part of the scalenus anticus muscle is removed ; on the left the figure 4 is placed close to the origin of the four following vessels ; 5, vertebral ; 6, internal mammary ; 7, thyroid axis ; 7', its supra scapular branch ; 7'', its transverse cervical branch ; 8, superior intercostal artery, supplying two spaces on the right side and one on the left, rising in common with the deep cervical which turns upwards behind the subclavian artery ; 9, a posterior scapular artery rising from the third part of the subclavian.

of the second dorsal vertebra. Arrived at that point, it bends downwards, inclining, at the same time, a little towards the middle line ; and at the lower border of the body of the third dorsal vertebra, on its left side, the arch terminates in the descending portion of the vessel. At its origin, the arch of the aorta is larger than elsewhere, and presents externally three small bulgings of nearly equal size, corresponding with the dilatations which form the *sinuses of Valsalva* or of the *aortic valves*, already described with the heart. Two of these sinuses are placed anteriorly and one posteriorly, and in the two anterior sinuses are seen the orifices of the two coronary arteries of the heart, the first branches given off by the aorta.

From the difference in the direction and connections of different portions of the arch it is described as consisting of an *ascending*, a *transverse*, and a *descending* portion.

The *ascending* portion of the arch of the aorta is placed at its commencement behind the sternum, on a level with the lower border of the third costal cartilage of the left side ; and it rises as high as the upper border of the second costal cartilage of the right side. Its length is about two inches or two inches and a quarter ; and its direction is curved.

In most cases there exists along the right side a dilatation, named the *great sinus of the aorta*. This dilatation varies in size in different bodies, and occasionally is not to be detected.

This portion of the aortic arch is enclosed in the pericardium, and, together with the pulmonary artery, is invested by a fold of the serous layer of that bag, in such a manner that both vessels are covered by the serous membrane, except where they are in contact with each other.

At its commencement the ascending part of the arch is concealed by the pulmonary artery, and by the right auricular appendage which overlaps it ; but, further up, the aorta passes to the right side and the pulmonary artery



to the left, and thus the aorta comes into view. It approaches very near to the sternum, from which it is separated only by the pericardium, by some connective tissue, and by the remains of the thymus gland lodged in the mediastinal space: higher up, the descending vena cava lies on the right side, and the pulmonary artery passes backwards on the left; while behind are placed the right branches of the pulmonary vessels.

The second or *transverse* part of the arch is covered on the left side by the left pleura and lung, and is placed immediately in front and to the left of the trachea, before its bifurcation into the bronchi: it touches likewise the œsophagus posteriorly. The upper border of the transverse part of the arch has in contact with it the left innominate vein; and from it are given off the large arteries (innominate, left carotid, and left subclavian), which are furnished to the head and the upper limbs. The lower or concave border overhangs the bifurcation of the pulmonary artery, and is connected with the left branch of that artery by the remains of the ductus arteriosus. At or near its end this part of the arch is crossed in front by the left vagus and phrenic nerves, with some offsets of the sympathetic; and the recurrent laryngeal branch of the vagus turns upwards beneath and behind it.

The *descending* portion of the arch rests against the left side of the body of the third dorsal vertebra, and is covered by the left pleura. To the right side of this part of the arch is the œsophagus with the thoracic duct.

**BRANCHES.**—The branches given off from the arch of the aorta are five in number. Two of these, named the *coronary* or cardiac arteries, comparatively small, arise from two of the sinuses of Valsalva, and are distributed to the walls of the heart. The other three are large primitive trunks, which supply the head and neck, the upper limbs, and, in part, the thorax, and usually arise from the middle or highest part of the arch, in the following order:—first, the *innominate* or *brachio-cephalic* artery, which soon subdivides into the *right subclavian* and the *right carotid* arteries; second, the *left carotid*; and, third, the *left subclavian* artery. The origin of the left carotid artery is usually somewhat nearer to the innominate artery than it is to the subclavian artery of its own side.

**PECULIARITIES.**—(For more extended information on the peculiarities of the aorta and of the blood-vessels in general, the student is referred to "The Anatomy of the Arteries," by Richard Quain, London, 1844.)

#### I. *Peculiarities of the Arch itself.*

*Variations in height.*—The arch sometimes reaches very nearly as high as the top of the sternum. Occasionally it has been found an inch and a half below that level, and in rare instances as much as three inches below it.

*Double arch.*—This very rare variety has been known to occur in two forms. In both of these the trachea and œsophagus passed through the circle formed by the two divisions of the arch, which united behind them. In one form the arch retained its inclination to the left side; the pulmonary artery, placed in its proper position, was united to the left division of the aorta by the obliterated ductus arteriosus; and from each division of the arch two branches arose, the carotid and subclavian. In the other form a symmetrical ring was completed by the two divisions, each giving rise to three vessels—subclavian, and external and internal carotid; while the pulmonary artery dipped into the circle from above, and sent out its branches beneath it.

*Right arch.*—Arching of the aorta to the right side has been observed to occur in three different forms. 1st. Accompanying total transposition of the heart and viscera. 2nd. Occurring without transposition of other parts, and with the left innominate artery, right carotid, and right subclavian given off in succession. 3rd. Occurring, in like manner, without transposition of other parts, its first branch being



the left common carotid, the second the right common carotid, the third the right subclavian, and the fourth the left subclavian, passing behind the œsophagus to reach its destination.

## II. *Peculiarities affecting the Primary Branches.*

*The situation of the branches.*—Instead of springing from the highest part of the arch, the branches are frequently moved altogether to the right, and take origin from the commencement of the transverse portion, or even from the end of the ascending portion of the arch. In the ordinary arrangement the origin of the left carotid is nearer to the innominate than to the left subclavian; but the branches sometimes arise at equal distances from each other, or are unusually widely apart. A very frequent change consists in the approximation of the left carotid towards the innominate artery.

*The number and arrangement of the branches.*—These are extremely various. The most frequent change met with is their *reduction to two*, from the left carotid being united in a common trunk with the innominate artery. In cases of rare occurrence, the carotid and subclavian arteries of the left side, as well as those of the right, are conjoined in an innominate artery.

On the other hand, the number of the primary branches has been found to be *augmented* to four, by the separation, as it were, of the innominate artery into the right carotid and subclavian arteries, both arising directly from the aorta. In those cases, the right subclavian artery is most frequently the last branch given off, proceeding from the back part of the arch, and passing behind the œsophagus to reach its destination; but sometimes it is given off in its proper order, as the first branch, and in rare instances, it has been the second or third branch given off, in which case it has passed behind those which preceded it, to reach the limb.

In those instances in which the right subclavian is the last vessel given off, and in some other abnormal arrangements, a small pouch-like dilatation is sometimes found on the arch, which is a vestige of the right aortic root, and is accounted for by the changes in development which have led to the unusual disposition of the branches.

A remarkable variety is on record, in which the aorta divided at once into two vessels, as is the usual arrangement in some quadrupeds, all the arteries for the head, neck, and upper limbs, taking origin by a single trunk. In those cases the single trunk referred to passed vertically upwards and divided into three branches, in the form of a cross.

An abnormal arrangement of three branches springing from a normally-arranged arch has been observed, in which the two carotids have arisen by a common trunk, and the two subclavians separately—the right subclavian, in most instances, being transferred beyond the other branches to the left end of the arch.

## III. *Peculiarities in which one or more Secondary Branches, usually given from the Subclavian, are derived directly from the Aorta.*

In nearly all instances belonging to this section, there is only one secondary branch taking origin from the aorta; and the occurrence may either accompany the ordinary arrangement of the primary branches, or co-exist with a diminution, or with an increase in their number. The additional branch, when it is a normal artery transposed, is almost invariably the left vertebral, which in nearly all those cases arises between the left carotid and left subclavian arteries; but it has also been observed to proceed from the aorta beyond the last-named trunk. Very rarely the additional branch is the right vertebral.

The *thyroidea ima*, a small supernumerary artery occasionally found ascending to the thyroid body, sometimes arises from the arch of the aorta.

*Development of variations in the aortic arch and its branches.*—Many of the most frequent variations in the arrangement of the arch of the aorta and its branches may be explained on referring to the development of those vessels, by supposing that one of the usual branches has become obstructed in early foetal life, and that the circulation has been carried on by the persistence of one of the original vessels which otherwise would have been obliterated.

Thus in the case of *double aortic arch*, both the fourth branchial vascular arches



remain pervious: in a case of *right aortic arch*, the fourth arch of the right side, instead of that of the left, has remained pervious and has taken on permanent development, while at the same time adjusting deviations from the usual process of development have occurred in parts of the other arches, which lead to a left innominate being the first great vessel rising from the arch, and to the right carotid and right subclavian arteries rising later in succession. Thus, too, transference of the right subclavian artery from its usual connection with the innominate of a natural left aortic arch to the fourth place of origin, and its remarkable passage behind the trachea and gullet, may probably proceed from the obstruction of the part of the fourth right arch which unites the aortic bulb with the aortic root, and is accompanied by persistence of the aortic root itself extending from the main aorta below upwards

Fig. 252.

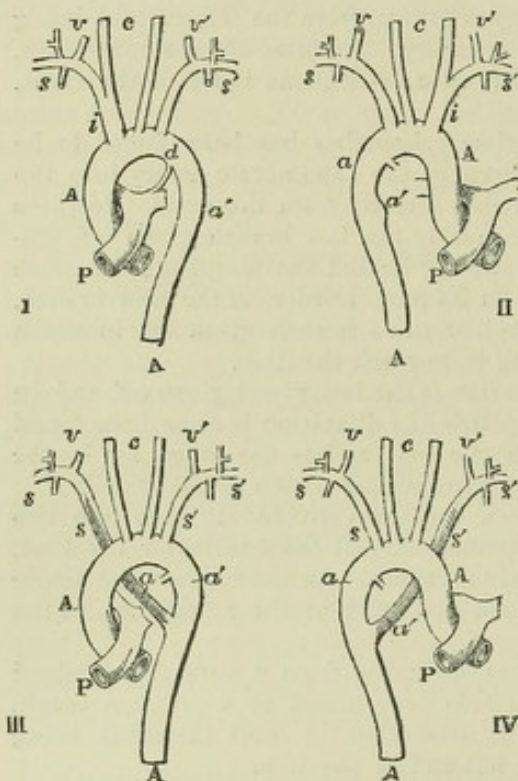


Fig. 252.—DIAGRAMS TO ILLUSTRATE THE RELATION OF SOME ABNORMAL DISPOSITIONS OF THE AORTIC ARCH AND ITS BRANCHES TO THE NORMAL CONDITION.

(I) The normal disposition as illustrated by Fig. 245, p. 326; (II), an abnormal right aortic arch; (III), a left aortic arch with the right subclavian artery displaced to the right aortic root; (IV), an abnormal right aortic arch with the left subclavian displaced to the left aortic root. Upper A, ascending part of the aortic arch; lower A, descending thoracic aorta; P, pulmonary trunk; d, ductus arteriosus; a, right aortic root or its remains; a', left aortic root; c, common carotid arteries; i, innominate artery; s, right, and s', left subclavian arteries; v, right, and v', left vertebral arteries.

to the subclavian artery. The similar transference of a left subclavian artery, in combination with the anomaly of a right aortic arch, may be due to similar abnormal states of development occurring on a different side. So, also, many of the other less marked variations in the number and position of the perma-

nent branches proceeding from the aortic arch probably owe their origin to cognate departures from the usual process of change in those parts of the original vascular arches with which their roots are connected.

By reference to development we are likewise enabled to understand how the right aortic arch of the bird, and the double aortic arch of reptiles, arise by obliteration or permanence of different members of a series of branchial arches comparable with those of fishes.

(Full reference to the history of cases of aortic varieties is given by Turner, "On Varieties of the Arch of the Aorta," Brit. & For. Med. Chir. Review, 1863; and an account of the origin of the varieties as explained by the observation of the development of the vessels is given in the same paper, and in that of A. Thomson, "Description of a Case of Right Aortic Arch," &c., Glasgow Med. Journ. 1862.)

## BRANCHES OF THE ARCH OF THE AORTA.

### THE CORONARY ARTERIES.

The coronary or *cardiac* arteries are two small vessels, named right and left, which arise from the root of the aorta in the upper parts of the two



anterior of the three sinuses of Valsalva, on a level with the margins of the semilunar valves.

The *right coronary artery*, about the size of a crow's quill, runs obliquely towards the right side of the heart, lodged in the groove which separates the auricle from the ventricle. It continues its course in the same groove, along the posterior aspect of the organ, until it reaches the line of separation between the two ventricles, where it divides into two branches. The smaller

Fig. 253.—VIEW OF THE HEART AND CORONARY ARTERIES FROM BEFORE (from R. Quain).  $\frac{1}{2}$

The pulmonary artery has been cut short close to its origin in order to show the first part of the aorta. 1, anterior part of the right ventricle; 2, left ventricle; 3, root of the pulmonary artery; 4, ascending part of the arch of the aorta; 4', the posterior or descending part of the arch; between these is seen the transverse or middle part from which the brachio-cephalic arteries take their origin; 4'', the descending thoracic aorta; 5, the appendix and anterior part of the right auricle; 6, those of the left auricle; 7, the right, and 7', the left innominate or brachio-cephalic veins joining to form the vena cava superior; 8, the inferior vena cava below the diaphragm; 9, one of the large hepatic veins; +, placed in the right auriculo-ventricular groove, points to the right or posterior coronary artery; ++, placed in the anterior inter-ventricular groove, points to the left or anterior coronary artery.

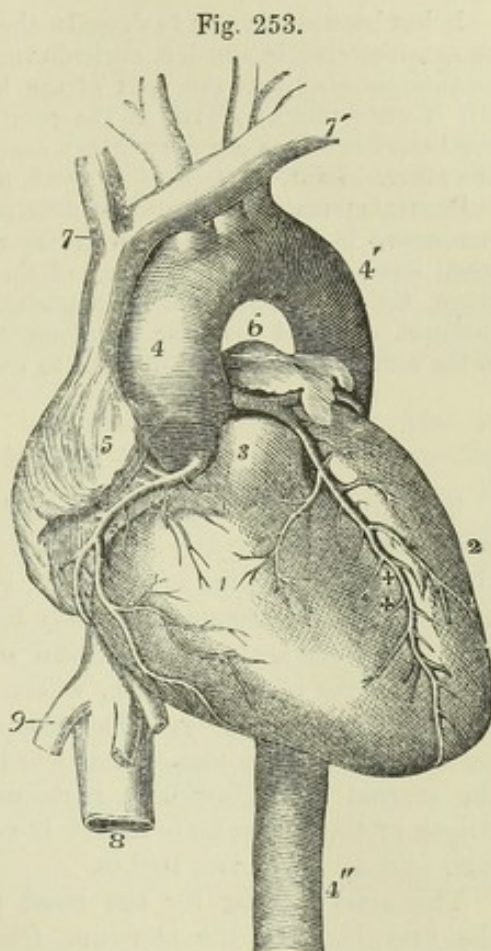


Fig. 253.

of these continues transversely in the groove between the left auricle and ventricle, approaching the termination of the transverse branch of the left coronary artery; while the other branch runs longitudinally downwards

along the posterior wall of the septum between the ventricles, giving branches to each ventricle and to the septum between them.

In its course the right coronary artery gives, besides the offsets already noticed, small branches to the right auricle and ventricle, and also to the first part of the pulmonary artery. Along the right border of the ventricle a rather large branch usually descends towards the apex of the heart, and gives offsets, in its progress, to the anterior and posterior surfaces of the ventricle.

The *left coronary artery* is rather smaller than the preceding, and arises from the left anterior sinus of Valsalva. It passes behind and then to the left side of the pulmonary artery, appearing between that vessel and the left auricular appendage. At first it descends obliquely towards the anterior interventricular sulcus, where it divides into two branches. Of these, one pursues a transverse direction, turning outwards and to the left side in the groove between the left ventricle and auricle, and approaching at the posterior aspect of the heart the transverse branch of the right coronary artery; the other branch, much the larger, descends on the anterior



surface of the heart along the line of the interventricular groove, to the right of the apex.

The left coronary artery supplies some small branches at its commencement to the pulmonary artery, to the coats of the aorta, and to the left auricular appendage; its two branches also furnish throughout their course smaller offsets, which supply the left auricle, both ventricles, and the interventricular septum.

It has been customary to describe the transverse branches of the coronary arteries as anastomosing in the left auriculo-ventricular sulcus, and the descending branches as anastomosing near the apex of the heart, and this description was never doubted till it was found by Hyrtl, as the result of separate injection of these vessels, that the branches of one coronary artery cannot be injected with material introduced into the other. (Nat. Hist. Review, 1861, p. 321.)

PECULIARITIES.—The coronary arteries have been observed in a few instances to commence by a common trunk, from which they diverged and proceeded to their usual destination. The existence of three coronary arteries is not a very rare occurrence, the third being small, and arising close by one of the others. Meckel, in one instance, observed four, the supplementary vessels appearing like branches of one of the coronary arteries transferred to the aorta.

#### THE INNOMINATE ARTERY.

The innominate, or *brachio-cephalic*, artery, the largest of the vessels which proceed from the arch of the aorta, arises from the commencement of the transverse portion of the arch, before the left carotid artery. From this point the vessel ascends obliquely towards the right, until it arrives opposite the sterno-clavicular articulation of that side, nearly on a level with the upper margin of the clavicle, where it divides into the right subclavian and the right carotid artery. The place of bifurcation would, in most cases, be reached by a probe passed backwards through the cellular interval between the sternal and clavicular portions of the sterno-mastoid muscle. The length of the innominate artery is very variable, but usually ranges from an inch and a-half to two inches.

This artery, lying for the most part within the thorax, is placed behind the first bone of the sternum, from which it is separated by the sterno-hyoid and sterno-thyroid muscles, and a little lower down by the left innominate vein, which crosses the artery at its root. The lower part of the innominate artery lies in front of the trachea, which it crosses obliquely: on its left side is the left carotid artery, with the thymus gland or its remains; and to the right is the corresponding innominate vein and the pleura.

No branches usually arise from this vessel.

PECULIARITIES.—The length of the innominate artery sometimes exceeds two inches, and occasionally it measures only one inch or less. Its place of division is a point of surgical interest, inasmuch as upon it in a great measure depends the accessibility of the innominate in the neck, and the length of the right subclavian artery. It has sometimes been found dividing at a considerable distance above the clavicle, and sometimes, but less frequently, below it. Though usually destitute of branches, this vessel has been observed to supply a thyroid branch, the thyroidea ima, and sometimes a thymic branch, or a bronchial, which descends in front of the trachea.

The *thyroidea ima* is an occasional artery. When present, it usually arises (as already stated) from the innominate trunk, but in rare instances it has been observed to come from the right common carotid artery, or from the aorta itself. It is of very different size, in different bodies, and compensates in various degrees for deficiencies



or absence of the other thyroid arteries. It ascends to its destination in front of the trachea, and its presence might therefore complicate the operation of tracheotomy.

#### COMMON CAROTID ARTERIES.

The common or primitive carotid arteries of the right and left sides of the body are nearly similar in their course and position whilst they are in the neck; but they differ materially in their place of origin, and consequently in their length and position, at their commencement. On the right side the carotid artery commences at the root of the neck behind the upper part of the sterno-clavicular articulation, at the bifurcation of the innominate artery; but on the left side the carotid arises within the thorax, from the highest part of the arch of the aorta, very near the origin of the innominate artery. The left carotid is therefore longer than the right, and it is at first placed at some depth within the thorax.

In consequence of this difference, it is convenient to describe, at first, the thoracic portion of the left carotid, or that part which intervenes between the arch of the aorta and the sterno-clavicular articulation,—after which the same description will suffice for both vessels.

*Within the thorax, the left carotid* ascends obliquely behind and at some distance from the upper piece of the sternum and the muscles (sterno-hyoid and sterno-thyroid) connected with that part of the bone; it is covered in front by the remains of the thymus gland, and is crossed by the left innominate vein. This part of the artery lies in front of the trachea, and of the œsophagus, which, at the root of the neck, deviates a little to the left side; the thoracic duct is also behind it. The left carotid artery here lies between the innominate and the left subclavian arteries, and the vagus nerve is to its outer side.

*In the neck* the common carotid artery of either side reaches from behind the sterno-clavicular articulation to the level of the upper border of the thyroid cartilage, where it divides into two great branches, of which one is distributed to the cranium and face, and the other to the brain and eye. These divisions have, from their destination, been named respectively the *external* and *internal carotid arteries*.

The oblique course taken by the common carotid artery along the side of the neck is indicated by a line drawn from the sterno-clavicular articulation to a point midway between the angle of the jaw and the mastoid process of the temporal bone. At the root of the neck, the arteries of opposite sides are separated from each other only by a narrow interval, corresponding with the width of the trachea; but, as they ascend, they are separated by a much larger interval, corresponding with the breadth of the pharynx and larynx. The carotid arteries have the appearance of being placed farther back at the upper than at the lower part of the neck, owing to the forward projection of the larynx above.

The common carotid artery is enclosed, together with the internal jugular vein and the vagus nerve, in a common membranous investment, continuous with the deep cervical fascia. Separated by means of this sheath from all the surrounding parts, except the vein and nerve just mentioned, the carotid artery is deeply placed at the lower part of the neck, but is comparatively superficial towards its upper end. It is covered below by the sterno-mastoid, sterno-hyoid, and sterno-thyroid muscles, in addition to the platysma and the layers of fascia between and beneath the muscles; and it is crossed opposite or near the lower margin of the cricoid cartilage by



the omo-hyoid muscle. From this point upwards to its bifurcation, the vessel is covered by the sterno-mastoid, by the platysma and fascia, and by the common integument; and lies in a triangular space bounded by the sterno-mastoid, the omo-hyoid, and the digastric muscles.

Fig 254.

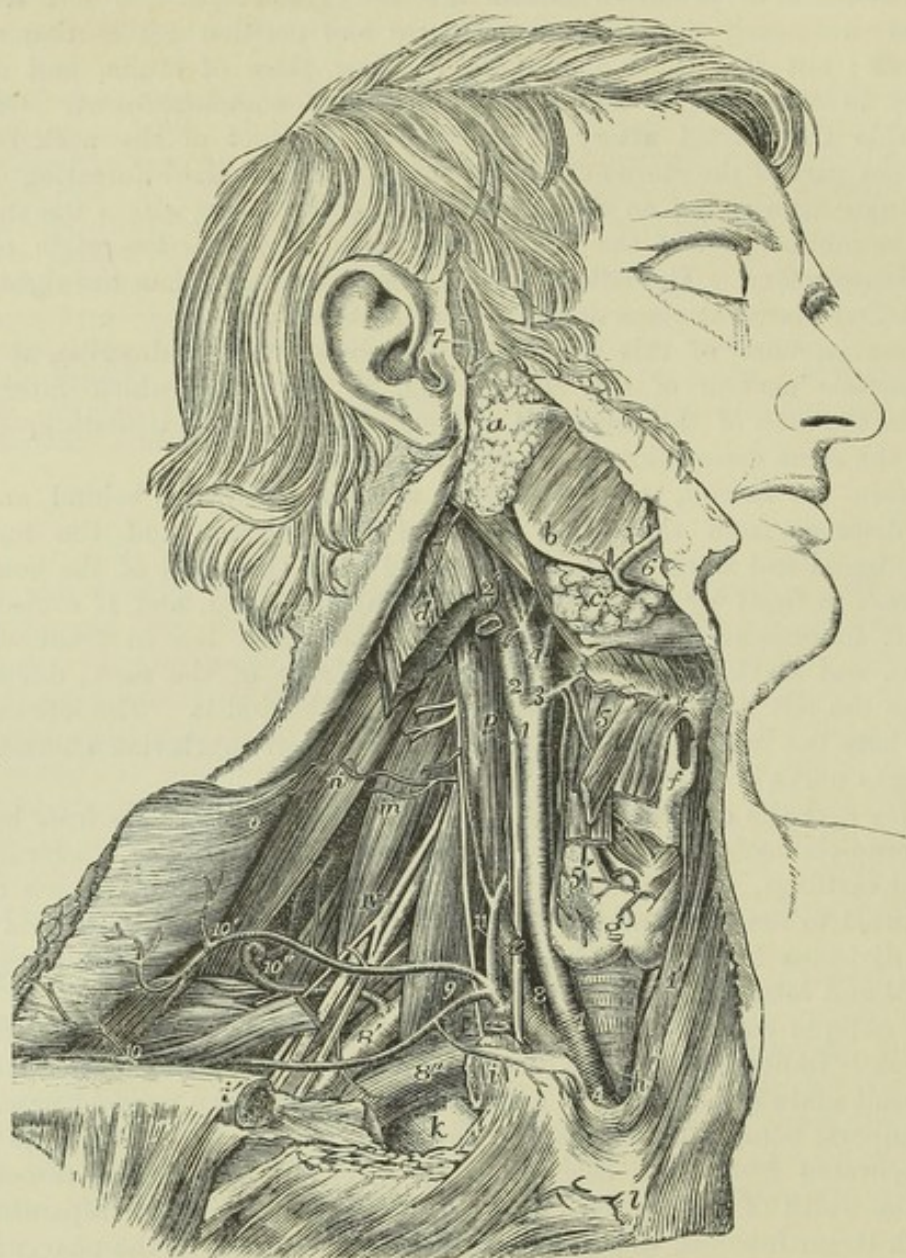


Fig. 254.—VIEW OF THE RIGHT COMMON CAROTID AND SUBCLAVIAN ARTERIES, WITH THE ORIGIN OF THEIR BRANCHES AND THEIR RELATIONS (from R. Quain).  $\frac{1}{3}$

The sterno-mastoid, sterno-thyroid, sterno-hyoid, and omo-hyoid muscles have been removed, the trapezius has been detached from the outer part of the clavicle and turned backwards, and the inner part of the clavicle has been removed: *a*, parotid gland near the place where the duct of Stenson leaves it; *b*, angle of the jaw and masseter muscle; *c*, submaxillary gland, enclosed between the digastric and stylo-hyoid muscles; *d*, divided upper part of the sterno-mastoid muscle; *e*, front of the hyoid bone; *f*, thyroid cartilage; *g*, isthmus of the thyroid gland; *h*, the trachea above the inter-clavicular notch of the sternum; *i*, *i'*, the sawn ends of the clavicle, the portion between them having been removed; *k*, the first rib, below which is seen the divided edge of the great pectoral muscle, and beside it the subclavius; *l*, front of the sternum; *m*, scalenus medius; *n*, levator anguli scapulæ; *o*, deep surface of the trapezius, which is turned aside; *p*, on the



longus colli muscle, pointing to the pneumogastric nerve; IV, the uppermost of the nerves of the axillary plexus; A, the innominate artery; 1, right common carotid artery; 1', placed on the left sterno-thyroid muscle, points to a part of the left common carotid; 2, internal carotid; 2', upper part of the internal jugular vein, which has been removed between 2 and 2'; 3, and 4, external carotid; 3, is placed at the origin of the superior thyroid artery; 4, at that of the lingual: farther up the vessel may be seen the separation of the sterno-mastoid twig and the facial and occipital branches from the main vessel; 5, is placed on the thyro-hyoid muscle between the hyoid and laryngeal branches of the superior thyroid artery; 5', the thyroid or glandular; 6, the facial artery passing over the base of the jaw; 7, the superficial temporal artery; 8, the first part, 8', the third part of the arch of the subclavian artery; 8'', the subclavian vein separated from the artery by the scalenus anticus muscle, shown by the removal of a portion of the clavicle; 9, is placed on the scalenus anticus muscle in the angle between the transversalis colli and supra-scapular branches of the thyroid axis; 10, outer part of the supra-scapular artery; 10', transverse cervical branches passing into the deep surface of the trapezius; 10'', the posterior scapular artery, represented as rising directly from the third part of the subclavian artery, and passing through the axillary plexus of nerves and under the levator anguli scapulæ; 11, on the scalenus anticus muscle, points to the inferior thyroid artery near the place where the ascending muscular artery of the neck is given off; the phrenic nerve lies on the muscle to the outside; at i, the supra-sternal twig of the supra-scapular artery is shown.

Posteriorly, the artery is supported by the cervical vertebræ, the longus colli and rectus capitis anticus muscles intervening. Hence the flow of blood through it may be commanded by pressure directed backwards against the vertebral column. The inferior thyroid artery crosses behind the carotid sheath.

On the inner side the vessel is in juxtaposition with the trachea below, and with the thyroid body (which often overlaps the artery), the larynx, and the pharynx higher up. Along its outer side are placed the internal jugular vein and the vagus nerve.

*Relation to Veins.*—The *internal jugular vein* is close to the artery at the upper part of the neck, but in approaching the thorax, the veins of both sides incline to the right, and hence that of the right side is separated from the artery by an angular interval, while that of the left side approaches the artery, and even lies in front of it at the lower part of the neck.

Crossing over the upper part of the common carotid artery to join with the jugular vein, are two or more *superior thyroid veins*, which occasionally form a sort of plexus over the artery. A *middle thyroid vein* not unfrequently crosses the artery about half way up the neck.

The *anterior jugular vein*, where it turns outwards under the sterno-mastoid muscle to join the subclavian, crosses the lower part of the artery. This vein is generally of small size, but occasionally is rather large, and is placed nearly over the carotid artery along the neck.

*Relation to Nerves.*—The descending branch of the hypo-glossal nerve, *descendens noni*, usually rests, together with the branches of cervical nerves which join it, on the fore part of the sheath of the carotid artery, and crosses it from the outer to the inner side: in some instances this branch descends within the sheath between the carotid artery and jugular vein. The *vagus nerve* lies within the sheath of the vessels between the artery and vein posteriorly: it was in one case observed to descend over the artery. The *sympathetic nerve* is placed along the back of the sheath, between it and the vertebral muscles, and the *recurrent laryngeal nerve* crosses inwards behind the upper part of the sheath.

The common carotid artery usually gives off no branch, and therefore continues of equal size in its whole length, except at its bifurcation, where a slight enlargement is observable.



Fig. 255.

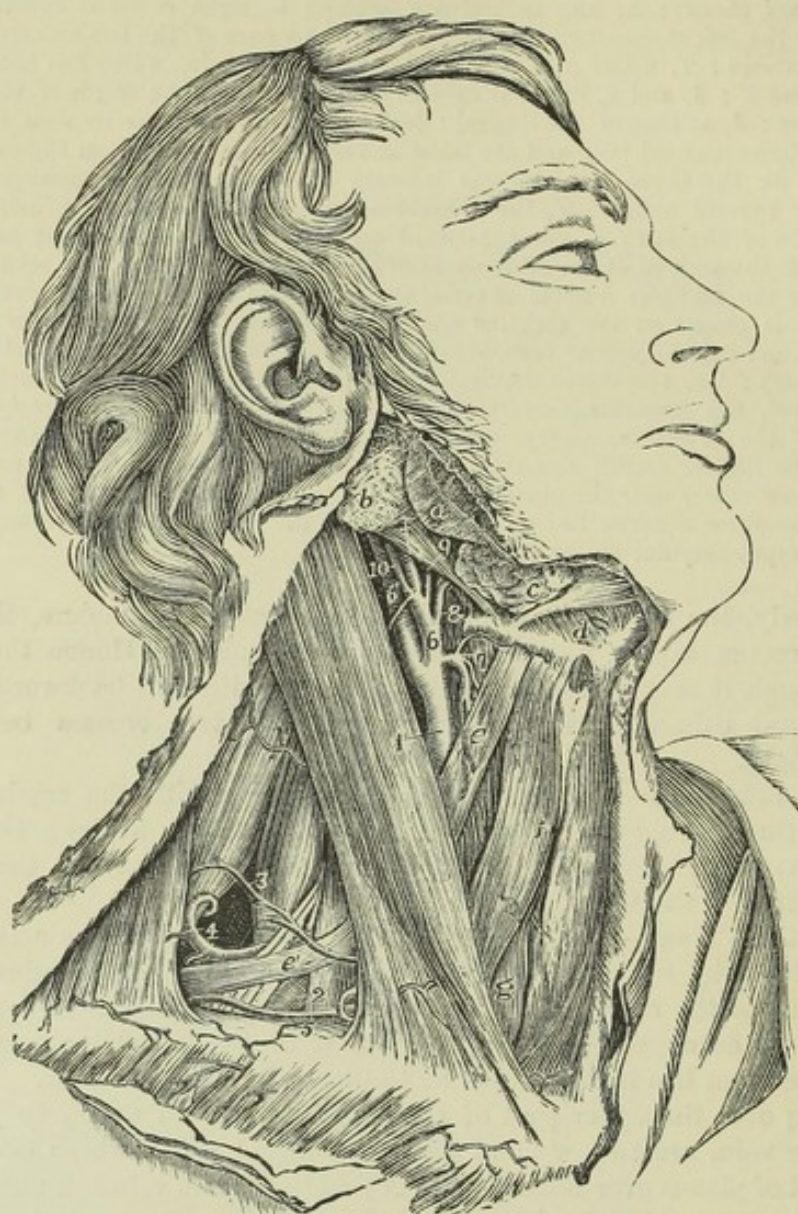


Fig. 255.—DISSECTION OF THE RIGHT SIDE OF THE NECK TO SHOW THE MUSCULAR TRIANGLES, THE CAROTID AND SUBCLAVIAN ARTERIES, &c. (from R. Quain).  $\frac{1}{3}$

*a*, angle of the jaw and masseter muscle; *b*, parotid gland; +, the posterior belly of the digastric muscle; *c*, submaxillary gland; *d*, upon the mylohyoid muscle below the anterior belly of the digastric muscle, and above the front of the hyoid bone; *e*, upper belly of the omohyoid muscle; *e'*, lower belly; *f*, sterno-hyoid muscle; *g*, sterno-thyroid; 1, upon the sterno-mastoid muscle, points by a line to the upper part of the common carotid artery; 2, upon the scalenus anticus muscle, points to the third part of subclavian artery; 3, upon the scalenus medius, points to the superficial transverse cervical artery crossing the axillary nerves; 4, points to the posterior scapular artery, passing under the levator scapulæ muscle; 5, placed upon the clavicle, points to the supra-scapular artery; 6, external carotid artery; 6', internal carotid artery; 7, upon the thyro-hyoid muscle, points to the superior thyroid artery giving superiorly its hyoid branch; 8, is placed upon the hyo-glossus muscle within the arch of the lingual artery; 9, placed on the stylo-hyoid muscle, indicates the facial artery; 10, origin of the occipital artery, from the root of which the small sterno-mastoid artery is given off; between the occipital and the facial arteries, +, upon the posterior belly of the digastric muscle, points to the continuation of the external carotid artery before entering the parotid gland.

The absence of branches from the trunk of the common carotid is connected with



the original absence of the neck in the foetus, and the comparatively late period at which, when the neck is formed, the carotid artery becomes elongated with it.

**PECULIARITIES.—Origin.**—The *right carotid* artery occasionally arises directly from the aorta, or in conjunction with the left carotid. When it arises from the aorta, it is usually the first vessel from the arch, the subclavian being displaced; but it has been found to occupy the second place,—the right subclavian, or, very rarely, the left carotid being the first.

The place at which the right carotid artery commences, varies with the point of bifurcation of the innominate artery. A change from the usual position on a level with the upper border of the clavicle was found by R. Quain in the proportion of about one case in eight and a half of those observed by him; and it was found to occur more frequently above than below that point.

The *left carotid* artery varies in its *origin* much more frequently than the right. In the greater number of its deviations from the ordinary place of origin, this artery arises from, or in conjunction with the innominate artery; and in those cases in which the right subclavian is a separate branch of the aorta, the two carotids most frequently arise by a common trunk.

In cases of transposition, or of right aortic arch without other abnormality, the left common carotid springs from a left innominate artery, which is the first vessel to rise from the arch, and the right carotid is the second vessel.

**Place of division.**—This often deviates somewhat from its usual position; it does so more frequently in an upward than in a downward direction. It is often as high as the os hyoides, and occasionally much higher. It is found from time to time opposite the middle of the larynx, and, in rare instances, opposite the lower margin of the cricoid cartilage, or even lower.

One case was observed by Morgagni, in which the carotid artery, measuring one inch and a half in length, divided at the root of the neck. ("De Sedibus et Causis Morborum," &c. Epist. 29, Art. 20.)

The common carotid artery has been found, as a very rare occurrence, to ascend in the neck *without dividing* into its two usual terminal branches; the internal carotid artery being altogether wanting.

In two recorded cases the common carotid artery was absent; the external and internal carotids arising directly from the arch of the aorta.

**Occasional branches.**—The common carotid artery sometimes gives origin at its upper part to the superior thyroid artery, and, in some rare cases, to a laryngeal or an inferior thyroid branch; also, in a few instances, to the vertebral artery.

## EXTERNAL CAROTID ARTERY.

The external carotid artery, distributed mainly to the face and to the walls of the cranium, is smaller than the internal carotid in young persons; but the two are nearly of equal size in adults. It reaches from the point of division of the common carotid, opposite the upper margin of the thyroid cartilage, to the neck of the condyle of the lower jaw-bone, or a little lower, and there divides into its two terminal branches, the temporal and the internal maxillary. It diminishes rapidly as it ascends, owing to the number and size of the branches which spring from it.

At first the external carotid lies nearer to the middle line of the body than the internal carotid; but it soon becomes superficial to that artery, at the same time curving slightly forwards as it ascends to its place of division. At its origin this artery is concealed by the sterno-mastoid muscle, emerging from beneath which, it is covered only by the platysma myoides and the fascia, and traverses the upper part of a triangular intermuscular space bounded by the sterno-mastoid, omo-hyoid and digastric muscles; it then becomes deeply placed, passing beneath the stylo-hyoid and digastric muscles, and finally becoming imbedded in the substance of the parotid gland. In the lower part of its course it is in contact with the pharynx



and hyoid bone; further up it is separated by a portion of the parotid gland from the back of the ramus of the lower jaw, and rests upon the styloid process and the stylo-pharyngeus muscle, which, with the glosso-pharyngeal nerve, are interposed between it and the internal carotid artery.

*Relation to Veins.*—This artery has usually no companion vein, though it may be crossed superficially by small branches of the contiguous veins; but when the internal maxillary vein joins the deep instead of the superficial jugular, it accompanies the external carotid.

*Relation to Nerves.*—Close to the digastric muscle the external carotid artery is crossed by the *hypoglossal nerve*, and at a short distance from its upper end, in the substance of the parotid gland, by the *facial nerve*. The *glosso-pharyngeal nerve* lies between it and the internal carotid; and the *superior laryngeal nerve* is under both vessels.

**BRANCHES.**—The branches of the external carotid artery are eight in number, viz. three directed forwards, the superior thyroid, the lingual, and the facial; two directed backwards, the occipital, and posterior auricular; and three extending upwards, the ascending pharyngeal branch, together with the temporal and internal maxillary, the two terminal branches into which the artery divides.

In addition to the principal branches here enumerated, the external carotid gives off small offsets to the parotid gland.

**PECULIARITIES.**—The peculiarities in the origin of this vessel have been noticed along with those of the common carotid artery.

The branches are not unfrequently crowded together on the main stem, near the commencement, or at a higher point. Occasionally they take origin at regular distances in the whole length of the vessel.

The usual number of branches may be diminished by the association with another artery of one of the ordinary branches, or by the union into a single trunk of two or three branches which are usually derived separately from the main artery: so also the number may be augmented by the transfer to this vessel of some branch not ordinarily derived from it, or by the addition of some unusual branch.

There is frequently present a small distinct branch for the sterno-mastoid muscle, which bends outwards over the hypoglossal nerve.

## BRANCHES OF THE EXTERNAL CAROTID ARTERY.

### I. SUPERIOR THYROID ARTERY.

The superior thyroid artery, the first of the anterior set of branches, is given off close to the commencement of the external carotid, immediately below the great cornu of the hyoid bone. From this point the artery curves forwards and downwards to the upper margin of the thyroid cartilage; it then descends a short distance beneath the omo-hyoid, sterno-hyoid and sterno-thyroid muscles, furnishing offsets to those muscles; and, reaching the anterior surface of the thyroid body, distributes branches to its substance, and communicates freely with the branches of the inferior thyroid artery.

#### BRANCHES.—

Besides the branches furnished to the muscles which cover it, and to the thyroid body, together with some to the lowest constrictor of the pharynx, the superior thyroid furnishes the following offsets, which have received distinctive names:—

(a) The *hyoid*, a small branch, running transversely inwards immediately below



Fig. 256.

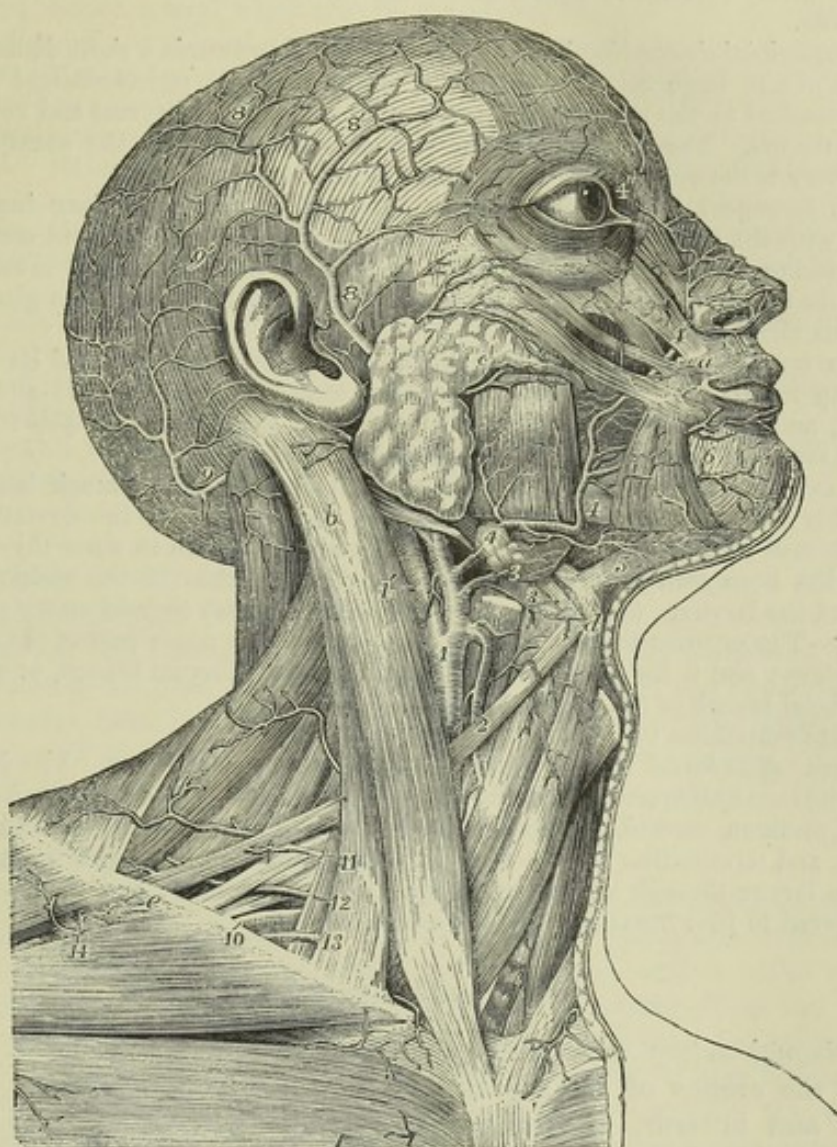


Fig. 256.—SUPERFICIAL VIEW OF THE ARTERIES OF THE HEAD AND NECK (from Tiedemann).  $\frac{1}{3}$

*a*, placed upon the orbicularis oris near the place where it is joined by the levator labii superioris, the zygomaticus minor and major and triangularis oris; *b*, upper part of the sterno-mastoid muscle; *c*, parotid gland near its duct; *d*, body of the hyoid bone near the place of meeting of the digastric, stylo-hyoid, sterno-hyoid and omo-hyoid muscles; *e*, is placed on the clavicle at the place where, superiorly, the omo-hyoid dips behind it and the trapezius muscle, and inferiorly the interval exists between the pectoral and deltoid muscles; 1, trunk of the common carotid artery near its division into the external and internal carotid arteries; 1', the internal carotid; 2, placed on the upper belly of the omo-hyoid muscle, points to the superior thyroid artery; 3, lingual artery and its hyoid branch; 4, placed on the submaxillary gland at the place where the facial artery is sunk in the gland, and again where the artery turns over the lower jaw; 4', termination of the facial artery by division into the angular and lateral nasal branches; 5, submental branch; 6, inferior labial branches; 7, transverse facial branch of the superficial temporal; 8, superficial temporal, passing over the zygoma and distributed by 8' 8'', its anterior and posterior divisions on the surface of the cranium; 9, occipital artery rising upon the cranium; 9', its distribution and anastomosis with the temporal and posterior auricular arteries; 10, outer part of the subclavian artery; 11, superficial cervical, and 12, posterior scapular arteries; 13, supra-scapular artery; 14, acromio-thoracic branches of the axillary artery.



the os hyoides, and assisting to supply the soft parts connected with that bone. This little artery sometimes unites, across the middle line, with its fellow from the opposite side.

(b) A *superficial descending* branch, which passes downwards a short distance over the sheath of the large cervical vessels, and ramifies in the sterno-mastoid and the muscles attached to the thyroid cartilage, as well as in the platysma and neighbouring integuments. The position of this branch with respect to the sheath of the carotid artery is the only circumstance which gives it interest.

(c) The *laryngeal* branch, or *superior laryngeal artery*, proceeding inwards in company with the superior laryngeal nerve, and piercing the thyro-hyoid membrane. Before entering the larynx this branch is covered by the thyro-hyoid muscle. On reaching the interior of the larynx, it ramifies in the small muscles, the glands, and the mucous membrane of that organ.

(d) The *crico-thyroid*, a small branch, to be noticed on account of its position rather than its size. It crosses the membrane connecting the thyroid and cricoid cartilages, and communicates with a similar branch from the other side: hence it may be a source of hæmorrhage in the operation of laryngotomy.

**PECULIARITIES.—Size.**—The superior thyroid artery is frequently much larger, and, on the other hand, it may be smaller than usual. In either case the deviation from the accustomed size is accompanied by an opposite alteration in other thyroid arteries. It has been seen extremely small, ending in branches to the sterno-mastoid muscle and the larynx. (See the observations on the inferior thyroid artery.)

**Origin.**—The superior thyroid is often transferred to the upper part of the common carotid artery; and it has been seen conjoined with the lingual branch, or with that and the facial branch of the external carotid.

There are sometimes two superior thyroid arteries.

**Branches.**—The *hyoid* branch is frequently very small, or absent. The *laryngeal* branch arises not unfrequently from the external carotid artery, and likewise, but rarely, from the common carotid. Examples have occurred of this branch being of very large size, and terminating in the thyroid body. The laryngeal artery occasionally enters the larynx through a foramen in the thyroid cartilage; and it has likewise been observed to pass inwards below the cartilage.

## II. LINGUAL ARTERY.

The *lingual artery* arises from the inner side of the external carotid, between the origins of the superior thyroid and facial arteries. Curving upwards and inwards, it reaches the upper margin of the hyoid bone, behind the tip of its great cornu; it then passes forwards under cover of the hyo-glossus muscle, resting at first on the middle constrictor of the pharynx, and afterwards on the genio-hyo-glossus muscle, in contact with which it ascends almost perpendicularly to reach the under surface of the tongue, and there makes its final turn forwards to the tip of that organ, receiving the name of ranine artery.

At the posterior border of the hyo-glossus muscle, the *hypoglossal* nerve crosses the artery, and passes forwards on a lower level, superficial to the muscle.

**BRANCHES.**—The branches of the lingual artery are as follows:—

(a) The *hyoid* branch, running along the upper border of the hyoid bone, and supplying the contiguous muscles and skin.

(b) The *dorsal artery of the tongue*, which is often replaced by several smaller branches. It arises from the deep portion of the lingual artery, beneath the hyo-glossus muscle, and ascends to supply the upper part, or dorsum, and the substance of the tongue, ramifying as far back as the epiglottis.

(c) The *sublingual* branch. Taking origin at the anterior margin of the hyo-glossus, this branch turns slightly outwards, under cover of the mylo-hyoid muscle, and between this and the sublingual gland. It supplies the substance of the gland, and gives branches to the mylo-hyoid and other muscles connected with the maxillary



bone. Small branches are also distributed to the mucous membrane of the mouth, and the inside of the gums.

(d) The *ranine* artery, which may be considered from its size and direction the continuation of the lingual artery. It runs forwards beneath the tongue, giving numerous branches as it proceeds, covered by the mucous membrane, and resting on the *genio-hyo-glossus* muscle. Having reached the tip of the tongue, it has been said to anastomose with the corresponding artery of the other side; but this is denied by Hyrtl. In the last part of its course it lies quite superficially at the side of the *frænum*.

PECULIARITIES.—The origin of the lingual artery sometimes takes place from a trunk common to it and the facial artery. It is occasionally joined with the superior thyroid.

*Branches*.—The *hyoid* branch is often deficient; and it appears that this branch varies in size inversely with the *hyoid* branch of the superior thyroid.

The *sublingual* branch varies in size. It is sometimes derived from the facial artery, and then perforates the *mylo-hyoid* muscle.

The lingual artery has been seen to give off as *unusual* branches, the *submental* and *ascending palatine*.

### III. FACIAL ARTERY.

The facial artery (*art. maxillaris externa*), taking origin a little above the lingual artery, is first directed obliquely forwards and upwards beneath the base of the maxillary bone; then changing its direction, it passes upwards over the base of the lower maxilla, in front of the *masseter* muscle. Commencing here its course upon the face, it is directed forwards near to the angle of the mouth, and ascends to the inner canthus of the eye, where it ends by anastomosing with the *ophthalmic* artery. In its whole course the artery is tortuous, a circumstance connected with the great mobility of the parts on which it rests.

In the neck, the facial artery, immediately after its origin, which is comparatively superficial, being covered only by the *platysma* and *fascia*, is crossed by the *digastric* and *stylo-hyoid* muscles, and is then concealed in the substance of the *submaxillary* gland. Emerging from the gland, it turns over the border of the jaw, covered by the *platysma*: here the pulsation of the artery is easily felt, and the circulation through it may be readily controlled by pressure against the bone. In its progress over the face, it is covered successively by the *platysma* and the *zygomatic* muscles, and rests upon the *buccinator*, the *levator anguli oris*, and the *levator labii superioris*.

The *facial vein* is separated by a considerable interval from the artery on the face. It takes nearly a straight course upwards, instead of inclining forwards near the angle of the mouth, and it is not so tortuous as the artery.

Branches of the *portio dura nerve* cross the vessel; and the *infra-orbital nerve* is beneath it, separated by the fibres of the *elevator* of the upper lip.

BRANCHES.—A. *Cervical branches*.—The following branches are derived from the facial artery below the lower jaw:—

(a) The *inferior* or *ascending palatine artery*, a branch which ascends between the *stylo-glossus* and *stylo-pharyngeus* muscles, and reaches the *pharynx* close to the border of the *internal pterygoid* muscle. After having given small branches to the *tonsil*, the *styloid* muscles, and the *Eustachian tube*, this artery divides near the *levator palati* muscle into two branches, one of which follows the course of the *circumflexus palati* muscle, and is distributed to the soft palate and its glands, while the other penetrates to the *tonsil*, and ramifies upon it with the branch to be next described.—The place of this artery upon the palate is often taken by the *ascending pharyngeal*.



(b) The *tonsillar* branch, which ascends along the side of the pharynx, and penetrating the superior constrictor of the pharynx, terminates in small vessels upon the tonsil and the side of the tongue near its root.

(c) The *glandular* branches, a numerous series which enter the substance of the submaxillary gland, whilst the facial artery is in contact with it; and some of which are prolonged upon the side of the tongue.

(d) The *submental* branch, the largest arising from the facial in the neck. Leaving the artery near the point at which it turns upwards to the face, it runs forwards below the base of the maxillary bone on the surface of the mylo-hyoid muscle and subjacent to the digastric. Giving branches in its course to the submaxillary gland and the muscles attached to the jaw, it approaches the symphysis of the chin and divides into two branches; one of these, running more superficially than the other, passes between the depressor muscle of the lower lip and the skin, supplying both; while the other dips between that muscle and the bone, and ramifies in the substance of the lip, communicating with the inferior labial branch.

**B. Facial branches.**—Of the branches derived from the facial artery upon the side of the face, some are directed outwards to the muscles, as to the masseter and buccinator, and require only to be indicated. Larger branches described with some detail are directed inwards, and are as follows :—

(a) The *inferior labial* branch. This arises soon after the facial artery has turned over the lower border of the maxilla, and running forwards beneath the depressor anguli oris, distributes branches to the skin and the muscles of the lower lip, anastomosing with the inferior coronary and submental branches, and with the inferior dental branch of the internal maxillary artery.

(b) The *coronary artery* of the lower lip. Arising near the angle of the mouth, as often in conjunction with the superior coronary as from the facial separately, this branch penetrates the muscular fibres surrounding the orifice of the mouth, takes a transverse and tortuous course between those fibres and the mucous membrane of the lip, and inosculates with the corresponding artery of the opposite side. Small twigs from it ascend to supply the orbicular and depressor muscles, the glands, and other structures of the lower lip; whilst others descend towards the chin, and communicate there with other branches.

(c) The *coronary artery* of the upper lip. Larger and more tortuous than the preceding branch, with which it often arises, this vessel runs across between the muscles and mucous membrane of the upper lip, and inosculates with its fellow of the opposite side. In addition to supplying the whole thickness of the upper lip, it gives two or three small branches to the nose. One of these, named the *artery of the septum*, runs along the lower border of the septum nasi, on which it ramifies as far as the point of the nose; another reaches the ala of the nose.

(d) The *lateral nasal artery*. This branch turns inwards to the side of the nose beneath the common elevator of the nose and lip, and sends branches to the ala and the dorsum of the nose. It anastomoses with the nasal branch of the ophthalmic, with the artery of the septum nasi, and with the infra-orbital artery.

(e) *Angular artery*. Under this name is recognised the terminal part of the facial artery, which inosculates at the inner side of the orbit with a terminal branch of the ophthalmic artery.

Communication between the superficial and deep branches of the external carotid is established by the anastomoses of the facial artery with the infra-orbital, buccal, inferior dental, and nasal branches of the internal maxillary; and between the external and the internal carotids by the anastomosis of the facial with the ophthalmic arteries.

**PECULIARITIES.—Origin.**—The facial artery not unfrequently arises by a common trunk with the lingual. Occasionally it arises above its usual position, and then descends beneath the angle of the jaw to assume its ordinary course.

**Size.**—This artery varies much in size, and in the extent to which it is distributed. It has been observed, very rarely however, to end as the submental, not reaching the side of the face; in some cases it supplies the face only as high as the lower lip. The deficiency of the facial artery is most frequently compensated for by an enlarge-



ment of the nasal branches of the ophthalmic at the inner side of the orbit; occasionally by branches from the transverse facial or internal maxillary arteries.

*Branches.*—The *ascending palatine* artery is in some instances transferred to the external carotid. This branch varies in size and the extent to which it reaches. Not unfrequently it is expended without furnishing any branch to the soft palate. When it is thus reduced in size, the pharyngeal artery takes its place on the soft palate.

The *tonsillar* branch is not unfrequently altogether wanting.

The *submental* branch has been observed to take its rise from the lingual artery. On the other hand, the facial artery, instead of the lingual, has been found to furnish the branch which supplies the sublingual gland.

#### IV. OCCIPITAL ARTERY.

The occipital artery, arising from the posterior part of the external carotid, usually opposite the facial or a little higher up, is directed upwards and backwards, beneath the posterior belly of the digastric muscle, to the interval between the transverse process of the atlas and the mastoid process of the temporal bone. From that point it turns horizontally backwards along the skull in the occipital groove of the temporal bone, internal to the mastoid process and the sterno-mastoid, splenius, digastric and trachelo-mastoid muscles, and resting on the superior oblique and complexus muscles. Lastly, changing its direction a second time, and piercing the cranial attachment of the trapezius, it ascends beneath the integument on the back of the head accompanied by the great occipital nerve, and divides into numerous branches upon the upper and back part of the cranium. While in the neck, the occipital artery crosses over the internal carotid artery, the vagus and spinal accessory nerves, and the internal jugular vein; and the hypoglossal nerve turns from behind over it at its origin.

*BRANCHES.*—The following branches are given from the occipital artery:—

(a) Small *muscular* offsets to the digastric and stylo-hyoid muscles, and one of larger size to the sterno-mastoid. This last is so regular a branch that it is known as the *sterno-mastoid* branch.

(b) An *auricular* branch to the back part of the concha of the ear, and two or three other muscular branches to the splenius and trachelo-mastoid.

(c) The *meningeal* branch. This runs up with the internal jugular vein, enters the skull through the foramen jugulare, and ramifies in the dura mater of the posterior fossa of the base of the skull.

(d) The *cervical* branch, *ramus cervicalis princeps*. To the upper and back part of the neck the occipital artery furnishes a branch thus designated. Descending a short way, this vessel divides into a superficial and a deep branch. The former ramifies beneath the splenius, sending offsets through that muscle to the trapezius; while the deep branch passes beneath the complexus, and anastomoses with branches of the vertebral artery, and with the deep cervical artery. The size of this branch varies very much.

(e) The *superficial* or *cranial* branches. These pursue a tortuous course between the integument and the occipito-frontalis muscle; and in proceeding upwards on the skull they separate into diverging branches, which communicate with the branches of the opposite artery, as well as with those of the posterior auricular artery, and of the temporal artery at the vertex and side of the skull.

A small twig, the *mastoid* branch, enters the skull through the mastoid foramen, and ramifies in the dura mater.

*PECULIARITIES.*—*Origin.*—The occipital artery is occasionally derived from the internal carotid, and from the ascending cervical branch of the inferior thyroid—an offset of the subclavian artery.

*Course.*—The occipital artery sometimes passes outside the trachelo-mastoid muscle, instead of internal to it. The chief portion of the vessel was found, in one instance, to pass over the sterno-mastoid muscle, only a small artery being placed in the usual



Fig. 257.

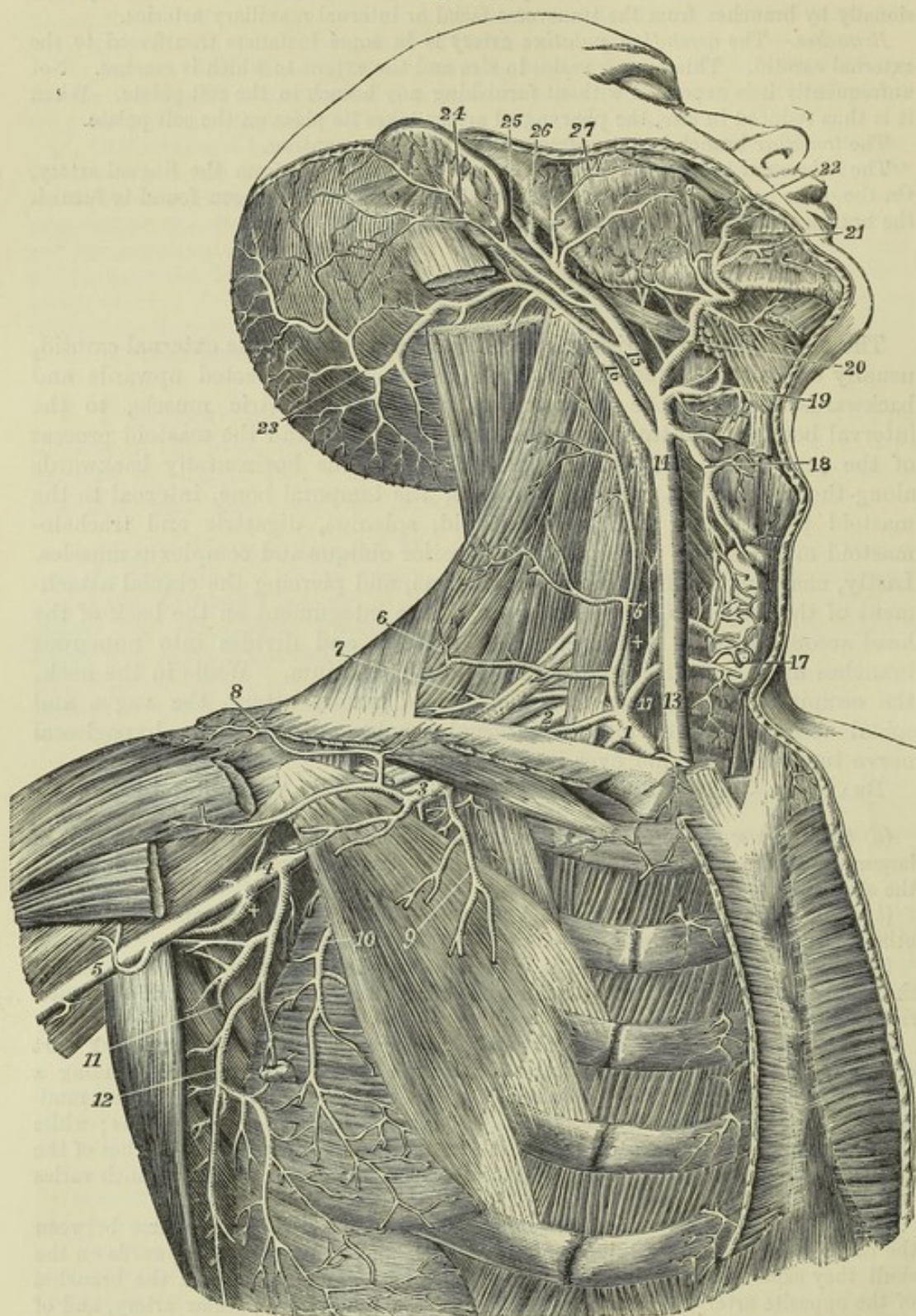


Fig. 257.—DEEP VIEW OF THE CAROTID, SUBCLAVIAN, AND AXILLARY ARTERIES (from Tiedemann).  $\frac{1}{2}$

The great pectoral, the sterno-mastoid, and the sterno-hyoid and sterno-thyroid muscles have been removed; the front part of the deltoid has been divided near the clavicle; the greater part of the digastric muscle has been removed, and the upper part of the splenius capitis and trachelo-mastoid divided near the mastoid process. *Subclavian Artery and its Branches.*—1, first or inner part of the subclavian artery, giving rise to the thyroid axis and internal mammary, and also to +, the vertebral artery; 2, third part of the



subclavian artery outside the scalenus anticus muscle ; 3, first part of the axillary artery giving rise to the acromio-thoracic, short thoracic, &c. ; 4, third part of the axillary artery, giving rise to the subscapular, circumflex, &c. ; 5, commencement of the brachial artery ; 6, superficial transverse cervical artery ; 6', placed on the scalenus anticus muscle marks the superficial ascending cervical branch ; 7, posterior scapular artery, arising from the subclavian artery behind the scalenus anticus muscle, and separate from the thyroid axis ; 8, acromial branches of the acromio-thoracic ; 9, pectoral branches of the same ; 10, long thoracic artery outside the pectoralis minor muscle ; +, posterior circumflex branch of the axillary artery, the anterior circumflex is seen rising from the opposite side of the same part of the axillary trunk ; 11, subscapular artery, passing between the subscapularis and teres minor muscles to proceed to the lower angle and dorsum of the scapula ; 12, thoracic descending branch of the subscapular artery. *Carotid Artery and its Branches.*—13, lower part, and 14, upper part of the right common carotid artery ; 15, trunk of the external carotid artery, brought fully into view by the removal of the digastric muscle ; 16, trunk of the internal carotid artery ; 17, 17, inside the thyroid axis of the subclavian artery, and on the inferior thyroid artery where it is distributed in the gland ; 18, superior thyroid artery, anastomosing in the gland with the inferior thyroid ; 19, lingual artery, brought into view by the removal of the lower part of the hyo-glossus muscle ; 20, facial artery, giving off the palatine, tonsillitic and submental ; 21, inferior labial ; 22, coronary artery ; 23, occipital artery ; 24, posterior auricular artery ; 25, superficial temporal artery ; 26, internal maxillary artery ; 27, transverse facial, given off in this instance directly by the external carotid artery.

position. The artery has, in a few instances, been seen to turn backwards below the transverse process of the atlas.

*Branches.*—The posterior auricular and the pharyngeal arteries sometimes take origin from the occipital.

#### V. POSTERIOR AURICULAR ARTERY.

The posterior auricular artery, a small vessel, arises from the external carotid a little higher up than the occipital. It ascends, under cover of the parotid gland, and resting on the styloid process of the temporal bone, reaches the angle formed by the cartilage of the ear with the mastoid process. It is crossed by the portio dura of the seventh nerve. Somewhat above the mastoid portion of the temporal bone it divides into two sets of branches, of which one set inclines forwards to anastomose with the posterior branch of the temporal artery, and the other backwards towards the occiput, on which it communicates with the occipital artery.

*BRANCHES.*—The following are the branches given off by the posterior auricular artery:—

(a) Small branches to the parotid gland and the digastric muscle.

(b) The *stylo-mastoid* branch. This twig enters the foramen of the same name in the temporal bone ; on reaching the tympanum, it divides into delicate vessels, which pass, some to the mastoid cells, others to the labyrinth. One branch is constantly found in young bodies to form, with the tympanic branch of the internal maxillary artery which enters the fissure of Glasser, a vascular circle around the auditory meatus, from which delicate offsets ramify upon the membrana tympani. This small tympanic branch sometimes arises from the occipital artery.

(c) *Auricular branches.*—As it passes the back of the ear, the auricular artery gives one or two branches which supply the posterior surface of the concha, and turn over the margin, or perforate the substance of the auricle to gain the anterior surface.

*PECULIARITIES.*—The posterior auricular artery is frequently very small, and has been seen to end in the stylo-mastoid branch. It is often a branch of the occipital.

#### VI. TEMPORAL ARTERY.

The temporal artery, one of the two branches into which the external carotid artery finally divides a little below the condyle of the lower jaw,



continues upwards in the direction of the parent vessel, whilst the other branch (the internal maxillary) curves forwards under cover of the jaw. The temporal artery is at first imbedded in the substance of the parotid gland, in the interval between the meatus of the ear and the condyle of the lower jaw. Thence it ascends over the root of the zygoma, against which it may readily be compressed. From this point onwards, it lies close beneath the skin, supported by the temporal muscle and fascia; and, about two inches above the zygoma, divides into two branches, which again subdivide and ramify beneath the integument on the side and upper part of the head.

**BRANCHES.**—Besides several small offsets to the parotid gland, some branches to the articulation of the lower jaw, and one or two to the masseter muscle, the temporal artery gives off the following branches:

(a) The *transverse* artery of the face. This branch arises whilst the temporal artery is deeply seated in the parotid gland, through the substance of which it runs nearly horizontally forwards; getting between the parotid duct and the zygoma, it rests on the masseter muscle, and is accompanied by one or two transverse branches of the facial nerve. It gives small vessels to the parotid gland, the masseter muscle, and the neighbouring integument; and divides into three or four branches, which are distributed to the side of the face, anastomosing with the infra-orbital and facial arteries.

(b) The *middle temporal* branch. This arises close above the zygoma, and immediately perforating the temporal fascia, sends branches to the temporal muscle, which communicate with the deep temporal branches of the internal maxillary artery. An offset from this artery runs to the outer angle of the orbit, where it gives branches to the orbicularis palpebrarum muscle.

(c) The *anterior auricular* branches, two or more in number, superior and inferior. These branches arise above the middle temporal. They are distributed to the fore-part of the pinna, the lobe of the ear, and a part of the external meatus, anastomosing with the ramifications of the posterior auricular artery.

(d) The *anterior temporal* branch, one of the two terminal branches of the temporal artery. This vessel inclines forwards as it ascends over the temporal fascia, and ramifies extensively upon the forehead, supplying the orbicular and occipitofrontal muscles, the pericranium, and the skin, and communicating with the supra-orbital and frontal branches of the ophthalmic artery. On the upper part of the cranium the branches of this artery are directed from before backwards. When it is desired to take blood from the temporal artery, the anterior temporal branch is selected for the operation.

(e) The *posterior temporal* branch. This is usually larger than the anterior, passes back on the side of the head, above the ear, and over the temporal fascia; its branches ramify freely in the coverings of the cranium, both upwards to the vertex, where they communicate with the corresponding vessel of the opposite side, and backwards to join with the occipital and posterior auricular arteries.

**PECULIARITIES.**—The *temporal artery* is frequently tortuous, especially in aged persons. Occasionally a large unusual branch runs forward above the zygoma to the upper part of the orbit. The temporal artery sometimes joins with the ophthalmic and furnishes large frontal arteries.

The *anterior temporal* branch is sometimes larger than the posterior, and passing backwards over the vertex of the head, communicates with the occipital.

The *transverse artery of the face* varies in size; occasionally it is much larger than usual, and takes the place of a defective facial artery. In some instances the transverse artery arises directly from the external carotid.

#### VII. INTERNAL MAXILLARY ARTERY.

The internal maxillary or deep facial artery, the larger of the two terminal branches of the external carotid, is concealed by the parotid gland at its origin below the condyle of the jaw; it curves horizontally forwards



between the jaw and the internal lateral ligament of the temporo-maxillary joint, then passes obliquely forwards and upwards on the outer surface of the external pterygoid muscle (not unfrequently beneath and within it), and opposite the interval between the two heads of that muscle, bends inwards to the spheno-maxillary fossa, where it ends by division into a number of branches.

To facilitate the arrangement of its numerous branches, this artery may be considered in three parts, viz. : 1, the part between the jaw and internal lateral ligament ; 2, the part in contact with the external pterygoid muscle ; and, 3, the part in the spheno-maxillary fossa.

Fig. 258.

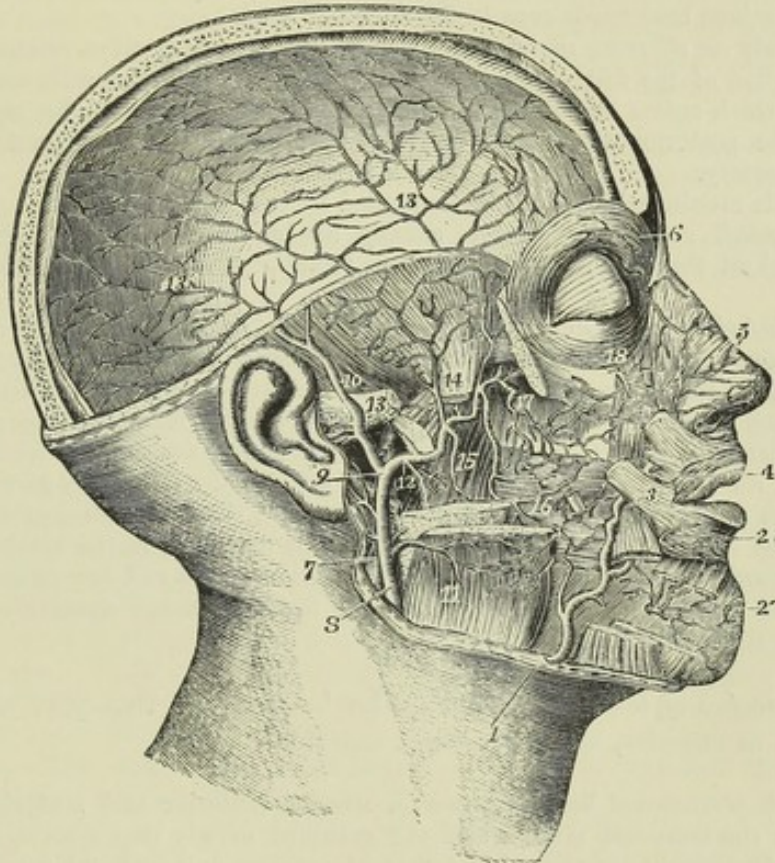


Fig. 258.—DEEP DISSECTION OF THE HEAD AND FACE, TO SHOW THE INTERNAL MAXILLARY ARTERY AND ITS BRANCHES (from Tiedemann).  $\frac{1}{3}$

The right half of the calvarium, the zygomatic arch, and the upper part of the lower jaw have been removed ; the external pterygoid muscle and some of the superficial muscles of the face have been divided, and the internal pterygoid and buccinator muscles are exposed : 1, facial artery, rising over the edge of the lower jaw ; 2, inferior labial branches ; 2', deep mental branch of the inferior maxillary artery ; 3, facial artery continued ; 4, superior coronary of the facial ; 5, lateral nasal branch ; 6, frontal branch of the ophthalmic artery, giving descending twigs to communicate with the angular branch of the facial and with the dorsal nasal ; 7, internal carotid artery ; 8, external carotid artery at the place where it passes through the parotid gland, which has been removed ; 9, division of the external carotid artery into superficial, temporal, and internal maxillary arteries ; 10, superficial temporal ; 11, masseteric branch of the external carotid artery ; 12, superiorly the trunk of the internal maxillary or deep facial artery, and inferiorly its inferior maxillary branch ; 13, placed on the zygoma, points to the middle meningeal branch, and above on the dura mater to its distribution ; 14, placed on the lower part of the temporal muscle separated from the coronoid process of the jaw, indicates the deep temporal branches of the artery ; 15, pterygoid branches ; 16, buccal artery ; 17, posterior superior dental, and deepest part of the internal maxillary artery where it enters the spheno-maxillary fossa ; 18, branches of the infra-orbital artery issuing upon the face.



**BRANCHES.—A. Branches of the first part.**—The branches of the first part of the artery all pass through osseous foramina.

(a) The *tympanic branch*, of small size and variable in origin, passes deeply behind the articulation of the lower jaw, and enters the fissure of Glasser, supplying the laxator tympani muscle, and the tympanic cavity, where it ramifies upon the membrana tympani. It anastomoses in the tympanum with the stylo-mastoid and Vidian arteries.

(b) The *middle or great meningeal artery*, by far the largest of the arteries which supply the dura mater, passes directly upwards under cover of the external pterygoid muscle, and enters the skull by the spinous foramen of the sphenoid bone. Within the cranium, it ascends to the anterior inferior angle of the parietal bone, and divides into numerous branches, which ramify in deep arborescent grooves on the inner surface of the bones, some passing upwards over the parietal bone as high as the vertex, and others backwards even to the occipital bone.

Immediately on entering the cranium the meningeal artery gives minute branches to the ganglion of the fifth nerve and to the dura mater near the sella turcica, and a small twig which enters the hiatus Fallopii, and anastomoses with the stylo-mastoid branch of the posterior auricular artery. It also inosculates with branches of the ophthalmic artery.

The middle meningeal artery is accompanied by two veins.

(c) The *small meningeal artery*, usually arising from the preceding branch, enters the skull through the foramen ovale, to supply the dura mater in the middle fossa.

(d) The *inferior dental artery*, passing downwards, enters the dental canal along with the inferior dental nerve, and subsequently escapes on the face by the mental foramen. As it enters the canal, it gives off the *mylo-hyoid branch*, which, with the nerve bearing the same name, runs in a groove on the inner surface of the jaw, below the dental foramen, and ramifies on the under surface of the mylo-hyoid muscle. In its course through the bone, the inferior dental artery gives off small offsets, which ascend to enter the minute apertures in the extremities of the fangs of the teeth, and supply the pulp of each; and before emerging at the mental foramen, it sends forwards a branch which supplies the incisor teeth and inosculates with its fellow of the opposite side. The terminal or facial branches anastomose with the inferior coronary and submental arteries.

**B.—Branches of the second part.**—The branches of this part are chiefly distributed to muscles, and are named muscular.

(a) The *deep temporal branches*, two in number (anterior and posterior), ascending between the temporal muscle and the cranium, supply that muscle, and anastomose with the branches of the other temporal arteries, and with minute branches of the lachrymal artery, through small foramina in the malar bone.

(b) The *pterygoid branches*, small, short offsets, irregular in number and origin, are distributed to the pterygoid muscles.

(c) The *masseteric* is a small but regular branch which passes from within outwards, above the sigmoid notch of the lower maxillary bone, to the deep surface of the masseter muscle. It is often joined at its origin with the posterior temporal branch.

(d) The *buccal branch* runs obliquely forwards upon the buccinator muscle with the buccal nerve; it is distributed to that and other muscles of the cheek, and anastomoses with the branches of the facial artery.

**C. Branches of the third part.**—These branches, like those of the first series, enter bony foramina or canals.

(a) The *alveolar or superior maxillary branch*, arising near the tuberosity of the maxillary bone, frequently in common with the infra-orbital branch, runs tortuously forwards upon the surface of the upper jaw, and gives off the *superior dental* and other branches which enter the foramina of the tuberosity, and supply the pulps of



the upper molar and bicuspid teeth, besides ramifying in the lining membran of the maxillary sinus. Other small branches supply the gums.

(b) The *infra-orbital* artery runs horizontally forwards into the infra-orbital canal, and having traversed that canal along with the superior maxillary nerve, emerges upon the face at the infra-orbital foramen.

Whilst still in the canal, it sends upwards into the orbit small branches, which enter the inferior rectus and the inferior oblique muscle of the eye and the lachrymal gland, and others downwards to supply the front teeth. On the face it gives branches upwards, to the lachrymal sac and inner angle of the orbit, anastomosing with the nasal branches of the ophthalmic and facial arteries, and sends other branches downwards, beneath the levator labii superioris, which join the ramifications of the transverse facial, buccal, and superior coronary arteries.

(c) The *descending* or *superior palatine* artery descends perpendicularly through the posterior palatine canal, with the palatine nerve, and runs along the hard palate. In front it ends in a small vessel which ascends through the incisor foramen, and anastomoses with the artery of the septum. While descending in the canal, this artery sends off twigs through the bone, which communicate on the soft palate with the ascending palatine artery.

(d) The Vidian branch traverses the Vidian canal with the nerve of the same name; it is distributed to the Eustachian tube and the top of the pharynx, and sends a small vessel into the tympanum.

(e) The *pterygo-palatine*, a very small branch, passes backwards through the pterygo-palatine canal to reach the top of the pharynx, to which, and to the Eustachian tube and sphenoidal cells, it is distributed.

(f) The *nasal* or *spheno-palatine* artery enters the spheno-palatine foramen, and divides into two or three branches, some of which ramify extensively over the spongy bones, while others supply the posterior ethmoidal cells and the antrum. One long branch, the *artery of the septum*, runs forwards along the septum nasi, ends in a small vessel which enters the incisor foramen, and inosculates with the descending palatine artery.

**PECULIARITIES.—Origin.**—The internal maxillary artery is very constant in its place of origin. It has, however, been seen to arise from the facial.

**Course.**—The artery often passes under cover of the external pterygoid muscle, crossing the inferior maxillary division of the fifth nerve. It has likewise been observed to issue from under cover of the external pterygoid by piercing the middle of that muscle. When the artery is placed beneath the muscle, it has been found lodged in a notch in the posterior margin of the external pterygoid plate, and bound down by fibrous structure.

**Branches.**—The *middle meningeal* artery occasionally furnishes the lachrymal artery (usually an offset of the ophthalmic),—a peculiarity which may be looked on as resulting from the enlargement of an ordinary anastomosing branch.

In a case in which the internal carotid artery was wanting, two tortuous branches from the internal maxillary entered the skull by the foramen rotundum and foramen ovale, to supply its place. (Quain, "On the Arteries," pl. 13, fig. 8.)

#### VIII. ASCENDING PHARYNGEAL ARTERY.

The pharyngeal artery, long and slender, the smallest branch of the external carotid which has received a distinctive designation, arises most commonly from half an inch to an inch above the origin of the external carotid; and in its straight course upwards rests on the rectus capitis anticus, close to the surface of the pharynx, between it and the internal carotid artery, and is thus directed up towards the base of the skull.

**BRANCHES.**—These are very small, and may be divided into three sets, viz., those to the pharynx; a set directed outwards; and meningeal branches.

(a) The *pharyngeal* branches pass inwards, for the most part, to the pharynx. One or two small and variable branches ramify in the middle and inferior constrictor muscles. Higher up than these is a larger and more regular branch, which runs



upon the upper constrictor, and sends small ramifications to the Eustachian tube, and to the soft palate and tonsil.

The last mentioned, or *palatine* branch, is sometimes of considerable size, and supplies the soft palate, taking the place of the inferior palatine branch of the facial artery, which in such cases is small. It divides into an anterior and a posterior twig, both of which anastomose with their fellows of the opposite side in the middle line.

Fig. 259.

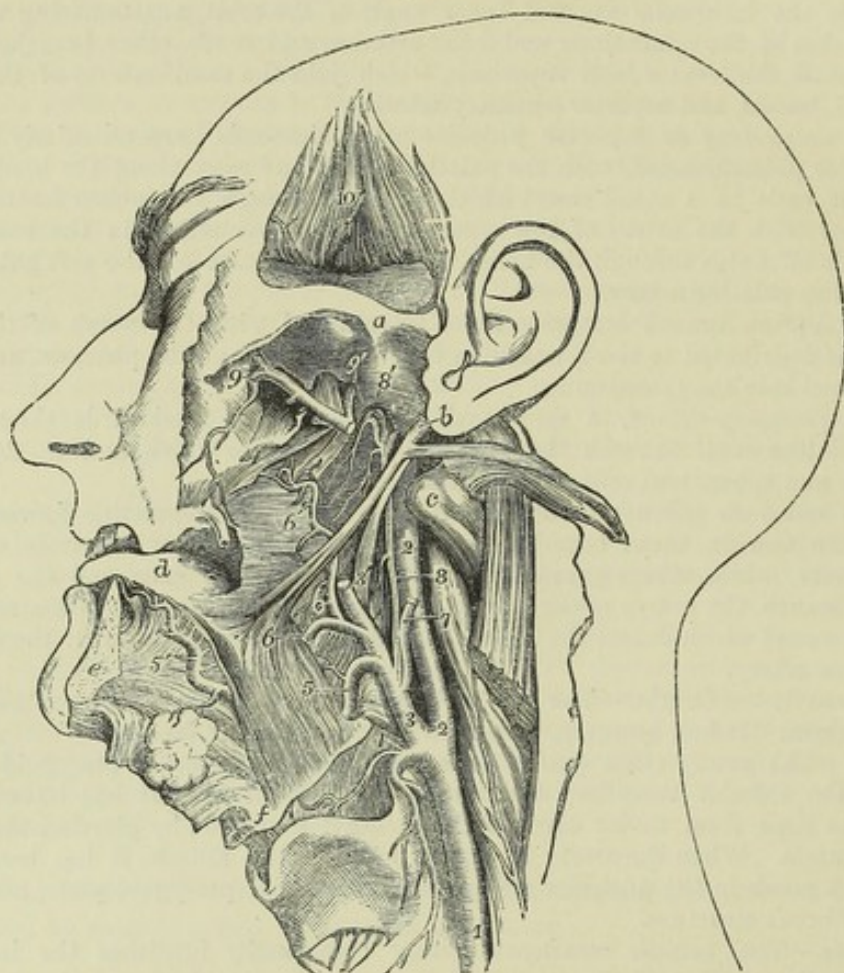


Fig. 259.—DEEP VIEW OF THE LINGUAL AND PHARYNGEAL ARTERIES (from R. Quain).  $\frac{1}{2}$

In the preparation from which this drawing has been taken half the lower jaw has been removed, and the tongue has been drawn forwards between the teeth; the external pterygoid muscle has been removed and the temporal muscle has been turned up from within the zygoma: *a*, the root of the zygoma, above the glenoid cavity; *b*, placed on the lobe of the ear, points by a line to the styloid process, from which the stylo-glossus and stylo-pharyngeus are seen passing downwards and forwards, and the stylo-hyoid detached from the hyoid bone is thrown backwards with the digastric muscle; *c*, transverse process of the atlas; *d*, upper surface of the tongue; *e*, sawn surface of the symphysis of the lower jaw; *f*, the angle of the hyoid bone; 1, left common carotid artery; 2, internal carotid artery; 3, external carotid artery; 3', placed on the stylo-pharyngeus muscle, points by a line to the upper part of the external carotid artery divided where it enters the parotid gland; 4, superior thyroid artery, its laryngeal branch passing upon the thyro-hyoid membrane; 5, lingual artery about to pass within the hyo-glossus muscle; 5', placed on the genio-hyo-glossus, points to the continuation of the lingual artery in the ranine; 6, the trunk of the facial artery cut short; 6', its tonsillar and pharyngeal branches; 7, occipital artery cut short; 8, ascending pharyngeal artery; 8', its upper part turning down upon the pharynx; 9, internal maxillary artery as it passes into the sphenomaxillary fossa, and gives the posterior dental and the infra-orbital arteries; 9', middle meningeal artery; 10, placed on the deep surface of the temporal muscle, which is turned up and shows some cut branches of the deep temporal arteries.



(b) The *external* branches, small and irregular, are distributed to the rectus anticus muscle, the first cervical ganglion of the sympathetic nerve, some of the cerebral nerves as they issue from the skull, and to lymphatic glands. Some of them anastomose with the ascending cervical branch of the subclavian artery.

(c) The *meningeal* branches are terminal twigs, which pass through the foramen lacerum posticum to end in the dura mater.

PECULIARITIES.—This artery varies greatly in its place of origin from the carotid. It occasionally springs from another source, as from the occipital or internal carotid, and, in a few instances, it has been seen double.

## INTERNAL CAROTID ARTERY.

The internal carotid artery is distributed to the brain, to the eye with its appendages, and in part to the forehead. It extends directly upwards from the termination of the common carotid artery, opposite the upper border of the thyroid cartilage, to the carotid foramen of the temporal bone. Entering the cranial cavity through the carotid canal, it crosses the foramen lacerum medium, and turning upwards on the side of the sphenoid bone, it passes forwards on the carotid groove of that bone. Thence it turns abruptly upwards on the inner side of the anterior clinoid process, and divides opposite the inner end of the Sylvian fissure of the brain, into the anterior and middle cerebral arteries.

*In the neck*, the internal carotid artery varies in length according to the height of the division of the common carotid. It rests on the rectus anticus major muscle, and has the pharynx and tonsil on its inner side. The internal jugular vein is in contact with it as far as the base of the skull, lying on its superficial and posterior aspect: and placed more deeply behind it are the vagus nerve and main trunk of the sympathetic. At its commencement the artery is covered only by the sterno-mastoid muscle, by the platysma myoides, and by fascia, and lies to the outer side of the external carotid. It soon, however, becomes concealed by the parotid gland, and lies internal and posterior to the external carotid trunk, and is crossed first by the occipital artery, and by the hypoglossal nerve and the digastric and stylo-hyoid muscles, three structures which lie superficial to both carotid arteries; and higher up, by the styloid process, the stylo-pharyngeus muscle and the glosso-pharyngeal nerve, which, together with, in some cases, the pharyngeal branch of the vagus nerve, pass forwards between the external and internal carotid arteries.

Within the *cranium*, the internal carotid artery has a very tortuous course, curving forwards and inwards within the carotid canal, then turning upwards to reach the sphenoid bone, on which it is at first directed horizontally forwards, and afterwards resumes the vertical position on the inner side of the anterior clinoid process. In this part of its course the artery is accompanied by the carotid and cavernous plexuses of the sympathetic nerve. After leaving the carotid canal, it lies in the floor of the cavernous sinus, and in contact with it externally are the nerves which pass through the sphenoidal fissure. Opposite the anterior clinoid process it pierces the layer of dura mater which forms the roof of the sinus, and becomes invested with arachnoid membrane.

By the winding course of the internal carotid artery in the skull the brain is probably in some degree protected from the force of the pulsations with which the blood is propelled from the heart. Occasionally the artery presents considerable tortuosity before entering the carotid canal, especially in apoplectic subjects, the trunk having probably been elongated by the force of the pulsations.



The vertebral artery is similarly tortuous before entering the cranium.

**BRANCHES.**—In the neck the internal carotid artery gives usually no branch. While within the carotid canal it sends a small offset to the tympanum, which anastomoses with the tympanic and stylo-mastoid arteries. Within the cavernous sinus some small branches proceed from it to supply the walls of the sinus and the adjacent dura mater.

Opposite the anterior clinoid process, the internal carotid gives off the *ophthalmic* artery; and at the Sylvian fissure of the brain, before dividing into the anterior and middle cerebral arteries, it gives off or is joined by the *posterior communicating* artery, a slender anastomotic branch which lies parallel to its fellow of the opposite side and unites the internal carotid with the posterior cerebral artery.

**PECULIARITIES.**—In very rare cases of abnormal arrangement of the arch of the aorta, the internal carotid artery has arisen as a primary trunk. A few examples are recorded of its entire absence.

The posterior communicating artery has been occasionally seen replaced by two very small vessels.

## BRANCHES OF THE INTERNAL CAROTID ARTERY.

### I. OPHTHALMIC ARTERY.

The *ophthalmic* artery, arising from the internal carotid artery by the side of the anterior clinoid process, enters the orbit by the foramen opticum, below and to the outer side of the optic nerve. It soon changes its direction, passing over the nerve to reach the inner wall of the orbit, along which it runs forwards, and terminates in branches which ramify on the forehead and side of the nose.

#### BRANCHES:—

(a) The *lacrimal* artery, arising on the outer side of the optic nerve, passes forwards along the upper border of the external rectus muscle to the lacrimal gland, in which the greater number of its branches are distributed. Some of the branches pass onwards to the eyelids and conjunctiva, joining with other palpebral branches; and one or two delicate *malar* branches pierce the malar bone and reach the temporal fossa, where they join branches from the deep temporal arteries. The lacrimal artery has also branches of communication through the sphenoidal fissure with small offsets from the middle meningeal artery.

(b) The *central artery of the retina*, a very small vessel, pierces the sheath and substance of the optic nerve about a quarter of an inch behind its junction with the eyeball, and runs imbedded within it to the retina, in which it ramifies in minute branches. A very delicate vessel, demonstrable in the foetus, passes forwards through the vitreous humour, to reach the posterior surface of the capsule of the crystalline lens.

(c) The *supra-orbital* branch ascends above the muscles, and coursing forwards to the supra-orbital notch, in company with the frontal nerve, terminates on the forehead. It distributes branches to the eyelids, and communicates with the temporal artery.

(d) The *ciliary* arteries are divisible into three sets, viz., short, long, and anterior ciliary. The *short* ciliary arteries, varying from twelve to fifteen in number, enclose the optic nerve as they pass forwards to reach the posterior aspect of the sclerotic coat, which they pierce, and enter the eyeball about a line or two from the entrance of the optic nerve. The *long* ciliary arteries, two in number, also enter the back of the eyeball, and then pass forwards, one on each side, between the choroid membrane and the sclerotic, as far as the ciliary ligament, where they divide into branches. The *anterior* ciliary arteries are derived from some of the muscular branches; they form a vascular circle around the fore part of the eyeball, and then



Fig. 260.

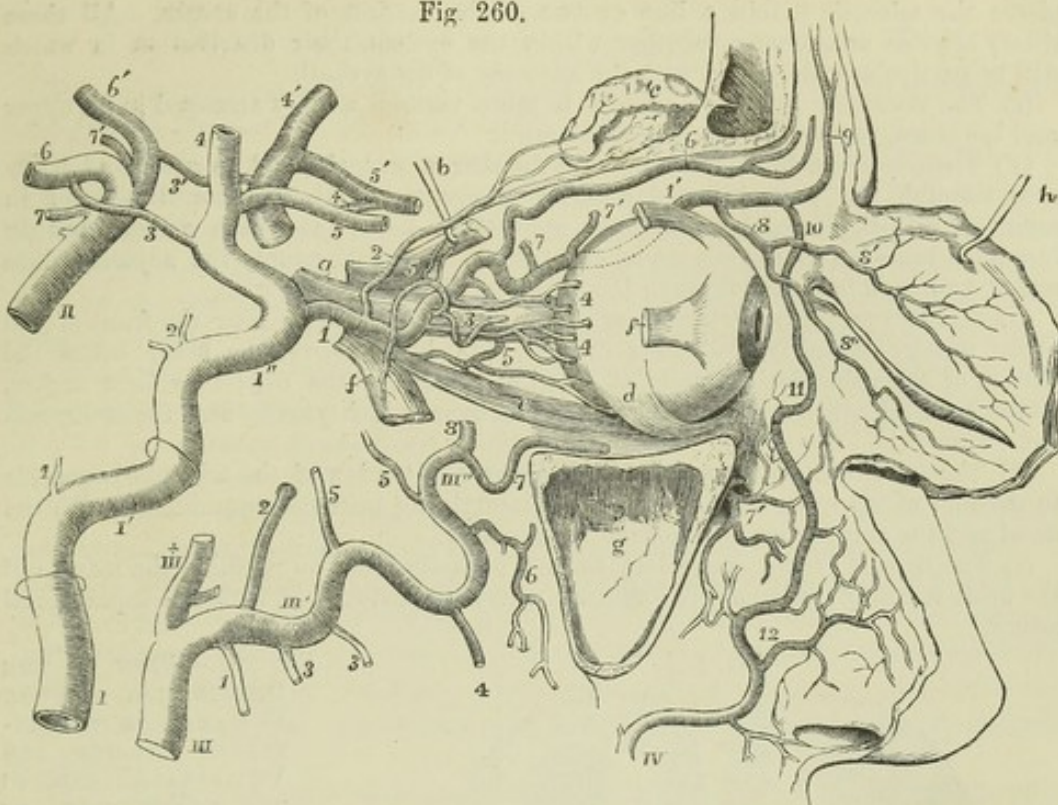


Fig. 260.—SEMIDIAGRAMMATIC VIEW OF THE ARTERIES OF THE ORBIT AND NEIGHBOURING PARTS, WITH THEIR BRANCHES AND ANASTOMOSES (founded on Hirschfeld and Leveillé, with additions).

The outer wall of the orbit has been removed, the sinus maxillaris is laid open, the eyelids are turned forwards, and the external and superior recti, and the superior oblique muscles have been partially removed. *a*, optic nerve; *b*, hook, holding up the posterior part of the superior rectus muscle, the anterior part of which is left attached to the eyeball; *c*, lachrymal gland, thrown up on the frontal bone; *d*, insertion of the inferior oblique muscle; *e*, inferior rectus; *f, f'*, anterior and posterior portions of the divided external rectus; *g*, maxillary sinus; *h*, hook, holding up the eyelids, of which the deep surface is exhibited.

I, internal carotid artery below the inferior aperture of the carotid canal of the temporal bone, which is indicated higher up by a ring surrounding the artery; I', the part of the artery situated within the temporal bone, a second ring indicating the place of the upper aperture of the temporal canal; I'', the part of the artery situated on the sphenoid bone; upon this artery, 1, twig to the mastoid cells and tympanum; 2, twigs in the cavernous sinus; 3, communicating to the posterior cerebral; 4, middle cerebral; 5, anterior cerebral.

II, basilar artery; upon this artery, 6, posterior cerebral; 7, superior cerebellar: the accented numbers, 3', 4', 5', 6', 7', indicate, on the left side, the arteries already named under the same numbers on the right side, and with these and the anterior communicating branch marked by +, complete the Circle of Willis.

III, upper part of the external carotid artery dividing into IIIx, the superficial temporal, and III', III'', the internal maxillary artery; upon the latter artery, 1, inferior dental branch; 2, middle meningeal; 3, 3, masseteric and pterygoid branches; 4, buccal; 5, 5, anterior and posterior deep temporal; 6, posterior superior dental; 7, infraorbital; 7', branches of the same issuing upon the face; 8, part of the internal maxillary, which turns into the spheno-maxillary fossa.

IV, facial artery, terminating at 11, in the angular, and giving off, at 12, the lateral nasal branches, and others which communicate with the infraorbital.

In the orbit the following numbers indicate the ophthalmic artery and its branches: 1, the ophthalmic artery at its origin from the internal carotid; 1', the same artery continued on the upper and inner side of the orbit; 2, lachrymal branch; 3, central artery of the retina; 4, some of the ciliary arteries; 5, 5, upper and lower muscular branches; 6, supraorbital; 7, 7', posterior and anterior ethmoidal arteries; 8, palpebral; 8', 8'', its superior and inferior divisions; 9, frontal; 10, nasal communicating with the angular of the facial.



pierce the sclerotic within a line or two of the margin of the cornea. All these ciliary arteries anastomose together within the eyeball, their distribution in which will be particularly described with the anatomy of the eyeball.

(e) The *muscular* branches, subject to much variety, usually arranged in an upper and lower set, supply the muscles of the orbit.

(f) The *ethmoidal* branches are two in number, a *posterior* and an *anterior*. They pass through the posterior and anterior internal orbital foramina, the latter in company with the nasal branch of the ophthalmic nerve; and both arteries, having furnished branches to the ethmoidal cells, enter the skull, supply the adjacent dura mater, and send branches through the cribriform lamella to the nose.

(g) The two *palpebral* branches, *superior* and *inferior*, arise near the front of the orbit, usually together, but soon diverge, one lying above, the other below the tendon of the orbicularis muscle at the inner angle of the eye; they form arches, one in each lid, and send branches to the caruncula lachrymalis and the lachrymal sac.

(h) The *nasal* branch courses forwards above the tendon of the orbicularis muscle to the root of the nose, where it ramifies, maintaining a free communication with the nasal and the angular branches of the facial artery.

(i) The *frontal* branch runs close to the preceding, but on reaching the margin of the orbit turns upwards on the forehead, where it anastomoses with the supraorbital artery.

Fig. 261.

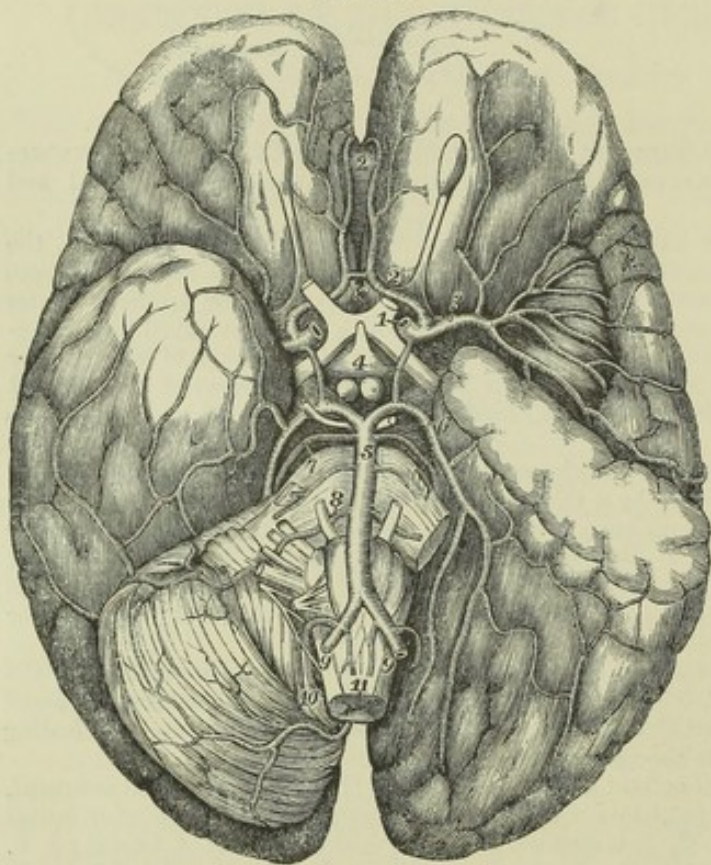


Fig. 261.—VIEW OF THE DISTRIBUTION OF THE BRANCHES OF THE INTERNAL CAROTID AND VERTEBRAL ARTERIES TO THE LOWER PARTS OF THE BRAIN (altered from Hirschfeld and Leveillé).  $\frac{1}{3}$

On the left side of the brain a portion of the middle lobe of the cerebrum has been removed so as to open up the fissure of Sylvius and expose the convolutions of the island of Reil; and the left half of the cerebellum has been removed to show the lower surface of the posterior cerebral lobe. 1, placed on the optic commissure, points to the divided stem of the left internal carotid artery where its cerebral distribution begins; 2, anterior cerebral branch, exposed fully by the removal of a portion of the left optic nerve; 2', placed on the knee or anterior bend of the corpus callo-

sum between its two arteries; x, placed on the lamina cinerea in front of the optic commissure, marks the anterior communicating artery; 3, middle cerebral artery, passing into the fissure of Sylvius and distributing its branches over the convolutions of the island of Reil and others beyond; 4, placed between the infundibulum and the corpora albicantia, points by a line to the left posterior communicating artery; 5, basilar artery; 6, posterior cerebral artery, its distribution exposed on the left side by the removal of half of the cerebellum; 7, placed on the pons Varolii, points to the right superior cerebellar artery; 8, anterior inferior cerebellar artery; between 7, and 8, one of the largest of the transverse branches of the basilar artery; 9, 9, right and left vertebral arteries; 10, posterior inferior cerebellar arteries; 11, anterior spinal arteries.



## II. ANTERIOR AND MIDDLE CEREBRAL ARTERIES.

The terminal branches of the internal carotid artery supply the anterior and greater part of the pia mater and brain.

The *anterior cerebral*, commencing at the subdivision of the internal carotid at the inner end of the fissure of Sylvius, turns forwards towards the middle line to reach the longitudinal fissure between the anterior lobes of the cerebral hemispheres, and is connected with the vessel of the opposite side by the *anterior communicating artery*, a branch not more than two lines in length. The two anterior cerebral arteries, lying close together, in the next place turn round the anterior border of the corpus callosum, run backwards on its upper surface, concealed by the cerebral hemispheres, and end by anastomosing with the posterior cerebral arteries. In their course they give numerous branches to the brain.

The *middle cerebral* artery, larger than the anterior, inclines obliquely outwards, taking the course of the fissure of Sylvius; within this it divides into several branches, which ramify in the pia mater investing the surfaces of the anterior and middle lobes of the brain, and join with the branches of both the anterior and posterior cerebral arteries. Numerous small branches, without ramifying in the pia mater, turn upwards at once, and enter the brain at the anterior perforated spot, through which they reach the corpus striatum.

One or two *choroid* arteries, which sometimes arise directly from the internal carotid, passing backwards, enter the fissure between the middle lobe and the crus cerebri, to reach the descending cornu of the lateral ventricle, in which they are distributed to the choroid plexus.

PECULIARITIES.—In rare instances, the anterior cerebral arteries have united into a single trunk, like the basilar artery behind, and have again divided into a right and left artery. The anterior communicating artery is frequently double.

## CIRCLE OF WILLIS.

A remarkable anastomosis exists between the branches of the vertebral and internal carotid arteries within the cranium, by which the circulation in the brain may be equalised, and any irregularity which might arise from the obliteration of one, or even two of the vessels, may speedily be remedied by a corresponding enlargement of the others. This anastomosis, known as the *circle of Willis*, results from a series of communications between the following branches. The anterior cerebral arteries are connected together, as already mentioned, in the longitudinal fissure by the anterior communicating artery. The right and left internal carotids, the trunks from which the anterior cerebral arteries arise, are united by the posterior communicating arteries to the posterior cerebral arteries, which arise behind from a single trunk—the basilar artery. Within or opposite to the area of this vascular circle are the following parts of the encephalon, viz., the commissure of the optic nerves, lamina cinerea, infundibulum and tuber cinereum, corpora albicantia, posterior perforated spot with part of the crura cerebri, and the origin of the third pair of nerves.

Frequently the posterior cerebral artery of one side arises by an enlarged posterior communicating artery from the internal carotid, and is connected only by a slender vessel with the basilar.



## SUBCLAVIAN ARTERIES.

The subclavian artery is only the commencing portion of a long trunk which forms the main artery of the upper limb, and which is artificially divided for purposes of description into three parts—the *subclavian*, *axillary*, and *brachial* arteries.

The subclavian artery, arising on the right side from the extremity of the innominate stem, and on the left from the arch of the aorta, passes a short way up into the neck, arches outwards over the pleura, and rests between the scalenus anticus and scalenus medius muscles on the first rib. At the outer border of the first rib it ceases to be called subclavian, and is continued into the axillary artery.

Each subclavian artery is conveniently divided into three parts,—the *first* part extending from the origin of the vessel to the inner border of the anterior scalenus muscle; the *second* consisting of the portion of the vessel situated behind that muscle; and the *third* reaching outwards to the external border of the first rib. In examining each of these portions in detail, it will be necessary in the first part to give separate descriptions for the right and the left sides, as there is a material difference in the anatomy of the two vessels.

THE FIRST PART OF THE RIGHT SUBCLAVIAN ARTERY commences close to the trachea, at the division of the innominate artery, behind the upper part of the sterno-clavicular articulation, and ends at the inner margin of the anterior scalenus muscle. Separating from the carotid artery, it arches upwards and outwards, and ascends above the level of the clavicle to an extent which varies in different cases. It is deeply placed, being covered by the platysma, the sterno-mastoid, the sterno-hyoid and sterno-thyroid muscles, and the deep cervical fascia. It is in contact with the pleura inferiorly, and is separated by an interval from the longus colli muscle behind.

*Relation to Veins.*—The *subclavian* vein lies lower than the first part of the right subclavian artery, close under the clavicle. In its course to join this vein, the *internal jugular* passes in front of the artery near the scalenus muscle, as do also, nearer the middle line, the *anterior jugular* and a *vertebral* vein.

*Relation to Nerves.*—The *vagus* nerve passes in front of the artery on the inner side of the internal jugular vein, and its *recurrent laryngeal* branch, turning round below the artery, ascends behind. Some cardiac branches of the *sympathetic* nerve pass down over the artery.

THE FIRST PART OF THE LEFT SUBCLAVIAN ARTERY arises from the upper surface of the arch of the aorta, at the left end of its transverse portion, and ascends to the margin of the first rib, behind the insertion of the anterior scalenus muscle. It is, therefore, longer than the first part of the right subclavian, and ascends at first almost vertically out of the chest, instead of arching, like that vessel, outwards across the neck. It is at first overlapped by the left lung, and is covered in front and on the left side by the pleura; it rests on the longus colli muscle, and lies, for a short space, in front of the oesophagus (here deviating to the left side), and the thoracic duct. To the inner or right side of the vessel are situated the left carotid and trachea, and further up the oesophagus and the thoracic duct.

*Relation to Veins.*—The internal jugular vein is immediately before the artery, where it turns outwards from the thorax, close to the scalenus muscle; and the left innominate vein is likewise anterior to it.



*Relation to Nerves.*—The *pneumogastric* nerve is anterior to the first part of the left subclavian artery, and parallel with it, the recurrent branch on this side turning round below the arch of the aorta. The *phrenic* nerve

Fig. 262.

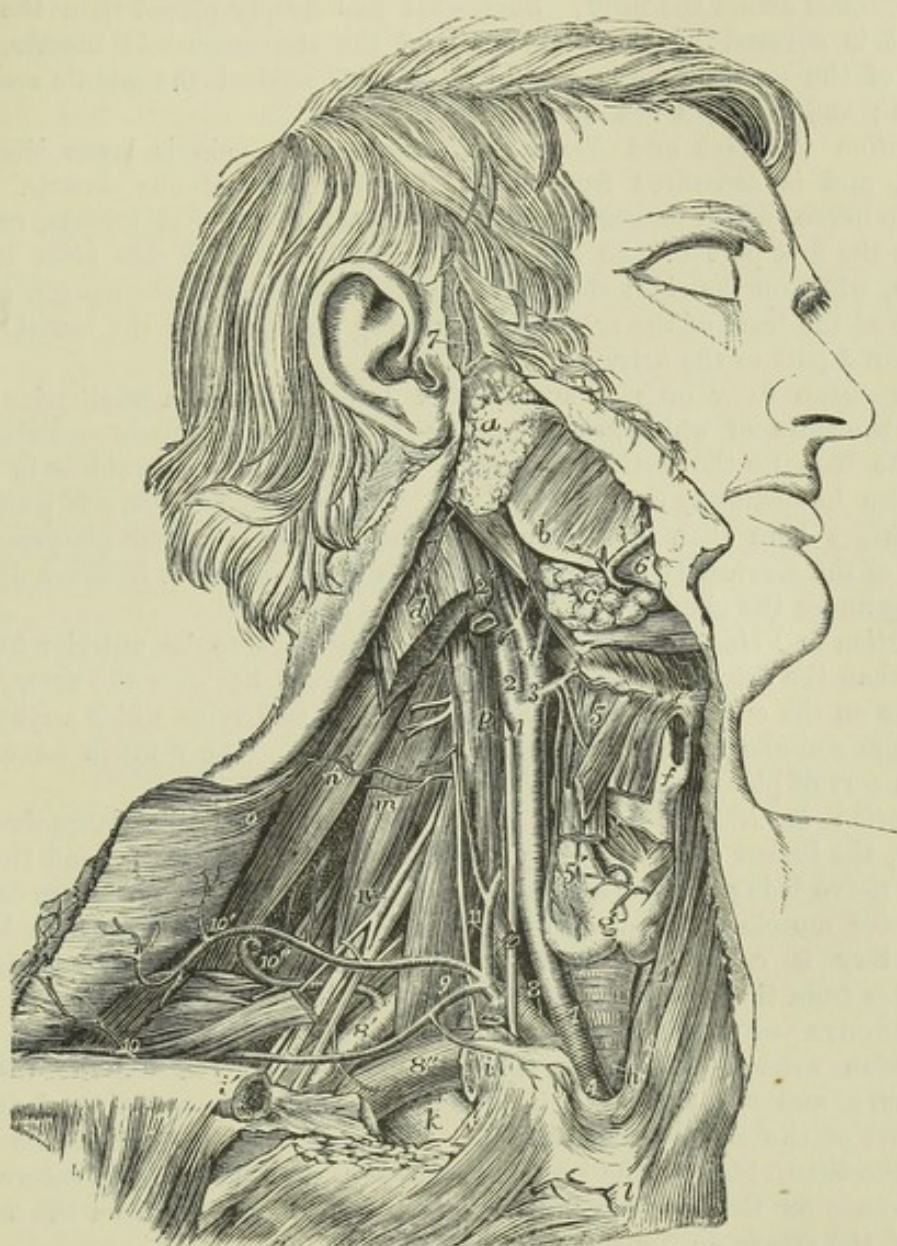


Fig. 262.—VIEW OF THE RIGHT COMMON CAROTID AND SUBCLAVIAN ARTERIES, WITH THE ORIGIN OF THEIR BRANCHES AND THEIR RELATIONS (from R. Quain).  $\frac{1}{2}$

For the description of the upper part of this figure, see p. 342. The following explanation relates to the subclavian artery and its branches: 8, the first part, 8', the third part, of the arch of the subclavian artery; 8'', the subclavian vein, shown by the removal of a portion of the clavicle; 9, is placed on the scalenus anticus muscle in the angle between the transverse cervical and supra-scapular branches of the thyroid axis; 10, outer part of the supra-scapular artery; 10', transverse cervical branches passing into the deep surface of the trapezius; 10'', the posterior scapular artery, represented as rising directly from the third part of the subclavian artery, and passing through the axillary plexus of nerves and under the levator anguli scapulæ; 11, on the scalenus anticus muscle, points to the inferior thyroid artery, near the place where the ascending muscular artery of the neck is given off; the phrenic nerve lies on the muscle to the outside; i, the supra-sternal twig of the supra-scapular artery.



descends over the artery along the inner margin of the scalenus muscle, immediately outside the thyroid axis. The *cardiac* nerves of the left side, descending from the neck, are close to the artery.

THE SECOND PART OF THE SUBCLAVIAN ARTERY, the short portion concealed by the anterior scalenus muscle, forms the highest part of the arch described by the vessel across the neck. Somewhat less deeply placed than the first part, it is covered by the platysma and the sterno-mastoid muscle, with layers of the cervical fascia. Behind, it rests against the middle scalenus muscle; and below, it lies on the pleura.

*Relation to Veins and Nerves.*—The subclavian vein is lower than the artery, and is separated from it by the anterior scalenus muscle. The phrenic nerve, which descends obliquely inwards over that muscle, usually crosses the first part of the subclavian artery of the left side close to the muscle, while on the right side, not having quite reached the margin of the muscle at the level of the artery, it is usually separated by the muscle from the second part of the artery.

THE THIRD PART OF THE SUBCLAVIAN ARTERY lies in a small triangular space, the sides of which are formed by the omo-hyoid muscle and clavicle, and the base by the anterior scalenus muscle; the omo-hyoid is in some instances immediately over the artery. The subclavian artery is nearer to the surface here than elsewhere, being covered only by the platysma and layers of the cervical fascia, but towards its termination it becomes deeper, sinking under the clavicle and the subclavius muscle.

*Relation to Veins.*—The subclavian vein continues to be anterior to, and lower than the artery. The *external jugular* vein lies over the artery, and receives on the outer side from the shoulder the two veins which accompany the supra-scapular and transverse cervical arteries. The veins in some cases form a sort of plexus over the artery.

*Relation to Nerves.*—Above the vessel are placed the large *brachial* nerves, the lowest cord formed by the union of the last cervical and the first dorsal nerve being behind and in contact with it. The small nerve of the *subclavius* muscle passes down over the artery, and the space which lodges the artery is crossed in front by the superficial descending (clavicular) branches from the *cervical* plexus of nerves.

BRANCHES.—Four branches are usually described as arising from each subclavian artery. Of these, three, namely, the *vertebral*, the *internal mammary*, and the *thyroid axis*, generally spring close together from the first part of the artery, near the inner side of the anterior scalenus muscle; while the fourth branch, the *superior intercostal*, is usually found internal to that muscle on the left side, but arising under cover of it, from the second part of the artery on the right.

The vertebral artery springs from the upper and back part of the subclavian, and ascends in the neck to reach the interior of the skull; the internal mammary proceeds from the lower side of the vessel, and descends into the fore part of the chest and abdomen; the thyroid axis arises from the front of the artery, and divides into three branches, one of which, the *inferior thyroid*, is distributed in the fore part of the neck, whilst the other two, the *suprascapular* and the *transverse cervical*, pass outwards across the neck to the shoulder; lastly, the superior intercostal and deep cervical arise by a common stem from the back part of the artery, and pass into the upper part of the thoracic wall and the posterior muscles of the neck. The deep cervical is reckoned by some writers as a fifth branch of the subclavian artery, but it usually rises in common with the superior intercostal artery.



Another branch, in the great majority of instances, arises from the third part of the artery. This is most frequently the *posterior scapular* artery, a branch which otherwise is derived from the transverse cervical, one of the divisions of the thyroid axis. This circumstance is of surgical interest, as the third part of the subclavian artery is the portion of the vessel usually tied for axillary aneurism. As the right subclavian artery is likewise accessible to the surgeon in its first part, it is proper to mention that the distance between the origin of the vessel and its first branch is usually between half an inch and an inch, and that it very rarely is less than half an inch or more than an inch and a half.

**PECULIARITIES.**—The variations in origin of the subclavian arteries have been considered along with the peculiarities of the arch of the aorta.

**Course.**—The height to which these vessels reach in the neck is liable to some variation. Most commonly the artery crosses the neck a little higher than the clavicle, but it is sometimes placed as high as an inch or even an inch and a half above the level of that bone. The greater extent of elevation above the clavicle, however, is especially seen in the artery of the right side. Occasionally the subclavian artery perforates the anterior scalenus muscle, and in a few rare cases it has been seen altogether in front of the muscle, and close to the subclavian vein. That vein has been also seen to pass with the artery behind the scalenus muscle.

**Branches.**—Besides the variation in amount of the branches already referred to, it may be noticed that, in a few cases, one or more of the three first branches have been found moved inwards from their usual position, or outwards to another division of the subclavian. Sometimes two, and much more rarely three branches arise from the third part of the vessel.

## BRANCHES OF THE SUBCLAVIAN ARTERY.

### I. VERTEBRAL ARTERY.

The vertebral artery, which is usually the first and largest branch of the subclavian, arising from the upper and back part of that vessel, passes upwards and a little backwards, and enters the transverse foramen of the sixth cervical vertebra—not unfrequently that of some higher vertebra. The vessel then ascends in a vertical direction through the series of foramina of the transverse processes, as far as to the upper border of the axis; there it inclines outwards to reach the corresponding foramen of the atlas, and after passing through that aperture winds backwards and inwards in the groove on the neural arch of that vertebra, and, piercing the dura mater, enters the skull through the foramen magnum. Finally, it proceeds upwards and forwards, and turning round from the side to the front of the medulla oblongata on the basilar process of the occipital bone, unites with the vessel of the opposite side, at the lower border of the pons Varolii, to form the basilar artery.

At its commencement, the vertebral artery lies behind the internal jugular vein, and on approaching the vertebræ passes between the longus colli and the scalenus anticus muscle. On the left side, the thoracic duct in ascending crosses in front of the vessel from within outwards.

While within the foramina of the cervical vertebræ, the artery is accompanied by a plexus of the sympathetic nerves and by the vertebral vein, which, as the vessels issue from the foramen of the sixth vertebra, is in front of the artery: the cervical nerves as they emerge from the intervertebral foramina lie behind it. The sub-occipital nerve passes out beneath



it, where it lies on the groove of the atlas, and at that point the artery is covered by the superior oblique muscle.

Within the skull it turns round the side of the medulla oblongata, between the origin of the hypoglossal nerve and the anterior root of the sub-occipital, and then lies between the anterior surface of the medulla and the basilar process of the occipital bone.

Fig. 263.

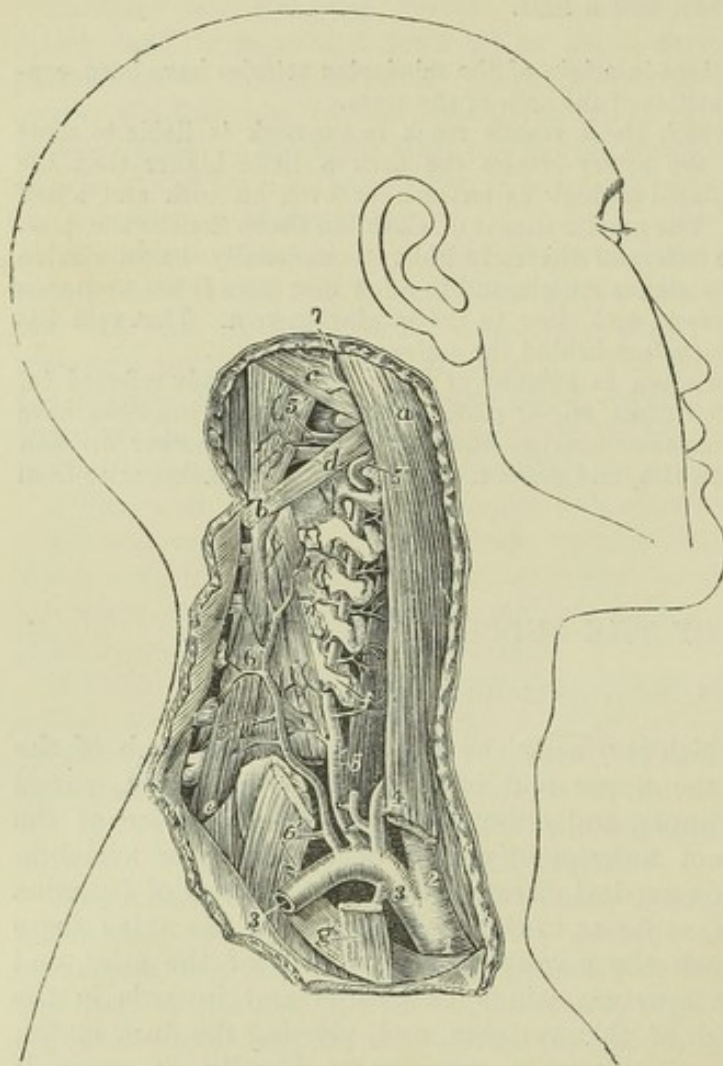


Fig. 263. — DEEP DISSECTION OF THE SUBCLAVIAN ARTERY ON THE RIGHT SIDE, SHOWING THE ORIGIN AND COURSE OF THE VERTEBRAL ARTERY (from Tiedemann).  $\frac{1}{3}$

*a*, Upper part of the sterno-mastoid muscle, its clavicular part divided below; *b*, spinous process of the axis; *c*, superior oblique muscle; *d*, placed on the inferior oblique muscle, points by a line to the posterior arch of the atlas vertebra; *e*, semi-spinalis colli; *f*, placed on the longus colli, points to the transverse process of the sixth cervical vertebra; *g*, on the first rib, points to the scalenus anticus muscle cut near its attachment; 1, innominate artery; 2, right common carotid; 3, right subclavian; below it, the origin of the internal mammary artery; above it, 4, the thyroid axis, its branches cut short; 5, vertebral artery, passing up through the canal of the transverse processes and giving branches to the muscles; 5', placed on the rectus major, points to its horizontal part on

the arch of the atlas; 6, placed on the lower part of the divided scalenus medius, points to the trunk of the deep cervical and first intercostal arteries; 6', placed on the scalenus medius, points to the deep cervical artery; 7, occipital artery emerging from below the sterno-mastoid and other muscles attached to the mastoid process.

#### BRANCHES.—A. *Cervical branches:*

(*a*) In the neck, the vertebral artery sends off at different points of its course several small branches named *spinal* arteries. Each of these entering the spinal canal through an intervertebral foramen divides into two branches; one of these passes along the roots of the spinal nerves, supplying the spinal cord and its membranes, and anastomoses with the other spinal arteries; the other branch ramifies on the back part of the bodies of the vertebræ in the same manner as similar branches derived from the intercostal and lumbar arteries.



(a) *Muscular* branches of variable size are distributed to the deep-seated cervical muscles.

*B. Cranial branches :*

(a) The *posterior meningeal* artery is a small branch which arises opposite the foramen magnum, and ramifies between the dura mater and the bone in the occipital fossa, and upon the falx cerebelli. There are sometimes two of these small vessels.

(b) The *posterior spinal* artery, arising at an obtuse angle from the vertebral, inclines backwards round the medulla oblongata to reach the back part of the spinal cord; aided by reinforcements from small arteries which ascend upon the cervical and dorsal nerves through the intervertebral foramina, it may be traced along the cord, lying behind the roots of the nerves, as a minute tortuous vessel, or rather a series of little inosculating vessels, as far as the second lumbar vertebra, where it terminates in ramifications on the cauda equina.

(c) The *anterior spinal* artery, somewhat larger than the preceding, arises near the end of the vertebral artery, and descends obliquely in front of the medulla oblongata. Immediately below the foramen magnum, it unites with the corresponding vessel of the opposite side, so as to form a single trunk, which descends a short distance only along the middle line in front of the spinal cord, forming the upper part or commencement of the anterior median artery of the cord. This anterior spinal branch of the vertebral artery supplies therefore only the upper part of the cord; the remainder being provided with a series of small arteries, which are derived in the neck from the vertebral and inferior thyroid arteries, in the back from the intercostal, and below this from the lumbar, ilio-lumbar, and lateral sacral arteries. These small vessels enter the spinal canal at irregular intervals through the intervertebral foramina, and passing along the roots of the nerves, communicate with each other along the middle line by means of ascending and descending branches; so that, by a succession of anastomoses, a very slender single vessel, of varying thickness, named the *anterior median artery*, appears to extend from the one end to the other of the cord. This vessel, or chain of inosculating vessels, supplies the pia mater and the substance of the cord—some entering the anterior median fissure. At the lower end of the spinal cord it sends branches downwards on the cauda equina.

On a part of the spinal cord near the lower end, and in front of the posterior roots of the nerves, may be found another small artery, about equal in size to the anterior spinal.

(d) The *posterior inferior cerebellar* artery, the largest of the branches, arises from the vertebral near the pons, and sometimes from the basilar artery: it turns backwards and outwards, between the hypoglossal and pneumogastric nerves, over the restiform body and near the side of the opening of the fourth ventricle, to reach the under surface of the cerebellum. Here, running backwards between the inferior vermiform process and the hemisphere, it divides into two branches: one of which continues backwards in the sulcus between the hemispheres; while the other, turning outwards, ramifies on the under surface of the cerebellum as far as its outer border, over which the ultimate divisions of each branch anastomose with those of the superior cerebellar arteries. This artery partly supplies the hemisphere and the vermiform process, and gives branches to the choroid plexus of the fourth ventricle.

**PECULIARITIES.—Origin.**—The right vertebral artery has been seen to arise from the common carotid of the same side, in some of those cases in which the right subclavian has been given as a separate vessel from the posterior part of the aorta. In very rare instances, the right vertebral artery arises from the aorta.

The left vertebral artery is not unfrequently derived from the aorta, in which case it generally arises between the left carotid and subclavian arteries, but sometimes it is the last of the branches from the arch.

The left vertebral artery in a few instances, and the right vertebral in one, have been found to arise by more than a single root; and an example of three roots to a vertebral artery has been placed on record. (R. Quain, plate 24, fig. 2.) Two roots may proceed from the subclavian artery, or one from the subclavian and one from the aorta.

**Course.**—Instead of entering the foramen of the sixth vertebra, the vertebral artery of one side not unfrequently enters higher up, through the foramen of the fifth, or



fourth, or more rarely of the third vertebra, or even, according to several anatomists, of the second. On the other hand, the vertebral artery has been seen to enter the foramen of the seventh vertebra.

*Branches.*—In the neck, the vertebral artery has been found, though very rarely, to give branches which are usually derived from the subclavian, such as the superior intercostal and the inferior thyroid.

#### BASILAR AND POSTERIOR CEREBRAL ARTERIES.

The *basilar artery*, the single trunk formed by the junction of the right and left vertebral in the middle line, extends from the posterior to the anterior border of the pons Varolii, along the median groove of which it lies under cover of the arachnoid. The length of this artery is therefore about equal to that of the pons, at the anterior border of which it divides into two terminal branches, the posterior arteries of the cerebrum.

*BRANCHES.*—Besides numerous small branches to the substance of the pons, the basilar artery gives off the following :—

(a) The *transverse arteries*, several on each side, pass directly outwards. One, the *artery of the acoustic nerve*, accompanies that nerve into the internal auditory meatus and labyrinth of the ear.

(b) The *anterior inferior cerebellar arteries* pass backwards, one on each side, to the anterior part of the under surface of the cerebellum, anastomosing with the inferior cerebellar branches of the vertebral arteries.

(c) The *superior cerebellar arteries* arise so close to the bifurcation of the basilar, that this artery is described by several anatomists as dividing into four branches. Each one turns backwards and outwards immediately behind the third nerve, and entering the groove between the pons Varolii and the crus cerebri, turns round the latter, close to the fourth nerve, to reach the upper surface of the cerebellum, where it divides into branches. Of these some extend outwards, and one or more backwards along the superior vermiform process, to reach the circumference of the cerebellum, where they anastomose with the branches of the inferior cerebellar arteries; while others run inwards to supply the vermiform process and the valve of Vieussens, and in part the velum interpositum.

The *posterior cerebral artery* on each side, resulting from the division of the basilar, passes outwards, parallel to the superior cerebellar artery, and separated from it at its origin by the third nerve, which comes forwards between the two vessels. It turns backwards round the crus cerebri, and then runs outwards and upwards on the under surface of the posterior lobe of the cerebrum, passing near the posterior extremity of the corpus callosum. It divides beneath the posterior lobe into many branches, which ramify upon the under, median, and outer surfaces, and anastomose with the other cerebral arteries.

*BRANCHES.*—Immediately after its origin the posterior cerebral artery gives off numerous small parallel branches, which perforate the substance of the brain between the crura, at the point which is called from this circumstance the posterior perforated spot. As it turns backwards, a short distance from its origin, this artery is joined by the *posterior communicating artery*, and in this way contributes as already described (p. 363) to form the circle of Willis. Lastly, the posterior cerebral gives origin to a small branch, the *posterior choroid*, which, arising external to the junction of the communicating artery, turns backwards over the crus cerebri and the tubercula quadrigemina, supplying these with branches, and ending in the velum interpositum and choroid plexus in the interior of the brain.

*PECULIARITIES.*—Traces of a septum are sometimes found in the interior of the basilar artery. (Davy, "Researches," &c., vol. i. p. 301.) This trunk has also been found perforated by a small foramen, owing to a partial fissuring of the vessel along the median line.



The posterior cerebral artery is occasionally given off on one side from the internal carotid artery.

II. THYROID AXIS.

The thyroid axis springs from the fore part of the subclavian artery, close to the inner side of the anterior scalenus muscle. It is a short thick trunk, and receives the name of "axis," because, at a line or two from its origin, it divides into branches, which diverge in different directions, viz., the inferior or ascending thyroid, the suprascapular, and a third branch, which is either the transverse cervical, or one of the branches into which that artery, when present, divides, viz., the superficial cervical.

PECULIARITIES.—The thyroid axis has been known to arise beyond the scalenus anticus muscle. It may be associated at its origin with another branch; thus, it sometimes gives origin to the internal mammary, and has been known to give origin to the vertebral, superior intercostal, or deep cervical arteries.

1. THE INFERIOR THYROID ARTERY passes directly upwards, resting on the longus colli muscle, and after a short course bends inwards and downwards behind the sheath of the large cervical vessels, and also behind the sympathetic nerve (the middle cervical ganglion of which, when present, often rests upon this vessel). The artery then makes another curve in the opposite direction, and is distributed to the under part of the thyroid body. Its branches communicate freely with those of the superior thyroid artery, and with the corresponding artery of the other side.

BRANCHES.—(a) The *ascending cervical* branch arises at the point where the inferior thyroid turns inwards behind the carotid artery; it proceeds upwards, close to the phrenic nerve, on the line of separation between the scalenus anticus and rectus anticus major, giving *muscular* branches to both, and a few which pass transversely outwards across the neck. These muscular branches communicate with others sent outwards from the vertebral artery. To the spinal canal the ascending cervical artery sends one or two branches (*spinal branches*), which enter the intervertebral foramina along the cervical nerves, and assist in supplying the bodies of the vertebrae, and the spinal cord and its membranes.

(b) A *laryngeal* branch of irregular size is usually supplied by the inferior thyroid artery; it ascends on the trachea and the back of the larynx, and is distributed to the muscles and mucous membrane in that situation.

(c) *Tracheal* branches ramify over the trachea, and anastomose below with the bronchial arteries.

(d) *Esophageal* branches are given off, and one or more descend upon the trachea into the chest.

PECULIARITIES.—*Origin*.—The inferior thyroid artery occasionally arises as an independent branch from the subclavian artery, and rarely from the common carotid or the vertebral. Instances have occurred—very rarely, however—of the presence of two inferior thyroid arteries, one passing over the common carotid artery.

The *ascending cervical artery* is occasionally derived from the subclavian or from one of the branches of that vessel, as from the transverse cervical or the suprascapular, or from a trunk common to those two arteries. It is sometimes much larger than usual, and takes the place of the occipital artery. A branch from it not unfrequently compensates for the small size of the deep cervical artery.

2. THE SUPRASCAPULAR ARTERY (transverse scapular, or transverse humeral), a smaller vessel than the transverse cervical, arises almost constantly from the thyroid axis, and runs from within outwards deeply at the root of the neck. At first it descends obliquely towards the clavicle, resting upon the scalenus anticus, and covered by the sterno-mastoid



muscle ; it then crosses the subclavian artery, and continues transversely outwards behind and parallel with the clavicle and subclavius muscle, and below the posterior belly of the omo-hyoid muscle. Approaching the upper margin of the scapula, under cover of the trapezius muscle, it inclines

Fig. 264.

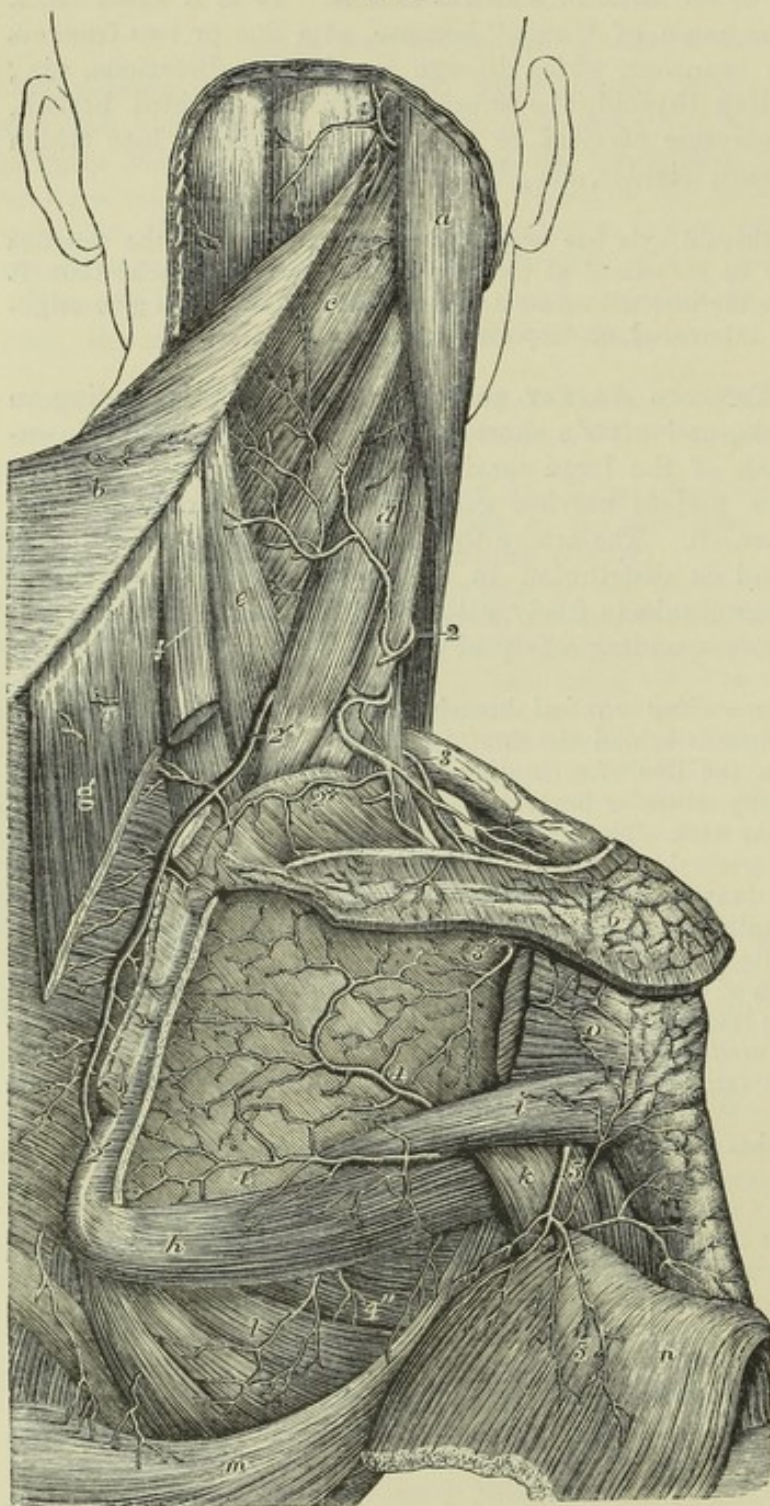


Fig. 264.—VIEW OF THE ANASTOMOSES OF ARTERIES ON THE SHOULDER AND DORSUM OF THE SCAPULA (from Tiedemann).  $\frac{1}{2}$

*a*, sterno-mastoid muscle ; *b*, trapezius turned towards the left side ; *c*, splenius capitis, and below it splenius colli ; *d*, levator anguli scapulae ; *e*, serratus posticus superior ; *f*, rhomboideus minor, and *g*, rhomboideus major, divided from the base of the scapula ; *h*, teres major, *i*, teres minor ; *k*, scapular head of the triceps brachii ; *l*, serratus magnus ; *n*, deep surface of the deltoid muscle turned down ; *o*, portion of the infraspinatus muscle attached to the great tuberosity of the humerus, the rest having been removed from the infraspinal fossa ; 1, occipital artery appearing between the trapezius and sterno-mastoid muscles ; 2, superficial cervical branch of the transverse cervical artery ; 2', 2'', posterior scapular artery ; 2+, its suprascapular branch ; 3, suprascapular artery ; 3', the same after passing through the scapular notch into the infraspinous fossa, where it anastomoses with 4, the dorsal

branch of the subscapular artery ; 4', inferior scapular branch of the subscapular ; 4'', some of the descending thoracic branches of the subscapular artery ; 5, posterior circumflex artery emerging from the quadrangular space, and sending branches upwards on the shoulder-joint, round the humerus, and downwards into the deltoid muscle ; 6, anastomosis of the acromial branches of the suprascapular with the acromio-thoracic artery.



downwards with the suprascapular nerve towards the suprascapular notch. At this point the nerve usually passes beneath the ligament stretched across the notch, while the artery more frequently turns over it to enter the supraspinous fossa, where, lying close to the bone, it gives off branches which ramify in the fossa beneath the supraspinatus muscle, and sends a small communicating branch into the subscapular fossa, and is itself continued down into the infraspinous fossa.

BRANCHES.—(a) *Muscular* branches are given by the suprascapular artery to the sterno-mastoid and other neighbouring muscles.

(b) The *supra-acromial* branch passes obliquely forwards through the attachment of the trapezius to reach the cutaneous surface of the acromion, on which it ramifies, anastomosing with offsets from the acromial thoracic artery.

(c) A small *subscapular* branch, given off as the artery passes over the notch, anastomoses with the posterior scapular and subscapular arteries in the subscapular fossa and substance of the subscapularis muscle.

(d) An *infraspinous* branch is continued from the suprascapular artery, and descending close upon the neck of the scapula, between the glenoid cavity and the spine of that bone, joins with the dorsal branch of the subscapular artery.

(e) Branches enter the bone and shoulder joint.

PECULIARITIES.—The suprascapular artery has in some cases been observed to spring directly from the subclavian, or to arise from that vessel by a common trunk with the transverse cervical, or more rarely with the internal mammary. It has also been found to proceed from the axillary artery, and from the subscapular branch of that vessel.

3. THE TRANSVERSE CERVICAL ARTERY, the third branch of the thyroid axis, passes outwards a short distance above the clavicle, and therefore higher than the suprascapular artery. It crosses over the scaleni muscles and the brachial plexus, sometimes passing between the nerves of the latter, and is crossed by the omo-hyoid muscle. Beneath the anterior margin of the trapezius, and near the outer edge of the levator anguli scapulæ, it divides into two branches, the superficial cervical and the posterior scapular.

The *superficial cervical* artery ascends beneath the anterior border of the trapezius, and distributes branches to that muscle, the levator anguli scapulæ, and sterno-mastoid muscles, as well as to the cervical glands and the integuments in the intervals between those muscles. When the posterior scapular arises separately from the subclavian, the name superficial cervical may be given to the whole remaining part of the transverse cervical artery.

The *posterior scapular* artery, whether arising from the transverse cervical artery or directly from the subclavian, passes backwards to the upper angle of the scapula, under cover of the levator anguli scapulæ, and then changing its direction, runs downwards beneath the rhomboidei muscles, as far as the inferior angle of that bone. It anastomoses freely on both surfaces of the scapula with the divisions of the suprascapular and subscapular arteries; and supplies branches to the rhomboidei, serratus magnus, and latissimus dorsi muscles, communicating at the same time with the posterior muscular branches of some of the intercostal arteries.

PECULIARITIES.—Not only does the transverse cervical branch of the thyroid axis present the variation of being nearly as often the superficial cervical alone as of comprising also the posterior scapular artery, but it occasionally happens that the vessel derived from the thyroid axis is very small, and represents only in part the superficial cervical artery; whilst a large vessel arising from the third part of the subclavian divides near the levator anguli scapulæ into two branches, of which one ascends and



represents the remaining and larger portion of the superficial cervical artery, while the other forms the posterior scapular.

The transverse cervical artery is sometimes derived directly from the subclavian, beneath or even beyond the scalenus anticus muscle. The transverse cervical sometimes gives off the ascending cervical artery.

When the *superficial cervical* is separated from the posterior scapular, it sometimes arises from other sources than the thyroid axis, as from the suprascapular or the subclavian artery.

### III. INTERNAL MAMMARY ARTERY.

The internal mammary artery, remarkable for its length and the number of its branches, arises from the under side of the subclavian, opposite the thyroid axis. It runs forwards and downwards behind the clavicle to the inner surface of the cartilage of the first rib, lying between this and the sac of the pleura: from this point it inclines a little inwards, and then descends vertically behind the costal cartilages, a short distance from the border of the sternum, as far as to the interval between the sixth and seventh cartilages, where it ends by dividing into two branches. One of the branches into which the artery divides, musculo-phrenic, inclines outwards along the margin of the thorax; while the other, under the names of abdominal or superior epigastric, continues onwards to the abdomen in the original direction of the trunk.

Covered at its origin by the internal jugular vein, like the other large branches of the subclavian artery, the internal mammary soon passes behind the subclavian vein, and is crossed in front by the phrenic nerve which lies between the vein and the artery. In the chest it has the costal cartilages and the internal intercostal muscles in front, and lies at first upon the pleura; but lower down it is separated from the pleura by the triangularis sterni muscle. This artery has two companion veins, which are united into a single trunk at the upper part of the chest.

BRANCHES.—The branches of this artery are numerous, and are distributed chiefly to the walls of the chest and abdomen.

(a) The *superior phrenic* or *comes nervi phrenici*, a very slender but long branch, arises high in the chest, and descends with the phrenic nerve, between the pleura and the pericardium, to the diaphragm, in which it is distributed, anastomosing with offsets from the musculo-phrenic and with the inferior phrenic arteries from the abdominal aorta.

(b) The *mediastinal* or *thymic* branches, of very small size, ramify in the loose connective tissue of the mediastinal space, and supply the remains of the thymus body, which, when in full development, receives its principal branches from the internal mammary artery. *Pericardiac* branches are given off directly to the upper part of the pericardium, the lower part of which receives some from the musculo-phrenic division. Branches named *sternal* are also supplied to the triangularis sterni muscle, and to both surfaces of the sternum.

(c) The *anterior intercostal arteries*, two in each space, arise from the internal mammary, either separately, or by a trunk common to the two, which soon divides. The arteries pass outwards, at first between the pleura and the internal intercostal muscles, and afterwards between the two layers of intercostals; they lie, one near the upper and one near the lower rib, in each of the upper five or six intercostal spaces, and inosculate with the corresponding intercostal branches derived from the aortic intercostals. These branches supply the intercostal and pectoral muscles, and give some offsets to the mamma and integument.

(d) The *anterior* or *perforating* branches pass forwards from the internal mammary artery through from four to six intercostal spaces, and turning outwards ramify partly in the pectoralis major, and partly in the integument on the front of the chest.



Those placed nearest to the mammary gland supply that organ, and in the female they are of comparatively large size, especially during lactation. Some offsets ramify on the sternum.

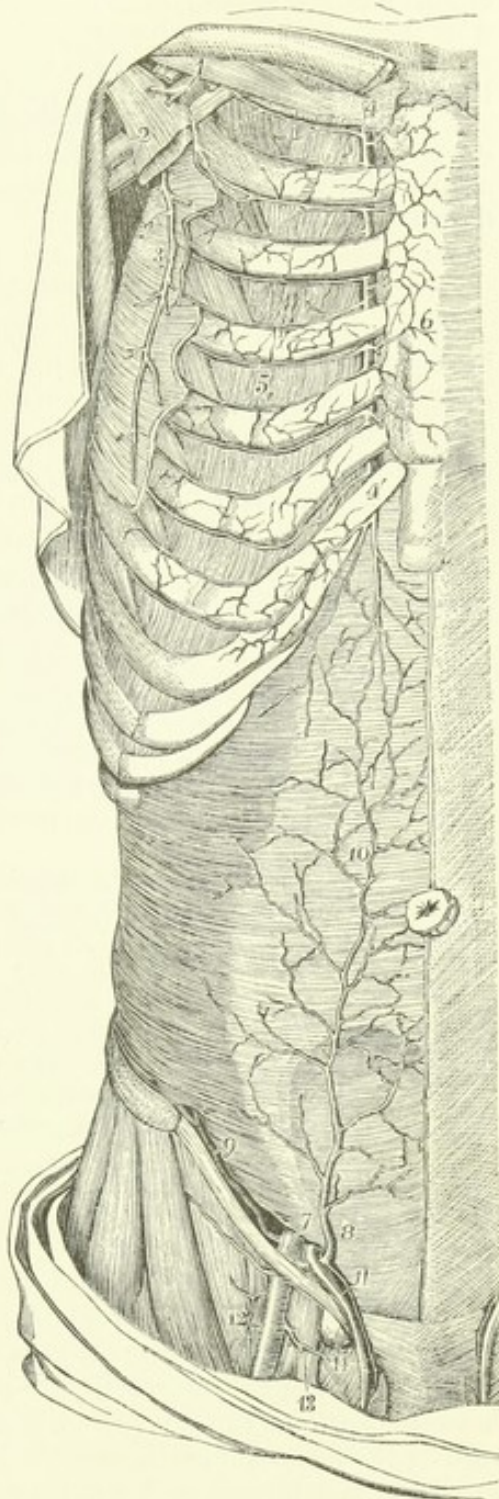
Fig. 265—DISSECTION OF THE RIGHT SIDE OF THE ANTERIOR THORACIC AND ABDOMINAL WALL, TO SHOW THE ANASTOMOSES OF THE INTERNAL MAMMARY, INTERCOSTAL, AND EPIGASTRIC VESSELS (slightly altered from Tiedemann).  $\frac{1}{4}$

The pectoral part of the serratus magnus, the external and internal oblique, and the rectus abdominis muscles, have been removed; 1, upon the subclavius muscle, points to the first part of the axillary artery above the pectoralis minor muscle, giving rise to the acromio-thoracic artery, which is cut short; 2, upon the pectoralis minor, points to the lower part of the axillary artery and vein; 3, the long thoracic artery; 4, on the cartilage of the first rib, marks the upper part of the internal mammary artery; 4', the lower part of the same artery giving its abdominal branch behind the cartilage of the seventh rib; 5, in the fourth intercostal space, marks the anastomosis of the internal mammary and intercostal arteries; 6, anterior branches of the internal mammary artery ramifying over the front of the sternum; 7, on the transversalis muscle immediately above the internal inguinal aperture, points to the last part of the external iliac artery, from which are seen rising, 8, the deep epigastric artery, and 9, the deep circumflex iliac; 10, the anastomosis of the epigastric with the abdominal branch of the internal mammary artery; 11, the spermatic cord and spermatic twig of the epigastric artery; 12, the femoral artery giving small twigs to the groin and the superficial pudic vessels; 13, the femoral vein; 14, a lymphatic gland closing the femoral ring.

(e) The *musculo-phrenic* artery, the outer of the two branches into which the internal mammary artery divides, inclines downwards and outwards behind the cartilages of the false ribs, perforating the attachment of the diaphragm at the eighth or ninth rib, and becoming gradually reduced in size as it reaches the last intercostal space. It gives branches backwards into the diaphragm; others, which pass outwards to form the anterior intercostals of each space, and are disposed precisely like those which are derived higher up from the main internal mammary; and some which descend into the abdominal muscles.

(f) The *abdominal branch* or *superior epigastric artery* of the internal mammary, descending into the wall of the abdomen, lies behind the rectus, between the muscle and its sheath; and afterwards, entering the muscle, terminates in its substance, at

Fig. 265.





the same time anastomosing with the epigastric artery. It also supplies twigs to the broad muscles of the belly, to the skin, and to the diaphragm; and one runs forwards upon the side and front of the xiphoid cartilage, where it anastomoses with that of the opposite side.

**PECULIARITIES.**—The internal mammary is occasionally found connected at its origin with the thyroid axis, or with the scapular arteries—these being detached from the thyroid. It occasionally springs from the second or third part of the subclavian artery (the latter being the more frequent position of the two). In very rare instances it has been found arising from the axillary, the innominate, or the aorta.

An unusual branch, of considerable size, occasionally comes off from it, and passes downwards and outwards, crossing several of the ribs, on their inner surface, in contact with the pleura. The internal mammary artery may likewise furnish a bronchial branch.

#### IV. SUPERIOR INTERCOSTAL AND DEEP CERVICAL ARTERIES.

**THE SUPERIOR INTERCOSTAL** artery generally arises from the upper and back part of the subclavian, behind the anterior scalenus muscle on the right side, and immediately at the inner side of the muscle on the left side. Taking its course backwards, it speedily gives off the deep cervical branch (*profunda cervicis*), and bending backwards and downwards in front of the neck of the first rib, ends in one or two intercostal spaces: on the right side it more frequently descends into the second space than on the left side. On the neck of the first rib, the artery is situated on the outer side of the first dorsal ganglion of the sympathetic nerve.

**BRANCHES.**—Besides giving off the deep cervical artery, the superior intercostal gives branches to the first and second intercostal spaces. The branch to the first space is similar in course and distribution to the aortic intercostals: that to the second space usually joins with one from the first aortic intercostal. A small offset is likewise sent backwards, through the first space, to the posterior spinal muscles, and also a small one through the corresponding intervertebral foramen to the spinal cord and its membranes.

**PECULIARITIES.**—*Origin.*—The superior intercostal artery has been found, in a few instances, to proceed from the vertebral artery or from the thyroid axis.

*Course.*—It has been observed to pass between the necks of one or two ribs and the corresponding transverse processes of the dorsal vertebræ; and a case has been recorded in which, after arising from the vertebral artery, it descended through the intertransverse foramen of the last cervical vertebra, and then continued, as in the instances just mentioned, between the necks of the ribs and the contiguous transverse processes of the vertebræ of the back. (Quain on the Arteries, plate 22, fig. 5.) The intercostal artery is sometimes, though very rarely, wanting.

**THE DEEP CERVICAL** artery, often described as a separate branch of the subclavian artery, arises in most cases from the superior intercostal. Resembling the posterior branch of an aortic intercostal artery, it generally passes backwards in the interval between the transverse process of the last cervical vertebra and the first rib, to reach the posterior aspect of the neck. Here it ascends in the interval between the transverse and spinous processes, as high as the second vertebra, under cover of the complexus muscle, between this and the semi-spinalis colli. Some of the branches communicate with those given outwards by the vertebral artery, whilst others ascend to anastomose with the cervical branch of the occipital artery.

**PECULIARITIES.**—*Origin.*—The deep cervical artery sometimes arises from the subclavian, and more rarely from the posterior scapular. It is not unfrequently supplemented by a branch turning backwards from the ascending cervical artery beneath the transverse process of the third cervical vertebra, or by another branch from the superior intercostal, or, in some instances, by a twig from the posterior scapular or inferior thyroid arteries.



*Course.*—This artery occasionally passes back between the sixth and seventh cervical vertebræ, and sometimes between the first and second dorsal, or even below the second. It has been seen to pass between the first rib and the transverse process which supports it.

### AXILLARY ARTERY.

The *axillary artery*, that part of the artery of the upper limb which intervenes between the subclavian and the brachial portions, extends from the outer border of the first rib to the lower margin of the tendons of the latissimus dorsi and teres major muscles. In this course it passes through the axilla, and its direction varies with the position of the limb, being curved downwards, or upwards, or being straight, according as the arm hangs by the side, or is elevated, or extended.

In front, the axillary artery is covered by the pectoralis major muscle, behind which it is crossed by the pectoralis minor. It may be conveniently divided into three parts: the first part lying internal to the pectoralis minor muscle, and resting on the thoracic wall; the second part behind that muscle, and passing from the thorax towards the shoulder; the third part beyond the muscle, and resting on the humerus.

In the *first* part of its course the vessel is in contact with the serratus magnus muscle on its inner side, and is covered by the costo-coracoid membrane, which, attached above to the clavicle, is continued below into a common sheath investing the artery and vein, and completed behind by a prolongation of the deep cervical fascia. In this part of its course the artery is placed with the trunks of the brachial plexus above and behind it, and the axillary vein in front of it and somewhat nearer the thorax: it is also crossed by the cephalic and acromio-thoracic veins as they dip down to terminate in the axillary vein.

In the *second* part of its course, behind the pectoralis minor, the axillary artery is completely surrounded by the trunks of the brachial plexus, and it is crossed in front by one of the roots of the median nerve: the vein is on the thoracic side of the artery, separated from it by nerves.

In the *third* part of its course, beyond the pectoralis minor, the axillary artery rests on the subscapular muscle and the insertions of the latissimus dorsi and teres major, while to the outer side is the coraco-brachialis muscle. The axillary vein is still on the thoracic side, but sometimes the venæ comites, by whose union it is formed, are continued up to this level, one on each side of the artery. The main branches resulting from the division of the brachial plexus of nerves are disposed behind and on each side of this part of the artery, as follows, viz., behind it, the circumflex and musculo-spiral; to its inner side, the ulnar and the two internal cutaneous; to the outer side, the external cutaneous and median. The external cutaneous and the circumflex nerves leave the artery in the axilla, and at the lower part of the axilla the median nerve is often before the vessel; in an operation, that nerve might serve as a guide to the position of the artery, for it could be distinguished from the other large nerves (ulnar and musculo-spiral) by the circumstance of its being the nearest to the pectoral muscle. Beyond the border of the pectoralis major, the artery is covered only by the skin and fascia on the inner side; and here the flow of blood may be controlled by pressure of the finger directed outwards against the humerus.

*BRANCHES.*—The branches of the axillary artery consist of the *external thoracic* branches furnished to the muscles of the chest, the *subscapular*



Fig. 266.

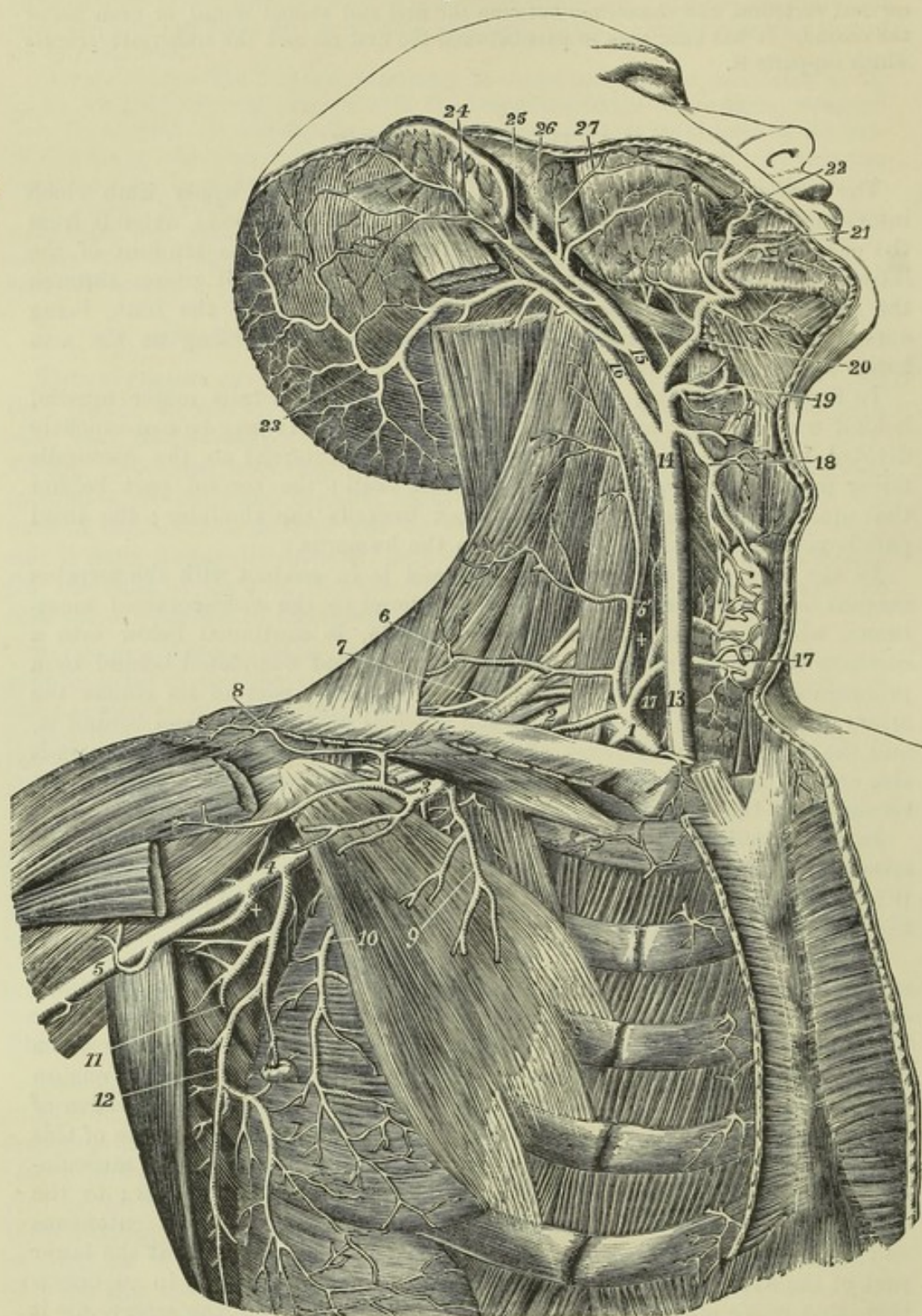


Fig. 266.—DEEP VIEW OF THE CAROTID, SUBCLAVIAN, AND AXILLARY ARTERIES (from Tiedemann).  $\frac{1}{2}$

The great pectoral, the sterno-mastoid, and the sterno-hyoid and sterno-thyroid muscles have been removed; the front part of the deltoid has been divided near the clavicle: the greater part of the digastric muscle has been removed, and the upper part of the splenius capitis and trachelo-mastoid divided near the mastoid process. *Subclavian Artery and its Branches.*—1, First or inner part of the subclavian artery giving rise to the thyrocervical axis and internal mammary, and also to +, the vertebral artery; 2, third part of the



subclavian artery outside the scalenus anticus muscle ; 3, first part of the axillary artery giving rise to the acromial thoracic, short thoracic, &c. ; 4, third part of the axillary artery giving rise to the subscapular, circumflex, &c. ; 5, commencement of the brachial artery ; 6, transverse superficial cervical artery ; 6', placed on the scalenus anticus muscle, marks the ascending superficial cervical branch ; 7, posterior scapular artery arising from the subclavian artery behind the scalenus anticus muscle and separate from the thyroid axis ; 8, acromial branches of the acromial thoracic ; 9, pectoral branches of the same ; 10, long thoracic artery outside the pectoralis minor muscle ; +, posterior circumflex branch of the axillary artery (the anterior circumflex is seen rising from the opposite side of the same part of the axillary trunk) ; 11, subscapular artery passing between the subscapularis and teres minor muscles to proceed to the lower angle and dorsum of the scapula ; 12, thoracic descending branch of the subscapular artery. *Carotid Artery and its Branches.*—13, lower part, and 14, upper part of the right common carotid artery ; 15, trunk of the external carotid artery brought fully into view by the removal of the digastric muscle ; 16, trunk of the internal carotid artery ; 17, 17, the thyroid axis of the subclavian artery, and the inferior thyroid artery where it is distributed in the gland ; 18, superior thyroid artery anastomosing in the gland with the inferior thyroid ; 19, lingual artery brought into view by the removal of the lower part of the hyoglossus muscle ; 20, facial artery giving off the palatine, tonsillar, and submental ; 21, inferior labial ; 22, coronary artery ; 23, occipital artery ; 24, posterior auricular artery ; 25, superficial temporal artery ; 26, internal maxillary artery ; 27, transverse facial given off in this instance directly by the external carotid artery.

branch to the shoulder, and the *anterior* and *posterior circumflex* branches to the upper part of the arm. The branches are not constant in their number, size, or mode of origin.

**EXTERNAL THORACIC BRANCHES.**—These branches vary much in number ; but, after the method of Haller, four are usually described.

1. The *superior thoracic* artery (*thoracica suprema*), a branch of inconsiderable size, arises at a point internal to the pectoralis minor muscle, and inclines downwards and inwards across the first two intercostal spaces, anastomosing with the internal mammary and intercostal branches contained in them, and terminates between the pectoral muscles.

2. The *acromial thoracic* artery (*art. thoracica humeraria*), of considerable size, and by far the most constant of the thoracic branches of the axillary, arises from its forepart at the inner border of the pectoralis minor muscle, and soon divides into branches which take different directions.

(a) The *acromial* branches pass partly to the deltoid muscle and partly to the upper surface of the acromion, and anastomose with the suprascapular and posterior circumflex arteries.

(b) The *humeral* branch passes down in the interval between the pectoralis major and deltoid muscles, accompanying the cephalic vein.

(c) The *thoracic* branches are distributed to the serratus magnus and pectoral muscles, and anastomose with the other thoracic arteries.

(d) The *clavicular* branch, very small, passes inwards to the subclavius muscle.

3. The *long thoracic* or *external mammary* artery is directed downwards and inwards, along the lower border of the pectoralis minor, and is distributed to the mamma, and to the serratus and pectoral muscles, and anastomoses with the external branches of the intercostal arteries.

4. The *alar thoracic* branch is a very small vessel and not constant, being frequently wanting, and having its place supplied by branches from the thoracic and subscapular arteries. It is distributed to the lymphatic glands and the fatty tissue in the axilla.

**SUBSCAPULAR ARTERY.**—This branch, the largest given off by the axillary artery, arises close to the lower border of the subscapular muscle, along which it proceeds downwards and backwards, towards the inferior angle of the scapula, accompanied by the subscapular nerve ; and it terminates in



branches to the subscapularis, serratus magnus, teres major and latissimus dorsi muscles. It soon becomes considerably diminished in size, owing to its giving off a large branch to the dorsum of the scapula. Its final ramifications anastomose with one another and with the branches of the posterior scapular artery.

The *dorsal branch* (*dorsalis scapulæ*) turns back from the subscapular artery, about an inch and a half from its origin, and is sometimes larger than the continuation of the vessel. Descending along the lower border of the scapula, it passes through the interval bounded internally by the subscapularis and teres minor, externally by the latissimus dorsi and teres major, and superiorly by the long head of the triceps muscle; and turning closely round the border of the scapula, which is frequently grooved to receive it, passes between the teres minor and the bone, and ramifies in the infraspinous fossa, where it anastomoses with the suprascapular and posterior scapular arteries.

Fig. 267.

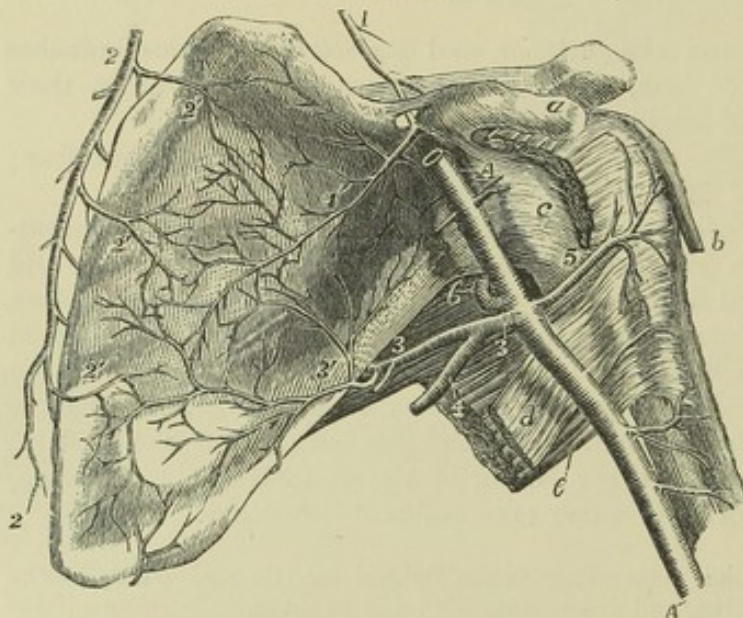


Fig. 267. — VIEW OF THE ARTERIES WHICH RAMIFY AND ANASTOMOSE ON THE VENTRAL SURFACE OF THE SCAPULA, AND OF THE ANTERIOR CIRCUMFLEX ARTERY (from R. Quain).  $\frac{1}{3}$

*a*, coracoid process; *b*, tendon of the long head of the biceps muscle emerging from the bicipital groove; *c*, the front of the capsular ligament of the shoulder-joint; *d*, tendon of the latissimus dorsi muscle; *e*, teres major; *1*, suprascapular artery descending to the suprascapular notch, over

the ligament of which the larger part of the artery passes into the suprascapular fossa; *A, A'*, the axillary and brachial artery; *1'*, its subscapular branch passing through the notch and ramifying in the subscapular fossa; *2, 2'*, posterior scapular artery descending parallel to the base of the scapula; *2'*, its subscapular branches; *3*, main stem of the subscapular artery at its origin from the axillary and continuation towards the dorsum of the scapula; *3'*, the branch to the ventral surface of the scapula proceeding to anastomose with the subscapular branches of the suprascapular and posterior scapular arteries; *4*, descending or thoracic branch of the subscapular artery; *5*, anterior circumflex artery; *6*, posterior circumflex passing back through the quadrilateral muscular space.

The *dorsalis scapulæ* gives off,—(*a*) *ventral* branches, slender vessels which ramify in the subscapular fossa between the subscapular muscle and the bone, and anastomose with twigs from the suprascapular and posterior scapular arteries; (*b*) branches to the teres muscles, and particularly a twig which descends between their origins; (*c*) terminal branches in the infraspinous fossa.

**CIRCUMFLEX ARTERIES.**—The *posterior circumflex* artery, a considerable vessel but smaller than the subscapular, arises opposite the lower border of the subscapular muscle, below the subscapular artery, and is directed back-



wards in company with the circumflex nerve, passing through the space between the teres muscles, the humerus, and the long head of the triceps muscle, and therefore separated by the long head of the triceps from the subscapular artery. It winds round the humerus, and terminates by ramifying in the deltoid muscle and on the shoulder-joint, and by anastomosing with the anterior circumflex and suprascapular arteries, as well as with the acromial thoracic.

The *anterior circumflex*, much smaller than the posterior circumflex, arises nearly opposite to it or lower down, and from the outer side of the axillary artery. It passes from within outwards and forwards, under the inner head of the biceps and the coraco-brachialis muscle, resting on the fore part of the humerus, until it reaches the bicipital groove. There it divides into two branches, one of which ascends in the groove with the long head of the biceps, to the head of the bone and the capsule of the joint; the other continues outwards, and anastomoses with the posterior circumflex branch.

**PECULIARITIES.**—The most important peculiarity in the trunk of the axillary artery consists in its giving off a much larger branch than usual,—an arrangement which has been observed in the proportion of one out of every ten cases. In one set of cases, this large branch forms one of the arteries of the fore-arm; most frequently the radial (about 1 in 33), sometimes the ulnar (1 in 72), and, rarely, the interosseous artery (1 in 506: R. Quain). In another set of cases, the large branch gives origin to the subscapular, the two circumflex, and the two profunda arteries of the arm; but sometimes only one of the circumflex, or only one of the deep humeral arteries, arises from it. In the second class of cases the divisions of the brachial plexus of nerves surround the common trunk of the branches instead of the main vessel. This disposition may with probability be explained by supposing that the trunk of the branches is the true brachial artery, but that in early life it has become obstructed below, and that there has become developed in its place, as an apparent brachial artery for the supply of the lower portions of the limb, a *vas aberrans*, such as is sometimes seen arising from the brachial artery, and uniting with one of its branches.

The superior thoracic artery is so frequently given off by the acromio-thoracic, that some anatomists have described that as the normal arrangement, giving the common trunk the name of *thoracic axis*. The long thoracic artery often arises from the acromial thoracic, or is replaced by enlargement of the normal branches of that artery, and not unfrequently is given off by the subscapular.

The *dorsalis scapulæ* sometimes springs directly from the axillary artery.

The posterior circumflex artery is sometimes removed from the axillary to the superior profunda branch of the brachial, in which case it ascends behind the tendons of the latissimus dorsi and teres major. In another class of cases not quite so numerous, the posterior circumflex gives off one or more branches usually derived from other sources: as for example (placing them in the order of frequency), the anterior circumflex, the superior profunda, the dorsal scapular, the anterior circumflex and superior profunda together, or some other rarer combination of those vessels. The posterior circumflex is sometimes double; and so is the anterior, but more seldom.

## BRACHIAL ARTERY.

The brachial or humeral artery, the continuation of the axillary, extends from the lower border of the posterior fold of the axilla, to about a finger's breadth below the bend of the elbow, or to a point opposite the neck of the radius, where it divides into the radial and ulnar arteries. The vessel gradually inclines from the inner side to the fore part of the limb, lying in the depression along the inner border of the coraco-brachialis and biceps muscles; and its direction may be marked out by a line drawn from



midway between the folds of the axilla to the middle point between the condyles of the humerus. To command the flow of blood through the artery at its upper part, pressure should be directed outwards, while over the lower end of the vessel the pressure should be made from before backwards.

The brachial artery lies beneath the integument and fascia of the arm as far as the bend of the elbow, where it sinks deeply in the interval between the pronator teres and supinator longus muscles, and is covered by the fibrous expansion given from the tendon of the biceps to the fascia of the fore-arm. It rests at first on the long head of the triceps muscle, the musculo-spiral nerve and the superior profunda artery intervening; it then inclines forwards over the insertion of the coraco-brachialis muscle, and lies thence to its termination on the brachialis anticus. At its outer side it is in apposition first with the coraco-brachialis, and afterwards and for the

Fig. 268.

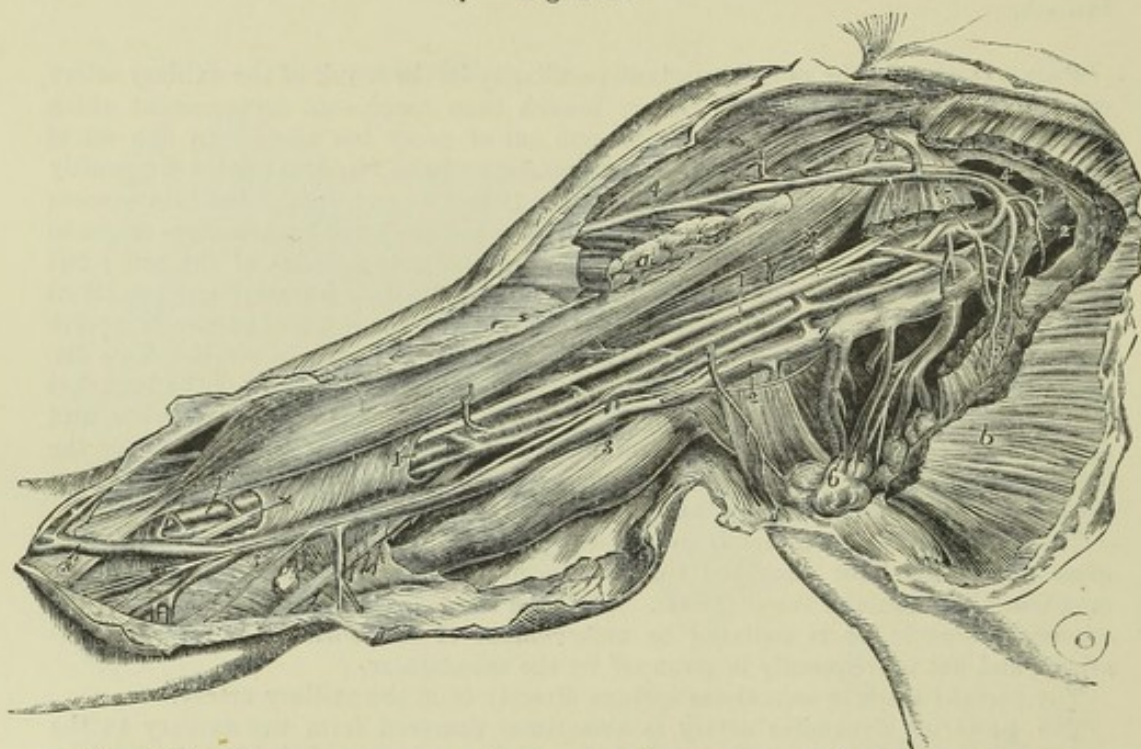


Fig. 268.—DISSECTION OF THE AXILLA AND INSIDE OF THE ARM TO SHOW THE AXILLARY AND BRACHIAL VESSELS (from R. Quain).  $\frac{1}{4}$

The greater and lesser pectoral muscles have been divided so as to expose the axillary vessels: *a*, the inserted portion of the pectoralis major; *b*, the pectoral portion; 1, 1, axillary artery; +, +, the median nerve formed by the two portions of the plexus which surround the artery; 1', placed on a part of the sheath of the brachial vessels, and 1'', on the lower part of the biceps muscle, point to the brachial artery surrounded by its venæ comites; 2, 2, axillary vein; 3, 3, the basilic vein; the upper figure is placed on the triceps muscle, the lower on the fascia near the junction of the ulnar vein: on the basilic vein are seen the ramifications of the internal cutaneous nerve; 4, on the deltoid and 4', on the clavicular part of the great pectoral muscle, mark the cephalic vein joining the acromio-thoracic and through it the axillary vein; 5, 5, placed on the divided portions of the pectoralis minor, point to the origin and branches of the acromio-thoracic artery; 6, placed on a group of axillary glands, indicates the alar thoracic and subscapular vessels; 7, placed on the trunk of the axillary vein, points by a line to one of the venæ comites of the brachial vein, which being joined by the other higher up passes into the axillary vein: the ulnar nerve is seen passing from below the basilic vein towards the inner condyle; near 1, placed on the coraco-brachialis muscle is seen the musculo-cutaneous nerve before it passes through that muscle; near 2, placed on the tendon of the latissimus dorsi muscle, a portion of the nerve of Wrisberg.



greater part of its length with the biceps, the inner border of one or both muscles sometimes slightly overlapping it.

*Relation to Veins.*—Venæ comites are in close contact with the brachial artery, short transverse branches of communication passing from one to another, so as at many points to encircle it. Superficial to the aponeurosis, the basilic vein is placed over or to the inner side of the artery in the lower half or more, or in the whole length of its course, according to the level at which the vein dips down to join the venæ comites; and at the bend of the elbow the median basilic vein crosses over the artery, the aponeurotic insertion of the biceps lying between them.

*Relation to Nerves.*—The median nerve descends in contact with the artery, lying on its outer side at the axilla, directly in front of it below the middle of the arm, and on the inner side at the elbow. Of the large branches of the brachial plexus which are closely connected with the axillary artery, none continue in the immediate neighbourhood of the brachial artery along the arm, except the median. The external cutaneous and circumflex separate at once from the vessel in the axilla, the musculo-spiral soon turns backwards in the musculo-spiral groove, and the internal cutaneous and ulnar nerves descend vertically on the inner side of the limb.

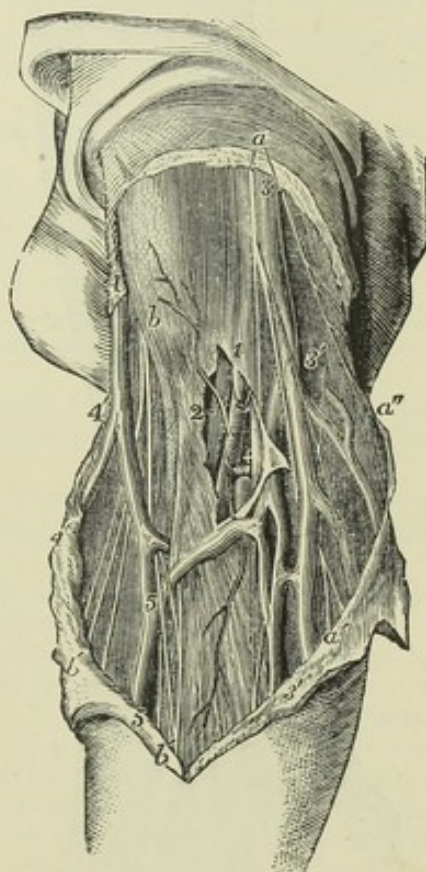
Fig. 269. — SUPERFICIAL DISSECTION OF THE BLOOD-VESSELS AT THE BEND OF THE ARM (from R. Quain).  $\frac{1}{2}$

*a*, two branches of the internal cutaneous nerve; *b*, placed over the biceps near its insertion and close to the external cutaneous nerve; *a'*, *a'*, the descending twigs of the same nerve; *b'*, anterior twigs of the same nerve accompanying the median vein; 1, placed on the fascia of the arm near the bend of the arm, above the place where it has been opened to show the lower part of the brachial artery with its venæ comites, of which one is entire, marked 2, and the other has been divided; +, is placed between this and the median nerve; 3, basilic vein; 3', 3', ulnar veins; 4, cephalic vein; 4', radial vein; 5, 5, median vein; 3', 5, median basilic vein; 4', 5, median cephalic vein.

**BRANCHES.**—The brachial artery gives some unnamed branches, which are directed outwards and backwards to the muscles in its immediate neighbourhood, viz., to the coraco-brachialis, biceps, and brachialis anticus. The following branches, which incline inwards, have received names, and require description :—

(a) The *superior profunda artery* (collateralis magna) arises from the inner and back part of the brachial, just below the border of the teres major, and inclines backwards, to reach the interval between the second and third heads of the triceps muscle. Accompanied by the musculo-spiral nerve, it winds round the back of the humerus, in the spiral groove, under

Fig. 269.





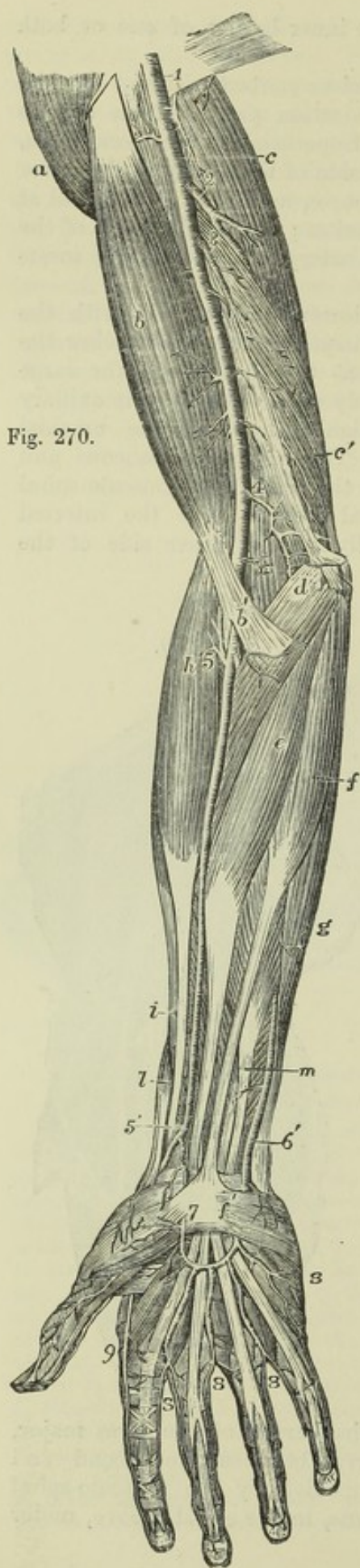


Fig. 270.

cover of the triceps, and perforating the external intermuscular septum, reaches the external and anterior aspect of the bone. There the artery lies deeply in the interval between the brachialis anticus and supinator longus muscles, considerably diminished in size by having given off several branches, and descends to the elbow, where it anastomoses with the recurrent branch of the radial artery.

Fig. 270.—SUPERFICIAL VIEW OF THE ARTERIES OF THE ARM, FORE-ARM, AND HAND IN FRONT (from Tiedemann).  $\frac{1}{4}$

*a*, deltoid muscle; *b*, biceps; *b'*, the aponeurotic insertion; *c*, scapular head of the triceps; *c'*, its internal head; *d*, pronator radii teres; *e*, flexor carpi radialis; *f*, palmaris longus; *f'*, its tendon spreading in the upper part of the palmar fascia, from which, on the inner side, the palmaris brevis muscle is seen rising; *g*, flexor carpi ulnaris; *h*, supinator radii longus; *i*, extensor carpi radialis longior; *l*, extensor ossis metacarpi pollicis; *m*, flexor digitorum communis sublimis; *1*, placed on the tendon of the latissimus dorsi, the lower part of the axillary artery, continued into the brachial; *2*, superior profunda; *3*, inferior profunda; *4*, ulnar anastomotic; *5*, near the division of the brachial artery into ulnar and radial, and recurrent radial artery; *5'*, lower part of the radial artery, where it gives off the superficialis volae, and turns round the wrist; *6'*, the lower part of the ulnar artery, near the place where it passes down to form the superficial palmar arch; *7*, the superficialis volae, which joins it; *8*, *8*, *8*, *8*, first, second, third, and fourth digital branches of the superficial arch to the inside of the little finger, adjacent sides of the 4th and 5th, 3rd and 4th, and 2nd and 3rd fingers; *9*, radialis indicis; on the thumb are seen the two branches of the princeps pollicis artery.

The superior profunda gives off branches in its first part to the deltoid, coraco-brachialis, and triceps; and many to the last-named muscle, whilst it is between it and the bone. In this position it also gives one long branch, which descends perpendicularly between the muscle and the bone to the back part of the elbow-joint on the outer side, where it anastomoses with the interosseous recurrent branch; and another which anastomoses on the inner side with the ulnar recurrent and the anastomotic or the inferior profunda.

(*b*) The *inferior profunda* artery (collateral ulnaris prima), of small size, arises from the brachial artery a little below the middle of the arm, and is



directed to the back part of the inner condyle of the humerus. Descending in company with the ulnar nerve, it pierces the intermuscular septum, then lies on the inner surface of the triceps muscle, to which it gives branches, and entering the interval between the olecranon and inner condyle, it terminates by inosculating with the posterior recurrent branch of the ulnar artery, and with the anastomotic branch of the brachial.

(c) The *nutrient artery* of the shaft of the humerus is a small branch given off by the brachial about the middle of the arm, or by one of its collateral branches. It inclines downwards, enters the oblique canal in the humerus near the insertion of the coraco-brachialis muscle, and is distributed in the interior of the bone.

(d) The *anastomotic artery* (*collateralis ulnaris secunda*), is a very constant branch of moderate size. Arising from the brachial artery about two inches above the bend of the arm, it is directed transversely inwards on the brachialis anticus muscle, above the inner condyle of the humerus, and, after perforating the intermuscular septum, turns outwards behind the humerus, between the bone and the triceps muscle, and forms with the superior profunda an arch across the humerus, immediately above the olecranon fossa (*arcus dorsalis humeri posticus*,—Haller). In front of the humerus the anastomotic artery furnishes a branch which ramifies in the pronator teres, and anastomoses with the anterior ulnar recurrent branch. Behind the inner condyle another offset joins with the posterior ulnar recurrent, and behind the humerus several branches are given to the joint and the muscle.

PECULIARITIES.—From their comparative frequency, and surgical interest, the peculiarities of the brachial artery, especially those which affect its trunk, deserve particular attention.

*Course*.—The brachial artery sometimes lies in front of the median nerve, instead of behind it.

The brachial artery has been seen, though rarely, to descend, accompanied by the median nerve, towards the inner condyle of the humerus, and regain its usual position at the bend of the elbow by passing forwards underneath a fibrous arch, from which the pronator teres in those cases arises, and which descends to the inner condyle from the occasional prominence called the supra-condyloid process, as has been previously described (p. 80). Sometimes this disposition occurs without the development of any bony prominence.

As an extremely rare condition, the artery has been found divided into two vessels near its commencement, the artery being single above and below, as also occurs with the femoral trunk.

In a very few cases the three arteries of the fore-arm, radial, ulnar, and interosseous, have arisen together from the end of the brachial trunk, at the usual distance below the elbow.

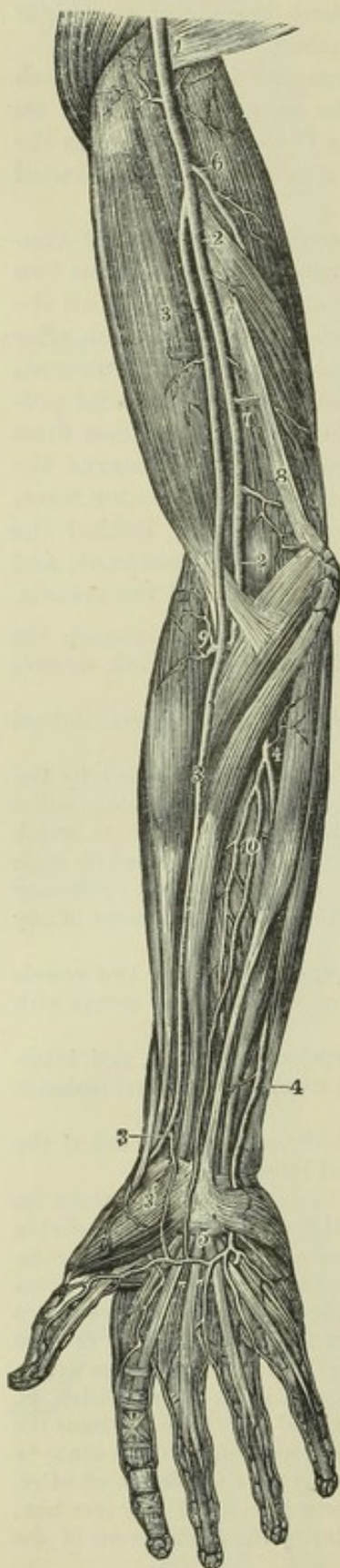
*High division*.—The most frequent change from the ordinary arrangement of the brachial artery is connected with its division into terminal branches.

Out of 481 examples recorded by Richard Quain from observations made, some on the right and some on the left side of the body, the vessel was found in 386 to divide at its usual position, a little below the elbow-joint. In one case only (and that complicated by another peculiarity, viz., the existence of a *vas aberrans* proceeding from the axillary to the radial), was the place of division lower than usual, being between two and three inches lower than the elbow-joint. In 64 cases the brachial artery divided *above* the usual point, at various heights upwards to the lower border of the axilla. The branch prematurely separated from the rest of the trunk in an early division, is, in the proportion of nearly three cases out of four, the radial artery; sometimes the ulnar is the branch given off; that is to say, a branch corresponding to the ulnar in its distribution below the middle of the fore-arm separates from a trunk which afterwards divides into the normal radial artery and the interosseous of the fore-arm, which last is normally derived from the ulnar artery. Rarely the interosseous of the fore-arm, or a *vas aberrans*, is the branch given off.



In all cases of the high origin of one or other of the arteries of the fore-arm the extent in which the two vessels thus formed run separately must vary according to the height at which the main artery divides. The point of division in the entire number of cases, without reference to the particular branch given off, is most frequently in the upper, less so in the lower, and least so in the middle third of the arm. But the early division of the main artery of the upper limb may, as mentioned in connection with the varieties of the axillary artery, take place within the axilla, in which case it follows that the brachial portion of the vessel is replaced, throughout its whole extent, by two separate trunks. In 94 cases out of 481 observed by R. Quain, or about one in five and one-ninth, there were two arteries instead of one in some part or in the whole of the arm.

Fig. 271.



The position of the two arteries, in these cases, is of much surgical interest. We shall here consider only their position in the arm, and subsequently trace them in their irregular course in the fore-arm. Usually they are close together, and occupy the ordinary position of the brachial artery; but there are some peculiarities in their position which require to be particularly noticed.

The *radial* artery, when thus given off in the arm, often arises from the inner side of the brachial, then runs parallel with the larger vessel (the brachial or ulnar-interosseous), and crosses over it, sometimes suddenly, opposite the bend of the elbow, still covered by the fascia. It has been found, but in a very few instances only, to perforate the fascia, and run immediately under the skin, near the bend of the elbow.

The *radial* artery, when thus given off in the arm, often arises from the inner side of the brachial, then runs parallel with the larger vessel (the brachial or ulnar-interosseous), and crosses over it, sometimes suddenly, opposite the bend of the elbow, still covered by the fascia. It has been found, but in a very few instances only, to perforate the fascia, and run immediately under the skin, near the bend of the elbow.

Fig. 271.—DISSECTION OF THE RIGHT ARM, SHOWING AN EXAMPLE OF HIGH SEPARATION OF THE RADIAL ARTERY FROM THE BRACHIAL, AND AN ENLARGED MEDIAN ARTERY IN THE FORE-ARM (from Tiedemann).  $\frac{1}{4}$

1, on the tendon of the latissimus dorsi, points to the upper part of the brachial artery; 2, the brachial artery after giving off the radial; 3, the radial rising in the upper third of the arm and descending in its usual situation in the fore-arm; 3', its superficial volar branch; 4, the ulnar artery in its usual course, forming at 5, the superficial palmar arch, from which three of the palmar digital arteries and the princeps pollicis take origin; the radial supplying the branches to the index finger and one side of the middle finger; 6, the superior profunda branch of the brachial artery; 7, muscular branches; 8, ulnar anastomotic; 9, recurrent radial; 10, anterior interosseous giving an unusually large median branch which descends over the wrist to unite with the superficial palmar arch.

When the *ulnar* is the branch given off high from the brachial, it often inclines from the position of the brachial, at the lower part of the arm, towards the inner condyle of the humerus. This vessel generally lies beneath the fascia as it descends, and superficially to the flexor muscles.



It is occasionally placed between the integuments and the fascia; and in a single instance was found beneath the muscles. In one instance recently occurring in the dissecting-room of the Glasgow University, the ulnar artery given off from the humeral at the middle of the arm was observed to descend superficially behind the inner condyle.

The *interosseous*, after arising from the axillary or brachial artery, is commonly situated behind the main artery, and, on reaching the bend of the elbow, passes deeply between the muscles, to assume its usual position in the fore-arm.

Lastly, when the radial has arisen high in the arm, the residuary portion of the brachial (*ulnar-interosseous*) has occasionally been observed descending, accompanied by the median nerve, along the intermuscular septum towards the inner condyle of the humerus, as far as the origin of the pronator teres (which in the cases recorded was found broader than usual), whence it turned outwards under cover of the muscle, to gain the usual position at the middle of the bend of the elbow.

Fig. 272.—ABERRANT ARTERY, SEPARATING FROM THE BRACHIAL AT THE MIDDLE OF THE ARM, PASSING WITH THE MEDIAN NERVE THROUGH THE INTERNAL INTER-MUSCULAR SEPTUM, AND JOINING FARTHER DOWN THE REGULAR ULNAR (from R. Quain).  $\frac{1}{4}$

*a*, biceps muscle; *b*, triceps; *c, c*, divided pronator teres; *d, d, d'*, median nerve, diverted from its usual course, and passing with the aberrant artery through the internal intermuscular septum; *e, e, e*, ulna nerve in its usual course; 1, brachial artery, giving off an aberrant artery at the middle of the arm; 2, the usual radial artery; 3, aberrant artery, with the median nerve twining round it, passing at 3' through the internal intermuscular septum; 3'', the same farther down, and communicating at 4' with the first part of the normal ulnar artery, 4, given off from the brachial.

The two arteries taking the place of the brachial are in some instances connected near the bend of the arm by an intervening trunk, which proceeds from the larger (or ulnar-interosseous) artery to the radial or the radial recurrent, and varies somewhat in its size, form, and course. More rarely the two unusual arteries are actually *re-united*.

The *aberrant arteries*, "*vasa aberrantia*," alluded to in the preceding statement, are long slender vessels, which arise either from the brachial or the axillary artery, and end by joining one of the arteries of the fore-arm, or one of their branches. In eight cases out of nine, observed by Quain, this unusual vessel joined the radial; in the remaining case it joined the radial recurrent, which arose irregularly from the ulnar artery. Monro and Meckel have each seen one case in which the aberrant vessel joined the ulnar. This peculiarity may be regarded, perhaps, as an approach to that condition in which there is division of the brachial artery and subsequent connection of its two parts by an intervening branch.

*State of the arteries in both limbs.*—In most cases of the high division of the brachial arteries the condition of the vessels is not the same in the right and left arms. In 61 bodies in which the high division existed, it occurred only on one side in 43; on both sides, in different positions, in 13; and on both sides, in the same position, in the remaining 5.

*Branches.*—It has been already mentioned (p. 381) that the *superior profunda*

Fig. 272.

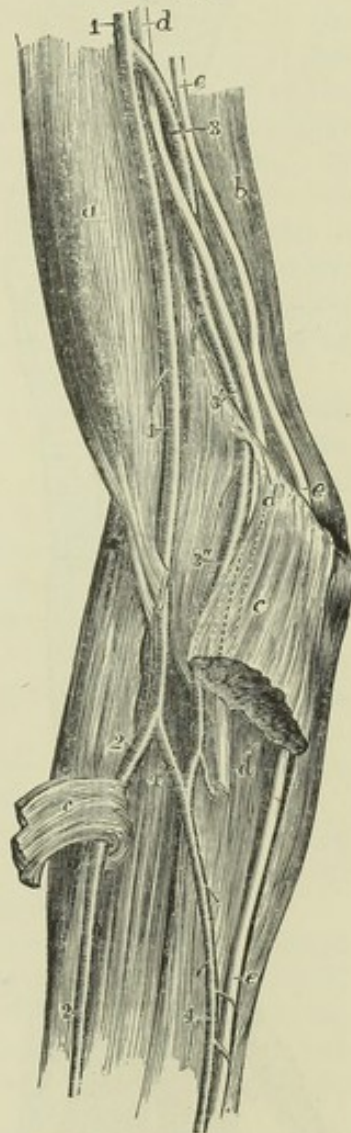
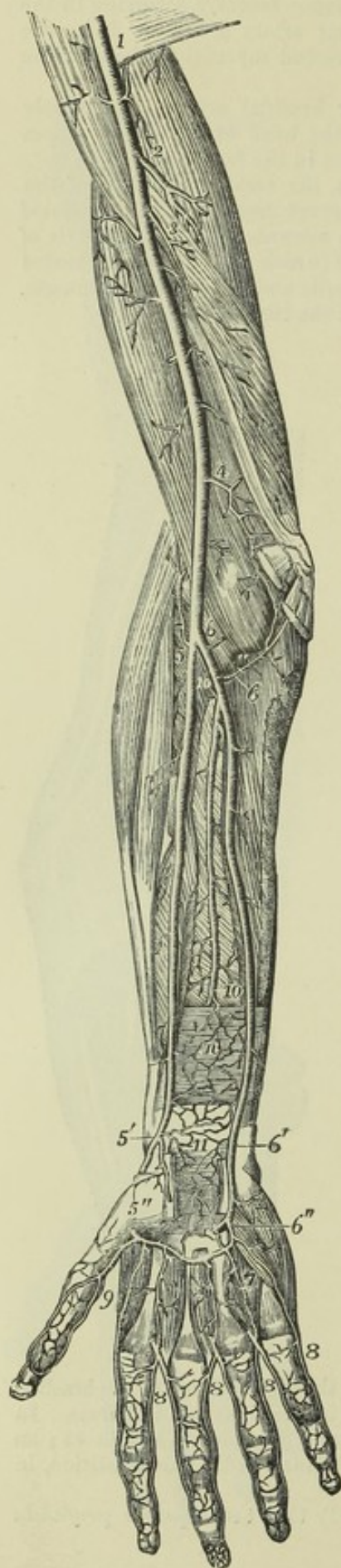



Fig. 273.



may give origin to the posterior circumflex artery, and that its own origin is sometimes transferred to a branch arising from the axillary artery.

The *inferior profunda* is likewise occasionally absent, and on that account has not been recognised by some anatomists as a regular branch of the brachial artery.

The *anastomotic* artery is sometimes much reduced in size, and in that case the inferior profunda takes its place behind the humerus.

Fig. 273.—DEEP ANTERIOR VIEW OF THE ARTERIES OF THE ARM, FORE-ARM, AND HAND (from Tiedemann).  $\frac{1}{4}$

The biceps brachii, the pronator teres and muscles rising from the inner condyle, the supinator longus, the lower part of the flexor longus pollicis and flexor profundus digitorum, the anterior annular ligament of the carpus and the muscles of the ball of the thumb have been removed; *n*, pronator quadratus muscle; 1, lower part of the axillary artery continued into the brachial; 2, superior profunda branch; 3, inferior profunda; 4, ulnar anastomotic; 5, upper part of the radial artery and radial recurrent; 5', lower part of the radial artery giving off the superficialis volæ branch; 5'', the radial artery emerging from between the heads of the abductor indicis muscle; 6, 6, the upper part of the ulnar artery with the anterior and posterior ulnar recurrent branches; 6', the ulnar artery approaching the wrist and descending into the superficial palmar arch which has been cut short; 6'', the deep branch of the ulnar artery uniting with the deep palmar arch; 7 (marked only on one), three interosseous branches from the deep palmar arch joining the palmar digital arteries 8, 8, 8, which have been cut away from their origin from the superficial arch to near their division into the collateral digital arteries; the ulnar collateral of the little finger is represented as rising in this instance from the deep ulnar artery; 9, placed between the princeps pollicis and radialis indicis branches of the radial artery; 10, lower part of the anterior interosseous artery passing behind the pronator quadratus muscle; 11, anastomosis of the anterior carpal branches of the radial and ulnar arteries with recurrent branches from the deep palmar arch.

### ULNAR ARTERY.

The ulnar artery, the larger of the two vessels into which the brachial divides, extends along the inner side of the fore-arm into the palm of the hand, where, joining a branch of the radial, opposite the muscles of the thumb, it forms the superficial palmar arch. In this course it inclines at first downwards and inwards, describing a slight curve, the convexity of which is directed inwards, and passes under cover of



the superficial muscles arising from the inner condyle of the humerus, viz., the pronator teres, flexor carpi radialis, palmaris longus, and flexor sublimis, until it reaches the flexor carpi ulnaris near the junction of the upper with the middle third of the fore-arm; at this point the artery comes into contact with the ulnar nerve, which was previously separated from it by a considerable interval, and changing its direction, descends vertically with the nerve towards the inner border of the palm of the hand. Descending along the radial border of the tendon of the flexor ulnaris muscle, the ulnar artery reaches the outer or radial side of the pisiform bone, where, still accompanied by the nerve, it passes over the cutaneous surface of the anterior annular ligament of the wrist into the palm of the hand. Its disposition in the hand will be separately described.

In the first half of its course through the fore-arm, the artery is deep-seated, being covered by the muscles arising from the inner condyle of the humerus which have been already enumerated. About the middle of the fore-arm it is overlapped by the fleshy part of the flexor carpi ulnaris; but below that, it becomes more superficial, being overlaid by the tendon of the muscle, and covered by the skin, the fascia of the fore-arm, and a thin layer of membrane by which the vessel is bound down to the muscle beneath. At first the ulnar artery lies on the insertion of the brachialis anticus into the coronoid process of the ulna; then on the flexor profundus in the rest of the fore-arm, and lastly, on the annular ligament of the carpus. Below the point at which it emerges from under the flexor carpi ulnaris (or a little below the middle of the fore-arm), the tendon of that muscle is on its inner or ulnar side.

*Relation to Nerves.*—The median nerve lies immediately on the inner side of the ulnar artery at its origin, but being directed down the middle of the fore-arm it soon passes over the vessel, separated from it at the point of crossing by the deep head of the pronator teres muscle. As the ulnar nerve descends behind the inner condyle of the humerus, it is removed from the ulnar artery by a considerable interval at the upper part of the fore-arm; but as the vessel inclines inwards, it approaches the nerve, and is accompanied by it in the lower half of its course—the nerve lying close to its inner side. A small branch of the ulnar nerve descends upon the lower part of the vessel.

*Relation to Veins.*—Two veins (*venæ comites*) accompany the ulnar artery, and are frequently united by branches crossing it.

**BRANCHES.**—The ulnar artery gives off in the fore-arm the anterior and posterior recurrent, the interosseous, and several muscular branches. At the wrist it gives off the anterior and posterior carpal branches.

**RECURRENT BRANCHES.**—The anterior ulnar recurrent artery, a small branch, arches inwards and upwards from the upper part of the ulnar artery, running on the brachialis anticus muscle, and covered by the pronator teres, both which muscles it partly supplies. On reaching the front of the inner condyle, it anastomoses with the inferior profunda and anastomotie arteries, derived from the brachial.

The posterior ulnar recurrent, larger than the preceding, comes off lower down; but not unfrequently the two vessels arise by a short common trunk. The posterior recurrent runs inwards and backwards beneath the flexor sublimis, and then ascends behind the inner condyle. In the interval between that process and the olecranon it lies beneath the flexor carpi ulnaris, and passing between the heads of that muscle along the ulnar nerve, supplies branches to the muscles, to the elbow joint, and to the nerve itself. This



branch communicates with the inferior profunda, the anastomotic; and, over the olecranon, likewise with the interosseous recurrent.

Fig. 274.

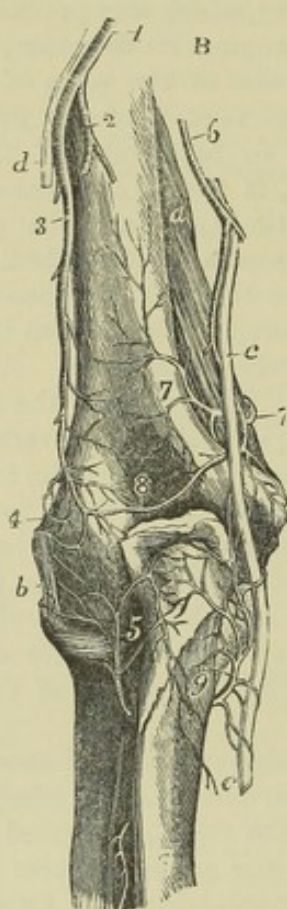
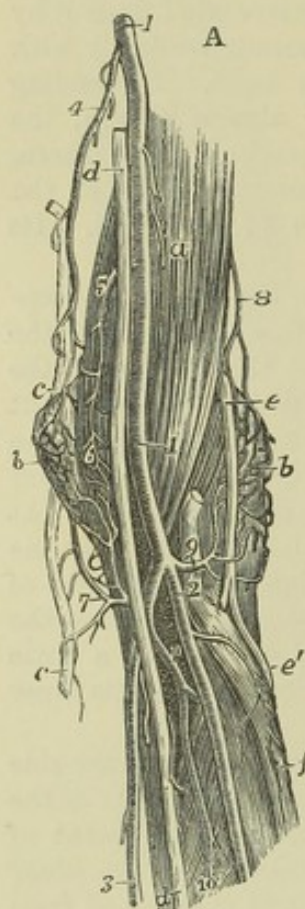


Fig. 274.—VIEW OF THE ANASTOMOSES OF ARTERIES NEAR THE ELBOW-JOINT: A, FROM BEFORE; B, FROM BEHIND (from R. Quain).  $\frac{1}{4}$

A. *a*, brachialis anticus muscle; *b*, external condyloid eminence covered by the supinator radii brevis and the anastomoses of the superior profunda and radial recurrent arteries; *c*, ulnar nerve; *d*, median nerve; *e*, musculo-spiral nerve; *e'*, its posterior interosseous branch: its radial branch is cut; *f*, oblique line of the radius; 1, brachial artery; 2, radial artery; 3, ulnar artery; 4, inferior profunda; 5, anastomotic; 6, anterior ulnar recurrent anastomosing with the anterior descending branches of the anastomotic; 7, posterior ulnar recurrent passing up behind the inner condyloid eminence to anastomose with the inferior profunda and posterior branch of the anastomotic; 8, spiral branch of the superior profunda; 9, placed on the tendon of the biceps muscle, points to the radial recurrent artery; 10, 10, interosseous artery and its anterior branch.

B. *a*, a part of the brachialis anticus muscle; *b*, external lateral ligament of the elbow-joint; *c*, ulnar nerve; *d*, a small part of the musculo-spiral nerve; 1, superior profunda artery; 2, its branch to the triceps muscle; 3, its spiral branch to the outer condyle; 4, its anastomosis with the recurrent radial artery; 5, recurrent of the posterior interosseous artery, passing up to anastomose with the preceding and with the anastomotic behind the joint; 6, inferior profunda; 7, posterior branch of the anastomotic artery; 8, anastomosis of the anastomotic and inferior profunda with the superior profunda and the posterior interosseous recurrent; 9, posterior ulnar recurrent artery passing up in the groove of the ulnar nerve to anastomose with the inferior profunda and anastomotic.

**INTEROSSEOUS ARTERY.**—The interosseous or *common interosseous* artery, the next, and the largest branch of the ulnar, is a trunk of considerable size, about an inch in length, which arises below the bicipital tuberosity of the radius, beneath the flexor sublimis, and passes backwards to reach the upper border of the interosseous ligament, where it divides into the *anterior* and *posterior interosseous* arteries.

The *anterior interosseous* descends upon the anterior surface of the interosseous ligament, accompanied by the interosseous branch of the median nerve and *venæ comites*, and overlapped by the contiguous borders of the flexor profundus digitorum and flexor longus pollicis muscles. It continues its course directly downwards as far as the upper border of the pronator quadratus muscle, then pierces the interosseous ligament, and descends to the back of the carpus.



The anterior interosseous artery gives off the following branches :—

(a) The artery of the median nerve, or the *median artery*, a long slender branch, which accompanies the median nerve and sends offsets into its substance. This artery is sometimes much enlarged, and in that case it presents several peculiarities to be hereafter noticed.

(b) *Muscular* branches to the flexor profundus, flexor longus pollicis, and pronator quadratus muscles.

(c) The *nutrient* arteries of the shafts of the radius and ulna, which diverging from one another, enter the oblique foramina in those bones to be distributed to the medullary membrane in their interior.

(d) An anterior inosculating branch, given off before the artery pierces the interosseous membrane, and descending beneath the pronator quadratus muscle to anastomose with the anterior carpal arteries.

(e) Terminal twigs inosculating with the posterior carpal arteries.

The *posterior interosseous* artery passes backwards through the interval left between the oblique ligament and the upper border of the interosseous ligament, and continuing its course downwards along the fore-arm, covered by the superficial layer of extensor muscles, gives branches to them and the deep-seated muscles, and reaches the carpus considerably diminished in size.

In addition to muscular branches, it gives off the following :—

(a) The *posterior interosseous recurrent*, which passes directly upwards, covered by the anconeus, to reach the interval between the olecranon and external condyle; at which place it divides into several offsets which anastomose with the superior profunda and the posterior ulnar recurrent.

(b) *Terminal* branches, which anastomose with the posterior or terminal branch of the anterior interosseous artery, and with the carpal branches of the radial and ulnar arteries.

**MUSCULAR BRANCHES** of the ulnar artery are distributed to the muscles in the course of the vessel along the fore-arm: some of these perforate the interosseous ligament to reach the extensor muscles.

**CARPAL BRANCHES.**—The *posterior ulnar carpal* branch, of variable size, arises a little above the pisiform bone, and winding back under the tendon of the flexor carpi ulnaris, reaches the dorsal surface of the carpus beneath the extensor tendons.

Its branches are the following :—

(a) A branch anastomoses with the posterior carpal artery derived from the radial, so as to form the *posterior carpal arch*, and from this arch are derived the *second* and *third dorsal interosseous arteries*, which descend on the spaces between the third and fourth and the fourth and fifth metacarpal bones, and are reinforced at the upper ends of those spaces by anastomoses with the posterior perforating branches of the deep palmar arch.

(b) A branch runs along the metacarpal bone of the little finger. Sometimes this *metacarpal branch* arises as a separate vessel, the posterior carpal being then very small.

The *anterior ulnar carpal* branch is a very small artery, which runs on the anterior surface of the carpus beneath the flexor profundus, anastomoses with a similar offset from the radial artery, and supplies the carpal bones and articulations.

**PECULIARITIES.**—*Origin.*—In the whole number of cases observed by Richard Quain, the ulnar artery was found to deviate from its usual mode of *origin*, nearly in the proportion of one in thirteen. The brachial artery was, more frequently than the axillary, the source from which it sprang; indeed, the examples of its origin from the main trunk at different parts appeared to decrease in number in proportion as the



place of origin was higher up the artery. (See on this subject the description of the peculiarities of the axillary and brachial arteries, pp. 381 and 385.)

Fig. 275.

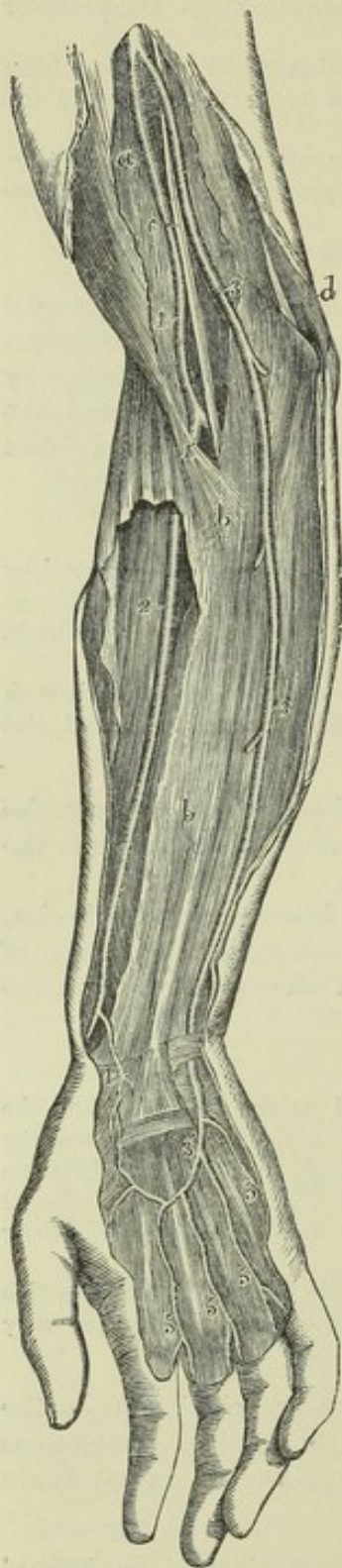

Fig. 275.—ABNORMAL SUPERFICIAL ULNAR ARTERY RISING HIGHER THAN USUAL FROM THE BRACHIAL.  $\frac{1}{4}$

This figure has been taken from a preparation in A. Thomson's collection; the drawing being planned after that of a similar case represented by R. Quain. Tab. xxxvi. Fig. 1.

*a*, biceps muscle covered by the deep brachial fascia; *b*, the same fascia in the fore-arm, which has been opened in a considerable extent to show the radial artery subjacent to it; *c*, median nerve; *d*, ulnar nerve; 1, on the biceps muscle, points to the brachial artery after having given off an ulnar artery higher up, and dividing at 1', into the radial artery and a deep vessel corresponding to the interosseous and a part of the usual ulnar; 2, on the supinator longus muscle, points to the radial artery; 3, 3, artery which is given off by the brachial in the arm, and which descending upon the fascia takes the place of the ulnar at the wrist; 3', the same continued into the superficial palmar arch, giving off digital branches nearly in the usual manner, and joined by a branch from the radial, 4, the superficial volar; 5, digital branches; towards the thumb a communication of the superficial arch with the princeps pollicis exists.

*Course.*—The position of the ulnar artery in the fore-arm is more frequently altered than that of the radial. When it arises in the usual way, the course of this artery is not often changed; but it has been seen to descend apart from the tendon of the flexor carpi ulnaris, instead of being close to its radial border.

In cases of high origin, it almost invariably descends over the muscles arising from the inner condyle of the humerus, only one exception to this rule having been met with. (R. Quain, plate 36, fig. 2.)

Most commonly it is covered by the fascia of the fore-arm; but cases also occur in which the vessel rests on the fascia, and either continues in that position or becomes subaponeurotic lower down, while the vessel thus disposed is distributed after the manner of the normal ulnar artery. The vessel from which the high ulnar separates is afterwards divided into the radial artery and the interosseous, the last of which is usually derived from the ulnar; it appears therefore probable that the abnormal arrangement results from early obstruction of the ulnar artery below the origin of the interosseous, and the development of a superficial vas aberrans, which unites the portion of vessel below the obstruction with the axillary or brachial trunk. The interosseous artery in such cases of abnormality thus comprises not only the ordinary interosseous branch, but likewise the portion of ulnar artery above the obstruction; and, in accordance with this view, we find that the recurrent branches are derived from it.

As to size, the ulnar artery presents some peculiarities which, being accompanied by deviations of an opposite and compensating character in the radial artery, will be noticed with that vessel.



*Branches.*—The *anterior* and *posterior ulnar recurrent branches* frequently arise by a common trunk. One or both have been seen to arise from the brachial artery.

The *anterior* and *posterior interosseous* arteries are occasionally given separately from the ulnar. The common interosseous trunk has been found to arise above its ordinary situation, taking origin from the brachial, and even (but more rarely) from the axillary artery. The anterior interosseous presents some striking varieties of excess in its branches, usually connected with a deficiency in the radial or ulnar arteries: the most important of these is enlargement of the median branch.

*Median artery.*—The branch accompanying the median nerve is sometimes much enlarged, and in such cases may be regarded as a reinforcing vessel. It is generally a branch of the anterior interosseous, but sometimes of the ulnar; and more rarely a median branch has been met with descending from the brachial artery. Accompanying the median nerve beneath the annular ligament into the palm of the hand, the median artery ends most frequently by joining the superficial palmar arch, sometimes by forming digital branches, in other cases by joining digital branches given from other sources.

#### SUPERFICIAL PALMAR ARCH.

The superficial palmar arch or artery (*arcus superficialis volæ*,—Haller) is the continuation of the ulnar artery into the hand. Changing its course near the lower border of the annular ligament, this artery turns obliquely outwards across the palm of the hand towards the middle of the muscles of the thumb, where it terminates by inosculating with a small branch of the radial artery—the superficial volar, generally passing through among the muscles of the thumb. In its course across the hand, the palmar artery describes a curve, having its convexity directed towards the fingers, and extending downwards somewhat lower than a line on a level with the phalangeal articulation of the thumb.

The superficial palmar artery rests at its commencement on the annular ligament of the wrist, and slightly on the short muscles of the little finger; then on the tendons of the superficial flexor of the fingers, and the divisions of the median and ulnar nerves, the latter nerve accompanying the vessel for a short distance. It is covered towards the ulnar border of the hand by the *palmaris brevis*, and afterwards by the palmar fascia and the integument.

*BRANCHES.*—The branches given off by the superficial palmar arch, which are generally numerous, are as follow:—

(a) The *deep* or *communicating* branch arises from the ulnar artery at the commencement of the palmar arch a little beyond the pisiform bone, sinks deeply between the flexor brevis and the abductor of the little finger, and inosculates with the palmar termination of the radial artery, thereby completing the deep palmar arch.

(b) Small branches, some following a retrograde course towards the annular ligament, are given off to the parts in the palm of the hand from the upper or concave side of the palmar arch.

(c) The *digital* branches, usually four in number, proceed downwards from the convexity of the palmar arch to supply both sides of the three inner fingers, and the ulnar side of the fore finger. The *first digital* branch inclines inwards to the ulnar border of the hand, and after giving minute offsets to the muscles of the little finger, runs along the inner margin of its phalanges. The *second* runs along the fourth metacarpal space, and at the root of the fingers divides into two branches, which proceed along the contiguous borders of the ring finger and little finger. The *third* is similarly distributed to the ring finger and middle finger; and the *fourth* to the



latter and the index finger. The thumb and the radial side of the index finger are supplied from the radial artery.

Fig. 276.

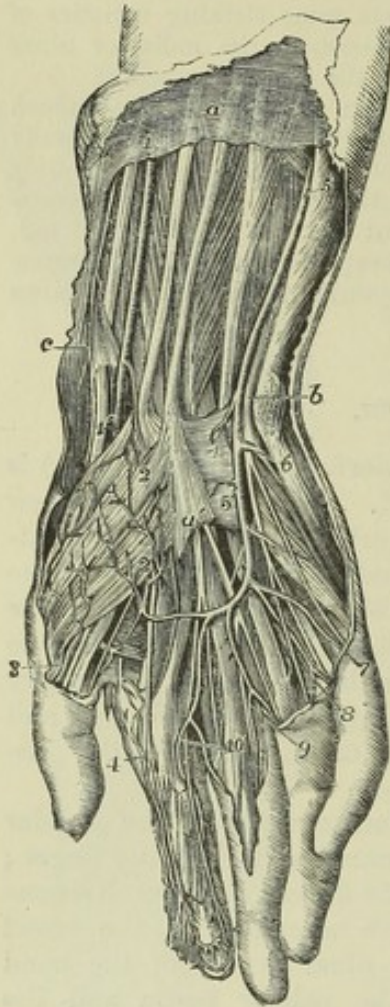


Fig. 276.—SUPERFICIAL DISSECTION OF THE LOWER PART OF THE FOREARM AND THE HAND, SHOWING THE RADIAL AND ULNAR ARTERIES, THE SUPERFICIAL PALMAR ARCH, AND THE ACCOMPANYING NERVES (from R. Quain).  $\frac{1}{3}$

*a*, placed on the deep fascia of the forearm, between the tendons of the palmaris longus and flexor carpi radialis muscles; *b*, points by a line crossing the pisiform bone to the ulnar nerve; *c*, points to the styloid process of the radius and twigs of the radial nerve; 1, radial artery lying on the flexor longus pollicis; 1', the radial artery passing behind the tendons of the extensor ossis metacarpi pollicis and extensor primi internodii pollicis; 2, superficialis volæ branch piercing the short muscles of the thumb and emerging below to join the superficial palmar arch; 3, external branch of the princeps pollicis; 4, radialis indicis; a branch from the superficial arch is seen joining the internal branch of the princeps pollicis; 5, ulnar artery lying upon the flexor digitorum profundus; 5', the same descending on the anterior annular ligament to form the superficial palmar arch; 6, deep branch of the ulnar artery passing between the abductor and flexor minimi digiti to join the deep arch, accompanied by the deep branch of the ulnar nerve; 7, branch of the superficial arch to the ulnar side of the little finger; 8, division of the common branch to the 4th and 5th fingers; 9, the same to the 3rd and 4th fingers; 10, the same to the 2nd and 3rd fingers; 7 and 8, are accompanied by the digital branches of the ulnar nerve, and 3, 4, 9, and 10, by the branches of the median nerve.

The digital arteries are placed at first superficial to the tendons, and then lie between them, accompanied by the digital nerves as far as the clefts of the fingers, where they are joined by the anterior interosseous arteries, branches of the deep arch. On the sides of the fingers, each artery lies beneath the corresponding nerve, and gives branches which supply the sheaths of the tendons and the joints, some of them anastomosing across the front of the bones with similar branches from the opposite side. At about the middle of the last phalanx, the two branches for each finger converge and form an arch, from which proceed numerous small offsets to supply the matrix of the nail and all the structures at the tip of the finger.

[The *peculiarities* observed in the branches of the superficial palmar arch will be noticed after the description of the deep arteries of the hand.]

### RADIAL ARTERY.

The *radial artery* appears by its direction to be the continuation of the brachial, although it does not equal the ulnar in size. It extends along the front of the forearm as far as the lower end of the radius, below which it



turns round the outer border of the wrist ; and descends to the back of the space between the metacarpal bones of the thumb and forefinger : there it passes forwards into the palm of the hand, and crosses towards the inner side, so as to form the deeper palmar arch. In consequence of the changes in its course, the direction and connections of the radial artery may be separately described in the forearm, on the wrist, and in the hand.

Fig. 277.—DEEP ANTERIOR VIEW OF THE ARTERIES OF THE ARM, FOREARM, AND HAND (from Tiedemann).  $\frac{1}{4}$

The biceps brachii, the pronator teres and muscles rising from the inner condyle, the supinator longus, the lower part of the flexor longus pollicis and flexor profundus digitorum, the anterior annular ligament of the carpus and the muscles of the ball of the thumb have been removed ; *n*, pronator quadratus muscle ; 1, lower part of the axillary artery continued into the brachial ; 2, superior profunda branch ; 3, inferior profunda ; 4, anastomotic ; 5, upper part of the radial artery and radial recurrent ; 5', lower part of the radial artery giving off the superficialis volæ branch ; 5'', the radial artery emerging from between the heads of the abductor indicis muscle ; 6, 6, the upper part of the ulnar artery with the anterior and posterior ulnar recurrent branches ; 6', the ulnar artery approaching the wrist and descending into the superficial palmar arch which has been cut short ; 6'', the deep branch of the ulnar artery uniting with the deep palmar arch ; 7 (marked only on one), three interosseous branches from the deep palmar arch joining the palmar digital arteries 8, 8, 8, which have been cut away from their origin from the superficial arch to near their division into the collateral digital arteries ; the ulnar collateral of the little finger is represented as rising in this instance from the deep ulnar artery ; 9, placed between the princeps pollicis and radialis indicis branches of the radial artery ; 10, lower part of the anterior interosseous artery passing behind the pronator quadratus muscle ; 11, anastomosis of the anterior carpal branches of the radial and ulnar arteries with recurrent branches from the deep palmar arch.

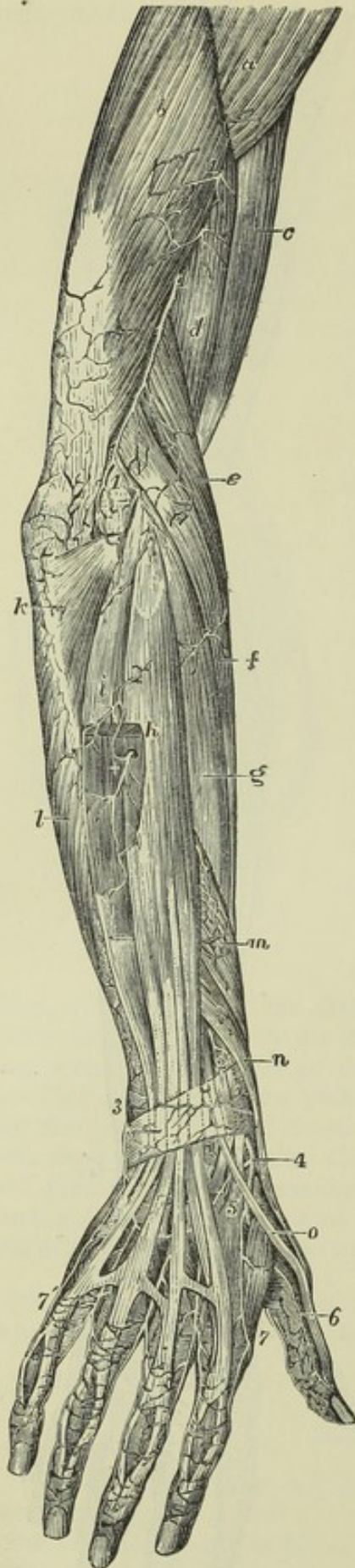
*In the forearm* the radial artery, commencing at the point of bifurcation of the brachial opposite the neck of the radius, descends at first somewhat obliquely outwards in a line with the brachial artery, and then nearly vertically along the outer part of the front of the forearm to the styloid process of the radius. Its course may be indicated by a line drawn from

D D 2

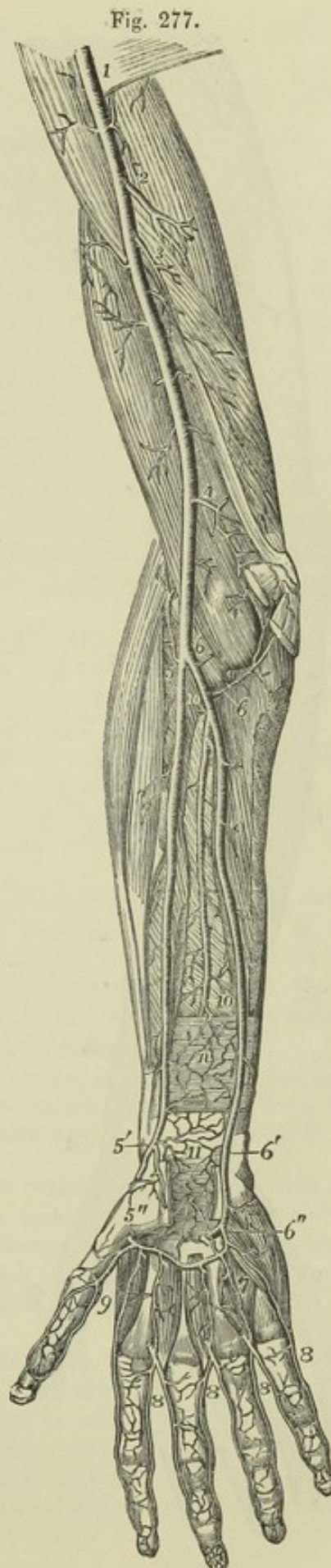



Fig. 278.



the middle of the bend of the elbow to the narrow interval between the trapezium bone and the tendons of the extensors of the thumb, which can be readily felt on the outer border of the wrist.

Fig. 278.—ARTERIES OF THE OUTER AND BACK PART OF THE ARM AND HAND, SUPERFICIAL VIEW (from Tiedemann).  $\frac{1}{4}$

*a*, deltoid muscle; *b*, external humeral head of triceps; *c*, biceps brachii; *d*, brachialis anticus; *e*, supinator longus; *f*, extensor carpi radialis longior; *g*, breviar; *h*, extensor communis digitorum and extensor minimi digiti; *i*, extensor carpi ulnaris; *k*, anconeus; *l*, flexor carpi ulnaris; *m*, extensor ossis metacarpi pollicis; *n*, extensor primi internodii pollicis; *o*, tendon of the extensor secundi internodii pollicis; 1, 1, branches of superior profunda artery appearing between the triceps and brachialis anticus, and descending on the outer supracondyloid eminence to anastomose with the branches of the recurrent radial artery; 2, above the posterior annular ligament points to the posterior carpal branch of the interosseous artery; 3, posterior carpal branch of the ulnar artery; 4, radial artery taking its course between the outer lateral ligament of the wrist-joint and the tendons of the extensor muscles before passing near 5, between the two heads of the abductor indicis: beneath the extensor tendons is seen the posterior carpal arch, giving the third and fourth dorsal interosseous arteries; 6, the inner dorsal artery of the thumb; 7, the outer dorsal artery of the index finger, and between 7, and 7', the remaining dorsal digital vessels in the spaces between the heads of the metacarpal bones, near their communications with the palmar digital vessels.

The radial artery is nearer to the surface than the ulnar, and is covered only by the common integument and fascia, except where it is overlapped by the fleshy part of the supinator longus, which must be drawn aside in order to bring the vessel into view. At first it is in contact with the tendon of the biceps, and is supported by the fatty tissue contained in the hollow in the front of the elbow, which separates it from the short supinator muscle. It then rests in succession on the insertion of the pronator teres, the thin radial origin of the flexor sublimis, the flexor pollicis longus, the pronator quadratus, and the lower end of the radius. It is at this last point that the pulse is usually felt during life. To the inner side of this vessel lie the pronator teres in the upper part of its course, and



the flexor carpi radialis in the remainder ; and on the outer side, in its whole course along the forearm, is the supinator longus muscle.

*Relation to Veins.*—The artery is accompanied by *venæ comites*, which have the usual arrangement of those veins.

*Relation to Nerves.*—The *radial* branch of the musculo-spiral nerve is placed on the outer side of the artery in the middle third of its course. At the elbow that nerve is separated from the artery by a considerable interval ; and towards the lower end of the fore arm it turns backwards beneath the tendon of the supinator longus, to reach the dorsal aspect of the limb, and thus loses all connection with the artery. Some filaments of the *external cutaneous* nerve pierce the fascia to reach the lower part of the artery, which they accompany to the back of the carpus.

At the wrist the radial artery turns outwards between the styloid process of the radius and the carpus, beneath the tendons of the extensors of the metacarpal bone and first phalanx of the thumb, and upon the external lateral ligament of the wrist-joint, to reach the back of the carpus. It then runs downwards for a short distance, is crossed by the tendon of the extensor of the second phalanx of the thumb, and reaching the upper end of the space between the first and second metacarpal bones, turns forwards into the palm of the hand, by passing between the heads of the first dorsal interosseous muscle.

As it turns round below the end of the radius the artery is deep-seated, but afterwards comes nearer to the surface. It is accompanied by two veins and by some filaments of the external cutaneous nerve, and is crossed by subcutaneous veins and by filaments of the radial nerve.

**BRANCHES.**—The branches of the radial artery may be arranged according as they are given off in the fore arm, on the wrist, and in the hand.

A. The branches which arise from the radial in the fore arm are the radial recurrent, the muscular branches, the anterior carpal, and the superficial volar.

(a) The *radial recurrent* artery, which varies much in size, arches upwards from the radial soon after its origin, running between the branches of the musculo-spiral nerve. It first lies on the supinator brevis, and then on the brachialis anticus, being covered by the supinator longus. In front of the outer condyle, and in the interval between the two last muscles, it anastomoses with the terminal branches of the superior profunda.

From the lower or convex side of this artery are given off several branches ; one, of considerable size, to the supinator and extensor muscles, and some beneath the latter to anastomose with the posterior interosseous branches. It also supplies the supinator brevis, and brachialis anticus in part.

(b) The *anterior radial carpal* is a small branch which arises from the radial artery, near the lower border of the pronator quadratus, and runs inwards in front of the radius. It anastomoses with the anterior ulnar carpal artery, so as to form an arch above and in front of the radio-carpal articulation, from which branches descend to supply the joints at the wrist.

(c) The *superficial volar* (*ramus superficialis volæ*), arising from the radial artery, near the place where it leaves the front of the forearm, passes onwards into the hand. In size it is variable ; in most instances it is very small, and ends in the muscles of the thumb ; but in others it attains considerable size, and crossing those muscles at their origins, terminates, as it is usually described, by inosculating with the radial extremity of the superficial palmar arch, which it thus completes.



Several unnamed *muscular* branches are given by the radial artery to the muscles on the fore part of the arm.

B. The branches which arise from the radial artery behind the wrist are, the posterior carpal, the metacarpal, the dorsal arteries of the thumb, and the dorsal artery of the index finger.

(a) The *posterior radial carpal* is a small but constant branch. It arises beneath the extensor tendons of the thumb, and running inwards on the back of the carpus anastomoses with the posterior ulnar carpal branch, completing the arch from which spring the dorsal interosseous arteries of the third and fourth spaces (p. 391). It anastomoses, also, with the terminal branch of the anterior interosseous of the fore arm.

(b) The *first dorsal interosseous* or *metacarpal* branch arises beneath the extensor tendons of the thumb, frequently in common with the posterior carpal branch, passes to the interval between the second and third metacarpal bones, communicates with the corresponding perforating branch of the deep palmar arch, and descending on the second dorsal interosseous muscle anastomoses with the palmar digital branch at its division between the fingers.

Fig. 279.

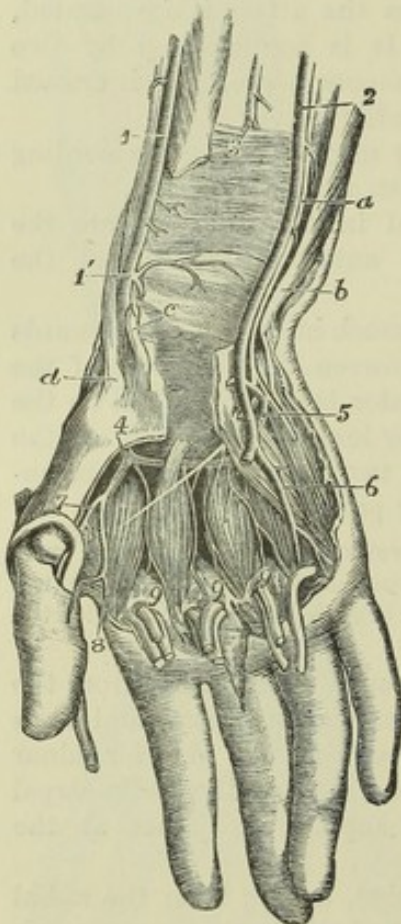


Fig. 279.—DEEP VIEW OF THE ARTERIES OF THE WRIST AND HAND, FROM BEFORE (from R. Quain).  $\frac{1}{2}$

The anterior annular ligament of the carpus has been divided and the lower part of the common flexors and flexor of the thumb has been removed; portions of these tendons are represented as turned down upon the fingers with parts of the lumbricales muscles; the superficial palmar arch is removed, and the interossei muscles are exposed. *a*, ulnar nerve; *b*, tendon of the flexor carpi ulnaris muscle; *c*, tendon of the flexor carpi radialis; *d*, inserted tendon of the extensor ossis metacarpi pollicis; 1, radial artery; 1', its lower part before passing back within the extensor tendons of the thumb, giving the anterior carpal and superficial volar branches; 2, ulnar artery; 3, anterior interosseous artery before passing behind the pronator quadratus muscle; 4, radial artery, appearing deeply in the palm between the first and second metacarpal bones and passing into the deep palmar arch; 5, deep branch of the ulnar artery dipping between the abductor and flexor brevis minimi digiti to join the deep arch, and accompanied by the deep branch of the ulnar nerve; 6, a palmar digital artery rising from the first part of the superficial palmar arch; 7, the princeps pollicis, and 8, the radialis indicis arteries rising from the radial artery; 9, 9, 9, interosseous branches of the deep palmar arch proceeding down on the interosseous muscles to join the palmar digital arteries from the superficial arch.

(c) The *dorsal arteries of the thumb*, two small branches, arising separately or together opposite the head of the metacarpal bone, run upon the dorsal aspect of the bones of the thumb, one at the radial, the other at the ulnar border.

(d) The *dorsal artery of the index finger*, a very small branch, arises



lower down than the preceding, and sending branches to the abductor indicis, runs along the radial side of the back of the index finger.

c. The branches derived from the radial after it has entered the hand, are, the great artery of the thumb, the radial branch of the index finger, and its large terminal branch, which forms the deep palmar arch.

(a) The *large artery of the thumb* (*arteria princeps pollicis*,—Haller) arises from the radial, where it is about to turn inwards across the palm of the hand. It descends in front of the abductor indicis, between the metacarpal bone of the thumb and the muscles covering it, to the space between the lower ends of the flexor brevis pollicis. At that point, and beneath the tendon of the long flexor, it divides into two *collateral branches*, which course along the borders of the phalanges, on the palmar aspect, and unite in front of the last phalanx, to form an arch similar in arrangement to that on the other fingers.

(b) The *radial branch for the index finger* generally arises close to the large artery of the thumb; but though constantly found, it varies in size and in its mode of origin. It descends between the abductor indicis and adductor pollicis muscles, and continues along the radial border of the index finger, forming the radial collateral branch of that finger, and anastomosing in the usual manner on the last phalanx with the ulnar collateral branch derived from the superficial palmar arch.

This artery very frequently gives off a communicating branch to the superficial arch, near the lower border of the adductor pollicis. But the most frequent communication between the radial artery and the superficial arch is by means of the small branch which proceeds from the former through the muscles of the thumb.

**PECULIARITIES.—Origin.**—In the observations of Richard Quain, the radial artery was found to arise higher up than usual in nearly one case in eight.

**Course.**—The radial artery more rarely deviates from its usual position along the fore arm than the ulnar.—It has, however, been found lying upon the fibrous expansion from the tendon of the biceps, and over the fascia of the fore arm, instead of beneath those structures. This vessel has been also observed on the surface of the long supinator, instead of on the inner border of that muscle. In turning round the wrist, it has been seen passing over the extensor tendons of the thumb, instead of within them. But these several peculiarities are of very rare occurrence. As was previously stated (p. 387), the vasa aberrantia occasionally derived from the brachial or axillary arteries most commonly end by joining the radial, or one of its branches.

**Branches.**—The *radial recurrent* is sometimes very large, or it may be replaced by several separate branches. When the radial itself arises high up, the recurrent artery usually comes from the residual brachial trunk, or sometimes from the ulnar artery, or more rarely from the interosseous. When given from the brachial trunk, the radial recurrent has been found crossing beneath the tendon of the biceps.

The *superficial volar* branch is small in a considerable number of cases, and is lost in the short muscles of the thumb, without forming any connection with the palmar arch, or with any of the digital arteries.

In some instances in which it is enlarged, it furnishes one or two digital branches, and along with this the anastomosis with the superficial arch may be absent. The superficial volar branch occasionally arises as much as an inch and a half higher than usual.

The *first dorsal interosseous* branch (metacarpal), which descends on the second *interosseous* space to the cleft between the index and middle fingers, is not unfrequently so large as to furnish the collateral digital branch to each of those fingers.

The *carpal* and *interosseous* (metacarpal) branches of the radial are sometimes small, their place being supplied by the perforating offset of the anterior interosseous, apparently by an enlargement of the ordinary anastomosis between them.

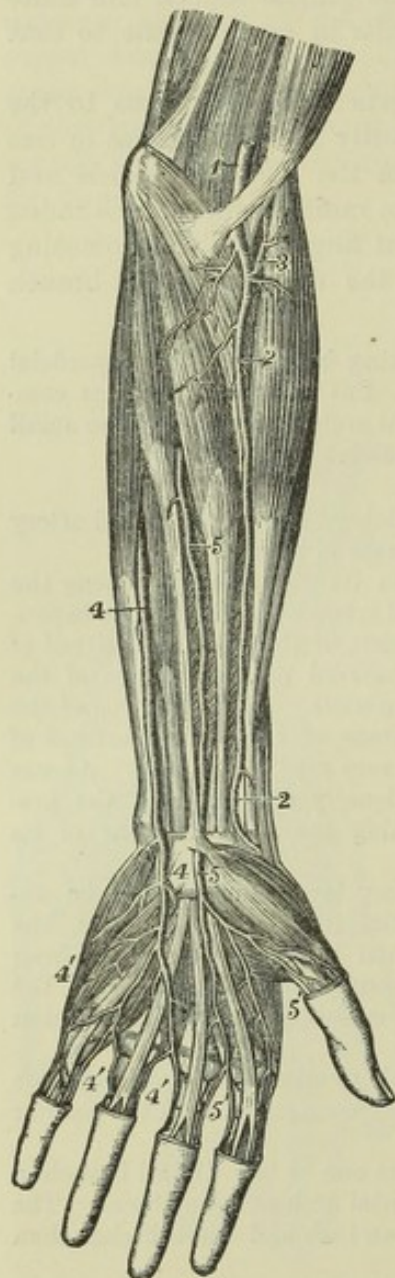


## DEEP PALMAR ARCH.

The deep palmar arch, the continuation of the radial artery, commences at the upper end of the first interosseous space between the heads of the abductor indicis, turns transversely across the palm towards the fourth metacarpal bone, and inosculates with the communicating branch of the ulnar artery. The convexity of the arch thus formed is directed downwards. It rests on the interosseous muscles and on the metacarpal bones immediately below their carpal extremities, and is covered by the flexor brevis pollicis, the flexor tendons of the fingers, and the muscles of the little finger. It is

nearer to the carpus than the superficial arch, and differs from it in retaining its size almost undiminished. It is in part accompanied by the deep branch of the ulnar nerve, which runs from the inner end of the arch outwards.

Fig. 280.



## BRANCHES :—

(a) The *recurrent* branches (*rami retrogradi*, —Haller), from the upper concave side, ascend and anastomose with the branches from the anterior carpal arch.

(b) The *superior perforating* branches, three in number, pass backwards through the upper extremities of the last three interosseous spaces to inosculate with the dorsal interosseous arteries.

(c) The *palmar interosseous* arteries, usually three in number, but very liable to variation, lie in front of the interosseous spaces, supply the muscles there, and anastomose at the clefts of the fingers with the digital branches from the superficial arch.

It is by an enlargement of these small vessels that the deep palmar arch sometimes supplies the corresponding digital arteries in the absence of those usually derived from the superficial arch.

Fig. 280.—DISSECTION OF THE LEFT ARM, SHOWING AN ENLARGED MEDIAN ARTERY WHICH REPLACES THE RADIAL AND ULNAR ARTERIES IN THE SUPPLY OF PALMAR DIGITAL ARTERIES TO HALF THE FINGERS (from Tiedemann).  $\frac{1}{4}$

1, lower part of the brachial artery; 2, radial artery, not giving any superficial volar branch; 3, recurrent radial branch; 4, ulnar artery passing superficially over the wrist and supplying at 4', digital arteries to half the hand; 5, the enlarged median artery passing in front of the annular ligament of the carpus, and supplying 5', digital vessels to the outer half of the hand.

## VARIOUS CONDITIONS OF THE ARTERIES OF THE HAND.

The arteries of the hand frequently vary from their usual mode of distribution.

(a) By far the larger number of deviations consist of a deficiency in either the



radial or ulnar system of arteries, accompanied by a corresponding increase in the other; and it may be observed that the defect is much more commonly on the part of the superficial, and the increase on the part of the deep set.

(b) In a second and smaller class of variations a deficiency in one or other of the two systems is supplied, either by the enlargement of branches which descend in front of the limb, as the superficial volar (from the radial), or the median artery (from the anterior interosseous), or by the enlargement of a metacarpal branch (from the radial) on the back of the hand.

In illustration of these general remarks, the following modes of arrangement of the vessels may be mentioned:—

In the greater number of cases the superficial palmar arch is diminished, and gives off fewer digital branches than usual. Generally only one branch is wanting, viz., that which supplies the adjacent sides of the fore and middle fingers; but sometimes two or three branches are absent, or even all four, as when the ulnar artery, after giving branches to the short muscles of the little finger, ends in the deep palmar arch. In the last-mentioned case, which is rare, it is obvious that the superficial arch is altogether wanting.

These various deficiencies in the superficial palmar arch and its branches are usually compensated for by an enlargement of the deep arch, the palmar interosseous branches of which, being increased in size, divide at the clefts of the fingers, and form such collateral digital branches as are not derived from the usual source. But a defective superficial arch may, as before mentioned, be reinforced from other vessels, viz., from the superficial volar, from an enlarged median artery, or from a large metacarpal branch.

It sometimes, but more rarely, happens, that the radial system of vessels is deficient; in which case the superficial arch (which belongs to the ulnar system) may supply all the digital arteries to the thumb and fingers, or one of these may be derived from the superficial volar, the median, or the radial interosseous artery.

#### DESCENDING AORTA.—THORACIC AORTA.

From the point at which its arch is considered to terminate—the lower margin of the third dorsal vertebra, the aorta descends along the fore part of the spine to the fourth lumbar vertebra, where it divides into the common iliac arteries. The direction of this part of the vessel is not vertical, for as it follows the bend of the spine, upon which it rests, it is necessarily concave forwards in the dorsal region, and convex forwards in the lumbar. Again, as its commencement is at the left side of the bodies of the vertebræ, and its termination also inclined a little to the left, whilst about the last dorsal vertebra the vessel is nearly upon the median line, there is produced another slight curve, the convexity of which is to the right side. Within the thorax, where the offsets are small, the aorta diminishes only slightly in size; in the abdomen the diminution is considerable, in consequence of large branches being furnished to the viscera of that cavity.

That part of the descending aorta which is situated in the thorax, is called the *thoracic aorta*; it extends from the lower border of the third dorsal vertebra on the left side, to the opening between the crura of the diaphragm in front of the last dorsal vertebra. It lies in the back part of the interpleural space or mediastinum, being placed before the spine and behind the root of the left lung and the pericardium; on the left side it is in contact with the corresponding pleura and lung, and close on the right side are the azygos vein, the thoracic duct, and the œsophagus. The œsophagus, however, towards the lower part of the thorax is in front of the artery, and near the diaphragm gets somewhat to the left side. The left or small azygos vein crosses behind the thoracic aorta.

The branches derived from the thoracic aorta are numerous, but small.



They are distributed to the walls of the thorax, and to the viscera contained within it—the latter being much the smaller and least numerous branches.

A. The *branches to the viscera* are very irregular in their number and place of origin. They are as follows :—

The *pericardiac branches* are some very small and irregular vessels which pass forwards and ramify on the pericardium.

THE BRONCHIAL ARTERIES are the proper nutritious arteries of the substance of the lung : they accompany the bronchial tubes in their ramifications through that organ, and they also supply the bronchial glands, and in part the œsophagus. These vessels vary frequently in number, and in their mode of origin. The bronchial artery of the right side arises from the first aortic intercostal artery, or by a common trunk with the left bronchial artery from the thoracic aorta ; on the left side there are generally two bronchial arteries, both of which arise from the thoracic aorta, one near the commencement of that trunk, and the other, named inferior bronchial, lower down. Each artery is usually directed to the back part of the corresponding bronchus, along which it runs, dividing and subdividing with the successive bronchial ramifications in the substance of the lung.

*Peculiarities of the bronchial arteries.*—The place of origin is liable to much variation. The artery of the right side has been found to arise singly from the aorta, from the internal mammary, or from the inferior thyroid. The bronchial arteries of the two sides have been seen to arise by a common trunk from the subclavian. (Haller.) Two common trunks, each furnishing a branch to the right and left lungs, have been observed in a single case to descend into the thorax after arising, one from the internal mammary, and the other from the superior intercostal artery. (R. Quain, pl. 26, f. 5.) Instances occur of two distinct bronchial arteries for each lung.

THE ŒSOPHAGEAL ARTERIES are variable in size and number. There are usually four or five, which arise from the fore part or right side of the aorta, and run obliquely downwards upon the œsophagus, supplying its coats.

Their lower branches anastomose with the ascending offsets of the coronary artery of the stomach, while their upper branches communicate with those of the inferior thyroid artery.

*Posterior mediastinal branches* of the aorta, small and irregular, supply the glands and loose tissue of the posterior mediastinum.

B. The branches furnished by the aorta to the walls of the thorax are named intercostal from their distribution.

THE INTERCOSTAL ARTERIES arise from the posterior part of the aorta, and run outwards upon the bodies of the vertebræ, to reach the intercostal spaces. They are usually ten in number—the upper intercostal space, and occasionally also the second, being supplied by the superior intercostal branch of the subclavian artery. Owing to the position of the aorta to the left side of the spine, the right aortic intercostals cross over the front of the vertebræ, furnishing small branches to their interior, and are longer than the arteries of the left side. The vessels of both sides pass outwards behind the pleura, and are crossed by the sympathetic nerve : those of the right side also pass behind the œsophagus, the thoracic duct, and the azygos vein.

In each intercostal space the artery, passing outwards more horizontally than the ribs, crosses the space obliquely, so as to gain the lower border of the upper rib near its angle. It lies upon the deep surface of the external intercostal muscle, and in the back of the space



is separated from the pleura by a fascia only, but further outwards it lies between the two layers of intercostal muscles. Extending forwards in con-

Fig. 281.—VIEW OF THE THORACIC AND UPPER PART OF THE ABDOMINAL AORTA, &c.  $\frac{1}{4}$

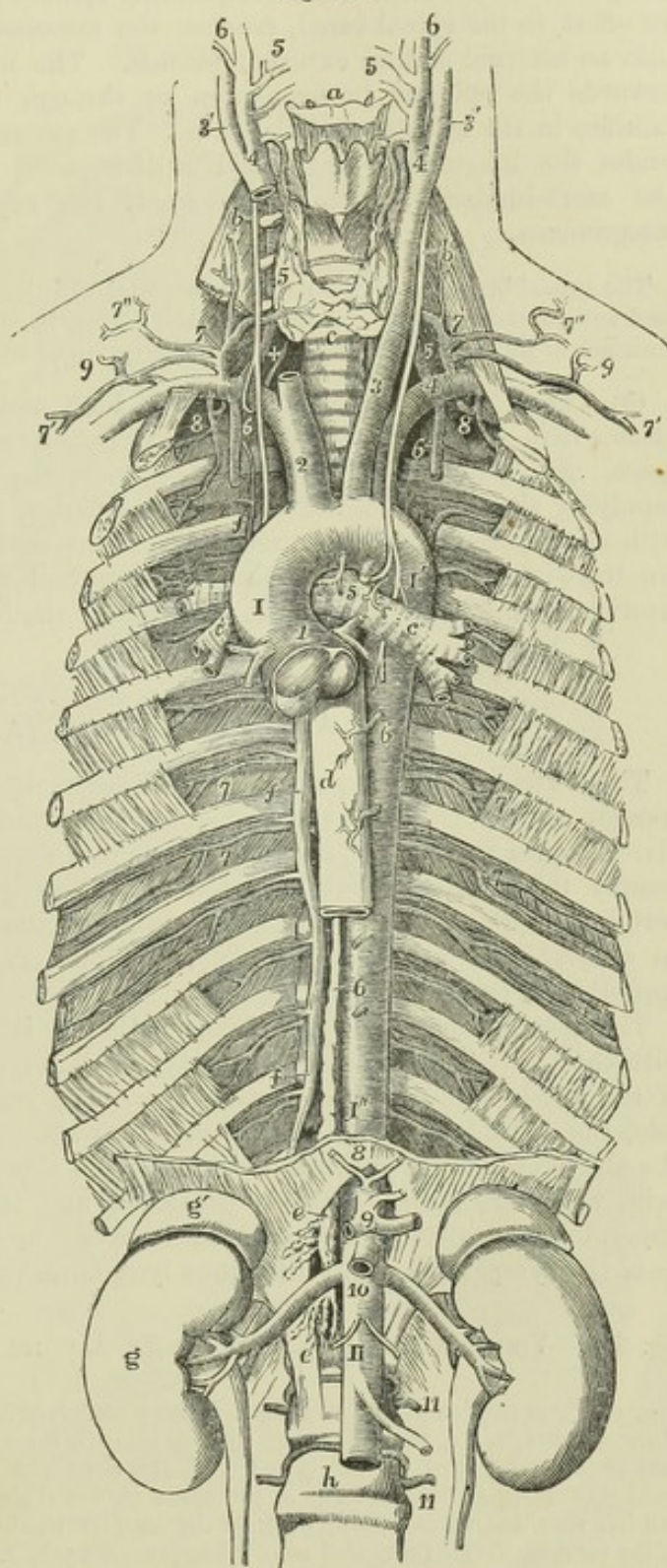
For the general description of this figure, see p. 334. The following numbers indicate the branches of the aorta; 1, placed between the origins of the right and left coronary arteries; 2, innominate; 3, left carotid; 4, left subclavian; 5, bronchial; 6, 6, œsophageal; 7, 7, intercostal arteries (sixth and seventh); 8, inferior phrenic; 9, celiac axis; 10, below the superior mesenteric and opposite the origin of the renal arteries; 11, 11, two of the lumbar arteries.

tact with the rib above, it finally anastomoses with one of the anterior intercostal branches derived from the internal mammary artery, and with the thoracic branches of the axillary artery.

The first of the aortic intercostal arteries has an anastomosis with the superior intercostal proceeding from the subclavian artery; and the last three are prolonged into the abdominal muscles, where they communicate with the epigastric artery in front, with the phrenic arteries at the side, and with the lumbar branches of the abdominal aorta lower down.

Each intercostal artery is accompanied, as it runs outwards between the ribs, by a corresponding vein, and by one of the dorsal nerves; the vein usually being uppermost, and the artery next below it.

Fig. 281.





*Branches.*—The named branches of the intercostal arteries are the following :—

(a) The *posterior or dorsal* branch of each intercostal artery passes backwards to the inner side of the anterior costo-transverse ligament, along with the posterior branch of the corresponding spinal nerve; and having furnished an offset to the spinal canal, reaches the muscles of the back, and divides into an internal and an external branch. The internal branch is directed towards the spinous processes, on or through the multifidus spinæ, and ramifies in the muscles and the skin. The external branch turns outwards under the longissimus dorsi, and is distributed between that muscle and the sacro-lumbalis; some twigs reach the superficial muscles and the integuments.

The *spinal* branches of the aortic intercostal arteries are distributed partly to the cord and its membranes, and partly to the bones, in the same manner as the spinal branches of the lumbar arteries, to the description of which the reader is referred.

(b) The *collateral intercostal* branch, long and slender, arises near the place where the main trunk comes in contact with the upper rib of the space, and inclining downwards approaches the border of the lower rib, supplying the bone and the intercostal muscles, and anastomosing in front with an anterior intercostal branch of the internal mammary artery. There are thus in each intercostal space two terminal branches of the intercostal arteries communicating with the branches of the internal mammary.

### ABDOMINAL AORTA.

The aorta, after having passed the diaphragm, is thus named. It commences on the front of the last dorsal vertebra, and terminates below by dividing into two trunks, named the common iliac arteries. The bifurcation usually takes place about half way down the body of the fourth lumbar vertebra, a little to the left of the middle line; a point which is nearly on a level with a line drawn from the one crista illi to the other, and opposite the left side of the umbilicus.

The anterior surface of the abdominal aorta is successively in apposition with the pancreas and the splenic vein, the left renal vein, the third portion of the duodenum, and the peritoneum. The vena cava lies along its right side, the right crus of the diaphragm being interposed at the upper part of the abdomen; close to the same side are the thoracic duct and the azygos vein, which are placed between the aorta and the right crus of the diaphragm. The aorta is also covered in front by meshes of nerves derived from the sympathetic, and numerous lymphatic vessels and glands.

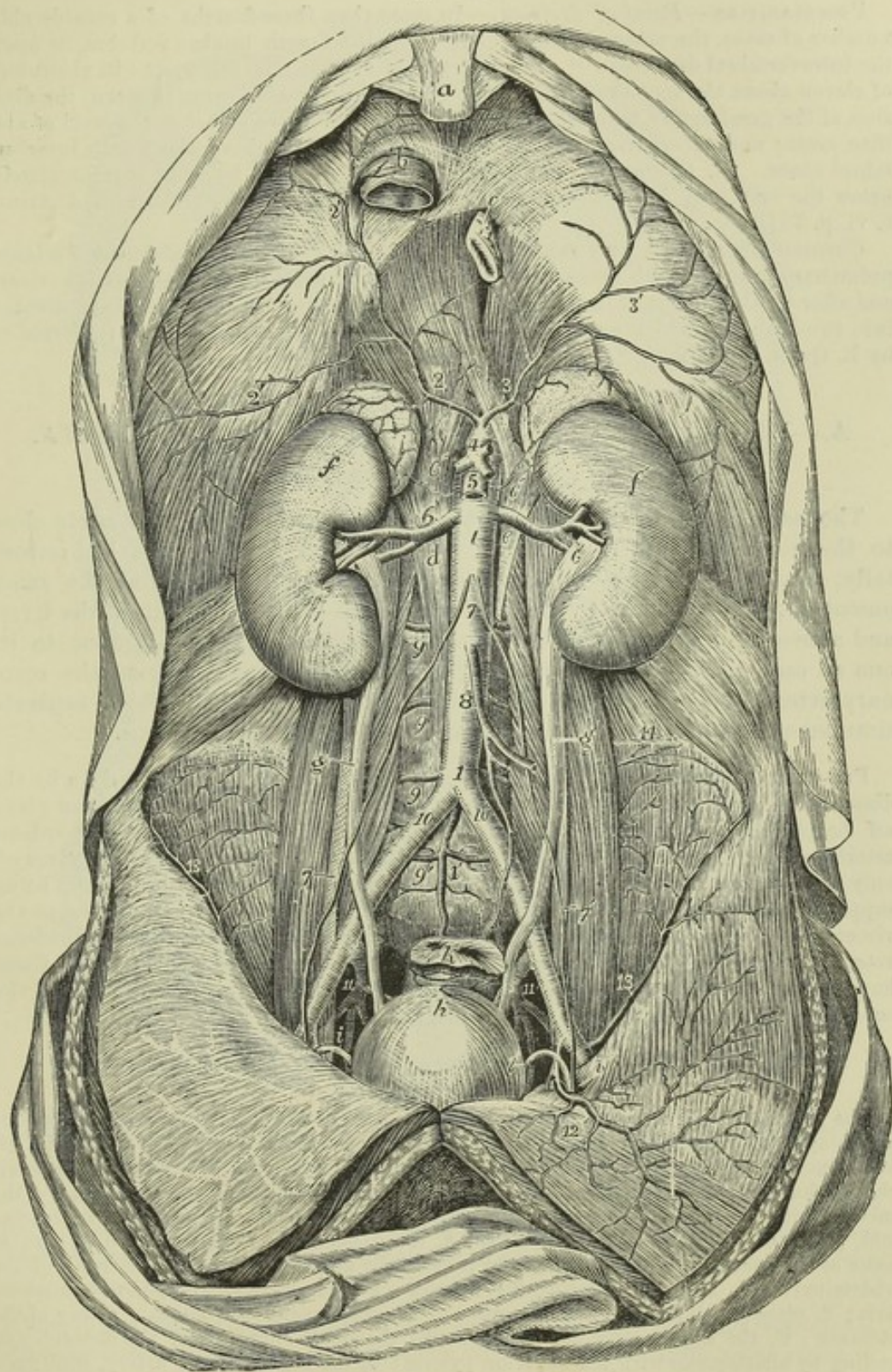
Fig. 282.—VIEW OF THE ABDOMINAL AORTA AND ITS PRINCIPAL BRANCHES (from Tiedemann). 4

*a*, ensiform portion of the sternum; *b*, vena cava inferior passing through the tendon of the diaphragm; *c*, the œsophagus passing through the muscular portion; *d*, tendinous part of the right, *e*, of the left crus; *f*, *f'*, the right and left kidneys with their suprarenal bodies; *g*, *g'*, the ureters; *h*, the upper part of the urinary bladder; *i*, *i*, the right and left vasa deferentia passing up from the bladder to the internal inguinal apertures; *k*, the rectum, divided and tied near its upper part; *1*, *1*, the abdominal aorta; *1'*, the middle sacral artery; *2*, *2'*, the right, *3*, *3'*, the left inferior phrenic arteries, represented as arising by a short common stem from the front of the aorta immediately below the meeting of the crura of the diaphragm; *4*, the trunk of the celiac axis; *5*, the superior mesenteric artery; *6*, *6*, the renal arteries; *6'*, *6'*, the suprarenal arteries arising partly



from the aorta and partly from the inferior phrenic; 7, placed on the front of the aorta below the origin of the spermatic arteries; 7, 7', placed on the psoas muscles, point to the right and left spermatic arteries as they descend to the internal inguinal apertures; 8, inferior mesenteric artery; 9, lumbar arteries, of which the lowest is here represented as proceeding from the middle sacral artery; 10, common iliac arteries; 11, between the external and internal iliac arteries; 12, left epigastric artery; 13, circumflex iliac; 14, branches of the ilio-lumbar.

Fig. 282.





**BRANCHES.**—The abdominal aorta gives numerous branches, which may be divided into two sets, viz., those which supply the viscera, and those which are distributed to the walls of the abdomen. The former consists of the coeliac artery, the superior mesenteric, the inferior mesenteric, the capsular, the renal, and the spermatic arteries; whilst in the latter are included the phrenic, the lumbar, and the middle sacral arteries. The three first of the visceral branches are single arteries.

**PECULIARITIES.**—*Point of division.*—In more than three-fourths of a considerable number of cases, the aorta divided either upon the fourth lumbar vertebra, or upon the intervertebral disc below it; in one case of nine it was below, and in about one of eleven above the spot thus indicated. In ten bodies out of every thirteen, the division of the great artery took place within half an inch above or below the level of the iliac crest; and it occurred more frequently below than above the fourth intervertebral space. (R. Quain, op. cit. p. 415.) An instance of bifurcation immediately below the origin of the right renal artery is recorded by Haller (Disputat. Anatom. t. vi. p. 781).

*Unusual Branch.*—A very remarkable case is recorded of the existence of a large pulmonary branch which arose from the abdominal aorta, close to the coeliac artery, and after passing upwards through the oesophageal opening in the diaphragm, divided into two branches, which were distributed to the lungs near their bases. (Referred to by R. Quain in his work "On the Arteries," p. 416.)

## A.—VISCERAL BRANCHES OF THE ABDOMINAL AORTA.

### I. CELIAC ARTERY OR AXIS.

The *coeliac artery*, a short and wide vessel, arises from the aorta close to the margin of the diaphragm. It is directed forwards nearly horizontally, and is not more than half an inch long. It is behind the small omentum, and lies close to the left side of the lobulus Spigelii of the liver, and above the pancreas, the two semilunar ganglia being contiguous to it, one on each side. This artery divides into three branches, viz., the coronary artery of the stomach, the hepatic and the splenic, which separate simultaneously from the end of the artery like radii from an axis.

**PECULIARITIES.**—The *coeliac axis* is occasionally partly covered at its origin by the diaphragm. It may be longer than usual, in which case its branches are not given off together; or it may be entirely wanting, the coronary, hepatic, and splenic arteries arising separately from the aorta. In some cases the coeliac artery gives off only two branches at its division (the coronary and the splenic), the hepatic being supplied from another source. Rarely, it gives more than three branches to the viscera, the additional vessel being a second coronary, or a separate gastro-duodenal artery. One or both phrenic arteries are sometimes derived from this trunk. Cases have been met with in which a connection existed between the coeliac axis and the superior mesenteric artery close to their origin.

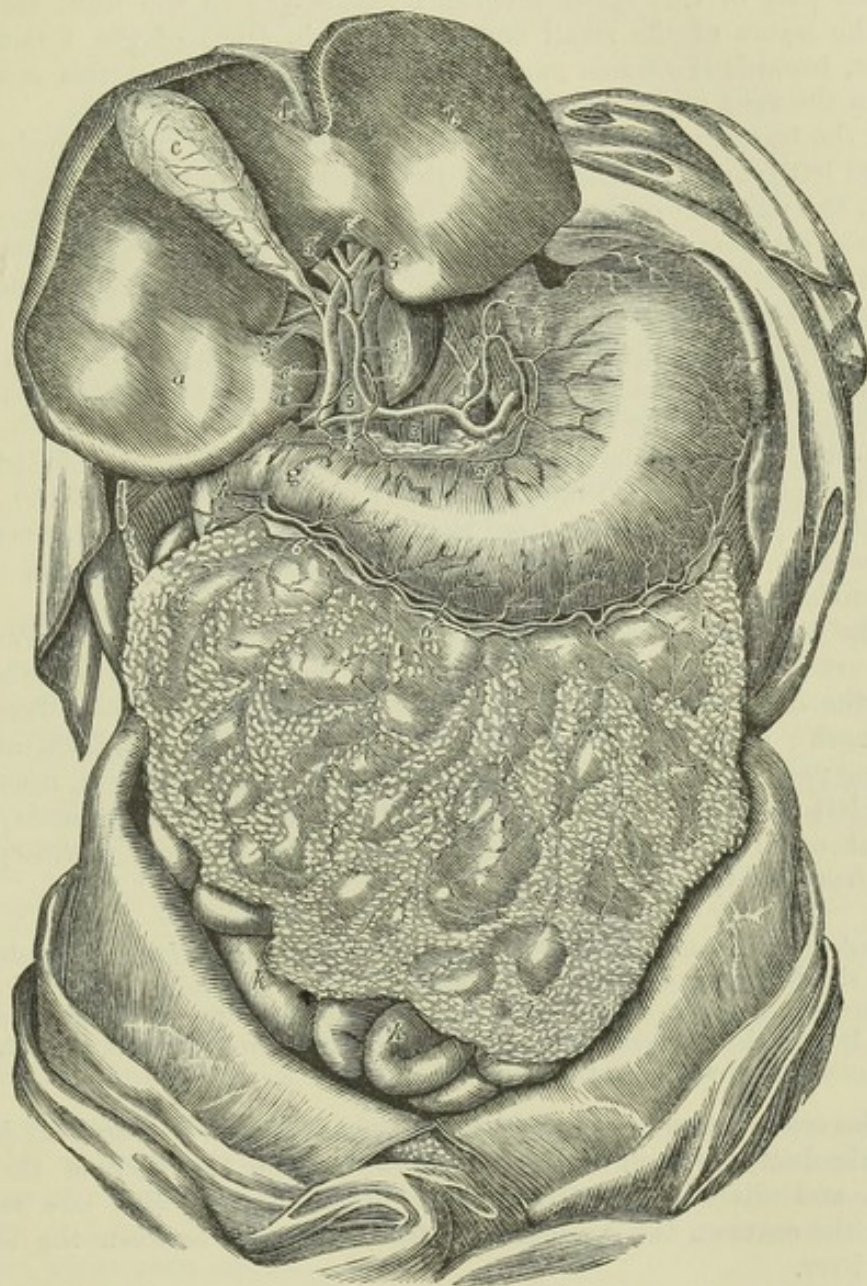
Fig. 283.—THE ARTERIES OF THE STOMACH, LIVER, AND OMENTUM  
(from Tiedemann).  $\frac{1}{2}$

The liver is turned up so as to show its lower surface with the transverse fissure or porta, and the vessels and ducts entering it. *a*, the right lobe of the liver; *b*, the left lobe; *c*, the gall bladder; *c'*, the biliary or hepatic ducts; *c''*, the ductus communis choledochus; *d*, the front of the antero-posterior fissure and the round ligament; *e*, the cardiac orifice of the stomach; *f*, on the great curvature of the stomach near its cardiac end, points to the spleen; *g*, the pylorus; *h*, the duodenum; *i*, the great omentum; *k*, some of the small intestines in the lower part of the abdomen; *l*, upon the trunk of the abdominal aorta, below the root of the inferior phrenic arteries, and above the coeliac axis; *2*, placed on the meeting of the crura of the diaphragm, the coronary artery of the stomach; *2'*, the same artery proceeding round the small curvature of the stomach and ending by anastomosis with the superior pyloric; *3*, the main hepatic artery, continued



at 3' as proper hepatic artery to the liver; 4, superior pyloric artery; 4', another pyloric branch; 5, placed on the main trunk of the vena portæ at the place where the hepatic artery and ductus communis choledochus are in front of it; 5', branches of the vena portæ in the transverse fissure; 6, gastro-duodenal artery; 6', its continuation as the right gastro-epiploic; 7, on the left crus of the diaphragm, the splenic artery; 8, its left gastro-epiploic branch proceeding round the great curvature of the stomach to communicate with the right gastro-epiploic artery; both of these vessels are seen giving long epiploic as well as gastric branches.

Fig. 283.



1. THE CORONARY ARTERY OF THE STOMACH, the smallest of the three visceral branches derived from the celiac artery, inclining upwards and to the left side, reaches the cardiac orifice of the stomach, and then proceeding along the smaller curvature of the stomach, from left to right, gives branches to both sides of that viscus and inosculates with the pyloric branch of the hepatic artery.

Where it first reaches the stomach, this artery sends upwards *oesophageal branches*, which anastomose with the aortic oesophageal arteries. The branches to the stomach,



descending on the fore and back part of the organ, anastomose with branches from the arterial arch on the great curvature.

The coronary artery of the stomach is sometimes given off directly from the aorta : and is occasionally replaced by two separate vessels. It sometimes furnishes an additional hepatic artery.

2. THE HEPATIC ARTERY is in the adult intermediate in size between the coronary and splenic arteries, but, in the foetus, it is the largest of the three. The main part of this vessel inclines upwards and to the right side, between the layers of the small omentum, and in front of the foramen of Winslow, towards the transverse fissure of the liver ; and in this course it lies upon the vena portæ and to the left of the bile duct.

Near the transverse fissure of the liver, the hepatic artery divides into right and left branches, which supply the corresponding lobes of that organ. The *left*, the smaller division, lying in front of the vena portæ, diverges at an acute angle from the other branch, and turns outwards to reach the left extremity of the transverse fissure of the liver, where it enters that organ.

The *right hepatic* artery inclines outwards to the right extremity of the transverse fissure, and divides into two or three branches before entering the liver. The ramifications of the hepatic artery in the liver accompany the divisions of the venæ portæ and hepatic ducts.

BRANCHES.—The named branches of the hepatic artery are as follow :—

(a) The *pyloric* artery, coming in contact with the stomach at the upper border of the pylorus, extends from right to left along the smaller curvature and inosculates with the coronary artery. It is sometimes a branch of the gastro-duodenal.

(b) The *gastro-duodenal* artery, of considerable size, separating from the hepatic artery before that vessel ascends in the small omentum, descends behind the duodenum, near the pylorus, and reaches the lower border of the stomach ; there it gives off the pancreatico-duodenal branch, and its remaining part, which receives the name of right gastro-epiploic, runs from right to left along the great curvature of the stomach, between the layers of the great omentum, and finally inosculates with the left gastro-epiploic derived from the splenic artery.

The *gastro-epiploic* artery gives branches upwards to both surfaces of the stomach, and long slender vessels downwards to the omentum.

The *pancreatico-duodenal* branch descends along the inner margin of the duodenum, between it and the pancreas, and, after furnishing several branches to both these organs, anastomoses with a small offset of the superior mesenteric artery.

(c) The *cystic* artery, given off by the right hepatic when crossing behind the cystic duct, turns upwards and forwards upon the neck of the gall-bladder, and divides into two smaller branches, of which one ramifies between the coats on the depending surface, the other between the bladder and the liver.

PECULIARITIES.—The hepatic artery sometimes arises from the superior mesenteric artery, or from the aorta itself. Accessory hepatic arteries are often met with, usually coming from the coronary artery of the stomach. The hepatic artery has been found to furnish a phrenic branch.

3. THE SPLENIC ARTERY, in the adult the largest branch of the celiac artery, supplies the spleen, and in part the stomach and pancreas. It is directed horizontally towards the left side. Waving and often tortuous in its course, it passes, together with the splenic vein which is below it, behind



the upper border of the pancreas, and divides near the spleen into several branches. The largest of these enter the fissure in that organ, and are distributed to its substance; three or four are reflected towards the bulging end of the stomach, upon which they ramify.

Fig. 284.

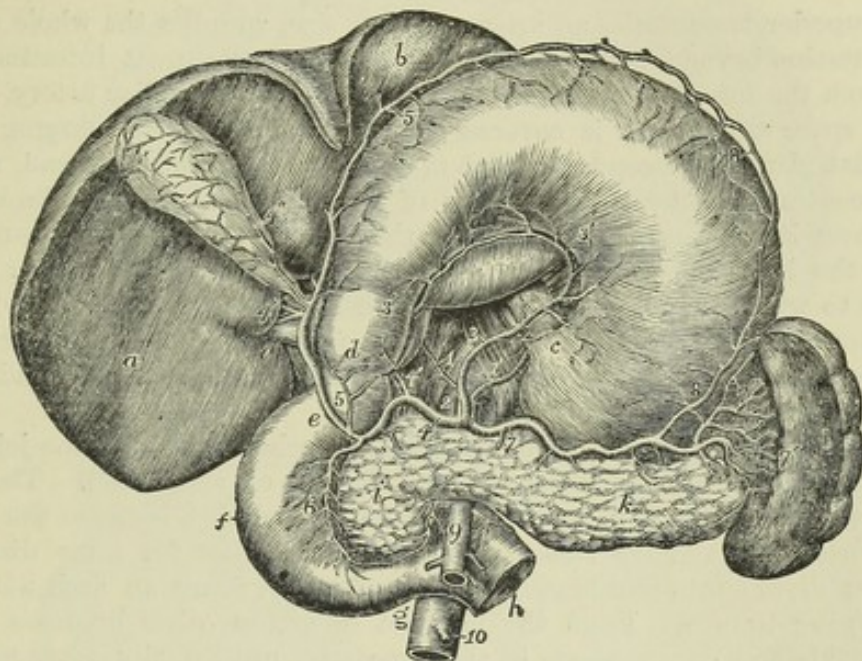


Fig. 284.—THE ARTERIES OF THE STOMACH, DUODENUM, PANCREAS, AND SPLEEN (from Tiedemann).  $\frac{1}{4}$

The stomach and liver are turned upwards so as to show their lower surface. The jejunum is divided at its commencement. *a*, lower surface of the right lobe of the liver; *b*, left lobe; *c*, cardiac orifice of the stomach; *d*, pylorus; *e*, first part, *f*, second or descending part, and *g*, third or lower part of the duodenum; *h*, commencement of the jejunum emerging from behind the superior mesenteric artery; *i*, the head, and *k*, the body of the pancreas; *l*, the spleen; 1, 1, right and left inferior phrenic arteries passing from the aorta upon the crura of the diaphragm; 2, placed on the aorta close to the coeliac axis; 3, 3', the coronary artery; 4, common hepatic; 4', proper hepatic artery; 4'', cystic branch; 5, gastro-duodenal giving the inferior pyloric; 5, on the great curvature of the stomach, the right gastro-epiploic; 6, pancreatico-duodenal; 7, common splenic; 7', proper splenic; 7'', one of the vasa brevia to the stomach; 8, 8, left gastro-epiploic artery uniting with the right on the great curvature of the stomach; 9, trunk of the superior mesenteric artery, giving a small branch to join the pancreatico-duodenal; 10, inferior mesenteric.

**BRANCHES.**—(*a*) *Pancreatic* branches, variable in size and number, are given off whilst the artery is passing along the pancreas, the middle and left part of which they supply with vessels. One of larger size not unfrequently runs from left to right in the direction of the pancreatic duct, and is called *pancreatica magna*.

(*b*) The *splenic* branches are the proper terminal branches of the artery; they are five or six, or even more, in number, and vary in length and size; they enter the spleen by the hilum or fissure in its concave surface, and ramify within that organ.

(*c*) The *short gastric* branches (*vasa brevia*) vary from five to seven in number; they are directed from left to right, some issuing from the trunk of the splenic artery, others from its terminal branches: they reach the left extremity of the stomach, where they divide and spread out between the coats, communicating with the coronary and left gastro-epiploic arteries.



(d) The left *gastro-epiploic* artery runs from left to right along the great curvature of the stomach, supplying branches to both surfaces of the stomach and to the omentum on the left side, and inosculates with the right *gastro-epiploic* branch from the hepatic artery.

## II. SUPERIOR MESENTERIC ARTERY.

The superior mesenteric, an artery of large size, supplies the whole of the small intestine beyond the duodenum, and half of the great intestine. It arises from the fore part of the aorta, a little below the *cœliac* artery. For a short space this artery is covered by the pancreas; on emerging from below that gland it descends in front of the duodenum near the end, and is thence continued between the layers of the mesentery. The splenic vein crosses over its root. In the mesentery the artery at first passes downwards and to the left side, but afterwards turns towards the right iliac fossa, opposite to which it inosculates with its own ileo-colic branch.

BRANCHES.—(a) The *inferior pancreatico-duodenal*, given off under cover of the pancreas, runs along the concave border of the duodenum, and joins with the *pancreatico-duodenal* artery.

(b) The *rami intestini tenuis*, or intestinal branches, supplying the jejunum and ileum, spring from the convex or left side of the vessel. They are usually twelve or more in number, and are all included between the layers of the mesentery. They run parallel to one another for some distance, and then divide into two branches, each of which forms an arch with the neighbouring branch. From the first set of arches other branches issue, which divide and communicate in the same way, until finally, after forming four or five such tiers of arches, each smaller than the other, the ultimate divisions of the vessels proceed directly to the intestine, spreading upon both sides, and ramifying in its coats.

(c) The *colic* branches arise from the right or concave side of the artery, and are three in number.

1. The *ileo-colic* artery, the first in order from below upwards, inclines downwards and to the right side, towards the ileo-colic valve, near which it divides into two branches: one of these descends to inosculate with the termination of the mesenteric artery itself, and to form an arch, from the convexity of which branches proceed to supply the junction of the small with the large intestine, and the *cæcum* and its appendix; the other division ascends and inosculates with the next mentioned branch. The ileo-colic artery is not always distinct from the termination of the superior mesenteric.

2. The *right colic* artery passes transversely towards the right side, beneath the peritoneum, to the middle of the ascending colon, opposite to which it divides into two branches, of which one descends to communicate with the ileo-colic artery, whilst the other ascends to join in an arch with the middle colic. This artery and the ileo-colic often arise by a common trunk.

3. The *middle colic* artery passes upwards between the layers of the meso-colon towards the transverse colon, and divides in a manner exactly similar to that of the vessels just noticed. One of its branches inclines to the right, where it inosculates with the preceding vessel; the other descends to the left side, and maintains a similar communication with the left colic branch, derived from the inferior mesenteric artery. From the arches of inosculations thus formed, small branches pass to the colon for the supply of its coats.



Those branches of the superior mesenteric artery which supply the ascend-

Fig. 285.

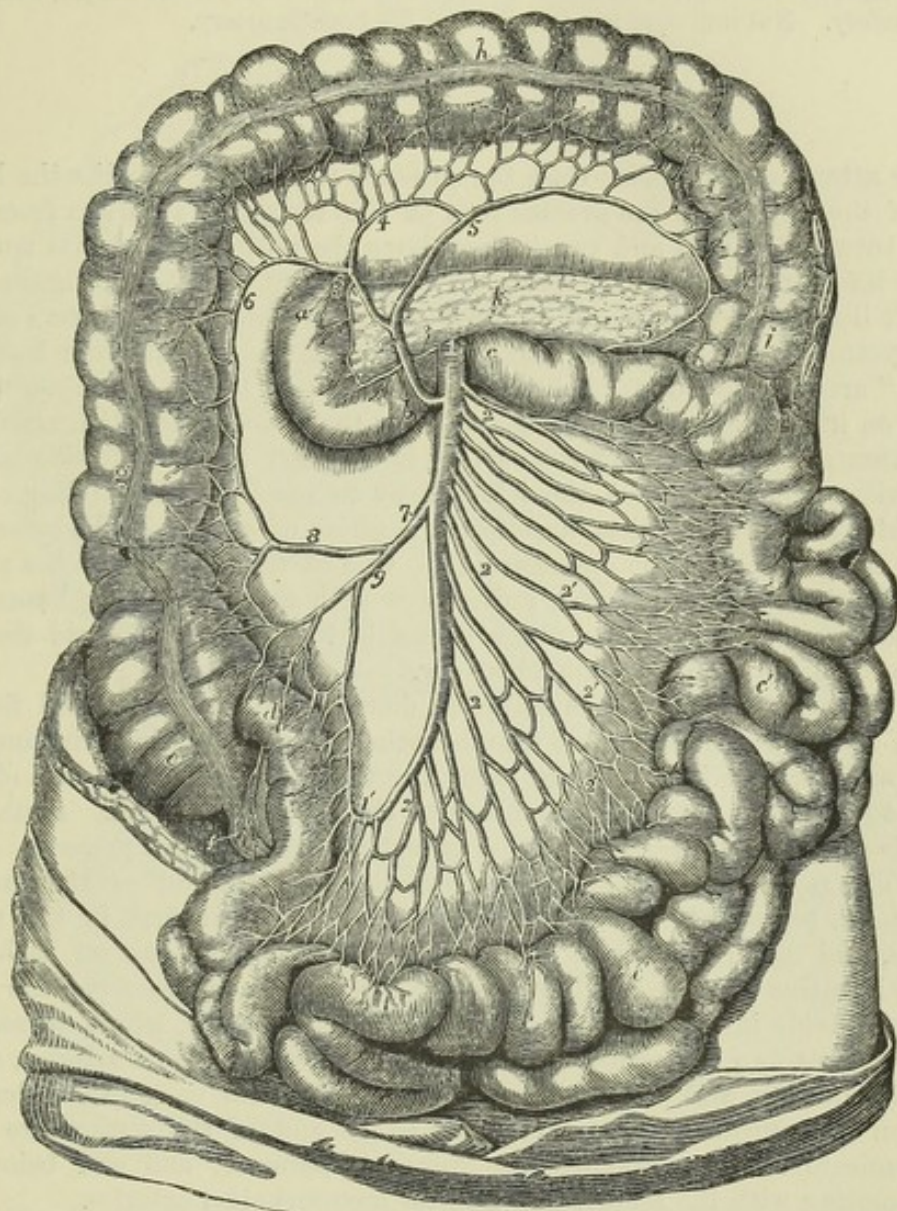


Fig. 285.—THE SUPERIOR MESENTERIC ARTERY, AND ITS BRANCHES  
(from Tiedemann).  $\frac{1}{4}$

The transverse arch of the colon is turned upwards; the transverse meso-colon is dissected so as to expose the duodenum and pancreas at its root; the small intestines are thrown towards the left side; *a*, the descending part of the duodenum; *b*, the lower part before it passes behind the superior mesenteric artery and root of the mesentery; *c*, the commencement of the jejunum to the left of the root of the mesentery; *c'*, *c'*, the jejunum and ileum; *d*, the termination of the ileum in the caput caecum coli; *e*, the caecum; *f*, the vermiform process; *g*, the ascending colon; *h*, the transverse arch; *i*, the descending colon; *k*, the pancreas; *l*, the trunk of the superior mesenteric artery; *l'*, the termination of that vessel where it loops round into a branch of the ileo-colic artery; *2*, *2*, *2*, *2*, the intestinal branches; *2'*, *2'*, *2'*, several of their loops in the mesentery; *3*, small pancreatico-duodenal branch passing to *3'*, to unite with the branch from the gastroduodenal; *4*, the middle colic branch; *5*, its left colic branch passing at *5'* to unite with the branch of the left colic of the inferior mesenteric; *6*, right branch; *7*, right colic and ileo-colic arteries in one trunk; *8*, right colic, uniting by a loop with the middle colic; *9*, the ileo-colic, uniting with the end of the superior mesenteric artery.



ing colon have a layer of peritoneum only on their anterior aspect : the others lie between two strata.

The superior mesenteric artery is occasionally connected at its origin with the coeliac artery. Not unfrequently it furnishes the hepatic artery.

### III. INFERIOR MESENTERIC ARTERY.

This artery, much smaller than the superior mesenteric, supplies the lower half of the colon, and the greater part of the rectum. It arises from the aorta, between an inch and two inches above the bifurcation of that trunk.

The inferior mesenteric artery inclines to the left side in the direction of the left iliac fossa, from which point it descends between the layers of the meso-rectum into the pelvis, and under the name of "superior hæmorrhoidal" artery, runs down behind the rectum. It lies at first close to the aorta, on its left side, and then crosses over the left common iliac artery.

BRANCHES.—(a). The *left colic* artery is directed to the left side behind the peritoneum, and across the left kidney to reach the descending colon. It divides into two branches, and forms a series of arches in the same way as the colic vessels of the opposite side. One of these two branches passes upwards along the colon, and inosculates with the descending branch of the middle colic ; whilst the other descends towards the sigmoid flexure, and anastomoses with the sigmoid artery.

(b) The *sigmoid* artery runs obliquely downwards to the sigmoid flexure of the colon, where it divides into branches ; some of which incline upwards and form arches with the preceding vessel, while others turn downwards to the rectum and anastomose with the following branch. Instead of a single sigmoid artery, two or three branches are sometimes present.

(c) The *superior hæmorrhoidal* artery, the continuation of the inferior mesenteric, passes into the pelvis behind the rectum, at first in the meso-rectum, and then divides into two branches which extend one on each side of the intestine towards the lower end. About five inches from the anus these subdivide into branches, about a line in diameter, which pierce the muscular coat two inches lower down. In the intestine, these arteries, about seven in number, and placed at regular distances from each other, descend between the mucous and muscular coats to the end of the gut, where they communicate in loops opposite the internal sphincter, and end below by anastomosing with the middle and inferior hæmorrhoidal arteries.

ANASTOMOSES ON THE INTESTINAL TUBE.—The arteries distributed to the alimentary canal communicate freely with each other over the whole length of that tube. The arteries of the great intestine derived from the two mesenteric arteries, form a range of vascular arches along the colon and rectum, at the lower end of which they anastomose with the middle and inferior hæmorrhoidal arteries, given from the internal iliac and pudic arteries. The branches from the left side of the superior mesenteric form another series of arches along the small intestine, which is connected with the former by the ileo-colic artery. Farther, a branch of the superior mesenteric joins upon the duodenum with the pancreatico-duodenal artery. The latter, at its commencement, is in a manner continuous with the pyloric artery ; and so likewise, through the coronary artery of the stomach and its ascending branches, a similar connection is formed with the œsophageal arteries, even up to the pharynx.



Fig. 286.

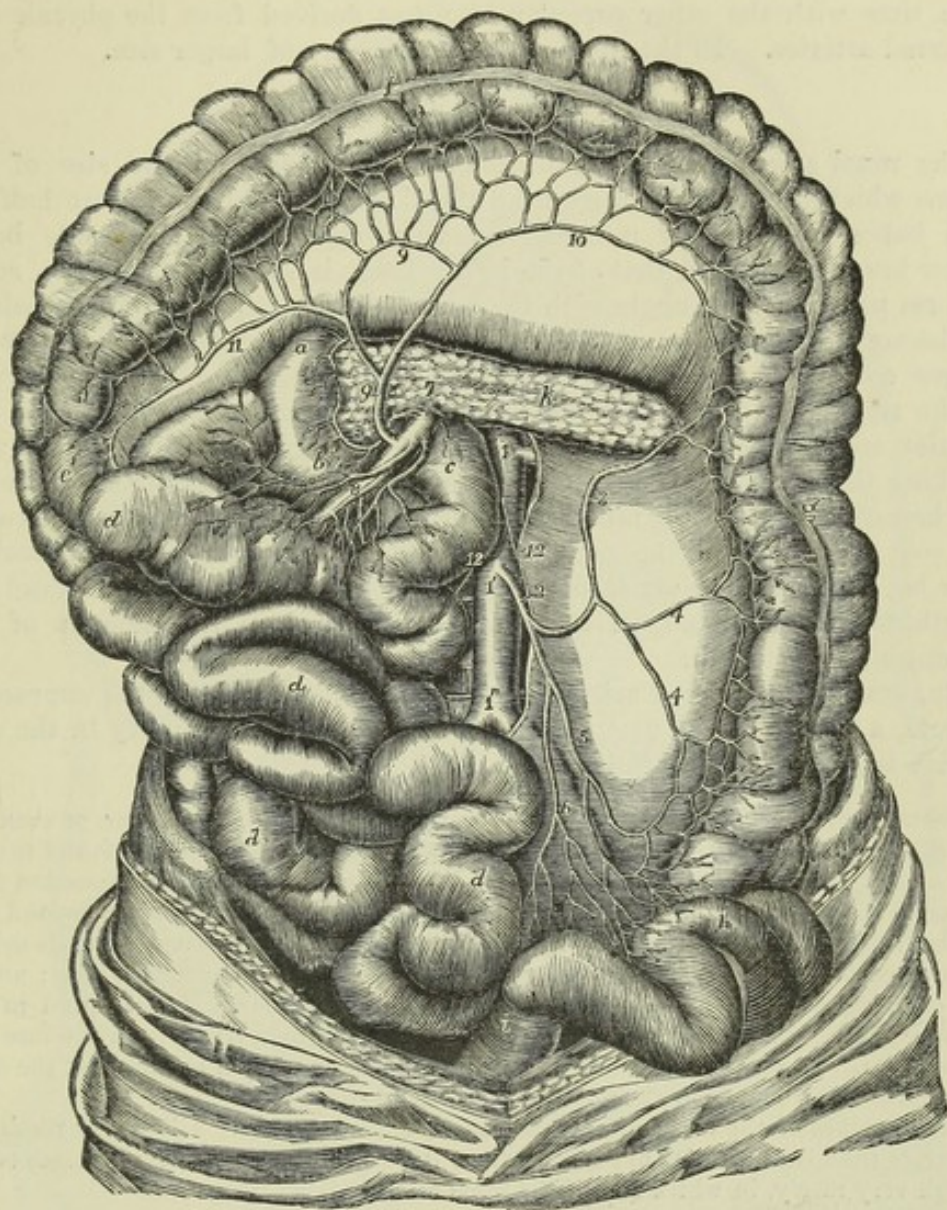


Fig. 286.—THE INFERIOR MESENTERIC ARTERY WITH ITS DISTRIBUTION AND COMMUNICATIONS (from Tiedemann). 4

The small intestines with the superior mesenteric artery are turned towards the right side, the pancreas is exposed, and the large intestine is stretched out: *a, b*, the duodenum; *c*, the commencement of the jejunum; *d*, the small intestine; *e*, the ascending colon; *f*, the transverse colon; *g*, the descending colon; *h*, the sigmoid flexure; *i*, the commencement of the rectum; *k*, the pancreas; *1*, placed on the trunk of the abdominal aorta at the origin of the renal arteries; *1'*, on the same at the origin of the inferior mesenteric; *1''*, near the division into common iliac arteries; *2*, inferior mesenteric, giving off first the left colic; *3*, ascending branch of the left colic; *4*, branches to the descending colon; *5*, the sigmoid branch; *6*, the superior hæmorrhoidal branch; *7*, the trunk of the superior mesenteric issuing from behind the pancreas; *8*, some of its intestinal branches; *9*, the middle colic artery; *10*, its left branch forming a loop of communication with the left colic; *11*, its right branch; *12*, the spermatic arteries.

#### IV. CAPSULAR OR SUPRARENAL ARTERIES.

The suprarenal or capsular arteries are two very small vessels which arise from the aorta on a level with the superior mesenteric artery, and incline



obliquely outwards upon the crura of the diaphragm to reach the suprarenal capsules, to which bodies they are distributed, anastomosing at the same time with the other capsular branches derived from the phrenic and the renal arteries. In the foetus these arteries are of larger size.

#### V. RENAL OR EMULGENT ARTERIES.

The renal arteries, of large diameter in proportion to the size of the organs which they supply, arise from the sides of the aorta, about half an inch below the superior mesenteric artery, that of the right side being rather lower down than that of the left. Each is directed outwards, so as to form nearly a right angle with the aorta. In consequence of the position of the aorta upon the spine, the right renal artery has to run a somewhat longer course than the left, in order to reach the kidney. The artery of the right side crosses behind the vena cava, and both right and left arteries are overlapped by the accompanying renal veins. Previously to reaching the concave border of the kidney, each artery divides into four or five branches, the greater number of which usually lie intermediate between the vein in front and the pelvis of the kidney behind. These branches, after having passed deeply into the fissure of the kidney, subdivide and are distributed in the gland, in the manner described in the account of the structure of that organ.

BRANCHES.—The renal artery furnishes a small branch to the suprarenal capsule, a second to the ureter, and several others which ramify in the connective tissue and fat behind the kidney.

PECULIARITIES.—The renal artery may be replaced by two, three, four, or even five branches; and the greatest difference as to the origin of these vessels is found to exist even on opposite sides of the same body. As they usually arise in succession from the aorta itself, it would seem as if the deviation were merely a degree beyond that in which the single artery divides into branches sooner than usual after its origin. In some cases a renal artery has been seen to proceed from the common iliac; and in one case, described by Eustachius, from the internal iliac. Portal found in one instance the right and left renal arteries arising by a common trunk from the fore part of the aorta. In another case, one of several arteries arose from the front of the aorta at its bifurcation; or from the left common iliac at its origin.

The branches of the renal artery, instead of entering at the hilus, may reach and penetrate the gland near its upper end, or on its anterior surface. Lastly, cases occur, though very rarely, in which one of the renal arteries is wanting.

#### VI. SPERMATIC AND OVARIAN ARTERIES.

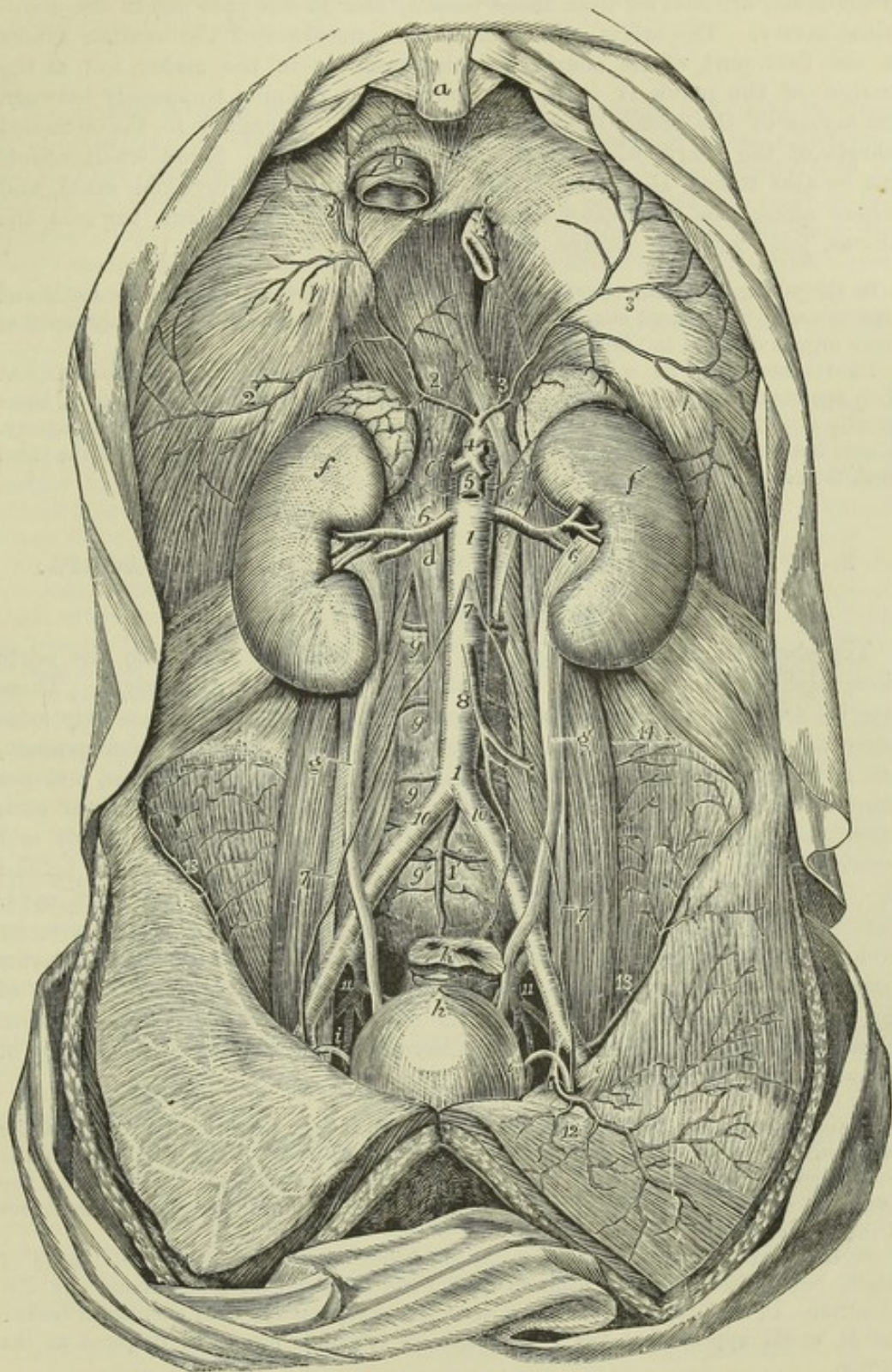
The spermatic arteries, two small and very long vessels, arise close together from the fore part of the aorta a little below the renal arteries. Each artery is directed downwards and outwards, resting on the psoas muscle; it crosses obliquely the ureter and, afterwards, the external iliac artery, and turns forward to the internal abdominal ring. There it comes in contact with the vas deferens, and, separating from the peritoneum, passes with the other constituents of the spermatic cord along the inguinal canal, and descends to the scrotum, where it becomes tortuous, and reaching the back part of the testis anastomoses with the artery of the vas deferens, and finally divides into branches which pierce the fibrous capsule of the testis.

Fig. 287.—VIEW OF THE ABDOMINAL AORTA AND ITS PRINCIPAL BRANCHES  
(from Tiedemann). 4

For the detailed description of this figure see p. 404; 6, renal arteries; 6', 6', suprarenal arteries arising from the aorta; other suprarenal arteries are seen proceeding



Fig. 287.



from the inferior phrenic; 7, placed on the abdominal aorta below the origin of the spermatic arteries; 7, 7', lower down the same arteries descending on the psoas muscles and crossing the ureters, that on the left side entering the internal inguinal aperture along with the vas deferens (*i*); 8, inferior mesenteric artery; 9, lumbar arteries; 9', the lowest lumbar artery rising in this instance from the middle sacral (1'); 10, 10', right and left common iliac arteries; 11, 11, placed between the external and internal iliac arteries on each side; 12, left epigastric artery; 13, circumflex iliac artery.



In the female, the *ovarian* arteries, corresponding to the *spermatic* arteries in the male, are shorter than these vessels, and do not pass out of the abdominal cavity. The origin, direction, and connections of the ovarian artery in the first part of its course are the same as in the male; but at the margin of the pelvis it inclines inwards, and running tortuously between the layers of the broad ligament of the uterus, is guided to the attached margin of the ovary, which it supplies with branches. Some small offsets can be also traced along the round ligament into the inguinal canal, and others along the Fallopian tube: one, continuing inwards towards the uterus, joins with the uterine artery.

In the young foetus the *spermatic* and *ovarian* arteries are short, as the testes and ovaries are at first placed close to the kidneys, but the arteries become lengthened as these organs descend to their ultimate positions.

PECULIARITIES.—The *spermatic* arteries occasionally arise by a common trunk. Two *spermatic* arteries are not unfrequently met with on one side; both of these usually arise from the aorta, though sometimes one is a branch from the renal artery. A case has occurred of three arteries on one side,—two from the aorta and the third from the renal.

## B.—PARIETAL BRANCHES OF THE ABDOMINAL AORTA.

### I. INFERIOR PHRENIC ARTERIES.

The *phrenic* arteries are two small vessels, which spring from the aorta close together on a level with the under surface of the diaphragm. These arteries are, however, somewhat irregular in their origin. When they arise separately from each other, which is by no means a constant arrangement, one is frequently derived from the *coeliac* artery close to the origin, and the other from the aorta immediately above. They soon diverge from each other, and passing across the crura of the diaphragm, incline upwards and outwards upon its under surface; the artery of the left side passing behind the *oesophagus*, whilst that of the right side passes behind the *vena cava*. Before reaching the central tendon of the diaphragm, each of the arteries divides into two branches, of which one runs forwards towards the anterior margin of the thorax, and anastomoses with the *musculo-phrenic* branch of the *internal mammary* artery, while the other pursues a transverse direction towards the side of the thorax, and communicates with the terminations of the *intercostal* arteries.

BRANCHES.—Each *phrenic* artery gives small branches (*superior capsular*) to the *suprarenal* capsule of its own side; the left artery sends some branches to the *oesophagus*, whilst the artery of the right side gives off small vessels, which reach the termination of the *vena cava*. Small offsets descend to the liver between the layers of the *peritoneum*.

PECULIARITIES.—The *phrenic* arteries are found to vary greatly in their mode of origin, but these deviations seem to have little influence on their course and distribution. In the first place they may arise either separately, or by a common trunk: and it would appear that the latter mode of origin is nearly as frequent as the former.

When the two arteries are joined at their origin, the common trunk arises most frequently from the aorta; though, sometimes, it springs from the *coeliac* axis.

When arising separately, the *phrenic* arteries are given off sometimes from the aorta, more frequently from the *coeliac* axis, and occasionally from the renal; but it most commonly happens that the artery of the right side is derived from one, and that of the left side from another of these sources. An additional *phrenic* artery (derived from the left *hepatic*) has been met with.



In only one out of thirty-six cases observed by R. Quain did the phrenic arteries arise in the mode ordinarily described; viz., as two separate vessels from the abdominal aorta. (Op. cit. p. 417.)

## II. LUMBAR ARTERIES.

The lumbar arteries resemble the intercostal arteries, not only in their mode of origin, but also in a great measure in the manner of their distribution. They arise from the back part of the aorta, and are usually four in number on each side. They pass outwards, each resting on the body of the corresponding lumbar vertebra, from the first to the fourth, and soon dip deeply under the psoas muscle. The two upper arteries are likewise under the pillars of the diaphragm; and those on the right side are covered by the vena cava. At the interval between the transverse processes, each lumbar artery divides into a *dorsal* and an *abdominal* branch.

BRANCHES.—(a) The *abdominal* branch of each lumbar artery runs outwards behind the quadratus lumborum,—the lowest of these branches not unfrequently in front of that muscle. Continuing outwards between the abdominal muscles, the artery ramifies in their substance, and maintains communications with branches of the epigastric and internal mammary in front, with the terminal branches of the intercostals above, and with those of the ilio-lumbar and circumflex iliac arteries below.

(b) The *dorsal* branch of each lumbar artery, like the corresponding branch of the intercostal arteries, gives off, immediately after its origin, an offset, named *spinal*, which enters the spinal canal. The dorsal branch then, proceeding backwards with the posterior primary branch of the corresponding lumbar nerve between the transverse processes of the vertebræ, divides into smaller vessels, which are distributed to the muscles and integuments of the back.

(c) The *spinal branch* enters the spinal canal through the intervertebral foramen, and, having given an offset which runs along the nerves to the dura mater and cauda equina, it communicates with the other spinal arteries, and divides into two branches, which are distributed to the bones in the following manner:—one curves upwards on the back part of the body of the vertebra above, near to the root of the pedicle, whilst the other descends in a similar manner on the vertebra below; and each communicates with a corresponding branch from the neighbouring spinal artery. As this arrangement prevails on both sides and throughout the whole length of the spine, there is formed a double series of arterial arches behind the bodies of the vertebræ, the convexities of which are turned towards each other. From the arches on opposite sides offsets are directed inwards at intervals to reinforce a median longitudinal vessel, which extends along the spine like the single artery on the front of the spinal cord. The arches are moreover joined together across the bodies of the vertebræ by transverse branches.

From this interlacement of vessels, numerous ramifications are distributed to the periosteum and the bones.

PECULIARITIES.—The *lumbar* arteries of opposite sides, instead of taking their origin separately from the aorta, occasionally commence by a common trunk, whose branches pass out laterally, and continue their course in the ordinary way. Two arteries of the same side are sometimes conjoined at their origin. On the last lumbar vertebra, the place of a lumbar artery is often taken by a branch from the middle sacral artery, and the ilio-lumbar compensates for the absence of the lumbar vessel amongst the muscles.

## MINUTE ANASTOMOSES OF THE VISCERAL AND PARIETAL BRANCHES OF THE ABDOMINAL AORTA.

The existence of minute anastomoses between some of the visceral branches of the abdominal aorta and those supplying the walls of the cavity has been recognised by several anatomists, and various examples have been noticed in the previous description. These communications have recently been more distinctly proved and their nature elucidated by W. Turner in a series of experimental injections, made with a view to their detection. ("Brit. and For. Med. Chirug. Review," July, 1863.)



These anastomoses constitute a well-marked vascular plexus, situated in the sub-peritoneal tissue, whence Turner proposes to call them the *sub-peritoneal arterial plexus*. It occupies the lumbar region from the diaphragm downwards into the iliac regions and pelvis, and establishes communication between the parietal vessels and those of the viscera, chiefly, though not exclusively, through branches of the arteries of those viscera which are situated behind the peritoneum. It belongs to the renal and suprarenal arteries, those of the pancreas and duodenum, the cæcum, and the ascending and descending parts of the colon. It extends also to the vessels of the rectum, and to the spermatic arteries in their descent through the abdomen, and into the inguinal canal and scrotum.

In all these situations it was found that the injected material (coloured gelatine) when thrown into the vessels of the viscus, so as to fill them completely, extended through the subperitoneal plexus in various ways, so as to reach one or other set of parietal vessels, such as the lumbar, ilio-lumbar, circumflex iliac, lower intercostal and epigastric arteries; and in the pelvis, the middle and lateral sacral arteries; and in the scrotum, the superficial pudic and perineal arteries.

The more direct inosculation of the hæmorrhoidal arteries on the rectum with the inferior hæmorrhoidal branches of the pudic artery are well known, and the importance of these and other similar anastomoses, as well as the more extensive and minute anastomosing plexus investigated by Turner, is obvious, with reference not merely to the nutrition of the subperitoneal tissue, but also to the debated question of the influence exerted by local superficial blood-letting on the state of the vessels of the deeper viscera.

### III. MIDDLE SACRAL ARTERY.

The middle sacral artery, the last of the branches of the abdominal aorta, is a small vessel of about the size of a crowquill, which arises from the extremity of the aorta just at the bifurcation. From this point the artery proceeds downwards upon the last lumbar vertebra and over the middle of the sacrum, as far as the coccyx, where it forms small arches of anastomosis with the lateral sacral arteries.

BRANCHES.—From its anterior surface some small branches come forward within the fold of the meso-rectum, and ramify upon the posterior surface of the intestine; and on each side others spread out upon the sacrum, and anastomose with the lateral sacral arteries, occasionally sending small offsets into the anterior sacral foramina.

The middle sacral artery sometimes deviates a little to the side, and proceeds, not from the bifurcation of the aorta, but from one of the common iliac arteries, usually from that of the left side. This artery represents the caudal prolongation of the aorta of animals.

### COMMON ILIAC ARTERIES.

The common iliac arteries, commencing at the bifurcation of the aorta, pass downwards and outwards, diverging from each other, and divide opposite the lumbo-sacral articulation into the internal and external iliac arteries.

The common iliac arteries measure usually about two inches in length. Both are covered by the peritoneum and the intestines, and are crossed by the ureters near their point of division, as well as by the branches of the sympathetic nerve which are directed towards the hypogastric plexus. They rest on the bodies of the vertebræ, and come into contact with the psoas muscles.

The common iliac artery of the right side is separated from the front of the last lumbar vertebra, the two common iliac veins being interposed. The artery of the left side is crossed by the branches of the inferior mesenteric vessels.

*Relation to Veins.*—The left iliac vein, supported on the last lumbar

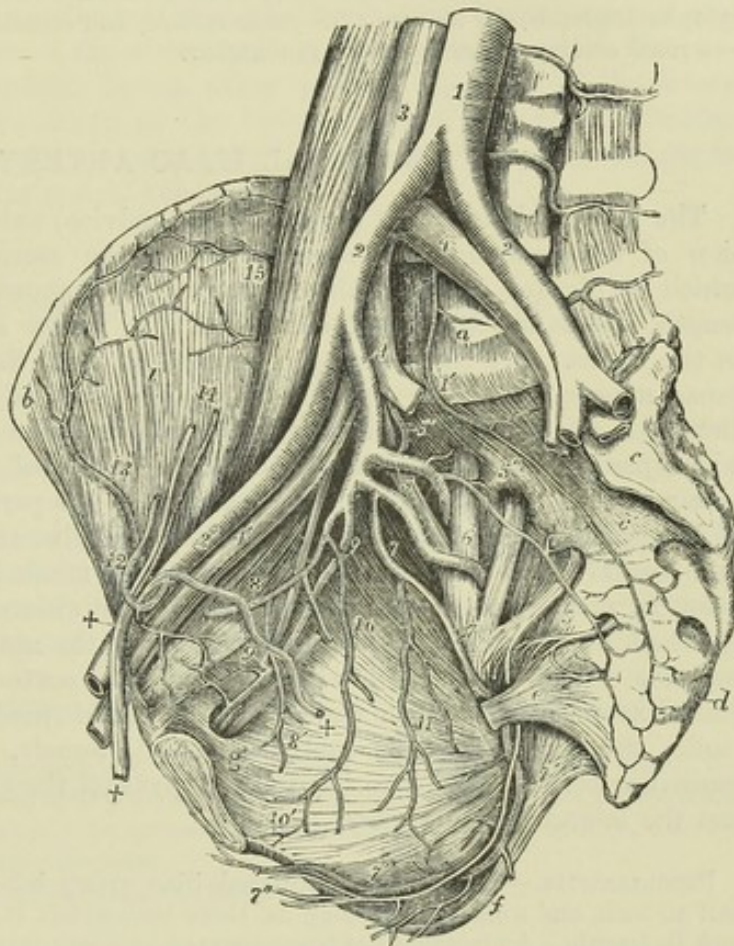


vertebra, lies to the inner side of, and below the left artery. On the right side there are three veins in proximity to the artery; the right iliac vein lying behind the lower part of the vessel, the left iliac vein crossing behind it, and the vena cava resulting from the union of the two others being on the right side of the artery at the upper end.

**PECULIARITIES.**—*The place of origin of the common iliac arteries coincides with that of the bifurcation of the aorta (p. 406).*

Fig. 288.—VIEW OF THE RIGHT SIDE OF A MALE PELVIS DISSECTED TO SHOW THE EXTERNAL AND INTERNAL ILIAC ARTERIES AND THEIR BRANCHES.  $\frac{1}{2}$

Fig. 288.



The viscera of the pelvis have been removed as well as the internal iliac veins: the larger nerves have been retained. *a*, body of the fifth lumbar vertebra; *b*, anterior and superior spine of the right ilium; *c*, left auricular surface of the sacrum; *c'*, third piece of the sacrum; *d*, first piece of the coccyx; *e*, short sacro-sciatic ligament; *f*, tuberosity of the ischium covered internally by the great sacro-sciatic ligament; *g*, obturator foramen; *i*, iliacus muscle; *1*, lower part of the abdominal aorta; *1'*, middle sacral artery; *2*, *2*, common iliac arteries; *2'*, right external iliac; *3*, lower part of the vena cava inferior; *4*, *4*, common iliac veins; the number on the right points by a line to the right internal iliac artery; *4'*, right external iliac vein; *5*, placed on the ilio-lumbar nervous trunk, points to the posterior division of the internal iliac artery giving off the gluteal; *5'*, ilio-lumbar artery; *5''*, lateral sacral artery with branches passing into the anterior sacral foramina; *6*, placed on the anterior division of the first sacral nerve, points to the sciatic artery coming from the anterior division of the internal iliac; *7*, pudic artery; *7'*, the same artery passing behind the spine of the ischium, and proceeding within the ischium and obturator internus muscle, accompanied by the pudic nerve towards the perinæum; towards *f*, inferior hæmorrhoidal branches are given off; *7''*, superficial perineal artery and nerve; *8*, hypogastric artery, with the obliterated remains of the umbilical artery cut short, and *8'*, superior vesical branches rising from it; *9*, obturator artery with the corresponding nerve and vein; *9'*, the pubic twigs which anastomose with descending twigs of the epigastric artery, and from which, by the enlargement of one of them, the aberrant obturator artery may proceed; *10*, inferior vesical; *11*, middle hæmorrhoidal vessels rising in this instance from the pudic; *12*, epigastric artery winding to the inside of +, +, the vas deferens and spermatic cord; *13*, circumflex iliac artery; *14*, spermatic artery and vein divided superiorly; *15*, twigs of the ilio-lumbar artery proceeding to anastomose with the circumflex iliac.



*The place of division* of these arteries is subject to great variety. In two thirds of a large number of cases, it ranged between the middle of the last lumbar vertebra and the upper margin of the sacrum; in one case out of eight it was above, and in one case out of six it was below that space. Most frequently the left artery was found to divide lower down than the right. (R. Quain.)

*The length* varies in most instances between an inch and a half and three inches, but it has been seen in some rare cases less than half an inch, and as long as four inches and a half. In one instance, recorded by Cruveilhier, ("Anat. descript." v. iii. p. 186,) the right common iliac artery was wanting, and the internal and external vessels of that side arose as distinct branches from the aorta.

*Branches.*—The common iliac artery often gives off a small unnamed branch to the lymphatic glands, the ureter or the psoas muscle, and sometimes even a larger branch—a renal artery, a lumbar, or the ilio-lumbar.

## INTERNAL ILIAC ARTERY.

The internal iliac artery (*hypogastrica, pelvica*) extends from the bifurcation of the common iliac artery towards the sacro-sciatic foramen, near which it divides into branches. It is usually about an inch and a half in length, and is smaller than the external iliac in the adult, but the reverse in the foetus. At its origin, the artery lies near the inner border of the psoas muscle; lower down, it rests against part of the pyriform muscle. Behind it are situated the internal iliac vein, and the communicating branch which passes from the lumbar to the sacral plexus of nerves: in front it is crossed by the ureter, which separates it from the peritoneum.

*BRANCHES.*—The branches of the internal iliac artery, though constant, and regular in their general distribution, vary much in their origin. They arise, in most instances, from two principal divisions of the parent trunk, of which one is anterior to the other. From the anterior division arise the superior vesical (connected with the pervious portion of the foetal hypogastric artery), the inferior vesical, middle hæmorrhoidal, obturator, internal pudic, and sciatic arteries, and also, in the female, the uterine and the vaginal arteries. The posterior division gives off the gluteal, the ilio-lumbar, and the lateral sacral arteries.

*PECULIARITIES.—Length.*—The internal iliac artery has been found as short as half an inch, and sometimes as long as three inches, but it is not often less than an inch in length. An instance has been observed in which this vessel was absent, and its branches were derived from a bend of the external iliac artery down into the pelvis (Preparation in Univ. Coll. Mus., London). The lengths of the common iliac and internal iliac arteries bear an inverse proportion to each other—the internal iliac being long when the common iliac is short, and *vice versa*. Moreover, when the common iliac is short, the internal iliac (arising higher than usual) is placed for some distance above the brim of the pelvis, and descends by the side of the external iliac to reach that cavity.

*The place of division* of the internal iliac into its branches varies between the upper margin of the sacrum and the upper border of the sacro-sciatic foramen.

*Branches.*—Sometimes all the branches of the internal iliac artery arise without the previous separation of that vessel into two portions.

In more than a fourth of R. Quain's cases a branch, corresponding usually to the ilio-lumbar artery, arose before the subdivision of the main trunk.

*HYPOGASTRIC ARTERY.*—*In the foetus*, the internal iliac artery, retaining almost the full size of the common iliac, curves forwards from that artery to the side of the urinary bladder, and ascends on the anterior wall of the abdomen to the umbilicus. There the vessels of opposite sides come in



contact with one another and with the umbilical vein, and coiling spirally round that vein in the umbilical cord, they proceed to the placenta. To that part of the artery which is placed within the abdomen, the term *hypogastric* is applied; the remaining portion, passing onwards through the umbilicus to the placenta, being the proper *umbilical* artery. After the cessation of the placental circulation at birth, the two hypogastric arteries become impervious from the side of the bladder upwards to the umbilicus, and are converted into fibrous cords. These two cords, which extend from the sides of the bladder to behind the umbilicus, being shorter than the part of the peritoneum on which they rest, cause a fold of the serous membrane to project inwards; and thus are formed two fossæ (fossæ of the peritoneum) on each side of the abdomen, in one or other of which the projection of a direct inguinal hernia takes place. The part of the artery intervening between the origin of the vessel and the side of the bladder remains pervious, although proportionally much reduced in size, and forms the trunk of the superior vesical artery.

## BRANCHES OF THE INTERNAL ILIAC ARTERY.

### I. VESICAL ARTERIES.

The urinary bladder receives several arteries, amongst which, however, may be specially recognised two principal branches, a superior and an inferior vesical artery.

The *superior vesical* artery is, at its commencement, that part of the hypogastric artery in the foetus which remains pervious after the changes that take place subsequently to birth. It extends from the anterior division of the internal iliac to the side of the bladder.

BRANCHES.—(a) It distributes numerous branches to the upper part and sides of the bladder.

(b) The *artery of the vas deferens*, or the *deferent artery*, arising from one of the lowest of these, is a slender artery which reaches the vas deferens, and accompanies that duct in its course through the spermatic cord to the back of the testicle, where it anastomoses with the spermatic artery.

(c) Other small branches ramify on the lower end of the ureter.

The *inferior vesical* artery (vesico-prostatic), derived usually from the anterior division of the internal iliac, is directed downwards to the lower part of the bladder, where it ends in branches which are distributed to the base of the bladder, to the side of the prostate, and to the vesiculæ seminales. One offset, to be presently described, descends upon the rectum.

The branches upon the prostate communicate more or less freely upon that body with the corresponding vessels of the opposite side, and, according to Haller, with the perineal arteries likewise.

Small twigs of this vessel also run towards the subpubic arch, and in instances of deficient pudic arteries replace one or more of their branches, as will be more fully noticed under those arteries.

Besides the superior and inferior vesical arteries, other smaller branches will be found to reach the bladder, and usually one slender vessel which is distributed particularly to the under surface of the vesiculæ seminales.

*Middle hæmorrhoidal* artery.—This branch is usually supplied to the rectum by the inferior vesical artery, but sometimes proceeds from other



Fig. 289.

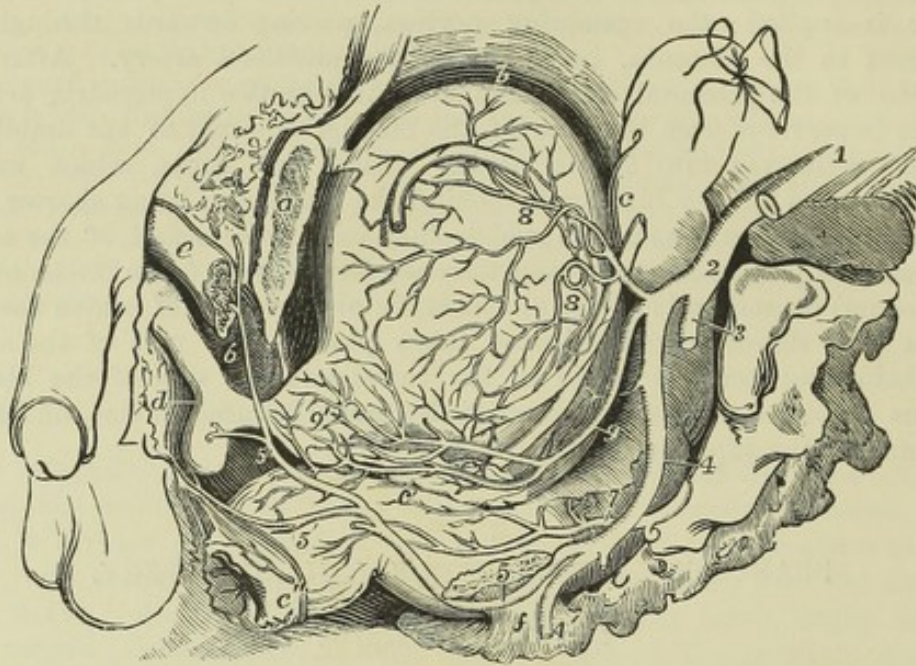


FIG. 289.—VIEW OF THE VISCERA OF THE MALE PELVIS FROM THE LEFT SIDE, SHOWING THE VESICAL AND PUDIC ARTERIES (from R. Quain).  $\frac{1}{3}$

*a*, the os pubis divided a little to the left of the symphysis; *b*, placed close to the upper part of the urinary bladder, upon which lies the vas deferens; *c*, placed on the upper part of the rectum, near the left ureter; *c'*, at the junction of the middle and lower parts of the rectum points to the vesicula seminalis; *c''*, the anus; *d*, the urethral bulb; *e*, the crus penis divided; *f*, the short sacro-sciatic ligament attached to the spine of the ischium; 1, common iliac artery; 2, internal iliac artery; 3, gluteal artery cut short; 4, common trunk of the sciatic and pudic arteries; 4', sciatic artery cut as it is passing out of the great sacro-sciatic foramen; 5, placed on the divided surface of the ischium near the spine, points to the pudic artery as it is about to re-enter the pelvis by the lesser sacro-sciatic foramen; 5', the superficial perineal branches of the pudic; 5'', the pudic artery, proceeding to give the artery of the bulb, and passing on to give 6, the artery of the crus penis and the dorsal artery of the penis; 7, placed on the middle part of the rectum, points to the descending branches of the superior hæmorrhoidal artery; 8, the superior and middle vesical arteries; 9, the inferior vesical artery, of considerable size in this instance, giving branches to the bladder, the vesicula seminalis, the rectum (middle hæmorrhoidal), and 9', to the prostate gland.

sources. It anastomoses with the branches of the other hæmorrhoidal arteries.

## II. UTERINE AND VAGINAL ARTERIES.

*The uterine artery* is directed downwards from the anterior division of the internal iliac artery towards the neck of the uterus. Insinuating itself between the layers of the broad ligament, it passes upwards on the side of the uterus, pursuing an exceedingly tortuous course, and sends off numerous branches, which enter the substance of that organ.

This artery supplies small branches to the bladder and the ureter; and, near its termination, communicates with an offset directed inwards from the ovarian artery.

*Vaginal artery*.—The vagina derives its arteries principally from a branch which corresponds with the inferior vesical in the male. The vaginal artery descends and ramifies upon the vagina, at the same time sending some



offsets to the lower part of the bladder over the neck, and others to the contiguous part of the rectum.

Fig. 290.

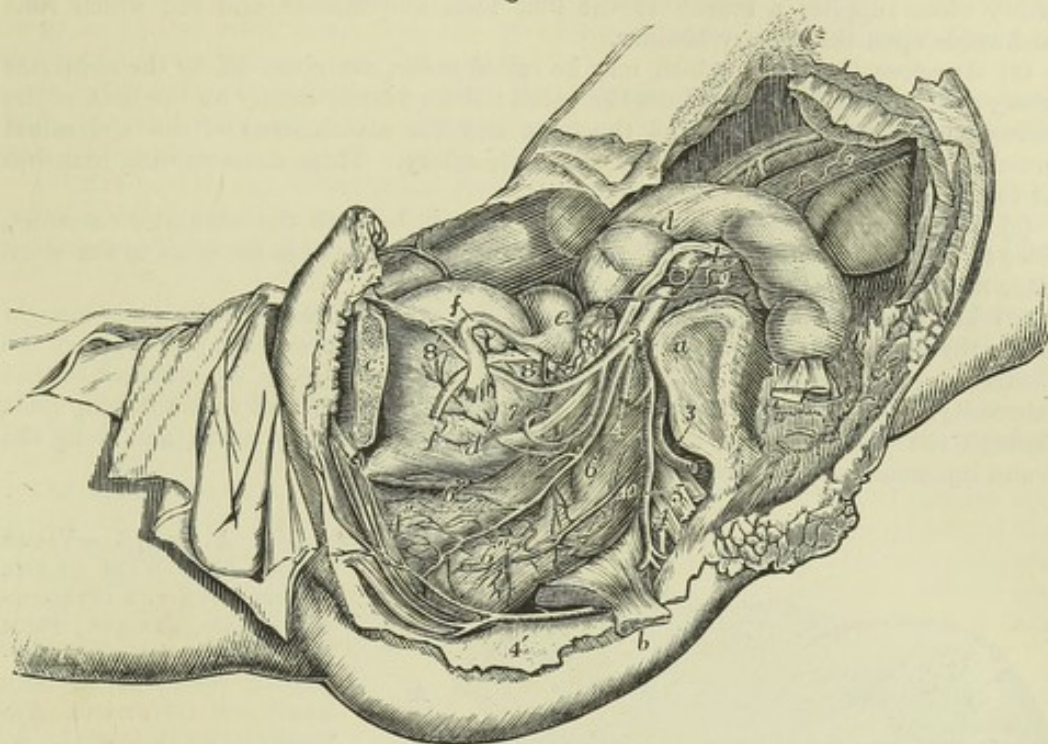


Fig. 290.—VIEW OF THE DISTRIBUTION OF THE ARTERIES TO THE VISCERA OF THE FEMALE PELVIS, AS SEEN ON THE REMOVAL OF THE LEFT OS INNOMINATUM, &c. (from R. Quain). 4

*a*, the left auricular surface of the sacrum; *b*, the spine of the ischium with the short sacro-sciatic ligament; *c*, the os pubis cut a little to the left of the symphysis; *d*, placed upon the sigmoid part of the colon, and *d'* on the lower part of the urinary bladder, point to the ureter; *e*, on the upper part of the body of the uterus, points by a line to the left ovary; *f*, on the upper part of the bladder, points to the left Fallopian tube; *f'*, round ligament of the uterus; *1*, left external iliac artery cut short; *2*, left internal iliac artery; *3*, gluteal artery cut short; *4*, *4*, left pudic artery from which a part has been removed; *4'*, the same artery after it has re-entered the pelvis proceeding towards the muscles of the perinæum, clitoris, &c.; *5*, placed on the sacral nerves, points to the sciatic artery; *6*, *6'*, inferior vesical and vaginal arteries; *6''*, branches from these to the rectum; *7*, uterine artery much coiled; *8*, the superior vesical, and *8'*, the remains of the hypogastric artery; *9*, *9*, the left ovarian artery, descending from the aorta, and emerging from below the peritoneum; *10*, the superior hæmorrhoidal artery spreading over the left side of the rectum.

### III. OBTURATOR ARTERY.

The obturator artery is in most instances derived from the internal iliac; it usually arises from the anterior portion of that vessel, but not unfrequently from its posterior division. The artery is directed forwards along the inside of the pelvis to reach the groove at the upper part of the thyroid foramen. By this aperture it passes out of the pelvis, and immediately divides into its terminal branches. In its course through the pelvis, the artery is placed between the pelvic fascia and the peritoneum, a little below the obturator nerve. Beneath the pubes it lies with its accompanying vein and nerve in an oblique canal, formed partly by a groove in the bone, and partly by fibrous tissue, after passing through which it divides imme-



diately into an external and an internal branch, which are deeply placed behind the external obturator muscle.

BRANCHES.—(a) *Within the pelvis*, besides others of smaller size, the obturator artery often supplies a branch to the iliac fossa and muscle, and one which runs backwards upon the urinary bladder.

(b) *Anastomotic vessels*, which may be called *pubic*, are given off by the obturator artery as it is about to escape from the pelvis: these vessels ramify on the back of the pubes, and communicate behind the bone and the attachments of the abdominal muscles, with small offsets from the epigastric artery. These anastomosing branches lie to the inner side of the crural ring.

(c) The *internal terminal branch* curves inwards beneath the obturator externus, close to the inner margin of the thyroid foramen, and furnishes branches to the obturator muscles, the gracilis, and the adductor muscles.

(d) The *external terminal branch* has a similar arrangement near the outer margin of the thyroid foramen; it descends as far as the ischial tuberosity, and supplies the obturator muscles, and the upper ends of the long muscles which are attached to that tuberosity. This branch usually sends off a small artery, which enters the hip-joint through the cotyloid notch, and ramifies in the synovial fatty tissue, and along the round ligament as far as the head of the femur.

Fig. 291.

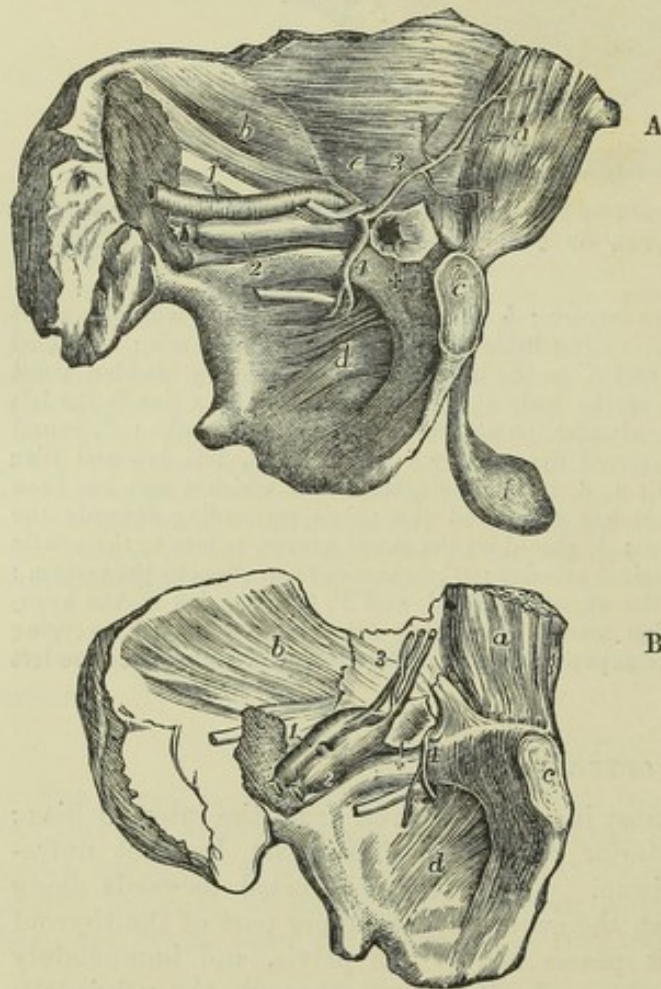


Fig. 291, A. and B.—VIEWS OF THE LEFT WALL OF THE PELVIS, WITH THE ATTACHED ABDOMINAL MUSCLES FROM THE INSIDE, SHOWING DIFFERENT POSITIONS OF THE ABERRANT OBTURATOR ARTERIES (from R. Quain).  $\frac{1}{4}$

In A, a case is represented in which the aberrant artery passes to the outside of a femoral hernial protrusion; in B, an instance is shown in which it surrounds the neck of the sac.

a, posterior surface of the rectus muscle; b, iliacus internus muscle; c, symphysis pubis; d, obturator membrane; e, placed on the fascia transversalis, points to the vas deferens passing through the internal inguinal aperture; f, the testicle; +, the neck of a femoral hernial sac; 1, the external iliac artery; 2, the external iliac vein; below 2, the obturator nerve; 3, the epigastric artery; 4, aberrant obturator artery, arising from the epigastric.

The two terminal branches of the obturator artery communicate with each other near the lower margin of the ob-

turator ligament, and anastomose with branches of the internal circumflex artery. The external branch also communicates with offsets from the sciatic artery near the tuber ischii.

PECULIARITIES.—The obturator artery frequently has its origin transferred to the



commencement of the epigastric artery, and sometimes to the external iliac at its termination.

In 361 cases observed by R. Quain, the origin of the obturator artery varied as follows:—In the proportion of 2 cases out of 3, it arose from the internal iliac: in 1 case out of 3½, from the epigastric: in a very small number of cases (about 1 in 72), it arose by two roots from both the above-named vessels; and in about the same proportion, from the external iliac artery.

Sometimes the obturator artery arises from the epigastric on both sides of the same body, but, in the majority of instances, this mode of origin of the vessel is met with only on one side.

When the obturator artery arises from the epigastric it turns backwards into the pelvis to reach the canal at the upper part of the thyroid foramen; and in this course it is necessarily close to the crural ring, the opening situated at the inner side of the external iliac vein, through which hernial protrusions descend from the abdomen into the thigh. In the greater number of instances the artery springs from near the root of the epigastric, and is directed backwards close to the iliac vein, and therefore lies to the outer side of the femoral ring; but in other instances, arising from the epigastric artery higher up, it occasionally crosses over the ring, and curves to its inner side. It is when it takes this last course that the obturator artery is liable to be wounded in the operation for dividing the stricture in a femoral hernia.

The anastomosis which normally exists between the obturator artery and the epigastric explains the nature of the change which takes place when the origin of the obturator artery is transferred from the one place to the other. In such cases one of the anastomosing vessels may be supposed to have become enlarged, and the posterior or proper root of the obturator artery to have remained undeveloped or to have been obliterated in a proportionate degree.

#### IV. PUDIC ARTERY.

The pudic or internal pudic artery is a branch of considerable size (smaller in the female than in the male), which is distributed to the external generative organs. The following description of this artery has reference to its arrangement in the male; its distribution in the female will be noticed separately.

The pudic artery arises from the anterior division of the internal iliac, sometimes by a trunk common to it and the sciatic artery. Proceeding downwards, it passes superficially or posteriorly close to the ischial spine, thus emerging from the pelvis along with the sciatic artery, through the great sacro-sciatic foramen. Continuing in a uniformly curved course, it re-enters the pelvis by the small sacro-sciatic foramen, immediately below the ischial spine, and passes forward on the inner side of the tuber ischii, in the substance of the obturator fascia.

Distant at first from the lower margin of the ischial tuberosity an inch or an inch and a half, it approaches the surface on the inner margin of the pubic arch, and lies subjacent to the triangular ligament or superficial layer of the subpubic fascia. Finally, piercing this fascia, it divides below the subpubic arch into the dorsal artery of the penis and the artery of the corpus cavernosum.

In the first part of its course, whilst within the pelvis, the pudic artery lies to the outer side of the rectum, and in front of the pyriformis muscle and the sacral nerves. Thence onwards it is accompanied by the pudic nerve and vein. On the ischial spine it is covered by the gluteus maximus muscle close to its origin. In the obturator fascia it lies external to the ischio-rectal fossa and internal to the obturator internus muscle, and beneath the triangular ligament it is crossed by the deep transverse perineal muscle.



**BRANCHES.**—(a) The *inferior* or *external hæmorrhoidal* arteries, two or three in number, incline inwards from the pudic artery as it passes outside the ischio-rectal fossa above the tuber ischii. These small vessels run across the ischio-rectal fossa, through the fat in that space, and are distributed to the sphincter and levator ani muscles, and to the parts surrounding the anus.

Fig. 292.

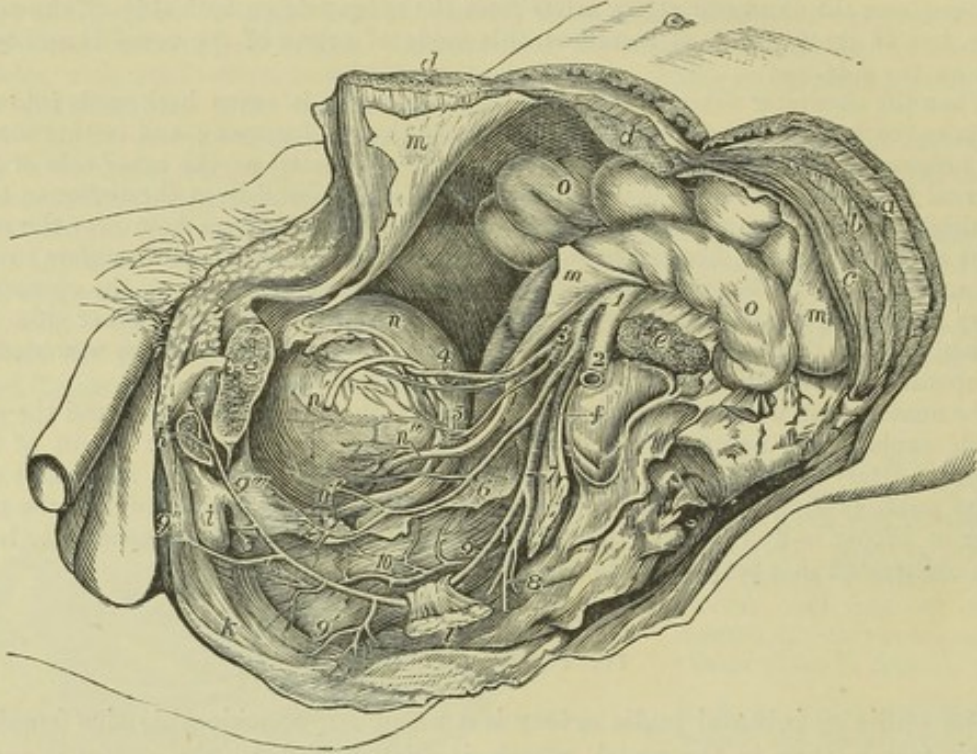


Fig. 292.—VIEW OF THE DISTRIBUTION OF THE ARTERIES TO THE VISCERA OF THE MALE PELVIS, AS SEEN ON THE REMOVAL OF THE LEFT OS INNOMINATUM, &c. (from R. Quain).  $\frac{1}{4}$

*a*, left external oblique muscle of the abdomen divided; *b*, internal oblique; *c*, transversalis; *d, d*, the parts of the rectus muscle divided and separated; *e*, psoas magnus muscle divided; *f*, placed on the left auricular surface of the sacrum, points by a line to the sacral plexus of nerves; *g*, placed on the os pubis, sawn through a little to the left of the symphysis, points to the divided spermatic cord; *h*, the cut root of the crus penis; *i*, the bulb of the urethra; *k*, elliptical sphincter ani muscle; *l*, a portion of the ischium near the spinous process, to which is attached the short sacro-sciatic ligament; *m*, the parietal peritoneum; *n*, the upper part of the urinary bladder; *n'*, *n'*, the left vas deferens descending towards the vesicula seminalis; *n''*, the left ureter; *o*, the intestines; *1*, the common iliac at the place of its division into external and internal iliac arteries; *2*, left external iliac artery; *3*, internal iliac; *4*, obliterated hypogastric artery, over which the vas deferens is seen passing, with the superior vesical artery below it; *5*, middle vesical artery; *6*, inferior vesical artery, giving branches to the bladder, and descending on the prostate gland and to the back of the pubes; *7*, placed on the sacral plexus, points to the common trunk of the pudic and sciatic arteries; close above *7*, the gluteal artery is seen cut short; *8*, sciatic artery cut short as it is escaping from the pelvis; *9*, placed on the rectum, points to the pudic artery as it is about to pass behind the spine of the ischium; *9'*, on the lower part of the rectum, points to the inferior hæmorrhoidal branches; *9''*, on the perinæum, indicates the superficial perineal branches; *9'''*, placed on the prostate gland, marks the pudic artery as it gives off the arteries of the bulb and of the crus penis; *10*, placed on the middle part of the rectum, indicates the superior hæmorrhoidal arteries as they descend upon that viscus.

(*b*) The *superficial perineal* artery, a long, slender, but regular vessel, supplies the scrotum and the upper part of the perinæum. Given off from the pudic artery in front of the hæmorrhoidal branches, it turns upwards parallel with the pubic arch, crosses the transverse muscle of the perinæum, and runs forwards under cover of the



superficial fascia, between the erector penis and accelerator urinæ muscles, supplying both. In this course the artery gradually becomes superficial, and is finally distributed to the skin of the scrotum and the dartos. It not unfrequently gives off the following branch.

Fig. 293. — DISSECTION OF THE PERINÆUM IN A YOUNG MALE SUBJECT, SHOWING THE BLOOD-VESSELS, &c.  $\frac{1}{2}$

This drawing is made from a preparation upon a modification of the plan of R. Quain's 61st and 62nd Plates. The right side shows a superficial, the left a deeper view.

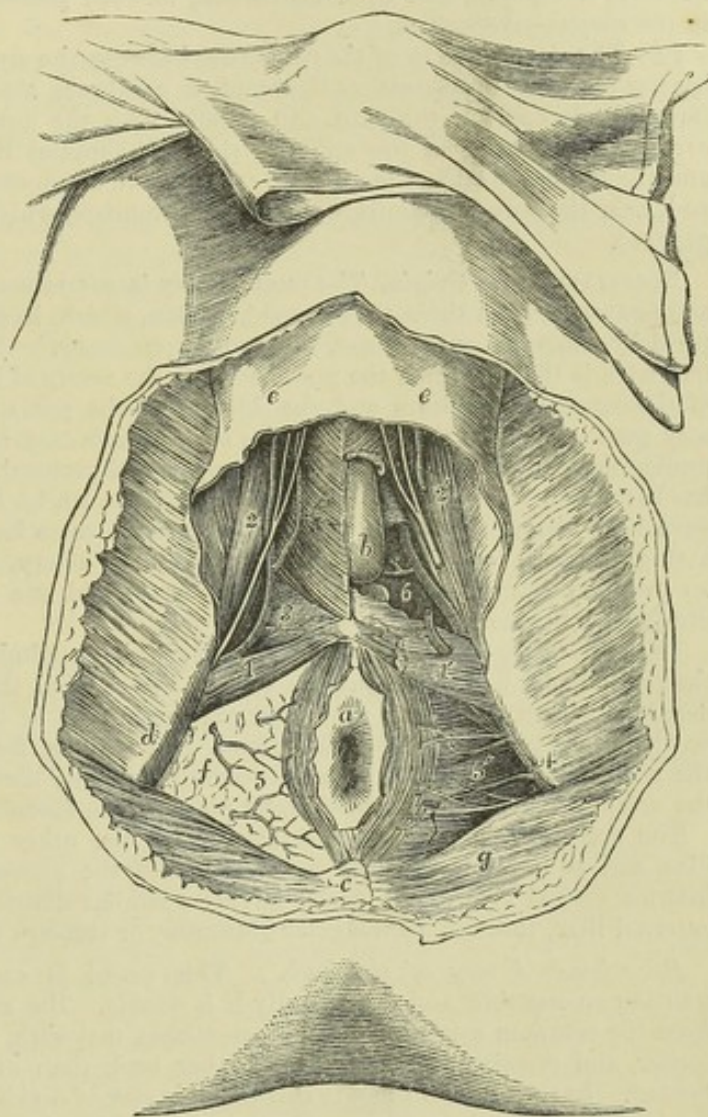
a, the anus, with a part of the integument surrounding it; b, left half of the bulb of the urethra exposed by the removal of a part of the bulbo-cavernosus muscle; c, coccyx; d, right tuberosity of the ischium; e, e, the anterior part of the superficial perineal fascia passing forward upon the scrotum, and removed from the surface of the muscles and its reflections into the deep fascia; f, right ischio-rectal fossa from which the fat and fascia have not been removed; g, gluteus maximus muscle; 1, placed on the right transversus perinæi muscle, points to the superficial perineal artery as it emerges in front (in this case) of the muscle; 1', placed on the left side on the surface of the triangular ligament near its reflection into

the superficial fascia, points to the superficial perineal artery cut short; 2, on the right ischio-cavernosus muscle, points to the superficial perineal arteries and nerves passing forward; 2', the same on the left side, the vessels and nerves having been divided there; 3, on the triangular ligament of the right side, points to the transverse perineal branch of the superficial perineal artery; 4, on the left tuberosity of the ischium, points to the pudic artery deep in the ischio-rectal fossa; 5, 5', the inferior hæmorrhoidal branches of the pudic arteries and nerves; 6, on the left side, placed in a recess from which the triangular ligament or anterior layer of the sub-pubic fascia has been removed to show the continuation of the pudic artery, its branch to the bulb, and one of Cowper's glands.

(c) The *transverse perineal* artery, a very small vessel, arises either from the pudic artery, or from the superficial perineal, near the transversus perinæi muscle. It lies across the perinæum, and terminates in small branches which are distributed to the transverse muscle, and to the parts between the anus and the bulb of the urethra.

(d) The *artery of the bulb*, is, surgically considered, an important vessel. It is very

Fig. 293.





short; arising from the pudic between the layers of the sub-pubic fascia, and passing transversely inwards, this artery reaches the bulb a little in front of the central point of the perinæum, and ramifies in the erectile tissue. It gives a branch to Cowper's gland.

(e) The artery of the *corpus cavernosum* (*profunda penis*), one of the terminal branches of the internal pudic, runs a short distance between the crus penis and the ramus of the pubes, and then continuing forward penetrates the crus, and ramifies in the corpus cavernosum.

(f) The *dorsal artery of the penis* runs between the crus and the pubic symphysis: having pierced the suspensory ligament, it continues along the dorsum of the penis immediately beneath the skin, and parallel with the dorsal vein, as well as with the corresponding artery of the opposite side. It supplies the integument of the penis, and the fibrous sheath of the corpus cavernosum, anastomosing with the deep arteries; and, near the corona glandis, divides into branches, which supply the glans and the prepuce.

**PECULIARITIES.—Origin.** The pudic artery is sometimes small, or it is defective in one or two, or even three of its usual branches, which, in those circumstances, are supplied by a supplemental vessel, the "*accessory pudic*." The defect most frequently met with is that in which the pudic ends as the artery of the bulb, whilst the arteries of the corpus cavernosum and the dorsum of the penis are derived from the accessory pudic. But all the three arteries of the penis may be supplied by the accessory pudic, the pudic itself ending as the superficial perineal. A single accessory pudic has been seen to supply both cavernous arteries, whilst the pudic of the right side gave both dorsal arteries. On the other hand, cases have occurred in which only a single branch was furnished by the accessory artery, either to take the place of an ordinary branch altogether wanting, or to aid one of the branches which was diminutive in size.

The *accessory pudic*, the occasional artery above alluded to, generally arises from the pudic itself, before the passage of that vessel from the sacro-sciatic foramen, and descends within the pelvis, and along the lower part of the urinary bladder. It lies on the upper part of the prostate gland, or it may be, for a short space, likewise on the posterior margin, and then proceeding forwards above the membranous part of the urethra, reaches the perinæum, by piercing the fascia of the sub-pubic arch.

The accessory pudic sometimes arises with the other branches from the internal iliac, and is not unfrequently connected with the prostatic or other branch of the inferior vesical artery. A vessel having a similar distribution may spring from the external iliac, through an irregular obturator, or through the epigastric artery.

**Branches.—Artery of the bulb.** This vessel is sometimes small, sometimes wanting on one side, and occasionally it is double. But a more important deviation from the common condition is one sometimes met with, in which the vessel, arising earlier, and crossing the perinæum farther back than usual, reaches the bulb from behind. In such a case there is considerable risk of dividing the artery in performing the lateral operation for stone. On the other hand, when this small vessel arises from an accessory pudic artery, it lies more forward than usual, and out of danger in case of operation.

The *dorsal artery of the penis* has been observed to arise from the deep femoral artery and to pass obliquely upwards and inwards to reach the root of the penis. Tiedemann gives a drawing of this variety.

**The pudic artery in the female.**—In the female this vessel is much smaller than in the male. Its course is similar, and it gives the following branches:

The *superficial perineal* branch is distributed to the labia pudendi. The *artery of the bulb* supplies the mass of erectile tissue above and at the sides of the entrance of the vagina, named the bulb of the vagina. Whilst the two terminal branches, corresponding to the artery of the corpus cavernosum and the dorsal artery of the penis, are distributed to the clitoris, and are named the *profunda* and *dorsal* arteries.



## V. SCIATIC ARTERY.

The sciatic artery, the largest branch of the internal iliac trunk, excepting the gluteal, is distributed to the muscles on the back of the pelvis. It descends upon the pelvic surface of the pyriformis muscle and the sacral plexus of nerves; and turning backwards beneath the border of that muscle, it passes between it and the superior gemellus, and thus escapes from the pelvis, along with the great sciatic nerve and the pudic artery, at the lower part of the great sciatic foramen. Outside the pelvis, this artery lies in the interval between the tuber ischii and the great trochanter, covered by the gluteus maximus.

BRANCHES.—The sciatic artery gives off several branches to the external rotator muscles of the thigh, on which it lies, and to the great gluteus by which it is concealed. Two others have received special names, viz., the following:—

(a) The *coccygeal*, inclines inwards, and piercing the great sacro-sciatic ligament, reaches the posterior surface of the coccyx, and ramifies in the fat and skin about that bone.

(b) The other named branch, *comes nervi ischiadici*, runs downwards, accompanying the sciatic nerve, along which it sends a slender vessel.

Some of the branches of this artery are distributed to the capsule of the hip-joint; whilst others, after supplying the contiguous muscles, anastomose with the gluteal, the internal circumflex, and the superior perforating arteries in the upper part of the long flexor muscles of the thigh.

## VI. GLUTEAL ARTERY.

The gluteal artery, the largest branch of the internal iliac, is distributed to the muscles on the outside of the pelvis. It inclines downwards to the great sacro-sciatic foramen, and escaping from the cavity of the pelvis, between the contiguous borders of the middle gluteal and the pyriform muscles, divides immediately into a superficial and a deep branch.

BRANCHES.—(a) The *superficial* branch running between the gluteus maximus and gluteus medius, divides into ramifications which are most copiously distributed to the gluteus maximus, and anastomose with the sciatic and posterior sacral arteries.

(b) The *deep* branch, situated between the gluteus medius and gluteus minimus, runs in an arched direction forwards, and divides into two other branches. One of these, the superior branch, follows the upper border of the gluteus minimus beneath the middle gluteal muscle and the tensor of the fascia lata, towards the anterior iliac spine, and, after having freely supplied the muscles between which it passes, anastomoses with the circumflex iliac and the ascending branches of the external circumflex arteries. The second or inferior branch descends towards the great trochanter, supplies the gluteal muscles, and anastomoses with the external circumflex and the sciatic arteries.

(c) A *nutrient* branch enters the hip-bone at the place where the artery emerges from the pelvis.

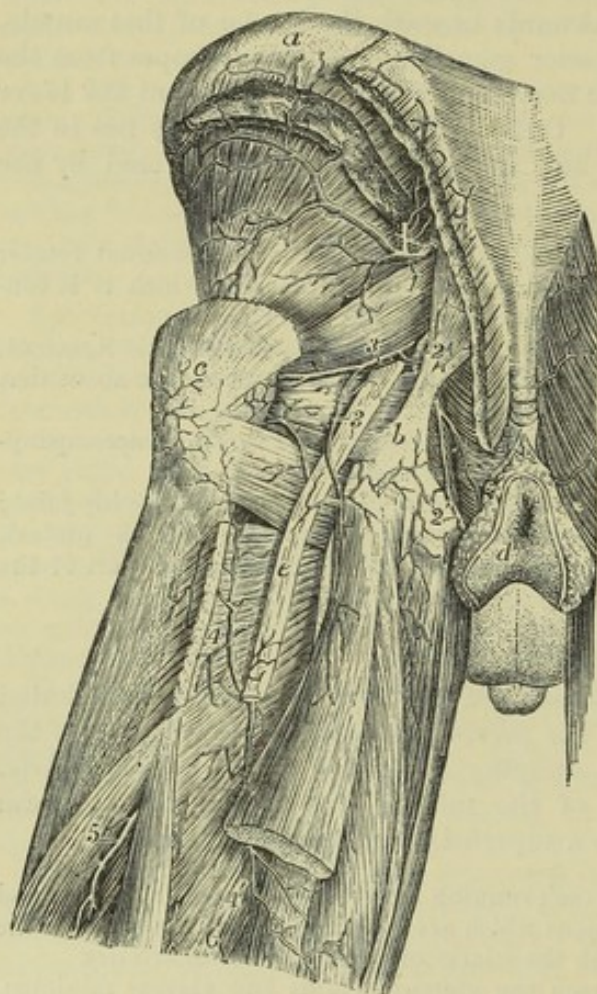
## VII. ILIO-LUMBAR ARTERY.

The ilio-lumbar artery resembles in a great measure one of the lumbar arteries. It passes outwards beneath the psoas muscle and the external iliac vessels, to reach the margin of the iliac fossa, where it separates into a *lumbar* and an *iliac* division. The first of these ramifies in the psoas and quadratus muscles, communicating with the last lumbar artery, and furnishing branches to the vertebral canal. The second or *iliac* division, turning downwards and outwards, either in the iliacus muscle or between it and the bone, anastomoses with the circumflex iliac artery, and even with the external branches of the epigastric.



**PECULIARITIES.**—The ilio-lumbar artery sometimes arises from the internal iliac, above the division of that trunk; and more rarely from the common iliac. The iliac and lumbar portions sometimes arise separately from the parent trunk.

Fig. 294.

Fig. 294.—ARTERIES OF THE BACK OF THE PELVIS AND UPPER PART OF THE THIGH (from Tiedemann).<sup>4</sup>

*a*, crest of the ilium; *b*, tuberosity of the ischium and lower attachment of the great sacro-sciatic ligament; *c*, great trochanter; *d*, integument round the anus; *e*, great sciatic nerve; 1, trunk of the gluteal artery as it issues from the great sacro-sciatic foramen, the superficial branches cut short, the deep arch seen passing round on the upper part of the gluteus minimus muscle; 2, placed on the great sacro-sciatic ligament, points to the pudic artery at the place where it winds over the back of the spine of the ischium; 2', the continuation of the artery towards the perinaeum on the inside of the tuberosity and ramus of the ischium; 3, 3, the sciatic artery, the upper figure placed on the piriformis muscle, the lower on the great sciatic nerve; 4, 4', first perforating artery passing through the upper part of the great adductor muscle and anastomosing with the posterior branch of the internal circumflex artery, which appears between the quadratus and the adductor muscles; 5 and 6, part of the second and third perforating arteries.

When the lowest of the lumbar arteries is wanting it is replaced by a branch from the ilio-lumbar, which is increased in size, and by a small offset from the middle sacral artery.

#### VIII. LATERAL SACRAL ARTERIES.

The *lateral sacral* arteries are usually two in number on each side, though occasionally they are united into one. The two arteries arise close together from the posterior division of the internal iliac. One is distributed upon the upper, and the other upon the lower part of the sacrum.

Both arteries pass downwards, at the same time inclining somewhat inwards, in front of the pyriform muscle and the sacral nerves, which they supply with twigs, and reach the inner side of the anterior sacral foramina. Continuing to descend, the lower one approaches the middle line, and anastomoses with the middle sacral artery.

**Dorsal Branches.**—The lateral sacral arteries give off a series of branches which enter the anterior sacral foramina. Each of these, after having furnished within the foramen a spinal branch, which ramifies on the bones and membranes in the interior of the sacral canal, escapes by the corresponding posterior sacral foramen, and is distributed upon the dorsal surface of the sacrum.



## EXTERNAL ILIAC ARTERY.

The external of the two arteries resulting from the division of the common iliac forms a large continuous trunk, which extends downwards in the limb as far as the lower border of the popliteus muscle, but, for convenience of description, it is named in successive parts of its course external iliac, femoral, and popliteal.

The external iliac artery, larger than the internal iliac artery, is placed within the abdomen, and extends from the division of the common iliac to the lower border of Poupart's ligament, where the vessel enters the thigh, and is named femoral. Descending obliquely outwards, its course through the abdominal cavity may be marked by a line drawn from the left side of the umbilicus to a point midway between the anterior superior spinous process of the ilium and the symphysis pubis. This line would also indicate the direction of the common iliac artery, from which the external iliac is directly continued.

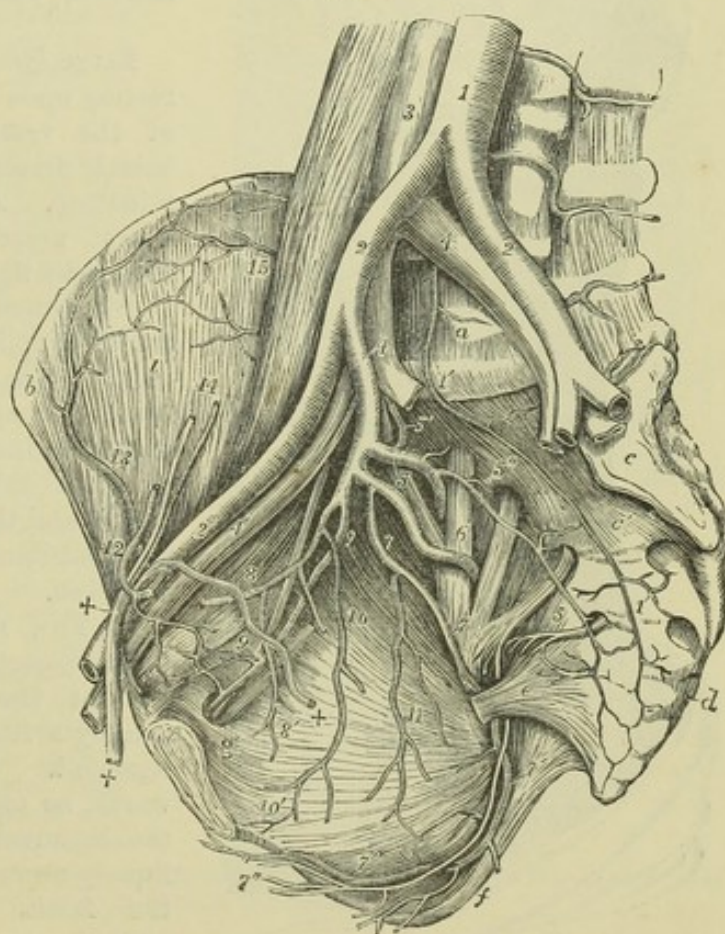
The vessel is covered by the peritoneum and intestines. It lies along the upper margin of the true pelvis, resting upon the inner border of the psoas muscle. The artery, however, is separated from the muscle by the fascia

Fig. 295.—VIEW OF THE PRINCIPAL ARTERIES AND THEIR DIVISIONS ON THE RIGHT SIDE OF A MALE PELVIS.

For the detailed description of this figure see Fig. 288, p. 419.

2', the right external iliac artery, accompanied by the corresponding vein 4', passing below into the femoral vessels under Poupart's ligament; 12, epigastric artery winding to the inside of +, +, the spermatic cord; the epigastric artery is cut short superiorly; 13, circumflex iliac artery anastomosing with 15, branches of the ilio-lumbar; 14, spermatic artery and vein descending to join the spermatic cord; +, within the pelvis, the vas deferens descending from the cord towards the bladder.

Fig 295.



iliaca, to which it is bound, together with the external iliac vein, by the sub-peritoneal tissue.



*Relation to Veins, &c.*—The external iliac vein lies at first behind the artery with an inclination to the inner side; but as both vessels approach Poupart's ligament at the fore part of the pelvis, the vein is on the same plane with the artery and quite to the inner side, being borne forwards by the bone. At a short distance from its lower end the artery is crossed by the circumflex iliac vein.

Fig. 296.

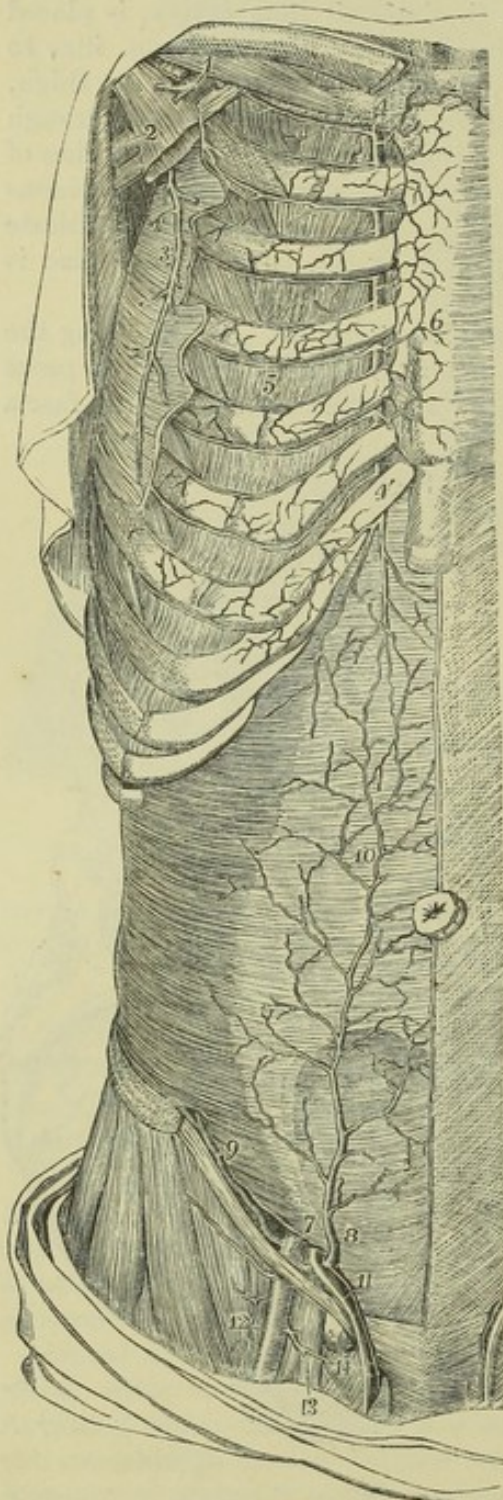

Fig. 296.—VIEW OF THE DISTRIBUTION AND ANASTOMOSIS OF THE EPIGASTRIC AND INTERNAL MAMMARY ARTERIES (from Tiedemann).  $\frac{1}{4}$

For the detailed description of this figure, see Fig. 265, p. 375.

7, placed on the transversalis muscle above the internal inguinal aperture, points to the last part of the external iliac artery at the place where it gives origin to 8, the epigastric and 9, the circumflex iliac artery; 10, anastomosis of the epigastric artery and the abdominal branch of the internal mammary in and behind the rectus muscle; 11, the spermatic cord receiving the external spermatic branch from the epigastric artery; 12, femoral artery; 13, femoral vein; 14, a lymphatic gland closing the femoral ring.

Large lymphatic glands are found resting upon the front and inner side of the vessel; and the spermatic vessels descend upon it near its termination. A branch of the *genito-crural nerve* crosses it just above Poupart's ligament.

**BRANCHES.**—The external iliac artery supplies some small branches to the psoas muscle and the neighbouring lymphatic glands, and, close to its termination, two other branches of considerable size, named the epigastric and the circumflex iliac, which are distributed to the walls of the abdomen.

1. THE EPIGASTRIC ARTERY (inferior epigastric) arises from the forepart of the external iliac artery, usually a few lines above Poupart's ligament. It first inclines downwards, so as to get on a level with the ligament, and then passes obliquely upwards and inwards between the fascia transversalis and the peritoneum, to reach the rectus muscle of the abdomen. It ascends almost vertically behind the rectus,



and rising within the sheath, is placed between it and the muscle, and terminates at some distance above the umbilicus in offsets which ramify in the substance of the muscle and anastomose with the terminal branches of the internal mammary and inferior intercostal arteries.

The epigastric artery is accompanied by two *veins*, which unite into a single trunk before ending in the external iliac vein.

In its course upwards from Poupart's ligament to the rectus muscle, the artery passes close to the inner side of the internal abdominal ring; and the vas deferens, entering through the ring, turns behind the artery in descending into the pelvis.

BRANCHES.—These are small, but numerous.

(a) The *cremasteric* artery, a slender branch, accompanies the spermatic cord, and supplying the cremaster muscle and other coverings of the cord, anastomoses with the spermatic artery.

(b) Several *muscular* branches arise from each side of the epigastric artery, ramify in the rectus muscle, and communicate with the branches of the lumbar and circumflex iliac arteries.

(c) *Superficial* branches perforate the abdominal muscles, and join beneath the skin with branches of the superficial epigastric artery.

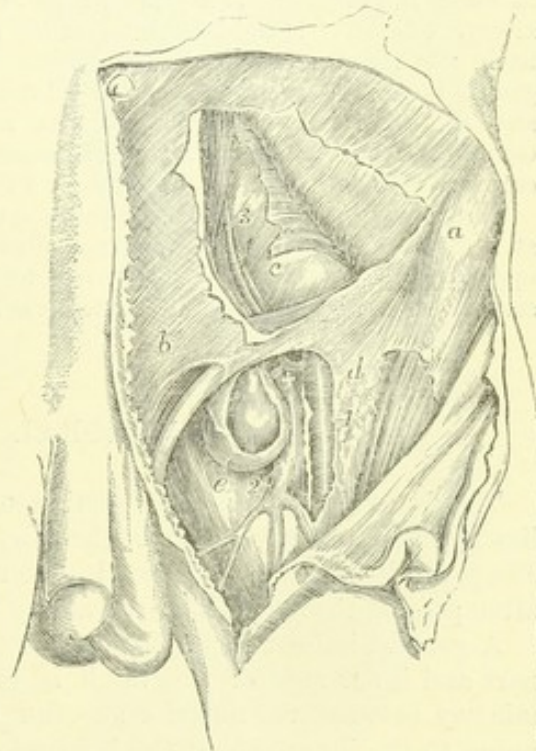
(d) The *pubic* is a small branch, which ramifies behind the pubes, and communicates by means of one or more descending twigs with a similar branch from the obturator artery.

Fig. 297.—VIEW OF THE RELATION OF THE VESSELS OF THE GROIN TO A FEMORAL HERNIA, &c. (from R. Quain).  $\frac{1}{4}$

Fig. 297.

In the upper part of the figure a portion of the flat muscles of the abdomen has been removed, displaying in part the transversalis fascia and peritoneal lining of the abdomen; in the lower the fascia lata of the thigh is in part removed and the sheath of the femoral vessels opened: the sac of the femoral hernial tumour has also been opened.

*a*, anterior superior spinous process of the ilium; *b*, aponeurosis of the external oblique muscle above the external inguinal aperture; *c*, the abdominal peritoneum and fascia transversalis; *d*, the iliac portion of the fascia lata near the saphenic opening; *e*, sac of a femoral hernia; 1, points to the femoral artery; 2, femoral vein at the place where it is joined by the saphena vein; 3, epigastric artery and vein passing up towards the back of the rectus muscle; +, placed upon the upper part of the femoral vein close below the common trunk of the epigastric and an aberrant obturator artery; the latter artery is seen in this case to pass close to the vein and between it and the neck of the hernial tumour.



2. THE CIRCUMFLEX ILIAC ARTERY, smaller than the preceding vessel, arises from the outer side of the iliac artery near Poupart's ligament, and is



directed outwards behind that band to the anterior superior iliac spine. Following thence the crest of the hip-bone, the artery gives branches to the iliacus muscle, furnishes others which are distributed to the abdominal muscles, and anastomoses with the ilio-lumbar artery. In its course outwards this artery lies in front of the transversalis fascia, at the junction of this with the fascia iliaca.

Two *veins* accompany the circumflex iliac artery; these unite below into a single vessel, which crosses the external iliac artery about an inch above Poupart's ligament, and enters the external iliac vein.

The *muscular* branch is given off near the iliac crest, and ascends on the fore-part of the abdomen between the transversalis and internal oblique muscles: having supplied those muscles, it anastomoses with the lumbar and epigastric arteries. This branch varies much in size, and is occasionally replaced by several smaller muscular offsets.

**PECULIARITIES.—Size.**—In those rare cases in which the principal blood-vessel of the lower limb is continued from the internal iliac (p. 441), the external iliac artery is correspondingly diminished, and ends in the muscles of the front of the thigh, taking the place of the profunda.

**Branches.**—The usual number of two principal branches of the external iliac artery may be increased by the separation of the circumflex iliac into two branches, or by the addition of a branch usually derived from another source, such as the internal circumflex artery of the thigh or the obturator artery.

The *epigastric* artery occasionally arises higher than usual, as at an inch and a half, or even two inches and a half, above Poupart's ligament; and it has been seen to arise below that ligament from the femoral, or from the deep femoral artery. The epigastric frequently furnishes the obturator artery; and two examples are recorded in which the epigastric artery arose from an obturator furnished by the internal iliac artery. (Monro, "Morbidity Anatomy of the Human Gullet," &c., p. 427. A. K. Hesselbach, "Die sicherste Art des Bruchschnittes," &c.) In a single instance the epigastric artery was represented by two branches, one arising from the external iliac, and the other from the internal iliac artery. (Lauth, in "Velpeau's Médecine Opératoire," v. ii. p. 452.) Some combinations of the epigastric with the internal circumflex, or with the circumflex iliac, or with both those vessels, have been noticed.

The *circumflex iliac* artery sometimes deviates from its ordinary position,—arising at a distance not exceeding an inch above Poupart's ligament. Deviations in the opposite direction are more rarely met with; it has in a few cases been observed to arise below the ligament, from the femoral artery.

## FEMORAL ARTERY.

The femoral artery is that portion of the artery of the lower limb which lies in the upper two-thirds of the thigh,—its limits being marked above by Poupart's ligament, and below by the opening in the great adductor muscle, after passing through which the artery receives the name popliteal.

A general indication of the direction of the femoral artery over the fore-part and inner side of the thigh is given by a line reaching from a point midway between the anterior superior iliac spine and the symphysis of the pubes to the inner side of the internal condyle of the femur. At the upper part of the thigh, it lies along the middle of a depression between the muscles covering the femur on the outer side, and the adductor muscles on the inner side of the limb, and which is known by the name of Scarpa's triangle. In this situation the beating of the artery may be felt, and the circulation through the vessel may be most easily controlled by pressure. Below the upper third of the thigh it is crossed by the upper and inner



Fig. 298.

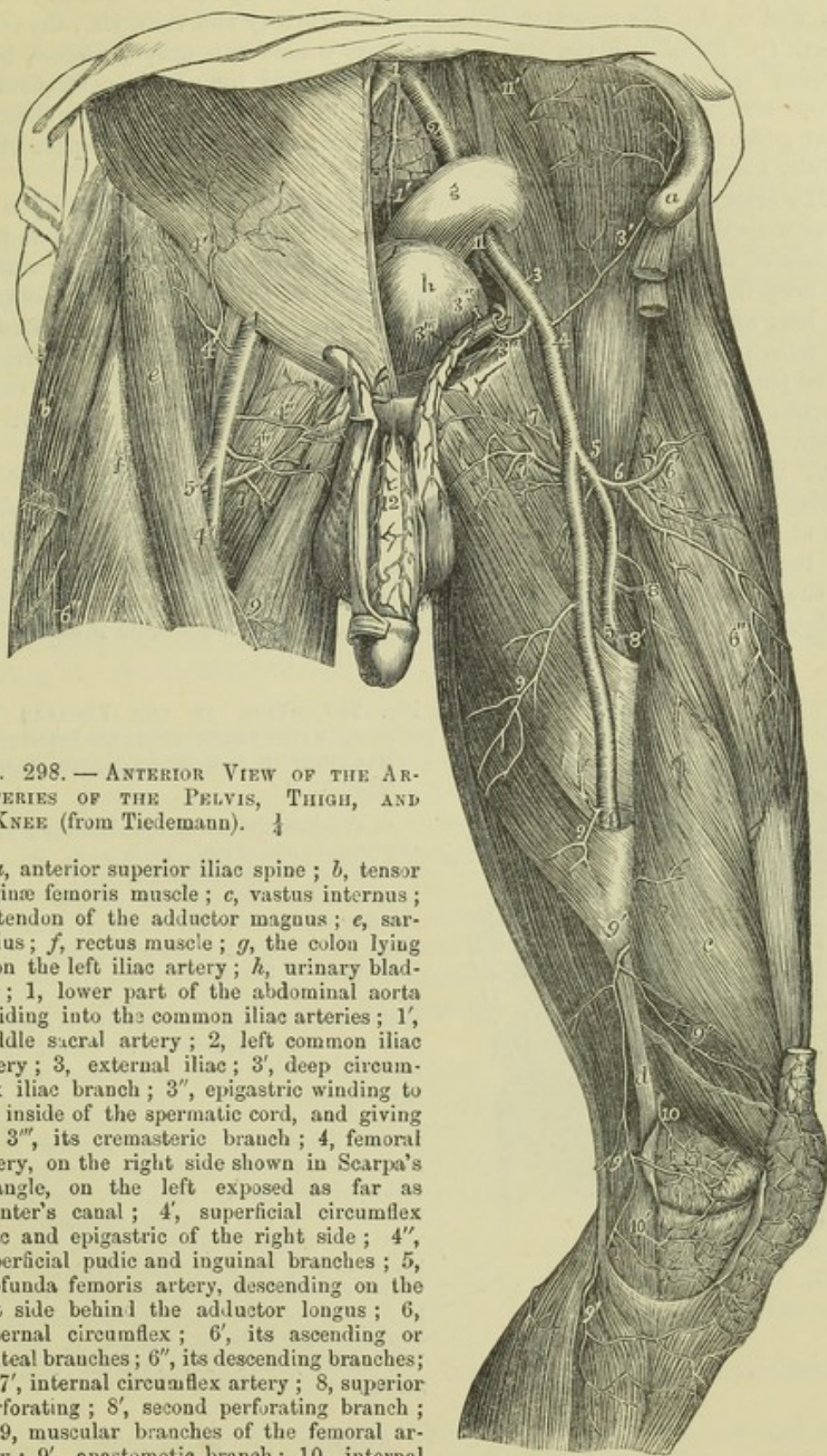


Fig. 298. — ANTERIOR VIEW OF THE ARTERIES OF THE PELVIS, THIGH, AND KNEE (from Tiedemann). 4

*a*, anterior superior iliac spine; *b*, tensor vaginae femoris muscle; *c*, vastus internus; *d*, tendon of the adductor magnus; *e*, sartorius; *f*, rectus muscle; *g*, the colon lying upon the left iliac artery; *h*, urinary bladder; 1, lower part of the abdominal aorta dividing into the common iliac arteries; 1', middle sacral artery; 2, left common iliac artery; 3, external iliac; 3', deep circumflex iliac branch; 3'', epigastric winding to the inside of the spermatic cord, and giving off 3''', its cremasteric branch; 4, femoral artery, on the right side shown in Scarpa's triangle, on the left exposed as far as Hunter's canal; 4', superficial circumflex iliac and epigastric of the right side; 4'', superficial pudic and inguinal branches; 5, profunda femoris artery, descending on the left side behind the adductor longus; 6, external circumflex; 6', its ascending or gluteal branches; 6'', its descending branches; 7, 7', internal circumflex artery; 8, superior perforating; 8', second perforating branch; 9, 9, muscular branches of the femoral artery; 9', anastomotic branch; 10, internal superior articular branch of the popliteal; 10', inferior branch.

border of the sartorius muscle which forms the outer wall of the triangle, and which conceals the vessel in the remainder of its course. In the first



part of its course the femoral artery is covered only by the skin and fascia lata, and by the sheath which invests both the artery and vein, viz., the crural sheath (p. 293). In the lower part of its course it is deeply placed, being covered not only by the sartorius muscle, but by a dense stratum of fibrous structure, which stretches across from the tendons of the long and great adductors to the vastus internus muscle, and encloses the space called *Hunter's canal*, in which the vessels lie.

The artery rests successively upon the following parts. First, upon the psoas muscle, by which it is separated from the margin of the pelvis and the capsule of the hip-joint; next, it is placed in front of the pectineus muscle, the deep femoral artery and vein being interposed; afterwards, it lies upon the long adductor muscle; and lastly, upon the tendon of the great adductor, the femoral vein being placed between the tendon and the artery. At the lower part of its course, it has immediately on its outer side the vastus internus muscle, which intervenes between it and the inner side of the femur.

At the groin the artery, after having passed over the margin of the pelvis, is placed slightly in front of or internal to the head of the femur; and at its lower end, the vessel lies close to the inner side of the shaft of the bone; but in the intervening space, in consequence of the projection of the neck and shaft of the femur outwards, while the artery holds a straight course, it is separated from the bone by a considerable interval.

Fig. 299.

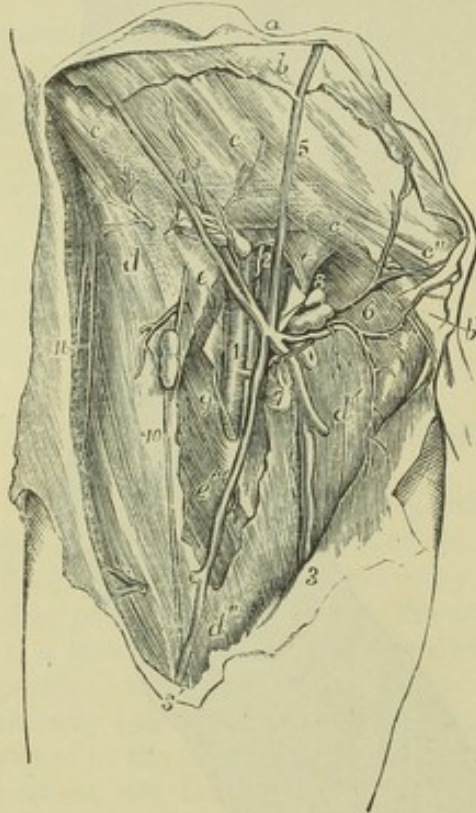


Fig. 299.—VIEW OF THE FEMORAL VESSELS, WITH THEIR SMALLER SUPERFICIAL BRANCHES IN THE RIGHT GROIN (from R. Quain).  $\frac{1}{4}$

*a*, the integument of the abdomen; *b*, the superficial abdominal fascia; *b'*, the part descending on the spermatic cord; *c*, *c*, the aponeurosis of the external oblique muscle; *c'*, the same near the external abdominal ring; *c''*, the inner pillar of the ring; *d*, the iliac part of the fascia lata; *d'*, the pubic part; *e*, *e*, the sheath of the femoral vessels laid open, the upper letter is immediately over the crural aperture; *e'*, placed on the sartorius muscle partially exposed, points to the margin of the saphenic opening; 1, femoral artery, having the femoral vein 2, to its inner side, and the septum of the sheath shown between the two vessels; 3, the principal saphenous vein; 3', its anterior branches; 4, the superficial circumflex iliac vein and arterial branches to the glands of the groin; 5, the superficial epigastric vein; 6, the external pudic arteries and veins; 7 to 8, some of the lower inguinal glands receiving twigs from the vessels; 9, internal, 10, middle, and 11, external cutaneous nerves.

*Relation to Veins.*—The femoral vein is very close to the artery, both being enclosed in the same sheath, and separated from each other only by a thin partition of fibrous membrane. At the groin the vein lies in the same plane as the artery, and on the inner side; but gradually inclining backwards, it is placed behind it, at the



lower end of Scarpa's space, and afterwards gets somewhat to the outer side. The deep femoral vein, near its termination, crosses behind the femoral artery; and the long saphenous vein, as it ascends on the fore part of the limb, lies to the inner side; but it not unfrequently happens that a superficial vein of considerable size ascends for some space directly over the artery.

*Relation to Nerves.*—At the groin the *anterior crural nerve* lies a little to the outer side of the femoral artery (about a quarter of an inch), separated from the vessel by some fibres of the *psoas* muscle and by the sheath and fascia. Lower down in the thigh, the *long saphenous* nerve accompanies the artery until this vessel perforates the *adductor magnus*. There are likewise small cutaneous nerves which cross the artery.

**BRANCHES.**—The femoral artery gives off the following branches:—some small and superficial, which are distributed to the integument and glands of the groin and ramify on the lower part of the abdomen, viz., the external pudic (superior and inferior), the superficial epigastric, and the superficial circumflex iliac; the great nutrient artery of the muscles of the thigh, named the deep femoral; several muscular branches; and lastly, the anastomotic artery, which descends on the inner side of the knee-joint.

The portion of the femoral artery extending from its commencement to the origin of the deep femoral, a part varying from an inch to two inches in length, is sometimes distinguished by surgical writers as the *common femoral*, and described as dividing into the *superficial* and *deep* femoral arteries.

**I. SUPERFICIAL INGUINAL BRANCHES.**—The *external pudic arteries* arise either separately or by a common trunk from the inner side of the femoral artery. The *superior*, the more superficial branch, courses upwards and inwards to the pubic spine, crosses the external abdominal ring, passing in the male over the spermatic cord, and is distributed to the integuments on the lower part of the abdomen, and on the external organs of generation. The *inferior* branch, more deeply seated, extends inwards, resting on the *pectineus* muscle, and covered by the *fascia lata*, which it pierces on reaching the inner border of the thigh, and is distributed to the scrotum in the male, or to the labium in the female, its branches inosculating with those of the superficial perineal artery.

The *superficial epigastric* artery, arising from the femoral vessel, about half an inch below Poupart's ligament, passes forwards through the *fascia lata*, and runs upwards on the abdomen in the superficial fascia covering the external oblique muscle. Its branches, ascending nearly as high as the umbilicus, anastomose with superficial branches of the epigastric and internal mammary arteries.

The *superficial circumflex iliac* artery runs outwards in the direction of Poupart's ligament towards the iliac spine, across the *psoas* and *iliacus* muscles: to both of these it gives small branches, as also some others which pierce the *fascia lata*; it is distributed to the integument.

All the preceding arteries give small branches to the lymphatic glands in the groin.

**II. THE DEEP FEMORAL ARTERY**—(*profunda femoris*) the principal nutritious vessel of the thigh, is an artery of considerable calibre, being nearly equal in size to the continuation of the femoral after the origin of this great branch. It usually arises from the outer and back part of the femoral artery, between an inch and two inches below Poupart's ligament. At its



commencement, it inclines outwards in front of the iliacus muscle, to such an extent as to be visible for a short distance external to the femoral artery; it then runs downwards and backwards behind that vessel, and passing behind the long adductor muscle, between it and the great adductor, near their femoral attachments, divides into terminal branches, which pierce the great adductor, and ramify in the muscles at the back and outer part of the thigh.

Fig. 300.

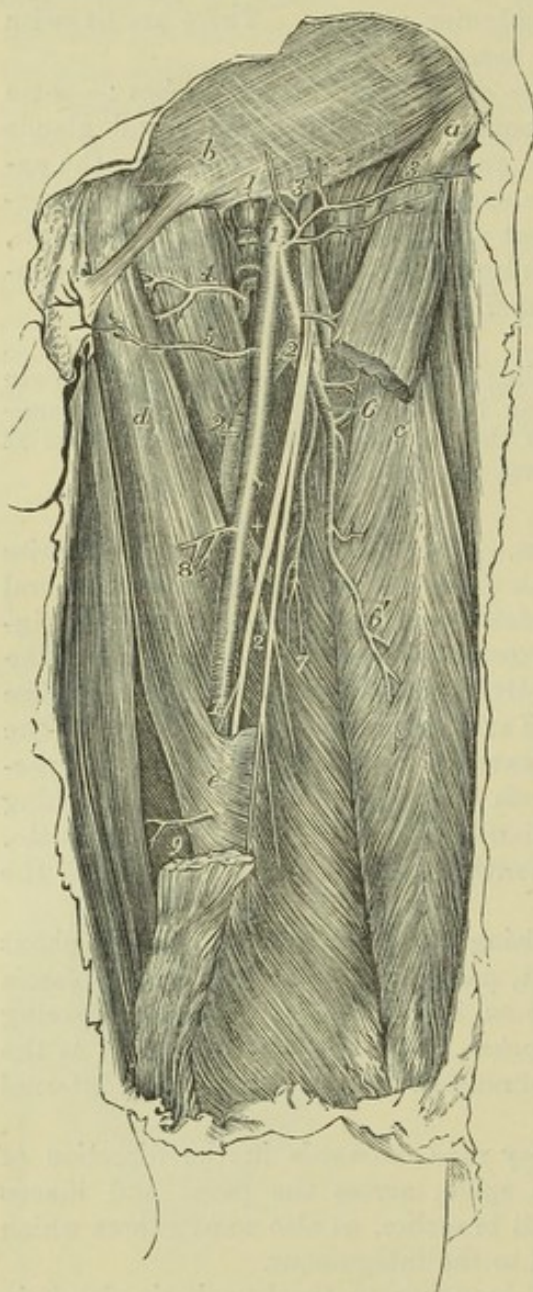


Fig. 300.—DEEP VIEW OF THE FEMORAL ARTERY AND ITS BRANCHES ON THE LEFT SIDE (from R. Quain).  $\frac{1}{4}$

The sartorius muscle has been removed in part, so as to expose the artery in the middle third of the thigh. *a*, the anterior superior iliac spine; *b*, the aponeurosis of the external oblique muscle near the outer abdominal ring, from which the spermatic cord is seen descending towards the scrotum; *c*, the upper part of the rectus femoris muscle; *d*, adductor longus; *e*, fibrous sheath of Hunter's canal covering the artery; 1, femoral artery; 1', femoral vein divided and tied close below Poupart's ligament; 2, profunda femoris artery; 3, anterior crural nerves; 4, internal circumflex branch; 5, superficial pudic branches; 6, external circumflex branch, with its ascending transverse and descending branches separating from it; 6', twigs to the rectus muscle; 7, branches to the vastus internus muscle; 8, and 9, some of the muscular branches of the femoral.

This artery lies successively in front of the iliacus, pectineus, adductor brevis and adductor magnus muscles. The femoral and profunda veins and the long adductor muscle are interposed between it and the femoral trunk.

The named branches of the deep femoral artery are the external and the internal circumflex, and the perforating arteries.

1. The *external circumflex* artery, a branch of considerable size, arises from the outer side of the profunda near its origin, and passing outwards for a short distance

beneath the sartorius and rectus muscles, and through the divisions of the anterior crural nerve, divides into three sets of branches.

(a) *Transverse* branches pass outwards over the crureus muscle, pierce the vastus externus, so as to get between it and the femur, just below the great trochanter, and



reach the back part of the thigh, where they anastomose with the internal circumflex and the perforating branches of the deep femoral, and with the gluteal and sciatic branches of the internal iliac.

(b) *Ascending* branches, directed upwards beneath the sartorius and rectus, and afterwards under the tensor muscle of the fascia lata, communicate with the terminal branches of the gluteal, and with some of the external descending branches of the circumflex iliac artery.

(c) *Descending* branches incline outwards and downwards upon the extensor muscles of the knee, covered by the rectus muscle. They are usually three or four in number, some being of considerable size; most of them are distributed to the muscles on the fore-part of the thigh, but one or two can be traced beneath the vastus externus muscle as far as the knee, where they anastomose with the arterial branches surrounding that joint.

2. The *internal circumflex* artery, smaller than the external circumflex, arises close to that branch from the inner and hinder part of the deep femoral artery, and is directed backwards between the pectineus and the psoas muscle to the inner side of the femur, so that only a small part of it can be seen without displacing these muscles. On reaching the tendon of the external obturator, along which the vessel passes to the back of the thigh, it divides into two principal branches.

(a) The *ascending* branch is distributed partly to the adductor brevis and gracilis, and partly to the external obturator muscle, near which it anastomoses with the obturator artery.

(b) The *transverse* branch passes backwards above the small trochanter, and appears on the back of the limb, between the quadratus femoris and great adductor muscles, where it supplies the hamstring muscles, and anastomoses with the sciatic artery and with the superior perforating branches of the deep femoral artery.

(c) An *articular* vessel, arising from the transverse branch opposite the hip-joint, enters the joint through the notch in the acetabulum, beneath the transverse ligament, and supplies the adipose tissue and the synovial membrane in that articulation. Some offsets are guided to the head of the femur by the round ligament. In some instances the articular branch is derived from the obturator artery; and sometimes the joint receives a branch from both sources.

3. The *perforating* arteries (*perforantes*) are branches which reach the back of the thigh by perforating the adductor brevis and adductor magnus muscles; they are four in number, including the terminal branch of the parent vessel.

(a) The *first perforating* artery passes backwards below the pectineus muscle, through the fibres of the adductor brevis and magnus, and is distributed to both these adductor muscles, to the biceps and great gluteal muscle, and communicates with the sciatic and internal circumflex arteries.

(b) The *second perforating* artery, considerably larger than the first, passes through the adductor brevis and magnus; after which it divides into ascending and descending branches, which ramify in the hamstring muscles, and communicate with the other perforating branches: an offset from it, named the *nutrient artery* of the femur, enters the medullary foramen of that bone.

(c) The *third perforating* artery pierces the adductor magnus muscle, below the insertion of the adductor longus, and is distributed in a manner similar to the second perforating artery.

(d) The *fourth perforating* artery, the termination of the deep femoral artery, passing backwards close to the linea aspera, is distributed to the short head of the biceps and to the other hamstring muscles, and communicates with branches of the popliteal artery, and with the lower perforating arteries.

III. MUSCULAR BRANCHES OF THE FEMORAL ARTERY. — In its course along the thigh, the femoral artery gives off several branches to the contiguous



muscles. They vary in number from two to seven. They supply the sartorius and the vastus internus, with other muscles which are close to

Fig. 301.

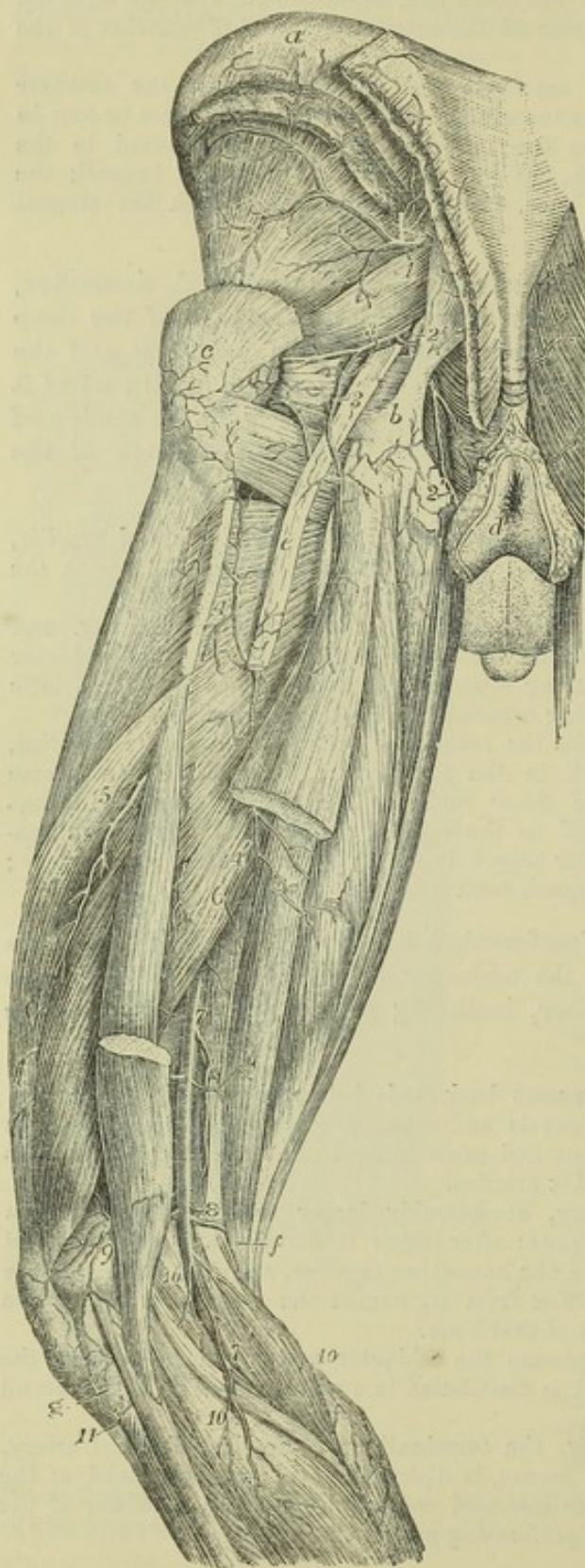


Fig. 301.—POSTERIOR VIEW OF THE ARTERIES OF THE PELVIS, THIGH, AND POPLITEAL SPACE (from Tiedemann).  $\frac{1}{4}$ .

*a*, the iliac crest; *b*, the great sacro-sciatic ligament attached to the tuberosity of the ischium; *c*, great trochanter; *d*, the integument close to the anus; *e*, great sciatic nerve; *f*, the line from this letter crosses the tendons of the inner hamstring muscles; *g*, head of the fibula; 1, gluteal artery; 2, pudic; 3, sciatic artery, giving its branches to the short external rotator muscles, to the sciatic nerve, and to the upper part of the long flexor muscles; 4, first perforating artery; 4', its branches to the flexor muscles; 5, branches of the second perforating; 6, branches of the third perforating; 7, popliteal artery, near this the origin of the superior muscular branches; 8, placed on the tendon of the adductor magnus near the origin of the superior articular branches; 9, the anastomosis of the external superior articular with other branches; 10, the sural branches; 11, the recurrent of the anterior tibial artery.

the femoral artery: their size appears to bear an inverse proportion to that of the descending branches of the external circumflex artery.

#### IV. ANASTOMOTIC ARTERY.

—Close to its termination the femoral artery gives off a branch, constant but of moderate size, named the *anastomotic artery* (*anastomotica magna*), which descends in the same line as the femoral artery itself (see fig. 298). Arising from that vessel when about to enter the popliteal space, it descends upon the tendon of the adductor magnus to the inner condyle of the femur, giving off several branches, and covered by some of the

fibres of the vastus internus muscle; it finally anastomoses with the



internal articular arteries, and with the recurrent branch of the anterior tibial artery.

(a) A *superficial* branch accompanies the saphenous nerve beneath the sartorius muscle to the integument on the inner side of the knee.

(b) The *external* branch, arising from the lower part of the vessel, crosses over the femur, supplies offsets to the knee-joint, and forms an arch a little above the articular surface, by anastomosing with the superior external articular artery.

**PECULIARITIES OF THE FEMORAL ARTERY AND BRANCHES.**—*Trunk.*—Four instances have been recorded of division of the femoral artery below the origin of the profunda into two vessels, which subsequently were reunited near the opening of the adductor magnus so as to form a single popliteal artery. In all these cases, the arrangement of the vessels appears to have been similar. To one of them (that first observed) special interest is attached, inasmuch as it was met with in a patient operated upon for popliteal aneurism. (This case was treated by Charles Bell, and recorded in "The London Medical and Physical Journal," vol. lvi. p. 134. London, 1826.)

The femoral artery is occasionally replaced at the back of the thigh by a trunk continuous with the internal iliac. Having passed from the pelvis through the large sacro-sciatic notch, this trunk accompanies the great sciatic nerve along the back of the thigh to the popliteal space, where its connections and termination become similar to those of the vessel presenting the usual arrangement. Four examples of this deviation from the common state of the blood-vessel have been recorded. Reference is made to these in a Paper in vol. 36 of the Medico-Chirurgical Transactions, giving an account of a specimen of remarkable deformity of the lower limbs of a man in whom the artery was so transposed on both sides.

*Branches.*—The *deep femoral* is occasionally given off from the inner side of the parent trunk, and more rarely from the back part of the vessel. Occasionally it arises at a distance of less than an inch, and sometimes of more than two inches, below Poupart's ligament. It was even found by Richard Quain arising, in one instance, above Poupart's ligament, and in another four inches below it; but in the latter instance the internal and external circumflex arteries did not arise from the profunda.

The *external circumflex* branch sometimes arises directly from the femoral artery; or it may be represented by two branches, of which, in most cases, one proceeds from the femoral, and one from the deep femoral: both branches, however, have been seen to arise from the deep femoral, and much more rarely, both from the femoral artery.

The *internal circumflex* branch may be transferred to the femoral artery above the origin of the profunda. Examples have also been met with in which the internal circumflex arose from the epigastric, from the circumflex iliac, or from the external iliac artery.

## POPLITEAL ARTERY.

The popliteal artery, placed at the back of the knee-joint, extends along the lower third of the thigh and the upper part of the leg, reaching from the opening in the great adductor to the lower border of the popliteus muscle. It is continuous above with the femoral, and divides at the lower end into the anterior and posterior tibial arteries.

This artery at first inclines from the inner side of the limb to reach a point behind the middle of the knee-joint, and thence continues to descend vertically to its lower end. Lying deeply in its whole course, it is covered for some distance at its upper end by the semi-membranosus muscle; a little above the knee it is placed in the popliteal space; inferiorly it is covered for a considerable distance by the gastrocnemius muscle, and at its termination by the upper margin of the soleus muscle.

At first the artery lies close to the inner side of the femur; in descending,



it is separated by an interval from the flat or somewhat hollowed triangular surface at the lower end of the bone ; it then rests on the posterior ligament of the knee-joint, and afterwards on the popliteus muscle.

*Relation to Veins.*—The popliteal vein lies close to the artery, behind and somewhat to the outer side till near its termination, where it crosses the artery and is placed somewhat on the inner side. The vein is frequently double along the lower part of the artery, and, more rarely, also at the upper part. The short saphenous vein, ascending into the popliteal space over the gastrocnemius muscle, approaches the artery as it is about to terminate in the popliteal vein.

*Relation to the Nerve.*—The *internal popliteal nerve* lies at first to the outer side of the artery, but much nearer to the surface than the vessel : the nerve afterwards crosses over the artery, and is placed behind and to the inner side below the joint.

**BRANCHES.**—The branches of the popliteal artery may be arranged in two sets, viz., the muscular and the articular.

1. The *muscular branches* are divided into a superior and an inferior group.

(a) The *superior branches*, three or four in number, are distributed to the lower ends of the hamstring muscles, and also to the vasti muscles, and anastomose with the perforating and articular arteries.

Fig. 302.

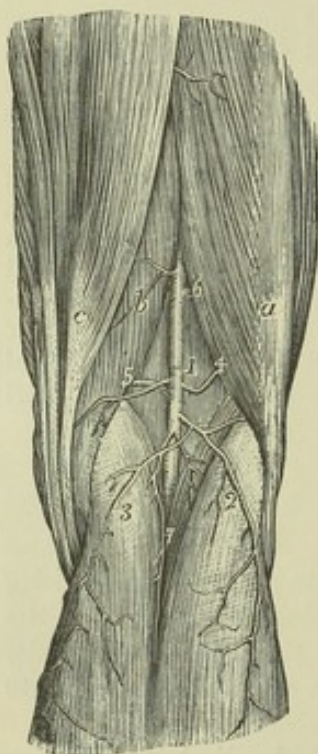

Fig. 302—VIEW OF THE POPLITEAL ARTERY AND ITS BRANCHES IN THE RIGHT LEG (from Tiedemann).  $\frac{1}{4}$

a, biceps muscle ; b, semi-membranosus ; c, semi-tendinosus ; 1, the popliteal artery ; 2, 3, the superficial sural branches ; 4, the outer, 5, the inner superior articular branch ; 6, the superior muscular ; 7, the inferior muscular or deep sural branches.

(b) The *inferior muscular branches*, or *sural arteries*, usually two in number, and of considerable size, arise from the back of the popliteal artery, opposite the knee-joint, and enter, one the outer and the other the inner head of the gastrocnemius muscle, which they supply, as well as the fleshy part of the plantaris muscle.

Over the surface of the gastrocnemius will be found at each side, and in the middle of the limb, slender branches, which descend a considerable distance along the calf of the leg, and end in the integument. These small vessels (superficial sural) arise separately from the popliteal artery, or from some of its branches.

2. The *articular arteries*. Two of these pass off nearly at right angles from the popliteal artery, one to each side, above the flexure of the joint, whilst two have a similar arrangement below it, and a fifth passes from behind into the centre of the joint.

(a) The *upper internal articular artery* winds round the femur just above the inner condyle ; and, passing under the tendon of the great adductor and the vastus internus, divides into two branches ; one of these, comparatively superficial, enters the substance of the vastus, and inosculates with the anastomotic branch of the femoral, and with the lower internal articular artery.



The other branch runs close to the femur, ramifies upon it, and also on the knee-joint, and communicates with the upper external articular artery.

(b) The *upper external articular* artery passes outwards a little above the outer condyle of the femur, under cover of the biceps muscle, and, after perforating the intermuscular septum, divides into a superficial and a deep branch. The latter, lying close upon the femur, spreads branches upon it and the articulation, and communicates with the preceding vessel, with the anastomotic of the femoral, and with the lower external articular artery; the superficial branch descends through the vastus to the patella, anastomosing with other branches and assisting in the supply of the joint.

(c) The *lower internal articular* artery passes downwards below the internal tuberosity of the tibia, lying between the bone and the internal lateral ligament; its branches ramify on the front and inner part of the joint, as far as the patella and its ligament.

(d) The *lower external articular* artery takes its course outwards, under cover of the outer head of the gastrocnemius in the first instance, and afterwards under the external lateral ligament of the knee and the tendon of the biceps muscle, passing above the head of the fibula. Having reached the fore part of the joint, it divides near the patella into branches, some of which communicate with the lower articular artery of the opposite side, and with the recurrent branch from the anterior tibial; whilst others ascend, and anastomose with the upper articular arteries.

In this manner the four articular branches form at the front and sides of the knee-joint a close network of vessels.

Fig. 203. — ANTERIOR VIEW OF THE DEEP ARTERIAL BRANCHES SURROUNDING THE KNEE-JOINT AND THEIR ANASTOMOSES (from Tiedemann).  $\frac{1}{4}$

*a*, the patellar articular surface of the femur; *b*, the posterior or cartilaginous surface of the patella which, with the ligamentum patellæ, has been turned down; *c*, the head of the fibula; 1, and 2, branches of the internal superior articular branch of the popliteal ramifying on the periosteum, and anastomosing with the external superior articular branch 3, and with other arteries within and below the joint; 4, branches of the internal inferior articular; 5, external inferior articular; 6, recurrent of the anterior tibial artery.

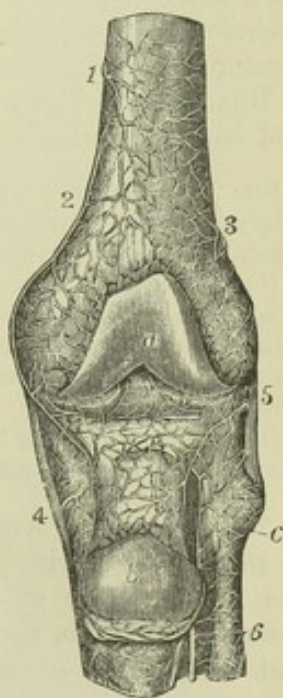
(e) The *middle or azygos articular* artery, is a small branch which arises opposite the flexure of the joint, and, piercing the posterior ligament, supplies the crucial ligaments and other structures within the articulation.

**PECULIARITIES.**—Deviations from the ordinary condition of the popliteal artery are not frequently met with. The principal departure from the ordinary arrangement consists in its high division into terminal branches. Such an early division has been found to take place most frequently opposite the flexure of the knee-joint, and not higher.

In a few instances, the popliteal artery has been seen to divide into the anterior tibial and peroneal arteries—the posterior tibial being small or absent. In a single case, the popliteal artery was found to divide at once into three terminal vessels, viz., the peroneal and the anterior and posterior tibial arteries.

The *azygos articular* branch frequently arises from one of the other articular

Fig. 303.





branches, especially from the upper and external branch. There are sometimes several small middle articular branches.

### POSTERIOR TIBIAL ARTERY.

The posterior tibial artery is situated along the back part of the leg, between the superficial and deep layers of muscles, and is firmly bound down to the deep muscles by the fascia which covers them. It extends from the lower border of the popliteus muscle, where it is continuous with the popliteal artery, down to the inner side of the calcaneum, where it terminates beneath the origin of the abductor pollicis muscle by dividing into the external and internal plantar arteries.

Placed at its origin opposite the interval between the tibia and fibula, it approaches the inner side of the leg as it descends, and lies behind the tibia; at its lower end it is placed midway between the inner malleolus and the prominence of the heel. Very deeply seated at the upper part, where it is covered by the fleshy portion of the gastrocnemius and soleus muscles, it becomes comparatively superficial towards the lower part, being there covered only by the integument and two layers of fascia, and by the annular ligament behind the inner malleolus. It lies successively upon the tibialis posticus, the flexor longus digitorum, and, at its lower end, directly on the tibia and the ankle-joint. Behind the ankle, the tendons of the tibialis posticus and flexor longus digitorum lie between the artery and the internal malleolus; whilst the tendon of the flexor longus pollicis is to the outer side of the artery.

*Relation to the Veins and Nerve.*—The posterior tibial artery, like the other arteries below the knee, is accompanied by two venæ comites. The posterior tibial nerve is at first on the inner side of the artery, but in the greater part of its course the nerve is close to the outer side of the vessel.

**BRANCHES.**—The posterior tibial artery furnishes numerous small branches, and one large branch—the peroneal artery.

**SMALL BRANCHES.**—(a) Several *muscular* branches arise from the posterior tibial artery, and are distributed principally to the deep-seated muscles in its neighbourhood, besides one or two of considerable size to the inner part of the soleus muscle.

(b) The *nutrient artery* of the tibia, which is the largest of its kind in the body, arises from the posterior tibial artery near the commencement, and, after giving small branches to the muscles, enters the nutrient foramen in the bone, and ramifies on the medullary membrane. This vessel not unfrequently arises from the anterior tibial artery.

(c) A *communicating* branch from the peroneal artery, passing transversely, joins the posterior tibial about two inches above the ankle-joint.

**THE PERONEAL ARTERY** lies deeply along the back part of the leg, close to the fibula. Arising from the posterior tibial artery about an inch below the lower border of the popliteus muscle, it inclines at first obliquely towards the fibula, and then descends nearly perpendicularly along that bone and behind the outer ankle, to reach the side of the os calcis. In the upper part of its course, this artery is covered by the soleus muscle and the deep fascia, and afterwards by the flexor longus pollicis, which is placed over it as far as the outer malleolus; below this point, the vessel is covered only by the common integument and the fascia. The peroneal artery rests at first against the upper part of the tibialis posticus muscle, and afterwards in the greater part of its course, it is surrounded by fibres of the flexor longus pollicis, lying close inside the projecting posterior ridge of the fibula. De-



scending beyond the outer malleolus, it terminates in branches on the outer surface and back of the os calcis.

Fig. 304.—DEEP POSTERIOR VIEW OF THE ARTERIES OF THE LEG (from Tiedemann).  $\frac{1}{4}$

*a*, insertion of the adductor magnus muscle; *b*, origin of the inner head of the gastrocnemius; *c*, outer head and plantaris; *d*, tendon of the semimembranosus muscle; *e*, popliteus; *f*, upper part of the soleus divided below its origin from the head of the fibula; *g*, peroneus longus; *h*, flexor longus pollicis; *i*, flexor communis digitorum; 1, upper part of the popliteal artery; 2, origin of the superior articular branches; 3, origin of the inferior articular branches; the middle or azygos branch is seen between these numbers; 4, division of the popliteal artery into anterior and posterior tibial arteries; 5, 5', posterior tibial; 6, peroneal artery; 6', its continuation as posterior peroneal; between 5' and 6', the communicating branch; 7, calcaneal branches; 8, external branches of the metatarsal of the *dorsalis pedis* artery.

The peroneal artery gives off the following branches:—

(a) *Muscular* branches from the upper part of the peroneal artery pass to the soleus, the tibialis posticus, the flexor longus pollicis, and the peronei muscles.

(b) A *nutrient* artery enters the fibula.

(c) The *anterior peroneal* artery arises about two inches above the outer malleolus, and immediately piercing the interosseous membrane, descends along the front of the fibula, covered by the peroneus tertius muscle, and dividing into branches, reaches the outer ankle, and anastomoses with the external malleolar branch of the anterior tibial artery. It supplies vessels to the ankle-joint, and ramifies on the front and outer side of the tarsus, inosculating more or less freely with the tarsal arteries.

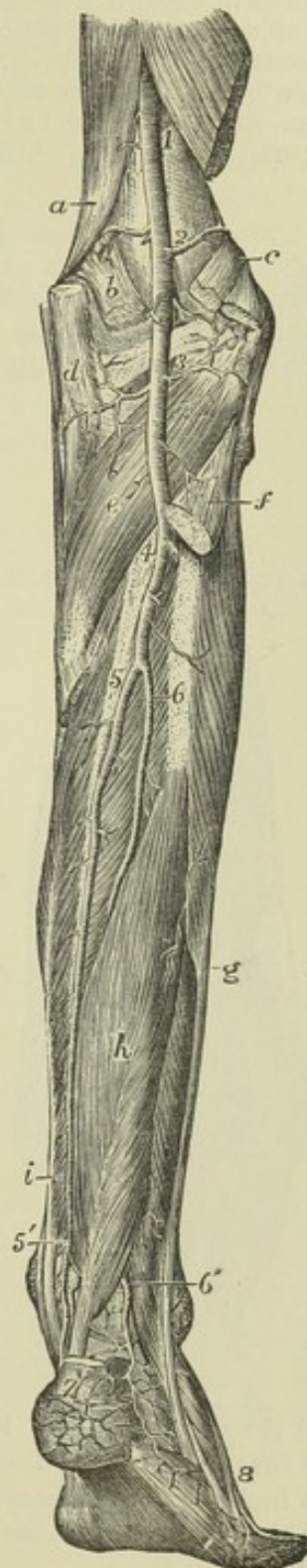
(d) The *terminal* branches anastomose with the external malleolar and with the tarsal arteries on the outer side of the foot; and behind the os calcis with ramifications of the posterior tibial artery.

(e) The *communicating* branch, lying close behind the tibia, about two inches from its lower end, is a transverse branch situated close to the bones, which connects the peroneal with the posterior tibial artery.

**PECULIARITIES.**—The *posterior tibial* artery, as well as the anterior tibial, is lengthened in those instances in which the popliteal artery divides higher up than usual. Not unfrequently the posterior tibial artery is diminished in size, and is subsequently reinforced either by a transverse branch from the peroneal in the lower part of the leg, or in rare instances, by two transverse vessels, one crossing close to the bone, and one over the deep muscles. In other instances the posterior tibial may exist only as a short muscular trunk in the upper part of the leg, while an enlarged peroneal artery takes its place from above the ankle downwards into the foot.

The *peroneal* artery has been found to arise lower down than usual, about three

Fig. 304.





inches below the popliteus muscle; and, on the contrary, it sometimes commences higher up from the posterior tibial, or even from the popliteal artery itself. In some cases of high division of the popliteal artery, the peroneal artery is transferred to the anterior tibial. It more frequently exceeds than falls short of the ordinary dimensions, being enlarged to reinforce the posterior tibial. In those rare instances in which it is lost before reaching the lower part of the leg, a branch of the posterior tibial takes its place. The anterior peroneal branch is sometimes enlarged to compensate for the small size of the anterior tibial artery in the lower part of the leg, or to supply the place of that artery on the dorsum of the foot; or it may be absent and be replaced by the anterior tibial. In a singular case, recorded by Otto, the peroneal artery was wholly wanting.

### PLANTAR ARTERIES.

The external and internal plantar arteries are the branches into which the posterior tibial divides in the hollow of the calcaneum, where it is covered by the origin of the abductor pollicis.

Fig 305.

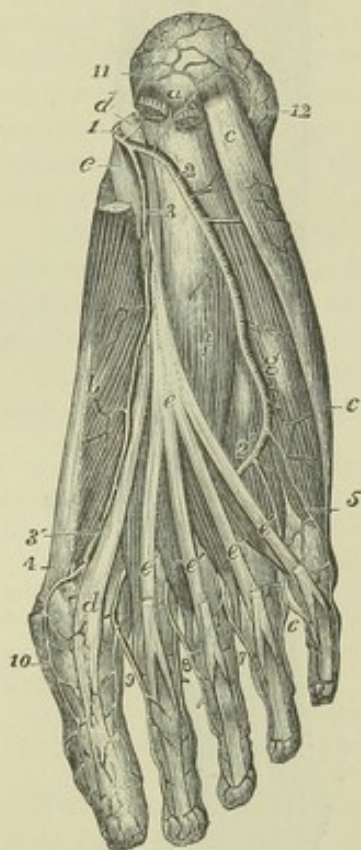


Fig. 305—SUPERFICIAL VIEW OF THE ARTERIES IN THE SOLE OF THE RIGHT FOOT (from Tiedemann).  $\frac{1}{3}$

*a*, tuberosity of the calcaneum close to the origin of the flexor brevis digitorum (cut short) and the abductor pollicis, of which a part is removed to show the long flexor tendons and plantar arteries; *b*, abductor pollicis; *c*, abductor minimi digiti; *d*, tendon of the flexor pollicis longus; *e*, tendon of the flexor communis longus; *e'*, its four slips, close to the lumbricales muscles, passing on to perforate the tendons of the flexor brevis; *f*, flexor accessorius; *g*, flexor brevis minimi digiti: 1, posterior tibial dividing into the plantar arteries; 2, 2', external plantar; 3, internal plantar; 3', the same passing forward to communicate with 4, the internal plantar digital branch for the great toe; 5, first digital or external plantar branch to the fifth toe; 6, placed in the angle of division of the second plantar digital artery, between the fourth and fifth toes; 7, the third plantar digital artery dividing similarly between the third and fourth toes; 8, the fourth plantar digital artery dividing similarly between the second and third toes; 9, the plantar digital artery dividing similarly between the first and second toes; 10, internal plantar artery of the great toe; 11, calcaneal branches of the plantar arteries, anastomosing with 12, the calcaneal branches of the posterior peroneal artery.

The *internal plantar* artery, much smaller than the external, is directed forwards, along the inner side of the foot. Placed at first under cover of the abductor pollicis, it passes forwards in the groove between that muscle

and the short flexor of the toes, near the line separating the middle from the inner portion of the plantar fascia, and on reaching the extremity of the first metatarsal bone, considerably diminished in size, it terminates by running along the inner border of the great toe, anastomosing with the digital branches.

**BRANCHES.**—The internal plantar artery gives off numerous small twigs, which may be distinguished in sets as follows:—(*a*) muscular branches to the abductor



pollicis and flexor brevis digitorum; (b) offsets which incline towards the inner border of the foot, and communicate with branches of the dorsal arteries; and (c) cutaneous offsets which appear in the furrow between the middle and inner portions of the plantar fascia.

The *external plantar artery*, of considerable size, at first inclines outwards and then forwards, to reach the base of the fifth metatarsal bone: it then turns obliquely inwards across the foot, to gain the interval between the bases of the first and second metatarsal bones, where it joins, by a communicating branch, with the dorsal artery of the foot; and thus is completed the *plantar arch*, the convexity of which is turned forward. At first the artery is placed, together with the external plantar nerve, between the calcaneum and the abductor pollicis; further on it lies between the flexor brevis digitorum and flexor accessorius. As it turns forwards it lies in the interval between the short flexor of the toes and the abductor of the little toe, being placed along the line separating the middle from the external portion of the plantar fascia, and covered by that membrane. The remainder of the artery, which turns inwards and forms the plantar arch, is placed deeply against the interosseous muscles, and is covered by the flexors of the toes and the lumbricales muscles.

#### BRANCHES.—

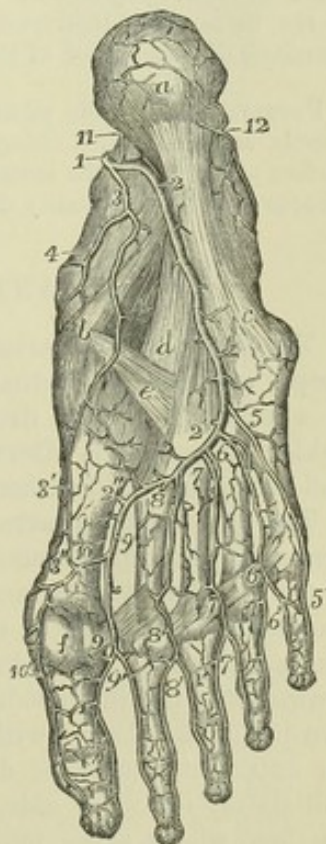
A. In its course to the fifth metacarpal bone the external plantar artery gives off (a) branches to the skin of the heel; (b) numerous muscular branches; (c) small

Fig. 306.—DEEP VIEW OF THE ARTERIES IN THE SOLE OF THE RIGHT FOOT (from Tiedemann).  $\frac{1}{3}$

All the muscles have been removed. *a*, the calcaneal tuberosity; *b*, the scaphoid bone and end of the calcaneo-scaphoid ligament; *c*, to *a*, calcaneo-cuboid ligament; *d*, its deep part; *e*, scaphoido-cuneiform ligament; *f*, one of the sesamoid bones of the great toe; 1, posterior tibial artery dividing into the plantar arteries; 2, 2', external plantar artery; 2', 2'', deep plantar arch terminating by communication with the dorsal artery of the foot; 3, 3', internal plantar artery; 3'', its communication with the internal digital of the great toe; 4, branches of the internal plantar to the inside of the foot; 5, 5', first digital or external plantar branch of the fifth toe; 6, second plantar digital artery; 6', interval of the division of the same between the fourth and fifth toes; 7, third plantar digital; 7', its distribution to the third and fourth toes; 8, fourth plantar digital; 8', its distribution to the second and third toes; 9, fifth plantar digital; 9', its distribution to the first and second toes; 10, internal plantar digital branch of the great toe; at the upper numbers, 6, 7, and 8, the posterior perforating branches of the interosseous arteries are partially indicated; at 2'', the large communication between the plantar arch and the dorsalis pedis artery; above 6', 7', and 8', are situated the anterior perforating arteries, not represented in the figure; 11, and 12, calcaneal branches of the plantar and posterior peroneal arteries.

offsets which run outwards over the border of the foot, and anastomose with the dorsal arteries; and (d) others which appear in the furrow between the middle and outer divisions of the plantar fascia.

Fig. 306.





B. *From the plantar arch* are given off the following more important branches :—

(a) The *posterior perforating* branches, three in number, pass upwards through the back part of the three outer interosseous spaces, between the heads of the dorsal interosseous muscles, and on reaching the dorsum of the foot inosculate with the interosseous branches of the metatarsal artery.

(b) The *digital* branches are four in number. The *first* digital branch inclines outwards from the outermost part of the plantar arch, opposite the end of the fourth metatarsal space, crosses under cover of the abductor minimi digiti, and runs along the outer border of the phalanges of the little toe. The *second* digital branch passes forwards along the fourth metatarsal space, and near the cleft between the fourth and fifth toes divides into two vessels, which course along the contiguous borders of those toes, and end on the last phalanges. The *third* digital branch is similarly disposed of on the fourth and third toes. The *fourth* ends in like manner on the third and second toes.

The digital artery which supplies the opposed sides of the first and second toes, and that which runs on the inner side of the first toe, arise deeply between the first and second metatarsal bones, usually from that part of the arch which is formed by the end of the dorsal artery of the foot.

Thus, as in the fingers, *collateral* arteries pass along the sides of the flexor surface of each of the toes. Near the base of the last phalanx these inosculate so as to form an arch, from the convexity of which minute vessels pass forwards to the extremity of the toe, and to the matrix of the nail.

An *anterior perforating* branch is sent upwards by each of the digital arteries of the three outer interspaces near its bifurcation, to communicate with the corresponding digital branch of the metatarsal artery of the dorsum of the foot.

PECULIARITIES.—The posterior perforating branches, which are usually very small vessels, are sometimes enlarged, and furnish the interosseous arteries on the upper surface of the foot; the metatarsal branch of the dorsal artery, from which the interosseous arteries are usually derived, being in that case very small.

## ANTERIOR TIBIAL ARTERY.

The anterior tibial artery, placed along the fore part of the leg, is at first deeply seated, but gradually approaches nearer to the surface as it descends. It extends from the division of the popliteal artery to the bend of the ankle; whence it is afterwards prolonged to the interval between the first and second metatarsal bones, under the name of *dorsal artery* of the foot.

The anterior tibial artery is at first directed forwards to reach the anterior surface of the interosseous ligament, passing through the divided upper end of the tibialis posticus, and through the interval left unoccupied by the interosseous ligament. It then extends obliquely downwards to the middle of the ankle-joint, in a direction which may be nearly indicated by a line drawn from the inner side of the head of the fibula to midway between the two malleoli. Lying with the tibialis anticus on its inner side, and having the extensor communis digitorum and, lower down, the extensor proprius pollicis on its outer side, the vessel is deeply placed at the upper part of the leg, where those muscles are fleshy; but it is comparatively superficial below, between their tendons, and comes forward upon the tibia. At the bend of the ankle it is covered by the annular ligament, and is crossed from without inwards by the tendon of the extensor proprius pollicis. In its



oblique course downwards the anterior tibial artery lies at first close to the

Fig. 307.—ANTERIOR VIEW OF THE ARTERIES OF THE LEG AND DORSUM OF THE FOOT (from Tiedemann)  $\frac{1}{2}$

The tibialis anticus muscle is drawn towards the inner side so as to bring the anterior tibial artery into view, the extensor proprius pollicis, the long common extensor of the toes, and the peroneus tertius muscles in their lower part, and the whole of the extensor communis brevis, have been removed. 1, external superior articular branch of the popliteal artery, ramifying on the parts surrounding the knee; and anastomosing with the other articular branches and with 2, the recurrent branch of the anterior tibial artery; 3, 3, anterior tibial, giving off muscular branches on each side; 4, dorsal artery of the foot; 5, external anterior malleolar artery coming off from the anterior tibial, and anastomosing with the anterior peroneal artery which is seen descending upon the lower part of the fibula: the internal malleolar is represented proceeding from the other side of the anterior tibial artery; 6, the tarsal branch of the dorsal artery, represented in this instance as larger than usual and furnishing some of the branches of the next artery; 7, the metatarsal branch, giving off the dorsal interosseous arteries; (in the first interosseous space the dorsal artery of the foot is seen to give off the anastomosing branch which unites with the deep plantar arch;) between 8, and 8, the collateral branches of the dorsal digital arteries.

interosseous ligament, and is then at a considerable distance from the spine of the tibia; but in descending it gradually approaches that ridge, and towards the lower part of the leg is supported on the anterior surface of the bone.

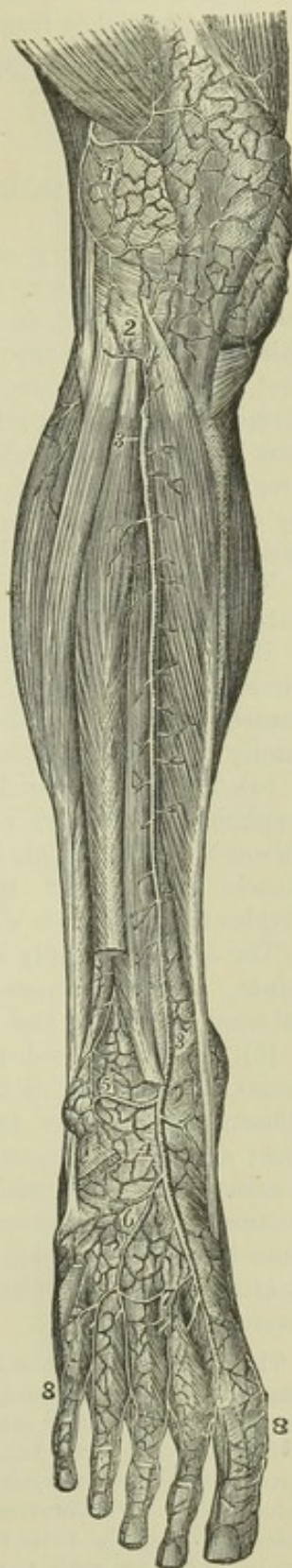
*Relation to Veins and Nerves.*—The anterior tibial artery is accompanied by two veins (*venæ comites*). The *anterior tibial nerve*, coming from the outer side of the head of the fibula, approaches the artery at some distance below the place where the vessel appears in front of the interosseous ligament. Lower down, the nerve for the most part lies in front of the artery, but often changes its position from the one side of the vessel to the other.

**BRANCHES.**—Besides numerous small muscular branches, the anterior tibial artery furnishes the following:—

(a) The *recurrent artery*, given off as soon as the anterior tibial reaches the front of the leg, ascends through the fibres of the tibialis anticus, and, ramifying on the outside and front of the knee-joint, anastomoses with the inferior articular and other branches of the popliteal artery.

(b) The *malleolar arteries*, two in number, external and internal, are given off near the ankle-joint, but are very variable in size and mode of origin. The *internal* branch passes beneath the tendon of the

Fig. 307.





tibialis anticus to the inner ankle, and communicates with branches of the posterior tibial artery. The *external* branch passes outwards under the tendon of the common extensor of the toes, and anastomoses with the anterior division of the peroneal artery, and also with some ascending or recurrent branches from the tarsal branch of the dorsal artery of the foot.—These malleolar arteries supply articular branches to the neighbouring joints.

### DORSAL ARTERY OF THE FOOT.

The dorsal artery of the foot (*dorsalis pedis*), the continuation of the anterior tibial artery, extends from the termination of that vessel at the bend of the ankle, to the posterior end of the first metatarsal space. At this spot it divides into two branches, of which one proceeds forwards in the first interosseous space, whilst the other dips into the sole of the foot, and terminates by inosculating with the plantar arch. The dorsal artery of the foot lies in the interval between the tendon of the proper extensor of the great toe, and that of the long extensor of the other toes; and is covered by a deep layer of fascia, which binds it to the parts beneath. Near its end it is crossed by the innermost tendon of the short extensor of the toes.

Two veins accompany this artery; the anterior tibial nerve lies on its outer side.

**BRANCHES.**—The principal branches of the dorsal artery of the foot are directed outwards and forwards upon the tarsus and metatarsus, and are named accordingly. Some small offsets also run obliquely inwards, and ramify upon the inner side of the foot.

(a) The *tarsal* branch arises from the artery usually where it crosses the scaphoid bone, but its point of origin varies in different instances. It inclines forwards and outwards upon the tarsal bones covered by the short extensor muscle of the toes, then curving backwards towards the cuboid bone, divides into branches which take different directions over the tarsus.

The *branches* supply the extensor brevis digitorum muscle and the tarsal joints, and anastomose with the external plantar, the metatarsal, the external malleolar, and the peroneal arteries.

(b) The *metatarsal* artery arises farther forwards than the preceding vessel, and is directed outwards like it, beneath the short extensor muscle. Sometimes there are two metatarsal arteries, the second being of smaller size; and not unfrequently, when there is but a single vessel of this name, it arises in common with the tarsal artery. Its direction is necessarily influenced by these circumstances; being oblique when it arises far back, and almost transverse when its origin is situated farther forwards than usual. It anastomoses with the tarsal and external plantar arteries, and gives off interosseous branches.

The three *interosseous* branches from the metatarsal artery are small straight vessels which pass forwards along the three outer interosseous spaces, resting upon the dorsal interosseous muscles. Somewhat behind the clefts between the toes each divides into two branches, which run forward along the contiguous borders of the corresponding toes, forming their dorsal collateral branches. Moreover, from the outermost of these interosseous arteries a small branch is given off, which gains the outer border of the little toe, and forms its external collateral branch. These arteries communicate with the plantar arch opposite the fore part of the interosseous spaces, by means of the *anterior perforating* branches, and at the back part of the interosseous spaces, by the *posterior perforating* branches.



(c) The first interosseous branch, or dorsal artery of the great toe, is con-

Fig. 308.—ANTERIOR VIEW OF THE ARTERIES OF THE LEG AND DORSUM OF THE FOOT (from Tiedemann).  $\frac{1}{4}$

The tibialis anticus muscle is drawn towards the inner side so as to bring the anterior tibial artery into view, the extensor proprius pollicis, the long common extensor of the toes, and the peroneus tertius muscles in their lower part, and the whole of the extensor communis brevis, have been removed. 1, external superior articular branch of the popliteal artery, ramifying on the parts surrounding the knee; and anastomosing with the other articular branches and with 2, the recurrent branch of the anterior tibial artery; 3, 3, anterior tibial, giving off muscular branches on each side; 4, dorsal artery of the foot; 5, external anterior malleolar artery coming off from the anterior tibial and anastomosing with the anterior peroneal artery which is seen descending upon the lower part of the fibula: the internal malleolar is represented proceeding from the other side of the anterior tibial artery; 6, the tarsal branch of the dorsal artery, represented in this instance as larger than usual and furnishing some of the branches of the next artery; 7, the metatarsal branch, giving off the dorsal interosseous arteries; (in the first interosseous space the dorsal artery of the foot is seen to give off the anastomosing branch which unites with the deep plantar arch;) between 8 and 8, the collateral branches of the dorsal digital arteries.

tinued forwards from the dorsal artery of the foot at the point where it dips down to the sole. This branch runs along the outer surface of the first metatarsal bone, and furnishes the small dorsal digital vessels of the great toe and adjacent side of the second toe.

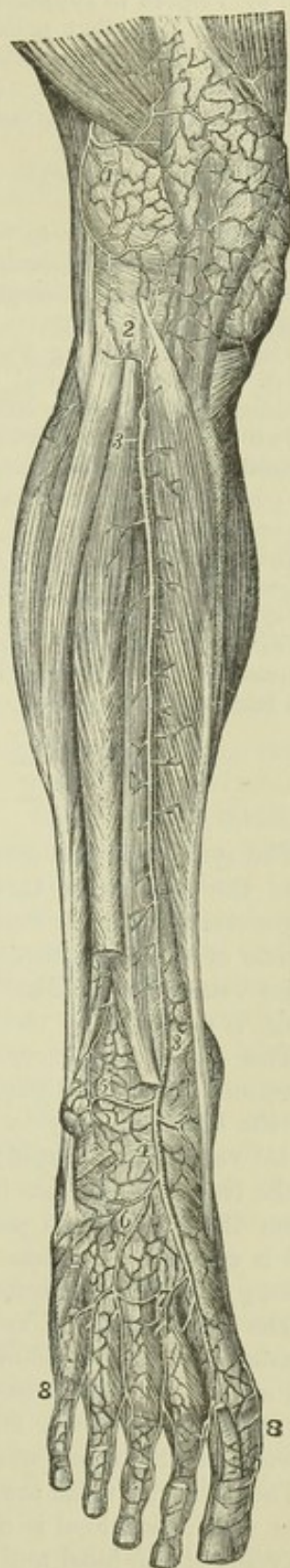(d) The plantar digital branch of the innermost space, given off from the dorsal artery between the heads of the first interosseous muscle, near the inosculation with the plantar arch, passing forwards divides into two smaller branches which proceed along the contiguous sides of the first and second toe.

(e) The plantar digital branch for the inner side of the great toe crosses beneath the first metatarsal bone, and runs along the inner side of the great toe on its plantar surface.

PECULIARITIES of the anterior tibial artery. *Origin.*

—In cases of early division of the popliteal artery, the place of origin of the anterior tibial is necessarily higher up than usual, being sometimes found as high as the bend of the knee-joint. In some of these cases (the posterior tibial artery being small or wanting), the anterior tibial is conjoined with the peroneal artery. When the anterior tibial arises higher than usual, the additional upper part of the vessel has been seen resting on the posterior surface of the popliteus muscle, and it has been likewise found between that muscle and the bone.

Fig. 308.





*Course.*—The anterior tibial artery, having its usual place of origin, has been found to deviate outwards towards the margin of the fibula in its course along the front of the leg, and then to return to its ordinary position beneath the annular ligament in front of the ankle-joint. This artery has been also noticed by Pelletan and by Velpeau to approach the surface at the middle of the leg, and to continue downwards from that point, covered only by the fascia and integument. Velpeau states that he found the artery to reach the fore part of the leg by passing round the outer side of the fibula. (Pelletan, "Clinique Chirurgicale," &c., p. 101: Paris, 1810. Velpeau, "Nouveaux Elémens de Médecine Opératoire," &c., t. i, pp. 137 and 537: Paris, 1837.)

*Size.*—This vessel more frequently undergoes a diminution than an increase of size.

It may be defective in various degrees. Thus, the dorsal branch of the foot may fail to give off digital branches to the great and second toes, which may be then derived from the internal plantar division of the posterior tibial. In a farther degree of diminution the anterior tibial ends in front of the ankle or at the lower part of the leg; its place being then taken by the anterior division of the peroneal artery, which supplies the dorsal artery of the foot; the two vessels (anterior tibial and anterior peroneal) being either connected together or separate.

Two cases are mentioned by Allan Burns, in which the anterior tibial artery was altogether wanting, its place in the leg being supplied by perforating branches from the posterior tibial artery, and on the dorsum of the foot by the anterior division of the peroneal artery.

The dorsal artery of the foot is occasionally larger than usual; in that case compensating for a defective condition of the plantar branch from the posterior tibial artery.

This artery has been repeatedly found to be curved outwards between its commencement at the lower border of the annular ligament and its termination in the first interosseous space.

## VEINS.

The systemic veins commence by small branches which receive the blood from the capillaries throughout the body, and unite to form fewer and larger vessels, which end at last by pouring their contents into the right auricle of the heart through two large venous trunks, the superior and inferior venæ cavæ. The blood which nourishes the substance of the heart itself, is returned by the coronary or cardiac veins to the same auricle.

The veins, however, which bring back the blood from the stomach, intestines, spleen and pancreas, have an exceptional destination; not conveying the blood directly to the heart, but joining to form a single trunk—the portal vein, which ramifies after the manner of an artery in the substance of the liver, and carries the blood within it to the capillaries of that organ. From these the blood passes into the ultimate twigs of the hepatic veins, and is conveyed by these veins into the inferior vena cava. The veins thus passing to the liver constitute the *portal system*.

The anastomoses of veins are much larger and more numerous than those of arteries. The veins of many parts of the body consist of a subcutaneous and a deep set, which have very frequent communications with each other. In some parts of the body, chiefly the limbs and surface, the veins are provided with valves, whilst in others no valves exist.

The systemic veins are naturally divisible into two groups: firstly, those from which the blood is carried to the heart by the superior vena cava, viz., the veins of the head and neck and upper limbs, together with those of the spine and a part of the walls of the thorax and abdomen, with which may be associated also the veins of the heart; and secondly, those from which



the blood is carried to the heart by the inferior vena cava, viz., the veins of the lower limbs, the lower part of the trunk, and the abdominal viscera. (For a general representation of the venous system, see fig. 224 at p. 298.)

### UPPER VENA CAVA.

The *upper vena cava* conveys to the heart the blood which is returned from the head, the neck, the upper limbs, and the thorax. It is formed by the union of the right and left brachio-cephalic veins. It extends from a little below the cartilage of the first rib on the right side of the sternum to the base of the heart, where it opens into the right auricle. Its course is slightly curved, the convexity of the curve being turned to the right side. It has no valves. At about an inch and a half above its termination, it is invested by the fibrous layer of the pericardium, the serous membrane being reflected over it. The upper cava lies immediately in front of the right pulmonary vessels, and between the right lung and the aorta, which partly overlap it. It receives several small veins from the pericardium and the mediastinum; and lastly, it is joined by the right azygos vein, immediately above the place where it becomes invested by the pericardium.

**PECULIARITY.**—In several instances, the two innominate veins, which usually join to form the vena cava superior, have been seen to open separately into the right auricle. This peculiarity is explained by reference to the development of the parts, and is more fully referred to at p. 485, in connection with the description of the great cardiac vein.

### INNOMINATE OR BRACHIO-CEPHALIC VEINS.

The blood returned from the upper limbs through the subclavian veins, and from the head and neck by the jugular veins, is poured into two trunks, named the brachio-cephalic or innominate veins. These vessels, resulting from the union of the subclavian with the internal jugular vein at each side, commence opposite the inner ends of the clavicles, and terminate a little below the cartilage of the first rib on the right side, where, by uniting, they form the upper vena cava. The right vein is very short, and nearly vertical in its direction; it is in apposition, on the right side, with the pleura and the upper part of the right lung. The vein of the left side, about three times longer than the right vein, pursues a course from left to right, at the same time inclining somewhat downwards: it crosses behind the upper part of the first bone of the sternum, separated from it by the sterno-hyoid and sterno-thyroid muscles, and by the thymus gland or its remains; it lies in front of the three primary branches given off from the arch of the aorta, and rests upon the highest part of the arch. The innominate veins have no valves.

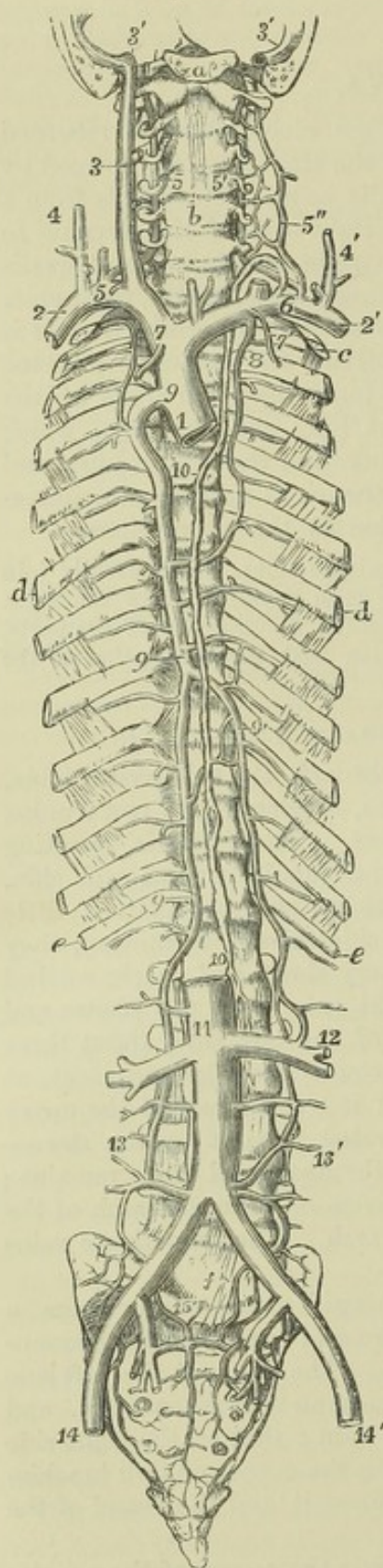
**LATERAL TRIBUTARIES.**—(a) The *inferior thyroid* veins emerge from a venous plexus situated on the thyroid body—those of opposite sides communicating by small branches across the trachea. The vein of the left side descends in front of the trachea, behind the sterno-thyroid muscles, and ends in the left brachio-cephalic or innominate vein: that of the right side inclines outwards in some degree, and opens into the corresponding brachio-cephalic vein, or into the angle of union between it and the vessel of the opposite side.

(b) The *internal mammary* veins follow exactly the course of the arteries of the same name—two veins accompanying each of the arteries. The two companion veins of the artery arise by small branches, derived from the



fore part of the walls of the abdomen, where they anastomose with the

Fig. 309.

Fig. 309.—SKETCH OF THE PRINCIPAL VENOUS TRUNKS, TOGETHER WITH THE THORACIC DUCT.  $\frac{1}{2}$ 

*a*, the basilar process of the occipital bone, through which and the temporal bones a transverse incision has been made so as to lay open the jugular foramen on both sides; *b*, the body of the fifth cervical vertebra; *c*, the first rib; *d*, the sixth; *e*, the twelfth; *f*, the body of the fifth lumbar vertebra; 1, trunk of the vena cava superior divided at the place of its entrance into the right auricle; 2, right, 2', left subclavian veins; 3, right internal jugular vein; the left is cut short immediately above the place where it joins the subclavian vein; 3', 3', lower part of the lateral sinuses of the dura mater; that of the left side is divided inferiorly; that of the right side shows at its junction with the jugular vein the bulb which lies in the jugular depression of the temporal bone; 4, right, and 4', left external jugular veins; 5, right, and 5', left vertebral veins anastomosing with 5'', external vertebral veins, before joining the subclavian veins; 6, placed on left subclavian vein below the opening of the last, and of the thoracic duct; below *b*, the inferior thyroid veins; 7, 7', the internal mammary veins; 8, the left superior intercostal vein joining the left brachio-cephalic vein, and anastomosing below with intercostal veins which join the trunk of the azygos; the right superior intercostal vein is seen joining the azygos vein; 9, main or right azygos vein; the uppermost figure points to the curved portion, which passes over the right bronchus before joining the vena cava superior; 9', the left azygos, represented here as crossing the vertebral column on the eighth vertebra; 10, the thoracic duct; the upper figure is on the fourth dorsal vertebra, the lower on the first lumbar close to the receptaculum chyli; 11, trunk of the inferior vena cava divided below the liver; the figure is immediately over the place of origin of the renal veins; below it is seen dividing on the fourth lumbar vertebra into the two common iliac veins; 12, the union of the left azygos vein with the left renal vein; 13, on the right side, the commencement of the right azygos vein in the lumbar region, joined by several lumbar veins; 13', the commencement of the azygos vein of the left side, joining similar veins on that side; 14, 14', the external iliac veins; 15, placed on the promontory of the sacrum, points on either side to the prolongation of the lower branches of the right and left lumbar veins into the pelvis, and their union with sacral and other branches of the internal iliac veins.

epigastric veins; from thence proceeding upwards between the cartilages of the ribs and the pleura, they receive the *anterior intercostal* veins which correspond with the branches of the internal mammary artery,

together with some small *diaphragmatic*, *thymic* and *mediastinal* veins, and



these finally uniting into a single trunk, each vein terminates in the brachio-cephalic of its own side.

(c) The *superior intercostal veins*. — The right superior intercostal vein receives the blood from the first or the first two or three spaces, communicating with the vessel in the space next below, and opens into the innominate trunk on the same side, or into the vena cava. Frequently the veins at the right side, corresponding with the superior intercostal artery, pass downwards separately, to open into the azygos vein, as that vessel arches forwards to join the upper vena cava: the separate vein thus formed is inferior in size to that on the left side. The *left superior intercostal vein* varies in length in different persons, being small when the azygos minor is large, and *vice versâ*. Usually it receives the veins from the three or four upper spaces, and is then directed forwards over the left side of the spinal column and the aorta to open into the left innominate vein. It receives in its course the left bronchial vein. The left vein is sometimes directed downwards to join an azygos vein on its own side.

### VEINS OF THE FACE, NECK, AND HEAD.

The blood returning from the head and neck flows on each side into two principal veins, the external and internal jugular. The veins of the head and neck have generally no valves. The external jugular vein is provided with a valve at its entrance into the subclavian vein, and in most cases with another about the middle of its course: and the internal jugular is also furnished with valves near its junction with the subclavian. These valves, however, are not efficient in stopping the regurgitation of the blood, or the passage of injections from below upwards.

The veins on the exterior of the cranium and face converge and unite, so as to form two trunks, the facial and the temporal veins.

#### THE FACIAL VEIN.

The *facial vein* lies obliquely along the side of the face, extending from the inner margin of the orbit downwards and outwards to the anterior border of the masseter muscle. Resting on the same plane as the facial artery, but farther back, and less tortuous, it has very nearly the same relations to contiguous parts. It commences at the side of the root of the nose by a vein formed by the junction of branches from the forehead, eyebrow and nose, and increases by receiving others during its course. Below the jaw it inclines outwards and backwards, covered by the cervical fascia and the platysma muscle; and soon unites with a large branch of communication derived from the temporal vein, to form the *temporo-maxillary or common facial vein*, a short vessel of considerable size, which joins obliquely the trunk of the internal jugular.

TRIBUTARIES.—(a) The *frontal vein* commences on the roof of the skull by branches, which descend obliquely inwards upon the forehead, maintaining communications in their course with the anterior branches of the temporal vein. It descends vertically, parallel with the corresponding vessel of the opposite side, with which it is connected by transverse branches, and ends in the angular vein. In some instances the veins of the two sides unite and form a short trunk, which again divides into two branches at the root of the nose. As it descends from the forehead, the frontal vein receives a branch from the eyebrow, and some, of smaller size, from the nose and upper eyelid.



(b) The *supra-orbital* vein (v. *supercilii*) runs inwards in the direction of the eyebrow, covered by the occipito-frontalis muscle. Its branches are connected externally with those of the external palpebral and superficial temporal veins; in its course it receives branches from the contiguous muscles and integument, and at the inner angle of the orbit inclines downwards to terminate in the frontal vein.

Fig. 310.

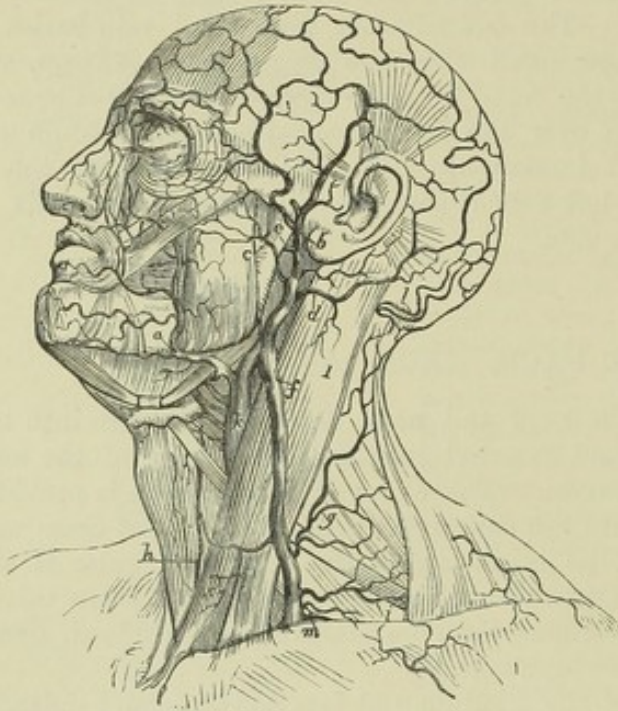


Fig. 310.—VIEW OF THE SUPERFICIAL VEINS OF THE HEAD AND NECK.

1, sterno-mastoid muscle; a, facial vein; b, temporal vein; c, transverse facial; d, posterior auricular; e, internal maxillary vein; f, external jugular vein; g, posterior external jugular; h, anterior jugular; i, posterior scapular and suprascapular veins; k, internal jugular vein; l, occipital veins; m, subclavian vein: above the inner side of the orbit are shown the frontal and supra-orbital veins, and their descending branches to anastomose with the angular or terminal branch of the facial vein.

(c) The *angular* vein, formed by the junction of the supra-orbital and frontal veins, is perceptible beneath the skin as it runs obliquely downwards and outwards near the inner margin of the orbit, resting against the side of the nose at

its root. This vessel receives on the inner side the *nasal veins*, which pass upwards obliquely to join it from the side and ridge of the nose; whilst some small *superior palpebral* veins open into it from the opposite direction. On a level with the lower margin of the orbit it becomes continuous with the facial vein.

(d) The *inferior palpebral* veins, two or three in number, are derived from the lower eyelid, from the outer side of the orbit, and from the cheek. They pass in a direction obliquely inwards above the zygomatic muscle, and then turn beneath it previously to their termination.

(e) *Communicating* branches from the pterygoid plexus (deep facial, anterior internal maxillary); and also some branches proceeding from the orbit, furnished by the *infra-orbital* of the internal maxillary vein, join the facial on a level with the angle of the mouth.

(f) *Labial, buccal, masseteric* and *mental* branches join the facial below the angle of the mouth.

(g) The *ranine* vein, a small vessel which lies along the under surface of the tongue, close to the frænum linguæ, is in apposition with the artery of the same name: its course is backwards and outwards, between the mylo-hyoid and hyo-glossus muscles, to open into the facial vein, or sometimes into the lingual.

(h) The *submental* vein, larger than the preceding, commences below the chin; it receives branches from the submaxillary gland, and from the mylo-hyoid muscle, and, keeping close under cover of the margin of the jaw-bone, joins the facial vein; but in some instances it enters the lingual or superior thyroid vein.

(i) *Submaxillary* branches from the gland join the facial vein either separately or united into one trunk.

(j) The *palatine* vein returns the blood from the plexus round the tonsil and



from the soft palate; it passes downwards, deeply seated by the side of the pharynx, to join one of the preceding veins, or terminate in the facial separately.

#### THE TEMPORAL VEIN.

The *temporal* vein, a vessel of considerable size, descends in front of the external auditory tube, reaching from the zygoma, upon which it rests, to the angle of the jaw. It results from the union of branches which are spread out upon the side of the head, some superficially, and others deeply seated. The *superficial* branches commence upon the arch of the skull, where they communicate with the ramifications of the frontal and occipital veins, as well as with those of the corresponding vein of the opposite side. Descending on the surface of the temporal fascia, they converge; those from the fore part inclining a little backwards, while the posterior branches run forwards over the ear; and the two sets joining together above the zygoma form the trunk of the temporal vein. The deeper branches, arising in the substance of the temporal muscle, unite to form a vein of some size, called the *middle temporal*, to distinguish it from branches still more deeply placed, and which open into the internal maxillary vein. The middle temporal vein falls into the common temporal trunk at its commencement above the zygoma. The temporal vein gradually sinks into the substance of the parotid gland as it descends behind the ramus of the jaw. Beneath the angle of that bone, it divides into two vessels, one of which turns backwards, and forms the commencement of the external jugular vein, while the other communicates with the facial vein near its termination.

**LATERAL TRIBUTARIES.**—These are numerous:—(a) *parotid* branches from the parotid gland; (b) *articular*, from the articulation of the jaw; (c) *anterior auricular* veins from the external ear; (d) the *transverse facial*, a branch of considerable size, corresponding with the transverse facial artery; (e) the *posterior auricular* directed forwards from behind, and joined by the stylo-mastoid vein; and (f) the *internal maxillary* vein, a large vessel, which requires more particular description.

#### THE INTERNAL MAXILLARY VEIN.

The *internal maxillary* vein corresponds somewhat in direction and position with the artery of the same name, and receives branches from the neighbouring parts, most of which are the *venæ comites* of the corresponding divisions of the internal maxillary artery. Thus three or four *deep temporal* branches descend from the temporal muscle; others come from the pterygoid, masseter, and buccinator muscles. The middle *meningeal* veins and some *palatine* veins also end in the internal maxillary; and lastly, branches from the surface of the upper jaw—*superior dental*, and another, of large size, from the lower jaw, emerging from the dental foramen—*inferior dental*. These different branches form a plexus of veins, named *pterygoid plexus*, which is placed in the lower part of the temporal fossa, between the temporal and the external pterygoid muscle, and in part between the pterygoid muscles. It communicates in front with the facial vein, and above, with the cavernous sinus by branches through the base of the skull. From this plexus proceed one or two short trunks, which join nearly at right angles with the temporal vein.

The **FACIAL COMMUNICATING** vein, extending between the temporal vein at the angle of the jaw and the facial vein, a little in front of it, is a short trunk, usually the larger of the two into which the temporal vein divides, and placed nearly transversely, so as to allow the flow of blood either from



the temporal into the internal jugular vein, or from the facial into the external jugular.

Fig. 311.

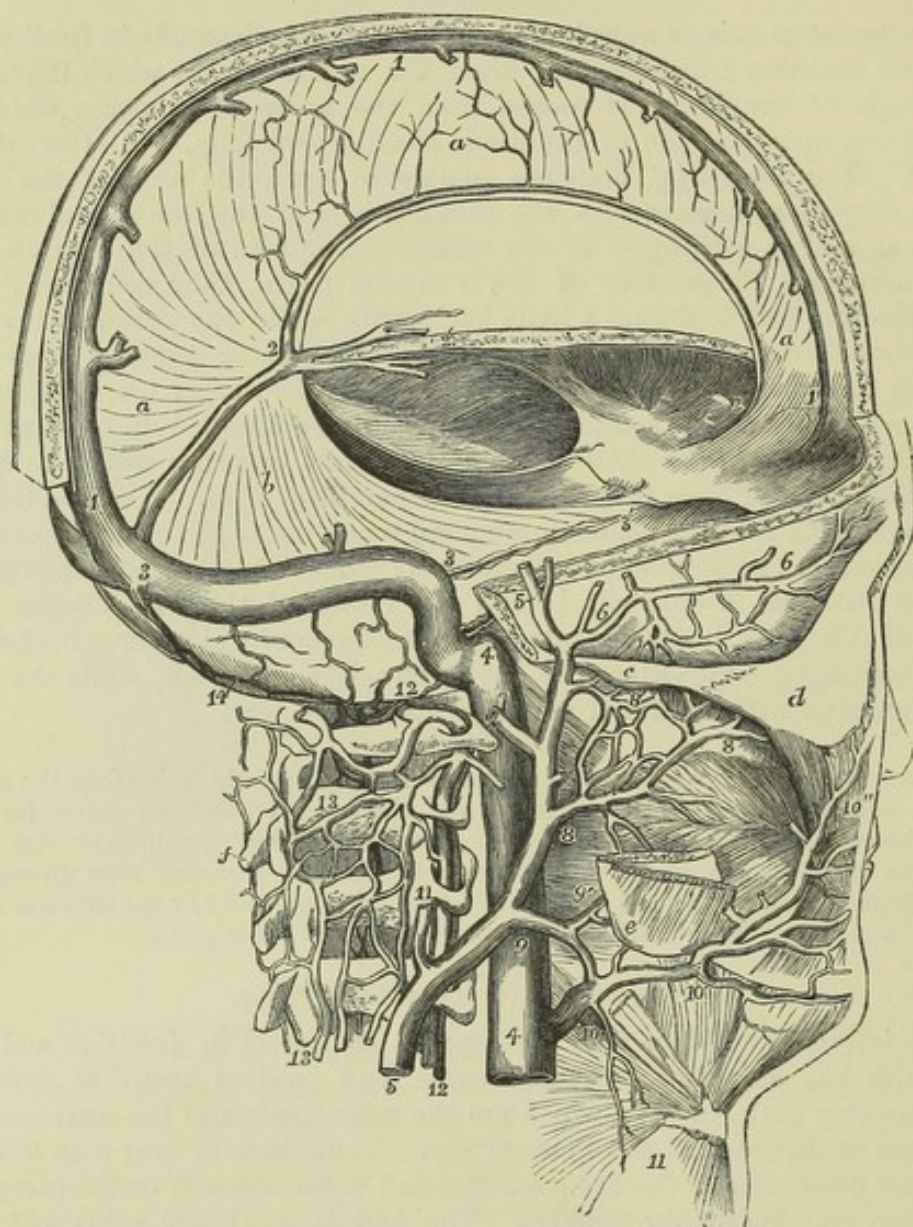


Fig. 311.—DIAGRAMMATIC VIEW OF THE SINUSES OF THE DURA MATER AND SOME OF THE DEEP VEINS OF THE NECK AND HEAD (modified from Cloquet and other sources).  $\frac{1}{2}$

The greater part of the calvarium has been removed ; but an arched strip has been kept in the fore and upper part of the region of the superior longitudinal sinus. The occiput has been entirely removed so as to expose the lateral sinus and its termination in the jugular vein. *a*, the falx cerebri ; *b*, the tentorium cerebelli of the right side ; *c*, zygomatic arch ; *d*, malar bone ; *e*, angle of the jaw ; *f*, spinous process of the axis vertebra ; 1, superior longitudinal sinus ; 2, inferior longitudinal sinus ; 2, 3, straight sinus ; 2', internal veins of the brain (veins of Galen) ; 3, lateral sinus, descending to 4, the commencement of the internal jugular ; 3', superior petrosal sinus ; 4, 4, the internal jugular vein ; 5, 5, superficial temporal vein, leading into the external jugular vein ; 6, middle temporal ; 7, posterior auricular ; 8, internal maxillary ; 8', pterygoid plexus and communications with the deep temporal veins ; 9, communicating branch between the facial, temporal and external jugular ; 9', pharyngeal branches ; 10, facial vein ; 10', submental branch ; 10'', continuation of the facial into the angular ; 11, an occasional branch from the neck ; 12, vertebral vein and artery ; 13, external spinal veins forming a plexus over the vertebral arches ; 14, occipital sinus communicating above the atlas with the spinal plexus.



## THE EXTERNAL JUGULAR VEIN.

The *external jugular vein* commences on a level with the angle of the lower maxilla, at the end of the temporal vein, and descends perpendicularly between the platysma and fascia, crossing the sterno-mastoid muscle. In consequence of the oblique direction of that muscle, the vein gets to its outer border, and continues behind it down to the lower part of the neck, where it pierces the fascia to terminate either as a single trunk, or by two or three branches in the subclavian vein. It is provided with a valve at its lower end, and in most cases with another about the middle of its course.

TRIBUTARIES.—The external jugular vein receives some large branches from behind, and superficial branches from the fore part of the neck. The largest branches are the following :—

(a) The *posterior branch*, lying at first between the splenius and trapezius muscles, passes down at the outside of the jugular vein, and below the middle of the neck opens into that vessel.

(b) The *supra-scapular* and *posterior scapular* veins, corresponding to the arteries of the same name, pass transversely inwards to join the external jugular vein close to its termination.

The *anterior jugular vein* arises from the convergence of some superficial branches in the submaxillary region. This vessel lies along the fore part of the neck, sometimes near the sterno-mastoid muscle, and either terminates by inclining outwards to join the external jugular vein, or, after giving to it a branch of communication, sinks beneath the sterno-mastoid muscle, and ends in the subclavian vein. The lower ends of the two anterior jugular veins are frequently united by a transverse branch placed behind the sterno-mastoid muscles and top of the sternum.

The external jugular vein is very variable in size. It is frequently very small, and may be absent altogether. The anterior jugular vein is likewise very variable.

## INTERNAL JUGULAR VEIN.

The *internal jugular veins*, receiving the blood from the brain and cranial cavity, are continuous at their upper extremities with the lateral sinuses within the cranium, and terminate inferiorly in the innominate or brachio-cephalic veins. The commencement of each internal jugular vein at the wide part (*jugular fossa*) of the foramen jugulare, is somewhat enlarged, and has been named the *sinus* or *gulf* of the internal jugular vein. Beneath the skull, the vein is supported by the rectus lateralis muscle, and lies close to the outer side of the internal carotid artery, as far as the cornu of the os hyoides. It is joined at this point by the common facial vein, and becomes considerably enlarged; it then descends parallel with the common carotid artery, lying at its outer side and enclosed in the same sheath, together with the vagus nerve. At the root of the neck it joins nearly at a right angle with the subclavian vein, and so forms the innominate or brachio-cephalic vein. Close to the lower termination of the jugular, or from half an inch to an inch above it, is placed a double valve as in other veins. ("Struthers, Anat. and Phys. Observ.," p. 173.)

TRIBUTARIES.—Previously to its junction with the facial vein, the internal jugular receives the lingual, pharyngeal, and occipital veins; one or more of which, however, very frequently end in the common facial trunk.

(a) The *lingual vein* begins at the side and upper surface of the tongue, and passes backwards, receiving branches from the sublingual gland; occasionally the ranine vein joins it, and sometimes also the pharyngeal.



(b) The *pharyngeal* vein commences at the back and sides of the pharynx, and sometimes ends in the superior thyroid vein, and at other times in the lingual, or separately in the internal jugular vein.

(c) The *occipital* vein, corresponding in course and distribution with the occipital artery, communicates with a plexus of veins upon the occiput, and terminates occasionally in the external jugular vein, but more frequently in the internal.

(d) The *common facial* vein has been already described.

(e) The *laryngeal* vein receives branches from the larynx through the thyro-hyoid membrane, and opens into the internal jugular, the common facial, or sometimes into the superior thyroid vein.

(f) The *superior thyroid* vein commences by branches in the thyroid body, in company with those of the superior thyroid artery, and runs transversely outwards.

(g) The *middle thyroid* vein, likewise derived from the thyroid body, is placed lower than the superior thyroid.

#### VENOUS CIRCULATION WITHIN THE CRANIUM.

The part of the venous system contained within the skull consists of veins properly so called, and of certain channels called *sinuses*, which receive the blood from those veins, and conduct it to the internal jugular veins. The sinuses alluded to are spaces left between the layers of the dura mater, the fibrous covering of the brain.

#### CEREBRAL VEINS.

The veins of the brain are divisible into those which ramify upon its surface, and those which are placed within its ventricles.

The *superficial* veins upon the upper surface of the hemispheres are for the most part lodged in the tortuous sulci between the convolutions; but some run over the convexity of the convolutions. Their general direction is towards the middle line; and on reaching the margin of the longitudinal fissure between the hemispheres, they receive branches from the flat mesial surface of the hemispheres, and, becoming invested by tubular sheaths of the arachnoid membrane, incline obliquely forwards and open in that direction into the superior longitudinal sinus.

The veins upon the sides and under surface of the brain are directed outwards, to open into the lateral and other sinuses at each side.

The *deep* veins of the brain commence by branches within the ventricles of that organ. Upon the surface of the corpus striatum, for example, several small venous branches are seen, which for the most part converge to form a slender vein which runs along the groove between the corpus striatum and optic thalamus, and opens into one of the veins of the choroid plexus. The minute veins of the *choroid plexus* pass backwards, and incline towards the middle line from each side, so as to form, by their union, two veins—*venæ Galeni*. These, lying parallel, run directly backwards, enclosed within the velum interpositum, and escape from the interior by passing through the great transverse fissure of the brain between the under surface of the corpus callosum and the tubercula quadrigemina. In this way they reach the anterior margin of the tentorium cerebelli, at its place of union with the falx cerebri, where they terminate by opening into the straight sinus.

The veins of the cerebellum are disposed in two sets. Those of the upper surface incline inwards and forwards for the most part, and run upon the upper vermiform process, over which they ascend a little to reach the straight sinus, in which they terminate; some, farther forward, open



into the veins of Galen. Those at the under surface run transversely outwards, and pour their contents into the occipital and the lateral sinuses.

Fig. 312.

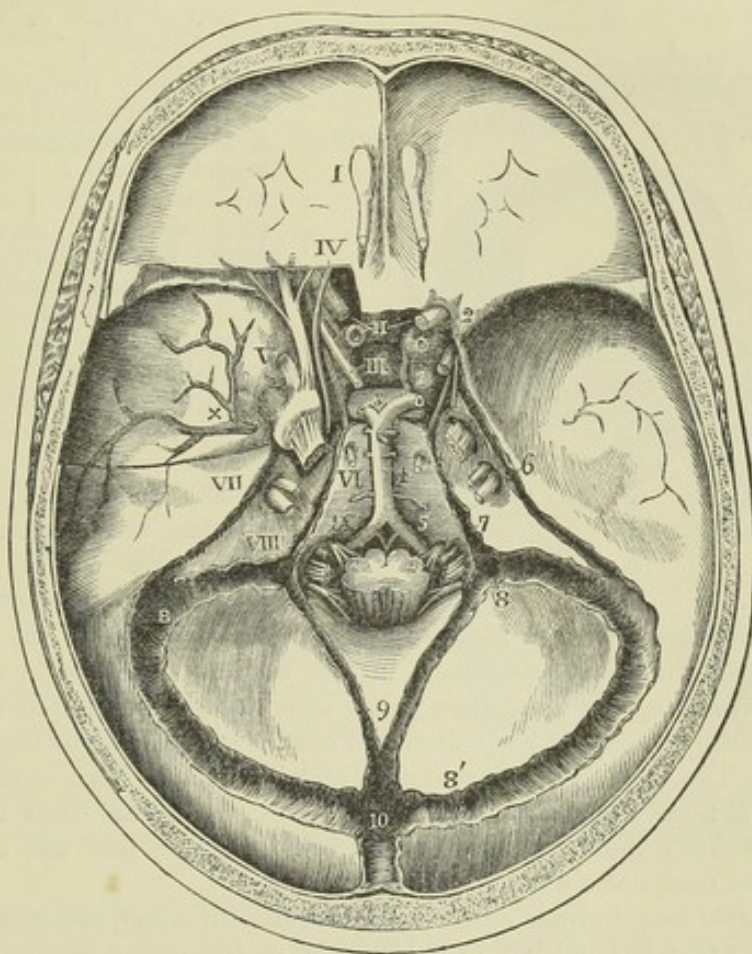


Fig. 312.—INTERNAL VIEW OF THE BASE OF THE SKULL, SHOWING THE SINUSES OF THE DURA MATER, &c.  $\frac{1}{2}$

The sinuses of the dura mater have been opened, a small portion of the roof of the orbit has been removed posteriorly on the left side, and the dura mater has been dissected so as to bring into view the arteries at the base of the skull, the venous sinuses and the issue of the cerebral nerves.

I., the olfactory bulb; II., the optic nerves, that on the left side cut short; III., placed on the pituitary body, indicates the third nerve; IV., the trochlear nerve; V., placed opposite to the middle of the three divisions of the fifth nerve as they pass out of the cranium; VI., the sixth nerve; VII., the facial and auditory nerves entering the meatus auditorius internus; VIII., placed opposite to the three portions of the eighth pair as they pass into their several foramina of the dura mater; IX., the hypoglossal nerve as it passes to the anterior condyloid foramen; 1, the right internal carotid artery as it makes its turn in the cavernous sinus on the groove of the sphenoid bone; 2, its ophthalmic branch proceeding into the orbit, below and to the outside of the optic nerve; 3, division of the basilar artery into the two posterior cerebral arteries, one of which is represented on the right side as giving off the communicating artery to the internal carotid; 4, basilar artery; 5, vertebral arteries giving the anterior spinal; x, great meningeal vessels spreading upwards from the foramen spinosum; 6, superior petrosal sinus; 7, inferior petrosal running back into the lower part of the lateral sinus; 8, termination of the lateral sinus in the internal jugular vein, and continuation of the lateral sinus; 8', commencement of the lateral sinus; 9, occipital sinuses; 10, torcular Herophili, and below that number in the figure, the superior longitudinal sinus.

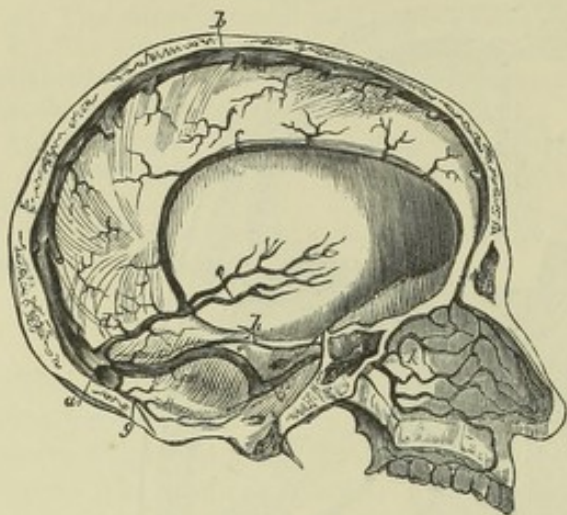
#### CRANIAL SINUSES.

The venous sinuses within the cranial cavity admit of being divided into



two sets, viz., those placed in the prominent folds of the dura mater, and those situated in the base of the skull.

Fig. 313.

Fig. 313. — SKETCH OF THE INTERNAL VEINS OF THE CRANIUM AND NOSE.  $\frac{1}{4}$ 

*a*, torcular Herophili; *b*, superior longitudinal sinus of the dura mater; *c*, inferior longitudinal sinus; *d*, straight sinus; *e*, internal veins of the brain, or veins of Galen; *g*, occipital sinus; *h*, superior petrosal sinus; *i*, inferior petrosal sinus; *k*, nasal veins on the septum; superiorly is shown the commencement from some of these of the superior longitudinal sinus, and lower down some of the nasal veins passing out by the spheno-palatine foramen.

The form and size of the sinuses are various. All of them are lined by a continuation of the internal mem-

brane of the veins, the dura mater serving as a substitute for the other coats.

The sinuses which are contained in the several processes or folds of the dura mater converge to a common point, which corresponds with the internal occipital protuberance, and is called the *confluence of the sinuses*, or *torcular Herophili*. The form of the torcular is very irregular. Five or six apertures open into it: viz., one from the longitudinal, and one from the straight sinus; two from the right and left lateral sinuses; and one or two from the posterior occipital sinuses.

The *superior longitudinal sinus* (s. *falciformis superior*), commencing at the crista galli, extends from before backwards, in the upper border of the falx cerebri, gradually increasing in size as it proceeds. It is three-sided, and is crossed obliquely at the inferior angle by several bands, the *chordæ Willisii*. The veins from the cerebral surface open into this sinus chiefly towards the back part; and in such a way that the apertures of the greater number of them are directed from behind forwards, contrary to the direction of the current within it. The longitudinal sinus communicates with the veins on the outside of the occipital bone, by a branch (one of the "emissary veins," Santorini) which passes through a hole in the parietal bone.

The *inferior longitudinal sinus* (s. *falciformis inferior*) is very small, and so much resembles a cylindrical vein, that it is sometimes named *inferior longitudinal vein*. Placed in the inferior concave border of the falx cerebri, it runs from before backwards, and opens into the straight sinus on reaching the anterior margin of the tentorium cerebelli. It receives branches from the surface of the falx cerebri, and sometimes from the flat surface of the hemispheres.

The *straight sinus* (s. *quartus*; s. *tentorii*) runs backwards in the base of the falx cerebri, gradually widening as it approaches the torcular Herophili, in which it terminates. Besides the inferior longitudinal sinus, the *venæ Galeni* and the superior veins of the cerebellum open into it.

The *lateral sinuses* (s. *transversi*) are of considerable size. Their direction conforms to that of the groove marked along the inner surface of the occipital and other bones, and extending from opposite the internal occi-



pital protuberance to the foramen jugulare. The sinus of the right side is usually larger than that of the left; both commence at the torcular Herophili, and terminate in the jugular veins. The lateral sinuses receive the blood transmitted from both the longitudinal sinuses, from the straight and occipital sinuses, from the veins upon the sides and base of the brain, from those on the under surface of the cerebellum, and from some of the veins of the diploë. The petrosal sinuses also join the lateral sinus on each side: and two *emissary* veins connect these with the veins at the back of the head and neck.

Fig. 314.—SKETCH OF THE VENOUS SINUSES IN THE BASE OF THE CRANIUM, WITH THE OPHTHALMIC VEIN.

*a*, sella turcica and circular sinus; *b*, cavernous sinus receiving *c*, the ophthalmic vein; *d*, superior petrosal; *e*, inferior petrosal sinus; *f*, transverse sinus; *g*, occipital; *h*, lateral; *i*, termination of the superior longitudinal in the torcular Herophili.

The *posterior occipital sinus* is sometimes a single canal, not unfrequently double, as if composed of two compartments. It lies along the attached border of the falx cerebelli, extending from the posterior margin of the foramen magnum to the confluence of the sinuses. It communicates in front with the posterior spinal plexuses of veins.

The sinuses placed at the base of the skull are as follows, taking them in their order from before backwards:

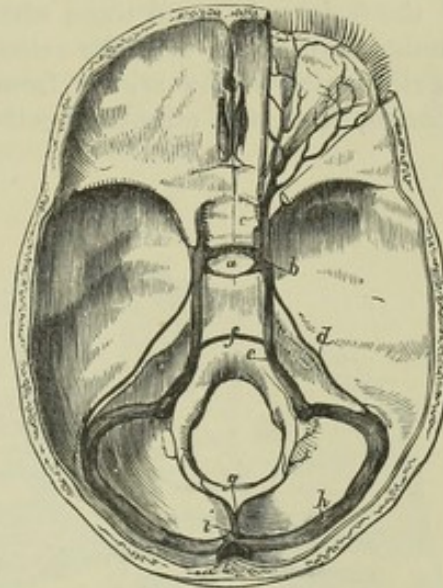
The *circular sinus* has the form of a ring, and is placed superficially in the margin of the dura mater round the pituitary body; it receives the blood from the minute veins of the pituitary body, and communicates at each side with the cavernous sinus. Sometimes it is only partially developed, the part in front of the gland being that usually present: sometimes, however, it is behind the gland.

The *cavernous sinuses* placed one on each side of the body of the sphenoid bone, over the bases of the great wings, and stretching from the sphenoidal fissure to the apex of the petrous portion of the temporal bones, are of considerable size, and of very irregular form. Each receives the ophthalmic vein at its fore part, and communicates internally with the circular sinus, and posteriorly with the petrosal sinuses. In the wall of each, separated by the lining membrane from the cavity of the sinus, pass forward the third, fourth, and sixth cranial nerves, the ophthalmic division of the fifth nerve, and the internal carotid artery.

The *upper petrosal sinus* is a narrow canal running along the upper margin of the petrous part of the temporal bone. Commencing at the back part of the cavernous sinus, it is directed outwards and backwards in the attached margin of the tentorium cerebelli; and descending a little, ends in the lateral sinus where this lies upon the temporal bone.

The *lower petrosal sinus*, wider than the upper, passes downwards and backwards along the inferior margin of the petrous bone, between this and

Fig. 314.





the basilar process of the occipital bone. It opens into the lateral sinus near the termination, or into the internal jugular vein.

The *anterior occipital* or *transverse sinus* (sinus basilaris) is placed at the fore part of the basilar process of the occipital bone, so as to establish a transverse communication between the opposite inferior petrosal and the cavernous sinuses.

#### OPHTHALMIC VEIN.

The ophthalmic vein opens into the cavernous sinus. Its branches are distributed in the different structures contained within the orbit, in company with the branches of the ophthalmic artery: some small ramifications arise from the eyelids, whilst others communicate with the angular branch of the facial vein; and those which accompany the supraorbital artery have similar connections with the veins upon the forehead. All these branches, together with others arising from the lachrymal gland, from the different muscles, from the ethmoidal cells, and from the globe of the eye, severally

Fig. 315.

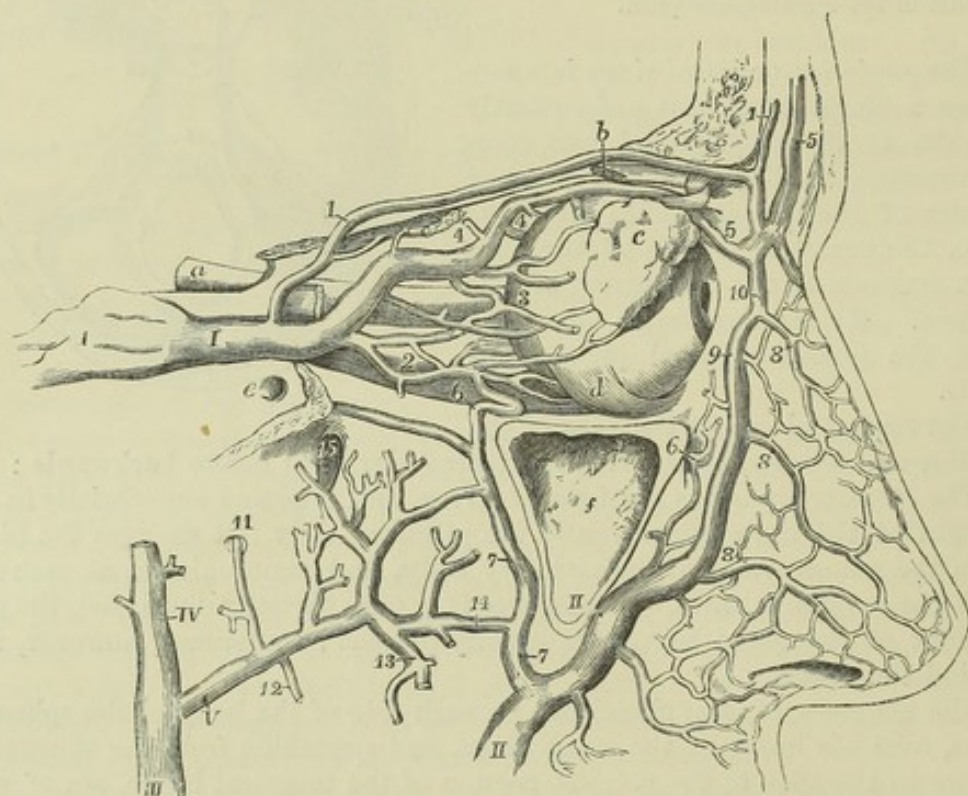


Fig. 315.—SKETCH OF THE OPHTHALMIC VEIN, AND OF ITS DISTRIBUTION AND COMMUNICATION WITH OTHER VEINS (altered from Hirschfeld and Leveillé).

The orbit is opened from the outer side and the dissection is similar to that for displaying the ophthalmic artery (represented in Figure 260, at p. 361); *a*, the optic nerve before it enters the optic foramen; *b*, the superior oblique muscle divided before it passes through its pulley; *c*, the lachrymal gland lying upon the eyeball; *d*, the insertion of the inferior oblique muscle; *e*, foramen rotundum; *f*, sinus maxillaris, opened externally; *I*, the ophthalmic vein joining the cavernous sinus; 1, supraorbital branch; 2, muscular and lachrymal branches; 3, ciliary; 4, anterior and posterior nasal or ethmoidal; 5, frontal; 6, infraorbital; *II*, facial vein; 7, communication with the internal maxillary; 8, external nasal; 9, angular, communicating at 10, with the frontal and supraorbital; *III*, external jugular vein commencing at the junction of *IV*, the temporal and *V*, the internal maxillary veins; 11, meningeal branch; 12, inferior dental; 13, muscular; 14, communication between the facial, malar and infraorbital; 15, placed in the sphenomaxillary fossa above branches connected with the pterygoid plexus.



named according to the arterial branches which they accompany, join to form a short single trunk, which leaves the orbit by the inner part of the sphenoidal fissure, where it is placed between the heads of the external rectus muscle, and terminates in the cavernous sinus.

Not unfrequently one of the frontal veins is much larger than the others, and descending vertically near the middle of the forehead, joins the facial and a branch of the ophthalmic vein on one side of the root of the nose.

## VEINS OF THE DIPLOË.

The veins of the diploë of the cranial bones are only to be seen after the pericranium is detached, and the external table of the skull carefully removed by means of a file. Lodged in canals hollowed in the substance of the bones, their branches form an irregular network, from which a few larger vessels issue. These are directed downwards at different parts of the cranium, and terminate, partly in the veins on the outer surface of the bones, and partly in the sinuses at the base of the skull.

Fig. 316. — VEINS OF THE DIPLOË OF THE CRANIAL BONES (after Breschet).  $\frac{1}{2}$

The external table has been removed from the greater part of the calvarium so as to expose the diploë and the veins which have been injected. 1, a single frontal vein; 2, 3, the anterior temporal vein of the right side; 4, the posterior temporal; 5, the occipital vein of the diploë.

According to Breschet there are four such veins on each half of the cranium, viz., a frontal, occipital, and two temporal.

The *frontal* is small, and issues by an aperture at the supra-orbital notch to join the vein in that situation. There is often only one frontal vein present.

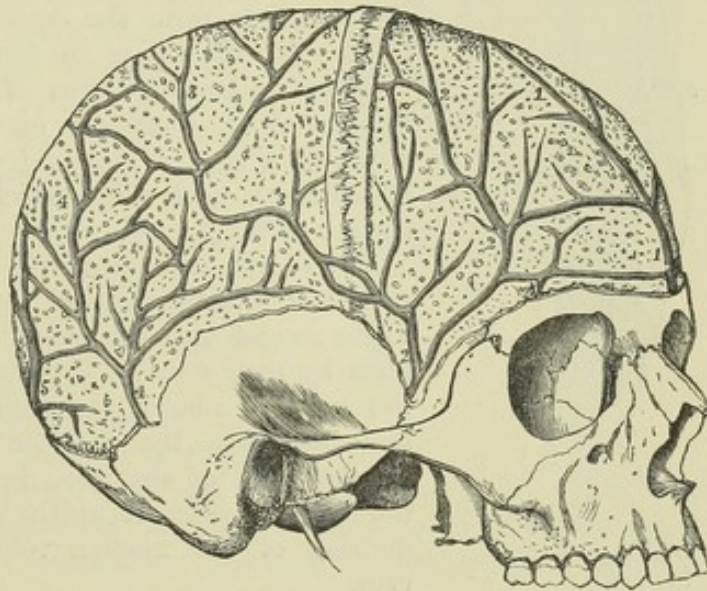
The *temporal* are distinguished as anterior and posterior. The anterior is contained chiefly in the frontal bone, but may extend also into the parietal, and opens into the temporal vein, after escaping by an aperture in the great wing of the sphenoid. The posterior ramifies in the parietal bone, and passes through an aperture at the lower and hinder angle of that bone to the lateral sinus.

The *occipital* is the largest of all; and leaves the occipital bone opposite the inferior curved line to open, either internally or externally, into the occipital sinus or the occipital vein. Its ramifications are confined especially to the occipital bone.

## VEINS OF THE UPPER LIMB.

The veins of the upper limb are divisible into two sets, the superficial, and the deep-seated. Both sets are provided with valves, and these are

Fig. 316.





more numerous in the deep than in the subcutaneous veins. Valves are constantly to be found at the entrance of branches into the main vessels.

#### SUPERFICIAL VEINS OF THE UPPER LIMB.

The superficial veins of the upper limb are much larger than the deep; they lie between the skin and the fascia. At the upper part of the fore

Fig. 317.

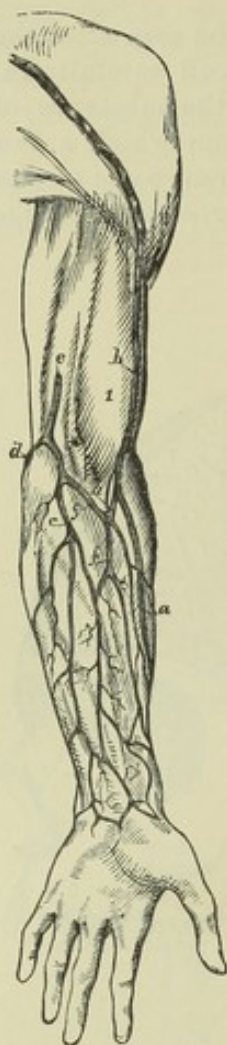


Fig. 317.—SKETCH OF THE SUPERFICIAL VEINS OF THE ARM AND FOREARM FROM BEFORE.  $\frac{1}{2}$

1, biceps muscle; *a*, radial veins; *b*, cephalic vein; *c*, ulnar veins; *d*, some of the posterior ulnar veins; *e*, basilic vein dipping below the fascia; *f*, median vein; *g*, median basilic; *h*, median cephalic.

arm they are most frequently collected into three trunks, the *radial*, *ulnar*, and *median* veins. At the bend of the elbow the median vein divides into an outer and an inner vessel, named respectively *median-cephalic* and *median-basilic*, one of which joins with the radial to form the *cephalic* vein, while the other joins with the ulnar to form the *basilic*. The two principal cutaneous veins of the forearm, the radial and the ulnar, commence on the dorsal surface of the hand, by a sort of plexus, formed by the convergence of numerous small veins, which proceed from the dorsal surface of the fingers.

The *radial cutaneous* vein commences by branches upon the dorsal surface of the thumb and fore finger. These ascend over the outer border of the wrist, and form by their union a large vessel, which passes along the radial border of the forearm, receiving numerous branches from the anterior and posterior surfaces. At the bend of the arm, in the groove external to the biceps muscle, it unites with the median-cephalic division of the median vein, to form the cephalic vein.

The *cephalic* vein ascends along the outer border of the biceps muscle and in the interval between the great pectoral and deltoid muscles, and finally, dipping in between those muscles, terminates in the axillary

vein, between the coracoid process and the clavicle.

The *ulnar cutaneous* veins are two in number, one on the front, the other on the back part of the forearm. The *posterior* ulnar cutaneous vein, begins on the back of the hand by branches, which unite to form a vein placed over the fourth metacarpal space, and called by some of the older anatomists "*vena salvatella*." This proceeds along the ulnar border of the forearm on the posterior aspect, and, below the bend of the elbow, turns forwards to join with the *anterior* ulnar cutaneous vein, which ascends from the anterior surface of the wrist. At the bend of the elbow, the common ulnar cutaneous unites with the median-basilic division of the median to form the basilic vein.

The *basilic* vein, usually of considerable size, ascending along the inner border of the biceps muscle, in front of the brachial artery, passes through



the fascia below the middle of the arm, and finally unites with one of the *venæ comites* of that vessel, or with the axillary vein, which it chiefly forms.

Fig. 318.—VIEW OF THE SUPERFICIAL VEINS AT THE BEND OF THE ARM (from R. Quain).  $\frac{1}{2}$

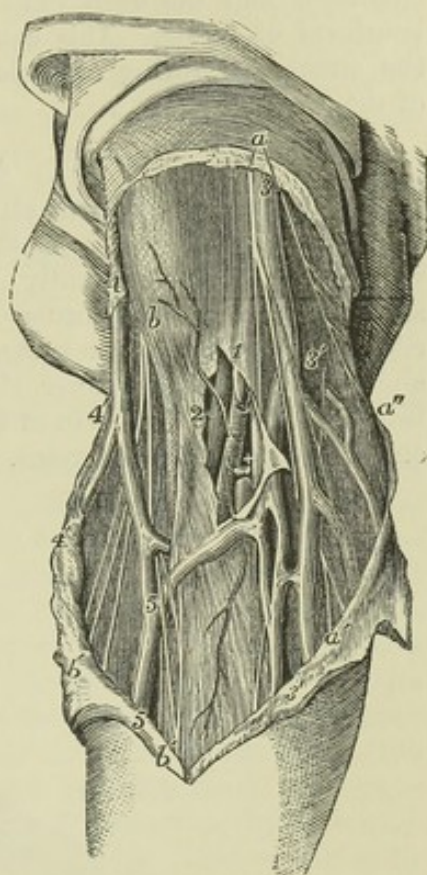
The full description of this figure will be found at p. 383. The following numbers indicate the veins:—At 1 and 2, the fascia is opened in front of a part of the brachial artery and its accompanying veins; the inner *vena comes*, marked 1, has been divided, the outer marked 2, is entire; +, the median nerve; 3, the basilic vein; 3', the ulnar veins; 4, the cephalic vein; 4', one of the radial veins; 5, the median vein; 5 to 4', median cephalic; 5 to 3', median basilic.

The *median cutaneous* vein results from the union, on the anterior part of the forearm, of several branches. It is a short trunk of variable length, which ascends between the ulnar and radial cutaneous veins on the front of the forearm, and terminates beneath the hollow in front of the elbow by dividing into the median-basilic and median-cephalic branches which diverge upwards from each other. Close to its bifurcation it receives a short branch, the *deep median* vein, which pierces the fascia to meet it, and forms a communication between it and the deep veins accompanying the arteries.

The *median-basilic* vein, inclining inwards to join the basilic vein, passes in front of the brachial artery, from which it is separated by the fibrous expansion given by the tendon of the biceps muscle to the fascia covering the flexor muscles; it is crossed by branches of the internal cutaneous nerve.

The *median-cephalic* vein, directed outwards, unites with the cephalic vein. Branches of the external cutaneous nerve descend behind it.

Fig. 318.



#### DEEP VEINS OF THE UPPER LIMB.

The brachial artery and its various branches in the arm, forearm, and hand, are each accompanied by two veins, named *venæ comites*. These companion veins lie one on each side of the corresponding artery, and are connected with each other at intervals by short cross branches, which in some places surround the artery. Their distribution so closely corresponds with that of the arteries that they need not be more particularly described.

The *brachial veins*, or *companion veins* of the brachial artery, terminate at the lower margin of the subscapularis muscle by joining the axillary vein; not unfrequently, however, one of them will be found to come forward and unite with the basilic, which soon after becomes continuous with the axillary vein.

Between the several veins of the upper limb numerous communications



exist in their whole course. Thus, those which lie beneath the integument are connected to each other by branches in the hand and forearm. The veins in each pair of *venæ comites* are also united by short transverse vessels crossing the artery which they accompany, whilst between those attending different arteries frequent connections exist. Lastly, the subcutaneous and the deep veins communicate freely, especially in the neighbourhood of joints. This general anastomosis ensures the continuance of the circulation during muscular action in the frequent and varied motions of the limb.

#### AXILLARY VEIN.

The *axillary vein* returns all the blood from the upper limb: its size is very considerable, and it is the highest of the veins of the upper limb in which valves are constantly found. It extends, like the corresponding artery, from the lower border of the axilla to the outer margin of the first rib; it is covered by the pectoral muscles and the costo-coracoid membrane, and is placed to the inner side of the axillary artery. It is continuous below with the basilic vein of the arm, either alone or in conjunction with one of the deep brachial veins.

Fig. 319.

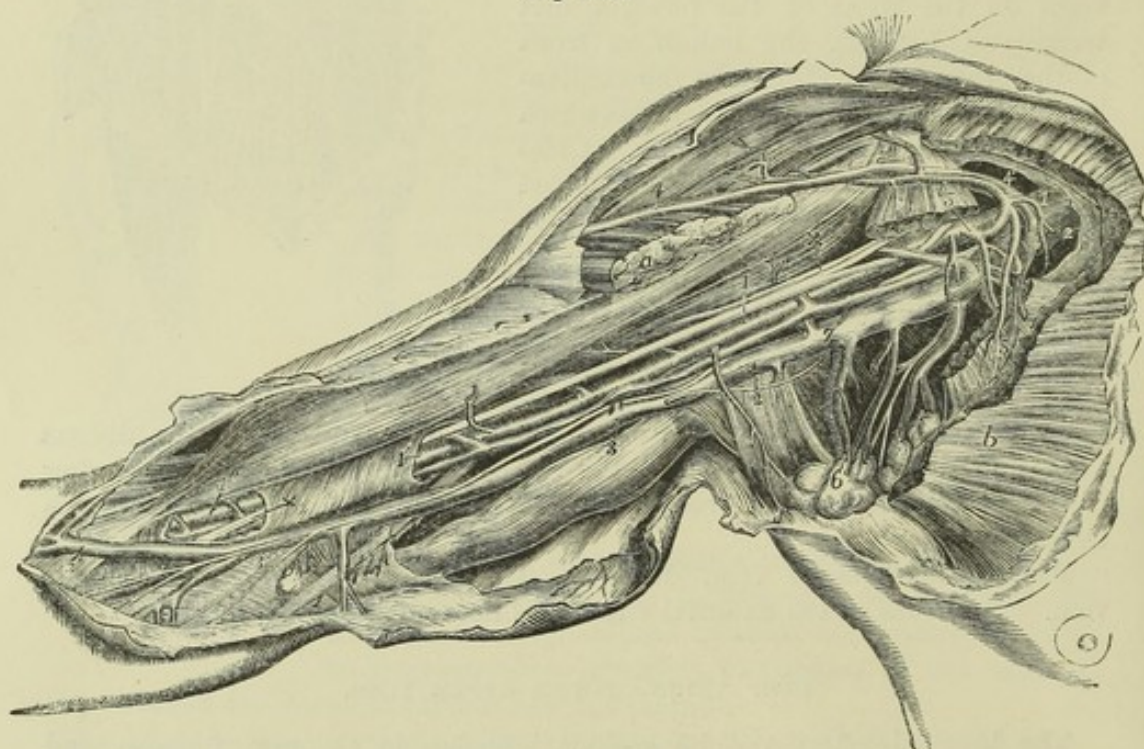


Fig. 319.—VIEW OF THE BLOODVESSELS OF THE RIGHT AXILLA AND ARM FROM THE INNER SIDE (from R. Quain).  $\frac{1}{4}$

The detailed description of this figure will be found at p. 382. The following numbers indicate the principal veins:—2, the axillary vein; 3, basilic vein; 3', median basilic; 4, 4', cephalic vein joining the acromial thoracic and axillary; 6, alar-thoracic and subscapular; 7, one of the brachial veins.

**TRIBUTARIES.**—The axillary vein receives the subcutaneous veins of the arm, viz. the basilic at its commencement, the cephalic towards its termination; and between these the companion veins of the brachial artery; it is also joined by the several veins corresponding with the branches of the axillary



artery, viz., the two *circumflex* and the *subscapular* veins from the shoulder, the *alar* vein from the axilla, and the inferior, superior, and acromial *thoracic* veins from the side of the chest.

## SUBCLAVIAN VEIN.

The *subclavian vein* is the continuation of the axillary, but is not like it constantly provided with valves, although a pair may often be found near its termination (Struthers, loc. cit.). It extends from the outer margin of the first rib to the inner end of the clavicle, behind which it terminates by joining with the internal jugular vein to form the innominate or brachio-cephalic vein. The subclavian vein crosses over the first rib and behind the clavicle, not reaching so high up in the neck as the subclavian artery; it is covered by the clavicle, and by the subclavius and sterno-mastoid muscles, and lies on a plane anterior to the artery, from which, while resting on the rib, it is separated by the scalenus anticus muscle and the phrenic nerve.

TRIBUTARIES.—(a). The *external* and *anterior jugular* veins (p. 459) open into the subclavian vein on the outer side of the scalenus anticus muscle.

(b). The *vertebral vein*, commencing in branches which proceed from the pericranium and the deep muscles lying behind the foramen magnum of the occipital bone, passes outwards and downwards to reach the intertransverse foramen of the atlas. Through this foramen, and through the canal formed by the corresponding foramina of the other cervical vertebræ, the vein descends with the vertebral artery. Emerging at the foramen in the sixth vertebra, it runs forwards and downwards to join the subclavian vein close to the termination: a small branch sometimes descends through the foramen in the seventh vertebra, and opens separately into the subclavian. The vertebral vein is joined in its course by several branches from the neighbouring muscles; also, immediately before its termination, by a branch corresponding with the deep cervical artery; and in the same situation by another branch of considerable size, which descends in front of the bodies and transverse processes of the vertebræ of the neck, and may be termed the external vertebral vein. It communicates frequently with the spinal veins in the neck, both those on the outer side, and those in the interior of the spinal canal.

## AZYGOS VEINS.

The azygos veins are longitudinal vessels formed by the union of the veins corresponding to the arteries of the intercostal spaces, and are placed on the sides of the spine. In the lower part of the thorax the two veins of opposite sides are disposed symmetrically, but higher up the blood gathered from some of the veins of the left side is poured into the trunk on the right, which becomes enlarged and unsymmetrical, and has on that account received the name of azygos, while the united lower veins from the corresponding parts on the left side constitute the small or left azygos.

The *azygos*, or *right azygos vein* (*vena sine pari*), commences sometimes by a small branch derived from the inferior cava, where that vessel turns forwards to reach its opening in the diaphragm; but much more frequently it begins below from the lumbar veins (ascending lumbar) of the right side, and sometimes from the renal vein. Passing from the abdomen into the thorax through the aortic opening in the diaphragm, or to the outer side of



that opening through the fibres of the diaphragm, the azygos vein ascends

Fig. 320.

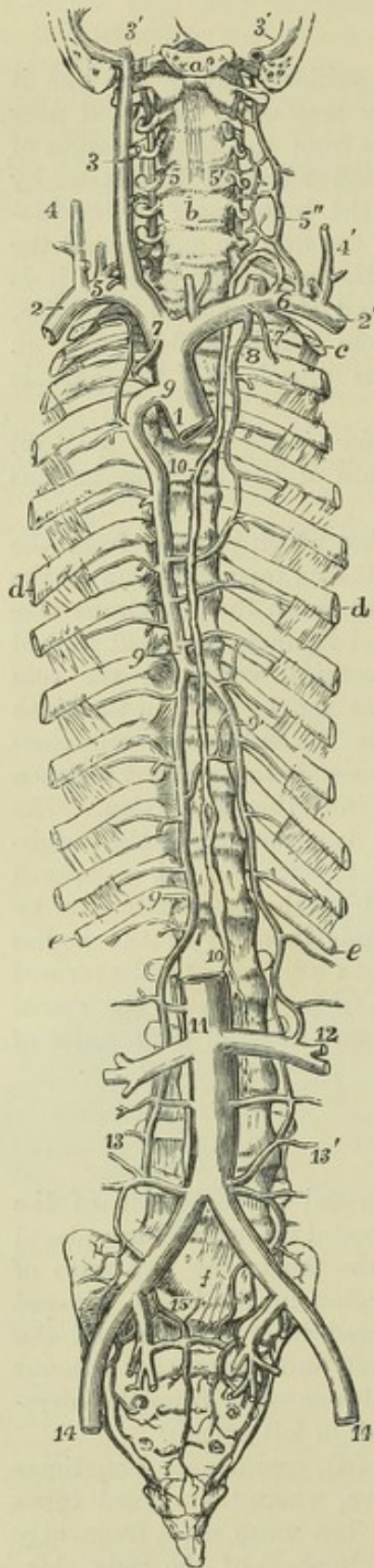


Fig. 320.—SKETCH OF THE PRINCIPAL SYSTEMIC VENOUS TRUNKS, THE AZYGOS, AND INTERCOSTAL VEINS.

For the detailed description of this figure see p. 454. The following indications relate to the accompanying part of the text:—8, the right, 8', the left, superior intercostal veins; 9, the main trunk of the azygos vein; the uppermost number marks its junction with the superior cava, the lowest its passage into the abdomen; 9', the left or hemiazygos; 10, thoracic duct; 11, inferior vena cava; 12, the union of a branch of the left azygos with the left renal vein; 13, 13', the right and left azygos veins continued down into the abdomen, and joining some of the lumbar veins; 15, union of lumbar, ilio-lumbar, and sacral veins.

on the bodies of the dorsal vertebræ, until it arrives opposite the root of the right lung, over which it arches forwards, and then opens into the upper vena cava, immediately above the point at which that vessel is invested by the pericardium. When passing through the opening in the diaphragm, this vein is accompanied by the thoracic duct, both being situated on the right side of the aorta. In the thorax, maintaining the same position with respect to the duct and the œsophagus, it passes in front of the intercostal arteries, and is covered by the pleura. It is joined by the several veins which accompany the aortic intercostal arteries of the right side; and at about the sixth or seventh dorsal vertebra, by the left or smaller azygos vein. It is also joined by several œsophageal and other small veins, and near its termination by the bronchial vein of the right lung; and it is generally connected with the right superior intercostal vein. As it communicates below with the vena cava inferior through one of the branches of that large vein, while it terminates above in the vena cava superior, it forms a connection between those two vessels. A few valves of imperfect formation have been found in the azygos vein; its branches (intercostal veins) are provided with distinct valves.

On the left side of the chest the veins of the three or four upper intercostal spaces are usually united into one trunk, forming the left superior intercostal vein, which (as already mentioned at



p. 455) is most frequently united with the left innominate vein, but sometimes is connected with the main azygos vein.

Of the remaining left intercostal veins, one or two, generally about the fifth and sixth, pass directly into the azygos; while the lowest in greater number unite almost constantly into one trunk, forming the left or small azygos, which crosses to join the main azygos in the neighbourhood of the seventh dorsal vertebra. There is frequently union between these three sets of veins or their intercostal branches, so that a part of one may be replaced by another, and the relative size of the veins may be subject to considerable variation.

The *left lower* or *small azygos* vein (*vena hemiazygos*) commences from one of the lumbar veins (ascending lumbar), or from the left renal vein, and having entered the thorax with the aorta, or through the crus of the diaphragm, ascends upon the spine in front of the left intercostal arteries, receiving the lower intercostal veins of the left side; and passing behind the aorta, it opens into the right azygos vein, opposite the sixth or seventh dorsal vertebra.

The azygos vein has been seen to receive the lower vena cava, and, in such cases, is of course extremely large.

In one instance, Meckel found the azygos ending in the subclavian vein.

All the intercostal veins of the left side have been observed in some instances to join a single vein, which ended in the left innominate; the arrangement corresponding with that on the right side of the body.

The *bronchial veins* return the blood employed in the nutrition of the lungs. Their course corresponds with that of the bronchi, which support them as they pass towards the root of the lungs. The bronchial vein of the right side opens into the trunk of the azygos vein near its termination, that of the opposite side ends in the superior intercostal vein.

### VEINS OF THE SPINE.

The spinal veins form plexuses of closely anastomosing vessels along the whole length of the spinal column. They have no valves.

The veins within and upon the spinal column may be distinguished into the following sets: *a.* The dorsal, placed deeply in the vertebral grooves, and resting upon the spines and arches of the vertebræ. *b.* The veins lodged within the bodies of the vertebræ. *c.* The anterior longitudinal, two long series of veins, or rather venous plexuses, extended behind the bodies of the vertebræ in the whole length of the canal. *d.* The posterior longitudinal veins, situated within the canal on the fore part of the arches of the vertebræ. *e.* The veins of the spinal cord. There are likewise branches of communication, some of which connect all the other sets together, and some which bring them into connection with the general venous system. (Breschet, "Essai sur les Veines du Rachis," 4to; "Traité Anatomique sur le Système Veineux," fol., 1829; Cloquet, "Traité d'Anatomie descriptive," &c.)

*a.*—The *dorsal veins*. The blood from the muscles and integument along the back of the spine is returned by a series of short veins, which ramify upon the arches and spinous processes of the vertebræ. They run forwards close to the spinous processes, and on reaching the interval between the arches of the vertebræ, pierce the ligamenta subflava, and terminate in a venous plexus within the canal. Towards the outer part of the intervertebral grooves other veins arise, which pass obliquely forwards, through the intertransverse spaces, in company with the posterior branches of the lumbar



and intercostal arteries, and open into the veins which accompany those vessels.

*b.*—The veins belonging to the bodies of the vertebræ (*venæ basis vertebrarum*,—Dupuytren) are comparatively large vessels contained in the canals within the bodies of the vertebræ; the arteries which accompany them being very small. They anastomose on the front of the bones with some of the superficial veins; and the trunk of each, having reached the spinal canal through the foramen in the posterior surface of the body of the vertebra, divides into two branches, which diverge and terminate in the large spinal veins behind the bodies of the vertebræ.

*c.*—The *anterior longitudinal spinal veins*.—The blood collected by the different vessels here described is poured into two large veins, or rather tortuous venous canals, which extend, one on each side, along the whole length of the spinal canal behind the bodies of the vertebræ. These vessels (the great spinal veins of Breschet) are alternately constricted and enlarged, the constricted points corresponding with the intervertebral foramina, where they are drawn forwards, and bound down by the branches of communication which pass outwards. In some parts the veins are double, or even triple, so as to form a plexus, and occasionally they are altogether interrupted. In the thoracic region their communicating branches open into the intercostal veins, in the loins into the lumbar veins, in the neck for the most part into the vertebral.

Fig. 321.

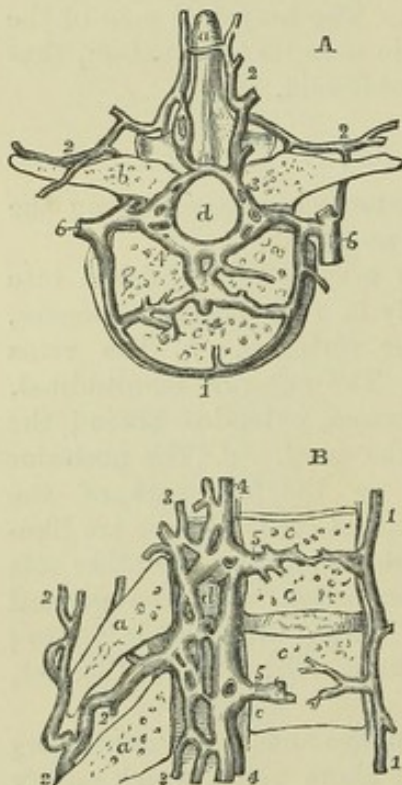


Fig. 321, A and B.—HORIZONTAL AND VERTICAL SECTIONS OF THE LOWER DORSAL VERTEBRÆ, SHOWING THE EXTERNAL AND INTERNAL VEINS OF THE SPINE (after Breschet). §

*a*, spinous process; *b*, transverse process; *c*, body; *d*, spinal canal; 1, anterior external veins of the body; 2, posterior external veins of the vertebral column communicating with the internal and forming a plexus over the laminae and processes; 3, the posterior, and 4, the anterior internal plexus of veins of the vertebral canal; 5, the internal veins of the body joining the internal spinal veins; 6, the lateral veins, which are joined by the internal and external spinal veins, and themselves unite with the intercostal.

*d.* The *posterior longitudinal spinal veins* are a complex interlacement of tortuous veins along the inner or anterior surface of the arches of the vertebræ. In the lower part of the canal this interlacement of veins is not so close as in the upper portion, where it usually conceals (if the injection has been successful) the whole surface of the dura mater. These veins converge to the intervertebral foramina, and join by rather small vessels with the intercostal veins.

*e.*—The *veins of the spinal cord* (Breschet) ramify upon the cord and its nerves, enclosed within the sheath formed by the dura mater. Though they communicate with the other spinal veins, they are not injected with them, even when the injecting process is most successful. Very small,



long, and tortuous, they run upon both surfaces of the cord, and form a diffused network. They become larger, for the most part, as they ascend, but near the base of the skull they are smaller than in the lumbar region. They communicate freely with the spinal veins and plexuses, by means of branches which accompany the nerves towards the intervertebral foramina. Near the base of the skull they unite to form two or three small trunks, which communicate by transverse branches with the vertebral veins, and terminate in the inferior cerebellar veins, or in the petrosal sinuses.

From a consideration of the connection and arrangement of the different parts of these complex veins, it would appear that the main currents of the blood in each part flow through them horizontally. The dorsal veins pour their blood into the longitudinal plexus on the inner surface of the arches of the vertebræ; thence it is collected, at each of the intervertebral foramina, by two or three small converging branches, which open into some of the veins outside the vertebral column in front, viz., into the lumbar, azygos, and cervical veins. Into these, also, the contents of the great spinal veins are conveyed by the short communicating branches already noticed.

### LOWER VENA CAVA.

The *lower or ascending vena cava* returns the blood from the lower limbs, and from the viscera of the pelvis and abdomen. It commences at the junction of the two common iliac veins on the side of the fifth lumbar vertebra, and thence ascends along the right side of the aorta, as far as the posterior border of the liver; it there becomes lodged in a groove in that organ, after which it inclines forwards to reach the opening in the diaphragm appropriated to it, and, after being enclosed in a fold of the pericardium, terminates in the right auricle of the heart. A large valve is situated at its entrance into the auricle, named the valve of Eustachius, which, however, as already explained in the description of the heart, is only a vestige of foetal structure, variable in size, and without influence in preventing reflux of the blood.

TRIBUTARIES.—Besides the common iliac veins, the inferior vena cava receives the following:—

a.—The *middle sacral vein*, taking its course upwards on the front of the sacrum, opens into the left common iliac vein, or into the commencement of the vena cava.

b.—The *lumbar veins* correspond in number with the arteries of the same name: they commence by small *dorsal* branches in the muscles of the back; and by others from the walls of the abdomen, where they communicate with the epigastric and other veins in the neighbourhood. Having reached the spine, they receive branches from the *spinal* plexuses, and proceed forward upon the bodies of the vertebræ, behind the psoas muscle: those on the left side, passing behind the aorta, terminate in the back of the vena cava. Some of these veins are frequently found to unite into a single trunk before their termination. The lumbar veins of the same side communicate with each other by branches which cross in front of the transverse processes. Not unfrequently a branch of this description is met with, called the *ascending lumbar vein*, which connects more or less completely the common iliac vein, the ilio-lumbar and lumbar veins, and the azygos vein.

c.—The *spermatic veins*, proceeding upwards from the testicle and forming a part of the constituents of the spermatic cord, enter the abdomen, and ascend on the psoas muscle behind the peritoneum. Below the



abdominal ring there are numerous convoluted branches forming the *spermatic plexus* (plexus pampiniformis). These branches gradually unite, and form a single vessel, which opens on the right side into the lower vena cava, and on the left into the renal vein. The spermatic veins sometimes bifurcate before their termination, each division opening separately; in this case, the veins of the right side may be found communicating with the vena cava and the renal vein.

In the female the *ovarian* veins have the same general course as the ovarian arteries; they form a plexus near the ovary (ovarian or pampiniform plexus) in the broad ligament, and communicate with the uterine plexus.

Valves exist in the spermatic veins in man (Monro); and, in exceptional cases, they have been also seen in the ovarian veins (Theile).

*d.*—The *renal* or *emulgent* veins are short, but of very considerable size. That of the left side is longer than that of the right, and passes in front of the aorta. They join the vena cava at nearly a right angle. The renal veins usually receive branches from the suprarenal capsules; the left has also opening into it the spermatic vein of the same side.

*e.*—The *capsular* or *suprarenal* veins, though actually small, are, relatively to the organs from which they arise, of considerable size. On the right side the vein ends in the vena cava, and on the left in the renal or phrenic vein.

*f.*—The *phrenic* veins follow exactly the course of the arteries supplied to the diaphragm by the abdominal aorta.

*g.*—The *hepatic* veins return from the liver the blood sent to that organ by the portal vein and hepatic artery. They converge to the groove in which the inferior vena cava lies, and pass at once obliquely into that vein. There are usually three sets of hepatic veins proceeding to this common point: those from the right and left lobes are oblique in their direction, those from the middle of the liver and the lobule of Spigelius have an intermediate position and course. The hepatic veins have no valves; but, owing to their oblique entrance into the vena cava, a semi-lunar fold is seen at the lower border of the orifice of each vein.

**PECULIARITIES.**—The lower vena cava presents some occasional deviations from its ordinary condition, which may be briefly noticed.

In the lower part of its course, it is sometimes placed to the left side of the aorta, and, after receiving the left renal vein, resumes its ordinary position by crossing over the great artery. Less frequently, the vena cava is placed altogether on the left side, and is continued upwards to the heart, without any change in its direction: this occurs in cases of transposition of the thoracic and abdominal viscera and of the great vessels.

In a more numerous class of cases, the left common iliac vein, instead of joining the right in its usual position, is connected with it only by a small branch, and then ascends on the left side of the aorta. After receiving the left renal vein, it crosses over the aorta, and terminates by uniting with the common iliac vein of the right side. In these cases, the vena cava inferior can be said to exist only at the upper part of the abdomen, and below this point there is a vein on each side of the aorta.

Lastly, the lower vena cava, instead of ending in the right auricle of the heart, has been seen to join the right azygos vein, which is then very large; so that the blood from the lower, as well as from the upper part of the body, is returned to the heart through the upper vena cava. In this case, the hepatic veins do not join the lower cava, but pass directly into the right auricle, at the usual place of termination of the great vein.

The left renal vein has been seen to cross behind the aorta.

In a remarkable case, observed by Rothe, one of the hepatic veins ended, not in



the lower cava, nor in the right auricle, but in the right ventricle of the heart, its orifice being guarded by valves. (Act. Acad. Joseph. Med. Chir. Vindobonensis, t. i. p. 233, tab. 5. Vindobonæ, 1788.)

### VEINS OF THE LOWER LIMB AND PELVIS.

The veins of the lower limb are divisible into two sets, those of one being deeply seated, those of the other running in the superficial fascia. All the veins of the lower limb, as high as the femoral venous trunk, are provided with valves, and these are more numerous than in the veins of the upper limb. The deep veins have more valves than the subcutaneous set.

Fig. 322.—OUTLINE OF THE SUPERFICIAL VEINS OF THE LOWER LIMB.

1, the saphenous aperture of the fascia lata; *a*, superficial epigastric vein; *b*, external pudic; *c*, superficial circumflex iliac; *d*, external or short saphenous beginning on the dorsum of the foot (see Fig. 326).

#### SUPERFICIAL VEINS OF THE LOWER LIMB.

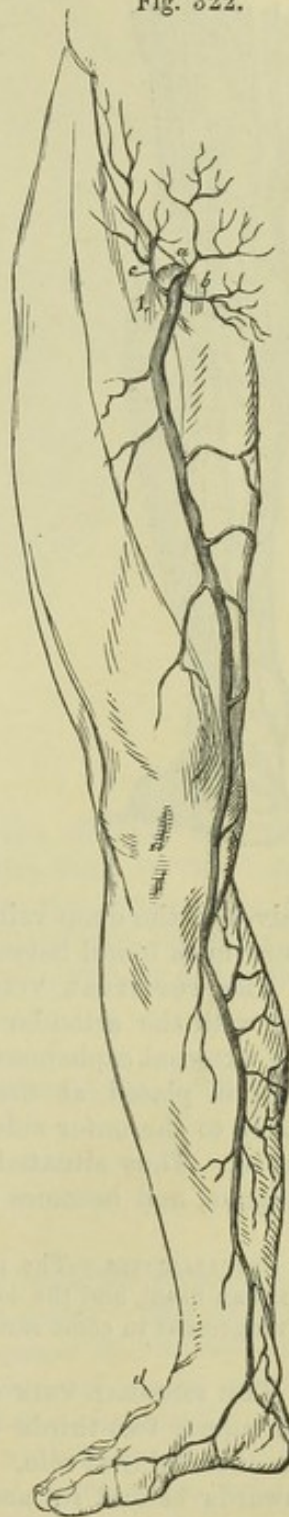
Immediately beneath the integument, on the dorsum of the foot, there exists a network of veins forming an arch, from which issue two principal trunks, which are named the internal or long and the external or short saphenous veins.

The *internal* or *long saphenous* vein extends from the ankle to within an inch and a half of Poupart's ligament. Taking rise from the plexus of veins on the dorsum of the foot, it passes upwards in front of the inner ankle, and along the inner border of the tibia, accompanied by the internal saphenous nerve. It inclines a little backwards as it passes the inner condyle of the femur, and ascending along the inner and fore part of the thigh, it terminates in the femoral vein, at the *saphenous opening* in the fascia lata, through which it passes.

In the leg it communicates with the deep veins accompanying the anterior and posterior tibial arteries, and in the thigh one or more branches pass between it and the femoral vein. This long vein has a variable number of valves. Sometimes six have been counted; in other cases only four, or even two. It contains more in its course through the thigh than in the leg.

TRIBUTARIES.—The long saphenous vein is joined in its course by numerous cutaneous vessels. Close to its termination it receives, besides a considerable *anterior* branch, the *superficial epigastric*, *external pudic*, and *superficial circumflex iliac* veins, corresponding severally to arterial branches of the same name.

Fig. 322.





It is also usually joined near its termination by a *posterior* branch of considerable size, coming from the posterior and inner part of the thigh.

The *external* or *short saphenous* vein proceeds from branches, which arise along the outer side of the dorsum of the foot. It passes behind the

Fig. 323.

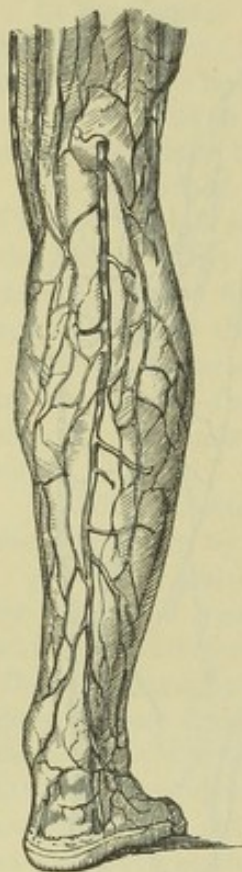


Fig. 323.—OUTLINE OF THE POSTERIOR OR SHORT SAPHENOUS VEIN.

The vein, commencing on the dorsum and outside of the foot, is seen to pass up behind the outer ankle and to dip beneath the fascia in the popliteal space.

outer ankle, and gradually inclines backwards to ascend along the border of the tendo Achillis and on the belly of the gastrocnemius muscle, accompanied by the external saphenous nerve; running upwards between the heads of the gastrocnemius, it unites with the popliteal vein. Opposite the ankle and along the leg it communicates with the deep veins: and it receives superficial accessory veins from the outer part of the foot and the back of the leg.

#### THE DEEP VEINS OF THE LOWER LIMB.

The deep veins accompany the arteries and their branches, following exactly their distribution. Those below the knee, being for the most part disposed in pairs, and presenting the disposition described in the corresponding veins of the upper limb, are named the *venæ comites* of the vessels with which they are associated. The *venæ comites* of the arteries of the leg, namely, the *anterior* and *posterior tibial* veins (the latter having previously received the *peroneal*), unite near the lower border of the popliteus muscle, and form by their junction the popliteal vein. The

valves of the deep veins of the leg are very numerous,—ten or twelve being sometimes found between the heel and the knee.

THE POPLITEAL VEIN, thus formed, receives smaller branches corresponding with the articular and muscular arteries, and the larger branch named the external saphenous vein. In its course through the ham, the popliteal vein is placed at first internal to the popliteal artery, then behind, and lastly to the outer side of it, but always posteriorly and between it and the nerve. Thus situated, it passes up through the aperture in the adductor magnus, and becomes continuous with the femoral vein.

PECULIARITIES.—The union of the veins which form the popliteal is often farther up than usual, and the lower part of the artery is accompanied by two veins. This arrangement in some rare cases extends to the entire length of the artery.

THE FEMORAL VEIN extends, like the artery which it accompanies, through the upper two-thirds of the thigh, and terminates at Poupart's ligament in the external iliac vein. Placed at first outside the artery, it gradually inclines inwards behind it, and on reaching Poupart's ligament, lies on the inner side, on the same plane with the artery, and separated from it only by a slight partition of the membranous sheath, by which they are both invested.

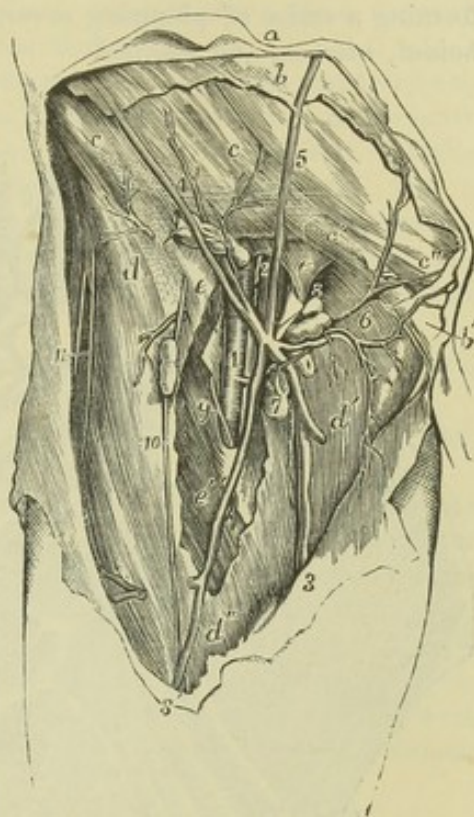


In the lower part of its course, the vein receives all the branches which accompany the offsets of the chief artery. In the upper part, the deep femoral vein opens into it, having first received all the branches from muscles supplied by the deep femoral artery. Near its termination the femoral vein is joined by the internal saphenous vein.

Fig. 324.

Fig. 324.—VIEW OF THE BLOOD-VESSELS OF THE GROIN AND NEIGHBOURING PARTS (from R. Quain). 4

The full description of this figure will be found at p. 436. The following numbers indicate the veins:—2, the femoral vein; 3, the large or internal saphenous vein; 3', anterior saphenous; 4, superficial circumflex veins with twigs to the inguinal glands; 5, superficial epigastric; 6, superficial pudic.



The femoral vein occasionally pursues a course different from that of the artery along the thigh. Extending upwards from the popliteal space, the vein in such cases perforates the adductor magnus above the ordinary position, and joining with the deep femoral vein first approaches the femoral artery at the groin. The same vein is sometimes double in a small part, or more rarely in almost its whole length.

#### EXTERNAL ILIAC VEIN.

The external iliac vein is the continuation of the femoral vein from Poupart's ligament to the junction of the internal iliac vein, in the neighbourhood of the sacro-iliac articulation. It is at first internal to the artery, and on the left side it continues in that position, but on the right side it gradually inclines somewhat behind the artery. It does not possess valves.

TRIBUTARIES.—Near its commencement at Poupart's ligament, the external iliac vein receives the *circumflex iliac* and the *epigastric* veins.

#### INTERNAL ILIAC VEIN.

The internal iliac vein is formed by the union of branches which accompany the corresponding branches of the internal iliac artery. The umbilical vein of the foetus, however, which in the cord accompanies the corresponding arteries, diverges from these arteries within the body, and passes upwards to the liver. The internal iliac vein lies behind the corresponding artery in front of the sacro-iliac articulation, and, after a short course upwards to the margin of the pelvis, joins with the external iliac vein to form the common iliac. No valves are found in the trunk of the internal iliac vein, but they exist in its branches.



**TRIBUTARIES.**—The tributaries of the internal iliac vein correspond in general to the various branches of the internal iliac artery, with the exception that the internal pudic vein does not receive the main supply of blood from the dorsal vein of the penis. The visceral veins are remarkable for their size and frequent anastomoses, and have been described as forming a series of plexuses, severally named the *vesical*, *prostatic*, *hæmorrhoidal*, *uterine*, and *vaginal*.

Fig. 325.

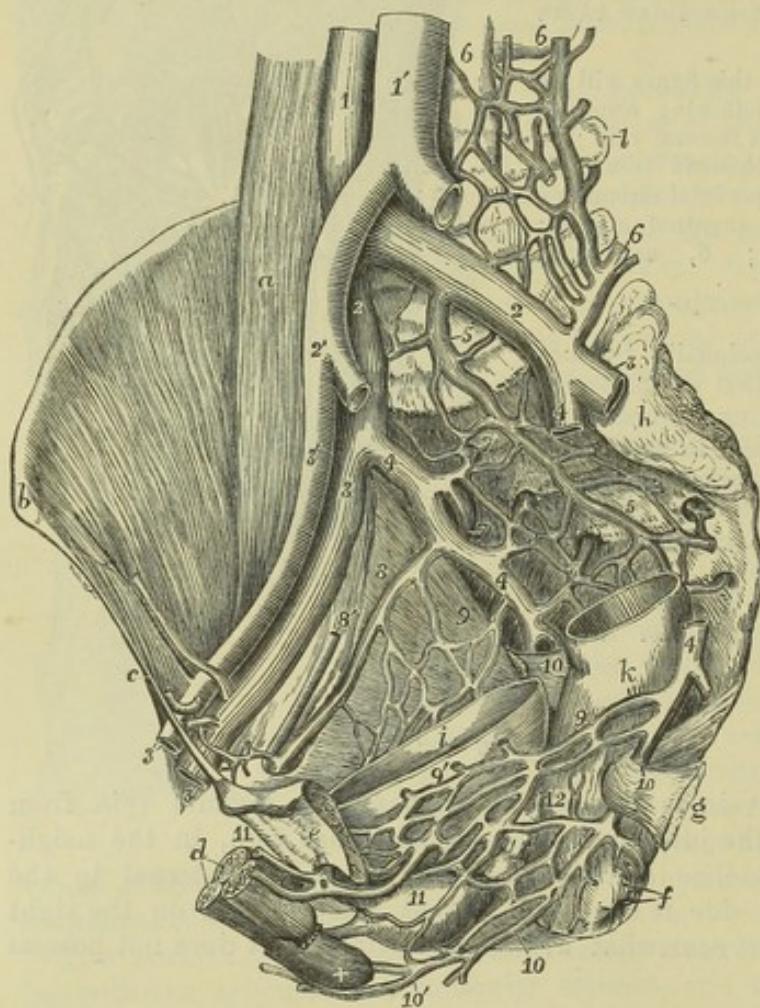


Fig. 325.—INTERNAL VIEW OF THE MALE PELVIS FROM THE LEFT SIDE, TO SHOW THE PRINCIPAL VEINS.  $\frac{1}{3}$

The greater part of the os innominatum and pelvic wall of the left side, and the upper parts of the rectum and urinary bladder, have been removed: the left common iliac and the right internal iliac arteries, and the left external and internal iliac veins, have been cut short. *a*, the right psoas magnus muscle; *b*, the anterior superior iliac spine; *c*, Poupart's ligament; *d*, the cavernous and spongy bodies of the penis divided near the root; +, the spongy body of the bulb, above which the membranous part of the urethra, the prostate, &c.; *e*, the left os pubis close to the symphysis; *f*, the anus; *g*, the spine of

the ischium with the short sacro-sciatic ligament; *h*, auricular sacro-iliac surface; *i*, interior of the urinary bladder; *k*, exterior of the rectum; *l*, transverse process of the fourth lumbar vertebra; 1, lower part of the vena cava inferior; 1', abdominal aorta; 2, common iliac veins; 2', right common iliac artery; 3, external iliac veins; 3', external iliac artery; 4, internal iliac veins, that of the right side entire, that of the left divided and in great part removed; 5, middle and other veins of the sacral plexus; 6, ilio-lumbar and lumbar veins; 7, right gluteal and upper lateral sacral veins; 8, 8', obturator vein and artery of the right side; 9, pelvic plexus of veins of the right side; 9', that of the left side connected with the lower vesical plexus; 10, placed on the right side on the short sacro-sciatic ligament immediately below the division of the internal iliac vein into the pudic and sciatic veins: on the left side, below 4, the sciatic vein is cut short; 10, lower down, the pudic vein; 10', the perineal veins; 11, placed on the prostate among the lower vesical veins, into one of which the left dorsal vein of the penis, 11, is seen to pass; 12, placed on the lower part of the rectum, may indicate the plexus of hæmorrhoidal veins.

The *vesical plexus* presents vessels over the whole of the bladder external



to its muscular coat, but they are particularly rich towards the base of the organ, and are there closely connected with the prostatic and hæmorrhoidal plexuses in the male, and with the vaginal plexus in the female.

The *prostatic plexus* receives two large vessels, one at each side, the divisions of the dorsal vein of the penis. These, coursing downwards and backwards on the sides of the prostate gland, expand into a close network at the base of the gland, which is quite encircled by it.

The *hæmorrhoidal plexus* consists of enlarged and copiously anastomosing veins in the walls of the lower part of the rectum, immediately underneath the mucous membrane. From it proceed superior, middle, and inferior hæmorrhoidal veins accompanying the arteries of the same name, and it communicates freely with the plexuses in front of it. The superior hæmorrhoidal vein being a branch belonging to the portal system, the hæmorrhoidal plexus forms a very direct communication between the portal and general venous systems.

The *vaginal plexus* surrounding the vagina, principally in its lower part, communicates freely with the hæmorrhoidal and vesical plexuses.

The *uterine plexus* pours its blood in greatest part into the ovarian veins, and is not considerable except in pregnancy.

The *dorsal vein of the penis* commences by branches which issue from the glans penis, and form in the first instance two veins, one at each side of the middle line, in the dorsal groove of the penis. These receive branches from the spongy body of the penis, and some superficial veins which accompany the external pudic arteries, and proceeding backwards unite and form a short trunk which enters the pelvis beneath the subpubic ligament. Here it divides into two branches, which are directed obliquely downwards over the prostate and the neck of the bladder, and are united with the prostatic plexus.

#### COMMON ILIAC VEIN.

The common iliac vein is formed by the confluence of the external and internal iliac veins. Extending from the sacro-iliac articulation upwards to near the junction of the fifth with the fourth lumbar vertebra, at a point a little to the right of the middle line, the two common iliac veins unite to form the lower or ascending vena cava. The right vein is shorter than the left, and is nearly vertical in its direction. The right vein is placed behind, and then to the outer side of its artery; whilst the left vein is to the inner side of the left common iliac artery, and then passes behind the right. These veins are destitute of valves.

#### PORTAL SYSTEM OF VEINS.

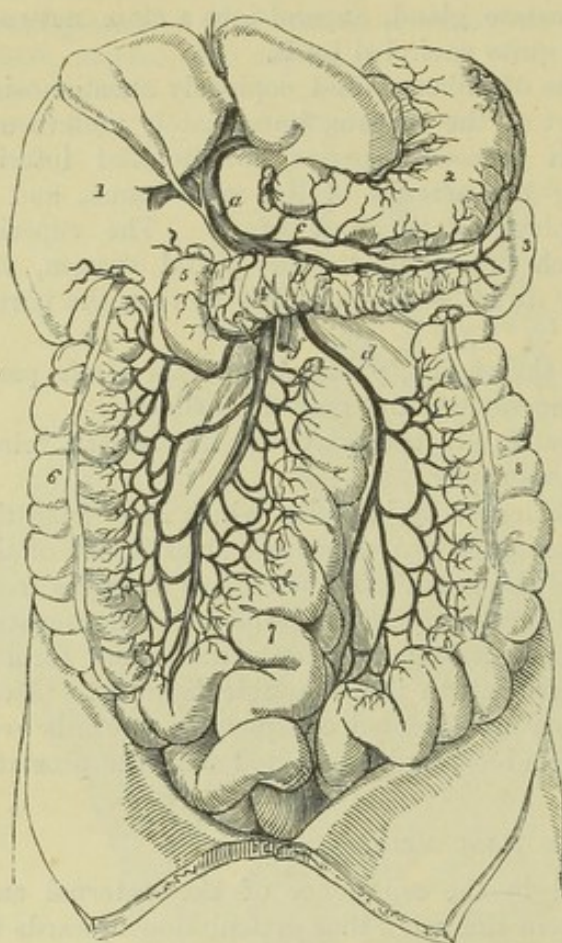
The portal vein differs from other veins of the body in being subdivided into branches at both its extremities. The branches of origin, by the union of which it may be said to be formed, are the veins of the chylipoietic viscera, viz., the stomach, intestine, pancreas, and spleen; the other branches, or those of distribution, ramifying after the manner of an artery in the substance of the liver, convey to the capillaries of that organ the blood collected in the main trunk. This blood, together with that of the hepatic artery, after having served for the secretion of the bile and the nourishment of the liver, is withdrawn from that organ by the hepatic veins, and carried by them into the vena cava inferior.

THE PORTAL VEIN OR VENA PORTÆ is about three inches in length. Commencing at the junction of the splenic and superior mesenteric veins, it



passes upwards and a little to the right to reach the transverse fissure of the liver. It is placed close behind the hepatic artery and the bile duct : and

Fig. 326.

Fig. 326.—VIEW OF THE PRINCIPAL BRANCHES OF THE VENA PORTÆ.  $\frac{1}{2}$ 

1, lower surface of the right lobe of the liver ; 2, stomach ; 3, spleen ; 4, pancreas ; 5, duodenum ; 6, ascending colon ; 7, small intestines ; 8, descending colon ; a, vena portæ dividing in the transverse fissure of the liver ; b, splenic vein ; c, right gastro-epiploic ; d, inferior mesenteric ; e, superior mesenteric vein ; f, superior mesenteric artery.

is surrounded by the filaments of the hepatic plexus of nerves, together with numerous lymphatics. All these are imbedded in loose connective tissue, and enclosed within the layers of the small omentum. Within the transverse fissure it is somewhat enlarged, and is there named *sinus of the portal vein*.

Near the right end of the transverse fissure, the vena portæ divides into two branches. That of the *right* side enters directly the substance of the corresponding

lobe of the liver, and spreads out into branches, each of which is accompanied by an offset of the hepatic artery and of the hepatic duct. The *left* branch, which is smaller, but necessarily longer, passes across to gain the left end of the transverse fissure, where it enters the liver and ramifies like the preceding branch.

**TRIBUTARIES.**—The principal branches which by their union contribute to form the vena portæ are the coronary vein of the stomach, the superior mesenteric and the splenic veins. The cystic vein is also sometimes a lateral tributary of the portal vein, but more frequently proceeds from its right branch.

The *coronary* vein of the stomach lies parallel with the artery of the same name. Its size is inconsiderable, and its direction transverse from the cardiac to the pyloric end of the stomach along the small curvature. On reaching the latter point it turns downwards, and opens into the trunk of the vena portæ.

**THE SPLENIC VEIN**, a vessel of very considerable size, returns the blood not only from the spleen, but also from the pancreas, the duodenum, the greater part of the stomach and omentum, the descending colon, and part of the rectum. It commences by five or six branches, which issue sepa-

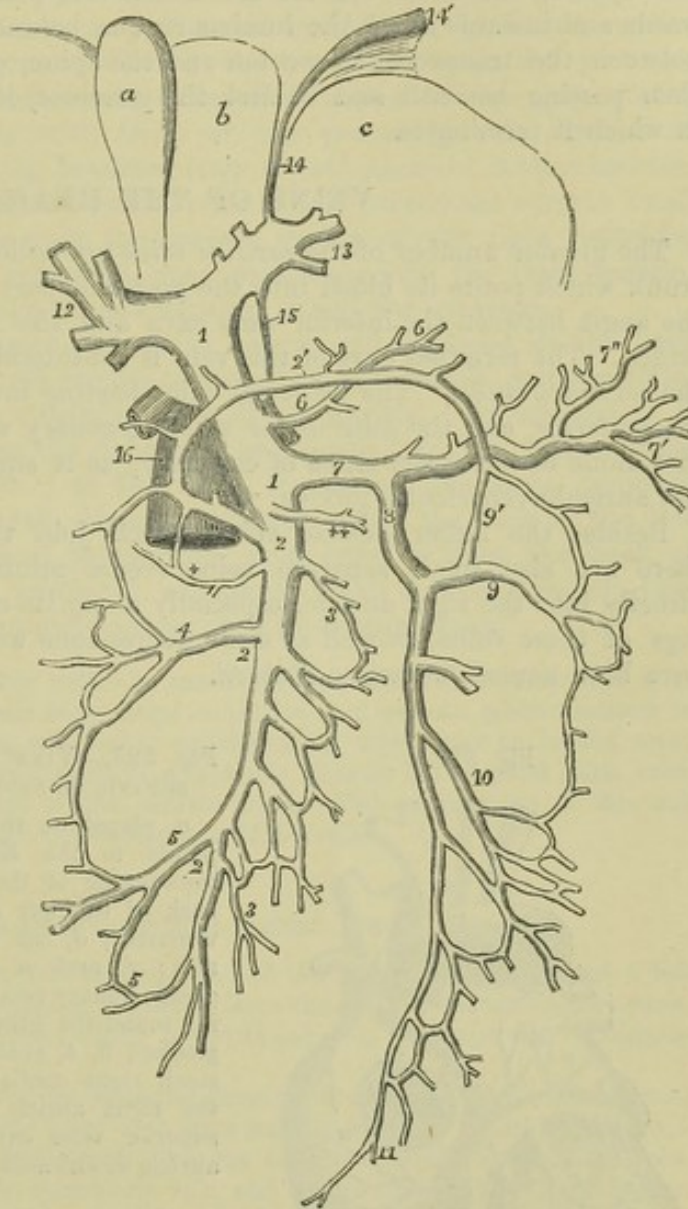


rately from the fissure of the spleen, and soon join to form a single vessel. It is directed from left to right beneath the pancreas, in company with the splenic artery, below which it is placed. On reaching the front of the spine it joins the superior mesenteric vein, nearly at a right angle. It receives

Fig. 327.—DIAGRAMMATIC OUTLINE OF THE PORTAL VEIN AND ITS RELATION TO THE LIVER, &c.  $\frac{1}{4}$

Fig. 327.

The liver is supposed to be turned upwards so as to present a portion of its under surface. *a*, gall-bladder; *b*, square lobe; *c*, left lobe; 1, trunk of the vena portæ; 2, great or superior mesenteric vein; 2', its middle colic branch, forming loops of communication between the right and left colic veins; 3, intestinal branches; +, small pancreatico-duodenal branch; 4, right colic branch; 5, ileocolic; 6, coronary vein of the stomach; ++, right gastro-epiploic; 7, splenic vein; 7', its branches to the spleen; 7'', its branches to the stomach; 8, inferior mesenteric vein; 9, left colic branch; 9', its communication with the middle colic; 10, sigmoid; 11, hemorrhoidal; 12, the right, and 13, the left division of the vena portæ in the transverse fissure of the liver; 14, the obliterated cord of the umbilical vein passing through the antero-posterior fissure to join the left division of the vena portæ; 15, the obliterated cord of the ductus venosus passing from the left division of the vena portæ to one of the hepatic veins connected with 16, the vena cava inferior, of which a part is represented in shade.



gastric branches (*vasa brevia*) from the left extremity of the stomach, the left gastro-epiploic vein, some pancreatic and duodenal branches, and also the inferior mesenteric vein.

**MESENTERIC VEINS.**—The superior mesenteric vein lies to the right side, and somewhat in front of the artery of the same name. The distribution of its branches corresponds with that of the superior mesenteric artery, and it returns the blood from the several parts supplied by that vessel, viz., from the small intestine, and from the ascending and transverse parts of the



colon. The trunk, formed by the union of its several branches, inclines upwards and to the right side, passing in front of the duodenum and behind the pancreas, where it joins with the splenic vein to form the *venæ portæ*.

The branches of the *inferior mesenteric vein* correspond with the ramifications of the artery of the same name. They commence at the lower part of the rectum in the hæmorrhoidal plexus, and unite into a single vessel near the sigmoid flexure of the colon. From this point the vein proceeds upwards and inwards along the lumbar region, behind the peritoneum, crossing between the transverse mesocolon and the spine, or farther to the left, and then passing beneath and behind the pancreas, it reaches the splenic vein in which it terminates.

### VEINS OF THE HEART.

The greater number of the *cardiac veins* are collected into a large common trunk which pours its blood into the posterior part of the right auricle, in the angle between the inferior vena cava and the right auriculo-ventricular orifice. The terminal part of this vein is considerably dilated, and is named the *coronary sinus*. The principal veins leading into it are named the *great*, the *posterior*, and the *anterior* or small coronary veins. Among these the first alone deserves the name of coronary, as it surrounds the heart in the left auriculo-ventricular groove.

Besides the larger cardiac veins which join the great coronary sinus, there are also small separate veins (*venæ minimæ cordis*), which open directly into the right auricle, especially along its right border. The openings of these veins, as well as some depressions which do not admit veins, have been named *foramina Thebesii*.

Fig. 328.

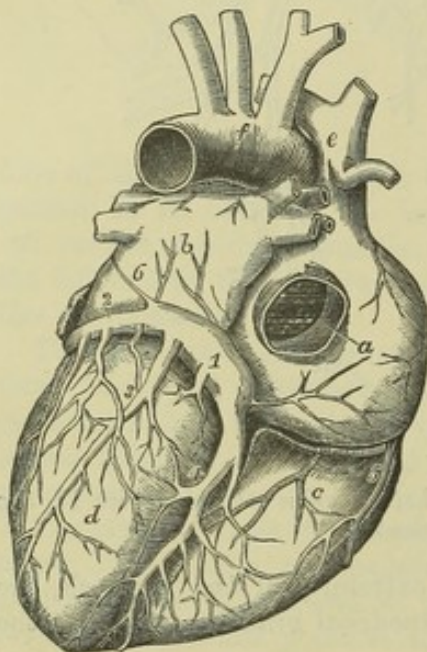


Fig. 328.—VIEW OF THE ADULT HEART, FROM BEHIND, TO SHOW THE CORONARY VEINS.  $\frac{1}{2}$

*a*, placed on the back of the right auricle, points to the Eustachian valve seen within the opening of the inferior vena cava; *b*, the back of the left auricle; *c*, back of the right ventricle; *d*, left ventricle; *e*, vena cava superior; *f*, arch of the aorta; 1, sinus of the great coronary vein; 2, great coronary vein turning round the heart in the auriculo-ventricular groove; 3, 4, posterior branches; 5, one of the small right cardiac veins passing directly into the right auricle; 6, the vestige of the left superior vena cava proceeding over the left auricle downwards to join the coronary sinus.

The veins of the heart are without valves excepting at their terminations.

The *great cardiac vein* (*vena cordis magna*) is a vessel of considerable size, and from the way in which it coils round the left side of the base of the heart, or rather of the ventricle, it may be named "coronary." Its chief branch

runs along the groove upon the fore part of the heart, corresponding with the septum of the ventricles. Commencing at the apex of the heart, it gradually increases in size as it approaches the base of the ventricles, and then inclining backwards and to the left side in the groove between the left



auricle and ventricle, ends in the coronary sinus : a valve of two segments closes its aperture in the sinus. In this course it receives branches from the ventricles, especially from the left, and also from the left auricle ; and as it passes round the thick margin of the left ventricle, it receives a vein of some size, which ascends to join it.

The *posterior cardiac* veins ascend on the back of the ventricles, especially on the left, and open into the coronary sinus by four or more valved orifices. One of these, larger than the rest (middle or posterior cardiac vein), ascends along the groove between the ventricles upon the posterior surface of the heart. It commences by small branches at the apex of the heart, which communicate with those of the preceding vein, and then ascends to the base, receiving branches from the substance of both ventricles.

The *small or anterior cardiac* veins (*venæ cordis parvæ*) are several small branches, which commence upon the anterior surface of the right ventricle, and passing upwards and outwards, open separately into the right auricle, after having crossed over the groove between it and the ventricle.

The *coronary sinus* is about an inch in length, and is placed at the back of the heart in the transverse groove between the left auricle and ventricle, where it is covered by the muscular fibres of the auricle. At one end it is joined by a small vein from the right side, and opens into the right auricle beneath the Thebesian valve ; at the other, it receives the large coronary vein, and a small straight vein directed obliquely along the back of the left auricle ; whilst between those points other veins enter it from the back of the heart. All the veins joining it, except the small oblique vein, are provided with more or less complete valves at their terminations.

The coronary sinus, together with the small oblique vein above referred to, considered with reference to their early foetal condition and certain malformations to which they are subject along with other neighbouring veins, may be looked upon rather as the persistent terminal parts of a typically distinct left superior vena cava, than as simply the main stem of the cardiac veins. The explanation of this will be found in what follows on the development of these veins.

#### DEVELOPMENT OF THE GREAT VEINS.

In the young foetus before the development of the allantois, a right and a left omphalo-mesenteric vein bring back the blood from the walls of the umbilical vesicle, and unite to form a short trunk, which is continued into the auricular extremity of the rudimentary heart.

In the first commencement of the placental circulation, or in the third week of foetal life (Coste), two umbilical veins have been seen coming from the placenta, and uniting to form a short trunk, which opens into the common omphalo-mesenteric vein. Very soon the right omphalo-mesenteric vein and right umbilical vein disappear. In connection with the common trunk of the umbilical and omphalo-mesenteric veins two sets of vessels make their appearance in the young liver. Those furthest from the heart, named *venæ hepaticæ advehentes*, become the right and left divisions of the portal vein ; the others are the hepatic veins, *venæ hepaticæ revehentes*. The portion of vessel intervening between those two sets of veins forms the *ductus venosus* (p. 329), and the part above the hepatic vein, being subsequently joined by the ascending vena cava, forms the upper extremity of that vein. Into the remaining or left omphalo-mesenteric vein open the mesenteric and splenic veins. The part above the latter forms the trunk of the portal vein ; and the portion of vessel between the union of this with the umbilical vein and the origin of the *venæ hepaticæ advehentes* is so altered that the portal trunk opens into the commencement of the right vena advehens.

At the time of the commencement of the placental circulation, two short transverse venous trunks, the *ducts of Cuvier*, open, one on each side, into the auricle of



the heart. Each is formed by the union of a superior and an inferior vein, named the primitive jugular and the cardinal.

The *primitive jugular vein* receives the blood from the cranial cavity by channels in front of the ear, which are subsequently obliterated; in the greater part of its extent it becomes the external jugular vein; and near its lower end it receives small branches, which grow to be the internal jugular and subclavian veins. The *cardinal veins* are the primitive vessels which return the blood from the Wolffian bodies, the vertebral column, and the parietes of the trunk. The inferior vena cava is a vessel of later development, which opens into the trunk of the umbilical and omphalo-mesenteric veins, above the *venæ hepaticæ revehentes*. The iliac veins, which unite to form the inferior vena cava, communicate with the cardinal veins. The inferior extremities of the cardinal veins are persistent as the internal iliac veins. Above the iliac veins the

Fig. 329.

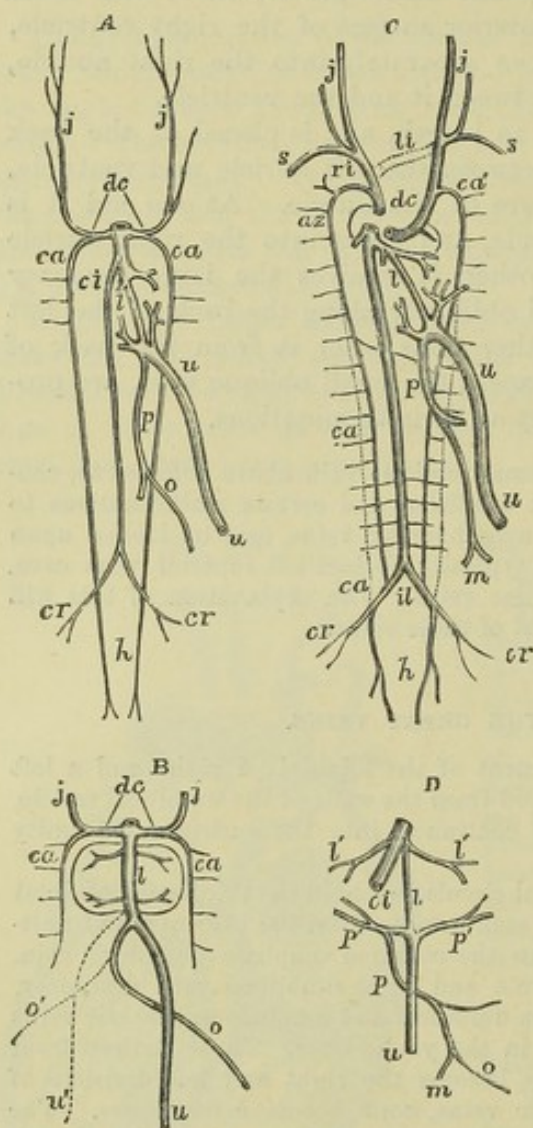


Fig. 329. — DIAGRAMS ILLUSTRATING THE DEVELOPMENT OF THE GREAT VEINS (after Kölliker).

A, plan of the principal veins of the fetus of about four weeks, or soon after the first formation of the vessels of the liver and the vena cava inferior.

B, veins of the liver at a somewhat earlier period.

C, principal veins of the fetus at the time of the first establishment of the placental circulation.

D, veins of the liver at the same period.

*dc*, the right and left ducts of Cuvier; *ca*, the right and left cardinal veins; *j, j*, the jugular veins; *s*, the subclavian veins; *az*, the azygos vein; *u*, the umbilical or left umbilical vein; *u'* in B, the temporary right umbilical vein; *o*, the omphalo-mesenteric vein; *o'*, the right omphalo-mesenteric vein; *m*, the mesenteric veins; *p*, the portal vein; *p', p'*, the *venæ advehentes*; *l*, the ductus venosus; *l', l'*, the hepatic veins; *ci*, vena cava inferior; *il*, the division of the vena cava inferior into common iliac veins; *cr*, the external iliac or crural veins; *h*, the hypogastric or internal iliac veins, in the line of continuation of the primitive cardinal veins.

In C, *li*, in dotted lines, the transverse branch of communication between the jugular veins which forms the left innominate vein; *ri*, the right innominate vein; *ca'*, the remains of the left cardinal vein by which the superior intercostal veins fall into the left innominate vein; above *p*, the obliquely crossing vein by which the hemiazygos joins the azygos vein.

cardinal veins are obliterated in a considerable part of their course; their upper portions then become continuous with two new vessels, the *posterior vertebral veins* of Rathke, which receive the lumbar and intercostal twigs.

As development proceeds, the direction of the ducts of Cuvier is altered by the descent of the heart from the cervical into the thoracic region, and becomes continuous with that of the primitive jugular veins. A communicating branch makes its appearance, directed transversely from the junction of the left subclavian and jugular veins, downwards, and across the middle line to the right jugular; and further down



in the dorsal region between the posterior vertebral veins a communicating branch passes obliquely across the middle line from right to left. The communicating branch between the primitive jugular veins forms the left innominate vein. The portion of vessel between the termination of the right subclavian vein and the termination of the communicating branch becomes the right innominate vein. The portion of the primitive jugular vein below the communicating vein, together with the right duct of Cuvier, forms the vena cava superior, while the cardinal vein opening into it is the extremity of the great vena azygos. On the left side, the portion of the primitive jugular vein placed below the communicating branch, and the cardinal and posterior vertebral veins, together with the cross branch between the two posterior vertebral veins are

Fig. 330.

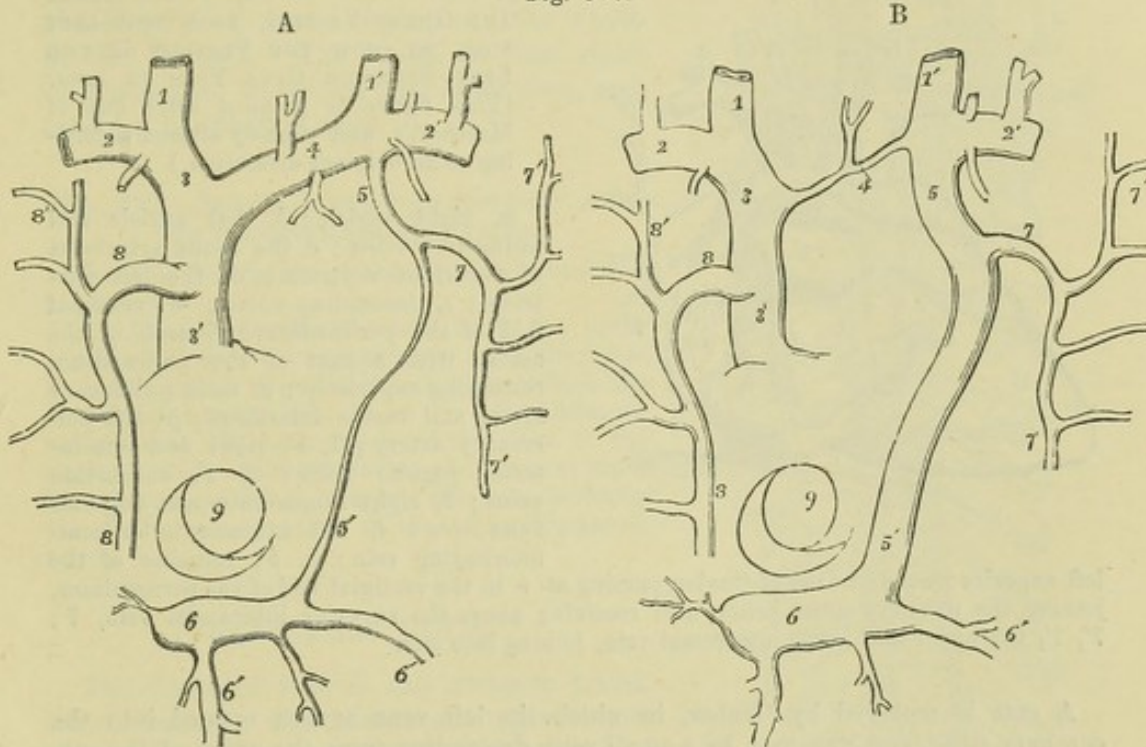


Fig. 330, A and B.—DIAGRAMMATIC OUTLINES OF THE VESTIGE OF THE LEFT SUPERIOR CAVA AND OF A CASE OF ITS PERSISTENCE (sketched after Marshall).  $\frac{1}{2}$

A, Brachio-cephalic veins with the superior intercostal, azygos, and principal cardiac veins.

B, the same in a case of persistence of the left superior cava, showing its communication with the sinus of the coronary vein. The views are supposed to be from before, the parts of the heart being removed.

1, 1', the internal jugular veins; 2, 2', subclavian veins; 3, right innominate; 3', right or regular superior cava; 4, in A, the left innominate; in B, the transverse or communicating vein between the right and left superior venæ cavæ; 5, in A, the opening of the superior intercostal vein into the innominate; 5', vestige of the left superior cava or duct of Cuvier; 5, 5', in B, the left vena cava superior abnormally persistent, along with a contracted condition of 4, the communicating vein; 6, the sinus of the coronary vein; 6', branches of the coronary veins; 7, the superior intercostal trunk of the left side, or left cardinal vein; 8, the principal azygos or right cardinal vein; 7', 8', some of the upper intercostal veins; 9, the opening of the inferior vena cava, with the Eustachian valve.

converted into the left superior intercostal and left superior and inferior azygos veins. The variability in the adult arrangement of these vessels depends on the various extent to which the originally continuous vessels are developed or atrophied at one point or another. The left duct of Cuvier is obliterated, except at its lower end, which always remains pervious as the coronary sinus. Even in the adult, traces of the existence of this vessel can always be recognised in the form of a fibrous band, or sometimes even a narrow vein, which descends obliquely on the left auricle; and in front of the root of the left lung there remains a small fold of the serous membrane



of the pericardium, the *vestigial* fold of the pericardium, so named by Marshall, to whom is due the first full elucidation of the nature and relations of the left primitive vena cava.

The left duct of Cuvier has been observed persistent as a small vessel in the adult. More frequently a right and left innominate vein open separately into the right auricle; an arrangement which is also met with in birds and in certain mammalia, and which results from the vessels of the left side being developed similarly to those of the right, while the cross branch remains small or absent. (Quain on the Arteries, plate 58, figs. 9 and 10.)

Fig. 331.

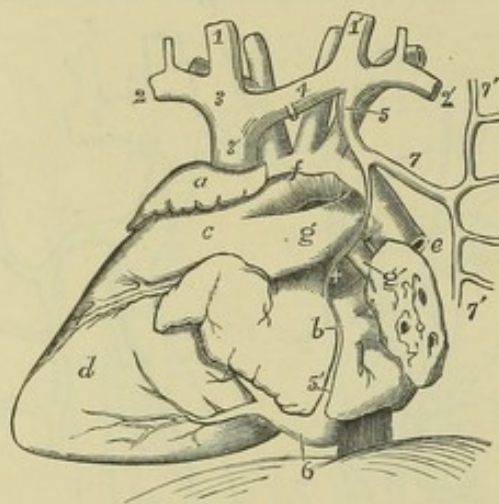


Fig. 331.—VIEW OF THE FETAL HEART AND GREAT VESSELS, FROM THE LEFT SIDE, TO SHOW THE VESTIGE OF THE LEFT SUPERIOR CAVA VEIN IN SITU. (This figure is planned after one of Marshall's, and slightly altered according to an original dissection.)

a, right auricle; b, left auricle and pulmonary veins; c, the conus arteriosus of the right ventricle; d, the left ventricle; e, descending aorta; +, vestigial fold of the pericardium; f, arch of the aorta, with a part of the pericardium remaining superiorly; g, main pulmonary artery and ductus arteriosus; g', left pulmonary artery; 1, 1', right and left internal jugular veins; 2, 2', subclavian veins; 3, right innominate and superior vena cava; 4, left innominate or communicating vein; 5, 5', remains of the

left superior cava and duct of Cuvier, passing at + in the vestigial fold of the pericardium, joining the coronary sinus below, and receiving above the superior intercostal vein, 7; 7', 7', the upper and lower intercostal vein, joining into one.

A case is recorded by Gruber, in which the left vena azygos opened into the coronary sinus, and was met by a small vein descending from the union of the subclavian and jugular. (Reichert and Dubois Reymond's Archiv. 1864, p. 729.) In this case, the jugular veins had been developed in the usual manner, while the left vena azygos continued to pour its blood into the duct of Cuvier.

(Consult Kölliker, *Entwicklungsgeschichte*, p. 414, et seq.; J. Marshall, on the Development of the great Anterior Veins in Man and Mammalia, in *Phil. Trans.*, part i., 1850; and Wenzel Gruber, *Über die Sinus Communis und die Valvulæ der Venæ Cardiacæ*, &c., in *Mém. de l'Acad. impér. des Scien. de St. Petersburg*, 1864; and in *Virchow's Archiv.*, Jan. 1865.)

## THE ABSORBENTS.

The absorbent vessels are divisible physiologically into two sets;—the *lacteals*, which convey the chyle from the alimentary canal to the thoracic duct; and the *lymphatics*, which take up the lymph from all the other parts of the body, and return it into the venous system. Anatomically considered, however, the lacteals are not different from the lymphatics, and may be regarded as the absorbents of the mucous membrane of the intestine. The larger lacteals and lymphatics are provided with valves, which give them, when distended, a somewhat moniliform appearance; and both are connected in their course with *lacteal* or *lymphatic* glands.



The general anatomy of the absorbents having been elsewhere detailed, only their course and position remain to be here described. They are gathered into a right and a left trunk, which open into the angles of union of the subclavian and internal jugular veins. The large vessel of the left side traversing the thorax is named the *thoracic duct*: it receives not only the lymphatics of its own side of the head and arm, but likewise the lymphatics of both lower limbs, and the whole of the lacteals. The vessel of the right side is named the *right lymphatic duct*, and receives lymphatics only.

Fig. 332.—SKETCH OF THE THORACIC DUCT WITH THE PRINCIPAL SYSTEMIC VEINS.

The full description of this figure will be found at page 454.

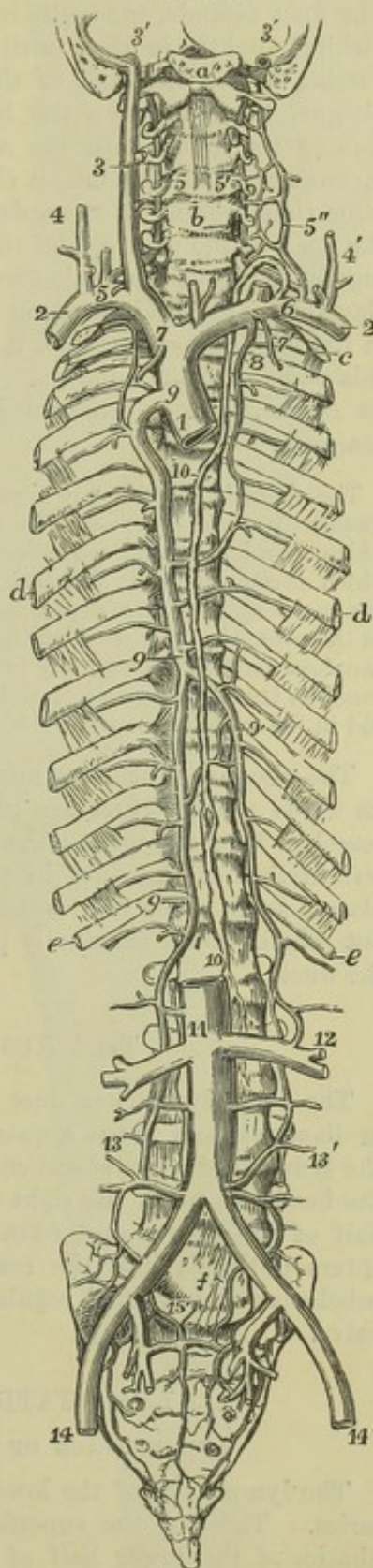
10, 10, indicate the thoracic duct; the lower number is close to the receptaculum chyli, the upper is on the fourth dorsal vertebra, above which the duct inclines to the left; 6, on the left subclavian vein, marks the termination of the duct in the angle of union of the subclavian and internal jugular veins; 5, on the right subclavian vein, indicates the similar termination of the right lymphatic trunk.

### THORACIC DUCT.

The thoracic duct is the common trunk which receives the absorbents from both the lower limbs, from the abdominal viscera (except part of the upper surface of the liver), and from the walls of the abdomen, from the left side of the thorax, left lung, left side of the heart, and left upper limb, and from the left side of the head and neck. It is from fifteen to eighteen inches long in the adult, and extends usually from the second lumbar vertebra to the root of the neck. Its commencement, however, is often as low as the third lumbar vertebra; and in some cases as high as the first lumbar, or even upon the last dorsal vertebra. Here there is usually a dilatation of the duct, of variable size, which is called *receptaculum chyli* (Pecquet), and is the common point of junction of the lymphatics from the lower limb with the trunks of the lacteal vessels.

The lower part of the thoracic duct is generally wider than the rest, being about three lines in diameter; it lies at first to the right side of or behind the

Fig. 332.





aorta; it then ascends on the right side of that vessel, in contact with the right crus of the diaphragm, to the thorax, where it is placed at first upon the front of the dorsal vertebræ, between the aorta and the azygos vein. The duct ascends, gradually inclining to the left, and at the same time diminishing slightly in size, until it reaches the third dorsal vertebra, where, passing behind the arch of the aorta, it comes into contact with the œsophagus, lying between the left side of that tube and the pleura. Continuing its course into the neck to the level of the upper border of the seventh cervical vertebra, it changes its direction and turns forwards, at the same time arching downwards and outwards so as to describe a curve over the apex of the pleura, and then terminates on the outer side of the internal jugular vein, in the angle formed by the union of that vein with the subclavian. The diminution in the size of the duct as it ascends is such that at the fifth dorsal vertebra it is often only two lines in diameter, but above this point it again enlarges. The duct is generally waving and tortuous in its course, and is constricted at intervals so as to give it a varicose appearance.

The thoracic duct is not always a single trunk throughout its whole extent; it frequently divides opposite the seventh or eighth dorsal vertebra into two trunks, which soon join again; sometimes it separates for a short distance into three divisions, which afterwards unite, and enclose between them spaces or islets. Cruikshank in one case found the duct double in its entire length; "in another triple, or nearly so." In the neck, the thoracic duct often divides into two or three branches, which in some instances terminate separately in the great veins, but in other cases unite first into a common trunk. In a case of right aortic arch the thoracic duct has been observed to end in the veins of the right side (A. Thomson).

The thoracic duct has numerous double valves at intervals throughout its whole course, which are placed opposite to the nodulated parts of the vessel. They are more numerous in the upper part of the duct. At the termination of the duct in the veins there is a valve of two segments, so placed as to allow the contents of the duct freely to pass into the veins, but which would effectually prevent the reflux of either chyle or blood into the duct.

### THE RIGHT LYMPHATIC DUCT.

The right lymphatic duct is a short vessel, about a line or a little more in diameter, and about a quarter or half an inch in length, which receives the lymph from the absorbents of the right upper limb, the right side of the head and neck, the right side of the chest, the right lung, and the right half of the heart, and from part of the upper surface of the liver. It enters obliquely into the receding angle formed by the union of the right subclavian and internal jugular veins, where its orifice is guarded by a double valve.

### LYMPHATICS OF THE LOWER LIMB

#### AND SURFACE OF THE LOWER HALF OF THE TRUNK.

The lymphatics of the lower limb are arranged in a superficial and a deep series. Those of the superficial series, together with the superficial lymphatics of the lower half of the trunk, converge to the superficial inguinal glands; with the exception of a few which dip into the popliteal space. Those of the deep series converge to the deep inguinal glands.



The *popliteal lymphatic glands*, usually very small, and four or five in number, surround the popliteal vessels, and are imbedded in a quantity of loose fat. They receive from below the deep lymphatics of the leg, and those which accompany the short saphenous vein; and from them proceed efferent vessels, which ascend with the femoral artery to the groin.

Fig. 333.—VIEW OF THE SUPERFICIAL LYMPHATIC VESSELS AND GLANDS OF THE RIGHT GROIN AND LOWER LIMB, AS SEEN FROM THE FRONT AND INNER SIDE (founded on Mascagni and others).  $\frac{3}{8}$

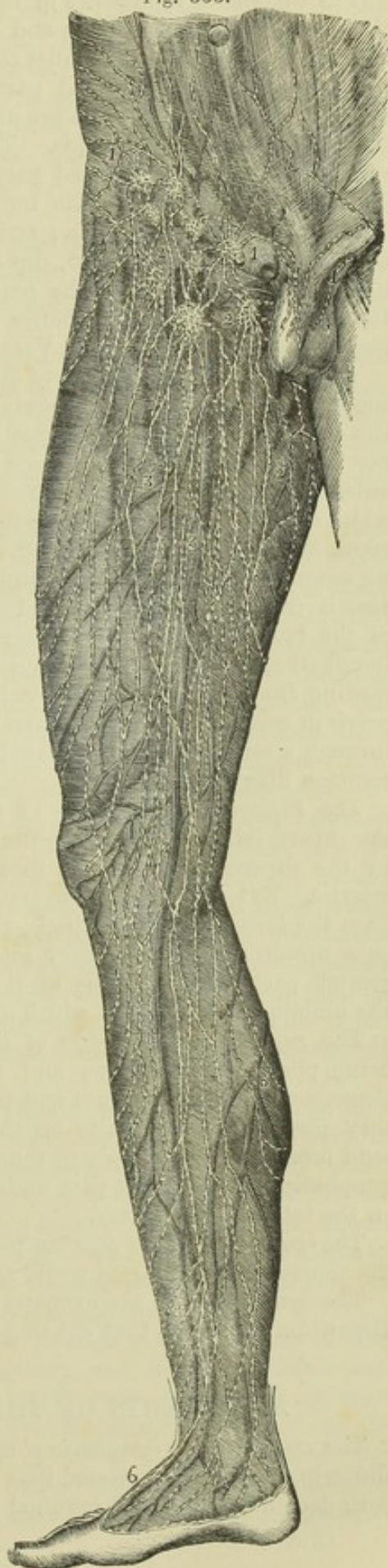1, 1, upper inguinal glands receiving the lower abdominal, the inguinal, penal, and scrotal lymphatic vessels; 2, 2, femoral or lower inguinal glands receiving the anterior internal and external femoral lymphatic vessels; 2', the internal lymphatic vessels; 3, 3, large plexus of lymphatic vessels in the course of the saphenous veins; 4, the same descending upon the leg; 5, posterior lymphatics of the calf of the leg; 6, lymphatic vessels of the dorsum of the foot; 7, those of the heel and inner ankle.

The *superficial inguinal glands* vary much in number, amounting on an average to eight or ten: they are divisible into a superior or oblique and an inferior or vertical set. The oblique glands lie in the line of Poupart's ligament and receive lymphatics from the integuments of the trunk and genital organs, together with a few from the upper and outer part of the limb: the vertical glands surround the upper part of the long saphenous vein, and extend two or three inches downwards along the course of that vessel; they receive the greater number of the lymphatics which ascend from the limb. The efferent vessels of the superficial inguinal glands perforate the fascia, come into connection with those situated deeply, pass into the abdomen by the side of the blood-vessels, and terminate in a chain of lymphatics which lie along the external iliac artery, and end in the lumbar glands.

The *deep-seated inguinal glands* are placed beneath the others, and surround the femoral artery and vein.

к к

Fig. 333.





The *superficial lymphatics of the lower limb* arise in two sets, one from the inner part of the dorsum and sole of the foot, the other from the outer. The *inner* vessels follow a similar course to that of the internal saphenous vein: passing partly in front and partly behind the inner ankle, they ascend along the inner side of the knee and front of the thigh, and terminate in the superficial inguinal glands. The *outer* vessels, ascending from the outer side of the foot, pass in great part obliquely across the popliteal space to join the inner set above the knee; in part they reach the inner set by crossing in front of the tibia; and a small number of them accompanying the external saphenous vein, dip down between the heads of the gastrocnemius muscle, and end in the popliteal glands. From the middle line of the back of the thigh lymphatics pass round on both sides to reach the inguinal glands. (Mascagni, *Vasorum Lymph. Historia*, 1787.)

The *deep-seated lymphatics of the lower limb* are associated in their whole course with the deep blood-vessels. In the leg they consist of three divisions, namely, anterior tibial, posterior tibial, and peroneal. Neither these nor the superficial absorbents pass through any lymphatic gland in the leg, unless it be those lymphatics which accompany the anterior tibial artery, near which a small gland is sometimes found on the front of the inter-osseous ligament, above the middle of the leg. The several sets of deep lymphatics in the leg enter the lymphatic glands situated in the popliteal space. The efferent vessels from those glands are joined by others in contact with the branches of the femoral artery, and enter the deep inguinal glands. Other deep lymphatics, derived from the muscles of the gluteal region, and many proceeding from the adductor muscles of the thigh, enter the cavity of the pelvis in company with the gluteal, sciatic, and obturator arteries, and pass through a series of glands situated in the neighbourhood of the internal and common iliac arteries.

The *superficial lymphatics of the lower half of the trunk* converge to the superficial inguinal glands, the direction of some of them being indicated by the superficial circumflex iliac and epigastric, and the external pudic arteries. Externally they converge to the groin from the gluteal region and from the lower part of the back, those from the back crossing others which pass upwards to the axillary glands. Anteriorly they descend from the greater part of the surface of the abdomen, crossing and mingling above the umbilicus with vessels which ascend towards the axillary glands.

The *superficial lymphatics of the penis* usually form three vessels, two being placed at the sides, and the other on the dorsum of the organ. Commencing in the prepuce and beneath the mucous lining of the urethra, they pass backwards, unite on the dorsum penis, and, again subdividing, send branches on each side to the oblique inguinal glands. The *deep-seated* lymphatics of the penis pass under the pubic arch, and end in the glands on the internal iliac artery.

The *lymphatics of the scrotum* pass to the superficial inguinal glands along the course of the external pudic arteries.

The lymphatics of the external generative organs in the female present a disposition similar to that existing in the male.

#### ABSORBENTS OF THE ABDOMEN AND PELVIS.

The *external iliac lymphatic glands*, from six to ten or more in number, clustering round the external iliac artery, receive the efferent vessels from both deep and superficial inguinal glands.



The *internal iliac lymphatic glands*, a numerous series placed on the internal iliac artery, and the *sacral glands*, placed in the hollow of the sacrum, receive the lymphatics from the pelvic viscera and parietes.

The *lumbar lymphatic glands* are very large and numerous; they are placed in front of the lumbar vertebræ, around the aorta and vena cava. To these proceed the efferent vessels of the glands already mentioned, as well as those which accompany several of the branches of the abdominal aorta.

The efferent absorbent vessels which proceed from the lumbar glands progressively increase in size, while their number diminishes, and at length they unite into a few trunks, which, with those of the lacteals, form the origin of the thoracic duct.

The *deep lymphatics of the abdominal wall* in part pass along the circumflex iliac and epigastric arteries to the external iliac glands; the greater number are directed backwards with the ilio-lumbar and lumbar arteries, and, being joined by the lymphatics from the muscles of the back, pass behind the psoas muscle to the vertebral column, where they enter the lumbar glands.

The *lacteals* (vasa lactea, chylifera) commence in the coats of the intestines, by a very close plexus, and extend to the thoracic duct, in which they all terminate: they are derived in far larger numbers from the small than from the large intestine, so that they abound in the mesentery, and particularly in that of the jejunum and ileum. Two series of absorbent vessels are found along the tube of the intestine, having different positions and directions: those nearest to the outer surface of the intestine run longitudinally in the course of the canal, lying beneath the peritoneal coat; whilst others, placed more deeply between the muscular and mucous coats, run transversely round the intestine, and are directed thence with the arteries and veins along the mesentery, enclosed between the two layers of the peritoneum. (Cruikshank, *Anatomy of the Absorbent Vessels*, p. 162.) Sometimes the more superficial absorbents of the intestine are named lymphatics, to distinguish them from the deep set which are those which absorb the chyle from the cavity of the intestine. According to Teichmann (*Das Saugader-system*, 1861, p. 75), the two plexuses have no capillary anastomoses, but communicate only through valved vessels: this they do freely. The lacteals, having entered the mesentery, take the course of the blood-vessels, and pass through numerous lymphatic glands (mesenteric glands).

The *mesenteric glands* vary in number from a hundred and thirty to a hundred and fifty; and in the healthy state are seldom larger than an almond. They are most numerous in that part of the mesentery which corresponds with the jejunum; and they seldom occur nearer to the attached border of the intestine than two inches. In mesenteric disease they are subject to enlargement, and become the seat of unhealthy deposits. Small glands in limited numbers are also disseminated irregularly between the folds of the peritoneum connected with the large intestines.

Having passed through these glands, the lacteals gradually unite as they approach the attached border of the mesentery, and so become diminished in number but increased in size, until at length, near the root of the superior mesenteric artery, only two or three trunks remain, which end in the thoracic duct. Sometimes, however, six or seven of these vessels open separately into the commencement of the duct. Those from the descending colon and its sigmoid flexure usually join some of the lumbar lymphatics, or



Fig. 334.

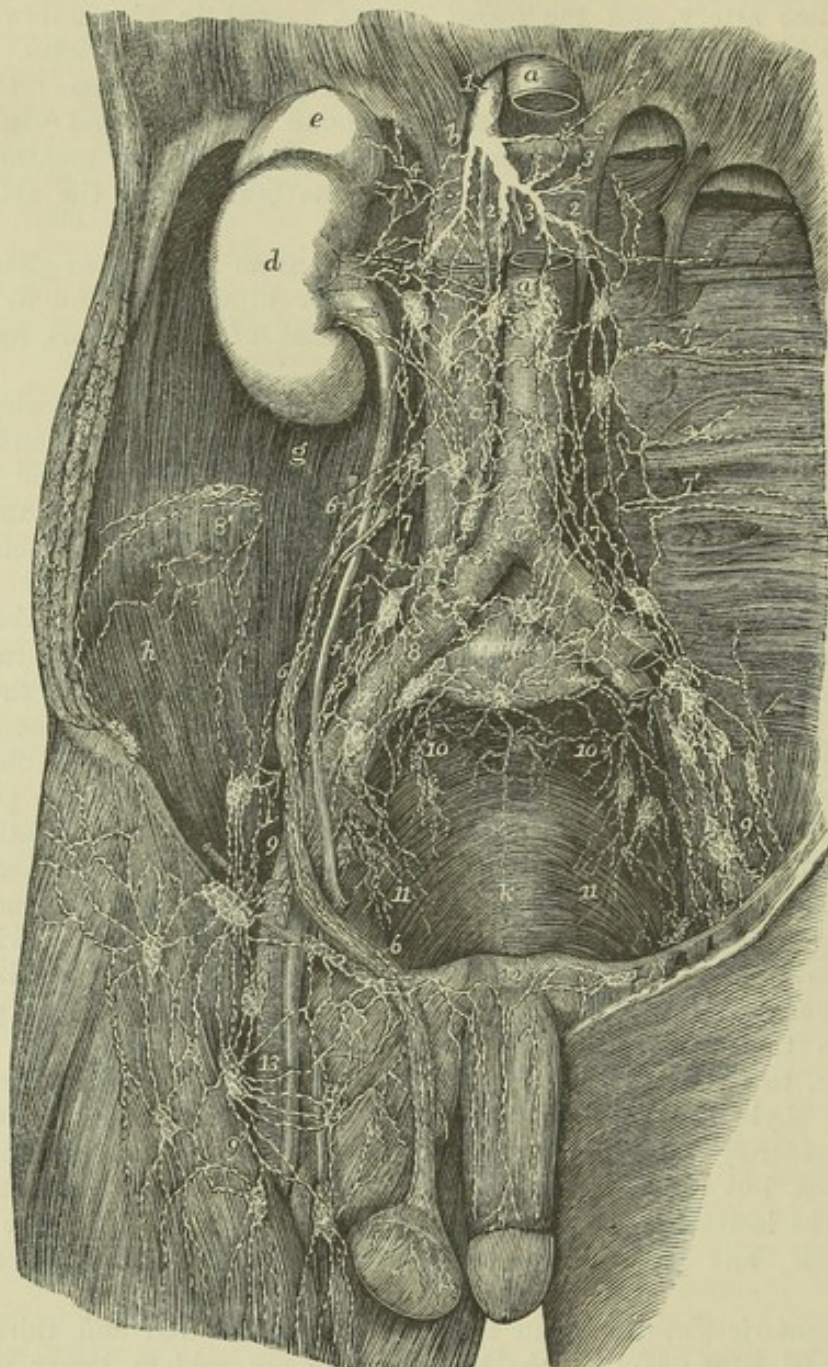


Fig. 334.—PRINCIPAL LYMPHATIC VESSELS AND GLANDS OF THE ABDOMEN AND PELVIS  
(modified from Mascagni).  $\frac{1}{4}$

*a*, the abdominal aorta, the upper part of it having been removed to show the deepest lumbar plexuses of lymphatics; *a'*, the vena cava inferior; *b*, the right, *c*, the left crus of the diaphragm; *d*, the right kidney; *e*, the suprarenal body; *f*, the ureter; *g*, the psoas muscle; *h*, the iliacus; *k*, the lower part of the sacrum within the pelvis; 1, the commencement of the thoracic duct; 2, 3, 2, the largest of the lymphatic and lacteal trunks which join the thoracic duct, the hepatic, splenic, gastric, &c.; 4, the suprarenal lymphatics; 5, the renal, joining some of the lumbar plexus; 6, the spermatic; 7, 7', the lumbar lymphatic vessels and glands; 7', 7', some of the lymphatics of the loins; 8, 8, those surrounding the common iliac vessels, and proceeding from the lymphatics of the pelvis and lower limb; 9, 9, the external iliac; 10, 10, the internal iliac receiving those from the sacrum, walls of the pelvis, and at 11, 11, and at *k*, those from the viscera (bladder and rectum); 12, lymphatics of the dorsum of the penis passing to those of the groin; 13, the deep femoral lymphatics and glands.



turn upwards and open by a separate trunk into the lower end of the thoracic duct.

The *absorbents of the stomach*, like those of the intestines, are placed, some beneath the peritoneal coat, and others between the muscular and mucous coats. Following the direction of the blood-vessels, they become arranged into three sets. Those of one set accompany the coronary vessels, and receiving, as they run from left to right, branches from both surfaces of the organ, turn backwards near the pylorus, to join some of the larger trunks. Another series, from the left end of the stomach, follow the vasa brevia, and unite with the lymphatics of the spleen : whilst those of the third set, guided by the right gastro-epiploic vessels, incline from left to right along the great curvature of the stomach, from which they pass backwards, and at the root of the mesentery terminate in one of the principal efferent *lacteal* vessels.

The *absorbents of the rectum*, likewise in two strata, are frequently of considerable size : immediately after leaving the intestine, some of them pass through small glands which lie contiguous to it ; finally, they enter the lymphatic glands situated in the hollow of the sacrum, or those higher up in the loins. At the anus their capillary network is continuous with that of the cutaneous absorbents.

The *lymphatics of the spleen* are placed, some immediately under its peritoneal covering, others in the substance of the organ. Both sets converge to the inner side of the spleen, come in contact with the blood-vessels, and, accompanying these, pass through a series of small glands, and terminate in the larger lymphatics of the digestive organs.

Lymphatics emerge from the *pancreas* at different points, and join those derived from the spleen.

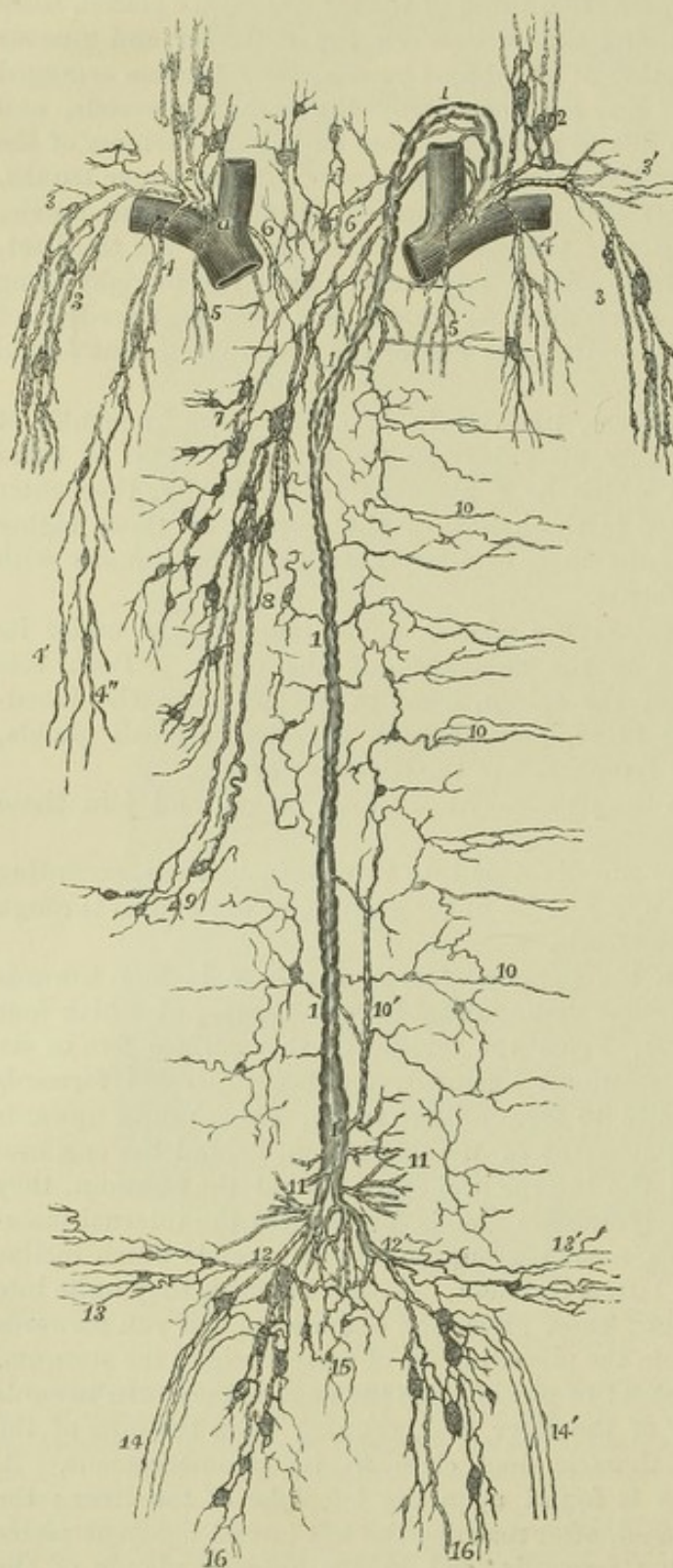The *lymphatics of the liver* are divisible into three principal sets, according as they are placed upon its upper or its under surface, or are spread through its substance with the blood-vessels.

The lymphatic vessels on the *upper surface of the liver* incline towards particular points, and so become distinguishable into groups, of which four are usually enumerated. 1. From the middle of this surface five or six branches run towards the falciform ligament, and being directed forwards on this membrane, they unite to form a large trunk, which passes upwards between two slips of the attachment of the diaphragm, behind the ensiform cartilage. Having reached the interpleural space behind the sternum, they ascend through a chain of lymphatic glands found upon the internal mammary blood-vessels. 2. The second group consists of vessels which incline outwards towards the right lateral ligament, opposite to which they unite into one or two larger lymphatics ; these pierce the diaphragm, and run forwards upon its upper surface to join the preceding set of vessels behind the sternum. In some cases, however, instead of passing into the thorax, they turn inwards on reaching the back part of the liver, and, running upon the crus of the diaphragm, open into the thoracic duct close to its commencement. 3. Another set of lymphatics is found upon the left lobe of the liver ; the vessels of which it is composed, after reaching the left lateral ligament pierce the diaphragm, and, turning forwards, end in the anterior glands of the mediastinum. 4. Finally, along the fore part of the liver some vessels will be observed to turn downwards and join those placed upon the under surface.

The *under surface of the liver* is covered by an open network of lymphatic vessels. On the right lobe they are directed over and under the gall-bladder to the transverse fissure, where some join the deep lymphatics ;



Fig. 335.

Fig. 335.—DIAGRAMMATIC OUTLINE OF THE PRINCIPAL ABSORBENT VESSELS AND DUCTS.  $\frac{1}{4}$ 

*a*, junction of the right jugular and subclavian veins in the right innominate; *b*, the same on the left side; 1, the thoracic duct, showing a division in its upper part; farther down a separation into two vessels enclosing a space between them, and at its lower extremity, 1', the receptaculum chyli; 2, the principal cervical lymphatic vessels with the larger glands near their terminations; 3, 3', the principal axillary lymphatic vessels and glands, joined by those from the shoulder and lower part of the neck; 4, 4', the right and left internal mammary and anterior mediastinal lymphatic vessels (represented as more widely separated than natural); on the right side, 4' and 4'', mark the junction with the internal mammary of the superior hepatic and anterior superior phrenic lymphatics; 5, some deeper mediastinal and pericardiac lymphatics; 6, 6', deep mediastinal lymphatics passing into the right lymphatic trunk and thoracic duct; 7, the bronchial and pulmonary; 8, oesophageal; 9, posterior diaphragmatic lymphatics; 10, the intercostal and neighbouring lymphatics of the posterior thoracic wall represented chiefly on the left side; at 10', is shown a small collateral trunk formed by the union of a number of the intercostal lymphatics; 11, 11, short trunks leading into the lower part of the thoracic duct, which receive some of the principal lymphatic vessels from the spleen, stomach, and pancreas, and the lacteal vessels from the intestines; 12, 12', several main vessels, which collect the principal

lymphatic vessels of the right and left lumbar plexus, and carry their contents into the thoracic duct; 13, 13', right and left renal lymphatics; 14, 14', right and left spermatic lymphatics; 15, aortic plexus, which farther down is continuous with the sacral; 16, 16', right and left lumbar plexus, which receive the principal lymphatics of the pelvis and lower limbs.



whilst others, passing through some scattered lymphatic glands, are guided by the hepatic artery to the right side of the aorta, where they terminate in the thoracic duct. Branches also proceed to the concave border of the stomach, between the folds of the small omentum, to join with the coronary lymphatics of that organ.

The *deep lymphatics of the liver* accompany the branches of the portal vein in the substance of the organ, and pass out of the gland by the transverse fissure. After communicating with the superficial lymphatics, and also with those of the stomach, they pass backwards, and join, at the side of the coeliac artery, with one of the large *lacteal* trunks previously to its termination in the thoracic duct.

The *lymphatics of the kidney* likewise consist of a deep and a superficial set. Those placed upon the surface of the organ are comparatively small; they unite at the hilus of the kidney with other lymphatics from the substance of the gland, and then pass inwards to the lumbar lymphatic glands. The lymphatics of the *suprarenal capsules* unite with those of the kidney. The lymphatic vessels of the *ureter* are numerous; they communicate with those of the kidney and bladder, and for the most part terminate by union with the former.

The *lymphatics of the bladder*, taking rise from the entire surface of that organ, enter the glands placed near the internal iliac artery; with these are associated the lymphatics of the prostate gland and vesiculæ seminales.

The *lymphatics of the uterus*, in the unimpregnated state of the organ, are small, but during the period of gestation they are greatly enlarged. Issuing from the entire substance of the uterus, the greater number descend, together with those of the vagina, and pass backwards to enter the glands upon the internal iliac artery; thus following the course of the principal uterine blood-vessels. Others, proceeding from the upper end of the uterus, run outwards in the folds of peritoneum which constitute the broad ligaments, and join the lymphatics derived from the ovaries and Fallopian tubes. The conjoined vessels then ascend with the ovarian arteries, near the origin of which they terminate in the lymphatic vessels and glands placed on the aorta and vena cava.

The *lymphatics of the testicle* commence in the substance of the gland, and upon the surface of the tunica vaginalis. Collected into several large trunks, they ascend with the other constituents of the spermatic cord, pass through the inguinal canal, and accompany the spermatic vessels in the abdomen to enter some of the lumbar lymphatic glands.

### LYMPHATICS OF THE THORAX.

The *lymphatic glands of the thorax*.—Along the course of the internal mammary blood-vessels there are placed six or seven small glands, through which pass the lymphatics situated behind the sternum; they may be named the *anterior mediastinal* glands. Between the intercostal muscles and in the line of the heads of the ribs on the side of the spine is a set of glands, named *intercostal*, which receive the lymphatics from the thoracic parietes and the pleura; their efferent ducts communicate freely with each other and open into the thoracic duct. Three or four *cardiac* lymphatic glands lie behind the aortic arch, and one before it: and another cluster, varying from fifteen to twenty in number, is found along the oesophagus, constituting the *oesophageal* glands. The *bronchial* glands, ten or twelve in number, are of much larger size than those just mentioned. The largest of



them occupy the interval between the right and left bronchi at their divergence, whilst others of smaller size rest upon the first divisions of these tubes

Fig. 336.

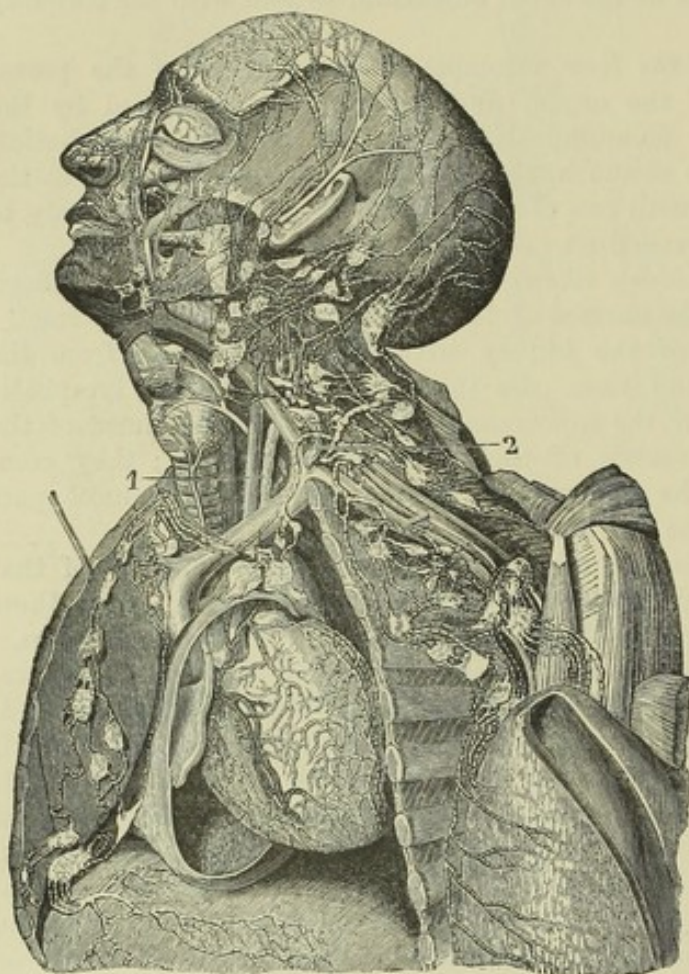


Fig. 336.—LYMPHATIC VESSELS OF THE HEAD AND NECK AND OF THE UPPER PART OF THE TRUNK (from Mascagni).  $\frac{1}{8}$

The chest and pericardium have been opened on the left side, and the left mamma detached and thrown outwards over the left arm, so as to expose a great part of its deep surface.

The principal lymphatic vessels and glands are shown on the side of the head and face, and in the neck, axilla, and mediastinum. Between the left internal jugular vein and the common carotid artery, the upper ascending part of the thoracic duct marked 1, and above this, and descending to 2, the arch and last part of the duct. The termination of the upper lymphatics of the diaphragm in the mediastinal glands, as well as the cardiac and the deep mammary lymphatics, are also shown.

for a short distance within the lungs. In early infancy their co-

lour is pale red ; towards puberty, we find them verging to grey, and studded with dark spots ; at a more advanced age they are frequently very dark or almost black. In chronic diseases of the lungs they sometimes become enlarged and indurated, so as to press on the air-tubes and cause much irritation. They are frequently the seat of tuberculous deposits.

The *deep lymphatics of the thoracic walls* are divisible into two sets, the sternal and the intercostal. The *sternal lymphatics*, commencing in the muscles of the abdomen, ascend between the fibres of the diaphragm at its attachment to the ensiform cartilage, and continue upwards behind the costal cartilages to terminate on the left side in the thoracic duct, and on the opposite side in the right lymphatic duct. They receive branches from the upper surface of the liver, and small branches from the anterior parts of the intercostal spaces. The *intercostal lymphatics*, passing backwards in each intercostal space, receive, as they approach the spine, branches coming forward through the intertransverse space, and enter the intercostal glands, through the efferent ducts of which their contents are poured on both sides of the body into the thoracic duct.

The *lymphatics of the lungs*, like those of other organs, form two sets, one being superficial, the other deep-seated. Those at the surface run beneath the pleura, where they form a network by their anastomoses,



Their number is considerable, but they are sometimes difficult of demonstration. The deep lymphatics run with the pulmonary blood-vessels. Both superficial and deep lymphatics converge to the root of the lung, and terminate in the bronchial glands. From these, two or three trunks issue, which ascend along the trachea to the root of the neck, and terminate on the left side in the thoracic duct, and on the right in one of the right lymphatic trunks.

The *lymphatics of the heart* follow the coronary arteries and veins from the apex of the organ towards the base, where they communicate with each other, and those of each side are gathered into one trunk. The trunk from the *right side*, running upwards over the aortic arch between the innominate and left carotid arteries to reach the trachea, ascends to the root of the neck, and terminates in the right lymphatic duct. The vessel from the left side, proceeding along the pulmonary artery to its bifurcation, passes through some lymphatic glands behind the arch of the aorta, and ascends by the trachea to terminate in the thoracic duct.

The *lymphatics of the œsophagus*, unlike those of the rest of the alimentary canal form only one layer, which lies internal to the muscular coat. They are connected with glands in the neighbourhood, and after having communicated by anastomoses with the lymphatics of the lungs, at and near the roots of those organs, they terminate in the thoracic duct.

The *lymphatics of the thymus gland* are numerous. According to Astley Cooper, two large vessels proceed downwards from them on each cornu, and terminate in the jugular veins by one or more orifices on each side. (Anatomy of the Thymus Gland, p. 14.)

## LYMPHATICS OF THE UPPER LIMB,

### AND OF THE BREAST AND BACK.

In the upper limb, as in the lower, the lymphatics are arranged in a deep and a superficial set. These two sets of vessels, together with the lymphatics of the surface of the greater part of the back, and those of the mamma and pectoral muscles, converge to the axillary glands.

The lymphatic glands found in the upper limb below the axilla are neither large nor numerous; a few, however, are found in the course of the brachial artery and even of the arteries of the forearm; and one or more small glands are found in connection with the superficial lymphatics, lying near the commencement of the basilic vein, a little above and in front of the inner condyle of the humerus.

The *axillary glands* are generally ten or twelve in number: they vary, however, considerably in their number as well as in their size, in different individuals; they are mostly placed along the axillary vessels, the lower member of this group receiving the lymphatics which ascend from the limb; but a few lie further forwards on the serratus magnus near the external mammary artery, and beneath the pectoral muscles, and receive lymphatics from the mamma and muscular walls of the chest; while others incline downwards at the posterior boundary of the axilla, and are joined by the lymphatics from the back.

From the glands of the axilla efferent lymphatic vessels, fewer in number, but larger in size than the afferent vessels, proceed along the course of the subclavian artery, in some parts twining round it. From the top of the thorax they ascend into the neck, close to the subclavian vein, and terminate, —those of the left side in the thoracic duct, those of the right side



Fig. 337

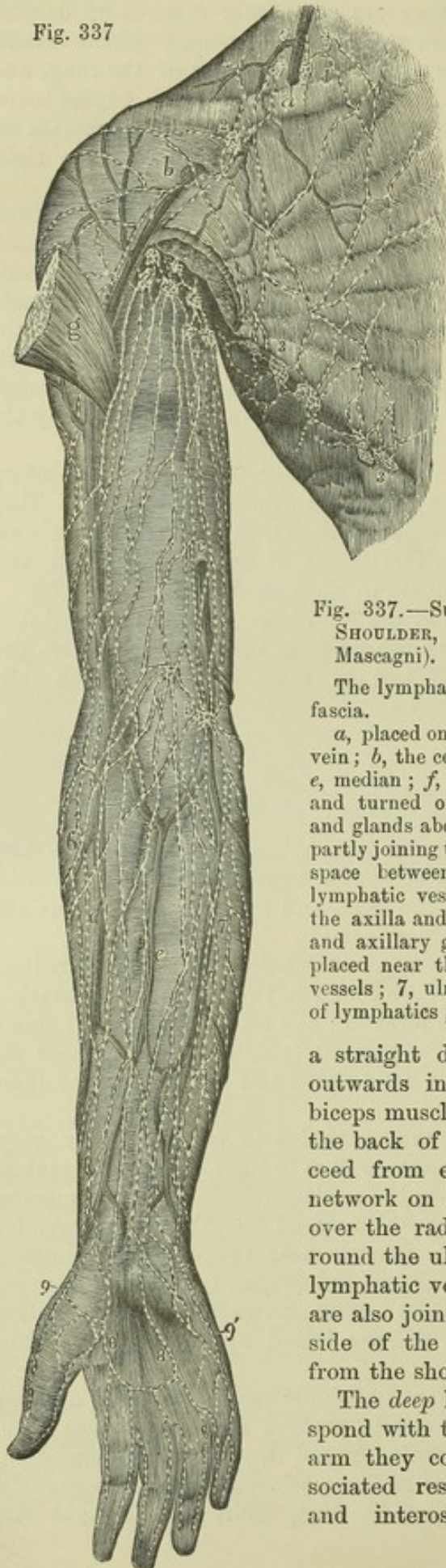

Fig. 337.—SUPERFICIAL LYMPHATICS OF THE BREAST, SHOULDER, AND UPPER LIMB, FROM BEFORE (after Mascagni).  $\frac{1}{2}$

The lymphatics are represented as lying upon the deep fascia.

*a*, placed on the clavicle, points to the external jugular vein; *b*, the cephalic vein; *c*, the basilic vein; *d*, radial; *e*, median; *f*, ulnar vein; *g*, great pectoral muscle cut and turned outwards; 1, superficial lymphatic vessels and glands above the clavicle; 2, those below the clavicle partly joining the foregoing and dipping into the triangular space between the deltoid and pectoral muscles; 3, lymphatic vessels and glands placed along the border of the axilla and great pectoral muscle; 4, upper brachial and axillary glands and vessels; 5, two small glands placed near the bend of the arm; 6, radial lymphatic vessels; 7, ulnar lymphatic vessels; 8, 8, palmar arch of lymphatics; 9, 9', outer and inner sets of vessels.

a straight direction, and those placed further outwards inclining gradually inwards over the biceps muscle to reach the axillary glands. On the back of the hand also two lymphatics proceed from each finger; and from the copious network on the back of the forearm vessels pass over the radial margin, and in greater number round the ulnar side to join those in front. The lymphatic vessels in the front of the upper arm are also joined by others which pass round each side of the limb, and by some which descend from the shoulder.

The *deep* lymphatics of the upper limb correspond with the deep blood-vessels. In the forearm they consist, therefore, of three sets, associated respectively with the radial, ulnar, and interosseous arteries and veins. In

in the right lymphatic duct. Sometimes they unite into a single trunk, which opens separately into the subclavian vein near its termination.

The *superficial lymphatics of the upper limb* are usually described as forming two divisions corresponding with the superficial veins on the outer and inner borders. On the front of the limb they arise from an arch formed in the palm of the hand by the union of two lymphatic vessels proceeding from each finger: becoming more numerous in the forearm, they are found thickly set over its surface, whence they pass upwards in the arm; the inner vessels in



their progress upwards some of them have communication near the wrist with the superficial lymphatics; and some of them enter the glands which lie by the side of the brachial artery near the bend of the elbow. They all terminate in the glands of the axilla.

The *lymphatics of the chest* consist of branches running under cover of the pectoral muscles, and of subcutaneous vessels, twigs of which are continued from those on the abdominal wall as low as the umbilicus, decussating with the vessels which converge to the inguinal glands.

The *superficial lymphatics of the back* converge to the axillary glands from its various regions; from the neck over the surface of the trapezius muscle, from the posterior part of the deltoid, and from the whole dorsal and lumbar regions as low as the crest of the ilium; the branches decussating inferiorly with vessels leading to the inguinal glands, and likewise crossing the middle line so as to decussate with branches of the opposite side. (Mascagni, Tab. xxii., xxiii., xxiv.)

### LYMPHATICS OF THE HEAD AND NECK.

The *lymphatic glands* found on different parts of the *head* and *face* are few and small: those in the *neck*, on the contrary, are comparatively very large and numerous.

The *cervical glands* are placed chiefly on the sides of the neck, and are divisible into a superficial and a deep series. Of the former, some lie beneath the base of the inferior maxillary bone; the remainder, arranged along the course of the external jugular vein, exist in greatest number in the angular space behind the lower end of the sterno-mastoid muscle, where that vein enters the subclavian vein: at this point the cervical glands approach and are connected with the glands of the axilla. The *deep cervical glands* are placed along the carotid artery and internal jugular vein, extending downwards on the sheath of those vessels as far as the thorax.

The lymphatic vessels of the cranium and face, together with those of the tongue, pharynx, larynx and other parts of the neck, pass into the cervical glands. From these efferent vessels issue, which progressively diminish in number during their descent, and unite into two trunks, of which the left one ends in the thoracic duct, and the other in the right lymphatic duct: sometimes, however, the main cervical lymphatic vessel terminates separately at the junction of the subclavian and internal jugular veins, or in one of those veins immediately before their union.

The *lymphatics of the cranium* consist of a temporal and an occipital set. Those of the *temporal* set descend in front of the ear, some of the vessels passing through one or two glands usually found near the zygoma, whilst others enter those situated on the parotid gland; all of them terminate in the lymphatic glands of the neck. The cranial lymphatics of the *occipital* set, accompanying the occipital artery, descend to the glands situated behind the ear, on and near the mastoid process of the temporal bone, and hence join the superficial lymphatics of the neck.

Within the cranial cavity, lymphatic vessels have been demonstrated in the pia mater and in the arachnoid membrane. None have been traced in the dura mater, nor have they been shown in the substance of the brain. The trunks of those derived from the pia mater pass out of the skull with the veins.

The *superficial lymphatics of the face*, more numerous than those of the



cranium, descend obliquely in the course of the facial vein, and join the submaxillary glands, from six to ten in number, which are placed beneath the

Fig. 338.

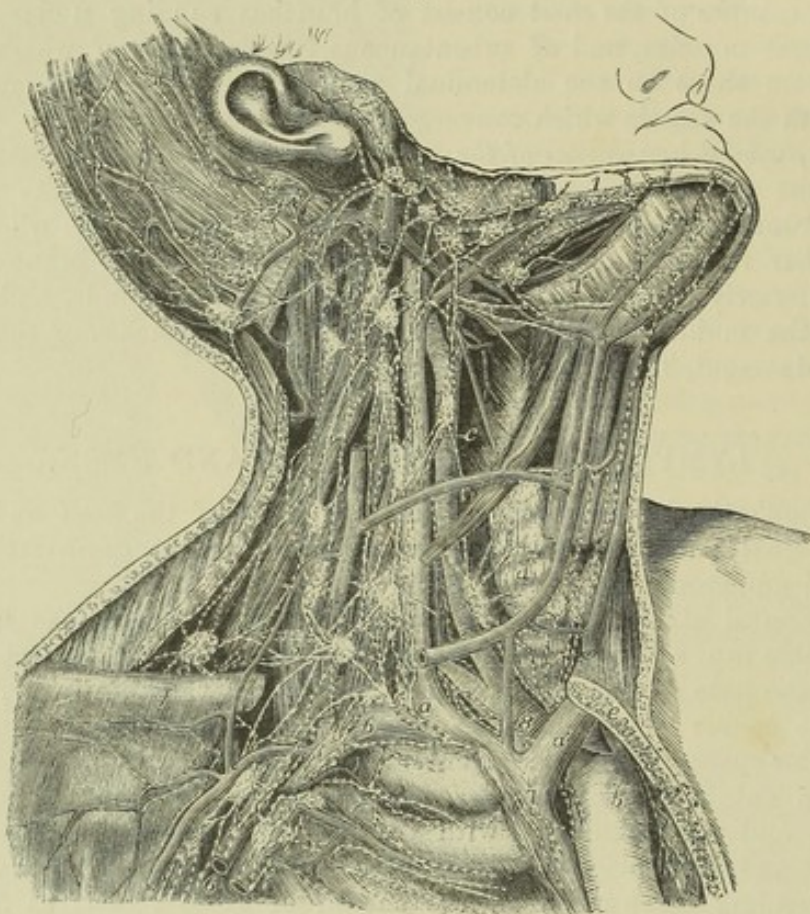


Fig. 338.—PRINCIPAL LYMPHATIC VESSELS AND GLANDS OF THE HEAD AND NECK ON THE RIGHT SIDE (after Bourgery in part).  $\frac{1}{3}$

The inner half of the right clavicle and part of the sternum have been removed so as to expose the arch of the aorta, and the innominate artery and veins: the posterior belly of the omo-hyoid muscle is removed; and the sterno-mastoid, sterno-hyoid, and sterno-thyroid muscles, and a part of the external jugular vein have been divided so as to expose the deeper parts.

*a*, the right innominate vein at the place where it is joined by the principal lymphatic trunk; *a'*, the left vein; *b*, arch of the aorta; *c*, common carotid artery; *d*, thyroid gland crossed by the anterior jugular vein; *e*, cut surface of the sternum; *f*, outer part of the clavicle; 1, submaxillary lymphatic vessels; 1', sublingual; 2, temporal, facial and parotid; 3, occipital and posterior auricular; 4, deep or descending cervical close to the great vessels; 5, transverse cervical; 6, deep pectoral and axillary; 7, on the vena cava superior, some of the right mediastinal; 8, on the innominate artery, some of the deeper cardiac and bronchial; to these last are seen descending some of the lymphatics from the thyroid gland and lower part of the neck.

base of the lower maxillary bone; a few of them in their descent pass through some glands situated on the buccinator muscle. The *deep* lymphatics of the *face*, derived from those of the temporal fossa and the cavities of the nose, mouth, and orbit, proceed outwards in the course of the internal maxillary vein; and, having reached the angle of the jaw, they enter the glands in that neighbourhood.



## NOTE TO PAGE 180.

At the page indicated, the action of the straight muscles of the eyeball has been shortly described, but no notice is taken of that of the oblique muscles. The omission was deemed advisable, from the difficulty of giving within a short space an intelligible account of a matter still involved in uncertainty; but the attention of the Editors having been drawn to it as a defect which it was desirable to remedy, they have endeavoured to do so in the present note.

The motions of the eye-ball take place round three axes, viz., a transverse, a vertical, and an antero-posterior. Those round the first two axes are effected more immediately by the straight muscles, which have also the power by the successive or concurrent contraction of different ones among them to direct the pupil to all the points of space within the cone by which the movements of direction are limited. The movements of rotation on an antero-posterior axis are no doubt effected chiefly by the oblique muscles; but it is still doubtful to what extent and in what circumstances these movements occur.

By the experiment of Donders, viz., that of turning the head downwards to the side after an ocular spectrum of a bright vertical line has been fixed in the eyes, and which it is easy to repeat with the same result, it is ascertained that the eyes turn accurately with the head, and are not balanced in the vertical position by the rotatory action of the oblique muscles, as was supposed by Hueck and others. The rotation of the eyes by the oblique muscles must therefore have some other object.

When the optic axis is directed straight forwards, the simple action of the superior oblique muscle (as ascertained by experiment on the dead subject) is to direct the pupil with some degree of rotation downwards and outwards; that of the inferior oblique to produce a similar movement in an upward and outward direction; and no doubt both muscles acting in concert on one eye, while the optic axis is still straight forward or is somewhat everted, may produce a horizontal outward movement of the pupil. But if on the other hand the eye is turned forcibly inwards, it is conceivable that, as then the points of insertion of the oblique muscles will be brought further forward, these muscles may along with other movements give an inward direction to the pupil.

The most important actions of the oblique muscles probably take place in combination with one or more of the straight muscles. Careful observations appear to have proved that the recti muscles are incapable of altering materially the form of the eyeball, or of diminishing its distance from the back of the orbit; and it is equally certain that the oblique muscles have little or no effect as antagonists in drawing forward the eyeball. It would appear, however, that while the external and internal recti muscles act exactly in the horizontal plane between them, so as not to produce any upward or downward direction along with their horizontal movements, the superior and inferior recti, from the obliquity of the line in which they proceed forwards towards their insertion, have both a tendency to direct the eye somewhat inwards. It seems very probable, according to the views stated in the papers referred to below, that the inward direction produced by the superior or inferior rectus may be corrected by the combination of the action of different oblique muscles with that of one or other of the recti muscles; *i. e.*, the inferior oblique with the superior rectus, and the superior oblique with the inferior rectus. In a similar manner the oblique muscles may also counterbalance an increased inward direction given by the internal rectus, and increase an outward direction given by the external rectus.

On the whole, it seems probable that the oblique muscles have the effect of maintaining accurately the parallelism of the two eyes by balancing the action of the several sets of straight muscles.

See for an account of this subject and its application to the study of different forms of paralysis of the muscles of the eye, a paper by Dr. John S. Wells in the *Ophthalmic Hospital Reports*, &c., vol. ii. 1859-60, p. 44; and a paper by Von Graefe on the *Physiology and Pathology of the Oblique Muscles of the Eye* in the *Archiv für Ophthalmologie*, vol. i. part i. p. 1.







## CORRIGENDA AND ADDENDA.

- Page 13, line 17th from bottom, *transpose* the words "posterior" and "anterior."
- 17, line 4th from bottom of the description of Fig. 15, *after* "three places" *insert* "to," and in the succeeding line, *before* "three" *insert* "to."
- 18, in title of Fig. 16, *omit* "figs. 80 and 81."
- 20, in description of Fig. 19, *add under C*, "one-third the natural size."
- 22, line 14th, *after* "corresponds to" *insert* "the."
- 23, *before* "THE THORAX," *insert* "II."
- — in the description of A, Fig. 21, *after* "interclavicular notch" *insert* "12."
- 29, *before* "THE BONES OF THE SKULL" *insert* "III."
- 35, line 2nd, *after* "foramina" *insert* "; 16, transverse suture."
- — line 27th, *after* "malar" *insert* ", and by the glenoid cavity with the inferior maxillary bone."
- 47, line 15th from bottom, for "fossa on its sides;" *read* "fossa; on its sides."
- 52, line 12th, for "from which the external pterygoid muscle arises," *read* "into which the external pterygoid muscle is inserted."
- 56, line 4th from bottom, *after* "the figure is" *insert* "the outer or deflected plate of the inferior turbinated bone, and over that."
- 73, line 13th from bottom, for "Crana" *read* "Crania."
- 79, line 22nd, for "musculo-spinal" *read* "musculo-spiral."
- 80, line 13th from bottom, *after* "upper part" *insert* "superiorly by an oblique line or ridge, and lower down."
- 94, in the description of Fig. 85, *before* "13, tuberosity, &c." *insert* "12, spine of the ischium."
- 101, at the middle, for "trochanteric" *read* "intertrochanteric."
- 106, lines 12th and 13th from bottom, for "to which the interosseous ligament is attached" *read* ", the interosseous ridge,"
- 107, line 16th, for "largest" *read* "larger."
- 108, line 8th, for "largest" *read* "larger."
- — under the Cuboid Bone, line 11th, for "surface" *read* "aspect."
- 115, line 3rd from bottom, *after* "ulna" *insert* "of the opposite side of the body;" and in the bottom line, *after* "radius" *insert* "of the same side of the body."
- 143, in the woodcut, Fig. 132, B, *omit* "12" close to the fifth metacarpal bone.
- 146, line 14th from bottom, for "metacarpal, interosseous, and palmar," *read* "interosseous and palmar metacarpal;" and in the 6th, 7th, and 8th lines from bottom, *transpose* the words "distal" and "palmar," and *delete* the words "and their interosseous ligaments are put upon the stretch."
- 147, line 17th from bottom, *omit* "symphysis or."
- 154, line 6th, *after* "membrane" *insert* "in the middle it is attached to the internal semilunar cartilage; and."
- 158, line 10th from bottom of the small print, *after* "the external" *insert* "and internal."
- 184 and 192, in the description of Figs. 160 and 166, for "c, front of the thyroid cartilage," *read* "c, placed on the front of the thyroid cartilage, points to the thyro-hyoid muscle."
- 194, in description of Fig. 167, line 4th, *after* "muscle" *insert* "; 15'."
- 196, line 5th, for "sixth vertebræ" *read* "sixth cervical vertebræ."




Page 205, in the woodcut, Fig. 173, the lower part of the coraco-brachialis muscle is misplaced behind the tendons of the latissimus and teres major: it ought to have been represented as cut across like the biceps. In Fig. 200, p. 254, the same error occurs.

- — line 2nd from top, for "b" read "6."
- — line 2nd from bottom, for "biceps" read "triceps."
- 221, in description of Fig. 182, line 7th, after "ulnaris;" insert "15", its insertion into the fifth metacarpal bone."
- 222, in description of Fig. 183, line 8th, after "tendon of," instead of "the flexor; 3, carpi ulnaris;" read "3, the flexor carpi ulnaris."
- 226, in the middle, after "masses of fibres" insert "proceed."
- 230, line 29th, instead of "aponeurosis" read "aponeurotic."
- 233, after the last line of the paragraph describing the serratus posticus inferior, insert "(See Fig. 71, p. 202)."
- 237, in the last line but one of the description of Fig. 191, after "posticus" insert "minor."
- 242, in the woodcut, Fig. 164, the ninth rib is erroneously marked "XI."
- 247, line 25th, for "Hutchison" read "Hutchinson."
- 249, in bottom line, for "Ponpart's" read "Poupart's."
- — line 5th from bottom, for "aba" read "alba."
- 261, insert a "comma" at the end of the first line of the paragraph in small print.
- 320, bottom line, prefix "\*."
- 333, in description of Fig. 249, line 5th from bottom, for "sphenic" read "splenic."
- 447, near middle, in 1st line after "BRANCHES," for "metacarpal" read "metatarsal."
- 577, line 2nd from bottom of foot-note, for "Twischenhirn," read "Zwischenhirn."
- 592, last line but one of description of Fig. 401, for "409" read "408."
- 765, in the diagrammatic view of a section of the lamina spiralis, &c., Fig. 522, the cellular structure filling the sulcus spiralis is represented too strongly and regularly.
- 929, line 17th from bottom, for "Fig. 659" read "Fig. 661."
- 931, line 17th from bottom, for "The glomerulus" read "The capsule."









✓



BOUND BY  
EDMONDS & REMNANTS  
LONDON



