

The pocket Gray, or, Anatomist's vade-mecum : compiled especially for students / by Edward Cotterell.

Contributors

Cotterell, Edward.

Publication/Creation

London : Ballière, Tindall & Cox, 1893.

Persistent URL

<https://wellcomecollection.org/works/v6ds7nt5>

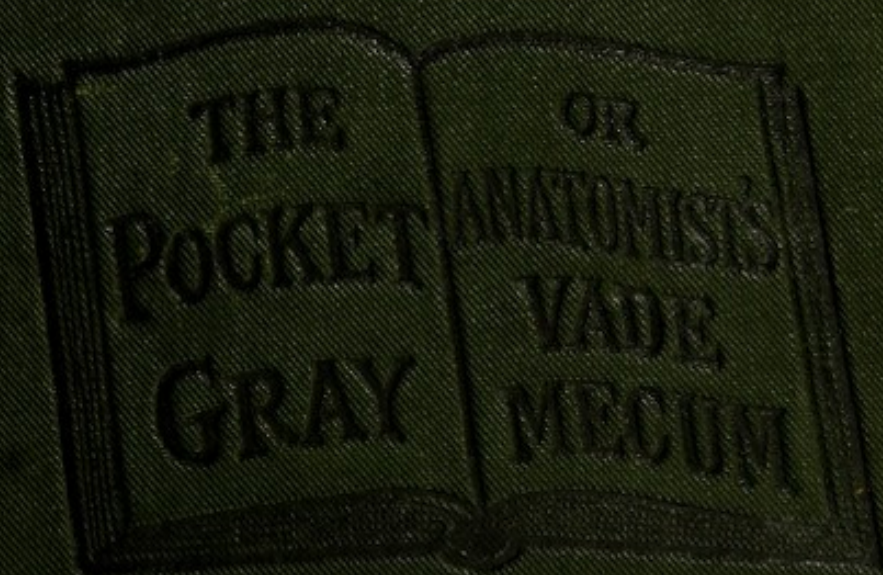
License and attribution

This work has been identified as being free of known restrictions under copyright law, including all related and neighbouring rights and is being made available under the Creative Commons, Public Domain Mark.

You can copy, modify, distribute and perform the work, even for commercial purposes, without asking permission.



Wellcome Collection
183 Euston Road
London NW1 2BE UK
T +44 (0)20 7611 8722
E library@wellcomecollection.org
<https://wellcomecollection.org>



3/8

BAILLIERE, TINDALL & COY.

J. Taylor.

Clifton House
Beeston Hill
Leeds



22101344443



POCKET ALPHABET

THE

OF



THE
POCKET GRAY;

OR,

Anatomist's Vade-Mecum.

COMPILED ESPECIALLY FOR STUDENTS

BY

EDWARD COTTERELL, F.R.C.S. ENG., ETC.,

SURGEON (OUT-PATIENTS), LONDON LOCK HOSPITAL; SURGEON TO THE
CANCER HOSPITAL; SURGEON TO THE WEST-END HOSPITAL FOR EPILEPSY
AND DISEASES OF THE NERVOUS SYSTEM; FORMERLY ASSISTANT-
DEMONSTRATOR OF ANATOMY, UNIVERSITY COLLEGE, LONDON.

FIFTEENTH THOUSAND.

4th ed.



LONDON :
BAILLIÈRE, TINDALL & COX,
20 & 21, KING WILLIAM STREET, STRAND.

BY THE SAME AUTHOR.

Now ready, with Illustrations, small 8vo., 3s. 6d.

ON SOME COMMON INJURIES TO LIMBS: Their Treatment and After-Treatment, including Bone-setting (so-called).

"This is a readable and useful little work."—*The Lancet*.

"Well worthy of perusal."—*Bristol Med. Chir. Journal*.

"This small work is a very practical and useful one."—*British Medical Journal*.

M15220

WELLCOME INSTITUTE LIBRARY	
Coll.	welMOmec
Call	
No.	Q54
	1893
	C84p

PREFACE TO THE FIRST EDITION

THIS little book is intended as a pocket remembrancer of Anatomy, and contains only the bare facts of that science. As such it is hoped it will prove useful to students.

In its compilation the author has made frequent references to the leading text-books ; especially to the works of Gray, Ellis, Quain, Heath, and Leonard, in order that it might be as reliable as possible.

Especial prominence has been given to those subjects which are most likely to be forgotten by students, whilst osteology has been omitted altogether ; it being a subject too large to be treated with justice in so limited a space.

September, 1879.

PREFACE TO THE FOURTH EDITION

THE success attending the first three editions of this little book has induced the compiler to thoroughly revise, and at the same time to somewhat enlarge, the work. The latest editions of all the leading text-books on Anatomy have been laid under contribution during the revision, in order that a reliable and handy pocket anatomist might be produced.

5 WEST HALKIN STREET,
BELGRAVE SQUARE, S.W.,
April, 1893.

THE POCKET GRAY

OR

ANATOMISTS' VADE-MECUM.

THE ARTICULATIONS.

The Classification of Joints.

Synarthrosis (Immovable Joints).

Varieties :—

Sutura Vera.

Sub-varieties :—

S. Dentata.

S. Serrata.

S. Limbosa.

Sutura Notha, or False Suture.

Sub-varieties :—

S. Squamosa.

S. Harmonia.

Schindylesis.

Gomphosis.

Amphiarthrosis, or Symphysis (allowing slight movement).

Diarthrosis (Movable Joints).

Varieties :—

Arthrodia, or Gliding Joint.

Enarthrosis, or Ball-and-Socket Joint.

Ginglymus, or Hinge Joint.

Diarthrosis Rotatoria, or Lateral Hinge Joint.

Condylod.

Reciprocal Reception.

ARTICULATIONS OF THE TRUNK.

I.—ARTICULATIONS OF THE VERTEBRAL COLUMN.

The Ligaments of the Bodies.

The **anterior common ligament**: a broad band of fibres, extending along front of bodies of vertebræ, from axis to sacrum.

It consists of two sets of fibres, *superficial* and *deep*; the former extending between the bodies of two or more vertebræ, the latter only between adjacent vertebræ. The fibres are attached principally to the intervertebral substances.

The **posterior common ligament** is within the spinal canal, and extends along back of bodies of the vertebræ from axis to sacrum, being broad opposite the intervertebral discs, and narrow opposite the bodies, except in the neck, where it is as wide as the bodies. It is attached to the discs and contiguous parts of the bodies of the vertebræ.

The **intervertebral substances**, found between the vertebræ from axis to sacrum. The circumference of each consists of laminae of white fibro-cartilage and fibrous tissue, enclosing a central part of pulpy elastic material. They are thickest in the lumbar region, and they give the peculiar curves to the column by their differences in thickness.

The Ligaments of the Laminæ.

The **ligamenta subflava** connect the laminae of the vertebræ from the axis to the sacrum. Each ligament is attached to the anterior inferior edge of the lamina above, and to the posterior superior edge of the lamina below.

The Ligaments of the Articular Processes.

Capsular ligaments surround the articular processes, those in the cervical region being the loosest. Each is lined by a synovial membrane.

The Ligaments of the Spinous Processes.

The **interspinous ligaments** extend between the spinous processes of the vertebræ, running from root to apex.

The **supraspinous ligament**: a fibrous cord, joining the tips of the vertebræ, and extending from the seventh cervical to the first sacral.

The **ligamentum nuchæ** continues the supraspinous ligament upwards. It consists of a *superficial* layer, extending from the spine of the seventh cervical to the external occipital protuberance, and a *deep* layer attached to the spines of the cervical vertebræ and the occipital crest.

The Ligaments of the Transverse Processes.

Intertransverse ligaments extend between the transverse processes, often absent in the cervical, thin in the lumbar, but round and well marked in the dorsal region.

II.—LIGAMENTS OF THE ATLAS AND AXIS.

The **atlanto-axoid articulation** consists of four joints—(a) lateral hinge, between odontoid process and anterior arch of

atlas, and between odontoid process and transverse ligament ;
(b) arthrodial, between the articular processes.

The **anterior atlanto-axial ligament** consists of a superficial and a deep part. The *superficial* part continues the anterior common ligament. It is attached above to the anterior tubercle of the atlas ; and below to the body of the axis and base of the odontoid process. The *deep* part is broad, and reaches from the lower border of the anterior arch of atlas to the base of odontoid process and body of axis.

The **posterior atlanto-axial ligament** : a thin layer, connected above to the lower border of the posterior arch of atlas, and below to the upper edge of laminae of axis.

The **transverse ligament** keeps the odontoid process in its place ; it is attached on each side to a tubercle on the inner surface of the superior articular process of the atlas. A thin bundle of fibres passes upwards from the middle of the posterior surface to the basilar process, and a like process downwards to the body of the axis. These two processes, together with the transverse ligament, form the *cruciform* ligament.

Capsular ligaments as in ordinary vertebrae, but supplemented at the posterior and inner part by an accessory ligament passing downwards and inwards to the base of the odontoid process.

III.—LIGAMENTS OF THE ATLAS AND OCCIPITAL BONE.

The **anterior occipito-atlantal ligament** consists of a superficial and a deep part. The *superficial*, rounded, passes from the basilar process of the occiput to the anterior tubercle of the atlas. The *deep* part is broad, and attached above to the anterior edge of the foramen magnum, and below to the upper margin of anterior arch of atlas.

The **posterior occipito-atlantal ligament**, thin and membranous, is attached above to posterior margin of foramen magnum ; below, to upper border of posterior arch of atlas. (*Perforated on each side by vertebral artery and suboccipital nerve.*)

The **lateral occipito-atlantal ligaments** : one on each side ; attached above to the jugular process of occiput, and below to the base of atlantal transverse process.

Capsular ligaments as in ordinary vertebrae.

IV.—LIGAMENTS OF THE AXIS AND OCCIPITAL BONE.

The **occipito-axial ligament** (*apparatus ligamentosus colli*) : a continuation of the posterior common ligament, connected

above with basilar groove of occiput, and below to posterior surface of the body of axis.

The **odontoid or check ligaments** consist of two cords passing from the sides of the apex of the odontoid process to the rough surface on the inner side of each condyle of the occipital bone. In the interval between the two the *ligamentum suspensorium dentis* passes from the apex of the odontoid process to the anterior margin of the foramen magnum.

Synovial membranes: two; one in front and one behind the odontoid process, the latter often communicating laterally with one of the occipito-atlantal joints.

V.—TEMPORO-MAXILLARY ARTICULATION.

The condyle of the lower jaw articulates with the anterior part of the glenoid fossa, and eminentia articularis of the temporal bone, the joint being divided into an upper and a lower synovial cavity by an interarticular fibro-cartilage.

The **external lateral ligament**, attached above to tubercle and lower border of zygoma; below, to outer surface and posterior edge of neck of lower jaw.

The **internal lateral ligament** is attached above to the spinous process of the sphenoid, and below to the inner margin of the dental foramen of lower jaw.

The **stylo-maxillary ligament**: a band of fibrous tissue extending from the styloid process to posterior border of ramus of the jaw, which is developed in connection with the deep cervical fascia (q. v.).

(*Stylo-hyoid ligament*: a fibrous cord extending from the styloid process to small cornu of hyoid bone.)

The **capsular ligament**: thin and loose, attached above to the edge of glenoid cavity and articular eminence; below, it surrounds neck of the condyle.

The **interarticular fibro-cartilage** has an oval shape; the upper surface is concavo-convex from before backwards, and slightly convex transversely; the lower surface is concave; the edge is attached to the capsule, and part of the external pterygoid muscle is inserted into its anterior margin.

Synovial membranes, two in number, one above and one below the fibro-cartilage; the upper being the larger.

VI.—ARTICULATION OF THE RIBS WITH THE VERTEBRÆ.

Articulations between the Heads of the Ribs and the Bodies of the Vertebrae.

Arthrodial joints held together by the following ligaments:—

The **anterior costo-vertebral or stellate ligament** is com-

posed of three fasciculi, which radiate from the anterior surface of the head of the rib. The *superior* fasciculus passes to the body of the vertebra above; the *inferior* fasciculus to the body of the vertebra below; the *middle* fasciculus to the intervertebral substance.

A **capsular ligament** surrounds articulation between the head of the rib and the articular surface formed by two vertebræ.

The **interarticular ligament** divides the joint into two parts, each of which has a separate *synovial membrane*. It passes between ridge on head of rib and intervertebral substance. (Absent in the 1st, 11th, and 12th ribs.)

Articulation of the Necks and Tubercles of the Ribs with the Transverse Processes.

Arthrodial joints held together by the following ligaments:—

The **anterior or superior costo-transverse ligament** passes from the upper border of neck of rib, to lower border of transverse process above. (Absent in 1st rib.)

The **middle costo-transverse or interosseous ligament**: a short thick band passing from the anterior surface of the transverse process to the posterior surface of neck of corresponding rib.

The **posterior costo-transverse ligament** passes from apex of transverse process to rough non-articular part of tubercle of rib. (Absent in 11th and 12th ribs.)

The **capsular ligament** surrounds articular surfaces, enclosing a small synovial membrane. (This articulation is absent in the 11th and 12th ribs.)

VII.—ARTICULATION OF THE CARTILAGES OF THE TRUE RIBS WITH THE STERNUM.

The **anterior chondro-sternal ligament**: a broad thin band, radiating from extremity of the rib cartilage to the sternum. The *superior* fasciculi pass obliquely upwards, the *inferior* downwards, and the *middle* horizontally.

The **posterior chondro-sternal ligament** is an indistinct band of fibres radiating from the posterior surface of the inner end of the costal cartilage to the back of the sternum.

The **capsular ligament** surrounds the joint, and encloses a synovial membrane. (In the 1st there is no synovial membrane; in the 2nd and 3rd there are 2; the joint being divided by an interarticular ligament passing between end of the rib cartilage and cartilage between 1st and 2nd pieces of the sternum. The 3rd has two synovial membranes; the 4th, 5th, 6th and 7th one each.)

Articulations of the Cartilages of the Ribs with each other.

The cartilages of the 6th, 7th, and 8th ribs articulate with each other by an oval-shaped facet, each having a capsule enclosing a synovial membrane.

Articulations of the Ribs with their Cartilages.

The costal end of each cartilage fits into a depression in the sternal end of the rib, and is bound down by periosteum.

VIII.—LIGAMENTS OF THE STERNUM.

The 1st and 2nd pieces are united by a piece of cartilage, kept together by the following two ligaments :—

The **anterior sternal ligament** consists of longitudinal fibres, which blend with the costo-sternal ligaments.

The **posterior sternal ligament** : similar to the preceding, placed on the back of the sternum.

IX.—ARTICULATION OF THE PELVIS WITH THE SPINE.

The following ligaments connect the 5th lumbar vertebra with the sacrum, and are similar to the common vertebral ones :—

1. The continuations of the **anterior and posterior common ligaments**.

2. The **intervertebral substance** between the last lumbar vertebra and the sacrum.

3. The **ligamenta subflava** between the laminæ of the last lumbar vertebra and the margins of upper opening of the sacral canal.

4. **Capsular ligaments**, between the articulating processes.

5. **Interspinous and supraspinous ligaments**.

Besides these, there are the following special ligaments :—

The **lumbo-sacral or sacro-vertebral ligament** : attached above to the front of tip of transverse process of the 5th lumbar vertebra ; below, to the outer border of the front of the lateral mass of the sacrum.

The **ilio-lumbar ligament** passes from the tip of transverse process of 5th lumbar vertebra, to the crest of ilium in front of sacro-iliac articulation.

X.—ARTICULATIONS OF THE PELVIS.

Articulations of the Sacrum and Ilium.

The **sacro-iliac articulation** is an amphiarthrosis, formed between the lateral surfaces of the sacrum and ilium. The auricular or anterior parts of the articular surfaces are covered with cartilage, and connected by the two following ligaments :—

The **anterior sacro-iliac ligament** : small bands passing obliquely from sacrum to ilium on the anterior surface.

The **posterior sacro-iliac ligament** consists of strong interosseous bands connecting the rough part of the ilium behind the cartilage, with the posterior part of the sacrum. There are two *superior*, passing from the 1st and 2nd transverse sacral tubercles, and one sometimes called the *oblique sacro-iliac* ligament, which reaches from the posterior superior iliac spine to the 3rd transverse sacral tubercle.

Ligaments between the Sacrum and Ischium.

The **great (or posterior) sacro-sciatic ligament**, attached by its base to the posterior inferior iliac spine, to the 4th and 5th transverse sacral tubercles, and to the lower part of the edge of the sacrum and coccyx ; passes downwards, outwards, and forwards, to be attached to the inner edge of the ischial tuberosity and to the inner margin of the ramus, forming the *falciform* ligament.

The **small (or anterior) sacro-sciatic ligament**, attached by its apex to the spine of the ischium, and by its base to the lateral margin of the coccyx and sacrum.

Foramina.—Between the great sacro-sciatic ligament and the innominate bone is a space divided into two by the small sacro-sciatic ligament ; the part above this ligament being the *great sacro-sciatic foramen*, and the part between the two ligaments the *small sacro-sciatic foramen*. The large foramen transmits pyriformis, together with gluteal, sciatic and pudic vessels and nerves, and nerves to the obturator internus, quadratus, and gemilli. The small foramen transmits the obturator internus, whilst its nerve, together with the pudic vessels and nerve, re-enters the pelvis by it.

Articulation of the Sacrum and Coccyx.

Amphiarthrodial joint.

The **anterior sacro-coccygeal ligament**, very indistinct, passes from anterior surface of sacrum to that of the coccyx.

The **posterior sacro-coccygeal ligament** passes from the margin of the lower orifice of the sacral canal to the posterior surface of the coccyx.

Interarticular ligaments between the cornua. **Lateral ligaments**, passing from the lower lateral angle of sacrum to transverse process of 1st piece of coccyx.

A **fibro-cartilage** is placed between the sacrum and the coccyx.

Articulation of the Pubes.

The **symphysis pubis**, amphiarthrodial joint bound together by the following ligaments :—

The **anterior pubic ligament** consists of several layers of fibres crossing the symphysis horizontally in front.

The **posterior pubic ligament** resembles the anterior, but is much less distinct, and connects the bones posteriorly.

The **superior pubic ligament** connects the bones superiorly.

The **sub-pubic ligament**, forming the upper boundary of the pubic arch, is a thick triangular arch of fibres, attached above to the fibro-cartilage, and laterally to the rami.

The **fibro-cartilage** consists of two parts, one on each bone ; the two are united in front, but posteriorly they are separated by a small cavity lined by a synovial membrane.

The **obturator membrane** closes the thyroid foramen, except at the upper and outer part, where a canal is left for the obturator vessels and nerve.

ARTICULATIONS OF THE UPPER EXTREMITY.

I.—STERNO-CLAVICULAR ARTICULATION.

An arthrodial joint connected together by the following ligaments :—

The **anterior sterno-clavicular ligament** is attached to upper and anterior part of the inner end of the clavicle, and to the upper and anterior part of the 1st piece of the sternum.

The **posterior sterno-clavicular ligament** passes between the inner end of the clavicle and the sternum on the posterior surface.

The **interclavicular ligament** passes along the top of the sternum from the inner end of one clavicle to the other.

The **costo-clavicular or rhomboid ligament** : a strong band of fibres passing from the upper surface of the sternal end of 1st costal cartilage, to a rough marking on the under surface of the inner end of the clavicle.

The **interarticular fibro-cartilage** is a nearly circular plate, thicker at the circumference than in the centre. It is attached above to the upper border of the clavicle, and below to the 1st costal cartilage at its junction with the sternum. There are two *synovial membranes*, one on each side of the cartilage.

II.—SCAPULO-CLAVICULAR ARTICULATION.

An arthrodial joint held together by the following ligaments :—

The **superior acromio-clavicular ligament** passes between the outer end of the clavicle and the upper surface of the acromion.

The **inferior acromio-clavicular ligament** covers the joint

below, being attached to the clavicle internally, and the acromion externally.

An **interarticular fibro-cartilage**, rarely complete, usually occupies the upper half of the joint. When it is complete, there are two *synovial membranes*.

The **coraco-clavicular ligaments** connect the clavicle and the coracoid process of the scapula ; they are :—

The **trapezoid ligament** (the *anterior* and *external* one) : attached below to the posterior half of the inner border of the coracoid process, and above to the oblique line on the under surface of the clavicle.

The **conoid ligament** (the *posterior* and *internal* one) is attached above by its base, to the conoid tubercle on the inferior surface of the clavicle, and the contiguous part ; by its apex to a rough depression at the base of the coracoid process. It is in contact posteriorly with the trapezoid ligament.

III.—PROPER SCAPULAR LIGAMENTS.

The **coraco-acromial ligament** passes over the shoulder-joint between the coracoid and acromion processes. Externally it is attached to the tip of the acromion, and internally to all the outer border of the coracoid process.

The **transverse or posterior ligament** stretches over the notch on the upper border of the scapula, and converts it into a foramen.

IV.—THE SHOULDER-JOINT.

This joint between the head of the humerus and the glenoid cavity is an enarthrodial or ball-and-socket joint. The long tendon of the biceps acts as a ligament to this joint.

The **capsular ligament** is attached to the circumference of the glenoid cavity, and to the neck (anatomical) of the humerus. It is very loose, and permits free movement of the joint. There is generally an aperture on the inner side, through which a piece of the synovial pouch protrudes to form the bursa under the subscapularis.

The **coraco-humeral or accessory ligament** helps to strengthen the capsule ; it is attached to the outer border of the coracoid process, and below to the neck of humerus, above great tuberosity, and it blends with the capsule at the margins of the bicipital groove.

Gleno-humeral folds.—The **superior or Flood's ligament** passes from glenoid ligament to fovea on head of humerus.

The **inferior or Schlemm's ligament** passes from the lower part

of the glenoid cavity to the neck of humerus on the inner side of the small tuberosity.

The **glenoid ligament** is a fibro-cartilaginous band attached to the edge of the glenoid cavity to deepen it, and is continuous with tendon of the long head of the biceps.

A **synovial membrane** lines the joint, and protrudes to form the bursa under the subscapularis. It is reflected round the tendon of the biceps, and lines the bicipital groove.

V.—THE ELBOW-JOINT.

The elbow is a ginglymus or hinge-joint, and is formed between the trochlear surface of the humerus and the greater sigmoid cavity of the ulna ; also between the capitellum of the humerus and the upper end of the radius.

The **anterior ligament** is attached, above to the front of the humerus just above the coronoid fossa ; and below to the coronoid process, and the front of orbicular ligament.

The **posterior ligament** is attached, above to the upper border of the olecranon fossa ; below, to the margin of the olecranon.

The **internal lateral ligament** is triangular in shape ; it is attached, above to the inner condyle of the humerus ; the fibres diverge as they descend, the *anterior* ones going to the inner margin of the coronoid process, the *posterior* to the inner margin of the olecranon.

The **external lateral ligament**, smaller than the preceding, is attached, above to a depression below the external condyle, and below to the orbicular ligament, some of the fibres being prolonged to the outer edge of the ulna.

The **synovial membrane** is very large, covering the articular surfaces of the humerus, ulna, and radius ; it also serves for the upper radio-ulnar articulation.

VI.—THE RADIO-ULNAR ARTICULATIONS.

Superior Radio-ulnar Articulation (lateral ginglymus).

The **orbicular ligament** surrounds the head of the radius. It is attached to the two ends of the lesser sigmoid cavity, and is wider above than below. The *outer* surface is connected with the external lateral ligament. The internal surface is lined with synovial membrane continuous with that of the elbow-joint.

Middle Radio-ulnar Articulation.

The **oblique or round ligament** is a fibrous cord passing downwards and outwards from the tubercle at the base of the coronoid process, to a little below the tubercle of the radius.

The **interosseous membrane** passes downwards and inwards (the opposite to the preceding) from the radius to the ulna ; it is attached to the interosseous ridge of each bone.

Inferior Radio-ulnar Articulation (lateral ginglymus).

The **anterior radio-ulnar ligament** passes from the anterior edge of the radial sigmoid cavity to the anterior surface of the head of ulna.

The **posterior radio-ulnar ligament** extends similarly upon the posterior surface.

The **triangular fibro-cartilage** passes transversely beneath the lower end of the ulna, between the styloid process and the radius. Its apex is attached to the base of the styloid process, and the base to the edge of the radius between the sigmoid cavity and the lower end.

The **synovial membrane** (*membrana sacciformis*) is very loose, and lines the contiguous surfaces of the radius and ulna, together with the upper surface of the triangular cartilage ; sometimes communicates with the synovial sac of wrist-joint.

VII.—THE WRIST-JOINT.

The wrist-joint is a condyloid joint, formed by the lower end of the radius and the triangular fibro-cartilage above ; and by the scaphoid, semilunar and cuneiform bones below. It is united by the following ligaments :—

The **external lateral ligament** passes from the tip of the styloid process of the radius to a depression on the outer surface of the scaphoid bone.

The **internal lateral ligament**, a fibrous cord, passes from the end of the styloid process of the ulna, and dividing into two, one part is attached to the pisiform bone, and the other to the inner side of the cuneiform bone.

The **anterior ligament**, broad and membranous, consists of three bundles of fibres, springing from the anterior edge of the lower end of radius, and the styloid process of the ulna ; below it is fixed into the anterior surfaces of the scaphoid, semilunar and cuneiform bones, some fibres being continued to the os magnum.

The **posterior ligament**, weaker than the preceding, springs from the posterior margin of the lower end of the radius, and is attached to the dorsal surfaces of the scaphoid, semilunar, and cuneiform bones.

A **synovial membrane** lines the joint.

VIII.—ARTICULATIONS OF THE CARPUS.

Articulations of the 1st Row of Carpal Bones, the pisiform excepted (arthrodial).

The **dorsal ligaments** pass transversely between the scaphoid and semilunar, the semilunar and the cuneiform.

The **palmar ligaments** connect the bones similarly upon the anterior surface.

The **interosseous ligaments** (2) close the upper part of the intervals between the scaphoid and semilunar, the semilunar and cuneiform bones.

Articulations of the 2nd Row of Carpal Bones (arthrodial).

The **dorsal ligaments** (3) pass transversely from bone to bone as in the 1st row.

The **palmar ligaments** (3), similar to those of the 1st row.

The **interosseous ligaments** (3) are thicker than those of the 1st row, and connect the os magnum and the trapezoid, the os magnum and the unciform bones and the trapezium and trapezoid.

Articulations of the two Rows of Carpal Bones together.

The **anterior or palmar ligaments** pass from the front of the 1st row to the palmar surface of the os magnum.

The **posterior or dorsal ligaments** are similarly placed upon the dorsal surface.

The **lateral ligaments** : the *external* connects the scaphoid and trapezium bones; the *internal* the cuneiform and unciform.

The **synovial membrane** is large : it lines the under surface of the bones of the 1st row, except the pisiform bone, and is reflected between their contiguous surfaces ; it then passes between the bones of the 2nd row, and lines their contiguous surfaces, giving also reflections between the carpal ends of the three inner metacarpal bones, and between the contiguous surfaces of the trapezium and 2nd metacarpal bone.

The **pisiform bone** is connected to the cuneiform by a thin capsule lined by a synovial membrane ; and inferiorly to the unciform and 5th metacarpal bones.

The **anterior annular ligament** extends from the trapezium and scaphoid across to the unciform process and pisiform bone.

The **posterior annular ligament** extends from the outer border of lower end of radius, to inner side of cuneiform and pisiform bones.

IX.—CARPO-METACARPAL ARTICULATION.

The Articulation of the Trapezium and 1st Metacarpal.

Reciprocal reception joint.

The **capsular ligament**, thick and loose, passes from the upper end of the 1st metacarpal to the rough edge round the articular surface of the trapezium. It is lined by a separate synovial membrane.

Articulations of the Carpus and the rest of the Metacarpus.

The **dorsal ligaments** connect the carpal with the metacarpal bones on the posterior surface ; each metacarpal receives two fasciculi, except the 5th, which has only one.

The **palmar ligaments** are similarly arranged on the anterior surface, except that the 3rd metacarpal has three fasciculi.

The **interosseous ligaments** connect the os magnum and unciform bones to the 3rd and 4th metacarpal bones.

The **synovial membrane** is continuous with that between the two rows of carpal bones, and has been described above.

Articulations of the Metacarpal Bones with each other.

The carpal ends are united by **dorsal and palmar ligaments** passing transversely.

The **interosseous ligaments** pass between the bones beneath the level of the articular facets. The *synovial membrane* is continuous with that between the two rows of carpal bones.

The **digital extremities** are connected by the transverse ligament, which blends with the palmar surface of each metacarpophalangeal articulation.

X.—METACARPO-PHALANGEAL ARTICULATIONS.

Condylloid joint.

The **anterior ligament**, fixed to the head of the metacarpal bone and the base of the 1st phalanx, intimately blends with the lateral ligaments.

The **lateral ligaments**, one on each side, attached above to the posterior tubercle and depression on the side of the head of the metacarpal bone, and below to the side of the 1st phalanx.

A synovial membrane lines the joint.

XI.—ARTICULATIONS OF THE PHALANGES.

Each of these is a small ginglymus or hinge joint, connected by an *anterior* and *two lateral* ligaments, and lined by a synovial membrane.

ARTICULATIONS OF THE LOWER LIMB.

I.—THE HIP-JOINT.

This is an enarthrodial joint, formed by the head of the femur and the acetabulum. The ligaments are :—

The **capsular ligament**, very strong and fibrous, surrounds the acetabulum above, springing just external to the cotyloid ligament ; where the bone is deficient it is attached to the transverse

ligament : below it is attached to the neck of the femur, in front into the anterior intertrochanteric line, superiorly to the root of the neck, and posteriorly to the middle of the neck of the bone. The fibres are circular and longitudinal. The circular are most distinct at the lower and posterior part, forming a collar at the lower and back part of the joint, known as the *zona orbicularis* or ligament of Bertin. The longitudinal fibres form thick bands known as *accessory ligaments*. There is often an opening in front for a protrusion of the synovial membrane to form the bursa under the psoas.

The **ilio-femoral ligament** (*Y ligament of Bigelow*) is accessory to the capsule. It is connected above with the anterior inferior iliac spine, and below it bifurcates and is attached to the anterior intertrochanteric line at its outer and inner parts.

Ischio-capsular ligament (accessory), from ischium below acetabulum, to the circular fibres at the lower and back part of the capsule.

Pubo - femoral ligament (accessory) passes from the iliopectineal eminence to the rough tubercle in front of the trochanter minor.

The **ligamentum teres** passes from the depression on the head of the femur and divides into two parts, which are attached to the margins of the notch at the bottom of the acetabulum. It consists of connective tissue and vessels, covered with a reflection of synovial membrane.

The **cotyloid ligament** is attached to the edge of the acetabulum, prismatic on section, the base being attached to the hip bone.

The **transverse ligament** is a narrow band which crosses the notch of the lower part of the acetabulum ; the nutrient vessels to the joint pass under it.

The **synovial membrane** is single, and is reflected over the inner surface of the capsule on to the neck of the femur, thence over the ligamentum teres to the bottom of the acetabulum, where it loosely covers some fat. (Frequently communicates with bursa under ilio-psoas tendon.)

II.—THE KNEE-JOINT.

This is a ginglymus, and is formed by the condyles of the femur, the head of the tibia, and the patella.

External Ligaments.

The **anterior** or **ligamentum patellæ** is the continuation of the tendon of the triceps extensor. Above it occupies the apex and rough marking on the lower and posterior surface of the patella ; below it is attached to the lower part of the tubercle of

the tibia. There is a bursa between the upper part of the tubercle and the ligament.

The **posterior ligament** (*ligamentum posticum Winslowii*), broad and thin, covers the back of the joint. It consists of a central and two lateral parts. The lateral parts spring above from the condyles of the femur, and are attached below to the head of the tibia. The central part is derived from an expansion of the semi-membranous tendon, and passes from the inner tuberosity of the tibia to the inner side of the upper part of the outer condyle of the femur.

The **internal lateral ligament**, broad and flat, is attached above to the inner condyle of the femur; below, to the margin of the inner tuberosity, to the internal fibro-cartilage, and to the inner surface of the shaft of the tibia for $1\frac{1}{2}$ inches.

The **long external lateral ligament**, a rounded cord, is attached above to the external condyle of the femur, and below to the external part of the head of the fibula.

The **short external lateral ligament**, very indistinct, lies parallel and behind the preceding, attached above to the outer condyle of the femur, and below to the styloid process of the fibula.

The **capsular ligament**, thin, fills up the intervals between the special ligaments; it is attached to the margins of the articular surfaces of the bones, and blends with the fascia lata of the thigh.

Internal Ligaments.

The **anterior or external crucial ligament** is attached to the depression in front of the spine of the tibia and to the external semilunar fibro-cartilage; it passes upwards, backwards, and outwards to the posterior part of the inner side of the external condyle of the femur.

The **posterior or internal crucial ligament** is attached to a depression behind the spine of the tibia, to the popliteal notch, and the posterior border of external semilunar fibro-cartilage, this latter slip being sometimes called the ligament of Wrisberg; it passes upwards, forwards, and inwards, the posterior fibres attached by side of oblique curve of inner condyle, the anterior ones to fore part of intercondylar fossa and to the anterior part of the outer surface of the inner condyle.

The **semilunar cartilages** are thicker at the circumferences than at the central margins, and serve to deepen the cavities for the head of the femur.

The **internal semilunar cartilage** is oval in shape, the antero-posterior diameter being the longer. Its anterior extremity is attached to the tibia *in front* of the anterior crucial

ligament, and the posterior extremity *in front* of the posterior crucial ligament.

The **external semilunar cartilage** is nearly circular: its anterior extremity is attached to the tibia in front of the spine, the posterior extremity to the back of the spine.

In shape the cartilages may be described thus: the internal as a smaller segment of a larger circle, and the external as a larger segment of a smaller circle.

Structures on the Head of the Tibia in the middle line from before backwards:—

1. Transverse ligament.
2. Anterior extremity of internal semilunar cartilage.
3. Anterior crucial ligament.
4. Anterior extremity of external semilunar cartilage.
5. The spine of tibia.
6. Posterior extremity of external semilunar cartilage.
7. Posterior extremity of internal semilunar cartilage.
8. Posterior crucial ligament.

The **transverse ligament** is a band of fibres which passes between the anterior extremities of the semilunar cartilages.

The **coronary ligaments** bind down the circumferences of the semilunar cartilages to the head of the tibia.

The **synovial membrane** is the largest in the body. It extends two inches above the articular end of femur under the extensors; thence it passes over the crucial ligaments to the head of the tibia, where it covers both sides of the semilunar cartilages, and lastly it lines the capsule. It also gives a covering to the popliteus tendon, where it is in the joint.

The **ligamentum mucosum** is a triangular fold of the synovial membrane, attached to the intercondyloid notch, and reaching to the patella.

The **ligamenta alaria** are two fringes of the synovial membrane, seen on either side of the ligamentum mucosum.

III.—THE TIBIO-FIBULAR ARTICULATIONS.

The Superior Tibio-fibular Articulations (arthrodial).

The **anterior superior ligament** passes from the head of the fibula upwards and inwards to the external tuberosity of the tibia.

The **posterior superior ligament** passes from the back part of the head of the fibula to the back part of the external tuberosity of the fibula.

A **synovial membrane** lines the joint.

The *Middle Tibio-fibular Articulation* consists of the interosseous membrane, the fibres passing down from the tibia to the

fibula, being attached to the interosseous ridges on the bones. Superiorly, there is an opening for the anterior tibial vessels; and inferiorly, one for the anterior peroneal vessels.

The Inferior Tibio-fibular Articulation.

The **inferior interosseous ligament** passes between the contiguous rough surfaces of the tibia and fibula, and is continuous above with the interosseous membrane.

The **anterior ligament** is triangular in shape, and passes between the adjacent margins of the tibia and fibula.

The **posterior ligament** is similarly placed upon the posterior part of the articulation.

The **transverse or inferior ligament** passes transversely across the back of the joint, from the external malleolus nearly to the internal malleolus, and serves to deepen the ankle-joint.

The **synovial membrane** is continuous with that of the ankle-joint.

IV.—THE ANKLE-JOINT.

This is a ginglymus or hinge-joint; the lower ends of the tibia and fibula embracing the upper articular surface of the astragalus.

The **anterior ligament**, broad and thin, is connected above with the edge of the articular surface of the tibia, and below with the margin of the superior articular surface of the astragalus.

The **posterior ligament** consists principally of transverse fibres, which blend above with the transverse ligament of the inferior tibio-fibular articulation, and are attached to the back part of the upper articular surface of the astragalus.

The **internal lateral or deltoid ligament** consists of two parts. The *superficial* part is attached by its apex to the internal malleolus, and by its base to the inner side of the astragalus, the sustentaculi tali, and the tuberosity of the scaphoid, blending with the inferior calcaneo-scaphoid ligament. The *deep* part passes from the apex of the malleolus to the side of the astragalus.

The **external lateral ligament** consists of three bundles of fibres. The *anterior* slip passes between the front of the external malleolus and the side of the astragalus in front of the superior articular process. The *middle* passes from the apex of the outer malleolus to the middle of the outer side of the os calcis. The *posterior* is attached to the bone just behind the deep groove on the posterior part of the outer malleolus, running transversely inwards to a depression on the posterior surface of the astragalus.

The **synovial membrane** lines the inner surface of the ligaments, and is reflected on to the articular surfaces of the bones. It also lines the inferior tibio-fibular articulation.

V.—ARTICULATIONS OF THE TARSUS.

Articulations between the Calcaneum and Astragalus.

There are two articulations between the calcaneum and the astragalus : a posterior one, peculiar to the two bones, and an anterior one, common to them and the scaphoid bone ; they are separated by the interosseous ligament. They are arthrodial joints.

The **external calcaneo-astragaloid ligament** passes from outer surface of the astragalus just below the external malleolus, to the outer surface of the os calcis.

The **posterior calcaneo-astragaloid ligament** connects the posterior parts of the two bones.

The **interosseous ligament** consists of a strong thick band passing from the groove between the articulating surfaces of the astragalus to a corresponding groove on the os calcis.

The Calcaneo-scaphoid Ligaments.

The **superior calcaneo-scaphoid ligament** arises from the groove between the astragalus and os calcis, being blended here with the internal calcaneo-cuboid ligament, and passes upwards and inwards to the outer side of the scaphoid bone.

The **inferior calcaneo-scaphoid** is a broad strong band passing from the anterior and inner end of the os calcis to the hollow on the under surface of the scaphoid bone. It supports the head of the astragalus, and is sometimes known as the **spring ligament**.

The articulation between the astragalus and scaphoid is an arthrodial joint. The only ligament is the

Superior astragalo-scaphoid, passing from the neck of the astragalus to the upper surface of the scaphoid bone.

The articulations between the Scaphoid, Cuboid, and Three Cuneiform bones are connected by the following ligaments :—

Dorsal ligaments, which pass from one bone to the other.

Plantar ligaments, similarly arranged upon the sole.

Interosseous ligaments (4), strong fibres passing between the rough non-articulating surfaces of the bones.

The Calcaneo-cuboid Ligaments are :—

The **superior calcaneo-cuboid ligament** passes between the dorsal surfaces of the os calcis and cuboid bones.

The **internal calcaneo-cuboid** or **interosseous ligament** attached to a deep groove on the os calcis between it and the

astragalus, here blending with the superior calcaneo-scaphoid ligament, and passing to the inner side of the cuboid bone.

The Inferior Ligaments, consisting of :—

The **long calcaneo-cuboid ligament** (*ligamentum longum plantæ*), attached to the under surface of the os calcis in front of the tuberosities ; it passes to the posterior margin of the peroneal groove of the cuboid ; some of the fibres arch over the sheath of the tendon, and are attached to the bases of the 2nd, 3rd and 4th metatarsal bones.

The **short calcaneo-cuboid ligament** is more deeply placed ; it reaches from the tubercle and depression on the under surface of the os calcis to the under surface of the cuboid behind the peroneal groove.

VI. — TARSO-METATARSAL ARTICULATIONS.

The metatarsal bones are connected to the tarsus by :—

Dorsal ligaments, one to each metatarsal bone from the tarsal bone it articulates with. The 2nd metatarsal has a slip from each cuneiform bone.

The **plantar ligaments**, disposed irregularly.

The **interosseous ligaments**, strong bands, three in number. The *internal* one passes from internal cuneiform to the 2nd metatarsal. The *middle* one passes between the external cuneiform and the 2nd metatarsal. The *external* connects the external cuneiform and the 3rd metatarsal.

The **synovial membranes** of the tarsus and metatarsus are six in number :—

One for the posterior calcaneo-astragaloid articulation.

One for the anterior calcaneo-astragaloid articulation and the scapho-astragaloid articulation.

One for the calcaneo cuboid articulation.

One for the articulations of the scaphoid, and the three cuneiform bones ; the cuneiform bones with each other ; the external cuneiform and the cuboid ; and the middle and external cuneiform bones with the bases of the 2nd and 3rd metatarsal bones.

One between first metatarsal and internal cuneiform.

One for 4th and 5th metatarsal with cuboid.

VII. — ARTICULATIONS OF THE METATARSAL BONES WITH EACH OTHER.

The bases of the metatarsal bones are connected by *dorsal*, *plantar*, and *interosseous* ligaments.

The digital ends are united by the *transverse metatarsal ligament*, which connects the 1st metatarsal with the others.

VIII.—METATARSO-PHALANGEAL ARTICULATIONS.

These articulations are precisely similar to the corresponding parts of the hand.

IX.—ARTICULATIONS OF THE PHALANGES.

The preceding remark equally applies to these articulations.

THE MUSCLES.

Explanation.

The — dash divides the origin from the insertion.

Nervous supply is indicated by () brackets.

F signifies that the attachment is fleshy.

T " " tendinous.

A " " aponeurotic.

A combination of any of these attachments may occur.

MUSCLES AND FASCIÆ OF THE HEAD AND NECK.

EPICRANIAL REGION.

FASCIA.—*Superficial*, closely united to the skin, slightly developed, except between bellies of occipito-frontalis muscle. At the back part it becomes continuous with superficial fascia of posterior muscles of the neck, and descends laterally over the temporal fascia, where it envelops the external muscles of auricle, and the superficial temporal vessels and nerves.

Occipito-frontalis : *Frontal part.* Os nasi and internal angular process of frontal bone, blended with orbicularis palpebrarum, pyramidalis nasi and corrugator supercilii(F)—epicranial aponeurosis(A) (Facial). *Occipital part.* Outer $\frac{2}{3}$ superior curved occipital lines, mastoid processes(FT) — epicranial aponeurosis, which is attached behind to curved line between fleshy heads(A) (Posterior auricular ; sometimes small occipital).

AURICULAR REGION.

Attrahens aurem : fore part of epicranial aponeurosis(F)—fore part of helix, and eminence on back of pinna, corresponding to the fossa of the antihelix(T) (Auriculo-temporal).

Attollens aurem : epicranial aponeurosis(F)—cranial surface pinna(T) (Small occipital).

Retrahens aurem : root of mastoid process(A)—lower part of cranial surface of concha(A) (Posterior auricular).

PALPEBRAL REGION.

Orbicularis palpebrarum: *Sphincter of eyelids. Orbital part.* Internal angular process of frontal, tendo-palpebrarum, nasal process of superior maxilla(F). *Palpebral part.* Tendo-palpebrarum(F)—external tarsal ligament(F) (Facial).

Internal tarsal ligament (tendo-palpebrarum or tendo-oculi) is attached to ridge on nasal process of superior maxilla in front of lachrymal groove, divides into two slips, each joining the inner end of the corresponding tarsal cartilage.

External tarsal ligament, connects the tarsal cartilages to outer part of orbit.

Corrugator supercilii: inner part of superciliary ridge of frontal(F)—under surface of orbicularis, opposite middle of orbital arch(F) (Facial).

Tensor tarsi: (Horner's muscle); ridge of os lachrymalis(F)—by a slip into each tarsal cartilage internal to the punctum(F) (Facial).

ORBITAL REGION.

Levator palpebræ superioris: inferior surface of small wing of sphenoid, anterior to foramen opticum and external to superior oblique(T)—anterior part of superior tarsal cartilage(A) (Upper division of 3rd).

Rectus superior: upper margin of optic foramen(T)—sclerotica(T) (Upper division of 3rd).

Rectus inferior: margin of optic foramen(T)—sclerotica(T) (Lower division of 3rd).

Rectus internus: optic foramen(T)—sclerotica(T) (Lower division of 3rd).

Rectus externus: *Upper head.* Optic foramen(T). *Lower head.* Optic foramen and process of bone at the lower margin of sphenoidal fissure(T)—sclerotica(T) (6th). *Between the two heads pass 3rd, 6th, nasal branch of 5th nerve and ophthalmic vein.*

Obliquus superior: inner part of optic foramen(T)—passes through "pulley," thence reflected backwards and outwards to be attached to sclerotica between superior and inferior recti(T) (4th). *The 4th nerve enters its upper surface.*

Obliquus inferior: depression on orbital plate of superior maxilla(F)—external surface of sclerotica between external and superior recti(T). (Lower division of 3rd) *Passes outward: from origin beneath inferior rectus and between eyeball and external rectus to its insertion.*

NASAL REGION.

Pyramidalis nasi: occipito-frontalis(F)—compressor naris(A) (Facial).

Compressor nasi: canine fossa of superior maxilla(F) — its fellow of opposite side(A) (Facial).

Levator labii superioris alæque nasi: top of nasal process of superior maxilla(F)—1st slip, cartilage of ala; 2nd slip, orbicularis oris(F) (Facial).

Depressor alæ nasi: incisor fossa of superior maxilla(F)—septum and ala of nose(F) (Facial).

Dilatator naris: *Anterior Slip.* Cartilage of ala(F)—inner border of integument of ala(F). *Posterior slip.* Nasal notch of superior maxilla(F)—inner border of integument of ala(F) (Facial).

SUPERIOR MAXILLARY REGION.

Levator labii superioris: superior maxilla and malar above infra-orbital foramen(F)—orbicularis oris(F) (Facial).

Levator anguli oris: canine fossa of superior maxilla, beneath infra-orbital foramen(F)—angle of mouth(F) (Facial).

Zygomaticus major: malar bone in front of zygoma(F)—angle of mouth(F) (Facial).

Zygomaticus minor: malar bone near maxillary suture(F)—angle of mouth(F) (Facial).

INFERIOR MAXILLARY REGION.

Levator labii inferioris, vel levator menti: incisor fossa of inferior maxilla(F)—integument of chin(F) (Facial).

Depressor labii inferioris, vel quadratus menti: external oblique line of inferior maxilla from symphysis to mental foramen(F)—orbicularis oris(F) (Facial).

Depressor anguli oris, vel triangularis menti: external oblique line of inferior maxilla(F)—angle of mouth(F) (Facial).

INTER-MAXILLARY REGION.

Orbicularis oris: *sphincter of mouth.* The *labial* part is free from attachment to bone, and forms red part of lips. The *outer* or *facial* part is connected with the muscles which converge to the angles of the mouth, and is attached in the upper lip to septum nasi, and in the lower lip to canine fossa of inferior maxilla(F) (Facial).

Buccinator: external surfaces of alveolar processes of superior and inferior maxillæ, as far forwards as 1st molar; pterygo-maxillary ligament(F)—angle of mouth where fibres decussate (F) (Facial).

The *pterygo-maxillary ligament* extends from the hamular process to the posterior edge of the mylo-hyoid ridge of inferior maxilla. It separates buccinator from superior constrictor of pharynx.

Risorius: fascia covering masseter(F)—apex of depressor anguli oris(F) (Facial). (*This muscle is part of the platysma of neck*)

TEMPORO-MAXILLARY REGION.

Masseter: *Superficial part.* Malar process of superior maxilla. Anterior $\frac{2}{3}$ of lower border of zygoma(TA)—angle and lower $\frac{1}{2}$ of outer surface of ramus(F). *Deep part.* Posterior $\frac{1}{3}$ lower border and inner surface of zygoma(F)—upper $\frac{1}{2}$ of ramus and outer surface of coronoid process(F) (Inferior maxillary).

The *masseteric fascia*, a continuation of the deep cervical fascia, is attached above to the zygoma; continuing backwards it invests parotid gland (parotid fascia), from the deep surface of which the stylo-maxillary ligament proceeds.

Temporal: temporal fascia and fossa(F)—internal surface and fore part of coronoid process of inferior maxilla as far as last molar(AT) (Inferior maxillary).

The *temporal fascia* is attached above to the temporal ridge, and divides below into two layers, which are attached to inner and outer edges of superior border of zygoma. It covers the temporal muscle, and between the two layers are the temporal branch of temporo-malar nerve, and the orbital branch of superficial temporal artery.

PTERYGO-MAXILLARY REGION.

External pterygoid: pterygoid ridge and surface below on great wing of sphenoid, outer surface of external pterygoid plate (F)—pterygoid depression in front of neck of inferior maxilla and inter-articular fibro-cartilage of temporo-maxillary joint(F) (Inferior maxillary).

Between sphenoidal and pterygoid attachments, the internal maxillary artery dips down to reach spheno-maxillary fossa, and the buccal nerve appears.

Internal pterygoid: inner surface of external pterygoid plate, tuberosity of palate bone, and tuberosity of superior maxilla(F)—angle and inner surface of ramus of inferior maxilla(TA) (Inferior maxillary).

On muscle are dental and gustatory nerves, dental artery, and internal lateral ligament of jaw.

SUPERFICIAL CERVICAL REGION.

Platysma myoides: clavicle and acromion, fascia covering deltoid, pectoralis major, and trapezius(F)—*Inner fibres.* Blend with opposite platysma. *Outer fibres.*—Lower jaw, prolonged

to angle of mouth and cheek(F) (Facial, Superficial cervical).
The higher fibres of this muscle form the risorius.

Sterno-cleido-mastoid: *Inner head.* Upper and anterior part of 1st piece of sternum(T). *Outer head.* Inner $\frac{1}{3}$ of superior surface clavicle(F)—external surface of mastoid process from base to apex(T), and outer $\frac{2}{3}$ of superior curved line of the occiput (A) (Spinal accessory, Deep branch of 2nd cervical).

Forms anterior boundary of posterior, and posterior boundary of anterior triangles of neck. Clavicular origin conceals: anterior scalenus, omo-hyoid. *Sternal origin conceals:* depressors of hyoid bone, great cervical vessels and pneumogastric nerve. *Union of two heads conceals:* middle scalenus, levator anguli scapulæ, cervical plexus. *Near insertion conceals:* splenius, digastricus, occipital artery, part of parotid.

The deep cervical fascia is attached behind to the superior curved line of the occiput, to the ligamentum nuchæ and to the spine of 7th cervical vertebra.

It passes forwards enclosing the trapezius, and then over the posterior triangle as a single layer until it reaches the posterior border of the sterno-mastoid, where it divides into two layers to enclose that muscle. At the anterior border of the sterno-mastoid, the two layers again blend together (except for about one inch above the sternum), and passing forwards, over the anterior triangle, it blends with the fascia of opposite side in the middle line.

Below where the two layers do not blend together, the more anterior one is attached to the front of the upper part of the sternum and to the interclavicular ligament, whilst the posterior one is connected to the inner edge of the upper part of the same bone. A small interval (*Burns' space*) is thus left, triangular in vertical section with the base at upper border of the sternum, which contains some loose areolar tissue, some fat, and often a lymphatic gland.

Superiorly this anterior layer passes over the parotid and masseter, forming the *parotid* and *masseteric* fascia, and is attached above and behind to the lower border of the zygoma, and below and in front, to the lower edge of the body of the lower jaw.

From the posterior surface of the fascia covering the anterior triangle a septum passes inwards, separating the submaxillary and parotid glands, and blends with the stylo-maxillary ligament.

Processes given off from the deep cervical fascia.

From the layer passing behind the sterno-mastoid there proceed:—

1. A layer which passes behind carotid vessels.
2. A layer which passes in front of carotid vessels.

These two layers blend together at the inner border of the carotid artery, forming the carotid-sheath to enclose carotid artery, internal jugular, and pneumogastric nerve. The united layers pass upwards in front of the longus colli and behind the œsophagus, to blend with like process from opposite side and form the *prevertebral fascia*.

3. A layer in *front* of thyroid body and trachea, but behind the sterno-hyoid and thyroid muscles, which joins with a corresponding process of the opposite side, and passing down to the root of the neck in front of the trachea and large vessels, blends with the fibrous layer of the pericardium.

4. A process to enclose the omo-hyoid muscle, which downwards to the clavicle and first rib, blending with coracoid membrane.

The *prevertebral fascia* (*v.* above) separates the prevertebral muscles from the pharynx and œsophagus, and is prolonged laterally over the scaleni, brachial plexus, and subclavian vessels to help form the axillary sheath.

The cervical fascia is attached in the middle line to the symphysis menti, the hyoid bone, and the anterior edge of the upper border of the sternum.

INFRA-HYOID REGION,

Sterno-hyoid: posterior surface of sternum, cartilage of 1st rib(F)—lower border of body of hyoid bone(A) (From junction of branches between descendens and communicans noni).

Sterno-thyroid: posterior surface of sternum, posterior sternoclavicular ligament, cartilage of 1st rib(F)—oblique line on side of thyroid cartilage(F) (From junction of branches between descendens and communicans noni).

Thyro-hyoid: oblique line on side of thyroid cartilage(F)—internal half of greater cornu and outer part of body of hyoid bone(F) (Hypo-glossal).

Omo-hyoid: upper border of scapula behind notch, and ligament over notch(A)—lower part of body of hyoid bone(F) (From junction of branches between descendens and communicans noni).

Consists of two bellies united by an intervening tendon. The posterior belly is bound down to clavicle and cartilage of 1st rib by a process of deep cervical fascia.

SUPRA-HYOID REGION.

Digastric: *Posterior belly.* Groove on internal surface of mastoid process(F). *Anterior belly.* Posterior surface of inferior

maxilla, by side of symphysis(F)—intervening tendon(T), which is bound down to hyoid bone by process of deep cervical fascia (*anterior*, Mylo-hyoid of inferior dental; *posterior*, Facial).

Stylo-hyoid: outer side of styloid process near root(T)—body of hyoid bone at union of great cornu and body(T) (Facial). *Perforated by tendon of digastricus.*

Mylo-hyoid: mylo-hyoid ridge on inner surface of inferior maxilla(F)—middle of body of hyoid bone(T), and joins fellow in median line(A) (Mylo-hyoid of inferior dental).

Parts beneath the mylo-hyoid: sublingual and part of submaxillary gland, with Wharton's duct; genio-hyoid, genio-hyo-glossus, hyo-glossus, stylo-glossus muscles, sublingual and ranine arteries; gustatory, and hypoglossal nerves; submaxillary ganglion.

Genio-hyoid: inferior genial tubercle on posterior surface of inferior maxilla near symphysis(T)—middle of body of hyoid bone(A) (Hypoglossal).

LINGUAL REGION.

Genio-hyo-glossus: superior genial tubercle on posterior surface of inferior maxilla near symphysis(T)—body of hyoid bone(F) (posterior fibres): inferior surface of tongue from root to tip(F) (anterior fibres) (Hypoglossal).

Hyo-glossus: side of body, from all great cornu of hyoid and from smaller cornu(F)—back and side of tongue(F) (Hypoglossal).

Parts beneath hyo-glossus: inferior lingualis, genio-hyo-glossus and middle constrictor muscles, lingual vessels, stylo-hyoid ligament, glosso-pharyngeal nerve.

Stylo-glossus: external surface of apex of styloid process and stylo-maxillary ligament(A)—dorsum and tip of tongue(F) (Hypoglossal).

PHARYNGEAL REGION.

Inferior constrictor: side of cricoid cartilage; oblique line on thyroid and surface behind it, inferior cornu of thyroid cartilage(F)—fibrous *raphé* in posterior median line of pharynx (F) (Pharyngeal plexus, External laryngeal).

Middle constrictor: great and small cornua of hyoid bone, stylo-hyoid ligament(F)—fibrous *raphé* in posterior median line of pharynx(F) (Pharyngeal plexus). *Superior laryngeal vessels and nerve pass between this muscle and the inferior, near origin.*

Superior constrictor: lower 3rd of posterior margin of internal pterygoid plate, hamular process, pterygo-maxillary ligament, posterior part of mylo-hyoid ridge of inferior maxilla, mucous membrane of mouth and side of tongue(F)—fibrous *raphé*

in posterior median line of pharynx(F), and pharyngeal spine on basilar process(F) (Pharyngeal plexus). *Internal carotid artery, pneumogastric and sympathetic nerves lie on outer surface.*

Stylo-pharyngeus: inner surface of base of styloid process(F)—pharynx and posterior border of thyroid cartilage(F) (Pharyngeal plexus, Glosso-pharyngeal). *Passes between external and internal carotid arteries.*

Salpingo-pharyngeus: lower edge of cartilage of Eustachian tube(T)—palato-pharyngeus(F) (Pharyngeal plexus).

PALATAL REGION.

Levator palati: under surface of apex of petrous portion of temporal, outer posterior part of cartilage of Eustachian tube(F)—middle line of soft palate(F) (Facial through large superficial petrosal of Vidian).

Tensor vel circumflexus palati: scaphoid fossa of sphenoid, outer part of Eustachian tube, spine of sphenoid, vaginal process of temporal(F) (*turns round hamular process*)—posterior border of hard palate, aponeurosis of soft palate(A) (Otic ganglion).

Azygos uvulæ: posterior nasal spine of palate bone(F)—tip of uvula(F) (Facial through large superficial petrosal of Vidian).

Palato-glossus (*anterior pillar of soft palate*): side and dorsum of tongue(F)—anterior and lateral surface of soft palate(F) (Pharyngeal plexus).

Palato-pharyngeus (*posterior pillar of soft palate*): posterior border of thyroid cartilage, side of pharynx(F)—*Anterior fibres* join opposite muscle at middle line lying between the levator and tensor. *Posterior fibres* join opposite fellow at middle line (F) (Pharyngeal plexus).

INTRA-LARYNGEAL REGION.

Crico-thyroideus: front and side of cricoid cartilage(F)—lower cornu and lower border of thyroid cartilage(F) (External branch of superior laryngeal).

Thyro-arytænoideus: lower half of receding angle of thyroid cartilage, crico-thyroid membrane(F).—Two sets of fibres. *Internal*, edge of vocal process(F)—*External*, outer border and anterior surface of arytenoid cartilage(F) (Inferior laryngeal).

Crico-arytænoideus lateralis: side of superior border of cricoid cartilage(F)—projection at external angle of base of arytenoid cartilage, and contiguous external surface(F) (Inferior laryngeal).

Crico-arytænoideus posticus : depression near ridge on posterior surface of cricoid cartilage(F)—projection at external angle of base of arytaenoid cartilage(F) (Inferior laryngeal).

Arytænoideus : single muscle in the median line, fills up posterior concave surface of arytaenoid cartilages. *Superficial* fibres pass from apex of one cartilage to base of other. *Deep* fibres pass between posterior surfaces of the cartilages (Inferior laryngeal).

ANTERIOR VERTEBRAL REGION.

Rectus capitis anticus major : four tendinous slips from anterior tubercles of transverse processes of 6th, 5th, 4th, 3rd cervical vertebræ(T)—basilar process of occipital(F) (Sub-occipital, Cervical plexus).

Rectus capitis anticus minor : root of transverse process and lateral mass of atlas(F)—basilar process of occipital(F) (Sub-occipital, Cervical plexus).

Rectus lateralis : superior surface of transverse process of atlas(F)—jugular process of occipital(F) (Sub-occipital). *Highest intertransverse muscle.*

Longus colli : *Superior oblique part.* Anterior tubercles of transverse processes of 3rd, 4th, 5th cervical vertebræ(T)—tubercle on anterior arch of atlas(T). *Inferior oblique part.* Bodies of first three dorsal(F)—transverse processes of 5th and 6th cervical(T). *Vertical part.* Bodies of lower two cervical and upper three dorsal(F T)—bodies of 2nd, 3rd, and 4th cervical vertebræ(T) (Lower cervical nerves).

LATERAL VERTEBRAL REGION.

Scalenus anticus : inner border and superior surface of 1st rib (scalene tubercle)(T)—anterior tubercles of transverse processes of 6th, 5th, 4th, 3rd cervical vertebræ(T) (Branches of lower cervical). *Phrenic nerve lies along anterior surface, subclavian artery passes behind at origin.*

Scalenus medius : rough elevation on superior border of 1st rib, behind groove for subclavian artery(F)—posterior transverse processes of lower six cervical vertebræ(T) (Branches of lower cervical).

Scalenus posticus : superior border of 2nd rib(T)—transverse processes of lower two or three cervical vertebræ(T) (Branches of lower cervical).

POSTERIOR VERTEBRAL REGION.

Rectus capitis posticus major : spinous process of axis(T)—outer $\frac{1}{3}$ inferior curved line of occiput and bone below(F) (Sub-occipital).

Rectus capitis posticus minor: posterior tubercle of neural arch of atlas(T)—inner part of inferior curved line of occiput and bone between this and foramen magnum(F) (Sub-occipital).

Obliquus inferior: spinous process of axis(F)—transverse process of atlas(T) (Sub-occipital).

Obliquus superior: superior surface of transverse process of atlas(T)—occipital bone, between the two curved lines(F) (Sub-occipital).

MUSCLES AND FASCIÆ OF UPPER EXTREMITY.

ANTERIOR THORACIC REGION.

The deep fascia of the pectoral region covers the large pectoral muscle, is attached above to the clavicle, internally to the sternum, becoming continuous externally with fasciæ of shoulder, axilla, and lateral thoracic region.

The *costo-coracoid membrane*, continuous with the deep fascia of this part, is attached above to the clavicle so as to enclose the subclavius muscle; the posterior layer is continuous with the axillary sheath derived from the deep cervical fascia. The lower edge (costo-coracoid ligament) reaches from the 1st rib to the coracoid process, and passes downwards over pectoralis minor. It is pierced by cephalic vein, acromial thoracic vessels, superior thoracic artery, and external anterior thoracic nerve.

The *axillary fascia* is placed across the axilla; it is derived in front from the sheaths of the pectoral muscles, and joins, at the posterior border of the axilla, the sheaths of the latissimus dorsi and teres major.

Pectoralis major: *superiorly*, sternal half of clavicle(F); *internally*, front of sternum, cartilages of upper six ribs(F); *inferiorly* aponeurosis of external oblique muscle of abdomen(F)—outer ridge of bicipital groove of humerus(T) (External and internal anterior thoracic). *Anterior boundary of axilla, separated from the deltoid above by cephalic vein and branch of acromial thoracic artery.*

Pectoralis minor: 3rd, 4th, and 5th ribs outside cartilages, aponeurosis over intercostal muscles(F)—anterior $\frac{1}{2}$ of superior surface and inner border of coracoid process of scapula(T) (Internal anterior thoracic). *Forms middle $\frac{1}{3}$ of anterior axillary boundary, and conceals 2nd part of axillary artery.*

Subclavius: 1st rib at junction of bone and cartilage(T)—groove on under surface of clavicle between the two tubercles(F) (Branch from 5th and 6th cervical). *Encased by costo-coracoid sheath.*

LATERAL THORACIC REGION.

Serratus magnus : eight or nine digitations from as many ribs, the 1st digitation being attached to 1st and 2nd ribs ; aponeurosis over intercostal muscles ; lower four slips digitate with external oblique muscle of abdomen(F)—vertebral border of costal surface of scapula ; viz., digitation from 1st and 2nd ribs to upper angle, from 3rd and 4th ribs to base ; the rest to inferior angle(F) (Posterior thoracic).

ACROMIAL REGION.

The *deep fascia* over the shoulder conceals the back part of the deltoid and the infra-spinatus muscle, and is attached to the clavicle, acromion, and spine of scapula.

Deltoideus : outer $\frac{1}{3}$ anterior border of clavicle, anterior edge of acromion, all lower edge of spine of scapula(F)—rough deltoid impression on outer surface of humerus just above the middle(T) (Circumflex).

Parts covered by deltoid : head and neck of humerus ; bursa between head of humerus and muscle ; tendons of insertion of subscapularis, pectorales major and minor, teretes major and minor, latissimus dorsi, supra-spinatus, infra-spinatus. Origins of coraco-brachialis, biceps (two heads), triceps (long and outer heads) : capsular, coraco-acromial, humeral, clavicular, costo-coracoid (external part) ligaments ; coracoid process : acromial thoracic branch of superior profunda, and circumflex vessels ; circumflex nerve.

ANTERIOR SCAPULAR REGION.

Subscapularis : all subscapular fossa, except at neck, angles, and inner border(F T A)—small tuberosity of humerus(T) and neck of humerus for one inch below(F) (Short subscapular and branch from lower subscapular). *Bursa placed between the tendon and root of coracoid process, communicating with shoulder-joint.*

POSTERIOR SCAPULAR REGION.

Supra-spinatus : supra-spinous fossa, except near neck of scapula ; upper side of spine, and fascia covering muscle(F)—upper of three facets upon great tuberosity of humerus(T) (Supra-scapular).

Infra-spinatus : infra-spinous fossa, except at neck, axillary border, and inferior angle ; from inferior surface of spine of scapula, and fascia covering muscle(F)—middle of three facets on great tuberosity of humerus(T) (Suprascapular).

Teres minor : from superior $\frac{2}{3}$ of axillary border of dorsum of

scapula, its investing fascia(F)—lowest of three facets upon great tuberosity of humerus(T) (Circumflex ; *has a gangliform swelling on it*). *Dorsal branch of subscapular artery bends backwards in front of this muscle to reach infra-spinous fossa.*

Teres major : from rough surface at inferior angle of dorsum of scapula, and axillary border for lower $\frac{2}{3}$, septum between it and teres minor(F) —inner edge of bicipital groove of humerus(T) (Subscapular). *A bursa is placed between tendon and humerus posteriorly, and between tendon and latissimus dorsi insertion anteriorly.*

ANTERIOR HUMERAL REGION.

The *deep fascia* of the arm is continuous with that of the shoulder, investing the muscles of this region. It gives off on either side an *intermuscular septum*, which is attached to the condyle and supra-condylar ridge.

Coraco-brachialis : apex of coracoid process of scapula, tendon of coracoid head of biceps(F)—rough ridge near middle of inner side of humerus ; some of the upper fibres join a fibrous arch which is attached above to the small tuberosity(T) (Musculo-cutaneous). *Brachial vessels to inner side.*

Biceps : *Long or glenoid head.* Just above glenoid cavity, within the shoulder-joint(T). *Short or coracoid head.* Apex of coracoid process of scapula(T)—rough and hinder part of tubercle of radius(T) and fascia of forearm (Musculo-cutaneous). *A bursa is placed on the smooth and fore part of tubercle. Inner border, the guide to brachial vessels below middle of humerus. A broad band, the semilunar fascia, is given off from inner side of tendon opposite the elbow-joint, covering brachial artery and joining deep fascia of forearm.*

Brachialis anticus : lower half of outer and inner surfaces of shaft of humerus, embracing insertion of deltoid, all inner intermuscular septum, and upper part of outer intermuscular septum(F)—rough surface in front of coronoid process of ulna(T) (Musculo-cutaneous, Musculo-spiral). *Brachial artery, median, musculo-spiral and musculo-cutaneous nerves lie on it.*

POSTERIOR HUMERAL REGION.

Triceps : *Long or middle head.* Depression on axillary border of scapula, close beneath glenoid cavity(T). *External head.* From root of great tuberosity to musculo-spiral groove on posterior surface of humerus(F). *Internal head.* Posterior surface of shaft of humerus, by side of and below musculo-spiral groove, internal and external intermuscular septa(F)—posterior surface

of olecranon process of ulna(T) (Musculo-spiral). *Bursa is placed between the tip of process and tendon.*

Sub-anconeus : by two fasciculi just above olecranon fossa of humerus(F)—synovial sac of elbow-joint(F) (Musculo-spiral).

ANTERIOR BRACHIAL REGION, SUPERFICIAL LAYER.

The *deep fascia* of the forearm continuous above with fascia of arm, is attached posteriorly to subcutaneous edge of ulna, and invests the muscles in this region.

Anterior annular ligament (v. p. 16) is continuous by its upper border with the deep fascia of the forearm.

Posterior annular ligament (v. p. 16) is the thickened lower part of the posterior part of the deep fascia.

Pronator radii teres : *Humeral head.* Internal supra-condylar ridge of humerus, internal condyle of humerus by common flexor tendon. *Ulnar head.* Inner border of coronoid process of ulna, fascia and septum(F)—rough impression about middle of outer surface of radius(T) (Median). *Median nerve enters forearm between the two heads of origin.*

Flexor carpi radialis : common flexor tendon from internal condyle of humerus(T), aponeurosis of forearm, intermuscular septa(F)—bases of 2nd and 3rd metacarpal bones(T) (Median). *External edge of muscle, guide to radial artery. Passes through groove in os trapezium, and has special sheath on outer side of annular ligament.*

Palmaris longus : common flexor tendon from internal condyle of humerus(T), aponeurosis of forearm(F), intermuscular septa(F)—Palmar fascia, and a slip to short muscles of thumb(T) (Median). *Passes over annular ligament.*

Flexor carpi ulnaris : *Humeral head.* Common flexor tendon from internal condyle of humerus(T). *Ulnar head.* Inner side of olecranon upper $\frac{3}{4}$ of posterior border of ulna(A)—Pisiform bone and prolonged to base of 5th metacarpal and hook of unciform bone(T) (Ulnar). *Radial side of muscle, guide to ulnar artery. Ulnar nerve enters forearm between two heads of origin.*

Flexor sublimis digitorum, vel perforatus : *Humeral head.* Common flexor tendon from internal condyle of humerus(T), internal lateral ligament(F), intermuscular septa(F). *Ulnar head.* Inner side of coronoid process of ulna. *Radial head.* Oblique line of radius below tubercle, and part of anterior border(A)—sides of middle phalanges of fingers, tendon being split for flexor profundus digitorum(T) (Median). *Tendons pass under annular ligament, in pairs, middle and ring-finger ones being anterior to those of index and little fingers.*

ANTERIOR BRACHIAL REGION, DEEP LAYER.

Flexor profundus digitorum, vel perforans: upper $\frac{3}{4}$ of anterior and internal surfaces of shaft of ulna, upper $\frac{3}{4}$ of ulnar half of interosseous membrane, aponeurosis from ridge of ulna(F)—bases of last phalanges(T). (*Inner half, Ulnar; Outer half, Anterior interosseous of median.*) *Tendons pass beneath annular ligament.*

Flexor longus pollicis: hollow on upper $\frac{2}{3}$ of anterior surface of shaft of radius, outer $\frac{1}{2}$ of interosseous membrane for same distance(F); base of coronoid process of ulna by a separate slip(F)—base of last phalanx of thumb(T) (Anterior interosseous). *Tendon passes beneath the annular ligament.*

Pronator quadratus: anterior surface and anterior border of shaft of ulna, for lower fourth(F)—for two inches into lower end of anterior surface and anterior border of radius(F) (Anterior interosseous).

RADIAL REGION.

Supinator longus: upper $\frac{2}{3}$ external supra-condylar ridge of humerus, external intermuscular septum(F)—root of styloid process of radius(T) (Musculo-spiral).

Extensor carpi radialis longior: lower $\frac{1}{3}$ of external supra-condylar ridge of humerus, external intermuscular septum(F)—base of posterior surface of metacarpal of index-finger(T) (Musculo-spiral). *Passes in groove, posterior to styloid process of radius.*

Extensor carpi radialis brevior: common extensor tendon from external condyle of humerus(T), external lateral ligament, intermuscular septum(F)—base of metacarpal bone of middle finger(T) (Posterior interosseous).

POSTERIOR BRACHIAL REGION, SUPERFICIAL LAYER.

Extensor communis digitorum: common extensor tendon from external condyle of humerus(T); intermuscular septum(F)—dorsa of last two phalanges of fingers(T) (Posterior interosseous). *The three tendons pass through a separate compartment of the annular ligament with the extensor indicis; below the ligament the internal tendon splits into two for the two inner fingers. The tendons of the middle, ring, and little finger are connected by tendinous slips.*

Extensor minimi digiti: common extensor tendon from external condyle of humerus, intermuscular septum(T)—2nd and 3rd phalanges of little finger joining common expansion(T) (Posterior interosseous). *Tendon passes through separate sheath of annular ligament, below which it splits into two, the external one*

being united by a cross piece with the tendon of common extensor going to little finger.

Extensor carpi ulnaris: common extensor tendon from external condyle of humerus(T), intermuscular septum(F) by aponeurosis from middle $\frac{1}{3}$ of posterior border of ulna(A)—prominence on ulnar side of base of 5th metacarpal bone(T) (Posterior interosseous). *Has separate sheath in annular ligament.*

Anconeus: posterior surface of external condyle of humerus(T) and deep fascia(F)—outer side of olecranon, impression on upper $\frac{1}{3}$ of posterior surface of ulna limited by oblique line(F) (Musculo-spiral). *The recurrent interosseous vessels lie beneath this muscle.*

POSTERIOR BRACHIAL REGION.

Supinator brevis: external condyle, external lateral ligament of elbow-joint, orbicular ligament of radius, depression below lesser sigmoid cavity, external edge of ulna for 2 in.(F)—surrounds upper $\frac{1}{3}$ of radius, is attached to all the neck, except at inner side, to the upper $\frac{1}{3}$ of posterior, and upper $\frac{1}{2}$ of external surfaces(F) (Posterior interosseous).

Extensor ossis metacarpi pollicis: middle $\frac{1}{3}$ of posterior surface of shaft of radius, special impression on superior and external part of posterior surface of ulna for same length, intervening interosseous membrane(F)—base of 1st metacarpal, slip to os trapezium(T) (Posterior interosseous). *The radial artery winds backwards beneath tendon near carpus.*

Extensor primi internodii pollicis, vel extensor brevis pollicis: posterior surface of radius and interosseous membrane below preceding muscle for about $1\frac{1}{2}$ in.(F)—base of 1st phalanx of thumb(T) (Posterior interosseous). *Goes through groove of annular ligament with extensor ossis metacarpi pollicis.*

Extensor secundi internodii pollicis, vel extensor longus pollicis: posterior surface of ulna, on inner side and below extensor ossis metacarpi pollicis for 4 inches, interosseous membrane(F)—base of last phalanx of thumb(T) (Posterior interosseous). *Tendon goes through separate sheath of annular ligament, and below is separated from other extensors of thumb by a triangular interval, which contains the radial artery.*

Extensor indicis: internal part of posterior surface of shaft of ulna for about 3 inches just below middle, and interosseous membrane(F)—joins tendon of extensor communis digitorum to 2nd and 3rd phalanges of index-finger(T) (Posterior interosseous).

THUMB, RADIAL REGION.

Abductor pollicis: ridge of trapezium, upper part of annular ligament(F)—outer side of base of 1st phalanx of thumb(T) (Median).

Opponens pollicis : anterior surface and ridge of trapezium, annular ligament(F)—whole length of radial side of shaft of 1st metacarpal(F).

Flexor brevis pollicis : anterior surfaces of trapezoid, os magnum, and bases of 2nd and 3rd metacarpal bones, lower part of annular ligament(F)—by two heads into radial and ulnar sides of base of 1st phalanx of thumb(T) (*Outer part*, median ; *Inner part* ulnar). *A sesamoid bone developed in each tendon of insertion. Deep palmar arch of radial, issues from behind inner head.*

Adductor pollicis : ridge on lower $\frac{2}{3}$ of anterior surface of shaft of 3rd metacarpal(F)—ulnar side of base of 1st phalanx of thumb(T) (Ulnar).

Note.—The following modification of some of the short muscles of the thumb is now frequently adopted :—

Flexor brevis pollicis : *Outer head.* Lower border of annular ligament—outer margin of the base of 1st phalanx of thumb (Median). *Inner head.* Inner side of base of 1st metacarpal bone—inner side of base of 1st phalanx of thumb (Ulnar).

Adductor obliquus pollicis : Sheath of flexor carpi radialis, anterior carpal ligaments, os magnum, bases of 2nd and 3rd metacarpal bones—inner side of base of 1st phalanx of thumb (Ulnar).

Adductor transversus pollicis corresponds to the old adductor pollicis.

LITTLE FINGER, ULNAR REGION.

Palmaris brevis : annular ligament, palmar fascia(F)—skin on ulnar side of palm(F) (Ulnar).

Adductor, vel opponens minimi digiti : process of unciform bone, lower part of annular ligament(F)—ulnar edge of 5th metacarpal(F) (Ulnar).

Flexor brevis minimi digiti : tip of process of unciform, annular ligament(F)—ulnar side of base of 1st phalanx of little finger (T) (Ulnar).

Abductor minimi digiti : pisiform bone, tendon of flexor carpi ulnaris(F)—ulnar side of base of 1st phalanx of little finger(T) (Ulnar).

MIDDLE PALMAR REGION.

Lumbricales (4) : radial side of deep flexor tendons (2 inner from ulnar margins of 2nd and 3rd tendons also) (F)—radial side of tendinous expansion on dorsa of 1st phalanges of fingers (T) (2 *outer* median, 2 *inner* ulnar).

Interossei dorsales (4) : *Abduct from median line of hand.* 1st muscle (*abductor indicis*) : *Outer head.* From upper $\frac{1}{2}$ of

ulnar border of 1st metacarpal(F). *Inner head.* Radial border of 2nd metacarpal(F). The others from posterior part of lateral surfaces of both metacarpals, between which they lie—1st and 2nd muscles to radial side of 1st phalanx of index and middle fingers respectively, 3rd and 4th in similar manner to ulnar side of middle and ring fingers(T). All join expansion of common extensor on 1st phalanx(T) (Ulnar).

Interossei palmares (3): *Adduct to median line of hand.* 1st from ulnar side of 2nd metacarpal, 2nd and 3rd from radial sides of 4th and 5th metacarpals respectively(F)—1st phalanx of finger from which they arise and on the same side as the origin (T) (Ulnar).

MUSCLES AND FASCIÆ OF BODY.

BACK, 1ST LAYER.

Trapezius: spinous processes of all dorsal and 7th cervical vertebræ, with supra-spinous ligaments, ligamentum nuchæ, inner $\frac{1}{3}$ rd of superior curved line of occiput(T)—outer $\frac{1}{3}$ rd of posterior surface of clavicle, superior edge of acromion, superior border of spine of scapula(F), and rough impression on spine about 1 in. from root(T) (Spinal accessory, Cervical plexus from 3rd and 4th). *Anterior margin forms posterior boundary of posterior triangle of neck.*

Latissimus dorsi: spinous processes of lower 6 dorsal, supra-spinous ligaments(A); from the posterior layer of the lumbar aponeurosis, by which it is attached to all the lumbar and sacral spines, and posterior $\frac{1}{2}$ of outer edge of iliac crest, beyond this for 1 in.(F), lower 3 or 4 ribs(F), and occasionally a slip from angle of scapula—bottom of bicipital groove of humerus (T) (Long subscapular). *In the back the latissimus is posterior to the teres major, but twisting upon itself it is inserted anteriorly to it.*

BACK, 2ND LAYER.

Levator anguli scapulæ: posterior tubercles of transverse processes of upper three or four cervical vertebræ(T)—vertebral border of scapula between spine and superior angle(F) (5th cervical and deep branches from cervical plexus 3rd and 4th). *Forms part of floor of posterior triangle of neck.*

Rhomboideus minor: ligamentum nuchæ, spinous processes of 7th cervical and 1st dorsal vertebræ(T)—vertebral border of scapula, opposite root of spine(F) (5th cervical).

Rhomboideus major: spines and supra-spinous ligaments of upper 4 or 5 dorsal vertebræ, below preceding(T)—vertebral

border of scapula between spine and inferior angle(F) (5th cervical). *Sometimes the fibres end in a tendinous arch near the bone.*

BACK, 3RD LAYER.

Serratus posticus superior : ligamentum nuchæ, spinous processes of 7th cervical and two or three superior dorsal vertebræ, supra-spinous ligament(A)—upper borders and outer surfaces of 2nd, 3rd, 4th, and 5th ribs external to angle(F) (External posterior branches of intercostal).

Serratus posticus inferior : spinous processes of 11th and 12th dorsal, 1st, 2nd, and 3rd lumbar vertebræ, and united to tendon of origin of latissimus dorsi and to the fascia lumborum(A)—inferior borders of lower four ribs external to angle(F) (External posterior branches of intercostal).

The vertebral aponeurosis. A thin membrane, attached to the spines of the dorsal vertebræ, and passing outwards to the angles of the ribs. Below it is joined to the upper edge of the inferior serratus and the tendon of latissimus, whilst above it passes beneath the superior serratus and splenius to become continuous with the deep fascia of the neck. It binds down the erector spinæ in the groove between the vertebral spines and the angles of the ribs.

Splenius : lower $\frac{1}{2}$ of ligamentum nuchæ, spinous processes of 7th cervical and upper 6 dorsal vertebræ, supra-spinous ligaments(A)—*Capitis*, apex and hinder border of mastoid process, outer $\frac{1}{3}$ superior curved line of occiput(T) ; *Colli*, posterior transverse processes of 1st, 2nd, and 3rd cervical vertebræ(T) (External posterior branches of cervical).

BACK, 4TH LAYER.

Erector spinæ : *Outer mass.* Sacro-lumbalis, musculus accessorius, cervicalis ascendens. *Inner mass,* Longissimus dorsi, transversalis colli, trachelo-mastoid.

Erector spinæ : posterior $\frac{1}{5}$ th inner lip of iliac crest, from the sacral transverse processes, and lower part of posterior surface of sacrum, from the sacral, lumbar and lower 3 dorsal spines, with supra-spinous ligaments(T). Divides opposite last rib into sacro-lumbalis and longissimus dorsi (External posterior branches of sacral and lumbar).

Sacro-lumbalis, vel ilio costalis : erector spinæ(F)—angles of lower 6 or 7 ribs(T) (External posterior branches of lumbar and dorsal).

Musculus accessorius : angles of lower 6 ribs(T)—angles of upper 6 ribs, and transverse process of 7th cervical(T) (External posterior branches of dorsal).

Cervicalis ascendens : angles of 3rd, 4th, 5th, and 6th ribs(T)—Posterior transverse tubercles of 6th, 5th, and 4th cervical vertebræ(T) (External posterior branches of cervical).

Longissimus dorsi. (*See erector spinæ, of which it forms nearly the whole of the inner mass.*)—*Internally.* Accessory processes of lumbar and transverse processes of dorsal vertebræ (TF). *Externally.* Lumbar transverse processes(F), middle layer of fascia lumborum. To all the ribs except first two or three by fleshy processes between tubercle and angle(F) (External posterior branches of lumbar and dorsal).

Transversalis colli : transverse processes of upper 6 dorsal vertebræ(T)—Posterior tubercles of transverse processes of 6th, 5th, 4th, 3rd, and 2nd cervical vertebræ(T) (External posterior branches of cervical).

Trachelo-mastoideus : transverse processes of upper 6 dorsal vertebræ(T), articular processes of 7th, 6th, 5th, and 4th cervical vertebræ(T)—posterior edge of mastoid process(F) (External posterior branches of cervical).

Spinalis dorsi : spinous processes of 11th and 12th dorsal and 1st and 2nd lumbar vertebræ(FT)—Spinous processes of upper $\frac{1}{2}$ or $\frac{2}{3}$ of dorsal vertebræ(T) (External posterior branches of dorsal and lumbar).

Spinalis cervicis : spinous processes of 5th and 6th cervical vertebræ(FT)—Spine of axis(T) (*sometimes into 3rd and 4th cervical vertebræ*) (External posterior branches of cervical). *This muscle is frequently wanting.*

Complexus : transverse processes of upper 6 dorsal and 7th cervical, articular processes of inferior 5 cervical, and spinous process of 7th cervical vertebræ(T)—Impression between superior and inferior curved lines of occiput(F) (Internal posterior branches of cervical, Suboccipital, Great occipital). *The inner part of this muscle is sometimes described as a separate muscle, called biventer cervicis.*

BACK, 5TH LAYER.

Semi-spinalis dorsi : transverse processes of 10th, 9th, 8th, 7th, and 6th dorsal vertebræ(T)—Spinous processes of upper four dorsal and last two cervical vertebræ(T) (Internal posterior branches of dorsal).

Semi-spinalis colli : transverse processes of upper 6 dorsal and articular processes of lower 4 cervical vertebræ(FT)—spinous processes of 2nd, 3rd, 4th, and 5th cervical vertebræ(T) (Internal posterior branches of cervical).

Multifidus spinæ : back of sacrum as low as 4th sacral foramen ; inner surface of posterior superior iliac spine, posterior

sacro-iliac ligament, mammillary processes of lumbar, transverse processes of dorsal, articular processes of lower 5 cervical vertebræ(FT)—spines and neural arches of vertebræ from 3rd sacral to 2nd cervical(F) (Internal posterior branches of sacral, lumbar, dorsal and cervical). *Fills groove on either side of spinous processes of vertebræ.*

Rotatores spinæ, vel dorsi (eleven in number): tip and upper edge of transverse process of a dorsal vertebra(F)—lower border of lamina of vertebra next above(A) (Internal posterior branches of dorsal).

Inter-spinales: placed in pairs, one on each side of inter-spinous ligament between spinous processes (Internal posterior branches of cervical, dorsal, and lumbar). *These muscles are wanting between 1st and 2nd cervical, and all the dorsal except first and last two pairs.*

Inter-transversales: lie between transverse processes. *Cervical* (seven pairs, two sets). One set attached to anterior, the other to the posterior tubercles. *Dorsal.* Single sets, from three to six in number, attached to the processes of the lower vertebræ. *Lumbar.* Four in number, the lower ones filling up the spaces between processes entirely (Internal posterior branches of cervical, dorsal, and lumbar).

Extensor coccygis: lower end of sacrum(T)—inferior part of coccyx(F). *Frequently absent; lies upon posterior surface.*

ABDOMINAL REGION.

Obliquus abdominis externus: eight digitations from inferior borders and outer surface of eight lower ribs, upper five digitating with serratus magnus, lower three with latissimus dorsi(F)—Anterior half of external lip of iliac crest, and aponeurosis in front of belly, which is attached to pubic spine and symphysis below(A), blends above with the fascia over the pectoralis major, and joins in the middle line with the opposite aponeurosis, forming the *linea alba*; the rest of the fibres forming *Poupart's* and *Gimbernat's ligaments*(A) (Inferior intercostal, Ilio-hypogastric, and Ilio-inguinal).

The *external abdominal ring* is an opening formed by a divergence of some of the lower fibres of the aponeurosis of the external oblique muscle; it is situated just above the crest of the pubes, and transmits spermatic cord in male and round ligament in female. *Boundaries—Below.* Pubic crest. *Above.* Arched fibres. *Laterally.* External and internal pillars; the external pillar is attached below to pubic spine, the internal pillar to pubic symphysis. The *intercolumnar fascia* passes between the pillars, and is prolonged downwards over the cord.

Poupart's Ligament. The part of the aponeurosis of the external oblique extending between anterior superior iliac spine and pubic spine. The inner attachment is prolonged along the pectineal line, forming *Gimbernats ligament*.

Obliquus internus: outer $\frac{1}{2}$ of Poupart's ligament, anterior $\frac{2}{3}$ middle lip of iliac crest, fascia lumborum between iliac crest and 12th rib(F)—inferior edges of cartilages of lower three ribs on posterior surface, aponeurosis blending with its fellow at linea alba; some of the lower fibres of the aponeurosis arch over spermatic cord, join tendon of transversalis just above pectineal line, forming the *conjoined tendon*, which is attached to pectineal line, and crest of pubes(T) (Inferior intercostals, Ilio-hypogastric). *Aponeurosis forms sheath to encase the rectus except at lower fourth posteriorly.*

Cremaster (*peculiar to male*): middle of Poupart's ligament and internal oblique(F)—crest of os pubis(T) (Ilio-inguinal).

Transversalis: outer $\frac{1}{3}$ Poupart's ligament, anterior $\frac{3}{4}$ inner lip iliac crest, inner surfaces of cartilages of lower six ribs(F), fascia lumborum(T)—lower fibres end in the *conjoined tendon*, inserted into pubes and pectineal line(T); rest of fibres terminate in an aponeurosis attached to linea alba(A) (Inferior intercostals, Ilio-hypogastric, Ilio-inguinal). *As low as midway between pubes and umbilicus, the aponeurosis is posterior to the rectus, but beyond that spot it is anterior.*

The Posterior aponeurosis of the Transversalis or fascia lumborum is attached to the lower border of the last rib above, and to the ilio-lumbar ligament and posterior part of the iliac crest below. Tracing it towards the spine, it splits to enclose the quadratus, and becomes attached to the lumbar transverse processes. From the posterior of these layers a process is given off to the lumbar spines, enclosing the erector spinæ.

Rectus abdominis: pubic crest and symphysis(T)—ensiform appendix, cartilages of 6th and 7th ribs, bone and cartilage of 5th rib(FT) (Inferior intercostal, Ilio-hypogastric). Traversed by three or four tendinous intersections, *lineæ transversæ*. *Sheath of rectus.* Aponeurosis of internal oblique splits at outer edge of muscle, one piece passing anteriorly, the other posteriorly. The posterior part is joined by aponeurosis of transversalis, and is deficient at lower fourth; the lower free border forms the *Fold of Douglas*. The anterior part blends with aponeurosis of the external oblique.

Pyramidalis: front of pubes and anterior pubic ligament(T)—linea alba(T) midway between umbilicus and pubes (Ilio-hypogastric). *Enclosed in sheath of rectus, and frequently absent.*

Quadratus lumborum : *anterior part.* Upper edge of transverse processes of 4th and 5th lumbar vertebræ—inner $\frac{1}{2}$ lower border 12th rib. *Posterior part.* Ilio-lumbar ligament, and inner lip of iliac crest for 2 inches external to it(A). Apices of transverse processes of upper four lumbar(T), inner $\frac{1}{2}$ inferior border of 12th rib(F) (Anterior branches of lumbar).

THORACIC REGION.

Intercostales externi (11) : outer lip of groove on inferior border of rib, from the tubercle to costal cartilage(F)—outer edge of superior border of rib below(F) (Intercostal). *Fibres run downwards and forwards. The corresponding spaces between the rib cartilages are occupied by the anterior intercostal aponeurosis.*

Intercostales interni (11) : inner lip of groove on inferior border of rib, extending from angle to sternum(F)—inner edge of superior border of rib below (Intercostal). *Fibres run downwards and backwards, but not so obliquely as the external muscles. The inner surface of each intercostal space between the tubercle and angle is occupied by the posterior intercostal aponeurosis. The intercostal vessels and nerve lie between the external and internal muscles.*

Infracostales (10) : inner surface of a rib, near angle(F)—inner surface of 1st, 2nd, or 3rd ribs below (FT) (Intercostal).

Triangularis sterni : side of ensiform appendix and sternum, as high as 3rd intercostal space, posterior surfaces of cartilages of 7th, 6th, and 5th ribs(F)—posterior surfaces of 2nd, 3rd, 4th, and 5th ribs at junction of bone and cartilage, aponeurosis posterior to internal intercostal muscles (TF) (Anterior branches of intercostal).

Levatores costarum (12) : apex and lower border of transverse process of dorsal vertebra(T)—superior border of rib below, extending from tubercle to angle(F) (Intercostal). *1st muscle arises from 7th cervical vertebra, and is inserted into outer border of 1st rib.*

DIAPHRAGMATIC REGION.

Diaphragma : posterior surface of ensiform appendix, internal surfaces of lower six ribs and cartilages(F), ligamenta arcuata(A) (externa et interna). Right crus, from bodies and intervertebral substances of 1st, 2nd, 3rd lumbar vertebræ(T). Left crus, from bodies and intervertebral substances of 1st and 2nd lumbar vertebræ(T)—central tendon (Phrenic). *The ligamentum arcua-*

tum internum arches over psoas, attached to body of 1st lumbar vertebra internally and to transverse process of 1st lumbar vertebra externally. The *ligamentum arcuatum externum* reaches from transverse process of 1st lumbar vertebra to lower border and apex of last rib, arching over quadratus.

Openings. AORTIC : between the crura and spine, transmits aorta, thoracic duct, and vena azygos major. ŒSOPHAGEAL : above and little to left of aortic, transmits œsophagus and pneumogastric nerves. CAVAL : in the right leaflet of tendon, transmits vena cava inferior, which is inseparably united to it. In each crus there is a fissure for the three splanchnic nerves, the left one transmitting in addition the vena azygos minor. The cord of the sympathetic perforates the outer part of the crus.

PERINEAL FASCIÆ. *Superficial Fasciæ.* In the anterior half of the perineum is the superficial perineal fascia (*fascia of Colles*), attached to rami of pubes and ischium, and from ischial tuberosity to central point of perineum ; here it joins the deep perineal fascia, by turning round the transversus perinei. It is continuous in front with the dartos, and from its deep surface there is a septum passing forwards to scrotum in the middle line.

Deep Perineal Fascia, or Triangular Ligament of the Urethra, consists of two layers. The *anterior* layer is attached to the symphysis and to rami of pubes and ischium on each side, and joins the superficial fascia where this curves over the transverse perinei. About an inch below the symphysis it is perforated by the urethra, and above this by the dorsal vein of the penis, and on either side of this opening the pudic artery and dorsal nerve of penis are transmitted. The *posterior* layer consists of two lateral portions separated in the median line by the urethra, and continuous with the recto-vesical fascia in the middle line, which here invests the prostate ; the outer portion joins the obturator fascia at the pubic and ischial rami, and is continuous with a thin fascia covering the perineal aspect of the levator ani, the *anal fascia*.

Parts between the two layers of the triangular ligament. Sub-pubic ligament, dorsal vein of penis, membranous part of urethra, compressor urethræ, Cowper's glands and ducts, internal pudic arteries giving off branches to bulb and glands of Cowper, and the artery to corpus cavernosum, the dorsal nerves of penis.

THE PELVIC FASCIA. Lines muscles of pelvis and forms floor of outlet of pelvis. Consists of the obturator and recto-vesical fasciæ.

The Obturator Fascia. Covers inner surface of obturator internus. It is attached above to ilio-pectineal line, to oblique line on posterior surface of body of pubes from symphysis to upper part of thyroid foramen. Posteriorly it is attached to the anterior edge of the sacro-sciatic notch and large sacro-sciatic ligament, whilst below it is attached to the rami of pubis and ischium. At the top of the thyroid foramen the fascia joins the obturator membrane, its bony attachment being here interrupted, and forms thus the floor of the short canal which transmits the obturator vessels and nerves. The upper part of the fascia is in the pelvic cavity and is lined by peritoneum, whilst the lower part forms the outer boundary of the ischio-rectal fossa, and encases the internal pudic vessels and nerve as they pass forwards.

The Fascia of the Piriformis is the continuation of the obturator fascia to the sacrum, and lies anterior to the pyramiformis and sacral plexus.

The Recto-vesical Fascia is attached in front to the posterior part of the pubis, close to the obturator fascia, but having the origin of the levator ani between. Laterally it is attached to the obturator fascia along a line from the upper part of the thyroid foramen to the ischial spine, whilst behind it joins the lower part of the pyramiformis fascia. From these attachments it passes downwards and inwards over the upper surface of the levator ani to the prostate, bladder and rectum, joining the fascia of the opposite side in front of the bladder, and between the bladder and the rectum, thus forming the floor of the pelvis. Along the attachment of the recto-vesical with the obturator fascia is a thickened band, the *white line* of the pelvic fascia.

Processes from the recto-vesical fascia :

Pubo-prostatic ligaments or *anterior true ligaments of the bladder.* Narrow fasciculi, one on each side, passing from the back of the pubes to the front of the prostate and neck of the bladder.

Lateral true ligaments of the bladder. This is the anterior ligament prolonged laterally, and passes to the side of the prostate, and to the side of the bladder above the vesiculæ seminales, enclosing the prostatic plexus, whilst posteriorly it is attached to the bladder between the vesiculæ, and is prolonged downwards over and enclosing them, being joined to a like process from the opposite side.

Ligament of the rectum. A piece of fascia descends from the ischium and is attached to the rectum on each side.

In the female the vagina receives a prolongation of the recto-vesical fascia corresponding to the prostatic sheath.

PERINEAL REGION.

Sphincter ani (externus): tip and back of coccyx and subcutaneous fatty layer on either side (TF)—central perineal tendon (F) (Hæmorrhoidal branch of 4th sacral and inferior Hæmorrhoidal of pudic).

Sphincter ani internus: the involuntary muscular fibres of the large intestine thickened about $\frac{1}{2}$ inch deep.

Bulbo-cavernosus, vel accelerator, vel ejaculator urinæ: central perineal tendon and *raphé*(F)—*Posterior fibres*. Under surface of triangular ligament(F). *Middle fibres* surround bulb and corpus spongiosum. *Anterior fibres*. Side of corpus cavernosum, and united with one on opposite side it encases dorsal vessels(A) (Muscular of perineal).

Erector penis, vel ischio-cavernosus: internal surface of tuber ischii(TF)—internal and external surfaces of crus penis(T) (Muscular of perineal).

Transversus perinæi: internal surface of pubic arch near tuber ischii(T)—central perineal tendon(F) (Muscular of perineal).

Levator ani: posterior surface of pubis near symphysis, spine of ischium, and between these two points from recto-vesical fascia, along attachment of obturator fascia(T)—central perineal tendon, sides of rectum and coccyx(F) (Superficial perineal, Anterior 4th sacral). *Forms floor of pelvic cavity*.

Compressor vel constrictor urethræ: internal surface of pubic arch, posterior surface of triangular ligament(A)—muscle of opposite side(T) (Dorsal of penis). *Surrounds membranous portion of urethra*.

Coccygeus: upper part of ischial spine, small sacro-sciatic ligament(TF)—side and anterior surface of coccyx and last piece of sacrum(F) (4th anterior sacral).

Note.—In the female the perinæal muscles are essentially the same: for erector penis, read *erector clitoridis*, inserted into side of clitoris. The *sphincter vaginae*, corresponding to ejaculator urinæ, is attached to the central tendon of the perineum, and passing forwards on each side of the vagina—corpora cavernosa and body of clitoris.

MUSCLES AND FASCIÆ OF LOWER EXTREMITY.

The FASCIA LATA of the thigh envelops the muscles and surrounds the limb. Above it is attached to the back of the sacrum and coccyx, to the iliac crest, to Poupart's ligament, pubic body and ramus, ischial tuberosity and ramus, and to the lower edge of the great sacro-sciatic ligament. The *ilio-tibial band* is a

thickened part attached above to the iliac crest and below to the head of the fibula and outer tuberosity of the tibia. The fascia lata is attached below to the head of the tibia and sides of the patella, being strengthened by aponeuroses from the vasti muscles. Behind the fascia passes across between the hamstring muscles, enclosing the popliteal space.

The Saphenous Opening. This is an aperture in the fascia lata in upper and inner part of the thigh, through which the internal saphenous vein passes. It is covered by the cribriform fascia. To describe it, the fascia is spoken of as consisting of two parts, a *pubic* portion on the inner side of the opening and continuous below with the *iliac* portion.

The *pubic* portion passes up over the pectineus, adductor longus and gracilis, and behind the femoral sheath, blending externally with sheath of psoas and attached internally to the pectineal line and Gimbernat's ligament.

The *iliac* portion, on the outer side of the saphenous opening, is attached externally to the iliac crest, Poupart's ligament, pubic spine and pectineal line, joining here the pubic portion. From the pubic spine it passes down and out with a free margin, the *superior cornu* or *falciform process of Burns*, forming the outer margin of the saphenous opening, and becoming continuous below and internally with the pubic portion, the margin here being well defined and named the *inferior cornu*.

Sheath of the Femoral Vessels. The upper part of the sheath surrounding the femoral vessels is called the *crural sheath*, which is formed by a prolongation from the transversalis fascia in front, and from the fascia covering the iliacus behind. It is divided into three compartments, the outer containing the artery, the middle one the vein, and the inner one, or *crural canal*, a lymphatic gland.

The *crural canal*, the innermost compartment of the femoral sheath, is about $\frac{1}{2}$ in. long, reaching from Gimbernat's ligament to the saphenous opening.

The upper opening of the crural canal is called the *crural ring*, which is on a level with Gimbernat's ligament, and is closed by a layer of sub-peritoneal fascia, the *septum crurale*.

Boundaries of the crural ring:—

In front, superficial and deep crural arches.

Behind, pubis, covered by pectineus ; pubic portion of fascia lata.

Internally, Gimbernat's ligament, conjoined tendon.

Externally, femoral vein.

The superficial crural arch is Poupart's ligament.

The deep crural arch is a thickened bundle of fibres of the

transversalis fascia, attached to Poupart's ligament outside the femoral vessels, and passing across the femoral sheath to the ilio-pectineal line behind Gimbernat's ligament.

ILIAC REGION.

Psoas magnus : transverse processes and sides of bodies of all the lumbar and body of 12th dorsal vertebræ(F) (the fleshy fibres are only attached to upper and lower margins of bodies, and intervertebral substances, being connected by a tendinous arch between)—small trochanter of femur, receiving some fibres from the iliacus(T) (Branches from lumbar plexus).

Psoas parvus : bodies of 12th dorsal and 1st lumbar vertebræ and intervertebral disc(F)—ilio-pectineal line(T) (Branch from lumbar plexus). *Frequently absent.*

Iliacus : upper $\frac{1}{2}$ of iliac fossa, ilio-lumbar ligament, ala of sacrum, and capsule of hip-joint(F)—tendon of psoas, triangular surface anterior to and below the small trochanter(F) (Anterior crural). *Passes beneath Poupart's ligament with the psoas.*

ANTERIOR FEMORAL REGION.

Tensor vaginæ femoris : outer edge of iliac crest for one inch, anterior superior iliac spine, and half notch below it(Δ)—fascia lata (ilio-tibial band) about $\frac{1}{3}$ down thigh, anterior to great trochanter(F) (Superior gluteal).

Sartorius : anterior superior iliac spine, and half notch below (Δ)—inner side of tibia, by side of tubercle, reaching by its upper edge as far back as internal lateral ligament(AT) (Middle cutaneous or special branch from anterior crural). *Longest muscle of body, crosses thigh obliquely, forming outer boundary of Scarpa's triangle; lies over the roof of Hunter's canal; lower tendon pierced by patellar branch of great saphenous nerve.*

Quadriceps extensor—composed of :—

Vastus externus : upper half of shaft of femur, thus : from base of neck, anterior and outer parts of base of great trochanter, and line from great trochanter to linea aspera, upper half of external lip of linea aspera, external intermuscular septum(AF)—common extensor tendon, and slip to outer side of patella(T) (Anterior crural).

Vastus internus : inner lip of linea aspera, lower part of spiral line, tendons of adductores longus and magnus (TA)—common tendon and inner side of patella(T) (Anterior crural).

Crureus : upper $\frac{2}{3}$ anterior and outer surfaces of shaft of femur, lower half external intermuscular septum(F)—common tendon(A) (Anterior crural).

Rectus femoris: 1st head. Anterior inferior iliac spine(T). 2nd head. Groove above acetabulum(T) — common extensor tendon into upper border of patella(T) (Anterior crural).

THE COMMON EXTENSOR TENDON is inserted into the upper and lateral edges of the patella, very few fibres being prolonged over bone to help form the ligamentum patellæ.

Subcrureus: two slips from anterior surface of shaft of femur in lower fourth(F)—synovial sac of knee-joint(F) (Anterior crural).

INTERNAL FEMORAL REGION.

Gracilis: internal margin of pubic border of hip-bone ; viz., opposite lower half of symphysis and upper half of pubic arch(A) —inner side of tibia superior to semi-tendinosus, but inferior to backward prolongation of insertion of sartorius(T) (Anterior branch of obturator).

Pectineus: Ilio-pectineal line and triangular surface anterior to it(F)—posterior to small trochanter and upper half of line leading from it to linea aspera(T) (Anterior crural, and Anterior branch of obturator).

Adductor longus: anterior surface of pubes below angle of crest and symphysis(T)—inner lip of linea aspera(F) (Anterior division of obturator). *Forms internal boundary of Scarpa's triangle.*

Adductor brevis: ramus of pubis, extending from adductor longus to middle of ramus(FA)—behind pectineus into line leading from small trochanter to linea aspera(F) (Obturator, generally anterior branch). *Anterior division of obturator nerve placed in front and posterior part behind, the internal circumflex artery between upper border and obturator externus.*

Adductor magnus: pubic arch, from symphysis to tuber ischii(A)—*Anterior part.* Line from great trochanter to linea aspera, inner lip of linea aspera, upper half of line leading to inner condyle(F). *Posterior part.* Tubercle above inner condyle (T) (Posterior division of obturator, Great sciatic). *Between the two parts of the muscle there is an interval, the femoral opening, which transmits the femoral vessels.*

HUNTER'S CANAL. A space extending from the apex of Scarpa's triangle to the opening in the adductor magnus, containing the femoral vessels and long saphenous nerve. It is formed by aponeurotic fibres passing from the adductores magnus and longus to the vastus internus.

GLUTEAL REGION.

Gluteus maximus: space between superior curved line and posterior $\frac{1}{3}$ of outer lip of iliac crest, aponeurosis over erector

spinæ, posterior surface of coccyx, last piece of sacrum, and great sacro-sciatic ligament(F)—gluteal ridge between linea aspera and great trochanter(AF), fascia lata(F) (Inferior gluteal).

Parts beneath the gluteus maximus: part of gluteus medius, the pyriformis, gemelli, inferior and superior, quadratus femoris, upper part of adductor magnus, tendon of obturator internus, origins of semi-membranosus, semi-tendinosus, and biceps. Superficial branch of gluteal artery, sciatic vessels and nerves, pubic vessels and nerve, nerve to obturator internus. Three bursæ, one over great trochanter, one over tuber ischii, one over vastus externus. Great sacro-sciatic ligament. Great trochanter and tuber ischii.

Gluteus medius: Bone between iliac crest and superior curved line above, and middle curved line below, fascia(F)—outer surface of great trochanter from tip posteriorly to base anteriorly(F) (Superior gluteal). *Conceals gluteal vessels and nerve.*

Gluteus minimus: posterior surface of hip-bone between middle and inferior curved lines(F)—impression on anterior part of great trochanter(F) (Superior gluteal).

Pyriformis: anterior surface of sacrum, from 2nd, 3rd, and 4th pieces between anterior foramina, upper margin of great sciatic notch, great sacro-sciatic ligament(F)—posterior part of upper edge of great trochanter(T) (2nd Sacral). *Goes through great sacro-sciatic foramen.*

Obturator internus: posterior surfaces of pubic arch, obturator membrane, and bone behind; from great sciatic notch, fascia(F)—front of inner surface of great trochanter with the gemelli(T) (Sacral plexus). *Passes through small sacro-sciatic foramen.*

Gemellus superior: outer surface of ischial spine(F)—superior border of great trochanter anterior to the pyriformis with obturator internus(T) (Sacral plexus).

Gemellus inferior: superior and outer border of tuber ischii (F)—superior border of great trochanter with obturator internus (T) (Sacral plexus).

Obturator externus: anterior half of outer surface of obturator membrane, rami of pubis and ischium(F)—digital fossa at root of great trochanter(T) (Posterior division of obturator).

Quadratus femoris: external border of tuber ischii(F)—tubercle on posterior inter-trochanteric ridge, and downwards as far as insertion of adductor magnus(F) (Sacral plexus).

POSTERIOR FEMORAL REGION.

Biceps: *Long head.* Lower and inner impression on tuber ischii(T). *Short head.* Outer lip of linea aspera, upper part of line to external condyle, external intermuscular septum(F)—by

two slips embracing the external lateral ligament upon the outer side of head of fibula and outer tuberosity of tibia(T) (Great sciatic). *Forms outer hamstring.*

Semi-tendinosus: Lower and inner impression on tuber ischii with the biceps(T), tendon of biceps(F)—upper part of internal surface of tibia, under cover of the sartorius(T) (Great sciatic).

Semi-membranosus: upper and outer impression on the tuber ischii(TA)—(1) hinder part of lower lip of groove on internal tibial tuberosity(T) beneath internal lateral ligament—(2) forms principal part of posterior ligament of knee—(3) into fascia over popliteus (Great sciatic).

ANTERIOR TIBIO-FIBULAR REGION.

Tibialis anticus: external tuberosity and upper $\frac{2}{3}$ of external surface of shaft of tibia, contiguous interosseous membrane, fascia and intermuscular septum(F)—inner surface of internal cuneiform; base of metatarsal bone of great toe(T) (Anterior tibial). *Passes through innermost compartment of annular ligament. Outer border conceals anterior tibial vessels.*

Extensor proprius hallucis: middle $\frac{3}{5}$ of anterior surface of shaft of fibula, contiguous interosseous membrane(F)—base of last phalanx of great toe(T) (Anterior tibial). *Anterior tibial vessels lie on the inner side, but the tendon crosses to inner side of vessels under annular ligament.*

Extensor longus digitorum: external tuberosity of tibia, head and upper $\frac{3}{4}$ of anterior surface of shaft of fibula, interosseous membrane(F)—by four tendons into the middle and last phalanges of four outer toes(T) (Anterior tibial).

Peroneus tertius: lower $\frac{1}{4}$ of anterior surface of shaft of fibula, interosseous membrane, intermuscular septum(F)—base of 5th metatarsal on dorsal surface(T) (Anterior tibial).

POSTERIOR TIBIO-FIBULAR REGION, SUPERFICIAL LAYER.

Gastrocnemius: *Inner head.* Impression on upper and posterior part of inner condyle(T), line above condyle(F). *Outer head.* Impression on external surface of outer condyle(T), upper and posterior part of condyle(F)—unites with tendon of soleus to form *tendo Achillis*, inserted into lower half of posterior surface of tuber calcis(T) (Internal popliteal).

Soleus: posterior surface of head, and upper $\frac{1}{3}$ of posterior surface of shaft of fibula, oblique line and middle $\frac{1}{3}$ of posterior edge of tibia(A)—*tendo Achillis* (Internal popliteal). *Posterior tibial vessels and nerve lie beneath.*

Plantaris : line above outer condyle, posterior ligament of knee-joint(F)—tuber calcis, with or by side of tendo Achillis(T) (Internal popliteal). *Tendon, longest in body.*

POSTERIOR TIBIO-FIBULAR REGION, DEEP LAYER.

The FASCIA of the leg invests the limb except the inner surface of the tibia ; it is continuous above with the fascia lata of the thigh, and below with the annular ligaments of the ankle, being attached in front to the anterior and inner borders of the tibia.

Popliteus : anterior half of impression on external surface of outer condyle(T), posterior ligament of knee-joint(F)—triangular space on posterior surface of shaft of tibia above oblique line(F) (Internal popliteal). *Forms floor of popliteal space ; arises in capsule of joint but outside synovial membrane.*

Flexor longus hallucis : lower $\frac{2}{3}$ of posterior surface of shaft of fibula, intermuscular septum(F)—base of last phalanx of great toe(T) (Posterior tibial). *Goes through groove in astragalus.*

Flexor longus digitorum : inner part of posterior surface of shaft of tibia, from oblique line to 3 in. from lower end, aponeurosis over tibialis posticus(F)—four tendons, joined by flexor accessorius, passing through slits in tendon of flexor brevis digitorum, to bases of last phalanges of four outer toes(T) (Posterior tibial).

Tibialis posticus : posterior surface of interosseous membrane except below, and aponeurosis superficial to it. External part of posterior surface of tibia from head to 2 in. from lower end. Internal surface of shaft of fibula(F)—tubercle on scaphoid bone, slips to cuneiform, cuboid, bases of 2nd, 3rd, and 4th metatarsals, and sustentaculum tali (I) (Posterior tibial).

FIBULAR REGION.

Peroneus longus : upper $\frac{2}{3}$ external surface of shaft of fibula, fascia, intermuscular septum(F)—internal cuneiform and base of 1st metatarsal(T) (Musculo-cutaneous). *Winds round grooves behind external malleolus and outer border of cuboid bone.*

Peroneus brevis : lower $\frac{2}{3}$ external surface shaft of fibula, intermuscular septum(F)—projection at base of 5th metatarsal(T) (Musculo-cutaneous).

THE ANTERIOR ANNULAR LIGAMENT consists of two parts. A *superior* or *vertical* part, attached to the anterior border of the tibia internally, and to the anterior border of the fibula externally, being continuous above with the fascia of the leg, and divided into two compartments, the internal one for the tibialis anticus tendon, the outer one for the extensor longus digitorum

and peroneus tertius tendons. An *inferior* or *horizontal* part attached internally to the inner malleolus and plantar fascia, and externally to the upper surface of the os calcis. It contains three compartments, the internal one for the tibialis anticus tendon, the middle one for the extensor proprius hallucis tendon, and the external one for the extensor longus digitorum and peroneus tertius tendons.

THE INTERNAL ANNULAR LIGAMENT passes between the inner malleolus and the inner margin of the os calcis, being continuous above with the deep fascia, and below with the plantar fascia. It is divided into three compartments. The one next the malleolus transmits the tibialis posticus tendon, the next one the flexor longus digitorum, and the lowest, on the astragalus, the flexor longus hallucis. Between these last two canals the posterior tibial vessels and nerve pass under the ligament.

THE EXTERNAL ANNULAR LIGAMENT passes from the outer malleolus to the os calcis, binding down the peronei tendons.

THE PLANTAR FASCIA consists of a central and two lateral parts.

The inner part covers the abductor hallucis, and is continuous with the dorsal fascia.

The outer part covers the abductor minimi digiti, and extends from the external tubercle of the os calcis to the base of the 5th metatarsal.

The central part is attached behind to the internal tubercle of the os calcis, and, extending forwards, splits up into five parts at the heads of the metatarsal bones, one part passing to each of the toes.

FOOT, DORSAL REGION.

Extensor brevis digitorum : external surface of os calcis in front of groove, annular ligament(F)—four tendons, inner one to base of 1st phalanx of great toe, rest to outer side of tendons of long extensor to 2nd, 3rd, and 4th toes(T) (Anterior tibial).

FOOT, PLANTAR REGION, 1ST LAYER.

Abductor hallucis : inner side of large tubercle on under surface of os calcis, plantar fascia, internal annular ligament, inner border of foot(F)—inner side of base of 1st phalanx of great toe(T) (Internal plantar).

Flexor brevis digitorum : front part of inner tubercle of os calcis(T), plantar fascia(F), intermuscular septa(F)—four tendons to middle phalanges of four outer toes(T) (Internal plantar.)

Abductor minimi digiti : outer tubercle and fore part of

inner tubercle of os calcis, plantar fascia, intermuscular septa(F)
—outer side of base of 1st phalanx of little toe (External
plantar).

FOOT, PLANTAR REGION, 2ND LAYER.

Flexor accessorius : *Inner head*. Inner concave surface of os calcis(F). *Outer head*. Outer surface of os calcis in front of outer tubercle, ligamentum longum plantæ(T)—long flexor tendons(F) (External plantar).

Lumbricales (4) : long flexor tendon, from two tendons, except most internal one(F)—inner sides of bases of 1st phalanx of four outer toes, and dorsal expansion(T) (Internal plantar, 1st ; External plantar, 2nd, 3rd and 4th).

FOOT, PLANTAR REGION, 3RD LAYER.

Flexor brevis hallucis : internal border of cuboid(T), tendon of tibialis posticus(T)—outer and inner sides of base of 1st phalanx of great toe(T) (Internal plantar).

Adductor obliquus hallucis : bases of 2nd, 3rd, and 4th metatarsals, sheath of peroneus longus(F)—outer side of base of 1st phalanx of great toe(T) (External plantar).

Flexor brevis minimi digiti : base of 5th metatarsal, sheath of peroneus longus(F)—outer side of base of 1st phalanx of little toe(T) (External plantar).

Adductor transversus pollicis vel Transversalis pedis : capsules of metatarso-phalangeal joints of three outer toes(F)—outer side of base of 1st phalanx of great toe(T) (External plantar).

FOOT, PLANTAR AND DORSAL INTEROSSEOUS REGION.

Interossei dorsales (4) : by two heads from adjacent sides of metatarsal bones(F)—side and dorsal expansion of 1st phalanx thus : the inner two go to 2nd toe, one on each side, outer two to outer sides of 3rd and 4th toes respectively(T) (External plantar). *Abduct from middle line of 2nd toe*.

Interossei plantares (3) : under and inner surfaces of three outer metatarsal bones(F)—inner side of base of 1st phalanx of same toes(T), and dorsal expansion on 1st phalanx (T) (External plantar). *Adduct to middle line of 2nd toe*.

ACTION OF MUSCLES.

HEAD AND NECK.

Scalp :

Moved forwards by anterior fibres of occipito-frontalis.

Moved backwards by posterior fibres of occipito-frontalis.

External Ear :

Raised by attrahens aurem.
Drawn forwards by attollens aurem.
Drawn backwards by retrahens aurem.

Membrana Tympani :

Tightened by tensor tympani.

Eyebrow :

Depressed by orbicularis palpebrarum.
Elevated by occipito-frontalis.
Wrinkled by corrugator supercilii.

Eyelids :

Closed by orbicularis.
Opened by levator palpebræ superioris.

Eye :

Elevated by rectus superior.
Depressed by rectus inferior.
Adducted by rectus internus.
Abducted by rectus externus.
Rotated down and out by superior oblique.
Rotated up and out by inferior oblique.

Mouth :

Closed by orbicularis oris.
Retracted by risorii, buccinatores.

Upper Lip :

Elevated by { levatores labii superioris.
 levatores labii superioris alæque nasi.
 zygomatici.

Lower Lip :

Elevated by { levatores labii inferioris.
 lower part of orbicularis.
Depressed by depressores labii inferioris.

Angle of Mouth :

Elevated by levator anguli oris.
Depressed by depressor anguli oris.

Lower Jaw :

Depressed by { platysmata.
 digastrici.
 mylo-hyoides.
 genio-hyoides.
 genio-hyo-glossi.

Lower Jaw (continued) :

Elevated by { masseters.
 { internal pterygoids.
 { temporals.

Moved forwards by external pterygoids.

Moved from side to side by external pterygoids acting alternately.

Tongue :

Protruded by genio-hyo-glossi (posterior fibres).

Retracted by { genio-hyo-glossi (anterior fibres).
 { hyo-glossi.
 { stylo-glossi.

Tip raised by superior linguales.

Tip depressed by inferior linguales, stylo-glossi.

Base raised by stylo-glossi, palato-glossi.

Base depressed by { genio-glossi.
 { stylo-glossi (posterior part).

Made concave from side to side by genio-hyo-glossi.

Pharynx :

Contracted by constrictors.

Elevated by { stylo-pharyngei.
 { salpingo-pharyngei.

Soft Palate :

Raised by { levatores palati.
 { azygos uvulæ.

Depressed by { palato-glossi.
 { palato-pharyngei.

Made tense by tensores palati.

Hyoid Bone :

Depressed by { omo-hyoides.
 { sterno-hyoides.
 { sterno-thyroïdes.
 { thyro-hyoides.

Raised by { digastrici.
 { stylo-hyoides.
 { mylo-hyoides.
 { genio-hyoides.
 { genio-hyo-glossi.

Glottis :

Opened by crico-arytænoidei postici.

Closed by { arytænoidei.
 { crico-arytænoidei laterales.

Vocal Cords :

Made tense by crico-thyroïdei.

Relaxed by thyro-arytænoidei.

Epiglottis :*Depressed by thyro-epiglottideus.***Head :**

<i>Extended by</i>	{	trapezii. splenii capitis. trachelo-mastoidei. complexus. recti postici minores. obliqui superiores.
<i>Flexed by</i>	{	platysmata. sterno-mastoidei. recti antici, majores et minores.
<i>Moved to same side by</i>	{	one sterno-mastoid. one trachelo-mastoid. one splenius capitis. rectus lateralis.
<i>Rotated and face turned to same side by</i>	{	rectus anticus major. rectus anticus minor. splenius capitis. trachelo-mastoid. rectus posticus major. obliquus inferior.
<i>Rotated and face turned to opposite side, sterno-mastoid.</i>		

BODY.**Spine :**

<i>Flexed by</i>	{	Cervical region { longi colli. scaleni antici. Dorsal region { recti abdominis. obliqui externi et interni. Lumbar region { psoæ.
<i>Extended by</i>	{	Cervical region { splenii colli. cervicales ascendentes. transversales colli. semi-spinales colli. inter-spinales. inter-transversales. supra-spinales. Dorsal and lum- { spinales dorsi. bar regions... { longissimi dorsi. sacro-lumbales. accessorii. multifidi spinæ. semi-spinales dorsi. interspinales dorsi. intertransversales dorsi.

Spine (continued) :

Rotated to same side by ... { splenius colli.
 { obliquus internus.
Rotated to opposite side by { multifidus spinæ.
 { rotatores spinæ.
 { semi-spinales.
 { obliquus externus.

Muscles of ordinary Inspiration :

External intercostals.

Internal intercostals (the parts between the rib cartilages).

Serrati postici superiores.

Levatores costarum.

Scaleni.

Diaphragm.

Quadrati lumborum (by fixing last rib).

Muscles of forced Inspiration :

Pectorales, majores et minores (arms being fixed).

Serrati magni (scapulæ being fixed).

Subclavii.

Latissimi dorsi (with arms fixed).

Sterno-mastoides.

Sterno-hyoides.

Cervicales ascendentes.

Muscles of forced Expiration :

Internal intercostals (between the bones).

Infra-costales.

Triangularis sterni.

Serrati postici inferiores.

Obliqui externi.

Obliqui interni.

Transversales.

Recti.

Pyramidales.

Levatores ani.

UPPER LIMB.

Scapula :

Moved forwards by ... { pectoralis minor.
 { serratus magnus.

Moved backwards by { trapezius.
 { rhomboidei, major et minor.

Moved upwards by ... { trapezius.
 { levator anguli scapuli.

Moved downwards by serratus magnus.

Shoulder :

Flexed by ... { pectoralis major.
 { deltoid, anterior $\frac{1}{2}$, the limb being
 raised.

Shoulder (*continued*):

<i>Extended by</i>	{	teres major. latissimus dorsi. deltoid, posterior $\frac{1}{2}$, the limb being raised.
<i>Adducted by</i>	{	coraco-brachialis. flexors and extensors. long head of triceps.
<i>Abducted by</i>	{	deltoid. supra-spinatus. long head of biceps.
<i>Rotated in by</i>	{	subscapularis. pectoralis major. latissimus dorsi. teres major.
<i>Rotated out by</i>	...	{	infra-spinatus. teres minor.

Elbow :

<i>Flexed by</i>	{	biceps. brachialis anticus. supinator longus. extensor carpi radialis longior. muscles attached to internal condyle of humerus.
<i>Extended by</i>	{	triceps. anconeus. muscles attached to external condyle of humerus.

Hand :

<i>Pronated by</i>	{	pronator radii teres. pronator quadratus.
<i>Supinated by</i>	{	biceps. supinator longus. supinator brevis.

Wrist :

<i>Flexed by</i>	{	flexor carpi radialis. flexor carpi ulnaris. palmaris longus. flexor sublimis digitorum. flexor profundus digitorum. flexor longus pollicis.
<i>Extended by</i>	{	extensores carpi radialis longior et brevior. extensor carpi ulnaris. extensor communis digitorum. extensor indicis. extensor minimi digiti. extensores pollicis.

Wrist (continued) :

Abducted by ... { extensores pollicis.
radial flexors and extensors.
Adducted by ulnar flexors and extensors.

LOWER LIMB.

Hip :

Flexed by ... { psoas magnus.
iliacus.
sartorius.
pectineus.
adductor longus.
adductor brevis.
rectus femoris.
Extended by gluteus maximus.
Adducted by ... { 3 adductors.
pectineus.
gracilis.
Abducted by ... { gluteus medius.
gluteus minimus.
tensor vaginæ femoris.
gluteus maximus.
pyriformis, gemelli and obturator
internus, when the hip is flexed.
Rotated out by ... { gluteus maximus.
psoas.
iliacus.
quadratus femoris.
obturator externus.
gemelli, pyriformis and obturator in-
ternus when the hip is extended.
Rotated in by ... { anterior fibres of 2 smaller glutei.
tensor vaginæ femoris (limb being
abducted).

Knee :

Flexed by ... { biceps.
semi-tendinosus.
semi-membranosus.
popliteus.
gracilis.
sartorius.
gastrocnemius.
plantaris.
Extended by quadriceps extensor.
Rotated out by biceps.

Tibia :

Rotated in by { popliteus (at commencement of flexion of knee-joint).
semi-membranosus.
semi-tendinosus.
gracilis.
sartorius.

Ankle :

Flexed by { tibialis anticus.
long extensors of toes.
peroneus tertius.

Extended by { gastrocnemius.
soleus.
plantaris.
tibialis posticus.
long flexors of toes.
peronei, longus et brevis.

Foot :

Inner border raised by { tibialis posticus.
tibialis anticus.
flexor longus hallucis.
flexor longus digitorum.

Outer border raised by { peronei.
extensor longus digitorum.

THE ARTERIES.**ARTERIES OF HEAD AND NECK.**

THE SUBCLAVIAN ARTERIES.—*Extent*: *Right*, from innominate opposite right sterno-clavicular articulation. *Left*, from transverse part of arch of aorta. Both pass into neck, arching outwards over pleura; lying on first rib, between scalenus anticus and medius, to end at outer border of it.

Divisions: The scalenus anticus, passing anteriorly to artery, is used to divide it into three parts, viz. :—

1st part, from origin of vessel to inner border of scalenus anticus.

2nd part, portion posterior to scalenus anticus.

3rd part, from outer edge of scalenus to external border of 1st rib.

RELATIONS OF THE 1ST PART OF THE RIGHT SUBCLAVIAN.

<i>In Front.</i>		<i>Below.</i>	<i>Behind.</i>
Skin.	Internal jugular	Pleura.	Longus colli muscle.
Superficial fascia.	gular	Recurrent laryngeal nerve.	Recurrent laryngeal
Platysma.	Vertebral		Sympathetic with cardiac branches
Deep fascia.	Pneumogastric, with lower cardiac branch		} Nerves.
Sterno-mastoid	Phrenic		
Sterno-hyoid			
Sterno-thyroid			
Fascia from ant. border of scalenus ant.			<i>Below and in Front.</i>
			Subclavian Commencement of innominate
			} Veins.

RELATIONS OF 1ST PART OF LEFT SUBCLAVIAN.

<i>In Front.</i>		<i>Inner Side.</i>	<i>Behind.</i>
Skin.	Internal jugular	Left carotid.	Longus colli.
Superficial fascia.	gular	Trachea.	Œsophagus.
Platysma.	Left innominate	Œsophagus.	Thoracic duct.
Deep fascia.	Vertebral	Thoracic duct.	Inferior cervical ganglion.
Sterno-mastoid	Phrenic nerve.	Pneumogastric.	Cord of sympathetic.
Sterno-hyoid		Lower cardiac branches of sympathetic.	
Sterno-thyroid			<i>Outer Side and Behind.</i>
Fascia from ant. border of scalenus ant.			Left lung.
			Pleura.

RELATIONS OF 2ND PART OF SUBCLAVIAN.

<i>In Front.</i>		<i>Behind.</i>	<i>Below.</i>
Skin.	Subclavian vein (below level).	Middle scalenus.	Pleura.
Superficial fascia.	Phrenic nerve.	Trunk of last cervical and 1st dorsal nerves.	<i>Above.</i>
Platysma.		Pleura.	Brachial plexus.
Deep fascia.			
Sterno-mastoid (clavicular origin)			
Scalenus anticus			

RELATIONS OF 3RD PART OF SUBCLAVIAN.

Contained in subclavian triangle, and enclosed in tube of deep cervical fascia.

	<i>In Front.</i>	<i>Below.</i>
Skin.	Supra-scapular artery.	1st rib.
Superficial fascia.	Clavicle.	
Descending cut. br. of cervical plexus.	Subclavius.	<i>Behind.</i>
Platysma.	Nerve to subclavius.	Scalenus medius.
Deep fascia.	<i>Above.</i>	
External jugular	Brachial plexus.	
Subclavian		
Br. from cephalic to ext. jugular		
Supra-scapular		
Transverse cervical		
} <i>Veins.</i>		

BRANCHES FROM THE 1ST PART.

VERTEBRAL: from upper and back part. Passes upwards and backwards, behind inferior thyroid artery and internal jugular vein, then between scalenus anticus and longus colli, to enter foramen in transverse process of 6th cervical vertebra. Ascends corresponding foramina as far as axis, having vertebral vein in front, and cervical nerves behind. It then passes outwards and upwards, through foramen in atlas, and winds backwards and inwards in vertebral groove of atlas, lying at the bottom of the suboccipital triangle between the straight and oblique muscles, having the trunk of the suboccipital nerve below it, and the posterior branch of same nerve crossing it posteriorly. It pierces posterior occipito-atlantal ligament and enters skull through foramen magnum. It then winds round bulb, passing between hypoglossal and anterior root of 1st cervical nerve to front of medulla, uniting with fellow, to form the basilar artery, at the lower border of the pons.

Cervical Branches:—

Lateral spinal: each enters spinal canal through an intervertebral foramen, dividing into *posterior* to supply cord and membranes, and *anterior* to supply bodies of vertebræ.

Muscular: to deep cervical muscles.

Cranial Branches:—

Posterior meningeal: (2) arise opposite foramen magnum, to falx cerebelli.

Posterior spinal: arises opposite posterior part of medulla, passes down back of cord behind roots of nerves, anastomising with spinal branches coming through intervertebral foramina.

Anterior spinal: given off near end of artery, descends in front of medulla, unites with opposite fellow just below foramen magnum to form a single artery, descends along the cord, anastomising like the posterior artery; supplies pia mater and cord.

Posterior inferior cerebellar: arises near pons, backwards and outwards between spinal accessory and pneumogastric nerves, to reach under surface of cerebellum; divides into two branches, one continuing back in sulcus between two hemispheres, the other outwards to supply under surface of cerebellum, and *anas.* superior cerebellar. Supplies hemisphere, vermiform process, and choroid plexus of 4th ventricle.

THYROID AXIS: a short thick trunk from front of artery near scalenus anticus, quickly dividing into:—

Inferior thyroid: passes upwards on longus colli; then inwards and downwards behind sheath of carotid and sympathetic, finally outwards and upwards to under part of thyroid body; *anas.* opposite fellow and superior thyroid.

Branches:—

Ascending cervical: arises as artery turns behind sheath, ascends parallel to phrenic nerve and between scalenus anticus and rectus anticus major, supplying them, the cord and its membranes.

Laryngeal: upwards on trachea to back of larynx, with recurrent laryngeal nerve.

Tracheal: to trachea; *anas.* bronchial.

Œsophageal: to supply œsophagus.

Supra-scapular: runs downwards at first, over scalenus anticus, crosses 3rd part of subclavian, then transversely outwards, behind and parallel to clavicle, to upper edge of scapula under cover of trapezius; inclining downwards with nerve to pass over supra-scapular notch, enters supra-spinous fossa in contact with the bone beneath supra-spinatus, which it supplies. It then winds over neck of scapula to infra-spinous fossa and *anas.* with posterior scapular and dorsal subscapular.

Branches:—

Muscular: to neighbouring muscles.

Supra-acromial: through trapezius to acromion; *anas.* acromial thoracic.

Subscapular: arises as artery passes over notch; *anas.* in subscapular fossa with posterior scapular and subscapular of axillary.

Infra-spinous : descends on neck of scapula to fossa ; *anas.* dorsal of subscapular and posterior scapular.

Articular : to shoulder joint. *Nutrient* : to scapula.

Transverse cervical : over *scaleni* muscles and brachial plexus to outer edge of levator anguli scapulæ, there dividing into :—

Superficial cervical : ascends beneath anterior edge of trapezius, supplying it together with glands, integuments and other muscles of that region ; *anas.* superficial branch of *arteria princeps cervicis*.

Posterior scapular : backwards to superior angle of scapula beneath levator anguli, then downwards along vertebral border of scapula under the rhomboids ; *anas.* supra-scapular, sub-scapular, supplying surrounding muscles.

INTERNAL MAMMARY : from under surface of subclavian just below thyroid axis, runs down behind clavicle to posterior surface of 1st costal cartilage, being crossed here by phrenic nerve ; downwards between pleura and cartilages as far as the 6th, there dividing into two terminal branches.

Branches :—

Comes nervi phrenici (superior phrenic) : arises high in chest, accompanies phrenic nerve between pleura and pericardium to diaphragm, supplying it ; *anas.* musculo-phrenic, inferior phrenic.

Mediastinal : to areolar tissue of anterior mediastinum and thymus gland.

Pericardiac : to upper part of pericardium.

Sternal : to *triangularis sterni* and sternum.

Anterior Intercostal : to upper five or six intercostal spaces, two in each space ; *inosculate* with aortic intercostal.

Perforating : perforate upper five or six intercostal spaces to supply pectoral muscles and mammary gland.

Musculo-phrenic : external of two terminal branches perforates diaphragm about 9th intercostal space, supplying diaphragm, and branches to lower intercostal spaces.

Superior epigastric : internal terminal branch, lies posterior to rectus within the sheath, terminating in that muscle ; *anas.* inferior epigastric of external iliac.

BRANCH FROM THE 2ND PART.

SUPERIOR INTERCOSTAL : from upper and back part behind *scalenus anticus*, bends backwards in front of neck of 1st rib to 1st and 2nd intercostal spaces, supplies small branches to cord and deep spinal muscles. On the neck of the 1st rib, the 1st intercostal nerve is external, and 1st thoracic ganglion of sympathetic, internal to artery.

Branch :—

Deep cervical : corresponds to posterior branch of an aortic intercostal ; passes between transverse process of 7th cervical vertebra and 1st rib, ascending beneath complexus to axis ; *anas.* vertebral, deep branch of arteria princeps cervicis of occipital.

THE COMMON CAROTID ARTERY.

THE COMMON CAROTID ARTERY : *On the right side,* arises from the innominate, at its bifurcation behind the right sterno-clavicular articulation. *On the left side,* from the highest or transverse part of aortic arch, and is consequently longer than the right artery, and more deeply placed in the thorax at its origin. It ascends obliquely to the neck.

Connections of the Left Common Carotid in the Thorax.

	<i>In Front.</i>	<i>Behind.</i>	<i>Outer Side.</i>
Skin.	Sterno-hyoid and	Trachea.	Left subclavian
Superficial fascia.	Sterno-thyroid	Œsophagus.	artery.
Deep fascia.	muscles.	Thoracic duct.	Left pneumogas-
Part of pectoralis	Left innominate	<i>Inner Side.</i>	tric and phrenic
major.	vein.	Innominate	nerves.
1st piece of ster-	Thymus gland.	artery.	
num.			

Extent.—In the neck the common carotid of either side extends from sterno-clavicular articulation to opposite upper border of thyroid cartilage, there dividing into external and internal carotids.

Course.—A line drawn from sterno-clavicular articulation, to point midway between mastoid process and angle of inferior maxilla.

Connections.—Crossed about midway by omo-hyoid, and enclosed in same sheath of deep cervical fascia as internal jugular vein and pneumogastric nerve.

Part below Superior Border of Omo-hyoid.

	<i>In Front.</i>		<i>Behind.</i>	<i>Inner Side.</i>
Skin.	Internal ju-	} <i>Veins.</i>	Longus colli.	Trachea.
Superficial fascia.	gular (over-		Inferior thyroid	Œsophagus.
Platysma.	laps on left		artery.	Thyroid body.
Deep fascia.	side)		Vertebral artery.	Superior thyroid
Sterno-mas-	Superior and		Sympathetic	artery.
toid (sternal	middle thy-	} <i>Nerves.</i>	Recurrent	
origin)	roid		laryngeal	
Sterno-hyoid	Anterior ju-		Pneumogas-	
Sterno-thy-	gular		tric	
roid	Descendens and		<i>Outer Side.</i>	
Omo-hyoid	communicans		Internal jugular.	
	noni.		Pneumogastric.	

Part above Omo-hyoid.

<i>In Front.</i>	<i>Behind.</i>	<i>Inner Side.</i>
Platysma.	Rectus capitis anticus.	Larynx.
Deep fascia.	Pneumogastric nerve.	Pharynx.
Sterno-mastoid.	Sympathetic „	Superior thyroid artery.
Descendens noni.		
Sterno-mastoid br. of supr. thyroid.		<i>Outer Side.</i> Internal jugular.

BRANCHES of the Common Carotid Artery. Only terminal, viz., external and internal carotid.

EXTERNAL CAROTID. *Extent.*—From bifurcation of common carotid opposite upper border of thyroid cartilage, to opposite neck of condyle of inferior maxilla, there dividing into temporal and internal maxillary.

Course.—Line of artery same as common carotid.

CONNECTIONS.

	<i>Superficial.</i>		<i>Behind.</i>	<i>Inner Side.</i>
Skin.	Facial	} Veins.	Pharynx.	Pharynx.
Superficial fascia.	Lingual		Styloid process.	Ramus of jaw.
Platysma.	Temporo-		Stylo-glossus.	Stylo-maxillary
Deep fascia.	maxillary	} Nerves.	Stylo-pharyn-	ligament.
Sterno-mas-	} Muscles.		geus.	Parotid gland.
toid			Glosso-pa-	Superior
Digastric			ryngeal	laryngeal
Stylo-hyoid			nerve	External
Parotid gland.			Internal carotid.	laryngeal
				} Nerves.

Anterior Branches of External Carotid.

Superior thyroid : given off just below great cornu of hyoid, curves downwards and forwards to thyroid body ; *anas.* fellow of opposite side, inferior thyroid.

Branches :—

Muscular : to muscles covering it.

Infra-hyoid : runs transversely inwards, along inferior border of hyoid ; *anas.* with opposite fellow.

Superficial descending, or Sterno-mastoid branch, passing downwards and outwards across sheath of common carotid, supplying sterno-mastoid and integument.

Superior laryngeal : accompanies superior laryngeal nerve, pierces thyro-hyoid membrane, supplies muscles, glands, and mucous membrane of larynx ; *anas.* opposite fellow.

Crico-thyroid : crosses crico-thyroid membrane transversely ; *anas.* opposite fellow.

Lingual : arises from anterior part of artery between superior thyroid and facial arteries, curves upwards and forwards to tip of great cornu of hyoid, thence forwards under hyoglossus muscle, digastric and stylo-hyoid, parallel with hypoglossal nerve, finally continued on genio-hyo-glossus to tip of tongue as ranine.

Branches :—

Supra-hyoid : along superior border of hyoid, supplying muscles, etc. ; *anas.* opposite fellow.

Dorsal of tongue : ascends to dorsum of tongue ; *anas.* opposite fellow, supplies mucous membrane, tonsil, epiglottis, soft palate, etc.

Sublingual : runs forwards and outwards to supply sublingual gland, adjacent muscles and mucous membrane.

Ranine : continuation of the lingual to tip of tongue, accompanies gustatory nerve ; *anas.* opposite fellow.

Facial : arises near angle of inferior maxilla, directed forwards and upwards beneath digastric and stylo-hyoid muscles in groove on deep surface of submaxillary gland to base of lower jaw, over which it ascends to face, being anterior to masseter muscle ; ascending to inner canthus, where it takes name of angular, it rests successively upon lower jaw, buccinator, and levator anguli oris, with vein to outer side ; *anas.* ophthalmic.

Cervical Branches :—

Ascending or inferior palatine : between stylo-glossus and stylo-pharyngeus to pharynx near border of internal pterygoid muscle ; after supplying muscles, tonsil, Eustachian tube, divides near levator palati into two branches, one going to supply soft palate, glands, etc., the other to tonsil, and *anas.* tonsillar and artery of opposite side.

Tonsillar : penetrates superior constrictor of pharynx to supply tonsil and root of tongue ; *anas.* ascending palatine.

Submaxillary (three or four) to supply submaxillary gland.

Submental : arises as artery turns round base of jaw, forwards over mylo-hyoid, supplying it and digastric, then to symphysis, there dividing into *superficial*, which turns round chin ; *anas.* inferior labial and mental, and a *deep* branch perforates mylo-hyoid, supplying deep muscles, *anas.* sublingual.

Facial Branches :—

Muscular : to masseter, buccinator, etc.

Inferior labial : runs beneath depressor anguli oris, to supply lower lip ; *anas.* inferior coronary, submental, mental.

Inferior coronary : arises near angle of mouth, tortuous course between mucous membrane of lower lip and orbicularis oris ; inosculates with opposite fellow.

Superior coronary : arises with or near preceding, having

corresponding course in upper lip ; inosculates with opposite fellow, supplies a branch, *artery of septum*, to columella of nose.

Lateral nasal : turns inwards beneath levator labii superioris alæque nasi to supply ala and dorsum of nose ; *anas.* opposite fellow, nasal of ophthalmic, and infra-orbital.

Angular : terminal branch ; inosculates at inner canthus with nasal of ophthalmic.

Posterior Branches of External Carotid :—

Occipital : arises from the posterior part of artery, about opposite the facial, upwards and backwards beneath digastric stylo-hyoid, sterno-mastoid, splenius, and trachelo-mastoid to interval between atlantal transverse process and mastoid process, then backwards in the occipital groove ; lastly, piercing the trapezius near insertion, it ascends in company with the great occipital nerve to the back of cranium. Hypoglossal nerve hooks round it at origin, and the artery crosses in the neck the internal carotid artery, pneumogastric and spinal accessory nerves and internal jugular vein.

Branches :—

Muscular to digastric, stylo-hyoid ; *sterno-mastoid* branch to supply that muscle.

Mastoid : through mastoid foramen to dura mater.

Posterior meningeal : ascends, in company with internal jugular vein, through jugular foramen to dura mater in posterior fossa.

Cervical (ramus princeps cervicis) : descends back of neck ; *superficial branch* passes beneath splenius, supplying it and the trapezius, *anas.* superficial cervical ; *deep branch*, goes beneath complexus, *anas.* vertebral, deep cervical of superior intercostal.

Cranial : to muscles and integuments of occiput ; *anas.* opposite fellow, posterior auricular and superficial temporal.

Posterior auricular : arises opposite apex of styloid process, ascends in parotid to groove between pinna and mastoid process, dividing into *anterior* or *auricular*, *anas.* posterior division of temporal ; and *posterior* or *mastoid*, *anas.* occipital. Crossed near mastoid process by portio dura of the 7th nerve.

Branches :—

Stylo-mastoid : enters stylo-mastoid foramen, supplying tympanum, mastoid cells, etc.

Auricular : to posterior part of concha.

Ascending branch of External Carotid :—

Ascending pharyngeal smallest branch, arises half an inch

above origin of trunk, ascends on rectus capitis anticus major to base of skull.

Branches :—

External : to rectus anticus, 1st cervical ganglion, 8th and 9th nerves, glands, etc.

Pharyngeal (three or four) : inwards to pharynx, supplying constrictors, Eustachian tube, and a *palatine* branch to soft palate.

Meningeal : one through foramen jugulare, another through anterior condylar foramen, and a third through foramen lacerum medium to supply dura mater.

Terminal Branches of External Carotid :—

Temporal : smaller of two terminal branches, continues in the line of external carotid. Imbedded at first in parotid, crosses over root of zygoma, upwards under skin for two inches, dividing into two terminal branches.

Branches :—

Transverse facial : arises in parotid, accompanies transverse branches of facial nerve and parotid duct across face, lies above the duct, supplying muscles, glands, etc. ; *anas.* facial, infra-orbital.

Middle temporal : arises just above zygoma, perforates temporal fascia, supplying muscle ; *anas.* deep temporal.

Orbital (may come from middle temporal) : along zygoma between layers of temporal fascia to outer canthus.

Anterior auricular : to anterior portion of external ear ; *anas.* posterior auricular.

Anterior temporal : one of terminal branches, ascends over temporal fascia, supplying muscles, etc. ; *anas.* frontal, supra-orbital.

Posterior temporal : curves backwards over temporal fascia and inosculates with opposite fellow ; *anas.* posterior auricular, occipital.

Internal maxillary : larger of terminal branches, arises in parotid, at first (maxillary portion) curving forwards between jaw and internal lateral ligament, parallel with auriculo-temporal nerve, then (pterygoid portion) forwards and outwards on outer (frequently on inner) surface of external pterygoid, finally (spheno-maxillary portion) enters spheno-maxillary fossa between two heads of origin of external pterygoid.

Branches from Maxillary portion :—

Tympanic : enters Glaserian fissure, supplies tympanum, and membrana tympani, generally gives off *deep auricular* to external auditory meatus ; *anas.* vidian, stylo-mastoid. (May come from middle meningeal.)

Middle or great meningeal: arises between internal lateral ligament and neck of condyle, passes between two roots of auriculo-temporal nerve, through foramen spinosum of the sphenoid, dividing into anterior and posterior branches; *anterior* going to anterior inferior angle of parietal, *posterior* to squamous of temporal; *anas.* opposite fellow, anterior and posterior meningeal. The trunk of the artery gives off *Gasserian*: to ganglion. *Petrosal*: enters hiatus Fallopii; *anas.* stylo-mastoid of posterior auricular. *Orbital*: through sphenoidal fissure to orbit. *Temporal*: through foramen in bone to join branches from deep temporal.

Small meningeal: through foramen ovale, supplies Gasserian ganglion and dura matter. (Generally a branch of the middle meningeal.)

Inferior dental: descends with inferior dental nerve through dental foramen on inner side of ramus of inferior maxilla, divides opposite 1st bicuspid into *incisor* and *mental*, the former going to incisor teeth; *anas.* opposite fellow: the latter comes out through mental foramen; *anas.* sub-mental, inferior labial, inferior coronary. *Mylo-hyoid branch* given off as artery enters dental foramen, runs in mylo-hyoid groove to muscle. *Gustatory branch* accompanies gustatory nerve.

Branches from Pterygoid portion:—

Deep temporal (2): anterior and posterior to temporal fossa between muscle and cranium; *anas.* other temporal, lachrymal through foramina in malar bone.

Pterygoid: to pterygoid muscles.

Masseteric: passes over sigmoid notch to deep surface of masseter.

Buccal: runs forward with buccal nerve between internal pterygoid and jaw to buccinator; *anas.* facial.

Branches of Spheno-Maxillary Portion:—

Superior or posterior dental, or alveolar: given off as artery passes into spheno-maxillary fossa; descends with branch of superior maxillary nerve, enters posterior dental canals, supplying molars, bicuspid, antrum, gums, etc.

Infra-orbital: continuation of trunk, accompanies superior maxillary nerve through infra-orbital canal, appearing on face beneath levator labii superioris; *anas.* facial and buccal. In the canal it gives off branches to orbit, and an *anterior dental* branch goes with nerve to supply front teeth; *anas.* posterior dental. On the face it supplies lachrymal sac and inner canthus; *anas.* ophthalmic; and gives branches downwards to *anas.* transverse facial, buccal and facial.

Descending, or superior palatine: through posterior palatine

canal with large palatine nerve, along hard palate, and through foramen of Stenson in anterior palatine fossa; *anas.* artery of septum from facial and naso-palatine.

Vidian: through vidian canal with nerve, supplies Eustachian tube and tympanum.

Pterygo-palatine: backwards through pterygo-palatine canal with pharyngeal nerve to upper part of pharynx.

Nasal, or *spheno-palatine*: enters spheno-palatine foramen, supplying posterior ethmoidal cells, etc. *Branch.* *Naso-palatine* or artery of septum, along vomer to *anas.* descending palatine.

INTERNAL CAROTID. *Extent.* From superior border of thyroid cartilage to Sylvian fissure of brain, there dividing into anterior and middle cerebral.

Course.—Extends directly upwards from common carotid to carotid canal of temporal bone; entering canal passes upwards, then forwards and inwards, then alongside of sella Turcica in the cavernous sinus, having the 6th nerve on the outer side; it turns upwards on inner side of anterior clinoid process, pierces dura mater, and divides at anterior perforated spot into branches. No branches given off from cervical part.

CONNECTIONS IN THE NECK.

<i>Superficial.</i>	<i>Inner Side.</i>	<i>Behind.</i>
Skin.	Pharynx.	Internal jugular vein.
Superficial fascia.	Ascending pharyngeal	Rectus capitis anticus
Platysma.	artery.	major.
Deep fascia.	Tonsil.	Sympathetic.
Sterno-mastoid.	Superior and	Pneumogastric.
Parotid gland.	External laryngeal	Superior laryngeal
External carotid.	nerves.	nerve.
<i>Outer Side.</i>		<i>Crossed superficially by</i>
Internal jugular		Digastric.
vein.		Stylo-glossus.
		Stylo-hyoid.
		Stylo-pharyngeus.
		Occipital artery.
		Posterior auricular
		artery.
		Hypoglossal nerve.
		Glosso-pharyngeal
		nerve.
		Pharyngeal of vagus.

Branch from Petrous portion:—

Tympanic: through a foramen in carotid canal to tympanum; *anas.* tympanic of internal maxillary and stylo-mastoid.

Branches from Cavernous portion :—

Receptaculi arteriæ : small branches to pituitary body, etc.

Ophthalmic : arises at inner side of anterior clinoid process, enters orbit through optic foramen, external to 2nd nerve ; it then crosses to inner angle of orbit to divide into two terminal branches, frontal and nasal.

Branches arising outside Optic Nerve :—

Lachrymal : accompanies lachrymal nerve over external rectus to lachrymal gland, gives off malar branches to *anas.* deep temporal and transverse facial. Branch sent back to *anas.* middle meningeal through sphenoidal fissure.

Central of retina : pierces optic nerve, runs in its substance to retina (*vide* Eye).

Branches arising over Optic Nerve :—

Posterior ciliary : divided into two sets. *Short* (10) perforate sclerotic and supply choroid. *Long* (2) pass forward between choroid and sclerotic, *anas.* anterior ciliary and supply iris and ciliary processes.

Supra-orbital : ascends with frontal nerve over muscles, etc., to supra orbital foramen ; passing out, ascends over frontal bone ; *anas.* temporal, facial and frontal.

Branches arising internal to Optic Nerve :—

Muscular, superior and inferior : to muscles of orbit, give off *anterior ciliary* arteries, which pierce sclerotic behind cornea.

Ethmoidal : *anterior* and *posterior* to ethmoidal cells, through anterior and posterior internal orbital canals respectively, supplying also dura mater, the anterior accompanying nasal nerve to skin of nose (*anterior nasal branch*).

Palpebral (2) : one for each lid, arise near pulley, form an arch in each lid, and supply lachrymal apparatus.

Terminal Branches :—

Frontal : turns upwards round inner margin of orbit ; *anas.* supra-orbital.

Nasal : over tendo oculi to root of nose ; *anas.* nasal and angular of facial.

Branches from Cerebral Portion of Internal Carotid :—

Anterior cerebral : arises at inner extremity of fissure of Sylvius, passes forwards in great longitudinal fissure. Opposite arteries united by *anterior communicating*. It then curves round fore-part of corpus callosum, supplying offsets to corpus callosum, frontal and parieto-occipital sulci, and to anterior perforated spot.

Middle cerebral : largest offset, enters fissure of Sylvius, dividing into branches for external surface of hemisphere, and

interior of brain, the latter entering anterior perforated spot. *Internal branches*: Caudate, antero-lateral, and lenticular striate. *External branches*: Frontal, opercular, temporal, and angular.

Posterior communicating: from posterior part of artery, runs backwards; *inos.* posterior cerebral of basilar.

Anterior choroid: from back part of artery, passes backwards and outwards to enter descending horn of lateral ventricle, just beneath edge of middle lobe; supplies hippocampus major, corpus fimbriatum, and choroid plexus.

THE BASILAR ARTERY: formed by union of the two vertebral arteries. *Extent*, from lower to upper border of pons, there splitting into posterior cerebrals.

Branches:—

Transverse (4 or 6): twigs to supply pons, and an offset to internal ear, with auditory nerve.

Anterior inferior cerebellar: backwards to anterior part of inferior surface of cerebellum; *anas.* posterior inferior cerebellar of vertebral.

Superior cerebellar: arises near termination, to cerebellum, winding round crus cerebri behind 3rd nerve; *anas.* opposite fellow, inferior cerebellar.

Posterior cerebral (2): one on each side, terminal of basilar, winds backwards round crus in front of 3rd nerve, passes upwards to under surface of posterior cerebral lobes, joined near crus by posterior communicating, and gives off: *Postero-median* to posterior perforated spot; *Posterior choroid* to choroid plexus through transverse fissure; *Postero-lateral* to optic thalamus; *Cortical branches* to occipital, cuneate, occipito-temporal, and uncinat convolutions; *anas.* anterior and middle cerebral.

CIRCLE OF WILLIS: a name given to the inosculations between the vertebral and internal carotid arteries at base of brain. The internal carotid sends forward the anterior cerebrals, which are connected by the anterior communicating. The basilar sends forwards the posterior cerebrals, which are joined to the carotid by the posterior communicating arteries.

ARTERIES OF UPPER LIMB.

THE AXILLARY ARTERY.

Extent.—From outer border of 1st rib to lower border of teres major insertion. Divided into three parts:—

1ST PART. *Extent*.—From outer border of 1st rib to upper border of pectoralis minor,

Relations.—*In front.* Pectoralis major, costo-coracoid membrane, cephalic vein, external anterior thoracic nerve, and branches of acromial thoracic artery.

Behind. 1st intercostal space and muscle, 1st serration of serratus magnus, posterior thoracic nerve.

Inner side. Axillary vein. *Outer side.* Brachial plexus.

2ND PART. *Extent.*—From superior to inferior border of pectoralis minor.

Relations.—*In front.* Pectorales major and minor.

Behind. Subscapularis, posterior cord of plexus.

Outer side. Outer cord of plexus.

Inner side. Vein, inner cord of plexus.

3RD PART. *Extent.*—From inferior border of pectoralis minor to lower border of teres major.

Relations.—*In front.* Pectoralis major.

Behind. Subscapularis, tendons of latissimus dorsi and teres major, musculo-spiral and circumflex nerves.

Inner side. Vein, ulnar and internal cutaneous nerve and nerve of Wrisberg.

Outer side. Coraco-brachialis, median and musculo-cutaneous nerves.

Branches :—

Superior thoracic (1st part) : arises opposite 1st intercostal space, supplies pectorales ; *anas.* internal mammary, intercostals.

Acromial thoracic (1st part) : arises from front of artery just above pectoralis minor.

Branches :—

Acromial : supply and perforate deltoid ; *anas.* branch of supra-scapular and posterior circumflex.

Humeral : accompanies cephalic vein.

Thoracic : two or three branches to supply side of thorax ; *anas.* intercostal.

Ascending : one or two twigs to clavicle and subclavius.

Long thoracic (2nd part) : passes downwards along inferior border of pectoralis minor to about 6th intercostal space, supplies pectorales and serratus magnus ; *anas.* intercostal and other thoracic branches. *In females* gives branches to mammary gland.

Alar thoracic (2nd part) : supplies glands and fat of the axillary space ; not a constant separate branch.

Subscapular (3rd part) : arises opposite lower border of subscapularis muscle, and courses with the long subscapular nerve to lower angle of scapula.

Branch :—

Dorsal : given off near origin to dorsum of scapula, passes backwards to the infraspinous fossa through triangular interval, bounded above and internally by the subscapularis, below by teres major, and externally by the long head of the triceps. In the triangular interval it gives off ventral branches to subscapular fossa, and a *descending* branch which runs along between the two teres muscles to the angle. Supplies subscapularis, latissimus dorsi, teres major, serratus magnus ; *anas.* suprascapular and posterior scapular.

Anterior circumflex (3rd part) : arises from outer side of artery, ascends bicipital groove to head of humerus ; *anas.* posterior circumflex.

Posterior circumflex (3rd part) : arises from back of artery opposite lower border of subscapularis, winds backwards through quadrilateral space, bounded above by the teres minor, below by the teres major, internally by the long head of the triceps, and externally by the neck of the humerus. Supplies deltoid, head of humerus, shoulder-joint, teres minor, and long head of triceps ; *anas.* acromial thoracic, anterior circumflex and superior profunda.

External mammary : commonly met with in females, supplies axillary and mammary glands.

THE BRACHIAL ARTERY.

Extent.—From lower border of teres major to half an inch below bend of elbow, runs along inner borders of coracobrachialis and biceps.

Relations.—*In front.* Integument, fascia, biceps and bicipital fascia, median basilic vein. Crossed by median nerve at insertion of coracobrachialis.

Behind. Long and inner heads of triceps, musculo-spiral nerve, superior profunda vessels, coracobrachialis, brachialis anticus.

Inner side. Internal cutaneous nerve to about middle of arm, ulnar nerve to insertion of coracobrachialis, median nerve from insertion of coracobrachialis to elbow.

Outer side. Coracobrachialis and biceps. Median nerve from origin of artery of insertion of coracobrachialis.

Branches :—

Superior profunda : arises opposite lower border of teres major, winds backwards and outwards with musculo-spiral nerve in the groove to triceps ; *anas.* posterior circumflex, recurrent radial, interosseous recurrent, anastomotic. Supplies triceps, anconeus.

Nutritious : arises about middle of humerus, and enters medullary foramen near insertion of coraco-brachialis.

Inferior profunda : arises opposite insertion of coraco-brachialis, accompanies ulnar nerve ; *anas.* posterior ulnar recurrent and anastomotica at elbow.

Anastomotica : arises two inches above elbow-joint, courses to hollow between olecranon and inner condyle of humerus ; *anas.* inferior profunda, anterior and posterior ulnar recurrent, and a branch across the back of olecranon with superior profunda. Supplies elbow-joint.

Muscular : to coraco-brachialis, biceps, brachialis anticus.

THE RADIAL ARTERY.

Extent.—From bifurcation of the brachial to ending of the deep palmar arch of hand.

Relations in the forearm.—*In front.* Integument, fascia, supinator longus.

Behind. Tendon of biceps, supinator brevis, pronator radii teres, flexores sublimis digitorum et longus pollicis, pronator quadratus, lower end of radius.

Inner side. Pronator radii teres, flexor carpi radialis.

Outer side. Supinator longus tendon, and for middle $\frac{1}{3}$ rd, radial nerve.

The artery courses along inner border of supinator longus tendon to carpus, winds round carpus beneath extensors of thumb, enters palm of hand through the heads of the 1st dorsal interosseous muscle, forming deep palmar arch.

Branches :—

Radial recurrent : arises just below elbow, ascends to between brachialis anticus and supinator longus, supplying them and the elbow-joint ; *anas.* superior profunda.

Muscular : to muscles attached to radial side of forearm.

Superficial volar : arises when the artery is about to wind round carpus, passes between muscles of ball of thumb ; *anas.* with ulnar and completing superficial palmar arch.

Anterior carpal : arises near lower border of pronator quadratus, passes inwards under tendons ; *anas.* anterior carpal of ulnar.

Posterior carpal : arises beneath extensor tendons of thumb ; *anas.* posterior carpal of ulnar, forming posterior carpal arch, which gives off 2nd and 3rd dorsal interosseous to 3rd and 4th spaces ; and *anas.* with posterior perforating of deep arch and the anterior interosseous.

Metacarpal (1st dorsal interosseous) : arises near or with the posterior carpal ; *anas.* perforating interosseous of deep arch,

digital of superficial arch ; supplies adjoining sides of index and middle fingers.

Dorsal of thumb (2) : arise near base of 1st metacarpal, course along sides of dorsum of thumb.

Dorsal of index-finger : courses along radial side of dorsum of index, supplying abductor indicis.

Princeps pollicis : arises as the artery enters palm, courses between 1st metacarpal and adductor obliquus pollicis to the base of 1st phalanx, where it divides into two terminal branches, which run along the sides of the palmar surface of thumb.

Radialis indicis : arises near the preceding, passes between 1st dorsal interosseous and adductor transversus pollicis to outer side of index-finger, sends a branch to superficial palmar arch ; *anas.* digital of superficial arch.

Deep palmar arch : *Extent*, from upper end of 1st interosseous space to base of 5th metacarpal. It lies over the bases of the metacarpal bones, and terminates by inosculating with the deep branch of the ulnar.

Branches :—

Recurrent : to front of carpus ; *anas.* carpal arteries.

Palmar interossei (3) : in the three inner interosseous spaces join digital of superficial arch at cleft of fingers, and an offset from inner branch joins digital branch to inner side of 5th finger.

Perforating : pierce three inner dorsal interossei ; *anas.* dorsal interosseous.

THE ULNAR ARTERY.

Extent.—From bifurcation of brachial to end in superficial palmar arch, coursing along outer side of flexor carpi ulnaris to the palm.

Relations in the forearm.—*In front.* Pronator radii teres, flexor carpi radialis, palmaris longus, flexor sublimis, median nerve in upper half ; lower half, overlapped by flexor carpi ulnaris tendon.

Behind. Brachialis anticus, flexor profundus digitorum.

Inner side. Flexor carpi ulnaris, the ulnar nerve in the lower $\frac{2}{3}$.

Outer side. Flexor sublimis digitorum.

Lies upon anterior annular ligament at wrist, external to the pisiform bone.

Branches :—

Anterior ulnar recurrent : arises near bifurcation of brachial, ascends between brachialis anticus and pronator radii teres, supplying them ; *anas.* inferior profunda, anastomotic.

Posterior ulnar recurrent : arises below the anterior, passes beneath flexor sublimis, ascends behind inner condyle, thence between heads of flexor carpi ulnaris, supplying joint and muscles around ; *anas.* inferior profunda, anastomotic.

Interosseous : about one inch long, arising just below radial tubercle, passes to interosseous membrane, there dividing into two terminal branches.

Branches :—

Anterior interosseous : passes down forearm, resting upon anterior surface of interosseous membrane, accompanied by interosseous branch of median nerve. At upper border of pronator quadratus one branch, the *anterior communicating*, goes in front to *anas.* with anterior carpal and deep arch : the other piercing interosseous membrane descends to back of carpus ; *anas.* posterior interosseous, posterior carpal of radial and ulnar. Supplies *nutrient* branches to radius and ulna, and branch to median nerve.

Posterior interosseous : passes backwards between oblique ligament and interosseous membrane, and between supinator brevis and extensor ossis metacarpi pollicis, runs down back of forearm between superficial and deep muscular layers as far as the wrist ; *anas.* posterior carpal of radial and ulnar, anterior interosseous.

Branch :—

Posterior interosseous recurrent : given off near origin, passes under anconeus to interval between olecranon and external condyle ; *anas.* superior profunda, anastomotic.

Muscular : to muscles on ulnar side of forearm.

Anterior carpal : courses beneath tendons of flexor profundus ; *anas.* anterior carpal of radial.

Posterior carpal : arises just above pisiform, winds back beneath flexor carpi ulnaris tendon, gives branch to inner side of 5th metacarpal, and then passes outwards to *anas.* with posterior carpal of radial, forming *posterior carpal arch* (*vide* Radial Artery).

Superficial palmar arch : continues the ulnar in the hand. It turns outwards a little below the anterior annular ligament, and forming an arch with the convexity downwards is directed to the thumb, where the arch becomes completed by joining the superficial volar or princeps pollicis. From the convex side of the arch it gives off four *digital* branches to supply three inner fingers and inner side of index-finger ; *anas.* communicating of deep arch, superficial volar, or branch from princeps pollicis. The *profunda* or communicating branch is given off at commencement of arch, passes down with the deep branch of ulnar nerve between abductor and short flexor of little finger to complete deep palmar arch.

ARTERIES OF BODY.

THE AORTA.

Large main trunk of systemic arteries, situated partly in thorax and partly in abdomen, commences at left ventricle, arches over root of left lung, descends in front of vertebral column, through diaphragm into abdomen, ending opposite body of 4th lumbar vertebra by bifurcating into two common iliacs. Conveniently divided into three parts: *arch of aorta, descending thoracic aorta, abdominal aorta.*

ARCH OF AORTA: divided, according to the direction, into ascending, transverse, and descending portions. In the concavity of the arch are contained root of left lung, branching of pulmonary artery with ductus arteriosus, cardiac plexuses, left recurrent laryngeal nerve, œsophagus and thoracic duct.

Ascending part: *Extent and Course.*—Two inches in length. From base of left ventricle, opposite lower border of 3rd costal cartilage, passing behind pulmonary artery, upwards and to the right, crossing the posterior surface of the sternum obliquely, and extending as high as superior border of 2nd right costal cartilage. Along the right side is a dilatation, the *great sinus of the aorta.*

Relations.—Is contained nearly completely in pericardium.

<i>In front.</i>	<i>Behind.</i>	<i>Right Side.</i>	<i>Left Side.</i>
Pulmonary artery.	Right pulmonary vessels.	Superior cava.	Pulmonary artery.
Right auricular appendix.	Root of right lung.	Right auricle.	
Pericardium.			
Right lung and pleura.			
Sternum.			

Branches.—Right and left coronary arteries distributed to heart (*vide* Heart).

Transverse part: commences at upper border of 2nd right costal cartilage, arching backwards over root of left lung, as far as inferior border of side of body of 4th dorsal vertebra.

Relations.

<i>In front.</i>	<i>Above.</i>	<i>Below.</i>	<i>Behind.</i>
Left vagus	Left innominate vein.	Bifurcation of pulmonary artery.	Trachea.
Left phrenic			Deep cardiac plexus.
Left superficial cardiac.	Nerves.	Ductus arteriosus.	œsophagus.
Left pleura and lung.		Left bronchus.	Thoracic duct.
Left superior intercostal vein.		Left recurrent laryngeal nerve.	Left recurrent laryngeal nerve.

Branches.—

Innominate ($1\frac{1}{2}$ to 2 inches long) : arises at commencement of transverse part, ascends to right beneath sternum, dividing opposite right sterno-clavicular articulation into *right common carotid* and *right subclavian* arteries (*vide* Arteries of Head and Neck, pp. 63 and 68).

Connections of the Innominate.—Lies behind manubrium and origins of sterno-hyoid and sterno-thyroid muscles, thymus gland and left innominate and right inferior thyroid veins. Trachea at first behind, but afterwards to left side, left carotid artery on left side below. On the right side lie the right innominate vein and right phrenic nerve. On the left side, the left common carotid. The innominate occasionally gives off a branch, the *arteria thyroidea ima*, which passes in front of trachea to thyroid gland.

Left common carotid (*vide* Arteries of Head and Neck, p. 68).

Descending part : from lower border of body of 4th, to that of 5th dorsal vertebra. Covered by root of lung and pleura of left side. On the right side is the œsophagus and thoracic duct.

No branches.

THE DESCENDING THORACIC AORTA.

Extent.—From lower border of 5th dorsal vertebra (left side) to aortic opening in front of body of 12th dorsal vertebra.

Course and Relations.—Lies in posterior mediastinum ; is at first to left of bodies of vertebra, but afterwards gets in front.

In front. Root of left lung and pericardium, crossed by œsophagus at lower end.

Behind. Bodies of vertebræ and small azygos vein.

Left side. Left lung and pleura, œsophagus below.

Right side. Œsophagus above, thoracic duct, and large azygos vein.

Branches :—

Bronchial : supply structure of lungs. For the left lung two branches come off from front of aorta (superior and inferior). The artery supplying right lung arises either with or from superior left branch, or from 1st intercostal of right side.

Pericardial : small twigs to posterior surface of pericardium.

Œsophageal (4 or 5) : from front of aorta, running obliquely downwards to supply œsophagus ; *anas.* with one another, inferior thyroid and coronary of stomach.

Posterior mediastinal : supply glands, etc. of posterior mediastinum.

Intercostal (9 pairs) : arise from posterior part of aorta, run transversely outwards on bodies of vertebræ, and behind pleura

to intercostal spaces. The right ones, crossing over front of spine, supply the bodies of vertebræ, and pass behind œsophagus, thoracic duct, and azygos veins. The arteries of both sides are crossed by sympathetic nerve. On reaching intercostal spaces, they divide into anterior and posterior branches; the *anterior* branch crosses the space obliquely upwards so as to get to lower border of the upper rib near the angle: at first it lies between external intercostal and fascia, subsequently between two intercostal muscles; *anas.* anterior intercostal of internal mammary, thoracic branches of axillary. Above the artery is a companion vein, and below the intercostal nerve. The *posterior* branch passes backwards between vertebra and costo-transverse ligament, sending inwards, *spinal* branch through intervertebral foramen to cord, membranes and body of vertebra, and backwards, *muscular* branch which divides into inner and outer branches to muscles of back. A branch, *the collateral intercostal*, is given off near the angle of the rib, which runs along the upper border of the lower rib; *anas.* anterior intercostal. Branches accompany the lateral cutaneous nerves of the thorax from the main trunks of the intercostals. The three lower branches pass forwards between muscles of abdominal wall; *anas.* epigastric and phrenic.

(The 1st and 2nd intercostal arteries come from the subclavian trunk, *vide* p. 67).

ABDOMINAL AORTA.

Extent.—From last dorsal vertebra to a little to the left side of body of 4th lumbar vertebra, there dividing into common iliacs.

Course and Relations.—Enters abdomen between pillars of diaphragm, occupying middle line of spine, but near its bifurcations inclines to left side.

In front, from above down. Small omentum, stomach, solar plexus, pancreas, splenic vein, left renal vein, 3rd part of duodenum, aortic plexus and peritoneum. It touches the pancreas and duodenum without any intervening peritoneum.

Behind. Bodies of lumbar vertebræ, left lumbar veins, receptaculum chyli and thoracic duct. Embraced by crura of diaphragm above.

On right side. Vena cava inferior, thoracic duct, large azygos vein, and right semilunar ganglion.

On left side. Left semilunar ganglion, and left cord of sympathetic.

Branches:—

Phrenic (2): arise close together on a level with under surface of diaphragm, pass across crura to under surface of midriff, the

left one passing behind œsophagus, the right one behind inferior vena cava.

Branches :—

Internal : to fore-part of diaphragm ; *anas.* fellow, and superior and musculo-phrenic of internal mammary.

External : to outer side of muscle ; *anas.* musculo-phrenic, lower intercostals.

Superior capsular : to supra-renal body.

Cœliac axis : arises between pillars of diaphragm, just above pancreas, half inch long, surrounded by solar plexus ; divides into three visceral branches.

Branches :—

CORONARY OF STOMACH : smallest of three branches, directed upwards and to left side between layers of small omentum to cardiac end of stomach ; gives off a few œsophageal branches, then turns to right along lesser curvature, giving branches on each side to viscus, finally *inosculates* with superior pyloric of hepatic.

HEPATIC : directed forwards and upwards and to right, between layers of small omentum, and anterior to *foramen of Winslow*, across to transverse fissure of liver, to left of bile duct and vena portæ ; at transverse fissure it divides into *right* and *left* hepatic, supplying corresponding lobes of the liver.

Branches :—

Superior Pyloric : extends on lesser curvature of stomach running from right to left ; *inosculates*, coronary.

Gastro-duodenal : passes behind 1st part of duodenum, divides at lower border into the two following branches :—

Right gastro-epiploic : runs along great curvature of stomach from right to left, *inosculates* with left gastro-epiploic of splenic, gives off branches upwards to viscus and downwards to omentum.

Superior Pancreatico-duodenal : runs between the duodenum and the pancreas down to *anas.* with inferior pancreatico-duodenal of superior mesenteric.

Right Hepatic, to right lobe of liver, giving off *Cystic* : to supply gall-bladder.

Left Hepatic, to left lobe, giving off branch to Spigelian lobe.

SPLenic : directed horizontally along upper border of pancreas to left side, supplying spleen and partly stomach and pancreas. Very tortuous ; divides near spleen into several terminal branches which enter hilus of that viscus.

Branches :—

Pancreatic : given off as artery runs along pancreas ; one of them (*arteria pancreatica magna*) accompanies the duct.

Left gastro-epiploic : directed to right side between layers of great omentum, along great curvature of stomach. *Inosculates* with right gastro-epiploic of hepatic.

Gastric branches (vasa brevia) (5 or 6) : extend to left extremity of stomach to supply its coats.

Supra-renal or middle capsular (2) arises a little below cœliac axis ; each runs transversely outwards over crus of diaphragm to supra-renal body ; *anas.* superior capsular of phrenic and inferior capsular of renal.

Superior mesenteric : arises quarter inch below cœliac axis, passes forwards between pancreas and upper border of 3rd part of duodenum, crosses duodenum, and directed downwards, to the left between the layers of the mesentery, terminates in offsets to small intestine, cæcum and colon.

Relations.—*In front and above.* Pancreas and splenic vein. *Behind.* Duodenum, 3rd part, and left renal vein. Surrounded by mesenteric plexus of nerves and accompanied by vena comes.

Branches :—

Inferior pancreatico-duodenal : directed along concave border of duodenum ; *anas.* superior pancreatico-duodenal.

Vasa intestina tenuis : to supply jejunum and ileum, twelve or fifteen in number ; spring from left side of artery ; about two inches from origin they bifurcate, the divided pieces unite with a neighbouring branch to form an arch, from which branches issue, which divide and communicate in the same way for four or five times, the resultant branches proceeding directly to intestine.

Ileo-colic : from right side of artery down to cæcum, branching to supply head of colon. A *descending* branch to lower part of ileum. An *ascending* to ascending colon and *anas.* with right colic.

Right colic (often a branch of ileo-colic) : from right side of trunk to middle of ascending colon, *ascending* branch *anas.* middle colic, *descending* branch *anas.* ileo-colic.

Middle colic : from upper part of right side of artery, *right* branch *anas.* right colic ; *left* branch *anas.* on descending colon, with left colic of inferior mesenteric.

Renal (2) : one from each side arising half inch below superior mesenteric, the right a little lower than the left one. Pass outwards to supply kidneys, the right one passing behind vena cava. Each divides near viscus into four or five branches, which enter it between vein and ureter. Is accompanied by plexus of nerves, supplies branches to supra-renal body (*inferior capsular*), ureter and fat around.

Spermatic : two small but very long arteries ; arise just below

renal, directed downwards and outwards over psoas, crossing ureter and external iliac artery (the right one crosses also the inferior vena cava) to internal abdominal ring, thence accompanied by spermatic vein, spermatic plexus, and vas deferens, it passes along inguinal canal, and out of the external ring to the scrotum, where it divides into branches which enter the posterior surface of the testis ; *anas.* artery of vas deferens and cremasteric. In the female the artery is termed *ovarian*, and runs between layers of broad ligament of uterus, to ovary and round ligament.

Inferior mesenteric : arises on left side of aorta, about one and a half inches above bifurcation. Lies at first on left side of aorta, then crosses over psoas, left common iliac and ureter, to back of rectum ; supplies descending part of colon, sigmoid flexure and part of rectum.

Branches :—

Left colic : directed upwards in front of left kidney, *ascending* branch *anas.* middle colic ; *descending* branch supplies descending colon ; *anas.* sigmoid and superior hæmorrhoidal.

Sigmoid : to sigmoid flexure ; *anas.* left colic and superior hæmorrhoidal.

Superior hæmorrhoidal : continuation of inferior mesenteric trunk, passes behind rectum and divides in meso-rectum into two branches, which pass down, one on either side, to about six inches from anus, where they subdivide to supply rectum ; *anas.* sigmoid, middle and inferior hæmorrhoidals.

Lumbar (5 pairs) : arise from back of aorta, pass outwards, resting on body of corresponding vertebra underneath psoas ; the two upper pairs under crura of diaphragm ; the right ones also under vena cava. Divide near transverse processes into :—

Abdominal : coursing outwards beneath quadratus, to end between muscles of abdominal wall ; *anas.* epigastric, internal mammary, intercostals, ilio-lumbar, circumflex iliac.

Dorsal : accompanies posterior primary branch of nerve, gives off *spinal* branch to supply meninges and cord ; *anas.* intercostal.

Middle sacral : a small branch given off just at bifurcation courses over 5th lumbar vertebra and middle of sacrum to coccyx ; *anas.* lateral sacral.

THE COMMON ILIAC ARTERY.

Extent.—From bifurcation of aorta, on body of 4th lumbar vertebra, to opposite lumbo-sacral articulation, there dividing into external and internal iliac. About 2 inches long.

Relations.—*In front.* Peritoneum, intestines, ureter, branches of sympathetic.

Differences between right and left artery.—The *right* one is the longer, the aorta being on the left side of spine ; on outer side is inferior vena cava and psoas. Companion vein at first behind, but external at upper part ; left iliac vein behind. The *left* one is crossed anteriorly by inferior mesenteric artery and has rectum in front, the companion vein being below and internal.

Collateral branches.—None named, supplies peritoneum, psoas, ureters, and lymphatics. One of the renal, lumbar or ilio-lumbar vessels may come off from it.

THE INTERNAL ILIAC ARTERY.

Extent.—From bifurcation of common iliac opposite lumbosacral articulation to great sacro-sciatic notch, there dividing into *anterior* and *posterior* trunks. $1\frac{1}{2}$ inches long.

From the extremity a partly obliterated artery, the hypogastric, extends forwards to side of bladder, forming part of posterior false ligament. In the *fœtus* this vessel is nearly as large as the common iliac, ascends the wall of abdomen to umbilicus, passing thence to placenta ; after birth the vessel becomes obliterated except $1\frac{1}{2}$ inches at commencement.

Branches from Anterior Trunk :—

Superior vesical : is the unobliterated part of hypogastric, extending from sacro-sciatic notch to side of bladder.

Branches supplied to side and upper part of bladder, and to ureter.

Middle vesical : supplies side of bladder.

Inferior vesical : supplies fundus of bladder, side of prostate and vesiculæ seminales in the male.

Branches :—

Artery of vas deferens : accompanies duct to *anas.* with spermatic. May come off from superior vesical.

Middle hæmorrhoidal : supplies lower part of rectum and in the female to vagina. May come off from trunk. *Anas.* superior hæmorrhoidal of inferior mesenteric, inferior hæmorrhoidal of pudic.

[**Uterine :** down to neck of uterus, passes between layers of broad ligament to supply body of viscus ; *anas.* ovarian.]

Vaginal : corresponds to inferior vesical in male, supplies vagina, fundus of bladder, and lower part of rectum.]

Obturator : directed to groove in upper part of thyroid foramen, passing out of pelvis and dividing into two branches at

upper border of obturator externus. In pelvis it is placed between pelvic fascia and peritoneum, and just below obturator nerve. It lies beneath the superior pubic ramus with companion vein and nerve in canal, formed above by bone and below by thyroid membrane.

Branches within pelvis :—

Iliac : enters iliac fossa, supplies iliacus and bone ; *anas.* ilio-lumbar.

Pubic : ascends posterior surface of pubis ; *anas.* opposite fellow, epigastric.

Branches outside pelvis :—

Internal terminal : curves inwards beneath obturator externus, supplies obturators, gracilis, and adductors ; *anas.* internal circumflex, and external branch of obturator.

External terminal : passes downwards and outwards beneath obturator externus to ischial tuberosity, supplies obturators, hamstrings and hip-joint ; *anas.* sciatic and internal branch of obturator.

Pudic or Internal Pudic :—

In the male. Proceeds out of pelvis by great sacro-sciatic notch below pyriformis, winds round ischial spine, re-enters pelvis by small notch, passes within the obturator fascia on inner side of tuber ischii, courses along pubic arch, ascends on and then perforates triangular ligament, dividing into dorsal of penis and artery of corpus cavernosum.

Relations. —In the pelvis, lies to outer side of rectum, in front of pyriformis and sacral plexus. Thence, in company with vein and nerve, it is on external wall of ischio-rectal fossa, and internal to obturator internus. Beneath triangular ligament crossed by deep transverse perineal muscle.

Branches :—

Inferior hæmorrhoidal : arises just inside tuber ischii, crosses transversely ischio-rectal fossa, supplies sphincter and levator ani ; *anas.* middle hæmorrhoidal and opposite fellow.

Superficial perineal : arises halfway in ischio-rectal fossa, runs parallel to pubic arch, between erector penis and accelerator urinæ, supplying them, together with scrotum ; *anas.* superficial pudic of femoral.

Transverse perineal : arises from superficial perineal or from trunk near it, courses transversely inwards, supplying integuments, etc.

Artery of bulb : arises near base of triangular ligament, passes between the two layers of triangular fascia, reaching bulb $\frac{1}{2}$ inch from base. Supplies a branch to Cowper's gland.

Artery of corpus cavernosum : lies between crus penis and

pubic ramus. Enters crus and is distributed to corpus cavernosum.

Artery to corpus spongiosum: a small branch to that body from the main trunk, or from the artery to the corpus cavernosum.

Dorsal artery of penis: lies between crus and pubic ramus, through suspensory ligament, along dorsum of penis having the median dorsal vein inside and the nerve outside. It ends in the glans and prepuce.

Artery in the female: the vessel is smaller and has similar course to that in male; the *superficial perineal* supplies labia pudendi. The *artery of bulb* supplies bulbus vestibuli. The terminal *dorsal* and *corpus cavernosum* arteries supply clitoris, being named *dorsalis* and *profunda clitoridis* respectively.

Sciatic: terminal branch of anterior trunk (*vide* arteries of lower limb, p. 91).

Branches from Posterior Trunk:—

Gluteal: *vide* arteries of lower limb (p. 91).

Ilio-lumbar: passes outwards beneath psoas and obturator nerve, but anterior to lumbo-sacral cord; divides in iliac fossa into *ascending* or *lumbar* branch, supplying psoas, quadratus lumborum, and giving a *spinal* branch through foramen between 5th lumbar vertebra and the sacrum. *Transverse* or *iliac* ramifies in iliacus, supplies bone; *anas. lumbar*, circumflex iliac.

Lateral sacral (2): *Superior*, the larger of the two distributed to upper part of sacrum, the *Inferior* to lower part of sacrum and coccyx; *anas. middle sacral* and opposite artery.

Branches (dorsal) are given off, which enter anterior sacral foramina for distribution on back of sacrum.

THE EXTERNAL ILIAC ARTERY.

Extent.—From bifurcation of common iliac opposite lumbo-sacral articulation to lower border of Poupart's ligament.

Course.—Line from $\frac{3}{4}$ inch below and little to left of umbilicus, to point of Poupart's ligament midway between symphysis pubis and anterior superior iliac spine.

Relations.—Covered by peritoneum and sub-peritoneal fat, crossed by ureter and circumflex iliac vein. The spermatic vessels and genito-crural nerve lie on it for a short distance.

To *outer side*, psoas, except at termination, when it is below. *Inner side*, vas deferens and lymphatic glands. The left vein is internal to its artery. The right one is at first internal, but at upper part beneath its artery.

Branches :—

Epigastric : from fore part of artery, just above Poupart's ligament, down to ligament, then upwards and inwards between peritoneum and fascia transversalis, being crossed by vas deferens near internal abdominal ring ; terminates between rectus abdominis and sheath in anastomoses with internal mammary and inferior intercostal.

Branches :—

Cremasteric : accompanies vas deferens, supplying cremaster ; *anas.* spermatic, artery of vas deferens.

Pubic : ramifies behind pubis ; *anas.* pubic of obturator.

Muscular : to rectus ; *anas.* superficial epigastric.

Circumflex iliac : from outer side of artery, near Poupart's ligament, directed to anterior superior iliac spine, then on iliac crest, supplying iliacus, etc. ; *anas.* ilio-lumbar.

ARTERIES OF LOWER LIMB.

THE SCIATIC ARTERY.

Largest branch of internal iliac, except gluteal, passes out through lower part of great sacro-sciatic foramen, between pyriformis and superior gemellus, in company with great sciatic nerve and pudic artery, outside the pelvis it lies between the tuber ischii and great trochanter.

Branches :—

Within the pelvis. **Muscular** to pyriformis, coccygeus and levator ani.

Outside pelvis :—

Coccygeal branch : pierces great sacro-sciatic ligament, inclined inwards, supplies gluteus maximus, integument, etc.

Comes nervi ischiatici : accompanies great sciatic nerve, finally enters the substance of it.

Muscular : branches to gluteus maximus and external rotators of thigh ; *anas.* gluteal, internal circumflex.

Anastomotie : to pit of great trochanter, supplies external rotators ; *anas.* gluteal, ascending of internal circumflex, and superior perforating.

Articular : to capsule of hip-joint.

THE GLUTEAL ARTERY.

Largest branch of internal iliac, escapes from pelvis above pyriformis, divides immediately into superficial and deep branches.

Superficial branch : runs between the two larger glutei, supplying gluteus maximus ; *anas.* sciatic, posterior sacral.

Deep branch : goes between two smaller glutei, subdivides into two :—

Superior division : goes to anterior superior iliac spine ; *anas.* circumflex iliac, ascending branches of external circumflex.

Inferior division : supplies gluteal muscles, and descends to great trochanter ; *anas.* external circumflex.

Nutrient branch : enters hip-bone just as artery emerges from pelvis.

THE FEMORAL ARTERY.

Extent.—From Poupart's ligament to the opening in the adductor magnus.

Course.—Thigh being adducted and rotated out, a line drawn from point midway between symphysis pubis and anterior superior iliac spine to most prominent part of internal condyle of femur.

Relations.—Superficial in upper $\frac{1}{3}$ rd, being contained in Scarpa's triangle, more deeply placed in lower $\frac{2}{3}$ rd.

In front. Skin, superficial and deep fascia, internal cutaneous branch of anterior crural nerve, sartorius, long saphenous nerve, aponeurotic arch over Hunter's canal.

Behind. Psoas, profunda vessels, pectineus, adductor longus, femoral vein (at lower part of Scarpa's triangle, and in Hunter's canal), tendon of adductor magnus.

Inner side. Femoral vein (in Scarpa's space), adductor longus.

Outer side. Sartorius (in Scarpa's space), vastus internus, femoral vein gets to outer side near ending.

Branches :—

Superficial epigastric : arises $\frac{1}{2}$ inch below Poupart's ligament, ascends through the saphenous opening to abdominal wall, as high as umbilicus, in the fascia, *anas.* superficial branches of deep epigastric, external mammary.

Superficial circumflex iliac : arises near preceding, runs outwards to iliac crest, supplies glands, fasciæ, and integument, psoas and iliacus ; *anas.* circumflex iliac, gluteal, external circumflex.

Superior external pudic : arises from inner side of artery $\frac{1}{2}$ inch below Poupart's ligament, pierces cribriform fascia of saphenous opening, runs upwards to pubic spine, crosses external ring and spermatic cord, supplying integument of lower part of abdomen and external organs of generation ; *anas.* internal pudic.

Deep external pudic : arises either separately or from a common trunk with the preceding, lies on pectineus, covered by fascia lata, which it pierces, and is distributed to scrotum in male and labium in female ; *anas.* superficial perineal.

Profunda femoris : arises from outer and back part of artery, 1 or 2 inches below Poupart's ligament, resting in Scarpa's triangle upon the iliacus, and subsequently upon adductores brevis and magnus, having the longus superficial to it. It ends in the lower third of thigh in a branch which perforates adductor magnus.

Branches :—

External circumflex : arises from the outer side of the profunda (sometimes from the femoral trunk), coursing outwards through the divisions of the anterior crural nerve, dividing into :

(a) *Transverse* branches, piercing vastus externus just below great trochanter ; *anas.* on back of thigh with internal circumflex, perforating branches of profunda, gluteal, and sciatic.

(b) *Ascending* pass beneath sartorius, rectus, and tensor vaginae femoris ; *anas.* with terminal of gluteal and external circumflex iliac.

(c) *Descending* branches are distributed to the extensors of the thigh ; *anas.* with superior articular arteries, a small offset passing, with the articular nerve from the nerve to vastus externus, to the knee-joint.

Internal circumflex : arises from the internal and back part of profunda, courses backwards between psoas and pectineus, dividing at the small trochanter into two branches, one ascending to the digital fossa of the great trochanter ; *anas.* sciatic and gluteal ; the other passes to the hamstrings, appears between adjacent borders of quadratus femoris and adductor magnus, gives off *muscular* branch at upper border of adductor brevis, which divides into superficial and deep branches to upper adductor muscles, the trunk of the artery then passes outwards and backwards ; *anas.* superior perforating, sciatic, and sometimes external circumflex. An *articular* branch enters the joint through the notch in acetabulum.

Perforating branches : four in number, reach the back of thigh by perforating the adductor magnus, and end in the back of thigh :—

First, begins opposite lower border of pectineus, perforates large and small adductors, distributed to biceps and gluteus maximus ; *anas.* sciatic and internal circumflex.

Second, comes off opposite middle of short adductor, perforating it and the magnus, distributed to hamstrings ; a *nutrient* artery (passing upwards) is given off ; *anas.* other perforating branches.

Third, arises at the lower border of adductor brevis, perforates magnus, as the second.

Fourth, or terminal branch, pierces adductor magnus near

opening for femoral vessels, supplies short head of biceps ; *anas.* popliteal and lower perforating.

Muscular or Anastomotic (3 or 4) internal to perforating, supply inner hamstrings ; *anas.* between themselves and branches of popliteal.

Muscular branches : two to seven in number, supplying sartorius and vastus internus.

Anastomotic branch : arises at the termination of the femoral, and courses in the line of the femoral to the internal condyle.

Branches :—

Deep branch, descends inner side of knee ; *anas.* internal articular, recurrent of anterior tibial ; gives off *external* branch, crosses the femur, supplying branches to knee-joint ; *anas.* superior external articular, forming an arch.

Superficial branch, accompanies long saphenous nerve to integument ; *anas.* inferior internal articular.

THE POPLITEAL ARTERY.

Extent.—From the opening in the adductor magnus to lower border of popliteus, dividing into anterior and posterior tibial.

Course.—Upper part inclines from inner side of femur to middle of intercondylar space, thence occupying middle line of popliteal space.

Relations.—The part of artery in the popliteal space is uncovered by muscles, but below it is covered by the gastrocnemius. It rests upon the femur, posterior ligament of knee-joint and popliteus. The vein lies to the outer side in the upper part, but crosses to the inner side near the termination. Superficial and slightly external to the artery is the internal popliteal nerve, in the upper part, but below it crosses to inner side. A small articular branch of the obturator nerve courses upon the artery.

Branches :—

Muscular : *Superior set* (3 or 4) : to lower end of hamstrings ; *anas.* perforating of profunda, superior articular.

Inferior set or *sural* (2) : arise from the posterior part of artery opposite knee-joint, supply both heads of gastrocnemius, plantaris and soleus.

Superficial : accompanies external saphenous nerve to end in integuments.

Superior articular : *Internal*. Arises just above condyles of femur, courses transversely beneath tendon of adductor magnus to front of knee, ending in vastus internus and joint ; *anas.* anastomotic and superior external articular.

External. Winds beneath biceps, perforates intermuscular

septum ; *anas.* descending branch of external circumflex, external of anastomotic and superior internal articular, forming an arch, inferior external articular ; supplies joint by superficial and deep branches.

Inferior articular : *Internal.* Passes down between internal tuberosity of tibia and internal lateral ligament ; *anas.* opposite artery, superior internal articular, recurrent anterior tibial.

External. Courses outwards under outer head of gastrocnemius and external lateral ligament ; *anas.* in front with other articular branches, anterior tibial recurrent.

Azygos articular : arises opposite flexure of joint, pierces posterior ligament, supplying crucial ligaments and other structures in the joint.

THE ANTERIOR TIBIAL ARTERY.

Extent.—From division of popliteal artery at lower border of popliteus, to bend of ankle.

Course.—At first directed outwards and forwards, through two heads of origin of tibialis posticus, to reach anterior surface of interosseous ligament ; thence a line drawn from inner side of head of fibula to midway between the two malleoli will mark its course.

Relations.—Tibialis anticus to inner side, the extensor communis digitorum above, and the extensor proprius hallucis below upon its outer side, covered below by annular ligament and crossed by extensor proprius hallucis tendon, rests below upon the anterior surface of the tibia. It is accompanied by two venæ comites. Anterior tibial nerve lies at first on outer side, then becomes superficial, and below is on the outer side.

Branches :—

Posterior Tibial Recurrent : passes behind popliteus to back of knee.

Superior Fibular : passes over neck of fibula, through soleus, to peroneus longus.

Anterior Tibial Recurrent : arises as artery reaches anterior surface of interosseous membrane, passes in tibialis anticus to external and anterior surfaces of knee-joint ; *anas.* articular of popliteal.

Malleolar : Two in number, arise just above ankle-joint, supplying it.

Internal. Passes beneath tibialis anticus tendon to inner malleolus ; *anas.* branches of posterior tibial.

External. Passes outwards beneath extensor longus digitorum ; *anas.* anterior peroneal, tarsal of dorsal of foot.

Muscular : to surrounding muscles.

DORSAL ARTERY OF FOOT.

Extent.—From bend of ankle to upper part of 1st interosseous space, ending by inosculating with plantar arch and giving 1st dorsal interosseous branch to 1st interosseous space.

Relations.—Lies between tendons of extensor proprius hallucis and extensor longus digitorum; near termination it is crossed by innermost tendon of extensor brevis digitorum. Bound down by fascia. Accompanied by two venæ comites. Anterior tibial nerve lies to outer side.

Branches:—

Tarsal: arises as artery crosses scaphoid, courses forwards and outwards beneath extensor brevis digitorum, supplying it, then backwards to cuboid; *anas.* external plantar, metatarsal, external malleolar, anterior peroneal.

Metatarsal: arises a little beyond the tarsal branch, directed outwards in an arched direction, beneath short extensor of toes to outer side of foot, near bases of metatarsal bones; *anas.* tarsal, external plantar. From the convexity of arch proceed three *interosseous* branches to three outer metatarsal spaces. They supply the interossei and divide at cleft of toes into digital branches; the most external one supplies also outer side of little toe. Each interosseous artery communicates at the cleft of the toes with the digitals of the sole by an *anterior perforating* branch, and at the back of the interosseous space with the plantar arch by a *posterior perforating* branch.

The 1st interosseous artery: arises as artery is about to dip down into sole. It lies over dorsum of 1st interosseous space, and divides at cleft to supply contiguous sides of 1st and 2nd toes, having previously given off a branch to inner side of 1st toe.

THE DORSALIS PEDIS IN THE SOLE: enters sole between heads of origin of 1st dorsal interosseous muscle, and completes plantar arch by inosculating with deep branch of external plantar.

Branch:—

Digital: passes forwards in 1st interosseous space to cleft, where it divides into two branches for contiguous sides of 1st and 2nd toes, having previously given off a branch of inner side of great toe.

THE POSTERIOR TIBIAL ARTERY.

Extent.—From lower border of popliteus to lower edge of internal lateral ligament, there dividing into internal and external plantar, at a spot midway between internal malleolus and heel.

Course.—At first midway between tibia and fibula, afterwards approaches tibia and lies on it.

Relations.—Upper $\frac{2}{3}$ covered by gastrocnemius and soleus. Lower $\frac{1}{3}$ superficial between inner border of tendo Achillis and inner border of tibia. Posterior tibial nerve is at first on inner side, but about one inch down crosses to outer side. Has venæ comites.

Relations of artery at inner malleolus, from within outwards. Tibialis posticus, flexor longus digitorum tendons, vein, artery, vein, nerve, flexor longus hallucis tendon.

Branches:—

Peroneal: arises one inch from popliteus, courses obliquely to fibula, then along inner border of that bone, between origins of tibialis posticus and flexor longus hallucis, to lower part of interosseous membrane, where it gives off *anterior peroneal*, and is continued as *posterior peroneal* over lower tibio-fibular articulation to outer side of malleolus, where it ends by *anas.* with external plantar and tarsal. Covered in upper part by soleus and deep fascia, then by flexor longus hallucis. Beyond the malleolus it is superficial.

Branches of peroneal:—

Muscular: to soleus, tibialis posticus, flexor longus hallucis, and peronei.

Nutrient: to the fibula, passes downwards.

Anterior peroneal: arises about two inches above malleolus, pierces or passes below interosseous membrane, and under cover of peroneus tertius reaches front of outer ankle and tarsus, supplying ankle-joint; *anas.* external malleolar, tarsal of dorsal of foot, and terminal of peroneal.

Communicating: to join communicating of posterior tibial.

Muscular: to soleus, and deep muscles of back of leg.

Nutritious: to tibia, arises near origin of posterior tibial, largest of kind in body, passes downwards.

Communicating: arises two inches above inner malleolus, courses beneath flexor longus hallucis; *anas.* communicating of peroneal.

Calcaneal: arises near ending, to supply integument, fat of heel, and muscles on inner side of foot.

INTERNAL PLANTAR.

The internal bifurcation of the posterior tibial, directed forwards along inner border of foot as far as base of 1st metatarsal bone. Thence along inner side of 1st toe to anastomose with inner digital branch. Covered at first by abductor hallucis, and

subsequently becomes more superficial by lying between that muscle and the extensor of toes ; it is accompanied by internal plantar nerve.*

EXTERNAL PLANTAR.

From inner part of foot, with external plantar nerve, to base of 5th metatarsal ; thence it passes inwards, resting on the interosseous muscles to the back part of the 1st interosseous space, and inosculates there with dorsalis pedis, completing plantar arch.

The *plantar arch* is placed across the tarsal end of the metatarsus, and is accompanied by the deep branch of the external plantar nerve.

Branches from the Plantar Arch :—

Recurrent : small branches passing back to tarsal joints ; *anas.* branches of internal plantar.

Posterior perforating (3) : ascend to dorsum of foot through posterior part of three outermost interosseous spaces ; *anas.* interosseous of metatarsal.

Digital (4) : supply both sides of three outer toes and outer half of 2nd ; inner three bifurcate at the cleft of toes ; give off at point of division, *anterior* perforating to *anas.* with interosseous of dorsum.

THE VEINS.

VEINS OF THE HEAD AND NECK.

Cerebral : noted for their thin coats, absence of muscular tissue and valves.

Superior (10 to 12 on each side) : lodged chiefly in sulci on cerebral surface, pass forwards and inwards to superior longitudinal sinus.

Anterior inferior : from under surface of anterior lobes ; terminate in cavernous sinus.

Inferior lateral (3 to 5) : terminate in lateral sinus.

Inferior median : from posterior lobe, etc., to straight sinus behind venæ Galeni.

Venæ Galeni (2, one from right, one from left ventricle) : formed by vena corporis striati and vena choroidea ; pass back and out of transverse fissure to straight sinus.

Cerebellar : superior, inferior, and lateral sets : the 1st open into straight, the 2nd into lateral, the 3rd into posterior petrosal sinuses.

* Ellis describes the internal plantar artery as ending in four *superficial* digital branches, which accompany digital branches of internal plantar nerve ; the outer three joining the digital branches of the plantar arch at the cleft of the toes.

Sinuses (15 in number): *Superior longitudinal*: begins at crista Galli, runs back in upper border of falx to torcular Herophili; receives superior cerebral, parietal and emissary veins. Intersected by fibrous bands, the chordæ Willisii.

Inferior longitudinal: along posterior part of free margin of falx cerebri to straight sinus.

Tentorial or straight: is placed at junction of tentorium and falx cerebri, goes to torcular Herophili; receives inferior longitudinal sinus, venæ Galeni, inferior median cerebral, and superior cerebellar veins.

Lateral (2): from torcular Herophili to foramen lacerum posterius, goes into internal jugular vein, receives superior longitudinal, superior petrosal, straight and occipital sinuses, and mastoid vein. Join inferior petrosal sinus to form internal jugular vein.

Occipital (2): smallest; from posterior margin of foramen magnum to torcular Herophili.

Cavernous (2): by side of sella Turcica, passes from sphenoidal fissure to apex of petrous part of temporal. Receives ophthalmic veins which connect the angular vein with this sinus; and inferior anterior cerebral veins. The ophthalmic veins are two in number: *superior*, the larger, accompanies artery; and *inferior*, running below optic nerve, is formed by lower ciliary and muscular branches, and communicates with pterygoid plexus; both pass through the sphenoidal fissure to empty into the cavernous sinus.

Circular: surrounds pituitary body, connects the cavernous sinuses.

Inferior petrosal (2): from termination of cavernous to internal jugular vein.

Transverse: connects the inferior petrosal sinuses across basilar process of occipital bone.

Superior petrosal (2): placed on superior border of petrous part of temporal, connecting lateral and cavernous sinuses; receives inferior lateral cerebral, and anterior lateral cerebellar veins.

Veins of the diploë: lodged in channels of the bones of the cranial vault. They are divided into *frontal*, joining the supra-orbital vein; *anterior temporal*, joining a deep temporal vein; *posterior temporal*, joining lateral sinus; and *occipital*, joining occipital vein or lateral sinus.

Emissary veins: small veins passing through foramina in the bones, and connecting the sinuses with the external veins of the head.

Facial: passes obliquely across side of face from inner canthus

to anterior border of masseter, being the continuation of the angular vein. Under the inferior maxilla near the angle it unites with a branch (communicating facial) from temporo-maxillary vein to form a short trunk (the common facial), which empties into the internal jugular vein. Also communicates with ophthalmic (*vide* cavernous sinus).

The facial vein receives ...	angular	{	supra-orbital.
			frontal.
			palpebral (superior)
			nasal.
	inferior palpebral.		
	dorsal and lateral nasal.		
	anterior internal maxillary ...	{	alveolar branches.
			infra-orbital.
			descending palatine.
			nasal.
	Vidian.		
	coronary	{	superior.
			inferior.
	buccal.		
	masseteric.		
labial.			
submental.			
inferior palatine.			
tonsillar.			
glandular (parotid and submaxillary).			
part of temporo-maxillary.			

Temporal : from side and vertex of head, passes down over zygoma, there receiving the middle temporal vein ; it then courses down between condyle of jaw and external auditory meatus into the substance of the parotid, where it joins the internal maxillary vein to form the temporo-maxillary trunk.

The temporal vein receives	{	anterior temporal.
		posterior temporal.
		middle temporal.
		parotid.
		anterior auricular.
		transverse facial.

Internal maxillary : is formed by branches corresponding with those of the internal maxillary artery. The branches form a plexus (pterygoid) placed between the pterygoid muscles. The trunk of the vein passes with artery round condyle to join temporal vein, and form temporo-maxillary trunk.

The pterygoid plexus is formed by	{	middle meningeal.
		deep temporal.
		pterygoid.
		masseteric.
		buccal.
		palatine.
		inferior dental.
		posterior dental.

The pterygoid plexus communicates with the facial vein by the anterior internal maxillary vein.

Temporo-maxillary: formed by union of temporal and internal maxillary veins; descends in parotid gland, divides into two branches, one of which communicates with the facial by the communicating facial, and the other receives the posterior auricular vein to form the trunk of the external jugular vein.

Posterior auricular: from plexus on side of head and back of ear, receives stylo-mastoid vein, and branches from external ear; joins into temporo-maxillary to form external jugular vein.

Occipital: from plexus at back part of vertex of skull, placed deeply between muscles of neck, and having same course as artery. Joins internal jugular; communicates with lateral sinus by *mastoid veins*.

External jugular: formed by junction of part of temporo-maxillary trunk and posterior auricular veins at angle of jaw in the substance of parotid. Descends beneath platysma over sternomastoid, pierces deep fascia near the clavicle to open into subclavian, or occasionally into the internal jugular. Has two pair of valves. Receives *posterior external jugular*, draining superficial region at back of neck, *supra-scapular*, *transverse cervical*, and frequently the *anterior jugular*.

Anterior jugular: drains integument and superficial muscles of anterior and middle regions of neck. Empties into subclavian or external jugular; communicates with fellow just above the sternum, also with facial and external jugular veins.

Internal jugular: from jugular foramen, being formed by junction of lateral and inferior petrosal sinuses. Passes vertically down the side of neck, on the outer side of carotid artery, within the sheath, uniting with subclavian near the inner margin of the scalenus anticus to form the vena innominata. One pair of valves placed $\frac{3}{4}$ inch above termination.

The internal jugular vein receives	{	pharyngeal.	
		lingual {	dorsal of tongue.
			lingual venæ comites.
			ranine.
		common	facial.
			occipital.
superior thyroid {	laryngeal.		
	crico-thyroid.		
		middle thyroid.	

Vertebral: drains occipital region and deep muscles of back of neck; enters foramen in transverse process of atlas, runs down behind artery through same foramina of the cervical vertebræ to 6th (or 7th), where it passes out to enter vena innominata. One pair valves guard its mouth.

The vertebral vein receives	{	posterior condylar.
		muscular.
		dorsi-spinal.
		meningo-rachidian.
		ascending cervical.
		deep cervical.
		1st intercostal.

VEINS OF THE UPPER EXTREMITY.

SUPERFICIAL SET.

Anterior ulnar: from the anterior of carpus and ulnar side of hand up along ulnar side of forearm to elbow-joint, to join the median basilic.

Posterior ulnar: from posterior ulnar border of hand and vein of little finger (*vena salvatella*), up along ulnar side of back of forearm to join median basilic just below the elbow-joint.

Radial: from dorsum of the thumb, radial side of index-finger and hand, along outer side of forearm to join median cephalic near bend of elbow, and form the cephalic vein.

Median: from palmar surface of hand up the middle of forearm communicating below the bend of elbow, with venæ comites of ulnar, and then divides into median cephalic and median basilic.

Median basilic: passes obliquely inwards over bicipital fascia, which separates it from the brachial artery. Empties into basilic as a formative branch.

Median cephalic: passes obliquely outwards from bend of elbow, between supinator longus and biceps. Empties into cephalic as a formative branch.

Basilic: formed by coalescence of anterior and posterior ulnar

with the median basilic veins. Ascends on the inner side of the arm to open into the axillary vein.

Cephalic: passes up between deltoid and pectoralis major, perforates costo-coracoid sheath, and opens into the axillary vein. It is occasionally connected with the external jugular by a branch over the clavicle (jugulo-cephalic).

The following are the deep veins, and accompany their respective arteries as *venæ comites*, intercommunicating with each other, and the superficial veins frequently.

Digital (2): empty into the superficial palmar.

Palmar superficial (2): empty into ulnar and radial.

Deep palmar: empty into radial *venæ comites*.

Interosseous (2): accompany the anterior and posterior interosseous arteries, commencing at the wrist, terminating in *venæ comites* of the ulnar.

Comites radialis: form, with the ulnar, the *comites* of brachial.

Comites ulnaris: with the radial, form *comites* of brachial.

Comites brachialis: receiving veins corresponding to the branches of the brachial artery, empty into the axillary vein.

Axillary: is the continuation of the basilic. Commences at lower border of the axillary space; receives veins corresponding to branches of its artery, and terminates in the subclavian at outer border 1st rib. [Valves at inferior border of subscapularis, terminations of subscapular and cephalic veins.]

Subclavian: continuation of axillary, joins internal jugular vein at the inner margin of the anterior scalenus to form *vena innominata*. Separated from its artery by scalenus anticus muscle and phrenic nerve. Receives external and anterior jugular veins. [Valves just external to entrance of external jugular, or about one inch from its termination.]

VEINS OF THE BODY.

Innominate: two large trunks, placed one on each side of the neck, and formed by the junction of the internal jugular and subclavian veins of the corresponding side. They end by uniting to form the superior vena cava. No valves.

The right innominate vein is short ($1\frac{1}{2}$ inches long), and commences at the inner end of the scalenus anticus, passes downwards to join left innominate at the inferior border of 1st right costal cartilage. Receives the right vertebral, right internal mammary, right inferior thyroid, right superior intercostal, and right superior phrenic veins. The right lymphatic duct opens at the angle of union of right subclavian and internal jugular veins.

*Connections :—**Superficially and Inner Side.*

Innominate artery.

Outer Side.

Right lung and pleura.

Right phrenic nerve.

The *left innominate* is 3 inches long, passes from left to right and downwards. The thoracic duct opens at the angle of union of the left subclavian and internal jugular veins.

*Connections :—**In Front.*

First piece of sternum.

Origin of sterno-hyoid.

Origin of sterno-thyroid.

Thymus gland.

Below.

Arch of aorta (transverse part).

Behind.

Innominate artery.

Left carotid artery.

Left subclavian artery.

Left phrenic nerve.

Left pneumogastric nerve.

The left innominate vein receives {
left vertebral.
left internal mammary.
left inferior thyroid.
left superior intercostal.
thymic.
mediastinal.
pericardiac.

Internal mammary: two with each artery, uniting in a single trunk, emptying into innominate veins.

Inferior thyroid (sometimes 3 or 4): from thyroid venous plexus, emptying into right and left innominate veins.

Superior intercostal: receives veins from upper two or three intercostal spaces except the first. The *right* one passes down and enters the azygos major, the *left* passes forward across arch of aorta to left innominate vein, and receives the left superior phrenic and left bronchial veins.

Vena cava superior: $2\frac{1}{2}$ to 3 inches long, formed by the junction of the right and left innominate veins behind the junction of the 1st right costal cartilage with the sternum; passes down to the right auricle opposite upper border of 3rd right costal cartilage. No valves. Receives pericardiac and mediastinal veins, and near its termination the azygos major vein.

*Connections :—**Left Side.*

Innominate artery, in upper part.

Ascending part of aortic arch, in lower part.

In Front.

Pleura.

Thymus gland.

Sternum.

Right Side.

Pleura.

Right phrenic nerve.

Behind, Lower Part.

Right division pulmonary artery.

Upper right pulmonary vein.

The vena cava enters the pericardium about $1\frac{1}{2}$ inches from its termination, and this part is covered with serous membrane except posteriorly.

Azygos major: commences opposite 1st or 2nd lumbar vertebra by a branch from right lumbar veins, up through aortic opening in diaphragm, passes along right side of column to 3rd dorsal vertebra, and, arching over root of right lung, empties into vena cava. Receives the ten lower right intercostal veins, vena azygos minor, several œsophageal, mediastinal, vertebral, and right bronchial veins. Imperfect valves, though its branches have complete ones.

Azygos minor inferior: commences in lumbar region of left side from lumbar veins, or branches of renal, through left crus of diaphragm to 9th dorsal vertebra, there crossing behind aorta and thoracic duct to terminate in azygos major. Receives four of five lower intercostal; some œsophageal and mediastinal veins.

Azygos minor superior: from branches formed by veins between left superior intercostal and azygos minor inferior veins; empties into one of the other azygos veins.

Bronchial: from lungs; the right terminating in azygos major; the left in the left superior intercostal.

SPINAL: dorsi-spinales; external to spinal canal, extend along whole length of back of spine, forming network, terminating in the vertebral (of neck), the intercostal (of thorax), lumbar and sacral veins.

Meningo-rachidian: situated between vertebra and duramater, consisting of *longitudinales spinales anteriores*: whole length of anterior surface of vertebral canal, terminating in dorsi-spinal.

Longitudinales spinales posteriores: whole length of posterior surface of vertebral canal, terminating in dorsi-spinal.

Veins of the vertebræ: *Venæ basis vertebrarum*: from bodies of vertebræ, terminating in anterior longitudinal.

Veins of the spinal cord: *Medulli-spinales*: cover cord, between pia and arachnoid, from sacrum to occiput; *anas.* freely with contiguous veins. No valves in any of the spinal veins.

Iliaca externa, interna, and communis: see Lower Extremity.

Vena cava inferior: formed by junction of the two common iliac veins in front and a little to the right of 5th lumbar vertebra, passes up on right side of aorta to posterior border of liver, where it becomes imbedded in a groove and receives the hepatic veins; thence it goes through special opening in

diaphragm between middle and right leaflets, enters pericardium, and opens into lower and back part of right auricle.

Connections :—

<i>In Front.</i>	<i>Behind.</i>	<i>Left Side.</i>
Mesentery.	Vertebral column.	Descending aorta.
Transverse part of duodenum.	Right crus.	
Pancreas.	Right renal artery.	
Portal vein.	Right lumbar arteries.	
Posterior border of liver.		
The inferior vena cava receives	{ lumbar branches.	
	{ right spermatic.	
	{ (ovarian in female).	
	{ right renal.	
	{ left renal { left spermatic.	
	{ left supra-renal.	
	{ right supra-renal.	
	{ inferior phrenic.	
	{ hepatic.	

CARDIAC VEINS : **Vena cordis magna :** from apex, up anterior interventricular groove to base of ventricles, curving to left side and back part of heart, empties into coronary sinus ; guarded by two valves ; receives posterior cardiac and left cardiac veins.

Venæ cordis media (posterior cardiac) : from apex up posterior interventricular groove, terminating in coronary sinus, guarded by valves.

Venæ parvæ (anterior veins) : three or four small branches from anterior surface of right ventricle, emptying into lower part of right auricle.

Venæ Thebesii : drain muscular substance, opening into right auricle.

Right or small coronary : from back of right auricle and ventricle, runs in aurico-ventricular groove to open in right end of coronary sinus.

The coronary sinus : is the part of the great cardiac vein which is placed in the left auriculo-ventricular groove. Is one inch in length, and opens in the right auricle, the opening being guarded by the Thebesian valve. Receives branches as above, and a small straight vein at the back of the left auricle, the oblique vein of Marshall, the remnant of the left innominate vein of the fœtus.

Pulmonary : four in number ; commence in capillary network upon the pulmonary alveoli, uniting to form a trunk for each lobe ; the one of the middle lobe of the right lung unites with the

one from the superior lobe, hence there are two veins from each side. No valves. Carry *arterial* blood and empty into the left auricle, the left veins crossing the descending thoracic aorta.

Connections at the root of the lung :—

<i>From Before Back.</i>	<i>From Above Down.</i>	
	<i>Right Side.</i>	<i>Left Side.</i>
Vein.	Bronchus.	Artery.
Artery.	Artery.	Bronchus.
Bronchus.	Vein.	Vein.

THE PORTAL SYSTEM.

The veins of the portal system collect the blood from the digestive tract. They form a trunk, the *vena portæ*, which enters the liver and breaks up into small branches in its substance. The following veins form the portal system :—

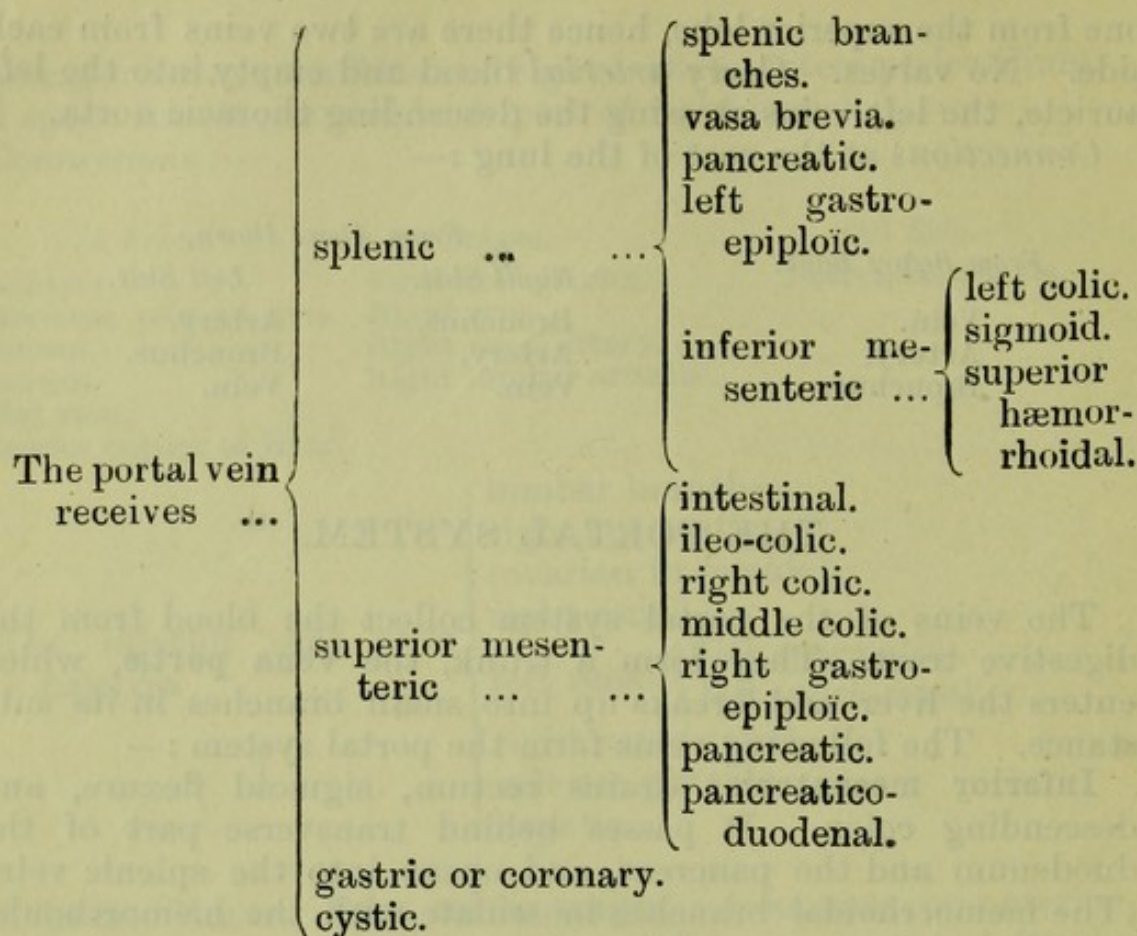
Inferior mesenteric : drains rectum, sigmoid flexure, and descending colon. It passes behind transverse part of the duodenum and the pancreas, and opens into the splenic vein. (The hæmorrhoidal branches inosculate with the hæmorrhoidal branches of the internal iliac.)

Superior mesenteric : drains small intestines, cæcum, ascending and descending colon. It passes upwards in front of superior mesenteric artery, in front of transverse part of duodenum, and behind pancreas joins the splenic vein at the upper border of the pancreas to form the portal vein.

Splenic : commences in five or six branches in hilum of spleen ; these unite to form a trunk which passes behind upper border of pancreas from left to right, and in front of inferior vena cava ; joins superior mesenteric at a right angle.

The gastric or coronary : a large vein accompanying coronary artery along lesser curvature of stomach, opening into the *vena portæ*.

The *vena portæ* : is formed by the union of the splenic and superior mesenteric veins in front of the inferior vena cava, and behind the head of the pancreas. Passes up behind first part of duodenum between the layers of the small omentum, behind and between the bile duct and hepatic artery, the duct being placed on the right and artery on the left, to transverse fissure of liver, where it divides into right and left branches to corresponding lobes, and also gives an offset to the Spigelian lobe. Connected with the branch to the left lobe is the *ductus venosus*, the remains of a foetal structure.



VEINS OF THE LOWER EXTREMITY.

SUPERFICIAL SET.

Internal or long saphenous : from plexus on dorsum and inner side of foot ; ascends, in front of inner ankle, behind inner margin of tibia, accompanied by internal saphenous nerve ; bends behind inner condyle of femur, ascends along inner side of thigh, through saphenous opening, empties into femoral $1\frac{1}{2}$ inches below Poupart's ligament, where it receives *superficial circumflex iliac, superficial epigastric, and superficial external pudic*. Communicates with internal plantar, tibial, etc. Two to six valves.

External or short saphenous : from plexus on dorsum and outer side of foot, up behind outer ankle to median line of leg, accompanied by external saphenous nerve ; empties into popliteal vein, between the heads of the gastrocnemius. Two valves, one near termination. Communicates with deep veins of foot.

DEEP SET.

Posterior tibial : formed from *external and internal plantar*, joining with the *peroneal*. Course same as artery.

Anterior tibial: continuation of *venæ dorsales pedis*, pierce interosseous membrane at upper part of leg, and form the popliteal vein, by junction with the *posterior tibial* veins, at the lower border of the popliteus muscle.


Popliteal (see anterior tibial): passes up to femoral aperture in adductor magnus, there becoming the femoral; receives *sural*, *articular*, and *external saphenous* veins. Four valves. Placed superficial to artery, which it crosses from within outwards.

Femoral (see above): passes from the opening in the adductor magnus up to Poupart's ligament, there becoming external iliac. Lies at first to outside of artery, but higher up crosses beneath to its inside. Receives *muscular* branches, *profunda femoris*, and the *internal saphenous*. Four or five valves.

External iliac (see above): from Poupart's ligament to sacroiliac synchondrosis, there uniting with the internal iliac to form common iliac. On *right* side, lies to inside of artery at first, but gradually passes behind it. On *left* side, altogether on inside of artery. Receives *deep epigastric* and *deep circumflex iliac*, and a *pubic* vein from the obturator.

Internal iliac: formed by the union of all of the *venæ comites* of the branches of the internal iliac artery, except the ilio-lumbar veins which open into the common iliac. It lies at first on the inner side, but finally gets behind the artery. It has no valves. The visceral veins opening into the internal iliac inosculate very freely and form a series of plexuses.

The internal iliac vein receives...	visceral branches	hæmorrhoidal plexus ...	{ superior and middle hæmorrhoidal.
		vesico-prostatic plexus...	{ vesical. dorsal of penis. deep veins of penis.
	parietal branches	uterine } vaginal }	{ in female.
		obturator.	
		internal pudic ...	{ veins of corpus cavernosum. veins of bulb. transverse perineal. superficial perineal.



Common iliac (see external iliac): from base of sacrum to terminate at intervertebral substance between 4th and 5th lumbar vertebræ, a little to the right of the middle line, there, with its fellow of opposite side, forming vena cava inferior. The right vein is the shorter, and nearly vertical. Receives *ilio-lumbar* and sometimes *lateral sacral* veins. *Middle sacral* empties into left common iliac. No valves.

Connections.—*Right* vein passes behind, and then to outer side of artery. *Left* vein is placed on inner side of artery, and then passes behind right common iliac artery to join right vein.

THE ABSORBENT SYSTEM.

The **thoracic duct** receives the absorbents from both lower limbs, abdomen, except upper surface of liver, from left half of thorax, left upper limb, and left side of head and neck.

Length.—15 to 18 inches.

Extent.—From 2nd lumbar vertebra, where it commences by a dilatation, the *receptaculum chyli*, to junction of left internal jugular with left subclavian vein.

Connections.—The abdominal part is placed on the front of the body of the 2nd lumbar vertebra, behind and to the right side of the aorta and on the inner side of the right crus; it then enters the thorax through aortic opening, on the right side of aorta, lying between it and the azygos major vein, and passes upwards to arch. Opposite the 4th dorsal vertebra it passes behind arch, and runs along the left side of the œsophagus, behind the left subclavian artery. At the level of the 7th cervical vertebra it turns outwards and arches over the apex of the left pleura to open at the angle of union of the left internal jugular and left subclavian veins.

The **right lymphatic duct**: receives the absorbents of the right limb, right side of chest, right half of head and neck, and upper surface of liver. It is about $\frac{1}{2}$ an inch long, and enters the venous system at the angle of union of the right internal jugular and right subclavian veins.

THE LYMPHATICS OF THE HEAD AND NECK.

Suboccipital glands (1 or 2) : receive lymphatics from back of scalp, efferent vessels join superficial cervical glands.

Mastoid glands (2 or 3) : receive lymphatics from back of ear, efferent vessels join superficial cervical glands.

Parotid lymphatic glands (3 or 4) : one being placed just anterior to tragus. Receives lymphatics from temporal region, efferent vessels pass to submaxillary and superficial cervical glands.

Internal maxillary glands : afferent vessels from temporal, nasal, zygomatic, and orbital fossæ, palate and upper part of pharynx ; efferent vessels pass to superior deep cervical glands.

Submaxillary lymphatic glands (8 to 10) : afferent vessels from face, floor of mouth, submaxillary and lingual glands ; efferent vessels to cervical glands.

Superficial cervical glands (4 to 6) : placed along the external jugular vein. Afferent vessels from external ear, skin of neck ; efferent vessels to the deep cervical glands.

Deep cervical glands (20 to 30) : *glandulæ concatenatæ*.

Superior : lie along internal jugular vein from division of common carotid to base of skull. Afferent vessels from internal maxillary and submaxillary glands, cranium, tongue, larynx, lower part of pharynx and thyroid body. Efferent vessels to inferior set.

Inferior : placed along lower part of internal jugular vein. Afferent vessels from other cervical glands and lower part of neck. Efferent vessels form a single trunk (*jugular lymphatic trunk*), opening into thoracic duct on left side, and into the right lymphatic duct on right side.

THE LYMPHATICS OF THE UPPER LIMB.

The lymphatics of the arm are arranged in a superficial and a deep set which enter the axillary glands, except a few superficial which join the gland over the internal condyle.

There are two sets of lymphatic glands in the arm, viz., superficial and deep.

The superficial lymphatic glands : two or three in front of the elbow, and one or two above the internal condyle.

The deep lymphatic glands : two or three along radial and ulnar arteries and inner side of brachial artery.

The axillary glands (10 or 12) : receive the lymphatics from the upper limb.

Axillary set : placed along axillary vessels, afferent vessels from limb.

Pectoral set: placed along long thoracic artery, afferent vessels from mamma and chest.

Subscapular set: placed along subscapular artery, afferent vessels from the back.

Infra-clavicular set: situated below the clavicle, in the hollow between pectoralis major and deltoid, afferent vessels from shoulder.

THE LYMPHATICS OF THE PELVIS AND ABDOMEN.

External iliac glands (6 to 10): lie along external iliac artery; afferent vessels from inguinal glands.

Internal iliac glands: placed along internal iliac artery; afferent vessels from pelvic viscera.

Sacral glands: placed in hollow of sacrum, receive lymphatics of rectum.

Lymphatics of bladder: placed near base of bladder; efferent vessels enter internal iliac glands.

Lymphatics of uterus: in the impregnated state enter internal iliac glands.

Lumbar lymphatic glands: *mesial* group, surround aorta and vena cava; afferent vessels from external and internal iliac, and sacral glands, lymphatics of kidney, supra-renal bodies, testicles, etc. The *lateral* group lie behind psoas, and receive the deep lymphatics of the abdominal wall. The efferent vessels of the whole enter the thoracic duct.

Mesenteric glands (130 to 150): disposed around the trunk and branches of the superior mesenteric artery; efferent vessels go to the thoracic duct.

Celiac glands (16 to 20): surround coeliac axis. The afferent vessels come from stomach, spleen, pancreas, and liver; the efferent vessels go to the thoracic duct.

THE LYMPHATICS OF THE THORAX.

Sternal glands (6 to 10): along internal mammary artery. The afferent vessels come from front of chest and abdominal walls, diaphragm and under part of mamma; the efferent vessels join anterior mediastinal glands and thoracic duct.

Intercostal glands: placed between the intercostal muscles behind. The afferent vessels come from chest wall; the efferent open into the thoracic and right lymphatic ducts.

Anterior mediastinal glands (3 or 4): between pericardium and sternum. The afferent vessels come from lower sternal glands, upper surface of liver and diaphragm; the efferent vessels pass to thoracic and right lymphatic ducts.

Superior mediastinal or cardiac glands (8 to 10) : placed in front of the arch of the aorta in the interpleural space. The afferent vessels come from the heart, pericardium and thymus gland ; the efferent vessels unite in two or three trunks which open into the thoracic and right lymphatic ducts.

Bronchial glands : are placed along the bronchi. The afferent vessels come from the lung ; the efferent vessels join to open into the thoracic and right lymphatic ducts.

Posterior mediastinal glands (8 to 12) : lie along descending thoracic aorta. The afferent vessels come from the œsophagus, pericardium, and diaphragm ; the efferent vessels go to the thoracic duct.

THE LYMPHATICS OF THE LOWER LIMB.

The lymphatics of the lower limb are divided into a superficial and a deep set. The *superficial*, except a few which pass to the popliteal glands, go to the superficial inguinal glands. The *deep* lymphatics enter the deep inguinal glands.

The popliteal glands (4 or 5) : are placed on the popliteal vessels. The afferent vessels come from the lymphatics of the leg ; the efferent go to the inguinal glands.

The superficial inguinal glands (8 to 10) :

Superior set : lie along Poupart's ligament. The afferent vessels come from trunk, buttocks, perineum, and genitals.

Vertical or femoral set : lie along the internal saphenous vein, and receive the superficial lymphatics of the limb. The efferent vessels of both sets join the deep glands, and the glands along the external iliac artery.

The deep inguinal glands : surround the femoral vessels (a constant one in the crural ring). The afferent vessels come from the superficial inguinal glands and the deep lymphatics of the limb ; the efferent vessels join the external iliac glands.

THE CEREBRO-SPINAL AXIS.

THE SPINAL CORD.

The **spinal cord** is the part of the cerebro-spinal axis which occupies the spinal canal. In the adult it occupies about $\frac{2}{3}$ of the length, but in the foetus, before the third month, it extends the whole length of the canal.

Extent.—The spinal cord extends from the lower border of the foramen magnum, where it is continuous with the medulla oblongata above, to the lower border of the 1st lumbar vertebra, there terminating in a slender filament, the *filum terminale*.

Contents of the Neural Canal.

Venus plexus between bone and dura mater.

Membranes { dura mater.
arachnoid.
pia mater, with ligamenta denticulata.

Cerebro-spinal fluid,

Spinal vessels { anterior spinal artery and vein.
two posterior spinal arteries and veins.

Spinal cord, with anterior and posterior roots of nerves.

Shape.—In transverse section, nearly round, except at the enlargements, where it is more elliptical.

Enlargements.—Presents two enlargements. The upper or *cervical* extends from the upper limit of the cord downwards to the 1st or 2nd dorsal vertebra.

The lower or *lumbar* commences opposite the 10th dorsal vertebra; is largest at the last dorsal, and thence tapers, forming the *conus medullaris*, from the tip of which the *filum terminale* descends.

The *filum terminale* (central ligament of the cord): passes from the end of the *conus medullaris* downwards in the middle of the *cauda equina*; becomes closely invested with dura mater opposite the 1st or 2nd sacral vertebra, and blends with the periosteum at the lower end of the sacral canal.

It is a process of pia mater, containing in its upper half the continuation of the central canal of the cord, together with a little grey matter for a short distance. The lower half consists of connective-tissue, bloodvessels and medullated nerve-fibres. The anterior spinal artery is continued along the front; it is a very slender vessel.

The nerve-roots.—Consist of anterior and posterior bundles, 31 pairs.

The *anterior* roots are arranged irregularly along the side of the cord; the *posterior* roots issue in a straight line along the postero-lateral groove. They are distinguished from the anterior roots by having a ganglion.

The nerve-roots pass outward to the intervertebral foramina, those in the upper part passing almost transversely; below they pass more obliquely, until in the lower part of the canal their course is vertical. The collected bundles of nerve-roots at the termination of the cord form the *cauda equina*.

FISSURES.

Anterior median fissure: along the anterior surface of the cord in the middle line. Extends into the substance of the

cord for about a third of its thickness, but deeper below than in the upper part. Does not reach grey matter. Lined with pia mater.

Posterior median fissure : not a true fissure, but only contains a septum of pia mater. Reaches down to grey matter.

Lateral fissures : *Antero-lateral* : not a true fissure, but a line corresponding to origin of anterior nerve roots.

Postero-lateral : corresponding to attachment of posterior nerve roots.

Columns of the cord :—

The cord being divided into two lateral halves by the median fissures, may again be subdivided into *anterior*, *lateral*, and *posterior* columns.

The *posterior* and *lateral* columns are divided by a groove or lateral sulcus, to which the posterior nerve-roots are attached.

The *anterior* and *lateral* columns are separated by the anterior roots of the nerves.

Posterior median column (only found in the upper part of the cord) is formed by a groove a little outside the posterior median fissure, dividing the posterior column into two parts, a posterior median column and posterior column proper.

STRUCTURE OF THE SPINAL CORD.

The spinal cord in transverse section consists of white matter externally, and grey matter internally.

The grey matter : consists of a crescent-shaped portion in each lateral half of the cord, united by an intervening process, the *posterior or grey commissure*.

Each crescent has two cornua, an *anterior*, thick and short, not reaching the surface of the cord ; and a *posterior*, long and slender, reaching to the postero-lateral fissure, just before reaching which it becomes enlarged, *caput cornu*, and becomes less opaque (*substantia gelatinosa* of Rolando). The size of the grey crescents varies in different parts of the cord, being largest in the cervical and dorsal regions. In the upper dorsal region there is a projection of the grey matter on the outer side of the crescent between the anterior and posterior cornu, called the *intermedio-lateral tract* or *lateral cornu*.

Central canal : extends through the whole length of the cord in the middle of the posterior or grey commissure. It is lined with spheroidal ciliated epithelium. Opens above into the floor of the 4th ventricle, and is continued below into the upper part of the *filum terminale*.

The white matter : encloses the grey matter in each lateral half of the cord, except where the posterior cornu comes to the

surface. The portion of white matter between the posterior or grey commissure and the anterior median fissure constitutes the *anterior* or *white commissure*.

THE BRAIN.

The brain consists of ...	medulla oblongata. cerebellum. pons Varolii.		
		mesencephalon...	{ Sylvian aqueduct. crura cerebri. corpora quadrigemina.
		thalamencephalon	{ 3rd ventricle. optic thalami. pineal body. posterior perforated spot. corpora albicantia. tuber cinereum. pituitary body. optic commissure. lamina cinerea.
	cerebrum ...	cerebral hemispheres...	{ convolutions. fissures. corpus callosum. lateral ventricles. 5th ventricle. septum lucidum. fornix. foramen of Monro. velum interpositum. choroid plexuses. corpora striata. claustrum. tænia semicircularis. nucleus amygdalæ. anterior commissure.

THE MEDULLA OBLONGATA, OR BULB.

Extent.—From the lower border of the foramen magnum to the lower border of the pons Varolii.

Connections.—Inferiorly it is connected with the spinal cord, superiorly it is continued into the pons, anteriorly it rests upon

the basilar groove, and posteriorly it lies in a depression between the hemispheres of the cerebellum, called the vallecule, and here bounds the lower half of the floor of the 4th ventricle.

Dimensions.— $1\frac{1}{4}$ inches long ; greatest breadth $\frac{3}{4}$ inch.

Shape.—Pyramidal, with base at the pons, and apex at the spinal cord.

Fissures.—Anterior and posterior median fissures, continuous with those of the cord.

Anterior median fissure : terminates just below the pons in the *foramen cecum*. The fibres of the pyramids decussate at the lower part of the fissure, and partly interrupt it.

Posterior median fissure : continues up from the cord to about half-way up the medulla, where it widens out into the 4th ventricle.

Structure of the medulla.—If the parts of the spinal cord are traced into the medulla, its structure will be easily understood.

The line of the posterior roots of the spinal nerves is continued by the upper bundles of the nerve-roots of the spinal accessory nerve, above this by the bundles of the vagus, and above this again, by the bundles of the glosso-pharyngeal nerve.

The line of exit of these nerve-roots represents the posterolateral groove of the spinal cord. As this line is traced upwards it turns outwards, so that about half-way up the medulla it appears upon the lateral surface, and in its upper part it lies close to the posterior margin of the *olivary body*, but is separated from it by a narrow groove.

The part behind these nerve-roots is termed the *posterior area of the medulla*, and corresponds to the posterior columns (posterior median and posterior lateral) of the cord.

The line of the anterior roots of the spinal nerves, when traced up into the medulla, deepens into a groove which is continued upwards nearly as far as the pons.

The bundles of the nerve-roots of the hypoglossal issue from this groove. The part of the medulla between this groove and the anterior median fissure is called the *anterior area*, and corresponds to the anterior column of the cord. The part between the anterior and posterior areas—that is, the part between the line of issue of the nerve-roots of the spinal accessory, vagus, and glosso-pharyngeal nerves, and line of issue of the nerve-roots of the hypoglossal—is called the *lateral area*, and corresponds to the lateral column of the cord.

Posterior columns : the posterior median column of the cord is continued up into the medulla as the *funiculus gracilis*, which expands as it approaches the 4th ventricle. This expansion is called the *clava* ; and upon reaching the 4th ventricle

the clavæ of opposite sides open out to form the lateral boundary of the ventricle in its lower part.

The posterior lateral column of the cord is continued upwards into the medulla, where it expands slightly, and is called the *cuneate funiculus*, which, on the same level with the clava, has an eminence, the *cuneate tubercle*.

Between the cuneate funiculus and the line of origin of the nerve-roots of the spinal accessory, vagus, and glosso-pharyngeal, there appears a longitudinal prominence, the *funiculus of Rolando*, which broadens out above into the *tubercle of Rolando*. It is formed by the approach of the posterior caput cornu to the surface.

The Restiform body.—In the upper part of the medulla, a set of fibres issue from the anterior median fissure, pass transversely outwards over the anterior pyramid and olivary body, and, continuing transversely, cross over the funiculus of Rolando and the cuneate funiculus, to turn upwards on these. They are the *external arciform* or *arcuate fibres*. Joined to these, just above the tubercle of Rolando, are some transverse fibres which come from the lateral column, known as the *lateral cerebellar tract*. These oblique fibres blend with the funiculus of Rolando, and with the cuneate funiculus, the whole forming the restiform body. Superiorly the restiform body diverges from its fellow and enters the cerebellum, of which it forms the inferior peduncle.

Lateral columns. The lateral column of the cord, as continued into the medulla, consists of three sets of fibres. One set crosses obliquely through the anterior column and across the anterior median fissure to the opposite side, where they form the greater part of the pyramid (the crossed pyramidal tract). A second set consists of the lateral cerebellar tract which join the restiform body, whilst the rest of the column passes upwards as far as the lower end of the olive which conceals it.

The *olivary body* is an oval prominence lying in the upper part of the medulla, between the pyramid and the restiform body. It is separated from the pons by a groove, which contains some of the external arcuate fibres.

On the inner side lie the nerve-roots of the hypoglossal; and on the outer side, but separated from it by a groove, the roots of the accessory, vagus, and glosso-pharyngeal nerves issue. Longitudinal fibres, prolonged from the lateral column, lie in the groove on the outer side of the olive, and occasionally a few bundles of longitudinal fibres are seen on the inner side. These, together with the arched fibres above and below, give it the appearance of being enclosed in a capsule.

The *fillet of the olivary body* is a small bundle of fibres derived from the capsule, and from the longitudinal fibres from the lateral tract. The fibres ascend in the crus cerebri.

Anterior columns: most of the fibres of the anterior columns of the cord are prolonged upwards deeply beneath the pyramids, but a bundle varying in size passes upwards on the outer side of the crossed portion of the lateral column (crossed pyramidal tract). These fibres form the *direct pyramidal tract*.

The **pyramids** are two oval prominences, broader above than below. They are placed one on each side of the anterior median fissure. They consist of two sets of fibres, the *outer* derived from the anterior column of the cord, the *inner* from the lateral column of the opposite side. The crossing of the two sets of these latter fibres constitutes the *decussation of the pyramids*.

The **fourth ventricle**. The central canal of the cord expands in the upper and posterior part of the medulla until opposite the middle peduncles of the cerebellum, where it again gradually narrows, and becomes continuous with the Sylvian aqueduct above. The ventricle is thus diamond-shaped. The lower end has been compared in shape to a pen, and is hence termed the *calamus scriptorius*.

The **floor** in the lower half is formed by the upper part of the posterior surface of the medulla, and in the upper half by the back of pons Varolii.

Structures on the floor.

Lower half.

Median groove.

Inferior fovea.—A triangular pit on each side of the median groove near the striæ acusticæ, the apex being placed upwards. From the base two grooves pass downwards, one towards the calamus scriptorius, and the other towards the lateral boundary. Three areas are thus marked off in each lateral half of the medullary portion :

1. *Fasciculus teres* (lower part), next to median groove.
2. *Ala cinerea*, included between the two grooves passing from the fovea. Contains nucleus of vagus below, and nucleus of glosso-pharyngeal above.
3. *Tuberculum acusticum* (lower half), most external, contains chief part of auditory nucleus.

Upper half.

Median groove.

Superior fovea.—A triangular depression in a line with the inferior fovea, dividing off each lateral half into three areas, viz. :—

1. *Fasciculus teres*, most internal, and continuous with that of the lower half.
2. *Locus cœruleus*, a depression extending from the superior fovea to the upper end of the ventricle.
3. *Tuberculum acusticum* (upper half).

Issuing from the median groove, and passing outwards on each side over the middle of the tuberculum acusticum are some white lines, the *striae acusticae*.

Lateral recess.—This is a lateral extension between the cerebellum and the medulla of the cavity of the ventricle at its widest part.

The roof: in the lower half is formed by pia mater, lined with epithelium. It has three apertures, one on each side in the lateral recess, and the third at the apex of the calamus scriptorius, the *foramen of Majendie*.

On each side where the pia mater is attached laterally to the ventricle it is thickened by white matter, and is termed the *ligula*; and at the apex of the calamus another thickening, the *obex*, occurs. Projecting from the roof on each side of the middle line is the choroid plexus.

In the upper half, the roof is formed by the converging superior peduncles of the cerebellum and the intermediate *superior medullary velum* or *valve of Vieussens*, continuous with the white matter of the cerebellum. Grey linear thickenings on the valve of Vieussens, continuous with the grey cerebellar cortex, constitute the *lingula*.

BOUNDARIES OF THE 4TH VENTRICLE.

	<i>Laterally.</i>	<i>Floor.</i>	<i>Roof.</i>
Below	Clavæ of funiculi graciles.	Medulla below.	Pia mater below.
	Funiculi cuneati.		Nodule of inferior vermi-
Above	Restiform bodies.	Pons above.	form process.
	Superior peduncles of cerebellum.		Valve of Vieussens, and Superior peduncles of cerebellum above.

Grey Matter of the Medulla.

1. *Remains of grey matter of cord*.
 - (a) Grey tubercle of Rolando, from posterior cornu, appears in front of restiform body.
 - (b) Remains of grey commissure, part continued into vagus and auditory nuclei, and part into fasciculus teres.
 - (c) Remains of anterior cornu, intersected by white fibres, giving rise to the *formatio reticularis* of medulla.

2. *Special deposits of grey matter.*

- (a) Nucleus of hypoglossal.
- (b) Nucleus for accessory part of spinal accessory.
- (c) Nucleus of vagus, passing above, under auditory nucleus, into nucleus of glosso-pharyngeal.
- (d) Nucleus of glosso-pharyngeal.
- (e) Nucleus of auditory nerve.
- (f) Corpus dentatum, or nucleus of the olivary body.
- (g) Accessory olivary nucleus.

THE PONS VAROLII.

Position.—Placed above the medulla, below the crura cerebri, and between the lateral halves of the cerebellum.

Dimensions.—About $1\frac{1}{2}$ inches long, and about 2 inches transversely.

Anterior surface is convex, grooved along the midline for the basilar artery; has transverse markings, and openings for the entrance of vessels.

Posterior surface: smaller than the anterior, and continuous with the posterior surface of the medulla; part of it forms the upper part of the floor of the 4th ventricle.

Laterally: crura cerebelli pass outwards and backwards from it.

Upper border: longer than the inferior, with a notch in the median line corresponding to the groove on the anterior surface.

Lower border: slightly arched, overlapping the upper part of the medulla.

Structure: Alternating layers of transverse and longitudinal fibres, with intermingled grey matter. The transverse fibres come from the middle peduncles of the cerebellum, and pass to the crura cerebri; the longitudinal are the continuation upwards of the fibres of the medulla.

Most anteriorly is a layer of transverse fibres of the middle peduncles; behind these, longitudinal fibres prolonged from the anterior pyramids of the medulla with intermingled transverse peduncular fibres. More posteriorly is a deep layer of transverse fibres, most marked at the lower part of the pons, where they form the *trapezium*, and behind these are longitudinal fibres prolonged from the *formatio reticularis* of the medulla, the lateral tract and the olivary fillet. A septum of commissural fibres exists at the posterior part of the pons.

The grey matter of the pons.—In addition to the grey matter scattered in the above-mentioned *formatio reticularis* are the following special deposits:—

(a) Superior olivary nucleus. Placed posteriorly near the outer side of the trapezium.

(b) Nucleus of the facial nerve. Lies in *formatio reticularis*, just behind superior olivary nucleus.

(c) Motor nucleus of the 5th nerve.

(d) Upper sensory nucleus of the 5th nerve, placed outside motor nucleus.

(e) Continuation upwards of principal auditory nucleus.

(f) Superior auditory nucleus, placed just outside principal nucleus.

(g) Accessory auditory nucleus.

(h) Nucleus of the 6th nerve, corresponding to the part of *fasciculus teres*, above the auditory *striæ* (*vide* 4th ventricle).

THE CEREBELLUM.

The **cerebellum** is contained in the occipital fossæ, being separated from the cerebrum above by the tentorium. It consists of two lateral hemispheres connected together by the *vermiform process*, which projects considerably upon the under surface, forming the *inferior vermiform process*; but on the upper surface only forms a slight ridge, the *superior vermiform process*, continuous with the hemispheres laterally.

The inferior surface of each hemisphere is convex, and between them there is a fossa, the *vallecula*, at the bottom of which the inferior vermiform process lies, and which is continuous posteriorly with a notch between the two hemispheres. The medulla is in contact with the anterior part of the *vallecula*, and the posterior part receives the *falx cerebelli*.

Laminæ and fissures. The surface of the cerebellum consists of *laminæ*, which are separated by sulci or fissures.

The *great horizontal fissure* divides each hemisphere into an upper and a lower part. It commences at the pons in front, and passes horizontally round the circumference to end at the notch behind.

Lobes. On the upper surface of the cerebellum are the following lobes :—

(a) *Central* : a small lobe, forming the anterior part of the superior vermiform process. It is continued on to the valve of Vieussens, forming the *lingula* (*vide* roof of 4th ventricle, p. 120).

(b) *Quadrangle* or *antero-superior* : comprising all the anterior part of the hemisphere, except the central lobe, and extending back to a fissure, which commences at the back part of the superior vermiform process, and separates it from the posterior lobe. The quadrangle lobes of each side are united by the

monticulus cerebelli, the large projecting part of the superior vermiform process.

(c) *Postero-superior* or *semilunar* : extends from the quadrate lobe to the great horizontal fissure, and united centrally by a thin median band, the *folium cæcuminis*.

On the under surface of the cerebellum are the following lobes :—

1. On each *hemisphere* from before backwards.

(a) *Flocculus* or *sub-peduncular lobe* : placed behind and below the middle peduncle.

(b) *Amygdala* or *tonsil* : projects into the vallecule on each side.

(c) *Digastric* or *biventral* : placed outside the amygdaloid lobe, and connected with the pyramid of the vermiform process.

(d) *Slender lobe* : placed posteriorly to the digastric.

(e) *Posterior-inferior lobe*.

2. On the *inferior vermiform process*, from before backwards.

(a) The *nodule* : the anterior termination of the inferior vermiform process, which projects into the 4th ventricle. Extending from each side of the nodule laterally to the flocculus, is a thin layer of white matter, the *inferior medullary velum*, continuous anteriorly with the central white substance of the vermiform process, and posteriorly with the epithelium lining the roof of the lower half of the 4th ventricle.

(b) The *uvula* : placed between the amygdala, and connected with them laterally by a commissure of grey matter, the *furrowed band*.

(c) The *pyramid* : a conical projection placed behind the uvula.

(d) *Tuber valvæ* or *commissura brevis* : a few transverse pieces in the notch connecting the slender lobes.

STRUCTURE.

White matter : in each hemisphere there is a central white mass, containing in its middle a grey nucleus, the *corpus dentatum*. The white centre sends processes into the laminae, and is prolonged anteriorly into the crus cerebelli, which divides into three peduncles, viz. :

Superior peduncle : passes to the base of the corpora quadrigemina and cerebrum. Connecting the bases of the two superior peduncles is the valve of Vieussens.

Middle peduncle (the cerebellar commissure): forms the transverse fibres of the pons.

Inferior peduncle: connects the cerebellum with the medulla and cord; it passes downwards at the back of the medulla, forming the restiform body.

The white matter in the vermiform processes consists of a central part, projecting into the laminae of the processes. Anteriorly it is continued into the inferior medullary velum.

Grey matter of the hemispheres:—

A cortical layer: forming a continuous covering of the cerebellum.

The *corpus dentatum*, or ganglion of the cerebellum, is a dentated capsule of grey matter enclosing white substance, situated in the middle of the white matter of the hemisphere. It is open at its anterior part, whence white fibres issue, passing to the superior peduncles and valve of Vieussens.

Nucleus emboliformis: covering hilum of corpus dentatum.

Nucleus globosus: placed on the inner side of the preceding, but at a lower level.

Nucleus fastigii: in the anterior part of the white centre of the vermiform process.

The arrangement of white and grey matter in the cerebellum gives on section an arborescent appearance, the *arbor vitae*.

THE MESENCEPHALON.

The **Sylvian aqueduct** (iter a tertio ad quartum ventriculum) is about $\frac{1}{2}$ an inch long. Posteriorly it is continuous with the narrowed upper end of the 4th ventricle, and anteriorly it opens out into the 3rd ventricle. It has a ciliated epithelial lining, and outside this a layer of grey matter, both being continuous with corresponding parts of the 4th ventricle. Laterally and below, are the crura cerebri, whilst posteriorly is the *lamina quadrigemina* bearing the corpora quadrigemina.

The grey matter of the aqueduct contains the nuclei of the 3rd and 4th nerves, and the upper nucleus of the 5th nerve.

The **crura cerebri** extend from the upper border of the pons, and diverging, pass under the optic tract into the cerebral hemispheres. Between the crura is the *interpeduncular space*, containing the posterior perforated spot, the corpora albicantia, pituitary body, infundibulum, and the tuber cinereum. Near the angle of divergence the roots of the 3rd nerve issue from a groove on the inner side, which groove indicates the separation of the ventral part (pes pedunculi) from the dorsal portion (tegmentum) of the crus.

There is a layer of grey matter placed between the pes pedunculi and the tegmentum, known as the *substantia nigra* or *locus niger*.

The *pes*, or *crusta pedunculi*, consists of longitudinal white fibres, principally continuous with the anterior pyramid of the medulla, and passing to the internal capsule.

The *tegmentum* consists of white longitudinal fibres and interspersed grey matter, continuous with the *formatio reticularis* of the medulla and pons, and passing above into the optic thalamus.

The **corpora quadrigemina** are four small bodies placed in pairs, two being situated anteriorly, sometimes called the *nates*, and two posteriorly, the *testes*.

Connections :—

<i>In Front.</i>	<i>Above.</i>	<i>Below.</i>
3rd ventricle.	Posterior border of	Aqueduct of
Posterior commissure.	corpus callosum.	Sylvius.

The corpora quadrigemina of opposite sides are separated by a longitudinal groove, which is connected below with the superior medullary velum ; above the pair of anterior bodies is crossed by the posterior commissure, and concealed by the overlying pineal gland. From the outer side of each corpus there proceeds a white tract, the *brachium*. The brachia from the posterior corpora go to the inner geniculate body, and the brachia from the anterior bodies pass between the inner geniculate body on the one hand, and the optic thalamus and the external geniculate body on the other hand, into the optic tract.

Structure. The posterior bodies consist of a grey nucleus enclosed in a thin capsule of white fibres. The white fibres separating the nuclei and the grey matter of the aqueduct are derived from the fillet of the olivary body. The nuclei of each side are connected by commissural grey matter.

The anterior bodies have four layers :—

1. White external layer, the *stratum zonale*.
2. Layer of grey matter, the *stratum cinereum*.
3. Layer of white longitudinal fibres passing to the brachium and optic tract, the *stratum opticum*.
4. Layer of white fibres derived from the olivary fillet, and decussating with fibres from the opposite side, the *stratum lemnisci*.

The **posterior commissure** : is a commissural layer of white fibres continuous with the stratum lemnisci, and connecting the two optic thalami posteriorly. It forms the posterior boundary

of the 3rd ventricle, being placed just above the upper opening of the aqueduct of Sylvius, and beneath the pineal body.

The **third ventricle** is the space between the optic thalami, extending from the opening of the Sylvian aqueduct under the posterior commissure, to the foramen of Monro. It is much deeper in front than behind.

Boundaries :—

<i>Roof.</i>	<i>Floor.</i>	<i>Laterally.</i>
Fornix.	Posterior perforated spot.	Optic thalamus.
Velum interpositum	Corpora albicantia.	Peduncles of pineal
with choroid	Tuber cinereum.	gland.
plexus of 3rd ven-	Infundibulum.	
tricle.	Optic commissure.	<i>Anteriorly.</i>
	Lamina cinerea.	Pillars of fornix.
<i>Posteriorly.</i>		Foramen of Monro.
Pineal gland.		Anterior commissure.
Sylvian aqueduct.		
Posterior commis-		
sure.		

Commissures : the *anterior commissure* will be described with cerebral hemispheres.

The *posterior commissure* has been described (*vide* p. 125).

The *middle or soft commissure* : a delicate band of grey matter passing between the optic thalami, near middle of ventricle.

The optic thalami. Two oblong masses of grey matter, covered with a thin layer of white fibres, the *stratum zonale*, and projecting above into the lateral ventricles.

Upper surface : there is a groove along this surface, running from behind obliquely forwards and inwards, which divides it into two pear-shaped pieces, the outer having its base forwards and projecting in front, forming the *anterior tubercle*, and the inner having its base behind and to the inner side, which forms the *posterior tubercle* or *pulvinar*. This surface is separated from the *mesial*, or surface bounding the 3rd ventricle, by the upper peduncle of the pineal body ; and between this and the pulvinar is a triangular depressed surface, the *trigonum tuberculæ*. This surface is partly covered by the fornix resting on the velum interpositum, and is separated externally from the caudate nucleus by the *tænia semicircularis*.

Posterior surface is formed chiefly by the pulvinar. Below and outside this is the eminence of the *outer geniculate body* ; and just below this is the *inner geniculate body*, the brachium from the anterior corpus quadrigeminum passing between them.

Under surface : placed on the tegmentum of the crus.

External surface : fibres of the crusta (internal capsule) pass between this surface and the lenticular nucleus.

The **pineal body** is a cone-shaped body placed at the back of the 3rd ventricle, and projecting between the anterior quadrigeminal bodies. Its base is connected with the optic thalami by a pair of peduncles (superior), and to the posterior commissure by two smaller peduncles (inferior). The 3rd ventricle projects backwards between the upper and lower peduncles.

The **posterior perforated spot** is a depression containing grey matter placed at the base of the brain, in the angle of divergence of the crura. It is bounded by the corpora albicantia in front, and by the pons behind. The anterior part corresponds to the under portion of the floor of the 3rd ventricle, and is perforated for bloodvessels to the optic thalami.

The **corpora albicantia** are two small whitish bodies, placed in front of the posterior perforated spot and behind the tuber cinereum. They consist of grey matter covered with white fibres, derived from the anterior pillars of the fornix.

The **tuber cinereum** is an eminence of grey matter, situated in front of the corpora albicantia, and extending forwards to the optic tract. From its centre a tubular conical process of grey matter, the *infundibulum*, passes downwards and forwards to the posterior lobe of the pituitary body.

The **pituitary body** is a reddish-grey vascular mass lying in the sella turcica. It consists of two lobes, the anterior being the larger.

The **optic commissure** or **chiasma** is the union of the two optic tracts, and is placed in the middle line just in front of the tuber cinereum. From the anterior part the two optic nerves proceed.

Decussation of the nerve fibres.—When the fibres of the tract reach the commissure, they pass across for the most part to form the optic nerve of the opposite side, but a few pass directly into the nerve of the same side. The posterior fibres of the chiasma are described as simply passing between the two inner geniculate bodies.

The **lamina cinerea** is a layer of grey matter lying above the optic commissure, and passing from the extremity of the corpus callosum backwards to the tuber cinereum; laterally it is connected with the grey matter of the anterior perforated spot.

THE CEREBRAL HEMISPHERES.

The **cerebral hemispheres** form as a whole an oval mass, with the larger end backwards, and separated into two equal portions

by the great longitudinal fissure. Each hemisphere presents three surfaces :

1. *Outer* : convex, occupying the vault of the cranium.
2. *Inner* : flat, forming one side of the longitudinal fissure.
3. *Under* : irregular, corresponding in shape to the anterior and middle fossæ, and to the upper surface of the tentorium. It has a deep cleft, the fissure of Sylvius, between the portions occupying the anterior and middle fossæ.

The surface of each hemisphere consists of grey matter, and is divided into convolutions or gyri by intervening sulci.

The **great longitudinal fissure** separates incompletely the two hemispheres, dividing them completely in front and behind ; but at the base near the middle they are united by the corpus callosum. The falx cerebri occupies the fissure.

The **anterior perforated spot** : is a depression containing grey matter placed at the outer side of the lamina cinerea, and under the anterior end of the corpus callosum. It is pierced by blood-vessels.

The FISSURES of the Hemispheres, or Interlobular Sulci.

The **fissure of Sylvius** commences below at the outer side of the anterior perforated spot, passes upwards and outwards between the frontal and temporo-sphenoidal lobes, and divides into two branches, an *anterior* or *ascending*, the shorter, passing into the frontal lobe, and a *posterior* or *horizontal*, passing behind the island of Reil, upwards and backwards to about the middle of the outer surface of the hemisphere.

The **fissure of Rolando** commences at the longitudinal fissure near the vertex, passes downwards and forwards nearly as far as the division of the Sylvian fissure. It separates the parietal and frontal lobes.

The **parieto-occipital fissure** consists of two portions, an *internal* or *perpendicular* fissure, seen on the inner surface of the hemisphere, and an *external*, extending on the outer surface, between the parietal and occipital lobes, for about an inch.

Lobes.—The hemispheres are divided into six lobes, viz. :—

1. *Frontal* : limited below by the Sylvian fissure, and behind by the fissure of Rolando.
2. *Parietal* : limited in front by the fissure of Rolando, and behind by the parieto-occipital fissure.
3. *Occipital* : Bounded in front by the parieto-occipital fissure ; forms the posterior part of the hemisphere.
4. *Temporo-sphenoidal* : occupies middle fossa at the base of the skull, being placed behind the Sylvian fissure, and below the parietal and occipital lobes.

5. *Central or Island of Reil* : contained in the Sylvian fissure ; triangular in shape.

6. *Olfactory* : lying on the under surface of the frontal lobe, sometimes termed the olfactory nerve.

THE CONVOLUTIONS ON THE OUTER SURFACE.

The frontal lobe :—

Convolution and sulci on orbital surface :—

The *tri-radiate* or *orbital sulcus* divides this surface into an inner, anterior, and posterior or outer convolutions. On the inner convolution is the olfactory sulcus, which contains the olfactory lobe.

On outer surface :—

The *ascending frontal* or *precentral convolution* is bounded behind by the fissure of Rolando, round the lower end of which it joins the ascending parietal convolution ; in front by the precentral sulcus.

The *longitudinal frontal convolutions* are three in number, *upper*, *middle*, and *inferior* ; they occupy the rest of the outer surface and are separated from each other by two sulci, and from the ascending convolution by the precentral sulcus.

The parietal lobe :—

Convolution and sulci :—

The *intra-parietal sulcus* commences near posterior limb of Sylvian fissure, passes upwards parallel to the lower half of the fissure of Rolando, and then turns backwards to end near parieto-occipital fissure.

The *postcentral sulcus* continues the line of the vertical part of the intra-parietal sulcus.

The *ascending parietal convolution* is bounded in front by the fissure of Rolando, behind by the intra-parietal and postcentral fissures, below by the fissure of Sylvius, and above it joins the superior parietal convolution.

The *superior parietal convolution* is bounded by the fissure of Rolando in front, behind by the parieto-occipital fissure, round which it joins the superior occipital convolution by the *first annectant gyrus*.

Inferior parietal subdivided into :—

The *supra-marginal convolution*, bounded in front and above by the intra-parietal fissure, round the lower end of which it joins the ascending parietal convolution ; behind by the posterior limb of the Sylvian fissure, round which it joins the superior temporo-sphenoidal convolution.

The *angular convolution* occupies the rest of the outer surface of the parietal lobe. Above is the superior parietal lobule, below the temporo-sphenoidal lobe, in front the supra-marginal gyrus, and behind the occipital lobe, to the middle convolution of which it is joined by the *second annectant gyrus*.

The **occipital lobe**: is divided into three convolutions, an *upper*, a *middle*, and an *inferior*, by two sulci.

The *superior occipital convolution* is connected anteriorly to the superior parietal lobule by the first annectant gyrus.

The *middle occipital convolution* joins the angular convolution by the second annectant gyrus, and to the middle temporo-sphenoidal convolution by the third annectant gyrus.

The *inferior occipital convolution* is connected to the inferior temporo-sphenoidal convolution by the fourth annectant gyrus.

The temporo-sphenoidal lobe:—

The *superior temporo-sphenoidal* or *parallel sulcus* runs parallel to posterior limb of the Sylvian fissure.

The *middle temporo-sphenoidal sulcus* lies parallel to the superior.

The *inferior temporo-sphenoidal sulcus* (inconstant) on the under surface, between inferior temporo-sphenoidal and external occipito-temporal gyri.

The *superior temporo-sphenoidal convolution* (infra-marginal) is bounded above by posterior limb of Sylvian fissure, and continuous behind with supra-marginal convolution.

The *middle temporo-sphenoidal convolution* joins posteriorly the angular, and by the third annectant gyrus merges into the middle occipital convolution.

The *inferior temporo-sphenoidal convolution* joins the inferior occipital convolution by the fourth annectant gyrus.

The **central lobe** or **Island of Reil** lies in the fissure of Sylvius at the base of the brain. *Boundaries*: In front, the *anterior sulcus of Reil*, which separates it from the posterior orbital convolution. Externally, the *external sulcus of Reil*, separating it from the gyri of the operculum, a collective name given to the portions of the inferior frontal, and lower end of the ascending frontal and parietal convolutions which lie between the ascending and posterior limbs of the Sylvian fissure. Posteriorly, by the posterior sulcus of Reil, separating it from the temporo-sphenoidal lobe. It is divided by the central sulcus into an *anterior* part, which is subdivided into three gyri breves, and a *posterior* part subdivided into two gyri longi.

The **olfactory lobe** extends from the anterior perforated spot as the olfactory tract, and ends in an enlargement, the olfactory

bulb. It lies in the olfactory sulcus of the frontal lobe. Behind the tract bifurcates, the outer root passing across commencement of Sylvian fissure to the uncinate convolution, and the inner one to the great longitudinal fissure to join the callosal convolution. The *tuber olfactorium* is the enlargement at the posterior edge of the upper surface of the olfactory tract.

CONVOLUTIONS, FISSURES AND LOBULES on the inner surface :—

The **calcarine fissure** commences at the posterior part of the inner surface of the occipital lobe by a forked extremity ; is joined about half-way by the perpendicular fissure, and ends near the posterior extremity of the corpus callosum.

The **calloso-marginal fissure** commences in front near the anterior perforated spot, and takes a course about midway between the corpus callosum and the edge of the longitudinal fissure, ending a little behind the upper end of the fissure of Rolando.

The **perpendicular fissure** (internal parieto-occipital) separates the occipital and parietal lobes on the inner surface, joining the calcarine fissure below.

The **cuneate lobule** is the area between the perpendicular and the calcarine fissures.

The **quadrate lobule** lies anterior to the cuneate, it is bounded behind by the perpendicular fissure, and in front by the ascending terminal limb of the calloso-marginal sulcus.

The **marginal convolution** extends along the edge of the longitudinal fissure. It commences at the anterior perforated spot, and is limited behind by the termination of the calloso-marginal sulcus.

The **gyrus fornicatus** or **callosal convolution** lies beneath the marginal convolution, being separated from it by the calloso-marginal sulcus. It commences near the anterior perforated spot, follows the curves of the corpus callosum, near the posterior end of which it becomes continuous with the uncinate gyrus.

The **uncinate convolution** (superior occipito-temporal) commences behind, just below the junction of the calcarine and perpendicular fissures, passes forwards to the front of the temporo-sphenoidal lobe. From the anterior end a short process (uncus) is prolonged backwards.

The **collateral fissure** lies along the lower border of the uncinate convolution ; it projects inwards and forms the *eminentia collateralis* in the descending cornu of the lateral ventricle.

The **dentate sulcus** (hippocampal) lies along the upper

border of the uncinatè convolution, and forms the hippocampus major in the descending cornu of the lateral ventricle.

The **dentate convolution** (fascia dentata) lies in the dentate fissure. It is formed by the superficial grey matter of the hemisphere, which here ends in a fringed margin.

The **inferior occipito-temporal convolution** lies just below the collateral fissure, and extends from the apex of the temporo-sphenoidal lobe to the posterior part of the hemisphere.

THE INTERIOR OF THE CEREBRUM.

The **centrum ovale minus** is the central white mass in each hemisphere seen on horizontal section, the section being made about $\frac{1}{2}$ an inch above the corpus callosum.

The **centrum ovale majus**, seen on section at the level of the corpus callosum, is the centrum ovale minus of each side, joined by the corpus callosum.

The **corpus callosum** lies at the bottom of the great longitudinal fissure. It is the commissure of the hemispheres, and consists principally of transverse fibres.

Length.—About 4 inches, extending to within $1\frac{1}{2}$ inches of the anterior, and $2\frac{1}{2}$ inches of the posterior extremities of the hemispheres.

Shape.—Broader behind than in front, thicker at each end than the middle, and thickest behind. It terminates posteriorly in a free thickened border, the *splenium*; in front it curves down towards the base of the brain, the bend being known as the *genu*, and the reflected part the *rostrum*.

Raphé: the longitudinal eminence along the centre of the upper surface.

Nerves of Lancisi (striæ longitudinales): longitudinal white fibres placed on each side of the raphé.

Covered band of Reil: longitudinal fibres outside the nerves of Lancisi, under cover of the convolution of the corpus callosum.

Connections.—Under surface connected behind with the fornix, and in front of this with the *septum lucidum*. The extremity of the rostrum is connected centrally with the lamina cinerea, and laterally with two white bands, the *peduncles of the corpus callosum*, which pass backwards and outwards over the anterior perforated spot towards the Sylvian fissure. Traced upwards, these fibres are continuous with nerves of Lancisi. The corpus callosum roofs in the bodies and anterior cornua of the lateral ventricles.

The **lateral ventricles** are two in number, one in each

hemisphere. Each ventricle consists of a body or central cavity, and three cornua, *anterior*, *posterior*, and *descending*.

Connections of the body :—

Roof.—Corpus callosum.

Internal wall.—Septum lucidum.

Floor.—From before backwards.

1. Caudate nucleus of corpus striatum.
2. Tænia semicircularis.
3. Part of optic thalamus in front of choroid plexus.
4. Choroid plexus of lateral ventricle.
5. Part of the fornix.

The *anterior cornu* is the anterior end of the ventricle which curves outwards round the caudate nucleus.

Connections :

<i>In Front.</i>	<i>Roof.</i>	<i>Floor and Externally.</i>	<i>Internally.</i>
Genu of corpus callosum.	Corpus callosum.	Caudate nucleus.	Septum lucidum.

The *posterior cornu* projects backwards and inwards into the occipital lobe.

Connections :—

<i>Outer Side.</i>	<i>Floor.</i>	<i>Inner Wall.</i>	<i>At Junction of Posterior and Descending Cornua.</i>
Fibres of corpus callosum passing to temporo-sphenoidal lobe.	White substance of occipital lobe.	Hippocampus minor, formed by the calcarine sulcus, projecting inwards.	Eminentia collateralis, formed by the inward projection of the collateral sulcus.

The *descending cornu* passes at first backwards and outwards round the posterior part of the optic thalamus, then downwards, forwards and inwards.

Connections :—

<i>Roof.</i>	<i>Floor.</i>	<i>Inner Wall.</i>	<i>Outer Wall</i>
Fibres of corpus callosum passing to temporo-sphenoidal lobe.	Hippocampus major.	Pia mater.	White substance of the hemisphere.
Amygdaloid tubercle.	Tænia hippocampi.		
	Choroid plexus.		

The *hippocampus major* ; a large white projection in the full extent of the floor of the descending cornu. It corresponds with the dentate sulcus. The anterior extremity becomes enlarged and indentated, forming the *pes hippocampi*.

Tænia hippocampi or *fimbria* : a narrow white band prolonged from the posterior pillar of the fornix, and lying along the inner margin of the hippocampus major.

The **septum lucidum** is a double vertical partition between the lateral ventricles, attached to the fornix and rostrum below, and to the under surface of the body of the corpus callosum above. Between the layers is the 5th ventricle, closed in the adult, but in the fœtus communicates with the 3rd ventricle by an opening placed between the pillars of the fornix.

The **fornix** consists of two white longitudinal strata beneath the corpus callosum, separated in front and behind, forming the pillars, but joined in the middle, forming the body.

The *body* is triangular in shape, the base being placed posteriorly, and here connected with the corpus callosum. In front of this it is connected with the septum lucidum along its upper surface. The lateral margins are free, lying against the choroid plexus of the lateral ventricles. The under surface lies upon the velum interpositum.

The *anterior pillars* pass downwards, forming the anterior boundary of the foramen of Monro, then through the grey matter on the outer side of the 3rd ventricle ; and on reaching the base of the brain they make a half figure-of-eight turn, forming the white envelope of the corpora albicantia ; they then ascend and pass into the anterior nucleus of the optic thalamus. The pillars receive near the foramen of Monro the fibres of the peduncles of the pineal gland, and those of the tænia semicircularis.

The *posterior pillars* : the two strata of the fornix diverge behind, being connected at first with the splenium of the corpus callosum ; thence curving round the pulvinar they pass into the descending cornu, the outer fibres being lost on the hippocampus major, the inner ones forming the tænia hippocampi.

Between the diverging posterior pillars a portion of the splenium with transverse markings is exposed ; this is known as the *lyra*.

The **foramen of Monro** is the interval between anterior pillars of the fornix and the optic thalami. It is Y-shaped, the two limbs anteriorly communicating with the lateral ventricles on either side, and junction of the two opening into the 3rd ventricle.

The **velum interpositum** is a triangular process of pia mater prolonged through the transverse fissure and lying over the 3rd ventricle and upper surfaces of the optic thalami. Its apex reaches the foramen of Monro, and the fornix lies upon its upper surface.

Choroid plexuses:—

Of the lateral ventricle are fringed vascular processes extending from the foramen of Monro to commencement of descending cornu, and attached along the lateral margins of the velum interpositum; thence it passes into the descending cornu, resting on the *tænia hippocampi* and hippocampus, forming the *choroid plexus of the descending cornu*.

Of the 3rd ventricle: from the under surface of the velum interpositum there depend two vascular fringes, diverging behind, and forming the choroid plexus of 3rd ventricle.

Veins of Galen: two veins running backwards along under surface of the velum interpositum, and uniting posteriorly into one trunk, which opens into the straight sinus.

The **corpora striata**, so called from their appearance on section, which displays alternate white and grey bands, are two in number, one in each hemisphere, and are sometimes termed the ganglia of the hemisphere. Each consists of an ovoid mass of grey matter lying outside and in front of the optic thalamus. The largest part (*lenticular nucleus*) lies in the white matter of the hemisphere outside the lateral ventricle, and a smaller part (*caudate nucleus*) appears in the floor of that space.

The *caudate nucleus* is pear-shaped, with the larger end placed anteriorly, occupying the floor and outer wall of the anterior cornu; the narrow posterior part lying along the floor and outer wall of the lateral ventricle passes into the roof of the descending cornu.

The *lenticular nucleus* lies outside and at a lower level than the caudate nucleus, from which it is separated by a layer of white fibres, the *internal capsule*. Outside the nucleus is another stratum of white fibres, the *external capsule*, and beyond this a thin lamina of grey matter called the *claustrum*, the outer surface of which lies next to the white substance of the island of Reil.

The *tænia semicircularis* is a narrow band of white fibres attached to the anterior pillar of the fornix in front, whence it passes backwards in the floor of the lateral ventricle, between the caudate nucleus and the optic thalamus; it then passes into the roof the descending cornu, at the end of which it enters a mass of grey matter, the *nucleus amygdalæ*, continuous with the superficial grey matter at the apex of the temporo-sphenoidal lobe, and placed just under the lenticular nucleus.

The **anterior commissure** is a bundle of white fibres lying in the anterior part of the 3rd ventricle, in front of the anterior pillars of the fornix. The fibres go through the caudate nucleus, and, passing under the lenticular nucleus, ultimately enter the amygdaloid nucleus.

The **transverse fissure of the cerebrum** is a cleft in the posterior part of the brain, which is seen when the velum interpositum and choroid plexuses of the lateral ventricles are removed. It extends from the tip of the descending cornu on one side, over the optic thalami, 3rd ventricle, and mesencephalon to the top of the descending cornu on the other side.

SYNOPSIS OF COURSE OF FIBRES IN THE CENTRAL HEMISPHERES.

1. **Peduncular fibres**, connecting cord and cerebellum with cerebrum :—

- (a) *From crusta*, chiefly through internal capsule to convolutions.
- (b) *From tegmentum*, chiefly to optic thalamus ; a part joins the inner capsule, and passes to occipital and temporo-sphenoidal lobes.

The peduncular fibres, in their course to the convolutions, are reinforced by fibres from the corpora striata and optic thalami.

2. **Transverse fibres**, connecting the two hemispheres :—

- (a) *Of corpus callosum*.
- (b) *Anterior commissure*.

3. **Collateral fibres**, connecting different parts of the same hemisphere.

- (a) *Fornix*.
- (b) *Tænia semicircularis*.
- (c) *Nerves of Lancisi*.
- (d) *Gyrus fornicatus*, the fibres of which are said to encircle the corpus callosum, near the middle line, meeting at the anterior perforated space.
- (e) *Uncinate fasciculus*, a white bundle at the bottom of the Sylvian fissure, uniting the frontal and temporo-sphenoidal lobes.
- (f) *Inferior longitudinal fasciculus*, a collection of fibres passing between temporo-sphenoidal and occipital lobes.
- (g) *Association fibres*, passing between and connecting together the different convolutions.

THE MEMBRANES OF THE BRAIN.

The **DURA MATER**, the most external, is a dense fibrous membrane, which is closely attached to the bones of the skull, forming their endosteum. The inner surface is smooth, and covered with epithelium. It is continuous with the dura mater

of the spinal cord through the foramen magnum. The fibrous part of the dura mater is divided into two layers, an outer, forming the endosteum, and an inner, lying under the epithelium, forming certain processes, and which, by its separation in certain situations, forms the *sinuses* (for sinuses of dura mater, *vide* p. 99). On the upper surface, near, and projecting into the longitudinal sinus, are the *Pacchionian bodies*, which are enlarged villi of the arachnoid projecting through the layers of dura mater.

Processes of the dura mater :—

The **falx cerebri**: placed vertically between the two hemispheres of the cerebrum, attached in front to the crista galli, behind to the upper surface of the tentorium, and between these to middle line of internal surface of skull.

The **tentorium cerebelli** is placed horizontally between the cerebrum and the cerebellum. It is attached in front to the anterior and posterior clinoid processes, superior edge of the petrous bone, and behind to the upper margin of the lateral sinus.

The **falx cerebelli** reaches vertically from the tentorium to the foramen magnum, dividing the two hemispheres of the cerebellum. It is attached posteriorly to the vertical crest of the occiput, and below to each side of the foramen magnum.

The **PIA MATER** consists of a delicate stroma supporting bloodvessels, and closely invests the brain, dipping into the sulci. At the transverse fissure it is prolonged into the lateral ventricles and over the 3rd ventricle, pushing the epitheloid lining of those cavities in front of it, and forming the velum interpositum and choroid plexuses of the lateral and 3rd ventricles. It is prolonged over the roof of the 4th ventricle, sending inwards two vascular fringes, the choroid plexuses of that cavity.

The **ARACHNOID** is a thin membrane lying outside the pia mater, but is not so closely applied to the brain, as it passes over the sulci without dipping into them. Between the pia mater and the arachnoid is the *subarachnoid space*, containing the subarachnoid fluid. The space between the the dura mater and arachnoid is now known as the *subdural space*.

The **subarachnoid space** is larger in some places than in others. The arachnoid stretches across between the two middle lobes at the base of the brain, forming the *anterior subarachnoid space*, which lies anterior to the pons and reaches as far forward as the optic nerves. Beneath the cerebellum it forms in a like manner the *posterior subarachnoid space*, by stretching between the under surface of the cerebellum and the posterior surface of the medulla.

At the bottom of the longitudinal fissure the subarachnoid space is also large.

The subarachnoid space communicates with the cerebral ventricles by the *foramen of Majendie*, an opening into the 4th ventricle in the expansion of pia mater across the roof. There are two other openings through the pia mater, placed one on each side of the upper roots of the glosso-pharyngeal nerve, under the flocculus.

THE MEMBRANES OF THE SPINAL CORD.

The DURA MATER is the most external membrane, and is continuous with that investing the brain ; but it does not form the endosteum of the vertebræ, nor has it any sinuses, but it is separated from the bones by areolar tissue and a plexus of veins. It is connected above with the edge of the foramen magnum ; at the top of the sacrum it becomes impervious, and is continued as a slender cord to blend with the periosteum of the coccyx. This membrane gives sheaths to all the spinal nerves.

The PIA MATER is less vascular, thicker, and more fibrous than that investing the brain. It has an external fibrous layer of longitudinal bundles having a fold, the *linea splendens*, dipping into the anterior fissure, and a smaller one passing into the posterior fissure. The pia mater ends in a slender cord, the *filum terminale*, which is within the prolongation of the dura mater.

The ARACHNOID is placed outside the pia mater, and loosely invests the cord. The subarachnoid space of the cord is large, and is divided by an imperfect fibrous septum on each side, the *ligamentum denticulatum*, into an anterior and a posterior portion. The posterior portion is further subdivided by the *septum posticum*, which passes from the posterior fissure backwards to the opposite part of the arachnoid, and contains the larger blood-vessels. Trabeculæ also pass between the nerve roots and the inner surface of the arachnoid, and between the posterior nerve roots and the *septum posticum*.

THE NERVES.

THE NERVES OF THE HEAD AND NECK.

THE CRANIAL NERVES, 12 pairs (Söemmering) ; 9 pairs (Willis).

1ST OR OLFACTORY. *Origin* by three roots. *External*, a band of white fibres passing outwards across Sylvian fissure to front of uncinate convolution. *Middle* or grey root, from grey matter of anterior perforated spot. *Internal*, white fibres passing in longitudinal fissure to callosal convolution.

Course.—The three roots unite in a prismatic band, the olfactory tract, which passes forwards on the under surface of the frontal lobe near the longitudinal fissure, resting on cribriform plate and expanding at end into olfactory bulb. There is an enlargement at the posterior part of the upper surface called the *olfactory tubercle*.

Distribution.—About twenty prolongations are given off from under surface of bulb through ethmoidal foramina ; they are divided into three sets to supply Schneiderian membrane : *inner* to septum, *middle* to roof of nose, *outer* to superior and middle turbinate bones.

Special function.—Smelling.

2ND OR OPTIC. *Origin*, from optic tract, which arises by two roots : *Outer*, from external geniculate body, optic thalamus and brachium of superior quadrigeminal body. *Inner*, from internal geniculate body.

Course.—Winds across inferior surface of crus cerebri, uniting with fellow to form optic commissure, which is bounded in front by the lamina cinerea and behind by the tuber cinereum ; the nerves separate at fore part of commissure, get ensheathed in arachnoid, and pass into orbit through optic foramen ; whilst passing through, each receives a tube of dura mater, which divides into two, the upper piece becoming orbital periosteum, and the lower, ensheathing the nerve, joins the sclerotic in front. The nerve pierces sclerotic and choroid coats of eyeball.

Distribution.—Expands to form retina.

Special function.—Nerve of sight.

3RD OR MOTOR OCULI. *Superficial origin* : Inner side of crus cerebri, just in front of pons. *Deep origin* : floor of aqueduct of Sylvius.

Course.—Enters canal in outer wall of cavernous sinus near

posterior clinoid process, lying above and internal to 4th nerve. As it passes forwards to enter orbit through sphenoidal fissure, the 4th nerve and frontal branch of 5th cross and become superior to it. It divides into two branches in the fissure, which enter orbit between the heads of the external rectus, the nasal branch of the 5th lying between the two; whilst in cavernous sinus it communicates with cavernous plexus.

Distribution.—Superior branch supplies superior rectus and levator palpebræ. Inferior divides into three, for internal rectus, for inferior rectus, and for inferior oblique, which latter gives off short or motor root to the lenticular ganglion.

Special function.—Motor nerve of eyeball.

4TH or TROCHLEAR. *Origin*—*Superficial*: valve of Vieussens, just behind corpora quadrigemina. *Deep*: floor of aqueduct of Sylvius.

Course.—Winds round outer border of crus and pierces free border of tentorium; passes forwards in outer wall of cavernous sinus below 3rd, but enters orbit through sphenoidal fissure above the other nerves and external rectus.

Distribution.—Enters orbital surface of superior oblique.

Special function.—Motor nerve of superior oblique.

5TH or TRIFACIAL. *Origin*—*Superficial*: by anterior or small motor, and posterior or large sensory roots, the latter having a ganglion on it, from the side of the pons. *Deep*: **Sensory**: 1st, floor of 4th ventricle; 2nd, posterior horn of grey matter of medulla, and upper part of cord. **Motor**: 1st, floor of 4th ventricle; 2nd, side of aqueduct of Sylvius.

Course.—The two roots pass forwards through oval opening in tentorium cerebelli, the posterior root entering the Gasserian ganglion, lodged on the petrous part of temporal bone. The anterior root passes under ganglion and is not connected with it, but goes through foramen ovale, uniting with the internal maxillary from the ganglion.

The **Gasserian ganglion**: lodged in a depression near the apex of petrous part of temporal, gives off from its anterior edge the *ophthalmic*, *superior maxillary*, and *inferior maxillary* trunks. The two former are purely sensory, the last by joining small motor root becomes a mixed nerve.

OPHTHALMIC or 1st division of the 5th (sensory and smallest branch): courses along outer wall of cavernous sinus below 3rd and 4th nerves, to enter orbit through sphenoidal fissure. Divides in sinus into three branches, two of which, frontal and lachrymal, enter orbit above external rectus, whilst the third or nasal passes between two heads of origin of that muscle.

Branches :—

Lachrymal : passes along outer wall of orbit to under surface of lachrymal gland, joins orbital of superior maxillary, finally pierces palpebral fascia, and joins branches of facial.

Frontal : largest branch, enters orbit just outside 4th nerve, passes forward on levator palpebræ and divides into :—

Supra-trochlear : directed outwards between pulley and supra-orbital notch ; distributed to forehead and communicates with infra-trochlear.

Supra-orbital : continuation of frontal, passes through notch, supplies palpebral filaments, and ends on forehead. Communicates with facial.

Nasal : enters orbit between the heads of the external rectus, passes forwards and inwards over optic nerve along inner side of orbit, through anterior ethmoidal foramen ; re-entering cranium, it passes down nasal slit by the side of the crista galli, dividing into two terminal branches, viz. :—

Internal : supplying mucous membrane of the septum.

External : runs along groove on internal surface of nasal bone, then passes between bone and lateral cartilage to supply skin of ala, and tip of nose. Communicates with facial.

Branches from nasal in the orbit :—

Ganglionic : arises between heads of external rectus, passes along outer side of optic nerve, entering the posterior superior angle of lenticular ganglion, of which it forms the long or sensory root.

Long ciliary (2 or 3) pass along inner side of optic nerve, join some short ciliary branches from ganglion, and, piercing sclerotic, are distributed to ciliary muscle and iris.

Infra-trochlear : given off as nerve enters anterior ethmoidal foramen ; it passes to inner angle of orbit, communicating beneath 'pulley' with the supra-trochlear of frontal. It supplies lachrymal apparatus, skin of eyelids and root of nose.

The LENTICULAR GANGLION is a small reddish-coloured body, placed between the optic nerve and the external rectus, at the back part of the orbit.

Branches of communication or roots :—

Long or sensory root : from the nasal of the ophthalmic, joins posterior superior angle.

Short or motor root : from the branch of the 3rd nerve supplying inferior oblique, joins posterior inferior angle.

Sympathetic : from the cavernous plexus, and frequently joined with the long or sensory root.

Branches of distribution :—

Short Ciliary Nerves : Ten or twelve given off in two bundles, large inferior and small superior. Pass forwards

above and below optic nerve, with long ciliary of nasal. The branches subdivide and, piercing sclerotic, run in grooves on its internal surface to end in ciliary muscle and iris.

THE SUPERIOR MAXILLARY NERVE (sensory) passes from the middle of the Gasserian ganglion through foramen rotundum, then across speno-maxillary fossa to enter the infra-orbital canal, and here receives the name of *infra-orbital*. Emerging on the face from the infra-orbital foramen under the elevator of the upper lip, it divides into a number of branches for the nose, the eyelid and the upper lip, and joins with branches of the facial nerve to form the infra-orbital plexus.

Branch in the Skull :—

Recurrent : given off near origin to dura mater and middle meningeal artery.

Branches given off in the Speno-maxillary fossa :—

Orbital or temporo-malar : enters orbit by speno-maxillary fissure and directly divides into :—

Temporal : passes along groove in outer wall of orbit, here communicating with the lachrymal ; it then goes through a foramen in the malar bone, and, entering the temporal fossa, joins branches from the facial and auriculo-temporal nerves. Piercing the temporal aponeurosis, it then becomes cutaneous.

Malar : passes to lower and outer angle of orbit, goes through malar foramen, and communicating with the facial becomes cutaneous.

Spheno-palatine (2) descend to Meckel's ganglion.

Posterior dental : comes off just before nerve enters canal, and divides into :—

External branch : passes downwards to the gums.

Internal branch : enters a canal in the superior maxilla, and runs along outer wall of antrum ; supplies the molar teeth and mucous membrane of the antrum. Communicates with anterior dental.

Branches arising within the infra-orbital canal :—

Anterior dental : descends in a canal in anterior wall of antrum, and divides into two branches :—

The *inner*, supplying incisors and canine teeth.

The *outer or middle dental*, supplying the bicuspid teeth.

Branches arising on the face :—

Inferior palpebral : supplies integument of lower lid, communicating with facial, and malar of orbital.

Lateral nasal : to integument of side of nose. Joins nasal of ophthalmic.

Superior labial : three or four branches to integument of upper lip.

The SPHENO-PALATINE or MECKEL'S GANGLION is deeply placed in the spheno-maxillary fossa, near the spheno-palatine foramen.

Roots :—

Motor from the facial. (Large superficial petrosal nerve.)

Sympathetic from the carotid plexus. (Large deep petrosal nerve.)

Sensory from the superior maxillary. (Spheno-palatine nerves.)

Branches of distribution :—

Ascending : three or four small branches to the periosteum of the orbit.

Descending : mostly continuous with spheno-palatine of superior maxillary nerve.

The *anterior* or *large palatine nerve* passes through large posterior palatine canal to hard palate, there dividing into branches which run forward in grooves in the bone nearly to the incisor teeth, joining the naso-palatine nerve by ascending nasal branches through anterior palatine canal. It supplies the gums and mucous membrane of hard palate. Whilst in the posterior palatine canal it gives off the *inferior nasal branches* which supply mucous membrane on middle and inferior spongy bones.

The *posterior* or *small palatine nerve* enters smaller posterior palatine canal to reach the soft palate, supplying levator palati and azygos uvulæ muscles.

The *external palatine nerve* passes through external palatine canal to the tonsil and soft palate.

Internal.

Superior nasal (4 or 5) through spheno-palatine foramen to supply the posterior and upper part of the superior meatus.

The *naso-palatine nerve* (nerve of Cotunnus) crosses roof of nasal fossa to septum, on which it passes downwards and forwards to the anterior palatine canal in the canal of Scarpa, the left nerve being anterior, and, communicating with the large palatine nerve, ends in the gums of the incisor teeth. Branches are given to the mucous membrane over the septum.

Posterior.

The *Vidian nerve* passes backwards through Vidian canal, here giving off the *upper posterior nasal branches* to the back part of the roof of the nose. On emerging from the canal it divides in the foramen lacerum into a *large deep petrosal nerve*, which joins the sympathetic on the carotid artery, and a *large superficial petrosal nerve*, which runs along a groove on the petrous bone to the hiatus Fallopii, and, passing into the Fal-

lopidian aqueduct, joins the geniculate ganglion on the facial nerve. As the motor root of Meckel's ganglion, it may be traced forwards from facial nerve.

The *pharyngeal nerve* may come off from the ganglion, or from the Vidian nerve, enters pterygo-palatine canal, and ends in the mucous membrane of the palate, near the Eustachian tube.

The INFERIOR MAXILLARY NERVE is the largest of the three divisions of the 5th. The large sensory root comes from the inferior angle of the Gasserian ganglion, which is joined near the foramen ovale by the small motor root from the trunk of the 5th nerve. The united trunk leaves skull by foramen ovale, and immediately divides into anterior and posterior trunks.

Branch from the trunk :—

Recurrent : passes backwards with the middle meningeal artery, through foramen spinosum, to supply dura mater.

Branches from the anterior division :—

Masseteric : pass outwards over sigmoid notch with artery, to deep surface of masseter.

Deep temporal (3) : *anterior*, from the buccal nerve, to supply front of temporal muscle ; *middle*, passes over external pterygoid to deep part of temporal muscle ; *posterior*, often united with masseteric nerve, to back part of temporal muscle.

Buccal (sensory) : comes out between heads of external pterygoid to reach buccinator, and is frequently joined to the middle temporal and external pterygoid nerves ; communicates with facial.

Pterygoid : *internal*, to deep surface of internal pterygoid, connected near origin with otic ganglion ; *external*, to external pterygoid (generally given off from buccal).

Branches from the posterior division :—

The **auriculo-temporal nerve** comes off by two roots, between which the middle meningeal artery passes ; passes under external pterygoid muscle to neck of jaw, then upwards, with temporal artery, beneath parotid to temporal fossa, where, becoming cutaneous, it is called the superficial temporal.

Branches of the Auriculo-temporal :—

Inferior auricular : to ear below meatus.

Superior auricular : to integument of tragus, pinna, and to membrana tympani.

Communicating : to otic ganglion and facial.

Superficial temporal : to top of skull with artery, joins temporal branches of facial.

Posterior temporal : to *attrahens aurem*, etc.

Parotid : to gland.

Temporo-maxillary: to joint.

The **inferior dental nerve** passes internal to external pterygoid muscle, and posterior to the lingual nerve; then between the ramus of jaw and internal lateral ligament, to the dental foramen, along which canal it runs with the dental artery. It supplies the molar and bicuspid teeth, and emerges at the mental foramen, having just previously divided into two branches, one of which (incisor) is continued in the bone, and the other (mental) is continued over the chin.

Branch before entering the dental foramen:—

Mylo-hyoid: descends in a groove on the inner side of ramus of jaw to outer side of mylo-hyoid muscle, supplying it and giving a branch to the anterior belly of the digastric.

Branches given off in the dental canal:—

Dental: to molars and bicuspid.

Incisor: to canines and incisors.

Mental: passes out of mental foramen, and divides into branches which supply integument of chin and lower lip, and communicate with the facial.

The **gustatory or lingual nerve** lies at first internal to the external pterygoid muscle; it then passes downwards in front of the inferior dental nerve, and is joined at an acute angle by the *chorda tympani* from the facial. Thence it passes downwards and forwards between internal pterygoid and ramus, over the superior constrictor of the pharynx and deep part of submaxillary gland, to the side of the tongue, and, passing under Wharton's duct, is continued to the tip of the tongue.

Branches:—

Communicating: with inferior dental at commencement; with facial through *chorda tympani*; branches are sent also to submaxillary ganglion and the hypoglossal nerve.

Distributory: to mucous membrane of sides and tip of tongue, the gums and sublingual gland, the terminal branches supplying anterior $\frac{2}{3}$ of mucous membrane of dorsum.

The **SUBMAXILLARY GANGLION** lies between the hyoglossus muscle and the deep part of the submaxillary gland.

Roots:—

Motor and sensory: the connecting branch from the lingual supplies sensory and motor from the facial, through the *chorda tympani*.

Sympathetic: from plexus round facial artery.

Branches:—

Five or six small twigs supply the submaxillary gland, the mucous membrane, and Wharton's duct.

The **OTIC GANGLION** (Arnold's) lies on the inner surface of

the inferior maxillary nerve, close to the foramen ovale, and is connected with the commencement of the nerve to the internal pterygoid muscle.

Roots :—

Motor and sensory : from the inferior maxillary, by the branch to the internal pterygoid.

Sympathetic : from plexus on middle meningeal artery, which lies just behind.

The *small superficial petrosal nerve* passes into the posterior part of the ganglion connecting it with the facial and glossopharyngeal nerves.

Branches :—

Communicating : to auriculo-temporal, and to chorda tympani.

Muscular : to the tensor tympani, and tensor palati.

SYNOPSIS OF THE FIFTH NERVE.

BRANCHES.

Ophthalmic.

Recurrent.

Lachrymal :

Lachrymal.

Palpebral.

Frontal :

Supra-orbital.

Supra-trochlear.

Nasal :

Ganglionic.

Long ciliary.

Infra-trochlear.

Nasal, internal and external.

Superior Maxillary.

Recurrent.

Orbital :

Malar.

Temporal.

Spheno-palatine :

Posterior dental, external and internal.

Anterior dental.

Infra-orbital.

Inferior palpebral.

Lateral nasal.

Superior labial.

Inferior Maxillary.*Recurrent.**Motor Part :*

Deep temporal.

Masseteric.

Buccal.

Pterygoid.

*Sensory Part.**Auriculo-temporal :*

Auricular, inferior and superior.

Parotid.

Temporal, posterior and superficial.

Temporo-maxillary.

Communicating.

Inferior Dental :

Mylo-hyoid.

Dental.

Mental.

Incisor.

Lingual :

Communicating to inferior dental, ganglion, and hypoglossal.

Distributory to tongue.

Nerve to Internal Pterygoid.

GANGLIONS IN CONNECTION WITH THE 5TH NERVE.

Ophthalmic Ganglion.*Roots :*

From nasal.

From 3rd nerve.

From sympathetic.

Branch of Distribution :

Short ciliary nerves.

Meckel's Ganglion.*Roots :*

Facial.

Carotid plexus.

Superior maxillary.

Internal Branches :

Nasal.

Nasopalatine.

Ascending :

Orbital.

Meckel's Ganglion (*continued*) :*Descending :*

Large palatine.
Small palatine.
External palatine.

Posterior :

Vidian.
Pharyngeal.

Submaxillary Ganglion.*Roots :*

Lingual.
Chorda tympani.
Sympathetic.

Distributory :

To gland, etc.

Otic Ganglion.*Roots :*

Inferior maxillary.
Sympathetic.
Small superficial petrosal.

Branches :

To auriculo-temporal.
Chorda tympani.
To Tensor tympani.
To Tensor palati.

The 6TH or ABDUCENS OCULI. *Origin*—*superficial* : from the outer side of corpus pyramidale, and from the lower border of the pons. *Deep* : floor of 4th ventricle beneath fasciculus teres.

Course.—Pierces dura mater to reach cavernous sinus ; lies to outer side of internal carotid, and below the other nerves. Enters orbit by sphenoidal fissure, between the heads of the external rectus, lying above ophthalmic vein.

Distribution.—External rectus.

Relations.—The following table shows how the nerves of the orbit change their position to one another. They lie from above down.

*In the Cavernous
Sinus.*

In the Sphenoidal Fissure.

Third.

Fourth. Frontal. Lachrymal.

Fourth.

(Above the muscles.)

Fifth.

Superior division of 3rd

Sixth.

Nasal branch of 5th

Inferior division of 3rd

Sixth

} Enter between the
heads of external
rectus

The 7TH or FACIAL (portio dura of 7th pair of Willis). *Origin—Superficial*: from the groove between the olivary and restiform bodies of medulla. *Deep*: floor of 4th ventricle, anterior and external to nucleus of 6th nerve.

Course.—Passes forwards and outwards to enter the internal auditory meatus; it lies upon a groove on the auditory nerve, with portio intermedia of Wrisberg between, and at the bottom of the meatus it enters the aqueductus Fallopii, along which it runs first outwards between cochlea and vestibule as far as hiatus Fallopii; then backwards in internal wall of tympanum, just above fenestra ovalis, at the turn presenting a swelling, the *geniculate ganglion*; and finally it passes downwards, to emerge from the bone at the stylo-mastoid foramen; it then passes forwards in the parotid, dividing behind the ramus of jaw into *temporo-facial* and *cervico-facial* branches, which further subdivide and intercommunicate, forming the *pes anserinus*.

Communications:—

In the meatus, with *auditory*.

In the aqueductus, with *Meckel's ganglion* by large superficial petrosal; *otic ganglion* by small superficial petrosal; *plexus on middle meningeal* by external superficial petrosal.

At exit from foramen, with *pneumogastric*, *glosso-pharyngeal*, *carotid plexus*, *great auricular*, *auriculo-temporal*.

On the face, with the *three divisions on the 5th*.

Branches within the Aqueduct:---

Communicating from the geniculate ganglion to the auditory.

Large superficial petrosal passes from geniculate ganglion through hiatus Fallopii, then through foramen lacerum to Vidian canal, where it joins the large deep petrosal to form the Vidian nerve (*vide p. 143*).

Communicating with the small superficial petrosal nerve (*vide p. 146*).

External superficial petrosal: from geniculate ganglion to plexus on middle meningeal artery.

Tympanic: to the stapedius.

Chorda tympani: given off just before exit from stylo-mastoid foramen, ascends to tympanum through *iter chordæ posterius*; it courses then between membrana tympani and base of pyramid, and between handle of malleus and long process of incus; it leaves tympanum by *iter chordæ anterieus*, and, passing through Huguier's canal, emerges at the inner end of the Glaserian fissure, then forwards between two pterygoids to join gustatory or lingual. It forms the sensory root of sub-maxillary ganglion, and ends in the tongue.

Communicating with the auricular branch (Arnold's nerve) of the pneumogastric.

Branches given off at exit from Foramen :—

Posterior auricular : passes up behind and between mastoid process and meatus, dividing into *auricular* to supply *retrahens aurem*, and *occipital* to integument of occiput ; communicates with auricular of pneumogastric, great auricular, and small occipital.

Stylo-hyoid : to muscle, joins carotid plexus.

Digastric : given off with former to supply posterior belly of digastric, and join glosso-pharyngeal.

Branches on the Face :—

Divides near ramus of inferior maxilla into temporo-facial and cervico-facial.

The TEMPORO-FACIAL crosses over external carotid and temporo-maxillary vein, communicating with auriculo-temporal and supplying pinna.

Branches of the Temporo-facial :—

Temporal : supply *atrahens aurem*, joining temporal of superior maxillary and auriculo-temporal of inferior maxillary ; anterior branches supply *orbicularis palpebrarum* and *occipito-frontalis*, joining lachrymal and supra-orbital nerves.

Malar : to supply eyelid muscles, and join supra-orbital.

Infra-orbital : *superficial*, to skin and superficial muscles of face, join *infra-trochlear*, and nasal (5th). *Deep*, to elevators of upper lip and angle of mouth, join *infra-orbital* of superior maxillary.

The CERVICO-FACIAL passes downwards and forwards in parotid, receiving communications from the great auricular nerve.

Branches of the Cervico-facial :—

Buccal : to buccinator and sphincter oris ; joins buccal of inferior maxillary.

Supra-maxillary : to muscles of lip and chin ; join mental branch of inferior dental.

Infra-maxillary : perforates deep cervical fascia beneath lower jaw, to join superficial cervical and supply platysma.

The 8TH or AUDITORY NERVE (*portio mollis* of 7th pair of Willis). *Origin*—*Superficial*, restiform body, floor of the 4th ventricle, by the *lineæ transversæ*. *Deep*—*upper root* : lateral angle of 4th ventricle ; *lower root* : inner auditory nucleus.

Course.—Passes round restiform body, from which it receives some fibres, to posterior border of crus cerebelli with facial ; it then enters the internal auditory meatus with the facial nerve, the latter lying in a groove on its upper surface, and divides at the bottom into *cochlear* and *vestibular* branches.

Distribution.—*Cochlear*, enters foramen spiralis and supplies

cochlea and posterior semicircular canal; *vestibular*, to vestibule and superior and external semicircular canals (*vide* Ear).

The 9TH OR GLOSSO-PHARYNGEAL NERVE of 8th pair of Willis. *Origin*—*Superficial*: from the upper part of the lateral tract of the medulla. *Deep*: floor of 4th ventricle.

Course.—Passes outwards over the flocculus to the jugular foramen. Leaves the skull with the pneumogastric and spinal accessory, but in a separate tube of dura mater and in front and internal of them, being contained in a canal in the petrous part of the temporal bone. It presents near point of exit two ganglion enlargements—the *jugular* and *petrous*. Issuing from the skull, the nerve passes between the internal carotid artery and jugular vein, downwards behind the muscles attached to the styloid process, to reach the lower border of the stylo-pharyngeus. Thence it is inclined inwards beneath the hyo-glossus to the tongue, pharynx, and tonsil.

The **jugular ganglion**: the smaller of the two, is situated at the upper part of the groove in the temporal bone through which the nerve passes. It involves only the outer side of the trunk of the nerve.

The **petrous ganglion** is placed in a depression on the inferior border of the petrous bone.

Branches:—

Connecting, from petrosal ganglion:

- (a) To upper cervical ganglion of sympathetic.
- (b) To auricular of pneumogastric.
- (c) To ganglion of root of the pneumogastric.

Tympanic (Jacobson's nerve): arises from the petrous ganglion, enters a minute canal in the bone between jugular foramen and carotid canal to reach the under wall of the tympanum, runs in a groove over the promontory, giving off several branches, and, leaving the upper end of the tympanum, is continued forwards as the *small superficial petrosal nerve* (*vide* p. 146). It divides into six branches, which form the tympanic plexus on the promontory.

Three *branches of communication*, to the carotid plexus and small deep petrosal nerve, to the great superficial petrosal nerve, and to the otic ganglion respectively.

Three *branches of distribution*, to the fenestra ovalis, fenestra rotunda, and membrane of the Eustachian tube respectively.

Carotid: Descend along the internal carotid artery, communicating with pharyngeal of pneumogastric and sympathetic.

Pharyngeal (3 or 4): join opposite the middle constrictor

with pharyngeal of pneumogastric and sympathetic, supplying the mucous membrane of the pharynx.

Muscular: to stylo-pharyngeus and mucous membrane over upper constrictor muscle.

Tonsillitic: to the tonsil forming plexus, the circulus tonsillaris, and thence to fauces and soft palate.

Lingual (2): one branch distributed to the base supplying the circumvallate papillæ, the other to the side of the tongue.

Special functions.—Nerve of sensation to the mucous membrane of pharynx, fauces and tonsil; of motion to stylo-pharyngeus muscle; and of taste of the tongue.

THE 10TH NERVE—THE PNEUMOGASTRIC or VAGUS of the 8th pair of Willis. *Origin—Superficial:* lateral tract behind olivary body. *Deep:* calamus scriptorius of 4th ventricle.

Course.—Passes from origin over the flocculus to jugular foramen, through which it passes in same sheath with spinal accessory and behind the glosso-pharyngeal; in the foramen it presents the ganglion of the root. Upon leaving the foramen, it is connected with the accessory part of the spinal accessory, and forms an enlargement, the ganglion of the trunk. The accessory part of the spinal accessory nerve passes over the ganglion, some fibres joining the trunk of the nerve, but the principal portions are continued into the pharyngeal and superior laryngeal branches. Thence the nerve passes down the neck in the carotid sheath, behind and between the artery and vein, to the root or the neck; there the course on each side of the body becomes different.

The *right* nerve passes between subclavian artery and vein, and down by side of trachea and behind right innominate vein to posterior part of the root of the lung, forming the posterior pulmonary plexus; thence proceed two cords, which run down on the œsophagus, communicate with nerve of opposite side (œsophageal plexus), join below into one trunk, which is distributed to the posterior surface of the stomach, joining solar and splenic plexuses.

The *left* nerve passes between the subclavian and carotid arteries, and behind the left innominate vein; thence in front of the arch of aorta to back part of root of left lung, forming a posterior pulmonary plexus; then along the anterior surface of œsophagus, to be distributed on the anterior surface of stomach, and join left hepatic plexus.

Connecting branches:—

The ganglion of the root is connected to the spinal accessory, petrous ganglion of the glosso-pharyngeal, facial and sympathetic nerves.

The ganglion of the trunk is connected with the hypoglossal, spinal accessory, sympathetic, and loop between 1st and 2nd cervical nerves.

Branches:—

Recurrent: from the upper ganglion, passes backwards to the dura mater of the posterior fossa.

Auricular (Arnold's): from the ganglion of the root, communicates with the petrous ganglion of the glosso-pharyngeal, and enters a foramen between the root of the styloid process and jugular fossa. It passes through the temporal bone communicating with the facial, and emerges by the auricular fissure just behind the external auditory meatus. Finally it divides into two branches, to supply the back of the pinna, which join the posterior auricular of the facial.

Pharyngeal: principally formed by fibres from the accessory of spinal accessory, passes in front of internal carotid artery to upper part of middle constrictor, where it joins glosso-pharyngeal, superior laryngeal, and sympathetic to form the pharyngeal plexus.

Superior laryngeal: from the ganglion of the trunk, passes down behind internal carotid artery, where it divides into *external laryngeal nerve*, which joins pharyngeal plexus and upper cardiac of sympathetic, supplies the crico-thyroid and inferior constrictor muscle and *internal laryngeal nerve*, which passes to thyro-hyoid membrane, is distributed to the mucous membrane of the larynx, and communicates with a branch from the recurrent laryngeal.

Inferior or recurrent laryngeal: the *right* nerve arises in front of subclavian artery, winds back round it, and passes up behind common carotid and inferior thyroid arteries to side of trachea. The *left* nerve arises from front of arch of aorta, round which it winds and passes up by side of trachea. Both nerves ascend in a groove between trachea and œsophagus, and enter larynx by piercing inferior constrictor muscle. The nerve supplies all the muscles of the larynx, except the crico-thyroid, the inferior constrictor, communicates with the internal branch of the superior laryngeal, and gives branches to the cardiac plexus, inferior cervical ganglion of the sympathetic, to the trachea, and to the œsophagus.

Cervical cardiac (2 or 3): Upper branches are small; join cardiac of sympathetic. Inferior, one on either side, arise just above 1st rib; the *right* one passes by the side of innominate artery and joins deep cardiac plexus; the *left* one descends in front of the arch of the aorta, and joins superficial cardiac plexus.

Thoracic cardiac : *right* ones from the trunk of the nerve, end in deep cardiac plexus. *Left* ones arise from left recurrent laryngeal.

Anterior pulmonary (2 or 3) : to anterior part of root of lung, joining with sympathetic to form the anterior pulmonary plexus.

Posterior pulmonary : numerous, to posterior part of root of lung, which join branches from 2nd, 3rd, and 4th thoracic ganglia of sympathetic, forming the posterior pulmonary plexus.

Œsophageal : to œsophagus, forming a plexus.

Gastric : the *right* nerve is distributed to posterior part of stomach, and ends in the solar, splenic and left renal plexuses. The *left* supplies the anterior surface and ends in the left hepatic plexus.

THE 11TH OR SPINAL ACCESSORY NERVE of 8th pair of Willis. *Origin—Superficial :* the *accessory* part from the lateral tract, the *spinal* part from the side of the cord as low down as the 6th cervical nerve. *Deep :* anterior horn of grey matter of medulla, and reaching from olivary body to 5th cervical nerve.

Course.—The *accessory* part passes out of the jugular foramen close to the pneumogastric, and sends one or two branches to the ganglion of the root. It does not blend with the ganglion of the trunk, but joins nerve below. The principal part joins pharyngeal and superior laryngeal branches, but offsets are sent to the cardiac and inferior laryngeal branches. The *spinal* part enters skull through foramen magnum and passes to jugular foramen ; it is enclosed in the same sheath of dura mater as the vagus. Issuing from the foramen, it passes downwards and backwards in front of the internal jugular vein to upper part of sterno-mastoid, which it pierces, at the same time communicating with the branch to the muscle from the cervical plexus. Crossing the occipital part of the posterior triangle, it enters the under surface of the trapezius, where it joins with branches of the 3rd and 4th cervical nerves to form a plexus in the substance of the muscle.

Distribution.—Supplies sterno-mastoid and trapezius muscles.

THE 12TH, or HYPOGLOSSAL NERVE, of 9th pair of Willis. *Origin—Superficial :* by ten or twelve filaments, from the groove between the olivary body and pyramid. *Deep :* nucleus at lower part of fasciculus teres.

Course.—The nerve passes through anterior condylar foramen, then downwards and forwards between vagus and spinal accessory, between internal carotid artery and internal jugular

vein to the lower border of the digastric muscle; curving round the occipital artery, it crosses the external carotid and lingual arteries, and passes between the mylo-hyoid and hyoglossus muscles; entering the genio-hyo-glossus, it is continued forward to the tip of the tongue.

Branches :—

Communicating. To the ganglion of the trunk of pneumogastric.

To the upper cervical ganglion of the sympathetic.

To the loop between 1st and 2nd cervical.

To the lingual branch from the pharyngeal plexus.

To the lingual of the 5th, on the hyo-glossus.

Distributing :—

Descendens cervicis vel hypoglossi vel noni : a slender branch, given off as the nerve hooks round occipital artery, passes down over carotid sheath, joining in a loop with 2nd and 3rd cervical (communicans noni); from this loop muscular branches are given to sterno-hyoid, sterno-thyroid, and the two bellies of the omo-hyoid.

Thyro-hyoid : passes round great cornu of hyoid bone to supply thyro-hyoideus.

Muscular : to stylo-glossus, hyo-glossus, genio-hyoid, genio-hyo-glossus and intrinsic muscles of the tongue.

THE SPINAL NERVES.

There are 31 pairs of spinal nerves, viz. : 8 cervical, 12 dorsal, 5 lumbar, 5 sacral, and 1 coccygeal. Each nerve arises from the spinal cord by an anterior (motor) and a posterior (sensory) root, the latter having a ganglion developed upon it. These roots join together in the intervertebral foramen, and upon issuing from it immediately split up again into two parts, the anterior and posterior primary divisions, each containing fibres from the two roots. The anterior primary divisions supply the parts in front of the spine, the posterior primary divisions the parts behind that column.

THE POSTERIOR PRIMARY DIVISIONS.

The posterior primary divisions of the spinal nerves are generally smaller than the anterior, and pass directly backwards, each quickly dividing into an *external* and an *internal* branch, to supply the muscles and integuments behind the spine. To this general rule there are a few exceptions, as posterior primary divisions of the 1st cervical, the 4th and 5th sacral, and the coccygeal nerves do not thus subdivide.

The sub-occipital nerve.—The posterior primary division of the 1st cervical or sub-occipital nerve passes over the arch of atlas, and, entering the sub-occipital triangle, divides into branches to supply the inferior oblique, which branch communicates with the 2nd cervical nerve, the recti postici major and minor, the superior oblique, and the complexus.

THE CERVICAL NERVES.—With the exception of the sub-occipital nerve, the posterior primary divisions of the cervical nerves divide into :—

External branches : for the muscles behind the spine.

Internal branches are larger than the external branches, and, with the exception of that from the 2nd cervical nerve (*great occipital*), pass to spinous processes, supplying the muscles on their way, and become cutaneous. The branch from the 3rd cervical nerve supplies the integument at the base of the occiput.

The *great occipital nerve* is the internal branch of the posterior primary division of the 2nd nerve. It passes through the complexus and trapezius, and ascends with the occipital artery to the back of the scalp, communicating with the small occipital nerve.

THE ANTERIOR PRIMARY DIVISIONS.

The anterior primary divisions of the first four cervical nerves form the cervical plexus, and those of the lower four, with part of the 1st dorsal nerve, compose the brachial plexus.

The anterior primary divisions of the 1st and 2nd cervical nerves differ in form from the rest.

The **sub-occipital nerve**, or anterior primary division of the 1st cervical nerve, passes outwards in the groove on the outer side of the upper articular process of the atlas, lying behind the vertebral artery, and giving a branch to the rectus lateralis and two anterior recti. It joins the 2nd nerve, and communicates with the sympathetic on the vertebral artery, with the pneumogastric and with the hypoglossal nerves.

The **second cervical nerve** : the anterior primary division of this nerve divides into an *ascending* part which joins the sub-occipital, and a *descending* part, which joins the 3rd cervical nerve.

The **Cervical Plexus** is formed by the union of the anterior primary divisions of the first four cervical nerves. It is situated between the sterno-mastoid and the middle scalenus muscles. Each nerve except the 1st divides into an *ascending branch*, which connects it with the nerve above, and a *descending branch*, which joins it to the nerve below. From the loop be-

tween the 2nd and 3rd nerves cutaneous branches are given off to the head and neck, and from the union of the 3rd and 4th nerves superficial branches pass for the shoulder and chest, together with muscular and communicating branches.

SUPERFICIAL ASCENDING BRANCHES :—

Superficial cervical nerve : from loop between 2nd and 3rd nerves, passes forwards over the middle of the sterno-mastoid, perforates the cervical fascia, and divides beneath platysma into :—

Ascending branch : accompanies external jugular vein, communicates with the facial, and becomes cutaneous, supplies front of upper half of neck.

Descending : supplies integument as low as sternum.

Great auricular : from 2nd and 3rd. Winds round margin of sterno-mastoid to reach parotid gland. Gives off :—

Facial : over parotid to integument of face.

Auricular : to back part of pinna ; communicates with posterior auricular.

Mastoid : supplying skin over mastoid process, joining with posterior auricular of facial and small occipital.

Small occipital : from 2nd and 3rd, ascends along posterior border of sterno-mastoid to scalp, lying between ear and occipital artery ; supplies integument.

Branch :—

Auricular : supplies attollens aurem and integument.

SUPERFICIAL DESCENDING BRANCH :—

Supra-clavicular : from 3rd and 4th.

Branches :—

Sternal : to integument as far as middle line.

Clavicular : to integument over pectoral muscle, often pierces clavicle.

Acromial : to integument of shoulder.

DEEP BRANCHES (Internal) :—

Communicating : from loop between 1st and 2nd, joins sympathetic, hypoglossal, and pneumogastric nerves.

Muscular : from 1st, to recti antici major and minor and lateralis muscles.

Communicans cervicis vel hypoglossi vel noni : from 2nd and 3rd, form a loop with descendens cervicis in front of carotid vessels.

Phrenic : from 3rd and 4th, and a branch from the 5th ; lies in front of scalenus anticus, descends on it in front of subclavian artery to enter the chest, having crossed the internal mammary artery at origin, behind the subclavian vein. In the thorax it descends in front of the root of the lung, being be-

tween the pericardium and the mediastinal pleura, to the diaphragm, which it perforates, and is distributed on its abdominal surface. The *right* nerve lies outside right innominate vein and superior vena cava. The *left* nerve crosses the arch of the aorta and left pneumogastric, and is longer than the right. Filaments from each supply the pericardium and pleura.

DEEP BRANCHES (External):—

Communicating: to spinal accessory in sterno-mastoid muscle.

Muscular: to sterno-mastoid from the 2nd, levator anguli scapulæ from the 3rd and 4th, scalenus medius from the 3rd and 4th, and trapezius from the 3rd and 4th.

NERVES OF THE UPPER EXTREMITY.

The BRACHIAL PLEXUS is formed by the union and subsequent division of the anterior primary divisions of the lower four cervical and part of the 1st dorsal nerves. The following is the usual method of union and redivision:—

The 5th and 6th cervical join together outside the scalenus medius to form an upper trunk.

The 7th cervical forms a middle trunk.

The 8th cervical and the 1st dorsal form a lower trunk.

Each of these trunks then subdivides into an anterior and a posterior branch.

The anterior branches from the upper and middle trunks form the *upper* or *outer cord* of the plexus.

The anterior branch of the lower trunk forms the *lower* or *inner cord* of the plexus.

The posterior branches of all the trunks unite to form the posterior or middle cord.

The subjoined scheme will make this arrangement clear:—

C 5 }	Upper trunk	{ Posterior }	} Posterior cord.
C 6 }		{ Anterior } Outer cord.	
C 7 }	Middle trunk	{ Anterior }	
C 8 }		{ Posterior }	
D 1 }	Lower trunk	{ Posterior }	} Posterior cord.
		{ Anterior—Inner cord.	

The plexus divides into branches for the upper limb opposite the coracoid process.

Branches above the Clavicle:—

Muscular: to the longus colli and scaleni.

Nerve to the rhomboidei, from the 5th cervical, passes through scalenus medius to the base of the scapula, then under levator anguli scapulæ, supplying it, and ending on the anterior surface of the rhomboid muscles.

Nerve to the subclavius, from the trunk formed by the 5th and 6th cervical, passes upwards in front of the 3rd part of the subclavian artery to the deep surface of the subclavius, often joins phrenic.

Communicating : from the 5th to join the phrenic on the scalenus anticus.

Posterior thoracic, or external respiratory nerve of Bell : from 5th and 6th, descends behind the plexus nearly to the lower border of the serratus magnus, which it supplies.

Supra-scapular : from the union of the 5th and 6th cervical, passes beneath trapezius to upper border of scapula, enters supra-spinous fossa through supra-scapular notch, gives off two branches to the supra-spinatus, and an articular one to the joint ; thence it passes to the infra-spinous fossa, and ends in the infra-spinatus.

Branches below the Clavicle :—

The several nerves are given off as follows :—

<i>Outer cord.</i>	<i>Inner cord.</i>	<i>Posterior cord.</i>
External anterior thoracic.	Internal anterior thoracic.	Subscapular.
Musculo-cutaneous.	Nerve of Wrisberg.	Circumflex.
Outer head of median.	Internal cutaneous.	Musculo-spiral.
	Ulnar.	
	Inner head of median.	

External anterior thoracic (outer cord) : crosses over axillary artery to under surface of the pectoralis major.

Internal anterior thoracic (inner cord) : passes between axillary artery and vein to the two pectoral muscles.

Subscapular : three, from posterior cord.

Upper : the smallest, perforates upper part of subscapularis.

Lower : ends the teres major, having previously given a filament to the subscapularis.

Middle or long : runs along lower border of subscapularis with the subscapular artery to supply the latissimus dorsi.

Circumflex (posterior cord) : passes, with posterior circumflex artery, bends behind humerus at the lower border of the subscapularis, through quadrilateral space formed by teres major, scapula, long head of the triceps and humerus, and divides into—

Upper branch : winds round neck of the humerus, supplying deltoid and skin.

Lower branch : gives a branch to teres minor, which has a gangliform swelling upon it ; also branches to deltoid and integument.

Articular : to the shoulder-joint.

Cutaneous appears at posterior border of deltoid, supplies skin over lower $\frac{2}{3}$ of muscle.

Internal cutaneous (inner cord) : lies on inner side of artery, becomes cutaneous about middle of arm, and divides into two branches.

Anterior : passes behind median basilic vein, supplies front of inner side of forearm as low as wrist.

Posterior : winds over internal condyle, supplying the back of inner side of forearm to about the middle.

Lesser internal cutaneous (nerve of Wrisberg) : lies to inner side of axillary vein, communicates with the intercosto-humeral, and then descends along inner side of brachial vessels to middle of the arm, where it becomes cutaneous and supplies integument of inner side as far as inner condyle. It communicates with the posterior branch of the larger internal cutaneous.

Musculo-cutaneous (outer cord) : perforates coraco-brachialis, passing to outer side of arm between biceps and brachialis anticus, supplying those three muscles ; filaments also are given to the elbow-joint ; becomes cutaneous just above elbow, and, passing *behind* median cephalic vein, divides into—

Anterior cutaneous branch : passes along radial border of forearm, supplying ball of thumb and joining the radial.

Posterior cutaneous branch : supplies integument of lower 3rd of back of forearm on the radial side ; joins branches of radial and musculo-spiral (external cutaneous branch).

Median : arises by two roots, one from the outer cord, the other from the inner cord of the plexus. At first the nerve lies to the outer side of the axillary artery, but about the middle of the arm it crosses the brachial artery to reach the inner side ; it then passes between the two heads of the pronator radii teres, and is continued straight down to 2 inches above the wrist beneath the flexor sublimis ; there it lies between the tendons of the flexor sublimis and flexor carpi radialis. Passing beneath the annular ligament, it becomes somewhat flattened, and divides into two parts for supplying the outer $3\frac{1}{2}$ fingers.

Branches in the Forearm :—

Muscular : to all superficial muscles in front of forearm except flexor carpi ulnaris.

Anterior interosseous : is given off just below the elbow-joint. It passes with the anterior interosseous artery on the membrane, between the flexor profundus and flexor pollicis, to end in the deep surface of pronator quadratus. Supplies all the deep muscles except inner half of flexor profundus.

Palmar cutaneous : pierces fascia just above annular ligament, ends in the integument of the palm, joining the palmar cutaneous of the ulnar nerve.

Terminal branches in the Hand:—

Muscular to thumb : supplies adductor, opponens, and outer head of flexor brevis pollicis.

Digital : five in number, supplying outer $3\frac{1}{2}$ fingers. 1st and 2nd supply the thumb, 3rd to radial side of index fingers also supplies 1st lumbricalis ; 4th supplies 2nd lumbricalis and adjacent side of index and middle fingers ; 5th supplies adjacent sides of ring and middle fingers, and joins a branch of the ulnar.

Ulnar (inner cord) : passes down the inner side of artery to middle of arm ; it then runs with inferior profunda artery through internal intermuscular septum to groove between olecranon and internal condyle. Thence it passes through the two heads of the flexor carpi ulnaris and descends under cover of that muscle, along ulnar side of forearm and internal to ulnar artery, as far as the pisiform bone ; it then courses over the annular ligament outside that bone, and divides into superficial and deep palmar branches.

Branches in the Forearm:—

Articular : to elbow and wrist joints.

Muscular : to flexor carpi ulnaris and inner half of flexor profundus.

Cutaneous : arises near middle of forearm, and divides into : *superficial* to integument, and *palmar*, accompanies ulnar artery to hand, supplying the palm : joins the cutaneous of median.

Dorsal cutaneous : comes off about 2 inches above wrist, winds round ulna beneath flexor carpi ulnaris, supplies inner side of little fingers, and adjacent sides of ring and little fingers on the dorsal aspect.

Palmar branches:—

Superficial : supplies palmaris brevis, ends in two digital branches for inner $1\frac{1}{2}$ fingers, the outer one communicating with the median.

Deep : accompanies deep palmar arch ; it supplies the small muscles of the 5th finger, and gives two branches to each interosseous space, one for each set of interossei ; branches are also given to the two inner lumbrical muscles. In the space between the thumb and index finger the nerve ends by supplying the adductor obliquus, adductor transversus, and inner head of the flexor brevis pollicis.

Musculo-spiral (posterior cord) : winds round in the musculo-spiral groove with superior profunda artery to the outer side of arm. Piercing the external intermuscular septum, it passes to the external condyle between the supinator longus and brachialis anticus, where it divides into radial and posterior interosseous nerves.

Branches in the Arm :—

Muscular : to the three heads of the triceps, to the anconeus, supinator longus, extensor carpi radialis longior, and brachialis anticus.

Cutaneous : Internal, comes off near axilla, supplies integument on back of arm to near olecranon. *External* (2), upper one perforates outer head of triceps, accompanies cephalic vein to elbow, supplying the integument of the lower half of arm in front. Lower one supplies integument of lower part of arm, and back part of radial side of forearm as far as the wrist.

Terminal branches :—

Radial : passes down by outer side of radial artery, under cover of the supinator longus, till within 3 inches of the end of the radius, where the nerve passes backwards beneath the tendon and, becoming cutaneous by piercing the fascia on outer side of forearm, divides into two branches :—

External : supplies ball and outer border of thumb, joining with the external cutaneous nerve.

Internal : joins a branch of the external cutaneous and dorsal of ulnar. It gives off four digital nerves, thus : 1st to inner side of thumb, 2nd to outer side of index, 3rd to adjacent sides of index and middle, 4th to adjacent sides of middle and ring fingers. It thus corresponds in its distribution with the median nerve.

Posterior interosseous : reaches the back of the forearm by piercing the supinator brevis ; there it passes between the superficial and deep layers of muscles to about middle of forearm, where it reaches the interosseous membrane, on which it lies, as far as the wrist ; it there ends in a gangliform enlargement, from which there are given off filaments to the ligaments, etc. Supplies all the supinators and extensors of carpus and fingers *except* supinator longus and extensor carpi radialis longior.

NERVES OF THE BODY.

DORSAL : twelve in number. The 1st comes from between the 1st and 2nd dorsal vertebræ, and the greater part joins the brachial plexus. The last nerve emerges from between the 12th dorsal and 1st lumbar vertebræ. Each nerve at its exit from the intervertebral foramen divides into an anterior and posterior primary division. The 1st and 12th nerves, however, require a separate description.

The **POSTERIOR PRIMARY DIVISIONS**, or *dorsal* branches, pass between the transverse processes and divide into external and internal branches to supply the muscles of the back. *Cutaneous*

branches are derived from each of these sets, the six upper ones coming from the internal branches and the six lower ones from the external branches.

The ANTERIOR PRIMARY DIVISIONS, or *intercostal nerves*, are twelve in number on each side; each communicates with the sympathetic.

The UPPER six pass forwards in the intercostal spaces below the vessels, lying at first between the pleura and external intercostal muscle, then between the external and internal intercostal muscles; after giving off the lateral cutaneous branch, it lies in the internal intercostal muscle, and then between the muscle and pleura, extending forwards to the sternum, to end as the anterior cutaneous nerves of the thorax by perforating internal intercostal and pectoralis major.

Branches :—

Lateral cutaneous: given off midway between head of rib and sternum: each branch, except that from the 2nd nerve, then divides into anterior and posterior branches, which supply the muscles, mammary gland, and integument.

The lateral cutaneous branch of the 2nd nerve, or *intercosto-humeral*, has no anterior branch; the posterior branch crosses the axilla, joins the nerve of Wrisberg, and supplies the integument of the inner side of the arm.

The 1st intercostal nerve has not generally a lateral cutaneous branch.

The LOWER six pass like the upper ones to the front of the intercostal spaces, thence between the internal oblique and transversalis to the sheath of the rectus, which they perforate, and terminate near the middle line as anterior cutaneous branches of the abdominal wall.

Branches :—

Lateral cutaneous: supply the integument of the abdomen, having anterior and posterior branches.

PECULIAR DORSAL NERVES: The 1st nerve: its *anterior primary division* is mostly consumed in the brachial plexus, but a small branch is given off to the 1st intercostal space, which has no lateral cutaneous branch. The 12th nerve does not lie in an intercostal space, but below the 12th rib in front of the quadratus lumborum; it then pierces the posterior aponeurosis of the transversalis, passing forwards between transversalis and internal oblique to end by perforating rectus; is remarkable for the large size of its lateral cutaneous branch, which does not divide, but supplies front of hip as far down as trochanter.

LUMBAR: five on each side. The ANTERIOR PRIMARY DIVISIONS increase in size from above down, and near their origin com-

municate with the sympathetic, the upper four forming the lumbar plexus; that of the 5th joins with the 1st sacral to form the *lumbo-sacral* cord. The POSTERIOR PRIMARY DIVISIONS pass between the transverse processes and divide into internal and external branches to supply the muscles and integument.

NERVES OF THE LOWER EXTREMITY.

LUMBAR PLEXUS: formed by the communications of the anterior primary divisions of the four upper lumbar nerves in the following manner:—

The 1st gives off the ilio-hypogastric, the ilio-inguinal, and a communicating branch to the 2nd.

The 2nd gives off the genito-crural, the external cutaneous, and a communicating branch to the 3rd, which also forms part of the anterior crural and obturator.

The 3rd gives off part of the anterior crural and part of the obturator.

The 4th gives off a branch to the anterior crural, one to the obturator, and a communicating one to the 5th.

The following scheme will make the arrangement clear:—

1 L.	{ Ilio-hypogastric. Ilio-inguinal. Communicating.		
2 L.	{ Communicating. Genito-crural. External cutaneous. Communicating.	Anterior Crural.	Obturator.
3 L.	Communicating.	Anterior Crural.	Obturator.
4 L.	Communicating.	Anterior Crural.	Obturator.
5 L.	Communicating.		

BRANCHES OF THE LUMBAR PLEXUS.

Ilio-hypogastric: from 1st lumbar, appears at upper part of outer border of *psaos*, crosses to iliac crest, and, piercing the *transversalis*, divides into:—

Iliac branch: crosses iliac crest behind lateral cutaneous of last dorsal to integument of buttock.

Hypogastric branch: pierces external oblique aponeurosis above abdominal ring to integument of hypogastric region.

Ilio-inguinal: from 1st lumbar; passes over *quadratus lum-*

borum and iliacus to iliac crest, pierces the transversalis and internal oblique ; it then accompanies the cord through canal and external ring, and is distributed to the integument of the groin and the scrotum.

Genito-crural : from 2nd lumbar, with a branch from 1st. Passes on the psoas to Poupart's ligament to divide into :—

Genital branch : crosses external iliac, accompanies spermatic cord, and supplies the cremaster muscle. In the female it accompanies the round ligament of the uterus.

Crural branch : passes beneath Poupart's ligament, perforates fascia on outer side of femoral artery, communicates with middle cutaneous nerve, supplies integument of upper and front of thigh.

External cutaneous : from loop between 2nd and 3rd lumbar ; perforates middle of outer border of psoas, and enters thigh just below anterior superior iliac spine, where it divides into :—

Anterior branch : contained at first in a tube of the fascia lata ; supplies outer part of anterior surface of thigh.

Posterior branch : supplies outer part of posterior surface of thigh to the middle.

Obturator : from 2nd, 3rd, and 4th lumbar ; passes from inner border of psoas, near brim of pelvis and above obturator artery, but below external iliac, to canal in upper part of thyroid foramen. *In this canal it divides into :—*

Anterior or superficial part : descends in front of adductor brevis, behind pectineus and adductor longus ; it supplies the hip-joint, gracilis, adductor longus, adductor brevis, femoral artery, and a branch to plexus near sartorius ; communicates with accessory obturator when this is present.

Posterior or deep part : passes through obturator externus and behind adductor brevis ; it supplies a large branch to adductor magnus, and gives branches also to obturator externus, adductor brevis when this latter is not supplied by the anterior branch, and a branch along popliteal artery to knee-joint.

Accessory obturator : from 3rd and 4th lumbar or from obturator trunk ; when present it supplies pectineus and hip-joint ; communicates with the anterior branch of the obturator.

Anterior crural : from 3rd and 4th, and partly from the 2nd lumbar ; emerges from lower part of outer border of psoas, and descends between that muscle and the iliacus, lying on the outer side of the iliac vessels. It supplies the iliacus and femoral artery whilst in the pelvis, and on emerging from it beneath Poupart's ligament, it divides into :—

Anterior or superficial portion : which gives off :—

Middle cutaneous : pierces fascia lata three inches below Poupart's ligament, dividing into two branches to supply the integument of the front of the thigh as far as the knee. Communicates with crural of genito-crural and internal cutaneous, and gives a branch to the sartorius.

Internal cutaneous : passes obliquely across to inner side of femoral artery, and divides into : *Anterior branch :* supplies integument of the lower 3rd of inner side of thigh ; communicates near the knee with long saphenous. *Posterior branch :* passes down posterior border of sartorius to knee, giving branches to plexus near that muscle, and finally is distributed to integument of the leg ; communicates in the thigh with the obturator, and near the knee with the internal saphenous.

Nerve to pectineus : generally two, which pass under femoral vessels to muscle.

Nerves to sartorius : given off with middle cutaneous.

Plexus patellæ : the patellar plexus is formed by communications between the anterior branch of the internal cutaneous, branches of the middle and external cutaneous nerves, together with the patellar branch of the internal or long saphenous nerve.

Deep or posterior part : which gives off :—

Internal or long saphenous : accompanies, lying on outer side, femoral vessels as far as opening in adductor magnus, where it passes inwards beneath sartorius. Here it becomes subcutaneous, and is continued with the internal saphenous vein along inner side of leg, behind inner border of tibia, and, passing in front of inner ankle, is distributed on inner side of foot as far as great toe. In its course it gives off a branch to plexus under sartorius formed by obturator and internal cutaneous nerves, to patellar plexus, and below the knee to the integument on the anterior and inner surfaces of the leg.

Muscular.—To the rectus, which gives branch to hip-joint. To the vastus externus, which gives an *articular* branch to the knee-joint, and accompanies descending branch of the external circumflex artery. To the vastus internus, which gives off an *articular* branch to the knee-joint, and accompanies the deep branch of the anastomotica magna artery. To crureus, two or three, the internal one supplying subcrureus and knee-joint.

SACRAL NERVES, five in number : upper four pass through anterior sacral foramina, the 5th through the sacro-coccygeal foramen. The roots of origin form the *cauda equina*. Each nerve divides into anterior and posterior primary branches.

The *posterior primary* branches of the upper three nerves divide into internal and external branches, the former supplying the multifidus spinæ, the latter the integument over sacrum, coccyx, and posterior gluteal region; the two lower nerves supply filaments to integument over coccyx, the 5th communicating with the coccygeal.

COCYGEAL NERVE: this nerve divides into an *anterior* branch, which pierces sacro-sciatic ligament and coccygeus, supplies integument over coccyx, and communicates with the 5th sacral, forming part of ano-coccygeal plexus; and a *posterior*, to supply coccygeal integument.

The **ANTERIOR PRIMARY BRANCHES** decrease in size from above downwards. The upper four issue from the anterior sacral foramina, the 5th emerging between sacrum and coccyx. Each nerve communicates with the sympathetic. The first three and part of the 4th nerves enter the sacral plexus, whilst the lower part of the 4th, the 5th, and the coccygeal nerve form a small plexus, ano-coccygeal, which lies on the pelvic surface of the coccygeus.

The **ano-coccygeal plexus**: formed as described above.

Branches:—

Muscular to:—

Coccygeus.
Levator ani.
Sphincter ani.

Visceral.

Vesical.
Rectal.
Vaginal (in female).

Cutaneous: to integument over coccyx.

NOTE.—The pudic nerve is sometimes taken with this plexus, the whole being then described as the ano-pudendal plexus.

The **SACRAL PLEXUS** is formed by the lumbo-sacral cord, anterior primary branches of the upper three and part of the 4th sacral nerves. Lies on anterior surface of pyriformis, behind the sciatic and pudic arteries.

Branches:—

Muscular: To pyriformis, from 2nd;

To obturator internus and gemellus superior, from lumbo-sacral cord and 1st, emerges from pelvis through great sacro-sciatic foramen, winds over ischial spine, passes in through small sacro-sciatic foramen to inner of muscle, having first supplied superior gemellus.

To quadratus femoris and gemellus inferior, given

off below preceding, passes anterior to gemelli and obturator internus tendon to anterior surface of quadratus, giving on its way a branch to gemellus inferior, and an articular branch to the hip-joint.

Superior gluteal: from lumbo-sacral cord and 1st sacral, passes out of great sacro-sciatic foramen, above the pyriformis, with the gluteal vessels; divides into a *superior* branch, which passes between the two smaller glutei, supplying the medius, and *inferior* branch, supplying the gluteus minimus and the tensor vaginæ femoris.

Pudic: comes off from the 3rd and 4th nerves, passes out of great sacro-sciatic notch between pyriformis and coccygeus internal to great sciatic nerve, winds over ischial spine, and re-enters pelvis through the small notch lying on inner side of pudic artery; it then enters, with accompanying vessels, a sheath of the obturator fascia in the outer wall of the ischio-rectal fossa and divides into its three branches.

Branches:—

Inferior hæmorrhoidal: crosses ischio-rectal fossa to supply external sphincter, skin of anus; communicates with inferior pudendal of small sciatic and superficial perineal nerves.

Perineal: largest terminal branch, accompanies perineal artery, and divides into:—

Cutaneous or superficial perineal, two in number: the *internal* passes with superficial perineal artery either under or over the transverse perinæi to supply the scrotum; the *external* gives a branch to the anus, and, piercing the deep layer of the superficial fascia, supplies the scrotum, joining the inferior hæmorrhoidal.

Muscular branches supply transversus perinæi, erector penis, ejaculator urinæ, sphincter and levator ani.

Nerve to bulb: pierces ejaculator urinæ and supplies bulb.

Dorsal nerve of the penis: accompanies pudic artery between the layers of the triangular ligament lying on the outer side of the artery, pierces the anterior layer of the ligament, and through the suspensory ligament to dorsum of penis, along which it runs as far as the glans, gives off many branches to supply the organ and compressor urethræ, and joins branches of the sympathetic. In the female this nerve is distributed to the clitoris.

Inferior gluteal: from the lumbo-sacral cord, 1st and 2nd sacral nerves; passes out of pelvis below the pyriformis, at the lower border of which it turns backwards, and, dividing into numerous branches, enters deep surface of gluteus maximus. Communicates near origin with the small sciatic.

Small sciatic : a cutaneous nerve to lower part of buttock and back of thigh ; it comes off from 2nd and 3rd sacral nerves. It passes below the pyriformis with the sciatic artery, and runs down the back of the thigh beneath the gluteus maximus, and below this beneath the fascia lata, which it pierces in the popliteal space.

Branches :—

Internal cutaneous : to integument of upper and inner side of thigh ; one larger one, the *inferior pudendal*, turns inwards over hamstrings, supplies scrotum, and joins a superficial perineal nerve.

External cutaneous : winds round gluteus maximus, supplies the integument over lower part of buttock.

Terminal : to integument of thigh, popliteal region, and calf of leg.

GREAT SCIATIC : the largest nerve in the body, and is the main continuation of the sacral plexus, lies in pelvis on pyriformis. It passes out of pelvis below the pyriformis, and between the tuber ischii and great trochanter, resting upon the gemelli, obturator internus quadratus, adductor minimus and magnus. It is at first external to the biceps, then between its two heads of origin, finally between it and semi-membranosus, is accompanied by the small sciatic nerve and sciatic artery, the latter supplying a branch to its substance (comes nervi ischiatici). Somewhere between the sacral plexus and lower part of the thigh, but generally about the middle, the nerve bifurcates into external and internal popliteal.

Branches of the Trunk :—

Articular : to hip-joint.

Muscular : given off under biceps to semi-membranosus, semi-tendinosus, both heads of biceps, and to the inner part of adductor magnus.

INTERNAL POPLITEAL : larger terminal branch, passes along middle of popliteal space to lower border of popliteus, where it gets the name of *posterior tibial* ; it is at first superficial to and outside the artery, but at the bottom of the space, under the gastrocnemius, it crosses to the inner side.

Branches :—

Articular (2) : one accompanies the lower internal articular artery, the second the azygos.

Muscular : to the *gastrocnemius*, one for each head, the outer one supplying also the *plantaris*. To the *soleus* and to the *popliteus* ; the nerve to the latter turns round lower border of muscle and enters it upon its anterior surface.

Tibial communicating : passes down leg between two heads

of the gastrocnemius, pierces the deep fascia about middle of leg, there joining the *peroneal communicating* from the external popliteal, and is now known as the external or short saphenous nerve; it then follows the course of the external saphenous vein round outer malleolus, and supplies integument of outer side of foot and little toe, communicating with the musculo-cutaneous on the dorsum.

POSTERIOR TIBIAL (branch of internal popliteal) : begins at the lower border of the popliteus, and runs with the posterior tibial vessels to interval between the external malleolus and heel, where it divides into external and internal plantar. It is at first inside the artery, but afterwards gets to the outer side.

Branches :—

Muscular : to soleus, tibialis posticus, flexor longus digitorum, and flexor longus hallucis, the latter accompanying the peroneal artery.

Plantar cutaneous : pierces internal annular ligament, to supply integument of heel and inner side of sole of foot.

Internal plantar : larger terminal branch of the posterior tibial; accompanies internal plantar artery along inner side of foot: the larger nerve thus accompanies the smaller artery. Corresponds in distribution to median nerve of hand. It passes between the abductor hallucis and flexor brevis digitorum to divide opposite the bases of the metatarsal bones into four branches, the outermost of which communicates with the external plantar.

Branches :—

Cutaneous : to sole of foot.

Muscular : to abductor hallucis and flexor brevis digitorum.

Articular : to tarsal and metatarsal articulations.

Digital (4) : the first supplies inner border of 1st toe and the flexor brevis hallucis, the 2nd supplies the opposite sides of the 1st and 2nd toes and the 1st lumbricalis, the 3rd supplies the opposite sides of the 2nd and 3rd toes and the 2nd lumbricalis, the 4th supplies the adjacent sides of the 3rd and 4th toes and joins a branch from the external plantar.

External plantar : passes across to outer side of foot with external plantar artery, supplying on its way the abductor minimi digiti and accessorius; at the outer border of the latter muscle it divides into two branches :—

Superficial : which divides into two digital nerves, one supplying the outer side of the little toe, the flexor brevis minimi digiti, and the two interossei of the 4th space; the other supplies the adjacent sides of the 4th and 5th toes and communicates with the internal plantar.

Deep or muscular: accompanies deep part of external plantar artery, supplying the adductor hallucis, transversus pedis, two outer lumbricales, interossei of inner three spaces.

EXTERNAL POPLITEAL or **peroneal**: passes across the popliteal space to the fibula; 1 inch below head of that bone it pierces the peroneus longus, and in that muscle divides into anterior tibial and musculo-cutaneous nerves.

Branches:—

Articular (2): generally given off together, accompany superior and inferior external articular arteries.

Cutaneous (2 or 3): supply integument of back and outer side of leg as far as lower 3rd.

Peroneal or fibular communicating: arises close to head of fibula and joins the tibial communicating the two forming the short saphenous nerve.

Anterior tibial: passes to front of interosseous membrane to reach outer side of anterior tibial artery, with which it descends to the ankle-joint, where it bifurcates into an internal and external branch.

Branches:—

Muscular: to tibialis anticus, extensor longus digitorum, peroneus tertius, and extensor proprius hallucis.

Articular: sends a branch to knee, which accompanies anterior tibial recurrent artery to joint.

External or tarsal: passes outwards beneath the extensor brevis digitorum and becomes ganglionic, supplies the extensor brevis, and the articulations of the tarsus and metatarsus.

Internal: accompanies dorsal artery to 1st interosseous space, supplies opposite sides of 1st and 2nd toes, communicating with the musculo-cutaneous.

Musculo-cutaneous: supplies fibular muscles and dorsal integument of foot. It passes between peronei and the long extensor of toes, piercing deep fascia at lower 3rd of leg.

Branches:—

Muscular: to peroneus longus and peroneus brevis.

Cutaneous: to lower part of leg.

Internal: passes over ankle to inner side of 1st toe and adjacent sides of 2nd and 3rd toes, communicates with internal saphenous and anterior tibial nerves.

External: supplies adjoining sides of 3rd, 4th, and 5th toes; communicates with short saphenous.

SYMPATHETIC NERVES.

The sympathetic system consists of :

1. The great gangliated cords.
2. The prevertebral plexuses, and branches proceeding from them.
3. Ganglia of union with cranial nerves—viz., ophthalmic, spheno-palatine, otic, and submaxillary. These have been described before with the 5th nerve.

THE GREAT GANGLIATED CORDS,

two in number, extend the whole length of the vertebral column. They consist of ganglia, united by intervening cords, and are placed partly in front and partly by the side of the vertebræ. Above they are connected with two plexuses entering the cranium, and below they join together in a loop over the coccyx. The parts of the cords are named according to the region they occupy—viz., cervical, dorsal, lumbar, and sacral. The cervical portion has three ganglia, whilst in the rest of its extent each cord contains ganglia equal in number to the vertebræ.

Each ganglion is connected with the anterior primary division of the corresponding spinal nerve by an afferent (white) filament, and an efferent (grey) connecting branch. The interganglionic cords are composed of white and grey fibres, the former being continuous with the filaments from the spinal nerves.

The **cervical part** of the gangliated cord lies behind the carotid sheath, just in front of the prevertebral muscles, and contains three ganglia.

1. The **UPPER CERVICAL GANGLION** lies on the rectus capitis anticus major behind carotid sheath, opposite the 2nd and 3rd cervical vertebræ.

Branches :—

Connecting : with 1st, 2nd, 3rd, and 4th cervical nerves.

Connecting : with the ganglion of trunk and the ganglion of the root of the pneumogastric, with the hypoglossal, with the petrous ganglion of the glosso-pharyngeal.

Ascending or carotid branch lies behind internal carotid artery, enters carotid canal, and divides into :—

(a) *External division :* distributed to internal carotid ; communicates with tympanic branch of glosso-pharyngeal, and forms the carotid plexus.

(b) *Internal division :* distributed over internal carotid artery, thus communicating with the external division, and prolonged to form the cavernous plexus.

The **carotid plexus** lies on the outer side of the internal carotid artery at its 2nd bend.

Branches :—

Connecting : to the 6th nerve and Gasserian ganglion.

The *large deep petrosal nerve* passes from the plexus through the hiatus Fallopii, to join the large superficial petrosal nerve at the Vidian canal, the junction of the two forming the Vidian nerve.

The *small deep petrosal nerve* passes backwards in a small canal in the processus cochleariformis, to join the tympanic plexus.

The **cavernous plexus** lies below and to the inner side of last bend of the internal carotid artery.

Branches :—

Connecting : to the 3rd, 4th, and ophthalmic of 5th nerve.

Ganglionic : the sympathetic root of the ophthalmic or lenticular ganglion passes into the orbit. It is generally joined to the branch of the 3rd nerve to the inferior oblique.

Pituitary : to that body.

Pharyngeal nerves and plexus : the pharyngeal nerves are given off from the front of the upper cervical ganglion, and pass forwards and downwards. They join with branches from the pneumogastric and glosso-pharyngeal nerves forming the pharyngeal plexus, which lies on the middle constrictor muscle. Branches from the plexus supply the constrictors, palato-glossus, palato-pharyngeus, and azygos uvulæ muscles.

The **upper cardiac nerves** : the *right upper cardiac nerve* comes off by two roots from the upper cervical ganglion. It passes downwards behind the carotid sheath, but in front of the lower thyroid artery and recurrent laryngeal nerve. It then goes either behind or in front of the subclavian artery, and, coursing along the innominate, ends in the deep cardiac plexus behind the arch of the aorta. In the middle of the neck it communicates with the external laryngeal, lower down with the upper cardiac branches of the pneumogastric, in the thorax with the recurrent laryngeal, and with other sympathetic branches in its whole course.

The *left upper cardiac nerve* has the same connections in the neck as the right nerve. On entering the thorax, it passes with left carotid artery to the arch of the aorta, and joins the superficial cardiac plexus.

Branches to Vessels.—Branches are given to the external carotid artery, which are prolonged to its branches.

2. The **MIDDLE CERVICAL GANGLION** generally lies on the inferior thyroid artery, opposite the 6th cervical vertebra.

Branches :—

Connecting : to the 5th and 6th cervical nerves.

Thyroid : to the thyroid body, communicating with external and recurrent laryngeal nerves, and with the upper cardiac nerve from the superior ganglion.

Middle or great cardiac nerve : on the *right* side passes in front or behind subclavian to the front of the trachea, and joins the deep cardiac plexus. Communicates in the neck with the upper cardiac and recurrent laryngeal nerves. On the *left* side it lies between the left carotid and left subclavian arteries, and joins the deep cardiac plexus.

3. The LOWER CERVICAL GANGLION lies between the transverse process of the 7th cervical and the neck of the 1st rib, behind the vertebral artery, internal to the superior intercostal artery.

Branches :—

Connecting : to the 7th and 8th cervical nerves.

Lower cardiac nerve : passes behind the subclavian artery, joins recurrent laryngeal, and enters the deep cardiac plexus.

Branches to vessels : branches are given to form a plexus round the vertebral artery.

The THORACIC PART of the gangliated cord lies by the side of the vertebræ in a line corresponding to the heads of the ribs. The ganglia are usually twelve in number.

Branches of the upper 6 ganglia are given off to the thoracic aorta, vertebræ, ligaments, and from the 3rd and 4th to the posterior pulmonary plexus.

Branches from the lower 6 ganglia :—

The **great splanchnic nerve :** formed by the union of branches from the 6th, 7th, 8th, 9th, and 10th ganglia. It passes inwards over the bodies of the vertebræ, perforates the crus, and ends in the semilunar ganglion.

The **small splanchnic nerve** comes from the 10th and 11th ganglia, passes with the great splanchnic nerve, and ends in the solar plexus.

The **smallest splanchnic nerve** comes from the 12th ganglion. It pierces the crus of the diaphragm, and ends in the renal plexus, and partly in the cœliac plexus.

The LUMBAR PART of the gangliated cord lies nearer the middle line than the thoracic.

The ganglia gives off branches to the aorta, and other branches to form the hypogastric plexus.

The SACRAL PART of the gangliated cord is united with its opposite fellow at the lower end of the sacrum by a cord, in the middle of which there is sometimes found a *coccygeal ganglion* or ganglion impar.

Branches are given from the ganglia to the pelvic plexus, and to the middle sacral plexus.

THE PREVERTEBRAL PLEXUSES OF THE SYMPATHETIC.

The **CARDIAC PLEXUS** lies against the aorta and pulmonary artery. It is divided into two parts, *superficial* and *deep*.

The **superficial cardiac plexus** lies in concavity of the arch of the aorta on the right of the ductus arteriosus. It is composed of the left upper cardiac nerve of the sympathetic, the lower cervical cardiac of the left vagus nerve, and branches from the deep plexus. In the plexus is the small *ganglion of Wrisberg*. The plexus gives branches to the anterior pulmonary plexus of the left side, and ends in the right coronary plexus which accompanies the right coronary artery.

The **deep cardiac plexus** lies between the arch of the aorta and the trachea. It consists of right and left halves united by branches. The right half lies above the right branch of the pulmonary artery; the left half lies on the left of the trachea, close to the ductus arteriosus.

Afferent branches :—

- a. All the cardiac branches from the cervical ganglion of the sympathetic, except the left upper nerve.
- b. All the cardiac of pneumogastric and recurrent laryngeal, except the lower cervical cardiac of the left vagus.

Efferent branches from the right side join the superficial cardiac plexus to form the right coronary plexus, and others are distributed to the right auricle.

Efferent branches of the left side mostly end in the left coronary plexus, which accompanies the left coronary artery, and in the superficial cardiac plexus.

The **SOLAR PLEXUS** is the largest prevertebral plexus. It lies behind the pancreas and inferior cava, in front of the aorta and crura of the diaphragm. It surrounds the origin of the celiac axis, extending laterally to the supra-renal bodies. It receives the large and small splanchnic nerves and part of the right pneumogastric. It contains several ganglia, and branches are given off from it to accompany the bloodvessels to the viscera, and to form secondary plexuses on those arteries.

The **semi-lunar ganglia**, one in each half of the solar plexus, lie on the inner side of the supra-renal bodies, the left one lying behind cava. The great splanchnic nerve enters the upper end.

The **diaphragmatic or phrenic plexus** accompanies the

arteries to the diaphragm. On the right side near the supra-renal body is *the phrenic ganglion*, connecting together the phrenic nerves of the spinal and sympathetic systems.

The **supra-renal plexus** is derived from the solar plexus and the outer part of the semi-lunar ganglion. It is joined by branches of one of the splanchnic nerves.

The **renal plexus** is derived from the semi-lunar ganglion, and partly from the solar and aortic plexuses, and the smallest splanchnic nerve. It lies along the renal artery, and contains numerous small ganglia.

The **spermatic plexus** comes off from the renal and aortic plexuses.

The **cœliac plexus** is derived from the solar plexus. It surrounds the cœliac axis, and subdivides into :—

The *coronary plexus* accompanies coronary artery along the smaller curvature of the stomach, communicating with the pneumogastric nerves.

The *hepatic plexus* accompanies hepatic artery into the substance of the liver. Communicates with the left vagus, and the right supra-renal plexus. Gives off the *cystic, pyloric, right gastro-epiploic* and *pancreatico-duodenal* plexuses.

The *splenic plexus* accompanies splenic artery to the spleen, and is joined by the right pneumogastric. It gives off the *left gastro-epiploic* and *pancreatic* plexuses.

The **superior mesenteric plexus** accompanies superior mesenteric artery.

The **aortic plexus** lies on the anterior surface of the abdominal aorta. It gives off the *inferior mesenteric* and part of the *spermatic* plexuses. It ends in the hypogastric plexus.

The **HYPOGASTRIC PLEXUS** lies between the two common iliac arteries ; it is formed by the terminations of the aortic plexus, together with branches from the lumbar ganglia. It divides below into two parts, which form the pelvic plexuses.

The **PELVIC PLEXUSES** : two in number. Each is composed of a division of the hypogastric plexus, joined with some branches from the sacral nerves and ganglia.

The following plexuses are derived from the pelvic plexuses :—

The **hæmorrhoidal plexus** to the rectum.

The **vesical plexus** to the bladder, with secondary plexuses in the male to the vas deferens and to the vesicula seminalis.

The **prostatic plexus** to the prostate gland, giving off the *cavernous nerves* of the penis.

(The **vaginal plexus** to the vagina.

The **uterine plexus** accompanying the uterine artery to the uterus.)

THE ORGANS OF DIGESTION.

THE TEETH.

Temporary teeth : the following is the dental formula for the temporary teeth, with the dates in months of their eruption :—

	Mo.	Mo.	Ca.	In.	In.	In.	In.	Ca.	Mo.	Mo.	
{ Upper ...	1	1	1	1	1	1	1	1	1	1 = 10	} = 20
{ Lower ...	1	1	1	1	1	1	1	1	1	1 = 10	
	24	12	18	9	7	7	9	18	12	24 months.	

Permanent teeth : Subjoined is the dental formula for the permanent teeth, with the date of their eruption.

	Wis.	Mo.	Mo.	Bi.	Bi.	Ca.	In.	In.	In.	In.	Ca.	Bi.	Bi.	Mo.	Mo.	Wis.	
{ Upper	1	1	1	1	1	1	1	1	1	1	1	1	1	1	1	1 = 16	} 32
{ Lower	1	1	1	1	1	1	1	1	1	1	1	1	1	1	1	1 = 16	
	18	12	6	10	9	11	8	7	7	8	11	9	10	6	12	18 years.	

THE TONGUE.

The **tongue** occupies the floor of the mouth ; its base is connected with the hyoid bone, the epiglottis, the pillars of the soft palate, and with the pharynx ; along its inferior surface the genio-glossus runs from base to tip, connecting it to the lower jaw and hyoid bone.

The **mucous membrane** on the under surface is smooth, forming a median fold, the *frænum linguae* ; on the sides it is continuous with the mucous membrane of the mouth. On the dorsum there is a *raphé* along the middle line, which ends posteriorly in the *foramen cæcum*. Posteriorly the epiglottis is connected to the tongue by three glosso-epiglottic folds, the middle one being called the *frænum epiglottidis*. The anterior two-thirds of the dorsum of the tongue is covered with papillæ ; they are of three kinds :—

The *circumvallate* papillæ (seven to ten) form a row on each side at the back of the tongue, meeting in the middle line thus, Λ , in front of the foramen cæcum.

The *fungiform papillæ* : found principally at the apex and on the sides.

The *filiform papillæ* are numerous, and are arranged in rows parallel to the circumvallate, but towards the tip of the tongue their direction becomes more transverse.

Taste buds, once supposed to be the organs of taste, are flask-shaped bodies found buried in the epithelium around the circumvallate papillæ.

Glands : near the circumvallate papillæ are found numerous mucous glands, known as the lingual glands.

THE MUSCLES OF THE TONGUE.—The *extrinsic* muscles of the tongue are the hyo-glossus, genio-glossus, palato-glossus, and the stylo-glossus. These have been described (*vide* p. 30).

The *intrinsic* muscles are entirely contained within the substance of the tongue, and are as follows :—

The **superior lingualis** : one on each side. Longitudinal fibres lying under the mucous membrane. It arises from the frænum epiglottidis, and from the fascia along the middle line ; the fibres pass obliquely outwards, the anterior fibres being longitudinal, to the side of the tongue.

The **inferior lingualis** (2) is a bundle of muscular fibres running along the under surface of the tongue from base to tip. It lies between the genio- and hyo-glossus muscles. It arises from the fascia at the base of the tongue, is joined anteriorly with some fibres of the stylo-glossus, and passes to the apex.

The **transversalis** is a horizontal layer of muscular fibres between the superior and inferior linguales. The fibres spring from the septum and pass outwards to the sides of the tongue.

The **septum** of the tongue is a vertical fibrous partition, extending, in the medullary portion, from the hyoid bone to the apex.

Arteries : lingual, ascending palatine of facial, ascending pharyngeal.

Nerves : lingual or gustatory to anterior two-thirds ; glosso-pharyngeal to side and posterior third ; hypoglossal to muscles.

THE PALATE.

The **palate** forms the roof of the mouth, and consists of two parts—the front being the hard palate, and the back the soft palate.

The **hard palate** consists of the palatal processes of the superior maxillæ and palate-bones, together with the mucous membrane and the periosteum lining them.

The **soft palate**, consisting of muscles, aponeurosis, vessels, nerves, etc., enclosed between two layers of mucous membrane, is attached in front to the posterior margin of the hard palate, the sides blending with the pharynx ; from the middle of the posterior edge the *uvula* projects, and from the bases of this arch, on each side, there are two folds of mucous membrane enclosing muscular fibres—the *pillars*, anterior and posterior, between which the *tonsil* lies. The narrowed passage between the anterior pillars, leading from the mouth to the pharynx, is called the *isthmus faucium*.

The *aponeurosis* of the soft palate is attached to the posterior edge of the hard palate, is joined by the tendon of the tensor palati, and becomes lost between the muscles.

Structure of the palate from before backwards :

1. Oral mucous membrane and mucous glands.
2. Palato-glossus.
3. Aponeurosis.
4. Tensor palati.
5. Anterior fibres of palato-pharyngeus.
6. Levator palati.
7. Azygos uvulæ in middle line.
8. Posterior fibres of the palato-pharyngeus.
9. Mucous glands and pharyngeal mucous membrane.

The **tonsils** occupy the recesses between the anterior and posterior pillars of the fauces. On the outer side of each is the superior constrictor, and beyond this the internal carotid artery.

THE SALIVARY GLANDS.

The **PAROTID GLAND** is the largest, and lies between the meatus and mastoid process behind, and the ramus of the jaw in front. Anteriorly, it overlaps the hinder part of the masseter.

Boundaries :—

<i>Externally.</i>	<i>Above.</i>	<i>Below.</i>	<i>Anteriorly and Below.</i>	<i>Behind.</i>
Skin. Platysma. Cervical fascia.	Zygoma.	Line from angle of jaw to mastoid process. Posterior belly of digastric.	Stylo-maxil- lary liga- ment.	Ext. meatus. Mastoid pro- cess. Sterno-mas- toid.

The deep surface is irregular, and is divided into three lobes :—

The **glenoid lobe** fills up glenoid cavity behind Glaserian fissure.

The **pterygoid lobe** passes forwards internal to the ramus of the jaw between the external and internal pterygoid muscles.

The **carotid lobe** surrounds the styloid process, and lies between the external and internal carotid artery.

The **socia parotidis** is a separate lobe projecting from the anterior surface.

Connections of the Socia :—

<i>Above.</i>	<i>Below.</i>	<i>Internally.</i>
Zygoma.	Duct. Supra-maxillary of facial nerve.	Masseter. Transverse facial artery.

The duct (Stenson's) is $2\frac{1}{2}$ inches long ; comes off from the anterior surface. Its opening in the mouth is opposite the 2nd upper molar tooth.

Course of the duct : line from bottom of lobule of ear to middle of upper lip. The transverse facial artery lies above the duct, and the buccal branches of the 7th nerve below.

The parotid gland is traversed by :—

<i>Arteries.</i>	<i>Veins.</i>	<i>Nerves.</i>
External carotid.	Internal maxillary.	Facial.
Posterior auricular.	Temporal.	Auriculo-temporal.
Internal maxillary.	Temporo-maxillary.	Facial of great auricular.
Temporal.		
Transverse facial.		

Nerve supply of gland : sympathetic and glosso-pharyngeal. The latter branch may be traced as follows : The tympanic (Jacobson) branch gives off small superficial petrosal, which passes through otic ganglion and joins the auriculo-temporal trunk, thus supplying the gland.

THE SUBMAXILLARY GLAND lies under cover of the body of the lower jaw.

Superficial lobe : separated by stylo-maxillary ligament from parotid, grooved above and behind by facial artery.

<i>Lies upon.</i>	<i>Superficial Coverings.</i>	<i>Below.</i>
Mylo-hyoid.	Platysma.	Anterior belly of digastric.
Stylo-hyoid.	Deep fascia.	
Hyo-glossus.	Facial vein.	

Deep lobe : passes with duct between mylo-hyoid and hyo-glossus.

The duct of Wharton : passes with deep lobe of gland behind mylo-hyoid, resting on the hyo-glossus. At first the lingual nerve lies above the duct and the hypoglossal below, but the duct gets above the nerve, as the former passes upwards and forwards to open on the papilla by the side of the frænum linguæ.

Nerves : sympathetic, and chorda tympani through sub-maxillary ganglion.

THE **SUBLINGUAL GLAND** occupies the sublingual fossa of lower jaw, lies under mucous membrane of floor of mouth, having its anterior extremity close to the frænum. Below is the mylo-hyoid, and internally is the genio-glossus.

Ducts of Rivini (18 to 20): open separately in the floor of the mouth. One larger one from the posterior part opens into or by the side of Wharton's duct, and is called the duct of Bartholin.

Nerves: sympathetic, and from chorda tympani through submaxillary ganglion.

THE PHARYNX.

The **Pharynx** is an oval musculo-membranous bag lying behind the nose, mouth, and larynx. It is about $4\frac{1}{2}$ inches long, and extends from the base of the skull to the lower border of the cricoid cartilage in front, and to the 5th cervical vertebra behind. It is widest opposite the hyoid bone. Behind, it is separated by a prevertebral layer of the deep cervical fascia from the longus colli and recti capitis antici muscles. Below, it is continuous with the œsophagus.

Attachments:—

Above: under surface of body of sphenoid, under surface of petrous of temporal.

In front: internal pterygoid plate, pterygo-maxillary ligament, lower jaw, base of tongue, cornua of hyoid bone, and stylo-hyoid ligament; thyroid and cricoid cartilages, corresponding to attachments of constrictor muscles.

Connections:—

<i>Laterally.</i>		<i>Behind.</i>	<i>Below.</i>
Styloid process.		Longus colli.	Œsophagus.
Stylo-hyoid.	} Muscles.	Recti capitis	
Stylo-pharyngeus.		antici.	
Stylo-thyroid.			
Pterygoid.			
Sterno-hyoid.			
Internal and common carotid arteries.			
Internal jugular vein.			
Glosso-pharyngeal.	} Nerves.		
Pneumogastric.			
Sympathetic.			
Spinal accessory.			
Hypoglossal.			
Thyroid gland.			

Muscles: inferior, middle and superior constrictors, stylo-pharyngeus, palato-pharyngeus, salpingo-pharyngeus. (*Vide* pp. 30, 31.)

Arteries: Ascending pharyngeal; pterygo-palatine; descending palatine; superior thyroid.

Openings: the *posterior nares* (2), placed in the upper part of the anterior wall; *Eustachian tubes* (2), open one on each side at the upper part; the *mouth*, situated just below the posterior nares; the *laryngeal* and *oesophageal* openings.

The **pharyngeal aponeurosis** forms the base of the walls of the pharynx, lying between the mucous membrane and the muscles. It is strong above, but thin below. It is attached above to the body of the sphenoid and petrous portion of the temporal, being strengthened in the middle line by a process of fascia attached to the pharyngeal tubercle on the basilar part of the occipital bone. Inferiorly it becomes lost between the muscular and mucous strata.

THE ŒSOPHAGUS.

The Œsophagus extends from pharynx to stomach, and is 9 inches long. It begins at the lower border of cricoid cartilage opposite the 5th cervical vertebra, and ends opposite the 10th dorsal.

Course and relations:—

In the neck: passes downwards and to the left.

<i>In front.</i>	<i>Behind.</i>	<i>Left side.</i>	<i>Right side.</i>
Trachea.	Vertebræ.	Left inferior	Right carotid.
Thyroid gland.	Left longus	thyroid.	Right inferior
Left inferior laryn-	colli muscle.	Left carotid.	laryngeal.
geal nerve.		Thoracic	
		duct.	
		Left sub-	
		clavian.	

In the chest.—*In the superior mediastinum*: passes downwards to the right to reach middle line opposite 5th dorsal vertebra.

<i>In front.</i>	<i>Behind.</i>	<i>Left side.</i>	<i>Right side.</i>
Left carotid.	Vertebræ.	Left sub-	Trachea.
Bifurcation of	Thoracic	clavian.	Right pleura.
trachea.	duct.	Left pneu-	Vena azygos
Left bronchus.	Vena azy-	mogastric.	major.
Right pulmonary	gos.	Left pleura.	
artery.	Upperright	Arch of	
	intercostal.	aorta.	

In the posterior mediastinum: passes forwards and downwards to the left, with the two pneumogastries, which form a plexus; the left nerve is rather anterior, and the right is more posterior.

<i>In front.</i>	<i>Behind.</i>	<i>Left.</i>
Pericardium and left auricle.	Vertebræ. Right intercostal vessels. Aorta (below).	Aorta. Left pleura.

In the abdomen: passes through œsophageal opening in diaphragm opposite the 9th dorsal vertebra, to end at the cardiac opening of the stomach opposite the 10th dorsal vertebra.

THE STOMACH.

Form: conical, with base or fundus to left side; the upper border is concave, and is called the *lesser* curvature; the lower border is convex, and is named the *greater* curvature. The left extremity is known as the *cardiac* end, and the right or small end is termed the *pyloric* extremity.

Position: occupies left hypochondriac and epigastric regions.

Orifices: *cardiac*, at the left end, communicating with the œsophagus; *pyloric*, at the right extremity, passing into the duodenum.

Dimensions: 10 to 12 inches long; 4 to 5 inches in diameter at widest part.

Connections:—

Left or cardiac end: fixed by œsophagus and gastro-phrenic ligament to diaphragm, lying beneath the ribs, and connected with the spleen by the gastro-splenic omentum.

Right or pyloric end: reaches gall-bladder, touching under part of left lobe of liver.

Anterior surface is in contact with, from left to right, diaphragm, abdominal parietes (epigastric region), under surface of left lobe of liver.

Posterior surface is connected with pancreas, crura of diaphragm, aorta, vena cava, solar plexus.

Superior border: attached to liver by small omentum.

Inferior border: gives attachment to great omentum.

ARTERIES.—*Coronary* and *superior pyloric* run along lesser curvature; *right* and *left gastro-epiploic*, along inferior or greater curvature; *vasa brevia*, from the splenic to fundus.

NERVES.—*Right pneumogastric*, to posterior surface; *left pneumogastric*, to anterior surface; *sympathetic*, from the solar plexus to both surfaces.

THE SMALL INTESTINES.

THE DUODENUM.

Length : 8 to 10 inches.

Shape : horse-shoe, with the convexity to the right side, the concavity enclosing the head of the pancreas.

Position : occupies right hypochondriac and epigastric regions.

Has no mesentery, and only partially invested by peritoneum.

Divided into three parts : superior transverse, vertical, and inferior transverse.

Connections :—

Superior transverse part : 2 inches long ; directed from pylorus upwards and backwards to the right, reaching the neck of the gall-bladder.

In front. Liver, gall-bladder.

Behind. Bile-duct, vena portæ, hepatic artery, gastro-duodenal artery.

Below. Head of pancreas.

Vertical part : 3 inches long ; passes from opposite neck of gall-bladder down to 3rd lumbar vertebra. Ducts of liver and pancreas enter this part.

In front. Hepatic flexure of colon.

Behind. Right kidney, supra-renal capsule, renal vessels, and vena cava.

Inner side. Head of pancreas, common bile-duct, and pancreatic duct.

Inferior transverse part : about 5 inches long ; passes from right to left across spine, ascending from 3rd to 2nd lumbar vertebra, ends in jejunum on left side of spinal column ; lies between layers of transverse meso-colon.

In front. Superior mesenteric vessels and plexus of nerves.

Behind. Aorta, vena cava, crura of diaphragm.

Above. Pancreas.

ARTERIES.—Pyloric, and pancreatico-duodenal of hepatic, inferior pancreatico-duodenal of superior mesenteric.

NERVES, from solar plexus.

THE JEJUNUM.

The jejunum occupies $\frac{2}{5}$ of the rest of the small intestines ; commencing on the left side of the 2nd lumbar vertebra, it terminates in the ileum ; it is wider, and its coats are thicker, more vascular, and of a deeper colour than the ileum.

THE ILEUM.

The ileum consists of the remaining $\frac{2}{3}$ of the small intestines, and terminates in the right iliac fossa by opening into the cæcum.

The following characteristics will serve to distinguish the three parts of the small intestines :—

<i>Duodenum.</i>	<i>Jejunum.</i>	<i>Ileum.</i>
The largest part.	More vascular than	Villi, small.
Thickest coats.	ileum.	Valvulæ conniven-
Brunner's glands.	Valvulæ conniven-	tes, not present
Valvulæ conniven-	tes.	or only slightly.
tes.	Villi, well marked.	Peyer's patches.
No mesentery.		

THE LARGE INTESTINE.

Extent : from the ileum to the anus.

Length : 5 or 6 feet.

Characteristics.—Larger size, more fixed than the small intestine ; has appendices epiploicæ. The longitudinal muscular fibres are arranged in three bands, which being shorter than the other coats, cause sacculation.

The cæcum is a dilated pouch in which the large intestine commences, situated in the right iliac fossa, and covered by peritoneum ; at the lower, inner, and back part, and generally attached by a mesentery to the cæcum, is the *appendix vermiformis*, a blind tubular projection, about 3 inches long, and about the size of a large quill.

The *ileo-cæcal valve* lies on the inner side of the cæcum ; is formed by the two inner coats of the ileum passing through the wall of the cæcum. The upper fold is horizontal, and called the *ileo-colic*. The lower is vertical, and termed the *ileo-cæcal*. The ridge on either side is called the *frænum*.

The COLON is divided into ascending, transverse, descending, and sigmoid flexure.

The *ascending colon* extends from the cæcum to the under surface of the liver to the right of the gall-bladder, where it turns to the left, forming the *hepatic flexure*. It lies in the right iliac and right hypochondriac region. The peritoneum covers the anterior and lateral surfaces.

Relations.—*In front.* The convolutions of the ileum.

Behind. Iliacus, quadratus lumborum, outer side of right kidney.

The **transverse colon** passes from right to left, from the gall-bladder to the spleen. It forms an arch, convex anteriorly : *the transverse arch of the colon*. It is entirely surrounded by peritoneum, which is attached posteriorly to the spine, forming the meso-colon.

Relations.—Above. Liver, gall-bladder, large curvature of stomach, lower end of spleen.

Below. Small intestines.

Anteriorly. Anterior layers of great omentum, parietes.

Posteriorly. Right kidney, 2nd part of duodenum, transverse meso-colon.

The **descending colon** passes from the end of the transverse colon by a bend, *the splenic flexure*. Between the splenic flexure and the diaphragm, opposite the 10th rib, is a fold of the peritoneum, the costo-colic ligament, which slings up the spleen. The gut then passes downwards to the iliac fossa, ending in the sigmoid flexure. The peritoneum invests its anterior and lateral surfaces.

Relations.—Behind. Left crus, left kidney, quadratus lumborum.

In front. Part of stomach.

Inner side. Outer border of left kidney.

The **sigmoid flexure** is placed in the left iliac fossa ; it commences at the margin of the crista ilii, curves like an S, and ends in the rectum opposite the left sacro-iliac articulation. It is attached by meso-colon to the iliac fossa.

The **RECTUM** extends from the sigmoid flexure to the anus (8 inches long). It is not sacculated, like the rest of the large intestine. It is divided into three parts :

The 1st part :—

Extent.—From the left sacro-iliac articulation to the middle of the 3rd piece of the sacrum (4 inches long).

Relations.—Completely surrounded by peritoneum, and attached to the sacrum by meso-rectum.

Behind. Pyriformis, sacral plexus.

Left side. Left ureter and branches of left internal iliac vessels.

In front. Posterior surface of the bladder (male), posterior surface of uterus (female).

The 2nd part :—

Extent.—From the ending of the 1st part to the tip of the coccyx (3 inches long).

Relations.—It has peritoneum on the upper part of anterior surface only.

In front. Triangular part at base of bladder, vesiculæ

seminales, vasa deferentia, under surface of prostate (male), posterior wall of vagina (female).

Laterally. Coccygeus.

The 3rd part :—

Extent.—From the tip of the coccyx to anus (1 inch long).

Relations.—Has no peritoneum.

In front. Fore part of prostate, membranous part of the urethra, bulb of corpus spongiosum (male), posterior wall of vagina (female).

Laterally and behind. Levatores ani, which, uniting, support it as in a sling.

THE LIVER.

Situation.—Right hypochondriac and epigastric regions.

Average weight.—Three to four pounds.

Upper surface. Convex, covered by peritoneum ; above is the diaphragm. It is divided into two unequal lobes (right and left) by a fold of peritoneum, called the *suspensory* or *broad ligament*.

Under surface. Concave, and is connected with the stomach, duodenum, hepatic flexure, right kidney, and right supra-renal body, covered with peritoneum, except where gall-bladder is attached ; and at the portal fissure, which gives attachment to the lesser omentum.

Posterior border. Connected to diaphragm by the coronary ligament ; is broad and round. Connected with crura and under surface of diaphragm by coronary ligament. Aorta and vena cava lie behind.

Anterior border. Sharp and free, and marked by a notch opposite the attachment of the suspensory ligament.

The **LIGAMENTS** are five in number ; four are composed of peritoneum, and are :—

The **suspensory, falciform, or broad ligament**, sickle-shaped, with the base forward. It is attached above to the diaphragm, extending on to the sheath of rectus as far as the umbilicus, and below from the notch in front, to the posterior edge of the liver. The posterior edge encloses the round ligament.

The **lateral ligaments**, right and left, extend from the sides of the diaphragm to the posterior border of the liver.

The **coronary ligament** is continuous with the lateral ligaments, and attaches the posterior margin of the liver to the diaphragm.

The **round ligament** is the obliterated umbilical vein and ductus venosus contained within the posterior or free edge of the suspensory ligament.

FISSURES :—

The **longitudinal fissure** is occupied by the round ligament, and divides the body into right and left lobes ; it is separated into two parts by its union with the transverse fissure.

The *anterior* part or **umbilical fissure** contains the remains of the umbilical vein, and lies between the left lobe and the lobus quadratus. The *posterior* part or **fissure of the ductus venosus** lies between the left lobe and the lobus Spigelii, and contains the remains of the ductus venosus.

The **transverse or portal fissure** is placed at right angles to the longitudinal fissure, between the lobus quadratus and the lobus Spigelii, and lodges the hepatic duct, artery, and portal vein, nerves and lymphatics. The artery lies on the left and in front ; the duct on the right and in front ; the vein behind.

The **fissure for the vena cava** is placed obliquely at the posterior margin of the liver, behind the gall-bladder, lying between the right lobe and the lobus Spigelii, and separated from the transverse fissure by the lobus caudatus. The hepatic veins enter the vena cava at the bottom of this fissure.

LOBES :—

Right and left lobes are separated from each other by the umbilical fissure on the under surface, and posteriorly by the fissure of the ductus venosus. The right is the larger, and contains the transverse fissure and fissure for the vena cava ; is subdivided into the three following lobes :—

The **lobus quadratus** : bounded by the umbilical and transverse fissures and the fossa of the gall-bladder.

The **lobus Spigelii** is the projection between fissures for the vena cava and ductus venosus, behind the transverse fissure.

The **lobus caudatus** connects the preceding lobe with the main mass of the right lobe, and lies behind the transverse fissure.

FOSSA :—

The **fossa for the gall-bladder** lies on the under surface of the right lobe, parallel to the umbilical fissure, and separates the quadrate lobe from the main mass of the right lobe.

THE GALL-BLADDER

is a conical bag placed in a fossa on the under surface of the right lobe of the liver. Its upper surface is attached to the liver, and its fundus and posterior surfaces are invested by peritoneum reflected from the adjacent surface of the liver.

Relations.—The body is in relation in front, with the liver, the 1st part of duodenum, the pylorus, and the hepatic flexure of colon. The fundus is in contact with the parietes opposite the 10th costal cartilage.

THE BILE-DUCTS.

The **hepatic duct**, formed by union of ducts from right and left lobes, issues from the liver at the bottom of the transverse fissure. It passes downwards and to the right in the layers of gastro-hepatic omentum, having the vena porta behind, and the hepatic artery on the left. It joins the cystic duct, the two forming the common bile-duct.

The **cystic duct** passes from the neck of the gall-bladder downwards, backwards and to the left, to join the preceding.

The **ductus communis choledochus** or **common bile-duct** is the result of the union of the hepatic and cystic ducts. It passes behind the 1st part of the duodenum, in front of the vena portæ, with the hepatic artery on the left, between the layers of the gastro-hepatic omentum, and, passing between the pancreas and 2nd part of the duodenum, enters the small intestine obliquely, a little below the middle of the descending part of the duodenum by an opening common to it and the pancreatic duct.

The **hepatic artery** from the cœliac axis enters the transverse fissure and divides into two branches for the right and left lobes.

The **portal vein**, having the hepatic artery on the left and in front, and the common bile-duct on the right, ascends between the layers of the gastro-hepatic omentum, in front of the foramen of Winslow, to the transverse fissure. The vessels, accompanied by nerves and lymphatics, are surrounded by areolar tissue, the *capsule of Glisson*, which passes with them into the liver.

The **hepatic veins** pass out of the liver at the bottom of the fissure of the vena cava, immediately joining that vessel.

THE PANCREAS.

Length : 6 to 8 inches.

Position.—Placed in the epigastric and both hypochondriac regions, directed transversely across posterior wall of abdomen.

Connections :—

In front. Stomach and small omentum.

Behind. Aorta, vena cava, mesenteric vessels, crura of diaphragm, splenic vein, commencement of vena portæ, left kidney, left supra-renal body and left renal vessels.

Upper border. From right to left ; 1st part of duodenum and hepatic artery, celiac axis, splenic vessels.

Lower border. From right to left ; 3rd part of duodenum, superior mesenteric vessels, inferior mesenteric vein.

Left end or tail. Touches lower part of anterior surface of spleen.

Right end or head. Embraced by duodenum, partly separated, behind by bile-duct, and in front by pancreatico-duodenal arteries.

Duct (canal of Wirsung) : extends transversely from left to right, opens into 2nd part of the duodenum in common with the ductus communis choledochus.

Arteries : splenic, pancreatico-duodenal of hepatic, and superior mesenteric.

Veins : open into splenic and superior mesenteric.

Nerves : from the solar plexus.

THE SPLEEN

is of an oblong, flattened form, the external surface being convex ; on the inner surface is a vertical ridge dividing it into two parts, the posterior of which is applied to the outer surface of the left kidney, whilst the anterior one receives the tail of the pancreas, and lies against the cardiac end of the stomach. Near this ridge is a fissure, *the hilus*, where the vessels enter. The anterior border is notched, and the lower end is pointed, and rests on the costo-colic ligament (*vide* p. 186), situated in the left hypochondriac region. It is covered by peritoneum, except at the hilus, where it passes forwards and inwards in a double line enclosing the vessels, as the gastro-splenic omentum, to the cardiac end of the stomach.

Relations.—Externally. Diaphragm, which separates it from the 9th, 10th, and 11th left ribs.

Internally. In front of the hilus. Cardiac end of stomach.

Behind the hilus. Left crus, left supra-renal body. *Below the hilus.* Tail of pancreas.

Above. Connected by suspensory ligament to the diaphragm.

Below. Costo-colic ligament and splenic flexure. *Posterior margin.* Left kidney.

Arteries : Splenic.

Nerves : Branches from solar plexus of the sympathetic.

THE PERITONEUM.

The **peritoneum** is the serous membrane of the abdominal cavity. It consists of a *parietal* layer lining the abdominal and pelvic walls, and a *visceral* layer reflected more or less over the

contained organs. In the male it is a closed sac, but in the female the free extremities of the Fallopian tubes open into the cavity. The continuity of the peritoneum may be traced in the following manner.

Commencing at the middle line, the peritoneum lines the right half of the abdominal wall, as far as the lumbar region, where it entirely surrounds the head of the cæcum and vermiform appendix. It only invests the front and sides of the ascending colon, though occasionally the whole circumference of the gut is enclosed, a meso-colon being then formed. The peritoneum then passes inwards, covering the lower part of the anterior surface of the right kidney, the front of the 3rd part of duodenum, and goes downward over the front of the vessels of the small intestines, encloses the small intestines, and is reflected upwards on the posterior surface of the vessels to the spine, thus forming the mesentery. From the spine it may be traced outwards over the lower part of the anterior surface of the left kidney to the descending colon and sigmoid flexure, and thence on to the abdominal parietes to the middle line. The descending colon is invested in a similar manner to the ascending, but the sigmoid flexure is completely surrounded, the sigmoid meso-colon being formed, which is attached to the fascia of the iliac fossa.

The peritoneum in the pelvis is continuous with that of the abdominal cavity. It encloses completely the 1st part of the rectum, and forms the meso-rectum. It is applied to the front and sides, and lower down to the front only of the 2nd part of the rectum, whence it is reflected in the male on to the base and upper part of the bladder, forming the *recto-vesical pouch*; which is bounded on each side by the peritoneum reflected forwards from the sides of the 2nd part of the rectum over the obliterated hypogastric artery and ureter, and forming the *posterior false ligament* of the bladder.

From the apex of the bladder the peritoneum passes upwards on to the anterior abdominal wall, enclosing the remains of the urachus and constituting the *anterior false ligament* of the bladder; whilst laterally it is reflected from the bladder along the line of the obliterated hypogastric artery to the iliac fossa, forming the *lateral false ligaments* of that viscus. Where the obliterated hypogastric artery passes between the abdominal wall and the side of the bladder it raises the peritoneum into a fold, which separates two shallow fossæ, the *internal* and *external inguinal pouches*, which correspond respectively to the internal and external abdominal rings.

In the female the peritoneum is reflected from the sides and

front of the 2nd part of the rectum to the upper part of the posterior wall of the vagina, and thence over posterior, upper, and anterior surfaces of the uterus to the bladder. Between the uterus and rectum is the *recto-vaginal* or *Douglas's pouch*, corresponding to the *recto-vesical* pouch in the male. The peritoneum passes off from the sides of the uterus laterally to the pelvis, forming the *broad ligaments*, in the upper border of which folds the Fallopian tubes run, the peritoneum being continuous with their open fimbriated extremities.

In the upper part of the abdomen the peritoneum is attached to the under surface of the diaphragm as far backwards as the posterior surface of the liver, and the œsophageal opening of the stomach. It is then reflected forwards on the upper surface of the liver, forming the ligaments of that organ; and passing round the anterior border it is applied to the under surface as far as the transverse fissure, where, meeting a peritoneal layer from the posterior surface (from the smaller sac), the two pass across to the stomach to form the small or gastro-hepatic omentum. Tracing it to the right from the longitudinal fissure, it invests the gall-bladder, under surface of the right lobe, and the front of the 2nd part of the duodenum, passing to the anterior surface of the right kidney, where it becomes continuous with the part already traced. To the left of the longitudinal fissure the peritoneum covers the left lobe of the liver, and is reflected over the front and left side of the œsophagus to the front of the cardiac end of the stomach, whence it passes off to invest the spleen, forming a reduplication, the gastro-splenic omentum, and is continued over the surface of the right kidney, forming the posterior layer of the lienorenal ligament, and descending colon to join the part already described.

Between the liver, stomach, and transverse colon is a second peritoneal sac, which communicates with the larger peritoneal cavity through the *foramen of Winslow*. To understand the disposition of the layers one has only to imagine the smaller sac to have been invaginated through the foramen of Winslow inwards and behind the stomach, and the arrangement becomes clear.

The two sacs traced vertically.

From transverse fissure of liver, two layers pass:—

To small curvature of stomach.

Two layers separate, one passing in front and the other behind stomach, thus enclosing it.

Join together at great curvature, forming anterior layers great omentum.

Pass down in front of and beyond transverse colon.

Bend upwards and backwards, and separate to enclose transverse colon; continue together to the posterior abdominal wall, until opposite the lower border of the pancreas, where they part, one layer passing upwards, and the other downwards.

The *ascending layer* passes :—

In front of pancreas and posterior part of diaphragm.

Then on to posterior surface of liver to the transverse fissure.

The *descending layer* passes :—

Along superior mesenteric vessels, round jejunum and ileum, and back to spine, forming mesentery.

Downwards in front of spine, lower part of aorta and sacral promontory.

Over upper part of rectum, forming meso-rectum.

Forwards.

Male.—To bladder, forming recto-vesical pouch and posterior false ligaments.

Female.—To vagina and uterus, forming posterior ligaments of uterus and recto-vaginal pouch. Then over uterus to bladder, forming utero-vesical pouch and posterior vesical ligaments.

Over bladder to anterior abdominal wall, covering urachus and obliterated hypogastric arteries as far as umbilicus.

Over under surface of diaphragm.

Reflected over upper surface of liver.

Round anterior border of liver to under surface as far as transverse fissure.

The two sacs traced horizontally, at the level of the foramen of Winslow.

From falciform ligament of liver :—

Over anterior abdominal wall and diaphragm.

Over outer part of left kidney.

Reflected outwards behind splenic vessels to spleen, forming posterior layer of lieno-renal ligament.

Over spleen as far as hilum.

To stomach, forming outer layer of gastro-splenic omentum.

Over anterior wall of stomach into anterior layer of gastro-hepatic omentum.

Turns round hepatic artery, forming anterior edge of foramen of Winslow (here the smaller sac commences).

Passing from right to left :—

Forms posterior layer of small omentum.

Over posterior surface of stomach.

Forms inner layer of gastro-splenic omentum.

Forms anterior layer of lieno-renal ligament.

Passing now from left to right :—

Continues over left kidney, aorta, and vena cava, here forming posterior boundary of foramen of Winslow (here smaller sac ends, and large sac again commences).

Over right kidney to liver.

Over under-surface of liver to left border, round which it may be traced over anterior surface, to falciform ligaments.

SYNOPSIS OF PROCESSES OF THE PERITONEUM.

Omenta—folds connected with the stomach.

Small or Gastro-hepatic Omentum.—From transverse fissure of liver to small curvature of stomach and 1st part of duodenum. Right border free, forming anterior boundary of foramen of Winslow.

Large or Gastro-colic Omentum.—Formed, as shown above, by the passing downwards and then folding upwards of the two layers passing from stomach, and thus encloses the lower part of the cavity of the smaller sac of the peritoneum.

Gastro-splenic Omentum.—Passes from great cul-de-sac of stomach to hilum of spleen, and contains the splenic vessels between its layers. Below it is continuous with the large omentum.

Mesenteries — folds connecting intestine to posterior abdominal wall.

The Mesentery.—Attached behind to left side of 2nd lumbar vertebra, passing along vertebra to right sacro-iliac synchondrosis. Contains superior mesenteric vessels, jejunum and ileum between its layers. The upper layer is continuous with inferior layer of transverse meso-colon, the lower layer with meso-cæcum.

Meso-cæcum.—Very short.

Ascending Meso-colon.—Often absent, and very short when present.

Transverse Meso-colon.—Formed by junction of two ascending layers of great omentum after they have enclosed transverse meso-colon; at the attachment to the spine the two layers separate, as explained, into ascending and descending layers.

Descending Meso-colon.—More frequently absent than ascending meso-colon.

Sigmoid Meso-colon.—A long process attached to brim of pelvis.

Meso-rectum.—Passes from front of sacrum to upper part of rectum.

Ligaments.—The peritoneum, as explained, is reflected from the abdominal walls to viscera, forming ligaments.

Ligaments of the Liver:—

Suspensory or Falciform.—Sickle-shaped fold passing from anterior abdominal wall to upper surface of liver. The anterior free border contains obliterated umbilical vein or round ligament.

Coronary.—Connects right lobe to diaphragm; consists of two layers, the anterior being derived from greater sac, and the posterior from lesser sac.

Lateral (2).—These are the right and left ends of the coronary ligament.

Ligaments (False) of the Bladder:—

Posterior False Ligaments (2).—The edges of the recto-vesical pouch.

Lateral False Ligaments (2).—Reflection from sides of bladder.

Superior False Ligament.—Reflection from bladder to anterior abdominal wall.

Ligaments of the Uterus:—

Broad Ligaments (2).—Pass from side of uterus to pelvis. The upper margin contains the round ligament; Fallopian tube and ovary between its folds.

Anterior Ligaments (2).—Margins of utero-vesical pouch.

Posterior Ligaments (2).—Margins of recto-vaginal pouch.

Ligament of Spleen, or lieno-renal ligament, passes from left kidney to spleen, the anterior layer is formed by the lesser sac, and the posterior by the larger one.

The **foramen of Winslow** is the canal behind the small omentum, by which the smaller peritoneal sac communicates with the general peritoneal cavity.

Connections:—

<i>In front.</i>		<i>Behind.</i>	<i>Above.</i>	<i>Below.</i>
Hepatic artery	Between the layers of the small omentum.	Vena cava.	Caudate lobe.	1st part of duodenum.
Portal vein				
Cystic duct		Right crus.		Commencement of hepatic artery.
Hepatic duct				

THE MEDIASTINA.

The **superior mediastinum** is the space above the pericardium extending upwards to the root of the neck.

Boundaries:—

Above. Superior aperture of the thorax.

Below. Plane passing from lower part of body of 4th cervical vertebra, to the junction of the body and manubrium of sternum.

In front. Manubrium and origins of sterno-hyoid and sterno-thyroid muscles.

Behind. First four dorsal vertebræ, and lower ends of longus colli muscles.

Contents. Trachea (lower end), œsophagus, thoracic duct, transverse part of arch of aorta, innominate artery, thoracic part of carotid and subclavian arteries, innominate veins, upper part of superior vena cava, phrenic and pneumogastric nerves, left recurrent and the cardiac nerves, lymphatic glands and remains of thymus gland.

The **anterior mediastinum** is the space between the two pleuræ in front of the pericardium; it is narrow above, but broader below.

Boundaries:—

In front. Sternum, with 5th, 6th, and part of 7th left rib cartilages, triangularis sterni, and left internal mammary vessels.

Behind. Pericardium.

Laterally. Pleura.

Contents. Anterior mediastinal glands.

The **middle mediastinum** contains the pericardium with its contents, the phrenic nerves and accompanying vessels, the arch of the large azygos vein, the roots of the lungs and bronchial lymphatic glands.

The **posterior mediastinum** lies behind the pericardium.

Boundaries:—

In front. Pericardium and roots of lungs.

Behind. Spinal column, from the lower border of the 4th dorsal to the 12th dorsal vertebra.

Laterally. Pleura.

Below. Diaphragm covered by pleura.

Above. Plane passing forwards from lower border of 4th dorsal vertebra.

Contents. Descending part of arch and thoracic aorta, œsophagus, pneumogastric and splanchnic nerves, azygos and left superior intercostal veins, thoracic duct, and posterior mediastinal glands.

THE HEART AND PERICARDIUM.

THE PERICARDIUM.

The **pericardium** is a fibro-serous membrane, containing the heart and the commencement of the great vessels. The *apex*

points upwards and surrounds the vessels coming from the heart for two inches. The *base* is fixed to the central tendon and adjoining muscular fibres of the diaphragm.

<i>In front.</i>	<i>Behind.</i>	<i>Laterally.</i>
Middle piece of sternum.	Roots of lungs.	Pleura.
Left costal cartilages (3rd to 7th).	Œsophagus.	Superior phrenic vessels.
Remains of thymus gland.	Descending aorta.	Phrenic nerve.
Overlapped by left lung and pleura.		

The serous layer of the pericardium lines the inner surface of the pericardium, and is continued on to the surface of the heart, being also prolonged over the vessels in the pericardium. The aorta and pulmonary artery are enclosed in one sheath, and it surrounds the ends of the four pulmonary veins, forming a pouch posteriorly between the veins of the right and left sides. The part of the superior vena cava within the pericardium is also invested by it.

The serous layer forms a reduplication in front of the root of the lung, enclosing the remains of the left superior vena cava; it reaches from the left superior intercostal vein downwards to the side of the left auricle, where it joins the serous investment round the left lower pulmonary vein. This reduplication is known as the *vestigial fold* of Marshall.

THE HEART.

The **heart** is a hollow muscular organ enclosed in the pericardium, and having an irregular conical shape. It is attached at its base to the great bloodvessels, being otherwise free within the pericardial sac.

Position.—The heart is placed obliquely, the base being directed upwards, backwards, and to the right; the apex downwards, forwards, and to the left. The *apex* corresponds to a point $\frac{3}{4}$ inch to the inner side, and $1\frac{1}{2}$ inches below the left mamilla, in the left 5th costal interspace.

The Limits of the Heart.

Superior. Line from lower border of 2nd left, to upper border of 3rd right costal cartilage.

Inferior. Line from 7th right chondro-sternal articulation to apex.

Right side. Line drawn nearly vertically $1\frac{1}{2}$ inches from mid-line of sternum, from upper to lower limit.

Left side. Line from lower border of 2nd left costal cartilage downwards and forwards to apex.

Position of the Valves.

Pulmonary. Opposite upper border of 3rd left costal cartilage near sternum.

Aortic. Opposite left $\frac{1}{2}$ of sternum, on level with lower border of 3rd costal cartilage.

Tricuspid. Opposite right $\frac{1}{2}$ of sternum, on level with 4th costal cartilage.

Mitral. Opposite junction of 4th left costal cartilage with sternum.

Divisions.—The heart is divided longitudinally by a septum into two halves, right and left, each of which is subdivided transversely into two cavities. Those four divisions are indicated on the heart's surface by grooves. Two longitudinal grooves, one situated on the anterior and the other on the posterior surface, indicate the lateral division, whilst a transverse furrow, the *auriculo-ventricular groove*, indicates its separation into auricles above the furrow and ventricles below it.

The Circulation.—The right auricle receives venous blood from the vena cava and coronary sinus; thence it passes into the right ventricle, whence it is conveyed to the lungs by the pulmonary artery. After being oxygenized the blood passes into the left auricle by the pulmonary veins; thence it is conveyed into the left ventricle, and from there to the aorta, whence it passes through the body.

THE CAVITIES OF THE HEART.

The RIGHT AURICLE consists of a principal cavity and an appendix auriculæ.

The principal cavity, or *sinus venosus*, is of an irregular form.

The *appendix auriculæ* is a small muscular pouch projecting from the anterior and upper angle of the auricle overlapping the root of the pulmonary artery.

Openings in the sinus.—*Superior vena cava*, in the upper and front part. *Inferior vena cava*, at the lowest and back part of the auricle. Between the two openings of the cava is a projection, the *tubercle of Lower*.

The *coronary sinus* opens between the inferior cava and the auriculo-ventricular opening.

Foramina Thebesii are the mouths of small cardiac veins.

The *auriculo-ventricular* opening in front of the inferior cava.

Openings of anterior cardiac veins (2 or 3) from the surface of the right ventricle.

Valves.—The *Eustachian valve* is a semilunar fold of endocardium in front of the anterior margin of the inferior vena cava ; passes upwards and to the left to anterior margin of annulus ovalis.

The *coronary valve*, or *valve of Thebesius*, protects the opening of the coronary sinus.

Remnants of foetal structure.—The *Fossa ovalis* is the remains of the foramen ovale on the lower and posterior part of the septum auricularum, just above and to the left of the opening of the inferior vena cava.

The *annulus ovalis* is an elevated margin of the fossa.

The *musculi pectinati* are the prominent muscular columns running over the surface of the appendix auriculæ.

The RIGHT VENTRICLE consists of a cavity, the upper and left angle of which is prolonged into a funnel-shaped cavity, the *infundibulum* or *conus arteriosus*, leading to the pulmonary artery. On the wall are projections, *columnæ carneæ*, formed of muscular bundles, of which there are three varieties : the first are merely prominent ridges ; the second are attached at the ends, being free in the middle ; the third are the *musculi papillares*, which project inwards, and are attached by their bases to the wall of the ventricle, the other end being connected with the *chordæ tendineæ*, or cords attached to the flaps of the auriculo-ventricular valve.

The *tricuspid valve*, which guards the right auriculo-ventricular opening, consists of three cusps, formed by a reduplication of the endocardium, with some fibrous tissue enclosed. The bases of the flaps are attached to a tendinous ring, while to their free ends are attached the *chordæ tendineæ*. *Position of cusps.* *Right one* against anterior wall of ventricle. *Left one* between auriculo-ventricular opening and septum. *Posterior* against septum. The valve prevents regurgitation of blood into the auricle during the heart's contraction.

The opening of the *pulmonary artery* is at the summit of the funnel-shaped cavity, and is guarded by the pulmonary semilunar valves. The semilunar valves are three folds of the lining membrane, a right, left, and posterior, which guard the orifice of the pulmonary artery. The free margin of each has in its middle a small nodule, the *corpus Arantii*, and between each valve and the beginning of the pulmonary artery is a dilatation called the pulmonary sinus, or *sinus of Valsalva*. The point correspond-

ing externally to these valves is the junction of the third left rib cartilage with the sternum.

The **LEFT AURICLE** consists of a principal cavity and an appendix auriculæ; the latter extends forwards and to the right side, projecting over the commencement of the pulmonary artery. Its interior presents *musculi pectinati* as on the right side.

OPENINGS.—The *pulmonary veins* (4) open into the cavity, two on either side.

The *auriculo-ventricular* opening is smaller than that on the right side.

On the septum may be seen a shallow depression, the remains of the *foramen ovale*.

The **LEFT VENTRICLE** is longer and more conical than the right, with its walls nearly three times as thick. The interior contains *columnæ carneæ*, *musculi papillares*, and *chordæ tendineæ*, as on the right side.

OPENINGS.—The *auriculo-ventricular* opening corresponds to the junction of 4th left costal cartilage with the sternum; it is closed by the *mitral valve*, which is attached to the circumference at the opening, similarly to the tricuspid. It consists of two flaps, the larger one being anterior.

The *aortic opening* is placed in front and to the right side of the preceding, and its position may be marked externally by a line drawn through left half of the sternum, on a level with the lower border of the 3rd left costal cartilage. The orifice is guarded by three semilunar valves, which are precisely similar to those on the pulmonary artery; the characteristics of which are, however, better marked.

The **endocardium** is the serous membrane lining the whole of the interior of the heart, and is continuous with the lining membrane of the bloodvessels.

The **coronary arteries** supply the substance of the heart.

The **right coronary artery** comes off from the anterior sinus of Valsalva (aorta), passes on the right side of the pulmonary artery between it and the appendix, then backwards along the right auriculo-ventricular groove as far as the posterior inter-ventricular groove, where it divides into two branches, one of which passes transversely in the left auriculo-ventricular groove and joins branch of left artery, whilst the other passes downwards in the posterior inter-ventricular groove to supply the ventricles and septum; *anas.* descending branch of left artery.

The **left coronary artery** arises from the left anterior sinus of Valsalva. It passes behind and then to the left of the pulmonary artery, and divides it into two branches, one of which

passes forwards and downwards in the anterior inter-ventricular groove, and the other outwards and backwards along the left auriculo-ventricular groove.

The **nerves** come from the cardiac plexuses.

ORGANS OF VOICE AND RESPIRATION.

THE LARYNX.

The **larynx** lies in the front and upper part of the neck, being placed below the tongue and hyoid bone and between the large vessels of the neck. It opens above into the pharynx and below into the trachea. It is subcutaneous in the middle line, being covered only by skin and cervical fascia, but laterally it is overlaid by the insertions of the sterno-hyoid and sterno-thyroid, by the thyro-hyoid and origin of the inferior constrictor. Is composed of cartilages held together by ligaments, and moved by muscles, the whole being lined with mucous membrane.

The **cartilages** of the larynx :—

The **thyroid cartilage** is the largest, consists of two wings or *alæ* united in front at an acute angle, and forming the projection known as the **pomum Adami**.

Outer surface : traversed by **oblique line**, passing upwards and backwards, giving attachment to sterno-thyroid and thyro-hyoid muscles.

Inner surface : presents in the middle line at the junction of right and left ala, the *receding angle*, to which are attached the root of the epiglottis, the superior and inferior vocal cords, the thyro-arytænoidei and thyro-epiglottidei muscles.

Superior border : sinous ; the two meeting together anterior in the mid-line form notch above pomum Adami.

Inferior border : connected with upper border of cricoid, by crico-thyroid membrane anteriorly, and crico-thyroid muscle laterally.

Posterior border : thick and rounded, receives insertion of stylo- and palato-pharyngei muscles, prolonged upwards into *superior cornu*, which passes upwards, backwards, and inwards, having thyro-hyoid ligament attached to tip ; and downwards into *inferior cornu*, shorter, passing downwards, forwards, and inwards, presenting on inner surface a small facet to articulate with cricoid.

The **cricoid cartilage** : shaped like signet ring, deep behind, and shallow in front.

Outer surface : anterior half gives attachment to crico-thyroid muscles, and beyond this to part of inferior constrictor.

Posterior half, broad and thick, presents ridge in middle line for attachment of some longitudinal fibres of œsophagus, on each side of ridge, a depression giving attachment to the crico-arytænoid posticus, and external to this, a small facet for articulation with inferior cornu of thyroid.

Inner surface : smooth, lined with mucous membrane.

Superior border : inclines from the front, upwards and backwards, gives attachment anteriorly and laterally to crico-thyroid membrane, and crico-arytænoides lateralis. Presents posteriorly in mid-line a notch, on each side of which is a facet for articulation with arytænoid cartilage.

Inferior border : horizontal, connected with 1st ring of trachea.

Arytænoid : are two small pyramidal cartilages, articulating with posterior part of upper border of cricoid.

Anterior surface : convex and rough, receives attachment of thyro-arytænoides muscle and superior vocal cord. At upper end is a tubercle, and below an oblique ridge.

Posterior surface : hollowed for attachment of arytænoides muscle.

Internal surface : narrow and smooth, covered with mucous membrane.

Base : has concave facet on under surface of muscular process, for articulation with cricoid cartilage, and prolonged into three angles.

External or muscular process : short and prominent, gives attachment to lateral and posterior crico-arytænoid muscles.

Anterior or vocal process : long and pointed, gives attachment to inferior vocal cord.

Internal : rounded.

Apex : looks backwards and inwards, surmounted by the cartilage of Santorini.

Cartilages of Santorini or cornicula laryngis : two small cartilages of conical shape, each attached to the apex of an arytænoid cartilage, and giving attachment to the arytæno-epiglottidean fold.

Cuneiform cartilages, or cartilages of Wrisberg, are two small cartilages, one on each side, found in the arytæno-epiglottidean fold.

The epiglottis covers the superior aperture of the larynx ; it is leaf-shaped.

Apex : attached to receding angle of thyroid by thyro-epiglottic ligament.

Base : broad, rounded, and free.

Anterior surface: covered in upper part by mucous membrane, which passes forwards as the three glosso-epiglottic folds, to connect it with the tongue; below it is attached to the hyoid bone by hyo-epiglottic ligament.

Posterior surface: covered by mucous membrane, concave from side to side, concavo-convex from above downwards; the convex part is known as the *cushion* or *tubercle* of the epiglottis.

The **LIGAMENTS** of the larynx are:—

The **thyro-hyoid membrane**: passes from the upper border of the thyroid cartilage to the upper border of the posterior surface of the hyoid bone. It is pierced by the superior laryngeal vessels and nerve of each side.

(The **lateral thyro-hyoid membrane** is the posterior edge of the preceding, passes from the superior cornu of the thyroid to the tip of the great cornu of the hyoid bone.)

The **crico-thyroid membrane** connects the thyroid and cricoid cartilages. Consists of two parts:—

Central: thick, triangular, with base downwards.

Lateral: thinner, passes from upper border of cricoid cartilage internally to ala of thyroid, ending in a free border, the true vocal cord, or inferior thyro-arytænoid ligaments.

The **superior thyro-arytænoid ligaments** are attached anteriorly to the angle between the alæ of the thyroid cartilage, just below the epiglottis, and posteriorly to the anterior surface of the arytænoid cartilage. They lie within the mucous membrane, forming the false vocal cords.

The **inferior thyro-arytænoid ligaments** are attached anteriorly to the angle between the alæ of the thyroid cartilage, and posteriorly to the anterior angle at the base of the arytænoid cartilage. The inner free edge, covered with mucous membrane, forms the true vocal cord, and below it is continuous with the lateral part of the crico-thyroid ligament.

Capsular ligaments, lined with synovial membrane, surround the articulations between the cricoid and inferior cornua of the thyroid, and also between the cricoid and two arytænoid cartilages.

The **hyo-epiglottic ligament** connects the lower part of the anterior surface of the epiglottis to the upper border of hyoid bone.

The **thyro-epiglottic ligament** connects the apex of the epiglottis to the upper part of the receding angle of the thyroid cartilage.

THE INTERIOR OF THE LARYNX.

The **cavity** of the larynx extends from the *superior* aperture to the lower border of the cricoid cartilage. The vocal cords

form an imperfect diaphragm, dividing the cavity into two parts. The chink between the true vocal cords is the *glottis* or *rima glottidis*, which is the narrowest part of the larynx. The whole is lined by mucous membrane.

The **superior aperture** of the larynx is triangular in shape, with base directed forwards. In front is the epiglottis, behind are the summits of the arytaenoid cartilages and cornicula, and laterally, the arytaeno-epiglottic folds pass between the lateral edges of the epiglottis backwards to the lips of the arytaenoid cartilages and cornicula, enclosing the cuneiform cartilages.

The **superior or false vocal cords**, one on each side, are two folds of mucous membrane enclosing the superior thyro-arytaenoid ligaments, and placed above the corresponding ventricle.

The **inferior or true vocal cords**, one on each side, are attached in front to the receding angle of the thyroid cartilage, and behind to the anterior angle or vocal process at the base of the arytaenoid cartilage. They are formed of mucous membrane, enclosing the inferior thyro-arytaenoid ligaments.

The **ventricles** of the larynx are the fossæ between the false and true vocal cords; the anterior part of each ventricle is prolonged upwards, between the false vocal cords and the alæ of the thyroid cartilage into a pouch, the **sacculus laryngis**. The opening of the sacculus into the ventricle is narrow, and its cavity contains numerous small glands.

The **muscles** of the larynx have been seen before (*vide* p. 31).

The **arteries** of the larynx are the laryngeal branches of the superior and inferior thyroid.

The **nerves** are the superior laryngeal, the inferior or recurrent laryngeal, and branches of the sympathetic.

THE TRACHEA.

The trachea extends from the lower border of the larynx (opposite the 5th cervical vertebra) to opposite the 3rd dorsal vertebra, there dividing into the two bronchi. In length it measures $4\frac{1}{2}$ inches.

Relations in the Neck.

<i>In front.</i>	<i>Laterally.</i>	<i>Behind.</i>
Anas. of ant. jugular veins.	Cervical fascia.	Œsophagus.
Isthmus of thyroid.	Common carotid artery.	
Inferior thyroid veins.	Lateral lobes of thyroid.	
Sterno-hyoid muscles.	Inferior thyroid artery.	
Sterno-thyroid muscles.	Inferior laryngeal nerve.	

In the Thorax.

Inclines a little to the left side.

<i>In front.</i>	<i>Right side.</i>	<i>Left side.</i>	<i>Posteriorly.</i>
1st piece of sternum.	Right pneumogastric nerve.	Left cardiac nerves.	Œsophagus.
Origin of sternomastoid.	Pleura.	Left pneumogastric nerve.	
Origin of sternothyroid.		Left recurrent laryngeal nerve.	
Remains of thymus gland.		Pleura.	
Left innominate vein.			
Commencements of innominate and left carotid arteries.			
Arch of aorta.			
Deep cardiac plexus.			

The *cartilages*, from sixteen to twenty in number, are tunnel-shaped, the anterior $\frac{2}{3}$ or convex part being cartilage, the posterior $\frac{1}{3}$ fibrous membrane.

The *right bronchus*, about an inch long, is shorter, more horizontal in direction, and of larger calibre than the left one. It passes from the trachea downward and outwards on a level with the 4th dorsal vertebra to the root of the corresponding lung, lying at first above and then behind the right pulmonary artery. The arch of the aorta and vena cava superior lie in front, and the vena azygos arches forwards above it.

The *left bronchus* is nearly two inches long, and passes downwards and forwards under the arch of the aorta to the root of the left lung, joining it at the level of the 5th dorsal vertebra. Behind it are the œsophagus, thoracic duct, and descending aorta. It lies at first below, and then behind, the left pulmonary artery.

THE LUNGS AND THE PLEURÆ.

The *lungs*, two in number, occupy the whole of the thorax except the mediastina (*vide* p. 196), which separate them from each other. They are conical in shape, and are covered with pleura. Each lung is free except at the median part or root, where it is attached to the bloodvessels and bronchi.

The *pleuræ* are two serous sacs enclosing and investing the

lungs. Each pleura consists of a visceral and parietal part. The *visceral* portion covers the lung, and the *parietal* part lines the inner surface of the chest walls, the upper surface of the diaphragm, and the sides of the pericardium. The visceral and parietal layers of the corresponding pleura become continuous in front and behind the root of the lung; and below the root a fold, the *ligamentum latum pulmonis*, extends downwards along the inner surface of the lung to the diaphragm. The mediastina are formed by the visceral layers of each side approaching one another towards the median line.

THE LUNGS.

Each lung is cone-shaped, with the base downwards.

The *apex* projects upwards into the root of the neck behind the clavicle and anterior scalenus muscle. Above the first rib, the first part of the subclavian artery lies in front, being separated from it by the pleura.

The *base* is concave, resting upon the diaphragm, and following the attachment of the midriff is placed lower externally and posteriorly than anteriorly.

The *outer surface* is convex, and corresponds to the chest wall.

The *inner surface* is concave, corresponding in part to the convex outer surface of the pericardium. It presents about its middle, and towards the posterior part, a slit, the *hilum pulmonis*, where the bronchi and vessels pass in to form the root.

The *anterior margin* is thin, and overlaps the pericardium, and presents on the left side a notch for the apex of the heart.

The *posterior margin* is rounded, and occupies the groove by the side of the vertebræ.

Fissures and Lobes.—The left lung is smaller and narrower than the right, and is divided into an upper and lower lobe by a fissure, which passes upwards and inwards from the outer surface nearly to the root. The right lung is larger and shorter than the left, and is divided into three lobes, upper, middle, and lower, by two fissures. One fissure passes obliquely from the outer surface upwards and inwards nearly to the root, and the second passes horizontally from the middle of the first, forwards to the anterior margin, cutting off a middle triangular lobe.

Each *root* consists of the corresponding bronchus, a branch of the pulmonary artery, two pulmonary veins, nutritive bronchial vessels, nerves, lymphatic vessels and glands, all held together by areolar tissue, and covered by the pleura.

Connections of the right root :—

<i>In front.</i>	<i>Behind.</i>	<i>Above.</i>	<i>Below.</i>
Right phrenic nerve.	Posterior pulmonary plexus.	Vena azygos.	Ligamentum latum pulmonis.
Anterior pulmonary plexus.	Right pneumogastric nerve.		
Superior vena cava.			
Part of right auricle.			

Connections of the left root :—

<i>In front.</i>	<i>Behind.</i>	<i>Above.</i>	<i>Below.</i>
Left phrenic nerve.	Posterior pulmonary plexus.	Arch of aorta.	Ligamentum latum pulmonis.
Anterior pulmonary plexus.	Descending part of arch of aorta.		
	Esophagus.		
	Thoracic duct.		
	Left pneumogastric nerve.		

Position of the constituents of the root :—

From before backwards in each lung :—

Pulmonary veins.
Pulmonary artery.
Bronchus.

From above downwards :—

Right side.

Bronchus.
Pulmonary artery.
Pulmonary veins.

Left side.

Pulmonary artery.
Bronchus.
Pulmonary veins.

THE PULMONARY ARTERY.

The **pulmonary artery** conveys venous blood from the right side of the heart to the lungs. It commences at the infundibulum of the right ventricle, is directed upwards in front of ascending part of aorta, and in same tube of pericardium, then passes upwards and backwards on left of 1st part of aorta to reach the concavity of the aortic arch, where it divides into right and left branches for the lungs. Near the bifurcation a fibrous cord, the *ligamentum ductus arteriosus*, passes from the left branch to the under surface of the aorta. It is the remains of the ductus arteriosus in the foetus,

Connections (contained in same sheath of pericardium with ascending aorta) :—

<i>In front.</i>	<i>Above.</i>	<i>Laterally.</i>
Ascending aorta.	Transverse aorta.	Coronary artery.
Left auricle.	Ligamentum ductus arteriosus.	Auricular appendix.

The **right pulmonary artery** is longer than the left, passes to the root of the right lung, behind the ascending aorta and superior vena cava, where it divides into three primary branches, one for each lobe.

The **left pulmonary artery** is connected at origin with arch of aorta by ligament of ductus arteriosus, passes in front of the descending aorta and left bronchus to the root of the left lung, there dividing into two primary branches for the two lobes.

DUCTLESS GLANDS ON THE TRACHEA.

THE THYROID GLAND.

The **thyroid gland** is situated at the upper part of the trachea, and consists of two lateral lobes united by neck or isthmus, which lies over 2nd, 3rd, and 4th rings of trachea.

Each lobe is conical, with smaller end upwards.

Connections :—

In front. Sterno-hyoid, steno-thyroid, omo-hyoid.

Behind. Trachea and larynx, œsophagus (left side).

Laterally. Sheath of carotid vessels.

THE THYMUS GLAND.

The **thymus gland** attains its full size at two years, after which it gradually shrinks away. It is situated partly in the anterior mediastinum, and partly in the neck, reaching from level of 4th costal cartilage upwards on trachea as high as lower border of thyroid. It consists of two lateral lobes with occasionally a middle connecting one.

Connections in early life :—

Base. Pericardium.

Behind. Trachea, pericardium, and great thoracic vessels.

In front. Sternum as low as 4th rib cartilages, origins of sterno-hyoid and sterno-thyroid muscles.

Externally. Pleura, sheath of carotid.

Internally. Opposite lobe and side of trachea.

THE URINARY ORGANS.

THE KIDNEYS.

The kidneys secrete the urine, and are situated in the posterior part of the lumbar region of the abdomen behind the peritoneum, extending from the 11th rib to nearly the crista ili, the right being placed lower than the left. The average length of each kidney is four inches, breadth two inches, and thickness one inch.

Relations.—The relations of the two kidneys differ somewhat, though each is partially covered anteriorly with peritoneum.

*Relations of the Right Kidney.**In front.*

Right lobe of liver.
2nd part of duodenum.
Ascending colon.

Behind.

Right crus of diaphragm.
Quadratus lumborum.
Psoas.
Last intercostal space and
12th rib.

*Relations of the Left Kidney.**In front.*

Cardiac end of stomach.
Lower border of spleen.
Tail of pancreas.
Descending colon.

Behind.

Left crus.
Quadratus lumborum.
Psoas.
11th and 12th rib.

Above each kidney is the supra-renal body.

Below each kidney is the iliac crest.

The *external border* is convex, and is placed outwards and forwards.

The *internal border* is concave, and at the centre is the fissure or *hilum*, where the vessels enter and the ureter leaves, lying from before backwards as follows: renal artery, vein, ureter.

Each kidney is connected with the bladder by a ureter, which serves to convey urine to the latter viscus; the top of each ureter is expanded, and forms the *pelvis of the kidney*, which is divided into three parts called *infundibula*, which are subdivided into *calices*. Into these calices small *papillæ* project, which are the apices of the *pyramids of Malphigi*. These latter form the medullary substance of the kidney, and are imbedded in the cortical substance, which encloses them completely except at the *papillæ*.

Supra-renal capsules : these are ductless glands, resembling in shape a cocked hat, and which embrace the upper extremity of each kidney.

Connections :—

Anteriorly—Right. Liver. *Left.* Pancreas and spleen.

Posteriorly. Diaphragm.

Below. Top of kidney.

THE URETERS.

The **ureters** connect the kidneys with the bladder, forming the excretory ducts of the former, 16 to 18 inches long.

Relations of the Ureter.

Behind.

Psoas.

Common or external iliac artery.

In front.

Peritoneum.

Spermatic vessels.

Ileum (right side).

Sigmoid flexure (left side).

The *right* ureter lies close to the outer side of the inferior vena cava.

In the Male.—In the pelvis each ureter enters the fold of peritoneum limiting laterally the recto-vesical pouch, and reaches the side of the bladder near the base, along which it runs downwards and forwards below the obliterated hypogastric artery, crossing the vas deferens ; finally it enters the interior of the bladder by passing very obliquely through its coats at the posterior angle of the base.

In the Female.—Passes in posterior ligament of uterus, over cervix and upper part of vagina, to posterior part of base of bladder, as in the male.

THE BLADDER.

The **bladder** receives the urine from the kidneys by the ureters.

Position.—In *infancy* it lies in the abdomen. In the *adult* it lies in the pelvis behind the pubes ; in the *male* in front of the rectum ; in the *female* it is placed in front of the uterus and vagina.

Differences in the sexes : the female bladder is larger transversely.

The *apex* is connected to the umbilicus by the urachus and by the obliterated hypogastric arteries, the part posterior to the urachus being covered with peritoneum.

The *body* is uncovered anteriorly by peritoneum, and in front are the triangular ligament of the urethra, the symphysis pubis, and the internal obturator muscles. Posteriorly it is covered by peritoneum, and is in relation with the rectum in the male, and uterus in the female, and with small intestines in both. Crossing obliquely on each side of the bladder is the obliterated hypogastric artery, which forms the lateral limit of the peritoneum; the vas deferens crosses obliquely the lower part of the lateral surface along the inner side of the ureter.

The *base* or *fundus* is directed forwards and downwards.

Relations of the Base.

<i>In the Male.</i>		<i>In the Female.</i>
<i>Below.</i>	<i>Behind.</i>	<i>Below.</i>
Rectum 2nd part.	Recto-vesical pouch of peritoneum.	Cervix uteri and anterior vaginal wall.

Connected with the base are the vesiculæ seminales and vasa deferentia, which bound a triangular space destitute of peritoneum.

Connections of the triangular space :—

<i>In front.</i>	<i>Laterally.</i>	<i>Behind.</i>
Prostate.	Vas deferens. Vesicula seminalis.	Rectum, to which it is attached by areolar tissue.

The *cervix* or neck of the bladder is the part continuous with the urethra.

LIGAMENTS.—There are two sets of ligaments of the bladder, true and false.

The **true ligaments** are two anterior and two posterior. They are formed of recto-vesical fascia, and are described on p. 47.

The **false ligaments**, five in number, are formed of peritoneum; there are two posterior, two lateral, and an anterior, the latter covering the urachus. They have been described on p. 191.

Interior of the Bladder.—Upon the inner surface of the base of the bladder, just behind the urethral orifice, is a triangular smooth surface or trigone, with the apex looking forwards. It is bounded laterally by two ridges passing to the openings of the ureters, the posterior angles being formed by those openings; at its apex there is an elevation, formed by the prostate, called the *uvula vesicæ*.

THE MALE ORGANS OF GENERATION.

THE PROSTATE GLAND.

The **prostate gland** adjoins the neck of the bladder and surrounds the beginning of the urethra, which is placed nearer the anterior than the posterior surface of the gland. It is said to resemble a horse-chestnut in shape, with the apex directed forwards. It measures about $1\frac{1}{2}$ inches across its base and half that in depth, and is held in position by the anterior true ligaments of the bladder.

The gland consists of three lobes, two lateral and one middle, and is perforated from base to apex by the urethra. The common seminal ducts open into the prostatic portion of the urethra, and are placed between the middle and lateral lobes.

Connections :—

<i>Anterior or Pubic Surface.</i>	<i>Posterior Surface.</i>	<i>Base.</i>	<i>Apex.</i>
Symphysis pubis.	Rectum.	Surrounds bladder-neck.	Rests on upper layer of triangular ligament.
Anterior ligaments of bladder.	<i>Laterally.</i>	Vesiculæ seminales.	
Branches of dorsal vein of penis.	Levator ani.	Vasa deferentia.	

The prostate is surrounded by a sheath derived from the recto-vesical fascia (*vide* p. 47) and by the prostatic plexus of veins.

COWPER'S GLANDS.

Cowper's glands are two small round bodies about the size of a pea, placed behind the membranous part of the urethra, between the two layers of the deep perineal fascia. Their ducts are about one inch long, and pass forwards to open in the bulbous part of the urethra.

THE PENIS.

The **penis** is divided into a root, body, and glans.

The *root* is connected to the pubic rami by two strong processes, the *crura*, and to the symphysis pubis by the suspensory ligament.

The *glans* forms the extremity ; at its summit is the opening of the urethra, the *meatus urinarius* ; passing from the bottom of this is a fold of mucous membrane continuous with the prepuce and called the *frenum præputii*. At the base of the glans is a projecting edge or *corona*, and behind that a constriction, the *cervix*. Sebaceous glands (of Tyson) are found on both.

The integument of the penis, attached to the neck of the glans, is doubled upon itself, forming the *prepuce* or *foreskin*.

The *body* is the part between the root and the glans, the upper surface being the *dorsum*.

The *corpora cavernosa* form the greater part of the body of the penis; they are two cylindrical tubes placed side by side, connected together for the anterior $\frac{3}{4}$ ths, the *septum pectiniforme* being between, but separated behind to form the two *crura*, which are attached to the projecting edges of the ischial and pubic rami; anteriorly the corpora cavernosa fit into the base of the glans. There is a groove on the upper surface for the dorsal vein of the penis and another groove on the lower surface for the corpus spongiosum; the corpora are attached to the pubic symphysis by the suspensory ligament.

The *corpus spongiosum* commences at the triangular ligament by an enlargement, the *bulb*, and runs forward in the groove on the under surface of the corpora cavernosa, expanding over their extremities to form the glans. The *bulb* is covered by the anterior or lower layer of the triangular ligament, and is embraced by the accelerator urinæ. The urethra pierces the bulb near its upper surface, and then runs forward in the middle of the corpus spongiosum.

The URETHRA in the male extends from the neck of the bladder to the end of the penis, and has a length of from eight to nine inches. It is divided into three parts, according to the structures through which it passes.

(1) The *prostatic* portion passes through the prostate gland from base to apex; this part is $1\frac{1}{4}$ inches long and spindle-shaped. On the floor is a longitudinal ridge, the *verumontanum* or *caput gallinaginis*, and on each side of this promontory is a depression, the *prostatic sinus*, in which the prostatic ducts open. Towards the anterior part of the verumontanum is a depression, the *sinus pocularis*, *vesicula prostatica*, or *utricle*, upon the elevated edges of which the ejaculatory ducts open.

(2) The *membranous* portion extends from the apex of the prostate to the bulb, and is $\frac{3}{4}$ inch long anteriorly, but only $\frac{1}{2}$ inch posteriorly from the bulb projecting here posteriorly; it is contained principally between the layers of the triangular ligament, and is surrounded by the compressor urethræ.

(3) The *spongy* portion is contained in the corpus spongiosum and occupies the rest of the canal, being six inches long; the portion contained in the bulb is somewhat dilated, and the ducts of Cowper's glands open on the floor; the canal enlarges again just below the meatus urinarius, which enlargement is named the *fossa navicularis*.

The floor of the urethra is sprinkled with *lacunæ*, which are the openings of the *glands of Littre*; one large one in the fossa navicularis is called the *lacuna magna*.

THE SCROTUM.

The **scrotum** contains the testicles and spermatic cords. It is divided in the middle line by a *raphé*; the left half is longer than the right, as the left testicle hangs down lower, the left spermatic cord being longer than its fellow.

Coverings of the Testis in the Scrotum :—

1. Skin.
2. Superficial fascia and dartos tissue.
3. Inter-columnar or spermatic fascia.
4. Cremaster muscle and fascia.
5. Infundibuliform fascia, continuous with the transversalis fascia.
6. Tunica vaginalis, consisting of a parietal and visceral layer, forms a closed sac. The visceral layer invests the body and epididymis of the testicle except behind, where the duct and vessels are attached, being here continuous with the parietal layer. It passes, on the outer side, a little between epididymis and body, forming the digital fossa.

THE SPERMATIC CORD.

The **spermatic cord** consists of the vas deferens with its vessels and nerves, spermatic vessels and nerves, the cremasteric artery, the genital branch of the genito-crural nerve, lymphatics, together with some areolar tissue; it extends from the internal abdominal ring to the testis, passing in its course along the inguinal canal, from which it emerges by the external abdominal ring, and thence in front of the pubes to the scrotum. The *vas deferens* is placed at the back of the cord, and may be recognised by its hard and cord-like feeling.

Boundaries of the Inguinal or Spermatic Canal :—

Extent : $1\frac{1}{2}$ inches long, from the internal to the external abdominal ring.

<i>Behind.</i>	<i>In front.</i>	<i>Floor formed by</i>	<i>Roof formed by</i>
Peritoneum and fascia transversalis for whole length.	Internal oblique (outer third).	Meeting of Poupart's ligament and fascia transversalis.	Arched fibres of internal oblique and transversalis, and apposition of layers of abdominal wall.
Conjoined tendon (inner two-thirds).	Aponeurosis of external oblique (for whole length).		

THE TESTES.

The **testes** are two glandular organs, each is suspended in the scrotum by the spermatic cord, which is attached to the posterior border. Each testis consists of two parts: the *body*, which is anterior, and the *epididymis*, placed posteriorly; to the lower end of this latter the duct or *vas deferens* is attached.

Coverings of the Testis:—

1. *Serous* or *tunica vaginalis* is derived from the peritoneum and consists of two parts, the visceral and parietal.

2. *Fibrous* or *tunica albuginea* covers the body of the testicle, sending in a vertical septum the *mediastinum* or *corpus Highmorianum*: this latter gives off secondary processes or *septa*, which serve to separate the lobules of the testicle.

3. *Tunica vasculosa* consists of the bloodvessels, connected together with areolar tissue.

The **epididymis** is a long narrow body, consisting of three parts, viz.: a superior portion projecting forwards on the upper end of the body, the *head* or *globus major*; a lower, the *tail* or *globus minor*, with which the *vas deferens* is continuous, and between these two, the *body* or central portion. The epididymis consists of a duct 20 feet long, exceedingly convoluted, and bound together by areolar tissue; it receives the *coni vasculosi* at the upper part of the testicle.

The **body** of the testicle consists of numerous lobules of pyramidal shape, which are formed by trabeculæ, mediastinum, and tunica albuginea, the base of the lobule being directed to the circumference of the testis, and the apex towards the mediastinum. Each lobule contains one or more *tubuli semiferi* held together by areolar tissue. Each tubule commences near the base, in either a blind extremity or by anastomotic loops, becoming straighter near the apex, and as they enter the mediastinum, they coalesce together to form twenty or thirty *tubuli recti*.

The *tubuli recti* or *vasa recta* pierce the mediastinum, interlace, and form the *rete testis*.

About twelve to twenty tubules pass from the upper part of the rete as the *vasa efferentia*.

The *vasa efferentia* perforate tunica albuginea, being at first straight, then convoluted, forming the *coni vasculosi*, which forms the *globus major*.

The *coni* open into the excretory duct at intervals (when unravelled) of about 3 inches.

The **vas deferens** commences at the lower part of the *globus*

minor, and ascends along the inner side of the posterior part of the epididymis ; thence it follows the spermatic cord through the canal and internal abdominal ring. In the pelvis it crosses to the inner side of the external iliac artery, and arches over the back of the bladder, crossing the obliterated hypogastric artery. At the base of the bladder it runs along the inner side of the vesiculæ seminales, here becoming sacculated ; narrowing again at the base of the prostate, it unites with the duct of the vesicula seminalis of the same side, and forms the *common ejaculatory duct*.

THE VESICULÆ SEMINALES.

The **vesiculæ seminales** are two sacculated pouches, placed at the base of the bladder. They are pyramidal in shape, the posterior part being the wider ; anteriorly they converge to enter the prostate near the middle line. The corresponding vas deferens lies on the inner side.

FEMALE ORGANS OF GENERATION.

The external organs of generation in the female are : the mons veneris, the labia majora, the labia minora, the clitoris, the meatus urinarius, and the orifice of the vagina. The term *vulva* includes the whole of these.

The **mons veneris** is the eminence in front of the pubes, covered with hair.

The **labia majora** are two prominent folds extending from the mons to the perineum. Externally they are covered with hair and integument, internally with mucous membrane ; the labia are joined together anteriorly and posteriorly, forming commissures. A small transverse fold of mucous membrane is found in the posterior commissure called the *fourchette* ; the space between this and the commissure is known as the *fossa navicularis*.

The **labia minora** or **nymphæ** are two folds of mucous membrane, extending for $1\frac{1}{2}$ inches downwards and outwards from the clitoris, finally losing themselves below in the labia majora. They surround the clitoris, the upper folds forming the *preputium clitoridis*, the inferior ones, attached to the glands, being the *frænum*.

The **clitoris**, corresponding somewhat in structure to the penis, is placed just before the anterior commissure. It consists of two corpora cavernosa attached to the pubic rami by two crura ; the free extremity or glans is formed by corpus spongiosum. Between the nymphæ, and bounded anteriorly by the clitoris, is

the *vestibule*, at the back part of which the *meatus urinarius* opens, being about 1 inch below the clitoris.

The Bulb of the Vestibule.—A mass of erectile tissue lying internal to the nymphæ, and resting on the inferior surface of the triangular ligament.

Below the meatus is the orifice of the vagina, closed more or less in the virgin by the *hymen*, which is a duplicature of mucous membrane, generally semilunar in shape. After its rupture small elevations, *carunculæ myrtiformes*, only remain.

The **glands of Bartholin**, analogous to Cowper's glands in the male, are situated on each side near the entrance of the vagina, and their ducts open on the nymphæ, external to the hymen.

The **urethra** in the female is only $1\frac{1}{2}$ inches long, and is embedded in the anterior wall of the vagina; it perforates the triangular ligament, as in the male. The *meatus urinarius*, the external orifice of the urethra, opens between the nymphæ, about an inch below and behind the clitoris.

The **vagina** is a dilatable canal extending from the vulva to the uterus; the anterior wall is about 4 inches and the posterior wall from 5 to 6 inches long. The upper end widens to receive the neck of the uterus.

The relations are :—

<i>Anteriorly.</i>	<i>Posteriorly.</i>	<i>Laterally.</i>
Base of bladder.	Rectum.	Broad ligament.
Urethra.	Pouch of Douglas.	Levator ani.

There is a ridge or *raphé* along the middle of the inner surface of both the anterior and posterior walls. The walls likewise present many transverse ridges or *rugæ*. The lower end of the vagina is embraced by the sphincter vaginae.

THE UTERUS.

The **uterus** or womb is a pear-shaped body, flattened from before backwards, placed in the pelvis between the bladder and rectum; superiorly it does not reach above the brim of the pelvis. The position corresponds to the pelvic axis. The uterus is covered by peritoneum behind, above, and in front except where it is attached to the base of the bladder; the peritoneum is reflected from off the sides to the pelvis, forming the *broad ligaments*. The average length of the uterus is 3 inches, and it is, for the purpose of description, divided into three parts :—

(1) The *fundus* is the broad upper end of the body, projecting into the abdomen between the attachments of the Fallopian tubes.

(2) The *body* extends from the fundus to the neck, narrowing as it approaches the latter; at the junction of the fundus and body is an angle to which the Fallopian tube is attached; a little anteriorly to this the *round ligament* is connected, below and behind the round ligaments the *ovarian ligaments* are attached.

(3) The *neck* or *cervix uteri* is surrounded below by the vagina, into which it projects, forming a vaginal part, which presents a transverse opening, the *os uteri*, the *os uteri externum*, or the *os tincae*.

The *cavity* of the uterus is triangular in shape, the superior angles leading to the Fallopian tubes. Where the body joins the neck there is a constriction, the *os uteri internum*.

The **ligaments** are two anterior or vesico-uterine, two posterior or recto-uterine, and two lateral or broad ligaments, all formed of peritoneum.

The *broad ligaments* are formed of a double layer of peritoneum passing from the surfaces of the uterus to the sides of the pelvis. Between the two layers of this ligament on each side are the Fallopian tube, the round ligament, the parovarium, the ovary, and its ligament.

The *round ligament* is a cord placed between the layers of the broad ligament, extending from the superior angle of the uterus to the internal abdominal ring; thence it passes into the inguinal canal to lose itself in the labium. It is enclosed for some part of the way in peritoneum, which is known as the *canal of Nuck*.

THE APPENDAGES OF THE UTERUS.

The **Fallopian tubes** are two in number, placed in the upper margin of the broad ligament. Each tube measures about 4 inches in length. The cavity commences by a narrow orifice called the *ostium internum*, and terminates in a *fimbriated extremity*, which embraces the ovary at certain times.

The **ovaries** are two in number, and correspond to the testes in the male; they are of a flattened ovoid form, placed in the posterior part of the broad ligament. Anteriorly the ovary is connected to the broad ligament; and internally to the uterus by a proper ligament, extending to the superior angle of the uterus, and called the ligament of the ovary. The superior, inferior, and posterior surfaces are free. The vessels enter the hilum at the attached anterior border.

The **parovarium** lies between the Fallopian tube and ovary, and is the remains of the Wolffian body.

THE NOSE.

The organ of smell consists of an *anterior prominent part*, situated on the face, and composed of bones, cartilages, muscles, and integument, and two *nasal fossæ*.

The **cartilages of the nose** are five in number :—

The *upper lateral cartilages* (2) : situated just below the free margins of the nasal bones. Each cartilage is triangular in shape ; *anteriorly* it joins its fellow and the cartilage of the septum ; *posteriorly* it is in connection with the nasal process of the superior maxilla, and *inferiorly* it joins the lower lateral cartilage.

The *lower lateral cartilages* (2) are peculiarly curved to form the nostrils ; *posteriorly* each cartilage is connected to the nasal process of the superior maxilla by fibrous membrane, in which are two or three sesamoid cartilages ; *above* it joins the upper cartilage and the cartilage of the septum.

The *cartilage of the septum* is thicker at the edges than at the centre ; its connections are : *anteriorly*, with the nasal bones, the two upper lateral cartilages and the lower lateral cartilages ; *posteriorly*, with the perpendicular plate of the ethmoid ; *inferiorly*, with the vomer and the palatal processes of the superior maxillæ.

The *nasal fossæ*, separated from each other by the *septum nasi*, open in front by the anterior nares and behind by the posterior nares. Each fossa may be described as possessing a roof, a floor, an inner and an outer wall.

The *roof* is formed by the nasal bones, the nasal spine of the frontal, the cribriform plate of the ethmoid, the under surface of the body of the sphenoid, alæ of the vomer, sphenoidal processes of the palate bones.

The *floor* consists of the palatal processes of the superior maxillary and of the palate bones.

The *inner wall* is constructed by cartilage of the septum, the crest of the nasal bones, the nasal spine of the frontal, the perpendicular plate of the ethmoid, the vomer, the rostrum of the sphenoid, and the crests of the superior maxillary and palate bones.

The *outer wall* : nasal process of the superior maxilla, the lachrymal bone, the ethmoid, inner surface of the superior maxilla, the inferior turbinate bone, the vertical plate of the palate bone, and the internal pterygoid plate of the sphenoid.

Meatuses.—The superior and inferior turbinate processes of the ethmoid bones, and the inferior turbinate bone project in-

wards from the outer wall, dividing each fossa into a *superior*, a *middle*, and an *inferior* meatus.

Openings :—

Superior meatus : sphenoidal and posterior ethmoidal cells.

Middle meatus : anterior ethmoidal cells, frontal sinus, and antrum of Highmore.

Inferior meatus : nasal duct.

The **septum** is the partition separating the two fossæ. It is formed by the perpendicular plate of the ethmoid, the vomer, the nasal spine of the frontal, the rostrum of the sphenoid, the crests of the superior maxillary and palate bones, and the cartilage of the septum. The space between the anterior nares and the anterior edge of the cartilage of the septum is filled by membrane, the *columna nasi*.

The **anterior nares** are the anterior openings of the nasal fossæ. They are separated from each other by the *columna nasi*, and within the margin are arranged short stiff hairs, *vibrissæ*.

The **posterior nares** open backwards into the pharynx. They are oval in shape, being about 1 inch long and $\frac{1}{2}$ inch across.

Sinuses.—The nasal fossæ communicate with the following sinuses in the neighbouring bones, the mucous membrane being continuous with them :—

1. Sphenoidal sinuses.
2. Posterior ethmoidal cells.
3. Anterior ethmoidal cells.
4. Frontal sinus.
5. Antrum.

The **mucous membrane** lining the cavity of the nose is called the *pituitary* or *Schneiderian* membrane. It is continuous with the various sinuses communicating with the nasal fossæ, with the conjunctiva through the nasal duct and lachrymal canals, with the mucous membrane of the pharynx through the posterior nares, and with the skin of the face through the anterior nares.

The **epithelium** covering the surface consists of three varieties :—

1. *Stratified squamous*, in the region of the nostrils.
2. *Columnar*, in the olfactory region.
3. *Ciliated columnar*, in the respiratory region and the sinuses.

Structure of the mucous membrane in the olfactory region.—The columnar cells taper at their attached ends, and, branching out, form a network with the neighbouring cells. Lying in this network are spindle-shaped cells, the *olfactory cells* of Max

Schultze, each having a superficial and a deep process. The *superficial* process passes to the surface between the columnar cells, terminating at the level of them. The *deep* process passes inwards, becomes varicose, and probably is directly continuous with the terminations of the olfactory nerve.

The Olfactory Nerve.—From the olfactory lobe there proceed about twenty branches through the cribriform plate of the ethmoid, which may be divided into three sets:—

1. *Inner*: pass along the grooves on the septum.
2. *Middle*: distributed to the roof.
3. *Outer*: passing to the upper turbinate bone, the anterior plain surface of the ethmoid and the middle turbinate bones.

Reaching the mucous membrane the nerves form tufts from which filaments are given off. These filaments communicate freely with contiguous twigs forming a plexus, and probably end in the olfactory cells.

THE EAR.

The ear is divided, for the purpose of description, into three parts, external, middle, and internal.

THE EXTERNAL EAR.

The external ear consists of the auricle or *pinna*, and the *external auditory meatus*.

The *pinna* is a plate of cartilage covered with integument, and attached to the commencement of the meatus; it has numerous ridges and depressions, as follows: the external rim is the *helix*, and anterior and parallel to it is another ridge, the *anti-helix*, which is bifurcated above to enclose the *fossa of the anti-helix*; between the helix and anti-helix is the *fossa of the helix*. Anterior to the anti-helix is a depression, the *concha*; projecting backwards over the meatus is the *tragus*, and opposite to the latter is the *anti-tragus*. The lowest part of the pinna is called the *lobule*.

The *external auditory meatus* reaches from the bottom of the concha to the *membrana tympani*. It is arched slightly upwards, and is directed forwards and inwards; it is formed partly by cartilage and partly by bone. The outer or cartilaginous part is continuous with the pinna, and is about $\frac{1}{2}$ inch long. The cartilage does not form a complete tube, being deficient at the upper and back part, the interval being filled by fibrous tissue. One or two fissures (*fissures of Santorini*) partially traverse the tube. The inner or osseous part is longer than the preceding, and at its inner end there is a groove round the sides

and floor for the insertion of the membrana tympani. In the outer part of the meatus are hairs and ceruminous glands, which latter secrete the ear-wax.

THE MIDDLE EAR OR TYMPANUM.

The tympanum is contained in the temporal bone. It communicates with the pharynx by the Eustachian tube, and is traversed by a chain of bones, which connect the membrana tympani with the internal ear.

The **cavity of the tympanum** is bounded *externally* by the meatus and membrana tympani, *internally* by the external surface of the internal ear, and it communicates posteriorly with the mastoid cells.

The **roof** is formed by a thin plate of bone separating the tympanum and the cranium.

The **floor** is formed by the roof of the jugular fossa.

The **outer wall** is formed by the membrana tympani and the bone around it; the following fissures are seen:—

The *Glaserian fissure*: through which the processus gracilis of the malleus and tympanic vessels pass.

Aperture of the iter chordæ posterius: leading to a canal which opens into the aquæductus Fallopii.

Aperture of the iter chordæ anterioris: leading to the canal of Huguier, and transmitting the chorda tympani.

The **inner wall** presents the following:—

The *fenestra ovalis*: leading into the vestibule.

The *ridge of the aquæductus Fallopii*: placed just above the preceding.

The *promontory*: placed below the fenestra ovalis, formed by the projection of the first turn of the cochlea.

The *fenestra rotunda* lies at the bottom of a funnel-shaped depression behind the promontory. It is closed by a membrane, the *secondary membrane of the tympanum of Scarpa*, which closes an aperture in the bone leading to the scala tympani of the cochlea.

The *pyramid* is placed just behind the fenestra ovalis; it contains the stapedius, the tendon of which projects through the apex.

The **posterior wall** presents many irregular apertures, which are the *openings of the mastoid cells*.

The **anterior wall** shows the following:—

The *canal for the tensor tympani*, opening just anteriorly to the fenestra ovalis.

The *processus cochleariformis*: a process of bone lying

between and separating the canal for the tensor tympani and the Eustachian tube.

The *Eustachian tube* leads into the pharynx, is partly cartilaginous and partly osseous ; the internal or cartilaginous part is trumpet-shaped, and terminates in an oval opening at the side and upper part of the pharynx. The osseous portion is placed along the angle of union of the squamous and petrous portions of the temporal bone, and is about $\frac{1}{2}$ inch long.

The **membrana tympani** is the membrane which separates the external and middle ears. It is inserted into the groove in the osseous portion of the external meatus, and is placed obliquely across the opening, forming with the floor of the meatus an angle of 45° . It contains the handle of the malleus between its layers, which makes the membrane concave externally. There is a small notch in the upper and anterior part of the groove of insertion known as the *notch of Rivini*, which is closed by a loose portion of the membrane, the *membrana flaccida* of Shrapnell.

Structure of the membrane, from without inwards :—

1. Prolongation of skin of meatus.
2. Fibrous tissue or *membrana propria*.
3. Mucous membrane of the tympanum.

The ossicles of the tympanum are :—

1. The Malleus.
2. The Incus.
3. The Stapes.

The **malleus**, or hammer, consists of :—

The *head* : the thickened upper part, presenting on the posterior surface a facet for articulation with the body of the incus.

The *neck* : a constriction below the head.

The *handle* : a long tapering process passing downward, and attached by its outer side to the *membrana tympani*.

The *processus gracilis* : a slender spicule passing from the neck into the Glaserian fissure.

The *processus brevis* : arises from the root of the handle and projects outwards to be attached to the *membrana tympani*.

The **incus**, or anvil, consists of :—

The *body* : articulating by a saddle-shaped facet with the head of the malleus.

The *processus brevis* : attached to the margin of the mastoid opening.

The *processus longus* : passes behind and parallel to the

handle of the malleus. The tip protrudes inwards, and ends in the orbicular process, which articulates with the head of the stapes.

The **stapes** closely resembles a stirrup. It consists of :—

The *head* : looking outwards, and articulating with the orbicular process of the incus.

The *base* : fixed to the margins of the fenestra ovalis.

The *crura* : pass from a constricted part, the neck, and pass inwards to the extremities of the base. The anterior crus is shorter and straighter than the posterior, and between the two a thin membrane is stretched.

The **ligaments** unite the chain of bones to the adjacent walls of the tympanum. They are :—

The *anterior ligament of the malleus* : passing between the root of the processus gracilis and the edge of the Glaserian fissure. This ligament was formerly described as a muscle passing from the malleus out of the Glaserian fissure, and termed the laxator tympani.

The *external ligament of the malleus* : passing between the processus brevis and notch of Rivini.

The *superior ligament of the malleus* : passing between the head of the malleus and the roof of the tympanum.

The *ligament of the incus* : passing between the processus brevis and the posterior wall of the tympanum.

The *annular ligament of the stapes* connects the base of the stapes with the edge of the fenestra ovalis.

The **muscles** :—

The *tensor tympani* arises from cartilage of the Eustachian tube, and from bony canal in which it lies. The tendon is reflected round the end of the processus cochleariformis, and is inserted into the inner border of the handle of the malleus, near its root.

The *stapedius* is lodged in the aqueductus Fallopii and pyramid. The tendon issues from the apex of the pyramid, and is inserted into the posterior part of the neck of the stapes.

THE INTERNAL EAR OR LABYRINTH.

Within the internal ear are the terminal ramifications of the auditory nerve. The internal ear or labyrinth is divided into *osseous* and *membranous* parts, the former enclosing the latter. Within the membranous labyrinth is a fluid, the *endolymph* ; and outside, between the membranous and osseous labyrinths, is a fluid, the *perilymph* or *liquor Cotonii*.

The **OSSEOUS LABYRINTH** consists of the vestibule, the cochlea, and the semicircular canals.

The **vestibule** is the central part of the labyrinth. Its outer wall corresponds to the inner wall of the tympanum, and in it is the *fenestra ovalis*, closed by the base of the stapes; on its inner wall is a depression, the *fovea hemispherica*, perforated by several holes for the divisions of the auditory nerve; behind this is a ridge, the *crista vestibuli*; and still further back is the internal opening of the *aqueduct of the vestibule*. On the roof is a depression, the *fovea hemi-elliptica*. At the posterior part are the five openings of the *semicircular canals*, and at the anterior part is the *apertura scalæ vestibuli*.

The **semicircular canals** are three arched osseous canals placed above and behind the vestibule, opening into that chamber by five rounded apertures, two adjacent canals having a common opening. Each canal forms about two-thirds of a circle, and presents at one end a dilated part, the *ampulla*. Two of the canals are vertical, and the third is horizontal.

The *superior* canal is vertical, and forms a projection on the upper border of the petrous part of the temporal bone. The inner extremity joins the opening of the posterior canal.

The *posterior* canal is vertical, its upper end being joined to the lower opening of the superior canal.

The *horizontal* or *external* canal is the smallest of the three, and lies horizontally just above the level of the *fenestra ovalis*.

The **cochlea** is cone-shaped, with the base turned to the internal meatus, and the apex opposite the canal for the tensor tympani, and consists of a tapering spiral canal of $2\frac{1}{2}$ turns, with the inner wall formed by its axis or *modiolus*; the canal is divided into two *scalæ* by a partition of bone and membrane, the *lamina spiralis*. The enclosed arched extremity of the cochlea is called the *cupola*, and the first turn of the canal bulging into the tympanum forms the promontory. The *lamina spiralis ossea* ends at the apex of the cochlea in a small point, the *hamulus*, between which and the modiolus is a small opening, the *helicotrema*, by which the two *scalæ* communicate.

The *modiolus* is pierced by small canals for the passage of nerves, and one larger one, the *central canal of the modiolus*, passes from the base to the last half-turn of the cochlea. At the base of the *lamina spiralis* is a small canal, the *spiral canal of the modiolus*, which winds round the axis, and contains a spiral ganglionated cord, the *ganglion spirale*.

The *scalæ* are known respectively as the *scala tympani* and the *scala vestibuli*.

The *scala tympani* is the lower one; it commences at the *fenestra rotunda*.

The *scala vestibuli* commences at the cavity of the vestibule, and communicates at the apex of the modiolus with the *scala tympani*, by the helicotrema.

The MEMBRANOUS LABYRINTH consists of sacs containing fluid (endolymph). The ramifications of the auditory nerve are distributed on the wall. These membranous sacs complete the septum between the *scala tympani* and the *scala vestibuli*, besides enclosing a third space, the *scala media* or membranous canal of the cochlea.

The membranous vestibule consists of two sacs, the *utricle* and the *sacculæ*.

The *utricle* or common sinus is larger than the *sacculæ*, and is situated in the posterior and upper part of the vestibule, being contained in the fovea hemi-elliptica. The apertures of the membranous semicircular canals open in the posterior part. At the anterior part is a thickened spot, the *macula acustica*, where the nerves enter. The interior contains, opposite the *macula*, attached to the wall, a small calcareous deposit, known as otoliths, otoconia or ear sand. Below there is a canal, which, joined to a similar tube from the *sacculæ*, extends along the aqueduct of the vestibule, and ends in a dilated pouch, the *saccus endo-lymphaticus*.

The *sacculæ* is smaller and rounder than the *utricle*, and lies in the fovea hemispherica. Like the *utricle*, it contains a *macula* and a collection of otoliths. Below there is a small canal, *canalis reuniens*, which connects it with the membranous canal of the cochlea.

The membranous semicircular canals are about one-third the size of the osseous ones, except at the ampullæ, where they dilate to nearly fill the bony canal. Each membranous canal is free on the convex surface, the concavity being fixed to the osseous canal. On the part of the interior surface of the ampulla, corresponding to the attachment to the bony canal, is a transverse projection, the *crista acustica*, covered by a layer of columnar epithelium, from each cell of which projects inwards a small filament, auditory hair. These auditory hairs are probably the ultimate endings of the auditory nerve.

The membranous cochlea consists of a membranous tube divided into three parts—the *scala tympani*, *scala vestibuli*, and canal of the cochlea, which latter contains the organ of Corti.

The lamina spiralis ossea partly divides the spiral canal into the *scala tympani* and *scala vestibuli*, the latter being superior. The septum is completed by the *membrana basilaris*, which is attached to the lower free edge of the lamina spiralis ossea,

and passed outwards to the wall of the cochlea, where it is fixed to a thickening of the periosteum called the *spiral ligament*.

The **canal of the cochlea** contains the organ of Corti. It lies on the outer part of the scala vestibuli, and is separated from it by the *membrane of Reissner*, which passes from the lamina spiralis upwards and outwards to the roof of the scala. Thus a triangular piece is cut off, bounded internally by the membrane of Reissner, externally and above by the outer wall of the cochlea, and below by the basilar membrane. The canal of the cochlea is connected below with the saccule by the *canalis reuniens*, and above it terminates in a blind cone-shaped extremity, partly bounding the helicotrema and fixed to the cupola. The part of the lamina spiralis within the canal of the cochlea becomes thickened, and is called the *limbus*, and terminates in a concave border, the *sulcus spiralis*. The basilar membrane is attached to the lower margin of the sulcus spiralis.

The **organ of Corti** is contained in the epithelium covering the basilar membrane.

Structure:—

The most prominent central part is formed by the inner and outer *rods of Corti*, which are placed longitudinally upon the basement membrane, the two sets inclining towards each other, the inner overlapping the outer, and thus forming a triangular interval, which extends along the whole of the canalis cochlearis. On the inner side of each inner rod is an epithelial cell, having short hairs attached to the terminal end, and the series is called the *inner hair cells*.

On the outer side of the outer rods are three or four rows of similar cells, known as the *outer hair cells*, the hairs of which project through a fine network covering them, called the *lamina reticularis*.

Over the whole is stretched the *membrana tectoria* or *membrane of Corti*, which is attached internally to the limbus, and passing outwards as far as the outer side of the external hair cells.

The Auditory Nerve.—The auditory nerve divides in the internal auditory meatus into two branches, which perforate the cribriform plate, and are distributed to the cochlea and the vestibule.

The *superior* branch supplies:—

1. The utricle.
2. The ampulla of the superior semicircular canal.
3. The ampulla of the horizontal semicircular canal.

The inferior branch is distributed to :—

1. The cochlea.
2. The sacculæ.
3. The ampulla of the posterior semicircular canal.

Nerves of the Cochlea.—The branches of the auditory nerve destined for the cochlea perforate a number of foramina at the bottom of a spiral groove, the *tractus spiralis foraminulentus*, placed in the centre of the base of the cochlea. These foramina lead to small canals, which at first pass through the modiolus, and then radiate outwards between the bony layers of the lamina spiralis. In the centre of the tractus spiralis foraminulentus is a larger foramen leading to the central canal of the modiolus, and transmitting nerve filaments for the last half-turn of the cochlea. Near the commencement of the lamina spiralis the nerve fibres pass through a ganglionic cord, the *ganglion spirale*, which is contained in the *canalis spiralis modioli*, each fibre probably having a bipolar cell from the ganglion connected with it. Thence the fibres pass outwards in distinct cords, and afterwards spread out into a layer which at the edge of the osseous lamina form bundles which pass through perforations at the edge of the bony lamina spiralis, and pass into the epithelium near the inner hair cells, and probably are distributed to both sets of hair cells.

THE EYE AND ITS APPENDAGES.

THE APPENDAGES OF THE EYE.

The **eye-brows** are two arched eminences over each orbit, consisting of thickened integuments and muscles, surmounted by hairs.

The **eye-lids** are two movable folds, an upper and a lower, the upper one being more movable, which by their closure protect the eye from injury. When the eye-lids are open the angles of junction of the upper and lower lids are called respectively the *external* and the *internal canthus*. In the inner canthus the lids are separated by a fold of conjunctiva, the *plica semi-lunaris*, which is occupied by the *caruncula lachrymalis*, and opposite the commencement of this, on each lid, is the *lachrymal papilla*, which is pierced by the *punctum lachrymale*, the external opening of the lachrymal canal.

Structure from without inwards : skin, areolar tissue, orbicularis muscle, tarsal cartilage, and palpebral ligament, Meibomian glands, conjunctiva ; the upper lid has also the aponeurosis of the levator palpebræ, which is attached along the fore-part of the upper surface of the tarsal cartilage.

The **lachrymal gland** occupies a depression in the external angle of the orbit; the anterior margin is connected to the back part of the upper eye-lid. The ducts (12 or 14) open by apertures, placed in a row, at the inner surface of the upper lid.

The **lachrymal canals** commence at the *puncta lachrymalia*, which are the openings of the canaliculi, and pass inwards to open into the *lachrymal sac*.

The **lachrymal sac** is placed in a groove formed by the lachrymal bone and the nasal process of the superior maxilla, being behind the tendo-oculi, and in front of the tensor tarsi; it is the dilated upper end of the nasal duct.

The **nasal duct** leads from the lachrymal sac to the inferior meatus of the nose, where it opens, the aperture being partly guarded by a valve formed of the mucous membrane. It is about $\frac{1}{2}$ inch long, and is directed downwards, and slightly outwards and backwards.

THE EYE.

The **eye-ball** is contained within the orbit; its shape is spherical, with the segment of a smaller sphere, corresponding to the cornea, placed anteriorly.

The eye-ball consists of three coats enclosing three refractive media :—

1st coat	{ Sclerotic.
			...	{ Cornea.
2nd coat	{ Choroid.
			...	{ Iris.
3rd coat	Retina.

The refractive media are :—

1. Aqueous humour.
2. Vitreous body.
3. The lens.

Surrounding the middle of the eye-ball is a covering of fascia, the *capsule of Tenon*, continuous posteriorly with the sclerotic at the entrance of the ciliary vessels, whilst anteriorly it is connected with it by loose tissue only, and is pierced by the tendons of the muscles of the eye-ball. It forms, so to speak, a synovial sac in which the eye-ball glides.

The **sclerotic coat** is opaque and fibrous, and occupies the posterior $\frac{5}{6}$ of the eye-ball, being continuous in front with the cornea.

The *outer surface* is white and smooth, receiving the insertions of the recti and obliqui muscles.

The *inner surface* is of a light-brown colour, due to a lining

of pigmented connective-tissue, the *membrana fusca*, which is connected by fine filaments to the choroid coat. Between the sclerotic and choroid coats is a lymph-space transmitting branches of the ciliary vessels and nerves.

The optic nerve passes through the posterior part of the sclerotic, about $\frac{1}{8}$ inch internal to the axis of the eye-ball, the point of perforation being called the *lamina cribrosa*. At its entrance, the outer sheath of the nerve blends with the sclerotic coat.

The sclerotic is thickest at its posterior part, gradually thinning until about $\frac{1}{4}$ inch from the cornea, where it thickens again.

The *bloodvessels* of the sclerotic are few in number, but near its junction with the cornea there is a vascular zone derived from the anterior ciliary branches of the ophthalmic artery.

The *cornea* is the anterior transparent part of the outer coat of the eye-ball, occupying about $\frac{1}{6}$ of the circumference of the globe. It projects forward beyond the curvature of the sclerotic, being the segment of a smaller circle. The posterior surface is concave, and projects further backwards than the anterior convex surface, being overlapped by the edge of the sclerotic.

Structure :—

The cornea is constructed of three parts :—

1. Stratified epithelium : continuous with that of the conjunctiva, and called the *anterior epithelial layer*.

2. Substantia propria : formed of modified connective-tissue, consisting of about sixty strata of fibres in which are spaces containing branched cells, the *corneal corpuscles*. The part of this connective-tissue just beneath the epithelium is denser than the rest, and is called the *anterior elastic lamina*.

Posterior to the substantia propria, and separating it from the epithelial layer lining the anterior chamber, is the *posterior elastic lamina*, or *membrane of Decemet*. At its circumference this membrane splits up into fibrous bundles, the *pillars of the iris*, which are covered with epithelium cells continuous with those lining the posterior elastic lamina. The cavities between these pillars are known as the *spaces of Fontana*.

Close to the junction of the cornea with the sclerotic, and a little anterior to the spaces of Fontana, is a similar but larger space, called the *canal of Schlemm*.

3. A layer of epithelium cells : the posterior epithelial layer which lines the posterior elastic lamina on the surface next to the anterior chamber.

The *choroid coat* is situated between the sclerotic and the retina, and is of a dark-brown colour. It is continued anteriorly

into the iris, but before its junction it forms a number of projections, folding inwards, and arranged in a circle, known as the *ciliary processes*. They are about seventy in number, and are placed in corresponding depressions upon the surface of the vitreous humour, and the suspensory ligament of the lens.

The choroid coat is thickest behind, where it is pierced by the optic nerve.

Externally it is connected to the sclerotic by loose connective-tissue traversed by vessels and nerves as before described. Internally it is covered by the pigmented cells of the retina.

Structure :—

The choroid consists of bloodvessels connected together by loose connective-tissue, and containing large branched and pigmented cells.

1. *Lamina supra-choroidea* : this is the external membranous layer, similar to the lamina fusca of the sclerotic. It consists of a thin membrane containing a network of elastic fibres, and covered with flat epithelium cells. Arranged irregularly in it are large pigmented cells, and scattered over it are a few lymphoid cells. It is loosely connected, as described, with the lamina fusca, and between the two is a lymph-space, containing vessels and nerves, which communicates with the capsule of Tenon.

2. The *choroid proper* is similar in structure to the lamina supra-choroidea, but contains in addition a large number of bloodvessels.

It consists of two layers, an outer and an inner. The outer part contains the larger branches of the vessels. The arteries, the short ciliary, pierce the sclerotic coat close to the optic nerve, pass forwards, and bend inwards to end in the inner layer.

The veins, *vasa vorticosa*, are external to the arteries and join together into four or five principal trunks, which pierce the sclerotic midway between the cornea and the optic nerve.

The inner coat, or *tunica Ruyschiana*, is formed by the capillary endings of the vessels of the outer coat; they pass forwards to $\frac{1}{8}$ inch from the cornea, joining those of the ciliary processes.

3. *Membrane of Bruch* : this is a structureless membrane, which lines the internal surface of the choroid.

The *ciliary processes* are of the same structure as the rest of the choroid. The bloodvessels are derived from the anterior ciliary branches.

The *ciliary muscle* consists of two sets of fibres, radiating and circular.

The *radiating* arise by tendon from the sclerotic close to the

junction with the cornea, between the spaces of Fontana and the canal of Schlemm, and are inserted into the choroid opposite the ciliary processes.

The *circular* : a zone of circular fibres internal to the radiating, at the base of the ciliary processes.

The *iris* is the coloured membrane suspended in the aqueous humour behind the cornea and in front of the lens. In the centre is an aperture, the *pupil*.

It is connected at its circumference to the choroid, being continuous with it; and anterior to this it is attached to the cornea by the pillars of the iris, or *ligamentum pectinatum*.

The anterior surface is coloured and marked by wavy lines converging towards the free edge of the pupil.

The posterior surface is darkly pigmented and marked with folds prolonged from the ciliary processes.

Structure :—

The framework of the iris is a delicate stroma of connective-tissue, containing bloodvessels, nerves, and pigment-cells.

The layers of the iris are thus arranged :—

1. Epithelial layer, continuous with the epithelial layer of the membrane of Descemet.

2. Stroma, consisting of cells and fibres, arranged radially towards the pupil, and containing yellow pigment-cells. On the posterior surface of the stroma are some thin layers of very dark pigment-cells, the *uvea*.

3. The muscular tissue, consisting of two forms :—

The *sphincter*, a narrow band of fibres placed posteriorly close to the pupil (3rd nerve).

The *dilator* (sympathetic nerve), commencing at the outer margin of the iris, with the fibres converging towards the pupil.

The *bloodvessels* of the iris consist of the two long ciliary arteries, which pierce the sclerotic close to the optic nerve, and pass forwards in the lymph-space between the lamina fusca of the sclerotic and the lamina supra-choroidea of the choroid to enter the outer surface of the iris, having previously divided into two branches. They anastomose with the corresponding vessels of the opposite side, and with those from the vascular zone of the sclerotic, formed by the anterior ciliary arteries.

These form the *circulus major*. Small branches from this circle converge towards the pupil, and freely inosculate with one another, forming the *circulus minor*.

The veins follow the same arrangement as the arteries, and communicate with the canal of Schlemm.

The nerves of the choroid and iris are about fifteen in number, and are the *ciliary nerves*, from the lenticular ganglion and the nasal branch of the 5th; they follow very closely the course of the bloodvessels.

The **retina** is the expanded termination of the optic nerve, and forms the internal tunic of the eye. It reaches forwards nearly as far as the ciliary processes, where it ends in a saw-edged border, the *ora serrata*, and from this border there is prolonged a thin layer as far as the ciliary processes, which blends with the uvea of the iris. This prolongation contains no nerve-fibres, and is called the *pars ciliaris retinae*.

The *outer* surface is covered with pigment-cells (formerly described as part of the choroid).

The *inner* surface contains:—

The *macula lutea*, or yellow spot, situated in the axis of the globe.

The *fovea centralis*, a depression in the preceding.

The *porus opticus*, or disc, about $\frac{1}{16}$ inch to the inner side of the yellow spot, where the optic nerve enters, coursing over which may be seen the central vessels of the retina.

Structure of the retina:—

The retina consists of eight layers arranged perpendicularly to its surface, together with some connecting fibrous structures.

The layers of the retina are as follows:

1. *Layer of nerve fibres*.—These are the fibres of the optic nerve, consisting of axis cylinder only, and arranged in bundles. The layer is thickest behind, and is entirely wanting at the yellow spot.

2. The *ganglionic layer*, or layer of nerve-cells, is a single stratum of large nerve-cells, except in the region of the yellow spot, where they are two or three deep, whilst over the spot itself they are from eight to ten deep and bipolar. From the inner end of each cell there extends obliquely into the preceding layer a single process, which is continuous with one of the nerve-fibres of that stratum. The other extremity of the cell is embedded in the next layer, and from it one or two branched processes proceed. Each cell has a nucleus and a nucleolus.

3. *Inner molecular layer*.—This is a thick layer of granular substance, consisting of a fine network, probably enclosing lymph. The branches from the outer end of the ganglion cells lose themselves in this layer, and the varicose extremities of the nuclear bodies of the next layer can be traced into it.

4. *Inner nuclear layer*.—This layer consists of nucleus-like bodies of four different kinds, and collectively known as the

inner granules. The following is a description of the different varieties of these cells :—

- (a) Round or oval bipolar cells, each end being prolonged into a fine process. The inner process is varicose, and passes into the inner molecular layer, and each is probably connected with a branched process from a ganglion cell. The outer processes pass into the next layer, and may or may not become branched before reaching it. These cells are the most numerous in this layer, and consist almost entirely of a nucleus and nucleolus.
- (b) The second variety consists of cells with nucleus and nucleolus, but without branches, and form a stratum next to the inner molecular layer.
- (c) This variety resembles the preceding, except that they have a single branch from their inner surface. These cells are arranged in the outer part of the layer.
- (d) Oval nuclei connected with the Müllerian fibres (described later on).

5. *Outer molecular layer.*—This layer resembles the inner molecular layer in structure, but is much thinner. It receives the branches from the bipolar cells of the inner nuclear layer.

6. *Outer nuclear layer.*—This layer consists of two kinds of oval nucleus-like bodies.

- (a) *The rod granules.*—These are the most numerous, and each consists of a bipolar cell containing an oval nucleus crossed by one or two bands of a lighter substance. The branches or rod fibres extend inwards and outwards, being marked with small varicosities. The inner branch ends in a slightly larger varicosity which sends a few fibrils into the outer molecular layer, whilst each of the outer branches ends in one of the rods of the next layer.
- (b) *The cone granules,* placed in the outer part of the layer, are fewer than the preceding except at the macula lutea, where only this variety is found. Each consists of an oval nucleus with a nucleolus. From the inner extremity of the cell there extends a thick process, reaching as far as the outer molecular layer, where it forms an expansion, and sends a few fine fibrils into that layer. The branch from the outer part of the cell is very short, and forms the base of a corresponding cone.

7. *Layer of Rods and Cones* :—

(a) *The rods*.—These are the more numerous, except at the yellow spot, where they are absent. They are arranged regularly in rows. Each rod is divided about its middle into an outer and an inner part, the latter being somewhat spindle-shaped, whilst at its inner extremity it passes through the so-called external limiting membrane, and is joined to an outer branch of a rod granule of the outer nuclear layer. The outer half of each rod has the appearance of a column of small superimposed discs. The end of each is rounded, and projects into the pigmentary layer.

(b) *The cones*.—Each cone consists of a spindle-shaped base resting upon a cone granule of the outer nuclear layer. From the outer end there proceeds a small tapering process, similar in construction to the outer part of the rods.

8. *The pigmentary layer*.—This stratum forms the external layer of the retina, and consists of a single layer of hexagonal pigmented cells, separated from one another by clear inter-cellular substance. From the inner surface which contains the pigment numerous fine fibrils proceed, extending between the outer parts of the layer of the rods.

The outer surface of this layer is smooth, has no pigment, and is in proximity to the membrane of Bruch of the choroid.

The Müllerian Fibres :—

These fibres serve as connective-tissue to the layers of the retina, passing from the inner to the outer surface. They are more numerous and distinct near the ora serrata than at the posterior part of the retina. Each fibre commences at the inner surface of the retina by a broad base, shaped like a foot. These bases are connected with each other at their edges, and thus give rise to the appearance of a basic limiting membrane to the retina, which is sometimes called the *membrana limitans interna*.

The fibre passes outwards through the three inner layers of the retina, and may or may not give a few fine projections into them. Arrived at the inner nuclear layer, they give off some processes to support the inner granules, and in addition each fibre has a large nucleus with a nucleolus, which forms the fourth variety of cells in this layer.

The fibres then pass outwards and reach the outer nuclear layer, where they break up into fine fibrils to fill up the intervals between the outer granules, and terminate at the bases of the

rods and cones in a well-defined line, known as the *membrana limitans externa*, from which very fine fibrils extend between the rods and cones for a short distance.

Structure of the yellow spot and the fovea centralis:—

Most of the layers are much thicker at the macula lutea than in any other part of the retina.

The ganglionic layer is increased until the cells are six or eight deep. The cells are bipolar, and are arranged somewhat obliquely, and as the nerve-fibres run outwards to join the ganglion-cells, this first layer becomes very thin at the edge of the fovea centralis. In the fovea the inner molecular, the inner nuclear, and the outer molecular layers merge into one another, and the outer nuclear layer becomes very much thinned. Only cones are found in the fovea, and these are longer and thinner than usual. The yellow colour of the macula is due to colouring matter occupying the interspaces of the four or five inner layers.

Structure of the ora serrata and pars ciliaris:—

At the ora serrata the layers gradually disappear, the outer layer of rods and cones being the first to go, the two inner layers (nerve-fibres and ganglion-cells) are wanting entirely at the ora, and the inner molecular layer, composed in this situation of Müllerian fibres, disappears suddenly. The two nuclear layers become merged into one, and are continued into the pars ciliaris as a layer of columnar cells. The pars ciliaris thus consists of the layers left, viz., a layer of columnar cells, each having a nucleus near its outer part, and bounded externally by the pigmentary layer.

Bloodvessels of the retina:—

The central artery of the retina passes through the optic nerve, and reaches the inner surface of the retina through the disc. It here divides into two branches, an upper and lower, which subdivides, and the branches pass outwards.

The outer branches give small offsets to end in capillaries round the fovea. The rest of the branches are distributed, as capillaries, to the inner four retinal layers. The veins follow the same distribution as the arteries.

The **vitreous body** is a soft gelatinous substance occupying about $\frac{4}{5}$ of the eye-ball. It supports the retina behind, and is hollowed out in front for the lens.

Between the retina and the vitreous, and enclosing the latter except in front, is a thin capsule, the *hyaloid membrane*.

This membrane passes forwards in front to the anterior part of the margin of the lens. It becomes stronger in this part, and is called the *zonule of Zinn*, the *zonula ciliaris*, or the *suspensory ligament of the lens*.

The zonule commences near the ciliary processes, and passes forwards to the front of the lens, and is attached in front to the lens capsule. In addition some fibres are attached to the extreme edge of the lens, and others become continuous with the posterior part of the capsule.

The interstices between these fibres are occupied by fluid, but after death they may be distended with air, and an appearance of a canal (*canal of Petit*) encircling the lens is produced (Quain).

Extending forwards from the optic disc through the vitreous, as far as the capsule of the lens, is the *canal of Stilling*, or *hyaloid canal*, which is the remains of a branch from the central artery of the retina in the fœtus. The substance of the vitreous contains throughout a number of corpuscles possessing amœboid movements.

The **lens** is a transparent double convex body enclosed in a transparent membrane, the lens capsule. It is in contact anteriorly with the iris; posteriorly it rests in a depression in the vitreous body, and it is surrounded by the suspensory ligament or zonule of Zinn. It is about $\frac{1}{8}$ inch in diameter, and about $\frac{1}{5}$ inch thick.

The outer part is soft, and encloses a hardened centre, the "nucleus." At the posterior part the lens is in direct contact with the capsule, but in front it is separated by a layer of flattened epithelium cells, which gradually merge at the edge of the lens into the lens fibres.

The **lens capsule** is the structureless membrane enclosing the lens, thick in front near its circumference, where it is strengthened by the fibres of the zonule, but very thin posteriorly.

The **aqueous humour** and the **aqueous chambers**.—The aqueous humour occupies the space between the anterior part of the lens capsule and the posterior part of the cornea.

The iris divides the chamber into two parts, known as the anterior and posterior chambers.

The *anterior chamber* is bounded in front by the cornea, behind by the iris, and opposite the pupil by the anterior part of the lens.

The *posterior chamber* is the triangular interval at the circumference of the lens between the ciliary processes, the iris, and the zonule of Zinn.

I N D E X.

- ABDOMINAL aorta, 84
 ring, external, 43
 internal, 191
 Abducens nerve, 148
 Abductor indicis, 39
 hallucis, 55
 minimi digiti, 39
 pedis, 55
 pollicis, 38
 Accessorius muscle, 56
 ad sacro-lumbalem, 41
 Accessory nerve of the obturator,
 165
 Acromial thoracic artery, 77
 Acromio-clavicular articulation, 12
 Action of muscles, 56
 Adductor brevis, 51
 obliquus hallucis, 56
 longus, 51
 magnus, 51
 minimi digiti, 39
 pollicis, 39
 Alar ligaments of the knee, 20
 Ampulla, membranous, 226
 of the semicircular canals,
 225
 Amygdaloid lobe of cerebellum, 123
 Anastomotic artery of brachial, 79
 femoral, 94
 Anconeus muscle, 38
 Angular artery, 71
 vein, 100
 Ankle-joint, 21
 Annular ligament of ankle, anterior,
 54
 external, 55
 internal, 55
 of wrist, anterior,
 16, 36
 posterior,
 16, 36
 Annulus ovalis, 199
 Anteriorelasticlamina of cornea, 230
 commissure, 135
 Anti-helix, 221
 Anti-tragus, 221
- Aorta, 82
 abdominal, 84
 thoracic, 83
 Aortic arch, 82
 opening, 46
 plexus, 176
 sinus, 82
 Aperture of the aorta, 46
 cava, 46
 coronary arteries,
 200
 Eustachian tube,
 223
 for the femoral artery, 51
 of the larynx, 204
 nares, 182, 220
 oesophagus, 182
 pulmonary artery,
 199
 veins, 200
 Aponeurosis, epicranial, 24
 of external oblique, 44
 over femoral artery, 51
 of internal oblique, 44
 lumbar, 44
 of the pharynx, 182
 plantar, 55
 of the soft palate, 179
 temporal, 27
 of the transversalis
 muscle, 44
 vertebral, 41
 Appendages of the eye, 228
 Appendix auriculæ, 198, 200
 vermiformis, 185
 Aqueduct of Sylvius, 124
 of the vestibule, 225
 Aqueous humour, 237
 Arachnoid membrane of the brain,
 137
 Arachnoid membrane of cord, 138
 Arbor vitæ cerebelli, 124
 Arch of aorta, 82
 Arch, crural or femoral, 49
 of diaphragm, 45
 palmar deep, 80

- Arch, palmar superficial, 81
 plantar, 98
 Arciform fibres, 118
 Arter., acromialis thoracic, 77
 anastomotica brachialis, 79
 magna, 94
 angularis faciei, 71
 aorta abdominalis, 84
 thoracica, 83
 articulares inferiores, 95
 superiores, 94
 articularis azygos, 95
 auricularis posterior, 71
 auditoria, 76
 axillaris, 76
 basilaris, 76
 brachialis, 78
 bronchiales, 83
 buccalis, 73
 capsularis inferior, 86
 media, 86
 superior, 85
 carotis communis dextra, 68
 sinistra, 68
 externa, 69
 interna, 74
 carpi ulnaris anterior, 81
 posterior, 81
 radialis anterior, 79
 posterior, 79
 centralis retinae, 75
 cerebelli inferior, 66
 inferior anterior, 76
 superior, 76
 cerebri anterior, 75
 media, 75
 posterior, 76
 cervicalis ascendens, 66
 cervicalis profunda, 68
 choroidea cerebri, 76
 ciliares anteriores, 75
 posteriores, 75
 circumflexa anterior, 78
 externa, 93
 ilii interna, 91
 superficialis, 92
 interna, 93
 posterior, 78
 coeliaca, 85
 colica dextra, 86
 media, 86
 sinistra, 86
 comes nervi ischiadici, 91
 phrenici, 67
 communicans cerebri an-
 terior, 75
 posterior, 76
 palmaris, 81
 rter., communicans plantaris, 96
 coronaria dextra, 200
 labii inferioris, 70
 superioris, 70
 sinistra, 200
 ventriculi, 85
 corporis bulbosi, 89
 cavernosi, 89
 cremasterica, 91
 crico-thyroidea, 69
 cystica, 85
 deferentialis, 88
 dentalis anterior, 73
 inferior, 73
 superior, 73
 diaphragmatica, 67, 84
 digitales manûs, 81
 pedis, 96, 98
 dorsales pollicis, 80
 dorsalis carpi radialis, 79
 carpi ulnaris, 81
 hallucis, 96
 indicis, 80
 linguae, 70
 pedis, 96
 penis, 90
 scapulæ, 78
 epigastrica, 91
 superficialis, 92
 ethmoidalis anterior, 75
 posterior, 75
 facialis, 70
 femoralis, 92
 frontalis, 75
 gastricæ, 85
 gastro-duodenalis, 85
 gastro-epiploica dextra, 85
 sinistra, 85
 glutea, 91
 hæmorrhoidalis inferior, 89
 media, 88
 superior, 87
 hepatica, 85
 hyoidea lingualis, 70
 thyroidea, 69
 hypogastrica, 88
 iliaca communis, 87
 externa, 90
 interna, 88
 ileo-colica, 86
 lumbalis, 90
 incisoria, 73
 infra-orbitalis, 73
 scapularis, 67
 innominata, 83
 intercostales anteriores, 67,
 84
 rami anteriores, 84

- Arter., intercostales posteriores, 84
intercostalis superior, 67
interossea, 81
 anterior, 81
 posterior, 81
interosseæ manûs, 80
 pedis, 96
intestinales, 86
ischiadica, 91
labialis inferior, 70
lachrymalis, 75
laryngealis inferior, 66
 superior, 69
lingualis, 70
lumbales, 87
 rami anteriores, 87
 posteriores, 87
malleolares, 95
mammaria, externa, 78
 interna, 67
masseterica, 73
maxillaris, interna, 72
mediana, 81
mediastinæ, 83
meningeæ media, 73
 parva, 73
meningeæ anteriores, 75
 posteriores, 65
mesenterica inferior, 87
 superior, 86
metacarpa radialis, 79
 ulnaris, 81
metatarsæ, 96
musculo-phrenica, 67
mylo-hyoidea, 73
nasalis, 75
 lateralis, 71
 septi, 74
nutritia femoris, 93
 humeri, 79
 tibiæ, 97
obturatoria, 88
occipitalis, 71
œsophageales, 83
ophthalmica, 75
ovariana, 87
palatina inferior, 70
palatina superior, 73
palmaris profunda, 81
palpebralis inferior, 75
 superior, 75
pancreaticæ, 85
pancreatico-duodenalis, 85
perforantes femorales, 93
 mammaria in-
 ternæ, 67
 manûs, 80
 pedis, 96
- Arter., pericardiacæ, 83
perinæi superficialis, 89
peronea, 97
 anterior, 97
pharyngea ascendens, 71
phrenicæ inferiores, 84
 superiores, 67
plantaris externa, 98
 interna, 97
poplitea, 94
princeps cervicalis, 71
 pollicis, 80
profunda cervicis, 68
 femoris, 93
 inferior, 79
 superior, 78
pterygoideæ, 73
pterygo-palatina, 74
pudenda externa, 92
 interna, 89
pulmonalis, 207
 dextra, 208
 sinistra, 208
pylorica superior, 85
radialis, 79
 indicis, 80
ranina, 70
recurrens interossea pos-
 terior, 81
 radialis, 79
 tibialis, 95
 ulnaris anter-
 80
 poster., 81
renales, 86
sacra-media, 87
sacra-lateralis, 90
scapularis posterior, 67
sciatica, 91
sigmoidea, 87
spermatica, 86
spheno-palatina, 74
spinales posteriores, 66
spinalis anterior, 66
splenica, 85
sterno-mastoidea, 69
stylo-mastoidea, 71
subclavia dextra, 63
 sinistra, 63
sublingualis, 70
submentalis, 70
subscapularis, 77
superficialis cervicalis, 67
 perinæi, 89
 volæ, 79
supra-orbitalis, 75
 scapularis, 66
tarsæ, 96

- Arter., temporales profundæ, 73
temporalis, 72
 anterior, 72
 media, 72
 posterior, 72
 superficialis, 72
thoracica acromialis, 77
 alaris, 77
 longa, 77
 superior, 77
thyroidea ima, 83
 inferior, 66
 superior, 69
tibialis antica, 95
 postica, 96
tonsillaris, 70
transversalis colli, 67
 faciei, 72
 perinæi, 89
 pontis, 76
tympanica, 72, 74
ulnaris, 80
uterina, 88
vaginalis, 88
vertebralis, 65
vesicalis inferior, 88
 media, 88
 superior, 88
vidiana, 74
Articular popliteal arteries, 94, 95
 nerves, 169, 171
Articulation, acromio-clavicular, 12
astragalo-scaphoid, 22
astragalus to os calcis, 22
atlanto-axoid, 6
 of bones of the tympanum, 224
calcaneo-cuboid, 22
 scaphoid, 22
of carpal bones, 15
carpo-metacarpal, 16
of cervical vertebræ, 6
chondro-costal, 10
 sternal, 9
of coccygeal bones, 11
coraco-clavicular, 13
of costal cartilages, 10
costo-clavicular, 12
 vertebral, 8
crico-arytænoid, 203
 thyroid, 203
of cuneiform bones, 22
cuneiform to cuboid, 22
cuneiform to scaphoid, 22
of dorsal vertebræ, 6
Articulation, femoro-tibial or knee, 18
 humero - cubital or elbow, 14
ilio-femoral or hip, 17
of lower jaw, 8
of lumbar vertebræ, 6
of the metacarpal bones, 16
metacarpo-phalangeal 16
metatarsal, 23
metatarso-phalangeal, 24
occipito-atlantal, 7
 axial, 7
os calcis to cuboid, 22
 to scaphoid, 22
peroneo-tibial, 20
phalangeal of fingers, 17
 of toes, 24
of pubic symphysis, 11
radio-carpal or wrist, 15
 cubital inferior, 15
 superior, 14
sacro-coccygeal, 11
 iliac, 10
 vertebral, 10
scaphoid to cuboid, 22
 to cuneiform, 22
scapulo-humeral, 13
sterno-clavicular, 12
tarso-metatarsal, 23
temporo-maxillary, 8
of the thumb, 16
tibio-tarsal or ankle 21
 of vertebræ, 5
Arcus externus diaphragmatis, 47
 internus diaphragmatis, 46
Arytæno-epiglottidean folds, 204
Arytænoid cartilages, 202
 muscle, 32
Ascending cervical artery, 66
 vein, 102
colon, 185
pharyngeal artery, 71
 vein, 102
Attollens aurem, 24
Attrahens aurem, 24

- Auditory artery, 76
 nerve, 150-228
 nucleus, 121
 Auricle of the ear, 221
 Auricles of the heart, 198
 left, 200
 right, 198
 Auricular artery, posterior, 71
 nerves, great, 157
 inferior, 144
 superior, 144
 posterior, 150
 Auricular vein, 101
 nerve of vagus, 153
 Auriculo-temporal nerve, 144
 Auriculo-ventricular aperture, left, 200
 Auriculo - ventricular aperture, right, 199
 Auricularis magnus nerve, 157
 Axillary artery, 76
 fascia, 33
 vein, 103
 Axis, coeliac, of artery, 85
 of cochlea, 225
 thyroid, 66
 Azygos, artery, 95
 veins, 105
 uvulæ muscle, 31

 Base of brain, 127
 Basilar artery, 76
 membrane, 226
 Basilic vein, 102
 Biceps femoris muscle, 52
 flexor cubiti, 35
 Bicuspid teeth, 177
 Bile ducts, 189
 Biventral lobe, 123
 Bladder, 210
 interior of, 211
 Bladder, connections of, 211
 ligaments of, 47, 191
 Bones of the ear, 223
 Brachial aponeurosis, 36
 artery, 78
 plexus, 158
 veins, 103
 Brachialis anticus, 35
 Brain, base of, 127
 membranes of, 136
 Broad uterine ligament, 218
 Bronchial arteries, 83
 glands, 113
 veins, 105
 Bronchus, left, 205
 right, 205
 Brunner's glands, 185

 Buccal artery, 73
 nerve, 144
 Buccinator muscle, 26
 Bulb of the urethra, 213
 artery of, 90
 Bulbus olfactorius, 139

 Cæcum coli, 185
 connections of, 185
 Calamus scriptorius, 119
 Calices of the kidney, 209
 Calciform papillæ, 209
 Canal, Hunter's, 51
 of cochlea, 227
 of Petit, 237
 of spinal cord, 115
 of Stilling, 237
 of the tensor tympani, 222
 Canine teeth, 177
 Capsular arteries, inferior, 86
 middle, 86
 superior, 85
 ligament of the hip, 17
 knee, 19
 shoulder, 13
 thumb, 16
 Capsule of crystalline lens, 237
 of Glisson, 189
 suprarenal, 210
 Caput gallinaginis, 213
 Cardiac nerve, inferior, 174
 middle, 174
 of pneumogastric, 153
 superior, 173
 plexus, 175
 veins, 106
 Carneæ columnæ, 199
 Carotid artery, external, 69
 internal, 74
 left common, 68
 right common, 68
 plexus, 173
 Carpal artery, radial anterior, 79
 posterior, 79
 ulnar anterior, 81
 posterior, 81
 Carpo-metacarpal articulation, 16
 Cartilage, arytaenoid, 202
 cricoid, 201
 cuneiform, 202
 of the ear, 221
 thyroid, 201
 triangular of the nose, 219
 Cartilages of the eyelids, 228
 of the nose, 219
 of Santorini, 202

- Cartilages of trachea, 205
 Caruncula lachrymalis, 228
 Carunculæ myrtiformes, 217
 Cauda equina, 114
 Cava, inferior, 105
 superior, 104
 Cavernous body, 213
 artery of, 90
 plexus, 173
 sinus, 99
 Central artery of the retina, 75
 passage of cochlea, 225
 lobe of brain, 130
 Centrum ovale cerebri, 132
 Cephalic vein, 102
 Cerebellar arteries, inferior, 66
 superior, 76
 Cerebellum, form of, 122
 lobes of, 122
 structure of, 123
 Cerebral artery, anterior, 75
 middle, 75
 posterior, 76
 Cerebrum, division into lobes, 129
 form of, 127
 interior, 132
 structure, 136
 Cervical fascia, 28
 ganglion, inferior, 174
 middle, 173
 superior, 172
 glands, 111
 nerves, anterior branches,
 156
 nerves, posterior branches,
 156
 plexus of nerves, 156
 plexus of nerves, deep
 branches, 157
 plexus of nerves, super-
 ficial, 157
 Cervicalis, ascendens artery, 66
 muscle, 42
 vein, 102
 profunda artery, 68
 vein, 102
 superficialis nerve, 157
 Cervico-facial nerve, 150
 Cervix uteri, 218
 Chamber of the eye, anterior, 237
 posterior, 237
 Check ligaments, 8
 Chiasma of the optic nerves, 127
 Chondro-costal articulations, 10
 sternal articulations, 9
 Chorda tympani nerve, 149
 Chordæ tendineæ, 199
 Chordæ vocales, 204
 Chordæ Willisii, 99
 Choroid arteries of the brain, 76
 coat of the eye, 230
 plexuses of the brain, 135-
 137
 veins of the eye, 231
 brain, 98
 Ciliary arteries, 75
 muscle, 231
 processes of the choroid, 231
 nerves of nasal, 141
 of lenticular ganglion
 141
 Circle of Willis, 76
 Circular sinus, 99
 Circumflex artery, anterior, 78
 external, 93
 internal, 93
 posterior, 78
 iliac artery, deep, 91
 iliac artery, superficial,
 92
 nerve, 159
 Clavicular cutaneous nerves, 157
 Clitoris, 216
 Coccygeal muscle, 48
 nerve, 167
 Cochlea, canal of, 227
 nerve of, 228
 Coeliac artery, 85
 plexus, 176
 Colic artery, left, 86
 middle, 86
 right, 86
 veins, 108
 Colon, 185
 Columnæ carneæ, 199
 Columns of the cord, 115
 Comes nervi ischiatici artery, 91
 phrenici artery, 67
 Commissure, anterior, 135
 of the cerebellum, 122
 of the cord, 115
 great, 132
 of the optic nerves, 127
 posterior, 125
 soft, 126
 Commissural fibres of the medulla,
 119
 Communicating artery of anterior
 cerebral, 75
 Communicating artery of posterior
 cerebral, 76
 Communicating artery in the palm,
 81
 Communicating peroneal nerve, 171
 Compressor of the nose, 26
 of the urethra, 48

- Concha, 221
 Cones of the retina, 234
 Conjoined tendon, 44
 Conjunctiva, 228
 Conoid ligament, 13
 Constrictor, inferior, 30
 middle, 30
 superior, 30
 Conus arteriosus, 199
 medullaris, 114
 Convolutions of the brain, 129
 of hemisphere, 129
 of longitudinal fissure, 131
 Coraco-brachialis muscle, 35
 clavicular articulation, 13
 humeral ligament, 13
 Cornea, 230
 structure, 230
 Cornicula laryngis, 202
 Cornua of gray crescent, 115
 of lateral ventricle, 133
 Corona glandis, 212
 Coronary vessels of the heart, 200
 of the lips, 70
 artery of the stomach, 85
 ligament of the liver, 187
 plexus of the stomach, 176
 plexus of the heart, 175
 sinus, 106
 Corpora albicantia, 127
 Arantii, 199
 cavernosa, 213
 geniculata, 126
 mamillaria, 127
 olivaria, 118
 quadrigemina, 125
 restiformia, 118
 Corpus callosum, 132
 dentatum cerebelli, 123
 fimbriatum uteri, 218
 geniculatum externum, 126
 internum, 126
 Highmorianum, 215
 olivare, 118
 spongiosum urethræ, 213
 striatum, 135
 thyroideum, 208
 Corrugator supercilii muscle, 25
 Costo-clavicular ligament, 12
 coracoid membrane, 33
 transverse ligaments, 9
 Cotunnus, nerve of, 143
 Cotyloid ligament, 18
 Covered band of Reil, 132
 Cowper's glands, 212
 Cremaster muscle, 44
 Cremasteric artery, 91
 Cremasteric fascia, 214
 Cribriform fascia, 49
 Crico-arytænoid articulation, 202
 muscle, lateral, 31
 posterior, 31
 thyroid articulation, 202
 membrane, 203
 muscle, 31
 Cricoid cartilage, 201
 Crista vestibuli, 225
 Crucial ligaments, 119
 Crura cerebelli, 123
 cerebri, 124
 of the diaphragm, 45
 of the fornix, 134
 Crural arch, 49
 deep, 49
 canal, 49
 nerve, 165
 ring, 49
 sheath, 49
 Cystic artery, 85
 duct, 189
 plexus of nerves, 176
 Decussation of the pyramids, 119
 Deep cervical artery, 68
 crural arch, 49
 transverse muscle of perinaeum, 48
 Deferential artery, 88
 Deltoid ligament, 21
 muscle, 34
 Dental artery, anterior, 73
 inferior, 73
 superior, 73
 Dental nerve, anterior, 142
 inferior, 145
 posterior, 142
 Dentate lamina, 123
 ligament, 138
 Depressor anguli oris, 26
 labii inferioris, 26
 alæ nasi, 26
 Descendens noni nerve, 155
 Descending colon, 186
 Diaphragm, 45
 arteries, 67, 84
 plexus of, 175
 Digastric muscle, 29
 nerve, 150
 Digital arteries of plantar, 98
 of radial, 80
 of ulnar, 81
 nerves of median, 161
 of plantar, 170
 of radial, 162
 of ulnar, 161

- Dilator of the nose, 26
 of the pupil, 232
 Dorsal artery of the foot, 96
 of the penis, 90
 of the scapula, 78
 of the tongue, 70
 nerves, anterior branches, 156
 posterior branches,
 155
 cutaneous of the
 hand, 161
 of the penis, 168
 Dorsi-spinal veins, 105
 Douglas's fold, 44
 Ductus ad nasum, 229
 arteriosus, 82, 207
 communis choledochus, 189
 cysticus, 189
 ejaculatorius, 216
 hepaticus, 189
 lymphaticus, 110
 pancreaticus, 190
 reuniens, 227
 Rivini, 181
 Stenonis, 180
 thoracicus, 110
 Whartonii, 180
 Duodenum, connections, 184
 Dura mater, 136
 of the cord, 138

 Ear, external, 221
 internal, 204, 224
 Eighth nerve, 150
 Ejaculator urinæ, 48
 Elastic layers of cornea, 230
 Elbow joint, 14
 Eminentia collateralis, 133
 Encephalon, 116
 Endocardium, 200
 Endolymph, 224
 Epididymis, 215
 Epigastric artery, 91
 superficial, 92
 veins, 109
 Epiglottis, 202
 Erector clitoridis, 48
 penis, 48
 spinæ, 41
 Ethmoidal arteries, 75
 Eustachian tube, cartilaginous part,
 223
 osseous part, 223
 valve, 199
 Extensor carpi radialis brevior, 37
 longior, 37
 carpi ulnaris, 38
 digiti minimi, 37

 Extensor digitorum brevis, 55
 communis, 37
 longus pedis, 53
 indicis, 38
 ossis metacarpi, 38
 proprius hallucis, 53
 primi internodii pollicis,
 38
 secundi internodii polli-
 cis, 38
 External cutaneous nerves of arm,
 160
 of thigh, 165
 saphenous nerve, 170
 vein, 108

 Eye-ball, 229
 brows, 228
 lashes, 228
 lids, 228
 muscles of, 25
 structure, 228

 Facial artery, 70
 nerve, 149
 vein, 99
 Falciform ligament of the liver, 187
 border of saphenous open-
 ing, 49
 Fallopian tube, 218
 Falx cerebelli, 137
 cerebri, 137
 Fascia axillary, 33
 brachial, 36
 cervical, deep, 28
 costo-coracoid, 33
 cremasteric, 194
 cribriform, 49
 of the forearm, 36
 iliac, 49
 intermuscular of the hume-
 rus, 35
 of the thigh, 48
 lata, 48
 of the leg, 54
 lumborum, 44
 masseteric, 27
 obturator, 47
 of the pyriformis, 47
 pelvic, 46
 perineal, deep, 46
 superficial, 46
 plantar, deep, 55
 recto-vesical, 47
 temporal, 27
 transversalis, 214
 Fasciculus teres, 120
 Femoral artery, 92
 vein, 109

- Femoro-tibial articulation, 18
 Fenestra ovalis, 222
 rotunda, 222
 Fibres of the cerebrum, 136
 of the cerebellum, 123
 of Müller, 230
 Fifth nerve, 140
 ventricle of brain, 134
 Filiform papillæ, 177
 Fillet of the olivary body, 119
 Filum terminale, 114
 First nerve, 139
 Fissure, longitudinal, 128
 parieto-occipital, 128
 of Rolando, 128
 of Sylvius, 128
 transverse, 136
 Fissures of Santorini, 221
 of the cord, 114
 of the cerebrum, 128
 Flexor accessorius muscle, 56
 brevis minimi digiti, 39
 pedis, 56
 carpi radialis, 36
 ulnaris, 36
 digitorum brevis pedis, 55
 longus pedis, 54
 profundus, 37
 sublimis, 36
 hallucis longus, 54
 brevis, 56
 pollicis longus, 37
 brevis, 39
 Flocculus cerebelli, 123
 Fold of Douglas, 44
 Follicles, Meibomian, 228
 Foramen of Munro, 134
 ovale, 199
 for vena cava, 46
 of Winslow, 195
 Foramina Thebesii, 199
 Fornix, 134
 Fossa navicular of the urethra, 213
 of the pudendum, 216
 ovalis, 199
 Fossæ of abdominal wall, 191
 Fourth nerve, 140
 ventricle, 113
 Fovea centralis, 236
 hemispherica, 225
 hemi-elliptica, 225
 Foveæ of fourth ventricle, 119
 Frænum linguæ, 177
 præputii, 212
 Frontal artery, 75
 nerve, 141
 lobe, 129
 vein, 100
 Fungiform papillæ, 177
 Funiculus cuneatus, 118
 gracilis, 117
 of Rolando, 118
 Galen, veins of, 135
 Gall bladder, 188
 Ganglia, cervical, inferior, 174
 middle, 173
 superior, 172
 lumbar, 174
 sacral, 174
 semilunar, 175
 of spinal nerves, 155
 thoracic, 174
 Ganglion of the vagus, 152
 Gasserian, 140
 impar, 174
 jugular, 151
 lenticular, 141
 Meckel's, 143
 ophthalmic, 140
 otic, 145
 petrosal, 151
 spheno-palatine, 143
 submaxillary, 145
 Gastric arteries, 85
 plexus, 176
 vein, 107
 Gastro-colic omentum, 194
 epiploic arteries, 85
 vein, 108
 hepatic omentum, 194
 Gastrocnemius muscle, 53
 Gemellus inferior muscle, 52
 superior muscle, 52
 Geniculate bodies, 126
 Genio-hyo-glossus, 30
 hyoid muscle, 30
 Genital organs, 212
 Genito-crural nerve, 165
 Gimbernat's ligament, 44
 Gland, lachrymal, 229
 parotid, 179
 pineal, 127
 pituitary, 127
 prostate, 212
 sublingual, 181
 submaxillary, 180
 Glands, axillary, 111
 Bartholin's, 217
 bronchial, 113
 Brunner's, 185
 cardiac, 113
 cervical, 111
 concatenate, 111
 Cowper's, 212
 inguinal, 113

- Glands, intercostal, 112
 intestinal, 112
 lingual, 178
 lumbar, 112
 mediastinal, 112
 Meibomian, 228
 mesenteric, 112
 oesophageal, 113
 of Pacchioni, 137
 pelvic, 112
 Peyer's, 185
 popliteal, 113
 sternal, 112
 Glans of the clitoris, 216
 of the penis, 212
 Glenoid ligament, 144
 Glisson's capsule, 189
 Globus major epididymis, 215
 minor epididymis, 215
 Glosso-pharyngeal nerve, 151
 nucleus, 119
 Glottis, 204
 Gluteal artery, 91
 nerve, superior, 168
 nerves, inferior, 168
 Gluteus maximus muscle, 51
 medius muscle, 52
 minimus muscle, 52
 Gracilis muscle, 51
 Granular layers of retina, 233
 Grey commissure of the cord, 115
 crescent of the cord, 115
 substance of the corpus striatum, 135
 substance of the medulla oblongata, 120
 substance of the third ventricle, 126
 tubercle of Rolando, 118
 Great omentum, 194
 Gustatory nerve, 145
 Gyrus fornicatus, 131
 Hæmorrhoidal artery, inferior, 89
 middle, 88
 superior, 87
 nerve, inferior, 168
 plexus, 176
 veins, 109
 Hamulus laminæ spiralis, 225
 Heart, 179
 Helicotrema, 225
 Helix, 221
 Hepatic artery, 85
 duct, 189
 plexus, 176
 veins, 106
 Hip joint, 17
 Hippocampus major, 133
 minor, 133
 Hunter's canal, 51
 Hyaloid membrane, 236
 Hymen, 217
 Hyo-glossus muscle, 30
 Hypogastric artery, 88
 plexus of nerves, 176
 Hypoglossal nerve, 154
 nucleus, 121
 Ileo-cæcal valve, 185
 Ileo-colic artery, 86
 Ileum, 185
 Iliac artery, common, 87
 external, 90
 internal, 88
 fascia, 49
 vein, common, 110
 external, 109
 internal, 109
 Iliacus muscle, 50
 Ilio-femoral articulation, 17
 hypogastric nerve, 164
 inguinal nerve, 164
 lumbar artery, 90
 Incisor branch of nerve, 145
 teeth, 177
 Incus, 223
 Inferior cornu of the lateral ventricle, 133
 maxillary nerve, 144
 Infra-costal muscles, 45
 orbital artery, 73
 nerves, 142, 150
 vein, 100
 scapular artery, 67
 trochlear nerve, 142
 Infra-spinatus muscle, 34
 Infundibulum of the brain, 127
 Inguinal canal, 214
 glands, 113
 Innominate artery, 83
 veins, 103
 Interarticular cartilage of the jaw, 8
 of the hip, 18
 of the knee, 19
 of the ribs, 9
 of the scapula, 13
 sacro-iliac, 11
 sterno-clavicular, 12
 of the symphysis, 12
 of the vertebræ, 6
 of the wrist, 15
 Interclavicular ligament, 12
 Intercolumnar fascia, 43
 Intercostal arteries, anterior
 branches, 84

- Intercostal arteries, posterior
 branches, 84
 artery, superior, 67
 muscle, external, 45
 internal, 45
 nerves, 163
 cutaneous anterior, 163
 lateral, 163
 veins, superior, 105
 Intercosto-humeral nerve, 163
 Intermuscular septa of the arm, 35
 of the foot, 55
 of the thigh, 48
 Internal cutaneous nerve of the arm,
 160
 of the thigh, 166
 saphenous vein, 108
 nerve, 166
 Interosseous arteries of the foot, 96
 of the hand, 80
 artery, anterior, 81
 posterior, 81
 ligament of the arm, 15
 of the leg, 20
 muscles of the foot, 56
 of the hand, 39
 nerve, anterior, 160
 posterior, 162
 Interspinal muscles, 43
 Intertransverse muscles, 43
 Intervertebral substances, 6
 Intestinal arteries, 86
 Intestine, large, 185
 small, 184
 Intumescencia gangliaformis, 149
 Iris, 232
 nerves of, 232
 structure of, 232
 vessels of, 232
 Island of Reil, 130
 Isthmus of the thyroid body, 208
 Iter a tertio ad quartum ventri-
 culum, 124
 Jacobson's nerve, 151
 Jejunum, 184
 Joint, ankle, 21
 elbow, 14
 hip, 17
 knee, 18
 lower jaw, 8
 shoulder, 13
 thumb, 16
 wrist, 15
 ugular ganglion, 151
 vein, anterior, 101
 external, 101
 internal, 101
 Kidney, 209
 connections of, 209
 Knee of the corpus collosum, 132
 joint, 18
 Labia pudendi externa, 216
 interna, 216
 Labia artery, inferior, 70
 Labyrinth, 224
 membranous, 226
 osseous, 224
 Lachrymal artery, 75
 canals, 229
 duct, 229
 gland, 229
 nerve, 141
 sac, 229
 Lacunæ of the urethra, 214
 Lamina cinerea, 124
 spiralis cochleæ, 225
 Laminæ of cerebellum, 122
 Large intestine, connections, 185
 Laryngeal arteries, 66, 69
 nerve, external, 153
 inferior, 153
 superior, 153
 pouch, 204
 Larynx, 201
 aperture of, 203
 cartilages of, 201
 interior of, 203
 ligaments, 203
 muscles, 31
 nerves, 153
 ventricle, 204
 vessels, 66, 69
 Lateral column of the medulla, 117
 of the cord, 115
 sinus, 99
 ventricles, 132
 Latissimus dorsi, 40
 Laxator tympani, 224
 Lens, 237
 Lenticular ganglion, 141
 Levator anguli oris, 26
 scapulæ, 40
 ani, 48
 labii superioris, 26
 alæque nasi, 26
 inferioris, 26
 palati, 31
 palpebræ superioris, 25
 Levatores costarum, 45
 Ligament of the lung, 206
 Ligaments of the bladder, 47, 191
 of the larynx, 203
 of the ovary, 218
 of the uterus, 218

- Ligament, acromio-clavicular, 12
 alar of the knee, 20
 annular, anterior of the ankle, 54
 external of the ankle, 55
 anterior of the wrist, 16
 posterior of the wrist, 16
 anterior of ankle, 21
 of elbow-joint, 14
 of knee-joint, 18
 of wrist-joint, 15
 of carpus, 16
 astragalo-scaphoid, 22
 atlanto-axial, anterior, 7
 posterior, 7
 transverse, 7
 calcaneo-astragaloid, 22
 cuboid, 22
 scaphoid, 22
 capsular of the hip, 17
 of the knee, 19
 of the shoulder, 13
 capsular of the thumb, 16
 carpal, dorsal, 16
 palmar, 16
 carpo-metacarpal, 16
 check, 8
 common, anterior of vertebrae, 5
 common, posterior, 6
 conoid, 13
 coraco-acromial, 13
 clavicular, 13
 humeral, 13
 coronary, 20
 costo-clavicular, 12
 coracoid, 33
 transverse, anterior, 9
 middle, 9
 posterior, 9
 vertebral, 8
 cotyloid, 18
 crico-thyroid, 203
 crucial, 19
 deltoid, 21
 dorsal of the carpus, 16
 of Gimbernat, 44
 glenoid, 14
 ilio-femoral, 18
 lumbar, 10
 interarticular of the clavicle, 12
 of the hip, 18
 of the jaw, 8
 of the knee, 19
- Ligament, interarticular of the pubes, 12
 of the ribs, 9
 of the wrist, 15
 interclavicular, 12
 interosseous of astragalus and os calcis, 22
 of carpus, 16
 of cuneiform bones, 22
 of metacarpal bones, 17
 of metatarsal bones, 24
 of radius and ulna, 15
 of the scaphoid and cuboid, 22
 of the tibia and fibula, 20
 inferior, of the tibia and fibula, 21
 interspinous, 6
 intertransverse, 6
 intervertebral, 6
 ischio-capsular, 18
 lateral, external of the ankle, 21
 lateral, internal of the ankle, 21
 external of the carpus, 16
 internal of the carpus, 16
 external of the elbow, 14
 internal of the elbow, 14
 phalangeal of the foot, 24
 phalangeal of the hand, 17
 external of the jaw, 8
 internal of the jaw, 8
 external of the knee, 19
 internal of the knee, 19
 external of the wrist, 15
 internal of the wrist, 15
 long plantar, 23
 lumbo-sacral, 10
 metacarpal, dorsal, 17
 palmar, 17
 metacarpo-phalangeal, 17
 metatarsal, dorsal, 23
 palmar, 23
 mucous, 20
 obturator, 12

- Ligament, occipito-atlantal, anterior, 7
lateral, 7
posterior, 7
occipito-axial, 7
odontoid, 8
orbicular of the radius, 14
of the patella, 18
peroneo-tibial, 20
of Poupert, 44
posterior of carpus, 16
of elbow, 14
of knee, 18
of scapula, 13
of wrist, 15
proper of the scapula, 13
pubic, anterior, 12
posterior, 12
superior, 12
pubo-femoral, 17
radio-ulnar, 14
rhomboid, 12
round of the hip, 18
round of the radius and ulna, 14
sacro-coccygeal, anterior, 11
posterior, 11
sacro-iliac, anterior, 11
posterior, 11
sacro-sciatic, great, 11
small, 11
sacro-vertebral, 10
of the scapula, anterior, 13
posterior, 13
sternal, anterior, 10
posterior, 10
sterno-clavicular, 12
stylo-hyoid, 8
maxillary, 8
sub-pubic, 12
supraspinous, 6
suspensory of penis, 213
tarso-metatarsal, dorsal, 23
plantar, 23
thyro-arytæmoid, 203
epiglottidean, 203
hyoid, 203
tibio-fibular, 20
transverse of the atlas, 7
of the fingers, 17
of the hip, 18
of the knee, 20
of metacarpus, 17
of metatarsus, 23
of scapula, 13
trapezoid, 13
- Ligament, triangular of the urethra, 46
of Winslow, posterior, 19
Ligamenta alaria, 20
subflava, 6
Ligamentum arcuatum, 45
denticulatum, 138
ductus arteriosi, 207
latum pulmonis, 206
longum plantæ, 23
mucosum, 20
nuchæ, 6
patellæ, 18
posticum Winslowii, 19
spirale, 227
subflavum, 6
teres, 18
Limbus, 227
Limiting membrane of retina, 235
Linea alba, 43
Lineæ transversæ, 44
Lingual artery, 70
glands, 111
nerve, 145, 152
vein, 102
Linguales muscles, 178
Liquor Cotunnii, 224
Liver, 187
connections of, 187
ligaments, 187
vessels, 189
Lobes of the cerebellum, 122
of the cerebrum, 129
of the testis, 215
of the liver, 188
Lobus auris, 221
caudatus, 188
quadratus, 188
Spigelii, 188
Locus niger, 125
perforatus anticus, 128
posticus, 127
Longissimus dorsi, 42
Longitudinal fibres of the brain, 136
fissure of the liver, 188
sinus, inferior, 99
superior, 99
Longus colli muscle, 32
Lumbar aponeurosis, 44
arteries, 87
anterior branches, 87
posterior branches, 87
ganglia, 174
glands, 112
nerves, anterior branches, 163

- Lumbar nerves, posterior branches, 164
 plexus, 164
 veins, 105
 Lumbo-sacral nerve, 167
 Lumbricales of the foot, 56
 of the hand, 39
 Lungs, 205
 connections, 206
 Lymphatic duct, right, 110
 Lymphatics of the arm, 111
 of the axilla, 111
 of the groin, 113
 of the lungs, 112
 of the mesentery, 112
 of the neck, 111
 of the pelvis, 112
 of the popliteal space, 113
 of the thorax, 112
 Lyra, 134
 Malleolar arteries, 95
 Malleus, 223
 muscles of, 224
 Mammary artery, internal, 67
 Masseter muscle, 27
 Masseteric artery, 73
 nerve, 144
 Maxillary artery, internal, 72
 nerve, inferior, 144
 superior, 142
 vein, internal, 100
 Meatus auditorius externus, 221
 urinarius, 212, 217
 Meatuses of the nose, 219
 Meckel's ganglion, 143
 Median basilic vein, 102
 cephalic vein, 102
 nerve, 160
 vein, 102
 Mediastinal arteries, 83
 Mediastinum of thorax, 195
 of testis, 215
 Medulla oblongata, 116
 grey matter, 120
 structure of, 117
 Medullary substance of the kidney, 209
 Medullary velum, inferior, 123
 superior, 120
 Meibomian follicles, 228
 Membrana basilaris, 226
 reticularis, 227
 sacciformis, 15
 tympani, 222
 Membrane of Corti, 227
 of Descemet, 230
 Membrane, hyaloid, 236
 of the labyrinth, 226
 obturator, 12
 of Reissner, 227
 Membranes of the brain, 136
 of spinal cord, 138
 Membranous labyrinth, 226
 part of the cochlea, 226
 part of the urethra, 213
 Meningeal artery, anterior, 75
 middle, 73
 posterior, 65
 small, 73
 Mesenteric artery, inferior, 87
 superior, 86
 glands, 112
 plexus, inferior, 176
 superior, 176
 vein, inferior, 107
 superior, 107
 Meso-cæcum, 194
 colon, left, 194
 right, 194
 transverse, 194
 Metacarpal arteries, 79, 81
 Metatarsal artery, 96
 Mitral valve, 200
 Modiolus of the cochlea, 225
 Molar teeth, 177
 Mons Veneris, 216
 Motor oculi nerve, 139
 Mucous ligament, 20
 Multifidus spinæ muscle, 42
 Musculi papillares, 199
 pectinati, 199
 Musculo-phrenic artery, 67
 Musculo-cutaneous nerve of the arm, 160
 Musculo-spiral nerve, 161
 Musc., abductor digiti minimi, 39
 digiti minimi
 pedis, 55
 hallucis, 55
 indicis, 40
 pollicis, 38
 accessorius pedis, 56
 accessorius ad sacro-lumbalem, 41
 adductor brevis, 51
 hallucis, 56
 longus, 51
 magnus, 51
 minimi digiti, 39
 obliquus, 39
 pollicis transversus, 39
 anconeus, 38
 arytænoideus, 32

Musc., attollens aurem, 24
 attrahens aurem, 24
 azygos uvulæ, 31
 biceps femoris, 52
 cubiti, 35
 biventer cervicis, 42
 brachialis anticus, 35
 buccinator, 26
 cervicalis ascendens, 42
 ciliaris, 231
 coccygeus, 48
 complexus, 42
 compressor naris, 26
 constrictor, inferior, 30
 medius, 30
 superior, 30
 coraco-brachialis, 35
 corrugator supercilii, 25
 cremastericus, 44
 crico-arytænoideus lateralis, 31
 crico-arytænoideus posticus, 32
 crico-thyroideus, 31
 crureus, 50
 deltoideus, 34
 depressor anguli oris, 26
 depressor labii inferioris, 26
 alæ nasi, 26
 diaphragma, 45
 digastricus, 29
 dilatator naris, 26
 pupillæ, 232
 ejaculator urinæ, 48
 erector clitoridis, 48
 penis, 48
 spinæ, 41
 extensor carpi radialis
 brevior, 37
 extensor carpi radialis
 longior, 37
 extensor carpi ulnaris, 38
 coccygis, 43
 digitorum brevis
 pedis, 55
 digitorum communis, 37
 digitorum longus
 pedis, 53
 indicis, 38
 minimi digiti, 37
 ossis metacarpi
 pollicis, 38
 proprius hallucis, 53
 primi internodii
 pollicis, 38

Musc., extensor secundi internodii
 pollicis, 38
 flexor accessorius, 56
 brevis digiti minimi
 39
 brevis digiti minimi
 pedis, 56
 brevis hallucis, 56
 brevis pollicis, 39
 carpi radialis, 36
 ulnaris, 36
 digitorum brevis
 pedis, 55
 digitorum longus
 pedis, 54
 digitorum profundus, 37
 digitorum sublimis
 36
 pollicis longus, 37
 gastrocnemius, 53
 gemellus inferior, 52
 superior, 52
 genio-hyo-glossus, 30
 hyoideus, 30
 gluteus maximus, 51
 medius, 52
 minimus, 52
 gracilis, 51
 hyo-glossus, 29
 iliacus, 50
 ilio-costalis, 41
 infra-costales, 45
 infra-spinatus, 34
 intercostales externi, 45
 interni, 45
 interossei manûs dorsales, 39
 interossei manûs palmares, 40
 interossei pedis dorsales, 56
 interossei pedis palmares, 56
 inter-spinales, 43
 inter-transversales, 43
 latissimus dorsi, 40
 levator anguli oris, 26
 scapulæ, 40
 ani, 48
 labii superioris, 26
 labii superioris
 alæque nasi, 26
 palati, 31
 palpebræ, 25
 levatores costarum, 45
 linguales, 178
 longissimus dorsi, 42
 longus colli, 32

- Musc., lumbricales manûs, 39
 pedis, 56
 massetericus, 27
 multifidus spinæ, 42
 mylo-hyoideus, 30
 obliquus abdominis exter-
 nus, 43
 obliquus abdominis inter-
 nus, 44
 obliquus capitis inferior,
 33
 superior, 33
 oculi inferior, 25
 superior, 25
 obturator externus, 52
 internus, 52
 occipito-frontalis, 24
 omo-hyoideus, 29
 opponens digiti minimi, 39
 pollicis, 39
 orbicularis oris, 26
 palpebrarum, 25
 palato-glossus, 31
 pharyngeus, 31
 palmaris brevis, 39
 palmaris longus, 36
 pectineus, 51
 pectoralis major, 33
 minor, 33
 peroneus brevis, 54
 longus, 54
 tertius, 53
 plantaris, 54
 platysma myoides, 27
 popliteus, 54
 pronator, quadratus, 37
 radii teres, 36
 psoas magnus, 50
 parvus, 50
 pterygoideus externus, 27
 internus, 27
 pyramidalis abdominis, 45
 nasi, 25
 pyriformis, 52
 quadratus femoris, 52
 lumborum, 45
 quadriceps extensor, 50
 rectus abdominis, 44
 capitis anticus major,
 32
 capitis anticus minor,
 32
 lateralis, 32
 posticus major,
 32
 posticus minor,
 33
 femoris, 51
 Musc , rectus capitis oculi externus,
 25
 oculi, inferior,
 25
 oculi internus,
 25
 oculi, superior,
 25
 retrahens aurem, 24
 rhomboideus major, 40
 minor, 40
 risorius, 27
 rotatores dorsi, 43
 sacro-lumbalis, 41
 salpingo-pharyngeus, 31
 sartorius, 50
 scalenus anticus, 32
 medius, 32
 posticus, 32
 semi-spinalis colli, 42
 dorsi, 42
 semi-membranosus, 53
 semi-tendinosus, 53
 serratus magnus, 34
 posticus inferior, 41
 serratus posticus, superior,
 41
 soleus, 53
 sphincter ani externus, 48
 internus, 48
 pupillæ, 232
 vaginæ, 48
 spinalis dorsi, 42
 splenius capitis, 41
 colli, 41
 stapedius, 224
 sterno-cleido-mastoideus, 28
 hyoideus, 29
 thyroideus, 29
 stylo-glossus, 30
 hyoideus, 30
 pharyngeus, 31
 subanconeus, 36
 subclavius, 33
 suberureus, 51
 subscapularis, 34
 supinator brevis, 38
 longus, 37
 supra-spinatus, 34
 temporalis, 27
 tensor palati, 31
 tarsi, 25
 tympani, 224
 vaginæ femoris, 50
 teres major, 35
 minor, 34
 thyro-arytænoideus, 51
 hyoideus, 29

- Musc., tibialis anticus, 53
 posticus, 54
 trachelo-mastoideus, 42
 transversalis abdominis, 44
 colli, 42
 transversus linguæ, 178
 pedis, 56
 perinæi, 48
 trapezius, 40
 triangularis sterni, 45
 triceps extensor, 35
 vastus externus, 50
 internus, 50
 zygomaticus major, 26
 minor, 26
- Mylo-hyoid artery, 73
 muscle, 30
 nerve, 145
- Nares, 220
- Nasal artery, 75
 artery, lateral, 71
 cartilages, 219
- Nasal duct, 229
 fossæ, 219
 nerve, 141
- Naso-palatine nerve, 143
 artery, 74
- Nerve of Jacobson, 151
 of Wrisberg, 160
- Nerve to the inferior gemellus and
 quadratus, 167
 latissimus, 159
 levator anguliscapulæ,
 158
 longus colli, 158
 obturator internus,
 167
 pectineus, 166
 pterygoid, internal, 144
 pyriformis, 167
 rhomboid muscles, 158
 scaleni, 158
 serratus magnus, 159
 subclavius, 159
 superior gemellus, 167
 tensor palati, 146
 tympani, 146
 vaginæ femoris, 168
 teres major, 159
 minor, 159
 vastus externus, 166
 internus, 166
- Nervous layer of the retina, 233
 tunic of eyeball, 235
- Nerv., abducens, 148
 accessorius obturatorius, 165
 spinalis, 154
- Nerv., acromiales cutanei, 157
 articularis poplitei, 169
 articularis poplitei obtura-
 torius, 165
 auditorius, 150
 auricularis magnus, 157
 pneumogastrici, 152
 auricularis inferior, 144
 posterior, 150
 auriculo-temporalis, 144
 buccales, 144, 150
 buccinatorius, 150
 cardiacus inferior, 174
 cardiacus medius, 174
 cardiacus pneumogastrici,
 153
 cardiacus superior, 173
 cervicales nervi facialis, 150
 cervicales rami anteriores, 156
 posteriores, 155
 cervicalis superficialis, 157
 cervico-facialis, 150
 chorda tympani, 149
 ciliaris ganglii ophthalmici,
 141
 ciliaris nasalis, 141
 circumflexus, 159
 claviculares cutanei, 157
 coccygealis, 167
 cochlearis, 228
 communicans fibularis, 171
 tibialis, 169
 cruralis, 165
 cutanei abdominis anteri-
 ores, 163
 cutanei abdominis laterales,
 163
 cutaneus externus brachialis,
 160
 cutaneus externus lumbalis,
 165
 cutaneus externus musco-
 spiralis, 162
 cutaneus intern. brachialis
 major, 160
 cutaneus intern. brachialis
 minor, 160
 cutaneus intern. femoris, 166
 cutaneus intern. musculo-
 spiralis, 162
 cutaneus infra-maxillar., 150
 supra-maxillar., 150
 medius femoris, 166
 musc.-cutanei, 160
 palmaris, 160
 plantaris, 170
 radialis, 162
 dorsalis manûs, 161

- Nerv., dentales posteriores, 142
 dentalis, anterior, 142
 inferior, 145
 descendens noni, 155
 diaphragmaticus, 157, 175
 digastricus, 150
 digitales mediani, 161
 plantares, 170
 radiales, 161
 ulnares, 161
 dorsales, rami anteriores, 163
 posteriores, 162
 dorsalis penis, 161
 ulnaris, 168
 facialis, 149
 frontalis, 141
 genito-cruralis, 165
 ramus femoralis, 165
 ramus genitalis, 165
 glosso-pharyngeus, 151
 glutei inferiores, 168
 gluteus superior, 168
 gustatorius, 145
 hæmorrhoidalis inferior, 168
 hepatici, 176
 hypoglossalis, 154
 ilio-hypogastricus, 164
 inguinalis, 164
 incisorius, 145
 infra-maxillaris facialis, 150
 orbitales nervi facialis,
 150
 orbitalis, 150
 trochlearis, 141
 intercostales, 163
 intercosto-cutaneianteriores,
 163
 intercosto-cutanei laterales,
 163
 intercosto-humeralis, 163
 interosseous anticus, 160
 posticus, 162
 ischiaticus major, 169
 minor, 169
 labialis, 142
 lachrymalis, 141
 laryngeus externus, 153
 inferior, 153
 superior, 153
 lingualis, 145, 152
 lumbales rami anteriores, 164
 posteriores, 164
 lumbo-sacralis, 164
 malaris nervi facialis, 150
 massetericus, 144
 maxillaris inferior, 144
 superior, 142
 medianus, 160
- Nerv., molles, 172
 motor oculi, 139
 musculo-cutaneus brachii,
 160
 musculo-cutaneus cruris, 171
 spiralis, 161
 mylo-hyoideus, 145
 nasalis, 141
 naso-palatinus, 143
 obturatorius, 165
 articularis, 165
 occipitalis major, 156
 minor, 157
 œsophageales, 154
 olfactorius, 139
 ophthalmicus, 140
 opticus, 139
 orbitalis, 142
 palatinus magnus, 143
 externus, 143
 minor, 143
 palpebrales, 142
 palmaris cutaneus, 160
 ulnaris profundus, 161
 superficialis, 161
 patellaris, 166
 perforans Casserii, 160
 perinaeales superficiales, 168
 peronealis, 171
 petrosus superficialis exter-
 nus, 149
 petrosus superficialis mag-
 nus, 149
 petrosus superficialis parvus,
 146
 pharyngei, 151
 pharyngeus, 144, 151, 153
 phrenicus, 157
 plantaris externus, 170
 profundus, 171
 internus, 170
 pneumogastricus, 152
 popliteus externus, 171
 internus, 169
 portio dura, 149
 mollis, 150
 pterygoidei, 144
 pudendus inferior, 169
 internus, 168
 pulmonares anteriores, 154
 posteriores, 154
 radialis, 162
 recurrens articularis, 171
 renales, 176
 sacrales, rami anteriores, 167
 posteriores, 167
 saphenus externus, 170
 internus, 166

- Nerv., sciaticus magnus, 169
 parvus, 169
 spermatici, 176
 spheno-palatini, 142
 splanchnicus major, 174
 minor, 174
 minimus, 174
 splenici, 176
 stylo-hyoideus, 150
 suboccipitalis, ramus an-
 terior, 156
 suboccipitalis, ramus pos-
 terior, 156
 subscapulares, 159
 superficialis cordis dexter, 173
 superficialis cordis sinister,
 173
 supra-maxillares nervi faci-
 alis, 150
 supra-orbitalis, 141
 scapularis, 159
 trochlearis, 141
 sympatheticus abdominis,
 175
 cervicis, 172
 pelvis, 176
 thoracis, 174
 temporales nervi facialis, 150
 profundi, 144
 superficialis, 144
 temporo-facialis, 150
 malar, 142
 thoracici anteriores, 149
 laterales, 163
 thoracicus posterior, 159
 thyro-hyoideus, 154
 tibialis anticus, 171
 posticus, 170
 trigeminus, 140
 trochlearis, 140
 tympanicus, 149, 151
 ulnaris, 161
 uterini, 176
 vaginales, 176
 vestibularis, 228
 Vidianus, 143
 Ninth nerve, 151
 Nodule, 123
 Nose, cartilages, 219
 cavity of, 219
 meatuses of, 219
 Nuclei of medulla oblongata, 114
 Nucleus caudatus, 128
 lenticularis, 128
 Nutritious artery of femur, 93
 of humerus, 79
 of tibia, 97
 Nymphæ, 216
 Obliquus abdominis externus, 43
 internus, 44
 capitis inferior muscle, 33
 superior muscle, 33
 oculi inferior, 25
 superior, 25
 Obturator artery, 88
 fascia, 47
 membrane, 12
 muscle, external, 52
 internal, 52
 nerve, 165
 Occipital artery, 71
 lobe, 130
 Occipital vein, 101
 sinus, 99
 nerves, 156, 157
 Occipito-atlantal articulation, 7
 ligaments, 7
 axial ligaments, 7
 frontalis muscle, 24
 Odontoid ligaments, 8
 Oesophagus, connections of, 182
 Oesophageal arteries, 83
 nerves, 154
 opening of diaphragm, 46
 Olfactory bulb, 130
 nerve, 139
 Olivary body, 118
 fasciculus, 119
 Omentum, great, 194
 small, 194
 splenic, 194
 Omo-hyoid muscle, 29
 Ophthalmic artery, 75
 ganglion, 141
 nerve, 140
 veins, 99
 Opponens pollicis muscles, 39
 Optic commissure, 127
 nerve, 139
 thalamus, 126
 tract, 127
 Ora serrata, 236
 Orbicular ligament of the radius, 14
 Orbicularis oris, 26
 palpebrarum, 25
 Organ of Corti, 227
 Orifice of the urethra, 212
 of the uterus, 218
 of the vagina, 216
 Ossicles of the tympanum, 223
 Os tinæ, 218
 Os uteri, externum, 218
 internum, 218
 Otic ganglion, 145
 Otoliths, 226
 Ovaries, 218

- Palate, soft, 166
 Palatine, arteries, superior, 73
 artery, inferior, 70
 nerve, external, 143
 large, 143
 small, 143
 Palato-glossus, 31
 pharyngeus, 31
 Palmar arch, deep, 81
 superficial, 77
 nerve of the ulnar, deep, 161
 superficial, 161
 fascia, 33
 Palmaris brevis muscle, 39
 longus muscle, 36
 Palpebræ, 208
 Palpebral arteries, 75
 ligament, 228
 Pancreas, 189
 connections, 189
 Pancreatic arteries, 85
 duct, 190
 Pancreatico-duodenal arteries, 85
 Papilla lachrymalis, 228
 Papillæ of the tongue, 177
 Parietal lobe, 129
 Parotid gland, 179
 Patellar nerve, 166
 plexus, 166
 Pectineus muscle, 51
 Pectoralis major muscle, 33
 minor muscle, 33
 Peduncle of the cerebellum, inferior, 124
 Peduncle of the cerebellum, middle, 124
 Peduncle of the cerebellum superior, 123
 Peduncle of the cerebrum, 124
 of the pineal body, 127
 Peduncular fibres, 136
 Pelvic fascia, 46
 plexus, 176
 Penis, 212
 Perforating arteries of femoral, 93
 of internal mammary, 67
 of the palm, 80
 of the sole, 96
 Perforans Casserii nerve, 160
 Pericardium, 196
 Perilymph, 224
 Perinaal artery, superficial, 89
 fascia, deep, 46
 superficial, 46
 nerves, superficial, 168
 Peritoneum, 190
 of female pelvis, 191
 of male pelvis, 191
 Peroneal artery, 97
 anterior, 97
 nerve, 171
 Peroneus brevis muscle, 54
 longus muscle, 54
 tertius muscle, 53
 Peroneo-tibial articulations, 20
 Pes hippocampi, 133
 Petrosal ganglion, 151
 sinus, inferior, 99
 superior, 99
 Petrosal nerve, large, 149
 small, 146
 Petrosal nerve, external, 149
 Peyer's glands, 185
 Pharyngeal ascending artery, 71
 nerve, 151
 vein, 96
 Pharynx, 181
 muscles of, 30
 openings of, 182
 Phrenic artery, 67, 84
 nerve, 157
 Pia mater of the brain, 137
 of the cord, 138
 Pigment cells of choroid, 231
 of iris, 232
 Pillars of the abdominal ring, 43
 of the fornix, 134
 of the iris, 232
 of the soft palate, 170
 Pineal body, 127
 Pinna, or auricle of the ear, 221
 Pituitary body, 127
 Plantar arch, artery of the, 98
 arteries, 97, 98
 fascia, 55
 ligament, long, 23
 nerve, external, 170
 internal, 170
 Plantaris muscle, 54
 Platysma myoides muscle, 27
 Pleura, 205
 Plexus, aortic, 176
 brachial, 158
 cardiac, superficial, 175
 deep, 175
 carotid, 173
 cavernous, 173
 cervical, 156
 choroides cerebri, 135
 coeliac, 176
 coronary, anterior, 175
 posterior, 175
 of the stomach, 176
 diaphragmatic, 175
 gulæ, 152
 hepatic, 176

- Plexus, hæmorrhoidal, 176
 hypogastric, 176
 lumbar, 164
 mesenteric, inferior, 176
 superior, 176
 œsophageal, 152
 ovarian, 176
 patellar, 166
 pelvic, 176
 pharyngeal, 173
 prostatic, 176
 pterygoid of veins, 101
 pulmonary, anterior, 154
 posterior, 154
 renal, 176
 supra, 176
 sacral, 167
 solar, 175
 spermatic of nerves, 176
 of veins, 106
 splenic, 176
 tympanic, 151, 173
 uterine, 176
 vaginal, 176
 vesical, 176
 Plica semilunaris, 228
 Pneumogastric nerve, 152
 Pomum Adami, 201
 Pons Varolii, 121
 structure of, 121
 Popliteal artery, 94
 glands, 113
 nerve, external, 171
 internal, 169
 vein, 109
 Popliteus muscle, 54
 Portal vein, 107
 Portio dura, 149
 mollis, 150
 Porus opticus, 233
 Posterior commissure, 125
 elastic layer of cornea, 230
 ligament of the knee, 19
 pyramid, 119
 Poupert's ligament, 44
 Pouch, laryngeal, 204
 Prepuce, 212
 Princeps cervicalis artery, 71
 pollicis artery, 80
 Processus cochleariformis, 222
 vermiformis, 122
 Profunda artery, inferior, 79
 of the neck, 68
 of the thigh, 93
 superior, 78
 Promontory, 222
 Pronator quadratus muscle, 37
 radii teres muscle, 36
 Prostatic gland, 212
 connections, 212
 Prostatic part of the urethra, 213
 sinuses, 213
 Psoas magnus muscle, 50
 parvus muscle, 50
 Pterygoid arteries, 73
 nerve, external, 144
 internal, 144
 plexus of veins, 101
 Pterygoideus externus muscle, 27
 internal muscle, 27
 Pterygo-maxillary ligament, 27
 palatine artery, 74
 Pubo-prostatic ligaments, 47
 Pudic arteries, external, 92
 artery, internal, 89
 nerve, internal, 158
 Pulmonary artery, 207
 nerves, 154
 veins, 106
 Pylorus, 183
 Pyloric arteries, 85
 Pyramid, anterior, 119
 decussation of, 119
 of the cerebellum, 123
 of the tympanum, 222
 posterior, 118
 Pyramidal fibres of the medulla, 118
 masses of kidney, 209
 Pyramidalis abdominis muscle, 45
 nasi muscle, 25
 Pyramids of Malpighi, 209
 Pyriformis muscle, 52
 Quadratus femoris muscle, 52
 lumborum muscle, 45
 Radial artery, 79
 nerve, 162
 veins, 102
 Radialis indicis artery, 80
 Radio-carpal articulation, 15
 Radio-ulnar articulations, 14
 Ranine artery, 70
 vein, 102
 Raphé of the corpus callosum, 132
 of the medulla, 117
 Receptaculum chyli, 110
 Recto-vesical fascia, 47
 pouch, 192
 Rectus abdominis muscle, 44
 capitis anticus major, 32
 minor, 32
 lateralis, 32
 posticus major, 32
 minor, 33
 femoris, 51

- Rectus oculi externus, 25
 inferior, 25
 internus, 25
 superior, 25
 Rectum, connections of, in the female, 186
 Rectum, connections of, in the male, 186
 Recurrent interosseous artery, 81
 radial, 79
 tibial, 95
 ulnar, anterior, 80
 posterior, 81
 Recurrent nerve of pneumogastric, 153
 Recurrent nerve of the tibial, 171
 Renal artery, 86
 plexus, 176
 vein, 106
 Restiform body, 118
 Rete testis, 215
 Retina, 233
 structure, 233
 Retrahens aurem, 24
 Rhomboideus major muscle, 40
 minor, 40
 Rima of the glottis, 204
 Risorius muscle, 27
 Rods of the retina, 234
 Root of the lung, 206
 Rotatores, dorsi, 43
 Round ligament of the hip-joint, 13
 of the liver, 187
 of the uterus, 218

 Saccule of the ear, 226
 Sacculus laryngis, 204
 vestibuli, 226
 Sacral artery, lateral, 90
 middle, 90
 ganglia, 174
 nerves, anterior branches, 167
 posterior branches, 167
 plexus, 167
 Sacro-coccygeal articulation, 11
 iliac ,, 10
 vertebral ,, 10
 lumbalis muscle, 41
 sciatic ligament, large, 11
 small, 11
 Salpingo-pharyngeus muscle, 31
 Salvatella vein, 102
 Saphenous vein, external, 108
 internal, 108
 opening, 49
 nerve, external, 170
 internal, 166
 Sartorius muscle, 50

 Scala tympani, 226
 vestibuli, 226
 Scalenus anticus muscle, 32
 medius, 32
 posticus, 32
 Scapular artery, posterior, 67
 ligaments, 13
 muscles, 34
 Scapulo-clavicular articulation, 12
 humeral articulation, 13
 Schneiderian membrane, 220
 Sciatic artery, 86
 nerve, large, 169
 small, 169
 Sclerotic coat of the eye, 229
 Scrotum, 214
 Second nerve, 139
 Secondary membrane of the tympanum, 222
 Semicircular canals, 225
 Semilunar cartilages, 19
 ganglia, 175
 valves of aorta, 200
 of pulmonary artery, 199
 Semi-membranosus muscles, 53
 Seminal ducts, 215
 Seminiferous tubes, 215
 Semi-spinalis colli muscle, 42
 dorsi muscle, 42
 Semi-tendinosus muscle, 53
 Septum auricularum, 198
 cochleæ, 226
 crurale, 49
 intermuscular, of the arm, 35
 of the thigh, 49
 lucidum, 134
 nasi, 220
 pectiniforme, 213
 scroti, 214
 of the tongue, 178
 ventriculorum, 198
 Serratus magnus muscle, 34
 posticus inferior, 41
 superior, 41
 Seventh nerve, 149
 Sheath of the rectus, 44
 Shoulder-joint, 13
 Sigmoid artery, 87
 flexure of the colon, 186
 valve, 185
 Sinus, cavernous, 99
 circular, 99
 coronary, 106
 lateral, 99
 longitudinal, inferior, 99
 superior, 99
 occipital, 99

- Sinus, petrosal, inferior, 99
 superior, 99
 pocularis, 213
 prostaticus, 213
 straight, of the skull, 99
 transverse, 99
 of Valsalva, 199
 Sixth nerve, 48
 Small intestine, 184
 omentum, 194
 Socia parotidis, 179
 Soft commissure, 126
 Soft palate, 178
 muscles of, 31
 Solar plexus, 175
 Soleus muscle, 53
 Spermatic artery, 86
 cord, 214
 plexus, 176
 veins, 106
 Spheno-palatine artery, 74
 ganglion, 143
 nerves, 142
 Sphincter ani externus, 48
 internus, 48
 of the pupil, 232
 vaginae, 48
 Spigelian lobe, 188
 Spinal accessory nerve, 154
 arteries, 66
 cord, 113
 membrane of, 138
 structure, 115
 nerves, 155
 roots of, 155
 veins, 105
 Spinalis dorsi muscle, 42
 Spiral tube of the cochlea, 225
 Splanchnic nerve, large, 174
 small, 174
 smallest, 174
 Spleen, 190
 connections, 190
 Splenic artery, 85
 omentum, 194
 plexus of nerves, 176
 vein, 107
 Splenius capitis muscle, 41
 colli, 41
 Spongy bones, 219
 part of the urethra, 213
 Stapedius muscle, 224
 Stapes bone, 223
 Stellate ligament, 8
 Steno's duct, 178
 Sterno-clavicular articulation, 12
 cleido-mastoid muscle, 28
 hyoid muscle, 29
 Sterno-thyroid, 29
 Stomach, form and divisions, 183
 connections of, 183
 Straight sinus, 99
 Striate body, 135
 Stylo-hyoid ligament, 8
 muscle, 30
 Stylo-hyoid nerve, 150
 glossus muscle, 30
 mastoid artery, 71
 maxillary ligament, 28
 pharyngeus muscle, 30
 Subanconeus muscle, 36
 Subarachnoid space, 137
 of the cord, 135
 Subclavian artery, left, 63
 right, 63
 vein, 103
 Subclavius muscle, 33
 Subcrureus, 51
 Subcutaneous malar nerve, 142
 Sublingual artery, 70
 gland, 181
 Submaxillary ganglion, 145
 gland, 180
 Submental artery, 70
 Suboccipital nerve, anterior branch, 156
 Suboccipital nerve, posterior branch, 156
 Subpeduncular lobe, 123
 Subpubic ligament, 12
 Subscapular artery, 77
 nerves, 159
 Subscapularis muscle, 34
 Sulci of brain, 129
 Sulcus, longitudinal, of the liver, 188
 spiralis, 225
 transverse, 188
 Superficialis cervicalis artery, 67
 volæ artery, 79
 Supinator radii brevis, 38
 longus, 37
 Supra-orbital artery, 75
 nerve, 141
 renal capsule, 190
 plexus, 176
 scapular artery, 66
 nerve, 159
 spinatus muscle, 34
 trochlear nerve, 141
 Suspensory ligament of the lens, 237
 of the liver, 195
 of the penis, 213
 Sympathetic nerve in the abdomen, 175
 in the head, 171
 in the neck, 172

- Sympathetic nerve in the pelvis, 176
 in the thorax, 174
 Symphysis pubis, 11
 Synarthrosis, 5

 Tænia hippocampi, 134
 semicircularis, 135
 Tarsal artery, 96
 cartilages, 228
 Tarso-metatarsal articulations, 23
 Teeth, 177
 Tegmentum, 125
 Temporal aponeurosis, 27
 artery, 72
 deep, 72
 middle, 72
 superficial, 72
 fascia, 27
 muscle, 27
 nerves, deep, 144
 superficial, 144
 vein, 101
 Temporo-facial nerve, 150
 malar nerve, 142
 maxillary articulation, 8
 sphenoidal lobe, 130
 Tendo Achillis, 53
 palpebrarum, 228
 Tendon of quadriceps extensor, 51
 Tensor palati muscle, 31
 tarsi, 25
 tympani, 224
 vaginæ femoris, 50
 Tentorium cerebelli, 137
 Teres major muscle, 35
 minor, 34
 Testes, 215
 Thalamus opticus, 126
 Thebesian foramina, 198
 valve, 199
 Third nerve, 139
 ventricle, 126
 Thoracic duct, 110
 ganglia, 174
 acromial artery, 77
 alar ,, 77
 long ,, 77
 superior ,, 77
 Thymus body, 208
 Thyro-arytænoid articulation, 203
 ligaments, 203
 Thyro-arytænoid muscle, 31
 epiglottidean ligament, 203
 hyoid membrane, 203
 muscle, 29
 nerve, 154
 Thyroid artery, inferior, 66
 lowest, 83
 Thyroid artery, superior, 69
 axis, 66
 body, 208
 cartilage, 201
 plexus of veins, 104
 vein, inferior, 104
 vein, middle, 102
 superior, 102
 Tibial artery, anterior, 95
 posterior, 96
 nerve, anterior, 171
 posterior, 170
 veins, anterior, 109
 posterior, 108
 Tibialis anticus muscle, 53
 posticus ,, 54
 Tibio-tarsal articulation, 21
 Tongue, 177
 muscles of, 30, 178
 Tonsil, 179
 Tonsillitic artery, 70
 Torcular Herophili, 99
 Trabeculæ carneæ, 199
 Trachea, 204
 Trachelo-mastoid muscle, 42
 Tragus, 221
 Transverse colon, 186
 fissure of the cerebrum,
 136
 of the liver, 188
 ligament of the aceta-
 bulum, 18
 of the atlas, 7
 of the fingers,
 17
 of the knee, 20
 of the meta-
 carpus, 17
 of the meta-
 tarsus, 23
 of the toes, 23
 perineal artery, 89
 sinus, 99
 tarsal articulation, 23
 Transversalis abdominis muscle, 44
 cervicalis artery, 67
 colli muscle, 42
 faciei artery, 72
 Transversus linguæ, 178
 pedis, 56
 perinæi, 48
 Trapezius muscle, 40
 Trapezoid ligament, 33
 Triangular cartilage of the nose, 219
 fibro-cartilage of wrist, 15
 ligament of urethra, 46
 surface of bladder, 211
 Triangularis sterni muscle, 45

- Triceps extensor cubiti, 35
 Tricuspid valve, 199
 Trigeminal nerve, 140
 Trigonum vesicæ, 211
 Trochlear nerve, *infra*, 140
 supra, 140
 Tube of the cochlea, 225
 Tuber cinereum, 127
 Tubercle of Rolando, 118
 Tubuli seminiferi, 215
 Tunica albuginea testis, 215
 Ruyschiana, 231
 vaginalis, 215
 vasculosa testis, 215
 Turbinate bones, 219
 Twelfth intercostal nerve, 163
 Tympanic artery, 72, 74
 Tympanum, 222

 Ulnar artery, 80
 nerve, 161
 veins, 102
 cutaneous anterior, 102
 posterior, 102
 Ureter, 210
 Urethra, female, 217
 orifice of, 217
 male, interior, 213
 Uterine arteries, 88
 plexus of nerves, 176
 veins and sinuses, 109
 Uterus, 217
 interior of, 218
 ligaments of, 218
 connections of, 217
 Utricle of the ear, 226
 Uvea iridis, 232
 Uvula cerebelli, 123
 palati, 178

 Vagina, connections, 217
 Vaginal arteries, 88
 plexus, 176
 veins, 109
 Vagus nerve, 152
 nucleus, 121
 Vallecule, 122
 Valve, Eustachian, 199
 of cæcum, 125
 mitral, 200
 semilunar, 199
 of Thebesius, 199
 tricuspid, 199
 of Vieussens, 120
 Valvulæ conniventes, 185
 Vas deferens, 215
 Vasa brevia, 188
 efferentia testis, 215

 Vasa rete testis, 215
 vorticosa, 231
 Vascular coat of eye, 230
 Vastus externus muscle, 50
 internus muscle, 50
 Vein, alveolar, 100
 angular, 100
 ascending cervical, 102
 lumbar, 105
 pharyngeal, 102
 auricular posterior, 101
 axillary, 103
 azygos, large, 105
 small, 105
 superior, 105
 basilic, 102
 brachial, 103
 bronchial, left, 105
 right, 105
 cardiac, anterior, 106
 great, 106
 small, 106
 cava, inferior, 105
 superior, 104
 cephalic, 103
 cerebellar, 98
 cerebral, 98
 choroid, 98
 ciliary, anterior, 99
 posterior, 99
 circumflex iliac, 108, 109
 coronary of the heart, 106
 of the stomach, 107
 of the corpus striatum, 98
 deep cervical, 102
 dorsal of the penis, 109
 dorsi-spinal, 105
 emissary, 98
 epigastric, deep, 109
 superficial, 108
 facial, 99
 femoral, 109
 frontal, 100
 of Galen, 98
 gastro-epiploic, 108
 hæmorrhoidal, 109
 hepatic, 106
 iliac, common, 110
 external, 109
 internal, 109
 infra-orbital, 100
 innominate, 103
 intercostal, 105
 superior, left, 104
 right, 104
 jugular, anterior, 101
 external, 101
 internal, left, 101

- Vein, jugular, internal, right, 101
 laryngeal, 102
 lingual, 102
 longitudinal of the spine, anterior, 105
 lumbar, 105
 mammary, internal, 104
 median of the arm, 102
 basilic, 102
 cephalic, 102
 maxillary, internal, 100
 mesenteric, inferior, 107
 superior, 107
 occipital, 101
 ophthalmic, 99
 ovarian, 106
 palpebral, inferior, 100
 superior, 100
 pancreatic, 108
 perineal, superficial, 109
 pharyngeal, 102
 phrenic, inferior, 106
 popliteal, 109
 portal, 107
 posterior, spinal plexus of, 105
 profunda, of the thigh, 109
 pterygoid plexus, 101
 pudic external, 108
 internal, 109
 pulmonary, 106
 radial cutaneous, 102
 ranine, 102
 renal, 106
 sacral, lateral, 110
 middle, 110
 saphenous, external, 108
 internal, 108
 spermatic, 106
 spinal, 105
 splenic, 107
 subclavian, 103
 supra-orbital, 101
 renal, 106
 scapular, 101
 temporal, 100
 thyroid, inferior, 104
 middle, 102
 superior, 102
 tibial, anterior, 109
 posterior, 108
 transverse-cervical, 101
 ulnar, 102
 cutaneous, anterior, 102
- Vein, ulnar, cutaneous, posterior 102
 uterine, 109
 vaginal, 109
 vertebral, 102
 vesical, 109
 of the vertebræ, 105
 Velum interpositum, 134
 Vena cava, inferior, 105
 superior, 104
 portæ, 107
 Ventricles of the brain, 126, 132
 fifth, 134
 fourth, 119
 lateral, 132
 third, 126
 of the heart, 199
 left, 199
 right, 200
 of the larynx, 204
 Vermiform appendix, 185
 processes, 122
 Vertebral artery, 65
 vein, 102
 Veru montanum, 213
 Vesica urinaria, 209
 Vesical artery, inferior, 88
 superior, 88
 plexus of nerves, 176
 of veins, 109
 Vesicula prostatica, 213
 Vesiculæ seminales, 216
 Vestibule of the ear, 225
 of the vulva, 217
 Vestigial fold of the pericardium 197
 Vidian artery, 74
 nerve, 143
 Vitreous body, 236
 fluid, 236
 Vocal cords, 204
 Vulva, 216
- Wharton's duct, 180
 White commissure of the cord, 115
 Winslow's foramen, 195
 Wrisberg's nerve, 160
 Wrist-joint, 15
- Yellow spot of eye-ball, 236
- Zygomaticus major muscle, 26
 minor muscle, 26



22

10/10

the 1990s, the number of people in the UK who are employed in the public sector has increased by 1.5 million (1990–1999) and the number of people in the public sector has increased by 2.5 million (1990–1999). The public sector has become a major employer in the UK, and its growth has been a major factor in the overall growth of the UK economy. The public sector has also become a major provider of social services, and its growth has been a major factor in the overall growth of the UK economy.

The public sector has also become a major provider of social services, and its growth has been a major factor in the overall growth of the UK economy. The public sector has also become a major provider of social services, and its growth has been a major factor in the overall growth of the UK economy. The public sector has also become a major provider of social services, and its growth has been a major factor in the overall growth of the UK economy.

The public sector has also become a major provider of social services, and its growth has been a major factor in the overall growth of the UK economy. The public sector has also become a major provider of social services, and its growth has been a major factor in the overall growth of the UK economy. The public sector has also become a major provider of social services, and its growth has been a major factor in the overall growth of the UK economy.

The public sector has also become a major provider of social services, and its growth has been a major factor in the overall growth of the UK economy. The public sector has also become a major provider of social services, and its growth has been a major factor in the overall growth of the UK economy. The public sector has also become a major provider of social services, and its growth has been a major factor in the overall growth of the UK economy.

The public sector has also become a major provider of social services, and its growth has been a major factor in the overall growth of the UK economy. The public sector has also become a major provider of social services, and its growth has been a major factor in the overall growth of the UK economy. The public sector has also become a major provider of social services, and its growth has been a major factor in the overall growth of the UK economy.

The public sector has also become a major provider of social services, and its growth has been a major factor in the overall growth of the UK economy. The public sector has also become a major provider of social services, and its growth has been a major factor in the overall growth of the UK economy. The public sector has also become a major provider of social services, and its growth has been a major factor in the overall growth of the UK economy.

