

Nettleship's diseases of the eye : a manual for students / [Edward Nettleship].

Contributors

Nettleship, Edward, 1845-1913.
Spicer, W. T. Holmes, 1860-

Publication/Creation

London : J. & A. Churchill, 1897.

Persistent URL

<https://wellcomecollection.org/works/r463drjb>

License and attribution

This work has been identified as being free of known restrictions under copyright law, including all related and neighbouring rights and is being made available under the Creative Commons, Public Domain Mark.

You can copy, modify, distribute and perform the work, even for commercial purposes, without asking permission.




Wellcome Collection
183 Euston Road
London NW1 2BE UK
T +44 (0)20 7611 8722
E library@wellcomecollection.org
<https://wellcomecollection.org>





22101249109



96

NETTLESHIP'S

DISEASES OF THE EYE



NETTLESHIP'S DISEASES OF THE EYE

A MANUAL FOR STUDENTS

SIXTH EDITION

REVISED AND EDITED BY

W. T. HOLMES SPICER

M.A., M.B., F.R.C.S.

OPHTHALMIC SURGEON TO THE METROPOLITAN HOSPITAL AND TO
THE VICTORIA HOSPITAL FOR CHILDREN



LONDON

J. & A. CHURCHILL

7, GREAT MARLBOROUGH STREET

1897

M20517

WELLCOME INSTITUTE LIBRARY	
Coll.	wellcome
Call	
No.	WW100
	1897
	N47n

To

JONATHAN HUTCHINSON, F.R.S.

CONSULTING SURGEON TO THE MOORFIELDS OPHTHALMIC
HOSPITAL AND TO THE LONDON
HOSPITAL, &c.

THIS

BOOK IS DEDICATED

IN GRATEFUL ADMIRATION OF HIS EMINENT QUALITIES

AS A

CLINICAL TEACHER AND INVESTIGATOR

THE
LIBRARY OF THE
MUSEUM OF NATURAL HISTORY
AND
ZOOLOGY
OF THE
CITY OF LONDON
IN THE
MUSEUM BUILDINGS
LONDON
W.C.2

AUTHOR'S PREFACE

TO

SIXTH EDITION

SOME months ago the Publishers suggested to me that if I were unable myself to prepare another edition of this work some one else should, if possible, be found who would do so. I was glad to find that my friend Mr Holmes Spicer was willing to undertake the task, and I have only to add that he is entirely responsible for all that has been done to improve the book and bring the present edition up to date.

E. N.

November, 1897.

PREFACE

TO THE

FIRST EDITION

THE aim of this little book is to supply students with the information they most need on diseases of the eye during their hospital course. It was apparent from the beginning that the task would be a difficult one, all the more as several excellent manuals, covering nearly the same ground, are already before the public. That not one of them singly appeared exactly to cover the ground most important for the first beginner in clinical ophthalmology encouraged me to attempt the present work.

The scope of the work has precluded frequent reference to authors, those named being chiefly such as have made recent additions to our knowledge in this country. I am greatly indebted to Dr Gowers, Dr Barlow, and other friends for much information, and for many valuable suggestions. My best thanks are due to Mr A. D. Davidson for his kind assistance in reading the sheets for the press.

WIMPOLE STREET;
October, 1879.

1877

1877

1877

1877

CONTENTS

PART I.—MEANS OF DIAGNOSIS

	PAGE
LIST OF ABBREVIATIONS	1

CHAPTER I

OPTICAL OUTLINES	1—17
----------------------------	------

Lenses and prisms; Refraction of the eye, and conditions of clear vision; Numeration of spectacle lenses; Table showing the equivalent numbers of lenses made by the inch scale and metrical scale respectively.

CHAPTER II

EXTERNAL EXAMINATION OF THE EYE	19—38
---	-------

Examination of:—(1) Surface of cornea; (2) Tension of eye; (3) Field of vision; (4) Colour perception; (5) Acuteness of sight; (6) Accommodation; (7) Pupils; (8) Colour of iris; (9) External blood-vessels of eye; (10) Mobility of eye and field of fixation; (11) Squint or strabismus, apparent strabismus, measurement of strabismus; (12) Diplopia; (13) Apparent size of objects; (14) Protrusion and enlargement of eye.

CHAPTER III

EXAMINATION OF THE EYE BY ARTIFICIAL LIGHT	39—63
--	-------

- (1) Focal or "oblique" illumination.
- (2) Ophthalmoscopic examination:—Use of the ophthalmoscope.

	PAGE
Indirect method :—Appearance of Optic Disc; scleral ring, physiological pit, <i>lamina cribrosa</i> ;—of Choroid:—of Retina:—vessels, yellow spot, <i>fovea centralis</i> .	
Direct method:—Examination of vitreous; Determination of refraction; Table of relation between refraction and length of eye; Examination of fine details by direct method.	
Retinoscopy.	

PART II.—CLINICAL DIVISION

CHAPTER IV

DISEASES OF THE EYELIDS . . .	64—72
-------------------------------	-------

Blepharitis; Styte; Meibomian cyst; Horns and warty formations; Molluscum contagiosum; Xanthelasma; Pediculus pubis. Ulcers:—Rodent cancer; Tertiary syphilis; Tubercle of conjunctiva; Lupus; Chancre. Congenital ptosis; Epicanthus; Congenital trichiasis.

CHAPTER V

DISEASES OF THE LACRIMAL APPARATUS . . .	73—78
--	-------

Epiphora, stillicidium lacrimarum, and lacrimation.
Epiphora from alterations of punctum and canaliculus; Dacryoliths.
Diseases of lacrimal sac and nasal duct:—Mucocoele and lacrimal abscess; Stricture of nasal duct; Lacrimal abscess in newborn infants.

CHAPTER VI

DISEASES OF THE CONJUNCTIVA . . .	79—99
-----------------------------------	-------

Purulent and gonorrhœal ophthalmia; Muco-purulent ophthalmia; Catarrhal, and other forms of muco-purulent ophthalmia; Follicular conjunctivitis; Membranous and diphtheritic ophthalmia;—Granular ophthalmia;—Results of granular ophthalmia; Pannus, Distichiasis and trichiasis, Organic entropion;—Chronic conjunctivitis;—Amyloid dis-

ease;—Spring catarrh;—Conjunctivitis from drugs;—Ophthalmia nodosa;—Primary shrinking of conjunctiva;—Snow blindness.

CHAPTER VII

DISEASES OF THE CORNEA . . . 100—125

A. Ulcers and non-specific inflammation.

Appearances of the cornea in disease:—"Steamy" and "ground-glass" cornea; Infiltration; Swelling; Ulceration; Nebula and leucoma.

Symptoms in ulceration:—Photophobia; Congestion; Pain.

Clinical types of ulcer:—Simple ulcer; Facetting ulcer;—Phlyctenular affections; Phlyctenular, or recurrent vascular ulcer; Marginal conjunctivitis. (Spring catarrh); Crescentic ulcer of old age; Infective ulcers; Abscess and suppurating ulcer; Hypopyon; Onyx; Kerato-malacia; Herpes; Superficial punctate keratitis.

Treatment of ulcers of cornea.

B. Diffuse keratitis.

Syphilitic keratitis. Other affections of the cornea:—Keratitis punctata; Corneal changes in glaucoma; Conical cornea; Buphthalmos (Hydrophthalmos); Calcareous film; Arcus senilis; Inflammatory arcus; Opacity from use of lead lotion; Staining of conjunctiva or cornea from use of nitrate of silver.

CHAPTER VIII

DISEASES OF THE IRIS . . . 126—138

Iritis, Symptoms:—Muddiness and discoloration of iris; Synechiæ; Corneal haze; Ciliary congestion; Pain; Lymph nodules; Hypopyon.

Results of iritis.

Causes:—Syphilis; Rheumatism; Gout; Sympathetic disease; Injuries and local causes;—Chronic iritis.

Treatment of iritis.

Congenital irideremia; Coloboma; Persistent pupillary membrane.

CHAPTER IX

	PAGE
DISEASES OF THE CILIARY REGION.	. 139—152
Episcleritis (or Scleritis), Sclero-keratitis and allied diseases:— Cyclitis (Irido-choroiditis, "Serous iritis"); Traumatic cyclitis (or Panophthalmitis).	
Sympathetic affections:—Sympathetic irritation; Sympathetic inflammation; Treatment.	

CHAPTER X

INJURIES OF THE EYEBALL	. 153—163
Contusion and concussion injuries:—Rupture of eyeball; Intra- ocular hæmorrhage; Detachment of iris; Dislocation of lens; Detachment of retina; Rupture of choroid; Paralysis of iris and ciliary muscle; Iritis; Commotio retinæ; Trau- matic myopia.—Treatment of blows on eye; Dislocation of lens.	
Surface wounds of eyeball:—Abrasion and foreign body on cornea; Foreign body on conjunctiva.	
Burns and scalds; Prognosis uncertain for some days:—Lime- burn; Serious results of severe burns.	
Penetrating wounds of eyeball:—Slight cases; Severe cases; Traumatic cataract; Cyclitis; Foreign body in eye. Treat- ment.—Rules as to the excision of wounded eyes. Electro- magnet for removing bits of iron.	

CHAPTER XI

CATARACT	. 164—184
Senile changes in lens.	
Definition of cataract:—General cataract:—Nuclear and cortical, each may be hard (senile) or soft (juvenile); Congenital. Partial cataract:—Lamellar; Pyramidal; An- terior and posterior polar. Cataract following wound or concussion of eyeball.	
Primary and secondary cataract.	

Symptoms and diagnosis of cataract.—Prognosis before and after operation.

Treatment:—Palliative; Atropine. Radical; Extraction, Dissection or solution, Suction.

Rules as to operating for cataract; Artificial ripening of cataract; Causes of failure after extraction; Hæmorrhage; Suppuration of globe; Iritis; Prolapse of iris; Influence of lacrimal disease.

Sight after removal of cataract.

Treatment of lamellar cataract.

Cataract following injury; Dislocation of lens.

CHAPTER XII

DISEASES OF THE CHOROID . . . 185—200

Participation by the retina and the vitreous.

Appearances in health; Appearances in disease:—Atrophy, Pigment in choroid and retina; Exudations, syphilitic, tubercular; Rupture; "Colloid" change; Hæmorrhages.

Clinical forms of disease:—Syphilitic choroiditis disseminata; Myopic changes; Central senile choroiditis; Pseudo-glioma; Other forms.

Coloboma; Albinism.

CHAPTER XIII

DISEASES OF THE RETINA . . . 201—222

Appearances in health:—Blood-vessels, yellow-spot, and "halo" around it; "Opaque nerve-fibres."

Appearances in disease:—Congestion; Retinitis, Diffuse, Localised, with white spots and hæmorrhages, Solitary patch.

Hæmorrhage; Pigmentation; Atrophy; Disc in Atrophy of retina; Detachment.

Clinical forms of disease:—Syphilitic retinitis; Albuminuric; Hæmorrhagic; Retinitis apoplectica and large single hæmorrhages; Embolism and thrombosis; Retinitis pigmentosa; Retinitis from intense light.

CHAPTER XIV

DISEASES OF THE OPTIC NERVE . . . 223—237

PAGE

Relation between changes at the Disc, disease of the optic Nerve, and affection of Sight.

Pathological changes in optic nerve.

Appearances of optic disc in disease:—Inflammation, optic neuritis, papillitis, or choked disc; Atrophy after papillitis; Papillo-retinitis.

Etiology of papillitis. Retro-ocular neuritis; Syphilis causing papillitis.

Atrophy of disc:—Appearances and causes; Clinical aspects; State of sight, field of vision, and colour perception; A. Double atrophy; B. Single atrophy.

CHAPTER XV

AMBLYOPIA AND FUNCTIONAL DISORDERS OF SIGHT

238—254

“Amblyopia” and “Amaurosis:”—Single amblyopia:—From suppression or congenital defect; from defective images; from retro-ocular neuritis. Double amblyopia:—Central amblyopia (Tobacco amblyopia).

Hemianopia; Hysterical amblyopia and Hyperæsthesia oculi; Asthenopia.

Functional disorders of vision; Endemic nyctalopia; Hemeralopia; Coloured vision; Micropsia; Muscæ volitantes; Diplopia; Malingering; Colour-blindness.

CHAPTER XVI

DISEASES OF THE VITREOUS HUMOUR . . . 255—259

Usually secondary to other disease of eye.

Examination for opacities:—Cholesterine; Blood; Blood-vessels in vitreous; Cysticercus.

Conditions causing disease of vitreous:—Myopia; Blows and wounds; Spontaneous hæmorrhage; Cyclitis, choroiditis, retinitis; Sympathetic disease.

CHAPTER XVII

PAGE

GLAUCOMA 260—279

Primary and secondary.

Primary glaucoma:—Premonitory stage; Chronic or Simple;

Subacute; Acute; Absolute.

Ophthalmoscopic changes; Cupping of disc.

Symptoms explained; Mechanism.

General and diathetic causes; Treatment; Prognosis.

Secondary glaucoma; Conditions causing it.

CHAPTER XVIII

TUMOURS AND NEW GROWTHS . . . 280—289

A. Of the conjunctiva and front of the eyeball.—Cauliflower wart; Lupus; Syphilitic tarsitis; Pinguecula; Pterygium; Lymphatic cysts; Dermoid tumour; Episcleritis simulating tumour; Fibro-fatty growth; Cystic tumours; Fibrous and Bony tumours; Epithelioma; Sarcoma.

B. Intraocular tumours.—Glioma of retina. Sarcoma of choroid; Tubercular tumour of choroid. Tumours of iris:—Sarcoma; Sebaceous tumour; Cysts; Granuloma.

CHAPTER XIX

INJURIES, DISEASES, AND TUMOURS OF THE ORBIT

290—298

Contusion and concussion injuries:—Emphysema of orbit; Traumatic ptosis.

Abscess and cellulitis of orbit; Inflammation and abscess of lacrimal gland.

Wounds:—Of eyelids; of orbit; Large foreign bodies in orbit.

Tumours of orbit; General symptoms.—Distension of frontal sinus; Ivory exostosis; Tumours growing from parts around the orbit; Pulsating exophthalmos; Cystic tumours; Solid intraorbital tumours. Nævus. Dermoid tumour in eye-brow.

CHAPTER XX

	PAGE
ERRORS OF REFRACTION AND ACCOMMODATION	299—332

Emmetropia; Ametropia.

Myopia.—Symptoms:—Insufficiency of internal recti. Posterior staphyloma and crescent; Other complications. Tests for. Causes. Measurement of degree. Treatment; Spectacles; Tenotomy.

Hypermetropia.—Symptoms:—Accommodative asthenopia. Tests for hypermetropia. Treatment; Spectacles.

Astigmatism.—Regular and irregular; Seat; Focal interval; Cylindrical lenses; Forms of regular astigmatism; Detection and Measurement; Spectacles.

Unequal refraction in the two eyes (Anisometropia).

Presbyopia:—Rate of progress; Treatment:—Range and region of accommodation in E., M., and H.

CHAPTER XXI

STRABISMUS AND PARALYSIS	333—353
--------------------------	---------

Definition of strabismus; Diplopia; True and false Image; Homonymous and crossed diplopia; Suppression of false image.

Causes:—Strabismus from over-action; from weakness; from disuse; from weakness following tenotomy; from paralysis.

Paralysis of Sixth nerve (external rectus); of Fourth nerve (superior oblique); of Third nerve; Ophthalmoplegia externa.—Primary and secondary strabismus; Giddiness in paralytic strabismus.

Affections of Internal muscle of eye:—Physiology and action of drugs on the Internal Muscles; Affections of Pupil alone; of Accommodation alone; of Pupil and Accommodation; Ophthalmoplegia interna.

Causes of external ocular paralyses:—Syphilitic growths; Meningitis; Tumours; Rheumatism. Causes of internal ocular paralyses. Treatment.

Nystagmus.

CHAPTER XXII

	PAGE
OPERATIONS	354—397
A. On the eyelids.	
Epilation; Eversion of lid; Meibomian cyst; Inspection of cornea; Spasmodic entropion; Organic entropion and trichiasis; Ectropion; Blepharoplasty; Ptosis; Canthoplasty; Peritomy; Symblepharon.	
B. On the lacrimal apparatus.	
Lacrimal abscess; Slitting canaliculus; Stricture of nasal duct, (1) Probing, (2) Incising, (3) Syringing.	
C. For strabismus.	
Tenotomy:—Graefe's; Critchett's; Liebreich's. Readjustment and Advancement.	
D. Excision of the eye and alternative operations. Abscission, Optico-ciliary Neurotomy, Evisceration.	
E. On the cornea.	
Foreign body; Paracentesis; Corneal section for ulcer; Conical cornea.	
F. On the iris.	
Iridectomy:—For artificial pupil; for glaucoma. Iridodesis; Iridotomy (Iritomy).	
Sclerotomy.	
G. For cataract.	
Extraction:—Linear; Graefe's "modified linear;" Short flap; Corneal section; Old flap. Complications during extraction. Treatment after extraction. Secondary operations. Discission or Solution; Suction. Treatment after solution and suction.	
Anæsthesia in Ophthalmic Surgery.	

PART III.—DISEASES OF THE EYE IN RELATION
TO GENERAL DISEASES

CHAPTER XXIII 398—428

A. GENERAL DISEASES

Eye diseases caused by:—Syphilis, acquired and inherited, diseases of optic nerve and oculo-motor nerves in relation to

	PAGE
syphilis; Smallpox; Scarlet fever, typhus, &c.; Diphtheria; Measles; Mumps; Chicken-pox and Whooping-cough; Mala- rial fevers; Relapsing fever; Epidemic cerebro-spinal Men- ingitis; Purpura and Scurvy; Pyæmia and Septicæmia; Lead poisoning; Alcohol; Tobacco; Bisulphide of carbon; Quinine; Kidney disease; Diabetes; Leucocythæmia; Per- nicious anæmia; Heart disease; Tuberculosis; Rheumatism and Gonorrhœal Rheumatism; Gout, personal and inherited; Struma; Entozoa.	

B. LOCAL DISEASE AT A DISTANCE FROM THE EYE

Eye symptoms caused by:—Megrin; Neuralgia and Sympathetic disease; Diseases of brain:—Cerebral tumour; Syphilitic disease; Meningitis; Cerebritis; Hydrocephalus; Diseases of spinal cord:—Myelitis; Locomotor ataxy. General paralysis of insane. Lateral and Insular Sclerosis.—Motor disorders of eyes and affections of the pupils in cerebral and spinal disease.

C. THE EYE SHARING IN A LOCAL DISEASE OF THE NEIGHBOURING PARTS

Eye symptoms caused by:—Herpes zoster of fifth nerve; Paralysis of fifth, of facial, and of cervical sympathetic nerves; Exophthalmic goitre; Erysipelas and Orbital Cellulitis.
The teeth in inherited syphilis (with woodcut, p. 428).

APPENDIX 429

Formulae (pp. 429—444).	
Shades. Protective glass.	
Test types, &c.	
Ophthalmoscopes.	
Perimeters.	
Tests for colour-blindness.	
Requirements of Candidates for Public Services (p. 445).	
Index	447

PART I

MEANS OF DIAGNOSIS

THE following abbreviations will be used in this work :

T.	Tension of the eyeball.	cm.	Centimetre.
E.	Emmetropia.	mm.	Millimetre.
M.	Myopia.	D.	Dioptre, the unit in the
H.	Hypermetropia.		metrical system of mea-
m. H.	Manifest hypermetropia.		suring lenses; a lens
l. H.	Latent hypermetropia.		whose focal length is
Pr.	Presbyopia.		1 m.
As.	Astigmatism.	y. s.	Yellow spot of the retina.
Acc.	Accommodation.	O. D.	Optic disc.
p.	Punctum proximum or	F.	Field of vision.
	near point.	V.	Visus, acuteness of sight,
r.	Punctum remotissimum or		power of distinguishing
	far point.		<i>form.</i>
p. l.	Perception of light.	<i>Symbols.</i>	— + A convex, — a con-
P.	Pupil.		cave, lens. ' Foot, " Inch,
m.	Metre.		''' Line.

CHAPTER I

OPTICAL OUTLINES

1. Rays of light are deviated or refracted when they pass from one transparent medium, *e. g.* air, into another of different density, *e. g.* water or glass.

2. If the deviation in passing from vacuum into air be represented by the number 1, that for crown glass (of

which ordinary lenses are made) is 1.5, and for rock crystal ("pebble" of opticians) 1.66. Such a number is the "refractive index" of the substance. Every ray is refracted except the one which falls perpendicularly to the surface (Fig. 1, *a*).

3. In passing from a less into a more refracting medium the deviation is always towards the perpendicular to the refracting surface; in passing from a more into a less refracting medium it is always, and to the same extent, away

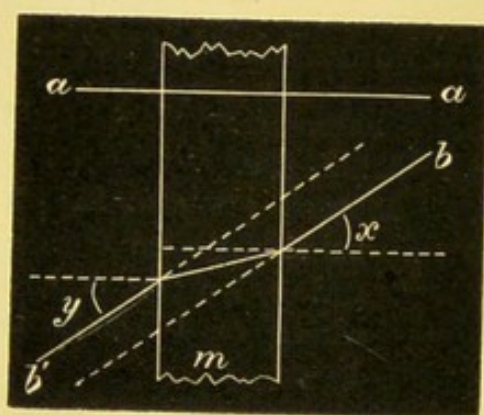


FIG. 1.—Refraction by a medium with parallel sides.

from the perpendicular (Fig. 1, *b*), *i. e.* the angle x in the figure = the angle y .

4. Hence, if the sides of the medium (Fig. 1, *m*) be parallel, the rays on emerging (*b'*) are restored to their original *direction* (*b*) and, if the medium be thin, very nearly to their original *path*.

5. But if, *as in a prism*, the sides of *m* form an angle (Fig. 2, *a*), the angles of incidence and emergence (x and y) still being equal, *b'* must

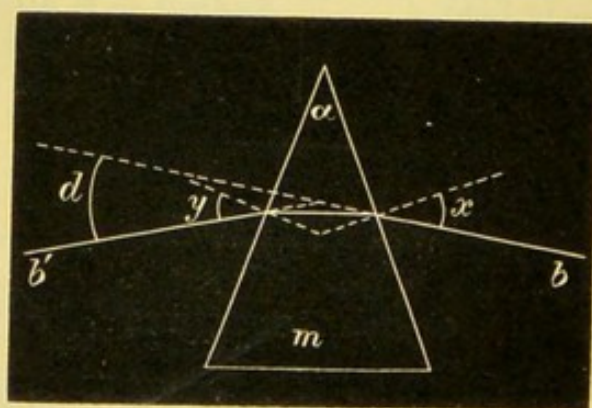


FIG. 2.—Refraction by a prism.

also form an angle with *b*. The angle *a* is the "refracting angle" or edge of the prism; the opposite side is the "base." The figure shows that light is always deviated

towards the base. The deviation (shown by the angle d), is equal to about half the refracting angle a if the prism be of crown glass. The *relative* direction of the rays is not changed by a prism; if parallel or divergent before incidence they are parallel or similarly divergent after emergence (Fig. 3).

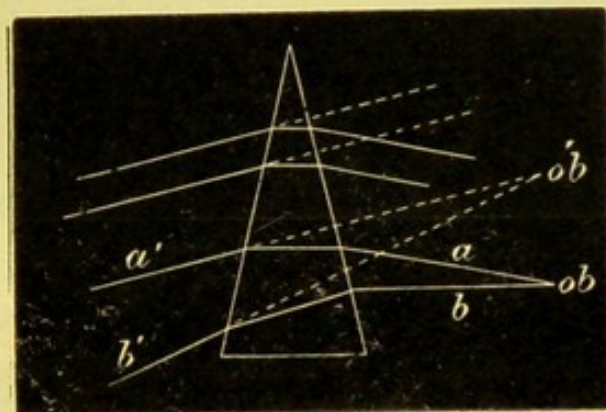


FIG. 3.—Apparent displacement of object by a prism.

6. An object seems to lie, or is “projected,” in the direction which the rays have *as they enter the eye*; ob (Fig. 3), seen by an eye at a' or b' , seems to be at $o'b$, where it would be if the rays $a' b'$ had undergone no deviation.

7. For very thin *prisms* the deviation (a and β , Fig. 4) remains the same for varying angles of incidence. For thin *lenses* this is expressed by saying that the angle d , Fig. 5, is the same for the rays $a a'$, $b b'$, and $c c'$, incident at different angles, but at the *same distance from the axis*.

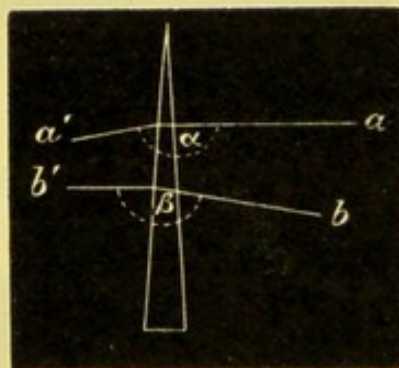


FIG. 4.—Refraction the same for different angles of incidence.

8. An ordinary lens is a segment of a sphere (plano-convex or plano-concave), or of two spheres whose centres are joined by the axis of the lens (biconvex or biconcave).

9. A lens is regarded as formed of an infinite number of

minute prisms, each with a different refracting angle. Fig. 6 shows two such elements of a convex lens, the angle (α) of

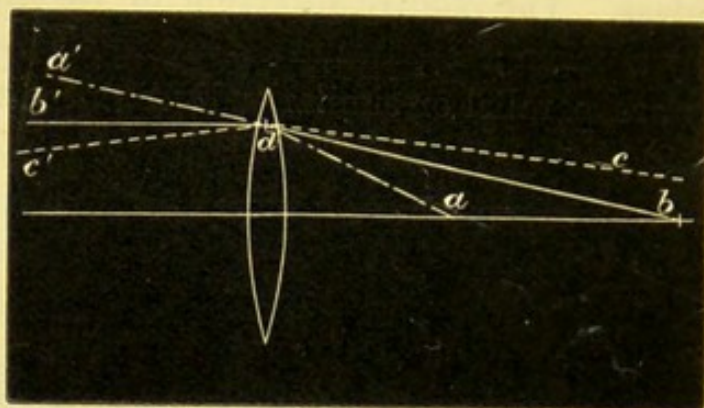


FIG. 5.—Refraction by a thin lens the same for all rays incident at the same distance from the axis.

the prism at the edge of the lens being larger, and therefore, in accordance with § 5, refracting more than β , the

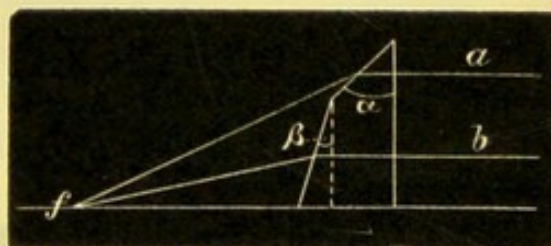


FIG. 6.—Prismatic elements of a convex lens.

angle of the prism near the axis. If two parallel rays, a and b , traverse this system a will be more refracted than b , and the rays will meet at f . Fig. 7 shows the corresponding facts for a concave lens

by which parallel rays are made divergent.

10. The only ray not refracted by a lens is the one pass-

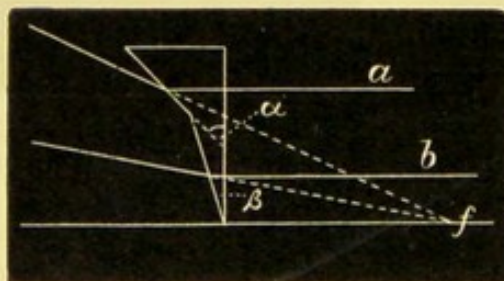


FIG. 7.—Prismatic elements of a concave lens.

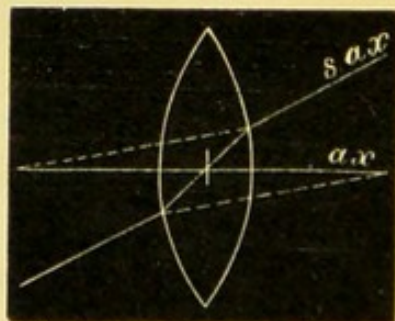


FIG. 8.—Axes of a lens.

ing through the centre of each surface (compare § 2), which is the *principal axis* (ax , Fig. 8). *Secondary axes* are rays

(such as *s. ax*) entering and emerging at points on the lens parallel to each other, and hence (*see* § 4) not altered in direction; all rays which pass through the central point of the lens are secondary axes (except the principal axis).

11. The *principal focus* (f , Fig. 10) of a lens is the point where the rays, *a a*, that were parallel before they traversed the lens meet, after they have passed through it; the deviation of each ray varying directly with its distance from the principal axis (Fig. 6).

But this is only approximately true. In an ordinary lens the rays (*a*, Fig. 9) which traverse the margin are refracted more, and meet sooner, than the rays (*b*) which lie nearer the axis; and the result is,

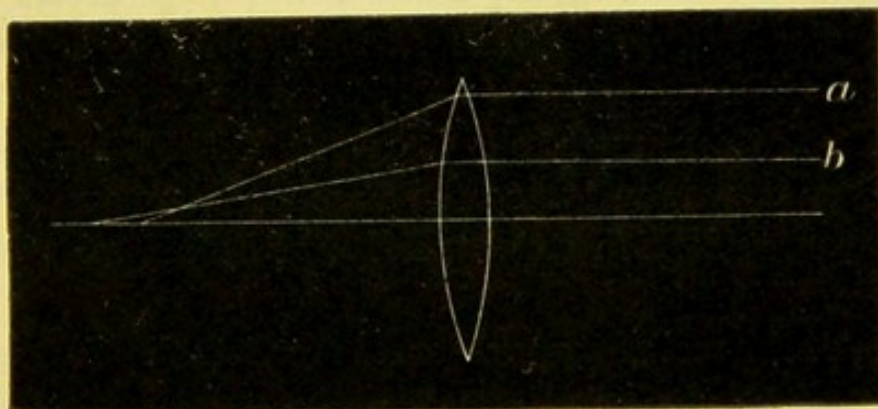


FIG. 9.—Spherical aberration.

not one focus, but a number of foci. "Spherical aberration" increases with the size of the lens. In the eye it is, to a great extent, prevented by the iris, which cuts off the light from the margin of the crystalline lens.

If parallel rays are incident from the side towards f (Fig. 10) they will be focussed at f' , at the same distance from the lens as f ; hence every lens has two principal foci—anterior and posterior.

12. The *path* of a ray passing from one point to another is the same, whatever its *direction*; the path of the ray bb' (Fig. 10) is the same, whether it pass from $c' f'$, or in the contrary direction.

13. From § 7 it follows that in Fig. 10 the angles a and a' are equal, and hence the ray b , diverging from cf , will not meet the axis at f , but at $c'f'$; cf and $c'f'$ are *conjugate*

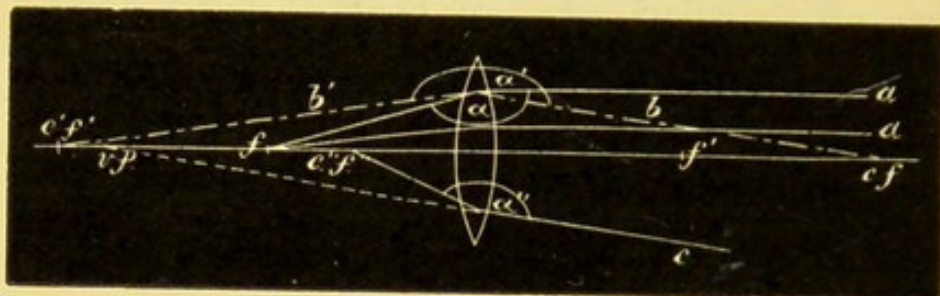


FIG. 10.—Foci of a convex lens.

points, and each is the *conjugate focus* of the other. The angle a or a' remaining the same, then if cf be further from the lens $c'f'$ will approach it. A ray (c) directed towards the axis will be focussed at $c''f''$, because the angle $a''=a$; no real point conjugate to $c''f''$ exists; but if the ray start from $c''f''$ it will, on taking the direction c , appear to have come from vf , which consequently is the *virtual focus* of $c''f''$ (see § 6).

14. All the foci of concave lenses are virtual. In Fig. 11, a , parallel to the axis, is made divergent (see Fig. 7), its

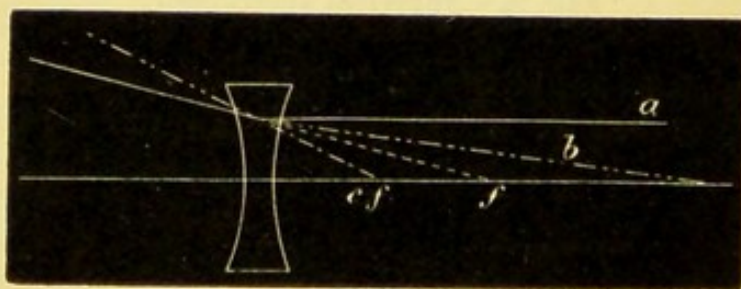


FIG. 11.—Foci of a concave lens.

virtual focus being at f ; similarly cf is the virtual conjugate focus of the point emitting the ray b .

15 In equally biconvex or biconcave lenses of crown glass the *principal focus* f is at the centre of curvature of either surface of the lens (*i. e.* $f=r$, the radius); in plano-convex (or concave) lenses $f=2r$.

16. *Images*.—The image formed by a lens consists of foci, each of which corresponds to a point on the object. Given the foci of the boundary points of an object, we have the position and size of its image.

In Fig. 12 the object $a b$ lies beyond the focus f . From

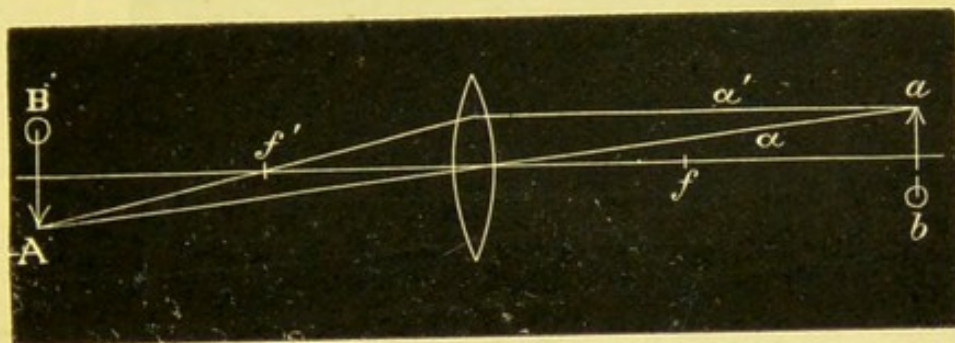


FIG. 12.—Real inverted image formed by a convex lens.

the terminal point a take two rays, a and a' , the former a secondary axis, and therefore unrefracted, the latter parallel to the principal axis, and therefore passing after refraction through the principal focus f' . These two rays (and all others which pass through the lens from the point a) will meet at A , the conjugate focus of a . Similarly the focus of the point b is found, and the real inverted conjugate image of $a b$ is formed at $A B$. The relative sizes of $a b$ and $A B$ vary as their distances from the lens.

If $a b$ be so far off that its rays are virtually parallel on reaching the lens, its image $A B$ will be at f' , and very small. If $a b$ be at f its rays will become parallel after refraction (§§ 11 and 12), and form no image. If $a b$ lies between f (or f') and the lens, the rays will diverge after refraction, and again will not form an image (see Fig. 10, $c'' f''$).

But in the last two cases a virtual image is seen by an eye so placed as to receive the rays. In Fig. 13 two rays from a take after refraction the course shown by a and a' , virtually meeting at A (see Fig. 10, $v f$); and an observer at x will see at $A B$ a virtual, magnified, erect image of $a b$.

The enlargement (in Fig. 13) is greater the nearer $a b$ is to f' , and greatest when it is at f' . But as $A B$ has no real

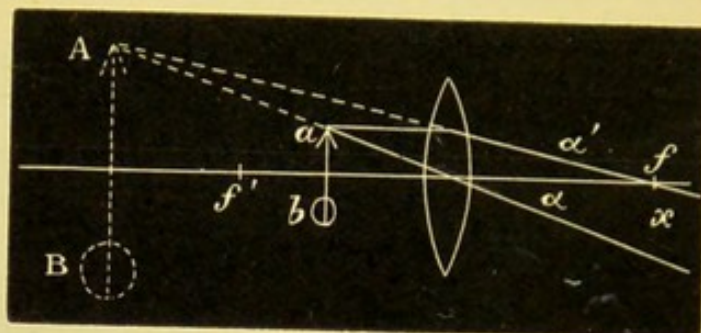


FIG. 13.—Virtual erect image formed by a convex lens.

existence, its apparent size varies with the known, or estimated, distance of the surface against which it is projected. A uniform distance of projection of about 12" (30 cm.) is taken in comparing the magnifying power of different lenses.

When $a b$ is at f' (Fig. 13) we shall find on trial that the image $A B$ can be seen well only by bringing the eye close up to the lens; at a greater distance only part of the image will be seen, and this part will be less brightly lighted. This is important in direct ophthalmoscopic examination (p. 52). Thus in Fig. 14 an observer placed

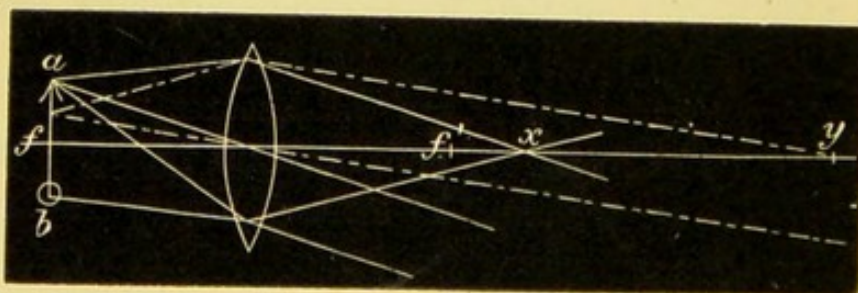


FIG. 14.—Virtual image; result of observer varying distance of his eye from the lens.

anywhere between the lens and x , receiving rays from every part of $a b$, will see the whole image. But if he withdraw to y , his eye will receive rays only from the

central part of $a b$, and will therefore not see the ends of the object.

It is easily shown by similar constructions that the images formed by concave lenses are always virtual, erect, and diminished, whatever the distance of the object (Fig. 15). (Compare Fig. 11.)

17. The size of the image (whether real or virtual) varies with (1) the focal length of the lens, and (2) the distance of the object from the principal focus.

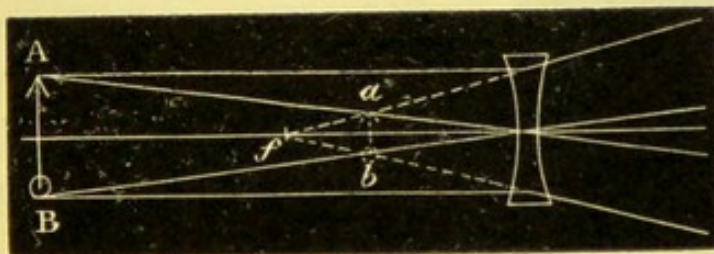


FIG. 15.—Image formed by a concave lens.

(1) The shorter the focus of the lens, the greater is its effect or the “stronger” it is; *the refractive power of a lens varies inversely as its focal length.*

(2) For a *convex* lens, the image (whether real or virtual) is larger (*i. e.* the effect greater) the nearer the object is to the principal focus (whether within or beyond it).

For a *concave* lens, the image is smaller (*i. e.* the effect greater) the further the object is from the lens (whether within or beyond the focus).

18. *Prisms*.—Any object viewed through a prism seems displaced towards the edge of the prism, and the amount of the displacement varies directly as the size of the refracting angle (§§ 5 and 6). The eye is directed towards the position which the object now seems to take, and this effect may be variously utilised:—1. *To lessen the convergence* of the visual lines without removing the object further from the eyes. In Fig. 16 the eyes, R and L,

are looking at the object (ob) with a convergence of the visual lines represented by the angle α . If prisms be now

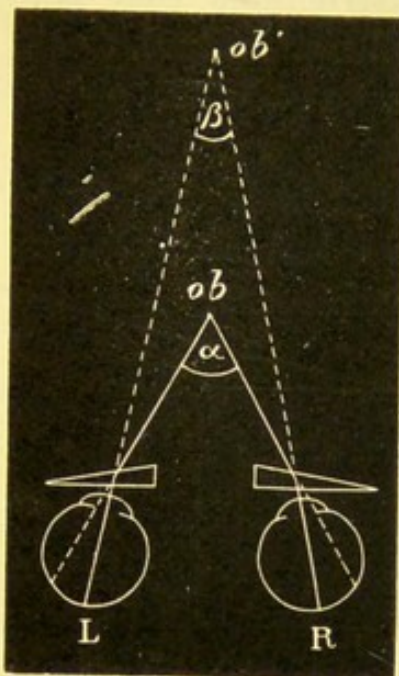


FIG. 16.—Effect of prisms in lessening convergence.

added with their edges towards the temples they deflect the light, so that it enters the eyes under the smaller angle β , as if it had come from ob' , and towards this point the eyes will be directed, though the object still remains at ob . The same effect is given by a single prism of twice the strength before one eye, though the actual movement is then limited to the eye in question. If spectacle lenses be placed so that the visual lines do not pass through their centres they act as prisms, though the strength of the prismatic action varies with the power of the lens

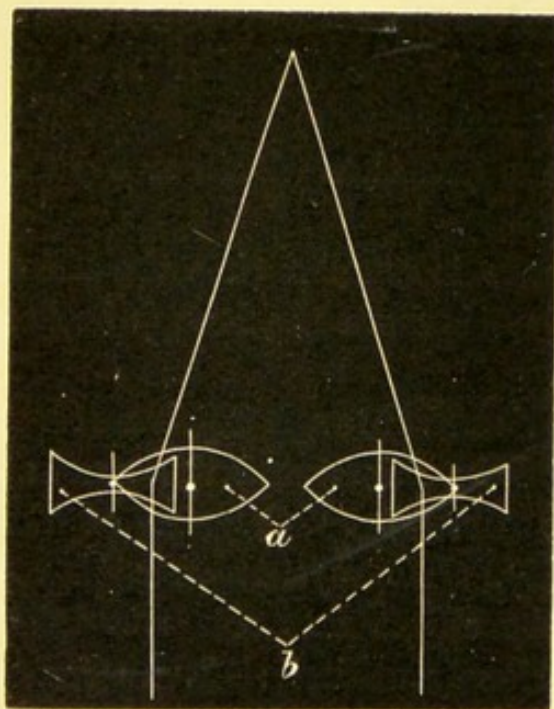


FIG. 17.—Lenses acting as prisms.

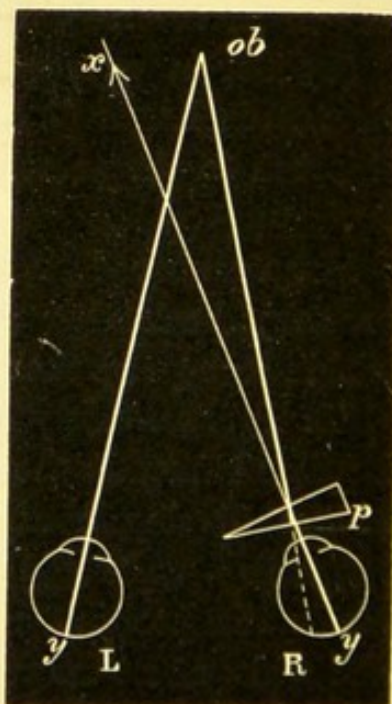


FIG. 18.—Diplopia removed by prism.

Table showing the Prismatic Effect of Decentering Lenses (Maddox).

Amount of Decentration in Millimetres.			
Lens.	5 mm.	10 mm.	15 mm.
1 D.	17'	35'	52'
2 D.	35'	1° 9'	1° 43'
3 D.	52'	1° 43'	2° 34'
4 D.	1° 10'	2° 18'	3° 26'
6 D.	1° 43'	6° 26'	5° 9'
8 D.	2° 18'	4° 35'	6° 50'

and the amount of this "decentration" (see § 9, Figs. 6 and 7). In Fig. 17 the visual lines pass outside the centres of the convex lenses (*a*) and inside those of the concave lenses (*b*). Each pair therefore acts as a prism with its edge outwards.—2. To *remove double vision* caused by slight degrees of strabismus. The prism so alters the direction of the rays as to compensate for the abnormal direction of the visual line. In Fig. 18 *R* is directed towards *x* instead of towards *ob*, and two images of *ob* are seen (see Chap. XXI). The prism (*p*) deflects the rays to *y*, the yellow spot, and single binocular vision is the result.—3. To *test the strength of the ocular muscles*. In Fig. 19 the prism at first causes diplopia by displacing the rays from the yellow spot (*y*) of the eye (*R*) (Chap. XXI). By a compensating rotation of the eye (cornea, outwards, shown in the figure by the change of the transverse axis

from 1 to 2, y is brought inwards to the situation of im , the images are fused and single vision restored; the

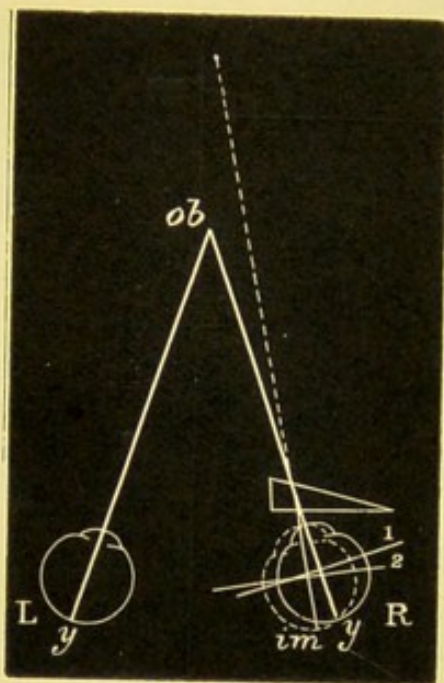


FIG. 19.—Prism used for testing strength of muscle.

effect of the prism is overcome by the action of the external rectus. This "fusion power" of the several pairs of muscles may be expressed by the strongest prism that each pair can overcome. The fusion power of the two external recti is represented by a prism of about 8° ; that of the two internals by 25° to 50° or more; that of the superior and inferior recti, acting against each other, by only about 3° .—

4. *Feigned blindness of one eye* may often be exposed by means of the diplopia (unexpected by the patient) produced by a prism.

The prism should be stronger than can be overcome by any effort, *e. g.* 8° or 10° , base upwards or downwards. The patient is best thrown off his guard if the prism be held before the sound eye. If he now exclaims that he sees double he must of course be seeing with both eyes.

19. *Refraction of the eye.*—The eye presents three refracting surfaces—the front of the cornea,* the front of the lens, and the front of the vitreous; and in the normally formed or emmetropic eye (E.), with the accommodation relaxed, the principal focus (§ 11) of these combined dioptric media falls exactly upon the layer of rods and cones of

* The posterior surface of the cornea being parallel with the anterior causes no deviation, and the aqueous has the same refractive power as the cornea. Hence the refractive effect of the cornea and aqueous together is the same as if the corneal tissue extended from the front of the cornea to the front of the lens.

the retina, *i. e.* the eye in a state of accommodative rest is adapted for parallel rays. The point at which the secondary axial rays (*see* § 10, Fig. 8) cross, the "posterior nodal point" (*n*, Fig. 20) lies, in the normally formed eye, at




FIG. 20.—Visual angle and retinal image. *Ob*, object; *v*, visual angle; *n*, nodal point where the axial rays cross; *d*, distance from *n* to the retina. The position of the retina in different states of refraction is shown by the three curved lines to the right, *H.* being represented by the line nearest to, and *N.* by the one furthest from, *n*, whilst the middle thin line shows the retina in *E.*

15 mm. in front of the yellow spot of the retina, and very nearly coincides with the posterior pole of the crystalline lens. The angle included between the lines joining *n* with the extremities of the object (*ob*) is the *visual angle* (*v*). If the distance (*d*) from *n* to the retina remain the same, the size of any image (*Im*) on the retina will depend on the size of the angle *v*, and this again on the size and distance of *ob*. But if the distance (*d*) alters, the size of the image (*Im*) is altered without any change in *v*. Now the length of *d* varies with the length of the posterior segment of the eye; it is greater in myopia (*M.*) and less in hypermetropia (*H.*); and hence the retinal image of an object at a given distance is, as the figure shows, larger in myopia and smaller in hypermetropia than in the normally formed eye. The length of *d* also varies with the position of *n*, and this is influenced by the positions and curvatures of the several refractive surfaces. *n* is slightly advanced by the increased convexity of the lens during accommodation, and much

more so if the same change of refraction be induced by a convex lens held in front of the cornea: hence convex lenses, by lengthening d , enlarge the retinal image. Concave lenses put n further back, and, by thus shortening d , lessen the image. If the lens which corrects any optical error of the eye be placed at the "anterior focus" of the eye,* 13 mm., or half an inch, in front of the cornea, n moves to its normal distance (15 mm.) from the retina, whatever the length of the eye, and the images are therefore reduced or enlarged to the same size as in the emmetropic eye. (For definition of astigmatism see Chap. XX.)

The length of the *visual axis*, a line drawn from the yellow spot to the cornea in the direction of the object looked at, is about 23 mm. The centre of rotation of the eye is rather behind the centre of this axis, and 6 mm. behind the back of the lens. The focal length of the cornea is 31 mm., and that of the crystalline lens varies from 43 mm. with accommodation relaxed, to 33 mm. during strong accommodation.

The *optical conditions of clear sight* are as follows:

(1) The image must be clearly focussed on the retina, *i. e.* the retina must lie exactly at the focus of the rays which proceed from the object looked at: (2) it must be formed at the centre of the yellow spot (Chap. II, § 11): (3) it must have a certain size, and this is expressed by the size of the corresponding visual angle (v . Fig. 20); with good indoor light v must be equal to at least five minutes $\frac{1}{12}$ th of a degree) in order that the form of the image may be perceived; an object subtending any smaller angle (down to about one minute) is still visible, though only as a point of light:† (4) the cornea, lens, and vitreous must

* The anterior focus is the point where rays, which were parallel in the vitreous, are focussed in front of the cornea.

† In bright light, as in the open air, the minimum visual angle is considerably less than 5 minutes.

be clear : (5) the illumination must be sufficient. — *Influence of the pupil.*—Other things being equal, the larger the pupil the worse is the sight, definition being lessened by the spherical aberration caused by the marginal part of the lens (Fig. 9). (See “Artificial Pupil.”)

The smaller the pupil, the less is the spherical aberration (p. 5), and, *cæt. par.*, the better the V. Also the smaller the pupil the less is the accommodation needed for near vision. If the pupil be so small as to subtend an angle (“angle of divergence”) of not more than 5 minutes with any point on the object, the object will be clearly seen without accommodation. By calculation it appears that if the pupil had a diameter = .66 mm. it would subtend an angle of divergence of 5 minutes at about .5 m. (18"); *i. e.* with a pupil of .66 mm. print should, in a good light, be clearly seen at 18" without any accommodation. That this is true may be proved by looking at fine print through a hole of the above size in a thin card held as close as possible to the eye.

Numeration of spectacle lenses.—Some system of numbering is required which shall indicate the refractive power of the lenses used for spectacles. Two systems are current.—In the *first system*, which was till lately universal, the unit of strength is a strong lens of 1" focal length. As all the lenses used are weaker than this, their relative strengths can be expressed only by using fractions. Thus, a lens of 2" focus, being half as strong as the unit (§ 17, 1), is expressed as $\frac{1}{2}$; a lens of 10" focus is $\frac{1}{10}$; of 20" focus $\frac{1}{20}$; and so on. The objections are, that fractions are inconvenient in practice; that the intervals between the successive numbers are very unequal; and that the length of the inch is not the same in all countries, so that a glass of the same *number* has not quite the same focal length when made by the Paris, English, and German inches respectively.*—In the *second system*, which has almost displaced the old one, the metrical scale is used, the unit is a

* 1" English = 25.3 mm., 1" French = 27 mm., 1" Austrian = 26.3 mm., 1" Prussian = 26.1 mm.


weak lens of 1 metre (100 cm.) focal length, known as a diopetre (D.), and the lenses differ by equal refractive intervals. A lens twice as strong as the unit, with a focal length of half a metre (50 cm.), is 2 dioptries (2 D.), a lens of ten times the strength, or one tenth of a metre focus (10 cm.), is 10 D., and so on. The weakest lenses are .25, .5, and .75 D., and numbers differing by .5 or .25 D. are also introduced between the whole numbers. A slight inconvenience of the metrical dioptric system is that the number of the lens does not express its focal length. This, however, is obtained by dividing 100 by the number of the lens in D.; thus the focal length of 4 D. = $\frac{100}{4} = 25$ cm. If it be desired to convert one system into the other, this can be done, provided that we know what inch was used in making the lens whose equivalent is required in D. The metre is equal to about 37" French and 39" English or German; a lens of 36" French (No. 36 or $\frac{1}{36}$ old scale), or of 40" English or German (No. 40 or $\frac{1}{40}$), is very nearly the equivalent of 1 D. A lens of 6" French ($\frac{1}{6} = \frac{6}{36}$) will therefore be equal to 6 D.; a lens of 18" French ($\frac{1}{18} = \frac{2}{36}$) = 2 D., &c.; a lens of 4 D. = $\frac{4}{36} = \frac{1}{9}$, *i. e.* a lens of 9" French, &c.

The following lenses are used for spectacles, and are, therefore, necessary in a complete set of trial glasses. The first column gives the number in D., the second the focal length in centimetres, the third the approximate numbers on the French inch scale, the denominator of each fraction showing the focal length in French inches. It will be seen that some metrical lenses have no exact equivalents on the inch system.—In this table, and throughout the book, convex lenses are indicated, according to custom, by the + sign; concave lenses by the — sign.

Prisms are numbered by their angle of refraction, which is (p. 3) about double the angle of deviation; another method is to name the prism by the number of degrees of deviation which it produces; to indicate that degrees of

deviation are meant the letter *d* should be used ; thus prism 2° *d* indicates that the prism produces a deviation of 2° (Maddox). Prisms cannot be used as spectacles of a greater strength than about 4° *d* in each eye on account of the dispersion of light which they produce.

1. D. (Dioptries).	2. Focal length in cm.	3. No. and Focal Length in Paris inches.
0.25.....	400
0.5	200	$\frac{1}{7.2}$
0.75.....	133	$\frac{1}{5.0}$
1.	100	$\frac{1}{3.6}$
1.25.....	80	$\frac{1}{3.0}$
1.5	66	$\frac{1}{2.4}$
1.75.....	57	$\frac{1}{2.2}$
2.	50	$\frac{1}{1.8}$
2.25.....	44	$\frac{1}{1.6}$
2.5	40	$\frac{1}{1.4}$
2.75.....	36	$\frac{1}{1.3}$
3.	33	$\frac{1}{1.2}$
3.5	28	$\frac{1}{1.0}$
4.	25	$\frac{1}{9}$
4.5	22	$\frac{1}{8}$
5.	20	$\frac{1}{7}$
5.5	18
6.	16	$\frac{1}{6}$
7.	14	$\frac{1}{5.2}$
8.	12.5	$\frac{1}{4}$
9.	11	$\frac{1}{4}$
10.	10	$\frac{1}{3.2}$
11.	9
12.	8.3	$\frac{1}{3}$
13.	7.7
14.	7	$\frac{1}{2.4}$
15.	6.7	$\frac{1}{2.2}$
16.	6.2	$\frac{1}{2.1}$
18.	5.5	$\frac{1}{2}$
20.	5



CHAPTER II

EXTERNAL EXAMINATION OF THE EYE

(1) To detect *irregularity of the corneal surface*; the patient faces the window and follows with his eyes an object, *e. g.* the uplifted finger, held about 18" from him and moved slowly in different directions. The image of the window reflected from the cornea will become distorted or broken as it passes over any irregularity, such as an abrasion or ulcer. Loss of surface of the corneal epithelium may be easily demonstrated by placing a drop of a solution of fluoresceine into the eye; this stains the surface from which the epithelium is removed, but leaves the rest of the cornea clear.

(2) To estimate the *tension of the eyeball* (T.); the patient looks steadily down, and gently closes the eyelids; the observer then makes light pressure on the globe through the upper lid, alternately with a finger of each hand as in trying for fluctuation, but much more delicately. The finger-tips are placed very near together, and as far back over the sclerotic as possible, not over the cornea. The pressure must be gentle, and be directed vertically *downwards, not backwards*. It is best for each observer to keep to one pair of fingers, not to use the index at one time and the middle finger at another. Patient and observer should always be in the same relative position, and it is best for both to stand and face one another. Always compare the tension of the two eyes. Be sure that the eye does

not roll upwards during examination, for if this occur a wrong estimate of the tension may be formed. Some test both eyes at once with two fingers of each hand. Normal tension is expressed by T. n. Recognisable increase and decrease are indicated by the + or - sign, followed by the figure 1, 2, or 3. Thus T. + 1 means decided increase; T. + 2, greater increase, but the eye can still be indented; T. + 3, eye very hard, cannot be indented by moderate pressure; T. - 1 - 2 - 3 indicate successive degrees of lowered tension. A note of interrogation (T. ? + or ? -) for doubtful cases, and T. n. for the normal, give nine degrees which may be usefully distinguished. Even good observers sometimes differ as to the minor changes of tension. Apart from variations in delicacy of touch it is to be remembered that eyes deeply set in the orbits are more difficult to test, and that T. in a few cases really does change at short intervals, *e. g.* within half an hour. Increase in the rigidity of the sclerotic, which often occurs in old age; or in its thickness, as the result of disease, may increase the apparent tension, though the internal pressure may be normal or even too low. When an eye contains bone it feels like wood covered with wash-leather.*

(3) *The field of vision* (F.) (properly, of *indirect vision*) is the entire surface from which, at a given distance, light reaches the percipient part of the retina, the eye being stationary (Fig. 21). If each part of the field be equidistant from the part of the retina to which it corresponds, the field will be hemispherical, with its inner or concave surface towards the eye; it may, however, be projected on to a flat surface, and for many clinical purposes this is sufficient. For roughly testing the field, *e. g.* in a case of chronic glaucoma, or of atrophy of optic nerve, or of hemianopsia, the following is

* Plates of bone, sometimes joined so as to form a cup, are not uncommonly found on the inner (retinal) surface of the choroid in eyes which have been long blind from irido-choroiditis.

generally enough. Place the patient with his back to the window; let him cover one eye, and look steadily at your eye or nose, as a centre, from a distance of 18" or 2'. Then hold up your hands with the fingers spread out in a plane with your face, and ascertain the greatest distance from the central point at which they remain visible when moved in

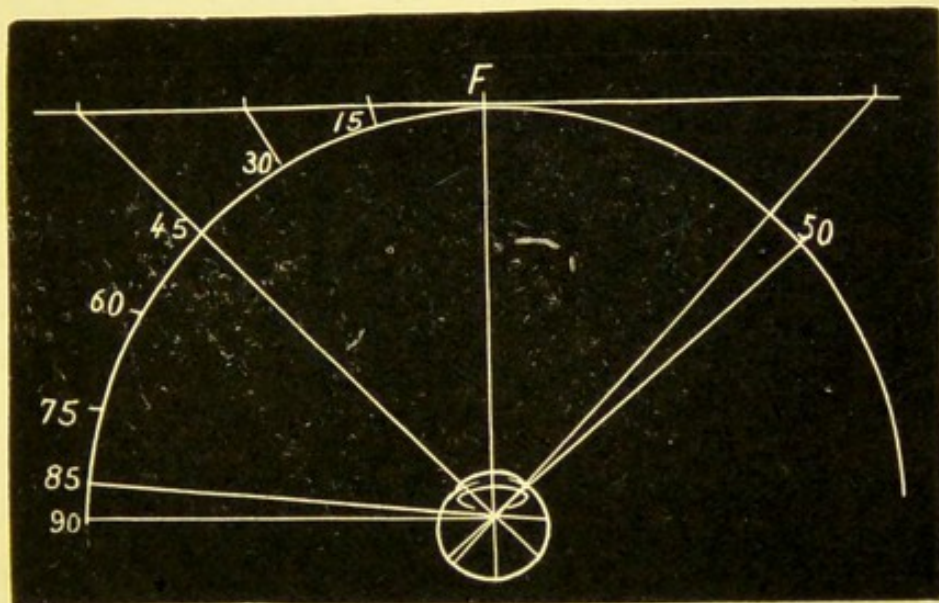


FIG. 21.—Field of vision with radius of 12", projected up to 45° on to a flat surface two feet square. F, fixation spot.

various directions—up, down, in, out, and diagonally. The patient must look steadily at the face, and *not allow his eye to wander* after the moving fingers.

A more exact method is to make the patient gaze, with one eye covered, at a white mark (the "fixation spot") on a large black-board at a distance of 12" or 18", and to move a piece of white chalk set in a long black handle, from various parts of the periphery towards the fixation spot, until the patient exclaims that he sees something white. If a mark be made on the board at about eight such peripheral points, a line joining them will give, with fair accuracy, the boundary of the visual field if this be not larger than 45° in any direction; but beyond that angle the object, if on a flat surface, will be much too far from the eye to make the

test accurate (*see* Fig. 21). A true map, unless the field be much contracted, can be made only by means of an instrument, the perimeter, which consists essentially of an arc marked in degrees, and moveable around a central pivot on which the patient fixes his gaze. Thus measured the field covers a somewhat oval portion of the hemisphere, the smaller

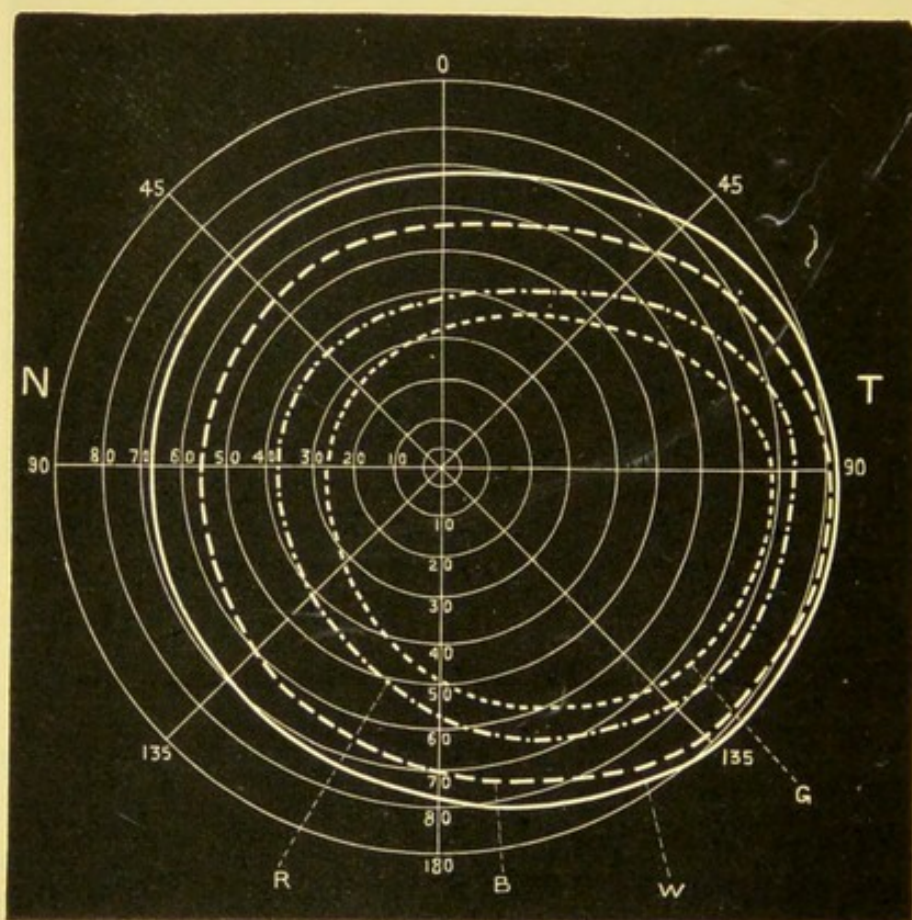


FIG. 22.—Field of vision of right eye as projected by the patient on the inner surface of a hemisphere, the pole of which forms the object of regard (half-diagrammatic). T, temporal, N, nasal side. W, boundary for white; B, for blue; R, for red; G, for green. (Landolt.)

end being upwards and inwards (Fig. 22). From the fixation point it extends 90° or more in the outward direction, but only about 65° or rather less inwards, upwards, and downwards. The visual fields of the two eyes overlap only

at their inner and central parts, so that binocular vision is impossible in the outer part of the field (Fig. 23).

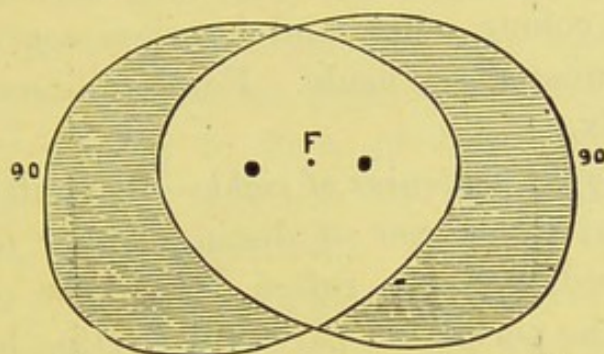


FIG. 23.—Binocular field of vision. The white part is the portion common to the two eyes, *i.e.* possessing binocular vision; the shaded (temporal) part shows the portion in which binocular vision is wanting. F. Fixation point. The two blind spots are marked by round spots. (Simplified, after Förster.)

(4) *Colour perception* is best expressed by the power of discriminating between various colours without naming them. The best test-objects are a series of skeins of coloured wool, or, for pocket use, smaller strips of coloured paper, or coloured stuffs. A colour-blind person will expose his defect by placing together, or “confusing” as similar, certain colours, usually mixed tints, which to the normal eye appear quite different. The set of wools now in common use was introduced by Professor Holmgren, of Upsala (*see* Appendix). Acquired colour-blindness (from atrophy of the optic nerves) may often be detected quite well by asking the names, if the patient has been well trained in colours. But for the congenitally colour-blind the “confusion test,” without names, is far better: first, because such persons can often distinguish ordinary coloured objects from one another by differences of *shade* (*i.e.* by differences in the quantity of white light which they reflect), and hence they escape detection unless tested with a large series of different colours in many shades, some of which shades, containing equal quantities of white,

will look, to them, exactly alike; and secondly, though such persons often use the names for colours freely, the words do not convey the same meaning to them as to those with normal colour sense, and hopeless confusion results from an examination so made. For details *see* Chapter XV and Appendix.

(5) *Testing the acuteness of sight.*—By acuteness of sight (V.) is meant the power of distinguishing *form*, and, as commonly used, the term refers only to the centre of the visual field, the peripheral part of the retina having a very imperfect power of distinguishing form and size. V. varies considerably in different persons whose eyes are normal. It is said to diminish somewhat in old age, without disease of the eyes (Donders). The standard taken as normal is the power of distinguishing square letters that subtend a visual angle of five minutes (Fig. 20 and p. 14), the limbs of which are of uniform thickness, each limb subtending an angle of 1 minute (Snellen's Test Types). Rays forming so small an angle are very nearly parallel, and may be considered as coming from an object at an infinite distance. The types are made of various sizes, each being numbered according to the distance (in feet or metres) at which it subtends a visual angle of 5 minutes. Thus, No. 6 subtends this angle at 6 m., No. 3 at 3 m., No. 1 at 1 m., &c. Numerically, acuteness of vision is expressed by a fraction, of which the denominator is the number of the type D, and the numerator the greatest distance (*d*) at which it can be read, $V = \frac{d}{D}$: if No. 6 is read at 6 m. $\frac{d}{D} = \frac{6}{6}$ or 1, *i. e.* V is normal: if only No. 18 can be read at 6 m. $\frac{d}{D} = \frac{6}{18}$; if only 60, then $\frac{d}{D} = \frac{6}{60}$. Any distance greater than about 3 m. may be selected for this test; *i. e.* No. 3 read at 3 m., or No. 5 at 5 m., generally shows the same acuteness as No. 6 read at 6 m. But at distances less than 3 m. the accommodation comes into play, and the illumination is often

brighter; hence No. 1 at 1 m. ($\frac{1}{1}$) does not necessarily show the same state of sight as No. 6 at 6 m. ($\frac{6}{6}$). It is therefore best, by recording the fractions unreduced, to indicate the distance at which the test was used. For testing near vision, Snellen's types are thought by some to be practically inferior to those of Jaeger and others, in which the letters have the form and proportions found in ordinary type. (See Appendix.) If V. be very bad (less than $\frac{6}{60}$ or $\frac{1}{10}$), it may be expressed accurately enough by noting the distance at which the outspread fingers can be counted when exposed to a good light and against a dark background. Below this point we can still distinguish good from bad, or uncertain, perception of light and shade (*p. l.*), by alternately exposing and shading the eye with the hand, without touching the face.

In using the test types it is necessary to ensure that the illumination shall not fall below a certain level; it has been found by Snellen that if it be reduced below 20 metre candles * the acuteness of vision rapidly declines.

(6) *Accommodation* (Acc.) is tested clinically by measuring the nearest point (*punctum proximum, p.*) at which the smallest readable type (Snellen's .5 or Jaeger's 1) can be clearly seen. The *region* of accommodation is the space in which it is available (see Presbyopia). The *amplitude*, *power*, or *range* of Acc. is expressed in terms of the convex lens, whose focal length = the distance from the cornea † to *p.*, this being the lens which adapts V. in an eye without Acc. from the farthest point of distinct vision (*punctum remotissimum, r.*) to *p.*: thus in Fig. 24 let *p.* be at 10 cm.; if Acc. be then relaxed, *i. e.* the eye be adapted for parallel rays, the rays from *p.* will be focussed at C. F.,

* A metre candle (m.c.) is the light given by a standard candle at one metre distance (Snellen, Bowman Lecture, 1896).

† Strictly from a point about $\frac{1}{2}$ " in front of the cornea, since the glass cannot be placed upon the eyeball.

behind the retina; but V. will again be clear at 10 cm. if a lens, l , of 10 cm. focus ($= 10$ D., see p. 16) be held close

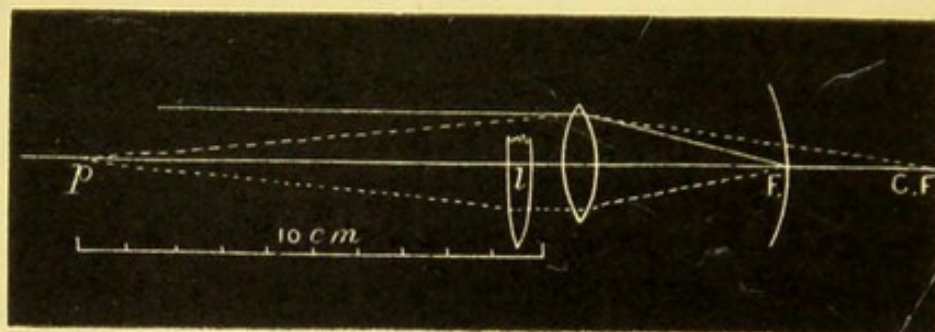


FIG. 24.—Accommodation represented by a convex lens.

to the cornea; because rays from p will be made parallel by l before entering the eye (Chap. I, §§ 11 and 12), and will therefore be focussed on the retina,

Convergence of the visual axes upon a point at any given distance is usually associated with accommodation for the same distance. The two functions can, however, be somewhat dissociated to an extent that varies with age and in different persons; *i. e.* Acc. can be either relaxed a little or increased a little, without changing any given degree of convergence; this independent portion is known as the *relative accommodation*.

(7) *The pupils* are to be examined as to their equality, size in ordinary light, mobility, and form. The pupils are often large and inactive, and sometimes oval, in amaurotic patients, in glaucoma, and in paralysis of the circular fibres of the iris (supplied by the third nerve). They may be too large, though active, in myopia and in conditions of defective nerve-tone. Wide, recent dilatation of one pupil or both, with dimness of sight but without ophthalmoscopic signs of disease, is usually traceable to atropine or belladonna, used by accident or design. When very small the pupil is seldom quite round.

The centre of the pupil usually lies a little to the nasal

side of the corneal centre.* The pupils should be round and, when equally lighted, equal in size. When one eye is shaded its pupil should dilate considerably, and on exposure contract quickly to its former size ("*direct reflex action*") : during this trial the other pupil will act, but to a much less extent ("*indirect reflex action*"). The pupils contract when the gaze is directed to a near object (say 6" distant), *i. e.* during accommodation and convergence, and dilate in looking at a distant object ; but the range of this "*associated action*" is much less than that of the reflex action. The pupil dilates when painful impressions are made on the sensory nerves of the skin, *e. g.* by the faradic brush or by pricking with a pin. The pupils may be motionless to light and shade from iritic adhesions (Chap. VIII) or from atrophy of the iris in glaucoma or other local disease ; such conditions should be carefully noted or excluded. Reflex action is lost when the eyes are blind from disease of the optic nerves or retinæ ; if only one eye be blind the direct action of the pupil is lost in that eye, but (unless there be disease of the third nerve) its indirect action is much increased. When one eye is blind the pupil is often rather larger than that of the other. Reflex action may also be lost without any affection of sight, and *without loss of associated action* (Chaps. XXI and XXIII).

Permanent inequality of the pupils without disease, either of eyes or of nervous system, is rare, but temporary dilatation of one pupil is not uncommon. When very active pupils are suddenly exposed after being shaded they often oscillate for a few seconds before settling, and finally remain a little larger than at the first moment of exposure. Considerable differences in the action of the pupils, both in *range* and *rapidity*, are compatible with health ; in general, however, the pupils become smaller, and lose both in range

* This eccentricity varies in degree and exact position in different persons. (Compare Irregular Astigmatism.)

and rapidity of action with advancing years: atropine also often causes only partial dilatation in old people. Marked inactivity, with small size, should excite suspicion of spinal or cerebral disease (Chap. XXIII). The pupils are smaller whenever the iris is congested, whether this be a merely local condition (*e. g.* in abrasion of cornea), or form part of a more general congestion, as in typhus fever* and in plethoric states, or be caused by venous obstruction, as in mitral regurgitation and bronchitis. They are large in anæmia, in conditions, such as aortic insufficiency, where the systemic arteries are badly filled, and during rigors; irritation of the sympathetic nerve in the neck is an occasional cause of mydriasis (Chap. XXI).

(8) Note the *colour of the iris*, and compare it with that of the fellow eye. Occasionally the two irides, although healthy, differ in colour, one being blue or grey, the other brown or greenish; more frequently a large sector-shaped patch of dark colour occupies part of the iris of one eye. Small pigmented spots are often seen on the iris. If the iris of an inflamed eye look greenish, that of its fellow being blue, we should suspect iritis; and if the iris of a defective eye be different from its fellow some morbid change should be suspected (Chap. VIII).

(9) Information derived from *the blood-vessels visible on the surface of the eyeball*.—Three systems of vessels have to be considered in disease; but most of them are too small to be easily seen in health. (1) The vessels proper to the conjunctiva (*posterior conjunctival vessels*), in which it is not important to distinguish between arteries and veins (Fig. 25, *Post. Conj.*, and Fig. 26). (2) The *anterior ciliary vessels*, lying in the subconjunctival tissue; their perforating arterial branches supply the sclerotic, iris, and

* The small pupil of typhus and the frequently large pupil of typhoid are ascribed by Murchison to the differences in the vascularity of the iris in these diseases. ('Continued Fevers,' p. 541.)

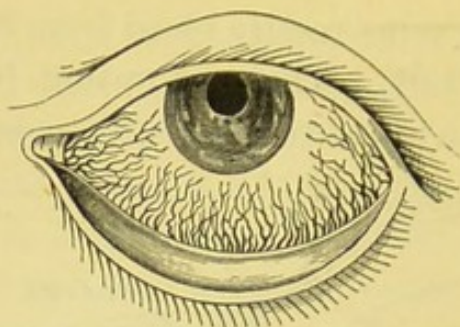


FIG. 26.—Conjunctival congestion (engorgement of the posterior conjunctival arteries and veins. (After Guthrie.)

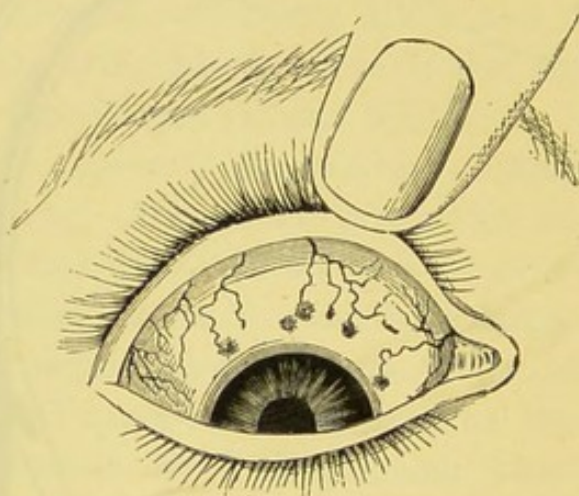


FIG. 27.—Congestion of the perforating branches of the anterior ciliary arteries. (Dalrymple.) The dusky spots at the seats of perforation are often seen in dark-complexioned persons.

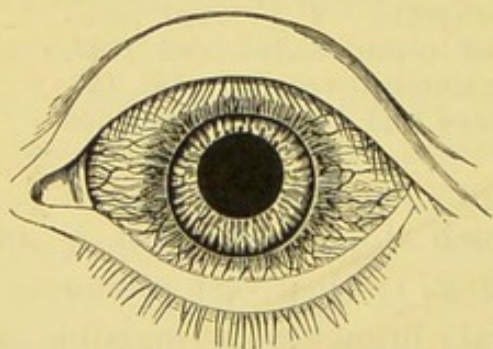


FIG. 28.—“Ciliary congestion” (engorgement of episcleral twigs of anterior ciliary arteries). (After Dalrymple.)

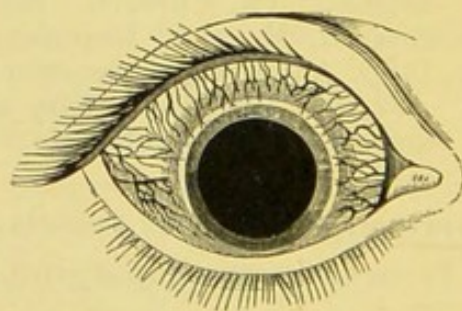


FIG. 29.—Congestion of anterior ciliary veins (episcleral venous plexus). (After Dalrymple.)

see Iritis and Diseases of Cornea); the perforating *veins* are very small, but more numerous than the perforating arteries (Fig. 25, v), and their episcleral twigs form a closely meshed network (Fig. 29). (3) The vessels proper to the margin of the cornea and immediately adjacent zone of conjunctiva (*anterior conjunctival vessels*, and their *loop-plexus on the corneal border*, Fig. 25, l, and Fig. 52); by these numerous minute branches, which are offshoots of the anterior ciliary vessels, Systems 1 and 2 anastomose.

(1) Speaking generally, congestion composed of tortuous, bright brick-red vessels moving with the conjunctiva when it is slid over the globe, and least intense just around the cornea (Fig. 26), indicates a pure conjunctivitis, and is usually accompanied by muco-purulent or purulent discharge. (2) A zone of pink congestion surrounding the cornea, and formed by small, straight, closely set, parallel vessels, radiating from the cornea, and not moving with the conjunctiva (anterior ciliary *arterial* twigs, Fig. 28), points to irritation or inflammation of the cornea, or iris. A more scanty zone of dark or dusky colour (Fig. 29), which, when severe, is finely reticulated (*Episcleral venous plexus*), often points to glaucoma, but may accompany other diseases, especially in old people. Congestion in the same region, more deeply seated, and of a peculiar lilac tint, especially if unequal in different parts of the zone, shows cyclitis or deep scleritis. (3) Congestion in the same zone also composed of small, superficially placed, bright red vessels, often encroaching a little on the cornea (*anterior conjunctival vessels* and *loop-plexus of cornea*, Fig. 52), shows a tendency to irritable corneal inflammation, which is often superficial. Localised or fasciculated congestion generally points to phlyctenular disease (Figs. 44 and 45). Although in the severe forms of all acute diseases of the front of the eye these types of congestion are usually mixed and but imperfectly distinguishable, much information

may often be derived from attention to the leading forms described.

(10) The *mobility of the eyeball* may be impaired in any or every direction, and in any degree. Commonly only one eye is affected. First, to test the lateral and vertical movements, direct the patient with both eyes open to look successively towards, or follow a pencil or finger moved in each of, the four directions, up, down, right, and left; next, to test the power of convergence he looks at the object held vertically in the middle line, rather below the horizontal, and gradually approached from 2' to about 6". In each position we must notice both eyes; thus, when the patient looks to his right we have to note the outward movement of his right and the inward movement of his left. The fixed marks for the inward and outward movements are the inner and outer canthi, and as the apparent range of movement judged in this way varies a little in different people, the corresponding movements of the two eyes should always be compared. In looking strongly outwards the corneal margin does not in all persons quite reach the outer canthus, but it should always reach the inner canthus during inward rotation. In children and stupid people the movements are often defective from inattention. In very myopic eyes the movements are somewhat defective in all directions. The vertical movements are best shown by noting the position of the cornea in relation to the border of the lower lid; the border of the upper lid is less trustworthy, since there may be some ptosis or other cause of inequality between the two sides.

The range of movement of the eye ("Field of fixation," or "Field of direct vision") can be measured on the perimeter in the same way as the ordinary field (of "indirect vision"). The test-object, *e.g.* a word of small print, moved along the various meridians from the centre towards the periphery, is followed by the eye under examination until it can no longer be read, *i.e.* until the visual axis can no

longer be directed to it. (A coarse test-object would be recognised by parts of the retina away from the yellow spot, and must, therefore, not be used.) In this way it is found that the normal range of movement of the eye extends through about 45° in each direction from the centre. The state of mobility of the eye, and the progress, in cases of ocular paralysis, may be accurately recorded in this way.*

(11) *Squint or strabismus* exists if the visual axes are not both directed to the same object. A squint may be the result either of over-action, or of weakness or paralysis of a muscle. The internal recti, by excessive contraction, often cause convergent squint; but most other forms of strabismus result from actual defect of nervous or muscular powers.

When a squint is well marked there is no difficulty in identifying the squinting eye as the one which is misdirected when an object is held up to the patient's attention: in most cases the patient always squints with the same eye, but a few persons can squint with either indifferently (*alternating squint*). Nor is there often any doubt as to whether the squint is internal (convergent) or external (divergent), *i. e.* whether the axis of the squinting eye crosses that of its fellow between the patient and the object he looks at, or crosses it beyond this object, or even positively diverges from it; upward or downward squint, though less common, is almost as evident. But to prove beyond doubt which is the squinting eye, direct the patient to look at a pencil held up in the middle line at about 18" from his face, and with a card or piece of ground glass cover the apparently sound, or "working" eye; the squinting eye will at once move so as to look at, or "fix" the pencil, proving that it had previously been misdirected. If the sound eye be watched behind the screen it will be seen to squint as soon as the affected eye "fixes" the object; this is known as the *secondary squint*, and its direction is

* For further details consult a paper by Landolt in 'Trans. Internat. Med. Congress,' 1881, vol. iii, p. 25 (London).

the same as that of the original or *primary squint*. Thus if the primary squint be convergent, the secondary will also be convergent. In squint from over-action, or from mere dis-use, of one muscle, the secondary and primary deviations are equal, but in paralytic squint the secondary often exceeds the primary. If the squinting eye retain full range of movement, *i. e.* move in companionship with its fellow in all directions, the squint is termed *concomitant*, in contradistinction to *paralytic*; hence in every case of squint it is necessary to test the mobility of the eyes. It is also important to note whether the squint is constant or only occasional (*periodic*).*

It was, until lately, usual to measure the squint (when necessary) by means of a scale placed on the lower lid and graduated in such a way as to indicate in lines (or mm.) the amount of deviation. The centre of this scale, marked zero, is placed over the centre of the lid, and therefore corresponding to the centre of the pupil if there be no squint; the number which corresponds to the centre of the pupil of the squinting eye gives the linear measurement of the deviation. A more accurate and rational method, introduced by Landolt, and known as the angular method, determines the size of the angle between the positions of the visual axis of the eye when squinting and when properly directed. In Fig. 30, L is the squinting left eye of the patient placed

* We sometimes meet with an *apparent squint*, either external or internal. The *optic* axis of the eye passes from a point rather to the inner side of the y. s. through the centre of the cornea, and forms a small angle ("angle a ") with the *visual* axis, the line which joins the y. s. to the object looked at, and which commonly cuts the cornea rather within its centre. As we judge of the apparent direction of a person's eyes by the centres of his corneæ (*i. e.* by the *optic* axes), a slight apparent outward squint will be produced if the angle, a , be (as in many hypermetropic eyes) larger than usual, and an apparent convergent squint if, as in myopia, it be smaller. Apparent squint is always slight, and the screen test described in the text gives a negative result.

at the centre of a perimeter; $L \times$, the direction of its visual axis; $L Ob$, the direction its visual axis should have;

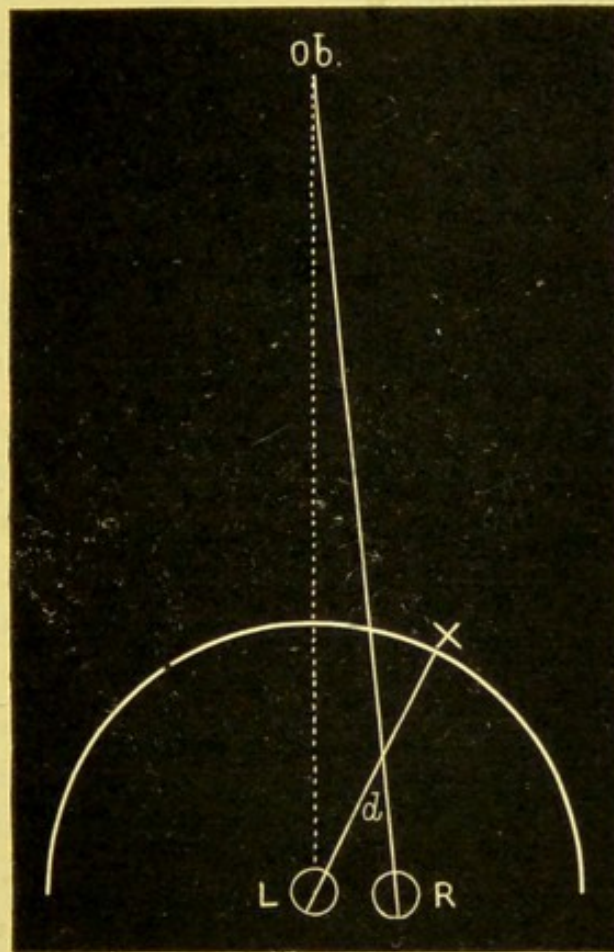


FIG. 30.—Angular measurement of squint. (After Landolt.)

Ob an object (as far off as possible) at which the patient is to look; \times a small candle flame which the observer, stationed close behind the perimeter, moves along the arc until he sees its image reflected from the centre of the squinting cornea; the size of the angle $\times L Ob$, read off on the perimeter, is nearly the same as that of the angle of deviation. A convenient method of estimating the amount of angular deviation, introduced by Hirschberg, consists in the observation of the corneal reflex from a candle or ophthalmoscope mirror held about a foot from the eye. When the eyes are properly directed, the position of the reflex occupies the centre of the pupil in each eye unless the

angle a be very large. If the eye squint inwards, the reflex falls to the outer side of the centre. The pupil being of moderate width, 3 mm., if—

- | | | |
|-----|--|-----------------------------|
| (1) | The reflex be nearer centre of p. than edge, | deviation is $< 10^\circ$. |
| (2) | „ at edge of p. | „ $12^\circ - 15^\circ$. |
| (3) | „ midway between edge of p. | |
| | and edge of C. | „ 25° . |
| (4) | „ at edge of C. | „ 45° . |

(12) *Diplopia* (*double sight*) is almost always a result of squint, and is usually most troublesome when the deviation is so slight as to be hardly perceptible. Diplopia caused by squint is of course binocular, and disappears when one eye is covered. Unocular diplopia (double sight with one eye), however, often occurs in commencing cataract, and sometimes in healthy but astigmatic eyes; it has also been met with in some cases of cerebral tumour. In the former cases it has a physical cause in the crystalline lens (*see* Cataract); in the latter it must depend upon some psychical change.

To find out what defect of movement is causing binocular diplopia, darken the room, and ask the patient to follow with his eyes a lighted candle, held about 6' from him, moved successively into different positions, and to describe the relative places of the double images in each position. Ascertain which of the two images belongs to each eye by placing before one eye a strongly coloured glass, or by covering one eye and asking which image disappears. In many cases the image formed in the squinting eye (the "false" image) is less bright or distinct, and this difference gives a valuable means of distinguishing the sound from the affected eye; but the patient does not always notice a difference between the two images, and there may then be difficulty in proving which eye is at fault. The patient's replies may be recorded on such a diagram as Fig. 120; other radii may of course be added for intermediate positions; the false image is marked by the dotted line, the true

one by the unbroken line. With this graphic representation of the candle as it appears to the patient, we can deduce from the apparent position of the false image what movements of the corresponding eye are at fault, and consequently, which muscle or muscles are defective. It is *essential that the patient should not move his head* during the examination, and that he remain throughout at the same distance from the candle. Remember that, in the extreme lateral movements, the nose eclipses one image. When the double images are very wide apart, *i. e.* when there is much squint, the patient often fails to notice the false image.

For the diagnosis of a case of diplopia it is often sufficient to ask in which directions the double sight is most troublesome, and how the images appear in respect to height, lateral separation, and apparent distance from the patient (Chap. XXI).

(13) *The apparent size* of an object depends, in the first place, on the size of its *retinal image*, and this, as already shown (§ 19, p. 12), depends upon (*a*) the size of the visual angle, and (*b*) the distance of the retina from the nodal point. It is clear that in Fig. 20 a smaller object placed nearer to the eye or a larger one placed further off might subtend the same angle as Ob, and therefore have a retinal image of the same size. There are, however, other factors contributing to our estimate of the size of objects, especially contrast of light and shade, estimation of distance, and effort of accommodation.

A white object on a black ground looks larger than a black object of the same size on a white ground. The further off an object is judged to be, the larger does it look.* The greater the accommodative *effort* used, whatever may be the distance of the object, the smaller does it

* Apparent distance is also influenced by the colour of the object. The chromatic aberration of the eye is said to afford the explanation, rays of different refrangibilities being focussed on slightly different parts of the retina.

appear; thus patients whose eyes are partly under the influence of atropine, and presbyopic persons whose glasses are too weak, complain that near objects, if looked at intently for a short time, become much smaller; whilst when one eye is under the action of eserine (causing spasm of the accommodation) objects appear larger than if held at the same distance from the other eye. Prisms with their bases towards the temples seem to diminish objects seen through them by necessitating excessive convergence of the eyes (the converse of Fig. 16).

(14) *Protrusion (proptosis) and enlargement of the eye.*—Unequal prominence of the two eyes is best ascertained by seating the patient in a chair, standing behind him, and comparing the summits of the two corneæ with each other, and with the bridge of the nose, or the line of the eyebrows. It can also be ascertained by placing the straight edge of a card from the eyebrow to the prominence of the cheek below the eye, and measuring the distance of the cornea from the card on the two sides. The appearance of prominence or recession, as seen from the front, depends very much on the quantity of sclerotic exposed; thus, slight ptosis gives a sunken appearance to the eyes, and in slight cases of Graves's disease the proptosis seems to increase when the upper lids are spasmodically raised. It is to be remembered that real prominence of the eye may depend on enlargement of the eyeball (myopia, staphyloma, intraocular tumour), as well as on its protrusion, and that if only one eye be myopic, the appearance will be unsymmetrical. Decided proptosis may follow tenotomy or paralysis of one or more ocular muscles. In hypermetropia, in which the eyeball is too short, and in the cases of paralysis of the cervical sympathetic, the eye often looks sunken.

(15) *The uses of prisms* have been explained at p. 9.

(16) Examination by *focal illumination* is described in Chap. III.

CHAPTER III

EXAMINATION OF THE EYE BY ARTIFICIAL LIGHT

THIS includes (1) examination by focal or oblique light ;
(2) examination by the ophthalmoscope.

(1) In using *focal, oblique, or lateral illumination* the anterior parts of the eye are examined with the light of a lamp concentrated by a convex lens. The method is used to detect or examine opacities of the cornea, changes in the appearance of the iris, alterations in the outline and area of the pupil from iritis, and opacities of the lens. Such an examination is to be made by routine in every case before using the ophthalmoscope. We require a somewhat darkened room, a convex lens of two or three inches focal length (one of the large ophthalmoscopic lenses), and a bright, naked lamp-flame.

The patient is seated with his face towards the light, which is at about 2' distance. The lens, held between the finger and thumb, is used like a burning-glass, being placed at about its own focal length from the patient's cornea, and in the line of the light, so as to throw a bright pencil of light on the front of the eye at an angle with the observer's line of sight. Thus all the superficial media and structures of the eye can be successively examined under strong illumination, the distance of the lens being varied a little, according as its focus is required to fall on the cornea, the iris, or the anterior or posterior surface of the crystalline lens (Fig. 31). By varying the position of the light and of the

patient's eye, making him look up, down, and to each side, we can examine all parts of the corneal surface, of the iris, of the pupillary area (*i. e.* the anterior capsule of the lens), and of the lens substance.

If the light be thrown at a very acute angle on the cornea or lens, opacities are much more visible than if it fall almost perpendicularly. By habitually magnifying the illuminated parts by a second lens held in the other hand, much additional information can be gained.

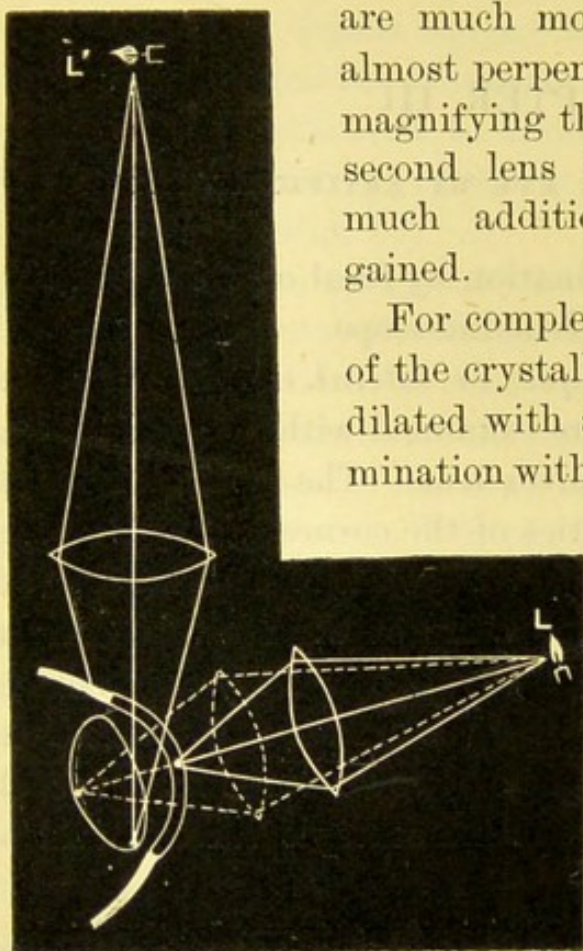


FIG. 31.—Focal illumination.

For complete exploration of all parts of the crystalline lens the pupil must be dilated with atropine, but careful examination without atropine will generally

enable us to detect opacities lying in or near the axis of the lens even if deeply seated. In examining the posterior pole of the lens the light must be thrown almost perpendicularly into the pupil, and the observer must place his

eye as nearly in the same direction as is possible without intercepting the incident light. Opacities of the cornea and anterior layers of the lens appear whitish, deep opacities in the lens, especially in old people, look yellowish, by focal light. Tumours, large opacities in the vitreous, and retinal detachments may be seen by this method if they lie close behind the lens. Minute foreign bodies in the cornea will often be seen by focal light when invisible, because covered by hazy epithelium, in daylight.

(2) *Ophthalmoscopic Examination*

The ophthalmoscope enables us to see the parts of the eye behind the crystalline lens, by making the observer's eye virtually the source of illumination for the observed eye. Rays of light entering the pupil in a given direction are partly reflected back by the choroid and retina, and on emerging from the pupil take the same or very nearly the same course that they had on entering (p. 5, § 12). Hence the eye of the observer, if so placed as to receive these returning rays, must also be so placed as to cut off the entering rays; as, therefore, no light can enter in the necessary direction, none can return to the observer's eye. This is why the pupil is usually black. Although with a large pupil, especially in a hypermetropic or myopic eye, the observer receives some of the returning rays (because he does not intercept all the entering light), and in this way sees the pupil of a fiery red instead of black, still for any useful examination the observer's eye must, as already stated, be in the central path of the entering (and emerging) rays. This end is gained by looking through a small hole in a mirror, by which light is reflected into the patient's pupil, and this perforated mirror is the ophthalmoscope. There are two ways of seeing the deep parts of the eyeball by this means.

A. *The indirect method* of examination, by which a clear, real, inverted image of the fundus, somewhat magnified, is formed in the air between the patient and the observer.

The fundus of the eye seen on this principle is magnified about five diameters, if the eye be normal. The image is larger in H and smaller in M. b. Notice that if the observer's head be moved slightly from side to side, the image will appear to move in the opposite direction.

B. *The direct method* of examination, by which (except when the eye is myopic) a virtual erect image is seen, more

magnified than in the former method and situated behind the patient's eye.

The emmetropic eye, with the accommodation fully relaxed, is adjusted for distant objects, *i. e.* parallel rays, and receives a clear image of such objects on the layer of rods and cones of the retina (p. 12). A clear image of the *fundus of the eye*, *i. e.* the retina, optic disc, and choroid, can be obtained in such an eye on condition that the eyes, both of patient and observer, be adjusted for infinite distance, *i. e.* for parallel rays; in other words, that the accommodation of both be relaxed. The fundus so seen is magnified about 20 diameters.

In order to use the ophthalmoscope * it is first necessary to learn to manage the mirror and light. (1) Seat the patient in a darkened room and place a lamp with a large, steady, naked flame on a level with his eyes, a few inches from his head, and about in a line with his ear. The lamp may be on either side, but is usually placed on his left, and it is better to keep to the same side until practice has given steadiness to the various combined movements which are necessary. (2) Sit down in front of the patient with his face fronting your own, feature to feature. It is most convenient for the observer's face to be a little higher than that of the patient. (3) Take the mirror of the ophthalmoscope (without any lens behind, and without the large lens) in your left hand for examining the patient's left eye (and *vice versa* for his right eye), hold it, mirror towards the patient, close to your own eye, and with the sight-hole placed so that (with your other eye closed) you see the patient through it. Now rotate the mirror slightly towards the lamp until the light reflected from the flame is thrown into the patient's pupil, and open your other eye. (4) You will so far have seen nothing except the front of the patient's eye, unless atropine have been used, for he will

* For choice of instruments see Appendix.

have looked at the centre of the mirror, and his pupil, strongly contracted, will look either black or very dull red. (5) Now tell him to look steadily a little to one side, into vacancy, or at an object on the other side of the room. The pupil will now become red—bright fiery red if it be rather large; a duller red if it be small or the patient's complexion be dark. In one position, when the eye under examination looks a little inwards, the red will change to a yellowish or whitish colour, and this indicates the position of the optic disc. (6) Learn to keep the light steadily on the pupil, during slow movements backwards and forwards and from side to side (taking care that the patient keeps his eye all the time in the same position, and does not follow the movements of the mirror); the test of steadiness will be that the pupil remains of a good red colour in all positions. Up to this point the examination may be made without atropine; and so far only a uniform red glare will have been seen, no details of the fundus being visible, unless the patient be either myopic or considerably hypermetropic.

In order to see the details of the fundus it is best to begin by learning the *Indirect Method* (Fig. 32), for, though rather less easy, it is more generally useful than the direct.

Take the mirror without any lens behind it in one hand * and one of the large convex "objective" lenses corresponding to *l* in the other. Always, if possible, have the pupil dilated with atropine, for by this means you learn to see the fundus much more quickly and easily. In examining the patient's right eye apply the mirror with your right hand to your right eye, holding the lens in your left hand; it is best to reverse everything for his left eye, but

* But many learn to see the image more quickly and easily by placing a convex lens of 4 D. behind the mirror. If the observer wears glasses for reading he should wear them, or put a lens of the same strength behind the mirror, for the indirect examination.

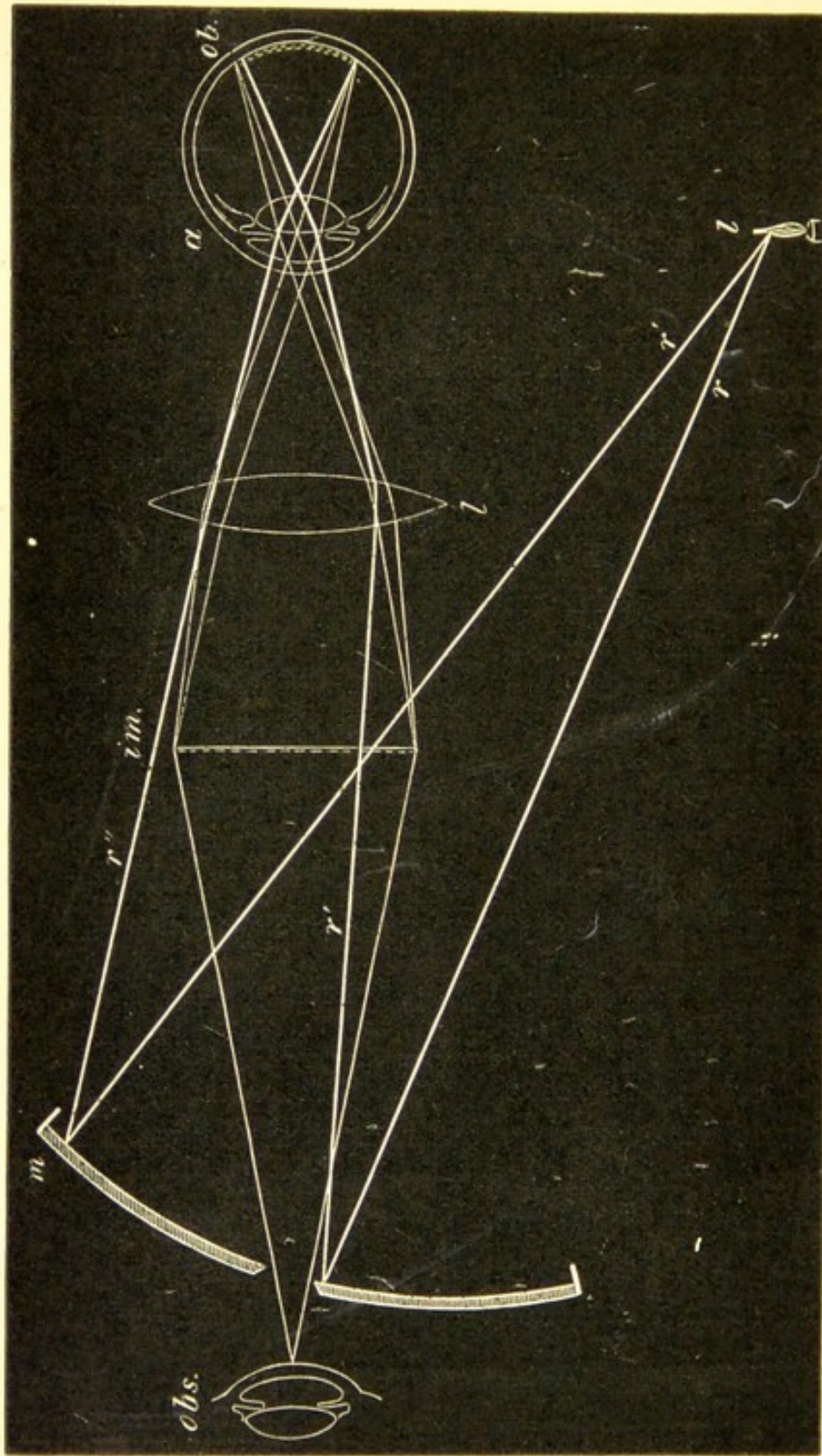


FIG. 32.—Ophthalmoscopic examination by the "indirect method." The thick lines r, r' , rays from the lamp, are reflected from the mirror m , in the directions r', r'' , traverse the lens l , and are focussed in front of the retina ob , on which they therefore throw a diffused light. From the fundus thus lighted, pencils of rays (shown by thin lines) are given off, which emerge from the eye parallel and form a clear inverted image, im , at the focus of the lens l ; this image is viewed through the sight-hole by the observer obs . The distance between obs and im is about 10", and from im to a about 5".

the position of the light need not be changed. The hand which carries the lens should be steadied by resting the little or ring finger against the patient's brow or temple.

We usually begin by looking for the optic disc, which is one of the most important and easily seen parts. As the disc lies to the nasal side of the posterior pole of the eye, the cornea must be rotated a little inwards, *i. e.* the back of the eye outwards, in order to bring the disc opposite the pupil, when the observer is immediately in front; the right eye, *e. g.*, must be directed to the observer's right ear, or to the uplifted little finger of his mirror hand. The patient must turn his eye, not his head, in the required direction. The lens should be held about 2"—3", and the observer's eye be about 15", from the patient's eye; the image of the fundus being formed in the air 2" or 3" in front of the lens will thus be situated about 10" from the observer.

The bright red glare (from the *choroid*) will be obvious enough; but most beginners find some difficulty in avoiding the reflection of the light from the patient's cornea, and in adjusting the accommodation and the distance of the head, so as to see the image clearly. The head must be slowly moved a little further from or nearer to the patient, and at the same time an attempt made to adjust the eyes (both being kept open) for a point between the observer and the lens. As a rule the disc and retinal vessels are seen clearly at the first sitting.

The *optic disc*—ending of the optic nerve in the eye above the lamina cribrosa, *optic papilla* (Figs. 33 and 35)—is round, well defined, much lighter in colour than the fiery red of the surrounding fundus, and numerous blood-vessels are seen to radiate from its centre, chiefly upwards and downwards. As soon as the disc can be easily seen the student must pass on to the study of the most important details of this part itself, and of the other parts of the

fundus. Some of these will be described here and others in the chapters on the Diseases of the Choroid and Retina, and on the Errors of Refraction.

The disc, as a whole, is greyish pink in colour with an admixture of yellow. It is nearly circular, but seldom perfectly so, being often apparently oval or slightly irregular. Two differently coloured parts are noticeable—a central patch, whiter than the rest, into which most of the blood-vessels dip; and a surrounding part of pink or greyish pink. In many eyes, especially in old persons, we distinguish a third part, a narrow boundary line of lighter colour, which represents the border of the sclerotic (*scleral ring*) (Fig. 33). The blood-vessels consist of several large trunks and a varying number of small twigs; the large trunks emerge from the central white part of the disc, and often bifurcate once or twice on its area; the small twigs may emerge separately from various parts of the disc, or form branches of the large trunks.

Variations.—The colour of the disc appears paler or darker according to the colour of the surrounding choroid, the brightness of the light used, and the patient's age and state of health. A curved line of dark pigment often bounds a part of the circumference of the disc (Fig. 35), and has no pathological meaning. The central white patch varies greatly in size, position, and distinctness; it may be so small as hardly to be perceptible, or very large; may shade off gradually or be abruptly defined; may be central or eccentric; when large it generally shows a greyish stippling or mottling (Fig. 35). This central white patch represents a hollow, the *physiological cup* or *pit* (compare Figs. 35 and 36), left by the nerve-fibres as they radiate out from the centres of the disc towards the retina, like the tentacles of an open sea-anemone; and through it the chief blood-vessels pass on their way between the nerve and the retina. This depression is generally shaped like a funnel

or a dimple with gradually sloping sides (Fig. 36); but sometimes the sides are steep, or even overhanging; in other eyes it is wide, shallow and enlarged towards the outer side of the discs. The physiological pit is whiter than the rest of the disc, because the greyish-pink nerve-fibres are absent at this part, and we can therefore see down to the opaque, white, fibrous tissue which, under the name of *lamina cribrosa*, forms the floor of the whole disc (Fig. 36). The stippled appearance often noticed in the pit is caused by the holes in this lamina, through which the bundles of nerve-fibres pass on their way to the retina; the holes appear darker because filled by non-medullated nerve-fibres, which reflect but little light.

The other parts of the fundus.—The groundwork is of a bright fiery red (the choroid, *not the retina*); in many eyes this colour is nearly uniform, but in persons of very light or very dark complexion we see a pattern of closely set, tortuous, red bands (vessels of the choroid), separated by

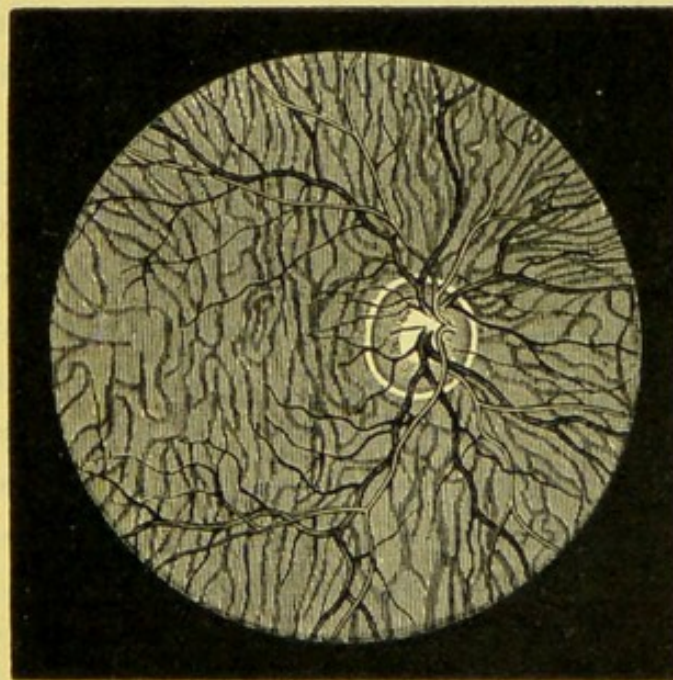


FIG. 33.—Ophthalmoscopic appearances of healthy fundus in a person of very fair complexion. Scleral ring well marked. Left eye, inverted image. (Wecker and Jaeger.)

spaces either of darker or of lighter colour (Fig. 33). (For details *see* Chap. XII.)

Upon this red ground the vessels of the retina divide and subdivide dichotomously. It will be noticed that the chief trunks pass almost vertically upwards and downwards, and that no large branches go to the part *apparently* inwards from the disc (to the left in the figure); that the visible retinal vessels are comparatively few and are widely spread; that they become progressively smaller as they recede from the optic disc; and that they never anastomose with each other. Special attention must be given to the part, apparently to the inner (nasal) side of the optic disc (really to its outer, temporal side), which is the region of most accurate vision, the yellow spot (y. s., *macula lutea*, or shortly "macula"). In this region, which comes into view when the patient looks straight at the ophthalmoscope, the choroidal red is duller and darker than elsewhere. It is skirted by large retinal vessels which give off numerous twigs towards its centre, though none of them can be seen quite to reach that point (compare Fig. 78, Chap. XIII). In many eyes nothing but these indefinite characters marks the y. s.; but in some, especially in dark eyes and young patients, a minute bright dot occupies its centre, and is encircled by an ill-bounded dark area, round which again a peculiar, shifting, white halo is seen. The minute dot is the *fovea centralis*, the thinnest part of the retina. The neighbourhood of the disc and y. s. forms the *central region* of the fundus. The *peripheral parts* are explored by telling the patient to look successively up, down, and to each side, without moving his head. To see the extreme periphery the observer must move his head as well as the patient his eye. Towards the periphery the choroidal trunk-vessels are often plainly visible even when none are distinguishable at the more central parts.

The vessels of the retina are easily distinguished from

those of the choroid by their course and mode of branching ; by the small size of all except the main trunks ; by their sharper outline and clearer tint ; but especially by the presence of a light streak along the centre of each (Fig. 33), which gives them an appearance of roundness, very different from the flat band-like look of the choroidal vessels. They are divisible into two sets : a darker, larger, somewhat tortuous set—the veins ; and a lighter, brighter red, smaller, and usually straighter set—the arteries ; the diameter of corresponding branches being about as 3 to 2. The arteries and veins run pretty accurately in pairs. Pressure on the eyeball, through the upper lids, causes visible pulsation of the arteries on the disc.

The indirect method of examination is most generally useful, because it gives a large field of view under a low magnifying power (about five diameters), and thus allows us to appreciate the general character and distribution of any morbid changes better than if we begin with the direct method, in which the field of view is smaller and the magnifying power much greater. It has also the great advantage of being equally applicable in all states of refraction, whereas if the patient be myopic his fundus cannot be examined by the direct method without the aid of a suitable concave lens, found experimentally, placed behind the mirror (p. 53). The inversion of the image seen by the indirect method is such that what appears to be upper is lower, and what appears to be R. is L.

In the *Direct Method* the examination is made by the mirror alone, or with a lens behind it, but without the intervention of the objective lens.

By this method the parts (unless the eye be myopic) are seen in their true position (Fig. 34), the upper part of the image corresponding to the upper part of the fundus, the right to the right, &c. : it is therefore often called the method of the “erect” or “upright” image ; though, as

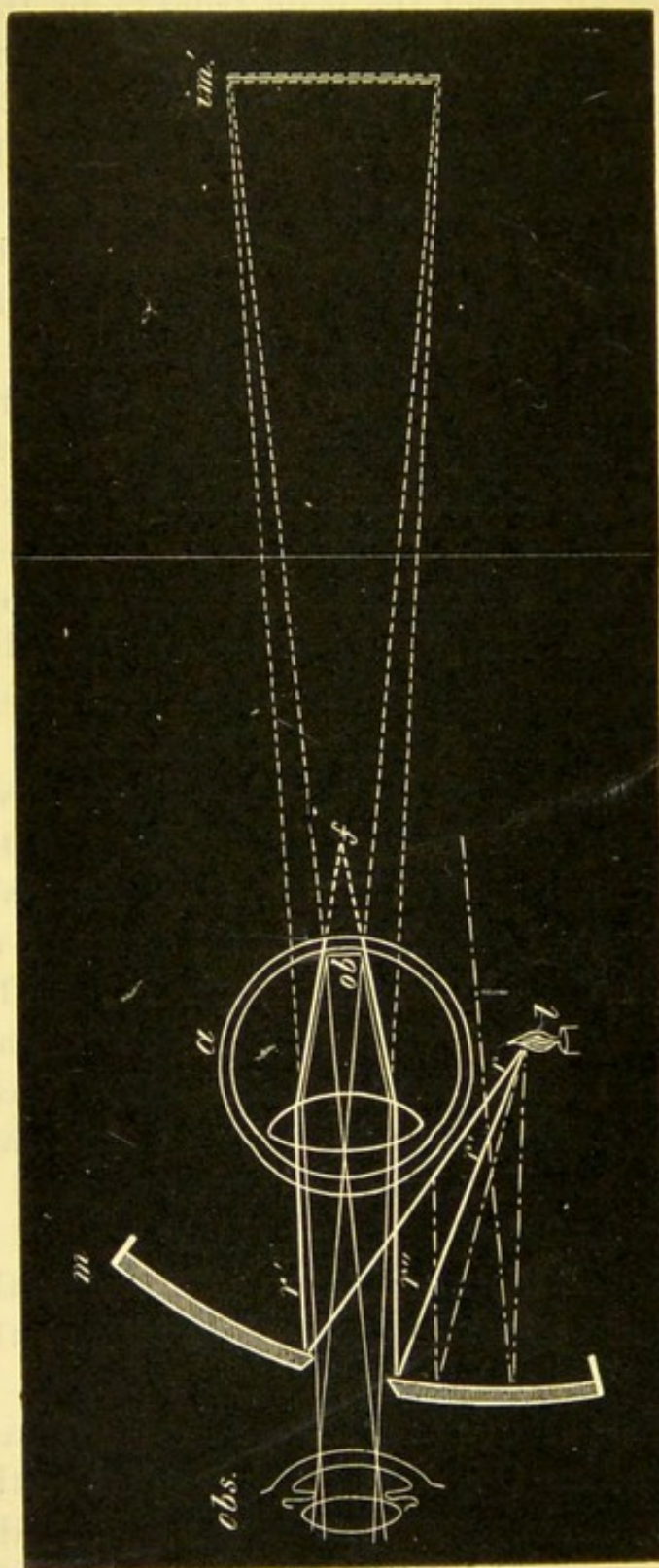


FIG. 34.—Examination of virtual erect image ("direct method"). Lettering as in Fig. 32. The rays r' , r'' entering the eye divergent would be focussed behind the retina as at f , and hence illuminate the fundus diffusely. The returning pencils (thin lines) are parallel or divergent (according as the eye is E. or H.) on leaving the eye, and appear to proceed from a highly magnified erect image im' , behind the eye. It is seen that only those lamp-rays which strike close to the sight-hole are available; if the hole be too large no rays will enter the pupil, and the fundus will not be illuminated.

will be seen below, these terms are not strictly convertible with "direct examination." It is used—(1) To test the action of the pupils in direct fixation; (2) To detect opacities in the media, or detachment of the retina; (3) To determine the fixation power by observing the corneal reflex; (4) To ascertain the condition of the patient's refraction, *i. e.* the relation of his retina to the focus of his lens-system; (5) For the minute examination of the fundus by the highly magnified, virtual, erect image (Fig. 35).

(1) The patient should be directed to look at the sight-hole of the mirror, and the light should be turned alternately on and off the eye; the change in shape and size of the pupil will then be seen as the light falls on the yellow spot.

(2) To examine the media, the patient should move his eyes freely in different directions while the light is thrown into the pupil from a distance of about 12 inches. Detachments of the retina may then be seen, as well as opacities in the cornea, lens, and vitreous. These latter will appear black against the red background of the eye. For more careful examination of fine opacities, a strong convex lens is placed behind the mirror, and the observer draws nearer to the patient.

(3) This method, attention to which was called by Priestley Smith, is practised in the following way. The patient is told to look at the mirror; the observer turns the light on one of the patient's eyes, and notices the exact position of the light reflex from the surface of the cornea; he then quickly turns the light to the other eye, and compares the position of the corneal light reflex in the two eyes. The corneal reflex generally stands a little nearer the inner than the outer edge of the pupil, as the visual axis usually lies to the inner side of the axis of the cornea; if both eyes be properly directed the position of the corneal

reflex will be symmetrical in the two eyes. In this way imperfect fixation or strabismus will be readily detected.

(4) To ascertain the refraction: if, when using the mirror alone at a distance of 12"—18", or more, from the patient's eye, we see some of the retinal vessels clearly and easily, the eye is either myopic or hypermetropic. If, when the observer's head is moved slightly from side to side, the vessels seem to move in the same direction, the image seen is a virtual one and the eye hypermetropic. The eye is myopic if the vessels seem to move in the contrary direction; the image in M. is, indeed, formed and seen in the same way as the inverted image seen by the "indirect" method of examination (compare Figs. 32 and 104), but except in the highest degrees of M. it is too large and too far from the patient to be useful for detailed examination. In low degrees of M. this image is formed so far in front of the patient's eye as to be visible only when the observer is distant perhaps 3' or 4'; whilst in E. and in the lower degrees of H. the (erect) image will not be easily seen at a greater distance than 12" or 18" (Fig. 14).—If, therefore, in order to get a clear image by the direct method, the observer has to go either very near to, or a long way from, the patient, no great error of refraction can be present.

The above tests only reveal qualitatively the presence of either M. or H., but by a modification of the method the quantity of any error of refraction, *e. g.* H., can be determined with great accuracy.—(*Determination of the refraction by the ophthalmoscope.*)—In E. the erect image can be seen only if the observer be near to the patient, and also completely relax his accommodation; for when the observer's head is withdrawn from the patient's eye the field of view and illumination rapidly diminish, hence in E. no useful view can be gained by the direct method without going very near to the eye.

In H., where the retina is within the focus of the lens-system, the erect image is seen when close to the patient's eye only by an effort of accommodation in the observer, but it can be also seen at a distance as well as close to the patient.

If now the observer, instead of increasing the convexity of his crystalline, place a convex lens of equivalent power behind his ophthalmoscope mirror, this lens will be a measure of the patient's H., *i. e.* it will be the lens which, when the patient's accommodation is in abeyance, will be needed to bring parallel rays to a focus on his retina. If a higher lens be used, the fundus will be more or less blurred.

Hence to measure H.:—(1) Acc. both in patient and observer must be fully relaxed (usually by atropine in the patient and by voluntary effort in the observer); (2) the observer must go as close as possible to the patient; (3) must then place convex lenses behind his mirror, beginning at the weakest and increasing the strength, till the highest is reached which still permits the details of the o. d., or, better, of the y. s., to be seen with perfect clearness. By practice the distance between the corneæ of patient and observer may be reduced to about 1". The light must be on the same side as the eye under examination. The right eye must examine the right, and *vice versâ*.

In the same way, though with less accuracy in the high degrees, M. can be measured by means of concave lenses; the lowest lens with which a clear erect image is obtained being slightly more than the measure of the M.

It is sometimes useful to know how much lengthening or shortening of the eye corresponds to a given neutralising lens. The following numbers, slightly altered from Knapp, are sufficiently near the truth. The distance between the eye of the observer and that of the patient is supposed to be not more than 1 inch.

H. of	1 D.	represents shortening of	·3 mm.
„	2	„	·5 „
„	3	„	1 „
„	5	„	1·5 „
„	6	„	2 „
„	9	„	3 „
„	12	„	4 „
„	18	„	6 „
M. of	1 D.	represents lengthening of	·3 „
„	2	„	·5 „
„	3	„	·9 „
„	5	„	1·3 „
„	6	„	1·75 „
„	9	„	2·6 „
„	12	„	3·5 „
„	18	„	5 „

Astigmatism (As.) may also be measured by this method, the refraction being estimated successively in the two chief meridians by means of appropriate retinal vessels (*see* Astigmatism). Any line, *e. g.* a horizontally running vessel, is seen by means of rays which pass through the meridian of the cornea at a right angle to its course; hence if a *vertical* vessel be clearly seen through a + 2 D. lens there is H. 2 D. in the *horizontal* meridian, &c.

This application of the direct method needs much practice. The lenses, of which there are twenty or more, are so placed that they can be revolved behind the mirror and brought in succession opposite the sight-hole. There are many forms of these "refraction ophthalmoscopes," varying in the details of their construction (*see* Appendix).

(5) The erect image is very valuable, on account of the high magnifying power (about 20 diameters in the E. eye), for the examination of the finer details of the fundus. The disc looks less sharply defined, because more magnified, than when seen by the indirect method; both the disc and the retina often show a faint radiating striation (the nerve-fibres); the *lamina cribrosa* is often more

brilliantly white; and the pigment epithelium of the choroid can be recognised as a fine uniform dark stippling.

If the refraction be E. or H. no lens is needed behind the mirror; if M., a concave lens must be placed behind the mirror, of sufficient strength to give a good, clear, erect image. The observer must come as near as possible to the patient.

By reference to Fig. 34 it will be seen that only those rays are useful which strike near the centre of the mirror, none others entering the patient's pupil; hence, if the aperture in the mirror be too large the fundus will not be well lighted. It should not be larger than 3 mm., nor smaller than 2 mm.

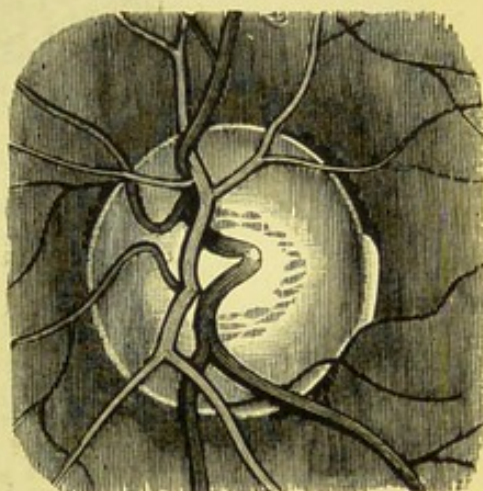


FIG. 35.—Ophthalmoscopic appearance of healthy disc, as seen in the erect image. Dark vessels, veins. Physiological pit stippled. $\times 15$ diameters. (After Jaeger.)

The Shadow Test (Retinoscopy, Skiascopy).

By this method the refraction is determined by noticing the direction of movement of the light thrown on to the retina by the mirror, when the latter is rotated. The degree of error of refraction is measured by the lens, which, placed close to the patient's eye in a case of ametropia, renders the movement and other characters of the illumination the same as in emmetropia.

The test is most accurate when used at a great distance from the patient; in practice a distance of about 1 m. (100—120 cm. or 3'—4') is chosen. The observer, seated in front of his patient, throws the light from an ophthal-

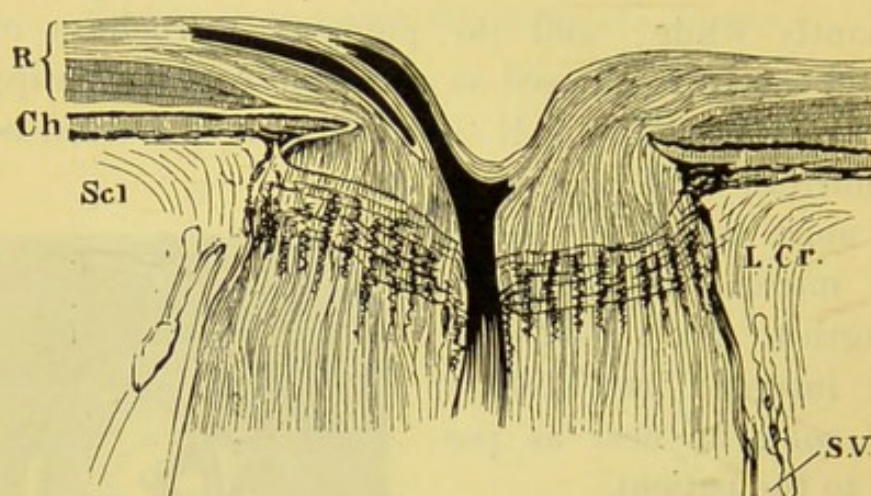
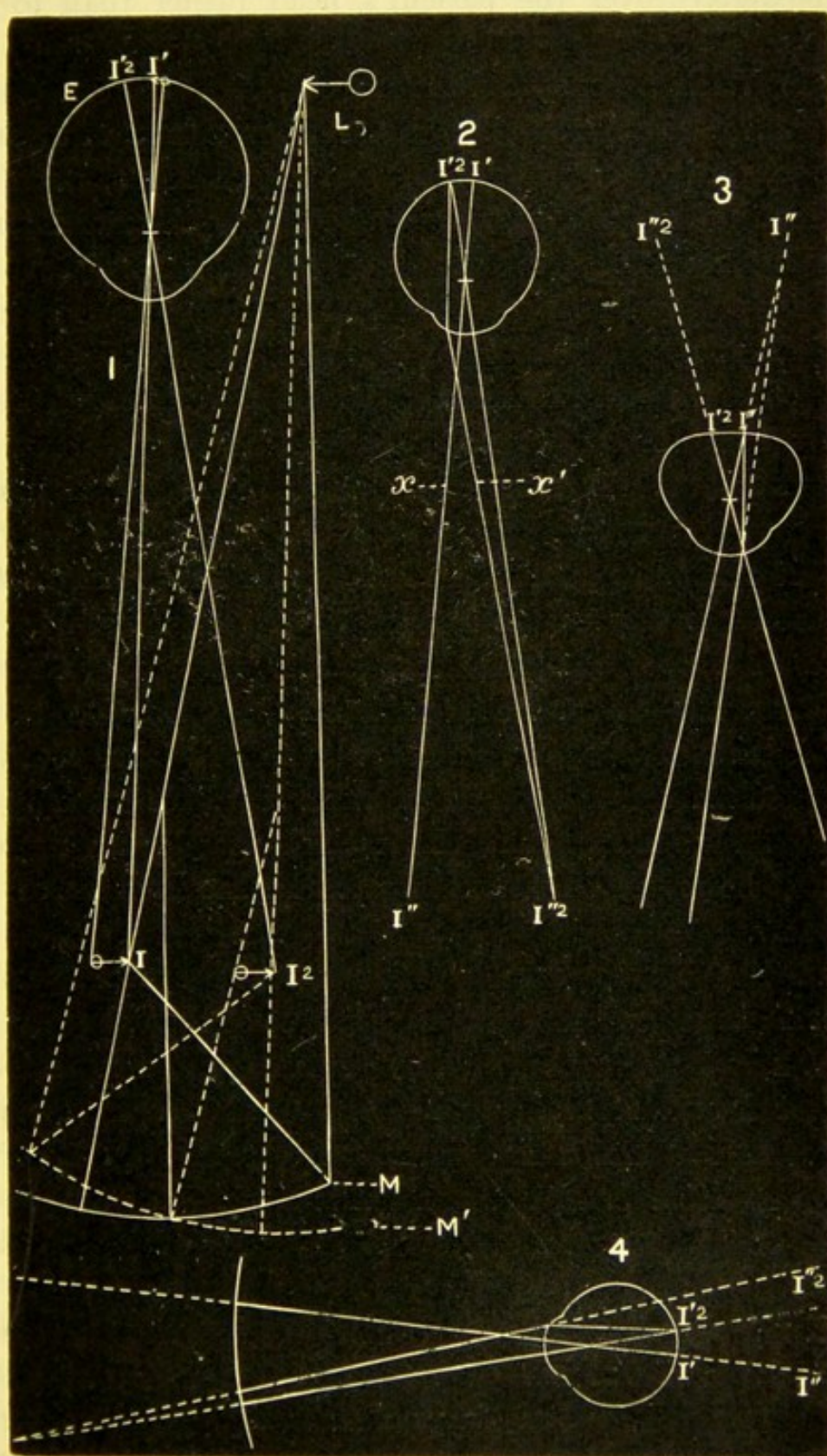


FIG. 36.—Vertical section of healthy optic disc, &c. \times about 15. R. Retina, outer layers shaded vertically, nerve-fibre layer shaded longitudinally. Ch. Choroid. Scl. Sclerotic. L. Cr. Lamina cribrosa. S. V. Subvaginal space between outer and inner sheath of optic nerve. The central vein and one of the divisions of the central artery are seen in the nerve and disc.

moscope mirror into the patient's pupil. He will then see the area of the pupil illuminated, and on slightly rotating the mirror will notice a movement in this lighted area, which movement will have a direction either the same as, or opposite to, that in which the mirror is turned ("with" or "against" the mirror). The lighted area is bordered by a dark *shadow*, and it is to the edge of this shadow that attention must be directed. This edge is parallel to the axis on which the mirror is turned, but moves in, and shows the refraction of, the meridian at right angles to it, *e. g.* the shadow whose edge passes vertically across the pupil moves across the horizontal meridian, the refraction of which it indicates, and *vice versa*. Retinoscopy may be practised with a concave or a plane mirror. With the former the shadow moves "against" the mirror in E. H. and low M., and "with" the mirror in M. of more than 1 D. With the latter these movements are exactly reversed. The light should be thrown as nearly as possible in the direction of the visual axis, and the lamp be placed

FIG. 37.—Retinoscopy (*with concave mirror*).

immediately over the patient's head rather than to one side.

(1) With a concave mirror (of about 22 cm. focus) (Fig. 37). In Fig. 37, 1, the mirror, M , forms an inverted image, I , of the light, L , at its principal focus, and I becomes the source of light for the eye, E . A second image of I , again inverted, is formed at I' on the retina of E . If the far point of E be at I this retinal image, I' , will be clear and distinct, but in every other case it will be more or less out of focus and indistinct. On rotating M to M' , I will move to I^2 and I' to I'^2 , and these movements (of I and I') will occur no matter what the refraction of E may be.

The observer placed behind M sees an image of I' formed in the same way as the image of the fundus seen by the direct method, and therefore either inverted and real, or erect and virtual, according as the refraction of the eye is M . or H . (p. 52). If the observer's eye be accurately adapted for this image of I' he will indeed see not only the light and shadow, but the retinal vessels; he neglects these, however, in attending to the movements of the shadow.

In the following description, L , I , and I^2 are disregarded, I' or I'^2 being considered as the source of light.

If E be *myopic* (Fig. 37, 2) the image of I' is real and inverted and formed at I'' , the far point of E (compare Fig. 104). On rotating the mirror (as in Fig. 37, 1), I' will move to I'^2 , and I'' will move to I''^2 , *i. e. the image seen by the observer moves in the same direction as (or "with") the mirror.*

If E be *hypermetropic* (Fig. 37, 3) or *emmetropic*, rays reflected from its retina leave the eye divergent or parallel, and are not brought to a focus after emerging; the observer therefore sees a virtual image erect at I'' , the virtual focus of I' (compare Fig. 13), and sees its movements actually as

they occur, *i. e.* in the same direction as the movements of the real image r' or r'^2 , and therefore "against" the movements of the mirror. Hence in H. and Em. *the shadow moves "against" the mirror.*

The above statement for myopia is true only if the observer be beyond the far point of the observed eye (*see Myopia*). In M. of 1 D. the rays returning from the patient's eye are focussed at a distance of 1 m., and if the observer intercept these rays before they meet (Fig. 37, 4) he will refer them towards r'' and r''^2 , and obtain an erect virtual but unfocussed image of r' , the movements of which will be the same as those in H. or E. (Fig. 37, 3), *i. e.* "against" the mirror. Hence, at a distance of about 1 m., movement "against" the mirror may indicate M. of about 1 D., or E. or H. The lowest M. which can give the characteristic movement at this distance is slightly more than 1 D., say 1.25 D.

(2) With a plane mirror (Fig. 38). Here the source of light for the observed eye is an erect and virtual image of the flame formed at the same distance behind the mirror as the lamp is in front of it. In Fig. 38, 1, this image is at l , the virtual focus of L. A second and inverted image of l is formed on the retina of E at r . The movements of these images, on rotation of the mirror, are the reverse of those of the image r (and its retinal image r'), Fig. 37, 1, obtained when the concave mirror is used. When the mirror M is rotated to M' , l will move in the opposite direction to l' , but its retinal image r will move to r' ; *i. e.* in the same direction as, or "with" the mirror. These movements of l and r occur in every eye, whatever its refraction. In E. and H., however, the movement of the retinal image is seen as it occurs (and therefore "with" the mirror); but in M. (Fig. 38, 2) the observer sees an inverted image of r formed at the far point of E, and its movements are exactly the reverse of those of the retinal image. Therefore, when

on rotating M to M' , I moves to I^2 the image I' seen by the observer moves to I'^2 , *i. e.* "*against*" the mirror. If the plane mirror be used at a distance of rather more than 1 m. (3'—4') from the patient a movement of the shadow "*with*" the mirror will occur in M . of 1 D. or less, for the reasons given previously (Fig. 37, 4); but if the observer be about 2 m. (say 7') away the characteristic movement "*against*" the mirror will be obtained unless the M . be less than .5 D.; since the far point of an eye with M . .5 D., and therefore the image seen, is at 2 m. As a plane mirror gives at a long distance a better illumination than a concave one, it can, if necessary, be used at a greater distance from the patient, and by this means low degrees of ametropia be very accurately measured. Generally, however, the distance given (3'—4') will be found most convenient.

In employing retinoscopy the patient is armed with a trial frame into which lenses are successively put until one is reached which just reverses the movement of the shadow. This lens indicates nearly, but not quite, the refraction of the eye under observation. In H . we must subtract (about) 1 D. from the lowest + lens which reverses the shadow, because we know that this movement would not occur till a myopia of at least 1 D. had been produced. In M ., for the same reason, 1 D. must be added to the lowest — lens which reverses the shadow.

Astigmatism is easily detected, and its amount measured by observing, on rotating the mirror, first from side to side, then from above downwards, whether the shadow has the same movement and characters in each direction; or by noting that when the shadow in one meridian is "*corrected*" by a lens, the meridian at right angles to it still shows decided ametropia. The lens is then found which corrects the latter meridian, and the As . equals the difference between the two lenses.

Apart from the direction in which the image (and shadow) moves, something may be learned from variations in (1) its brightness; (2) its rate of movement; (3) the form, straight or crescentic, of its border. The image is brightest, its movement quickest and most extensive, in very low M. and in Em. The higher the ametropia, whether M. or H., the duller is the illumination, the slower and less extensive its movement, and the more crescentic and ill defined its shadow border. The *brightness* of the image depends on how clearly r (Fig. 37, 1) is focussed on the retina; the more accurately r' is an image of r , the brighter and larger will r'' (Fig. 37, 2 or 3) be; and as the flame is rectangular, the borders of the image will be nearly straight. These conditions occur when the eye is exactly adapted for the distance of r , *i. e.* in M. of 1 D. or less. If the M. be higher than 1 D., r will be out of focus, and therefore be spread over a larger retinal area, and being formed by the same number of rays as before, it will be less bright. The image r'' (Fig. 37, 2) will be correspondingly diffused and dull, and being formed nearer to the patient's eye, as for example at x , it will move only from x to x' in the same time as r'' takes in moving to r''^2 , and hence its movement is slower and less extensive. The same is true in H. (Fig. 37, 3), because the higher the H., the more diffused is r' and the nearer is r'' to the patient's eye. In both cases, high M. and high H., the border of the shadow is crescentic because the diffused image forms a nearly round area on the retina.

Retinoscopy is a valuable means of objectively determining the quantity of any error of refraction, and as it is more easily learnt, and on the whole more accurate in its results, than estimation by the direct method (p. 53) it has in the hands of many almost displaced the latter method during the last four or five years, as a preliminary to testing the patient with trial lenses. For the quick dis-

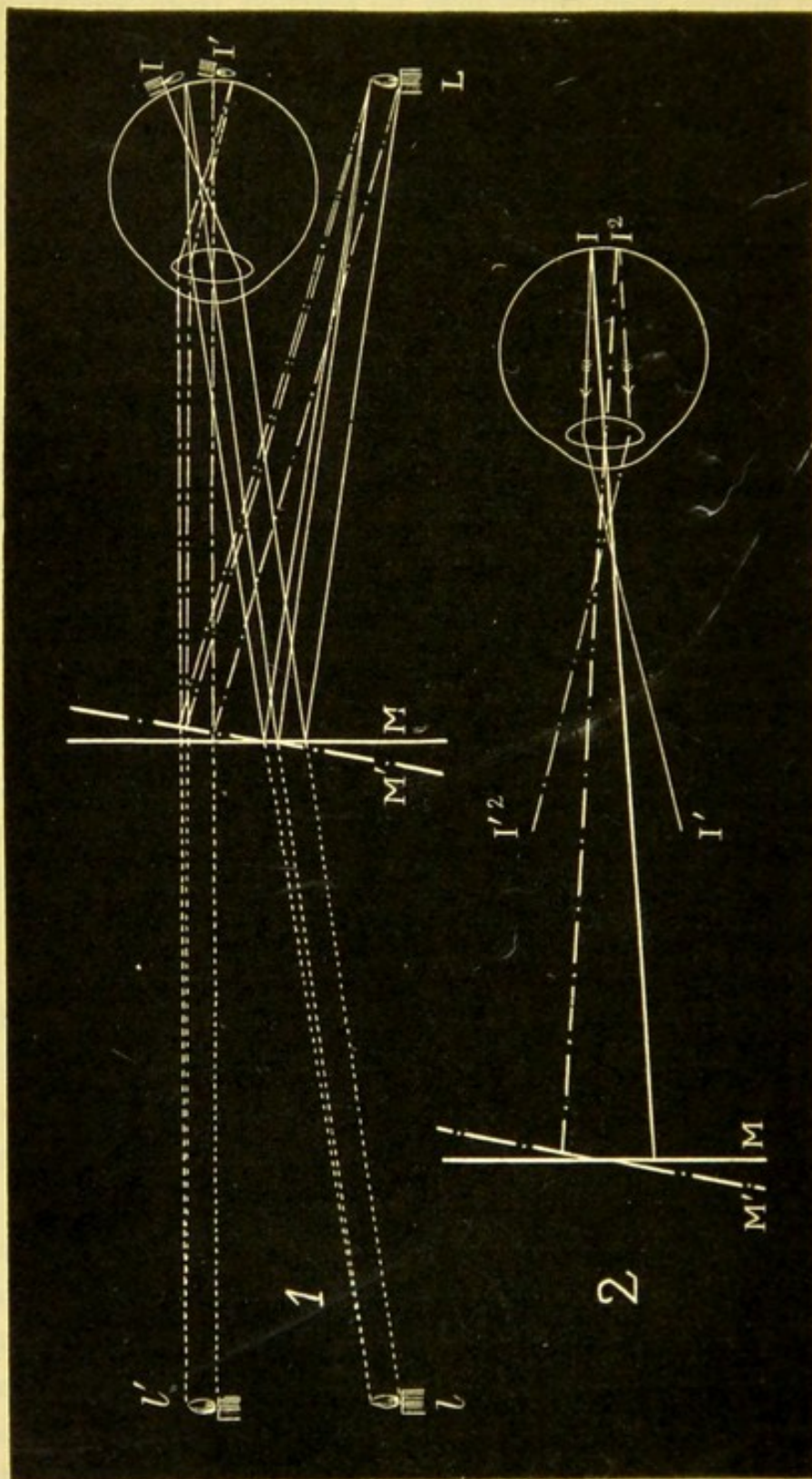


FIG. 38.—Retinoscopy (with plane mirror).

covery of very slight astigmatism, and of the direction of the chief meridians in astigmatism of all degrees, retinoscopy probably excels all other methods.

Retinoscopy, however, carries with it none of the collateral advantages afforded by a thorough training in the more difficult "direct method;" for in retinoscopy we see nothing and think nothing of the condition of the fundus of the eye. Accurate retinoscopy is not quicker than measurement by this direct method; indeed, with a good instrument the latter method certainly has the advantage in rapidity.

PART II

CLINICAL DIVISION

CHAPTER IV

DISEASES OF THE EYELIDS

THE border of the lid, which contains the Meibomian glands, the follicles of the eyelashes, and certain modified sweat-glands and sebaceous glands, is often the seat of troublesome disease. Being half skin and half mucous membrane, it is moist and more susceptible than the skin itself to irritation by external causes; being a free border, its circulation is terminal, and therefore especially liable to stagnation. Its numerous and deeply-reaching glandular structures, therefore, furnish an apt seat for chronic inflammatory changes.

Blepharitis (ophthalmia tarsi, tinea tarsi, sycosis tarsi) includes all cases in which the border of the eyelid is the seat of subacute or chronic inflammation. There are several types. The skin is not much altered, but chronic thickening of the conjunctiva near the border of the lid is generally observed. The disease may affect both lids or only one, and the whole length or only a part.

In the commonest and worst form the glands and eyelash follicles are the principal seats of the disease. The symptoms are firm thickening and dusky congestion of the border region, with exudation of sticky secretion from its edge, gluing the lashes together into little pencils.

Very mild cases present merely overgrowth of lashes and excess of Meibomian secretion. But generally the disease progresses; little excoriations, and ulcers covered by scab, form along the free border, and often minute pustules appear; the thickening and vascularity increase; the lashes are loosened, and free bleeding occurs if they are pulled out. After months or years of varying activity some or all of the hair-follicles become altered in size and direction, or quite obliterated, and the lashes stunted, misplaced, or entirely lost. As the thickening gradually disappears, little lines, or thin seams, of scar form just within the edge of the lid, and often cause slight eversion. The resulting exposure of the marginal conjunctiva, added to the scantiness of the cilia, causes the disagreeably raw and bald appearance termed *lippitudo*; and epiphora, from eversion, tumefaction, or narrowing of the puncta, often results. Often, however, the disease leads to nothing worse than the permanent loss of a certain number of the lashes.

In another type the changes are quite superficial—marginal eczema; the patient is liable, perhaps through life, to soreness and redness of the borders of the lids, and little crusts, scales, or pustules form at the roots of the lashes, the growth of the lashes not being much interfered with. In such people the eyes look weak or tender; the condition is made worse by exposure to heat, dust, and wind, and by long spells of work (*see* Chronic Lacrimal Conjunctivitis, p. 96).

Ophthalmia tarsi generally begins in childhood, and an attack of measles is a common exciting cause. It seldom becomes severe or persistent except from neglect of cleanliness in a child with sluggish circulation; the patients are generally anæmic, often scrofulous, and the condition is then often the result of a previous more acute ophthalmia. In adults severe sycosis of the eyelids may accompany

sycosis of the beard, but, as a rule, no tendency to such disease of the skin is observed.

Treatment.—When the inflammatory symptoms are severe nothing has such a marked effect as pulling out all the lashes. Cases of a few weeks' standing may be cured and recurrences in older cases very much relieved by one or two such epilations, together with local remedies. Local applications are always needed (1) for the removal of the scabs, (2) to subdue the inflammatory symptoms. A warm alkaline and tar lotion, with which the lids are to be carefully soaked for a quarter of an hour night and morning, followed by a weak mercurial ointment applied along the edges of the lids after each bathing, is an efficient plan if the mother will take pains. In bad cases painting, or pencilling, the border of the lid with nitrate of silver, ether in strong solution, or the diluted stick, or the use of weak copper drops is very useful in addition to the ointment. In old cases with much epiphora the canaliculus is to be slit up. The patients generally need a long course of iron. (F. 1, 2, 3, 6, 18, 19, 20, 28, 29.)

A *stye* is the result of suppurative inflammation of the connective tissue, or of one of the glands, in the margin of the lid. Owing to the close texture of the tarsus and the vascularity of the parts, the pain and swelling are often severe, and even alarming to the patient. The matter generally points around an eyelash; but if seated in a Meibomian gland, it may point either to the border of the lid or to the conjunctiva, rarely to the skin.

Styes almost always show some derangement of health, especially of the stomach or reproductive organs. Over-use of the eyes, especially if ametropic, is the exciting cause in some cases; exposure to cold wind in others. Styes are very apt to recur, singly or in crops, for several weeks or months.

Treatment.—A stye may sometimes be cut short, if seen

quite early, by the vigorous use of an antiphlogistic lotion; but an incision followed by hot fomentations or a poultice is usually more efficacious; the puncture must be made parallel to the free border, and extend rather deeply; a Beer's knife or broad needle (Figs. 157 and 142) may be used. The health always needs attending to, and a purgative iron mixture often suits better than anything else.

Some persons are subject to very small pustules or styes, much more superficial than the above, and less closely associated with derangement of health.

A Meibomian gland is often the scene of chronic overgrowth, a little tumour in the substance of the lid being the result (*Meibomian cyst, chalazion*). In a few weeks or months the growth becomes as large as a pea, forming a firm, hemispherical, painless swelling, over which the skin is freely moveable. A dusky spot where the tarsal tissues are thinned marks the conjunctival aspect, and when spontaneous rupture has occurred, a flattened mass of granulation is found there. The deeper part of the gland is the common seat of disease; if, as sometimes happens, the part near the edge of the lid is affected, the tumour usually remains very small. Occasionally the growth pushes forwards, and adhesion to the skin occurs; even then it is easily distinguished from a sebaceous cyst by the firmness of its deep attachment. During its course the cyst may inflame and even suppurate, and in the latter case it forms one variety of "stye." The same tumour may inflame several times, and finally suppurate and shrink. Like styes, these tumours are apt to continue forming one after another. They are much commoner in young adults than earlier or later in life, but they are now and then seen in infants. Patients as often apply for the disfigurement as for any discomfort which these little growths occasion.

Treatment.—The cyst is to be removed from the inner

surface of the lid; but if it point forwards, the incision may be in the skin. The tumour generally consists of a soft, pinkish, gelatinous mass, or of a gruelly or puriform fluid, without a cyst wall. Sometimes the contents are very firm and adherent (*see Operations*).

Small yellow dots are sometimes seen on the inner surface of the lids, due to little cheesy collections in the Meibomian glands, and causing irritation by their hardness. They should be picked out with the point of a knife.

Warty formations are not very common on the border of the lid, and are of little consequence except in elderly people, in whom they should be looked upon with suspicion as possible starting-points of rodent cancer. A small fleshy, yellowish-red, flattened growth is sometimes met with just upon the tarsal border, and apparently seated at the mouth of a Meibomian gland. It causes some irritation, and should be pared off. *Small pellucid cysts* are also not uncommon on the lid border. Cutaneous horns are occasionally seen on the skin of the eyelids.

Molluscum contagiosum is partly an ophthalmic disease, because so often seated upon the eyelids. One or more little rounded prominences, showing a small dimpled orifice at the top, plugged by dry sebaceous matter, are seen in the skin, varying from the size of a mustard seed to a cherry, but usually not larger than a sweet-pea; at first they are hemispherical, but afterwards become constricted at the base. The skin is tightly stretched, thinned, and adherent. The larger specimens sometimes inflame, and their true nature may then, without due care, be mistaken. Each molluscum must be removed, the white, lobulated, gland-like mass which forms the growth being squeezed out through the incision made by a knife or scissors.

Xanthelasma palpebrarum appears as one or more yellow patches like pieces of wash-leather in the skin, varying from mere dots to the size of a kidney bean, quite soft in texture,

and very little raised. The disease is commonest near the inner canthus, and unless symmetrical is usually on the left side. It occurs chiefly in elderly persons who have previously been subject to become very dark around the eyes when out of health. The patches are due to infiltration of the deeper parts of the skin by groups of cells loaded with yellow fat. The frequency of xanthelasma in the eyelids is, perhaps, related to the normal presence of certain peculiar granular cells, some of which contain pigment, in the skin of these parts.

The *Pediculus pubis* (crab-louse) in very rare cases will reach the eyelashes and flourish there. The lice cling close to the border of the lid, and look like little dirty scabs; the eggs are darker, and may also be mistaken for bits of dirt. The absence of inflammation and the rather peculiar appearances will lead, in doubtful cases, to the use of a magnifying glass, by which the question will be at once settled.

Ulcers on the eyelids may be malignant, tubercular, lupous, or syphilitic; and in the last case the sore may be either a chancre or a tertiary ulcer.

Rodent cancer (rodent ulcer, flat epithelial cancer) is by far the commonest form of carcinoma affecting the eyelids; cases of eyelid cancer occasionally present both the clinical and pathological characters of ordinary epithelioma. The peculiarities of rodent cancer are that it is of very slow growth, that ulceration almost keeps pace with the new growth, and that it does not cause infection of lymphatics. It seldom begins before, generally not until considerably after, middle life, and its course often extends over many years. Beginning as a "pimple" or "wart," it slowly spreads, but years may pass before the ulcer is as large as a sixpence. When first seen we generally find a shallow ulcer, covered by a thin scab, most often involving the skin at the inner end of the lower lid. Its edge is raised,

sinuous, nodular, and very hard, but neither inflamed nor tender. Slowly extending both in area and depth, it attacks all tissues alike, finally destroying the eyeball and opening into the nose. In a few very chronic cases the disease remains quite superficial, and cicatrisation may occur at some parts of the ulcerated surface. Now and then a considerable nodule of growth forms in the skin before ulceration begins.

The diagnosis is generally easy. A long-standing ulcer of the eyelids in an adult is nearly certain to be rodent cancer. *Tertiary syphilitic ulcers* are much less chronic, more inflamed and punched out, and devoid of the very peculiar, hard edge of rodent ulcer; moreover they are very rare. *Lupus* seldom occurs so late in life as rodent cancer, presents more inflammation and much less hardness, and is often accompanied by lupus elsewhere on the cutaneous or mucous surfaces. Lupus is seldom difficult to distinguish on the eyelids from tertiary syphilis, the latter being more acute, more dusky, and showing more loss of substance, with none of the little, ill-defined, soft tubercles seen in lupus.

When a *chancre* occurs on the eyelid* the induration and swelling are usually very marked, the surface abraded and moist, but not much ulcerated; the glands in front of the ear and behind the jaw become much enlarged.

Several cases are on record in which a hard chancre formed on the palpebral conjunctiva, so far from the border of the lid as to be quite concealed. In such cases the swelling bears considerable resemblance to a large Meibomian cyst; there are enlarged glands and well-marked constitutional symptoms.

Treatment of rodent cancer.—Early removal is of great importance, and probably the more so in proportion to the

* An interesting monograph on this subject was read by Dr De Beck at the American Ophth. Soc., July, 1886.

youth of the patient. Chloride of zinc paste or the actual cautery is necessary in addition to the knife in bad cases; scraping may also be employed. The disease is very apt to return locally. Even in very advanced cases, where complete removal is impossible, the patient may be made much more comfortable, and life probably prolonged, by vigorous and repeated treatment.

Tubercle of the conjunctiva is generally primary; it begins in the upper lid in the tarsal conjunctiva, or in the retro-tarsal fold; as a rule, the upper lid is swollen, and when everted presents either a punched-out ulcer with a grey base, or a mass of small grey miliary tubercles. The pre-auricular gland is very frequently enlarged, and may suppurate. If left alone the disease may spread to the eyeball, or invade the substance of the lid, and may lead to secondary infection of other parts of the body. The diseased parts should be excised, or thoroughly scraped and cauterised, and the operation should be repeated as long as any trace of the disease remains.

Congenital ptosis is a not very rare affection. It may be double or unilateral, is present from birth, and its causation is unknown. I believe it is never complete. It sometimes seems to diminish in the first few years of life, but probably never disappears. Although the lid droops, the skin is often scanty, the lid being tight and deficient in the natural folds. Operations have been devised for producing deep cicatricial bands, by means of subcutaneous sutures passed from the brow to the tarsus (Bowman, Pagenstecher, Wecker). Panas has devised a new operation more recently. These rather tedious procedures avoid the risk of further shortening of the lid which attends the simpler operation of removing an elliptical fold of skin. I have obtained considerable improvement from Pagenstecher's operation.

Epicanthus is a rare condition, in which a fold of skin

stretches across from the inner end of the brow to the side of the nose, hiding the inner canthus. If it does not disappear as the child's nose develops, an operation—removal of a piece of skin from the bridge of the nose (sometimes combined with canthoplasty)—is indicated.

Congenital trichiasis.—This condition is not very uncommon in children; the lashes of the lower lid, instead of having their normal direction, are turned upwards and backwards, and come into contact with the globe, giving rise to irritation of the conjunctiva and cornea. To restore the lashes to their proper direction, an elliptical piece of skin should be removed from the lower lid.

CHAPTER V

DISEASES OF THE LACRIMAL APPARATUS*

THESE may be divided into the affections of the secreting parts—the lacrimal gland and its ducts; and those of the drainage apparatus—the puncta, canaliculi, lacrimal sac, and nasal duct. In the great majority of cases the fault lies entirely in the drainage system.

The flow of tears over the edge of the lid, “watery eye,” is called *epiphora*, or *stillicidium lacrimarum*. No useful purpose is served by keeping the two names, and only the former will be here used. *Lacrimation* indicates the increased flow which often accompanies inflammation of the eyeball.

The drainage system may be at fault in any part from the puncta to the lower end of the nasal duct.

The slightest change in the position of the lower punctum causes epiphora. In health the punctum is directed backwards against the eye; if it look upwards or forwards the tears do not all reach it, and some will then flow over the lid. Thus in paralysis of the facial nerve the patient sometimes comes to us for epiphora before he notices the other symptoms; the watering is caused partly by loss of the compressing and sucking action of the punctum that is effected in winking, by those fibres of the orbicularis which lie in relation with the lacrimal sac, partly by a slight falling of the lid away from the eye and a consequent displacement of the punctum. The various chronic diseases of the border of the lids (*ophthalmia tarsi*), and also granular disease of the conjunctiva (*granular lids*),

* For Diseases of Lacrimal Gland see Diseases of Orbit, Chap. XIX.

are common sources of (1) tumefaction, with narrowing, of the puncta and canaliculi; (2) cicatricial stricture of the same parts; in both cases the puncta are displaced as well as constricted. Narrowing even to complete obliteration of the puncta is sometimes seen as the result of former inflammation, of which all traces have long since passed away. Wounds by which the canaliculi are cut across cause their obliteration, and epiphora is the result.

In all the above cases the epiphora is accompanied by a visible change in the size or position of the punctum, none of the signs of inflammation in the lacrimal sac or stricture in the nasal duct being present; and simple division of the canaliculus will cure, or much relieve, the watering (*see Operations*). This is, however, seldom necessary in the epiphora of facial paralysis.

The canaliculus is occasionally plugged by the growth in it of a mycelial fungus, which, mingled with pus-cells and mucus, forms a yellowish, or greenish, putty-like concretion. These masses sometimes calcify, and are then called dacryoliths.*

Epiphora not explained by the above causes is usually due to obstruction in the nasal duct, and is accompanied by distension and disease of the lacrimal sac from the same cause. *Primary* disease of the lacrimal sac is rare.

Obstruction of the nasal duct is usually caused by chronic thickening of the mucous and submucous tissues lining the canal. Dense, hard thickening causes a stricture, often very tight and unyielding; but obstruction is often present though the canal be of full size or perhaps even dilated,† excess of mucus being apparently the chief cause. Disease of the duct occurs at all ages, and is much com-

* The same term is applied to concretions, still more rare, in the ducts of the lacrimal gland.

† There can be little doubt that the healthy nasal duct varies much in size in different persons (Noyes).

moner in females than males.* In some cases the change evidently forms a part of a chronic disease of the nasopharyngeal mucous membrane, but in many no cause can be assigned. Sometimes stricture is the result of periostitis or of necrosis, and of these conditions syphilis (either acquired or inherited), scarlet fever, and smallpox are the commonest causes. Injuries to, and growths in the nose, or invading it, account for a few cases.

A stricture may be seated at any part of the duct; but the upper end, where there is often a natural narrowing, is the commonest spot.

Obstruction of the nasal duct, by preventing the escape of tears, leads to *distension of the lacrimal sac*, to chronic thickening of its lining membrane, and increased secretion of mucus. The mucus may be clear or turbid. At length a point is reached at which the distension can be seen as a little swelling under the skin at the inner canthus (*mucocoele* or *chronic dacryo-cystitis*). This swelling can generally be dispersed by pressure with the finger, the mucus and tears either regurgitating through the canaliculi or being forced through the duct into the nose. In cases of old standing the sac is often much thickened, and may contain polypi, and the swelling cannot then be entirely dispersed by pressure.

A mucocoele is always very apt to inflame and suppurate, the result being a *lacrimal abscess*. Most cases of lacrimal abscess, indeed, have been preceded by mucocoele. Its formation gives rise to great pain, and to tense, brawny, dusky swelling, which, extending for a considerable distance around the sac, is sometimes mistaken for erysipelas. The matter always points a little below the tendo palpebrarum; the pus often burrows in front of the sac, forming little pouches in the cellular tissue, and if allowed

* In a group of 113 consecutive cases I find 89 females and 24 males.

to open spontaneously, a fistula, very troublesome to cure, is likely to follow. If seen early, before there is decided pointing, it is best to open the abscess by slitting the lower canaliculus freely into the sac, and passing a knife down the nasal duct; anæsthesia is usually necessary. If interference be delayed the skin over the sac soon becomes thinned and the abscess is then best opened through the skin by a free puncture inclined downwards and a little outwards; no anæsthetic is necessary, and the resulting scar is insignificant. When the thickening has subsided, under the use of warm lead lotion dressing, the stricture of the duct is to be treated; but the mucocele will form again, and another abscess may occur at any time unless a free passage can be restored down the nasal duct.

Obstinate chronic conjunctivitis is often set up by unrelieved lacrimal obstruction (p. 96). It has long been known that severe suppurative inflammation is very likely to occur after any operation performed on the cornea when there is pus in the lacrimal sac (*see* Cataract). These evidences of local irritation and infection are now known to depend upon septic organisms which, owing to the obstruction, collect in the lacrimal sac.

Treatment of mucocele and lacrimal stricture.—The object aimed at is the permanent dilatation of the stricture; but, whether this can be gained or not, a free opening from the canaliculus into the sac should be maintained, so that the secretions may be often and easily squeezed out.

Dilatation by probing (Chap. XXII) is the ordinary and best treatment for all strictures, whether there be mucocele or not, the rule being to use the largest probe that will pass readily. The probing is repeated every few days or less often, according to the duration of its effect, and often needs to be continued for weeks or months. The patient may sometimes learn to use the probe himself. When the stricture is tough and tight, it is best at once to

divide it by thrusting a strong-backed, narrow knife down the duct, and afterwards to use probes. In cases where the stricture is quite soft, and the obstruction due rather to general thickening of the mucous membrane and over-secretion of mucus, than to dense fibrous thickening, frequent washing out of the duct with water, or weak astringents, by means of a lacrimal syringe, is quite as beneficial as, and less painful than, probing. The diligent use of astringent lotions to the conjunctiva is also useful, particularly in soft strictures, some of the lotion reaching the sac and duct. In cases of long standing, where other treatment has failed and the sac is much thickened, or when it is necessary to perform an operation like extraction of cataract, excision of the lacrimal sac, or its complete obliteration by the actual cautery, should be resorted to; extirpation of the lacrimal gland is also occasionally practised. For refractory children, and for patients who cannot be seen often, a style of silver or lead, passed in exactly the same way as a probe, but worn constantly for many weeks, is very useful; but it may slip into the sac out of reach unless furnished with a bend or head so large as to be somewhat unsightly. As a rule, probing should not be begun until the inflammatory thickening and tenderness following a lacrimal abscess have subsided. If the probe be used too often, or with much violence, or if false passages be made, the case may easily be made worse instead of better. It must be confessed, indeed, that in many lacrimal cases, whether the stricture be soft or firm, treatment, however skilful, gives only partial relief to the epiphora.

Suppuration of the lacrimal sac, on one or both sides, sometimes takes place in new-born infants without apparent cause; if there be much redness the abscess should be opened, but the suppuration is sometimes chronic, and will cease under the use of astringent lotions. The cases of

epiphora with contracted punctum, which are sometimes met with in older children, may perhaps be the consequences of this infantile suppuration.

Cases in which the sac or duct is obliterated by injury can seldom be relieved.

CHAPTER VI

DISEASES OF THE CONJUNCTIVA

THE conjunctiva, like the urethra, is subject to purulent inflammation, and, like the respiratory mucous membrane, is liable to the muco-purulent and to the membranous or diphtheritic forms of disease. All cases in which there is yellow discharge are in greater or less degree contagious. The congestion, which forms a part of conjunctivitis, is much influenced by age; the younger the patient the less is the congestion in proportion to the discharge—a fact to be borne in mind in examining patients at both ends of the scale.

Purulent ophthalmia (O. neonatorum, Gonorrhœal O., Blennorrhœa of the conjunctiva) is generally due to contagion from the same disease, or from an acute or chronic discharge from the urethra or vagina, which may or may not be gonorrhœal. It is commonest in new-born infants whose eyes have been inoculated from the mother during birth; next in adults with gonorrhœa; it is also seen sometimes in young girls who have non-venereal discharge from the genitals.

The active cause of this form of conjunctivitis is a micro-organism, the gonococcus, first discovered by Neisser in 1879. These are found in the pus-cells of the conjunctival discharge, and also in the superficial cells of the conjunctiva itself; they are arranged in pairs, which are generally aggregated together. The gonococcus is said (1) to be absent in some of the milder forms of infantile ophthalmia; (2) when cultivated to be capable of producing purulent ophthalmia by inoculation; (3) to be usually present in

the vaginal discharge of women whose babies have purulent ophthalmia. Gonorrhœa was experimentally produced by inoculation with pus from purulent ophthalmia long before the days of bacterial pathology. Like gonorrhœa, purulent ophthalmia may occur more than once. It varies greatly in severity, but is, on the whole, much worse in adults than in infants, perhaps because there is much more adenoid tissue in the conjunctiva of adults than of babies (Widmark).

From an examination of the records of 158 cases of purulent ophthalmia in adults occurring in the wards at Moorfields* the disease is found to be commoner in males than in females in the proportion of 126 to 32, and the right eye is more frequently attacked than the left. The influence of age on the prospect of recovery is very great; early adult life is the time when the resistance is greatest; practically every eye that was attacked when the patient was over forty was lost. The other modifying causes are the duration of the urethral discharge at the time of inoculation, and the time of beginning treatment; inoculation during the later stages of the gonorrhœa led to milder attacks in the eye, and the earlier the patient came under treatment the better the result. In many of the cases there was a history of "weak eyes" before the attack; this may have been due to a congestion of the anterior part of the eye from the circulation of the gonorrhœal poison in the blood, or to a previous condition of the eyelids produced by blepharitis or granular disease.

The disease sets in from twelve to about forty-eight hours after inoculation; in infants the third day after birth is almost invariably given as the date when discharge was first noticed. Itchiness and slight redness of conjunctiva soon pass on to intense congestion of conjunctiva, with chemosis, tense inflammatory swelling of the lids, great

* Holmes Spicer, 'Ophth. Hosp. Rep.,' vol. xiii, p. 211.

pain and discharge. The discharge at first is serous, or like turbid whey, but soon becomes more profuse, creamy (purulent), and yellow, or even slightly greenish. Dark, abrupt ecchymoses are often present. The lids, always swollen, hot, and red, in bad cases become very tense and dusky. The upper lid hangs down over the lower, and is often so stiff that it cannot be completely everted. The conjunctiva is succulent and easily bleeds.

The disease if untreated declines spontaneously, and the discharge almost ceases in about six weeks, the palpebral conjunctiva being left thick, relaxed, and more or less granular. Cicatricial changes, identical with, but less severe than, those resulting from chronic granular lids, and analogous to those which occur in stricture of the urethra, sometimes follow; considerable permanent thickening of the ocular conjunctiva may also occur.

There is a great risk to the cornea in this disease, partly from strangulation of the vessels, partly from the local influence of the discharge. If within the first two or three days the cornea becomes hazy and dull, like that of a dead fish, there is great risk that total or extensive sloughing will occur. In many of the milder cases ulcers form a little below the centre, and rapidly cause perforation. In other cases clear deep ulcers form close to the edge of the cornea. There is less risk of ulceration of the cornea in the purulent ophthalmia of infants than in that of adults. Either one or both eyes may be attacked: in adults one eye often escapes; in infants, where the inoculation occurs during birth, both eyes almost always suffer.

Treatment.—If only one eye be affected, and the patient be old enough to obey orders, the sound eye must be covered with the shield introduced by Dr Buller; take two pieces of india-rubber plaster, one $4\frac{1}{2}$ ", the other 4" square, cut a round window in the middle of each, and stick them together, with a small watch-glass inserted into

the window. The plaster is fixed by its free border, and by other strips, to the nose, forehead, and cheek, and the patient looks through the glass; the lower outer angle is left open for ventilation; particular attention is to be paid to the fastening on the nose. All concerned are to be warned as to the risk of contagion and the means of conveying it. The essential curative measures are—(1) Frequent removal of the discharge by the free use of weak antiseptic or astringent lotions (F. 3, 12, 13, 16, 17, 22). Every hour, day and night, the lids are gently opened and the discharge removed with soft bits of moistened rag or cotton wool. In adults, where the swelling is often extreme and very brawny, the cleansing must be done very gently, lest the congestion and irritability be increased. (2) Iodoform, at first extensively tried, has, I believe, not given satisfaction in this disease.—Many surgeons greatly prefer weak nitrate of silver (F. 3) to all other remedies. (3) Strong solutions of nitrate of silver, or the mitigated solid nitrate (F. 1 and 2), are of great service in shortening the attack and lessening the risks, and, whatever other treatment be adopted, they should be used in all severe cases unless specially contra-indicated. The above-mentioned analysis (p. 80) showed the very great superiority of strong nitrate of silver (grs. x or xx to $\frac{3}{4}$) over all other kinds of treatment. A ten- or twenty-grain solution is brushed freely over the conjunctiva of the lids, everted as well as possible, and freed from discharge. If the mitigated stick is used more care is needed; and to prevent too great an effect, it is to be washed off with water, after waiting about fifteen seconds. These strong applications must be made by the surgeon. The pain caused by them is lessened, and the benefit increased, by free bathing with cold or iced water afterwards. The application is not to be repeated until the discharge, which will be markedly lessened for some hours, has begun to increase again; once a day is

enough in many cases. (4) Between the cleansings either warm or cold applications; warmth is often preferred by the patient. (5) In the early stage, in adults, several leeches to the temple will give relief, or, if the swelling be very tense, we may divide the outer canthus with scissors or knife, and thus both bleed and relax the parts at the same time. Removal of the ring of conjunctiva which overlaps the cornea is valuable when the chemosis is severe. (6) The lids should be often anointed with a simple ointment.

The following additional precautions are important:—Strong nitrate of silver applications are unsafe in the earliest stage, before free discharge has set in, and also in cases where, even later in the disease, there is much hard brawny swelling of the ocular conjunctiva and comparatively little discharge; cases, in fact, approaching the condition known as diphtheritic ophthalmia. In these, either very cold or very hot applications, leeches, cleanliness, and weak lotions should be chiefly relied upon. Ice and leeches are seldom advisable for infants. It is of extreme importance to begin treatment very early, for the cornea is often irreparably damaged within two or three days. The patients, if adults, are often in feeble health, and need supporting treatment. Ulceration of the cornea does not contra-indicate the use of strong nitrate of silver if the discharge is abundant. Treatment must be continued so long as there is any discharge, for a relapse of purulent discharge often takes place if remedies are discontinued too soon. I once saw hæmorrhage continuing for some time, without apparent cause, from the conjunctiva of the lid, in a child recovering from purulent ophthalmia. Serious conjunctival hæmorrhage has been noted by Pomeroy and Schmidt-Rimpler.

The systematic *prevention of ophthalmia neonatorum* by the cleansing and disinfection of the eyes of every infant

immediately after birth, sometimes preceded by disinfection of the maternal passages, has been introduced by Credé, and largely carried out in many lying-in hospitals, especially on the Continent. Credé applies a few drops of a 2% solution of nitrate of silver (about 8 grs. to 3j) to the conjunctival sac once. Various other agents or weaker solutions of silver have been used. The general result of such measures has been to reduce the number of cases in an astonishing degree; and as it is calculated that about a third of all the blind in Europe have become so by the ravages of this disease, considerable importance is to be attached to the general adoption of Credé's principle by medical men and midwives.*

Muco-purulent conjunctivitis.—The commonest and best characterised of the acute ophthalmias is the so-called *catarrhal ophthalmia*. The name is a bad one, for neither does the disease form part of a general catarrh of the respiratory tract, nor does it show the tendency to relapse so characteristic of catarrh, nor does it seem to be caused by cold. The disease attains its height very quickly, almost always attacks both eyes, and gets well spontaneously in about a fortnight. There is great congestion, much gritty pain, which often prevents sleep, spasm of the lids, free muco-purulent discharge, and, in many cases, ecchymotic patches in the conjunctiva. The lids are somewhat swollen and red, but never tense, and the cornea seldom suffers.

This disease seems to be much oftener communicated from person to person than purulent ophthalmia, for which it is sometimes taken. It varies much in severity, even in different members of the same household, who catch it almost at the same time, but it attacks all ages

* Particulars and statistics may be found in 'Edinburgh Med. Journ.,' April, 1883 (Dr A. R. Simpson), and in more recent papers.

indiscriminately. It is, I believe, commonest in warm weather, or perhaps at the change from cold to warm. It is rare to find that the patient has suffered from the disease before. Any mild antiseptic lotion will cut it short, nitrate of silver (F. 3) being the best.

Troublesome *ophthalmia, with muco-purulent discharge*, is common in children *after exanthemata*, especially measles. It runs a less definite course than the preceding disease, shows but little tendency to spontaneous cure, and is very often complicated with phlyctenular ulcers of the cornea, blepharitis, and eruptions on the face; the patients are frequently strumous. The discharge is seldom so abundant as in the disease just considered. The treatment is often troublesome, and many changes have to be tried; weak nitrate of silver lotions (F. 3), with the use of the yellow ointment (F. 25, 26), or boracic acid ointment, both to the skin and conjunctiva, or calomel dusted into the eye, are the best local means; atropine alone often increases the irritation. Careful attention to health is necessary. The patients should not be confined to the house, but, with a large shade over both eyes, should take plenty of exercise in fine weather. *The eyes should not be bandaged in any form of ophthalmia, and poultices are very seldom suitable.*

Follicular conjunctivitis.—This occurs generally in children or young adults, and is characterised by the formation of small clear elevations, consisting of adenoid tissue, in the conjunctiva of the lower lid; in some cases they are present also in the retro-tarsal fold of the upper lid. These granulations often give rise to no symptoms, and are only part of a general tendency to adenoid enlargement. They occur mainly as the result of overcrowding, living in unventilated rooms, or are due to the over-use of atropine. This condition may have no significance, but it undoubtedly predisposes the patient to acute attacks of

conjunctivitis of various kinds, either of the muco-purulent or granular varieties.

Some forms of acute conjunctivitis, with little or no discharge, are seen both in children and adults, which do not conform to the above types, and are of comparatively slight importance. Many such appear to depend on changes of weather or exposure to cold, and are complicated with phlyctenulæ. A few are distinctly rheumatic. The conjunctiva is involved more or less in herpes zoster of the ophthalmic division of the fifth nerve, in erysipelas of the face, in the early stage of measles, and slightly in eczema of the face. Slight degrees of chronic conjunctivitis are set up by various local irritants, dust, smoke, cold wind, &c., and by the strain attending the use of the eyes without glasses in cases of hypermetropia. Mention must be made of the cases sometimes seen in children, where an ophthalmia appears to form part of an impetiginous or herpetic eruption on the face, with which it is simultaneous. These again differ from the commoner cases, in which the lids, cheek, and lining membrane of the nose are irritated into an eruption by tears and discharge from a pre-existing conjunctivitis.

Muco-purulent ophthalmia, of any kind, becomes a very important affair if it breaks out in schools or armies, &c., where granular disease of the eyelids is prevalent (p. 91).

Membranous and diphtheritic ophthalmia.—In a few cases of ophthalmia, either purulent or muco-purulent, the discharge adheres to the conjunctiva in the form of a membrane (*membranous or croupous ophthalmia*). Still more rarely, in addition to membrane on the surface, the whole depth of the conjunctiva is stiffened by solid exudation, which much impairs the mobility both of the lids and eyeballs, and, by compressing the vessels, prevents the formation of free discharge, and places the nutrition of the cornea in great peril. It is to the latter cases that the

term *diphtheritic* has been limited by most authors; but we find many connecting links between the two types, and between each of them and the ordinary purulent and muco-purulent cases.

It is of much consequence in practice, both for prognosis and treatment, to recognise the presence of membranous discharge and of solid infiltration in any case of ophthalmia; for the liability to severe corneal damage is much increased by either of these conditions, especially by the latter. The membrane may cover the whole inside of the lids, or it may occur in separate, or in confluent patches; it often begins at the border of the lid, and is seldom found on the ocular conjunctiva. It can be peeled off, the conjunctiva beneath bleeding freely unless infiltrated and solid; in the latter case the membrane is more adherent, the conjunctiva is of a palish colour, and scarcely bleeds when exposed, and there is little or no purulent discharge. In most cases the solid products, whether membrane or deep infiltration, pass after some days into a stage of liquefaction, with free purulent secretion. In rare cases the membrane forms and re-forms for months. As regards cause, (1) very rarely the process creeps up to the conjunctiva from the nose in cases of primary diphtheria, or is caused by inoculation of the conjunctiva with membrane; whilst in a few the ophthalmia forms the first symptom of general diphtheria, or of masked or anomalous scarlet fever. (2) More commonly it is part of a diphtheritic type of inflammation following some acute illness. (3) It may be caused by the over-use of caustics in ordinary purulent ophthalmia. (4) It may be due to contagion, either from a similar case or from a purulent ophthalmia, or a gonorrhœa, the diphtheritic type depending on some peculiarity in the health or tissues of the recipient. Membranous and diphtheritic ophthalmia are seen most often in children from two to eight

years old, less commonly in adults and infants. It is commoner in North Germany than in other parts of Europe, but severe and even fatal cases are well known in our own country. In two cases I have seen the same condition attack the skin of the eyelids and cause sloughing patches.

In *treatment* the cardinal point is not to use nitrate of silver in any form when there is scanty discharge and much solid infiltration of the conjunctiva. The agents to be relied upon are (1) either ice or hot fomentations,—ice, if it can be used continuously and well; fomentations, to encourage liquid exudation and determination to the skin if the cold treatment cannot be carried out, or fails to make any impression on the case; (2) leeches, if the patient's state will bear them; (3) great cleanliness. The presence of membrane is no bar to the use of caustics, provided that the conjunctiva is succulent, red, and bleeds easily. Mr Tweedy strongly advises quinine lotion used very frequently (F. 21).

Granular ophthalmia (trachoma) is a very important malady, characterised by slowly progressive changes in the conjunctiva of the eyelids, in consequence of which this membrane becomes thickened, vascular, and roughened by firm hemispherical elevations, instead of being pale, thin, and smooth. The change usually begins in the conjunctiva of the lower lid, extending to the submucous tissue of both lids at a later period, and giving rise to the growth of much organised new tissue in the deep parts of the conjunctiva. This tissue is afterwards partly absorbed and partly converted into dense, tendinous scar, which by very close shrinking often gives rise to much trouble. It is stated by Reid and others that trachoma follicles come to the surface, open, discharge their contents, and leave minute ulcers; but it cannot be said clinically that trachoma is an ulcerative disease, and the prominences are

not "granulations" in the pathological sense.* There have been, and still are, extraordinary differences of opinion as to the origin and nature of the "granulations" or "trachoma bodies" in this disease. The latest researches favour the view that they are derived from natural lymphatic follicles. Fig. 39 shows a section through some recent trachoma bodies.



X 14

FIG. 39.—Microscopical section through four recent trachoma bodies ("sago-grain granulations"), from the lower lid of a young Irish soldier whose eyes became affected in the Egyptian campaigns. The epithelial cells become almost indistinguishable from those of the growth where they cover the largest nodule. No reticulum can be made out between the cells of which the growths are composed.

The disease shows itself in two forms :

(a) The papillæ undergo considerable enlargement without the appearance of granulations on the surface; the conjunctiva covering the tarsus of the upper lid is most affected, and appears red and velvety. This is known as the *papillary* form.

(b) The other variety shows itself by the presence on both lids of a number of rounded, pale, semi-transparent bodies like little grains of boiled sago; the so-called "vesicular," or "sago-grain," or "follicular" granulations (Fig. 40).

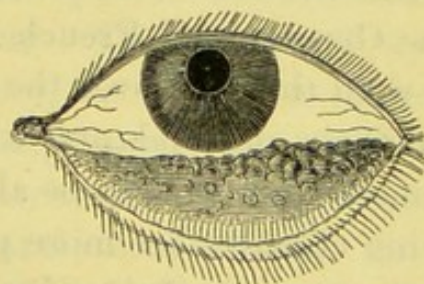


FIG. 40.—Granular lower lid. (After Eble.)

The two forms of conjunctival affection may occur separately, but are usually combined.

* I am aware that Raehlmann makes a contrary statement.

In the earlier stages there may be congestion of the conjunctiva with a good deal of discharge; after a time the discharge lessens, but the granulations remain: in some cases the amount of congestion and discharge is never great, and there is little to call attention to the eyes.

Granular disease is very important because it greatly increases the susceptibility of the conjunctiva to take on acute inflammation and to produce contagious discharge; makes it less amenable to treatment, and very liable to relapses of ophthalmia for many years; and often gives rise to deformities of the lid and to serious damage of the cornea. In crowded poor-law schools we see many cases of granular lids in which there is no history of an acute attack having ever occurred, but in ordinary practice it is rare to see such.

Chronic granular disease is the result (1) of prolonged overcrowding, or rather of long residence in badly ventilated and damp rooms; it used to be very abundant in the army and navy, and is still seen in great perfection in workhouse schools; (2) a generally low state of health, no doubt, increases the susceptibility to it; (3) it is, *cæteris paribus*, commonest and most quickly produced in children; (4) certain races are peculiarly liable to suffer, *e. g.* the Irish, the Jews and some other Eastern races, and some of the German and French races. The Irish and Jews carry it with them all over the world, and transmit the liability to their descendants wherever they live. Negroes in America are said to be almost exempt; (5) damp and low-lying climates are more productive of it than others; thus it is rare in Switzerland. Possibly what are now race tendencies may be the expression of climatic conditions acting on the same race through many generations. It is difficult clinically to decide whether the trachoma growths, apart from the discharge, are caused by contagion, or by the influence of non-vital causes, such as damp and impure

air. They are probably due to an increase of normally existing adenoid tissue which acts as a filtering agent to prevent the entrance of deleterious matters into the blood. When accompanied by discharge, the disease is contagious; and it is generally held that the discharge from a case of trachoma is specific, *i. e.* that it will give rise by contagion, not only to muco-purulent or purulent ophthalmia, but to the true granular disease.

Sattler in 1881-2 believed that he had discovered a specific microbe for trachoma; his results have been substantially confirmed by Michel and others, but proof is still wanting that the diplococcus of Sattler is the cause of trachoma. Most of the micro-organisms hitherto described have been found by Ridley in the normal conjunctiva.

Those who practise in the army, or who have charge of such institutions as pauper schools, will find that in practice the causes of the chronic granular condition are inextricably mixed up with all kinds of facilities for contagion, and that it will be necessary to fight against two enemies—the causes predisposing to chronic granular disease, and the sources of contagious discharge. The former is to be combated by improved hygienic conditions, especially by free ventilation, dry air, abundant open-air exercise, and improvement of the general vigour. The sources of contagion are endless, especially since, as has been stated, granular patients are liable to relapses of muco-purulent discharge from almost any slight irritation. Frequent inspection of all the eyes, rigid separation of all who show any discharge or are known as especially subject to relapses, arrangements for washing such as will prevent the use of towels and water in common, extreme care against the introduction of contagious cases from without,—such are the chief preventive measures. Extra precautions will be needed in time of war or famine, or when measles or

scarlet fever are prevalent, or during marches through hot, sandy, or windy districts.

The *curative treatment*, when discharge is present, does not differ from that of the acute ophthalmias already given. The use of strong astringents (solid sulphate of copper) or caustics (nitrate of silver in strong solution, or in the mitigated solid pencil), or perchloride of mercury (F. 11), however, is generally needed in order to make much impression on the granular state of the lids. The lids being thoroughly everted, are touched all over with one or other application, and this is repeated daily, or less often; some experience being required before we can decide how often to touch the eyelids in each case. By careful treatment on this principle most patients may be kept comfortably free from active symptoms, many relapses may be prevented, the duration of the disease shortened, and the risks of secondary damage to the cornea much lessened. Do what we will, however, granular disease when well established is most tedious, and fastens many risks and disabilities on its subjects for years to come.

For routine treatment on a large scale nothing is so effectual as nitrate of silver, either a ten- or twenty-grain solution or the mitigated solid point (F. 1 and 2). But silver has the disadvantage of sometimes permanently staining the conjunctiva after long use, and in very chronic cases I think either sulphate of copper or the lapis divinus (F. 5) is to be preferred, especially as the patient may sometimes be taught to evert his own lids and use it himself. The solid mitigated nitrate of silver needs washing off with water at first, but in old cases it is often better not to do so.

Various operative measures have been recommended for shortening the duration of the disease; among these are the burning of the individual granulations with the galvano-cautery, and expression or scarification of the granulations.

The method of expression is carried out by everting the lid, grasping it between roller forceps and squeezing out the contents of the granulations; it is often combined with the application of strong perchloride of mercury to the lid.

These methods undoubtedly lead to a considerable improvement in the condition of the lids, which is sometimes permanent; but with the adoption of very severe methods there is always a risk of increasing the contraction of the conjunctiva.

Results of granular disease.—Friction by the granulations of the upper lid (Fig. 41 *a*), especially in cases of long standing where some scarring is present (*b*), often causes cloudiness of the cornea, partly from ulceration, but mainly from the growth of a layer of new and very vascular tissue in the superficial layers of the cornea (*pannus*)* (Fig. 42). In later periods the conjunctiva and deeper tissues are shortened and puckered by the scar following absorption of the “granulations” (Fig. 41, *b*). These changes, when severe, often lead to inversion of the border of the lid (*entropion*); when slighter, some or all of the lashes may be distorted so as to rub against the cornea, without

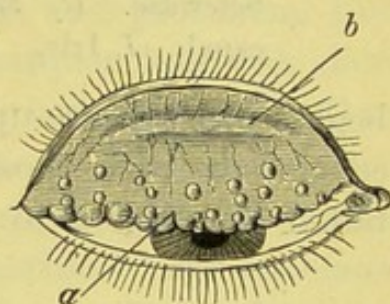


FIG. 41.—Granular upper lid. *a*. Granulations. *b*. Line of scar in typical position, parallel with border of lid.

* It is doubtful how far the development of pannus is due to friction, or to extension of the trachoma over the sclerotic to the cornea. Trachoma bodies may certainly be sometimes seen on the ocular conjunctiva. Raehlmann states that the first sign of pannus consists in a collection of lymph-cells in the cornea beneath Bowman's membrane; subsequently a layer resembling adenoid tissue is found there containing blood and lymphatic vessels. That friction may alter the epithelium is proved by certain cases in which the upper half of the cornea loses its polish during a temporary papillary roughening of the upper lid.

actually turning inwards (*distichiasis*, *trichiasis*); and these conditions are often combined with pannus. Pannus

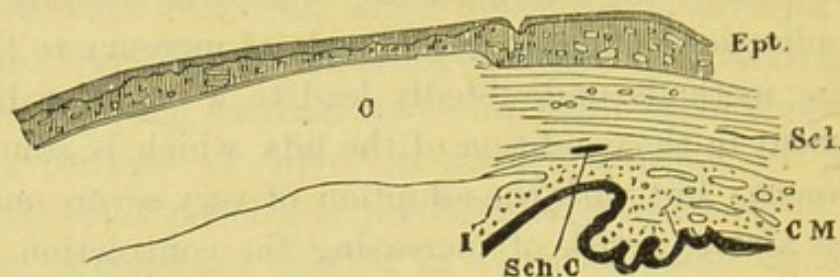


FIG. 42.—Section showing layer of new and vascular tissue (*pannus*) between epithelium (*Ept.*) and cornea (*C.*). *Scl.* Sclerotic. *C. M.* Ciliary muscle. *Sch. C.* Schlemm's canal. *I.* Iris. \times about 10 diameters.

begins beneath the upper lid; its vessels are superficial and continuous with those of the conjunctiva, and are distributed in relation to the parts covered by the lid, not in reference to the structure of the cornea (Fig. 43). The proper corneal tissue suffers but little except where ulcers occur; but when the vascularity is extreme it may soften and bulge, even without ulcerating.

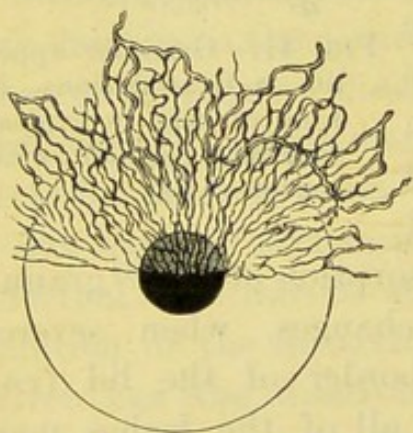


FIG. 43.—Pannus affecting upper half of cornea.

Pannus disappears when the granular lid, or the displacement of lashes is cured. Very severe and universal pannus is sometimes best treated by the induc-

tion of acute conjunctivitis, the inflammation being followed by obliteration of vessels and clearing of the cornea; this treatment needs judgment and caution. An infusion of the seeds known in commerce as "*Jequirity*" (F. 44), introduced into Europe by De Wecker, is used for the purpose; it probably depends for its action upon a non-organised ferment such as is found in some other seeds. A very acute attack of diphtheritic or purulent ophthalmia with

much swelling comes on a few hours after the infusion has been used, lasts a few days, and is followed by a more or less shrinking of the trachoma bodies and of the vessels. It occasionally causes glandular swellings in the neck and considerable general disturbance. Repeated attacks may be induced with safety at intervals of a few weeks. Much difference of opinion exists as to the clinical value of jequirity, owing to its having been often employed too strong and in unsuitable cases; it is not safe unless there are vessels on the cornea, and, safety apart, it is of little or no use if the conjunctiva be succulent and producing pus. It should be reserved for old, dry, granular lids with more or less pannus, and in such I have repeatedly had excellent results from it. Removal of a zone of conjunctiva and subconjunctival tissue (*syndectomy*, *peritomy*) from around the cornea is free from risk and sometimes very beneficial in old cases which, though severe, are not bad enough for inoculation. In old cases of granular disease, even where no complications have arisen, the upper lids often droop from relaxation of the loose conjunctiva above the tarsal cartilage, and the patient acquires a sleepy look.

For the cure of the displaced lashes and incurved eyelids we may—(1) repeatedly pull out the lashes with forceps; (2) extirpate all the lashes by cutting out a narrow strip of the marginal tissues of the lid; (3) attempt by operation to restore the lashes to their proper direction (Chap. XXII); (4) employ electrolysis; for a few lashes I now use sewing needles, inserting several at a time into the hair follicles, and passing the current through all at once, by means of a broad eyelid forceps. Such operations well selected and carefully performed give very good results; but as the inner surface of the lid continues to shorten, and this shortening tends to reproduce the original state of things, some of these procedures give only temporary relief.

Chronic conjunctivitis, chiefly of the lower lid, is a common disease, especially in elderly people. There is more or less soreness and smarting, redness and papillary roughness of the inner surface of the lid or of both lids, but very little discharge and no trachoma granulations. The caruncle is red and fleshy, as it is in all forms of palpebral conjunctivitis, and there is often soreness of the lids at the canthi. Lapis divinus is one of the best applications, and yellow ointment is sometimes useful (F. 5 and 25).

Lacrimon conjunctivitis.—Troublesome chronic conjunctivitis, often complicated by small pustules at the roots of the lashes, or by chronic blepharitis, is a common result of lacrimal obstruction. Micro-organisms of several kinds associated with pus formation have been found in these little abscesses, as well as in pus from the lacrimal sac. Palpebral conjunctivitis of long standing with watering, gummy discharge, and more or less blepharitis, should, especially if confined to one eye, always lead to the suspicion of mucocele or chronic lacrimal abscess.

The rare disease described as Amyloid of the Conjunctiva seems scarcely to have been noticed in this country. Detailed accounts of its clinical and pathological characters may be found in Knapp's 'Archives of Ophthalmology,' vols. x and xi, and an excellent abstract of one of these papers appeared in the 'Ophthalmic Review' for August, 1882.

Spring catarrh.—A peculiar and apparently specific chronic disease, affecting the conjunctiva of the globe and upper lid. In the former situation it takes the form of confluent broad patches of fleshy-looking thickening, of a light brown pink colour, slightly overlapping the edge of the cornea for a considerable part of its circumference. In the latter situation it occurs as large, pale, flat-topped granulations, which are sometimes made to assume polygonal outlines by their pressure upon one another. They

begin, like trachoma, at the inner and outer end of the lid; either variety may occur separately. The disease is worst in the warm part of the year, but it lasts in some cases many years, and gives but little trouble; the growths on the upper lid do not produce pannus. The thickening is said to consist chiefly of epithelium, and not to affect the deep tissues.

Treatment by nitrate of silver is unnecessary; occasional touching of the larger granulations by the galvanocautery is the best treatment. Unlike trachoma, it occurs commonly in all classes of society, and is probably not contagious; hence its differential diagnosis in children at school is very important. Hitherto it has not been much noticed in this country, but probably it is not so rare as has been thought.

Conjunctivitis from drugs.—The local use of atropine sometimes gives rise to a peculiar inflammation of the conjunctiva and skin of the lid—“*atropine irritation.*” The conjunctiva of the lids becomes vascular, thickened, and even granular, and usually the skin is reddened, slightly excoriated, and somewhat shining. This effect of atropine is commonest in old people. Some persons are very susceptible, and cannot bear even a drop or two without suffering in some degree. Scopolamine, daturine, and duboisin cause less irritation, and may be used instead; but it is better, if possible, not to use mydriatics at all for a few days. An ointment containing lead and zinc should be applied to the lids, and zinc or silver lotion to the conjunctiva; sometimes glycerine suits better than ointment. In susceptible persons I have not found this peculiar inflammation prevented, either by the use of solutions made with antiseptics, or of solutions quite freshly made. Eserine sometimes causes identical symptoms. Congestion of the conjunctiva has been seen among those employed in aniline dye works; conjunctivitis was seen by Trousseau in 4 to

5 per cent. of patients treated for psoriasis by chrysophanic acid. If continued long enough arsenic will in some persons produce redness and congestion of the conjunctiva. The action of jequirity is described on p. 95.

Ophthalmia nodosa (Saemisch).—This singular affection is brought about by the irritation of caterpillar hairs introduced into the conjunctival sac. The hairs set up a nodular inflammation of the conjunctiva which may extend to the iris and deeper parts of the eye. The hairs should be removed from the conjunctiva, and the inflammatory symptoms treated as they arise.*

Primary shrinking of the conjunctiva (Pemphigus of Conjunctiva).—A very peculiar and rather rare disease, in which, with the phenomena of chronic inflammation, the whole conjunctiva slowly atrophies and contracts, owing to the formation in it of cicatricial tissue. During the earlier stages the thickening of the tarsus and the congestion with scarring of the palpebral conjunctiva have sometimes led to the disease being mistaken for trachoma; the two maladies are, however, quite distinct. Finally the whole conjunctival sac disappears, and the free borders of the lids, fixed closely to the globe, are directly continuous with the cornea, which, irritated and dried by exposure and want of secretion, becomes opaque and covered by crusts ("xerosis"). No treatment seems of any use.

In some of the cases there has been a history of general pemphigus, and reason to believe that the disease of the conjunctiva resulted from a modified form of pemphigus eruption.

Snow blindness.—Long exposure of the eyes to the glare from snow gives rise to an acute conjunctivitis attended with intense pain, photophobia, and occasionally conjunctival hæmorrhages. Similar attacks result from temporary or even momentary exposure to the intense light of the electric

* See paper by Lawford, 'Ophth. Trans.,' vol. xiv, 210.

arc; this is more likely to occur in the operation of electric welding, where the thickness of the arc is very great.

The effect on the eye seems to be of the same nature as the scorching or blistering of the skin which is sometimes produced under the same circumstances. According to Snell,* spectacles made up of six layers of glass, alternately red and blue, are worn as a protection to the eyes by the workmen engaged in this occupation.

* Brit. Med. Assoc., Bristol, 1894.

CHAPTER VII

DISEASES OF THE CORNEA

A. Ulcers and non-specific inflammatory diseases

INFLAMMATION of the cornea may be circumscribed or diffuse, and, though usually affecting the proper corneal tissue, may be limited to the epithelium on either of its surfaces. It may be a local process leading to formation of pus or to ulceration; or the expression of a constitutional disease, such as inherited syphilis; or it may form part, and perhaps only a minor part, of disease involving also the deeper parts of the eyeball—the iris (kerato-iritis), or sclerotic (sclero-keratitis), for example.

The different varieties of corneal ulceration and suppurative inflammation form a very large and important contingent of ophthalmic cases. The cornea, although a fibrous structure, is further removed from the blood-vessels than almost any other tissue, and its delicate surface is much exposed; it is therefore extremely susceptible both to external irritants and to disturbances of nutrition from defective supply, or bad quality, of blood; ulceration of the cornea always means deficient vitality. Lastly, its surface is so delicate, and its perfect transparency and regularity so important, that slight injuries and irritations are of more moment here than in any other part of the body.

When inflamed the cornea always loses its transparency. If only the anterior epithelium be involved the surface

loses its polish, and looks like clear glass which has been breathed upon—"steamy," or finely pitted—a condition occurring in many states of disease. Thickening of the epithelium, and still more, exudation into the corneal tissue, are shown by a white, greyish, or yellowish tint.—If the corneal tissue be opalescent, while the surface is at the same time "steamy," the term "ground-glass" gives a good idea of the appearance, though to make the simile correct the glass ought to be milky throughout, as well as ground on the surface. Rapid suppurative inflammation is preceded by a stage of diffused opalescence; hence rapid opalescence is a sign of imminent danger in such diseases as purulent ophthalmia, severe burns, or paralysis of the fifth nerve. Fluorescence of the cornea has been seen as the result of the use of quinine lotions to the eye, and appears to be due to the deposit of crystals of quinine in the cornea.

Before describing the most important types of corneal ulcer, it is convenient to mention the principal *changes attendant on ulceration of the cornea* in general.—An ulcer of the cornea is preceded by a stage of infiltration, and the inflamed spot is generally a little raised. After the centre of the spot has broken down into an ulcer, the extent, density, and colour of the infiltration at its base and edges are important guides to its future course. The ulcer when healed leaves a hazy or opaque spot (*leucoma* if dense, *nebula* if faint), which is slight and may disappear entirely if superficial, but will in part be permanent if the ulcer have been deep. These opacities are likely to clear, *cæteris paribus*, in proportion to the youth of the patient; time also is a very important element, *nebulæ* often continuing to clear slowly for years; local stimulation aids in the removal of the opacities, one of the best applications being the ointment of yellow oxide of mercury (F. 25, 26). Other modes of local stimulation have been recommended,

such as tattooing, massage, electrolysis, and the use of various powders. Several successful attempts have been made to transplant circular portions of the clear cornea removed from the rabbit by a trephine, to replace portions of the human cornea, rendered opaque by disease. To do this successfully it is necessary to leave behind Descemet's membrane in the diseased cornea (v. Hippel). Ulcers which have little or no infiltration often heal slowly, but leave a permanent facet or flattening; such facets destroy the regular curvature of the cornea, and thus often cause more damage to vision than a considerable degree of mere clouding. During repair blood-vessels often form and pass from the nearest part of the corneal edge to the ulcer, to disappear when healing is complete; phlyctenular ulcers, however, are vascular from the beginning. Corneal imperfections are, of course, most damaging to vision when placed over the pupil.

The chief *symptoms* of corneal ulceration are—(1) *photophobia*, with its consequence, spasm of the orbicularis, *blepharospasm*; (2) *congestion*; (3) *pain*. All three symptoms vary extremely in degree in different cases.—As a broad rule with many exceptions, we may say that intolerance of light is worse in children than in adults, worse with superficial than with deep ulcers, and worse in persons who are strumous and irritable than in those with healthy tissues and good tone. Photophobia should always lead to a careful inspection of the cornea, and we shall then sometimes be surprised to find how slight a change gives rise to this symptom in its severest form.—The degree of congestion varies with the seat and cause of the ulcer, and with the patient's age, being usually greatest in adults. The visible congestion is, as in iritis, due especially to distension of the subconjunctival twigs of the *ciliary zone* (Fig. 25, Ant. Cil., and Fig. 28), but there is often congestion of the conjunctival vessels as well. In some forms of marginal

ulcer only those vessels which feed the diseased part are congested. Great pain in and around the eye often attends the earlier stages of corneal abscess, and is common in many acute ulcers; as a symptom, it of course always needs careful attention; it is generally relieved by those local measures which are best for the disease itself.

TYPES OF CORNEAL ULCERATION

(1) The *simple ulcer* begins as a little greyish-white spot, at first elevated and bluntly conical, afterwards showing a minute shallow crater; the congestion and photophobia vary, but are often slight. The ulcer is usually single, but it is apt to recur in the same, or the other eye. The infiltration often extends into the corneal tissue, and the residual opacity remains for a long time, if not permanently. The patients are always badly nourished. In most cases the ulcer quickly heals, but now and then the infiltration passes into an abscess, or a spreading, suppurating ulcer.

Less commonly we meet with a central ulcer, or a succession of ulcers, of a much more chronic character, and attended with little or no infiltration. After lasting for months the loss of tissue is only partly repaired, and a shallow depression or a flat facet is left with but little loss of transparency. Some of the best examples are seen in anæmic, or strumous patients with granular lids of long standing.

(2) *Phlyctenular conjunctivitis* (phlyctenular keratitis, pustular ophthalmia, marginal keratitis, strumous ophthalmia, lymphatic conjunctivitis).—The formation of little papules, or pustules, on or near the corneal margin is exceedingly common, either independently, or as a complication of some existing ophthalmia. Although there are many varieties and degrees of phlyctenular inflammation

in respect to the seat, extent, and course of the disease, the following features are common to all. They show a strong tendency to recur during several years; they are seldom seen in very young children, and comparatively seldom after middle life; they occur often in children who have a tendency to enlargement of their lymphatic glands; blepharitis is often seen in the same patients; the first attack often follows closely after an acute exanthem, and especially after measles; the cases are much influenced by climate and weather, and their condition often varies extremely from day to day without making either progress or regress.

An elevated spot, like a papule, commonly about the size of a small mustard seed, is seen either on the white of the eye near the cornea, or upon, or just within, the corneal border. It is preceded and accompanied by localised congestion. Its top sometimes becomes as yellow as that of an acne pustule, but more often when seen it has become

abraded, and apthous-looking. Pustules at a little distance from the cornea (Fig. 44), although generally larger than those seated on the corneal border, occasion less photophobia, and are more easily cured. Pustules at the corneal border, though often very small, cause trou-

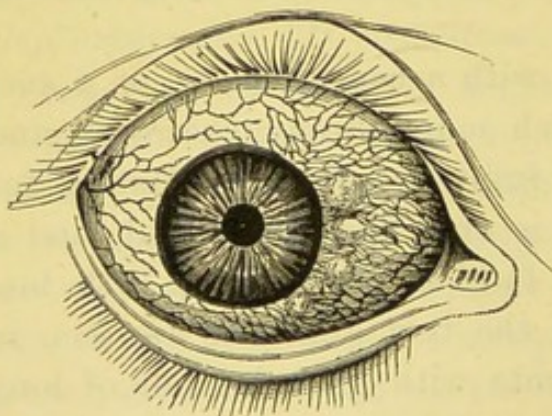


FIG. 44. — Phlyctenular ophthalmia, conjunctival form. (Dalrymple.)

blesome, and even very severe photophobia; they are troublesome in proportion rather to their number than their size, and if so numerous as to form a ring around the cornea their cure is often very tedious.

A pustule is always liable, even when it has begun on

the conjunctiva, to advance as a superficial ulcer on to the cornea, though it never extends in the opposite direction over the sclerotic. Such a *phlyctenular ulcer*, if it do not stop near the corneal border, will make, in an almost radial direction, for the centre, carrying with it a leash of vessels which lie upon the track of opacity left in the wake of the ulcer (Fig. 45). Finally, the ulceration stops, the vessels dwindle and disappear, but the path of opacity seldom clears up entirely. The term *recurrent vascular ulcer* is used when such ulcers are solitary; but they are often multiple as well as recurrent, and then, in the end, we find the cornea covered by a thin, irregular network of superficial vessels on a patchy, uneven, hazy surface, the so-called "*phlyctenular pannus*."

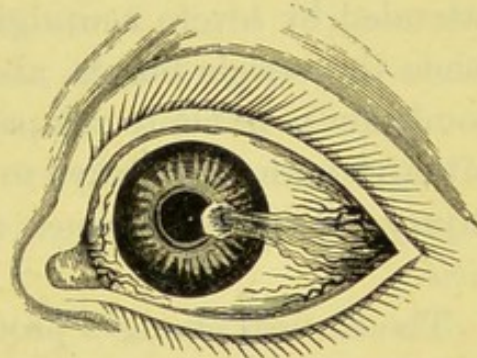


FIG. 45.—Phlyctenular ulcer.
(Travers.)

A common variety of phlyctenular inflammation, aptly called *marginal conjunctivitis* (perhaps allied to the "*spring catarrh*" of Continental authors), occurs in the form of a slight, granular-looking, often vascular swelling, beginning as a crescent above or below, but often extending all round the edge of the cornea. If the process continue the cornea is invaded by a densely vascular, superficially ulcerated, and yet thickened zone. It is to be distinguished from a deeper variety of marginal keratitis alluded to at p. 115.

In another variety a single pustule just within the border of the cornea ulcerates deeply, becomes surrounded by swollen, softened, suppurating tissue, and may perforate; such cases are seen in weakly women and strumous children.—In very rare cases, what appears to be an ordinary conjunctival pustule persists, grows deeply, and may even perforate the sclerotic in the form of an ulcer; or it may

infiltrate the sclerotic and the ciliary body beneath, forming a soft, semi-suppurating tumour, whence the inflammation is likely to spread to the vitreous and destroy the eye. Stopping short of these extreme results, such a case forms one type of episcleritis (Chap. IX).

Occasionally a large, sometimes solitary blister forms under the anterior corneal epithelium; it rises quickly, is attended by severe neuralgic pain, which is often relieved when the vesicle bursts, about a day after the onset. The condition is liable to relapse in the same cornea, and seems often though not always to have its origin in a superficial injury. It is sometimes called *Relapsing Bullous Keratitis*.

The corneal changes produced by the friction of granular lids have been considered under that subject. The pannus of granular lids usually differs from the "phlyctenular pannus" just mentioned in being denser and more uniform beneath the upper lid (Fig. 43); any doubt is dispelled by everting the lid. But it must be borne in mind that ulceration of the cornea often occurs as a complication of trachomatous pannus (p. 93).

(3) In old persons a crescentic ulcer sometimes forms in the situation of, or actually upon, an arcus senilis. Though these cases generally do well they should be watched, for at first they may be indistinguishable from more serious forms about to be described.

In rare cases, the ulcer instead of healing shows a tendency to spread, and gradually to invade the whole cornea, the characteristic feature being the undermining of the adjacent healthy cornea by the advancing edge of the ulcer. Perforation never takes place, but with occasional periods of quiescence the whole surface of the cornea is invaded, and rendered permanently opaque. This form of *chronic serpiginous* ulcer is more common in tropical countries than in England, and seems to yield to no treatment short of the

actual cautery. It is sometimes known as *rodent ulcer* of the cornea.

(4) *Acute infective corneal ulcers.* Several varieties of dangerous corneal ulcer may be grouped together as probably depending upon local infection, and there seems to be no doubt that destructive inflammation of the cornea may occur *in utero*. Differing widely in rapidity and depth, they agree in being often the result of slight injuries by chips of metal, beards of corn, &c., in tending to spread at one border whilst healing at another, in the absence of "vessels of repair" such as are usually formed during the healing of other ulcers, and in being often complicated with hypopyon (Fig. 47).

The most important variety is the *acute serpiginous* ulcer, which begins as a grey spot showing slight ulceration, and having a sharply cut border *one part of which is more densely opaque than the rest* (Fig. 46); this infiltrated, advancing edge is the distinguishing mark of the ulcer. If the ulcer have lasted some little time a portion of its edge, usually that nearest the corneal border, will be more or less filled up; in such a state the most conspicuous part of the ulcer is crescentic (Fig. 46). Unless quickly checked the process often spreads widely, eats deeply, becomes complicated with iritis and hypopyon, and leads to perforation of the cornea.

Probably many cases of corneal abscess and acute suppurating ulcer of less distinct type than the above are, like it, due to infection.

Abscess may occur at any age, but, like serpiginous ulcer,

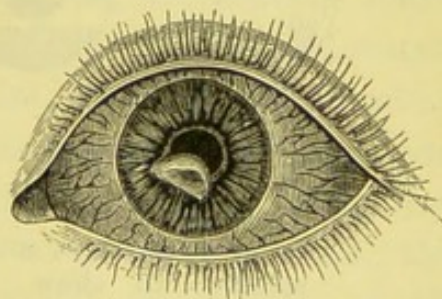


FIG. 46.—Acute serpiginous ulcer of cornea with crescentic border of infiltration. (From a sketch by Dr. Herbert Habershon.)

is commonest in those who are old, underfed, or damaged by drink; the simple ulcer of children, however, may go on to abscess. Abscess usually forms at the centre of the corneal area as a small round raised spot, with great pain and congestion; rapidly enlarging, it usually bursts forwards, leaving a round ulcer covered with lymphous pus, but it may perforate the hinder surface of the cornea; hypopyon often occurs. The purulent infiltration may spread rapidly and destroy almost the whole cornea.

Hypopyon signifies a collection of pus or puro-lymph at the lowest part of the anterior chamber; its upper boundary is usually, but not always level (Fig. 47). It may

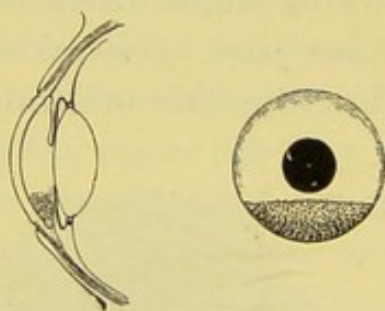


FIG. 47.—Hypopyon, seen from the front, and in section, to show that the pus is behind the cornea.

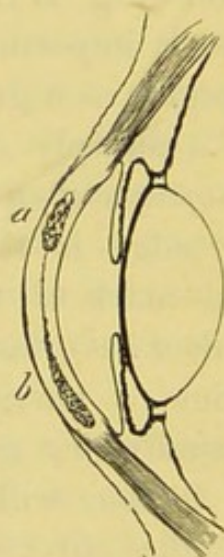


FIG. 48.—a. Abscess. b. Onyx.

occur with any ulcer, whether deep or not, which is accompanied by purulent infiltration of the surrounding cornea; or with corneal abscess. The pus may be derived either from an abscess breaking through the posterior surface of the cornea, or from suppuration of the epithelium covering Descemet's membrane, or from the surface of the iris. Simple iritis now and then gives rise to hypopyon. The diameter of the anterior chamber being rather greater than the apparent diameter of the clear cornea, a very small hypo-

pyon may be hidden behind the overlapping edge of the sclerotic.—In some cases of severe corneal suppuration (*a*, Fig. 48) the pus sinks down between the lamellæ of the cornea (*b*). To this condition the term *onyx* is applied and should be limited, though it is sometimes used in other senses. The term, however, may very well be discarded. Onyx and hypopyon often co-exist, and then the distinction between them can hardly be made without tapping the anterior chamber. Hypopyon if liquid will, but onyx will not, change its position if the patient lies down; as, however, the pus of hypopyon is often gelatinous or fibrinous, this test loses much of its value. The distinction can sometimes be made by means of oblique illumination, if the cornea in front of an hypopyon remain clear.

(5.) *Kerato-malacia*, or primary sloughing of the cornea, occurs in young children who are the subjects of grave disturbances of nutrition. The first manifestation of the affection is a dryness of the conjunctiva, which is no longer moistened by the tears; small triangular patches of roughened epithelium, covered with foam, similar to those which appear in adults with night-blindness, so called *xerotic patches*, are found on each side of the cornea. The dryness spreads to the cornea, which soon becomes dull; this is followed by infiltration and rapid destruction of the whole or part of the cornea. In the typical cases there is little intolerance of light and no discharge. *Kerato-malacia* appears in England mostly in hand-reared infants who are insufficiently nourished in consequence of unsuitable food or of prolonged diarrhoea; it may occur after severe attacks of measles, scarlet fever, &c., and frequently comes on during the late stages of not very severe ophthalmia neonatorum in children who are the subjects of congenital syphilis. It also occurs in breast-fed infants in countries where long religious fasts are practised. The children are extremely ill, and very frequently die.

(6) *Febrile herpes* of the cornea appears as small vesicles which rupture, and leave shallow punched-out ulcers. These sometimes spread generally over the surface, having a defined grey infiltrated edge, but occasionally the ulceration takes the form of a stem with irregular broad buds or branches not unlike a liverwort, the disease being superficial from beginning to end, and showing no tendency to the formation of pus, but spoiling the surface of the cornea (*dendritic creeping ulcer*).

In rare cases of keratitis beginning as vesicles, small filaments are seen adhering to the surface of the cornea; these filaments are seen under the microscope to consist of a twisted strand made up of epithelial cells and mucus. This affection has been called *filamentary keratitis* (Leber, Nuel, Hess).

Superficial punctate keratitis (Fuchs) probably also belongs to this group. It begins with the symptoms of an acute catarrh of the eyes and nose. The corneal changes consist of minute grey opacities with a slightly raised surface; the symptoms of irritation soon disappear, but the opacities persist for a longer period. They do not ulcerate, and as a rule the vision is unimpaired.

(7) For Herpes zoster and Neuro-paralytic keratitis see Chap. XXIII.

(8) Ulceration of the cornea from exposure occurs in paralysis of the orbicularis, in some cases of cicatricial contraction of the lid, in severe cases of exophthalmic goitre, and in persons who are comatose for any length of time. It is often possible to avoid this by closing the lids with a strip of adhesive plaster, but it may be necessary to pare the edges of the lid and stitch them partly together.

Treatment of ulcers of the cornea

The principles of local treatment for the various types of corneal ulceration are :—(1) To favour healing by keeping

the surface at rest. (2) To relieve pain, photophobia, and severe congestion. (3) To promote absorption of pus, whether in the corneal layers or in the anterior chamber. (4) To check the spread of local infection by scraping, actual cautery, and antiseptics. (5) By incision to evacuate pus between the corneal layers (abscess), or in the anterior chamber (hypopyon), when abundant or increasing. (6) To stimulate the surface of ulcers which have begun to heal, or of indolent ones which are stationary. (7) Counter-irritation by a seton in certain chronic cases. (8) When the corneal ulceration is caused by granular lids, or associated with any form of acute ophthalmia, the treatment of the conjunctiva is usually more important than that of the cornea. (9) Where nutrition is defective, as in keratomalacia, it is highly necessary to inquire into and remedy any defect in feeding; cod-liver oil is generally of great value in such cases.

Often we have no difficulty in deciding upon the treatment. But in some cases, especially the severer ones, much judgment is needed; and it is sometimes impossible to predict with certainty what measures will be best.

Ulcers of the cornea are so often a sign of bad health that every care should be bestowed upon the patient's general state.

Treating the matter clinically, we shall find that local stimulation is best for a large number of the cases as they first come under notice, including phlyctenular cases, chronic superficial ulcers of various kinds, and even many recent ulcers if not threatening to suppurate. As a general rule this plan alone is not suitable when there is much photophobia, but exceptions occur, especially in old-standing cases. The most convenient remedy is the ointment of amorphous yellow oxide of mercury (F. 12 and 13), of which a piece about as large as a hemp-seed is to be put inside the eyelids once or twice a day. If smarting con-

tinue for more than half an hour the ointment should be washed out with warm water; and if the irritability increase after a few days' use of the ointment the preparation must be weakened or discontinued. The same ointment, combined with atropine, gives excellent results in cases of superficial ulcer with much photophobia (F. 14). Calomel flicked into the eye daily or less often is also an admirable remedy. Nitrate of silver in the form of solid mitigated stick (F. 1) is useful if carefully applied to large conjunctival pustules, and occasionally to indolent corneal ulcers; its use, however, needs some skill, and is seldom really necessary:—solutions of from 5 to 10 grains to the ounce may be cautiously used by the surgeon instead of the yellow ointment, and are particularly valuable in old vascular ulcers and in ulcers with conjunctivitis.—When in doubt it is best to depend for a few days on atropine alone, used once or twice a day.

In all cases of corneal disease attended with intolerance of light, the patient is to wear a large shade over *both* eyes, or, better, a pair of "goggles;" a little patch over one eye does not relieve photophobia. If the intolerance of light be excessive it is sometimes useful to douche the face and eyes with a stream of cold water. The patients should be allowed to go out; many a child is kept within doors, to the injury of its health, who, with suitable protection, can go out daily without the least detriment to its eyes.

In chronic and relapsing cases, with photophobia and irritability, where all other methods have had a good trial, a seton gives the best results, whether the eye be much congested or not. The silk must be very thick, the punctures should be at least an inch apart, and be so placed that the scars may be hidden by the hair on the temple or behind the ear. The seton is to be moved daily, and if acting badly may be dressed with savin ointment; it should be worn at least six weeks. Severe inflammation,

and even abscess, sometimes set in a few days after the insertion of the thread, and in very rare cases secondary bleeding has occurred from a branch of the temporal artery. To avoid wounding this artery the skin is to be held well away from the head.

Very severe, recent phlyctenular cases are occasionally difficult to influence, and remain practically "blind" with spasm of the lids for weeks. There is seldom any risk, provided that the cornea be examined at intervals of a few days, and in the end such cases do well. Calomel dusted on the cornea sometimes helps more than any other local measure, and change of air, especially to the sea-side, frequently effects a more rapid cure than any local treatment.

Cases for which the stimulating treatment is suitable seldom need the eye to be bandaged, though, as mentioned, they often need a shade or goggles.

The remaining methods are applicable to the severer forms of ulceration—the serpiginous ulcer, deep suppurating ulcers, abscess, and generally all ulcers with hypopyon, and all acute ulcers in elderly persons. In many cases of severe type, at an early stage, the pain may be relieved and the ulceration stopped by *very hot* fomentations (of water, poppyhead, or belladonna) to the eyelids for twenty minutes every two hours, the eye being tied up in the intervals with a large pad of cotton wool and bandage, and atropine used two or three times a day; the patient must rest, have good food, often with alcohol, and take quinine, or bark and ammonia. If, nevertheless, the ulceration spread, or a hypopyon form or increase, incision of the cornea and the use of topical remedies are called for. Of such remedies the best seem to be the actual cautery, preceded by scraping with a sharp spoon, and followed by iodoform or boracic acid. The actual cautery may be either the fine galvano-cautery, or a very small Paquelin;

the edge of the ulcer is to be well burnt before the heat is applied to the floor, and I like to burn a little beyond the opaque edge. Instead of the cautery, pure carbolic acid or strong solutions of nitrate of silver, applied directly to the ulcer, often succeed in checking its course.

Iodoform, which is probably the most useful corneal antiseptic, may be used in powder or strong ointment (20 or 30 gr. to ℥j; F. 30) freely three times a day or more; it gives no pain. Boracic acid may be used in the same way. For dendritic ulcers absolute alcohol rubbed thoroughly into the ulcerated surface, or pure carbolic acid or perchloride of mercury of 2 or 4 per cent. strength applied with a camel-hair brush are generally successful.

Hypopyon, if large (Fig. 47) or increasing, must be let out, and on the whole, for most cases, Saemisch's plan of cutting through the cornea quite across the ulcer is the best for this purpose, because if there be pent-up pus in the cornea this section will allow its removal at the same time; the section should be made with a Graefe's cataract knife (Fig. 151) entered with its back towards the lens at one border of the ulcer, carried across the anterior chamber, and brought out at the other side of the ulcer. It is sometimes an advantage to keep up leakage by reopening the wound with a probe for a few days. Corneal section also often instantly relieves the severe pain of these cases; the section may sometimes be made with equally good effect in the lower part of the cornea away from the ulcer. If the ulcer have already perforated and the eye be worth saving, iridectomy should be done, either by drawing the prolapsed iris freely through the perforation and cutting it off, or by making an incision in a sound part of the cornea. I believe that careful scraping and burning will do much to reduce the severity of infective corneal ulcers.

Some of these ulcers are accompanied by a good deal of muco-purulent conjunctivitis, for which a ten-grain solu-

tion of nitrate of silver, painted inside the lower lid with a brush about once a day, may generally be used; its effect must be watched, and its employment discontinued if it increase irritability.

Use of atropine and eserine in severe ulcers of the cornea.—Formerly either atropine, or belladonna lotion, was used for nearly every case of severe corneal ulcer. Atropine often relieves pain, prevents or lessens iritis, and probably lessens engorgement of the vessels of the iris and ciliary region; it may generally be used, sparingly, as an auxiliary in suppurating and serpiginous cases, but it tends to increase any existing conjunctival inflammation. During the last few years eserine has come into use for certain cases which would formerly have been treated chiefly by atropine. The deep, funnel-shaped, suppurating ulcer which sometimes develops from a marginal pustule is the most suitable for treatment by eserine, whether complicated with hypopyon or not. Although in a bad case of this sort, hot fomentations and the compress are necessary, I have seen a certain number of less severe ones recover under eserine alone, used about six times a day (F. 39). Eserine probably acts partly by enlarging the surface of the iris and dilating the ciliary arteries, thus favouring absorption and increasing the nutrition of the cornea. For this reason in keratomalacia, where the cornea suffers from insufficient nourishment, it should be used without delay. The opacity sometimes clears up in a remarkable way under its use; possibly, also, it acts locally on the ulcerated surface. There is no clinical proof that eserine lowers tension unless the tension has been previously increased, as it seldom is in corneal ulcers. Eserine causes congestion of the deep vessels of the ciliary region, and after a time increases the photophobia and irritability of the eye; these symptoms usually coincide with disappearance of the corneal infiltration and the commencement of

vascularisation of the ulcer, and when this stage is reached the eserine should be discontinued.

The alternate use of heat and cold for short periods is recommended in some obstinate cases of corneal ulceration, the object being to improve nutrition by causing frequent changes in the quantity and rate of the blood-supply.

B. *Diffuse Keratitis*

Syphilitic, interstitial or parenchymatous keratitis

In this disease the cornea in its whole thickness undergoes a chronic inflammation, which shows no tendency either to the formation of pus or to ulceration. After several months the inflammatory products are either wholly or in great part absorbed, and the transparency of the cornea restored in proportion.

The changes in the cornea are usually preceded for a few days by some ciliary congestion and watering. Then a faint cloudiness is seen in one or more large patches, and the surface, if carefully looked at, is found to be "steamy." These nebulous areas may lie in any part of the cornea. In from two to about four weeks the whole cornea has usually passed into a condition of white haziness with steamy surface, of which the term "ground

glass" gives the best idea. Even now, however, careful inspection, especially by focal light, will show that the opacity is by no means uniform, that it shows many whiter spots, or large denser clouds, scattered about in the general mist; in very severe

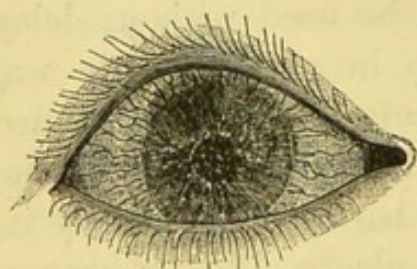


FIG. 49.—Interstitial keratitis.

cases the whole cornea is quite opaque and the iris hidden; but as a rule the iris and pupil can be seen, though very

imperfectly (Fig. 49). In many cases iritis occurs and posterior synechiæ are formed; cyclitis with deposit in the back of the cornea is a very frequent accompaniment of the corneal affection; in a large proportion of cases of interstitial keratitis there is evidence of early participation of the uveal layer in the inflammatory process. Blood-vessels derived from branches of the ciliary vessels (Fig. 25) are often formed in the layers of the cornea (Fig. 50);

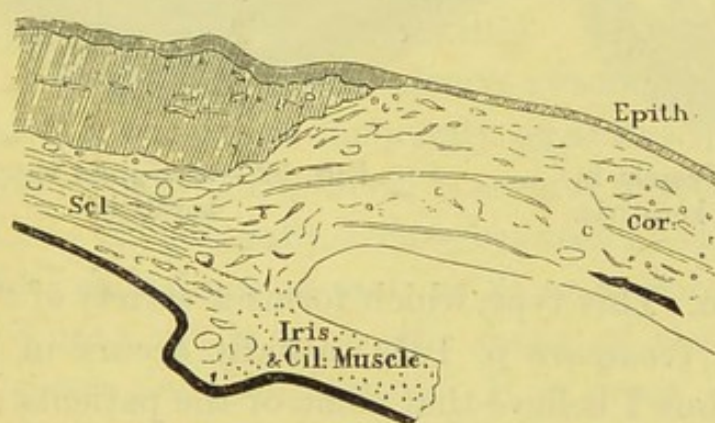


FIG. 50.—Thickening of cornea and formation of vessels in its layers in syphilitic keratitis. Subconjunctival tissue thickened. \times about 10 diameters. Compare with Fig. 42.

they are small but set thickly, and in patches; as they are covered by a certain thickness of hazy cornea, their bright scarlet is toned down to a dull reddish-pink colour ("salmon patch" of Hutchinson). The separate vessels are visible only if magnified (p. 51), when we see that the trunks, passing in from the border, divide at acute angles into very numerous twigs, lying close to each other, and taking a nearly straight course towards the centre (Fig. 51). These salmon patches when small are often crescentic, but if large tend to assume a sector shape.—In another type the vascularity begins as a narrow fringe of looped vessels which are continuous with the loop-plexus of the corneal margin (Fig. 52, compare Fig. 25, *l*), and gradually extend from above and below towards the centre. The

vessels in these cases are somewhat more superficial, and the corneal tissue in which they lie is always swollen by

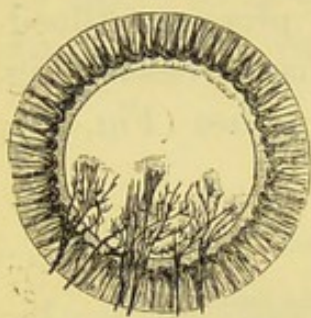


FIG. 51.—Vessels in interstitial keratitis.

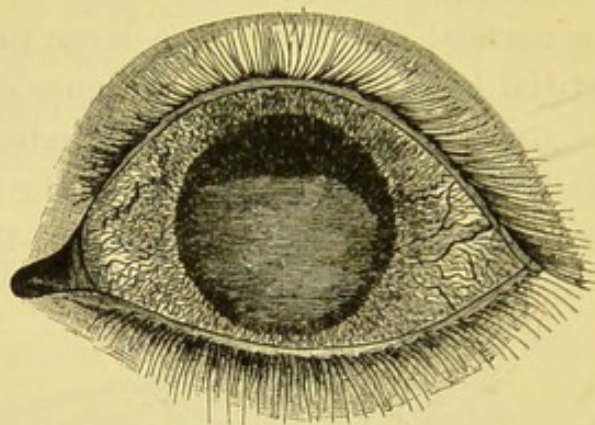


FIG. 52.—Marginal vascular keratitis.

infiltration. This type, which forms a variety of "*marginal keratitis*" (compare p. 105), usually occurs in syphilitic subjects, but I believe that some of the patients are at the same time strumous. A similar condition, sometimes leading to secondary glaucoma, occurs now and then in elderly people.—In extreme cases of either type of vascular keratitis the vessels cover the whole cornea, except a small central island.

The degree of congestion and the subjective symptoms in syphilitic keratitis vary very much; as a general rule there is but moderate photophobia and pain, but when the ciliary congestion is great these symptoms are sometimes very severe and protracted.

The attack can be shortened and its severity lessened by treatment; but the disease is always slow, and from six to twelve months may be taken as a fair average for its duration from beginning to end. Very bad cases with excessively dense opacity sometimes continue to improve for several years, and may recover an unexpected degree of sight. Perfect recovery of transparency is less common, even in moderate cases, than is sometimes supposed, but

the slight degree of haziness which so often remains does not much affect the sight. The epithelium usually becomes smooth before the cornea becomes transparent; but in severe cases irregularities of surface may remain and render the diagnosis difficult. Very minute vessels (as in Fig. 51) seen by direct ophthalmoscopic examination with a high + lens (p. 51), nearly straight, and branching at acute angles with short abrupt rectangular bends here and there, are often left, and when found are good evidence of previous interstitial keratitis.

Syphilitic keratitis is almost always symmetrical, though an interval of a few weeks commonly separates its onset in the two eyes; rarely the interval is several months, a year, or even more. It generally occurs between about the ages of 6 and 15; sometimes as early as $2\frac{1}{2}$ or 3 years; in rare instances it may set in after 40; many of the very late cases are severe and complicated. If it occur very early the attack is generally mild. Relapses of greater or less severity are common. Not only does iritis occur with tolerable frequency, but we occasionally meet with deep-seated inflammation in the ciliary region, giving rise either to secondary glaucoma, or to stretching and elongation of the globe in the ciliary zone, or to softening and shrinking of the eyeball.* Dots of opacity may sometimes be seen on the back of the cornea at its lower part, before the cornea itself is much altered (p. 121): sometimes, too, the interstitial exudation is much more dense at the lower part of the cornea than elsewhere. Syphilitic keratitis in strumous children often shows more irritability, photophobia, and conjunctival congestion, than in others; but

* When the cornea has cleared, ophthalmoscopic signs of past choroiditis (Chap. XII) are often found at the fundus. The choroiditis often dates much further back than the keratitis, but there is little doubt that it may relapse, or occur as an accompaniment of the corneal disease. (Chap. XXIII.)

it is very seldom that ulceration occurs, and although in the worst cases the cornea becomes softened and yellowish, and for a time seems likely to give way, actual perforation is one of the rarest events. Pannus from granular disease may coexist with syphilitic keratitis.

Treatment.—A long but mild course of mercury is certainly of use. It is customary to give iodide of potassium also, and it probably has some influence. If the patients be very anæmic, and they often are so, iron, or the syrup of its iodide, is more advisable than iodide of potassium, as an adjunct to the mercury. Locally it is well to use atropine by routine until the disease has reached its height, on the ground that iritis may be present. Setons in my experience are seldom of use; but in cases attended by severe and prolonged photophobia and ciliary congestion iridectomy is occasionally followed by rapid improvement; this operation, however, is seldom needed or justifiable unless there be decided glaucomatous symptoms. When all inflammatory symptoms have subsided, the local use of yellow ointment or calomel (F. 24 and 25), appears to aid the absorption of the residual opacity.

The form of keratitis above described is caused by *inherited* syphilis. In rare cases it has been seen as the result of secondary *acquired* syphilis. Other cases of diffuse keratitis occur in which syphilis has no share, but they are seldom symmetrical, nor do they occur early in life. That diffuse chronic keratitis, affecting both eyes of children and adolescents, is, when well characterised, almost invariably the result of hereditary syphilis, is proved by abundant evidence. A large proportion of its subjects show some of the other signs of hereditary syphilis in the teeth, skin, ears (deafness), physiognomy, mouth, or bones. When the patients themselves show no such signs, a history of infantile syphilis in the patient or in some brothers and

sisters, or of acquired syphilis in one or other parent, may often be obtained.* That this keratitis stands in no causal relation to struma is clear, because the ordinary signs of struma are not found oftener in its victims than in other children, because persons who are decidedly strumous do not suffer from this keratitis more often than others, and because the forms of eye disease which are universally recognised as "strumous" (ophthalmia tarsi, phlyctenular disease, and relapsing ulcers of cornea) very seldom accompany this diffuse keratitis. (Illustrations of the teeth in inherited syphilis are given in Fig. 161, Chap. XXIII.)

Other affections of the Cornea

The cornea is more or less involved in several diseases in which the primary, or the principal, seat of mischief lies in another part of the eye. It is important for purposes of diagnosis to compare these *secondary or complicating affections* with the primary diseases of the cornea already described.

In iritis the lower half of the cornea often becomes steamy, and more or less hazy. In some cases a number of small, separate, opaque dots are seen on the posterior elastic lamina (Descemet's membrane), often so minute as to need magnifying (pp. 40 and 51). These dots are sharply defined, the large ones looking very like minute drops of cold gravy-fat, the smallest like grains of grey sand; in cases of long standing they may be either very white or highly pigmented. They are generally arranged in a triangle, with its apex towards the centre and its base

* I have found other personal evidence of inherited syphilis in 54 per cent. of my cases of interstitial keratitis, and evidence from the family history in 14 per cent. more—total 68 per cent.; and in most of the remaining 32 per cent. there have been strong reasons to suspect it.

at the lower margin of the cornea, the smallest dots being near the centre (Fig. 53) ; but in some cases (sympathetic

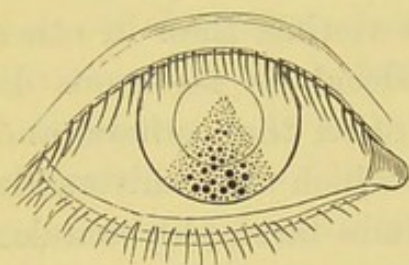


FIG. 53.—Keratitis punctata. (From a sketch by Dr. Herringham.)

ophthalmitis especially) the dots are scattered over the whole cornea. They are of course difficult to detect in proportion as the corneal tissue itself is hazy.

The term *keratitis punctata* is used to express this accumulation of dots on the back of the cornea ; and by some authors is allowed to include also allied

cases in which small spots with hazy outlines are seen in the cornea proper. Keratitis punctata is, almost without exception, secondary to some demonstrable disease of the cornea, iris, or choroid and vitreous. But a few cases are seen, chiefly in young adults, where the corneal dots form the principal, if not the sole, visible change ; the number of such cases diminishes, however, in proportion to the care with which other lesions are sought (p. 143). Snellen has found microscopically that these dots on Descemet's membrane consist of colonies of bacteria.*

It is now and then difficult to say, in a mixed case, whether the iritis or keratitis have been the initial change ; but when this doubt arises the cornea has generally been the starting point ; and with care we are seldom at a loss to decide whether the case be one of syphilitic keratitis with iritis, of scleritis with corneal mischief and iritis, or of primary iritis with secondary haze of cornea. (See Chaps. VIII and IX.)

Slight loss of transparency of the cornea occurs in most cases of *glaucoma*. The earliest change is a fine, uniform steaminess of the epithelium. In very severe, acute cases, the cornea becomes hazy throughout, though not in a high

* 'Ophth. Rev.,' 1894, p. 259.

degree. The same haze occurs in chronic cases of long standing with great increase of tension, but the epithelial "steaminess" often then gives place to a coarser "pitting," with little depressions and elevations (vesicles), especially on the part which is uncovered by the lids.

Conical cornea.—In this condition the central part of the cornea very slowly bulges forward, forming a bluntly conical curve. The focal length of the affected part of the cornea is thereby shortened, and the eye becomes myopic. The curvature, however, is not uniform, and hence irregular astigmatism complicates the myopia (Chap. XX).

The disease, which is rare, occurs chiefly in young adults, especially women, and is often associated with chronic dyspepsia; its onset is sometimes dated from a severe, exhausting illness; it appears to be due to defective nutrition of that part of the cornea which is furthest from the blood-vessels. In advanced cases the protrusion of the cornea is very evident, whether viewed from the front or from the side, but slight degrees are less easily distinguished from ordinary myopic astigmatism. In high degrees the apex of the cone, which is situated rather below the centre of the cornea, often becomes nebulous. The disease may progress to a high degree, or stop before great damage has been done. Concave glasses alone are of little use; but they are sometimes useful in combination with a screen perforated by a narrow slit or small central hole, which allows the light to pass only through the centre, or through some one meridian, of the cornea. In advanced cases an operation must be performed which, by substituting a contracting cicatrix for the corneal tissue at or near the apex of the cone, shall lead to a diminution of the curvature (Chap. XXII).

In *Buphthalmos* (*Hydrophthalmos*) the corneal changes are often very conspicuous, although not essential. In this rare and very peculiar malady there is a general and

slowly progressive enlargement of cornea, anterior part of sclerotic, and iris, together with extreme deepening of the anterior chamber and slight increase of tension. The cornea often becomes hazy or semi-opaque. The disease, which may perhaps be looked upon as a congenital or infantile form of glaucoma, is either present at birth or comes on in early infancy, and usually causes blindness. Operative treatment generally fails, but eserine is said to be useful. (*See Glaucoma.*)

A rare but peculiar form of corneal disease, generally seen in elderly persons, is the *transverse calcareous film*, forming an oval patch of light grey opacity, which runs almost horizontally across the cornea. It lies beneath the epithelium, and consists of minute crystalline granules, chiefly calcareous.

Arcus senilis is caused by fatty degeneration of the corneal tissue just within its margin (Fig. 54). It first appears beneath the upper lid, next beneath the lower, thus forming two narrow white or yellowish crescents, the horns of which finally meet at the sides of the cornea; it always begins, and remains most in-

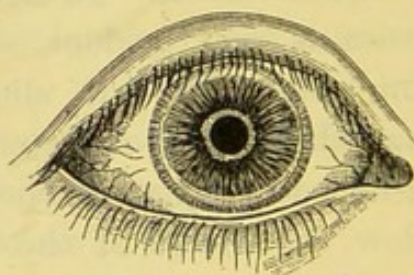


FIG. 54.—*Arcus senilis*. (From a sketch by Dr. Herringham.)

tense, on a line slightly within the sclero-corneal junction, and the degeneration is most marked in the superficial layers of the cornea, beneath the anterior elastic lamina; in other words, the change is greatest at the part most influenced by the marginal blood-vessels. Arcus, though seldom seen except in senile persons, is not found to interfere with the union of a wound carried through it, though the tissue of the arcus is often very tough and hard.

Less regular forms of arcus are seen as the result of

prolonged or relapsing inflammations near the corneal border, whether ulcerative or not. It is generally easy to distinguish such an arcus, because the opacity is denser and more patchy, and its outlines less regular than in the primary form; when arcus is seen unusually early in life it is generally of this inflammatory kind, for simple arcus is rare below forty.

Congenital opacity of the cornea sometimes occurs in more than one generation or in more than one member of a family; one form of congenital opacity closely resembles the arcus senilis in form and situation.

Opacity of a very characteristic kind is likely to follow the use of a lotion containing *lead* when the surface of the cornea is abraded. An insoluble, densely opaque, very white film of lead salts is precipitated on, and adheres very firmly to, the ulcerated surface; the spot is sharply defined, and looks like white paint. If precipitated on a deep and much inflamed ulcer, the layer of tissue to which the film adheres is often thrown off, but when there is only a superficial abrasion or ulcer, the lead adheres very firmly, and can only be scraped off imperfectly. But even in the latter cases the film is probably after a time thrown off or worn off, if we may judge by the fact that nearly all the lead opacities which come under notice are comparatively new. The practical lesson is never to use a lead lotion for the eye when there is any suspicion that the corneal surface is broken.

The prolonged use of *nitrate of silver*, whether in a weak or strong form, is sometimes followed by a dull, brownish-green, permanent discoloration of the conjunctiva, and even the cornea may become slightly stained.

CHAPTER VIII

DISEASES OF THE IRIS

Iritis

INFLAMMATION of the iris may be caused by certain specific blood diseases, especially syphilis; or may be the expression of a tendency to relapses of inflammation in certain tissues under the influence largely of climate and weather; it often occurs in the course of ulcers, and of wounds and other injuries, of the cornea; also with diffuse keratitis and sclerotitis. Iritis also forms a very important part of the remarkable and serious disease known as sympathetic ophthalmitis.

Acute iritis, whatever its cause, is shown by a change in the colour of the iris, indistinctness or "muddiness" of its texture, diminution of its mobility, and the formation of adhesions (*posterior synechiæ*) between its posterior (uveal) surface and the capsule of the lens; there is, besides, in most cases, a dulness of the whole iris and pupil, caused by muddiness of the aqueous humour, and partly also by slight corneal changes (p. 121). The eyeball is congested and the sight usually dimmed. There may or may not be pain, photophobia, and lachrymation.

The congestion is often almost confined to a zone, about one twelfth or one eighth of an inch wide, which surrounds the cornea, its colour pink (not raw red), the vessels small, radiating, nearly straight, and lying beneath the conjunctiva (*ciliary or circumcorneal congestion*, Fig. 28). These are the episcleral branches of the anterior ciliary arteries

(Fig. 25). Quite the same congestion is seen in many other conditions, *e. g.* corneal ulceration (p. 102) ; whilst on the other hand, in some cases of iritis, the superficial (conjunctival) vessels are engorged also, especially in their anterior divisions, which are chiefly offshoots of the ciliary system. We therefore never diagnose iritis from the character of the congestion alone ; but the disease being proved by the other symptoms, the kind and degree of congestion help us to judge of its severity.

The altered colour of the iris is due to its congestion, and the effusion of lymph and serum into its substance ; a blue or grey iris becomes greenish, a brown one is but little changed. The inflammatory swelling of the iris also accounts both for the blurring (muddiness) of its beautifully reticulated structure, and for the sluggishness of movement, noticed in the early period. Lymph is soon thrown out at one or more spots on its posterior surface, and still further hampers its movements by adhering to the lens-capsule ; and most cases do not come under notice till such synechiæ have formed. The quantity of solid exudation, whether on the hinder surface or into the structure of the iris, varies much ; it is usually greatest in syphilitic iritis, when distinct nodules of pink or yellowish colour are sometimes seen projecting from the front surface, generally close to the pupil. In rare cases pus thrown off by the iris into the aqueous, subsides and forms hypopyon ; a corresponding deposit of blood constitutes hyphæma. Firm adhesions to the lens-capsule may be present without much evidence of exudation into the structure of the iris. Exudative changes are usually most abundant at the inner ring of the iris, where its capillary vessels are far the most numerous (Fig. 55).

Apparent discoloration of the iris is, however, often due entirely to suspension of blood-corpuscles, or inflammatory products, in the aqueous humour ; sometimes this altered

fluid coagulates into a slightly turbid gelatinous mass, which almost fills the chamber ("spongy exudation"). The aqueous sometimes becomes yellow without losing transparency.

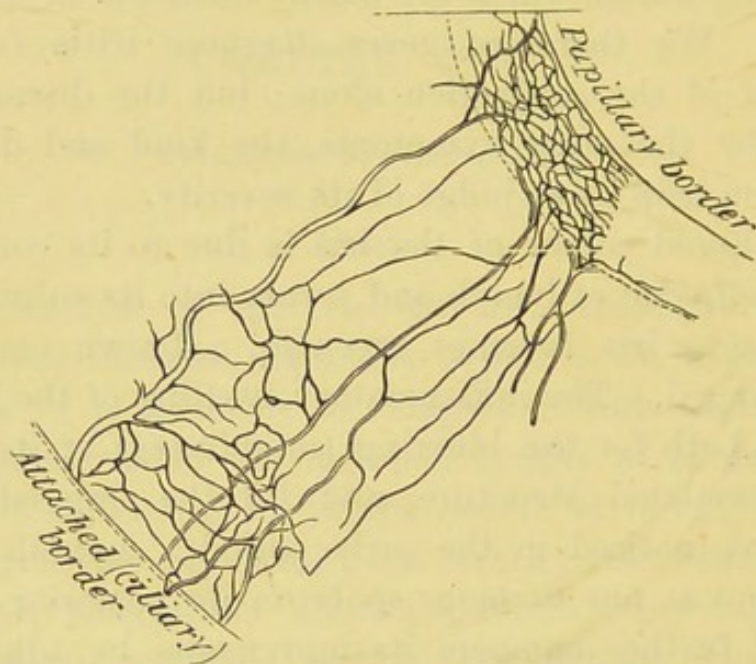


FIG. 55.—Vessels of human iris artificially injected; capillaries most numerous at papillary border, and next at ciliary border.

The tension of the eyeball, usually unaltered in acute iritis, may be a little increased; rarely it is considerably diminished, and in such cases there are generally other peculiarities.

The condition of the pupil alone is diagnostic in all except very mild or incipient cases of iritis. It is sluggish or motionless, and not quite round; it is also rather smaller than its fellow (supposing the iritis to be one-sided), because the surface of the iris is increased (and the pupil, therefore, encroached on) whenever its vessels are distended (p. 28). Atropine causes it to dilate between the synechiæ; the synechiæ, being fixed, appear as angular projections when the iris on each side of them has retracted. If there be only one adhesion it will merely notch the pupil

at one spot; if the adhesions be numerous the pupil will be crenated or irregular (Fig. 56). If the whole pupillary ring, or still more if the entire posterior surface of the iris be adherent, scarcely any dilatation will be effected; the former condition is called annular or circular synechia, and its result is "*exclusion*" of the pupil; the latter is known as *total posterior synechia*. If the synechiæ be new

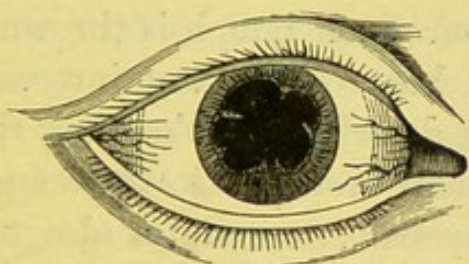


FIG. 56.—Iritic adhesions (posterior synechiæ) causing irregularity of pupil. (Wecker and Jaeger.)

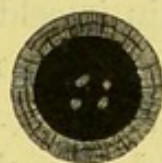


FIG. 57.—Spots of pigment and lymph at seat of former iritic adhesions.

and the lymph soft the repeated use of atropine will break them down, and the pupil will become round; but even then some of the uveal pigment, which is easily separable from the posterior surface of the iris, often remains behind, glued to the lens-capsule by a little lymph (Fig. 57). The presence of one or more such spots of brown pigment on the capsule is always conclusive proof of present or of past iritis. The pupillary area itself in severe iritis is often filled by greyish or yellowish lymph, which spreads over it from the iris; if such exudation become organised, a dense white membrane or a delicate film (often, however, presenting one or more little clear holes) is formed over the pupil ("*occlusion*" of the pupil). The iris may be inflamed without any lymph being effused from its hinder surface, and then the pupil, though sluggish, acting imperfectly to atropine, and never dilating widely, will present no posterior synechiæ nor any adhesion of pigment spots to the lens, but it will always be discoloured (serous

iritis); iritis of this kind often occurs with ulceration of the cornea, and as a complication of deeper inflammations (p. 143).

Pain referred to the eyeball and to the parts supplied by the first, and sometimes by the second division of the fifth nerve, is common with iritis, especially in the early period. It is, however, a very variable symptom, and gives no clue to the amount of structural change, being sometimes quite insignificant when much lymph is thrown out. The pain is seldom constant, but comes on at intervals, is often worst at night, and is described as shooting, throbbing, or aching. It is commonly referred to the temple or forehead, as well as to the eyeball; sometimes also to the side of the nose and to the upper teeth. Photophobia and watering are generally proportionate to the pain.

The duration of acute iritis varies from a few days when mild, to many weeks when severe. The defect of sight is proportionate to the haziness of the cornea, aqueous, and pupillary space, but in some cases is increased by changes in the vitreous. Iritis sometimes sets in very gradually, causing no marked congestion or pain, but slowly giving rise to the formation of tough adhesions, and often to the growth of a thin membrane over the pupillary area; in some of these cases the iris becomes thickened and tough, and its large vessels undergo much dilatation, whilst in others keratitis punctata occurs. (*See Cyclitis*, p. 143; *Diseases of Cornea*, p. 122; and *Sympathetic Ophthalmitis*, p. 146.)

Permanent results of iritis.—Reference has been made to the adhesions, which are often permanent, and to the spots of uveal pigment on the lens-capsule, which are always so; either condition tells a tale of past iritis, and is thus a valuable aid to diagnosis. A blue iris which has undergone severe inflammation may remain greenish. Patches of atrophy may follow severe plastic exudations into the

iris, and are recognised by their whitish colour and thinness. Large patches of new pigment occasionally form, extending from the pupillary border on to the anterior surface.

When the pupil is "excluded" or "occluded," the remainder of the iris being free, fluid collects in the posterior aqueous chamber, and by bulging the iris forwards, and diminishing the depth of the anterior chamber, except at its centre, gives the pupil a funnel-like appearance; if the bulging be partial, or be divided by bands of tough membrane, the iris looks cystic. *Secondary glaucoma* is likely to follow, and the tension of the globe should therefore be carefully noted whenever bulging is present; in not a few of these cases, however, we find the eye soft and beginning to shrink, the sequel, perhaps, of a glaucomatous state. "Total posterior synechia" always shows a severe, though often a chronic, iritis; it is often accompanied by deep-seated disease, and followed by opacity of the lens (secondary cataract), and in some cases ultimately the lens becomes absorbed. Relapses of iritis are believed to be induced by the presence of synechiæ, even when there is no protrusion of the iris by fluid; but their influence in this direction has, I believe, been much overrated.

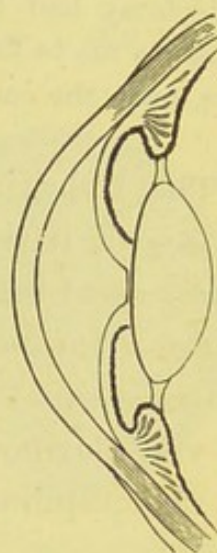


FIG. 58. — Diagram to show the result upon the iris of exclusion of pupil (p. 129). (From a specimen.)

It must, however, be observed that there is still much difference of opinion on the point last referred to. The iritis of syphilis is held by some to be liable to recur, and to be by no means limited to the secondary stage; and we still often hear it stated that iritic adhesions, by preventing free movement of the iris, operate as sources of irritation, and thus predispose to relapse. I have seldom succeeded in getting a history of recent syphilis in cases of recurring iritis, whilst

in a number of cases of old iritis, with the history that the attack occurred during secondary syphilis years before, I have scarcely found one with well-marked history of relapses. On the other hand, I have several times seen severe relapses in rheumatic cases after iridectomy had been performed as a preventive. All the evidence seems to me to favour the view that recurrences of iritis depend, as a rule, upon the constitutional cause of the disease.

The following are the most important points as to the causes of iritis, and the chief clinical differences between the several forms.

Constitutional causes.—Syphilis.—The iritis is acute; it shows a great tendency to effusion of lymph and formation of vascular nodules (plastic iritis), most commonly situated at the pupillary border of the iris (*see* Fig. 59); and the nodules, when very large, may even suppurate: it is symmetrical in a large proportion, probably at least two thirds, of the cases. But asymmetry and absence of lymph-nodules are common. It occurs almost entirely in secondary syphilis (either acquired or inherited), and seldom relapses.

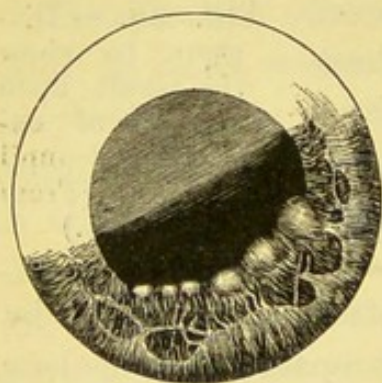


FIG. 59.—Nodules occurring in the secondary stage of syphilis, situated at the pupillary border of the iris (from a drawing by Mr. W. G. Laws).

Cases of iritis, associated generally with cyclitis and dots on the back of the cornea, also occasionally appear many years after syphilitic infection. Its significance is thus entirely different

from that of the iritis which often complicates syphilitic keratitis (p. 116).

Rheumatism is the cause of most cases of relapsing unsymmetrical iritis. The most common forms of rheumatism which are followed by iritis are the chronic muscular and tendinous, and the gonorrhœal varieties: iritis does not

occur as a sequel of acute rheumatic fever (see Chap. XXIII). There is but little tendency to effusion of lymph, and nodules are never formed, but there is occasionally fluid hypopyon (pp. 108 and 127); the congestion and pain are often more severe than in syphilitic iritis. An attack is usually unsymmetrical, though both eyes commonly suffer by turns. It relapses at intervals of months or years. Even repeated attacks sometimes result in but little damage to sight. *Gout* is apparently a cause in some cases of both acute and insidious chronic iritis. It is perhaps doubtful whether the gout or the chronic rheumatism from which the same patients sometimes suffer is the cause of the iritis. In its tendency to relapse, and to affect only one eye at a time, gouty resembles rheumatic iritis. The children of gouty parents are occasionally liable to a very insidious and destructive form of chronic iritis, with disease of the vitreous, keratitis punctata, and glaucoma (p. 143 and Chap. XXIII).

Chronic iritis (plastic irido-choroiditis) (see also p. 141).—In a few cases symmetrical iritis, of a chronic, progressive, and destructive character, is complicated with choroiditis, disease of vitreous, and secondary cataract. These cases, for which it is at present impossible to assign any cause, either general or local, are chiefly seen in adults below middle life.

Tuberculosis of the iris occurs in the young either in the form of miliary deposits or as a single nodular growth; owing to the deep position of the iris, such deposits are

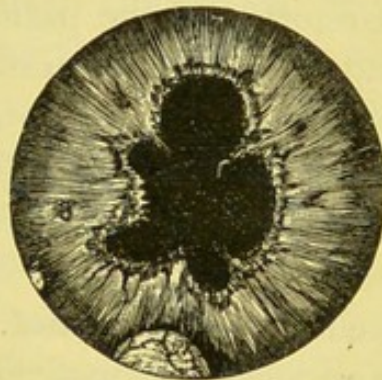


FIG. 60.—Plastic iritis with nodules in the angle of the anterior chamber, not syphilitic. Compare with Fig. 59 (from an original drawing by Holmes Spicer).

secondary to tuberculosis in some other part of the body.

Sympathetic iritis.—See Sympathetic Ophthalmitis.

Local causes.—*Injuries.*—Perforating wounds of the eyeball, particularly if irregular, contused, and complicated with wound of the lens, are often followed by iritis, and more often if the patient be old than young. If the corneal wound suppurate, or become much infiltrated, the iritis is likely to be suppurative, and the inflammation to spread to the ciliary processes and cause destructive panophthalmitis. Iritis may follow a wound of the lens-capsule without wound of the iris, and with only a mere puncture of the cornea. Examples of traumatic iritis from these several causes are seen after the various operations for cataract. The iritis following extraction of senile cataract is often prolonged, attended by chemosis, much congestion, and the formation of tough membrane behind the iris (*see* Cataract).—Iritis may also follow superficial wounds and abrasions of the cornea, or direct blows on the eye; but it is of great importance, whenever the question of injury comes in, to ascertain whether or not there has been a perforating wound. Iritis often accompanies ulcers and other inflammations of the cornea, especially when deep, or complicated with hypopyon, or occurring in elderly persons. Iritis may accompany deep-seated disease of the eye.

Treatment.—(1) In every case where iritis is present atropine is to be used often and continuously, in order to break down adhesions already formed, and to allow any lymph subsequently effused to be deposited outside the ordinary area of the pupil. A strong solution (four grains of sulphate of atropine to one ounce of distilled water) or an ointment (*see* Appendix) is to be placed in the conjunctival sac every hour in the early period. Even if the synechiæ are, when first seen, already so tough that the

atropine has no effect on them, it may prevent the formation of new ones on the same circle. Atropine also greatly relieves pain in iritis, and lessens the congestion, and through these means it no doubt helps materially to arrest exudation. Mild acute iritis may sometimes be cured by atropine alone.

(2) If there be severe pain with much congestion, three or four leeches should be applied to the temple, to the malar eminence, or to the side of the nose. They may be repeated daily, in the same or smaller numbers, with advantage for several days, if necessary; or after one leeching, repeated blistering may be substituted. Some surgeons use opiates instead of, or in addition to, leeches. Leeches occasionally increase the pain. Severe pain in iritis can nearly always be quickly relieved by artificial heat, either fomentations or dry heat, as hot as can be borne, to the eyelids. To apply dry heat, take a piece of cotton wool the size of two fists, hold it to the fire, or against a tin pot full of *boiling* water, till quite hot, and apply it to the lids; have another piece ready, and change as soon as the first gets cool; continue this for twenty minutes or more, and repeat it several times a day.* Paracentesis of the anterior chamber should be resorted to in severe iritis if the aqueous humour remain very turbid after a few days of other treatment; it may be repeated every day or two unless there is marked improvement.

(3) Rest of the eyes is very important. Many an attack is lengthened out, and many a relapse after partial cure is brought on, by the patient continuing at, or returning too soon to, work. It is not in most cases necessary to remain in a perfectly dark room; to wear a shade in the room with the blinds down is generally enough, provided that no attempt be made to use the eyes. Work

* I owe my knowledge of the value of dry heat to Mr Liebreich.

should not be resumed till at least a week after all congestion has gone off.

(4) Cold draughts of air on the eye and all causes of "catching cold" are to be very carefully avoided by keeping the eye warmly tied up with a large pad of cotton wool.

(5) The cause of the disease is to be treated, and into this careful inquiry should always be made. If the iritis be syphilitic, treatment for secondary syphilis is proper, mercury being given just short of salivation for several months, even though all the active eye symptoms quickly pass off. The rheumatic and gouty varieties are less definitely under the influence of internal remedies; iodide of potassium, alkalies, colchicum, salicylate of soda, and turpentine, each have their advocates; when the pain is severe tincture of aconite is sometimes markedly useful; mercury is seldom needed, but in protracted and severe cases it may be given with advantage. It is sometimes advisable to combine quinine or iron with the mercury in syphilis, or to give them in addition to other remedies in rheumatic cases.

(6) As a rule no stimulants are to be allowed, and the bowels should be kept well open.

(7) Iridectomy is needed for cases of severe iritis, even when there is no increase of tension, if judicious local and internal treatment have been carefully tried for some weeks without marked relief to the symptoms. It is chiefly in cases of constitutional origin, either syphilitic or rheumatic, and in the iritis accompanying ulcers of the cornea, that iridectomy is useful; it is not admissible in sympathetic iritis, nor in iritis after cataract extraction. Iridectomy has been largely employed to prevent relapses of iritis, but the operation has much less effect in this way than has often been supposed; it should not, therefore, be employed until the other means of cure have been fairly tried. It

must be borne in mind that unless iridectomy is necessary, it is injurious, by producing an enlarged and irregular pupil through which, for optical reasons (p. 5), the patient will often not see so well as through the natural pupil, even though this be partially obstructed. In regard to all methods of local treatment we must bear in mind that acute iritis occurs in all degrees of severity, and that the mildest cases often need only atropine and rest.

Traumatic iritis, in the earliest stage, is best combated by atropine, continuous cold obtained by laying upon the closed eyelids pieces of lint wetted in iced water and changed every few minutes, and by leeches. *Cold is not to be used in any other form of iritis*, and is useless even for traumatic cases after the first day or so; later, warmth is more appropriate.

Congenital irideremia (absence of iris) is occasionally seen, and is often associated with other defects of the eye, especially opacities in the lens.

Coloboma of the iris (congenital developmental cleft in the iris) gives the effect of a very regularly made iridectomy. It is always downwards or slightly down-in, and is often, but not always, symmetrical. It occurs in different degrees, and sometimes a mere line or seam in the iris indicates the slightest form of the defect. It often occurs without coloboma of the choroid.

Pupillary and capsulo-pupillary membranes.—In early foetal life the capsule of the lens is vascular, supplied with blood by the hyaloid artery; when the iris grows in from the anterior part of the choroid, and comes into contact with the capsule, its vessels anastomose with those of the capsule, and the membrane so formed fills the pupil. Normally this membrane disappears entirely with the vessels of the lens capsule; sometimes the part attached to the capsule only disappears, leaving behind the anterior part of the structure, which is known as the pupillary

membrane. In this, bands of tissue, resembling that of the iris, run from one part of the anterior surface of the iris to another, springing from near the pupillary edge. Sometimes the whole thickness of the membrane remains, in which case bands of tissue pass from the anterior surface of the iris to the capsule; this forms the capsulo-pupillary membrane. Some of the latter cases have probably been described as the remains of intra-uterine iritis.

CHAPTER IX

DISEASES OF THE CILIARY REGION

THIS chapter is intended to include cases in which the ciliary body itself, or the corresponding part of the sclerotic, or the episcleral tissue, is the sole seat, or at least the headquarters, of disease. From the abundance of vessels and nerves in the ciliary body, and the importance of its nutritive relations to the surrounding parts, we find that many of the morbid processes of the ciliary region show a strong tendency to spread, according to their precise position and depth, to the cornea, iris, or vitreous, and by influencing the nutrition of the lens to cause secondary cataract. Although alike on pathological and clinical grounds it is necessary to subdivide the class into groups, we may observe that the various diseases of this part show a general agreement in some of their more important characters; thus all of them are protracted and liable to relapse, and in all there is a marked tendency to patchiness, the morbid process being most intense in certain spots of the ciliary zone, or even occurring in quite discrete areas. It is convenient to make three principal clinical groups, the differences between which are accounted for to a great extent by the depth of the tissue chiefly implicated. The most superficial may be taken first.

(1.) *Episcleritis* (more correctly *Scleritis*) is the name given to one or more large patches of congestion in the ciliary region, with some elevation of the conjunctiva from

thickening of the subjacent tissues. The congestion generally affects the conjunctival as well as the deeper vessels, and the yellowish colour of the exudation tones the bright blood-red down to a more or less rusty tinge, which is especially striking at the central, thickest part of the patch. The thickening seldom causes more than a low, widely spread mound of swelling.

Episcleritis is a rather rare disease. It occurs chiefly on the exposed parts of the ciliary region, and especially near the outer canthus; but the patches may occur at any part of the circle, and exceptionally the inflammation is diffused over a much wider area than the ciliary zone, extending far back out of view. The iris is often a little discoloured and the pupil sluggish, but actual iritis is the exception. There is often much aching pain. The disease is subacute, reaching its acme in not less than two or three weeks, and requiring a much longer time before absorption is complete. Fresh patches are apt to spring up while old ones are declining, and so the disease may last for months; indeed, relapses at intervals, and in fresh spots, are the rule. It usually affects only one eye at a time, but both often suffer sooner or later. After the active changes have disappeared, a patch of the underlying sclerotic, of rather smaller size, is generally seen to be dusky as if stained: it is doubtful whether such patches represent thinning of the sclerotic from atrophy, or only staining; it is but seldom that they show any tendency to bulge as if thinned.—In rare cases the exudation is much more abundant, and a large swelling is formed, which may even contain pus; such cases pass by gradations into conjunctival phlyctenulæ, and are generally seen in children (*compare* p. 104).

Episcleritis is seldom seen except in adults, and is commoner in men than women. Inquiry often shows that the sufferer is, either from occupation or temperament,

particularly liable to be affected by exposure to cold or by changes of temperature. Some of the patients are rheumatic, some gouty. Similar patches, but of a brownish, rather translucent appearance, are occasionally caused by tertiary syphilis, acquired or inherited ("*gummatous scleritis*").

In the treatment, protection by a warm bandage, rest, the yellow ointment (F. 25), the use of repeated blisters, and local stimulation of the swelling are generally the most efficacious. Atropine is very useful in allaying pain. Internal remedies seldom seem to exert much influence except in syphilitic cases. Salicylate of soda has been highly spoken of by some. Systematic kneading of the eye through the closed lids ("*massage*"), and scraping away the exudation with a sharp spoon, after turning back the conjunctiva, have also been recommended, and are worth trial.

(2.) *Sclero-keratitis and sclero-iritis* ("*scrofulous scleritis*," "*anterior choroiditis*").—A more deeply seated, very persistent or relapsing, subacute inflammation, characterised by congestion, of a violet tint (deep scleral congestion, p. 31, 2), abruptly limited to the ciliary zone, and affecting some parts of the zone more than others (tendency to patchiness). Early in the case there is a slight degree of bulging of the affected part, due partly to thickening; whilst patches of cloudy opacity, which may or may not ulcerate, appear in the cornea close to, and often continuous with, its margin; iritis generally occurs later; pain and photophobia are often severe. After a varying interval, always weeks, more often months, the symptoms recede; at the focus of greatest congestion, or it may be around the entire zone, the sclerotic is left of a dusky colour, sometimes interspersed with little yellowish patches, and permanent haziness of the most affected parts of the cornea remains. The disease is almost certain to relapse

sooner or later; or a succession of fresh inflammatory foci follow each other without any intervals of real recovery, the whole process extending over months or years. After each attack more haze of cornea and fresh iritic adhesions are left. The sclerotic, in bad cases of some years' standing, is much stained, and may become bulged (ciliary or anterior staphyloma), and the cornea becomes more opaque and altered in curve; the eye is then useless, though but seldom liable to further active symptoms.

The characteristic appearance of an eye which has been moderately affected is the dusky colour of the sclerotic, and

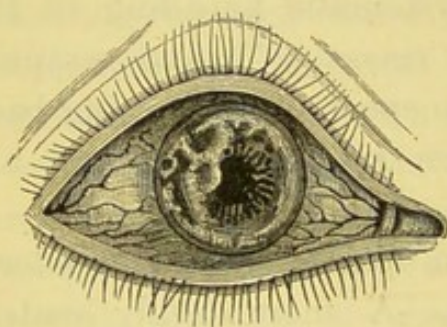


FIG. 61.—Relapsing Sclero-keratitis. (From nature.)

the irregular, patchy opacities in the cornea (Fig. 61), which are often continuous with the sclerotic. The disease does not occur in children, nor does it begin late in life; most of the patients are young or middle-aged adults, and unlike the former variety, most are women. It is not associated with any special

diathesis or dyscrasia, but generally goes along with a feeble circulation and liability to "catch cold;" in some cases there is a definite family history of scrofula or of phthisis. Predisposed persons are more likely to suffer in cold weather, or after change to a colder or damper climate, or after any cause of exhaustion, such as suckling.

Treatment is at best but palliative. Local stimulation by yellow ointment or calomel is very useful in some cases, particularly in those which verge towards the phlyctenular type. In the early stages, especially when the congestion is very violent and altogether subconjunctival, atropine often gives relief, and it is of course useful for the iritis. Repeated blistering is also to be tried, though not all cases

are benefited by it. I have not seen much benefit from setons. Warm, dry applications to the lids are, as a rule, better than cold. Mercury, in small and long-continued doses, is certainly valuable when the patient is not anæmic and feeble, but it is to be combined with cod-liver oil and iron. Protection from cold and bright light by "goggles" is a very important measure, both during the attacks and in the intervals between them. There is no rule as to symmetry; both eyes often suffer sooner or later, but sometimes one escapes whilst the other is attacked repeatedly. Transition forms occur between this disease and episcleritis.

(3.) *Cyclitis with disease of vitreous and keratitis punctata* ("serous cyclitis," chronic serous irido-choroiditis, "serous iritis").—A small but important series of cases, in which there is congestion, as in mild iritis, and dulness of sight, but usually no pain or photophobia. It has been found by Treacher Collins that the ciliary body in addition to its other functions performs the part of a secreting gland concerned in the nutrition of the vitreous body and in the elaboration of the aqueous fluid. When this gland is diseased it gives rise to exudation into the vitreous, and to a turbidity of the aqueous from which are deposited the dots on the cornea which are commonly known as *keratitis punctata*. Flocculi are found in the anterior part of the vitreous, or numerous small dots of deposit are seen on the posterior surface of the cornea (*keratitis punctata*, Fig. 54); the anterior chamber is often too deep, and insidious iritis often follows. Patches of recent choroiditis (Chap. XII) are sometimes to be seen at the fundus. In bad cases buff-coloured masses of deposit form in the lower part of the angle between iris and cornea; or distinct nodules may be present on the iris near its periphery, but not, as in syphilitic iritis, at the pupillary border (Fig. 60). Persistence, variability, and liability to relapse are almost a

marked here as in other members of the cyclitic group. The tension is often slightly augmented at the beginning, but usually becomes normal again. Sometimes, however, the eye passes into a permanent state of chronic glaucoma, probably from blocking of the ligamentum pectinatum with cells (*see* Glaucoma); but usually the final condition in bad cases depends on the extent of the iritic adhesions, for when the synechiæ are numerous and tough, and the iris is much altered in structure, or the pupil blocked by exudation, secondary glaucoma is likely to arise from imprisonment of fluid behind the iris (Fig. 58). When seen quite early the diagnosis will probably be "serous iritis" or "ciliary congestion," unless the eye be carefully examined; for the pupil is generally free in all parts, or shows, at most, one or two adhesions after atropine has been used. In a few cases the punctate deposits on the back of the cornea constitute almost the only objective change, but these are rare. The refraction sometimes becomes temporarily myopic in serous cyclitis.

The cases occur in adolescents or young adults, and the disease is often sooner or later symmetrical. Many mild cases recover perfectly, and in most others the final result is satisfactory. In respect to cause, there is strong reason to believe that many of these cases are the result of gout in a previous generation, the patient himself never having had the disease (Hutchinson). The disease seems often to be excited in predisposed persons by prolonged overwork or anxiety, combined with under-feeding or defective assimilation; the patients often describe themselves as delicate; some are phthisical. On the other hand, in some of the worst cases, leading to secondary cataract, and ultimately to shrinking of the eyes (p. 133), the patient appears to be, from first to last, in good health, and free from any ascertainable morbid diathesis.

In the *treatment* prolonged rest of the eyes is important.

Atropine is usually necessary, but if there be increase of tension its effect must be carefully watched, and in cases where there are no iritic adhesions, eserine may have to be substituted. If the increase of tension keeps up, and seems to be damaging the sight, iridectomy is necessary. Small doses of iodide of potassium and mercury appear to be useful in the earlier stages, given with proper precautions, and accompanied by iron and cod-liver oil. Change of climate would probably often be very beneficial. In the worst cases, where the changes are like those resulting from sympathetic ophthalmitis, no treatment seems to have any effect.

Cases of acute inflammation are occasionally seen in which most of the symptoms resemble those of acute iritis, but with the iris so little affected that it is evidently not the headquarters of the morbid action. The tension may be much reduced, whilst repeated and rapid variations, both in sight and objective symptoms, occur. Again, some cases of syphilitic inflammation, which are classed as syphilitic "iritis," might be more correctly called "cyclitis." In some cases of heredito-syphilitic keratitis there is much cyclitic complication (p. 119), and this is always difficult to treat.

Plastic inflammation of the ciliary body, following injury (*traumatic iritis* or *irido-cyclitis*), is the usual starting-point of the changes which set up sympathetic inflammation of the fellow-eye; the tension is often lowered, and the symptoms are subacute. The onset of *purulent traumatic cyclitis* (*panophthalmitis*) is signalised by congestion, pain, chemosis and swelling of lids, and the appearance of opacity at the wound. The inflammation quickly spreads to the iris, ciliary body, and vitreous; and then to the capsule of Tenon and the muscles, so that the eye becomes glued to the surrounding parts, and fixed. If the lens be transparent a yellow or greenish reflection is, after a few

days, sometimes seen behind it, indicating the presence of pus in the vitreous humour; but usually the cornea and aqueous are too turbid, even should the lens be clear, to allow deep inspection. Suppurative panophthalmitis occasionally sets in acutely and without apparent cause in eyes which have long been blind from corneal disease or from glaucoma. It may also occur in pyæmia (Chap. XXIII). (*See also* Pseudo-glioma.)

SYMPATHETIC IRRITATION AND SYMPATHETIC OPHTHALMITIS

Certain morbid changes in one eye may set up either functional disturbance or destructive inflammation in its fellow. The term *sympathetic irritation* is given to the former, and *sympathetic ophthalmitis* (or *ophthalmia*) to the latter. Though these conditions may be combined, they more often occur separately, and it is very important to distinguish between them.

Although at present the exact nature of the changes which precede sympathetic inflammation is unknown, and their path has not been fully traced out, we are sure (1) that the changes start from the region most richly supplied with vessels and nerves, viz. the ciliary body and iris; (2) that the first changes recognised by the surgeon in the *sympathising eye* are generally in the same structures; (3) that the *exciting eye* has nearly always been wounded, and in its anterior part, and that plastic inflammation of its uveal tract is always present; (4) that inflammatory changes have in some cases been found in the ciliary nerves, and in the coverings of the optic nerve, of the exciting eye.

Within the last few years the hypothesis of transmission along the ciliary nerves, which had many adherents, has been almost given up in favour of the theory of infection.

Deutschmann has shown (1882-4) that the introduction of certain septic organisms into the interior of the eyeball, in rabbits, is followed by acute inflammatory changes in the other eye; and Gifford (1886), and others more recently, have obtained results which tend to confirm the infection theory. Most of Deutschmann's subjects died in a few days, and though in many of them the ocular changes were those of inflammation traceable along the optic nerve-sheaths of the "exciting" eye, by way of the chiasma, and down the optic nerve to the optic disc of the "sympathiser," still in one or two the morbid process had spread to the vitreous and uveal coat. Berlin* had previously suggested that the second eye was infected by a special organism which could flourish only in the eye-tissues, and which was carried by the blood from the first eye; and Hutchinson† afterwards independently propounded a nearly identical view. Though there are difficulties to be explained and gaps to be filled in our knowledge before the infection theory in any form can be accepted, yet at the present time it claims more and stronger adherents than any other; and the difficulties are perhaps not greater than for any other theory.

In almost every case sympathetic inflammation is set up by a perforating wound, either accidental or operative, in the ciliary region of the other eye, *i. e.* within a zone, nearly a quarter of an inch wide, surrounding the cornea. The risk attending a wound in this "dangerous zone" is increased if it be lacerated, or heal slowly, or if the iris or ciliary body be engaged between the lips of the sclerotic, or if the eye contain a foreign body; under all conditions, indeed, which make the occurrence of plastic or purulent irido-cyclitis probable. Sympathetic inflammation may also be set up by a foreign body lodged in the eye, whether the wound be in the ciliary region or not; by an eye con-

* Berlin, 1880.

† Hutchinson, 1885.

taining a tumour, perhaps even if the eye have not been perforated by operation or ulceration; by a purely corneal wound, or a perforating ulcer, if complicated by adhesion of the iris, with dragging on the ciliary body.

Symptoms in the exciting eye.—The exciting eye, when it is causing sympathetic *irritation*, generally shows ciliary congestion and photophobia, and often suffers neuralgic pain. In an eye which is causing sympathetic *inflammation*, obvious iritis, often with lowered tension, is usually present; but the iritis is often painless and without noticeable congestion, and thus may easily be overlooked; it is especially important to remember that the exciting eye, though its sight is always damaged, need not be blind, and that under certain circumstances it may in the end be the better eye of the two.

Symptoms in the sympathising eye.—*a. Sympathetic irritation.*—The eye is, in common speech, “weak” or “irritable.” It is intolerant of light, and easily flushes and waters if exposed to bright light, or if much used; the accommodation is weakened or irritable, so that continued vision for near objects is painful, or even impossible; and the ciliary muscle seems liable to give way for a short time, the patient complaining that near objects now and then suddenly become misty for a while. Neuralgic pains, referred to the eye and side of the head, are also common. Temporary darkening of sight, indicating suspension of retinal function, and subjective sensations of coloured spots, clouds, &c., occur in certain cases. Such attacks may occur again and again in varying severity, lasting for days or weeks, and finally ceasing without ever passing on to structural change. Sympathetic irritation is always, and as a rule promptly, cured by removal of the exciting eye; but occasionally the symptoms persist for some time afterwards. A condition which cannot be distinguished from hysterical blindness is sometimes seen in the “sym-

pathising" eye, but the term sympathetic irritation does not then seem suitable.*

b. Sympathetic inflammation (ophthalmitis).—The disease may arise out of an attack of "irritation," but more commonly it sets in without any such warning. It may be acute and severe, or so insidious as to escape the notice of the patient until well advanced. It is in nearly all cases a prolonged and a recurring disease; when once started it is self-maintaining, and its course usually extends over many months, or even a year or two. In mild cases a good recovery eventually takes place, but in a large majority the eye becomes blind. The disease usually takes the form of a plastic irido-cyclitis or irido-choroiditis with exudation from the entire posterior surface of the iris, leading to total posterior synechia (p. 129). Its chief early peculiarities are a great liability to dotted deposits on the back of the cornea (p. 122), clouding of the vitreous by floating opacities, and often neuro-retinitis; there is a dusky ciliary congestion with marked engorgement of the large vessels which perforate the sclerotic in the ciliary region. In acute and severe cases the congestion is intense, there is severe pain, photophobia, and tenderness on pressure, and the iris, besides being thick, is changed in colour to a peculiar buff or yellowish brown, and shows numerous enlarged blood-vessels. Attacks of intense neuralgia of the fifth nerve characterise some cases. In cases of all degrees the tension is often increased, the eye becoming decidedly glaucomatous for a longer or shorter time. Many dotted opacities appear in the lens, which afterwards becomes completely cataractous, and in some cases is finally quite absorbed. In the worst cases the eye finally shrinks, but in many it remains glaucomatous with

* Mr Gunn tells me that he has noticed that marked oscillation of the iris (p. 27) often occurs when sympathetic irritation is about to give place to inflammation.

total posterior synechia, corneal haze, and more or less ciliary staphyloma. In the mildest cases (the so-called "serous" form) the disease never goes beyond a chronic iritis with punctate keratitis and disease of the vitreous, with which neuro-retinitis often, perhaps always, co-exists.

Sympathetic ophthalmitis generally begins between six weeks and about three months after the injury to the exciting eye; very seldom sooner than three weeks, *i. e.* not until time has elapsed for well-marked inflammatory changes to occur at the seat of injury. On the other hand, the disease may set in at any length of time, even many years, after the lesion of the exciting eye. It occurs at all ages. Distinct inflammatory changes are probably always present in the exciting eye; but, as already stated, these may be very slight and difficult of detection. When carefully observed, these changes are found to precede by some days, if not longer, the onset of structural disease in the sympathising eye, the morbid process apparently taking some time to travel from one eye to the other.

Treatment.—By far the most important measure refers to prevention. When once sympathetic inflammation has begun we can do little to modify its course. The clear recognition of this fact leads us to advise the excision* of every eye which is at the same time useless, and liable to cause sympathetic mischief, *i. e.* of all eyes which are blind from injury or destructive corneal disease; and to give this advice most urgently when the blind eye is already tender or irritable, or is liable to become so, when it has been lost by wound, and when it is probable that it may contain a foreign body. Any lost eye in which there are

* Feeling doubtful whether either abscission or optico-ciliary neurotomy confers as great safety from sympathetic disease as does excision, I have not performed those operations. The more newly revived evisceration has not yet been performed often enough for trustworthy conclusions to be drawn on this point.

signs of past iritis, even if there be no history of injury, is best removed, especially if shrunken. But much judgment is needed if the damaged eye, though irritable and likely to cause mischief, still retains more or less sight. Every attention must then be paid to the exact position of the wound, the evidence as to its depth, the evidence of hæmorrhage, and especially to the condition of the lens, and to the presence of the yellowish haziness behind the lens which indicates lymph or pus in the vitreous (p. 145). The date of the injury and the condition of the wound, whether healed by immediate union, or with scarring, puckering, or flattening, are very important points. *Irritation* of the fellow-eye may set in a few days after the injury; but since *inflammation* very seldom begins sooner than two or three weeks, we may, if we see the case early, watch it for a little time. Complete and prolonged rest in a darkened room is a very important element in the prevention of sympathetic irritation and inflammation, and should always be insisted on when we are trying to save an injured eye (*compare* p. 135). In rare cases sympathetic inflammation sets in *after* the removal of the exciting eye, even after an interval of several weeks—a contingency which emphasises the importance of excising every condemned eye at the earliest possible moment.

When sympathetic ophthalmitis has set in we can do comparatively little.

A. *The exciting eye*, if quite blind or so seriously damaged as to be for practical purposes certainly useless, is to be excised at once, though the evidence of benefit from this course is slender. But it is not to be removed if there is reason to hope for restoration of useful sight in it; if there is simply a moderate degree of subacute iritis, with or without traumatic cataract, and with sight proportionate to the state of the lens, the eye is to be carefully treated,

since it may very probably in the end be the better of the two (p. 148).

B. *The sympathising eye.*—The important measures are (1) atropine, used very often, as for acute iritis; (2) absolute rest and exclusion of light by residence in a dark room and with a black bandage over both eyes; (3) repeated leeching if the symptoms are severe, or counter-irritation by blisters or by a seton in chronic cases. (4) Mercury is believed by some to be beneficial. Quinine is sometimes given. (5) As a rule no operation is permissible whilst the disease is still active, since iridectomy, performed whilst there are active symptoms, is followed by closure of the gap with fresh lymph. Operations in severe cases which have become quiet are seldom of use, the eye being generally then past recovery.

The *prognosis* is, as will be gathered, very grave; even in the mildest cases, when seen quite early, we must be very cautious, for the disease often slowly progresses for many months.

CHAPTER X

INJURIES OF THE EYEBALL

A CLEAR distinction is to be made between contusion and concussion injuries, and wounds of the eyeball.

(1.) *Contusion and concussion injuries.*—*Rupture of the eyeball* is commonly the result of severe direct blows. The rent is nearly always in the sclerotic, either a little behind, or close to the corneal margin, with which it is concentric; the cornea itself is but seldom rent by a blow. The rupture is usually large, involves all the tunics, and is followed by immediate hæmorrhage between the retina and choroid, and into the vitreous and anterior chambers; the lens and some of the vitreous often escape; sight is usually reduced to perception of light or of large objects. The conjunctiva, however, often escapes untorn, and in such a case if the lens pass through the rent in the sclerotic, it will be held down by the conjunctiva, and form a prominent, rounded, translucent swelling over the rupture. The diagnosis of rupture is generally easy, even if the rent be more or less concealed. The eyeball often shrinks; but occasionally it recovers with useful vision. Immediate excision is generally best when the wound is "compound;" but if the conjunctiva be not torn, and occasionally even when it is, we should wait a few days until the disappearance of the blood from the anterior chamber allows the deeper parts to be seen. The treatment is the same as for wounds of the eye (p. 159). When the lens is lying beneath the conjunctiva it should be removed when the scleral wound has healed, if we decide to save the eye.

It may here be mentioned that copious hæmorrhage, accompanied by severe pain, sometimes occurs between the choroid and sclerotic as the result of sudden diminution of tension, either by an operation, such as extraction of cataract or iridectomy, or by a glancing wound of the cornea. Eyes in which this occurs are for the most part already unsound and often glaucomatous.

Blows often cause *internal damage without rupture of the hard coats* of the eye. The iris may be torn from its ciliary attachment (*coredialysis*), so that two pupils are formed (Fig. 62), or the lens may be loosened or displaced

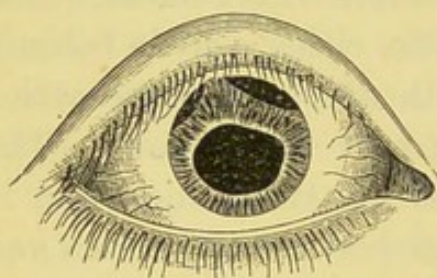


FIG. 62.—Separation of iris following a blow.

(p. 183) by partial rupture of its suspensory ligament, so that the iris, having lost its support, will shake about with every movement (*tremulous iris*). Such lesions are likely to be obscured for a time by bleeding into the anterior chamber and into the vitreous.

The lens often becomes opaque afterwards (p. 182). Detachment of the retina is often found after severe blows, which have caused hæmorrhage into the vitreous.—Blows on the front of the eye may cause *rupture of the choroid*, or hæmorrhage from choroidal or retinal vessels. These changes are found at the central part of the fundus, and if the yellow spot is involved visual acuteness is much damaged. The rents in the choroid appear, after the blood has cleared up, as lines or narrow bands of atrophy bordered by pigment, and often slightly curved towards the disc (Fig. 74). Hæmorrhages from the choroidal vessels without rupture of the choroid, usually leave some residual pigment after absorption. In an eye predisposed to detachment of retina, a blow will sometimes determine its occurrence.—*Paralysis of the iris and ciliary muscle,*

with partial, sometimes irregular dilatation of the pupil, are often the sole results of a blow on the eye; the defect of sight can be remedied by a convex lens. Complete recovery is moderately common, the ciliary muscle recovering before the iris. Partial dilatation or imperfection of the pupil after a blow is sometimes dependent on rupture of the sphincter, one or more notches in the pupillary border of the iris indicating the seat of the lesion or lesions. (For Traumatic Iritis *see* p. 134.)

Great defect of sight following a blow, neither remedied by glasses nor accounted for by blood in the anterior chamber, will generally mean copious hæmorrhage into the vitreous, with one or another of the changes just mentioned in the retina and choroid. The red blood may sometimes be seen by focal light, but often its presence can only be inferred from the opaque state of the vitreous. Probably in most of these cases the blood comes from the large veins of the ciliary body, but sometimes from the vessels of the choroid or retina. There may be no external ecchymosis. The tension of the globe is to be noted; it is not often increased unless inflammation has set in, or the eye has been previously glaucomatous, and in some cases it is below normal. The prognosis should be very guarded whenever there is reason to think, from the opaque state of the parts behind the lens, that much bleeding has taken place, or that the retina is detached, or when the iris is tremulous or partly detached, or if any rupture of the choroid can be made out. Blood in the anterior chamber is often completely absorbed in a day or two, or even sometimes in a few hours; but in the vitreous humour absorption, though rapid, is less complete, and permanent opacities are often left. The use of atropine, the frequent application, during the first twenty-four hours, of iced water, or of an evaporating lotion to the lids, and occasional leeching if there be inflammatory symptoms, will do

all that is possible for the first week or two after a severe blow with internal hæmorrhage. If the lens be loosened, it may at any time act as an irritating foreign body, or set up a glaucomatous inflammation (Dislocation of Lens, p. 183). Now and then optic neuritis occurs in the injured eye as the immediate effect of the blow. Hæmorrhage behind the choroid is believed by some to account for certain well-known cases in which, after a blow, there is defect of sight without visible change, or with localised temporary haze of retina ("*commotio retinæ*"). Temporary myopia or astigmatism may also follow a blow on the eye; they depend on altered curvature of the lens, and are sometimes entirely removed by paralysing the ciliary muscle with atropine (*see also* Hysterical Amblyopia).

(2) *Wounds*.—A. Superficial *abrasions* of the cornea cause much pain, with watering, photophobia, and ciliary congestion. They are frequently due to a scratch by a finger-nail of a baby at the breast. The abraded surface is often very small, and shows no opacity; it is detected by watching the reflection of a window from the cornea (p. 19), whilst the patient slowly moves the eye. Now and then the symptoms return after a long interval of cure. Many, if not all, of the cases of relapsing bullæ of the cornea seem to have originated in a slight superficial injury.

Minute fragments of metal or stone flying from tools, &c., often partly embed themselves in the cornea ("*foreign body on the cornea*"), and give rise to varying degrees of irritability and pain. The fragment soon becomes surrounded by a hazy zone of infiltration, but it remains easily visible unless it be very small or covered by mucus or epithelium. When in doubt always examine the cornea by focal light with magnifying power (p. 40).

The pupil is often smaller than its fellow, and the colour of the iris altered, in cases of superficial injury to the

cornea, indicating congestion of the iris (p. 27). Actual iritis sometimes occurs, but not unless the corneal wound inflame.

Treatment.—(For removal of foreign bodies *see* Operations.) After surface injuries a drop of castor oil may be applied, and the eye kept closed for the day with a pad of wadding and a bandage. Atropine is required if there be much irritation or threatened iritis. If hypopyon appear the case becomes one of hypopyon ulcer (p. 108).

Foreign bodies often adhere to the inner surface of the upper lid; whenever a patient states that he has "something in his eye" and nothing can be found on the cornea, the upper lid must be everted and examined.

Large bodies sometimes pass far back into the upper or lower conjunctival sulcus, and lie hidden for weeks or months, causing only local inflammation and some thickening of the conjunctiva. Search must be made, if needful, with a small scoop or probe whenever the suspicion arises (*see* Orbit).

B. *Burns, scalds, and injuries by caustics, &c.*—The conjunctiva and cornea are often damaged by splashes of molten lead, or by strong alkalies or acids, of which lime, either quick or freshly slaked, is the commonest. The eyeball is not often scalded, the lids closing quickly enough to prevent the entrance of steam or hot water. As the full effect in such cases is not apparent for some days, a cautious opinion should be given in the early stages.

The effects of such accidents are manifested by (1) inflammation of the cornea passing into suppurative keratitis with hypopyon, in bad cases; (2) scarring and shortening of the conjunctiva, and in bad cases adhesion of its palpebral and ocular surfaces—*symblepharon*.

The most superficial burns whiten and dry the surface, and in a few hours the epithelium is shed. This is shown

on the cornea by a sharply outlined, slightly depressed area. The surface is clear if the damage be quite superficial and recent, but more or less opalescent, or even yellowish, if the case be a few days old, and the burn be deep enough to have caused destruction or inflammation of the true corneal tissue. When there is much opacity it does not completely clear, and considerable flattening of the cornea and neighbouring sclerotic often occurs at the seat of deep and extensive burns. The conjunctival whitening is followed by mere desquamation and vascular reaction, or by ulceration and scarring, according to the depth of the damage.

Treatment.—In recent cases, seen before reaction has begun, a drop of castor oil once or twice a day, a few leeches to the temple, and the use of a cold evaporating lotion, or of iced water, will sometimes prevent inflammation. If seen immediately after the accident, the conjunctival sac is to be carefully searched for fragments, or washed with very weak acid or alkaline solution if a liquid caustic of the opposite character have done the damage. If inflammatory reaction be already present, treatment by compress, hot fomentations, and the other means recommended for suppurating ulcers (p. 114), is most suitable. There is often much pain and chemosis (*see* Operation for Symblepharon).

c. *Penetrating wounds and gunshot injuries.*—When a patient says that his eye is wounded, the first step is to examine the seat, extent, and character of the wound, ascertain the interval since the injury, and test the sight of the eye; the next to make out all we can about the wounding body, and especially whether any fragment has been left within the eyeball.

Very large foreign bodies, such as pieces of glass, sometimes lie for long in the eye without causing much trouble, the large wound having given exit to the contents of the

globe, and been followed by rapid shrinking without inflammation.

Treatment.—Penetrating wounds are least serious when they implicate the cornea alone, or the sclerotic behind the ciliary region, *i. e.* $\frac{1}{4}$ inch or more behind the cornea. Penetrating wounds of the cornea without injury to the iris or lens, and without any prolapse of iris, are rare; they generally do very well, and if the case be not seen until one or two days after the injury, the wound will often have healed firmly enough to retain the aqueous, and it may be difficult to decide whether the whole thickness of the cornea have been penetrated or not. Wounds of the sclerotic seldom unite without the interposition of a layer of lymph; when seen early they should, if gaping, clean, and uncomplicated by evidence of internal injury, be treated by the insertion of fine sutures, which should be passed only through the conjunctiva, followed by the use of ice (p. 137).

But penetrating wounds are usually very serious to the injured eye; the iris is frequently lacerated and included in the track of the wound; the lens is punctured, and becomes swollen and opaque from absorption of the aqueous humour (*traumatic cataract*, p. 182); it is liable in its swollen state to press on the ciliary processes, and cause grave symptoms; extensive bleeding perhaps takes place into the vitreous; within the first few days purulent inflammation may destroy the eye (p. 145). The fellow-eye is, of course, often in danger of sympathetic inflammation.—Every case has therefore to be judged from two points of view, the damage to the injured eye, and the risk to the sound one; and the question whether to sacrifice, or attempt to save the former, is sometimes very difficult to decide.

(I) In the two following cases the eye should be sacrificed at once. (1) If the wound, lying wholly or partly in

the "dangerous region" (p. 147), be so large and so complicated with injury to deeper parts that no hope of useful sight remains. (2) If, even though the wound be small, it lie in the dangerous region, and have already set up severe iritis (pp. 134 and 145).

(II) There is a large class of cases in which it is certain, or very probable, that the eye contains a foreign body, although the injury is not of itself fatal to sight, and has not as yet led to inflammation, or to shrinking, of the eye.

The first question, then, is whether the foreign body can be seen; the second, whether or not it is steel or iron, and therefore possibly removable by a magnet. A foreign body, if lying on or embedded in the iris, the lens being intact, should be removed, usually with the portion of iris to which it is attached; if loose in the anterior chamber its removal may be difficult. If it can be seen embedded in the lens and the condition of the eye be otherwise favorable, a scoop extraction may be done in the hope of removing the fragment with the lens; or the lens may be allowed, or by a needle operation (p. 176) induced, to undergo partial absorption and shrinking, so as to enclose the foreign body more firmly and, when subsequently extracted, bring it away. If we are certain that the foreign body has passed into the vitreous, whether through the lens or not, and whether by gunshot or not, we can seldom save the eye. The foreign body can in such a case seldom be seen, but a track of opacity through the lens, with blood in the vitreous, or even the latter alone, with conclusive history that the wound was made by a fragment or a shot, and not by an instrument or large body, will generally decide us in favour of excision.—These rules need some modification when the foreign body is of iron or steel, since it is possible in certain cases, by means of a strong electro-magnet, to remove such fragments, even

when lying in the vitreous. This may be done either through the wound of entrance, more or less enlarged, or through a fresh wound made where the body is seen, or believed to lie. Many forms of magnet have been employed, the most successful usually being those in which a probe-ended instrument, powerfully magnetised by being attached to the core of an electro-magnetic coil, is introduced into the eye in search of the body. Though a certain number of eyes have now been saved with useful sight by means of the magnet, it must be remembered that the extraction of the foreign body does not ensure the safety of the eye; that the eye may inflame or shrink, and remain as potent a source of sympathetic disease as before, especially so if iritis or threatened panophthalmitis were present at the time of operation.* Foreign bodies occasionally become embedded at the fundus, beyond the dangerous region, and cause no further trouble. In gunshot cases the shot often passes out through a counter-opening, and remains without doing harm to the orbit, though the eye is destroyed. Occasionally the choroid and retina are damaged by hæmorrhage caused by a shot or bullet traversing the orbit close to, but without demonstrable lesion of, the sclerotic.

(III) There remain cases of less severe character, in which there is no foreign body in the eye: (1) the wound is in the dangerous region and complicated with traumatic cataract; (2) in the dangerous region without traumatic cataract; (3) the injury is entirely corneal, and therefore not in the dangerous zone, but the lens and iris are wounded; (4) there is wound of cornea and iris only, the

* Mr Snell, of Sheffield, who has probably had a larger experience of this method than anyone else, has published (June, 1883) an excellent monograph, in which all the cases hitherto recorded are given, in addition to his own. Hirschberg's monograph on the subject (1885) brings the subject up to later date.

lens escaping. In group (2) there will often be much difficulty in deciding what to do, it being presumed that the wounded eye shows no iritis or other signs of severe inflammation; some of the most difficult cases are those of wounds by sharp instruments close to the corneal border, with considerable adhesion of the iris, or in which there is evidence that the track lies between the lens and the ciliary processes, the lens not being wounded, and useful sight remaining. If the patient be seen within two or three weeks of the injury, and the sound eye show no irritation, we may safely watch the case for a few days. If decided sympathetic irritation (p. 146) be present, and do not yield after a few days' treatment, excision is advisable, even though the lens of the wounded eye be uninjured. In regard to group (1), excision is without doubt the safest course in all cases, whether or not the eye be causing sympathetic symptoms or be itself especially irritable; for there is little prospect of regaining useful vision in an eye with a ciliary wound and traumatic cataract. In group (3) excision is necessary if the wound be very large or irregular, and in some cases with small wound but persistent symptoms. In group (4) removal of the eye is very seldom justifiable, unless, the iris having healed into the wound, chronic inflammatory changes are present, or severe iritis and threatened panophthalmitis come on. The patient in all open cases must be warned, and must be seen every few days for many weeks.

When sympathetic ophthalmitis has set in before the patient asks advice, the rule as to the excision of the exciting eye is different (p. 151).

The treatment of wounded eyes which are not excised is the same as for traumatic iritis and cataract, viz. atropine, rest, and local depletion (*see* pp. 137 and 182). If seen before inflammation (iritis) has begun, ice is to be used. If the iris have prolapsed into the wound the protrusion

should be drawn further out and a large piece of iris cut off, so that the ends when replaced by the curette may retract and remain quite free from the wound (*see* Iridectomy); this may be done as much as a week after the injury. Even when seen within an hour or two of the wound, the prolapse can seldom, in my experience, be either returned by manipulation or made to retract by eserine or atropine.

It is sometimes important to determine whether an excised eye contain a foreign body. If nothing can be found in the blood or lymph, &c., by feeling with a probe, it is best to crush the soft parts, little by little, between finger and thumb, when the smallest particle will be felt. If a shot have entered and left the eye, the counter-opening may, if recent, be found from the inside, although no irregularity be noticeable outside the eyeball.

CHAPTER XI

CATARACT

CATARACT means opacity of the crystalline lens, and is due to changes in the structure and composition of the lens-fibres. The capsule is often thickened, but otherwise not much altered. The changes seldom occur throughout the whole lens at once, but begin first in a certain region, *e. g.* the centre (*nucleus*) or the superficial layers (*cortex*), whilst in some forms of partial cataract the change never spreads beyond the part first affected.

Senile changes in the lens.—With advancing age the lens, which is from birth firmest at the centre, becomes harder, and acquires a very decided yellow colour; its refractive power usually decreases, its surface reflects more light, and its substance becomes somewhat fluorescent. The result of all these changes is, that at an advanced age the lens is more easily visible than in early life, the pupil becoming greyish instead of being quite black. This greyness of the pupil may easily be mistaken for cataract, but ophthalmoscopic examination shows that the lens is transparent, the fundus being seen without any appreciable haze. It has hitherto been supposed that the lens became smaller in old age, but the researches of Priestley Smith have lately shown that the lens continues to increase in all dimensions so long as it remains transparent. As a rule, however, cataractous lenses are undersized.

The consistence of a cataract depends chiefly on the patient's age. The wide physical differences between

cataracts depend less on variations in the cause, position, or character of the opacity than on the degree of natural hardness which is proper to the lens at the time when the opacity sets in. Below about thirty-five all cataracts are "soft."

Forms of General Cataract

(1) *Nuclear cataract*.—The opacity begins in, and remains more dense at, the nucleus of the lens, thinning off gradually in all directions towards the cortex (Fig. 65); the nucleus is not really opaque, but densely hazy. As the patients are generally old, nuclear cataract is usually senile and hard, and also often amber-coloured or light brownish, like "pea-soup" fog.

(2) *Cortical cataract*.—The change begins in the superficial parts, and generally takes the form of sharply defined lines or streaks, or triangular patches, which point towards the axis of the lens, and whose shape is dependent on the arrangement of the lens-fibres (Fig. 66). They usually begin at the edge (*equator*) of the lens where they are hidden by the iris, but when large enough they encroach on the pupil as whitish streaks or triangular patches. They affect both the anterior and posterior layers of the lens, and the intervening parts may be quite clear. Sooner or later the nucleus also becomes hazy (mixed cataract), and the whole lens eventually gets opaque.

Some cases of the large class known as "senile" or "hard" cataract are nuclear from beginning to end, *i. e.* formed by gradual extension of diffused opacity from the centre to the surface; more commonly they are of the mixed variety.

A few cataracts beginning at the nucleus, and many beginning at the cortex, are not senile in the sense of

accompanying old age, and are therefore not hard. Some such are caused by diabetes, but in many it is impossible to say why the lens should have become diseased.* Meyhöfer, observing that opacities in the lens are disproportionately common in glass-blowers, suggests that radiant heat may act as a direct cause of cataract (1886). Many of them are known as "soft" cataracts when complete. They generally form quickly, in a few months. A few are congenital. Whether nuclear or cortical, they are whiter and more uniform-looking than the slower cataracts of old age, and the cortex often has a sheen like satin or mother-of-pearl, or looks flaky like spermaceti.

In some cortical cataracts we find only a great number of very small dots or short streaks (dotted cortical cataract); this form is generally stationary or nearly so for years. Occasionally a single large wedge-shaped opacity will form at some part of the cortex, and remain stationary and solitary for many years. Sometimes in suspected cataract, though no opaque striæ are visible by focal illumination, one or more dark streaks ("striæ of refraction"—Bowman) are seen with the mirror, altering as its inclination is varied, and having much the same optical effect as cracks in glass; these "flaws" should always be looked on as the beginning of cataract.

Partial Cataract

Three forms need special notice.

(1) *Lamellar (zonular) cataract* is a peculiar and well-marked form in which the superficial laminæ and the

* Lowered blood-supply from atheroma of the carotid has lately been suggested as a cause in some cases (Michel). Cataract does not seem to be often related to renal disease; but when renal albuminuria is present in a case of cataract, the prognosis for operation is decidedly less favorable than usual.

nucleus of the lens are clear, a layer or shell of opacity being present between them (Fig. 68). Examination shows a degenerated layer between the nucleus and cortex; in all the cases the nucleus has been found degenerated. It is probable that the opacity is present at birth; it certainly never forms late in life. The association of lamellar cataracts with rickets, and with a marked deformity of the permanent teeth, consisting of an abruptly limited deficiency of the enamel on the part furthest from the gums, is a very common one. The teeth affected are the first molars, canines, and incisors of the permanent set; the dental changes are quite different from those which are pathognomonic of inherited syphilis. The great majority of the subjects of lamellar cataract give a history of infantile convulsions. The cataract is probably due to some temporary interference with the nutrition of the lens in intra-uterine life, during the deposition of the affected layers. Mr Hutchinson has collected many facts in favour of the belief that the dental defect is due to stomatitis interfering with the calcification of the enamel before the eruption of the teeth, and that mercury is the cause of the stomatitis. On this hypothesis the coincidence of the dental defect and of the cataract is due to mercury having been given for the convulsions from which these children suffer. It is reasonable to suppose, however, that the defect of the crystalline lens and of the enamel, both of them epiblastic structures, may be caused by some common influence. The size of the opaque lamella or shell, and therefore its depth from the surface of the lens, are subject to much variation, and it may be much smaller than is shown in the figure. The opacity is often stationary for years, perhaps for life, but cases are sometimes met with in which we cannot doubt, from the history, that the opacity has, without extending perceptibly, become more dense; instances of lamellar opacity

spreading to the whole lens are, however, apparently very rare.

(2) *Pyramidal cataract*.—A small, sharply-defined spot of chalky-white opacity is present in the middle of the pupil (at the *anterior pole* of the lens), looking as if it lay upon the capsule. When viewed sideways it seems to be superficially embedded in the lens, and also sometimes stands forwards as a little nipple or pyramid (Fig. 63). It consists of the degenerated products of a localised inflammation just beneath the lens-capsule, with the addition of organised lymph derived from the iris and deposited on the front of the capsule, the capsule itself being puckered and folded (Fig. 64). It is a stationary form, scarcely ever becoming general.

Pyramidal cataract is the result of central perforating ulceration of the cornea in early life, and of this ophthal-

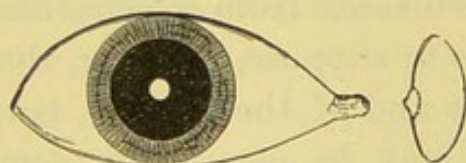


FIG. 63.—Pyramidal cataract seen from the front and in section.

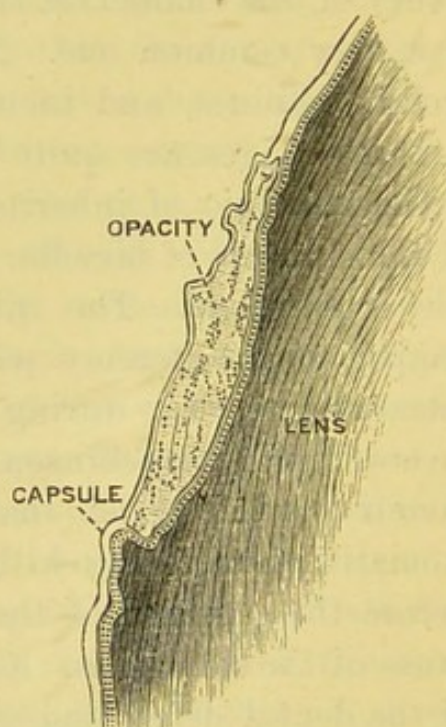


FIG. 64.—Magnified section of an anterior polar cataract of eleven years' formation. A complete layer of hyaline capsule lined by cells is shown behind the opacity, and a hyaline layer in front of it (after Treacher Collins).

mia neonatorum is nearly always the cause; it is therefore often associated with corneal nebula. The contact between the exposed part of the lens-capsule and the inflamed cornea, which occurs when the aqueous has escaped through the hole in the ulcer, appears to set up the

localised subcapsular inflammation. Iritis in very early life may also cause similar opacities at the points of adhesion between the iris and lens.

The term *anterior polar cataract* is applied both to the form just described and to certain rare cases in which general cataract begins at this part of the lens.

(3) Cataract, which afterwards becomes general, may begin as a thin layer at the middle of the hinder surface of the lens (*posterior polar cataract*) (Fig. 67). There are many varieties, but in general the pole itself shows the most change, the opacity radiating outwards from it in more or less regular spokes. The colour appears greyish, yellowish, or even brown, because seen through the whole thickness of the lens. Sometimes the opacity is due to formations adherent to the back of the capsule, *i. e.* in front of the vitreous; but this can seldom be proved during life.—Cataract beginning at the posterior pole is often a sign of disease of the vitreous depending on choroidal mischief; it is common in the later stages of retinitis pigmentosa and severe choroiditis, and in high degrees of myopia with disease of the vitreous. The prognosis, therefore, should always be guarded in a case of cataract where the principal part of the opacity is in this position.

When a cataract forms without known connection with other disease of the eye, it is said to be "*primary*." The term *secondary cataract* is used when it is the consequence of some local disease, such as severe iridocyclitis, glaucoma, detachment of the retina, or the growth of a tumour in the eye. Primary cataract is symmetrical in most cases, but an interval, which may even extend to several years, usually separates its onset in the two eyes. Secondary cataract, of course, may or may not be symmetrical.

Diagnosis of cataract.—The subjective symptoms of cataract depend almost solely on the obstruction and distortion of the entering light by the opacities. Objectively, cataract

is shown in advanced cases by the white or grey condition of the pupil at the plane of the iris; in earlier stages by whitish opacity in the lens when examined by focal light (p. 39), and by corresponding dark portions (lines, spots, or patches) in the red pupil when examined by the ophthalmoscope mirror.

Both subjective and objective symptoms differ with the position and quantity of the opacity. When the whole lens is opaque the pupil is uniformly whitish; the opacity lies almost on a level with the iris, no space intervening, and consequently, on examining by focal light we find that the iris casts no shadow on the opacity; the brightest light from the mirror will not penetrate the lens in quantity enough to illuminate the choroid, and hence no red reflex will be obtained. Such a cataract is said to be mature or "ripe," and the affected eye will be in ordinary terms "blind." If both cataracts be equally advanced, the patient will be unable to see any objects; but he will distinguish quite easily between light and shade when the eye is alternately covered and uncovered in ordinary daylight (good *perception* of light, p. l.), and will tell correctly the *position* of a candle flame (good *projection*). The pupils should be active to light and not dilated, the tension normal.

In a case of incipient cataract the patient complains of gradual failure of sight, and we find the acuteness of vision (p. 24) impaired, probably more in one eye than in the other, and more for distant than for near objects. In the earliest stages of senile cataract some degree of myopia may be developed (Chap. XX), or, owing to irregular refraction by the lens, the patient may see with each eye two or more images of any object close together (*polyopia uniocularis*). If he can still read moderate type, the glasses appropriate for his age and refraction, though giving some help, do not remove the defect. If, as is usual, he be presbyopic, he will

be likely to choose over-strong spectacles, and to place objects too close to his eyes, so as to obtain larger retinal images (p. 13), and thus compensate for want of clearness. In nuclear cataract, as the axial rays of light are most obstructed, sight is often better when the pupil is rather large, and such patients tell us that they see better in a dull light, or with the back to the window, or when shading the eyes with the hand. In the cortical and more diffused forms this symptom is less marked.

On examining by focal light (the pupil having been dilated) an *immature nuclear cataract* appears as a yellowish, rather deeply-seated haze, upon which a shadow is cast by the iris on the side from which the light comes (3, Fig. 65).

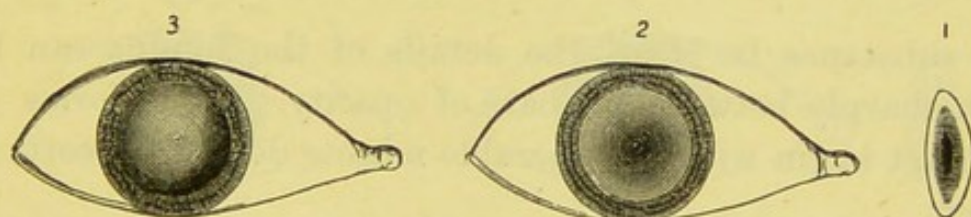


FIG. 65.—Nuclear cataract. 1. Section of lens; opacity densest at centre. 2. Opacity as seen by transmitted light (ophthalmoscope mirror) with dilated pupil. 3. Opacity as seen by reflected light (focal illumination). The pupil is supposed to be dilated by atropine.

On now using the mirror this same opacity appears as a dull blur in the area of the red pupil, darkest at the centre, and gradually thinning off on all sides, so that, at the margin of the pupil, the full red choroidal reflex may still be present; the details of the fundus, if still visible, are obscured by the hazy lens, the haze being thickest when we look through the centre of the pupil (2, Fig. 65). If the opacity be dense and large, a faint dull redness will be visible, and that only at the border of the pupil.

Cortical opacities, if small and confined to the equator (or edge) of the lens, do not interfere with sight; they are easily detected with a dilated pupil by throwing light very

obliquely behind the iris. When large and encroaching on the pupil they are visible in ordinary daylight. They occur in the form of dots, streaks, or wedges; seen by focal light they are white or greyish, and more or less sharply defined according as they are in the anterior or posterior layers (3, Fig. 66). With the mirror they appear black or greyish, and of rather smaller size (2, Fig. 66); and if the interven-

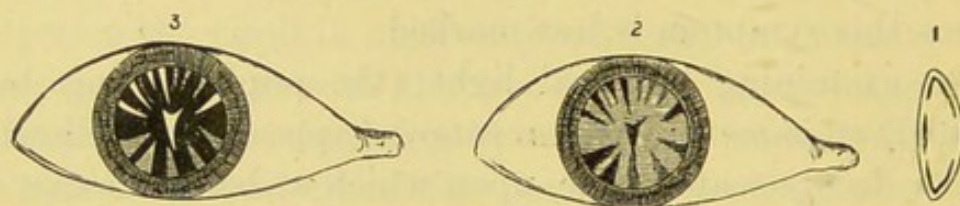


FIG. 66.—Cortical cataract. References as in preceding figure.

ing substance be clear, the details of the fundus can be seen sharply between the bars of opacity. Some forms of cataract begin with innumerable minute dots in the cortical layer.

Posterior polar opacities are seldom visible without careful focal illumination, when we find a patchy or stellate figure very deeply seated in the axis of the lens (3, Fig. 67); if large it looks concave like the bottom of a shallow cup. With the mirror it is seen as a dark star (2, Fig. 67), or

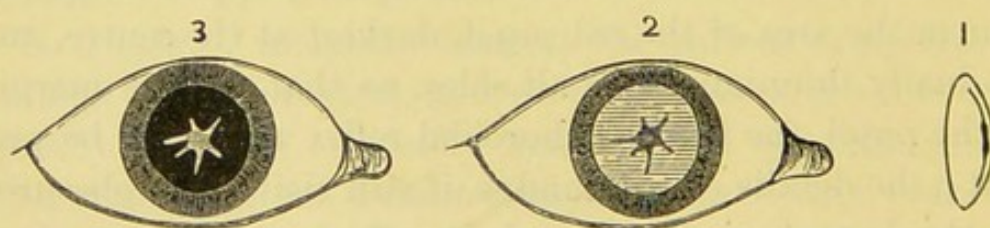


FIG. 67.—Posterior polar cataract. References as before.

network, or irregular patch, but smaller than when seen by focal light.

The diagnosis of *lamellar cataract* is easy if its nature be understood, but by beginners it is often diagnosed as "nuclear." The patients are generally children or young

adults; they complain of "near sight" rather than of "cataract;" for the opacity is not usually very dense, and whether the refraction of their eyes be really myopic or not, they (like other cataractous patients) compensate for dull retinal images by holding the object nearer, and so increasing the size of the images (p. 13). The acuteness of vision is always defective, and cannot be fully remedied by any glasses. They often see rather better when the pupils are dilated, either by shading the eyes or by means of atropine; in the latter case convex glasses (+ 4 or + 4.5 D.) are necessary for reading. The pupil presents a deeply-seated, slight greyness (4, Fig. 68), and when dilated with atropine

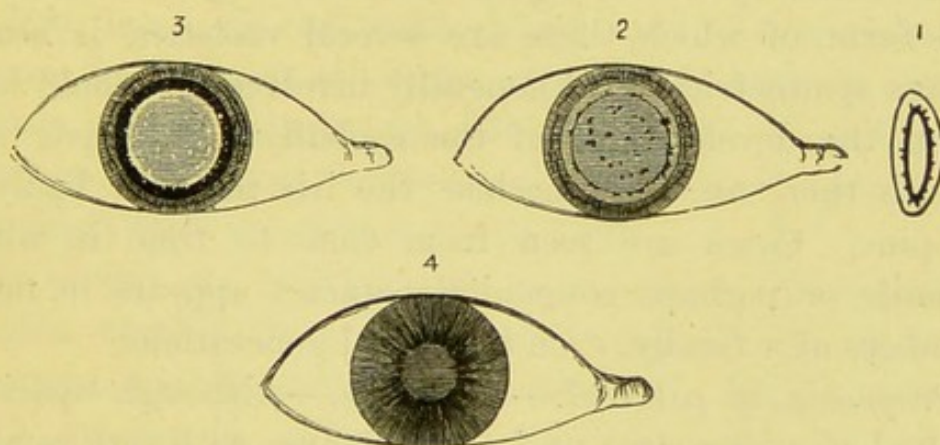


FIG. 68.—Lamellar cataract. Figs. 1, 2, 3, as before. Fig. 4 shows *slight* greyness of the undilated pupil owing to the layers of opacity being deeply seated.

the outline of the shell of opacity is exposed within it. This opacity is sharply defined, circular and whitish by focal light, interspersed in many cases with white specks, which at its equator appear as little projections (3, Fig. 68). By focal illumination we easily make out that the opacity consists of two distinct layers, that there is a layer of clear lens substance (cortex) in front of the anterior layer, and that the margin (equator) of the lens is clear. By the mirror the opacity appears as a disc of nearly uniform greyish or dark colour, sometimes with projections, or

darker dots, and surrounded by a zone of bright red reflection from the fundus corresponding to the clear margin of the lens (2, Fig. 68). The opacity often appears rather denser at its boundary, a sort of ring being formed there ; and in some cases quite large spicules or patches project from the part. Not only does the size of the opaque lamella, and therefore its depth from the surface of the lens, differ greatly in different cases, but its thickness or degree of opacity varies also. The disease is nearly always symmetrical in the two eyes. Occasionally there are two shells of opacity, one within the other, separated by a certain amount of clear lens substance.

The lens may be cataractous at birth (*congenital cataract*). This form, of which there are several varieties, is nearly always symmetrical, and generally involves the whole lens. Often the development of the eyeball is defective, and though there are no synechiæ, the iris may act badly to atropine. Cases are seen from time to time in which juvenile or perhaps congenital cataract appears in many members of a family, even in several generations.

Prognosis of cataract.—*a. Course.*—Although opacities in the lens never clear up,* they advance with very varying rapidity in different cases. As a rough rule, the progress of a general cataract is rapid in proportion to the youth of the patient. Cataracts in old people commonly take from one to three years in reaching maturity—sometimes much longer ; there are cases of nuclear senile cataract where the opacity never spreads to the cortex, and the cataract never becomes “complete,” though it may become dry and “ripe” for operation. If the lens be allowed to remain very long after it is opaque, further degenerative changes generally occur ; it may become harder and smaller, calcareous and fatty granules being formed in it ; or the cortex may liquefy whilst the nucleus remains hard (*Morgagnian cataract*).

* Except sometimes in diabetes (Chap. XXIII).

A congenital cataract may undergo absorption and shrink to a thin, firm, membranous disc. Soft cataract in young adults, from whatever cause, is generally complete in a few months.

b. Sight.—The prognosis *after operation* is good when there is no other disease of the eye, and when the patient (although advanced in years) is in fair general health. It is not so good in diabetes, nor when the patient is in obviously bad health, the eyes being then less tolerant of operation. — In the lamellar and other congenital varieties it must be guarded, for the eyes are often defective in other respects, and sometimes very intolerant of operation: the intellect, too, is sometimes defective, rendering the patient less able to make proper use of his eyes.—In traumatic cataract of course everything depends on the details of the injury (pp. 153, 182), but as a rule the younger the patient the better the prospect of a quiet and uncomplicated absorption of the lens.

In every case of immature cataract, the vitreous and fundus should be carefully examined by the ophthalmoscope, and the refraction ascertained. The presence of high myopia is unfavorable, and the same is true of opacities in the vitreous, indicating, as they usually do, that it is fluid. Any disease of the choroid or retina will of course be prejudicial in proportion to its position and extent. In every case before deciding to operate, the state of the conjunctiva and lacrimal passages (p. 178), the tension of the eye, and the size and mobility of the pupils to light, are to be carefully noted.

Treatment.—In the early stages of senile and nuclear cataract, sight is improved by keeping the pupil moderately dilated with a weak mydriatic solution (one eighth of a grain of atropine to the ounce), used about three times a week. Dark glasses, by allowing some dilatation of the pupil, also assist. Stenopaic glasses are sometimes

useful. With these exceptions, nothing except operative treatment is of any use.—The management of lamellar cataract requires separate description.

Operations for the removal of cataract are of three kinds: (1) *Extraction of the lens entire* through a large wound in the cornea, or at the sclero-corneal junction, the lens-capsule remaining behind. By a few operators the lens is removed entire in its capsule. (2) For soft cataracts, *gradual absorption*, by the agency of the aqueous humour admitted through needle punctures in the capsule, just as after accidental traumatic cataract (needle operations, *solution, discission*). The operation needs repetition two or three times, at intervals of a few weeks, and the whole process therefore occupies three or four months. (3) For soft cataracts, *removal by curette or suction syringe*, introduced into the anterior chamber through a small wound near the margin of the cornea, the whole lens having been freely broken up by a discission operation a few days previously (Chap. XXII). The use of the suction syringe is attended by risk of irido-cyclitis; evacuation of the swollen lens along the groove of a curette just passed into the wound is much safer, and is almost equally effectual. The great advantage of this method over that of gradual absorption is the saving of time, almost the whole lens being removed at one sitting.

Extraction is necessary for cataracts after about the age of forty. The lens from this age onwards is so firm that its absorption after discission occupies a much longer time than in childhood and youth; moreover, as already stated, the swelling of the lens after wound of the capsule is less easily borne as age advances, and hence solution operations become not only slower but attended by more danger. Indeed, though suction and solution operations are applicable up to about the age of thirty-five, extraction is often practised in preference at a much earlier age.

If one eye present a complete cataract whilst the sight of the other is perfect, or at least serviceable, removal of the cataract will confer little immediate benefit on the patient. Indeed, if one eye be still fairly good, the patient will often be dissatisfied by finding his operated eye less useful than he expected, perhaps even not so useful as the other. In senile cataract, therefore, it is usually best not to operate so long as the lens of the other eye remains nearly clear; but as soon as it becomes sufficiently affected to interfere seriously with vision, extraction of the cataract from the first eye is advisable, provided that the patient has a fair prospect of life. The cataract in the first eye may be over-ripe and less favorable for operation if it be left until the second eye is quite ready. The removal of a single cataract in young persons is often expedient on account of appearance. In all cases of single cataract it must be explained that after the operation the two eyes will not work together on account of the extreme difference of refraction. (*See Anisometropia.*)

Even when both cataracts are mature at the same time, it is safer to remove only one at once, because the after-treatment is more easily carried out upon one eye than both, and because after the double operation any untoward result in one eye adds to the difficulty of managing its fellow; while a bad result after single extraction enables us to take especial precautions, or to modify the operation for the second eye. Even if the patient be so old or feeble that the second eye may never come to operation, we shall consult his interests better by endeavouring to give him one good eye than by risking a bad result in attempting to restore both at the same time.

Cataract occurring after the age of forty can seldom be safely extracted until it is complete or "ripe" (p. 170). The transparent portions of an immature cataract cannot be completely removed, partly because they are sticky, partly

because they cannot be seen; and, remaining behind in the eye, they act as irritants, and often set up iritis. Incomplete juvenile cataract (*e. g.* lamellar cataract) may be safely ripened by tearing the capsule with a needle (*see* Discission and Suction); but hard cataract cannot be so treated because the lens is too hard to absorb the aqueous well, and the senile eye is intolerant of injury to the lens (p. 183).

Several years ago, Professor Förster, of Breslau, proposed a plan for hastening the completion of very slow senile cataracts; immediately after the iridectomy he bruises the lens by rubbing the cornea firmly over the pupil with a cataract spoon or other smooth instrument; the capsule is not ruptured, but the lens-fibres are broken up or so changed that they often become opaque a few weeks or months after. Others adopt the safer plan of bruising the lens directly by means of a small bulbous spatula passed through the corneal wound. These methods are very uncertain, sometimes having no effect, but the latter modification may be employed without risk in suitable cases.

The *principal causes of failure* after extraction of cataract are—

(1) *Hæmorrhage* between the choroid and sclerotic coming on, usually with severe pain, immediately after the operation. The blood fills the eyeball, and often oozes from the wound and soaks through the bandage.

(2) *Suppuration*, beginning in the corneal wound, spreading to the iris and vitreous, and in many to the entire cornea, and ending in total loss of the eye. It occasionally takes a less rapid course, and stops short of a fatal result. The alarm is given in from twelve hours to about three days after operation by the occurrence of pain, inflammatory œdema of the lids (particularly the free border of the upper lid), and the appearance of some muco-purulent discharge. On raising the lid the eye is found to be greatly congested, its conjunctiva œdematous, the edges of the wound yellowish, and the cornea steamy

and hazy. In very rapid cases the pupil, especially near to the wound, will already be occupied by lymph. Suppuration is probably always caused by infection, though the source of the mischief of course often remains hidden. Chronic dacryocystitis (p. 76) is a very dangerous concomitant of cataract operations, the pus escaping through the puncta and infecting the wound. Suppuration is more probable if the wound lie in clear corneal tissue than if it be partly scleral, and if the patient be in bad or feeble health.

The use of hot fomentations for an hour three or four times a day, leeches if there be much pain, and internally a purge, followed by quinine and ammonia, and wine or brandy if the patient be feeble, should be at once resorted to. As to other measures, opinions differ. From what I have seen of my own and others' cases I am, at present, inclined to agree with Horner and those who direct most attention to the vigorous antiseptic treatment of the wound itself; I have found that the actual (galvano-) cautery applied deeply along the whole length of the wound, or washing out the wound, and the anterior chamber if necessary, with freshly prepared chlorine water, are more successful than any other measures; they should be assisted, however, by hot fomentations, and the use of iodoform or of weak lotions of chloride of zinc or bichloride of mercury, and by leaving the eye open.* But only in the cases of moderate rapidity and intensity can we hope, even partly, to arrest the disease, for the great majority of these cases go on to suppurative panophthalmitis, or to severe plastic irido-cyclitis with opacity of cornea and shrinking of the eyeball.

(3) *Iritis* may set in between about the fourth and tenth days. Here also pain, œdema of the eyelids, and chemosis are the earliest symptoms. There is lachrimation,

* Mr C. T. Collins, then house surgeon at Moorfields, suggested to me the last-named measure.

but no muco-purulent discharge, and the cornea and wound usually remain clear. The iris is discoloured (unless it happen to be naturally greenish brown), and the pupil dilates badly with atropine. Whenever, in a case presenting such symptoms, a good examination is rendered difficult on account of the photophobia, iritis should be suspected. If the early symptoms are severe, a few leeches to the temple are very useful. Atropine and warmth are the best local measures. If atropine irritate (p. 97), scopolamine, daturine, or duboisine should be tried (F. 34, 36, 37).

This inflammation is plastic, ending in the formation of more or less dense membrane in the pupil. Such membrane, by contracting and drawing the iris with it towards the operation scar, often displaces the pupil (Fig. 158 shows this in an extreme degree). The membrane is formed partly by exudation from the iris and ciliary processes (*iritis, cyclitis*), partly by the lens-capsule and its proliferated endothelial cells (*capsulitis*). Mixed forms of chronic keratitis and iritis sometimes occur, the corneal haze spreading from the wound in the form of long lines or stripes. Iritis of obstinately plastic type is liable to occur after extraction of cataract in diabetes.

(4) The iris may become incarcerated in or prolapse through the wound at the operation, or a few days afterwards by the reopening of a weakly united wound. When iridectomy has been done the prolapse appears as a little dark bulging at one or both ends of the wound, and often causes prolonged irritability without actual iritis. The best treatment is to draw the protruding part further out, and to cut it off as freely as possible, as in accidental wounds (p. 163). The occurrence of prolapse is a reason for keeping the eye tied up longer. The capsule also may be incarcerated in, or adherent to the wound after extraction, suction, or curette (simple linear) extraction.—*After opera-*

tions are needed if the pupil be much obstructed by capsular opacities or by the results of iritis; but nothing should be done until active symptoms have subsided and the eye been quiet for some weeks.

Sight after the removal of cataract.—In accounting for the state of the sight we have to remember that the acuteness of sight naturally decreases in old age (p. 24); that slight iritis, producing a little filmy opacity in the pupil, is common after extraction; and that some eyes, with good sight, remain irritable for long after the operation, and therefore cannot be much used. Thus, putting aside the graver complications, we find that, even of the eyes which do best, only a moderate proportion reach normal acuteness of vision. Cases are considered good when the patient can with his glasses read anything between Nos. 1 and 14 Jaeger and $\frac{6}{18}$ Snellen; but a much less satisfactory result than this is very useful. About 5 per cent. of the eyes operated upon are lost from various causes. The eye is rendered extremely hypermetropic by removal of the lens, and frequently there is a good deal of astigmatism due to flattening of that meridian of the cornea which is at a right angle with the operation wound. Strong convex glasses are necessary for clear vision; these should seldom be allowed until three months after the operation, and at first they should not be continuously worn. Two pairs are needed: one makes the eye emmetropic, and gives clear distant vision (+ 10 or 11 D.); the other (about + 15 D.) is for reading, sewing, &c., at about 10" (25 cm.), as during strong accommodation. When there is astigmatism it should usually be corrected. As all accommodation is lost, the patient has no *range* of distinct vision.

Lamellar cataract.—If the patient can see enough to get on fairly well at school, or in his occupation, it may be best not to operate; but when, as is the rule, the opacity is dense enough to interfere seriously with his prospects,

something must be done. The choice lies between artificial pupil when the clear margin is wide and quite free from spicules, and solution or extraction when it is narrow, or when large spicules of opacity project into it from the opaque lamella (Fig. 68). My own experience is decidedly in favour of removing the lens in the majority of cases. A very good rule is to operate on only one eye at a time, thus allowing the choice of a different operation on its fellow.

When a cataractous eye is absolutely blind (no p. l., see p. 25), some more deeply seated disease must be present, and no operation should be undertaken; and when projection and p. l. are bad (p. 169) great caution is needed.

Cataract following injury.—Severe blows on the eye may be followed by opacity of the lens, the capsule and often the suspensory ligament being no doubt torn in some part (*concussion cataract*) (p. 154). Lawford has shown that rupture of the posterior capsule may occur from a blow, while the anterior capsule remains intact ('Ophth. Rev.,' vi, 281). Such a cataract may remain incomplete and stationary for an indefinite period, but often it becomes complete. *Traumatic cataract* proper is the result of wound of the lens-capsule; the aqueous passing through the aperture is imbibed by the lens-fibres, which swell up, become opaque, and finally disintegrate and are absorbed. The opacity begins within a few hours of the wound; it progresses quickly in proportion as the wound is large and the patient young; but both the symptoms and consequences are often more severe in old persons. A free wound of the capsule, followed by rapid swelling of the whole lens, may give rise, especially after middle life, to severe glaucomatous symptoms and iritis. In from three to six months a wounded lens will generally be absorbed, and nothing but some chalky-looking detritus remain in connection with the capsule. A very fine puncture of the

lens is occasionally followed by nothing more than a small patch or narrow track of opacity, or by very slowly advancing general haze. Occasionally partial opacities of the lens caused by injury clear up entirely. The objects of *treatment* are to prevent iritis by atropine, and by leeching if there be pain (p. 135); it is usually safest to leave the wounded lens to become absorbed, but we must be prepared to extract it by linear operation or suction, at any time, should glaucoma, iritis, or severe irritation arise. A *concussion* cataract, however, is seldom completely absorbed; the lens shrinks and may then become loosened, and fall either into the vitreous or aqueous chamber. I believe, therefore, that it is usually best to remove by operation a cataract following a blow. It will often be observed, in both these forms of cataract, that the opacity appears at the posterior surface of the lens quite early, whether the wound have penetrated deeply or not.

Dislocation of the lens in its capsule is usually caused by a blow on the eye, but may be spontaneous; it is, as a rule, only partial. The iris is often tremulous where its support is lost (p. 154), and bulged forward at some other part where the lens rests against it; by focal light, or by the ophthalmoscope, the free edge of the lens can be seen as a curved line passing across the pupil, more easily if the pupil be dilated. More rarely the dislocation is complete, either into the vitreous or into the anterior chamber. A full-sized lens dislocated into the anterior chamber causes acute glaucoma. Glaucoma, acute or chronic, may also follow at any time after a dislocation, either partial or complete, into the vitreous. Dislocated lenses often become opaque and shrunken, and then either remain loose or become adherent, and in either event are likely, sooner or later, to set up irritation and pain. Such a lens may sometimes be made to pass at will through the pupil by altering the position of the head. The edge of a trans-

parent lens in the vitreous appears (by the mirror) as a dark line; when in the anterior chamber it appears as a bright line (by focal illumination). If the lens be dislocated into the anterior chamber it is necessary to extract it; a myotic should first be used to prevent backward displacement of the lens into the vitreous. If the lens be floating freely in the vitreous it is impossible to remove it; if it be only partially dislocated it may be removed by the hook or spoon. *Congenital* dislocation (*ectopia lentis*) is due to defective development of the suspensory ligament; it is often accompanied by other defects of development, such as coloboma.

For dislocation of lens beneath conjunctiva in rupture of eye see p. 153.

CHAPTER XII

DISEASES OF THE CHOROID

THE choroid is, next to the ciliary processes, the most vascular part of the eyeball, and from it the outer layers of the retina certainly, and the vitreous humour probably, are mainly nourished. Inflammatory and degenerative changes often occur, some of them entirely local, as in myopia; others symptomatic of constitutional or of generalised disease, such as syphilis and tuberculosis. Choroiditis, unlike inflammation of its continuations, the ciliary body and iris, is seldom shown by external congestion or severe pain; and as none of its symptoms are characteristic, the diagnosis rests chiefly on ophthalmoscopic evidence.

Blemishes or scars, permanent and easily seen, nearly always follow disease of the choroid, and such spots and patches are often as useful for diagnosis as cicatrices on the skin, and deserve as careful study. The retina lying over an inflamed choroid often takes on active changes, or becomes atrophied afterwards; but in other cases, marked by equally severe changes, the retina is uninjured. Indeed, there is sometimes difficulty in deciding which of these two structures was first affected, especially as changes in the pigment epithelium, which is really part of the retina, are as often the result of deep-seated retinitis, or retinal hæmorrhage, as of superficial choroiditis. Patches of accumulated pigment, though usually indicating spots of former choroiditis, are sometimes the result of bleeding,

either from retinal or choroidal vessels, and their correct interpretation may therefore be difficult.

Appearances in health.—The choroid is composed chiefly of blood-vessels and of cells containing dark brown pigment. The quantity of pigment varies in different eyes, and to some degree in different parts of the same eye; it is scanty in early childhood, and in persons of fair complexion; more abundant in persons with dark or red hair, brown irides, or freckled skin; more plentiful in the region of the yellow spot than elsewhere. In old age the pigment epithelium becomes paler. When examining the choroid we need to think of four parts: (1) the retinal pigmented epithelium (which is for ophthalmoscopic purposes choroidal), seen in the erect image as a fine dark stippling; (2) the capillary layer (chorio-capillaris), just beneath the epithelium, forming a very close meshwork, the separate vessels of which are not visible in life; (3) the larger blood-vessels, often easily visible; (4) the pigmented connective-tissue cells of the choroid proper, which lie between the larger vessels.

In the majority of eyes these four structures are so toned as to give a nearly uniform, full red colour by the ophthalmoscope, blood-colour predominating. In very dark races the pigment is so excessive that the fundus has an uniform slaty colour. In very fair persons (and young children) the deep pigment (4) is so scanty that the large vessels are separated by spaces of lighter colour than themselves (Fig. 33). In dark persons these same spaces are of a deeper hue than the vessels, the latter appearing like light streams separated by dark islands (*see* upper part of Fig. 71). Near to the disc and y. s. the vessels are extremely abundant and very tortuous, the interspaces being small and irregular; but towards and in front of the equator the veins take a nearly straight course, converging towards the *venæ vorticosæ*, and the islands are larger and elongated. The

veins are much more numerous and larger than the arteries (Fig. 70), but we cannot often distinguish between them in life. The vessels of the choroid, unlike those of the retina, present no light streak along the centre (*cf.* p. 49). The pigment epithelium and the capillary layer tone down the above contrasts, and so in old age, when the epithelial pigment is bleached, or if the capillary layer be atrophied after superficial choroiditis (Fig. 71, *a* and *b*), the above distinctions become very marked.

A vertical section of naturally injected human choroid is shown in Fig. 69; the uppermost dark line (1) is the pigment epithelium; next are seen the capillary vessels (2), cut across; then the more deeply seated large vessels (3), and the deep layer of stellate pigment-cells of the choroid proper (4).—Fig. 70 is from an artificially injected human choroid seen from the inner surface. The shaded portion is intended to represent the general effect produced by all the vessels and the pigment epithelium. The lowest part shows the large vessels with their elongated interspaces, as may be seen in a case where the pigment epithelium and chorio-capillaris are atrophied (Fig. 71, *b*); in a dark eye the interspaces in Fig. 70 would be darker than the vessels. The middle part shows the capillaries without the pigment epithelium. Both figures are magnified about four times as much as the image in the indirect ophthalmoscopic examination.



FIG. 69.—Human choroid, vertical section. Naturally injected. $\times 20$.

Ophthalmoscopic Signs of Disease of the Choroid

The changes usually met with are indicative of *atrophy*. This may be partial or complete; primary, or following inflammation or hæmorrhage; in circumscribed spots and patches, or in large and less abruptly bounded areas.

Secondary changes are often present in the corresponding parts of the retina. The chief signs of atrophy of the choroid are—(1) the substitution of a paler colour (varying from pale red to yellowish white) for the full red of health, the subjacent white sclerotic being more or less

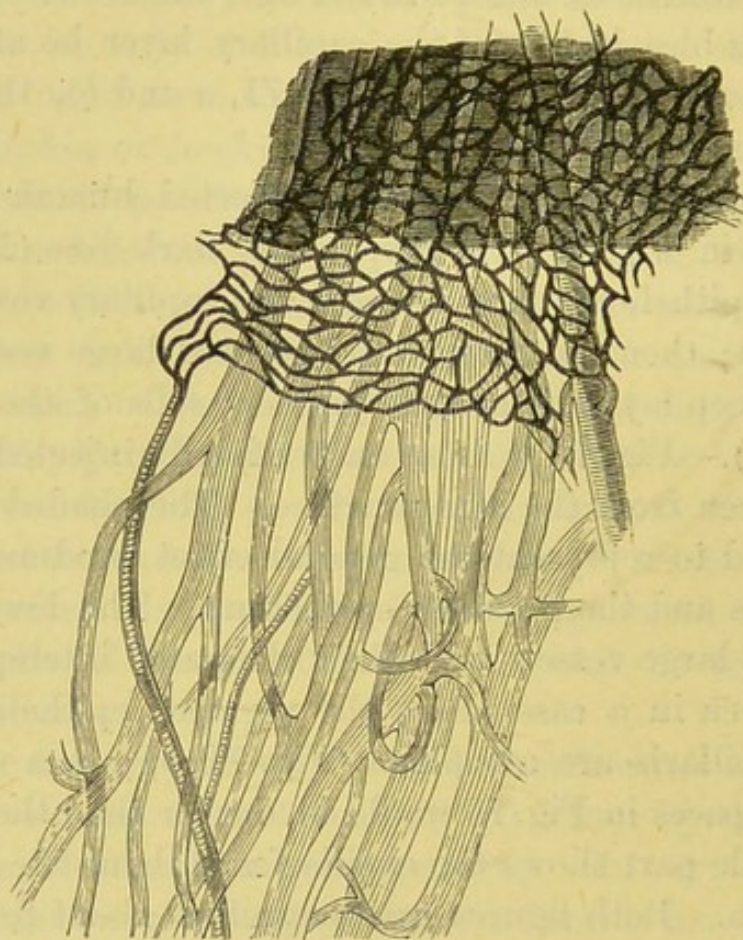


FIG. 70.—Vessels of human choroid artificially injected. Arteries cross-shaded. Capillaries too dark and rather too small. The uppermost shaded part is meant to represent the effect of the pigment epithelium. $\times 20$.

visible where the atrophic changes have occurred; (2) black pigment in spots, patches, or rings, and in varying quantity, upon or around the pale patches. These pigmentations result, 1st, from disturbance and heaping together of the normal pigment; 2nd, from increase in its quantity; 3rd, from blood-colouring matter left after extravasations. Patches of primary atrophy (*e. g.* in myopia)

are never much pigmented unless bleeding have taken place. The amount of pigmentation in atrophy following choroiditis is closely related to that of the healthy choroid, *i. e.* to the complexion of the person.

Pigment at the fundus may lie in the retina as well as in, or on, the choroid, and this is true whatever may have been its origin, for in choroiditis with secondary retinitis the choroidal pigment often passes forward into the retina. When a spot of pigment is distinctly seen to cover a retinal vessel that spot must be not only in, but very near the anterior (inner) surface of, the retina; and when the

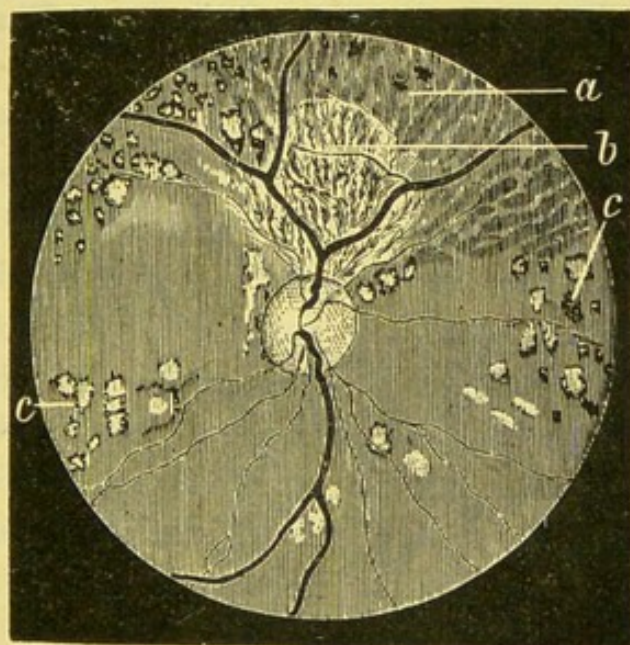


FIG. 71.—Atrophy after syphilitic choroiditis, showing various degrees of wasting (Hutchinson). *a.* Atrophy of pigment epithelium. *b.* Atrophy of epithelium and chorio-capillaris; the large vessels exposed. *c.* Spots of complete atrophy, many with pigment accumulation.

pigment has a linear, mossy or lace-like pattern (Fig. 81), it is always in the retina; these are the only conclusive tests of its position.

It is important, and usually easy, to distinguish between partial and complete atrophy of the choroid. In *superficial atrophy*, affecting the pigment epithelium and capillary

layer, the large vessels are peculiarly distinct (Fig. 71, *a* and *b*). Such "capillary" or "epithelial" choroiditis often covers a large surface, the boundaries of which are sometimes well defined, sinuous and map-like, but are as often ill marked; in the latter case we must carefully compare different parts of the fundus, and also make allowance for the patient's age and complexion. Complete atrophy is shown by the presence of patches of white or yellowish-white colour of all possible variations in size, with sharply cut circular or undulating borders, and with or without pigment accumulations (Fig. 71, *c*). The retinal vessels pass unobscured over patches of atrophied choroid, proving that the appearance is caused by some change deeper than the surface of the retina.

If the patient comes with *recent choroiditis* we also often see patches of palish colour, but they are less sharply bounded, and frequently of a greyer or whiter (less yellow) colour than patches of atrophy; moreover the edge of such a patch is softened, the texture of the choroid being dimly visible there, because only partly veiled by exudation. If the overlying retina be unaffected its vessels are clearly seen over the diseased part, but if the retina itself is hazy or opaque the exact seat of the exudation often cannot be at once decided; and this difficulty is often increased by the hazy state of the vitreous.

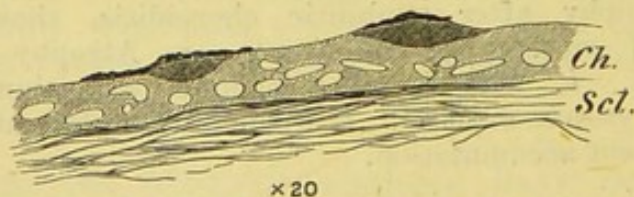


FIG. 72.—Minute exudations into inner layer of choroid in syphilitic choroiditis. Pigment epithelium adherent over the exudations, but elsewhere has been washed off. *Ch.* Choroid. *Scl.* Sclerotic.

Syphilitic choroiditis begins in, and is often confined to, the inner (capillary) layer of the choroid (Fig. 72), and hence it often affects the retina. In miliary tuberculosis

of the choroid the overlying retina is clear, and the growth is, for the most part, deeply seated (Fig. 73). After very

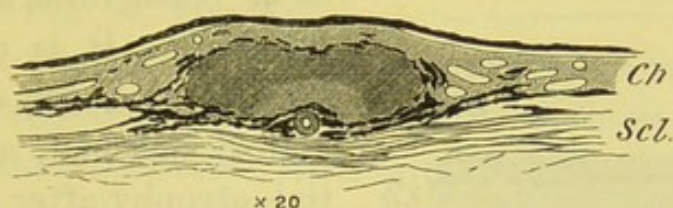

FIG. 73.—Section of miliary tubercle. Inner layers of choroid comparatively unaffected. The lighter shading, surrounding an artery in the deepest part of the tubercle, represents the oldest part, which is caseating; an artery is seen cut across in this part of the tubercle.

severe choroiditis, or extensive hæmorrhage, absorption is often incomplete; we find then, in addition to atrophy, grey or white patches, or lines, which, in pattern and appearance, remind us of keloid scars in the skin, or of patches and lines of old thickening on serous membranes.

Very characteristic changes are seen after *rupture of the choroid* from sudden stretching caused by blows on the front of the eye. These ruptures, always situated in the central region, occur in the form of long tapering lines of atrophy, usually curved towards the disc, and sometimes branched (Fig. 74); their borders are often pigmented. If seen soon after the blow the rent is more or less hidden by blood, and the retina over it is hazy.

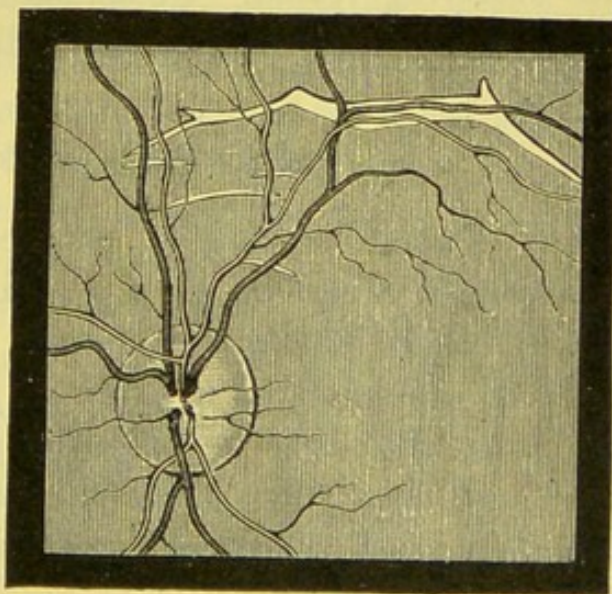


FIG. 74.—Ruptures of choroid.
(Wecker.)

The pathological condition known as “colloid disease” of the choroid consists in the growth of very small hyaline

nodules, soft at first, afterwards becoming hard like glass, from the thin *lamina elastica* which lies between the pig-




FIG. 75.—Partial atrophy after syphilitic choroiditis. Minute growths from inner surface of choroid, showing how they disturb the outer layers of the retina. $\times 60$.

ment epithelium and choriocapillaris. It is common in eyes excised for old inflammatory mischief, and in partial atrophy after choroiditis (Fig. 75). But little is known of its ophthalmoscopic equivalent, or its clinical characters. Probably it may result from various forms of choroiditis,

and may also be a natural senile change.

Hæmorrhage from the choroidal vessels is not so often recognised as from those of the retina, but may be seen sometimes, especially in old people and in highly myopic eyes. The patches are more rounded than retinal hæmorrhages, and we can sometimes recognise the striation of the overlying retina. Occasionally they are of immense size. Patches of atrophy may follow.

Clinical Forms of Choroidal Disease

(1) Numerous discrete patches of choroidal atrophy (sometimes complete, as if a round bit had been punched out, in others incomplete, though equally round and well defined) are scattered in different parts of the fundus, but are most abundant towards the periphery; or, if scanty, are found only in the latter situation. They are more or less pigmented, unless the patient's complexion is extremely fair (Fig. 71, c).

(2) The disease has the same distribution, but the patches are confluent; or large areas of incomplete atrophy, passing by not very well defined boundaries into the healthy choroid around, are interspersed with a certain

number of separate patches; or without separate patches there may be a widely spread superficial atrophy with pigmentation (Fig. 71, *a* and *b*).

These two types of *choroiditis disseminata* run into one another, different names being used by authors to indicate topographical varieties. Generally both eyes are affected, though unequally; but in some cases one eye escapes. The retina and disc often show signs of past or present inflammation.

Syphilis is by far the most frequent cause of symmetrical disseminated choroiditis. The choroiditis begins from one to three years after the primary disease, whether this be acquired or inherited; occasionally at a later period.

The discrete variety (Fig. 71, *c*), where the patches, though usually involving the whole thickness of the choroid, are not connected by areas of superficial change, is the least serious form, unless the patches are very abundant. A moderate number of such patches, confined to the periphery, cause no appreciable damage to sight. The more superficial and widely-spread varieties, in which the retina and disc are inflamed from the first, are far more serious. The capillary layer of the choroid seldom again becomes healthy, and with its atrophy, even if the deeper vessels be not much changed, the retina suffers, passing into slowly progressive atrophy. The retina often becomes pigmented (Fig. 81), its blood-vessels extremely narrowed, bordered by white lines or sheathed in pigment, and the disc passes into a peculiar hazy yellowish atrophy ("waxy disc," Hutchinson—"choroiditic atrophy," Gowers). The appearances may closely imitate those in true retinitis pigmentosa, and the patient, as in that disease, often suffers from marked night-blindness. Such patients continue to get slowly worse for many years, and may become nearly blind.

Syphilitic choroiditis generally gives rise, at an early

date, to opacities in the vitreous; these either form large, easily seen, slowly floating, ill-defined clouds, or are so minute and numerous as to cause a diffuse and somewhat dense haziness ("dust-like opacities," Förster) (Chap. XVI). Some of the larger ones may be permanent. In the advanced stages, as in true retinitis pigmentosa, posterior polar cataract is sometimes developed.

There are no constant differences between choroiditis in acquired and in inherited syphilis; in many cases it would be impossible to guess, from the ophthalmoscopic changes, with which form of the disease we had to do. But there is, on the whole, a greater tendency towards pigmentation in the choroiditis of hereditary than in that of acquired syphilis, and this applies both to the choroidal patches and to the subsequent retinal pigmentation.

In the treatment of syphilitic choroiditis we rely almost entirely on the constitutional remedies for syphilis—mercury and iodide of potassium. In cases which are treated early, sight is much benefited, and the visible exudations quickly melt away under mercury; but I believe that even in these complete restitution seldom takes place, the nutrition and arrangement of the pigment epithelium and bacillary layer of the retina being quickly and permanently damaged by exudations into or upon the chorio-capillaris (as in Fig. 72). In the later periods, when the choroid is thinned by atrophy, or its inner surface roughened by little outgrowths (Fig. 73), or when adhesions and cicatricial contractions have occurred between it and the retina, nothing can be done. A long mercurial course should, however, always be tried if the sight be still failing, even if the changes all look old; for in some cases, even of very long standing, fresh failure takes place from time to time, and mercury has a very marked influence. In acute cases rest of the eyes in a darkened room, and the employment of the artificial leech or of dry cupping at intervals of a few

days, for some weeks, are useful. But it is often difficult to ensure such functional rest, for the patients seldom have pain or other discomfort.

Disseminated choroiditis sometimes occurs without ascertainable evidence of syphilis, chiefly about the age of puberty. Such cases often differ in some of their ophthalmoscopic details from ordinary syphilitic cases, especially in the immunity of the retina and disc; and also in the absence of tendency to recur. It is but seldom that any definite cause, such as exposure to bright light, can be plausibly assigned.

In choroiditis from any cause iritis may occur (*cf.* p. 143).

(3) The choroidal disease is limited to the central region. There are many varieties of such localised change.

In *myopia* the elongation which occurs at the posterior pole of the eye very often causes atrophy of the choroid contiguous to the disc, and usually only on the side next the yellow spot (*see Myopia*). The term "*posterior staphyloma*" is applied to this form of disease when the eye is myopic, because the atrophy is a sign of posterior bulging of the sclerotic. The term "*sclerotico-choroiditis posterior*" is often used, though we but seldom see evidence of exudative changes or hæmorrhagic effusions at the fundus in myopia. A similar crescent, but seldom of great width, is very commonly seen bounding the lower margin of the disc in astigmatic eyes; its widest part nearly always corresponds with the direction of the meridian of greatest curvature of the cornea (Chap. XX). A narrow and less conspicuous crescent or zone of atrophy around the disc is seen in some other states, notably in old persons, and in glaucoma. Separate round patches of complete atrophy ("punched-out" patches) at the central region may occur in myopia with the above-mentioned staphyloma, and must not then be ascribed to syphilitic choroiditis; in

other cases of myopia ill-defined partial atrophy is seen about the y. s., sometimes with splits or lines running horizontally towards the disc.

Central senile choroiditis.—Several varieties of disease confined to the region of the y. s. and discs are seen, and chiefly in old persons. One of these, known as central senile areolar choroiditis, is characterised by a white patch, often very large, occupying the whole central region of the fundus; the particularly striking and rather rare form shown in Fig. 76 may be a late stage of the former. In others a larger but less defined area is affected; some of these appearances undoubtedly result from large choroidal or retinal extravasation. In these areated forms the large deep vessels are often much narrowed, or even converted into white lines devoid of blood colour, by thickening of their coats.—In another form (*guttate*, Fig. 77) the central region is occupied by a number of small white or yellowish-white dots, sometimes visible only in the erect image. This condition is very peculiar, and appears to be almost stationary; the discs are sometimes decidedly pale; when very abundant the spots coalesce, and some pigmentation is found. The pathological anatomy and general relations of this disease are incompletely known, but the white dots are probably due to a hyaline degeneration of the pigment epithelium of the retina; it was first described by Hutchinson and Tay, and is tolerably common. It is symmetrical, and the changes may sometimes be mistaken for a slight albuminuric retinitis (p. 205). No treatment seems to have any influence. Every case of immature cataract should, when possible, be examined for central choroidal changes.

(4) *Suppurative choroiditis and irido-choroiditis.*—In this affection an exudation into the vitreous is produced, which appears as a yellow mass in the fundus of the eye. The inflammation spreads to the ciliary body and iris, and

the whole globe becomes congested; panophthalmitis may set in, or the eye may undergo softening and shrink.

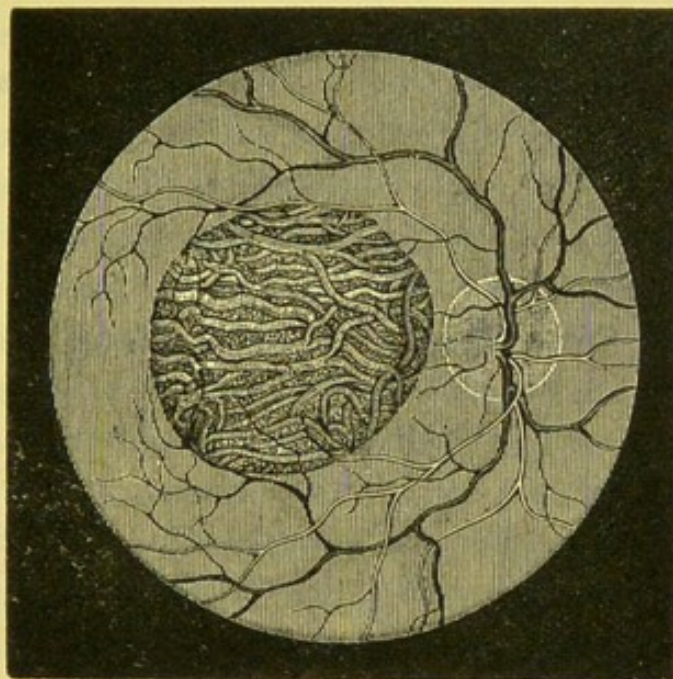


FIG. 76.—Central choroiditis. (Wecker and Jaeger.)

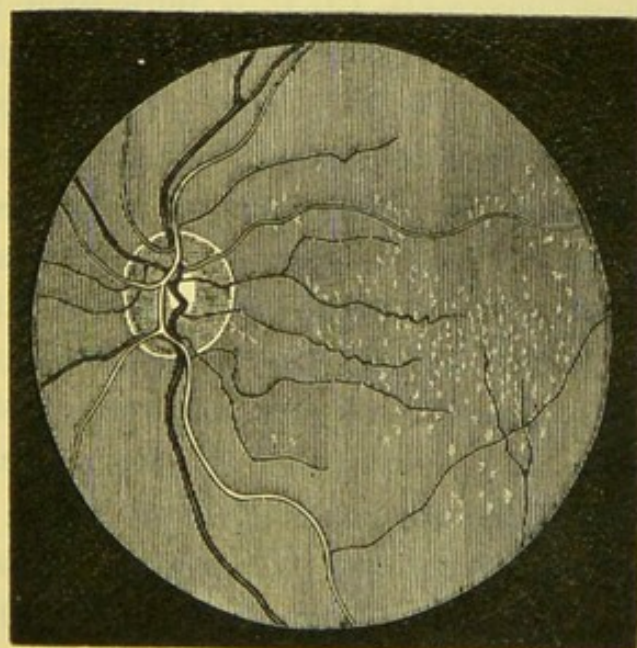


FIG. 77.—Central guttate senile choroiditis.

This is due to (1) infection by pyogenic organisms from penetrating wounds or perforating ulcers; (2) infection

from within by septic embolism as in pyæmia (metastatic choroiditis), or by extension of inflammation from behind as in thrombosis of the orbital veins, and in meningitis. The latter occurs mostly in children, and is sometimes known as *pseudo-glioma* from its resemblance to glioma of the retina. In these cases iritic adhesions are usually present, T. is —, the eye somewhat shrunken, the anterior chamber deep at its periphery, whilst absent or shallow at the centre. There is often the history of some illness with a definite inflammation of the eye before the change is noticed in the pupil. The differential diagnosis from glioma is occasionally very difficult, and in case of doubt it is better to excise the eye (*see Glioma, Chap. XVIII*).

(5) *Anomalous forms of choroidal disease*.—Single large patches of atrophy, with pigmentation, not located in any particular part, are occasionally met with. Probably some of these have followed the absorption of tubercular growths in the choroid, while others are the result of large spontaneous hæmorrhages (p. 191); a blow by a blunt object on the sclerotic causing local bleeding, or inflammation and subsequent atrophy, may account for such a patch at the anterior part of the fundus.—Single large patches of exudation are also met with, and are perhaps tubercular (*see p. 143*).—*Choroidal disease* in disseminated patches seems sometimes to depend upon numerous scattered hæmorrhages into the choroid, which may occur at different dates, and may lead to patches of partial atrophy with pigmentation. The local cause of such hæmorrhages is obscure; the disease may occur in one eye or both, and in young adults of either sex. It may perhaps be called hæmorrhagic choroiditis (*compare Chap. XVI*). Although the changes produced are very gross, some of these patients regain almost perfect sight,—a fact perhaps pointing to the deep layers of the choroid as the seat of disease. It is possible that over-use of the eyes, or expo-

sure to great heat or glare, sometimes causes choroiditis (pp. 195 and 222).

Single spots of choroidal atrophy, especially towards the periphery, should, no less than abundant changes, always excite grave suspicion of former syphilis, and often furnish valuable corroborative evidence of that disease. The periphery cannot be fully examined unless the pupil be widely dilated. A few small, scattered spots of black pigment on the choroid, or in the retina, without evidence of atrophy of the choroid, often indicate former hæmorrhages. Such spots are seen after recovery from albuminuric retinitis with hæmorrhages, after blows on the eye, and sometimes without any relevant history.

Congestion of the choroid is not commonly recognisable by the ophthalmoscope. That active congestion does occur is certain, and it would seem that myopic eyes are especially liable to it, particularly when over-used or exposed to bright light and great heat. Serious hæmorrhage may undoubtedly be excited under such circumstances. In conditions of extreme anæmia the whole choroid becomes unmistakably pale.

Coloboma of the choroid (congenital deficiency of the lower part) is shown ophthalmoscopically by a large surface of exposed sclerotic, often embracing the disc (which is then much altered in form, and may be hardly recognisable), and extending downwards to the periphery, where it often narrows to a mere line or chink. The surface of the sclerotic, as judged by the course of the retinal vessels, is often very irregular, from bulging of its floor backwards. The coloboma is occasionally limited to the part around the nerve, or may form a separate patch. Coloboma of the choroid is often seen without coloboma of the iris, and when both exist, a bridge of choroidal tissue generally separates them in the region of the ciliary body. Cases of so-called coloboma of the choroid at the yellow spot are

probably examples of severe foetal or infantile inflammation of that part.

Albinism is accompanied by congenital absence of pigment in the cells of the epithelium and stroma of the whole uveal tract (choroid, ciliary processes, and iris). The pupil looks pink, because the fundus is lighted, to a great extent, indirectly through the sclerotic. Sight is always defective, and the eyes photophobic and usually oscillating. Many almost albinotic children become moderately pigmented as they grow up.

CHAPTER XIII

DISEASES OF THE RETINA

OF the many morbid changes to which the retina is subject, some begin and end in this membrane, such as albuminuric retinitis and many forms of retinal hæmorrhage; in others the retina takes part in changes which begin in the optic nerve (neuro-retinitis), or in the choroid (choroido-retinitis); very serious lesions also occur from embolism or thrombosis of the central retinal vessels. The retina may be separated ("detached") from the choroid by serous fluid or blood. The retina may also be the seat of malignant growth (glioma), and probably of tubercular inflammation.

In health the human retina is so nearly transparent as to be almost invisible by the ophthalmoscope during life, or to the naked eye if examined immediately after excision. We see the retinal blood-vessels, but the retina itself, as a rule, we do not see. The main blood-vessels are derived from the *arteria* and *vena centralis*, which enter the outer side of the optic nerve, about 6 mm. behind the eye; the veins and arteries are generally in pairs, the veins not being more numerous than the arteries; all pass from or to the optic disc (Fig. 33). At the disc anastomoses, chiefly capillary, are formed between the vessels of the retina and those of the choroid and sclerotic. As no other anastomoses are formed by the vessels of the retina, the retinal circulation beyond the disc is terminal; and further,

as the vessels branch dichotomously, and the branches anastomose only by means of their capillaries, the circulation of each considerable branch is terminal also. The capillaries, which are not visible by the ophthalmoscope, are narrower than those of the choroid, and their meshes become much wider towards the anterior and less important parts of the retina.

At the y. s. (Fig. 78), the only part used for accurate sight, the capillaries are very abundant (*compare* Fig. 69); but at the very centre of this region (*fovea centralis*), where all the layers except the cones and outer granules are excessively thin, there are no vessels, the capillaries forming fine, close loops just around it. The nerve-fibres in this part of the retina are finer than in other parts; they seem also to be much more abundant, for Bunge has found that in a case of central scotoma, where only a very small part ($\frac{1}{40}$) of the F. was lost, quite a large tract of fibres ($\frac{1}{4}$ of the whole) was atrophied in the optic nerve. The *fovea centralis* corresponds to an area at the centre of F., measuring only $1\frac{1}{2}^{\circ}$ in diameter; the part recognised as the *macula lutea* has an area, on the F., of about 7° (Bunge).

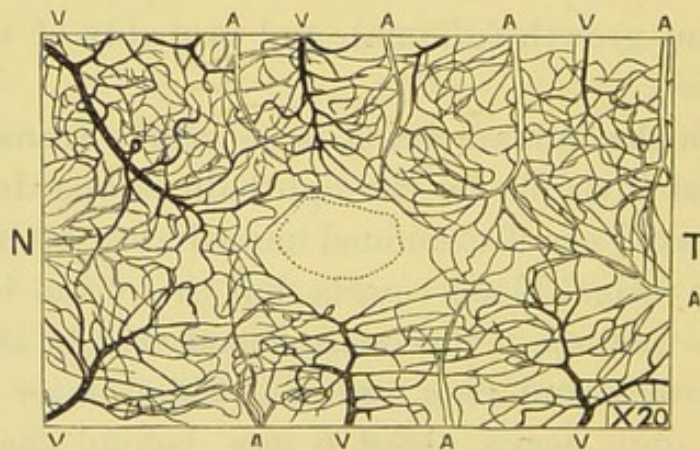


FIG. 78.—Blood-vessels of human retina at the yellow spot (artificial injection). The central gap corresponds to the fovea centralis. A. Arteries. v. Veins. N. Nasal side (towards disc). T. Temporal side. The meshes are many times wider at the periphery of the retina.

In children, especially those of dark complexion, a peculiar white, shifting reflection, or shimmer, is often seen at the y. s. region, and along the course of the

principal vessels. It changes with every movement of the mirror, and reminds one of the shifting reflection from "watered" and "shot" silk. Around the y. s. it takes the form of a ring or zone, and is known as the "halo round the macula" (p. 48). When the choroid is highly pigmented, even if this shifting reflection be absent, the retina is visible as a faint haze over the choroid like the "bloom" on a plum. Under the high magnifying power of the erect image the nerve-fibre layer is often visible near the disc as a faintly-marked radiating striation. The sheaths of the large central vessels at their emergence from the physiological pit (p. 46) show many variations in thickness and opacity.

In rare cases the medullary sheath of the optic nerve-fibres, which should cease at the lamina cribrosa, is continued through the disc into the retina, and causes the ophthalmoscopic appearance known as "opaque nerve-fibres." This congenital peculiarity may affect the nerve-fibres of the whole circumference of the disc, or only a patch or tuft of the fibres; it may only just overleap the edge of the disc, or may extend far into the retina; and islands of similar opacity are sometimes seen in the retina quite separated from the disc. It is to be particularly noted that the central part (physiological pit) of the disc is not affected, because it contains no nerve-fibres. The affected patch is pure white, and quite opaque; its margin thins out gradually, and is striated in fine lines, which radiate from the disc like carded cotton wool; the retinal vessels may be buried in the opacity, or run unobscured on its surface, and are of normal size. The deep layers of the affected parts of the retina being obscured by the opacity, an enlargement of the normal "blind spot" is the result. One eye, or both, may be affected. There is seldom any difficulty in distinguishing this condition from opacity due to neuro-retinitis.

Ophthalmoscopic Signs of Retinal Disease.

Congestion.—No amount of capillary congestion, whether passive or active, alters the appearance of the retina; and as to the large vessels, it is better to speak of the arteries as unusually large or tortuous, or of the veins as turgid or tortuous, than to use the general term congestion. Capillary congestion of the optic disc may undoubtedly be recognised; but even here caution is needed, and much allowance must be made for differences of contrast depending on variations in the tint of the choroid, for the patient's health and age, and for the brightness of the light used, or, what is the same thing, for the size of the pupil. Caution is also needed against drawing hasty inferences from the slight haziness of the outline of the disc, which may often be seen in cases of hypermetropia, and which is certainly not always morbid.

The only ophthalmoscopic proof of true *Retinitis* is loss of transparency of the retina, and two chief types are soon recognised according as the opacity is diffused, or consists chiefly of abrupt spots and patches. Hæmorrhages are present in many cases of retinitis; but they may also occur without either inflammation or œdema. The state of the disc varies much, but it seldom escapes entirely in a case of extensive or prolonged retinitis. In a large majority of cases of recent retinitis the visible changes are limited to the central region, where the retina is thickest and most vascular.

(1) The lessened transparency which accompanies *diffuse retinitis* simply dulls the red choroidal reflex, and the term "smoky" is fairly descriptive of it. The same effect is given by slight haziness of any of the anterior media, but a mistake is excusable only when there is diffused mistiness of the vitreous from opacities which are too small to be easily distinguished (Chap. XVI), and the

difficulty is then increased because this very condition of the vitreous often co-exists with retinitis. A comparison of the erect and inverted images is often useful; for if the diffused haze noticed by indirect examination be caused by retinitis, the direct examination will often resolve what seemed an uniform haze into a well-marked spotting or streaking. When the change is pronounced enough to cause a decidedly white haze of the retina there is no longer any doubt. The retinal arteries and veins are sometimes enlarged and tortuous in retinitis, and in severe cases they are generally obscured in some part of their course. These forms of uniformly diffused retinitis are usually caused either by syphilis, embolism, or thrombosis.

(2) Near the y. s. a number of small, intensely white, rounded spots are seen (Fig. 79), either quite discrete or

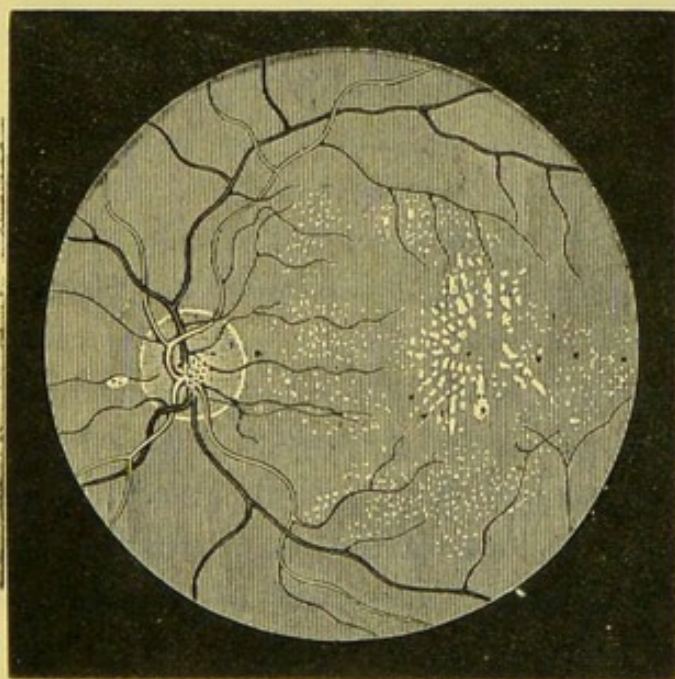


FIG. 79.—Renal retinitis at a late stage. (Wecker and Jaeger.)

partly confluent. When very abundant and confluent they form large, abruptly outlined patches, with irregular borders, some parts of these patches being striated, others stippled.

(3) A number of separate patches are scattered about the central region, but without special reference to the y. s. They are of irregular shape, white or pale buff, and sometimes striated (Fig. 80); they are easily distinguished

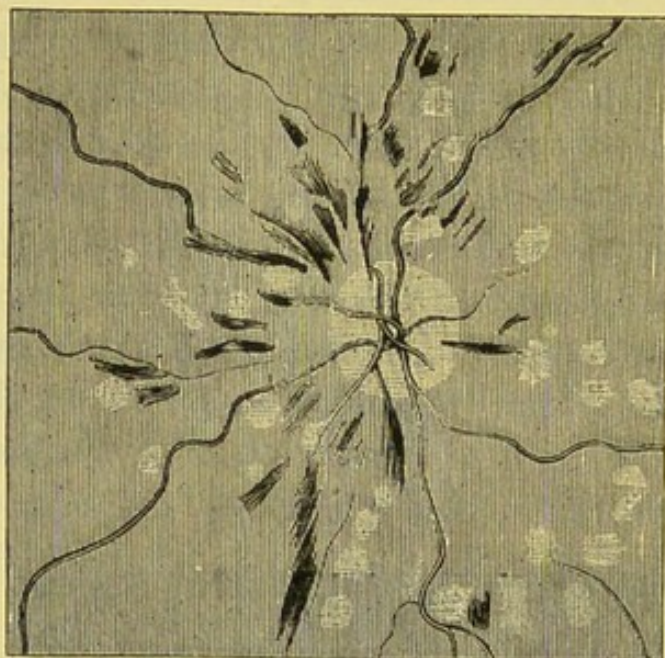


FIG. 80.—Recent severe retinitis in renal disease. (Gowers.)

from patches of choroidal atrophy (p. 190) by their colour, the comparative softness of their outlines, and the absence of pigmentation.

In types 2 and 3 some hæmorrhages are usually present; the retina generally may be clear, but more often there is diffused haze and evidence of swelling. The hæmorrhages may be so numerous and large as to form the chief feature, and then the retinal veins will be very tortuous and dilated.

Forms 2 and 3, which nearly always affect both eyes, are generally associated with renal disease, but in rare cases similar changes are caused by cerebral disease and other conditions (pp. 214 and 229).

(4) Rarely a single large patch or area of white opacity is seen with softened, ill-defined edges, any retinal vessels

that may cross it being obscured. Such a patch of retinitis is usually caused either by subjacent choroiditis (p. 190), or by local phlebitis or thrombosis.

Hæmorrhage into (or beneath) the retina is known by its colour, which is darker than that of an ordinary choroid, but redder and lighter than that of a very dark choroid. Blood may be effused into any of the retinal layers, and the shape of the blood patches is mainly determined by their position. When effused into the nerve-fibre layer, or confined by the sheath of a large vessel, the extravasation takes a linear or streaked form and structure following the direction of the nerve-fibres; extravasations in the deeper layers are rounded. Very large hæmorrhages, many times as large as the disc, sometimes occur near the yellow spot, and probably all the layers then become infiltrated, while sometimes the blood ruptures the anterior limiting membrane of the retina and passes into the vitreous.

Retinal hæmorrhages may be large or small, single or multiple; limited to the central region or scattered in all parts; linear, streaky or flame-shaped, punctate or blotchy; they may lie alongside large vessels, or have no apparent relation to them. The hæmorrhage may, as already mentioned, be the primary change, or may only form part of a retinitis or papillo-retinitis. A hæmorrhage which is mottled, and of dark, dull colour, is generally old. The rate of absorption varies very much; hæmorrhage after a blow is very quickly absorbed, while effusions caused by the rupture of diseased vessels in old people, or accompanying retinitis from constitutional causes, often last for months, and leave permanent traces.

Pigmentation of the retina has been referred to in connection with choroiditis (p. 189). Whenever pigment in the fundus forms long, sharply-defined lines, or is arranged in a mossy, lace-like or reticulated pattern, we may safely infer that it is situated in the retina, and generally that it

lies along the sheaths of the retinal vessels (compare Fig. 81 with Fig. 71). Pigment in or on the choroid never

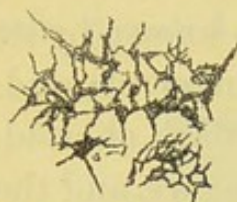


FIG. 81.—Study of pigment in the retina in a specimen of secondary retinitis pigmentosa, seen from the inner (vitreous) surface.

takes such a pattern, being usually in blotches or rings. The two types, however, are often mingled in cases of choroiditis with secondary affection of the retina; indeed, whenever we decide that the retina is pigmented, the choroid must be carefully examined for evidences of former choroiditis.

Spots of pigment may be left after the absorption of retinal hæmorrhages. Such spots can generally be distinguished from those following choroiditis by their more uniform appearance and by the absence of signs of choroidal atrophy.

Atrophy of the retina, of which pigmentation of the retina, when present, is always a sign, has for its most constant indication a marked shrinking of the retinal blood-vessels with thickening of their coats. When the atrophy follows a retinitis or choroido-retinitis (retinitis pigmentosa, syphilitic choroido-retinitis, &c.) all the layers are involved, and the outer layers (those nearest the choroid) earlier than the inner; but when it is secondary to disease of the optic nerve (optic neuritis, progressive atrophy, and glaucoma) only the layers of nerve-fibres and ganglion-cells are atrophied, the outer layers being found perfect even after many years. A retina atrophied after retinitis often does not regain perfect transparency, and if there have been choroiditis the retina remains especially hazy in the parts where this has been most severe.

The disc after severe retinitis or choroido-retinitis always passes into atrophy, often of peculiar appearance, being pale, hazy, homogeneous-looking, and with a yellowish or brownish tint (p. 193).

Detachment (separation) of the retina.—As there is no continuity of structure between the choroid and retina, the two may be easily separated by effusion of blood or serous fluid, the result either of injury or disease, by morbid growths, and by the traction of fibrous cords in the vitreous. Such fibrous bands and strings develop in the vitreous in some cases of irido-cyclitis, and perhaps in myopic eyes without signs of inflammation. Occasionally rents may be seen in the separated retina. It has been suggested that such rents occurring whilst the retina was still *in situ* might initiate the detachment by allowing the intrusion of vitreous between the retina and choroid; and this explanation may possibly hold good in very myopic eyes. The retina is separated at the expense of the vitreous (which is proportionately absorbed), but always remains attached at the disc and ora serrata, unless as the result of wound or great violence. The depth, area, and situation of the detachment are subject to much variety. Fig. 82 shows a diagrammatic section of an eye in which the lower part of the retina is separated. The pigment epithelium always remains on the choroid.

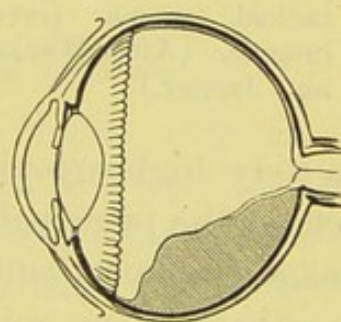


FIG. 82.—Section of eye with partial detachment of retina.

The separated portion is usually far within the focal length of the eye; its erect image is therefore very easily visible by the direct method (p. 49), when it appears as a grey or whitish reflection in some part of the field, the remainder being of the natural red colour; the detached part is grey or whitish, because the retina has become opaque. With care we can accurately focus the surface of the grey reflection, observe that it is folded, and see one or more retinal vessels meandering upon it in a tortuous course; they appear small and of dark colour, and have

lost their central light streak. If the separation be deep the outline of its more prominent folds (Fig. 83) can be seen standing out sharply against the red background, and in some cases the folds flap about when the eye is quickly moved. In extreme cases we can see the detached

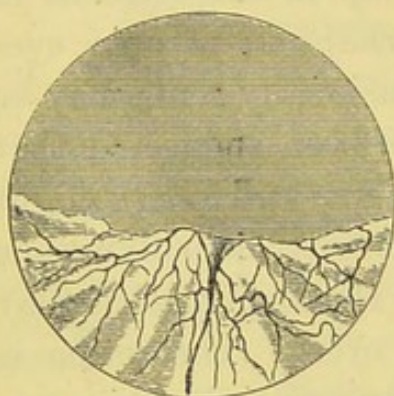

FIG. 83.—Ophthalmoscopic appearance of detached retina (erect image). (After Wecker and Jaeger.)

part by focal light. When the detachment is recent, especially if shallow, the choroidal red is still seen through it; the diagnosis then rests on the observation of whether the vessels in any part are darker, smaller, and more tortuous than elsewhere, and upon ophthalmoscopic estimation of the refraction of the retinal vessels (p. 54) at different parts of the fundus, for the detached part will be much more hypermetropic than the rest.

In very high myopia a shallow detachment may still lie behind the principal focus, and therefore not yield an erect image without a suitable concave lens; in such a case, and in others where minute rucks or folds of detachment are present, examination by the direct method leads to a right diagnosis; as the image of the detached portion is not in focus at the same moment as its surrounding parts, *parallactic movement** is obtained, and the vessels are tortuous. Deep and extensive detachment is often associated with opacities in the vitreous or lens, or with iritic adhesions; and any of these conditions interfere with the conclusive application of the above tests. In some cases of detachment large patches and streaks of choroidal disease are to be found. The treatment of detachment of the retina

* On closing one eye and viewing two objects, one beyond the other, but in the same line, one object seems to move over the other when the head is moved from side to side.

is very unsatisfactory, improvement if obtained being seldom permanent, even when treatment is undertaken soon after the detachment has occurred. Puncture of the sclerotic over the detachment is occasionally followed by marked improvement, and the result is said to be better if the sclerotic be laid bare by dissecting up the conjunctiva before the puncture, and if the puncture be rather broad (about 2 to 4 mm.); the subretinal fluid rapidly drains away. The conjunctival wound should be sutured. Profuse sweating and salivation, induced by pilocarpine (F. 41), have been recommended in recent cases. Mere rest in bed for some days in a subdued light, with the eyes tied up, is often followed for a time by decided improvement of sight. The best results seem to have been obtained by this means, combined with scleral puncture, in recent cases.

Clinical Forms of Retinal Disease.

The symptoms of retinal disease relate only to the failure of sight which they cause, and this may be either general, or confined to a part of the field, according to the nature of the case. Neither photophobia nor pain occurs in uncomplicated retinitis.

Syphilitic retinitis is generally associated with, and secondary to, choroiditis (pp. 192—194), but the retinitis may be primary. The vitreous in this disease, as in syphilitic choroiditis, is often hazy, and the opacities are sometimes seated deeply, just in front of the retina. The changes are those of diffuse retinitis (p. 204, 1), with slight "smoky" haze, often confined to the region of the yellow spot or disc; but in bad cases the haze passes into a whiter mistiness, and extends over a much larger region; sometimes long, branching streaks or bands of dense opacity are met with, and hæmorrhages may occur. The disc is always hazy, and at first too red, while the retinal vessels, both arteries and veins, are somewhat turgid and

tortuous; rarely the disc becomes opaque and swollen (papillitis, p. 225). At a late period, in unfavorable cases, the vessels shrink slowly, almost to threads, the retina often becomes pigmented at the periphery, and the pigmented epithelium disappears.

Syphilitic retinitis is one of the secondary symptoms, seldom setting in earlier than six or later than eighteen months after the primary disease. It occurs in congenital as well as acquired syphilis. It generally attacks both eyes, though often with an interval. Its onset is often rapid, as judged by its chief symptom, failure of sight, and it may be stated that, as a rule, the degree of amblyopia is much higher than would be expected from the ophthalmoscopic changes. Night-blindness is often a pronounced symptom. Its course is chronic, seldom lasting less than several months, and it shows a remarkable tendency, for many months, to repeated and rapid exacerbations after temporary recoveries, but with a tendency to get worse rather than permanently better. Amongst the early symptoms are often a "flickering," and micropsia; these with the history of variations lasting for a few days, and of marked night-blindness, often lead to a correct surmise before ophthalmoscopic examination. There is, however, nothing pathognomonic in any of the symptoms. An annular defect in the visual field ("ring scotoma") may often be found if sought; in the late stages the field is contracted.

Mercury produces most marked benefit, and when used early it permanently cures a large proportion of the cases; but in a number of cases, perhaps in those where there is most choroiditis, the disease goes slowly from bad to worse for several years, in spite of very prolonged mercurial treatment. Of the efficacy of prolonged disuse of the eyes, and of local counter-irritation or depletion, strongly recommended by many authors, I have had but little experience.

Albuminuric retinitis (papillo-retinitis).—The changes are strongly marked, and so characteristic that it is possible, in most cases, to say from an ophthalmoscopic examination alone that the patient is suffering from kidney disease. In the sclerosis of the arteries which accompanies chronic renal disease, the retinal arteries frequently have an unusually bright and sharp central light streak, and are of a lighter colour than normal; they have much the same appearance as would be presented by a piece of bright copper wire (Gunn). Where these arteries cross the veins, the blood-current in the latter is interrupted.

The *earliest change* (the stage of œdema and exudation) is a general haze, of greyish tint, in the central region of the retina, mostly with some hæmorrhages and soft-edged whitish patches (3, p. 203), and with or without haze and swelling of the disc. In this stage the sight is often unimpaired, so the cases are seldom seen by ophthalmic surgeons till a few weeks later, when the translucent, probably albuminous exudations in the swollen retina have passed into a state of fatty or fibrinous degeneration, a change which affects both the nerve-fibres and connective tissue.

In the *second stage* we find a number of pure white dots, spots, or patches, in the hazy region, and especially grouped around the yellow spot. Their peculiarity is their sharp definition and pure, opaque white colour; indeed, when small and round they are almost glistening. When not very numerous they are generally confined to the yellow-spot region, from which they show a tendency to radiate in lines (Fig. 79); when very small and scanty they may be overlooked unless we examine the erect image; but frequently large patches are formed by the confluence of small spots, and the borders of these patches are striated, crenated, or spotted. At this stage the soft-edged patches (Fig. 80) have often to a great extent disappeared, or

become merged into more general opacity of the retina; the disc is hazy and somewhat swollen, especially just at its margin, and the retina, as judged by the undulations of its vessels, and confirmed by post-mortem examination, is much thickened. Hæmorrhages are generally still present, and occasionally they constitute the most marked feature; they are usually striated. Sometimes an artery is seen sheathed by a dense white coating.* In another group papillitis is the most marked change, though some bright white retinal spots are always to be found by careful examination.

The usual tendency is towards subsidence of the œdema, and absorption of the fatty deposits and extravasations, generally with improvement of sight—the *third stage*, or stage of absorption and atrophy.

In the course of several months the white spots diminish in size and number, until only a few very small ones are left near the yellow spot, with, perhaps, some residual haze: the blood-patches are slowly absorbed, often leaving small round pigment spots (p. 208), and the retinal arteries may be shrunken. In cases of only moderate severity almost perfect sight is restored. But when the optic disc suffers severely (severe papillitis), or if the retinal disease be excessive, and attended by great œdema, sight either improves very little, or, as the disc passes into atrophy and the retinal vessels contract, it may sink to almost total blindness. Such a condition may be mistaken for atrophy after cerebral neuritis (p. 227); but the presence of a few minute bright dots or of some superficial disturbance of the choroid, at the yellow spot, or of some scattered pigment spots left by extravasations, will generally lead to a correct inference. In the cases attended by the greatest swelling and opacity of retina and disc, death often occurs

* Illustrations of this are given in Gowers' 'Medical Ophthalmoscopy,' pl. xii, fig. 1, and in 'Trans. Ophth. Soc.,' vol. ii, pl. ii.

before retrogressive changes have taken place. In extreme cases the retina may become deeply detached from the choroid.

Albuminuric retinitis is almost invariably symmetrical, but seldom quite equal in degree or result in the two eyes.

The kidney disease in the malady under consideration is nearly always chronic. The retinitis may occur in any chronic nephritis, and in the albuminuria of pregnancy. Whatever be the form of the kidney disease, the retinitis usually occurs with other symptoms of active kidney mischief, such as headache, vomiting, loss of appetite, and often anasarca; but occasionally the retinitis is the first recognisable sign. The quantity of albumen varies very much. In the absence of anasarca the symptoms are often put down to "biliousness," and as in such cases the failure of sight is the most troublesome symptom, the ophthalmoscope often leads to the correct diagnosis. A second attack of retinitis sometimes occurs in connection with a relapse of renal symptoms. Many of the best marked cases of albuminuric retinitis occur in the albuminuria of pregnancy, and the prognosis for sight is good in many of these if the symptoms come on sufficiently late in the pregnancy to permit of the cause being removed by the induction of artificial labour; but some of them (probably cases of old kidney disease) do very badly, and pass into atrophy of the nerves.

Though the diagnosis of renal disease, based on the presence of the symmetrical retinal changes above described, will usually be verified by the physician, we do unquestionably now and then meet with cases of similar retinitis in which no kidney disease can be clinically proved. Trousseau describes several cases of this sort in which albumen appeared later.* Such cases need further attention. The cases of cerebral neuro-retinitis mentioned at

* 'Bull. de l'Hôpital des Quinze-vingts,' iv, 4, 173.

p. 229, and rare cases of retinitis, exactly like renal retinitis but confined to one eye, have also to be allowed for. Retinal changes more or less like those above described are also found in other chronic general diseases, *e. g.* diabetes, pernicious anæmia, and leucocythæmia (Chap. XXIII).

The term *retinitis hæmorrhagica* has been given to cases characterised by very numerous linear or flame-shaped retinal hæmorrhages, chiefly of small size, all over the fundus, or limited to the area of one vein, generally with extreme venous engorgement and retinal œdema, but in some cases without these features. It usually occurs in only one eye at a time, and comes on rapidly. The patients are often gouty, or the subjects of disease of cardiac valves, or of the arterial system. Thrombosis of the trunk of the *vena centralis retinæ* is probably the determining cause of the condition* when there is much venous distension and retinal œdema; multiple disease of minute retinal vessels when these symptoms are absent. Retinitis hæmorrhagica, of whichever type, is not common.

Other cases are seen where extravasations, varying much in size, number, and shape, are scattered in different parts of the fundus of one or both eyes. Some of them are probably allied to the above, but often the nature of the case is obscure, or the hæmorrhages are related to senile degeneration of vessels. Such cases have been called *retinitis apoplectica*.

Lastly, in an important group, a single very large extravasation occurs on the surface of the retina beneath the internal limiting membrane from rupture of a large retinal vessel, probably a vein—*subhyaloid hæmorrhage*. The hæmorrhage is generally in the yellow-spot region; in process of absorption it becomes mottled, the densest parts remaining longest, and, if seen in that condition for the first time, the case may be taken for one of multiple

* Hutchinson; Michel, Graefe's 'Arch. f. Ophth.,' xxiv, 2.

hæmorrhages. These large extravasations cause great defect of sight, which comes on in an hour or two, but not with absolute suddenness. Absorption, in the several groups of cases just mentioned, is very slow.

Hæmorrhages may occur from blows on the eye. They are usually small and quickly absorbed, differing in the latter respect very much from the cases before described.

Leukæmic retinitis is characterised by retinal hæmorrhages or by extravasations of white blood-corpuscles into the retina; the veins are enlarged, flattened, and tortuous; the colour of the choroid is often pale yellow. Retinal hæmorrhages and optic neuritis also occur in *progressive pernicious anæmia*.

Diabetic retinitis (see Chap. XXIII).

Embolism of the central artery of the retina, or of one or more of its main divisions, gives rise to a characteristic retinitis, the cause of which can in most cases be recognised at once if it be recent; whilst in old cases the appearances, taken with the history, lead to a right diagnosis. *Thrombosis* of the artery causes similar changes.

The leading symptom of embolism is the occurrence of an instantaneous defect of sight, which is found on trial to be limited to one eye; sometimes the feeling is as if one eye had suddenly become "shut," the blindness being as sudden as that from quickly closing the lids; but whether the defect amounts to absolute blindness or not depends on the position and size of the plug. Many of the patients have evidence of cardiac disease. Chorea has been present in a few. In any case, owing to the temporary establishment of collateral circulation by the capillary anastomoses at the disc (p. 201), the patient sometimes notices an improvement of sight a few hours after the occurrence. This improvement, however, is but slight, the collateral channels being quite insufficient to meet the demand; nor is it often permanent, because the retina suffers very quickly

from the almost complete stasis, œdema, and inflammation rapidly setting in and leading to permanent damage.

If the case be seen within a few days of the occurrence, the red reflex of the choroid around the yellow spot and disc is quite obscured, or partially dulled, by a diffused and uniform white mist. The opacity is greatest just around the centre of the yellow spot, where the retina is very vascular (Fig. 78), and where its cellular elements (ganglion and granule layers) are more abundant than elsewhere; but at the very centre of the white mist a small, round, red spot is generally seen, so well defined that it may be mistaken for a hæmorrhage; it represents the *fovea centralis*, where the retina is so thin that the choroid continues to shine through it when the surrounding parts are opaque; it is spoken of by authors as the "cherry-red spot at the macula lutea." This appearance is very seldom seen except after sudden arrest of arterial blood-supply, by embolism or thrombosis of the arteria centralis, and perhaps by hæmorrhage into the optic nerve compressing the vessels; and of these causes embolism appears to be the commonest. The haze surrounds, and generally affects, the disc also, which soon becomes very pale. The small veins in the yellow-spot region often stand out with great distinctness, being enlarged by stasis, and conspicuous from contrast with the white retina. Small hæmorrhages are often present. The larger retinal vessels, both arteries and veins, are more or less diminished at and near the disc, the arteries in the most typical cases being reduced to mere threads; both arteries and veins are, however, sometimes observed to increase in size as they recede from the disc. The arteries, however, are not always extremely shrunken in cases of retinal embolism, the variations depending upon the position and size of the plug, *i. e.* upon whether the occlusion is complete or not. The sudden and complete failure of supply to a single branch of a retinal artery is

sometimes followed by its emptying and shrinking to a white cord almost immediately. In other cases the branch may for a time be little, if at all, altered in size, and yet its blood column may be quite stagnant, as is proved by the impossibility of producing pulsation in it by the firmest pressure on the globe, whilst the other branches respond perfectly to this test (p. 49). Sometimes this pressure test, which showed blockage of some or all branches shortly after the onset, again produces pulsation a few days later without visible evidence of collateral circulation, thus proving the re-establishment of the main channel.

In from one to about four weeks the cloudiness clears off, and the disc passes into moderately white atrophy; the arteries, or some of them (according to the position of the plugging), are either reduced to bloodless white lines, or simply narrowed.

Sight is almost always lost, or only perception of large objects retained, whatever be the final state of the blood-vessels. In the rare cases, where an embolus passes beyond the disc, and is arrested in a branch at some distance from it, the changes are confined to the corresponding sector of the retina, and a limited defect of the field is the only permanent result. It is scarcely necessary to say that no treatment can be of any use in cases of lasting occlusion of the retinal arteries. It will be obvious, too, that these lesions will be limited to one eye, though a similar accident is occasionally seen afterwards in the other.

In a few cases sudden simultaneous blindness of *both* eyes has occurred with extremely diminished retinal arteries ("*ischæmia retinæ*"), and iridectomy has been followed by return of sight, lower tension causing re-establishment of circulation. (*See also* Quinine blindness).

Retinitis pigmentosa is a very slowly progressive symmetrical disease, leading to atrophy of the retina, with collection of black pigment in its layers and around its blood-

vessels, and secondary atrophy of the disc.—The earliest symptom is inability to see well at night, or by artificial light (night-blindness). Concentric contraction of the visual field soon occurs (Fig. 84). These defects may reach a high degree, whilst central vision remains excellent in bright daylight. The symptoms are noticed at an earlier stage by patients in whom the choroid is dark, and absorbs much light.

Ophthalmoscopic examination, where these symptoms have been present for some years, shows—(1) at the equator or periphery a greater or less quantity of pigment, arranged in a reticulated or linear manner (Fig. 81), often with some small, separate dots; (2) in advanced cases, evidence of removal of the pigment epithelium, but no




FIG. 84.—Extreme concentric contraction of field of vision (R.) in a case of advanced retinitis pigmentosa. The central dot shows the fixation point. The black shows the part lost.

patches of choroidal atrophy; (3) the pigment arranged in a belt, which is generally uniform, the pattern being most crowded at the centre, and thinning out towards the borders of the belt; (4) that the changes are always symmetrical, and the symmetry very precise. These appearances are quite characteristic of true retinitis pigmentosa. In addition, we find (5) diminution in size of the retinal blood-vessels, the arteries in

advanced cases being mere threads; (6) a peculiar hazy, yellowish, "waxy" pallor of the optic disc (p. 193); (7) sometimes the pigmented parts of the retina are quite hazy; (8) posterior polar cataract and disease of the vitreous are often present in the later stages. The latter changes (5 to 8), however, are found in many cases of late retinitis con-

secutive to choroiditis, and are not peculiar to the present malady.

The disease begins in childhood or adolescence, progresses slowly but surely, and, as a rule, ends in blindness some time after middle life. A few cases of apparently recent origin are seen in quite aged persons, and a few are considered to be truly congenital. The quantity of pigment visible by the ophthalmoscope varies much in cases of apparently equal duration, and is not in direct relation to the defect of sight; cases even occur, which certainly belong to the same category, in which no pigment is visible during life, the retina being merely hazy, though microscopical examination reveals abundance of minutely divided pigment (Poncet). The pathogenesis of the disease is not finally settled; it is at present doubtful whether there is from the first a slow sclerosis of the connective-tissue elements of the retina, with passage inwards of pigment from the pigment epithelium, or whether the disease begins in the superficial layer of the choroid and the pigment epithelium. Its cause is obscure. It is undoubtedly strongly heritable, and many high authorities believe that it is really produced by consanguinity of marriage, either between the parents or near ancestors of the affected persons. Some of its subjects are of full mental and bodily vigour; but many are badly grown, suffer from progressive deafness, and are defective in intellect. Although want of education, as a consequence of defective sight and hearing, may sometimes account for this result, we cannot thus explain the various defects and diseases of the nervous system which are not infrequently noticed in kinsmen of the patients. That the subjects of this disease should be discouraged from marrying is sufficiently evident. In a few cases galvanism has been followed by improvement both of vision and visual* field, but no other treatment has any influ-

* Gunn, 'Ophth. Hosp. Reports,' x, 161, and others.

ence. Complications such as cataract and myopia are not uncommon, and must be treated on general principles.

It is sometimes very difficult to distinguish widely diffused and superficial choroiditis, with pigmentation of retina and atrophy of the disc, from true retinitis pigmentosa. The question will generally relate to cause, as between retinitis pigmentosa and choroido-retinitis from syphilis (p. 193).

Retinal disease from intense light.—A number of cases have now been observed in which blindness of a small area at the centre of the field has been caused by staring at the sun, usually during an eclipse. Corresponding to this functional defect, ophthalmoscopic evidences of choroiditis or choroido-retinitis have been found at the yellow spot. The defect often lasts for months, if not permanently.*

White connective-tissue strands are sometimes found in the retina either as the result of hæmorrhages or as a primary inflammatory process; blood-vessels of new formation are frequently seen, and from them repeated hæmorrhages occur into the retina or vitreous (*retinitis proliferans*).

Retinitis circinata (Fuchs) occurs chiefly in old people, and consists in a grey degeneration of the retina at the yellow spot, surrounded by a brilliant white deposit of small dots which become confluent into large areas surrounding the central grey degeneration. The exact nature of this affection is unknown.

* For accounts of cases and experiments on this affection see 'Lond. Med. Record,' October, 1883; also 'Ophthalmic Review,' April and May.

CHAPTER XIV

DISEASES OF THE OPTIC NERVE

THE optic nerve is often diseased in its whole length, or in some part of its course, either within the skull, in the orbit, or at its ocular end.

The effect of disease of the optic nerve in producing (1) ophthalmoscopic changes in its visible portion (the optic disc, or *papilla optica*), and (2) defect of sight, varies greatly according to the seat, nature, and duration of the disease. The appearance of the disc may be entirely altered by œdema and inflammation, without the nerve-fibres losing their conductivity, and therefore without loss, or even defect, of sight; on the other hand, inflammatory or atrophic changes, causing destruction of the nerve-fibres, may arise in the nerve at a distance from the eye, and, whilst producing great defect of sight, cause little or no immediate change at the disc. Although we are here concerned chiefly with the ophthalmoscopic and visual sides of the question, a few words are needed as to the morbid changes in the nerve.

The pathological changes to which the optic nerve is liable include those which affect other nerve-tissues. Inflammation (*optic neuritis*, *papillitis*), varying in seat, cause, and rapidity, and resulting in recovery or atrophy, may originate in the nerve itself, may pass down it from the brain (descending neuritis), or may extend into it

from parts around; atrophy may occur from pressure by tumours, or distension of neighbouring cavities (*e. g.* the third ventricle), or from laceration of the nerve or its central vessels in the orbit, or damage from fracture of the optic canal; and the optic nerve is very subject to *primary atrophy*.

Lastly, the optic nerve being surrounded by a lymphatic space ("subvaginal space"), which is continuous through the optic foramen with the meningeal spaces in the skull, and is bounded by a tough, fibrous "outer sheath," is liable to be affected by morbid processes going on in that space. This subvaginal or inter-sheath space, bounded externally by the outer sheath of the optic nerve, is lined internally by the inner sheath which is closely adherent to the nerve itself (Fig. 36). The relationship between optic neuritis and cerebral disease is still imperfectly understood. Widely differing kinds of intra-cranial disease, such as tumour or meningitis, produce an increase of fluid in the cavities of the brain. The increased pressure within the skull so produced leads to a distension of the subvaginal space of the optic nerve; this is frequently found *post mortem*.

By many it is held that this alone is a sufficient cause of the optic neuritis, either by compressing the retinal veins and producing "choked disc" (*v.* Graefe), or by setting up irritation in the nerve (Leber). The fact that optic neuritis very generally subsides after trephining the skull (Victor Horsley), even when the tumour is not removed, gives strong support to this *pressure* theory.

On the other hand, it has been proved microscopically by many observers that the inflammation is not confined to the head of the nerve, but extends backwards along its trunk to the substance of the brain, and is continuous with the inflammatory focus in the brain; this occurs not only in meningitis, but in remotely situated tumours, which are always surrounded by an area of hyperæmia. According

to this view the inflammatory appearances in the head of the optic nerve are due to a *descending neuritis*.*

As already stated in previous chapters, inflammation may extend into the disc from the retina or choroid near to it, and may occur in consequence of the sudden arrest of the blood-current caused by embolism and thrombosis of the central retinal vessels, in their course through the nerve.

The ophthalmoscopic signs of papillitis are caused by varying degrees of œdema, congestion, and inflammation of the disc. It is no longer useful to maintain the old ophthalmoscopic distinction between "swollen disc," or "choked disc," and "optic neuritis." The latter term was formerly reserved for cases showing little œdema but much opacity, changes which were supposed especially to indicate inflammation passing down the nerve from the brain; but if œdema and venous engorgement predominated ("choked disc"), the changes were attributed to compression of the optic nerve by fluid in its sheath-space, or with less reason to pressure on the ophthalmic vein at the cavernous sinus. The changes are often mixed, or vary at different stages of the same case. The terms "neuritis" and "papillitis" will be here used to the exclusion of "choked disc."

The most important early changes in optic papillitis are blurring of the border of the disc by a greyish opalescent haze, distension of the large retinal veins, and swelling of the disc above the surrounding retina. Swelling is shown by the abrupt bending of the vessels, with deepening of their colour and loss of the light streak,—they are, in fact, seen foreshortened; also by noticing that slight lateral movements of the observer's head, or lens, cause an apparent movement of the vessels over the choroid behind, because the two objects are on different levels ("parallactic

* See Gowers, "Medical Ophthalmoscopy," 'Trans. Internat. Med. Congress,' 1881; papers by S. Mackenzie, Brailey, Edmunds and Lawford, and Taylor, 'Trans. Ophth. Soc.'

test," p. 210). The patient may die, or the disease may, after a longer or shorter time, recede at this stage. But further changes generally occur, the haziness becomes a decided opacity, which more or less obscures the central vessels, and covers and extends beyond the border of the papilla (Fig. 85), so that the disc appears enlarged; its

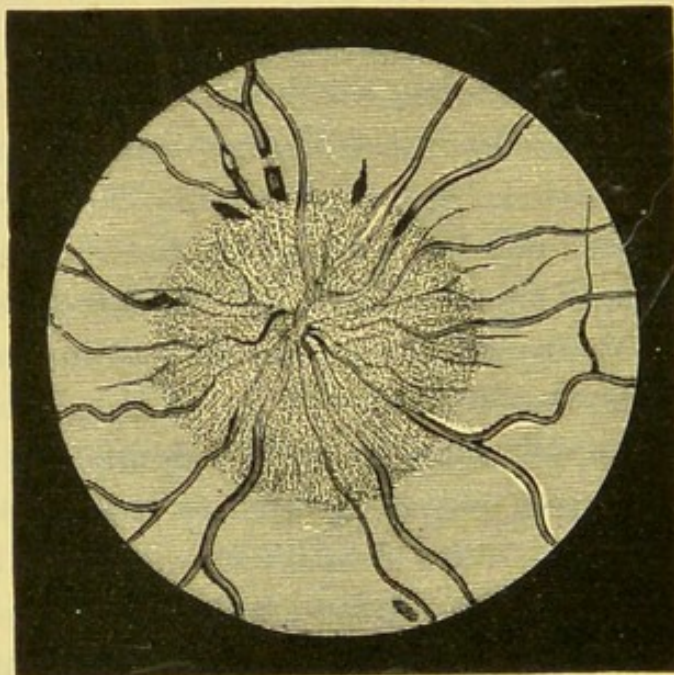


FIG. 85.—Ophthalmoscopic appearance of severe recent papillitis. Several elongated patches of blood near border of disc. (After Hughlings Jackson.) Compare with Fig. 86.

colour becomes a mixture of yellow and pink with grey or white, and it looks striated or fibrous, appearances due to a white opacity of the nerve-fibres mingled with numerous small blood-vessels and hæmorrhages. The veins become larger and more tortuous, or even kinked or knuckled; the arteries are either normal or somewhat contracted; there may be blood-patches. The swelling of the disc may be very great, and is appreciated either by the above-mentioned foreshortening of the vessels, by the parallactic test, or by ophthalmoscopic measurement (p. 54).

Such changes may disappear, leaving scarcely a trace;

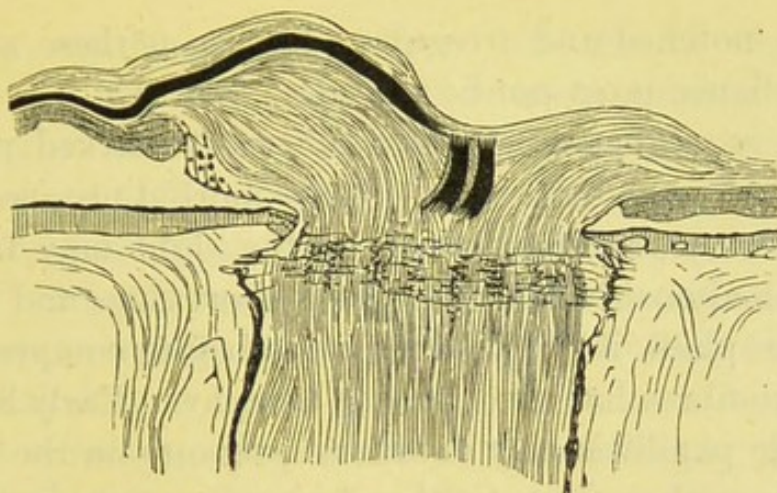


FIG. 86.—Section of the swollen disc in papillitis, showing that the swelling is limited to the layer of nerve-fibres (longitudinal shading); other retinal layers not altered in thickness. (*Compare with Fig. 37.*) \times about 15.

or a certain degree of atrophic paleness of the disc, with some narrowing of the retinal vessels and thickening of their sheaths, or other slight changes, may remain. But in many cases the disc gradually, in the course of weeks or months, passes into a state of "post-papillitic" or "consecutive" atrophy; the opacity first becomes whiter and smoother looking ("woolly disc"); then it slowly clears off, generally first at the side next the yellow spot, and the retinal vessels simultaneously shrink to a smaller size, though they often remain tortuous for a long time (Fig. 87). As the mist lifts, the sharp edge, and finally the whole surface of the disc, now of a staring white colour, again come into view. A slight haziness often remains, and the boundary of the disc

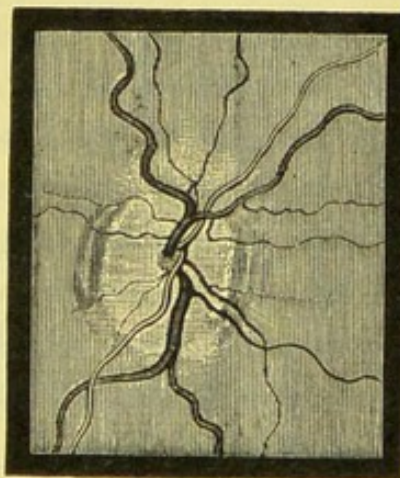

FIG. 87.—Atrophy of disc after papillitis. Upper and lower margins still hazy; veins still tortuous; arteries nearly normal; disturbance of choroidal pigment at inner and outer border. Sight in this case remained fairly good. The disc is not represented white enough.

is often notched and irregular; but upon these signs too much reliance must not be placed.

Sight is seldom much affected* until marked papillitis has existed some little time. If the morbid process quickly cease, often no failure occurs; or the sight may fail, may even sink almost to blindness for a short time, and recovery may take place, if the changes cease before compression of the nerve-fibres has given rise to atrophy. Early blindness in double papillitis may be due to pressure on the chiasma or tracts rather than to the changes we see in the eyes. Gradual failure late in the case, when retrogressive changes are already visible at the disc, is a bad sign. The sight seldom changes, either for better or worse, after the signs of active papillitis have quite passed off; and though the relations between sight and final ophthalmoscopic appearances vary, it is usually true (1) that great shrinking of the central retinal vessels indicates a high grade of atrophy and great defect of sight, and is generally accompanied by extreme pallor, with some residual haziness, of the disc (advanced post-papillitic atrophy); (2) that considerable pallor, and other slight changes, such as white lines bounding the vessels, or streaks caused by increase of the connective tissue of the disc, are compatible with fairly good sight if the central vessels are not much shrunk.

Advanced atrophy, undoubtedly following papillitis, does not, however, always show signs of the past violent inflammation; the appearances may, indeed, be indistinguishable from those caused by primary atrophy (p. 231).

Papillitis is double in the great majority of cases. If single, it generally indicates disease in the orbit. It is

* Dr Hughlings Jackson was the first to notice and insist upon the frequency of papillitis without failure of sight. The discovery was of immense value, for double papillitis, without other changes in the eye, is one of the most important objective signs we possess of the existence of tumour, or inflammation, within the skull.

true that single papillitis, from intracranial disease, is occasionally met with; and that in many double cases inequalities are often seen between the two eyes, as to time of onset, degree, and final result.

The changes are not always limited strictly to the disc and its border (pure papillitis), for in some cases a wide zone of surrounding retina is hazy and swollen, exhibiting hæmorrhages and white plaques, or lustrous white dots (*papillo-retinitis*). It is not always easy to say, in such a case, whether the changes are due to renal disease, with great swelling of the disc (p. 213), or to some intracranial malady. In renal cases there is albuminuria, the kidney is in an advanced stage of disease,* and the patients are seldom young; in the cases of neuro-retinitis most closely resembling renal cases, but caused by cerebral disease, there is no albumen, and the white deposits are seldom arranged quite as in renal retinitis (Fig. 79), whilst the papillitis is greater than is usual in renal cases.

Ætiology (compare Chap. XXIII).—Papillitis occurs chiefly in cases of irritative intracranial disease, viz. in meningitis, both acute and chronic, and in intracranial new growths of all kinds, whether inflammatory (syphilitic gummata), tubercular, or neoplastic. It is very rare in cases where there is neither inflammation nor tissue growth, as in cerebral hæmorrhage and intracranial aneurism. Further, it must be stated that no constant relationship has been proved between papillitis and the seat, extent, or duration of the intracranial disease. Papillitis has occasionally been found without coarse disease, but with widely diffused minute changes, in the brain. Thus the occurrence of papillitis, although pointing very strongly to organic disease within the skull, and especially to intracranial tumour, is not of itself either a localising or a differentiating symptom. Inflammation about the sphe-

* Gowers, p. 187.

noidal fissure, and tumours, nodes, and inflammations in the orbit, are occasional causes of papillitis, which is then usually one-sided, and often accompanied by extreme œdema and venous distension; in some of these there is protrusion of the eye with affection of other orbital nerves, and the exact seat and nature of the disease may be obscure. Optic neuritis from intracranial disease seldom recurs after subsidence.*

Other occasional causes of double papillitis, with or without retinitis, are lead poisoning, the various exanthemata (including recent syphilis), sudden suppression of menses, simple chronic anæmia, rapid copious loss of blood, especially from the stomach, and, perhaps, exposure to cold. In a few cases well-marked double papillitis occurs without other symptoms, and without assignable cause.

Certain cases of failure of sight, usually single, with slight neuritic changes at the disc, followed by recovery or by atrophy, must be referred to a local, primary optic neuritis some distance behind the eye (*retro-ocular* or *retro-bulbar neuritis*). The changes are, clinically, very different from those above described (*see* p. 241, 3).

Syphilitic disease within the skull is a common cause of papillitis, but the eye changes alone furnish no clue to the cause, nor to its mode of action, which may be—(1) by giving rise to intracranial gumma, not in connection with the optic nerves, but acting as any other tumour acts (*see* above); (2) by direct implication of the chiasma or optic tracts in gummatous inflammation; (3) in rare cases neuritis, ending in atrophy and blindness, occurs in secondary syphilis, with head symptoms pointing to meningitis; (4) there are few cases of double papillitis in late secondary syphilis, without either head symptoms or signs

* A well-marked case has been recorded by Dr James Anderson in the 'Ophthalmic Review' for May, 1886.

of ocular disease other than in the discs; these may properly be called "syphilitic optic neuritis."

ATROPHY OF THE OPTIC DISC

By this is meant atrophy of the nerve-fibres of the disc, and of the capillary vessels which feed it. The disc is too white; milk-white, bluish, greyish, or yellowish, in different cases. Its colour may be quite uniform, or some one part may be whiter than another; the stippling of the *lamina cribrosa* (p. 47) may be more visible than in health, or on the other hand, entirely absent, as if covered or filled up by white paint (Figs. 88 and 89). The central retinal vessels

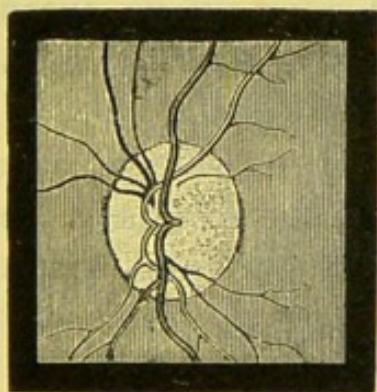


FIG. 88.—Simple atrophy of disc. Stippling of lamina cribrosa exposed. (Wecker.)

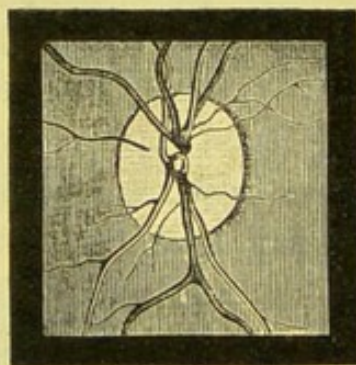


FIG. 89.—Atrophy of disc from spinal disease. Lamina cribrosa concealed. Vessels normal. (Wecker.)

may be shrunken or of full size, and their course natural or too tortuous; both these points bear upon the diagnosis of cause and the prognosis. The choroidal boundary may be too sharply defined, or, as in Fig. 87, too hazy; it may be even and circular, or irregular and notched. The sclerotic ring (p. 46) is often seen with unnatural clearness, exposed by wasting of the overlying nerve-fibres. Mere pallor of the disc, such as we see in extreme general anæmia,

must not be mistaken for atrophy ; the change is then one of colour only, without unnatural distinctness, loss of transparency, or disturbance of outline.

Varieties.—(1) The nerve-fibres undergo atrophy during the absorption and shrinking of the new connective tissue formed in severe neuritis (post-papillitic atrophy, p. 227 ; embolism, p. 217).

(2) When the disc participates secondarily in inflammation of the retina or choroid it also participates in the succeeding atrophy (pp. 193, 208).

(3) Atrophy of any part of the optic nerve or chiasma, from pressure—as by a tumour or by distension of the third ventricle in hydrocephalus—from injury, or local inflammation, leads to secondary atrophy, which sooner or later reaches the disc. Such cases often show the conditions of pure atrophy, without adventitious opacity or disturbance of outline, and often without change in the retinal vessels. They are not very common.

(4) The optic nerves are liable to chronic sclerotic changes, with thickening of the connective-tissue framework and atrophy of the nerve-fibres, without the occurrence of papillitis. The change in these cases appears often to begin at the disc, but the exact order of events in this large and important group is not fully known.—Groups 3 and 4 furnish the cases which are known clinically as “primary” or “progressive” atrophy of the optic disc.

Clinical aspects of atrophy of the discs.—As in optic neuritis, so in atrophy and pallor of the disc, there is no invariable relation between the appearance (especially the colour) of the disc and the patient's sight. A considerable degree of pallor, which it may be impossible to distinguish from true atrophy, is sometimes seen with excellent central vision (p. 24), though usually accompanied by some defect of the visual field. Again, the discs often look

alike, although the sight is much better in one eye than the other.

Patients with atrophy of the disc come to us because they cannot see well, or are quite blind. There are usually




FIG. 90.—Irregular contraction of fields of vision in a case of progressive atrophy of optic nerves. The loss is symmetrical, but more advanced in the L., where it has extended over the fixation point; in the R. it has just reached the fixation point at one place. The black represents the parts lost.

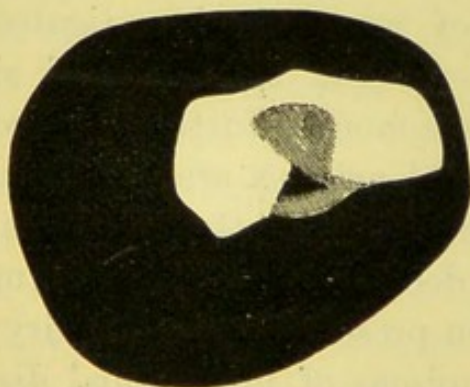


FIG. 91.—Irregular contraction, with central loss, of L. visual field, from progressive atrophy of optic nerve in locomotor ataxy. The black represents the blind parts; the shading shows partial loss of vision.

no other local symptoms except such as may be furnished by the pupils. In post-papillitic atrophy the pupils are generally too large, and sluggish or motionless to light; in most cases of primary progressive atrophy in the early stages they are of ordinary size, or smaller than usual,

and act very imperfectly (Chap. XXIII). When only one eye is affected, the other being quite healthy, the pupil of the amaurotic eye has no direct action to light (p. 26), and is often a little larger than its fellow.

The visual field, in cases of atrophy, is generally contracted, or shows irregular invasions or sector-like defects (Figs. 90 and 91). Colour-blindness is a marked symptom in nearly all cases, but is not always proportionate to the loss of visual acuteness, being in some much greater and in others much less than the state of central vision would lead us to expect. Green is the colour lost soonest in nearly all cases, and red next.

A. Cases in which *both discs are atrophied* may be conveniently classified as follows in regard to diagnosis and prognosis.

(1) If the changes point decidedly to recently past papillitis (p. 227), there is some prospect of improvement; but, on the other hand, sight may for a time get worse. The case must, of course, be investigated most carefully as to the cause of the neuritis. If sight have been stationary for some months further change is unlikely.

(2) If the retinal arteries are much shrunken, whether neuritis has occurred or not, the prognosis is bad (p. 228).

If we cannot decide after careful examination whether papillitis has been present or not, inquiry should be made as to former symptoms of intracranial disease; since consecutive atrophy cannot always be distinguished from primary (p. 228).—But in a large number of those cases which present no ophthalmoscopic evidences of previous papillitis the history will be quite negative as to cerebral symptoms; and these will, for the most part, fall into the two following groups.

(3) There are symptoms of chronic disease of the spinal cord, usually of locomotor ataxy; or, much more rarely, symptoms of general paralysis of the insane.

(4) No cause can be assigned for the atrophy; these cases are less common than has been supposed.

The sclerosis leading to atrophy of the discs in locomotor ataxy (3) usually comes on early in that disease, often before well-marked spinal symptoms have appeared. The optic atrophy always becomes symmetrical, though it generally begins some months sooner in one eye than in the other; it always progresses, though sometimes not for years, to complete, or all but complete, blindness. The discs are usually characterised by an uniformly opaque, grey-white colour, the lamina cribrosa being often concealed, although neither the central vessels nor the disc margins are obscured in the least (Fig. 89). The central vessels are often not materially lessened in size, even when the patient is quite blind.

Cases of progressive atrophy are seen which resemble the above, but where no signs of spinal cord disease are present, even though the patient has been long blind (4). It is known that in some of these patients ataxic symptoms come on sooner or later, and it is highly probable that, could the cases be followed up for a sufficient number of years, this termination would be found to be common;* indeed, pre-ataxic optic atrophy is now a recognised method of onset of the disease. Undoubtedly in some cases the optic nerve atrophy is not followed by locomotor ataxy, but some of the other signs of tabes dorsalis may be present, as the Argyll-Robertson pupil or the loss of knee-jerk. We should probably be justified in grouping such cases under the heading of arrested tabes. Cases of

* I have found decided spinal symptoms in 58 of a series of 76 consecutive cases of progressive atrophy, and of the remaining 18, several showed one or more symptoms which were probably of spinal origin. Peltsohn finds about 40% of all cases of non-neuritic progressive optic atrophy, in Hirschberg's clinic, to be associated with spinal or cerebro-spinal disease ('Knapp's Arch.,' xvi, 142).

Classes 3 and 4 are far commoner in men than women. In a few the atrophy is caused by a tumour compressing the chiasma, without setting up papillitis.

In making the prognosis of cases of progressive, uncomplicated amblyopia or amaurosis, with more or less atrophy of discs, special attention is to be paid to whether the failure was synchronous or not, and whether it is now equal in the two eyes. The state of the field of vision in cases seen early is also of much importance; peripheral contraction, as distinguished from central defect, is a bad sign, for progressive atrophy seldom begins with defect in the centre of the field. In cases of gradual, uncomplicated failure of sight, where the symptoms have, from the beginning, been equally symmetrical, the atrophic changes are usually but slight in comparison with the defect of sight (p. 241, 4).

B. *Single amaurosis with atrophy of the disc*, in a majority of cases, indicates former embolism of the central artery (p. 217), some local affection of the trunk of the optic nerve, "retro-ocular neuritis" (p. 241), or pressure on the nerve by tumour just in front of the chiasma. But here it must be remembered that in cases of progressive atrophy, accompanying or preceding spinal disease, a very long interval occasionally separates the onset of the disease in the two eyes,* and we may see the first eye before the commencement of the disease in the second.

Blindness of one eye following immediately after a fall or blow on the head indicates damage to the nerve from fracture of the optic canal (p. 232, 3), or hæmorrhage into the nerve-sheath. If the nerve is torn across, visible atrophy of the disc sets in in a few weeks. The blow has generally been on the front of the head, and on the same side as the affected eye. A similar condition follows

* This interval may be three or four years, and an interval of from one to two years is not very rare.

wound or rupture of the nerve in the orbit, by a thrust, stab, or gunshot injury. Laceration of the central retinal vessels alone, behind the point at which they enter the nerve, is said to cause appearances like those due to embolism and thrombosis. In cases of injury to the optic nerve improvement is rare.

CHAPTER XV

AMBLYOPIA AND FUNCTIONAL DISORDERS OF SIGHT

THE term amblyopia means dulness of sight, but its use is generally restricted to cases of defective acuteness of sight (p. 24), short of blindness, in which there is little or no ophthalmoscopic change. Amaurosis indicates a more advanced affection—complete blindness without visible changes. These terms, then, refer to the patient's symptoms, whilst papillitis and atrophy imply changes seen by the observer. Amblyopia may depend upon disease in the retina, in any part of the optic nerve or tract, or in the optic centres; and it may be temporary or permanent. It is always most important to distinguish single from symmetrical cases.

Two common and important forms of unsymmetrical amblyopia may be considered first.

(1) *Amblyopia from suppression of image* ("congenital amblyopia").—It is well known that many children with convergent squint see badly with the squinting eye; that this defect varies in degree, and may be so great that fingers can hardly be counted; that, at any rate in the higher grades, the defect is chiefly, or only, present in that part of the visual field which is common to both eyes (Fig. 23), and is irremediable; whilst in the lower degrees the defect may be more or less removed by separate practice of the defective eye.* It has been assumed by one school that this amblyopia is due to a congenital defect

* Of such improvement I have myself had very little experience.

(presumably of the visual centre) which determines the incidence of the squint, just as defect due to an ulcer of the cornea may do. Another view supposes that the child, born with two good eyes, but being obliged to squint owing to hypermetropia, learns to suppress the consciousness of the image in the squinting eye in order to avoid the inconvenience of double vision (p. 36), and that this habit, if begun very early in life, causes permanent amblyopia of the eye, due to a defective development of the perceptive faculty in the corresponding centre. For the former view it is urged that no one has ever watched the onset of this amblyopia, since it is always present at the youngest age when tests can be applied; that we meet with cases of unexplained defect of one eye without squint; and that this supposed power of suppression cannot be learnt in later life, as is shown by the permanence of diplopia in all cases of paralytic squint acquired after childhood. In favour of the suppression theory we may argue, that while such defect might be acquired early, it could not be expected to come on late, after the visual centre in question had been educated; precisely as want of training of the ocular muscles in early infancy, from defective sight due to disease, leads to incurable nystagmus (Chap. XXI) much more frequently than do similar defects of sight acquired after the muscles have been got into harmonious use;—that in many of the cases of defect without squint a history of previous squint can be obtained;*—and that if the defect were congenital it would involve the whole field equally, not only that part which is common to the two eyes. In alternating concomitant squint, whether convergent or divergent, there is no diplopia, although the vision of each eye is as a rule equally good; the patient has the power of instantaneously

* I believe that the spontaneous disappearance of hypermetropic squint, which is not uncommon, has received too little attention.

suppressing the consciousness of the image in whichever happens to be the squinting eye,—a fact in favour, so far as it goes, of the suppression theory. On the other hand, it is true that in cases of anisometropia great variations are encountered in the degree of perfection to which the more ametropic eye can be raised by glasses,—a fact perhaps in favour of the congenital amblyopia theory.

(2) *Amblyopia from defective retinal images*.—In cases of high hypermetropia or astigmatism, when clear images have never been formed, the correction of the optical defect by glasses at the earliest practicable age often fails, at any rate for a time, to give full acuteness of sight. Want of education in the appreciation of clear images is probably the chief cause, though defective development of the retina may also come into play. We may explain in the same way the common cases in which, with anisometropia (Chap. XX), the sight of the more ametropic eye, even when corrected by the proper glasses, remains defective, although no squint has ever existed; and in some degree also the defect often observed after perfectly successful operations for cataract in children. Amblyopia of this kind when discovered late in life is seldom altered by correcting the optical error, but in children the sight often improves when suitable glasses are constantly worn.

Great defect of one eye, from the causes just mentioned, or gradual painless failure from disease, often exists unknown for years, until accidentally discovered by closing the sound eye, or by trying the sight of each eye separately, *e. g.* in an examination for the army or other public service. The patient in such cases is naturally concerned at what he thinks is a recent defect, but caution is needed in accepting his view, unless he has previously been in the habit of “sighting” objects with the eye in question, as in rifle shooting. But *sudden* failure of one eye is, as a rule, dated correctly.

In cases of amblyopia not belonging to the above categories, a definite date of onset will generally be given. Two principal divisions may be formed, according as the amblyopia affects one eye or both.

(3) Cases of recent failure of one eye with little or no ophthalmoscopic change occur rather rarely, and generally in young adults; the onset is often rapid, with neuralgic pain, sometimes very severe, in the same side of the head. There may be pain in moving the eye, or tenderness when it is pressed back into the orbit. The degree of amblyopia varies much, but is often especially marked at the centre of the field. The disc of the affected eye is sometimes hazy and congested. The attack is often attributed to exposure to cold. Most of the cases recover under the use of blisters and iodide of potassium, but in a certain number the defect is permanent, and the disc becomes atrophied. Such cases are most probably caused by a *retro-ocular neuritis*, often slight and transient (p. 230), and the cases are perhaps analogous to peripheral paralysis of the facial nerve.

(4) Much commoner is a progressive and equal failure in both eyes, often amounting in a few weeks, or months, to great defect (14 or 20 Jaeger, or V. from $\frac{1}{5}$ to $\frac{1}{10}$), with no other local symptoms except perhaps a little frontal headache, but often with nervousness, general want of tone, and loss of sleep and appetite. Ophthalmoscopic changes, never pronounced, may be quite absent: at an early period the disc is often decidedly congested, and slightly swollen and hazy, but these changes are all so ill-marked that competent observers may give different accounts of the same case; later, the side of the disc near the y. s., and finally in bad cases the whole papilla, become pale, and the diagnosis of incomplete atrophy is given. The defect of sight is described as a "mist," and is usually most troublesome in bright light and for distant objects, being less

apparent early in the morning and towards evening. The pupils are normal, or at most rather sluggish to light. The defect of V. is limited to, or most intense at, the central part of the field (*central scotoma*), occupying an oval patch which extends from the fixation point (corresponding to the y. s.) outwards, towards and often as far as the blind spot (corresponding to the optic disc). The affected area is also found to be colour-blind for red and green; but this loss of colour perception being usually incomplete, alike in degree and superficial extent (Fig. 92), will often escape detection if

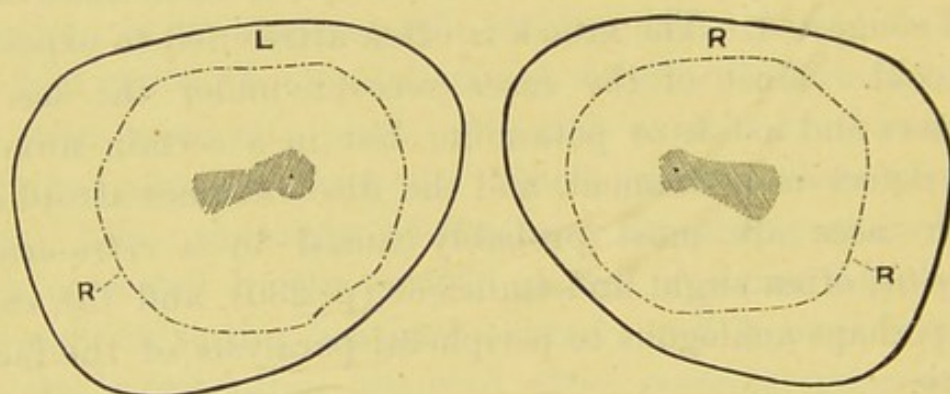


FIG. 92.—R. right, L. left, visual field in a case of central amblyopia from tobacco smoking. The shaded area is the part over which acuteness of vision and colour perception are lowered (relative central scotoma), no part of the field being absolutely blind. The dotted line marked R. shows the boundary of the field for red (*see* Fig. 22).

large colour tests be used; whilst it will readily be found by using a small coloured spot of from 5 to 15 mm. square. The patient, closing one eye, “fixes” the finger or nose of the observer, who then removes the coloured spot from the fixation point in various directions towards the periphery; the colour, instead of appearing brightest at the centre of the field (p. 253), will be dull or unrecognisable there, becoming brighter and easily recognised towards the periphery. There is no contraction of the field, and thus, since surrounding objects are seen as well as ever, and the

patient has no difficulty in going about, his manner differs from that of one with progressive atrophy, who finds difficulty in guiding himself, because his visual field is contracted (p. 234).

The patients are almost without exception males, and at or beyond middle life. With very rare exceptions they are smokers, and have smoked for many years, and a large number are also intemperate in alcohol.—The exceptions occur chiefly in a very few patients in whom a similar kind of amblyopia is hereditary, is liable to affect the female as well as the male members, and may come on much earlier in life. The ætiology of such cases is obscure, and in some few of them there is no evidence of heredity.

In the common cases it is now generally agreed that tobacco has a large share in the causation, and in the opinion of a number of observers it is the sole excitant. The direct influence of alcohol, and of the various causes of general exhaustion, such as anxiety, underfeeding, and general dissipation, is still to some extent an open question (*see* Chap. XXIII, Diabetes). My own opinion, based on the examination of a large number of cases, is that tobacco is the essential agent, and that the disuse or greatly diminished use of tobacco is the one essential measure of treatment. It is important to remember that the disease may come on when either the quantity or the strength of the tobacco is increased, or when the health fails and a quantity which was formerly well borne becomes excessive. Hence cases of *double central amblyopia* may, as a rule, except in the rare form above mentioned, be named *tobacco amblyopia*. The symmetry of tobacco amblyopia is not always precise, and it appears, in very rare cases, to be delayed.*

The prognosis is good if the patient come early, and if the failure have been comparatively quick. In such cases

* J. Hutchinson, jun., 'Ophth. Hosp. Reports,' xi, 1886.

really perfect recovery may occur, and very great improvement is the rule. In the more chronic cases, or cases where already the whole disc is pale, a moderate improvement, or even an arrest of progress, is all we can expect. If smoking be persisted in, no improvement takes place and the amblyopia increases up to a certain point, but complete blindness very seldom, if ever, occurs. In the treatment, disuse of tobacco is the one thing essential. Relapse sometimes occurs if smoking be resumed. Drink should, of course, be moderated. It is usual to give strychnia, subcutaneously or by mouth, for a considerable period, but whether any medicine acts otherwise than by improving the general tone is doubtful; subcutaneous injections of strychnia, carefully carried out, have not given definite results in my own cases. Others believe that the constant current is useful. There is reason to believe that the disease depends on a chronic inflammation of the central bundles of the optic nerve, beginning at, or a short distance behind the eye.*

Hemianopia (usually called *hemiopia*) denotes loss of half the field of vision. When uniocular the defect is seldom quite regular, and generally depends upon detachment of the retina or a very large retinal hæmorrhage.—It is usually binocular, and then indicates disease at or behind the optic chiasma. In the great majority of cases the R. or L. lateral half of each field is lost. Sometimes only a quarter of each field is lost. The line of separation between the blind and seeing halves is usually sharply defined and nearly straight, only deviating a degree or two at the fixation point so as just to leave central vision intact over an area about corresponding to the fovea centralis (Fig. 93). In other cases the separating line is undulating, and a comparatively large central area of the field remains intact. The boundary between sight and

* 'Trans. Ophth. Soc.,' vol. i, p. 124, and iii, p. 160.

blindness in hemianopia, though usually abrupt, is sometimes gradual. The retention of central vision over a considerable central area has been explained on the assumption that the y. s. area receives nerve-fibres from both optic tracts, and Bunge and others have lately found microscopical evidence that such is really the case; in cases like Fig 93, the apparent deviation of the dividing line may

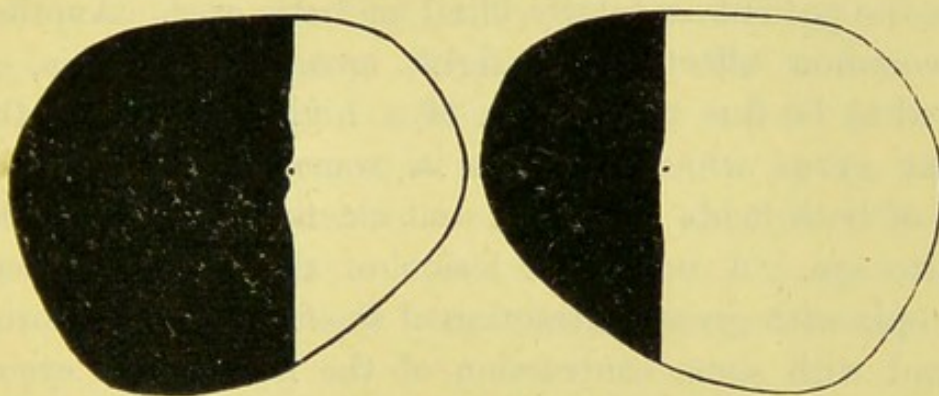


FIG. 93.—Fields of vision in a case of L. homonymous lateral hemianopia. The dividing line comes within one or two degrees of the fixation point (shown by the central dot) in each eye. The lesion causing this hemianopia is probably in the optic tract, or not higher than the corpora geniculata.

perhaps be explained by the difficulty which the patient has in keeping the eye perfectly fixed when the test object comes close to the centre. Loss of the R. half of each *field*, meaning loss of function of the L. half of each *retina*, points to disease of the L. optic tract* or its continuations, or of some part of the L. occipital lobe or angular gyrus. The hemiopic pupillary reaction (Wernicke) assists us in localising the disease. If, when light is thrown on the blind half of the retina, the pupil contracts as well as when it is thrown on the seeing half in the two eyes, the lesion is in the cortex; but if it does not contract, the

* Because the L. optic tract consists chiefly of fibres which supply most of the L. half of each retina, those of them destined for the R. eye crossing over at the optic commissure.

lesion is in the optic tract. Loss of the two nasal halves is extremely rare. Loss of the two temporal halves (temporal hemianopia) points to disease at the anterior part of the chiasma. Even when hemianopia has lasted for years the optic discs seldom show any change. When the lateral hemianopia co-exists with hemiplegia the loss of sight is on the paralysed side; "the patient cannot see to his paralysed side" (Hughlings Jackson). If double hemiopia occurs the patient is totally blind in both eyes. Another less common affection of sight, crossed amblyopia, is believed to be due to a lesion of a higher centre in the angular gyrus which presides in some degree over the whole of both fields of vision, but chiefly over that of the opposite eye. A unilateral lesion of this kind produces amblyopia with great contraction of the field of the opposite eye, and with some contraction of the field of the eye of the same side. The symptoms are much like those of hysterical amblyopia in one eye. If such a lesion were double, it would presumably produce a high degree of amblyopia, with contraction of the fields in both eyes, the activity of the pupils being retained. A few cases of hemianopia for colours alone have been recorded.*

Hysterical amblyopia and amaurosis take various forms, and real defect may be mixed up with feigning.—In hysterical hemianæsthesia the eye on the affected side is sometimes defective, or quite blind. In other cases of hysteria both sides are defective, but one worse than the other; there is concentric contraction of the visual fields, sometimes with, sometimes without, colour-blindness, a varying degree of defective visual acuteness, and sight is often disproportionately bad by feeble light (hence the term "anæsthesia of the retina" is sometimes used). There may, however, be, in addition, irritative symptoms—watering, photophobia, and spasm of accommodation, and

* See exhaustive paper by Mackay, 'B. M. J.,' November 10, 1888.

then the term "hyperæsthesia retinae" or "oculi" seems more appropriate. Amblyopia with the above characters has been known to follow a blow upon the eye affected which was so slight as not to cause the least ophthalmoscopic change (*compare* p. 156); again, when one eye has been suddenly lost by wound or embolism a condition indistinguishable from hysterical blindness may rapidly come on in the other (*compare sympathetic irritation*). It is important to note that in hysterical amblyopia, even of high degree and long standing, the reflex action of the pupil, direct as well as indirect (p. 27), is fully preserved, and the ophthalmoscopic appearances are quite normal. The prognosis is nearly always good, though recovery is sometimes slow, and relapses may occur. In some of the worst cases I have seen there has been considerable ametropia.

True hysterical amblyopia seems allied, from the ophthalmic standpoint, with a much larger and more important class, best epitomised by the term *asthenopia*, in which photophobia, irritability, and want of endurance of the ciliary muscle (*accommodative asthenopia*), or sometimes of the internal recti (*muscular asthenopia*), with some conjunctival irritability, are the main symptoms, acuteness of sight being usually perfect, and the refraction nearly or quite normal. Of the retinal, conjunctival, and muscular factors, any one may be more marked than the others, and it would seem that, given a certain state of the nervous system, which may be described as impressionable, or hyperæsthetic, over-stimulation of any one is liable to set up an over-sensitive state of the other two. These patients often complain also of dazzling pain at the back of the eyes, and headache, or neuralgia in the head. All the symptoms are worse after the day's work, and sometimes on first waking in the morning, and they are liable to vary much with the health. Artificial light always

aggravates them, because it is often flickering and insufficient, but especially because it is hot. The symptoms often last for months or years, causing great discomfort and serious loss of time.

Causation.—The patients are seldom children or old people. Most are women, either young or not much past middle life, often very excitable, and often with feeble circulation. If men, they are emotional, fussy, and often hypochondriacal. Some cause, such as prolonged and intense application at needlework or reading, can often be traced, and in such cases the symptoms may come on so suddenly that the patient becomes within a few hours, or a day or two, quite incapacitated for reading. Sometimes bright colours, glittering things, or exposure to kitchen fire seems specially injurious. Or, again, there is a history of phlyctenular ophthalmia, or superficial ulcers, which have left the fifth nerve permanently unstable. Accommodative asthenopia with hypermetropia or astigmatism is at the bottom of nearly all the cases in which vision is supposed to have been injured by railway and other accidents; the lowered tone caused by the shock is often more apparent in the ciliary muscle, because this muscle is in almost constant action and has no substitute.

Treatment.—The refraction and the state of the internal recti should always be carefully tested, and any error corrected by lenses, which may often be combined with prisms, with their bases towards the nose (p. 9). Plain coloured glasses are sometimes useful. But glasses will not cure the disease, and we must not promise too much from their use. The patient may be assured that there is no ground for alarm, and that the symptoms will probably pass off sooner or later. He should be discouraged from thinking about his eyes, and he need seldom be quite idle. The artificial light used should be sufficient and steady (not flickering), and should be shaded to prevent

the heat and light from striking directly on the eyes. Bathing the eyes freely with cold water, and the occasional employment of weak astringent lotions, are useful, and cold air often acts beneficially. The eyes are often much better after a rest of a day or two. Outdoor exercise, and only moderate use of the eyes, therefore, should be enjoined. General measures must be taken according to the indications, especially in reference to any ovarian, uterine, or digestive troubles, or to sexual exhaustion in men.

FUNCTIONAL DISEASES OF THE RETINA

*Functional night-blindness (endemic nyctalopia)** is caused by temporary exhaustion of the retinal sensibility from prolonged exposure to diffused bright light.—The circumstances under which it occurs usually imply not only great exposure to bright light, but lowered general nutrition, and probably some particular defect in diet. It often co-exists with scurvy. Sleeping with the face exposed to bright moonlight is believed to bring it on. It is commonest in sailors after long tropical voyages under bad conditions, and in soldiers after long marching in bright sun. In some countries it prevails every year in Lent when no meat is eaten, and again in harvest-time. It is now but rarely endemic in our country, but scattered cases occur in spring-time, especially in children, and it still occasionally prevails in large schools.

In this malady two little dry films, consisting of fatty or sebaceous matter and epithelial scales, often form on the conjunctiva at the inner and outer border of the

* Some confusion has arisen as to the use of the words *nyctalopia* and *hemeralopia*; they are used by Continental writers and those who follow them in a sense directly opposed to the common English use of them. It is better, therefore, to discard them for their English equivalents, *night-blindness* and *day-blindness*.

cornea. Their meaning is obscure. A micro-organism, the *Bacillus xerosis*, has been described as peculiar to this affection, growing in the conjunctival film; its presence seems to be accidental. There are no ophthalmoscopic changes. This night-blindness is soon cured by protection from bright light and improvement of nutrition, and especially by cod-liver oil. That the affection is local in the eye is shown by the fact that darkening one eye with a bandage, during the day, has been found to restore its sight enough for the ensuing night's watch on board ship, the unprotected eye remaining as bad as ever.

Day-blindness (hemeralopia) occurs in certain cases of congenital amblyopia.

Coloured vision is sometimes complained of, and red is the colour usually noticed. Red vision (erythroptia) is most common some time after extraction of senile cataract, and is associated with fatigue; everything looks rosy red, "as if there was a most beautiful sunset," as one patient said. Overworked, anxious, neurotic children sometimes complain that after reading or sewing "everything turns red," or "red and blue." I have not heard green or yellow mentioned. It has also been seen in women much exhausted by fasting.

Micropsia.—Patients sometimes complain that objects look too small. When not due to insufficiency of accommodative power (*excessive effort*, p. 37) it is generally a symptom of disease of the outer layers of the retina, especially in the central region, and syphilitic retinitis is the commonest cause (p. 211). Both micropsia and its opposite, megalopsia, are sometimes seen in hysterical amblyopia.

By *muscæ volitantes* are understood small dots, rings, threads, &c., which move about in the field of vision, but do not actually cross the fixation point, and never interfere with sight. They are most easily seen against the sky, or

a bright background such as the microscope field. They depend upon minute changes in the vitreous, which are present in nearly all eyes, though in much greater quantity in some than others. They vary, or seem to vary, greatly with the health and state of the circulation, but are of no real importance. They are most abundant and troublesome in myopic eyes.

Diplopia, see Chap. XXI; also pp. 36 and 170 for Unocular Diplopia.

For Affections of Sight in Megrin and Heart Disease see Chap. XXII.

Malingering.—Patients now and then pretend defect or blindness of one or both eyes, or exaggerate an existing defect, or sometimes secretly use atropine in order to dim the sight. The imposture is generally evident enough from other circumstances, but detection is occasionally very difficult. Malingering and intentional injuries of the eye are very rare here, but common in countries where the conscription is in force.

The pretended defect of sight is usually confined to one eye. If the patient be in reality using both eyes, a prism held before one (by preference "the blind" one) will produce double vision (p. 12). The stereoscope, and also coloured glasses, may be made very useful in detecting imposture. Another test, when only moderate defect is asserted, is to try the eye with various weak glasses, and note whether the replies are consistent; very probably a flat glass or a weak concave may be said to "improve" or "magnify" very much. Again, atropine may be put into the *sound* eye, and when it has fully acted the patient be asked to read small print; if he reads easily with both eyes open the imposture is clear, for he must be reading with the so-called "blind" eye. If absolute blindness of one eye be asserted, the state of the pupil will be of much help (unless the patient have used atropine); for if its

direct reflex action be good (p. 27) the retina and nerve cannot be much diseased (but as to this point *compare* Hysterical Amblyopia, p. 246).

Pretended defect of both eyes is more difficult to expose, and, indeed, it may be impossible to absolutely convict the patient if he be intelligent and instructed. The state of the pupils, of the visual fields, and of colour perception are amongst the best tests.

Colour-blindness may be congenital or acquired. When acquired it is symptomatic of disease of the optic nerve, or, as for example in hysterical amblyopia, of some affection of the visual centre.

Congenital colour-blindness is not often found unless looked for. According to recent and extended researches in various countries, a proportion varying from about 3 to 5 per cent. of the males are colour-blind in greater or less degree, and it appears to be more common in the lower than in the upper classes. These facts show the importance of carefully testing all men whose employment renders good perception of colour indispensable, such as railway signalmen and sailors. Colour-blindness is usually partial, *i. e.* for only one colour or one pair of complementary colours, but is occasionally total. The commonest form is that in which pure green is confused with various shades of grey and of red (red-green blindness); blindness for blue and yellow is very rare. The blindness may be incomplete, perception of very pale or very dark red or green, *e. g.*, being enfeebled, whilst bright red and green are well recognised; or it may be complete for all shades and tints of those colours. Congenital colour-blindness is very often hereditary, but nothing further is known of its cause. It is very rare in women (0.2 per cent.). The acuteness of vision (*i. e.* perception of form) is normal. Both eyes are affected.*

* But on this point further research is needed.

The detection of colour-blindness, either congenital or acquired, is easy if, in making the examination, we bear in mind the two points already referred to at p. 23, viz.—(1) Many persons with perfect colour *perception* know very little of the *names* of colours, and appear colour-blind if asked to name them; (2) the really colour-blind often do not know of their defect, having learnt to compensate for it by attention to differences of shade and texture. Thus a signalman may be colour-blind for red and green; yet he may, as a rule, correctly distinguish the green from the red light, because one appears to him “brighter” than the other. The quickest and best way of avoiding these sources of error has been mentioned at p. 23. A certain standard colour is given to the patient without being named, and he is asked to choose from the whole mass of skeins of wool all that appear to him of nearly the same colour and shade (no two being really quite alike). If, for example, he cannot distinguish green from red he will place the green test skein side by side with various shades of grey and red. Wilful concealment of colour-blindness is impossible under this test if a sufficient number of shades be used.

As it is necessary to detect slight as well as high degrees, the first or preliminary test should consist of very pale colours, and a pale pure green is to be taken as the test, No. I (*see* plate in the Appendix); Nos. 1 to 5 are liable to be confused with this colour. For ascertaining whether the defect be of higher degree or not, stronger colours are then used; a bright rose colour, *e. g.* II *a*, may be confused with blue, purple, green, or grey of corresponding depth (Nos. 6 to 9); and a scarlet, II *b*, with various shades and tints of brown and green (Nos. 10 to 13).

It may here be noted that the visual field is not of the same size for all colours (Fig. 22), green and red having the smallest fields, and that the perception of all colours is,

like perception of form (p. 24), sharpest at the centre of the field. With diminished illumination some colours are less easily perceived than others, red being the first to disappear, and blue persisting longest, *i. e.* being perceived under the lowest illumination; but in dull light the colours are not confused, as in true colour-blindness. In congenital colour-blindness, as we have seen, red-green-blindness is the commonest form; and in cases of amblyopia from commencing atrophy of the optic nerve, green and red are almost always the first colours to fail, blue remaining last.

CHAPTER XVI

DISEASES OF THE VITREOUS

THE vitreous humour is nourished by the vessels of the ciliary body, retina, and optic disc, and is probably influenced by the state of the choroid also; and in most cases disease of the vitreous is associated with (and dependent on) disease of one or other of the structures named.

Thus, in connection with various surrounding morbid processes, the vitreous may be the seat of inflammation, acute or chronic, general or local, and of hæmorrhage. It may also degenerate, especially in old age, its cells and solid parts undergoing fatty change, become visible as opacities, whilst its general bulk becomes too fluid. The only alteration that we can directly prove in the vitreous during life is loss of transparency, from the presence of opacities moving, or more rarely fixed, in it, but according as such opacities move quickly or slowly we infer that the humour itself is, or is not, more fluid than in health.

Opacities in the vitreous may take the form of large dense masses, or of membranes like muslin, crape, "bees' wings" of wine, bands, knotted strings, or isolated dots; and they may be either recent, or the remains of long antecedent exudation, hæmorrhage, or degeneration, or newly formed blood-vessels. Again, the vitreous may become uniformly misty, owing to the diffusion of numberless dots ("dust-like" opacities), which need careful

focussing by direct examination, with a convex lens (about + 12 D.) behind the mirror, to be separately seen.

Opacities in the vitreous are usually detected, with great ease, by direct ophthalmoscopic examination at about 12" from the patient, but are generally situated too far forward (*i. e.* too far within the focus of the lens-system) to be seen clearly at a very short distance without a + lens behind the mirror (p. 51). If the patient move his eye sharply and freely from side to side and from above downwards, the opacities will be seen against the red ground, as dark figures which continue to move after the eye has come to rest; they are thus at once distinguished from opacities in the cornea or lens, or from dimly seen spots of pigment at the fundus, which stop when the eye stops. The opacities in the vitreous move, just as solid particles and films move in a bottle, after the bottle has been shaken; the quickness and freedom of their movement in the one case, as in the other, depending very much on the consistence of the fluid. When the opacities pass across the field quickly, and make wide movements, we may be sure that there is *synchysis* or fluidity of the vitreous humour; if they move very lazily, its consistence is probably normal; if only one or two opacities be present, they may only come into view now and then. Moving opacities in the vitreous obscure the fundus both to the direct and indirect ophthalmoscopic examination, in proportion to their size, density, and position; a few isolated dots scarcely affect the brightness of the ophthalmoscopic image.

The opacities may lie quite in the cortex of the vitreous, and be anchored at the fundus, so as to have but little movement. Such opacities, generally single, are found lying over or near to the disc, and may be the result either of inflammation or of hæmorrhage; they are often membranous, more rarely globular, and not perfectly opaque.

Such an opacity should be suspected when, by indirect ophthalmoscopic examination, a localised haze or blurring of some part of the disc or its neighbourhood is noticed. The opacity must then be searched for by the direct method, the patient's eye being at rest; by altering the distance from the patient, or by turning on various convex lenses (or concave, if the eye be very highly myopic) the opacity will come sharply into view. The patient's refraction must be approximately known in order to make this examination properly (p. 52). Densely opaque white membranes may also form over the disc or upon the retina, the nature and situation of which are diagnosed in the same way.

Diffused haziness of the vitreous causes a corresponding degree of dimness of outline and darkening of the details of the fundus, as if these were seen through a thin smoke. The disc, in particular, appears red, without really being so. Much the same appearances are caused by diffused haze of the cornea or lens, but the presence of these changes will, of course, have been excluded by focal illumination. There are even cases of vitreous disease where no details can be seen, even by careful examination, though plenty of light reaches and returns from the fundus. In these the light is scattered by innumerable little particles, each of which is transparent, so that the light, without being absorbed, is distorted and broken up, as in passing through ground glass, or white fog, or a partial mixture of fluids of different densities, such as glycerine and water. This fine general haze is found chiefly in syphilitic choroïdo-retinitis, in which infiltration of the vitreous with cells is known to occur. It is not always easy, nor indeed possible, to distinguish with certainty between diffuse haze of the vitreous and diffuse haze of the retina (p. 204).

Crystals of cholesterin sometimes form in a fluid vitreous, and are seen with bright illumination as minute, dancing,

golden spangles, when the eye moves about (*sparkling synchysis*). They proportionately obscure the fundus. Large opacities just behind the lens may be seen by focal light in their natural colours. In rare cases of choroido-retinitis, minute growths, consisting chiefly of blood-vessels, form on the retina, and project into the vitreous; they are rather curiosities, than of practical importance.

Parasites (*Cysticercus cellulosæ*) occasionally come to rest in the eye, and in development penetrate into the vitreous; they are rarely seen in England, but are comparatively common in some parts of Germany. Very rarely a foreign body may be visible in the vitreous.

The following are the conditions in which disease of the vitreous is most commonly found:

(1) Myopia of high degree and old standing; the opacities move very freely, showing fluidity of the humour, and are sharply defined. They are often the result of former hæmorrhage.

(2) After severe blows, causing hæmorrhage from the vessels of the choroid, or ciliary body. When recent, and situated near the back of the lens, the blood can often be seen by focal light; if very abundant, it so darkens the interior of the eye that nothing whatever can be seen with the mirror.

(3) After perforating wounds. The opacity will be blood if the case be quite recent. Lymph or pus in the vitreous gives a yellow or greenish-yellow colour, easily seen by focal light, or even by daylight (p. 145), and usually most dense towards the position of the wound.

(4) In rare cases large hæmorrhages into the vitreous occur spontaneously in healthy eyes, with hæmorrhages into the retina (not to be confused with retinitis hæmorrhagica, p. 216). Relapses often occur, and detachment of retina may ensue. The subjects are generally young adult males liable to epistaxis, constipation, and irregularity of circula-

tion (Eales) ; gout may have some influence (Hutchinson). This affection seems sometimes to be related to the form of choroiditis referred to at p. 198.

In all of the above cases detachment of the retina is likely to occur sooner or later, and if both be present, the differential diagnosis may be difficult (p. 209).

(5) Syphilitic choroiditis and retinitis. There is often diffuse haze, in addition to large, slowly floating opacities. The change here is due to inflammation, and the opacities may entirely disappear under treatment (pp. 193, 204, 211). These are the cases in which new vessels in the vitreous are most common.

(6) Some cases of cyclitis and cyclo-iritis (p. 145). The opacities are inflammatory.

(7) In the early stage of sympathetic ophthalmitis. The opacities are inflammatory.

(8) In various cases of old disease of choroid, usually in old persons, and without proof of syphilis. No doubt many of these indicate former choroidal hæmorrhages.

(9) Cases occur in which no cause, either local or general, can be assigned for the presence of opacities in the vitreous.

CHAPTER XVII

GLAUCOMA

IN this peculiar and very serious disease, the characteristic objective symptom is increased tightness of the eye-capsule (sclerotic and cornea), "increased tension;" all the characteristic features of the disease depend upon this. The disease is much commoner after middle life, when the sclerotic becomes less distensible, than before; and it is commoner in hypermetropic eyes, where the sclerotic is thick, than in myopic eyes, where it is thinned by elongation of the globe.

Glaucoma may be primary, coming on in an eye apparently healthy, or the subject of some disease, such as senile cataract, which has no influence on the glaucoma; or it may be secondary, caused by some still active disease of the eye, or by conditions left after some previous disease, such as iritis. It is always important, and seldom difficult, to distinguish between primary and secondary glaucoma.

Glaucoma differs in severity and rate of progress from the most acute to the most chronic and insidious form; but in every form it is a progressive disease, and unless checked by treatment goes on to permanent blindness. The disease is very often symmetrical, attacking the second eye after a varying interval.

It is customary and useful to speak of glaucoma as either acute, subacute, or chronic. But many intermediate forms are found, and the same eye may, at different stages in its history, pass through each of the three conditions.

We may, indeed, here observe that acute and subacute outbursts are generally preceded by a so-called "premonitory" stage, in which the symptoms are not only chronic and mild, but remittent; the intervals of remission becoming shorter and shorter, till at length the attacks become continuous, and the glaucomatous state is fully established. Rapid increase of presbyopia (Chap. XX), shown by the need for a frequent change of spectacles, is a common premonitory sign, though it is often overlooked.

Chronic glaucoma sets in with a cloudiness of sight, or "fog," varying in density and often clearing off entirely for days or even weeks ("premonitory stage"). But in some cases, the failure progresses without remissions from first to last. During the attacks of "fog," artificial lights are seen surrounded by coloured rings ("rainbows" or "halos"), due to haze of the cornea, which are to be distinguished from those due to mucus on the cornea. The attacks of fog are often noticed only after long use of the eyes, as in the evening or when exhausted, the sight being better in the early part of the day and after food. Even when the sight has become permanently cloudy, complete recovery no longer occurring between the attacks, variations of sight still form a marked feature. There is no congestion, and neuralgic pain, though not uncommon, is often entirely wanting. The disease has to be distinguished from incipient nuclear cataract, disease of the optic nerve, syphilitic retinitis, and attacks of megrim.

If we see the patient during one of the brief early fits of cloudy sight, or after the fog has settled down permanently, the following changes will be found. A greater or less defect of sight, not remedied by glasses, is present in one eye, or if in both, more in one than the other; the pupil is a little larger and less active than normal; the anterior chamber may be shallow, and there is usually slight dulness of the eye from steaminess of cornea, or

haze of the aqueous humour, and some engorgement of the large perforating vessels situated at a little distance from the cornea (Figs. 25 and 27); the tension is somewhat increased (usually about + 1, p. 19); and the field of vision may be contracted, especially on the nasal side.—The optic disc will be found normal, pale, or sometimes congested, in early cases; pale and cupped all over (pp. 265 and 266), at a later stage. There may be spontaneous pulsation of all the vessels on the disc; or the arteries, if not pulsating spontaneously, will do so on *very slight* pressure on the eyeball (p. 49).—If the case be of old standing the tension will often be much increased, the pupil dilated and sluggish, though not motionless, the lens hazy, the field of vision much contracted (Fig. 94), acuteness of vision extremely defective, the cornea in some cases clear, in others dull. In nearly all cases of glaucoma the temporal part of the field (nasal part of the retina) retains its function longest; and in advanced cases the patient will often show this by his manner or statements; occasionally the field becomes extremely contracted before central vision fails. In some few cases of simple glaucoma scotomata appear at the central parts of the field without contraction.

An eye in which the above symptoms have set in may progress to total blindness in the course of months or several years without a single “inflammatory” symptom, without either pain or redness—*chronic painless glaucoma* (*simple glaucoma*); and since the lens often becomes partially opaque, and of a greyish or greenish hue, cases of chronic glaucoma are sometimes mistaken for senile cataract.

But more commonly, in the course of a chronic case, periods of pain and congestion occur, with more rapid failure of sight; or the disease sets in with “inflammatory” symptoms at once. In these cases of *subacute glaucoma*,

besides the symptoms named above, we find dusky, reticulated congestion of the small and large episcleral vessels in the ciliary region (Fig. 28), with pain referred to the eye, the side of the head, or of the nose, and rapid failure of sight. The increase of tension, steaminess, and partial anæsthesia of the cornea, the enlarged and sluggish pupil, and the shallowness of the anterior chamber, are all more marked than is usual in chronic cases, and the media are too hazy to allow a good ophthalmoscopic examination.




FIG. 94.—Irregular contraction of R. and L. fields of vision in chronic glaucoma; from two different cases. The black parts show complete loss; the shaded area shows partial loss. Each field remains best in the outer part. (*Compare with Figs. 90 and 91.*)

These symptoms, ending after a few weeks or months in complete blindness, may remain at about the same height for months after that event, with slight variations, the eye gradually settling down into a permanent state of severe, but chronic, non-inflammatory glaucomatous tension. Short attacks of subacute glaucoma, with intervals of perfect recovery, sometimes occur (*remittent glaucoma*); permanent glaucoma usually supervenes.

Acute glaucoma (*inflammatory or congestive glaucoma*) differs from the other forms only in suddenness of onset, rapidity of loss of sight, and severity of congestion and pain. The congestion, both arterial and venous, is intense; in extreme cases the lids and conjunctiva are swollen, and

there is photophobia, so that the case may be mistaken for an acute ophthalmia. All the specific signs of glaucoma are intensified; the pupil considerably dilated and motionless to light, the cornea very steamy, the anterior chamber very shallow, and tension + 2 or 3. Sight will fall in a day or two down to the power of only counting fingers, or to mere perception of light, and if the case have lasted a week or two even p. l. is usually abolished. The pain is very severe in the eye, temple, back of the head, and down the nose; not unfrequently it is so bad as to cause vomiting, and many a case has been mistaken for a "bilious attack" with a "cold in the eye," for "neuralgia in the head," or "rheumatic ophthalmia." Some cases, however, though very acute, are mild and remit spontaneously; but these, like the ones mentioned in the preceding paragraph, often pass on into the severe type now described.

Absolute glaucoma is glaucoma that has gone on to permanent blindness. Such an eye continues to display the tension and other signs of the disease, and remains liable to attacks of pain and congestion for varying periods, but in many "absolute" cases, especially when the original attack has been acute, changes occur sooner or later, leading to staphylomata, cataract, atrophy of iris, and finally to softening and shrinking of the globe.

As a rule glaucoma runs the same course in the second eye as in the first, but sometimes it will be chronic in one and acute or subacute in the other.

Explanation of the symptoms.—The causes which produce the temporary attacks or "premonitory symptoms" lead, if continued, to atrophy of the inner layers of the retina (p. 208) and of the disc, and to consequent blindness. The increase of tension damages the retina both by direct compression and by impeding its circulation, the latter being probably the more important factor in the early stages. If the media be clear enough to allow a good

view, the retinal arteries are seen to be narrow, and often pulsating spontaneously, and the veins engorged. The periphery of the retina suffers soonest and most from this lowering of arterial blood-supply, and hence probably the contraction of the visual field; but the inner layers (*compare* p. 208) of the retina, over its whole extent, suffer if the pressure be kept up (1) from this same insufficiency of arterial blood, and the changes, including hæmorrhage, which follow impeded venous outflow; (2) from direct compression of the retina; (3) from stretching and atrophy of the nerve-fibres on the disc. The floor of the disc (*lamina cribrosa*), being the weakest part of the eye-capsule, is slowly pressed backwards, the nerve-fibres being dragged upon, displaced, and finally atrophied; the direct pressure on the nerve-fibres, as they bend over the edge of the disc, helps in the same process. Hence finally the disc becomes not only atrophied, but hollowed out (Fig. 95) into the well-known "glaucomatous cup." This

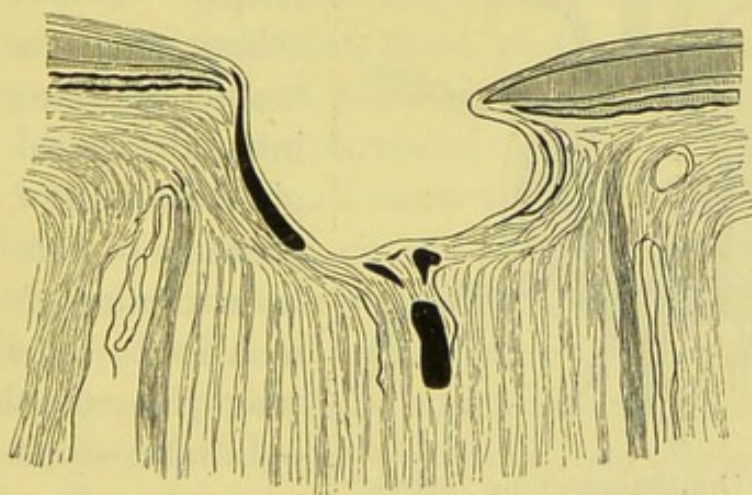


FIG. 95.—Section of very deep glaucoma cup. (*Compare* Fig. 36.)

cup, when deep, has an overhanging edge, because the border of the disc is smaller at the level of the choroid than at the level of the *lamina cribrosa*; its sides are quite steep even when the cup is shallow (Fig. 96).

With the ophthalmoscope this cupping is shown by a

sudden bending of the vessels just within the border of the disc, where they look darker because foreshortened; if the cup be deep they may disappear beneath its edge

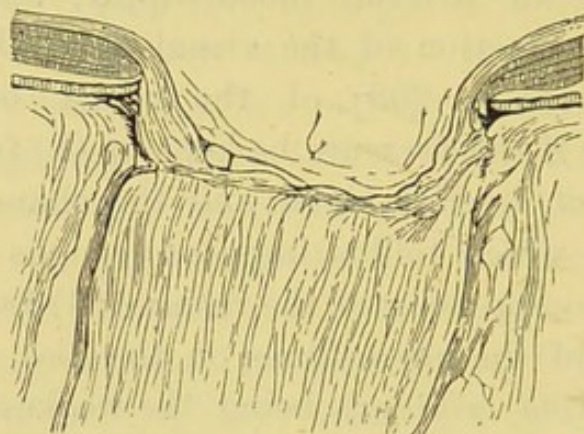


FIG. 96.—Section of less advanced glaucoma cup.

to reappear on its floor, where they have a lighter shade (Fig. 97). The vessels seldom all bend with equal

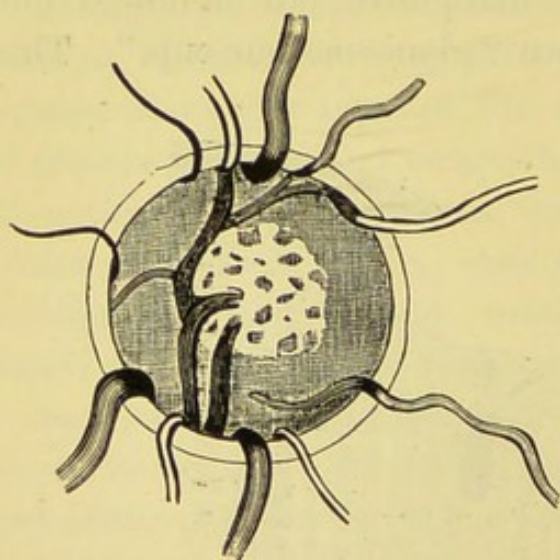


FIG. 97.—Ophthalmoscopic appearance of deep cupping of the disc in glaucoma. (Altered from Liebreich.)
× about 15.

abruptness, some parts of the disc being more deeply hollowed than others, or some of the vessels spanning over the interval instead of hugging the wall of the cup. Increase of tension must be maintained for several months to produce cupping recognisable by the ophthalmoscope. When recent acute glaucoma has been cured by operation, the disc, though not

cupped, often becomes rather hazy and very pale.—Although usually the excavation extends from the first over the whole surface of the disc, it appears sometimes to begin at the thinnest part (the physiological pit), and

spread centrifugally towards the border. A deep cup is sometimes partly filled up by fibrous tissue, the result of chronic inflammation, and its true dimensions are not then appreciable by the ophthalmoscope.

The shallowness of the anterior chamber is probably due to advance of the lens; it is by no means a constant symptom. Compression of the ciliary nerves accounts, in early cases, for the sluggish and usually dilated pupil, and for the corneal anæsthesia. In old-standing cases the iris is often atrophied and shrunk to a narrow rim; in uncomplicated glaucoma iritic adhesions are never seen. The corneal changes depend partly on "steaminess" of the epithelium, partly upon haze of the corneal tissue from œdema (Fuchs). In recent cases, especially if acute, the aqueous humour and the lens appear to become somewhat turbid. In old cases, as already stated, the lens often becomes slowly cataractous. There is some doubt whether the vitreous becomes hazy in glaucoma; it is certainly very seldom so when the cornea and lens are clear, and the point cannot be settled when these media are hazy. The internal pressure tends, in acute cases, to make the globe spherical, by reducing the curvature of the cornea to that of the sclerotic; it also in all cases weakens the accommodation, at first by pressing on the ciliary nerves, later by causing atrophy of the ciliary muscle; these facts together explain the rapid decrease of refractive power (*i. e.* rapid onset or increase of presbyopia) which is sometimes noticed by the patient (p. 261).—The choroidal circulation is obstructed by the increase of pressure, and in severe glaucoma, especially of old standing, the *anterior ciliary veins* (forming the episcleral plexus) (Figs. 25 and 29), as well as the arteries (Fig. 27), become very much enlarged.

Mechanism of glaucoma.—The increased tension is due to excess of fluid in the eyeball. Impeded escape is probably the chief cause of this excess, and recent research

has proved that changes are present in nearly all glaucomatous eyes, which must lessen, or prevent, the normal outflow. But increased secretion, and internal vascular congestion, undoubtedly play an important part in certain cases. Some authorities have attributed the phenomena of glaucoma to vaso-motor changes in the size of the blood-vessels, but such hypotheses are wanting in proof. Both conditions would have most effect when the sclerotic was most unyielding, *i.e.* in old age, and in hypermetropic eyes (p. 260). It is probable that there is a constant movement of fluid from the vitreous humour through the suspensory ligament of the lens, and also from the anterior part of the ciliary processes, into the anterior chamber, as shown by the dotted line in Fig. 98. The fluid escapes

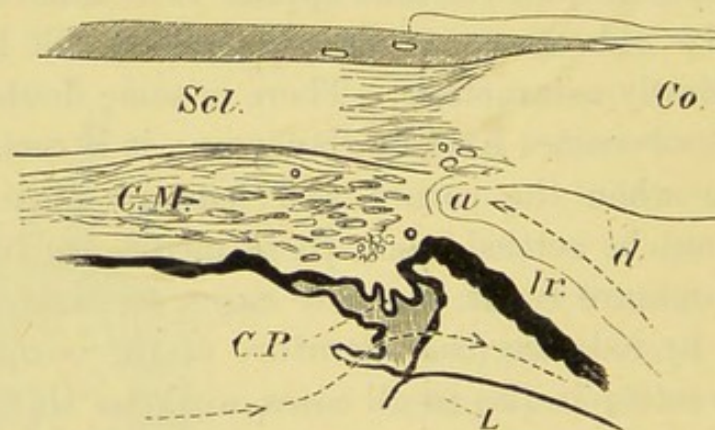


FIG. 98.—Section through the ciliary region in a healthy human eye. *Co.*, cornea; *Scl.*, sclerotic; *C.M.*, ciliary muscle; *C.P.*, two ciliary processes, one larger than the other; *Ir.*, Iris; *L.*, the marginal part of the crystalline lens; *a*, angle of anterior chamber; *d*, membrane of Descemet, which ceases (as such) before reaching the angle *a*. The dotted line shows the course probably taken by fluid from the anterior part of the vitreous into the posterior aqueous chamber, where it is augmented by aqueous humour secreted by the anterior part of the ciliary process, thence through the pupil (not shown) into the anterior aqueous chamber, to an angle *a*. Suspensory ligament of lens not shown. $\times 10$.

from the anterior chamber into the lymphatics and perhaps into the veins of the sclerotic, through the meshes of the *ligamentum pectinatum* (*Fontana's spaces*), which close the

angle *a* (*filtration angle*); and it has been proved that very little fluid can pass through any other part of the cornea. In glaucoma the angle *a* is nearly always closed, in recent cases by contact, in old cases by permanent cohesion, between the periphery of the iris and the cornea (Figs. 99

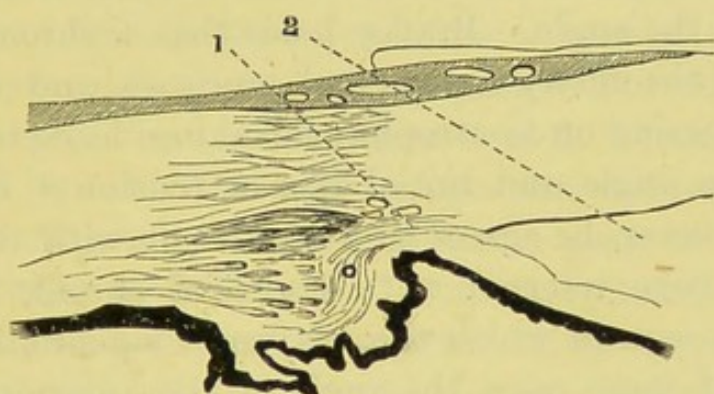


FIG. 99.—Ciliary region from a case of acute glaucoma of one month's duration. (1 and 2, situations of iridectomy wounds in two cases.) $\times 10$.

and 100). No complete explanation of this advance of the iris has yet been given. Adolf Weber holds that the

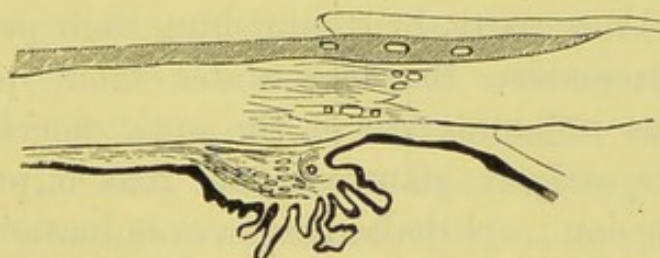


FIG. 100.—Ciliary region in chronic glaucoma of three years' standing. $\times 10$.

ciliary processes becoming swollen from various causes, push the iris forwards, and so start the glaucomatous state. Priestley Smith* believes that the primary obstruction is at the narrow chink between the edge of the lens and the tips of the ciliary processes ("circumlental space"), and that the block may depend upon one or more of three

* Priestley Smith, 'Trans. Ophth. Soc.,' vol. vi, 1886.

factors—increase in the size of the lens due to advancing years,* abnormal smallness of the ciliary area as in hypermetropia, and abnormal enlargement of the ciliary processes. Obstruction of this space leads to rise of pressure in the vitreous, followed by advance of the lens and ciliary processes against the base of the iris and consequent closure of the angle. Brailey holds that a chronic inflammation of the ciliary muscle and processes, and of the iris, quickly passing on to atrophic shrinking, leads to narrowing of the angle and initial rise of tension;† in a later paper, however, he agrees to some extent with the view of Weber, above referred to.‡ Cases of chronic glaucoma have been seen in which the iris was congenitally absent; in some of these cases the angle of the anterior chamber has been found blocked by the rudimentary iris.

But there are cases which show that the matter is not, always, so simple. Stilling, of Strasburg, contended that the waste fluids escape by the central canal of the vitreous into the optic nerve, and partly also by filtration through the circumpapillary portion of the sclerotic, and that a sclerosis of these parts, by diminishing their permeability, leads to glaucoma; Brailey§ states from pathological research that inflammation of the optic nerve is always present quite early in glaucoma, and that it precedes the increased tension; ophthalmoscopic examination in certain cases lends support to this statement.|| It may be added, in support of these views, that in some cases of glaucoma the angle of the anterior chamber remains freely open, and

* The increase in the size of the lens as age advances has been proved beyond doubt by Priestley Smith's researches. *Ibid.*, vol. iii, (1883).

† Brailey, 'Ophth. Hosp. Reps.,' vol. x, pp. 14, 89, 93 (1880).

‡ Brailey, *ibid.*, p. 282 (1881).

§ Brailey, *ibid.*, pp. 86, 277, 282.

|| Nettleship, 'St. Thomas's Hosp. Reps.,' vol. xiv.

that the ophthalmoscopical appearances of glaucoma are occasionally seen without increase of T. (For other causes see Secondary Glaucoma, p. 277.)

An over-supply of fluid affects the tension differently in different cases. Congestion and ordinary inflammations of the retina and uveal tract do not cause glaucoma, and dilatation of the arteries by vaso-motor paralysis is said to be accompanied by diminished tension. But tumours in, and even upon, the eye often give rise to secondary glaucoma, and probably the active congestion and transudation of fluid and small cells, which occur near to a quickly growing tumour, are the chief factors; certainly the glaucoma stands in no constant relation either to the size or position of the tumour. A relation is observed in some cases between glaucoma and neuralgia of the fifth nerve; and T. is said to be lowered in paralysis of this nerve. Probably the pain acts by causing associated congestion, and thus setting up glaucoma in a predisposed eye.

General and diathetic causes.—In an eye predisposed, by the changes above mentioned in the ciliary region, any cause of congestion may precipitate an acute attack. Congestion of the eyes in connection with disturbances of the general circulation from heart disease, bronchitis, or portal engorgement, or due to loss of sleep from gout, neuralgia, worry, &c., or caused by the over-use of presbyopic eyes without suitable glasses, or by a blow, or prolonged ophthalmoscopic examination, or exposure to cold wind, may all bring it about. Atropine has sometimes caused an attack, because, by lessening the width, it increases the thickness of the iris, and so crowds it into the angle of the anterior chamber. Iridectomy on one eye occasionally sets up acute glaucoma in the other, probably by causing general excitement and disturbance, and it is now customary to use eserine as a preventive in the second eye after iridectomy in the first. Glaucoma is uncommon

before the age of forty, and is most frequent between fifty-five and sixty-five;* the rare cases seen in young adults and children are generally chronic, and often associated with other changes in the eyes, particularly myopia. Acute cases are often dated from a period of overwork of the eyes, or want of sleep, as from sitting up nursing, &c. Patients who have had glaucoma in one eye should be emphatically warned as to the danger of over-using the eyes, or of working without proper glasses, and against dietetic errors. Primary glaucoma is, according to the newest statistics,† as a whole, rather commoner in women than men; and whilst the acute (congestive) forms are much commoner in women, very chronic glaucoma is rather commoner in men.

Treatment.—Iridectomy, or an equivalent operation, is, with very few exceptions, the only curative treatment. Eserine or pilocarpine (gr. $\frac{1}{2}$ —ij to 3j) used locally, however, diminishes the tension in acute glaucoma, and a few attacks seem to have been permanently cured by it. But although seldom really curative, eserine is of great temporary value in cases where an operation has to be deferred. It has little or no effect on the tension unless it cause marked contraction of the pupil. Eserine acts (1) by stretching the iris and drawing it away from the angle of the anterior chamber; (2) by the contraction of the ciliary muscle which it causes, the meshes of the tissue bounding this angle are more widely opened. Eserine causes congestion of the ciliary processes, and probably this explains why, if it do not soon relieve, it sometimes aggravates, the symptoms. It is of use chiefly in recent, and especially in

* Statistics of 1000 cases collected by Priestley Smith, loc. cit. (1886). Gallenga (Turin), in 330 cases, finds the frequency greatest between 60 and 70.

† Priestley Smith, loc. cit. (1886); in 1000 cases 569 women and 431 men.

acute cases; a solution of half a grain or a grain of the sulphate in the ounce is to be used about every two hours, and continued if relief be obtained. If in a few hours it increase the pain and do not lessen the T. it should be abandoned. The pain in acute cases may be much relieved by leeching, warmth to the eye, derivative treatment such as purgation and hot foot-baths, and soporifics. Cocain is used with the eserine by some surgeons, and seems to increase its efficacy.

Iridectomy cures glaucoma by permanently reducing the tension to the normal or nearly normal degree. It is found that the best results are obtained if—(1) the path of the incision lie in the sclerotic from 1 to 2 mm. from the apparent corneal border (Fig. 99); (2) the wound be large, allowing removal of about a fifth of the iris; (3) the iris be removed quite up to its ciliary attachment, which is best done by first cutting one end of the drawn-out loop of iris, then tearing it from its ciliary attachment along the whole extent of the wound, and cutting through the other end separately. (*See Operations.*) Puncture of the sclerotic behind the ciliary region has been recommended by Priestley Smith to relieve the tension in the vitreous chamber before proceeding to the iridectomy, or in cases where after iridectomy the tension in the vitreous chamber still remains abnormally high. Evacuation of the aqueous humour by paracentesis of the anterior chamber gives only temporary relief.

A mere wound in the sclerotic, differing but little in position and extent from that made for iridectomy, is sufficient to relieve + T., and to cure some cases of glaucoma permanently, and this operation (*subconjunctival sclerotomy*) was largely adopted by some operators a few years ago. Iridectomy, however, has held its ground as the more effectual operation. Sclerotomy is open to objection—(1) because the position and length of the wound

are not perfectly under control; if too far forward and too short it is ineffectual, if too far back and too long there is risk of wounding the ciliary processes and getting hæmorrhage into the vitreous; even shrinking of the operated eye and sympathetic inflammation of the other have occurred; (2) because the iris may prolapse into the wound, and need removal, and the operation then becomes an iridectomy; (3) when the anterior chamber is very shallow sclerotomy cannot be supposed to aid the exit of fluid so much as the removal of a piece of the iris.

Several other operations, the principle of which is to make a puncture at the sclero-corneal junction, have been tried, but have not gained general confidence.

Whichever operation be employed in glaucoma the formation of the operation scar in the sclerotic is certainly a most important factor.

Iridectomy in acute glaucoma no doubt acts, at first, by removing a portion of the iris from the blocked angle (Fig. 99), and thus allowing the normal escape of fluid. Some high authorities hold, however, that its permanent effect is due to the formation, at the seat of the wound, of a layer of tissue more pervious to the eye-fluids than the sclerotic ("filtration-scar"); an iridectomy for glaucoma which heals slowly is at any rate believed to be more favorable than one which heals immediately, *i. e.* with no new tissue, and a slight bulging of the scar is held by some surgeons to be rather desirable than otherwise. That a mere sclerotomy may be sufficient points in the same direction. Such a porous scar never forms if the incision be in the cornea.

An operation, usually iridectomy, is to be done in all cases of acute and subacute glaucoma, whether there be great pain or not, so long as some sight still remains, and even if all p. l. be lost, provided that the blindness be of only a few days' duration. Even if the eye be

permanently quite blind, iridectomy or sclerotomy is sometimes preferable to excision of the globe for the relief of pain.

Chronic ("simple") glaucoma should, in my opinion, always, if possible, be operated upon early, as soon as the diagnosis is certain and before the field is much damaged; the prognosis is then fairly good. In advanced chronic glaucoma, when the field has become much contracted, visual acuteness much lowered, and the disc pale and considerably cupped, the rule is less clear, for it is well known that the effect of operation in such cases is far from constant. But as no other treatment is of use, and iridectomy is certainly often beneficial, it should usually be performed, especially if the disease affect both eyes. The patient's prospect of life must be allowed for in chronic glaucoma; if he be old and feeble, life may end before the disease have progressed to blindness.

There is often difficulty in deciding upon the best course in the so-called "premonitory" stage, which consists, in truth, of transient attacks of slight glaucoma. When it is clear that attacks of temporary mistiness and rainbows are glaucomatous, and that they are getting more frequent, iridectomy should seldom be deferred; but if the patient can be seen at short intervals eserine should have a fair trial before operation is resorted to. It is to be remembered that iridectomy done when sight is still good may, by allowing spherical aberration (p. 14), and causing corneal astigmatism (p. 181), increase the defect; and this, though not of necessity a contra-indication, must be taken into account.

The prognosis after operation is, in general terms, better in proportion as the disease is acute and recent. If operated on within a few days of the onset of acute symptoms, provided that fingers can still be counted at the time of operation, sight is often restored to the state in

which it was at the onset, *i. e.* if the disease be recent, nearly perfect sight will be restored. Even in cases combining the maximum of acuteness and severity, in which vision has for the last few days been reduced to mere p. l., the operation is often successful in restoring some degree of useful sight. But the prognosis is not always so favorable in acute glaucoma, especially if the patient's health be much broken down; and if there be, as is by no means uncommon, evidence that sight had been already damaged by chronic glaucoma before the acute attack set in, the prognosis must be guarded. In simple chronic glaucoma we can only hope as a rule to stop the disease where it is and prevent the sight from getting worse.

The full effect of the operation is not seen for several weeks, though a marked immediate effect is produced in acute cases. In cases of long standing T. may remain permanently rather + after operation, without bad effect, provided it be very much less than before the operation; the eye tissues can in some degree adapt themselves to increased pressure.

A second iridectomy in the opposite direction, or a sclerotomy, should be done if T., having been reduced to normal, or very slightly +, after the first operation, rise definitely, and be accompanied by a return of other symptoms; but several weeks should generally elapse, for slight waves of glaucomatous tension may occur before the eye has fully recovered from the first operation, and these may often be relieved by other means. Cases which relapse definitely, or which steadily get worse after the first operation, are always very grave, and the second operation must not be confidently expected to succeed. If after iridectomy in acute glaucoma the symptoms are not relieved, even for a time, or become worse, some complication is to be suspected, such as hæmorrhage from the retina or choroid, or a tumour. (*See Secondary Glaucoma.*)

Other treatment.—If we are obliged to delay the operation, the other means mentioned at p. 272 should be prescribed, including eserine. The diet should as a rule be liberal, unless the patient be plethoric. It is very important to ensure sound sleep and mental calm. After the operation, until the eye has become quiet, all causes likely to induce congestion must be carefully avoided, such as use of the eyes, stooping or straining, and prolonged ophthalmoscopic examination. Atropine must never be used. We should be on the alert for the earliest symptoms in the second eye after operation on the first (p. 261), and the use of eserine may be advisable as a prophylactic.

In a few cases of very chronic or subacute character, with great increase of T., iridectomy seems to aggravate the disease, being followed not even by temporary benefit, but by persistence of + T., increased irritability, and still further deterioration of sight ("*glaucoma malignum*"). Perhaps the tilting forward of the lens, which sometimes follows iridectomy, may account for the result.

Glaucoma may occur independently in cataractous eyes, and in eyes from which the lens has been extracted, with or without iridectomy.

Secondary glaucoma may be acute or chronic, according as it is a consequence of active disease or of sequelæ. It may be caused by circular iritic synechia with bulging of the iris (p. 131). Various forms of chronic irido-keratitis and irido-choroiditis (p. 133), especially the sympathetic form (p. 149), are liable to be accompanied by it: in the former it may be due to choking of the spaces of Fontana by inflammatory products, and perhaps to excessive secretion from the ciliary processes; in the sympathetic disease, to total posterior synechia. It may follow perforation of the cornea with large anterior synechia. The eye often becomes temporarily glaucomatous in the course of traumatic cataract from the pressure of the swollen lens on

the iris and ciliary processes, especially in patients past middle life (p. 182). In none of these cases is there much danger of mistaking secondary for idiopathic glaucoma.

But secondary glaucoma may result from various deeper changes. When the lens is dislocated (p. 183), either behind or in front of the iris, it often sets up glaucoma, sometimes of a very severe type, apparently by pressing on the ciliary processes or iris. There is generally the history of a blow; and in posterior dislocation, even if the edge of the displaced lens cannot be seen, the iris is usually tremulous, and its surface concave or flat at one part, whilst bulging or prominent at another. If we are sure that a lens dislocated into the vitreous is causing the symptoms, it should be extracted with a scoop (*see Operations*); and if lying in the anterior chamber should also usually be removed. If the eye become glaucomatous immediately after a severe blow (p. 155) the condition of the lens may not be ascertainable, and then an iridectomy must be done and the eye be watched; vitreous is very likely to escape at the operation if there be dislocation of the lens, for the latter condition implies rupture of the suspensory ligament.—Hæmorrhage into an eye whose retina is detached (*e.g.* in high degrees of myopia) may give rise to acute glaucoma with severe pain.—A glaucomatous attack generally occurs during the growth of an intraocular tumour (p. 286). It is often impossible to distinguish such a case, in an adult, from one of idiopathic glaucoma of the same severity and standing; for even if the lens be not opaque—and it often is so—the other media will probably be too hazy to allow an ophthalmoscopic examination: the growth itself is usually of a dark colour, and both idiopathic glaucoma and choroidal sarcoma are diseases of advanced life. In almost every case, however, the glaucoma will be “absolute,” and will be known to have been so for weeks or months, and there will also

be the negative fact that the fellow-eye shows no signs of glaucoma. If a glaucomatous eye, which has been absolutely blind for several months, remain painful and congested, and its media too opaque for ophthalmoscopic examination, it should be excised as likely to contain a tumour. Tumours in the eyes of children also cause secondary glaucoma, but there is seldom any difficulty in making the diagnosis; the patient is far below the age for primary glaucoma, and the growth is usually conspicuous from its whitish colour.—Secondary glaucoma now and then supervenes in cases of albuminuric retinitis, and of embolism or thrombosis of the retinal vessels, and in cases of retinal hæmorrhage from other causes (*"hæmorrhagic glaucoma"*). In glaucoma with hæmorrhage the diagnosis can sometimes be completed only after an unsuccessful operation has shown that the case is not a simple one.

CHAPTER XVIII

TUMOURS AND NEW GROWTHS OF THE EYEBALL AND
CONJUNCTIVA*A. Tumours and Growths of the Conjunctiva and Front of
the Eyeball*

Cauliflower warts, with narrow pedicles, like those on the glans penis, but flattened like a cock's comb by pressure, are sometimes seen on the ocular and palpebral conjunctiva. Each wart with a small portion of healthy conjunctiva around its pedicle must be snipped off, or the growth is likely to recur.

Tuberculosis of the conjunctiva is found in the form of small grey miliary granulations in the conjunctiva of the upper lid; in late stages the surface becomes ulcerated, ragged, and uneven, and the eyeball itself may be attacked; the gland in front of the ear at the same time frequently becomes enlarged and suppurates. The treatment should be repeated free scraping with a sharp spoon, either with or without cauterisation, to remove the tuberculous nodules as they appear. It is scarcely necessary to make a distinction between this affection and lupus, which is of the same nature, but which usually attacks the conjunctiva by extension from the skin.

The eyelid, especially the tarsus, is now and then the seat of diffused gummatous inflammation in the tertiary stage of syphilis. The infiltration gives rise to a hard, indolent swelling of the whole lid (*syphilitic tarsitis*).—

Chancres and tertiary syphilitic ulcers may occur on the lids (p. 70).

Pinguecula, a yellowish spot, looking like adipose tissue, in the conjunctiva, close to the inner or outer edge of the cornea, consists of thickened conjunctiva and subconjunctival tissue, and contains no fat. It is commonest in old people, and in those whose eyes are exposed to local irritants. Though of no consequence, advice is often asked about it.

Pterygium is a triangular patch of thickened ocular conjunctiva, the apex of which encroaches upon the cornea; it is almost always seated on the exposed part of the eye. It varies much in area, thickness, and vascularity, and though usually stationary may be progressive. It is to be distinguished from opacity of the cornea, and from the cicatricial band (symblepharon) which often forms between lid and globe after burns or wounds of the conjunctiva. It is rarely seen except in those who have spent some years in hot countries. The best treatment is, after dissecting up the growth, to double it inwards upon itself, drawing its apex into the chink between sclerotic and conjunctiva by means of a deep suture, which is brought out again near the caruncle; or to transplant the growth into a cleft in the conjunctiva below the cornea: excision or ligature is less effectual; it is important to bring the healthy conjunctiva over the wound by sutures after removal of the pterygium. Adhesion of swollen conjunctiva to a marginal ulcer of cornea is the starting-point of pterygium, or it may gradually extend from the edge of a pinguecula (Fuchs).

Small thin cysts, sometimes elongated and beaded, with clear watery contents, are not uncommon in the ocular conjunctiva near to one of the canthi. They are formed by distension of valved lymphatic trunks.

Dermoid tumours (solid) of the eyeball are much scarcer

than the cystic dermoids of the eyebrow (p. 298). They are whitish, smooth, hemispherical, and firm. They generally lie in the palpebral fissure, and are either wholly conjunctival and moveable, or partly corneal and fixed. They are solid, and hairs may grow from their surface. They may be combined with other congenital anomalies of the eye or lids. The corneal portion of such a tumour cannot always be perfectly removed.

The swelling in some cases of *episcleritis* (syphilitic or not) may be mistaken for a tumour (p. 140). A few cases of innocent tumour on the edge of the cornea have been described as fibroma; it is not certain that some of these may not have been chronic gummata. *Moles* or patches of pigmentation of the ocular conjunctiva are sometimes seen; as a rule they are of no importance, but in later life they sometimes become sarcomatous.

A congenital *fibro-fatty growth* sometimes occurs in the form of a yellowish, lobulated, tongue-like protrusion between the lid and the globe, and usually at the outer and upper side of the orbit.

Cystic tumours may be met with beneath the palpebral conjunctiva. The very rare form known as *Dacryops* is a bluish tumour caused by occlusion and distension of a duct of the lacrimal gland; but other cystic conjunctival tumours are met with which cannot be so explained (p. 296). *Fibrous*, and even *bony tumours* are occasionally seen in the substance of the upper lid, perhaps starting from the tarsus; in one case a tooth was removed from the lower lid by Carver (Nagel, p. 432), and soft *polypoid growths* have been met with in the sulcus between lid and globe.

Malignant tumours arise much less commonly on the front of the eye than in the choroid or retina. They may be either epithelial or sarcomatous. An injury is often stated to be the cause of the growth.

Epithelioma may begin on the ocular conjunctiva, in which case it remains moveable, or at the sclero-corneal junction, when it quickly encroaches on the cornea, infiltrates its superficial layers, and becomes fixed. It may be pigmented. When such a growth is not seen until late, it may perhaps be as large as a walnut, may cover or surround the cornea, and present a papillary or lobulated surface. The glands in front of the ear may be enlarged.

Sarcoma in this region may or may not be pigmented. It generally arises at the sclero-corneal junction, and when small the conjunctiva is traceable over the growth. But in advanced cases it may be impossible from the clinical features to diagnose the nature of a tumour in this part.

Moveable tumours (*epithelioma*) not involving the cornea may be cut off, but are very likely to recur; and recurrence is still more likely in the case of growths fixed to the cornea or sclerotic. Removal of the eyeball at an early date, especially in the case of sarcomata, is the best course in the majority of cases.

The lacrimal sac is occasionally the seat of new growth, or of tubercle which may be mistaken for chronic mucocele.

B. *Intraocular Tumours.*

By far the commonest forms are glioma of the retina and sarcoma of the choroid.

Glioma of the retina is a disease of infancy or early childhood, the patients being generally under three years old when first brought for treatment; it may, however, be present at birth, and is said occasionally to begin as late as the eleventh or twelfth year. Glioma is very soft, composed of small round cells which grow from the granule layers of the retina, and it either grows outwards, causing detachment of the retina, or inwards into the vitreous;

often several more or less separate lobules are present. It often fills the eyeball in a few months, and then spreads by contact to the choroid, and to the sclerotic and orbit. It is especially prone to travel back along the optic nerve to the brain; and it may cause secondary deposits in the brain and in the scalp, and more rarely in distant parts. If the eye be removed before either the optic nerve or the orbital tissues are infiltrated the cure is radical, but in the more numerous cases, where the patient is not seen till what may be called, clinically, the second stage (*see below*), a fatal return in the orbit or within the skull is the rule. Glioma sometimes occurs in both eyes, and in several children of the same parents.

The earliest symptom is a shining whitish appearance deep in the eye, and the eye is soon noticed to be blind; as there is neither pain nor redness, advice is seldom sought at this stage. T. is n. or rather -. When the peculiar appearance has become very striking, or if the eye becomes painful, the child is brought to be seen. In this (the second) stage there is generally some congestion of the scleral vessels, and a white, pink, or yellowish reflection from behind the lens (which remains clear), steaminess of the cornea, mydriasis, T. +, anterior chamber shallow and of uniform depth; there may be enlargement or prominence of the eyeball. On examination by focal light some vessels can generally be seen on the whitish background, and white specks, indicating degeneration, are sometimes present.

In young children the above appearances are sometimes simulated by inflammatory changes in the vitreous, with detachment of the retina, the result of spontaneously arrested severe irido-choroiditis (*compare p. 198*).

Sarcoma of the choroid and ciliary body is a growth of late or middle life, being rarely seen below the age of thirty-five. The majority of these tumours are pigmented (melanotic),

some being quite black, others mottled or streaked. A few are free from pigment. Some are spindle-celled or mixed, others composed of round cells; some are truly alveolar, but in many specimens there is very little connective-tissue stroma, and no very defined arrangement of the cells. These tumours are moderately firm, but friable: some are very vascular, and hæmorrhages often occur into them. The tumour grows from a broad base, and usually forms a well-defined rounded prominence, pushing the retina before it; blood or serous fluid is effused round its base, so that the retinal detachment is more extensive than the tumour. These tumours often grow slowly so long as they are wholly contained within the eye, and several years may elapse before the growth passes out of the eye and invades the orbit. Orbital infection does not usually occur till the globe is filled to distension by the growth; but it may happen much earlier, the cells travelling out along the sheaths of the perforating blood-vessels and producing large extraocular growths, while the primary intraocular tumour is still quite small. The lymphatic glands do not enlarge, but there is great danger of secondary growths in distant parts, especially in the liver, a risk not entirely absent even when the eye tumour is small. Hence early removal of the globe is of the utmost importance, and a good, though not too confident, prognosis may be given when the optic nerve and tissues of the orbit show no signs of disease.

Metastatic growths.—In nearly every case malignant tumour of the choroid is primary, but it is important to know that growths may occur here secondary to those in other parts of the body; in one case, quoted by Manz, both eyes were affected, the original growth being cancer of the breast.

Symptoms and course.—If the case be seen early, when defect of sight is the only symptom, the tumour can often

be seen and recognised by its well-defined rounded outline, some folds of detached retina often being visible near it; the pupil, cornea, and tension will probably be natural. When the tumour originates in the central region the sight is immediately affected, and the patient seeks advice very early; the differential diagnosis then lies between localised plastic choroiditis and tumour. In tumour there is often some detachment of the retina at or near the area of the disease, but there is no evidence of retinitis, and no patches of black pigment about the swelling. By ophthalmoscopic estimation the diseased area is found to be more or less raised. An inflammatory exudation of similar size commonly causes haze of the neighbouring retina, and opacities in the vitreous; if of some weeks' duration, part of it will usually have become absorbed, leaving exposed sclerotic with accumulations of pigment. Sooner or later the tumour in its growth sets up symptoms of acute or subacute glaucoma, and sometimes iritis; subsequently secondary cataract forms. It is in this glaucomatous (second) stage that relief is usually sought. Unless some part of the tumour happen to be visible outside the sclerotic, or project into the anterior chamber, a positive diagnosis will often now be impossible, owing to the opacity of the media; although by exclusion we may often arrive at great probability. If the eye be left alone, or iridectomy be performed, glaucomatous attacks and pain will recur, and the eye will enlarge and gradually be disorganised by the increasing growth, which will then quickly fill the orbit and fungate. But sometimes a deceptive period of quiet follows the glaucomatous attack; even decided shrinking and softening of the eye may occur; but the growth will sooner or later make a fresh start and become apparent. It is chiefly in very old patients that this slow course is noticed. Sarcoma is especially likely to form in eyes previously injured, or already shrunken from disease.

Thus it is apparent that in a majority of cases of choroidal tumour we can only guess at the truth. We suspect a tumour and urge excision in the following cases:—

(1) When an eye that has been for some time failing or blind from deep-seated disease becomes painful, congested, and glaucomatous (there being no glaucoma of the other eye), and particularly if there be secondary cataract (*see* p. 279). (2) Similar eyes with normal or diminished tension are best excised as possibly containing tumour. (3) In extensive detachment of retina confined to one eye, without history of injury or evidence of myopia, the patient should be warned, or the eye excised, according to circumstances.

In all cases of suspected glioma or sarcoma the eye should be opened at once, and if a tumour be found, the cut end of the optic nerve of the excised eye should be carefully looked at; if this be pigmented or thickened, another piece should be at once removed, and the orbit searched by the finger for evidence of growth; the surface of the eye should also be carefully examined for external growths. When infection of the nerve or orbit is suspected the orbit should be cleared out, and chloride of zinc paste applied (as at p. 297).

Tumours of the iris are rare. Melanotic as well as unpigmented sarcomata are occasionally met with.* The definite development of melano-sarcoma of the iris has been known to be preceded for many years by an apparently innocent pigmented spot on the iris. In eyes blind and degenerated after irido-cyclitis, the uveal pigment may increase in amount, and creep round the pupillary border to the anterior surface of the iris; these areas of new pigment might be mistaken for melanotic growths. Sebaceous or epithelial tumours are also seen; they are

* A well-reported case, with numerous references, is given by Little, in 'Trans. Ophth. Soc.,' vol. iii, 1883.

nearly always the result of transplantation of epithelium, or of a hair, into the iris through a perforating wound of the cornea; they are frequently cystic (implantation cysts).—In rare cases cystic tumours with thin walls are formed between the layers, or connected with the posterior surface of the iris, particularly in eyes which have been operated on or otherwise injured.

Diffuse sarcoma of iris.—Sarcoma of the iris may be white or pigmented: it usually takes the form of a single large prominent growth. I have twice seen a sarcoma of the iris take the form of a diffused thickening, with a mottled or tortoiseshell aspect; such a diffuse form is more difficult to diagnose, and probably more dangerous, if left alone, than a definite tumour.

Cases of disease of the iris are seen from time to time, the special feature of which is the presence of one or more nodular growths, usually of small size; iritis is generally present. It is often impossible to determine the nature of the growth until the case has been watched, or microscopical examination or inoculation experiments have been made. These cases, which have often been described as granuloma of the iris, are certainly sometimes tubercle, sometimes chronic gummata, sometimes part of a severe so-called serous iritis, and sometimes the nature of the growth is doubtful. Inoculation of tuberculous material into the anterior chamber of rabbits has repeatedly been followed by the formation of multiple nodules, similar in appearance to those in some of these cases, and some of the growths in human cases have given the microscopical reactions of true tubercle. The disease is probably tubercular when the growths are multiple, non-vascular, and grey, especially when accompanied by enlarged glands in the patient, or a family history of tubercle.

Large masses of confluent tubercle occasionally form in the choroid or other parts of the uveal tract, leading to

disorganisation of the eye, with mixed symptoms of intra-ocular growth and inflammation. As it is probable that this ocular tubercle may be a source of general tuberculosis, excision of the eye is the best course in any doubtful case, where it is clear that the eye is lost.

The cornea is much less liable to tubercular infiltration than the iris, but small growths have been observed in it, both as the result of inoculation and in the course of spontaneous tubercle of the iris.

C. Tumours of the Orbit, *see* Chap. XIX.

CHAPTER XIX

INJURIES, DISEASES, AND TUMOURS OF THE ORBIT

(1) *Contusion and concussion injuries.*—*Bruising* of the eyelids from direct blows ("black eye") may usually with care be distinguished from the deeper extravasation following fracture of the walls of the orbit. In ordinary "black eye" the ecchymosis comes very quickly and remains superficial, and, if it affect either the palpebral or ocular conjunctiva, does not pass far back. The ecchymosis following fracture of the orbital plate of the frontal bone comes more gradually, is deep-seated, often entirely beneath, rather than in, the skin and conjunctiva, diminishes in density towards the front and borders of the lids, and when considerable, causes proptosis. But if a fracture involve the rim of the orbit, the above characters are likely to be mixed, and therefore misleading. Wasting of the adipose tissue of the orbit, and consequent sinking back of the eye, sometimes follow severe blows, with much extravasation of blood (enophthalmos).

Fracture of the inner wall of the orbit into the nose, the sinuses opening into it, or the nasal duct, is often followed by *emphysema of the orbital cellular tissue*. This can occur only when the mucous membrane is torn. The emphysema comes on quickly from "blowing the nose," and is shown by a soft, whitish, doughy swelling of the lids, which crepitates finely under the finger; the globe is more or less protruded and its movements limited. The emphysema

disappears in a few days if the lids be kept bandaged. These fractures are usually caused by blows over the inner angle of the orbit, but occasionally by blows on the malar region.

Partial ptosis is an occasional result of blows upon the upper lid. It is generally accompanied by paralysis of accommodation and dilatation of the pupil, and it seldom lasts more than a few weeks.—Ocular paralysis following injury to head (*see* Chap. XXI).

(2) *Orbital abscess* and *orbital cellulitis* may follow injuries, but their origin is often obscure. Cellulitis may spread to the orbit from the face in erysipelas, from the throat in severe tonsillitis, or from the socket of an inflamed tooth.—Diffused acute inflammation of the cellular tissue is difficult to distinguish from acute orbital abscess, since in both there are the signs of deep inflammation, with displacement of the eye and limitation of its movements, chemosis of the conjunctiva, and brawny swelling and redness of the lids. An acute abscess soon points between the globe and some part of the rim of the orbit, but even in cellulitis the swelling may be greater at some one part, and give rise to a feeling deceptively like fluctuation.

Orbital abscess may be so chronic as to simulate a solid tumour until the pus nears the surface; even then an exploratory incision may be needed to set the question at rest. Abscess of the orbit, whether acute or chronic, is very often the result of periostitis, and a large surface of bare bone is often found with the probe.

In acute cases, as soon as fluctuation is certain, an incision is to be made with a narrow, straight knife, generally through the skin, or, if practicable, through the conjunctiva. Chronic cases of doubtful nature may be watched for a time. It may be necessary to go deeply into the orbit, either with the knife, probe, or dressing forceps, before matter is reached. A drainage-tube should be

inserted if the abscess be deep. The proptosis does not always disappear when the abscess is opened; it may increase owing to hæmorrhage, and there may be much thickening of the tissues. Sight may be injured or lost by stretching of, or pressure on, the optic nerve, and the cornea may lose sensation, and ulcerate, from damage to the ciliary nerves behind the globe.

Thrombosis of the cavernous sinus, which may result from several causes, produces local symptoms which it is difficult, often impossible, to distinguish from those of cellulitis beginning in or limited to the orbit. The thrombosis, however, often spreads to the other cavernous sinus and the other orbit; and in any case it produces the gravest head symptoms, which, as a rule, end fatally in a short time.*

The lacrimal gland is but seldom the seat of inflammation or abscess. In chronic cases the enlarged gland is distinctly felt projecting, and can generally be recognised by its well-defined and lobulated border; but the enlargement cannot always be distinguished from that caused by a morbid growth in the gland, or corresponding part of the orbit. In acute inflammation there are the usual signs, local heat, tenderness, and pain, with swelling, which may obscure the boundaries of the gland. If the enlargement be great, the eyeball is displaced, and the oculo-palpebral fold of the conjunctiva in front of the gland is pushed downwards, and projects more or less between the lid and the eye.—When an abscess forms, it usually points to the skin, and should seldom be opened from the conjunctival surface. If it be allowed to burst spontaneously through the skin, a troublesome fistula may follow.—There is limited swelling and tenderness of the lid at the upper

* An able paper on this little-known subject has been communicated to the Ophthalmological Society by Dr. Sidney Coupland (Oct., 1886).

outer angle, not passing back beneath the orbital rim. The abscess points through the conjunctiva, above the outer end of the tarsal cartilage, and is thus distinguished from a suppurating Meibomian cyst.

(3) *Wounds*.—Wounds of the *eyelids* need no special treatment beyond very careful apposition by sutures, sometimes with a small harelip pin, so as to secure primary and accurate union. Lacerated wounds of the ocular conjunctiva, if extensive, need a few fine sutures, and they seldom lead to any deformity. When a rectus tendon has been torn through I have never succeeded in getting the ends to unite.

Penetrating wounds through the lids or conjunctiva, which pass deeply into the orbit, may be much more serious than they appear at first sight, since the wounding body may have caused fracture of the orbit, and damage to the brain-membranes, or a piece of the wounding instrument may have been broken off and lie embedded in the roomy cavity of the orbit, without at first exciting disturbance or causing displacement of the eye. Some extraordinary cases are on record,* in which very large foreign bodies have lain in the orbit for a long time undetected. The optic nerve is occasionally torn across without damage to the globe. Every wound of the eyelids or conjunctiva should, therefore, be carefully explored with the probe, and, whenever possible, the instrument which caused the wound should be examined.

When a foreign body is suspected or known to be firmly embedded, and is not removable through the original wound, it is generally best to divide the outer canthus, and prolong the incision into the conjunctiva; in some cases an incision through the skin over the margin of the orbit, at the situation of the foreign body, will be preferable. Single shot, embedded and causing no symptoms,

* In Mr. Lawson's well-known treatise and elsewhere.

should not be interfered with unless they can be easily reached.

Wounds of the orbit, by gunshot or other explosives, when extensive and caused by numerous shots or fragments of sand, gravel, &c., driven into the tissues, are, of course, serious, particularly if the eyeball itself be injured. Such injuries may cause tetanus.

TUMOURS OF THE ORBIT

A tumour of any notable size in the orbit always causes protrusion of the eye (proptosis), with or without lateral displacement and limitation of its movement. As a rule there are no inflammatory symptoms. An exact diagnosis of the seat, attachments, and nature of an orbital tumour is, of course, often impossible before operating; and it may be further observed that there has occasionally been great difficulty in deciding whether the symptoms pointed to a tumour, or to some form of chronic hypertrophy of cellular tissue or quiet gummatous inflammation.

A tumour in the orbit may originate in some of the loose orbital tissues, in the lacrimal gland, in the periosteum, upon or within the eyeball, or from the optic nerve; or it may have encroached upon the orbit from one of the neighbouring cavities. Fluctuating tumours in the orbit may be cystic or ill-defined, and may or may not pulsate. Solid tumours in the orbit may be moveable, or be fixed by broad attachments to the wall of the cavity. Sight is often damaged or destroyed in the corresponding eye by compression or infiltration of the optic nerve.

(1) *Distension of the frontal sinus* by retained mucus causes a well-marked, fixed, usually very chronic swelling, not adherent to the skin, at the upper inner angle of the orbit above the *tendo oculi*. Hard at first, it fluctuates when the bony wall has been absorbed. Its course is

usually slow, but acute suppuration may supervene, and the swelling be mistaken for a lacrimal abscess (p. 75). There is generally a remote history of injury. The aim of treatment is to re-establish the opening, closed probably as the result of fracture, between the floor of the sinus and the nose. The most prominent part of the swelling is freely opened; a curved probe is then passed, if possible, from the sinus through the infundibulum into the nose; if the opening has been completely closed, it is sometimes necessary to perforate the base of the sinus by a trocar. A seton or drainage-tube is then passed through the hole, brought out at the nostril, and must be worn for several weeks or months. Cases of the same nature are sometimes seen in which the swelling is at a lower level and further back in the orbit; they are not connected with the frontal sinus, but are probably due to distension of some of the cavities of the ethmoid.

(2) Pedunculated *ivory exostoses* sometimes grow from the walls of the same sinus or its neighbourhood; beginning early in life, they increase very slowly, cause absorption of their containing walls, and often in the end undergo spontaneous necrosis and fall out. Their removal while still fixed is very difficult and dangerous, owing to the proximity of the dura mater.

(3) Tumours encroaching on one or both orbits from the base of the skull, the antrum, the nasal cavity, or the temporal fossa, generally admit of correct diagnosis.

The suspicion of tumour on the inner or lower wall of the orbit should always lead to an examination of the palate, pharynx, and teeth, of the permeability of each nostril, of the functions of the cranial nerves, of the state of the glands behind the jaw on both sides, and to an inquiry as to epistaxis or discharge from the nose.

(4) *Pulsating tumours of the orbit* and cases of *proptosis with pulsation* are in most cases due to arterio-venous

intercommunication in the cavernous sinus, in consequence of which the ophthalmic vein and its branches become greatly distended with partially arterialised blood. In a large proportion the symptoms follow rather gradually after a severe injury to the head. In others they come on suddenly with pain and noises in the head, without apparent cause, and these idiopathic cases are usually in senile persons. In several examples of both forms a communication has been found, post mortem, between the internal carotid artery and the cavernous sinus, the result of wound from fracture of the base of the skull in the traumatic cases, and of rupture of an aneurysm in the idiopathic ones. The typical symptoms are proptosis, with chemosis, pulsation of the eyeball, paralysis of orbital nerves, a soft pulsating tumour under the inner part of the orbital arch, and a bruit. A bruit with proptosis and conjunctival swelling may be present without demonstrable tumour or pulsation. Ligature of the common carotid has been practised with good results in a large number of cases; subsequent excision of the eye and evisceration of the orbit for a dangerous return of symptoms in one or two. An unruptured aneurysm of the internal carotid does not cause the symptoms just described. Aneurysm of the intra-orbital arteries and arterio-venous communications in the orbit, if they occur, are excessively rare.—Erectile tumours, well defined and separable, but not causing decided pulsation, are sometimes met with in the orbit, and can be dissected out.

(5) A fluctuating tumour which does not pulsate, is not inflamed, and not connected with the frontal sinus or lacrimal gland, may be a chronic orbital abscess (p. 291), a hydatid, or a cyst containing bloody or other fluid and of uncertain origin. An exploratory puncture should be made after sufficiently watching the case, and the further treatment must be conditional. Perfectly clear, thin fluid

probably indicates a hydatid, and in this case the swelling is likely to return after a puncture, and the cyst will need removal through a free opening. The echinococcus hydatid often contains daughter-cysts, some of which escape puncture. Suppuration may take place around any species of hydatid.

(6) Examination leads to the diagnosis of a *solid tumour limited to the orbit*. We must try to determine whether the growth began in the eyeball or optic nerve, or in some of the surrounding tissues. We therefore examine the globe for symptoms of intraocular tumour (p. 283).

Solid growths independent of the eyeball may arise as follows:—(a) From the *periosteum*; these are firmly attached by a broad base, are generally malignant, and seldom admit of successful removal. (b) The *lacrimal gland* (compare p. 292) may be the seat of various morbid growths, including carcinoma; a great part of the growth is in the position of the gland, and can be explored by the finger. Although such a growth is often attached firmly to the orbital wall, its position, lobulated outline, and well-defined boundary will often lead to a correct diagnosis. Tumours of the lacrimal gland should always be removed if they are increasing, for we can never feel sure that they are innocent. (c) Solid tumours originating in some of the softer orbital tissues, especially the form known as cylindroma, or plexiform sarcoma, occur more rarely. (d) Tumours of the optic nerve, usually myxomatous, occur, though rarely;* they generally cause neuro-retinitis and blindness, but no absolutely pathognomonic symptoms; they may sometimes be extirpated without removing the globe.

When an orbital tumour is found during operation to be adherent to bone or to infiltrate soft parts which cannot be removed, chloride of zinc paste (F. 14) should be applied

* For references see Knapp's 'Archives of Ophthalmology,' xii, 292.

on strips of lint, either at once, or the next day when oozing has ceased. If the periosteum be affected it is to be stripped off, and the paste applied to the bare bone. Hæmorrhage from the depth of the orbit can always be controlled by a firm, graduated compress.

In every case of suspected primary orbital tumour the question of syphilis must be carefully gone into; although neither periosteal nor cellular nodes are common in the orbit, both are known to occur and to disappear under proper treatment.

Nævus may occur on the eyelids and in the orbit, and implicate the conjunctiva, both of the lids and eyeball. Deep nævi may degenerate and become partly cystic. Some cases of nævus of the face are associated with nævus of the choroid; in such the eyes are generally very defective.

Dermoid tumours (cystic) are not uncommon at the outer end of the eyebrow; more rarely they occur near the inner canthus. Lying deeply, beneath the orbicularis, they are not adherent to the skin, like sebaceous cysts; the subjacent bone is sometimes hollowed out. They often grow faster than the surrounding parts, and should then be extirpated, the thin cyst wall being carefully and completely removed through an incision parallel with, and situated in, the eyebrow. They usually contain sebaceous matter and short hairs; occasionally, clear oil.

CHAPTER XX

ERRORS OF REFRACTION AND ACCOMMODATION

As stated at p. 12, § 19, when the length of the eye is normal, and the accommodation relaxed, only parallel rays are focussed on the retina, and, conversely, pencils of rays emerging from the retina are parallel on leaving the eye (Fig. 101, and p. 5, §§ 11 and 12), and this, the condition

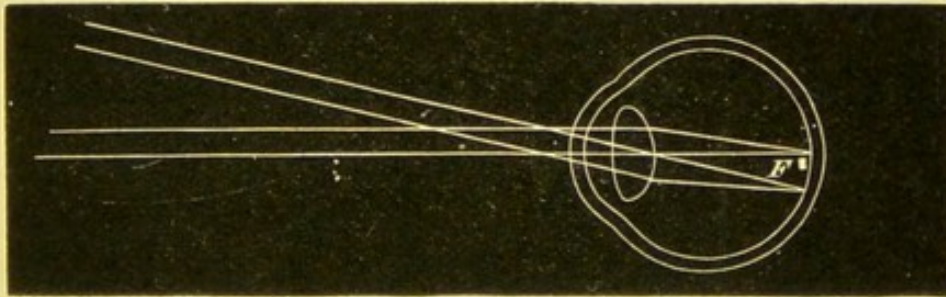


FIG. 101.—Pencils of parallel rays entering or emerging from an emmetropic eye.

of the normal eye in distant vision, is called emmetropia (E.). All permanent departures from the condition in which, with relaxed accommodation, the retina lies at the principal focus, are known collectively as ametropia.

In E. rays from any near object, *e. g.* divergent rays from

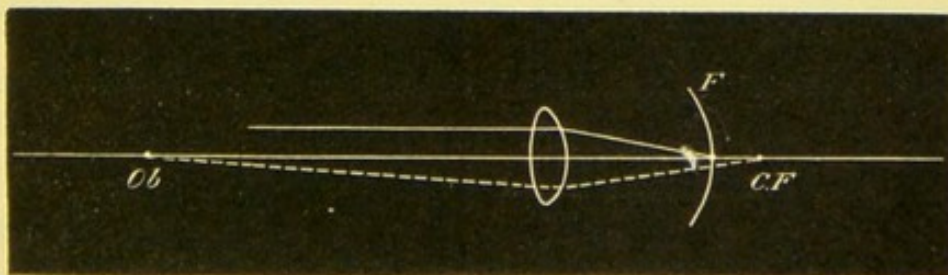


FIG. 102.—Emmetropia.—Distant objects (parallel rays) focussed on retina; near objects (divergent rays) focussed behind retina.

Ob, Fig. 103, are focussed behind the retina at *cf*, every conjugate focus being beyond the principal focus (p. 6, § 13). Reaching the retina before coming to a focus, such rays will form a blurred image, and the object *Ob* will therefore be seen dimly. But by using accommodation the convexity of the crystalline lens can be increased and its focal length shortened, so as to make the conjugate focus of *Ob* coincide exactly with the retina (*cf*, Fig. 103).

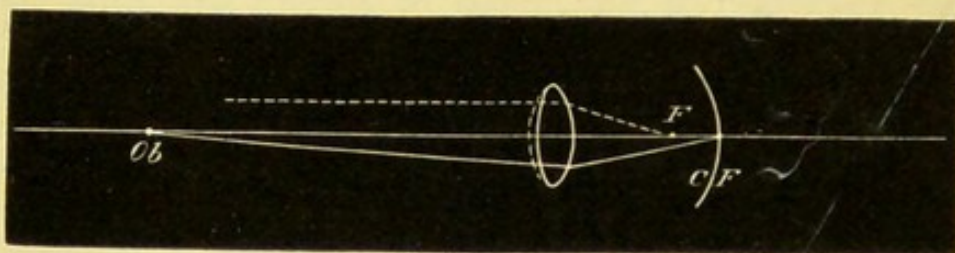


FIG. 103.—Eye during accommodation.—Near objects (divergent rays) focussed on retina; distant objects (parallel rays) focussed in front of retina. The dotted line in front of the lens shows its increase of convexity.

Under this condition the object *Ob* will be clearly seen, whilst the focus of a distant object, which in Fig. 102 was formed on the retina, will now lie in front of it (*F*, Fig. 103), and the distant object will appear indistinct. The nearest point of distinct vision (*p*) and the farthest (*r*) have been defined at p. 25.

MYOPIA (M.)

In Fig. 102, if the retina were at *cf* instead of at *F*, a clear image would be formed of an object at *Ob*, without any effort of accommodation, whilst objects farther off would be focussed in front of the retina. This state, in which the posterior part of the eyeball is too long, so that, with the accommodation at rest, the retina lies at the conjugate focus of an object at a comparatively small distance, is called Short-sight or Myopia (M.) (*Axial Myopia*).

In Fig. 104 the inner line at R is the retina, and F the principal focus of the lens-system, *i.e.* the position of the retina in the normal eye. Rays emerging from R will, on leaving the eye, be convergent, and, meeting at the conjugate focus R' , will form a clear image in the air.

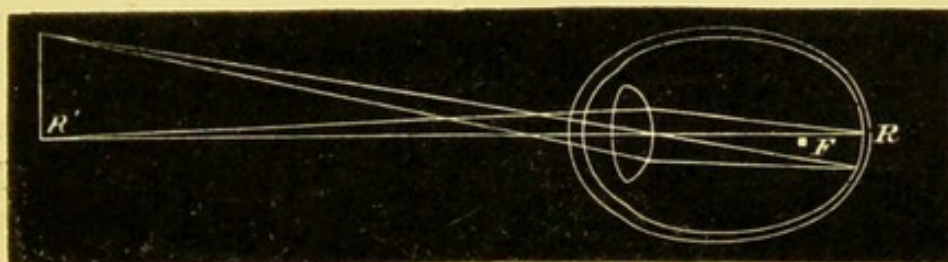


FIG. 104.—Myopia.—Retina beyond principal focus, hence only near objects (divergent rays) focussed on retina.

Conversely, an object at R' will form a clear image on the retina (R) (*compare* Figs. 10 and 12). The image of every object at a greater distance than R' will be formed more or less in front of R , and every such object must, therefore, be seen indistinctly. But objects nearer than R' will be seen clearly by exerting accommodation, just as in the normal eye (Figs. 102 and 103).

In M. the indistinctness of objects beyond the far point (r) is lessened by partially closing the eyelids. This habit is often noticed in short-sighted people who do not wear glasses, and from it the word myopia is derived.

The distance of r (R' , Fig. 104) from the eye will depend on the distance of its conjugate focus R , *i.e.* upon the amount of elongation of the eye. The greater the distance of R beyond F , the less will be the distance of its conjugate focus R' ($= r$); in other words, the higher will be the M., and the more indistinct will distant objects be. If the elongation of the eye be very slight, R nearly coinciding with F , R' ($= r$) will be at a much greater distance (*compare* p. 7, § 16), and distant objects will be less indistinct. As the retinal images formed in a myopic eye

are larger than normal (p. 13), myopic persons can distinguish smaller objects at the same distance than those with normal eyes.

Symptoms of M.—In low degrees the patient's complaint is that he cannot see distant objects clearly; in moderate and high degrees it is rather that he can see distinctly only when things are held very close, for objects a few feet off are so indistinct that many such persons neglect them. Adults often tell us that their distant sight was good till about eight or ten years of age, that it then began to shorten, and that the defect after increasing for several years at length became stationary.

In high degrees of M. the patient is apt to complain of special difficulty in seeing at night, probably because, (1) the mobility of the eye being below normal, the field of fixation (p. 32) is diminished, and (2) the elongation of the eye by altering the position of the retina leads to some narrowing of the field of indirect vision (p. 20).*

In many cases no other complaint is made, but in a certain number complications are present. There is often intolerance of light, an additional cause for the half-closed lids and frowning expression so often noticed. Aching of the eyes is a very common and troublesome symptom, and is especially frequent if the M. is increasing; it is often brought on, and always made worse, by over-use of the eyes, but sometimes it is very troublesome when quite at rest, and even in bed at night. One or both internal recti often act defectively, so that convergence of the optic axes for near vision becomes difficult, painful, or impossible, and various degrees of divergent strabismus result; this occurs oftenest, but by no means only, in the higher degree of M. where r is so near that binocular vision involves a strong effort of convergence. When this "mus-

* Wecker and Landolt, 'Traité,' t. 1, i, p. 595. Landolt, 'Refraction and Accommodation of the Eye,' p. 425.

cular asthenopia," or "insufficiency of convergence," is slight or intermittent it causes indistinctness or "dancing" of the print, and sometimes actual diplopia, besides the other discomforts above mentioned; but diplopia is seldom present when a constant divergent squint has been established.

This tendency to divergence in M. is also partly due to the natural association between relaxation of the ciliary muscles and of the internal recti,—the converse of convergent squint in H.

The lower degrees of M. are sometimes accompanied by involuntary contraction of the ciliary muscle ("spasm of accommodation") by which M. is temporarily increased; and the habitual approximation of objects, which thus becomes necessary, is one cause of still further elongation of the eye and increase of the structural M. Floating specks (*muscae volitantes*, p. 247) are especially common and troublesome in myopia.

Objective signs and complications.—In high degrees of M. the sclerotic is enlarged in all directions (Fig. 107); the eye being too large often looks too prominent, and its movements are somewhat impeded. But apparent prominence of the eye may depend on many other causes (p. 38, 14).

The existence of M. is made certain by the ophthalmoscope in four different ways.—(1) By direct examination, the image of the fundus formed in the air

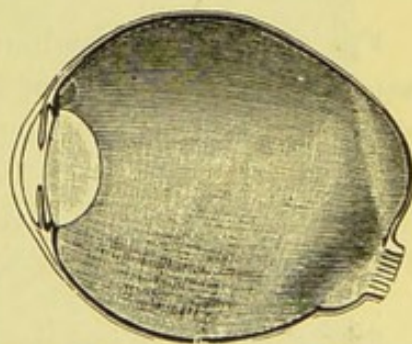


FIG. 105.—Section of a highly myopic eyeball. The retina has been removed.

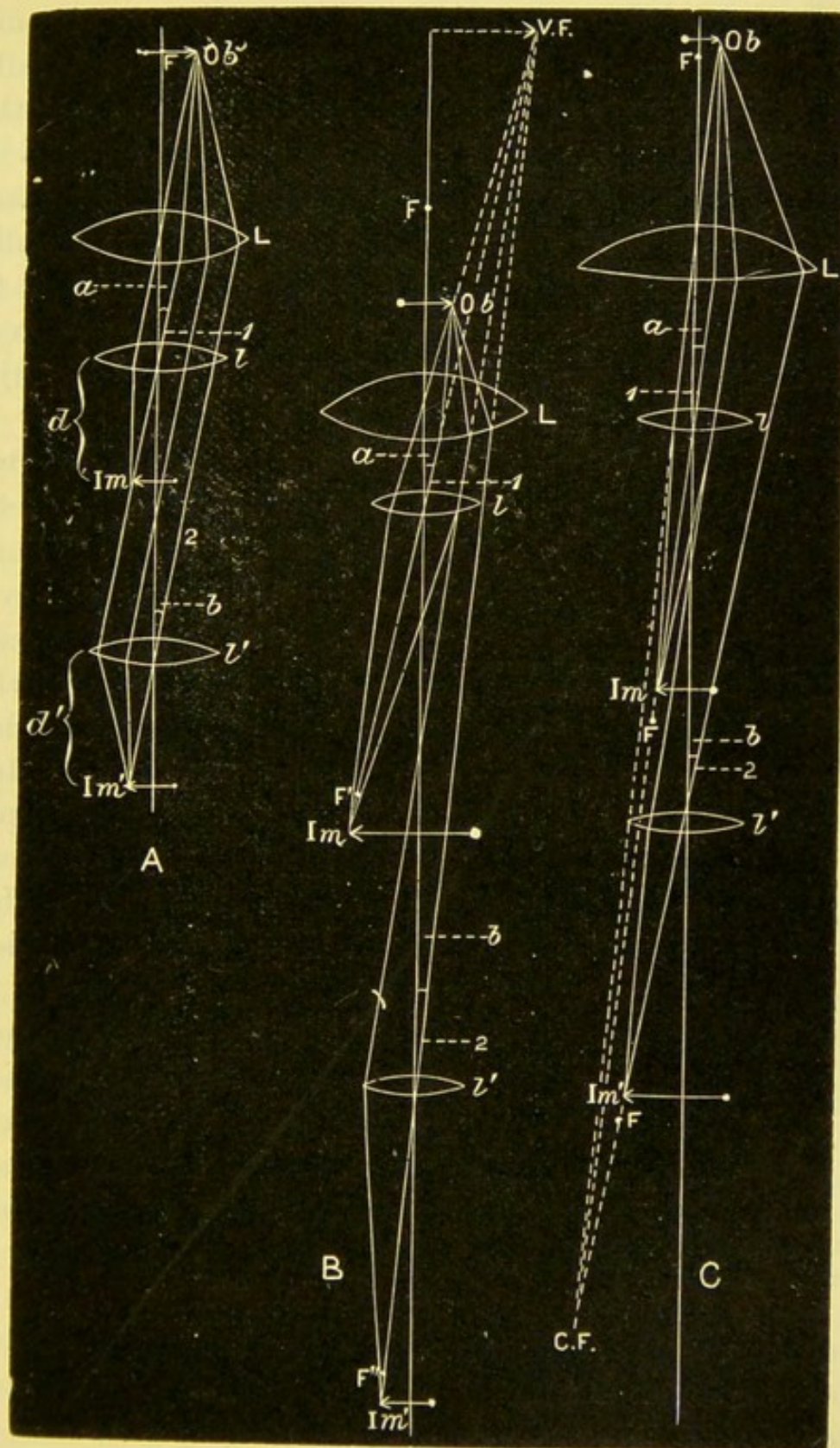
(Fig. 104) is clearly visible to the observer if he be not nearer to it than his own near point. The image is inverted and magnified, the enlargement being greater the further it is formed from the patient's eye, *i. e.* the lower the M.

Description of Fig. 106, which shows the effect on the size of the inverted image caused by withdrawing the objective lens from the eye, in the indirect ophthalmoscopic examination.

FIG. A shows that in emmetropia the image remains of the same size on withdrawal of the lens. *Ob* is the retina lying at the principal focus of the dioptric media of the eye, represented by *L*; *l* and *l'* show the objective lens at different distances from the eye; *Im* and *Im'* the ophthalmoscopic images formed in each case.—Rays from any point on *Ob* emerge from *L* parallel, and are united by *l* at the point *Im* (the principal focus of *l* for the rays indicated) on the secondary axis 1, which forms with the principal axis the angle α . If *l* be removed to *l'* it will still intercept some of the same bundle of parallel rays, and these will be united in *Im'*, at the same distance as before, on the secondary axis 2, which forms with the principal axis the angle $b =$ the angle α . The relative sizes of *Im* and *Im'* depend on (1) their respective distances d and d' from the lens, and (2) on the size of the angles α and b . As in the present case $d = d'$ and $\alpha = b$, *Im* must = *Im'*.

FIG. B shows the diminution of the image in hypermetropia. The lettering is as before, but *F* is the principal focus of *L*, and *v.F.* the virtual focus of the retina *Ob*. The letters d and d' are omitted, but can easily be supplied. The angle b is now smaller than α because the rays emerge from *L* divergent (as if from *v.F.*), and hence (d and d' being nearly equal) *Im'* must be smaller than *Im*.

FIG. C shows the increase of the image in myopia; the retina *Ob* is now beyond *F*; *C.F.* is the "far point" of the eye, conjugate to *Ob*. The angle b is now larger than α because the rays emerge from *L* convergent (towards *C.F.*), and hence (d and d' still being nearly equal) *Im'* must be larger than *Im*.



(p. 9, § 17). For very low degrees this test is not easy to use, because of the great distance (3' or 4' *e. g.*) that must intervene between observer and patient; but it is easily applied if the image be not more than 2' in front of the patient (p. 52, 4).

(2) By indirect examination the disc in M. appears smaller than usual. If now the object lens be gradually withdrawn from the patient's eye, the disc will seem to grow larger. This appearance, which depends on a real increase in the size of the aerial image, is less evident the lower the M. (Fig. 106, C).

(3) By direct examination no clear view of the fundus is obtained if the distance between patient and observer be less than that between patient and inverted aerial image (Fig. 104, κ'); and as κ' is in front of the myopic eye, the image will always be invisible if the observer go close to the patient. Hence, if on going close to the patient the observer cannot, either by relaxing or using his accommodation (*see* p. 52), see any details of the fundus clearly, the patient is myopic (opacities of the media being, of course, excluded). This test is applicable to all degrees of M., accommodation being completely relaxed.

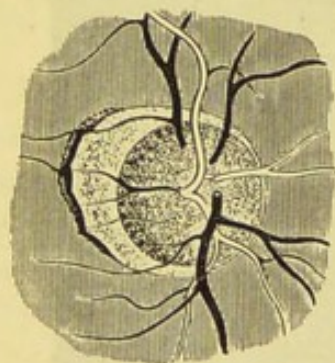


FIG. 107.—Myopic crescent or small posterior staphyloma. (Wecker and Jaeger.)

(4) By *retinoscopy* with a plane mirror (p. 59), the shadow obtained on rotating the mirror moves against the direction of rotation. The tests (1), (2), and (4) are, on the whole, most generally useful for beginners.

In a large proportion of cases the elongation of the eye causes atrophy of the choroid on the side of the optic disc next to the y. s. (the apparent inner side in indirect examination). This atrophy gives rise to a crescentic patch (Fig. 107) of yellowish-white or greyish

colour, whose concavity is formed by the border of the disc, whilst its convex side curves towards the y. s.; it is known as a "myopic crescent," also as a "posterior staphyloma" (p. 195), because it indicates a localised bulging of the sclerotic (Fig. 105). It varies in size from the narrowest rim to an area several times that of the disc, and may form a zone entirely surrounding the disc (Fig. 108), instead of a crescent; there may also be several spots of atrophied or thinned choroid, beyond the bounds of the crescent, and these also occur in horizontal lines near the y. s. Extensive choroidal changes are generally assumed to be the result of cho-

roiditis ("Myopic Choro-
roiditis") (p. 195). As a rule, the higher the M. the more extensive are the choroidal changes, but the relation is by no means constant, and occasionally even in high degrees we find no crescent. Hæmorrhages may occur from the choroid in the same region, and leave some residual pigment (pp. 188 and 195).

Owing to the steepness of the bulging, the disc is often tilted, and appears oval, because seen at "three-quarter face" instead of "full face" (Fig. 108). It is sometimes very pale on the side next the y. s. when the staphyloma is large.

There is in M. a great liability to liquefaction of, and the formation of opacities in, the vitreous, and, still worse, to detachment of the retina. A large proportion of all retinal detachments occur in myopic eyes. A blow on the eye sometimes appears to have caused the detachment.

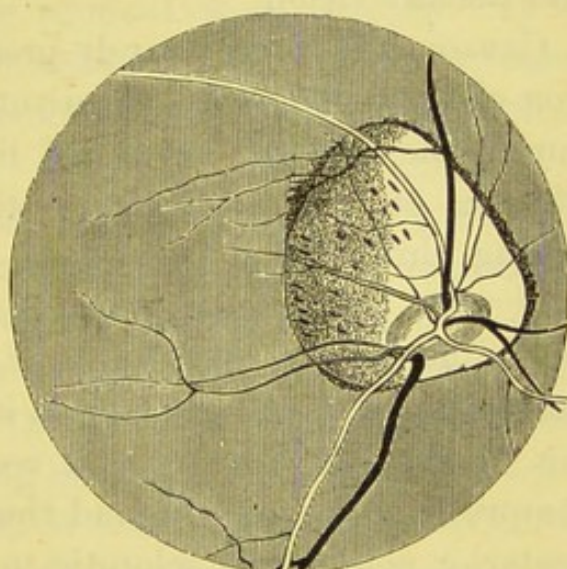


FIG. 108.—Large annular posterior staphyloma. (Liebreich.)

though often not until after a considerable interval. In high degrees of M. the lens frequently becomes cataractous, the cataract generally being cortical and complicated with disease of the vitreous (pp. 169, 210, &c.).

Thus we arrive at a sum total of serious difficulties and risks to which myopic persons are subject, especially when the myopia is of high degree. It is only when the degree is low (2 D. or less), and the condition stationary, that the popular idea of "short-sight" being "strong sight" is at all borne out, or that the later onset of presbyopia (p. 330) counterbalances the disadvantages of bad distant vision.

Causes.—M. is very rarely present at birth; the elongation of the globe which constitutes M. comes on gradually during the growing period of life, and especially between the ages of ten and twenty;* the eye begins to elongate during childhood. Though M. is strongly hereditary, it may also begin independently, especially from the prolonged use of the eyes for near work. The strain on the internal recti, counterbalanced, it may be, by a corresponding tension on the external recti, is believed to act by compressing the eyeball, and thus causing the unprotected posterior pole of the sclerotic to bulge. The concomitant tension of the ciliary muscle probably aids by bringing on congestion of the uveal tract (as it certainly appears to do of the disc), and thus predisposes to softening and yielding of the tunics; to this congestion the habit of stooping over the book or work contributes by retarding the return of blood. It is evident that if such causes are able to start the disease they must constantly tend to increase it. M. seldom increases after the age of twenty-five, unless under special circumstances; but general enfeeblement of

* Recent examinations by Schleich and Germann upon several hundred infants show that the human eye is almost invariably hypermetropic at birth.

health, as after severe illness or prolonged suckling, seriously increases the risk of its progress, even after middle life. Any condition in which during childhood better vision is gained by holding objects very close is likely to bring on M.; and so we find it disproportionately common amongst those who from childhood have suffered from corneal nebulæ, partial (especially lamellar) cataract, severe choroiditis, or a high degree of astigmatism. A bad supply, or bad arrangement, of light, bad print, and seats or desks so proportioned as to encourage children to stoop over their lessons, are now generally believed to be largely answerable for the production of myopia. It is, however, to be noted that some of the very worst cases occur in persons who have never used their eyes for close observation of any kind.

The *treatment* is divisible into (1) prophylactic and (2) remedial.—1. Much may be done to prevent M., or to check its increase when it has begun, by regulating the light, books, and desks used by children, so as to remove the temptations to stooping. Children should not be allowed to read or work by flickering or dull light; and as we write and read from L. to R. it is best, whenever possible, to admit the light from the left, so that the shadow of the pen is thrown towards the right, away from the object looked at. A myopic child should not be allowed to fully indulge his bent, which is generally strong, for excessive reading.—2. By means of suitable glasses (*a*) distant objects may be seen clearly, *i. e.* the eye be rendered emmetropic, (*b*) reading and working become possible at a greater distance. The strain on the internal recti usually ceases when the gaze is directed into the distance, whether vision be distinct or not; glasses for distant vision have therefore no effect on the progress of the myopia, and are of value only for educational purposes, that the patient may see what is about him as clearly as other people;

their use is therefore to a great extent optional. But if we can increase the distance of the natural far point (r) from the eyes, we lessen the tension on the internal recti in near vision, diminish the temptations to stooping and to reading by bad light, and so help to check the progress of the disease; hence glasses for near work are very important in the higher degrees of M. (3 D. and more) in early life. When M. has been stationary for years, however, the decision even on this point may be left to the patient.

Before ordering glasses for either purpose we must measure accurately the degree of M. In Fig. 109, let r be the far point, and let it be 25 cm. in front of the patient's eye, so that he can see nothing clearly at a greater distance than 25 cm. (*a*) He is required to see distant objects (objects seen under parallel rays) clearly. A concave lens is interposed of strength sufficient to give to parallel rays a degree of divergence, as if they came from r (Fig. 109). The focal length of this lens will be the same as its distance from r ; and, as it is placed close to the eye, its focal length will be very nearly the same as (a little shorter than) the patient's far point. Therefore, if we measure the distance of r from the patient's eye, a lens of nearly the same focal length will neutralise his M. He will choose a lens rather higher than this test would lead us to expect if the M. be uncomplicated;* whilst if, owing to complications, there be considerable defect of vision, he will often choose a somewhat lower glass. Hence it is a good rule to begin the trial with a lens weaker than the

* It is sometimes stated that the glass chosen for distance is rather *weaker* than is indicated by the distance of r from the crystalline lens, the associated accommodation having caused an apparent increase of M. This is true only in low degrees of M., and not always in them; most patients choose a rather *stronger* lens than is indicated by r , *i.e.* a lens whose focus is shorter by the distance between its own central point and the cornea.

one which, judging by the above test, we expect the patient to choose, and to try successively stronger ones till the

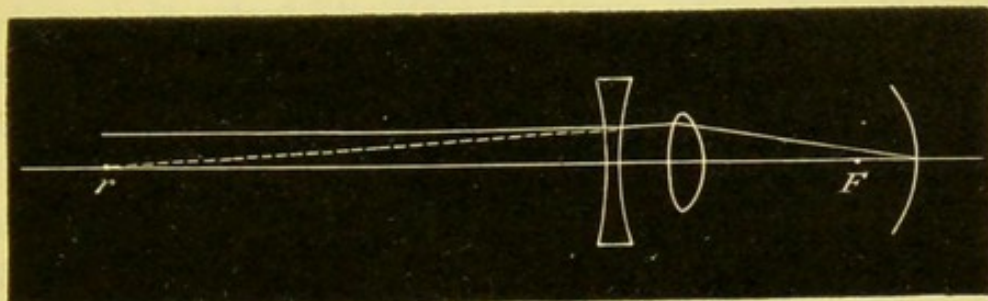


FIG. 109.—Myopia corrected by concave lens.

best result is reached. The weakest concave glass which gives the best attainable sight for the *distant* test types (p. 24) is the measure of the M., and this glass, *but not a stronger one*, may be safely worn for distant vision. Beginners often test M. patients with concave glasses for near types; neither + nor - glasses give any information about the *refraction* when used for near objects, since they merely either substitute, or *give* into use, the *accommodation*.

(b) A glass is needed with which the patient will be able to read or sew at a distance greater than his natural far point. Theoretically, a *convex* correcting glass (a) would suit, since the rays follow a course which, in relation to the rays from any object, is the same as that of the rays entering a normal eye. But this glass can seldom safely be allowed in the higher degrees of M. The lens which fully corrects the myopia diminishes the size of the retinal images so much (p. 13) that the patient is tempted to enlarge them again by bringing the object nearer; again, the accommodation is often defective in the higher degrees of M., and, as the fully correcting lens requires full accommodation, it will lead to over-straining if this function be weakened, and so cause discomfort, if nothing worse. For these two reasons the rule is to give, for near work, a glass which will diminish the myopia, but not fully correct it

Glasses for near work are seldom needed unless M. exceed 3 D.

Let M. be 7 D., then r will be at 14 cm. (p. 15) from the eye. If a glass be required with which the patient shall be able to read at 30 cm., or which shall remove r from 14 cm. to 30 cm., *i. e.* shall leave the patient with M. 3 D., we must correct the difference between 7 D. and 3 D. ($7\text{ D.} - 3\text{ D.} = 4\text{ D.}$); a concave lens of 4 D. will make rays from 30 cm. diverge as if they came from 14 cm. But even this partial correction may diminish the images so much that, if vision be imperfect, from extensive choroidal changes, reading at the increased distance will be difficult, and the patient will prefer to bring the object nearer again at the expense of his accommodation, and will thus be inconvenienced instead of bettered; it is, therefore, often advisable, even for partial correction, to order a weaker lens than is optically correct.

Preponderance of the external over the internal recti (insufficiency of convergence, p. 303), if not cured by partially correcting glasses, may be treated by division of the external rectus of one or both eyes. This operation may always be done when the patient is a marked divergent squint, even if the squint be neutralise—Prismatic spectacles (p. 9), the bases of the prism turned towards the nose, are occasionally serviceable for treated; * wears of slight muscular insufficiency. By deflecting & re-centering light towards their bases (Fig. 16), the prisms give to rays from a certain near point a direction as if they came from a greater distance, and thus lessen the need for convergence of the optic axes. The prisms may be combined with concave lenses.

M. may also be caused by an increase of the curvature, or of the refractive power, of the media (*myopia of curvature*). Thus in conical cornea (p. 123) the curvature of the central part of the cornea is increased (*i. e.* its focal

length shortened), and the principal focus of the lens-system lies in front of the retina, often very far in front, without any change of place of the parts at the back of the eye. M., usually of low degree, often comes on in commencing senile cataract (p. 170) from a shortening of the focal length of the crystalline lens, doubtless due to increase of refractive index (p. 1). M. is sometimes simulated in H., and actual M. increased, by needless and uncontrollable action of the ciliary muscle (spasm of accommodation). Removal of the lens has lately been extensively practised in the treatment of myopia of high degree, 15 D. and upwards. The published results of operations show that this treatment is of advantage in preventing the progressive stretching of the tunics of the eye, and in making vision more comfortable (*see* Chap. XXII).

HYPERMETROPIA (H.)

H. is optically the reverse of M. It is one of the commonest conditions we have to treat. The eyeball is too short (*axial hypermetropia*), so that when the accommodation is relaxed the retina lies within the principal focus of the eye. As rays from an object within the principal focus of a convex lens emerge from the lens divergent (Figs. 10 and 13), so pencils of rays leaving a hypermetropic eye are divergent (Fig. 113); and, conversely, only rays already convergent can be focussed on the retina. H. always dates from birth, and does not afterwards increase, except slightly in old age. But it may diminish and even give place to M. by elongation of the eye. In Fig. 110 the curved line representing the retina is in front of F (*compare* Fig. 102). Parallel rays will, after passing through the lens, meet the retina before focussing and form a blurred image, whilst divergent rays, meeting the

retina still further from their focus, will form an even worse image (*compare* Fig. 103); hence neither distant nor near objects will be seen clearly. But by using accom-

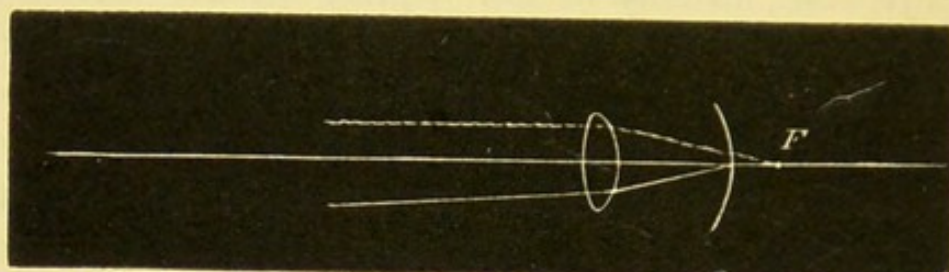


FIG. 110.—Hypermetropia. Parallel rays focussed behind retina.
Rays already convergent focussed on retina.

modation the focal length can be shortened until the focus falls upon the retina (Fig. 111), and distant objects are

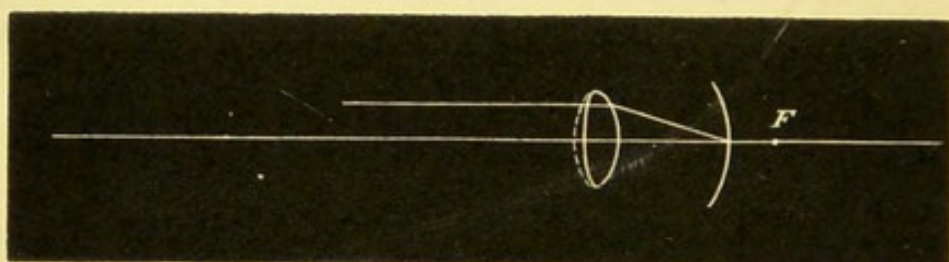


FIG. 111.—Hypermetropia corrected by accommodation. Parallel rays focussed on retina.

then seen clearly; and additional accommodation will give also distinct vision of near objects (*compare* Fig. 103). A

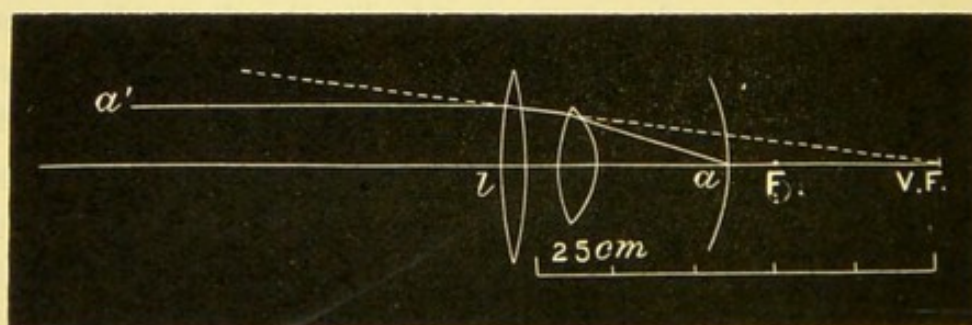


FIG. 112.—Hypermetropia corrected by a convex lens whose focus coincides with the virtual focus of the retina.

little consideration will show that the competence of the ciliary muscle to give these results will depend in any

given case (1) on the degree of advancement of the retina in front of F , *i. e.* on the degree of shortening of the eye; and (2) on the strength of Acc., *i. e.* on the extent to which the focal length of the lens can be altered.

The same result may be gained by placing a convex lens in front of the eye, instead of using the accommodation. In a given case, Acc. being relaxed, let the ray (a , Fig. 112) on leaving the eye diverge from the axis, as if it proceeded from a point $v. F.$ (*compare* Fig. 13) 25 cm. behind the cornea. If the ray a' , parallel with the axis, pass through a convex lens, l , of 25 cm. focal length held close to the eye, it will be made to converge towards this same point, and therefore in accordance with § 12 (p 5) will be focussed on the retina at a .

Fig. 113 may be taken for a section of a very highly hypermetropic eye, the rays emerging from which are

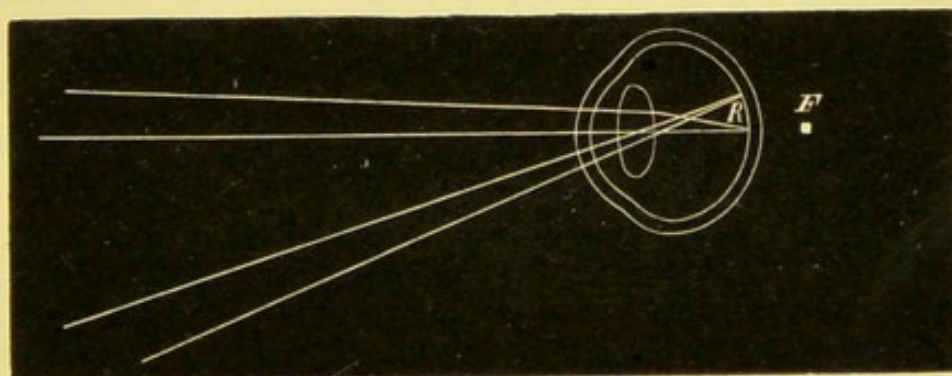


FIG. 113.—Course of the rays emerging from a hypermetropic eye.

divergent. The image formed on the retina of a hypermetropic eye is smaller than that of the same object placed at the same distance from a normal eye (p. 13).

In old age the refractive power of the crystalline lens seems normally to diminish, and therefore an eye originally emmetropic becomes unable to focus parallel rays on the retina; this condition causes slight *acquired hypermetropia*, and begins at the age of sixty-five.

Symptoms and results of H.—The *direct* symptoms are

due to insufficiency of the accommodation; for distinct vision of any object, whether near or distant, requires Acc. proportionate to the degree of shortening of the eye, and the absolute power (amplitude) of Acc. is not increased in H., at any rate not enough to meet the demand.

If H. is slight or moderate and Acc. vigorous, no inconvenience is felt either for near or distant vision. But if Acc. have been weakened by disease or ill-health, or have failed with age, the patient will complain that he can no longer see near objects clearly for long together; that the eyes ache or water, or that everything "swims" or becomes "dim" after reading or sewing for a short time (*accommodative asthenopia*). There is not usually much complaint of defect for distant objects. Many slight or moderately H. patients find no inconvenience till twenty-five or thirty years of age, when Acc. has naturally declined by nearly one half. Women are often first troubled after a long lactation, and other persons after prolonged study or desk-work, or when suffering from chronic exhausting diseases. Children often complain of watering, blinking, and headache, rather than of dimness (*see also* p. 248).

In very high degrees of H., as a large part of the Acc. is always needed from childhood upwards for distant sight, even the strongest effort does not suffice to give clear images of near objects, which consequently such a person never sees well. Such patients often partially compensate for the dimness of near objects by bringing them still nearer, thus enlarging the visual angle and increasing the size of the retinal images (p. 13). This symptom may be mistaken for M., but can be distinguished by the want of uniformity in the distance at which the patient places his book, and by his being often unable, at any distance whatever, to see the print easily or to read fluently. In the highest degrees even distinct distant vision is not constantly maintained, the patient often being content to

let his accommodation rest except when his attention is roused.

As age advances, a point is reached, even in moderate degrees of H., at which Acc. no longer suffices even for distant, and much less for near vision. Such persons tell us that they early took to glasses for near work, but add that lately the glasses have not suited, and that they are now unable to see clearly either at long or short distances. Ophthalmoscopic examination shows no change except H., and suitable convex glasses at once raise distant vision to the normal.—Occasionally photophobia, conjunctival irritation, and redness are present in H., but the first-named symptom is less common than in M. (*see p. 246*). The most important *indirect result* of H. is *convergent strabismus* (*see p. 336*).

The *treatment* of H. consists in removing the necessity for over-use of Acc. by prescribing convex spectacles which, in proportion to their strength, supply the place of the increased convexity of the crystalline lens induced by Acc. In theory, the whole Acc. ought to be corrected by glasses in every case, and the eye be rendered emmetropic. But in practice we find it often better to give a weaker glass, at least for a time.

If Acc. in a H. eye be in abeyance (paralysed by atropine) vision for distant objects will be distinct only if the rays pass through a convex lens, held in front of the eye, whose focus coincides with the virtual focus of the retina (*p. 314, Fig. 112*). The strength of this lens is the measure of the H.; thus the patient has H. 2 D. if a convex lens of 50 cm. focal length is necessary for this purpose.

But if Acc. be intact, then, as it has constantly to be used for distant sight, the patient is often unable to relax it fully, when a corresponding convex lens is placed in front of the eye; he will relax only a part, and this part will be

measured by the strongest convex lens with which he can see the distant types clearly. That part of the H. which can be detected by this test is called "manifest" (m. H.). The part remaining undetected, because corrected by the involuntary use of Acc., is latent (l. H.). The sum of the m. H. and l. H. is the total H.

Now most H. people can habitually use some Acc. for distance (and a corresponding excess for near vision) without inconvenience, and hence the full correction of H. is by no means always needful, or even agreeable to the patient. In many cases the correction of the m. H. is enough to relieve the asthenopic symptoms, at any rate for a considerable time; but we often find that after wearing these glasses for some weeks or months the symptoms return, and a fresh trial will show a larger amount of m. H., which must then again be corrected by a corresponding increase in the strength of the glasses. This process may have to be repeated several times until after a few months the total H. becomes manifest, and may be corrected. This method is most suitable for adults in whom the use of atropine to paralyse Acc., and allow the immediate estimation of the total H., is inconvenient or impossible; or for whom the glasses which correct the total H., as estimated by the ophthalmoscope, without atropinisation, are found, if ordered at once, to be inconveniently strong. But for children there is seldom any gain, and often no little inconvenience, from following this gradual plan; with them the better way is to estimate the total H., and to order glasses slightly (about 1 D.) weaker than that amount.

To examine for H.—(1) For m. H. Note the patient's vision for distant types at 6 m., then hold in front of his eyes a very weak convex lens (+ .5 D.), and if he sees as well, or better, with it, go to the next stronger lens, and so on until the strongest has been found which allows the

best attainable distant vision ; this lens is the measure of the m. H.

(2) For H. (total). The easiest and most certain plan is to direct the patient to use strong atropine drops (F. 33) three times a day for at least two days, and then to test his distant vision with convex glasses. As in (1), the strongest lens which gives the best attainable sight is the measure of the H.

Ophthalmoscopic tests.—(3) The image of the disc seen by the indirect method becomes smaller when the lens is withdrawn from the eye (Fig. 106, B).

(4) The shadow test is described at p. 55.

(5) By direct examination an erect image is seen at whatever distance the observer be from the patient (p. 53). The observer may learn, as stated at p. 53, to estimate H. with almost as great accuracy with a refraction ophthalmoscope as by trial lenses, and this plan, like the shadow test, is extremely valuable with children who are too young or too backward to give good answers. The total, or nearly the total H. may often be found in this way without atropine if the examination be made in a dark room, for then Acc. is generally quite relaxed, however persistently it may have acted when the patient was able to look attentively at objects in the light. The objective estimates (4 and 5), however, are more easily made after the use of atropine.

The next question is, whether the glasses are to be worn always, or only when Acc. is specially strained, *i. e.* in near work. They are to be worn constantly (1) whenever we are attempting to cure a squint by their means ; (2) in all cases of high H. in children, whether with or without strabismus. But patients who come under care for the first time as young adults, in whom the H. is, as a rule, of moderate or low degree, may generally be allowed to wear them only for near work. Elderly persons require

two pairs—one for distance, neutralising the m. H., the other stronger, neutralising the presbyopia also, for near work (p. 330) ; the use of the former may, however, be left to the patient's choice.

ASTIGMATISM (As.)

In the preceding cases (M. and H.) the refracting surfaces of the eye (the front of the cornea and the two surfaces of the lens) have been regarded as segments of spheres.

All the rays of a cone of light which issue from a round spot and pass through such a system are (neglecting "spherical aberration," Fig. 9) equally refracted, and meet one another at a single point—the *focus* of the system. For if such a cone of incident light be looked upon as composed of a number of different planes of rays, situated radially around the axis of the cone, the rays situated in any plane (say the vertical) will, after passing through the lens-system, meet behind it at its focus, whilst those forming any other plane (as the horizontal) will meet at the same point ; and the same will be true of all the intermediate planes.

But let the curvature, and therefore the refractive power, of one of the media (for instance, the cornea) be greater in one meridian, say the vertical, than in the horizontal, then the vertical-plane rays will meet at their focus, whilst the horizontal-plane rays at the same distance, not having yet met, will, if received on a screen, form a horizontal line of light. If the intermediate meridians had regularly intermediate focal lengths, they would form, at the same place, lines of intermediate lengths, and the image of the round spot of light, if caught on a screen at this distance, would form a horizontal oval. To a retina receiving such an image, the round point of light

would appear drawn out horizontally. Such an eye is called astigmatic, because unable to see a point as such; all round points appearing drawn out more or less into lines.

A little reflection will show that in the same case, at the focal point of the horizontal-plane rays, the rays of the vertical plane will already have met and crossed, and that the image at this point will form a vertical oval.

If the screen be placed midway between these two extreme points, the image will be circular, but blurred, because the vertical-plane rays will have crossed and begun to separate, while the horizontal ones will not yet have met, and each set will be equally distant from its focus. The meridians of the astigmatic medium which refract most (shortest focus) and least (longest focus) are the "*principal meridians*." The distance between their foci is the "*focal interval*," and represents the degree of astigmatism.

The astigmatism of the eye may be *regular* or *irregular*. In *regular astigmatism*, the meridians of greatest and least refractive power, "*principal meridians*," are always at right angles to each other; and every meridian is nearly a segment of a circle. Of the principal meridians, the most refractive (the one with shortest focal length) is, as a rule, vertical, or nearly so, and the least refractive, therefore, horizontal, or nearly so. The cornea is the principal seat of this asymmetry. The crystalline lens, however, is also astigmatic, to a less degree, and its meridians of greatest and least curvature are usually so arranged as in some degree to neutralise those of the cornea; it thus partially corrects the corneal error. Corneal astigmatism is often caused by operations for cataract or iridectomy (p. 181).

Regular astigmatism is corrected by a lens which equalises the refraction in the two principal meridians.

Such a lens must be a segment of a cylinder, instead of, like an ordinary lens, a segment of a sphere. Rays traversing a cylindrical lens in the plane of the axis of the cylinder are not refracted since the surfaces of lens in this direction are parallel; but rays traversing it in all other planes are refracted, more or less, and most in the plane or meridian at a right angle with the axis.

Irregular astigmatism may be caused either by irregularities of the cornea, arising from ulceration, inflammation, or conicity* (p. 123); or by various conditions of the crystalline lens, such as differences of refraction in its various sectors, tilting or lateral dislocation of the lens, so that its axis no longer corresponds, as it should nearly do, with the centre of the cornea. Irregular astigmatism causes much distortion of the ophthalmoscopic image, especially when the object lens is moved from side to side. It is seldom much benefited by glasses.

Returning to *Regular Astigmatism*, it will be seen that the optical condition of the eye depends upon the position of the retina in respect to the focal interval. In the following diagram (Fig. 114) let the most refractive meridian be vertical, and its focus be called *a*, the least refracting meridian horizontal and its focus *b*. (The astigmatism is here represented as caused by altered *position of the retina* in different planes, instead of by altered *curvature of the cornea* in different planes, the diagram being, of course, only intended to aid the comprehension of the principle.) (1) Let *a* fall on the retina (1, Fig. 114), and *b*, therefore, behind it. There is E. in the vertical meridian, and therefore H. in the horizontal meri-

* There can be little doubt from clinical observation with a refraction ophthalmoscope, that corneal As. is often complicated by the curvature of each meridian being naturally more or less elliptical instead of circular, and this without any tendency towards "conical cornea," as commonly understood.

dian; this is simple H. As. (2) Let b fall on the retina (2, Fig. 114), and a in front of it. The horizontal meridian is, therefore, E., and the vertical meridian M.; simple M. As. (3) Let a and b both lie behind the retina (3, Fig. 114). There is H. in both meridians, but more in the horizontal than the vertical meridian; compound H. As. (4) a and b are both in front of the retina (4, Fig. 114). There is M. in both meridians, but more in

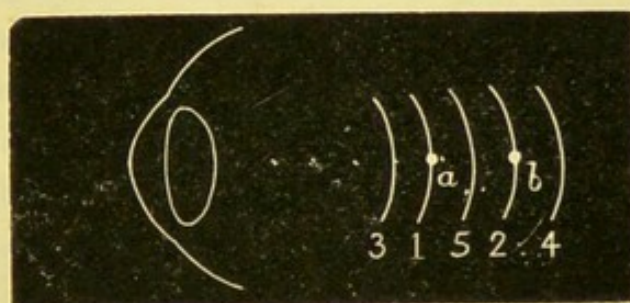


FIG. 114.

the vertical than the horizontal; compound M. As. (5) a is in front of the retina, and b behind it (5, Fig. 114). There is M. in the vertical and H. in the horizontal meridian; mixed As.

The general symptoms of As. resemble those caused by the simpler defects of refraction; but attention to the patient's complaints, and to the manner in which he uses his eyes, will, in the higher degrees, often give the clue to its presence. Low degrees, especially of simple H. As., often give rise to no inconvenience till rather late in life. As. is most commonly met with in connection with H., because H. is so much commoner than M. But it is said to occur with greater *relative* frequency in M., when, if complications be present, it may, if not of high degree, be readily overlooked unless specially sought for. The higher grades of As. cause much inconvenience, no objects being seen clearly; and spherical glasses, though of use if the As. be compound, are nearly useless if it be simple. As. is always to be suspected if, with the best attainable

spherical glasses, distant vision is less improved than it ought to be (supposing, of course, that no other changes are present to account for the defect). No definite rule can be laid down as to the degree of defect which should raise the suspicion of As.; indeed, in the higher degrees of even simple M. and H., acuteness of vision is often below normal (pp. 240 and 307). It is possible that in young persons with vigorous accommodation the astigmatism of the cornea is partly corrected by the ciliary muscle acting unequally on the different meridians of the lens, and that the seemingly greater frequency of astigmatism in the presbyopic is due to the impairment of this power.

As. may be measured either by trial with glasses, by the shadow test (p. 57), or by ophthalmoscopic estimation (p. 53) of the refraction of the retinal vessels in the two chief meridians. A comparatively easy qualitative test is found in the apparent shape of the disc, which, instead of being round, is more or less oval. In the erect image the long axis of the oval corresponds to the meridian of

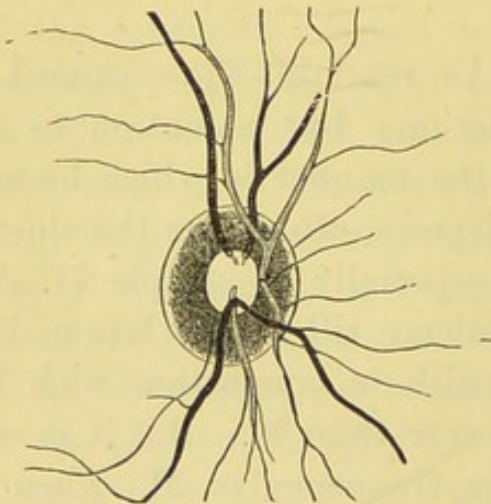


FIG. 115.—Erect image of disc in Astigmatism, with meridian of greatest refraction nearly vertical. (Wecker and Jaeger.)

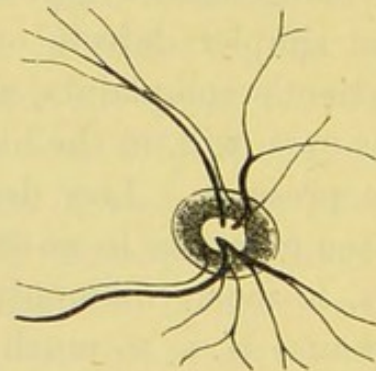


FIG. 116.—The same disc, seen by the indirect method. (Wecker and Jaeger.)

greatest refraction, and is therefore, as a rule, nearly vertical (Fig. 115).

In the inverted image (Fig. 116) the direction of the oval is at right angles to the above, provided that the object lens be nearer than its own focal length to the eye. As. is suspected when, in the erect image, an undulating retinal vessel appears clear in some parts and indistinct in others, an appearance which may be taken for retinitis if the examination be confined to the erect image. It may be imitated by looking at a wavy line through a cylindrical lens.

In the indirect examination the shape of the disc changes on withdrawing the lens from the patient's eye. It will be remembered that in M. the image increases as the lens is withdrawn (p. 306, 2), that in E. its size remains the same, whilst in H. it diminishes (Fig. 106). Thus in a case of simple M. As. in the vertical meridian, that dimension of the disc which is seen through the vertical meridian will enlarge on distancing the lens; from being oval horizontally, when the lens is close to the eye, it becomes first round and then oval vertically on withdrawing the lens. In the other forms of As. the same holds true; the image enlarges, either absolutely as in M. As., or relatively as in H. As., in the direction of the most refracting meridian.

The subjective tests for As. are very numerous, but all depend on the fact that if an astigmatic eye look at a number of lines drawn in different directions, some will be seen more clearly than others. The form of this test is not a matter of great consequence, provided that the lines are clear, not too fine, and are easily visible with about half the normal V. at from 3 m. to 6 m. The forms resembling a clock-face with bold Roman figures at the ends of the radii are very convenient, and I prefer the pattern recommended by Mr. Brudenell Carter (*see* Appendix) to any other that I have used. On this face are three parallel black lines separated by equally wide white spaces, and which collectively form a "hand" that can be turned round into the positions of best and worst vision.

The easiest case for estimation is one of simple H. As., in which the eye is under atropine. Many cases of simple M. As. are almost as easy to test. In a given case let the eye be E. in the vertical meridian, and H. in the horizontal. With Acc. paralysed, rays refracted by the vertical meridian will be accurately focussed on the retina, whilst the focus of those refracted by the horizontal meridian will be behind the retina (Fig. 114, 1), and consequently form on it a blurred image. Now the rays which strike in the plane of the vertical meridian are those which come from the borders of horizontal lines; hence the patient under consideration will see the lines at a distance of 3 m. to 6 m. quite clearly when the "hand" is horizontal, except their ends, which will be blurred. The rays which strike in the plane of the horizontal meridian are those which proceed from the sides of vertical lines, and as this meridian is hypermetropic, the lines in the "hand," when placed vertically, will be indistinct, except their ends, which will be sharply defined. We now leave the "hand" vertical, and test the refraction for the lines in this position (*i. e.* for the horizontal meridian) in the ordinary way (p. 319, 2), and find, *e. g.*, that with + 2 D. they are seen most clearly, though not perfectly. On substituting for the spherical glass, + 2 D. cylinder with its curvature horizontal (*i. e.* its axis vertical), the lines of the hand and all the figures on the clock will be seen perfectly; the vertical lines and figures will be seen through the horizontal meridian corrected by the cylinder lens, and the horizontal figures through the unaided vertical meridian, the rays which pass through the cylinder in this meridian not being refracted.

In a case of simple M. As. in the vertical meridian the lines of the "hand" will be dull or invisible when horizontal, whilst when vertical they will be clear. On trial a concave cylinder will be found, which with its curvature vertical (axis horizontal) makes the lines of the hand

quite clear when horizontal, and all the figures quite plain.

The cases of compound and mixed As. are less easily dealt with by this test. It is generally best to find, in the usual way, the spherical glass which gives the best result for the distant types; and then, arming the eye with this glass, to test for As., with the clock-face and cylindrical lenses, as in the simple cases described above. As the letters of Snellen's distant types are made up of lines running in various directions, As. can be very well tested with these, and in actual practice the clock-face is not necessary in most cases.

We may use, instead of a cylindrical glass, a narrow slit in a round plate of metal, which can be placed in the direction of either of the chief meridians, the spherical glass being then found with which, in each meridian, the patient sees best. One chief meridian may be ascertained by finding the direction of the slit which gives the best sight with the spherical glass chosen in the preliminary examination, and the other meridian by finding the glass which gives the best result with the slit at a right angle to the former direction.

Another method (that of Javal) consists in making the patient highly myopic for the time being, by means of a convex lens (unless he be myopic already); then accurately finding his far point for the least myopic meridian, and lastly finding the concave cylinder which is needed to reduce the opposite meridian to the same refraction.

Ophthalmoscopic estimation and retinoscopy, however, save much time, especially in mixed As. If As. be measured by direct ophthalmoscopic examination, we may remember that the axis of the correcting cylinder will be parallel to the vessel used as a guide to either of the chief meridians; and that in retinoscopy the same axis is parallel to the *edge* of the shadow. Thus if a vertical

vessel be clearly seen with + 2 D., the horizontal vessels being best seen with no lens, retinoscopy will also show H. 2 D. for the shadow moving horizontally, *i. e.* with a vertical edge, and the patient will choose a cylinder of + 2 D. with its axis vertical, *i. e.* its curvature horizontal because the horizontal meridian of his eye has H. 2 D., the vertical meridian being E.

Whatever means be employed, the degree of As. is expressed by the difference between the glasses chosen for the two chief meridians; or by the cylindrical lens which, added to the chosen spherical, gives the best result for the lines or the distant types. When cylindrical glasses are ordered the whole of the astigmatism should be corrected. It is not usually necessary to correct astigmatism of less than 1 D.; but exceptions to this rule are not uncommon, some patients deriving marked relief from the correction of lower grades.

Vision is often defective in As., and in the high degrees we are often obliged to be content with a very moderate improvement at the time of examination. This may sometimes be explained by the retina never having received clear images, *i. e.* never having been accurately practised (p. 240); V. in such cases often improves after proper glasses have been worn for some months. In other cases irregular As. is the cause of the defect. Much also depends on the intelligence of the patient; some persons are far more appreciative of slight changes in the power, or in the direction of the axis, of the cylinder than others, and this apart from the absolute acuteness of sight.

Unequal refraction in the two eyes (An-iso-metropia).—It is common to find that one eye has more H., more M., or more As. than its fellow; or that one is normal while the other is ametropic. When the difference is not more than is represented by 1.5 D., and V. is good in both (*see* p. 240), the refraction may with advantage be equalised by

giving the glasses which correct each eye, and the development of divergent squint (p. 341, 3) may sometimes be prevented by the increased stimulus to binocular vision thus given. But equalisation is seldom possible if the difference be greater, though, especially in myopic cases, advantage is sometimes gained by partial equalisation. On the other hand, some patients, probably those who do not possess binocular vision, will not permit even a partial equalisation. When no attempt is made to harmonise the eyes, the spectacles ordered should suit the *less* ametropic eye. Often, when one eye is E. and the other M., each is used separately for different distances, and both remain perfect; but if one be As. or very H. it is generally defective from want of use.

Contrary to what might be expected, anisometropia is seldom, if ever, corrected by unequal action of the two ciliary muscles.

PRESBYOPIA (Pr.)

Presbyopia (old sight, often called "long-sight") is the result of the gradual recession of p , which takes place as life advances, and which causes curtailment of the range or amplitude of Acc. (p. 25). From the age of ten (or earlier) onwards, p is constantly receding from the eye. When it has reached 9" (22 cm.), *i. e.* when clear vision is no longer possible at a shorter distance than 22 cm., Pr. is said to have begun. The standard is arbitrary, 22 cm. having been fixed by general agreement as the point beyond which p cannot be removed without some inconvenience, the point where age begins to tell on the practical efficiency of the eyes unless glasses are worn. In the normal eye this point is reached soon after forty, and the rate of diminution is so uniform that the glasses required to bring p to 22 cm. may often, if necessary, be determined merely from the patient's age. But as there are exceptions to

this rule, even for normal eyes, and as allowance has to be made for any error of refraction (H. or M.), it is unsafe in practice to rely upon age except as a general guide.

The slow failure of Acc., causing Pr., depends upon senile changes in the lens, which render it firmer and less elastic, and therefore less responsive to the action of the ciliary muscle. There can be little doubt, however, that failure of the ciliary muscle itself, or of its motor nerves, also forms an important factor in those cases where Pr. comes on earlier or more quickly than usual; but it is a curious fact that in these cases of premature Pr. the mobility of the iris is not affected (*see also* p. 261).


As Pr. depends on a natural recession of the near point, it occurs in all eyes, whether their refraction be E., M., or H. In M., however, Pr. sets in later than in a normal eye, because for the same *range* of Acc. the *region* is always nearer than in the normal eye. In H., on the contrary, Pr. is reached sooner than is normal, because for the same *range* of Acc. the *region* is always further than in the normal eye. Thus in an E. eye a power of Acc. = 4.5 D. gives a *range* from $r = \text{infinity}$ to $p = 22$ cm. (the focal length of 4.5 D., *see* p. 25), *i. e.* Pr. is just about to begin; at æ. 50 , Acc. = 2.5 D., and $p = 40$ cm. (the focal length of 2.5 D.). In a case of M. 3 D., æ. 50 , the *range* being = 2.5 D., the *region* of Acc. lies between 33 cm. (the r for this eye) and 18 cm. (= focal length of $3 + 2.5$, or 5.5 D.); Pr. has not yet begun. In a case of H. 3 D. with 4.5 D. of Acc. 3 D. of it are used in correcting the H., *i. e.* in bringing r to infinity, and only 1.5 D. remains; p is therefore at 66 cm. (= focal length of $4.5 - 3$, or 1.5 D.), and a + lens of 3 D. is needed to bring p to 22 cm.; there is Pr. = 3 D. The only cases in which Pr. cannot occur are in M. of more than 4.5 D. Thus if M. = 7 D., r is at 14 cm., and though, with advancing years, p will recede to 14 cm., it cannot go further, cannot reach 22 cm.; the

patient, who never could see at a greater distance than 14 cm., has simply lost the power to see at a shorter distance. Fig. 117 shows these facts in a graphic manner.


Treatment.—Convex spectacles are found, by the aid of the Table at p. 332, with which the patient can read at 22 cm.

In practice it is always advisable to examine for H. or M., by taking the distant vision, and trying the patient for m. H. (p. 318) and M. (p. 310). If m. H. be found, arm the patient with the glass which neutralises it and makes him E., and then add the convex glass that should, by the

FIG. 117.—Region and range of Acc. in E., M., and H.



Range of Acc. diminishes with age.



The numbers along the top show the range of Acc. in Dioptres from infinity (∞) (or beyond it in H.) to 15 D. The numbers beyond ∞ represent Dioptres of Acc. necessary to correct H. Observe that the *range* of Acc. is always the same at the same age, though its *region* varies with the refraction of the eye.

Table, be required to bring p to 22 cm. If M. be found, subtract its amount from the corresponding convex glass.

In prescribing for Pr. we must often order rather less than the full correction. For instance, if Acc. be almost entirely lost, p is practically removed to r , and the glass which will bring p to 22 cm. will also bring r to the same, or nearly the same point, and the patient will be able to see clearly only just there. Now, 22 cm. is too near for sustained vision, and such patients often prefer a glass which gives them a near point of from 30 to 40 cm. (12" to 16"), though in choosing it they sacrifice the power of easily reading very small print. The difficulty experienced by these patients in reading with glasses which give $p = 22$ cm. depends on the unaccustomed strain thereby thrown on the internal recti; and it may be removed or lessened by adding to the convex glasses, prisms, with their bases towards the nose (Fig. 16); or by decentering the ordinary convex lenses inwards (Fig. 17).

Presbyopia Table for Emmetropic Eyes

Age.	Distance of p .		Pr. expressed by the lens necessary to bring p to 22 cm. or 9".	
	cm.	Inches.	Dioptries.	Paris Inch Scale.
40.....	22.....	9.....	0.....	0
45.....	28.....	11.....	+1.....	$+\frac{1}{3.6}$
50.....	43.....	17.....	2.....	$\frac{1}{1.8}$
55.....	67.....	27.....	3.....	$\frac{1}{1.2}$
60.....	200.....	72.....	4.....	$\frac{1}{9}$
65.....	infinity	4.5	$\frac{1}{8}$
70.....	acquired H. = 1	D.	5.5	$\frac{1}{6.5}$
75.....	„ H. = 1.5	D.	6	$\frac{1}{6}$
80.....	„ H. = 2.5	D.	7	$\frac{1}{5}$

CHAPTER XXI

STRABISMUS AND OCULAR PARALYSIS

STRABISMUS exists whenever the two eyes are not (as they ought to be) directed towards the same object. The eye is "directed towards" an object when the image is formed on the most sensitive part of the retina (the yellow spot); the straight line joining the centre of this image with the centre of the object is the "visual axis" (*see* footnote to p. 34). The action of the ocular muscles is normally such as to keep both visual lines always directed to the object under regard, binocular but single vision being the result. Although each eye receives its own image, only one object is perceived by the sensorium, because the images are formed on parts of the retinae which "correspond" or are "identical" in function, *i. e.* which are so placed that they always receive identical and simultaneous stimuli.

But if, owing to faulty action of one or more of the muscles, one eye deviate, and the visual lines cease to be directed towards the same object, the image will no longer be formed on the *y. s.* in both eyes. In one of them it must fall on some other and non-identical part of the retina, and the result is that two images of the same object are seen (*Diplopia*, p. 36). In Fig. 118 *y* is the *y. s.* in each eye, and the visual line of the R. eye (the thick dotted line) deviates inwards; hence the image of the object (*ob.*) which is formed at *y* in the L. eye, will in the R. eye fall on a non-identical part to the inner side of *y*. *ob.* will be seen in its true position by the L. eye.

To the R. eye, however, it will appear to be at *F. ob.*, because the part of the R. retina which now receives the image of *ob.* was accustomed, when the eye was normally directed, to receive images from objects in the

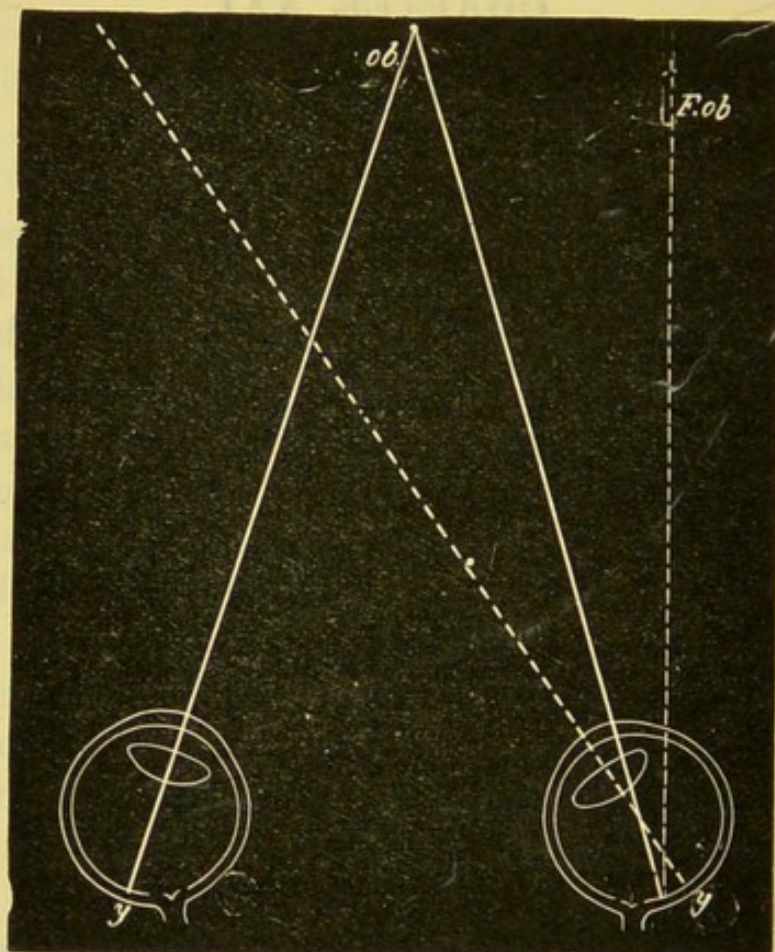


FIG. 118.—Shows the position of the double images in diplopia from convergent or crossed strabismus. The images are homonymous, or correspond in position to the eyes.

position of *F. ob.*; and in consequence of this early habit *F. ob.* is the position to which every image formed on this part of the retina is referred.

Hence if the eye deviate towards its fellow (convergent squint—as in Fig. 118), the false image will seem to the squinting eye to be in the opposite direction; the image (*F. ob.*) for the R. eye being referred to the patient's R., and that for the L. eye (*ob.*) to his L.; in convergent or crossed strabismus the double images correspond in posi-

tion to the eyes, or are *homonymous*.—Similar reasoning will show that if the eye deviate away from its fellow (Fig. 119, divergent strabismus), the position of the double

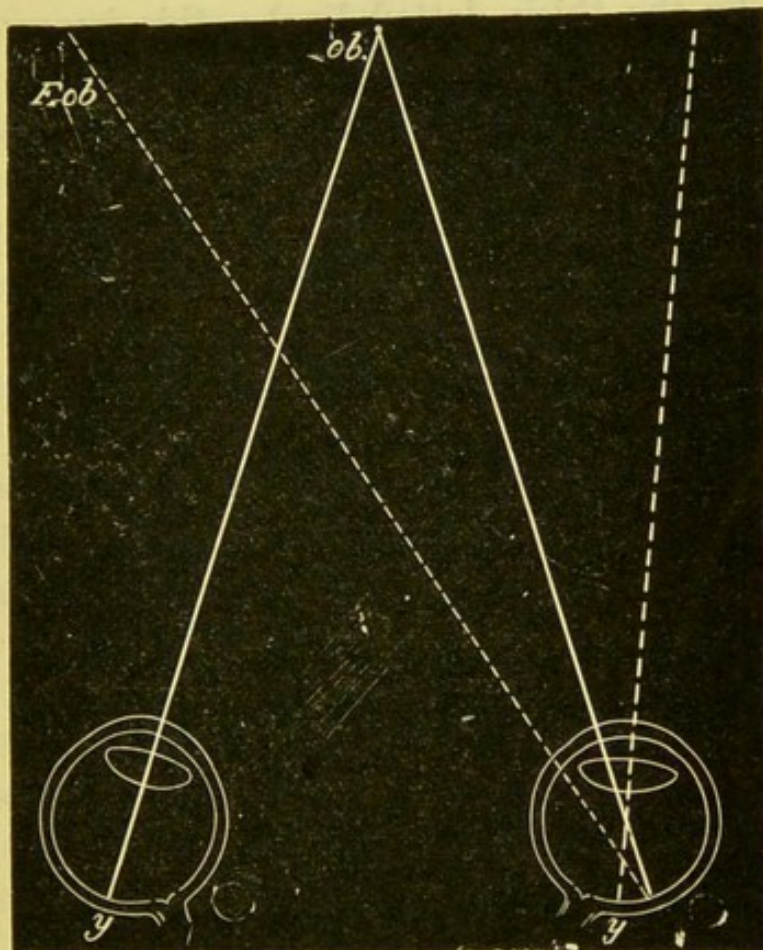


FIG. 119.—Position of double images in divergent strabismus.
The images are crossed.

images must be reversed, and the image belonging to the R. eye appear to be to the left of the other; hence in divergent squint the double images are *crossed*.

Since the image of *ob.* in the squinting (R.) eye is formed on a portion of the retina, more or less distant from the most perfect part (the y. s.), it will not appear so clear or so bright as the image formed at the y. s. of the sound (or “working”) eye; it is called the “false” image, that formed in the working eye being the “true” one. The greater the deviation of the visual line (*i. e.* the greater

the squint) the wider apart will the two images appear and the less distinct will the "false" image be.

The y. s. (*y*) of the squinting (R.) eye will receive an image of some different object lying in its visual line (shown by the thick dotted line); this image, if sufficiently marked to attract attention, will be seen, and will appear to lie upon the image of *ob.* seen by the "working" (L.) eye; two equally clear objects will be seen superimposed. But, as a rule, only one of these images is attended to, the perception of the other being habitually suppressed, even sooner than that of the "false image" (p. 238); the suppressed image always belongs to the squinting eye.

Squinting is not always accompanied by double vision because:—(1) if the deviation be extreme, the false image is formed on a very peripheral part of the retina, and is so dim as not to be noticed; conversely, the less the squint the more troublesome is the diplopia, when present; (2) as already mentioned (p. 239), after a time the "false image" is suppressed; or the eye may have been very defective before the squint came on.

For the method of examining for strabismus and diplopia, see pp. 33 to 36.

Strabismus may arise from any one of the following muscular conditions:—(1) over-action; (2) weakness following over-use; (3) disuse of an eye whose sight is imperfect; (4) stretching and weakening of a tendon after tenotomy; (5) from paralysis of one or more of the muscles.

Fuchs* has shown that considerable variations occur in the attachments of the recti and obliqui to the sclerotic. Such variations in the attachment and power of the muscles probably operate as predisposing causes of the squint in groups 1, 2, and 3.

* Fuchs, 'Graefe's Arch.,' xxx, abstracted in 'Ophth. Review,' vol. iv, 143 (1885).

1. Over-action of the internal recti gives rise to the convergent squint of hypermetropia. The association of convergent squint with hypermetropia was first observed by Donders, and explained by him in the following way:—The relationship between accommodation and convergence is a remarkably close one; most people are unable to accommodate without, at the same time, converging their visual axes. Moreover a given degree of accommodation carries with it a constant degree of convergence. Hypermetropes are obliged to use their Acc. to see even distant things clearly; they are generally unable to dissociate this Acc. from its usual amount of convergence. So that in fixing an object at 50 cm. distance, requiring Acc. of 2 D., a hypermetrope of 2 D. uses 4 D. of Acc. in order to see it clearly. But 4 D. of Acc. in the normal eye goes with convergence for a point at 25 cm. distance. Such a person, therefore, has to do two things at once, to look at an object distant 50 cm., and to make his visual axes meet at 25 cm. The former he does by directing an eye (*e. g.* the R.) to the object 50 cm. off; the latter by converging the visual axis of the L. so that it meets that of the R. at 25 cm. In this case the L. eye will squint inwards, but both internal recti will act equally in bringing about the convergence, and both eyes will use as much accommodation as a pair of normal eyes would do at 25 cm. In most cases the squint always affects the same eye, and this is generally accounted for by some original defect of the eye itself (such as a higher degree of H. or As., or a corneal opacity); but people who see equally well with each eye often squint with either indifferently (*alternating squint*). This explanation, though it accounts for a large number of the cases of concomitant convergent squint, is not a complete one—squint is not present in every case of H.; it is not always most marked in the highest degrees of squint; and some cases of convergent squint occur in Emm. and My.

Schweigger believes that a want of muscular balance is the main cause of strabismus, and that in convergent squint the internal recti preponderate over the external; in H. there is a congenital tendency towards preponderance of the internal recti, and in myopia of the external. Hansen Grut thinks that the preponderance is dependent on the innervation of the muscles. In cases of long standing the range of movement of the squinting eye is often deficient.

This "concomitant" convergent strabismus (p. 33, § 11) generally comes on early in childhood, as soon as the child begins to look attentively and use Acc. vigorously in regarding near objects. In examining cases we shall be struck by finding that (*a*) in some the squint is noticed only when Acc. is in full use,—that it appears and disappears under observation, according as the child fixes its gaze on a near object or looks into space (*periodic squint*).

Periodic squint often occurs, chiefly when the child is nervous or tired; several patients have assured me that their occasional convergent squint scarcely ever came on except when eating.

(*b*) In others the squint is constant, but is more marked during strong Acc.; (*c*) it is constant, invariable, and of high degree; (*d*) in most cases patients who see equally well with each eye often squint with either indifferently (*alternating squint*). The squint causes diplopia, and to avoid this inconvenience patients for the most part soon learn to ignore (or "suppress") the image formed in the squinting eye, the result usually being that this eye becomes very defective. This power of suppressing the false image is learnt most easily in very early life. In alternating squint no permanent suppression occurs, and consequently both eyes remain good (*refer to arguments at p. 238*).

The squint sometimes disappears spontaneously as the child grows up; this might be explained by an increased

power of dissociating Acc. from convergence, or by a diminution of H. from elongation of the eye, or by a general tendency in all persons, and of this there is other evidence, to weakening of the internal recti with advancing age.

Treatment of convergent hypermetropic squint

(a) If the squint be periodic, it can be cured by the constant use of spectacles which nearly correct total H.

(b) The same is true in some cases where the squint, though constant, is alternating or varies in degree, being greater during Acc. for near than for distant objects.

(c) If the squint be constant in amount and of some years' standing, operation is usually necessary. As the squinting eye is then usually very defective (p. 238), the removal of the deformity is the chief object of the operation, binocular vision being comparatively seldom restored. Hence, in view of the tendency to spontaneous cure already mentioned, I think it better, as a rule, not to operate on children below the age of six, especially as in younger children we cannot always tell whether or not the squint be still periodic. The most rational treatment for children under four (when glasses may often be begun) is to cover the eyes alternately with a blind, for some hours daily, to ensure each eye being alternately used; but this plan can seldom be carried out.

When operation is decided upon, it is a safe rule to divide only one internal rectus at a sitting. At the end of a few weeks, if the squint still be considerable, the operation is performed on the other eye.*

Muscular asthenopia or actual divergence is very likely to come on some years later if both tendons are needlessly

* Regulations for operating in convergent strabismus in relation to its degree have been laid down by various authors; recently by Hirschberg ('Centralbl. f. A.,' 1886, p. 5).

divided. It is safer to leave slight convergence than to run this risk. (*See also Divergent Strabismus.*)

2. Divergent squint from weakness of the internal recti (*insufficiency of convergence*) depends upon relaxation or absolute weakening of the internal recti. It is commonest in M., but is not infrequent in H., and even in E. This form of squint sets in gradually, with difficulty in using the eyes for long together for reading, &c., the internal recti not being able to keep up convergence (*muscular asthenopia*); in this stage it may often be detected by covering one eye whilst the patient looks attentively at some near object, for the covered eye will diverge when thus excluded (*latent divergent squint*), though in the interest of binocular vision convergence may be maintained for a short time when both eyes are open. The position of the eyes may be more exactly ascertained by the use of Maddox's rod. The image of a candle flame seen through this rod appears as a long band of light, and does not excite desire for binocular fusion of images, so that the eyes take up positions in regard to each other which are natural to them. If the rod be held horizontally before one eye and a distant candle be observed, a vertical band of light will be seen; the position of this band with regard to the flame seen with the other eye will indicate the relative position of the eyes. Latent divergent strabismus is sometimes a temporary condition due to over-use of the eyes, or want of general vigour, in young adults. Anything which lessens the importance of binocular vision predisposes to divergent squint, *e. g.* defective sight of one eye from anisometropia. Latent divergence is extremely apt to pass gradually into manifest permanent divergent squint. In this form of strabismus the eye can be moved into the inner canthus, even in extreme cases, by making the patient look sideways, though not by efforts at convergence, and it is thus but rarely that the cases simulate paralysis.

Tenotomy of the external rectus, and even "advancement" of the weakened muscle, are often needed. In slight cases the symptoms are sometimes quite cured by wearing prisms with their bases towards the nose; but, as far as I know, one can seldom predict success with any certainty from their use. One of the most troublesome features in muscular asthenopia is its great variability with the patient's state of health; the symptoms sometimes disappear entirely in a bracing climate, returning as soon as the patient comes back to his less invigorating home air.

3. Strabismus from disuse is also nearly always divergent, depending, as it does, on relaxation of the internal rectus. It occurs in cases where convergence is no longer of service, as when one eye is blind from opacity of the cornea, or other cause, or where the refraction of the two eyes is very different (p. 328). Tenotomy of the external, with or without advancement of the internal rectus may be performed.

4. Stretching and weakening of the internal rectus after division of its tendon for convergent squint may give rise to divergence, simulating that caused by paralysis of the internal rectus. The caruncle in these cases, however, is generally much retracted, and this, together with the history of a former operation, will prevent any mistake in diagnosis. Such a squint can always be lessened, and often quite removed, by an operation for readjustment or advancement of the defective muscle.

5. *Paralytic squint*.—The deviation is caused by the unopposed action of the sound muscles. When the palsied muscle tries to act, the eye fails, in proportion to the weakness, to move in the required direction. In many cases there is only slight paresis, and the resulting deviation is too little to be objectively noticeable; but in such cases the diplopia, as mentioned already, is very troublesome, and it is for this symptom that the patient comes

under care. Further, in these slight cases the symptoms often vary with the effort made by the patient. In paralysis of the third nerve the several branches are often affected in different degrees, and the strabismus and diplopia are then complex. When paralysis of any ocular muscle is of long standing, secondary contraction of the opponent seems sometimes to occur, and complicates the symptoms. Further difficulty in diagnosis is occasionally caused by the sound yokefellow * of the paralysed muscle acting too much, in obedience to efforts made by the latter; when this happens the squint will sometimes, even when both eyes are uncovered, affect the sound instead of the paralysed eye, *i. e.* it will alternate. (*Compare Secondary Squint*, p. 33.)

The commonest forms of paralytic squint are due to affection, separately, of the external rectus (sixth nerve), superior oblique (fourth nerve), or of one or all of the muscles supplied by the third nerve (internal superior and inferior recti, inferior oblique, levator palpebræ).†

Paralysis of the external rectus (sixth nerve) causes a convergent squint, from preponderance of the internal rectus, which, except in the slightest cases, is usually very noticeable. Movement straight outwards is impaired, and if the paralysis be complete the eye cannot be moved outwards beyond the middle line of the palpebral fissure. There is homonymous diplopia; the two images, when in the horizontal plane, are upright and on the same level; the distance between them increases as the object is moved towards the paralysed side, but it diminishes, or the images

* Yoked or conjugate muscles are the muscles of opposite eyes which act together in producing lateral and vertical movements; *e. g.* the internal rectus of one eye acts with the external rectus of the other in movement of the eyes to the R. or L.

† In 77 cases of paralysis of a single oculo-motor nerve I found the third nerve affected in 31 cases, the fourth in 9, and the sixth in 37.

even coalesce, in the opposite direction. Thus in paralysis of the left external rectus (Fig. 123, uppermost figure), the images separate more as the object is moved to the patient's left, but approach one another, and finally coalesce, as it is moved over to his right. In slight cases the diplopia ceases when the patient looks at an object a few inches off, but reappears when he gazes straight forwards at a distant object. In the upper part of the field the false image is sometimes lower, and in the lower part of the field higher than the true one. I have many times noticed that the pupil is larger in the affected eye than in the other, a condition which we should not expect.

In *paralysis of the superior oblique (fourth nerve)* there is either no visible squint, or only a slight deviation upwards and inwards. But when the eyes are directed below the horizontal, very troublesome diplopia arises from the defective downward and outward movement, and loss of rotation of the vertical meridian inwards, to which the lesion gives rise. In downward movements, especially downwards and towards the paralysed side, the eye remains a little higher than its fellow; in trying to look straight down (inferior rectus and superior oblique) the unopposed action of the inferior rectus carries the cornea somewhat inwards (convergent squint), and at the same time rotates the vertical axis outwards, whilst the cornea remains on a rather higher level than its fellow; in following an object from the horizontal middle line down-outwards, it will be seen that the vertical meridian of the cornea does not, as it should, become inclined inwards.

In many cases, however, the slight defects of movement caused by paralysis of the superior oblique are not clearly marked, and the diagnosis has to be based on the characters of the diplopia (*compare* p. 36). In all positions below the horizontal line the false image is below the true one, and displaced towards the paralysed side (homonymous); thus,

if the R. muscle be at fault, the false image will be below and to the patient's R. (Fig. 120, arrow-head figure); further, it is not upright, but leans towards the true image. The difference in height between the images is greatest in movements towards the sound side; the lateral separation is greater the further the object is moved downwards; the leaning of the false image is greatest in movements towards the paralysed side. When the patient looks on the floor, *i. e.* projects the images on to a horizontal surface, the false image seems nearer to him than the true one. The images are always near enough together to cause inconvenience, and as the diplopia is confined to, or is worst in, the lower half of the field, the half most used in daily life, paralysis of the superior oblique is very annoying, especially in going up or down stairs, in looking at the floor, counting money, eating, &c.

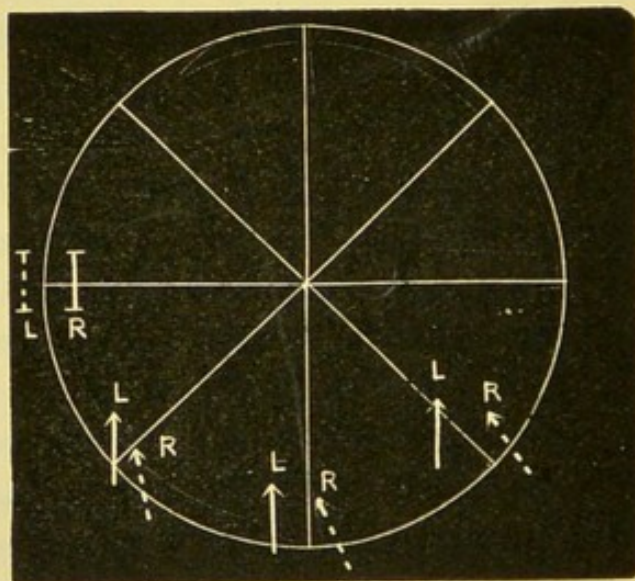


FIG. 120.—Chart showing position of double images, as seen by the patient, in paralysis of L. external rectus and R. superior oblique.

Paralysis of the third nerve, when complete, causes ptosis, loss of inward, upward, and downward movements, loss of accommodation, and partial mydriasis, well-marked divergent strabismus from unopposed action of the external rectus, and crossed diplopia. The downward and outward

movement, with rotation of the vertical meridian inwards effected by the superior oblique, remains. The mydriasis is much less than that produced by atropine. In many cases the paralysis is incomplete, affecting some branches (and muscles) more than others, and the symptoms are then less typical. Isolated paralysis of a single third-nerve muscle is rare.

Peculiarities of paralytic strabismus.—(1) If a patient suffering, *e. g.*, from paresis of one external rectus, look at an object distant about two feet, and the sound eye be then covered by holding a card (or a piece of ground glass) before it, the paralysed eye will make an attempt (more or less successful according to the degree of palsy) to look at the object. The movement affected will call for a greater effort than if the sixth nerve were healthy, and as the eye muscles always work in pairs, the same effort will be transmitted to the internal rectus of the healthy eye. The latter will, in consequence, describe a larger movement than the paralysed eye, *i. e.* the secondary squint will be greater than the primary (p. 34). This test is sometimes of use in distinguishing which is the faulty eye in cases where the squint is slight, and the patient unable to distinguish between the false and true images (p. 36). (2) Giddiness is often present when the patient walks with the sound eye closed. This symptom depends on an erroneous judgment of the position of surrounding objects, which is caused by the weakened muscle not being able to achieve a movement of the eye corresponding in magnitude to the effort made. It is absent when both eyes are open, and when the paralysed eye is covered. It often helps us more than does the former symptom in determining which is the faulty eye; but it varies much in severity in different cases, and may be quite absent. Patients with ocular palsy often keep one eye closed, *nearly always the paralysed one*, to avoid diplopia.

Paralysis of the ocular muscles is seldom symmetrical;

in the rare cases where it is so the disease is usually intracranial. In uncomplicated symmetrical "ophthalmoplegia externa" (paralysis of all the external muscles, the iris and ciliary muscles escaping) the disease is usually nuclear, whilst in cases of symmetrical disease of oculo-motor nerve-trunks both external and internal muscles are paralysed; but even in nuclear ophthalmoplegia the disease may spread forwards and attack the centres for the iris and ciliary muscle, and the differential diagnosis may then be exceedingly difficult to make. In the later stages of nuclear ophthalmoplegia other cranial nerves (especially the optic and fifth) may be involved, and symptoms of spinal or bulbar disease be present (p. 351).

The fibres of the third and fourth nerves arise from a column of nerve-cells beneath the floor of the aqueduct of Sylvius. It is probable that the centre for accommodation lies in front, with that for the sphincter of the pupil next, the centres for the other muscles following, but their exact order is not yet known. The nuclei of the internal and external recti are in communication by the posterior longitudinal fibres, so that their combined action in lateral movements of the eyes is secured. There is a centre for the convergence of the eyes close to the middle line.

Affections of the Internal Muscles of the Eyeball

Physiological outline.—The nerves of the iris are—*a*, the third for contraction of the pupil; *b*, the cervical sympathetic for its dilatation; and *c*, the fifth supplying sensory fibres. The sympathetic fibres (*b*) come from the cord probably through the anterior root of the second dorsal nerve, and reach the eye—(1) through the Gasserian ganglion from the carotid plexus; (2) through the lenticular ganglion from the cavernous plexus; (3) it is stated that sympathetic (dilator) fibres accompany the fifth nerve directly from its origin. The filaments of the fifth (*c*) form (1) the long root of the lenticular ganglion (which gives off the short ciliary nerves); (2) the long ciliaries, two or three in number, independent of the ganglion.—The human iris contains a circular (sphincter) unstriped muscle close to the pupil.

and a dilator muscle consisting of a thin layer of plain muscular tissue passing from the sphincter to the circumference of the iris.

If the third nerve be divided, or paralysed, the pupil dilates moderately (never extremely) and becomes motionless to light and accommodation, and accommodation is lost.—Of contraction of pupil and spasm of accommodation from irritation of the nerve, we have little clinical knowledge; but experimental stimulation of the nerve produces those effects.—Section, or paralysis, of the cervical sympathetic causes some contraction of pupil, and destroys its power of dilating when shaded; stimulation of it, or of the anterior root of the second dorsal (in monkeys—Ferrier), causes well-marked dilatation, which, however, is less than that due to atropine; irritation of the skin, stimulating the dilator nerve, causes slight, momentary dilatation.

All the drugs which act upon the iris act on the ciliary muscle too, but the iris is affected sooner, for a longer time, and by weaker solutions than the ciliary muscle.

Atropine, and all the mydriatics except cocaine, dilate the pupil and paralyse the accommodation; the effect of atropine on the pupil in old people is often, and in children sometimes very small; the mydriasis of atropine is greater than that due to paralysis of third nerve, but is somewhat increased if the third nerve be cut. It acts in old-standing paralysis of iris (third nerve) and of cervical sympathetic, but in both conditions the mydriasis is apt to be rather less than full; the mydriasis is said to be rather increased by stimulating the long ciliary nerves, and diminished by cutting the fifth, owing to the sympathetic fibres contained in it.—Atropine dilates the pupil of a freshly excised (rabbit's) eye, and of the eye of an animal bled to death, and it acts a little if put on to the human eye very soon after death.—From the above it is inferred that atropine acts directly upon the muscular fibres, paralysing them, and not upon the nerve-fibres. Atropine does not act upon the iris of birds (containing striped muscle).

Eserine and pilocarpine contract the pupil and cause spasm of accommodation; they have the same action in long-standing paralysis of iris (third nerve), and after section of the third nerve and of the sympathetic; they have very little effect if atropine have been used, but they immediately overcome the mydriasis of cocaine.—Eserine and pilocarpine, therefore, probably act directly on the muscular fibres, stimulating them.

Cocaine dilates the pupil, but does not prevent its action to light

and accommodation, and has but little action on the ciliary muscle; hence it does not act by paralysing either the third-nerve fibres or the muscular fibres. It causes further dilatation of a pupil dilated by atropine or by section of third nerve; whilst it does not dilate the pupil if the cervical sympathetic have been cut or paralysed for some little time. It also causes retraction of the eyelids and contraction of the superficial blood-vessels of the eye. Hence cocaine probably acts by stimulating the sympathetic nerve-fibres. (Consult Michael Foster's 'Physiology;' Ferrier, 'Functions of Brain' [2nd edit], and 'Proc. of Roy. Soc.,' 1883; Gowers, 'Diseases of Nervous System,' vol. i; Jessop, 'Proc. of Roy. Soc.,' 1885-6; Marshall, 'Lancet,' 1885, ii, 286; Author's own cases.)

The following forms of paralysis, or altered innervation, of iris and ciliary muscle agree tolerably with the above physiological facts.

A. *Pupil alone*.—(1) Paralysis of dilatation: pupil in good light, equal to or smaller than the other; but when shaded, dilates little, if at all, so that in dull light it is much the smaller (*paralytic miosis*); accommodation not affected. This uncommon condition is, when well marked, generally one-sided, and due to paralysis of cervical sympathetic by pressure, *e.g.* by aneurism or tumour, or enlarged glands at the root of the neck, or injury to the brachial plexus; it should therefore always lead to careful examination. A degree of miosis and non-dilatability of pupils is common in old age. (2) The opposite state (*spasmodic mydriasis*) is very rare as a permanent symptom, though temporary, varying dilatation of one pupil is sometimes seen in young or neurotic persons. Persistent spasmodic mydriasis is said to occur in the early (irritative) stage of lesions, which afterwards produce paralytic miosis;* in this state we should expect the pupil, though dilated, to act both to light and to accommodation, as after cocaine. (3) Of paralytic mydriasis (paralysis of third-nerve fibres of the sphincter muscle) without paralysis of accommoda-

* Gowers, 'Diseases of Nervous System,' i, 152.

tion we know but little,* except in a slight degree as a residue after recovery from the double condition (paralysis of sphincter iridis, and ciliary muscle), the pupil often not recovering so well, or so soon, as the accommodation (*compare* the action of the drugs above given). (4) Paralysis of iris (*iridoplegia*), without defect of accommodation, usually affects only the action to light (*reflex iridoplegia*), the associated action remaining. It occurs as a very early symptom in locomotor ataxy, sometimes without any other symptoms of that disease, and should always lead to full investigation. It is probably due to degeneration in that part of the nucleus of the third which presides over the reflex action of the pupil.

B. *Paralysis of accommodation alone (cycloplegia)* is often seen after diphtheria. It is often incomplete, and the pupils are usually unaffected; but if the cycloplegia be complete there is sometimes mydriasis. In ataxy there is occasionally cycloplegia with a pupil active to light. Accommodation is sometimes quite lost without any alteration of pupil in what is spoken of as premature presbyopia, but this is not called cycloplegia, not being supposed to be paralytic.

c. *Ciliary muscle and iris affected*.—(1) *Cycloplegia with mydriasis*; loss of accommodation; pupil dilated to about 5 mm. and motionless; the ordinary condition in complete paralysis of third nerve. It is now and then seen without failure of any other part of the third nerve, and the pupil may then be quite widely dilated. When an old person gets paralysis of the third the pupil is often very little dilated. (2) Total iridoplegia, with cycloplegia ("*ophthalmoplegia interna*"); accommodation lost; pupil motionless to reflex and associated stimuli, and of medium size; this is sometimes a later stage of A (4), but it may be primary,

* See several cases reported by the author in 'Ophth. Hosp. Reps.,' vol. xi, iii, pp. 260—264.

due to nuclear disease; the paralysis, both of iris and ciliary muscle, is often incomplete. In paralysis of sixth nerve the pupil of the paralysed eye is often rather larger than that of the other.

Causes of ocular paralysis.—It is convenient to separate the external and mixed forms from those in which only the internal muscles are involved, since the local lesions are, as a rule, different in the two groups.

Paralysis of the third, fourth, or sixth nerve may be the result of tumours or other growths in the orbit, but in such cases, as a rule, the paralysis forms only one amongst other well-marked local symptoms. In the vast majority of uncomplicated ocular palsies we are quite unable to decide, either from the state of the eye or the orbital parts, whether the lesion be in the orbit or within the cranium. Meningitis, morbid growths, and syphilitic periostitis at the base of the skull, or involving the sphenoidal fissure, often cause ocular palsy, seldom confined to one nerve; aneurism of the internal carotid in the cavernous sinus occasionally does so. Syphilitic gumma of the nerve-trunk is probably the commonest cause of single paralysis; the intra-cranial portion of the nerves is known to be often the seat of such growths, but small neural gummata probably occur also on the orbital part of the nerves. Injuries to the head often cause ocular paralysis; the paralysis is usually noticed very soon after the accident, and is probably always a sign of fracture of the base involving the middle fossa, or of some part of the walls of the orbit. Direct damage to, or thickening subsequent to fracture near the pulley, seems to account for some cases of traumatic paralysis of the superior oblique. Pain in the temple or front of the head is very common in ocular palsies due to periostitis and gummata. In certain cases neither the symptoms nor history enable us to locate the seat or prove the cause of the paralysis;

the term "rheumatic" is often applied to such cases, on the assumption that the palsy is peripheral and caused by cold,—that it is, in fact, to be compared to peripheral paralysis of the facial nerve; no doubt some of these are in reality syphilitic. Paralysis, usually of short duration and affecting only one nerve, is not uncommon at an early stage of locomotor ataxy.—Ophthalmoplegia externa generally sets in slowly, is bilaterally symmetrical and permanent; it usually indicates sclerotic disease of the nerve-centres, often caused by syphilis; but it is sometimes caused by tumour centrally placed, or by symmetrical gummata on nerve-trunks. Occasionally ocular palsies are "functional," or occur in company with symptoms apparently of hysterical nature, and pass off. Paralysis of oculo-motor muscles is in rare cases congenital, occurring in several members of the same family. These cases are perhaps of the same nature as those of congenital ptosis, absence or imperfect development of muscles. Occasionally paralysis of oculo-motor nerves from birth has been attributed to instrumental labour.

In respect to the causation of the purely internal paralyses we have but little positive knowledge. Mydriasis with cycloplegia and no other paralysis would be accounted for by disease of the short (third nerve) root of the lenticular ganglion. Iridoplegia and ophthalmoplegia interna are probably the result of chronic, very strictly localised disease of the centres for the pupil and accommodation (Gowers), which have been shown to form separate parts of the nucleus of the third nerve. Complete ophthalmoplegia interna would also be expected if the lenticular ganglion (Hutchinson), or the intraocular ganglionic cells of the choroid (Hulke), were disorganised; but such changes have not yet been proved *post mortem*. Paralysis from blows on the eye is referred to on p. 155. (See also Diphtheria, Chap. XXIII.)

Treatment of ocular paralyses.—In estimating the results of treatment it is well to remember that some cases recover spontaneously, that in many the defect is a paresis rather than paralysis, and that in the latter cases the symptoms often vary in severity from day to day, or even whilst under observation at a single visit, according to the attention given and effort made by the patient. The questions of syphilis and of injury to the head must always be carefully inquired into, especially when only one nerve is paralysed. When several nerves are involved, tumour, aneurism, or syphilis (either gummatous inflammation at the base, or sclerotic nuclear disease) is to be suspected. Iodide of potassium and mercury are the only internal remedies likely to be beneficial, and unless syphilis be quite out of the question they should have a full trial; many cases recover quickly under moderate doses of iodide. Faradisation of the paralysed muscles is sometimes used. Operation for paralytic squint of old standing may sometimes be undertaken.*

Nystagmus (involuntary oscillating movement of the eyes) is generally associated with serious defect of sight dating from very early life, such as opacity of the cornea after ophthalmia neonatorum, congenital cataract, choroido-retinitis, or disease of the optic nerve. It is, however, also seen in young babies associated with constant rhythmical rolling or nodding movements of the head (spasmus nutans); the nystagmus in these cases usually disappears spontaneously. Nystagmus is present in cases of infantile amblyopia without apparent cause, and constantly in albinos. Nystagmus is often developed during adult life in coal-miners; it has been attributed to the insufficiency of light furnished by the safety lamps, and with more probability to the necessity which the miner is under of

* Rules for operations for paralytic squint have been laid down by Alfred Graefe ('Arch. f. Oph.,' xxxiii, 3, 179).

constantly looking in an unnatural direction, upwards or sideways, for example; it is often present only when the collier takes up his mining posture. It is occasionally seen in other occupations, *e. g.* among compositors. Nystagmus occurs as a symptom in some cases of disseminated sclerosis, and in other forms of central nervous disease.

Usually both eyes oscillate, but when only one eye is defective, it alone may oscillate.—The movements in nystagmus, whatever may be the cause of the condition, vary much in rapidity, amplitude, and direction in different cases, and even in the same case at different times; they are generally worse when the patient is nervous, and often there is a particular position of the eyes in which the oscillation is least. Nystagmus often becomes much less marked as life advances. Treatment is useless.

CHAPTER XXII

OPERATIONS

A. OPERATIONS ON THE EYELIDS

1. *Epilation of eyelashes*.—Position : patient seated ; surgeon standing behind. The forceps to be broad-ended, with smooth or very finely roughened blades, which meet accurately in their whole width. Stretch the lid tightly by a finger placed over each end. Pull out the lashes at first quickly in bundles, and finish by carefully picking out the separate ones that are left.

2. *Eversion of upper lid*.—Position as for 1, or the surgeon may stand in front. The patient looks down, a probe is laid along the lid above the upper edge of the “cartilage ;” the lashes, or the edge of the lid, are then seized by a finger and thumb of the other hand, and turned up over the probe, which is simultaneously pushed down. After a little practice the probe can be dispensed with, and the lid everted by the forefinger and thumb of one hand alone, one serving to fix and depress the lid, the other to turn it upwards.

3. *Removal of Meibomian cyst*.—Position as for 1. In-



FIG. 121.—Meibomian scoop.

struments : a small scalpel or Beer's knife (Fig. 157) and a curette, or small scoop (Figs. 121 and 153). (1) Evert

the lid; (2) make a free crucial incision into the tumour from the conjunctival surface; (3) remove the growth, either by squeezing the lid between finger- and thumb-nail, or by means of the scoop. The cavity fills with blood, and may thus for a few days be larger than before. These tumours have no distinct cyst wall.

4. *Inspection of cornea* in purulent ophthalmia, &c. Position: if the patient be a baby or child, the back of its



FIG. 122.—Desmarres' lid elevator.

head is to be held between the surgeon's knees, its body and legs being on the nurse's lap; if an adult, the same as for 1. If the lids cannot be easily separated by a finger of each hand, enough to allow a view of the cornea, retractors should be used (a convenient pattern is shown in Fig. 122), by which one lid, or both, can be raised and held away from the globe. If this instrument be gently used we avoid all risk of causing perforation of the cornea should a deep ulcer be present, an accident which may happen in cases attended by much swelling or spasm of the lids if the fingers be used.

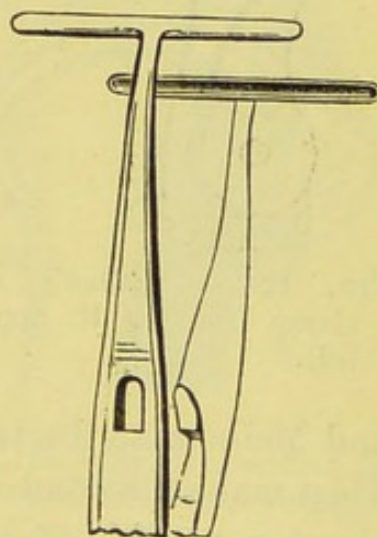


FIG. 123.—Entropion forceps.

5. *Entropion*.—*Spasmodic entropion of the lower lid*, with relaxed skin, in old people. Position as for 1. A fold of skin close to the edge of the lid and of width proportionate to the degree of inversion is removed; the orbicularis

muscle is then exposed, and some of its fibres should also be removed; the wound is then closed with sutures. Another good plan is to enter a threaded needle close to the edge of the lid, bring it out half an inch vertically below, tie the intervening skin and muscle tightly, and allow the thread to cut its way out; two or three such stitches will be wanted at equal distances apart: the resulting scars, being vertical, are rather conspicuous.

6. *Organic entropion and trichiasis*.—When the whole row of lashes is turned inwards, and the inner surface of the lid much shortened by scarring, *radical extirpation* of all the lashes is the quickest and most certain means of giving permanent relief, but it leaves an unsightly baldness, and exposes the cornea to unnatural risk from dust, &c. Position: recumbent; the surgeon stands behind the patient. Anæsthesia seldom necessary. Instruments: a horn or bone lid-spatula (Fig. 125, s), or a lid clamp (Fig. 124), a Beer's knife (Fig. 157), and forceps.

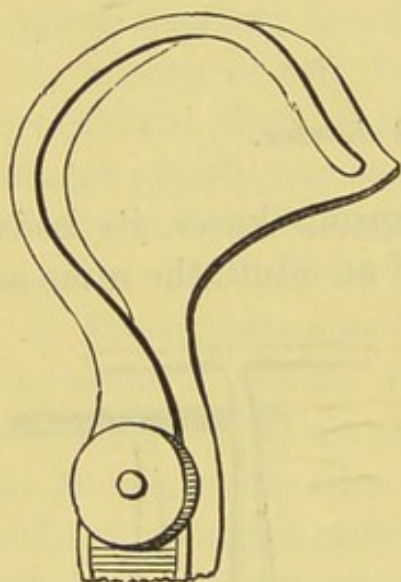


FIG. 124. — Snellen's lid clamp (for the R. upper lid).

Make an incision from end to end (beginning just outside the punctum) between the hair-follicles and Meibomian ducts, as if to split the lid into two layers. Then make a second incision through the skin and tissues, about a twelfth of an inch above the border of the lid, parallel with, but in a plane at right angles to, the first. The strip of skin and tissues included between these two cuts will now be almost free, except at its ends, which are to be united by a cross-cut, and the strip dissected off; it should include the hair-follicles in their whole depth. Examine the white edge of the "cartilage," now exposed;

for any hair-follicles accidentally left behind; they will appear as black dots, and are to be carefully removed.

In the same or slighter cases the inversion of the border of the lid may be much lessened by complete division of the "cartilage" from the conjunctival surface along a line parallel with, and 3 mm. from the free border (*Burow's operation*) (Fig. 126, Bu). The wound gapes and the inverted border of the lid falls forward, and is kept in its natural place by the cornea. The only instruments needed are a scalpel and scissors. Position as for 1, or recumbent. The lid is kept well everted whilst the incision is being made. A puncture is made with the knife parallel to the edge of the lid, close to the inner or outer end, one blade of the scissors passed through this puncture and made to run along the outer surface of the "cartilage" between it and the orbicularis muscle, and then the "cartilage" divided by closing the blades parallel to the border. The wound should be at right angles to the surface. A bluish line should be seen through the skin on replacing the lid. This operation gives complete relief for the time, but may need repetition in a few months.

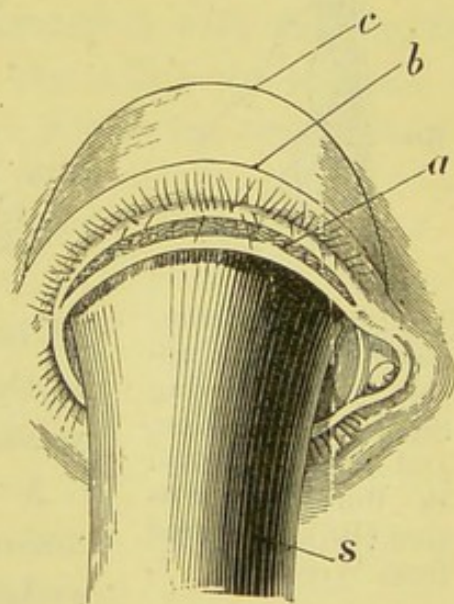


FIG. 125.—Arlt's operation for trichiasis. (After Schweigger.)

Various operations are performed for transplantation of the displaced lashes forwards and upwards, so as to restore their natural direction. *Arlt's operation*.—The free border of the lid is split from end to end (leaving the punctum), as for extirpation of the lashes, but more deeply (Fig. 125, *a*). A second incision (*b*), extending beyond the ends

of the first, is now made through the skin parallel to, and about two lines from, the border of the lid, and down to, but not through the "cartilage;" thirdly, a curved incision (*c*) is made, joining *b* at each end and including a semi-lunar flap of skin, of greater or less width according to the effect desired; fourthly, this flap is dissected off without injury to the orbicularis, and the wound, bounded by the lines *b* and *c*, closed by sutures. The anterior layer of the

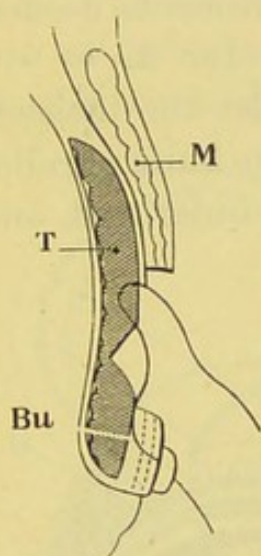


FIG. 126.—Diagrammatic section of upper lid; showing Snellen's operation, and line of section in Burow's operation (Bu). (Altered from Wecker.)

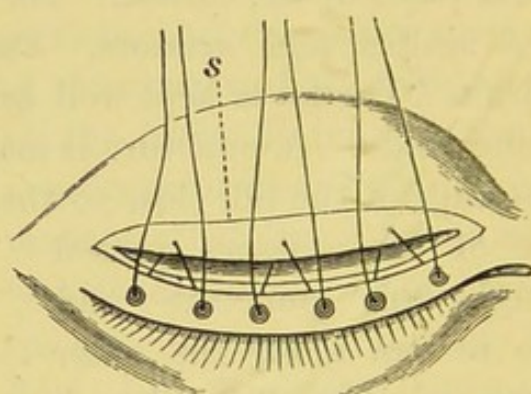


FIG. 127.—Snellen's operation for trichiasis. (After Wecker.) *s*. Edge of retracted skin and muscle.

lid border, which contains the lashes, is thus tilted forwards and drawn upwards.

A third operation (Streatfeild's) consists in the simple removal of a wedge-shaped strip of the "cartilage"

(with its superjacent skin and muscle) from the whole length of the lid, at a distance of a line or two from its border. No sutures are used.

Snellen operates as follows:—The incision (*b*, Fig. 125) is carried down to the tarsus, the muscle and skin separated from it and pushed upwards, and a wedge, shown by the groove in Fig. 126, cut from the exposed tarsus, as in Streatfeild's operation. The border of the lid is now everted, and kept in its new position by passing two or

three threads, as shown in Figs. 126 and 127, and tying them over beads. The skin wound need not be sutured. Various other operations have been introduced from time to time for entropion by Spencer Watson and others by which a flap of skin is inserted between the lashes and the edge of the lid; the cutaneous hairs on the transplanted flap, however, occasionally irritate the cornea.

All these operations (except 1) are apt to need repetition sooner or later.

The above operations are most suitable when the whole length of the upper lid is affected; in most hands Arlt's proceeding probably gives better average results than any other. In cases of partial trichiasis, where only a few lashes are misdirected, *electrolysis of the hair-follicles* is a valuable proceeding; a needle connected with the negative pole of a battery is passed into the follicle by the side of the shaft of the hair, the positive pole being applied to the skin of the temple. The hair is loosened, comes away, and does not grow again; this has to be done to each of the displaced lashes. Where only a part of the border is affected, transplantation of a strip of mucous membrane from the patient's lip into the gap made by splitting the diseased part of the lid (Fig. 128) is the best operation. This may be done as follows (van Millingen):—(1) Split the affected part of the lid as in Arlt's operation, but turn the cut forwards into the skin a little at each end, as shown in Fig. 128. (2) Separate a strip of mucous membrane from the lower lip parallel to its length, leaving its ends attached; the strip should be longer and wider than the gap it is to fill. (3) Take two needles, each with a long thread attached, and pass one through each end of the lid incision from the skin surface into the angle of the wound, draw the needles through, carry them down to the lip, and pass each one through the corresponding end of the bridge of mucous membrane from the deep to the free surface.

(4) Cut the attached ends of the bridge, turn the strip over on the thumb-nail, and clean its under surface with scissors (taking care not to cut the thread at each end).
(5) Draw the strip up into its new position by pulling on the upper ends of the threads, and tie the threads. A very fine stitch may be inserted at the centre of flap if thought necessary, but this can be dispensed with. The split in the lid should be cleaned from clot before the strip is brought into position. The strip usually lives and adheres well under an antiseptic dressing; the stitches may be left to come out.

7. *Ectropion*.—Ectropion from thickening of the conjunctiva, aided by relaxation of the tissues of the lower lid, seen chiefly in old people, may be treated by the removal of a V-shaped piece of the whole thickness of the

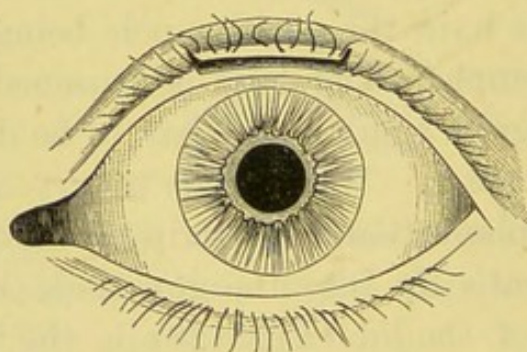


FIG. 128.—Van Millingen's operation.—1st stage: the portion of lid containing misdirected lashes split parallel to its surfaces, leaving the lashes in the anterior layer. The incision at each end is carried a short distance into the skin at a right angle with the split.

lid, the edges being brought together with a harelip pin. In Kuhnt's operation the lid is split by an incision in the intermarginal space, and a V-shaped portion of the inner or conjunctival half is removed, the edges being drawn together by sutures. In Snellen's operation the everted mucous membrane is drawn back into the sulcus between lid and globe by a suture, entered into the conjunctiva at

two points $\frac{1}{8}$ inch apart, passed deeply, brought out on the cheek, and tied over a bit of india-rubber tube ; the thread is tightened from day to day until it has nearly cut through. An operation of which the principle is nearly the same, but the execution more complicated, is described by Argyll Robertson.* Slighter cases may be satisfactorily treated by the excision, or destruction by burning deeply with a fine galvanic cautery, of a strip of the palpebral conjunctiva parallel to the border of the lid ; the contraction of the scar draws the margin of the lid into place.

For ectropion from cicatricial changes in the skin a plastic operation is generally needed. At the same time the eyelids should be united by fine sutures, after paring a narrow strip from the border of each lid just within the line of the lashes (blepharoplasty), a proceeding which at once assists the restitution of the displaced lid, and gives protection to the cornea ; the lids may be separated a few weeks later.—The operation for the cure of the ectropion will naturally vary with the seat, extent, and cause of the deformity, but we may conveniently distinguish three varieties of organic ectropion, according as the condition has followed (1) a wound of the eyelid with faulty union ; (2) a deeply adherent scar from abscess, disease of bone, or deep ulceration of the lid ; or (3) extensive scarring of the face from burns, lupus, &c. When the cause is quite localised, and there is not much loss of tissue (groups 1 and 2), the scar may be included in a V-shaped incision, the flap separated and pushed up till the lid is in position, and the lower part of the wound then brought together by a pin or sutures, so that what was a V now becomes a Y, the edges of the flap being attached by sutures to the limbs of the Y, Fig. 129. As the lid has generally become too long from prolonged eversion, we often have at the same time to shorten it by removing a small triangle from its outer end, and uniting

* A. Robertson, 'Edin. Clin. and Path. Journ.,' Dec., 1883.

the edges of the gap. When the position of the deformity prevents the above operation, it is necessary to introduce

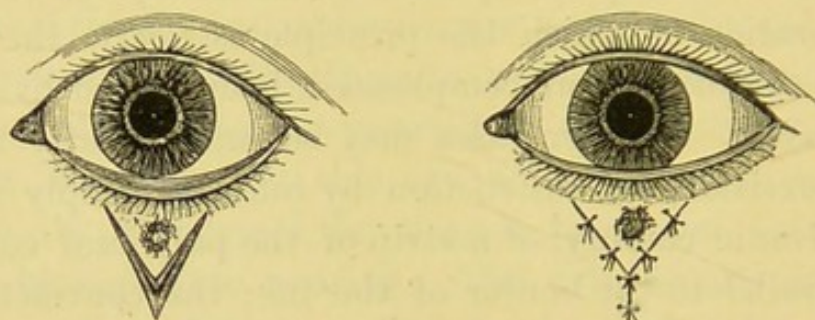


FIG. 129.—V Y operation. (From Ritterich.)

new skin into the gap, made by dissecting out the cicatricial tissue and putting the everted lid into position. This may be done by bringing a flap with a broad pedicle, either by sliding or twisting into the gap; or by the method (introduced into our country by Dr Wolfe) of transplanting from a distant part a single graft of skin without a pedicle, large enough to fill the gap; or, again, by filling the gap with several small pieces of skin. Where there is extensive destruction of skin (group 3) these grafting methods seem particularly valuable. If a single large graft be used the important points are to make it considerably larger than the deficiency it is to supply, to free the under surface of the graft very thoroughly of all subcutaneous tissue, and apply warm dressings. The single graft operation has now been tried many times, and with a good proportion of successes.

8. Paralytic and congenital *ptosis* have often been treated by the removal of an oval piece of skin from the upper lid, parallel to its length, the orbicularis muscle not being touched. This simple method, however, has but little effect unless the piece removed be so large as to shorten the lid materially, and thus endanger the power of complete closure. More complicated operations, intended to raise the lid by producing contraction of the subcutaneous tissues, or adhesion between these parts and the tendon of

the occipito-frontalis at the eyebrow without the removal of any skin, have been recommended by Pagenstecher, Dransart, Meyer, and Panas. I have had, and have seen in the hands of others, satisfactory results from Panas's operation in several cases.

9. *Canthoplasty*, for lengthening the palpebral fissure at the outer canthus. The canthus is divided by scissors or a knife as far as may seem necessary. The contiguous ocular conjunctiva is then slightly dissected up and attached by sutures to the cut edges of the skin, so as to prevent reunion, one suture being placed in the angle of the wound, one above and one below (Fig. 130).

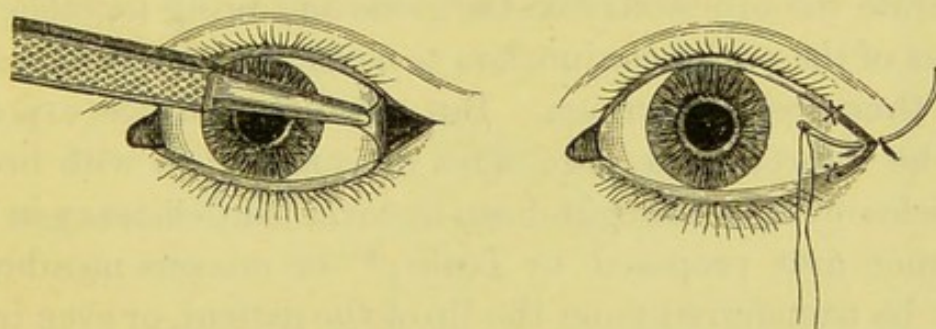


FIG. 130.—Canthoplasty. (From Ritterich.)

10. *Peritomy*, for obstinate cases of partial pannus. Anæsthesia is necessary. Instruments: speculum, fixation forceps, scissors, and Beer's knife. With the knife a circular incision is carried through the conjunctiva, round the cornea, at 5 mm. ($\frac{1}{5}$ "), or less, from its border. The zone of conjunctiva so included, together with the whole of its subconjunctival tissue down to the sclerotic, is now carefully removed by the scissors. The bare surface thus left granulates, and finally contracts to a narrow band of white scar-tissue, by which the vessels running to the cornea should be obliterated. The subconjunctival fascia is often found much thickened in these cases. Care must be taken not to make the incision too far from the cornea, lest the insertions of the recti be damaged. The strip

removed should extend completely round the cornea; removal of only a part of the zone is not satisfactory. The symptoms are generally made worse for a time, and the final result is not reached for several months. In some cases the operation has, in my experience, been very successful; whilst in others, without apparent reason, it has quite failed of its purpose. A similar effect may be sometimes produced by making a small linear burn with the galvano-cautery all round the cornea.

Symblepharon (adhesion of lid to globe after destruction of conjunctiva), unless very extensive, can be greatly improved by operations. In slight cases we have merely to separate the adhesion from the globe and bring together the edges of the ocular conjunctiva to cover the surface exposed, and thus prevent reunion. But when the surface exposed by the dissection is large, flaps of conjunctiva with broad pedicles must be brought down to cover the deficiency in the manner first proposed by Teale;* or mucous membrane may be transferred from the lip of the patient, or even from the conjunctiva of a rabbit. Snellen has lately used a flap of neighbouring skin with a pedicle, pushing it through a sort of button-hole in the lid, and attaching it in the gap made by separating the adhesions.

B. OPERATIONS ON THE LACRIMAL APPARATUS

1. *Lacrimal abscess.* (See p. 75.)

2. *Slitting up the lower canaliculus.*—This is best done by means of a knife with a blunt or probe point, and a blade narrow enough to enter the punctum. The best forms of these knives are Weber's knife, with a probe end (Fig. 132); Bowman's, with nearly parallel borders and a rounded end (Fig. 133); and Liebreich's (Fig. 134). Posi-

* Teale, 'Ophth. Hosp. Reports,' iii, p. 253 (1861).

tion as for 1. (1) The lower lid is drawn tightly outwards and downwards by the thumb. (2) The canaliculus knife is passed *vertically* into the punctum, then turned horizontally and passed on through the neck of the canaliculus till it reaches the bony (inner) wall of the lacrimal sac. It is then raised up from heel towards point,



FIG. 132.—Weber's canaliculus knife.



FIG. 133.—Bowman's canaliculus knife.



FIG. 134.—Liebreich's knife for canaliculus and nasal duct.

and thus made to divide the canaliculus, care being taken that the neck is freely divided. Liebreich's knife cuts its own way without being raised. The lower canaliculus may also be divided with a Beer's knife (Fig. 157), which is run along a fine grooved director (Fig. 131), previously introduced. In cases of mucocoele it is good practice to divide the wall of the sac freely, and some surgeons open the upper as well as the lower canaliculus. The canaliculus requires to be kept open every three or four days till its cut edges are healed, or they will unite again.

3. *Probing the nasal duct.*—After dividing the canaliculus pass a good-sized lacrimal probe horizontally along its floor till it strikes the inner (bony) wall of the sac. Then raise it to the vertical position, and push it steadily

FIG. 131.—Canaliculus director.



down the duct (downwards and a very little outwards and backwards) till the floor of the nose is reached. Bowman's earlier probes were in six sizes, of which the largest was $\frac{1}{20}$ inch in diameter. Bowman afterwards adopted much larger probes with bulbous ends; and several such patterns are now in use. The probe used should be the largest that will pass easily.

4. *A stricture of the duct* may be incised with any of the canaliculus knives, although Weber's and Bowman's are too slender to be used with safety. Liebreich's is intended to be so used, and a special knife for the purpose had previously been introduced by Stilling. The knife is used as a probe, being pushed quite down the duct, then partly withdrawn, turned in another direction, and pushed down again. There is generally bleeding from the nose.

In all these procedures we must be certain that the probe or knife rests against the bony (nasal) wall of the lacrimal sac before it is raised into the vertical direction. If the probe be stopped at the entrance of the canaliculus into the sac (as may easily happen if the canal be not thoroughly slit in its whole length), the lid will be pulled upon and puckered whenever the instrument is pushed towards the nose; but if the probe have reached the sac, backward and forward movements will not usually cause puckering of the lid. If in the former case the instrument be turned up, and an attempt made to pass it down the duct, a false passage will probably be made.

The direction of the two nasal ducts is either parallel, or such that if prolonged upwards they would converge slightly; they very seldom diverge. The probe when in the duct should, even if, as usual, its lower end be curved forwards, rest against and indent the eyebrow; if it stand forwards from the brow it is usually in a false passage.

Lacrimal syringes are of two kinds: (1) Anel's syringe, with a nozzle fine enough to pass into the unopened

punctum (Fig. 135). By injecting a little water into the duct through the canaliculus we can sometimes clear out slight, apparently mucous obstruction, and relieve epiphora

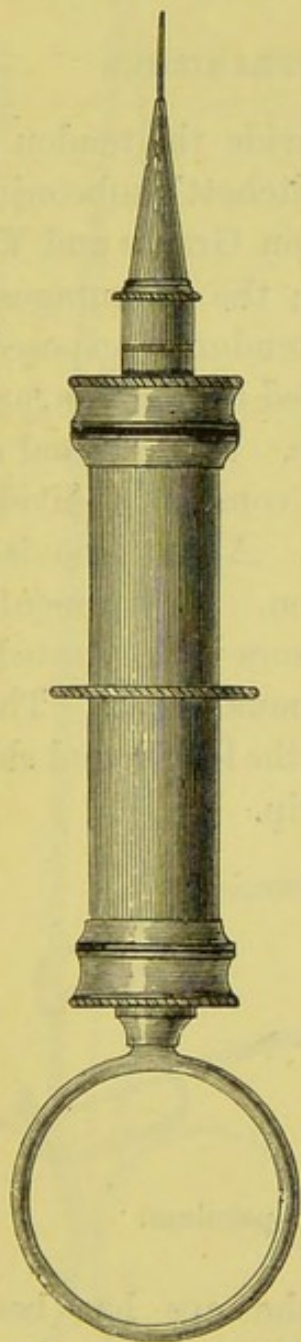


FIG. 135.—Anel's syringe,
full size.

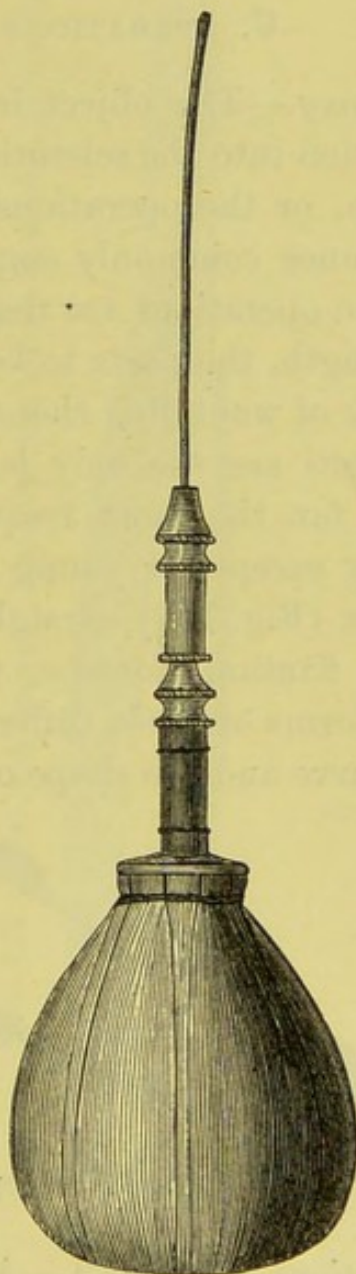


FIG. 136.—Bowman's syringe,
about half full size.

without cutting or probing; and by the same method we can often decide whether or not there is an obstruction needing the severer treatment. (2) Hollow probes attached

to syringes of various patterns are used for passing down the duct and syringing at the same time. Fig. 136 shows a simple form sold as Bowman's.

C. OPERATIONS FOR STRABISMUS

Tenotomy.—The object is to divide the tendon close to its insertion into the sclerotic. Critchett's subconjunctival operation, or the operations of Von Graefe and Von Arlt are the ones commonly employed; the advantages of the latter two operations are that the tendon is exposed in its whole length, the parts to be divided can be seen, and there is no risk of wounding the sclerotic. The internal and external recti are the only tendons commonly divided, the internal far the more frequently. Anæsthesia is seldom necessary except for young children. Instruments: stop speculum (Fig. 137), straight scissors with blunted points, toothed fixation forceps, strabismus hook. There are several forms of hook, differing in the length and sharpness of the curve and the shape of the tip.

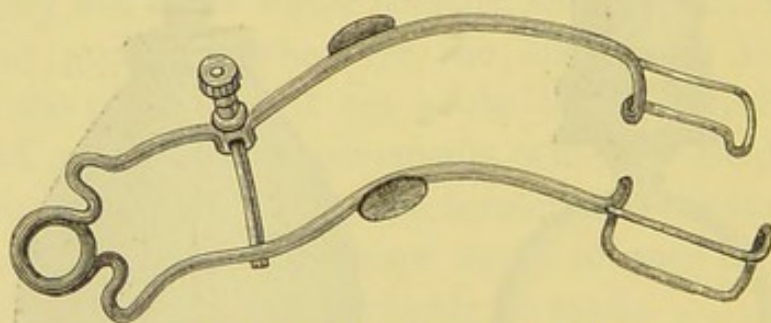


FIG. 137.—Stop spring speculum.

Operations.—*Graefe's.*—After the eye has been thoroughly cocainised the speculum is introduced, and an incision is made transversely over the insertion of the tendon sufficient to expose its whole width; the conjunctiva being pushed aside, Tenon's capsule is opened below the tendon; the hook is then passed under the tendon, and

the latter divided with the scissors. The conjunctival wound may be closed by a single stitch. Von Arlt's opera-

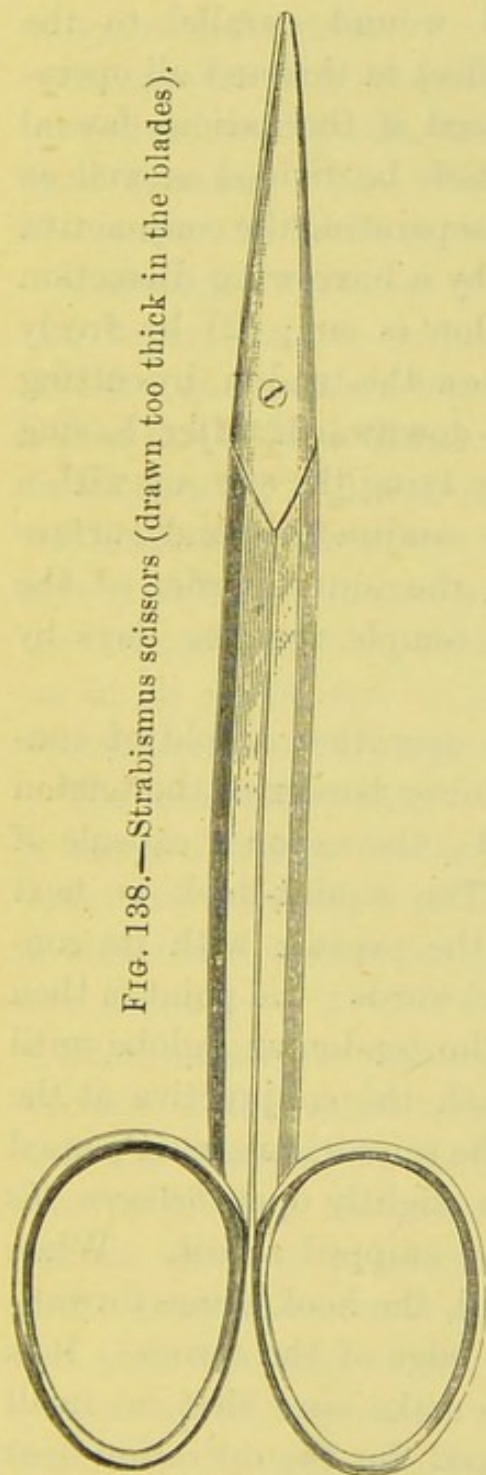


FIG. 138.—Strabismus scissors (drawn too thick in the blades).

FIG. 139.—Fixation forceps; the teeth are shown in section at the end.





FIG. 140.—Strabismus hook (the bent part is represented too thin).



tion differs from the one just described in that the squint-hook is dispensed with; after the tendon is exposed it is

grasped by the fixation forceps and divided. It certainly has the merit of being much less painful, and can be used with children frequently without a general anæsthetic. Snellen makes the conjunctival wound parallel to the muscle to avoid gaping. The effect in this and all operations may be considerably increased if the various fascial or indirect connections of the muscle be divided as well as its tendon. This is done (1) by separating the conjunctiva from the fascia and its muscle by a burrowing dissection with the scissors before the tendon is cut; (2) by freely dividing the fascia above and below the tendon, by cutting with the scissors upwards and downwards after having divided the tendon itself; (3) by tying the eye out with a silk suture passed through the conjunctiva and surface fibres of the sclerotic, close to the outer border of the cornea, and attaching it to the temple for two days by strapping.

Critchett's operation.—In this operation a fold of conjunctiva is pinched up over the lower border of the tendon close to its insertion and divided; the exposed capsule of Tenon is similarly divided. The squint-hook is next passed through the opening in the capsule with its concavity downwards and point backwards; the point is then made to sweep round between the tendon and globe until its end is seen projecting beneath the conjunctiva at the upper border of the tendon. The scissors are next passed into the wound with the blades slightly open *between the hook and the eye* and the tendon snipped across. When the whole tendon has been divided, the hook comes forward beneath the conjunctiva to the edge of the cornea. It is well by introducing the hook to make sure that no small strands of the tendon have escaped, for the operation does not succeed unless the division is complete.

No after-treatment is needed, but the patient is more comfortable if the eye be tied up for a few hours.

The difficulties for beginners are—(1) to be sure of opening the fascia; (2) to avoid pushing the tendon in front of the scissors, especially when only the upper part remains undivided.

Simple division of one internal rectus without separation and division of fascia diminishes the squint by about two lines (4 mm.). The effect, however, is often much less if the patient be adult or nearly so.

Liebreich's operation is Critchett's with the addition of the separation of conjunctiva from the fascia, and the division of the fascia beyond the edges of the tendon described at p. 370. These additions to simple tenotomy can be more easily and thoroughly applied to Graefe's operation when the incision is over the tendon, and after a considerable trial I have ceased to use Liebreich's method. In any case of considerable convergent squint, or squint operated on in an adolescent or adult, I prefer Graefe's method, which admits of the maximum effect being easily obtained.

The immediate effect of the tenotomy of a rectus muscle is lessened after a few days by the reunion of the tendon with the sclerotic, but after a few weeks or months it is sometimes again increased by the stretching of this new tissue.

Readjustment or advancement consists in bringing forwards to a new attachment the tendon of a rectus (generally the internal) which has become attached too far back after a previous tenotomy, or is acting inefficiently, as in various cases of primary divergent squint; advancement of the external rectus is also used in simultaneous conjunction with tenotomy of the internal in high degrees of convergent squint, especially when the squint is of many years' duration. Indeed, whether performed for divergent or convergent strabismus, tenotomy of the opponent muscle is generally needed. There are several different operations, but in all of them the tendon is held in its new position

by sutures. The operation is tedious, but may often be done under cocain. The instruments are the same as for tenotomy.

I now generally perform the operation as follows (essentially the method described by Tweedy):*—(1) A stitch of fine silk is first put through conjunctiva and surface fibres of sclerotic close to the inner edge of cornea and exactly on the horizontal line; this is to serve as a guide in case the eyeball rotates afterwards. (2) The tendon is exposed by a vertical wound in the conjunctiva about 5 mm. from the corneal border, the fascia opened above and below, and a hook passed under the tendon. (3) A stitch is passed through the upper part of the muscle alone (not including conjunctiva), some way from its attachment, and tied round the included part of the muscle, and the needle then passed beneath conjunctiva and fascia and brought out above the upper edge of the cornea; the lower part of the muscle is treated in the same way; the tendon is then divided from the sclerotic with scissors, and (if thought necessary) shortened by cutting off the portion in front of the sutures. The needle carrying the central (guide) thread is now passed from behind forwards through the muscle between the other two sutures and overlying conjunctiva and tied. The upper and lower stitches are then tied tightly. The conjunctiva is a good deal dragged upon above and below, but soon stretches, or the sutures partly cut through. The opponent rectus is divided before the sutures are tied. The eyes should both usually be kept quietly tied up for several days, and the stitches be left in for a week, or until they come away (if silk).

D. EXCISION OF THE EYE

Instruments as for squint. The operator may stand either behind or in front. (1) Divide the ocular conjunc-

* Tweedy, 'Lancet,' March 22nd, 1884.

tiva all round, close to the cornea. (2) Open Tenon's capsule, and divide each rectus tendon and the neighbouring fascia on the hook; the two obliques are seldom divided on the hook. (3) Make the eye start forwards by pressing the speculum back behind the equator of the globe. (4) Pass the scissors backwards along the sclerotic till their open blades can be felt to embrace the optic nerve (recognised by its toughness and thickness), and divide it by a single cut, while steadying the globe with a finger of the other hand. Finish by dividing the oblique muscles and remaining soft parts, close to the globe. Apply pressure for a minute or two, and then tie up tightly for six or eight hours with an elastic pad of small sponges overlaid by cotton wool. There is scarcely ever serious bleeding. The artificial eye may be fitted in from three to four weeks.*

After some weeks or months a button of granulation tissue occasionally grows from the scar at the bottom of the conjunctival sac, and should be snipped off.

The operation is more difficult when the eye is ruptured or shrunken, or the surrounding parts much inflamed and adherent. The order of division of the muscles is immaterial. The important points are to leave as much conjunctiva as possible, so as to form a deep bed for the glass eye, and by keeping the scissors close to the globe during the whole operation, to avoid unnecessary laceration of the tissues.

When, as in some cases of intraocular tumour, it is desired to remove another piece of the optic nerve, the nerve should be felt for with the finger, seized and drawn

* The glass eye must be renewed as often as it gets rough, generally at least once a year. Some persons have much difficulty in tolerating it, and they must be content to wear it for only a part of the day. It is always to be removed at bedtime.

forward with the forceps, and cut off further back with the scissors.

Substitutes for excision of the eyeball.—*Abscission* is the removal of a staphylomatous cornea with the front part of the sclerotic, leaving the hinder part of the globe, with the muscles attached, to serve as a moveable stump for carrying the artificial eye. Four or five semicircular needles carrying sutures are made to puncture and counter-puncture the sclerotic, just in front of the attachments of the recti; the part of the globe in front of the needles is cut off, the needles drawn through, and the sutures tied. The operation is admissible only when the ciliary region is free from disease, and has therefore a very limited application; even in the most favorable cases the stump is not entirely free from the risk of setting up sympathetic inflammation, and I therefore never perform it. It is said that if the sutures are passed only through the conjunctiva or the muscles, the risk is less than when they are passed through the sclerotic.

The operation of *optico-ciliary neurotomy*, in which the optic nerve and all the ciliary nerves are divided without removal of the globe, with the view of preventing sympathetic disease, appears to me to be bad surgery. The sensibility of the cornea, abolished by the operation, often returns, proving that the ciliary nerves have reunited. The cut ends of the optic nerve have also been found reunited, and though union may be prevented by exsection of a considerable piece of the optic nerve, the same cannot be done with the ciliary nerves. The operation therefore cannot be relied upon to destroy these, nor, it may be added, any of the other possible paths (p. 147) along which sympathetic irritation and inflammation may travel; indeed, sympathetic inflammation has been observed to follow the operation in at least one case.

Evisceration of the eye, long ago performed in certain cases by sundry operators, has been systematically practised and advocated by Mr Mules,* of Manchester, and Professor Gracfe, of Halle. The front of the eye is removed at the sclero-corneal junction, and the whole contents of the globe emptied out with any convenient instrument, very great care being taken to remove every trace of choroid and ciliary body. Mr Mules then, after enlarging the scleral opening by a vertical slit, introduces into its cavity an hermetically closed, hollow

* Mules, 'Trans. Ophth. Soc.,' v, 200 (1885).

glass ball, and stitches the sclerotic carefully over it with fine catgut, the conjunctiva being separately sewn afterwards. The parts should be irrigated during the whole operation. There is more reaction than after excision, and if the sclerotic be much inflamed, or if suppuration occur, the stitches may give way. The introduction of the glass globe is not an essential part of the proceeding, its object being merely to improve the stump. Graefe advocates evisceration as less likely than excision to be followed by meningitis—a terrible accident, which every now and then occurs. Mules defends it as likely to be, equally with excision, a safeguard against sympathetic disease whilst allowing a better stump for the artificial eye.

E. OPERATIONS ON THE CORNEA

1. *Removal of foreign bodies.*—Instruments: a steel spud (Fig. 141), or a broad needle with double cutting edge (Fig. 142). A 2 per cent. solution of cocain is to be




FIG. 141.—Corneal spud.



FIG. 142.—Broad needle.

dropped in two or three times within five minutes. The operator stands behind the patient, who is seated in a chair, and, keeping the lids apart with his index and ring fingers, steadies the eyeball by placing his middle finger against its outer or inner side. The chip is gently picked or tilted off by placing the edge of the spud beneath it, or, if firmly embedded, a certain amount of scraping may be necessary. If the foreign body be barely embedded in the epithelium, a touch with a little roll of blotting-paper will often detach it. When a fragment of iron has been present for more than a couple of days its corneal bed is usually stained by rust, and a little plate or ring of brown corneal slough can often be picked off after the removal of the chip; but, as a rule, this minute slough may be left to separate spontaneously. *After-treatment.*—Tie the eye up, so as to protect the corneal surface from friction and irritation.

Atropine is to be used if there be marked congestion and photophobia.

When a splinter is deeply and firmly embedded, especially if it have penetrated the cornea and is projecting into the anterior chamber, its removal is often very difficult. Unless great care be taken the splinter in such a case may be pushed on into the chamber, and the iris or lens be wounded. This may sometimes be prevented by passing a broad needle through the cornea at another part, and laying it against the inner surface of the wound, so as to form a guard or foil to the foreign body, the latter being removed by spud or forceps from the front.

A foreign body in the anterior chamber should in recent cases always be removed, and the piece of iris on which it lies must generally be excised. In cases of old standing we may judge by the symptoms whether to operate or not.

2. *Paracentesis* of the anterior chamber.—Position as for 1, or recumbent; general anæsthesia not necessary. Instruments: a paracentesis needle (Fig. 143) with a very small, short, triangular blade, bent at an obtuse angle (like a minute bent keratome); or a broad needle (Fig. 142). The former is more safe, as the blade is too short to reach the iris or lens, even if the patient should jerk his head. If the contents of the chamber do not follow the needle on its withdrawal, a small probe (Fig. 143) is passed

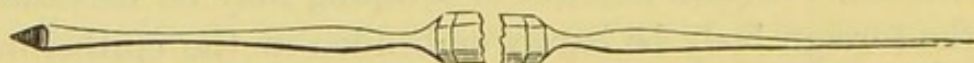

FIG. 143.—Paracentesis needle and probe mounted on same handle.

into the wound. In cases where the operation needs repeating every day or two the original wound can generally be reopened with the probe. Speculum and fixation forceps should be used unless the patient has good self-control.

3. *Corneal section* for hypopyon ulcer.—Position recum-

bent; general anæsthesia seldom needed. Instruments: a Graefe's or Beer's cataract knife (Figs. 151 and 157), speculum and fixation forceps. The incision is carried through the whole thickness of the cornea from one side of the ulcer to the other, being both begun and finished in sound tissue. Or it may be placed entirely in sound cornea, or at the sclero-corneal junction, leaving the ulcer untouched; the last position avoids all risk of wounding the lens.

The knife is entered at an angle with the plane of the iris, its edge straight forwards; when its point is seen, or judged to have perforated the cornea, the handle is depressed until the back of the knife lies parallel with the iris, and the blade then pushed straight across the ulcer to the point chosen for counter-puncture; often in practice it is simply pushed on till it cuts out. The aqueous ought not to escape until the point of the knife is engaged in its counter-puncture, but an earlier escape cannot always be avoided. If it be desired to keep the wound open, its edges are to be separated by a probe every second or third day. The wound closes quickly at first unless kept open, but after having been opened a few times it sometimes remains patent for longer.

4. *Cauterisation* of the cornea is best performed with a very fine galvano-caustic terminal. The finest terminal of Paquelin's instrument may be used, but its action cannot be so well localised owing to the greater bulk of the heated metal. If the eye be much congested I generally apply solid cocain hydrochlorate to the part to be burnt, and to the part where the fixation forceps will be applied.

Operations for conical cornea.—The object is to produce a scar at the apex of the cone, which by contracting shall reduce the curvature, and so diminish the high degree of irregular myopic astigmatism to which the condition gives rise.

There are several methods. (1) Graefe's treatment consisted in first carefully shaving off the apex of the cone without entering the anterior chamber, and then producing an ulcer by touching the raw surface with solid mitigated nitrate of silver (F. 1), and so obtaining a scar. This method is more painful and less safe than others, and is now seldom used. (2) In another operation the apex of the cone is cut off with a cataract knife, the anterior chamber being entered, and the wound either left to close or united by sutures; there are several different modes of removing the little piece. (3) Sir William Bowman removed the outer layers of the cone by means of a very delicate cutting trephine, and left the surface to heal and contract. (4) The galvanic cautery is now being a good deal used instead of the knife or trephine; I have found that the opacity left by the cautery is apt to engage a larger area than that caused by the cutting operations, but more experience is needed before deciding on the relative merits of Nos. 2 and 4.

After-treatment.—Atropine and compressive bandage until the wound has closed; antiphlogistic treatment, and heat locally, if inflammatory symptoms arise.

All operations for conical cornea are difficult to perform and somewhat uncertain in result, but in many cases vision improves, from barely seeing very large letters before operation, to reading small print afterwards. The final result is never gained for several months. An artificial pupil may be necessary if a large corneal opacity finally remain.

F. OPERATIONS ON THE IRIS

A portion of the iris is very often removed by operation (iridectomy), with various objects. The principal of these are—(1) the direct improvement of sight by altering the position and size of the pupil (artificial pupil); (2) to

influence the course of an active disease—glaucoma, iritis, ulcer of cornea with hypopyon; (3) to remove the risks attending “exclusion” and “occlusion” of the pupil, by restoring communication between the anterior and posterior chambers; (4) as a stage in the extraction of cataract.

Iridectomy often causes astigmatism by giving rise to flattening of that meridian of the cornea which forms a right angle with the operation wound, and by bringing the edge of the cornea and lens into use permits the spherical aberration (Fig. 9) which the iris naturally prevents; striæ, if present in the lens, add to these difficulties, all of which are, *cæteris paribus*, greater if the artificial pupil be large and uncovered by the upper lid. Thus it is evident that an artificial pupil should seldom be made for the optical improvement of sight unless the opacity in or over the natural pupil be such as to interfere seriously with visual acuteness.

Artificial pupil.—The object is to remove the portion of iris in the position best adapted to sight; thus, in cases of leucoma the iridectomy is made opposite the clearest part of the cornea. When the state of the cornea allows it, the new pupil should be made down-inwards or straight downwards; the next best place is outward or out-upward; and straight upwards is, of course, least useful, because the new pupil will be covered by the lid. The coloboma should generally be small, and often only the inner (pupillary) part of the chosen portion is to be removed, the outer (ciliary) part being left (Fig. 144), so as to prevent the light passing through the margin of the lens (p. 15). After such an operation the pupil will be oval or pear-shaped, and widest towards the centre. The incision should lie in the corneal tissue if only the pupillary part of the iris is to be removed; but if only a narrow zone of cornea remain clear the incision must lie a little outside the sclero-corneal junction, lest its scar should interfere with the



FIG. 144.—
Iridectomy
downwards
and inwards
for artificial
pupil.

transparency of the remaining clear cornea. The loop of iris should be cut off with a single snip.

In iridectomy for glaucoma the coloboma is to be large, the iris to be removed quite up to its ciliary attachment, and the incision to lie as far back in the sclerotic as possible (1 to 2 mm. from the border of the cornea is not too far). The coloboma should be wider towards the wound than towards the pupil (so as to form a "keyhole pupil") (Fig. 145). The loop of iris, when drawn out, is usually cut first in one angle of the wound, then torn from



FIG. 145.—
Iridectomy
for glaucoma.
(De Wecker.)

its ciliary attachment by carefully drawing it over to the other angle of the wound, and its other end cut there.

The difficulty of making an artificial pupil (for optical purposes) of the best shape, *i. e.* broad towards the natural pupil and narrow towards the circumference, is, owing to the small size of the parts, much greater than would be at first supposed, and several methods are in use. In Mr Critchett's *iridodesis* a loop of iris is drawn out, and strangulated by a fine ligature tied round it over the incision; the little loop soon drops off, and the result is a pear-shaped pupil, with its broad end towards the centre. Irritation, and even destructive irido-cyclitis, sometimes follow, and the operation has therefore been abandoned. Another plan is to draw out a small loop of iris with a blunt hook (Tyrrell's hook), and to cut off only the pupillary portion; this method is uncertain, but, on the whole, it gives good results.

Iridotomy (iritomy).—In this operation an artificial pupil is formed by the natural gaping of a simple incision in the iris. It is only applicable when the lens is absent. Through a small incision in the cornea, between the centre and margin, the scissors (shears) shown at Fig. 146 are passed; the more pointed blade is passed behind the iris as

far as is deemed necessary, and the iris and false membrane divided by a single closure of the blades. It is sometimes necessary to make a second cut at an angle with the first, so as to include a V-shaped tongue of iris which will shrink and allow a larger pupil.

Iridotomy is most useful when the iris has become tightly drawn towards the operation scar by iritis occurring after cataract extraction (Fig. 158). The line of the cut in the iris should lie, as nearly as may be, *across* the direction of its fibres, and should always be as long as possible. In cases of this sort, or when, even without such dragging of the iris towards the scar, the pupil is filled by iritic or cyclitic membrane after cataract extraction, iridotomy yields a better pupil than iridectomy, with less disturbance of, and no dragging upon, the ciliary body.

The operation of iridectomy.—Position recumbent; the operator usually stands behind. Anæsthesia is often advisable, but many operators prefer cocain; I myself prefer general anæsthesia whenever the operation is critical or likely to be difficult. Instruments: stop speculum (Fig. 137), fixation forceps, bent keratome (Fig. 147), iris forceps, bent at various angles according to the position of the iridectomy (Fig. 149), iris scissors, de Wecker's or those with elbow bend (Fig. 148), of which some patterns have one or both blades probe-pointed, a eurette (Fig. 153) or small metallic spatula for replacing the

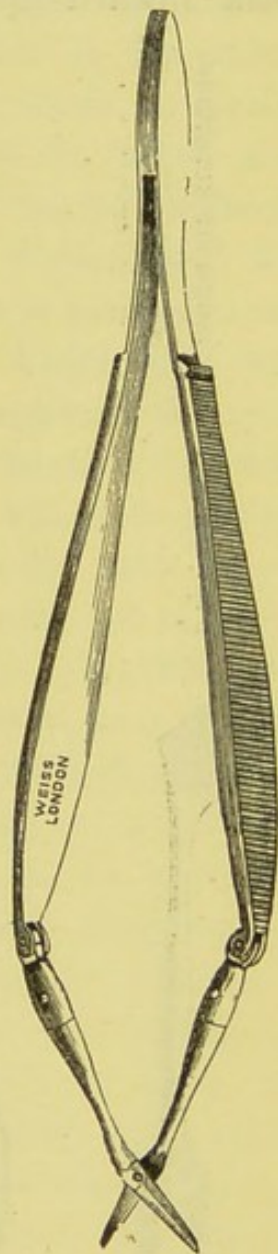


FIG. 146.—Iridotomy scissors.

cut ends of the iris, and preventing their incarceration in the angles of the wound. The iridotomy scissors (Fig. 146) are very convenient, especially for downward and inward operations, and for the left hand. Most

FIG. 147.—Bent triangular keratome.

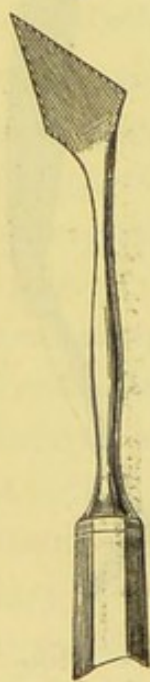


FIG. 148.—Iridectomy scissors.

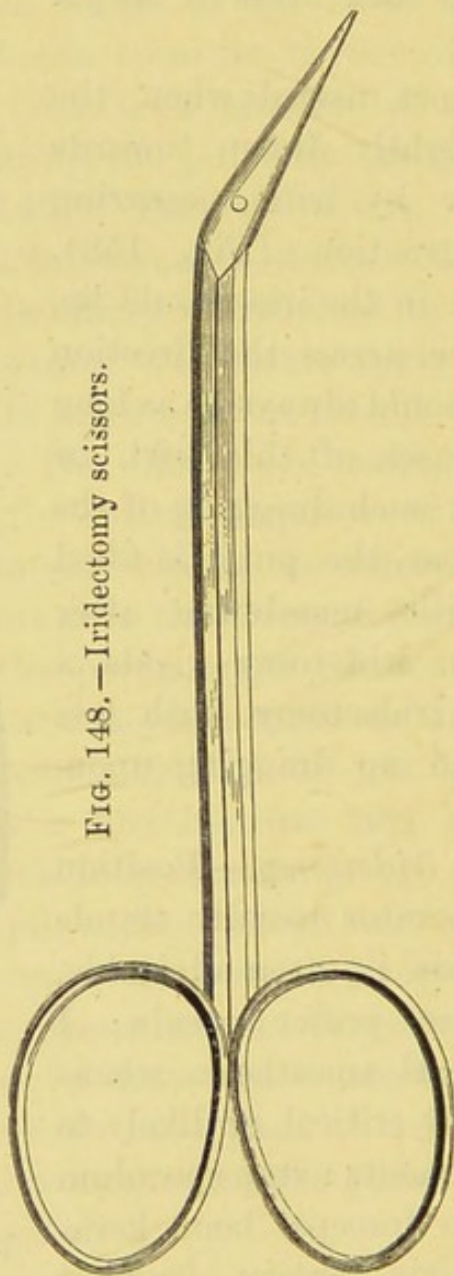



FIG. 149.—Iris forceps.



operators prefer Graefe's cataract knife (Fig. 151) to the triangular keratome, in iridectomy for glaucoma.

The conjunctiva is held by the fixation forceps near the cornea, at a point opposite to the place selected for puncture. (1) The keratome is to be entered slowly, steadily

pushed on across the anterior chamber till the wound is of the desired size, then slowly withdrawn, and, in withdrawal, its blade carefully turned to one side, so as to lengthen the internal wound. Two points need attention: as soon as the point of the knife is visible in the anterior chamber, it must be tilted slightly forwards to avoid wounding the iris and lens; and care must be taken not to tilt it sideways, for if this be done the wound, instead of lying parallel with the border of the cornea, will lie more or less across that line. The incision is made almost as much by lifting the eye against the knife with the fixation forceps, as by pushing the knife against the eye. The forceps are now laid down, or if fixation be still necessary, they are given to an assistant, who is to gently draw the eye into the position required for the next step; in so doing he is to draw away from the eye, not to push the ends of the forceps against the sclerotic. (2) The iris forceps are introduced, closed, into the wound, and passed very nearly to the pupillary border of the iris, before being opened, and made to grasp it. By seizing the pupillary part of the iris its inner circle is certain to be brought outside the wound, when the forceps are now withdrawn; if the iris be seized in the middle of its breadth a button-hole may be cut out, and the pupillary part left standing. Often the iris is carried into the wound by the gush of aqueous as the keratome is withdrawn, and it is then seized without passing the forceps so far into the chamber. (3) The loop of iris having been cut off, either at a single snip, or by cutting first one end and then the other, as in glaucoma (p. 380), the tip of the curette or spatula is passed into each angle of the wound to free the iris, should it be entangled; it is important to make sure that no iris is left incarcerated in the track of the wound. The speculum is now removed, and the eye, or both eyes, bandaged over a pad of cotton wool, either with a four-

tailed bandage of knitted cotton, or two or three turns of a soft cotton or flannel roller.

The anterior chamber is refilled in twenty-four hours, except in cases of glaucoma, when the wound frequently leaks more or less for several days. It is as well in all cases to keep the eye bandaged for a week, the wound being but feebly united, and likely to give way from any slight blow or other accident. When the incision lies in, or partly in the sclerotic, some bleeding generally occurs; when the eye is much congested this hæmorrhage is considerable, and the blood may run into the anterior chamber either during or after the excision of the iris; it can be drawn out by depressing the lip of the wound with the curette, but if the chamber again fills, no prolonged efforts need be made, since the blood is usually absorbed without trouble in a few days. In diseased, especially glaucomatous eyes, however, its absorption is often slow. Secondary hæmorrhage sometimes occurs from a diseased iris several days after the operation.

Sclerotomy is an operation for dividing the sclerotic near to the margin of the cornea. It is employed in glaucoma instead of iridectomy, or after iridectomy has failed. The pupil is to be contracted as much as possible by eserine before the operation. It is often performed subconjunctivally, a Graefe's cataract knife (Fig. 151) being entered through the sclerotic near the margin of the cornea,* passed in front of the iris, and brought out at a corresponding point on the other side, so as to include nearly one third of the circumference; the puncture and counter-puncture are then enlarged by slow sawing movements; the central quarter of the sclerotic flap and the whole of the conjunctiva (except at the punctures) are left undivided. The knife is then slowly withdrawn. The whole

* De Wecker makes it 1 mm. from the clear cornea. In my own operations the distance is generally about 2 mm.

operation is to be done very slowly, that the aqueous humour may escape gradually; any rush of fluid is likely to carry the iris into the wound and cause a permanent prolapse, a result to be carefully avoided. If prolapse occur the iris should be excised, and the operation then becomes a very peripheral iridectomy. A moderate degree of bulging and separation of the lips of the two scleral wounds takes place for a week or two, when the scar flattens down, and finally a mere bluish line is left. Sclerotomy is also performed with a triangular keratome (Fig. 147), the incision being just as for a very peripheral iridectomy, but no iris being removed or allowed to prolapse. Sclerotomy is difficult to perform well, is not free from risk, and on the whole has not answered early expectations; it is, however, valuable as a reserve for certain cases. In Fig. 150, *I* shows the line of incision in iridectomy for glaucoma, and *S* the line in sclerotomy.

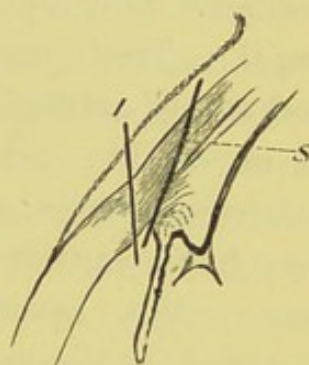

FIG. 150.—Diagrammatic section of ciliary region, showing path of wound in iridectomy for glaucoma (*I*) and in sclerotomy (*S*).

(Compare Fig. 100, 1 and 2.)

G. OPERATIONS FOR CATARACT

1. *Extraction of cataract* has been systematically practised for nearly a century and a half. The operation has passed through several important changes, and procedures differing more or less from each other are still in use. All the operations are difficult to perform well, and much practice is needed to ensure the best prospect of success. The sources of possible failure are many, and as in avoiding one we are very apt to fall into another, it cannot be expected that any one operation will, in all its details, ever be universally adopted. At present the majority of surgeons

adhere more or less closely to the operation known as the "modified linear" method of von Graefe, in which iridectomy forms a step in the proceeding. Many operators, however, dispense with iridectomy on account of the cosmetic and optical advantages of a round pupil. That many cataracts can be easily and safely extracted without iridectomy admits of no doubt; and it appears equally certain that some cases, especially where the lens is very hard, cannot be dealt with properly in this way. Any operator of experience is fully justified in leaving the iris intact unless there




FIG. 151.—Graefe's cataract knife.




FIG. 152.—Cataract spoon.

be difficulty in delivering the lens through the pupil, or difficulty in perfectly replacing the iris afterwards, or the patient be very restless; in either of these events iridectomy should be performed at the moment when required. Eserine used just before and a few times after the operation appears to assist in preventing prolapse of the iris afterwards. If prolapse occurs, as it may, several days after operation, it is best to remove it carefully, as in a case of accidental wound (p. 163).

All operations for extraction of hard cataract agree in the following points:—(1) An incision is made in the cornea, at the junction of cornea and sclerotic, or even



FIG. 153.—Cystitome (upper end) and curette (lower end).

slightly in the sclerotic, large enough to give exit to the crystalline lens unbroken, and unaltered in shape. The knife now almost universally employed is the narrow, thin straight knife of von Graefe (Fig. 151). (2) The capsule is freely opened with a small sharp-pointed instrument (cystitome or pricker, Fig. 153). (3) The lens is removed through the rent in the capsule (the latter structure remaining behind), either by pressure and manipulation outside the eye, or by means of a traction instrument (scoop or spoon, Fig. 152) passed into the eye just behind the lens. Few operators, however, use the scoop, except for certain emergencies and special cases.—(4) Iridectomy is very often performed as the second stage. This part of the operation was originally introduced, less with the object of facilitating the exit of the lens, than with that of preventing prolapse of the iris and lessening the after risks of iritis. But these untoward results do not occur so often with cocain and antiseptics as formerly; and, as already stated, many now omit iridectomy. A few of the many surgeons who adhere to iridectomy prefer to perform it some weeks or months before the extraction of the lens (“*preliminary iridectomy*”); the theory being that iritis is less likely to follow if the cut edges of the iris are soundly healed before the lens rubs against them on its way out. Patients, however, will not, or cannot, always submit to this subdivision of the operation for cataract, and for this and other reasons of expediency preliminary iridectomy cannot be employed so largely as may, perhaps, on theoretical grounds be desirable. In my own practice I keep it for cases where special risks or difficulties are present, as, *e. g.*, where the patient has only one eye.

The following are the chief varieties of operation for cataract at present practised.

(a) *Simple linear extraction* (best described here, though not applicable to hard cataract). A small incision (4 to

6 mm.) is made by a keratome (Fig. 147) well within the margin of the cornea, with a small iridectomy if necessary. After opening the capsule the lens is squeezed out piecemeal, or coaxed out by depressing the outer lip of the wound with the curette (Fig. 153). Only quite soft cataracts, or those in which the nucleus, though firm, is very small, can be so dealt with.

The wish to extend the principle of a straight wound to full-sized hard cataracts, led von Graefe, in 1865, to introduce (*b*) the "*modified linear*" or "*peripheral linear*" extraction, in which the incision lies slightly beyond the sclero-corneal junction (Fig. 155, 2), and consequently involves the conjunctiva, of which a flap is made. The incision is intended to form an arc of the largest possible circle, *i. e.* of the scleral, not of the corneal curve; its plane, therefore, must lie as nearly as may be in a radius of the scleral curve, and at a considerable angle with that of the iris (Fig. 156, 2). A large iridectomy is performed as the second stage. The incision is made with the Graefe knife (Fig. 151), which is at first directed towards the centre of the pupil and then brought up to the seat of counter-puncture. The edge is turned somewhat forward during the greater part of the proceeding, and the cut completed by sawing movements if needful. The disadvantages of the peripheral linear extraction are—the frequency of bleeding from the conjunctiva into the anterior chamber, the parts being thus obscured; a considerable risk of loss of vitreous, owing to the peripheral position of the wound, and sometimes a difficulty in making the lens present well; a small but appreciable risk that the operated eye will set up sympathetic inflammation, the wound lying in the "dangerous region" (p. 147); lastly, there is a tendency to make the wound rather too short in order to avoid some of these risks, and thus difficulties are introduced in the clean removal of the lens.

Its great advantage lies in the rapid healing and consequent small attendant risk of suppurative inflammation.

A variety of this operation consists in placing the incision rather further down, and at the same time giving it a somewhat sharper curve, so that it forms an arc of a smaller circle than before, but is still not concentric with the cornea (Fig. 155, 3, upper section). The puncture is directed somewhat downwards (as at the right-hand end of the figure), and its plane, which at the puncture and counter-puncture is almost parallel with the iris, alters to nearly a right angle at the summit of the flap. The track of the wound, if shaded, would appear as in the figure.

(c) *Short flap* (de Wecker).—The incision, made with the same knife, lies exactly at the sclero-corneal junction, and is of such an extent that it has a height of about 3 mm. ($\frac{1}{4}$ of the diameter of the cornea) (Fig. 154). A narrow rim of conjunctiva remains attached to the flap. The iridectomy, if made, is small (as in Fig. 144). For very bulky cataracts this incision is not quite large enough.



FIG. 154.—
Short flap.

(d) The incision has nearly the same curve and plane as in b, but the greater part of it lies considerably within the

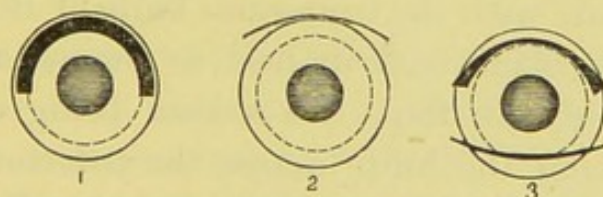


FIG. 155.—Paths of incision for extraction of cataract. 1, old flap; 2, peripheral linear; 3 (upper fig.), a variety of the peripheral linear; (lower fig.) corneal section. The wound appears as a narrow slit (2) or a broad tract (1), when seen from the front, according to the inclination of its plane. The dotted circle shows the average outline of the lens. Compare Fig. 156.

margin of the cornea (*corneal section*), and iridectomy is usually dispensed with. Liebreich and Bader made the

section downwards, its plane forming an angle of about 45° with that of the iris (Fig. 155, 3, lower section). In Lebrun's corneal operation an almost identical section is made upwards; the upper section of 3, Fig. 155, if placed further in the cornea, would nearly represent it. The corneal operations, without iridectomy, are easy to perform, compared with those in which the section lies further back; the wound, however, does not, on the whole, heal so quickly, and it is more likely to reopen about the fourth or fifth day.

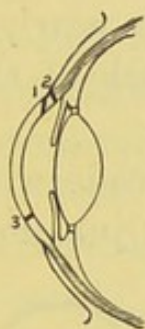


FIG. 156.—The same sections seen in profile showing the plane of the incision in 1, 2, and the lower section of 3.

(e) *Old flap extraction* (Daviel, Beer, now very little used).—The incision was slightly within the visible margin of the cornea, concentric with it, and equal to at least half its circumference (1, Fig. 155), thus forming a large arc of a small circle, the plane of the incision being parallel with that of the iris (1, Fig. 156); no iridectomy was made. The inci-



FIG. 157.—Beer's cataract knife.

sion was made with the triangular knife of Beer (Fig. 157), in which the blade near its heel is somewhat wider than the height of the flap, the section being completed by simply pushing the knife across the anterior chamber flat with the iris, its back corresponding to the base of the intended flap. The inner length of the wound is less than the outer by the thickness of the obliquely cut cornea at each end (1, Fig. 155).

The flap operation was usually done without either anæsthesia, speculum, or fixation forceps. The after-treatment was troublesome. But the great height of the flap, in proportion to its width, renders it very liable to

gape, or even to fall forwards; and this, with the fact that the whole wound lies in corneal tissue, considerably increases the risks of large and dangerous prolapse of the iris and of rapid suppurative inflammation of the cornea. For these reasons the old flap extraction has been almost abandoned in favour of the peripheral linear, corneal section, and short flap operations, which yield a much larger average of useful eyes.

Historically, the flap operation was the earliest; then came the linear operation; thirdly, the modified or peripheral linear operation, with iridectomy; then the modern corneal operations and short flap, the aim of which is to gain the substantial advantages both of the old flap and the modified linear methods, without the great risks of the former or the imperfections of the latter; lastly, iridectomy has, as stated above, been again abandoned, more or less completely, by many operators.

Of other operations the most important is Pagenstecher's, in which the lens is removed by a scoop in its unbroken capsule. It is most applicable to cataracts which are over-ripe or are complicated with old iritis, and to Morgagnian cataract (p. 174).

(For methods of dealing with unripe senile cataract see p. 178.)

The chief *complications* which may arise *during extraction of cataract* are—(1) Too short an incision; this is best remedied by enlarging with a small bent “secondary knife.” (2) Escape of vitreous before expulsion of the lens; this is a signal for the prompt removal of the lens with a scoop (Fig. 152), the vitreous being afterwards cut off level with the wound by scissors. (3) Portions of the lens remaining behind after the chief bulk has been expelled; they should be coaxed out by gentle manipulation after removal of the speculum.

After-treatment of extraction.—The patient is best in bed

for from four to seven days. The dressing consists of a piece of soft linen overlaid by a pad of cotton wool or alem-broth tissue, and kept in place by a four-tailed bandage of knitted cotton, or a narrow flannel or open tissue roller. Both eyes are to be bandaged. It is advantageous to apply outside the bandage a light wire cage to prevent the patient from striking or rubbing the eye during sleep. The room is usually kept partly dark for about a week, all dressings and examinations being made by the light of a candle.

Some operators keep their cataract patients from the first in daylight, and with no other dressing than some strips of isinglass plaster to maintain closure of the lids. Others bandage only the operated eye. Old people occasionally get delirious if kept in bed and in the dark after extraction of cataract or iridectomy, and for such, at any rate, the ordinary rules as to bandaging, darkness, and confinement to bed must be relaxed. In my experience the subjects of this delirium have usually been alcoholics; but I believe that imprudent use of strong mydriatics may produce it in some old persons who have not been habitual drinkers.

During the first few hours there will be some soreness and smarting, and at the first dressing, from twelve to twenty-four hours after operation, a little blood-stained fluid; but after this there should be no material discomfort, and nothing more than a little mucous discharge, such as old people often have. The dressings are removed, and the lids gently cleansed with warm water once or twice a day, their edges being separated by gently drawing down the lower lid, so as to allow any retained tears to escape: this cleansing is very grateful to the patient. Some surgeons open the lids and look at the eye the day after the operation; but many prefer to leave them closed for several days unless there are signs that the case is doing badly (p. 178). It is a good practice to use one drop of atropine daily after the third day, to prevent adhesions should iritis

set in ; but if no iridectomy have been made, I prefer not to use atropine till about the fifth day, because if the wound should reopen whilst the pupil is dilated prolapse of iris is more likely to occur than if the pupil be small. When first examined the eye is always rather congested from having been tied up ; but there should be no chemosis, the wound should be united so as to retain the aqueous, and its edges should be clear. The pupil is expected to be black unless it is known that portions of lens matter have been left behind. If all be well, the bandage may be left off during the daytime at the end of a week or ten days, a shade being worn ; but it should be re-applied at night for the first two or three weeks to prevent accidents from movements during sleep. At the end of a fortnight, if the weather be fine, the patient may begin to go out, the eyes being carefully protected from light and wind by dark goggles, and he may be out of the surgeon's hands in from three to four weeks.

After-operations.—When iritis occurs (p. 179) the pupil becomes more or less occluded by false membrane, and the subsequent contraction of this membrane may draw the iris towards the scar, so that the pupil is at once blocked and displaced (Fig. 158). In slight cases, where

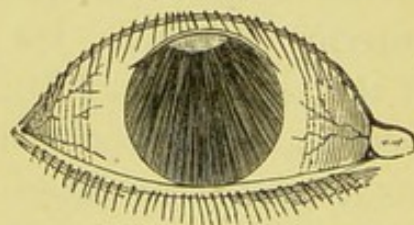


FIG. 158.—Diagram of occlusion and displacement of pupil from iritis, after upward extraction of cataract.

the pupil is not dragged out of place, sight is greatly improved by simply tearing across the membrane and capsule with a fine needle, and treating the case as after discission of soft cataract. In doing this the needle should be passed deeply enough to tear the posterior capsule also, so that the vitreous by bulging forward may keep the opening in the capsule patent (*compare* Discission of Soft Cataract), in which care is taken *not* to go so

deeply. But in severer cases an artificial pupil must be made, either by iridectomy or iridotomy (p. 380).

2. *Solution (discission) operations.*—In these the lens is gradually absorbed by the action of the aqueous humour admitted through a wound in the capsule (pp. 176 and 182).—(1) The pupil is fully dilated by atropine; (2) the lids are held open by the fingers, or a stop speculum and fixation forceps used; (3) a fine cataract needle (Fig. 159)



FIG. 159.—Cataract needle.

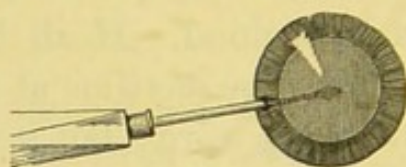


FIG. 160.—Discission of cataract.

is directed to a point a little within the border of the cornea (usually the outer border), and when close to its surface is plunged quickly and rather obliquely into the anterior chamber. Its point is then carried to the centre of the pupil (Fig. 160), dipped back through the lens-capsule, and a few gentle movements made so as to break up the centre of the anterior layers of the lens; (4) the needle is then steadily withdrawn. Special care is taken not to wound, nor even touch, the iris, either on entering or withdrawing the needle, not to stir up the lens too freely, nor to go so deeply as to perforate the posterior capsule and so engage the vitreous. A general anæsthetic is necessary only for young children or excessively nervous patients; but it should always be in readiness and the patient prepared.

After-treatment.—The pupil to be kept widely dilated with atropine (F. 33), a drop being applied after the operation, and at least six times a day afterwards, or much oftener if there be threatening of iritis. Ice or iced water is usually to be applied constantly for twenty-four to forty-

eight hours after the operation,* as for threatened traumatic iritis (p. 137), and the patient to remain in bed in a darkened room for a few days. A little ciliary congestion for two or three days need cause no uneasiness; but the occurrence of pain, increase of congestion, and alteration in the colour of the iris (commencing iritis) are indications for the application of leeches near the eye, and the more frequent use of atropine.

If the cataract is complete, no marked change will be seen for some weeks; if partial (*e. g.* lamellar), in a day or two the part of the lens near the needle wound, and in a few days the whole lens, will become opaque. In from six to eight weeks the lens will have become notably smaller (flattened or hollowed on the front surface). If the eye be perfectly quiet, but not unless, the operation may now be repeated in exactly the same way, and with the same after-treatment and precautions, but the needle may be used more freely. The bulk of the lens will generally disappear after the second operation, but the needle may have to be used a third or a fourth time for the disintegration of small residual pieces, or in order to tear the capsule if it have not retracted enough to leave a clear central pupil. A small whitish dot remains in the cornea at the seat of each needle puncture.

Extraction by suction.—This operation (like *simple linear extraction*, p. 387) is applicable to completely soft cataracts. The pupil is to be dilated by atropine. The lens-capsule is opened as in discission, but more freely. Then an incision is made obliquely through the cornea, between its centre and margin, with a keratome (Fig. 147) or broad needle (Fig. 142), and the nose of the syringe passed through the wound and gently dipped into the lacerated lens-substance. By very gentle suction the semi-fluid lens-

* I have to thank my colleague, Mr Gunn, for this valuable suggestion.

matter is then drawn gradually into the syringe. The instrument is not to be passed behind the iris in search of fragments. Nearly the whole of the lens can thus be removed. The after-treatment is the same as for needle operations. Two forms of syringe are in use: Teale's, in which the suction is made by the mouth applied to a piece of flexible india-rubber tubing; Bowman's, in which the suction is obtained by a sliding piston worked by the thumb moving along the syringe. It is often better, and in lamellar cataract necessary, to break up the lens freely with a fine needle a few days before using the syringe, and thus allow it to be thoroughly macerated and softened in the aqueous humour; atropine and ice must be used freely in the interval between this needle operation and the suction; and the surgeon must be prepared to interfere before the day appointed for the suction, should severe pain or increase of tension occur from the rapid swelling of the lens (p. 182). Suction is more difficult to perform, and perhaps less safe, than simple linear extraction, but I have myself no objection to make against it.

Anæsthesia in ophthalmic surgery.—Before the introduction of cocain (October, 1884) there was much diversity of practice in respect to anæsthesia, many surgeons preferring to perform extraction of cataract, tenotomy for squint, and simple iridectomy, without anæsthesia, whilst others preferred ether or chloroform for nearly all operations. Cocain has immensely facilitated operating without general anæsthesia, but of course some will continue to use ether or chloroform, where others feel able to rely solely on the local anæsthetic. In using cocain for the eye we have to remember that it does not affect the sensibility of the borders of the lids, nor in any constant manner that of the iris, unless used many times for at least half an hour, nor that of the muscles and deeper parts, unless injected under the conjunctiva. Hence the introduction

and pressure of the speculum are always more or less felt, there is usually some little pain when the iris is seized and drawn out, and decided pain when, in tenotomy, the tendon is stretched on the hook (unless subconjunctival injection have been resorted to). It must further be remembered that the patient is conscious and knows that something critical is being done, and that his good behaviour depends almost as much on absence of fear as on absence of feeling; and, again, that the painlessness of one step of an operation (*e. g.* the section in extraction of cataract) contrasts strongly with the sensation or pain felt in another stage (*e. g.* the iridectomy), and that the patient will be likely to start or jump, unless warned, at such a stage. My own experience leads me to use cocain in all cataract extractions and discissions (unless for some peculiar reason ether or chloroform be needed), for nearly all tenotomies and operations for corneal ulcer and conical cornea, and for some simple iridectomies; and to avoid it usually in iridectomy for glaucoma and for synechiæ, whether anterior or posterior. I have not myself used it much for lacrimal cases; nor have I excised the eyeball under its influence; but it may be used for both purposes with fair success. For small lid tumours, subcutaneous injection is very successful. For granular lids or lupus of conjunctiva, a strong solution (10 to 20 per cent.) may be painted on before touching with actual cautery or caustics; but it is better for such cases, and also whenever the eyeball is congested and painful, to use the solid cocain salt, powdered and rubbed over the surface with a brush or the finger. For cataract a solution of 2 per cent., or a single disc containing $\frac{1}{200}$ grain, repeated three times within five minutes of the operation, is generally quite enough. Solutions should be freshly made.

PART III

DISEASES OF THE EYE IN RELATION TO GENERAL DISEASES

CHAPTER XXIII

IN stating very shortly the most important facts bearing on the connection between diseases of the eye and of other parts of the body, it is convenient to make the following subdivisions:—(A) the eye changes as part of a general disease; (B) the ocular disease as symptomatic of some local malady at a distance; (C) the eye sharing in a local process, affecting the neighbouring parts.

(For the clinical details of the various eye diseases referred to in this chapter, *see* Part II.)

A. General diseases, in which the eye is liable to suffer.

Syphilis is, directly or indirectly, the cause of a large proportion of the more serious diseases of the eye.

1. *Acquired syphilis*.—Primary stage.—Hard chancres are occasionally seen on the eyelid, and even far back on the conjunctiva (p. 70).

Secondary stage (sore throat, shedding of hair, eruption and condylomata).—*Iritis* is common between two and eight or nine months, and does not occur later than about eighteen months, after the contagion; in from two thirds to three fourths of the cases both eyes suffer; there is a marked

tendency to exudation of lymph (plastic iritis), shown by keratitis punctata, haze of cornea, and less commonly by lymph-nodules on the iris. In some cases there are symptoms of severe cyclitis, leading to detachment of retina and secondary cataract, with little iritis; but the cyclitis of acquired syphilis does not give rise to ciliary staphyloma (*compare* p. 143). Syphilitic iritis is sometimes protracted, and may relapse after complete subsidence. *Choroiditis* and *retinitis* generally set in rather later, from six months to about two years after the chancre; seldom as late as four years.* The two conditions are most often seen together, but either may appear singly; and in each the vitreous generally becomes inflamed. These conditions are essentially chronic, the retinitis being often, and the choroiditis sometimes, liable to repeated exacerbations or recurrences; whilst in some cases the secondary atrophic changes progress slowly for years, almost to blindness, often with pigmentation of the retina. Syphilitic choroiditis and retinitis usually affect both eyes, but often in an unequal degree, and even when severe the disease is occasionally limited to one eye.—*Keratitis*, indistinguishable from that of inherited syphilis, is amongst the rarest events in the acquired disease; when it occurs it is usually in the secondary stage of the disease.

Later periods.—Ulceration of the skin and conjunctiva of the lids, gummatous infiltration of the lids and sclerotic, and nodes in the orbit (whether cellular or periosteal) occur but rarely. *Oculo-motor paralysis* is one of the frequent ocular results of syphilis. It may depend upon gumma (syphilitic neuroma) of the affected nerve or nerves in the orbit or in the skull, or upon gummatous inflammation of the dura mater at the base of the skull, matting the nerves together, or on disease of nerve-centres. The

* A few cases are on record in which it appeared not to have begun till about ten years after infection.

gummatous nerve-lesions seldom occur very late in tertiary syphilis.

The optic disc is often inflamed or atrophied as an indirect result of syphilitic disease of the eye or of the nervous system; but the terms "syphilitic optic neuritis" and "syphilitic optic atrophy" are not often applicable in any more direct sense (*compare* p. 229).—The retinitis of the secondary stage affects the disc, and, when atrophy of the retina and choroid occur, the disc becomes wasted in proportion; whilst in rare cases the retinitis of secondary syphilis is replaced by well-marked papillitis. Such cases must not be confused with others, still more rare, in which double papillitis, passing into atrophy, occurs with all the symptoms of severe meningitis in secondary syphilis. Tertiary syphilitic disease, anywhere within the cranium, commonly causes optic neuritis, in the same way as do other coarse intracranial lesions (p. 223); but neuritis may also be caused more directly by gummatous inflammation of the trunk of the optic nerve, or of the chiasma. Primary progressive atrophy of the discs occurs in association with locomotor ataxy and ophthalmoplegia externa of syphilitic origin; probably in a few instances the optic atrophy occurs alone, or for a time precedes the other changes in syphilitic, as it is known to do in non-syphilitic ataxy.

Sight is liable to be rapidly damaged from severe acute loss of blood, especially from the stomach; usually both eyes suffer, but often unequally. When seen quite early papillitis has been found, but the cases are often not seen till the appearances of atrophy have come on.

2. *Inherited syphilis*.—*Iritis* corresponding to that in the acquired disease is seen in a small number of cases, and occurs between the ages of about two and fifteen months. It often gives rise to much exudation, leading to occlusion of the pupil, and is frequently accompanied by deeper changes (cyclitis and disease of vitreous). It is very often sym-

metrical, and is much commoner in girls than boys. *Choroiditis* and *retinitis*, of precisely the same forms as in acquired syphilis, occur at the corresponding period of the disease, *i. e.* between six months and about three years of age; and they show as much (some observers think more) tendency to the degenerative and atrophic results already described; in severe cases there are not uncommonly signs of cerebral degeneration. In the later stages, *keratitis*, which is the commonest eye disease caused by inherited syphilis, occurs. It is commonest between six and fifteen years old, but is sometimes seen as early as two or three years, and is occasionally deferred till after thirty. The disease is frequently complicated with *iritis* and *cyclitis*, and though tending to recovery, shows a considerable liability to relapse. It almost always attacks both eyes, though sometimes at an interval of many months. When the patient is unusually young, the disease as a rule runs a mild and short course.—The *oculo-motor palsies* occur but rarely in inherited syphilis, but a few well-authenticated cases are on record.

Smallpox causes inflammation and ulceration of the cornea, leading, in the worst cases, to its total destruction, but in a large number to nothing worse than a chronic vascular ulcer. The corneal disease comes on some days after the eruption (tenth to fourteenth day from its commencement), and after the onset of the secondary fever. *Iritis*, uncomplicated and showing nothing characteristic of its cause, sometimes occurs some weeks after an attack of smallpox. Only in very rare cases do variolous pustules form on the eye, and even then they are always on the conjunctiva, not on the cornea.

Scarlet fever, *typhus*, and some other exanthemata may be followed by rapid and complete loss of sight, lasting a day or two, showing no ophthalmoscopic changes, and ending in recovery. Such attacks are believed to be

uræmic or at any rate dependent on some toxic condition of the blood. A peculiarity of these cases is the preservation of the action of the pupils to light.—Very severe purulent or membranous ophthalmia sometimes occurs during scarlet fever.

Diphtheria.—By far the commonest result is paralysis (often incomplete) of both the ciliary muscles (*cycloplegia*); the pupils are not affected except in severe cases, when they may be rather large and sluggish.* The symptoms generally come on from four to six weeks after the commencement of the illness, last about a month, and disappear completely. Diphtheritic cycloplegia is usually, but not invariably, accompanied by paralysis of the soft palate. In most of the cases seen by ophthalmic surgeons the attack of diphtheria has been mild, sometimes extremely so, the case often being described as “ulcerated throat;” but inquiry often yields a history of other and severer cases in the family, and of general depression and weakness in the patient out of proportion to his throat symptoms. We find that most of the patients who apply with diphtheritic cycloplegia are hypermetropic, doubtless because those with normal (and *a fortiori*, with myopic) refraction are much less troubled by paresis of accommodation, and often do not find it necessary to seek advice. Concomitant convergent squint is sometimes developed in hypermetropic children during the diphtheritic paresis, owing to the increased efforts at accommodation (p. 338). Paralysis of the external muscles is occasionally seen; I have never myself seen any except the external rectus affected, and recovery has been rapid.

Diphtheritic and membranous ophthalmia are occasionally caused by direct inoculation of the conjunctiva of the attendant by diphtheritic material from the patient's

* Further observations are wanted.

throat; or in the patient himself by extension up the nasal duct to the conjunctiva. But in many cases of "diphtheritic" and "membranous" ophthalmia the disease seems to be local, the inflammation taking on this special form without ascertainable relation to any infectious disease. No doubt there is often something peculiar in the patient's health, or in the state of his eye-tissues, which gives a proclivity to this kind of inflammation. Thus diphtheritic ophthalmia of all degrees is more common in young children than in adults; the worst cases generally occur after measles, or during or after scarlet fever, broncho-pneumonia, or severe infantile diarrhoea; old granular disease of the conjunctiva also confers a liability to a diphtheritic type of inflammation, and the same tendency is sometimes seen in ophthalmia neonatorum and in gonorrhœal ophthalmia.

Measles is a prolific source of ophthalmia tarsi in all its forms, and of corneal ulcers, particularly of the phlyctenular forms. It also gives rise to a troublesome mucopurulent ophthalmia, and under bad hygienic conditions this may be aggravated, by cultivation and transmission, into destructive disease of purulent, membranous, or diphtheritic type. Double optic neuritis has been seen in several patients after measles.

Mumps.—Enlargement of the lacrimal gland sometimes accompanies or follows that of the parotid. Cases have been reported by Hirschberg and others in which the lacrimal gland, but not the parotid, was enlarged. Dr Swan M. Burnett* called attention to haze of disc with venous engorgement of retina and failure of sight during mumps. Edema of lids and conjunctiva, and in one case paresis of third nerve, pointed to effusion into the orbit. The symptoms as a rule quickly subsided.

* Burnett, 'Amer. Journ. of Med. Sci.,' Jan., 1886, p. 86.

Chicken-pox is sometimes followed by a transient attack of mild conjunctivitis.

Whooping-cough often, like measles, leaves a proneness to corneal ulcers. In a few rare cases the condition known as *ischæmia retinæ* (sudden, temporary, arterial bloodlessness) has occurred. Conjunctival orbital or cerebral hæmorrhages may occur during the violent attacks of coughing; the latter may occasion muscular paralyses.

Influenza.—In the epidemics of the last few years many ocular complications have been reported, optic neuritis, iritis, glaucoma, and muscular defects of various kinds; but considering the almost universal prevalence of the scourge, such complications must be considered uncommon.

Malarial fevers, especially the severe forms met with in hot countries, are sometimes the cause of retinal and other intra-ocular hæmorrhages, and even of considerable neuro-retinitis; when there is much pigment in the blood the swollen disc may have a peculiar grey colour. When renal albuminuria is caused by malarial disease, albuminuric retinitis may occur. Simple optic neuritis with failure of sight, followed by recovery, seems to occur sometimes, and amblyopia of more than one form is said to be produced by malarial poisoning; some cases have recovered under quinine. Loss of sight from malarial fever must not be confused with blindness due to the quinine administered for its cure (p. 408).

Relapsing fever is sometimes followed, during convalescence, by inflammatory symptoms with opacities in the vitreous (cyclitis), with or without iritis; recovery takes place. These cases are commoner in some epidemics than in others. In a large outbreak Lubinski saw no eye cases in patients under twenty years of age, and none in females.

Epidemic cerebro-spinal meningitis also, in a few cases, gives rise to acute choroiditis, with pain, chemosis, and

great tendency to rapid exudation of lymph into the vitreous and anterior chambers, and often leading to disorganisation of the eye and blindness.* It is believed that the inflammation may extend to the eye along the optic nerve, or may occur independently in the brain and the eye. Deafness from disease of the internal ear is even commoner than the eye disease.

Purpura has been observed in a few cases to be accompanied by retinal or subretinal hæmorrhages; they are sometimes perivascular and linear, and in other cases form large blotches. They have also, but rarely, been found in *scurvy*. Ecchymosis may also be seen in and around the eyelids in *scurvy*. In that form of *scurvy* which occurs in infants (especially rickety infants) extravasation may also occur † into the orbit, and probably between the roof of the orbit and its very loosely attached periosteum, thus causing proptosis and swelling of the lids, as well as discoloration.

In *pyæmia* one or both eyes may be lost by septic emboli lodging in the vessels of the choroid or retina, and setting up suppurative panophthalmitis. The symptoms are swelling of the lids, loss of sight, congestion, especially of the perforating ciliary vessels (Fig. 27), chemosis, discoloration, and dulness of aqueous and iris. There may or may not be some protrusion and loss of mobility, and conjunctival discharge. Pain, sometimes very severe, may be almost absent; probably its presence indicates rise of tension. A yellow reflex is often seen from the vitreous. The eyeball generally suppurates if the patient

* Possibly a few of the cases in which similar eye conditions are seen without apparent cause may be the accompaniments of slight and unrecognised meningitis. (See *Pseudo-glioma*, p. 198.)

† Barlow, 'Med.-Chir. Trans.,' vol. lxvi; Keating's 'Encyclopædia of Dis. of Children,' art. "Scurvy;" and Holmes Spicer, 'Trans. Ophth. Soc.,' vol. xii.

live long enough. Sometimes both eyes are affected, together or with an interval.—In cases of *septicæmia* abundant retinal hæmorrhages of large size may occur in both eyes; they come on a few days before death, and are thus of grave significance. As they are not present in typhoid and other fevers of corresponding severity, their presence is sometimes an aid in differential diagnosis.*

Lead poisoning is an occasional cause of optic neuroretinitis leading to atrophy, of atrophy ensuing upon chronic amblyopia, and of rapid, usually transient amblyopia. The two former are the most common; the atrophy, whether primary or consecutive to papillitis, is generally accompanied by very marked shrinking of retinal arteries, and great defect of sight or complete blindness; it is generally symmetrical, but one eye may precede the other. Other symptoms of lead poisoning, usually chronic, but occasionally acute, are nearly always present. Care must be taken not to confuse albuminuric retinitis from kidney disease induced by lead with the changes here alluded to, which are due in some more direct manner to the influence of the metal.

The deposition of lead upon corneal ulcers has been referred to at p. 125.

Alcohol.—Some observers still hold that alcohol, especially in the form of distilled spirits, may cause a particular form of symmetrical amblyopia (the so-called *amblyopia potatorum*). Optic neuritis and paralyses of various single oculo-motor nerves are described by Thomsen as occurring in cases of alcoholic paralysis. The difficulty of arriving at the truth depends chiefly upon the fact that most drinkers are also smokers, and that tobacco, whether smoked or chewed, is allowed by all authorities to be one of the causes (or, as most now hold, the sole cause) of a similar disease. The question whether alcohol directly

* Gowers, 'Medical Ophthalmoscopy,' 2nd edit., p. 255.

causes disease of the optic nerves will not be settled until observers are much more careful than they have hitherto been to record as typical cases of alcoholic amblyopia only those in which the patient does not use even the smallest quantity of tobacco in any shape.

Tobacco.—Whatever may be the truth (and it is confessedly difficult to arrive at) as to the direct influence of alcohol, and of the various substances often combined with it, there is no doubt whatever that tobacco, whether smoked or chewed, does act directly on the optic nerves, and in such a manner as to give rise to definite, and usually very characteristic symptoms. The amblyopia seldom comes on until tobacco has been used for many years. The quantity needed to cause symptoms is, *cæteris paribus*, a matter of idiosyncrasy, and very small doses may produce the disease in men who, in other respects also, are unable to tolerate large quantities of the drug. Predisposing causes exert a very important influence: amongst these are to be specially noted increasing age; nervous exhaustion from overwork, anxiety, or loss of sleep; chronic dyspepsia, whether from drinking or other causes; and probably sexual excesses and exposure to tropical heat (or light). A large proportion of the patients drink to excess, and thus make themselves more susceptible to tobacco, by injuring both the nervous system and the stomach. But some remarkable cases are seen in men who have for long been total abstainers, in others who have lately become abstainers without lessening their tobacco, and in yet others who are strictly moderate in alcohol, are in robust health, and in whom increasing age is the only recognisable predisposing cause. The strong tobaccos produce the disease far more readily than the weaker sorts, and chewing is more dangerous than smoking. Probably alcohol in very moderate doses counteracts, rather than increases, the injurious effect of

tobacco upon the nervous system and optic nerves (Hutchinson).

The vapour of *bisulphide of carbon*, if inhaled in a concentrated form and for long periods, produces at first excitement, then general and severe loss of nerve power, with extreme mental and muscular debility and impotence. In some of the cases the sight fails chiefly in the centre of the field (central scotoma), with haze and pallor of the discs (chronic neuritis). The cases are met with either in india-rubber works or oil-mills, in both of which the bisulphide is largely used.*

Quinine, taken in very large doses, at short intervals, has in a few cases caused serious visual symptoms. Sight in both eyes may be totally lost for a time, but recovery more or less perfect takes place eventually, sometimes in a few days, sometimes not for months. There is a great contraction of the visual field even after perfect recovery of central vision; the discs are pale and the retinal arteries extremely diminished. The symptoms are therefore those of almost arrested supply of arterial blood to the retina.

Kidney disease.—The common and well-known retino-neuritis associated with renal albuminuria, and of which several clinical types are found, has been already described. It need only be noted that the disease is commonest with chronic granular kidneys and in the kidney disease of pregnancy, but that it is also seen in the chronic forms following acute nephritis and in lardaceous disease, and that children suffering from chronic renal disease seem as liable to it as adults. Retinitis with renal albuminuria is usually a sign that the kidney disease is far advanced, and the prospect of life very bad. According to Miley, hospital patients seldom live more than six months after the onset of the retinitis ('Trans. Ophth. Soc.,' viii, 132). C. S.

* For full particulars see 'Trans. Ophth. Soc.,' vol. v, pp. 149—175 (1885). Another case is reported by Gunn, *ibid.*, vi, 372 (1886).

Bull finds that the average duration of life is somewhat longer, according to returns from patients of all classes. There is no doubt that the prospect of life for patients who are able to live carefully is considerably better than for others. It seems likely that there is also a group of cases in which the retinal change precedes the signs of kidney disease, these signs appearing later; thickening of the coats of the smaller retinal arteries, giving them when seen by the ophthalmoscope an appearance of bright copper wire, is not unfrequently seen associated with renal disease of the chronic granular form, as has been pointed out by Gunn;* examination of the urine often does not reveal the presence of renal disease, and it is probable that a sclerosis of the small arteries of the body generally may be fairly well advanced without the appearance of any signs of affection of the kidney. Detachment of the retina is an occasional result in extreme cases. The prognosis as regards vision is best in the cases depending on albuminuria of pregnancy. The retinal œdema and exudation are probably caused by the blood-state; but the disease of the small blood-vessels, and the cardiac hypertrophy, no doubt add to and complicate the changes. Indeed, the different types of retinal disease which are met probably depend in great measure on the varying parts played by the three factors alluded to. The failure of sight caused by albuminuric retinitis has often led to the correct diagnosis of cases which had been treated for dyspepsia, headache, or "biliousness."

Diabetes sometimes causes cataract. In young or middle-aged patients the cataract usually forms quickly, and is of course soft. As it is always symmetrical, the rapid formation of double, complete cataract, at a comparatively early age, should always lead to the suspicion of diabetes. In old persons the progress of diabetic cataract is much slower,

* Gunn, 'Trans. Ophth. Soc.,' vol. xii, p. 124.

and often shows no peculiarities. The relation of the lenticular opacity to the diabetes has not been satisfactorily explained: the presence of sugar in the lens, the action of sugar or its derivatives dissolved in the aqueous and vitreous, the abstraction of water from the lens owing to the increased density of the blood, and, lastly, degeneration of the lens from the general cachexia attending the disease, have all been offered in explanation.—It is important to know that diabetic cataract sometimes disappears entirely if the health improves, the lens completely clearing up.* In a few cases retinitis occurs; sometimes with great œdema and copious (probably capillary) hæmorrhages into the retina and vitreous, in other cases with numerous white patches but no œdema. Plastic iritis sometimes occurs in diabetes, both with and without previous operation; Schirmer draws attention to the importance of examining the urine for sugar in cases of intractable iritis. Central amblyopia from disease of the optic nerves has also been observed, even it is said in patients who were not smokers,† and according to Hirschberg affords a grave prognosis.

Leucocythæmia is often accompanied by retinal hæmorrhages, less commonly by whitish spots bordered by blood, and consisting of white corpuscles; these spots may be thick enough to project forwards. Occasionally there is general haziness of the retina. In severe cases the whole fundus is remarkably pale, whether there be other changes or not.‡ The changes are usually symmetrical.

* See cases recorded in 'Trans. Ophth. Soc.,' vol. v, p. 107 (1885).

† See Leber, in the 'Graefe-Saemisch Handbuch,' and a paper by Dr Edmunds and the author, 'Trans. Ophth. Soc.,' vol. iii, 1883. A doubtful case in a woman is recorded in the same paper; and another, also not completely satisfactory, by Samuel, in 'Hirschberg's Centralblatt,' 1882, p. 202. Paper by Moore, 'New York Med. Journ.,' 1888.

‡ For a full account of the changes see Gowers, 'Medical Ophthal-

Progressive pernicious anæmia is marked by a strong tendency to retinal hæmorrhages; these are usually grouped chiefly near the disc, and are striated (Gowers). White patches are also common, and occasionally well-marked neuritis occurs. I have seen hæmorrhages of different dates, and in one case, shown to me by Dr Sharkey, there had evidently been a large extravasation from the choroid at an earlier period. The disc and fundus participate in the general pallor. In *simple anæmia* optic neuritis or retinitis with hæmorrhages are met with: the amount of swelling of the nerve is sometimes very great; it may pass on to atrophy with permanent impairment of vision. The retinitis sometimes has the appearance of typical renal retinitis; it may be one-sided.

Heart disease is variously related to changes in the eyes and alterations of sight. Aortic incompetence often produces visible pulsation of the retinal arteries. This pulsation often differs from that seen in glaucoma in extending far beyond the disc, and in not being so marked as to cause complete emptying of the larger vessels during the diastole. In glaucoma the pulsation is confined to the disc. The difference is explained by the different mode of production in the two cases: in the one incomplete closure of the aortic orifice lowers the pressure in the whole blood-column during the diastole, and allows a reflux of blood from the eye; in the other heightened intraocular tension, telling chiefly on the comparatively yielding tissues of the optic disc increases the resistance to the entrance of arterial blood. Valvular disease of the heart is generally present in the cases of sudden lasting blindness of one eye, clinically diagnosed as embolism of the *arteria centralis retinæ*; but in some of these thrombosis of the artery

moscopy.' Dr Sharkey has shown me a case with diffuse retinitis very numerous punctiform hæmorrhages, chiefly peripheral, and dilatation with extreme tortuosity of the veins.

or of its companion vein, or blocking of the internal carotid* and ophthalmic arteries, has been found *post mortem*. Brief temporary failure, or even loss, of sight may occur in the subjects of valvular heart disease, and in some persons who are liable to recurring headache (*see* Megrin). Repeated attacks of this kind sometimes lead to permanent blindness of one eye, and atrophy of the disc comes on; possibly repeated temporary failures of retinal circulation at length give rise to thrombosis. In another group of cases sight fails during successive pregnancies or lactations, recovering between times: some of these may be mere accommodative asthenopia; others may be due to renal retinitis. Others again are due to uræmic poisoning without ophthalmoscopic signs; in the last-named the failure affects both eyes, and usually develops suddenly. The seat of the affection is probably the cerebral cortex. It is probable that high arterial tension predisposes to intraocular hæmorrhage in cases where the small vessels are unsound, and that the frequent association of retinal hæmorrhage with cardiac disease is thus explained.

Tuberculosis is sometimes accompanied by the formation of tubercles in the choroid. These may occur in acute miliary tuberculosis, whether the meninges be involved or not; but owing to the difficulty of thorough ophthalmoscopic examination in such patients, and the frequently very small size of the choroidal growths, they are much more often seen after than before death. Chronic tubercular tumours of the brain may be accompanied by tubercles of slow growth and larger size in the choroid, and occasionally these attain such dimensions, and cause such active symptoms, as to simulate malignant tumours† (p. 288). It

* Gowers, 'Medical Ophthalmoscopy,' p. 29.

† For interesting cases of and remarks on choroidal tuberculosis in its various forms and relations, *see* communications by Mackenzie,

is also probable that certain cases of localised choroidal exudation, not accompanied by serious general symptoms or by inflammatory symptoms in the eye, may be of tubercular nature (p. 196, 4).

Barlow* has seen tubercles in the choroid *post mortem* in 16 cases; in 13 with, 3 without, tubercular meningitis. Sometimes they took the form of extremely minute dots, "tubercular dust." In 44 children who died of tubercular disease (42 showing miliary tubercles in the meninges) Dr Money† found tubercles in the choroid of one or both eyes in 14.

Rheumatism.—In acute rheumatism Dr Barlow informs me that he has more than once seen well-marked congestion of the eyes and photophobia; but neither iritis nor other inflammatory changes occur. The subjects of chronic rheumatism are, however, liable to relapsing inflammation of the eye, usually taking the form of iritis, but sometimes falling entirely on the scleral or episcleral tissues; whilst in others, less common, the changes are apparently confined to the conjunctiva—rheumatic conjunctivitis. But, however superficial the inflammation (or congestion) may be, there is no muco-purulent discharge. Some of these patients give a history of acute articular rheumatism as the starting-point of their chronic troubles, others of a prolonged subacute attack, lasting for many months, whilst in others again the articular symptoms have never been severe. In yet another series a liability to fascial or muscular rheumatism, or to recurrent neuralgia from exposure to cold or damp, is the only "rheumatic" symptom of which a history is given; in some of these the neuralgia is probably gouty, but we have no exact knowledge of the

Barlow, Coupland, and others in 'Trans. Ophth. Soc.,' vol. iii, p. 119, *et seq.* (Oct., 1882).

* Barlow, *ibid.*, p. 132.

† Money, 'Lancet,' 1883 ii, 813.

nature of this chronic rheumatism of which complaint is so commonly made. It is to be remembered that the eye is now and then the first part to be attacked by an inflammation, which later events show to be clearly related to rheumatism or to gout.

Gonorrhœal rheumatism is not unfrequently the starting-point of relapsing iritis and the other conditions named above, as well as of chronic relapsing rheumatism. Rheumatic iritis occurring for the first time with gonorrhœal rheumatism is, in my experience, more often symmetrical than other forms of arthritic iritis, or than the later attacks of iritis in the same patient—a fact which sometimes makes the distinction between rheumatic and syphilitic iritis difficult.

This statement is based on records of 104 cases of iritis with well-marked rheumatic symptoms, and 6 with gonorrhœa but no rheumatism, in all of which syphilis was, so far as possible, excluded. (*a*) In 34 of this series the first attack of iritis came on during, or very soon after, gonorrhœal rheumatism; and in exactly one half of these the iritis was double. In 6 others (making 40 in all) there were iritis and gonorrhœa, but no rheumatism ("gonorrhœal iritis"), and here the proportions were the same. (*b*) In the remaining 70 cases the first iritis had no relation to gonorrhœa; and in the sub-series the attack was single in 56 and double in, at the most, 13 (two or three being doubtful), or about one fifth. No corresponding difference obtained in regard to relapses, the vast majority of the recurrent attacks in both sub-groups (*a* and *b*) affecting only one eye at a time.

Gonorrhœal iritis.—Some cases of gonorrhœal iritis have been described, in which there is iritis due to gonorrhœa without arthritis being actually present. Probably in these cases the iritis is the first indication of gonorrhœal rheumatism. A variety of quiet conjunctivitis, not due to infection, has also been described without pain, and hardly any discharge.

Rheumatic inflammation of the conjunctival or scleral

type occurring in gonorrhœa must be carefully distinguished from purulent ophthalmia due to infection with gonorrhœal pus.

In some cases of acute inflammation of joints in infants suffering from purulent ophthalmia, the arthritis is believed to be gonorrhœal, but derived from the conjunctiva instead of the urethra.* In a case of this sort fluid obtained from the knee-joint was found by Deutschmann to contain gonococci.

It is believed that rheumatism is the cause of some cases of non-suppurating orbital cellulitis, and of relapsing episcleritis. Rheumatism is also believed to cause some other of the ocular paralyses.

Gout.—Gouty persons are not very infrequently the subjects of recurrent iritis indistinguishable from that which occurs in rheumatism. The pathology of rheumatism is so little understood, that it is not possible to distinguish it in some of its forms from gout; but that the subjects of true "chalk gout" are liable to relapsing iritis is undoubted. There is, on the whole, more tendency to insidious forms of iritis in gout than in rheumatism. It is also generally believed that the subjects of gout, or persons whose near relatives suffer from it, are particularly subject to glaucoma; acute glaucoma was, indeed, the "arthritic ophthalmia" of earlier authors. Hæmorrhagic retinitis generally due to thrombosis of one or more of the retinal veins is also commoner in gouty persons than in others; it may be single or double, and is to be distinguished from albuminuric retinitis.—It has also been observed that the children or descendants of gouty persons, without being themselves subject to gout, are liable, in early adult life, to an insidious form of irido-

* Clement Lucas, 'Brit. Med. Journ.,' 1885, ii, pp. 57 and 699; Fendick, *ibid.*, p. 830; Saswornitzky, abstracted in 'Knapp's Archives,' xv, 232 (1886); Deutschmann, 'Arch. f. Ophth.,' xxxvi, 1, p. 109.

cyclitis (p. 144), which sometimes leads to serious consequences; * both eyes are likely to be attacked sooner or later. The cases in this group probably seem rarer than they are, from the impossibility in many instances of getting a full family history.

Several different clinical types may be recognised in the large group of maladies referred to in this section under the name of "iritis." Besides cases of pure iritis, we meet with examples of cyclitis, in some cases with increase, in others with decrease of tension; in other groups either the sclerotic or conjunctiva are chiefly affected (true "rheumatic ophthalmia" without iritis); a fourth group, in which the pain is disproportionately severe, may be spoken of as neuralgic, and these neuralgic cases are marked by sudden onset, short duration, and great frequency. In a large majority, however, the iris is the headquarters of the morbid action. All "arthritic" eye diseases tend strongly to relapse; they usually attack only one eye at a time, though both suffer sooner or later; and they are all much influenced by conditions of weather, being commonest in spring and autumn.

The strumous condition is a fruitful source of superficial eye diseases, which are for the most part tedious and relapsing, are often accompanied by severe irritative symptoms, but, as a rule, do not lead to serious damage. The best types are—(1) the different varieties of ophthalmia tarsi; (2) all forms of phlyctenular ophthalmia; (3) many superficial relapsing ulcers of cornea in children and adolescents, though not distinctly phlyctenular in origin, are certainly strumous; (4) many of the less common but very serious varieties of cyclo-keratitis in adults occur in connection with lowered health, susceptibility to cold, and sluggish but irritable circulation, if not with decidedly scrofulous manifestations.

* Hutchinson, 'Lancet,' Jan., 1873.

Leprosy may have its seat in almost any part of the eye, but it usually occurs first in the superficial parts, and leads to ectropion, with exposure of the cornea, and xerosis of the conjunctiva; or there may be a deposit of lepromata in the cornea leading to its perforation, and to panophthalmitis; iritis and cyclitis may also occur, and leprous invasion of the retina has also been seen.

Entozoa sometimes come to rest and develop in the eye or orbit. The commonest intraocular parasite is the *Cysticercus cellulosæ*; it is excessively rare in this country, but commoner on the Continent. The cysticercus may be found either beneath the retina, in the vitreous, or upon the iris, and may sometimes be recognised in each of these positions by its movements. The parasite has been successfully extracted from the vitreous; when situated on the iris its removal involves an iridectomy. Sometimes it develops under the conjunctiva, where I have seen it set up suppurative inflammation. The *echinococcus* hydatid with multiple cysts may develop to a large size in the orbit, and cause much displacement of the eyeball.

B. Eye disease, or eye symptoms, indicative of local disease at a distance.

Megrim is well known to be sometimes accompanied, or even solely manifested, by temporary disorder of sight. This generally takes the form of a flickering cloud (*scintillating scotoma*) with serrated borders, which, beginning near the centre of the field, spreads eccentrically, so as to produce a large defect in the field, a sort of hemianopsia; the borders of the cloud may be brilliantly coloured. It is referred to both eyes, and is visible when the lids are closed. The attack lasts only a short time, and perfect sight returns. In many patients this amblyopia is the precursor of a severe sick headache, but in others it constitutes the whole attack; it scarcely ever follows the headache. Less definite and characteristic symptoms (dimness, cloudi-

ness, or muscæ) are complained of by some patients (*compare* p. 412).

Neuralgia of the fifth nerve, especially of its first division, in a few cases precedes or accompanies failure of sight in the corresponding eye, with neuritis or atrophy of the disc (p. 241, 3). A liability to neuralgia of the face and head is not unfrequently observed in persons who subsequently suffer from glaucoma.—Intense neuralgic pain in the face or head sometimes causes dimness of sight of the same eye whilst the pain lasts.—The old belief that injury to branches of the fifth nerve can cause amaurosis is not borne out by modern experience,* injury to the optic nerve by fracture of the skull furnishing the true explanation of such cases (p. 236).

Sympathetic ophthalmitis is the only known instance in which inflammation of the eyeball is caused by local disease of an independent part.

Diseases of the central nervous system may be shown in the eye either at the optic disc (papillitis and atrophy) or in the muscles (strabismus and diplopia).

The diseases which most often cause *papillitis* are intracranial tumours, syphilitic growths, and meningitis. Abscess of the brain and softening from embolism and thrombosis less commonly cause it, and cerebral hæmorrhage scarcely ever.† Papillitis has been found in a few cases of acute and subacute myelitis :‡ it does not occur in spinal meningitis.

In a very large proportion (Gowers thinks at least

* References to many of the earlier cases supposed to prove this relation between the fifth and optic nerves are given by Brown-Séquard in Holmes's 'System of Surgery,' 3rd ed., vol. ii, p. 206.

† A case by Dr Bristowe in 'Trans. Ophth. Soc.,' vol. vi, p. 363 (1886).

‡ Gowers, loc. cit., p. 161; Dreschfeld, 'Lancet,' Jan. 7th, 1882; and Sharkey and Lawford, 'Trans. Ophth. Soc.,' vol. iv, p. 232.

four fifths) of all the cases of *cerebral tumour* (including syphilitic growths) optic neuritis occurs at some period. The severity and duration of the neuritis vary much, and probably depend in many cases on the rate of progress, as well as on the character of the morbid growth. It not uncommonly sets in at no long interval before death, whilst in other cases it is very chronic. There is not much in the characters or course of the papillitis to help us in the localisation of intracranial tumour; and although a very high degree of papillitis, with signs of great obstruction to the retinal circulation, generally indicates cerebral tumour, there are many cases in which the presence of papillitis does not help us to decide the nature of the intracranial disease, whether tumour, meningitis, or syphilitic disease.

Analysing 96 cases of fatal cerebral tumour, Edmunds and Lawford found that optic neuritis was observed in 19 of 41 cases where the disease was at or towards the convexity (or 46 per cent.); whilst it was seen in 41 of 55 cases where the disease was chiefly at the base (or 75 per cent.). In 43 cases the tumour was either in the basal ganglia or the cerebellum, and in 37 of these (=86 per cent.) optic neuritis occurred ('Trans. Ophth. Soc.,' vol. iv, 172, 1884).

Tumours also sometimes cause simple optic atrophy by pressing upon or invading some part of the optic fibres.

Intracranial syphilitic disease is a common cause of papillitis, the disease being either a gummatous growth in the brain, or a growth or thickening beginning in the dura mater, or basilar meningitis. The prognosis is much better than in cerebral tumours if vigorous treatment be adopted early; indeed, in all cases of papillitis where intracranial disease is diagnosed, and syphilis even remotely possible, mercury and iodide of potassium should be promptly given.

Meningitis often causes papillitis, but in this respect much depends on its position and duration. Meningitis limited to the convexity, whatever its cause, is seldom accompanied by ophthalmoscopic changes; on the other hand, basic meningitis very often causes neuritis.

Amongst 16 cases of injury to the head ending in death Edmunds and Lawford never found optic neuritis without basic meningitis; whilst they found no neuritis when the damage was limited to the convexity (Ophth. Soc., Oct., 1886).

The neuritis in basic meningitis is probably proportionate to the duration and intensity of the intracranial mischief, being comparatively slight in acute and rapidly fatal cases, whether tubercular or not. In tubercular meningitis, papillitis is very common,* and its occurrence seems especially related to the presence of inflammatory changes about the chiasma (Gowers); and even the neuritis occurring in cases of cerebral tumour seems often to be caused by secondary meningitis set up by the growth.† In a form of meningitis in young children, named by Drs. Gee and Barlow "posterior basic," optic neuritis is infrequent, though the patients often live some little time.—When patients recover from meningitis, the neuritis may pass into atrophy and cause amaurosis; such cases are well known to ophthalmic surgeons: it is probable that some of them may be instances of recovery from tubercular meningitis.—In rare cases papillitis occurs with severe head symptoms, ending in death, but without macroscopic changes in the brain or membranes. Microscopical changes in the brain substance, justifying the term cere-

* Garlick found it in 23 of 26 fatal cases ('Med.-Chir. Trans.,' vol. lxii). Money (loc. cit.) discovered it in only 16 of 42 fatal cases. Slight papillitis is very easily overlooked in delirious or fretful children.

† Edmunds and Lawford, 'Trans. Ophth. Soc.,' iii, 138 (1883).

britis, have been found in one such case by Dr Sutton, and in another by Dr Stephen Mackenzie.* It must not be forgotten that optic neuritis may be caused by various altered conditions of the blood; and that it is occasionally seen without any evidence either of central nervous disease or of blood changes.

Hydrocephalus rarely causes papillitis, but often at a late stage causes atrophy of the optic nerves from the pressure of the distended third ventricle on the chiasma. Dr Barlow informs me that he has several times seen a very gross form of choroiditis ending in immense patches of atrophy; I have recorded one such case and seen others.

The diseases most commonly causing *atrophy not preceded by papillitis* are the chronic progressive diseases of the spinal cord, especially locomotor ataxy. The atrophy in these cases is slowly progressive and double, though seldom beginning at the same time in both eyes; it almost always ends in blindness, although sometimes not until after many years. Similar atrophy sometimes occurs in the early stages of general paralysis of the insane, but chiefly in cases complicated by marked ataxic symptoms. It is also, but much more rarely, seen in lateral and in insular sclerosis. In the latter amblyopia with slight neuritic changes is occasionally seen, and sight may improve or almost recover after having been defective for some time. In cases of homonymous lateral hemianopia we find that sometimes the blind half of the field is separated from the seeing half by a straight line which seems to pass through the fixation point (Fig. 93); but more commonly this dividing line deviates towards the blind half in the central part of the field, thus leaving a small central area of perfect vision. Careful observations show that the dividing line probably never actually passes through the fixation point; the explanation of this is that fibres from the macular region pass through both optic

* Also a case by Dr Silk, 'Brit. Med. Journ.,' May 26th, 1883.

tracts and both hemispheres, so that central vision is not destroyed by disease of either tract.

Motor disorders of the eyes.—Some of the commoner causes of ocular palsy have been already given. It may be mentioned here that basic meningitis often causes paralysis of one or more of the ocular nerves, with squinting (and double vision if the patient be conscious); and further, that the palsy in such cases often varies, or appears to vary, from day to day.

Locomotor ataxy and general paralysis of the insane are sometimes preceded by paralysis (usually, but not always, temporary) of one or more of the eye muscles, causing diplopia; and there may for years be nothing else to attract attention. The same diseases may also be ushered in by internal ocular paralysis. The most frequent variety is loss of the reflex action of the pupils to sensory stimulation of the skin and to light, whilst their associated action remains, "reflex iridoplegia;" when shaded and lighted they remain absolutely motionless, but they contract with convergence of the eyes, and dilate again when the eyes cease to converge (p. 26) ("Argyll-Robertson symptom").* This phenomenon is often, though by no means always, associated with a contracted state of the pupils; hence the term "spinal miosis" is often, but incorrectly, used. This reflex paralysis of the iris is one of the most valuable of the early signs of locomotor ataxy. We do not, however, yet know how often it may occur in healthy persons or without eventual spinal disease; it certainly has comparatively little significance in old persons. Recent observations show that, at least in general paralysis of the insane, loss of reflex dilatation to sensory stimulation of the skin (p. 27) is probably the earliest pupillary change.† The complementary symptom, loss of associated, with

* Argyll Robertson, 'Edinburgh Med. Journ.,' 1869, p. 703.

† Bevan Lewis, 'Trans. Ophth. Soc.,' vol. iii, 1883.

retained reflex, action of the pupils, has not been fully studied. Any of the other internal paralyses may also in certain cases occur as precursors of ataxy.—Paralysis of one third nerve coming on with hemiplegia of the opposite side may, but does not necessarily, indicate disease of the *crus cerebri* on the side of the palsied third nerve.*—Ophthalmoplegia externa has been already mentioned; it may here be added that cases occur in which this condition appears to be “functional,” in which, at any rate, the symptoms come on quickly and pass off completely, recurring perhaps at a later period; of these cases I have seen several in young adults.

Double ophthalmoplegia externa is the extreme type of a large and important class of ocular palsies, to which much attention has been given recently, characterised by the paralysis of certain *movements* (usually associated movements of the two eyes), not of the *muscles* supplied by a certain nerve. There may be, *e. g.*, loss of power of both eyes to look upwards (both superior recti), or loss of power to look to the right (R. external and L. internal rectus); and yet in the latter case the L. internal rectus, if differently associated, as with the R. internal during convergence, may act perfectly well. Such associated paralyses are explained by lesions (usually sclerotic, occasionally tumour) affecting the centres for certain combined movements, which are more central anatomically and higher physiologically than the centres of origin of the nerve-trunks. Cases of paralysis of both third or both sixth nerves, and also of complete ophthalmoplegia, are sometimes due to symmetrical coarse disease (syphilitic gummata, for instance) of the affected nerve-trunks. The symptoms in all the cases referred to in this paragraph may be temporary or permanent, acute or chronic, and

* For exceptions see Robin, ‘*Troubles Oculaires dans les Maladies de l’Encéphale*,’ 1880, p. 95.

caused by various fine or coarse anatomical changes; and they are frequently associated with other and graver nervous symptoms. It is of great importance in cases of multiple and associated ocular paralysis to make out, if we can, whether the symptoms point to peripheral disease (disease of nerve-trunks), or to disease of the nuclei of origin of the nerves, or to lesion of the centres for certain movements.

Cases of *recurrent paralysis* of ocular nerves, most frequently of the third nerve, have been described, associated with periodic headache on the same side; from the few *post-mortem* examinations that have been made, the symptoms appear to be due to small innocent growths in the trunk of the affected nerve.*

Insular (disseminated) sclerosis is often accompanied by nystagmus, characterised by irregularity both of the amplitude and rapidity of the movements, and by pallor and atrophy of the optic nerves.

Hysterical eye symptoms (*see* pp. 246, 351).

C. Cases in which the eye shares in a local process affecting the neighbouring parts.

In *herpes zoster* of the first division of the fifth nerve the eye participates. When only the supra-orbital or supra-trochlear branches are attacked the eyeball usually escapes, or is only superficially congested. But if the eruption occur on the parts supplied by the nasal branch (*i. e.* if the spots extend down to the tip of the nose) there is usually inflammation of the proper tissues of the eyeball (ulceration or infiltration of cornea, and iritis); for the sensitive nerves of the cornea, iris, and choroid are derived, through the long root of the ophthalmic ganglion, from the nasal branch. Occasionally the eye suffers, however, when the nasal branch escapes. The pain and swelling of the herpetic region are often so great that the attack gets the

* *See* Holmes Spicer and Ormerod, 'Trans. Ophth. Soc.,' vol. xvi.

name of "erysipelas." In rare cases atrophy of the optic nerve, and paralysis of the third and other neighbouring nerves occur with the herpes.*

In *paralysis of the first division of the fifth* the cornea and conjunctiva are anæsthetic; the cornea may be touched or rubbed without the patient feeling at all. In many cases ulceration of the cornea, usually uncontrollable and destructive in character, takes place. This is probably due to anæsthesia of the cornea; the loss of sensation (1) allows injuries and irritations to occur unperceived, and (2) by removing the reflex effect of the sensory nerves on the calibre of the blood-vessels, permits inflammation to go on uncontrolled.

In *paralysis of the facial nerve* the eyelids cannot be shut, and the cornea remains more or less exposed. When a strong effort is made to close the lids the eyeball rolls upwards beneath the upper lid. Epiphora is a common result of facial palsy. Severe ulceration of the cornea may result from the exposure.

Paralysis of the cervical sympathetic causes some narrowing of the palpebral fissure from slight drooping of the upper lid, apparent recession of the eye into the orbit, and more or less miosis from paralysis of the dilator of the pupil (p. 348). No changes are observed in the calibre of the blood-vessels of the eye, or in the secretion of tears. The pupil is said to be less contracted after division of the sympathetic trunk than when the trunk of the fifth (and with it the oculo-sympathetic fibres) is cut, and knowledge of this may be now and then useful in diagnosis (*cf.* p. 347).

In *exophthalmic goitre* (Graves's disease, Basedow's disease) the most prominent symptoms are protrusion of the

* A useful paper on facial herpes, with many references, by Mr Jessop, is published in vol. vi of the 'Ophthalmological Society's Transactions' (1886).

eye, excited action of the heart, enlargement of the thyroid, and certain nervous phenomena; the protrusion is almost invariably bilateral, though not unfrequently greater on the right side. The upper lids do not follow the eyeball in looking down (v. Graefe's sign); infrequency of involuntary winking (Stellwag's sign) and abnormal width of the palpebral aperture are also found.

In severe cases the proptosis may be so great as to prevent full closure of the lids, and in these dangerous ulceration of the cornea is to be feared. In such cases it is beneficial to shorten the palpebral fissure by uniting the borders of the lids at the outer canthus, or even to unite the lids in their whole length (p. 358). No changes are present in the fundus, except occasional dilatation of arteries and spontaneous arterial pulsation. The seat of the lesion causing this peculiar malady is not yet known; it was formerly supposed to be due either to some morbid condition of the sympathetic, or to disease of the heart; there is more to support the view that it is due to a primary localised lesion of the medulla oblongata. More recent observations have tended to show that all the symptoms may be caused by excessive formation of thyroid secretion, and by its absorption by the blood.*

Erysipelas of the face sometimes invades the deep tissues of the orbit, and causes blindness by affecting the optic nerve and retina; on recovery the eye is found to be blind, and the ophthalmoscope shows either simple atrophy of the disc, or signs of past retinitis also. Other forms of orbital cellulitis may lead to the same result. (See p. 291.)

Note on the teeth in inherited syphilis, with description of Fig. 161.—None of the *first set* of teeth are character-

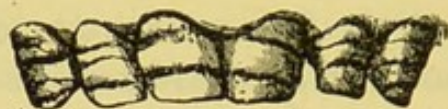* See discussion, Carlisle meeting of British Medical Association, 'Brit. Med. Journ.,' 1896, ii, p. 893.

istically altered, though the incisors frequently decay early.

In the *permanent set* only two teeth, the central upper incisors, are to be relied upon ; but the other incisors, both upper and lower, and the first molars, are often deformed from the same cause. The characteristic change in the central upper incisors appears to depend upon defective formation of the central lobe of the tooth (Fig. 161, 2, 5, and 6). Soon after the eruption of the tooth this lobe wears away, leaving at the centre of the cutting edge a vertical notch (No. 1). If the cause have acted so intensely as entirely to prevent the development of the central lobe, we find, instead of the notch, a narrowing and thinning of the cutting edge in comparison with the crown, and this, according to its degree, produces a resemblance to a screw-driver, or to a peg (Nos. 3 and 4). The teeth are also usually too small in every dimension, so that the incisors are often separated from one another by considerable spaces. In extreme cases all the incisors are peggy and much dwarfed. The changes are usually symmetrical, but No. 5 shows one tooth typically deformed and the other normal.

Fig. 161 (No. 7) shows in an extreme degree the changes due to absence of enamel from the permanent teeth ("mercurial," "stomatitic," "strumous," and "rickety" teeth). The change occurs in lines running horizontally across the whole set of permanent incisors and canines. When slight it affects only the part near the edge, the enamel beginning as a sudden terrace or step, a little distance from the edge ; in bad cases several such "terraces" are present, and the whole tooth is rough, pitted, and discoloured. The first permanent molars show a corresponding change on the grinding surface. It is this imperfection that is found present in nearly all cases of lamellar cataract (p. 167), though the dental condition is common enough in persons without that or any other form of cataract.

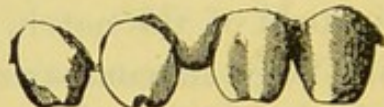FIG. 161.



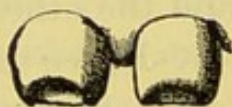7



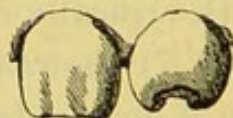1



4



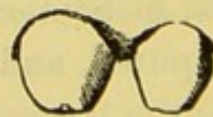6



5



2



3

APPENDIX

FORMULÆ, ETC.

NITRATE OF SILVER.

1. *Mitigated Solid Nitrate of Silver* (B. P. 1885):

Nitrate of Silver 1,
Nitrate of Potash 2.

Fused together and run into moulds to form short, pointed sticks.

Used for granular lids and purulent ophthalmia.

The strength above given is known as No. 1, and is that which I generally use; three weaker forms are made, known as Nos. 2, 3, and 4, containing respectively 3, $3\frac{1}{2}$, and 4 parts of Nitrate of Potash to 1 of Nitrate of Silver.

Pure Nitrate of Silver is never to be used to the conjunctiva.

2. *Solutions of Nitrate of Silver*:

(1) Nitrate of silver gr. x or xx,
Distilled Water ʒj .

Used by the surgeon for purulent ophthalmia, granular lids, and chronic conjunctivitis, and some cases of ulcer of the cornea.

3. (2) Nitrate of Silver gr. j or ij,
Distilled Water ʒj .

Used by the patient in various forms of ophthalmia; only a few drops to be used at a time, and not more than three times a day.

All Solutions of Nitrate of Silver should be kept in glass-stoppered bottles; any trace of organic matter decomposes the salt, and a black deposit of metallic silver falls to the bottom; the action of light favours this decomposition: amber-tinted glass is said to counteract the chemical action of light. Dark blue bottles should not be used, as they only hide the deposit of reduced silver.

SULPHATE OF COPPER.

4. A crystal of *Pure Sulphate of Copper*, smoothly pointed, may be used for touching granular lids of old standing.

5. *Lapis Divinus* :

Sulphate of Copper 1,

Alum 1,

Nitrate of Potash 1.

Fused together, and Camphor equal to $\frac{1}{30}$ of the whole added. The preparation is run into moulds to form sticks. It should be kept in a stoppered bottle.

Largely used for the treatment of chronic granular lids.

6. Solutions of Sulphate of Copper or of *Lapis Divinus*, gr. j in $\mathfrak{z}\text{j}$ of distilled water, are also very useful for many forms of chronic conjunctivitis.

LEAD LOTION :

7. Liquor Plumbi Subacetatis (B. P.) $\mathfrak{z}\text{j}$,

Distilled Water Oj.

(1 in 160.)

Used in chronic conjunctivitis *when the cornea is sound*, and in inflammation of the eyelids and lacrimal sac.

SPIRIT LOTION :

8. Rectified (or Methylated) Spirit $\mathfrak{z}\text{iv}$,

Water $\mathfrak{z}\text{xvj}$.

Used as an evaporating lotion to allay or prevent inflammation of the wound after operations on the eyelids.

9. *Lead and Spirit Lotion* :

Spirit Lotion Oj,

Liquor Plumbi Subacetatis (B. P.) $\mathfrak{z}\text{ij}$.

Used in the same cases when there is no fear that the cornea is abraded or ulcerated. A better antiphlogistic than spirit alone.

MERCURY.

10. Weak *Solutions of Perchloride of Mercury* are extensively used for cleansing the conjunctiva, eyelids, &c., before, during, and after operations. A solution of 1 grain in 5000 of water (common or distilled) (= gr. j in fl. $\mathfrak{z}\text{xij}$) may be freely used for the above purposes, and a stronger one (1 to 2500) (= gr. j in fl. $\mathfrak{z}\text{vj}$) as a lotion for catarrhal ophthalmia, &c. Some surgeons use much stronger solutions. The *Moorfields Pharmacopœia* has a lotion containing 1 grain in fl. $\mathfrak{z}\text{viiij}$, or 1 in 3500.

11. Solutions of Perchloride of Mercury in glycerine and distilled water of the strength of 2 or 4 per cent. have been introduced for the conjunctiva in cases of trachoma, either alone or after expression of the follicles; perchloride of this strength has also been used for some cases of ulcer of the cornea.

SULPHATE OF ZINC:

12. Sulphate of Zinc gr. j or ij,
Water or Rose Water ℥j.

CHLORIDE OF ZINC:

13. Chloride of Zinc gr. ij,
Water ℥j.
If there is a deposit, add of Dilute Hydrochloric
Acid just enough to make a clear solution.

14. *Chloride of Zinc Paste (Caustic):*

The exact composition of this paste varies in different hospitals; the following is the formula in use at Moorfields:

Chloride of Zinc 480 grains,
Wheat Flour 180 grains,
Water, or Liquor Opii Sedativus, fl. ℥j.

ALUM:

15. A stick of pure crystalline alum * forms a very useful application for mild or long-standing cases of granular conjunctiva, and for many forms of chronic palpebral conjunctivitis. It may be used by the patient himself without the slightest risk.

16. *Lotion:*

Alum gr. iv to gr. x,
Water ℥j.

The above lotions are in common use in the milder forms of acute and chronic ophthalmia. The Chloride of Zinc occasionally irritates; it is specially used in purulent and severe catarrhal ophthalmia instead of the weak Nitrate of Silver lotions. The stronger Alum lotion is often used in the same cases. The Alum and Sulphate of Zinc lotions may be used unsparingly to the conjunctiva; the Chloride, even in severe cases, not more than six times a day.

* So far as I know, Mr Martindale is the only London chemist who keeps this alum pencil.

BORACIC ACID LOTION:

17. Boracic Acid 4,
Water 100 by weight.

Used as an antiseptic before and after operations on the eyeball, and in the treatment of conjunctivitis and of suppurating ulcers of the cornea.

Boracic Acid in very fine powder may be used for dusting on to the cornea in cases of severe suppurating ulcer; it causes scarcely any pain, and may be applied as often as three times a day (p. 114). The crystals are difficult to powder finely, but an almost impalpable amorphous powder, obtained by preventing regular crystallisation, can be had.

Mr Martindale has made for me some soluble styles containing about 60 per cent. of boracic acid for use in cases of lacrimal obstruction with much secretion of mucus (p. 77).

Solutions of boric acid often tarnish steel; instruments should therefore not be left in them.

CARBONATE OF SODA:

18. Carbonate of Soda gr. x,
Water ℥j.

Used for softening the crusts in severe ophthalmia tarsi. A small quantity of the lotion, diluted with its own bulk of hot water, to be used for soaking the edges of the eyelids for ten or fifteen minutes night and morning.

TAR AND SODA:

19. Carbonate of Soda ℥iss,
Liquor Carbonis Detergens ℥j to ℥ss,
Water to Oj.

Used in the same cases as the last.

BORAX:

20. Biborate of Soda gr. x to xx,
Water ℥j.

Used in the same cases as the last.

QUININE LOTION:

21. Sulphate of Quinine gr. iij,
Acid. Sulph. dil. (B. P.) just enough to dissolve,
Water ℥j.

Used in diphtheritic ophthalmia.

CARBOLIC ACID LOTION.

22. Absolute Phenol 5,
Water by weight 100.

Used in purulent ophthalmia. It is important to use absolutely pure carbolic acid for the conjunctiva. Severe irritation often follows if any other varieties are employed.

23. Pure carbolic acid is useful as an application by the surgeon himself to the surface of infective or obstinate ulcers of the cornea.

Lotion of *Salicylic Acid* is so irritating to the surface of the eye that it can seldom be used. The same objection applies to salicylic wool used for dressing the eye after operations.

24. *Calomel Powder* :

Used for dusting on the cornea in some cases of ulceration. It is flicked into the eye from a dry camel-hair brush.

25. *Yellow Oxide of Mercury* ("Yellow Ointment," "Pagenstecher's Ointment") :

Yellow Oxide of Mercury gr. xxiv,
Vaseline ℥j.

(1 in 20.)

26. Weaker preparations, containing gr. viij or less of the Yellow Oxide to ℥j (1 in 60 or less), are often better borne.

Used in many cases of corneal ulceration and recent corneal nebulæ, a morsel as large as a hemp-seed being inserted within the lower lid by means of a small brush, once or twice a day. It is also suitable for ophthalmia tarsi.

In some of the Continental eye hospitals, where it is the custom for this remedy, amongst others, to be applied by the surgeon himself, stronger preparations are used.

27. *Yellow Ointment with Atropine* :

Yellow Oxide of Mercury gr. viij or less,
Atropine gr. $\frac{1}{8}$,
Vaseline ℥j.

Used in the same way as 25 and 26.

28. *Red Oxide of Mercury* :

Red Oxide of Mercury gr. xxiv or less,
Vaseline ℥j.

Used for ophthalmia tarsi, &c. Was formerly used for corneal ulcers and nebulæ; but the Yellow Oxide, which being made by precipitation is not crystalline, is now generally preferred because less irritating.*

* The ointment known as "Singleton's Golden Eye Ointment" appears to contain the crystalline red oxide in fine powder as its active

29. *Nitrate of Mercury (Citrine Ointment) :*

Unguentum Hydrargyri Nitratis (B. P.) ʒj,
Vaseline or Prepared Lard ʒvij.

Used in the same cases as 28.

30. *Iodoform :*

Iodoform may be used either in substance, or as an ointment made with Vaseline.

Iodoform gr. x to gr. xxx or more,
Vaseline ʒj.

Ung. Iodoformi (B. P. 1885) :

Iodoform gr. xlvij,
Benzoated Lard ʒj.

30 a. *Iodol*, which is odourless, may be used in the same way. The precipitated iodoform (impalpable powder) should be used in preference to the ordinary, or crystalline, form, for the eye.

BORIC ACID OINTMENT (B. P. 1885) :

31. Boric Acid 68 gr. to ʒj of Paraffin.

32. COCAIN.

Cocain was brought into clinical use in September, 1884, at Vienna, and in London and elsewhere early in October.

A 2 per cent. solution of a salt of cocain dropped into the conjunctival sac causes smarting for about half a minute, followed by numbness, rising to complete anæsthesia of ocular conjunctiva and cornea in about two to five minutes; in three to five minutes after the maximum is reached, feeling begins to return, but slight numbness continues for about twenty minutes. There is often a feeling of coldness as sensation is returning. Cocain also causes widening of the palpebral fissure by retraction of the upper and lower lids, whitening of eyeball from contraction of blood-vessels, mydriasis, very slight weakness of Acc., and perhaps lowering of the eye tension. These effects last about half an hour, except the mydriasis, which remains in some degree about twenty-four hours. The pupil dilated by cocain remains active to light and Acc.; if atropine be added the pupil becomes larger than from either drug singly. Eserine quickly and fully overcomes the effect of cocain. Acc. is completely paralysed for a very short time if cocain be used every few minutes for about an hour. These effects of cocain (except the last) are explicable on the

ingredient. A sample, kindly analysed for me by Mr S. Plowman, contained 70 grains of the oxide to the ounce.

supposition that it causes spasm of the sympathetic nerve-fibres to the eyelids, iris, and superficial blood-vessels; whether a similar contraction of the arteries of the ciliary muscle, brought about by the repeated use of the drug, explains the fleeting paralysis of Acc. is open to question. Cocain has no ascertainable action on the vessels of the retina and choroid. Cocain is thought by some to aid the action of Eserine in chronic glaucoma, when the two are used together; this is intelligible if cocain acts by contracting the ciliary arteries.

In ophthalmology cocain is used chiefly for anæsthesia before operations on the eyeball, and painful applications to the palpebral conjunctiva. For the former, a freshly made 2 per cent. solution of perfectly pure hydrochlorate of cocain in freshly boiled distilled water is the safest preparation; but gelatine discs of the pure salt, if free from hygroscopic tendency, may be safely used. Solutions in oil or vaseline are uncleanly and not suitable for surgical purposes. Watery solutions of cocain should be used quite fresh; even if made with boracic acid or camphor water they often, if kept, grow fungi, and are then unsafe. Cocain if too freely used causes dryness, loosening, and even separation of the corneal epithelium: the desiccation of the corneal epithelium is said to occur in direct proportion to the frequency of use of the cocain, and of exposure of the cornea to the air, rather than to the strength of the solution employed. Not more three applications need be made, within five minutes, before operations for cataract, &c. Cocain has been accused of producing glaucoma, but, as far as the few recorded cases show, without much reason. For deadening granular lids, or similar conditions, a much stronger solution must be painted over the affected surface (I use a 20 per cent. solution or the solid salt). For small tumours about the lid, &c., a 1 or 2 per cent. solution is injected in different directions at the base of the growth.

If the eye be congested or inflamed cocain acts much less perfectly on the conjunctiva; but it acts as well upon an ulcerated as upon a healthy cornea. As the cocain takes effect only on the part which it touches, the solution must be made to flow all over the cornea and conjunctiva; and as it penetrates little, if at all, it must be injected under the conjunctiva if we wish to render the later (tenotomy) stage of a squint operation painless, or to excise the eyeball under its influence. Cocain as ordinarily used does not seem greatly to affect the sensibility of the iris; injection into the anterior chamber for this purpose is not practicable even if safe.

Cocain is used in acute iritis in conjunction with Atropine, with the idea that it will assist the anodyne and mydriatic effects of the latter.

My own experience does not enable me to speak strongly on this point.

For producing rapid but brief paralysis of Acc. (in ametropia) a solution containing 2 per cent. of cocain and 2 per cent. of Homatropine is recommended by Mr Lang, and is convenient in suitable cases; the maximum effect is gained in from 20 to 60 minutes, but soon begins to decline.

Faintness and other signs of nervous depression have been reported as due to cocain, even when used to the eye alone. I believe that these symptoms are generally due to reaction after the mental strain attending an operation of which the patient is conscious; for before cocain was used we were familiar with the occurrence of faintness and vomiting from time to time when eye operations had been undergone without anæsthesia.

MYDRIATICS AND MYOTICS:

33. (1) *Strong Atropine Drops:*
Sulphate of Atropine gr. iv,
Distilled Water ʒj.

Used in cases where the rapid and full local action of the drug is required. For many purposes Atropine drops may be used considerably weaker than the above. Atropine (a single drop, of 2 grains to ʒj, or about .5 per cent.) begins to dilate the pupil in about fifteen minutes, and to paralyse the accommodation a few minutes later; it produces wide dilatation of the pupil (8 to 9 mm.) in 30 to 40 minutes, and full paralysis of accommodation in about 2 hours. Both remain at their height for 24 hours, and the effect does not pass off entirely till from 3 to 7 days, the accommodation recovering rather sooner than the pupil. If stronger solutions be used several times, the action continues longer. The effects of Atropine are only very temporarily and imperfectly overcome by Eserine. Atropine slightly lowers the tension of the healthy eye, but usually increases the tension in glaucoma.

- (2) *Weak Atropine Drops:*
Sulphate of Atropine gr. $\frac{1}{4}$ to $\frac{1}{40}$,
Distilled Water ʒj.

Used when, for optical purposes, it is desired to keep the pupil dilated for a long time, as in immature nuclear cataract. A single drop about three times a week will generally suffice. Very weak Atropine acts more on the pupil than on the accommodation.

Solutions of Sulphate of Atropine keep for an indefinite time; the flocculent sediment which often forms does not impair their efficiency.

The mydriatics and myotics may be used in the form of ointment with vaseline; a smaller percentage of the drug is then necessary, and toxic effects are less likely to follow: the alkaloids themselves must be used, their salts not being soluble in fats and oils.

(3) *Ung. Atropinæ*:

Atropine (Alkaloid) gr. iv,

Pure Vaseline ℥j.

This ointment is needlessly strong for most purposes; 1 grain to 1 ounce is usually enough.

(4) *Lamellæ Atropinæ* (B. P. 1885) gr. $\frac{1}{5000}$ in each.

34. *Scopolamine*:

Scopolamine Hydrobromate gr. $\frac{1}{4}$ to gr. 1.

Pure Vaseline ℥j.

This is a powerful mydriatic, and may be used where Atropine is not tolerated; it is more powerful than the latter, and does not produce local irritation so readily.

35. *Tropacocain*.—A 3 per cent. solution in normal saline solution is used for anæsthesia of the cornea; its effect begins more rapidly and lasts longer than that of cocain, and it is said to be less toxic; it does not produce mydriasis as a rule.

36. *Daturine*:

Sulphate of Daturine gr. iv,

Distilled Water ℥j.

Used as a mydriatic in cases where Atropine causes conjunctival irritation.

37. *Duboisine*:

Sulphate of Duboisine gr. j,

Distilled Water ℥j.

A mydriatic, acting more quickly and powerfully, and passing off in a shorter time, than Atropine. It is tolerated in cases where Atropine causes conjunctivitis. To be used with caution, as well-marked toxic symptoms are sometimes caused.

Duboisine begins to act on the pupil and accommodation in less than 10 minutes, produces full mydriasis in less than 20 minutes, and complete cycloplegia in about one hour. The maximum effect does not last quite so long as, and the effect passes off completely rather sooner than, that of Atropine. Duboisine seldom breaks down iritic adhesions which have already resisted Atropine. Its chief use seems to be for cases in which Atropine causes irritation.

38. *Homatropine* :

Hydrobromate of Homatropine gr. iv,
Distilled Water ℥j.

A mydriatic, acting rather more quickly and passing off much sooner than Atropine; very convenient, therefore, for dilating the pupil for ophthalmoscopic examination.

Homatropine begins to act on the pupil and accommodation in from 5 to 15 minutes: the greatest dilatation of pupil (usually, however, rather less than that obtained by Atropine) is reached in about 50 minutes, and complete or nearly complete cycloplegia in an hour or rather less (with the solution of gr. iv to ℥j). The full effect is only maintained, however, for an hour, more or less, and both pupil and accommodation usually recover completely in 24 hours or less. Its action is quicker and rather more powerful if it be used with cocain, 2 per cent. of each in distilled water.

39. *Eserine* (Physostigmine) (Alkaloid of Calabar Bean) :

(1) Sulphate of Eserine gr. iv,
Distilled Water ℥j.

Used in mydriasis and paralysis of the accommodation, whether caused by Atropine or by nerve lesions, in some forms of corneal ulcer, and in acute glaucoma.

(2) A weaker solution (gr. j to ℥j) is often better borne.

Eserine begins to contract the pupil and cause spasm of the accommodation in about 5 minutes: its maximum effect is reached in 20 to 45 minutes. Its full effect on the accommodation lasts only an hour or two, but the pupil does not completely recover for many hours, sometimes 2 or 3 days. A very weak solution acts more on the pupil than on the accommodation. Eserine causes pain in the eye and head, arterial ciliary congestion, and twitching of the orbicularis; the pain, sometimes severe, seldom lasts long. Eserine lessens the tension in primary glaucoma; its effect is increased in this disease if used with cocain, on account of the contraction of the ciliary arteries brought about by the latter.

(3) *Lamellæ Physostigminæ* (B. P. 1885) gr.
 $\frac{1}{1000}$ in each.

All the mydriatics and myotics may be obtained in the form of small gelatine discs of known strength (made by Savory and Moore, and by Martindale), which are sometimes more convenient than the solutions. Of the mydriatics, Homatropine, Scopolamine and Duboisine are much the most expensive.

40. *Belladonna Fomentation* :

Extract of Belladonna ʒj to ʒij,
Water Oj.

Warmed in a cup or small basin and used as a hot fomentation in suppurating and serpiginous ulcers of cornea.

41. *Pilocarpine for Subcutaneous Injection* :

Hydrochlorate of Pilocarpine gr. v,
Distilled Water ʒj.

Dose, m iij, gradually increased, to be injected daily or less often.

Used in cases of retinal detachment, choroiditis, and retinitis.

42. *Pilocarpine Drops*, gr. iv to ʒj.

Pilocarpine is a myotic like Eserine, but its action is much weaker.

43. *Fluorescine* for staining the cornea.

Fluorescine 2 per cent.,
Bicarbonate of Soda 3 per cent. in distilled water.

A drop placed between the lids will stain the cornea where its covering epithelium is imperfect. A drop of cocain used after the fluorescine precipitates it and makes the staining more obvious.

44. "Jequirity" seeds, obtained from a leguminous plant, are used in South America for the cure of granular lids (p. 94). They can now be readily obtained in moderately fine powder. The infusion is made by soaking the powder in cold water for a couple of hours, or, better, in water at 120° F., allowing it to stand till cool, and straining through muslin; it is then ready for use, but will remain active for several days. When obviously decomposed (fœtid) it is no longer active. The simple powder dusted into the conjunctiva is said to be active, but two or three trials which I made with it were negative.

The action of Jequirity probably depends upon a nitrogenous ferment, not, as was for a time believed, upon a specific microbe. A substance possessing the peculiar properties of the natural seed has been separated by more than one experimenter, but does not appear to be procurable in the market; it is difficult to make, and its composition seems to vary.

As the intensity of action of Jequirity infusions of the same strength varies very much in different persons, and is sometimes very severe, it is best to use a weak preparation (1 grain of powder in 100 grains of water or ʒj to fl. ʒxiiss) for all cases at first. A single prolonged application, or several applications within a few minutes, to the everted lids will suffice.

45. BANDAGES for the eyes may be of thin flannel or soft calico. A linen or cotton bandage, about ten inches long, with four tails of

tape, or a loop of tape embracing the back of the head (Liebreich's bandage), is very convenient after the more serious operations. An ordinary narrow flannel bandage is better when much pressure is wanted, or if the patient be unruly. The soft, elastic, woven bandage, known as the "Leicester" bandage, is even pleasanter than flannel.

When absolute exclusion of light is desired, it is best to use a bandage made of a double fold of some thin black material.

Fine old linen is better than lint for laying next the skin in dressings after operations.

46. SHADES may be bought at the opticians' and chemists'; or may be made of thin cardboard covered with some dark material, or of stout dark blue paper, like that used for making grocers' sugar bags. Shades of black plaited straw are also very light and convenient (Allen and Hanburys, Vere Street, W.).

Shades, to be effectual, should extend to the temple on each side, so as to exclude all side light.

47. PROTECTIVE GLASSES.

Various patterns of glasses are made for the purpose of protecting the eyes from wind, dust, and bright light. The glasses are either flat, or hollow like a watch-glass, and are coloured in various shades of blue or smoke tint. The most effectual are the ones known as "goggles;" in these the space between the glass and the edge of the orbit is filled by a carefully fitting framework of fine wire gauze or black crape, by which side wind and light are excluded. A small air-pad of thin india-rubber tubing makes the frame fit still more closely.

Other forms, known as "horseshoe" or "D," and "domed" or "hollow," glasses are also in common use.

48. TEST TYPES.

Snellen's types for testing both near and distant vision under an angle of 5 minutes can be obtained, in several languages, in the form of a small book, from Williams and Norgate, 14, Henrietta Street, Covent Garden. They can also be had, mounted or unmounted, more cheaply at most of the instrument makers.

The types which I generally use for testing near vision are those used at the Moorfields Hospital, where they may be obtained. These types nearly resemble those of Jaeger, and though less correct theoretically than the corresponding types of Snellen's scale, are more

convenient in practice for testing the reading power. There are several other sets of test types which it is unnecessary here to particularise.

49. OPHTHALMOSCOPES.

It is impossible to say that any ophthalmoscope is the best. When expense is not a great object it is always better to have one of the so-called "refraction ophthalmoscopes." In these a number of small lenses are capable of being introduced one after the other behind the mirror. The use of the lenses is explained at p. 53. For medical ophthalmoscopy it is not essential to have so many lenses; about four concave and two convex will enable an erect image to be easily obtained in most cases; Liebreich's "small" ophthalmoscope and Oldham's ophthalmoscope are both very convenient forms for such use, and cost less than half as much as the refraction instruments. Every ophthalmoscope case should contain two large "objective" lenses for the indirect examination, focal illumination and magnifying; one may be of $2\frac{1}{2}$, the other $3\frac{1}{2}$ inches focus. For the detection of incipient opacities in the lens, for direct examination without Atropine, and for retinoscopy, a plane mirror is very useful in addition to the ordinary concave one. Such a plane mirror may be had cheaply as a separate instrument for the waistcoat pocket, but I much prefer it and the concave one for indirect examination, mounted back to back (*see* below).

Of the refraction ophthalmoscopes there are now a great many patterns differing in the number and size of the lenses, the size of the mirror and lens-bearing disc, and other details. Usually the disc contains 20 to 24 lenses, and one empty circle. In the simpler forms about half the lenses are + and half -. But in others the number of powers is immensely increased by combining lenses of different strengths, *e.g.* the disc may contain 24 + lenses, whilst a single moveable - lens, rather stronger than the highest + is placed behind the disc over the sight-hole; by placing it opposite the sight-hole and then bringing the various + lenses over it in succession, a series of 25 - powers, or 49 in all, will be obtained. In order to avoid the error caused by looking obliquely through a lens, all the better instruments (*e.g.* Loring's, Couper's, Morton's, and others) are so arranged that the mirror can be sufficiently inclined to receive the light, whilst the lens-bearing disc remains at right angles to the observer's line of sight. Generally speaking, the English and American instruments are much better made than the French. Of the simpler forms with only one mirror, the one introduced by Gowers, and made for two guineas by Coxeter, of Grafton Street, W.C., is fairly efficient. Of the

more expensive forms, costing from three to four guineas, several very good ones have been derived from an early model by Mr Laidlaw Purves, and are made by Mr W. Ferrier, 56, Beresford Street, Walworth, S.E. The latest form of this instrument, made by Mr Ferrier for myself, has 3 mirrors (2 of them back to back in a single ring) mounted on a rotating carriage like the "nose-piece" of a microscope; it is extremely convenient and accurate. For the application of the "nose-piece" principle to the ophthalmoscope we are indebted to Mr Lindsay Johnson. Mr Couper's and Mr Morton's models (made by Curry and Paxton, 195, Great Portland Street, W.) are very excellent and deservedly popular. In a good refraction ophthalmoscope the mirror should be thin and the sight-hole perforated; the lens-disc thin and working as close to the back of the mirror as possible; the lenses evenly mounted, centred truly, either thoroughly covered up or easily accessible for cleaning, and not less than 5 mm. in diameter.

50. PERIMETERS.

The most convenient forms have an arrangement for registering the field automatically on a chart fixed behind the centre of the arc. A very complete, but complicated and expensive one, is McHardy's (about £8); Priestley Smith's, much simpler and cheaper, is for most purposes as useful. (Both these are made by Curry and Paxton.) Blix's self-registering perimeter is well spoken of by Dr Berry,* and may be had from Mr Prescott, 33, Lothian Road, Edinburgh.

51. The "CLOCK-FACE" for testing astigmatism (p. 325) can be had from Carpenter and Wesley, 24, Regent Street, Waterloo Place, and from Curry and Paxton.

52. The set of COLOURED WOOLS recommended by Prof. Holmgren, of Upsala, for testing colour-blindness, can be obtained for about five and sixpence from Curry and Paxton.

In the coloured plate, copied by permission from Prof. Holmgren's work '*De la cécité des couleurs, &c.*' 1877, the horizontal stripes I, IIa, and IIb, show the colours which it is, as a rule, most convenient to use as tests; and the short vertical stripes are the colours most likely to be confused with these by those affected with the ordinary forms of colour-blindness. Thus, No. 1 will be confused with one or more of such buffs, pinks, &c., as Nos. 1 to 5; in slight degrees of colour-defect the confusions will be limited to these pale colours.

In higher degrees of colour-blindness stronger or more saturated

* '*Subjective Symptoms in Eye Disease*,' p. 91 (1886).

colours will be confused; IIa, for example, or even a stronger rose colour may be confused, on the one hand, with a full blue or purple, Nos. 6 and 7; or, on the other, with full grey or green, Nos. 8 and 9. Taking a different series of equally saturated colours, the scarlet IIb may be confidently identified with dark green or brown, Nos. 10 and 11, or with light bright green and yellow brown, Nos. 12 and 13.

The confusion colours, Nos. 1 to 13 on the plate, are given merely as samples of the colours most commonly confused with the respective test colours; in practice a much larger series should be employed; the more critical the patient, the larger is the number of shades and colours requisite; even markedly colour-blind persons do not always match exactly the same colours with the tests. Coloured worsteds are used because it is easier to obtain a very large series in this material than in any other.

The manner in which a colour-blind person behaves will often excite suspicion of his defect. He will perhaps place doubtfully side by side with I, such a colour as No. 2 or 5, to see whether or not they are alike, and finally will decide that they are not quite of the same colour, though "rather alike." In such cases, and again in others, where perhaps the patient does not understand what is wanted, the diagnosis may often be made certain in the following manner:—Take two colours over which the patient is stumbling, or on which he cannot express himself, say Nos. IIa and a lighter shade of 9, add a third of the same dominant colour as 9, but of a markedly different shade, such as 10 or 12; now ask him which pair is more alike, Nos. IIa and 9, or Nos. 9 and 10; if he says IIa and 9 are more alike he is colour-blind, and is judging of their similarity by the *shade*, that is the amount of white contained in each of them, and not by their *colour*. It is easy to vary this test according to the requirements of the case.

Another good method is to tell the patient to pick out all the skeins of one colour, say green, without requiring him to match them precisely with any test skein; if decidedly colour-blind, he will confidently select not only those which are green, but a number of others, usually the grey ones. Or we may say, Do you see any green skeins among them? If colour-blind he will say No, or hesitate, or make the same mistakes as above.

A special arrangement of the wools, enabling a quick, accurate, and uniform record of colour perception to be made, has been designed by Dr Wm. Thomson, of Philadelphia ('Trans. Amer. Ophth. Soc.,' 1880, p. 142).

Of the many other tests for colour-blindness the following may be mentioned:

Stilling's Tables (to be obtained through Williams and Norgate) consist of coloured letters or patterns printed on a groundwork of one of the "confusion colours." They are preferred by some to Holmgren's wools.

Donder's method determines the colour-sense (or colour-defect) quantitatively by means of a light of known intensity, which passes through apertures filled by differently coloured glasses; these are recognised at a specified distance if the colour-sense is normal.

Mr Jeaffreson (of Newcastle) has constructed an ingenious apparatus in which the coloured wools, fixed in radii upon a rotating disc, can be successively brought opposite to stationary patches of the respective confusion colours, which are placed just beyond the circumference of the disc ('Lancet,' July 17th, 1886).

Bull (of Christiania) has introduced a quantitative test, based upon the smallest amount of colour which, mixed with grey, can be recognised by the normal eye (to be obtained from Trübner and Co.). Rows of coloured spots, those in each row containing a different quantity of grey, are painted in oil colours on a black background. The normal eye will distinguish the colours even in the greyest row; the colour-blind will, according to the degree of defect, confuse complementary colours in some or all of the rows. I find Bull's tables very useful, but like all painted and lithographed surfaces they reflect too much light, and thus, unless held exactly in the right position, they shine and their colour is altered. Unless very carefully used, Bull's and Jeaffreson's tests are, I think, less trustworthy than a good set of wools.

An explanation of the coloured plate is given on p. 442; it is not intended to be used as a test, but only as an illustration of the colours commonly confused.

I.



1




2



3



4



5



II a.




6



7



8



9



II b.



10



11



12



13



[Faint, illegible text block]

[Faint, illegible text block]

[Faint, illegible text block]

[Faint, illegible text block]

[Faint, illegible text block]

[Faint, illegible text block]

REQUIREMENTS OF CANDIDATES FOR ADMISSION INTO THE PUBLIC SERVICES.

Commissions in the Army.—All branches of the service, including the Medical Department. If a candidate's vision in each eye separately without glasses be $= \frac{6}{6}$ and Sn. 0·6 at any distance selected by himself, he will be considered fit. If the vision in each eye separately without glasses be less than $\frac{6}{36}$, the candidate will be considered unfit. If vision with each eye separately and without glasses be $\frac{6}{36}$, the candidate may be considered fit if with correcting glasses his vision $= \frac{6}{6}$ with one eye and $\frac{6}{12}$ with the other, provided that he can read Sn. 0·8 with one or both eyes without glasses at any distance he may select. Squint, colour-blindness, or disease of the eyes will cause rejection.

Royal Navy.—Requirements: emmetropia; perfect acuteness of vision and range of accommodation; normal colour-sense; absence of strabismus or muscular defects of the eyes.

Home Civil Service.—Tests at discretion of medical adviser to the commissioners, according to whatever standard the particular situation may require.

Indian Civil Service.—Vision with correcting lenses must be not less than $\frac{6}{6}$ in one eye and $\frac{6}{6}$ in the other. If the candidate have myopia or myopic astigmatism the combined spherical and cylindrical glasses must not exceed 2·5 D. in each eye. If the candidate have hypermetropia or hypermetropic astigmatism the combined spherical and cylindrical glasses must not exceed 4 D. in each eye, and the vision when under atropine must $= \frac{6}{6}$ in one eye and $\frac{6}{6}$ in the other with + 4 D. or less. A corneal nebula in one eye will not disqualify if vision be not less than $\frac{6}{12}$ in one eye, provided that the other be emmetropic and possesses normal vision. Defects of vision from changes in the deeper structures of either eye may disqualify. Colour-vision must be normal, and there must be no ocular paralysis.

Indian Medical Service.—Myopia of 5 D. is permitted if vision with glasses be $\frac{6}{12}$ in one eye and $\frac{6}{6}$ in the other, if there be no morbid changes in either eye. If posterior staphyloma be present, vision must be equal

to the above standard, and the ametropia must not exceed 2.5 D. If myopic astigmatism be present the combined spherical and cylindrical glasses must not exceed 5 D.; vision with correction must be $\frac{6}{12}$ in one eye and $\frac{6}{8}$ in the other. Total hypermetropia of 5 D. will not disqualify for service provided that vision = $\frac{6}{12}$ in one eye and $\frac{6}{8}$ in the other, with 5 D. or less when under atropine. Hypermetropic astigmatism does not disqualify provided that the combined correcting lenses do not exceed 5 D., and the acuteness reaches the above-mentioned standard. A corneal nebula will not disqualify if vision be not less than $\frac{6}{12}$, the other eye having V. = $\frac{6}{8}$. Colour vision must be normal; there must be no ocular paralysis.

Indian Pilot Service.—Requirements: emmetropia; perfect acuteness of vision and range of accommodation; perfect colour perception; no muscular defects.

Indian Marine.—The error of refraction must not exceed 1 D. hypermetropia or myopia; colour vision and ocular movements must be normal.

The Mercantile Marine.—The examination consists of three parts: (a) form vision test; (b) colour vision test; (c) colour ignorance test.

Form vision.—The tests are Snellen's letters or dots for those who cannot read.* Candidates may use both eyes or either eye, but must not use glasses of any kind. If the candidate at 16 feet from the test can read correctly three of the five letters in the fifth line from the top, or four letters in either of the two lines below, he may be considered to have passed the test.

Colour vision is tested by Holmgren's wools.

The colour ignorance test is to ascertain whether the candidate knows the names of the three colours, red, green, and white, and the test is confined to naming these colours; it is done either by skeins of wool or by the lantern.

* The tests may be obtained through any bookseller of Messrs Eyre and Spottiswoode.

INDEX

- Abbreviations, 1
- Aberration, chromatic, 37
 - spherical, 5
- Abrasion of cornea, 106, 156
- Abscess of cornea, 107
 - of lacrimal gland, 292
 - — — sac, 75, 78
 - orbital, 291
- Abscission of eyeball, 374
- Accommodation, errors, 299
 - examination, 25
 - influence of age upon, 331
 - paralysis of, 349
 - region and range of, 331
 - relative, 26
 - spasm of, 313
- Accommodative asthenopia, 247, 316
- Action of drugs on iris and ciliary muscle, 347
- Acuteness of sight, 24
- Advancement of muscle, operation for, 371
- Albinism, 200
- Albuminuric retinitis, 213, 408
- Alcohol, amblyopia, 406
- Amaurosis, 238
 - single, 236
- Amblyopia, 238
 - Amblyopia, alcohol, 406
 - bisulphide of carbon, 408
 - central, 241
 - congenital, 239
 - diabetic, 410
 - from defective retinal images, 240
 - — suppression of images, 238
 - hereditary, 243
 - hysterical, 246
 - in ametropia, 240
 - potatorum, 406
 - quinine, 408
 - tobacco, 241, 406
- Ametropia (*any permanent error in refraction of the eye*), 299
- Amyloid of conjunctiva, 96
- Anæmia, pernicious, eye diseases in, 411
- Anæsthesia in ophthalmic surgery, 396
 - of retina, 246
- Angle of incidence, 2
 - — emergence, 2
 - visual, 13
 - *a*, 34
- An-iso-metropia (*unequal refraction in the two eyes*), 328
- Anterior chamber, foreign body in, 376

- Anterior chamber, paracentesis, 376
 — focus of eye, 14
 — polar cataract, 168
 — staphyloma, 142
 Apparent size of objects, 37
 Aqueous, turbidity of, 127
 Arcus, inflammatory, 125
 — *senilis*, 124
 Argyll Robertson's symptom, 422
 Arlt's operation for entropion, 357
 Arterial pulsation, 411
 Artificial eye, 373
 — pupil, 379
 — vitreous, 374
 Asthenopia (*weakness of eyes ; any condition in which the eyes cannot be used for long together*), 247
 — accommodative, 247, 316
 — muscular, 247, 340
 Astigmatism, 320
 — after extraction of cataract and iridectomy, 181, 321
 — clock-face for, 325
 — detection of, 54, 62
 — irregular, 322
 — methods of testing, 324
 — principal meridian, 321
 — regular, 321
 — traumatic, 156
 — visual acuteness in, 328
 Atrophy of choroid, 187
 — — — in myopia, 307
 — optic (*see also* Neuritis), 231
 — — after embolism, 219
 — — — neuritis, 227
 — — — orbital cellulitis, 426
 — — clinical aspects of, 232
 — — fields of vision in, 234
 Atrophy, optic, from pressure, 232
 — — hereditary, 243
 — — in ataxy, 235, 421
 — — — hydrocephalus, 232, 421
 — — post-papillitic, 227
 — — primary, 232, 421
 — — prognosis in, 234
 — — progressive, 232, 421
 — — pupils in, 233
 — — uniocular, 236
 — — varieties of, 232
 Atropine, action on healthy eye, 26, 27, 347, 436
 — in cataract, 173
 — — corneal ulcers, 112, 115
 — — glaucoma, 271
 — — iritis, 134
 — irritation, 97
 Axial myopia, 300
 Axis, optic, 34
 — principal, of a lens, 4
 — secondary, of a lens, 4
 — visual, of eye, 34
 Bandages, 439
 — after cataract operations, 392
 — — excision of eye, 373
 — in iritis, 136
 — — ophthalmia, 85
 — — ulcers of cornea, 113
 Basedow's disease, 425
 Binocular field of vision, 22
 Bisulphide of carbon, amblyopia from, 408
 Black eye, 290
 Blephorrhœa of conjunctiva, 79
 Blepharitis, 64
 — treatment of, 66
 Blepharoplasty, 361
 Blepharospasm, 102

- Blindness of one eye, undiscovered, 240
- Blood in A. C., 154
 - — vitreous, 258
- Blood-vessels of choroid, 186
 - — eye, external, 28
 - — retina, 49, 201
- Blows on the eye, 154
- Bone in eye, 20
- Bony tumour of lid, 282
- Buller's shield, 81
- Buphthalmos, 123
- Burns of eye, 157
- Burow's operation, 357

- Canaliculus, diseases of, 73
 - operations, 364
- Cancer, rodent, 69
- Canthoplasty, 363
- Capsulo-pupillary membrane, 137
- Cataract, 164
 - artificial maturation of, 178
 - atropine in, 175
 - cause of, 166
 - concussion, 182
 - congenital, 174
 - consistence of, 164
 - cortical, 165, 171
 - diabetic, 409
 - diagnosis, 169
 - discission, 176, 394
 - dotted cortical, 166
 - extraction, 176, 385
 - — after operations, 393
 - — causes of failure, 178
 - — iritis after, 179
 - — suppuration after, 178
 - forms of general, 165
 - glasses, 181
 - hard, 165
 - immature, 171
 - in myopia, 308
 - lamellar, 166, 172, 181
 - mature, 170
 - mixed, 165
 - Morgagnian, 174
 - nuclear, 165
 - operations, 176, 385
 - over-ripe, 174
 - polar, anterior, 169
 - — posterior, 172
 - primary, 169
 - prognosis, 174
 - pyramidal, 168
 - ripening of, 178
 - secondary, 169
 - senile, 165
 - sight after removal, 181
 - soft, 165
 - solution, 176, 394
 - suction, 176
 - symptoms, 170
 - traumatic, 182
 - treatment, 175
 - zonular (*see* Lamellar)
- Caustics, injuries by, 157
- Cavernous sinus, thrombosis of, 292
- Cellulitis of orbit, 291, 426
- Central choroiditis, 196
 - nervous system, eye diseases, 418
 - scotoma, 242, 410
- Centre of rotation of eye, 14
- Cerebral tumour, neuritis in, 225, 419
 - syphilis, neuritis in, 419
- Cerebritis, neuritis in, 421
- Cerebro-spinal meningitis, eye diseases, 404
- Chalazion, 67
- Chancre on conjunctiva, 70

- Chancre on eyelids, 70, 398
 Chemosis (*œdema of conjunctiva*), 80
 Cherry-red spot, 218
 Chicken-pox, eye disease, 404
 Chloride of zinc paste, 431
 Cholesterin in vitreous, 257
 Chorio-capillaris, 186
 Choroid appearances in disease, 187
 — — — albinism, 200
 — atrophy of, 187
 — colloid of, 191
 — coloboma of, 199
 — congestion of, 199
 — diseases of, 185
 — hæmorrhages in, 192
 — healthy, 186
 — hyaline degeneration, 192
 — lamina elastica, 192
 — myopic changes, 195
 — nævus of, 298
 — rupture, 154, 191
 — sarcoma, 284
 — tubercle, 191, 198, 412
 — vessels of, 49, 186
 Choroidal atrophy in myopia, 195, 307
 — exudation, 190
 — hæmorrhages, 191, 307
 Choroiditic atrophy of disc, 193
 Choroiditis, anomalous forms of, 198
 — anterior, 141
 — central guttate, 194, 196
 — — senile, 196
 — *disseminata*, 193
 — *hæmorrhagica*, 198
 — in hydrocephalus, 421
 — — myopia, 195
 — superficial, 190
 — suppurative, 196
 Choroiditis syphilitica, 190
 Ciliary arteries, 28
 — body, sarcoma of, 284
 — congestion, 29, 126
 — muscle in astigmatism, 324
 — — — myopia, 303, 308
 — — paralysis of, 154, 349, 402
 — region, diseases of, 139
 Circumcorneal zone, 29, 126
 Clear sight, optical conditions, 14
 Cocain, 347, 434
 Coloboma of choroid (*congenital cleft in choroid*), 199
 — — iris (*cleft in iris, congenital or the result of iridectomy*), 137
 Colour-blindness, 252
 — in atrophy, 234
 — tests for, 442
 Colour-perception, testing, 23
 Coloured vision, 250
 Colours, fields of vision for, 22, 253
 “*Commotio retinae*,” 156
 Congenital absence of iris, 137
 — cataract, 174
 — coloboma, 137, 199
 — dermoid cysts, 298
 — — tumour, 281
 — dislocation of lens, 184
 — fibro-fatty growths, 282
 — irideremia, 137
 — ptosis, 71
 Congestion, choroidal, 199
 — ciliary, 29, 126
 — circumcorneal, 29
 — conjunctival, 31
 — episcleral, 31
 — in iritis, 126
 — of optic disc, 225
 — — retina, 204
 Conjunctiva, amyloid of, 96

- Conjunctiva, burns of, 157
- cauliflower warts of, 280
- cysts of, 281
- diseases, 79
- lupus of, 280
- nitrate of silver, staining of, 125
- primary shrinking of, 98
- tubercle of, 71, 280
- tumours of, 280
- Conjunctivitis, 79
- after exanthems, 85
- catarrhal, 84
- chronic, 96
- croupous, 86
- diphtheritic, 86, 402
- follicular, 85
- from atropine, 97
- — cold, 86
- — drugs, 97
- — eserine, 97
- gonorrhœal, 79
- granular, 88
- — results of, 93
- — treatment of, 92
- impetiginous, 86
- in eczema, 86
- — erysipelas, 86
- — herpes zoster, 86, 424
- lacrimal, 96
- lymphatic, 103
- marginal, 105
- membranous, 86, 402
- muco-purulent, 84
- *neonatorum*, 79
- — prevention of, 84
- nodosa, 98
- phlyctenular, 103
- purulent, 79
- — treatment of, 81
- Conjunctivitis, pustular, 103
- rheumatic, 86, 413
- strumous, 103
- Contagion, conjunctival, 79, 84
- Convergent squint (*see* Strabismus)
- Convulsions and lamellar cataract, 167
- Coredialysis, 154
- Cornea, abrasion, 106, 156
- abscess, 108
- arcus senilis, 124
- burns, 157
- conical, 123
- — operations for, 377
- diseases of, 100
- fluorescence of, 101
- focal length of, 13
- foreign body in, 156
- ground glass, 101
- herpes of, 110
- inflammation of, 100
- inspection of, 19, 355
- irregularity of surface of, 19
- lead deposit, 125
- opacity, congenital, 125
- operations, 375
- reflex, 51
- removal of foreign bodies from, 375
- steaminess, 101, 122
- transplantation of, 102
- transverse calcareous film, 124
- tubercle of, 289
- ulceration, 81, 101
- — atropine in, 115
- — cauterisation of, 377
- — crescentic, 106
- — dendritic, 110
- — eserine in, 115
- — fomentations, 113

- Cornea, ulceration from exposure, 110
 — — infective, 106
 — — paracentesis, 114
 — — phlyctenular, 103
 — — section for, 114
 — — serpiginous, acute, 107
 — — — chronic, 106
 — — seton for, 112
 — — suppurating, 107
 — — treatment, 110
 — — varieties of, 103
 — — vascular recurrent, 105
 Cr  d  's method, 84
 Crescents in astigmatism, 195
 — — myopia, 195, 306
 Crystalline lens, focal length of, 13
 — — spherical aberration of, 5, 15
 Cup, physiological, 46
 — in glaucoma, 265
 Cutaneous horn, 68
 Cyclitis, 143
 — suppurative, 145
 — syphilitic, 399
 — traumatic, 145
 Cyclo-iritis (*see* Sclero-)
 Cyclo-ker  titis (*see* Sclero-)
 Cycloplegia (*paralysis of ciliary muscle*), 155, 349, 402
 — diphtheritic, 402
 Cysticercus cellulos  , 258, 417
 Cystic tumours in orbit, 296
 Cysts of conjunctiva, 281, 282
 — — iris, 287
 — — margins of lids, 68
 — — Meibomian, 67
 Dacryo-cystitis, chronic (*inflammation of lacrimal sac*), 75
 Dacryoliths, 74
 Dacryops, 282
 "Dangerous zone," 147
 Daturin, 437
 Day-blindness, 250
 Decentred lens, 11
 Delirium after eye operations, 392
 Dermoid cysts of eyebrow, 298
 — tumour of eyeball, 281
 Detachment of retina, 209
 — — — in myopia, 307
 Diabetes, eye diseases in, 409
 Diabetic amblyopia, 410
 — cataract, 409
 — retinitis, 410
 Dioptre, 15
 Dioptric system of spectacle lenses, 15
 Diphtheria, eye disease, 402
 Diphtheritic paralysis of accommodation, 402
 — — — recti muscles, 402
 — ophthalmia, 86, 402
 Diplopia (*see also* Strabismus and Paralysis), 36, 333
 — chart, 344
 — crossed, 335
 — examination, 36
 — homonymous, 335
 — uniocular, 36
 Direct examination, 42, 49
 Discission of cataract, 176, 394
 Dislocation of lens, 183
 Disseminated choroiditis, 193
 — sclerosis, eye diseases in, 424
 Distichiasis, 94
 Double sight, 36
 Drugs, action on ciliary muscle and iris, 347
 Duboisin, 437

- Ecchymosis in catarrhal ophthalmia, 84
 — of eyelids, 290
 Echinococcus, 417
 Ectopia lentis, 184
 Ectropion, operations for, 360
 Eczema, marginal, 65
 Embolism of eye in pyæmia, 405
 — — central artery, 217
 Emmetropia, 299
 Emphysema of orbit, 290
 Endemic nyctalopia, 249
 Enophthalmos, 290
 Entozoa in eye, 417
 Entropion, operations for, 355
 — organic, 94, 356
 — spasmodic, 355
 Epicanthus, 71
 Epilation, 66, 354
 Epiphora, 65, 73
 Episcleritis, 139, 282
 Epithelioma of conjunctiva, 283
 "Erect image," 49
 Erysipelas of face, blindness from, 426
 Erythroptia, 250
 Eserine, 438
 — action on healthy eye, 347, 438
 — in glaucoma, 272, 438
 — — ulcers of cornea, 115
 Eversion of upper lid, 354
 Evisceration, 374
 Examination, focal, 39
 — of blood-vessels of eye, 28
 — — colour-perception, 23, 252
 — — cornea, 19
 — — eye, external, 19
 — — field of vision, 20
 — — mobility of eye (field of fixation), 32
 Examination of pupils, 26
 — — refraction of eye, 51
 — — tension, 19
 — ophthalmoscopic, 41
 — — direct, 42, 49
 — — indirect, 41, 43
 Excision of eye, 372
 — — — in sympathetic disease, 150
 — — — rules for, 159, 287
 Exclusion of pupil, 131
 Exophthalmic goitre, 425
 Exophthalmos, pulsating, 295
 Exostoses, ivory, of orbit, 295
 Extraction of cataract (*see* Cataract)
 Eye disease in relation to general diseases, 398
 — protrusion of, 38
 — refracting surfaces of, 12
 Eyeball, foreign bodies in, 160
 Eyelids, diseases of, 64
 — tumours, 282
 — ulcers, 69
 — wounds of, 293
 Facial nerve, paralysis of, 425
 "False image," 36
 "Far point," 25
 Feigned blindness, 12, 251
 Fibro-fatty growth, 282
 Field of fixation, 32
 — — vision, 20
 Fifth nerve paralysis, 425
 Filtration scar, 274
 Focal illumination, 39
 — interval, 321
 Focus, anterior, of eye, 13
 — conjugate, of a lens, 6
 — principal, of a lens, 5

- Focus, virtual, of a lens, 6
 Foreign body in eye, 160
 — — — orbit, 293
 — — — on cornea, 156
 Förster's operation, 178
 Fourth nerve paralysis, 343
Fovea centralis, 48, 202
 Frontal sinus, distension of, 294
 Functional disorders of sight, 238
 Fundus, central region of, 48
 — of eye, examination of, 43
 Fusion power of ocular muscles, 12

 General diseases causing eye disease, 398
 — paralysis of insane, eye diseases, 421
 Giddiness from ocular paralysis, 345
 Glasses, protective, 440
 — (*see* Spectacles)
 Glaucoma, 260
 — absolute, 264
 — acute, 263
 — atropine in, 271
 — causes, 271
 — chronic, 261
 — cornea in, 124, 263, 267
 — cupping, 265
 — eserine in, 272
 — field of vision in, 262
 — hæmorrhagic, 279
 — "inflammatory," 263
 — *malignum*, 277
 — mechanism, 267
 — neuralgia preceding, 271
 — operations, 272, 380
 — premonitory stage, 261
 — primary, 260
 — prognosis, 275
 Glaucoma, remittent, 263
 — sclerotomy, 273
 — second operation, 276
 — secondary, 131, 260, 277
 — — to anterior synechia, 277
 — — — dislocation of lens, 183, 278
 — — — posterior synechia, 131, 144, 277
 — — — sympathetic iritis, 149, 277
 — — — tumour, 278, 286
 — *simplex*, 262
 — subacute, 262
 — theory of iridectomy, 273
 — treatment, 272
 — vitreous humour in, 267
 Glioma of retina, 283
 Goitre, exophthalmic, 425
 Gonorrhœal iritis, 414
 — ophthalmia, 79
 Gout, cyclitis, 144, 415
 — eye diseases, 415
 — iritis, 133, 415
 Grafting, 362
 Granular lids, 88
 — ophthalmia, 88
 — — results, 93
 Granuloma of iris, 288
 Graves's disease, 425
 Gummatous scleritis, 141
 — tarsitis, 280
 Gunshot injuries, 158, 293

 Hæmorrhage after extraction, 178
 — — iridectomy, 384
 — choroidal, 154, 191, 192, 307
 — conjunctival, 84
 — — renal retinitis, 207
 — into anterior chamber, 154

- Hæmorrhage into vitreous, 155, 258
 — intraocular, 154
 — orbital, 290, 405
 — retinal, 207, 216, 405, 410
 — — causing glaucoma, 278
 Hard cataract, 165
 Heart disease, eye diseases in, 411
 Hemeralopia (*day-blindness*), 250
 Hemianopia, 244, 421
 Hereditary amblyopia, 243
 — disease of retina, 221
 — gout, eye diseases, 415
 — syphilis, eye diseases, 400
 Herpes of conjunctiva, 86
 — — cornea, 110
 — zoster, 424
 Homatropine, 438
 Homonymous diplopia (*see* Diplopia)
 Hyalitis (*inflammation of vitreous*)
 (*see* Vitreous)
 Hydatid of orbit, 296
 Hydrocephalus, 421
 Hydrophthalmos, 123
 Hyperæsthesia of retina, 246
 Hypermetropia, 313
 — acquired, 315
 — axial, 313
 — haze of disc, 204
 — tests for, 318
 Hyphæma (*blood in lower part of anterior chamber*), 154
 Hypopyon (*pus in lower part of anterior chamber*), 108, 127
 — ulcer, corneal section, 375
 Hysterical amblyopia, 246
 — ocular paralysis, 351
 Image formed by lenses, 7
 — retinal, size of, 37
 Image, retinal, size of, in E., H., and My., 13
 — — influence of lenses on, 13
 Indirect examination, 41, 43
 Influenza, 404
 Injuries of eyeball, 153
 — — orbit, 290
 Insufficiency, muscular, 303
 Intraocular tumours, 283
 — hæmorrhage (*see* Hæmorrhage)
 "Inverted image," 41
 Iridectomy, 378
 — distortion of image after, 15, 379
 — in cataract extraction, 386
 — — corneal opacity, 379
 — — — ulcer, 114
 — — glaucoma, 273, 380
 — — iritis, 136
 Irideremia, congenital, 137
 Irido-choroiditis, 143
 — plastic, 133
 Irido-cyclitis, 145, 196
 — traumatic, 145
 Iridodesis, 380
 Iridoplegia (*paralysis of iris*), 349
 — reflex, 349, 422
 Iridotomy, 380
 Iris, absence of, 137
 — coloboma, 137
 — colour, 28, 127
 — cysts, 287
 — diffused sarcoma of, 288
 — diseases, 126
 — epithelial tumour, 287
 — granuloma, 288
 — normal action of, 347
 — operations, 378
 — paralysis, 154, 348
 — sarcoma of, 288
 — tremulous, 154

- Iris, tubercle, 288
 — tumours, 288
 — vessels of, 128
 — wounds of, 159
 Iritis, 126
 — after extraction, 179
 — atropine in, 134
 — causes of, 132
 — chronic, 133
 — glaucoma secondary to, 130, 149
 — gonorrhœal, 414
 — gouty, 133, 415
 — hypopyon, 127
 — in corneal ulcer, 107, 134
 — — diabetes, 409
 — — interstitial keratitis, 119
 — iridectomy, 136
 — leeches in, 135
 — pain in, 130
 — paracentesis, 135
 — plastic, 133, 149, 180
 — pupil in, 128
 — results, 130
 — rheumatic, 132, 413
 — separation of, 154
 — serous, 129, 143
 — spongy exudation, 128
 — suppurative, 127, 145, 178
 — sympathetic, 149
 — syphilitic, 132, 398
 — tension in, 128
 — traumatic, 137, 145
 — treatment, 134
 — tubercle of, 133, 288
 — tumours of, 287
 — with nodules, 127, 133
 Iritomy, 380
 Irritation, sympathetic, 146
Ischæmia retinae, 219
 Ivory exostoses, 295
 Jequirity, 439
 — in trachoma, 94
 Keratitis, diffuse, 116
 — filamentary, 110
 — interstitial, 116, 401
 — — iritis in, 119
 — marginal, 103
 — parenchymatous, 116
 — *punctata*, 121, 143, 149
 — — *superficialis*, 110
 — relapsing bullous, 106
 — strumous, 103
 — syphilitic, 116, 399, 401
 Kerato-malacia, 109
 Kidney disease, eye diseases in, 408
 Lacrimal abscess, 75
 — apparatus, diseases, 73
 — canaliculi, diseases, 74
 — conjunctivitis, 76, 96
 — gland diseases, 292
 — — abscess, 292
 — — tumours of, 297
 — obstruction, 74
 — puncta, alterations, 73
 — sac diseases, 75
 — — abscess, 75
 — — — excision of, 77
 — stricture, 74, 365
 — — treatment of, 76
 Lacrimation, 73
 Lamellar cataract, 166, 172, 181
 — — and convulsions, 167
 — — treatment, 181
Lamina cribrosa, 47
 Lateral sclerosis, eye diseases, 421
 Lead opacity of cornea, 125
 — poisoning, eye diseases, 406
 Lens, axes of, 4

- Lens, concave, 4
 — convex, 4
 — crystalline, changes preceding cataract, 166
 — — dislocation, 183
 — — examination, 40
 — — myopia due to changes in, 313
 — — senile changes, 164
 — equator of, 165
 — foci of, 5
 — images formed by, 7
 — refraction by, 4
 — refractive power of, 9
 — signs for convex and concave, 16
 — spherical aberration, 5
 Lenses, decentring of, 10
 — numeration of, 15
 — table of spectacle, in dioptries and inches, 17
 Leprosy, eye disease in, 417
 Leucocythæmia, eye diseases in, 410
 Leucoma, 101
 Lice on eyelashes, 69
 Light, effect of intense, 222
 Limeburn, 157
 Linear extraction, 387
 Lippitudo, 65
 Locomotor ataxy, cycloplegia, 422
 — — diplopia, 422
 — — iridoplegia, 349, 422
 — — optic atrophy, 232, 421
 Lupus, 70, 280
 — conjunctival, 280

Macula lutea, 48, 202
 Maddox rod, 340
 Magnet for removal of iron chips, 160

 Malarial fever, eye diseases, 404
 Malignant tumours (*see* Tumours)
 Malingering, 12, 251
 Marginal keratitis, 103
 Measles, eye diseases, 403
 Megalopsia, 250
 Megrim, eye symptoms, 417
 Meibomian concretions, 68
 — cyst, 67, 354
 Membranous ophthalmia, 86, 402
 Meningitis after excision, 375
 — epidemic cerebro-spinal, eye diseases, 404
 — ocular paralysis, 350
 — optic neuritis, 419
 — syphilitic, 418
 — tubercular, 412, 420
 Mercurial teeth, 427
 Metastatic growths, 285
 Micrococcus of trachoma, 91
 — — purulent ophthalmia, 79
 Micropsia, 250
 Miosis (*persistent contraction of pupil*), 425
 — in spinal disease, 422
 — paralytic, 348
 Miotics, action of, 438
 Mobility of eye, examination, 32
 — — — in myopia, 32, 302
Molluscum contagiosum, 68
 Moon-blindness, 249
 Morgagnian cataract, 174
 Mucocoele, 75
 Mucopurulent ophthalmia, 84
 Mules' operation, 374
 Mumps, eye diseases in, 403
Musca volitantes, 250, 303
 Muscles, variation in attachment of, 336
 Muscular asthenopia, 247, 340

- Mydriasis (*persistent dilatation of pupil*), paralytic, 348
 — spasmodic, 348
 — traumatic, 155
 Mydriatics, action, 436
 Myopia, 300
 — axial, 300
 — causes, 308
 — choroidal changes, 195, 307
 — complications, 303
 — crescent, 195, 306
 — examination, 303
 — from conical cornea, 312
 — — incipient cataract, 313
 — of curvature, 312
 — retinal images in, 13, 301
 — spectacles, 309
 — strabismus in, 302
 — symptoms, 302
 — tests for, 303
 — traumatic, 156
 — treatment, 309
- Nævus of lids and conjunctiva, 298
 Nasal duct, diseases of, 74
 — — probing, 77, 365
 "Near point," 25
 Nebula, 101
 Nerve, facial, paralysis, 425
 — fifth, paralysis, 425
 — fourth, paralysis, 343
 — optic, inflammation (*see* Neuritis)
 — — atrophy (*see* Atrophy)
 — sixth, paralysis, 342, 350
 — sympathetic, paralysis, 425
 — third, paralysis, 344
 Nerve-fibres, optic, opaque, 203
 Nerves, ocular, nuclei of origin, 346
 — — physiology, 346
- Neuralgia, eye symptoms, 417
 — preceding glaucoma, 271, 418
 — — neuritis, 418
 Neuritis, optic, appearances, 225
 — — axial, 244
 — — descending, 223
 — — etiology, 224, 229
 — — in cerebral tumour, 418
 — — — cerebritis, 420
 — — — lead-poisoning, 230
 — — — meningitis, 419
 — — — syphilitic brain disease, 230, 419
 — — loss of blood in, 230, 400
 — — pathology, 223
 — — retro-ocular, 230, 241
 — — sight in, 228
 Neuro-retinitis, 229
 Neurotomy, optico-ciliary, 374
 Night-blindness, 193
 — functional, 249
 Nitrate of silver in corneal ulcer, 112
 — — — — ophthalmia, 82
 — — — staining conjunctiva, 125
 Nodal point of eye, 13
 Nyctalopia (*night-blindness*) 193
 — endemic, 249
 Nystagmus, 352
 — in disseminated sclerosis, 353
 — miners', 352
- Objects, apparent size of, 37
 Oblique illumination, 39
 Occlusion of pupil, 129
 Ocular paralysis (*see* Paralysis)
 Onyx, 109
 Opaque optic nerve-fibres, 203
 Operation for abscess of orbit, 291
 — — abscission of eye, 374

- Operation for artificial pupil, 378
- — canthoplasty, 363
 - — cataract, 176, 385
 - — — causes of failure, 178
 - — — extraction, 385
 - — — modified linear, 388
 - — — needling, 394
 - — — old flap, 390
 - — — short flap, 389
 - — — simple linear, 387
 - — — solution, 394
 - — — suction, 395
 - — cauterisation of cornea, 377
 - — conical cornea, 377
 - — distended frontal sinus, 295
 - — ectropion, 360
 - — electrolysis of hair-follicles, 359
 - — entropion, organic, 356
 - — — spasmodic, 355
 - — epilation, 354
 - — eversion of eyelids, 354
 - — evisceration of eyeball, 374
 - — excision of eye, 372
 - — foreign body on cornea, 375
 - — hypopyon, 114, 376
 - — inspection of cornea in photophobia, 355
 - — iridectomy, 378, 381
 - — iridodesis, 380
 - — iridotomy, 380
 - — lacrimal abscess, 75
 - — — stricture, 364
 - — Meibomian cyst, 354
 - — paracentesis of anterior chamber, 376
 - — peritomy, 363
 - — ptosis, 362
 - — readjustment, 371
- Operation for sclerotomy, 384
- — slitting canaliculus, 364
 - — strabismus, 368
 - — symblepharon, 364
 - — trichiasis, 356
- Ophthalmitis, sympathetic, 149
- Ophthalmoplegia externa*, 346, 423
- *interna*, 349
- Ophthalmoscope, 441
- how to use, 42
 - refraction, 54
- Ophthalmoscopic examination, 41
- — direct method, 41, 49
 - — indirect method, 41, 43
- Optic disc, atrophy, 231, 421
- — congestion, 225
 - — healthy, 45
 - — physiological cup, 46
 - — nerve, diseases of, 223 (*see also* Neuritis and Atrophy)
 - — — from syphilis, 230, 400
 - — injury to, 236
 - — pathological changes, 223
 - — sclerosis, 232
 - — sheath of, 224
 - — tumours, 297
- papilla, 45
- Optical outlines, 1
- Optico-ciliary neurotomy, 374
- Orbicularis, paralysis, 73, 425
- spasm, 102
- Orbit, abscess of, 291
- cellulitis of, 291
 - diseases of, 290
 - emphysema of, 290
 - foreign body in, 293
 - hæmorrhage, 290, 405
 - pulsating tumours of, 295
 - tumours, 294

- Orbit, wounds of, 293
Oscillation of pupil, 27, 149
- Pannus (*extensive superficial vascularity of cornea*), 93
— phlyctenular, 105
— trachomatous, 93
Panophthalmitis, 145
— pyæmic, 405
— traumatic, 145, 159
Papillitis (*inflammation of optic disc*) (*see* Neuritis)
Papillo-retinitis, 213, 229
Paracentesis of anterior chamber, 376
— for corneal ulcer, 114
— — glaucoma, 273
— — iritis, 135
Parallactic movement, 210
Paralysis, associated, 423
— central, 423
— diphtheritic, 402
— in spinal disease, 422
— ocular, 341, 422
— — causes, 350
— — recurrent, 424
— — treatment, 352
— of cervical sympathetic nerve, 425
— — ciliary muscle, 154, 349, 402
— — external ocular muscles, 341
— — — rectus (6th N.), 342, 350
— — facial nerve, 425
— — fifth nerve, 425
— — internal ocular muscles, 155, 349
— — iris, 155, 348
— — superior oblique (4th N.), 343
— — third nerve, 344
— peripheral, 423
Paralysis, syphilitic, 399
Paralytic mydriasis, 348
— myosis, 348
Pediculus pubis, 69
“Pemphigus” of conjunctiva, 98
Perimeter, 22, 442
Periostitis of orbit, 291
Peritomy, 95, 363
Phlyctenular affections, 85, 103
— pannus, 105
Photophobia, 102, 111
Physiological cup, 46
Physiology of internal muscles of eye, 346
Pigment in retina, 207, 219
— — choroid, 188
Pilocarpine, action on healthy eye, 347
— for detached retina, 211
Pinguecula, 281
Polyopia uniocularis, 170
Polypus, lacrimal, 75
Posterior nodal point, 12
— polar cataract, 169, 172
— staphyloma, 195, 307
— synechia, 128
— — total, 129
Preliminary iridectomy, 387
Presbyopia, 329
— in myopia, 330
— table, 332
Primary optic atrophy, 232, 421
Prism, action of, 2, 9
— numbering of, 16
— uses of, 9, 312
Prismatic spectacles, 312
Probing nasal duct, 365
Progressive optic atrophy, 232, 421
Projection, 3
Prolapse of iris, 180

- Prolapse of iris in cataract extraction, 180, 393
 — — — in sclerotomy, 274, 385
 Proptosis, 38, 292
 — in orbital disease, 294
 Protective glasses, 440
 Pseudo-glioma, 198
 Pterygium, 281
 Ptosis (*falling of upper lid*), congenital, 71
 — from granular lids, 95
 — operations, 362
 — paralytic, 344
 — traumatic, 291
 Pulsating tumour of orbit, 295
 Pulsation, retinal, in aortic disease, 411
 Punctum, displacement of, 74
 Pupil (*see also* Iris, Synechia)
 — actions in health, 26
 — contraction from congestion, 28
 — examination, 26
 — exclusion, 129
 — in diphtheritic cycloplegia, 402
 — — iritis, 128
 — — optic atrophy, 233
 — — spinal disease, 422
 — inactivity of, 27
 — influence on sight, 16
 — occlusion of, 129
 — paralysis of dilatation, 348
 — size of, in anæmia, 28
 — total posterior synechia, 129, 277
 — why black, 41
 Pupillary membrane, remains of, 137
 Purpura, eye disease, 405
 Pustular ophthalmia, 103
 Pyæmia, eye disease, 405
 Quinine amblyopia, 408
 "Rainbows" in glaucoma, 261
 Readjustment of ocular muscles, 371
 Recurrent vascular ulcer, 105
 Reflex iridoplegia, 349, 422
 Refraction, 1
 — by a prism, 2
 — — cylindrical lens, 322
 — determination by ophthalmoscope, 53
 — — — retinoscopy, 55
 — errors, 299
 — of light, 1
 — — the eye, 12
 Refractive index, 1
 Regulations for admission to public Services (*see* Appendix)
 Relapsing fever, eye diseases, 404
 Relative accommodation, 26
 Renal disease, eye diseases, 408
 Retina, anæsthesia, 246
 — appearances in disease, 204
 — — — health, 48, 201
 — atrophy, 208
 — blood-vessels, 48, 201
 — concussion, 156
 — congestion, 204
 — detachment, 209, 307
 — diseases, 201
 — functional diseases, 249
 — glioma, 283
 — hæmorrhage in, 207, 216, 404, 410
 — hyperæsthesia, 246
 — pigmentation, 207, 219
 — "shot-silk" appearance, 203
 — vessels of, 48
 Retinal embolism, 217, 412

- Retinal hæmorrhage, 216, 404, 410
 — image, 14
 — — influence of lenses on size, 13
 — thrombosis, 217, 411
 Retinitis, albuminuric, 213, 408
 — *apoplectica*, 216
 — *circinata*, 222
 — diabetic, 410
 — diffused, 204
 — from anæmia, 411
 — — intense light, 222
 — — leucocythæmia, 217, 410
 — — malarial disease, 404
 — *hæmorrhagica*, 216, 415
 — *pigmentosa*, 219
 — *proliferans*, 222
 — renal (*see* Albuminuric)
 — syphilitic, 211, 399
 — with choroiditis, 185, 189, 208
 — — optic neuritis, 229
 Retinoscopy, 55
 Rheumatism, eye diseases, 413
 — in ophthalmia neonatorum, 415
 Ring scotoma, 212
 Ripening cataract, operation, 178
 Rodent ulcer, 69
 Rotation of eye, centre of, 14
 Rupture of choroid, 154, 191
 — — eyeball, 153

 Saemisch's operation, 114, 376
 Sago-grain granulations, 89
 Salmon-patch, 117
 Sarcoma of choroid, 284
 — — ciliary body, 284
 — — front of the eye, 233
 — — iris, 288
 — — sclerotic, 283
 Scalds of eye, 157

 Scarlet fever, eye disease, 401
 Scarring of conjunctiva, 93
 Scleral puncture, 273
 — ring, 47
 Scleritis, 139
 — gummatous, 141
 Sclero-iritis, 141
 Sclero-keratitis, 141
 Sclerosis of optic nerves, 232
 Sclerotic rupture, 153
 — wounds, 158
 Sclerotico-choroiditis, posterior, 195
 Sclerotomy, 273, 384
 Scotoma (*an area of defect or blindness in the visual field*), 242
 — central, 242
 — scintillating, 417
 Scurvy, eye disease, 405
 Secondary cataract, 169
 — divergence, 341
 — glaucoma, 260, 277
 — operations for cataract, 393
 — squint, 33
 Senile changes in accommodation, 331
 — — — choroid, 196
 — — — lens, 164
 — failure of vision, 24
 Septicæmia, eye diseases, 405
 Serous iritis, 129, 143
 Serpiginous ulcer, 106
 Setons in ulcers of cornea, 112
 Shades, 440
 Shadow test, 55
 Short-sight, 300
 Sight, acuteness, 24
 — tests for, 24
 — after cataract operations, 181

- Sight field, 20
 — — for colours, 252
 — optic neuritis, 228
 — optical conditions of clear, 14
 Silver staining of conjunctiva, 125
 Skiascopy, 55
 Sloughing of cornea, 81, 109
 Smallpox, eye disease, 401
 Snellen's operation for trichiasis, 358
 Snow-blindness, 98
 Soft cataract, 165
 Solution of cataract, 176
 Sparkling synchysis, 257
 Spasm of accommodation, 303
 Spectacles in astigmatism, 328
 — — an-iso-metropia, 328
 — — hypermetropia, 318
 — — myopia, 310
 — — presbyopia, 332
 — lenses, table of, 17
 — prismatic, 312
 Spinal cord disease, eye diseases, 421
 Spongy exudation in iritis, 128
 Spring catarrh, 96, 105
 Squint (*see* Strabismus)
 Staphyloma (*a bulging of the sclerotic or cornea*), 142
 — anterior, 142
 — posterior, 195, 307
Stillicidium lacrimarum, 73
 Stomatitic teeth, 427
 Strabismus, 33, 333
 — alternating, 33, 337
 — angular measurement of, 34
 — apparent (foot-note), 34
 — causes, 337
 — concomitant, 34, 338
 — convergent, 34, 337
 — definition and varieties, 33, 333
 Strabismus, divergent, 33, 340
 — examination, 33
 — from disuse, 341
 — in hypermetropia, 337
 — — myopia, 302
 — latent divergent, 340
 — measurement of, 34
 — operation for, 368
 — paralytic, 34, 341
 — peculiarities of, 345
 — periodic, 34, 338
 — primary, 34
 — secondary, 33
 — spontaneous disappearance of, 239, 338
 Streatfeild's operation for trichiasis, 358
 Striæ of refraction, 166
 Strumous eye diseases, 416
 — ophthalmia, 103
 Sty, 66
 Suction of cataract, 176
 Suppression of image, 238
 Suppuration after extraction, 178
Sycosis tarsi, 64
 Symblepharon, 157, 364
 Sympathetic inflammation, 146, 149
 — irritation, 146, 148
 — nerve, paralysis of, 425
 — ophthalmitis, 149
 — — theories of, 146
 — — treatment of, 150
 Synchysis, sparkling, 258
 Syndectomy, 95
 Synechia (*adhesion of iris*), annular, 129
 — anterior, 159
 — causing glaucoma, 131
 — posterior, 126
 — total posterior, 129

- Syphilis, acquired, choroiditis, 398
 — — eye diseases, 398
 — — iritis, 398
 — — keratitis, 120, 399
 — — ocular paralysis, 399
 — — retinitis, 399
 — brain disease, 230, 400, 419
 — inherited, choroiditis, 401
 — — eye diseases, 400
 — — iritis, 400
 — — keratitis, 116, 401
 — — retinitis, 401
 — sclerotitis, 141
 — tarsitis, 280
 — ulcers of eyelids, 70
 Syphilitic optic atrophy, 400
 — — neuritis, 400
 — teeth, 426
 Syringes, lacrimal, 367
 — for cataract suction, 396

 Tarsitis, syphilitic, 280
 Teeth in lamellar cataract, 427
 — syphilitic, 426
 Tenotomy, 368
 Tension of the eyeball, examination,
 19
 — — — — diminished, 145
 — — — — increased, 260
 — — — — in glaucoma, 260, 262
 — — — — intraocular tumours,
 278
 — — — — iritis, 128
 — — — — — paralysis of the fifth
 nerve, 271
 — — — — variation, 20
 Test-types, 24, 440
 Third nerve paralysis, 344
 Thrombosis of cavernous sinus, 292
 — — retinal artery, 217, 411
 Thrombosis of retinal vein, 216
Tinea tarsi, 64
 Tobacco amblyopia, 241, 406
 Total posterior synechia, 129
 Toxic amblyopia, 241
 Trachoma, 88
 — coccus of, 91
 Traumatic astigmatism, 156
 — cataract, 182
 — cycloplegia, 155
 — irido-cyclitis, 145
 — iridoplegia, 155
 — iritis, 137
 — myopia, 156
 — panophthalmitis, 145, 159
 — ptosis, 291
 Trichiasis, 94
 — congenital, 72
 Tubercle of choroid, 191, 198, 412
 — — conjunctiva, 71
 — — iris, 288
 Tuberculosis, eye diseases, 412
 Tumours, intraocular, 283
 — malignant, 282
 — metastatic, 285
 — of eye, 280
 — — eyelids, 280
 — — front of eyeball, 280
 — — orbit, 294
 Typhus fever, eye disease, 401

 Ulcers of cornea (*see* Cornea)
 — — lids, lupous, 70
 — — — rodent, 69
 — — — syphilitic, 70
 Undiscovered blindness of one eye,
 240
 Unequal refraction of the two eyes,
 328
 Uræmic amaurosis, 412

- V Y operation for ectropion, 361
 Van Millingen's operation for tri-
 chiasis, 359
 Venæ vorticosæ, 186
 Vessels of anterior part of eyeball,
 28
 Virtual image, size, 7
 Vision (*see* Sight)
 — field of (*see* Field and Sight)
 Visual angle, 12
 — axis, 13
 Vitreous, diseases of, 255
 — dust-like opacities, 255
 — examination, 51, 256
 — hæmorrhage, 258
 — — traumatic, 258
 — humour, cholesterin in, 257
 — — in irido-cyclitis, 143, 259
 — — — myopia, 258, 307
 — — — retinitis, 259
 — — opacities, 255
 — — parasites in, 258
 — in choroiditis, 194, 258
 Warts, 68
 — conjunctival, 280
 “Watered silk” appearance of
 retina, 203
 Waxy disc, 193, 220
 Wernicke's test, 245
 Whooping-cough, eye disease, 404
 Woolly disc, 227
 Wounds of eyeball, 158
 — — — rules as to treatment, 159
 — — eyelids, 293
 — — orbit, 293

Xanthelasma palpebrarum, 68
 Xerophthalmia, 98
 Xerosis of conjunctiva, 98, 250

 Yellow spot, 58

 Zone, circumcorneal, 29
 — dangerous, 147
 Zonular cataract (*see* Lamellar)





No. 2.

London, 7, Great Marlborough Street
April, 1903.

A SELECTION
FROM
J. & A. CHURCHILL'S CATALOGUE,
COMPRISING
MOST OF THE RECENT WORKS PUBLISHED BY THEM.

N.B.—J. & A. Churchill's larger Catalogue, which contains over 600 works, with a Complete Index to their Subjects, will be sent on application.

Human Anatomy : a Treatise by various Authors. Edited by HENRY MORRIS, M.A., M.B. Lond., F.R.C.S., Surgeon to, and Lecturer on Surgery at, the Middlesex Hospital. Third Edition. Roy. 8vo, with 846 Illustrations, of which 267 are in several colours, 30s. net.

Heath's Practical Anatomy : a Manual of Dissections. Ninth Edition. Edited by J. ERNEST LANE, F.R.C.S., Surgeon and Lecturer on Anatomy at St. Mary's Hospital. Crown 8vo, with 321 Engravings, of which 32 are coloured, 12s. 6d.

Wilson's Anatomist's Vade-Mecum. Eleventh Edition, by HENRY E. CLARK, M.R.C.S. Eng., F.F.P.S. Glasg., Examiner in Anatomy F.P.S. Crown 8vo, with 492 Engravings and 26 Coloured Plates, 18s.

An Atlas of Human Anatomy. By Rickman J. GODLEE, M.S., F.R.C.S., Surgeon and late Demonstrator of Anatomy, University College Hospital. With 48 Imp. 4to Plates (112 figures), and a volume of Explanatory Text. £4 14s. 6d. net.

Human Osteology. By Luther Holden. Eighth Edition, edited by CHARLES STEWART, F.R.S., Conservator of the Museum R.C.S., and ROBERT W. REID, M.D., F.R.C.S., Regius Professor of Anatomy in the University of Aberdeen. 8vo, with 59 Lithographic Plates and 74 Engravings, 16s.

By the same Author.

Landmarks, Medical and Surgical. Fourth Edition. 8vo, 3s. 6d.

7, GREAT MARLBOROUGH STREET.

J. & A. Churchill's Recent Works.

A Manual of Practical Anatomy. By the late

Professor ALFRED W. HUGHES, M.B., M.C. Edin., Professor of Anatomy, King's College, London. Edited and completed by ARTHUR KEITH, M.D., Lecturer on Anatomy, London Hospital Medical College. In three parts, royal 8vo. Part I., with 38 Coloured Plates, and 116 Figures in the Text, 10s. 6d. Part II., with 4 Coloured Plates and 151 Figures in the Text, 8s. 6d. Part III., with 12 Coloured Plates and 204 Figures in the Text, 10s. 6d.

The Essentials of Regional Anatomy. By

RICHARD J. BERRY, M.D., F.R.S., F.R.C.S., (Edin.), Lecturer on Anatomy in the New School of Medicine of the Royal Colleges, Edinburgh. Second Edition. 8vo, interleaved, 3 vols., 5s. each, net.

Anatomy of the Joints of Man. By Henry

MORRIS, Senior Surgeon to the Middlesex Hospital. With 44 Lithographic Plates (several coloured). 8vo, 16s.

A Manual of General Pathology, for Students

and Practitioners. By W. S. LAZARUS-BARLOW, B.A., M.D., Pathologist and Lecturer on Pathology, Westminster Hospital. 8vo, 21s.

By the same Author.

The Elements of Pathological Anatomy and

Histology for Students. With 7 Coloured Plates and 171 Figures in the Text. Royal 8vo, 24s. net.

Pathological Anatomy of Diseases. Arranged

according to the nomenclature of the R.C.P. Lond. By NORMAN MOORE, M.D., F.R.C.P., Assistant Physician to St. Bartholomew's Hospital. Fcap. 8vo, with 111 Engravings, 8s. 6d.

A Manual of Clinical and Practical Pathology.

By W. E. WYNTER, M.D., M.R.C.P., and F. J. WETHERED, M.D., F.R.C.P. With 4 Coloured Plates and 67 Engravings. 8vo, 12s. 6d.

The Pathologist's Handbook: a Manual for

the Post-mortem Room. By T. N. KELYNACK, M.D., late Demonstrator in Morbid Anatomy, Owens College, Manchester. With 126 Illustrations, fcap. 8vo, pegamoid, 4s. 6d.

A Manual of Antenatal Pathology and Hy-

giene. The Fœtus. By J. W. BALLANTYNE, M.D., F.R.C.P.E., F.R.S. Edin., Lecturer on Antenatal Pathology and Teratology in the University of Edinburgh. With 69 Illustrations (14 coloured), roy. 8vo, 20s. net.

The Human Brain: Histological and Coarse

Methods of Research. By W. BEVAN LEWIS, L.R.C.P. Lond. 8vo, with Wood Engravings and Photographs, 8s.

7, GREAT MARLBOROUGH STREET.

J. & A. Churchill's Recent Works.

- The Physiology and the Pathology of the Cerebral Circulation: an Experimental Research.** By LEONARD HILL, M.D., Hunterian Professor, R.C.S. With 41 Illustrations. Royal 8vo, 12s.
- Elements of Human Physiology.** By Ernest H. STARLING, M.D., F.R.C.P., F.R.S., Jodrell Professor of Physiology in University College, London. Fifth Edition, with 321 Illustrations. 8vo, 12s. 6d.
- Essentials of Human Physiology for Medical Students.** By D. NOËL PATON, M.D., B.Sc., Lecturer on Physiology, School of Medicine of the Royal Colleges, Edinburgh. With 110 Illustrations. 8vo., 12s. net.
- Elementary Practical Physiology, including Histology, Chemical and Experimental Physiology.** By DE BURGH BIRCH, M.D., F.R.S.E., Professor of Physiology in the Yorkshire College of the Victoria University. With 62 Engravings. Crown 8vo, 6s. 6d.
- Practical Lessons in Elementary Biology, for Junior Students.** By PEYTON T. B. BEALE, F.R.C.S., Lecturer on Elementary Biology and Demonstrator in Physiology in King's College, London. Crown 8vo, 3s. 6d.
- Medical Jurisprudence: its Principles and Practice.** By ALFRED S. TAYLOR, M.D., F.R.C.P., F.R.S. Fourth Edition, by THOMAS STEVENSON, M.D., F.R.C.P., Lecturer on Medical Jurisprudence at Guy's Hospital. 2 vols. 8vo, with 189 Engravings, 31s. 6d.
- Lectures on Medical Jurisprudence and Toxicology.** By FRED. J. SMITH, M.D., F.R.C.P., Lecturer on Forensic Medicine and Toxicology at the London Hospital. Crown 8vo, 7s. 6d.
- The Theory and Practice of Hygiene.** (Notter and Firth). By J. LANE NOTTER, M.D., Professor of Hygiene in the Army Medical School; and W. H. HORROCKS, M.B., B.Sc., Assistant Professor of Hygiene in the Army Medical School. Second Edition. With 15 Plates and 134 other Illustrations. Royal 8vo, 25s.
- Manual of Hygiene.** By W. H. Hamer, M.D., D.P.H., F.R.C.P., Lecturer on Public Health, St. Bartholomew's Hospital, Assistant Medical Officer of Health of the Administrative County of London. With 93 Illustrations. 8vo, 12s. 6d. net.
- A Handbook of Hygiene and Sanitary Science.** By GEO. WILSON, M.A., M.D., LL.D., D.P.H. Camb. Medical Officer of Health for Mid-Warwickshire. Eighth Edition. Post 8vo, with Engravings, 12s. 6d.
- Public Health and Preventive Medicine.** By C. J. LEWIS, M.D., D.Sc. Edin., and ANDREW BALFOUR, M.D., B.Sc. Edin., D.P.H. Camb. With 11 Plates and 189 Figures in the Text. Imp. 8vo, 25s. net.

7, GREAT MARLBOROUGH STREET.

J. & A. Churchill's Recent Works.

Hygiene and Public Health: a Treatise by various Authors. Edited by THOMAS STEVENSON, M.D., and SHIRLEY F. MURPHY. In 3 vols., royal 8vo, fully Illustrated. Vol. I., 28s.; Vol. II., 32s.; Vol. III., 20s.

A Simple Method of Water Analysis, especially designed for the use of Medical Officers of Health. By JOHN C. THRESH, M.D.Vic., D.Sc. Lond., D.P.H. Camb. Third Edition, enlarged. Fcap. 8vo, 2s. 6d.

Elements of Health: an Introduction to the Study of Hygiene. By LOUIS C. PARKES, M.D., D.P.H. Lond., Medical Officer of Health for Chelsea, Lecturer on Public Health at St. George's Hospital. Post 8vo, with 27 Engravings, 3s. 6d.

Diet and Food considered in relation to Strength and Power of Endurance, Training and Athletics. By ALEXANDER HAIG, M.D., F.R.C.P. Fourth Edition. Crown 8vo, 2s.

The Prevention of Epidemics and the Construction and Management of Isolation Hospitals. By ROGER MCNEILL, M.D. Edin., D.P.H. Camb., Medical Officer of Health for the County of Argyll. 8vo, with several Hospital Plans, 10s. 6d.

Second Treatise on the Effects of Borax and Boric Acid on the Human System. By Dr. OSCAR LIEBREICH, Professor in the University of Berlin. With Plates, post 4to, 2s. 6d.

A Manual of Bacteriology, Clinical and Applied. With an Appendix on Bacterial Remedies, &c. By RICHARD T. HEWLETT, M.D., Professor of General Pathology and Bacteriology in King's College, London. Second Edition. With 20 Plates, and 66 Figures in the Text, post 8vo, 12s. 6d.

An Introduction to the Bacteriological Examination of Water. By W. H. HORROCKS, M.B., B.Sc., Lond., Assistant Professor of Military Hygiene in the Army Medical School, Netley, Major, Royal Army Medical Corps. With 5 Lithographic Plates, 8vo, 10s. 6d.

Hospitals and Asylums of the World: their Origin, History, Construction, Administration, Management, and Legislation. By Sir H. C. BURDETT, K.C.B. 4 vols., royal 8vo, and Portfolio. Complete, £12 12s. net. Vols. I. and II.—Asylums, £6 15s. net. Vols. III. and IV.—Hospitals, with Plans and Portfolio, £9 net.

Mental Diseases: Clinical Lectures. By T. S. CLOUSTON, M.D., F.R.C.P. Edin., Lecturer on Mental Diseases in the University of Edinburgh. Fifth Edition. Cr. 8vo, with 19 Plates, 14s.

7, GREAT MARLBOROUGH STREET.

J. & A. Churchill's Recent Works.

- Lunacy and Law.** An Address on the Prevention of Insanity, delivered before the Medico-Psychological Association of Great Britain and Ireland by Sir WM. R. GOWERS, M.D., F.R.S. 8vo, 1s.
- The Insane and the Law: a Plain Guide for** Medical Men, Solicitors, and Others. By G. PITT-LEWIS, K.C., R. PERCY SMITH, M.D., F.R.C.P., and J. A. HAWKE, B.A., Barrister-at-Law. 8vo, 14s.
- A Dictionary of Psychological Medicine,** giving the Definition, Etymology, and Synonyms of the Terms used in Medical Psychology; with the Symptoms, Treatment, and Pathology of Insanity; and THE LAW OF LUNACY IN GREAT BRITAIN AND IRELAND. Edited by D. HACK TUKE, M.D., LL.D., assisted by nearly 130 Contributors, British, Continental and American. 2 vols., 1,500 pages, royal 8vo, Illustrated, 42s.
- The Force of Mind: or, the Mental Factor** in Medicine. By ALFRED T. SCHOFIELD, M.D., Hon. Physician to Friedenheim Hospital. Second Edition. Crown 8vo, 5s. net.
- The Mental Affections of Children: Idiocy,** Imbecility, and Insanity. By WM. W. IRELAND, M.D. Edin., formerly Medical Superintendent of the Scottish Institution for the Education of Imbecile Children. Second Edition. With 21 Plates, 8vo, 14s.
- Mental Affections of Childhood and Youth** (Lettsomian Lectures for 1887, etc.). By J. LANGDON-DOWN, M.D., F.R.C.P., Consulting Physician to the London Hospital. 8vo, 6s.
- The Journal of Mental Science.** Published Quarterly, by Authority of the Medico-Psychological Association. 8vo, 5s.
- Manual of Midwifery,** including all that is likely to be required by Students and Practitioners. By ALFRED L. GALABIN, M.A., M.D., F.R.C.P., Obstetric Physician and Lecturer on Midwifery and Diseases of Women to Guy's Hospital. Fifth Edition. Post 8vo, with 298 Engravings, 15s.
- The Practice of Midwifery: a Guide for Prac-** titioners and Students. By D. LLOYD ROBERTS, M.D., F.R.C.P., Lecturer on Clinical Midwifery and Diseases of Women at the Owens College; Consulting Obstetric Physician to the Manchester Royal Infirmary. Fourth Edition. Fcap. 8vo, with Coloured Plates and Wood (226) Engravings, 10s. 6d.
- Obstetric Aphorisms: for the Use of Students** commencing Midwifery Practice. By JOSEPH G. SWAYNE, M.D., Lecturer on Midwifery in the Bristol Medical School. Tenth Edition. Fcap. 8vo, with 20 Engravings 3s. 6d.

7, GREAT MARLBOROUGH STREET.

J. & A. Churchill's Recent Works.

A Short Practice of Midwifery, embodying the
Treatment adopted in the Rotunda Hospital, Dublin. By HENRY
JELLETT, M.D., B.A.O. Dub., late Assistant Master, Rotunda Hospital.
Third Edition. With 124 Illustrations. Crown 8vo, 8s. 6d.

By the same Author.

A Short Practice of Midwifery for Nurses.
With 67 Illustrations, crown 8vo, 6s.

Lectures on Obstetric Operations: including
the Treatment of Hæmorrhage, and forming a Guide to the Manage-
ment of Difficult Labour. By ROBERT BARNES, M.D., F.R.C.P.,
Consulting Obstetric Physician to St. George's Hospital. Fourth
Edition. 8vo, with 121 Engravings, 12s. 6d.

By the same Author.

A Clinical History of Medical and Surgical
Diseases of Women. Second Edition. 8vo, with 181 Engravings, 28s.

Outlines of Gynæcological Pathology and
Morbid Anatomy. By C. HUBERT ROBERTS, M.D. Lond., Physician
to the Samaritan Free Hospital for Women. With 151 Illustrations,
8vo, 21s.

Diseases of Women. (Student's Guide Series.)
By ALFRED L. GALABIN, M.A., M.D., F.R.C.P., Obstetric Phy-
sician to, and Lecturer on Midwifery and Diseases of Women at,
Guy's Hospital. Fifth Edition. Fcap. 8vo, with 142 Engravings, 8s. 6d.

A Short Practice of Gynæcology. By Henry
JELLETT, M.D., B.A.O. Dub., late Assistant Master, Rotunda
Hospital, Dublin. With 125 Illustrations, crown 8vo, 7s. 6d.

Manual of the Diseases peculiar to Women.
By JAMES OLIVER, M.D., F.R.S.E., M.R.C.P., Physician to the
Hospital for Diseases of Women, London. Fcap. 8vo, 3s. 6d.

By the same Author.

Abdominal Tumours and Abdominal Dropsy
in Women. Crown 8vo, 7s. 6d.

Sterility. By ROBERT BELL, M.D., F.F.P. & S. Glasg.,
Senior Physician to the Glasgow Hospital for Diseases peculiar to
Women. 8vo, 5s.

Nursing, General, Medical, and Surgical, with
Appendix on Sickroom Cookery. By WILFRED J. HADLEY, M.D.,
F.R.C.P., Physician to the London Hospital. Crown 8vo, 3s. 6d.

7, GREAT MARLBOROUGH STREET.

J. & A. Churchill's Recent Works.

A Manual for Hospital Nurses and others engaged in Attending on the Sick. By E. J. DOMVILLE, Surgeon to the Devon and Exeter Hospital. Eighth Edition. Crown 8vo, 2s. 6d.

A Short Manual for Monthly Nurses. By CHARLES J. CULLINGWORTH, M.D., F.R.C.P., Obstetric Physician to St. Thomas's Hospital. Revised by the Author, with the assistance of M. A. ATKINSON, Matron of the General Lying-in Hospital, Lambeth. Fifth Edition. Fcap. 8vo, 1s. 6d.

Lectures on Medicine to Nurses. By Herbert E. CUFF, M.D., F.R.C.S., Medical Superintendent, North Eastern Fever Hospital, London. Third Edition. With 29 Illustrations. Crown 8vo, 3s. 6d.

Antiseptic Principles for Nurses. By C. E. RICHMOND, F.R.C.S. Fcap. 8vo, 1s.

A Practical Treatise on Disease in Children. By EUSTACE SMITH, M.D., F.R.C.P., Physician to the King of the Belgians, and to the East London Hospital for Children, etc. Second Edition. 8vo, 22s.

By the same Author.

Clinical Studies of Disease in Children. Second Edition. Post 8vo, 7s. 6d.

Also.

The Wasting Diseases of Infants and Children. Sixth (cheap) Edition. Post 8vo, 6s.

The Diseases of Children. By James F. GOODHART, M.D., F.R.C.P. Seventh Edition, with the assistance of G. F. STILL, M.D., F.R.C.P., Assistant Physician to the Hospital for Sick Children, Great Ormond Street. 8vo, 12s. 6d. net.

On the Natural and Artificial Methods of Feeding Infants and Young Children. By EDMUND CAUTLEY, M.D., Physician to the Belgrave Hospital for Children. Crown 8vo, 7s. 6d.

Materia Medica, Pharmacy, Pharmacology, and Therapeutics. By W. HALE WHITE, M.D., F.R.C.P., Physician to, and Lecturer on Pharmacology and Therapeutics at, Guy's Hospital. Seventh Edition, based upon the B.P. of 1898 and the Indian and Colonial Addendum. Fcap. 8vo, 7s. 6d.

Southall's Organic Materia Medica. Sixth Edition, adapted to the B.P. of 1898. Edited by JOHN BARCLAY, B.Sc. Lond. Crown 8vo, 7s. 6d.

7, GREAT MARLBOROUGH STREET.

J. & A. Churchill's Recent Works.

An Introduction to the Study of Materia Medica, designed for Students of Pharmacy and Medicine. By HENRY G. GREENISH, F.I.C., F.L.S., Professor of Pharmaceutics to the Pharmaceutical Society. With 213 Illustrations, 8vo, 15s.

Materia Medica and Therapeutics. By Charles D. F. PHILLIPS, M.D., LL.D., F.R.S. Edin.

Vegetable Kingdom—Organic Compounds—Animal Kingdom. 8vo, 25s.

Inorganic Substances. Second Edition. 8vo, 21s.

Practical Pharmacy: an Account of the Methods of Manufacturing and Dispensing Pharmaceutical Preparations; with a chapter on the Analysis of Urine. By E. W. LUCAS, F.C.S., Examiner at the Pharmaceutical Society. With 283 Illustrations. Roy. 8vo, 12s. 6d.

Galenic Pharmacy: a Practical Handbook to the Processes of the British Pharmacopœia. By R. A. CRIPPS, M.P.S. 8vo, with 76 Engravings, 8s. 6d.

Practical Pharmacy. By Barnard S. Proctor. Third Edition. 8vo, with Engravings and Fac-simile Prescriptions, 14s.

The Galenical Preparations of the British Pharmacopœia: a Handbook for Medical and Pharmaceutical Students. By C. O. HAWTHORNE, M.D., C.M., late Lecturer on Materia Medica and Therapeutics, Queen Margaret's College, Glasgow. 8vo, 4s. 6d.

The Pharmaceutical Formulary: a Synopsis of the British and Foreign Pharmacopœias. By HENRY BEASLEY. Twelfth Edition by J. OLDHAM BRAITHWAITE. 18mo, 6s. 6d.

By the same Author.

The Druggist's General Receipt-Book. Tenth Edition. 18mo, 6s. 6d.

Also.

The Book of Prescriptions: containing upwards of 3,000 Prescriptions collected from the Practice of the most eminent Physicians and Surgeons, English and Foreign. Seventh Edition, 18mo, 6s. 6d.

A Companion to the British Pharmacopœia. By PETER SQUIRE. Revised by PETER WYATT SQUIRE, F.L.S., F.C.S. Seventeenth Edition. 8vo, 12s. 6d.

By the same Authors.

The Pharmacopœias of thirty of the London Hospitals, arranged in Groups for Comparison. Seventh Edition. Fcap. 8vo, 6s.

7, GREAT MARLBOROUGH STREET.

J. & A. Churchill's Recent Works.

Pereira's Selecta è Prescriptis: containing

Lists of Terms used in Prescriptions, with Explanatory Notes, etc.
Also, a Series of Abbreviated Prescriptions with Translations.
Eighteenth Edition, by JOSEPH INCE. 24mo, 5s.

Year-Book of Pharmacy: containing the Transactions of the British Pharmaceutical Conference. Annually. 8vo, 10s.

Manual of Botany, in two Vols., crown 8vo.

By J. REYNOLDS GREEN, Sc.D., M.A., F.R.S., Professor of Botany to the Pharmaceutical Society.

Vol. I.: Morphology and Anatomy. Second Edition, with 788 Engravings. 7s. 6d.

Vol. II.: Classification and Physiology, Second Edition, with 466 Engravings, 10s.

By the same Author.

An Introduction to Vegetable Physiology.

With 184 Illustrations, 8vo, 10s. 6d.

The Student's Guide to Systematic Botany,

including the Classification of Plants and Descriptive Botany. By ROBERT BENTLEY, late Emeritus Professor of Botany in King's College and to the Pharmaceutical Society. Fcap. 8vo, with 350 Engravings, 3s. 6d.

Medicinal Plants: being Descriptions with

original figures, of the Principal Plants employed in Medicine, and an account of their Properties and Uses. By Prof. BENTLEY and Dr. H. TRIMEN, F.R.S. In 4 vols., large 8vo, with 306 Coloured Plates, bound in Half Morocco, Gilt Edges, £11 11s. net, or, with Plates, not coloured, cloth binding, £5 5s. net.

Therapeutic Electricity and Practical Muscle

Testing. By W. S. HEDLEY, M.D., in charge of the Electro-therapeutic Department of the London Hospital. With 110 Illustrations. Roy. 8vo, 8s. 6d.

Practical Therapeutics: a Manual. By

EDWARD J. WARING, C.I.E., M.D., F.R.C.P., and DUDLEY W. BUXTON, M.D., B.S. Lond. Fourth Edition. Crown 8vo, 14s.

By the same Author.

Bazaar Medicines of India, and Common

Medical Plants. With Full Index of Diseases, indicating their Treatment by these and other Agents procurable throughout India, etc. Fifth Edition. Fcap. 8vo, 5s.

7, GREAT MARLBOROUGH STREET.

J. & A. Churchill's Recent Works.

Climate and Fevers of India, with a Series
of Cases (Croonian Lectures, 1882). By Sir JOSEPH FAYRER, Bart.,
K.C.S.I., M.D. 8vo, with 17 Temperature Charts, 12s.

The Malarial Fevers of British Malaya. By
HAMILTON WRIGHT, M.D. (MCGILL), Director of the Institute for
Medical Research, Federated Malay States. With Map and Charts.
Royal 8vo, 3s. net.

Psilosis or "Sprue": its Nature and Treat-
ment; with Observations on various Forms of Diarrhœa acquired in
the Tropics. By GEORGE THIN, M.D. Second and Enlarged Edition,
with Illustrations. 8vo, 10s.

A Manual of Family Medicine and Hygiene
for India. Published under the Authority of the Government of
India. By Sir WILLIAM J. MOORE, K.C.I.E., M.D. Seventh Edition
revised by Major J. H. TULL WALSH, I.M.S. Post 8vo, with 70
Engravings, 12s.

By the same Author.

A Manual of the Diseases of India: with a
Compendium of Diseases generally. Second Edition. Post 8vo,
10s.

The Prevention of Disease in Tropical and
Sub-Tropical Campaigns. (Parkes Memorial Prize for 1886.) By
Lieut.-Col. ANDREW DUNCAN, M.D., B.S. Lond., F.R.C.S., H.M.
Indian Medical Service. 8vo, 12s. 6d.

Hooper's Physicians' Vade-Mecum: a Manual
of the Principles and Practice of Physic. Tenth Edition. By W. A.
GUY, F.R.C.P., F.R.S., and J. HARLEY, M.D., F.R.C.P. With 118
Engravings. Fcap. 8vo, 12s. 6d.

A Text-Book of Medicine. Begun by the late
C. HILTON FAGGE, M.D.; completed and re-written by P. H.
PYE-SMITH, M.D., F.R.S. Fourth Edition. 2 vols. royal 8vo, 42s.

Manual of the Practice of Medicine. By
FREDERICK TAYLOR, M.D., F.R.C.P., Physician to, and Lecturer
on Medicine at, Guy's Hospital. Sixth Edition. Post 8vo. with
Engravings, 16s.

7, GREAT MARLBOROUGH STREET.

J. & A. Churchill's Recent Works.

A System of Clinical Medicine for Practitioners and Students, giving an account of the Diagnosis, Prognosis, and Treatment of Disease. By THOS. D. SAVILL, M.D., M.R.C.P. In 2 vols., post 8vo, with 4 Coloured Plates, and 200 Figures in the Text.

VOL. I.—Local Diseases and Pyrexial Disorders. 12s. 6d. net.

VOL. II.—Diseases of the Skin, the Nervous System, etc. (*shortly*).

A Dictionary of Practical Medicine. By various writers. Edited by JAS. KINGSTON FOWLER, M.A., M.D., F.R.C.P., Physician to Middlesex Hospital and the Hospital for Consumption. 8vo, cloth, 21s.

The Practice of Medicine. By M. Charteris, M.D., Professor of Therapeutics and Materia Medica in the University of Glasgow. Eighth Edition. Edited by F. J. CHARTERIS, M.B., Ch. B. Crown 8vo, with Engravings on Copper and Wood, 10s.

A Text-Book of Bacteriology for Students and Practitioners of Medicine. By G. M. STERNBERG, M.D., Surgeon-General, U.S. Army. Second Edition. With 9 Plates and 198 Figures in the Text. 8vo, 26s.

How to Examine the Chest: a Practical Guide for the use of Students. By SAMUEL WEST, M.D., F.R.C.P., Assistant Physician to St. Bartholomew's Hospital. Third Edition. With 46 Engravings. Fcap. 8vo, 5s.

Atlas of the Pathological Anatomy of the Lungs. By the late WILSON FOX, M.D., F.R.S. With 45 Plates (mostly Coloured) and Engravings. 4to, half-bound in Calf, 70s. net.

By the same Author.

A Treatise on Diseases of the Lungs and Pleura. Edited by SIDNEY COUPLAND, M.D., F.R.C.P., Physician to Middlesex Hospital. Roy. 8vo, with Engravings; also Portrait and Memoir of the Author, 36s. net.

The Student's Guide to Diseases of the Chest. By VINCENT D. HARRIS, M.D. Lond., F.R.C.P., Physician to the City of London Hospital for Diseases of the Chest, Victoria Park. Fcap. 8vo, with 55 Illustrations (some Coloured), 7s. 6d.

Guy's Hospital Reports. By the Medical and Surgical Staff. Vol. XL. Third Series. 8vo, 10s. 6d.

St. Thomas's Hospital Reports. By the Medical and Surgical Staff. Vol. XXIX. New Series. 8vo, 8s. 6d.

7, GREAT MARLBOROUGH STREET.

J. & A. Churchill's Recent Works.

Text-Book of Medical Treatment (Diseases and Symptoms). By NESTOR I. C. TIRARD, M.D., F.R.C.P., Professor of the Principles and Practice of Medicine, King's College, London. 8vo, 15s.

Student's Guide to Medical Diagnosis. By SAMUEL FENWICK, M.D., F.R.C.P., and W. SOLTAU FENWICK, M.D., B.S. Ninth Edition. Crown 8vo, with 139 Engravings, 9s.

By the same Authors.

Outlines of Medical Treatment. Fourth Edition. Crown 8vo, with 35 Engravings, 10s.

Also.

Ulcer of the Stomach and Duodenum. With 55 Illustrations. Roy. 8vo, 10s. 6d.

Also.

Cancer and other Tumours of the Stomach. With 70 Illustrations, royal 8vo, 10s. 6d.

Also, by Dr. Samuel Fenwick.

Clinical Lectures on some Obscure Diseases of the Abdomen. Delivered at the London Hospital. 8vo, with Engravings, 7s. 6d.

And

The Saliva as a Test for Functional Diseases of the Liver. Crown 8vo, 2s.

The Schott Methods of the Treatment of Chronic Diseases of the Heart, with an account of the Nauheim Baths, and of the Therapeutic Exercises. By W. BEZLY THORNE, M.D., M.R.C.P. Fourth Edition. 8vo, with Illustrations, 6s.

The Liver. By Lionel S. Beale, M.B., F.R.S., Consulting Physician to King's College Hospital. With 24 Plates (85 Figures), 8vo, 5s.

By the same Author.

On Slight Ailments: and on Treating Disease. Fourth Edition. 8vo, 5s.

The Blood: how to Examine and Diagnose its Diseases. By ALFRED C. COLES, M.D., B.Sc. Second Edition. With 6 Coloured Plates. 8vo, 10s. 6d.

The Physiology of the Carbohydrates; their Application as Food and Relation to Diabetes. By F. W. PAVY, M.D., LL.D., F.R.S., F.R.C.P., Consulting Physician to Guy's Hospital. Royal 8vo, with Plates and Engravings, 10s. 6d.

7, GREAT MARLBOROUGH STREET.

J. & A. Churchill's Recent Works.

Uric Acid as a Factor in the Causation of

Disease. By ALEXANDER HAIG, M.D., F.R.C.P. Physician to the Metropolitan Hospital and the Royal Hospital for Children and Women. Fifth Edition. 8vo, with 75 Illustrations, 14s.

Bronchial Asthma: its Pathology and Treat-

ment. By J. B. BERKART, M.D., late Physician to the City of London Hospital for Diseases of the Chest. Second Edition, with 7 Plates (35 Figures). 8vo, 10s. 6d.

Treatment of Some of the Forms of Valvular

Disease of the Heart. By A. E. SANSOM, M.D., F.R.C.P., Physician to the London Hospital. Second Edition. Fcap. 8vo, with 26 Engravings, 4s. 6d.

Medical Ophthalmoscopy: a Manual and Atlas.

By Sir WILLIAM R. GOWERS, M.D., F.R.C.P., F.R.S. Third Edition. Edited with the assistance of MARCUS GUNN, M.B., F.R.C.S., Surgeon to the Royal London Ophthalmic Hospital. With Coloured Plates and Woodcuts. 8vo, 16s.

By the same Author.

A Manual of Diseases of the Nervous System.

VOL. I.—Nerves and Spinal Cord. Third

Edition, by the Author and JAMES TAYLOR, M.D., F.R.C.P. Roy. 8vo, with 192 Engravings, 15s.

VOL. II.—Brain and Cranial Nerves: General

and Functional Diseases of the Nervous System. Second Edition. Roy. 8vo, with 182 Engravings, 20s.

Also.

Clinical Lectures on Diseases of the Nervous

System. 8vo. 7s. 6d.

Also.

Epilepsy and other Chronic Convulsive

Diseases: their Causes, Symptoms, and Treatment. Second Edition. 8vo, 10s. 6d.

Also.

Diagnosis of Diseases of the Brain. Second

Edition. 8vo, with Engravings, 7s. 6d.

Also.

Syphilis and the Nervous System: being a

Revised Reprint of the Lettsomian Lectures for 1890. Delivered before the Medical Society of London. 8vo, 4s.

The Nervous System, Diseases of. By J. A.

ORMEROD, M.D., F.R.C.P., Physician to the National Hospital for the Paralysed and Epileptic. With 66 Illustrations. Fcap. 8vo, 8s. 6d.

7, GREAT MARLBOROUGH STREET.

J. & A. Churchill's Recent Works.

Text-Book of Nervous Diseases for Students

and Practitioners of Medicine. By CHARLES L. DANA, M.D., Professor of Nervous and Mental Diseases in Bellevue Hospital Medical College, New York. Fourth Edition. With 246 Illustrations. 8vo, 20s.

Diseases of the Nervous System. Lectures

delivered at Guy's Hospital. By Sir SAMUEL WILKS, Bart., M.D., F.R.S. Second Edition. 8vo, 18s.

Handbook of the Diseases of the Nervous

System. By JAMES ROSS, M.D., F.R.C.P., late Professor of Medicine in the Victoria University, and Physician to the Royal Infirmary, Manchester. Roy. 8vo, with 184 Engravings, 18s.

Stammering: its Causes, Treatment, and

Cure. By A. G. BERNARD, M.R.C.S., L.R.C.P. Crown 8vo, 2s.

Secondary Degenerations of the Spinal Cord

(Gulstonian Lectures, 1889). By HOWARD H. TOOTH, M.D., F.R.C.P., Assistant Physician to the National Hospital for the Paralysed and Epileptic. With Plates and Engravings. 8vo, 3s. 6d.

Diseases of the Nervous System. Clinical

Lectures. By THOMAS BUZZARD, M.D., F.R.C.P., Physician to the National Hospital for the Paralysed and Epileptic. With Engravings. 8vo, 15s.

By the same Author.

Some Forms of Paralysis from Peripheral

Neuritis; of Gouty, Alcoholic, Diphtheritic, and other origin. Crown 8vo, 5s.

Also.

On the Simulation of Hysteria by Organic

Disease of the Nervous System. Crown 8vo, 4s. 6d.

On the Typhoid Bacillus and Typhoid Fever,

being the Goulstonian Lectures delivered before the Royal College of Physicians in March, 1900, by P. HORTON-SMITH, M.D., F.R.C.P. With Illustrations, 8vo, 2s. 6d.

Gout in its Clinical Aspects. By J. Mortimer

GRANVILLE, M.D. Crown 8vo, 6s.

Diseases of the Liver: with and without

Jaundice. By GEORGE HARLEY, M.D., F.R.C.P., F.R.S. 8vo, with 2 Plates and 36 Engravings, 21s.

Rheumatic Diseases (Differentiation in). By

HUGH LANE, Surgeon to the Royal Mineral Water Hospital, Bath. Second Edition, much Enlarged, with 8 Plates. Crown 8vo, 3s. 6d.

7, GREAT MARLBOROUGH STREET.

J. & A. Churchill's Recent Works.

Diseases of the Abdomen, comprising those
of the Stomach and other parts of the Alimentary Canal, Oesophagus,
Cæcum, Intestines, and Peritoneum. By S. O. HABERSHON, M.D.,
F.R.C.P. Fourth Edition. 8vo, with 5 Plates, 21s.

On Gallstones, or Cholelithiasis. By E. M.
BROCKBANK, M.D. Vict., M.R.C.P. Lond., Honorary Physician to the
Ancoats Hospital, Manchester. Crown 8vo, 7s.

Obstinate Hiccough; the Physiology, Patho-
logy, and Treatment, based on a collection of over 150 cases from
British and Foreign Works. By L. F. B. KNUTHSEN, M.D. Edin.
Royal 8vo, 6s.

Headaches: their Nature, Causes, and Treat-
ment. By W. H. DAY, M.D., Physician to the Samaritan Hospital.
Fourth Edition. Crown 8vo, with Engravings, 7s. 6d.

A Handbook of Medical Climatology, embody-
ing its Principles and Therapeutic Application, with Scientific Data
of the chief Health Resorts of the World. By S. EDWIN SOLLY, M.D.,
M.R.C.S., late President of the American Climatological Association.
With Engravings and Coloured Plates. 8vo, 16s.

The Mineral Waters of France, and its
Wintering Stations (Medical Guide to). With a Special Map. By A.
VINTRAS, M.D., Physician to the French Embassy, and to the French
Hospital, London. Second Edition. Crown 8vo, 8s.

Surgery: its Theory and Practice. By William
J. WALSHAM, F.R.C.S., Surgeon to, and Lecturer on Anatomy at,
St. Bartholomew's Hospital. Seventh Edition. Post 8vo, with 483
Engravings (including 28 Skiagrams), 15s.

A Synopsis of Surgery. By R. F. Tobin,
Surgeon to St. Vincent's Hospital, Dublin. Second Edition. Crown
8vo, interleaved, leather binding, 6s. 6d.

Surgical Emergencies: together with the
Emergencies attendant on Parturition and the Treatment of Poison-
ing. By PAUL SWAIN, F.R.C.S., Surgeon to the South Devon
and East Cornwall Hospital. Fifth Edition. Crown 8vo, with 149
Engravings, 6s.

Illustrated Ambulance Lectures: (to which is
added a NURSING LECTURE) in accordance with the Regulations of the
St. John's Ambulance Association for Male and Female Classes. By
JOHN M. H. MARTIN, M.D., F.R.C.S., Hon. Surgeon to the Blackburn
Infirmary. Fourth Edition. Crown 8vo, with 60 Engravings, 2s.

7, GREAT MARLBOROUGH STREET.

J. & A. Churchill's Recent Works.

Operations on the Brain (a Guide to). By ALEC FRASER, Professor of Anatomy, Royal College of Surgeons in Ireland. Illustrated by 42 life-size Plates in Autotype, and 2 Woodcuts in the text. Folio, 63s. net.

Abdominal Surgery. By J. Greig Smith, M.A., F.R.S.E. Sixth Edition. Edited by JAMES SWAIN, M.S., M.D. Lond., F.R.C.S. Eng., Assistant-Surgeon to the Bristol Royal Infirmary, Professor of Surgery, University College, Bristol. 2 vols., 8vo, with 224 Engravings, 36s.

The Physiology of Death from Traumatic Fever; a Study in Abdominal Surgery. By JOHN D. MALCOLM, M.B., C.M., F.R.C.S.E., Surgeon to the Samaritan Free Hospital. 8vo, 3s. 6d.

The Surgery of the Alimentary Canal. By ALFRED ERNEST MAYLARD, M.B. Lond. and B.S., Senior Surgeon to the Victoria Infirmary, Glasgow. With 27 Swantype Plates and 89 Figures in the Text, 8vo, 25s.

By the same Author.

A Student's Handbook of the Surgery of the Alimentary Canal. With 97 Illustrations. Crown 8vo, 8s. 6d.

Hare-Lip and Cleft Palate. By R. W. MURRAY, F.R.C.S., Surgeon, David Lewis Northern Hospital, late Surgeon, Liverpool Infirmary for Children. With 25 Illustrations, 8vo, 3s.

Surgery. By C. W. Mansell Moullin, M.A., M.D. Oxon., F.R.C.S., Surgeon and Lecturer on Physiology to the London Hospital. Large 8vo, with 497 Engravings, 34s.

The Practice of Surgery: a Manual. By THOMAS BRYANT, Consulting Surgeon to Guy's Hospital. Fourth Edition. 2 vols. crown 8vo, with 750 Engravings (many being Coloured), and including 6 chromo plates, 32s.

The Operations of Surgery: intended for use on the Dead and Living Subject alike. By W. H. A. JACOBSON, M.Ch. Oxon., F.R.C.S., Surgeon Guy's Hospital, and F. J. STEWARD, M.S. Lond., F.R.C.S., Assistant Surgeon, Guy's Hospital. Fourth Edition. 2 vols., roy. 8vo, with 550 Illustrations, 42s.

Muco-Membranous Entero-Colitis; Symptoms, Complications, Etiology, and Treatment. By MAURICE DE JANGENHAGEN, M.D., Consulting Physician at Plombières, Vosges, France. Fcap. 8vo, 3s. 6d.

7, GREAT MARLBOROUGH STREET.

J. & A. Churchill's Recent Works.

A Course of Operative Surgery. By CHRISTOPHER HEATH, Surgeon to University College Hospital. Second Edition. With 20 Coloured Plates (180 figures). 30s. net.

By the same Author.

A Manual of Minor Surgery and Bandaging. Twelfth Edition, revised by BILTON POLLARD, F.R.C.S., Surgeon to University College Hospital. Fcap. 8vo, with 195 Engravings, 6s. 6d.

Also.

Injuries and Diseases of the Jaws. Fourth Edition. Edited by HENRY PERCY DEAN, M.S., F.R.C.S., Assistant Surgeon to the London Hospital. 8vo, with 187 Wood Engravings, 14s

Also.

Clinical Lectures on Surgical Subjects delivered at University College Hospital. First Series, 6s.; Second Series, 6s.

Clinical Essays and Lectures. By HOWARD MARSH, F.R.C.S., Surgeon to, and late Lecturer on Surgery at, St. Bartholomew's Hospital. With 26 Illustrations, 8vo, 7s. 6d.

Ovariectomy and Abdominal Surgery. By HARRISON CRIPPS, F.R.C.S., Surgical Staff, St. Bartholomew's Hospital. With numerous Plates, royal 8vo, 25s.

Diseases of Bones and Joints. By CHARLES MACNAMARA, F.R.C.S., Surgeon to, and Lecturer on Surgery at, the Westminster Hospital. 8vo, with Plates and Engravings, 12s.

Surgical Pathology and Morbid Anatomy. By ANTHONY A. BOWLBY, F.R.C.S., Assistant Surgeon to St. Bartholomew's Hospital. Fourth Edition. Crown 8vo, with 186 Engravings, 10s. 6d.

By the same Author.

Injuries and Diseases of Nerves, and their Surgical Treatment. 8vo, with 20 Plates, 14s.

Chloroform: a Manual for Students and Practitioners. By EDWARD LAWRIE, M.B. Edin., Lieut.-Col. I.M.S., Residency Surgeon, Hyderabad. Illustrated, crown 4to, 5s. net.

A Pocket Guide to Anæsthetics for the Student and General Practitioner. By THOMAS D. LUKE, M.B., F.R.C.S., Edinburgh. With 43 Engravings, crown 8vo, 5s. net.

7, GREAT MARLBOROUGH STREET.

J. & A. Churchill's Recent Works.

Diseases of the Thyroid Gland and their Surgical Treatment. By JAMES BERRY, B.S. Lond., F.R.C.S., Surgeon to the Royal Free Hospital and Lecturer on Surgery at the London School of Medicine for Women. With 121 Illustrations, 8vo, 14s.

The Human Foot: its Form and Structure, Functions and Clothing. By THOMAS S. ELLIS, Consulting Surgeon to the Gloucester Infirmary. With 7 Plates and Engravings (50 Figures). 8vo, 7s. 6d.

Short Manual of Orthopædy. By HEATHER BIGG, F.R.C.S. Ed., Part I. Deformities and Deficiencies of the Head and Neck. 8vo, 2s. 6d.

Face and Foot Deformities. By FREDERICK CHURCHILL, C.M. 8vo, with Plates and Illustrations, 10s. 6d.

Royal London Ophthalmic Hospital Reports. By the Medical and Surgical Staff. Vol. XV., Part 3. 8vo, 5s.

Ophthalmological Society of the United Kingdom. Transactions. Vol. XX. 8vo, 12s. 6d.

Manual of Ophthalmic Surgery and Medicine. By W. H. H. JESSOP, M.A., F.R.C.S., Ophthalmic Surgeon to St. Bartholomew's Hospital. With 5 Coloured Plates and 110 Woodcuts. Crown 8vo, 9s. 6d.

Nettleship's Diseases of the Eye. Sixth Edition. Revised and Edited by W. T. HOLMES SPICER, M.B., F.R.C.S., Ophthalmic Surgeon to St. Bartholomew's Hospital and the Victoria Hospital for Children. With 161 Engravings and a Coloured Plate illustrating Colour-Blindness. Crown 8vo, 8s. 6d.

Diseases and Refraction of the Eye. By N. C. MACNAMARA, F.R.C.S., Surgeon to Westminster Hospital, and GUSTAVUS HARTRIDGE, F.R.C.S., Surgeon to the Royal Westminster Ophthalmic Hospital. Fifth Edition. Crown 8vo, with Plate, 156 Engravings, also Test-types, 10s. 6d.

On Diseases and Injuries of the Eye: a Course of Systematic and Clinical Lectures to Students and Medical Practitioners. By J. R. WOLFE, M.D., F.R.C.S.E. With 10 Coloured Plates and 157 Wood Engravings. 8vo, 21s.

Elementary Ophthalmic Optics, including Ophthalmoscopy and Retinoscopy. By J. HERBERT PARSONS, B.S., B.Sc., F.R.C.S., Curator, Royal London Ophthalmic Hospital. With 66 Illustrations, 8vo, 6s. 6d.

7, GREAT MARLBOROUGH STREET.

J. & A. Churchill's Recent Works.

Normal and Pathological Histology of the

Human Eye and Eyelids. By C. FRED. POLLOCK, M.D., F.R.C.S., and F.R.S.E., Surgeon for Diseases of the Eye to Anderson's College Dispensary, Glasgow. Crown 8vo, with 100 Plates (230 drawings), 15s.

Atlas of Ophthalmoscopy. Composed of 12

Chromo-lithographic Plates (59 Figures drawn from nature) and Explanatory Text. By RICHARD LIEBREICH, M.R.C.S. Translated by H. ROSBOROUGH SWANZY, M.B. Third Edition, 4to, 40s. net.

Refraction of the Eye: a Manual for Students.

By GUSTAVUS HARTRIDGE, F.R.C.S., Surgeon to the Royal Westminster Ophthalmic Hospital. Eleventh Edition. Crown 8vo, with 105 Illustrations, also Test-types, etc., 6s.

By the same Author.

The Ophthalmoscope: a Manual for Students.

Fourth Edition. Crown 8vo, with 65 Illustrations and 4 Plates, 4s. 6d.

Glaucoma: its Pathology and Treatment. By

PRIESTLEY SMITH, Ophthalmic Surgeon to the Queen's Hospital, Birmingham. 8vo, with 64 Engravings and 12 Zinco-photographs. 7s. 6d.

Methods of Operating for Cataract and

Secondary Impairments of Vision, with the results of 500 cases. By Major G. H. FINK, H.M. Indian Medical Service. Crown 8vo, with 15 Engravings, 5s.

Diseases of the Eye: a Practical Handbook

for General Practitioners and Students. By CECIL EDWARD SHAW, M.D., M.Ch., Ophthalmic Surgeon to the Ulster Hospital for Children and Women, Belfast. With a Test-Card for Colour-Blindness. Crown 8vo, 3s. 6d.

The Accessory Sinuses of the Nose, their

Surgical Anatomy and the Diagnosis and Treatment of their Inflammatory Affections. By A. LOGAN TURNER, M.D. Edin., Surgeon for Diseases of the Ear and Throat, Deaconess Hospital, Edinburgh. With 81 Illustrations, imp. 8vo, 12s. net.

Diseases of the Ear, including the Anatomy

and Physiology of the Organ, together with the Treatment of the Affections of the Nose and Pharynx, which conduce to Aural Disease (a Treatise). By T. MARK HOVELL, Senior Aural Surgeon to the London Hospital, and Lecturer on Diseases of the Throat in the College. Second Edition. 8vo, with 128 Engravings, 21s.

7, GREAT MARLBOROUGH STREET.

J. & A. Churchill's Recent Works.

Diseases and Injuries of the Ear. By Sir WILLIAM B. DALBY, F.R.C.S., M.B., Consulting Aural Surgeon of St. George's Hospital. Fourth Edition. Crown 8vo, with 8 Coloured Plates and 38 Wood Engravings. 10s. 6d.

By the same Author.

Short Contributions to Aural Surgery, between 1875 and 1896. Third Edition. 8vo, with Engravings, 5s.

A System of Dental Surgery. By Sir John TOMES, F.R.S., and C. S. TOMES, M.A., F.R.S. Fourth Edition. Post 8vo, with 289 Engravings, 16s.

Dental Anatomy, Human and Comparative: A Manual. By CHARLES S. TOMES, M.A., F.R.S. Fifth Edition. Post 8vo, with 263 Engravings, 14s.

Decay in Teeth: an Investigation into its Cause and Prevention. By J. SIM WALLACE, M.D., D.Sc., L.D.S.R.C.S. Second Edition. 8vo, 5s.

Dental Materia Medica, Pharmacology and Therapeutics. By CHARLES W. GLASSINGTON, M.R.C.S., L.D.S. Edin.; Senior Dental Surgeon, Westminster Hospital; Dental Surgeon, National Dental Hospital, and Lecturer on Dental Materia Medica and Therapeutics to the College. Crown 8vo, 6s.

Dental Medicine: a Manual of Dental Materia Medica and Therapeutics. By FERDINAND J. S. GORGAS, M.D., D.D.S., Professor of the Principles of Dental Science in the University of Maryland. Sixth Edition. 8vo, 18s.

A Manual of Dental Metallurgy. By Ernest A. SMITH, Assay Office, Sheffield. Second Edition. With 38 Illustrations, crown 8vo, 6s. 6d.

A Manual of Nitrous Oxide Anæsthesia. By J. FREDERICK W. SILK, M.D. Lond., M.R.C.S., Assistant Anæsthetist to Guy's Hospital, Anæsthetist to the Dental School of Guy's Hospital, and to the Royal Free Hospital. 8vo, with 26 Engravings, 5s.

Practical Treatise on Mechanical Dentistry. By JOSEPH RICHARDSON, M.D., D.D.S. Seventh Edition, revised and edited by GEORGE W. WARREN, D.D.S. Royal 8vo, with 690 Engravings, 22s.

7, GREAT MARLBOROUGH STREET.

J. & A. Churchill's Recent Works.

A Handbook on Leprosy. By S. P. Impey, M.D., late Chief and Medical Superintendent, Robben Island Leper and Lunatic Asylums, Cape Colony. With 38 Plates, 8vo, 12s.

Diseases of the Skin (Introduction to the Study of). By P. H. PYE-SMITH, M.D., F.R.S., F.R.C.P., Physician to Guy's Hospital. Crown 8vo, with 26 Engravings, 7s. 6d.

A Manual of Diseases of the Skin, with an Analysis of 20,000 Consecutive Cases and a Formulary. By DUNCAN E. BULKLEY, M.D., New York. Fourth Edition, royal 16mo, 6s. 6d.

Skin Diseases of Children. By Geo. H. Fox, M.D., Clinical Professor of Diseases of the Skin, College of Physicians and Surgeons, New York. With 12 Photogravure and Chromographic Plates and 60 Illustrations in the Text. Royal 8vo, 12s. 6d.

The Operative Surgery of Malignant Disease. By HENRY T. BUTLIN, F.R.C.S., Surgeon to St. Bartholomew's Hospital. Second Edition, with 12 Engravings. 8vo, 14s.

By the same Author.

Malignant Disease (Sarcoma and Carcinoma) of the Larynx. 8vo, with 5 Engravings, 5s.

Cancers and the Cancer Process: a Treatise, Practical and Theoretic. By HERBERT L. SNOW, M.D., Surgeon to the Cancer Hospital, Brompton. 8vo, with 15 Plates. 15s.

By the same Author.

The Re-appearance (Recurrence) of Cancer after apparent Extirpation. 8vo, 5s. 6d.

Also.

The Palliative Treatment of Incurable Cancer. Crown 8vo, 2s. 6d.

The Diagnosis and Treatment of Syphilis. By TOM ROBINSON, M.D. St. And., Physician to the Western Skin Hospital. Second Edition. Crown 8vo, 3s. 6d.

By the same Author.

The Diagnosis and Treatment of Eczema. Second Edition. Crown 8vo, 3s. 6d.

Also.

Illustrations of Diseases of the Skin and Syphilis, with Remarks. Fasc. I. with 3 Plates. Imp. 4to, 5s. net.

7, GREAT MARLBOROUGH STREET.

J. & A. Churchill's Recent Works.

Cancerous Affections of the Skin (Epithelioma and Rodent Ulcer). By GEORGE THIN, M.D. Post 8vo, with 8 Engravings, 5s.
By the same Author.

Pathology and Treatment of Ringworm. 8vo, with 21 Engravings, 5s.

Ringworm, and some other Scalp Affections: their Cause and Cure. By HAYDN BROWN, L.R.C.P. Ed. 8vo, 5s.

Urinary and Renal Derangements and Calculous Disorders. By LIONEL S. BEALE, F.R.C.P., F.R.S., Physician to King's College Hospital. 8vo, 5s.

Chemistry of Urine: a Practical Guide to the Analytical Examination of Diabetic, Albuminous, and Gouty Urine. By ALFRED H. ALLEN, F.I.C., F.C.S., Public Analyst for the West Riding of Yorkshire, &c. 8vo, with Engravings, 7s. 6d.

Clinical Chemistry of Urine (Outlines of the). By C. A. MACMUNN, M.A., M.D. 8vo, with 64 Engravings and Plate of Spectra, 9s.

Atlas of Electric Cystoscopy. By E. HURRY FENWICK, F.R.C.S., Surgeon to the London Hospital and St. Peter's Hospital for Stone. Royal 8vo, with 34 Coloured Plates, embracing 83 Figures. 21s. net.

By the same Author.

Electric Illumination of the Bladder and Urethra, as a Means of Diagnosis of Obscure Vesico-Urethral Diseases. By E. HURRY FENWICK, F.R.C.S., Surgeon to London Hospital and St. Peter's Hospital for Stone. Second Edition. 8vo, with 54 Engravings, 6s. 6d.

Also.

Operative and Inoperative Tumours of the Urinary Bladder: a Clinical and Operative Study based on 500 cases. With 39 Illustrations, 8vo, 5s. net.

Also.

Tumours of the Urinary Bladder. Fas. I. Royal 8vo, 5s. net.

Also.

Ulceration of the Bladder, Simple, Tuberculous, and Malignant: a Clinical Study. With Illustrations, 8vo, 5s.

Also.

The Cardinal Symptoms of Urinary Disease: their Diagnostic Significance and Treatment. 8vo, with 36 Illustrations, 8s. 6d.

Also.

Obscure Diseases of the Urethra. With 63 Illustrations, 8vo, 6s. 6d.

7, GREAT MARLBOROUGH STREET.

J. & A. Churchill's Recent Works.

By SIR HENRY THOMPSON, BART., F.R.C.S.

Diseases of the Urinary Organs. Clinical Lectures. Eighth Edition. 8vo, with 121 Engravings, 10s. 6d.

Some Important Points connected with the Surgery of the Urinary Organs. Lectures delivered in the R.C.S. 8vo, with 44 Engravings. Student's Edition, 2s. 6d.

Practical Lithotomy and Lithotrity; or, an Inquiry into the Best Modes of Removing Stone from the Bladder. Third Edition. 8vo, with 87 Engravings, 10s.

The Preventive Treatment of Calculous Disease, and the Use of Solvent Remedies. Third Edition. Cr. 8vo, 2s. 6d.

Tumours of the Bladder: their Nature, Symptoms, and Surgical Treatment. 8vo, with numerous Illustrations, 5s.

Stricture of the Urethra, and Urinary Fistulæ: their Pathology and Treatment. Fourth Edition. 8vo, with 74 Engravings, 6s.

The Suprapubic Operation of Opening the Bladder for Stone and for Tumours. 8vo, with Engravings, 3s. 6d.

The Clinical Examination of Urine, with an Atlas of Urinary Deposits. By LINDLEY SCOTT, M.A., M.D., with 41 original Plates (mostly in colours). Crown 4to, 15s. net.

The Surgical Diseases of the Genito-Urinary Organs, including Syphilis. By E. L. KEYES, M.D., Professor of Genito-Urinary Surgery, Syphilology, and Dermatology in Bellevue Hospital Medical College, New York (a revision of VAN BUREN and KEYES' Text-book). Roy. 8vo, with 114 Engravings, 21s.

Selected Papers on Stone, Prostate, and other Urinary Disorders. By REGINALD HARRISON, F.R.C.S., Surgeon to St. Peter's Hospital. 8vo, with 15 Illustrations, 5s.

Syphilis. By Sir Alfred Cooper, F.R.C.S., Consulting Surgeon to the West London and the Lock Hospitals. Second Edition. Edited by EDWARD COTTERELL, F.R.C.S., Surgeon (out-patients) to the London Lock Hospital. 8vo, with 24 Full-page Plates (12 coloured), 18s.

7, GREAT MARLBOROUGH STREET.

J. & A. Churchill's Recent Works.

On Maternal Syphilis, including the presence and recognition of Syphilitic Pelvic Disease in Women. By JOHN A. SHAW-MACKENZIE, M.D. With Coloured Plates. 8vo, 10s. 6d.

Diseases of the Rectum and Anus. By Sir ALFRED COOPER, F.R.C.S., Senior Surgeon to St. Mark's Hospital for Fistula; and F. SWINFORD EDWARDS, F.R.C.S., Senior Assistant Surgeon to St. Mark's Hospital. Second Edition, with Illustrations. 8vo, 12s.

Diseases of the Rectum and Anus. By HARRISON CRIPPS, F.R.C.S., Assistant Surgeon to St. Bartholomew's Hospital, etc. Second Edition. 8vo, with 13 Lithographic Plates and numerous Wood Engravings, 12s. 6d.

By the same Author.

Cancer of the Rectum. Especially considered with regard to its Surgical Treatment. Jacksonian Prize Essay. Third Edition. 8vo, with 13 Plates and several Wood Engravings, 6s.

Also

The Passage of Air and Fæces from the Urethra. 8vo, 3s. 6d.

A Medical Vocabulary: an Explanation of all Terms and Phrases used in the various Departments of Medical Science and Practice, their Derivation, Meaning, Application, and Pronunciation. By R. G. MAYNE, M.D., LL.D. Seventh Edition, by W. W. WAGSTAFFE, B.A., F.R.C.S., and G. D. PARKER, M.B. Crown 8vo, 12s. 6d.

A Short Dictionary of Medical Terms. Being an Abridgment of Mayne's Vocabulary. 64mo, 2s. 6d.

Dunlison's Dictionary of Medical Science. Containing a full Explanation of its various Subjects and Terms, with their Pronunciation, Accentuation, and Derivation. Twenty-second Edition. By RICHARD J. DUNGLISON, A.M., M.D. Royal 8vo, 30s.

Terminologia Medica Polyglotta: a Concise International Dictionary of Medical Terms (French, Latin, English, German, Italian, Spanish, and Russian). By THEODORE MAXWELL, M.D., B.Sc., F.R.C.S. Edin. Royal 8vo, 16s.

A German-English Dictionary of Medical Terms. By Sir FRED. TREVES, Bart, K.C.V.O., Surgeon to the London Hospital; and HUGO LANG, B.A. Crown 8vo, half-Persian calf, 12s.

A Handbook of Physics and Chemistry, adapted to the requirements of the first examination of the Conjoint Board and for general use. By HERBERT E. CORBIN, B.Sc. Lond., and ARCHIBALD M. STEWART, B.Sc. Lond. Second Edition. With 128 Illustrations, crown 8vo, 6s. 6d.

7, GREAT MARLBOROUGH STREET.

J. & A. Churchill's Recent Works.

A Manual of Chemistry, Theoretical and Prac-

tical. By WILLIAM A. TILDEN, D.Sc., F.R.S., Professor of Chemistry in the Royal College of Science, London; Examiner in Chemistry to the Department of Science and Art. With 2 Plates and 143 Woodcuts, crown 8vo, 10s.

Chemistry, Inorganic and Organic. With Ex-

periments. By CHARLES L. BLOXAM. Eighth Edition, by JOHN MILLAR THOMSON, F.R.S., Professor of Chemistry in King's College, London, and ARTHUR G. BLOXAM, Head of the Chemistry Department, the Goldsmiths' Institute, New Cross. 8vo, with 281 Engravings, 18s. 6d.

By the same Author.

Laboratory Teaching; or, Progressive Exer-

cises in Practical Chemistry. Sixth Edition, by ARTHUR G. BLOXAM. Crown 8vo, with 80 Engravings, 6s. 6d.

Watts' Organic Chemistry. Edited by William

A. TILDEN, D.Sc., F.R.S., Professor of Chemistry, Royal College of Science, London. Second Edition. Crown 8vo, 10s.

Practical Chemistry, and Qualitative Analysis.

By FRANK CLOWES, D.Sc. Lond., Emeritus Professor of Chemistry in the University College, Nottingham. Seventh Edition. Post 8vo, with 101 Engravings and Frontispiece, 8s. 6d.

Quantitative Analysis. By Frank Clowes,

D.Sc. Lond., Emeritus Professor of Chemistry in the University College, Nottingham, and J. BERNARD COLEMAN, Assoc. R. C. Sci. Dublin; Professor of Chemistry, South-West London Polytechnic. Sixth Edition. Post 8vo, with 125 Engravings, 10s.

By the same Authors.

Elementary Practical Chemistry and Qualita-

tive Analysis. Third Edition. With 68 Engravings, Post 8vo, 3s. 6d.

Also

Elementary Quantitative Analysis. With 62

Engravings, Post 8vo, 4s. 6d.

Qualitative Analysis. By R. Fresenius. Trans-

lated by CHARLES E. GROVES, F.R.S. Tenth Edition. 8vo, with Coloured Plate of Spectra and 46 Engravings, 15s.

By the same Author.

Quantitative Analysis. Seventh Edition.

VOL. I., Translated by A. VACHER. 8vo, with 106 Engravings, 15s.

VOL. II., Translated by C. E. GROVES, F.R.S. 8vo, with 143 Engravings, 20s.

7, GREAT MARLBOROUGH STREET.

J. & A. Churchill's Recent Works.

Inorganic Chemistry. By Sir Edward Frank-
LAND, K.C.B., D.C.L., LL.D., F.R.S., and FRANCIS R. JAPP, M.A.,
Ph.D., F.I.C., F.R.S. 8vo, with numerous Illustrations, 24s.

Inorganic Chemistry (A System of). By
Sir WILLIAM RAMSAY, K.C.B., Ph.D., F.R.S., Professor of Chemistry
in the University College, London. 8vo, with Engravings, 15s.

By the same Author.

Elementary Systematic Chemistry for the Use
of Schools and Colleges. With Engravings. Crown 8vo, 4s. 6d.
Interleaved, 5s. 6d.

Valentin's Practical Chemistry and Qualitative
and Quantitative Analysis. Edited by Dr. W. K. HODGKINSON,
F.R.S.E., Professor of Chemistry and Physics at the Royal Military
Academy, and Artillery College, Woolwich. Ninth Edition. 8vo, with
Engravings and Map of Spectra. 9s. (The Tables separately, 2s. 6d.)

Practical Chemistry, Part I. Qualitative Exer-
cises and Analytical Tables for Students. By J. CAMPBELL BROWN,
Professor of Chemistry in Victoria University and University College,
Liverpool. Fourth Edition. 8vo, 2s. 6d.

The Analyst's Laboratory Companion: a Col-
lection of Tables and Data for Chemists and Students. By ALFRED
E. JOHNSON, F.I.C. Second Edition. Cloth, 5s.; leather, 6s. 6d.

The Chemistry of the Terpenes. By F.
HEUSLER, Ph.D. Translated and enlarged by F. J. POND, M.A.,
Ph.D. 8vo, 17s. net.

Commercial Organic Analysis: a Treatise on
the Properties, Modes of Assaying, Proximate Analytical Examination,
etc., of the various Organic Chemicals and Products employed in the
Arts, Manufactures, Medicine, etc. By ALFRED H. ALLEN, F.I.C.

Third Edition.

VOL. I., 18s.; VOL. II., Part I., 14s.; VOL. II., Part
II., 14s.; VOL. II., Part III., ; VOL. III., Part I., 18s.

Second Edition.

VOL. III., Pt. II., 18s.; VOL. III., Pt. III., 16s.;
VOL. IV., completing the work, 18s.

Volumetric Analysis: or the Quantitative
Estimation of Chemical Substances by Measure, applied to Liquids,
Solids, and Gases. By FRANCIS SUTTON, F.C.S., F.I.C., Public
Analyst for the County of Norfolk. Eighth Edition. 8vo, with
116 Engravings, 20s.

7, GREAT MARLBOROUGH STREET.

J. & A. Churchill's Recent Works.

Chemical Technology; or, Chemistry in its Applications to Arts and Manufactures. Edited by CHARLES E. GROVES, F.R.S., WILLIAM THORP, B.Sc., and W. J. DIBDIN, F.I.C.

VOL. I.—Fuel and its Applications. By E. J. MILLS, D.Sc., F.R.S., and F. J. ROWAN, C.E. Royal 8vo, with 606 Engravings, 30s.

VOL. II.—Lighting.—Fats and Oils, by W. Y. DENT. STEARINE INDUSTRY, by J. MCARTHUR. CANDLE MANUFACTURE, by L. FIELD and F. A. FIELD. THE PETROLEUM INDUSTRY AND LAMPS, by BOVERTON REDWOOD. MINERS' SAFETY LAMPS, by B. REDWOOD and D. A. LOUIS. Royal 8vo, with 358 Engravings and Map, 20s.

VOL. III.—Gas Lighting. By Charles Hunt. With 2 Plates and 292 Engravings, 8vo, 18s.

VOL. IV.—Electric Lighting. By A. G. COOKE, M.A., A.M.I.E.E. PHOTOMETRY. By W. J. DIBDIN, F.I.C., F.C.S. Royal 8vo., with 10 Plates and 181 Engravings, 20s.

Cooley's Cyclopædia of Practical Receipts, and Collateral Information in the Arts, Manufactures, Professions, and Trades: including Medicine, Pharmacy, Hygiene, and Domestic Economy. Seventh Edition, by W. NORTH, M.A. Camb., F.C.S. Vols., Roy. 8vo, with 371 Engravings, 42s.

Chemical Technology: a Manual. By Rudolf VON WAGNER. Translated and Edited by Sir WILLIAM CROOKES, F.R.S., from the Thirteenth Enlarged German Edition as remodelled by Dr. FERDINAND FISCHER. 8vo, with 596 Engravings, 32s.

Technological Handbooks. Edited by John GARDNER, F.I.C., F.C.S., and JAMES CAMERON, F.I.C.

Brewing, Distilling, and Wine Manufacture. Crown 8vo, with Engravings, 6s. 6d.

Oils, Resins, and Varnishes. Crown 8vo, with Engravings, 7s. 6d.

Soaps and Candles. Crown 8vo, with 54 Engravings, 7s.

Chemistry an Exact Mechanical Philosophy. By FRED. G. EDWARDS. Illustrated, 8vo, 3s. 6d.

The Quarterly Journal of Microscopical Science. Edited by E. RAY LANKESTER, M.A., LL.D., F.R.S.; with the co-operation of ADAM SEDGWICK, M.A., F.R.S., W.F. R. WELDON, M.A., F.R.S., and SYDNEY J. HICKSON, M.A., F.R.S. Each Number, 10s.

7, GREAT MARLBOROUGH STREET.

J. & A. Churchill's Recent Works.

Methods and Formulæ used in the Preparation
of Animal and Vegetable Tissues for Microscopical Examination, including the Staining of Bacteria. By PETER WYATT SQUIRE, F.L.S. Crown 8vo, 3s. 6d.

The Microscope and its Revelations. By the late WILLIAM B. CARPENTER, C.B., M.D., LL.D., F.R.S. Eighth Edition, by the Rev. W. H. DALLINGER, LL.D., F.R.S. With 23 Plates and more than 800 Wood Engravings. 8vo, 28s. Half Calf, 32s.

The Microtometist's Vade-Mecum: a Handbook
of the Methods of Microscopic Anatomy. By ARTHUR BOLLES LEE. Fifth Edition, 8vo, 15s.

Photo-Micrography (Guide to the Science of).
By EDWARD C. BOUSFIELD, L.R.C.P. Lond. 8vo, with 34 Engravings and Frontispiece, 6s.

A Treatise on Physics. By Andrew Gray, LL.D., F.R.S., Professor of Natural Philosophy in the University of Glasgow. Vol. I. Dynamics and Properties of Matter. With 350 Illustrations, 8vo. 15s.

An Introduction to Physical Measurements,
with Appendices on Absolute Electrical Measurements, etc. By Dr. F. KOHLRAUSCH. Third English Edition, by T. H. WALLER, B.A., B.Sc., and H. R. PROCTER, F.I.C., F.C.S. 8vo, with 91 Illustrations, 12s. 6d.

Tuson's Veterinary Pharmacopœia, including
the Outlines of Materia Medica and Therapeutics. Fifth Edition Edited by JAMES BAYNE, F.C.S., Professor of Chemistry and Toxicology in the Royal Veterinary College. Crown 8vo, 7s. 6d.

The Veterinarian's Pocket Remembrancer:
being Concise Directions for the Treatment of Urgent or Rare Cases, By GEORGE ARMATAGE, M.R.C.V.S. Second Edition. Post 8vo, 3s.

Chauveau's Comparative Anatomy of the
Domesticated Animals. Revised and Enlarged, with the Co-operation of S. ARLOING, Director of the Lyons Veterinary School, and Edited by GEORGE FLEMING, C.B., LL.D., F.R.C.V.S., late Principal Veterinary Surgeon of the British Army. Second English Edition. 8vo with 585 Engravings, 31s. 6d.

Human Nature, its Principles and the Principles
of Physiognomy. By PHYSICIST. Part I., Imp. 16mo, 2s. Part II., completing the work, 2s. 6d.

Encyclopædia Medica. Edited by Chalmers Watson, M.B., M.R.C.P.E. In about 12 Volumes, 20s. each net. Vols. I. to XII. now ready.

7, GREAT MARLBOROUGH STREET.

INDEX TO J. & A. CHURCHILL'S CATALOGUE.

- Allen's Chemistry of Urine, 22
 ——— Commercial Organic Analysis, 26
 Armatage's Veterinary Pocket Remembrancer, 28
 Ballantyne's Antenatal Pathology and Hygiene, 2
 Barnes' (R.) Obstetric Operations, 6
 ——— Diseases of Women, 6
 Beale (L. S.) on Liver, 12
 ——— Slight Ailments, 12
 ——— Urinary and Renal Derangements, 22
 Beale (P. T. B.) on Elementary Biology, 3
 Beasley's Book of Prescriptions, 8
 ——— Druggists' General Receipt Book, 8
 ——— Pharmaceutical Formulary, 8
 Bell on Sterility, 6
 Bentley and Trimen's Medicinal Plants, 9
 Bentley's Systematic Botany, 9
 Berkart's Bronchial Asthma, 13
 Bernard on Stammering, 14
 Berry's (Jas.) Thyroid Gland, 18
 ——— (R. J.) Regional Anatomy, 2
 Bigg's Short Manual of Orthopædy, 18
 Birch's Practical Physiology, 3
 Bloxam's Chemistry, 25
 ——— Laboratory Teaching, 25
 Bousfield's Photo-Micrography, 28
 Bowlby's Injuries and Diseases of Nerves, 17
 ——— Surgical Pathology and Morbid Anatomy, 17
 Brockbank on Gallstones, 15
 Brown's (Haydn) Ringworm, 22
 Brown's Practical Chemistry, 26
 Bryant's Practice of Surgery, 16
 Bulkley on Skin, 21
 Burdett's Hospitals and Asylums of the World, 4
 Butlin's Operative Surgery of Malignant Disease, 21
 ——— Malignant Disease of the Larynx, 21
 Buzzard's Diseases of the Nervous System, 14
 Buzzard's Peripheral Neuritis, 14
 ——— Simulation of Hysteria, 14
 Cameron's Oils, Resins, and Varnishes, 27
 Cameron's Soaps and Candles, 27
 Carpenter and Dallinger on the Microscope, 28
 Cautley on Feeding Infants, 7
 Charteris' Practice of Medicine, 11
 Chauveau's Comparative Anatomy, 28
 Churchill's Face and Foot Deformities, 18
 Clouston's Lectures on Mental Diseases, 4
 Clowes and Coleman's Quantitative Analysis, 25
 Clowes and Coleman's Elementary Practical Chemistry, 25
 Clowes' Practical Chemistry, 25
 Coles on Blood, 12
 Cooke's Electric Lighting, 27
 Cooley's Cyclopædia of Practical Receipts, 27
 Cooper's Syphilis, 23
 Cooper and Edwards' Diseases of the Rectum, 24
 Corbin and Stewart's Physics and Chemistry, 24
 Cripps' (H.) Ovariectomy and Abdominal Surgery, 17
 ——— Diseases of the Rectum and Anus, 24
 ——— Cancer of Rectum, 24
 ——— Air and Faces in Urethra, 24
 Cripps' (R. A.) Galenic Pharmacy, 8
 Cuff's Lectures to Nurses, 7
 Cullingworth's Monthly Nurses, 7
 Dalby's Diseases and Injuries of the Ear, 20
 ——— Short Contributions, 20
 Dana on Nervous Diseases, 14
 Day on Headaches, 15
 De Langenhagen on Entero-Colitis, 16
 Dibdin's Photometry, 27
 Domville's Manual for Nurses, 7
 Duncan (A.) on Prevention of Diseases in Tropics, 10
 Dunglison's Med. Dictionary, 24
 Edwards' Chemistry, 27
 Ellis's (T. S.) Human Foot, 18
 Encyclopædia Medica, 28
 Fagge's Principles and Practice of Medicine, 10

[Continued on next page.]

7, GREAT MARLBOROUGH STREET.

INDEX TO J. & A. CHURCHILL'S CATALOGUE—continued.

- Fayrer's Climate and Fevers of India, 10
 Fenwick (E. H.), Electric Illumination of Bladder, 22
 ———— Obscure Diseases of the Urethra, 22
 ———— Atlas of Electric Cystoscopy, 22
 ———— Symptoms of Urinary Disease, 22
 ———— Tumours of Bladder, 22
 ———— Ulceration of Bladder, 22
 Fenwick's (S.) Medical Diagnosis, 12
 ———— Ulcer of Stomach, 12
 ———— Cancer of Stomach, 12
 ———— Obscure Diseases of the Abdomen, 12
 ———— Outlines of Medical Treatment, 12
 ———— The Saliva as a Test, 12
 Fink's Operating for Cataract, 19
 Fowler's Dictionary of Practical Medicine, 11
 Fox (G. H.) on Skin Diseases of Children, 21
 Fox (Wilson), Atlas of Pathological Anatomy of the Lungs, 11
 ———— Treatise on Diseases of the Lungs, 11
 Frankland and Japp's Inorganic Chemistry, 26
 Fraser's Operations on the Brain, 16
 Fresenius' Qualitative Analysis, 25
 ———— Quantitative Analysis, 25
 Galabin's Diseases of Women, 6
 ———— Manual of Midwifery, 5
 Gardner's Brewing, Distilling, and Wine Manufacture, 27
 Glassington's Dental Materia Medica, 20
 Godlee's Atlas of Human Anatomy, 1
 Goodhart's Diseases of Children, 7
 Gorgas' Dental Medicine, 20
 Gowers' Diagnosis of Brain Disease, 13
 ———— Diseases of Nervous System, 13
 ———— Medical Ophthalmoscopy, 13
 ———— Syphilis and the Nervous System, 13
 ———— Epilepsy, 13
 ———— Lunacy and Law, 5
 Granville on Gout, 14
 Gray's Treatise on Physics, 28
 Green's Manual of Botany, 9
 ———— Vegetable Physiology, 9
 Greenish's Materia Medica, 8
 Groves, Thorp, and Dibdin's Chemical Technology, 27
 Guy's Hospital Reports, 11
 Habershon's Diseases of the Abdomen, 15
 Hadley on Nursing, 6
 Haig's Uric Acid, 13
 ———— Diet and Food, 4
 Hamer's Manual of Hygiene, 3
 Harley on Diseases of the Liver, 14
 Harris's (V. D.) Diseases of Chest, 11
 Harrison's Urinary Organs, 23
 Hartridge's Refraction of the Eye, 19
 ———— Ophthalmoscope, 19
 Hawthorne's Galenical Preparations, 8
 Heath's Injuries and Diseases of the Jaws, 17
 ———— Minor Surgery and Bandaging, 17
 ———— Operative Surgery, 17
 ———— Practical Anatomy, 1
 ———— Clinical Lectures, 17
 Hedley's Therapeutic Electricity, 9
 Heusler on the Terpenes, 26
 Hewlett's Bacteriology, 4
 Hill on Cerebral Circulation, 3
 Holden's Human Osteology, 1
 ———— Landmarks, 1
 Hooper's Physicians' Vade Mecum, 10
 Horrocks' Bacteriological Examination of Water, 4
 Horton-Smith on Typhoid, 14
 Hovell's Diseases of the Ear, 19
 Hughes and Keith's Practical Anatomy, 2
 Human Nature and Physiognomy, 28
 Impey on Leprosy, 21
 Ireland's Mental Affections of Children, 5
 Jacobson's Operations of Surgery, 16
 Jellett's Midwifery, 6
 ———— for Nurses, 6
 ———— Gynecology, 6
 Jessop's Ophthalmic Surgery and Medicine, 18
 Johnson's (A. E.) Analyst's Companion, 26
 Journal of Mental Science, 5
 Kelynack's Pathologist's Handbook, 2
 Keyes' Genito-Urinary Organs and Syphilis, 23

[Continued on next page.]

7, GREAT MARLBOROUGH STREET.

INDEX TO J. & A. CHURCHILL'S CATALOGUE—continued.

- Knuthsen on Hiccough, 15
 Kohlrausch's Physical Measurements, 28
 Lane's Rheumatic Diseases, 14
 Langdon-Down's Mental Affections of Childhood, 5
 Lawrie on Chloroform, 17
 Lazarus-Barlow's General Pathology, 2
 ————— Pathological Anatomy, 2
 Lee's Microtome's Vade-Mecum, 28
 Lewis and Balfour's Public Health, 3
 Lewis (Bevan) on the Human Brain, 2
 Liebreich (O.) on Borax and Boracic Acid, 4
 Liebreich's (R.) Atlas of Ophthalmoscopy, 19
 Lucas's Practical Pharmacy, 8
 Luke's Anæsthetics, 17
 MacMunn's Clinical Chemistry of Urine, 22
 Macnamara's Diseases and Refraction of the Eye, 18
 ————— Diseases of Bones and Joints, 17
 McNeill's Isolation Hospitals, 4
 Malcolm's Physiology of Death, 16
 Marsh's Clinical Essays and Lectures, 17
 Martin's Ambulance Lectures, 15
 Maxwell's Terminologia Medica Polyglotta, 24
 Maylard's Surgery of Alimentary Canal, 16
 Mayne's Medical Vocabulary, 24
 Microscopical Journal, 27
 Mills and Rowan's Fuel and its Applications, 27
 Moore's (N.) Pathological Anatomy of Diseases, 2
 Moore's (Sir W. J.) Diseases of India, 10
 ————— Family Medicine, etc., for India, 10
 Morris's Human Anatomy, 1
 ————— Anatomy of Joints, 2
 Moullin's (Mansell) Surgery, 16
 Murray's Hare-Lip and Cleft Palate, 16
 Nettleship's Diseases of the Eye, 18
 Notter's Hygiene, 3
 Oliver's Abdominal Tumours, 6
 ————— Diseases of Women, 6
 Ophthalmic (Royal London) Hospital Reports, 18
 Ophthalmological Society's Transactions, 18
 Ormerod's Diseases of the Nervous System, 13
 Parkes' (L. C.) Elements of Health, 4
 Parsons' Ophthalmic Optics, 18
 Paton's (Noël) Physiology, 3
 Pavy's Carbohydrates, 12
 Pereira's Selecta à Prescriptis, 9
 Phillips' Materia Medica and Therapeutics, 8
 Pitt-Lewis's Insane and the Law, 5
 Pollock's Histology of the Eye and Eyelids, 19
 Proctor's Practical Pharmacy, 8
 Pye-Smith's Diseases of the Skin, 21
 Ramsay's Elementary Systematic Chemistry, 26
 ————— Inorganic Chemistry, 26
 Richardson's Mechanical Dentistry, 20
 Richmond on Antiseptics, 7
 Roberts' (C. Hubert) Gynaecological Pathology, 6
 Roberts' (D. Lloyd), Practice of Midwifery, 5
 Robinson's (Tom) Eczema, 21
 ————— Illustrations of Skin Diseases, 21
 ————— Syphilis, 21
 Ross's Diseases of the Nervous System, 14
 St. Thomas's Hospital Reports, 11
 Sansom's Valvular Disease of the Heart, 13
 Savill's Clinical Medicine, 11
 Schofield's Force of Mind, 5
 Scott's Atlas of Urinary Deposits, 23
 Shaw's Diseases of the Eye, 19
 Shaw-Mackenzie on Maternal Syphilis, 24
 Short Dictionary of Medical Terms, 24
 Silk's Manual of Nitrous Oxide, 20
 Smith's (Ernest), Dental Metallurgy, 20
 ————— (Eustace) Clinical Studies, 7
 ————— Disease in Children, 7
 ————— Wasting Diseases of Infants and Children, 7
 ————— (Fred. J.) Medical Jurisprudence, 3
 Smith's (J. Greig) Abdominal Surgery, 16

[Continued on next page.]

7, GREAT MARLBOROUGH STREET.

INDEX TO J. & A. CHURCHILL'S CATALOGUE—continued.

- Smith's (Priestley) Glaucoma, 19
 Snow's Cancers and the Cancer Process, 21
 ——— Palliative Treatment of Cancer, 21
 ——— Reappearance of Cancer, 21
 Solly's Medical Climatology, 15
 Southall's Organic Materia Medica, 7
 Squire's (P.) Companion to the Pharmacopœia, 8
 ——— London Hospitals Pharmacopœias, 8
 ——— Methods and Formulæ, 28
 Starling's Elements of Human Physiology, 3
 Sternberg's Bacteriology, 11
 Stevenson and Murphy's Hygiene, 4
 Sutton's (F.) Volumetric Analysis, 26
 Swain's Surgical Emergencies, 15
 Swayne's Obstetric Aphorisms, 5
 Taylor's (A. S.) Medical Jurisprudence, 3
 Taylor's (F.) Practice of Medicine, 10
 Thin's Cancerous Affections of the Skin, 22
 ——— Pathology and Treatment of Ringworm, 22
 ——— Psilosis or "Sprue," 10
 Thompson's (Sir H.) Calculous Diseases, 23
 ——— Diseases of the Urinary Organs, 23
 ——— Lithotomy and Lithotripsy, 23
 ——— Stricture of the Urethra, 23
 ——— Suprapubic Operation, 23
 ——— Surgery of the Urinary Organs, 23
 ——— Tumours of the Bladder, 23
 Thorne's Diseases of the Heart, 12
 Thresh on Water Analysis, 4
 Tilden's Chemistry, 25
 Tirard's Medical Treatment, 12
 Tobin's Synopsis of Surgery, 15
 Tomes' (C. S.) Dental Anatomy, 20
 ——— (J. & C. S.) Dental Surgery, 20
 Tooth's Spinal Cord, 14
 Treves and Lang's German-English Dictionary, 24
 Tuke's Dictionary of Psychological Medicine, 5
 Turner on Sinuses of the Nose, 19
 Tuson's Veterinary Pharmacopœia, 28
 Valentin and Hodgkinson's Practical Chemistry, 26
 Vintras on the Mineral Waters, etc., of France, 15
 Wagner's Chemical Technology, 27
 Wallace on Dental Caries, 20
 Walsham's Surgery: its Theory and Practice, 15
 Waring's Indian Bazaar Medicines, 9
 ——— Practical Therapeutics, 9
 Watts' Organic Chemistry, 25
 West's (S.) How to Examine the Chest, 11
 White's (Hale) Materia Medica, Pharmacy, etc., 7
 Wilks' Diseases of the Nervous System, 13
 Wilson's (Sir E.) Anatomist's Vademecum, 1
 Wilson's (G.) Handbook of Hygiene, 3
 Wolfe's Diseases and Injuries of the Eye, 18
 Wright (H.) on Fevers of British Malaya, 10
 Wynter and Wethered's Practical Pathology, 2
 Year Book of Pharmacy, 9

N.B.—J. & A. Churchill's larger Catalogue of about 600 works on Anatomy, Physiology, Hygiene, Midwifery, Materia Medica, Medicine, Surgery, Chemistry, Botany, etc. etc., with a complete Index to their Subjects, for easy reference, will be forwarded post free on application.

AMERICA.—J. & A. Churchill being in constant communication with various publishing houses in America are able to conduct negotiations favourable to English Authors.

LONDON: 7, GREAT MARLBOROUGH STREET.



✓



