

Quain's elements of anatomy / [Jones Quain].

Contributors

Quain, Jones, 1796-1865.

Publication/Creation

London ; New York : Longmans, Green, 1890-1896 (London : Bradbury, Agnew.)

Persistent URL

<https://wellcomecollection.org/works/jcsn4x8q>

License and attribution

This work has been identified as being free of known restrictions under copyright law, including all related and neighbouring rights and is being made available under the Creative Commons, Public Domain Mark.

You can copy, modify, distribute and perform the work, even for commercial purposes, without asking permission.



Wellcome Collection
183 Euston Road
London NW1 2BE UK
T +44 (0)20 7611 8722
E library@wellcomecollection.org
<https://wellcomecollection.org>

QUAIN'S ANATOMY

E. A. SCHÄFER & G. D. THANE

VOL. I. PT. I.
EMBRYOLOGY

E. A. SCHÄFER


M15201



22101445851

D. III.

19/9



Digitized by the Internet Archive
in 2014 with funding from
Wellcome Library

W. Stalder

PRESENTED BY
PUBLISHERS

QUAIN'S
ELEMENTS OF ANATOMY

EDITED BY

EDWARD ALBERT SCHÄFER, F.R.S.

PROFESSOR OF PHYSIOLOGY AND HISTOLOGY IN UNIVERSITY COLLEGE, LONDON,

AND

GEORGE DANCER THANE,

PROFESSOR OF ANATOMY IN UNIVERSITY COLLEGE, LONDON.

IN THREE VOLUMES.

VOL. I.—PART I.

EMBRYOLOGY

By PROFESSOR SCHÄFER.

ILLUSTRATED BY 200 ENGRAVINGS, MANY OF WHICH ARE COLOURED.

Tenth Edition.

LONDON:

LONGMANS, GREEN, AND CO.,

1890.

2012.1.18.0

RECEIVED BY
WELLINGTON

2012.1.18.0

WELLINGTON

LONDON
BRADBURY, AGNEW, & CO. LTD., PRINTERS, WHITEFRIARS.

15201

| | |
|-------------------------------|----------|
| WELLCOME INSTITUTE LIBRARY | |
| Coll. | wellcome |
| Call | |
| No. | Q54 |
| | 1890- |
| | Q19 |
| | |
| | |

CONTENTS OF PART I.

| | PAGE | | PAGE |
|---|--------|--|------|
| INTRODUCTION : | | Segmentation of the Body | 2 |
| GENERAL CONSIDERATIONS | 1 | Homology | 4 |
| Plan of Organisation | 2 | Symmetry of Form. | 4 |
| The Vertebrate type | 2 | Descriptive terms | 4 |
| EMBRYOLOGY. | | | |
| STRUCTURE OF OVARIAN OVUM ; MATURA- | | Further details regarding the develop- | |
| TION OF OVUM | 6, 9 | ment of special parts of the Brain | 63 |
| Formation of Polar Globules | 9 | The fifth cerebral vesicle : Bulbar vesicle | |
| Fertilization | 11 | or Metencephalon | 63 |
| Meaning of Polar Globules. | 12 | The fourth cerebral vesicle : Cerebellar | |
| Theory of Minot | 12 | vesicle or Epencephalon. | 66 |
| Theory of Weissmann | 14 | The third cerebral vesicle : Mesen- | |
| Recent Literature of the Ovum | 14 | cephalon : Mid-brain. | 67 |
| SEGMENTATION OF THE OVUM ; FORMA- | | The second cerebral vesicle : Thalamen- | |
| TION OF THE BLASTODERM | 16, 17 | cephalon | 67 |
| Gastrula Condition of the Vertebrate | | The first cerebral vesicle : Prosencephalon | 68 |
| Ovum | 21 | The Olfactory Lobes | 71 |
| Views concerning the Gastrulation of | | Formation of the Fissures and Convolutions | 71 |
| Vertebrates | 22 | DEVELOPMENT OF THE NERVES | 73 |
| Inversion of Blastodermic Layers in some | | Spinal nerves | 73 |
| Mammals | 23 | Cranial nerves | 75 |
| Historical view of Blastoderm | 23 | Optic nerves | 79 |
| Characters of the Blastodermic Layers | 24 | Olfactory lobe | 79 |
| Parablast theory of His | 25 | Sympathetic nerves and ganglia | 81 |
| Mesenchyme theory of Hertwig | 26 | Recent Literature of the development of | |
| Recent Literature of Blastoderm | 27 | the Nervous System | 81 |
| EARLY CHANGES IN BLASTODERM | 30 | DEVELOPMENT OF THE EYE | 83 |
| Neural Canal. | 30 | Of the Retina | 86 |
| Notochord | 32 | Of the Lens | 86 |
| Separation of the Embryo | 34 | Capsule of the Lens | 87 |
| Cleavage of Mesoblast | 36 | Vitreous humour | 87 |
| Formation of Body Cavity | 36 | Corneal epithelium | 87 |
| Formation of Mesoblastic Somites | 36 | Sclerotic | 88 |
| Cerebral Vesicles | 37 | Choroid coat | 88 |
| Heart and Vascular System | 38 | Accessory structures | 89 |
| Recent Literature of Early Changes in | | Lachrymal gland | 89 |
| Blastoderm | 41 | Lachrymal canals and ducts | 89 |
| DEVELOPMENT OF THE FETAL MEM- | | DEVELOPMENT OF THE EAR ; THE LABY- | |
| BRANES ; ATTACHMENT OF OVUM TO | | RINTH | 89 |
| UTERUS | 42 | Accessory parts of the Organ of Hearing, | |
| Formation of the Amnion and Chorion | 42 | External and Middle Ear | 93 |
| Formation of the Allantois | 43 | DEVELOPMENT OF THE NOSE | 95 |
| Changes in the Uterus and mode of | | Recent Literature of the development of | |
| attachment of Ovum to Uterus | 46 | the Sense Organs | 98 |
| The Placenta | 53 | DEVELOPMENT OF THE ALIMENTARY CANAL | 99 |
| Separation of the Decidua at birth, and | | Of the Mouth and parts in connection | |
| regeneration of the Uterine Mucous | | with it | 99 |
| Membrane | 55 | Pharynx | 101 |
| Recent Literature of the Decidua | 55 | Tongue | 102 |
| DEVELOPMENT OF THE NERVOUS SYSTEM | 57 | Esophagus, Stomach, and Intestines | 103 |
| Of the Spinal Cord | 57 | The Mesentery | 104 |
| Of the Brain | 61 | The Spleen | 108 |

| | PAGE | | PAGE |
|--|------|---|------|
| Formation of the Anus | 108 | Destination of the fourth and fifth Arte- rial Arches. | 150 |
| FORMATION OF THE GLANDS OF THE ALI- MENTARY CANAL | 109 | Development of the principal Veins. | 151 |
| The Lungs | 109 | Peculiarities of the foetal Organs of Circu- lation | 155 |
| The Trachea and Larynx | 110 | The Foramen Ovale | 155 |
| The Thyroid Body | 110 | The Eustachian Valve | 155 |
| The Thymus | 111 | The Ductus Arteriosus | 156 |
| The Liver | 112 | The Umbilical Vessels | 156 |
| The Pancreas | 113 | Course of the blood in the Fœtus | 156 |
| Recent Literature of the development of the Alimentary Canal and Glands | 113 | Changes in the Circulation at Birth | 157 |
| DEVELOPMENT OF THE URINARY AND GENERATIVE ORGANS | 115 | The Lymphatic System | 157 |
| The Wolffian duct and body | 117 | Recent Literature of the development of the Vascular System | 158 |
| Supra-renal Capsules | 120 | DEVELOPMENT OF THE SEROUS CAVITIES AND OF THE MUSCLES AND SKELETON | 159 |
| The permanent Kidneys | 122 | The Serous Cavities | 159 |
| The Urinary Bladder | 122 | Development of the Muscles | 159 |
| The Müllerian duct | 122 | Formation of the head Muscles and evi- dences of head segmentation | 161 |
| The Germinal Epithelium | 124 | Development of the Vertebral Column | 162 |
| Development of the Ovary. | 124 | Ribs and Sternum | 163 |
| Of the Testicles | 125 | The Limbs | 163 |
| Descent of the Testicles | 126 | The Cranium | 165 |
| The External Organs | 127 | Formation of the visceral skeleton of the Head; cartilaginous bars of the visceral arches | 166 |
| Table of Generative Organs | 130 | Formation of the Auditory Ossicles | 167 |
| Recent Literature of the development of the Urinary and Generative Organs | 132 | Recent Literature of the development of the Serosus Cavities, Muscles, and Skeleton | 169 |
| FORMATION OF THE VASCULAR SYSTEM | 134 | | |
| Development of the Heart | 134 | | |
| Peculiarities of the Fœtal Heart | 146 | | |
| Development of the principal Arteries | 146 | | |

ELEMENTS OF ANATOMY.

INTRODUCTION.

ANATOMY, in its most extended sense, is the science which deals with the structure of organized bodies. It is divided into departments according to its subjects ; such as Human Anatomy ; Comparative Anatomy, or the study of the structure of different animals ; and Vegetable Anatomy, comprehending the structure of plants.

On examining the structure of an organized body, we find that it is made up of members or *organs*, by means of which its functions are executed, such as the root stem and leaves of a plant, and the heart, brain, stomach and limbs of an animal ; and farther, that these organs are themselves made up of certain constituent materials named *tissues* or *textures*, such as the cellular, woody, and vascular tissues of the vegetable, or the osseous, muscular, connective, vascular, nervous, and other tissues, which form the animal organs.

Most of the tissues occur in more than one organ, and some of them indeed, as the connective and vascular, in nearly all, so that a multitude of organs, and these greatly diversified, are constructed out of a small number of constituent tissues ; and parts of the body, differing widely in form, construction, and uses, may agree in the nature of their component materials. Again, as the same tissue possesses the same essential characters in whatever organ or region it is found, it is obvious that the structure and properties of each tissue may be made the subject of investigation apart from the organs into whose formation it enters.

The foregoing considerations have led to the subdivision of anatomy into two branches, the one of which, under the name "General Anatomy," or "Histology," treats of the minute structure of the component tissues of the body ; the other, named "Special or Descriptive Anatomy," treats of its several organs, members, and regions, describing the outward form and internal structure of the parts, their relative situation and mutual connection, and the successive conditions which they present in the progress of their formation or development.

To the description of the origin and formation of organs in the embryo, a special chapter is devoted in this work, under the name Embryology.

The study of anatomy may be viewed in two different aspects ; viz., the physiological and the morphological. In the former, anatomy supplies the materials relating to structure from which an explanation is sought of the uses or functions of organs by the physiologist ; and for this purpose the study of histology is of particular service. In its morphological aspect, anatomy investigates and combines the facts relating to the structure and relations of organs, from which may be deduced general principles as to the construction of the human body or that of

animals. In the determination of these general principles, or laws of morphology, it is necessary to combine the knowledge of the anatomy and development of animals with that of man.

PLAN OF ORGANIZATION.

Vertebrate type.—The general plan of construction of the human body agrees closely with that which prevails in a certain number of animals, viz., mammals, birds, reptiles, amphibia, and fishes, and is known as the vertebrate type of organization. The main feature of that type, and that from which its name is derived, belongs to the internal skeleton, and consists in the existence of a median longitudinal column, which extends through the whole trunk, and is composed in the fully developed state of a series of bones termed *vertebræ*. This *vertebral column* is formed in the early embryo around a simple rod-like structure, the primitive skeletal axis, which is called the *notochord*, and which in most vertebrate animals disappears to a greater or less extent in the course of development. The more solid portions of the *vertebræ* immediately surrounding the notochord are known as the *bodies* or *centra* (figs. 2 and 3), and constitute a pillar around which the other parts are grouped with a certain regularity of structure. At one extremity of this pillar is situated the *head*, showing in almost all the animals formed upon this type a greater development of its constituent parts; and at the other the *tail* in which an opposite character or that of diminution prevails; while on the sides of the main part or *trunk*, there project, in relation with some of the vertebral elements, two pairs of symmetrical *limbs*.

The head and trunk contain the organs or viscera most important to life, such as the alimentary canal and the great central organs of the vascular and nervous systems, while the limbs, from which such principal organs are absent, are very variable and differ widely in the degree of their development among the various animals formed upon the vertebrate type. In man and the higher animals the trunk is divisible into neck, chest, abdomen, and pelvis.

The vertebrate form of skeleton is invariably accompanied by a determinate and conformable disposition of the other most important organs of the body, viz.:—*firstly*, the existence on the dorsal aspect of the vertebral axis of an elongated cavity or canal which contains the brain and spinal cord, or central organs of the nervous system; and *secondly*, the existence on the ventral aspect of the vertebral axis of a larger cavity, the visceral cavity, body cavity or *coelom*, in which are contained the principal viscera connected with nutrition and reproduction, such as the alimentary canal, the heart and lungs, the great blood-vessels, and the urinary and generative organs.

The general disposition of the parts of the body and of the more important viscera in their relation to the vertebral axis are shown in the accompanying diagrams of the external form and longitudinal and transverse sections of the human embryo at an early period of its existence.

Segmentation of the body.—The vertebrate type of organisation in the repetition of similar structural elements in a longitudinal series, has a segmented character, especially in the axial portion of the body, and this segmentation affects more or less, not merely the skeletal parts of its structure, but also, to some extent, its other component organs.

A segmented plan of construction is by no means restricted to vertebrate animals, but exists in several other classes of the animal kingdom, as is most conspicuously seen in the Arthropoda, such as insects and crustacea, and in the Annelida or worms. These animals, however, although showing a serial repetition of parts of like structure, are not considered to belong to the vertebrate type of organization.

In the human embryo, as in that of all vertebrate animals, the segmentation is most marked in the muscular system, the nervous and osseous systems becoming for the most part correspondingly marked off: in the adult the osseous and nervous systems retain in great measure the segmentation which has thus been produced, although in the muscular system it has

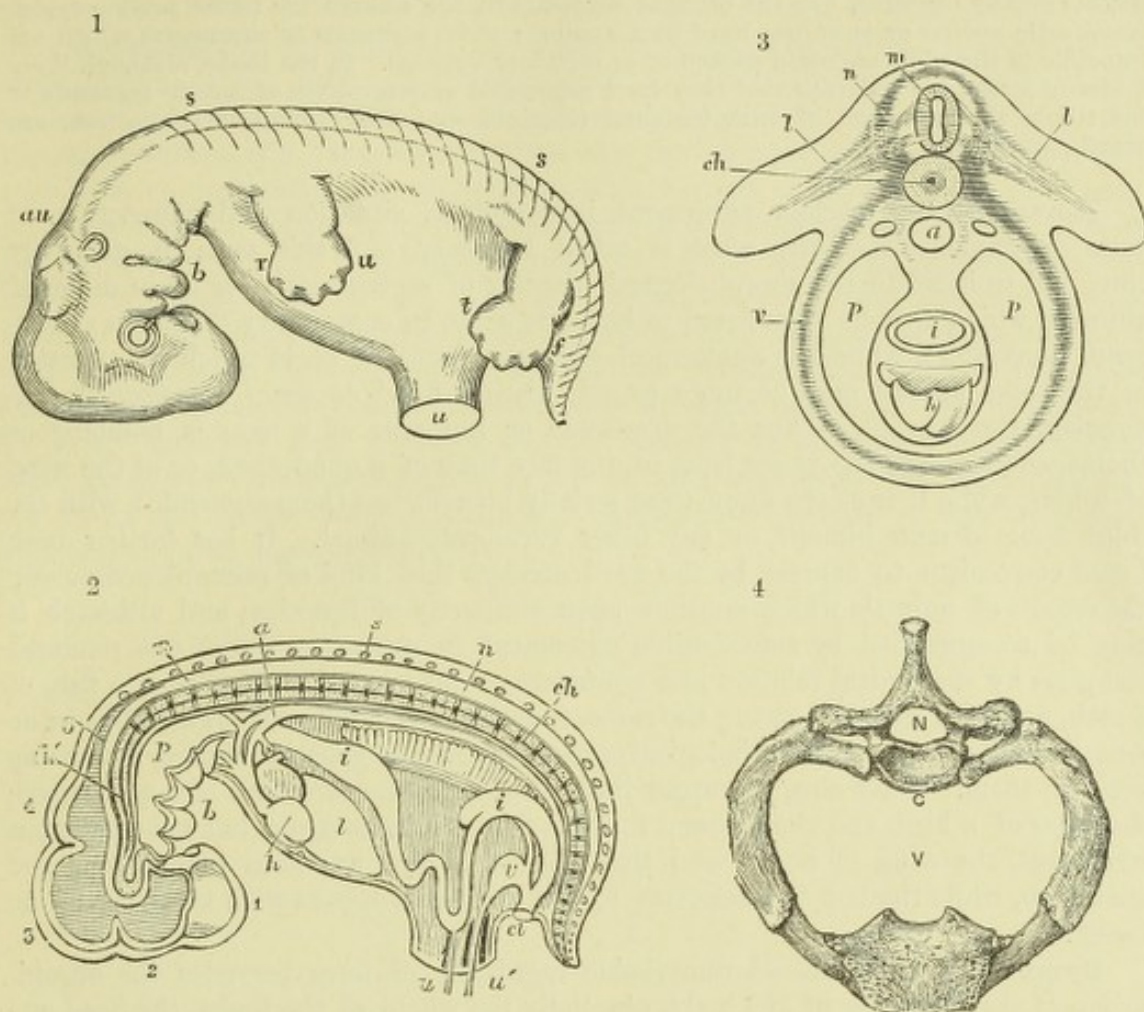


Fig. 1.—DIAGRAM OF AN EARLY HUMAN EMBRYO. (Allen Thomson.)

s, s, indications of the vertebral divisions along the line of the back; *r, u*, upper limb; *t, f*, lower limb; *u*, umbilical cord. In the cranial part the divisions of the brain are indicated, together with the eye, and *au*, the auditory vesicle; near *b*, the visceral arches and clefts of the head, forming *inter alia* the rudiments of the upper and lower jaws.

Fig. 2.—SEMI-DIAGRAMMATIC VIEW OF A LONGITUDINAL SECTION OF THE EMBRYO REPRESENTED IN FIGURE 1; SHOWING THE RELATIONS OF THE PRINCIPAL SYSTEMS AND ORGANS. (Allen Thomson.)

1, 2, 3, 4, 5, primary divisions of the brain in the cranial part of the neural canal; *n, n*, spinal cord in the vertebral part of the canal; *s*, spinous process of one of the vertebrae; *ch*, chorda dorsalis running through the axis of the vertebral centra; *ch'*, the same extending into the base of the cranium; *a*, dorsal aorta; *p*, pharyngeal cavity; *i, i*, alimentary canal; *h*, ventricular part of the heart, with which the arterial bulb is seen joining the aorta by arches; *b*, visceral arches of head; *l*, liver; *w*, Wolffian body; *v*, urinary vesicle or allantois, joining the intestine in the cloaca, *cl*; *u, u'*, umbilicus.

Fig. 3.—TRANSVERSE SECTION (DIAGRAMMATIC) OF THE TRUNK OF THE EMBRYO THROUGH THE UPPER LIMBS. (Allen Thomson.)

m, spinal cord; *n*, neural or dorsal arch, including bone, muscle, skin, roots of the nerves, &c.; *ch*, chorda dorsalis, surrounded by the vertebral body or centrum; *v*, ventral or visceral arch, or wall of the body; *p, p*, body cavity; *i*, alimentary canal; *h*, heart; *l, l*, the rudimentary limbs.

Fig. 4.—FIRST DORSAL VERTEBRA WITH THE FIRST RIB AND UPPER PART OF THE STERNUM, SEEN FROM ABOVE. $\frac{1}{2}$.

C, centrum; *N*, neural cavity; *V*, cavity of the chest, visceral cavity.

become greatly obscured. To the original segments in the embryo the terms *protovertebræ*, *mesoblastic somites* or *myotomes* have been applied; those segments or metameres which are traceable in the adult are often spoken of as *vertebral segments*. In the limbs, although there is strong reason for believing that they have originated as outgrowths of certain segments of the trunk, the repetition of such vertebral elements, and their primitive connection, are greatly obscured.

Homology.—A certain agreement in structure, situation and connection of parts or organs constitutes what is called *homology*, and this term is generally employed to indicate the morphological identity of representative parts in different animals, which may be considered to have its cause in community of origin (*homogeny*, Lankester), while the anatomical correspondence of parts which are repeated in the same animal may be more exactly distinguished as *serial homology* (*homodynamy*, Gegenbaur). Thus the arm-bone or humerus of a man is homologous (homogenetic) with the upper bone of the fore limb of a quadruped, or of the wing of a bird, while it is at the same time serially homologous (homodynamic) with the thigh bone of man himself, or any other vertebrate animal. It has farther been found convenient to express by the word *analogy* that kind of resemblance among the organs of animals which depends upon similarity of function, and although it may be accompanied by considerable agreement in structure, yet is not rendered complete by anatomical relation and connection: for example, the gills of a fish, of a crab, and of a mussel, serving the same function, are analogous organs, but in no sense homologous, as all morphological correspondence, or genetic relation, is wanting between them. Thus also, the upper limb of a man, the fore limb of a quadruped, the wing of a bird, and the pectoral fin of a fish are homologous but not analogous structures, the wing of a bat and the wing of a bird are both homologous and analogous, while the last is analogous to but not homologous with the wing of an insect.

Symmetry of form.—A remarkable regularity of form pervades the organization of certain parts of the body, especially the whole of the limbs, the head and neck, and the framework, at least, and external walls of the trunk of the body. Thus, if we conceive the body to be divided equally by a plane which passes from its dorsal to its ventral aspect (*median plane*), the two halves, in so far as regards the parts previously mentioned, correspond almost exactly with each other, excepting by their lateral transposition,—and the human body thus shows in a marked manner the character of *bilateral symmetry*. There is, however, a departure from this symmetrical form in the developed condition of certain of the internal organs, such as the alimentary canal from the stomach downwards, the heart and first part of the great blood-vessels, the liver, spleen, and some other viscera.

Descriptive terms.—In the description of parts so numerous, so various in form, and so complex in their connections as those composing the human body, there is difficulty in finding terms which shall indicate with sufficient precision their actual position and their relation to the rest of the organism. This difficulty is farther increased by the exceptional erect attitude in which the trunk of the human body is placed as compared with the horizontal position in animals. Hence, a number of terms have long been in use in human anatomy which are understood in a technical or restricted sense. For example, the *median plane*, already referred to, being that by which the body might be divided into right and left lateral halves, and the *middle* or *median line* being that in which the median plane meets the surface of the body, the words *internal* and *external* are used to denote relative nearness to and distance from this plane on either side, and may be replaced by *mesial* and *lateral*. The terms *sagittal*, *frontal*, and *coronal*, are also used in indication of direction within the body: sagittal denoting a dorso-ventral direction in or parallel to the median plane, frontal or coronal a transverse direction perpendicular to that

plane. The words *anterior* and *posterior*, *superior* and *inferior*, and several others indicating position, are employed in human anatomy strictly with reference to the erect posture of the body. But now that the more extended study of comparative anatomy and embryonic development is largely applied to the elucidation of the human structure, it is very desirable that descriptive terms should be sought which may without ambiguity indicate position and relation in the organism at once in man and animals. Such terms as *dorsal* and *ventral*, *neural* and *visceral*, *cephalic* and *caudal*, *central* and *peripheral*, *proximal* and *distal*, *axial* and *appendicular*, *pre-axial* and *postaxial*, are of this kind, and ought, whenever this may be done consistently with sufficient clearness of description, to take the place of those which are only applicable to the peculiar attitude of the human body, so as to bring the language of human and comparative anatomy as much as possible into conformity. In many instances, also, precision may be obtained by reference to certain fixed relations of parts, such as the *vertebral* and *sternal* aspects, the *radial* and *ulnar*, and the *tibial* and *fibular* borders, the *flexor* and *extensor* surfaces of the limbs, and similarly in other parts of the body.

EMBRYOLOGY.¹

By E. A. SCHÄFER.

FORMATION OF THE BLASTODERM.

STRUCTURE OF THE OVUM AND CHANGES PRIOR TO SEGMENTATION.

THE human body with all its tissues and organs is the product of the development of a single nucleated cell, the egg-cell, germ-cell, or ovum, which is formed within the principal reproductive organ of the female or ovary. The commencement of development is preceded by certain changes in the ovum, which usually occur soon after its discharge from the ovary, and consist (1) in the emission of certain constituents of the nucleus which form the so-called polar globules; (2) in the accession of the nucleus of a sperm-cell or spermatozoon, which is formed within the reproductive organ of the male (testicle), and which, blending with the remaining part of the nucleus of the ovum, appears to take the place of the part which was discharged in the form of the polar globules.

An account of the structure of the ovum, and of the manner in which the above changes are effected, may therefore appropriately precede the description of the actual course of development of the ovum.

Structure of the ovarian ovum.—The human ovum resembles that of all other mammals (with the exception of monotremes) in its minute size. Immediately before the time of its discharge from the Graafian follicle of the ovary in which it has been formed, it is a small spherical vesicle measuring about $\frac{1}{125}$ th inch ($\cdot 2$ mm.) in diameter, and is just visible as a clear speck to the naked eye. When it is examined with the microscope, it is found to be invested by a comparatively thick, clear covering. This, when the centre of the ovum is exactly focussed, has the appearance in optical section of a clear girdle or zone encircling the ovum (fig. 5), and was hence named *zona pellucida* by von Baer (1827). But on more careful examination with higher magnifying powers, and especially by the examination of sections, there is not much difficulty in making out the existence of striæ passing radially through the membrane (fig. 6, *zp*). On this account, and especially since a similar radially striated membrane forms a characteristic part of the investment of the ovum in many animals belonging to widely different classes, it is more convenient, in place of the name *zona pellucida*, which has been exclusively used to designate this investment in mammals, to employ the more general term *zona radiata*, or to speak of it simply as the *striated membrane* of the ovum.

The *zona radiata* of the mammalian ovum is sufficiently tough to prevent the escape of the contents of the ovum, even when subjected to a considerable amount of pressure. If, however, the pressure be excessive, the tunic splits, and the soft

¹ It is mainly owing to the researches of His, published principally in the important monograph "Anatomie menschlicher Embryonen" (Leipzig, 1880-1885), that our knowledge of the development of the human embryo is now far more complete than was the case when the last edition of this work was undertaken, and we are therefore able to keep more closely than was before possible to the human species in following the course of development of the ovum. For the elucidation, however, of many of the details of development, especially in its earlier stages, it will still be necessary to refer continually to facts which have been made out only from the study of the embryology of other mammals, as well as birds, reptiles, fishes, and even invertebrata.

contents are extruded (fig. 5, *b*). The striæ in the membrane are believed to be minute pores, and are supposed, while the ovum is yet within the Graafian follicle, to permit the passage of granules of nutrient material into the interior of the ovum. After the ovum is discharged from the follicle, the spermatozoa may perhaps find their way into the ovum through these pores. According to Retzius the protoplasm of the ovum is united with the follicle-cells by fibres which pass through the pores of the zona.

Immediately surrounding the zona radiata, as the ovum lies within the mature Graafian follicle, is a thin stratum of granular substance, probably deposited upon the exterior of the ovum by the innermost cells of the discus proligerus, which immediately encircle the ovum within the follicle. When the Graafian follicle bursts and the ovum is set free, this granular material appears to imbibe water, and, as is specially noticeable in the ovum of the rabbit, swells up into a clear gelatinous envelope, which has been termed, from a possible homology with the white of the bird's egg, the *albumen*. But in the mammal this structure has not the nutritive importance to the embryo which is possessed by the corresponding formation in the bird, and it disappears during the passage of the ovum down the Fallopian tube.

The substance of the ovum within the tunica radiata is known as the *vitellus* or *yolk* (fig. 6, *vi*). It is a soft semi-fluid substance, composed mainly of protoplasm, which is filled with globules and granules (yolk-granules) of different

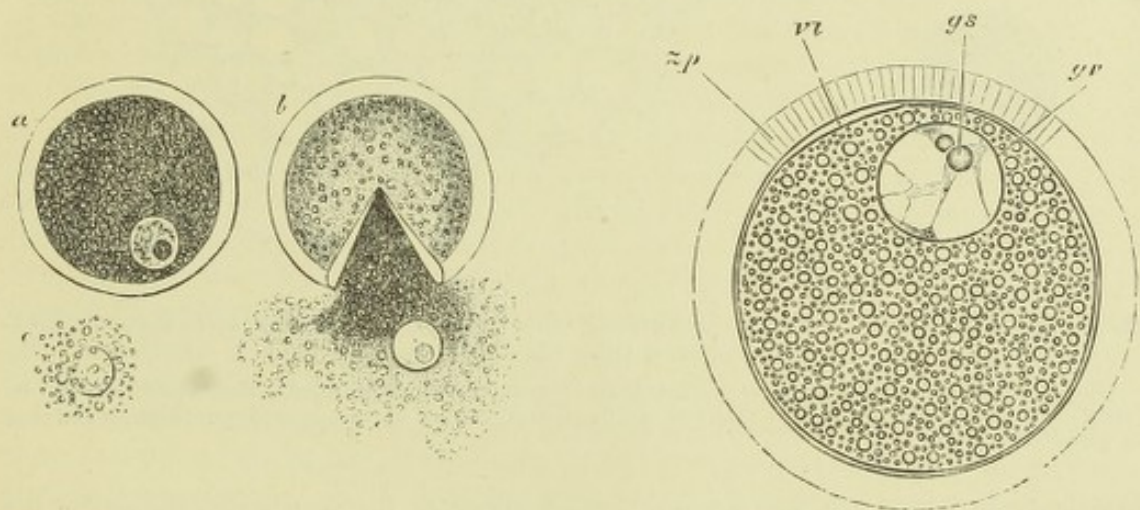


Fig. 5.—OVARIAN OVUM OF A MAMMIFER. (Allen Thomson.)

a, the entire ovum, viewed under pressure; the granular cells have been removed from the outer surface, the germinal vesicle is seen in the yolk substance within; *b*, the external coat or zona burst by increased pressure, the yolk protoplasm and the germinal vesicle having escaped from within; *c*, germinal vesicle more freed from the yolk substance. In all of them the macula is seen.

Fig. 6.—OVUM OF THE CAT; HIGHLY MAGNIFIED. SEMI-DIAGRAMMATIC. (E. A. S.)

zp, zona pellucida, showing radiated structure; *vi*, vitellus, round which a delicate membrane is seen; *gv*, germinal vesicle; *gs*, germinal spot.

sizes, but all small, and possessing a high index of refraction. Examined in the fresh condition, the protoplasm between the granules looks perfectly clear and structureless, but after treatment with suitable reagents, it may be seen to consist of a fine reticulum, which is especially fine and close near the periphery of the ovum, and also around the germinal vesicle, at which places the yolk granules are in less amount than elsewhere. The substances which occur within an ovum other than the nucleus and protoplasm, may, as in cells generally, be collectively designated "deutoplasm"; they are regarded as furnishing a supply of nutrient matter to the protoplasm during the earlier stages of development.

Embedded in the protoplasmic vitellus, usually eccentrically, is a large spherical

nucleus, which was termed by its discoverer, Purkinje, the *germinal vesicle*.¹ This, which is about $\frac{1}{500}$ th inch in diameter, has all the characters of the nucleus of a cell. It consists of a nuclear membrane enclosing a clear material or matrix, embedded within which may be seen strands of karyoplasm, enclosing one or more well-marked nucleoli (fig. 6, *gv*). Frequently there is but one nucleolus, which is then large and prominent, and has received the name of *germinal spot* (*macula germinativa*, Wagner, 1835).

There is some doubt whether, before fertilization, there is another membrane (vitelline membrane) enclosing the vitellus within the zona radiata. The evidence of the presence of such a membrane is by no means clear, although its existence has been maintained by very competent observers (v. Beneden, Balfour).

The mammalian ovum (that of monotremes alone excepted) differs from that of other vertebrates in the relatively small amount of nutritive material (yolk granules, deutoplasm) which is embedded in its protoplasm. In fishes, amphibia, reptiles, and especially in birds, the amount of such nutritive material is vastly greater than that of the protoplasm itself, so that the very existence of the latter is obscured in most parts of the ovum, and it is only in the immediate neighbourhood of the germinal vesicle that the protoplasm can be distinctly

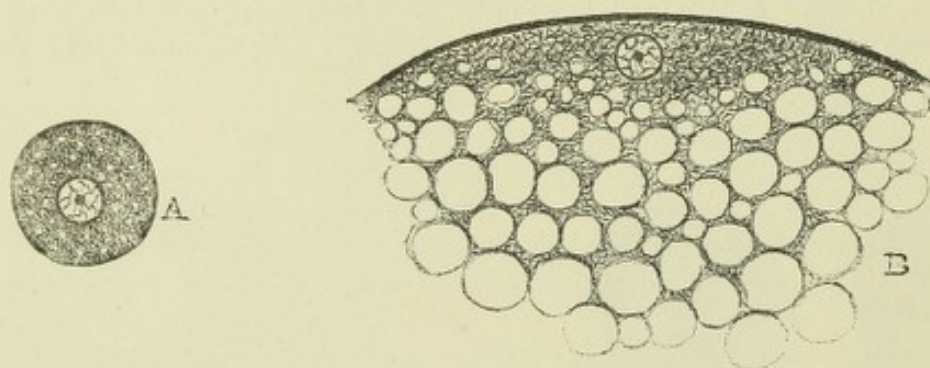


Fig. 7.—DIAGRAM OF A HOLOBLASTIC (ALECITHAL) OVUM (A) AND OF A MEROBLASTIC (TELOLECITHAL) OVUM (B). (E. A. S.)

Only a small part of the latter is represented. The yolk or food material is represented in both by clear globules, which in B are seen vastly to preponderate, except in the immediate neighbourhood of the germinal vesicle.

recognized (fig. 7, B). It is here also that, after fertilization, the more active changes in the ovum occur, and it is this part alone in which in the bird and most other oviparous vertebrates the process of division or segmentation of the yolk and consequent formation of embryonic cells proceeds. Hence these ova are said to undergo a process of incomplete segmentation, only a part of the ovum appearing to undergo development, and they are accordingly termed *meroblastic* to distinguish them from those (like the mammalian ova) in which the yolk or nutritive material is everywhere in relatively small proportion to the protoplasm, the *whole* of which undergoes division after fertilization, and participates in the formation of the embryo (*holoblastic* ova). This small amount of nutritive material in the mammal is obviously related to the fact that the mammalian ovum early acquires an attachment to the maternal system from which it is then able directly to derive its nutriment, whereas the meroblastic ovum of oviparous vertebrates necessarily contains all the nutriment required by the developing bird, reptile, or fish, until it is sufficiently advanced in development to emerge from the egg and obtain food independently. Although, however, the mammalian ovum is holoblastic, it is none the less clear, from a comparison of the early stages of its development with that of the bird, that the ancestors of the mammalia must have had ova of the meroblastic type.

Balfour has further conveniently distinguished between those ova in which there is a great accumulation of nutritive or yolk material at one pole (*telolecithal* ova, as in the bird, reptile, and fish amongst vertebrates), those in which the accumulation of yolk is in the middle of the ovum (*centrolecithal* ova, as in arthropods), and those in which it is scattered pretty equally in small amount throughout the protoplasm without any very marked accumulation

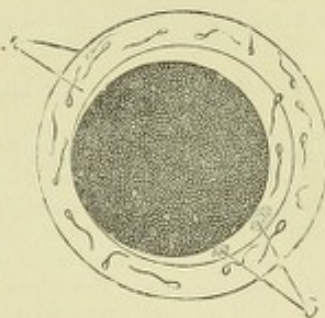
¹ Purkinje discovered the germinal vesicle in the bird's ovum in 1825; that of mammals was first noticed by Coste in 1833.

(*alveithal* ova, as in mammals, *Amphioxus*, echinoderms). It is clear that these conditions of arrangement of the proto- and deuto-plasm within the ovum are the main factors in determining variations in the process of segmentation.

Maturation of the ovum. Formation of polar globules.—Either before its escape from the Graafian follicle, or immediately after, the ovum undergoes a peculiar change, preparatory to, but nevertheless altogether independent of fertilization, which consists of a process of unequal cell-division or germination, and results in the extrusion from the vitellus of two minute spherical bodies (fig. 8), which have

Fig. 8.—OVUM OF THE RABBIT FROM THE FALLOPIAN TUBE, TWELVE HOURS AFTER IMPREGNATION. (Bischoff.)

On the zona *a*, spermatozoa are seen, and others in the perivitelline space; *b*, the polar globules.



been termed the *polar globules* or *directive corpuscles*, from a supposition that their presence determines the pole at which the first segmentation will take place should the ovum become fertilized. It is, however, uncertain whether there is any constant relationship of this kind, but it is none the less clear that the extrusion of the polar globules is an event of the highest importance for the due development of the ovum, since until this has happened the ovum appears to be incapable of complete fertilization and segmentation.¹ What is actually extruded is a small part of the nucleus of the ovum, or, to speak more precisely, two small parts of its nucleus in succession, probably surrounded by a very thin investment of protoplasm. Prior to this extrusion, the germinal vesicle approaches the periphery of the vitellus, loses its distinctness of outline, and after passing through phases which are characteristic of a nucleus which is about to divide, does actually undergo a division into two, the one part being extruded into a space (perivitelline), which has become formed in consequence of the shrinking or contraction of the ovum, and the other part remaining in the vitellus, only, however, to repeat the process of division, and to form a second extruded globule. The remainder of the germinal vesicle, which is now termed the *female pro-nucleus*, leaves the periphery of the vitellus for a situation nearer to the centre, where, if fertilization should supervene, it awaits the advent of the *male pro-nucleus*, which is formed from a spermatozoon. After the two pro-nuclei have come together, a new and complete nucleus is formed by their conjugation.

The actual formation of polar globules has not hitherto been observed in the human ovum, although there is no doubt whatever that it takes place. In the rabbit various stages in the process have been traced by E. v. Beneden and Rein, and it has also been noticed in other mammals. But the details of the process have been made out most precisely (by Fol, Hertwig, and others) in the transparent ova of echinoderms, and more recently and minutely (by E. v. Beneden, Carnoy, Boveri, Zacharias, and others) in *Ascaris megalocephala*, a thread-worm parasitic in the horse, in which all the changes can be followed in one and the same ovum, or the various phases fixed by means of reagents in different ova, and these may afterwards be stained and studied with the utmost minuteness. The successive changes in such ova are represented in figs. 9 and 10. The polar globules remain visible for a time in the perivitelline fluid, and are even seen, should the ovum become fertilized, during the early stages of segmentation, but they ultimately disappear and are not known to take any further part in the subsequent changes which the ovum undergoes.

The fact that throughout the whole animal kingdom the extrusion of polar globules from the ovum as it becomes mature is almost universal, and that a similar process has also been observed to occur in plants indicates the great importance of the phenomenon. The significance will be further discussed after the process of fertilization of the ovum has been described.

¹ The ovum may, however, receive a spermatozoon before the completion of the formation of polar globules.

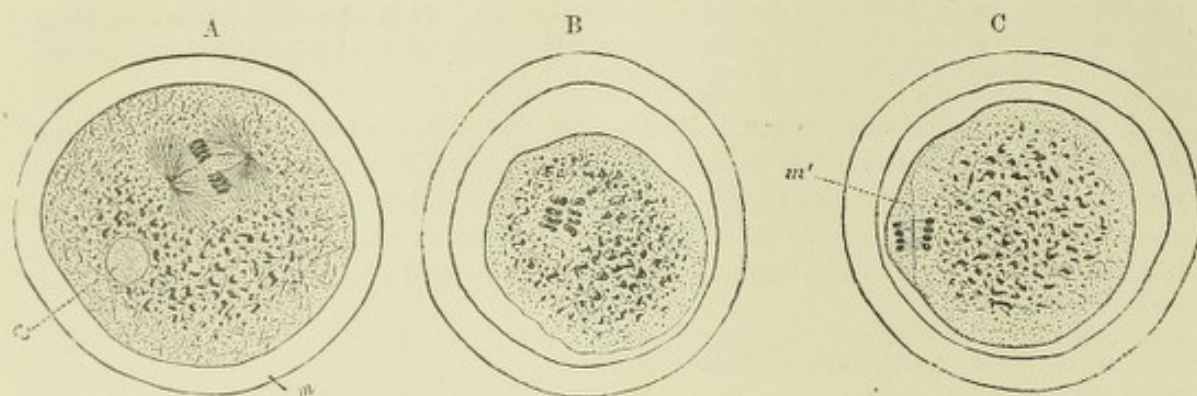


Fig. 9.—FORMATION OF THE FIRST POLAR GLOBULE IN THE EGG OF *ASCARIS MEGALOCEPHALA*. (v. Gehuchten.)

A. The ovum with the germinal vesicle transformed into a spindle of (achromatic) fibrils: from the poles of the spindle other fibrils radiate into the protoplasm. At the equator of the spindle eight portions of chromatin are visible; *cs*, head of a spermatozoon which has previously entered the ovum, and is becoming transformed into the male pro-nucleus; *m*, gelatinous membrane of the ovum.

B. The chromatin particles are seen separated into two sets. The achromatic fibrils are not shown in this preparation. The ovum is considerably shrunken.

C. Half of the germinal vesicle is extruded into a perivitelline space, and along with a portion of protoplasm is becoming separated off from the ovum as a polar globule. The extruded half includes four of the chromatin particles; the other four remain in the ovum; *m'*, membrane dividing the polar globule from the ovum.

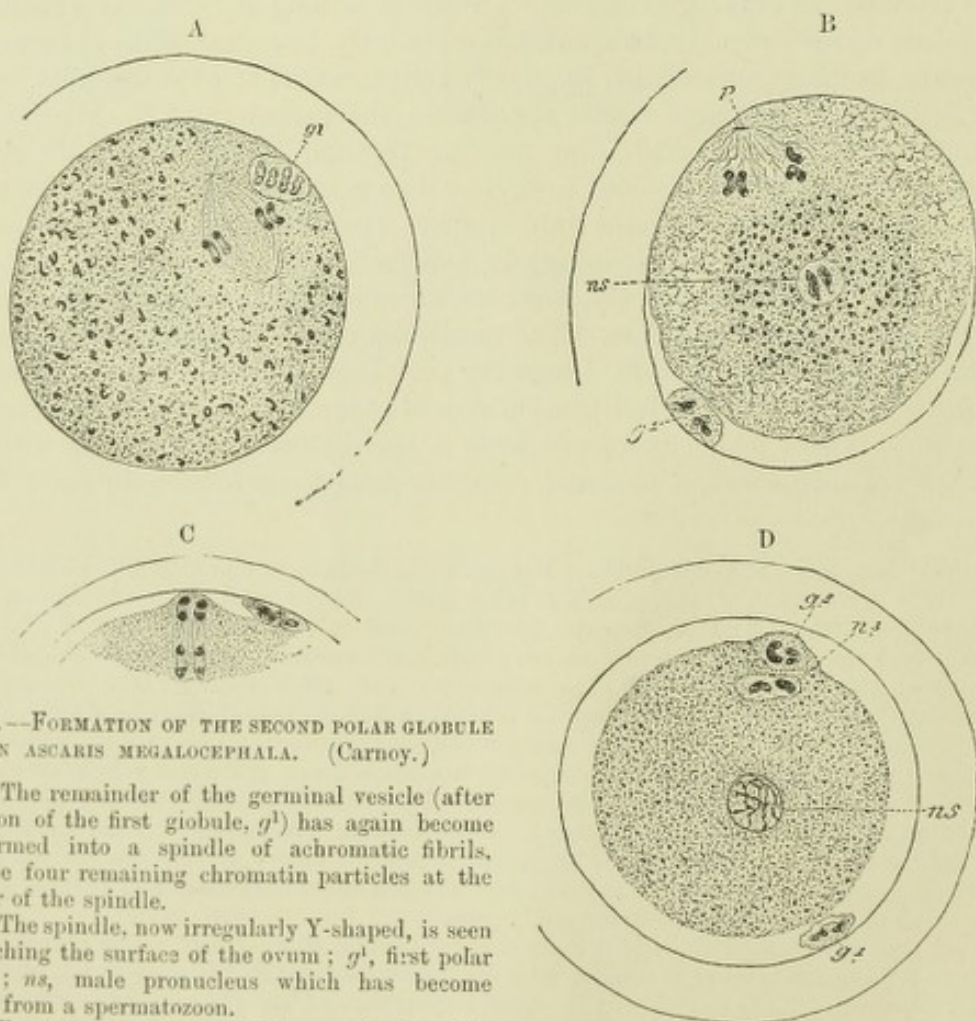


Fig. 10.—FORMATION OF THE SECOND POLAR GLOBULE IN *ASCARIS MEGALOCEPHALA*. (Carnoy.)

A. The remainder of the germinal vesicle (after extrusion of the first globule, *g*¹) has again become transformed into a spindle of achromatic fibrils, with the four remaining chromatin particles at the equator of the spindle.

B. The spindle, now irregularly Y-shaped, is seen approaching the surface of the ovum; *g*¹, first polar globule; *ns*, male pronucleus which has become formed from a spermatozoon.

C. Extrusion of half of the germinal vesicle remainder.

D. Completion of the process; the second polar globule, *g*², is now separated from the ovum; it contains two of the chromatin particles. The other two remain in what is left of the germinal vesicle, *n*² which now forms the female pronucleus; *ns*, male pronucleus; *g*¹, first polar globule.

Fertilization.—The ovum, after its expulsion from the Graafian follicle is received upon the fimbriated end of the Fallopian tube. The fimbriae are covered by a prolongation of the ciliated lining of the tube, and the action of the cilia serves to propel the minute ovum into and along the tube towards the uterus. In this passage it may, if impregnation have occurred, meet with the spermatozoa, one or more of which may penetrate the zona pellucida, and fertilize the ovum. It is possible in some instances for fertilization to occur on the fimbriated extremity of the tube, or in the body of the uterus, but it is probable that in most cases it happens in the tube itself.

It is probable that normally only a single spermatozoon enters the vitellus. If it should happen that two or more enter, normal development does not as a rule occur. Exceptions to this rule have, however, been recorded.

The changes in the ovum which accompany fertilization have, like those which result in the formation of the polar globules, been studied most satisfactorily in the transparent ova of echinoderms and in *Ascaris*. In the former (fig. 11) the spermatozoa

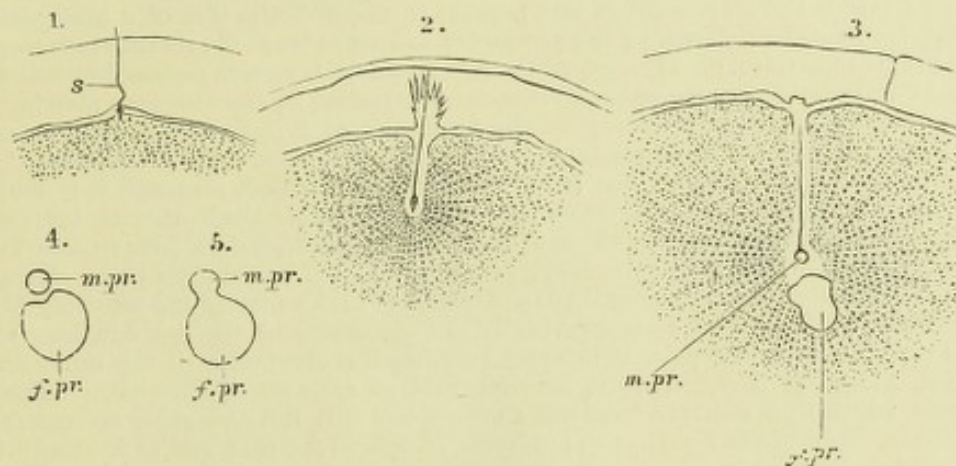


Fig. 11.—FERTILIZATION OF THE OVUM OF AN ECHINODERM. (Selenka.)

s, spermatozoon; m.pr, male pronucleus; f.pr, female pronucleus.

1. Accession of a spermatozoon to the periphery of the vitellus; 2. Its penetration, and the radial disposition of the vitelline granules; 3. Transformation of the head of the spermatozoon into the male pronucleus; 4, 5. Blending of the male and female pronuclei.

may be seen to penetrate the gelatinous investment which here takes the place of a zona pellucida, and the head, of one only as a rule, to imbed itself in the periphery of the ovum, which becomes slightly protruded at the point of contact. According to v. Beneden's account, the spermatozoon always enters in *Ascaris* at a particular part of the ovum (polar disc), at which part there is an aperture in the vitelline membrane (micropyle). When once it has passed into the ovum, this aperture becomes closed, and the head of the spermatozoon rapidly increases in size, and acquires the appearance of a nucleus which, in contra-distinction to the remains of the germinal vesicle, or female pro-nucleus, is termed the *male pro-nucleus*. Soon it leaves the periphery, and passes towards the centre of the ovum in the direction of the female pro-nucleus. In its passage through the protoplasm it appears to exercise a peculiar attraction upon the granules in that substance, for these become arranged in its vicinity in radiating lines. The tail of the spermatozoon has in the meantime disappeared, whether by being cast off or by blending with the protoplasm of the ovum has not certainly been made out. As the male pro-nucleus approaches the female pro-nucleus, the latter moves somewhat to meet it, and presently the two pro-nuclei come into contact and together form a new nucleus, com-

plete in all its structure and functions. With the blending of the two pro-nuclei the act of fertilization is completed, and the ovum is now capable of forming new cells by division. Since the head of the spermatozoon is formed from the nucleus of a seminal cell, part of which appears to be thrown off prior to the complete maturation of the spermatozoon (Renson, Brown), and the female pro-nucleus is the nucleus of an egg or germ-cell, part of which has been removed in the form of the polar globules, the process of fertilization may be described as consisting essentially of the conjunction of part of the nucleoplasm of a sperm cell with part of the nucleoplasm of a germ cell, the result being the production of a complete nucleus endowed with active properties of division and reproduction.

Although, as has been already stated, the changes which have just been described are most clearly to be seen, and have been most completely studied, in the ova of echinoderms and *Ascaris*, similar processes have been found to occur in most if not in all animals, and have even been made out, although not very distinctly, in mammals (in the rabbit by v. Beneden). There is no doubt, therefore, that the phenomena of fertilization are essentially the same throughout the whole animal kingdom. As to the exact details of the process there is still much discrepancy in the accounts given by recent observers. Of all those that given by v. Beneden of the process of fertilization, and of the subsequent division of the resulting nucleus in *Ascaris*, is the most explicit, and appears to negative the idea of a complete fusion taking place between the elements of the pro-nuclei, at least so far as the chromatin is concerned. According to this account (v. fig. 12), each of the two pronuclei is seen to possess, previous to their conjunction, two short chromatin rods (*chromosomes*) imbedded in clear nuclear matrix. These rods undergo various changes, resulting in the formation of a skein within each pro-nucleus (II., III.), but eventually the skein resolves itself into two V-shaped loops or filaments (IV., V.). On conjunction the matrix of the two nuclei may appear to blend, although it is doubtful if they actually fuse together, but the chromatin filaments retain their distinct individuality. The nucleus which is thus formed by the conjunction, contains, therefore, four similar V-shaped chromatin filaments, which now split longitudinally (VI., VII.), and after being arranged for a time at the equator of the now spindle-shaped nucleus (VIII.), four of the resulting filaments pass towards the one pole, and form eventually the chromatin of the one daughter nucleus, and four towards the other pole, eventually forming the chromatin of the other daughter nucleus (XI., XII.). It is stated by v. Beneden that of each set of chromatin filaments, or chromosomes, which thus separate from one another, one half the number is derived from the male and the other from the female pro-nucleus. If this is the case, and if it should further be shown that in every subsequent process of division of the resulting cells, the chromatin filaments of the daughter cells are derived half from male chromatin filaments and half from female, it necessarily follows that every cell nucleus must be regarded as containing both male and female morphological elements.

Meaning of the polar globules.—Theory of Minot.—The question of the hermaphroditism of cells was first raised by C. S. Minot in connection with the separation of the polar globules. According to the view advocated by Minot, every cell which results from the division of a fertilized ovum is hermaphrodite, for the fertilized ovum is formed by the union of both male

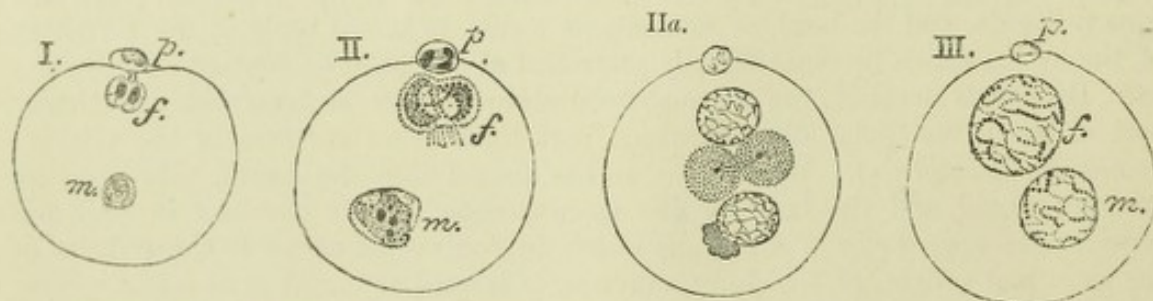


Fig. 12.—FORMATION AND CONJUGATION OF THE PRO-NUCLEI IN *ASCARIS MEGALOCEPHALA*.
(E. v. Beneden.)

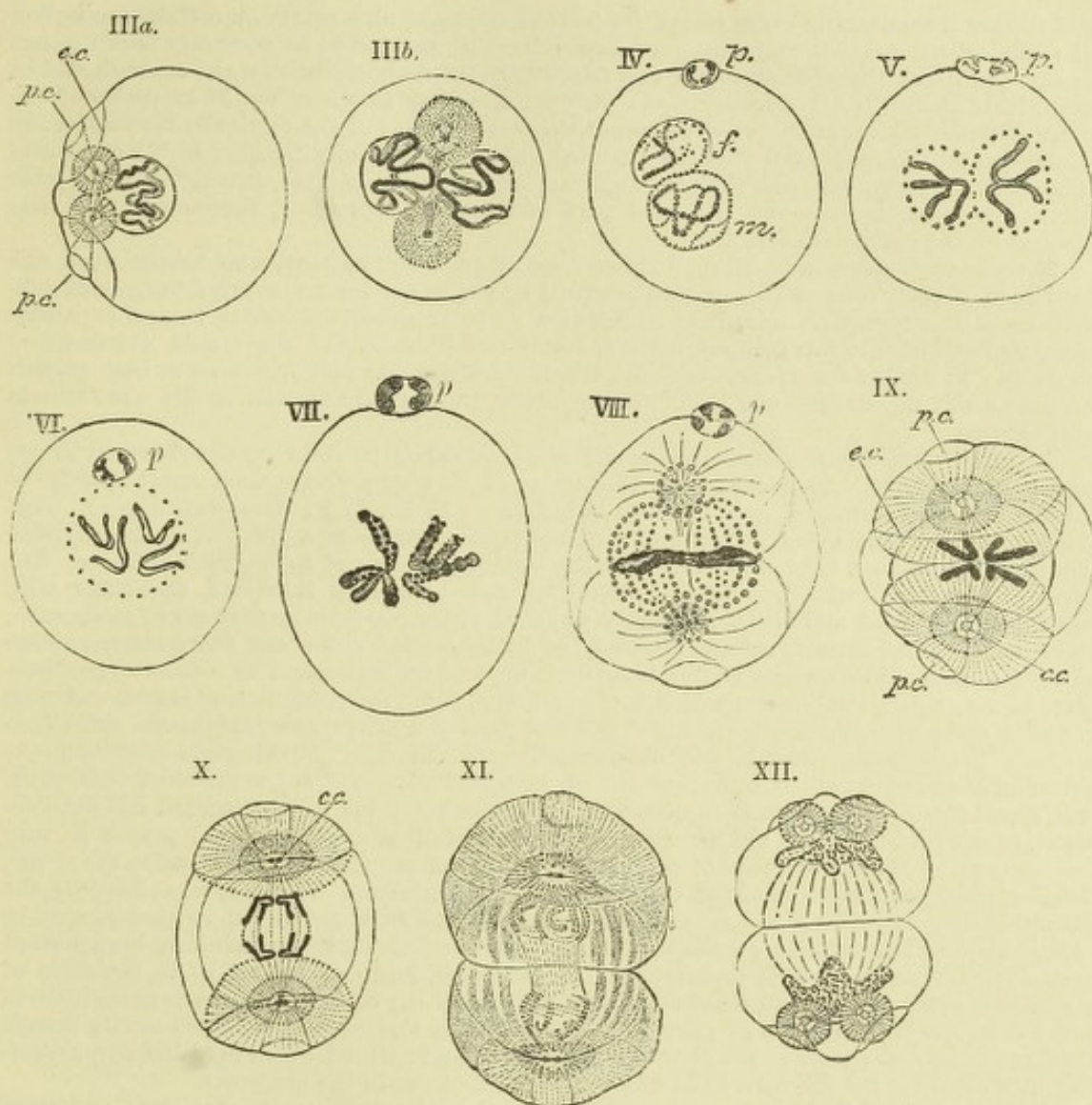
f, female pronucleus; *m*, male pronucleus; *p*, one of the polar globules.

I. The second polar globule has just been extruded; both female and male pronuclei contain two chromatin particles; those of the male pronucleus are becoming transformed into a skein.

II. The chromatin in both pronuclei now forms a skein.

IIa. The skein in the pronuclei is more distinct. Two attraction-spheres, each with a central particle, united by a spindle of achromatic fibres, have made their appearance near the pronuclei. The male pronucleus has the remains of the body of the spermatozoon adhering to it.

III. The pronuclei are enlarged; the skein formation of the chromatin is complete.



IIIa. Only the female pronucleus is shown in this figure. The skein of this is contracted and thickened. The attraction-spheres are near one side of the ovum, and are connected with its periphery by a cone of fibres forming a polar circle *p.c.*; *e.c.* equatorial circle.

IIIb. The pronuclei have approached one another, and the spindle-system is now arranged across their common axis.

IV. Contraction of the skein and formation of two V-shaped chromatin filaments in each pronucleus.

V. The V-shaped chromatin filaments are now quite distinct; the male and female pronuclei are in close contact.

VI., VII. The V-shaped filaments are splitting longitudinally; their structure of fine granules of chromatin is apparent in VII., which is more highly magnified. The conjugation of the pronuclei is apparently complete in these figures, but according to v. Beneden's description, the outlines of both can, under favourable conditions, be still made out. The attraction spheres and achromatic spindle, although present, are not shown in IV., V., VI. and VII.

VIII. Equatorial arrangement of the four chromatin loops in the middle of the now elongated ovum; the achromatic substance forming a spindle-shaped system of granules with fibrils radiating from the poles of the spindle (attraction-spheres) into the protoplasm; commencing division of the ovum into two cells.

IX. Shows diagrammatically the commencing separation of the chromatin filaments of the conjugated nuclei, and the system of fibres radiating from the attraction-spheres. *p.c.* polar circle; *e.c.* equatorial circle; *c.c.* central particle.

X. Further separation of the chromatin filaments. Each of the central particles of the attraction-spheres has divided into two.

XI. The chromatin filaments are becoming developed into the skeins of the daughter nuclei. These are still united by achromatic fibres. The protoplasm of the ovum is becoming divided.

XII. The daughter nuclei exhibit a chromatin network. Each of the attraction-spheres has divided into two, which are joined by achromatic fibres, and are connected with the periphery of the cell in the same manner as the parent sphere shown in IIIa.

and female elements, and every one of its descendants must also contain a certain proportion of each. For the sexual conjugation of two cells it is assumed to be necessary that the one should get rid of the male elements, and retain only the female, and that the other should be exclusively male. This is effected in the one case, according to Minot, by the extrusion of the polar globules, which, in this view, represent the male element of the originally hermaphrodite generative cell, so that when they are extruded this remains wholly female; in the other case there is also a separation, and the separated part becomes disintegrated, leaving only the male portion, or spermatozoon—the separated part in this case represents, therefore, the female element of the generative cell.

Theory of Weismann.—Minot's theory was adopted by Balfour, who looked upon the formation of polar cells as having been acquired by the ovum for the express purpose of preventing parthenogenesis. According to this view no polar globules should be formed in parthenogenetic ova, and it was believed by both Minot and Balfour that they would not be found to occur. It has, however, since been discovered by Weismann and Blochmann that parthenogenetic ova do extrude one polar globule, although the ordinary ova of the same animal extrude two.

It is clear that this fact renders a modification necessary in the view advocated by Minot and Balfour. Such modification, or substitute, as it may perhaps more appropriately be termed, has been furnished by Weismann in his theory of heredity (*Vererbungstheorie*). This theory assumes that every animal and vegetable cell contains two different kinds of living substance. These are termed by Weismann the *nuclear plasma* and the *nutritive plasma*. The former is endowed, with germinative, directing and hereditary functions, the latter with assimilation of food and the more purely physical functions (contraction, nerve-conduction, secretion, &c.), but these functions are assumed to be carried out under the direction of the nuclear plasma. The nuclear plasma is further supposed by Weismann to consist of two substances, viz., a *germinal plasma* which is the primitive form, and which alone is endowed with heredity, and a *histogenetic plasma* which has been derived from the germinal plasma, and which controls the division, growth, and differentiation of the cell. Fertilization consists in the bringing to the ovum of a certain amount of germinal plasma from a different individual, and Weismann assumes that it is necessary for the ovum, prior to fertilization and development, to get rid both of its old histogenetic plasma and of so much germinal plasma as may be brought to it by the spermatozoon, and that it effects this by the extrusion (1) of one (histogenetic) polar globule, (2) of the other (germinal) globule. If this is what happens, the primitive or germinal plasma is never wholly eliminated from the ovum, so that it may be looked upon as transmitting all the accumulated ancestral characters which have been derived from the vast number of its predecessors. A portion is, however, got rid of in the form of the second polar globule, and what remains is not necessarily of quite the same constitution in every case, nor is the portion of germ plasma brought by the spermatozoon necessarily always similar: these differences in the germinal plasma of the fertilized ovum may account, according to Weismann, for the individual differences which occur in the progeny.¹

Weismann and Ischikawa have shown that in some animals the segmentation of the ovum may have advanced through one or two stages before the entry of a spermatozoon. In this case the spermatozoon (male pro-nucleus) blends with the nucleus of only one of the cells which have resulted from the segmentation. Probably the sexual cells are the ultimate result of this conjugation.

RECENT LITERATURE.

Beneden, E. v., *Recherches sur la maturation de l'œuf et la fécondation*. Arch. de biol., iv., 1884; *Fertilization and Segmentation in Ascaris Megalocephala*, Journal of Microscopic Science, 1888 (Bulletin de l'académie r. des sciences de Belgique, 1887, t. xiv.); *Sur la fécondation chez l'ascaride mégalocéphale*, Anatomischer Anzeiger. Jahrg., iii., 1888.

Beneden, E. v. et Neyt, A., *Nouvelles recherches sur la fécondation et la division mitotique chez l'ascaride mégalocéphale* (Bullet. de l'acad. royale des sciences de Belgique, 3 sér. t. xiv., 1887).

Blochmann, F., *Ueber die Richtungskörper bei Insekteneiern*, Morphol. Jahrbuch, Bd. xii., 1887. Also in Morph. Jahrb. xv., 1889. and Verhandl. d. naturhist. med. Vereins zu Heidelberg. 1888.

Boveri, T., *Zellenstudien, H. 1, Die Bildung der Richtungskörper bei Ascaris megalocephala und Ascaris lumbricoides*, Jenaische Zeitschr. f. Naturwiss., Bd. xiv., 1887; *Zellenstudien, H. 2, Die Befruchtung und Theilung des Eies von Ascaris megalocephala*, Jena. Zeitschr., 1888; *Zellenstudien, H. 3, Ueber das Verhalten der chromatischen Kernsubstanz bei der Bildung der Richtungskörper u. bei der Befruchtung*, Jena. Zeitschr., 1890.

Bütschli, O., *Gedanken über die morphologische Bedeutung der sogenannten Richtungskörperchen*, Biolog. Centralbl., Bd. iv., 1884.

¹ It is difficult to do any justice to Weismann's theory in a short space, and the above is to be taken as only furnishing a rough sketch of its general outline. For a complete account the reader is referred to Weismann's publications upon the subject (see Literature).

- Caldwell, W. H., *The Embryology of Monotremata and Marsupialia*, part i., Philosophical Transactions of the Royal Society of London for the year 1887.
- Carnoy, J. B., *Les globes polaires de l'ascaris clavata*, La Cellule, t. iii., 1887; *La vésicule germinative et les globes polaires chez quelques nématodes*, La Cellule, t. iii., 1887; *La vésicule germinative et les globes polaires de l'Ascaris megalocephala*, La Cellule, t. ii., 1887; *Some Remarks on the recent Researches of Zacharias and Boveri upon the Fecundation of Ascaris megalocephala*. Report of the 57th meeting of the British Association for the Advancement of Science at Manchester, 1887.
- Cunningham, J. T., *E. v. Beneden's Researches on the Maturation and Fecundation of the Ovum*, Quart. Journ. of Microsc. Science, Jan., 1885.
- Gehuchten, A. v., *Nouvelles observations sur la vésicule germinative et les globes polaires de l'Ascaris megalocephala*, Anat. Anz., No. 25, 1887.
- Grützner, P., *Physiologische Untersuchungen über die Zeugung*, Deutsche medic. Wochenschr., 1884.
- Henking, H., *Ueber Reductionsteilung der Chromosomen in den Samenzellen von Insecten*. Monthly International Journal of Anatomy and Physiology, vol. vii., 1890.
- Hertwig, Oscar, und Richard, *Ueber den Befruchtungs- und Theilungsvorgang des thierischen Eies unter dem Einfluss äusserer Agentien*, Jena. Zeitschr. f. Naturwiss., Bd. xx., 1887.
- Hertwig, R., *Ueber den Einfluss des Chloralhydrats auf die inneren Befruchtungsercheinungen*, Anatom. Anzeiger, 1886.
- Kölliker, A. v., *Das Karyoplasma und die Vererbung, eine Kritik der Weismann'schen Theorie von der Continuität des Keimplasma*, Zeitschr. f. wissensch. Zoologie, Bd. xlv., 1886.
- Kultschitzky, N., *Die Befruchtungsvorgänge bei Ascaris megalocephala*, Arch. f. microsc. Anat., Bd. xxxi., 1888; *Ueber die Eireifung und die Befruchtungsvorgänge bei Ascaris marginata*, Ebendas., Bd. xxxii., 1888.
- Kupffer, C., *Die Befruchtung des Forelleneies*, Bayerische Fischerei-Zeitung, 1886.
- Minot, Ch. S., *Theorie der Gonoblasten*, Biol. Centralbl., Bd. ii., 1882.
- Mondino, C., e Sala, L., *Sur les phénomènes de maturation et de fécondation dans les œufs des ascarides*. Arch. ital. de biol. xii., 1889.
- Nagel, W., *Das menschliche Ei*, Arch. f. micr. Anat., Bd. xxxi., 1888.
- Nussbaum, M., *Ueber die Veränderungen der Geschlechtsproducte bis zur Eifurchung. Ein Beitrag zur Lehre der Vererbung*, Arch. f. mikrosk. Anat., Bd. xxiii., 1884; *Bildung u. Anzahl d. Richtungsk. bei Cirripeden*, Zool. Anzeiger, 1889.
- Platner, G., *Ueber die Befruchtung bei Arion empiricorum*, Archiv f. mikr. Anat., Bd. xxvii., 1886; *Die Bildung d. ersten Richtungsipindel im Ei von Aulastomum gulo*, Arch. f. mikrosk. Anat., xxxiii., 1889.
- Rein, G., *Beiträge zur Kenntniss der Reifungsercheinungen und Befruchtungsvorgänge am Säugethiere*, Archiv f. mikr. Anat., 1883.
- Retzius, G., *Zur Kenntniss v. Bau d. Eierstockseies, &c.*, Hygiea, Festband, 1889.
- Schultze, O., *Ueber Reifung und Befruchtung des Amphibieneies*, Anatom. Anz., No. 6, 1886.
- Sehlen, D. v., *Beitrag zur Frage nach der Mikropyle des Säugethiereies*, Archiv. für Anat. u. Physiol., Anat. Abth., 1882.
- Selenka, E., *Zur Befruchtung des thierischen Eies*, Biol. Centralb. V., No. 1. 1885.
- Sheldon, L., *The Maturation of the Ovum in Peripatus*, Quart. Journ. of Microscopical Science, vol. xxx., 1889.
- Tafari, *La fécondation et la segmentation étudiées dans les œufs des rats*, Arch. ital. de biologie, xi., 1889.
- Thomson, A., *Recent Researches on Oogenesis*, Quart. Journ. of Micr. Science, vol. xxvi., June, 1886.
- Waldeyer, *Karyokinesis and its Relation to the Process of Fertilization* (Translation), Quarterly Journal of Microscopical Science, xxx., 1889 (contains an account of recent researches on these subjects).
- Weismann, A., *Ueber die Vererbung*, Jena, 1883; *Die Continuität des Keimplasmas als Grundlage einer Theorie der Vererbung*, Jena, 1885; *Richtungskörper bei parthenogenetischen Eiern*, Zoolog. Anz., No. 233, 1886; *Ueber die Zahl der Richtungskörper und über ihre Bedeutung für die Vererbung*, Jena, Fischer, 1887; *Essays upon heredity and kindred biological problems* (translations)—Oxford, Clarendon Press, 1889; *Ueber die Paracopulation im Daphnidenei, &c.*, 1889.
- Weismann, A., u. Ischikawa, C., *Ueber die Bildung der Richtungskörper bei thierischen Eiern*, Berichte der naturf. Gesellsch. zu Freiburg i. Br., Bd. iii., 1887; also Zool. Jahrb., Bd. iv., 1889-90; *Ueber partielle Befruchtung*, Freiburg i. Br., 1888; Biol. Centralbl., Bd. viii., 1888.
- Zacharias, O., *Neue Untersuchungen über die Copulation der Geschlechtsproducte und den Befruchtungsvorgang bei Ascaris megalocephala*, Arch. f. mikrosk. Anat., Bd. xxx., 1887; *Ueber die Bildung der Richtungskörper bei thierischen Eiern*, Biol. Centralb., Bd. viii., 1888; *Ueber Abweichungen vom Typus der Conjugation der Geschlechtskerne*, Anat. Anzeiger, iii., 1888.
- Ziegler, E., *Können erworbene pathologische Eigenschaften vererbt werden und wie entstehen erbliche Krankheiten und Missbildungen?* Beiträge zur pathol. Anat. u. Physiol., herausgegeben von Ziegler und Nauwerk, 1886.

EARLY CHANGES IN THE OVUM CONSEQUENT ON FERTILIZATION—SEGMENTATION—FORMATION OF THE BLASTODERM—THE PRIMITIVE STREAK AND GROOVE.

Segmentation of the ovum.—Immediately after the completion of the process of fertilization, the ovum begins to show signs of division into two cells or segments. The division is preceded by the formation of a spindle-shaped system of achromatic

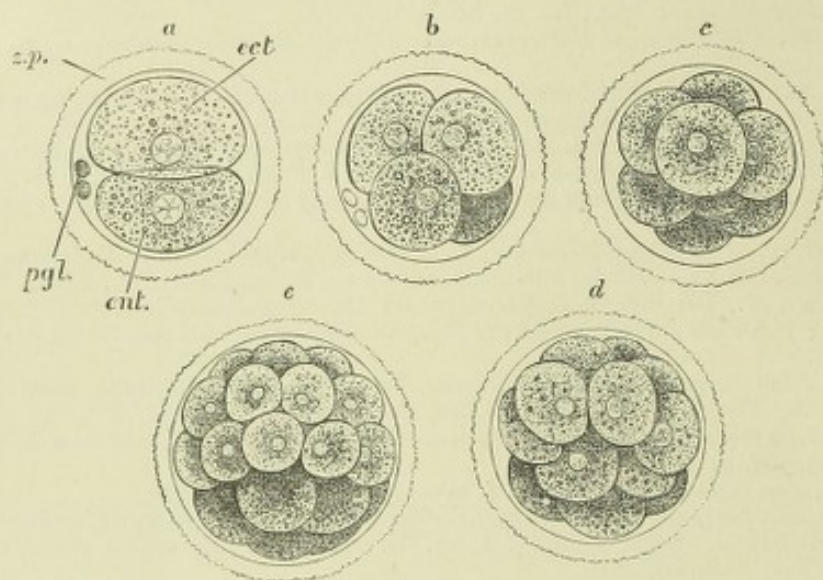


Fig. 13.—FIRST STAGES OF SEGMENTATION OF A MAMMALIAN OVUM: SEMI-DIAGRAMMATIC.
(Drawn by Allen Thomson after E. v. Beneden's description.)

z.p., zona pellucida; *p.gl.*, polar globules; *a*, division into two segments; *ect*, larger and clearer segment; *ent*, smaller, more granular segment; *b*, stage of four segments; *c*, eight segments, the ectomeres partially enclosing the entomeres; *d, e*, succeeding stages of segmentation showing the more rapid division of the clearer segments and the enclosure of the darker segments by them.

fibres and by changes in the nucleus which are similar to those which take place in the division of an ordinary cell (v. Histology). According to v. Beneden's observations in *Ascaris* these changes occur in each of the two pro-nuclei (fig. 12), and one-half the number of resulting V-shaped filaments then passes from each to form each daughter nucleus, which thus contains male and female chromatin elements in equal amount. Each of the two segments which are thus formed speedily again divides in the same manner, so that four cells or segments now occupy the interior of the ovum. By a further process of binary division eight cells are formed, then sixteen, thirty-two, and so on until the originally simple ovum is eventually subdivided into a large number of small segments, each of which is a nucleated cell, which are aggregated into a solid spherical mass, not much larger than the original ovum, and known as the *mulberry mass*. The cells are not similar throughout, for those at the surface are clearer and less granular than those which occupy the interior of the mass. According to v. Beneden's observations in the rabbit and bat, this difference in the appearance of the cells is traceable even in the first pair of daughter cells, one of which is larger and clearer than the other, which is darker and more granular (fig. 13, *a*).¹ The cells or segments which result from the division of each of these retain their respective characters, and since the clearer cells divide somewhat more rapidly than the darker ones, there are for a time at certain stages of the process of segmentation more of the clear cells; thus, at one stage there are eight clear cells, and only four darker ones, the latter having not yet undergone division, and later there are

¹ This statement is denied by Kölliker and other observers, who assert that there is no difference in the size and appearance of the first segments.

sixteen clear cells and only eight darker cells, for the same reason. Further, it is found that as the segmentation proceeds the clearer cells occupy the superficial part of the ovum and almost entirely enclose the granular cells which fill the interior (fig. 14, *a*).

The ovum next undergoes a rapid increase in size owing to the segregation of fluid between the clear superficial layer of cells and the enclosed granular segments, which thus become separated from one another except at one part (fig. 14, *b*). At the same time the superficial cells multiply, and, becoming flattened out like a pavement epithelium, form a membrane enclosing the contained fluid. The ovum is now a thin-walled transparent sac, occupied by fluid and enclosed by two membranes, one

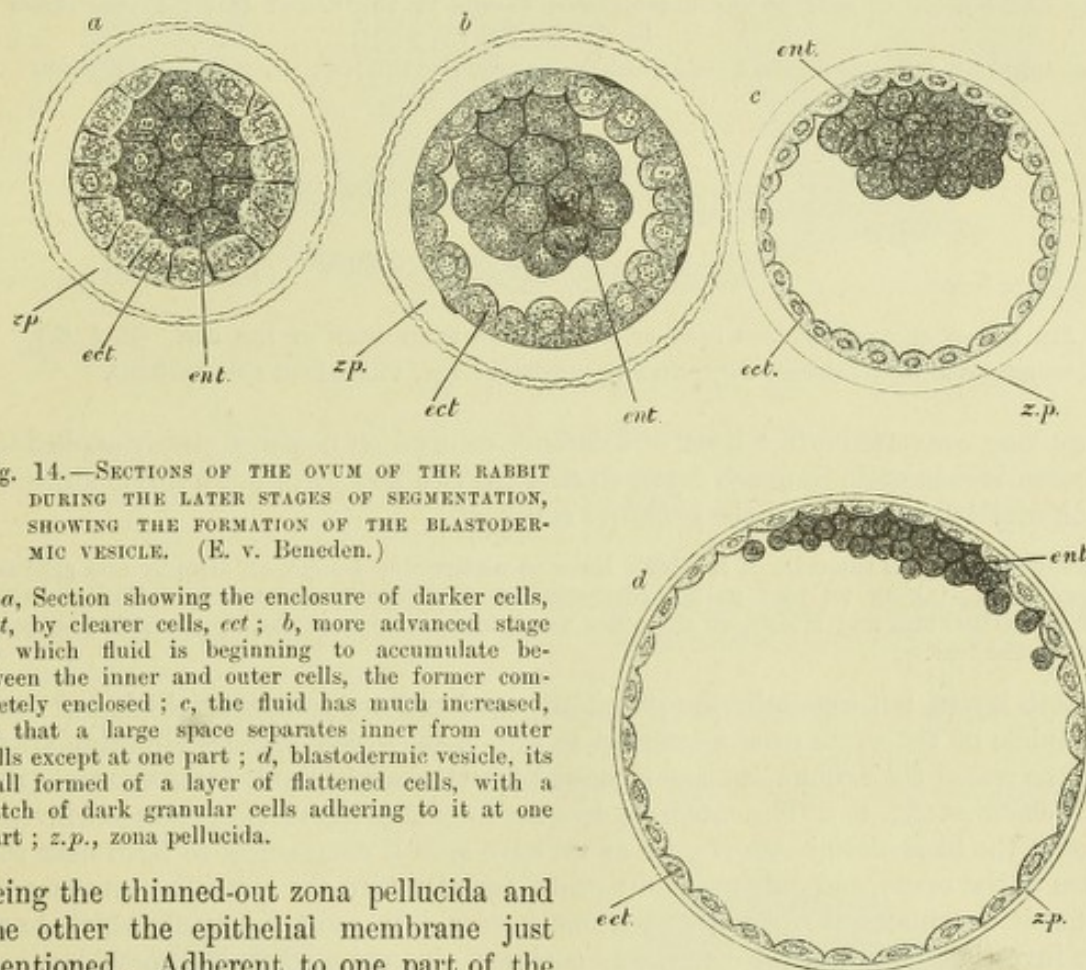


Fig. 14.—SECTIONS OF THE OVUM OF THE RABBIT DURING THE LATER STAGES OF SEGMENTATION, SHOWING THE FORMATION OF THE BLASTODERMIC VESICLE. (E. v. Beneden.)

a, Section showing the enclosure of darker cells, *ent*, by clearer cells, *ect*; *b*, more advanced stage in which fluid is beginning to accumulate between the inner and outer cells, the former completely enclosed; *c*, the fluid has much increased, so that a large space separates inner from outer cells except at one part; *d*, blastodermic vesicle, its wall formed of a layer of flattened cells, with a patch of dark granular cells adhering to it at one part; *z.p.*, zona pellucida.

being the thinned-out zona pellucida and the other the epithelial membrane just mentioned. Adherent to one part of the inner surface of this membrane is the little mass of dark granular cells which formerly occupied the whole interior of the mulberry mass, and these cells give to the part of the ovum where they occur a darker appearance, when it is viewed by transmitted light. At this stage of development the ovum has been termed the *blastodermic vesicle* (fig. 14, *c*, *d*), although the actual blastoderm is not yet formed.

Formation of the blastoderm.—Soon the granular cells are found to be no longer accumulated into a small mass but to be spreading out in the form of a lenticular patch over the inner surface of the vesicle. As this extension proceeds the innermost cells separate off as a distinct layer, the separation starting from the centre and progressing outwards.

A section through the middle of the ovum now shows three layers (fig. 15): an outer, which is the epithelial membrane of the blastodermic vesicle (Raubert's layer); an inner, which may be termed the *primitive entoderm*, from the fact that it becomes the innermost layer of the blastoderm, and an ill-defined middle stratum of somewhat

granular cells, which represents the remainder of the inner granular mass of the blastodermic vesicle after the separation of the subjacent layer. The three layers were believed by v. Beneden to represent the three permanent layers of the blastoderm. But it has been conclusively shown (by Rauber and Kölliker in the rabbit, and by Lieberkühn and Heape in the mole) that the middle stratum of this stage of development is not the permanent middle layer of the blastoderm, for it is

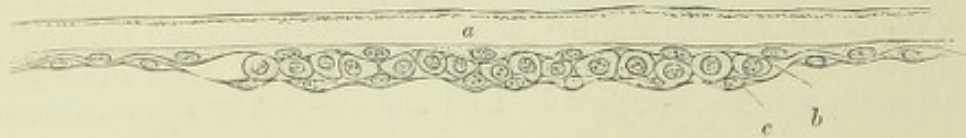

Fig. 15.—SECTION OF PART OF THE BLASTODERMIC VESICLE OF THE RABBIT AT SIX DAYS. (From E. van Beneden.)

a, upper layer (Rauber's cells) forming with *b*, the primitive ectoderm; *c*, primitive entoderm.

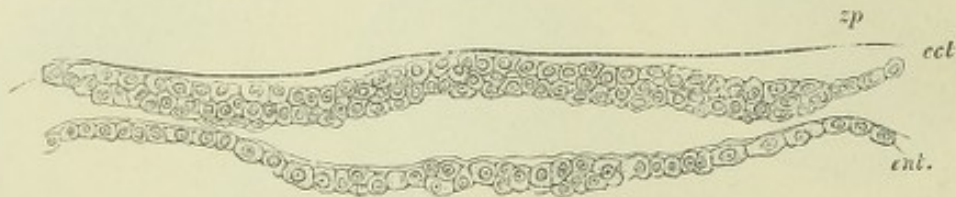


Fig. 16.—A SECTION THROUGH PART OF A BILAMINAR BLASTODERM OF THE CAT. (E. A. S.)

ect., primitive ectoderm; *ent.*, primitive entoderm; *z.p.*, thinned-out zona pellucida.

before long converted into a layer of columnar cells which becomes closely applied to, and soon blends with, Rauber's layer, so that the two now form but a single stratum, which may be denominated the *primitive ectoderm*.

Kölliker describes the cells of Rauber's layer as undergoing a kind of atrophy and gradual disappearance, taking no part in the formation of the primitive ectoderm. The observations of Lieberkühn and Heape, on the other hand, tend to support the view which has been given in the text.

Both layers, but especially the primitive ectoderm, are somewhat thickened near the middle of the ovum over a circular or oval area, which appears slightly darker than the rest of the ovum when this is viewed by transmitted light: it is known as the *embryonic area* (fig. 17). The entoderm does not for a long time form a complete investment to the blastodermic vesicle, for as we have seen it commences to form near the centre of the ovum, and only gradually grows round within the epithelial investment, so that it terminates peripherally by a free border. In most mammals which have been investigated, it has not completely enclosed the ovum when the mesoblast has begun to form, but in the cat its growth appears to progress more rapidly, so that, for a time, the blastodermic vesicle has two complete and distinct epithelial investments. Whether complete or incomplete, the two layers together constitute what is known as the *bilaminar blastoderm* (fig. 16), the formation of which marks a distinct stage in the development of all the metazoa.

But the blastoderm does not long remain in the bilaminar condition. In the rabbit and mole, and probably in most mammals, long before the primitive entoderm has completely extended itself around the ovum, there occurs a considerable thickening of the primitive ectoderm at one end—the posterior—of the somewhat oval embryonic area. This thickening has at first a crescentic form, with the concave edge looking forwards, and from the middle of this edge a longitudinal thickening extends for a certain distance towards the centre of the embryonic area. The thickening is produced by a proliferation of the cells of the primitive ectoderm, and its consequent downgrowth towards the primitive entoderm, and it is visible when the ovum is viewed from above by transmitted light, as a streak or shadow which is known as the *primitive*

streak (figs. 18, 19). Almost as soon as the primitive streak has become fully formed, it may be observed to be scored along its length, except at the anterior end which is that directed towards the centre of the embryonic area, by a narrow groove—the *primitive groove*. The proliferating primitive ectoderm comes into close relationship below this groove with the primitive entoderm, and the two may be partly or

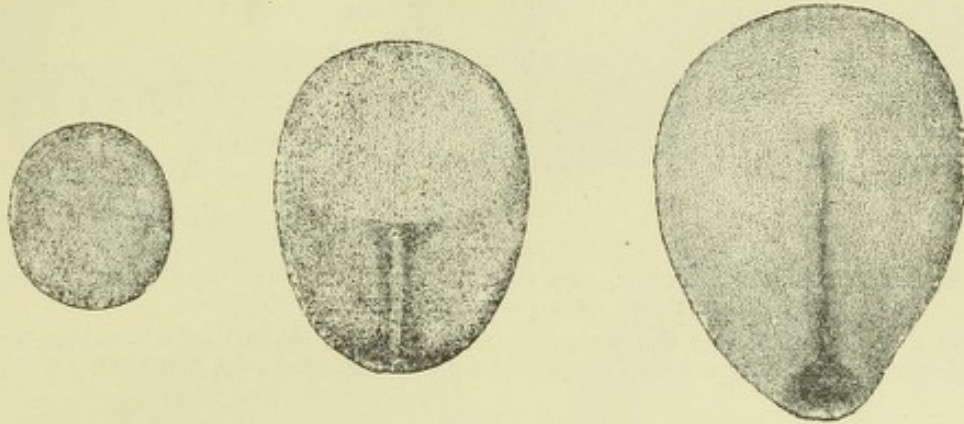


Fig. 17.—EMBRYONIC AREA OF MOLE IMMEDIATELY PRIOR TO APPEARANCE OF PRIMITIVE STREAK AND FORMED OF TWO LAYERS ONLY.

Fig. 18.—EMBRYONIC AREA OF THE MOLE SHOWING THE PRIMITIVE STREAK AND GROOVE ENDING POSTERIORLY IN A CRESCENTIC THICKENING.

The area is bilaminar in front, trilaminar in the posterior half.

Fig. 19.—A SOMEWHAT LATER STAGE IN WHICH THE PRIMITIVE STREAK REACHES TWO-THIRDS OF THE LENGTH OF THE EMBRYONIC AREA, AND ENDS BEHIND IN A KNOB OR THICKENING.

Figs. 17, 18, and 19 are copied from Heape. They are magnified 49 times.

entirely blended, but the union is closest at the anterior end of the primitive streak where a continuous column of cells unites the primitive ectoderm and entoderm, so that the two layers are here indistinguishable.

The proliferation of the cells of the primitive streak subsequently proceeds chiefly at the sides of the primitive groove, and the cells which are produced by this proliferation extend themselves laterally between the ectoderm and entoderm to form a

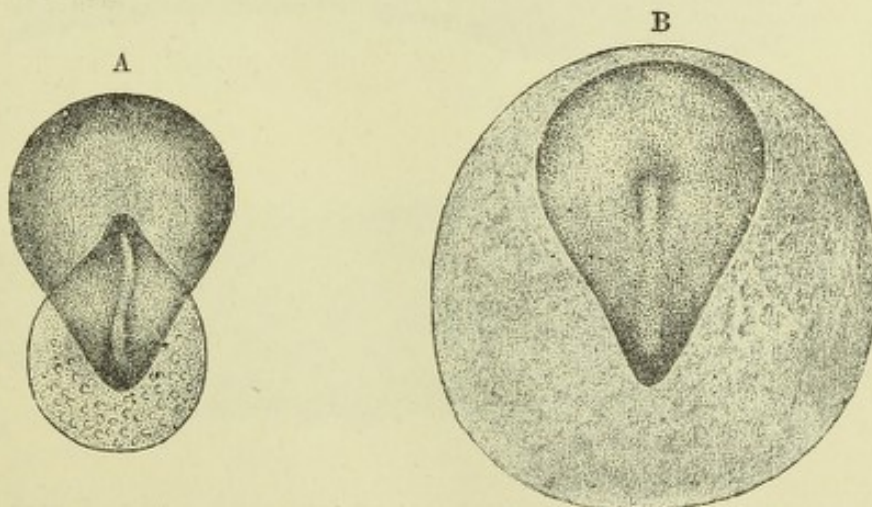


Fig. 20, A. and B.—VIEWS OF THE EMBRYONIC AREA OF THE RABBIT SHOWING TWO STAGES IN THE EXTENSION OF THE MESOBLAST. (Kölliker.)

In A. the mesoblast extends on either side of the primitive streak over the posterior part of the embryonic area and also behind the primitive streak beyond the limits of that area.

In B. the mesoblast extends over a circular area which surrounds the embryonic area. The embryonic area is also trilaminar, except in the middle line in front of the primitive streak.

third or intermediate layer. This is mainly derived, as was first pointed out by Kölliker, from the primitive ectoderm of the groove, but since in this situation the two primary layers become eventually more or less blended, it is probable that the primitive entoderm cells also take part in its formation, although this part is in the mammal evidently a subordinate one. It is further maintained by many embry-

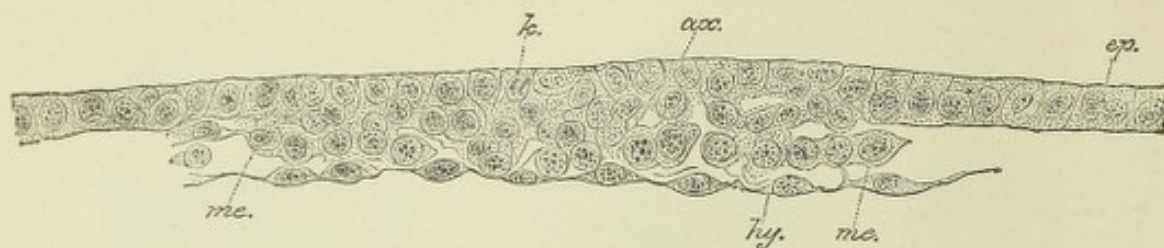


Fig. 21.—SECTION ACROSS THE POSTERIOR END OF THE EMBRYONIC AREA OF A RABBIT AT THE TIME OF THE FIRST SIGN OF A PRIMITIVE STREAK. (Kölliker.)

ep., epiblast; *ax.*, its axial part undergoing proliferation (this is shown by the karyokinetic figures, *k.*); *me.*, mesoblast becoming derived from the proliferating axial epiblast; *hy.*, hypoblast.

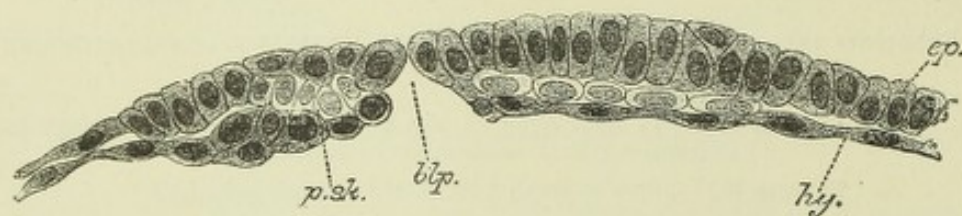


Fig. 22.—LONGITUDINAL SECTION THROUGH THE MIDDLE LINE OF PART OF AN EMBRYONIC AREA (MOLE) IN WHICH THE PRIMITIVE STREAK HAS BEGUN TO FORM. (Heape.)

The blastoderm is perforated in front of the (short) primitive streak (? blastopore, *blp.*); a few mesoblast cells are seen anterior to the perforation; *ep.*, epiblast; *hy.*, hypoblast; *p.sk.*, primitive streak.

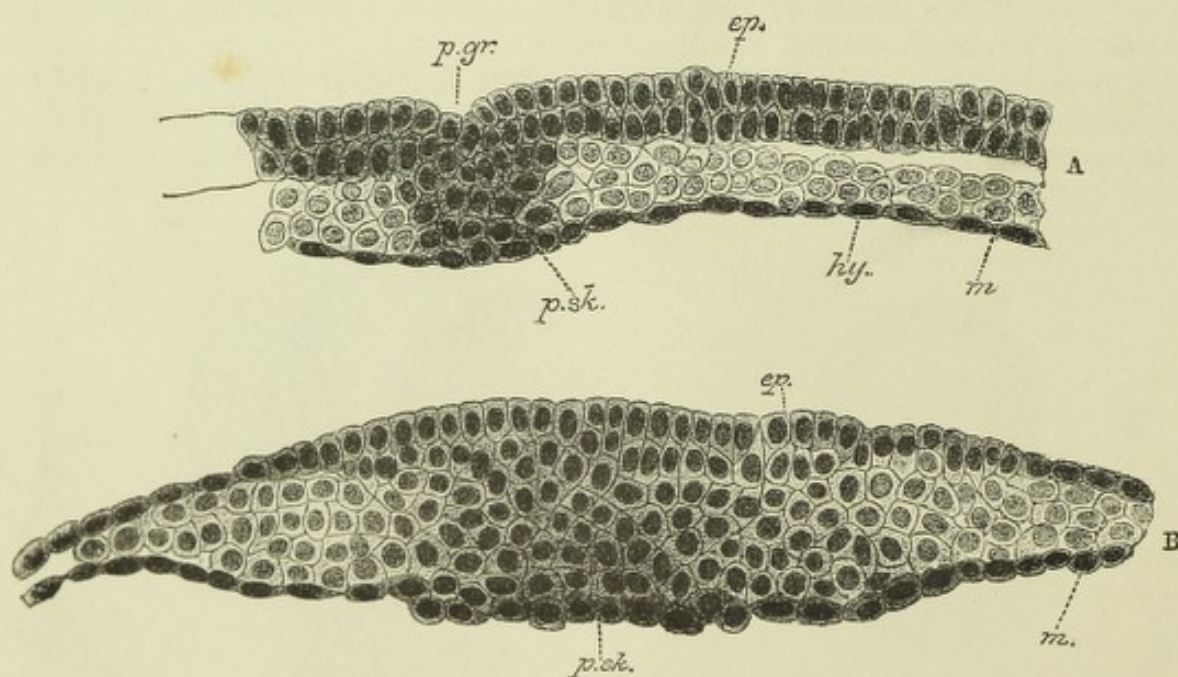


Fig. 23.—TWO SECTIONS ACROSS THE EMBRYONIC AREA OF A BLASTODERM AT THE STAGE SHOWN IN FIG. 19. (Heape.)

A. Section across the anterior end of the primitive streak and groove.

B. Section across the posterior enlargement of the primitive streak. The epiblast and hypoblast are seen to be united along the primitive streak, *p.sk.*; laterally the mesoblast, *m.*, the cells of which have grown out from the uniting column of axial cells, separates the two primary layers.

p.gr., primitive groove; *ep.*, epiblast; *hy.*, hypoblast; *m.*, mesoblast.

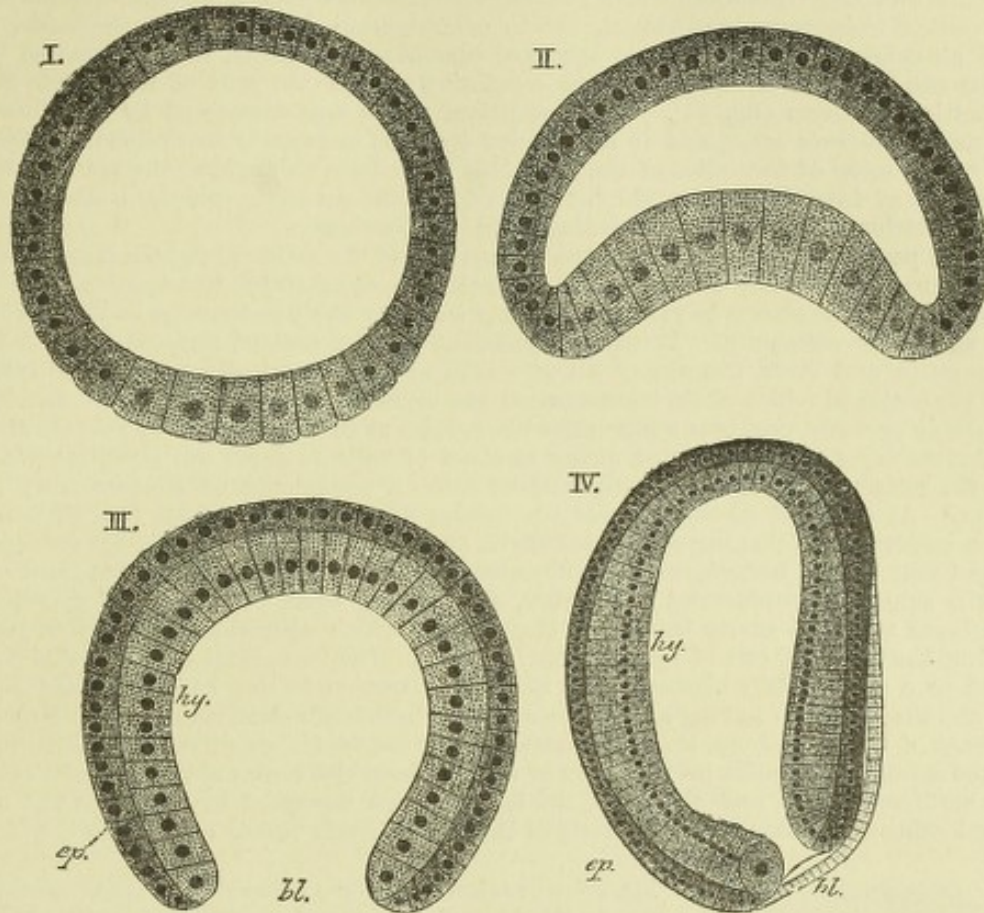


Fig. 24.—FOUR STAGES IN THE DEVELOPMENT OF AMPHIOXUS ILLUSTRATING THE FORMATION OF THE GASTRULA. (Hatschek.)

I. Spherical blastoderm; the cells at the lower pole are larger than the others, and filled with granules.

II. Invagination of the lower pole producing a cupping of the vesicle.

III. Completion of the invagination; the blastoderm is now bilaminar, and forms a cup with narrowed mouth, the blastopore, *bl*, and a double wall of epiblast, *ep*, and hypoblast, *hy* (or primitive ectoderm and primitive entoderm).

IV. The ovum is now elongated; the cavity of the gastrula forms a primitive alimentary canal, the orifice of which is the blastopore, which is directed dorsally. Extending from this along the dorsal surface (right in the figure) a shallow groove is seen in optical section: this is the rudiment of the nervous system.

ologists that cells from the lateral parts of both primary layers are added to the intermediate layer, and assist in its extension. According to the observations of Bonnet in the sheep, there is an addition to the middle layer from the peripheral (thickened) portion of the hypoblast; this has been long held to be the case with the blastoderm of the bird, and the cells thus derived (parablastic) have been considered to have the special function of forming the connective tissues and blood. Whether, however, this is actually so, must be regarded as at present undecided. However produced, the appearance of a middle layer causes the originally bilaminar blastoderm to be trilaminar, and its three layers have received the names of ectoderm, mesoderm, and entoderm, or epiblast, mesoblast, and hypoblast.

The gastrula condition of the vertebrate ovum.—It will be observed that in the mammal the two primary layers of the blastoderm, at least their principal part, are formed by a separation into two strata of the cells of the inner granular mass which occupies the interior of the ovum after segmentation. The bilaminar condition may therefore be said to result from a process of delamination in an originally simple mass or stratum. But in

Amphioxus amongst vertebrates,¹ and in many invertebrates with holoblastic (alecithal) ova, the bilaminar blastoderm is produced, not by delamination, but by the invagination of one pole of an originally simple hollow spherical blastodermic vesicle, the invaginated portion becoming the primitive entoderm and the remaining part of the wall of the vesicle forming the primitive ectoderm (fig. 24). This condition, which was discovered by Kowalewsky, is known as the *gastrula stage*, and it is regarded by most embryologists, following Haeckel, as typical of the mode of formation of the bilaminar blastoderm throughout the animal kingdom. The aperture of invagination by which the cavity of the entoderm communicates for a time with the exterior has been termed the *blastopore* (Lankester).

It is not possible in this account of the embryology of the mammal (which must necessarily be very short) to examine at any length the evidence upon which the opinion rests that a gastrula stage can be shown to exist at an early stage in the development of the meroblastic ova of the lower vertebrata. It will be sufficient for the present purpose to state that in fishes, reptiles, and birds, the ova of all of which are of a markedly meroblastic type, that part of the ovum in which alone segmentation has occurred, and in which active development subsequently proceeds, produces a bilaminar blastoderm as in the mammal by the separation off as a distinct layer of a lower or inner stratum of cells to form the primitive entoderm, whilst the remaining cells arrange themselves into an upper or outer stratum, the primitive ectoderm.² At one part of the circular blastoderm which has thus been formed there now occurs a crescentic thickening of the ectoderm, on the surface of which a pit or depression becomes formed by an invagination of the ectoderm. This pit extends inwards until it abuts against a subjacent entodermal thickening, and it may even penetrate the entoderm and communicate with the cavity below the blastoderm (which afterwards becomes in part converted into the posterior end of the alimentary canal). The invagination in question has been regarded as a rudimentary blastopore, its time of formation having become shifted to a later period, and the entoderm having already been formed by delamination altogether independently of, in place of resulting from, the invagination, as in the typical mode of gastrula formation.

In the mammal a similar invagination of the ectoderm also occurs at the posterior extremity of the embryonic area, and this invagination has been described by Heape in the mole as communicating for a time with the cavity of the blastodermic vesicle (fig. 22, *blp*), which sub-

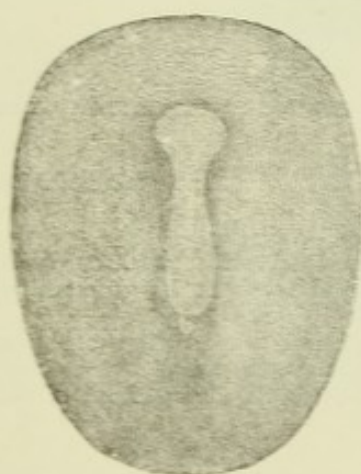


Fig. 25.—SURFACE VIEW OF AN EMBRYONIC AREA OF THE MOLE IN WHICH THE MEDULLARY GROOVE HAS BEGUN TO APPEAR IN FRONT OF THE PRIMITIVE STREAK. AT THE JUNCTION OF THE TWO A SMALL APERTURE IS SEEN: THIS IS THE DORSAL OPENING OF THE OBLIQUE NEURENTERIC CANAL. (Heape.)

sequently becomes converted in part into the alimentary canal. In birds and reptiles as well as mammals the invagination in question soon becomes extended forward along the middle line of the blastoderm as a linear groove (primitive groove), which indents an ectodermal thickening (primitive streak), and if the posterior invagination represents a blastopore, this groove must be looked upon as an extension of such blastopore, a view which derives support from the fact that there appears to be a tendency for the primitive groove, at least its anterior end, to penetrate to the entoderm, and thus to form here also a canal of communication between the cavity below the entoderm and the exterior. Such a canal is design-

nated "neurenteric," because the anterior end of the primitive streak and groove becomes eventually enclosed by the neural tube, and the canal then effects a (temporary) communication between the neural tube and the enteric canal.

Another important point of resemblance between this invagination and the blastopore of the typical gastrula is the fact that the middle layer of the trilaminar blastoderm begins to develop from the margins of the invagination. But in this respect again there is a difference, for whereas in the simplest and most typical forms, such as *Sagitta* amongst invertebrates, and *Amphioxus* amongst vertebrates, the middle layer (mesoblast) originates as a pair of hollow protrusions of the primitive entoderm (coelom-invaginations of Hertwig, figs. 28, 29); in mammals and birds it makes its first appearance in the form of solid outgrowths from the primitive streak.³

Other views concerning the gastrulation of vertebrates.—Kupffer regards the part

¹ Also, according to Hofmann, to some extent in elasmobranch fishes.

² No layer corresponding with Rauber's layer of the mammal is known to exist in lower vertebrates, unless that layer is to be regarded as the homologue of the external (corneous) stratum of the epiblast, which is found at a later stage in fishes and amphibia.

³ Rückert has described an imperfect form of coelom-invagination in elasmobranch fishes, and Hertwig in amphibia.

which has been above alluded to as invaginated ectoderm (primitive groove) as the homologue of part of the entoderm of more typical forms. If this view be correct, many of the difficulties in the way of regarding the aperture of the invagination as the blastopore, and in explaining the differences in the mode of origin of the mesoblast are removed; but, on the other hand, other difficulties are introduced, and the subject is left by no means clear.

Another view, which was formerly extensively held, regards the blastopore of the meroblastic vertebrate ovum as bounded by the thickened edge of the bilaminar blastoderm (Haeckel). According to this view, the cavity of the gastrula is entirely filled up by a mass of unsegmented or but partially segmented yolk, which also projects for a considerable distance through the blastopore, forming in fact the great mass of the ovum. The primitive groove is regarded as a linear prolongation of this thickened edge of the blastoderm towards the centre of the blastoderm (Balfour), so that the embryo, which develops in front of the primitive streak, thus comes to have a pseudo-central position in the blastoderm instead of developing altogether from its margin as in the lower vertebrata and in invertebrates. In conformity with this idea, it may be noted that at the thickened rim of the blastoderm of these meroblastic ova, the two primary layers are continuous with one another as in the primitive streak. In elasmobranchs an intermediate condition is observed, viz., a short groove, the margins of which are freely continuous with the margin of the blastoderm. If, as His and others have described (*vide infra*), the mesoblast is in part (vascular and connective tissue part) derived from the thickened rim of the blastoderm, this would furnish another point of resemblance between the primitive streak and that margin.

Ed. v. Beneden has promulgated an entirely different opinion as to the mammalian blastopore from those above described. He regards the condition of the ovum, after the completion of segmentation and before the formation of a blastodermic vesicle, as representing the gastrula stage, and looks upon the point where the granular inner mass of cells comes to the surface between the clear cells which form the outer investment as the blastopore (fig. 14, a). In conformity with this view he considers the layer of clear cells to represent the whole of the primitive ectoderm, and the granular inner mass the primitive entoderm. But since all the more recent observations upon early mammalian ova agree in affirming the formation of the three blastodermic layers from the granular inner mass, and that Rauber's layer either takes no part at all, or only a subordinate part in the formation of the ectoderm of the embryonic area, v. Beneden's view, in spite of the superficial resemblance of the ovum at this stage to certain gastrula forms, has not met with general acceptance from embryologists.

Inversion of the blastodermic layers in some mammals.—In the guinea-pig (Bischoff), rat and mouse (Fraser, Selenka), and in some other rodents, an inversion of the usual position of the blastodermic layers is found to occur, the epiblast being innermost, the hypoblast outermost. The foundation of this inversion is laid early by a process of invagination and formation of a central cavity in the mass of entomeres, so that when the blastoderm is differentiated, the innermost cells which are next the (secondary) cavity thus formed become the epiblast, and the outermost the hypoblast, the mesoblast subsequently forming between the two by proliferation of epiblast at the primitive groove, as in other mammals. (For details as to this process of invagination, the student is referred to the papers by Selenka.)

Historical.—The existence of several laminæ in the germinal substance of the egg was first suggested by C. F. Wolff in his celebrated work *Theoria Generationis*, published in 1759, and in his later Memoir *On the Development of the Intestine*, first published in Nov. Comment. Acad. Petropol. in 1767 and republished in German by J. F. Meckel in 1812. It is, however, to the researches of Pander, conducted under the direction of Döllinger of Würzburg, and published in 1817, and those of v. Baer (1826-1837), that we owe the first consistent attempt to connect the development of the several organs and systems of the embryo with the different constituent parts or layers of the blastoderm. Pander recognised a trilaminar structure of the blastoderm and distinguished the three layers composing it, in their order from above downwards, or from without inwards in the egg, as the serous, vascular, and mucous layers.

In 1850-54 a further important advance was made in the knowledge of the constitution of the blastodermic layers, by the discovery by Remak that the greater part of the middle layer soon after its formation comes to be divided into two laminæ, separated by a space which corresponds to the perivisceral cavity (*coelom*)—a fact which had been partially stated by von Baer. So marked a division of the middle layer and distinction of the parts which are afterwards developed from its two laminæ, has seemed sufficient to some authors to warrant the recognition of four distinct layers in the blastoderm; but it will be found on the whole more convenient to consider the fundamental layers as only three, to which, following the nomenclature of Foster and Balfour, the designations of epiblast, mesoblast, and hypoblast are applied, terms which are synonymous with those of ectoderm, mesoderm, and entoderm, employed by many authors.

The terms ectoderm and entoderm were first applied to the two fundamental layers, shown by Huxley in 1849 to constitute the whole body of coelenterates, and which were correctly regarded by him as homologous with the two layers of the bilaminar blastoderm, to which we

have applied the terms primitive ectoderm and primitive entoderm. Since the middle layer is developed from one or both of these primitive layers their permanent representatives are morphologically different, having lost the elements which go to form the middle layer, and it is therefore convenient to accentuate this distinction by the adoption of different terms to represent the permanent layers.

The generalisation that the formation of a bilaminar blastoderm is typically produced by the invagination of a hollow spherical unilaminar blastodermic vesicle is due to Haeckel, and was based largely upon the important researches of Kowalevsky, especially those on *Sagitta* and *Amphioxus*. The process of delamination which in some animals produces the two primary layers was originally regarded by Ray Lankester as the typical mode of formation, but is now generally admitted to be a secondary modification. Finally, it has been shown (Balfour, Lankester, R. and O. Hertwig), as is set forth below, that the coelom or body cavity is typically developed, not by a process of splitting of the mesoblast (although in some animals this may occur as a secondary modification), but as hollow protrusions from the primitive alimentary cavity, the cells which bound these protrusions forming the mesoblast. Thus from an originally single blastodermic layer by successive processes of invagination or folding, the three permanent laminae are ultimately produced.

Such folds may be regarded as formed mechanically by local hypertrophic multiplication of the cells of the laminae, an increased surface being thus found for the increased number of cells. In analogous manner the folds which accompany the formation and separation of the body and the development of the several organs, *e.g.*, the nervous system, alimentary canal, amnion, may also be regarded as resulting mechanically from cell-multiplication. This mechanical theory of development was first enunciated by Pander, and has of late years been applied extensively by several embryologists, notably by His (*Entwickl. d. Huhns*, 1868, and *Unsere Korperform*, 1874), and Rauber.

Characters of the blastodermic layers.—The three layers of the blastoderm show from the first distinctive characters (fig. 26). The outer layer, or epiblast, is epithelial in nature and consists of somewhat irregularly columnar cells closely set side

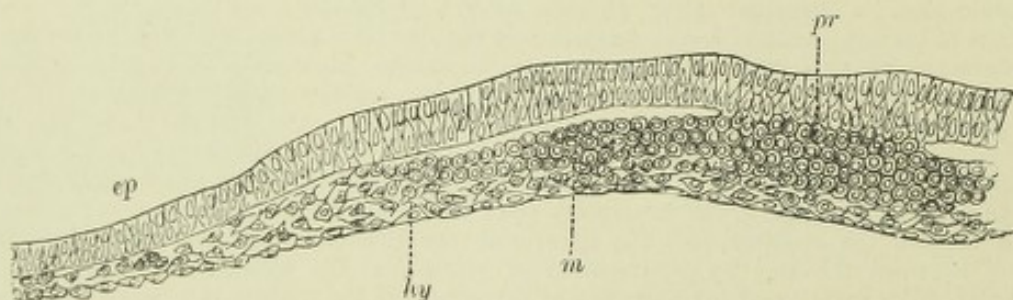


Fig. 26.—TRANSVERSE SECTION THROUGH THE FRONT END OF THE PRIMITIVE STREAK AND BLASTODERM OF THE CHICK. (From Balfour.)

pr, primitive groove; *m*, mesoblast; *ep*, epiblast; *hy*, hypoblast.

by side, forming a single stratum for the most part, except near the middle line, and becoming thinner and flatter towards the margins of the embryonic area.

The inner layer or hypoblast is also epithelial, but the cells are at first all flattened, and appear therefore quite thin and linear in sections of the blastoderm. At a later stage, the hypoblast cells become markedly columnar and enlarged, so that they considerably exceed the epiblast cells in size.

The middle layer, or mesoblast, which differs, as we have seen, in its mode of origin, being formed secondarily from one or both of the primary layers, also differs from them entirely in its appearance and structure. Instead of consisting of cells closely joined together into a continuous membrane after the manner of an epithelium, the mesoblast is at first composed of cells which are not thus closely arranged, but have, on the contrary, a considerable amount of intercellular fluid between them. They are most irregular in shape, and are often branched and united with one another, so that much of the mesoblast early resembles an embryonic connective tissue.

Before proceeding to describe the commencing development of the embryo it will be instructive to enumerate the parts which are formed respectively from the three blastodermic layers. The following is the relation given in tabular form :—

| | |
|---------------------|--|
| From the Epiblast. | <p>The whole of the nervous system, including not only the central organs (brain and spinal cord), but also the peripheral nerves and sympathetic.</p> <p>The epithelial structures of the organs of special sense.</p> <p>The epidermis and its appendages, including the hair and nails.</p> <p>The epithelium of all the glands opening upon the surface of the skin, including the mammary glands, the sweat glands, and the sebaceous glands.</p> <p>The muscular fibres of the sweat glands.</p> <p>The epithelium of the mouth (except that covering the tongue and the adjacent posterior part of the floor of the mouth, which is derived from hypoblast), and that of the glands opening into it. The enamel of the teeth.</p> <p>The epithelium of the nasal passages, of the adjacent upper part of the pharynx, and of all the cavities and glands opening into the nasal passages.</p> |
| From the Mesoblast. | <p>The urinary and generative organs (except the epithelium of the urinary bladder and urethra).</p> <p>All the voluntary and involuntary muscles of the body (except the muscular fibres of the sweat glands).</p> <p>The whole of the vascular and lymphatic system, including the serous membranes and spleen.</p> <p>The skeleton and all the connective tissue structures of the body.</p> |
| From the Hypoblast. | <p>The epithelium of the alimentary canal from the back of the mouth to the anus, and that of all the glands which open into this part of the alimentary tube.</p> <p>The epithelium of the Eustachian tube and tympanum.</p> <p>The epithelium of the bronchial tubes and air sacs of the lungs.</p> <p>The epithelium lining the vesicles of the thyroid body.</p> <p>The epithelial nests of the thymus.</p> <p>The epithelium of the urinary bladder and urethra.</p> |

PARABLAST THEORY OF HIS. MESENCHYME THEORY OF HERTWIG.

The observations of His upon the development of the blood and connective tissues in the bird led him to regard these tissues as originating, not from the mesoblast which in the chick grows out from the sides of the primitive groove, but from cells which,

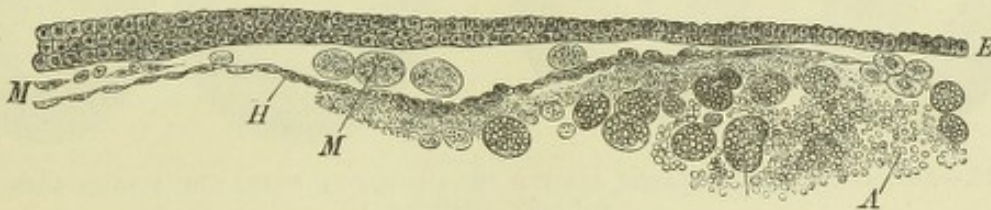

Fig. 27.—VERTICAL SECTION THROUGH THE BLASTODERM OF A HEN'S EGG TAKEN NEAR THE PERIPHERY. (Stricker.)

E, epiblast; *H*, hypoblast, passing at the periphery into an undifferentiated mass of yolk, *A*, containing large cells filled with yolk granules; *M* (towards the centre of the blastoderm), mesoblast; *M* (nearer the periphery), granular cells, apparently derived from *A*, and lying between the epiblast and hypoblast.

originating either in the yolk or in the thickened rim of the spreading blastoderm, wander in centripetally between the primary layers and fill up all the interstices of the centrifugally-growing true mesoblast. These in-wandering cells being derived, not like the other cells of the embryonic area from the more active primarily differentiated central parts of the blastoderm, but from the peripheral non-embryonic portion, were collectively named by His *parablast*, and the tissues (blood and blood-vessels, and all the connective tissues) supposed to be formed from them were termed *parablastic* (all the other tissues of the embryo being termed, in contra-distinction, *archiblastic*).

His's theory was enunciated as long ago as 1868, although he afterwards introduced into it certain modifications. For a considerable time it met with little acceptance, but of

late years it has obtained, in its modified form as above given, the adherence of many embryologists, and especially of R. and O. Hertwig, Kupffer, Kollmann, and Waldeyer. R. and O. Hertwig have given the name of *mesenchyme* to His's parablast, while retaining the designation of middle germinal layer or mesoderm for the rest of the mesoblast, from which it differs (1) in its structure, consisting of loosely arranged wandering cells, as distinguished from the epithelium-like lamellæ, of which according to their description the rest of the mesoderm is composed; (2) in its derivation, arising as separate cells from the entoderm instead of in the form of a coherent layer; and (3) in its further development and destination, giving origin to the connective tissues and blood-vessels, and perhaps to the plain muscular tissue, whereas the mesoderm proper gives origin to the skeletal muscles and to the epithelium of the serous cavities, and of the genital and urinary organs. They describe the true mesoderm as consisting of two epithelial lamellæ, which form distinct layers of the blastoderm, so that according to this view the complete blastoderm would consist of *four* layers (epiblast, outer or somatic mesoblast, inner or splanchnic mesoblast and hypoblast) besides the mesenchyme; to which must be added a median strand of cells set aside for the formation of the notochord.

It appears evident from the researches of Kowalevsky in *Sagitta* and *Amphioxus* that what is to be regarded as the typical origin of the mesoblast in Metazoa¹ takes the form of a pair of diverticula from the primitive archenteric cavity (fig. 28, Ia; fig. 29, I), which hollow diverticula become pinched off from the remainder of that cavity, and, their cavities becoming compressed laterally, are converted into the coelom or body-cavity (serous cavities of vertebrata), the two walls of this cavity on either side forming respectively the inner and outer mesodermic layers of R. and O. Hertwig. In *Sagitta*, the diverticula occur in the neighbourhood of the

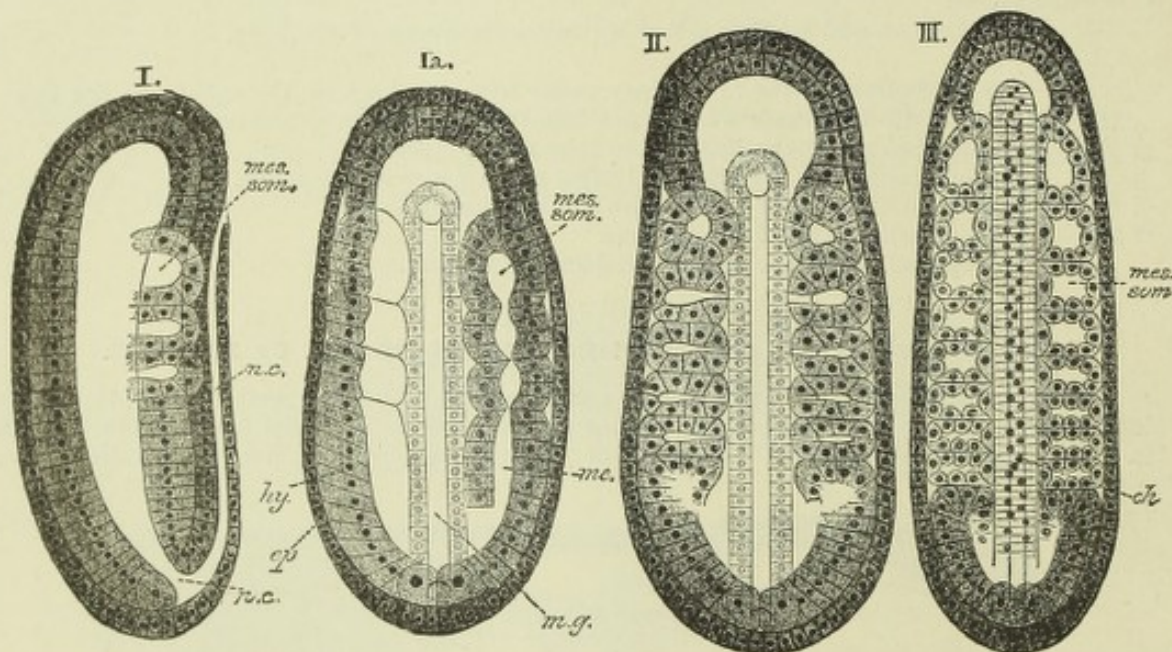


Fig. 28.—FORMATION OF MESOBLASTIC SOMITES IN AMPHIOXUS, SHOWN IN LONGITUDINAL OPTICAL SECTION. (Hatschek.)

Ia., dorsal view of an embryo in which the mesoblast is beginning to form as two longitudinal folds of the hypoblast which are becoming subdivided from before back by constrictions into separate somites. I., the same viewed in profile, showing the anterior three somites of one side, with their cavities in free communication with the enteric cavity. The neural canal, *n.c.*, is continued posteriorly by a neurenteric canal into the enteric cavity; *ep.*, epiblast; *hy.*, hypoblast. II., dorsal view of a more advanced embryo. The somites are more numerous and are completely separate. In all but the most anterior pair the communication with the enteric cavity is still seen. III., dorsal view at a still later stage. The somite cavities are now completely closed. The cellular rod, *ch.*, shown running along the middle of the embryo is the notochord.

blastopore, which is also the typical seat of origin of the mesoblast, but in *Amphioxus* they are formed by longitudinal folds of the wall of the archenteric cavity, which grow from before backwards, and become separated up into segments in their progress. In most vertebrates above *Amphioxus* the mesoblastic outgrowths are from the first solid, not hollow (although a split may early, and does eventually in any case, occur in them, the coelom being thus produced), nor do they originate so distinctly from the entoderm, but arise rather at the junction

¹ Except the Coelenterata which have only the two primary layers.

of this with ectoderm at the margin of the blastopore, and in the higher forms, especially mammals, may even be largely derived from ectoderm. It is nevertheless for many reasons probable that the origin in a pair of hollow diverticula, as above described, is to be looked upon as the typical one, and that as a solid outgrowth, subsequently becoming split or hollow, as a secondary modification.¹ It is questionable, however, whether there is so considerable a difference between the external and internal portions of the wall of the diverticulum that

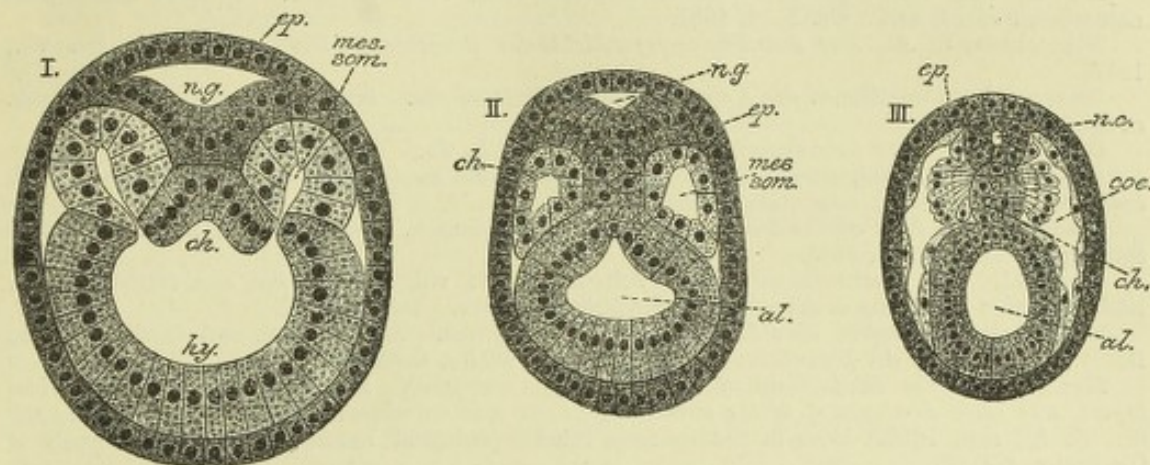


Fig. 29.—SECTIONS ACROSS AN AMPHIOXUS EMBRYO OF ABOUT THE STAGES SHOWN IN FIG. 28, I. TO III. (Hatschek.)

n.g., neural groove; n.c., neural canal; ch, rudiment of notochord; mes. som., mesoblastic somite. In I., its cavity is in free communication with the alimentary cavity; ep, epiblast; hy, hypoblast; al, alimentary cavity. In III. the cavity of the somite has extended on either side of the alimentary canal and forms a coelom, or body cavity (co).

these two plates of mesoblast should be regarded each one as of equal morphological importance with the epi- and hypoblast.

It may also be doubted whether the parablasic or mesenchyme elements are essentially different in their origin from the rest of the mesoblast.² In forms which are regarded as most typical, such as *Sagitta* and *Amphioxus*, they are not distinct in origin from that layer. In the simpler forms amongst the Craniata, as *Cyclostomata* and *Amphibia*, no origin distinct from the rest of the mesoblast has been described for these elements, nor has it been seen in mammals, in which, indeed, it is difficult to conceive an independent source for them. It is only in the highly modified meroblastic ova that appearances have been noted which have seemed to justify the ascribing a peripheral origin to the parablasic elements. But the evidence which has been hitherto adduced in favour of this view cannot be regarded as sufficient to justify its unconditional adoption, and it must be regarded as equally open to consideration whether the derivation from that part of the blastoderm which is most closely connected with the source of nutriment, viz., the yolk, of those elements which are to form the blood and blood-vessels, and otherwise to minister to the nutrition of the early embryo is not to be explained by the modified physiological conditions of these telolecithal ova.

RECENT LITERATURE.

Balfour, F. M., *On the structure and homologies of the germinal layers of the embryo*. Quart. Journ. Microsc. Sc., vol. xx., 1880.

Balfour, F. M. and F. Deighton, *A renewed study of the germinal layers of the chick*. Quart. Journ. Microsc. Scienc., vol. xxii., 1882.

Beneden, Ed. van, *Recherches sur l'embryologie des mammifères. La formation des feuillets chez le lapin*. Archiv. de biologie, t. i., 1880; *Sur l'évolution de la ligne primitive, la formation de la notocorde et du canal cordal chez les mammifères (lapin et murin)*. Bulletin de l'académie royale de Belgique. Ann. v., sér. iii., t. xii., 1886.

Beneden, Ed. van und Ch. Julin, *Observations sur la maturation, la fécondation et la segmentation de l'œuf chez les chiroptères*. Arch. de biol., t. i., 1880.

Bonnet, R., *Ueber den Primitivstreifen und die Chorda der Wiederkauer*. Sitzungsber. d. Gesellschaft f. Morphologie u. Physiologie zu München, 1886; *Beiträge zur Embryologie der Wiederkauer*. Arch. für Anat., 1884, 1889.

¹ R. and O. Hertwig, "Die Coelomtheorie," Jena, 1881.

² Cf. Balfour, "Comparative Embryology," vol. ii. pp. 296, 297.

- Boveri, T.**, Ueber Differenzirung der Zellkerne während der Furchung des Eies von *Ascaris megalocephala*. Anat. Anzeig., 1887.
- Bütschli, O.**, Beiträge zur Gastrulatheorie. Morpholog. Jahrbuch, Bd. ix., H. 3, 1884.
- Caldwell, W. H.**, The embryology of Monotremata and Marsupialia. Philosophical Trans., vol. clxxviii., 1888.
- Durham, H.**, Note on the presence of a neurenteric canal in *Rana*. Quarterly Journal of Microscopical Science, N. Ser., vol. 26, 1886.
- Duval, M.**, De la formation du blastoderme dans l'œuf d'oiseau. Annales des sciences naturelles, 6 sér. t. xviii., No. 1—3, 1884.
- Fleischmann, A.**, Zur Entwicklungsgeschichte der Raubthiere. Biolog. Centralbl., Bd. vii., 1887.
- Gasser, Der Parablast u. der Keimwall der Vogelkeimscheibe.** Sitzungsber. d. naturw. Gesellsch. zu Marburg, 1883.
- Gerlach, L.**, Ueber die entodermale Entstehung der Chorda. Biol. Centralbl., 1881.
- Giacomini, C.**, Sul canale neurenterico et sul canale anale nelle vesicole blastodermiche di coniglio. Giorn. della r. accademia di medic. di Torino, No. 4, 5, 1888.
- Haddon, A.**, Note on the blastodermic vesicle of mammals. Proceedings of the Royal Dublin Society, N. Ser., vol. iv., 1885.
- Haeckel, Die Gastræatheorie.** Jena Zeitschrift, Bd. viii.; Nachträge zur Gastræatheorie. Ibid., Bd. xi.; Ursprung u. Entwickl. d. thierischen Gewebe. Ibid., Bd. xi.
- Hatschek, B.**, Studien über Entwicklung des Amphioxus. Arbeiten a. d. zool. Instit. zu Wien, Bd. iv., 1881; Ueber die Entwicklung des Amphioxus. Biolog. Centralbl., Bd. vi., 1887.
- Heape, W.**, The development of the mole (*Talpa europæa*). The formation of the germinal layers, and early development of the medullary groove and notochord. Quart. Journ. of Microsc. Sc., N. S., xci., 1883. Also in Studies from the Morphological Laboratory in the University of Cambridge, vol. iii.
- Hensen, Ueber die Ableitung der Umkehr der Keimblätter des Meerschweinchens.** Verhandlungen des physiologischen Vereins in Kiel, 1881.
- Hertwig, O.**, Die Entwicklung des mittleren Keimblattes der Wirbelthiere. Jena Zeitschrift für Naturw., Bd. xvi., 1882.
- Hertwig, O. und R.**, Die Cölomtheorie. Versuch einer Erklärung des mittleren Keimblattes. Jena, 1881; Studien zur Blättertheorie. Jena, 1883.
- His, W.**, Der Keimwall des Hühnerkeims u. d. Entstehung der parablastischen Zellen. Zeitsch. f. Anat. u. Physiol., Anat. Abth., 1876; Die Lehre vom Binde-substanzkeim (Parablast), Rückblick nebst kritischer Besprechung einiger neuerer entwicklungsgeschichtlicher Arbeiten. Archiv für Anat. u. Physiol., Anatom. Abtheil., 1882.
- Hoffmann, C. K.**, Die Bildung des Mesoderms, die Anlage der Chorda dorsalis und die Entwicklung des Canalis neurentericus bei Vogelembryonen. Amsterdam, 1883.
- Hubrecht, A. A. W.**, Die erste Anlage des Hypoblastes bei den Säugethieren. Eine Erwiderung an Herrn Prof. Ed. van Beneden. Anatomischer Anzeiger., iii. Jahrg., No. 30, 1888.
- Johnson, Alice**, On the fate of the blastopore and the presence of a primitive streak in the Newt (*Triton cristatus*). Quart. Journ. of Microsc. Science, N. S., No. xvi., 1884.
- Keibel, F.**, Van Beneden's Blastoporus und die Rauber'sche Deckschicht. Anatomisch. Anz., 1887; Die Entwicklungsvorgänge am hinteren Ende des Meerschweinchenembryos. Arch. f. Anat. u. Physiol., Anat. Abth., H. 5 u. 6, 1888.
- Koller, C.**, Untersuchungen über die Blätterbildung im Hühnerkeim. Arch. f. mikr. Anat., 1881; Beiträge zur Kenntniss des Hühnerkeims im Beginne der Bebrütung. Wiener Sitzungsber., Bd. lxxx., 1881.
- Kölliker, Die Entwicklung der Keimblätter des Kaninchens.** Würzburg Festschrift. Leipzig, 1882; Die embryonalen Keimblätter u. d. Gewebe. Zeitschr. f. wiss. Zool. xl., 1884; Ueber die Nichtexistenz eines embryonalen Bindegewebskeims (Parablasts). Sitzungsber. d. phys. medic. Ges. zu Würzburg, 1884.
- Kollmann, J.**, Der Mesoblast und die Entwicklung der Gewebe bei Wirbelthieren. Biolog. Centralblatt, Bd. iii., 1884; Der Randwulst u. d. Ursprung d. Stützsubstanz. Arch. f. Anat. u. Physiol., Anat. Abth. 1884.
- Kowalevsky, Entwicklungsgeschichte der Sagitta.** St. Petersburg Memoirs, xvi., 1871; Entwicklungsgesch. d. Amphioxus, &c. Arch. f. mikr. Anat., Bd. xiii., 1877; Ueber die ersten Entwicklungsprozesse der Knochenfische. Zeitschr. f. wissenschaft. Zoologie, Bd. xliii., H. 3, 1886.
- Kupffer, C.**, Das Ei von *Arvicola arvalis* und die vermeintliche Umkehr der Keimblätter an demselben. Münchener Sitzungsberichte, H. 5, 1882; Die Gastrulation an den meroblastischen Eiern der Wirbelthiere und die Bedeutung des Primitivstreifs. Archiv f. Anat. und Physiol., Anat. Abtheil., 1882; Ue. d. Canalis neurentericus der Wirbelthiere. Sitzungsberichte der Gesellsch. f. Morphol. u. Physiologie zu München, 1887.
- Lankester, On the primitive cell-layers of the embryo, &c.** Annals and Mag. of Nat. Hist., xi., 1873; Notes on embryology and classification. Quarterly Journ. of Micr. Science, xvii., 1877.
- Mitsukuri, K., and Ishikawa, C.** On the formation of the germinal layers in *Chelonia*. Journal of the College of Science, Imperial University, Japan, vol. i., 1888.
- Morgan, Notes on the fate of the amphibian blastopore.** John Hopkins University Circulars, 1889.
- Perényi, I.**, Die Entwickl. der Keimblätter u. d. Chorda in neuer Beleuchtung, Anat. Anzeiger, 4.
- Platt, Studies on the primitive axial segmentation of the chick.** Bulletin of the Zool. Museum at Harvard College, 1889.
- Rabl, C.**, Ueber die Bildung des Mesoderms. Anatomischer Anzeiger, iii. Jahrg., No. 23—25, 1888.

Rauber, *Ueber d. Ursprung des Blutes u. der Bindesubstanzen*. Sitzungsab. d. Naturf. Gesellsch. zu Leipzig, 1877; *Die Entwicklung der Gewebe des Säugethierkörpers und die histologischen Systeme*. Ber. der Naturf. Ges. zu Leipzig, 1883.

Ravn, **E.**, *Ueber die mesodermfreie Stelle in der Keimscheibe des Hühnerembryo*. Archiv f. Anatomie u. Physiologie, Anat. Abth., 1886.

Repiachoff, **W.**, *Bemerkungen über die Keimblätter der Wirbelthiere*. Zool. Anzeiger, vi., 1883.

Romiti, **G.**, *Sur l'origine du mésoderme et ses rapports avec le vitellus*. Arch. ital. de biologie, t. ii., 1882.

Roux, **W.**, *Beiträge zur Entwicklungsmechanik des Embryo. Ueber die künstliche Hervorbringung halber Embryonen durch eine der beiden ersten Furchungskugeln, &c.* Virchow's Archiv, Bd. cxiv., 1888.

Rückert, *Ueber die Gastrulation der Selachier*. Biologisches Centralblatt, Bd. vi.

Ryder, *The inversion of the blastodermic layers in Hesperomys*. American Naturalist, vol. xxi.

Schanz, **F.**, *Das Schicksal des Blastoporus bei den Amphibien*. Jenaische Zeitschr. f. Naturwissensch., Bd. xiv., 1887.

Selenka, **Emil**, *Keimblätter und Primitivorgane der Maus*. Wiesbaden, 1883; *Die Blätterumkehrung im Ei der Nagethiere*. Wiesbaden, 1884; *Ueber die Gastrulation der Knochenfische und Amnioten*. Biolog. Centralbl., 1887.

Shiple, **A. E.**, *On the formation of the mesoblast, and the persistence of the blastopore in the lamprey*. Proceedings of the Royal Society, 1886; *On some points in the Development of Petromyzon fluviatilis*. Quarterly Journal of Micros. Science, No. 107, 1887.

Solger, *Studien z. Entwicklungsgesch. des Coeloms u. des Coelomepithels der Amphibien*. Morph. Jahrb., x.

Spee, **F.**, *Beitrag zur Entwicklungsgeschichte der früheren Stadien des Meerschweinchens bis zur Vollendung der Keimblase*. Arch. für Anat. u. Physiol., Anat. Abth., Heft. i. u. ii., 1883.

Spencer, *On the fate of the blastopore in Rana temporaria*. Zool. Anzeiger, 1885.

Uskow, **N.**, *Die Blutgefäßkeime u. deren Entwicklung bei einem Hühnerembryo*, Mém. de l'acad. de St. Petersb., xxxv., 1888.

Waldeyer, **W.**, *Archiblast und Parablast*. Arch. f. mikr. Anat. 1883; *Die neueren Forschungen im gebiet der Keimblattlehre*. Berliner klinische Wochenschrift, No. 17, 1885.

Wolff, **W.**, *Die beiden Keimblätter und der Mittelkeim*. Archiv f. mikroskopische Anatomie, Bd. xxviii., H. 4, 1886.

Zumstein, **J. J.**, *Ueber das mesoderm der Vogelkeimscheibe*, Dissert., Bern, 1887.

EARLY CHANGES IN THE BLASTODERM, RESULTING IN THE FORMATION OF THE EMBRYO.

FIRST APPEARANCE OF THE EMBRYO; FORMATION OF THE NEURAL GROOVE AND MESOBLASTIC SOMITES.

Neural canal.—The blastoderm in mammals, as we have seen, eventually completely encloses the cavity of the ovum, and even in the large telolecithal ovum of the bird, it gradually extends so as to cover a large part of the yolk. But only a small portion of this membrane takes part in the formation of the body of the embryo, that portion namely which lies immediately in front of the primitive groove, and it is here that what may be regarded as the first trace of the embryo makes its appearance—very soon after the outgrowth of mesoblast from the sides of that

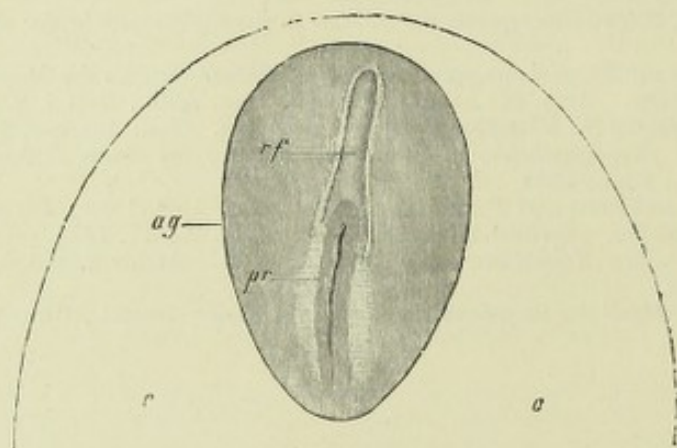


Fig. 30.—EMBRYONIC AREA, WITH OUTLINE OF PART OF THE VASCULAR AREA, FROM A RABBIT'S OVUM OF SEVEN DAYS. $\frac{25}{1}$. (From Kölliker.)

oo, vascular area ; ag, embryonic area ; pr, primitive streak and groove ; rf, medullary groove.

groove—in the form of a shallow furrow (fig. 30, *rf*), wide behind where it embraces the anterior end of the primitive streak, and at first narrow in front, and bounded on either side and anteriorly by a fold of epiblast ; which folds, in fact,

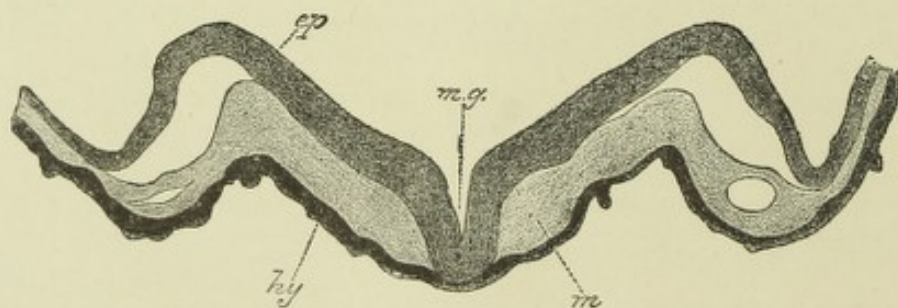


Fig. 31.—SECTION ACROSS THE ANTERIOR PART OF THE MEDULLARY GROOVE OF AN EARLY EMBRYO OF THE GUINEA PIG. (E. A. S.)

ep, folds of epiblast rising up on either side of the middle line, and thus bounding the medullary groove ; *mg*, middle of medullary groove ; *hy*, hypoblast, which is in contact with the medullary epiblast at the middle of the groove, but is elsewhere separated from it by mesoblast, *mc*, which has burrowed forwards between the two primary layers. A cleft is seen in the mesoblast on either side ; this is the commencement of the anterior part of the cœlom.

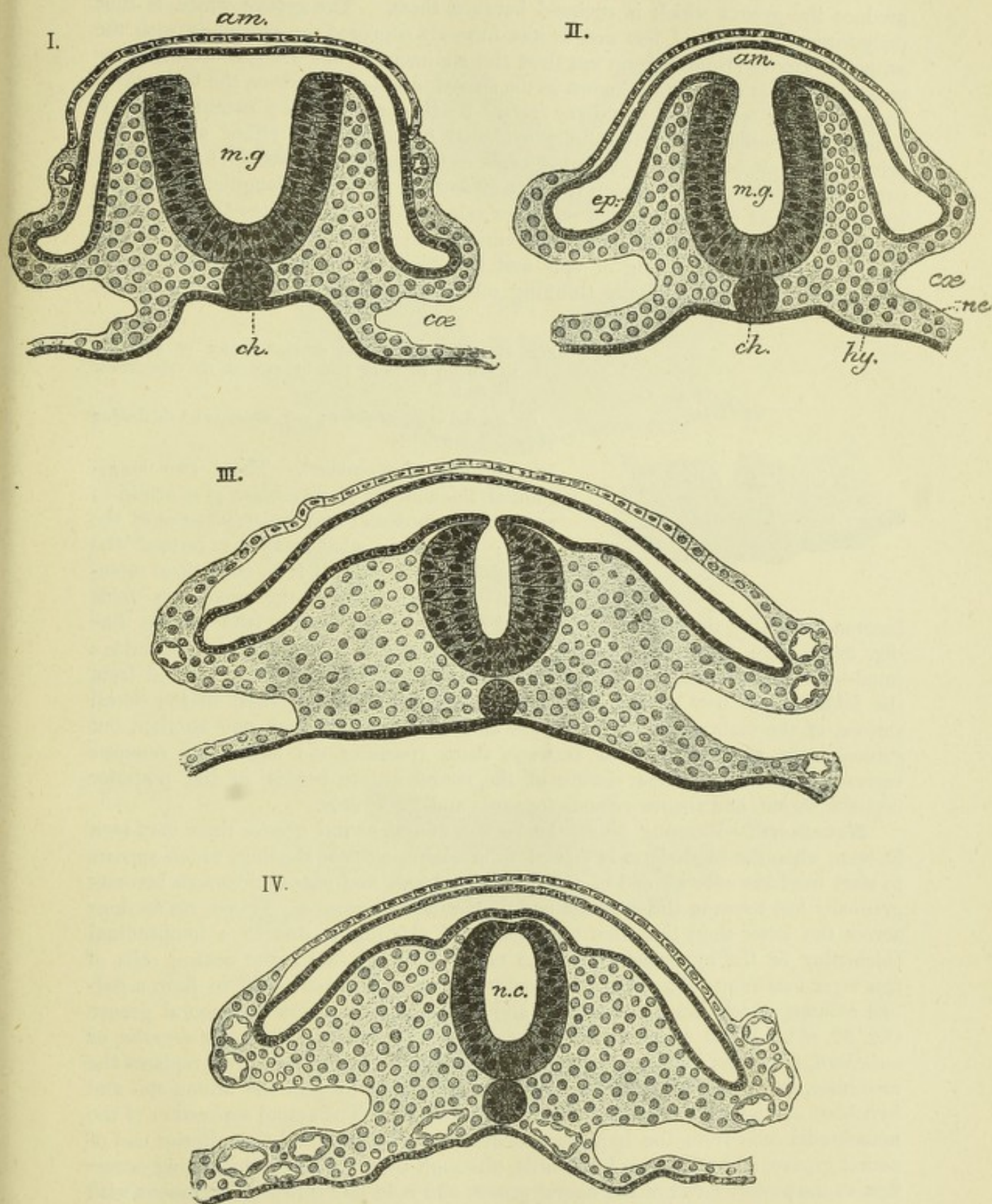


Fig. 32.—SECTIONS SHOWING STAGES IN THE CONVERSION OF THE MEDULLARY GROOVE INTO THE NEURAL CANAL. FROM THE TAIL END OF AN EMBRYO OF THE CAT. (K. A. S.)

ep, me, hy, epiblast, mesoblast, and hypoblast; *m.g.*, medullary groove; *n.c.* (in IV.), neural canal; *ch*, notochord; *coe*, coelom; *am*, tail fold of the amnion.

produce the groove which is enclosed between them. The groove which is thus early formed in front of, but not, as was formerly supposed, in continuity with the primitive groove (Dursy), is no less than the rudiment of the whole central nervous system, and it is accordingly known as the *neural* or *medullary groove*, the folds which bound it being termed the *medullary folds*. By the time that the neural groove is formed, the mesoblast has generally extended forwards from either side of the primitive streak, burrowing between the epi- and hypoblast, and as the folds become developed, this mesoblast fills up the space below the epiblast, triangular in section, which each fold encloses, so that on either side of the neural groove there is now a longitudinal thickening of mesoblast, entirely separated from its fellow of the opposite side by the meeting of epi- and hypoblast at the bottom of the neural groove (fig. 31), and gradually thinning off laterally into what is known as the

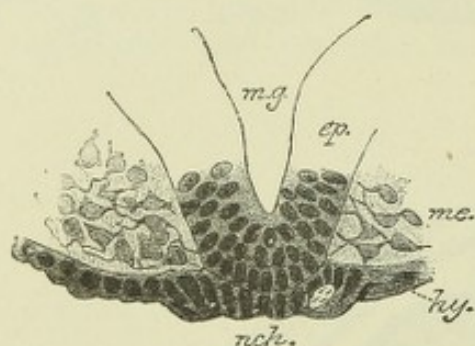


Fig. 33.—MIDDLE OF THE SECTION SHOWN IN FIG. 31, MAGNIFIED TO SHOW THE DETAILS OF ITS STRUCTURE. (E. A. S.)

ep, *me*, *hy*, *m.g.*, as above; *nch*, notochordal thickening of median hypoblast.

lateral plate of mesoblast. These two longitudinal thickenings of mesoblast give origin to most of the muscular and skeletal tissues of the body; they form what may be termed the *paraxial* as distinguished from the *lateral* mesoblast. Somewhat later the medullary folds

become bent over the neural groove, and meet one another in the middle line (fig. 32). Here they blend together, and the groove becomes converted into a canal—the *neural canal*. Of the two layers of epiblast which are formed from the folds, one is now the roof of the canal, the other is the epiblast of the dorsal surface of the embryo. The layers are at first in contact with one another, but subsequently mesoblast passes between them (forming the *membrana reuniens superior* of Remak). The closure of the neural groove begins in the posterior cephalic region, and thence extends forwards and backwards.

Notochord.—Running along the bottom of the neural groove there may soon be seen, when the blastoderm is viewed from above, a linear shading, which appears to start from the anterior end of the primitive streak and passing forwards becomes gradually lost towards the anterior end of the neural groove. Transverse sections across the latter show that this appearance of shading is due to a longitudinal thickening of the hypoblast along the middle line (fig. 33); the central cells of this layer becoming enlarged and gradually separating themselves off to form a rod-like column, which lies between epi- and hypoblast just below the neural groove (fig. 32, *ch*). When so separated, the column is known as the *chorda dorsalis*, or *notochord*, a structure which, along the middle line of the early embryo, replaces the mesoblast, and which is at first, as before said, continuous with the united epi- and hypoblast at the anterior end of the primitive streak. The actual separation of the notochordal cells from the hypoblast occurs first a little behind the anterior end of neural groove, and progresses backwards, although the hypoblastic thickening occurs first at the posterior end of the neural groove and is in fact directly continuous with the united column of epiblast and hypoblast which forms the anterior end of the primitive streak. The neurenteric canal passes through the thickened posterior extremity of the notochord, where this is continuous with the anterior end of the primitive streak (see fig. 34). It is continued in mammals a short distance along the notochord as a canal (prolonged forwards into a groove) (fig. 34, 5), which has been

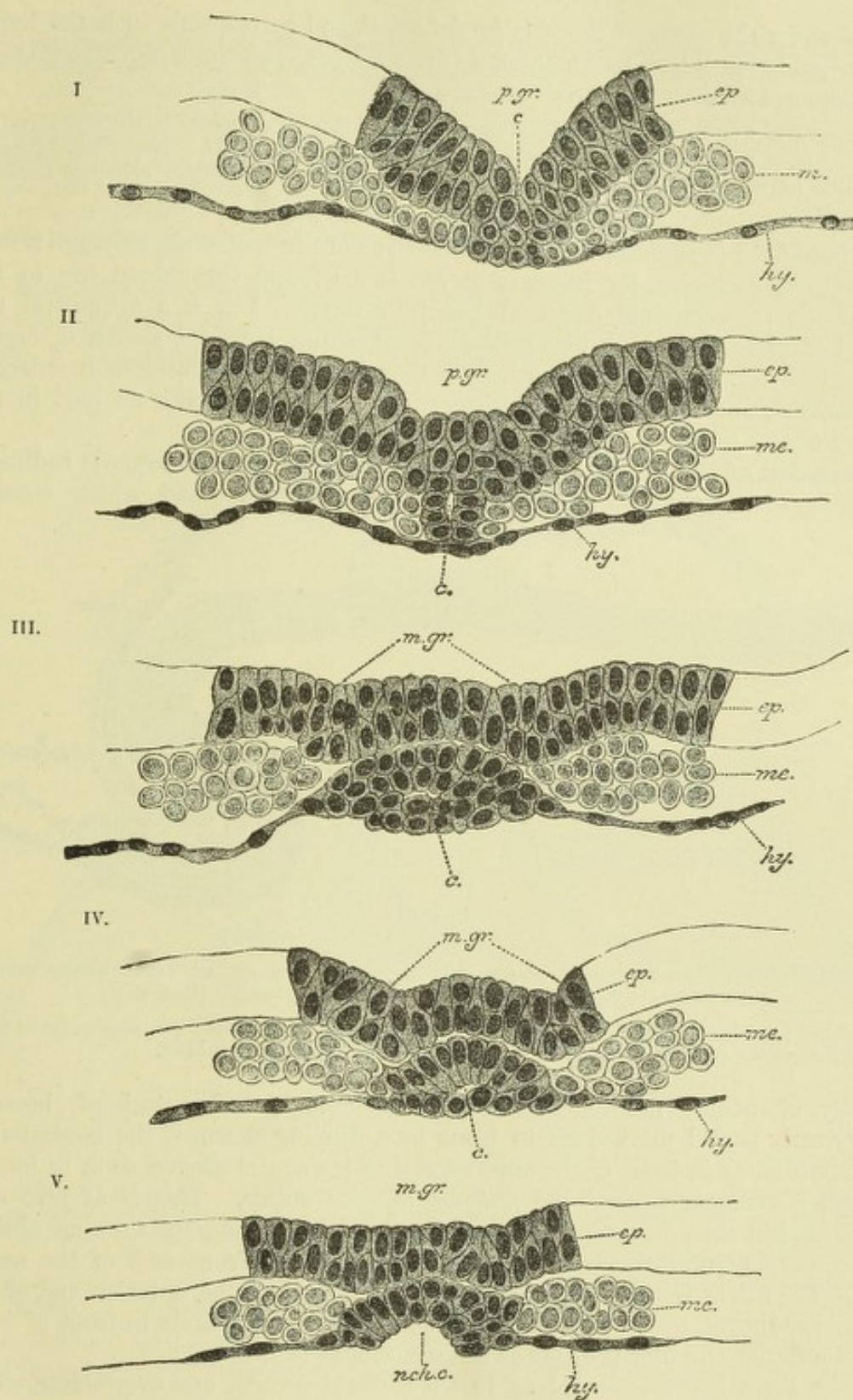


Fig. 34.—A SERIES OF TRANSVERSE SECTIONS THROUGH THE NEURENTERIC AND NOTOCHORDAL CANAL OF A MOLE EMBRYO. (Heape.)

The embryo was slightly more advanced than the one represented in Fig. 25. The dorsal opening is shown in I., continued into the primitive groove; the canal passes thence through the column of cells which unites the epiblast and hypoblast at the front of the primitive streak (II.), into the notochordal thickening of the hypoblast (III.), along which it extends for some distance (IV.), and eventually opens ventrally (V.) into a median groove, which is formed in the notochordal thickening (n.ch.c.)

ep, me, hy, epiblast, mesoblast, hypoblast; *p.gr.* (in I. and II.), primitive groove; *c*, neurenteric or notochordal canal; *m.gr.* (in III., IV., and V.), medullary groove.

described under the name of the *notochordal canal*, and corresponds with the hypoblastic invagination, which in *Amphioxus* (fig. 29, I., *ch*) also forms the first stage in the development of the notochord.

A flattening out and even eventually a duplication of this canal occurs in the chick and in various mammals at a somewhat later stage than that given in fig. 34. According to Spee, its cleft-like cavity may pass laterally into the commencing mesoblastic cleavage (coelom-invagination?).

The notochord is essentially an embryonic structure in mammals, although it does not completely disappear, for traces of it are to be found throughout life in the centre of the intervertebral discs. When fully developed it is a cylindrical rod composed of clear epithelium-like cells, enclosed within a special sheath of homogeneous substance. These cells, although they may become considerably enlarged and vacuolated, undergo no marked histogenetic change and take no part in the formation of any tissue or organ of the adult.

Separation of the embryo from the blastoderm.—The embryonic rudiment which thus first makes its appearance in the blastoderm, and which consists

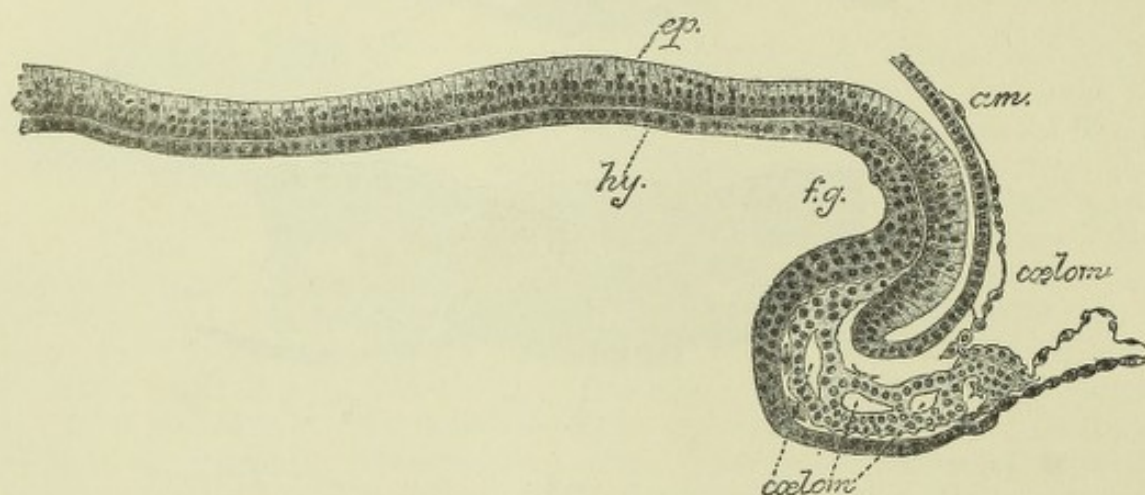


Fig. 35.—MESIAL SAGITTAL SECTION THROUGH THE ANTERIOR END OF AN EARLY SHEEP EMBRYO SHOWING THE COMMENCING FORMATION OF THE FORE-GUT. (Bonnet.)

ep., epiblast; *hy.*, hypoblast; *f.g.*, foregut, formed by folding over of layers; *am.*, amnion (head fold). Below the foregut the cephalic coelom is becoming formed as clefts in the mesoblast.

essentially of neural groove, mesoblastic thickenings, and notochord, becomes at a very early period marked off in front by a dipping down of the blastodermic layers immediately in front of the anterior end of the neural groove, so as to form a transverse curvilinear sulcus—the *anterior limiting sulcus*. This is at first wide and shallow, but soon deepens and narrows, and takes at the same time an oblique direction, curving downwards and backwards under the front end of the neural groove. The sulcus is really due to a growth forwards of the anterior end of the embryonic rudiment, over the part of the blastoderm immediately in front of it, so that this anterior end now projects as a distinct head (fig. 35).

All the three layers are involved in the forward growth and overfolding which produces the head, so that a prolongation from the blastodermic cavity, which is of course lined by hypoblast, becomes included in the head, and the anterior part of the primitive alimentary canal, or *fore-gut* (*f.g.*) is thereby produced. Formed in this way its front end is necessarily blind, and for a long while there is no mouth nor any communication between the fore-gut and the exterior of the embryo. The mouth becomes formed later by invagination from the exterior.

In the rabbit, and also in the chick, the blastoderm at this time is still bilaminar in and near the middle line in front of the embryo, for the growth of the mesoblast has not yet

extended to this part. The head end of the embryo grows forward over this bilaminar portion, and since the embryo, as it becomes differentiated, tends to sink below the general surface of the blastoderm, the head which now overlies the bilaminar part produces a depression of this part towards the interior of the vesicle, so that the head of the embryo becomes enclosed by the bilaminar wall of the depression (fig. 36). The enclosing membrane, which is well marked in the rabbit, has been termed by v. Beneden the *pro-amnion*: by an extension of mesoblast and of the mesoblastic cleavage between its layers, it afterwards becomes split into somatopleure and splanchnopleure, and the former becomes continuous with the true amnion (see p. 42).

The stage of pro-amnion, if it exists at all, must disappear very early in the human embryo.

Soon after the appearance of the anterior limiting sulcus, two lateral limiting sulci are seen running external and parallel to the medullary folds; these lateral sulci, as they dip down, mark off the body of the embryo from the rest of the

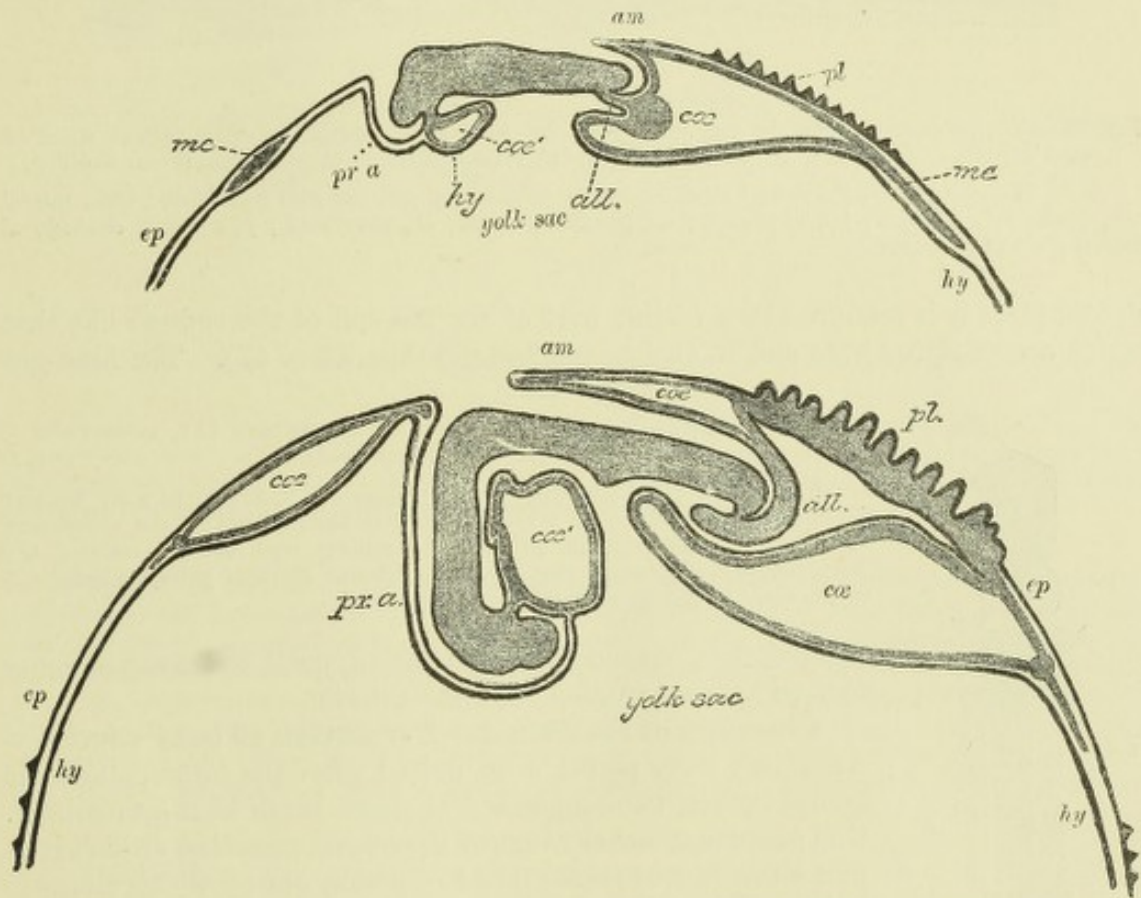


Fig. 36.—DIAGRAMMATIC LONGITUDINAL SECTIONS THROUGH THE EMBRYO OF THE RABBIT. THE SECTIONS SHOW THE MANNER IN WHICH THE PRO-AMNION IS FORMED BY A DIPPING DOWN OF THE HEAD AND ANTERIOR PART OF THE BODY INTO A DEPRESSION OF THE BLASTODERM, WHICH AT THIS PART IS FORMED OF EPIBLAST AND HYPOBLAST ONLY. THE DIAGRAMS ALSO ILLUSTRATE THE MODE OF FORMATION OF THE ALLANTOIS AND OF THE TAILFOLD OF THE AMNION IN THIS ANIMAL. (v. Beneden and Julin.)

ep, epiblast; *hy*, hypoblast; *mc*, mesoblast; *cc*, parts of the coelom; *cc'*, pericardial coelom, the heart not being represented; *pr.a.*, pro-amnion; *pl*, seat of formation of the placenta; *all.*, allantois; *am*, amnion.

blastoderm, but they do not for some time progress far in development, the middle part of the future alimentary tract long remaining in free continuity with the cavity of the blastodermic vesicle (fig. 45, and fig. 49, *d*), but becoming gradually more pinched off from it. That part of the cavity of the original blastodermic vesicle which does not form a part of the alimentary canal, but remains connected with it by a wide neck of communication, is known as the *yolk-sac*. At a later stage, when the body walls are formed, and the yolk-sac, relatively greatly diminished in size, lies altogether outside the body of the foetus, it is merely connected by a long narrow duct, which runs

along the umbilical cord, with the intestine. This is termed the *umbilical duct*, and the yolk-sac itself has received (in mammals) the name of *umbilical vesicle* (figs. 50, 51).

Lastly, at the tail end of the embryo a *hind-gut* is produced. In the human embryo this appears to be formed by a protrusion from the posterior blind end of the enteric groove, and after the formation of the allantoic tube, but in most mammals

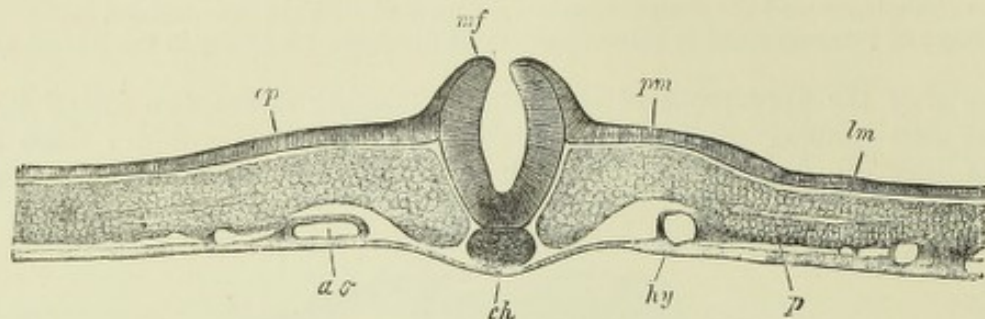


Fig. 37.—TRANSVERSE SECTION OF THE TAIL END OF AN EMBRYO CHICK OF THE LATTER HALF OF THE SECOND DAY, AT THE PLACE WHERE THE VERTEBRAL SOMITES CEASE. ⁸³. (From Kölliker.)

m.f., medullary folds, the neural canal beginning to close; *p.m.*, paraxial mesoblast; *l.m.*, lateral mesoblast; *ep.*, epiblast; *hy*, hypoblast; *ao*, primitive aorta; *ch*, notochord; *p*, celomic cleavage of lateral plate of mesoblast.

and in birds it is produced by a folding over of the tail end of the embryo like that which occurs at the head end to enclose the fore-gut (figs. 45 to 47). The hind-gut

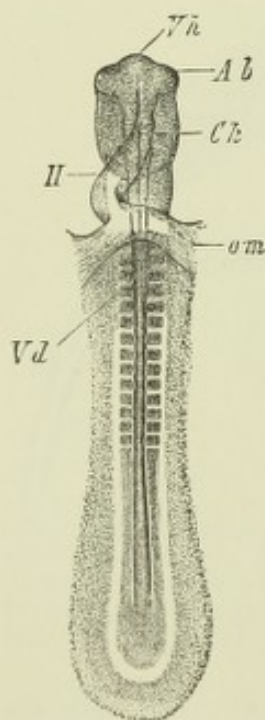


Fig. 38.—EMBRYO CHICK AT THE END OF THE SECOND DAY, SEEN FROM BELOW. ¹². (From Kölliker.)

Vh, forebrain; *Ab*, primary ocular vesicles; *Ch*, notochord; *H*, tubular heart; *om*, vitelline veins; *Vd*, entrance to the forepart of the alimentary canal within the cephalic fold; in the middle part of the embryo, the protovertebral somites are seen (to the number of thirteen pairs) on each side of the canal of the spinal marrow and notochord.

remains for a considerable time blind, until the anus becomes formed by invagination from the exterior.

Cleavage of mesoblast. Formation of body cavity.—

At a very early period, soon indeed after the formation of the neural groove, two important changes begin in the mesoblast. One of these is the cleavage of the lateral mesoblast (which is at first a continuous sheet) into two plates, one of which clings to the epiblast, and the other to the hypoblast. The cleft is at first small (fig. 37, *p*), but accumulation of fluid within it soon converts it into a cavity, which gradually spreads until the separation is very extensive (fig. 39, *p.p.*). The layer of mesoblast which clings to the epiblast eventually forms part of the body-wall, and is known as the *somatopleure*; that which clings to the hypoblast forms eventually part of the wall of the alimentary

tract, and is known as the *splanchnopleure*. The cavity between these, which is formed by enlargement of the original cleft, is the *cælom* or *body cavity* (pleuro-peritoneal cavity of authors).

Formation of mesoblastic somites.—The other change occurs not in the lateral but in the paraxial mesoblast, and consists in the occurrence at regular intervals transversely along the mass, of a process of thinning which produces its complete separation into distinct segments, so that when the embryo is viewed from above or below, these segments appear on either side of the neural groove as a linear series of small quadrangular masses (fig. 38), which were originally termed

protovertebræ, on the supposition (now known to be erroneous) that they are the rudiments of the future vertebræ; they are more appropriately termed the *mesoblastic somites*.

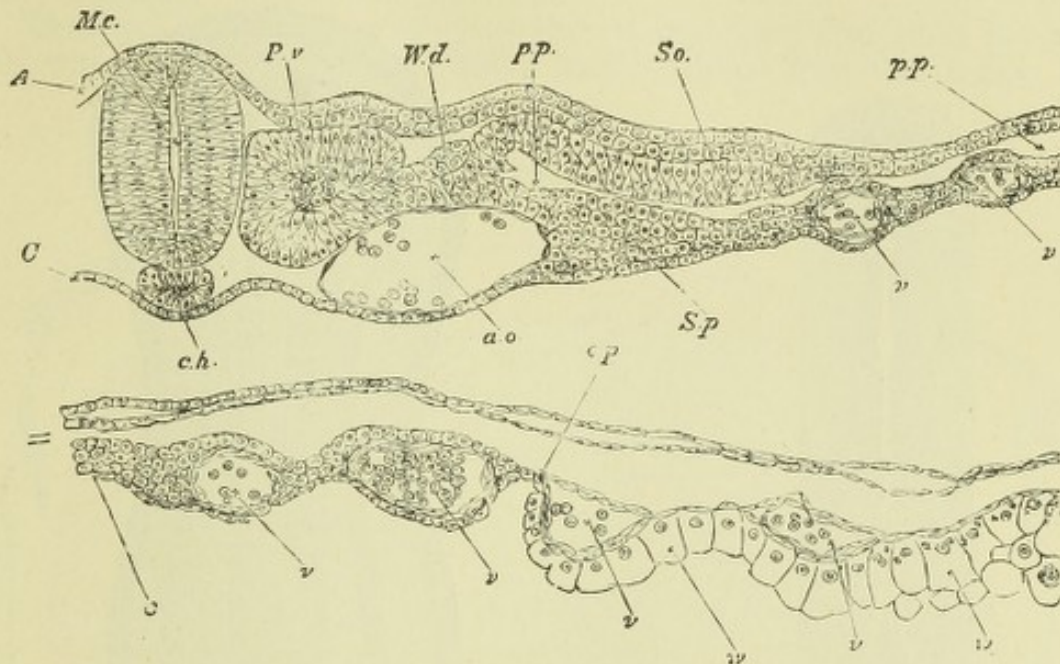


Fig. 39.—TRANSVERSE SECTION THROUGH THE DORSAL REGION OF AN EMBRYO CHICK OF 45 HOURS. (From Balfour.)

A, epiblast; C, hypoblast; Mc, medullary canal; Pv, protovertebra or mesoblastic somite; Wd, intermediate cell-mass in which the Wolffian duct is becoming formed; So, somatopleure; Sp, splanchnopleure; pp, pleuro-peritoneal cavity (celom); op, inner margin of *area opaca*; w, thickened hypoblast of *area opaca*; ao, left primitive aorta; v, blood vessels; ch, notochord.

In *Amphioxus* (figs. 28, 29), the protovertebræ are formed in common with the body cavity, and are successively separated off from before backwards from the cœlomic fold as hollow cuboid somites, each of which extends upwards around the neural canal and downwards along the sides of the alimentary canal, and subsequently divides into a dorsal or paraxial part which forms the protovertebræ, and a ventral part which forms the lateral mesoblast. At first the hollow somites communicate individually with the alimentary cavity, but they become shut off from this long before the division which has just been mentioned. The ventral segments run together eventually, to form a continuous serous cavity. In sections of bird or mammalian embryos (fig. 39), the protovertebræ, although on the whole compact masses of mesoblast, yet often show a tendency to have their central cells loosely arranged, so as to give the appearance of an irregular cleft in their interior, and sometimes a definite cavity is formed in them, which may even be continuous with the cœlomic cleft in the lateral mesoblast.

Protovertebræ begin to be marked off in the paraxial mesoblast, a short distance from the anterior end of the neural groove, in what will eventually become the cervical region of the embryo. They are produced in succession from before backwards, one or two only being at first visible on either side, and others being gradually added as the embryo grows in length, until a large number may at length be counted, extending from immediately behind the cephalic region to the region of the primitive streak.

Cerebral vesicles.—Meanwhile a change of importance has taken place in connection with the anterior end of the neural groove, which has become enlarged, and soon exhibits a succession of highly characteristic median dilatations, separated from one another by slight constrictions (fig. 34). These dilatations, at a later stage, after they have become roofed in, along with the rest of the neural groove, are known as the *cerebral vesicles*. There is at first a simple enlargement, and behind this two others form in succession, so that the *primary vesicles* are three in

number, but subsequently the most anterior (*fore-brain*) and posterior (*hind-brain*) each forms two vesicles, whereas the middle vesicle (*mid-brain*) remains permanently undivided. Five vesicles are therefore then to be seen, and these give rise eventually

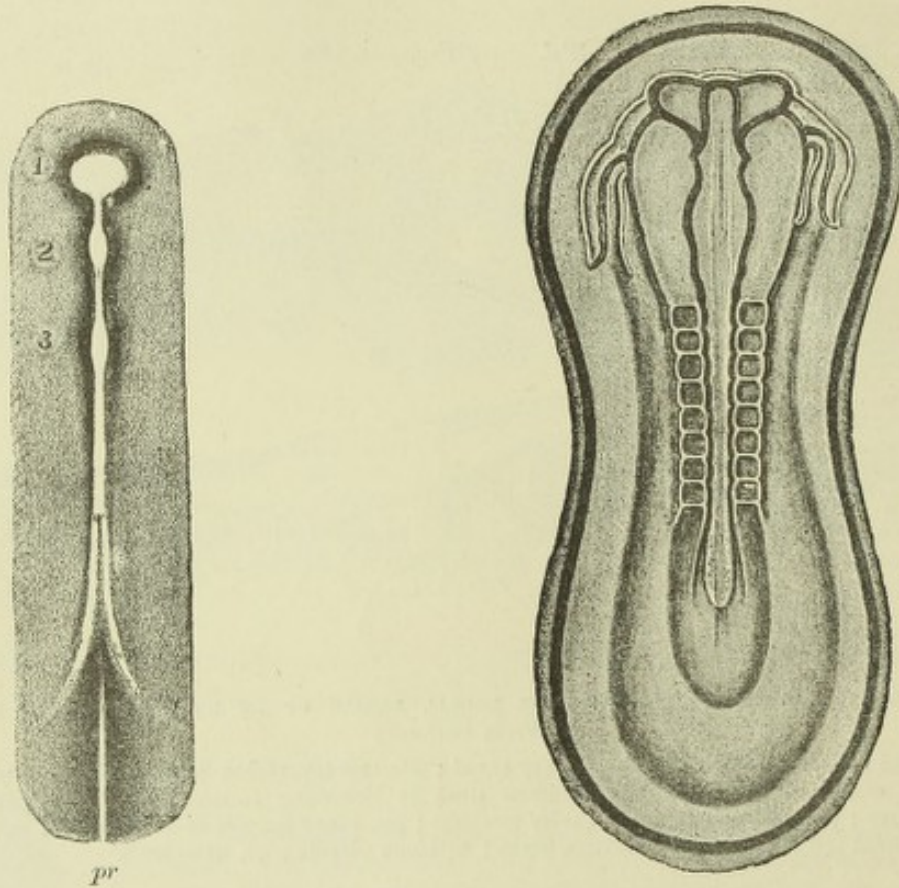


Fig. 40.—SURFACE VIEW OF AN EARLY EMBRYO OF THE GUINEA PIG SHOWING THE COMMENCEMENT OF THE THREE PRIMARY CEREBRAL VESICLES (1, 2, 3) AS ENLARGEMENTS OF THE MEDULLARY GROOVE. Semi-diagrammatic.

pr, primitive streak and groove.

Fig. 41.—RABBIT EMBRYO OF THE 9TH DAY, FROM THE SURFACE. ♂. (Kölliker.)

The medullary groove is enlarged anteriorly and the primary optic vesicles are growing out from the first cerebral enlargement. On either side of the head, the (double) tubular heart is seen. Eight pairs of protovertebræ are formed.

to the five fundamental divisions of the brain, while from the sides of the fore-brain the rudiments of the optic nerves and retinae grow out as hollow protrusions.

Heart and vascular system.—While this change is progressing in the neural canal, and the protovertebræ are becoming formed in the paraxial mesoblast, the first sign of a vascular system is beginning to make its appearance in the mesoblast on either side of the head in the form of a simple tubular vessel (fig. 41), which becomes developed in the splanchnopleure in this situation. As the splanchnopleure and its accompanying hypoblast fold round on either side under the head to form the fore-gut, these two simple tubes necessarily come together in the middle line, and they then fuse together longitudinally to form a single tube, the primitive heart (fig. 38); this tube runs for a short distance in the mesoblast immediately under the fore-gut, and then divides into two branches, which pass laterally, so as to partially encircle the fore-gut, and thence course backwards along the body of the embryo on either side of the notochord. These two vessels form the primitive arteries (*primitive aortæ*), the part of each which encircles the fore-gut as it passes dorsalwards being known as the *first aortic arch*. On the other hand, the posterior

end of the single tubular heart bifurcates at an obtuse angle to form two large venous roots (*primitive veins*), which receive the blood from the vascular area on the yolk-sac when this is developed, and pass it on to the heart. These two primitive veins become the *vitelline veins*.

The heart begins to beat very soon after its appearance, even whilst still filled only with a colourless fluid, and before receiving blood from the vascular area.

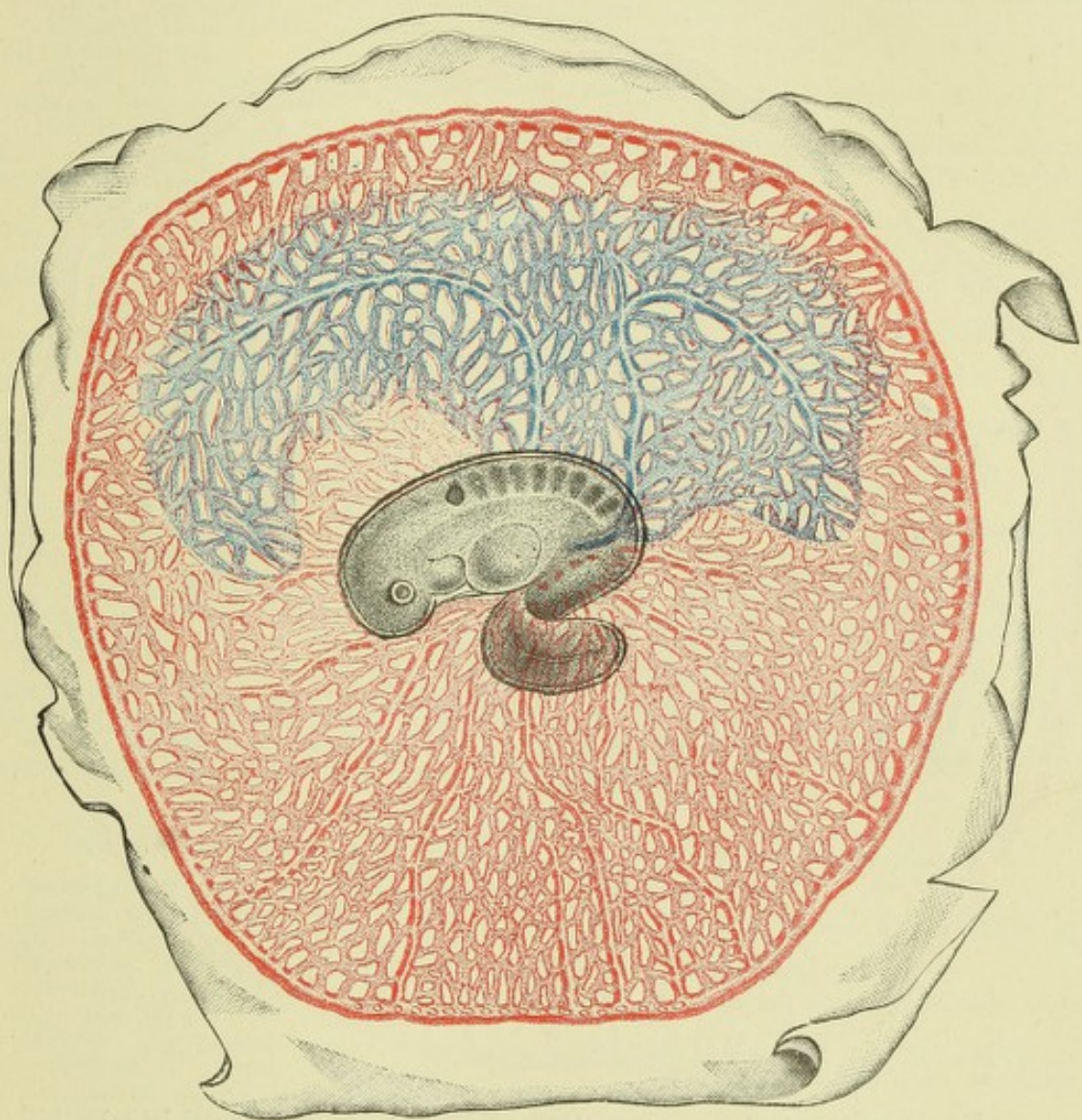


Fig. 42.—VASCULAR AREA OF THE RABBIT OF 10 DAYS. (v. Beneden and Julin.)

The arteries and arterial capillaries are represented red, the venous capillaries and veins blue.

Afterwards, when receiving and propelling the red blood from that area, and especially after it has become elongated and bent upon itself, it is one of the most prominent objects seen on examining the embryo; projecting as it does freely into the yet widely open cœlom immediately behind and beneath the cephalic region of the body.

The first vessels to be developed are formed in mesoblast altogether outside the body and within a circular area (*vascular area*), which surrounds the developing embryo for a certain distance. The first appearance of red blood occurs in the form of isolated red points (*blood-islands* of Pander), which are scattered about within this area, and are especially numerous at its circumference, where they form an

almost continuous chain. These red points are small groups of coloured nucleated blood corpuscles which have been developed within certain of the mesoblast cells in the manner explained in another portion of this work (see Histology, Development of blood-corpuscles and blood-vessels). The mesoblast cells in question form the blood-vessels of the vascular area by becoming united with one another into a capillary network, which becomes connected mesially with branches of the primitive aortæ

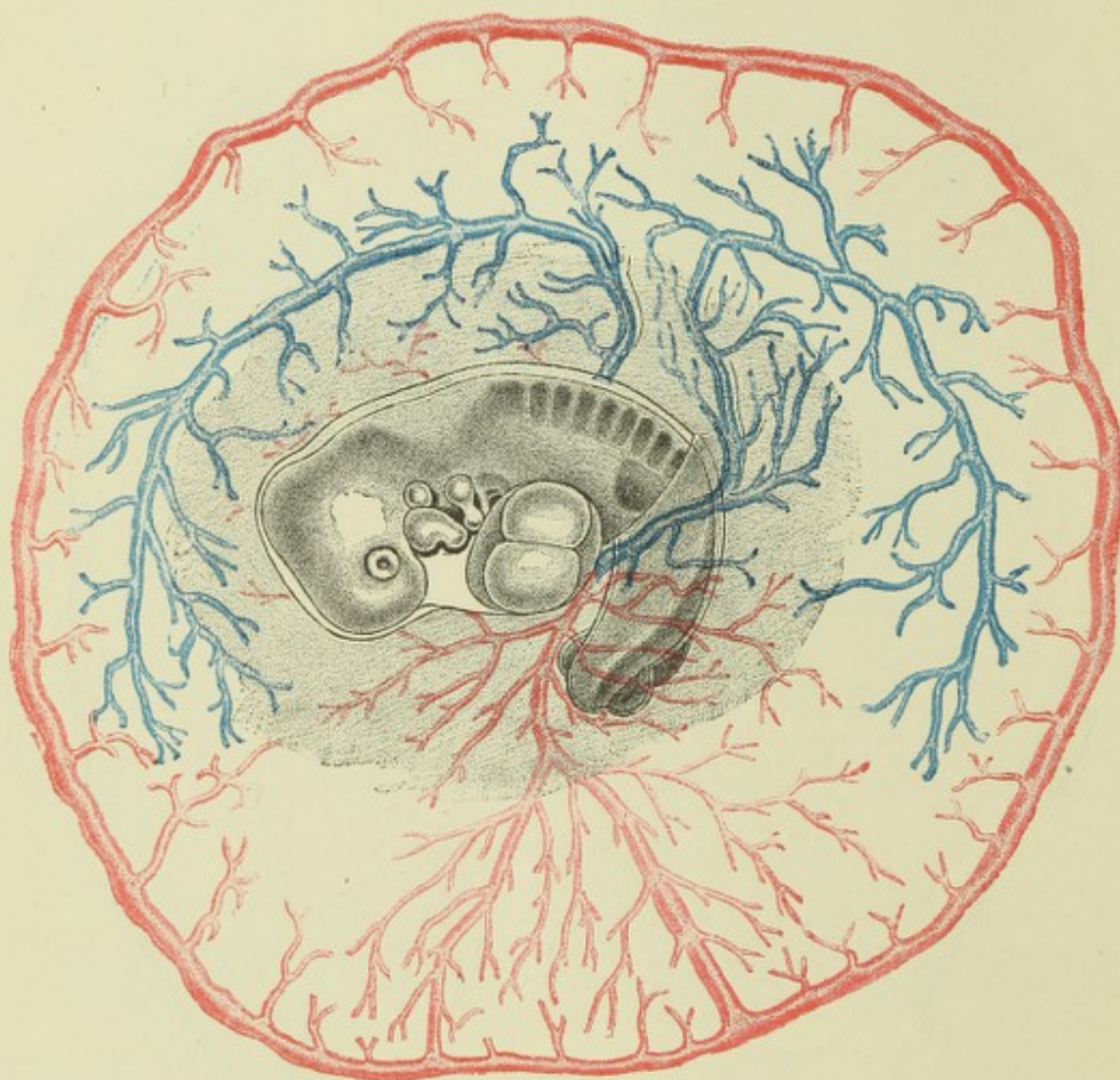


Fig. 43.—VASCULAR AREA OF THE RABBIT OF 11 DAYS. (v. Beneden and Julin.)

The arteries are represented red, the veins blue; the capillaries are not shown.

In both the stages illustrated, the terminal sinus is seen to be arterial.

(*vitelline arteries*), and peripherally with a circular vessel (*terminal sinus*), arterial in mammals but venous in the chick, which forms the circumferential boundary of the vascular area. From the capillary network of the vascular area the blood is collected into two vitelline veins, which course backwards and inwards to carry the blood of the area to the venous roots of the heart. This is the first circulation, or the circulation of the vascular area. It is also called the vitelline circulation, because the vascular area is developed in the mesoblast of the splanchnopleure layer which encloses the vitellus, and its capillaries are an important means of bringing the food material of the vitellus to the embryo.

RECENT LITERATURE.¹

Beneden, v., and Julin, *Recherches sur la formation des annexes fœtales chez les mammifères (Lapin et Cheiroptères)*. Arch. de biologie, t. v., 1884.

Carius, *Ueber die Entwicklung der Chorda u. der primitiven Rachenhaut bei Mierschweinchen und Kaninchen*. Inaug. Diss., Marburg, 1888: *Ueber den Kopffortsatz des Kaninchens*. Marburg Sitzungsber., 1887; *Ueber die Ausbildung des hinteren Körperendes bei Cavia*. Ibid., 1888.

Chiarugi, *Anatomie d'un embryon humain de la longueur de mm. 2.6 en ligne droite*. Arch. ital. de biologie XII.

Ehlers, E., *Nebendarm und Chorda dorsalis*. Nachrichten d. kgl. Gesellsch. d. Wissensch. zu Göttingen, 1885.

Fol, H., *Description d'un embryon humain de cinq millimètres et six dixièmes*. Recueil Zool. Suisse, 1884; *Recherches sur le développement des protovertèbres chez l'embryon du poulet*. Archives des sciences physiques et naturelles, 1884.

Giacomini, *Sul canale neurenterico et sul canale anale, &c.* Giorn. de r. accad. di medic. di Torino, 1888.

Keibel, F., *Zur Entwicklungsgesch. der Chorda bei Säugern*. Arch. f. Anat. u. Physiol., Anat. Abth., 1889.

Kölliker, v., *Ueber die Chordaköhle und die Bildung der Chorda beim Kaninchen*. Sitzungsber. der physikal.-med. Ges. in Würzburg, 1883.

Lieberkühn, N., *Ueber die Chorda bei Säugethieren*. Arch. für Anat. und Physiol., Anat. Abth., 1884.

Perenyi, J. v., *Entwicklung des Amnion, des Wolff'schen Ganges und der Allantois bei den Reptilien*. Zool. Anzeiger, No. 274, 1888.

Ravn, *Ueber die mesodermfreie Stelle in der Keimscheibe des Hühnerembryo*. Arch. f. Anat., 1886.

Romiti, G., *De l'extrémité antérieure de la corde dorsale et de son rapport avec la poche hypophysaire ou de Rathke chez l'embryon du poulet*. Archives italiennes de biol., t. VII., 1886.

Shore and Pickering, *The pro-amnion and amnion in the chick*. Journal of Anatomy and Physiology, 1889.

Solger, B., *Studien zur Entwicklungsgeschichte des Coeloms und des Coelomepithels der Amphibien*. Morphol. Jahrbuch X., 1885.

Spee, F. v., *Ueber die Entwicklungsvorgänge vom Knoten aus in Säugethierkeimscheiben*. Anat. Anzeiger iii., 1888; *Beobachtungen an einer menschlichen Keimscheibe mit offener Medullarinne u. Canalis neurentericus*. Arch. f. Anat. u. Physiol., Anat. Abth., 1889.

Strahl, H., *Ueber die Entwicklung des Canalis myelo-entericus und der Allantois der Eidechse*. Archiv für Anat. und Physiol., Anat. Abtheil., 1881 and 1883.

Works dealing with the general subject of Embryonic Formation and Development.

Balfour, *A Treatise on Comparative Embryology*. London, 1880.

Foster and Balfour, *The Elements of Embryology*. Second Edition, 1883. Edited by Sedgwick & Heape.

Haddon, *An introduction to the study of Embryology*. London, 1887.

Hertwig, O., *Lehrbuch der Entwicklungsgeschichte des Menschen u. d. Wirbelthiere*. 2te Auflage, Jena, 1888.

His, W., *Untersuchungen ue. d. erste Anlage d. Wirbelthierleibes. Die erste Entwicklung des Hühnchens im Ei*. Leipzig, 1868; *Unsere Körperform u. das physiol. Problem ihrer Entstehung*, 1871; *Anatomie menschlicher embryonen*, 1881—1885.

Kölliker, v., *Entwicklungsgeschichte des Menschen u. d. höheren Thiere*. 2te Auflage. Leipzig, 1879.

Rauber, *Formbildung u. Formstörung in der Entwicklung von Wirbelthieren*. Morph. Jahrb. vi., 1880.

¹ The early changes in the blastodermic layers are dealt with in several of the papers enumerated on pp. 27 to 29.

DEVELOPMENT OF THE FOETAL MEMBRANES; ATTACHMENT OF OVUM TO UTERUS.

Having thus sketched out the manner in which the principal organs of the body first make their appearance, we may briefly consider the formation of certain structures which have a purely embryonic existence, and are concerned either with the nutrition of the foetus and its attachment to the mucous membrane of the uterus (chorion, allantois, placenta), or serve the purpose of protecting the embryo against mechanical injuries by suspension in a bag of fluid (amnion).

Formation of the amnion and chorion.—The amnion, which is only found in reptiles, birds, and mammals (amniota), is a membranous bag occupied by a clear albuminous fluid, and covers the whole of the embryo. It is developed from folds of

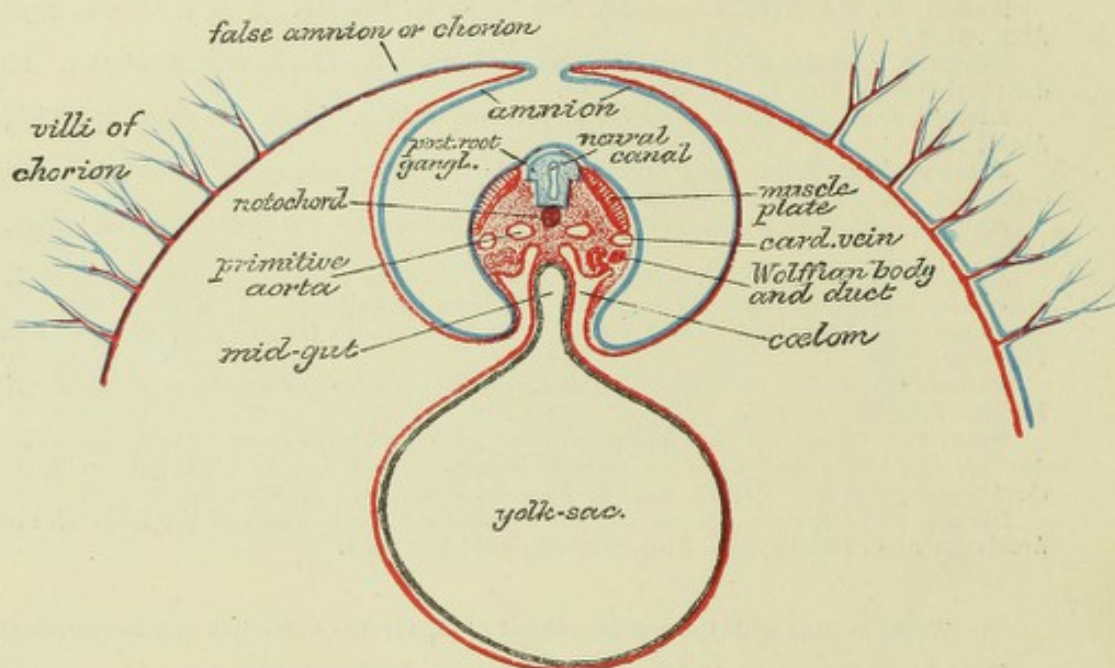


Fig. 44.—DIAGRAM OF A TRANSVERSE SECTION OF A MAMMALIAN EMBRYO SHOWING THE MODE OF FORMATION OF THE AMNION. THE AMNIOTIC FOLDS HAVE NEARLY UNITED IN THE MIDDLE LINE.

Epiblast, blue ; mesoblast, red ; hypoblast and notochord, black.

somatopleure, which are reflected from the head and tail ends and lateral boundaries of the embryo at an early stage.¹ With the sinking of the embryo into the blastodermic vesicle or yolk, these folds grow up over the back (fig. 44) until they meet and coalesce with one another along the middle line, in such a manner as to form two distinct membranes, one of which, the inner, is the *amnion* (true amnion), while the outer membrane (termed the *false amnion*) becomes applied to the greatly thinned remnant of the zona pellucida, and eventually forms a complete external covering to the ovum and its contents. This external covering of the ovum has been long known as the *chorion*—a name which has, however, been applied by some embryologists to other structures.² It is fixed to the uterus by villi, which are

¹ The head fold is preceded at a yet earlier stage by the bilaminar *pro-amnion*, the formation of which has been already alluded to (p. 35).

² The term "*chorion*" has been applied to various structures by embryologists. Originally used to denote the external covering of the developing ovum, it was employed successively for the zona pellucida ("primitive chorion"), the epithelial enclosing membrane of the blastodermic vesicle, and finally for the external amniotic fold or false amnion, when this becomes formed. Lately it has been used to express the external albuminous envelope of the undeveloped ovum, so that it is probable that much confusion may arise unless the meaning of the term be in each case clearly defined. It

attached to the uterine mucous membrane, and these villi subsequently become ramified and vascular when the growth of the allantois has brought the umbilical blood-vessels to the chorion; but except in the placenta, they at length all become atrophied and disappear.

It will be seen from the manner in which the true and false amnion are formed by a fold of somatopleure, that these membranes are composed of both epiblast and mesoblast. In the false amnion the epiblast becomes the outer layer; in the true amnion it is the inner layer. The mesoblast of the one is separated from that of the other by a space occupied by fluid,¹ and continuous with the coelom, with which

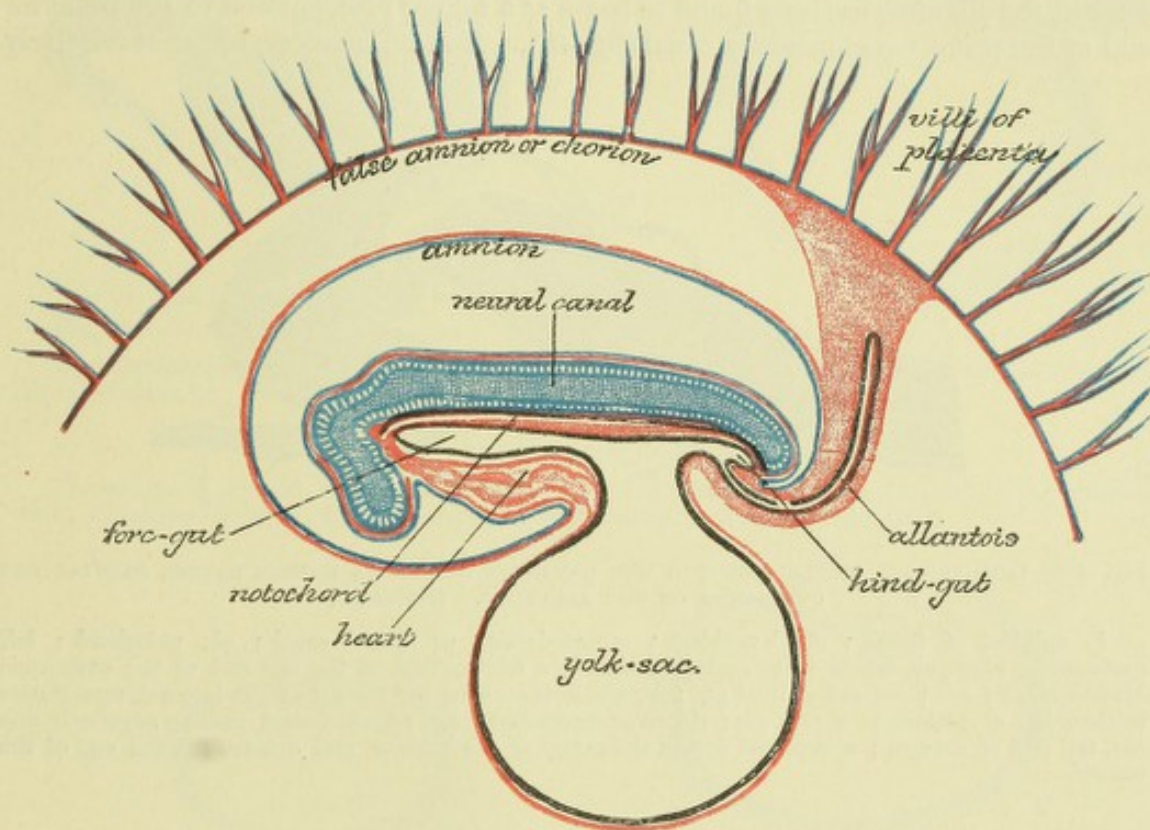


Fig. 45.—DIAGRAM OF A LONGITUDINAL SECTION OF A MAMMALIAN EMBRYO, AFTER THE COMPLETION OF THE AMNION.

in fact it remains continuous until the body walls of the embryo have entirely grown round and coalesced on the ventral surface—the final point of coalescence being the umbilicus. With this enclosing growth of the body walls the line of reflection of the amniotic fold is also carried downwards, so that the amnion is eventually attached around the umbilical cord, by which the fœtus appears suspended in the amniotic fluid (fig. 50).

In the guinea-pig, in which the epiblast is the innermost layer, the amnion is not formed as a fold, but results from an extension of the mesoblastic cleavage around the dorsal aspect of the central cavity; this cavity thus becomes the cavity of the amnion.

Formation of the allantois.—Both the amnion and the chorion are entirely extra-embryonic structures, i.e., they are external to the body of the embryo, and,

will be used throughout this article in the sense in which it has hitherto almost invariably been employed in human embryology, to denote that external membrane of the ovum from which the villi (chorionic villi) which grow into the uterine mucous membrane spring, and this it will be seen presently, is that part of the external investment of the blastodermic vesicle, which, when the amnion is formed, becomes the external amniotic fold or false amnion.

¹ Except in the later stages of gestation, when the amniotic and chorionic mesoblast become loosely united by jelly-like connective tissue.

although they minister to its protection and nutrition, take no part in the formation of any of its organs. But the case is different with the structure next to be described, viz., the allantois, a part of which does in fact eventually become converted into portions of the urinary and generative systems, although the greater part is also extra-embryonic, its function being to minister, through its accompanying blood-vessels, to the nutritive and respiratory exchanges of the foetus.

The time of development of the allantois seems to vary much in mammals, and there is reason to believe that it is found in the human embryo at a very early period—indeed the earliest human embryos that have hitherto been described already possess an allantois. In most animals in which its development has been studied the allantois has been found to begin as a hollow prolongation of the posterior end of the primitive alimentary canal (fig. 46). It soon, however, becomes relatively

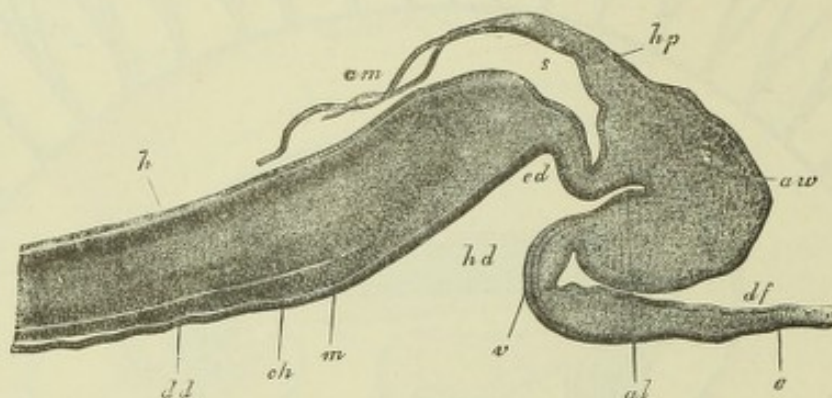


Fig. 46.—LONGITUDINAL SECTION THROUGH THE POSTERIOR END OF AN EMBRYO RABBIT, SHOWING THE OUTGROWTH OF THE ALLANTOIS. (Kölliker.)

h, epiblast of trunk; *dd*, hypoblast; *m*, medullary or neural canal; *ch*, notochord; *hd*, commencing hind-gut, which is becoming formed by a folding-over of the tail end of the embryonic blastoderm; *v*; *ed*, blind end of hind gut; *al*, allantois growing out from hind gut into *aw*, mesoblastic thickening; *e*, epithelium of yolk sac; *df*, splanchnopleure; *hp*, somato-pleure passing superiorly into *am*, tail fold of amnion; *s*, is placed within the cavity of the amnion, and denotes the tail end of the embryo.

shifted in position so as to come off from the ventral wall of the hind-gut, growing into the posterior extension of the mesoblastic cleft and eventually into the space between the false and true amnion, and carrying along with it its mesoblastic covering (figs. 36, 45). It is therefore composed eventually of two parts, viz., (1) a hypoblastic sac which communicates, at first widely but afterwards by a narrowed orifice, with the hind-gut, and (2) an investment of mesoblast. This last is usually greatly thickened and very vascular, and is directly supplied with blood by two arteries (allantoic or umbilical arteries), which appear at first as a direct continuation of the primitive aortæ. As the allantoic vesicle expands into the cavity of the false amnion, it carries the vascular mesoblast along with it, so that this mesoblast is thus brought to the inner surface of the chorion, over which its blood-vessels then spread so as to convert this hitherto non-vascular membrane into one which is richly supplied with blood-vessels. The chorion has grown in the form of ramified villi into the substance of the uterine mucous membrane or decidua even before this advent of the vascular tissue of the allantois, but the chorionic villi now receive blood-vessels and thus become vascularized, the interchanges between the foetal and maternal vascular systems, which are afterwards confined to one region only of the chorion and decidua—that which forms the placenta—occurring in the first instance over the whole superficies of the ovum.

Like the amnion, an allantois is only formed in the embryo of reptiles, birds, and mammals.¹ It varies chiefly in the extent to which its hypoblastic part becomes developed. In reptiles,

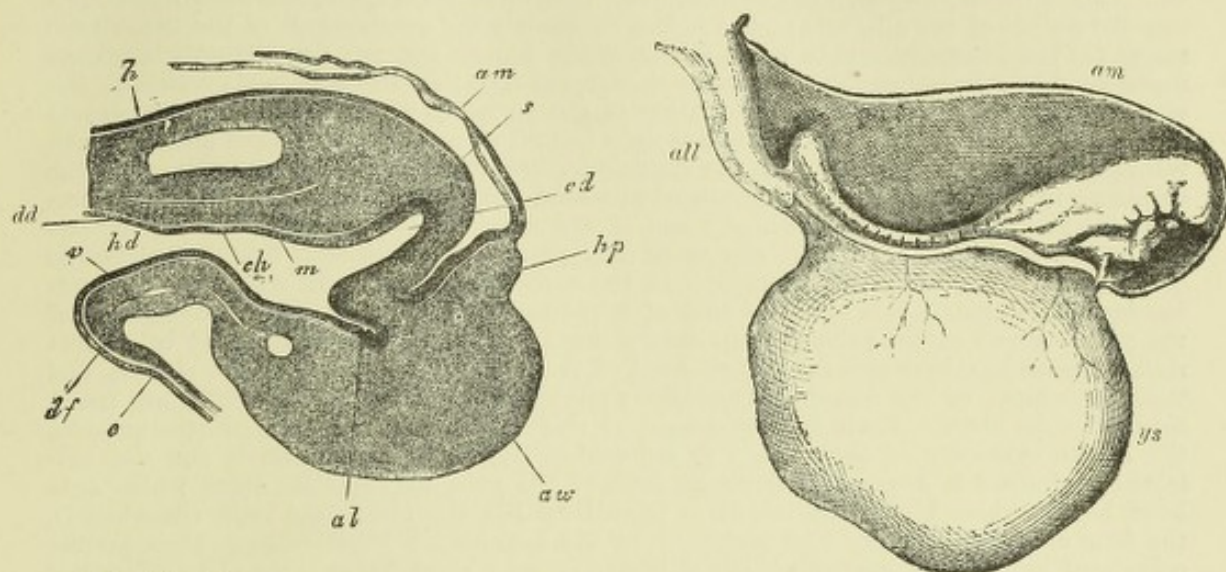


Fig. 47.—LONGITUDINAL SECTION AT A SLIGHTLY LATER STAGE THAN THAT SHOWN IN FIG. 46.

The allantoic protrusion now springs from the ventral wall of the hind gut. Lettering as in fig. 46. (From Kölliker.)

Fig. 48.—EARLY HUMAN EMBRYO. (From His after Coste.)

The embryo is enclosed within the amnion *am*, and is attached at its caudal end by the allantoic stalk, *all*, to the chorion. The yolk sac, *ys*, is still distinct from the allantoic stalk.

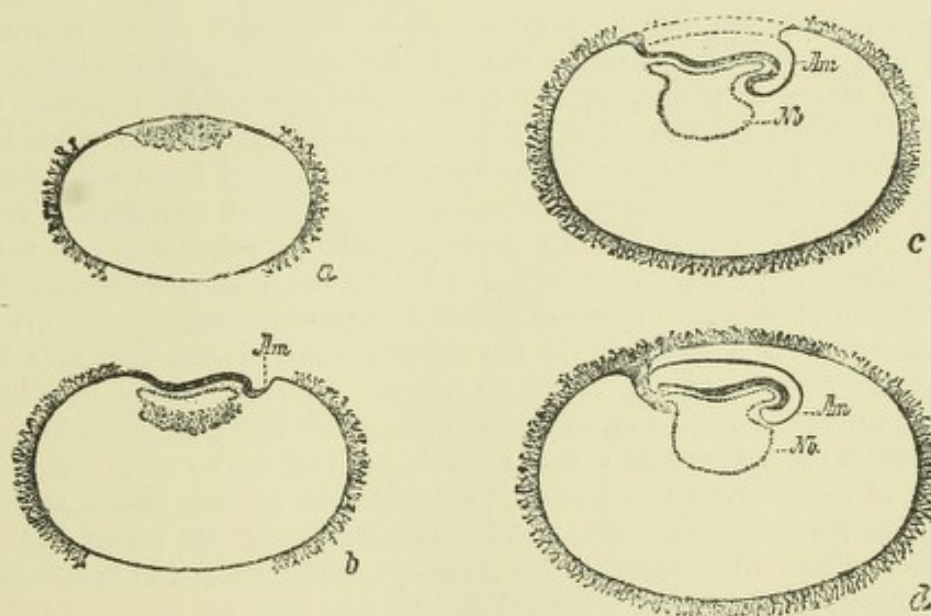


Fig. 49.—DIAGRAM OF LONGITUDINAL SECTIONS THROUGH THE HUMAN OVUM AT SUCCESSIVE STAGES SHOWING THE DIPPING DOWN OF THE EMBRYO-RUDIMENT INTO THE BLASTODERMIC VESICLE, AND THE FORMATION OF THE FOREGUT, AMNION, AND STALK OF THE ALLANTOIS BY THE FOLDING OF THE BLASTODERM. (His.)

Am, head fold of the amnion (pro-amnion in *b* and *c*); *Nb*, yolk sac. *a* and *d* are conditions of the embryo which have been seen and described; *b* and *c* are intended to show how the conditions found in *d* may be brought about, and especially how the stalk of the allantois may be regarded as a direct continuation of the posterior end of the embryo, which according to His does not lose at any time its connection with the chorion or villous external membrane of the ovum. The curved dotted lines in *c* indicate the formation of the amnion and false amnion by the upgrowing of lateral folds (which have not as yet met in the median line).

¹ For a discussion of the origin and meaning of the amnion and allantois, see Balfour, "Comparative Embryology," II., p. 256.

in birds, and in some mammals, e.g. ruminants, this portion forms a large sac which occupies the greater part of the cavity of the false amnion, and is filled by fluid (allantoic fluid) in which many urinary products can be recognized. (The ducts of the embryonic renal organs open into the pedicle of the allantois.) But in most mammals the development of the hypoblastic sac is far less extensive, and in some, including the human embryo, the allantois is mainly represented by a large mesoblastic outgrowth carrying the allantoic (umbilical) vessels to the chorion. There is also considerable variation in the period at which the allantois begins to develop. In the human embryo it is certainly formed at a very early period, probably even before the amnion is completed. In the guinea-pig, also, it appears early, although after the amnion. In this animal it is first developed as a solid outgrowth of mesoblast which projects from the line of junction of the hinder end of the amniotic bag with the blastoderm, and before the formation of a hind gut or of any part of the alimentary tube, a hypoblastic diverticulum being altogether wanting. In the earliest human ova in which the allantois has been investigated, it is already a tube of hypoblast which forms a direct prolongation of the posterior end of the primitive alimentary canal (fig. 49, *d*), and is enclosed in a short stalk of mesoblast, by which the posterior end of the embryo is attached to the chorion, and through which, by the allantoic (umbilical) blood-vessels, the chorionic villi are freely supplied with blood. From the attachment of this stalk to the placenta (chorionic part), the hinder extremity of the amnion is reflected. The stalk in question is not the umbilical cord, since it does not include the stalk of the yolk sac (vitelline duct), which only later becomes bound up with it. It is termed by His the abdominal stalk (*Bauchstiel*), the term allantois being by him restricted to the hypoblastic diverticulum. It is further considered by His to be probable that the human embryo never becomes completely detached from the chorion, but that it always retains its attachment to the outer membrane of the ovum at the hinder end, this abdominal stalk being regarded as a direct prolongation of the tail end of the embryo (fig. 49). If this should prove to be the case, the human ovum would form an exception to the usual rule of a complete separation of embryo from chorion at the formation of the amnion, and subsequent re-attachment by outgrowth of allantois.

Changes in the uterus. Mode of attachment of ovum to uterus.¹—

The mucous membrane of the pregnant uterus is known as the *decidua*. It is thicker and more pulpy than in the ordinary non-pregnant condition, and the glands are longer in proportion, but it is otherwise of similar structure except in the part where the placenta is about to be formed; here it undergoes important modifications. The ovum, which has been fertilized and has passed through the first stages of development in the Fallopian tube, although considerably larger than the undeveloped ovum, is still an extremely minute object when it reaches the uterus. Here it speedily becomes imbedded in the soft and thickened mucous membrane, and this is soon reflected over and completely encloses the ovum, which thus comes to lie in a cavity within the decidua which is altogether shut off by the reflected part from the true cavity of the uterus. Different names have been given to these parts of the uterine mucous membrane which immediately enclose the ovum to distinguish them from that which lines the original cavity of the uterus. Thus the layer of membrane which has grown around the ovum is known as the *decidua reflexa*; the part where the ovum first becomes attached to the uterus and where the placenta is afterwards formed, is the *decidua serotina*, while the membrane lining the true cavity of the uterus, is termed *decidua vera* (figs. 50, 51).

With the subsequent growth and consequent expansion of the ovum the enclosing decidua reflexa expands also *pari passu*, encroaching more and more upon the true cavity of the uterus and coming into contact everywhere with the decidua vera. Eventually it blends entirely with the decidua vera, so that the two layers are indistinguishable and the original cavity of the uterus is obliterated (except at the cervix uteri).

¹ The following account of the formation of the decidua and of the placenta is confined as much as possible to what has been observed in the human subject. In other mammals important variations in the mode of attachment of the ovum and in the formation and structure of the placenta are found to occur.

Both the decidua vera and the decidua reflexa originally contain tubular and somewhat tortuous glands, which were discovered by Sharpey, and were by him supposed to minister, in the first instance, both to the nutrition and to the attachment of the ovum, the latter by affording depressions for the chorionic villi to penetrate into the substance of the decidua. It has, however, since been shown that these villi do not directly pass into the glands, but rather tend to become attached to the interglandular surface, and indeed at the decidua serotina, where subsequently the main attachment of the chorionic villi occurs, the gland-lumina may become almost entirely obliterated before the villi are here formed. But the greatly enlarged glands of the decidua vera very probably furnish a secretion to assist the nourishment of the ovum previously to the full establishment of the placental circulation.

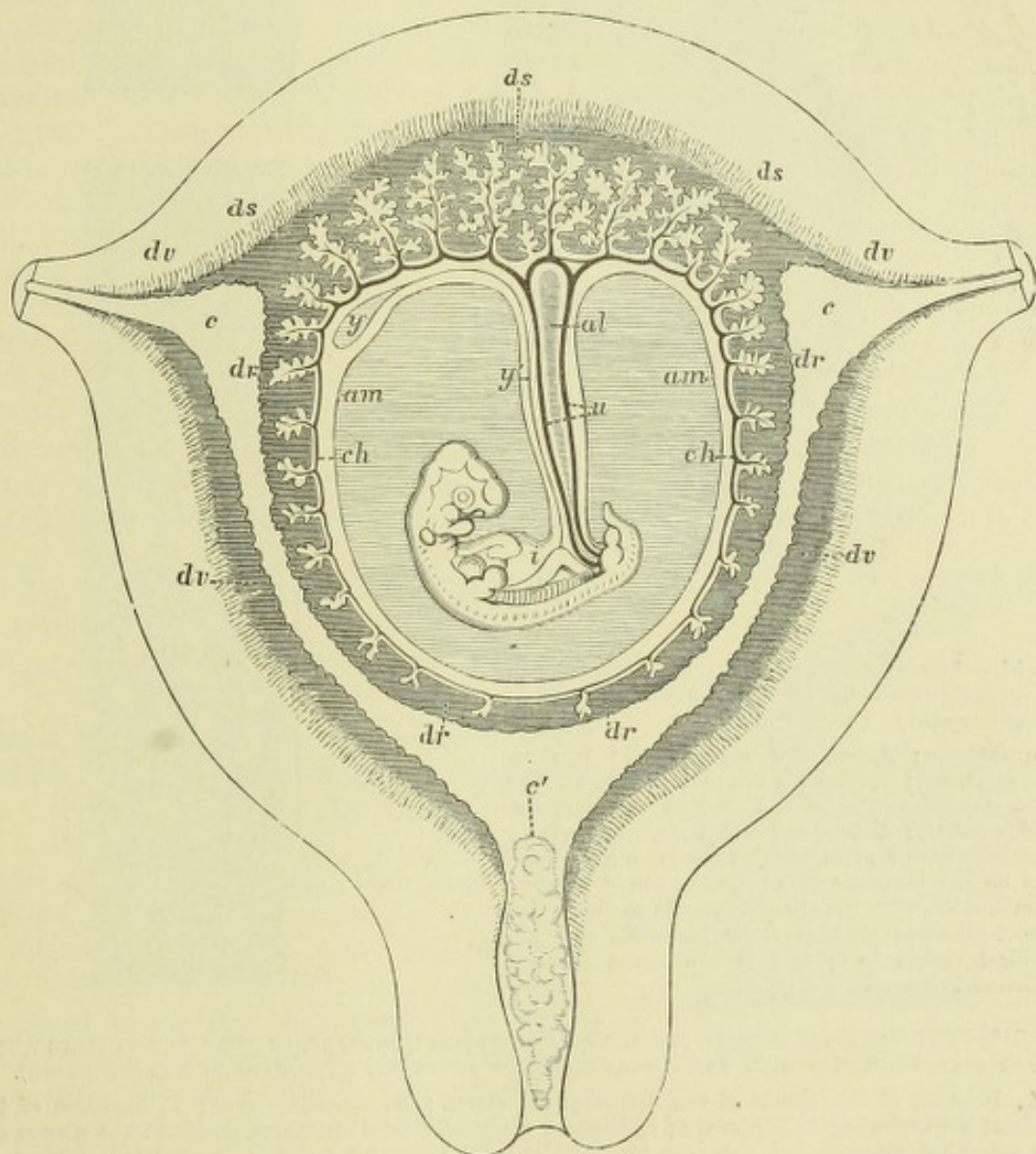


Fig. 50.—DIAGRAMMATIC SECTION OF THE PREGNANT HUMAN UTERUS AT THE SEVENTH OR EIGHTH WEEK. (Allen Thomson.)

c, c, openings of Fallopian tubes into the cavity of the uterus; *c'*, cervix, filled by a plug of mucus; the letters *c* and *c'* are placed within the original cavity of the uterus; *dv*, decidua vera; *dr*, decidua reflexa; *ds*, decidua serotina; *ch*, chorion with its villi growing into the decidua reflexa and *d*. serotina; in the former the villi are becoming atrophied; *u*, umbilical cord, the dotted lines indicate bloodvessels within it; *al*, allantois; *y*, yolk sac (umbilical vesicle); *y'*, its stalk, passing in the umbilical cord and connected with the intestine of the embryo, *i*; *am*, amnion.

The decidua undergoes remarkable structural changes during the early months of pregnancy, some of these changes being common to all three parts of the membrane,

whilst others are special to that part (d. serotina) which enters into the construction of the placenta. The following is a brief account of these changes.¹

With the supervention of pregnancy the mucous membrane lining the uterus becomes thickened and the tubular glands become both dilated and greatly elongated.

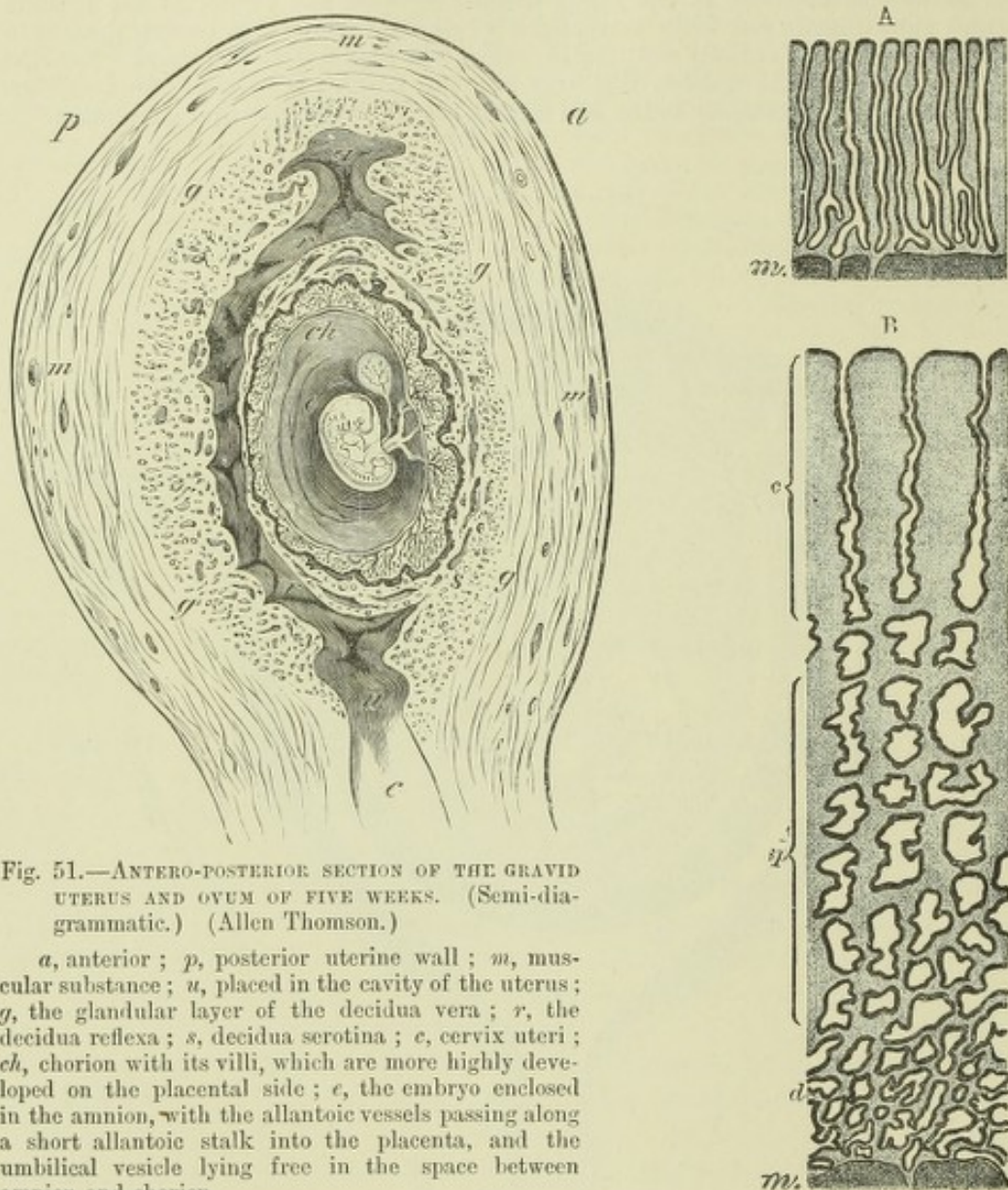


Fig. 51.—ANTERO-POSTERIOR SECTION OF THE GRAVID UTERUS AND OVUM OF FIVE WEEKS. (Semi-diagrammatic.) (Allen Thomson.)

a, anterior; *p*, posterior uterine wall; *m*, muscular substance; *u*, placed in the cavity of the uterus; *g*, the glandular layer of the decidua vera; *r*, the decidua reflexa; *s*, decidua serotina; *c*, cervix uteri; *ch*, chorion with its villi, which are more highly developed on the placental side; *e*, the embryo enclosed in the amnion, with the allantoic vessels passing along a short allantoic stalk into the placenta, and the umbilical vesicle lying free in the space between amnion and chorion.

Fig. 51*.—DIAGRAMMATIC SECTIONS OF THE UTERINE MUCOUS MEMBRANE, SHOWING THE CHANGES WHICH THE GLANDS UNDERGO WITH THE SUPERVENTION OF PREGNANCY (from Kundrat and Engelmann).

A, Diagram of the glands of the non-pregnant uterus; *m*, muscular layer; *B*, condition of the glands at the beginning of pregnancy; *c*, compact layer near free surface of decidua: the glands are here somewhat enlarged but not very tortuous, and the mucous membrane is rendered compact by hypertrophy of the interglandular tissue; *sp*, spongy layer, containing the middle portion of the glands greatly enlarged and tortuous, producing a spongy condition in the mucous membrane; *d*, deepest portion of the glands, elongated and tortuous, but not much enlarged.

This thickening of the membrane and enlargement of the glands goes on until the fifth month, so that by this time the decidua vera is nearly half an inch in thickness and its glands have undergone so considerable an elongation that they now no longer pass nearly straight through the membrane but run in a tortuous manner from the

¹ For a more complete account of the changes in the uterus, and of the placenta, the reader is referred to the list of papers at the end of this section, but especially to the works of Kundrat and Engelmann, Leopold, and Minot, and for the comparative structure of the placenta to the classical investigations of Turner.

inner-surface to the vascular layer, so that a vertical section of the membrane exhibits them cut quite as often obliquely or transversely as longitudinally. They are also generally dilated, but the dilatation is by far most marked at the mouths of the glands, which come thus to have a funnel-like shape, and in the deeper part of the membrane, where the dilatations look in sections like a series of cavities, lined by cubical or flattened epithelium, and separated from one another by a relatively small amount of interglandular substance. This gives a spongy appearance to the part in question, and it has been accordingly termed the *stratum spongiosum* of the decidua (fig. 51*, B, *sp*). The deepest part of the glands, that, namely, which is in contact with and is imbedded in the superficial portion of the muscular coat, does not share in this dilatation, and its epithelium also retains the columnar character. The part of each gland between the funnel-shaped mouth and the dilatations above described, also becomes enlarged, but not to so great an extent, the hypertrophy of the mucous membrane being here chiefly confined to the interglandular tissue, which becomes filled with large epithelium-like cells (*decidual cells* of Friedlander) and with numerous and large capillary blood-vessels. This layer of the decidua has been termed the *stratum compactum* in contradistinction to the *stratum spongiosum* external to it (fig. 51*, B, *c*).

After the fifth month, by which time the great increase in size of the ovum with its contained embryo has brought the decidua reflexa into close contact with the decidua vera, the latter begins to undergo an atrophic process, the result to all appearance of the compression and distension to which it is thus subjected. Its tissue becomes thinner and less vascular, and both the funnel-shaped mouths of the glands and those parts of the glands which run through the *stratum compactum* become gradually obliterated, so that eventually hardly any trace remains. In the

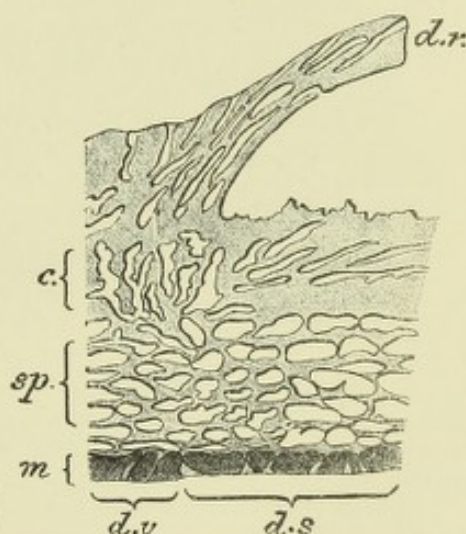
Fig. 52.—DIAGRAMMATIC SECTION THROUGH THE DECIDUA AT THE EDGE OF THE PLACENTA (from Kundrat and Engelmann).

c, *sp*, *m*, as in fig. 51*, B; *d v*, decidua vera; *d s*, decidua serotina; *d r*, decidua reflexa.

stratum spongiosum the spaces which have resulted from the dilatation of the gland tubes lose the lining epithelium, and become flattened out conformably to the surface, so that they now appear as a layer of compressed lacunæ, separated by thin fibrous trabeculæ (fig. 52, *sp*).

Similar changes occur in the decidua reflexa. That this is truly a fold of mucous membrane is evidenced by the fact that gland tubes can be seen to open upon both its surfaces. These gland tubes early become enlarged, and acquire an oblique or tortuous course, with dilatations in their deeper parts, i.e., in the middle of the thickness of the *d. reflexa*, so as to form here also a sort of spongy tissue. But the decidua reflexa sooner becomes expanded by the growing ovum into a relatively thin membrane, and the atrophic changes in the glands occur at an earlier stage, so that by the time that it has coalesced with the decidua vera hardly any traces of them can be discerned.

In the decidua serotina (placental decidua) similar changes have been described in the glands, the final result being the formation of a spongy layer, with irregular clefts flattened out conformably to the surface, and from which the epithelium has entirely disappeared, accompanied by complete atrophy and disappearance of all the parts of the glands which are superficial to this layer, the only portions which remain nearly unaltered being the deepest parts of the tubes, which are partly



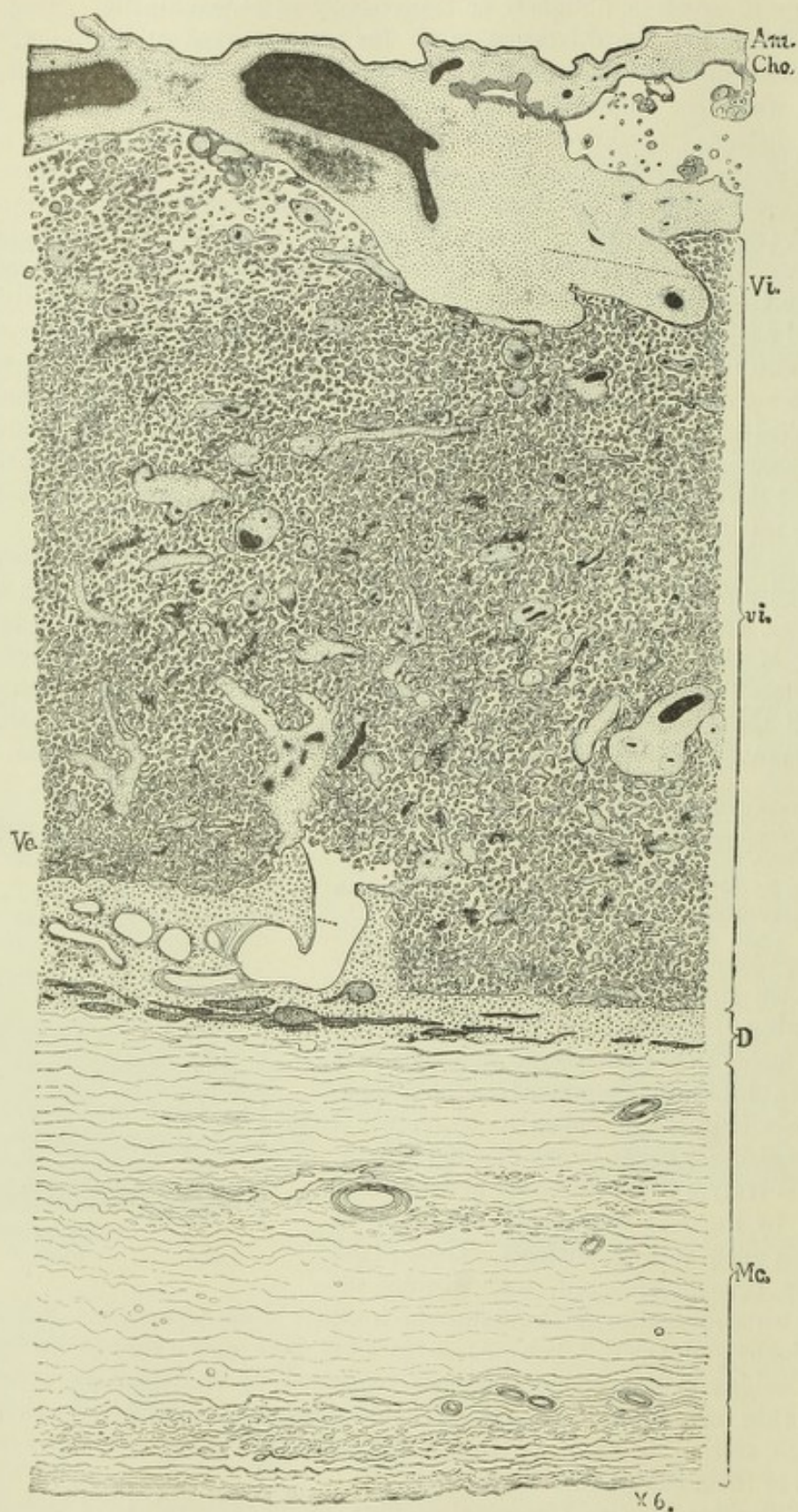


Fig. 53.—SECTION THROUGH A NORMAL PLACENTA OF SEVEN MONTHS IN SITU (Minot).

Am, amnion ; *Cho*, chorion ; *Vi*, root of a villus ; *vi*, sections of the ramifications of villi in the intervillous spaces, the larger bloodvessels within them are represented black : *D*, deep layer of the decidua, showing flattened remnants of enlarged glands in spongy stratum ; *Vc*, uterine vein (? artery) opening out of placental sinus ; *Mc*, muscular wall of uterus.

imbedded in the muscular coat of the uterus, and retain their epithelium. After separation of the placenta from the uterine wall at parturition, the uterine mucous membrane, with its epithelium and glands, becomes renewed from this deepest portion of the decidua serotina.

The most important changes of structure occur in the superficial part of the placental decidua, after the disappearance of the glands. The exact manner in which these changes take place has not been followed out, but the ultimate result is the replacement of the whole of this portion of the decidua, with the exception of a

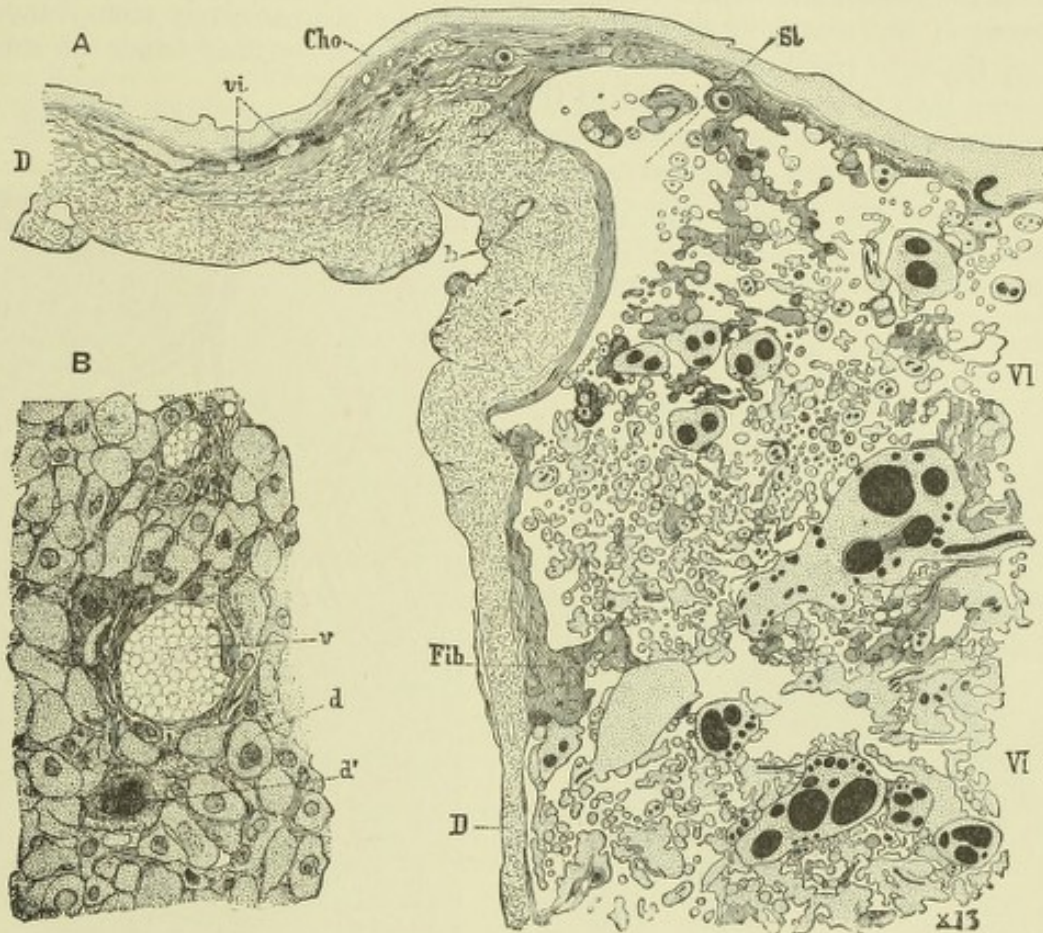

Fig. 54.—SECTIONS ILLUSTRATING THE STRUCTURE OF THE PLACENTA (Minot).

A, vertical section through the margin of a placenta at full term; D, D, deep layer of decidua; Vi, chorionic villi variously cut, their bloodvessels injected; Sl, marginal space of the placenta, nearly free from villi; vi, aborted villi beyond the placenta; Fib, canalized fibrine of Langhans, produced, according to Minot, by transformation of the superficial layer of the chorionic epiblast.

B, decidua tissue from a placenta at full term; v, a bloodvessel; d, d', decidua cells; the latter with several nuclei.

comparatively narrow *basal layer* next to the spongy structure, into a series of intercommunicating vascular sinuses, which together constitute an immense flattened space (intervillous space), bounded internally (toward the uterine wall) by the basal layer just referred to, and externally by the chorion; also, according to some authors, by a thin layer of decidua, the *subchorionic membrane* of Turner, which is described as lying immediately under the chorion of the ovum but so intimately incorporated with it as to be with difficulty demonstrable as a separate stratum except at the edge of the placenta.

From the basal layer, partitions of fibrous decidua tissue pass towards the chorionic surface, and serve to partially sub-divide the labyrinth of vascular spaces or sinuses into a number of loculi (cotyledons). Each of these loculi is occupied by an

arborescent tuft of villi continuous with the foetal chorion, and traversed by blood-vessels which are supplied from the branches of the umbilical arteries. These blood-vessels form a capillary loop in each villus, and these capillary loops are separated from the maternal blood in the placental sinuses not only by the capillary walls and the connective tissue of the villus, but also by a double layer of flattened epithelium-like cells derived either from the chorionic epithelium (Minot),¹ or from the decidua tissue, and, perhaps, in part representing an endothelial membrane belonging to the placental sinuses, which, according to Waldeyer, are lined by endothelium prolonged from that of the uterine vessels.

Some of the chorionic villi are attached (1) by comparatively stout bands of fibrous tissue to the basal stratum of the decidua, (2) by finer bands of similar substance both to one another and to the septal prolongations of the decidua; others hang freely into the placental sinuses. These sinuses are supplied directly with arterial blood from tortuous branches of the uterine arteries which pass through the

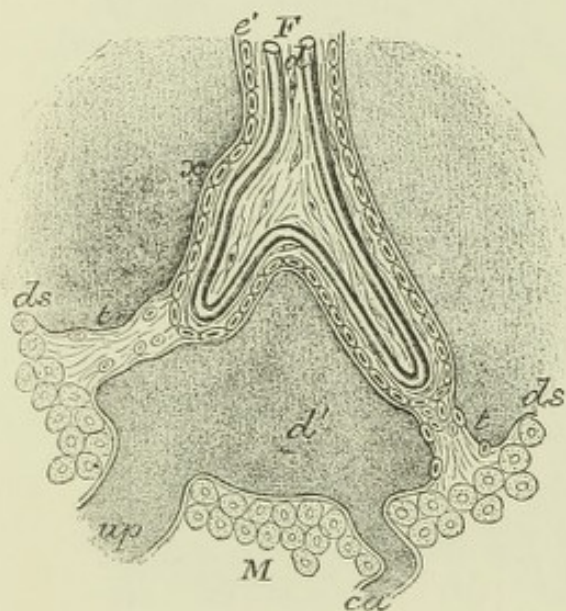


Fig. 55.—DIAGRAM SHOWING THE TISSUES COVERING THE VILLI IN THE HUMAN PLACENTA, AND THEIR RELATION TO THE DECIDUA ACCORDING TO TURNER.

F, foetal tissue; *M*, maternal tissue; *d*, blood-vessels in villus; *d'*, blood in placental sinus; *e'*, layer of cells covering villus; *x*, basement membrane covering villus (? endothelium) continued from uterine vessels; *ds*, decidua serotina; *t*, tissue uniting villus to decidua; *ca*, *up*, uterine vessels opening into sinus.

spongy stratum of the decidua serotina and through the basal stratum of the placenta to open into the sinuses without the intervention of capillaries. From the sinuses veins, which run very obliquely through the decidua, carry off the blood, and eventually pass into the veins of the muscular wall. The foetal villi are thus bathed by slowly flowing maternal arterial blood, and respiratory and nutritive exchanges may occur between the two kinds of blood, but there is no actual mixing

¹ Minot describes both the villi and the sinuses of the placenta as bounded by the chorionic epithelium. This would agree very well with recent observations in the bat, hedgehog, and other mammals, which show that these spaces are originally developed in hypertrophied epiblast (see next page).

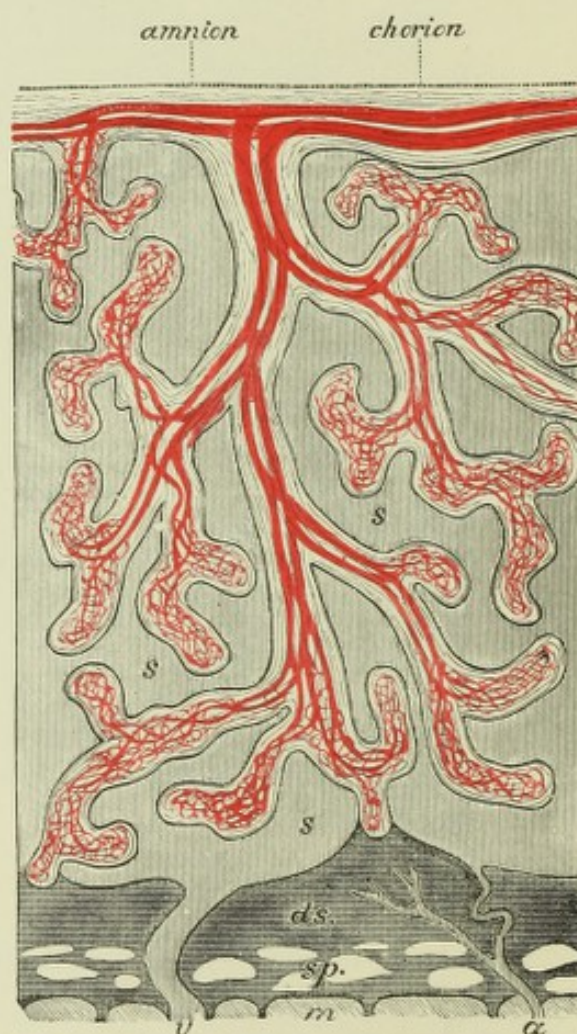


Fig. 56.—DIAGRAM OF THE PLACENTA (E. A. S.).

am, amnion; *ch*, chorion; *s*, placental sinus; *ds*, decidua serotina; *sp*, spongy layer; *m*, muscularis; *a*, *v*, uterine artery and vein opening into placental sinus.

of the two fluids, nor is it possible to inject the foetus from the mother through the placenta, or the mother from the foetus.

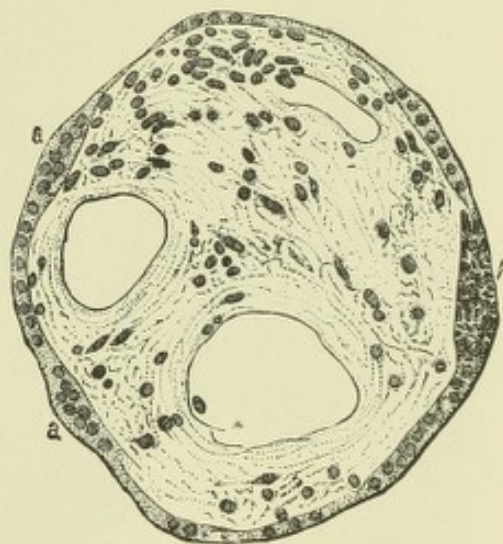
The question, which has been more than once raised, whether the intervillous spaces normally contain blood, may be now regarded as settled in the affirmative. It has been usually held that they represent capillaries or veins of the decidua, which have become dilated and fused together to such an extent as to occupy the whole thickness of the placental part of that membrane, with atrophy of the intervening decidual tissue, which merely remains as a covering to the villi. But since the placental sinuses appear to be bounded superficially by the chorionic covering of the ovum, and it is in most places not possible to detect any decidual tissue between them and the chorion, it has been conjectured by some writers (Kölliker, Langhans) that they have become formed by extravasation of blood into a space between the ovum and the decidua, into and across which space the chorionic villi have grown. Although the development of these structures is insufficiently known in Primates, it has been shown in various mammals (Selenka, Duval, Hubrecht, Masius) that the first attachment of the blastodermic vesicle to the uterine wall is effected by the external layer of the epiblast, which sometimes splits off over the embryonic area as a distinct layer, and which, in some animals (*e.g.*, hedgehog), becomes greatly thickened, and is connected by epiblastic villi to the decidua. This external layer of epiblast, for which Hubrecht has proposed the general name of *trophoblast*, causes the absorption of the uterine epithelium both of the surface and of the glands (where this epithelium has not previously been cast off) and comes directly in contact with the enlarging decidual vessels, the endothelium of which is actively proliferating. Within the thickened trophoblast clefts now make their appearance and are presently found to be occupied by maternal blood, which is derived from the vessels of the adjacent hypertrophied decidua. This blood flows therefore into spaces in the trophoblast, which are only bounded by foetal epiblast, and this *primary placental circulation* may be formed before any foetal blood-vessels have reached the chorion. Subsequently, when the vascular mesoblastic villi become formed they extend into these spaces, pushing before them the epiblast; by this layer they remain permanently covered and it also lines the enlarged spaces into which they have extended.

The **placenta** is composed of two parts, one foetal, composed of chorion with its villi; the other maternal, formed from decidua serotina. In its completely

Fig. 57.—TRANSVERSE SECTION OF A VILLUS FROM A PLACENTA OF SEVEN MONTHS (Minot).

Three blood-vessels are seen within the villus, imbedded in a jelly-like connective tissue containing cells and fibres; *a, a*, cell-layer covering villus (epiblast according to Minot; according to others of decidual origin); *f*, a thickened portion of this cell-layer, which has undergone a fibrinous transformation (canalised fibrin).

developed condition, it is a circular discoid mass, weighing about a pound, 7 or 8 inches in diameter, thickest at the centre ($1\frac{1}{4}$ inch), and thinning away towards the edges, which are continuous with the comparatively thin coalesced decidua and chorion. Its inner surface is smooth and concave, and is closely covered by the amnion as by a serous membrane; under this the larger branches of the umbilical vessels course before dipping into the substance of the placenta. From near the centre of the organ the umbilical cord passes off to the foetus. Its outer surface is incorporated with the uterine wall, but when detached from this by tearing through the spongy tissue of which the deeper part of the decidua is formed (as occurs in parturition at the expulsion of the foetus), the outer surface appears ragged and irregular, in striking contrast to the smooth amnion-covered inner surface. Examined under the microscope, the chorionic tissue (villi) of the placenta is found to be composed of jelly-like connective tissue, with branched and anastomosing cells (fig. 57); in some parts of the larger stems white fibres are seen. What remains of the decidual



tissue has a fibrous appearance, with very numerous decidual cells, which frequently obscure the fibres (fig. 54, B). In and after the fifth month of pregnancy, a number

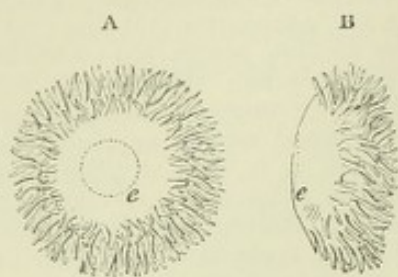


Fig. 58. — FRONT AND SIDE VIEWS OF AN EARLY HUMAN OVUM FOUR TIMES THE NATURAL SIZE (from Reichert).

This ovum is supposed to be of thirteen days after impregnation. The surface bare of villi is that next the wall of the uterus, showing at *e*, the opacity produced by the thickened embryonic disc. The villi covered chiefly the marginal parts of the surface.

of large multinucleated giant cells are found scattered about in the tissue. They occur most abundantly in the outermost layer of the decidua serotina, and have been described by Friedlander and by Leopold as growing at a later stage (eighth or ninth month) into the veins which pass through this layer, so

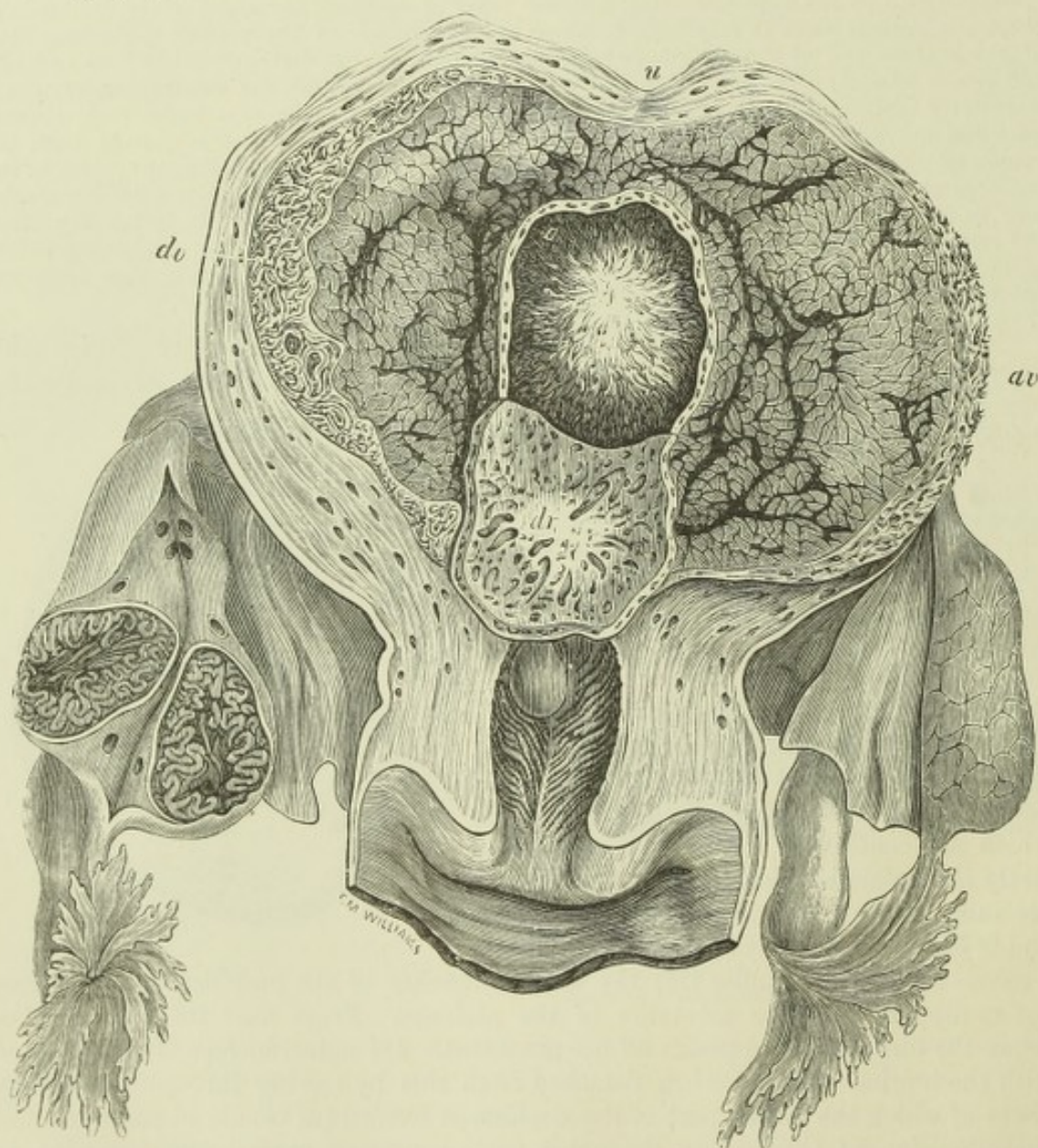


Fig. 59. — VIEW OF THE INTERIOR OF THE HUMAN GRAVID UTERUS AT THE TWENTY-FIFTH DAY (from Farre after Coste).

u, uterine wall; *o*, ovum with villous chorion; *dr*, decidua vera; *dr*, decidua reflexa, divided round the margin of the ovum, and turned down so as to expose its pitted surface, which has been removed from the ovum. The right ovary is divided, and shows in section the plicated condition of the early corpus luteum.

as to produce a partial blockage of these veins, preparatory to the detachment of the placenta from the layer.

The villi do not at first cover the whole surface of the ovum, but are deficient at the embryonic, and perhaps also at the opposite, pole. In the earliest human ovum which has hitherto been described, that of Reichert (fig. 58), the villi, which are quite simple, occur in a broad zone around the circumference of the ovum, leaving the (somewhat flattened) poles smooth and free from villi, and on one of these poles a thickening of the wall of the vesicle could be detected, which was probably the embryonic area. But in all other early human ova which have been noticed, the chorion, which is now formed by the false amnion, is covered with ramified villi (shaggy chorion), and these are already vascularized from the allantois, and have grown into the substance of the decidua reflexa and the decidua serotina, the formation of the placenta having already begun.

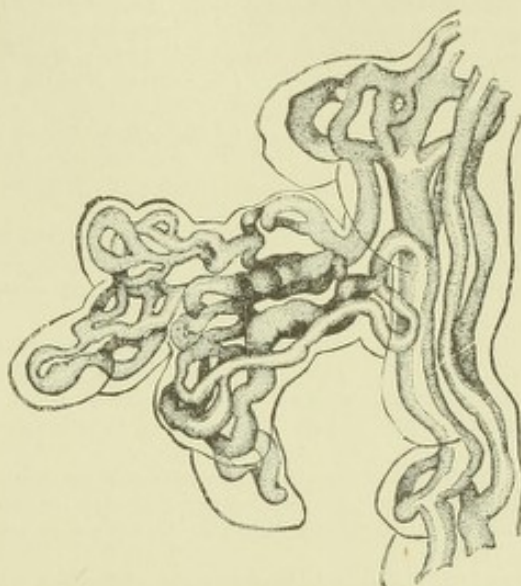


Fig. 60.—PORTION OF AN INJECTED VILLUS FROM A PLACENTA OF ABOUT FIVE MONTHS (Minot).

Separation of the decidua at birth, and regeneration of the uterine mucous membrane.—In parturition, the pressure of the contracting muscular walls upon the uterine contents, and especially upon the amniotic fluid, causes a bulging of the membranes (consisting of the combined deciduæ, the chorion, and the amnion) through the os uteri. When the membranes are ruptured, the amniotic fluid first escapes, and subsequently the fœtus is expelled. With further contraction of the uterus, the placenta becomes detached from the uterine wall, separating along the plane of the dilated parts of the glands (stratum spongiosum of the decidua serotina), and as it is expelled, the separation extends around the decidua lining the rest of the uterus, which appears in the "after-birth" along with the chorion and amnion as a thin membranous skirt to the edge of the placenta. The deepest part of the decidua containing the bases of the uterine glands is everywhere left in connection with the muscular tissue, and from these basal portions of the glands, first the whole of the uterine glands, and subsequently the lining epithelium of the uterus become gradually regenerated.

RECENT LITERATURE.

- Allen, W., *Omphalo-mesenteric remains in mammals*. Journ. Anat. and Physiol., xvii., 1883.
 Beneden, Ed. van, *De la fixation du blastocyste à la muqueuse utérine chez le murin (Vespertilio murinus)*. Bullet. de l'Acad. roy. de Belgique, Sér. iii., T. xv.; *De la formation et de la constitution du placenta chez le murin (Vespertilio murinus)*. Bulletins de l'Acad. roy. de Belgique, T. xv., 1888.
 Beneden, E. v., et Julin, *Recherches sur la formation des annexes fœtales chez les mammifères*. Arch. de biologie, v. 1884.
 Bonnet, R., *Die Uterinmilch und ihre Bedeutung für die Frucht*. Beiträge zur Biologie, 1882; *Die Eihäute des Pferdes*. Verhandl. d. anat. Gesellschaft, 1889.
 Bumm, *Zur Kenntniss der Uteroplacentalgefässe*. Archiv f. Gynäkologie, xxxv., xxxvii.; *Zur Anat. d. Placenta*. Würzburg Sitzungsab., 1889.
 Cadiat, *L'allantoide*. Gaz. méd. de Paris, 4 sér. vi., 1887.
 Caldwell, W. H., *On the arrangement of the embryonic membranes in marsupial animals*. Quarterly Journal of Microsc. Science, xxiv., 1884.
 Colucci, G., *Di alcuni novi dati di struttura della placenta umana*, 1887.

Duval, M., *Les placentas discoïdes en général, à propos du placenta des rongeurs*. Comptes rendus de la société de biologie, Sér. viii., T. v., 1888; *Le placenta des rongeurs*. Journal de l'anat. et de la physiol., xxv.

Ercolani, G. B., *Nuove ricerche di anatomia normale e patologica sulla placenta dei mammiferi e della donna*. Mem. d. accademia d. scienz. d. Bologna, 1883. (French in Archives italiennes de biologie, iv.)

Fleischmann, Ueber die erste Anlage der Placenta bei den Raubthieren. Sitzb. der physik. medic. Soc. zu Erlangen, 1886; *Embryologische Untersuchungen*. Heft i. *Untersuchungen über einheimische Raubthiere*. Wiesbaden, 1888; *Mittelblatt und Amnion der Katze*. Erlangen, 1888.

Frommel, R., *Entw. d. Placenta v. Myotis murinus*. Wiesbaden, 1888 (Centralbl. f. Gynäk., 1889).

Hart, B., *The mechanism of the separation of the placenta, &c.* Proc. Roy. Soc. of Edinburgh, xv., 1889.

Heinz, R., *Untersuchungen über den Bau und die Entwicklung der menschlichen Placenta*. Inaug.-Diss. Breslau, 1888.

Heinricius, G., *Die Entwickl. der Hunde-Placenta*. Sitzungsab. d. Berlin. Akad., 1889; Arch. f. mikr. Anat. 33, 1889.

Hoffmann, C. K., *Ueber das Amnion des zweiblättrigen Keimes*. Archiv f. mikrosk. Anatomie, xxiii., 1884.

Hofmeier, *Zur Anatomie d. Placenta*. Würzburg Sitzungsab., 1889.

Hubrecht, *The placentation of Erinaceus Europæus, with remarks on the phylogeny of the placenta*. Quarterly Journal of Microsc. Science, 1889.

Kastschenko, N., *Das menschliche Chorionepithel und dessen Rolle bei der Placenta*. Arch. f. Anat. u. Physiol., Anat. Abth., 1885.

Keibel, F., *Zur Entwicklungsgesch. der menschlichen Placenta*. Anat. Anzeiger, iv., 1889.

Klein, *Ueber die Entstehung der Placenta marginata*. Arch. f. Gynäk., xxxvi.

Kundrat und Engelmann, *Untersuchungen über die Uterusschleimhaut*. Stricker's med. Jahrb., 1873.

Kupffer, C., *Die Entstehung der Allantois und die Gastrula der Wirbelthiere*. Zoologischer Anzeiger, ii., 1879; *Decidua und Ei des Menschen am Ende des ersten Monats*. Münchener Wochenschrift, 1888.

Langhans, *Die Lösung der mütterlichen Eihäute*. Archiv für Gynäkol., viii., 1876; *Ueber die Zellschicht des menschlichen Chorions*. Henle's Festgabe, 1882.

Leopold, *Studien über die Uterusschleimhaut während Menstruation, Schwangerschaft und Wochenbett*. Archiv f. Gynäkol., xi., 1877; *Ueber den Bau der Placenta*. Archiv f. Gynäkologie, xxxv., 1889.

Lieberkühn, N., *Der grüne Saum der Hundeplacenta*. Arch. f. Anat. u. Physiol., Anat. Abth., 1889.

Marius, J., *De la genèse du placenta chez le lapin*. Arch. de biologie, ix., 1889.

Masquelin et Swaen, *Premières phases du développement du placenta maternel chez le lapin*. Arch. de biol., i., 1880.

Minot, *Uterus and embryo*. Journal of Morphology, Vol. ii., 1889 (includes a tolerably full Bibliography of the subject).

Nitabuch, R., *Beiträge zur Kenntniss der menschlichen Placenta*. Inaug.-Diss. Bern, 1888.

Osborn, H. F., *Observations upon the fetal membranes of the Opossum and other Marsupials*. Quarterly Journal of Microsc. Science, xxiii., 1883.

Rohr, K., *Die Beziehungen d. mütterl. Gefäße z. d. intervillösen Raumen, &c.* Virchow's Archiv, 1888.

Ruge, K., in Schröder, K., *Der schwangere u. kreisende Uterus*. Bonn, 1886.

Ryder, J. A., *The origin of the Amnion*. American Naturalist, xx., 1886; *A theory of the origin of placental types, and on certain vestigiary structures in the placenta of the mouse, rat, and field-mouse*. American Naturalist, xxi., 1887.

Strahl, H., *Die Allantois von Lacerta viridis*. Sitzungsab. d. Marburger Gesellsch., 1883; *Ueber den Bau der Placenta; Die Anlagerung des Eies an die Uteruswand*. Arch. f. Anat. u. Physiol., Anat. Abth., 1889; *Zur vergleichenden Anat. d. Placenta*. Verhandl. d. anat. Gesellschaft, 1889; *Placenta von Putorius furo*. Anat. Anz., iv., 1889.

Tafari, A., *La circulation dans le placenta de quelques mammifères*. Archives italiennes de biol., viii., 1887.

Turner, Wm., *Lectures on the comparative anatomy of the placenta*. Edinburgh (Black), 1876; *Some general observations on the placenta, with especial reference to the theory of evolution*. Journ. of Anat. and Physiol., xii., 1877; *On the placentation of the Apes, with a comparison of the structure of their placenta with that of the human female*. Phil. Trans., lxi., 1879; *An additional contribution to the placentation of the Lemurs*. Proceedings of the Royal Society, Vol. xlv., 1888.

Waldeyer, W., *Ueber den Placentarkreislauf des Menschen*. Sitzb. d. k. Akad. d. Wissensch. zu Berlin, vi., 1887; *Die Placenta von Inuus nemestrinus*. Ibid., 1889; *Menschen- und Affen-placenta*. Archiv f. mikr. Anat., Bd. 35, 1890.

DEVELOPMENT OF THE NERVOUS SYSTEM.

As has been already described, the whole of the central nervous system takes origin from the thickened walls of a dorsally situated axial groove, subsequently converted into a canal, which runs forwards in front of the primitive streak, and the anterior end of which becomes enlarged and converted by constrictions into three successive vesicles, around which the several parts of the brain are formed, and which are known as the primary cerebral vesicles. The remainder of the neural canal is of nearly uniform diameter, and its walls become converted into the substance of the spinal cord, while the cavity itself becomes eventually the central canal of the cord. The walls of the neural groove are of course composed of epiblast, and it therefore follows that the whole structure of the central nervous system is laid down in epiblast, and consists in the main of more or less modified epiblastic elements, except where mesoblastic tissues subsequently penetrate into it, conveying blood-vessels into its substance. As was shown by Balfour, the same is in all probability true for all the nerves of the body, cranial and spinal, which either, as with the fibres of the anterior roots of the spinal nerves, grow directly out from the neural epiblast, or, as with the fibres of the posterior roots, are formed and grow from masses of epiblast cells, which are separated off at the junction of the neural and general epiblast to form the ganglia, from which the posterior root fibres appear to take origin (His). An exception must, however, be recorded for the olfactory tracts and bulbs and optic tracts and nerves, which, although derived from the neural epiblast, yet have a different mode of origin from all other nerves, both cranial and spinal, since they arise not as solid outgrowths of that epiblast, but as hollow protrusions from the brain, which only become solid at a later stage of development. We have then to consider the manner in which are developed (1) the spinal cord; (2) the several parts of the brain; and (3) the spinal and cranial nerves and their ganglia, as well as the ganglia and nerves of the so-called sympathetic nervous system.

DEVELOPMENT OF THE SPINAL CORD.

Soon after the neural canal is closed (fig. 32, p. 31), it takes the form, along the greater part of the length of what is afterwards to become spinal cord, of a cleft-like cavity, with thick sides, and a relatively thin dorsal and ventral boundary (roof and floor). The parietes of the canal are wholly composed of long columnar epithelium cells, whose free borders, which are at first smooth, but later become ciliated, line the cavity, and whose attached extremities rest upon a homogeneous limiting membrane which early makes its appearance, bounding the embryonic cord, and separating it from the surrounding structures. These cells, therefore, extend at first through the whole thickness of the embryonic cord, and they have the closely-set, palisade-like character, with the nuclei at different depths, such as it is usual to find in long columnar epithelium.

After a time, it is found that the cells (which have become always longer with the increasing thickness of the wall of the neural canal) show a tendency to branch and to unite with the branches of neighbouring cells. In this way a network or spongework is produced, which extends throughout the greater part of the thickness of the embryonic cord; at the same time the inner parts of the cells which immediately line the canal retain their palisade-like arrangement, while the external or attached ends often exhibit a radiating disposition, which gives a characteristic radial character to the external layer of the reticular structure. The reticulum is

termed *myelospongium*, and the cells by which it is formed are spoken of as *spongioblasts* (His) (fig. 61).

Between the inner ends of the columnar epithelium cells or spongioblasts there is seen at a comparatively early period (four and five weeks in the human embryo) a number of rounded cells, with a considerable amount of clear protoplasm, forming

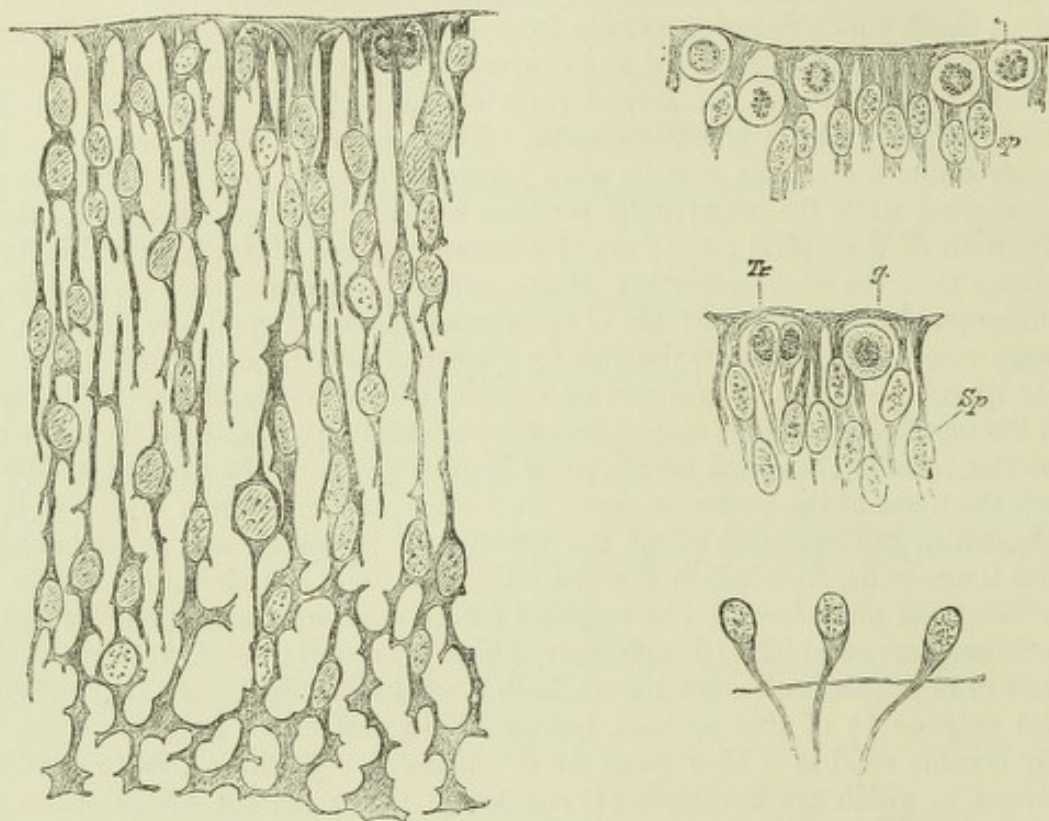


Fig. 61.—MYELOSPONGIUM FROM SPINAL CORD OF THREE AND A HALF WEEKS HUMAN EMBRYO (His) $\frac{750}{1}$.

Fig. 62.—INNER ENDS OF SPONGIOBLASTS WITH GERMINAL CELLS, *g*, BETWEEN THEM; FROM SPINAL CORD OF HUMAN EMBRYO (His).

Fig. 63.—INNER ENDS OF SPONGIOBLASTS (*Sp*); A GERMINAL CELL (*g*) AND TWO TRANSITIONAL CELLS (*Tr*) FROM SPINAL CORD OF HUMAN EMBRYO (His).

Fig. 64.—THREE NEUROBLASTS, EACH WITH A NERVE-FIBRE PROCESS GROWING OUT BEYOND THE BASEMENT MEMBRANE OF THE EMBRYONIC SPINAL CORD (His).

an interrupted layer in this innermost zone. Their nuclei are mostly in one stage or another of karyokinesis (fig. 62). They are termed by His the *germinal cells*, and according to him they give origin to the cells next to be described.

The third kind of cell (*neuroblast*) met with in the cord of the early embryo is one with a relatively large oval nucleus, and little protoplasm, but with a tapering protoplasmic prolongation directed outwards towards the surface of the cord. These cells are found in groups, at first only in or near the layer of germinal cells (fig. 63), but subsequently in the outer layers (fig. 64). The prolongations are the commencements of the nerve-fibres, and they mostly converge either straight or with an arcuate course towards what will subsequently be the place of exit of the fibres of the anterior roots.

The outermost layer of the embryonic cord after the differentiation of the various kinds of cells above described is free from nuclei, and is composed of the partly reticulated, partly radially arranged external or attached extremities of the

spongioblasts. This may be taken to represent the white matter of the cord at this stage (all the rest representing grey substance) : but there are at first no nerve fibres in it, the only structures which can be at all compared to nerve fibres being the prolongations of the neuroblasts, and these lie either as arcuate fibres altogether in the outer part of the grey substance, or are passing out of the cord as the beginnings of the anterior roots from a mass of neuroblasts which forms the rudiment of the anterior cornu of grey matter (fig. 65). This mass constitutes in the human embryo of six weeks (fig. 66) the chief portion of each half of the cord. It forms a considerable projection which laterally almost reaches the surface, but ventrally is separated from it by a thickening of the external or radial zone, due to the appearance of longitudinally coursing nerve fibres within it : this is the beginning of the anterior

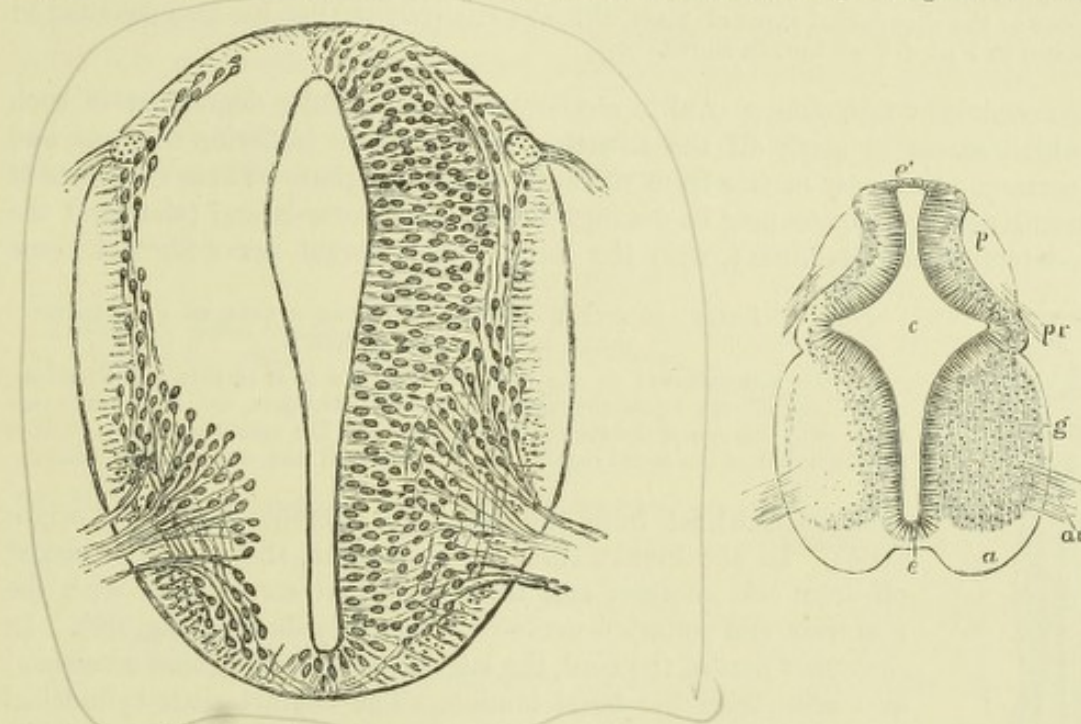


Fig. 65.—SECTION OF SPINAL CORD OF FOUR WEEKS HUMAN EMBRYO (His).

The posterior roots are continued within the cord into a small longitudinal bundle which is the rudiment of the posterior white column. The anterior roots are formed by the convergence of the processes of the neuroblasts. The latter, along with the elongated cells of the myelospongium compose the grey matter. The external layer of the cord is traversed by radiating fibres which are the outer ends of the spongioblasts. The anterior commissure is beginning to appear. This figure is much more magnified than the next one.

Fig. 66.—TRANSVERSE SECTION OF THE CERVICAL PART OF THE SPINAL CORD OF A HUMAN EMBRYO OF SIX WEEKS (from Kölliker). $\frac{3}{4}$

c, central canal ; *e*, its epithelial lining ; *at* (*e'* superiorly), the original place of closure of the canal ; *a*, the white substance of the anterior columns ; *g*, grey substance of antero-lateral horn ; *p*, posterior column ; *ar*, anterior roots ; *pr*, posterior roots.

white column (*a*). By this time, also, although to a rather less extent, the posterior white columns have, simultaneously with the posterior roots, begun to make their appearance on either side of the narrow dorsal part of the neural canal (*p*). There is, however, only a relatively thin layer of grey matter (neuroblasts) separating the posterior white columns from the palisade-like lining of the canal, and as yet no sign of nerve fibres in the situation of the lateral columns, which are only represented by a thin layer of the radial myelospongium. The roof and floor of the canal are also quite thin and undeveloped.

At this period there is still no sign of either anterior or posterior (dorsal or ventral) fissures of the cord. These become formed as the cornua of the grey matter grow out from the central mass, and as the anterior and posterior white columns

increase in extent. The anterior fissure is simply a cleft left between the enlarging lateral halves of the cord; the anterior commissure is formed across the bottom of the cleft, which is thereby separated from the central canal. As for the posterior fissure, it is uncertain whether it is in part formed from the dorsal portion of the constricted canal, which has become occupied by an ingrowth of pia mater, and converted into a mere septum of connective tissue, or whether this fissure with its connective tissue septum becomes formed independently of the central canal, which, as the fissure extends, gradually atrophies until it is eventually converted into the rudimentary epithelial tube which is persistent during life.

In the sacral region of birds, the central canal expands into the rhomboidal sinus, and in the *filum terminale* of the human cord it remains relatively large. An open enlargement analogous to the rhomboidal sinus of birds, although relatively smaller, has been described by Tiedemann in a nine-week human foetus.

The cord is at first oblong oval in section, with an angular depression in each side which serves to mark off the situation of the future posterior columns and their corresponding grey matter from the antero-lateral region. These two parts of the lateral neural epiblast may be distinguished as the dorso-lateral (alar) and the ventro-lateral (basal) laminae; with the former, the afferent nerve-fibres become

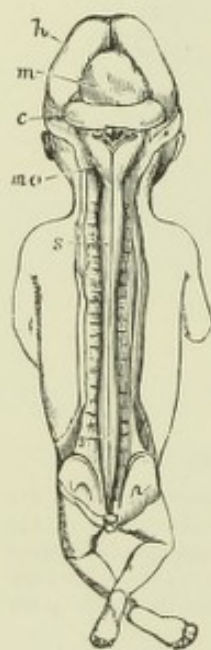


Fig. 67.—BRAIN AND SPINAL CORD EXPOSED FROM BEHIND IN A FŒTUS OF THREE MONTHS (from Kölliker).

h, the hemispheres; *m*, the mesencephalic vesicle or corpora quadrigemina; *c*, the cerebellum; below this are the medulla oblongata, *mo*, and fourth ventricle, with remains of the membrana obturatoria. The spinal cord, *s*, extends to the lower end of the sacral canal, and shows brachial and crural enlargements.

connected, whilst from the latter the efferent fibres take origin (His). In the human embryo of six weeks, they are well marked off from one another, and their respective connections with the posterior and anterior nerve-roots are very distinct (fig. 66). In the upper part of the cord, the lateral nerve-roots (spinal accessory) also arise from the basal lamina. The characteristic cylindrical form of the cord is only attained with the development of the lateral columns. The cervical and lumbar enlargements are manifest at the end of the third month.

Up to the fourth month, the cord and the vertebral canal increase in length *pari passu*, but the vertebral column then begins to grow more rapidly than the cord, so that by the time of birth the coccygeal end of the cord is opposite the third lumbar vertebra, while in the adult its limit is the lower end of the first lumbar. Along with this relative shifting of the cord and its containing tube, the lower nerve-roots lose their regular rectangular course, and become oblique. They alone, with the *filum terminale*, occupy the lower end of the neural canal, where they form the *cauda equina*.

The nerve fibres of the white columns are at first entirely non-medullated, and the white substance has a greyish transparent appearance. The medullary sheath is not formed simultaneously in all parts, but appears at different times in different parts corresponding with the tracts of conduction; the last of these tracts to become medullated are the pyramidal tracts.

The membranes are formed from mesoblast of the protovertebræ, which extends over and under the cord, and becomes enclosed along with that structure within the developing vertebral canal. The septa of connective tissue which are seen penetrating into the substance of the cord from the pia mater grow in from this mesoblast, carrying blood-vessels amongst the nervous elements. The *neuroglia* or

general sustentacular substance of both white and grey matter is probably derived from the spongioblasts, and is therefore, like the nerve-cells themselves, of epiblastic or gin.

DEVELOPMENT OF THE BRAIN.

We have already traced the development of the cephalic part of the neural tube as far as the formation of the primary cerebral vesicles. These, which are at first three in number (fig. 40), become subdivided so as to form five in all, which may be termed in succession from before back, the first, second, third, fourth, and fifth secondary vesicles. Of these five parts the first two, which represent the cerebral and thalamic parts of the future brain (third ventricle), are derived from the first primary vesicle, and the last two, the cerebellar and bulbar parts (fourth ventricle), from the third primary vesicle, while the third, middle, or quadrigeminal part, represents the undivided second primary vesicle (Sylvian aqueduct). These relationships, as well as the several parts of the brain which are eventually respectively formed in connection with the vesicles, are shown in the subjoined table.

| | | | |
|--|---|---|--|
| I. Anterior primary vesicle or fore-brain | First secondary vesicle (<i>prosencephalon</i>) | { | Anteriorend of third ventricle, foramina of Monro, lateral ventricles, cerebral hemispheres, olfactory bulbs and tracts, corpora striata, corpus callosum, fornix. |
| | Second secondary vesicle (<i>thalamencephalon</i>) | | |
| II. Middle primary vesicle or mid-brain | Third secondary vesicle (<i>mesencephalon</i>) | { | Aqueduct of Sylvius, corpora quadrigemina, crura cerebri. |
| III. Posterior primary vesicle or hind-brain | Fourth secondary vesicle (<i>epencephalon</i>) | { | Fourth ventricle { Cerebellum. Pons. Medulla oblongata. |
| | Fifth secondary vesicle (<i>metencephalon</i>) | | |

The first and most striking change which occurs in the primary brain is the outgrowth on either side of the first primary vesicle of a hollow protrusion (*primary optic vesicle*), which becomes developed eventually into optic nerve and retina (fig. 68). The changes which it undergoes in the formation of these structures will be considered when the development of the eye is dealt with; suffice it for the present to say that the free hollow communication (optic stalk), which at first exists between the forebrain and optic vesicle, becomes gradually narrowed and at length obliterated, and that as development proceeds, the connection of the optic stalk becomes relatively shifted backwards, so that when the anterior part of the fore-brain is distinct from the posterior part, or thalamencephalon, the optic vesicle is connected wholly with the latter, a relationship which is maintained permanently, although partially obscured afterwards by the later connection which is formed between the optic tract and the mid-brain. Subsequently another pair of hollow outgrowths sprouts from the fore-brain, and these rapidly extend forwards, laterally and backwards; they form the *vesicles of the cerebral hemispheres*. From the roof of the fore-brain (second vesicle) a median hollow protrusion grows upwards and forwards for a certain distance towards the vertex, and from the floor of the same vesicle another somewhat similar protrusion passes downwards and backwards towards the roof of the mouth. The former is the rudiment of the *pineal gland*, the latter of the *infundibulum*, which becomes involved in the formation of the pituitary body.

The principal parts of the brain appear as thickenings in different parts of the

walls of the vesicles. Thus the corpora striata are formed in the floor of the hemisphere vesicles, whilst the principal mass of each hemisphere is formed from the roof and sides (mantle) of those vesicles, and the olfactory lobes are hollow out-

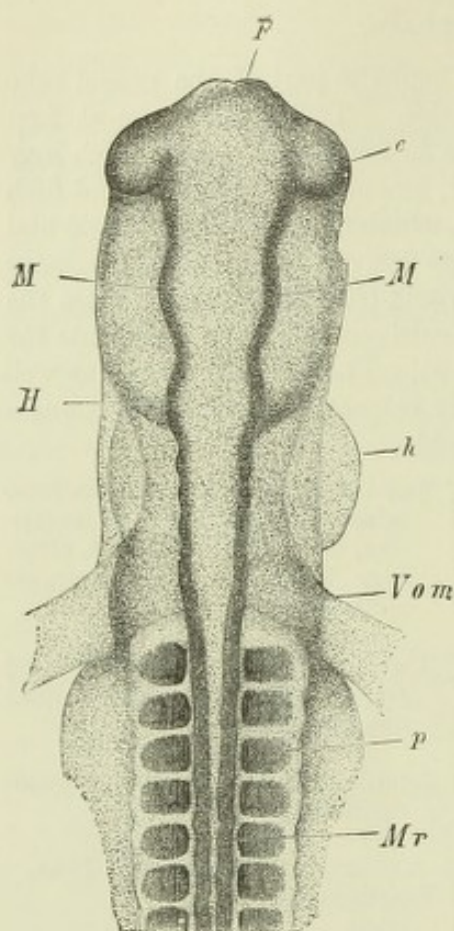


Fig. 68. — FORE-PART OF THE EMBRYO SHOWN IN FIG. 38, VIEWED FROM THE DORSAL SIDE. $\frac{1}{10}$. (From Kölliker.)

F, fore-brain; *e*, ocular vesicles; *M*, mid-brain; *H*, hind-brain; *h*, part of the heart seen bulging to the right side; *Vom*, omphalo-mesenteric or vitelline veins entering the heart posteriorly; *Mr*, medullary canal, spinal part; *p*, proto-vertebral somites.

growths from them. The cavities of the hemisphere-vesicles become the lateral ventricles, and the cavity of the part of the fore-brain (or first secondary vesicle) from which they spring, forms the anterior extremity of the third ventricle. The optic thalamus is formed by a thickening of the lateral wall of the second vesicle, the cavity of which comes to be the main part of the third ventricle; the corpora quadrigemina are thickenings in the roof, and the crura cerebri thickenings of the sides and floor of the third vesicle, which becomes the aqueduct of Sylvius; the cerebellum and pons are respectively thickenings of the roof and floor and the crura cerebelli of the sides of the fourth vesicle (anterior part of hind-brain), the cavity of which becomes the anterior (superior) part of the fourth ventricle; and finally, the medulla oblongata is developed as a thickening of the wall of the fifth vesicle, the cavity of which expands from

the central canal of the spinal cord to form the calamus scriptorius of the fourth ventricle.

On the other hand, certain parts of the walls of the vesicles become thin and greatly expanded, and even eventually project into the cavities as folds of epithelium

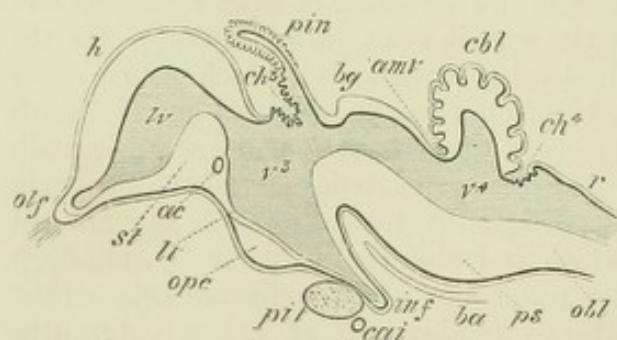


Fig. 69. — OUTLINE OF A LONGITUDINAL SECTION THROUGH THE BRAIN OF A CHICK OF TEN DAYS (after Mihalkovics).

h, cerebral hemisphere; *olf*, olfactory lobe and nerve; *st*, corpus striatum; *lv*, lateral ventricle; *ac*, anterior commissure; *lt*, lamina terminalis; *ope*, optic commissure; *pit*, pituitary gland; *inf*, infundibulum; *cai*, internal carotid artery; *v³*, third ventricle; *ch³*, choroid plexus of third ventricle; *pin*, pineal gland; *bg*, corpora bigemina; *amv*, anterior medullary velum; below which two last references are the aqueduct of Sylvius and crura cerebri; *cbl*, cerebellum; *v⁴*, fourth

ventricle; *ba*, basilar artery; *ps*, pons Varolii; *ch⁴*, choroid plexus of the fourth ventricle; *obl*, medulla oblongata; *r*, roof of fourth ventricle.

covering ramified vascular expansions of pia mater (choroid plexuses). These vascular expansions occur along the lower border of the mesial surface of each hemisphere-vesicle (choroid plexuses of lateral ventricles); along the roof of the second vesicle (choroid plexus of third ventricle), and in the roof of the fifth vesicle (choroid plexus of fourth ventricle).

While these changes are going on in its walls the embryonic brain does not remain straight as at first, with its axis in a line with that of the spinal cord, but undergoes certain flexures (fig. 70), the general result of which is to bend the anterior end towards the ventral surface. The first of these flexures to make its appearance is a sharp bend opposite the base of the mid-brain and around the anterior end of the notochord. The result of this flexure, which produces a complete doubling round of the anterior part of the brain, is that the mid-brain is for a time the most prominent part of the encephalon. Later, the growth of the cerebral vesicles, and of the thalamencephalon, brings these parts again into prominence, and tends to obscure the flexure, which is, however, never actually obliterated. The second cerebral flexure, which is also very sharp and well marked, occurs in the region of the hind-brain (pons Varolii). It is in the opposite direction to the first one, its concavity being directed towards the dorsum of the embryo, and it produces the appearance of a deep depression at the part of the brain where it occurs. The third flexure is a more gradual one. It occurs at the junction of the hind-brain with the cord, the embryonic medulla oblongata being bent ventralwards from the line of direction of the medulla spinalis.

The result of these flexures is that the axis of the embryonic brain takes a crook-shape, passing from the end of the spinal axis at first ventral, then dorsal, and then again ventral, finally bending sharply backwards towards its termination at the foramen of Monro.

The second and third flexures become eventually almost entirely obliterated with the further growth of the brain.

FURTHER DETAILS REGARDING THE DEVELOPMENT OF SPECIAL PARTS OF THE BRAIN.

The fifth cerebral vesicle: bulbar vesicle, or metencephalon.—This part of the embryonic brain, afterwards to become the **medulla oblongata**, often shows at its first appearance—especially in the chick—a series of slight constrictions (fig. 68), which have by some been taken to indicate a segmentation of the neural tube. But even where they occur they are quite temporary, and the fifth vesicle soon becomes a well marked dilatation opening out from the anterior end of the embryonic spinal cord. Its wall, like that of all the other cerebral vesicles, is composed of cells similar to those of the rest of the neural tube, and the histogenetic changes which occur to form the nervous tissue are also entirely similar.

Sections across this part of the neural tube are of a compressed oval outline in the lower part (fig. 71, A, B), but in the upper part, which afterwards becomes the lower part of the fourth ventricle, the thinning out and lateral expansion of the dorsal wall of the tube gives to sections of this and the next (fourth) vesicle the shape of an irregular triangle, or shield, the base of the triangle being directed towards the dorsum (roof) and the sides bent more or less sharply inwards about their middle to unite with one another ventrally at the apex of the triangle (figs. 72, 73). This bend serves to mark a division of each side of the tube into two parts, a dorso-lateral and a ventro-lateral, which correspond, both in their situation and in their relationship to afferent and efferent nerves, with the alar and basal laminae of the embryonic cord (p. 60), with which they are in fact continuous. The thinning out and lateral expansion of the roof in the region of the fourth ventricle tends to open up the angle which the ventral laminae form with one another, and to throw the dorsal laminae more to the side, so that what were previously the lateral boundaries of the neural tube come to occupy the so-called floor of the fourth ventricle, and since in this region the roof becomes

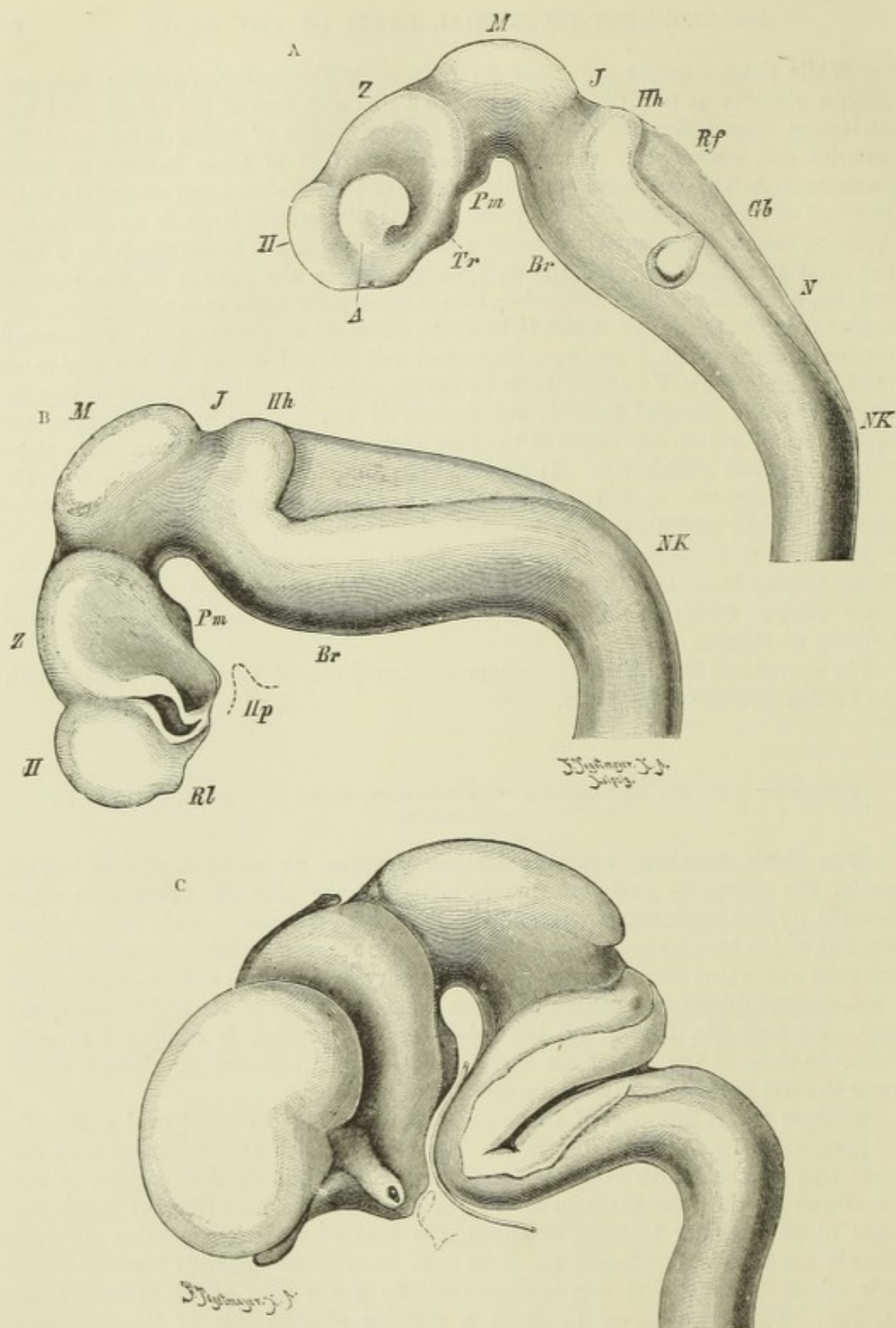


Fig. 70.—PROFILE VIEWS OF THE BRAIN OF HUMAN EMBRYOS AT THREE SEVERAL STAGES, RECONSTRUCTED FROM SECTIONS (His).

A. Brain of an embryo of about 15 days (the embryo itself is shown in fig. 117) magnified 35 diameters.

B. Brain of an embryo about three and a half weeks old. The optic vesicle has been cut away.

C. Brain of an embryo about seven and a half weeks old. The optic stalk is cut through.

A, optic vesicle; H, vesicle of cerebral hemisphere, first secondary vesicle; Z, thalamencephalon, second secondary vesicle; M, mid-brain; J, isthmus between mid- and hind-brain; Hh, fourth secondary vesicle; N, fifth secondary vesicle; Gb, otic vesicle; Rf, fourth ventricle; Nk, neck curvature; Br, pons curvature; Pm, mammillary process; Tr, infundibulum; Hp (in B), outline of hypophysis-fold of buccal epiblast; Rl, olfactory lobe. In C the basilar artery is represented along its whole course.

reduced to a thin layer of flattened epithelium, the substance of this part of the medulla oblongata is wholly formed by a thickening of the shifted lateral boundaries. In these, the bend marking the distinction between the ventral and dorsal laminae—now by change of position mesial and external—continues to be evident, and is in fact recognizable even in sections of the fully-developed brain.

Of the longitudinal columns of the medulla oblongata the restiform bodies first become prominent (third month in the human embryo). The (anterior) pyramids are obvious in the fifth month, and the olivary tubercle about the sixth. But before any of these, and indeed with

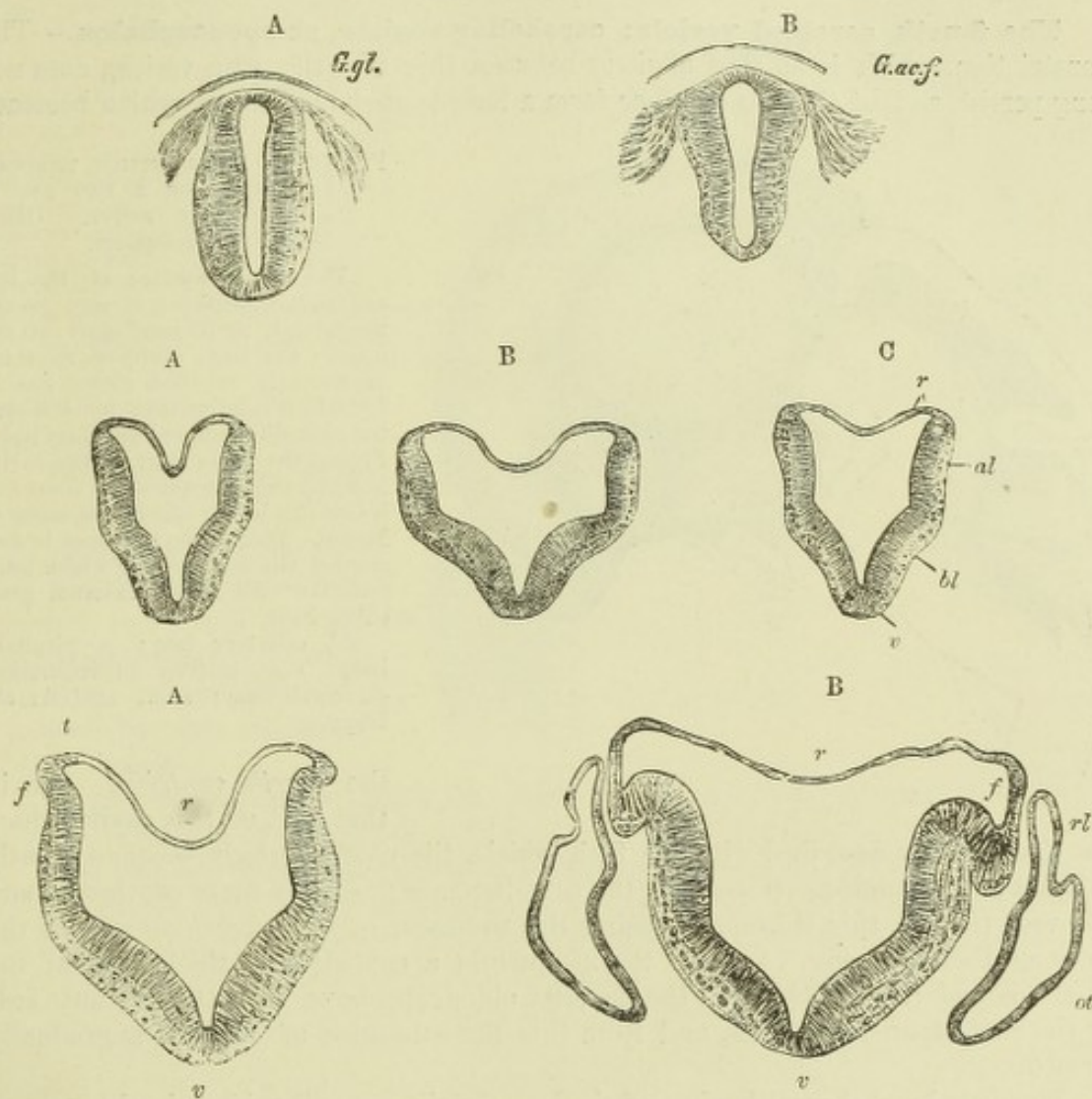


Fig. 71.—SECTIONS ACROSS THE REGION OF THE CALAMUS SCRIPTORIUS OF THE BRAIN REPRESENTED IN FIG. 70, A. (His.)

A, region of the glossopharyngeal ganglion.
B, of the auditory-facial ganglion.

Fig. 72.—SECTIONS ACROSS THE FOURTH VENTRICLE OF A SOMEWHAT OLDER EMBRYO (His.)

A, section taken through the lower part.
B, across the widest part (trigeminus region).
C, through upper part (cerebellar region).
r, roof of neural canal; *al*, alar lamina; *bl*, basal lamina; *v*, ventral border.

Fig. 73.—SECTIONS ACROSS THE LOWER HALF OF THE FOURTH VENTRICLE OF A STILL OLDER EMBRYO, SHOWING GRADUAL OPENING OUT OF THE NEURAL CANAL AND THE COMMENCING FOLDING OVER OF THE ALAR LAMINA (at *f*).

r, ventral border; *t*, tænia; *ot*, otic vesicle; *rl*, recessus labyrinthi.
In the succeeding stage (not here represented) the angle at *v* has almost disappeared, the fold *f* has extended over the alar lamina, and the two thickened halves are in the same horizontal plane, covered by a greatly expanded and thinned out roof.

the earliest appearance of the nerve roots, the white bundles—not yet medullated, however—which are known as the ascending root of the fifth, and the ascending root of the vagus and glossopharyngeal (solitary bundle) begin to make their appearance, both being at first on the surface of the medulla. They gradually, however, become covered in by a folding over of the dorsal part of the alar lamina, and thus come later to lie imbedded in the substance of each lateral half of the medulla. This fold is shown in its commencement in fig. 73, A and B, f. According to His the bundles grow downwards towards the spinal cord from the places of entrance of the corresponding nerve roots, emerging from the ganglia, as in the case of the posterior spinal roots; and after entering the medulla grow gradually along the course of the future so-called ascending roots, so that the latter are at first visible only in sections taken near the places of entrance of the nerve roots into the medulla.

The fourth cerebral vesicle: cerebellar vesicle, or epencephalon.—The constriction, which is at first obvious between this and the fifth vesicle, does not long persist, so that the two together form a long boat-shaped cavity which becomes

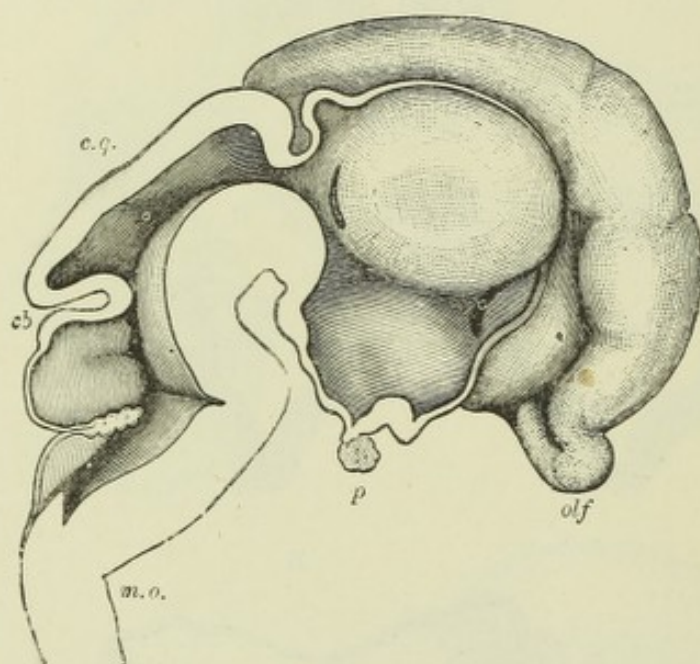


Fig. 74.—MEDIAN SECTION THROUGH THE BRAIN OF A TWO AND A HALF MONTHS FETUS. (His.) Magnified 5 diameters.

The mesial surface of the left cerebral hemisphere is seen in the upper and right hand part of the figure; the large cavity of the third ventricle is bounded above and in front by a thin lamina; below is seen the infundibulum and pituitary body. Filling the upper part of the cavity is the thalamus opticus; in front and below this is the slit-like foramen of Monro. Behind the thalamus is seen another slit-like opening which leads into the still hollow external geniculate body.

olf, olfactory lobe; *p*, pituitary body; *c.q.*, corpora quadrigemina; *cb*, cerebellum; *m.o.*, medulla oblongata.

the *fourth ventricle*. As in that part of this cavity which has already been described with the fifth vesicle, the roof inferiorly becomes greatly thinned and expanded. Superiorly the tube becomes gradually more contracted and the roof thicker, this thickening being the rudiment of the *cerebellum* and of the *valve of Vieussens* (fig. 74). In the meanwhile a considerable thickening of the lateral boundaries, which, as in the medulla oblongata, have been thrown outwards by the roof expansion, occurs, and from this the substance of the *pons* is gradually formed.

The dorsal and ventral laminæ of the lateral walls are still evident in this part of the embryonic brain. With the former, the sensory fibres of the fifth nerve are immediately connected; with the latter, the motor fibres of the fifth and also the sixth and seventh nerves.

In the human embryo the **cerebellum** is seen as early as the second month, forming a thin plate arching over the anterior part of this vesicle (fig. 74). From this plate, which enlarges only gradually, is formed the middle lobe; later the lateral lobes grow out at the sides. The cerebellar surface is at first smooth, but a subdivision into the subordinate lobes occurs in the fifth month, and the folia appear about the sixth. In the seventh month all the parts of the organ, except the amygdalæ, are formed.

Of the cerebellar peduncles, the inferior appear in the third month, the middle in the fourth, and the superior in the fifth. The transverse fibres of the pons develop *pari passu* with the lateral lobes, appearing about the fourth month.

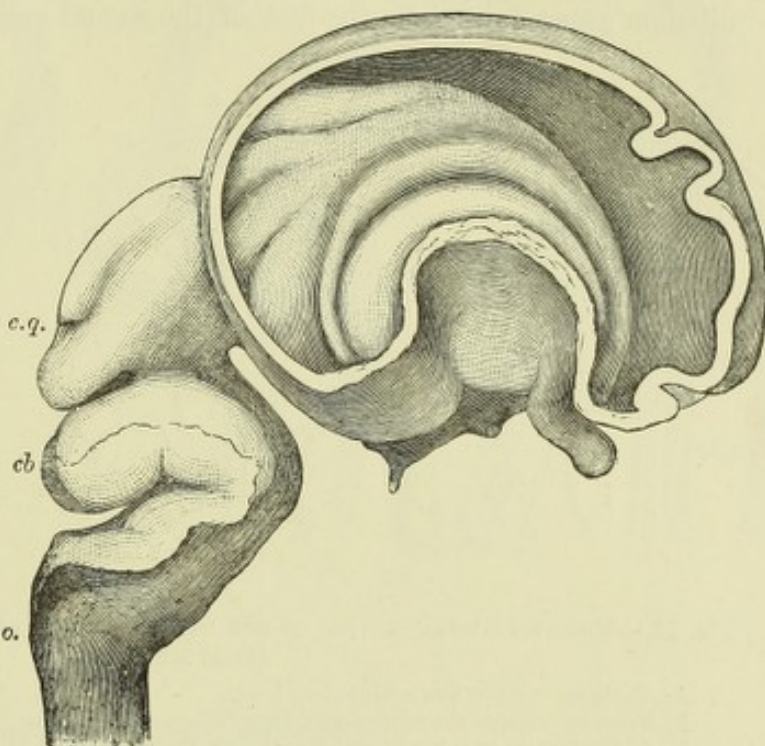
The third cerebral vesicle: mesencephalon: mid-brain.—In this region no expansion of the vesicle with thinning of the roof occurs, as in the others, but, on the contrary, the roof undergoes considerable thickening (fig. 74). About the third month, this thickening becomes separated into two by a median groove. These correspond with the corpora bigemina of lower vertebrates; it is only in mammals that they become further subdivided by a transverse furrow. This appears in man about the fifth month, and the eminences, which are at first large in proportion to the size

Fig. 75.—FETAL BRAIN OF THE THIRD MONTH. (His.)

The brain is represented in profile, but the external wall of the right hemisphere has been removed to show the interior of the lateral ventricle with the corpus striatum curving round the bend of the fossa of Sylvius. The curved projections above the corpus striatum are infoldings of the mesial wall of the hemisphere vesicle. The lettering as in fig. 74.

of the brain, thus become the *corpora quadrigemina*.

The fibres of the third nerve originate in the ventral lamina of this part of the neural tube: the *tegmen* and *crusta* become formed as thickenings along the same lamina: the vesicle itself becomes the *aqueduct of Sylvius*.



In the constriction between the third and fourth vesicles (*isthmus* of His) the fourth nerve takes origin in the ventral plate of the neural tube.

The second cerebral vesicle (thalamencephalon).—It is from this part of the neural tube that the *primary optic vesicles* are developed in the earliest period, and they are for some time in free communication with its cavity along the hollow optic stalks. But with the formation of the optic nerves and optic tracts, the stalks become solid, and are, moreover, connected posteriorly with the mid-brain by a prolongation backwards of the tracts. The **optic thalamus** of each side is formed by a thickening of the lateral wall of the vesicle (figs. 74, 78). The interval between the thalami forms the cavity of the *third ventricle*. Across it the **grey commissure** subsequently stretches. The floor becomes prolonged downwards into the infundibulum, and takes part in the formation of the *pituitary body* (figs. 69, 74). The roof, on the other hand, becomes like that of the fifth vesicle, thin and expanded, and remains as a single layer of flat epithelium cells inflected into the ventricle and subsequently occupied by vascular growths of pia mater (choroid plexus of third ventricle, fig. 69, *ch³*). But at the posterior part of the roof there is a transverse thickening to form the posterior commissure, and in front of this the roof grows upwards and forwards, but subsequently backwards (in man) as a hollow median process to form the *pineal gland* (epiphysis cerebri). The median process soon takes on a tubular shape (fig. 69, *pin*), and, after a time, becomes branched, and forms a number of tubular follicles lined by ciliated epithelium, and invested by vascular pia mater. These follicles tend, in man and mammals, as development proceeds, to become solid and occupied by calcareous deposit. But in some reptiles the pineal

tube remains single, and appears as the long stalk—partly hollow, and partly solid—of a rudimentary median or parietal eye, which occupies an aperture in the middle line of the skull (de Graaf, Baldwin Spencer). The **pituitary body** (hypophysis cerebri) is chiefly formed by a diverticulum of the buccal epiblast (diverticulum of Rathke) which grows upwards towards the base of the second cerebral vesicle, and dilates into a flask-shaped expansion which is at first simple, but subsequently grows out to form a small mass of epithelial tubes, the lumen of which becomes eventually obliterated. Against the posterior wall of this flask-shaped dilatation the infundibulum grows down from the floor of the second vesicle, and its extremity becomes

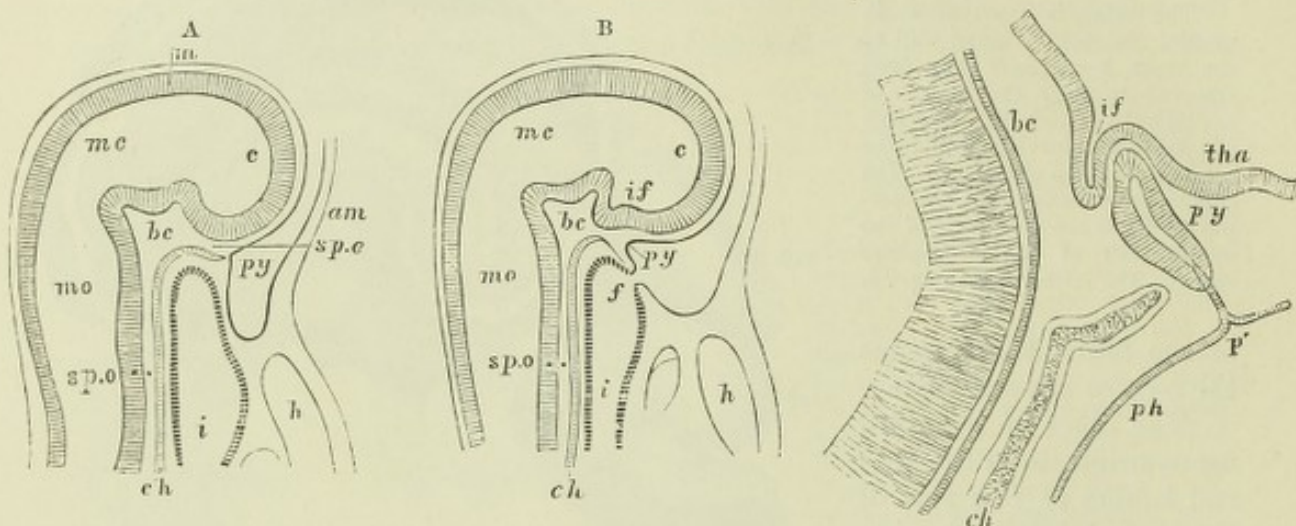


Fig. 76.—MEDIAN SAGITTAL SECTION OF THE HEAD IN EARLY EMBRYOS OF THE RABBIT. Magnified. (From Mihalkovics.)

A. From an embryo five millimetres long.

B. From an embryo six millimetres long.

In A, the faucial opening is still closed; in B, the septum is perforated at *f*; *c*, anterior cerebral vesicle; *mc*, mesencephalon; *mo*, medulla oblongata; *m*, medullary epiblast; *if* (in B), infundibulum; *spe*, sphenothymoidal, *bc*, sphenoidal, and *spo*, sphenothymoidal parts of the basis cranii; *i*, foregut; *ch*, notochord; *py*, buccal pituitary involution; *am*, amnion; *h*, heart.

Fig. 77.—MEDIAN SAGITTAL SECTION OF THE INFUNDIBULUM AND PITUITARY DIVERTICULUM IN A RABBIT EMBRYO, AFTER THE OPENING OF THE FAUCES. (From Mihalkovics.)

bc, basis cranii with basilar artery; *if*, infundibulum; *tha*, floor of thalamencephalon; *py*, pituitary diverticulum, now closed; *p'*, stalk of original communication with the mouth; *ph*, pharynx; *ch*, notochord in the sphenothymoidal part of the cranial basis.

intimately connected with the dilatation, but without communicating with its cavity, although bound up together by the same vascular connective tissue. In connection with this extension of the infundibulum, nerve cells and fibres become formed; in lower vertebrates they persist and retain their connection with the brain. The notochord extends in the basis cranii as far as the pituitary body. Just before reaching this, it bends ventralwards towards Rathke's diverticulum, and here blends with the buccal epiblast (Bonnet).

Dohrn has shown that in *Petromyzon* the hypophysis develops as a separate median diverticulum of the external epiblast which is formed between the nasal pit in front and the buccal invagination (stomodæum) behind, and grows straight backwards as a canal of some length towards the point of the notochord, where follicles develop from it and become connected with the infundibulum. Later, its orifice is found to open in common with that of the nasal pit.

The first cerebral vesicle: prosencephalon.—This is represented by the common point at the front of the third ventricle, whence the hemisphere vesicles diverge through the foramina of Monro, and by these vesicles themselves. The original vesicle is therefore relatively small, although its lateral outgrowths form by

far the largest portion of the brain in higher vertebrates. The **corpora striata** appear as thickenings of the floor of the hemisphere vesicles, and outside them the

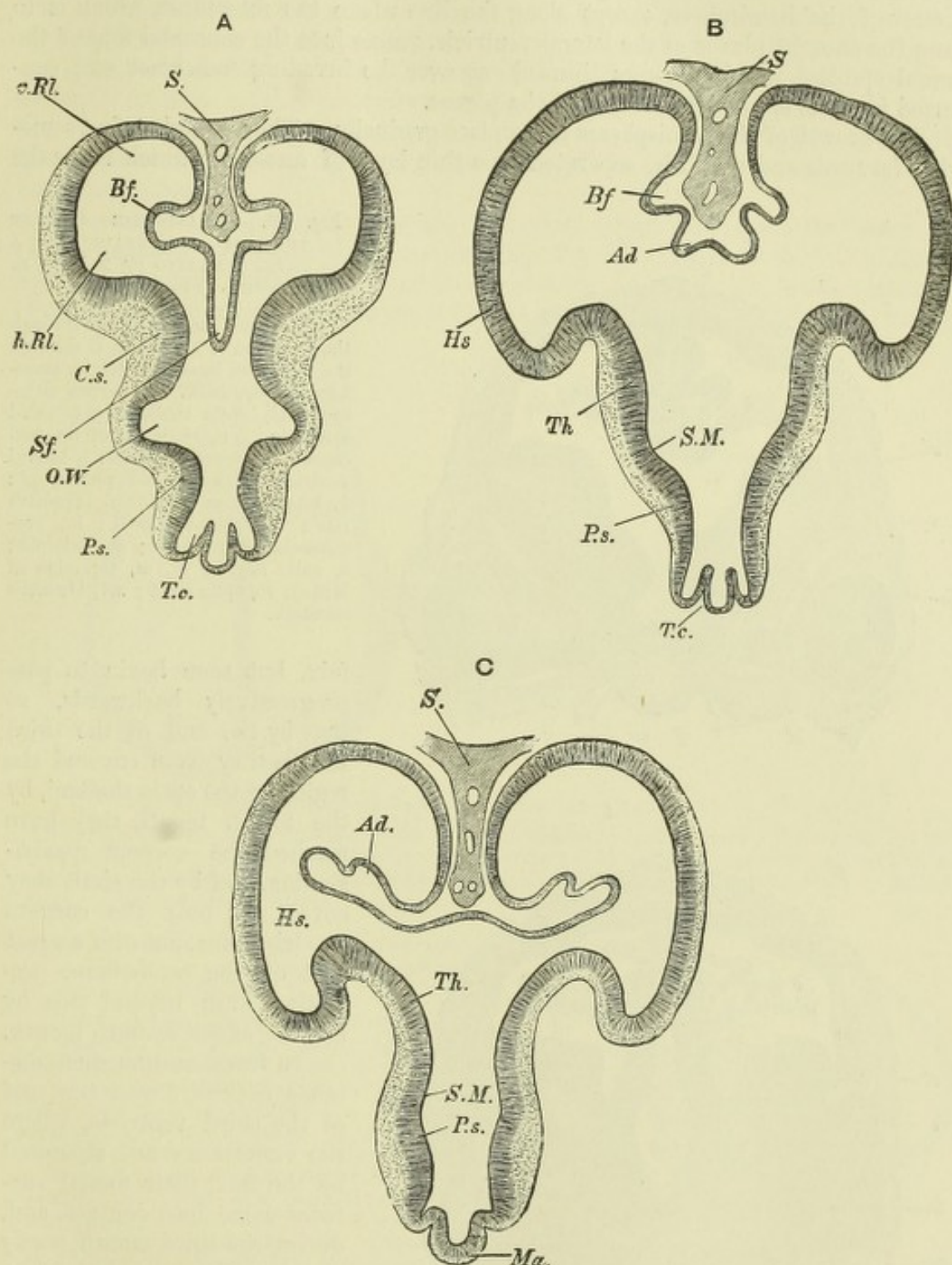


Fig. 78.—THREE SECTIONS THROUGH THE FORE-BRAIN OF A FOUR AND A HALF WEEKS EMBRYO. (His.)

A. Through the lower anterior part of the fore-brain; *S*, falx; *Sf*, fold of roof passing below falx towards the third ventricle; *Bf*, fold forming the sulcus ammonis; *v.Rl*, *h.Rl*, anterior and posterior parts of olfactory lobe; *Cs*, corpus striatum; *O.W*, groove continuous with optic stalk; *P.s*, pars subthalamica; *T.c*, tuber cinereum.

B. Section a little further back. *Sf* is replaced by a less prominent but broader fold of the roof, *Ad*, which subsequently receives the choroidal vessels, and is therefore the choroidal fold; *Hs*, hemisphere vesicle; *Th*, thalamus; *S.M*, sulcus of Monroe, below and behind the thalamus.

C. Still further back; *Ad*, choroidal fold here projecting into lateral ventricles, but still free from mesoblast and bloodvessels; *Ma*, mammillary tubercle. The other lettering as before.

grey and white matter of the island of Reil becomes differentiated. The rest of the wall of the hemisphere vesicle (*mantle* of Reichert), although remaining for a time thinner than the floor, eventually thickens to form the whole of the grey and white matter of the hemisphere, except along the line where the mesoblast, which is to form the choroid plexus of the lateral ventricle, passes into the choroidal fold of the neural epiblast, which becomes thinned out over the invading mesoblast and converted into the epithelial covering of the plexus.

The growth of the hemispheres takes place gradually. They extend at first somewhat forwards and upwards, separated by a thin layer of mesoblast which forms the

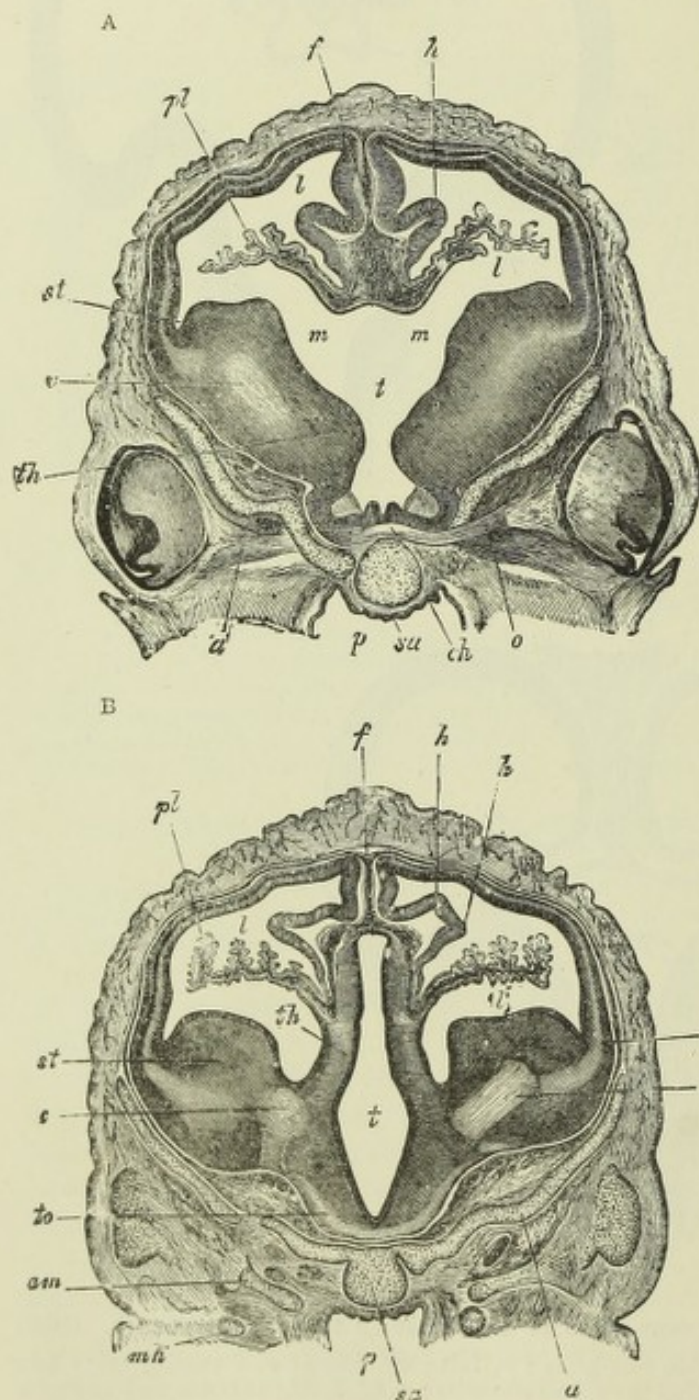


Fig. 79. — TRANSVERSE SECTIONS THROUGH THE BRAIN OF A SHEEP'S EMBRYO OF 2.7 CM. IN LENGTH. (From Kölliker.)

In A the section passes through the foramina of Monro, in B through the third and lateral ventricles somewhat further back. *st*, corpus striatum; *th*, optic thalamus; *t*, third ventricle; *c, c'*, rudiment of internal capsule and corona radiata; *pl*, lateral ventricle with choroid plexus; *h*, hippocampus major; *f*, primitive falx; *a*, orbito-sphenoid; *sa*, pre-sphenoid; *p*, pharynx; *ch*, chiasma; *o*, optic nerve; *m, m*, foramina of Monro; *to*, optic tract; *mk*, Meckel's cartilage.

falx, but soon begin to pass progressively backwards, so that by the end of the third month they have covered the region of the optic thalami, by the fourth month they have reached the corpora quadrigemina, and by the sixth they cover not only the corpora quadrigemina, but also a great part of the cerebellum, projecting even beyond this by the end of the seventh month.

In front, and for some distance backward over the roof of the third ventricle, where the vesicles are not separated by the falx, their mesial surfaces come into contact, and, during the third month, partly grow together, but in such a manner as to leave anteriorly just in front of the third ventricle, a triangular area

free in the middle, but completely surrounded at its periphery by the united parts. Thus is formed the cavity which is known as the *fifth ventricle* or *ventricle of the septum lucidum*, which at no time has any communication with the vesicles of the cerebral hemispheres, nor with any other of the cerebral vesicles.

The commissures of the cerebral hemispheres are also formed in the united portion of the mesial walls of the vesicles; the anterior is the earliest to appear, thus coinciding with the early appearance of the corpora striata, which it unites in front. The anterior part of the fornix, with its pillars, and the corpus albicans (which is at first single and median) are next formed, followed at a later period by the posterior pillars, which are seen running backwards on each side into the cornu ammonis as soon as this structure becomes distinct. The corpus callosum is the last of the commissures to be formed. Its anterior part appears first, but as the hemispheres extend backwards the formation of the commissure accompanies the backward extension.

The **olfactory lobes** are formed as hollow outgrowths from the lower and lateral parts of the hemisphere vesicles (figs. 70, 74). In man they soon show a division into two parts, an anterior and posterior; of which the latter remains in close connection with the hemisphere vesicle, while the anterior grows out towards

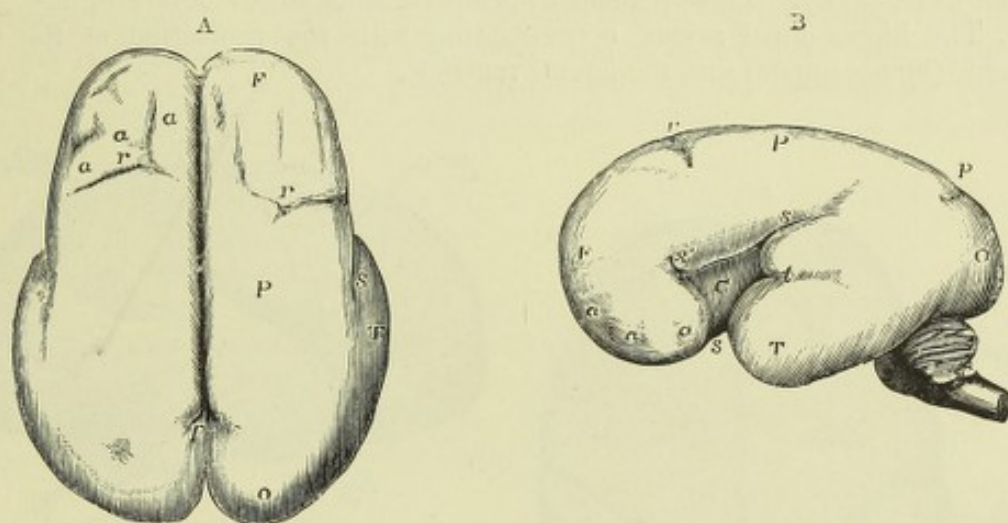
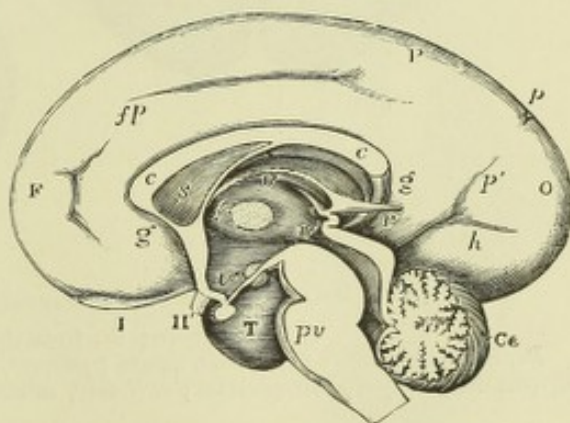


Fig. 80.—THE SURFACE OF THE FETAL BRAIN AT SIX MONTHS. (R. Wagner.)

This figure shows the formation of the principal fissures. A, from above; B, from the left side. F, frontal lobe; P, parietal; O, occipital; T, temporal; a, a, a, slight appearance of sulci in the frontal lobe; s, Sylvian fissure; s', its anterior division; within it, C, the central lobe; r, Rolandic sulcus; p, parieto-occipital fissure.

Fig. 81.—VIEW OF THE INNER SURFACE OF THE RIGHT HALF OF THE FETAL BRAIN OF ABOUT SIX MONTHS. (Reichert.)

F, frontal lobe; P, parietal; O, occipital; T, temporal; I, olfactory bulb; II, optic nerve; fp, calloso-marginal fissure; p, p', parts of the parieto-occipital fissure; h, calcarine fissure; g, g, gyrus fornicatus; c, c, corpus callosum; s, septum lucidum; f, placed between the middle commissure and the foramen of Monro; v, in the upper part of the third ventricle; v', in the back part of the third ventricle; v'', in the lower part of the third ventricle above the infundibulum; r, recessus pinealis; pv, pons Varolii; Ce, cerebellum.



the olfactory area of the external epiblast. After the first month these lobes are relatively small in size and their cavities become gradually obliterated, but in some animals, as in the horse, they are large, and their cavities are permanently in communication with the anterior cornua of the lateral ventricles. Their further development is given subsequently (p. 79).

Formation of the fissures and convolutions. — The enlargement of the cranium does not always keep pace with the growth in extent of the walls of the

hemisphere vesicles, so that it happens that the former are thrown into folds separated by sulci, and the surface loses its smooth appearance. Such relatively rapid growth occurs during the second and third month in the human embryo, resulting in the production of a number of infoldings of the surface, which are mostly transverse to the (bent) axis of the brain, although one or two on the mesial surface run parallel to that axis. These infoldings of the surface, which may be termed *temporary* or *primitive sulci*, necessarily have a corresponding projection into the cavity of the thin-walled hemisphere vesicle (fig. 75). During the fourth month, probably owing to a relatively more rapid expansion of the cranium, most of these primitive sulci become obliterated, and the cerebral surface is again almost smooth. Three, however, of the primitive sulci remain as permanent fissures of the brain,¹ and since the fissure of Sylvius is also now formed, although in a somewhat different manner, the hemisphere of the human foetus at the beginning of the fifth month is marked by four well characterised sulci having corresponding projections into the interior of its cavity. These permanent primitive sulci are the following:—

1. The hippocampal sulcus, corresponding with the projection of the cornu ammonis (hippocampus) into the lateral ventricle.

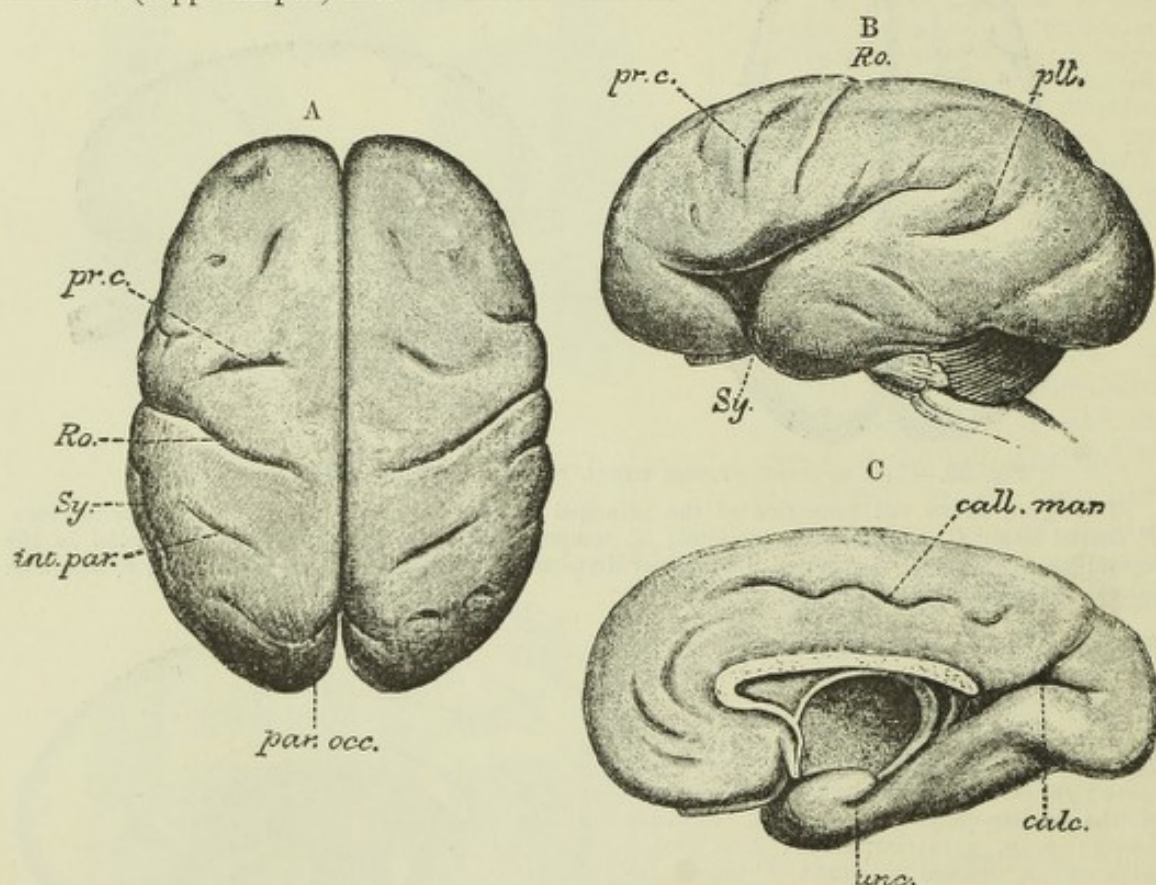


Fig. 82.—FETAL BRAIN OF THE BEGINNING OF THE EIGHTH MONTH. (Mihalkovics.)

A., from above; B., from the side; C., mesial surface.

Ro, Rolandic sulcus; Sy, Sylvian fissure; par.occ, parieto-occipital; calc, calcarine; pr.c, precentral; pll, parallel; int.par, intraparietal; call.mar, calloso-marginal; unc, uncus.

2. The parieto-occipital sulcus, corresponding with the bend of the posterior cornu of that ventricle.

3. The calcarine sulcus, corresponding with the projection of the calcar avis.

4. The Sylvian fissure, corresponding with the curve of the lateral ventricle.

To these may be reckoned the longitudinal infolding of the mesial wall of the

¹ It is, however, uncertain whether the temporary sulci develop into or whether they are replaced by corresponding permanent sulci. See on this subject a paper by D. J. Cunningham in the *Journal of Anatomy*, April, 1890.

hemisphere just below the hippocampal sulcus, which is caused by the ingrowth of the choroid plexus of the lateral ventricle.

According to Ecker, the fissure of Sylvius is the first of the primitive sulci to appear. It is visible before the end of the third month, as a wide, shallow depression, which divides the lower margin of the hemisphere into two nearly equal portions, and at the bottom of which is seen the thickening of the floor of the vesicle from which the corpus striatum and the island of Reil are developed. This fissure appears to be formed by a curving of the still thin-walled hemisphere vesicle over that thickening, around which the vesicle bends; and its anterior and posterior parts ultimately meet along the line which marks the posterior limb of the Sylvian fissure in the developed brain. The anterior limb is produced much later by a further folding over of that part of the mantle which is in front of the fossa Sylvii. The fissure remains until nearly the end of fetal life as a widely open depression, at the bottom of which the island of Reil is readily visible. It closes gradually from behind forwards.

The other sulci are distinguished from the four above-numerated in the fact that they are depressions of the surface merely, and not infoldings of the whole thickness of the wall of the hemisphere vesicle.¹ They begin to appear about the end of the fifth month, the fissure of Rolando being the first to show (figs. 80 and 81).

By the end of the sixth month the precentral and inferior frontal sulci, the intraparietal, the superior occipital, the parallel, the inferior temporal, the callosomarginal, and the collateral fissures have become visible, as well as the anterior limb of the Sylvian fissure.

By the end of the seventh month (see fig. 82) most of the remaining principal convolutions and fissures have appeared, and those which were previously present have increased both in length and depth. They are, however, all comparatively short and simple. During the eighth month, they continue to increase in length and depth, and the remaining sulci become gradually developed, but even in the ninth month there are none of the accessory or secondary furrows which add so much to the complexity of the developed brain. The last of the principal sulci to make their appearance are the inferior occipito-temporal.

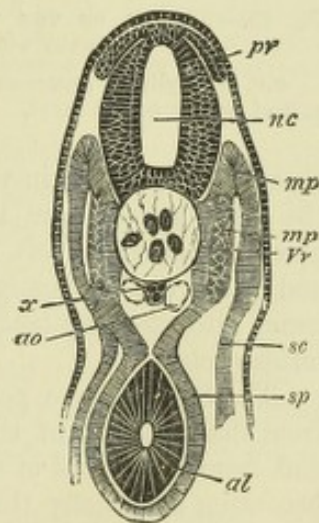
DEVELOPMENT OF THE NERVES.

Spinal nerves.—At an early period of development, in some cases even before the closure of the neural groove, in others during or shortly after that event, there

Fig. 83.—TRANSVERSE SECTION THROUGH THE TRUNK OF AN EMBRYO SHARK, TO SHOW THE NEURAL CREST. (Balfour.)

nc, neural canal; *pr*, ganglion rudiment running from neural crest; *x*, sub-notochordal rod; *ao*, aorta; *sc*, parietal mesoblast; *sp*, visceral mesoblast; *mp*, muscle plate; *mp'*, portion of muscle plate converted into muscle; *Vr*, portion of proto-vertebra which will give rise to the vertebra; *al*, alimentary canal.

grows out bi-laterally from the angle of junction of the neural with the general epiblast (fig. 89), and consequently at the dorsal aspect of the neural tube a continuous ridge or crest of epiblast, which was first described by Balfour in elasmobranch fishes: this is termed the *neural crest*. At intervals along the sides of the neural crest, corresponding with the middle of each mesoblastic somite or proto-vertebra, special clavate enlargements or outgrowths of the neural crest occur (fig. 83, *pr*). These grow downwards along the dorso-lateral aspect of the neural canal, between the protovertebra and the canal. They remain for a time attached above



¹ An exception must, however, be made for the collateral fissure, which corresponds with the collateral eminence within the ventricle.

to the dorsal aspect of the neural tube, but that attachment becomes subsequently lost, and they then form completely isolated portions of epiblast, composed of oval cells, and lying at the side of the embryonic cord between it and the muscle plates of the protovertebræ (fig. 84). These are the rudiments of the posterior-root ganglia. The remainder of the neural crest disappears: at least in most vertebrata.

Some little time after the separation of these ganglion-rudiments, the ventral or anterior roots of the spinal nerves begin to grow out from the ventro-lateral aspect of the neural tube. They were originally described by Balfour in elasmobranchs, as forming bud-like outgrowths from the neural epiblast, the outgrowths being composed of spindle-shaped cells (fig. 84, *ar*). But according to the recent and extended

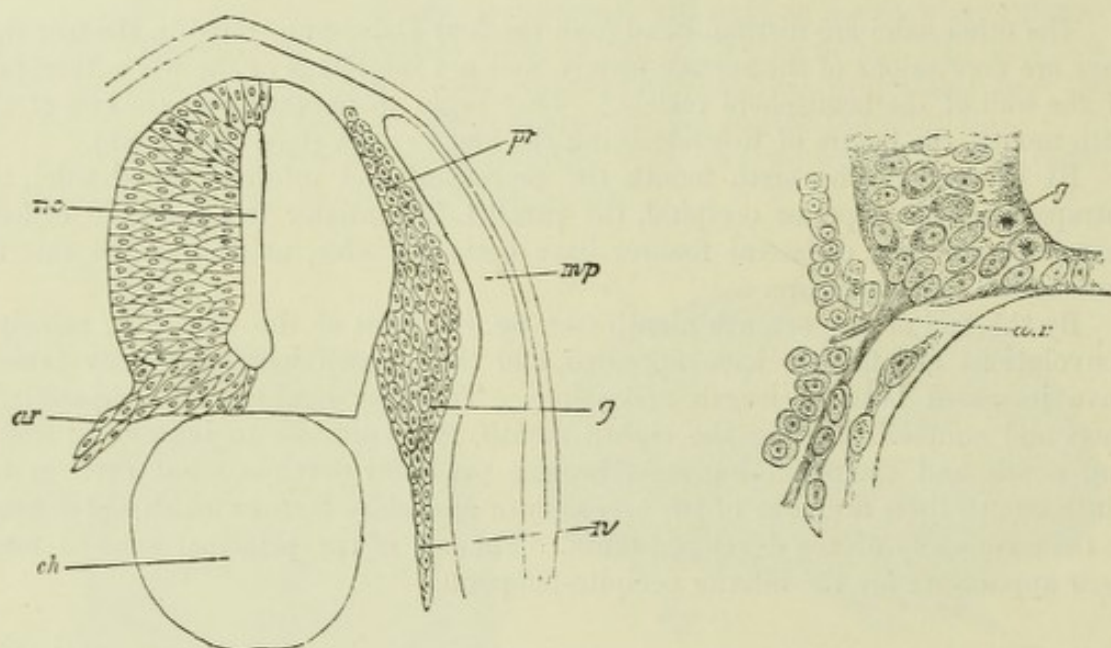


Fig. 84.—SECTION THROUGH THE DORSAL PART OF THE TRUNK OF A TORPEDO EMBRYO. (Balfour.)

pr, *g*, *n*, spinal ganglion rudiment; *ar*, anterior root; *ch*, notochord; *nc*, neural canal; *mp*, muscle-plate.

Fig. 85.—SECTION OF THE VENTRO-LATERAL ANGLE OF THE SPINAL CORD OF A PRISTIURUS EMBRYO SHOWING THE OUTGROWTH OF AN ANTERIOR ROOT-RUDIMENT. (His.)

a.r., axis cylinder processes of neuroblasts, forming the anterior root; *g*, germinal cells in innermost part of wall of neural canal.

observations of His in various classes of vertebrates, what actually grow out to form the anterior roots, are the fibrous prolongations (axis-cylinder processes) of neuroblasts (*v. antea*, p. 58), which processes converge to the point of exit of the root and penetrate gradually into the adjoining mesoblast (fig. 85, *a. r.*), where they come into close contact with the previously formed ganglion rudiments of the posterior roots.¹

The fibres of the posterior roots are developed, according to His, as processes from the oval cells of the ganglion rudiment. These cells are in fact neuroblasts, and from either end of each cell, which is thus rendered bipolar (fig. 86), a process becoming eventually the axis-cylinder of a nerve-fibre grows out, one towards the central organ, the other towards the periphery. The centrally directed processes soon reach and grow into the embryonic cord at its dorso-lateral aspect, where they are presently seen in sections occupying an oval area near the periphery of the cord;

¹ The place at which the anterior roots spring from the cord is not opposite to the corresponding posterior root, but midway between that root and the succeeding one.

this area is the beginning of the posterior white column (fig. 87): the further course and attachments of the ingrowing fibres in the cord are not accurately known, but they appear to bifurcate and extend both upwards and downwards (Ramón y Cajal). The peripherally directed fibres grow downwards and join the bundle of fibres of the anterior root, to form together with them the mixed spinal nerve (fig. 88).

The axis-cylinder processes which are to form the fibres of the anterior roots

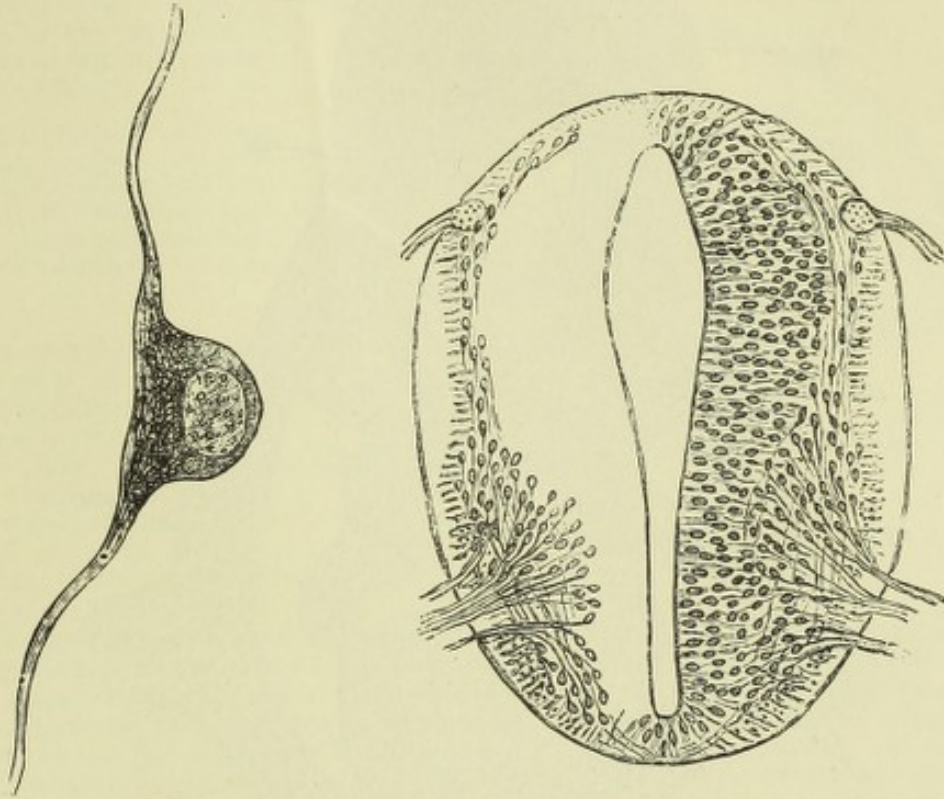


Fig. 86.—BIPOLAR CELL FROM SPINAL GANGLION OF A $4\frac{1}{2}$ WEEKS EMBRYO. (His.) 1490

Fig. 87.—SECTION OF SPINAL CORD OF FOUR WEEKS HUMAN EMBRYO. (His.)

The posterior roots are continued within the cord into a small longitudinal bundle which is the rudiment of the posterior white column. The anterior roots are formed by the convergence of the processes of the neuroblasts. The latter, along with the elongated cells of the myelospongium compose the grey matter. The external layer of the cord is traversed by radiating fibres which are the outer ends of the spongioblasts. The anterior commissure is beginning to appear.

begin to make their appearance about the beginning of the fourth week in the human embryo (His). Their growth towards the periphery is slow; even by the end of the second month they have not reached the tips of the fingers and toes.

Cranial nerves.—The neural crest is continuous along the dorsal aspect of the cerebral part of the neural tube as far as, and even beyond the mid-brain. As in the spinal part, clavate enlargements occur here also, but at somewhat irregular intervals, and form ganglion rudiments which become separated from the dorsal aspect of the tube, and acquire a new attachment on the lateral and ventral aspect. Such ganglion rudiments have been described for the third, fifth, seventh, eighth, ninth, and tenth nerves.

In the chick the ganglion rudiments belonging to the cranial nerves appear as a thickening of the cephalic epiblast, just where it is folding round into the as yet unclosed neural canal (fig. 89, *vg*). This thickening, according to Golowine, is continuous laterally with a modified portion of the external epiblast (sensory epiblast), and soon becomes subdivided into three ganglionic groups, and these, later, into separate ganglions. There is a corresponding subdivision of the sensory

epiblast into rudiments of special sense organs, which become gradually shifted downwards and outwards away from the ganglion rudiments, and form the so-called

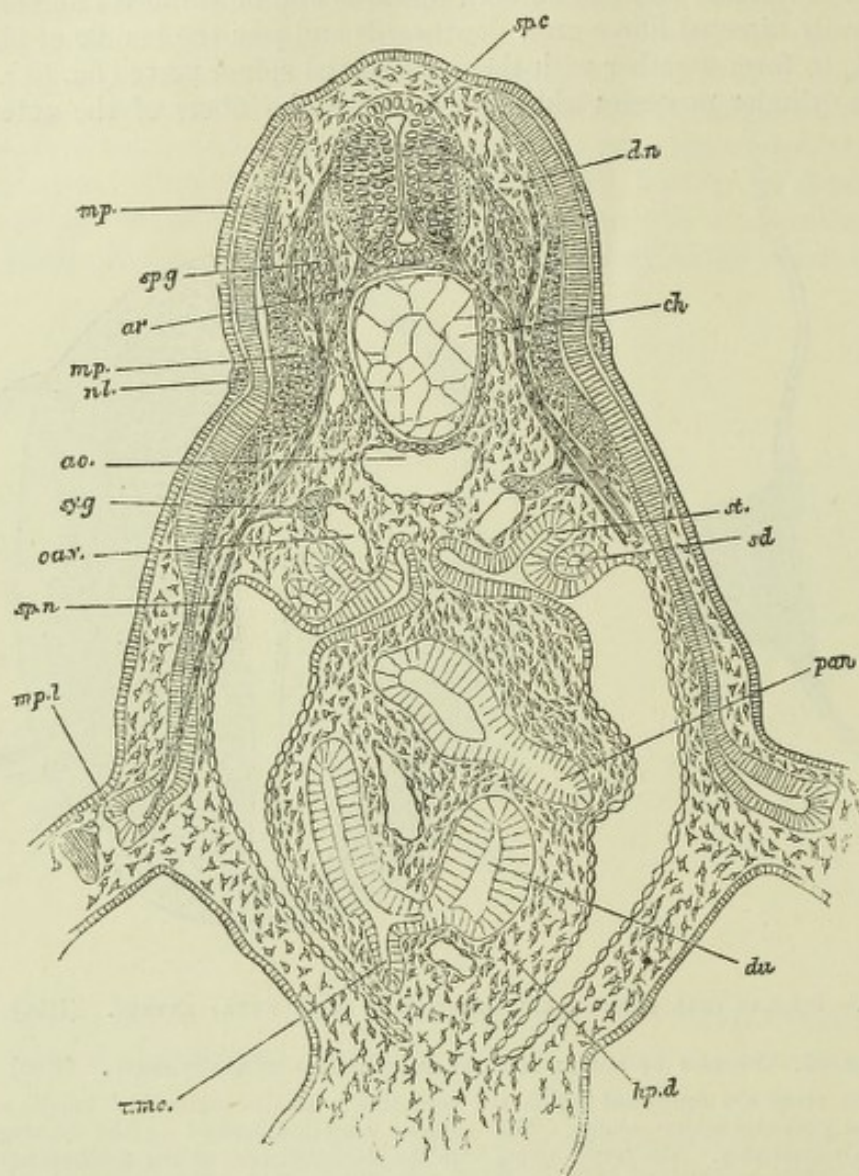


Fig. 88.—TRANSVERSE SECTION THROUGH THE ANTERIOR PART OF THE TRUNK OF AN EMBRYO OF SCYLLIUM. (Balfour.)

sp.c, spinal cord; *sp.g*, ganglion of posterior root; *ar*, anterior root; *dn*, dorsal; *sp.n*, ventral branch of spinal nerve; *mp*, muscle plate; *mp'*, part of muscle plate already converted into muscle; *mp.l*, part of muscle plate extending into the limb; *nl*, nervus lateralis; *ao*, aorta; *ch*, notochord; *sy.g*, sympathetic ganglion; *ca.v*, cardinal vein; *sd*, segmental duct; *st*, segmental tube; *du*, duodenum; *hp.d*, junction of hepatic duct with it; *pan*, rudiment of pancreas connected with another part of duodenum; *umc*, opening of umbilical canal (vitelline duct).

“branchial sense-organs” of Beard. They become connected subsequently with outgrowths from the posterior nerve-rudiments.

These rudimentary sense organs have been described in mammals also (by Froriep). They appear to represent the special sense organs of the gill clefts of fishes, which were first described by Leydig (1850). Beard is of opinion that the nose and ear are also specialised branchial sense organs, the only ones that are persistent in higher vertebrates. This differentiation of a special sensory portion of epiblast into rudiments of special sense-organs, occurs according to Golowine's observations in the chick, not only in the head but also in the trunk, where they in all probability represent rudiments of “organs of the lateral line,” such as are seen in fishes.

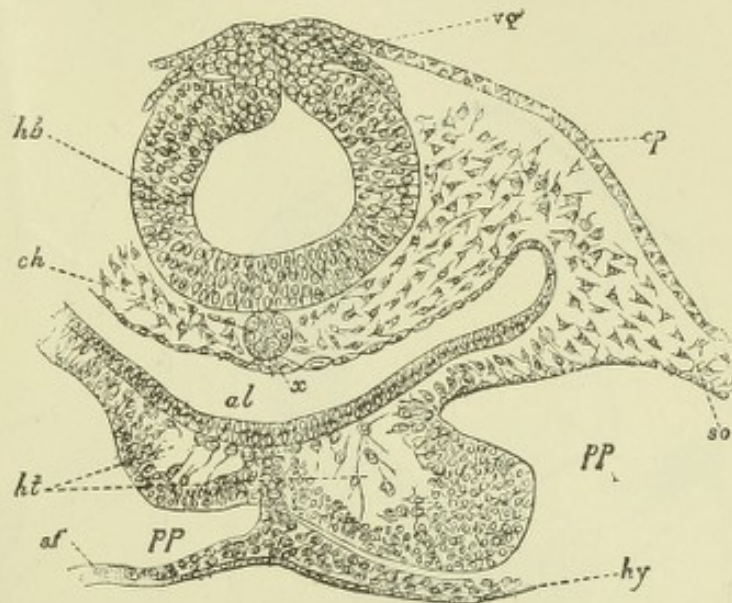
Various observers have described the ganglion rudiments as actually becoming formed at

least in part at the expense of the sensory epiblastic thickenings. In connection with this question it is worthy of note that from the sensory thickening which forms the olfactory area a ganglionic rudiment becomes formed which joins the olfactory lobe of the brain, and gives origin to the olfactory nerve-fibres (His).

Even in the adult, as was shown by Thomsen, traces of pre-existent ganglionic structure can be found in the root of the third nerve, and similar traces of ganglionic structure have

Fig. 89.—TRANSVERSE SECTION THROUGH THE POSTERIOR PART OF THE HEAD OF AN EMBRYO CHICK OF 30 HOURS. (From Balfour.)

hb, hind-brain; *vy*, vagus nerve; *ep*, epiplast; *ch*, notochord; *x*, sub-notochordal rod; *al*, throat; *ht*, heart; *pp*, body-cavity; *so*, parietal mesoblast; *sf*, visceral mesoblast; *hy*, hypoblast.



also been described by Gaskell in the roots of the fourth nerve, in the motor root of the fifth, and in the root of the seventh nerve. If these, as Gaskell supposes, indicate the pre-existence of sensory elements in the roots, it is probable that these nerves and ganglia have all been originally developed like the posterior gangliated roots of the spinal nerves, as outgrowths from the neural crest. Whether they are joined by outgrowths corresponding to the efferent fibres of the spinal nerves, or whether they originally contain the elements of the efferent fibres, and thus resemble the spinal nerves of *Amphioxus*, in which there are no anterior roots, but both sensory and motor nerves are contained in the posterior roots, is not at present known. What is however clear is that the ganglion cells and afferent fibres in the roots of the third, fourth, motor of fifth and seventh nerves, eventually entirely disappear, the efferent fibres alone remaining, while in the roots of the sixth, eleventh, and twelfth nerves efferent fibres only are found, and ganglionic rudiments are not developed at all.

As is shown in another part of this work (Neurology) the nuclei of origin of the efferent cranial nerves are disposed in two longitudinal series. One of these series comprises the nuclei of origin of the somatic efferent nerves of Gaskell, which correspond with the largest fibres of a typical anterior spinal root, and the series of nuclei is a continuation of the cell-column of the anterior horn; the nuclei of this series are those of the hypoglossal, or twelfth, the sixth, fourth, and third. The other series comprises the nuclei of origin of the splanchnic efferent nerves of Gaskell, which correspond with the medium-sized and smallest fibres of a typical anterior spinal root, and the series is a continuation mainly of the cells of the lateral horn or intermediolateral tract, and partly, perhaps, of the cells of the base of the posterior horn; the nuclei of this series are those of the spinal accessory, those of the efferent fibres of the vagus and glosso-pharyngeal, the facial, and the motor nucleus of the fifth.

According to the observations of His, the distinction into an anterior or ventral (somatic) and a lateral (splanchnic) group of efferent fibres is well marked in the embryo by the fact that the two kinds of efferent fibres take origin from entirely different parts of the basal lamina of the neural tube, those which correspond with the somatic efferent fibres originating from groups of neuroblasts near the middle line, while the others take their rise near the junction of the basal with the alar lamina (see fig. 90). With the alar lamina itself the afferent fibres are connected, but they do not arise from groups of cells within it, as do the efferent fibres within the basal lamina: on the contrary, they effect their connection with the lamina by growing into it from a ganglion in the manner already described for the posterior roots of the spinal nerves, and they then appear in most cases to grow downwards in the direction of the spinal cord. This is stated by His to be the case with the

sensory root of the trigeminus, which thus forms the white bundle known as the ascending root of the fifth, but which in its actual growth is descending; and also with the afferent fibres of the glosso-pharyngeal and vagus which grow downwards in the medulla to form the so-called solitary bundle.¹ These are traceable in the adult as far down as the middle and lower cervical region respectively, but in the embryo are at first quite short, and limited to near the place of attachment of the

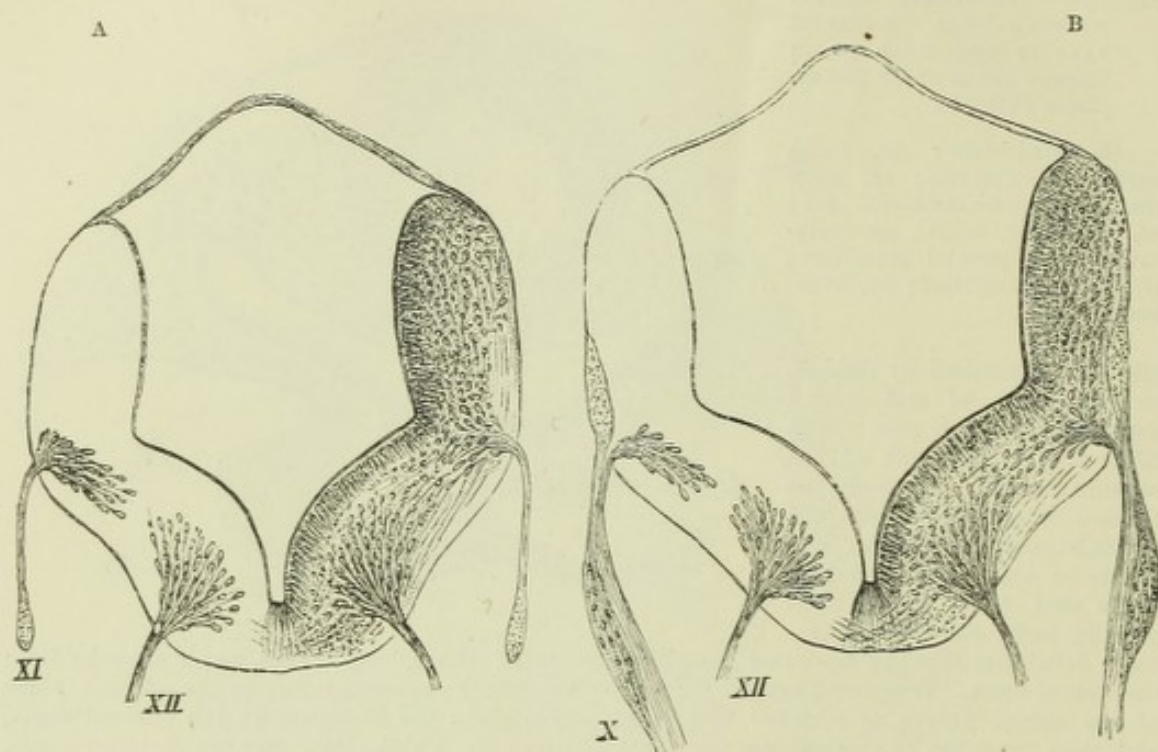


Fig. 90, A and B.—SECTIONS ACROSS THE HIND-BRAIN OF A HUMAN EMBRYO, 10 mm. long. (His.) ⁴⁰/₁.

In A, the origin of the spinal accessory and hypoglossal nerves is shown, the fibres of both arising from groups of neuroblasts in the basal lamina of the neural tube. In B, one of the roots of the hypoglossal is still seen, and in addition the root of the vagus nerve. This is represented as in part arising like that of the spinal accessory in A, from a group of neuroblasts in the basal lamina, and in part from a bundle of longitudinally coursing fibres placed at the periphery of the alar lamina, and corresponding in situation to the commencing posterior white columns shown in fig. 87.

nerve roots, becoming gradually longer as development proceeds. The solitary bundle is at first superficial, like the ascending root of the fifth, but it subsequently becomes covered in by the bending over of the alar plate, and the formation of nervous substance in this. The ganglion-rudiments from which the ingrowth of these afferent fibres takes place, become the Gasserian ganglion of the fifth, and the jugular ganglia of the glosso-pharyngeal and vagus.

The auditory nerve-roots appear also to be formed by an ingrowth from the cells of its ganglion-rudiment into the alar plate. Subsequently the ganglion-rudiment becomes subdivided into three parts, one forming an intracranial ganglion, and the others giving rise to the branches of the nerve to the cochlea and vestibule respectively (fig. 90, C). The part belonging to the cochlea (ganglion cochleæ) forms ultimately the spiral ganglion; while the one on the vestibular branch forms the gangliform swelling of Scarpa. From a separated part of the ganglion cochleæ the nerve to the posterior semicircular canal passes, as well as that to the macula of the saccule; from the vestibular ganglion the nerves to the other ampullæ and to the utricle, are derived. The geniculated ganglion of the facial is derived from the same ganglionic

¹ These bundles, therefore, are homologous with the rudiments of the posterior white columns which are derived from the ingrowing fibres of the spinal ganglia (*v. antea*, p. 74).

mass as furnishes the ganglia of the auditory nerve, but its cells are early distinguishable by their larger size and clearer appearance. From these cells fibres, which are probably afferent (His), grow centrally into the hind-brain and peripherally along

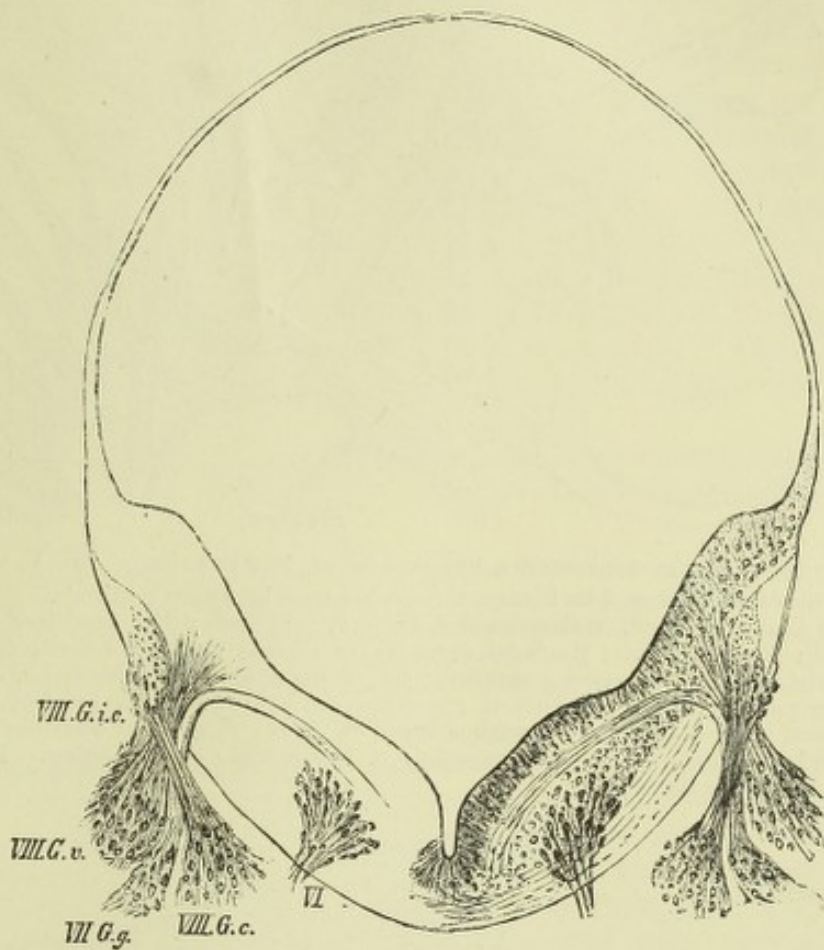


Fig. 90, C.—SECTION FROM THE SAME EMBRYO AT THE EXIT OF THE FACIAL NERVE. (His.)
(Several sections have been combined to form this figure.)

VI., fibres of sixth nerve taking origin from group of neuroblasts in basal lamina; VII.G.g, ganglion geniculi of the facial; VIII.G.i.c, intracranial ganglion of auditory; VIII.G.v, ganglion vestibuli; VIII.G.c, ganglion cochleæ.

the nerve, mingling with its efferent fibres. Some of these afferent fibres may form the chorda tympani, but there are many more than are found in that nerve.

The **optic nerves** take origin as hollow outgrowths of the brain, which afterwards become solid, while nerve-fibres become developed in their walls. Their mode of origin will be further treated of in connection with the development of the eye.

The **olfactory lobe**, which consists of the olfactory bulb and tract (often spoken of as the first or olfactory nerve), and the part of the base of the brain from which the tract arises, makes its appearance as a protrusion of the antero-ventral part of each cerebral hemisphere, extending towards the thickened olfactory area of the epiblast (see fig. 70, B, *Rl*; and fig. 74, *olf*). This primitive olfactory lobe is early seen to be divided into anterior and posterior parts by a broad sulcus (fig. 95). Of the two parts, the anterior becomes considerably elongated, and ultimately forms not only the tract and bulb but also the trigonum olfactorium, and a small area on the mesial side of this (termed by His *Broca's area*); whilst from the posterior, the larger part of the anterior perforated space (mesial to the lateral olfactory root) and the peduncle of the corpus callosum (gyrus

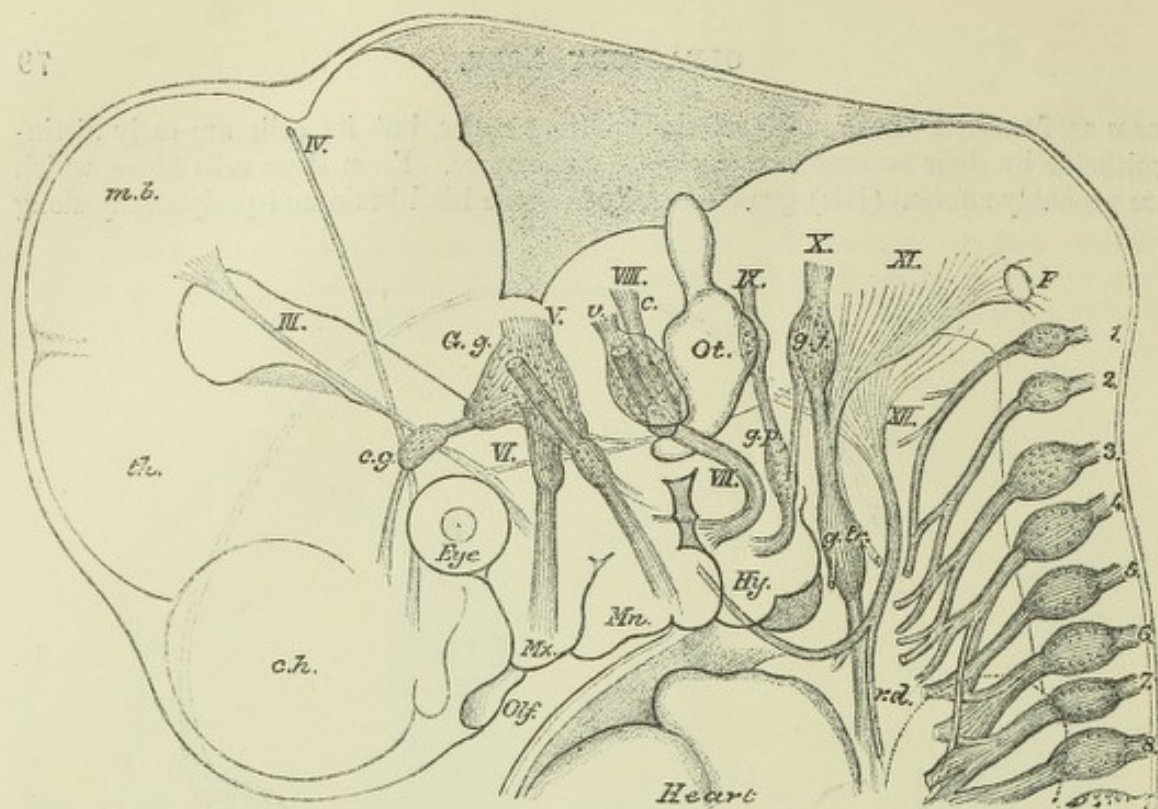


Fig. 91.—CRANIAL NERVES OF A HUMAN EMBRYO, 10.2 mm. long. (His.) 2p.

The cranial nerves are indicated by Roman, the spinal nerves by Arabic numerals.

c.h., cerebral hemisphere; th., thalamencephalon; m.b., mid-brain; Mx., maxillary process; Mn., mandibular arch; Hy., hyoid arch; the facial nerve is seen to send a branch (chorda tympani) across the hyomandibular cleft; G.g., Gasserian ganglion; c.g., ciliary ganglion; v., vestibular, and c., cochlear part of auditory; g.p., ganglion petrosum of glossopharyngeal; g.j., ganglion jugulare of vagus; an anastomosis is seen between these; g.tr., ganglion trunci of vagus; P., ganglion described by Froriep as belonging to the hypoglossal; r.d., ramus descendens of hypoglossal; ot., otic vesicle. The eye is also represented, and a part of the heart.

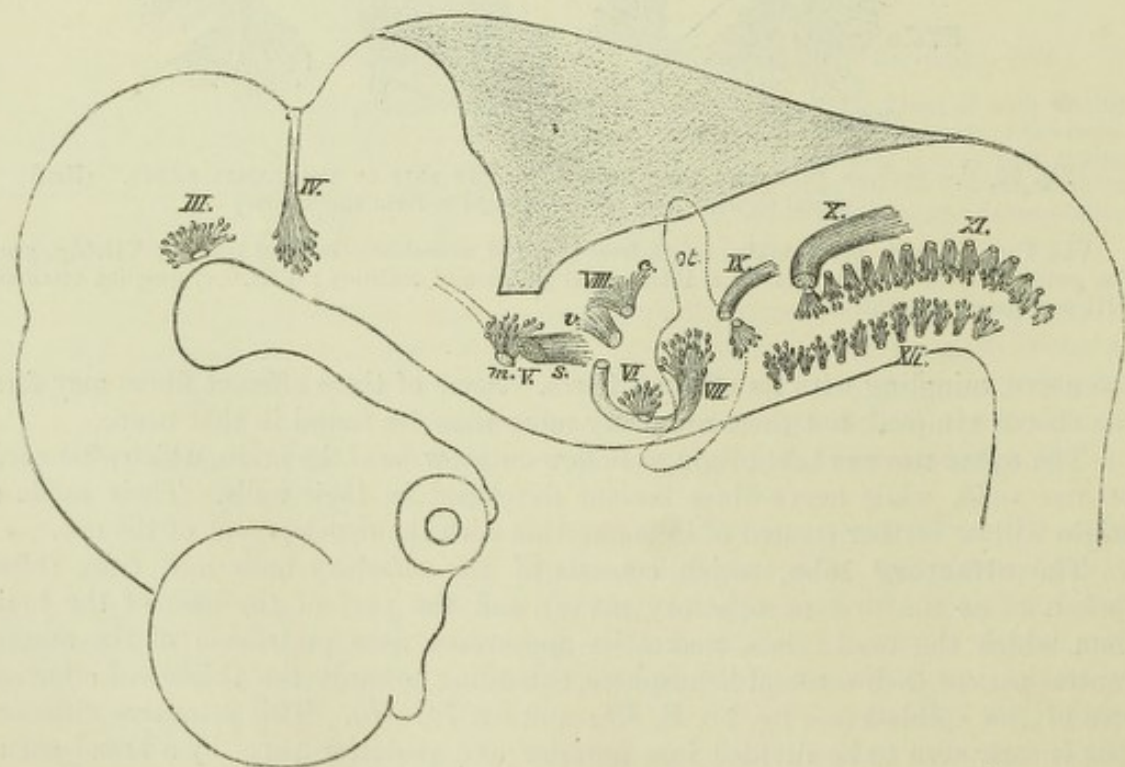


Fig. 92.—DIAGRAM SHOWING THE CENTRIPETAL AND CENTRIFUGAL ROOTS OF THE CRANIAL NERVES OF THE SAME EMBRYO. (His.)

The places of exit of the nerves are marked by dotted circles or ovals. The efferent nerves (III., IV., mV, VI, VII, part of IX, XI, and XII), are seen to arise within the nerve centre from groups of neuroblasts; the afferent fibres (V.s., VIII, v and c, most of IX, and X), pass a certain distance inwards, and for the most part also caudalwards in the nerve-centre, and there end. The ganglion rudiments from which they have grown are not shown here. They will be found in the preceding figure.

subcallosus of Zuckerkandl) are developed. These parts are separated even in the adult by a sulcus, along which the mesial or internal olfactory root runs.

The olfactory nerve fibres arise, according to His, from neuroblasts which become formed within the thickened epiblast of the olfactory area (see p. 95). This epiblast at a certain period of development resembles the neural epiblast, and whilst some of the cells become spongioblasts, others become pear-shaped, or spindle-shaped, and their processes grow as nerve fibres towards the olfactory lobe. Not only, however, do these fibres emerge from the olfactory epiblast, but some of the neuroblasts themselves also pass out, and these form a ganglion which lies between the olfactory lobe and the olfactory area. Subsequently this ganglion, the cells of which are prolonged at either end into nerve fibre processes, becomes attached to and partially invests the olfactory bulb, with which it ultimately blends, forming the part whence the olfactory nerve fibres pass to the Schneiderian membrane (layer of olfactory-glomeruli and nerve fibres), whilst bands of fibres on the other hand grow centripetally and become the olfactory roots. These are in fact comparable to the centripetal (so-called "ascending") roots of the trigeminus, glossopharyngeal, and vagus.

It is not until the third month that the part of the olfactory lobe which forms the bulb, begins to grow forwards away from the trigonum, and thus to form the olfactory tract.

The cranial nerves, except the optic and olfactory, and the relations they bear to one another and to the visceral arches of the head, are shown in fig. 91 as they occur in the human embryo of about four weeks. Fig. 92 distinguishes diagrammatically the nerves which grow into the nerve centres (centripetal or afferent nerves) from those which grow out from the centres (centrifugal or efferent nerves), and the extent of growth inwards of the former in the same embryo.

The sympathetic nerves and ganglia.—That these are merely outgrowths of the cerebrospinal nervous system, nearly all recent observations, both morphological and physiological, clearly show. But even before this fact had come to be generally recognized, it was known that they are developed in connection with the spinal nerves (Balfour), and indeed as offshoots from the posterior spinal ganglia (Schenk and Birdsell, Onodi). They appear for a time as enlargements upon the main stem of each spinal nerve, but afterwards become connected with this by a short branch (*r. communicans*) (fig. 88), and with one another by a longitudinal commissure. The branch in question contains the splanchnic fibres of the spinal nerve, and the sympathetic ganglia are its splanchnic or vagrant ganglia (Gaskell). The splanchnic ganglia of the cranial nerves are probably formed in a similar way, but their mode of development has not as yet been worked out.

The ciliary ganglion appears to be formed as an outgrowth of the Gasserian ganglion (fig. 91, *c.g.*) much in the same way as the sympathetic trunk ganglia are formed as offshoots of the posterior spinal ganglia. In elasmobranchs it is derived from the ophthalmicus profundus ganglion, itself an offshoot of the Gasserian (Ewart).

Paterson has recently described the sympathetic chain of ganglia as developing in mammals (rodents) from a continuous rod of mesoblast lying on either side of the aorta, and as becoming only secondarily segmented and connected with the cerebro-spinal nerves. But observations upon earlier embryos than were used by Paterson are necessary before the mesoblastic origin of the rod can be admitted.

RECENT LITERATURE.

- Ahlborn, *Ueber die Bedeutung der Zirbeldrüse*. Zeitschr. f. wissensch. Zoologie. Bd. xl., 1884.
 Barnes, Will., *On the development of the posterior fissure of the spinal cord and the reduction of the central canal in the pig*. Proc. Americ. Acad. Arts and Sciences, 1884.
 Beard, J., *On the cranial ganglia and segmental sense organs of fishes*. Zoolog. Anzeiger, 1885; *The system of branchial sense organs and their associated ganglia in Ichthyopsida*. Quarterly Journal of Micr. Science, 1885; *The development of the peripheral nervous system of vertebrates*. Quarterly Journal of Micr. Science, Oct., 1888.
 Bedot, M., *Recherches sur le développement des nerfs spinaux chez les Tritons*. Recueil zoolog. Suisse, i., 2, 1884.

- Beer, B., *On the development of the Sylvian fissure in the human embryo*. Journal of Anatomy and Physiology, 1890.
- Béraneck, E., *Recherches sur le développement des nerfs crâniens chez les lézards*. Recueil zoolog. Suisse, 1884; *Étude sur les replis médullaires du poulet*. Recueil zoolog. Suisse, iv., 1887.
- Chiarugi, *Sullo sviluppo di alcuni nervi cerebrali e spinali*. Anat. Anzeiger, 1889.
- Cunningham, D. J., *The complete fissures of the human cerebrum, and their significance in connection with the growth of the hemisphere and the appearance of the occipital lobe*. Journal of Anatomy, April, 1890.
- Dohrn, A., *Die Entstehung der Hypophysis bei Petromyzon Planeri*. Mittheil. aus der zoolog. Station zu Neapel, iv., i., 1883; *Ueber die erste Anlage und Entwicklung der motorischen Rückenmarksnerven bei den Selachiern*, Mittheil. aus der zoolog. Station zu Neapel, Bd. viii., 1888.
- Ewart, J. C., *On the development of the ciliary or motor oculi ganglion*. Proc. Roy. Soc., xlvii., 1890.
- Froriep, A., *Ueber ein Ganglion des Hypoglossus u. Wirbelanlagen in der Occipitalregion*, Arch. f. Anat. u. Physiol., Anat. Abth., 1882; *Ueber Anlagen von Sinnesorganen am Facialis, Glossopharyngeus und Vagus und über die genetische Stellung des Vagus zum Hypoglossus und über die Herkunft der Zungenmuskulatur*, Arch. f. Anat. u. Physiol., Anat. Abth., 1885.
- Goette, A., *Ueber die Entstehung und die Homologien des Hirnanhangs*, Zool. Anzeiger, 1883.
- Golowine, E., *Sur le développement du système ganglionnaire chez le poulet*, Anat. Anzeiger, 1890.
- Graaf, H. W. de, *Bijdrage tot de kennis van den bouw en de ontwikkeling der epiphyse bij Amphibiën en Reptiliën*. Proefschrift, Leiden, 1886.
- His, W., *Ueber das Auftreten der weissen Substanz und der Wurzelfasern am Rückenmark menschlicher Embryonen*, Archiv f. Anat. u. Phys., Anat. Abth., 1883; *Zur Geschichte des menschlichen Rückenmarks und der Nervenwurzeln*, Abhandl. d. math.-phys. Kl. d. kgl. Sächs. Gesellsch. d. Wissensch., Bd. xiii., No. 6, 1886; *Die Entwicklung der ersten Nervenbahnen beim menschlichen Embryo. Uebersichtliche Darstellung*, Archiv f. Anat. u. Physiol., Anat. Abth., 1888; *Zur Geschichte des Gehirns sowie der ventralen und peripherischen Nervenbahnen beim menschlichen Embryo*, Abhandl. d. math.-phys. Kl. d. kgl. Sächs. Gesellsch. der Wissensch., Bd. xiv., 1888; *Die Formentwicklung des menschlichen Vorderhirns*, Abhandl. d. königl. Sächsischen Gesellschaft, Bd. xv., 1889; *Die Neuroblasten u. deren Entstehung im embryonalen Mark*, Abhandl. d. königl. Sächs. Gesellschaft, Bd. xv., 1889.
- His, W., jun., *Zur Entwicklungsgesch. d. Acustico-facialis-gebietes beim Menschen*, Arch. f. Anat. u. Physiol., Anat. Abth., 1889.
- Hoffmann, C. K., *Ueber die Metamerie des Nachhirns u. Hinterhirns u. ihre Beziehung z. d. segmentalen Kopfnerven bei Reptilienembryonen*, Zool. Anzeiger, xii.
- Johnson, A., and Sheldon, Lillian, *On the development of the cranial nerves of the newt*, Proceed. of the Royal Society, vol. xl., 1887.
- Kaczander, J., *Ueber die Beziehungen des Medullarrohrs zu dem Primitivstreifen*, Wiener Medicin. Jahrb., 1886.
- Kraushaar, R., *Entwicklung der Hypophysis und Epiphysis bei Nagethieren*, Zeitschr. f. wissenschaftl. Zoologie, 1884.
- Kupffer, *Primäre Metamerie der Neuralrohre der Vertebraten*, München. Sitzungsab., Bd. xv.
- McClure, *The primitive segmentation of the vertebrate brain*, Zool. Anzeiger, xii.
- Marshall, A. Milnes, *On the early stages of development of the nerves in birds*, Journal of Anatomy and Physiology, 1877; *The development of the cranial nerves in the chick*, Quarterly Journal of Microsc. Science, 1878; *On the head cavities and associated nerves of elasmobranchs*, Quarterly Journal of Microsc. Science, 1881.
- Mihalkovics, v., *Wirbelsäule u. Hirnanhang*, Archiv f. mikr. Anatomie, 1875; *Entwicklungsgeschichte des Gehirns*, Leipzig, 1877.
- Onodi, A. D., *Ueber die Entwicklung der Spinalganglien und der Nervenwurzeln*, Internat. Monatsschr. f. Anat. u. Histologie, i., 3, 1884; *Ueber die Entwicklung des sympathischen Nervensystems*, Arch. f. mikr. Anat., Bd. xxvi., 1885.
- Orr, H., *Note on the development of Amphibians, chiefly concerning the central nervous system, &c.* Quarterly Journal of Microsc. Science, xxix., 1889.
- Osborn, *The origin of the corpus callosum*, Morph. Jahrbuch, 1887.
- Paterson, A. M., *On the fate of the muscle-plate, and the development of the spinal nerves and limb plexuses in birds and mammals*, Quarterly Journal of Microsc. Science, Aug., 1887; *The development of the sympathetic nervous system in mammals*. Proc. Roy. Soc., April, 1890.
- Rabl, C., *Bemerkung über die Segmentierung des Hirns*, Zoolog. Anz., 1885.
- Rabl-Ruckard, *Gehirn der Knochenfische*, Arch. f. Anat. u. Physiol., Anat. Abth. 1882 und 1883.
- Robinson, A., *On the development of the posterior columns, of the posterior fissure, and of the central canal of the spinal cord*. Owens' College Studies, 1890.
- Rüdinger, *Ueber die Bildung der Augenblasen*, Sitzungsab. der Gesellsch. f. Morphol. zu München, 1889.
- Spencer, B., *On the presence and structure of the pineal eye in Lacertilia*, Quarterly Journal of Microsc. Science, 1886.
- Strahl, H., and Martin, E., *Die Entwicklung des Parietalauges bei Anguis fragilis und Lacerta vivipara*, Arch. f. Anat. u. Phys., Anat. Abth. 1888.
- Vignal, W., *Sur le développement des éléments de la moelle des mammifères*, Archives de physiologie, 1884; *Recherches sur le développement de la substance corticale du cerveau et du cervelet*, Archives de physiologie, 1888.
- Wijhe, J. W. van, *Ueber Somiten und Nerven im Kopfe von Vogel- und Reptilienembryonen*, Zoolog. Anzeiger, 1886.
- Zuckerkandl, E., *Ueber das Riechcentrum*, Stuttgart, 1887.

DEVELOPMENT OF THE EYE.

The first development of the eye occurs as a hollow protrusion of the anterior cerebral vesicle—primary optic vesicle—in the manner already mentioned (see fig. 68, *e*, and fig. 93). The vesicle thus formed abuts externally against the external epiblast of the side of the head (fig. 96); and this external epiblast opposite the most prominent point of the primary optic vesicle, becomes thickened and in-

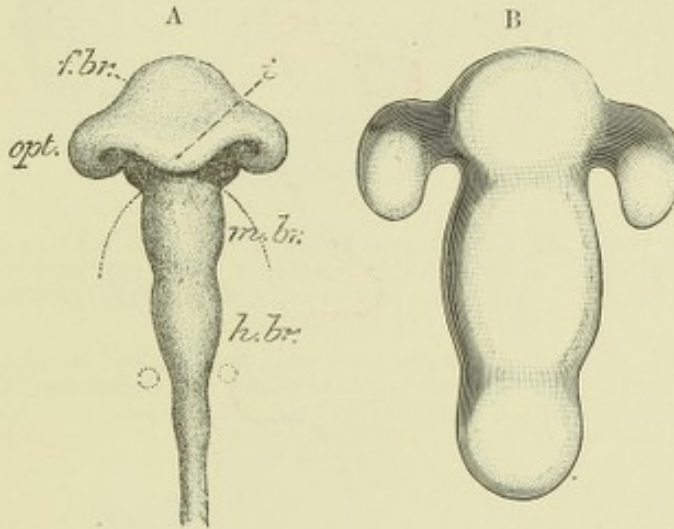


Fig. 93, A.—BRAIN OF CHICK OF 2ND DAY, VIEWED FROM BELOW, TO SHOW THE FORMATION OF THE OPTIC VESICLES BY OUTGROWTH OF THE SIDE OF THE FORE-BRAIN, AND AT THE SAME TIME BY THE FOLDING OVER OF THE ENLARGED PART, THE PRODUCTION OF A GROOVING OR CUPPING OF THE VESICLES. (His.)

f.br., *m.br.*, *h.br.*, fore-, mid-, and hind-brain; *opt.*, optic vesicle; *i*, infundibulum.

Fig. 93, B.—BRAIN OF HUMAN EMBRYO OF THREE WEEKS, SHOWING THE PRIMARY OPTIC VESICLES AS OUTGROWTHS FROM THE FOREBRAIN. (His.)

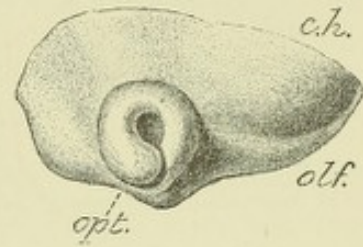


Fig. 94.—SIDE VIEW OF ANTERIOR PART OF BRAIN OF MORE ADVANCED HUMAN EMBRYO, SHOWING THE PRIMARY OPTIC VESICLE FOLDED AND CUPPED. (His.)

c.h., cerebral hemisphere (part of); *olf.*, olfactory lobe; *opt.*, optic cup.

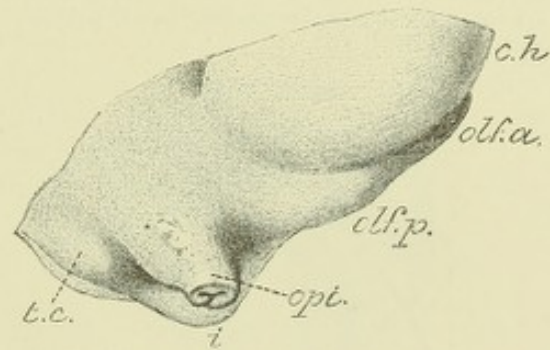


Fig. 95.—SIDE VIEW OF THE SAME PART OF THE BRAIN IN A STILL MORE ADVANCED EMBRYO, THE EYE HAVING BEEN CUT AWAY. (His.)

opt., cut end of optic stalk, showing the manner in which it is folded; *i*, infundibulum; *olf.p.*, posterior part of olfactory lobe; *olf.a.*, anterior part of the same; *c.h.*, cerebral hemisphere; *t.c.*, tubes cinereum.

vaginated, so as to form at first a hollow cup-shaped depression with thickened walls (figs. 97, 98), and subsequently by the closing in of the epiblast at the mouth of the cup, a hollow island of epithelial cells (fig. 99). This island, which is the rudimentary lens, lies between, but is entirely distinct from the external epiblast on the one hand, and the neural epiblast of the primary optic vesicle on the other hand. Its formation is accompanied by a cupping in of the primary optic vesicle (figs. 94, 97, 98), which is invaginated before it, and this invagination is increased by an ingrowth of mesoblast, which occurs between the lens and the cupped optic vesicle, and which subsequently forms the vitreous humour. Invaginated in this way the cavity of the original optic vesicle becomes almost entirely obliterated, and appears merely as a cleft between the two layers which form the wall of the so-called "optic cup." The inner of these two layers is from the first thicker than the outer, and in it are developed all the parts of the future retina from the membrana limitans interna

to the layer of rods and cones, while from the outer thinner layer the hexagonal pigmented epithelium of the retina, with its continuation into the uvea, is formed.

The invagination of the primary optic vesicle does not occur only opposite the

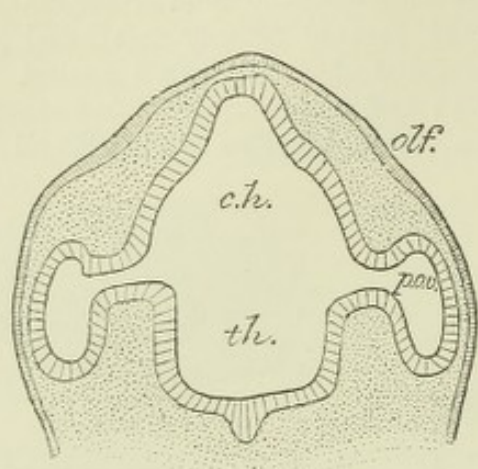


Fig. 96.—PART OF A SECTION THROUGH THE HEAD OF AN EARLY HUMAN EMBRYO, SHOWING THE CONNECTION OF THE PRIMARY OPTIC VESICLES WITH THE FOREBRAIN. (His.)

olf., olfactory area of epiblast; *c.h.*, part of forebrain which gives rise to cerebral hemispheres; *th.*, thalamencephalon; *p.o.v.*, primary optic vesicles.

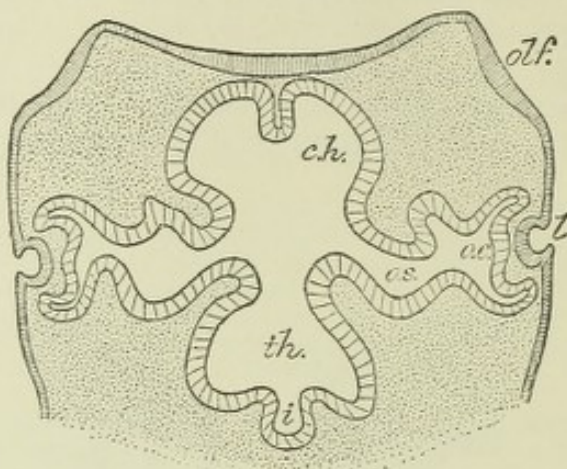


Fig. 97.—SECTION THROUGH THE SAME PART OF A MORE ADVANCED EMBRYO, IN WHICH THE LENS INVAGINATION IS FORMED, AND THE PRIMARY OPTIC VESICLES ARE CUPPED. (His.)

o.c., optic cup; *o.s.*, optic stalk; *l*, lens invagination; *c.h.*, cerebral hemispheres; *th.*, thalamencephalon; *i*, infundibulum; *olf.*, olfactory area.

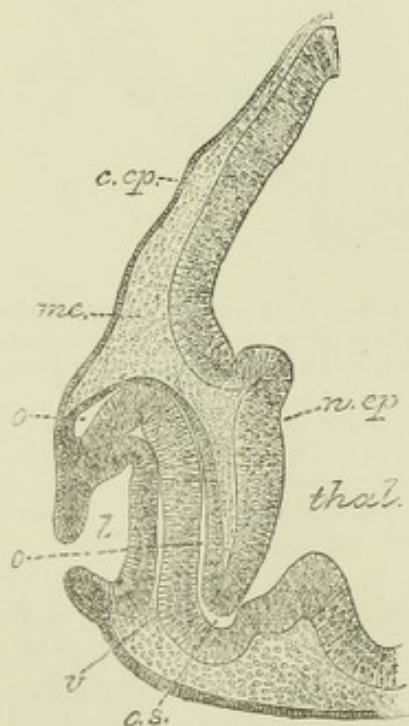


Fig. 98.—VERTICAL SECTION THROUGH THE MIDDLE OF THE DEVELOPING EYE OF A CHICK OF THE THIRD DAY. (E. A. S.)

The section passes longitudinally through the deficiency in the lower part of the optic cup, and shows the mesoblast extending in between the lens invagination and the pigment layer of the optic cup.

thal., thalamencephalon; *n.ep.*, neural epiblast; *c.ep.*, cutaneous epiblast; *o.s.*, optic stalk; *o*, cavity of primary optic vesicle; *me*, mesoblast; *v*, mesoblast passing behind lens to form vitreous; *l*, lens invagination.

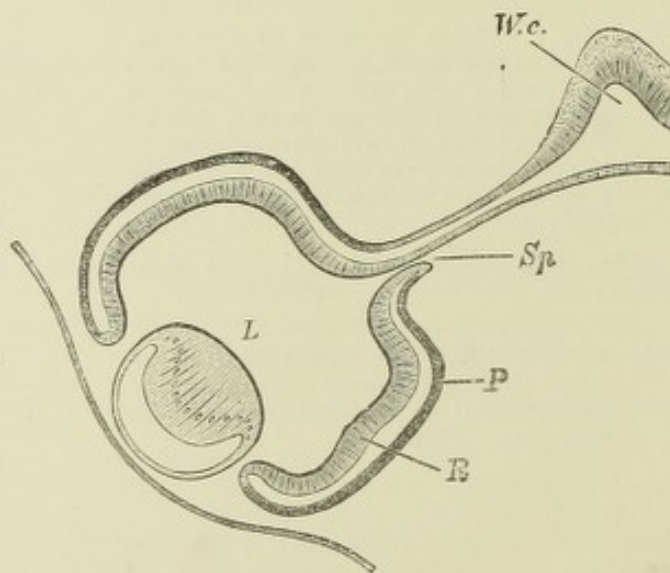


Fig. 99.—SECTION THROUGH THE EYE AND OPTIC STALK OF A HUMAN EMBRYO OF FIVE WEEKS. (His.)

W.c., connection of optic stalk with thalamencephalon; *Sp*, cleft or fold in the stalk, where the arteria centralis retinae passes in; *P*, pigment layer; *R*, retina; *L*, lens.

place where the lens is becoming involuted, but also below, or ventral, to that place, so that a section exactly through the middle of the optic cup at right angles to the axis of this part of the head, shows a gap in the boundary of the cup through which the mesoblast is passing into the space between the lens and the invaginated optic vesicle (fig. 98, *v*). This gap or cleft soon becomes closed, but the suture or line of closure long remains apparent from the fact that when pigment begins to be deposited in the eye, this so-called *choroidal fissure* remains for some time unpigmented (until the sixth week in man).

The ventral invagination is in mammals continued for a considerable distance into the stalk of the optic vesicle (fig. 95), and the simultaneous inclosure of mesoblastic tissue leads to the introduction of the central blood-vessels of the retina within the optic nerve. In birds no such infolding of the stalk occurs.

The lower invagination of the optic cup serves not only to permit of the passage of mesoblast behind the lens for the formation of vitreous humour, but also to establish a direct connection between the nerve-fibres which are formed along the course of the optic stalk (future optic nerve) and the centre of the inner layer of the optic cup (future retina) (O. Hertwig).

The malformation termed *coloboma iridis* is attributed to a persistence of the choroidal cleft, which extends behind the iris along with the retinal pigment or uvea, as far as the margin of the pupil.

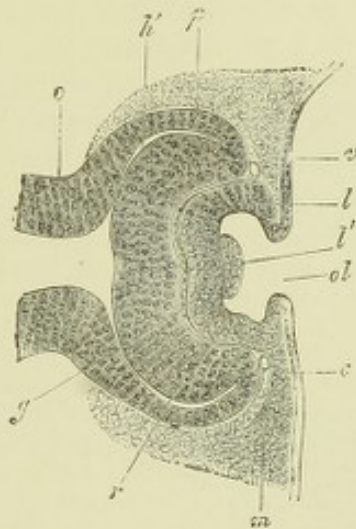


Fig. 100.—HORIZONTAL SECTION THROUGH THE EYE OF AN EMBRYO RABBIT OF TWELVE DAYS AND SIX HOURS. (Kölliker.)

o, optic stalk; *h'*, remains of the cavity of the primary optic vesicle; *p*, proximal lamella of the optic cup (pigmentum nigrum); *r*, distal lamella (retina); *l*, lens invagination, widely open at *ol*; *l'*, papillar elevation in the bottom of the lens vesicle; *m*, mesoblast; *g*, mesoblast of vitreous; *v*, a blood-vessel at the anterior border of the optic cup; *c*, cutaneous epiblast.

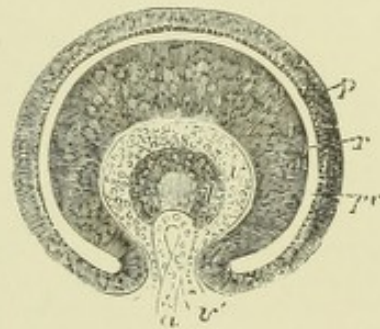


Fig. 101.—EYEBALL OF A HUMAN EMBRYO OF FOUR WEEKS CUT ACROSS, AND THE ANTERIOR HALF REPRESENTED FROM BEHIND. (Kölliker.)

pr, the remains of the cavity of the primary optic vesicle; *p*, outer layer forming the retinal pigment; *r*, the thickened inner part giving rise to the columnar and other structures of the retina; *v*, commencing vitreous humour within the optic cup; *v'*, the cleft through which a vascular loop, *a*, projects from below; *l*, the lens with a central cavity.

The hollow optic stalks are at first freely in communication with the thalamo-encephalon, or third ventricle. Nerve-fibres grow along their walls, from neuroblasts which develop in the retinal epiblast, and pass towards the nerve-centre (His), and the cavities of the stalks become thereby gradually obliterated, the radially striated epithelial-like arrangement of the wall being, however, long evident. A new connection becomes subsequently established between the posterior part of the optic stalks (optic tracts) and the mesencephalon, whilst the middle parts become united with one another to form the chiasma.

The development of the **retina** from the inner layer of the optic cup, has not been fully worked out. In its earlier stages it closely resembles in structure the wall of the cerebral vesicles, consisting of elongated epithelium-like cells, apparently arranged in several interlocking layers. Of these cells some become developed into nerve-fibres and nerve-cells (inner granules and ganglionic layer), others into sustentacular tissue, similar to the neuroglia of the central nervous system (molecular layers, Müllerian fibres), whilst the outermost layer forms the sense-epithelium (W. Müller), or layer of outer granules, which is sharply marked off against the layer of hexagonal pigment cells by the *membrana limitans externa*, as is the nerve-fibre layer from the vitreous humour by the *membrana limitans interna*. For a long time there is no trace of the rods and cones. These begin to appear some little time before birth in man and most animals, but in animals which are born blind, such as kittens, not until after birth (M. Schultze), in the shape of small protuberances of the sense-epithelium cells growing beyond the *limitans externa*, and forming at first the inner segments of the rods and cones, and subsequently the outer segments also. The latter as they are developed become imbedded in the inner surface of the hexagonal pigment cells, which have become developed from the outer layer of the optic cup.

The anterior third of the optic cup does not undergo the changes above

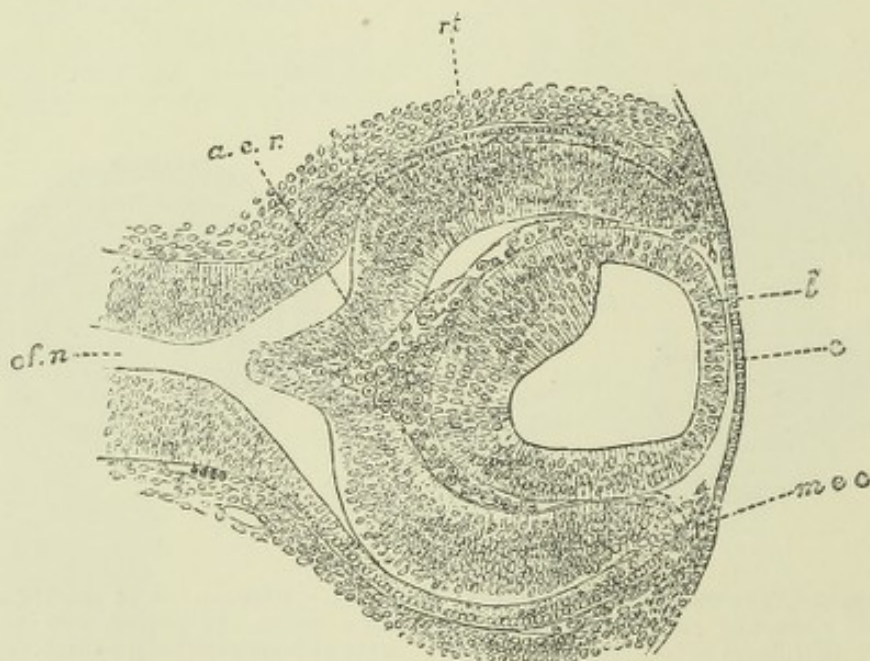


Fig. 102.—SECTION THROUGH THE EYE OF A RABBIT EMBRYO, MORE ADVANCED IN DEVELOPMENT THAN THAT SHOWN IN FIG. 98. (Balfour.)

c, epithelium of cornea; *l*, lens; *m.e.c.*, mesoblast growing in to form the substantia propria of the cornea; *c.f.n.*, optic nerve; *rt*, retina; *a.c.r.*, mesoblast for the formation of the vitreous humour, and the arteria centralis retinae.

described. Its two layers become here developed into the comparatively simple pars ciliaris retinae, and in front of the ciliary region they extend forwards and inwards in front of the lens and in close contact with the back of the iris, where they form the thickly pigmented epithelium, which is known as the uvea and terminates at the margin of the pupil.

Further development of the lens.—The hollow epiblastic vesicle from which the lens develops is composed of a thick posterior and a thin anterior layer which pass into one another at the equator of the lens, and enclose a clear fluid. In mammals, the vesicle when first formed also contains a small mass of epithelium cells which have become separated off from the posterior wall (fig. 100), but these

afterwards disappear. The thin anterior layer remains throughout life as a simple layer of cubical cells, and forms the so-called lens-epithelium; but the cells of the posterior layer grow forwards into the cavity of the lens-vesicle as the lens-fibres: those in the middle being the longest and straight, while the rest are slightly curved with their concavity towards the equator, and become gradually shorter towards the circumference, where they pass through gradually shortening columnar cells (*transitional zone*) into continuity with the anterior epithelium. By the growth of these fibres the cavity of the lens-vesicle becomes obliterated.

In this manner the central part of the lens is formed, and it consists in the main of fibres which pass in an antero-posterior direction. The remainder of the lens is formed of fibres which are so disposed as to curve round its margin and over the ends of the first formed fibres; they are, moreover, deposited in successive layers and in three (or more) separate sections, so that their ends abut against one another in front and behind along tri-radiate (or multi-radiate) lines, such as may be seen in the macerated lens. These later deposited fibres are all formed at the equator (at the transitional zone), where chiefly cell-multiplication takes place, and they grow hence meridionally backwards over the ends of the already developed antero-posteriorly disposed fibres of the central part of the lens.

The **capsule of the lens** is early visible as a thin homogeneous membrane, the origin of which is still undetermined. According to some observers (Lieberkühn, Arnold, Löwe) it is derived from a thin layer of mesoblast, which passes in between the lens and the optic cup; according to others (Kölliker, Kessler, Balfour), it appears before any mesoblast has passed in, and they therefore regard it as a cuticular deposit from the lens cells. In the human embryo, His figures mesoblast as existing from the first between the lens invagination and the optic cup (*v. fig. 97*).

In connection with this question it must be remembered that the substantia propria of the cornea (see below), which is formed of connective tissue, and is therefore mesoblastic in nature, also at first makes its appearance as a homogeneous deposit before any mesoblast cells have passed in behind the corneal epithelium.¹ Its chemical nature, and its continuity at the equator with the suspensory ligament and hyaloid membrane, certainly point to the lens capsule as being a connective tissue, *i.e.* a mesoblastic structure.

Although the foetal lens like that of the adult is itself non-vascular, it is nevertheless externally freely supplied with blood-capillaries, which form a vascular tunic completely surrounding it outside the capsule. These capillaries are supplied by a branch of the *arteria centralis retinae* which passes forwards through the centre of the vitreous humour; in front, at the margin of the pupil, they come into continuity with the vessels of the iris. The most anterior part of this vascular tunic forms a membrane which closes the aperture of the pupil in the middle periods of foetal life. In the human eye the whole tunic, together with the artery which supplies its vessels, becomes atrophied and is lost sight of before birth, but in some animals the *pupillary membrane* remains apparent for a few days after birth.

The **vitreous humour** appears to be formed from the mesoblastic tissue which has passed in between the lens and the inner layer of the optic cup by a gradual formation of a large quantity of ground-substance, whilst the cells of the tissue almost entirely disappear. The development of the hyaloid membrane has not been fully traced out, and the same may be said with regard to the zonule of Zinn. They are probably both formed by part of the same mesoblast as forms the vitreous humour (Lieberkühn, Angelucci).

The *corneo-sclerotic coat*, the *choroid coat*, and the *iris* are all derived from the mesoblast surrounding the optic cup.

The **corneal epithelium** is a portion of the external epiblast, which originally rests against the front of the lens rudiment. The **substantia propria corneae** first appears in the chick as a thin homogeneous layer lying immediately within

¹ Kessler, however, looks upon this homogeneous deposit as being also a cuticular deposit formed by the epithelial cells.

this epithelium. Into this homogeneous layer mesoblast cells pass from the margin, greatly thickening it and producing eventually the regular layers of fibrous tissue, which are characteristic of the cornea. No cells pass into the most anterior or into the most posterior stratum, which remain homogeneous (anterior and posterior

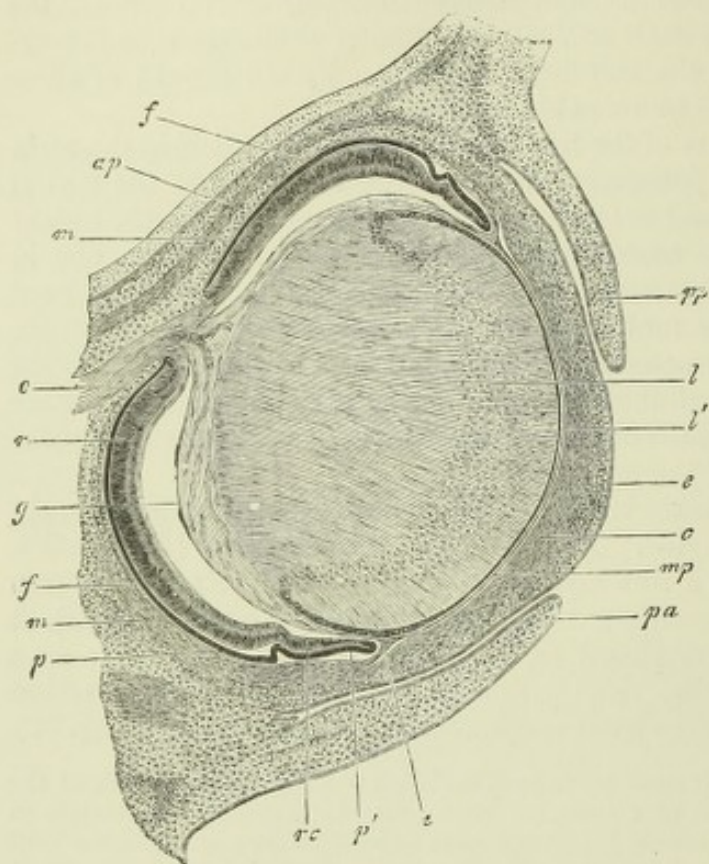


Fig. 103. — HORIZONTAL SECTION THROUGH THE EYE OF AN EMBRYO RABBIT OF 18 DAYS. $\frac{30}{1}$. (Köl liker.)

o, optic nerve; *p*, hexagonal pigment layer; *r*, retina; *rc*, ciliary part of the retina; *p'*, forepart of the optic cup (rudiment of the iris pigment); *g*, vitreous, shrunk away from the retina, except where the vessels from the arteria centralis retinae enter it; *i*, iris; *mp*, membrana pupillaris; *c*, cornea with epithelium *e*; *pp*, *pa*, palpebrae; *l*, lens; *l'*, lens epithelium; *f*, sclerotic; *m*, recti muscles.

homogeneous lamellæ of Bowman). The epithelium of the posterior homogeneous lamella, or membrane of Descemet, is derived from mesoblast cells which grow in like the corneal corpuscles from the margin and spread themselves over the posterior surface of the cornea, thus separating this from the iris and anterior surface of the lens. For a

long while, however, there is no anterior chamber; this eventually appears as a cleft-like space between the cornea and the structures immediately behind it.

In mammals, all the above stages of formation have not been described. A complete layer of mesoblast is early visible lying between the corneal epiblast and the lens epiblast, and continuous around the margin of the lens with the mesoblast of the vitreous chamber. In this mesoblast a cleft makes its appearance, separating it into two parts, one of which adheres to the corneal epiblast, where it forms the substance of the cornea, the other to the lens capsule forming the pupillary membrane. This cleft is the rudiment of the anterior chamber. It does not become actually distended with fluid until a short time before birth (Köl liker).

The **sclerotic** is formed entirely from mesoblast around the optic cup, probably continuous with that which forms the cornea, although it is only later that the cornea and sclerotic come to be completely amalgamated.

The **choroid coat** is formed from the mesoblast which is immediately in contact with the outer layer of the optic cup, and the forward growth of the middle tunic closely follows that of the margin of the cup. The latter ceases at first at the margin of the lens, but subsequently grows forwards over the front of the lens as a thin double layer, which is closely covered externally with a continuation of the choroidal mesoblast. This is the **iris**, over the back of which both the layers of the cup-margin eventually acquire pigment and remain permanently as the uvea. The ciliary body is formed by a kind of hypertrophy of the optic cup, which develops radial folds, enclosing thin portions of mesoblastic choroidal tissue, in which, as in the rest of the choroid, numerous blood-vessels and branched pigment-cells become formed.

Accessory structures.—The **eyelids** make their appearance gradually as folds of integument, subsequently to the formation of the eyeball (fig. 103). About the third month of foetal life the two folds, one forming the upper and the other the lower lid, meet and unite by a growth together of the epithelium at the margins of the folds, so as to cut off the conjunctival sac from the exterior. A short time before birth they again become disunited.

A third fold (of the conjunctiva) appears at the inner canthus, and in many vertebrates develops into a well-marked third eyelid, the *membrana nictitans*. In man it remains rudimentary, forming the *plica semilunaris*.

The glands, hairs, and other structures belonging to the eyelids, are developed in the same way as the corresponding structures in the rest of the integument.

The **lachrymal gland** is developed in the third month as a number of outgrowths from the deeper layer of the epithelium, at the upper and outer part of the conjunctival sac. The outgrowths are at first solid, and branch into the surrounding connective tissue as with other racemose glands, subsequently becoming hollowed out and differentiated into ducts and acini.

The **lachrymal canals and ducts** are usually described as being directly developed by the enclosure of the fissure which separates the lateral nasal process from the maxillary process (see Development of Nose, p. 95, and figs. 111, 112), and which passes in the early embryo from the eye to the upper part of the nasobuccal cavity (lachrymal fissure). But it has been shown, chiefly by the researches of Born, that in most animals the canal is at first formed as a thickening of the rete mucosum of the epidermis, which sinks into the corium along the line of that fissure. The thickening subsequently becomes separated from the rest of the epidermis, and hollowed out to form an epithelial tube, which leads from the conjunctiva into the nasal cavity.

The bifurcation of the duct where it opens on the conjunctiva is produced, according to Ewetsky, by a broadening out of the epithelial cord at the inner canthus, and its subsequent separation into two parts by an ingrowth of connective tissue in its middle, the two parts developing into the upper and lower lachrymal canals.

DEVELOPMENT OF THE EAR.

The essential part of the ear, viz., the epithelial lining of the labyrinth, is developed in much the same way as the crystalline lens, as an invagination of the external epiblast, which at first appears as a pit of thickened epithelium (*auditory pit*, fig. 104, A.), but is gradually converted by a growing together of the margins of the pit into a hollow island of epiblast, the *auditory* or *otic vesicle* (fig. 104, B). This process occurs somewhat after the formation of the eye is laid, and at quite a different part of the head, viz., on either side of the hind-brain just over the upper end of the first post-oral visceral cleft. The vesicle comes at first into close contact with the hind-brain, except where the ganglionic rudiment of the auditory nerve projects between them, but it subsequently becomes entirely surrounded by mesoblast, which separates it from both the neural and external epiblast.

The hind-brain does not send out a hollow process towards the otic vesicle corresponding to the optic processes of the fore-brain, but the auditory nerve develops from a solid outgrowth of the neural crest in the same way as the posterior roots of the spinal nerves and parts of many other of the cranial nerves (see p. 78).

The otic vesicle is at first flask-shaped, with the somewhat elongated mouth of the flask directed externally towards the original point of connection with the

exterior. In elasmobranch fishes this connection is never closed, but remains throughout life in the form of a small duct-like tube which passes up through the cranial wall and opens on the epidermis. In other vertebrates the connection with the exterior becomes closed—in the chick during the third day—and what remains

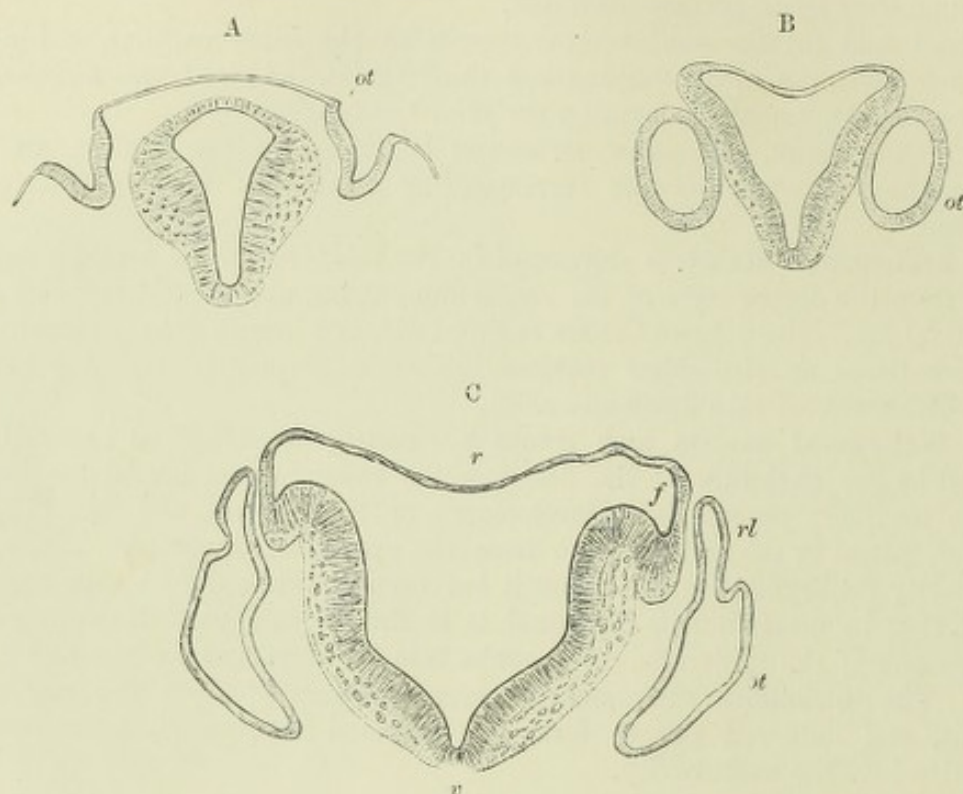


Fig. 104.—SECTIONS THROUGH REGION OF THE HIND-BRAIN OF HUMAN EMBRYOS, SHOWING THREE STAGES IN THE DEVELOPMENT OF THE OTIC VESICLE.

A, auditory pits ; B, simple auditory vesicles ; C, auditory vesicles beginning to be fashioned into parts of the membranous labyrinth.

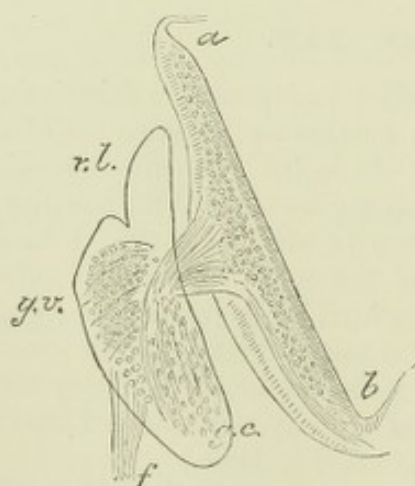


Fig. 105.—OUTLINE OF THE RIGHT LABYRINTH OF A $3\frac{1}{2}$ WEEKS HUMAN EMBRYO, TO SHOW ITS RELATIONS TO THE PARTS OF THE AUDITORY NERVE. (W. His, jun.)

a.l., section of hind brain ; *g.v.*, ganglion vestibuli in contact with the upper part of the labyrinth ; *g.c.*, ganglion cochleæ in contact with the lower part. The fibres of the corresponding parts of the auditory nerve which have grown from these ganglia into the hind brain, are seen to cross one another ; *f*, facial nerve.

of the original mouth, or canal of connection with the exterior, is visible as a distinct but small process from the upper and inner angle of the vesicle, and is known as the *recess of the labyrinth* (fig. 104 c, *rl*). Eventually it develops into a long epithelial tube, which passes through the petrous bone, with an expanded end lying within the skull underneath the dura mater. This tube and its expanded termination form respectively the *endolymphatic canal* and *sacculæ* (fig. 106).

In the meantime the auditory vesicle becomes elongated and begins to be irregular. Its ventral end projects as a distinct hollow process, at first straight, but soon becoming curved ; this is the rudiment of the epithelial *canal of the cochleæ*.

Other hollow projections appear near the dorsal end of the vesicle; these form the two superior semicircular canals; the horizontal canal appears a little later.

The mode of formation of the canals is somewhat peculiar. They first appear as flattened semicircular hollow protrusions of the wall of the vesicle. Their sides then come together and coalesce, except near the circumference of the semicircle, which now forms a tube connected at both ends with the vesicle. Subsequently a separation or breach of continuity occurs over the area of coalescence, so that the rest of the tube is free. One of the ends becomes dilated into an ampulla and connected with a branch of the auditory nerve.

Whilst these processes are occurring at the dorsal and ventral ends of the now elongated vesicle, a fold, or constriction, of the wall is beginning to make its appearance about the middle, and thus the posterior part which is connected with the semicircular canals becomes gradually separated (as the utricle) from the anterior part, which forms the saccule, and is connected with the cochlea. This fold extends into the beginning of the recess of the labyrinth, and separates it longitudinally for a

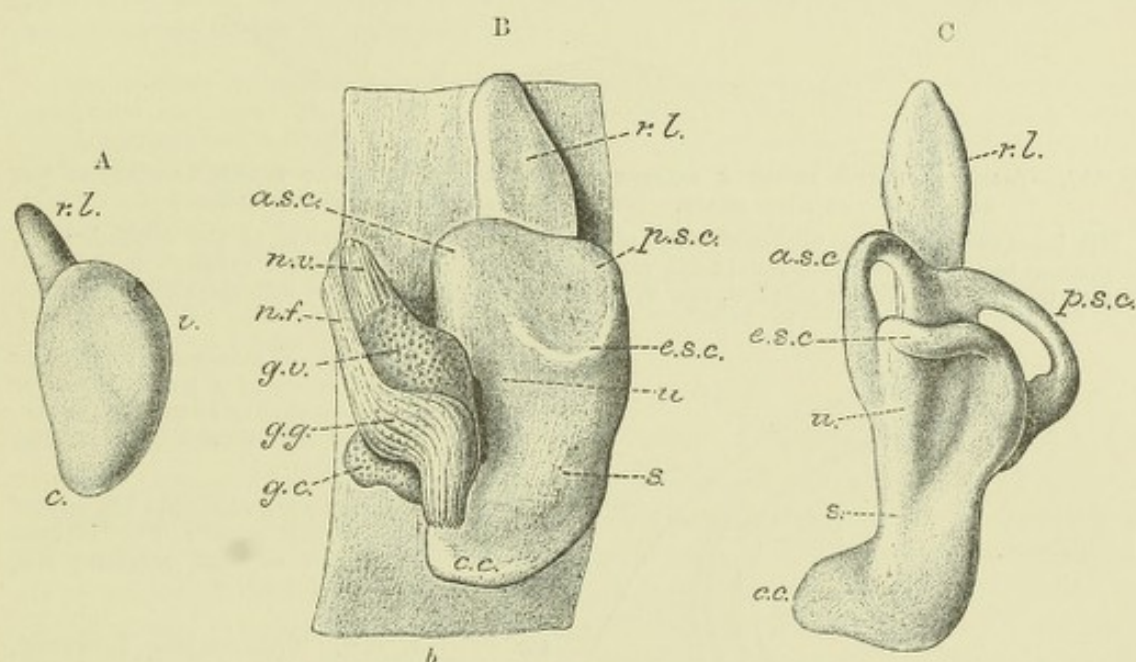


Fig. 106.—STAGES IN THE DEVELOPMENT OF THE MEMBRANOUS LABYRINTH. (W. His, jun.)

A. Left labyrinth of a human embryo of about four weeks, viewed from the outer side. *r*, vestibular part; *c*, cochlear part; *r.l.*, recessus labyrinthi (aquæductus vestibuli).

B. Left labyrinth with parts of the facial and auditory nerves of a human embryo of about 4½ weeks. *b.b.*, surface of the hind brain; *u*, utricular; *s*, saccular part of labyrinth; *a.s.c.*, *p.s.c.*, *e.s.c.*, rudimentary folds representing the two vertical and the horizontal semicircular canals; *r.l.*, upper part of recessus labyrinthi becoming enlarged into the endolymphatic saccule; *c.c.*, rudiment of cochlea; *n.v.*, vestibular branch of auditory nerve; *g.v.*, vestibular ganglion (ganglion of Scarpa); *g.c.*, cochlear ganglion; *n.f.*, facial nerve, with geniculate ganglion, *g.g.*

C. Left labyrinth of a human embryo of about five weeks, viewed from without and below. Lettering as before. The horizontal canal is still only a fold. The ampullæ are beginning to be visible on the two vertical canals.

short distance into two tubes, one of which opens into the utricle, and the other into the saccule, forming the only permanent means of communication between their contents. Another fold, or constriction, appears presently, somewhat lower down, and converts the connection between the saccule and the cochlea rudiment into the narrow duct of Hensen (*canalis re-uniens*).

In the meantime the cochlea-rudiment at the ventral end of the now labyrinthic vesicle, becomes elongated into a tube, which, as it grows, becomes coiled upon itself in such a manner as to produce the spiral structure of this part of the auditory

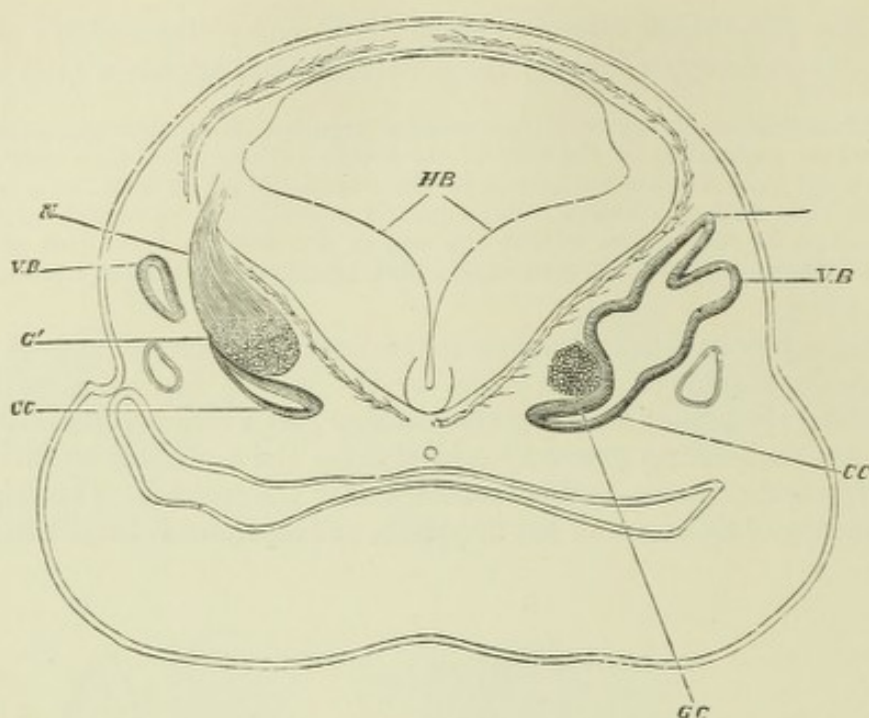


Fig. 107.—TRANSVERSE AND SLIGHTLY OBLIQUE SECTION OF THE HEAD OF A FETAL SHEEP, IN THE REGION OF THE HIND BRAIN. (From Foster and Balfour after Boettcher.)

HB, inner surface of the thickened walls of the hind brain; RB, recess of the vestibule; VB, commencing vertical semicircular canal; CC, canal of the cochlea; GC, cochlear ganglion of the right side; on the left side. G', the ganglion, and N, the auditory nerve connected with the hind brain.

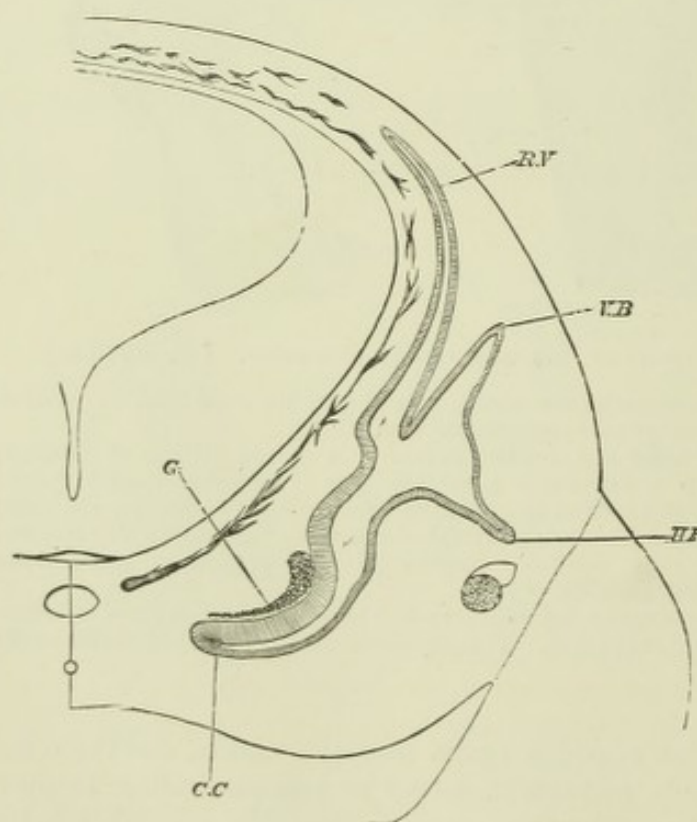


Fig. 108.—TRANSVERSE SECTION OF THE HEAD OF A FETAL SHEEP OF FOUR-FIFTHS OF AN INCH IN LENGTH. (From Foster and Balfour after Boettcher.)

RV, recessus vestibuli; VB, vertical semicircular canal; CC, cochlear canal; G, cochlear ganglion; HB, horizontal canal.

organ. This coiling, however, only occurs in mammals; in birds, the cochlea is a short straight blind tube.

All these parts of the labyrinth are, when first formed, simple epithelial tubes surrounded by and imbedded in embryonic connective tissue. As development proceeds, and the skull begins to form, a cartilaginous capsule becomes developed around the several parts of the labyrinth, and this at length becomes ossified.

The cartilaginous capsule does not closely invest the epithelial structures; they are immediately surrounded by embryonic connective tissue, which forms an internal periosteal lining to the capsule and a special covering to the epithelial tube. These two connective tissue membranes are everywhere separated from one another by gelatinous connective tissue, composed

of semi-fluid ground substance and branching corpuscles, except along one border, where they are in continuity. But in the cochlea the gelatinous tissue is above and below the epithelial tube, the place of the modiolus being occupied by embryonic tissue which is not gelatinous, and is connected with that lining the capsule by similar non-gelatinous tissue separating the turns of the cochlea from one another, and also running in the position of the future spiral lamina.

The bone, which is formed by ossification of the cartilaginous capsule, is of a spongy nature, but it becomes coated internally by layers of compact bone deposited by the periosteal lining. The modiolus and septa of the cochlea, as well as the osseous spiral lamina, are formed wholly in connective tissue without any preformation in cartilage.

The perilymphatic spaces throughout the whole labyrinth are produced by a gradual vacuolation and disappearance of the gelatinous tissue which surrounds the membranous labyrinth. In the cochlea this conversion into perilymph begins in the proximal turn of the spiral and extends hence towards the distal end. It is only with the development of these perilymph-spaces (scalæ) that the cochlear tube, which was previously oval in section, acquires the characteristic triangular section which we see in the fully-formed organ.

The auditory nerve is large and early becomes separated into its two main divisions, vestibular and cochlear. Each division has a large ganglion upon it (fig. 105), which extends to the anterior wall of the epithelial vesicle, and as the ventral end of the vesicle elongates and assumes the spiral disposition, the cochlear nerve and ganglion extend along with it and take the same coiled or spiral form.

The cells which form the wall of the epithelial tube become variously modified in different parts of the labyrinth to produce the characteristic structures which there occur, viz.: the hair-cells, the rods of Corti, the sustentacular cells of Deiters and the epithelium lining the labyrinth. The membrana tectoria appears as a cuticular deposit over the columnar cells which are becoming developed into the organ of Corti.

ACCESSORY PARTS OF THE ORGAN OF HEARING. EXTERNAL AND MIDDLE EAR.

While the epithelium of the internal ear is formed by an involution of cutaneous epiblast in the manner which has just been explained, the middle ear with the Eustachian tube, and the external auditory meatus with the pinna are formed from the remains of the first visceral cleft, and from the parts of the mandibular and hyoidean arches which immediately bound the cleft. This cleft at an early period forms an almost complete communication between the pharynx and the exterior,¹ but the broad cleft becomes gradually converted into a flattened tube, and this is presently found to be closed, both by the epiblast and hypoblast, which are from the first in contact at the bottom of the cleft, and also by an ingrowth of mesoblast, the rudiment of the membrana tympani being thus formed. There is at first no enlargement of the flattened tube to represent the tympanic cavity, and the ossicles are developed not within, but altogether outside the tube, in a mass of gelatinous connective tissue, which is continuous with that forming the embryonic membrana tympani; they are formed for the most part by ossification of parts of the cartilaginous bars, which extend from the otic capsule into the mandibular and hyoidean visceral arches (see Development of Skeleton). As the tympanic cavity becomes formed by a gradual enlargement of the blind end of the closed hyomandibular cleft, the gelatinous tissue retires before it, and as this tissue disappears, the ossicles and the chorda tympani which were previously entirely enveloped by it, are left projecting into the tympanic cavity, covered only by thin mucous membrane. The process of formation of that cavity is not, in fact, completed until after birth, when air becomes admitted into it through the Eustachian tube.

¹ *Vide* footnote on p. 102.

The embryonic tympanic membrane is at first close to the exterior, the external meatus being scarcely existent, although the several parts of the external ear are very

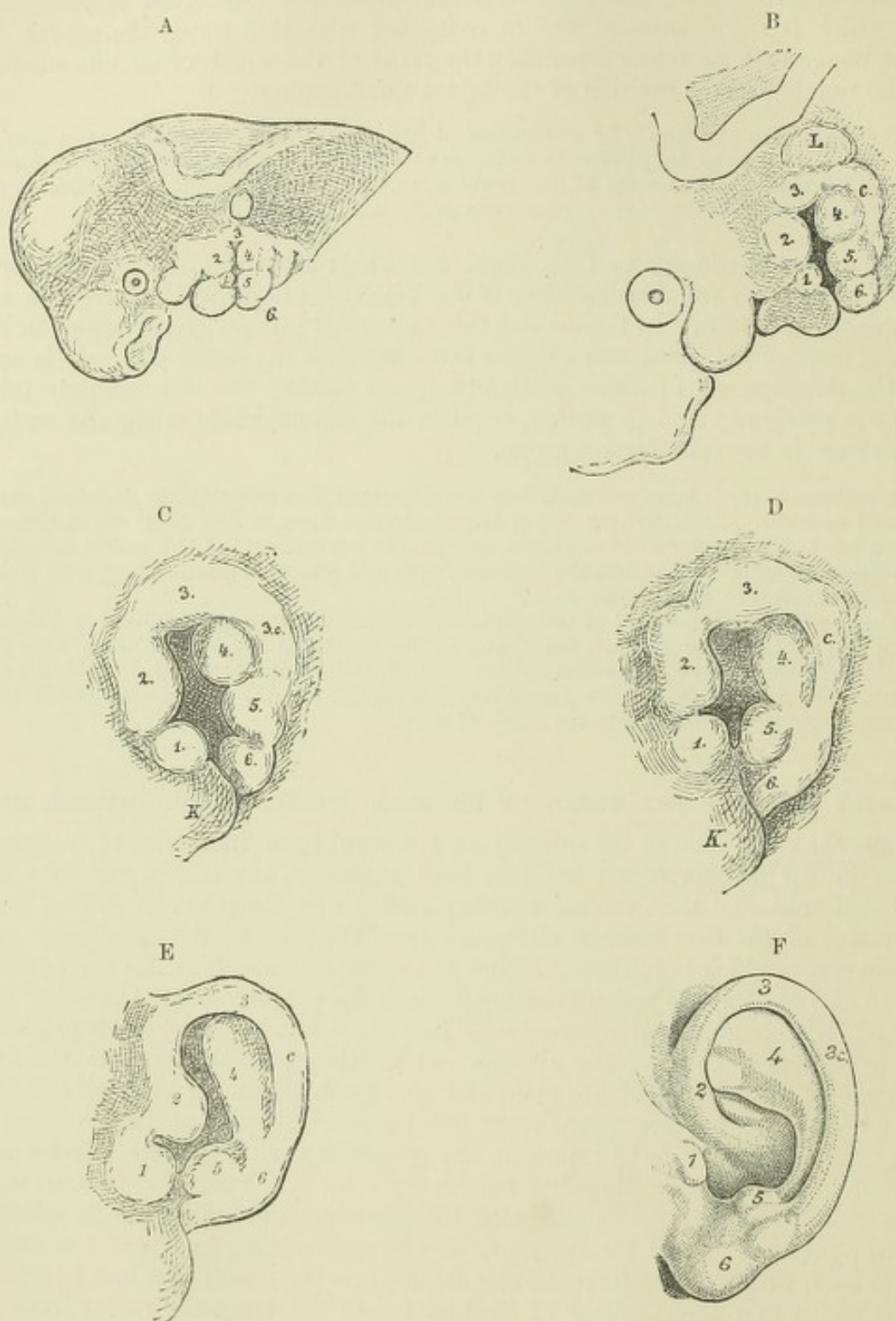


Fig. 109.—SKETCHES SHOWING THE GRADUAL DEVELOPMENT OF THE PARTS OF THE EXTERNAL EAR FROM PROMINENCES UPON THE MANDIBULAR AND HYOIDIAN VISCERAL ARCHES. (His.) Various magnified.

F is an outline sketch showing the several parts of a well-developed adult ear, $\frac{2}{3}$ rd natural size.

1, 2, prominences on the mandibular arch; 3, prominence between the two arches, immediately over the cleft, prolonged posteriorly into c, behind the hyoidian arch; 4, 5, and 6, prominences on the hyoidian arch; L, in B, otic vesicle (seen also in A); K, lower jaw.

Of the prominences enumerated 1 forms the tragus; 2, 3, and 3c, the helix; 4, the antihelix; 5, the antitragus; and 6, the lobule (*vide* F).

early distinguishable as slight protuberances upon the margins of the shallow cleft-like depression which is all that represents the meatus at this stage (fig. 110, A). But as the body wall becomes thicker, the cleft becomes deepened and more tubular, and the protuberances upon the mandibular and hyoidean arches become gradually so transformed and arranged around the external orifice as to be recognizable as the several parts of the future pinna. The transformations may readily be understood from the study of the accompanying series of sketches from His, which show these parts in gradually advancing stages in the human embryo (fig. 109).

DEVELOPMENT OF THE NOSE.

The olfactory organ arises in all vertebrates at an early period of embryonic life as a depression of external epiblast (*olfactory pit*) on either side of the fore-brain. The epiblast in this region becomes thickened, forming an *olfactory area*, and a de-

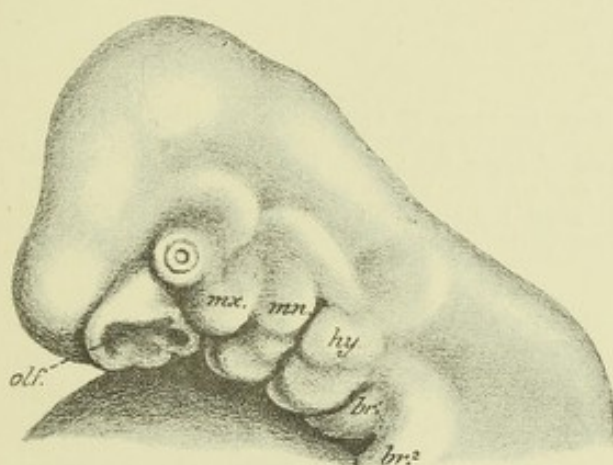


Fig. 110.—PROFILE VIEW OF THE HEAD OF A HUMAN EMBRYO OF NEARLY FOUR WEEKS. (His.)

olf., olfactory depression passing posteriorly into a deep pit, the rudiment of Jacobson's organ; *mx.*, maxillary process; *mn.*, mandibular arch; *hy.*, hyoidean arch; *br.*¹, *br.*², first and second branchial arches.

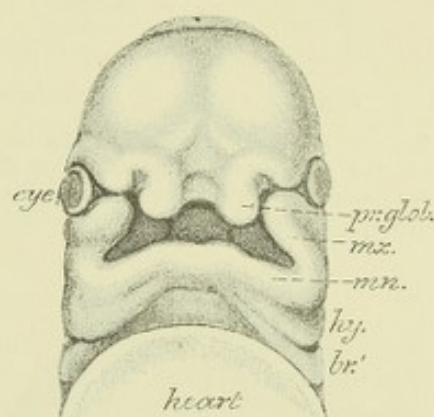


Fig. 111.—HEAD OF AN EMBRYO MORE ADVANCED IN DEVELOPMENT THAN THAT SHOWN IN FIG. 110, FROM BEFORE. (His.)

pr.glob., globular extremity of the mesial nasal process. The other letters as in fig. 111.

pression then forms in this area surrounded by a raised margin (figs. 96, 97, *olf*). The depression soon appears pyriform, the smaller end extending as a groove towards the stomodæum or buccal invagination (see fig. 110, *olf*); near this end a special pit is early visible, and becomes developed into Jacobson's organ.

The thickened boundaries of each olfactory pit and groove are formed by the so-called *mesial* and *lateral nasal processes* (figs. 111, 112). The mesial nasal processes are united at their base by a depressed median part of the *fronto-nasal process*, but are at first separated below, where they terminate in distinct tubercles, termed by His the *globular processes*. As development proceeds they extend backwards along the roof of the embryonic mouth, forming the *nasal laminae*. Eventually the globular processes coalesce in the middle line to form the intermaxillary process and the middle part of the lip, while from the depressed surface between them the lower part of the nasal septum and the philtrum are formed, and by a coalescence of the nasal laminae the rest of the nasal septum is produced. In rodents a notch leads from the nasal septum through the upper lip to the mouth, and represents an imperfect union of the globular processes.

Above the depressed surface just referred to, is a triangular part of the fronto-nasal process which forms an angle with it. This angle eventually becomes the

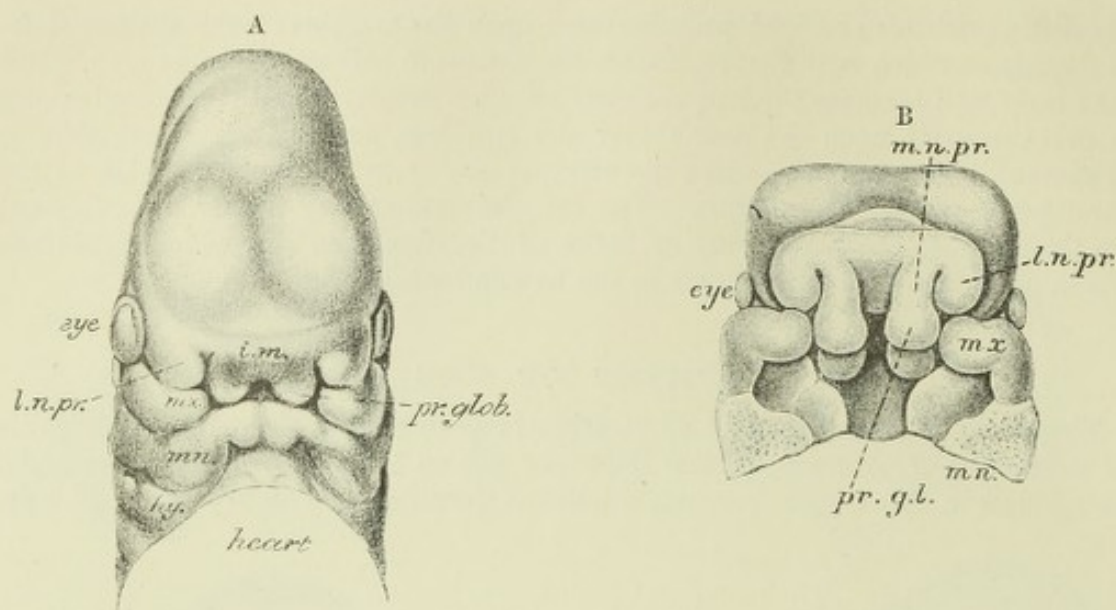


Fig. 112.—HEAD OF AN EMBRYO STILL MORE ADVANCED IN DEVELOPMENT. (His.)

A, from above; B, roof of mouth after removal of lower jaw; *i.m.*, placed on the fronto-nasal process and just above its intermediate depressed part; *l.n.pr.*, lateral nasal process; *m.n.pr.*, mesial nasal process; the other letters as before. The nasal laminae of the globular processes and the palatine projections of the maxillary processes are seen in B.

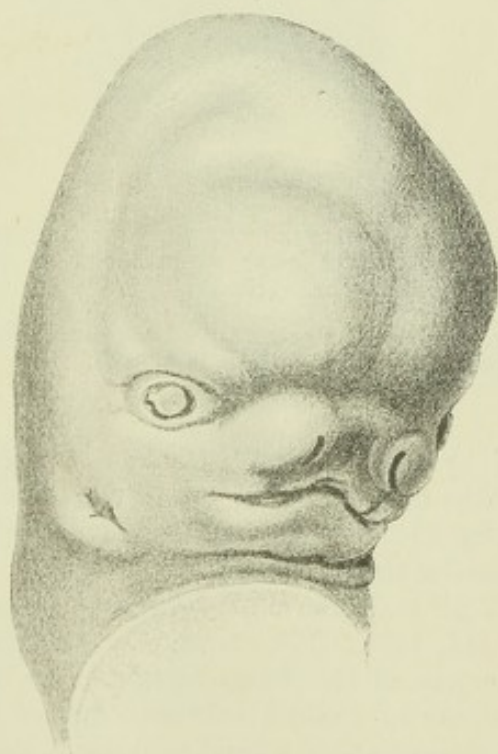

Fig. 113.—HEAD OF AN EMBRYO OF ABOUT SEVEN WEEKS. (His.)

The external nasal processes have united with the maxillary and globular processes to shut off the olfactory pit from the orifice of the mouth.

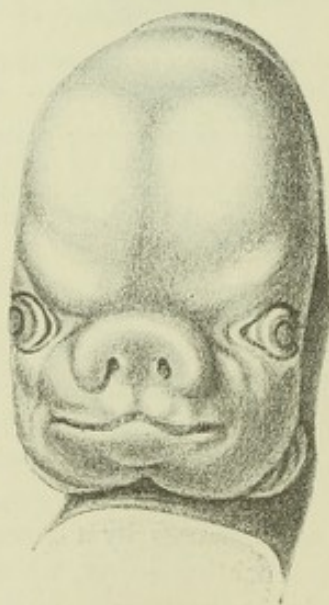

Fig. 114.—HEAD OF AN EMBRYO MORE ADVANCED IN DEVELOPMENT, WITH THE PARTS OF THE NOSE AND MOUTH BEGINNING TO ASSUME THEIR PERMANENT RELATIONSHIPS. (His.)

point of the nose, and the triangular surface above it the bridge; the alæ nasi are formed by the lateral nasal processes. These processes are less prominent than the mesial (fig. 112). They curve round the olfactory depressions, and meet the maxillary

processes; between the two processes (lateral nasal and maxillary) the lachrymal groove passes from the eye to the nose (figs. 111, 112). The maxillary processes also abut in front against the outwardly curving ends of the *processus globulares*, which together form as just mentioned, an intermaxillary process, and the three eventually coalesce to form the upper boundary of the mouth, which is thus shut off from the anterior orifice of the nasal fossæ (fig. 113). But further back the

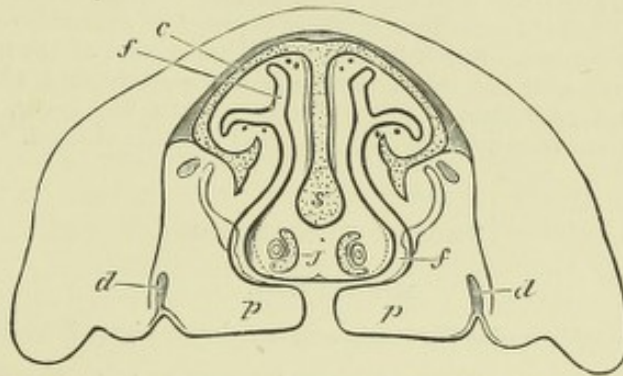


Fig. 115.—OUTLINE OF A TRANSVERSE VERTICAL SECTION THROUGH THE NOSE AND UPPER JAWS OF A SHEEP'S EMBRYO WITH OPEN PALATE. (From Kölliker.)

The lower jaw and tongue are removed; *m*, the mouth; *d*, dental germs; *p*, the palate plates approaching each other in the middle; *f*, the nasal fossæ; *c*, nasal cartilage; *s*, septal cartilage; *j*, the two organs of Jacobson with their cartilages internally.

olfactory depressions, which are now developed into cleft-like cavities, and are increasing in complexity by the development of the projections which are to form the turbinate bones, are still freely in communication with the buccal cavity, and it is only by the growth of the palatine processes of the maxillæ (fig. 115, *p*) and their coalescence in the middle line with one another, and with the lower part of the nasal septum, that the nasal cavities are cut off from the mouth and from one another, and now only open posteriorly into the upper part of the pharynx by the posterior nares (*choanæ*).

The median or septal part of the external nose, with its columella below, is formed, as above stated, of the coalesced mesial nasal processes, the *alæ nasi* being developed from the lateral nasal processes. The septum is at first broad and depressed, so that the nostrils are widely separated from one another (fig. 114), a condition which remains to a certain extent permanent amongst some of the dark races of mankind.

From the above description it will be seen that the olfactory organs are at first altogether distinct from the mouth, that they subsequently pass backwards, as grooves, deepening into distinct clefts, along the roof of the mouth and forming in fact the upper part of the embryonic buccal cavity, and that finally they are again gradually separated from that cavity by the growth of a horizontal septum to form at first the hard and afterwards the soft palate.

The median union of the palate begins in front about the eighth week and reaches the back part and is completed about the tenth week. Imperfect coalescence of these parts produces the malformations of hare-lip and cleft palate in their various degrees. Usually, however, in man the coalescence is completed at a comparatively early period of foetal life, although a vestige of the original separation may be found in front at the junction of the maxillary processes with the coalesced globular processes (intermaxillary), as the naso-palatine canal or incisor foramen, which is occupied by connective tissue, blood-vessels, and a branch of the fifth nerve. In many mammals, however, an actual communication remains throughout life between the nostrils and mouth in this situation.

The organ of Jacobson is early visible on either side of the nasal septum at its lower part in the form of a narrow tube, oval in section, running horizontally in the substance of the septum and opening anteriorly near the upper orifice of the naso-palatine canal. When the cartilage of the septum becomes formed, a special curved plate of cartilage is seen partially enclosing this organ; but both the organ itself and the cartilage are less conspicuous in man than in most mammals. According to Gegenbaur the rudiment which has been described in

the human embryo as the organ of Jacobson is not really that structure, but represents a special gland which occurs in some lemurs in the lower part of the nasal septum.

The epiblast of the olfactory area early becomes thickened, and resembles in structure the neural epiblast (His). As in the latter, some of the cells (neuroblasts) become pyriform and nerve-fibre processes grow out from them, whilst the remainder form long sustentacular columns, which partially anastomose to form a spongework. The neuroblasts subsequently pass out towards the olfactory lobe as already described (p. 81).

All the complexities of the nasal fossæ (and they are far more complex and labyrinthic in many animals than in man) are produced by folds and outgrowths of the original simple depressions, and the thickened epithelium of these depressions extends over all parts of the cavities which are thus formed. But it is only in the upper part of the nasal fossæ that the connexion by nerve-fibres with the olfactory lobe becomes established, and it is in this part only that the true sense-epithelium becomes developed. In the lower, or respiratory part of the fossæ the epithelium remains relatively thin and becomes ciliated.

RECENT LITERATURE.

Eye and Nose.

Born, G., *Die Nasenhöhle u. der Thränennasengang der amnioten Wirbelthiere*, Morph. Jahrb., 1879 u. 1883.

Disse, J., *Die Ausbildung der Nasenhöhle nach der Geburt*, Arch. f. Anat. u. Physiol., Anat. Abth. 1889.

Ewetzky, Th., *Zur Entwicklungsgeschichte des Thränennasenganges beim Menschen*, Archiv f. Ophthalmol., Bd. xxxiv., 1888.

Gottschau, *Zur Entwicklung der Säugethierlinse*, Anat. Anzeiger, 1886.

His, W., *Anatomie menschlicher Embryonen*, Leipzig, 1880—85; *Unsere Körperform, &c.*, Leipzig, 1875; *Die Formentwicklung des menschlichen Vorderhirns*, Abhandl. d. k. Sächsischen Gesellschaft, 1889.

Keibel, F., *Zur Entwicklung des Glaskörpers*, Arch. f. Anat. u. Phys., Anat. Abth., 1886.

Kessler, *Zur Entwicklung des Auges der Wirbelthiere*, Leipzig, 1877.

Kölliker, A., *Zur Entwicklung des Auges und Geruchsorgans menschlicher Embryonen*, Festschrift der Schweizer. Universität Zürich gewidmet, Würzburg, 1883.

Korányi, A., *Beiträge zur Entwicklung der Krystalllinse bei den Wirbelthieren*, Internat. Monatsschr. für Anatomie u. Physiologie, 1886.

Legal, *Die Nasenhöhle u. der Thränennasengang*, Morph. Jahrb., 1883.

Ear.

Baginsky, B., *Zur Entwicklung der Gehörschnecke*, Verhandl. d. physiol. Gesellschaft zu Berlin, 1885-86.

Beard, J., *On the segmental sense organs of the lateral line and on the morphology of the vertebrate auditory organ*, Zool. Anzeiger, No. 161, 1884.

Boettcher, A., *Ueber Entwicklung u. Bau des Gehörlabyrinths*, Verhandl. d. kaiserl. Leop. Carol. Acad., Dresden, Bd. 35.

His, W., jun., *Zur Entwicklungsgeschichte des Acustico-facialis-Gebietes beim Menschen*. Arch. f. Anat. u. Physiol., Anat. Abth., 1889, Supplement Bd.

Hoffmann, C. K., *Ueber die Beziehung der ersten Kiementasche zu der Anlage der Tuba Eustachii und des Cavum tympani*, Archiv f. mikrosk. Anat. xxiii., 1884.

Noorden, v., *Die Entwicklung des Labyrinths bei Knochenfischen*, Arch. f. Anat. u. Physiol., Anat. Abth., 1883.

Rüdinger, N., *Zur Entwicklung der häutigen Bogengänge der inneren Ohres*, Sitzungsber. d. Akademie d. Wissensch. zu München, Bd. xviii., 1888.

Tuttle, Alb. H., *The relation of the external meatus, tympanum and Eustachian tube to the first visceral cleft*, Proc. American Academy of Arts and Sciences, 1884.

Vassaux, *Recherches sur les premières phases du développement de l'œil chez le lapin*. Arch. d'ophthalm., 1888.

DEVELOPMENT OF THE ALIMENTARY CANAL.

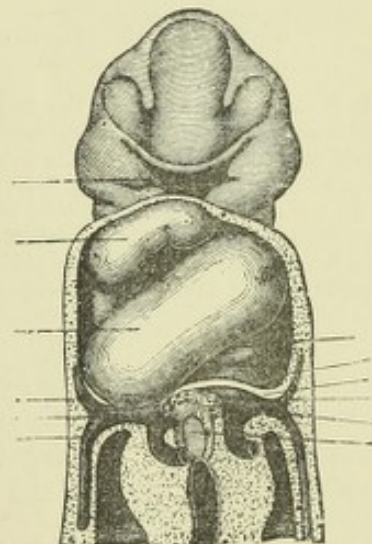
The early development of the primitive alimentary canal has already been briefly described in treating of the first formation of the embryo (pp. 34, 35), and it was there explained how the dipping downwards and inwards of the blastodermic layers on either side of the embryo tends to separate or pinch off the part of the blastodermic vesicle which is immediately underneath the body of the embryo as a distinct tube (mid-gut) from the remainder of the vesicle, which is now known as the yolk-sac, while at the same time similar changes occurring in front and behind produce the blind anterior and posterior extremities of the tube which are known as the fore- and hind-gut respectively. Although the downfolding in question eventually involves all the layers of the embryonic blastoderm, the epiblast and the part of the mesoblast which adheres to it, and together with it forms the splanchnopleure, do not participate in the process until after the formation of the amnion, so that the alimentary canal for some time after its formation is enclosed only by the hypoblast and its adherent mesoblast (splanchnopleure), and projects freely into the wide coelom or space between the splanchnopleure and somatopleure. The mid-gut also remains for a time in free communication with the yolk sac, although the communication becomes gradually narrowed into the vitelline duct. As the somatopleure afterwards grows down on either side of the alimentary canal, and becomes pinched in around the vitelline duct and stalk of the allantois, which are thus united into the umbilical cord, that part of the coelom which is within the body and around the alimentary canal becomes shut off as the pleuroperitoneal cavity from the remainder, which lies altogether outside the body, and forms the cavity of the false amnion.

Development of the mouth and of the parts in connection with it.—The fore-gut terminates blindly at first underneath the head in the region of the

Fig. 116.—FRONTAL VIEW OF THE UPPER PART OF A HUMAN EMBRYO OF ABOUT FIFTEEN DAYS, RECONSTRUCTED FROM SERIAL SECTIONS. (His.) ⁴⁹

The pericardium is opened to show the heart; between this and the fore-brain is seen the primitive buccal cavity. A description of this figure is given on p. 138.

hind-brain, and the notochord, with the fore- and mid-brain, curve downwards over the blind extremity, the fore-brain thus causing a rounded prominence in front of and ventral to the extremity of the alimentary tube (see fig. 45). With the development of the heart another prominence becomes formed on the ventral side of the fore-gut, a little further back. Between the two prominences, the one caused by the projection of the fore-brain and the other of the heart, a wide, shallow pit is enclosed (fig. 116), at the bottom of which the epiblast which lines it is in contact with the hypoblast of the fore-gut, and the two layers fuse to form an epithelial membrane, which now forms a septum between the primitive buccal epiblastic involution or stomodæum and the fore-gut (fig. 117, *p.v.*). This stage is met with in the human embryo before the twelfth day (His), in the rabbit embryo at about the ninth day (Mihalkovics), and in the chick on the fourth day.



The stomodæum deepens at its upper and anterior part, where it forms a pocket-like protrusion, which grows a certain distance into the angle formed by the sharp bend which the hinder part of the fore-brain now makes with the mid-brain.

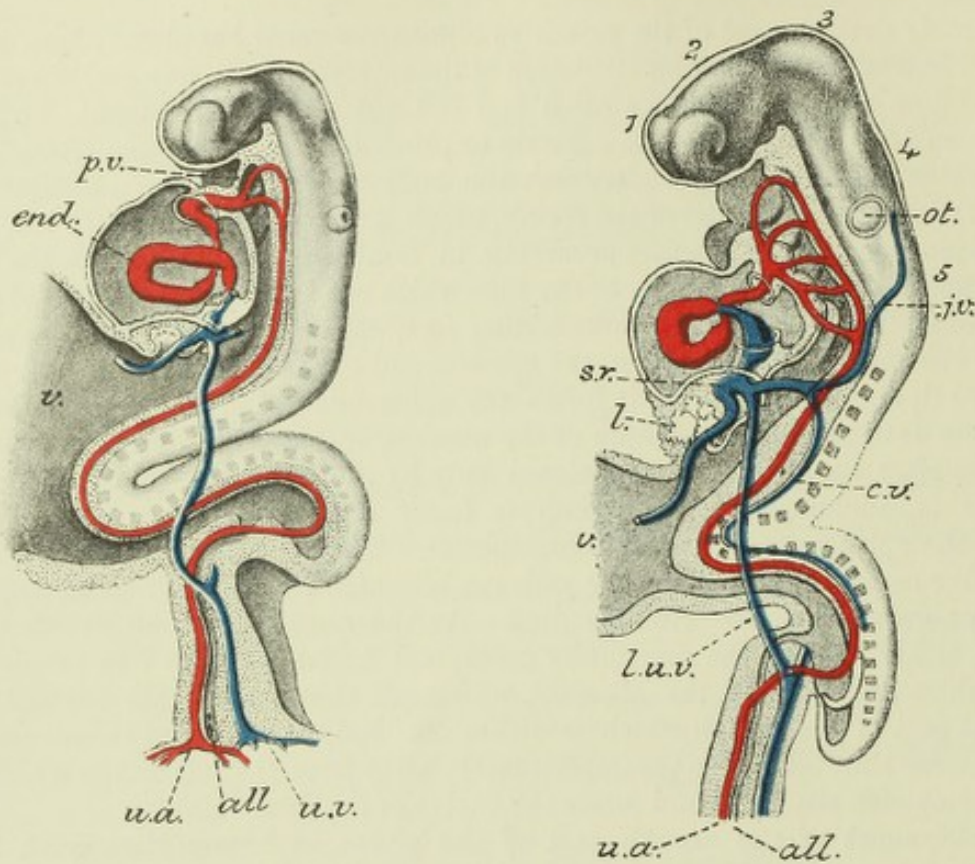


Fig. 117.—PROFILE VIEW OF A HUMAN EMBRYO OF ABOUT 15 DAYS, WITH THE ALIMENTARY CANAL SHOWN IN LONGITUDINAL SECTION. (His.)

Fig. 118.—SIMILAR VIEW OF A SOMEWHAT OLDER EMBRYO. (His.)

1, 2, 3, 4, 5, are opposite the respective secondary cerebral vesicles; from the side of the fore-brain the primary optic vesicle is seen projecting; *ot.* otic vesicle; *p.v.*, septum between mouth and pharynx (primitive velum); *l.*, commencing liver in septum transversum; *v.*, vitelline stalk; *all*, allantois enclosed within allantoic stalk; *j.v.*, jugular vein; *c.v.*, cardinal vein; *s.r.*, sinus venosus within septum transversum; *u.a.*, umbilical (allantoic) artery; *l.u.v.*, left umbilical vein. The sharp curve of the trunk of the embryo towards the yolk-sac is normal at this stage.

In fig. 117 the otic vesicle is still open, and there are only two aortic arches; in fig. 118 the otic vesicle is closed; there are now five aortic arches. The primitive velum has disappeared.

This pocket (Rathke) is the *hypophysis cerebri*, or pituitary involution of the buccal epiblast, and comes presently into connection with the infundibular protrusion of the neural epiblast, the two together forming the pituitary body (see p. 68). It lies just above and in front of the pharyngeal septum.

The remains of this septum (when it has become broken through to allow of a communication between stomodæum and fore-gut), have been termed the *primitive velum*, but the septum has nothing whatever to do with the formation of the permanent velum palati, or with the isthmus of the fauces. The plane of the septum forms in fact an angle with the plane of the future isthmus faucium, so that the primitive mouth or stomodæum does not by any means correspond with the permanent mouth. In fact the floor of the mouth, including the tongue, is developed *behind* the septum, and therefore in connection with the fore-gut rather than with the stomodæum, whereas the uppermost part of the pharynx, including the choanæ, is *in front* of the septum, and therefore belongs to the stomodæum.

The shallow and widely open stomodæum soon deepens and is now seen to be specially bounded by certain prominences placed above, below, and at the sides, within and from which the several parts of the face are eventually produced (figs. 111, 119). These prominences are the *fronto-nasal* which projects over the stomodæum, and is formed primarily by the prominence of the fore-brain, but afterwards acquires a considerable thickening of mesoblast, which extends into it from the basis cranii; the *mandibular* or *first visceral arch*, which

Fig. 119.—PROFILE VIEW OF A HUMAN EMBRYO OF ABOUT THREE WEEKS, SHOWING ALL THE CEPHALIC VISCERAL ARCHES AND CLEFTS.

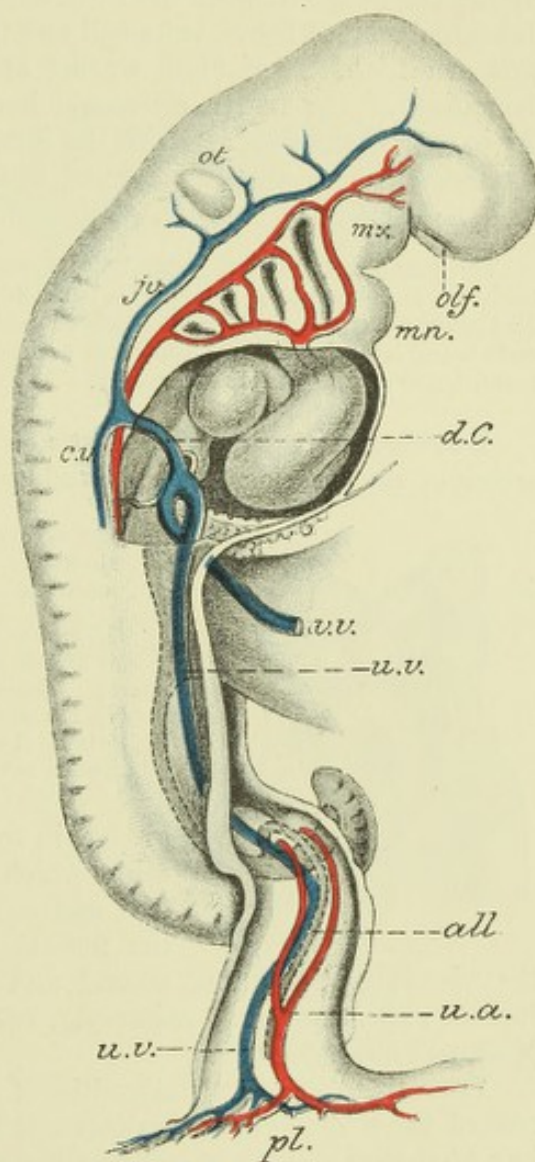
mx, maxillary process; *mn*, mandibular arch; *d.C*, duct of Cuvier; *ju*, jugular vein; *c.v*, cardinal vein; *v.v*, vitelline vein; *u.v*, umbilical vein; *u.a*, umbilical artery; *all*, allantois; *pl*, placental attachment of allantoic stalk; *olf*, olfactory depression; *ot*, otic vesicle.

after passing obliquely round the fore-gut, takes a horizontal direction on its ventral side, and meets its fellow in the middle line, the two together forming the ventral boundary of the stomodæum; and the *maxillary process*, which grows from the base of the mandibular arch, and projects on either side of the stomodæum, filling up the gap between the fronto-nasal process and the mandibular arch, and forming the lateral boundary.

The separation of the stomodæum into an upper or olfactory and respiratory part and a lower permanent buccal cavity, together with the changes which occur in the fronto-nasal and maxillary processes to produce the result, has already been referred to in describing the development of the nose (pp. 95 to 97).

Pharynx.—The remainder of the alimentary canal below the mouth is nearly simple, at first consisting, as before mentioned, of a tubular portion in front—the fore-gut; a shorter tubular portion behind—the hind-gut; and a middle part which is freely open to the yolk (fig. 117).

The hind-gut remains simple throughout, except that the allantois grows out from its ventral aspect.¹ But in front a differentiation soon makes its appearance, the cephalic part becoming enlarged to form the pharynx, while almost immediately behind this another enlargement forms the stomach. The hypoblast lining the cavity of the pharynx grows out on either side successively at four distinct levels, and to a less extent the epiblast dips in opposite the hypoblastic outgrowths. In this way eventually four deep clefts between the pharynx and the exterior become formed; these are known as the *cephalic visceral clefts* (figs. 110, 119, in external



¹ In the human embryo the allantois appears to be formed by a direct continuation of the lateral folds, which have united to form the main alimentary tube, while the part of the tube behind the allantois (bursa) appears as a blind protrusion (His).

appearance; figs. 117, 118, seen from within).¹ Between them, and also in front of the first cleft, the pharyngeal wall is greatly thickened so as to exhibit the appearance of curved bars bounding the clefts; these bars are known as the *cephalic visceral arches*, and are five in number, viz.: the *first* or *mandibular*, in front of the first visceral cleft, between it and the mouth: this is the seat of formation of the lower jaw; the *second* or *hyoid arch*, between the first and second clefts; the *third* or *thyro-hyoid arch*, between the second and third clefts, which in fishes and amphibia develops gill-plates, and is therefore also known as the *first branchial arch*; the *fourth* between the third and fourth clefts, corresponding with the second branchial arch of fishes, but small and inconspicuous in man and mammals; and the *fifth* or *second branchial* still smaller and more inconspicuous, forming the posterior boundary of the fourth cleft, and hardly recognizable as a distinct bar in man. After the fourth week, and with the increasing flexure of the head, the arches become somewhat shifted over one another, so that the fourth arch is concealed by the third, and the third by the second.

The mandibular arches early become united on the ventral aspect; from the fifth week their union is complete (fig. 111, *mn*) and in man shows eventually no sign of a median groove. The other arches do not at first reach the middle line (His), the space between their central ends being occupied by the heart and pericardium; as these shift backwards a smooth infra-mandibular surface is left externally.

Development of the tongue.—Within the pharynx, the second and third arches of the two sides are separated by a forked elevation (*furcula*) with a median

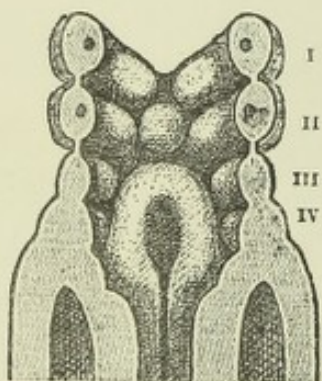


Fig. 120.—POSTERIOR ASPECT OF THE VISCERAL ARCHES OF THE EMBRYO SHOWN IN FIGS. 116, 117, AS SEEN FROM THE INTERIOR OF THE PHARYNX. (His.)

The first or mandibular pair of arches join in the middle line; the second arches are separated by a rounded prominence (tuberculum impar). Behind (below) this is the forked prominence (furcula) bounding a median groove which will become the laryngeal orifice. In the sections of each of the first two arches, the included artery is seen. The Roman numerals are opposite the corresponding arches.

groove, in front of which is a rounded tubercle (*t. impar*, His), which arises in the angular space between the first and second arches (fig. 120). The groove around the furcula (*sinus arcuatus*, His) passes laterally into the visceral clefts. The second and third arches afterwards unite between the furcula and tuberculum impar (fig. 121, A). Thus united, the junction forms an X-shaped mass.

From these conjoined extremities of the second and third arches on either side, the root of the tongue grows upwards and forwards as two prominences, which diverge in a V-shaped manner to embrace the anterior or papillary part of the organ which is developed from the tuberculum impar (fig. 121, B). At the angle of the V is a deep depression (*foramen cæcum*); this leads into a diverticulum, which forms the median rudiment of the thyroid body. When the parts of the tongue are united, there is still for a considerable time a V-shaped groove marking the line of union (fig. 122), and even in the adult there is often a distinct trace of this groove (*sulcus terminalis*, His). Parallel to this, and somewhat in front of it, the papillæ vallatæ are developed, and in front of these the other lingual papillæ make their appearance (about the end of the second month).

¹ According to His, who is confirmed by Born and by Kölliker, these clefts are not as a rule developed into complete apertures in birds or mammals; although the membranes which close them are composed only of juxtaposed epi- and hypoblast, the mesoblast having disappeared.

The furcula gives rise to the epiglottis in front (above) the aryepiglottic folds on either side, and the arytenoid cartilages behind (below); the median groove in it leads to the entrance of the larynx.

Laterally the 2nd arch passes into and forms the palato-glossal arch, and in the visceral cleft behind this the tonsil develops; but the 3rd arch does not form the palato-pharyngeal arch; this is developed from the palatine outgrowths of the maxillary processes.

The visceral arches were first described by Rathke, in 1825. They are often distinguished as the *post-buccal* visceral arches; certain parts in front of (above) the mouth

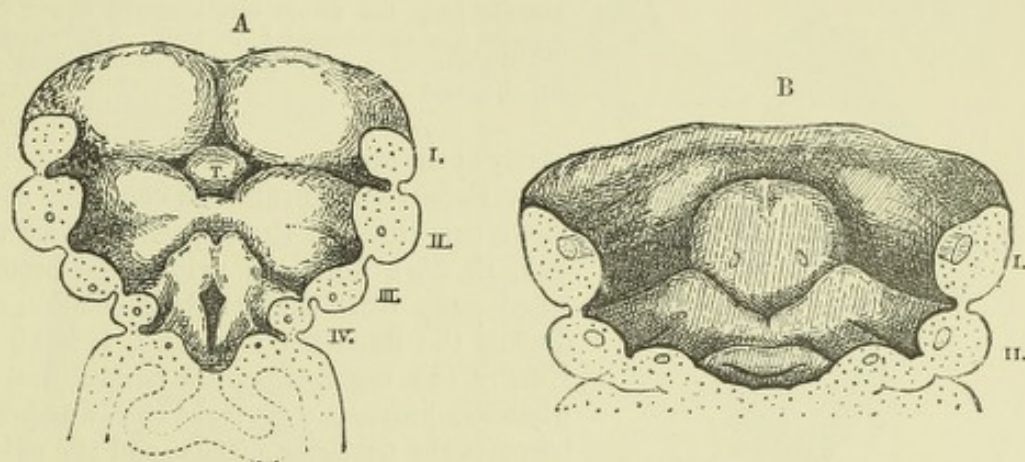


Fig. 121.—SIMILAR VIEWS OF THE SAME PARTS IN OLDER EMBRYOS. (His.) A. $\frac{18}{1}$, B. $\frac{16}{1}$

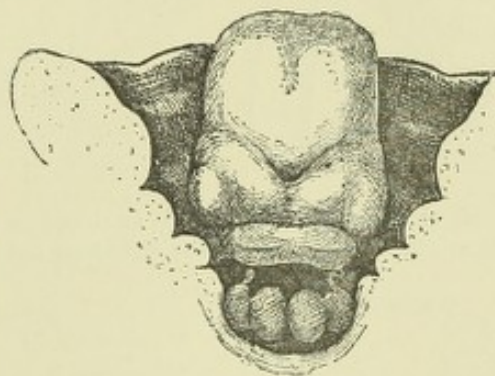
T, tuberculum impar.

being considered by some morphologists to represent *præ-buccal* arches. The visceral clefts, lying between the arches are, as has been stated, four in number. The first is often known as the *hyomandibular* cleft: it is this one which is concerned with the formation of the

Fig. 122.—SIMILAR VIEW IN A CONSIDERABLY OLDER EMBRYO, BUT LESS MAGNIFIED. (His.)

Eustachian tube and middle ear as already described. The three remaining clefts, which represent gill-slits of fishes and amphibia, appear, from the results of recent observations, to be closed in amniotic vertebrates at all periods of foetal life (see note on previous page). In some fishes the branchial arches and clefts are more numerous than in other vertebrates, and in a few the hyoid arch also develops a gill.

Through each of the visceral arches an arterial arch derived from the aortic bulb passes from front to back reuniting dorsally in front of the notochord to form the aorta. In branchiate vertebrates, branches of these vessels are distributed to the gills. Cartilaginous bars pass, in most vertebrates, from the base of the skull into each visceral arch, and ossification occurring in or around them, form definite parts of the skeleton as will be afterwards described. In man and mammals these cartilaginous bars are only found in the first three visceral arches, unless the thyroid cartilage is to be regarded as representing the anterior (ventral) ends of the bar of the 4th arch (Callender). The fourth and fifth visceral arches may be considered as belonging to the neck rather than to the head, and the congenital fissures of the neck which sometimes occur as a malformation, and which usually open externally far down in the cervical region, have been regarded as due to persistence of one or more of the branchial clefts, shifted in position by the cervical elongation which takes place in later embryonic life.



Œsophagus, stomach, and intestines.—Immediately behind the pharynx, the fore-gut contracts again to form the Œsophagus, which, in the early embryo, corresponding with the imperfect development of the neck, is very short (figs. 123, 125, A)

and gradually widens out into the dilatation which represents the stomach.¹ This organ, which is at first nearly straight (fig. 125, A, *Mg*), soon begins to show the con-

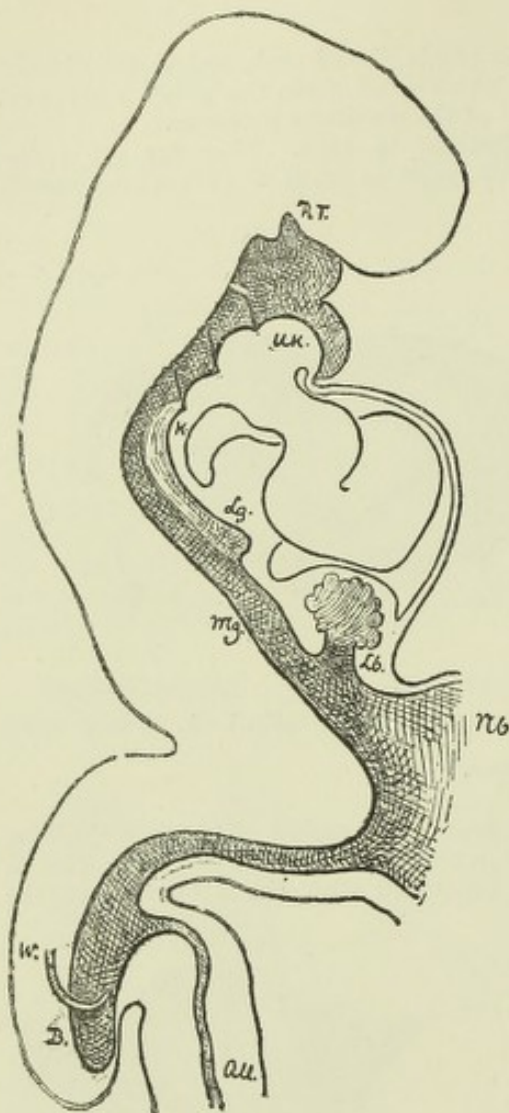


Fig. 123.—SKETCH OF A LONGITUDINAL SECTION THROUGH THE ALIMENTARY CANAL OF A HUMAN EMBRYO, SOON AFTER THE DISAPPEARANCE OF THE PRIMITIVE VELUM. (His.) 49

The alimentary canal is shaded throughout; *U.K.*, section of mandibular arch; *R.T.*, hypophysis; behind it the remains of the pharyngeal septum; *Lg.*, commencing lung, the future orifice of the larynx being opposite *K*; *Mg.*, stomach; *Lb.*, liver; *Nb.*, yolk stalk; *W.*, Wolfian duct; *B.*, blind portion of hind gut; *all.*, allantois.

vexity of the greater curvature on the side next the vertebral column, and the concavity of the lesser curvature on the opposite border (fig. 125, B, *Mg*), while the pyloric end becomes tilted away from the vertebral column, producing the duodenal loop (fig. 125, C, D). Finally the organ becomes turned over on what was previously its right side, which now becomes the posterior surface, and the pyloric extremity being also tilted over, the duodenal loop is thus thrown over to the right side of the abdomen (fig. 126). The small intestine is also at first quite short and straight, with a wide aperture to the yolk-sac (fig. 125, A, *Nb*), but gradually lengthens as the communication with the yolk-sac becomes more contracted, and (besides the loop formed by the tilting of the pylorus) develops a long V-shaped loop opposite the attachment of the vitelline duct (fig. 125, C, D, and fig. 127).

The loop of intestine to which the vitelline duct is attached passes, for a time, into the umbilical cord, close to its attachment, enclosed in a protrusion of the peritoneal cavity (fig. 124). It occasionally remains in this situation until late in foetal life.

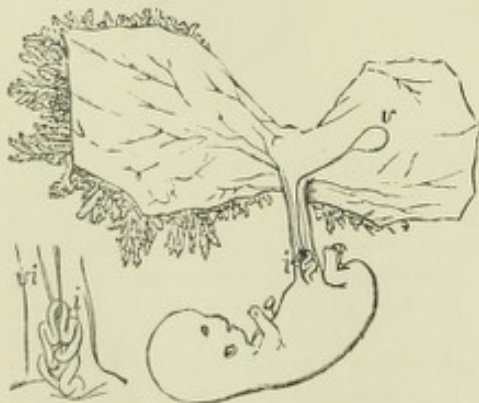

Fig. 124.—SKETCH OF THE HUMAN EMBRYO OF THE TENTH WEEK, SHOWING THE COIL OF INTESTINE IN THE UMBILICAL CORD. (Allen Thomson.)

The amnion and villous chorion have been opened and the embryo drawn aside from them; *v.*, umbilical vesicle, connected with the coil of intestine, *i.*, by a small, almost linear tube. The figure at the side represents the first part of the umbilical cord magnified; *i.*, coil of intestine; *vi.*, vitelline-intestinal duct, alongside of which are seen omphalo-mesenteric blood-vessels.

The **mesentery** is developed by a thinning out and extension of the mesoblastic tissue which lies between the intestine and the vertebral column. It forms a continuous membrane along the whole length of the alimentary canal from the stomach to the rectum, although the part attached to the

¹ It has been shown (Balfour, Meuron) in most vertebrates—mammals excepted—that at a certain period of development the lumen of the cesophagus becomes for a time completely obliterated at its upper extremity.

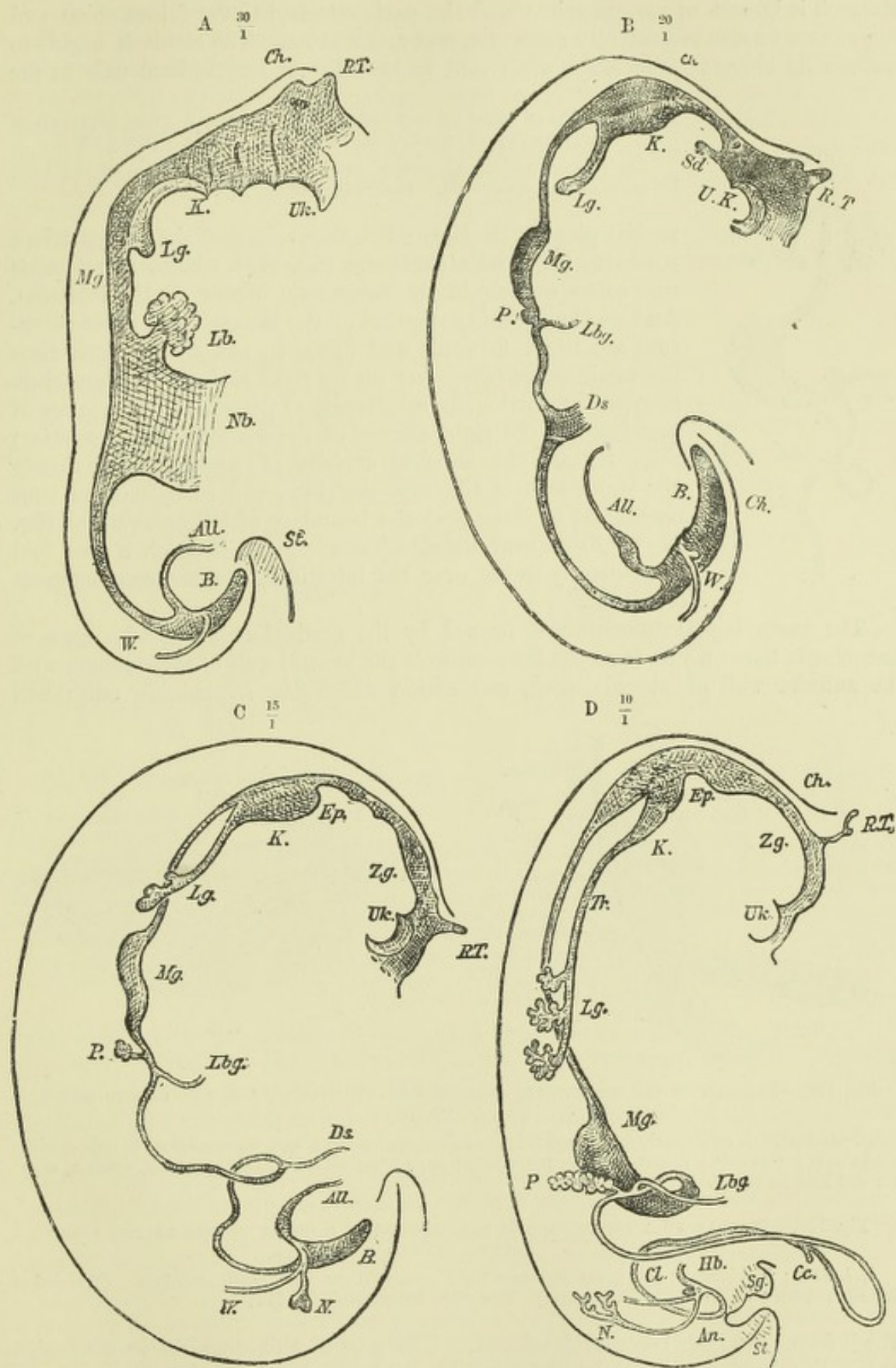


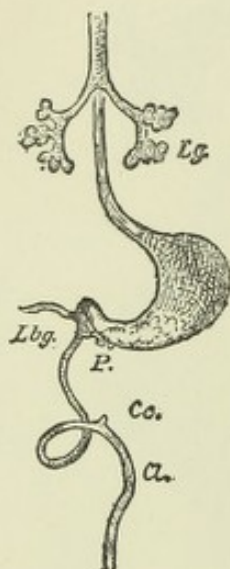
Fig. 125.—PROFILE SKETCHES OF SUCCESSIVE STAGES IN THE DEVELOPMENT OF THE ALIMENTARY CANAL IN THE HUMAN EMBRYO. (His.)

Ch., notochord; *Sd.* (in B), median rudiment of thyroid; *P.*, pancreas; *Lbg.*, bile duct; *Ds.*, vitelline duct; *Zg.* (in C and D), tongue; *N.*, permanent kidney; *cl.* (in D), cloaca; *An.*, anus in course of formation; *Sg.*, sexual prominence; *St.*, tail; *Cc.*, caecum coli; *Tr.*, trachea; *K.*, larynx. The other lettering as in fig. 123.

stomach is known as mesogastrium and the parts attached to the future colon and rectum are termed respectively mesocolon and mesorectum. The stomach begins to assume its characteristic shape while still lying with its longitudinal axis in the

Fig. 126.—FRONT VIEW OF ALIMENTARY CANAL, RATHER LESS ADVANCED IN DEVELOPMENT THAN THAT SHOWN IN FIG. 125, D. (His.) $\frac{10}{1}$

The pharynx and upper part of œsophagus, and termination of the large intestine are not represented. Lettering as in fig. 125.



median plane of the body; it is then seen that the mesogastrium passes to its greater curvature (fig. 127), which, therefore, is that corresponding to the mesenteric border of the intestine. And as the pyloric extremity of the stomach and lesser curvature are tilted forwards and upwards, and at the same time the whole organ turns over on its right side, the mesogastrium becomes proportionally lengthened to permit of this change of position, and the right surface of the stomach (now posterior) rests against the anterior surface of what was previously the right side of the mesogastrium, the mesogastrium thus coming to form the posterior boundary of the omental sac (fig. 128). From near its attachment to the stomach a free fold subsequently grows over the intestines, and becomes the great omentum.

The gastro-hepatic omentum is formed by the gradual thinning of a mass of mesoblastic tissue which from the first connects the ventral wall of the stomach with the anterior wall of the abdomen, and within which the hypoblastic outgrowth

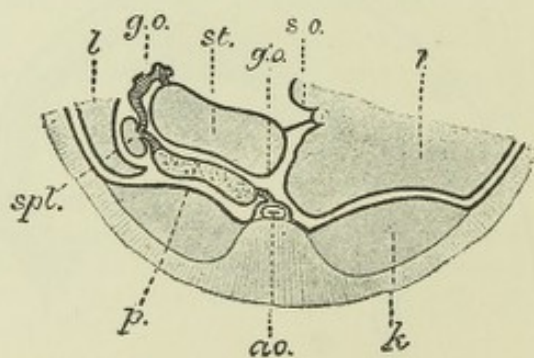
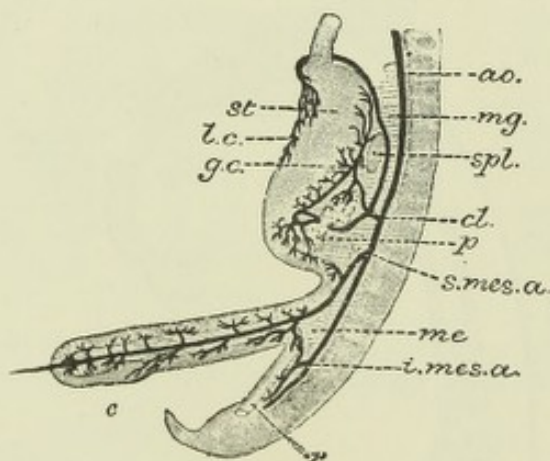


Fig. 127.—DIAGRAM OF THE MESENTERY, STOMACH AND INTESTINE OF A HUMAN EMBRYO OF SIX WEEKS. (Toldt.)

st, stomach; *g.c.*, greater curvature; *l.c.*, smaller curvature; *mg*, mesogastrium; *spl*, spleen; *p*, pancreas; *c*, caecum; *r*, rectum; *me*, mesentery; *ao*, aorta; *cl*, coeliac axis; *s.mes.a*, *i.mes.a*, superior and inferior mesenteric arteries.

Fig. 128.—DIAGRAM OF A SECTION ACROSS THE ABDOMEN OF A HUMAN EMBRYO OF THE THIRD MONTH. (Toldt.)

l, *l*, liver; *k*, kidneys; *g.o.*, great omentum; *g'.o.*, omental sac; *s.o.*, small omentum. (The dotted line has not been carried quite far enough.) The other letters as in fig. 127.

which forms the liver becomes developed. The part of this mesoblastic connexion which lies between the liver and stomach becomes the gastro-hepatic or lesser omentum, and its free border which was at first directed downwards (caudalwards) becomes with the descent of the stomach directed anteriorly (ventrally), and eventually with the turning of that organ laterally it also is directed towards the right, and thus comes to form the anterior boundary of the entrance into the omental sac.

The large intestine is not at first marked off from the small by any difference in calibre. Its commencement is distinguishable about the sixth week in the human embryo by the appearance of the cæcum, which gradually grows out (figs. 125, D, and 127), forming at first a lateral protrusion of uniform calibre, but subsequently remaining narrow at its blind extremity to form the vermiform appendix, while the remainder of the cæcum and the colon increase in size. This protrusion occurs on the U-shaped loop above described, and a little beyond the attachment of the vitelline duct.

With the increasing length of the gut it becomes thrown into coils, and the earliest and most important of these is that by which the limb of the U-shaped loop

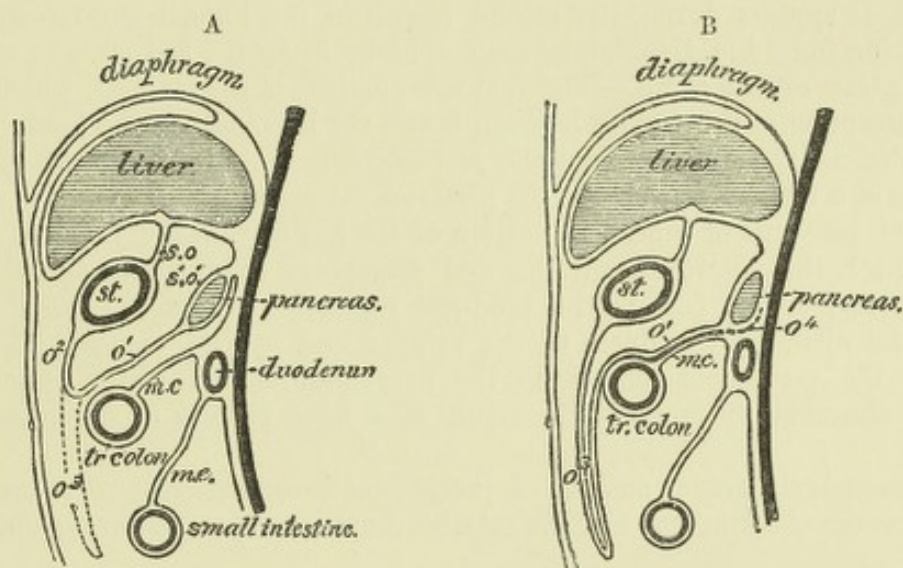


Fig. 129.—DIAGRAMS ILLUSTRATING THE DEVELOPMENT OF THE GREAT OMENTUM. (O. Hertwig.)

A, earlier stage.

B, later stage.

st, stomach; s.o, small omentum; s.o., omental sac; o', mesogastrium, springing from the posterior wall of the abdomen, near which in A it encloses the pancreas; o², attachment of mesogastrium to greater curvature of stomach; o³, fold of mesogastrium or great omentum growing over coils of small intestine; mc, mesentery; m.c, transverse mesocolon; o⁴ (in B), dotted line showing the situation of that lamella of the mesogastrium which at first assisted in enclosing the pancreas but which has now disappeared. The next part of this lamella has coalesced with the adjacent lamella of the transverse mesocolon, and has also disappeared. The coalescence is indicated by the black line.

with which the large intestine is continuous turns over on to the right side of the peritoneal cavity, and thus throws the colon in an archlike disposition across the commencement of the small intestine, and parallel with the longitudinal axis of the stomach (commencement shown in fig. 126). Within this arch of the large intestine the coils of the jejunum and ileum become disposed as the intestine lengthens. Their mesentery spreads out at its intestinal attachment so as to adapt itself to the increasing length of the gut, while its vertebral attachment, relatively much shorter, loses to a great extent its primitive disposition, and acquires oblique and transverse lines of attachment; this is notably the case with the transverse mesocolon.

Although the mesentery in most parts increases in length and expansion with the further growth of the intestine, the contrary is the case with the mesentery of the duodenum, and of the ascending and descending colon. All these parts possess at first a complete mesentery like the rest of the intestine, but that of the duodenum disappears entirely, so that this part of the intestine becomes fixed to the posterior wall of the abdomen, and the same process takes place to a lesser and variable extent with the ascending and descending mesocolon. Since the transverse colon lies across the abdomen immediately below the stomach, it and its mesentery, transversely disposed, also lie immediately below and behind the mesogastrium (now folded into the great omentum). The two membranes come in fact into close contact, and eventually com-

pletely adhere (4th month and onwards); and this causes the pancreas to appear to lie altogether behind the peritoneal cavity, in place of being situated between the two layers of the mesogastrium as is at first the case in the human embryo, and as is frequently found in other mammals during life.

The free or floating part of the great omentum is formed by an extension of that part of the omental fold which turns upwards towards the greater curvature of the stomach from the surface of the transverse colon. The fold is at first clearly double, and in some animals remains so, but in man its two layers coalesce a little while after birth, and after a year or two can no longer be separated. It extends gradually, first over the transverse colon (third month), later over the coils of the small intestine.

The **spleen** becomes formed within the substance of the mesogastrium (fig. 127, *spl*). It is developed wholly from mesoblast, and in close connection with the pancreas. It appears during the second month in the human embryo, and grows slowly during foetal life, the Malpighian corpuscles being the last parts to appear.

Formation of the anus.—The anal invagination of the epiblast, which eventually by absorption of the septum between it and the hypoblast of the hind-gut opens into the alimentary tube, is termed the *proctodæum*. The junction with the hind-gut occurs at a little distance from the posterior extremity, so that there is a blindly terminating post-anal or subcaudal portion of the gut beyond the junction with the proctodæum; this, however, shrinks and disappears even before the absorption of the septum. This part of the hind-gut represents a cloaca, since it receives through the allantois the ducts of the urinary and genital organs. The separation of the permanent anus from the urogenital orifice, which occurs in all mammals above monotremes, is the result of a later process of development (see p. 127).

In mammals the actual amount of proctodæal invagination is very small. The septum between the hind-gut and the exterior (anal membrane) is throughout formed

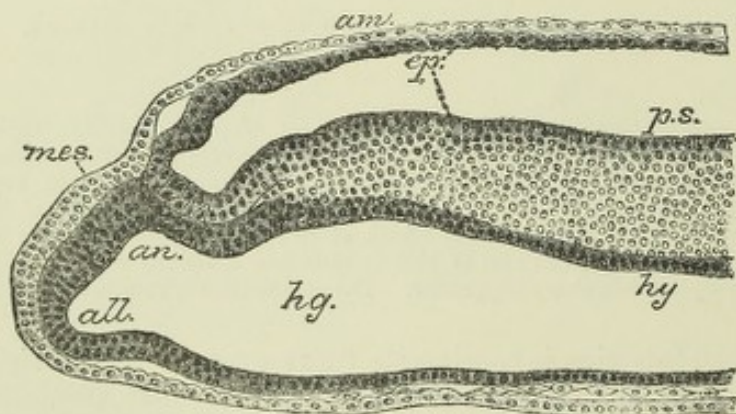


Fig. 130.—LONGITUDINAL SECTION THROUGH THE POSTERIOR END OF A SHEEP'S EMBRYO, SHOWING THE ANAL MEMBRANE. (Bonnet.)

ep, epiblast; *hy*, hypoblast; *mes*, mesoblast; *h.g.*, hindgut; *am*, amnion; *an*, anal membrane; *p.s.*, primitive streak; *all*, allantois-rudiment.

by two epithelial layers only, viz., hypoblast and epiblast, which here are in contact with one another without the intervention of mesoblast (fig. 130, *an*). This condition of juxtaposition of the two layers is in fact directly derived from the union of the two layers which occurs at the primitive streak and groove, and if the latter be looked upon as representing the blastopore, the anus may in a sense be considered to be formed from a part of that aperture. In some lower vertebrates the anus has been shown to be directly produced from the blastopore.

FORMATION OF THE GLANDS OF THE ALIMENTARY CANAL.

Under this head may be included not only those organs which are ordinarily so termed, but also the lungs, and the thymus and thyroid bodies, since the early development of these three organs resembles that of the true secreting glands.

All the organs above enumerated are formed as epithelial involutions, either solid at first and afterwards becoming hollowed out, or hollow from the first. As these epithelial buds grow into the mesoblast, they may either bifurcate or give off lateral branches, and in this manner all the ramifications of the ducts of the compound racemose glands are produced. The blind extremities generally end eventually in enlarged tubular or saccular dilatations. All the epithelium of the gland-sacculles and ducts is derived from the original epithelial sprout, while the basement membranes and connective tissue and blood-vessels of the gland are derived from the surrounding mesoblast. The salivary glands and most other glands of the mouth, and part of the hypophysis, which must also be reckoned as a glandular development, are formed in this way by involution of the buccal or stomodæal epiblast; while the lungs, liver, pancreas, thyroid, thymus, and all the small glands of the rest of the alimentary canal are formed of involutions of the hypoblast. The development of the teeth, which also first make their appearance as involutions of stomodæal epiblast (enamel germs), will be described after their structure has been dealt with (in the part of this work which is devoted to Splanchnology).

The lungs.—The lungs begin to develop from the ventral part of the pharynx at its junction with the œsophagus, in the beginning of the third day in the chick,

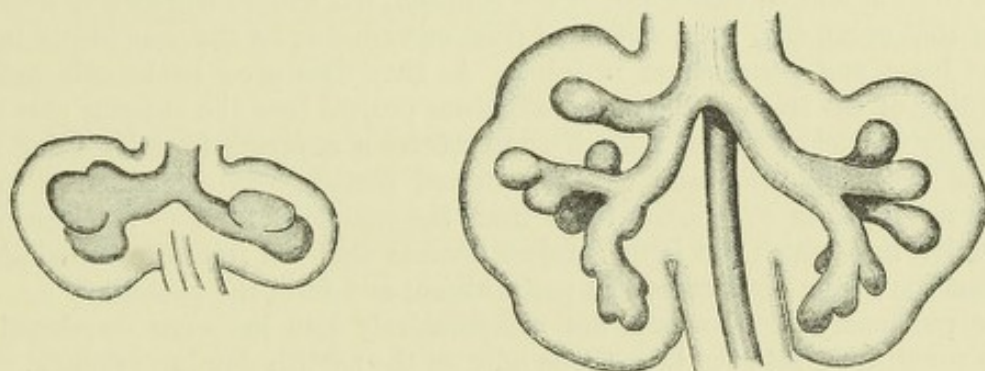


Fig. 131.—LUNG RUDIMENTS OF HUMAN EMBRYO OF ABOUT 4 WEEKS, SHOWING THE BUD-LIKE ENLARGEMENTS WHICH REPRESENT THE LOBES OF THE FUTURE LUNGS. (His.)

Three buds are seen on the right side, two on the left.

Fig. 132.—LUNGS OF A HUMAN EMBRYO MORE ADVANCED IN DEVELOPMENT. (His.)

and in the human embryo at a correspondingly early period (fig. 123, *Lg*). The lung rudiment is at first single and median, and takes the form of an elongated vertical diverticulum of the fore-gut, communicating freely with that tube, and of course lined by hypoblast. Soon the diverticulum sprouts out at its lower extremity in the form of two tubes which grow downwards on either side behind and on either side of the heart, into a mass of mesoblastic tissue, which keeps pace in its growth with the hypoblastic lung rudiment, and from which the connective tissues of the future lung become ultimately developed. The extremities of the tubes in question are early seen to be dilated and lobulated (fig. 131), three lobules being present on the right tube, and two on the left, the division of the lungs into their lobes being thus early indicated.

The further outgrowth of the lobulations produces the rudiments of the principal branches of the bronchi, one for each future pulmonary lobe, and each of these branches then gradually

progresses in growth, giving off as it proceeds lateral diverticula, which form the secondary bronchi, and these again giving off others until the whole complicated bronchial ramification is eventually produced. Like the first sprouts from the median diverticulum, all the secondary and other sprouts are dilated at their termination, and have a lobulated aspect (fig. 125, *Lg* :

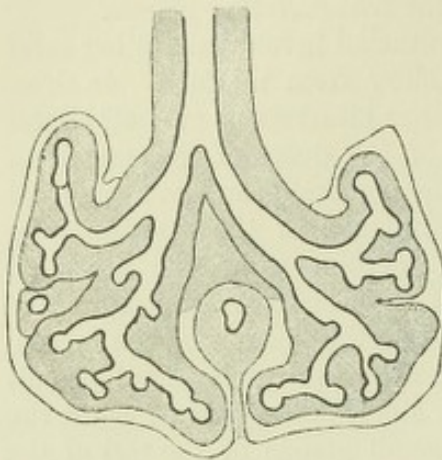


Fig. 133.—LUNGS OF A HUMAN EMBRYO STILL MORE ADVANCED. (His.)

figs. 131, 132, 133. This is due to the fact that they are undergoing a further division or sprouting. This process goes on until the sixth month of intrauterine life, by which time all the dilated ends of the growing and sprouting tubes have reached the surface of the lung. These dilated extremities which now appear grouped together, and apparently springing several from a common tube, form the infundibula, but their walls are not at first beset with air-cells. The formation of these takes place when the bronchial ramification is completed (sixth month, Kölliker), as small, closely-set, pouch-like protrusions of the walls of the infundibula, and of the terminal bronchial tubes.

The **trachea and larynx** are formed by a separation from the œsophagus of the original median diverticulum, from the lower angles of which the bronchial rudiments have sprung, the separation commencing below, and leaving a relatively small connection between the two

tubes above: this connection is the rudimentary glottis. As development advances, both the tracheo-laryngeal and the œsophageal tubes lengthen, the latter relatively more than the former, so that the lung rudiments no longer lie, as was the case at first, in front of and on either side of the stomach, but extend downwards somewhat short of that organ (fig. 125), separated from one another by the œsophagus behind, and the heart and pericardium in front. As they thus grow backwards with the lengthening of the trachea, the lung rudiments project into the anterior part of the body-cavity or cœlom (dorsal portion), and receive a covering from its lining membrane, at first only below and on the external surface, but subsequently on the internal aspect, so as to separate them from the œsophagus. The portions of the body-cavity into which the lungs project become shut off from the remainder on the formation of the diaphragm and pericardium, and form the pleuræ.

The pulmonary blood-vessels are comparatively late in being developed, the arteries penetrating into the lung tissue only on the twelfth day in the chick.

The **thyroid body** is developed partly as a median diverticulum of the pharyngeal hypoblast opposite the ventral ends of the second visceral arches (fig. 125, *B, Sd*); partly as a (bilateral) diverticulum of the posterior wall of the fourth visceral cleft. The median diverticulum in most animals early becomes separated from the pharyngeal hypoblast, and is thus converted into an island of epithelium imbedded in mesoblast. In the human embryo, as His has shown (fig. 134, *A, thr*), it remains for some time in the form of a hollow bifid vesicle, which is connected with the upper surface of the tongue by a small duct (*ductus thyreoglossus, d*); subsequently, however, the vesicle becomes solid, and the duct is obliterated and disappears, with the exception of a small portion near the orifice, which becomes converted into the *foramen cœcum* of Morgagni, *f.c.*

Occasionally even in the adult a comparatively long duct is found, leading downwards and backwards from the foramen cœcum. This, which has been termed the *ductus lingualis*, is the remains of the original thyrolingual duct connecting the median part of the thyroid with the tongue. It may further happen that the lower part of this connection also remains in the shape of a tubular prolongation of the median portion of the thyroid towards the root of the tongue (*ductus thyroideus*; when well developed this forms the *pyramid*). The so-called accessory thyroid bodies (supra-hyoid, præhyoid glands, &c.) which are occasionally found near the hyoid bone, are also referable to the thyrolingual duct (His, *Anatomie*

menschlicher Embryonen, iii., p. 101, where reference to the literature of these accessory thyroids may be found).

The bilateral diverticula, which assist in the formation of the thyroid body, spring from the fourth visceral cleft (Born) (fig. 135, *thr'*). They have at first the appearance of simple saccular glands partially encircling the developing larynx (fig. 134, *thr'*). In front of this they come into connection with the median rudiment, and eventually blend with it. Like that rudiment, they become entirely separated from the hypoblastic surface from which they have taken origin, their cavity disappears, and they

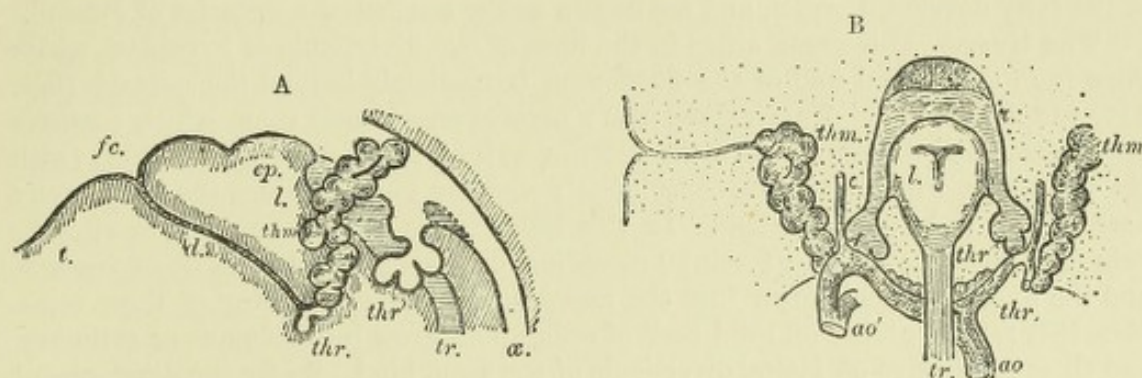


Fig. 134.—SKETCHES SHOWING THE CONDITION OF THE THYROID AND THYMUS GLANDS IN A HUMAN EMBRYO OF ABOUT FIVE WEEKS. (His.)

A, profile sketch from the left side.

B, frontal sketch from behind.

t, tongue; *d*, ductus thyroglossus; *ep*, epiglottis; opposite *l*, larynx; *tr*, trachea; *æ*, esophagus; *thr*, median rudiment of thyroid; *thr'*, lateral rudiment of thyroid; *thm*, developing thymus, seen on the left side of B to be connected with a visceral cleft; *ao* (in B), ascending aorta; *ao'*, descending aorta; *c*, carotid.

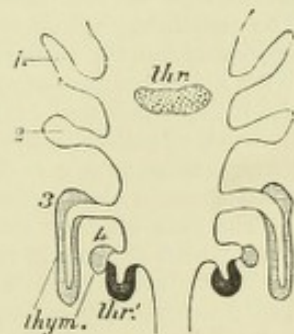
are converted into ramifying and anastomosing cell-cylinders, between which vascular connective tissue becomes developed. The cell-cylinders subsequently become hollowed out, and finally are subdivided by growth of the connective tissue into small vesicles, which gradually become larger from accumulation of colloid in their interior.

In most Vertebrates, the lateral and median parts of the thyroid remain distinct; the former are the organs known as *supra-pericardial bodies* in elasmobranchs, and as *accessory thyroids* in other animals. Only in mammals do they become united into one organ as in man.

The **thymus** is also developed as a growth of the epithelium (hypoblast) of some of the visceral clefts; in birds from the third and fourth (fig. 135, *thym*), in reptiles from the second, third, and fourth, and in lower Vertebrates from several clefts (de

Fig. 135.—DIAGRAM SHOWING THE VISCERAL CLEFTS FROM WHICH THE THYMUS AND LATERAL PARTS OF THE THYROID ARE DEVELOPED IN THE CHICK. (de Meuron.)

1, 2, 3, 4, indicate the corresponding visceral clefts; *thym*, rudiments of thymus; *thr*, median rudiment of thyroid; *thr'*, lateral rudiments of thyroid.



Meuron). In mammals the thymus appears as a (bilateral) tubular prolongation backwards of the extremity of the third visceral cleft (Kölliker), receiving, according to de Meuron, an accession from the hypoblast of the fourth cleft, as in birds. The tube, which has a narrow lumen, and comparatively thick epithelial lining, is surrounded by vascular connective tissue, within which numerous lymphoid cells become accumulated, and grows downwards along the side and in front of the trachea, where, in mammals, it generally unites

with its fellow to form a median organ. Its lower end then gives off solid, bud-like excrescences, and lateral buds come off again from these, so that this part of the organ acquires a ramified, lobulated appearance like an acinous gland. The acini are, however, solid, and remain so, although the upper end of the tube still has a narrow lumen.

The lymphoid cells next invade the epithelium, growing into every part of the tubular gland, and converting it into a mass of adenoid tissue. In this process the epithelium becomes broken up into small isolated portions, some of which remain in the medullary portion of the lobules as the epithelial nests which are seen in sections of the fully developed organ, and are known as the concentric corpuscles of Hassall.

The liver.—This organ arises in the form of two diverticula of hypoblast, which grow from the ventral wall of the duodenum immediately beyond the stomach (figs. 117, 118, *l*, 123, *Lb*). They extend into a mass of mesoblastic tissue which connects the stomach and duodenum with the anterior wall of the abdomen, and which (with the mesentery, with which it is continuous round the gut) separates the body-cavity here into a right and left half. In this tissue is the omphalomesenteric or vitelline vein (and later the umbilical vein) proceeding on either side to the sinus venosus, and the liver diverticula grow into the mesoblast above and in front of these veins. Here they ramify, giving off solid buds of cells which grow into columns or cylinders, and these again give off lateral diverticula of the same kind. So far the development of the liver resembles that of a compound tubular or acino-tubular gland, except that the ramifications of the original gland diverticula are from the first solid instead of hollow. But soon an important difference appears in the fact that the cylinders unite and anastomose with one another everywhere to form a close network, and from the cords of this network solid sprouts are again constantly being given off to form fresh cylinders, thus producing a yet closer and more intricate network. In the meantime, capillary blood-vessels are formed in the mesoblastic tissue in which this formation of cell-cylinders of hypoblast is going on, and these vessels, which form a network interlocking with that of the anastomosing cell-cylinders, become connected with branches of the vitelline vein on the one hand (*venae advehentes*), and on the other with veins (*venae revehentes*) which pass towards the sinus venosus, and eventually are found opening as the hepatic veins into the inferior vena cava.

The two original hollow diverticula are the rudiments of the right and left hepatic ducts. The common bile duct is formed later by a protrusion of that part of the duodenal wall with which the original diverticula are connected. This protrusion also eventually receives the duct of the pancreas, which becomes shifted towards it. As the common bile duct lengthens, the liver becomes separated from the duodenum, with which it was at first in close connection. The portal and interlobular bile ducts are formed by the hollowing out of some of the anastomosing cell-cylinders, so that a lumen is produced within them surrounded by hepatic cells, which lose their original polyhedral character, and become changed into the columnar epithelium of the ducts, the anastomoses between the cell-cylinders here disappearing. The remaining cylinders form the secreting substance of the liver. The biliary canaliculi appear as minute passages between the cells, and come into continuity with the bile ducts. With a further development of the connective tissue of the organ, the glandular substance of the liver, which was at first continuous throughout, becomes separated into lobules, and the network of cell-cylinders tends with multiplication of their cells to become fused into a continuous mass within each lobule, the bile canaliculi forming by numerous lateral junctions and anastomoses a close network of intercellular passages within the lobule.

The gall bladder and cystic duct are formed by a diverticulum from the common bile duct, which appears in the second month.

In the elasmobranch fishes, and in amphibia, there is only a single hepatic diverticulum. The anastomosing cell-cylinders which sprout from this are not solid, but hollow, with a narrow lumen, and the liver has from the first and retains permanently the character of a compound gland formed of anastomosing tubules. In reptiles the cylinders also have from the first a narrow lumen. In birds and mammals the cylinders are solid, as in man.

As the liver grows, it projects on either side into the pleuroperitoneal cavity. The mesoblast which unites it to the anterior wall of the abdomen, becomes thinned out to form

the suspensory ligament. That which unites it to the ventral wall of the stomach and duodenum also becomes thinned out; it forms the small or gastro-hepatic omentum. The liver is at first an exactly symmetrical organ, the right and left lobes being equal in size and symmetrically placed. After the fourth month the right lobe begins relatively to increase in size, and at birth the proportion of this to the left lobe is as 1.6 to 1. The liver also at first grows very rapidly, so that by the second month it nearly fills the abdomen, and causes a well marked prominence on the ventral aspect of the embryo. At this time it is calculated to constitute nearly one half the weight of the body. The proportion, however, gradually decreases, until at term the relative weight of the liver to the whole body is as 1 to 18. The further changes which the blood-vessels which pass to the liver undergo will be considered with the development of the venous system.

The **pancreas** is developed as a hollow hypoblastic diverticulum from the dorsal wall of the duodenum opposite the hepatic diverticula, and somewhat later than these (fig. 125, B, C, D, p). This hollow process grows into the mesogastrium or gastroduodenal mesentery, which at this time is well developed, and ramifies within this, producing by its off-shoots the ducts and alveoli as with other compound acinous glands. As the duodenal loop becomes formed, and this and the pyloric end of the stomach are turned over towards the right side, the pancreas loses its median symmetrical position, and with the mesentery which encloses it now lies across the back of the abdomen. This is the condition in which the gland is found in most mammals. But in man, with the fusion of the mesogastrium (great omentum) to the transverse mesocolon, the posterior layer of the mesenteric fold which encloses the pancreas becomes absorbed (Toldt), and the gland becomes fixed across the back of the abdomen, and is now apparently altogether behind the peritoneum (see fig. 12, 129).

RECENT LITERATURE.

Bemmelen, J. F. van, *Entwikkeling en metamorphose der kieuw of visceral-spalten en der aortabogen bij embryonen van *Tropidonotus natrix* en *Lacerta muralis**, Kin. Akad. v. Wet. Amsterd. Afd. Natuusk., 1885; *Die Visceraltaschen u. Aortenbogen bei Reptilien u. Vögeln*, Zool. Anzeiger, 1886; *Die Halsgegend der Reptilien*, Zool. Anz., 1887.

Bonnet, R., *Ueber die Entwicklung der Allantois und die Bildung des Afters bei den Wiederkäuern und über die Bedeutung der Primitivrinne und des Primitivstreifs bei den Embryonen der Säugethiere*, Anat. Anzeiger, 1888.

Born, G., *Ueber die Derivate der embryonalen Schlundbogen und Schlundspalten*, Archiv f. mikr. Anat., Bd. xxii., 1883.

Cadiat, *Du développement des fentes et arcs branchiaux chez l'embryon*, Journal de l'anat., &c., 1883.

Chievitz, J. C., *Beiträge zur Entwicklungsgeschichte der Speicheldrüsen*, Arch. f. Anat. u. Physiol., Anat. Abth., 1885.

Demon, F., *Développement de la portion sousdiaphragmatique du tube digestif*, Lille, 1884.

Dohrn, A., *Die Thyroidea bei Petromyzon, Amphioxus u. Tunicaten*, Mitth. aus der zool. Station z. Neapel, 1886.

Fischelis, Ph., *Beiträge zur Kenntniss der Entwicklungsgeschichte der Gl. thyroidea u. Gl. thymus*, Arch. f. mikr. Anat., Bd. xxv., 1885.

His, W., *Ueber den Sinus præcervicalis und die Thymusanlage*, Archiv f. Anat. u. Physiol., Anat. Abth., 1886; *Zur Bildungsgeschichte der Lungen beim menschlichen Embryo*, Archiv f. Anat. und Physiol., Anat. Abtheilung, 1887; *Schlundspalten u. Thymusanlage (Brief an P. Mall)*, Arch. f. Anat. u. Physiol., Anat. Abth., 1889.

Kastschenko, N., *Das Schicksal der embryonalen Schlundspalten bei Säugethieren*, Archiv f. mikrosk. Anat., Bd. xxx., 1887; *Das Schlundspaltengebiet des Hühnchens*, Arch. f. Anat. u. Phys. Anat. Abth., 1887.

Liessner, E., *Ein Beitrag zur Kenntniss der Kiemenspalten und ihrer Anlagen bei amnioten Wirbelthieren*, Morpholog. Jahrbuch, Bd. xiii., 1888.

Mall, F. P., *Entwicklung der Branchialbogen und Spalten des Hühnchens*, Arch. f. Anat. u. Physiol., Anat. Abth., 1887; *The branchial clefts of the dog, with special reference to the origin of the thymus gland*, Studies from the Biol. Laboratory of John Hopkins University, iv., 1888.

Meuron, P. de, *Recherches sur le développement du thymus et de la glande thyroïde*, Recueil zool. Suisse, iii., 1886; *Sur le développement de l'œsophage*, Compt. rend., 1886.

Minot, Ch. S., *Evolution of the Lungs*, Proceed. of the Zoolog. Society of London, 1886.

Ostroumoff, A., *Ueber den Blastoporus u. d. Schwanzdarm bei Eidechsen u. Schleichern*, Zool. Anzeiger, 1889.

Philip, R. W., *Beiträge zur Lehre über die Entwicklung der Trachea*, Mitth. aus d. embryol. Inst. d. Univers. Wien, Bd. ii., 1883.

- Piersol, G. A.**, *Ueber die Entwicklung der embryonalen Schlundspalten und ihre Derivate bei Säugethieren*, Zeitschr. f. wiss. Zool., Bd. xlvii., 1888.
- Rabl, C.**, *Zur Bildungsgeschichte des Halses*, Prager medic. Wochenschr., 1886 u. 1887.
- Retterer, E.**, *Du développement de la région anale des mammifères*, C. r. de la société de biologie, 1890.
- Robinson, A.**, *Observations on the earlier stages in the development of the lungs of rats and mice*, Journal of Anatomy and Physiology, 1889.
- Schwink, T.**, *Ueber den Zwischenkiefer und seine Nachbarorgane bei Säugethieren*, 1888.
- Stieda**, *Untersuchungen ueber die Entwickl. der Glandula thymus, Glandula thyroidea und Glandula carotica*. Leipzig, 1881.
- Swartz, D.**, *Untersuchungen des Schwanzendes bei den Embryonen der Wirbelthiere*, Zeitsch. f. wiss. Zool. xlviii., 1889.
- Toldt, C.**, *Bau u. Wachstumsveränderungen der Gekröse des menschlichen Darmkanales*, Wiener Denkschriften, 1879; *Die Darmgekröse u. Netze im gesetzmässigen u. im gesetzwidrigen Zustand*. Ibid., 1889.
- Uskow, N.**, *Bemerkungen zur Entwicklungsgeschichte der Leber und der Lungen*, Archiv f. mikrosk. Anatomie, Bd. xxii., 1883.
- Wölfler, A.**, *Ueber die Entwickl. u. den Bau der Schilddrüse*. Berlin, 1880.

DEVELOPMENT OF THE URINARY AND GENERATIVE ORGANS.

The urinary and generative organs originate in connection with the *intermediate cell-mass*, a portion of mesoblast which is seen in sections of the early embryo lying

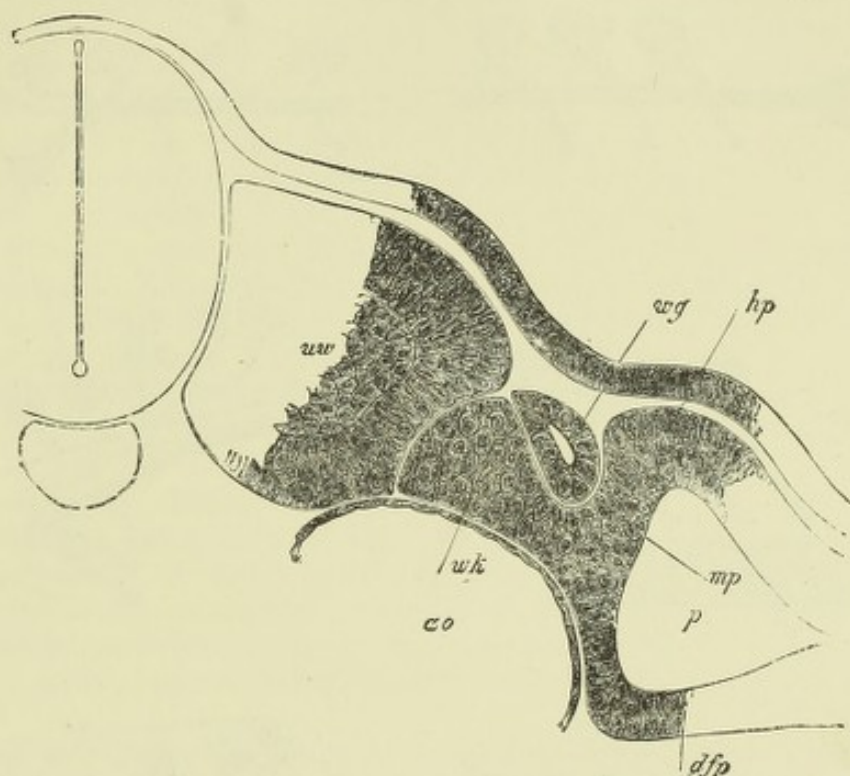


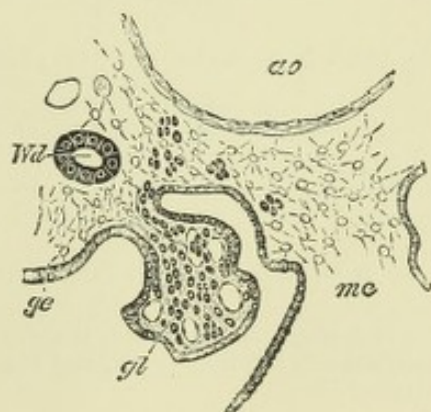
Fig. 136.—PART OF A TRANSVERSE SECTION OF A CHICK EMBRYO OF 2 DAYS, 6 HOURS. (Kölliker.) ²⁵⁰

uw, protovertebra; *mp*, lateral mesoblast; *dfp*, splanchnopleuric mesoblast; *hp*, somatopleuric mesoblast; *p*, pleuro-peritoneal cleft (coelom); *wg*, Wolffian duct; *wk*, part of intermediate cell-mass from which Wolffian body will become developed.

between the paraxial mesoblast and the pleuro-peritoneal cleft, and abutting against the external epiblast (fig. 39, p. 37).

Fig. 137.—SECTION THROUGH AN EXTERNAL GLOMERULUS OF THE PRONEPHROS FROM A CHICK OF ABOUT 4 DAYS' INCUBATION. (Balfour.)

gl, glomerulus; *ge*, peritoneal epithelium; *Wd*, Wolffian duct; *ao*, aorta; *mc*, mesentery.



Some of the cells of this intermediate cell-mass become differentiated into a longitudinally running cord, which subsequently acquires a lumen, and is then known as the *Wolffian duct* (from its discoverer, Caspar Friedrich Wolff) (fig. 136, *wg*). Posteriorly the duct opens into the cloaca. The anterior part of the duct becomes connected with invaginations of the peritoneal epithelium, between which vascular glomeruli project freely into the peritoneal cavity (fig. 137). These glomeruli constitute the *head kidney*, *fore-kidney* or *pronephros*.¹ Along its inner side, somewhat further back-

¹ Hertwig. According to Balfour and Sedgwick, these glomeruli form the anterior part of the Wolffian body, and the head kidney is represented by the Müllerian invaginations referred to later on (see p. 122 and fig. 145).

wards, a series of transversely coursing tubes becomes developed in the intermediate cell-mass. These tubes are connected for a time with other involutions of the peritoneal epithelium (fig. 141), but subsequently lose their connection with that

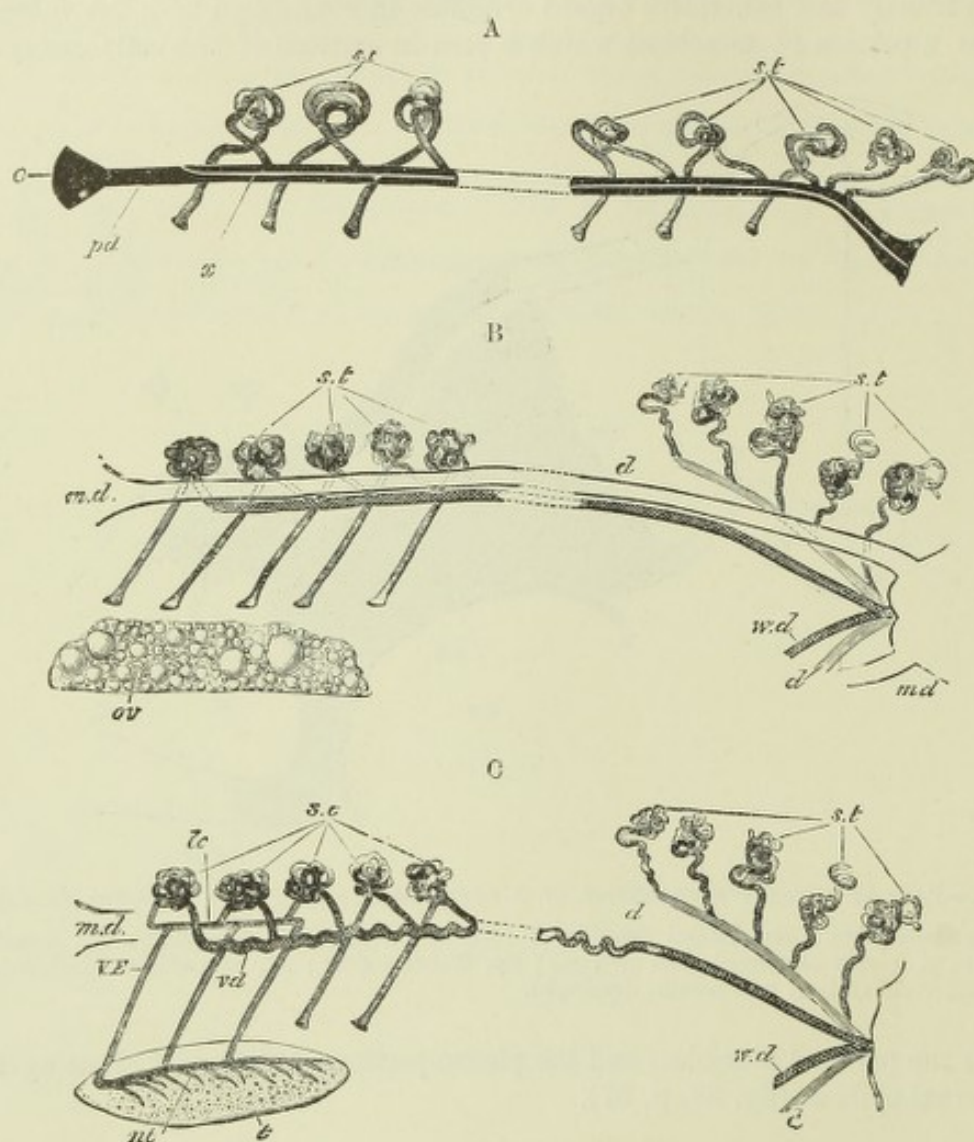


Fig. 138.—DIAGRAMS OF THE ARRANGEMENT OF THE URINARY AND GENITAL ORGANS IN ELASMOBRANCHS. (Balfour.)

A.—DIAGRAM OF THE PRIMITIVE CONDITION OF THE KIDNEY IN AN ELASMOBRANCH EMBRYO.

pd, segmental duct; opening at *c*, into the body cavity and at its other extremity into the cloaca; *x*, line of separation between the Wolffian duct above and the Müllerian duct below; *st*, segmental tubes, opening at one end into the body cavity and at the other into the segmental duct.

B.—DIAGRAM OF THE ARRANGEMENT OF THE URINO-GENITAL ORGANS IN AN ADULT FEMALE ELASMOBRANCH.

m.d., Müllerian duct; *w.d.*, Wolffian duct; *st*, segmental tubes; five of them are represented with openings into the body cavity, and five posteriorly correspond to the metanephros; *ov*, the ovary; *d*, ureter.

C.—DIAGRAM OF THE ARRANGEMENT OF THE URINO-GENITAL ORGANS IN AN ADULT MALE ELASMOBRANCH.

m.d., rudiment of Müllerian duct; *w.d.*, Wolffian duct, serving at *vd* as vas deferens; *st*, segmental tubes, two represented with openings into the body cavity; *d*, ureter; *t*, testis; *nt*, canal at the base of the testis; *v.e.*, vas efferentia; *lc*, longitudinal canal of the Wolffian body.

epithelium, and acquiring glomeruli at one part, at another part open into the Wolffian duct. They form the *mid-kidney*, *Wolffian body* or *mesonephros*, which

presently projects as a distinct vascular organ along the dorsal part of the peritoneal cavity on either side of the mesentery. Subsequently another duct becomes developed along the outer side of the Wolffian body, along which it runs backwards to open also into the cloaca: in front it communicates with the pleuroperitoneal cavity by one or more funnel-shaped apertures (fig. 143, *z*). This is the *Müllerian duct*, so named after Johannes Müller; in some of the lower vertebrates it arises in common with the Wolffian duct. From the lower end of each Wolffian duct a hollow protrusion (fig. 125, C and D, *N*) grows upwards into a mass of mesoblast continuous with that of the Wolffian body; with the branches of this protrusion glomeruli and convoluted tubes also become connected, and thus the *permanent kidney* (*hind-kidney*, *metanephros*) is produced. Lastly, the cœlomic epithelium covering the inner side of the Wolffian body becomes thickened (fig. 143, *a*), and within it are found larger cells, from which the generative products in both sexes (ova and spermatozoa) are eventually derived. This epithelium is accordingly known as the *germinal epithelium*. The duct of Müller becomes in the female the oviduct or Fallopian tube; in the male it becomes atrophied. The Wolffian duct in the male becomes the epididymis and vas deferens; while the vasa efferentia and tubes of the rete testis are formed as outgrowths from the Wolffian body; in the female these parts have no permanent function.

The head kidney, although permanent and functional in fishes, is only a rudimentary organ in the embryo of higher vertebrates, and soon disappears. The Wolffian body is well developed in all vertebrates; in fishes and amphibia it is an important part of the permanent urinary apparatus, and also serves to carry away the male sexual products (fig. 138). In higher vertebrates (amniota) it no longer continues to perform excretory functions, but still supplies the efferent apparatus of the testis.

The details of the development of these parts may next be considered.

The Wolffian duct and body.—The commencement of the Wolffian duct is seen at a very early period of development (second day in the chick, eighth day in the rabbit) as a thickening of the intermediate cell-mass in the anterior region of the trunk (fifth somite) (fig. 39, *Wd*). The outgrowth projects towards the epiblast, and

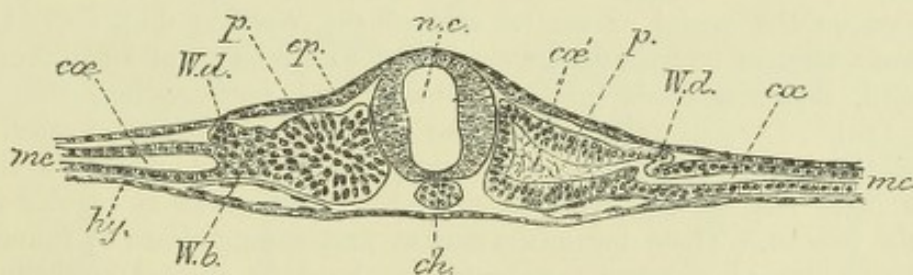


Fig. 139.—TRANSVERSE SECTION OF AN EMBRYO CHICK OF THIRTY-SIX HOURS. 150 (E. A. S.)

n.c., medullary tube; *p.*, protovertebra; *ep.*, epiblast; *me*, lateral mesoblast split into splanchnopleure and somatopleure; *cc*, pleuro-peritoneal cavity between them; *cc'*, cavity of protovertebra, continuous on the right side with the lateral mesoblastic cleavage; *W.d.*, Wolffian duct; *W.b.*, mesoblast of Wolffian body; *ch.*, notochord.

develops from before backwards; a solid cord of mesoblast thus becomes formed, which gradually becomes detached from the remainder of the intermediate cell-mass, lying close to the epiblast (fig. 139, *ung*). Soon after it is thus formed, a lumen appears in it and extends both forwards and backwards. The posterior end, which is still solid, is presently found to be attached to the epiblast, and apparently continues to grow backwards along and at the expense of the epiblast until it reaches the posterior end

of the body, where it becomes detached from the epiblast, and is connected with and opens into the hind-gut (cloaca).

I have here followed what has appeared to me the most probable account of the origin of the duct (Martin, Strahl), but it is right to state that in the opinion of some observers (Hensen, Spee, Flemming) the formation and growth of the duct in connection with the epiblast is primary, especially in mammals, and the duct is originally formed by a longitudinal thickening and involution of the epiblast, which only secondarily becomes connected with the intermediate cell-mass. Compare also Haddon, Origin of segmental duct, Proc. Roy. Dublin Society, Vol. V.

In teleosteans (Rosenburg) and amphibia (Götte) the Wolffian duct has been described as developing in the form of a longitudinal groove-like invagination of the somatopleural mesoblast (Balfour, Comp. Emb., vol. ii., pp. 580, 582), but more recent researches appear to indicate that in these animals also the epiblast may be concerned in its formation.

The Wolffian body develops in the intermediate cell-mass between the Wolffian duct and the body-cavity as a series of transverse tubes which lie at right angles to the course of the Wolffian duct, and open into it at regular intervals. The usual

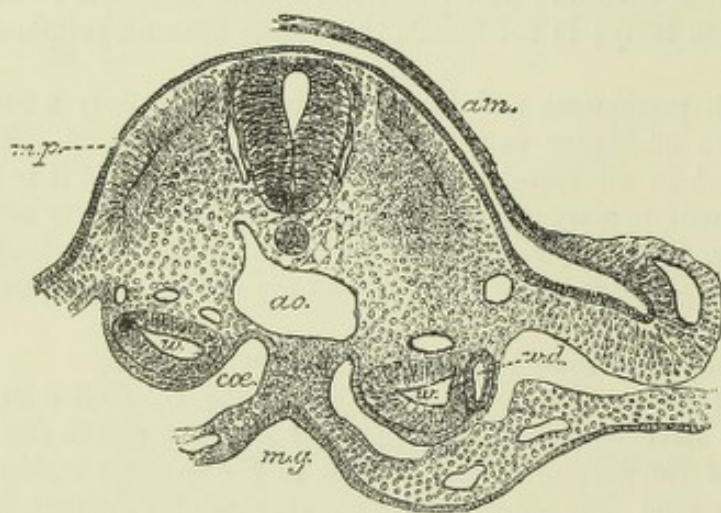


Fig. 140.—TRANSVERSE SECTION OF THE TRUNK OF A CAT EMBRYO, SHOWING THE VESICULAR STAGE OF THE WOLFFIAN TUBULES.
(E. A. S.)

m.p., muscle plate; *ao.*, aorta; *m.g.*, mid-gut; *am.*, amnion; *w.*, vesicle of Wolffian body; *w.d.*, Wolffian duct; *coe.*, coelom.

mode of formation of these tubes—which are sometimes termed *segmental tubes*—appears to consist in the accu-

mulation at regular intervals, corresponding with the somites, of rounded masses of mesoblast on the mesial or ventral side of the Wolffian duct (fig. 142, *w.b.*), which masses become afterwards hollowed out so as to form small vesicles, at first isolated, but afterwards growing towards and opening into the Wolffian duct (fig. 140).¹ Corresponding with these vesicles there become formed invaginations of the epithelium of the body-cavity (fig. 141, *st*), which is thickened along the inner side of the Wolffian projection, and grows at regular intervals towards the vesicles. These ingrowths may at first communicate by funnel-shaped openings, which in some lower vertebrates are lined by ciliated epithelium, with the body-cavity, but the openings in higher vertebrates become closed again before communication with the Wolffian duct is established. Finally, the connection between the Wolffian tubes and the peritoneal epithelium is completely severed, and the condition of simple or curved transverse tubes, blind at their inner ends and opening at their outer ends into the Wolffian duct, is produced (fig. 142, B). After a time the blind extremities are seen to be enlarged and spoon-shaped, and glomeruli

¹ According to v. Wijhe the hollow condition is the primary one in elasmobranchs, and the cavity of each vesicle represents an intermediate part of the coelom of the segment (meso-coelom), the dorsal coelom being represented by the cavity of the proto-vertebra and the ventral coelom by the pleuroperitoneal space. I have myself observed this condition of a hollow intermediate cell-mass communicating on the one hand with the cavity of the protovertebra and on the other with the cleft of the lateral mesoblast, in a chick of 36 hours (see fig. 139).

In mammals the Wolffian vesicles are more numerous than the segments.

are observed developing in the bowl of the spoon from mesoblast cells, which presently become entirely enclosed by the end of the tube. Subsequently a second

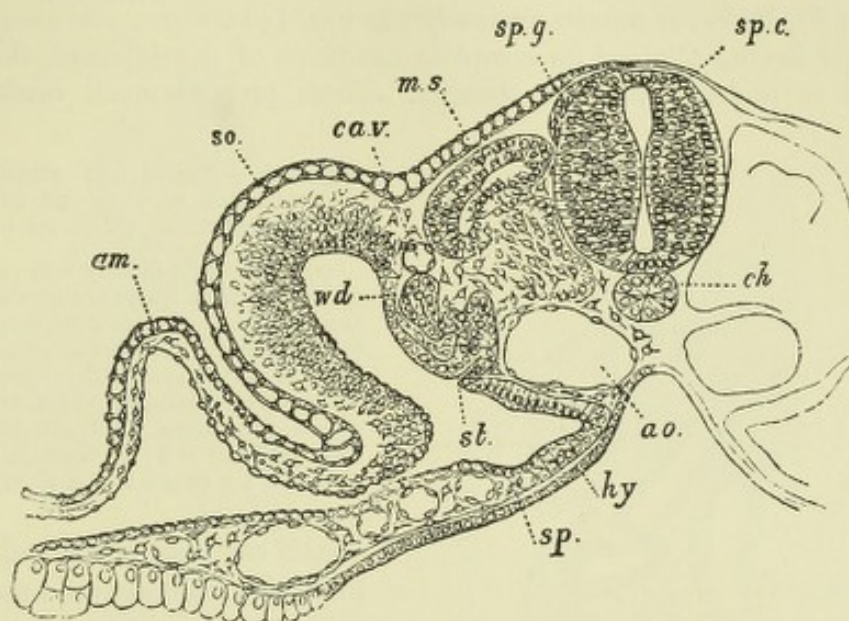


Fig. 141.—TRANSVERSE SECTION THROUGH THE TRUNK OF A DUCK EMBRYO WITH ABOUT TWENTY-FOUR MESOBLASTIC SOMITES. (Balfour.)

am, amnion; *so*, somatopleure; *sp*, splanchnopleure; *wd*, Wolffian duct; *st*, segmental tube with peritoneal involution; *ca.v*, cardinal vein; *m.s*, muscle-plate; *sp.g*, spinal ganglion; *sp.c*, spinal cord; *ch*, notochord; *ao*, aorta; *hy*, hypoblast.

and a third set of tubes become developed in a similar manner, but without peritoneal invaginations, and also open directly into the Wolffian duct. Lastly, other tubes

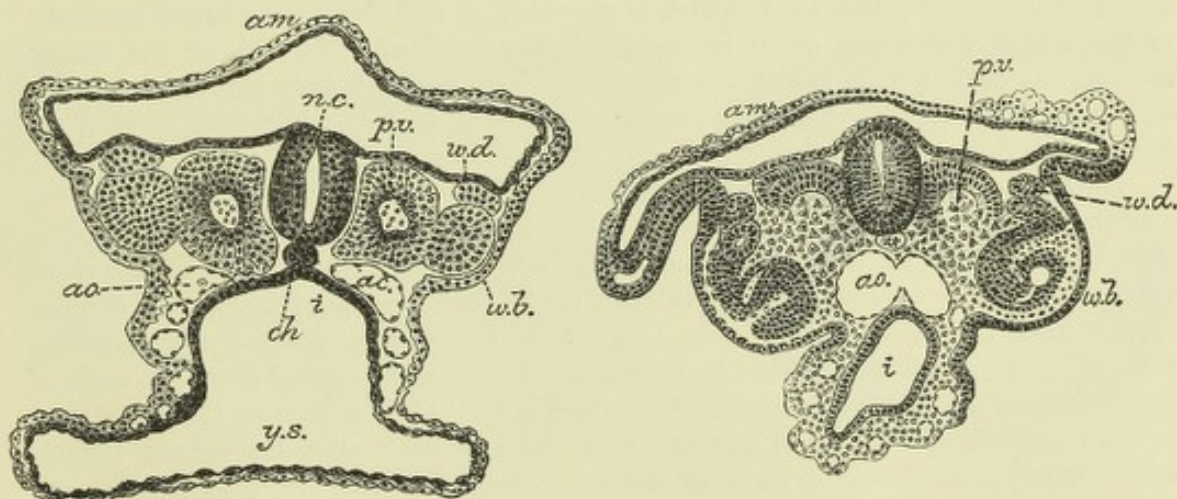


Fig. 142.—TRANSVERSE SECTIONS OF SHEEP EMBRYOES, SHOWING TWO STAGES IN THE DEVELOPMENT OF THE WOLFFIAN BODY. (Bonnet.)

w.d, Wolffian duct; *w.b*, Wolffian body; *p.v*, protovertebra; *ch*, notochord; *n.c*, neural canal; *am*, amnion; *ao*, aorta; *i*, intestine; *y.s*, yolk-sac.

with glomeruli become formed between, and open into those which are already connected with that duct. All these tubes are short and straight when first developed, but afterwards lengthen and become converted into convoluted uriniferous tubes, which, like those of the permanent kidneys, begin in a dilated extremity enclosing a tuft of capillary blood-vessels (glomerulus), which are supplied by branches of the primitive aortæ.

When completely formed, the Wolffian bodies are seen on opening the abdomen of the embryo as long prominent vascular organs projecting into the peritoneal cavity on either side of the intestine, and showing in section numerous Malpighian corpuscles and uriniferous tubules variously cut (fig. 143).

Soon after having attained its complete condition of development, the Wolffian body begins to undergo atrophic changes. These proceed much further in the

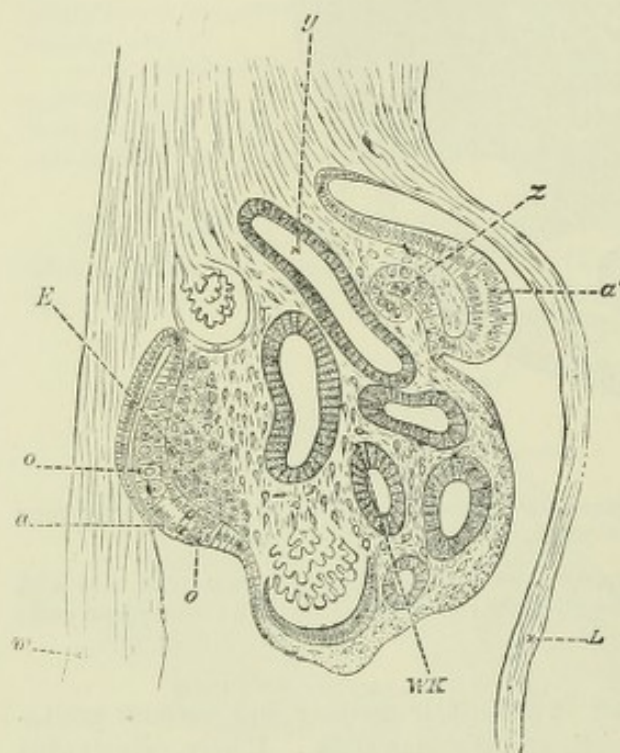


Fig. 143. — TRANSVERSE SECTION OF THE WOLFFIAN BODY OF THE CHICK ON THE FOURTH DAY. (Waldeyer.)

m, mesentery; *L*, body wall; *a'*, thickened epithelium from which the involution of the anterior part of the Mullerian duct *z*, is taking place; *a*, thickened germinal epithelium in which are seen primitive ova, *o*; *E*, modified mesoblast which will form the stroma of the ovary; *WK*, tubules of Wolffian body variously cut; *y*, Wolffian duct. Two glomeruli are shown in the Wolffian body.

female sex than in the male, but the tubules of the organ do not entirely disappear in either sex. In the female they form the rudimentary organ which is known as the *par-ovarium* (*epoophoron* of Waldeyer), while the main tube of that structure represents a remnant of the Wolffian duct. But in many animals, *e.g.*, the sow, the Wolffian duct remains as the *duct of Gartner*, a

strong, slightly undulated tube, which is traceable, at first free in the broad ligament of the uterus, and lower down becoming incorporated with the wall of the uterus and vagina, upon which last it becomes lost. Traces of this tube can sometimes be seen in sections across the body or cervix of the adult human uterus, and even lying in the wall of the vagina.

In the male the Wolffian duct forms the tube of the epididymis, the vas deferens, and the ejaculatory duct; the seminal vesicle being formed as a diverticulum from its lower part. The coni vasculosi and tubuli efferentes are in all probability formed by the persistence of some of the tubules of the Wolffian body. The Malpighian corpuscles of these tubules have long disappeared, but previous to their disappearance solid columns of epithelial cells, afterwards becoming tubules, grow from the walls of those corpuscles towards the germinal epithelium (fig. 153), where, in the male, they become continuous with and enclose cells derived from that epithelium (which subsequently form the epithelium of the seminiferous tubes), and thus produce the walls of the seminiferous tubules and the rete testis. In the female sex there is also a growth of solid cellular columns towards the germinal epithelium, but no connection becomes established between them, and the columns do not become tubular. The organ of Giraldés and the vasa aberrantia of Haller are probably the remains of one or more Wolffian tubules.

Suprarenal capsules.—These organs are intimately connected in their development with the Wolffian bodies. According to the observations of Weldon some of the cellular columns which grow from the Malpighian corpuscles of the upper part of the Wolffian body towards the germinal epithelium give offsets which pass upwards towards the inferior vena cava, and there become developed into the cortical substance of the suprarenal capsules. (Mihalkovics, on the other hand, states that the strands of cells which grow from the upper part of the

Wolffian body to take part in the formation of the suprarenal capsules have been derived by proliferation from the germinal epithelium.) It had long been believed that the two parts of these organs, cortical and medullary, are separate in origin; the former being derived, as was thought, from cells which are of mesoblastic origin, the latter being developed in connection with the sympathetic ganglia. In elasmobranchs and some other lower vertebrates, they

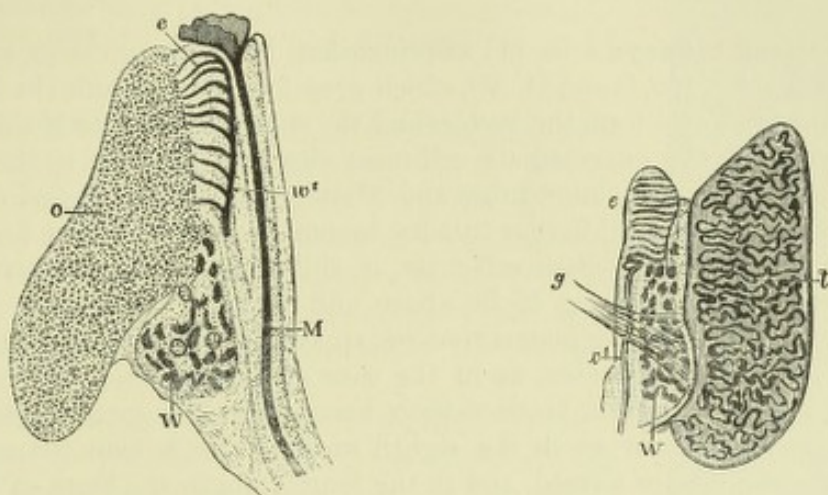


Fig. 144.—INTERNAL ORGANS OF A FEMALE HUMAN FŒTUS OF $3\frac{1}{2}$ INCHES LONG, OR ABOUT 14 WEEKS. MAGNIFIED (from Waldeyer).

o, the ovary full of primordial ova; *e*, tubes of the upper part of the Wolffian body forming the epoophoron (parovarium of Kobelt); *W*, the lower part of the Wolffian body forming the paroophoron of His and Waldeyer; *w'*, the Wolffian duct; *M*, the Mullerian duct; *m'*, its upper fimbriated opening.

Fig. 145.—INTERNAL GENITAL ORGANS OF A MALE HUMAN EMBRYO OF $3\frac{1}{2}$ INCHES LONG (from Waldeyer).

t, body of the testicle with seminal canals formed; *e*, epididymis, or upper part of Wolffian body; *W*, Wolffian body, lower part, becoming paradidymis or organ of Giralddès; *w'* Wolffian duct, becoming vas deferens; *g*, gubernaculum.

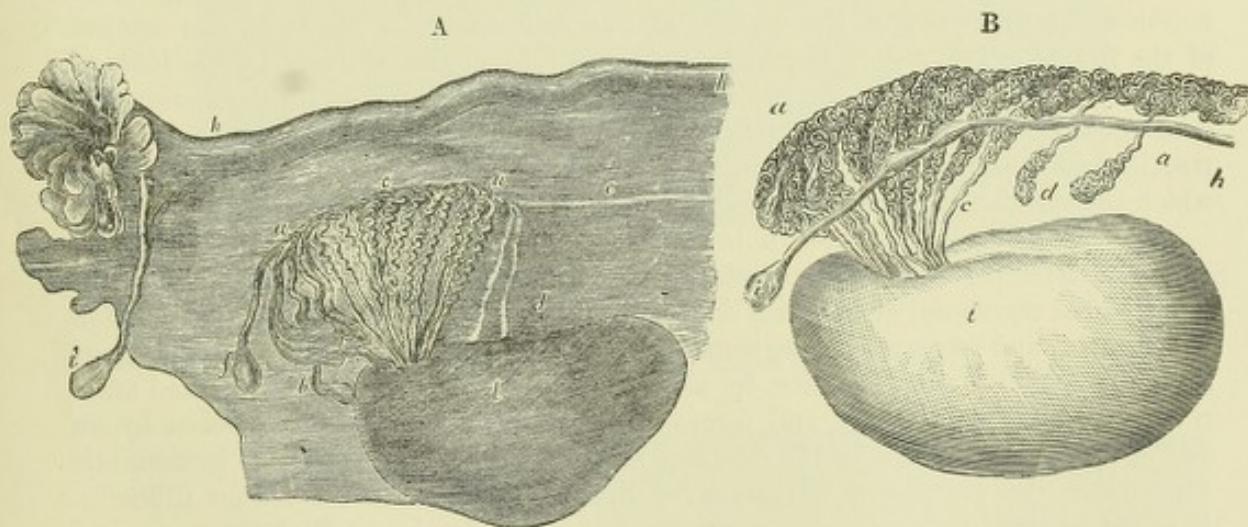


Fig. 146.—TWO FIGURES EXHIBITING A COMPARISON BETWEEN PARTS OF THE GENERATIVE ORGANS IN THE TWO SEXES (from Farre, after Kobelt).

A.—ADULT OVARY, PAROVARIIUM AND FALLOPIAN TUBE.

a, a, Epoophoron (parovarium) formed from the upper part of the Wolffian body; *b*, remains of the uppermost tubes, sometimes forming hydatids; *c*, middle set of tubes; *d*, some lower atrophied tubes; *e*, atrophied remains of the Wolffian duct; *f*, the terminal bulb or hydatid; *h*, the Fallopian tube, originally the duct of Muller; *i*, hydatid attached to the extremity; *l*, the ovary.

B.—THE ADULT TESTIS AND EPIDIDYMIS.

a, a, convoluted tubes in the head of the epididymis developed from the upper part of the Wolffian body; *b* and *f*, hydatids in the head of the epididymis; *c*, con. vasculosi; *d*, vasa aberrantia; *h*, remains of the duct of Muller with *i*, the hydatid of Morgagni, at its upper end; *t*, body of the testis.

consist throughout life of two separate portions, one median and single, the other, derived from the sympathetic ganglia, paired; in birds, reptiles, and mammals these distinct portions are combined into the two paired organs (Balfour). But in these also, as has been shown by Mitsukuri for mammals, the medullary or nervous part is at first distinct and outside the cortical, into which it gradually insinuates itself, retaining, however, its connection with the neighbouring sympathetic ganglia.

The **permanent kidneys** arise (1) as protrusions from the posterior end of the Wolffian ducts (see fig. 125, C and D, *N*), which grow forwards towards the lower part of the Wolffian bodies, and form the ureters and the collecting tubules of the kidney; (2) from a portion of the intermediate cell-mass situated posterior to the Wolffian body, and within which convoluted tubes and Malpighian corpuscles, and eventually the remaining parts of the uriniferous tubules become developed. But before these changes occur in this intermediate cell-mass, it shifts its position relatively to the Wolffian body, eventually coming to lie above and behind that organ. The convoluted tubes, with their Malpighian corpuscles, appear to be developed independently of the ureter and collecting tubes, as in the case of the Wolffian tubules and the Wolffian duct, a communication between them being only subsequently established.

The glomeruli are apparent in the eighth week in the human foetus. In the third month the papillæ are formed, and in the fourth month the loops of Henle are seen. The tubes are wider in the foetus than in the adult; the expansion of the kidney as growth advances must therefore be due mainly to an increase in length of the tubules, since new tubules and glomeruli do not appear to be formed. The human kidney is at first lobulated, the lobules corresponding in number to the Malpighian pyramids, but by the end of the first year after birth, the kidneys have usually nearly lost their lobulated appearance.

The **urinary bladder** is formed by a spindle-shaped dilatation of the stalk of the allantois (second month). The upper pole of the spindle extends as the *urachus* into the umbilical cord; it not unfrequently remains hollow for some length within the cord (Luschka). The lower pole of the spindle which passes towards the cloaca becomes the first part of the urethra of the male, and the whole of the urethra of the female. The rest of the male urethra is formed and enclosed by the folds of integument which produce the penis (see p. 128). The ureters, which are originally prolonged from and open into the Wolffian ducts, subsequently become shifted in position, so as eventually to open into the enlargement of the allantoic stalk, from which the bladder is formed.

The Müllerian duct.—In lower vertebrates, as was shown by Balfour for elasmobranchs, this duct takes origin by the splitting off of the ventral part of a longitudinal segmental or Wolffian duct, the dorsal part remaining as the Wolffian duct proper, and receiving the segmental and uriniferous tubes, while the ventral part retains the funnel-shaped orifice, by which the segmental duct communicated anteriorly with the body cavity, and comes to open posteriorly into the cloaca by an orifice distinct from that of the Wolffian duct (fig. 138 and fig. 147). In amniotic vertebrates, the process of formation of a Müllerian duct is somewhat different. It arises on the outer side of the already fairly well developed Wolffian body, and some little distance from the anterior end of that organ, as a thickening of the peritoneal epithelium (fig. 143, *a'*), which thickening becomes invaginated towards the adjacent Wolffian duct, in the form of three successive funnel-shaped depressions (fig. 148), somewhat similar to those which are connected with the previously formed Wolffian segmental tubes. The invaginations are connected together by a continuous epithelial ridge, forming a cord which becomes disconnected from the peritoneal cavity except at the anterior invagination, and subsequently acquires a lumen. The short tube which is thus formed, soon begins to grow backward as a solid rod of cells, which comes in close contact as it proceeds with the Wolffian

duct (fig. 149). To this duct it presently adheres intimately, and then continues

Fig. 147.—FOUR SECTIONS THROUGH THE ANTERIOR PART OF THE SEGMENTAL DUCT OF A SCYLLIUM EMBRYO. (Balfour.)

The figure shows how the segmental duct becomes split into the Wolffian duct dorsally and the Müllerian duct or oviduct ventrally; *Wd*, Wolffian duct; *od*, Müllerian duct or oviduct; *sd* (in D), segmental duct.

to grow backwards for a certain distance as a thickening of the epithelium of that tube, the thickening becoming gradually separated off from before backwards, and the lumen passing along it. Further back it ceases to grow thus in connection with the Wolffian duct, but is prolonged as an independent cellular cord, which lies in a groove along the side of the Wolffian duct (Balfour and Sedgwick).

Entering the *genital cord*,¹ the two Müllerian ducts lie at first on the mesial side of the corresponding Wolffian ducts, but lower down pass behind them; they finally come again between these ducts, lying close together, and, according to Mihalkovics, approach close to the sinus urogenitalis, which by this time is formed out of the ventral part of the cloaca (see p. 128) without actually opening into it for some time. The Müllerian ducts fuse together below into a single tube (fourth month); the fusion begins not at the lower end,

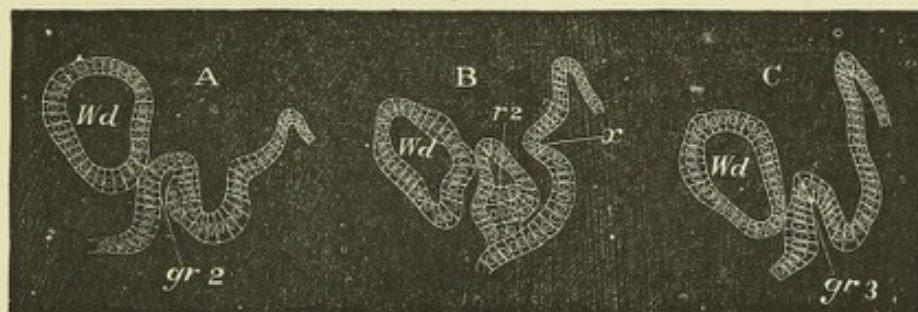
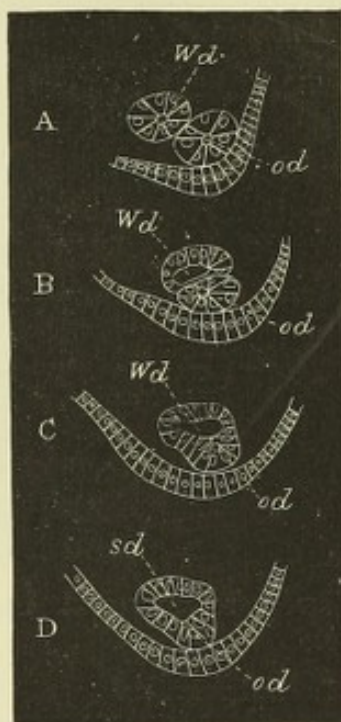


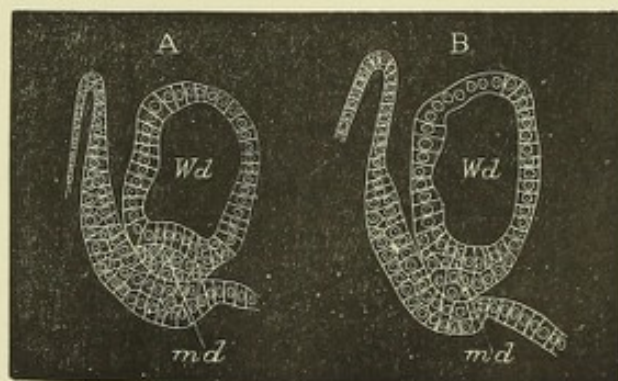
Fig. 148.—SECTIONS FROM THE CHICK SHOWING TWO OF THE PERITONEAL INVAGINATIONS WHICH GIVE RISE TO THE ANTERIOR PART OF THE MÜLLERIAN DUCT. (Balfour and Sedgwick.)

*gr*², second invagination; *gr*³, third invagination; *r*², epithelial ridge between them; *Wd*, Wolffian duct. These structures form the pronephros of Balfour and Sedgwick (see note, p. 115).

Fig. 149.—TWO SECTIONS FROM THE CHICK SHOWING THE JUNCTION OF THE TERMINAL SOLID PORTION OF THE MÜLLERIAN DUCT WITH THE WOLFFIAN DUCT. (Balfour and Sedgwick.)

In A, the terminal portion of the duct is quite distinct; in B it has united with the wall of the Wolffian duct. *md*, Müllerian duct; *Wd*, Wolffian duct.

but a short distance away from this (fig. 150, 3), and proceeds both downwards towards the future orifice and upwards for a



¹ A name given to the thickened mass of tissue which surrounds the Wolffian ducts as they course together to the cloaca behind the stalk of the allantois (afterwards the base of the bladder).

certain length, the amount of this upward extension of the fused ducts varying in different animals.

The united part of the Müllerian ducts afterwards forms the foundation of the vagina and uterus in the female, and the prostatic vesicle, or uterus masculinus in

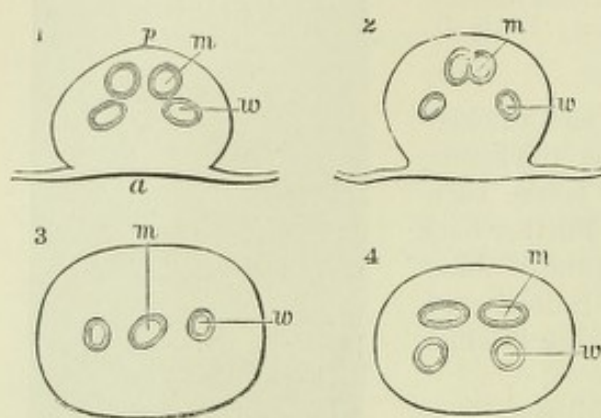


Fig. 150.—TRANSVERSE SECTIONS OF THE GENITAL CORD IN A FEMALE CALF EMBRYO. MAGNIFIED FOURTEEN DIAMETERS. (Köl liker.)

1, near the upper end ; 2 and 3, near the middle ; 4, at the lower end ; a, anterior, p, posterior aspect ; m, Müllerian ducts united or separate ; w, Wolffian ducts.

the male ; the upper or fore part of the Müllerian duct disappears in the male, in the female it forms the oviduct (Fallopian tube).

The hydatids of Morgagni are believed to represent in the male the remnant of part of the Müllerian duct.

In the human embryo of the third month the uterus is bifid, and it is by the upward extension of the median fusion that the triangular body of the uterus is produced. The bifid condition corresponds with the bicorned uterus of many animals, and the process of fusion above described explains the occasional malformation of a partial or complete division of the uterus and vagina into two passages. Up to the fifth month there is no distinction between vagina and uterus. Then the os uteri begins to be seen, and the cervix uteri subsequently becomes manifest as a part, which is at first thicker and larger than the rest of the organ.

In some animals the prostatic vesicle of the male is prolonged into cornua and tubes like the uterus of the female.

The germinal epithelium.—This name was given by Waldeyer to the thickened epithelium lying along the inner side of the Wolffian projection (fig. 143, a). The cells become at first columnar, and then two, three, or even several layers thick, while at the same time the mesoblast below them becomes increased in amount, and thus a marked projection is produced, which in some vertebrates forms a distinct ridge—the *genital ridge*. Amongst the cells of the germinal epithelium, some are seen which are larger and more spherical than the others, these are the *primordial ova* (fig. 143, o), and occur in both sexes ; in fact, up to a certain point, the difference of sex of the embryo is not apparent.

Development of the ovary.—In the female sex the germinal epithelium soon becomes much thickened, and begins to grow down into the mesoblastic stroma in the form of columns of epithelium cells, which enclose amongst them some of the primordial ova.¹ These columns constitute the *egg-tubes* of Pflüger (fig. 152). They are separated from one another by mesoblast, which grows towards and into the germinal epithelium simultaneously with the down-growth of the egg-tubes, and there is thus produced a complete interlocking of strands of connective and epithelial tissue, which together constitute the ovary. The egg-tubes next become broken up into rounded groups or “nests” of germinal epithelial cells, each of which may enclose one or more primordial ova. The primordial ova eventually develop into ordinary ova, two or more frequently fusing together to form a single ovum (Balfour), while from the remaining cells in the “nest” the epithelium of the Graafian follicle is eventually produced. In many of the cell nests, primordial ova cannot at first be

¹ Mihalkovics states that the cells which are to form the follicular epithelium first sink into the stroma, and that afterwards the primordial ova follow them, and become enclosed by them.

distinguished, but become formed subsequently by an increase in size of one or more of the cells. The further changes which take place in the Graafian follicle are described with the structure of the ovary (*v. Splanchnology*). The remainder of




Fig. 151.—TRANSVERSE SECTION THROUGH THE OVARY OF AN EMBRYO SHARK (*SCYLLIUM*), SHOWING THE GERM-EPITHELIUM FORMING PRIMITIVE OVA. (Balfour.)

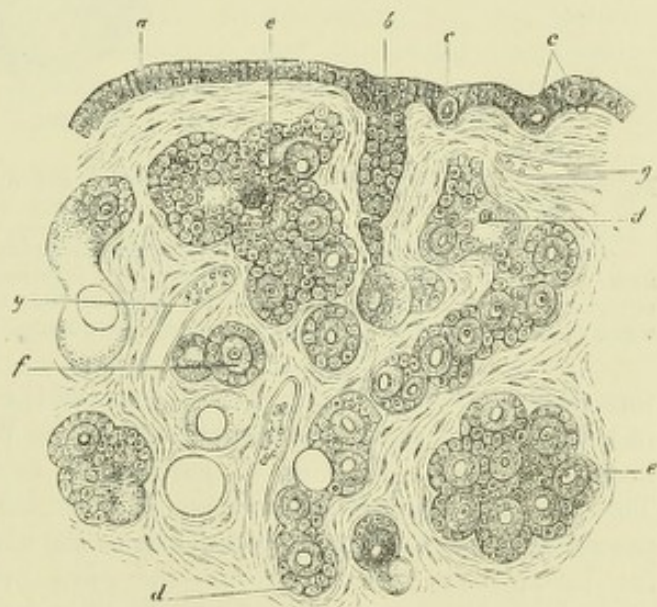
At *po*, the germ-epithelium and primitive ova; the lightly-shaded part is the ovarian stroma, covered elsewhere by flattened epithelium.

the germinal epithelium which is left covering the surface after the formation of the egg-tubes, constitutes the permanent epithelium of the ovary.

Most, if not all, of the permanent ova are produced, at least in the human subject, long before birth. In the human ovary the nests of cells which are to form the Graafian follicles

Fig. 152.—SECTION OF THE OVARY OF A NEWLY-BORN CHILD. HIGHLY MAGNIFIED. (Waldeyer.)

a, Germinal epithelium dipping in at *b*, to form an ovarian tube; *c, c*, primordial ova lying in the germ-epithelium; *d, d*, longer tube becoming constricted so as to form nests of cells; *e, e*, larger nests; *f*, distinctly formed follicle with ovum and epithelium; *g, g*, blood-vessels.



are more equally diffused through the substance of the ovary than in most animals, in many of which the young follicles remain forming a stratum near the surface. In the human embryo of from four months up to the period of birth, the ovary seems to be formed of little else than a mass of young ova, closely surrounded by flattened cells of the germinal epithelium and constituting thus minute Graafian follicles; the amount of stroma being at this time relatively small. It has been calculated that the ovaries may at this stage contain as many as 70,000 primordial ova.

Development of the Testicle.—The germinal epithelium does not undergo so marked an hypertrophy in the male as in the female. But it becomes thickened, and enlarged cells, corresponding to the primordial ova in the female, are found in it. Further, small strands of the epithelium dip down into the subjacent mesoblast,

which grows simultaneously into the epithelium, and eventually cell-nests are separated and included in the mesoblastic tissue. Whether these nests are derived from the division of the primordial ova only, or whether they also include other cells of the germinal epithelium is not clear. It would appear that from these cell-nests the epithelium of the seminiferous tubules is developed, although all stages of the process have not been observed. The cell-nests eventually become connected with the outgrowths from the Wolffian bodies (fig. 153, *st*), which as already mentioned,

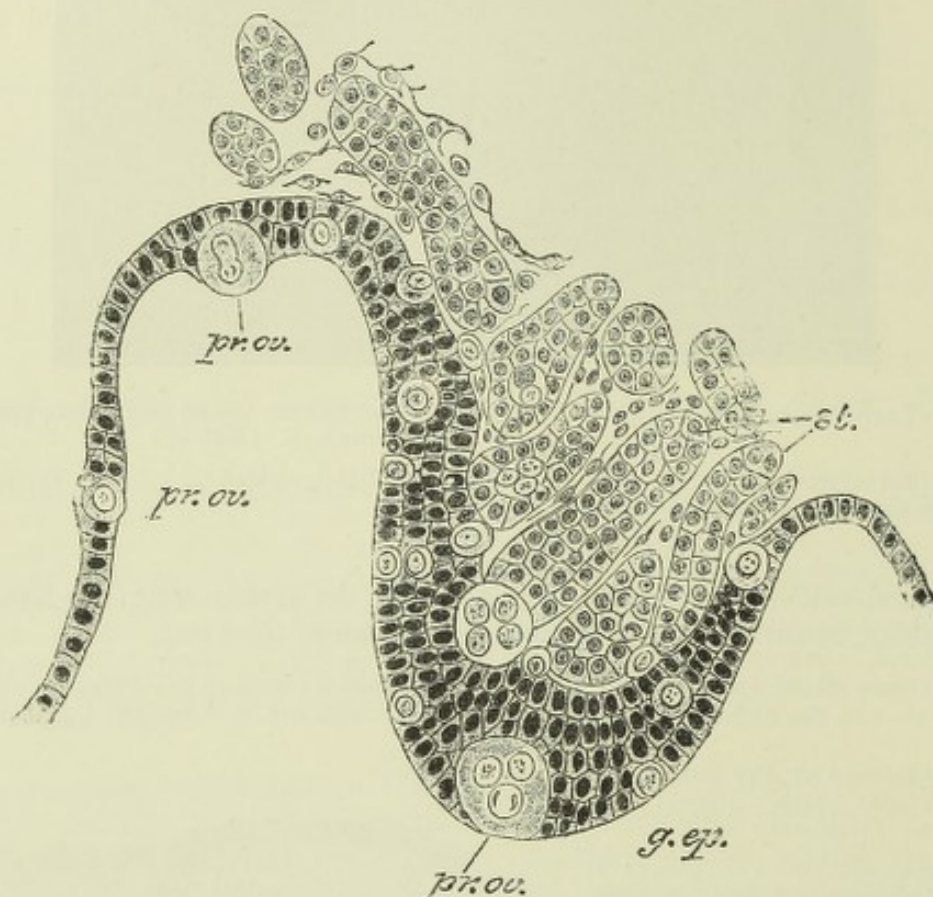


Fig. 153. —SECTION OF THE GERMINAL EPITHELIUM AND ADJACENT STROMA IN A MALE CHICK EMBRYO. (Semon.)

g. ep., germinal epithelium forming a thickened ridge-like projection; *pr. ov.*, primitive ova of various sizes, some in the germinal epithelium and others somewhat beyond the limit of this epithelium; *st.*, strands of cells which have grown from the Wolffian body towards the germinal epithelium, and one of which appears connected with an enlarged primitive ovum.

form the rete testis and the efferent tubes of the testicle. The reproductive gland is in both sexes at first attached directly to the Wolffian body (fig. 156, A, *ot*), which itself is attached by a fold of peritoneum to the back of the abdominal cavity. This fold becomes the *mesovarium* or *mesorchium* as the case may be. A band also passes from the Wolffian body upwards to the diaphragm, and another fold containing involuntary muscular fibres—the *plica gubernatrix*—runs down towards the groin from the lower part of the Wolffian body and the duct. This band, as the Wolffian body becomes atrophied, is found to be attached to the reproductive organ, constituting the *gubernaculum testis* in the male, and the *round ligament of the ovary* in the female (fig. 156, *g*).

Descent of the Testicles.—The testicles originally lie in the lumbar region of the abdomen. From this part they become shifted, at first to the intestinal abdominal ring, opposite which they are found in the sixth month, and which they enter in the seventh month, then down the inguinal canal into the scrotum, which

they usually enter by the end of the eighth month. But previously to this, a pouch of peritoneum—the *processus vaginalis*—has descended into the scrotum along the abdominal ring, pushing before it part of the internal oblique muscle and the aponeurosis of the external oblique, which form respectively the cremasteric muscle

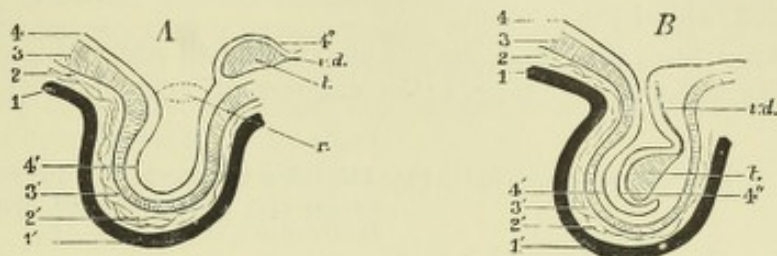


Fig. 154.—DIAGRAMS TO ILLUSTRATE THE DESCENT OF THE TESTICLE AND THE FORMATION OF ITS COVERINGS. (O. Hertwig.)

In A the testicle is lying close to the internal abdominal ring. In B it has passed into the sac of the tunica vaginalis. 1, skin of abdomen; 1', skin of scrotum; 2, superficial abdominal fascia; 2', Cooper's fascia; 3, muscular and aponeurotic layer of abdominal wall; 3', cremaster muscle and spermatic fascia; 4, peritoneum; 4', processus vaginalis; 4'', visceral layer of processus vaginalis covering testicle; t, testicle; v.d., vas deferens; r, internal abdominal ring.

and spermatic fascia (fig. 154). This pouch, after the descent of the testicle into it, becomes shut off from the abdominal cavity, and forms the cavity of the tunica vaginalis. The descent of the testicle into the scrotum is intimately connected with changes in the gubernaculum. The gubernaculum extends, as before mentioned, from the integument of the groin, which afterwards forms the scrotum, upwards through the abdominal ring to the lower part of the epididymis. When the processus vaginalis is formed, the gubernaculum lies behind the serous sac. The descent of the testicle is accompanied by a shortening of the gubernacular cord, which thus *appears* to draw the organ downwards into the scrotum, and the testicle following the line originally taken by the gubernacular cord, also passes down along the posterior wall of the processus vaginalis, which it therefore invaginates from behind.

In many animals the testicles remain throughout life in the abdominal cavity. In others they only descend into the scrotum during the period of "heat." Cases of cryptorchismus, in which one or both testicles have failed to reach the scrotum, and have remained either in the inguinal canal or within the abdominal cavity, are not unfrequent in the human subject.

The ovaries also undergo a considerable change of position, accompanied by a shortening of the band which corresponds with the gubernaculum testis in the male. This band, as it passes by the united part of the Müllerian ducts which are forming the body of the uterus, becomes attached laterally to that organ, and the descent of the ovary is normally arrested at the side of the uterus. In rare cases, however, the ovaries pass through the abdominal ring by the canal of Nuck, and may even be found in the labia majora, where they resemble in position the testicles within the scrotum.

The External Organs.—The external organs are up to a certain time entirely of the same form in both sexes, and the several organs which afterwards distinguish the male and female externally have a common origin (see fig. 155). A cloaca exists till after the fifth week, and the genital eminence from which the clitoris or penis is formed makes its appearance in the course of the fifth or sixth week in front of and within the orifice of the cloaca. In the course of the seventh and eighth weeks this orifice is seen to be divided into two parts; but the exact manner in which the separation of the two apertures takes place has not been accurately traced. The process

is connected with the formation of the urogenital cord as an independent structure, and results in the division of the cloaca into a dorsal or anal and a ventral or urogenital part (*urogenital sinus*). Somewhat later, in the ninth or tenth week, a transverse integumental band completes the division, which band forms the whole of the perineum of the female, and the part of the perineal integument in the male which is situated behind the scrotum.

Of the two apertures the dorsal one or anus is of small size, and is surrounded by a small circular integumental ridge; the anterior or urogenital aperture forms a

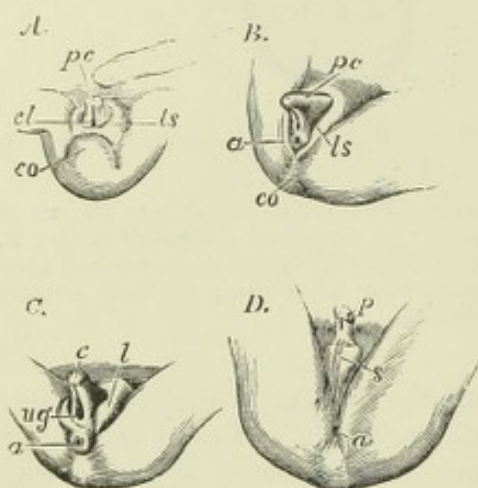


Fig. 155.—DEVELOPMENT OF THE EXTERNAL SEXUAL ORGANS IN THE MALE AND FEMALE FROM THE INDIFFERENT TYPE. (Ecker.)

A, the external sexual organs in an embryo of about nine weeks, in which external sexual distinction is not yet established, and the cloaca still exists; B, the same in an embryo somewhat more advanced, and in which, without marked sexual distinction, the anus is now separated from the urogenital aperture; C, the same in an embryo of about ten weeks, showing the female type; D, the same in a male embryo somewhat more advanced. Throughout the figures the following indications are employed; *pc*, sexual eminence (penis or clitoris); to the right of these letters in A, the umbilical cord; *p*, penis; *c*, clitoris; *cl*, cloaca; *ug*, urogenital opening; *a*, anus; *ls*, cutaneous elevation which becomes labium or scrotum; *l*, labium; *s*, scrotum; *co*, caudal or coccygeal elevation.

narrow vertical slit wider behind than before, and running forward as a furrow into the rudiment of the penis, or clitoris.

The well marked eminence in the integument which forms this rudiment, at first indifferent in the two sexes, is surrounded by a deep circular fold of the integument which encompasses its base, and which is the foundation of the *mons veneris* and *labia majora* in the female, and when united by median fusion, of the *scrotum* in the male. The lips of the urogenital furrow, which in the female are converted into the *nymphæ*, and in the male unite as the integument below the penis, are both at first precisely the same in all embryos. In the open condition, which continues until the eleventh or twelfth week, the parts appear alike in both sexes, and resemble the more advanced female organs. The rudiments of *Bartholin's* or *Cowper's glands* appear at an early period as involutions of epithelium, near the root of the rudimentary clitoris or penis, on each side of the genito-urinary passage.

In the female, the outer circular fold of integument enlarges at the sides so as to cover the clitoris as the *labia majora*. The clitoris itself remains relatively small, and the groove on its under surface becomes less and less marked, owing to the opening out, and subsequent extension backwards, of its margins to form the *nymphæ*. The vascular bulbs, sunk more deeply in the tissues than in the male organ, remain distinct and separate, except at one point where they run together in the *glans clitoridis*. The *hymen* begins to appear about the fifth month as a fold of the lining membrane at the opening of the genital passage into the urogenital sinus. Within the vestibule, which is the shortened but widened remains of the urogenital sinus, the urethral orifice is seen, the urethra itself undergoing considerable elongation.

In the male, on the contrary, the *penis* continues to enlarge, and the margins of the groove along its under surface gradually unite from the primitive urethral orifice behind, as far forwards as the *glans*, so as to complete the long canal of the male *urethra*, which is therefore a prolongation of the urogenital sinus. This is accomplished about the fifteenth week. When the union remains incomplete, the abnormal

condition named *hypospadias* is produced. In the meantime the *prepuce* is formed, and, moreover, the lateral cutaneous folds also unite from behind forwards, along the middle line or *raphé*, and thus complete the *scrotum*, into which the testicles descend in the course of the eighth month of foetal life, as before described.

The corpora cavernosa, which are at first separate, become united in their distal portions in both sexes ; but the corpus spongiosum urethræ which is also originally divided in all embryos, and in the female remains so in the greater part of its extent, becomes enlarged in the male in the glans penis, and its two parts become united mesially both above and below the urethra, so as to enclose the whole of that tube from the bulb forwards to the glans.

The following Table and Diagrams exhibit the corresponding parts of the urino-generative organs in the two sexes :—

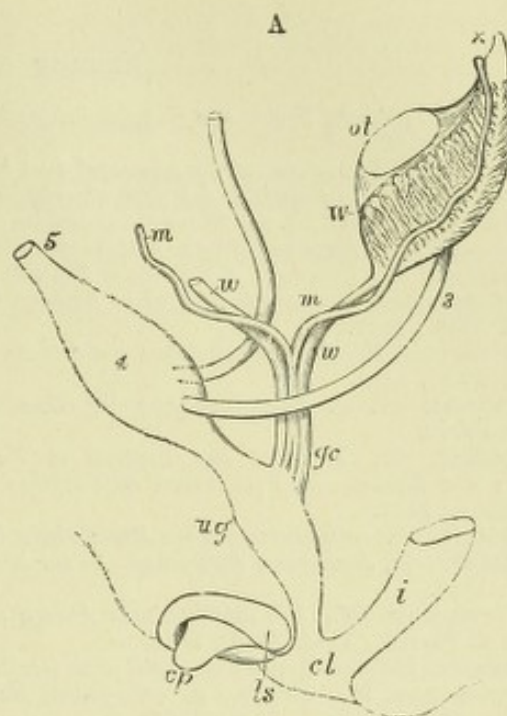
TABLE OF CORRESPONDING PARTS OF THE GENITO-URINARY ORGANS OF THE TWO SEXES, AND THE EMBRYONIC ORGANS FROM WHICH THEY ARE DEVELOPED.

| | EMBRYONIC ORGAN. | FEMALE ORGAN. | MALE ORGAN. |
|-------------------|---|--|--|
| GENITAL RIDGE. | | | |
| | Germinal epithelium | Graafian follicles and ova | Epithelium of seminiferous tubules. |
| | Mesoblast of ridge | Stroma of ovary | Connective tissue of testicle. |
| MÜLLERIAN DUCT. | | | |
| | Superior extremity | Fimbriated extremity of Fallopian tubes | Hydatids of Morgagni. |
| | Middle part | Fallopian tubes | Cornua uteri masculini, which sometimes occur. |
| | Inferior united part..... | Uterus and vagina | Uterus masculinus. |
| WOLFFIAN BODY. | | | |
| | Superior tubes | Smaller tubes of epoophoron (parovarium) | Vasa efferentia and coni vasculosi. |
| | Inferior tubes | Paroophoron | Paradidymis (organ of Giraldès). |
| | Outgrowths from upper { Malpighian corpuscles... } | Interstitial cells near hilum of ovary | Walls of seminiferous tubules (?) and rete testis. |
| WOLFFIAN DUCT. | | | |
| | Superior and middle parts ... | Main tube of epoophoron | Epididymis. |
| | Inferior part | Duct of Gartner | Vas deferens. |
| | Outgrowths from posterior part | Ureter : and uriniferous tubules of kidney (?) ... | Ureter : and uriniferous tubules of kidney (?) . |
| UROGENITAL SINUS. | | | |
| | Upper part | Urethra | Prostatic portion of urethra as far as verumontanum. |
| | Lower part | Vestibule..... | Lower prostatic and membranous part of urethra. |
| | Epithelial involutions on { either side of sinus | Glands of Bartholin | Glands of Cowper. |
| | Genital eminence and folds... | Clitoris and nymphæ | Penis. |
| | Integument on either side { of orifice of sinus | Labia majora .. | Scrotum. |

Fig. 156.—DIAGRAMS TO SHOW THE DEVELOPMENT OF MALE AND FEMALE GENERATIVE ORGANS FROM A COMMON TYPE. (Allen Thomson.)

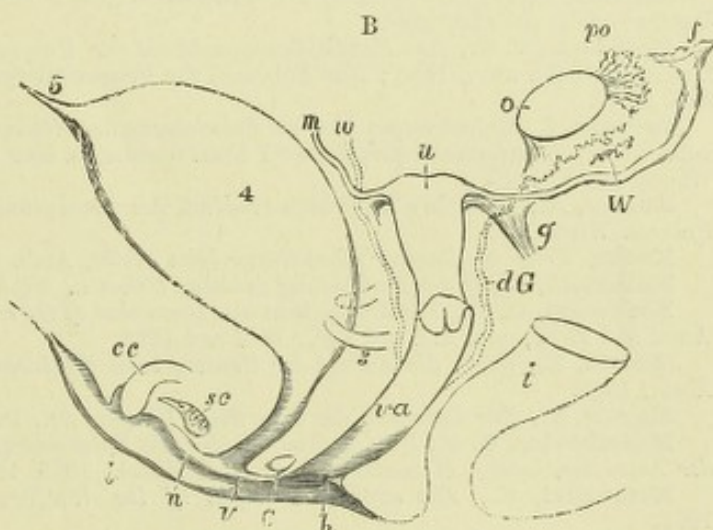
A.—DIAGRAM OF THE PRIMITIVE URO-GENITAL ORGANS IN THE EMBRYO PREVIOUS TO SEXUAL DISTINCTION.

3, ureter; 4, urinary bladder; 5, urachus; *ot*, the genital ridge from which either the ovary or testicle is formed; *W*, left Wolffian body; *w.w.*, right and left Wolffian ducts; *m.m.*, right and left Müllerian ducts uniting together and running with the Wolffian ducts in *gc*, the genital cord; *ug*, sinus urogenitalis; *i*, lower part of the intestine; *cl*, cloaca; *cp*, elevation which becomes clitoris or penis; *ls*, fold of integument from which the labia majora or scrotum are formed.



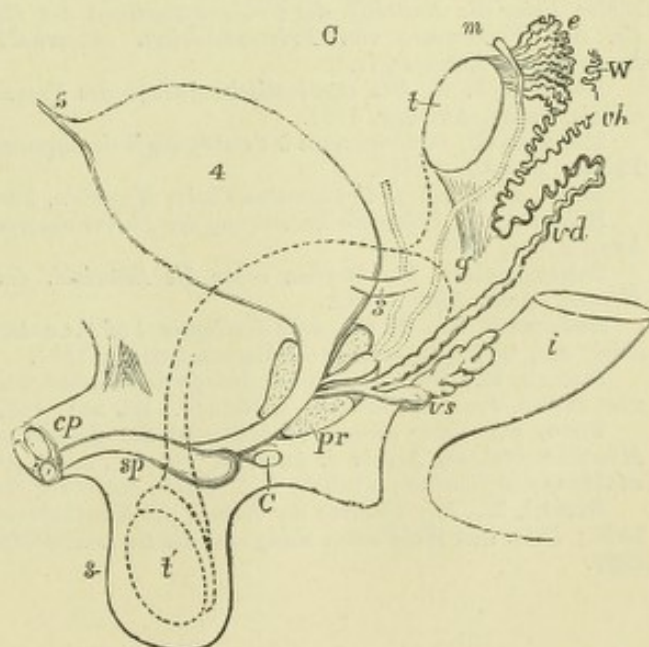
B.—DIAGRAM OF THE FEMALE TYPE OF SEXUAL ORGANS.

o, the left ovary; *po*, parovarium (epoophoron of Waldeyer); *W*, scattered remains of Wolffian tubes near it (paroophoron of Waldeyer); *dG*, remains of the left Wolffian duct, such as give rise to the duct of Gartner, represented by dotted lines; that of the right side is marked *w*; *f*, the abdominal opening of the left Fallopian tube; *u*, uterus; the Fallopian tube of the right side is marked *m*; *g*, round ligament, corresponding to gubernaculum; *i*, lower part of the intestine; *va*, vagina; *h*, situation of the hymen; *C*, gland of Bartholin (Cowper's gland), and immediately above it the urethra; *cc*, corpus cavernosum clitoridis; *sc*, vascular bulb or corpus spongiosum; *n*, nympha; *l*, labium; *v*, vulva.



C.—DIAGRAM OF THE MALE TYPE OF SEXUAL ORGANS.

t, testicle in the place of its original formation; *c*, caput epididymis; *vd*, vas deferens; *W*, scattered remains of the Wolffian body, constituting the organ of Giraldès, or the paradidymis of Waldeyer; *vh*, vas aberrans; *m*, Müllerian duct, the upper part of which remains as the hydatid of Morgagni, the lower part, represented by a dotted line descending to the prostatic vesicle, constitutes the occasionally existing cornu and tube of the uterus masculinus; *g*, the gubernaculum; *vs*, the vesicula seminalis; *pr*, the prostate gland; *C*, Cowper's gland of one side; *cp*, corpora cavernosa penis cut short; *sp*, corpus spongiosum urethrae; *s*, scrotum; *t'*, together with the dotted lines above, indicates the direction in which the testicle and epididymis descend from the abdomen into the scrotum.



RECENT LITERATURE.

- Ackeren, F. v., *Beitr. sur Entwicklungsgeschichte d. weiblichen Sexualorgane des Menschen*, Zeitschr. f. wiss. Zool., 1889.
- Beard, J., *The origin of the segmental duct in Elasmobranchs*, Anat. Anzeiger, 1887.
- Benda, C., *Die Entwickl. des Säugethierhodens*, Verhandl. der anatom. Gesellschaft, 1889.
- Bierfreund, M., *Ue. die Einmündungsweise der Müller'schen Gänge in d. Sinus urogenitalis bei dem menschlichen Embryo*, Zeitsch. f. Geburtshülfe u. Gynäk., xvii.
- Bonnet, R., *Ueber die ektodermale Entstehung des Wolff'schen Ganges bei den Säugethieren*, Münchener med. Wochenschr., 1887; *Embryologie der Wiederkäufer*, Arch. f. Anat. u. Physiol., Anat. Abth., 1889.
- Bramann, F., *Beitrag zur Lehre von dem Descensus testicularum, &c.*, Arch. f. Anat. u. Physiol., Anat. Abth., 1884.
- Brandt, Ue. d. Zusammenhang der Glandula suprarenalis mit dem Parovarium, &c., Biol. Centralbl. lx.
- Cadiat, O., *Mémoire sur l'utérus et les trompes (développement)*, Journ. de l'anatomie, 1884; *Du développement du canal de l'urètre et des organes génitaux de l'embryon*, Journ. de l'anatomie, 1884.
- Dohrn, *Ueber die Gartner'schen Kanäle beim Weibe*, Arch. f. Gynäkologie, xxi., 1883.
- Emery, C., *Recherches embryologiques sur le rein des mammifères*, Archives italiennes de biologie, t. iv., 1883.
- Flemming, W., *Die ektoblastische Anlage des Urogenitalsystems beim Kaninchen*, Archiv. f. Anat. u. Physiol., Anat. Abth., 1886.
- Gasser, *Embryonalreste am männlichen Genitalapparat*, Marburg. Sitzungsber., 1882.
- Gottschau, M., *Struktur u. embryonale Entwickl. der Nebennieren bei Säugethieren*, Arch. f. Anat. u. Physiol., Anat. Abth., 1883.
- Haddon, *Suggestion respecting the epiblastic origin of the segmental duct*, Proceed. of the Royal Dublin Society, Feb. 16, 1887.
- Hoffmann, C. K., *Zur Entwicklungsgeschichte der Urogenitalorgane bei den Anamnia*, Zeitschr. f. wiss. Zool., Bd. xlv., 1886; *Zur Entwickl. der Urogenitalorgane bei den Reptilien*, Zeitschr. f. wiss. Zool. xlviii.
- Janosik, I., *Bemerkungen über die Entwicklung der Nebenniere*, Archiv. f. mikrosk. Anatomie, Bd. xxii., 1883; *Histologisch-embryologische Untersuchungen über das Urogenital-system*, Sitzungsber. d. Wiener Akad., 1885.
- Kallay, A., *Die Niere im frühen Stadium des Embryonallebens*, Mitth. aus d. embryol. Inst. d. Univers. Wien, 1885.
- Kocks, *Ueber die Gartner'schen Gänge beim Weibe*, Arch. f. Gynäkologie, xx., 1883.
- Kollmann, *Ueber die Verbindung zwischen Cölon u. Nephridium*, Festschrift. Basel, 1882.
- Lockwood, C. B., *The development and transition of the testis, normal and abnormal*, Journal of Anat. and Phys., vols. xxi. and xxii., 1887 and 1888.
- Martin, E., *Ueber die Anlage der Urniere beim Kaninchen*, Archiv. f. Anat. u. Physiol., Anat. Abth., 1888.
- Martin, P., *Zur Entwickl. der cavernösen Körper, &c.*, Deutsche Zeitschr. f. Thiermed., xvi.
- Mihalkovics, G. v., *Untersuchungen über die Entwicklung des Harn- und Geschlechtsapparates der Amnioten*, Intern. Monatsschr. f. Anat. u. Histol., 1885, 1886.
- Mitsukuri, K., *The ectoblastic origin of the Wolffian duct in Chelonia*, Zool. Anzeiger, 1888.
- Nagel, *Ueber den Wolff'schen Körper des menschl. Embryo*, Zeitschr. f. Geburtshülfe u. Gynäk., 1889; *Ueber die Entwickl. des Urogenitalsystems des Menschen*, Arch. f. mikr. Anat., xxxiv., 1889; *Ue. das Vorkommen von Primordialeiern ausserhalb der Keimdrüsenanlage beim Menschen*, Anatomischer Anzeiger, iv.
- Perényi, J. v., *Die ektoblastische Anlage des Urogenitalsystems bei Rana esculenta und Lacerta viridis*, Zoolog. Anzeiger, 1887.
- Renson, G., *Contributions à l'embryologie des organes d'excrétions des oiseaux et des mammifères*, Thèse. Bruxelles, 1883.
- Roth, *Ueber einige Urnierenreste beim Menschen*, Festschrift. Basel, 1882.
- Rückert, J., *Ueber die Entstehung der Excretionsorgane bei Selachiern*, Arch. f. Anat. u. Physiol., Anat. Abth., 1888.
- Schmiegelow, E., *Studien ueber die Entwickl. des Hodens u. Nebenhodens*, Arch. f. Anat. u. Physiol., Anat. Abth., 1882.
- Sedgwick, A., *On the early development of the anterior part of the Wolffian duct and body in the chick, &c.*, Quarterly Journal of Microsc. Science, 1881.
- Semon, R., *Die indifferente Anlage der Keimdrüsen beim Hühnchen und ihre Differenzirung zum Hoden*, Jenaische Zeitschr. f. Naturw., Bd. xxi., 1887.
- Spee, F., *Ueber directe Betheiligung des Ektoderms an der Bildung der Urnierenanlage des Meerschweinchens*, Archiv. f. Anat. u. Physiol., Anat. Abth., 1884; *Ueber weitere Befunde zur Entwicklung der Urniere*, Mittheil. f. d. Verein Schleswig-Holstein, 1886.
- Strahl, H., *Zur Bildung der Kloake des Kaninchenembryo*, Archiv. f. Anat. u. Phys., Anat. Abth., 1886; *Ueber den Wolff'schen Gang und die Segmentalbläschen bei Lacerta*, Marburger Sitzungsberichte, 1886.

Tourneux, F., *Sur les premiers développements du cloaque, du tubercule génital, et de l'an us chez l'embryon de mouton*, Journal de l'anatomie, 1888 ; *Sur le développement du tubercle génital chez le fœtus humain, &c.*, Journ. de l'anatomie, xxv. ; *Sur le mode de formation du périnée chez l'embryon du mouton*, Compt. rend. de la Société de Biologie, 1890.

Tourneux, F., et Legay, Ch., *Mémoire sur le développement de l'utérus et du vagin*, Journ. de l'anatomie, 1884.

Weldon, W. F. R., *Note on the origin of the suprarenal bodies of vertebrates*, Proceed. of the Royal Society, vol. 37, 1885 ; *On the suprarenal bodies of vertebrata*, Quarterly Journal of Micr. Science, 1885.

Wieger, G., *Ueber die Entstehung u. Entwickl. der Bänder des weiblichen Genitalapparates, &c.*, Arch. f. Anat. u. Physiol., Anat. Abth., 1885.

Wijhe, J. W. v., *Die Betheiligung des Ektoderms an der Entwicklung des Vornierenganges*, Zool. Anz., 1886.

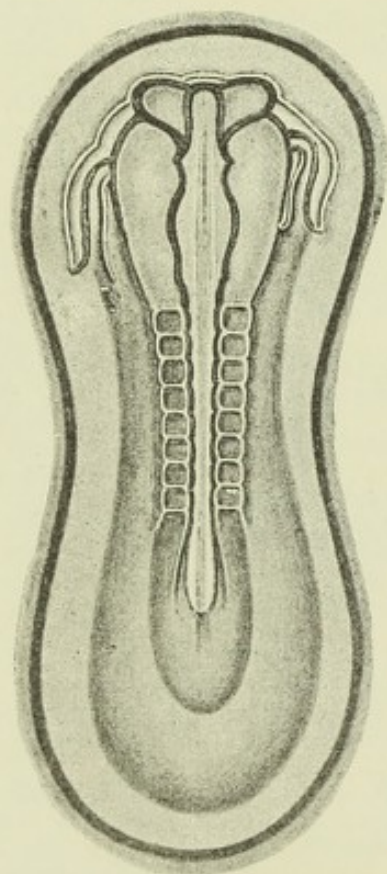
FORMATION OF THE VASCULAR SYSTEM.

DEVELOPMENT OF THE HEART.

In mammals, the heart appears in the form of two tubes lying in the cephalic region, one on either side of the embryo. These are seen at a very early period, prior, in fact, to the separation of any part of the alimentary canal from the yolk sac, and to the closure of the neural groove. This bilateral condition was first observed by Hensen in the rabbit; it has been seen by His in the human embryo.

The situation and mode of formation of the bi-tubular heart are well illustrated by the accompanying figures from Kölliker. They exhibit the condition in the

Fig. 157.—RABBIT EMBRYO OF THE 9TH DAY, FROM THE SURFACE. $\frac{2}{3}$. (Kölliker.)



The medullary groove is enlarged anteriorly and the primary optic vesicles are growing out from the first cerebral enlargement. On either side of the head, the bilateral tubular heart is seen. Eight pairs of protovertebrae are formed.

rabbit embryo of about eight or nine days—the time when the heart first makes its appearance. Fig. 157 shows such an embryo in surface view. The neural groove, as also the sections show, is widely open, although the rudiments of the cerebral enlargements are apparent in it, and also the enlargements for the primary optic vesicles. There are eight pairs of proto-vertebrae, the paraxial mesoblast in front of these and on either side of the cerebral enlargements being undivided. Outside this undivided cephalic mesoblast is a short tube dipping in front into it, and passing behind into a venous trunk, the vitelline or omphalomesenteric vein of the same side. The tube lies within and is immediately surrounded by a clear space, which is continued forwards beyond it on either side of the fore-brain; this space is prolonged from the mesoblastic cleft or pleuro-peritoneal cavity (coelom).

The two short tubes form the double rudiment of the heart. The situation which they occupy becomes, when the lateral walls fold over to form the foregut, the ventral wall of the pharynx, and the two tubes are thus brought together in the middle line underneath the head part of the alimentary canal. Here they soon become fused together to form a single median tube, the hinder end of which is still continuous with the two vitelline veins, while the anterior end bifurcates near the anterior end of the foregut into two branches which arch dorsalwards on either side of that tube, and then pass backwards on each side of the notochord as the two primitive aortae.

These changes in the position of the primitive heart are partly shown in surface view in figs. 158, 159, but they can only properly be appreciated by the study of transverse sections. Fig. 160 is a transverse section through the anterior head region of the embryo shown in fig. 157. This is anterior to the heart region, but shows the commencing folding over of the splanchnopleure to form the foregut.

The mesoblastic cleft (cœlom, *ph*) is somewhat dilated, but is not doubled in, as in the heart region. The lateral mesoblast ceases a short distance beyond it. Fig. 161 is a section through the middle of the head region of the same embryo. Here, while

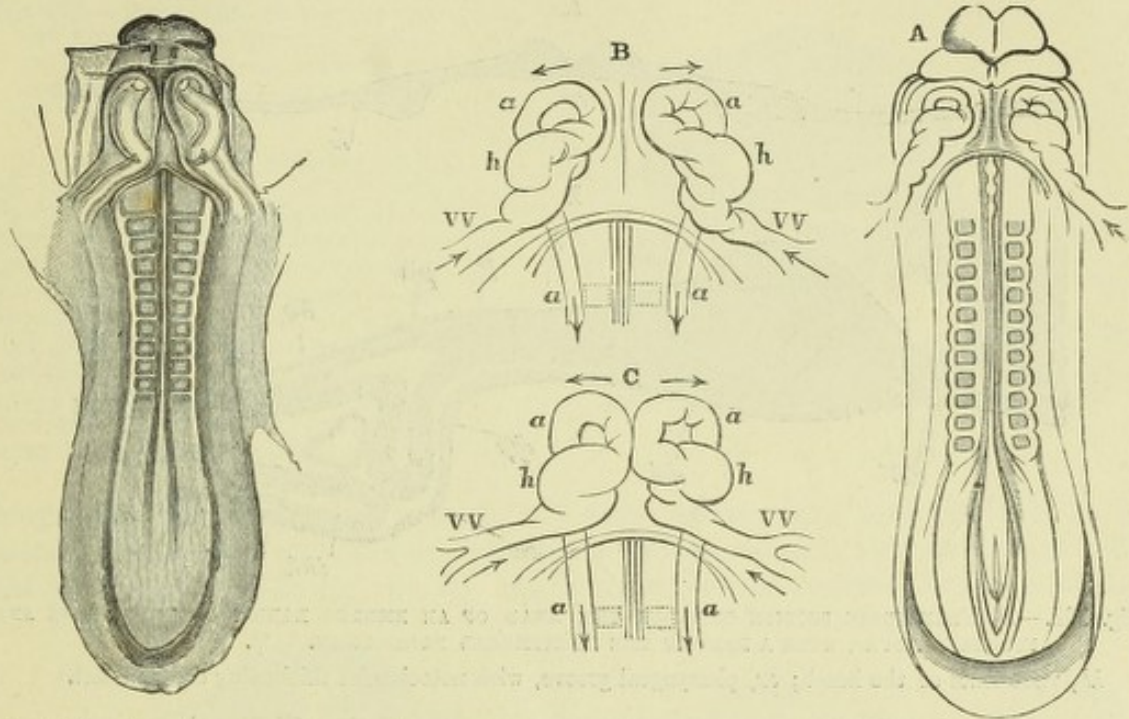


Fig. 158.—EMBRYO RABBIT OF EIGHT DAYS AND EIGHTEEN HOURS, WITH 9 PROTOVERTEBRÆ, VIEWED FROM THE VENTRAL ASPECT. $\frac{2}{1}$. (Kölliker.)

Fig. 159.—SKETCHES SHOWING MORE ADVANCED CONDITION OF THE BITUBULAR HEART OF THE RABBIT. $\frac{2}{1}$. (Allen Thomson.)

A, view from below of an embryo in which the formation of the heart was somewhat more advanced than in fig. 158, and of which an outline of the heart is repeated in B. C, from another embryo, shows the two halves of the heart in the commencement of their coalescence. *h*, the part of the bent tube which becomes the ventricle; *a*, primitive aortic arches and descending aortæ; VV, vitelline veins entering the heart posteriorly. The arrows indicate the course of the blood.

the other parts of the section are much the same as in front, the dilatation of the cœlom, which is in fact the rudiment of the future pericardium, is occupied by an

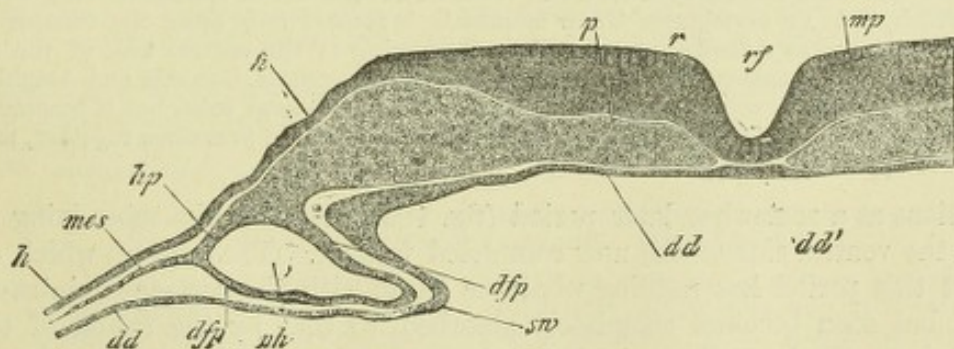


Fig. 160.—SECTION FROM THE SAME EMBRYO FURTHER FORWARD THAN THAT SHOWN IN THE PRECEDING FIGURE. (Kölliker.)

p, paraxial mesoblast; *rf*, medullary groove; *r*, ridge bounding groove; *mp*, medullary plate of hind brain; *h*, epiblast; *hp*, somatopleure; *ddp*, splanchnopleure; *ph*, anterior part of cœlom; *mes*, mesoblast beyond the cœlom; *dd*, hypoblast; *dd'*, notochordal thickening; *sw*, lateral wall of the developing pharynx.

invagination, or fold, of the splanchnic mesoblast. This fold becomes subsequently entirely separated and the aperture or line of invagination closed; it forms the

muscular wall of the heart. It encloses a second tube composed of flattened epithelium cells; this so-called *endothelial tube* (His) becomes the lining epithelium of the endocardium.

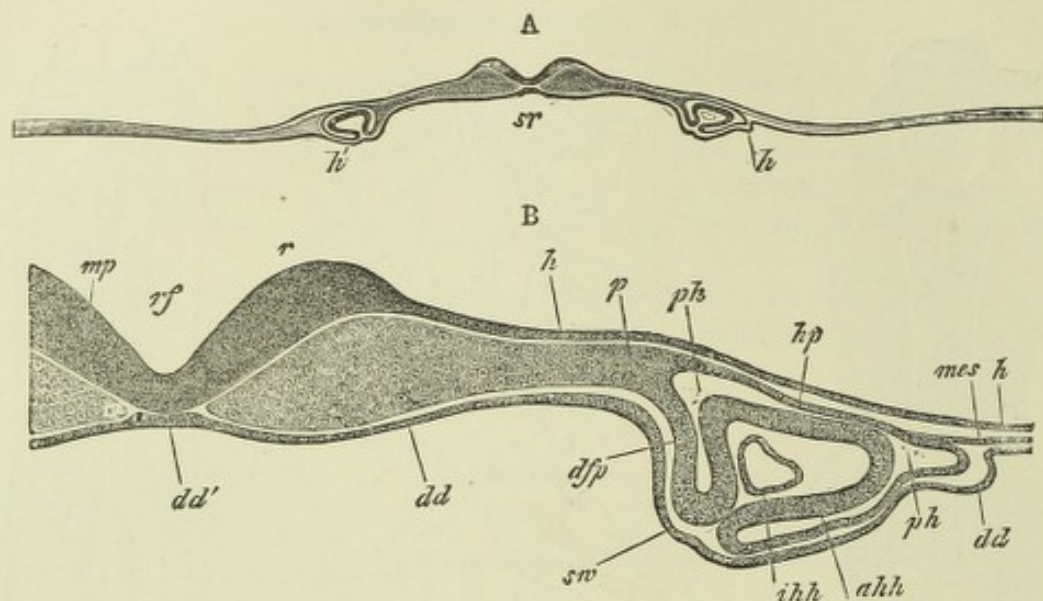


Fig. 161.—A, TRANSVERSE SECTION THROUGH THE HEAD OF AN EMBRYO RABBIT OF EIGHT DAYS AND FOURTEEN HOURS, WITH A PART OF THE PERIPHERAL BLASTODERM. $\frac{1}{2}$. (Kölliker.)

lh, rudiments of the heart; sr, pharyngeal groove, with notochordal thickening of hypoblast.

B.—PART OF THE SAME MORE HIGHLY MAGNIFIED. $\frac{1}{12}$. (Kölliker.)

Lettering as in fig. 160. In addition:—akh, fold of splanchnopleure to form wall of heart; ihh, endothelial tube of heart.

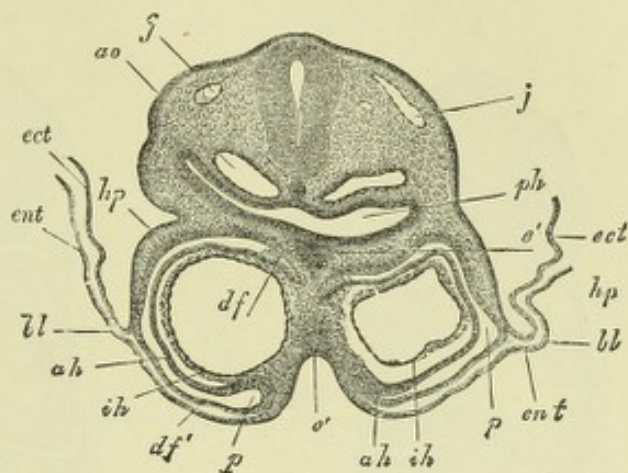
There is some doubt as to the source of this endothelial tube of the heart. In the preceding edition of this work it was stated that it is "derived from the deeper part of the visceral mesoblast;" this statement being apparently founded upon the statements and figures given by Kölliker. His ascribes it, like the endothelium of the blood-vessels, to an ingrowth from the vascular area. The appearance of the section shown in fig. 161 B, seems to lend colour to the belief that the invagination which has taken place to form the heart is not the splanchnic mesoblast only, but has included also the hypoblastic layer of the splanchnopleure; the notch which is seen in the hypoblast near sw, appearing to indicate an interrupted connection with the endocardial tube. Should future investigations show that this is actually the mode of formation of the tube, the mammalian heart would be developed in essentially the same manner as has been shown by Rückert to occur in *Pristiurus* (an Elasmobranch), where this organ, which, as in all vertebrates below mammals, is formed only after the foregut is completed, is developed as a median outgrowth or thickening of the ventral wall of the foregut. A similar mode of formation has also been noticed in Cyclostomata, Ganoids, and Amphibia. In reptiles and birds the first appearance of the heart is as a bilateral tube, but it becomes visible only after the foregut is formed, and the two tubes lie from the first close together, and from the surface appear as a single median tube.

Sections at a somewhat later period (fig. 162) show the two tubes lying in contact on the ventral side of the now completed foregut. The septum which divides them at this period has nothing whatever to do with the permanent intra-cardiac septum, but soon becomes completely absorbed, so that by the fusion of the two lateral tubes a single median tube is the result (fig. 163). This median tube remains attached by a suspensory membrane resembling a mesentery (*mesocardium posterius*) (mp, fig. 163) to the ventral wall of the pharynx, but the *mesocardium anterius*, which also at first results from the fusion, disappears, except at the lower end, and otherwise the tube becomes free, except where the vitelline veins pass to it from the yolk sac, a lateral attachment to the body wall being here subsequently formed on each side (*mesocardium laterale* of Kölliker). After it is thus formed, the heart is for a time median in position and symmetrical (fig. 164, A), but already in the

mammal shows distinct indications of division into its several parts; indeed, these parts are apparent even while the two tubes are still distinct, as the accompanying sketches of the rabbit's heart clearly show (fig. 159). The heart does not, however,

Fig. 162.—TRANSVERSE SECTION THROUGH THE REGION OF THE HEART IN A RABBIT EMBRYO OF NINE DAYS, SHOWING THE COMMENCING FUSION OF THE TWO TUBES. (Kölliker.)

jj, jugular veins; *ao*, descending aortæ; *ph*, pharynx; *hp*, epiblast of body-wall; *ih*, endothelial lining of the still divided heart; *ah*, outer wall of the heart; *p*, pericardial cælom; *df*, *df'*, visceral mesoblast (somatopleure); *e'*, prolongation of the hypoblast of the foregut and the anterior wall of the pericardial cavity into the partition between the two halves of the heart; *bl*, bilaminar portion of blastoderm forming pro-amnion; *ect*, *ent*, its two layers (epiblast and hypoblast).



long retain its symmetrical position. It soon becomes bent upon itself, so as to assume the shape of an S, the anterior part of the tube bending over to the right and the posterior to the left (fig. 164, B). At the same time the posterior, or sino-auricular

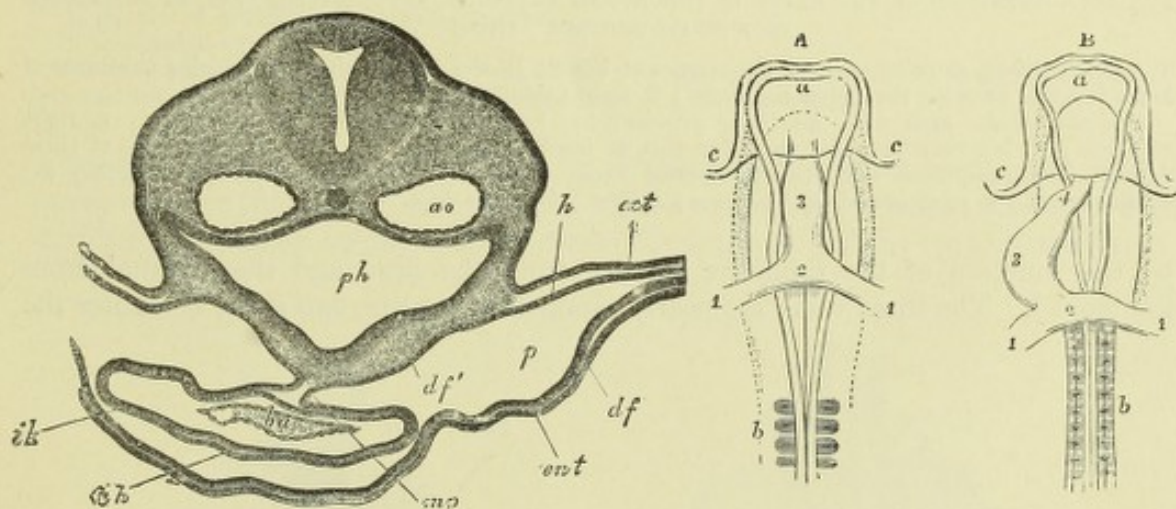


Fig. 163.—SECTION THROUGH THE REGION OF THE HEART IN A RABBIT EMBRYO OF 10 DAYS, AFTER THE TWO TUBES HAVE UNITED INTO A SINGLE MEDIAN ORGAN. (Kölliker.)

ao, descending aortæ; *ba*, bulbus aortæ; *ah*, its external wall; *mp*, posterior mesocardium, uniting the heart to the ventral wall of the pharynx, *ph*, and here separating the pleuropericardial cælom, *p*, into two halves, which are, however, united on the ventral side of the heart; *ent*, hypoblast of yolk sac; *df*, its mesoblast; *df'*, mesoblast of pharynx; *ect*, epiblast.

Fig. 164.—OUTLINES OF THE ANTERIOR HALF OF THE EMBRYO CHICK VIEWED FROM BELOW, SHOWING THE HEART IN ITS EARLIER STAGES OF FORMATION. (After Remak.)

A, embryo of about 28 to 30 hours; B, of about 36 to 40 hours; *a*, anterior cerebral vesicle; *b*, proto-vertebral segments; *c*, cephalic fold; 1, 1, vitelline or omphalo-mesenteric veins entering the heart posteriorly; 2, their union in the posterior part of the heart; 3, the middle part of the tube corresponding to the ventricle; 4 (in B) the arterial bulb.

end of the heart, gradually comes to lie behind or dorsal to the ventricular part, which arches transversely from left to right, where it turns sharply upward (towards the head), and terminates in the bulb. The tube is divided by slight constrictions into successive portions, viz.: (1) the part formed by the junction of the principal veins, sinus venosus; (2) the auricular part; (3) the ventricular part; and (4) the aortic bulb.

The *sinus venosus* may be described as consisting of two lateral enlargements or horns, and of a transverse part connecting these horns. The veins which it at this time receives are the umbilical, the vitelline, and the ducts of Cuvier (formed

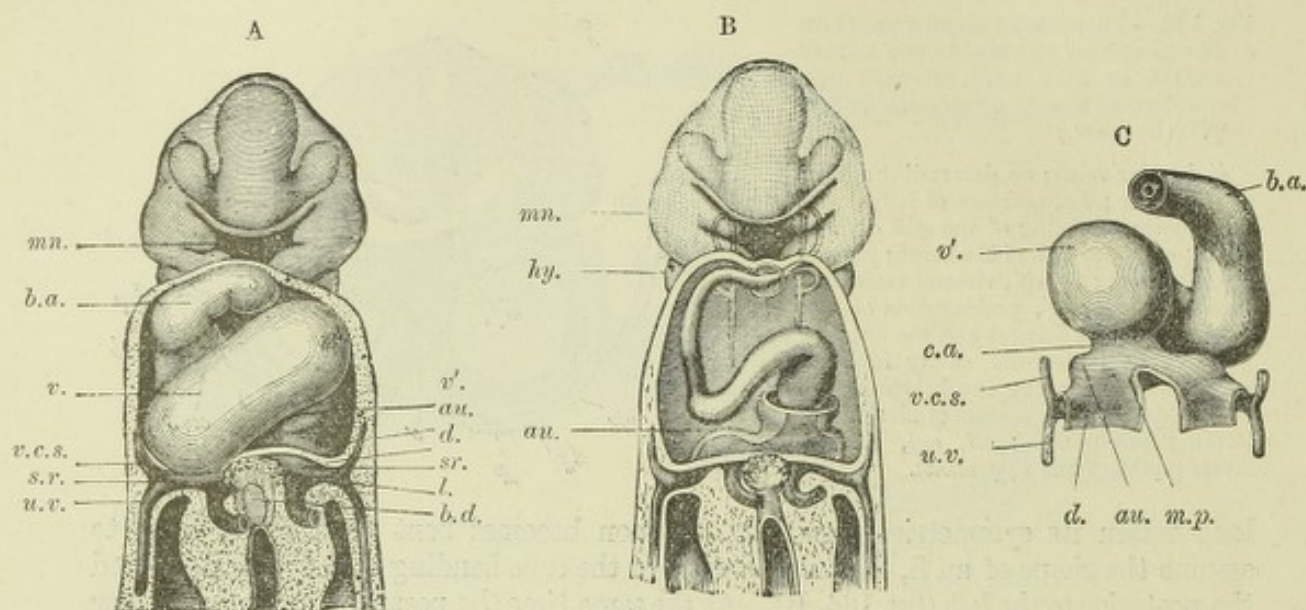


Fig. 165.—CONDITION OF THE HEART IN THE HUMAN EMBRYO OF ABOUT FIFTEEN DAYS, RECONSTRUCTED FROM SERIAL SECTIONS. (His.) 49

A, from before, showing external appearance of heart; B, the same with the muscular substance of heart removed showing the endothelial tube; C, from behind.

mn, mandibular arch with maxillary process; *hy*, hyoidean arch; *b.a.*, bulbus aortæ; *v.*, right ventricle; *v'*, left ventricle; *au.*, auricular part of heart; *c.a.*, canalis auricularis; *s.r.*, horn of sinus venosus with umbilical vein (*u.v.*), superior vena cava (*v.c.s.*), and vitelline vein entering it; *d.*, diaphragm; *m.p.*, mesocardium posterius; *l.*, liver; *b.d.*, bile duct.

by the junction of the primitive jugular from the head and the cardinal from the trunk). The three veins are nearly symmetrical on the two sides, and enter the

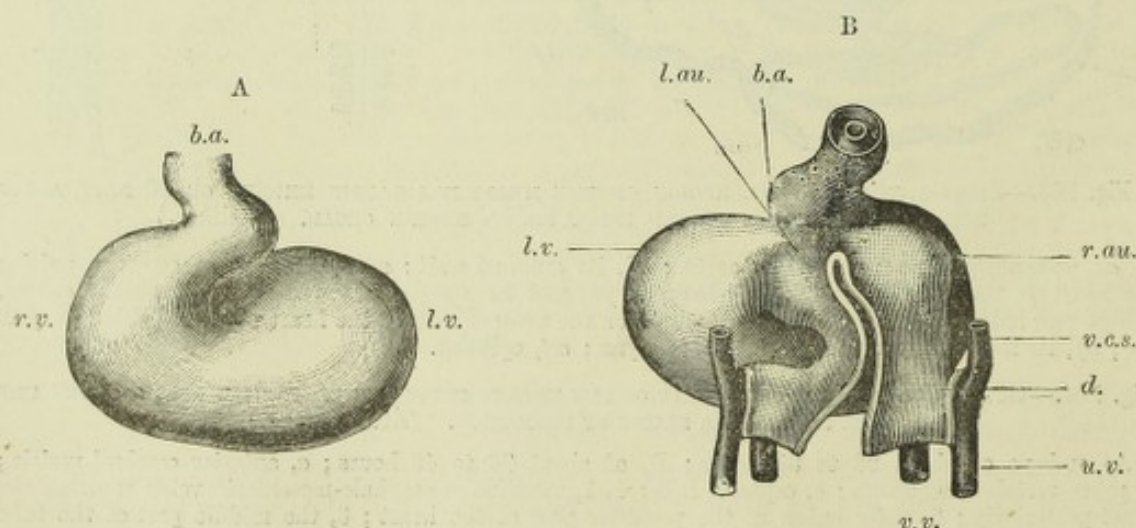


Fig. 166.—HEART OF A SOMEWHAT MORE ADVANCED HUMAN EMBRYO. (His.) 49

A, from before; B, from behind.

r.v., right ventricle; *l.v.*, left ventricle; *b.a.*, bulbus aortæ; *r.au.*, right auricle; *l.au.*, left auricle; *v.c.s.*, vena cava superior; *u.v.*, umbilical vein; *v.v.*, vitelline vein; *d.*, diaphragm.

corresponding horn of the sinus (fig. 168). The sinus is at first in free communication with the common auricular cavity, but the junction presently becomes narrowed, and the resulting aperture, which eventually acquires a slit-like character,

is found to open from the right horn of the sinus into the right part of the common auricle. The sinus now forms a transversely disposed sac, lying below and behind the common auricle, with a larger right and a smaller left horn (the latter being

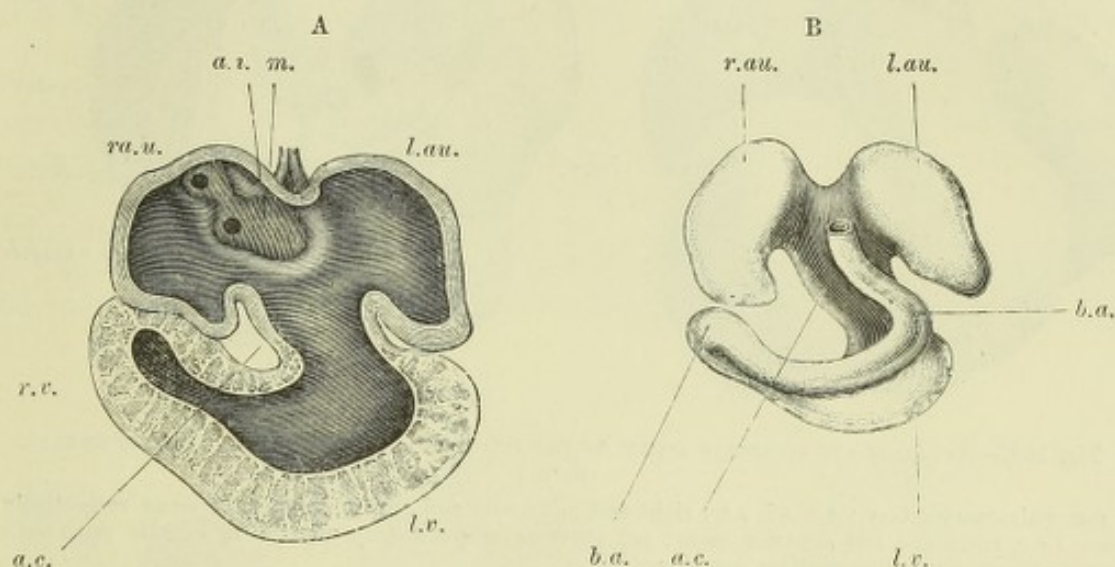


Fig. 167.—HEART OF HUMAN EMBRYO SLIGHTLY MORE ADVANCED THAN THAT SHOWN IN FIG. 166. (His.)

A, interior of auricle and ventricle displayed.

B, endothelial tube.

a.c., auricular canal; a.i., area interposita of His; m., posterior mesocardium; r.au., l.au., right and left auricles; l.v., left ventricle; r.v., right ventricle; b.a., bulbus aortae.

tapered off into the left duct of Cuvier); in this condition it has been termed by His *saccus reuniens* (fig. 169, B, and fig. 171). The umbilical and vitelline veins soon open into it by a common trunk, which becomes the upper end of the vena cava inferior.

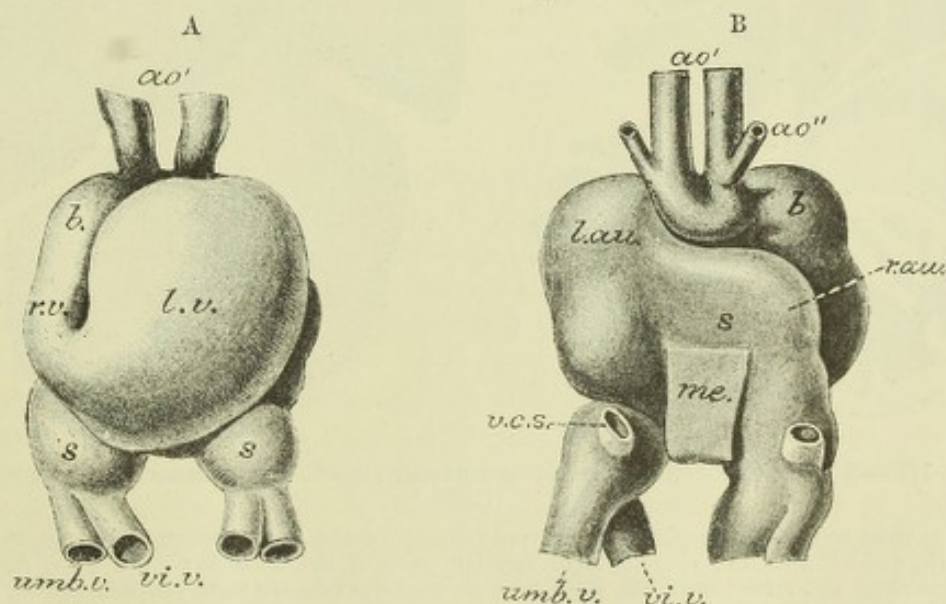


Fig. 168.—HEART OF RABBIT EMBRYO. (Boyd.)

A, from before; B, from behind.

s.s., sinus venosus; l.v., left ventricle; r.v., right ventricle; b., bulbus aortae; ao', first aortic arch; ao'', second aortic arch; r.au., right auricle; l.au., left auricle; umb.v., umbilical vein; vi.v., vitelline vein; v.c.s., vena cava superior.

The slit-like orifice of the sinus in the back of the right auricle is guarded by two valve-like folds of the endocardium, which project into the cavity of the auricle (right

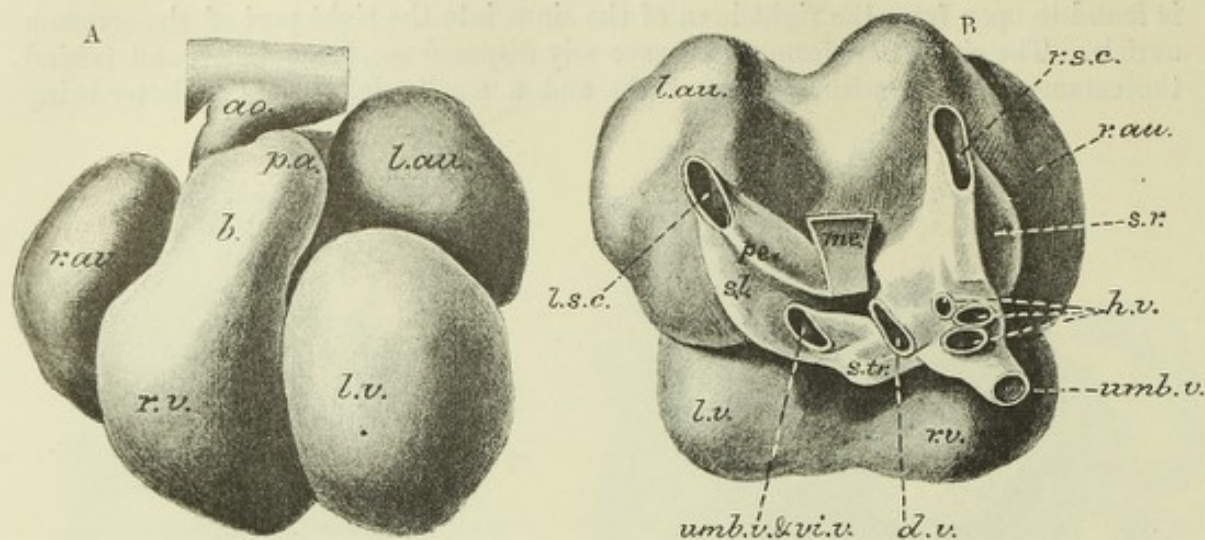


Fig. 169.—ANTERIOR AND POSTERIOR ASPECT OF THE HEART OF A SOMEWHAT OLDER RABBIT EMBRYO. (Born.)

p.a., pulmonary artery; *s.r.*, *s.l.*, *s.tr.*, right and left horns and transverse part of sinus respectively; *r.s.c.*, *l.s.c.*, right and left superior cavæ; *pe.*, aperture of pulmonary vein; *h.v.*, hepatic veins; *d.v.*, ductus venosus; *me.*, mesocardium posterius. The other letters as in fig. 168.

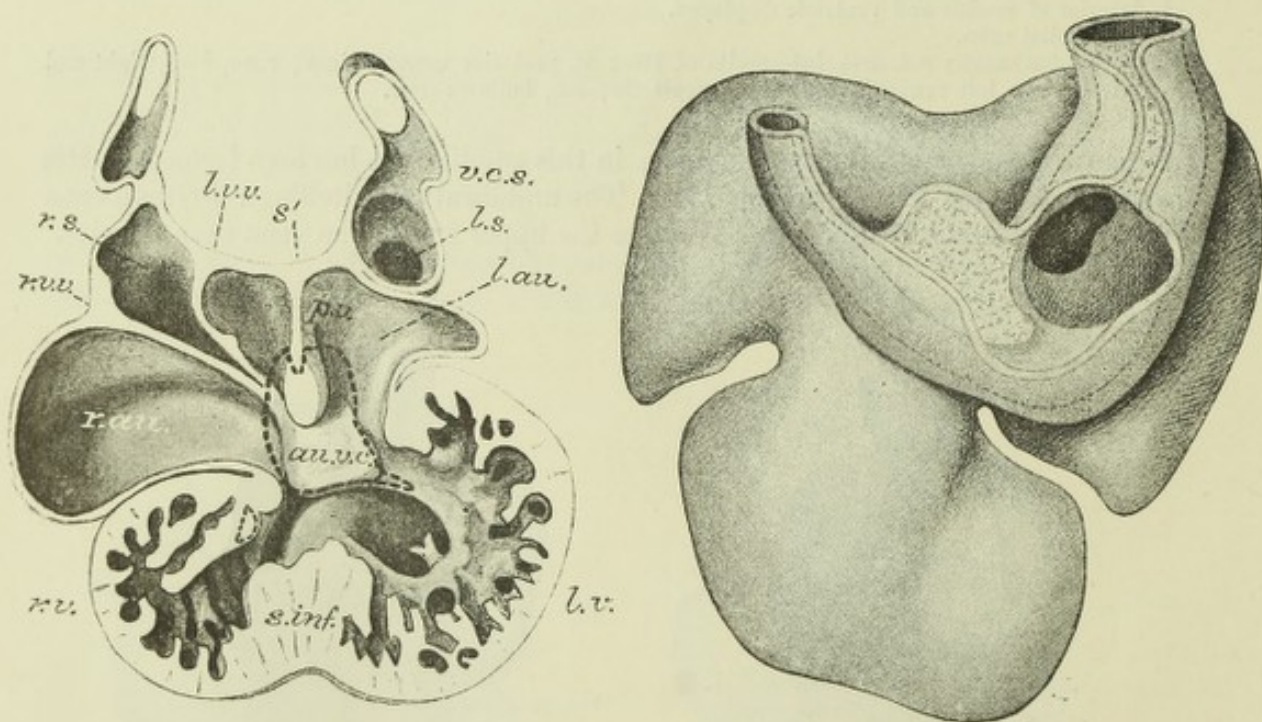


Fig. 170.—SECTION THROUGH THE HEART OF A RABBIT EMBRYO AT THE STAGE SHOWN IN FIG. 169. (Born.)

r.s., *l.s.*, right and left horns of sinus receiving from above the respective superior venæ cavæ; *r.au.*, *l.au.*, right and left auricles; *r.v.*, *l.v.*, right and left parts of the ventricle; *r.v.v.*, *l.v.v.*, right and left valves guarding the orifice from the right horn of the sinus into the right auricle; *au.v.c.*, one of the two endocardial cushions which are beginning to sub-divide the common auriculo-ventricular aperture. The dotted line encloses the extent of the endocardial thickening; *s'*, first septum superior growing down between the auricles and prolonged below by a thickening of endocardium. Close to this septum in the left auricle is seen the opening of the pulmonary vein; *s.inf.*, inferior septum of the ventricles.

Fig. 171.—VIEW FROM BEHIND OF THE HEART OF A HUMAN EMBRYO OF ABOUT 4 WEEKS, MAGNIFIED. (His.)

The two superior cavæ, right and left, and the inferior cava are seen opening separately into the sinus which is a transversely elongated sac communicating only by a narrow orifice with the right auricle.

and left venous valves) (fig. 170, *r.v.v.*, *l.v.v.*). These pass above into a muscular fold of the auricular wall, which extends over the roof of the auricle heart parallel to the septum atriorum, and is known as the *septum spurium* (fig. 173, B).¹ It disappears at length, probably by uniting with the septum atriorum. Subsequently the venous orifice opens out, and the right horn of the sinus, which is now seen to receive all the great veins except the left duct of Cuvier, becomes gradually incorporated with the cavity of the auricle. The transverse part of the sinus and its left horn are continuous with the left duct of Cuvier (fig. 171), and eventually the transverse part forms the coronary sinus. From the right venous valve the *Eustachian valve* is formed, and the development of the *Thebesian valve* is also connected with its lower end (Schmidt). The left venous valve disappears.

The transversely placed ventricular part of the heart receives at first at its left end the orifice of the common auricle, which opens into its posterior wall (fig.

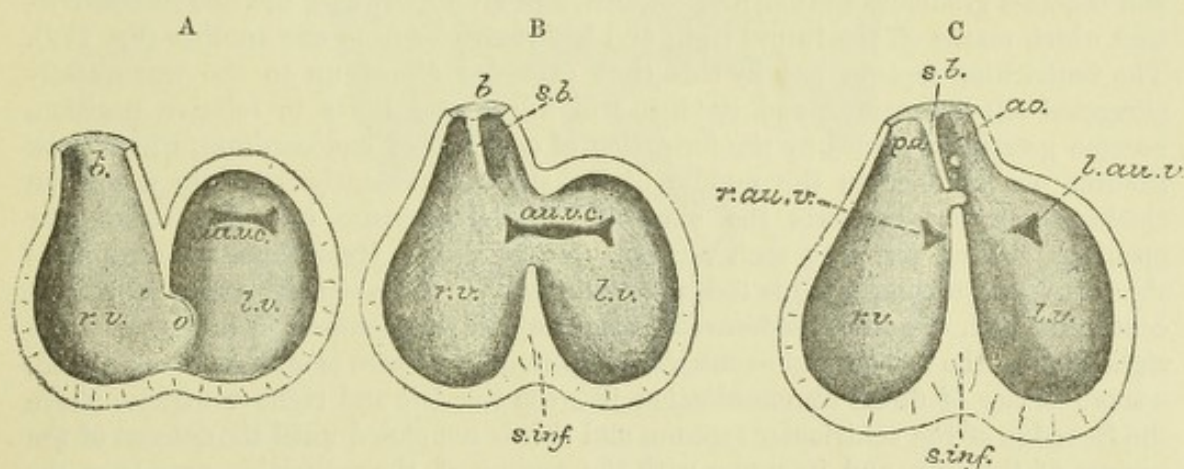


Fig. 172.—DIAGRAM TO SHOW THE FORMATION OF THE SEPTUM OF THE VENTRICLES AND BULB, AND THE MODE OF DIVISION OF THE COMMON AURICULO-VENTRICULAR APERTURE. (Born.)

au.v.c. (in A and B), auriculo-ventricular aperture, partially divided into two by endocardial cushions; *r.au.v.*, *l.au.v.*, right and left auriculo-ventricular apertures which have resulted from the division of the common aperture; *r.v.*, *l.v.*, right and left ventricles; *b.*, bulbus aortae, replaced in C, by *p.a.* and *a.o.*, pulmonary artery and aorta; *s.b.*, septum bulbi; *s.inf.*, septum inferius ventriculorum; *o.* (in A), orifice between the two ventricles.

172, A, *a.v.c.*). At its right end it turns sharply upwards into the aortic bulb, into which it gradually tapers, although there is at a certain point a constriction of the endothelial tube, where the semilunar valves are subsequently formed (*fretum Halleri*). Soon the right and left halves of the ventricle are separated externally by a groove which extends from below, partially encircling the tube (fig. 169). If the interior of the heart is examined at this stage, it is seen that a muscular septum, corresponding internally to this groove, is growing upwards and backwards from the antero-inferior part of the tube, and is gradually separating it into two parts, which become the right and left ventricles respectively (fig. 170, *s.inf.*). This septum (*septum inferius* of His) is placed obliquely to the long axis of the tube, and extends eventually nearly to the level of the auriculo-ventricular orifice, which has by this time become shifted along the posterior wall of the tube, so as to open into it about its middle instead of at the right end, as was previously the case (fig. 172, B). The septum of the ventricles remains incomplete for some time, a communication between the two ventricles being maintained above it. Eventually the septum inferius unites with prolongations, (1) from the endocardial cushions which divide the common auriculo-ventricular orifice into right and left

¹ This muscular prolongation may, as Born suggests, be of use in assisting the action of the valves, and in preventing their being forced backwards into the sinus when the auricle contracts.

orifices ; (2) from the endo-cardial aortic septum, which divides the bulb into aorta and pulmonary artery. Thus the septum of the ventricles is completed by endo-cardial connective tissue, a fact which is indicated even in the adult heart by the existence of the thin septum membranaceum which forms the uppermost part of the inter-ventricular septum.

The common auricle in the meantime becomes shifted relatively upwards over the back of the ventricles, carrying the sinus along with it, but it still lies behind rather than over the ventricles, and the aperture of communication passes from behind forwards, from the left part of the auricle into the corresponding half of the ventricle. This constricted aperture soon becomes elongated into a short canal, which is known as the *auricular canal*. Its orifice into the ventricle is from the first somewhat flattened, and bounded by two lips, an upper and a lower. As development proceeds, it broadens out towards the median plane of the ventricular tube, and becomes gradually shifted, first towards, and eventually over the line of constriction which marks off the future right and left ventricles from one another (fig. 172). The ventricular septum has by this time extended almost up to the transversely elongated slit-like orifice, and its lips, still upper and lower in relative position, become greatly thickened by the formation of cushions of endocardium, which grow towards one another in the middle of the slit, and presently fuse into a median thickening which converts the single H-shaped aperture into two triangular openings, leading one into each ventricle (fig. 172, C). Meanwhile, the septum of the ventricles growing towards the base abuts against, and at length comes into direct continuity with the fused endocardial cushions, but this connection is nearer to the right than to the left auriculo-ventricular aperture.² There is still, as above stated, a small orifice of direct communication between the left and right ventricles above the free edge of the ventricular septum, and this is not closed until the descent of the septum of the bulb, and its union with the septum of the ventricles, completes the interventricular septum.

The above account of the division of the auricular canal is based upon that given by Born for the rabbit, and in some respects differs from the description which was given by His from an examination of human embryos. According to His, the endocardial cushions, which by their union subdivide the auricular canal, are preceded by and connected with a growth of endocardial tissue, which springs from the posterior auricular wall, and they together form a septal prolongation (*septum intermedium*), which projects like a stopper into the auricular canal, and divides the latter into the two auriculo-ventricular orifices, and also grows down beyond that canal to meet the uprising ventricular septum (fig. 173). The shortening of this canal is in part effected by a kind of intussusception which takes place, and which causes its wall to be folded into the ventricular cavity ; these folds, with probably some thickening of endocardium, form the bases of the lateral flaps of the auriculo-ventricular valves (fig. 175). The bases of the mesial or septal flaps are formed by a downward growth of the edges of the endocardial septum between the two orifices. Both lateral and mesial flaps become continuous with the spongy muscular substance which at this time occupies most of the cavity of the ventricles (fig. 175). As development proceeds, the flaps, which are at first thick and soft, become thin and membranous, and become free from muscular substance except near their free edges. These muscular bands become tendinous near their insertion into the valves, and thus form the *chordæ tendineæ* ; the parts which are not thus transformed become the *papillary muscles*.

The septum of the auricles appears at the upper and back part of the auricular

² Hence the right auriculo-ventricular orifice lies close to the ventricular septum, but the left orifice is separated from it by an interval, into which the root of the aorta becomes continued (Born).

cavity, where its situation is externally marked by a groove. The free edge of this septum grows forwards and downwards, and the septum (fig. 170, *s'*) gradually separates the auricular cavity into a right and left half, the separation being completed by the junction of its free edge, which shows a distinct endocardial thickening,

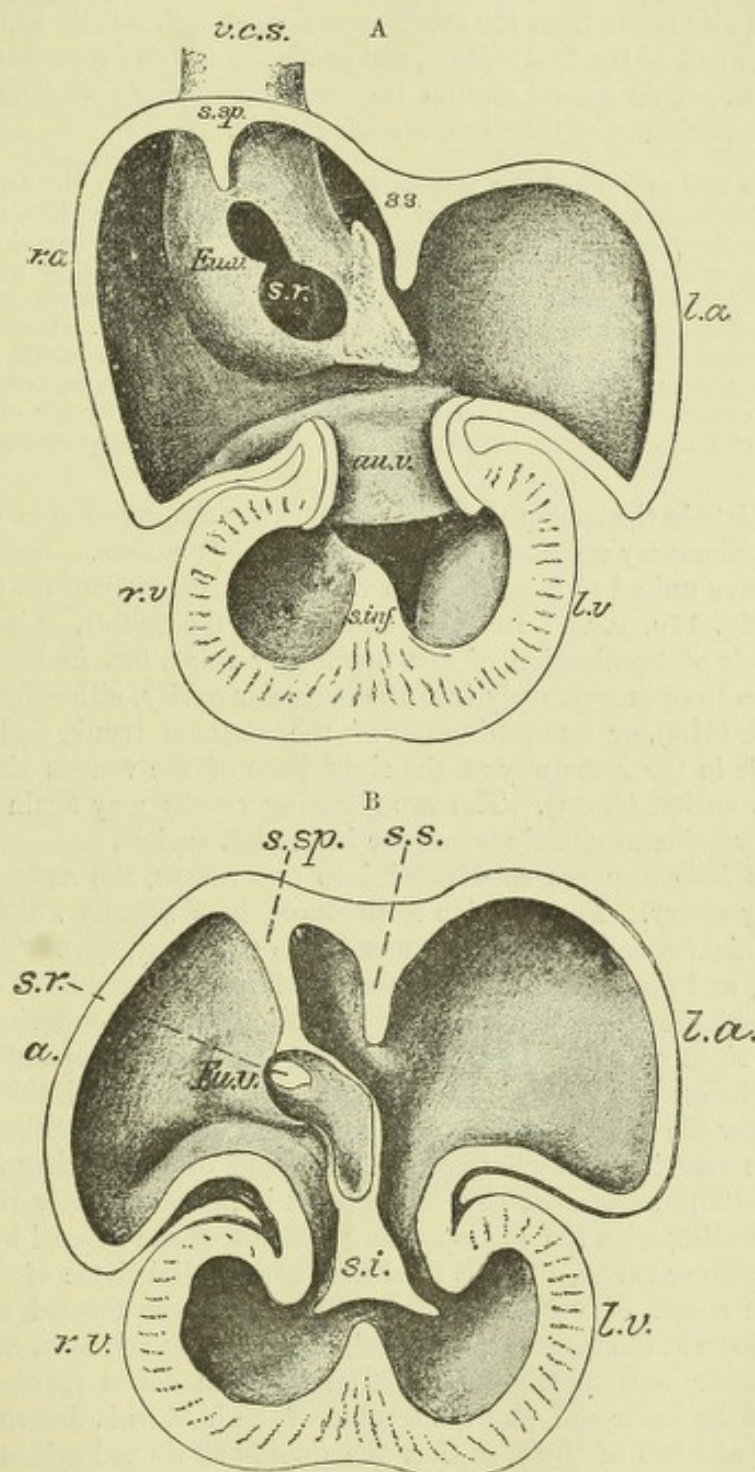


Fig. 173.—TWO STAGES IN THE FORMATION OF THE SEPTUM INTERMEDIUM IN THE HEART OF THE HUMAN EMBRYO. (His.)

In A the septum is represented as growing from a triangular area to the left of the sino-auricular orifice; in B it has coalesced with the endocardial cushions, and lies like a stopper in the auricular canal.

r.a., *l.a.*, right and left auricle; *r.v.*, *l.v.*, right and left ventricle; *s.r.*, sinus venosus; *Eu.v.*, Eustachian valve; *s.sp.*, septum spurium; *s.s.*, septum superior; *s.inf.*, septum inferior; *s.i.*, septum intermedium; *v.c.s.*, vena cava superior dextra.

with the fused cushion-like thickenings which are subdividing the common auricular orifice. But before the originally free communication between the two auricles is thus closed, a new aperture makes its appearance above and at the back of this septum, and gradually enlarges, so that a passage is thus re-established, but in a different situation. This new orifice is the *foramen ovale*, it becomes closed by a second septum, which also starts from the superior auricular wall, a little to the right of the original attachment of the first septum, and gradually grows forwards and downwards over the orifice. This second septum becomes the *limbus Vieussenii*, the first one forms the so-called *valve of the foramen ovale* (Born).

According to His' account of the process in the human embryo, the septum atriorum is formed by an anterior, or lower, and a posterior, or upper, sickle-shaped projection, which between them enclose the foramen ovale, and form respectively the *limbus Vieussenii* and the valve of the foramen ovale; the connective tissue growth which he describes as growing from the posterior auricular wall towards the auriculo-ventricular orifice takes an important part in the formation of the lower septal projection (septum intermedium). There is reason, however, to believe that the process, as above described by Born for the rabbit, is materially the same in all the higher vertebrates, including man, and that the successive growth of both septa from the upper and posterior auricular wall was not noticed by His on account of the lack of a series of human embryos sufficiently complete to show all the stages of growth.

Somewhat late in the course of development (after the appearance of the auricular septum), the pulmonary veins are seen entering the left auricle. Before reaching the auricle they have united to form a single vessel, and this opens into the auricle near the septum (fig. 170, *p.v.*). In some animals, as the rabbit, this represents the permanent mode of termination of the pulmonary veins, but in man the right and left veins come to open separately into the auricular cavity, either by division of the common trunk (His), or by opening out of the common trunk, and its absorption into the auricle in the same way as the right horn of the venous sinus is absorbed into the right auricle (Born). The two resulting vessels may again divide, so that four pulmonary veins ultimately terminate in the left auricle.

The *aortic bulb* becomes subdivided into two vessels, the ascending aorta and the pulmonary artery. The division is produced by a septum which arises as two longitudinal thickenings of the lining membrane (endocardium). These grow from opposite sides, and gradually meeting, fuse together in the middle of the bulb. The folds take an oblique course down the bulb, for above they are anterior and posterior, but below are right and left, hence the resulting vessels after separation are anterior and posterior below and right and left above. The endocardial thickenings extend somewhat below the origin of the bulb, and unite with one another and with the septum of the ventricles, which they complete, and of which they form the membranous part. The ventricular part of the heart is now completely divided into two, each communicating with the corresponding division of the arterial bulb. There are at first no semilunar valves, the soft thickened endocardial tissue of the bulb appearing to exercise a sort of valvular action. The valves are formed as three projections of this tissue at the base of each vessel, at first thick and soft, but subsequently becoming thinner and membranous. The common aortic trunk has four such thickenings at the lower end, and the septum of the bulb as it descends is prolonged into the right and left of these, so that the dumb-bell-shaped orifice is divided into two triangular apertures, the bulging sides of which are formed by the endocardial cushions and become developed into the semilunar valves (fig. 174).

The aortic septum begins between the fourth and fifth aortic arches, and is so disposed, that the fourth arch continues the aortic half of the bulb, the fifth the pulmonary half. After the completion of the septum, an external groove makes its appearance along the line of the endocardial thickenings, and deepening gradually, splits the bulb into two separate vessels.

Fig. 174.—DIAGRAM SHOWING THE DIVISION OF THE LOWER PART OF THE BULBUS AORTÆ, AND THE FORMATION OF THE SEMILUNAR VALVES. (After Gegenbaur and His.)

A, undivided truncus arteriosus with four endocardial cushions; B, advance of the two lateral cushions resulting in the division of the lumen; C, projection of three endocardial cushions in each part; D, the separation into aorta and pulmonary trunks completed.

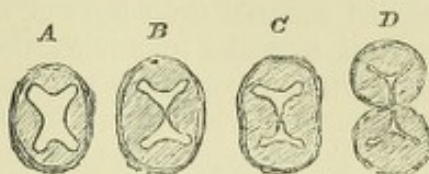
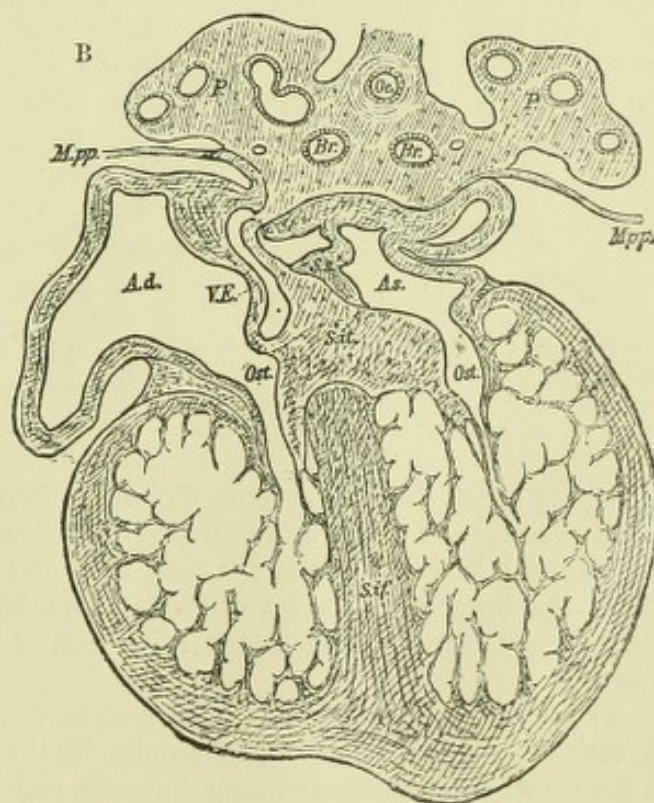
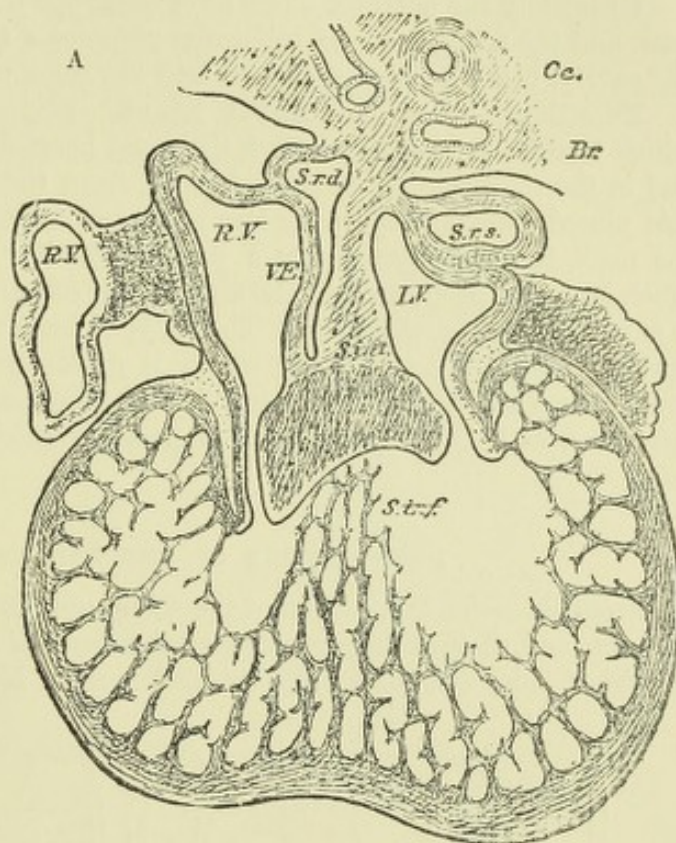


Fig. 175.—SECTIONS THROUGH THE HEART OF HUMAN EMBRYOS, SHOWING TWO STAGES IN THE FORMATION OF THE CARDIAC SEPTA AND OF THE AURICULO-VENTRICULAR VALVES. (His.)

A, from an embryo of 5 or 6 weeks. *R.V.*, right auricle; *L.V.*, left auricle; *S.r.d.*, right horn of sinus; *S.r.s.*, left horn of sinus; *V.E.*, Eustachian valve; *s.int.*, septum superior and endocardial cushion (septum intermedium, His); *s.inf.*, septum inferius ventriculorum. This septum, as well as the bulk of the ventricle, is a muscular sponge at this stage. *Oe.*, œsophagus; *Br.*, bronchus.

B, from a somewhat more advanced embryo. *Ad.*, *As.*, right and left auricle; *Ost.*, auriculo-ventricular apertures; *S.s.*, septum superior of auricles; *S.it.*, endocardial cushion (septum intermedium); *S.if.*, septum inferius ventriculorum, now denser and more muscular; *Mpp.*, pericardial attachment.



Distinct muscular tissue is seen in the cardiac wall, even as early as the stage of an S-shaped tube, although the heart begins to pulsate regularly long before this. The muscular layer is separated from the epithelial lining of the cavities (endothelial tube of His) by a layer of clear gelatinous tissue, bridged across by fine fibres (embryonic connective tissue). This layer is most abundant in the ventricular part and aortic bulb, and here the endothelial tube is consequently much smaller than the muscular tube. Subsequently, in the ventricle, the gelatinous tissue is invaded by muscular bands which grow

into it from the compact outer layer of muscle, and unite with one another to form a spongework of muscular trabeculae, while the endothelium of the cavity becomes depressed between and over these trabeculae, and lines all the spaces between them, which thus communicate with the cavity of the ventricle. The ventricles are therefore now in the same condition in which they are found permanently in many of the lower vertebrates (e.g. frog).

Ultimately the compact outer layer of muscle becomes greatly increased in thickness, and the spongework of trabeculae occupies a relatively much smaller portion of the cavity, being developed in part into the columnae carneae of the adult heart.

Peculiarities of the foetal heart.—Besides the peculiarities of structure, which have been above described, the foetal heart differs in position, in relative size, and in the thickness of its several parts, from the organ after birth. Thus it is at first placed immediately under the head, but subsequently, with the development of the neck, it gradually assumes a position farther back. In early foetal life it is much larger in proportion to the size of the body than at a later period, and at birth it is still proportionally large. The walls of both ventricles are of equal thickness during foetal life, a peculiarity which is evidently connected with the fact that in consequence of the communication of the pulmonary artery, through the ductus arteriosus, with the aorta, the blood pressure which they have to overcome is the same.

DEVELOPMENT OF THE PRINCIPAL ARTERIES.

From the point of insertion of the aortic bulb into the ventral wall of the foregut, first one, and then in succession four other *arterial arches*, become formed, and pass on either side, one into each visceral arch. Half encircling this part of the

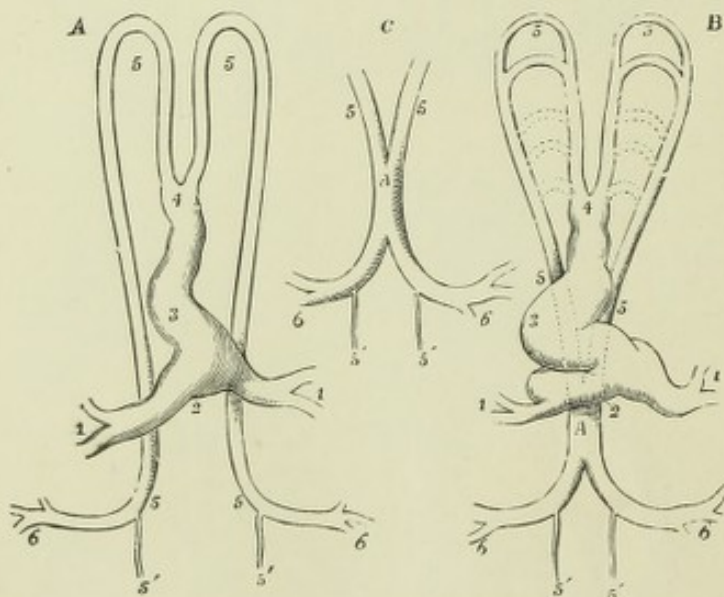


Fig. 176.—DIAGRAMMATIC OUTLINES OF THE HEART AND PRIMITIVE VESSELS OF THE EMBRYO CHICK AS SEEN FROM BELOW AND ENLARGED. (A. T.)

A, soon after the first establishment of the circulation; B, C, at a somewhat later period; 1, 1, the veins returning from the vascular area; 2, 3, 4, the heart, now in the form of a notched tube; 5, 5 (upper), the two primitive aortic arches; 5, 5 (lower), the primitive double aorta; A, the single or united aorta; 5', 5', the continuation of the double aorte beyond the origin of the large omphalo-mesenteric arteries, 6, 6. The division above 4 is represented as carried rather too far down.

alimentary canal, they are continued above it into two *descending* or *primitive aortae*. These two vessels run down the trunk on either side of the notochord, yielding, as they descend, lateral offsets to the body walls and to the yolk sac. Finally they give off, at the lower or posterior extremity, two large vessels, which accompany the allantois, and furnish blood to the foetal part of the placenta (*umbilical* or *allantoic arteries*).

The primitive aortae do not long remain double. As was first shown by means of sections by Allen Thomson, they unite in the middle line, the union beginning in the dorsal region and extending forwards and backwards; in the latter direction

even beyond the origin of the allantoic arteries, the middle sacral artery being in fact the extremity of the aorta.

Occasionally the union remains incomplete, a median septum being sometimes found as a malformation of the descending aorta.

The common iliaes are formed by persistence of the roots of the allantoic arteries; when the lower limbs are formed they give off to these the external iliaes.

Since their discovery by Rathke in 1825, the arterial arches have been regarded with much interest as corresponding with those from which the blood-vessels of the gills in fishes and amphibia are derived. Along with the (subdivided) aortic bulb they give rise, by various transformations, to the permanent pulmonary and aortic stems and the principal vessels which spring from them. Most of what is known regarding the mode of their transformation in different animals is due to the researches of Rathke. In the human embryo the subject has been recently investigated by His, whose account will be here mainly followed.

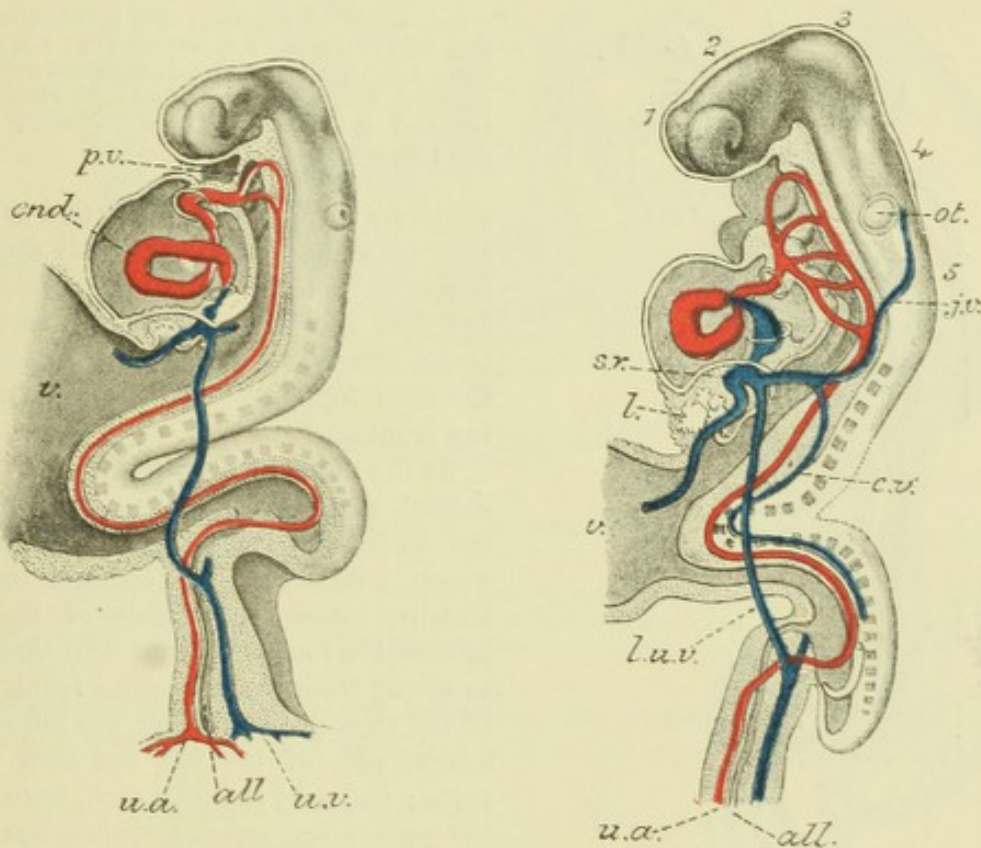


Fig. 177.—PROFILE VIEW OF A HUMAN EMBRYO OF ABOUT FIFTEEN DAYS, WITH THE ALIMENTARY CANAL IN LONGITUDINAL SECTION. (His.)

Two arterial arches are formed at this stage.

Fig. 178.—SIMILAR VIEW OF A SOMEWHAT OLDER EMBRYO, SHOWING FIVE ARTERIAL ARCHES.

1, 2, 3, 4, 5, are opposite the respective secondary cerebral vesicles; from the side of the fore-brain the primary optic vesicle is seen projecting; *ot*, otic vesicle, still open in 177; *p.v.*, septum between mouth and pharynx (primitive velum). This has disappeared in 178; *l.*, commencing liver in septum transversum; *v.*, vitelline stalk; *all*, allantois enclosed within stalk; *j.v.*, jugular vein; *c.v.*, cardinal vein; *s.r.*, sinus venosus within septum transversum; *u.a.*, left umbilical (allantoic) artery; *u.v.*, left umbilical vein. The sharp curve of the trunk of the embryo towards the yolk-sac is normal at this period of development.

From the point of insertion of the aortic bulb the arterial arches have a radial disposition as they pass into their respective visceral arches (fig. 181). They at first effect, as above stated, a complete communication between the aortic bulb and the descending aorta, but subsequently in most cases the communication becomes obliterated, and the completeness of the vascular arch is thus obscured, the only arches which in mammals remain pervious through their whole extent up to the

time of birth being the fourth and fifth arches of the left side, which form the arch of the aorta and the ductus arteriosus respectively. This obliteration begins early in the first and second arches, so that in many animals by the time the posterior arches are formed the anterior are partially obliterated; but in man this is not the case, all five pairs of arches being present and fully pervious for a certain time (figs. 178, 179, from His).

As development proceeds, the point of insertion of the aortic bulb, which is at first opposite the first arterial arch, becomes, along with the rest of the heart,

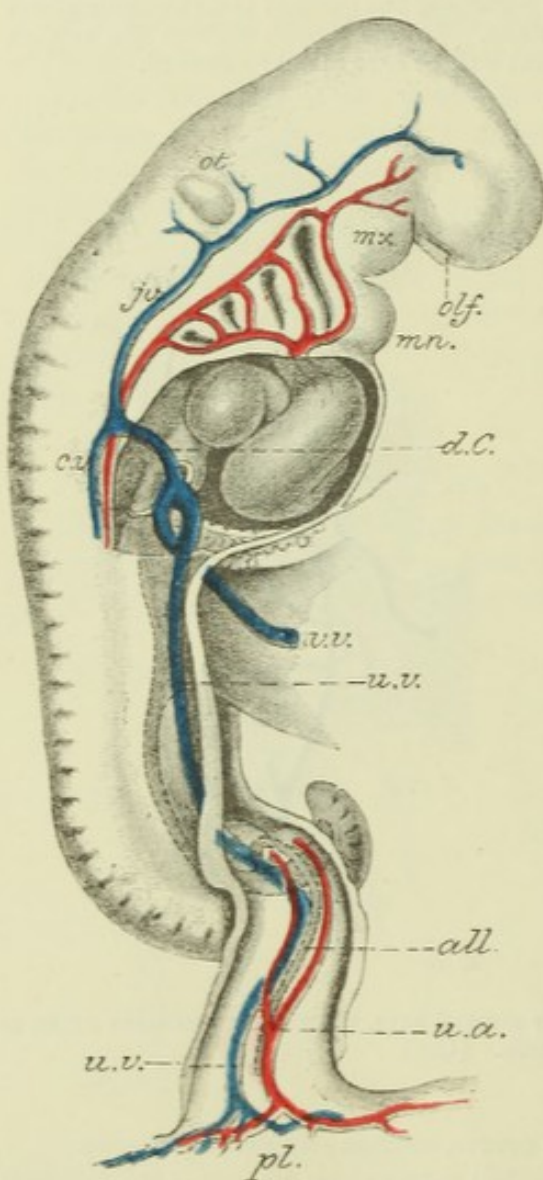


Fig. 179.—PROFILE VIEW OF A HUMAN EMBRYO OF ABOUT THREE WEEKS, SHOWING THE CEPHALIC VISCERAL ARCHES AND CLEFTS AND THEIR RELATIONS TO THE ARTERIAL ARCHES. (His.)

mx., maxillary process; *mn.*, mandibular arch; *d.C.*, duct of Cuvier; *j.v.*, jugular vein; *c.v.*, cardinal vein; *v.v.*, vitelline vein; *u.v.*, umbilical vein; *u.a.*, umbilical artery; *all.*, allantois; *pl.*, placental attachment of allantoic stalk; *olf.*, olfactory depression; *ot.*, otic vesicle.

relatively shifted backwards, and on each side the arterial arches presently appear to come off from the bulb in two sets, viz.: the first and second from an ascending trunk, afterwards the external carotid, and the third, fourth, and fifth from a descending trunk.

As the point of insertion is still further shifted, the third arch becomes added to the ascending trunk, the lower part of which now forms the common carotid. Finally, by a continuance of the same process, the fourth arch on each side comes to spring from the ascending trunk: that of the right side forming the innominate artery, that of the left the arch of the aorta; and only the fifth arch, from which the pulmonary arteries spring, has for a time a descending direction.

From the dorsal part of the first arch a branch passes towards the brain—this becomes the upper part of the internal carotid. When the first and second arches become obliterated—a change which next occurs—this branch remains in continuity

with the third arch by the unobliterated dorsal portions of the first and second arches (upper extremity of primitive aortæ); these portions, together with the third arch, form the lower part of the internal carotid, the posterior communication between the third and fourth arch becoming obliterated. The branches of the external carotid are produced from the remains (ventral) of the first and second arches; the maxillary and temporal arteries from the first, the lingual and ascending pharyngeal arteries, and probably also the occipital and auricular, from the anterior part of the second arch.

The division of the bulb into aortic and pulmonary trunks begins just at the time when the extremity of the aortic bulb has become shifted backward so as

to be opposite the point of junction between the fourth and fifth pairs of arches, so that now all the arches above this point become separated off in connexion with the trunk of the aorta (ascending aorta); the one below it remaining in connexion with

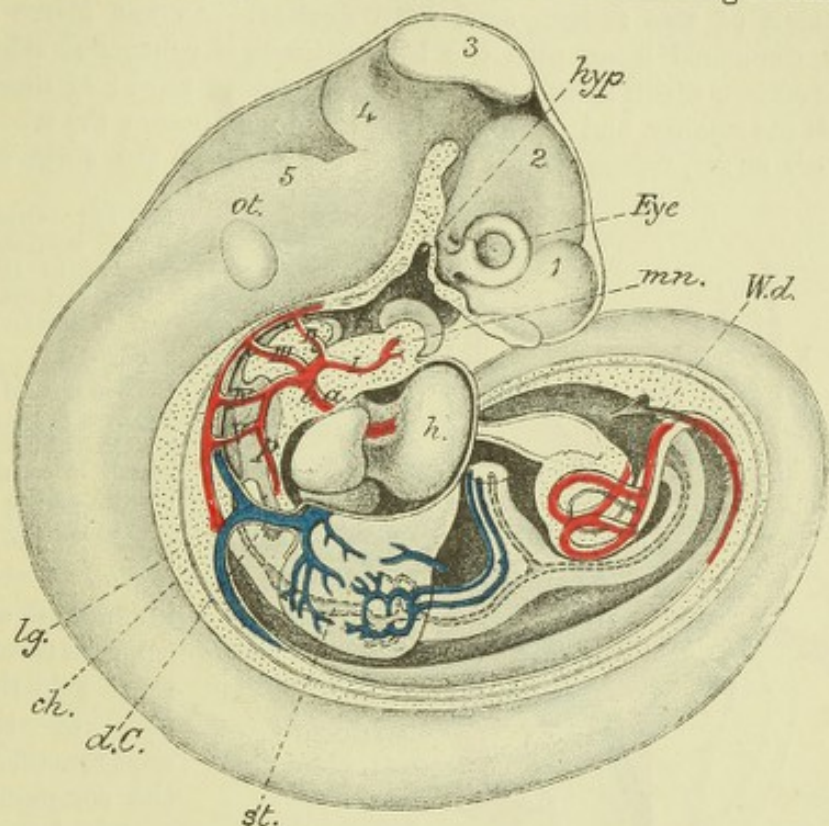


Fig. 180.—PROFILE VIEW OF A HUMAN EMBRYO OF ABOUT 3 OR 4 WEEKS, SHOWING THE PRINCIPAL ARTERIES AND VEINS. (His.)

1, 2, 3, 4, 5, the secondary cerebral vesicles; *hyp*, hypophysis; *ot*, otic vesicle; *mn*, mandibular arch; *lg*, lung rudiment; *st*, stomach; *Wd*, Wolfian duct opening into cloaca; *I*, *II*, *III*, *IV*, *V*, the arterial arches springing from *b.a*, bulbus arteriosus; *p*, pulmonary artery; *d.C*, duct of Cuvier.

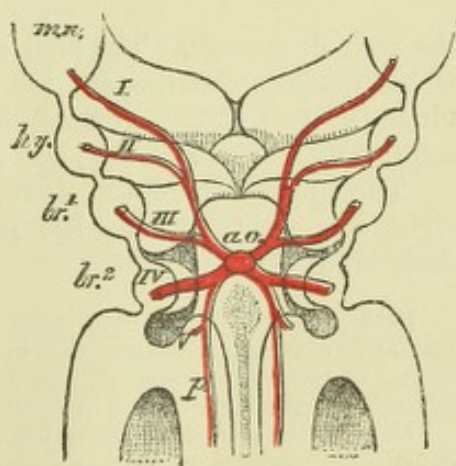
the pulmonary trunk. After the separation, the aortic bulb, now a double tube, becomes still further shifted back, and with it the fourth and fifth arches. Since

Fig. 181.—VIEW FROM BEHIND OF THE ANTERIOR PART OF THE MOUTH AND PHARYNX OF A HUMAN EMBRYO OF 3½ WEEKS, SHOWING THE ARTERIAL ARCHES RADIATING FROM THE ATTACHMENT OF THE AORTIC BULB. (His.)

ao, point of attachment of aortic bulb in the anterior wall of the pharynx; *mn*, *hy*, *br*¹, *br*², first four visceral arches; *I*, *II*, *III*, *IV*, the corresponding arterial arches; *V*, fifth arterial arch giving off the pulmonary artery, *p*.

the inferior laryngeal nerve passes under the latter, this nerve must also become shifted downwards along with these arches. To allow for this shifting of the bulb, the common carotids become proportionally lengthened.

From the descending primitive aortæ on either side a series of inter-segmental arteries pass; the uppermost of these become united to form the vertebral arteries (which subsequently unite superiorly in the middle line to produce the basilar), the lower form intercostal arteries. A branch for the upper extremity comes off from



the commencement of the vertebral; it subsequently far exceeds the parent vessel in size, and forms the subclavian, this name being extended to what was originally the commencement of the vertebral from the descending aorta.

Destination of the fourth and fifth arches.—As was above stated, the aortic trunk, connected below with the left ventricle, is connected above with the four superior arches, which spring from its two ascending rami; of these rami the right is much the smaller, and its root forms the innominate; the root of the left, which is much larger, represents the part of the arch of the aorta between the

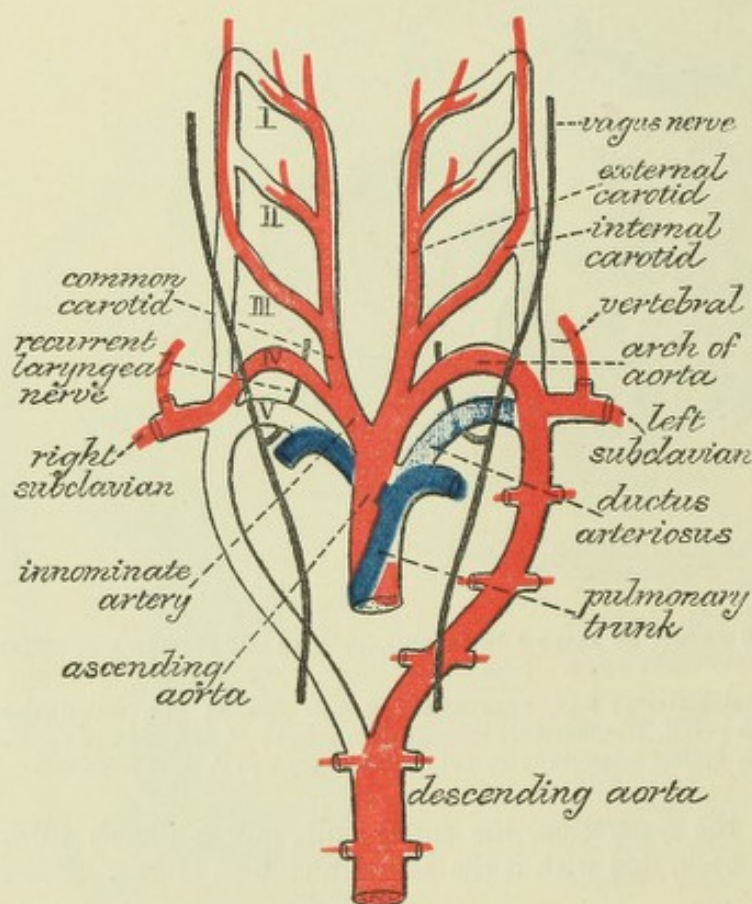


Fig. 182.—DIAGRAM TO SHOW THE DESTINATION OF THE ARTERIAL ARCHES IN MAN AND MAMMALS. (Modified from Rathke.)

The truncus arteriosus, and the five arterial arches springing from it are represented in outline only, the permanent vessels in colours—those belonging to the aortic system red, to the pulmonary system blue.

innominate and the left common carotid. On the right side the proximal part of the fourth arch remains, and forms the common subclavio-vertebral trunk; on the left side the whole arch persists and forms the remainder of the arch of the aorta.

The fifth arch of the right side only persists as far as the origin of the branch to the right lung, the remainder of

the arch disappears. The fifth arch of the left side persists throughout its whole length during foetal life, and joins the fourth arch as the *ductus arteriosus*. After birth, the part of the arch beyond the branch to the corresponding lung becomes impervious on this side also, and is converted into the *ligamentum arteriosum*.

The upper part of the descending primitive aorta disappears entirely on the right side; that of the left side forms the commencement of the permanent descending aorta.

Rathke described both pulmonary arteries as being given off from the fifth left arch in mammals, although admitting that in birds and reptiles each is formed from the corresponding arch. In birds the permanent aortic arch is the fourth arch of the right side, and not of the left side as in mammals, and in reptiles both aortic arches remain pervious.

Many of the abnormalities which are observed in the disposition of these arteries, may be explained by regarding them as a persistence of embryonic conditions.

The development of the arterial arches of the bird has been recently again examined by Mackay, whose account differs in important particulars from that of Rathke, and indeed of nearly all previous investigators. He describes the subclavian artery as arising from the third arch, not from the fourth (this was also given as its origin by Sabatier), springing from the ventral part of the arch, and running outwards superficial to the pneumogastric nerve and jugular vein. The third arch and its dorsal upward prolongation, form the common carotid, not the

internal carotid, as stated by Rathke, and the ventral prolongation of the truncus arteriosus forms, not the external carotid, but a small branch from the subclavian, or innominate artery, to the front of the trachea. These observations have not been as yet extended to mammals.

Zimmermann has described, both in the rabbit and in the human embryo, an arterial arch between the aortic and pulmonary arches. If this is of constant occurrence it must be reckoned as the fifth arch, and the pulmonary will become the sixth.

The histogenetic changes involved in the development of the blood-vessels are described in the chapter on Histology.

The first vessels appear, as has been already stated, in the mesoblast of the vascular area; the lamina of mesoblast in which they are formed is sometimes distinguished as the *vascular lamina*. They are said (by His and others) to grow inwards from the vascular area, but the manner in which the principal arteries and veins of the body are first developed is not clear, beyond the fact that they are at first merely endothelial tubes. The muscular tissue of the primitive aortæ is derived from the lower part of the proto-vertebra (E. Müller).

DEVELOPMENT OF THE PRINCIPAL VEINS.

In this subject also the description given by His of the condition and changes of the veins in the human embryo will be followed, although it differs in certain particulars from that which has usually been received.

In the early embryo, before the development of the allantois, two *vitelline* or *omphalo-meseraic veins*, right and left, bring back the blood from the vascular area upon the yolk sac, and unite to form a common trunk, which is continued as the sinus venosus into the auricular extremity of the rudimentary heart.

At the commencement of the placental or allantoic circulation (fourth week in man) two *umbilical veins* are seen coming from the placenta and opening into the sinus near the vitelline veins (fig. 168). Into this also opens on either side a transverse vein, the *duct of Cuvier* or *superior vena cava*, which is formed by the junction of the *primitive jugular vein*, bringing blood from the head, and the *cardinal vein*, which returns the blood from the Wolffian bodies, the vertebral column and the body walls (figs. 179, 180). The trunk or sinus into which all these veins pour their blood is now transversely disposed, immediately below the diaphragm, and forms the *saccus reuniens* of His, which has been already alluded to (p. 139).

The vitelline or omphalomeseraic veins enter the abdomen along the vitelline duct and ascend at first along the front of the alimentary canal, but higher up they are seen on either side of that tube (duodenum and stomach). Here transverse communications form between the two veins, two in front of and one behind the duodenum, so that this is encircled by two vascular rings (figs. 180, 183). Above these venous circles the direct communication with the sinus becomes lost, the intermediate venous vessel on either side becoming broken up within the substance of the liver (which has by this time developed around them) into a vascular network, the middle part of which becomes capillary.

The vessels which pass from the upper venous ring to the capillary network are known as *venæ advehentes*, they become the branches of the portal vein; those which pass from it into the sinus are the *venæ revehentes*, they become the hepatic veins.

The lower communication between the vitelline veins takes the form of a complete longitudinal fusion of the two vessels, at least for some distance. This fused part receives veins from the intestine and stomach, and becomes the commencement of the portal vein.

The umbilical veins are for a long time double within the abdomen, although they have fused within the umbilical cord into a single trunk. They diverge from this and pass up to the sinus on either side in the somatopleure, just where this is becoming bent round into the amnion. After a time, however, it is found that this direct communication with the sinus is partially interrupted by the development of a

vascular network, and that on the left side a fresh communication has become established with the upper venous circle of the vitelline veins. The interruption subsequently becomes complete on both sides (fig. 183), and on the right side the greater

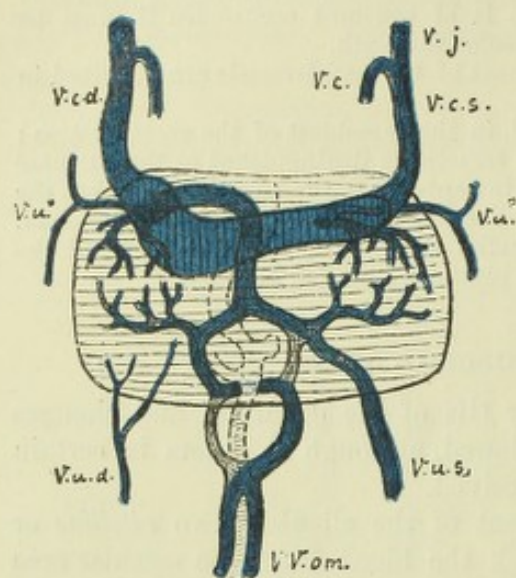


Fig. 183.—VENOUS TRUNKS OF A HUMAN EMBRYO OF ABOUT THREE-AND-A-HALF WEEKS. (His.)

v.c.d., *v.c.s.*, superior venæ cavæ, right and left; *v.j.*, *v.c.*, primitive jugular and cardinal vein; *v.u.d.*, *v.u.s.*, umbilical veins, right and left; *v.u."*, *v.u."*, upper detached portions of umbilical veins; *v.v.om.*, omphalomesenteric or vitelline veins forming the vena portæ. The permanent veins are coloured blue.

part of the vein becomes atrophied (on both sides the part which originally opened into the sinus reuniens remains evident for a time). The left vein, on the other hand, increases in bulk with the development of the placental circulation. For a short time the whole of its blood, as well as that of the vitelline vein, passes through the capillaries of the liver. But a branch

is soon seen passing from the upper venous circle direct into the right hepatic vein, near its entrance into the sinus. This forms the *ductus venosus* or *vena ascendens*, and it now carries most of the blood of the umbilical vein direct to the heart. Subsequently the direct communication of the left hepatic vein with the

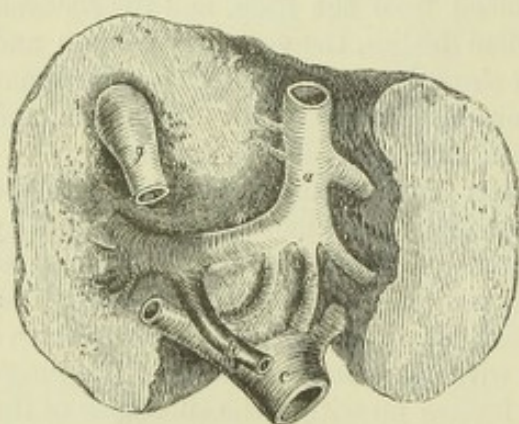


Fig. 184.—UNDER SURFACE OF THE FETAL LIVER, WITH ITS GREAT BLOOD-VESSELS, AT THE FULL PERIOD.

a., the umbilical vein, lying in the umbilical fissure, and turning to the right side, at the transverse fissure (*o*), to join the vena portæ (*p*); *d.*, the ductus venosus, continuing straight on to join the vena cava inferior (*c*); some branches of the umbilical vein pass from *a* into the substance of the liver; *g.*, the gall-bladder, cut.

sinus becomes obliterated, and a new communication becomes established with the ductus venosus; and, finally, when, with the growth of the lower limbs and of the other abdominal and pelvic organs, the inferior vena cava becomes developed, this also joins the upper end of the ductus venosus.

The lower part of the portal vein is formed, as we have seen, by the united vitelline veins. The upper part is formed as a single trunk out of the double venous annulus by atrophy of the right half of the lower ring and the left half of the upper (fig. 183). The spiral turn around the duodenum is thus produced, and thus it is also that the portal vein at first appears more directly connected with the right venæ advehentes than with the left.

Most of these embryonic veins are at first of relatively large size and have an irregular sinus-like character, which disappears at a later stage of development.

At the time of commencement of the placental circulation, two short transverse venous trunks, the *ducts of Cuvier*, open, as has been above stated, one on each side, into the auricle of the heart. Each is formed by the union of a superior and an inferior vein, named respectively the *primitiv jugular* and the *cardinal*.

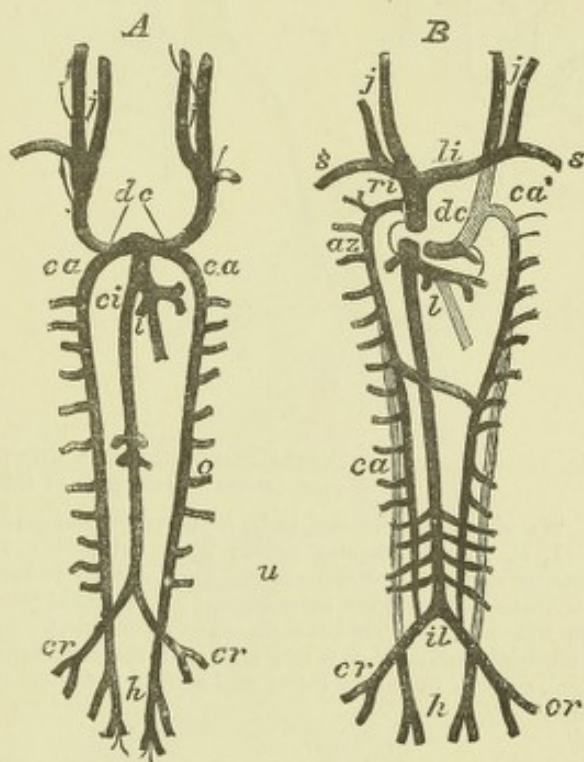
The *primitive jugular vein* receives the blood from the cranial cavity by channels in front of the ear, which are subsequently obliterated: in the greater part of its extent it becomes the external jugular vein; and near its lower end it receives small branches, which grow to be the internal jugular and subclavian veins (fig. 185). The *cardinal veins* are the primitive vessels which return the blood from the Wolffian bodies, the vertebral column, and the parietes of the trunk. The inferior vena cava is a vessel of later development, which opens into the trunk of the umbilical and vitelline veins, above the *venæ hepaticæ revehentes*. The iliac veins,

Fig. 185.—DIAGRAM OF THE CONDITION OF THE GREAT VEINS IN THE EMBRYO, AND OF THEIR TRANSFORMATION INTO THE PERMANENT VEINS. (After Kölliker.)

j, jugular veins uniting with the subclavian, *s*; *c.a.*, cardinal veins becoming the azygos as in B; *d.c.*, ducts of Cuvier formed by the union in B of jugular and cardinal, and becoming the superior vena cava on the right side, but disappearing on the left side; *ca'*, part of left cardinal vein which disappears; *ci*, vena cava inferior; *l*, hepatic veins and ductus venosus; *il*, common iliac veins; *cr*, external iliacs; *h*, hypogastric becoming the internal iliacs.

which unite to form the inferior vena cava, communicate with the cardinal veins. The inferior extremities of the cardinal veins are persistent as the internal iliac veins. Above the iliac veins the cardinal veins are obliterated in a considerable part of their course; the upper portions then become continuous with two new vessels, the *posterior vertebral veins* of Rathke, which receive the lumbar and intercostal twigs.

As development proceeds, the direction of the ducts of Cuvier is altered by the descent of the heart from the cervical into the thoracic region, and becomes the same as that of the primitive jugular veins. A communicating branch makes its appearance, directed transversely from the junction of the left subclavian and jugular veins, across the middle line to the right jugular; and further down in the thoracic region between the posterior vertebral veins, a communicating branch passes obliquely across the middle line from right to left. The communicating branch between the primitive jugular veins is converted into the left brachiocephalic or innominate vein. The portion of vessel between the right subclavian vein and the termination of the communicating branch becomes the right brachiocephalic vein. The portion of the primitive jugular vein below the communicating vein, together with the right duct of Cuvier, forms the vena cava superior, while the cardinal vein opening into it is the extremity of the great vena azygos. On the left side, the portion of the primitive jugular vein placed below the communicating branch, and the cardinal and posterior vertebral veins, together with the cross branch between the two posterior vertebral veins, are converted into the left superior intercostal and left superior and inferior azygos veins. The variability in the adult arrangement of these vessels depends on the different extent to which the originally continuous vessels are developed or atrophied at one point or another.



The left duct of Cuvier is obliterated. But even in the adult, traces of this vessel can always be recognised in the form of a fibrous band, or sometimes a narrow vein,

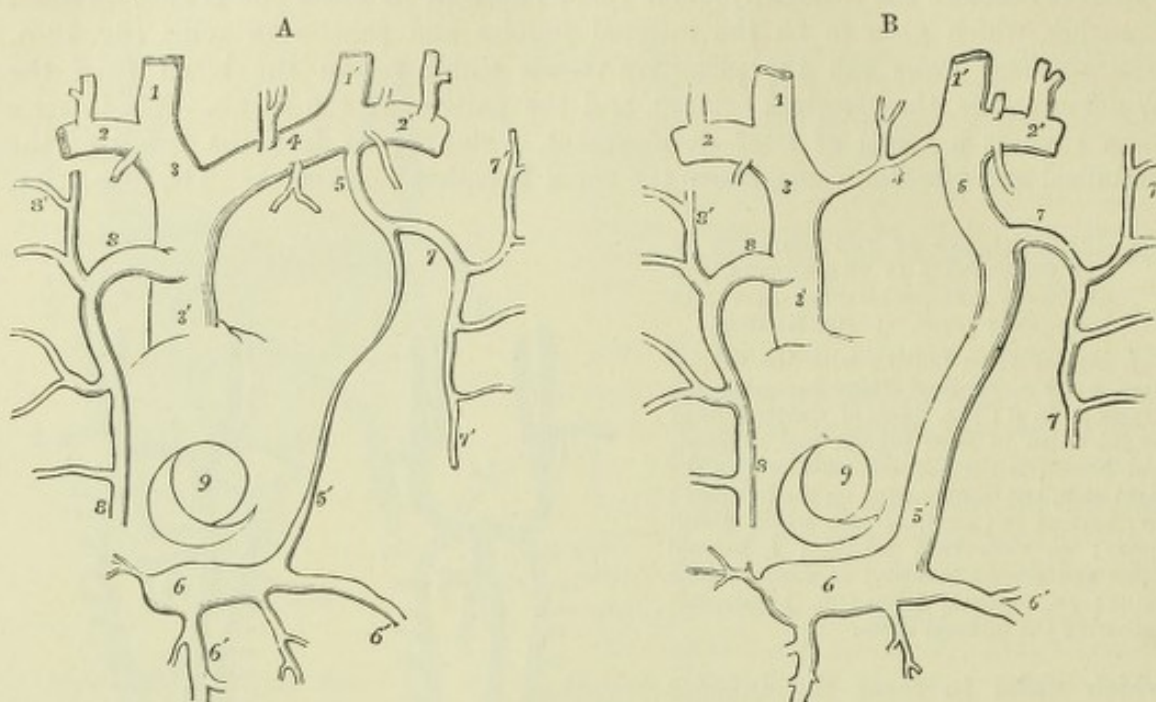


Fig. 186.—A and B.—DIAGRAMMATIC OUTLINES OF THE VESTIGE OF THE LEFT SUPERIOR CAVA AND OF A CASE OF ITS PERSISTENCE. (Sketched after Marshall.) $\frac{1}{2}$.

The views are supposed to be from before, the parts of the heart being removed or seen through.

1, 1', internal jugular veins; 2, 2', subclavian veins; 3, right innominate; 3', right or regular superior cava; 4, left innominate, normal in A, rudimentary in B; 5, in A, the opening of the superior intercostal vein into the innominate; 5', vestige of the left superior cava or duct of Cuvier; 5, 5', in B, the left vena cava superior abnormally persistent; 6, coronary sinus; 6', coronary veins; 7, superior intercostal trunk of the left side (left cardinal vein); 8, the principal azygos (right cardinal vein); 7', 8', some of the upper intercostal veins; 9, the opening of the inferior vena cava, with the Eustachian valve.

which descends obliquely over the left auricle; and in front of the root of the left lung there remains an indication of its former presence in the form of a small fold

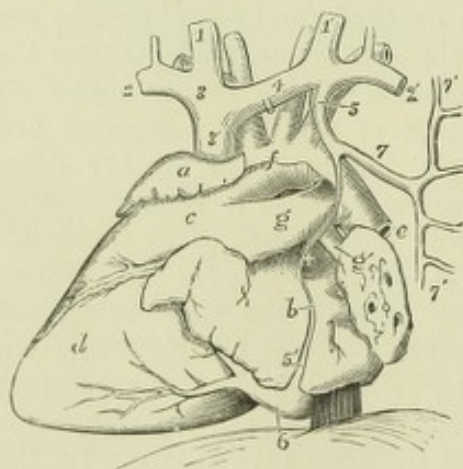


Fig. 187.—VIEW OF THE FETAL HEART AND GREAT VESSELS, FROM THE LEFT SIDE, TO SHOW THE VESTIGE OF THE LEFT SUPERIOR VENA CAVA IN SITU. (This figure is planned after one of Marshall's.)

a, right auricle; b, left auricle and pulmonary veins; c, the conus arteriosus of the right ventricle; d, the left ventricle; e, descending aorta; +, vestigial fold of the pericardium; f, arch of the aorta, with a part of the pericardium remaining above; g, main pulmonary artery and ductus arteriosus; g', left pulmonary artery; 1, 1', right and left internal jugular veins; 2, 2', subclavian veins; 3, 3', right innominate and superior vena cava; 4, left innominate; 5, 5', remains of the left superior cava and duct of Cuvier, passing at + in the vestigial fold of the pericardium, joining the coronary sinus, 6, below, and receiving above the superior intercostal vein, 7; 7', 7', the upper and lower intercostal vein.

of the serous membrane of the pericardium, the *vestigial fold* of Marshall, to whom is due the first full elucidation of the nature and relations of the left primitive vena cava superior.

The left duct of Cuvier has been observed persistent as a small vessel in the adult. Less frequently a right and a left innominate vein open separately into the

right auricle, an arrangement which is also met with in birds and in certain mammals, and which results from the vessels of the left side being developed similarly to those of the right, while the cross branch remains small or absent.

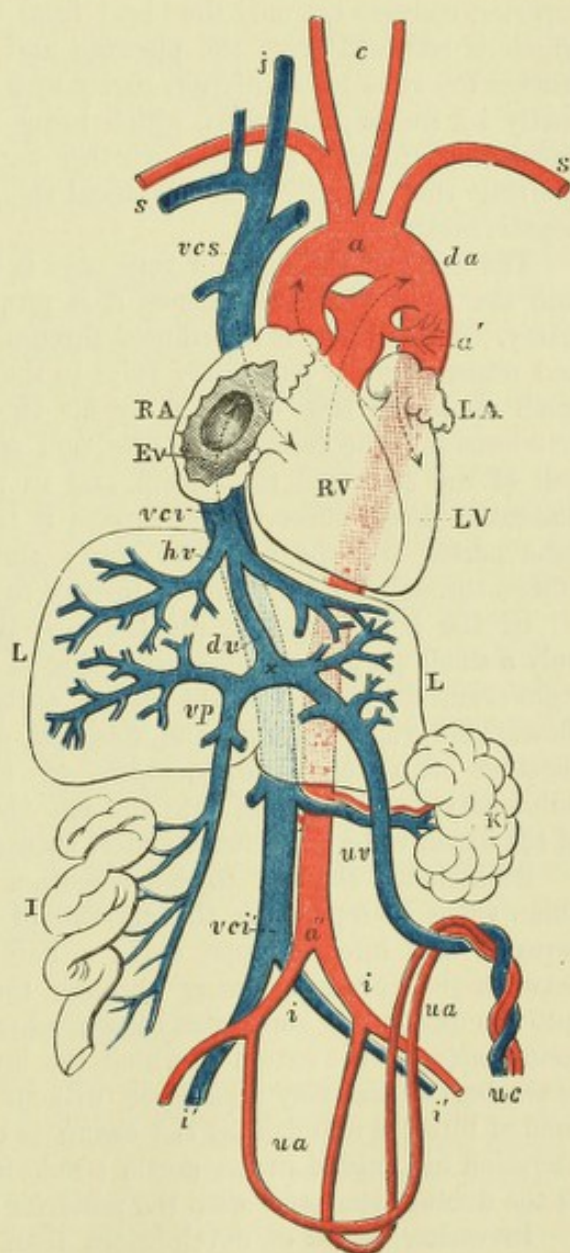
A case is recorded by Gruber in which the left vena azygos opened into the coronary sinus, and was met by a small vein descending from the union of the subclavian and jugular. Here, then, the jugular veins had been developed in the usual manner, while the left vena azygos continued to pour its blood into the duct of Cuvier.

PECULIARITIES OF THE FETAL ORGANS OF CIRCULATION.

It may be useful here to recapitulate shortly the peculiarities of structure existing in the advanced stage of the formation of the fetal organs of circulation,

Fig. 188.—DIAGRAMMATIC OUTLINE OF THE ORGANS OF CIRCULATION IN THE FETUS OF SIX MONTHS. (Allen Thomson.)

RA, right auricle of the heart; RV, right ventricle; LA, left auricle; Ev, Eustachian valve; LV, left ventricle; L, liver; K, left kidney; I, portion of small intestine; *a*, arch of the aorta; *a'*, its dorsal part; *a''*, lower end; *vc*, superior vena cava; *vc'i*, inferior vena where it joins the right auricle; *vc'i'*, its lower end; *s*, subclavian vessels; *j*, right jugular vein; *c*, common carotid arteries; four curved dotted arrow lines are carried through the aortic and pulmonary opening, and the auriculo-ventricular orifices; *da*, opposite to the one passing through the pulmonary artery, marks the place of the ductus arteriosus; a similar arrow line is shown passing from the vena cava inferior through the fossa ovalis of the right auricle, and the foramen ovale into the left auricle; *hv*, the hepatic veins; *vp*, vena portæ; *x* to *vc'i*, the ductus venosus; *uv*, the umbilical vein; *ua*, umbilical arteries; *uc*, umbilical cord cut short; *i* *i'*, iliac vessels.



with reference to their influence in determining the course of the blood during intra-uterine life, and the changes which occur in them upon the establishment of pulmonary respiration at birth.

The **foramen ovale** retains the form of a free oval opening in the septum atriorum up to the fourth month, but in the course of that month and the next the growth of the valvular plate which fills up the floor of the fossa ovalis, becomes complete, so that in the last three and a half months the blood can only pass from the right into the left auricle, not in a contrary direction.

The **Eustachian valve** constitutes a crescentic fold of the lining structure of the heart, which is so situated as to direct the blood entering the auricle by the inferior cava towards the opening of the foramen ovale.

The **ductus arteriosus** establishes a communication between the main pulmonary artery and the aorta, by which the blood from the right ventricle is carried mainly into the dorsal aorta.

The two large **hypogastric** or **umbilical arteries**, prolonged from the iliac arteries, passing out of the body of the fœtus, proceed along the umbilical cord, to be distributed in the fœtal portion of the placenta. From the placenta the blood is returned by the **umbilical vein**, which, after entering the abdomen, communicates by one branch with the portal vein, and is continued by another, named *ductus venosus*, into one of the hepatic veins, through which it joins the main stem of the vena cava inferior.

Course of the blood in the fœtus.—The right auricle of the fœtal heart receives blood from the two vena cavæ and the coronary sinus. The blood brought by the superior cava is simply the venous blood returned from the head and upper half of the body; whilst the inferior cava, which is considerably larger than the superior, conveys not only the blood from the lower half of the body, but also that which is returned from the placenta and the liver. This latter stream of blood reaches the vena cava inferior, partly by a direct passage—the *ductus venosus*—and partly by the hepatic veins, which bring to the vena cava inferior all the blood circulating through the liver, whether derived from the supply of placental blood entering that organ by the umbilical vein, or proceeding from the vena portæ or hepatic artery.

The blood of the superior vena cava is believed to pass through the right auricle into the right ventricle, whence it is propelled into the trunk of the pulmonary artery. A small part is distributed through the branches of that vessel to the lungs, and returns by the pulmonary veins to the left auricle; but, as these vessels remain small up to the time of birth, by far the larger part passes through the ductus arteriosus into the descending aorta, and is thence distributed in part to the lower half of the body and the viscera, and in part along the umbilical arteries to the placenta. From these several organs it is returned by the vena cava inferior, the vena portæ, and the umbilical vein; and, as already noticed, reaches the right auricle through the trunk of the inferior cava.

Of the blood entering the heart by the inferior vena cava, it is supposed that only a small part is mingled with that of the superior cava, so as to pass into the right ventricle; by far the larger portion is thought to be directed by the Eustachian valve through the foramen ovale into the left auricle, and thence, together with the small quantity of blood returned from the lungs by the pulmonary veins, to pass into the left ventricle, whence it is sent into the arch of the aorta, to be distributed almost entirely to the head and upper limbs.

Sabatier was the first to call attention particularly to the action of the Eustachian valve in separating the currents of blood entering the right auricle by the superior and inferior venæ cavæ. This separation, as well as that occurring between the currents passing through the aortic arch and the ductus arteriosus into the descending aorta, was illustrated experimentally by John Reid. A striking confirmation of the extent to which the last mentioned division of the two currents of the fœtal blood may take place, without disturbance of the circulation up to the time of birth, is afforded by the examples of malformation in which a complete obliteration has existed in the aortic trunk immediately before the place of the union of the ductus arteriosus with the posterior part of the aortic arch.

In earlier stages of development than those above described, it is certain that there is little or no separation of the two kinds of blood, for both the umbilical veins from the placenta and the veins from the yolk sac and body generally, pour their blood together into the sinus venosus, and the mixed blood is then forced through a single somewhat narrowed orifice (*porta vestibuli* of His) into the auricle.

CHANGES IN THE CIRCULATION AT BIRTH.

The changes which occur in the organs of circulation and respiration at birth, and which lead to the establishment of their permanent condition, are more immediately determined by the inflation of the lungs with air in the first respiration, the accompanying rapid dilatation of the pulmonary blood-vessels with a greater quantity of blood, and the interruption to the passage of blood through the placental circulation. These changes are speedily followed by shrinking and obliteration of the ductus arteriosus, and of the hypogastric arteries from the iliac trunk to the place of their issue from the body by the umbilical cord; by the cessation of the passage of blood through the foramen ovale, and somewhat later by the closure of that foramen, and by the obliteration of the umbilical vein as far as its entrance into the liver, and of the ductus venosus behind that organ.

The process of obliteration of the arteries appears to depend at first mainly on the contraction of their coats, but this is very soon followed by a considerable thickening of their substance, reducing rapidly their internal passage to a narrow tube, and leading in a short time to final closure, even although the vessel may not present externally any considerable diminution of its diameter. It commences at birth, and is perceptible after a few respirations have occurred. It makes rapid progress in the first and second days, and by the third or fourth day the passage through the umbilical arteries is usually completely interrupted. The ductus arteriosus is rarely found open after the eighth or tenth day, and by three weeks it has in almost all instances become completely impervious.

The process of closure in the veins is slower; but they remain empty of blood and collapsed, and by the sixth or seventh day are generally closed.

Although blood ceases at once to pass through the foramen ovale from the moment of birth, or as soon as the left auricle becomes filled with the blood returning from the lungs, and the pressure within the two auricles tends to be more equalised during their diastole, yet the actual closure of the foramen is more tardy than any of the other changes now referred to. It is gradually effected by the union of the forepart of the valve of the fossa ovalis with the margin of the limbus of Vieussens on the left side; but the crescentic margin is generally perceptible in the left auricle as a free border beyond the place of union, and not unfrequently the union remains incomplete, so that a probe may be passed through the reduced aperture. In many cases a wider aperture remains for more or less of the first year of infancy, and in certain instances there is such a failure of the union of the valve as to allow of the continued passage of venous blood, especially when the circulation is disturbed by over-exertion, from the right to the left auricle, as occurs in the malformation attending the morbus cœruleus.

THE LYMPHATIC SYSTEM.

The development of the lymphatic system has been studied in the chick by Budge. Here there exist a network of lymphatics agreeing in their general distribution with the blood-vessels in the vascular area. This is the first lymphatic circulation; a second one is formed later, corresponding with the allantoic circulation. The lymphatics of both systems communicate with the cœlom, but only those of the second circulation communicate with veins. The lymphatics lie in the vascular area above and close to the blood-vessels, but are separated near the embryo by a layer of mesoblast continuous with the splanchnopleure.

The method of development of lymphatic vessels and lymphatic glands, is dealt with in the chapter on Histology.

RECENT LITERATURE.

- Blaschek, A.**, *Untersuchung über Herz, Pericard, Endocard und Pericardialhöhle*, Mittheil. aus dem embryol. Institut der Universität Wien, 1885.
- Born, G.**, *Entwicklung des Säugethier-herzens*, Archiv f. mikr. Anat., Bd. 33, 1889.
- Budge, A.**, *Untersuchungen über die Entwicklung des Lymphsystems beim Hühnerembryo*, Arch. f. Anat. u. Physiol., Anat. Abtheil., 1887.
- Fürstig, J.**, *Untersuchungen über die Entwicklung der primitiven Aorten mit besonderer Berücksichtigung der Beziehungen derselben zu den Anlagen des Herzens*, Schriften herausgegeben von der Naturf. Gesellsch. bei der Univers. Dorpat, I., 1884.
- Greenfield, W. S.**, *Case of malformation of the heart, &c.*, Journal of Anat. and Physiol., 1890.
- Hochstetter, F.**, *Beiträge zur Entwicklungsgeschichte des Venensystems der Amnioten*, Morpholog. Jahrbuch, Bd. xiii., 1888.
- Mackay, J. Yale**, *The development of the branchial arterial arches in birds, with special reference to the origin of the subclavians and carotids*, Philosophical Transactions, B, 1888.
- Marius, J.**, *Quelques notes sur le développement du cœur chez le poulet*, Arch. de biol., 1889.
- Mayer, P.**, *Ueber die Entwicklung des Herzens und der grossen Gefässstämme bei den Selachiern*, Mitth. d. zool. Station zu Neapel, Bd. vii., 1887.
- Müller, Erik**, *Studien über den Ursprung der Gefässmuskulatur*, Archiv. f. Anat. u. Physiol. Anat. Abth., 1888.
- Rabl, C.**, *Ueber die Bildung des Herzens der Amphibien*, Morphol. Jahrbuch, 1886; *Ueber die Bildung der Herzanlage*, Wiener Medicin. Presse, 1886.
- Röse, C.**, *Beiträge zur Entwicklungsgeschichte des Herzens*, Dissert. Heidelberg, 1888, and Morphol. Jahrb. xv.
- Rückert, J.**, *Ueber den Ursprung des Herzendothels*, Anat. Anzeiger, 1887; *Ueber die Entstehung der endothelialen Anlagen des Herzens und der ersten Gefässstämme bei Selachier-Embryonen*, Biolog. Centralb., Bd. viii., 1888.
- Schimkewitsch, W.**, *Ueber die Identität der Herzbildung bei den Wirbel- und wirbellosen Thieren*, Zoolog. Anz., 1885.
- Schwink, F.**, *Ueber die Entwicklung der Herzendothels der Amphibien*, Anat. Anzeiger, 1890.
- Türstig, J.**, *Mittheilungen über die Entwicklung der primitiven Aorten nach Untersuchungen an Hühnerembryonen*, Dissert. Dorpat., 1886.
- Van Bemmelen, J. F.**, *Die Visceraltaschen und Aortenbogen bei Reptilien und Vögeln*, Zool. Anzeiger, 1886.
- Zimmermann, W.**, *Ueber ein zwischen Aorten- u. Pulmonalbogen gelegenen Kiemenarterienbogen beim Kaninchen*, Anat. Anzeiger, 1889.

DEVELOPMENT OF THE SEROUS CAVITIES AND OF THE MUSCLES AND SKELETON.

The **serous cavities**—peritoneum, pleuræ, pericardium—are derived from the original split or cleavage of the mesoblast, which constitutes the coelom or general body cavity (pleuro-peritoneal cavity of older authors). This cleft is formed in the head as well as in the trunk, and when the heart is formed as a double tube, each half is enclosed within a portion of that cavity, which later on, when the body walls bend round and meet to enclose the fore-gut, comes, like the heart itself, to occupy a position on the ventral aspect of the alimentary tube. The part of the coelom which thus contains the heart is not for some time entirely distinct, but communicates dorsally by two comparatively narrow channels with the anterior part of the general body cavity, here separated into lateral halves, which ultimately become the pleuræ,¹ by the alimentary canal. Subsequently these communications become obliterated, and the heart-coelom separated as a distinct cavity (pericardial cavity). Below, where the great veins enter the heart, they pass into a mass of mesoblastic tissue, which is connected with the anterior body wall (where it receives the umbilical and vitelline veins), and also with the lateral wall (where it receives the ducts of Cuvier), and which, as the heart bends, so that the venous end passes behind the ventricle and bulb, is carried along with the veins up behind that organ, and thus forms an obliquely placed thick septum, at first incomplete, but subsequently becoming entirely closed, which separates the heart within the pericardial part of the body cavity in front and above from the stomach and alimentary canal within the peritoneal part of that cavity behind and below. The thick septum, besides containing the saccus reuniens and the portions of the great veins (vitelline, umbilical, ducts of Cuvier) which open into that cavity, also contains the rudiments of a part of the diaphragm and the mesoblastic part of the liver, into which the hypoblastic part grows from the adjacent duodenum; it has been termed by His the *transverse septum* (see figs. 177, 178). As development proceeds, the septum becomes gradually differentiated into its several parts. The great veins become still further shifted behind the heart, and the saccus reuniens becomes incorporated with that organ. The liver, which is at first contained entirely within the septum, becomes split off from its upper layer, which now forms the thin portion of the diaphragm, while the cavity of the peritoneum extends from either side, and separates them from one another, except along the attachment of the broad ligaments.

The diaphragm is completed by a growth of mesoblast which occurs on each side, and cuts off the antero-dorsal portions of the body-cavity into which the lungs are invaginated (*recessus pulmonales*) from the posterior or peritoneal part.

The serous membranes are formed by differentiation of the lining mesoblast of the coelom.

The formation of the omenta, and the changes which the mesenteric folds of peritoneum undergo, have been already mentioned in connection with the development of the abdominal viscera.

Development of the muscles.—The muscles of the trunk are formed from the protovertebræ. These are at first, as previously described, separate masses of mesoblast, the cells of which have at the periphery of the mass a tendency to a radial disposition (fig. 189, A), whilst toward the centre they are loosely arranged,

¹ The manner in which the pleuræ are invaginated by the growing lungs has already been alluded to (p. 110).

and may even leave a more or less distinct space unoccupied by cells (protovertebral cavity). This cavity has occasionally been noticed (Lockwood, Bonnet) to be continuous laterally with the mesoblastic (coelomic) cleavage (fig. 189, B; see also

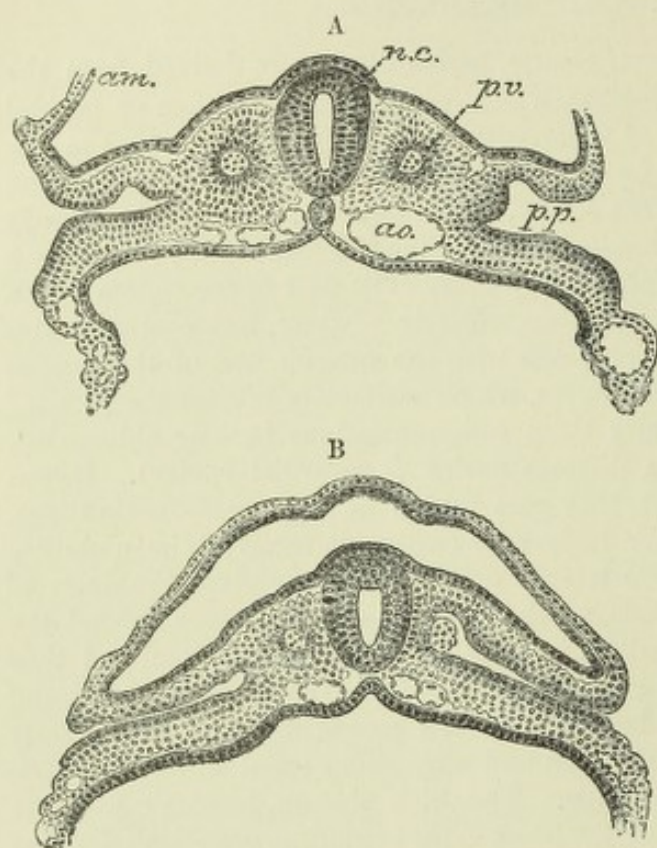


Fig. 189.—TWO SECTIONS OF A SHEEP EMBRYO. (Bonnet.)

A, shows the cavity within the protovertebrae. In B, the protovertebra on the left side of the section is united with the lateral mesoblast; on the right side its cavity also is continuous with the coelomic cleft in that mesoblast. *am.*, amnion; *n.c.*, neural canal; *p.v.*, protovertebra; *a.o.*, aorta; *p.p.*, pleuro-peritoneal space (coelom).

fig. 139, p. 117), and it is probably the morphological equivalent of the coelom in this part of the mesoblast. Whether there be originally a cavity or not in it, the protovertebra presently becomes filled up with cells and then forms a fairly compact mass of cells which are mostly irregularly arranged, but externally (next to the cutaneous epiblast) become regularly disposed into an epithelium-like plate of columnar cells. This is known as the *muscle plate*, and when the

inner part of the protovertebra becomes broken up as a distinct mass and joins with the neighbouring protovertebrae to form the membranous vertebral column (see below), the muscle plates still remain distinct: in them therefore the original

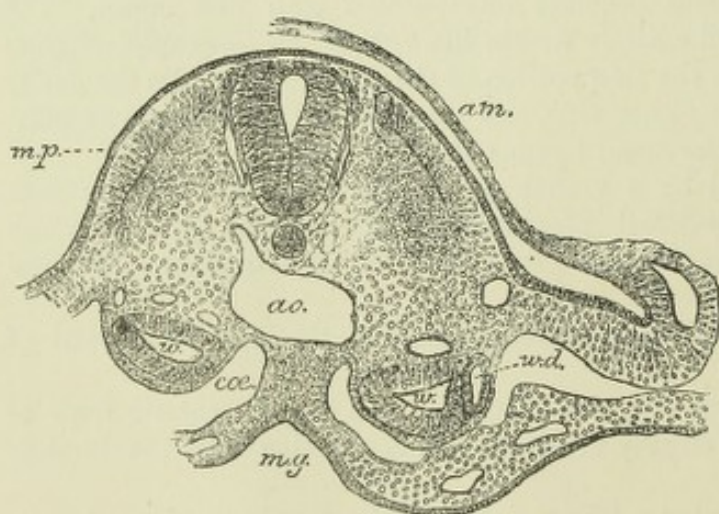


Fig. 190.—TRANSVERSE SECTION OF THE TRUNK OF A CAT EMBRYO, SHOWING MUSCLE PLATES. (E. A. S.)

m.p., muscle plate; *a.o.*, aorta; *m.g.*, mid-gut; *am.*, amnion; *w.*, vesicle of Wolffian body; *w.d.*, Wolffian duct.

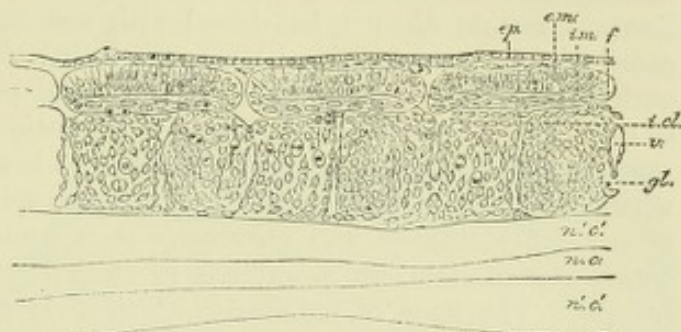
mesoblastic segmentation continues to be exhibited. They do not long remain as a single epithelium-like layer, for the extremities of this layer fold sharply round and become continuous with a cell-stratum,

which immediately lines the internal surface of the columnar layer and forms an *inner muscle-plate* (fig. 190). It is uncertain whether the cells of this inner muscle-plate are derived from part of the columnar layer which has folded over, or whether they spring from other cells of the protovertebra. Soon after their appearance as a distinct layer of the muscle-plate they begin to elongate in the sagittal (antero-

posterior) direction (fig. 191, *i.m.*), and it may presently be observed that they are becoming developed into longitudinal groups or segments of muscle-fibres which stretch between the original intervals between the protovertebræ. The destination of the outer layer of the muscle-plate has not been traced with certainty. Balfour

Fig. 191.—HORIZONTAL LONGITUDINAL SECTION OF THREE PROTOVERTEBRÆ IN A SNAKE EMBRYO.
(v. Ebner.)

ep, cutaneous epiblast; *e.m.*, external layer of muscle-plate; *f*, its margins folded round into *i.m.*, internal layer of muscle-plate composed of flattened cells which are becoming elongated into muscular fibres; *n.c.*, neural canal, in outline only; *n'.c'*, neural epiblast forming its walls. Between these and the muscle-plate is a continuous mesoblastic tissue which has been derived from the inner parts of the protovertebræ, partly interrupted by the ganglion rudiments, *gl.* The original intervals between the protovertebræ here are still indicated by vessels, *v.* *i.cl.*, cleft in the deeper protovertebral tissue (according to Ebner this is the remains of the original protovertebral cavity).



described it as also eventually becoming transformed into muscle-fibres (in elasmobranchs), but others have failed to confirm this opinion, and it is by some believed that it may assist in the formation of the cutis vera.

Although the muscle-plates are originally mainly concerned with the formation of the muscles which move the central skeletal axis, it is probable that all the skeletal muscles both of the trunk and limbs are eventually derived from them (see below, p. 163).

Formation of the muscles of the head and evidences of head segmentation.—Although perhaps no part of the cranium actually represents a vertebra, there is nevertheless abundant evidence of an original segmentation of the head corresponding with the mesoblastic somites of the trunk. Such segmentation is shown by the existence of the visceral arches, which in the typical and least modified vertebrates (*e.g.*, elasmobranchs) are at least nine in number, by the successive separation of the part of the body cavity which extends into the head into separate portions, or head cavities, one corresponding to each visceral arch, the parietes of which develop into muscles, and which therefore correspond with the muscle-plates of the protovertebræ of the trunk (this is in fact the typical mode of formation of mesoblastic somites, *v.* page 26), and lastly by the mode of development of the cranial nerves and their relations to the visceral and branchial arches, which correspond in a general way with the relations of the ventral branches of the spinal nerves to the ribs.

The formation and destination of the head cavities have been investigated of late years (chiefly in elasmobranchs, but also in reptiles and birds) by Balfour, Milnes Marshall, and van Wijhe, and the result of these investigations tends to show that, in all, nine portions of the original head cavity become separated off on either side, their formation proceeding from behind forwards. Each somite cavity becomes subsequently divided into a dorsal part corresponding with the protovertebræ of the trunk and a ventral part, corresponding with the pleuroperitoneal cavity, and lying in the middle of the corresponding visceral arch (¹). Both parts give rise by differentiation of their parietes to muscles; the visceral arch portions to the muscles of the jaw and hyoid and branchial apparatus; the dorsal portions, some (first, second, and third) to the muscles which move the eyes, some (seventh, eighth, and ninth) to the muscles which connect the head with the shoulder girdle, whilst some, *viz.*, the fourth, fifth, and sixth, are said to disappear. The first head cavity forms the eye muscles, which are supplied by the third nerve; the second, the muscle supplied by the fourth (superior oblique); and the third, the muscle supplied by the sixth (external rectus). In higher vertebrates, the formation of the head cavities and their subsequent destination have not been as yet clearly followed out, although indications of their existence are not wanting.

¹ According to v. Wijhe the intermediate part of the typical somite cavity represents a segmental (artriferous) organ, but this intermediate part is not seen in the head, although it begins to appear in the immediately succeeding somites.

Development of the vertebral column.—The vertebral column is developed around the notochord, except at the anterior end of that structure, which is imbedded in the basis cranii. It is formed from protovertebral mesoblast. The outer part of each protovertebra is transformed into a muscle-plate, and thus the original mesoblastic segmentation is maintained. The inner parts of the protovertebræ do not, however, remain distinct, but blend with one another on each side of the neural canal to form a longitudinal mass, which extends to the side of and subsequently encloses the notochord, and finally sends dorsal prolongations over the neural canal, so that this also receives a continuous mesoblastic investment, forming the *membrana reuniens superior* of Remak. The investment is only incomplete opposite the points where the nerve roots are connected with the spinal cord, and in it there is no sign of any differentiation into vertebræ. It is continuous with a similar investment within the cranium, which extends in front of the notochord into the fronto-nasal process. The mass of mesoblast, which thus encloses the notochord and neural canal, is often spoken of as the membranous vertebral column and cranium, but it represents much more than the cartilaginous and bony structures of those parts, all the investing membranes of the cord and brain and the ligaments of the vertebræ being also derived from it. From it septa pass between the muscle-plates and serve to give attachment to the developing muscle-fibres.

The first appearance of the permanent vertebræ is in the form of cartilage, which becomes formed in this mesoblastic investment on either side of the neural canal, nearly opposite the interval between each two muscle-plates, to form the neural arch. This part of the vertebra therefore alternates with the original mesoblastic somites as represented by the muscle-plates.

According to Froriep, the lateral halves of each cartilaginous neural arch become united below the notochord before the appearance of the rudiments of the cartilaginous bodies, and the latter appear as median accumulations of cartilage, immediately posterior to the hypochordal part of the cartilaginous arch. In most of the vertebræ this hypochordal part of the arch soon disappears as a distinct structure, but in the atlas vertebra the primitive condition is maintained.

The serial arrangement of the musculature represents phylogenetically the original segmentation of the vertebrate body. The segmentation of the vertebral column, on the other hand, has been arrived at later, and has been carried out in dependence upon the muscular segmentation.¹

The cartilage makes its appearance on the fourth day in the chick, on the eleventh or twelfth day in the rabbit, and in the fourth or fifth week in man (Kölliker). It is completed by the sixth or seventh week, soon after which ossification commences. To form the intervertebral discs, the mesoblast between the bodies of the vertebræ acquires a fibro-cartilaginous character, while at the same time the notochord, which gradually elsewhere becomes reduced in size and eventually disappears, here undergoes enlargement, and its cells form an irregular network in the central intervertebral pulp. Its remains are found at all periods of life in the middle of the discs (Luschka).

In the osseous fishes there is an intervertebral dilatation of the notochord, the growth of which proceeds to such a considerable extent as to give rise to a mass of soft gelatinous substance, which occupies the conical hollows of the biconcave vertebral bodies. But in birds, reptiles, and amphibia, where synovial articulations are developed between the vertebral bodies, the notochord soon disappears from the intervertebral spaces, although its remains are seen for some time in the bodies themselves (Gegenbaur).

In mammals, the notochord is constricted within the cartilaginous vertebral body, but dilated in the intermediate parts of this rod, the whole cord being moniliform. At a somewhat later period small dilatations are also to be seen in the epiphysial cartilages (fig. 193).

¹ A. Froriep, "Zur Entwickl. der Wirbelsäule, &c.," Archiv f. Anatomie, 1883 and 1886.

Ribs and Sternum.—The ribs are formed by separate cartilaginous transformation in extensions of the protovertebral mesoblast between the muscle-plates. According to some, they grow out from the cartilaginous vertebræ, but become separate before ossification begins. Similar deposits are formed in connexion with the other vertebræ (except the coccygeal in man), but they here become united by ossification with and form parts of the vertebræ (see Osteology, Vol. II.). At their ventral

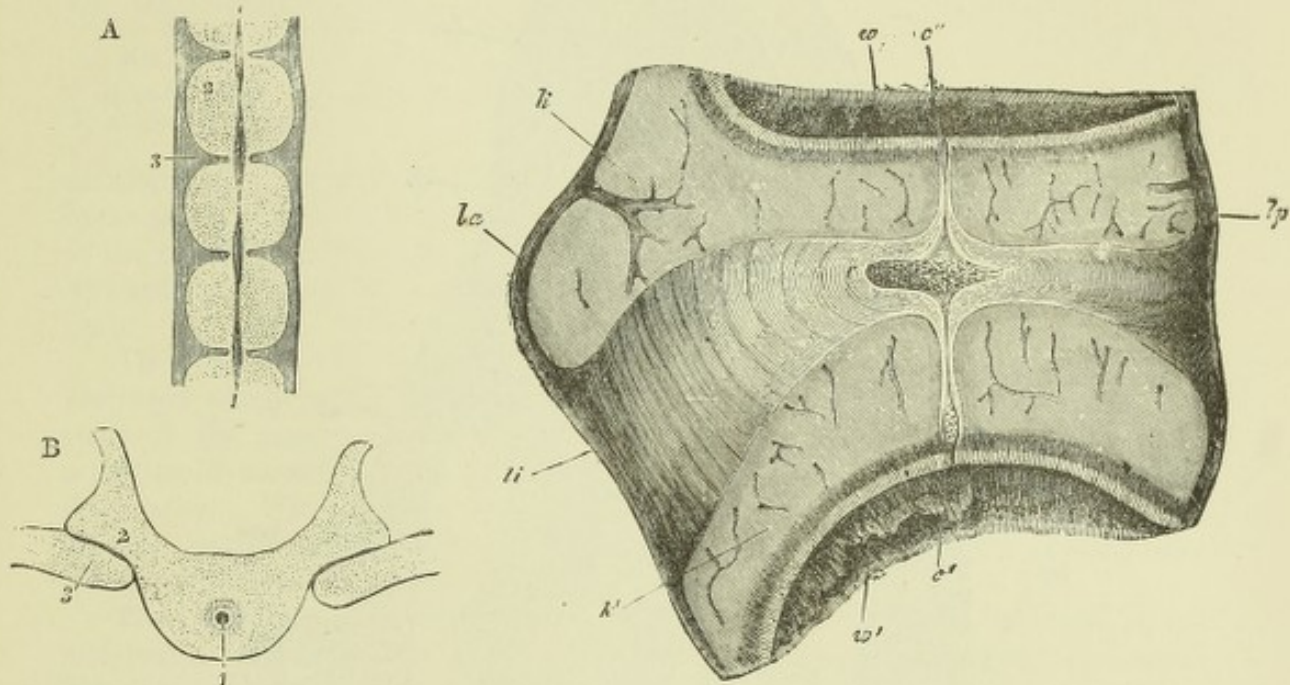


Fig. 192.—SECTIONS OF THE VERTEBRAL COLUMN OF A HUMAN FŒTUS OF EIGHT WEEKS. (From Kölliker.)

A, transverse longitudinal section of several vertebræ. 1, 1, chorda dorsalis, its remains thicker opposite the intervertebral discs; 2, is placed on one of the bodies of the permanent vertebræ; 3, on one of the intervertebral discs.

B, transverse horizontal section through a part of one dorsal vertebra. 1, remains of the chorda dorsalis in the middle of the body; 2, arch of the vertebra; 3, head of a rib.

Fig. 193.—SAGITTAL SECTION OF A DORSAL INTERVERTEBRAL LIGAMENT OF AN ADVANCED SHEEP'S EMBRYO. (Kölliker.)

l.a, l.p, anterior and posterior ligaments; *l.i*, intervertebral ligament; *k, k'*, cartilaginous ends of two vertebral bodies, *w, w'*; *c*, enlargement of notochord in the ligament; *c', c''*, enlargements in the cartilaginous ends of the vertebræ.

extremities the first seven (thoracic) cartilaginous ribs become united on either side into a longitudinal cartilaginous plate, and this afterwards joins its fellow of the opposite side to form the sternum (manubrium and body). The xiphoid is of later formation (Parker). This mode of development of the sternum explains many of the malformations in the shape of fissures of the sternum of different gradation which have been observed.

The Limbs.—The limbs arise as outgrowths from the lateral part of the trunk in the thoracic and pelvic regions in the third day in the chick and in the third and fourth week in the human embryo. They appear as flattened semilunar thickenings of the parietal mesoblast covered by epiblast, budding out from a lateral ridge which is seen in the early embryo near the line of cleavage of the mesoblast and close to the outer margins of the muscle-plates, and several of which subsequently send prolongations into each limb¹; they are therefore connected with several mesoblastic somites, as is also indicated by their nerve supply.

¹ This is the case in elasmobranchs (see fig. 194, from Balfour), but, according to Paterson,

Each limb consists of a part which is sunk in the substance of the lateral ridge, and in which the thoracic or pelvic girdle becomes developed, and of a free or

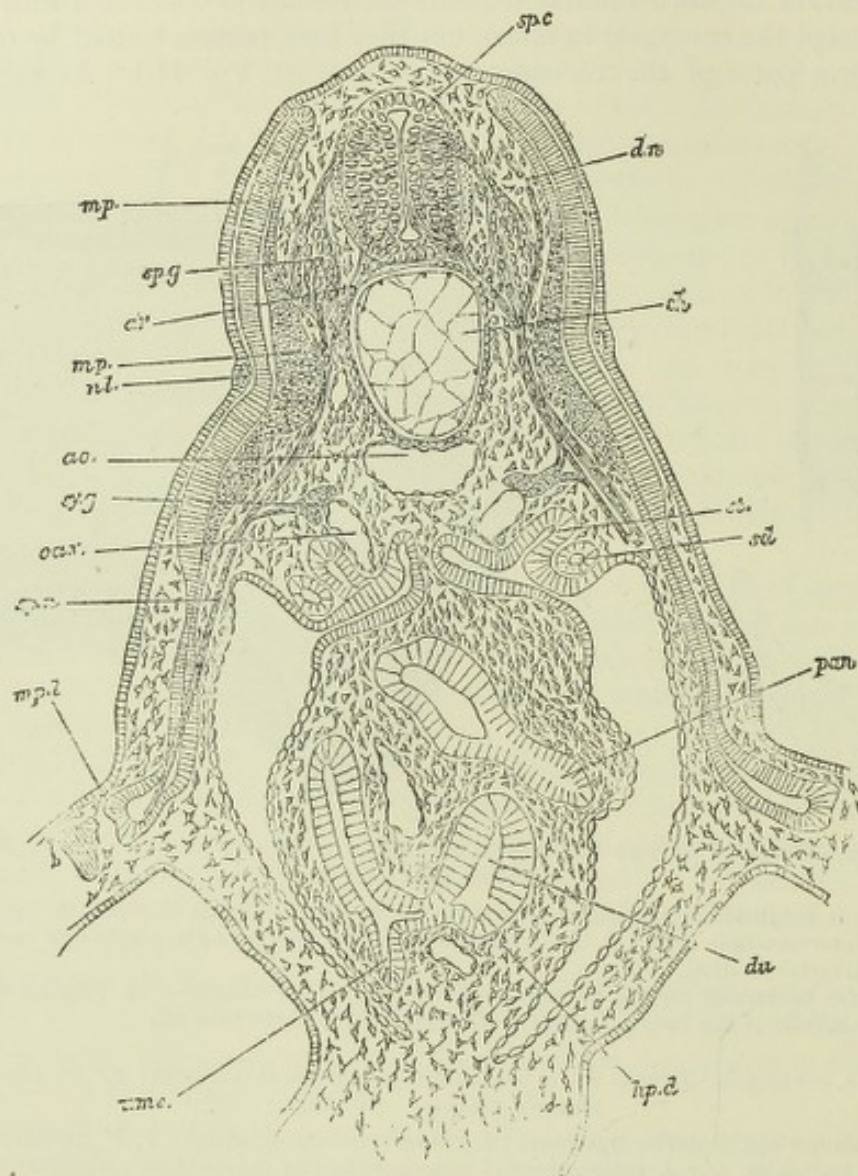


Fig. 194.—TRANSVERSE SECTION THROUGH AN ANTERIOR PART OF THE TRUNK OF AN EMBRYO OF SCYLLIUM. (Balfour.)

sp.c, spinal cord; *sy.g*, ganglion of posterior root; *ar*, anterior root; *dn*, dorsal; *sp.n*, ventral branch of spinal nerve; *mp*, muscle plate; *mp'*, part of muscle plate already converted into muscle; *mpl*, part of muscle plate extending into the limb; *nl*, nervus lateralis; *ao*, aorta; *ch*, notochord; *sy.g*, sympathetic ganglion; *ca.v*, cardinal vein; *sd*, segmental duct; *st*, segmental tube; *du*, duodenum; *hp.d*, junction of hepatic duct with it; *pan*, rudiment of pancreas connected with another part of duodenum; *umc*, opening of umbilical canal (vitelline duct).

projecting part (fig. 195). This is at first quite simple, and represents the distal segment of the limb (hand or foot). The other two segments (forearm and leg; arm and thigh) are successively marked off between it and the girdle by the development of transverse furrows representing the joints (fifth and sixth week). At about the same time four notches appear in the flattened distal extremity, marking off the intervals between the fingers and toes, and the middle segment (fore-arm or leg) begins to be flexed upon the proximal (arm or thigh), the

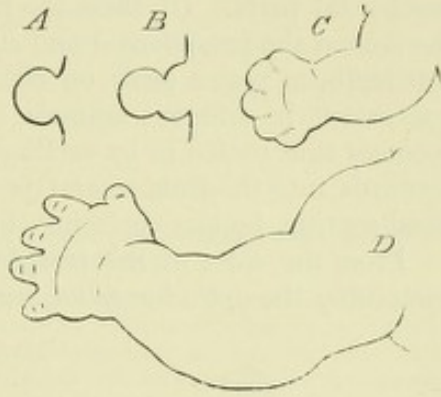
the limbs do not receive such prolongations from the muscle-plates in birds and mammals; the muscles develop *in situ* from previously indifferent mesoblast.

concavity looking forwards in the upper limb and backwards in the lower limb. The limbs also come to be folded ventrally against the body of the embryo.

From the manner in which the flattened limb-bud grows out from the lateral ridge, it is obvious that its surfaces must at first be dorsal and ventral. The dorsal surface afterwards becomes extensor and the ventral flexor. The anterior edge is respectively the radial and tibial; the posterior, the ulnar and fibular. As

Fig. 195.—OUTLINES OF THE ANTERIOR EXTREMITIES OF HUMAN EMBRYOS AT DIFFERENT AGES. (After His.)

A, at four weeks; *B*, at five weeks; *C*, at seven weeks; *D*, at nine or ten weeks.



development proceeds, a half rotation occurs in opposite directions in the two limbs, resulting in the middle flexure (elbow, knee) being directed forwards in the upper, backwards in the lower limb.

The bones of the limbs are laid down as cartilages which appear as separate differentiations of the more centrally placed mesoblast, a portion of mesoblast remaining for a time undifferentiated opposite each synovial articulation. Within this a cleft subsequently appears, and enlarges to form the synovial cavity, the mesoblast which bounds the cleft developing eventually into the synovial membrane and capsular ligaments of the joint.

The cranium.—In the head the notochord extends as far forwards as the mid-brain. Here also it is invested by a continuous mass of mesoblast, which sends lateral prolongations over the neural canal as in the trunk (*membrana reuniens*).

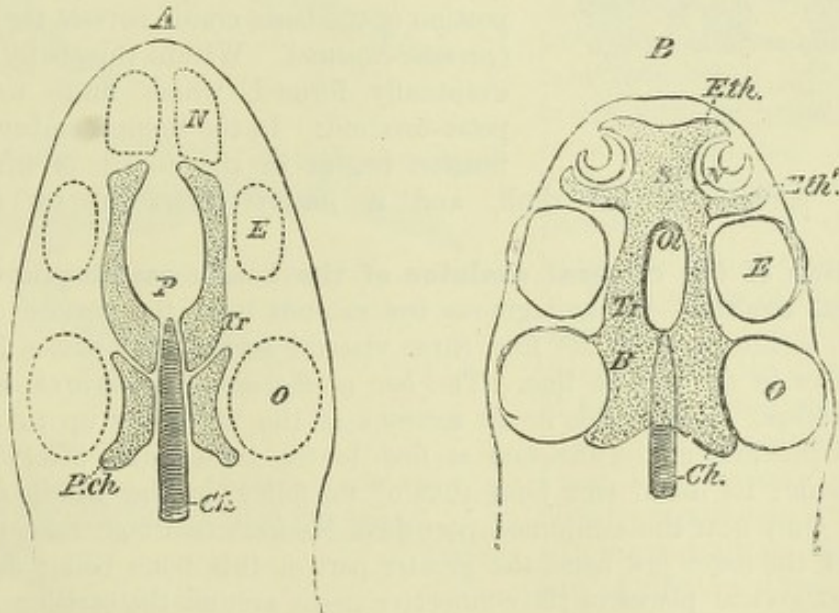


Fig. 196.—DIAGRAMS OF THE CARTILAGINOUS CRANIUM. (Wiedersheim.)

A, First stage.

Ch, notochord; *Tr*, trabeculae cranii; *P.ch*, parachordal cartilages; *P*, situation of pituitary body; *N*, *E*, *O*, situations of olfactory, visual and auditory organs.

B, Second stage.

B, basilar cartilage (investing mass of Rathke); *S*, nasal septum and ethmoidal cartilage; *Eth*, *Eth'*, prolongations of ethmoidal around olfactory organ, completing the nasal capsule; *Ol*, foramina for passage of olfactory nerve-fibres; *N*, *E*, *O*, *Ch*, *Tr*, as before.

The main difference in development between the cranium and vertebral column consists in the fact that no separate cartilaginous deposits to form vertebrae occur

within the head, nor can any parts be distinguished which strictly represent *vertebræ*. The cartilage of the basis cranii makes its appearance in the form of two longitudinal bars lying on either side of the notochord (*parachordal cartilages*), and of two other bars (*trabeculae cranii* of Rathke) which embrace the pituitary body, and which become united together in front and with the parachordals behind to form a continuous mass, which posteriorly completely invests the notochord (fig. 196). The cartilaginous basis cranii may therefore be distinguished into the parachordal and prechordal parts. Of these the first represents the basi-occipital and basi-sphenoid, the second the presphenoid and ethmoid portions. From the basis cranii continuous cartilaginous plates grow on either side over the cerebral vesicles to a greater or less extent in different animals, least in mammals, where only the occipital region becomes thus roofed in by cartilage. Anteriorly the united *trabeculae cranii* stretch forwards into the fronto-nasal process, where they form the ethmoid cartilage and nasal septum, besides enclosing the nasal pits externally (*cartilaginous nasal capsule*).

From the sides of the presphenoid portion the orbito-sphenoids (lesser wings), containing the optic foramina, are developed, and from the sides of the basi-sphenoid,

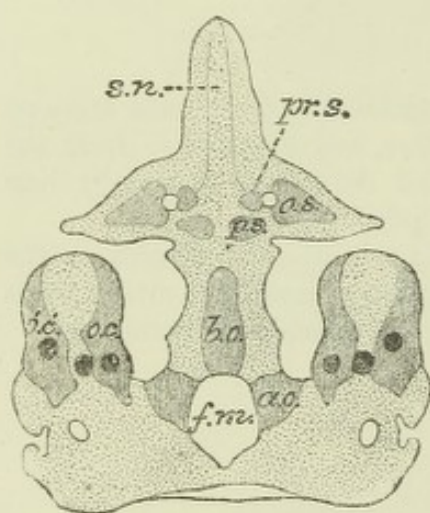


Fig. 197.—VIEW FROM BELOW OF THE CARTILAGINOUS CRANIUM WITH ITS OSSIFIC CENTRES IN A HUMAN FETUS OF ABOUT FOUR MONTHS. (After Huxley.)

The cartilage is dotted to distinguish it from the bone which is shaded with lines.

b.o., basi-occipital; a.o., lateral occipitals; f.m., foramen magnum; o.c., o'.c', bony deposits in the periotic capsule; p.s., post-sphenoid; pr.s., pre-sphenoid; o.s., orbito-sphenoid; s.n., septum nasi.

the greater wings or alisphenoids. A cartilaginous capsule, connected with the parachordal portion of the basis cranii, invests the otic vesicle (*periotic capsule*). Within this, bony centres are eventually formed, which unite to form the petro-mastoid. In the human embryo, chondrification begins in the fourth or fifth week in

the basilar portion of the skull, and is nearly completed by the eighth week.

Formation of the visceral skeleton of the head: cartilaginous bars of the visceral arches.—A cartilaginous bar extends from the periotic capsule and basis cranii, within each of the first three visceral arches, and passes forwards to meet its fellow in the middle line. The bar of the mandibular arch is known as *Meckel's cartilage*. It is visible in all sections of the foetal jaw up to the seventh month. Its proximal end is attached at first to the basis cranii, afterwards to the periotic capsule; its distal end joins that of its fellow in the middle line of the lower jaw. Only near this conjoined part does Meckel's cartilage take part in the formation of the lower jaw bone, the greater part of this bone being developed by ossification at several places in the connective tissue around the cartilage. In some animals a short cartilaginous bar is formed in the maxillary process (*palato-ptyergoid bar*, fig. 198, A, *ppg*). Close to it the palatine and pterygoid bones are formed in membrane, but the bar itself entirely disappears. The second or hyoid bar arises from the skull close behind the attachment of Meckel's cartilage, and passes along the second arch. It disappears in part, but in part is converted into the styloid process, stylo-hyoid ligament, and lesser cornu of the hyoid bone. The body of the hyoid bone (basi-hyal) is an intermediate formation between the second and third arches. The bar of the third arch is known as the *thyro-hyoid*. Its lower end forms the greater cornu of the hyoid bone; but its attachment to the skull early disap-

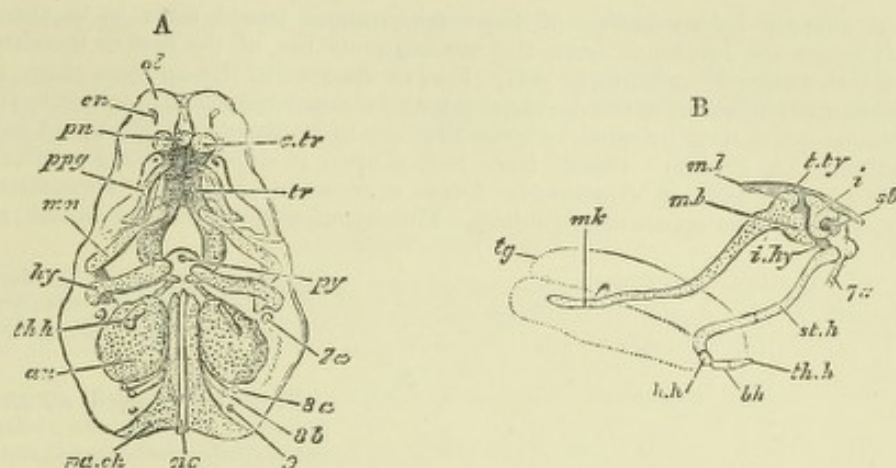


Fig. 198, A.—ELEMENTS OF THE SKULL OF AN EMBRYO PIG, 2-INCH LONG, VIEWED FROM BELOW : SEMIDIAGRAMMATIC. (From Balfour after Parker.)

pa.ch, parachordals; *nc*, notochord; *au*, otic capsule; *py*, pituitary; *tr*, trabeculae; *c.tr*, cornu of the trabecula; *pn*, prenasal cartilage; *en*, external nares; *ol*, olfactory region; *p.pg*, palatopterygoid bar enclosed in the maxillo-ptyergoid process; *mn*, mandibular bar; *hy*, hyoidean bar; *th.h*, thyrohyoid bar; *7a*, aperture for facial nerve; *8a*, for glossopharyngeal; *8b*, for vagus; *9*, for hypoglossal.

Fig. 198, B.—SIDE VIEW OF THE MANDIBULAR AND HYOID ARCHES IN AN EMBRYO PIG OF 1 1/2 INCH IN LENGTH. (From Balfour, after Parker.)

tg, tongue; *mk*, Meckel's cartilage; *ml*, body of malleus; *mb*, its manubrium or handle; *t.ty*, tegmen tympani; *i*, incus; *st*, stapes; *i.hy*, inter-hyal ligament; *st.h*, stylo-hyal cartilage; *h.h*, hyohyal; *bh*, basibranchial; *th.h*, rudiment of first branchial arch; *7a*, facial nerve.

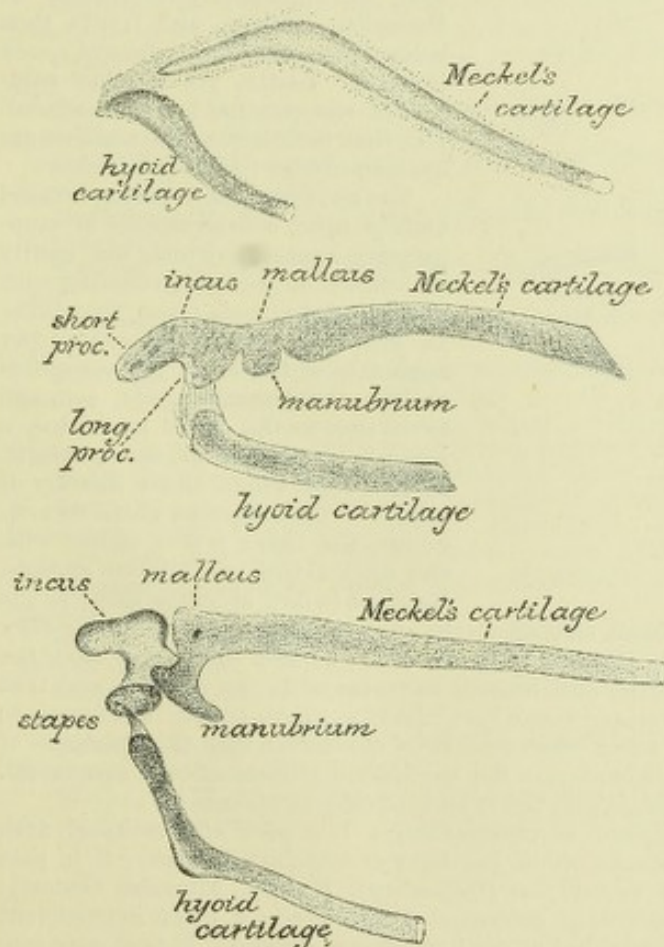


Fig. 199.—PREPARATIONS SHOWING THREE STAGES OF THE CARILAGINOUS BARS OF THE 1ST AND 2ND ARCHES IN THE EMBRYO OF THE SHEEP. (Salensky.)

pears, or in some animals may not be found at all. This bar is in all cases of less importance than the first two, from the proximal parts of which important structures connected in lower vertebrates with the suspensory apparatus of the lower jaw, in the higher vertebrates with the apparatus for sound transmission to the internal ear are developed.

Formation of the auditory ossicles.—If the embryonic development of the bars is studied in man and other mammals, it is found that at a certain period of foetal life Meckel's cartilage is directly continuous with the cartilaginous malleus, above which, and at first in direct continuity with it, is the cartilaginous incus (fig. 199); these two ossicles therefore appear as the enlarged and modified proximal end of Meckel's cartilage. Somewhat later the incus becomes detached from the malleus, but the latter long remains in continuity with Meckel's cartilage (fig. 200).

The most obvious interpretation of these appearances would seem to be that both the malleus and incus are developed from the cartilaginous bar of the first or mandibular arch. This view is not, however, universally held. For, as the several illustrations show, the second or hyoid bar is also connected to the developing incus, through which it is joined to the periotic capsule. Hence it has been inferred by some that the incus belongs to the hyoid bar, and not to the mandibular (A. Fraser). Others have looked upon it as representing a hyomandibular cartilage, like that which in Sauropsida forms a common suspensory apparatus for both mandibular and hyoidean apparatus (Huxley). This hyomandibula itself, however, may repre-

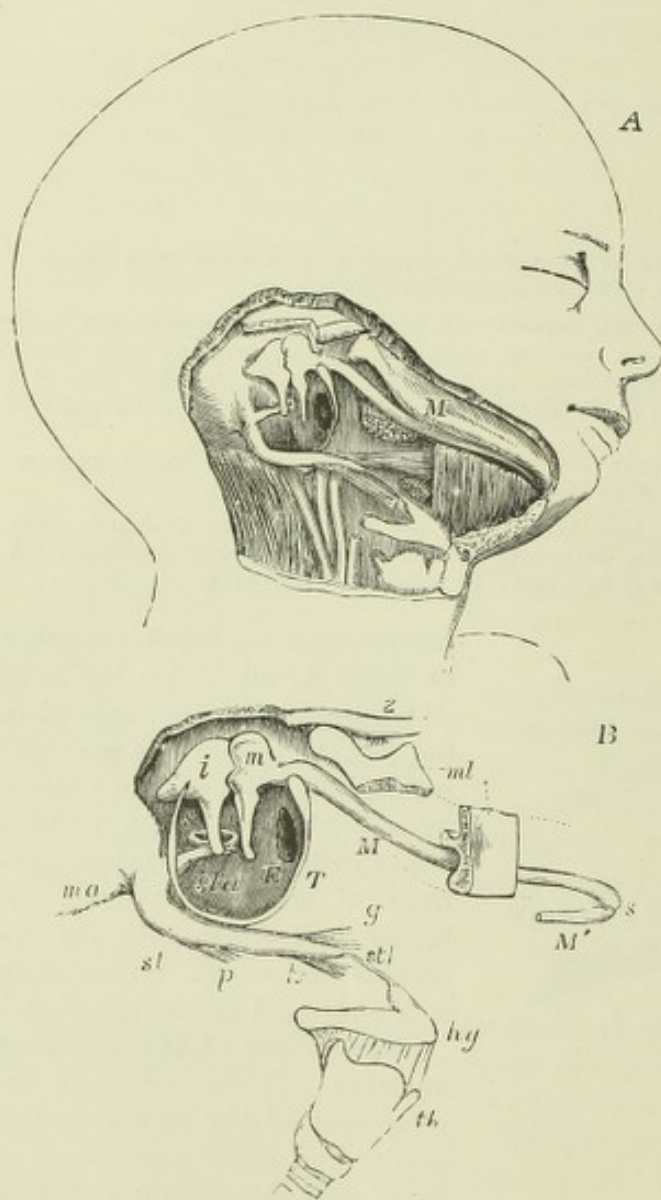


Fig. 200.—CONDITION OF MECKEL'S CARTILAGE AND THE HYOID BAR IN THE HUMAN FETUS OF ABOUT 18 WEEKS. (Kölliker.)

B, is an enlarged sketch by Allen Thomson, showing the relationship of the several parts better than in A.

z, zygomatic arch; *ma*, mastoid process; *mi*, portions of the lower jaw left in situ, the rest having been cut away; *M*, Meckel's cartilage of the right side, continued at *s*, the symphysis, into that of the left side *M'*, of which only a small part is shown; *T*, tympanic ring; *m*, malleus; *i*, incus; *s*, stapes; *sta*, stapedius; *st*, styloid process; *p*, *h*, *g*, stylopharyngeus, stylohyoid, and styloglossus muscles; *stl*, stylohyoid ligament attached to the lesser cornu of the hyoid bone, *hg*; *th*, thyroid cartilage.

sent an upward prolongation of Meckel's cartilage, and would then belong to the 1st visceral arch (Peters). Lastly, yet another solution of the question has been offered, viz., that both incus and malleus are hyomandibular (Albrecht, Gadow).

The last mentioned opinion is based mainly upon considerations of comparative anatomy, which can hardly be left out of account in dealing with the morphology of these structures. In lower Vertebrata the suspensory apparatus of the lower jaw comprises besides the hyomandibula, common to it and to the hyoid apparatus, a large bone, known as the quadrate, by means of which, either directly or with the intercalation of an os articulare, the lower jaw is united with the basis cranii and periotic capsule. Reichert looked upon the incus as the

homologue of the quadrate, and the malleus as that of the os articulare; and the same view was taken by Gegenbaur. Huxley, on the other hand, came to the conclusion that the homologue of the quadrate bone of reptiles and birds is to be found in the malleus, and that the incus represents a portion of the hyomandibular bar, which, as above stated, is common to both first and second arches. Various other observers have concluded that the quadrate of lower vertebrates is represented in mammals by the zygomatic process of the squamosal. Gadow, however, looks upon it as represented by the tympanic ring of mammals.

The stapes has been variously described as representing: 1, a part of the hyoid arch (Reichert); 2, a part of the periotic capsule which has become detached (Parker); 3, in part or wholly, the hyomandibula of lower vertebrates (Gegenbaur, Huxley, Albrecht, Gadow); 4, hyomandibula and detached periotic cartilage conjoined (Gradenigo); 5, as an independent circular deposit of cartilage around the stapedia artery¹ (Salensky, Fraser). It is at any rate closely connected with the hyoid bar, which forms from above down the tympano-hyal and

¹ This artery disappears in man, but is persistent in many mammals.

styloid processes, the stylo-hyoid ligament and the lesser cornua of the hyoid bone (ceratohyal).

The remaining bones of the visceral skeleton of the head, viz., the maxillary, malar, palatine, pterygoid, vomer, nasal, and lachrymal, are all formed in membrane. An account of their development is given in the Osteology (Vol. II.).

RECENT LITERATURE.

- Ahlborn**, *Ueber die Segmentation des Wirbelthierkörpers*, Zeitschr. f. wiss. Zool., xl.
- Albrecht**, *Sur la valeur morphologique de l'articulation mandibulaire, du cartilage de Meckel et des osslets de l'ouïe*, Bruxelles, 1883; *Sur la valeur morphologique de la trompe d'Eustache*, &c., Bruxelles, 1884.
- Balfour**, *On the development of the skeleton of the paired fins of Elasmobranchii*, &c., Proc. Zool. Soc., 1881.
- Baur**, *On the quadrate in the Mammalia*, Quarterly Journal of Microsc. Science, August, 1887.
- Bemmelen**, v., *Ueber die Herkunft der Extremitäten u. Zungenmuskulatur bei Eidechsen*, Anat. Anzeiger, 1889.
- Braun**, M., *Ueber den Schwanz bei Säugethiereembryonen*, Deutsche Zeitschr. f. Thiermedizin, ix., 1883.
- Cadiat**, *Du développement de la partie cephalo-thoracique de l'embryon, de la formation du diaphragma*, &c., Journal de l'anatomie, T. xiv., 1878.
- Dohrn**, *Bemerkungen ü. d. neuesten Versuch einer Lösung des Wirbelthierkopf-Problems*, Anat. Anzeiger, 1890. Also numerous papers in *Mittheilungen d. zool. Station zu Neapel*.
- Dollo**, *On the malleus of the Lacertilia and the malar and quadrate bones of Mammalia*, Quarterly Journal of Microsc. Science, 1883.
- Ebner**, V. v., *Urwirbel und Neugliederung der Wirbelsäule*, Sitzungsber. der Wiener Akad., 1888.
- Fraser**, *On the development of the ossicula auditus in the higher Mammalia*, Phil. Trans., 1882.
- Froriep**, A., *Zur Entwicklungsgeschichte der Wirbelsäule, insbesondere des Atlas und Epistropheus und der Occipitalregion*, Arch. f. Anat. u. Entwicklungsgesch., 1883 and 1886.
- Gadow**, *On the modifications of the first and second visceral arches, with especial reference to the homologies of the auditory ossicles*, Philos. Trans., 1888.
- Gegenbaur**, *Die Metamerie des Kopfes und die Wirbeltheorie des Kopfskelets*, Morphol. Jahrb., xiii., 1887.
- Gradenigo**, G., *Die embryonale Anlage des Mittelohres: die morphologische Bedeutung der Gehörknöchelchen*, Wiener med. Jahrbücher, 1887.
- His**, W., *Mittheilungen zur Embryologie der Säugethiere u. des Menschen*, Archiv f. Anat. u. Physiol., Anat. Abth., 1881.
- Hoffmann**, C. K., *Ue. die morphologische Bedeutung des Gehörknöchelchens bei d. Reptilien*, Zool. Anzeiger, xii.
- Köstlin**, *Der Bau des knöchernen Kopfes in den vier Klassen der Wirbelthiere*, Stuttgart, 1884.
- Lockwood**, C. B., *The early development of the pericardium, diaphragm, and great veins*, Proceed. of the Royal Society, 1887.
- Noorden**, W. v., *Beitrag zur Anatomie der knorpeligen Schädelbasis menschlicher Embryonen*, Arch. f. Anat. u. Phys., Anat. Abth., 1887.
- Parker**, W. K., *Various important papers on the structure and development of the skull in the Philosophical Transactions of the Royal Society and the Transactions of the Zoological Society*.
- Rabl**, C., *Theorie des Mesoderms*, Morphol. Jahrb., xv.
- Ravn**, E., *Ue. die Bildung der Scheidewand zwischen Brust- und Bauchhöhle in Säugethiereembryonen*, Arch. f. Anat. u. Physiol., Anat. Abth., 1889; *Untersuchungen ue. d. Entwickl. des Diaphragmas*, &c., Arch. f. Anat. u. Physiol., Anat. Abth., 1889.
- Salensky**, *Beiträge zur Entwicklungsgeschichte der knorpeligen Gehörknöchelchen bei Säugethiern*, Morphol. Jahrb., vi.
- Strahl u. Carius**, *Beitr. zur Entwickl. des Herzens u. d. Körperhöhlen*, Arch. f. Anat. u. Physiol., Anat. Abth., 1889.
- Strazza**, G., *Zur Lehre über die Entwicklung der Kehlkopfmuskeln*, Wiener med. Jahrbücher, 1888.
- Uskow**, N., *Ueber die Entwicklung des Zwerchfells, des Pericardiums und des Cöloms*, Archiv f. mikrosk. Anatomie, Bd. 22, 1883.
- Wijhe**, J. W. van, *Ueber die Kopfsegmente und die Phylogenie des Geruchsorgans der Wirbelthiere*, Zoolog. Anzeiger, 1886; *Die Kopfregion der Cranioten beim Amphioxus*, Anat. Anzeiger, iv.

INDEX OF PART I.

- ABDOMINAL stalk, 46
 Accessory thyroids, 111
 Alæ nasi, 96
 Albrecht on auditory ossicles, 168
 Alecithal ova (α , not, $\lambda\eta\kappa\upsilon\theta\omicron\varsigma$, oil-bottle), definition, 9
 invagination of, 22
 Alimentary canal, development of, 99
 Allantoic arteries. *See* UMBILICAL.
 fluid, 46
 tube, 36
 Allantois ($\alpha\lambda\lambda\alpha\iota\varsigma$, sausage, $\epsilon\iota\delta\omicron\varsigma$, form), formation of, 43
 first appearance of, 44
 structure of, 44
 in what animals found, 45
 hypoblastic sac of, 46
 pedicle of, 46
 variation of period of development, 46
 connection, with alimentary canal, 101, n.
 with bladder, 122
 Amnion ($\alpha\mu\acute{\nu}\iota\omicron\nu$, a bowl in which victim's blood was caught, the caul), earliest appearance of in human embryo, 46
 false, 42
 formation of, 42
 in guinea pig, 43, 46
 resulting from invagination, 24
 true, 42
 Amniota, 42
 Amphibia, liver in, 112
 Wolffian duct in, 118
 heart in, 136
 Amphioxus ($\alpha\mu\phi\acute{\iota}$, double, $\delta\epsilon\acute{\upsilon}\varsigma$, a point), alecithal ova of, 9
 invagination of blastoderm of, 22, 24
 origin of mesoblast in, 22, 26
 mesenchyme in, 27
 notochord in, 34
 mesoblastic somites in, 37
 Amygdalæ ($\alpha\mu\gamma\delta\acute{\alpha}\lambda\eta$, almond), 66
 Anal membrane, the, 108
 Analogy, $\alpha\acute{\nu}\acute{\alpha}$, according to, $\lambda\acute{o}\gamma\omicron\varsigma$, ratio), definition of, 4
 examples of, 4
 Anatomy, definition of, 1
 departments of, 1
 Angelucci on zonule of Zinn, 87
 Annelida (*annellus*, little ring), 2
 Anterior perforated space, 79
 Anus, formation of, 108, 128
 Aorta ($\alpha\omicron\rho\tau\acute{\eta}$, $\alpha\epsilon\iota\rho\omega$, to lift), primitive, formation of, 38
 descending primitive, 146
 arch of, 148, 150
 bulb of, 144, 147, 148
 descending permanent, 150
 Aortic arches. *See* ARTERIAL ARCHES
 Aqueduct of Sylvius, 62, 67
 Archenteric cavity, primitive ($\alpha\rho\chi\acute{\eta}$, beginning, $\epsilon\nu\tau\epsilon\rho\omicron\nu$, intestine), 26
 Archiblastic cells of His, 25
 Arteria centralis retinae, 85, 87
 Arterial (aortic) arches, formation of, 38, 146
 division of aortic septum by, 144
 origin of principal arteries from, 146, 147, 148
 destination of fourth and fifth, 150
 Arteries ($\alpha\rho\tau\eta\rho\acute{\iota}\alpha$, $\alpha\iota\rho\omega$, to lift), development of, 146
 from arterial arches, 148, 149
 from arches in birds, 150
 ascending pharyngeal, 148
 auricular, 148
 basilar, 149
 carotid, 148, 150
 common iliacs, 147
 innominate, 150
 intercostal, 149
 inter-segmental, 149
 lingual, 148
 maxillary, 148
 middle sacral, 147
 occipital, 148
 pulmonary, 148, 150
 subclavian, 150
 temporal, 148
 umbilical, 44, 146, 156
 vertebral, 149
 vitelline, 40
 Arthropoda ($\alpha\rho\theta\rho\omicron\nu$, a joint, $\pi\omicron\upsilon\varsigma$, a foot), segmental plan of, 2
 centrolecithal ova of, 8
 Aryepiglottic folds, 103
 Arytenoid cartilages ($\alpha\rho\upsilon\tau\alpha\iota\nu\alpha$, a pitcher), 103
 Ascaris megalocephala, polar globules observed in, 9
 fertilisation in, 11, 12
 segmentation of, 16
 Auditory pit, 89
 vesicle, 89
 nerve, 78, 89, 93
 ossicles, 167, 168
 Auricular canal, 142
 Axis, primitive skeletal, 2

 BAER, VON, zona pellucida of, 6
 on bilamination of middle layer of blastoderm, 23
 Balfour, F. M., on amnion and allantois, 45, n.
 blastodermic layers, nomenclature of, 23
 coelom, typical development of, 24
 head cavities, 161
 limbs, 163 n.
 lens-capsule, 87

Balfour, F. M.—*continued*.

- Müllerian duct, 122, 123
 - muscle plate, outer, 161
 - nerves, epiblastic, origin of, 57
 - spinal, anterior roots of, 74
 - neural crest, 73
 - oesophagus, obliteration of lumen of, 104, n.
 - ova, formation of, 124
 - parablast, 27, n.
 - primitive groove, 23
 - polar globules, theory of, 14
 - supra-renals, 122
 - sympathetic system, 81
 - Wolffian body, 115, n.
 - duct, 118
 - vitelline membrane, 8
- Bars, cartilaginous, of mandibular arch, 166, 168
- palato-pterygoid, 166
 - hyoid, 166, 168
 - thyro-hyoid, 166
- Bartholin, glands of, 128
- Basal layer of placental decidua, 51
- attachment of villi to, 52
- Basis cranii, 166
- Bat, placental sinuses in, 52
- Bauchstiel (abdominal stalk), 46
- Beard on branchial sense-organs, 76
- Beneden, v., vitelline membrane, 8
- formation of polar globules, 9
 - entrance of spermatozoon in *Ascaris*, 11
 - division of nucleus in *Ascaris*, 12, 16
 - blastodermic layers, 18
 - blastopore, theory of, 23
 - pro-amnion of, 35
- Bile ducts, 112
- Birdsell on sympathetic nerves, 81
- Bischoff on inversion of blastodermic layers, 23
- Bladder, urinary, 122
- Blastoderm (βλαστός, a bud, δέρμα, skin), formation of, 17, 18
- three layers of, 17
 - gastrula condition of, 21
 - stage typical, 22
 - bilaminar, 21
 - layers, inversion of, 23
 - historically considered, 23, 24
 - characters of layers of, 24
 - table of development from layers of, 25
 - four layers of, 26
 - separation of embryo from, 34
- Blastodermic vesicle, definition of, 17
- growth in the cat of, 18
 - invagination of, 22, 23, 24
 - as yolk-sac, 35
 - first attachment of to uterus, 53
- Blastopore (βλαστός, a bud, πόρος, a passage), discussion of in meroblastic ova, 22, 23
- diverticula, near to in *Sagitta*, 26
 - connection of anus with, 108
- Blochmann on extrusion of one polar globule by parthenogenetic ova, 14
- Blood, origin from parablastic cells, 21, 25
- corpuscles, 40
- Blood islands of Pander, 39
- Blood vessels, formation of, 40
- Body, segmentation of, 2
- Body-cavity. *See* CÆLOM
- Bonnet on middle blastodermic layer, 21
- on connection of notochord with buccal epiblast, 68
 - protovertebral cavity, 160
- Born on the lachrymal canal, 89

Born—*continued*.

- cephalic clefts, 102, n.
 - thyroid, 111
 - septum spurium, 141, n.
 - auricular canal, 142, 144
 - ventricular septum, 142, n.
 - foramen ovale, valve of, 144
 - pulmonary veins, 144
- Boveri on polar globules in *Ascaris*, 9
- Bowman, anterior and posterior homogeneous lamellæ of, 88
- Brain, development of, 61
- flexures of, 63
 - fissures and convolutions of, 71
- Branchial sense-organs of Beard, 76
- Bronchi, 109
- Brown, H. H., on extrusion of part of nucleus of seminal cell, 12
- Budge on lymphatic system, 157
- CÆCUM (blind), 107
- Calamus scriptorius (writing pen), 62
- Callender on 4th visceral arch, 103
- Canalis re-unions, 91
- Capsule of lens, 87
- whence derived, 87
- Capsule, cartilaginous nasal, 166
- periotic, 166
- Carnoy on polar globules in *Ascaris*, 9
- Cat, blastodermic vesicle of, 18
- Cauda equina, 60
- Centra (κέντρον, a point), of vertebræ, 2
- Centrolecithal (κέντρον, centre, λήκυθος, oil-bottle), ova in arthropods, 8
- Cerebellar peduncles, 66
- Cerebellum, 62
- formation of, 66
 - amygdalæ of, 66
- Cerebral vesicles, 37
- table of development from, 61
 - fifth, or bulbar, 63
 - fourth or cerebellar, 66
 - third, mid-brain, 67
 - second, 67
 - first, 68
- Chick, pro-amnion in, 34
- rudiments of cranial nerve ganglia in, 75
- Choanæ (χόανος, a pit for melting metal in), 97, 100
- Chorda dorsalis, 32. *See* NOTOCHORD.
- Chorda tympani, 79
- Chordæ tendineæ, 142
- Chorion (χόριον, skin), definition, 42 and n.
- junction of allantois with, 44, 46
- Choroid coat, 87, 88
- Choroid plexuses, 62, 67, 70
- Choroidal fissure, 85
- Chromatin, filaments of, 12, 16
- Chromosomes (χρώμα, colour, σώμα, body), 12
- Ciliary body, 88
- Circulation, foetal peculiarities of, 155
- course of, 156
 - changes of at birth, 157
- Cloaca, 108, 122, 123, 127
- Cochlea (κοχλίας, a snail with a spiral shell), canal of, 90
- ganglion of, 78
 - in birds, 92
 - modiolus of, 93
 - bone of, 93
 - spiral lamina of, 93

- Cœlenterates (κοῖλος, hollow, ἔντερον, intestine), 23
- Cœlom (κοῖλος, hollow), layers of, 2, 23
typical origin from invagination, 24, 26
formation of, 36, 99
connection of mesoblastic somites with, 37, 160
formation of pleuræ from, 110
of pericardium from, 135 !
serous cavities from, 159
Cœlom-invaginations, 22
connection of, with notochordal invagination, 34
- Coloboma iridis (κολόβωμα, a part taken away in mutilation), 85
- Columns of cord, anterior white, first rudiment of, 59
posterior white, 59, 75, 78, n.
structure of, 60
- Commissure, anterior of cord, 60
grey, 67
posterior, 67
- Commissures of cerebral hemispheres, 71
- Congenital fissures of neck, 103
- Connective tissue, origin from parablatic cells, 21, 25
- Cornea (horny), substantia propria of, 87
epithelium of, 87
- Cornu (horn), anterior, first rudiment of, 59
- Cornu Ammonis (from resemblance to the horns of the statue of Zeus-Ammon), 72
- Corpora quadrigemina (four-fold bodies), 62, 67
striata, 62, 69, 73
- Corpus albicans (white body), 71
- Corpus callosum (the thick body), 71
peduncle of, 79
- Corti, rods of, 93
- Coste, discovery of germinal vesicle by, 8, n.
- Cotyledons of placenta (κατόλη, anything hollow), 51
- Cowper, glands of, 128
- Craniata, 27
- Cranium, 165
- Crura cerebri (crus, leg), 62
- Crusta (crust or rind), 67
- Cryptorchismus (κρυπτός, hidden, ὄρχις, testicle), 127
- Cunningham, D. F., on sulci of brain, 72, n.
- Cutis vera, formation of from outer muscle plate, 161
- Cuvier, ducts of, 138, 139, 141, 151, 152, 153
vestiges of, 154
- Cyclostomata (κύκλος, a circle, στόμα, mouth),
parablatic elements in blastoderm of, 27
heart in, 136
- Cystic duct (κύστις, the bladder), 112
- Decidua (decidere, to fall off), 44
structure of, 46
reflexa, 46
serotina, 46
vera, 46
function of glands of, 47
thickness of vera, 48
stratum spongiosum of, 49
stratum compactum of, 49
atrophy of glands of, 49
placental, 51
giant cells in serotina, 54
separation of at birth, 55
- Decidual cells of Friedlander, 49
- Definition of anatomical terms, 4, 5
mesial,
lateral,
frontal,
sagittal (sagitta, an arrow),
coronal (corona, a crown),
dorsal (dorsum, a back),
ventral (venter, belly),
neural (νεῦρον, a cord),
visceral,
cephalic (κεφαλὴ, head),
caudal (cauda, tail),
axial,
- Deiters, sustentacular cells of, 93
- Delamination, process of in blastoderm, 21
non-occurrence in invertebrata, 22
Lankester on, 24
- Descemet, membrane of, 88
- Descriptive terms, 4
- Deutoplasm, 7, 8
- Diaphragm (διά, through, φράγμα, a fence,) 159
- Directive corpuscles, 9. See POLAR GLOBULES.
- Discus proligerus, albumen deposited on ovum by, 7
- Dohrn on pituitary body, 68
- Döllinger, researches of Pauder under, 23
- Ductus arteriosus, 146, 150, 156
lingualis, 110
thyroglossus, 110
thyroideus, 110
venosus, 152, 156
- Duodenal loop, 104
- Dursy on continuity of primitive with neural groove, 32
- Duval on epiblastic connection of blastodermic vesicle to uterine wall, 53
- EAR, a specialised branchial sense-organ, 76
development of, 89
accessory parts, 93
- Echinoderms (ἐχίνος, urchin, δέρμα, skin), im-
pregnation in, 11, 12
- Ecker on the Sylvian fissure, 73
- Ectoderm (ἐκτός, outside, δέρμα, skin), primitive
18, 19, 24
invagination of, 22, 23
- Egg tubes, 124
- Elasmobranchs (ηλάσμα, lamina, βράγχια, gills),
cœlom invagination in, 22, n.
primitive groove in, 23
neural crest in, 73
spinal nerves, anterior roots in, 74
origin of ciliary ganglion in, 81
auditory vesicle in, 90
supra-pericardial bodies in, 111
liver in, 112
Wolffian vesicles in, 118, n.
supra-renal capsules in, 121
Müllerian duct in, 122
heart in, 136
muscle plate, outer, in, 161
visceral arches in, 161
head cavities in, 161
limbs in, 163, n.
- Embryo, human, segmentation where most
marked, 2
- Embryo, separation of, from blastoderm, 34
- Embryology (ἐμβρύον, a thing newly born, λόγος,
word), definition, 1

- Embryonic area, 18
 Endocardium (*ἐνδόν*, within, *καρδία*, heart), 136
 Endolymphatic canal, 90
 Engelmann on placenta, 48, n.
 Enteric canal (*ἐντέρον*, intestine), 22
 groove, 36
 Entoderm (*ἐντός*, inside, *δέρμα*, skin), primitive,
 17, 18, 19, 24
 blastopore, relation to, 22, 23
 perforation of by primitive groove, 22
 Entomeres, mass of (*ἐντός*, within, *μέρος*, part),
 23
 Epencephalon (*ἐπί*, over, *ἐγκέφαλος*, brain), 66
 Epiblast (*ἐπί*, over, *βλαστός*, germ), 21
 homology with Rauber's layer, 22, n.
 character of cells, 24
 formation of medullary folds by, 32
 formation of ganglia by, 73, 75
 sensory epiblast, 76
 formation of lens from, 83
 Epiglottis (*ἐπί*, upon, *γλωττίς*, mouth of the
 windpipe), 103
 Epiphysis cerebri (*ἐπιφύω*, to grow upon, *cere-*
 brum, brain), 67
 Epophoron (*ἐπί*, upon, *ὄον*, egg, *φέρω*, to carry)
 of Waldeyer, 120
 Eustachian tube, 93
 valve, 141, 155
 Ewetsky on bifurcation of lachrymal canal, 89
 External amniotic fold, 43, n.
 Eye, development of, 83
 retina, 86
 hyaloid membrane of, 87
 corneo-sclerotic coat of, 87
 choroid coat of, 87, 88
 iris of, 87, 88
 anterior chamber of, 88
 Eyelids, 89
- FALLOPIAN tube, 7
 fimbriae of, 11
 development of, 117, 124
 False amnion, 42, 43, n.
 Falx cerebri (a sickle), 70
 Fertilization, 11
 Filum terminale (terminal thread), 60
 Fissure of Sylvius, 72, 73
 of Rolando, 73
 Flemming on Wolffian duct, 118
 Fol on polar globules in echinoderms, 9
 Foramen cæcum of Morgagni (blind opening), 102,
 110
 Foramen of Monro, 63, 68
 ovale, 144
 closure of, 155, 157
 Fore brain, 38
 Fore-gut, first formation of, 34
 Fornix (an arch), 71
 Foster on nomenclature of the blastodermic
 layers, 23
 Fraser on inversion of blastodermic layers, 23
 auditory ossicles, 168
 Fretum Halleri (a strait or channel), 141
 Friedlander, decidua cells of, 49
 on giant cells in decidua serotina, 54
 Frierip on branchial sense-organs in mammals,
 76
 vertebral column, 162
 Furcula, the (forked prop), 102, 103
- GADOW on auditory ossicles, 168
 Gall bladder, 112
 Ganglia (*γάγγλιον*, a swelling), posterior-root, 74
 rudiments of, in cranial nerves, 75, 76
 Gasserian, 78, 81
 jugular, 78
 cochleæ, 78
 spiral, 78
 geniculate, 78
 sympathetic, 81
 ciliary, 81
 ophthalmicus profundus of elasmobranchs,
 81
 Ganoids (*γάνος*, bright, *εἶδος*, form), heart in, 136
 Gartner, duct of, 120
 Gaskell on cranial ganglia, 77
 nuclei of cranial nerves, 77
 sympathetic ganglia, 81
 Gastrula (*γαστήρ*, belly), 21
 views of formation, 22, 23
 Gegenbaur on homodynamy, 4
 Jacobson's gland, 97
 remains of notochord, 162
 auditory ossicles, 168
 Generative organs, male, 117, 120, 125
 external, 127
 female, 124
 table of, 130
 Genital cord, 123
 ridge, 124
 Germ cell, 12
 Germinal cells, 58
 Germinal epithelium, 117
 connection with Wolffian tubules, 120
 formation of ovary from, 124
 of testicle from, 125
 Germinal spot, 8
 Germinal vesicle, structure of, 8
 Giant cells of placenta, 54
 Gill slits, 103
 Giraldès, organ of, 120
 Girdle, thoracic and pelvic, 164
 Globular processes of His, 95
 Glomeruli (*glomus*, ball of thread), 119, 122
 Golowine on ganglion rudiments, 75
 special sense-organ rudiments, 76
 Götte on Wolffian duct, 118
 Graaf, de, on pineal eye, 68
 Graafian follicle, 6
 union of cells of, with ovum, 7
 changes prior to escape of ovum, 9
 formation of, 124, 125
 Gradenigo on the stapes, 168
 Gruber on a case of venous abnormality, 155
 Gubernaculum testis (a helm), 126
 changes of in descent of testicle, 127
 Guinea-pig, formation of amnion in, 43
 allantois in, 46
 Gyrus subcallosus of Zuckerkandl, 81
- HADDEN, on origin of segmental duct, 118
 Haeckel, on gastrula stage and gastrulisation,
 22, 23, 24
 Haller, vasa aberrantia of, 120
 Hare lip, 97
 Hassal, concentric corpuscles of, 112
 Head, first appearance of, 34
 muscles of, 161
 evidences of segmentation of, 161
 skeleton of, 166
 visceral skeleton of, 166

- Heape, on blastodermic layers in the mole, 18
rudimentary blastopore in the mole, 22
- Heart, formation of, 38, 136
beginning of beat, 39
endothelial tube of, 134
folding and division of, 137, 141, 142
saccus reuniens, 139
septum spurium of, 141
valves of, 141, 142
fretum Halleri of, 141
septum inferius of, 141
auricular canal of, 142
septum intermedium of, 142
chordæ tendineæ of, 142
foramen ovale of, 144
limbus Vieussensii of, 144
muscle of, 145
columnæ carneæ of, 146
fetal, peculiarities of, 146
- Hedgehog, placental sinuses in, 52, n.
epiblastic attachment to uterus in, 53
- Henle, loops of, 122
- Hensen, canalis re-uniens of, 91
on Wolffian duct, 118
heart, bilateral, 134
- Hermaphroditism (Ἑρμῆς, Ἀφροδίτη, a male and female god), 12
- Hertwig, O. and R., on polar globules in echinoderms, 9
coelom-invaginations of, 22
coelom, typical development of, 24
mesodermic layers of, 26, 27, n.
mesenchyme of, 26
- Hind brain, 38
- Hind gut, formation of, 36
connection with allantois, 46
with Wolffian duct, 118
- His, W., abdominal stalk of, 46
on accessory thyroid bodies, 110
allantois, 101, n.
arterial arches, 147
ascending roots in medulla, 66
auricular canal, 142
axis cylinders, growth of, 75
blood-vessels, 151
Broca's area, 79
cephalic clefts, 102, n.
endothelial tube of heart, 136
on epiblastic origin of ganglia and posterior roots, 57
germinal cells of, 58
on geniculate ganglion, 79
globular processes of, 95
on heart, bilateral, 134
isthmus of, 67
on laminae of cord, 60
lens capsule, 87
mechanical theory of development, 24
mesoblast, origin of in part from thickened rim of blastoderm, 23
nerve fibres, somatic and splanchnic, 77
olfactory epiblast, 98
nerve fibres, origin of, 77, 81
parablast, theory of, 25, 26
on pinna, 95
porta vestibuli of, 156
on pulmonary veins, 144
researches of, 6, n.
saccus reuniens of, 139
septum atriorum, 144
inferius of, 141
between stomodæum and fore-gut, 99
- His—continued.
septum, transverse of, 159
sinus arcuatus, 102
on spinal nerves, roots of, 74
spongioblasts of, 58
sulcus terminalis, 102
thyroid, 110
on tuberculum impar, 102
visceral arches, 102
- Histology (ἱστοῦν, a web; λόγος, word), definition, 1
- Hofmann, gastrulation in elasmobranchs, 22, n.
- Holoblastic ova (ὅλος, whole; βλαστός, a germ), definition of, 8
invagination of, 22
- Homodynamy (ὁμός, the same; δυνάμις, power), 4
- Homogeny (ὁμός, the same; γένος, descent), 4
- Homology (ὁμός, the same; λόγος, word), definition of, 4
serial homology, 4
examples of, 4
- Hubrecht, on epiblastic connection of blastodermic vesicle with uterus, 53
- Huxley, on two layers of coelenterates, 23
auditory ossicles, 168
- Hymen, the (the god of marriage), 128
- Hyoid, the (Ἱδῶς, the form of the Greek letter Ἦ), 166, 169
- Hypoblast (ὑπό, under; βλαστός, germ), 21
characters of cells of, 24
formation of notochord from, 32
allantois from, 44, 46
- Hypophysis cerebri (ὑποφύω, to grow from below), 68, 100. *And see* PITUITARY BODY.
- Hypospadias (ὑπό, under; σπάω, to tear), 129
- IMPREGNATION, 11
- Incisor foramen, 97
- Incus (an anvil), 167, 168
- Infundibulum, the (a funnel), 61, 67, 68
of lung, 110
- Intermediate cell mass, the formation of
Wolffian duct from, 115
of permanent kidney from, 122
- Intermaxillary process, 95
- Intervertebral disc, 162
- Intervillous space, 51
question of blood in, 53
- Intestines, 104
large, 106
- Invagination in holoblastic ova, 22
aperture of, 22
resemblance to blastopore, 22
- Inversion of blastodermic layers, 23
- Iris, 86, 87, 88
- Ischikawa on segmentation of ovum before fertilization, 14
- Island of Reil, 70, 73
- Isthmus faucium, 100
of His, 67
- JACOBSON'S organ, 95, 97
- KARYOKINESIS (κάρυον, a kernel; κίνησις, movement) of germinal cells, 58
- Karyoplasm (κάρυον, a kernel; πλάσμα, a mould) of germinal vesicle, 8
- Kessler, on lens capsule, 87
substantia propria of cornea, 87, n.

- Kidney, head or fore, 115, 117
mid, 116
hind or permanent, 117, 122
- Kölliker on Rauber's layer, 18
intermediate layer of blastoderm, 20
placenta, 53
lens capsule, 87
the anterior chamber, 88
cephalic clefts, 102, n.
air cells of lung, 110
thymus, 111
heart, 134
endothelial tube of heart, 136
mesocardium laterale of, 136
cartilage of vertebrae, 162
- Kollmann, parablastic theory of His, adherence to, 26
- Kowalevsky, researches on Sagitta and Amphioxus, 24, 26
- Kundrat on placenta, 48, n.
- Kupffer, gastrulation, view of, 22
His' parablastic theory, adherence to, 26
- LABIA majora (greater lips), 128
- Labyrinth, the, the recess of, 90
perilymphatic spaces of, 93
- Lachrymal canals and ducts, 89, 97
fissure, 89
gland, 89
- Laminae of cord, alar, basal (dorso-lateral) (ventro-lateral), 60, 63, 65, 66, 77
- Langhans on placental sinuses, 53
- Lankester, on homogeny, 4
blastopore, 22
primary layers of blastoderm produced by delamination, 24
- Larynx, 110
- Lemurs (*lemur*, ghost), nasal gland in, 98
- Lens, 83, 86
vesicle of, 87
transitional zone of, 87
capsule of, 87
- Leopold on placenta, 48, n.
giant cells in decidua serotina, 54
- Leydig on special sense organs of gill clefts, 76
- Liebkühn on blastodermic layers in mole, 18
on lens capsule, 87
zonule of Zinn, 87
- Ligamentum arteriosum, 150
- Limbs, 4, 163
segments of, 164
rotation of, 165
bones of, 165
- Limbus (a band) Vieussensii, 144, 157
- Literature, recent, of the ovum, 14
blastoderm, 27
embryo, formation of, 41
general subject of embryonic formation and development, 41
decidua, 55
nervous system, development of, 81
sense organs, 98
alimentary canal and glands, lungs, 113
urinary and generative organs, 132
blood system, 158
serous cavities, muscles and skeleton, 169
- Liver, 106, 112
weight of, 113
formation of veins of, 151, 152
- Lockwood, on protovertebral cavity, 160
- Lungs, development of, 109
- Luschka, on urachus, 122
notochord, remains of, 162
- Lymphatic system, 157
- MACKAY on arterial arches of the bird, 150
- Macula germinativa (germinal spot), 8
- Malleus (a hammer), 167, 168
- Malpighian corpuscles of spleen, 108
of Wolffian body, 120
of permanent kidney, 122
- Marshall, vestigial fold of, 154
Milnes, on head cavities, 161
- Martin on Wolffian duct, 118
- Masius on epiblastic connection of blastodermic vesicle with uterus, 53
- Mechanical theory of development, 24
- Meckel, J. F., 23
- Meckel's cartilage, 166, 167, 168
- Medulla oblongata, 62
formation of, 63
- Medullary folds, formation of, 30, 32
groove. See NEURAL GROOVE.
- Membrana limitans of retina, externa, 86
interna, 83, 86
- nictitans, 89
- reuniens, superior of Remak, 32, 162, 165
- tectoria, 93
- tympani, 93
- Membranes of cord, development of, 60
- Meroblastic ova (*μέρος*, a part, *βλαστός*, a germ), definition of, 8
gastrular stage in, 22
Haeckel, view concerning blastopore in, 23
mesenchyme in, 27
- Mesenchyme (*μέσος*, middle, *χυμός*, juice), 26, 27
- Mesencephalon (*μέσος*, middle, *ἐγκεφάλος*, brain), 67
connection with optic stalks, 85
- Mesentery, the (*μέσος*, middle, *ἐντερων*, intestine), 104, 107
- Mesoblast, formation of, 20, 21
origin, varieties of, 22
His' view of origin, 23
character of cells, 24
connection with mesenchyme, 26
paraxial and lateral, 32
cleavage of, 36
formation of vessels in, 39
growth of with allantois, 44
- Mesoblastic somites, 37, 159, 162
cavity in, 37, 160
- Mesocardium, anterior, posterior, lateralis, 136
- Mesocolon (*κόλον*, great intestine), 106
- Mesogastrium (*γαστήρ*, belly), 106, 107
- Mesonephros (*νεφρός*, kidney), 116
- Mesorchium (*ὄρχις*, testicle), 126
- Mesorectum, 106
- Mesovarium, 126
- Metameres (*μετά*, following, *μέρος*, a part), 4
- Metanephros (*μετά*, behind, *νεφρός*, kidney), 117
- Metazoa (*μετά*, after, *ζῶον*, animal), 18, 26
- Metencephalon (*μετά*, behind, *ἐγκεφάλος*, brain), 63
- Meuron, de, on obliteration of human oesophagus, 104, n.
thymus, 111
- Micropyle (*μικρός*, small, *πίλη*, opening), 11
- Mid brain, 38

- Mihalkovics on stomodæum in rabbit, 99
supra-renal capsules, 120
Mullerian ducts, 123
ovary, 124, n.
Minot, polar globules, theory of, 12, 14
on placenta, 48 n.
chorionic epithelium, bounding placental
sinuses, 52, n.
Mitsukuri on supra-renals, 122
Modiolus, the (nave of a wheel), 93
Mole, primitive ectoderm in, 18
blastopore in, 22
Monotremes (*μόνος*, single, *τρήμα*, a hole), 6
amount of yolk of, 8
cloaca in, 108
Morbus cœruleus (the blue disease), 157
Morgagni, hydatids of, 124
Morphology (*μορφή*, form, *λόγος*, word), deter-
mination of, 2
Mouth, formation of, 99
non-correspondence of primitive with per-
manent, 100
Mulberry mass, 16
Müller, E., on muscular tissue of primitive
aorta, 151
Johannes, Müllerian duct named after,
117
W., sense epithelium of, 86
Müllerian duct, 117, 122, 123, 124, 127
invaginations, 115, n.
Mullerian fibres, 86
Muscle plate, 160
inner, 160
outer, 161
Muscles, 159
Myelospongium (*μυελός*, marrow, *σπόγγος*,
sponge), 58
Myotomes (*μύος*, a muscle, *τέμνω*, I cut), 4
- NASAL processes, 95
laminae, 95
septum, 95
Naso-palatine canal, 97
Nerves, fifth ascending, root of, 66, 78
vagus and glosso-pharyngeal, ascending root
of, 66, 78
fifth sensory fibres of, 66, 78
motor fibres of, 66
sixth, seventh, 66
third, fourth, 67
spinal, formation of, 73
roots of, 74
axis, cylinders of, 75
traces of ganglia in cranial, 77
cranial, 75
auditory, 78, 89, 93
sympathetic, 81
nuclei of origin of cranial, 77
inferior laryngeal, shifting of, 149
Nerve fibres, origin from neuroblasts, 58, 59
origin of somatic and splanchnic, 77
olfactory, 81
Nervous system, general view of development, 57
Neural canal, 32
parietes of, structure of, 57
crest, 73, 75
groove, formation and closure of, 30, 32
formation of cerebral vesicles from, 37
Neurenteric canal (*νεῦρον*, nerve, *ἐντερων*, in-
testine), 22
piercing of notochord by, 32
- Neuroblasts (*νεῦρον*, nerve, *βλαστός*, germ), 58,
59, 74, 98
Neuroglia (*νεῦρον*, nerve, *γλία*, glue), origin of,
60
Nose, a specialised branchial sense organ, 76
formation of, 95
Notochord (*νώτος*, the back, *χορδή*, a string of
gut), 2
formation of, 32
an embryonic structure, 34
structure of, 34
connection with buccal epiblast, 68
formation of vertebræ round, 162
connection with cranium, 165
Notochordal canal, 34
Nuck, canal of, 127
Nuclei of origin of cranial nerves, 77
Nucleolus of ovum, 8
Nucleoplasm of germ and sperm cells, 12
Nucleus (a kernel) of ovum, changes in, 6, 9
chromatin filaments of, 12
Nymphæ, 128
- ŒSOPHAGUS (*οἶσω*=*φέρω*, to carry, *φαγεῖν*, to
eat), 103, 104, n.
Olfactory (*olfacio*, to smell) area, 95
bulb, 81
epithelium, 98
glomeruli, 81
pit, 95
lobes, 62, 71
junction of ganglionic rudiment with, 77
formation of, 79
Olivary tubercle, 65
Omental sac, 106
Omentum, great, 106, 108
gastro-hepatic, or small, 106, 113
Omphalomesenteric vein (*ὀμφαλός*, navel, *μεσασαίον*,
mesentery. See VITELLINE VEIN.
Onodi on sympathetic nerves, 81
Optic chiasma (*χίασμα*, two lines placed cross-
wise), 85
cup, 83
nerves, origin from fore-brain, 38, 67, 79
stalks, formation of, 85
thalamus, 62, 67
tracts, 67, 85
vesicles, primary, 61, 67, 83
Organ, definition, 1
Organization, plan of, 2
"Organs of the lateral line," 76
Os articulare (joint bone), 168
Otic vesicle (*οὖς*, *ωτικός*, ear, of the ear), 89
Ovary, 6, 124, 125
round ligament of, 126
change of position of, 127
Oviparous (*ovum*, egg, *παίω*, to produce) verte-
brata, 8
Ovum (egg), alecithal, 9
attachment of to uterus, 46
centrolecithal, 8
deutoplasm of, 7
development, changes prior to, 6
gastrula of, 21
germinal vesicle of, 8
holoblastic, 8
human, exception to rule of separation from
chorion, 46
human, villi in earliest described, 55

Ovum—continued.

- fertilization of, 11
- mammalian, descent of, 8
- maturation of, 9
- meroblastic, 8
- permanent, 125
- polar globules, extrusion from, 9
- primordial, 124
- segmentation of, 16
- size of, 6
- striae of, 6
- structure of, 6
- yolk of, 7
- zona pellucida or zona radiata of, 6

PALATE, the, 97

- cleft, 97
- Pancreas (*πᾶν*, all, *κρέας*, flesh), 108, 113
- Pander, researches on blastoderm, 23
 - mechanical theory of, 24
 - blood islands of, 39
- Papillary muscles, 142
- Parablastic cells (*παρά*, beside, *βλαστός*, germ), 21, 25, 27
- Parachordal cartilages (*παρά*, beside, *χορδή*, string; near the notochord), 166
- Parker, on formation of xiphoid, 163
- stapes, 168
- Parovarium (*παρά*, beside; *ovarium*, ovary), 120
- Pars ciliaris retinae, 86
- Parthenogenesis (*παρθένος*, virgin; *γένεσις*, origin), polar globules in, 14
- Parturition, separation of membranes in, 55
- Paterson on origin of sympathetic system, 81
 - limb muscles, 163, n.
- Penis, 128, 129
- Pericardium (*περί*, about; *καρδία*, heart), 135, 159
- Peritoneum (*περί*, about; *τείνω*, to stretch), 159
- Perivitelline space (*vitellus*, yolk), 9
- Peters on hyomandibula, 168
- Petromyzon (*πέτρος*, a stone; *μύζω*, to suck; lamprey), pituitary body in, 68
- Pflüger, egg tubes of, 124
- Pharyngeal septum, 100
- Pharynx, 101
- Philtrum (*φίλτρον*, loveliness), 95
- Pineal gland (*pinca*, a fir-cone), 61, 67
 - as rudimentary eye, 68
- Pinna, the (a feather), 95
- Pituitary body (*pituita*, phlegm), 61, 67
 - formation of, 68
 - in Petromyzon, 68
 - connection with stomodæum, 100
- Placenta (a cake), 44
 - formation of, 49, 51
 - basal layer of, 51
 - subchorionic membrane of, 51
 - loculi or cotyledons of, 51
 - structure of sinuses of, 52
 - intervillous spaces of, 51, 53
 - weight and size of, 53
 - microscopical structure of, 53, 54
- Placental decidua, 51
 - sinuses, structure of, 52
- Plane, median, 4
- Plasmæ of Weismann, nuclear, nutritive, germinal, histogenetic, 14
- Pleuræ (*πλευρά*, a rib), 110, 159
- Pleuro-peritoneal cavity. See CÆLOM

Plica gubernatrix (guiding fold), 126

- semilunaris, 89
- Polar disc, 11
 - globules, 6
 - formation of, 9, 12
 - where observed, 9
 - of *Ascaris megalocephala*, 9
 - of plants, 9
 - Minot's theory of, 12
 - Weismann's theory of, 14
- Pons (bridge), 62
 - formation of, 66
- Porta vestibuli (gate of the vestibule), 156
- Præ-hyoid glands, 110
- Pregnancy, changes of uterus in, 48
- Primary placental circulation, 53
- Primitive groove, formation of, 19
 - as extension of blastopore, 22
 - as homologue of part of entoderm, 23
 - Balfour's view of, 23
 - connection with neural groove, 30, 32
 - streak, formation of, 19
 - an ectodermal thickening indented by blastopore, 22
 - origin of mesoblast from, 22
 - connection with notochord, 32
 - velum (*velum*, a curtain), 100
- Pristiurus, heart in, 136
- Proamnion, 35, 42, n.
- Process, nasal, 95
 - fronto-nasal, 95, 101
 - maxillary, 97, 101
 - globular, 95
 - tympano-hyal, 168
 - styloid, 169
- Processus vaginalis, 127
- Proctodæum (*πρωκτός*, the anus), 108
- Pronephros (*πρό*, before; *νεφρός*, kidney), 115
- Pro-nucleus, female, male, 9, 11, 12
 - chromatin filaments, in, 16
- Prosencephalon (*πρός*, besides; *ἐγκέφαλος*, brain), 68
- Prostatic vesicle, 124
- Protovertebræ (*πρωτός*, first; *vertebra*, I turn), 37
 - See MESOBLASTIC SOMITES.
- Protovertebral cavity, 37, 160
- Pulmonary blood-vessels, 110
- Pupillary membrane, 87, 88
- Purkinje, germinal vesicle of, 8
- Pyramidal tracts, the last to be medullated, 60
- Pyramids, anterior, 65

QUADRATE, the, 168

- RABBIT, polar globules observed in, 9
 - pro-amnion in, 35
 - stomodæum in, 99
- Ramón y Cajal, on posterior roots of spinal nerves, 75
- Rathke, diverticulum of, 68
 - on hypophysis cerebri, 100
 - visceral arches, 103
 - arterial arches, 147, 150
 - posterior vertebral veins of, 153
 - trabeculae cranii of, 166
- Rauber, layer of, 17, 18, 22, n., 23
 - on the mechanical theory of development, 24

- Recessus pulmonales (recesses of the lungs), 159
 Reichert on villi in earliest ovum, 55
 mantle of, 70
 on incus and stapes, 168
 Reid, John, on fetal circulation, 156
 Rein on the polar globules in the rabbit, 9
 Remak on bilamination of middle blastodermic layer, 23
 membrana reuniens superior of, 32, 162
 Renal organs, embryonic ducts of, opening into allantoic pedicle, 46
 Renson on extrusion of part of nucleus of seminal cell, 12
 Restiform bodies, 65
 Retina (*rete*, a net), origin from fore-brain, 38
 development of, 83, 86
 membranae limitantes of, 83, 86
 rods and cones of, 84, 86
 hexagonal pigmented epithelium of, 84, 86
 central blood-vessels of, 85, 87
 ganglionic layer, 86
 sense epithelium of, 86
 Retzius on the zona radiata, 7
 Rhomboidal sinus, 60
 Ribs, development of, 163
 Rodents, inversion of blastodermic layers in, 23
 Paterson on sympathetic in, 81
 nasal septum in, 95
 Rosenburg on Wolffian duct, 118
 Round ligament, 126
 Rückert on coelom invagination in elasmobranchs, 22, n.
 heart in *Pristiurus*, 136

 SABATIER, on origin of subclavian artery, 150
 Eustachian valve, action of, 156
 Saccule, 78, 90
 Saccus reuniens, 139, 151
 Sagitta, origin of mesoblast in, 22
 Kowalevsky on, 24, 26
 mesenchyme in, 27
 Salensky on the stapes, 168
 Sauropsida (*σαύρα*, a lizard; *ὄψις*, look), hyomandibular arch in, 168
 Scala (*scala*, a stair) of cochlea, 93
 Scarpa, gangliform swelling of, 78
 Schenk, on sympathetic nerves, 81
 Schmidt, on Thebesian valve, 141
 Schneiderian membrane, 81
 Schultze, M., on rods and cones, 86
 Sclerotic (*σκληρός*, hard), 88
 Scrotum, 127, 128
 Sedgwick, on Wolffian body, 115, n.
 Müllerian duct, 123
 Segmental tubes, 118
 Segmentation of ovum, complete, incomplete, 8
 main factors of, 9
 before fertilization, 14
 after fertilization, 16
 Selenka, on inversion of blastodermic layers in rat and mouse, 23
 epiblastic connection of blastodermic vesicle with uterus, 53
 Semicircular canals, 78, 91
 Seminal cell, 12

 Septum lucidum (transparent partition), ventricle of, 70
 spurium, 141
 inferius, 141
 membranaceum, 142
 intermedium, 142, 144
 transverse, the, 159
 Serous cavities, 159
 Sexual cells, origin of, 14
 conjugation of, Minot's theory of, 14
 Sinus arcuatus (arched hollow), 102
 venosus, 112, 138, 151
 urogenitalis, 123, 128
 Skull, formation of, 166
 chondrification of, 166
 Somatopleure (*σῶμα*, body; *πλευρά*, the side) 35
 formation of, 36, 99
 origin of amnion from, 42
 Somites (*σῶμα*, body), mesoblastic, 4
 Spee, on connection of mesoblastic cleavage with notochordal canal, 34
 epiblastic origin of Wolffian duct, 118
 Spencer, Baldwin, on pineal eye, 68
 Sperm cell, 12
 Spermatozoon (*σπέρμα*, seed; *ζῶον*, animal), accession of, to ovum, 6, 9
 fertilization by, 11
 fate of tail of, 11
 maturation of, 12
 Spinal accessory, origin from basal lamina, 60
 Spinal cord, development of, 57
 outermost layer of, 58
 anterior cornu of, first rudiment of, 59
 columns of, 59
 fissures of, 59
 anterior commissure of, 60
 dorso-lateral and ventro-lateral laminae of, 60
 filum terminale of, 60
 cauda equina of, 60
 growth of, pari passu with vertebral canal, 60
 membranes of, 60
 Splanchnopleure (*σπλάγχνον*, the inwards; *πλευρά*, the side), 35
 formation of, 36, 99
 Spleen, 108
 Spongioblasts (*σπόγγος*, sponge; *βλαστός*, germ), 58
 origin of neuroglia from, 61
 Stapes (a stirrup), 168
 Sternum, 163
 Stomach, 104
 Stomodæum (*στόμα*, mouth), 68, 99
 connection with nose, 95
 Strahl, on Wolffian duct, 118
 Stratum compactum, 49
 spongiosum, 49, 55
 Subchorionic membrane of Turner, 51
 Sulci of brain, primitive, 72
 principal, 73
 Sulcus, anterior limiting and lateral limiting, 34, 35
 terminalis, 102
 Supra-hyoid glands, 110
 -pericardial bodies, 111
 Suprarenal capsules, 120
 Suspensory ligament, 113
 Symmetry of form, 4
 bilateral, 4

- Sympathetic ganglia, 81
 connection of, with supra-renal capsules, 122
- TEETH, 109
 Tegmentum (a cover), 67
 Teleosteans (τέλειος, complete, ὀστέον, bone),
 Wolffian duct in, 118
 Telolecithal ova (τέλος, end, and λίκνθος, oil-bottle), 8, 27, 30
 Terminal sinus, 40
 Testicle, 117, 125
 descent of, 126, 127
 Testis. See TESTICLE.
 Textures, general, 1
 Thalamencephalon (θάλαμος, chamber, ἐγκέφαλος, brain), 61, 67
 connection with optic stalks, 85
 Thebesian valve, 141
 Thomsen on ganglionic traces in third nerve, 77
 Thomson, Allen, on primitive aorta, 146
 Thymus (θύω, to offer as a sacrifice), 111
 Thyroid (θυρεός, a shield), 102
 formation of, 110
 pyramid of, 110
 Tiedemann on rhomboidal sinus, 60
 Tissues, general, 1
 Toldt on mesentery of pancreas, 113
 Tongue, 100
 formation of, 102
 foramen cæcum of, 102
 papillæ of, 102
 sulcus terminalis of, 102
 Trabeculæ cranii (*trabs*, a beam, diminutive of), 166
 Trachea (τραχὺς, rough), 110
 Trigonum olfactorium (τρίγωνος, triangular), 79
 Trophoblast (τροφή, nourishment, βλαστός, germ), of Hubrecht, 53
 Truncus arteriosus, 151
 Tuberculum impar (unpaired tubercle), 102
 Turner on placenta, 48, n.
 subchorionic membrane of, 51
 Type, vertebrate, main features of, 2
- UMBILICAL cord, 36, 43, 104, 122, 151
 Umbilical duct, 36
 Umbilical vesicle, 36
 Umbilicus (the navel), 43
 Urachus (ὄφρον, urine; ἔχω, to hold), 122
 Ureter (ὀρέω, to make water), 122
 Urethra, 122, 128
 Uriniferous tubules, 119
 Uterus, mode of attachment of ovum to, 46
 changes in pregnancy, 48—55
 regeneration of after parturition, 55
 formation of, 124
 bifid stage of, 124
 os and cervix of, 124
 Uterus masculinus, 124
 Utricle (utriculus, a little womb), 91
 Uvea (*uva*, a cluster of grapes), 84, 85, 86, 88
- VAGINA (a sheath), 124
 Valve of Vieussens, 66
 Vasa aberrantia of Haller, 120
 Vascular area, 39, 151
 lamina, 151
- Veins, azygos, 153
 cardinal, 151, 152, 153
 connection of, with heart, 138, 139
 iliac, 153
 inferior cava, 152, 153
 innominate, 153
 intercostal, superior, 153
 jugular, 153
 jugular, primitive, 151, 152, 153
 primitive, formation of, 39
 portal and hepatic, 151, 152
 posterior vertebral, 153
 pulmonary, 144
 subclavian, 153
 superior cava, 151, 153
 umbilical, 138, 151, 152, 156
 vitelline, 39, 40, 112, 138, 151, 152
 Velum palati (curtain of the palate), 100
 Vena ascendens, 152
 Venæ, advehentes and revehentes, 112, 151, 152
 Venous annulus of duodenum, 151, 152
 Ventricles, lateral, 62
 third, 62, 67
 fourth, 62, 66
 fifth, 70
 Vererbungstheorie of Weismann, 14
 Vermiform appendix, 107
 Vertebra (*verto*, I turn), 2
 permanent, 162
 Vertebral column, development, 2, 162
 bodies, 2
 segments, 4
 Vertebrate type, 2
 Vesicles of the cerebral hemispheres, 61
 Vestibule, 78
 Villi (*villus*, shaggy hair) of chorion, 43
 vascularisation of, 44, 52
 connection with glands of decidua, 47
 zone of, 55
 Visceral arches, formation of ossicles of ear from, 93
 first, or mandibular, 101, 102
 cephalic, 102
 second or hyoid, 102
 third or thyro-hyoid, 103
 palato-pharyngeal, 103
 post- and præ-buccal, 103
 blood supply of, 103
 cartilaginous bars of, 103, 166
 Visceral clefts, 103
 first formation of middle ear from, 93
 cephalic, 101
 hyomandibular, 103
 fourth, formation of thyroid from, 110, 111
 Vitelline arteries, 40
 circulation, 40
 duct, 46, 104, 151
 membrane, 8
 veins, 39, 40, 112, 138, 151, 152
 Vitellus, structure of, 7. See YOLK.
 Vitreous humour (*vitrum*, glass), 83, 85, 87
- WAGNER, macula germinativa of, 8
 Waldeyer on His' parablastic theory, 26
 placental sinuses, 52
 epophoron of, 120
 germinal epithelium of, 124
 Weismann, theory of, 14
 Weldon on supra-renal capsules, 120
 Wijhe, v., on Wolffian vesicles, 118, n.
 head cavities, 161
 typical somite cavity, 161, n.

- Wolff, C. F., first suggestion of laminae in blasto-
derm by, 23
duct of, 115
- Wolffian body, 115, n., 116, 117, 118, 122
atrophic changes of, 120
connection with testis, 120, 126
veins of, 151
- Wolffian duct, 115, 116, 117, 118
remnant of, in parovarium, 120
as duct of Gartner, 120
male generative organs, 120
permanent kidney, 122
connection with Müllerian duct, 123
- Wolffian vesicles, 118, 118, n.
- Yolk, structure of, 7
sac, 35, 99, 104
vitelline circulation round, 40
- ZACHARIAS, polar globules in *Ascaris*, 9
Zimmermann on arterial arches, 151
Zona pellucida (transparent zone), 6, 7
penetration of, by spermatozoon, 11
Zonule of Zinn, 87
Zuckerlandl, gyrus subcallosus of, 81

END OF PART I.



OCTOBER, 1890.

A LIST OF WORKS ON
MEDICINE, SURGERY
AND
GENERAL SCIENCE,
PUBLISHED BY
LONGMANS, GREEN & CO.,
39, PATERNOSTER ROW, LONDON.

Medical and Surgical Works.

ASHBY. NOTES ON PHYSIOLOGY FOR THE USE OF STUDENTS PREPARING FOR EXAMINATION. By HENRY ASHBY, M.D. Lond., F.R.C.P., Physician to the General Hospital for Sick Children, Manchester; formerly Demonstrator of Physiology, Liverpool School of Medicine. Fifth Edition, thoroughly revised. With 134 Illustrations. Fcap. 8vo, price 5s.

ASHBY AND WRIGHT. THE DISEASES OF CHILDREN, MEDICAL AND SURGICAL. By HENRY ASHBY, M.D. Lond., F.R.C.P., Physician to the General Hospital for Sick Children, Manchester; Lecturer and Examiner in Diseases of Children in the Victoria University; and G. A. WRIGHT, B.A., M.B. Oxon., F.R.C.S. Eng., Assistant Surgeon to the Manchester Royal Infirmary and Surgeon to the Children's Hospital. With 138 Illustrations. 8vo, price 21s.

BARKER. A SHORT MANUAL OF SURGICAL OPERATIONS, HAVING SPECIAL REFERENCE TO MANY OF THE NEWER PROCEDURES. By ARTHUR E. J. BARKER, F.R.C.S., Surgeon to University College Hospital, Teacher of Practical Surgery at University College, Professor of Surgery and Pathology at the Royal College of Surgeons of England. With 61 Woodcuts in the Text. Crown 8vo, price 12s. 6d.

BENNETT. CLINICAL LECTURES ON VARICOSE VEINS OF THE LOWER EXTREMITIES. By WILLIAM H. BENNETT, F.R.C.S., Surgeon to St. George's Hospital; Member of the Board of Examiners, Royal College of Surgeons of England. With 3 Plates. 8vo. 6s.

BENTLEY. A TEXT-BOOK OF ORGANIC MATERIA MEDICA.

Comprising a Description of the Vegetable and Animal Drugs of the British Pharmacopœia, with some others in common use. Arranged Systematically and Especially Designed for Students. By ROBERT BENTLEY, M.R.C.S. Eng., F.L.S., Fellow of King's College, London; Honorary Member of the Pharmaceutical Society of Great Britain, &c. &c.; one of the three Editors of the "British Pharmacopœia," 1885. With 62 Illustrations on Wood. Crown 8vo, price 7s. 6d.

COATS. A MANUAL OF PATHOLOGY. By JOSEPH COATS,

M.D., Pathologist to the Western Infirmary and the Sick Children's Hospital, Glasgow; Lecturer on Pathology in the Western Infirmary; Examiner in Pathology in the University of Glasgow; formerly Pathologist to the Royal Infirmary, and President of the Pathological and Clinical Society of Glasgow. Second Edition. Revised and mostly Re-written. With 364 Illustrations. 8vo, price 31s. 6d.

COOKE. TABLETS OF ANATOMY. By THOMAS COOKE,

F.R.C.S. Eng., B.A. B.Sc. M.D. Paris, Senior Assistant Surgeon to the Westminster Hospital, and Lecturer at the School of Anatomy, Physiology, and Surgery. Being a Synopsis of Demonstrations given in the Westminster Hospital Medical School in the years 1871-75. Eighth Thousand, being a selection of the Tablets believed to be most useful to Students generally. Post 4to, price 7s. 6d.

DICKINSON.—WORKS by W. HOWSHIP DICKINSON, M.D.

Cantab., F.R.C.P., Physician to, and Lecturer on Medicine at, St. George's Hospital; Consulting Physician to the Hospital for Sick Children; Corresponding Member of the Academy of Medicine of New York.

ON RENAL AND URINARY AFFECTIONS. Complete in Three Parts, 8vo, with 12 Plates and 122 Woodcuts. Price £3 4s. 6d. cloth.

* * The Parts can also be had separately, each complete in itself, as follows:—

- PART I.—*Diabetes*, price 10s. 6d. sewed, 12s. cloth.
 „ II.—*Albuminuria*, price £1 sewed, £1 1s. cloth.
 „ III.—*Miscellaneous Affections of the Kidneys and Urine*, price £1 10s. sewed, £1 11s. 6d. cloth.

THE TONGUE AS AN INDICATION OF DISEASE; being the Lumleian Lectures delivered at the Royal College of Physicians in March, 1888. 8vo, price 7s. 6d.

ERICHSEN.—*WORKS* by JOHN ERIC ERICHSEN, F.R.S., LL.D.
(Edin.), Hon. M. Ch. and F.R.C.S. (Ireland), Surgeon Extraordinary to H.M. the Queen;
President of University College, London; Fellow and Ex-President of the Royal College
of Surgeons of England; Emeritus Professor of Surgery in University College; Con-
sulting-Surgeon to University College Hospital, and to many other Medical Charities.

**THE SCIENCE AND ART OF SURGERY; A TREATISE
ON SURGICAL INJURIES, DISEASES, AND OPERATIONS.**

The Ninth Edition, Edited by Professor BECK, M.S. & M.B. (Lond.),
F.R.C.S., Surgeon to University College Hospital, &c. Illustrated by 1025
Engravings on Wood. 2 Vols. 8vo, price 48s.

**ON CONCUSSION OF THE SPINE, NERVOUS SHOCKS,
and other Obscure Injuries of the Nervous System in their Clinical and
Medico-Legal Aspects.** New and Revised Edition. Crown 8vo, 10s. 6d.

GAIRDNER AND COATS. ON THE DISEASES CLASSIFIED
by the REGISTRAR-GENERAL as TABES MESENTERICA. LEC-
TURES TO PRACTITIONERS. By W. T. GAIRDNER, M.D., LL.D.
On the PATHOLOGY of PHTHISIS PULMONALIS. By JOSEPH
COATS, M.D. With 28 Illustrations. 8vo, price 12s. 6d.

GARROD.—*WORKS* by Sir ALFRED BARING GARROD, M.D.,
F.R.S., &c.; Physician Extraordinary to H.M. the Queen; Consulting Physician to
King's College Hospital.

**A TREATISE ON GOUT AND RHEUMATIC GOUT
(RHEUMATOID ARTHRITIS).** Third Edition, thoroughly revised
and enlarged; with 6 Plates, comprising 21 Figures (14 Coloured), and 27
Illustrations engraved on Wood. 8vo, price 21s.

**THE ESSENTIALS OF MATERIA MEDICA AND THERA-
PEUTICS.** The Twelfth Edition, revised and edited, under the super-
vision of the Author, by NESTOR TIRARD, M.D. Lond., F.R.C.P.,
Professor of Materia Medica and Therapeutics in King's College, London, &c.
Crown 8vo, price 12s. 6d.

GARROD. AN INTRODUCTION TO THE USE OF THE
LARYNGOSCOPE. By ARCHIBALD G. GARROD, M.A., M.B.
Oxon., M.R.C.P. With Illustrations. 8vo, price 3s. 6d.

GRAY. ANATOMY, DESCRIPTIVE AND SURGICAL. By
HENRY GRAY, F.R.S., late Lecturer on Anatomy at St. George's
Hospital. The Twelfth Edition, re-edited by T. PICKERING PICK,
Surgeon to St. George's Hospital; Member of the Court of Examiners, Royal
College of Surgeons of England. With 605 large Woodcut Illustrations, a
large proportion of which are Coloured, the Arteries being coloured red, the
Veins blue, and the Nerves yellow. The attachments of the muscles to the
bones, in the section on Osteology, are also shown in coloured outline. Royal
8vo, price 36s.

HASSALL.—*WORKS* by **ARTHUR HILL HASSALL, M.D.** *London, Member of the Royal College of Physicians of England; late Senior Physician to the Royal Free Hospital; Founder of, and Consulting Physician to, the Royal National Hospital for Consumption and Diseases of the Chest, &c.*

SAN REMO CLIMATICALLY AND MEDICALLY CONSIDERED. New Edition, with 30 Illustrations. Crown 8vo, price 5s.

THE INHALATION TREATMENT OF DISEASES OF THE ORGANS OF RESPIRATION, INCLUDING CONSUMPTION. With numerous Illustrations. Crown 8vo, price 12s. 6d.

HOLMES. **A SYSTEM OF SURGERY,** Theoretical and Practical, in Treatises by various Authors. Edited by **TIMOTHY HOLMES, M.A.,** Surgeon to St. George's Hospital; and **J. W. HULKE, F.R.S.,** Surgeon to the Middlesex Hospital and to the Royal London Ophthalmic Hospital. Third Edition, in Three Volumes, with Coloured Lithographic Plates and numerous Illustrations engraved on Wood. 3 Vols., royal 8vo, price £4 4s.

LADD. **ELEMENTS OF PHYSIOLOGICAL PSYCHOLOGY: A TREATISE OF THE ACTIVITIES AND NATURE OF THE MIND FROM THE PHYSICAL AND EXPERIMENTAL POINT OF VIEW.** By **GEORGE T. LADD,** Professor of Philosophy in Yale University. With 113 Illustrations. 8vo, price 21s.

LITTLE. **ON IN-KNEE DISTORTION (GENU VALGUM): Its Varieties and Treatment with and without Surgical Operation.** By **W. J. LITTLE, M.D., F.R.C.P.,** Author of "The Deformities of the Human Frame," &c. Assisted by **MUIRHEAD LITTLE, M.R.C.S., L.R.C.P.** With 40 Woodcut Illustrations. 8vo, price 7s. 6d.

LIVEING.—*WORKS* by **ROBERT LIVEING, M.A. & M.D. Cantab., F.R.C.P. Lond., &c.,** Physician to the Department for Diseases of the Skin at the Middlesex Hospital, &c.

HANDBOOK ON DISEASES OF THE SKIN. With especial reference to Diagnosis and Treatment. Fifth Edition, revised and enlarged. Fcap. 8vo, price 5s.

NOTES ON THE TREATMENT OF SKIN DISEASES. Fifth Edition. 18mo, price 3s.

ELEPHANTIASIS GRÆCORUM, OR TRUE LEPROSY; Being the Goulstonian Lectures for 1873. Cr. 8vo, 4s. 6d.

LONGMORE.—*WORKS* by *Surgeon-General Sir T. LONGMORE*, C.B., F.R.C.S., *Honorary Surgeon to H.M. Queen Victoria; Professor of Military Surgery in the Army Medical School.*

THE ILLUSTRATED OPTICAL MANUAL; OR, HANDBOOK OF INSTRUCTIONS FOR THE GUIDANCE OF SURGEONS IN TESTING QUALITY AND RANGE OF VISION, AND IN DISTINGUISHING AND DEALING WITH OPTICAL DEFECTS IN GENERAL. Illustrated by 74 Drawings and Diagrams by Inspector-General Dr. MACDONALD, R.N., F.R.S., C.B. Fourth Edition. 8vo, price 14s.

GUNSHOT INJURIES. Their History, Characteristic Features, Complications, and General Treatment; with Statistics concerning them as they are met with in Warfare. With 58 Illustrations. 8vo, price 31s. 6d.

MITCHELL. DISSOLUTION AND EVOLUTION AND THE SCIENCE OF MEDICINE: An Attempt to Co-ordinate the necessary Facts of Pathology and to establish the First Principles of Treatment. By C. PITFIELD MITCHELL, M.R.C.S. 8vo, price 16s.

MUNK. EUTHANASIA; OR, MEDICAL TREATMENT IN AID OF AN EASY DEATH. By WILLIAM MUNK, M.D., F.S.A., Fellow and late Senior Censor of the Royal College of Physicians, &c. Crown 8vo, price 4s. 6d.

MURCHISON.—*WORKS* by *CHARLES MURCHISON, M.D.*, LL.D., F.R.S., &c., *Fellow of the Royal College of Physicians; late Physician and Lecturer on the Principles and Practice of Medicine, St. Thomas's Hospital.*

A TREATISE ON THE CONTINUED FEVERS OF GREAT BRITAIN. Third Edition, Edited by W. CAYLEY, M.D., F.R.C.P. With 6 Coloured Plates and Lithographs, 19 Diagrams and 20 Woodcut Illustrations. 8vo, price 25s.

CLINICAL LECTURES ON DISEASES OF THE LIVER, JAUNDICE, AND ABDOMINAL DROPSY; Including the Croonian Lectures on Functional Derangements of the Liver, delivered at the Royal College of Physicians in 1874. New Edition, Revised by T. LAUDER BRUNTON, M.D. 8vo, price 24s.

NEWMAN. ON THE DISEASES OF THE KIDNEY AMENABLE TO SURGICAL TREATMENT. Lectures to Practitioners. By DAVID NEWMAN, M.D., Surgeon to the Western Infirmary Out-Door Department; Pathologist and Lecturer on Pathology at the Glasgow Royal Infirmary; Examiner in Pathology in the University of Glasgow; Vice-President Glasgow Pathological and Clinical Society. 8vo, price 16s.

OWEN. A MANUAL OF ANATOMY FOR SENIOR STUDENTS.

By EDMUND OWEN, M.B., F.R.S.C., Surgeon to St. Mary's Hospital, London, and co-Lecturer on Surgery, late Lecturer on Anatomy in its Medical School. With 210 Illustrations. Crown 8vo, price 12s. 6d.

PAGET.—WORKS by Sir JAMES PAGET, Bart., F.R.S., D.C.L.

Oxon., LL.D. Cantab., &c., Sergeant-Surgeon to the Queen, Surgeon to the Prince of Wales, Consulting Surgeon to St. Bartholomew's Hospital.

LECTURES ON SURGICAL PATHOLOGY, Delivered at the Royal College of Surgeons of England. Fourth Edition, re-edited by the AUTHOR and W. TURNER, M.B. 8vo, with 131 Woodcuts, price 21s.

CLINICAL LECTURES AND ESSAYS. Edited by F. HOWARD MARSH, Assistant-Surgeon to St. Bartholomew's Hospital. Second Edition, revised. 8vo, price 15s.

QUAIN. QUAIN'S (JONES) ELEMENTS OF ANATOMY.

The Tenth Edition. Edited by EDWARD ALBERT SCHÄFER, F.R.S., Professor of Physiology and Histology in University College, London; and GEORGE DANCER THANE, Professor of Anatomy in University College, London. (In three volumes.)

VOL. I., PART I., now ready. **EMBRYOLOGY.** By Professor SCHÄFER. Illustrated by 200 Engravings, many of which are coloured. Royal 8vo, 9s.

QUAIN. A DICTIONARY OF MEDICINE; Including General

Pathology, General Therapeutics, Hygiene, and the Diseases peculiar to Women and Children. By Various Writers. Edited by RICHARD QUAIN, M.D., F.R.S., Physician Extraordinary to H.M. the Queen, Fellow of the Royal College of Physicians, Consulting Physician to the Hospital for Consumption, Brompton. Sixteenth Thousand; pp. 1,836, with 138 Illustrations engraved on wood. 1 Vol. medium 8vo, price 31s. 6d. cloth. To be had also in Two Volumes, price 34s. cloth.

RICHARDSON. THE ASCLEPIAD. A Book of Original Research in

the Science, Art, and Literature of Medicine. By BENJAMIN WARD RICHARDSON, M.D., F.R.S. Published Quarterly, price 2s. 6d. Volumes for 1884, 1885, 1886, 1887, 1888 & 1889, 8vo, price 12s. 6d. each.

SALTER. DENTAL PATHOLOGY AND SURGERY. By .

JAMES A. SALTER, M.B., F.R.S., Examiner in Dental Surgery at the Royal College of Surgeons; Dental Surgeon to Guy's Hospital. With 133 Illustrations. 8vo, price 18s.

SCHÄFER. THE ESSENTIALS OF HISTOLOGY, DESCRIPTIVE AND PRACTICAL, FOR THE USE OF STUDENTS.

By E. A. SCHÄFER, F.R.S., Jodrell Professor of Physiology in University College, London. Second Edition, Revised. With 283 Illustrations. 8vo, price 6s.; or Interleaved with Drawing-paper, price 8s. 6d.

SMITH (H. F.). THE HANDBOOK FOR MIDWIVES. By HENRY FLY SMITH, B.A., M.B. Oxon., M.R.C.S. Second Edition, thoroughly revised. With 41 Woodcuts. Crown 8vo, price 5s.

STEEL.—WORKS by JOHN HENRY STEEL, F.R.C.V.S., F.Z.S., A.V.D., Professor of Veterinary Science and Principal of Bombay Veterinary College.

A TREATISE ON THE DISEASES OF THE DOG; being a Manual of Canine Pathology. Especially adapted for the use of Veterinary Practitioners and Students. 88 Illustrations. 8vo, 10s. 6d.

A TREATISE ON THE DISEASES OF THE OX; being a Manual of Bovine Pathology specially adapted for the use of Veterinary Practitioners and Students. 2 Plates and 117 Woodcuts. 8vo, 15s.

A TREATISE ON THE DISEASES OF THE SHEEP; being a Manual of Ovine Pathology for the use of Veterinary Practitioners and Students. With Coloured Plate, and 99 Woodcuts. 8vo, 12s.

"STONEHENGE." THE DOG IN HEALTH AND DISEASE. By "STONEHENGE." With 84 Wood Engravings. Square crown 8vo, 7s. 6d.

WEST. LECTURES ON THE DISEASES OF INFANCY AND CHILDHOOD. By CHARLES WEST, M.D., &c., Founder of and formerly Physician to the Hospital for Sick Children. Seventh Edition, revised and enlarged. 8vo, 18s.

WILKS AND MOXON. LECTURES ON PATHOLOGICAL ANATOMY. By SAMUEL WILKS, M.D., F.R.S., Consulting Physician to, and formerly Lecturer on Medicine and Pathology at, Guy's Hospital, and the late WALTER MOXON, M.D., F.R.C.P., Physician to, and some time Lecturer on Pathology at, Guy's Hospital. Third Edition, thoroughly Revised. By SAMUEL WILKS, M.D., LL.D., F.R.S. 8vo, price 18s.

WILLIAMS. PULMONARY CONSUMPTION: ITS ETIOLOGY, PATHOLOGY, AND TREATMENT. With an Analysis of 1,000 Cases to Exemplify its Duration and Modes of Arrest. By C. J. B. WILLIAMS, M.D., LL.D., F.R.S., F.R.C.P., Senior Consulting Physician to the Hospital for Consumption, Brompton; and CHARLES THEODORE WILLIAMS, M.A., M.D. Oxon., F.R.C.P., Senior Physician to the Hospital for Consumption, Brompton. Second Edition, Enlarged and Re-written by Dr. C. THEODORE WILLIAMS. With 4 Coloured Plates and 10 Woodcuts. 8vo, price 16s.

YOUATT.—WORKS by WILLIAM YOUATT.

THE HORSE. Revised and enlarged by W. WATSON, M.R.C.V.S. Woodcuts. 8vo, 7s. 6d.

THE DOG. Revised and enlarged. Woodcuts. 8vo, 6s.

General Scientific Works.

ARNOTT. THE ELEMENTS OF PHYSICS OR NATURAL PHILOSOPHY. By NEIL ARNOTT, M.D. Edited by A. BAIN, LL.D. and A. S. TAYLOR, M.D., F.R.S. Woodcuts. Crown 8vo, 12s. 6d.

BENNETT AND MURRAY. A HANDBOOK OF CRYPTOGAMIC BOTANY. By A. W. BENNETT, M.A., B.Sc., F.L.S., and GEORGE R. MILNE MURRAY, F.L.S. With 378 Illustrations. 8vo, price 16s.

CLODD. THE STORY OF CREATION. A Plain Account of Evolution. By EDWARD CLODD, Author of "The Childhood of the World," &c. With 77 Illustrations. Crown 8vo, 3s. 6d.

CROOKES. SELECT METHODS IN CHEMICAL ANALYSIS (chiefly Inorganic). By W. CROOKES, F.R.S., V.P.C.S., Editor of "The Chemical News." Second Edition, re-written and greatly enlarged. Illustrated with 37 Woodcuts. 8vo, price 24s.

CULLEY. A HANDBOOK OF PRACTICAL TELEGRAPHY. By R. S. CULLEY, M.I.C.E., late Engineer-in-Chief of Telegraphs to the Post Office. Eighth Edition, completely revised. With 135 Woodcuts and 17 Plates, 8vo, 16s.

DURRANT. LAWS AND DEFINITIONS CONNECTED WITH CHEMISTRY AND HEAT. With Explanatory Notes on Physical and Theoretical Chemistry, also special Tests and Examples for Practical Analysis. By R. G. DURRANT, M.A., F.C.S., Assistant-master at Marlborough College. 3s.

EARL. THE ELEMENTS OF LABORATORY WORK. A Course of Natural Science for Schools. By A. G. EARL, M.A., F.C.S., late Scholar of Christ College, Cambridge; Science Master at Tonbridge School. With 57 Diagrams and numerous Exercises and Questions. Crown 8vo, price 4s. 6d.

FORBES. A COURSE OF LECTURES ON ELECTRICITY. Delivered before the Society of Arts. By GEORGE FORBES, M.A., F.R.S. (L. & E.) With 17 Illustrations. Crown 8vo, 5s.

GALLOWAY. THE FUNDAMENTAL PRINCIPLES OF CHEMISTRY PRACTICALLY TAUGHT BY A NEW METHOD. By ROBERT GALLOWAY, M.R.I.A., F.C.S., Honorary Member of the Chemical Society of the Lehigh University, U.S.; Author of "A Treatise on Fuel, Scientific and Practical," &c. Crown 8vo, 6s. 6d.

GANOT. ELEMENTARY TREATISE ON PHYSICS; Experimental and Applied, for the use of Colleges and Schools. Translated and edited from GANOT's *Éléments de Physique* (with the Author's sanction) by E. ATKINSON, Ph.D., F.C.S., Professor of Experimental Science, Staff College, Sandhurst. Twelfth Edition, revised and enlarged, with 5 Coloured Plates and 923 Woodcuts. Large crown 8vo, price 15s.

NATURAL PHILOSOPHY FOR GENERAL READERS AND YOUNG PERSONS; Being a Course of Physics divested of Mathematical Formulæ, and expressed in the language of daily life. Translated from GANOT's *Cours de Physique* (with the Author's sanction) by E. ATKINSON, Ph.D., F.C.S. Sixth Edition, carefully revised; with 34 pages of New Matter, 2 Coloured Plates, and 518 Woodcuts, and an Appendix of Questions. Crown 8vo, price 7s. 6d.

GIBSON. A TEXT-BOOK OF ELEMENTARY BIOLOGY. By R. J. HARVEY GIBSON, M.A., F.R.S.E., Lecturer on Botany in University College, Liverpool. With 192 Illustrations. Crown 8vo, price 6s.

GOODEVE.—*WORKS* by T. M. GOODEVE, M.A., Barrister-at-Law; Professor of Mechanics at the Normal School of Science and the Royal School Mines.

PRINCIPLES OF MECHANICS. New Edition, re-written and enlarged. With 253 Woodcuts and numerous Examples. Crown 8vo, 6s.

THE ELEMENTS OF MECHANISM. New Edition, re-written and enlarged. With 342 Woodcuts. Crown 8vo, 6s.

A MANUAL OF MECHANICS: an Elementary Text-Book for Students of Applied Mechanics. With 138 Illustrations and Diagrams, and 141 Examples taken from the Science Department Examination Papers, with Answers. Fcp. 8vo, 2s. 6d.

HELMHOLTZ.—*WORKS* by HERMANN L. F. HELMHOLTZ, M.D., Professor of Physics in the University of Berlin.

ON THE SENSATIONS OF TONE AS A PHYSIOLOGICAL BASIS FOR THE THEORY OF MUSIC. Second English Edition; with numerous additional Notes, and a new Additional Appendix, bringing down information to 1885, and specially adapted to the use of Musical Students. By ALEXANDER J. ELLIS, B.A., F.R.S., F.S.A., &c., formerly Scholar of Trinity College, Cambridge. With 68 Figures engraved on Wood, and 42 Passages in Musical Notes. Royal 8vo, price 28s.

POPULAR LECTURES ON SCIENTIFIC SUBJECTS. With 68 Woodcuts. 2 Vols. crown 8vo, 15s., or separately, 7s. 6d. each.

HERSCHEL. OUTLINES OF ASTRONOMY. By Sir JOHN F. W. HERSCHEL, Bart., K.H., &c., Member of the Institute of France. Twelfth Edition, with 9 Plates, and numerous Diagrams. Square crown 8vo, price 12s.

HUDSON AND GOSSE. THE ROTIFERA OR 'WHEEL ANIMALCULES.' By C. T. HUDSON, LL.D., and P. H. GOSSE, F.R.S. With 30 Coloured and 4 Uncoloured Plates. In 6 Parts. 4to, price 10s. 6d. each; Supplement, 12s. 6d. Complete in Two Volumes, with Supplement, 4to, £4 4s.

* * * The Plates in the Supplement contain figures of almost all the Foreign Species, as well as of the British Species, that have been discovered since the original publication of Vols. I. and II.

IRVING. PHYSICAL AND CHEMICAL STUDIES IN ROCK-METAMORPHISM, based on the Thesis written for the D.Sc. Degree in the University of London, 1888. By the Rev. A. IRVING, D.Sc. Lond. Senior Science Master at Wellington College. 8vo, 5s.

JORDAN.—WORKS by WILLIAM LEIGHTON JORDAN, F.R.G.S.

THE OCEAN: A Treatise on Ocean Currents and Tides and their Causes. 8vo, 21s.

THE NEW PRINCIPLES OF NATURAL PHILOSOPHY. With 13 Plates. 8vo, 21s.

THE WINDS: An Essay in Illustration of the New Principles of Natural Philosophy. Crown 8vo, 2s.

THE STANDARD OF VALUE. 8vo, 6s.

KOLBE. A SHORT TEXT-BOOK OF INORGANIC CHEMISTRY. By Dr. HERMANN KOLBE, Professor of Chemistry in the University of Leipzig. Translated and Edited by T. S. HUMPIDGE, Ph.D., B.Sc. (Lond.), Professor of Chemistry and Physics in the University College of Wales, Aberystwyth. With a Coloured Table of Spectra and 66 Woodcuts. Second Edition. Crown 8vo, price 7s. 6d.

LARDEN. ELECTRICITY FOR PUBLIC SCHOOLS AND COLLEGES. With numerous Questions and Examples with Answers, and 214 Illustrations and Diagrams. By W. LARDEN, M.A. Crown 8vo, 6s.

LINDLEY AND MOORE. THE TREASURY OF BOTANY, OR POPULAR DICTIONARY OF THE VEGETABLE KINGDOM: with which is incorporated a Glossary of Botanical Terms. Edited by J. LINDLEY, M.D., F.R.S., and T. MOORE, F.L.S. With 20 Steel Plates, and numerous Woodcuts. 2 Parts, fcp. 8vo, price 12s.

LLOYD. A TREATISE ON MAGNETISM, General and Terrestrial. By H. LLOYD, D.D., D.C.L. 8vo, 10s. 6d.

LOUDON. AN ENCYCLOPÆDIA OF PLANTS. By J. C. LOUDON. Comprising the Specific Character, Description, Culture, History, Application in the Arts, and every other desirable particular respecting all the plants indigenous to, cultivated in, or introduced into, Britain. Corrected by Mrs. LOUDON. 8vo, with above 12,000 Woodcuts, price 42s.

MARTIN. NAVIGATION AND NAUTICAL ASTRONOMY. Compiled by Staff-Commander W. R. MARTIN, R.N., Instructor in Surveying, Navigation, and Compass Adjustment; Lecturer on Meteorology at the Royal Naval College, Greenwich. Sanctioned for use in the Royal Navy by the Lords Commissioners of the Admiralty. Royal 8vo, 18s.

MEYER. MODERN THEORIES OF CHEMISTRY. By Professor LOTHAR MEYER. Translated, from the Fifth Edition of the German, by P. PHILLIPS BEDSON, D.Sc. (Lond.), B.Sc. (Vict.), F.C.S., Professor of Chemistry, Durham College of Science, Newcastle-on-Tyne; and W. CARLETON WILLIAMS, B.Sc. (Vict.), F.C.S., Professor of Chemistry, Firth College, Sheffield. 8vo, 18s.

MILLER.—*WORKS* by WILLIAM ALLEN MILLER, M.D., D.C.L., LL.D., late Professor of Chemistry in King's College, London.

THE ELEMENTS OF CHEMISTRY, Theoretical and Practical.

PART I. CHEMICAL PHYSICS. Sixth Edition, revised by HERBERT McLEOD, F.C.S. With 274 Woodcuts. 8vo, price 16s.

PART II. INORGANIC CHEMISTRY. Sixth Edition, revised throughout, with Additions by C. E. GROVES, Fellow of the Chemical Societies of London, Paris, and Berlin. With 376 Woodcuts. 8vo, price 24s.

PART III. ORGANIC CHEMISTRY, or the Chemistry of Carbon Compounds. *Hydrocarbons, Alcohols, Ethers, Aldehydes and Paraffinoid Acids.* Fifth Edition, revised and in great part re-written, by H. E. ARMSTRONG, F.R.S., and C. E. GROVES, F.C.S. 8vo, price 31s. 6d.

MITCHELL. MANUAL OF PRACTICAL ASSAYING. By JOHN MITCHELL, F.C.S. Sixth Edition. Edited by W. CROOKES, F.R.S. With 201 Woodcuts. 8vo, price 31s. 6d.

MORGAN. ANIMAL BIOLOGY. An Elementary Text Book. By C. LLOYD MORGAN, Professor of Animal Biology and Geology in University College, Bristol. With numerous Illustrations. Crown 8vo, 8s. 6d.

ODLING. A COURSE OF PRACTICAL CHEMISTRY, Arranged for the use of Medical Students, with express reference to the Three Months' Summer Practice. By WILLIAM ODLING, M.A., F.R.S. Fifth Edition, with 71 Woodcuts. Crown 8vo, price 6s.

OLIVER. ASTRONOMY FOR AMATEURS: A PRACTICAL MANUAL OF TELESCOPIC RESEARCH IN ALL LATITUDES ADAPTED TO THE POWERS OF MODERATE INSTRUMENTS. Edited by JOHN A. WESTWOOD OLIVER, with the assistance of T. W. BACKHOUSE, F.R.A.S.; S. W. BURNHAM, M.A., F.R.A.S.; J. RAND CAPRON, F.R.A.S.; W. F. DENNING, F.R.A.S.; T. GWYN ELGER, F.R.A.S.; W. S. FRANKS, F.R.A.S.; J. E. GORE, M.R.I.A., F.R.A.S.; SIR HOWARD GRUBB, F.R.S., F.R.A.S.; E. W. MAUNDER, F.R.A.S.; and others. Illustrated. Crown 8vo, 7s. 6d.

PAYEN. INDUSTRIAL CHEMISTRY; A Manual for use in Technical Colleges or Schools, also for Manufacturers and others, based on a Translation of Stohmann and Engler's German Edition of PAYEN's *Précis de Chimie Industrielle*. Edited and supplemented with Chapters on the Chemistry of the Metals, &c., by B. H. PAUL, Ph.D. With 698 Woodcuts. Medium 8vo, price 42s.

REYNOLDS. EXPERIMENTAL CHEMISTRY for Junior Students. By J. EMERSON REYNOLDS, M.D., F.R.S., Professor of Chemistry, Univ. of Dublin. Fcp. 8vo, with numerous Woodcuts.

PART I.—*Introductory*, price 1s. 6d.

PART II.—*Non-Metals*, with an Appendix on Systematic Testing for Acids, price 2s. 6d.

PART III.—*Metals and Allied Bodies*, price 3s. 6d.

PART IV.—*Chemistry of Carbon Compounds*, price 4s.

PROCTOR.—WORKS by RICHARD A. PROCTOR.

LIGHT SCIENCE FOR LEISURE HOURS; Familiar Essays on Scientific Subjects, Natural Phenomena, &c. 3 Vols. crown 8vo, 5s. each.

THE ORBS AROUND US; a Series of Essays on the Moon and Planets, Meteors, and Comets. With Chart and Diagrams, crown 8vo, 5s.

OTHER WORLDS THAN OURS; The Plurality of Worlds Studied under the Light of Recent Scientific Researches. With 14 Illustrations, crown 8vo, 5s.

THE MOON; her Motions, Aspects, Scenery, and Physical Condition. With Plates, Charts, Woodcuts, and Lunar Photographs, crown 8vo, 5s.

UNIVERSE OF STARS; Presenting Researches into and New Views respecting the Constitution of the Heavens. With 22 Charts and 22 Diagrams, 8vo. 10s. 6d.

LARGER STAR ATLAS for the Library, in 12 Circular Maps, with Introduction and 2 Index Pages. Folio, 15s., or Maps only, 12s. 6d.

NEW STAR ATLAS for the Library, the School, and the Observatory, in 12 Circular Maps (with 2 Index Plates). Crown 8vo, 5s.

THE STUDENT'S ATLAS. In 12 Circular Maps on a Uniform Projection and 1 Scale, with 2 Index Maps. Intended as a *vade-mecum* for the Student of History, Travel, Geography, Geology, and Political Economy. With a letter-press Introduction illustrated by several cuts. 5s.

OLD AND NEW ASTRONOMY. In 12 Parts. Price 2s. 6d. each; supplementary section, 1s. (in course of publication); complete, 36s. cloth. [*Nearly ready.*]

STUDIES OF VENUS-TRANSITS; an Investigation of the Circumstances of the Transits of Venus in 1874 and 1882. With 7 Diagrams and 10 Plates. 8vo, 5s.

ELEMENTARY PHYSICAL GEOGRAPHY. With 33 Maps and Woodcuts. Fcp. 8vo, 1s. 6d.

LESSONS IN ELEMENTARY ASTRONOMY; with Hints for Young Telescopists. With 47 Woodcuts. Fcp. 8vo, 1s. 6d.

FIRST STEPS IN GEOMETRY: a Series of Hints for the Solution of Geometrical Problems; with Notes on Euclid, useful Working Propositions, and many Examples. Fcp. 8vo, 3s. 6d.

EASY LESSONS IN THE DIFFERENTIAL CALCULUS: indicating from the Outset the Utility of the Processes called Differentiation and Integration. Fcp. 8vo, 2s. 6d.

THE STARS IN THEIR SEASONS. An Easy Guide to a Knowledge of the Star Groups, in 12 Large Maps. Imperial 8vo, 5s.

STAR PRIMER. Showing the Starry Sky Week by Week, in 24 Hourly Maps. Crown 4to, 2s. 6d.

THE SEASONS PICTURED IN 48 SUN VIEWS OF THE EARTH, and 24 Zodiacal Maps, &c. Demy 4to, 5s.

ROUGH WAYS MADE SMOOTH. Familiar Essays on Scientific Subjects. Crown 8vo, 5s.

HOW TO PLAY WHIST: WITH THE LAWS AND ETIQUETTE OF WHIST. Crown 8vo, 3s. 6d.

HOME WHIST: an Easy Guide to Correct Play. 16mo, 1s.

[*Continued.*]

PROCTOR.—*WORKS by RICHARD A. PROCTOR—continued.*

OUR PLACE AMONG INFINITIES. A Series of Essays contrasting our Little Abode in Space and Time with the Infinities around us. Crown 8vo, 5s.

STRENGTH AND HAPPINESS. Crown 8vo, 5s.

STRENGTH: How to get Strong and keep Strong, with Chapters on Rowing and Swimming, Fat, Age, and the Waist. With 9 Illustrations. Crown 8vo, 2s.

THE EXPANSE OF HEAVEN, Essays on the Wonders of the Firmament. Crown 8vo, 5s.

THE GREAT PYRAMID, OBSERVATORY, TOMB, AND TEMPLE. With Illustrations. Crown 8vo, 5s.

PLEASANT WAYS IN SCIENCE. Crown 8vo, 5s.

MYTHS AND MARVELS OF ASTRONOMY. Crown 8vo, 5s.

CHANCE AND LUCK; a Discussion of the Laws of Luck, Coincidences, Wagers, Lotteries, and the Fallacies of Gambling, &c. Crown 8vo, 2s. boards, 2s. 6d. cloth.

NATURE STUDIES. By GRANT ALLEN, A. WILSON, T. FOSTER, E. CLODD, and R. A. PROCTOR. Crown 8vo, 5s.

LEISURE READINGS. By E. CLODD, A. WILSON, T. FOSTER, A. C. RUNYARD, and R. A. PROCTOR. Crown 8vo, 5s.

SCELLEN. **SPECTRUM ANALYSIS IN ITS APPLICATION TO TERRESTRIAL SUBSTANCES,** and the Physical Constitution of the Heavenly Bodies. Familiarly explained by the late Dr. H. SCHELLEN. Translated from the Third Enlarged and Revised German Edition by JANE and CAROLINE LASSELL. Edited, with Notes, by Capt. W. DE W. ABNEY, R.E. Second Edition. With 14 Plates (including Angström's and Cornu's Maps) and 291 Woodcuts. 8vo. Price 31s. 6d.

SCOTT. **WEATHER CHARTS AND STORM WARNINGS.** By ROBERT H. SCOTT, M.A., F.R.S. With numerous Illustrations. Crown 8vo, 6s.

SLINGO AND BROOKER. **ELECTRICAL ENGINEERING FOR ELECTRIC LIGHT ARTISANS AND STUDENTS.** (Embracing those branches prescribed in the Syllabus issued by the City and Guilds Technical Institute.) By W. SLINGO, Principal of the Telegraphists' School of Science, &c., &c., and A. BROOKER, Instructor on Electrical Engineering at the Telegraphists' School of Science. With 307 Illustrations. Crown 8vo, price 10s. 6d.

SMITH. **GRAPHICS; OR, THE ART OF CALCULATION BY DRAWING LINES,** applied to Mathematics, Theoretical Mechanics and Engineering, including the Kinetics and Dynamics of Machinery, and the Statics of Machines, Bridges, Roofs, and other Engineering Structures. By ROBERT H. SMITH, Professor of Civil and Mechanical Engineering, Mason Science College, Birmingham.

PART I. Text, with separate Atlas of Plates—Arithmetic, Algebra, Trigonometry, Vector, and Locor Addition, Machine Kinematics, and Statics of Flat and Solid Structures. 8vo, 15s.

THORPE. A DICTIONARY OF APPLIED CHEMISTRY.

By T. E. THORPE, B.Sc. (Vict.), Ph.D., F.R.S., Treas. C.S., Professor of Chemistry in the Normal School of Science and Royal School of Mines, South Kensington. Assisted by Eminent Contributors. 3 vols., £2 2s. each.
[Vol. I. now ready.]

TYNDALL.—WORKS by JOHN TYNDALL, F.R.S., &c.

FRAGMENTS OF SCIENCE. 2 Vols. Crown 8vo, 16s.

HEAT A MODE OF MOTION. Crown 8vo, 12s.

SOUND. With 204 Woodcuts. Crown 8vo, 10s. 6d.

RESEARCHES ON DIAMAGNETISM AND MAGNE-CRYSTALLIC ACTION, including the question of Diamagnetic Polarity. Crown 8vo, 12s.

ESSAYS ON THE FLOATING-MATTER OF THE AIR in relation to Putrefaction and Infection. With 24 Woodcuts. Crown 8vo, 7s. 6d.

LECTURES ON LIGHT, delivered in America in 1872 and 1873. With 57 Diagrams. Crown 8vo, 5s.

LESSONS IN ELECTRICITY AT THE ROYAL INSTITUTION, 1875-76. With 58 Woodcuts. Crown 8vo, 2s. 6d.

NOTES OF A COURSE OF SEVEN LECTURES ON ELECTRICAL PHENOMENA AND THEORIES, delivered at the Royal Institution. Crown 8vo, 1s. sewed, 1s. 6d. cloth.

NOTES OF A COURSE OF NINE LECTURES ON LIGHT, delivered at the Royal Institution. Crown 8vo, 1s. sewed, 1s. 6d. cloth.

FARADAY AS A DISCOVERER. Fcp. 8vo, 3s. 6d.

WATTS' DICTIONARY OF CHEMISTRY. Revised and entirely

Re-written by H. FORSTER MORLEY, M.A., D.Sc., Fellow of, and lately Assistant-Professor of Chemistry in, University College, London; and M. M. PATTISON MUIR, M.A., F.R.S.E., Fellow, and Prælector in Chemistry, of Gonville and Caius College, Cambridge. Assisted by Eminent Contributors. To be Published in 4 Vols. 8vo. Vols. I. & II. 42s. each. [Now ready.]

WEBB. CELESTIAL OBJECTS FOR COMMON TELESCOPES.

By the Rev. T. W. WEBB, M.A. Fourth Edition, adapted to the Present State of Sidereal Science; Map, Plate, Woodcuts. Crown 8vo, price 9s.

WILLIAMS. MANUAL OF TELEGRAPHY. By W. WILLIAMS,

Superintendent Indian Government Telegraphs. With 93 Woodcuts. 8vo, 10s. 6d.

TEXT-BOOKS OF SCIENCE.

- PHOTOGRAPHY.** By Captain W. DE WIVELESLE ABNEY, C.B., F.R.S. With 105 Woodcuts. Price 3s. 6d.
- THE STRENGTH OF MATERIALS AND STRUCTURES:** the Strength of Materials as depending on their quality and as ascertained by Testing Apparatus; the Strength of Structures, as depending on their form and arrangement, and on the materials of which they are composed. By Sir J. ANDERSON, C.E., &c. With 66 Woodcuts. Price 3s. 6d.
- INTRODUCTION TO THE STUDY OF ORGANIC CHEMISTRY; the CHEMISTRY OF CARBON and its COMPOUNDS.** By HENRY E. ARMSTRONG, Ph.D., F.R.S. With 8 Woodcuts. Price 3s. 6d.
- ELEMENTS OF ASTRONOMY.** By Sir R. S. BALL, LL.D., F.R.S., Andrews Professor of Astronomy in the Univ. of Dublin, Royal Astronomer of Ireland. With 136 Woodcuts. Price 6s.
- RAILWAY APPLIANCES.** A Description of Details of Railway Construction subsequent to the completion of Earthworks and Structures, including a short Notice of Railway Rolling Stock. By JOHN WOLFE BARRY, M.I.C.E. With 207 Woodcuts. Price 3s. 6d.
- SYSTEMATIC MINERALOGY.** By HILARY BAUERMAN, F.G.S., Associate of the Royal School of Mines. With 373 Woodcuts. Price 6s.
- DESCRIPTIVE MINERALOGY.** By HILARY BAUERMAN, F.G.S., &c. With 235 Woodcuts. Price 6s.
- METALS, THEIR PROPERTIES AND TREATMENT.** By C. L. BLOXAM and A. K. HUNTINGTON, Professors in King's College, London. With 130 Woodcuts. Price 5s.
- PRACTICAL PHYSICS.** By R. T. GLAZEBROOK, M.A., F.R.S., and W. N. SHAW, M.A. With 80 Woodcuts. Price 6s.
- PHYSICAL OPTICS.** By R. T. GLAZEBROOK, M.A., F.R.S., Fellow and Lecturer of Trin. Coll., Cambridge. With 183 Woodcuts. Price 6s.
- THE ART OF ELECTRO-METALLURGY,** including all known processes of Electro Deposition. By G. GORR, LL.D., F.R.S. With 56 Woodcuts. Price 6s.
- ALGEBRA AND TRIGONOMETRY.** By WILLIAM NATHANIEL GRIFFIN, B.D. Price 3s. 6d. **NOTES ON, with SOLUTIONS OF QUESTIONS.** Price 3s. 6d.
- THE STEAM-ENGINE.** By GEORGE C. V. HOLMES, Whitworth Scholar; Secretary of the Institution of Naval Architects. With 212 Woodcuts. Price 6s.
- ELECTRICITY AND MAGNETISM.** By FLECKING JENKIN, F.R.S.S. L. & E. With 177 Woodcuts. Price 3s. 6d.
- THEORY OF HEAT.** By J. CLERK MAXWELL, M.A., LL.D. Edin., F.R.S.S. L. & E. With 41 Woodcuts. Price 3s. 6d.
- TECHNICAL ARITHMETIC AND MENSURATION.** By CHARLES W. MERRIFIELD, F.R.S. Price 3s. 6d. **KEY.** Price 3s. 6d.
- INTRODUCTION TO THE STUDY OF INORGANIC CHEMISTRY.** By WILLIAM ALLEN MILLER, M.D., LL.D., F.R.S. With 72 Woodcuts. Price 3s. 6d.
- TELEGRAPHY.** By W. H. PREECE, F.R.S., M.I.C.E., and J. SIVEWRIGHT, M.A., C. M. G. With 160 Woodcuts. Price 5s.
- THE STUDY OF ROCKS, AN ELEMENTARY TEXT-BOOK OF PETROLOGY.** By FRANK RUTLEY, F.G.S. of Her Majesty's Geological Survey. With 6 Plates and 88 Woodcuts. Price 4s. 6d.
- WORKSHOP APPLIANCES,** including Descriptions of some of the Gauging and Measuring Instruments — Hand-Cutting Tools, Lathes, Drilling, Planing, and other Machine Tools used by Engineers. By C. P. B. SHELLEY, M.I.C.E. With 291 Woodcuts. Price 4s. 6d.
- STRUCTURAL AND PHYSIOLOGICAL BOTANY.** By Dr. OTTO WILHELM THOMÉ, Rector of the High School, Cologne, and A. W. BENNETT, M.A., B.Sc., F.L.S. With 600 Woodcuts and a Coloured Map. Price 6s.
- QUANTITATIVE CHEMICAL ANALYSIS.** By T. E. THORPE, F.R.S., Ph.D. With 88 Woodcuts. Price 4s. 6d.
- QUALITATIVE ANALYSIS AND LABORATORY PRACTICE.** By T. E. THORPE, Ph.D., F.R.S., and M. M. PATTISON MUIR, M.A. and F.R.S.E. With Plate of Spectra and 57 Woodcuts. Price 3s. 6d.
- INTRODUCTION TO THE STUDY OF CHEMICAL PHILOSOPHY; THE PRINCIPLES OF THEORETICAL AND SYSTEMATICAL CHEMISTRY.** By WILLIAM A. TILDEN, D.Sc. London, F.R.S. With 5 Woodcuts. With or without Answers to Problems. Price 4s. 6d.
- THE ELEMENTS OF MACHINE DESIGN.** By W. CAWTHORNE UNWIN, F.R.S., Professor of Engineering at the Central Institute of the City and Guilds of London Institute. Part I., GENERAL PRINCIPLES, FASTENINGS, AND TRANSMISSIVE MACHINERY. Eleventh Edition, Revised and Enlarged. With 304 Diagrams and Illustrations, price 6s.
- PLANE AND SOLID GEOMETRY** By H. W. WATSON, M.A. Price 3s. 6d.

