

**The anatomy of labour as studied in frozen sections, and its bearing on clinical work / by A.H.F. Barbour.**

**Contributors**

Barbour, A. H. Freeland 1856-1927.

**Publication/Creation**

Edinburgh : W. & A. K Johnston, 1899.

**Persistent URL**

<https://wellcomecollection.org/works/bxnecbwn>

**License and attribution**


This work has been identified as being free of known restrictions under copyright law, including all related and neighbouring rights and is being made available under the Creative Commons, Public Domain Mark.

You can copy, modify, distribute and perform the work, even for commercial purposes, without asking permission.



Wellcome Collection  
183 Euston Road  
London NW1 2BE UK  
T +44 (0)20 7611 8722  
E [library@wellcomecollection.org](mailto:library@wellcomecollection.org)  
<https://wellcomecollection.org>











22101648428










Digitized by the Internet Archive  
in 2015

<https://archive.org/details/b20412757>









A. A. Young

THE ANATOMY OF LABOUR

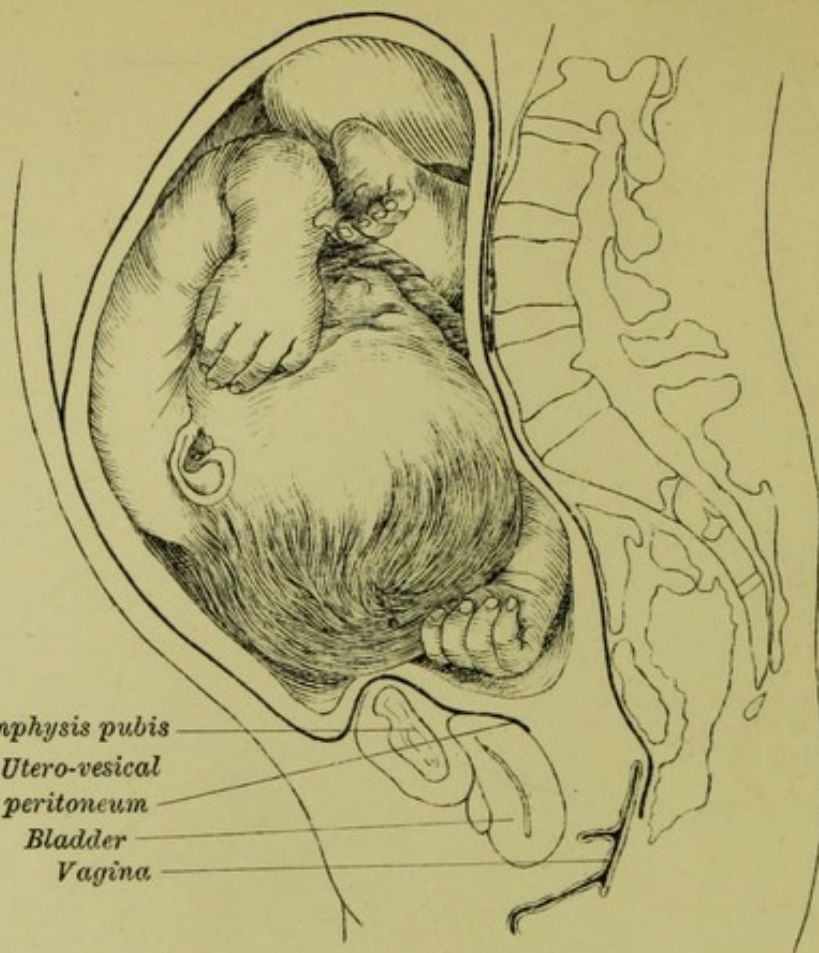




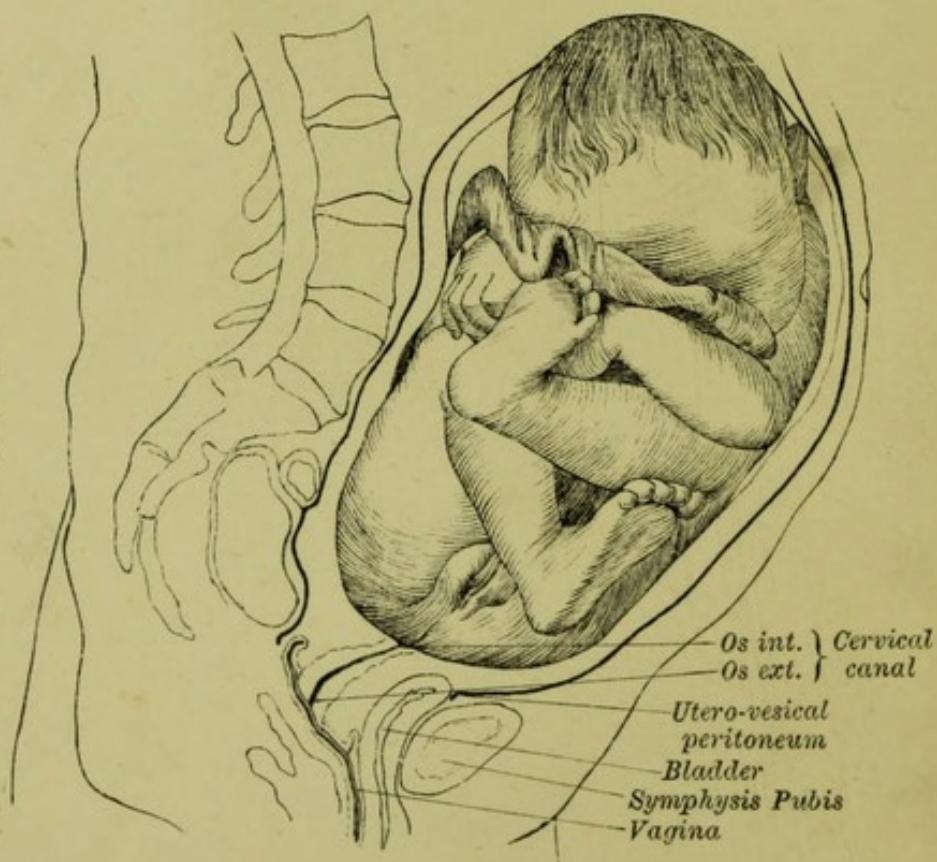


From BRAUNE'S SECTION before Labour: a head presentation—right occipito-anterior.

Symphysis pubis  
Utero-vesical  
peritoneum  
Bladder  
Vagina



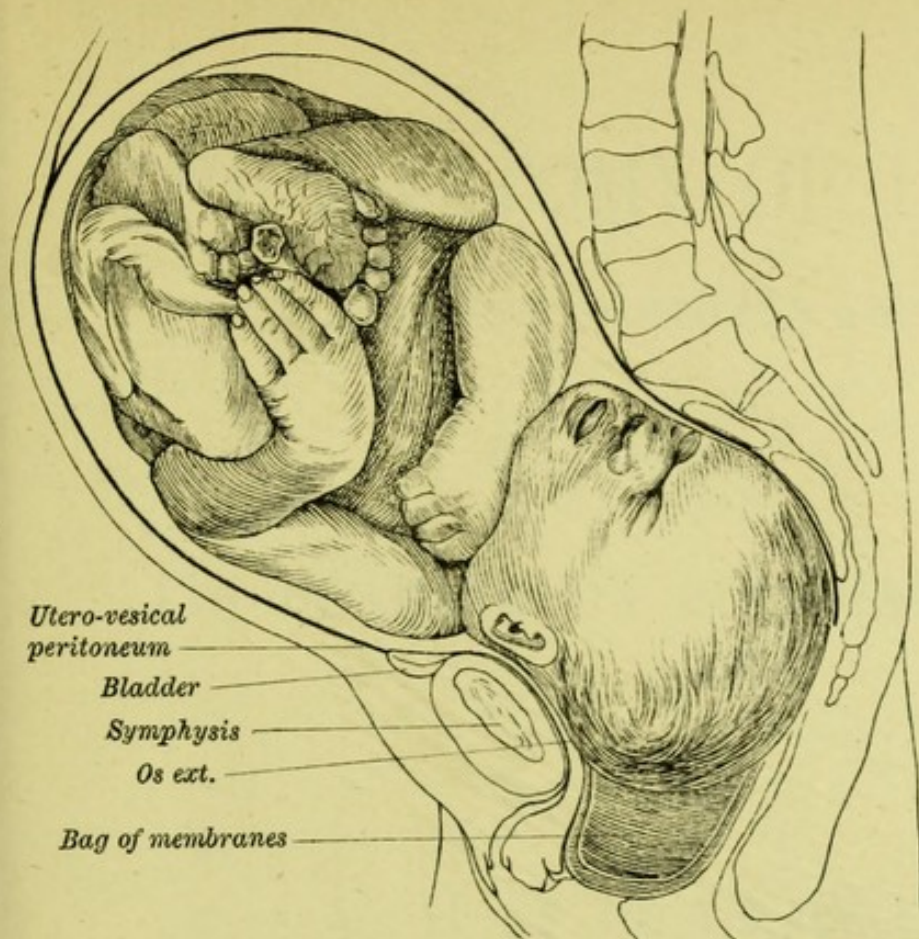
From WALDEYER'S SECTION before Labour: a breech presentation with sacrum to the left.



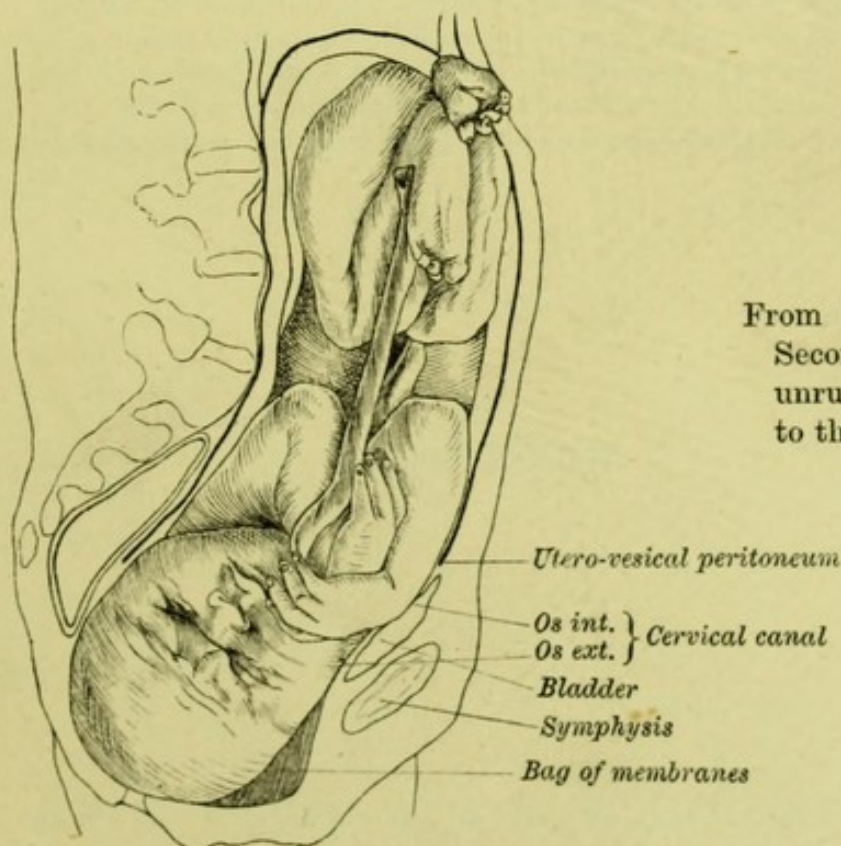
# PL. I.—THE FŒTUS BEFORE LABOUR

Compare the length of the fœtal ovoid, the flexure of the limbs, and the attitude during the latter period by a pain. For description see the two corresponding plates. Compare further (in Waldeyer's and Chiari's) the cervical canal, the vagina, and the






From BRAUNE'S SECTION of the Second Stage (during a pain): unruptured bag of membranes at the vulva, and head in part in vagina.



From CHIARI'S SECTION of the Second Stage: with membranes unruptured, and head descended to the perineum.

#### DURING THE SECOND STAGE.

the head in the two periods; further, the change in long axis produced in the chapters.  
the position of the utero-vesical peritoneum and bladder.





# THE ANATOMY OF LABOUR

*AS STUDIED IN FROZEN SECTIONS*

AND

## ITS BEARING ON CLINICAL WORK

BY

A. H. F. BARBOUR

M.A., B.SC., M.D., F.R.C.P.E., F.R.S.E

Lecturer on Midwifery and Diseases of Women, School of Medicine,  
Assistant Physician for Diseases of Women, Royal Infirmary,  
Assistant Physician to the Royal Maternity Hospital,  
and Physician to the Women's Dispensary, Edinburgh ;  
Corresponding Fellow of the Royal Academy of Medicine, Turin.

Second Edition

EDINBURGH: W. & A. K. JOHNSTON

---

1899



11349050

Printed at  
The Edinburgh Press  
9 & 11 Young Street



119946

WELLCOME INSTITUTE LIBRARY	
Coll.	welMOmec
Call No.	
	W02300
	1899
	B23a

TO  
J. MATTHEWS DUNCAN, M.D., LL.D.,  
F.R.Ss., L. & E.

*THIS BOOK*

WITH THE  
ATLAS OF THE ANATOMY OF LABOUR  
AS EXHIBITED IN FROZEN SECTIONS  
*IS DEDICATED*

THE UNIVERSITY OF CHICAGO

LIBRARY OF THE UNIVERSITY OF CHICAGO




## P R E F A C E

DURING the past ten years a second series of twenty-five sections has been published, calling for another review of the present state of our knowledge of the Anatomy of Labour as studied by this method. As the new facts learned simply support and supplement the conclusions already arrived at, I have, in preparing this edition, added Chapter VII. instead of recasting the whole. A corresponding addition has been made to the Second Part (pp. 88-132), giving the Literature of the same period.

My thanks are due to Dr CHIPMAN for preparing an Index, and otherwise assisting me in revising the letterpress.

4 CHARLOTTE SQUARE, EDINBURGH,  
*January 1899.*





## PREFACE TO FIRST EDITION

THE following pages were primarily intended as a Handbook to my "Atlas of the Anatomy of Labour, as exhibited in Frozen Sections." They gather up the results obtained from the study of all the sections hitherto published; and, to bring these within the reach of a larger number of readers, this little book has been made as far as possible complete in itself.

Though the study of the Anatomy of Labour by frozen sections is a breaking of new ground, yet enough has been done to prove that this virgin soil will yield an abundant harvest, and to justify a survey of what has already been gathered in. I have limited myself as much as possible to the study of *frozen* sections, as these give us the closest approximation to the condition during life; but it has been necessary to supplement this with what has been learned from the study of fresh specimens as well as spirit-hardened sections, especially as regards the condition of the cervix before labour and of the interior of the uterus after it.

The book falls into two parts: the first of which



gives, along with the description of my own sections, the general results, thrown into a connected form, of all the work that has been done in this department; while the second part gives the literature of the subject arranged so as to exhibit in full detail the observations of others.

I have to thank Mr J. A. MELVILLE for much assistance in preparing the Tables, and in passing this work through the Press.

24 MELVILLE STREET, EDINBURGH,  
*April 1889.*

# TABLE OF CONTENTS

---

## PART I.

	PAGE
CHAP. I. INTRODUCTORY — ON SECTIONAL ANATOMY AND ITS	
BEARING ON CLINICAL WORK . . . . .	1
Sectional Anatomy : its place in Obstetrics . . .	1
History . . . . .	1
Function . . . . .	5
Relation to Dissection . . . . .	5
Relation of Sectional Anatomy to Clinical Work .	6
Caution in reasoning from Frozen Sections	
to the Living Subject . . . . .	8
History of the New Era in Obstetrics . . . . .	9
Technique . . . . .	10
Subject Matter of this Book . . . . .	11
CHAP. II. BEFORE LABOUR . . . . .	12
Description of Material . . . . .	12
Uterus, General : Form and Dimensions . . . . .	14
Position . . . . .	15
Relations—Peritoneum with Intes-	
tines . . . . .	15
Pelvic Floor, with Structure in	
Relation to it . . . . .	17
Cellular Tissue . . . . .	18
Ureters . . . . .	19
Uterus in detail : Walls in Section . . . . .	19
Cavity and its Lining . . . . .	20
The Membranes . . . . .	20
Decidua . . . . .	20
Chorion and Amnion . . . . .	21
Placenta . . . . .	22
Contents of Uterus . . . . .	23
Fœtus . . . . .	23
Cervix . . . . .	23



	PAGE
CHAP. II. BEFORE LABOUR— <i>continued</i> .	
Practical Significance of these Anatomical Facts . . . . .	24
The Clinical Examination of Full-time Pregnancy . . . . .	25
The Anatomical Relations before Labour begins . . . . .	28
The Lower Uterine Segment . . . . .	28
Meaning of the Term . . . . .	28
Cervix—Relations and Structure . . . . .	29
Historical Note on Cervix and Lower Segment . . . . .	30
Length of Cervical Canal during Pregnancy . . . . .	33
Structure of Lower Uterine Segment . . . . .	34
Origin of Lower Uterine Segment . . . . .	36
CHAP. III. FIRST STAGE OF LABOUR . . . . .	39
Signification of "First Stage" . . . . .	39
Its Duration . . . . .	39
Means by which Cervix is Dilated . . . . .	40
Frozen Sections from this Stage . . . . .	41
Series of Sections of a VI.-Para who died in this Stage . . . . .	42
Clinical History . . . . .	42
Technique . . . . .	43
The Uterus: its Shape . . . . .	44
Walls . . . . .	45
Lower Segment . . . . .	46
Vessels in Uterine Walls . . . . .	47
Cervix . . . . .	48
Placenta . . . . .	48
Membranes . . . . .	49
Fœtus . . . . .	50
Structures in Pelvic Floor, Bladder . . . . .	50
Vagina . . . . .	51
Rectum . . . . .	51
Facts from foregoing Series relating to First Stage . . . . .	51
Comparison with the other Sections of the First Stage . . . . .	52
Winter's Two Sections . . . . .	52
Saexinger's Section . . . . .	53
Schroeder's Section . . . . .	54
Bearing of these Anatomical Facts on Clinical Phenomena . . . . .	54
Nature of Body dilating Cervical Canal . . . . .	55
Hæmorrhage in First Stage . . . . .	55
Structure pulling on Cervix . . . . .	56



	PAGE
CHAP. III. FIRST STAGE OF LABOUR— <i>continued</i> .	
Two Practical Deductions from the Thinning of Lower Portion of Uterine Walls	56
Behaviour of Cervix itself in First Stage . . .	57
Pelvic Organs in First Stage . . . . .	57
Detailed Description of my Series of Sections from the First Stage . . . . .	58
CHAP. IV. SECOND STAGE OF LABOUR . . . . .	68
Definition and Duration of Second Stage . . .	68
General Statement as to Labour: The Factors . . .	68
The Mechanism . . . . .	69
Relation of Shape of Foetal Head to Movement of Flexion . . . . .	70
Relation of Shape of Pelvis to Movement of Rotation . . . . .	71
Summary of Movements in the Mechanism of Labour . . . . .	73
Frozen Sections from the Second Stage . . . . .	75
Size of Canal within the Bony Pelvis as seen in Frozen Sections . . . . .	76
Form and Relations of Uterus in Second Stage . .	78
Relations of Pelvic Contents in the Second Stage	
Genital Tract as seen in Frozen Sections from same Stage . . . . .	80
Division of Genital Tract into Areas . . .	81
Vessels in Uterine Wall . . . . .	83
Placenta and Membranes in Second Stage . .	83
Foetus as seen in Frozen Sections of Second Stage	84
Contour of Foetal Head . . . . .	85
Relations of Head in Pelvis . . . . .	86
Bearing of Anatomical Facts on the Clinical Study of the Second Stage . . . . .	87
Teaching of Sectional Anatomy as to the Powers in the Second Stage . . . . .	88
Condition of Uterus during a Pain . . .	88
Differentiation of Muscular Wall into two Portions . . . . .	89
Teaching of Sectional Anatomy as to the Passages in the Second Stage . . . . .	90
Relation of Peritoneum . . . . .	90
Space taken up in Pelvis by Soft Parts . .	90
Displacement of Bladder . . . . .	91

	PAGE
CHAP. IV. SECOND STAGE OF LABOUR— <i>continued</i> .	
Bearing on Degree of its Distension . . . . .	91
,,     Fistula . . . . .	91
Bearing of Thinning of Wall of Passages on Rupture of Uterus . . . . .	91
Teaching of Sectional Anatomy as to the Fœtus in the Second Stage . . . . .	92
Teaching of Sectional Anatomy as to the Me- chanism of Labour . . . . .	92
CHAP. V. THIRD STAGE OF LABOUR . . . . .	94
Introductory : Definition and Duration of Third Stage	94
Condition of Placenta and Membranes at its Commencement . . . . .	94
Physiological Processes implied in it . . . . .	95
Stratz's Frozen Sections . . . . .	95
Summary of the Anatomical Facts seen in them . . . . .	97
Their Bearing on the Physiological Question of the Separation of the Placenta . . . . .	97
Information gained from Uteri from Porro's Operation	98
Amount of Retraction of the Placental Site with- out Separation of the Placenta . . . . .	99
The Membranes . . . . .	100
Their Relations before Labour . . . . .	100
Their Behaviour during Labour . . . . .	101
Anatomical Facts bearing on the Expulsion of the Placenta and Membranes . . . . .	103
Division of Genital Tract into an Upper and a Lower Portion . . . . .	103
Bearing of Position of the Placenta on the Manner of its Expulsion . . . . .	104
The Expulsion of the Membranes . . . . .	105
Bearing of Anatomical and Physiological Data on Clinical Work : Management of the Third Stage	105
Time of Separation of Placenta . . . . .	106
How to aid Nature in the Delivery of the Placenta and Membranes . . . . .	107
CHAP. VI. AFTER LABOUR : THE PUERPERIUM . . . . .	110
Application of the Term "Puerperium" . . . . .	110
Frozen Sections from this Period . . . . .	111
Sections made immediately after Delivery . . . . .	111
Relations of Uterus . . . . .	114



	PAGE
CHAP. VI. AFTER LABOUR: THE PUERPERIUM— <i>continued</i> .	
Other Pelvic Organs . . . . .	114
Cellular Tissue . . . . .	114
Uterus in Detail: Form and Dimensions . . . . .	115
Walls . . . . .	115
Section made Five Days after Delivery . . . . .	116
Relations of Uterus . . . . .	116
Vagina . . . . .	116
Uterus in detail . . . . .	117
Examination of Uteri removed from the Body . . . . .	117
Attachment of Peritoneum . . . . .	118
Dimensions of Uterus . . . . .	118
Difference in Walls of Uterus . . . . .	119
Inner Surface . . . . .	121
Naked-eye Appearance . . . . .	122
Microscopic Examination . . . . .	123
Historical Note . . . . .	123
Decidua . . . . .	123
,, Over Lower Segment . . . . .	124
Application of Anatomical Facts to Clinical Work . . . . .	126
Position and Size of Uterus immediately after Delivery . . . . .	126
Length and Direction of Genital Tract . . . . .	127
Bearing on Washing-out of Uterus . . . . .	127
Interior of Uterus favourable to Septic Absorption . . . . .	127
Vagina . . . . .	128
Bladder . . . . .	128
Peritoneum and Cellular Tissue . . . . .	128
Cellulitis . . . . .	128
Uterus Five Days after Delivery . . . . .	128
Detailed Description of Sections of the Case of Kyphotic Pelvis referred to in the Text . . . . .	129
Detailed Description of the Section of the I.-Para referred to in the Text . . . . .	131
NOTES AND TABLES TO CHAP. I. TO VI. . . . .	133
CHAP. VII. A REVIEW OF THE SECTIONS PUBLISHED FROM 1888 TO 1898 . . . . .	161
The twenty-five sections of the last ten years . . . . .	162
The cause of Death . . . . .	163
Technique . . . . .	164
Use of Casts . . . . .	164



CHAP. VII. A REVIEW OF THE SECTIONS PUBLISHED FROM 1888 TO 1898— <i>continued</i> .	PAGE
Table of all the thirty-eight sections published . . . . .	164
The form of the Pelvis . . . . .	166
Method of describing this . . . . .	167
Variability in Obliquity of Brim apart from Posture . . . . .	170
Disposition of Peritoneum . . . . .	170
Position of Bladder . . . . .	171
Its elevation in Labour . . . . .	173
Position and form of Uterus . . . . .	173
Height of Fundus in First Stage . . . . .	174
in Second ,, . . . . .	174
Contour in Pregnancy and Labour . . . . .	176
Cubic capacity . . . . .	176
Soft parts around Genital Tract . . . . .	178
The Cervix before Labour . . . . .	179
The Uterine Wall before Labour, in First Stage . . . . .	180
in Second ,, . . . . .	181
Effect of Retraction . . . . .	182
The Cervix in the Second Stage . . . . .	183
Space occupied by Soft Parts in Second Stage . . . . .	184
The Fœtus . . . . .	185
Attitude in Pregnancy . . . . .	185
Relation of Head to Pelvis . . . . .	187
The mechanism of Labour . . . . .	189
Significance of Flexion . . . . .	190
Moulding of Fœtal Head . . . . .	191
Extension of Body of Fœtus . . . . .	192
Internal Rotation . . . . .	192
Its Cause . . . . .	193
Placenta and Membranes . . . . .	194
Area of Insertion . . . . .	195
Behaviour in Labour . . . . .	195
Placental Circulation in the Second Stage . . . . .	198
The Puerperium . . . . .	199
NOTES TO CHAPTER VII. . . . .	202

## PART II.

## LITERATURE.

*See separate Index.*

# ILLUSTRATIONS

---

PL. I. THE FÆTUS BEFORE LABOUR AND DURING THE SECOND STAGE— from Sections by Braune, Waldeyer, and Chiari . . . . .	<i>Frontispiece</i>
PL. II. BEGINNING OF FIRST STAGE—from a Section by the Author . . . . .	<i>To face page 48</i>
PL. III. TOWARDS THE END OF THE FIRST STAGE—from a Section by Schroeder . . . . .	<i>To face page 54</i>
PL. IV. THE GENITAL TRACT DURING THE SECOND STAGE— from Sections by Braune, Chiari, and Chiara . . . . .	<i>To face page 78</i>
PL. V. TOWARDS THE END OF THE SECOND STAGE—from Pl. XXII. of the author's Atlas reduced to one-third . . . . .	<i>To face page 160</i>
PL. VI. THE GENITAL TRACT towards the close of the Second Stage—from the Section given in Pl. V. . . . .	<i>To face page 181</i>
PL. VII. THE FÆTUS—from the Frozen Section given in Pl. V. . . . .	<i>To face page 192</i>
PL. VIII. THE BEGINNING OF THE THIRD STAGE—from Pestalozza's Section . . . . .	<i>To face page 195</i>
PL. IX. MICRO-PHOTOGRAPHS OF THE PLACENTA—from the Frozen Section given in Pl. V., to show its relation to the uterine wall and the amount of blood in the sinuses. . . . .	<i>To face page 196</i>
PL. X. SECTION OF A PLACENTA—removed by Porro's opera- tion, showing the sinuses distended with maternal blood . . . . .	<i>To face page 198</i>
PL. XI. SECTION FROM THE SAME PLACENTA—under a high power; to show the relation of the maternal and foetal blood streams . . . . .	<i>To face page 200</i>

---

	PAGE
FIG. 1. Diameters of Foetal Head . . . . .	70
FIG. 2. Diameters of Bony Pelvis . . . . .	72
FIG. 3. Two modes of presentation of the Placenta: A. After Schultze. B. After Matthews Duncan . . . . .	194



	PAGE
FIG. 4. Management of the Third Stage (from Crédé) . . . . .	108
FIG. 5. IMMEDIATELY AFTER DELIVERY—from a Section by Stratz . . . . .	112
FIG. 6. IMMEDIATELY AFTER DELIVERY—from a Section by the Author . . . . .	113
FIG. 7. Diagram for describing Form of Pelvis in a Frozen Section . . . . .	167
FIG. 8. Front and side views of a cast of the Uterine Cavity in the eighth month of Pregnancy . . . . .	175
FIG. 9. Front and side views of a cast of the Uterus and Vagina towards the close of the Second Stage of Labour . . . . .	177
FIG. 10. Section passing through the right oblique diameter of a Pelvis from the eighth month of Pregnancy . . . . .	180
FIG. 11. Frozen Section made immediately after Delivery . . . . .	200
FIG. 12. Showing the mean height at which the Promontory is found in Frozen Sections, the Cadaver being in the dorsal posture . . . . .	205
FIG. 13. Frozen Section of a Cadaver with an unusually high set of the Promontory . . . . .	207
FIG. 14. Frozen Section of a Cadaver with an unusually low set of the Promontory . . . . .	208
FIG. 15. Showing relation of Axis of the Abdomen to that of the Pelvic Inlet . . . . .	209



## CHAPTER I.

### INTRODUCTORY—ON SECTIONAL ANATOMY AND ITS BEARING ON CLINICAL WORK.

THE Science and Art of Obstetrics is like the façade of an ancient temple. The entablature which crowns it is the practice of the art—the relieving of pain and the saving of life. The columns which support it are three: Anatomy, which deals with the structure and relation of the parts; Physiology, which deals with the working of the parts; and Pathology, which deals with diseased parts and disturbed working. A column consists of base, shaft and capital; and what the capital is in the column, Sectional Anatomy<sup>1</sup> is in Obstetrical Anatomy generally. This is borne out both by the history of Sectional Anatomy and by its function.

The place of  
Sectional  
Anatomy in  
Obstetrics.

To trace the history of Sectional Anatomy we must first glance over that of Obstetrical Anatomy as investigated by *dissection*, and in doing so we find that it was the anatomy of the non-pregnant uterus which first received attention. Not to go further

History of  
Sectional  
Anatomy.

---

<sup>1</sup> For brevity we use the term "Sectional Anatomy" instead of "Anatomy as studied by making sections."



back than the Revival of Learning, the earliest contributions at this period<sup>1</sup> did little more than free our knowledge from the erroneous ideas which had accumulated round it, and bring it back to where it had been left by the magnificent contribution of Soranus of Ephesus in the end of the first century. Other valuable contributions, for all of which we are indebted to the anatomists of the Italian schools, followed; till, at the close of the sixteenth century, the naked-eye anatomy of the unimpregnated uterus was placed on a sure basis. The anatomy of the pregnant organ, however, was as yet practically untouched;<sup>2</sup> and the harvest of this virgin soil was first reaped in the eighteenth century by Albinus, Roederer, and the illustrious William Hunter. These men laid the base of the column of Obstetrical Anatomy, and the shaft has slowly been raised by the work of many hands.

An English writer can hardly mention William Hunter without paying to his writings a tribute of admiration as at once a masterpiece and model of good work in obstetrical anatomy. As we turn over the plates in his Atlas, unsurpassed for careful dissection and accurate drawing, or read his terse and lucid account of the uterus with its contents and mem-

---

<sup>1</sup> In the work of Berengario da Carpi. For the detailed facts with regard to the early contributions of anatomy to obstetrics, see Part II. pp. 75-78.

<sup>2</sup> Fragmentary contributions had been made, but the subject was not worked at systematically.



branes, we are at a loss whether to admire more the patient labour in accumulating a wealth of obstetrical material such as no man has done before or since, or the painstaking care with which that material has been examined and described. There could be no higher ideal of anatomical work than that which William Hunter set before him in the preparation of his Atlas. In the preface to it he says that there are two kinds of anatomical drawing. "One is the simple portrait, in which the object is represented exactly as it was seen; the other is a representation of the object under such circumstances as were not actually seen, but conceived in the imagination. . . . That figure, which is a close representation of nature, and which is finished from a view of one subject, will often be, unavoidably, somewhat indistinct or defective in some parts; the other being a picture of fancy, made up perhaps from a variety of studies after nature, may exhibit in one view what could only be seen in several objects; and it admits of a better arrangement, of abridgment, and of greater precision. The one may have the elegance and harmony of the natural object, the other has commonly the hardness of a geometrical diagram; the one shows the object or gives perception, the other only describes or gives an idea of it. A very essential advantage of the first is, that as it represents what is actually seen, it carries the mark of truth, and becomes almost as infallible as



the object itself." His work, he said, was to be "a faithful representation of what was actually seen," and a proof of the consistency with which he carried out his ideal is afforded by the fact that, while more recent anatomical work has by new methods added to, it has not overturned any of his results.<sup>1</sup>

This rapid review of Obstetrical Anatomy as investigated by dissection leads us up to Sectional Anatomy, which belongs to this century. It is true that the idea of representing anatomical structures as they might appear in section is a very old one. We meet with it first in the anatomical drawings of Leonardo da Vinci who died in 1519; for the impulse to study anatomy and represent anatomical relations came from the Old Masters in their effort to represent accurately the human figure. Berengario da Carpi, the first anatomist who attempted to represent what he dissected, gives us a quaint drawing of a female figure with a section of a uterus in her hand—a foreshadowing of the more accurate anatomical representations of the next century and of the mode of investigation by means of section.

We must distinguish, however, the *representing* of portions of the body as they might appear in section from the *making* of sections as a means of investigation; and, as we have said, sectional anatomy as a

---

<sup>1</sup> We advise the student who cannot get access to the original to read here the abstract of Hunter's work given at page 1 of Part II.



method of research belongs to this century. The difficulty of fixing the soft tissues so that they could be cut into slices was overcome by the Russian anatomist Pirogoff,<sup>1</sup> to whom belongs the merit of being the first systematically to employ freezing as a help to investigation. Fixing the soft tissues by this method, he exposed parts beneath with hammer and chisel or with a saw; the former he aptly describes as *sculptura anatomica*, the latter as *sectiones ductae in triplicem directionem*. The results of his investigations were published in 1859 in his colossal *Atlas of Topographical Anatomy*, in which nearly a thousand sections are re-produced *ad naturam*. In 1858 Le Gendre published his beautiful *Atlas of Homolographic Anatomy*, having received in the previous year a grant from the Academy of Science at Paris for his valuable work in sectional anatomy.

The history of Sectional Anatomy thus shows that it is preceded by and rests upon dissectional anatomy. Its function, as leading up from dissection to Clinical Work, also bears this out.

In studying the structure of the human body, it might at first sight appear the better method to start with the body as a whole, with which we are familiar, and proceed to examine it by making sections. But the first slice would at once bring us into a *terra incognita*; to be shown a frozen section

Function of  
Sectional  
Anatomy.

Relation of  
Sectional  
Anatomy to  
Dissection.

---

<sup>1</sup> For details of his method and history of Sectional Anatomy, see Le Gendre and Pirogoff, Part II. pp. 6 and 7.



of the chest, for example, and told that this is lung and that is heart, would give us little more than names. We must first become familiar with the organs, each by itself: the unit is the organ. This familiarity comes only through dissection. The study of Sectional Anatomy must therefore be preceded by and rest upon dissection, as the capital rests upon the shaft of a column.

Relation of  
Sectional  
Anatomy to  
Clinical Work.

This study of the organs as individuals necessarily sacrifices, however, their relations to each other and the body as a whole; for, to see them each completely, we must isolate and thus displace them. But when we have become familiar with the individual organs, Sectional Anatomy steps in and, making each fall into its place, marshals them as parts of a larger whole. We are thus led up to the relation of the capital to the superstructure—that is, Clinical Work. For in the practice of the art of Obstetrics, as in all Clinical Work, we deal with organs only as parts of a whole, the unit now being not the organ but the body. Accordingly, Sectional Anatomy forms the immediate basis of clinical work, supporting it as the capital does the entablature.

Looking more closely at the relation of these two, Sectional Anatomy and Clinical Work, we find that the services which the former renders to the latter are manifold, as the following illustrations show. Suppose we wish to learn accurately the topography of organs, we take any one plane of the body to start



with and make, say, a vertical mesial section. This gives us the relations in that plane. Similar sections are made again and again in successive parallel planes, until the whole body becomes to the observer practically transparent. We thus come to learn the exact relations of the parts to each other and to the surface landmarks. We see them; nothing is left to conjecture. It is not too much to say that before the days of Sectional Anatomy the representations of these relations were more or less successful products of the imagination: witness the fact that not a single drawing of the pelvic contents previously given was true to Nature.

The potentiality of this method is still more evident when we have to do with a function involving progressive stages. Here the element of time comes into the question. Taking any one section to start with, and having a similar one repeated at short enough intervals of time, we are able to pass from stage to stage of the process as we do from page to page of a history; and when a series of frozen sections has been obtained at successive stages, we have the whole history of the process actually displayed before our eyes. Now, Labour is such a process. We might describe it as the movements of a given body along a given track under the action of certain forces. It was as difficult to follow these movements before the introduction of Sectional Anatomy, as to observe those of a running horse before the days of instan-



taneous photography. Now, we can catch every successive movement of the horse's limbs and fix them so as to compare them deliberately; and Sectional Anatomy, in the same way, seizes labour in its different stages, as well as the child in its different movements; and when the series of sections is complete, we shall be able to trace the process throughout. A new era is thus inaugurated in Obstetrics, and many products of the imagination will now be replaced by facts. The traditional horse with legs spread out still runs on canvas as no horse ever ran, and has even been defended by students of art. Traditional views of labour, too, still linger in our text-books; and nothing but a resolute determination to get at and hold by the facts will get rid of them.

Caution in  
reasoning  
from Frozen  
Sections to  
Clinical Work.

A certain caution is necessary, however, in reasoning from the frozen section to the living subject. We must remember that even frozen sections give only the condition after death; and what is the exact change in the form and relations of organs, due to the stoppage of the circulation with the loss of tone in the muscles and other post-mortem changes, we have no data for saying. There is difficulty also in being sure that the condition found in a given specimen is not pathological: this can only be got over by observations made in a large number of cases. While, therefore, frozen sections come closest to the actual condition in life, we must be



cautious in applying clinically the facts learned from them. With care, however, we can eliminate these sources of error; and it is possible to attach too much importance to them.<sup>1</sup>

The new era in Obstetrics was inaugurated by Braune's first section, made in the anatomical department at Leipzig in March 1870. The cadaver was that of a woman who had committed suicide in the last month of pregnancy; and, instead of dissecting it, Braune had it frozen and made a vertical mesial section, which forms the basis of our exact knowledge of the anatomical relations *before labour* begins. Curiously enough within three months there was brought into the anatomical rooms a cadaver, which proved to be that of a woman who had died *during* labour. She had drowned herself while labour pains were going on; and, though the membranes are unruptured, the position of the child's head shows that labour has advanced into the Second Stage. These two sections were published by Braune in 1872 in his *Atlas Die Lage des Uterus und Fœtus am Ende der Schwangerschaft*—a work which, like Hunter's, has placed obstetrical science

History of the  
New Era in  
Obstetrics.

---

<sup>1</sup> Thus Schroeder (see Part II. p. 42) sets down to post-mortem change the fact that anatomists make the uterus retroverted, while gynecologists find it anteverted. This difference of view cannot be ascribed, however, to the cause mentioned—as sections are given by Pirogoff, Heitzmann, and Fürst, all of which show the uterus anteverted: it really furnishes an illustration of how sectional anatomy supplements and corrects the teaching of dissection.



again deep in the debt of the anatomists. Braune's second section was followed in 1878 by Chiara's, also from the Second Stage, but showing a pathological condition, and that the rarest—a foetus undergoing spontaneous evolution, "caught in the act" as the title of the Atlas aptly puts it. During the last ten years<sup>1</sup> ten more sections have been published—making thirteen in all. We may arrange them according to the stages of labour as follows:—

BEFORE LABOUR . . .	Section by Braune,
" . . .	"   " Waldeyer ;
FIRST STAGE . . .	Sections (two)   " Winter,
" . . .	Section   " Saexinger ;
" . . .	"   " myself,
" . . .	"   " Schroeder ;
SECOND STAGE . . .	"   " Braune,
" . . .	"   " Chiari,
" . . .	"   " Chiara ;
PUERPERIUM . . .	"   " myself,
" . . .	"   " Stratz,
" . . .	"   " myself.

It will be observed that we have no sections of cadavera from the Third Stage. Stratz, however, has published two of the uterus removed from the body ; and uteri removed by Porro's operation teach us some anatomical facts with regard to the placenta and uterus which throw light on this stage.

Technique. Every one has adopted with very slight variations

---

<sup>1</sup> To the beginning of 1889.



the same mode of making the sections. The cadaver is placed for a few days in a freezing mixture of pounded ice and salt, the layer being at least a foot thick all round, and the box in which the mixture is placed has a perforated bottom to allow the water to escape freely. The mixture is thoroughly stirred up at least thrice a day. At the end of three days, the body will be frozen through. Our sections were cut with an ordinary hand-saw of upright pitch, the preparation being fixed between flat boards in which slits had been made to guide the saw in the desired line of section. The surface of each section was washed, and a tracing taken on glass; this was transferred to paper, and the details filled in and then coloured *ad naturam*. While being drawn and coloured, the sections were kept imbedded in ice; and when the drawing was finished, each section was placed for a day or two in alcohol and then mounted in glycerine jelly between plates of glass.

We purpose in the following pages to gather up what is taught by these sections, devoting one chapter to each stage of labour. The facts are few and isolated. We have only, so to speak, one or two scattered leaves torn out of the history of labour. Not till we have a complete series of sections from every stage shall we be able to read the story of labour without a break.

Subject-matter  
of this Book.



## CHAPTER II.

### BEFORE LABOUR.

Description of  
Material.

FROM full-time pregnancy and before labour has begun, we have two sections—made by W. Braune, Professor of Anatomy at Leipzig,<sup>1</sup> and W. Waldeyer, Director of the Anatomical Institute at Berlin.<sup>2</sup> As the cause of death<sup>3</sup> in both of these cases was quite independent of pregnancy, we have two sections which show us what we may take to be the normal condition; and, after all allowance for post-mortem

---

<sup>1</sup> See Part II. p. 8. As regards the relation of the two Parts of this book we may mention once for all that the facts given in Part I. will not always be found in Part II., nor is the order of statement the same; inasmuch as the former is based on a direct study of the sections, while the latter consists of abstracts of the original descriptions. The student will find also many interesting facts in the abstracts which lay beyond our present scope.

<sup>2</sup> See Part II. p. 10.

<sup>3</sup> The first is from a case of suicide by hanging in the last month of pregnancy; and, beyond the marks of strangulation on the neck, there were no signs of injury. The second is from a multipara, at full time, who had borne nine children; both legs were cut off through the thighs close to the pelvis by a locomotive, and she died a few hours afterwards from bleeding: there is a fracture of the first sacral vertebra and the horizontal ramus of the pubes on the right side, but this does not disturb the relation of the pelvic organs to each other although it affects their position with reference to the bony landmarks.



change has been made, give a close approximation to the condition in life. They are worthy of study from two points of view; as furnishing an anatomical basis for the clinical investigation of full-time pregnancy, and also as showing the relations before labour begins, so that we are in a position at once to appreciate the anatomical changes produced in labour.

Along with these sections made before labour, we shall consider certain points in a series of sections made by myself from a third case—in which death occurred when labour was just beginning. The detailed description of this case and of the sections will be found in its proper place at the end of the chapter on the First Stage of Labour; but the facts with regard to the disposition at the sides of the uterus of the peritoneum, cellular tissue and ureters, fall to be considered here, inasmuch as they are peculiarities of the anatomical relations of pregnancy and not changes produced in labour.

It must be remembered that, with regard to the first two sections, we are limited to what is seen in the vertical mesial plane, or in other words to a study of relations along the middle line of the body. The third series of sections supplements these by giving the relations at the sides.

In studying these sections, we shall first gather up the more important anatomical facts. In the statement of these the reader will find that they fall



naturally into groups, which we give here as a clue to the paragraphs which follow.

Uterus, general: form (*i.e.*, contour in section) and dimensions;

position;

relations — peritoneum with intestines,  
pelvic floor with vagina, bladder and  
rectum, cellular tissue with vessels and  
ureters.

Uterus in detail: body—walls in section,

lining,

contents;

cervix.

We shall afterwards look at the bearing of these facts from the two points of view above mentioned—the examination clinically of cases of pregnancy at full-time, and the determining of the anatomical relations before labour begins.

Form and Dimensions of Uterus.

The full-time pregnant uterus appears in the vertical mesial sections as oval in form, with a long vertical axis (from os internum to outside of fundus) of rather more than 9 in. ( $9\frac{1}{2}$  or  $9\frac{1}{4}$  in.),<sup>1</sup> a short antero-pos-

---

<sup>1</sup> Where the two sections agree, the result is stated without qualification; where they differ, the condition in each case is given as an alternative—Braune's section first and then Waldeyer's. Thus, here, the vertical axis measures in Braune's  $9\frac{1}{2}$  in. and in Waldeyer's  $9\frac{1}{4}$  in., while the antero-posterior axis is in both 6 in. It should be noted that the long axis of the section is rather less than the greatest length of the uterus, owing to the obliquity of the latter in the body; in Waldeyer's preparation, the actual length was ascertained after the section had thawed, and was found to be 10 in.



terior axis of 6 in., and a vertical circumference of 24 in. or more ( $26\frac{1}{2}$  or 24 in.). Its contour is uneven, the wall being indented by the symphysis and promontory and moulded on the spinal column. On cross-section<sup>1</sup> also, it appears oval in form; and the moulding is even more striking here, for the spinal column causes a remarkable bulging inwards of its posterior wall. Further, the transverse diameter<sup>2</sup> is shorter than the vertical.

The highest part of the uterus in the middle line is opposite to a point on the skin of the abdomen about a foot (12 or  $11\frac{1}{2}$  in.) from the upper margin of the symphysis.<sup>3</sup> Its front surface is in contact with the abdominal wall up to the umbilicus—above which point it is separated from the latter by intestines, or remains still in contact as far as the fundus. Behind, as already said, it lies along the spinal column when the body is recumbent (*v.* Pl. I.)

Position of the  
Uterus.

The peritoneum of the full-time pregnant uterus has in front and behind<sup>4</sup> the same relations as in the

Peritoneum  
with Intes-  
tines.

<sup>1</sup> As seen in the series of sections made by myself, *vide* postea p. 58. Figures are given here only to express the relative length and breadth in concrete form; as they give the measurements of individual specimens and not the average of a number of cases, their value is restricted.

<sup>2</sup> The exact measurements for this uterus are—vertical axis 10 in., antero-posterior  $5\frac{1}{4}$  in., transverse  $8\frac{3}{4}$  in.

<sup>3</sup> Opposite also to the cartilage between the first and second lumbar vertebræ—a more exact landmark, but not of service for clinical work.

<sup>4</sup> It descends in front for  $2\frac{1}{3}$  or  $1\frac{1}{3}$  in. below the brim, separating



non-pregnant condition. It thus presents a remarkable contrast to the peritoneum at the sides, which is lifted up by the growing uterus so that it does not descend into the pelvis (*v. Pl. II.*). In fact, the base of the broad ligament might be described as being at the brim of the pelvis—stretching from the ilio-pectineal eminence to immediately in front of the sacro-iliac joint, whilst its attachment to the sides of the pelvis runs upwards and backwards along the iliac fossa to a point in front of the posterior iliac spine. There is thus a large triangular area at the sides of the uterus uncovered by peritoneum. The utero-sacral ligaments also are found at a higher level, passing from the cervix backwards at about the level of the brim of the pelvis;<sup>1</sup> this raising of its lateral boundaries makes the pouch of Douglas much deeper than in the non-pregnant condition. The vertical height of the peritoneal cavity is increased, the arch of the diaphragm being opposite to the cartilage between the eighth and ninth dorsal vertebræ.<sup>2</sup> In both sections

---

the uterus and bladder for  $1\frac{1}{2}$  in., or no more than touching the latter organ. Behind the uterus, it descends to a much greater distance—to a point  $5\frac{1}{2}$  in. below the conjugate of the brim in Braune's section; from the fracture of the sacrum in Waldeyer's, this distance cannot be measured in it. It covers the posterior vaginal wall for  $\frac{3}{4}$  or  $\frac{1}{4}$  in.

<sup>1</sup> The detailed description of the peritoneum at the sides of the uterus, as studied in coronal sections, will be found at pp. 61 *et seq.* The results substantially agree with those of Polk gained by dissection. See Part II. p. 13.

<sup>2</sup> Braune says "seventh dorsal vertebra;" this must be to one



the liver is pushed upwards so as to be opposite to the ninth and tenth dorsal vertebrae, and in Braune's it descends to the eleventh also. Intestines are not seen in the middle line of the abdomen except between the fundus uteri and the liver. They do not descend at all behind the uterus; and in only one of the sections (Braune's), between it and the abdominal wall as far as the umbilicus. In the pelvis, we see behind the uterus a portion of the rectum; and in the pouch of Douglas, a coil of the ileum or a loop of the sigmoid flexure of the colon.

Turning now to the pelvic floor we find the empty bladder lying wholly in the pelvis, its highest point not rising above the middle of the symphysis. It is oval in section with a vertical axis parallel to the symphysis, and measuring  $2\frac{1}{2}$  in.<sup>1</sup> The vagina has its walls in apposition, so that it appears in section as a mere cleft extending 3-4 in., upwards and backwards and parallel to the plane of the brim. The pelvic floor itself, as seen in section, has its lower border projecting more than in the non-pregnant condition.<sup>2</sup> It is divided into two segments by the vagina. Of these

Pelvic floor  
with structures  
in relation  
to it.

---

side of the middle line. He mentions the ninth or tenth as the height for the non-pregnant condition—so that the roof of the peritoneal cavity is in pregnancy lifted up from one to two inches.

<sup>1</sup> In Braune's section. In Waldeyer's, its lower limit is not distinct enough to measure the cavity. See Pl. I.

<sup>2</sup> The amount of pelvic-floor projection, that is the distance of the most prominent point of the floor from a line joining the tip of the coccyx and the lower edge of the symphysis, is 4 in. in Braune's section (in Waldeyer's the injury to the pelvis and soft



the anterior is triangular in section—comprising the anterior vaginal wall, bladder with urethra, and some cellular tissue; and from its relation to the pubes is called the pubic segment. The posterior segment is quadrilateral—comprising the posterior vaginal wall, the structures in the perineum, the anus with the soft parts between it and the coccyx; and from its relation to the sacrum is called the sacral segment.<sup>1</sup>

Cellular  
Tissue.

Cellular tissue appears as a thin layer separating rectum from posterior vaginal wall below the pouch of Douglas; also as a broad band between cervix and bladder, and as a well-marked deposit between bladder and pubes, and in the substance of the perineum.<sup>2</sup> The cellular tissue at the sides of the uterus, as it may be studied in the third series of sections, is disposed as follows:—We find the band between the uterus and bladder expanding as we pass outwards into a well-marked deposit between the bladder, uterus and levator ani. The tissue in the substance of the broad ligaments is enormously increased as compared with the non-pregnant condition. At the brim of the pelvis we have from ilio-pectineal eminence to

---

parts prevents its being estimated) instead of 1 or  $1\frac{1}{2}$  in. as in the non-pregnant condition.

<sup>1</sup> We follow Berry Hart's division of the pelvic floor. See Part II. p. 48.

<sup>2</sup> Waldeyer found this loose fatty tissue forming a firmer layer both on bladder and on cervix, though scarcely so dense as fascia. Further, the bladder was more intimately united to the anterior fornix than to the cervix.



sacro-iliac joint only cellular tissue (not peritoneum) between the uterus and the pelvic wall; and this extensive deposit extends upwards and backwards between the layers of the broad ligament into the iliac fossa.

The ureter has the following course in the cellular Ureters. tissue. Crossing in front of the common iliac artery, just above the brim of the pelvis, it runs down the iliac fossa immediately under the peritoneum and passes within the brim of the pelvis directly in front of the sacro-iliac joint. Here it leaves the wall of the pelvis and passes downwards, forwards, and inwards, to the neck of the bladder.<sup>1</sup> The anatomical relations are such that the ureters are not liable to be compressed between the uterus and the bony pelvis.

Let us now look at the uterus more in detail; Walls of the  
Uterus in  
Section. and, first, at the appearance of the walls in section. Their average thickness in full-time pregnancy is about one-half of that of the non-pregnant organ; but there are variations throughout—the wall at the fundus, for example, being rather thinner than the adjacent parts. The posterior wall is of pretty uniform thickness ( $\frac{1}{4}$  in. in Braune's section, and  $\frac{1}{5}$  in. in Waldeyer's), but the anterior becomes thinner in its

<sup>1</sup> According to Polk (Part II. p. 13), the direction of the ureters is indicated by a line drawn from the bifurcation of the common iliac to the spine of the pubes; they being  $\frac{1}{2}$  to 1 in. below the brim at the bifurcation, 1 in. below at the end of the transverse diameter, and 2 in. at the spine of the pubes.



lower part before it is continued into the cervix.<sup>1</sup> We shall return to this thinner portion when we are discussing the Lower Uterine Segment. In both Braune's and Waldeyer's sections, the orifices of large sinuses are seen all through the substance of the walls. Braune figures no sinus marking the os internum; Waldeyer says that there are several, and figures one in the posterior wall.

Uterine cavity  
and its lining.

The muscular walls of the uterine cavity are lined for rather less than one-fifth of their area (which is about 200 sq. in.) by placenta, and for rather more than four-fifths by membranes.<sup>2</sup>

The Mem-  
branes.

Resting immediately upon the wall is the decidua; within this, the chorion; and most internal, the amnion enclosing the liquor amnii; at the placental portion of the uterus, the chorion and decidua blend in that organ, while the amnion simply passes over it. As in these pages we are dealing with the anatomy of labour rather than that of pregnancy, we refer to the structure of these only in so far as a knowledge of it is necessary in a study of the changes occurring in labour.

Decidua.

The decidua consists of the vera and reflexa—which have become practically one membrane.<sup>3</sup>

<sup>1</sup> In Braune's there is a remarkable thickening in the middle third of the anterior wall (to 10 mm. or  $\frac{2}{3}$  in.).

<sup>2</sup> For the data of this calculation, see p. 49.

<sup>3</sup> The hypertrophied mucous membrane of the pregnant uterus is called the "decidua," because it is shed with the ovum as leaves are shed by a deciduous tree. In the early months of pregnancy,



At an early period of pregnancy it appears as if made up of two layers<sup>1</sup>—a superficial compact and a deeper spongy one: this appearance is due to the changes which the glands of the uterine mucous membrane undergo during pregnancy—their ducts become obliterated by pressure and hence the compact appearance above; the lower portions of them hypertrophy and appear as epithelium-lined spaces in the decidua, making it seem sponge-like in section. The connective tissue of the mucous membrane becomes transformed into the characteristic elements of the decidua—large cells, sometimes rounded or polygonal, sometimes fusiform, sometimes stellate with long and short processes, having a round or oval nucleus (sometimes round) so large that it half fills the smaller cells.

The chorion consists of a band of compressed Chorion and  
Amnion.

---

we distinguish three parts of the decidua (first described by Hunter): the decidua vera, which lines the cavity of the uterus generally; the decidua serotina, on which the ovum rests; and the decidua reflexa which has grown up round the ovum—"reflexa" because it was thought the ovum, when entering the uterus from the tube, carried the decidua before it so as to cause that membrane to be reflected round it; "serotina" (*i.e.*, late), because thought to be formed subsequently or later over the area from which the reflexa was supposed to have been stripped.

<sup>1</sup> The results of the examination of the decidua which establish the existence of these layers at different periods of pregnancy will be found in Part II. pp. 36-39; but the distinction into the two layers is not referred to by Waldeyer, and could not be found at the first stage in either Schroeder's section or my own. Braune does not describe the decidua microscopically.



fibrillated tissue, below which is a more cellular layer; and the amnion, of a single layer of cubical epithelial cells resting on a delicate connective-tissue which unites it to the chorion.

**Placenta.**

The placenta has entering into its formation both the chorion (which contributes the foetal villi with their vessels) and the decidua (which contributes the maternal connective-tissue framework, and blood-vessels), while the amnion simply passes over it to be reflected on to the umbilical cord.<sup>1</sup> In Braune's section the placenta has not been cut across. In Waldeyer's it is attached over the fundus and is  $\frac{1}{2}$  in. thick; as it is not divided mesially we cannot estimate its area in proportion to that of the uterus. In my section it is  $\frac{5}{8}$  in. thick; and has an average diameter of 7 inches, giving an area of

---

<sup>1</sup> The student can make clear to himself the relation of the membranes and the part they play in the development of the placenta by the following simple device. Putting the amnion on one side, inasmuch as it is spread uniformly all over the cavity up to the cord on to which it is reflected, so that it can be stripped off as a separate bag up to that point, we have remaining chorion and decidua, a foetal and a maternal structure, which we might represent by the two hands, right and left. The hands apposed palm to palm will represent these membranes as they are over the non-placental portion of the uterus, where they lie in two layers and not very thick; while the fingers flexed and interdigitated, or placed so that those on one hand fit exactly into the spaces between those on the other, will figure the placenta in which the chorion and decidua become dove-tailed—the fingers of the one hand being villi, those of the other being maternal tissue.



38½ square inches or about one-fifth of the area of the whole inner surface.

As we have described the placenta and membranes in speaking of the lining of the walls, there remain to be considered of the uterine contents only the liquor amnii, umbilical cord, and foetus. Very little of the first is seen in the vertical mesial sections, the wall of the uterus being in contact with the surface of the foetus, or separated from it by a thin layer. The cord, containing within the investing amnion its two arteries and one vein embedded in a gelatinous embryonic connective tissue (Wharton's jelly), is not in these sections coiled round the body.

Contents of  
Uterus.

The general contour of the foetus is an oval, of which the long axis is not greatly in excess of the short; the flexures of the different parts are not acute, the limbs being not compressed but, so to speak, comfortably disposed, and the spine gently curved.<sup>1</sup> The long axis measures 9 or 9·2 in.; so that, as the length of the full-time foetus extended is 20 to 21 in., it is folded up within the uterus into an ovoid of less than half its actual length.

Foetus.

The cervix, which is not mesially divided in Braune's section, appears in Waldeyer's as a narrow tube 1½ in. long, and plugged with mucus, across the upper end of which the membranes pass without any change in their structure except that the layers of cells

Cervix.

<sup>1</sup> See page 84, where these foetuses are compared with those from the first and second stages of labour. See also Pl. I.



become thinner; the os externum is on a level with the lower margin of the symphysis or a little higher. As the condition of the cervix in the later months of pregnancy has given rise to a great deal of discussion, which has been renewed in connection with the question of the nature and origin of the Lower Uterine Segment, we shall consider it under that heading at the close of this chapter.

Practical significance of these anatomical facts.

So much for the anatomical facts. We pass now to their practical significance; and, from what we said in the introductory chapter, we may expect that this will be twofold. To put it shortly, they teach both geography and history: for they give the topography of the pregnant uterus and its surroundings at full-time—the anatomical basis for physical examination; and they demonstrate the condition of parts before labour begins—the first page in the history of the process. We must remember, however, that what follows rests on the study of only three sections; and, further, it is quite possible that some of the conditions in one or other of these may be pathological. The conclusions are accordingly not to be looked upon as final; but, as other sections are published, we shall have to revise, correct and add. Though a section yield but one grain of new fact, yet that grain is worth a bushel of reasoning which has no anatomical foundation. It tells us truth:



whether it be the whole truth and nothing but the truth, we shall only learn through time.

Keeping before us this twofold practical significance, we ask, first, what anatomical basis we find in these sections for the *physical examination of full-time pregnancy*. They tell us that, on laying both hands on the abdomen of a patient pregnant at full-time, we shall find between the hands an ovoid mass, measuring, say, ten inches vertically by eight transversely; further, they show that there will be no intestine between this mass and the abdominal wall which will slip over it with nothing between. For the same reason on percussion, the note will be dull at least to the umbilicus; above this, a coil of intestine may make the superficial note tympanitic, but on deep percussion the dulness will extend to twelve inches from the symphysis.

The clinical examination of Pregnancy:

by palpation,

by percussion.

Palpation, however, it is plain, will enable us more certainly to fix the height of the fundus. In recording this height, the position relative to the brim of the pelvis, umbilicus, and ensiform cartilage is commonly used: thus it is said that while at the fourth month the uterus has risen above the brim, it reaches the umbilicus by the sixth, and the ensiform cartilage by the eighth. Though such expressions are convenient enough for practical use, yet they lack scientific accuracy. The brim is a wide word, for the central point in its conjugate diameter is (in Braune's section)  $3\frac{1}{4}$  in. higher than its

Height of Fundus.



lowest point at the symphysis, and its posterior end (*i.e.*, the promontory) is  $1\frac{3}{4}$  in. higher still. The umbilicus, also, varies in position. The symphysis is the best point to start from; and the height of the fundus is most accurately got by measuring from this point with callipers, so as to get a chord of which the distance along the skin is the arc. The length of this chord (*i.e.*, the direct distance from symphysis to fundus) is in both of these sections  $9\frac{1}{8}$  in., or, adding the thickness of the abdominal wall,  $9\frac{1}{2}$  in.<sup>1</sup> Further, the uterus is plastic, 'like a bladder of water not quite full,' as is seen in the way in which it moulds itself on the pelvis and spinal column. Hence, when relaxed, it is difficult to define; when contracting (and the alternate contractions and relaxation in pregnancy are diagnostic of the enlarged uterus) the outline is more distinct, and the consistence firmer.

Vaginal  
examination.

These sections further inform us that, on vaginal examination, the direction of the vagina is, as in the non-pregnant condition, parallel to the plane of the brim, its length being not much increased. Its walls are in apposition—Nature's provision against the admission of septic air, and a hint to the obstetrician

---

<sup>1</sup> Sutugin's results (*Edinburgh Obstetrical Society's Transactions*, 1874-75, p. 44), got by measuring on the living subject, give an average of 25·2 cm. in 53 primiparæ and 25·6 cm. in 48 multiparæ—the mean being 25·4 cm. or 10·1 in. This shows a difference of  $\frac{1}{2}$  in. in 10 in. between the measurement on frozen sections and that on the living subject,—a surprisingly small difference.



not to examine pregnant women frequently and thus expose them to the risk of introducing septic matter.

There are other points which have a clinical bearing: *e.g.*, the higher position of the diaphragm and liver, and the way in which the intestines are pushed aside by the uterus so as to be crowded into the lumbar regions. The lifting up of the peritoneum, too, is significant; as it gives us an explanation of so-called incomplete rupture of the uterus (in which, while the tear has gone through the muscular wall, the peritoneal cavity has not been opened into), and also indicates the situation of pelvic peritonitis in pregnancy. Peritoneal relations.

The course of the ureters is likewise of interest, Ureters. and raises the question whether the uterus can press on them so as to produce disturbance of the kidneys and albuminuria. These sections answer that there is only one point (on the ischium) where the ureters may be compressed, and that the chances of their compression are small. We must therefore look elsewhere than in a mechanical cause for the explanation of albuminuria.<sup>1</sup>

---

<sup>1</sup> I should merely refer in passing to a case I recently recorded which pointed to another cause. The foetus died in utero at the sixth month. As long as it lived, there was albumen; when it died, the albumen disappeared, although there was an interval of three weeks before its expulsion—that is to say, before there was any change in the mechanical conditions. Here we had albuminuria due to some condition of the mother dependent on the life of the foetus, and not owing to the pressure of the uterus. See *Edinburgh Medical Journal*, February 1885.



The anatomical relations before Labour begins.

As to *the anatomical conditions before Labour begins*, the following points are specially noteworthy.<sup>1</sup> The walls of the uterus are of pretty uniform thickness, with the exception of the lower part of the anterior wall (the Lower Uterine Segment) which is thinner than the rest. Venous sinuses are to be seen in great numbers throughout the wall. The cervical canal is a tube, slit-like or somewhat fusiform in section. The vagina has its walls in apposition, appearing as a cleft in the floor of the pelvis. The bladder is in the pelvis, and the utero-vesical peritoneum descends for some distance below the brim.

So much for the three frozen sections made at the end of pregnancy and the clinical significance of the facts which they reveal.

Before going on to the Uterus in Labour, we must make a digression from the strict subject-matter of this book—*frozen sections*—to consider the question of “the lower uterine segment.” This is a subject which is at present exciting a great deal of interest; and, although its immediate clinical bearing may not be evident, it is of great scientific importance for the appreciation of the anatomical changes in labour.

#### THE LOWER UTERINE SEGMENT.

Meaning of term.

When looking at the wall of the uterus in vertical mesial section, we saw that it was not all of the same

---

<sup>1</sup> See Berry Hart's inquiry as to this: Part II. p. 48.



thickness, but that the lower part of the anterior wall, before it is continued into the cervix, is thinner than the rest. When we come to look at the section of the uterine wall after the work of labour is done, we shall see that this difference, slight before labour begins, is now distinctly marked: that the "lower segment" in fact presents a striking contrast to the rest of the wall; for while the former has become thicker and shorter and firmer, the latter has remained thin, shortened, and flaccid. This differentiation of the wall into two segments, which takes place even in normal labour, and which not only is of scientific interest, but also has important clinical bearings, is still more marked in cases of obstructed labour—in which it was first noted and described.

This lower segment is continued into the cervix, the structure and relations of which must now be described. In the non-pregnant condition the cervix uteri is marked off from the body through not being covered anteriorly by peritoneum (which is reflected on to the bladder at the utero-vesical fold), and having a mucous membrane differing from that of the body of the uterus; for it has the folded surface known as the arbor vitae and racemose glands, while the body has the characteristic uterine glands—tubular, sometimes bifurcating, running down obliquely to the muscular wall. This wall is of a closely-felted texture—contrasting with the uterine wall, in

Cervix—  
relations and  
structure.



which the muscular bundles can be easily separated into plates. In front it is in relation in its upper two-thirds with the cellular tissue which separates it from the bladder, while its lower third projects into the vagina; behind, it is covered in its upper third with peritoneum, while in its lower two-thirds it is free in the vagina: at the sides its upper half is covered by the cellular tissue of the broad ligaments, while below it is free. The canal is  $1\frac{1}{2}$  inches in length. It has at its upper end the os internum, marked by the change in the mucous membrane internally and by the reflection of the peritoneum on the outer surface of the anterior wall; and has at its lower end the os externum, where the red cervical mucous membrane, with its single layer of low columnar epithelium is replaced by the pale vaginal mucous membrane with its many layers of squamous epithelium.

Historical  
note on Cervix  
and Lower  
Segment.

There are few subjects in Obstetrics round which more discussion has raged than the "Cervix in Pregnancy and Labour," and some facts with regard to the history of this discussion are necessary as an introduction to the consideration of the Lower Segment.

During the fifty years after Stoltz (1826) first attacked the generally accepted view that the cervix was in part taken up to form the cavity for the growing ovum, the phase of the discussion was whether the cervical canal became shorter during pregnancy. This was a point which could be settled clinically, and the investigations of Duncan, Müller, and Martin showed that there was a canal of pretty constant length



during the whole of pregnancy.<sup>1</sup> We shall see that recent anatomical investigation confirms this conclusion.

The discussion entered a new phase when Bandl's paper on Rupture of the Uterus drew attention to the peculiarity of that portion of the uterus of which we have just spoken as "the lower uterine segment," that it tends to thin in obstructed labour, and becomes marked off from the contracting and thicker wall above (the junction between them being now known as Bandl's ring). This lower segment he held to be *cervical* in origin.

The question which we have to answer here is not so much "Whether there is a shorter canal at the end than at the beginning of pregnancy?" as, "What is the structure and origin of the lower uterine segment?"

I have collected from the literature and thrown into a tabular form all the recently described uteri which throw light upon this question; but have not gone further back than the last ten years, as it is only since the appearance of Bandl's paper in 1876 that attention has been directed specially to the "lower segment." The specimens have been described in

---

<sup>1</sup> In his paper "On the Cervix Uteri in Pregnancy" in the *Edinburgh Medical Journal* for March 1859, Matthews Duncan, from an examination of five uteri, arrives at these conclusions as to the cervical canal:—(1) The length of the cavity of the cervix undergoes little or no change during pregnancy; and (2) The capacity of the cervical cavity becomes gradually greater as pregnancy advances, and this is effected by an increase of its diameters or breadth, advancing from below upwards, that is from the external to the internal os of the cervix.



papers by Bandl,<sup>1</sup> Macdonald,<sup>2</sup> Leopold,<sup>3</sup> Küstner,<sup>4</sup> Langhans and Müller,<sup>5</sup> Sängner,<sup>6</sup> Marchand,<sup>7</sup> Lusk,<sup>8</sup> Bayer,<sup>9</sup> Hofmeier,<sup>10</sup> and Benckiser;<sup>11</sup> there are also the frozen sections of Braune and Waldeyer, already referred to. The table will be found at the end of this Part.

The results of these observers appear at first sight as tangled and inextricable as the muscular fibres which they were examining, but a careful study of their papers shows that this is often due to the mixing together of fact and theory. After picking out the facts and arranging them systematically, we find that there is more agreement than appears at first sight. Much confusion is avoided by our keeping in mind the following three considerations:—

1. That the question of the structure of the lower uterine segment is quite distinct from that of its origin.

2. That one or two preparations are not enough on which to base a generalised description of the uterus at a given month of gestation.

3. That we are not justified in asserting that because uterus A at the fourth month shows one structural condition, while uterus B at the fifth month shows another, therefore it is generally true that the uterus passes from condition A to condition B between the fourth and fifth month. Such a conclusion assumes that at the fourth month uterus B was in identically the same structural condition as uterus A now is—a purely gratuitous assumption.

---

<sup>1</sup> See Part II. p. 14.

<sup>4</sup> *Ibid.* p. 19.

<sup>7</sup> *Ibid.* p. 21.

<sup>10</sup> *Ibid.* p. 30.

<sup>2</sup> *Ibid.* p. 17.

<sup>5</sup> *Ibid.* p. 20.

<sup>8</sup> *Ibid.* p. 22.

<sup>11</sup> *Ibid.* p. 33.

<sup>3</sup> *Ibid.* p. 18.

<sup>6</sup> *Ibid.* p. 21.

<sup>9</sup> *Ibid.* p. 22.



Keeping these three considerations in mind, I brought together all the uteri that have been described in the above-mentioned papers, and arranged them according to the month of gestation. In the table<sup>1</sup> I give only pregnant uteri and that from the fourth month onwards, as those before that month do not bear on the point at issue. In addition to their being described, many of these preparations have been figured; but, unfortunately, the drawings given are often of little value. "Schematisch dargestellt" is a favourite formula, which means that the drawing represents not what *is*, but what the observer *would like other people to see*, in his preparation. Very few set before themselves Hunter's ideal of anatomical drawing,—“a simple portrait representing the object as it is actually seen,” which “carries the mark of truth, and becomes almost as infallible as the object itself.”

In what follows in this chapter and in the table we avoid, as far as possible, using the terms *cervix* and *os internum*, as their use prejudges the case and forestalls the verdict as to the origin of the segment before the evidence has been heard. We shall simply speak of “the walls of the canal” and “its upper end.”

The third and fourth columns of our table show that we have *a canal of pretty constant length*<sup>2</sup> lined by the characteristic mucous membrane. Its walls are thicker than those of the non-pregnant cervix; and, in the later months at any rate, they contrast

Length of  
Cervical Canal  
during preg-  
nancy.

<sup>1</sup> Pp. 134-141. The table is in some respects fuller than the Abstracts in Part II.

<sup>2</sup> The average length is—for the 4th month (5 uteri) 4·6 cm., for the 5th month (3 uteri) 4·3 cm., for the 6th and 7th months (10 uteri) 4 cm., for the 8th month (3 uteri) 4·5 cm., for the 9th month (4 uteri) 3·5 cm., for the 10th month (12 uteri) 3·6 cm. That for the 4th and 5th is almost the same as for the 7th and 8th months, and there is a slight diminution for the 9th and 10th.



sharply in texture with the wall of the uterine cavity immediately above. Both Bayer and Hofmeier draw attention to the fact that, while the wall of the lower segment of the uterus can be split up easily into separate muscular plates, the wall of the canal has a felted texture which cannot be separated into layers, except at its external portion where they both find the muscular fibre of the lower segment prolonged into it.

Structure of  
the Lower  
Uterine Seg-  
ment.

In the *structure* of the Lower Uterine Segment we note the following peculiarities in the peritoneum, muscular wall, and mucous membrane.

The peritoneum is loosely attached, so that it can be readily stripped off from the utero-vesical pouch up to a certain line, which we may call "the line of firm attachment of the peritoneum." The fifth column gives the distance of this line from the upper end of the canal in front, measured along the uterine wall, which distance varies from one to three inches. Bandl gives it as .8 in. above the upper end of the segment.

The muscular wall appears in section as consisting of plates which have a generally longitudinal arrangement. Of these the special feature is the ease with which they can be separated. In fact, the greater separability of the muscular bundles or plates, along with the diminution in thickness of the wall as a whole, is the chief anatomical feature by which the lower uterine segment differs from the rest of the uterus. The external bundles of fibres anteriorly are continued downwards into the anterior lip of the cervix and anterior fornix of the vagina. The internal bundles are, according to Bayer, of



unequal length and overlapping, so that, looked at from the mucous-membrane side, they appear like the tiles of a house.

As to the blood-vessels of the lower segment, Bayer frequently refers to a large vein situated opposite to the firm attachment of the peritoneum, *i.e.*, opposite to the upper limit of the segment.

With regard to the mucous membrane of this segment there is a greater variation in the conditions found. Bandl described it as a decidua, but present only in patches, between which the muscular wall was bare; Langhans, Müller, and Hofmeier found a decidua similar to that which lined the rest of the uterus; Küstner and Marchand found, in two cases, a mucous membrane transitional between that of the cervix and decidua. It was covered with epithelium—the cells furthest down resembling those of the cervix, while as they passed upwards they became cubical. Where this surface-epithelium was present, the membranes were not united to the uterine wall. Bayer found that, while the lower part of the segment showed next the cervical canal a cervical mucous membrane, and above this a transitional mucous membrane such as Küstner describes, the upper part was lined with decidua resembling that of the rest of the uterus.

The relation of the membranes also varies greatly. While in most cases they have been found closely adherent down to the upper end of the canal, in some they were loosely attached or even quite free for a considerable distance above it.

We may accordingly sum up the results of this table regarding the structure of the lower uterine segment as follows:—(1) That in the middle line anteriorly the peritoneum covers it, as it does the rest of the uterus, but is less firmly united to it; (2) that the muscular wall resembles generally that



of the rest of the uterus, differing, however, in thickness and separability of the plates; (3) that its mucous membrane is typical decidua, which in a few cases shows in the lower portion characters transitional from cervical mucous membrane.

Origin of the  
Lower Uterine  
Segment.

As to the *origin* of the Lower Uterine Segment, it is no longer a question of a mechanical taking up of the cervix to form the lower portion of the cavity of the uterus, the cervix thereby becoming shorter and shorter as gestation advances; but the idea that the cervix may contribute to the formation of the lower portion of the uterus by a process of growth plus a drawing-up, has been revived by the investigations of Bandl, Küstner, and Bayer.

To reconcile the fact of there being 4 in. from os externum (10 cm. anteriorly and 11 cm. posteriorly) to the point which Braune took to be the os internum in his section of the second stage of labour, with the persistence through pregnancy of a much shorter canal (of pretty constant length) lined by cervical mucous membrane, Bandl suggested the remarkable hypothesis that the greater portion of the muscular layer of the cervix is taken up into the lower segment of the uterus, while the mucous membrane remains below round the cervical canal. This pulling-up of the muscular tissue of the lower segment of the uterus implied a stretching of the decidua over the lower pole of the ovum and a breaking up of it into patches; hence the membranes were less intimately attached over the lower segment of uterus.

The presence of a transitional mucous membrane (differing from normal decidua in the smallness of the cells and their being more closely packed, and in the covering of the surface



with an unbroken layer of epithelium) in the two pregnant uteri described by Küstner, led that observer, looking at the lower uterine segment from the standpoint of its mucous membrane, to adopt the view that the segment must be cervical in origin.<sup>1</sup>

The most elaborate research, however, into the origin of this segment is that given by Bayer in his "Morphology of the Uterus."<sup>2</sup> This contribution is, from the amount of anatomical material he brings forward, of great value; and we have therefore gathered up and criticised his results at the end of this Part.<sup>3</sup>

After a careful study of these papers, we come to the conclusion that no sufficient evidence has been produced that the lower segment, which resembles in its essential structure the rest of the uterus, is cervical in origin; and until new evidence is brought forward we see no reason to ascribe to it an origin different from the rest of the wall of the uterus. We, therefore, still place the os internum *where the canal lined with cervical mucous membrane ceases.*

Even supposing some future observer should demonstrate that this lower uterine segment is cervical in origin, this would not alter the fact that in its essential features it is allied to the rest of the body of the uterus rather than to the cervix. The result of establishing Bayer's hypothesis would only prove that the muscular tissue of the cervix can be converted

---

<sup>1</sup> See Note A at the end of this Part.

<sup>2</sup> See Part II. p. 22.

<sup>3</sup> See Note B at the end of this Part.



into muscular tissue like that of the uterus, and cervical mucous membrane into uterine decidua. And the discussion as to what is os internum would be on a par with one as to what was the true gate of the Queen's Park after the commissioners had allowed a portion of the park to be taken into the city and covered with streets and houses.

There are several points with regard to this segment which have, I think, a common explanation. It comprises almost entirely the anterior wall and sides of the uterus, it is thinner than the rest of the wall, its muscular bundles are more easily separable, and the peritoneum over it more easily detached. The weight of the uterine contents must, by exerting pressure on the walls, influence their growth. This will tell more on the lower part of the anterior wall than on the rest of the uterus, and thus account for the situation and character of the lower segment.



## CHAPTER III.

### FIRST STAGE OF LABOUR.

WE now come to the story of labour as it is told in Frozen Sections. It falls into three portions known as the three Stages, and called—‘First,’ ‘Second,’ and ‘Third.’ To each of these we devote a chapter. The First Stage differs essentially from the two that follow, in being one of preparation only. The work of labour consists in the emptying of the uterus, which implies the expulsion of the contents through a canal; and it is the Second and Third Stages which have to do with this—the former with the expulsion of the foetus, the latter with that of the placenta and membranes. But at the end of pregnancy there is no canal leading from the uterus through which the contents can pass, it has to be made. Accordingly the canalisation of the cervix, or, as we usually say, its dilatation (with that of the immediately adjoining lower uterine segment) must first be effected. And it is this process which constitutes *the First Stage of Labour*.

Signification of  
“First Stage.”

This First Stage evidently must end whenever the cervix is fully dilated. When it begins is not so easily determined. As it is effected by contractions of the uterus which are usually painful, its

Its duration.



theoretical commencement is when the patient feels the pains of labour; but contractions occur in pregnancy also, and the "pains of labour" are sometimes painless. Then again, if we take actual dilatation of the cervix as the test, it is difficult to be sure as to the condition of its upper part; and the canal may be patulous or relaxed before labour begins.<sup>1</sup> It is this variability in the condition of the cervix during the last weeks of pregnancy and the occurrence of painless contraction causing dilatation, which render unprofitable any discussion as to whether the cervix may not, in the last weeks of pregnancy, contribute to the formation of the cavity of the uterus; and cases from these weeks do not bear upon the question raised in last chapter (*v. p. 36*).

Means by  
which the  
Cervix is  
dilated.

The means by which the cervix is dilated are of course the contractions of the muscular wall of the uterus. It is evident that these will act in a double way—pressing on the contents and forcing them downwards through the ring, and pulling the ring upwards over them: in a word, the uterine contractions operate on the cervix both by causing its expansion and by traction on it. With regard to these modes of dilating, we have in the case of the former to take into account the nature of the body pressed into the ring; and, in the case of the latter, the structure pulling on the ring as well as the ring itself.

---

<sup>1</sup> See Litzmann's results, Part II. p. 18.



This introductory statement will prepare us to look at the Frozen Sections. From the First Stage of labour we have five cases. The first one was made in December 1884 by Karl Schroeder,<sup>1</sup> then Professor of Midwifery in Berlin; the second in December 1885 by myself; the third in December 1887 by J. von Saexinger, Professor of Midwifery in Tübingen; and the last two, in October 1887 and February 1888, by G. Winter, Lecturer on Midwifery in Berlin.

Frozen Sections from this Stage.

The causes of death in the different cases (heart and lung affections with albuminuria, acute enteritis, sepsis, and eclampsia) were in all independent of labour, except perhaps in one of Winter's where there was with eclampsia a considerable amount of 'accidental' hæmorrhage. From what was said in the introductory paragraph of this chapter as to when labour begins, it will be seen that it is not easy to be sure as to the place of each section in the First Stage. With regard to all of them it is specially noted that pains were present before death, but for how long was not in any case determined with precision. The cervix was not traversable throughout in one of Winter's cases, but was so to one finger in the other as it was in Saexinger's case also; in my own the canal admitted three fingers easily, and in Schroeder's was of the size of the palm of the hand.

---

<sup>1</sup> Died in February 1887; a great blow to scientific Midwifery. I am glad of this opportunity of acknowledging the profit I derived from his teaching at Berlin in 1880.



In all of them except my own, we have only a vertical mesial section. In mine, there are in addition coronal and transverse sections, which give of course a larger body of facts—many, however, not bearing exclusively on this stage; still, for continuity of description, they must be taken up here. We shall therefore, in the first place, give a general<sup>1</sup> statement of what is found in my series of sections. Then we shall bring together the anatomical facts relating specially to the First Stage; and comparing with them the facts brought out in the other sections,<sup>2</sup> look at their bearing on the clinical phenomena.

*Series of Sections of a VI.-para who died in the First Stage of Labour.*<sup>3</sup>

The clinical facts are as follows.

Clinical  
History.

Patient was a vi.-para, expecting confinement during a few days; had been indulging excessively in alcohol for a week with exposure to cold, which brought on acute enteritis. No foetal movements had been felt for three days. Palpation showed uterus to extend to near the xiphoid cartilage, and the foetus with head in the pelvis and back to the right side: no foetal movements could be felt. Auscultation showed no foetal heart. On vaginal examination, the head

<sup>1</sup> The detailed description will be found at the end of this chapter.

<sup>2</sup> For detailed description of these sections, see Part II. pp. 39-42 and 79-85.

<sup>3</sup> This Series is published in the Author's *Atlas of the Anatomy of Labour, etc.*; W. & A. K. Johnston, Edinburgh and London, 1889. For detailed description see p. 58 at end of this chapter.



of the child was in the pelvis and lying transversely—cervix admitting one finger. During the twelve hours before death and subsequent to examination, she had occasional pains; and the os dilated to admit three fingers. The occiput was to the right, and both fontanelles were on the same level. As the child was dead, there was no indication for artificial delivery.

The method of preparation of the sections will no doubt be of interest.

The whole cadaver could not be obtained; but within *Technique*. twelve hours after death the pelvis and lower portion of the abdomen, up to half an inch above the umbilicus anteriorly and the third lumbar vertebra posteriorly, were removed, and placed in a freezing mixture for three days. The removal of the intestines from round the uterus, and the absence of upper lumbar vertebræ and of abdominal wall above the umbilicus prevent us from drawing any conclusions as to the relations of the fundus uteri. The height of the fundus, however, corresponds with that given by Schultze and confirmed by Waldeyer, viz., about the upper border of the second lumbar vertebra. The cervix, also, is about the level of the ischial spines, so that the opening into the abdominal cavity in its upper part has not made the uterus sink much downwards.

As in the other sections published the body had been frozen in the horizontal posture, I froze this one in the erect one; this fact must be kept in mind in examining the sections. Tatham Thomson has reproduced with beautiful accuracy the natural colour of the frozen sections.

After a vertical mesial section<sup>1</sup> had been drawn and coloured, I made a transverse one passing through the fourth lumbar vertebra,<sup>2</sup> in order to see the relation of the uterus to the

---

<sup>1</sup> Plate II. of the Author's Atlas.

<sup>2</sup> Given in Pl. iv. fig. 1, of the Atlas.



spinal column and the ureters. A series of five coronal sections<sup>1</sup> was made to bring out the side relations of the uterus and cervix, especially the peritoneum, connective tissue, and ureters. A second transverse section<sup>2</sup> was made behind the last coronal one, through the posterior part of the pelvis—passing through the second sacral vertebra, and parallel to the plane of the brim—to ascertain the relations of the foetal head to the posterior wall of the pelvis. When the tissues were thawed, portions were cut out and hardened for microscopic examination.

In summing up, in the same order as in the last chapter,<sup>3</sup> the salient points in this series of sections (since we have already taken up the peritoneum, connective tissue, and ureters), it remains to consider the uterus—its form and dimensions, walls, and vessels; cervix; placenta and membranes; foetus; and structures in the pelvic floor.

The Uterus—  
form and  
dimensions.

In considering the uterus, it is interesting to note that the circumference of the uterine cavity in the vertical section (28 inches) is almost the same as the circumference in the horizontal section (24·2 inches); while, if we complete the segment<sup>4</sup> in the coronal section, we have a circumference of about 26 inches. These measurements give an area of its inner surface

<sup>1</sup> Pls. v. and vi. of the Atlas. A coronal section is one made in the direction of the coronal suture and dividing the body into an anterior and a posterior segment.

<sup>2</sup> Given in Pl. iv., fig. 2, of the Atlas.

<sup>3</sup> For method of description, see p. 13.

<sup>4</sup> See Pl. II. The section is described at p. 64.



of about 215 square inches.<sup>1</sup> Further, it lies moulded on the spinal column.

The horizontal section confirms Lahs' description of the uterus in relaxation, and explains how during a contraction it comes forward against the abdominal wall. The measurements given above show also that during contraction, so long as the contents of the uterus are fluid, it will assume an approximately spherical form. In judging of its plasticity as brought out in frozen sections, we must make full allowance for the loss of tone in the walls post-mortem and the fact that expansion during freezing must exaggerate the former moulding of the walls upon the surrounding parts. For example, if we were freezing water in an india-rubber bag enclosed in a wicker-work frame, we should find that the expansion in freezing would force the india-rubber (which corresponds to the wall of the uterus) into every interstice of the wicker-work. It is, therefore, riding the hobby of the plasticity of the uterus a little too hard when Waldeyer draws attention to the fact that in his section the posterior wall of the uterus is moulded upon the intervertebral discs. This plasticity of the uterus, however, is a very important fact to remember in abdominal palpation. We know of no abdominal tumour which may be more difficult to outline than the pregnant uterus—due to the dimpling of its plastic walls under the fingers.

In the vertical mesial section the uterine walls appear of almost uniform thickness from fundus down to the level of the promontory of the sacrum,

Walls of the  
Uterus.

---

<sup>1</sup> This is really the measurement of the outer surface of the ovum which corresponds to that of the inner surface of the uterus before labour began; to get the extent of its surface now, we must deduct eleven square inches for dilated cervix, making 204 square inches.



with the exception of a slight increase at the placental site ; in the horizontal section they appear thinner at the sides. Below this level both walls become thinner—the anterior by one-half (from  $\cdot 2$  in. above the brim to  $\cdot 1$  in. below it), the posterior to a slightly less degree (from  $\cdot 2$  in. to  $\cdot 12$  in.). This thinning is even more marked in the side walls (from  $\cdot 28$  in. to  $\cdot 12$  or  $\cdot 08$  in.). Below this very thin portion the wall becomes thick again in what we shall see to be the cervix.

At first thought, this thinning might be ascribed to *post-mortem changes* from greater pressure on the lower segment of the uterine wall by its contents, as the cadaver was frozen in the erect posture ; exactly as in a pitcher of water, the pressure is greatest over the bottom. It did not, however, diminish at all after thawing and removal of what was above ; nor does the microscopic examination of the walls show that the tissue was more compressed here. Further, if this thinness in the lower segment were due to the fact that the body was frozen in the erect posture, we should expect a corresponding thinning in the posterior wall in both Braune's and Waldeyer's sections (which would in them correspond to the bottom of the pitcher) as the cadaver in each case was frozen in the dorsal posture. All of these facts show that gravitation acting on post-mortem tissues does not account for the thinning. It must have been there during life : produced either during pregnancy in the growth of the walls of the uterus or during labour by the contractions of the first stage.

Lower Uterine  
Segment.

In speaking of the lower uterine segment, we noted that it was marked out by being thinner than the rest of the uterus. In our section, this thinner por-



tion of the wall extends, at least at the sides of the uterus (see Pl. II.), further than in several uteri which I have examined at the end of pregnancy. We are not justified in reasoning from one specimen; but if the condition in our sections be borne out by others made in the first stage, it follows that, *as the result of uterine contractions* altogether independent of a pathological degree of resistance, we have the uterine wall differentiating itself into two portions—an upper active one which thickens, and a lower passive one which thins. If this be so, the dilatation of the cervix can only to a very slight degree result from stretching through traction on its ring by the contracting uterine walls, but must be almost entirely due to dilatation through expansion of the ring by the bag of membranes or presenting part.

As to veins in the uterine wall, these are especially numerous at the placental site. There are few in the lower segment of the uterus; in fact, the only veins of any size are two,—a sinus which has been considered by some observers to mark the os internum and termed the “Kranzvene,” *i.e.*, circular or coronary vein, and another large sinus, running in the posterior wall, which loops down between the utero-sacral ligaments.

Vessels in  
Uterine Walls.

The former of these is very large in the middle line anteriorly, measuring .4 in. in the vertical mesial section, and .68 in. immediately to the left of it. We have followed it with a probe from the posterior wall forwards on both sides



to coronal section v., and traced it through the succeeding sections on the right side. This circular vein has been noted before in vertical mesial sections, but its course at the sides of the uterus has not before been followed. From its great size we can well suppose that its rupture during labour would cause serious hæmorrhage, and we can thus explain cases of bad bleeding with the body of the uterus contracted. The other large vein in the posterior wall (which forms a loop downwards between the utero-sacral ligaments) has not been noted in other sections. We draw attention to it here, as it might be mistaken for the "circular vein."

#### Cervix.

The cervix lies mainly to the right of the middle line. The level of the os externum cannot be exactly determined on account of the folding of the lips; but it may be said to be rather lower than the ischial spines, and to be about half an inch behind them. Although the distance between the external lips appears in coronal section (see Pl. II.) as rather less than half an inch, this gives no idea of the dilatation of the cervix during life, as it easily admitted three fingers.

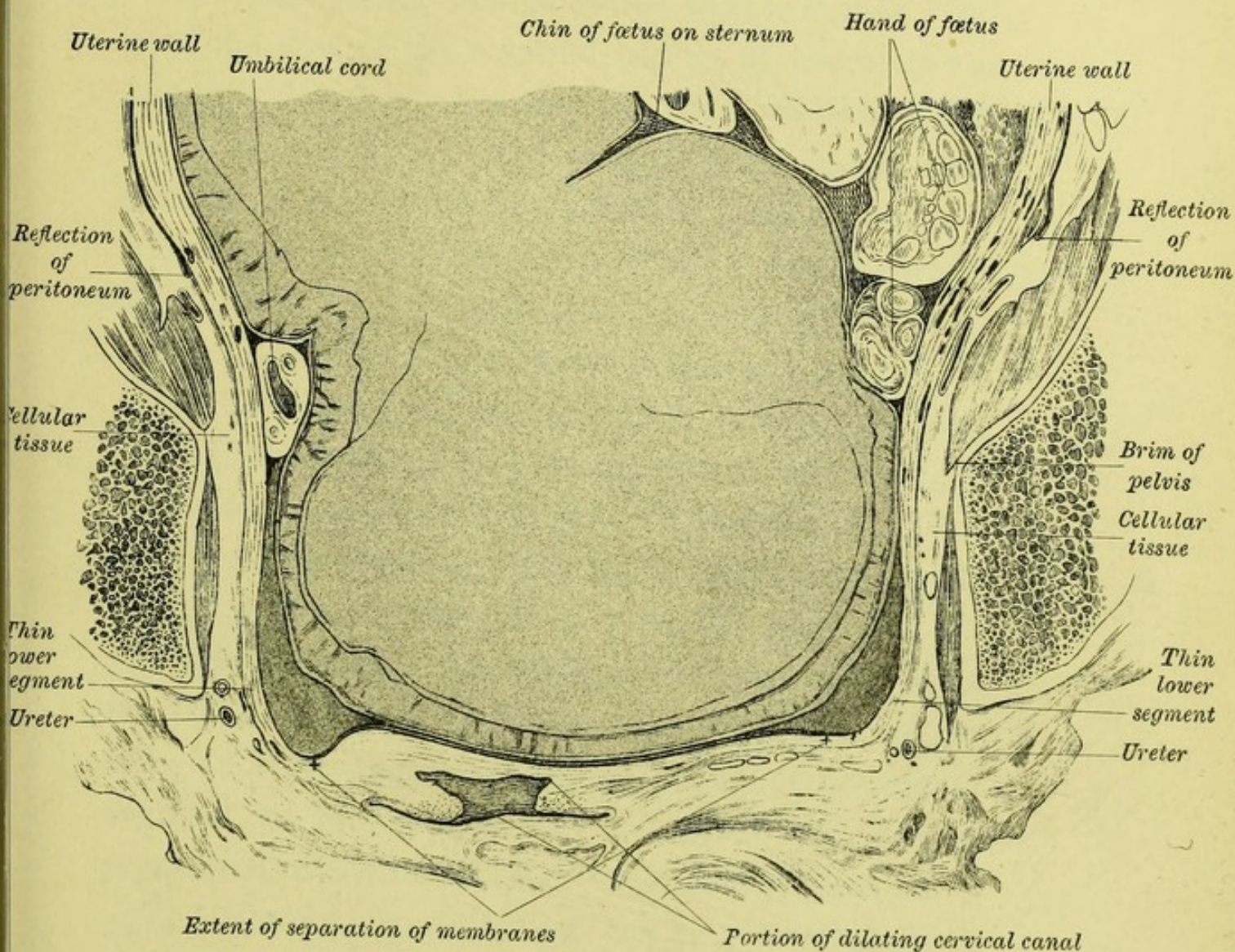
We place the os internum, in front, almost one inch below the level of the coronary sinus, at the point where the felted tissue of the cervix passes into the laminated uterine wall and where the arbor vitæ stops; the change in the character of the muscular wall at this point is quite marked. Posteriorly the arbor vitæ comes not quite up to the circular vein, so that we place the os internum  $\cdot 15$  in. below that level.

#### Placenta.

The placenta is situated in the anterior wall, rather more to the left than to the right of the middle line.



PL. II.—BEGINNING OF FIRST STAGE, from the Axial Coronal Section in Pl. VI. of the Author's "Atlas of the Anatomy of Labour etc."  
The section runs through the transverse diameter and axis of the brim.




*Note the dilatation and taking-up of the cervix, the separation of the membranes, and the thinning of the lower uterine segment.*

*Note also, as regards the Uterus before Labour (v. Chap. II.), the reflection of peritoneum above the brim at the sides of the uterus, the cellular tissue round its lower segment, and the ureters.*

*Note further, as regards the Mechanism of Labour (v. Chap. IV.), the side walls of the bony canal and the shortening of its transverse diameters by the soft parts; and the foetal head in the pelvis, divided antero-posteriorly, with both fontanelles on a level while the chin is on the sternum.*







In this case the area of attachment may be regarded as approximately circular with an average diameter of 7 inches, giving an area of  $38\frac{1}{2}$  square inches. We gave the area of the internal surface of the uterus as 204 square inches. We may say, therefore, that rather less than one-fifth of the area is lined by placenta, and rather more than four-fifths by membranes.

The membranes line the uterine cavity, to which Membranes. they are intimately adherent up to a point .7 in. above the limit of the cervix anteriorly, and .5 in. above the same level posteriorly. At the sides they are adherent up to the circular sinus on the right side, and to a point 1 inch above it on the left. They form over the os internum a bag stretching across the dilated portion of the cervix. We see that they are still adherent over the whole of the thin portion on the right side, and over the greater portion on the left; so that stretching and thinning of the lower segment of the uterus does not necessarily imply separation of the membranes over its whole extent.

The amnion is .0015 in. thick, consisting of a single row of low columnar cells (.0003 in. high) resting on a band of an almost homogeneous tissue; next comes the chorion, a rather thicker (.0021 in.) membrane; and finally the decidua, which is about as thick as the amnion, consisting of cells in several layers, and not showing anywhere spaces giving it a spongy texture, although here and there pockets of epithelial (?) cells are seen.



## Fœtus.

The head of the fœtus lies transversely, with a very slight Naegele obliquity.<sup>1</sup> A coronal section shows us both fontanelles on a level, so that this head would be described as partially extended; but the chin of the child is still on the sternum (see Pl. II.).

This section shows us, therefore, that we *may have a certain amount of so-called "extension" without the head's being really extended*. In speaking of the movements of the head, whatever terminology may be used with a skull and pelvis for teaching purposes, it will be best in clinical description to base our terminology on what is recognised by the hand per vaginam. Thus "extension" should mean "a dipping of the anterior fontanelle," and take no account of the relation of the chin to the sternum. The same effect would be produced by a rotation of the whole child round its transverse axis. We shall return to this under the Second Stage.

Structures in  
Pelvic Floor.  
Bladder.

The bladder is unusually low in the pelvis, its upper half lying opposite the lower half of the symphysis, while its lower half is below the plane of the outlet. This low position is due to two facts,—the patient had a lax pelvic floor with a tendency to bulging in the anterior vaginal wall, and the body was frozen in the erect posture.

It is empty, and has the Y shape antero-posteriorly—the

---

<sup>1</sup> By 'Naegele's Obliquity' is meant that the head, instead of having one of its antero-posterior planes parallel to the plane of the brim and the sagittal suture deepest in the pelvis, lies canted over—like a badly ballasted boat which has the deck *oblique* instead of parallel to the surface of the water and the keel no longer the deepest part.



limbs measuring together 1·6 inch ; transversely it is more expanded, measuring 2·1 inches. The empty organ has, therefore, its greatest dimension from side to side. Below, it is closely incorporated with the anterior vaginal wall ; above, it is separated from the uterus by a thin layer of fatty tissue, which expands at the sides into a triangular deposit, filling in the space between bladder, uterus, and levator ani.

The vagina passes backwards, parallel to the plane Vagina. of the brim, and diverging to the right of the middle line. It is rather longer than in the non-pregnant condition ( $3\frac{1}{2}$  in. instead of 3 in.). Transversely, at the level of the cervix, it measures 1·7 in. The lateral fornices are obliterated by the folding of the lips and compression from the erect posture. Its walls are not much hypertrophied, and the thickness of tissue between the finger in the anterior fornix and the foetal head is only  $\frac{1}{4}$  inch, of which one-half may be set down as vaginal wall.

The rectum, commencing mesially at the anus, Rectum. passes to the right, and then appears to the left of the middle line.

Selecting now from the foregoing the facts relating specially to the First Stage of Labour, we find the cervix dilated so as to admit three fingers, the membranes detached over the lower portion of the uterus to the extent of ·7 in. anteriorly from the os internum and ·5 in. posteriorly from the same ; the extent of separation is, on the left side, rather less than either

Facts from  
foregoing series  
of Sections  
relating to the  
First Stage.



of these figures, but greater (an inch and a-half) on the right side. If, instead of measuring along the wall of the uterus, we do so along the bag of membranes, we find the lower pole of the ovum to be free for an area measuring  $3\frac{5}{8}$  in. antero-posteriorly, and  $3\frac{7}{8}$  in. transversely. Further, the wall of the uterus is remarkably thin over a considerable area of its lower portion, both in front and at the sides. It is slightly thinner also posteriorly, but not nearly to such an extent or degree.

Comparison  
with the other  
Sections of the  
First Stage.  
Winter's two  
Sections.

In comparing the other sections with my own, we take Winter's first as being the earliest in the stage. In the case of eclampsia with partial placenta prævia (a II.-para at full time), in which the cervix admitted the finger below but was closed above, we find that the portion of uterine wall immediately above the cervix is both in front and behind somewhat thinner than the rest of the wall, although the diminution in thickness is not nearly so great as in my section; the placenta<sup>1</sup> is attached over the lower part of the anterior wall, which masks the extent of the thin part as the uterine wall is generally thinner over the placental site. The wall is free of membranes for rather more than half-an-inch in front from the os internum, and for twice that

---

<sup>1</sup> Winter's section is of great interest, as giving us an anatomical basis for partial placenta prævia—the placenta coming down to within four-fifths of an inch from the os internum, and being as yet not detached.



distance behind; the free bag of membranes consists of amnion and chorion united together. Further, the walls of the cervical canal are being taken up unequally, the posterior being more shortened and thinned than the anterior.

In the case of eclampsia with accidental hæmorrhage (a primipara at the eighth month), in which the cervix admitted the finger throughout, we have the part of the wall above the cervix thinner in front and behind, the thinning being more marked (to one-third the thickness of the wall above) in front. Further, the wall is free of membranes anteriorly for  $1\frac{4}{5}$  in., posteriorly for  $\frac{2}{5}$  in.; the free bag of membranes thus formed consists at the sides of chorion and amnion, in the centre of amnion only—the chorion having given way here and retracted from the amnion. Finally, the posterior wall of the cervical canal is, as in the preceding case, more taken up and thinner than the anterior.

In Saexinger's Section (primipara at eighth month), in which the finger passed through the os externum and internum, we have the thinning of the lower portion more pronounced anteriorly, both in degree (to one-half the thickness of wall above) and extent (to one-third of its length); also, the uterus is in contact with the bladder over an unusual area—the peritoneum being reflected half-an-inch above the pubes, leaving  $2\frac{3}{4}$  in. of the thin wall in relation to that organ. Unfortunately, no statement is given

Saexinger's  
Section.



as to the separation of the membranes or the composition of the bag. The high position of the peritoneum, reflected half-an-inch above the pubes, is a striking feature in this section. With this high position of the peritoneum, we find the bladder, which in all the other sections from this stage is in the pelvis, extending to 1·8 in. above the brim, its elevation not being accounted for by distension with urine, which is only moderate.

Schroeder's  
Section.

In Schroeder's (a IV.-para within a week of full time), in which the os was dilated to the size of the palm of the hand, we have anteriorly a thin lower portion one-third of the thickness of the wall above, which passes somewhat suddenly into the thicker portion about 2·5 in. from the os internum. The wall is free of membranes for about two inches from the os internum in front and behind. The posterior wall of the cervix is evidently being taken up before the anterior: for, looking into the uterus, we can see the folded cervical mucous membrane posteriorly (*v.* Pl. III.); and that lip is thinner than the anterior.

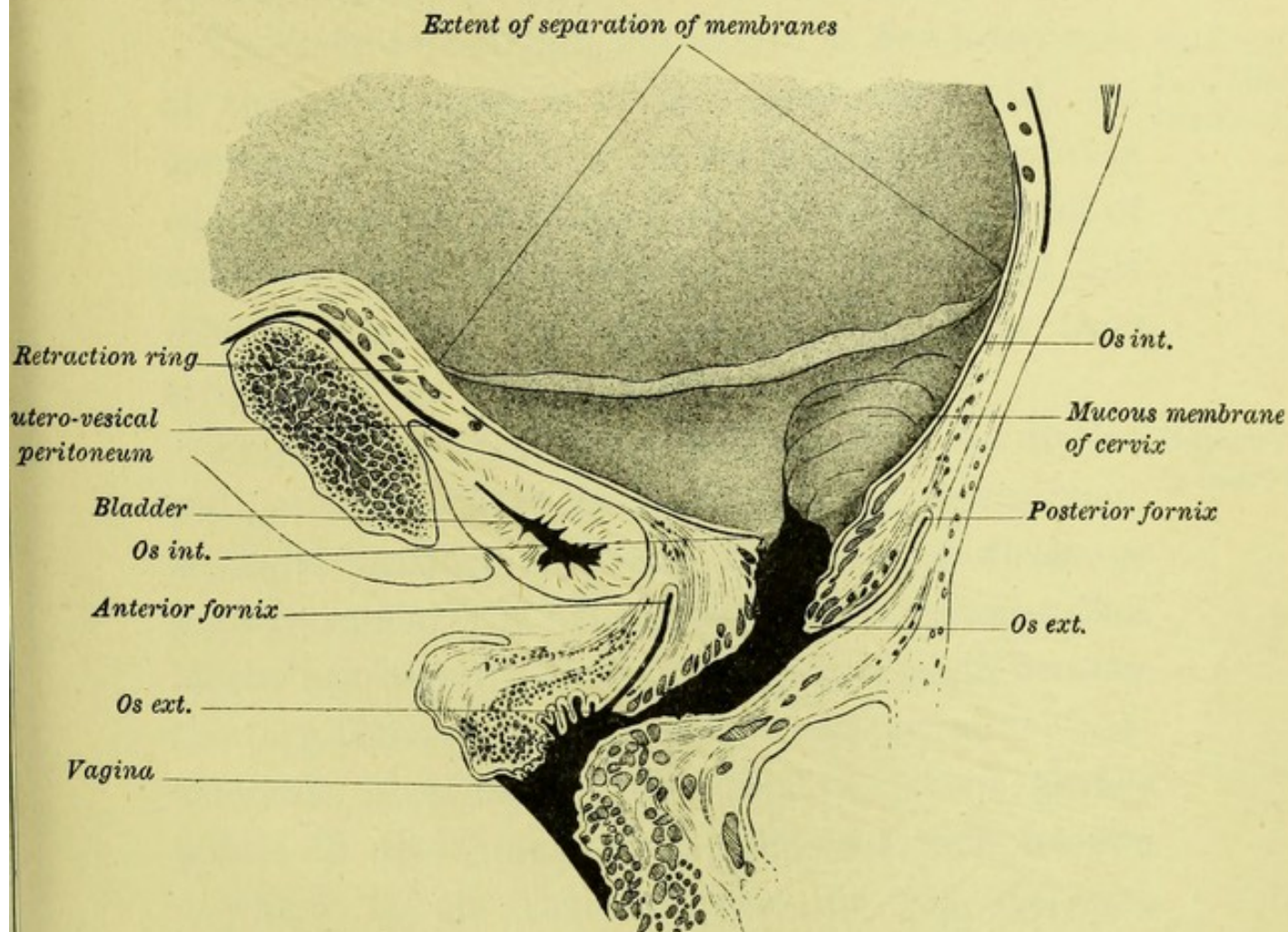
Bearing of  
these Anatomical  
facts on  
Clinical  
Phenomena.

We turn now to the bearing of these anatomical facts on the clinical phenomena. We saw in the opening paragraph of this chapter that the process in the First Stage is the dilatation of the cervix to such an extent as to allow the child to pass, and that




PL. III.—TOWARDS THE END OF THE FIRST STAGE,  
from Schroeder's Section.

The head of the foetus and liquor amnii have been removed, and the bag of membranes so far cut away to show their line of attachment.



*Note the dilatation of the cervix, the more advanced taking-up of its posterior wall, the thinning of the lower segment anteriorly below the retraction ring, the extent of separation of the membranes, and the bladder not drawn up.*







the factors to be taken into account in this process were the nature of the structure being forced into the cervical canal to dilate it, the nature of the structure pulling on the cervix, and the cervix itself.

The body forced into the cervix is the lower pole of the ovum, that is of the membranes with the contained liquor amnii—for we may leave the foetus out of account, and think of the uterus as full of water only. In the course of the formation of this dilating bag of the membranes, they have been stripped off the uterine wall.<sup>1</sup>

Nature of  
Body dilating  
Cervical Canal.

From the raw surface thus formed on the uterine wall, as well as from the fissures in the cervix, there is slight bleeding producing the coloured discharge known popularly as “the shows,” for it indicates that labour has begun. The hæmorrhage is slight because the torn-through decidua is not very vascular; considerable bleeding at this stage of labour always points to detachment of the placenta from its site—which is *the* vascular area in the full-time pregnant uterus—whether it be normally situated (accidental hæmorrhage) or over the lower portion of the uterus (placenta prævia). This strip-

Hæmorrhage  
in First Stage.

---

<sup>1</sup> It is evident that this segment of uterus free of membranes will, as dilatation goes on, be much shorter than one would at first sight suppose. The distance from the line of attachment on the uterine wall to the os internum will be shorter than the distance from the same line to the tip of the bag of membranes: for the uterine wall, instead of forming a cap over the cone, is pulled upwards so as to form a band round the base.



ping off takes place, as a rule, in the plane of the decidua, so that the bag consists of amnion and chorion with shreds of decidua upon it. Occasionally, the bag consists of amnion and chorion alone, the decidua having apparently not separated;<sup>1</sup> while still more rarely, as in Winter's Section, the chorion splits, and the amnion, being pressed through the rent, comes to form alone the dilating bag—the chorion retracting from it. The looseness of connection between the chorion and amnion allows of their being easily separated. When this happens, there is danger that a portion of the chorion be left behind in the uterus after delivery.

Structure  
pulling on  
the Cervix.

Two practical  
deductions  
from the thin-  
ning of lower  
portion of  
uterine wall.

The structure pulling on the cervix consists of the lower portion of the uterine wall. The greater thinness of this part compared with the rest of the wall in all the sections of the First Stage is noteworthy, and points to the fact that the uterine contractions expend themselves in thinning the wall here as well as in pulling up the cervix over the presenting part. From this there are two practical deductions. The first is that the dilatation of the cervix is effected more by the expanding action of the liquor amnii forced into the bag of membranes than by the upward traction on the cervix; and therefore that premature<sup>2</sup> rupture of the membranes will mean a slow first

<sup>1</sup> Küstner found this in twelve out of fifty-two cases.—v. Part II. p. 39.

<sup>2</sup> That is, *before dilatation*—which over, the Stage is completed.



stage—a fact which is fully borne out by clinical experience. The second deduction is that the thinning of the lower segment may go on to rupture.<sup>1</sup>

As to how the ring of the cervix itself behaves, it is interesting that in three of the four cases it is being dilated unequally, and the posterior lip taken up more rapidly than the anterior.<sup>2</sup> When we remember that the axis of the uterus is not continued into that of the cervix, but meets it at an angle open to the front, we can see that the expanding power of the lower pole will act at a greater advantage over the posterior than the anterior part of the cervix, and will unroll it more quickly.

Behaviour of  
Cervix in  
First Stage.

The elongation of the lower portion of the uterus does not necessarily imply any displacement of the pelvic organs. The bladder, which we shall see is elevated in the second stage, remains usually within the pelvis—in three out of the four sections. In one case, however, it has moved upwards along with excessive elongation of the portion of the uterine wall in relation to it.

Pelvic Organs  
in First Stage.

---

<sup>1</sup> As Benckiser has observed in a case of hydrocephalus; see Part II. p. 45. His frozen section from the sixth month (p. 44 of Part II.) is not referred to in the text as it is from a premature case and of the uterus only.

<sup>2</sup> Schroeder regards this as abnormal; Winter as normal, and gives the above explanation.



## DETAILED DESCRIPTION OF MY SERIES OF SECTIONS FROM THE FIRST STAGE.<sup>1</sup>

All of the sections except the second and fourth coronal ones were drawn and coloured from the frozen preparations, and are thus reproduced in the Atlas; the two mentioned were drawn from the thawed sections mounted in glycerine jelly.

### VERTICAL MESIAL SECTION (PL. II.).<sup>2</sup>

This section passes through the two lower lumbar vertebræ, sacrum and coccyx, posteriorly; and symphysis pubis anteriorly. *Pelvis* is roomy: conjugate of brim (from upper margin of symphysis) 4.75 in. (12 cm.); of cavity 5.375 in. (13.7 cm.); of outlet to end of sacrum 4.25 in. (10.79 cm.), to tip of coccyx 3.1 in. (8 cm.).

The *Peritoneum* extends anteriorly to a point opposite lower margin of symphysis, posteriorly to opposite the middle of the last sacral vertebra or  $\frac{1}{2}$  cm. below posterior fornix.

The *Uterus* lies moulded on the spinal column. It measures vertically 10 in. (25.5 cm.) from the highest point of the fundus; antero-posteriorly, at level of last lumbar vertebra, 5.25 in. (13.4 cm.). Its wall measures at fundus 5 mm. thick. The anterior wall at central part of placental site 8 mm., at other parts of same 5 mm. Below this, the anterior wall thins as we pass downwards, becoming 4 mm. at the symphysis and 2 mm. at the bottom of the utero-vesical pouch of peritoneum. The posterior wall measures from 5 to 6 mm. till below the promontory; it then thins, becoming 3 mm. at the hollow of the sacrum, but thickens again and reaches 11 mm. at the end of the pouch of Douglas.

The vertical circumference of its cavity is 28 in. (70 cm.).

There are numerous dilated sinuses at the placental site, a few over the fundus, and very few over the anterior and posterior walls. There is, in the anterior wall, a large vein 1 cm. in diameter cut across opposite the lower edge of the pubes, and 5 mm. above the utero-vesical fold of peritoneum; a probe passed into it shows that it runs backwards round the lower segment of the uterus corre-

<sup>1</sup> See p. 42.

<sup>2</sup> The Plates referred to are those given in the Author's *Atlas of the Anatomy of Labour, etc.*



sponding in direction to the vessel in the posterior wall marked coronary vein. Two large veins appear in the section of the posterior wall opposite to the third sacral vertebra; they lie 5.5 cm. above the end of the vagina—here divided in the left lateral fornix.

They are only  $2\frac{1}{2}$  cm. above the posterior fornix, as was determined after this bit of the pelvis was thawed. A probe passed into the lower of these (coronary vein) goes downwards and forwards, and shows that this vein is the same as that marked coronary vein in fig. 1, Pl. VI. A probe passed into the upper of the two shows that this vein appears again in the uterine wall opposite to the uterosacral ligament.

The *Placenta* is in relation to the anterior uterine wall for  $6\frac{1}{2}$  in. (16 cm.). It is 1.8 cm. thick in the centre, and thins equally towards its circumference. The vessels on the foetal surface are distended with blood; and the umbilical cord is seen in section below the placenta and opposite the promontory. The membranes appear only as a fine line running round the uterine cavity.

The *Cervix*, lying to the right of the middle line, is not shown in the section; but it corresponds to the 1-cm.-thick uterine wall in front of the upper part of the vagina. The *vagina* is cut through the left fornix and the section is  $3\frac{1}{2}$  in. (9 cm.) long; the actual length measured to the posterior fornix is  $4\frac{1}{3}$  in. (11 cm.). Its general direction runs parallel to the plane of the brim; the sigmoid curvature is flattened, its walls are compressed, and the cavity is empty. The *bladder* is Y-shaped and empty; the urethra is sigmoid in form and 4.5 cm. in length. The *rectum* is not distended and is compressed against the coccyx.

The *Fœtus* is divided coronally. The head lies almost entirely in the pelvic cavity, scarcely a fourth of it rising above the brim. Its sagittal plane cuts the axis of the brim at a slight angle. The posterior parietal bone overlaps the anterior, the skin being thicker over it. There is some blood extravasation beneath the scalp of both parietal bones. Its thorax is divided through the sternum, and the pelvis through the hip joints; in the abdomen the large liver is seen, and in the pelvis the distended bladder and rectum. Professor Sir Douglas MacLagan kindly had the contents of the bladder analysed for me and gave this report:—"Total quantity sent  $1\frac{1}{2}$  drachms; colour pinkish; reaction acid; under microscope bladder and renal epithelium, some blood discs and some small oil globules; it contains some blood as shown both by its colour, its coagulating by heat, and by the guiacum test; it gave crystals of



nitrate of urea by the ordinary method, and crystals of uric acid on the addition of a little hydro-chloric; and lastly it ultimately became alkaline and gave the common crystals of triple phosphate." The *liquor amnii* is stained with meconium, and is seen in small quantity in front of the body of the child and behind the posterior thigh. None is seen between the breech and the fundus, nor below the head.

#### TRANSVERSE SECTION (PL. IV. FIG. 1).

Passing through the fourth lumbar vertebra. This section was made to show the relation of the uterus to the spinal column and to the ureters.

The erector spinae is cut through.

In the *Connective Tissue* in front of the spinal column, the aorta is seen in section. [The vena cava was not indicated in the tracing.] The ureters lie on each side of the body of the vertebra—the right one  $\cdot 4$  in. (1 cm.), the left one  $\cdot 2$  in. ( $\frac{1}{2}$  cm.) distant from it.

The *Uterus* is cut through about the junction of its middle and upper parts: it measures antero-posteriorly  $5\frac{1}{2}$  in.<sup>1</sup> (14 cm.), and transversely  $8\frac{3}{4}$  in. (22 cm.); the wall measures anteriorly (placental site)  $\cdot 32$  in. (8 mm.) thick, and posteriorly  $\cdot 2$  to  $\cdot 28$  in. (5 to 7 mm.), and laterally  $\cdot 12$  to  $\cdot 16$  in. (3 to 4 mm.); the cavity is 24 in. (60 cm.) in circumference, and lined continuously by the membranes. Sinuses are seen in section at placental site and in posterior wall—especially its right half.

The *Placenta* is in relation to uterine wall for 7·3 in. (18·5 cm.).

The *Fœtus* is cut horizontally through the abdomen, its large liver occupying most of the section:—the left leg, lying anteriorly, is cut through the knee-joint and upper portion of the tibia; the right leg, lying posteriorly, is likewise cut through the knee-joint, and the right foot is divided in the metatarsal region.

#### TRANSVERSE SECTION (PL. IV. FIG. 2).

This Section (along the plane *cd* in Plate III.) passes through the upper and middle third of the second sacral vertebra and parallel to the plane of the brim; it takes in only the posterior part of pelvis, stopping short at the plane of axial-coronal Section v. (Pl. vi. fig. 1).

<sup>1</sup> As the section is slightly oblique (from behind forwards) to the long axis of the uterus, the antero-posterior diameter appears as  $5\frac{1}{2}$  in. instead of  $5\frac{1}{4}$  in. (as in the vertical mesial section).



The sacro-iliac joint is not straight, but shows a projection on the sacrum fitting into a corresponding depression in the ilium.

The erector spinae appears in section.

The *Peritoneum* is reflected on the right side opposite the middle of the ilium, and on the left side opposite the sacro-iliac joint, thus forming the pouch of Douglas. It also passes first to the left and then behind the rectum, which is thus surrounded by it except along its right border. The *Cellular Tissue* is abundant round the rectum, and external to the lateral folds of the peritoneum, forming here the substance of the utero-sacral ligaments. The *Ureters* are seen in section in front of the iliac bones, lying close to the uterine wall, but one centimetre distant from the bone.

The *Rectum* is divided, lying to the left of the middle line, and measuring transversely 1.4 in. ( $3\frac{1}{2}$  cm.); a small fold of it is also divided to the right of the middle line.

The *Uterine Wall* measures throughout about .16 in. (4 mm.) thick.

The head of the *Fœtus* is in contact with the uterine wall opposite the sacrum, but separated at the sides by a little liquor amnii.

A series of axial-coronal sections was made along parallel planes (indicated in the diagram, Plate III. of Atlas). The object of these was to study the side relations of the uterus (which has not been done hitherto), especially the distribution of the peritoneum and cellular tissue and the course of the ureters. (Plates v. and vi. give the complete series made on the right half of the body. In the case of the fifth section both sides are given.)

#### FIRST CORONAL SECTION.<sup>1</sup>

Passing through the horizontal ramus of the pubes and the ramus of the ischium. The obturatores, internus and externus, appear on the obturator membrane, and the levator ani is seen passing into the perineal body.

The *Peritoneum* comes down to the lower margin of the ramus of the pubes. There is a considerable amount of cellular tissue lying round the lower segment of the uterus separating it from bladder and levator ani; and the fatty tissue of the ischio-rectal fossa is well seen.

The *Rectum* is divided immediately above the anus; above it is the vagina, with thin layer of connective tissue between. The

---

<sup>1</sup> Not reproduced in the Atlas.



*Vagina* extends to 1·08 in. (2·7 cm.) to right of middle line. Still higher up is the *Bladder*, with the opening of the right ureter, into which a probe was passed; it extends to  $1\frac{1}{8}$  in. (3 cm.) from the middle line.<sup>1</sup>

The *Uterine wall* is cut very obliquely above. At the upper margin of the pubes it measures ·2 in. (·5 cm.), and above the bladder ·12 in. (·3 cm.) in thickness. The cavity of the uterus is seen to be lined with the membranes up to a point about ·2 in. (5 cm.) from the middle line.<sup>1</sup>

The *Placenta* has been divided at its lower margin, and the cord where it passes round the neck of the child.

The section grazes the left side of the head of the *Fœtus*, passing through the left ear; and the left elbow is seen above the cord.

#### SECOND CORONAL SECTION (PL. v. FIG. 1).

Along the plane 2 in Plate III., passing through the horizontal ramus of the pubes immediately behind the obturator foramen, and through the tuberosity of the ischium. The obturator internus and levator ani also appear.

The *Peritoneum* descends only to the upper margin of the pubes. There is fatty tissue above the obturator internus between the uterus and the brim of the pelvis continuous with that above the brim, also between uterus and obturator internus; this extends downwards between the levator ani and the uterus—forming here a well-marked triangular space in which the ureter lies. The *Ureter* appears running obliquely outwards and backwards; its cross-section is ·32 in. (8 mm.) from the wall of the uterus, ·8 in. (2 cm.) from the corner of the vagina, the same distance from the bony wall of the pelvis, and just internal to the levator ani.

*Vagina* and *Rectum* are both divided.

The *Uterine wall*, with the placenta, is divided obliquely in its upper part. The side wall measures at a little distance above the brim ·32 to ·4 in. (·8 to 1 cm.); at the brim, ·16 in. (·4 cm.); above the vagina, ·08 to ·12 in. (·2 to ·3 cm.)

The *Membranes* are seen to line the uterine cavity from above downwards until we come to within an inch of the middle line, where they hang free.

---

As it extended the same distance to the left of the mesial line, the bladder was a mesial organ.



The *Placenta* is divided obliquely, and the cord where it passes round the neck of the child.

The *Fœtus* is divided antero-posteriorly through the head and left shoulder.

### THIRD CORONAL SECTION (PL. VI. FIG. 2).

Along the plane 3 in Pl. III., dividing innominate bone through acetabulum and cutting the ischium in the posterior part of its tuberosity. The obturator internus, posterior fibres of levator ani, and muscles of abdominal wall appear in section.

The *Peritoneum* descends to  $\cdot 6$  in. ( $1\frac{1}{2}$  cm.) above the brim. Fatty cellular tissue appears as a considerable deposit above the brim and outside the peritoneum, narrowing to a band  $1\cdot 2$  in. (3 cm.) broad as it passes downwards between the brim of the pelvis with obturator internus and uterus, then spreading out below into the large deposit of the ischio-rectal fossa. In this tissue lies the *Ureter*  $\cdot 12$  in. ( $\cdot 3$  cm.) from the vagina,  $\cdot 08$  in. ( $\cdot 2$  cm.) from the uterus, and 1 in. (2·7 cm.) from the bony wall of the pelvis.

The *Vagina* extends for  $1\cdot 4$  in. ( $3\frac{1}{2}$  cm.) into the section, and the *Rectum* for  $\cdot 8$  in. (2 cm.); but these figures represent more than half the width of these organs as they are deflected to the right of the middle line.

The wall of the *Uterus* is moulded on the brim of the pelvis. Above the brim it measures  $\cdot 2$  to  $\cdot 28$  in. ( $\cdot 5$  to  $\cdot 7$  cm.); at the brim,  $\cdot 12$  in. ( $\cdot 3$  cm.); above the vagina,  $\cdot 08$  in. ( $\cdot 2$  cm.). The uterine cavity is lined with the *Membranes* down to within  $1\cdot 4$  in. ( $3\frac{1}{2}$  cm.) of the middle line.

The *Fœtus* is divided antero-posteriorly about half-an-inch to the left of its mesial plane.

### FOURTH CORONAL SECTION (PL. V. FIG. 2).

Along plane 4 in Pl. III., and dividing innominate bone through anterior inferior iliac spine, posterior part of the acetabulum, and lesser sciatic notch just in front of ischial spine.

The iliacus and obturator internus, and the portion of levator ani arising from ischial spine, appear in section.

*Peritoneum* descends to within  $1\frac{1}{2}$  in. (4 cm.) of brim of pelvis. There is a small quantity of *fatty tissue* on iliacus muscle; and a



thin layer between the uterus and the obturator internus which becomes thicker as it passes downwards on levator ani to surround the vagina and rectum. The section of the ureter lies  $\cdot 8$  in. (2 cm.) from the vagina,  $\cdot 2$  in. ( $\cdot 5$  cm.) from the uterus, and  $\cdot 2$  in. ( $\frac{1}{2}$  cm.) from the bony pelvis.

Three-and-a-half cm. of the *Vagina*, and a complete section (1.12 in. or 2.8 cm.) of the rectum appear. The *Uterine wall* measures in thickness above the brim,  $\cdot 24$  in. ( $\cdot 6$  cm.); at the brim,  $\cdot 08$  in. ( $\cdot 2$  cm.) Below the brim it thins to  $\cdot 04$  in. ( $\cdot 1$  cm.) to become thicker again  $\cdot 2$  in. ( $\cdot 5$  cm.) at the cervix, which is divided through the substance of the anterior lip. There is some cellular tissue between walls of vagina and rectum.

The *Membranes* line the uterine cavity from above downwards to within 1.4 in. ( $3\frac{1}{2}$  cm.) of the middle line.

The *Cord* is divided as it passes round the neck of the foetus.

The head, neck, and thorax of the *Foetus* are divided antero-posteriorly; the vertex of the skull to the left of the middle line, the base and the cervical portion of the spinal column almost mesially, the bodies of the cervical vertebræ appearing in section. The posterior end of the parietal bone is depressed below the occipital.

#### FIFTH CORONAL SECTION (PL. VI. FIG. 1).

Of both halves of the body along plane 5 in Plate III., and at right angles to and bisecting the plane of the brim from side to side. The ilium is cut across  $\frac{1}{8}$  in. ( $\cdot 3$  cm.) behind the anterior superior spine above, and immediately behind the acetabulum below. The ischium is cut through just behind the ischial spine, and the coccyx in its second vertebra. The space between the coccyx and ischium corresponds to the anterior part of the great sacro-sciatic notch. The bony pelvis measures between the anterior superior iliac spines 8 in. (20.3 cm.); across the brim (its transverse diameter),  $5\frac{3}{8}$  in. (13.5 cm.); between the ischial bones (just above their spines),  $5\frac{3}{8}$  in. (13.7 cm.); and along its side walls (from brim to just above the sciatic notch),  $1\frac{4}{5}$  in. (4.8 cm.).

Part of muscles of abdominal wall, the iliacus, obturator internus, levator ani, and gluteus maximus are seen in the section.

*Peritoneum* (of the lateral vesical pouches) descends to the middle of the iliac fossa on the left side, or within 1.6 in. (4.4 cm.) of the brim of the pelvis, and a little lower on the right side to



within 1·2 in. (3 cm.) of the brim. There is a considerable amount of *fatty tissue* between the pelvic layer of utero-vesical peritoneum and iliacus muscle, and also below its reflection; but only a thin band between the uterine layer and uterine wall, which band represents the commencement of the broad ligament. The tissue below the reflection is continued downwards into the pelvis, contains the ureters and pudic vessels, and spreads down on the levator ani to embrace the vagina and rectum.

The *Ureters* lie on a lower level than the ischial bones—the right being ·2 in. (·5 cm.), and the left ·4 in. (1 cm.) distant from the bone; the right is 1·2 in. (3 cm.), the left 2 in. (5½ cm.) from the corresponding vaginal fornix.

The *Vagina* is divided in a line with the os externum and measures across 1·7 in. (4·4 cm.); three-fourths of it lie to the right of the middle line of the body.

The *Cervix* is divided obliquely, so that the anterior wall, then the cavity, and then the posterior lip appear. The transverse diameter of the cavity appears as 1 in. (2½ cm.), but the side walls are folded in so that their lower ends are only ·5 in. (1·3 cm.) across. The *Rectum*, which measures across ·9 in. (2·3 cm.) is also deflected (but less markedly) to the right. The *Uterus* is divided so that the section passes obliquely through the cervix which lies to the right of the middle line. Its wall measures ·24 to ·28 in. (6 to 7 mm.) above the brim, ·16 in. (4 mm.) to the right, and ·12 in. (3 mm.) to the left, at the brim; ·1 in. (2½ mm.) on the right; ·08 in. (2 mm.) on the left, opposite the ischium. The wall becomes thicker again ·16 to ·24 in. (4 to 6 mm.) as it comes into relation with the vagina. Several *sinuses* are cut across in the walls above the brim, and opposite to the lower part of the ischium and the sciatic notch. There is one divided ·8 in. (2 cm.) distant from the cavity of the cervix on the left side and 1 in. (2·5 cm.) on the right. As already said, this last was shown by the probe to be the same vein as that seen in the hollow of the sacrum in the vertical mesial section. It is probably also the same as the one divided opposite to the symphysis; but the cutting up of the wall into sections prevented our following the vein by probe all round.

The *Membranes* line the uterine cavity, being intimately adherent to it from above downwards to a point 2 in. (5 cm.) distant from the cavity of the cervix on the left side and to ·7 in. (1·8 cm.) on the right. They cross the cavity of the cervix and do not bulge into it.



The *Placenta* appears on the left wall of the uterus but not on the right. The cord is divided where it passes round the neck and the limbs of the child.

The *Fœtus* is divided antero-posteriorly, the section passing to the right of the upper cervical vertebra and through the right orbit above, and immediately to the left of the sagittal suture. The vertex of the skull rests on the pelvic floor, with both fontanelles on a level. The posterior end of the parietal bone is slightly depressed beneath the occiput; there is no space between chin and thorax. Both hands appear in section in front of the face. The child's head might be described as rudely rectangular: the occipito-frontal diameter, measured from the occipital protuberance to the glabella, is about  $3\frac{3}{4}$  in. ( $9\frac{1}{2}$  cm.); but from the occipital protuberance to the frontal eminence is 4 in. (10 cm.) between the bones and  $4\frac{1}{2}$  in. ( $11\frac{1}{2}$  cm.) between the skin surfaces. The occipito-mental diameter is 5 in. (12.5 cm.), and the sub-occipito-bregmatic  $4\frac{1}{4}$  in. (10.6 cm.), both including the thickness of the skin. There is liquor amnii over the occipital and frontal regions of the head, but none over the vertex.

So much for the various sections that were made. The portions of the pelvis lying behind the fifth coronal section and between the transverse sections, after being thawed, showed the following points.

On the right side we see the *ureter* crossing over the common iliac artery immediately above the brim of the pelvis, or, more exactly, at the point opposite to the centre of the fifth lumbar vertebra and 1.4 in. ( $3\frac{1}{2}$  cm.) from the middle line; from this it runs obliquely downwards, outwards, and forwards along the left iliac fossa, until it lies so as to come opposite to the upper border of the sacro-sciatic notch (2 cm.) internal to the ilium, and the same distance anterior to the sacro-iliac joint.

The outer portion of the right broad ligament appears as a fold of peritoneum. The commencement of this fold is seen in the fifth coronal section, and from this point it runs upwards and backwards along the iliac fossa.

The right *ovary* is at the level of the crest of the ilium and about opposite its centre, hanging almost vertical. The right *tube* runs at first vertically downwards in front of the ovary, then curves backwards and upwards to end about the upper margin of the iliac fossa at a point opposite to posterior-superior spine. It thus hangs from back to front in a kind of festoon.



The left side shows the ureter crossing the artery at about the brim of the pelvis  $1\frac{3}{4}$  in. (4.37 cm.) from the mesial plane ; opposite to the promontory, it is in relation to the attachment of the mesorectum, but diverges from it below the brim. The left broad ligament lies about an inch and a half further back than the right, the two folds coming into relation with the ilium about an inch above the brim of the pelvis ; its course as well as that of the tube, however, is masked by adhesions.

The left *ovary* lies about an inch higher than the right and about an inch and a half further back, being almost above the posterior-superior iliac spine.

### MICROSCOPIC EXAMINATION.

Portions of the anterior wall up to Section I. and of the posterior wall behind Section V. were put aside for microscopic examination. The microscopic examination of tissues taken from a body which has been already frozen is not entirely satisfactory, as the freezing and subsequent thawing break up to a certain extent the tissues. The following points were, however, ascertained. The membranes are everywhere in relation to the wall of the uterus, except in the lower portion to be referred to immediately.

A section taken from the posterior wall above the promontory shows their general arrangement. The membranes form a layer from about .005 in. to .008 in. thick. First comes a well-defined band representing the cells of the amnion—.0003 in. high, the whole membrane being .0015 in. thick ; beneath this, a brightly stained layer with nuclei—the chorion (.0021 in. thick) ; beneath this again, a darker granular layer—the decidua (.001 to .002 in. thick). The differentiation of the decidua into its compact and spongy layers cannot be made out.

On the posterior wall, the membranes become somewhat crumpled in the area immediately above the circular vein ; and below it hang in a free fold. On the anterior wall, they are crumpled behind the pubes, but can be traced in relation to the walls as far down as the plane of the first coronal section. The arbor vitæ of the mucous membrane of the cervix can be traced posteriorly almost up to the circular vein but not beyond it.



## CHAPTER IV.

### SECOND STAGE OF LABOUR.

Definition and  
Duration of  
Second Stage.

IN Pregnancy, attention was directed chiefly to the abdomen and the topographical relations there. And there was little in the pelvis to note except the absence of peritoneum at the sides of the uterus; and in the First Stage interest gathered round the cervix. In the Second Stage it extends to the pelvis—the delivery of the child, through the already dilated cervix and through the vagina and vulva, constituting the ‘second’ stage in the progress of labour. This stage begins when the cervix has been fully dilated, and ends when the child is wholly born. To put the reader in a position to appreciate the light which sectional anatomy throws on this stage, we shall start with some facts with regard to the mechanism of labour; and for the sake of the student approaching this subject for the first time, we shall express them in what to those versed in it must seem an elementary form.

General State-  
ment as to  
Labour: the  
Factors;

The head of the foetus is its largest part and that which offers most resistance to birth; and, although it is within certain limits plastic so that it can be moulded, its size and shape form an important factor in this stage of labour. Again,



the bony pelvis which encases the soft yielding canal of cervix, vagina and vulva is firm and practically unyielding, for the pelvic joints of the human female give only to a limited extent in labour; accordingly, the size and shape of the pelvis form another important factor. We may say, therefore, that the phenomena of this stage turn on the relation of head and pelvis to one another as regards shape and size. We may put aside size—for the size of a head is practically to be measured in terms of that of the pelvis it has to pass through; and conversely a pelvis of normal size is one through which a head of normal size can be born. But from certain peculiarities in the shape of these two factors (pelvis and skull), the birth of the child implies movements of accommodation the result of which is to cause the head to pass through the bony pelvis in that manner in which a minimum of resistance is offered to the muscular power of the uterus—this last constituting, along with the action of the abdominal muscles, a third factor in labour.<sup>1</sup> These accommodation movements are described as the “Mechanism of Labour,” a phrase which is used in a peculiar sense as signifying not the means by which certain movements are produced, but the movements themselves.

We are not yet in a position to state precisely the shape of the child's head before and during labour, nor yet the shape of the pelvis as lined by the soft parts. It is evident that it is to Sectional Anatomy that we must look for exact data, and only one of the sections published gives us these in full.<sup>2</sup> Accordingly, we take provisionally the average of measurements made in the foetal skull and dry pelvis.

The size and shape of the foetal head is described in terms

---

<sup>1</sup> With regard to this factor we note that the contractions of the uterus occur only at intervals and are usually accompanied by pain, whence their name “pains of labour.”

<sup>2</sup> See page 66.



Relation of  
shape of Fœtal  
Head to  
movement of  
Flexion.

of three diameters, running from behind forwards in its mesial plane<sup>1</sup>—a sub-occipito-bregmatic, an occipito-frontal, and an occipito-mental<sup>2</sup> (see Diagram). In the unmoulded skull,

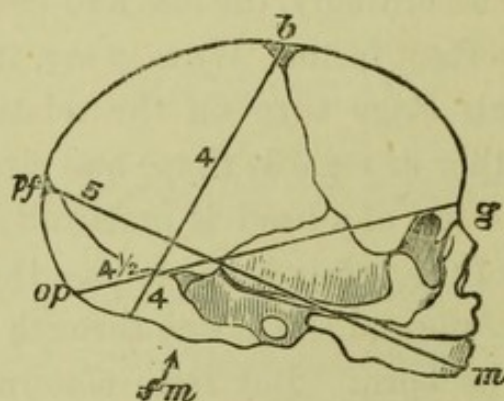


FIG. 1.

#### DIAMETERS OF FŒTAL HEAD.

- |     |                                  |   |
|-----|----------------------------------|---|
| 4.  | Sub-occipito-bregmatic diameter. |   |
| 4½. | Occipito-frontal                 | „ |
| 5.  | Occipito-mental                  | „ |

these are roughly represented by the three figures 4 in., 4½ in., and 5 in. Now, as at the beginning of labour, the child's head does not present its shortest diameter—the sub-occipito bregmatic—to the entrance of the bony canal, there must be an accommodation movement to take advantage of the

<sup>1</sup> These are the diameters concerned in the mechanism of labour in the normal pelvis; the transverse diameters, expressing the form of the head from side to side, become significant in the rickety pelvis.

<sup>2</sup> The posterior ends of these diameters are (see Diagram) in the occiput, respectively a point midway between the foramen magnum (*fm*) and the occipital protuberance (*op*), the protuberance itself, and the posterior fontanelle (*pf*); the anterior ends are indicated by the names—bregma i.e. anterior fontanelle (*b*), frons i.e. forehead (for which the glabella *g* is taken), and mentum i.e. chin (*m*). In stating these average measurements and the points from which they are measured, we follow A. R. Simpson's *Uniformity in Obstetrical Nomenclature*: Edin. Med. Journ., Sept. 1886.



peculiarity of its shape.<sup>1</sup> This movement consists in substituting the 4-in. sub-occipito diameter for one of the longer diameters; and will be effected by a motion like that of letting the head fall on the breast (speaking of the foetus as outside of the body), and hence the term “flexion”<sup>2</sup> is applied to it.

The mechanism of labour, therefore, implies first a *movement of flexion*, the *raison d'être* of which is in the shape of the foetal head.

Again the shape of the bony pelvis may be described in terms of three diameters—an Antero-posterior or Conjugate, an Oblique,<sup>3</sup> and a Transverse. These, taken in the three important planes of the bony canal—at its beginning in the brim, at its middle in the cavity, and at its end in the outlet,—

Relation of  
shape of Pelvis  
to movements  
of Rotation.

<sup>1</sup> The results of sectional anatomy throw doubt on the occurrence of this movement in a full-sized pelvis; see end of this chapter.

<sup>2</sup> This term “Flexion” is open to the objection that we do not know whether there is in labour an approximation of the chin to the sternum (see p. 50). All we know clinically is what can be learned by the fingers placed on the vertex of the head as it lies within the circle of the soft parts that embrace it—“the girdle of contact” (Lahs). Limiting ourselves to this area, we should describe the movement as a dipping of the posterior fontanelle or of the occiput—a dipping by which it comes to be relatively lower than the anterior fontanelle or forehead, not a descent which might take place without any change in this relation. It is evident that the chin's being on the sternum does not exclude a movement of flexion, *as we have defined it*, for dipping of the occiput would be equally effected by a rotation of the foetus as a whole round its transverse axis.

<sup>3</sup> There are really two Obliques, called “right” and “left,” according to the sacro-iliac joint from which they run; but their length is practically the same, and it is the right one which we have chiefly to do with in considering the position of the head at the commencement of labour—in about 99 per cent. of head presentations, the head lies in this diameter, and in three-fourths of these with the occiput to the front and left.



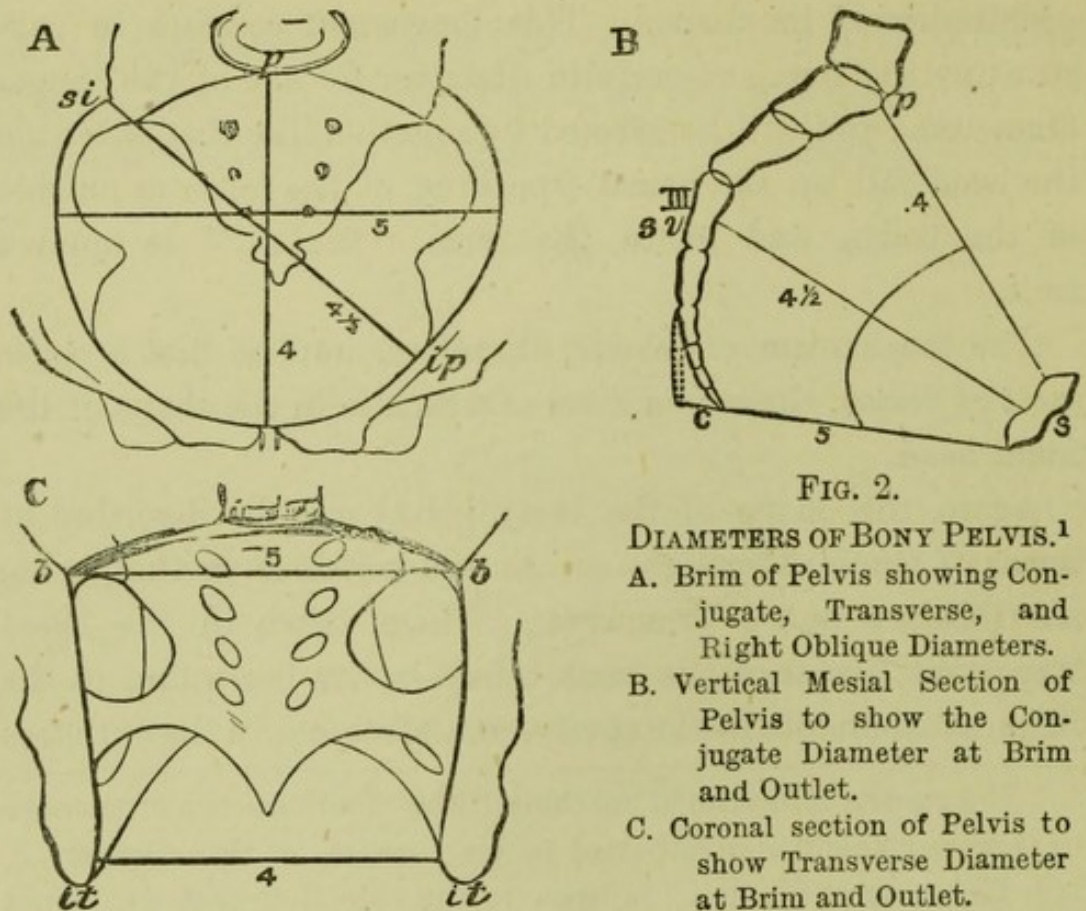


FIG. 2.

DIAMETERS OF BONY PELVIS.<sup>1</sup>

- A. Brim of Pelvis showing Conjugate, Transverse, and Right Oblique Diameters.  
 B. Vertical Mesial Section of Pelvis to show the Conjugate Diameter at Brim and Outlet.  
 C. Coronal section of Pelvis to show Transverse Diameter at Brim and Outlet.

may be expressed roughly in inches by the following figures.

	Conjugate.	Oblique.	Transverse.
Brim . . . .	4	4½	5
Cavity . . . .	4½	4½	4½
Outlet . . . .	5	(4½)	4

<sup>1</sup> The exact points between which these diameters run are the following: BRIM—*Conjugate* from centre of promontory (*p*) to nearest point of symphysis (*s*) just below its upper edge, *Obliques* each from corresponding sacro-iliac synchondrosis (*si*) to the ilio-pectineal eminence (*ip*) or a point above the acetabulum of the opposite side, *Transverse* between most distant points of brim (*bb*); CAVITY—*Conjugate* from middle of third sacral vertebra (*III sv*) to middle of symphysis, *Obliques* from sacro-iliac joints (at level corresponding to the Conjugate of the cavity) to middle of acetabu-



From this table it is clear that the longest diameter at the outlet is the conjugate, and therefore that the child's head leaves the pelvis most easily in that diameter. It enters the bony canal, however, usually in one of the oblique diameters, and therefore to travel through the pelvis in the easiest way it rotates from the  $4\frac{1}{2}$ -in. oblique into the 5-in. conjugate. There is thus a movement of rotation of the head within the pelvis; and as the shoulders likewise rotate in passing through, and necessarily cause the head, when born and lying external, to rotate a second time—the former movement is called one of “*internal rotation*,” to distinguish it from the latter which is an “*external rotation*,” and, as already said, primarily a movement of the shoulders. The Mechanism of Labour therefore includes an *internal* and an *external rotation* of the head, the *raison d'être* of which is in the shape of the bony pelvis.

As the head, then, descends through the pelvis, the occiput dips below the forehead by *flexion*, and the head passes from an oblique into the conjugate of the outlet by *internal rotation*. Further, in

Summary of  
movements in  
the Mechanism  
of Labour.

---

lum, *Transverse* between widest points in same plane; OUTLET—*Conjugate* from tip of coccyx bent back (c) to lower edge of symphysis, *Obliques* not measurable, *Transverse* between inner edges of ischial tuberosities (*it*). The figures in the table are significant rather as giving the proportionate than the absolute length of the diameters. The student will note that as a matter of length the transverse and conjugate diameters change places at brim and outlet—the conjugate, which is the short diameter at the brim, being the long one at the outlet: this, with the fact that the conjugate is at the brim of a normal pelvis 4 in., gives the clue for remembering the *architecture* of the female pelvis; for the length of the conjugate determines its whole build. As, however, we are looking at the pelvis from the standpoint of *the passage of the head*, and the head never enters the pelvis in the conjugate, we have emphasised the length of the conjugate *at the outlet* as the important figure.



emerging through the vulva, the occiput fixes under the symphysis pubis; and the bregma, forehead and face slip over the perineum, the chin leaving the sternum by a process of *extension*. Finally, the shoulders, in their passage through, rotate like the head and cause it to execute a movement of *external rotation*. These four are the essential, distinct and successive movements in the mechanism of labour. To these some would prefix a special movement of descent; this causes confusion, inasmuch as descent is taking place all through. Though the mechanism of labour may be analysed into four such parts, it is often difficult to distinguish them clinically. The progress of the head through the pelvis is like that of a ship through the sea; it flexes and extends as a ship pitches, it rotates as a ship rolls, it descends as a ship advances; but, though we may analyse the motion into these three, the course of the occiput is their resultant—a curve as complicated as that followed by a ship's bow. In clinical work the student will find it an advantage to concentrate his attention on the occiput, which leads in normal labour, and express the mechanism in terms of it alone:<sup>1</sup> occi-

---

<sup>1</sup> An additional advantage is that it reduces description of the mechanism of labour for the various presentations of the head to a common formula: the part of the head that leads (and after which each presentation and position is named) dips, rotates to the symphysis, fixes there (while the rest of the head sweeps over the perineum), and then rotates back again in the direction from which it came. This is just as true of the chin in a face presentation as of the occiput in a vertex presentation.



put dips, comes to symphysis, fixes there (while the face sweeps over the perineum), and then rotates as far if not farther back in the direction of its position before labour began.

This brief review of the mechanism of labour in a case in which the head comes first or presents,<sup>1</sup> will place the student in a position to study the Frozen Sections that have been published.

From the Second Stage we have three sections—by Braune of Leipsic, Chiari of Prague, and Chiara of Milan. Frozen Sections from the Second Stage.

Braune's<sup>2</sup> is that of a primipara (?), aged about 35, who drowned herself while labour pains were going on. No further history is given of the case; but, before freezing the cadaver, it was ascertained that the head of the child was in the pelvis, the bag of membranes unruptured and bulging in the vagina as a tumour the size of an apple.

Chiari's<sup>3</sup> case is likewise a primipara, aged 29, who died of tuberculosis. There is no further history, but it is noted that, before freezing, the fundus was found three finger-breadths above the umbilicus, and the back of the child to the left side. The vaginal orifice showed the remains of the hymen; and a short dis-

---

<sup>1</sup> In 96 per cent. of labours, and being the "natural" presentation, inasmuch as the life of the child is in danger when its breech comes first.

<sup>2</sup> See Part II. p. 45.

<sup>3</sup> See Part II. p. 50.



tance ( $1\frac{1}{2}$  cm.) within it, the finger felt the distended bag of membranes; and behind this lay the foetal head almost filling the pelvis, slightly moveable, and with the posterior fontanelle to the left.

Chiara's<sup>1</sup> case is a IV.-para, who died of syncope during spontaneous version of the foetus. Former labours were normal. The midwife had ruptured the membranes; and, pains coming on, an arm and loop of cord were driven down. A surgeon called in tried repeatedly to turn but failed, and sent the patient to the hospital where she died a few minutes after admission.

Although Chiara's case is from a pathological labour, we place it alongside of Braune's and Chiari's. Braune's is put before Chiari's; because while in both cases the membranes are unruptured, the child's head is rather higher in the pelvis in the former.

With these sections before us, the question presents itself to what extent they make us modify the general statement as to the Mechanism of Labour given above.

And first, as to the size of the canal through which the child passes. (See Pl. IV.)

Size of canal  
within the  
bony pelvis  
as seen in  
frozen sections.

These sections show us the canal in vertical mesial section only; and therefore till other sections are published we must limit ourselves to the bony pelvis as seen in such a section—in one word, to its size in terms of the conjugate diameters.

---

<sup>1</sup> See Part II. p. 47.



The question is not what is the available space which the child can use, but what space does it really use—which will evidently vary in different cases. We have plotted out in a tabular form the measurements in the conjugate (*i.e.*, the antero-posterior mesial) diameter, for these three cases. The first column gives the measurement in the bony pelvis;<sup>1</sup> the second, that of the actual space taken up by the child; the last, the difference of these two, *i.e.*, the thickness of soft parts:—

	BRAUNE.			CHIARI.			CHIARA.		
	Conjugate of Bony Canal.	Conjugate of space occupied by Fœtus.	Difference, <i>i.e.</i> , thickness of soft parts.	Conjugate of Bony Canal.	Conjugate of space occupied by Fœtus.	Difference, <i>i.e.</i> , thickness of soft parts.	Conjugate of Bony Canal.	Conjugate of space occupied by Fœtus.	Difference, <i>i.e.</i> , thickness of soft parts.
BRIM	4·2 in.	3·8 in.	·4 in.	4·4 in.	3 in.	1·4 in.	4 in.	3·8 in.	·2 in.
CAVITY	4·9 in.	4·2 in.	·7 in.	4·5 in.	3·1 in.	1·4 in.	4·7 in.	4 in.	·7 in.
OUTLET	4 in.	3 in.	1 in.	...	...	...	5·2 in.	2·8 in.	2·4 in.

\* *Note.*—We shall omit consideration of the outlet, because in Braune's and Chiari's the child's head has not yet descended so far as to dilate it, and in Chiara's the dilatation was by the arm and therefore pathological.

In comparing these figures, we must note that, in Braune's, brim and cavity are occupied by the largest part of the head, which has not yet reached the outlet, and that the conjugate of the outlet therefore runs to the tip of the coccyx not pushed back; that,

<sup>1</sup> These do not correspond exactly to the 4, 4½, 5, given at p. 72, which is only an approximation. The diameter there given for the outlet (5) was to the tip of the coccyx *bent back* in labour, which was not the case in all of these sections. Further, the conjugate of the brim is measured to the nearest point of the symphysis, and not to its upper edge as in Part II. pp. 46 and 52.



in Chiari's, the head of the child is past the brim which is grasping the shoulders only, also that at the brim the bladder walls are separated .35 in. by urine, and that the rectal walls are separated to .8 in.; and that, in Chiara's, the soft parts at the brim are subjected to a pathological degree of compression, for the process of spontaneous evolution implies an abnormal forcing of the child into the pelvis. And now we understand that (taking Braune's to express the normal condition) the 1.4 in. at the brim in Chiari's is partially distended bladder, and the 1.4 in. in the cavity is partially distended bladder and rectum; while the .4 in. has become .2 in. at the brim in Chiara's, because there is abnormal drawing up of the bladder out of the way, and compression of the soft parts that remain.

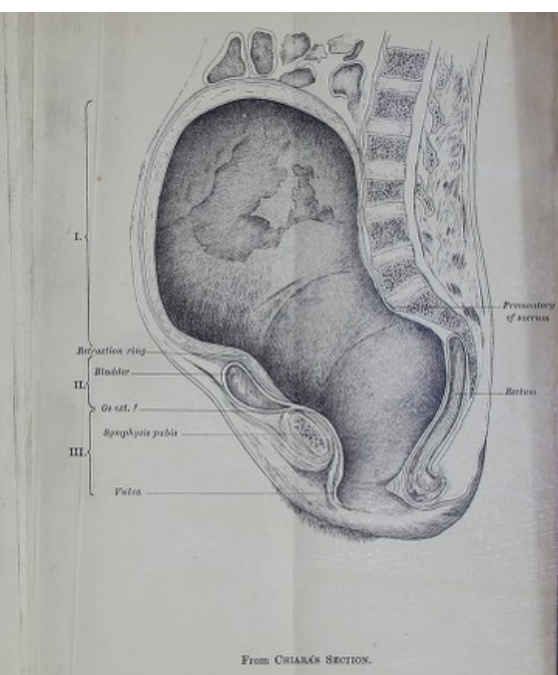
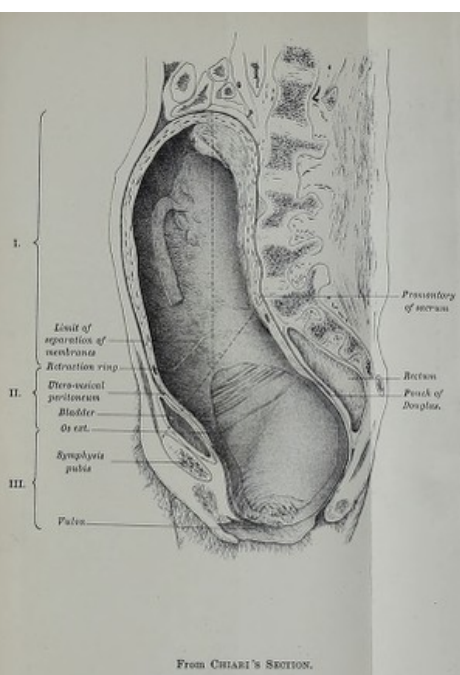
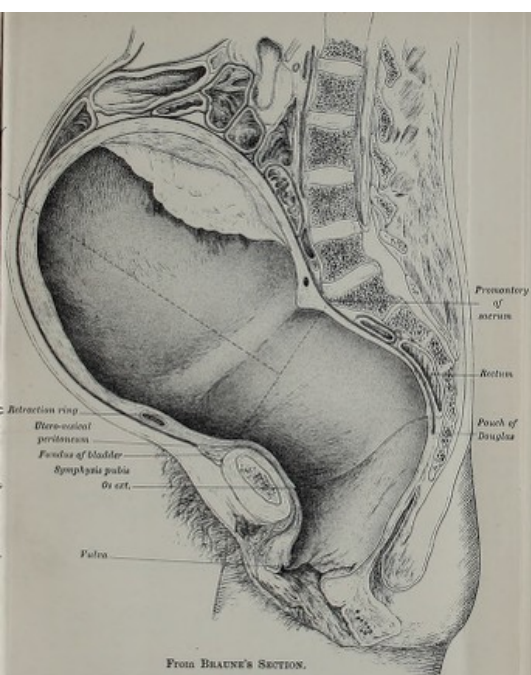
Form and Relations of uterus in Second Stage, as shown by frozen sections.

We have next to consider what is the form and relation of the uterus. We are at once struck with the difference in the contour of the uterus in Braune's and Chiara's compared with Chiari's. In the first two, the section of the portion of the uterus above the brim approaches a circle;<sup>1</sup> the long diameter (at right angles to the brim) being only slightly longer than the antero-posterior.<sup>2</sup> (See Pl. IV.)

<sup>1</sup> The globular shape may be in Chiara's preparation partly due to the child's head being above the brim, but in Braune's this is not the case.

<sup>2</sup> Long diameter in Braune's 8 in. (20 cm.), Chiara's  $8\frac{3}{4}$  in. ( $22\frac{1}{4}$  cm.); antero-posterior diameter in Braune's  $7\frac{1}{2}$  in. ( $18\frac{1}{2}$  cm.), Chiara's  $8\frac{1}{2}$  in. ( $20\frac{1}{2}$  cm.). In Chiari's the former is almost twice






PL. IV.—THE GENITAL TRACT during the Second Stage.

Note the extent to which the space in the bony pelvis is diminished by the soft parts—especially the bladder and rectum; that the utero-vesical peritoneum with part of the bladder is drawn above the brim; the form of the uterus and direction of its long axis in Braune's and Chiari's Sections compared with Chiari's; the division of the genital tract, by the retraction ring and os externum, into three areas (I, II, III.); the thinning of the wall below the retraction ring; the non-appearance of venous sinuses in Braune's and Chiari's compared with Chiari's.







In Braune's and Chiari's the fundus is at the same level—the junction of the second and third lumbar vertebræ; in Chiara's, it is higher at the upper border of first lumbar—probably due to the fact that we have a larger portion of the foetus (comprising its head) still above the brim. The uterus is separated from the spine by intestine in Braune's, while in Chiari's it lies along it. The peritoneum in front does not descend into the pelvis at all, but stops short—the utero-vesical reflection being in both cases .7 in. above the brim, *i.e.*, a line joining symphysis and promontory; while posteriorly it descends within the pelvis for  $4\frac{3}{4}$  in. and  $3\frac{1}{4}$  in.<sup>1</sup> respectively.

As to the pelvic contents, the vaginal cleft is opened up so that its cavity forms a continuous part of the genital tract, with which it will be described. The bladder has become in part an abdominal organ, its highest point being .7 in. and .8 in. above the brim in Braune's and Chiari's respectively—in Chiara's it is much higher, 2 in. (Pl. IV.)

Relations of  
Pelvic Contents  
in the Second  
Stage.

No data are given by Chiari or Chiara for fixing its lower limit; but Braune says that while behind the symphysis its

---

the length of the latter, so that the contour is an elongated oval; the long diameter being 6.4 in. (16 cm.) and the short 3.6 in. (9 cm.).

<sup>1</sup> Chiari's Section; not mesial, therefore peritoneum may have descended lower than his figure indicates. The utero-vesical peritoneum is not indicated in Chiara's Section.



walls are so thin that they are scarcely recognisable, above and below (where pressure is not so great) they are easily made out—from which it is evident that the lower limit of the bladder is below the symphysis. Its cavity is empty in Braune's, but contains some urine in both the others.

The rectum is slightly distended in each case, taking up from  $\cdot 5$  to  $\cdot 8$  in. of the available room in the cavity. Some cellular tissue is seen round the rectum in all three, and in relation to the bladder in Chiari's; but it is not sufficient in amount to materially diminish the available space.

The sacral segment<sup>1</sup> of the pelvic floor is pushed downwards, so that the pelvic-floor projection is very much increased. Unfortunately, we have no data for comparing this with those in the first stage or before labour, as the sections do not pass through the coccyx. The anus and perineal body are evidently both on a lower level than before labour.

Genital Tract  
as seen in  
Frozen Sec-  
tions from  
same Stage.

We now come to the genital canal itself, and we look upon uterus, cervix, and vagina, as a continuous tract (see Plate IV.). The length of this tract measures along its axis from inside the fundus to vulva, in Braune's 1 ft. 2 in., in Chiari's 1 ft., in Chiara's 1 ft. 1 in. In Braune's and Chiara's the axis has a single curve on it, that is to say we have a straight line from fundus to opposite the floor of the pelvis which then curves forwards; in Chiari's,

<sup>1</sup> For the contrast between the behaviour of the two parts of the pelvic floor in labour, see Abstract of Berry Hart's *Thesis* in Part II. p. 48.



on the other hand, there is also a slight backward curve in the upper part owing to the direction of the uterus along the spine. In one word, the axis of the uterus in the first two corresponds to the axis of the brim of the pelvis; in the last, it forms an angle with it.

Looking at the inner surface of this canal with the foetus removed, we find it to be divided by two slight ridges into three areas: the lower ridge corresponds to the os externum; the upper to a portion of the uterus where its muscular wall becomes suddenly thicker.<sup>1</sup> Then, looking at the walls in section, we find variations in thickness throughout, the common feature being that the walls become thin where the middle area begins. From fundus to os externum we have (in Braune's) 10·8 in., of which two-fifths (4·2 in.) is middle area, and (in Chiari's) 7·7 in. of which two-sevenths (2·2 in.) is middle area.<sup>2</sup> The greater relative length of this middle area in Braune's is accounted for by two facts,—first the uterus is contracting and this area is consequently more elongated, and secondly the child's head has passed beyond it in Chiari's, and therefore does not stretch it to the same extent.

This appearance of the inner surface of the canal and of its walls in section shows us that in the Second Stage of labour we lose the division of uterus into body and cervix, and see instead two areas which present a striking contrast in their behaviour in labour—the upper area shortens, and its walls become

Division of  
Genital Tract  
into Areas.

<sup>1</sup> Described by Braune as the 'os internum.'

<sup>2</sup> As Chiara does not say whether the lower ridge in his section is the os externum, we cannot give the proportion for his case.



progressively thicker as labour advances; the lower area elongates, and its walls become thinner. The difference between these two areas is physiological rather than anatomical; the upper plays an active, and the lower a passive rôle in labour. The lower, in fact, is in its behaviour more allied to the lowest area of all—comprising the vagina and vulva; so that, as far as the physiology of labour goes, we might divide the whole genital tract into two parts—the line of demarcation being the thickening of the wall in section and the ridge on the surface referred to. To this ridge, the name “contraction ring”<sup>1</sup> has been applied. For the reasons given in the note, we shall, however, call it *retraction* ring. Below this retraction ring the wall is of nearly uniform thick-

---

<sup>1</sup> It was Bandl who first drew attention to this thickening of the uterine wall, its occurrence in cases of obstructed labour, and the connection between the thinning of the part below and rupture of the uterus. Hence the thickening is spoken of as “Bandl’s ring.” Schroeder has drawn attention to its production in cases of normal labour where there is no obstruction, and applied the term “Contraction Ring” to it. This name is better than “Bandl’s ring,” which suggests its being pathological and connected with rupture. The word “contraction” is happy as suggesting that the active contracting portion stops here; still, it expresses something temporary—present only during a pain. Now, the thickening persists and steadily increases during labour. “Ring” also is misleading, unless we remember that the thickening is most marked anteriorly and at the sides. “Retraction ridge,” or better still “retraction rim or edge,” would be more strictly accurate, for it really marks the lower edge of the retracting part of the uterus.



ness. As to the vaginal walls which form the third area, the posterior is stretched almost to the same extent in both sections (to 5·5 in. and 5 in.), and is one-tenth of an inch thick; it is of about the same thickness as that of the middle area in Braune's and of one-third its thickness in Chiari's. The anterior vaginal wall is shorter (2·2 in. and 2·3 in.) in both sections than the posterior; it is also thinner in Chiari's, but thicker in Braune's.

The section of the uterine walls, in Braune's and Chiara's, has another feature worthy of note; Vessels in  
Uterine Wall. no venous sinuses are seen in the surface of the section with the exception of one large one in Braune's at the seat of the retraction ring. In all the other sections, both from pregnancy and the first stage and in Chiari's from the second, the cut-across mouths of the venous sinuses are a feature in the section of the wall. The only explanation of this is that the wall is in Braune's and Chiara's in a state of contraction which has caused compression of the sinuses and obliteration of their lumina.

The placenta is in Braune's and Chiari's situated on the posterior wall. As it is not divided mesially, we can make Placenta and  
Membranes in  
Second Stage. no deduction as to the area of its attachment in proportion to that of uterine cavity; but it is important to note that in neither case has any portion of it become separated,—Chiari, in fact, expressly describes it as “nirgends abgelöste, sondern überall festhaftende” (nowhere separated, but everywhere firmly attached). In Chiari's it is remarkably thick



in its upper third ( $\cdot 7$  in.), compared with the rest of it (average,  $\cdot 2$  in.). Whether this be due to the uterine walls, having contracted more in this situation or simply to a variation in thickness in the cotyledons of the placenta, we cannot say. As the uterine wall is not thicker here, the latter is probably the explanation. In Chiara's preparation the placenta is obscured by blood-clot.

The condition of the membranes is described in Chiari's only. They are closely attached all over the uterine cavity down to the level of the retraction ring. Here is seen a raised white sinuous line running round the uterus, below which the membranes can "with the slightest pull be drawn off the uterine wall." This raised white line is due to a peculiar folding of the chorion and decidua, which have here become detached from the uterine wall and thrown into a number of convolutions over which the amnion passes without dipping down between them.

Fœtus as seen  
in frozen sec-  
tions of Second  
Stage.

With regard to the fœtus, we must put on one side Chiara's case, in which the normal attitude has been destroyed by spontaneous evolution. This leaves us two from the Second Stage; and we also have two from Pregnancy to compare with them. Putting together these four fœtuses removed from the body, we find some interesting points suggested by their comparison.

In the first two, *Before Labour* (see Plate I.), the general contour is an oval, of which the long axis is not greatly in excess of the short; the flexures of the different parts of the body are not very acute, the limbs being, so to speak, "comfortably disposed;" the long axis is not straight, but slightly curved on the mother's spinal column. Owing to the



flexion of the head on the chest, comparatively little of the child's face is seen. In those from the First Stage we have a similar disposition of the limbs, but the head is in two of them dropped on one shoulder—its long axis forming a lateral angle with the long axis of the body; as the foetus was in both cases dead, this lateral drooping of the head is probably due to the limpness of the body. In the two during the *Second Stage* (see Plate 1.), the general contour of the body is that of an elongated oval. The flexures of the limbs are increased; their disposition, with the foldings of the skin, suggesting compression. More of the face is seen than in the case of the foetus before labour, the degree of flexion of the head being diminished. The long axis of the oval in Braune's case corresponds nearly to the axis of the brim, in Chiari's it curves on the promontory of the sacrum. It is worthy of note that although the liquor amnii has not escaped in either of these cases, the breech of the child is in contact with the fundus uteri.

The comparison of these foetuses shows us that, during the Second Stage, the foetus becomes elongated,<sup>1</sup> and its limbs packed together so that the outline is more regular; further, the flexion of the head diminishes rather than increases.

As regards the exact contour of the foetal head, no one of the sections except my own has divided it so that we can measure the diameters. By

Contour of  
Foetal head.

---

<sup>1</sup> The length of the foetal ovoid in the eight cases is as follows :—

Before Labour, . . .	Braune and Waldeyer,	9	and 9·2 in.
First Stage, . . .	Barbour and Schroeder,	10	and 10·7 in.
„ . . .	Winter and Saexinger,	9	and 8·8 in.
Second Stage, . . .	Braune and Chiari,	12·5	and 11·2 in.



fortunate accident, one of my axial-coronal sections (p. 66) has bisected the head antero-posteriorly, and given us the following measurements:—

Sub-occipito-bregmatic diameter	.	.	4 $\frac{1}{4}$ in.
Occipito-frontal.	.	.	4 $\frac{1}{2}$ in.
Occipito-mental.	.	.	5 in.

These measurements are not of the skull only, but include the skin and sub-cutaneous fat; they have the special interest that they are of the unmoulded head before the mechanism of labour has begun.<sup>1</sup>

Relations of  
head in pelvis.

Limiting attention, now, to the two foetuses of the Second Stage, and looking at them as they lie in the canal, we note the following anatomical relations (see Plate I.).

In Braune's section, the head has descended until its vertex has reached a point 4·2 in. below the brim, measured along the axis of the latter prolonged; it is in the left oblique diameter of the pelvis with the occiput to the front, which may have been its original position at the commencement of labour, but is more probably produced by rotation from a right occipito-posterior one. The portion of the head which is engaging is a plane parallel to a line joining the supra-orbital ridge and the top of the ear; and, if we look at the drawing of the child removed from the body, the part which is highest (and would be lowest or 'present' in labour) is a point 1 $\frac{1}{2}$  in. above the posterior fontanelle, *i.e.*, the fontanelle would need to dip

<sup>1</sup> Though the child had been dead for some days, and the head might possibly be more flaccid, yet being surrounded by liquor amnii its shape would not be affected by pressure.



1½ in. lower to become the lowest or presenting part of the head. Both of these facts show that flexion is only partial here. In Chiari's the head has descended to the perineum—the vertex being 4·9 in. below the brim. It is lying in the transverse diameter of the pelvis, with the occiput to the left side. This points to its having been in a left occipito-anterior position, and having descended through the pelvis in the transverse diameter without as yet rotating. The attitude of the child in almost full-faced view shows that flexion is partial.<sup>1</sup>

Having thus described in detail the anatomical facts bearing on the Second Stage of labour which these sections teach us, we have now to gather them up and look at their bearing on clinical work. Since we are not yet in a position to describe the history of labour from frozen sections alone, it will be best to group the isolated facts under the heads of “the factors” and “the mechanism.” In the first paragraph of this chapter we indicated that there are three factors in labour.

Bearing of  
Anatomical  
Facts in the  
clinical study  
of the Second  
Stage.

---

<sup>1</sup> Therefore, while the head has descended almost to the outlet passing through the various planes of the pelvis only semi-flexed, its occipito-frontal plane (*i.e.*, a transverse plane passing through its occipito-frontal diameter) is not parallel to, but forms an angle open to the back with the plane of the outlet of the pelvis (*i.e.*, a transverse plane passing through the conjugate of the outlet). No movement of “Synclitism” (parallelising) has taken place, *i.e.* the head has not adjusted itself so as to make that plane which was parallel to the plane of the brim when the head entered the pelvis, likewise parallel to the plane of the outlet as the head leaves the pelvis.



POWERS—by which we understand the muscular action of the uterus, and that of the abdominal muscles as accessory to it ;

PASSAGES—the yielding canal of cervix, vagina, and vulva, which is encased in the bony pelvis ;

BODY PASSING—the fœtus, especially its largest part, the foetal head.

Further, we analysed the mechanism into the four movements of

FLEXION,  
INTERNAL ROTATION,  
EXTENSION,  
EXTERNAL ROTATION.

Teaching of  
Sectional  
Anatomy as to  
“powers” in  
Second Stage.  
Condition of  
uterus during a  
pain.

As to the “Powers,” they teach us that during a contraction the axis of the uterus is thrown into the axis of the bony pelvis, thus taking up the position most favourable for the emptying of its contents through that canal. Further, it becomes globular so as to appear in section circular rather than oval. Both of these facts are familiar to us from clinical examination: the hand feels the uterus during a contraction coming up so to speak against the abdominal wall, and becoming rounded. With this rising from the spinal column there is associated its becoming firm instead of flaccid. While in the non-contracting condition it lies moulded on the column which indents it, the change of contour in contracting makes it so to speak kick against the spine and spring forwards. This recoil from the



spine, however, does not sufficiently account for its erection so as to throw its axis into that of the pelvic brim; the pulling on its attachments must also operate. Another effect of contraction is that the venous sinuses in the wall become compressed so that the circulation is arrested. Whether this arrest means the rendering of the muscle anæmic or not we have not yet data for determining, but the interference with the placental circulation and oxygenation of the blood of the foetus will be the same. This is the practical point: the intermittence of the contractions in labour allows for the oxygenation of the foetal blood in the interval; while a condition of tonic contraction, such as results from the administration of ergot, will be prejudicial to the foetus. Summing up the foregoing, we may say in one word, that *during a pain, the uterus erects itself, becomes globular, and has its circulation arrested.*

The above-described anatomical change in the muscular wall of the uterus is transient and intermittent, ceasing when a pain has passed off. There is another change of a different character, which is continuous and increases progressively during the whole course of labour. This change is confined to the upper part of the genital tract. The fundus and greater part of the body of the uterus not only become shorter and thicker during a contraction (as any muscle does) but retain this shortening and thickening after the pain has passed off, so that with

Differentiation  
of muscular  
wall into two  
portions.



successive contractions the shortening and thickening progress. To this progressive shortening and thickening of the muscular wall of the uterus the name of "retraction" has been given, to distinguish<sup>1</sup> it from "contraction"—an intermittent and transient change.

Teaching of  
Sectional  
Anatomy as to  
the passages  
in the Second  
Stage.

Relation of  
peritoneum.

Space taken up  
in pelvis by  
soft parts.

In looking at the "Passages" we must say one word, first, as to the disposition of the peritoneum. While, in pregnancy, the peritoneum is lifted up out of the pelvis by the growing uterus at the sides only, in labour, it is lifted up in the front as well—the peritoneum of the pouch of Douglas alone retaining in labour as in pregnancy the disposition it had in the non-pregnant condition. During labour, therefore, the portion of the genital tract within the pelvis is stripped of peritoneum at the front and sides, being there surrounded by cellular tissue only. The next point of interest is that the soft parts reduce the length of the conjugate diameter of the genital canal as given in the bony pelvis by about two-fifths of an inch at the brim, and seven-tenths of an inch in the cavity. They do so still more when bladder and rectum are distended, and hence the importance of keeping these organs empty during the

---

<sup>1</sup> Whether retraction takes place independent of contraction or simply accompanies it; *i.e.*, whether, as the result of tapping the uterus and simply allowing its contents to drain off, its walls would become shorter and thicker and its potential cavity smaller, *without pains*, is an open question.



second stage. The upward displacement of the fundus of the bladder in labour (the highest point of the *empty* organ being almost an inch above the brim) is calculated to mislead us as to the amount of urine in it. The fundus of the empty organ is almost an inch above the brim, and hence a moderate amount of urine will produce a swelling in the lower region of the abdomen, such as we are accustomed to associate with considerable distension of the bladder.<sup>1</sup> But while the bladder is in part drawn up, the greater portion of it lies compressed between the head and the symphysis pubis. Prolonged pressure causes sloughing, and thus we see how vesico-vaginal fistula may follow a prolonged labour.

Displacement of bladder : bearing on degree of distension, and on fistula.

We have already spoken of the differentiation of the passage into two parts, and of the thinning of the wall of the tract below the retraction ring. This is not appreciable in normal labour. It is only in cases of obstruction to the emptying of the uterine contents, of which the commonest examples in midwifery practice are seen in contracted pelves and in cross-births, that the difference between the thick portion above and the thin one below is appreciated by the hand. On palpating the abdomen immediately above the symphysis, we feel the uterine contents below with unusual distinctness through the thin part of the wall, and above this the margin of the

Bearing of thinning of wall of passages on rupture of uterus.

---

<sup>1</sup> See Berry Hart on this point, Part II. p. 49.



retracted portion.<sup>1</sup> This thinning, if it goes on, ends in rupture of the wall.

Teaching of  
Sectional  
Anatomy as to  
the foetus in  
the Second  
Stage;

With regard to the third factor in labour, the "Body passing," we need here only mention that the diameters given for the foetal head at the beginning of this chapter are borne out by the frozen sections of the foetal head from the first stage; that in the Second Stage, the general contour of the body is elongated and the amount of the flexion of the head not increased.

and as to the  
Mechanism of  
Labour.

Finally, with regard to the Mechanism of Labour, the information is so far negative. As to where it begins, it is noteworthy that in the three frozen sections of multiparæ from the first stage, *i.e.*, before the mechanism has begun, the child's head is already in the pelvis. It is an accepted clinical fact that in primiparæ the head is already in the pelvis before labour begins, but it is usually said that in multiparæ it is not. If the head be in the pelvis on the completion of the first stage, it follows that the Mechanism of Labour (which begins with the Second) does not begin when the head is at the brim but when it is in the cavity. With regard to the movement of flexion we note that we find the foetus with its head already flexed as the result of its attitude in pregnancy,—it *grows* in the attitude of flexion. Whether this is increased in normal labour

---

<sup>1</sup> Called Bandl's Ring. Compare note on p. 82.



so as to constitute a distinct movement of flexion<sup>1</sup> in the Mechanism, as described provisionally at the beginning of this chapter, is *sub judice*. In these sections internal rotation has not yet occurred.

---

<sup>1</sup> As to the sense in which the term flexion is used, see foot-note, p. 71.



## CHAPTER V.

### THIRD STAGE OF LABOUR.

Introductory:  
Definition and  
Duration of  
Third Stage.

IN studying the Second Stage of Labour, our attention is fixed on the child; and we follow it through the genital tract until it is outside the vulva, which ends the stage. But all the contents of the uterus are not yet expelled: there remain the structures lining the cavity in which the foetus lay—viz., the placenta and membranes. The delivery of these constitutes the 'Third Stage,' which begins when the child is born and ends when they are outside the vulva. We have accordingly to return to the uterus; and must, in the first place, consider whether anything has happened to these structures while the birth of the child has been taking place, so that we may know their relations at the commencement of the Third Stage.

Condition of  
Placenta and  
Membranes  
at its com-  
mencement.

In describing the placenta in the Sections from the second stage, we noted that it was still attached to the uterine wall as before labour. The membranes also, in the only section in which their condition was specially examined, were found likewise still un-separated as far down as the retraction ring. The formation of the bag of membranes in the first



stage to dilate the cervix so as to allow the foetus to pass through, necessitated detachment—the nature and amount of which have been already described.<sup>1</sup>

With this exception we have, therefore, placenta and membranes<sup>2</sup> still attached to the uterine wall when the Third Stage begins. This stage, therefore, implies two processes—the separation of the placenta and membranes, and their expulsion. The natural method in which these are effected constitutes its physiology; and it is an intelligent grasp of this latter which enables us to bring our study of the anatomical changes to bear on clinical work. For a knowledge of the way in which Nature manages this stage is the only sound basis for scientific treatment.

Physiological  
processes  
implied in it.

In this chapter we have accordingly the following order of inquiry marked out:—

1. The *anatomical facts* of significance with regard to the Third Stage, and the light these throw on the *physiological* processes of the *separation* and the *expulsion* of the placenta and membranes;
2. The bearing of these anatomical and physiological data on the *management* of this stage.

No sections of the whole pelvis have as yet been published from this stage of labour. The only material as yet available consists of two frozen sections of the uterus alone from cases of partial placenta prævia and eclampsia, and some spirit-

Stratz's  
Frozen  
Sections.

<sup>1</sup> See p. 55.

<sup>2</sup> See also Thiede's case, Part II. p. 53.



hardened sections of uteri removed in Porro's operation. The frozen sections were made by Stratz<sup>1</sup> of Berlin, and we have reproduced them in our *Atlas of the Anatomy of Labour*. In the case of placenta prævia, the patient was delivered *in articulo mortis* by turning, and died with the placenta still in the uterus.

The uterus with the contained placenta measures about 9 in. vertically and  $3\frac{1}{2}$  in. antero-posteriorly; its walls vary in thickness from  $\frac{3}{4}$  in. in the lower third to  $1\frac{1}{4}$  in. in the upper two-thirds. The placenta itself measures 6 in. vertically,  $1\frac{3}{4}$  in. antero-posteriorly in its thick upper third and about  $1\frac{1}{4}$  in. in its thin lower two-thirds. It is no longer attached at any point to the uterus, nor is a blood-clot seen at its site. It is grasped on all sides by the uterine wall and lies with its edge at the os externum. The membranes are still adherent though folded—especially at the fundus.

The other section (that from the case of eclampsia) was from a patient delivered by forceps, also *in articulo mortis*.

The uterus with contained placenta and blood-clot is  $9\frac{1}{2}$  in. long, and  $3\frac{1}{4}$  in. thick; while its wall varies from  $\frac{1}{2}$  in. to 1 in. in thickness in the lower three-fourths, it is only  $\frac{1}{8}$  in. thick over the fundus—where the placenta is still attached. Its cavity contains in the upper portion placenta only, in the lower blood-clot as well. The placenta is attached over the fundus and anterior wall for  $4\frac{1}{2}$  in. and is free below for  $1\frac{1}{4}$  in. The attached portion averages  $1\frac{1}{4}$  in. in thickness, while the free portion is thinner.

---

<sup>1</sup> See Part II. p. 54.



Putting the measurements of these preparations together, we have the uterus during the Third Stage measuring from 9 in. to  $9\frac{1}{2}$  in. long, and from 3 in. to  $3\frac{1}{2}$  in. thick (*i.e.*, antero-posteriorly); while the placenta within is from  $5\frac{1}{2}$  in. to 6 in. long, and 1 in. to  $1\frac{3}{4}$  in. thick. In the first case, the noteworthy anatomical facts are—that the uterine walls do not vary greatly in thickness, although the lower portion is on the whole thinner than the part above; that there is no blood-clot underneath the placenta; that the uterus grasps the placenta on all sides, there being no space into which the latter bulges; and that the placenta lies so that it will slide out of the uterus with its edge or a point near coming first. In the second preparation, the most remarkable feature is the relative thinness of the uterine wall over the fundus which is no thicker than the wall before labour; and the fact that over this area the placenta is still attached.

Summary of  
the Anatomical  
facts seen in  
Stratz's  
sections.

So much for the anatomical facts. We look now at their bearing on the physiological question of the separation of the placenta.

The remarkable contrast in the uterine wall opposite to the separated and the non-separated portions of the placenta in the second preparation suggests the question:—Is not the retraction (*i.e.*, the progressive and permanent shortening) of the wall at the site of the placenta the cause of separation? At the first

Their bearing  
on the  
Physiological  
question of the  
separation of  
the Placenta.



glance we should say "yes," and this has been the hitherto received view.

It has been tacitly assumed that the wall of the uterus shrank during the second stage of labour to such a degree that the placenta was not able to follow this shrinking, and hence separated itself from the wall. By the German School of Midwifery it has been further taught that the separation begins at the centre, the placenta arching itself off the wall, that the concavity of the arch fills up with blood (constituting a hæmatoma), and that this "retro-placental hæmatoma" is an important agent in continuing the separation. The blood is described as acting partly by dissecting off the placenta and membranes from their site, partly by the clot's offering a bulkier mass for the uterus to contract on, in forcing the placenta onwards (*v.* Fig. III. A).

Information  
gained from  
Uteri from  
Porro's  
operation.

It is self-evident that the consistence of the placenta (for it is not a rigid but a spongy mass) must admit of a certain amount of retraction of its site without separation; and the question is how much? To answer this we must return to further anatomical considerations derived from uteri removed by Porro's operation<sup>1</sup>; and it was the study of such uteri which drew my attention to the point I wish to make clear. In the three Porro uteri figured and described in Plates VII. and VIII. of the *Atlas*, we see a placental site which has shrunk in two to 4 in. by  $4\frac{1}{2}$  in., and in the third to 5 in. by  $5\frac{1}{2}$  in.<sup>2</sup>, giving areas

<sup>1</sup> In which the child is cut out by Cæsarean Section; and the uterus, containing placenta and membranes, amputated.

<sup>2</sup> In Benckiser's preparation, it has shrunk to 5 in. vertically (*v.* Part II. p. 55).



of 14·2 sq. in. and 21·6 sq. in. respectively, and yet there is no trace of the placenta's having separated itself from the wall of the uterus.

Compare such areas with that of the placental site when labour is just beginning. In only one series of sections made at that period was the placental site divided transversely as well as vertically, so that we could estimate its extent, and we found it to be about 38·5 sq. in.<sup>1</sup> As the size of the placenta varies greatly in different cases we are not justified from these figures in affirming that the site may shrink to about one-half without separation. We must have measurements from a large number of cases so as to get the average size of the placental site before labour begins ; but in the meantime it is instructive to put these figures side by side and note that on the one hand we have a placental area of 38·5 sq. in. at the beginning of labour, and, on the other, areas shrunk during labour to 14 and 21 sq. in. without separation of the placenta.

Amount of retraction of the placental site without separation of the Placenta.

That the placental site can shrink to an absolute area of 14 or 21 sq. in. without separation, and that this may be either rather less or rather more than one-half of its area before labour had begun, are anatomical facts, but not nearly so significant as the following one—that with this amount of retraction the uterine wall embraces the placenta all round. In other

---

<sup>1</sup> See p. 49.



words, the placenta has not become separated before the uterus begins to act on it *as a whole*. When this has taken place, the operating force is no longer retraction of the site alone, but retraction of the walls throughout: the uterus of the third stage now acts on the placental mass as that of the second stage did on the foetal mass; and there is no uterine cavity in the sense of an empty space into which the placenta can arch itself, for the uterus grips the placenta on all sides.

The  
Membranes.

So much for the placenta in this stage. We pass now to the membranes. Stratz does not give particulars as to the condition of these in his preparations; so that what follows is based on the study of the Porro uteri, as indicating what is the condition of the membranes at the commencement of the Third Stage, and what will be the result of uterine contractions on these structures during it. The most instructive way of looking at this subject is to compare what is found in these sections with the condition before labour begins.

Their relations  
before Labour.

The following are the general relations of the membranes to the uterine cavity and to the placenta before labour has begun: most external is the muscular wall; resting immediately on it is the decidua; within this is the chorion, and finally the amnion containing the liquor amnii. On one part of the wall the chorion and decidua blend in the placenta. The minute structure of these layers is as follows. The amnion consists of a single layer of columnar epithelial cells



resting on a delicate connective tissue, which unites it to the chorion. The chorion is composed of a band of compressed fibrillated tissue below which is a more cellular layer. The decidua consists of the vera and reflexa, which have become practically one membrane. It consists of two zones—a superficial compact and a deeper spongy or reticulated one. The appearance of two zones or layers in it is due to the changes which the glands of the uterine mucous membrane undergo during pregnancy. The ducts of the gland become obliterated by pressure, and hence the membrane has a compact appearance above; the lower portions of them hypertrophy, and appear as epithelium-lined spaces in the decidua, giving it a spongy appearance (on section) which is distinctly marked in the middle of gestation though not evident at full time.<sup>1</sup>

So much for the relation of the membranes before labour has begun. What are the changes which occur during labour? Or the question might be thus stated: Here is a bag containing water (for we may leave the foetus out of account); the wall of this bag consists of several layers; what will happen if you tap the bag? How will the layers behave? Their behaviour will depend on the nature of each and of its union with the adjacent ones. With regard to the nature of the individual layers, the amnion is the strongest and most elastic of the three membranes; the chorion, while thicker, is not so strong; the decidua, although appearing as thick as the amnion, is friable and without much cohesion

Their  
behaviour  
during  
Labour.

---

<sup>1</sup> See p. 21.



between its parts; the muscular wall possesses contractility. As regards their union, the amnion is united to the chorion by a delicate gelatinous connective tissue, which forms a plane of weakness in the membranes; the chorion is intimately united to the decidua, being first rooted in it by the primitive villi, after which the two membranes become so blended that it is difficult to trace a line of demarcation under the microscope; the decidua is united to the muscular wall just as the mucous membrane of the unimpregnated uterus is, there being no *muscularis mucosæ*. The peculiar development of the glands produces the spongy portion of the decidua. The persistence of these glands in the deepest part of the decidua throughout pregnancy, and the fact that the line of separation runs so as to leave after delivery a layer of the decidua with portions of the spaces lining the muscular wall, are significant with regard to the regeneration of the mucous membrane. These spaces serve as storehouses of epithelium (for we cannot attribute any secreting function to them during gestation) from which the epithelium is developed in the puerperium to line the interior of the uterus.

After the bag is tapped and its contents withdrawn the following changes occur. The muscular wall contracts and becomes, of course, thicker. The decidua and chorion behave practically as one membrane, and are thrown into a series of wavy folds, which



may become detached<sup>1</sup> at the crests of the waves from the uterine wall. The amnion separates itself in places from the chorion, and is thrown into smaller papillary folds.

We ask now what are the anatomical facts which bear on *the expulsion* of the placenta and membranes? We have at present no sections from this Stage showing the process of expulsion, but there is one anatomical fact which accounts for phenomena observed clinically during it, and gives a basis for its scientific management. It presented itself already in the Second Stage,<sup>2</sup> will occupy our attention again immediately after delivery,<sup>3</sup> and is very significant for the intervening period, *i.e.*, the Third Stage. This fact is the division at the retraction ring of the genital tract into two parts—an upper thick-walled and a lower thin-walled portion, the former playing an active and the latter a passive rôle in labour. So long as the placental mass is above the retraction ring it can be driven onwards by the action of the uterine walls alone; but whenever it passes below this, the abdominal muscles or

Anatomical facts bearing on the expulsion of Placenta and Membranes.

Division of genital tract into an upper and lower portion.

---

<sup>1</sup> This partial separation of the decidua with the chorion is evidently due to the diminution in area of the inner surface of the uterine wall; the muscular wall contracts, and the membranes, not possessing contractility, are crumpled up. The separation of the amnion from the chorion may, I think, be explained by a difference in the elasticity of these membranes, and is by no means a constant occurrence.

<sup>2</sup> See p. 82.

<sup>3</sup> See p. 115.



the action of gravity must be brought into play in order to expel it. This is the important point in the physiology of the expulsion of the placenta and membranes (see Figs. 5 and 6 on pp. 112, 113).

Bearing of position of Placenta on its manner of expulsion.

A second and less important point is that, from the way in which the placenta lies in the uterus, it will come out with its edge (or a point not very far distant from the edge) first, if the placenta has

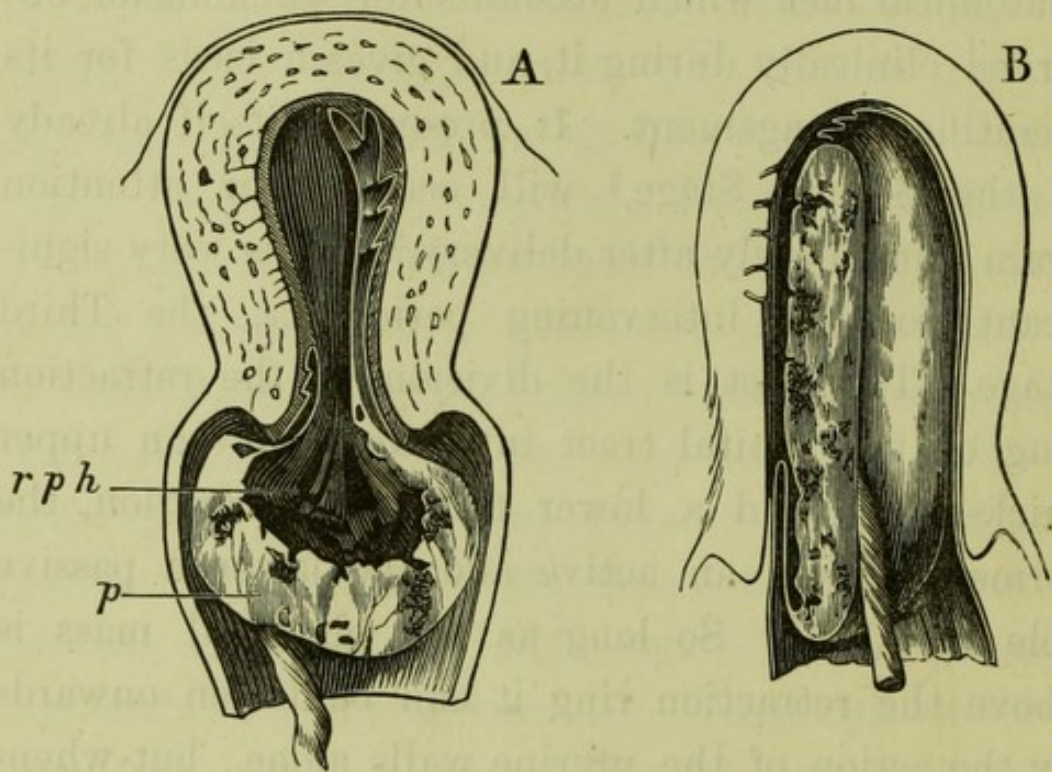


FIG. 3.

#### TWO MODES OF PRESENTATION OF THE PLACENTA.

- A. That described by Schultze in which the placenta descends inverted—the foetal surface coming first; *p* placenta, *rph* retro-placental hæmorrhage.
- B. That described by Matthews Duncan in which the edge of the placenta comes first.

been implanted on either of the walls; but should its insertion have been over the fundus, it will come out with its foetal surface first.



We have in the III.-Stage uterus a pressure acting equally all round above, and a line or area of less resistance corresponding to the space within the retraction ring. When the pressure operates it will, in the first instance, tell most on that portion of the placenta which is in the line of least resistance: hence with a placenta situated on one of the uterine walls, the edge or a point on the foetal surface not very distant from it will form the presenting part, and the placenta will descend not at all or only partially inverted (Fig. III. B); should, however, the placenta be over the fundus, a more or less central point on the foetal surface will be opposite to the line of least resistance and thus come to present, and the placenta will descend entirely inverted (FIG. III. A).

Turning now to the membranes, we note that they do not offer a mass sufficient to be acted on by the expelling power; and they are delivered by the placenta's dragging them after it. The ease with which the chorion tears and the looseness of its attachment to the amnion are the important anatomical points with regard to the delivery of these structures, because the former membrane can thus easily break away from the bulkier placental mass and be left in whole or in part in the uterus.

The expulsion  
of the  
Membranes.

We pass now from the anatomical and physiological facts in connection with the Third Stage to look at their bearing on clinical work, and especially on the management of this Stage. Supposing then that we lay the hand on the abdomen immediately after the

Bearing of  
anatomical and  
physiological  
data on Clinical  
Work: Man-  
agement of the  
Third Stage.



delivery of the child, we find the uterus as a body measuring three to three and a half inches thick antero-posteriorly, and from nine to nine and a half inches vertically, rounded and firm at its upper end but not defined below, and freely moveable in the lower part of the abdomen. It is firm and well-defined above, because the uterine walls have retracted till they are from half-an-inch to one inch thick, and there is nothing between them but placenta and membranes and perhaps some blood.

Time of  
separation of  
Placenta.

The placenta is probably not yet separated, or only its lower border; for, as has been already said, the evidence from sectional anatomy is that the placenta is not separated during the second stage of labour.

It is true that the sections published from that stage belong to its earlier half; and it is quite possible that others made at its termination may show a different state of affairs. But the evidence at present justifies the assumption that at the end of the second stage we have the placenta attached to the uterine wall as at the commencement of labour. From the purely clinical standpoint it has, however, been taken for granted by many that the placenta begins to be separated when the child is being born. Of this no proof has been advanced. The only clinical fact apparently supporting it is the appearance of asphyxia in the child if it lies for a little with only the head born. But the interference with the placental circulation which this asphyxia implies, may be due to compression of the cord, or to disturbance in the circulation of the placental site from uterine contraction and retraction; and the fact that there is no danger from bleeding during the second stage (for



it is from the site of a detached placental lobule that the dreaded bleeding in labour comes) points to the absence of separation.

In managing the Third Stage we therefore wait for some time without interference, to allow the exhausted uterine muscle (exhausted by the expulsion of the child) to regain its power, and to give time for the natural separation of the placenta to be effected. During this period all that we do—and this is only necessary where hæmorrhage is feared—is to keep the hand on the uterus. We can thus tell at once, from the data given above as to what the size of the uterus should be, whether its cavity is becoming distended with blood; and, further, the stimulus of the hand favours contraction and consequent retraction.

How to aid  
Nature in the  
delivery of the  
Placenta and  
Membranes.

After *waiting twenty minutes* or so for the natural separation and expulsion to take place, and (should it not have occurred) keeping in mind the physiological method, we aid nature in the following way. Should the placenta be in the upper part of the canal we stimulate the uterine muscle into more active contraction by rubbing or kneading the fundus gently. If this fails we squeeze the placenta out by compressing the uterus. Getting a good antero-posterior grasp of it with one or both hands we act on the placental mass within in much the same way as the uterine walls do when they are contracting efficiently. Compression must not be too sudden or forcible, lest we shoot out the bulky placenta,



tearing it from the membranes and leaving them behind.

Should the placenta be in the lower part of the genital tract, we have to push the mass downwards in the axis of the cavity and outlet. The

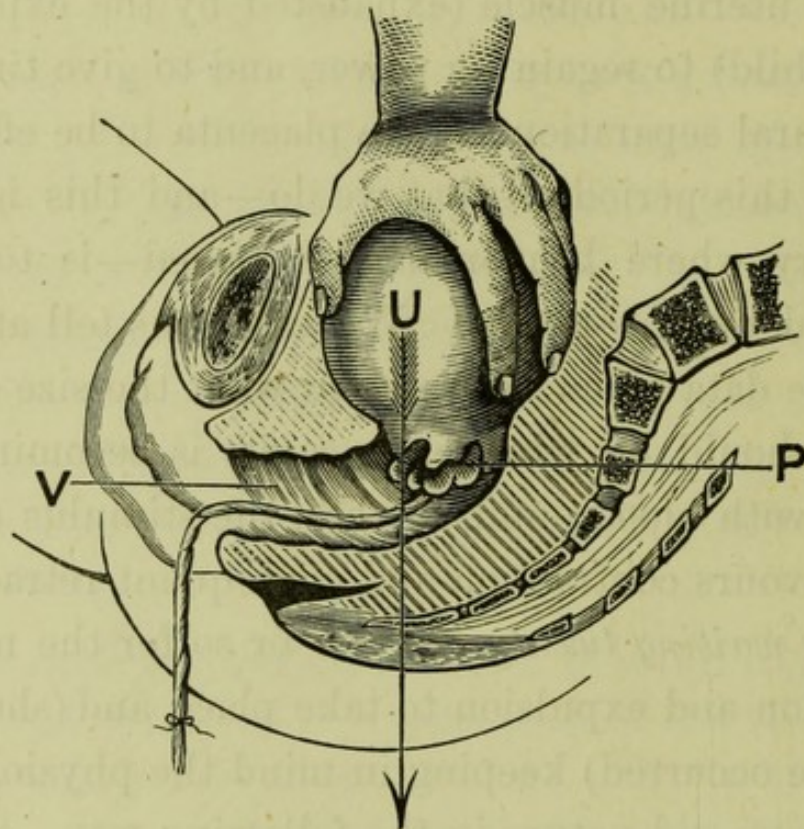


FIG. 4.

#### MANAGEMENT OF THE THIRD STAGE.<sup>1</sup>

The position of the hand shows how the uterus is to be grasped while the placenta is still within it.

The arrow shows the direction in which pressure is to be made when the placenta has passed below the retraction ring.

hand laid on the abdomen feels low down a soft mass becoming conical and firmer above. Grasping the firmer part (*i.e.*, the retracted portion, now empty)

<sup>1</sup> This figure is taken from Cr  d  's paper, although we do not in all points accept the method of delivering the placenta advocated by him.



and pushing with it downwards and backwards, we make the placenta move onwards (Fig. 4).

Should the placenta have come still further down and be lying entirely in the vagina, pressure above the brim (while the perineum is hooked back with the finger) will make it slip out.

The membranes, as already said, are dragged out by the placenta. If additional traction on them is necessary, it should be made by running the fingers along the rope formed by twisting them, and pressing it downwards and backwards so as to pull in the direction of the uterine canal.



## CHAPTER VI.

### AFTER LABOUR: THE PUERPERIUM.

Application  
of term  
Puerperium.

LABOUR ends when the placenta and membranes lie outside of the vulva. We have the uterus emptied of its contents and stripped of the membranes that lined it in pregnancy (with the exception of a thin layer of the decidua), the cervix stretched and lacerated, the vagina also stretched, and the perineum torn. The healing of the raw surfaces and the return of the hypertrophied uterus (after the work of labour is done) almost to the size which it had before the ovum began to grow within it with the restoration of its mucous-membrane lining, constitute a process occupying a period of about six weeks to which the name "puerperium" has been given. It is labour, therefore, *plus the puerperium* that undoes the changes of pregnancy. Over-against the nine months' "evolution" of pregnancy we have to place not merely the few hours of labour but these *plus* the six weeks' "involution" of the puerperium.

Though scientifically the Puerperium does not end until the placental site is no longer recognisable and the uterus is completely involuted, which does not occur before the six weeks are ended, yet practically



we make the puerperium terminate earlier—when, in fact, the patient is able to go about again; and its interest chiefly gathers round the changes of the first ten days.

From this period there have been recently<sup>1</sup> published three frozen sections by Stratz,<sup>2</sup> and myself;<sup>3</sup> two of which are within a few hours after delivery, and the third within 5½ days. To relieve the text from a mass of detail, I have thrown the facts with regard to these sections into a tabular form.<sup>4</sup>

On comparing the two frozen sections made immediately after delivery (*v.* Figs. 5 and 6), we observe the curious fact that they are from the opposite types of pelvic deformity which produce, respectively, a very short and a very long conjugate. In Stratz's Section we see a rickety pelvis with a conjugate shortened to 3·2 in., while in my own one we have a kyphotic pelvis with a conjugate lengthened to 6·6 in. The fact of the abnormality of the pelvis<sup>5</sup> must be kept

Frozen

Sections from  
this period.Sections made  
immediately  
after delivery.

---

<sup>1</sup> Legendre and Pirogoff also give frozen sections (see Part II. pp. 57 and 58), but they do not exhibit the anatomical detail necessary for our purpose.

<sup>2</sup> See Part II. p. 72.

<sup>3</sup> Reproduced in the Author's *Atlas of the Anatomy of Labour etc.*, Pl. x. fig. 1, and Pl. xi.

<sup>4</sup> See p. 148.

<sup>5</sup> In the rickety pelvis, the promontory stands low and the sacrum passes more horizontally backwards than in the normal; in the kyphotic one, the promontory stands high and the sacrum slopes more vertically downwards. Further, the symphysis pubis runs more horizontally backwards (in the erect posture,—down-



in mind when we are judging of the relation of structures; in each of these sections we see that the peculiar position of the promontory not only affects the relation of organs to the conjugate of the brim but has

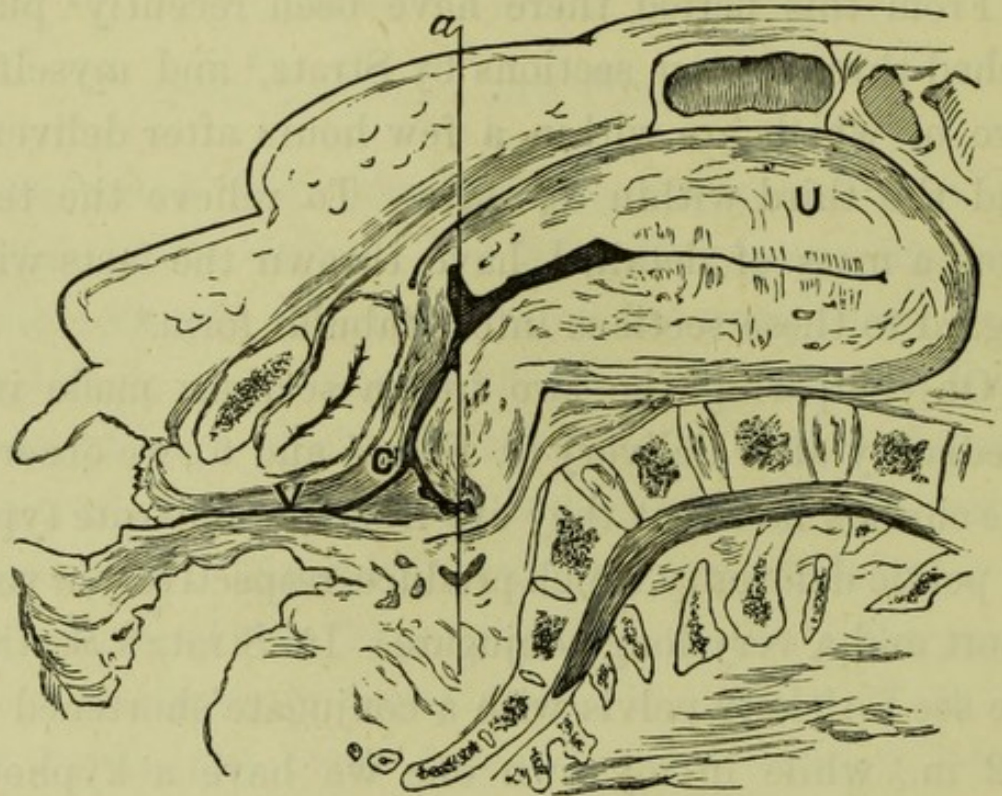


FIG. 5.

STRATZ'S FROZEN SECTION MADE IMMEDIATELY AFTER DELIVERY ( $\frac{1}{4}$ ).

Position of pelvis and letters as in Fig. 6. Note the thinness of the walls of the canal below *a*. The horizontal direction of the vagina (vertical, of course, were the body erect) is abnormal, being due to the fact that the projection of the rickety promontory has kept the uterus high in the abdomen and the walls of the canal below taut.

actually displaced them. Thus, in Stratz's Section, the vertical direction of the vagina and rectum, with the stretched meso-rectum, points to upward traction on the pelvic organs due to the contracted brim's keeping

---

wards in Fig. 6), in the kyphotic which has the effect of relatively lowering its upper edge.



the uterus up and almost entirely out of the pelvis; conversely, in my section, the high-standing promontory, with the long inclined plane of the sacrum sloping down from it, has favoured the sliding down

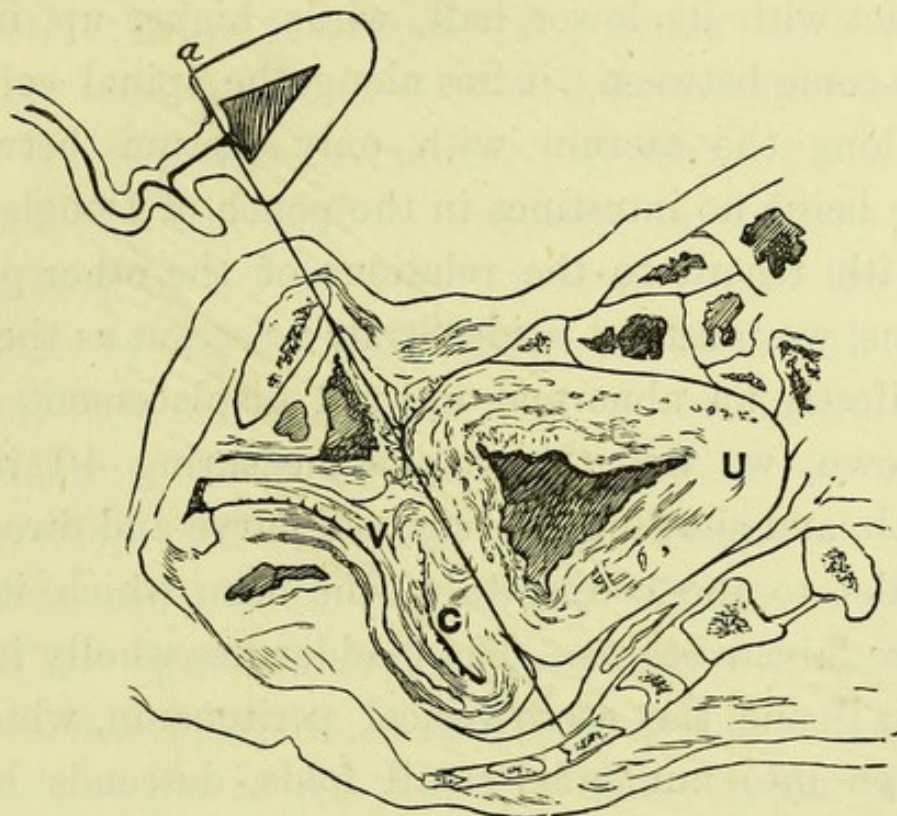


FIG. 6.

FROZEN SECTION MADE IMMEDIATELY AFTER DELIVERY ( $\frac{1}{4}$ ).

The section shows the pelvis and lower part of the abdomen. The body is in the dorsal posture, with the promontory of the sacrum to the right and below, and the symphysis pubis to the left and above. The genital canal falls into two portions at the line *a* (see p. 115). *U* is on the firm, thick, contracted portion; *C* on a fold of canal below; *V* on vagina. Note the folding and doubling up of the canal at and below *a*, showing its limpness. The small diagram to the left, representing the genital tract alone, is intended to make clear this special point.

of the uterus into the pelvis and the doubling up of the flaccid lower segment. We are now in a position to compare the anatomical facts exhibited in these two sections and given in the table (p. 148).

The Uterus stands with its fundus above the



Relations of  
Uterus.

symphysis, in the first case 8 in. and in the second 5·7 in.; but, in the latter case, it has been shortened rather more than 2 in. by the folding up of its flaccid portion. It has, in front, the abdominal wall in contact with its lower half, while, higher up, intestines come between; it lies along the spinal column or along the sacrum with only rectum between, there being no intestines in the pouch of Douglas.

Other pelvic  
organs.

With regard to the relations of the other pelvic organs, we must set aside Stratz's Section as there is manifestly an abnormal upward displacement. In my own, we find the vagina measuring 4·1 in. in length, and showing the sigmoid curve and direction parallel to the conjugate of the brim which it has before labour begins. The bladder lies wholly in the pelvis;<sup>1</sup> and the utero-vesical peritoneum, which is thrown into numerous small folds, descends below the brim. The intestines do not descend into either the utero-vesical pouch or pouch of Douglas.

Cellular  
tissue.

There is a considerable patch of cellular tissue, measuring ·8 in. vertically and from ·2 in. to ·5 in. antero-posteriorly between the cervix and the bladder. To ascertain the relations of the cellular tissue at the sides of the uterus I made three cross sections—one in the plane of the brim, a second in the cavity of the pelvis, and a third parallel to the latter but one inch lower down. These show a great increase

---

<sup>1</sup> As also in Le Gendre's and Pirogoff's Sections—Part II. pp. 57, 58.



in the cellular tissue at the base of the broad ligament (which is an inch in breadth) and round the posterior fornix.

Returning now to the uterus itself, we find that, in both sections, it consists of a firmer thick-walled portion and a flaccid thin-walled one (the separation between these is indicated by the line *a* in Figs. 5 and 6); and that it measures, in the one case,<sup>1</sup> 9 in. long by 3·1 in. antero-posteriorly, in the other 5·3 in. by 3·5 in.—the difference in length being chiefly due to the doubling up of the flaccid lower segment in the latter case. The vertical circumference (measured along the middle line of the wall) is 19 in. and 14·5 in. respectively. Before comparing these last figures with the circumference of 24–26 in. before labour,<sup>2</sup> we must deduct from them the length of both walls of the cervix. This, in the case of Stratz's Section, leaves 15½ in. If other sections should show that these figures give a fair average circumference before and after labour, we have the uterine walls shortened in labour, as the result of retraction, by one-third. Further, in Stratz's Section, we see that the flaccid portion is relatively much longer anteriorly (3·4 in.) than posteriorly (1·4 in.), the retraction ring standing higher in front than behind.

The anterior and posterior walls are, in Stratz's Section, on the whole of about the same thickness

Uterus in  
detail—form  
and  
dimensions.

<sup>1</sup> Stratz's Section.

<sup>2</sup> See p. 15.



( $1\frac{1}{2}$  in.) in their upper half, the posterior being the bulkier; they thin to rather less than an inch ( $\cdot 9$  in.) where they unite at the fundus, and also in their lower half—the anterior being  $\cdot 8$  in. and the posterior 1 in. at the retraction ring. In my section the thinness at the fundus is not present, the wall there being 1·2 in. thick; but both walls thin as we pass downwards to the flaccid portion, where the anterior reaches  $\cdot 5$  in. and the posterior  $\cdot 75$  in.

Section made  
 $5\frac{1}{2}$  days after  
delivery.

Passing now from the uterus a few hours after delivery to that  $5\frac{1}{2}$  days after,<sup>1</sup> we find a remarkable change in its position and appearance. We have in this case to do with a normal pelvis and, therefore, we may accept the results—the only qualification being that we are dealing with but one specimen.

Relations of  
uterus.

The uterus lies almost entirely in the pelvis with its fundus only  $\cdot 4$  in. above the brim; but, owing to the obliquity of the latter, this gives a height above the symphysis of 3 in., so that the uterus could be palpated through the lower region of the abdomen for that distance. It has the abdominal wall touching it for 2 inches, there being no intestines between; and it lies along the sacrum, so that there are no intestines in the pouch of Douglas.

Vagina.

The vagina is 2·6 in. long and runs parallel to the conjugate of the brim; its rugæ are very well marked,

---

<sup>1</sup> Author's *Atlas of Anatomy of Labour, etc.*, Pl. XI.



producing a distinctly crenated appearance in section—the perineal tear is a raw surface measuring .6 in. by .7 in. The empty bladder is in the pelvis, and the utero-vesical peritoneum descends 2 inches below the brim.

The appearance of the uterus as a whole differs from that found immediately after delivery, there being no indication of its separation into two parts—a firm and a flaccid one; and the contour resembles much more that of the non-pregnant organ. It is 5.5 in. long and 3.7 in. antero-posteriorly, and has a cavity 4.5 in. in length. The exact measurements of the walls are 1.5 in. to 1.75 in. thick anteriorly, 1 in. at fundus, and 1.25 in. to 1.5 in. posteriorly; they do not become distinctly thinner before passing into the cervix.

Uterus in  
detail.

In addition to the frozen sections of the cadaver, there have been recently described post-partum uteri removed from the body with the special purpose of determining the extent and nature of the flaccid lower segment of the uterus. It is evident that, for the examination of its surface, the uterus must be laid open instead of being merely sliced through as in a frozen section; and, further, for microscopic examination, the tissue must be specially prepared, since the process of immediately freezing fresh tissues without the use of hardening fluids makes them unfit for fine microscopic work. The description of

Examination  
of uteri re-  
moved from  
the body.



these in detail, we have also thrown into a tabular form. The table<sup>1</sup> will be found on pages 150 to 159.

The first four columns give period after delivery, name of reporter, history of case, and nature of preparation: these last two are very important, for the character of the labour and the cause of death affect the condition of the uterus, and spirit preparations give different results from those of fresh material. The

Attachment of  
peritoneum.

fifth column shows the relations of the peritoneum anteriorly; and on running the eye downwards we see that almost every one has observed that it is not firmly attached over the lower part of the anterior wall but can be easily stripped off up to a "line of firm attachment;" the position of the line (which is unfortunately given in only a few cases) ranges from 2 in. to 4·8 in. above the anterior lip, the latter measurement being in a case of obstructed labour.

Dimensions  
of uterus.

From column six, we learn that the length of the uterus from os externum to outside the fundus varies considerably in different cases during the first days of the puerperium (from 6·5 in. to 8·4 in.), nor can we trace a progressive diminution. We must remember, however, that in the majority of the cases there are present pathological conditions which affect

---

<sup>1</sup> The table does not profess to be exhaustive, as it includes only those reports which came within the scope of my research. The attempt to classify the facts brings out such defects of description that some of the cases seem scarcely worth recording, but it may be of service as indicating the kind of information wanted in the description of such specimens. See also Part II., pp. 58-75.



involution. The next column exhibits the characters of the uterus in detail—its walls and inner surface. With regard to the walls, I have observed in examining post-partum uteri that there is a marked difference between the anterior and posterior walls which makes it desirable that they should be treated separately; and in tabulating the facts I have, where possible, done this.

We take from the table (supplemented by Literature in Part II., pp. 58-75), the measurements of the anterior and posterior walls where these are given. Difference in walls.

CASE 1. Flaccid portion is 3 in. long or of more than one-third of the length of the whole anterior wall, and .3 in. thick or one-third of the thickness of thickest part of wall above.

CASE 2. Flaccid portion is 2.3 in. long, and .4 in. thick or one-fourth of the thickness of the wall above.

CASE 3. Flaccid portion is 2 in. long or less than one-fourth of the length of the whole anterior wall, and about one-third of the thickness of the wall above.

The posterior wall is not described in Case 2. In Case 1 it is of pretty uniform thickness throughout; with the exception of a cleft about two-fifths of an inch above the point where cervical mucous membrane ends, in which cleft it thins to nearly one-half and then thickens again as quickly. Case 3 also shows, immediately above the limit of the cervical mucous membrane, a cleft in which the wall thins to one-half.

CASE 7. The flaccid portion measures 4.8 in. in length anteriorly and rather less posteriorly, being rather



more than half the length of the uterus. Anteriorly it is one-sixth of the thickness of the wall above (placental site), posteriorly it is an eighth.

CASE 8. The flaccid portion is equally long on both walls (4·8 in.) and more than one-half of the length of the uterus; in the cervical part it is ·6 in. thick but higher up only ·4 in. or in front, one-third the thickness of the wall above and, behind, one-fourth.

CASE 11. The flaccid portion is 3·6 in. long or almost one-half of the length of the wall of the uterus, and (above the cervix) in front one-third but behind more than one-half of the thickness of the wall above.

CASE 12. Flaccid portion is, anteriorly, 4 in. long or rather less than one-half of whole length of wall; and ·8 in. thick or less than one-half of thickness of part above. The posterior wall was ruptured in its cervical portion.

CASE 13. The thinner portion measures on the anterior wall 3 in. and on the posterior  $2\frac{1}{2}$  in. in length, or rather more than one-third of the length of the whole wall in case of the former, rather less than one-third in the latter; both are about one-half the thickness of the wall above.

CASE 15. The flaccid portion of anterior wall is 4·5 in. long or more than half the length of the part above, and ·3 in. thick or less than one-third of the thickness of wall above. The posterior wall is rather thicker (·7 in.) in its lower third than in its upper two-thirds (where the placenta was situated).

CASE 16. We have a portion of the anterior wall one-half the thickness of the wall above.

CASE 17. Anteriorly, there is a thinner portion immediately above the cervix.

We may sum up these results with regard to the



walls in the following general statement:—That the anterior and posterior walls of the uterus present during the first days of the puerperium a different appearance in section, the anterior thinning in its lower third or fourth somewhat suddenly so as to be only one-third or one-fourth of the thickness of the wall above; while the posterior either does not thin at all or does so more gradually, or if there is a sudden thinning (*v.* Fig. 5), it is immediately above the cervical canal; and, further, the peritoneum can be stripped off the anterior<sup>1</sup> wall up to that line where the wall suddenly thickens. The differentiation of the anterior wall into two parts is more noticeable in cases where labour has been unduly prolonged.

We now proceed to the examination of the inner Inner surface. surface of the lower portion of the uterus, with which the facts noted in our table chiefly deal. But before doing this, and that we may be in a position to appreciate its peculiarities, we must look at the surface of the uterus generally. And here we touch on questions in regard to which there has been and still is difference of opinion; as these deal with microscopic features and post-mortem changes take place rapidly here, it is not to be wondered at that various conclusions have been come to.

---

<sup>1</sup> Attention has not been directed to the peritoneum posteriorly. I have noted that, while loosely attached below, it cannot be stripped off to a line of firm attachment as distinctly as on the anterior wall, and that it is closely united far down in the middle line.



Before considering these, we must give a rough sketch of the naked-eye appearance which a post-partum uterus presents when laid open.<sup>1</sup>

Naked-eye  
appearance.

Resembling in form a pear sliced through the middle or a balloon without the car, it is seen to consist above of a broad almost circular area (the expanse of the two walls measuring 7 in. across and  $5\frac{1}{2}$  in. from above downwards), which passes below into a band about 4 in. wide and 2 in. vertically. This band is the opened-out cervix and we see that it is of a bluish-red colour (due to numerous ecchymoses), and, save for the stem and branches of the arbor vitæ, has a comparatively smooth surface; its lower border, where it abuts on the pale vagina, is broken by a deep wedge-shaped cleft and numerous smaller fissures. The wider and somewhat circular area above the thrown-back zone of the cervix consists of two parts—a ragged and dark-purple patch about one-sixth of the whole in size (and having shreds of blood-clot hanging from it), surrounded by a brick-red surface mottled with numerous tags. The former is the placental site, the latter the decidua-covered part of the uterus. On scrutinising this latter surface, we see that its appearance is not quite uniform—the lower fourth being paler and somewhat smoother than the rest, through having shorter and scantier tags.

---

<sup>1</sup> Based on two uteri—from a case of phthisis that died two days after delivery, and a case of convulsions that died four days after.



Passing now to the microscopic examination of the inner surface we come to the debateable ground referred to. Microscopic examination.

Wm. Hunter, who in many points anticipated the results of more recent microscopical investigation, described the post-partum uterus as lined by a "stratum" of the decidua membrane which had been left upon it after the delivery of the rest of the membranes.<sup>1</sup> Matthews Duncan<sup>2</sup> supported this view of Hunter's against that of Cruveilhier and Heschl who believed that the uterus was laid bare down to the muscle; and Priestley found the remains of the uterine glands in the post-partum uterus. It is however to Friedländer, Kundrat and Engelmann, Langhans, Leopold, Küstner, Turner and other recent workers,<sup>3</sup> that we are indebted for detailed descriptions of the membranes and what is left inside the uterus after delivery. Historical Note.

We saw that the innermost membrane, *i.e.* the one next the uterine wall, is decidua—which we may regard as "at once the outside membrane of the secundines and the internal membrane of the uterus." Being simply the mucous membrane of the uterus hypertrophied during the early months and then atrophied through the pressure of the growing ovum, it consists of the original uterine glands imbedded in characteristic cells.<sup>4</sup> In the middle months of pregnancy, the glands are distinctly seen in the lower stratum of the decidua giving it a honeycombed appearance in section; whence the name 'spongy' Decidua.

<sup>1</sup> See Part II. p. 4.

<sup>2</sup> See Part II. p. 56.

<sup>3</sup> See Part II. pp. 37-39.

<sup>4</sup> See p. 21.



applied to it in contradistinction to the 'compact' layer above. There is difference of opinion as to which of these strata is torn through. Some have found the tear in the compact layer; others, finding it in the spongy one, have regarded the sponginess as mechanically favouring the tearing-through; and others have failed to find anywhere any spongy layer at all at full time. The fact seems to be that the membranes tear through at one time in one plane of the decidua, at another time in another, but always so as to leave a 'stratum' of decidua on the muscular wall; and that the significance of the gland spaces, even if abundant enough to give a distinctive 'spongy' character to one part of the decidua, is only vital and not mechanical. The reason for the persistence of the original uterine glands throughout pregnancy is to serve as storehouses from which the epithelium may be served out to form the new mucous lining of the uterus after delivery.

Decidua over  
the lower  
segment.

The facts in the column of our table dealing with the surface relate to the difference between the decidua found over the Lower Segment of the uterus and that higher up—a question which bears on the nature and origin of that segment. Running our eye over the table we observe that, in the cases in which the surface of the posterior wall has been examined by itself, cervical mucous membrane is continuous with typical decidua; on the anterior wall and also in cases in which a description not distinguishing the



walls is given, we find above the cervical surface an area which is smoother and has shorter and scantier tags of torn-through tissue, and sometimes ridges not unlike those of the arbor vitae. Microscopic examination, whether of scrapings or of sections of this area, show that we have here undoubtedly decidua, and with the following characteristics:—the gland spaces are scantier and sometimes more elongated than the decidua further up, and the decidual cells are also smaller. In a few cases, an epithelium like that of the glands has been found on the free surface of the section. From these peculiarities the term 'transitional' has been applied to this epithelium, *i.e.* transitional between cervical mucous membrane and decidua: but this has been done on insufficient grounds, for although the decidual cells of the Lower Segment are smaller than those above, there is no sufficient evidence that they are metamorphosed from cervical tissue, and the epithelium of the glands is uterine not cervical in character. The presence of a surface epithelium is noteworthy. It has been found in only a limited number of cases.<sup>1</sup> We have no data for saying whether it is the new epithelium grown in the puerperium; or whether it was present during pregnancy; nor for saying whether its occurrence is physiological or pathological.<sup>2</sup>

---

<sup>1</sup> See also Lower Uterine Segment before Labour, p. 35.

<sup>2</sup> Its exceptional occurrence points to this latter. May there not



Application of  
anatomical  
facts to clinical  
work.

Position and  
size of uterus  
immediately  
after delivery.

Let us now apply the anatomical facts just learned to clinical work. It is to Sectional Anatomy that we must look for data as to the length of the uterus (both of the whole organ and of its cavity) at various periods after delivery, and as to its height in the abdomen. The length of its cavity on successive days of the puerperium has been measured by the sound; but the results got by this means are variable, owing to the irregularities in the cavity of the post-partum uterus. The size of the uterus has also been inferred from its height above the symphysis measured by callipers; but the two frozen Sections immediately after delivery show us how materially its height is affected by the character of the pelvis and the condition of the Lower Segment. As we have so few sections, we can only state the conditions found in them severally.

After delivery, we have, in Case 1, with a cavity of 8 inches and a total length of about 9 in., a height above the symphysis of 8 in.; and in Case 2, with a total length of 5·4 in., a height above the symphysis of 5·6 in.

Taking along with the two frozen sections immediately after delivery the first uteri in the table (*v.* pp. 150, 152), we find the average length of the uterus to be approximately 8 in., the cavity being 1 in. shorter. Further, it is owing to the flexibility of

---

be in inflammatory conditions an extension of a degenerated cervical epithelium upwards into the interior of the uterus, analogous to the downward extension familiar as 'erosion' in cervical catarrh?



the flaccid portion that the firm body, which lies immediately beneath the abdominal wall, can be moved about easily in the abdomen.

If we add 4 inches for the length of the vagina, we have from vulva to fundus a canal 11 in. long: it follows approximately the curve of the pelvis, and has its walls in apposition throughout (unless separated by blood-clot)—the successive portions of the genital tract coming into apposition from above downwards as the contents are removed, so that air is present in no part of the tract during labour or the puerperium.

Length and direction of genital tract.

Therefore, to wash out the uterus for septicæmia in the puerperium we require a tube 11 in. long and with a wide curve (like a prostatic catheter); and, further, the point must be carried up into the retracted portion, or else the fluid will simply distend the flaccid lower segment and go no farther.

Bearing on washing out of uterus.

As we are speaking of septicæmia we may notice in passing what favourable conditions the interior of the post-partum uterus furnishes for the production and absorption of septic material. The breaking-down blood-clot of the placental site and the dead portions of decidua in the uterus are fertile soil for the growth of germs; and the raw surface left over the whole interior of the uterus, the cervix bare of its epithelium and deeply fissured in many places, as well as the torn perineum, greedily absorb through their lymphatics the septic matter thus prepared; or should the thrombi at the placental site themselves

Interior of uterus favourable to septic absorption.



become septic, poisonous material may pass directly into the circulation.

Vagina.

The vagina, after the child and placenta have passed through it, takes up again the form and direction it had before labour and appears only slightly longer. Its walls, which as already said immediately come into apposition, retain their epithelial covering and so do not present raw surfaces for septic absorption if we except the perineal tear which may extend into the posterior wall. The bladder becomes again wholly a pelvic organ. The peritoneum takes up again the disposition it had before pregnancy, descending into the pelvis in front of and also to the sides of the uterus.

Bladder.

Peritoneum  
and cellular  
tissue.

Cellulitis.

The increased amount of cellular tissue is of importance as furnishing a nidus for cellulitis, to which the early days of the puerperium are specially liable.

Uterus five  
days after  
delivery.

About five days after delivery we find the uterus lying almost entirely within the pelvis, its fundus being only  $1\frac{1}{2}$  in. above the brim. Owing to the obliquity of the latter, however, it can be felt through the abdominal wall for 3 in. above the symphysis. Its cavity is 4.5 in. long and the walls about 1 in. in thickness. The differentiation of the Body into an upper portion and a lower segment, which while recognisable in Pregnancy is characteristic of Labour, is now lost; and the uterus, though still much larger, has returned to the form we are familiar with before the ovum begins to grow within it.



## DETAILED DESCRIPTION OF SECTIONS OF THE CASE OF KYPHOTIC PELVIS

REFERRED TO IN THE TEXT,

*Where death took place one-and-a-half hours after delivery.*

### VERTICAL MESIAL SECTION OF PELVIS.<sup>1</sup>

The *post-partum uterus* fills the pelvic cavity. The body is of a pyramidal shape, measuring 4 in. (10 cm.) vertically and 3·8 in. (9·5) across its base. The cervix has been compressed vertically, and flattened out antero-posteriorly and transversely; it measures 1·2 in. (3 cm.) vertically and 2·4–2·8 in. (6·7 cm.) antero-posteriorly; its posterior wall is folded in. The cervical canal bulges outwards in its middle, and this bulging portion has been cut into although the os internum and os externum both lie to the right of the section. The anterior surface of the body of the uterus is in contact with the peritoneum-covered surface of the bladder for 4 in. (1 cm.), the anterior abdominal wall for 1·2 in. (3 cm.), the intestines for 3·2 in. (8 cm.). The posterior surface has intestine touching it for 1·6 in. (4 cm.); below this the peritoneum of the pouch of Douglas extends for 4·4 in. (11 cm.). The uterine walls measure: posterior, 1–1·2 in. (2·5–3 cm.); anterior, 1·2–1·4 in. (3–3·5 cm.) in thickness. The placental site is clearly seen on the anterior wall, which also shows sections of large venous sinuses all through its substance. The uterine cavity is triangular in shape, and measures 2·6 in. (6·5 cm.) vertically, and 2·4 in. (6 cm.) antero-posteriorly; it contains blood-clot. The cervical canal has not been cut into except in its folded middle portion.

The *vagina* measures 4·2 in. (10·5 cm.) in length. The walls are slightly folded, especially the anterior, and are in close apposition.

The *bladder* contains a little urine. It is triangular in shape, with the apex forwards and the base in a line with the urethra. The superior and posterior walls are thicker (1·8 cm.) than that behind the pubes (·2–·3 cm.). The urethra is 1·2 in. (3 cm.) long, and its walls are thickened.

The *peritoneum* is not thrown into folds over the uterus, but is markedly folded over the bladder and anterior abdominal wall.

<sup>1</sup> Reproduced in the Author's *Atlas of the Anatomy of Labour etc.*, Pl. x.



The utero-vesical pouch has its walls in apposition throughout. The pouch of Douglas extends to the level of the first coccygeal vertebra, and contains some serum in its upper part.

The *cellular tissue* between the uterus and bladder is increased in amount. The retro-pubic tissue is flattened out over the pubes; it contains a large vein. The cellular tissue between the rectum and posterior vaginal wall is also apparently increased in amount.

#### OBLIQUE ANTERO-POSTERIOR SECTION MADE AT THE LEVEL OF THE BRIM OF THE PELVIS.

The *ovary* is folded on itself at 1 in. (2·5 cm.) from its distal (non-uterine) end; when unfolded, it measures 1·5 in. (3·8 cm.) in length. Thus folded it lies antero-posteriorly, and is moulded between the uterus and the side-wall of the pelvis. The *fallopian tube* curves round the anterior convexity of the fold, and has been cut obliquely near the fimbriated end.

#### ANTERO-POSTERIOR HORIZONTAL SECTION OF LEFT HALF OF PELVIS, MADE IN THE CAVITY.

The *peritoneum* on the surface of the bladder is well shown. As its distribution here was not made out till the section was thawed, we did not observe whether the corrugations were present—as seen in the vertical mesial section. The peritoneum of the pouch of Douglas comes forward to a point opposite the centre of the acetabulum. The distance between its reflection here and that of the utero-vesical pouch is 1·2 in. (3 cm.); this corresponds to the base of the broad ligament and consists of loose *cellular tissue*. This loose tissue extends backwards as a thin layer, outside the peritoneum, as far as the rectum; and forwards to behind the symphysis.

#### ANTERO-POSTERIOR SECTION OF LEFT HALF OF PELVIS, MADE PARALLEL TO THE LAST BUT ONE INCH LOWER DOWN.

The *peritoneum* of the pouch of Douglas is seen—the layers separated by a little serum. The *cellular tissue* round the lateral fornix is very abundant, and passes backwards alongside of the rectum; this is therefore the downward prolongation of the tissue of the utero-sacral ligaments. This deposit is the “parametric tissue” of Virchow.



## DETAILED DESCRIPTION OF THE SECTION OF THE I.-PARA

REFERRED TO IN THE TEXT,

*Who died from sewer-gas poisoning five-and-a-half days after delivery.*<sup>1</sup>

I was called to see this case three days after delivery. She was suffering from severe vomiting and diarrhoea, with a constant temperature of about 102°. There were no physical signs of pelvic inflammation, and she died from collapse five-and-a-half days after delivery.

Body was frozen in the dorsal posture. The section is perfectly mesial, passing through the symphysis and tip of the coccyx, and dividing the urethra throughout its course. The pelvis is normal and roomy, with a conjugate at the brim of  $4\frac{1}{8}$  inches (10·3 cm.), and at the outlet of  $4\frac{3}{4}$  inches (11·9 cm.).

The *uterus* lies almost entirely in the pelvis, the highest point of the fundus being  $1\frac{3}{8}$  inches above the brim; but while projecting so little beyond the brim, it could be felt through a considerable portion of the lower part of the abdomen, its highest point standing at the level of the promontory or 3 in. (7·5 cm.) above the pubes. The abdominal wall is for 2 in. (5 cm.) in contact with the fundus, there being no intestines between. The *utero-vesical* fold of peritoneum is 2 inches below the brim, and opposite to the lower third of the symphysis. The *pouch of Douglas*, which comes down just to the level of the posterior fornix, is opposite to the junction of the first and second coccygeal vertebrae; it contains no intestines. The *bladder* lies at the lower third of the pelvis, and has a Y-shape with a very short posterior limb. The *urethra*, which is divided throughout, measures  $1\frac{5}{8}$  inch (4 cm.). The *vagina*, which is  $2\frac{5}{8}$  inches (6·5 cm.) long, runs parallel to the plane of the brim. The rugæ are very well marked, producing a distinctly crenated appearance. The left labium minus has been drawn aside to show the vaginal orifice and extent of perineal tear, the raw surface measuring  $\frac{5}{8}$  in. (1·5 cm.) antero-posteriorly and  $\frac{6}{8}$  in. (1·8 cm.) vertically. The

---

<sup>1</sup> This section is published in the Author's *Atlas of the Anatomy of Labour, etc.*, Pl. XI.



uterine walls measure anteriorly  $1\frac{1}{2}$  to  $1\frac{3}{4}$  inch (3.75 cm.) thick ; at fundus, 1.1 inch (2.75 cm.); posteriorly,  $1\frac{1}{4}$  to  $1\frac{1}{2}$  inch (3.1 cm. to 3.75 cm.).

The *placenta* was situated over the fundus. To the naked eye there is no trace of a lower uterine segment, the anterior wall being of nearly equal thickness throughout.



## NOTES AND TABLES TO CHAPS. I. TO VI.

	PAGES
TABLE 1. Cervical Canal and Lower Uterine Segment during Gestation . . . . .	134-141
NOTE A. Küstner's view of the Lower Uterine Segment .	142
NOTE B. Statement and Criticism on Bayer's view of the Lower Uterine Segment . . . . .	143
TABLE 2. Frozen Sections from the Puerperium . .	148
TABLE 3. Uteri described from the Puerperium . .	150



TABLE I.—FACTS NOTED WITH REGARD TO CERVICAL CANAL AND

Month of Gestation.	Reporter.	Length of Canal	Condition of Canal and its Walls.	Attachment of Peritoneum.
4th . . .	BANDL . . .	4.5 cm. . . .	Walls 1.5 cm. thick, showing an internal dense connective tissue layer and an external softer muscular layer.	....
4th . . .	BENCKISER .	5 cm. . . .	Canal gapes somewhat at os externum, then narrows and is sigmoid in section, and not till 1.5 cm. from os internum is dilated by mucous plug, above which it narrows again and then suddenly opens out in uterus. Its mucous membrane, which begins somewhat above os externum, shows numerous recesses, especially midway, and averages .3 cm. thick; where mucous plug is, it is thin and scarcely recognisable to naked eye; but at os internum the mucous-membrane boundary is pronounced, for decidua (.2 to .3 cm. thick) begins with distinct cushion. Walls average 1 cm. thick—the anterior being rather the thicker. Texture closely felted and rich in connective tissue.	Firmly attached before to 3.5 cm., behind to 1.6 cm. from os internum; descends between uterus and bladder to 2.5 cm. from the same; descent posteriorly not determined.
4th . . .	BENCKISER .	. . .	Canal curved with concavity forwards. Its mucous membrane has distinct crypts and is .3 cm. thick as far as 1 cm. above os internum; here it thins, the wall being dilated and filled with mucus, and passing with funnel-shaped dilatation into uterine cavity. Into this funnel projects decidua. Below this decidual cushion is cervical mucous membrane poor in glands. The walls suddenly thicken to 1.5—1.7 cm. at the cervix, which is set on the uterus as a cylinder with equally thick walls. Its texture is entirely different from that of the body, the plate-like structure of which stops at the os internum: while the internal plates cross from anterior to posterior wall, the external ones of the anterior wall go to anterior lip, vaginal wall, and bladder; and those of the posterior go to posterior lip and vaginal wall. The middle plate, interwoven with connective tissue and vessels, form the chief bulk of cervix.	Anteriorly, closely attached to 3.5 cm. from os internum and reflected on bladder at os internum; posteriorly, firmly 3 cm. above os internum and reflected on rectum above posterior fornix.



## LOWER SEGMENT IN UTERI FROM VARIOUS MONTHS OF GESTATION.

## LOWER UTERINE SEGMENT.

Muscular Wall.	Veins.	Decidua.	Attachment of Membranes.
....	....	....	....
Thickness of musculature of body greatest (1.3 cm.) above os internum both before and behind; laminated texture present throughout body. The attempt to separate into plates gave a recognisable but not very marked difference in the size of the muscle-rhomboids of the lower and upper segments, and it was quite impossible to split up the cervical tissue in this manner. Bundles could be followed into the anterior wall of vagina and cervix, and into posterior lip and vaginal wall.	Vessels vary greatly, being numerous at placental site and few in anterior wall—the first large one being in front 2.5 cm. and behind 1.5 cm. above os internum; few in cervix.	Decidua begins at os internum with distinct cushion, and shows characteristic glandular structure. On the posterior wall it passes without change into placenta about 2 cm. above os externum.	Separated over area of half-a-crown. Cavity of amnion shows no foldings at os internum or Fallopian-tube openings.
Thickest just above os internum (1.3 cm. anteriorly and 1 cm. posteriorly); above this it diminishes equally. Average thickness is .8 cm., structure throughout laminated. It is only toward outer surface that we recognise a distinct difference in coherence of lamellae of wall just above os internum and that of rest of uterus: there, the individual plates at their origin from the peritoneum are distinct and easily separable, as they are not above firm attachment of peritoneum.	Vessels most developed at placental site, sparing in anterior wall, frequent as small arteries in cervix, with no circular sinus at firm attachment.	A .3-to-.4-cm.-thick decidua projects into the funnel-shaped dilatation of the cervix: the dilated glands of this give the naked-eye appearance of cervical membrane, but the microscopic characters are those of decidua. Above the decidual cushion at os internum, the decidua thins to .15 or .2 cm.—its average thickness.	Detached above cervical canal over the area of a pennypiece; they appear smooth in frozen section with only slight wrinkles near the os internum, but in the thawed and gradually hardened portion are wrinkled over lower two-thirds of cavity.



## FACTS NOTED WITH REGARD TO CERVICAL CANAL AND LOWER SEGMENT

Month of Gestation.	Reporter.	Length of Canal.	Condition of Canal and its Walls.	Attachment of Peritoneum.
4th . . .	BAYER . . .	4.5 cm. . . .	Canal still intact, upper end not being opened out.	Firm attachment opposite upper end of canal.
5th . . .	BAYER . . .	5 cm. . . .	Starlike knot in lower third of cervix; above this, spindle-shaped figure; and higher up, longitudinal fibres joining large vein with upper end of canal.	1.5 cm. above upper opening of canal.
5½th . .	LANGHANS AND MÜLLER.	4 cm. . . .	Fusiform canal, with upper end .5 cm. across.	....
6th . . .	KÜSTNER . .	2.5 to 3 cm. .	Shows plug of mucus extending into uterine cavity.	....
6th . . .	HOFMEIER . .	Anterior wall, 3.5 cm.; posterior wall, 4 cm.	Upper end expanded to 1.5 cm.; canal filled with mucus.	More than 4.4 cm. above end of canal
7th . . .	BAYER . . .	4.3 cm. . . .	....	6.4 cm. above upper end of canal.
7th . . .	HOFMEIER . .	4 cm. . . .	Firm round cylinder.	5 cm. above end of canal and utero-vesical fold.
7th . . .	HOFMEIER . .	4 cm. . . .	Dilated for .5 cm.	4 to 5 cm. above end of canal.



IN UTERI FROM VARIOUS MONTHS OF GESTATION.—*Continued.*

## LOWER UTERINE SEGMENT.

Muscular Wall.	Veins.	Decidua.	Attachment of Membranes.
Muscular fibre in two layers,—outer passing downwards to anterior fornix; inner, to upper part of wall and canal. 3 cm. above anterior lip is a spindle-shaped figure extending upwards to embrace vein.	Large sinus in section opposite upper end of canal.	True decidua extends to canal.	Vera and reflexa still separate.
Muscular fibres arranged longitudinally, and passing down to upper end of canal and knots in cervix.	Large vein at same level as firm attachment of peritoneum, $1\frac{1}{2}$ cm. above upper opening of canal.	On <i>anterior</i> wall, from canal to attachment of membranes, a thin folded decidua with small trabeculæ, which just at canal becomes compacter, and has continuous surface epithelium. On <i>posterior</i> wall there is, first, cervix-like epithelium on ampullary tissue without decidual elements; then broken-down cervical tissue abutting on typical decidua.	Less firmly attached for some little distance above cervical canal—anteriorly, for 2 cm.; posteriorly, for $1\frac{1}{2}$ cm.
....	....	Same character as in rest of uterus, except septa of spongy layer thinner; where membranes free, decidua thicker and without surface epithelium.	Up to .5 cm. from end of canal.
....	....	Lined in places with surface epithelium. Folds of flat arbor vitæ seen over segment.	2 cm. above end of canal.
....	....	....	Somewhat firm over whole lower segment.
Muscular fibres run longitudinally; thickness of wall (3 cm.), one-half of that higher up (7 cm.).	Veins stop in anterior wall at same level as firm attachment of peritoneum; they come lower down posteriorly.	Tissue unfit for examination, but cervical mucous membrane traced 1 cm. up posterior wall.	Membranes loosely attached anteriorly for same distance as firm attachment of peritoneum (6.4 cm.); not quite so high, posteriorly (5.1 cm.).
Exquisitely laminated structure, and equally thick throughout.	....	Decidua easily separable over whole uterus.	Chorion has been separated throughout from decidua.
Half as thick above end of canal as in rest of uterus. Plate-like arrangement seen distinctly passing into firm fibrous tissue of cervix.	....	....	Less firm over lower segment.



## FACTS NOTED WITH REGARD TO CERVICAL CANAL AND LOWER SEGMENT

Month of Gestation.	Reporter.	Length of Canal.	Condition of Canal and its Walls.	Attachment of Peritoneum.
7th . . .	MARCHAND .	3 cm.	....	....
8th . . .	BANDL . . .	4.5 cm. . . .	Walls 1.5 cm. thick.	About 2 cm. above upper end of segment.
9th . . .	BANDL . . .	3 cm. . . .	....	About 2 cm. above upper end of segment.
9th . . .	HOFMEIER . .	3 to 3.5 cm. .	Canal intact, dilated in middle.	5 cm. above end of canal.
9th . . .	KÜSTNER . .	2 cm. . . .	....	....
9th . . .	SÄNGER . . .	5.5 cm. . . .	Canal dilated, and containing mucus.	....
10th . . .	BAYER . . .	3 cm. . . .	Canal lined by typical mucous membrane, which extended for 1 cm. on the posterior wall of the lower segment.	8 cm. above end of canal.
10th . . .	BAYER . . .	3 cm. . . .	....	6 cm. above end of canal.
10th . . .	BAYER . . .	3 cm. . . .	Undilated, and showing palmæ plicatæ.	7.5 cm. above end of canal.



IN UTERI FROM VARIOUS MONTHS OF GESTATION.—*Continued.*

## LOWER UTERINE SEGMENT.

Muscular Wall.	Veins.	Decidua.	Attachment of Membranes.
....	....	Posteriorly, palmæ plicatæ up to attachment of membranes; anteriorly, thickened decidua.	1.5 cm. above end of canal.
Not well developed. (See also p. 141 at *.)	(See also p. 141 at †.)	(See also p. 141 at †.)	(See also p. 141 at §.)
Lower segment one-third of thickness of rest of uterine wall. (See also p. 141 at *.)	(See also p. 141 at †.)	(See also p. 141 at †.)	(See also p. 141 at §.)
Lower segment four-sevenths of the thickness of the rest.	....	....	Up to cervical canal, but somewhat loosely in lower part.
....	....	Transitional mucous membrane lined with surface epithelium up to attachment of membranes; ciliated cells found; drawn out palmæ plicatæ seen.	2 to 2.5 cm. above end of canal.
....	....	Spongy layer abuts on cervical mucous membrane at end of canal.	Membranes attached up to canal.
Lower segment consists of superimposed plates, separable without difficulty, and outer layer of anterior wall passing down to a knot behind bladder; the plates ending with their free ends towards the mucous membrane on the anterior wall, but towards the external surface on the posterior wall.	Vein not described.	Anteriorly, cervical surface epithelium extends $\frac{1}{2}$ cm. into lower segment, the cells becoming dwarfed; above is transitional mucous membrane of loose texture, with small decidual cells, and glands more numerous below. Posteriorly, for 1 cm., there is typical mucous membrane, which abuts on decidua.	Separated behind for 7 cm.; in front for 2 cm., but can easily be separated for 6 cm. further.
There are plates surrounding the lower uterine segment and springing from a common knot in the substance of the anterior wall. The anterior wall of the lower segment consists of two layers, and the plates of the inner (which can be very easily separated) end with overlapping free ends on the internal surface.	Vein in section at same level as firm attachment of peritoneum.	....	Membranes artificially separated.
....	Large one opposite firm attachment of peritoneum.	The layer over the lower segment is thin.	....



## FACTS NOTED WITH REGARD TO CERVICAL CANAL AND LOWER SEGMENT

Month of Gestation.	Reporter.	Length of Canal.	Condition of Canal and its Walls.	Attachment of Peritoneum.
10th . .	HOFMEIER . .	2·7 c.m. . . .	Funnel-shaped opening-up of upper portion, due either to pathological stretching or commencing pains.	7 cm. above end of dilated canal.
10th . .	HOFMEIER . .	3 cm. . . .	<i>Ibid.</i>	7 cm. above end of dilated canal.
10th . .	BANDL . . . .	3 cm. . . .	Mucous membrane in folds, 4 cm. long.	About 2 cm. above upper end of segment.
10th . .	LUSK . . . .	4½ cm. . . .	Wall hypertrophied and canal containing mucous plug.	....
10th . .	LUSK . . . .	4·5 cm. . . .	<i>Ibid.</i>	....
10th . .	LUSK . . . .	4·5 cm. . . .	<i>Ibid.</i>	....
10th . .	WALDEYER . .	3·8 cm. . . .	Walls 1·8 cm. thick above, and 1 cm. below. Mucous membrane thickens from above downwards.	....
10th . .	MACDONALD . .	3·75 cm. . . .	Walls 1·1 cm. thick.	....
10th . .	MÜLLER . . . .	4·37 cm. . . .	Canal calibre of pencil.	....
Full Time.	LEOPOLD <sup>1</sup> . .	4·75 cm. . . .	Canal undilated.	....

<sup>1</sup> Leopold also describes uteri from other months of gestation, and finds the length of the cervical canal for 4th month (two uteri) 4·5 cm., for 5th month (two uteri) 4 cm., for the 6th and 7th months



IN UTERI FROM VARIOUS MONTHS OF GESTATION.—*Continued.*

## LOWER UTERINE SEGMENT.

Muscular Wall.	Veins.	Decidua.	Attachment of Membranes.
....	....	....	Quite firm from upper end of dilated canal.
8 cm. thick in lower segment, 1 cm. elsewhere.	....	....	Detached over area of several cm. in circumference above upper end of canal.
* Much thinner and softer than the rest of the uterus; shows longitudinal bundles springing from the outer portion of the muscular wall above. These bundles are easily separable and arranged in two layers, of which the external passes to the vagina, the internal ends in the sub-mucous connective tissue and in the vaginal portion of the cervix.	† A few small ones cut across opposite upper end of canal; begin to be numerous again at upper end of segment.	‡ Only in patches over segment; cervical mucous membrane sometimes extends for 2 cm. on to segment.	§ Only exceptionally are they closely attached over the segment, generally by mere spider-threads.
Walls thinner than those of rest of body; but no appreciable difference in mucous membrane or muscular structure.	....	....	Membranes adhere closely to lower segment and borders of internal orifice.
<i>Ibid.</i>	....	....	<i>Ibid.</i>
<i>Ibid.</i>	....	....	<i>Ibid.</i>
Slightly thinner above end of canal.	Large vein opposite upper end of canal, posteriorly.	....	Crosses upper end of canal.
No Bandl's ring.	....	....	Down to very edge of end of canal.
Anterior wall bulges some distance above end of canal.	Vein in section where anterior wall bulges.	Covered with spongy layer.	....
....	....	Decidua flattened, and passing abruptly into cervical mucous membrane at upper end of canal.	Close over os internum.

(three uteri) 5 cm., and from the 8th month (two uteri) 4.5 cm.; in every case he describes the cervical mucous membrane as passing abruptly into decidua at the upper end of the canal.



## NOTE A.

## KÜSTNER'S VIEW OF THE LOWER UTERINE SEGMENT.

We give at p. 65 of Part II. the full statement of Küstner's position. So far as we understand it, it is as follows:—Suppose the front of the hand to represent the inner surface of the uterus—palm representing body of uterus, fingers representing cervix, while skin stands for mucous membrane, and a stimulus applied to it for the growing ovum. The received view is that if the stimulus is applied hypertrophy affects the skin over the whole palm, but stops sharply short at the roots of the fingers; Küstner, on the other hand, holds that the hypertrophy has not thus a constant line of stoppage, but may affect the fingers down to the first joint or stop short before it reaches them at all. In anatomical language, the received view is that the stimulus of the growing ovum causes the mucous membrane of the body of the uterus to hypertrophy into decidua, and that this change extends down to the cervix but stops at *os internum*; Küstner's view is that the change does not necessarily stop there, but that decidua may extend some distance down the cervix or may not reach so far as the cervix at all. His position is intelligible, but it requires proof. Note once more **exactly** what it is: Stimulus produces growth, but the area affected is not constant.

Bayer, to whose paper Note B refers, rejects Küstner's position and adopts so far the accepted view: that the stimulus of the growing ovum radiates over a perfectly well-defined area and stops there. This is the case, he holds, for the first four months of pregnancy; but he further maintains that by that time the growing ovum has dilated the uterus up to the point where the hypertrophied skin ceases, and that, as growth further advances, the formation of decidua gradually extends beyond the original definite limit: the skin of the first joint of the finger (to return to our illustration) hypertrophies. The weak point in this position is that the stimulus which operates on the cervix and makes it form a decidua must be purely mechanical. Granting, for the sake of argument, that the cervix is opened up, it would be merely stretched and nothing more, and this form of stimulus should lead rather to atrophy of mucous membrane than growth.

Briefly contrasting these two views, we may say that hypertrophy



of the cervical mucous membrane before the ovum has begun to distend the cervix (Küstner) is intelligible; but absence of that hypertrophy before dilatation and then production of it afterwards, is unintelligible.

---

### NOTE B.

#### STATEMENT AND CRITICISM OF BAYER'S VIEW OF THE LOWER UTERINE SEGMENT.

Putting on one side Bayer's study of the muscular fibre of the uterus by dissection, in which his results agree pretty much with those of Von Hoffmann and Kreitzer, except that he attaches great importance to the muscular fibres passing into the uterus from the round and utero-sacral ligaments, we look only at his sections.

He takes the arrangement of the cellular tissue between the muscular bundles (the dark colour of which contrasts with the paler muscular fibre) as a key to the musculature. He finds in the lower portion of the anterior wall of the non-pregnant uterus two muscular knots—one at the os internum, the other in the lower third of the cervix. From the former fibres spread over the greater portion of the cervix, from the latter into the substance of the anterior lip and fornix. By these knots the anterior wall of the cervix is differentiated into two zones corresponding to the vaginal and supra-vaginal portions. During pregnancy, the lower knot comes, he says, to stand opposite the upper end of the canal, while the part between it and the upper knot becomes the lower uterine segment.

Now for the proof of this from his pregnant uteri. Under the "*pregnant uterus and the laws of its unfolding*," he describes a beautiful vertical mesial section of a pelvis, with a three months' pregnant uterus; also the uterus alone from fourth, fifth, and seventh months; sections of the lower uterine segment from the ninth and tenth month; and pelvis with uterus at full time. In the third-month uterus, although the homogeneous appearance of the wall prevents our recognising the knots of muscular tissue, he says that we see the action of the utero-sacral ligaments pulling



upwards and backwards the posterior wall as well as the upper part of the anterior. Opposed to this we have the vaginal wall pulling on the lower muscular knot, whence also the ampulla-like dilatation of the cervix. Further, one portion of the round ligament pulls against the utero-sacral, while the other pulls on the lower of the two muscular knots, and causes the ante flexion of the uterus. We see here, he says, the action of the factors which produce the lower uterine segment, viz., the traction of the utero-sacral and round ligaments, and the counter pressure of the ovum. In the fourth month's uterus, he finds the muscular fibre of the anterior wall divided into two layers, of which the outer passes to the lower, the inner to the upper knot. In the fifth month he finds that the knot in connexion with the external layer has not materially moved from its position in the non-pregnant uterus, while the knot at the lower end of the inner layer has moved for a considerable distance upwards. The outer layer has, in fact, been fixed by its firm attachment to the anterior fornix; the inner layer has slid upwards on it. "*The sliding of inner layer upon outer layer governs the whole changes of pregnancy during the early months.*" This is, according to Bayer, a law of the unfolding of the pregnant uterus.

In criticising these statements of Bayer's, the views advanced in his paper should be considered with his drawings of the preparations before us.

In studying the latter, the following points strike us.

(1.) In the unimpregnated uterus, the two knots appear in one line instead of standing the lower at the end of an outer, the upper at the end of an inner layer of muscular fibres.

(2.) In the uterus, at the third month of pregnancy, the knots in the anterior wall are not described; the explanation of the sharp ante flexion of the uterus as due to conjoined action of the utero-sacral and round ligaments is quite intelligible, but the specimen is evidently pathological, and we are not justified in reasoning from it to the condition of a normal uterus at the same period. If, on examining a patient we found the uterus sharply ante flexed, drawn backwards in the pelvis, with the cervix looking downwards and forwards, we should put it down as a case of pregnancy in a retroposed uterus.

(3.) The fourth-month uterus presents the same condition of the cervix as the non-pregnant uterus. The bundles of muscular fibre



seem to embrace the spindle-shaped figure or knot referred to rather than pass into it.

(4.) In the fifth-month uterus, so far as one can judge from the plate, the spindle-shaped figure has the same position at the fifth month as at the fourth, being in both instances opposite the upper end of the cervical canal; the difference between the two is in the vein, which in the fourth month lies in the heart of, in the fifth month some distance above the fusiform figure. As far as the arrangement of muscular fibres goes, we do not see in this preparation any support of Bayer's view; it only seems to show that the relation of the vein to the muscular fibre is not constant.

(5.) In the uteri at the seventh month and onwards we lose sight altogether of the upper muscular knot. Bayer's description of the muscular fibre in the fully formed segment agrees with that of Ruge and Hofmeier, in stating it to be of muscular plates having a general longitudinal arrangement and unlike those in the rest of the uterus in their being more easily separable from each other. He differs from the others, however, in making the layers of unequal length, the shortest being most internal.

The lower uterine segment is thereafter defined only from the firm attachment of the peritoneum and the presence of a large vein. But the fact that the firm attachment of the peritoneum is found at a higher level at the tenth month than at the fifth, cannot be taken as evidence that the upper end of the cervix has moved upwards to a corresponding extent during the same time. For observe that "firm attachment of peritoneum" is not synonymous with "reflexion of peritoneum." If the lower uterine segment were not covered at all with peritoneum that might point in the direction of its being cervical in origin; but it is covered with peritoneum, although the connection is lax. Further, Bayer describes the external layer of muscular fibre lying immediately under the peritoneum as not materially changing its position. The lower knot does not move upwards. It is difficult to understand how the peritoneum, which is separated from the sliding internal layer by the stationary external layer, should yet be carried up along with the former. The position of the coronary vein seems to vary in different uteri. I referred to this in comparing Bayer's fourth and fifth month uteri; and draw attention also to the fact that, while Bayer (like Braune) generally finds it at the upper end of the lower segment, in Waldeyer's section and my own it



is at the lower end; while in many sections it is not mentioned at all.

As to the *mucous membrane* covering the lower segment in the later months of gestation, while describing a transitional membrane on the anterior wall close to the cervical canal, he finds the rest of the segment covered with a true decidua. He regards the change in the mucous membrane as connected with the unfolding of the cervix, but cervical mucous membrane does not produce decidua different from that produced by the body; and the transitional mucous membrane is, therefore, only decidua at a younger stage. His examination of the mucous membrane leads him to the conclusion that the determination of the os internum from the boundary of the mucous membrane is entirely fallacious, and that further investigation along this line is superfluous. In this summary way he ejects from the court, on the ground of being quite untrustworthy, one of the most important witnesses for the opposite side.

But, it will be said, granting that the evidence of the mucous membrane is valid, what do you make of Küstner's transitional mucous membrane? This has only been found *in a limited number of cases*. Küstner and Bayer both find that the layer of surface epithelium ceases where the membranes become adherent. Now, although the microscopic characters of the mucous membrane are not given in the great majority of cases in the table, still I think we are justified in assuming that where the membranes were adherent up to the beginning of the canal this surface epithelium was not present. For we could not have the reflexa blended with vera, and yet surface epithelium present on the latter. Further, not all the cases where the membranes were separated could be described as cases where the surface epithelium was present, for the separation of the membranes may have been artificial. The condition, therefore, described by Küstner we must regard as exceptional; and it is quite possible that it may be pathological.

Further, in the uterus examined by Küstner and Marchand, and from which are taken the microscopical preparations figured in the paper of the latter, the transitional epithelium is not found on the anterior wall of the uterus; which shows a thickened decidual swelling having no surface epithelium. Commenting on this Marchand says, "This circumstance is not prejudicial to the fact that the upper part of the cervix in the later stage of pregnancy takes part in the formation of the uterine cavity; it proves only that



this dilatation (or more correctly, flattening out) of the cervix takes place chiefly at the sides." Bayer, on the other hand, affirms, and in this we think he is right, that the lower segment develops chiefly from the anterior wall; and it is noteworthy that at this very place Marchand finds no transitional formation.



TABLE II.—FROZEN SECTIONS

PERIOD AFTER DELIVERY.	REPORTER.	CLASS OF PRE- PARATION.	HISTORY.	PERITONEUM.	UTERUS AS A WHOLE: LENGTH, POSITION, ETC.
$\frac{1}{2}$ hour.	C. H. STRATZ . .	Body frozen in dorsal posture, 24 hours after death.	I.-para, æt. 28; died from loss of blood with fatty heart.	*Utero-vesical fold 2·3 cm. above brim; fold of Douglas at bend of posterior fornix.	22 cm. long (cavity 20 cm.), and 7·7 cm. ant.-post. It lies in abdomen and pelvis (rachitic, with conjugate of 8 cm.) with its fundus a hand's breadth above the umbilicus, or 20 cm. above the symphysis (the brim being too oblique to measure from); is in contact with abdominal wall up to umbilicus, above which the intestines come between; posteriorly, is in contact with spinal column to cartilage between 2nd and 3rd lumbar vertebræ.
1½ hours.	A. H. F. BARBOUR	Body frozen in dorsal posture, within 3 days after death.	I.-para, æt. 23; death from post-partum hæmorrhage.	Is crumpled over the bladder and abdominal wall; utero-vesical fold is 4 cm. below brim; pouch of Douglas 1 cm. below posterior fornix.	13·5 cm. long measured in a straight line, but 19·5 cm. along its walls; and 8·7 cm. ant.-post. It fills the pelvis (Kyphotic, with conjugate of 17 cm.); has fundus only 2·5 cm. above brim because of the high promontory, but 14 cm. above the symphysis; is anteriorly in contact with abdominal wall to 6 cm. above symphysis, above which intestines come between; is posteriorly in contact with sacrum, with rectum between and some serum in pouch of Douglas.
5½ days.	A. H. F. BARBOUR	Body frozen in dorsal posture, 14 hours after death.	I.-para; died from sewer-gas poisoning.	Utero-vesical fold 5 cm. below brim; pouch of Douglas at level of posterior fornix.	13·9 cm. long (cavity 11·2 cm.). Uterus fills the pelvis (normal, with conjugate of 10·3 cm.); fundus 3·5 cm. above the brim; is anteriorly in contact with abdominal wall to 5 cm. above symphysis, above which omentum comes in; is posteriorly in contact with sacrum (rectum only between).

\* The measurements are given in these Tables in centimetres, in th



## FROM THE PUERPERIUM.

CERVIX.	LOWER SEGMENT.			REST OF UTERUS.		
	LENGTH.	THICKNESS.	WALLS.	LENGTH.	THICKNESS.	WALLS.
Its canal lying almost in the axis of the brim forms an angle of 120° open to the back with that of the uterus above which is parallel to the spine, and the same angle with the vagina below—which rises vertically upwards. It measures 5·5 cm. along its anterior wall, 2·5 cm. along the posterior, from the os externum to the os internum which can be traced as a continuous ring 3 cm. in diameter.	3 cm. in front, only 1 cm. behind—the wall being folded.	Thinnest part '8 cm. anteriorly, '3 cm. posteriorly; retraction ring 2 cm. in front, 2·5 cm. behind.	Posterior wall folded in.	From contraction ring to upper end of uterine cavity is 12 cm. in front, 17 cm. behind.	Greatest thickness of uterine muscle is 3·7 cm. anteriorly, 4·5 cm. posteriorly, at fundus 2·2 cm.	Placental site is over the fundus. Vessels in wall, compressed and obliterated. Muscular tissue in neighbourhood of retraction ring dotted with blood extravasations. Individual bundles are separated from each other by the hæmorrhage, which is striking in front round the retraction ring.
Its general axis is a continuation of that of the uterus and forms a right angle with that of the vagina.	Not measurable, as folded in.	1·2 cm. anteriorly, 1·9 cm. posteriorly.	Flabby; and, with cervix, folded in below the firmer fundus.	Body, pyramidal in shape, is 9·9 cm. vertically, 9·5 cm. antero-posteriorly.	Anteriorly 2·7 to 3 cm., posteriorly 2·5 to 2·8 cm., at fundus 3 cm. At placental site, is about '7 cm. thicker.	Large sinuses seen cut across in anterior wall under placental site.
Its canal measures from os externum to angle of flexion 3 cm.; and forms with that of the body above an angle of 120° open to the front, and an angle of 150° with that of the vagina below.	Not recognisable to naked eye.			8·5 cm.	3·75 cm. to 4·5 cm. thick, anteriorly; at fundus 2·5 cm.; posteriorly, 3·1 cm. to 3·75 cm.	Placenta over fundus.

Text in inches. To bring centimetres to inches multiply by  $\frac{1}{2}$ .



TABLE III.—UTERI DESCRIBED

PERIOD AFTER DELIVERY.	REPORTER.	HISTORY.	CLASS OF PREPARATION.	PERITONEUM.	UTERUS: SHAPE, POSITION, MUSCULAR ARRANGEMENT, ETC.	
<b>Case 1.</b> — Immediately.	H. BAYER . . .	IV.-para, set. 23; delivered by forceps; died of heart disease.	Out of body.	Firm attachment 8 cm. above os ex- ternum. Bladder widely separated from cervix so that vesico-uterine pouch comes to 5 cm. above os externum.	Section of uterus shows an external length of 19 cm. externally, with a cavity of 17 cm. Breadth, 12 cm. ex- ternally.	Anterior.*
						Posterior.
<b>Case 2.</b> — Almost im- mediately.	D. B. HART . . .	Multipara; died from ex- hausting hæ- morrhage be- tween 7th and 8th months.	Out of body.	Firm attachment 5·7 cm. above os externum.	....	Anterior.
<b>Case 3.</b> — Shortly.	H. BAYER . . .	VII.-para, set. 32; died with symptoms of meningitis.	Out of body.	Firmly attached 5 cm. above os exter- num.	In whole body, the arrange- ment of the muscular fibres was longitudinal. Just above the firm attachment of the peritoneum began the usual tile-like arrange- ment, which could not be followed far downwards. Section shows external length of 20 cm., with a cavity of 18·75 cm.	Anterior.
						Posterior.
<b>Case 4.</b> — Shortly after.	O. KÜSTNER . .	XI.-para, set. 46; died from eclampsia.	Hardened in spirit, out of body.	Firm attachment $\frac{3}{4}$ cm. above furrow where body passes into cervix.	....	Anterior and posterior walls not dis- tinguished.
<b>Case 5.</b> — $\frac{1}{2}$ hour.	M. THIRDE . . .	I.-para, set. 17; with hy- datid mole.	Fresh, out of body.	....	...	Anterior and poste- rior walls not distin- guished.

\* Unfortunately, the distinction between anterior and posterior



## FROM THE PUERPERIUM.

WALLS.			SURFACE.		
IN BODY.†	IN LOWER SEGMENT.	IN CERVIX.	CERVIX.	LOWER SEGMENT.	BODY.†
4·3 cm. thick at thickest part.	Thins suddenly at a point 7·5 cm. from the os externum to one-fifth that thickness (·8 cm.); at the same point is a large vein and the firm attachment of the peritoneum (not the uterovesical fold which is 2 cm. lower); the thin portion projects as a spur into the canal at a point 2·5 cm. above the os externum.	....	Starting from os externum, we have for 3·5 cm. the usual cervical mucous membrane (1 cm. beyond the spur).	Then we have a 'transitional' decidua, much fissured and exposing muscular wall. This decidua has glands in layers, deep ones elongated, superficial ones angular or round; vessels surrounded by decidual cells, and spindle-cells in deepest layers; no surface epithelium, and that of glands is cubical—not cylindrical.	Remains of normal decidua above contraction swelling.
2·5 cm. thick.	Thins in a cleft 5 cm. above os externum to 1·25 cm.	2 cm. thick.	On its surface, starting at os externum, we have 4 cm. of cervical mucous membrane with papillae and large follicles below, smoother and with smaller follicles above.	Remains of normal decidua immediately succeed cervical mucous membrane.	
Greatest thickness (placental site) is 4 cm.	Lower segment is 3 cm. long, and 1 cm. thick; at its upper end is the circular vein.	Cervix is 2·5 cm. long, and from ·7 to 1 cm. thick.	On surface, cervical mucous membrane.	Lower segment has placental remains over upper half.	On body, is placental site.
1·5 cm. thick.	Thins gradually downwards to one-third (·5 cm.) at 5 cm. from the os externum.	....	Has first the usual cervical epithelium.	'Transitional' decidua (cells smaller than typical decidual ones, no surface epithelium nor cervical glands).	And normal decidua begins where wall thickens and peritoneum is firmly attached (or ·5 cm. below it).
2 cm. thick.	Thins abruptly at 3 cm. above os externum, from 2 cm. to 1 cm.	....	Has for 3 cm. usual cervical mucous membrane.	Typical decidua immediately follows cervical mucous membrane.	
The cavity of body is 8½ cm. long; the wall being from 3 to 4 cm. thick.	Lower segment appears as a furrow ½ cm. across (1 cm. when drawn out); thickness 1 cm.	Cervix is 1½ to 2 cm. thick.	Palmæ plicatæ on surface for 2½ cm. from os externum.	In the furrow is decidua of the same structure as in the body (though exclusively the fundal layer), but the tags are more delicate and scarce.	On surface of body is normal decidua with tags 1 to 2 cm. long.
Lower segment not distinguished from body; the thickness above cervix is ·9 cm., further up 1 to 1·1 cm., and at fundus 1·3 to 1·4 cm.		Wall of cervix 2 cm. thick.	For 2½ cm. from os externum we have canal lined with palmæ plicatæ.	Immediately above palmæ plicatæ, decidua with hydatid chorionic villi begins.	

walls is not always made, when made it has been given.

† i.e. Part of uterus above Lower Segment.



## UTERI DESCRIBED FROM

PERIOD AFTER DELIVERY.	REPORTER.	HISTORY.	CLASS OF PREPARATION.	PERITONEUM.	UTERUS: SHAPE, POSITION, MUSCULAR ARRANGEMENT, ETC.	
Case 6. — 3 hours.	O. KÜSTNER . .	X.-para, who died from bleeding.	Hardened in spirit, out of body.	Firm attachment is 6.1 cm. above the border of the anterior lip, 3.6 cm. above the anterior fornix.	Total length externally is 19.5 cm. The mucous membrane surface consists of three areas: (1) From the fundus to place where the wall suddenly falls to half its thickness above (boundary between zones 1 and 2 is 2 cm. above firm attachment of peritoneum); (2) 2d zone is from this line to commencement of palmæ plicatæ; (3) 3d zone shows the characteristic palmæ plicatæ.	Anterior and posterior walls not distinguished.
Case 7. — 3½ hours.	A. BENCKISER .	I.-para, æt. 28; flat pelvis; died after cranioclasm after long labour.	Uterus only: frozen while fresh.	Reflected on to the bladder 6 cm. above anterior lip, and firmly attached 6 cm. higher.	Measures 24 cm. long—cavity being 21 cm. and divided into two parts—the upper measuring 8 cm. and having thick walls and narrow lumen, the lower having thin walls. In the anterior wall, the texture is matted in the thick portion, plate-like in the thin portion up to reflection of peritoneum on bladder, where tissue becomes firmer again. In the posterior wall the tissue becomes firmer at 4.5 cm. from the tip of the posterior lip.	Anterior.  Posterior.
Case 8. — 7 hours.	M. THIEDE . .	I.-para, ætat. 36, died from eclampsia.	Fresh; out of body.	Firmly attached at level of Bandl's ring; below it is moveable on wall.	Surface shows three areas distinctly marked out. In both the upper portions the surface is, with the exception of the placental site, pale-red and covered with shreds; and the muscular wall shines distinctly through at points. The lower third is of a dark bluish colour, has a soft velvety texture, and is covered with sticky mucus. On washing this off, the palmæ plicatæ are seen extending up to the middle third.  Total length=22 cm., of which 6 cm. is cervix.	Anterior.  Posterior.  Both Walls.



## THE PUERPERIUM—Continued.

WALLS,			SURFACE,		
IN BODY.	IN LOWER SEGMENT.	IN CERVIX.	CERVIX.	LOWER SEGMENT.	BODY.
Wall is thickest at placental site (1·7 cm.), at fundus it is 1 cm. thick.	2 cm. above firm attachment of peritoneum thickness falls from 1·7 cm. to ·8 cm.	5 cm. above os externum, wall thickens to 1·3 cm. and to 1·7 cm. immediately above the fornix.	For 5 cm. we have the characteristic palmæ plicatæ.	<p>The surface of zone 2 (3·1 cm. across) is smooth, almost shining; and the shreds are fewer and flatter than in zone 1. The surface is also paler and shows small heights and hollows; no gland openings are to be seen.</p> <p>In the upper part of zone 2, we have characteristic decidua with compact and ampullary layers; the gland spaces are wide, drawn-out, and lying in more than three layers. Beginning at the free surface, the dominating cell is first round or polygonal; underneath this, still in the compact layer, we come on an elongated spindle cell—which also predominates in the net-work of the ampullary layer. The round cells are ·015 mm. in diameter, the spindle ·03 to ·06 mm. The free border of the decidua ends sharply, and shows nowhere torn-through gland spaces and nowhere surface epithelium.</p> <p>In the middle or lower part of zone 2, we have mucous membrane very thin—the glands scarcer. The mucous membrane consists of closely-packed round cells like those on the surface above. The surface is wavy, but ends sharply and shows no epithelium.</p> <p>On the limit of the lower segment towards the cervix, we have a great number of drawn-out elongated glands lined with cylindrical epithelium.</p>	In zone 1 we have the typical inner surface of the post-partum uterus covered with its shreds.
<p>In thin portion ·4 to ·5 cm. thick and 12 cm. in length, above which it suddenly thickens to 2½–3½ cm. (placental site).</p> <p>Greatest thickness 5 cm., thinning more gradually than the anterior as it passes downwards to ·5–·7 cm.</p>			Shows folds along and across.	Shows shreds of decidua.	....
3·5 cm. thick at thickest part; 2·8 cm. over fundus.	1 cm. thick immediately above cervical canal, and at 6 cm. above its upper end thickens to 2 cm.	1·5 cm. thick in cervix.	....	....	....
4·5 cm. thick at thickest part.	1·5 cm. thick immediately above cervical canal; and at 6 cm. above its upper end thickens to 2·7 cm.	1·5 cm. thick in cervix.	....	....	....
Above Bandl's ring, the musculature is an irregular mesh-work of fibres pushing itself between longitudinal bundles.	In the lower segment, the musculature is apparently formed of longitudinal bundles.	The tissue of wall below Müller's ring is close, studded with small hæmorrhages and has a delicate epithelial lining. The musculature is thicker than that of lower segment, partly through transverse bundles and partly through serous infiltration.	A scraping from the upper limit shows besides small round cells a high cylindrical epithelium arranged in long layers—the cells in part ciliated, in part covered with a dark, almost double contour.	A scraping from the surface of the lower segment is membranous and made up of a conglomerate of large decidual cells, with here and there glands of decidua vera but no high cylindrical epithelium.	....



UTERI DESCRIBED FROM						
PERIOD AFTER DELIVERY.	REPORTER.	HISTORY.	CLASS OF PREPARATION.	PERITONEUM.	UTERUS: SHAPE, POSITION, MUSCULAR ARRANGEMENT, ETC.	
Case 9. — 10 hours.	A.H.F. BARBOUR.	I.-para, æt. 18; eclampsia at 7th month, died 28 hours after first eclamptic seizure.	Fresh; out of body.	....	Length, 6½ in. (16·25 cm.) ex- ternally; cavity 6 in. (15 cm.) from os externum to fundus.	Anterior and posterior walls not distinguished.
Case 10. — 13 hours.	O. KÜSTNER . .	I.-para, æt. 23; death from eclamp- sia.	Hardened in spirit; out of body.	Reflection at Bandl's ring or above it.	Length 18·5 cm.	Anterior and posterior walls not distinguished.



## THE PUERPERIUM—Continued.

WALLS.			SURFACE.		
IN BODY.	IN LOWER SEGMENT.	IN CERVIX.	CERVIX.	LOWER SEGMENT.	BODY.
....	....	Length $1\frac{1}{2}$ in. (3.75 cm.).	Surface is of a purplish-red colour.	The surface of the uterus is of a mottled red colour. There are three distinct appearances: on the posterior wall is an area, 3 in. by 3 in. (7.5 cm. by 7.5 cm.), which is ragged and of a purplish colour—the placental site; upper third of anterior wall is smoother and paler than the rest of the cavity, which has a mottled appearance due to little shreds of brick-red tissue adhering to it. The smooth appearance of the wall is evidently due to its being lined by a membrane which ends in a fringe; on stripping it off, one produces the mottled appearance which characterises the parts where the membrane is not present. Where still adherent, decidua is broken up by old hæmorrhages round which is condensed homogeneous tissue or a young connective tissue.	
The length from fundus to Bandl's ring is 12 cm.; Thickness of wall averages 2.6 cm.; at ring is 1.5 cm.	From Bandl's ring to os externum is 6.5 cm., of which 2.5 to 3 cm. is undoubtedly cervix.		For 2.5 to 3 cm. from os externum, colour of mucosa is of a deep, bluish red, upper boundary of the colour being on level at vaginal fornix. Torn surfaces seen over it. The palmæ plicatæ are distinctly seen, and at first glance mark it out from lower segment. Epithelium absent over the portion rich in folds, i.e., below Müller's ring; on the other hand, we have it well-preserved in the glands, sometimes cubical, sometimes cylindrical.	Mucosa pale-red in colour. The surface is smooth, covered with shreds which are very short and less stringy than those of the rest of the body and more like torn surfaces. Closer examination shows here also ridges, but much lower and further apart than those of the cervix. The sieve-like appearance of open glands is much better marked than in the body—the spaces being like pin heads, but fewest on the ridges. The gland spaces are at the bottom very small, flat, compressed and parallel to the section. The decidua has broad trabeculae—the meshes being smaller than the interglandular tissue. It thus resembles decidua at 4th to 6th month, not that at end of pregnancy. The individual decidual cells are also smaller—being only two to three instead of six to ten times the size of an epithelial cell. The most striking and radical difference is the epithelium: not only is it well-preserved in the glands but the surface shows over a large area a well-preserved border of epithelium. In the glands, epithelium is constant in the fundal layer—low cylindrical cells with an easily recognised nucleus; in the ampullary layer they are absent, the spaces being often filled with granular debris. On the surface, the individual cells stand very high, and are cloudy; the nucleus varies in position; the cells are not simple cylinders but irregular in form, wedge-shaped with the apex up or down, and fitted-in past each other so that the layer appears in many places not single but one-and-a-half or double. No membrana propria could be seen. Epithelium was not ciliated (perhaps due to hardening in alcohol).	Mucous surface covered with flat shreds easily washed off, below which the mucosa is pale red. Above the ring is a layer of decidua, which is thickest just at it, with tags $\frac{1}{2}$ to 1 cm. long.
	Wall 8 cm. thick. On microscopic examination, the mucous membrane is 1.5 to 3 mm. thick, ending sharply at the muscular walls: the upper compact, middle ampullary, and deep fundal layers are easily recognised; although the compact layer is very thin, being only $\frac{1}{4}$ th to $\frac{1}{2}$ th of the thickness of the ampullary. (Perhaps result of microscopic mounting.)	Wall of cervix is 1 cm. thick. Mucous membrane is 3 to 4 mm. thick, and is not separated into three layers. The connective-tissue elements are enlarged—congestion striking, especially in the surface; and considerable hæmorrhages.			



UTERI DESCRIBED FROM						
PERIOD AFTER DELIVERY.	REPORTER.	HISTORY.	CLASS OF PREPARATION.	PERITONEUM.	UTERUS: SHAPE, POSITION, MUSCULAR ARRANGEMENT, ETC.	
<b>Case 11.</b> — 17 hours.	M. THIEDE . .	I.-para, æt. 34; died from lung œdema with nephritis at commence- ment of 10th month.	Fresh; out of body.	Firmly attached at Bandl's ring.	Total length, 19 cm., of which lower segment is 4 cm.	Anterior.
						Posterior.
						Both Walls.
<b>Case 12.</b> — 17 hours after abdo- minal sec- tion for rup- ture.	M. THIEDE . .	IV.-para, ætat. 29, tried to be delivered with forceps, admitted to Maternity with rupture in posterior wall of cer- vix.	Fresh; out of body.	Firmly attached at Bandl's ring.	Total length, 22 cm. anteri- orly and 17 cm. posteriorly.	Anterior.
						Poste- rior.
						Both Walls.
<b>Case 13.</b> — 40 hours.	A. H. F. BARBOUR	Died of eclamp- sia.	Hardened in spirit, out of body.	....	Total length, 19 cm. verti- cally; whole uterine cavity is 16.5 cm. long. Uterus was lying with the fundus on a level with line joining the iliac crests; it was firmly contracted.	Ante- rior.
						Posterior.
<b>Case 14.</b> — 2 days.	A. H. F. BARBOUR	Labour nor- mal, died from phthisis, uterus was quite flaccid, and was cut open while fresh to see the appear- ance of the cavity.	Fresh; out of body.	....	Total length, 20.5 cm. verti- cally; 11.5 cm. transversely. Cavity 19 cm. from fundus to os externum.	Anterior and posterior walls not delineated



## THE PUERPERIUM—Continued.

WALLS.			SURFACE.		
IN BODY.	IN LOWER SEGMENT.	IN CERVIX.	CERVIX.	LOWER SEGMENT.	BODY.
thickest part, 1 cm. thick.	Above Müller's ring 1·3 cm. thick, at Bandl's ring, 2·5 cm.	Length of canal 6 cm.	Surface smooth. Marked off from lower segment by a ridge projecting 1 mm. beyond surface. Below the ridge, on surface is a somewhat firm fibrous meshy tissue, with round and spindle cells in it more than twice the size of the connective-tissue cells in the non-pregnant uterus. The glands are few and far between, of rounded outline and lined with epithelium—the cells being granular and enlarged. On the surface, the epithelial border is away. In the deeper part, the tissue is not so compact.	The gland spaces lie in many layers; in part pressed flat, in part drawn out irregularly into corners, and lined with cells broader than high.	....
thickest part, 3 cm. thick.	Above Müller's ring 1·8 cm. thick, at Bandl's ring 2·9 cm. thick.	Length of canal 5 cm.		These same low cells are found on the surface for some distance, "and must be looked upon as the future epithelial covering."	
Bandl's ring begins suddenly the complex interlacing of the fibres. In the substance of wall at same level is a cross-section of a large vein.	Tissue irregularly ragged with many small spaces. We find the looser tissue of large decidual cells, the characteristic dense tissue of the cervical canal being absent. The musculature consists only of longitudinal bundles.	Texture of wall seems equally firm, and of smooth surface. Numerous blood-vessels. Musculature is thicker than that of lower segment, the longitudinal bundles seeming to be increased with transverse layers.			
thickest part, 5 cm. thick; 3·5 cm. at commencement of lower segment.	Thickness 2 cm.	Length 6 cm.	Fresh scraping from upper part shows it to be covered with epithelium. The glands are fewer than in lower segment.	Length, 3½ to 4 cm.; not covered with epithelium. Marked off from the cervix by a projecting swelling of characteristic decidua.	Length of cavity 11·5 cm. Immediately above Bandl's ring are the characteristic uterine glands lined with flattened epithelium.
thickest part, 5 cm. thick.	Thickness 2 cm.	Length 2 cm. Thickness 2·5.			
all 2 cm. thick at fundus. The change in the character of the muscular fibre at Bandl's ring is very marked—the cross bundles coming in suddenly.					
3 cm. thick above, thins to 1·7 cm. at 7 cm. from the anterior lip.			Cervix is 3·8 cm. long. The free surface of the mucous membrane has lost its rugæ; the epithelium is present in sections of the glandular spaces below the surfaces.	The inner surface of the posterior wall shows some inequalities in the form of regular flattened ridges separated by slight furrows, and has a distinct outline. The surface of the anterior wall is more rugged, and its outline is obscured by blood-clot which passes into these irregularities. The placental site, on the anterior wall and fundus, is composed of heights and hollows covered with blood-clot which extends into the irregularities. The rest of the uterus has a layer of tissue superficial to the muscular wall varying from 5 to 1 mm. in thickness; this represents the spongy layer; on the surface it is ragged and breaking down; in the deeper part, spaces like the glandular cavities are seen; but the epithelium is not preserved.	
2·5 cm. thick above, thins to 1·7 cm. at 6 cm. above posterior lip.					
....			Internal surface 5 cm. long. The surface is of a purplish red colour and marked by furrows along its lower border; the zone of bluish ecchymosed cervix contrasts markedly with the paler vagina below and the uterine cavity above. Epithelium is present in vagina, but not in cervix.	The length of the internal surface of the uterus is 14 cm. The surface is slightly ragged and of a reddish colour in its upper three-fourths, smooth and pale in its lower fourth. The post-mortem changes inside the uterus and cervix prevent any definite observations on the condition of the mucous membrane.	



UTERI DESCRIBED FROM						
PERIOD AFTER DELIVERY.	REPORTER.	HISTORY.	CLASS OF PREPARATION.	PERITONEUM.	UTERUS: SHAPE, POSITION, MUSCULAR ARRANGEMENT, ETC.	
Case 15. — 4 days.	A.H.F. BARBOUR.	Multipara; died from u- ræmia; deli- very hastened by forceps, for convulsions.	Fresh; out of body.	Reflected on to blad- der at 3.1 cm. above anterior lip; and firmly attached 11.2 cm. above the same.	Measured externally from os externum to fundus 20 cm.; transversely, at widest part, 13.7 cm.	Anterior.
						Poste- rior.
Case 16. — 8 days.	M. THIEDE . .	II.-para, æt. 24; died of ileotyphus.	Fresh; out of body.	Firm attachment appears to have come lower down.	Total length is 17.5 cm., of which 5 cm. is cervical canal.	Anterior.
						Poste- rior.
						Both Walls.
Case 17. — 9th day of puerperium.	H. BAYER . . .	XVI.-para; died suddenly with throm- bosis of the right saphen- ous and femo- ral veins, and embolism of the right lung.	Out of body; boiled and macerated.	Firm attachment is 6½ cm. from the an- terior lip. The at- tachment of the bladder is unusually high—up to same level.	Whole uterus is 13 cm. long. The cavity runs straight, not bent forwards; and the anterior wall is slightly concave.	Anterior.
						Posterior.



## THE PUERPERIUM—Continued.

W A L L S.			S U R F A C E.		
IN BODY.	IN LOWER SEGMENT.	IN CERVIX.	CERVIX.	LOWER SEGMENT.	BODY.
2.5 cm. thick above and 1.6 cm. thick at firm attachment of the peritoneum.	.8 cm. between firm attachment and cervix.	....	Anteriorly, the arbor vitæ is distinctly seen for 4 cm., above which surface is smoother; so that while central column is visible for 6.7 cm., no lateral branches are seen. Posteriorly, the arbor vitæ extends for 2 cm. Above the arbor vitæ comes, on both anterior and posterior walls, a zone, averaging 3.5 to 4 cm. in width, of faded yellow leaf colour and mottled surface.		
1.7 cm. at placental site.	1.9 cm. between placental site and cervix.	2 cm. at cervix.			
2.7 cm. thick at thickest part.	1.3 cm. thick above cervix.	Below the surface of the cervix, the tissue is in the upper part still somewhat dense; but deeper it is in meshes.	In its lower part, connective-tissue hyperplastic but dense, cells enlarged and arranged in small bundles, with between them sections of vessels and glands. The surface epithelium is like that of the non-pregnant uterus. Further up, the epithelium becomes lower; cells being small and delicate, and sometimes $1\frac{1}{2}$ cells deep. The glands are fewer and larger, the epithelium lower and broader.	Somewhat thick remains of decidua; in places, however, quite thin; and we find a considerable area covered with the low epithelium.	....
3 cm. thick at thickest part.	1.7 cm. thick above cervix.				
Wall 1.3 cm. thick at fundus.	The arrangement of the muscular fibre is not distinctly marked off; while longitudinal in lowest part, it shows transverse bundles also above.				
The wall is 2 cm. thick at fundus, 2.7 cm. at thickest part of anterior wall. Placenta partially on the anterior wall.	Above the cervix we find a thinner portion of the wall limited by the firm attachment of the peritoneum and bladder and by a large vessel.	2 cm. above the tip of the anterior lip is a vessel surrounded by connective tissue fibres, and from this knot stream fibres to the anterior lip and for-nix.	Cervix has reproduced itself for 3 cm.		
Above the knot, 2 cm. from the tip of the anterior lip, lies the tile-like arrangement of plates which arise partly from the peritoneum, partly from the middle folded layer, and run towards the inner surface of the cervical canal.			...	....	
3 cm. thick at thickest part.	There is no thinning in the posterior wall corresponding to that in the anterior.				



p placenta ; rr retraction ring ; ps promontory of sacrum ; uvp utero-vesical reflection of peritoneum ; b bladder ; u urethra ; oe os externum ; avw anterior vaginal wall ; pv posterior vaginal wall ; cs caput succedaneum ; v vulva ; a stretched anus ; pb perineum.

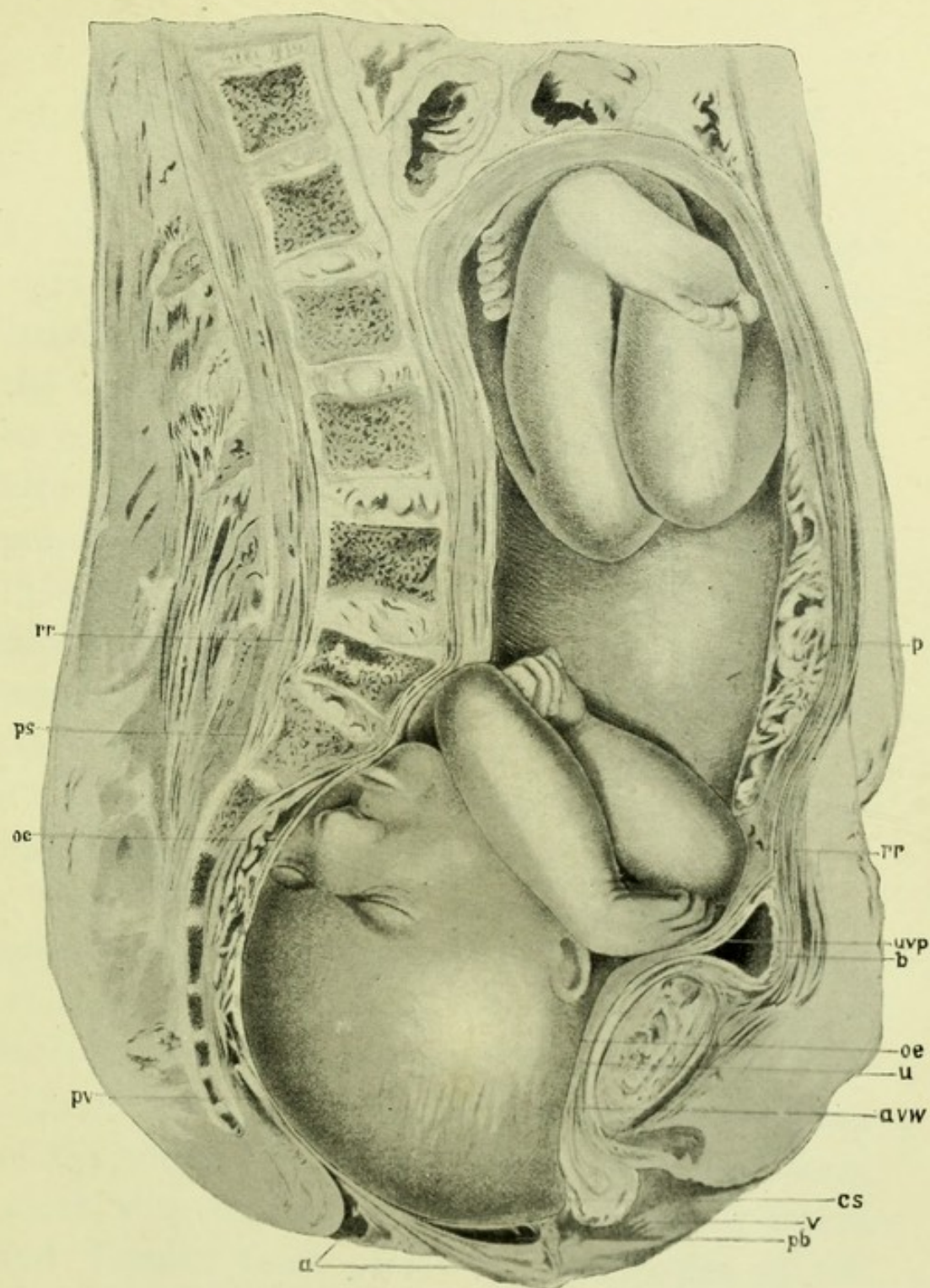
*The Second Stage is farther advanced than in Chiari's Section, Pl. I.*

*The membranes have ruptured : the head is rotating, and is dilating the vulva ; the body of the foetus is transverse, the back being towards the mother's left side ; the head lies between the right oblique and conjugate diameters. The flexion of the head on the chest is less marked than in pregnancy. (Compare Plate I.). While the arms and legs are flexed, there is a space between the knees and arms due to the undoing of the flexion of the spinal column ; the head is at the vulva, the anus stretched, and there is a well marked caput succedaneum.*

(See also page 216.)



PL. V.—TOWARDS THE END OF THE SECOND STAGE, from Pl. XXII.  
of the Author's Atlas reduced to one-third.



*For description of Plate see opposite page.*







## CHAPTER VII.

### A REVIEW OF THE SECTIONS PUBLISHED FROM 1888 TO 1898.

IN the summer of 1889, after the preceding chapters were written, I had the rare fortune to obtain the cadaver of a patient who died towards the close of the second stage of labour. The labour was going on normally, and the cause of death—failure of the heart—was such as not to affect its character. The preparation was unique, and I looked to it to throw light on various important points, such as the condition of the cervix, the position of the utero-vesical peritoneum and bladder, the form of the foetus, and the behaviour of the placenta and membranes. On all of these valuable information was obtained.\* The Section is reproduced in Plate v.

From the same stage, sections were published subsequently by Leopold, von Mars, and Zweifel, which, though they are all from cases of pathological labour, throw light on the normal process.

From the third stage, the first sections yet made of the whole cadaver were obtained by Pestalozza, which, with sections of the uterus alone, by Pinard and Varnier, have placed our knowledge of this stage on a firm foundation.

---

\* The results were first published by Dr Webster and myself in the *Laboratory Reports of the Royal College of Physicians, Edin.*, Vol. II.



The condition before labour and the changes of the first stage have also been elucidated by numerous sections by Leopold, Lusk, Pestalozza, Tibone, Braune and Zweifel, Pinard and Varnier, Testut and Blanc, Webster and myself; while the anatomy of the puerperium has been made the subject of a valuable enquiry by Webster.

There has thus accumulated a sufficient wealth of material to call for a review of the present state of our knowledge, and to consider how the new facts support and supplement the conclusions of the foregoing pages.

The twenty-five sections of the last ten years.

These conclusions were arrived at from a study of the thirteen sections referred to on page 10, which represented the work done in this department to the close of 1888. During the succeeding ten years twenty-five more sections have been published which are of service for our enquiry.\* Arranged according to the stages of labour, they are as follows:

BEFORE LABOUR .	. Sections by Leopold,* Pinard and Varnier † Braune and Zweifel, ‡ Barbour and Webster.
FIRST STAGE .	. Sections by Leopold,* Lusk, §§ Pestalozza, § Tibone,    Pinard and Varnier, † Testut and Blanc, ¶ Barbour and Webster.
SECOND STAGE .	. Sections by Leopold,* von Mars**, ZWEIFEL, †† Barbour and Webster.
THIRD STAGE .	. Sections by Pestalozza, § Pinard and Varnier. †
PUERPERIUM .	. Sections by Barbour and Webster. ††

\* Sections from pregnancy before the eighth month are not included, such as those by Leopold, Pinard and Varnier, Soffiantini, Waldeyer and Webster; Acconci has not reproduced his interesting section.

\* See Part II., p. 119.

§ See Part II., p. 93.

\*\* See Part II., p. 90.

† See Part II., p. 105.

|| See Part II., p. 117.

†† See Part II., p. 115.

§§ See Part II., p. 132.

‡ See Part II., p. 85.

¶ See Part II., p. 102.

†† See Part II., p. 96.



It is interesting to note what these patients died of, as illustrating the most frequent causes of sudden death in connection with labour. In nineteen cases which died during labour, the cause of death is given. Seven died from eclampsia, three from heart-failure, two from phthisis, and two from pulmonary œdema. One of the cases of heart-failure showed almost complete obliteration of the coronary arteries by endo-arteritis, but no fatty degeneration of the muscle; another died in a condition of asphyxia from the congestion of an enlarged thyroid, the sudden congestion being produced by labour. Five died from causes in the uterus, three being cases of placenta prævia, and two of rupture of the uterus.

In estimating the value of a section the cause of death must always be taken into account. It is evident that, for the study of normal labour, cases of death from accidental causes, or such, at least, as will not affect the anatomical changes in labour, will be of most service.

In examining the wealth of material represented by these sections, we select only those anatomical facts which have a clinical bearing.

In collecting them and comparing them with those stated in the previous chapters, the great value of this method of research comes out incidentally. Nothing learned from these new sections overturns any of the conclusions already arrived at. The new material simply strengthens and supplements what has gone before.



## Technique.

No improvements have been introduced in the technique adopted of making sections already described (v. p. 11). In addition to vertical and transverse sections, those made in the oblique diameters of the pelvis have shown the soft parts in relation to the head as it lies in one of these diameters.

## Use of casts.

In working up my last material I have used not only sections but casts. A section gives us relations only along its plane. The range of our enquiry is much extended when we take casts of cavities and masses. These furnish a permanent record of the form of the surface, and also of bulk or capacity when we are dealing with a mass or cavity. I have used this method both in cases from pregnancy and labour. After the mesial section had been made and drawn, the halves of the frozen foetus were lifted out and put together, separated by a plate of glass, corresponding in thickness to the portion removed by the saw. A cast was thus obtained of the whole foetus. Further, the genital tract was cleared from liquor amnii and other frozen débris, and the two halves of it put together, also separated by a plate of glass, and a cast taken which was an exact reproduction of the cavity.

Table of all  
the thirty-  
eight sections  
published.

Placing these twenty-five sections alongside of the thirteen, we have thirty-eight in all, and in the following table I have arranged them in the order of the date of publication, grouping them according



to the stage of labour. Enough details are given only to identify the section, and to allow future sections to be placed in the series. They are also numbered, and for the sake of brevity will be referred to under their numbers.

*Before Labour.*

1. BRAUNE . . . . (1872) Multipara : full-time : vertex, R.O.A.
2. WALDEYER . . . . (1886) X.-para : full-time : breech, L.S.A.
3. BRAUNE AND ZWEIFEL . (1890) I.-para : full-time : vertex, occiput to right.
4. BARBOUR AND WEBSTER . (1891) VI.-para : VIII months : breech, L.S.A.
5. PINARD AND VARNIER . (1892) I.-para : VIII month : vertex, occiput to left.
6. PINARD AND VARNIER . (1892) II.-para : VIII month : vertex, L.O.A.
7. LEOPOLD . . . . (1897) Multipara : VIII month : breech, sacrum to left.

*First Stage.*

8. SCHROEDER . . . . (1886) IV.-para : vertex, L.O.A. : membranes separated for 4 ins. antero-posteriorly.
9. BARBOUR . . . . (1888) VI.-para : vertex, occiput to right : membranes separated for 3½ in.
10. WINTER . . . . (1889) II.-para : vertex, occiput to right : placenta prævia.
11. WINTER . . . . (1889) I.-para— : accidental hæmorrhage.
12. SAEXINGER . . . . (1889) I.-para : vertex, occiput to the left.
13. BARBOUR AND WEBSTER . (1891) Multipara : vertex, occiput to right, cervix dilated to ½ in.
14. PESTALOZZA . . . . (1892) VI.-para : vertex, L.O.A. : membranes separated for 4 in.
15. PINARD AND VARNIER . (1892) I.-para : vertex, R.O.P. : membranes separated for 4½ in.
16. TESTUT AND BLANC . . (1892) I.-para : vertex, occiput to left.
17. TIBONE . . . . (1894) II.-para : breech, L.S.A. : placenta prævia.
18. LEOPOLD . . . . (1897) I.-para : vertex, occiput to left : membranes separated 1½ in.
19. LEOPOLD . . . . (1897) I.-para : vertex, occiput to right.
20. LUSK . . . . (1897) VII.-para : vertex, L.O.A.

*Second Stage.*

21. BRAUNE . . . . (1872) I.-para : vertex : membranes unruptured, head in vagina.
22. CHIARA . . . . (1878) IV.-para : spontaneous evolution.
23. CHIARI . . . . (1878) I.-para : membranes not ruptured, head near perineum.
24. VON MARS . . . . (1890) VIII.-para : uterus ruptured, head at vulva.



25. BARBOUR AND WEBSTER . (1891) I.-para : membranes ruptured, head distending perineum.  
 26. ZWEIFEL . . . . (1893) VII.-para : uterus ruptured, head through vulva.  
 27. ZWEIFEL . . . . (1893) I.-para : placenta prævia, child turned and leg pulled down.  
 28. LEOPOLD . . . . (1897) Multipara : placenta prævia, child turned and leg pulled down.

*Third Stage.*

29. PESTALOZZA . . . . (1897) Multipara : placenta unseparated.  
 30. PESTALOZZA . . . . (1897) „ twin placenta unseparated

*After Delivery.*

31. STRATZ . . . . (1886) I.-para : 1 hour.  
 32. BARBOUR . . . . (1888) „ 1½ hours.  
 33. BARBOUR . . . . (1888) „ 5½ days.  
 34. BARBOUR AND WEBSTER . (1891) Multipara : immediately.  
 35. WEBSTER . . . . (1892) „ 2nd day.  
 36. WEBSTER . . . . (1892) „ 3rd day.  
 37. WEBSTER . . . . (1892) „ 4th day.  
 38. WEBSTER . . . . (1892) „ 6th day.

The form of  
the pelvis,

In looking at the series of sections we have first to consider the form of the pelvis as it appears in a vertical mesial section, and the relation of the pelvic cavity to the abdominal cavity. Hitherto the pelvis has been described from the dry specimen and taken out of the body. In a frozen section we see it in the body, fixed in the position it occupied during life; further, the relation of the pelvic to the abdominal cavity is preserved. The importance of this from an obstetric point of view is evident when we remember that the full-time pregnant uterus is largely an abdominal organ, while its contents have to pass through the pelvis.

Looking at the pelvis in the body we note that the relation of the promontory of the sacrum to the symphysis gives the key to the pelvis, because the position of the promontory



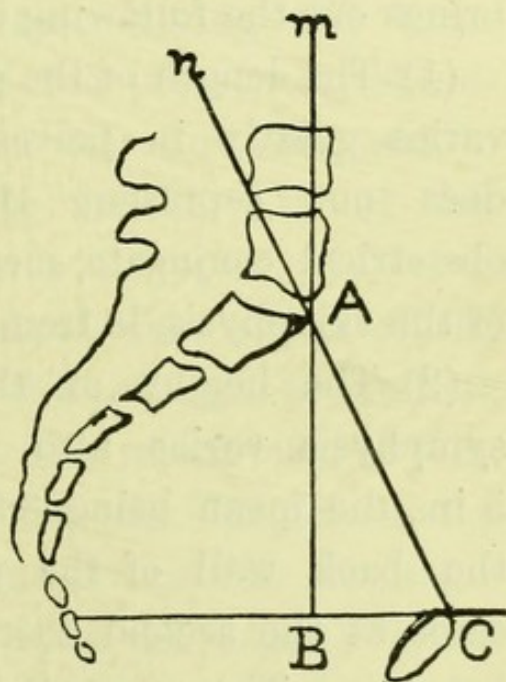
determines the build of the pelvis.\* Further, the position of the promontory varies considerably in pelvis which are obstetrically normal. This variation will influence both the position of the head in multiparæ before labour, and its engagement.

For comparing one section with another we require some method of description, which will take into account the relation of the axis of the abdomen to the brim of the pelvis, and also localise more exactly the promontory. A line m.A.B. (Fig. 7) drawn through the promontory in the long axis of the body will indicate the former.† A second line, C.B.,

Method of describing this.

FIG. 7.

*Diagram for describing form of a pelvis in a frozen section. For description, see text.*



\* The various types of deformed pelvises can be grouped round this factor. Thus the promontory is moved slightly downwards in the simple flat, markedly downwards in the flat rickety and malacosteon, downwards and to the side in the scoliotic and Nægele, backwards in the kyphotic.

† It also corresponds roughly to the horizontal plane when the patient is recumbent. For fuller particulars as to the position of this line, see Figs. 12, 13, 14, in note A, at the end of this chapter.



drawn at right angles to it and passing through the centre \* of the upper margin of the symphysis, represents the level of the latter, and marks off on A.B. the height to which the promontory stands above this level. This line prolonged to the sacrum, also shows how much of the latter bone is above the same level. The length of C.B. indicates how far the promontory stands back from the symphysis. The hypotenuse of the right angled triangle A.B.C. is the anatomical conjugate. An examination of all the sections † in this series, available for this enquiry, brings out the following results.

(1) The length of the anatomical conjugate (A.C.) varies greatly in pelves obstetrically normal. It does not represent the available space. The obstetrical conjugate, measured to the nearest point of the symphysis, is from  $\frac{1}{5}$  to  $\frac{2}{5}$  of an inch shorter.

(2) The height of the promontory above the symphysis varies also considerably, from 2·6 to 5 in., the mean being 3·8 in. The line C.B. strikes the back wall of the pelvis in the majority of cases at the second coccygeal vertebra, or a point below it. Thus the whole sacrum and a portion of the coccyx is above the level of the upper margin of the symphysis, and the pelvic contents come to lie opposite to the lower region of the abdomen.

---

\* This point is chosen as being more definite than the highest point of the symphysis, and also as it is the termination of the anatomical conjugate.

† The table, with the details of the fourteen sections, will be found in note A. at the end of this chapter.



(3) The length of A.B. depends as much on the size of the angle A.C.B. as it does on the length of A.C. The effect of the length of the conjugate on the position of the promontory has been hitherto recognised; and its importance is seen in its being used in describing different types of pelvis. The inclination of the brim has been assumed as constant, or, at least, as affected only by posture. Frozen sections show us, however, that this angle is equally variable, varying in these specimens from  $35^{\circ}$  to  $65^{\circ}$ . Its variability is independent of the length of the conjugate. Thus in two cases having the same conjugate of 4.5 in., we find the promontory standing above the symphysis, in one case 2.8, and in the other 3.8 in., according to the size of this angle.

(4) The length of C.B. shows how much of the pelvic cavity is brought into line with the abdominal. It varies from 2.4 to 4 in., the mean being 2.8 in. Its length depends partly on the length of the conjugate, but still more on the size of the angle C.A.B. This angle is the same as m.A.n., which represents the inclination of the long axis of the abdomen to the brim of the pelvis. The more acute this angle is, or the shorter the line C.B., the more will the uterus come to rest on the symphysis in pregnancy, and the farther forward will it have to throw itself in labour, so as to come into the axis of the inlet.



Variability in obliquity of brim apart from posture.

The new point brought out by these sections is the variability of the angle A.C.B. apart from posture. Hence we can no longer assume a fixed inclination of the pelvis to the horizon for a given posture, nor can we, from the length of the conjugate alone, determine the relative position of the promontory.

Disposition of peritoneum.

Passing from the pelvis to the soft parts, we look first at the disposition of the peritoneum, which is of importance as regards inflammatory collections, and still more for operations in which the peritoneal cavity is involved. It is evident that the point of the reflection of the peritoneum in a mesial section need not necessarily represent its lowest dip, as the utero-vesical fold or the pouch of Douglas may lie to one side of the mesial plane. The difference, however, is so slight as not to be of practical moment, and the information obtained is more reliable than that got from dissection.

Before labour, we find it reflected anteriorly at distances varying from 3 in. below the brim up to the level of the brim itself.\*

In the sections from the first stage,† it is reflected at points varying from  $2\frac{3}{4}$  in. below the brim to  $\frac{1}{2}$  in. above it. In all the sections from the second stage it is reflected above the brim—from  $\frac{1}{4}$  in. to 1 in.

---

\* It is at the brim in two cases (3, 6),  $\frac{3}{4}$  in. below it in (2), 2 in. in (1), and 3 in. in (4).

† Thus it is at  $2\frac{3}{4}$  in. below the brim in (13),  $2\frac{1}{4}$  in. (9),  $1\frac{1}{2}$  in. (8, 9), 1 in. (14),  $\frac{1}{2}$  in. (11); while in three it is above the brim for varying distances— $\frac{1}{4}$  in. (16),  $\frac{1}{2}$  in. (12, 17).



usually the latter.\* In the third stage we find it 1 in. below the brim,† while immediately after delivery it is 2 in. below the brim.‡

We thus find great variability in the extent to which the peritoneum descends anteriorly. There is a tendency to its elevation during the first stage of labour, and still more during the second. In the third stage it is found again below the brim, and at a still lower point, after the delivery of the placenta.

Posteriorly,§ we find that there is also considerable variation in the depth of the pouch of Douglas, but that its level does not tend to be affected by labour, as that of the utero-vesical pouch is.

The disposition of the peritoneum at the sides of the uterus has been noted in only a few cases; but these, with one exception, confirm the description given at p. 16.

The position of the bladder is of great clinical im-  
portance, both with regard to the use of the catheter  
and the risk of its being injuriously compressed  
between the presenting part and the symphysis.

Position of  
Bladder.

---

\*  $\frac{1}{4}$  in. in (25), and 1 in. in (21, 23, 27).

† Section 30.

‡ (32, 34). In Stratz's section (31) it is 1 in. above the brim, but the structures here are evidently displaced by the contracted pelvis.

§ The amount of pelvic peritoneum found below the brim is represented by the following figures. Before labour,  $5\frac{1}{2}$  in. (1), 5 in. (4),  $4\frac{1}{2}$  in. (3),  $3\frac{1}{2}$  in. (2, 6). In the first stage 5 in. (11, 15),  $4\frac{1}{2}$  in. (9, 10, 12),  $3\frac{3}{4}$  in. (13), 3 in. (11). In the second stage  $5\frac{1}{2}$  in. (23),  $4\frac{1}{2}$  in. (21),  $2\frac{1}{2}$  in. (25); while it is at the brim in (27). In the third stage  $4\frac{1}{2}$  in. (30). After delivery  $4\frac{1}{2}$  in. (32), and 5 in. (34, 35, 36).



Of the five sections giving the position of the bladder before labour, we find the bladder behind and below the pubes in three (1, 2, 4). In one of these cases (4), it is distended, and has expanded transversely more than vertically (as 4·8 in. to 1·4 in.). In the fourth case (6), the empty bladder comes to the level of the brim; while in the fifth (3), 2 in. of it are below the brim and empty, while 2 in. are abdominal and partially distended. The bladder is, therefore, before labour, usually a pelvic organ, exceptionally in part abdominal—a fact which must be borne in mind in judging as to its elevation during labour.

In all the thirteen first stage sections save two,\* the empty bladder is behind and below the symphysis.

In all sections from the second stage the bladder is one-half pelvic, and one-half abdominal, its height above the brim varying from 1 in. to 2 in.† When empty, only 1 in. is abdominal.

To determine whether the elevation of the bladder during the second stage is real or only apparent, its compression against the pubis simulating elevation,

---

\* In one (12) one-half of the bladder is abdominal and distended, while in the other (16), the empty bladder rises 1 in. above the pubes. As the membranes were ruptured, this section might almost belong to the second stage, although from the amount of dilatation of the cervix I have put it in the first stage.

† 1 in. (23, 21), 1½ in. (25, 27), 2 in. (22); in the latter cases there was a small amount of urine in it, which partly accounts for its elevation.



we may draw a line from the lower margin of the symphysis and parallel to the brim, and note the relation of the bladder to that line.

As regards the sections before labour, we find Elevation of bladder in labour. three-fourths of the bladder below this line in two of them (1, 4), one-fourth in one of them (6), and one-ninth in another (3), while of the first stage sections four-fifths lie below it in two (13, 18), three-fourths in five (8, 9, 10, 16, 17), two-thirds in two (1, 14), and one-half in two (11, 12), while in one only (15), is the lower limit at this line. We find thus that in the majority of cases, the great proportion of the bladder is seen to lie below this level. In the second stage sections the lower limit of the bladder is always above this line— $\frac{1}{4}$  in. (23),  $\frac{1}{2}$  in. (21, 26),  $\frac{2}{3}$  in. (25), and at the level of the brim in (22). In the third stage we find the empty bladder again lying three-fourths below this level, and the same obtains after delivery. The neck of the bladder, therefore, is raised during the second stage and compressed against the pubes, while a portion even of the empty organ is abdominal.

We come now to consider the uterus itself, and Position and form of uterus. look first at its position and form.

In the sections before labour, from full-time pregnancy, we find the uterus in three cases lying with its long axis parallel to the spinal column, the fundus being on a level with a point between the first and second lumbar vertebra. Its height above the



pubes is in two of these (1, 2), 10 in., and in one (3) 11 in. In a fourth case (3) its axis is thrown forward into the axis of the brim; the fundus is opposite the third vertebra, and stands only  $8\frac{1}{2}$  in. above the pubes.

Height of  
fundus in first

Alongside these sections from before labour we may place those from the first stage, since the changes during that period do not affect the height of the fundus. In (14) it is opposite the first vertebra, being 11 in. above the pubes: in (15) and (17) between the first and second, or  $9\frac{1}{2}$  in. above the pubes; while in (8), in which the uterus lies in the axis of the brim, it is opposite the third, or only 8 in. above the pubes.

and second  
stages.

Comparing now with these the sections from the second stage, we note that the height of the fundus depends on whether the uterus is contracting or not.\* Its level will evidently be lower when it is thrown into the axis of the pelvis than when it is lying along the spinal column. Plate v. shows the height of the fundus in the only new section published, which gives the topographical relations, and should be compared with those already given in Plate iv. The fundus is here opposite the first lumbar vertebra, or  $9\frac{1}{2}$  in. above the pubes. Although the head has descended so as to distend the perineum, the fundus has not sunk, but stands relatively higher. This is due to the extension of the foetus, to which we shall refer later on.

---

\* See p. 88.



The form of the uterus as a whole can only be properly studied on casts. Figs. 8 and 9 show the uterus from an eighth month pregnancy and the second stage of labour. In the latter case, the cast reproduces the whole genital tract—*i.e.* the cervix and vagina as well as the uterine cavity.

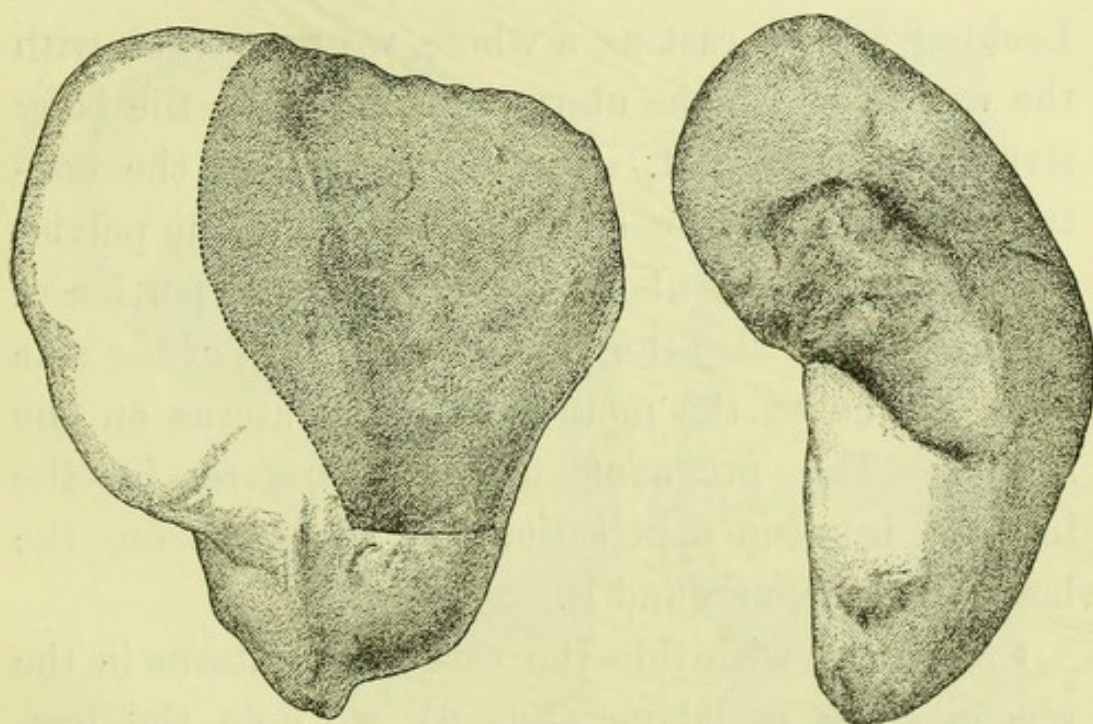


FIG. 8.

*Front and side views of a cast of the uterine cavity in the 8th month of pregnancy. The shaded area in the front view is the placental site; the knee-shaped bend in the side view corresponds to the sacral promontory.*

Fig. 8 gives an accurate representation of the capacity and contour of the interior of the uterus at the eighth month of gestation, the foetus lying with the breech downwards. The uterus is pear-shaped. While its form suggests that of a pear, its dimensions are, however, more nearly those of a globe, the



Contour of  
uterus in  
pregnancy  
and labour.

greatest vertical circumference being  $22\frac{1}{4}$  in., and the greatest transverse 20 in. The narrower lower segment was occupied by the breech of the foetus, the fundus being more prominent to its right side over the foetal head. The lower segment bulges more downwards on the right side, because the one buttock of the child was lower than the other. Looking at the cast as a whole, we are struck with the way in which the uterus is moulded on the bony structures around it. The front view of the contracted lower portion corresponds to the true pelvis; the expanded part above is the abdominal portion of the uterus; so also the knee-shaped bend of the side view is due to the moulding of the uterus on the sacrum. The pregnant uterus, therefore, in the interval between contractions, is moulded on the bony structures around it.

Comparing with this the cast of the uterus in the second stage of labour (Fig. 9), we note the irregularity of its contour which follows the outline of the foetus, although it is also broken in upon by the prominences of the retraction ring and the os externum. We may say generally, therefore, that while the pregnant uterus moulds itself on the spinal column and pelvis, the uterus, during the second stage, moulds itself on the child.

Cubic  
capacity of  
uterus.

The cubic capacity of the uterus and the bulk of its contents can be determined from these casts. The water displacement of the cast shown at Fig. 8



is  $137\frac{1}{4}$  cub. in., that of the child from the same case is  $111\frac{1}{4}$  cub. in. The difference between these gives the bulk of the amniotic fluid and cord, viz. 26 cub. in. By a similar method it was ascertained that the amount of liquor amnii still present in the uterus in the case from the second stage of which

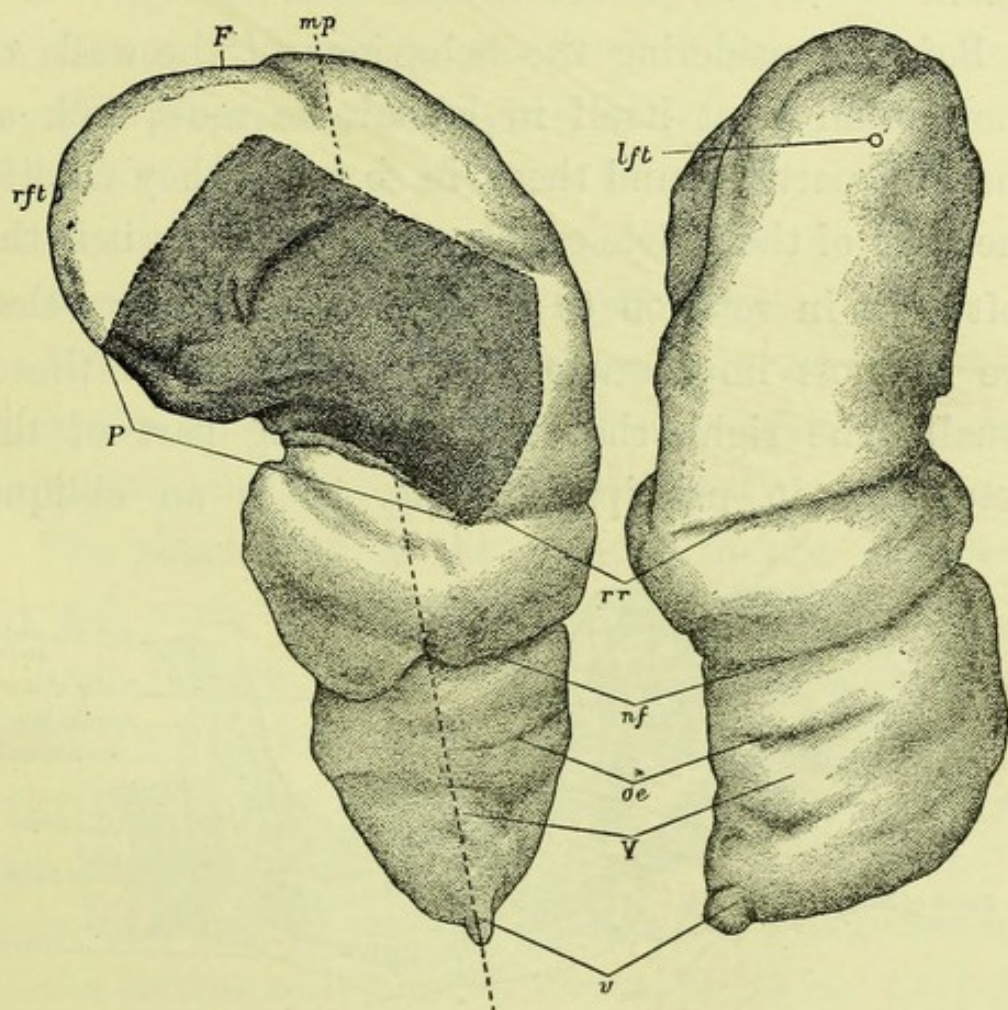


FIG. 9.

*Front and side views of a cast of the uterus and vagina, towards the close of the Second Stage of Labour, from the case of which the mesial section is given in Plate VI.*

*m.p.*, mesial plane of body, corresponding to section in Plate VI.; *F* fundus uteri; *rft lft*, right and left Fallopian tubes; *P* placental area; *rr* retraction ring; *nf* furrow corresponding to neck of foetus; *oe* os externum; *V* vagina; *v* vulva.



the cast is given in Fig. 9, was 19 cub. in. In another section (20), the cubic contents of the uterus in pregnancy was ascertained by Lusk. They were, for the whole contents, 97.6 cub. in., for the foetus, 92.1 cub. in., making the amniotic fluid 5.5 cub. in., the amount of liquor amnii being surprisingly small.

Soft parts  
around  
genital  
tract.

Before considering the behaviour of the walls of the genital tract itself in labour, we must look at the soft parts around these, in so far as they modify the form of the pelvic canal. Before labour, it is the soft parts in relation to the oblique diameters that are of most importance; as it is in one of these, usually the right, that the presenting part of the foetus lies in primiparæ. Fig. 10 is an oblique

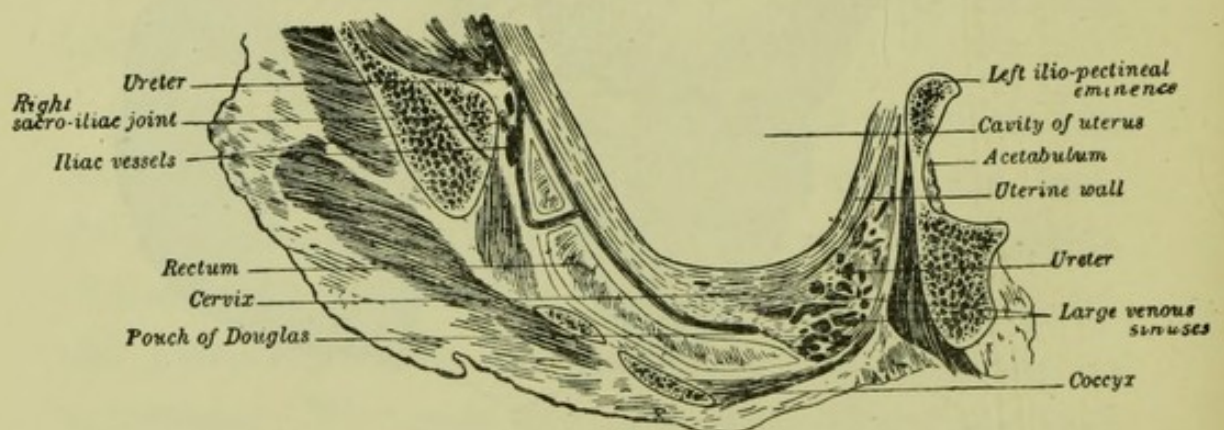


FIG. 10.—Section, passing through the right oblique diameter of a pelvis from the 8th month of pregnancy. The foetus and the liquor amnii have been lifted out, so that the uterine cavity appears empty.

section of the pelvis in the direction of the right oblique diameter. It shows how the available space in this diameter is encroached upon by the obturator



internus, which is of significance for the movement of internal rotation. In this section we have at the posterior end of the right oblique diameter  $\frac{5}{8}$  in. of soft parts,  $\frac{3}{8}$  being uterine wall, and  $\frac{2}{8}$  cellular tissue, while anteriorly there are about  $\frac{2}{8}$  in. divided equally between wall and tissue—*i.e.* the available space in the bony pelvis is diminished by 1 in. of soft parts. In labour these will be compressed into smaller bulk by the pressure of the presenting part. Below the brim anteriorly, we have in addition the obturator internus muscle encroaching on the pelvis as a muscular pad, almost  $\frac{1}{2}$  in. in thickness.

For the relation of the soft parts to the transverse diameter, in which the head of the fœtus often lies in multiparæ, Pl. II. may be consulted.

The shortening of the antero-posterior diameters by soft parts belongs to the second stage.

This is also the natural place to consider what light these more recent sections have thrown on the cervix and lower uterine segment. Where the section has divided the cervix, we find a canal of 1·5 in. in (7), 1 in. in (3), ·6 in. in (4). Section (2), which belongs to the former series, shows a canal of 1·4 in. Leopold, in discussing his sections from the various periods of pregnancy, finds that they give no support to the view that the cervix contributes to the formation of the lower segment. The most exhaustive discussion of this subject is, however, in Von Franke's monograph, in which, from the study of a much

The cervix  
before labour.



larger number of specimens, he comes to the same conclusions as we have already stated.\*

We pass now to the consideration of the uterus in labour.

The uterine  
wall before  
labour,

To appreciate the change in the uterine wall during labour, we must ascertain the relative thickness of its various parts before labour begins. The uterine wall varies greatly in thickness in different sections, from .1 in. to .5 in. The wall is, as a rule, thinner at the placental site, and at the fundus; but the point of chief interest is its relative thickness in the lower region of the uterus, the part which is known as the lower uterine segment. In every section the anterior wall becomes thinner in its lower fourth, to a varying degree; in three cases (1, 2, 3) it thins to about one-third, and in one (4) to one-half. The posterior wall, on the other hand, in most cases becomes thicker in the same region, becoming in two cases (2, 4), twice as thick, in one (1) one-half as thick; while in one only (3) does it remain of the same thickness.


in the first,

In the sections from the first stage, the relative thinness of the anterior wall in its lower portion is not appreciably increased. The posterior wall has, however, thinned in its lower fourth, so that this

---

\* See pp. 33, 134. In addition to specimens from the museum at Würzburg he has collected all the uteri described in the literature, noting the same facts with regard to them as in our own tables. See Note B, at the end of this chapter.

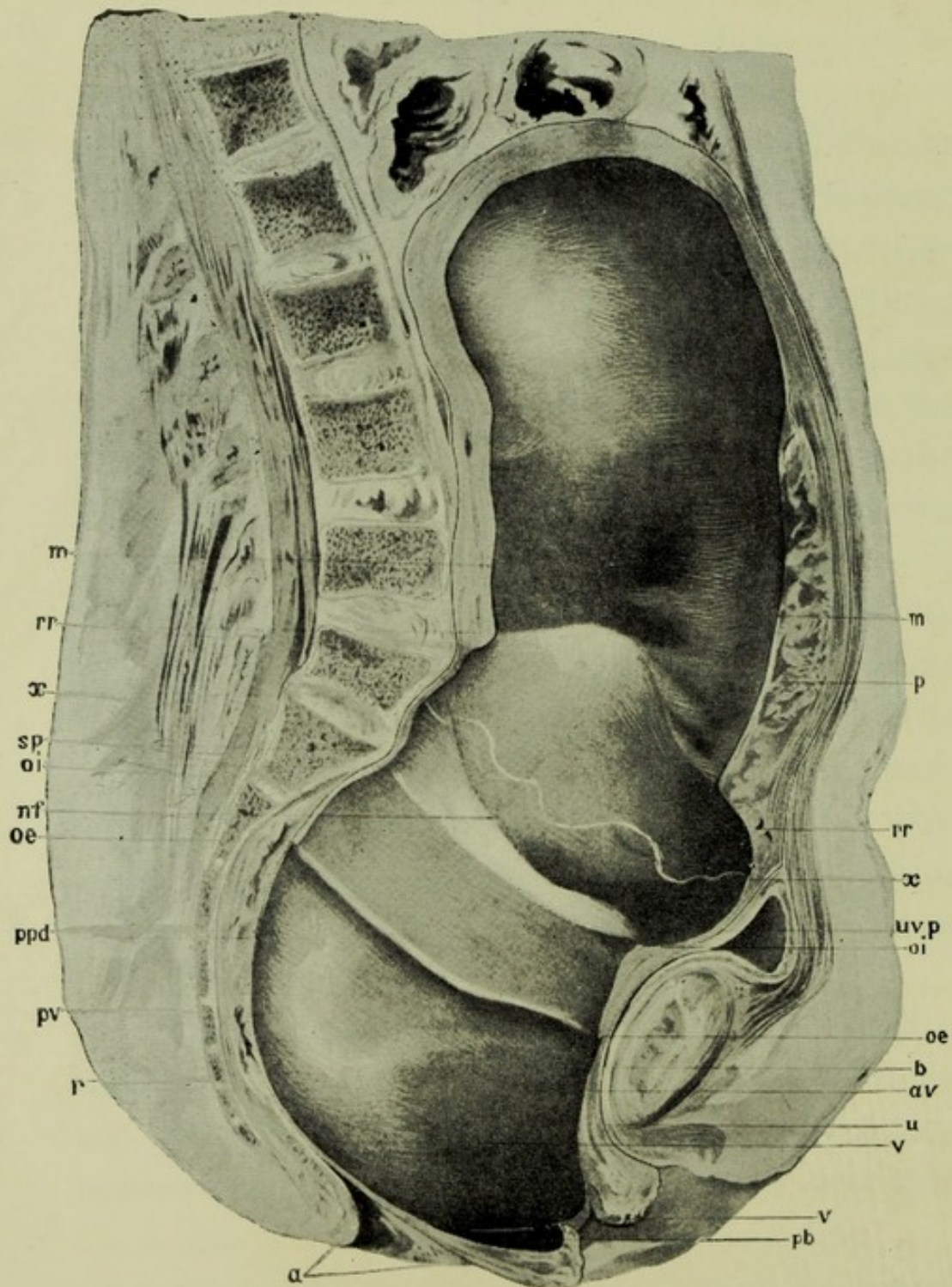






PL. VI.—THE GENITAL TRACT towards the close of the Second Stage, from the section given in Pl. V.

m membranes, attached down to wavy line x, but separated below; p placenta; rr retraction ring; sp sacral promontory; uvp utero-vesical peritoneum; ppd pouch of Douglas; nf ridge corresponding to neck of child; oi os int. and oe os ext., cervix being shaded; b limit of bladder behind pubes; u urethra; av, pv anterior and posterior vaginal walls; r rectum; a stretched anus; v vulva; pb perineum stretched.



The fundus is at the level of the first lumbar vertebra or  $9\frac{1}{2}$  in. above the pubes; the utero-vesical peritoneum is above the trim, and the bladder in part an abdominal organ; the genital tract falls into two parts at the retraction ring (Compare Pl. IV.); the cervical canal measures 1.7 in. anteriorly, and 1.3 in. posteriorly; the anterior wall of the vagina is of its usual length of 2 in., while the posterior is elongated to 7 in., and correspondingly thinned; the membranes are separated up to a point immediately below the retraction ring; the placenta is not separated; the rectum is compressed, and the anus and perineum stretched.



part is only slightly thicker (8, 9, 12, 13, 15, 16, 18), and sometimes even thinner than the portion above (10, 14).

For following the changes in the uterine wall <sup>and second</sup> during the second stage, only one section (25) is <sup>stages.</sup> available, as the others are from cases of pathological labour. This one, is, however, of special value, as it is from a more advanced period of labour than those described in chap. iv. We therefore give it in Pl. VI., which should be compared with Pl. IV. The uterus lies along the spine, and is not in a state of contraction. Its walls may be divided into two sections, differing strikingly in thickness. The lower limit of the thick portion is marked as the retraction ring, because here the process of retraction ceases. Above this ring the walls thicken throughout by retraction, the thickening being greatest in the posterior wall ( $\cdot 5$  in.), less at the fundus ( $\cdot 4$  in.), and the anterior wall ( $\cdot 3$  in.), and least at the placental site ( $\cdot 2$  in.). Below the ring, in the lower uterine segment and cervix, it suddenly thins to  $\cdot 1$  in. in front and behind.

In judging of thickenings in the uterine wall regard must always be paid to the contour of the contained foetus. We have already seen how, in the second stage, the uterine wall moulds itself on the foetus, and any furrows in the latter, as at its neck, will produce corresponding bulgings of the muscle. Hence the thickness of the wall must be



estimated, not merely as it appears in the frozen sections, but after a portion has been removed and thawed, and then hardened again, so that microscopic sections may be made. This was done here, and it was evident that the thickening was due to the rearrangement of the muscular bundles. Further, the ring is to be followed round over the back of the child, on which it has produced a distinct furrow. This preparation, therefore, confirms the fact pointed out on page 81, that the genital tract becomes differentiated into an active portion which thickens, and a passive one which thins, the first portion ending in a more or less well-marked retraction ring.

The relative length of these different portions of the genital tract measured along its anterior and posterior walls are as follows :—

	Anterior Wall.	Posterior Wall.
Fundus to retraction ring .	9·5 in.	6·5 in.
Retraction ring to os internum .	1·8 „	1·2 „
Os internum to os externum .	1·7 „	1·3 „
Os externum to vulva. .	2·0 „	7·0 „
	<hr/>	<hr/>
Total .	<u>15·0 in.</u>	<u>16·0 in.</u>

Effect of  
retraction.

These figures show in the upper segment greater retraction of the posterior wall. This is evident from the appearance of the section in which the retracted portion of this wall is manifestly thicker, and ends at a higher level. The lower segment is more elongated anteriorly than posteriorly, and the cervix likewise, though to a less extent. The



anterior vaginal wall is, compared with its length in pregnancy of 2 in., only slightly elongated, while the posterior wall has been stretched to more than double its usual length of 3 in.

We see, therefore, that the greater retraction of the posterior wall has occurred chiefly at the expense of the vagina. The presence of the placenta has evidently interfered with retraction anteriorly, since the wall at the placental site is thinner than even at the fundus.

Passing now to the cervix in the second stage of labour, we enter on debatable ground, owing to the difference of opinion as to the position of the os internum. In Braune's classical section (21) it was placed at the level of the retraction ring, making the cervix measure 4·4 anteriorly, and 4·8 posteriorly. No anatomical reasons were given for placing it there, as no microscopic examination was made.\* Chiari's section (23), in which the position of the os internum was fixed by microscopic examination, shows a cervix measuring 1·2 in. anteriorly, and 1 in. posteriorly, *v. Pl. I.* This threw doubt on the position of the os internum as described by Braune. In the section given in Plate VI,† we have a cervix measuring anteriorly 1·7 in., and 1·3 in. posteriorly,

The cervix in the second stage.

---

\* See Note C on "Braune's os internum and the retraction ring."

† The microscopic sections are given in Plate XXIV. of the Author's *Atlas of the Anatomy of Labour*, Third Edition.



which corresponds with the condition of the cervix described by Chiari. The greater length is probably due to the more advanced condition of labour, the head distending the perineum. These three are the only sections from normal labour\* in the second stage.

The length of the cervix has also been noted in two sections in which the foetus was turned and partially extracted for placenta prævia. In one of these (27) Zweifel describes the cervix as measuring 3·8 in. anteriorly, and 3 in. posteriorly; while Leopold in his section (28), under similar conditions, finds a cervix measuring in front and behind 1 in. The position of the os internum, as defined by Zweifel, is open to criticism (see note C at the end of this chapter), and against his section we must set Leopold's, made under similar conditions.

The evidence, therefore, from sectional anatomy is that the cervical canal becomes elongated by about one-half during the second stage, the canal of 1 in. becoming 1½ in. in length.

Space occupied by soft parts in second stage.

The amount of space taken up by the soft parts, in the antero-posterior diameters of the pelvis, can also be studied in the section given at Pl. VI. We have already considered this subject at p. 77; and putting this section alongside of those there described,

---

\* Chiari's section (22) is from a case of spontaneous evolution, and the details of the cervix are not given, while Von Mar's (24) and Zweifel's (26) are from cases of rupture of the uterus.



we may say that the antero-posterior diameter of the bony pelvis is diminished by soft parts at the brim by  $\frac{1}{2}$  in., and in the cavity and at the outlet by  $\frac{3}{4}$  in.

In considering the foetus, we have to study the form and size of the foetal ovoid, and the disposition of the head and limbs. The foetus.

The length of the foetal ovoid at full time varies from 8·8 to 11 in., the mean being 10 in.\* One evident cause of this variation is the size of the child. We may say that the length of the foetus in flexion is about one-half of the length of the same foetus extended.

The head is in every case, except one, flexed on the chest to a varying extent. It does not always look straight downwards, but is occasionally turned slightly either to the right or to the left. This turning of the head is a simple modification of the attitude of the foetus, and must be distinguished from rotation of the head in labour.† Attitude of  
foetus in  
pregnancy.

---

\* There are eleven cases which are available for measuring the length of the ovoid, four being before labour, and seven early in the first stage. The exact length of the different sections are—8·8 (1), 9·1 (7), 9·2 (10), 9·6 (2), 9·7 (3), 10 (9, 17), 10·4 (18, 19), 10·8 (8), 11 (14).

† I have used the term “turned” advisedly instead of “rotated,” so as to prevent confusion with the rotation which is the result of labour. The frequency of this condition will be evident from the following data :—Of thirteen sections, we find the head looking directly forwards in six (3, 7, 10, 12, 17, 19), while in four (2, 4, 8, 15) it is turned to the left, and in three (6, 4, 18) to the right. This position of the head relative to the trunk is in some cases due to the head’s adapting itself to the space in the pelvis, but in the majority is independent of this.



Further, the head is usually\* inclined on one shoulder. At first sight one might attribute this to the inclination of the pelvic axis on that of the abdomen. If this was the explanation, we should find it only in head presentations, and in these it should be always on the shoulder of the child that is posterior. It is present, however, in breech presentations; and in head presentations the inclination is as often on the anterior as the posterior shoulder.

Extension of the arms and legs, to a varying extent may also be present without any disturbance of the presentation. In one case, however, we find extension of both legs associated with a breech presentation.

In Leopold's Atlas,† which deals with the uterus in pregnancy as well as labour, the preponderance of breech presentations over vertex strikes attention—there are six of the former to four of the latter. On analysing the cases, we find that the breech presentations occurred in cases which are short of full time, and that in at least two of them the presentation was found to be a vertex some hours before death. These breech presentations we must regard

---

\* Of thirteen cases in which this can be studied, in only two (10, 17) is the head bent *straight* forwards. In two breech cases (2, 4), there is an inclination to the right and the left shoulders respectively; while of the head presentations, there is an inclination on the anterior shoulder in five (3, 6, 8, 15, 19), and on the posterior shoulder there is an inclination in four (9, 12, 14, 18).

† See Part II., pp. 121 *et seq.*



as accidental occurrences, due to a convulsion of the foetus in the death agony. The influence that the cord may have on the position of the foetal limbs is also evident in at least two of the sections; coils of the cord keeping the limbs in an abnormal position.

To sum up as regards the attitude of the foetus, we may say that frozen sections, which give us an opportunity of studying the attitude of the foetus in utero with precision, show that there are minor deviations from the classical description adopted in the text-books. The occurrence of these must be borne in mind, and we must not attribute to labour changes in the relation of the head and trunk which may have been present before labour began.

Before considering the movements of the mechanism of labour, we must look at the relation of the head of the child to the pelvis.

Relation of  
foetal head to  
pelvis.

Selecting from this series the cases of head presentation, we find that in none of them is the head at the brim synclitic, *i.e.* its occipito-frontal or suboccipito-bregmatic plane is never parallel to the plane of the brim, but always cuts it at an angle. The sagittal suture is not in the axis of the inlet, but either behind or in front of it—usually the latter. Hence it follows that a larger portion of the one parietal bone—usually the posterior—is below the brim than of the other. To bring out this point I have tabulated the cases, noting in the table how far the head has descended into the pelvis. The extent



to which the head has descended is estimated by measuring the distance of its lowest point on a perpendicular from the conjugate. The proportion of the posterior segment of the head lying below the conjugate is also given.

Section.	Period.	Distance of Vertex below Brim.	Prop. of Post. Half of Head lying within the Conjugate of the Brim.
3	9 months	2·5 in.	3·87 in. out of 7 in.
5	7½ months	2·25 in.	4 in. out of 6 in.
6	8 months	2·4 in.	5·75 in. out of 7 in.
9	1st stage	2·75 in.	3·50 in. out of 7·75 in.
10	„	2·75 in.	3·84 in. out of 7·1 in.
12	„	2·25 in.	2·12 in. out of 6·04 in.
13	„	2·75 in.	3·8 in. out of 7·25 in.
14	„	2·50 in.	4 in. out of 7 in.
18	„	1·62 in.	2 in. out of 4·75 in.

In six out of the nine cases, then, there is a larger proportion of the posterior half of the head within the pelvis. In three (9, 12, 18) the opposite is the case, more of the anterior half of the head lying within the pelvis. Two of these happen to be contracted pelvises. The evidence then from sectional anatomy with regard to the relation of the head to the brim, goes to show that before labour and during the first stage, in the normal pelvis the head does not lie in the axis of the pelvis, but with its sagittal suture rather nearer the symphysis, so as to bring more of the posterior half of the head within the brim.



In estimating the clinical importance of this fact, we must remember that the frozen sections were made with the body recumbent, while in the first stage the patient is often erect; also, that they represent the relation of the head in the interval between the pains, and that the effect of uterine contraction is to throw the fundus forwards. The erect posture and uterine contractions will both tend to correct this anterior inclination of the head. There does not seem, therefore, to be sufficient grounds for the assumption of Pinard and Varnier that the engagement of the head implies a movement which does away with this posterior asynclitism gradually as the head descends.\*

Passing now to the mechanism of labour, these sections allow us to follow it further than we were able to do in the previous series. We saw before (*vide* pp. 85, 92) that the foetus grows in the attitude of flexion, and that it was questionable whether this increased in normal labour to such an extent as to warrant its description as a definite movement. In all the sections since published, with one exception, the chin of the child is in every case on the sternum before labour begins, and, during the second stage, until the head is born. The one exception is Pinard and Varnier's occipito-posterior case, in which the chin is extended to the extent of  $1\frac{1}{4}$  in. It is in-

The mechanism of labour.

---

\* See note D at the end of this chapter on the "Engagement of the head."



Significance of  
flexion.

interesting to note this exception as occurring in an occipito-posterior, where clinical experience tells us we are most likely to meet with extension. But the chief value of the separation of the chin from the sternum in this single instance is that it shows that the approximation of chin to sternum in the other cases is not a post-mortem change due to the sinking down of the body of the foetus before freezing, otherwise it would have been present here also. The evidence then of frozen sections necessitates a revision of our description of the mechanism of labour, in which flexion has hitherto had an important place; for no fact will strike an observer more,\* in studying this array of sections, than the persistence with which the foetal chin is on the sternum. Frozen sections teach us that flexion

---

\* To emphasise the point, we quote from the various texts the descriptions of the position of the head:—

“Assai piu marcata è la flessione della testa sul piano anteriore del tronco; la flessione è spinta al Massimo essendovi forzato addossamento del mento al piano sternale.” (Pestalozza, p. 6.)

“La tête fléchie au point que le menton est étroitement appliqué sur la région sternale, est *asynclitique* et *présente son pariétal postérieur*.” (Pinard and Varnier, p. 85.)

“La tête . . . très fléchie, puisque la région sus-hyoïdienne est étroitement appliqué contre la paroi antérieure du thorax.” (Pinard and Varnier, p. 19.)

“Der Kopf in Beugstellung zur Brust sich befindet.” (Braune and Zweifel, (pp. 17-18.)

“La tête est fortement fléchie sur le thorax.” (Testut and Blanc, p. 7.)

“La testa così inclinata allo stretto superiore è già flessa, con non rara anticipazione del primo movimento meccanico del parto.” (Pestalozza, p. 5.)



plays a very subordinate *rôle* as a movement in the mechanism of labour, as compared with, say, internal rotation—in fact, that it is a question whether we are justified in speaking of it as a movement of labour at all. “Flexion” is not a movement, but an attitude. This does not imply that a movement of flexion may not occasionally take place; there may be a disturbance of the normal attitude of the head, as of any other part of the body, and this disturbance may be corrected by a movement of flexion. But to say this is quite a different thing from describing flexion as an integral part of the mechanism of labour, and putting it alongside of internal rotation.

The head of the foetus is also moulded (see Pl. VII.). Moulding of  
foetal head. While there is marked a-symmetry of the head, due to a bulging of the anterior parietal bone, which is not supported by the soft parts, there is no overlapping of these bones at the sagittal suture. On the other hand, they are both seen to overlap the occipital at the lambdoidal suture in a cross section of the head.\* It is possible that the overlapping of one parietal bone over the other, found in the head moulding after birth, may be due to a recoil of the bones from their distorted position in passing through the pelvis. The caput succedaneum is also well marked. It is worthy of note that in two frozen sections in the

---

\* Author's Atlas, Third Ed. Pl. xix. Fig. ii.



first stage (19, 20), a caput succedaneum had begun to form *before* the rupture of the membranes.

Extension of  
body of foetus.

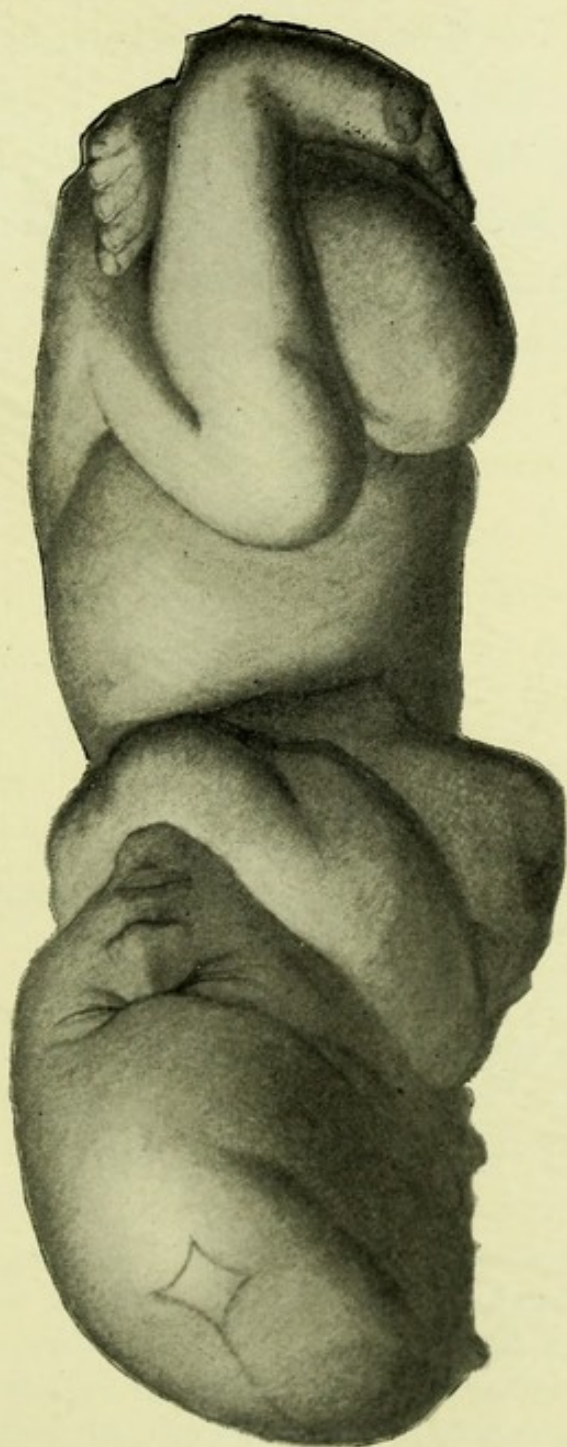
Further, the body of the foetus tends, as a whole, to become extended during its expulsion. Plate VII. is of peculiar interest, as being the only representation which we have of the foetus towards the close of the second stage. It should be compared with those given in Plate I. It is from a later period than that shown in Chiari's section, in which the membranes were yet unruptured and the head not rotated. The extension of the trunk is still more marked here, producing a space between the flexed arms and legs.

Internal  
rotation.

Being from a later period in labour, this section throws light also on the movement of internal rotation and its cause. It is seen to be primarily a movement of the head, not of the trunk. Olshausen advanced the view that antero-posterior flattening of the uterus on the escape of the liquor amnii acted on the trunk of the child, and through this, on the head, causing internal rotation. The mobility of the head on the shoulders makes such a theory improbable, and the evidence of sectional anatomy is against it; and we have seen that it is not uncommon to have a certain amount of rotation of the head, independent of labour. Looking at this foetus in the body (*vide* Plate V.), we see that while the back is lying to the front and left, the head lies between the right oblique and conjugate diameters. Partial forward rotation of it has therefore occurred, with




PL. VII.—THE FŒTUS from the frozen section given in Pl. V.



*The length from vertex to breech is 13 in., the flexion of the spinal column and of the head on the chest is less pronounced than in pregnancy; the head is turned to the left, as the result of internal rotation; its diameters are occipito-frontal  $4\frac{1}{2}$  in., occipito-mental  $5\frac{1}{2}$  in., and sub-occipito-bregmatic  $4\frac{1}{4}$  in.; while the occipito-frontal and sub-occipito-bregmatic circumferences are both  $12\frac{1}{4}$  in.; below the left arm is seen a furrow which passes round the back and is produced by the retraction ring.*

*This fœtus should be compared with those given in Pl. I.*







the trunk remaining in the position in which it is usually found in primiparæ before labour.

When we ask what is the cause of the change in the position of the head, we find that it is a simple question of accommodation. The section given in Fig. 10 (page 178) shows how the space in the oblique diameter becomes encroached upon in the lower straits of the pelvis by muscle and cellular tissue. The cross sections of the canal at various points given by Zweifel show that the space increases in the conjugate, while it diminishes in the transverse, passing through the pelvis. In this, combined with the action of the pelvic floor\* in directing forwards the part of the child which first of all comes in contact with it, must be sought the cause of internal rotation. Its cause.

The other four of the five sections in this series, from the second stage, are from cases of pathological labour—two from rupture of the uterus, and two from placenta prævia. In

---

\* The shape of the pelvis in any one plane does not give a complete account of rotation. In limiting his attention to the plane of the greatest circumference of the head, and to the form of a given plane of the pelvis, Zweifel omits all reference to the action of the pelvic floor on the vertex. We cannot give a complete account of the process in terms of horizontal planes. The obstetric canal is a basin with a floor; and the form of the canal, vertically as well as transversely, must be taken into account. Zweifel's *rationale* of internal rotation has this great value, that it emphasises the form of the canal in cross section; but it is incomplete, inasmuch as it makes no reference to the vertical relations—in one word, to the action of the pelvic floor in directing the vertex forwards, which Berry Hart has specially drawn attention to.



both the cases of placenta prævia, the patient died after the child was turned and one leg brought down. The chief interest of the preparations is in regard to the length of the cervix, in which connection we have already referred to them.

The sections from cases of rupture of the uterus show this lesion developing under anomalous conditions. They were multiparæ, with previous normal deliveries, and no history of obstruction or of unusually long labour before the rupture occurred. Zweifel ascribes the rupture in his case to post-mortem contractions; and Von Mars to spastic uterine contractions. The os externum is at the same level in these two cases as in section 25. The retraction ring is distant from it anteriorly 3 in. in Zweifel's, and  $6\frac{1}{2}$  in. in Von Mars' section.

Placenta and  
membranes.


So much for the changes of the foetus in labour. We have now to consider the behaviour of the placenta and membranes.

As regards the situation of the placenta there are twenty-four cases in which it is cut across in the vertical mesial section. In nine (5, 7, 9, 10, 12, 13, 19, 25, 27) of these it is on the anterior wall, while in three (4, 14, 18) it is on the anterior wall and fundus. In two (11, 29) it is on the posterior wall alone, while in six others (3, 6, 15, 16, 21, 23) it is on the posterior wall and fundus; in one (2) the insertion is fundal, while in three (17, 26, 28) it is prævia. In this series of sections, therefore, the anterior wall is the most frequent situation.\*

---

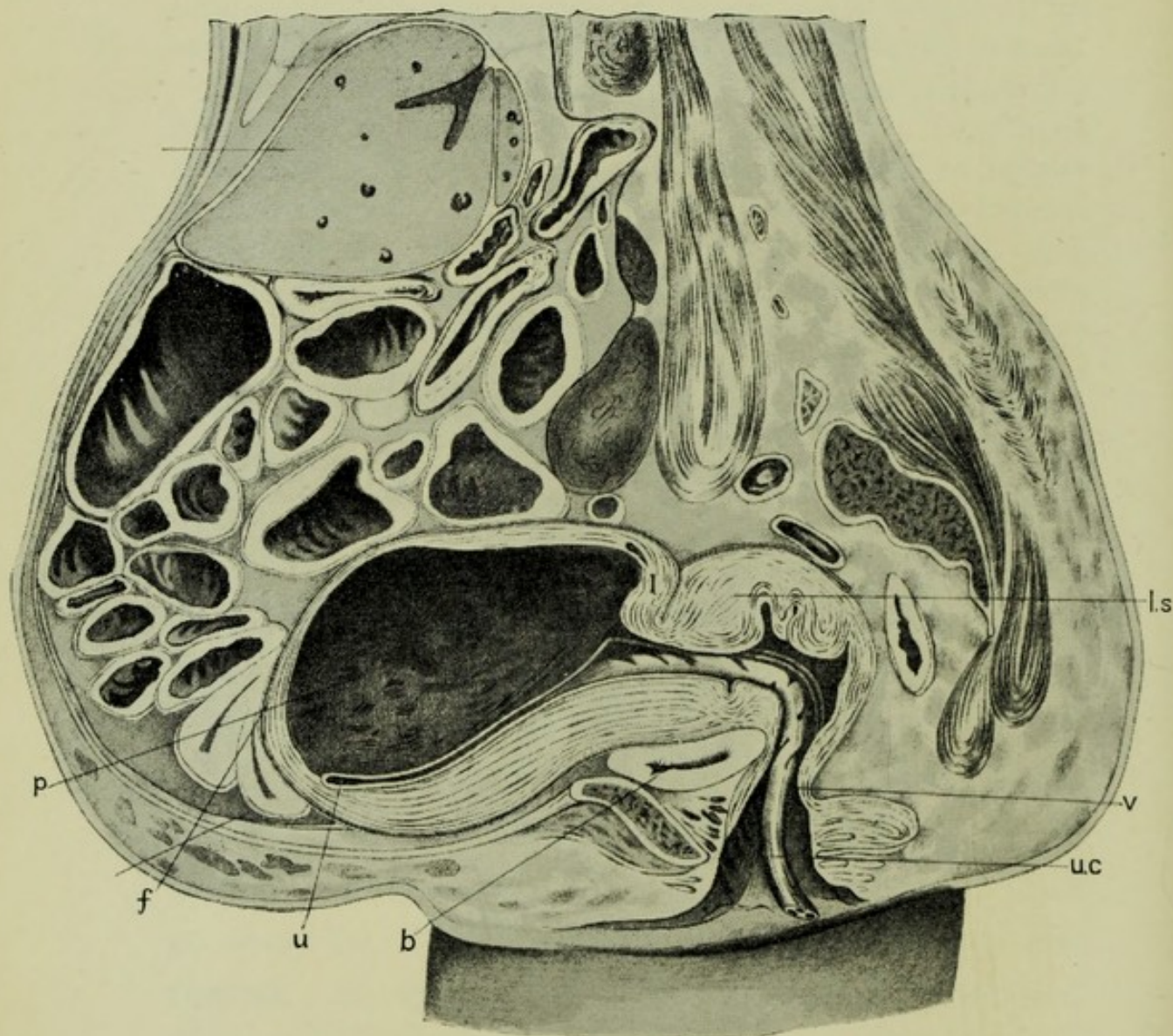
\* Leopold also found the placenta more frequently on the anterior wall (Part II. p. 130), and draws attention to the interesting clinical fact that under these circumstances the Fallopian







PL. VIII.—THE BEGINNING OF THE THIRD STAGE, from Pestalozza's  
Section.



*Freezing in the erect posture has produced a pendulous abdomen, and exaggerate l the anteversion of the uterus. f fundus; p placenta; u uterine cavity, with walls in apposition; ls lower segment; v vagina; uc umbilical cord; b bladder.*

*The uterus measures 8 in. vertically, and 4 in. antero-posteriorly. The latter measurement is made up of, anterior wall 1 in., placenta  $2\frac{3}{4}$  in., posterior wall  $\frac{1}{4}$  in. There is no empty space in the uterus.*

*The placenta extends over 8 in. of the posterior wall, and is as yet unseparated. The membranes are detached from the lower uterine segment.*



The extent of its insertion can be learned with precision only from casts, which show the whole area of the uterine cavity. In Fig. 8 (p. 147) we see that the placental site extends from the fundus to within 4 in. of the os internum, and occupies one-third of the area of the inner surface of the uterus—48 out of 147 sq. in. This is a larger extent than that given for my former case (v. p. 49) in which the area was only one-fifth—38·5 out of 204 sq. in. In that case, however, the results were obtained by calculating from the extent of the area as seen in vertical and transverse section. It is evident, also, that the area will depend on the size of the placenta, which is variable.

As regards the behaviour of the placenta in labour, we are now in a position to follow this throughout; Plate v. shows it during the second stage,\* and Plate VIII. at the commencement of the third. In neither of these is there separation of the placenta. The micro-photograph given in Plate IX. shows crumpling and relaxation of the tissues, which prepares for separation, but no actual detachment.

Pinard and Varnier's sections† of the uterus, removed from the body at the commencement of the

---

tubes run parallel to the long axis of the uterus; if the placenta is on the posterior wall, the tubes converge anteriorly. Pinard and Varnier, on the other hand, found the placenta more frequently situated on the posterior wall in their anatomical researches (Part II. p. 106).

\* With this the cast Fig. 9 should be compared, where, with a uterine cavity of 148 in., we have a placental area of 22·7.

† "*Vide*, Part II.," pp. 107, 109.



third stage, also show the placenta not separated but thickened, bulging at the borders, and in some cases folded, but without separation except at the lower border. It is worthy of note that two of those recent sections show placentæ from twins and triplets, which means that before labour there must have been an unusually large uterine cavity with its area extensively covered by placental tissue. If the placenta were to be separated by the diminution of its site alone, it would have occurred under these conditions. And yet, in the other section described by Pestalozza, with twin placentæ, there is no separation, nor in Pinard and Varnier's triplets except at the lower margin of the larger placental mass.

The conditions found in these more recent sections correspond in every point with the description of the third stage given in chap. v., and we have nothing to add to it. While Pestalozza's section has brought no new anatomical facts to light, we have reproduced it here as "it represents what is actually seen and carries the mark of truth." In importance it ranks with the sections from pregnancy and the second stage given in Plates I. and V. It shows exactly what we have in the hand when we grasp the uterus in the third stage.\*

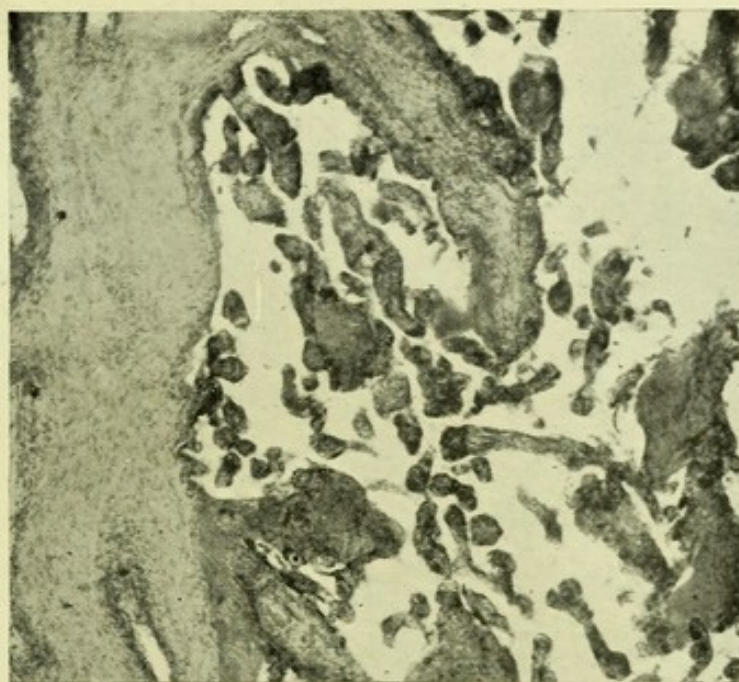---

\* The diameters of the uterus, 8 in.  $\times$  4 in., are not exactly the same as those given at p. 97—9½ in.  $\times$  3½ in. They are, however, more accurate, as they are of the uterus frozen in the body. In the other case there is antero-posterior flattening, with proportionate elongation—the result of the uterus being frozen out of the body.

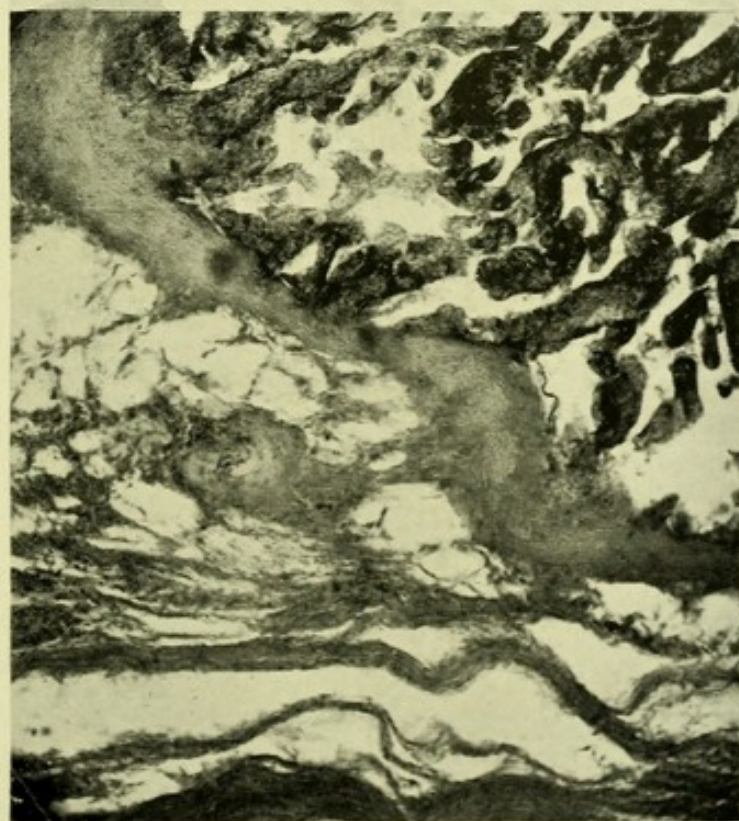

PL. IX.—MICRO-PHOTOGRAPHS of the PLACENTA, from the frozen section given in Pl. V., to show its relation to the uterine wall and the amount of blood in the sinuses.

*Trabecula*



*Sinus with villi*




*Muscular wall of uterus*

*Villi*

*In the lower section the placenta is still continuous with the uterine wall, although separation is apparently commencing at the base of the trabecula. In the sinus to the right very little maternal blood is seen between the villi.*

*The same trabecula is shown at a higher point in the upper section. Here also scarcely any blood is seen between the villi ; the same is the case in the other sections made through this placenta.*







As regards the expulsion of the placenta this is a point which can only be settled clinically. From the position of the placenta in utero during the third stage, as shown by sectional anatomy, it is evident that the lower border, or a point near it, will be the first to slip out of the uterine cavity.\*

The behaviour of the membranes during labour, as seen in these new sections, confirms the description given in the previous chapters. In the first stage they are separated from the lower segment to a varying extent, so as to form the bag of membranes. In the second stage this separation is seen to have occurred up to the retraction ring—as far as *xx* in Pl. VI. In the third stage, they do not undergo retraction, like the underlying muscular wall, but are thrown into waves. This crumpling means partial separation—at the crest, but not at the trough of the wave. Complete separation does not occur until the placenta is born and drags the membranes after it.

The mem-  
branes in  
labour.

Passing now to the changes in the placental circulation which take place during this process, we have

---

\* Pinard and Varnier have figured a section in which the cord presents and the placenta is being expelled inverted, by the mechanism which Baudelocque described, and maintain that this is the more frequent occurrence. Clinical experience shows, however, that it is rare to have the insertion of the cord presenting at the os internum, as it does in this specimen. It is quite possible that when the placenta is situated over the fundus, instead of the anterior or posterior wall, it will leave the uterus by this mechanism (v. p. 105).

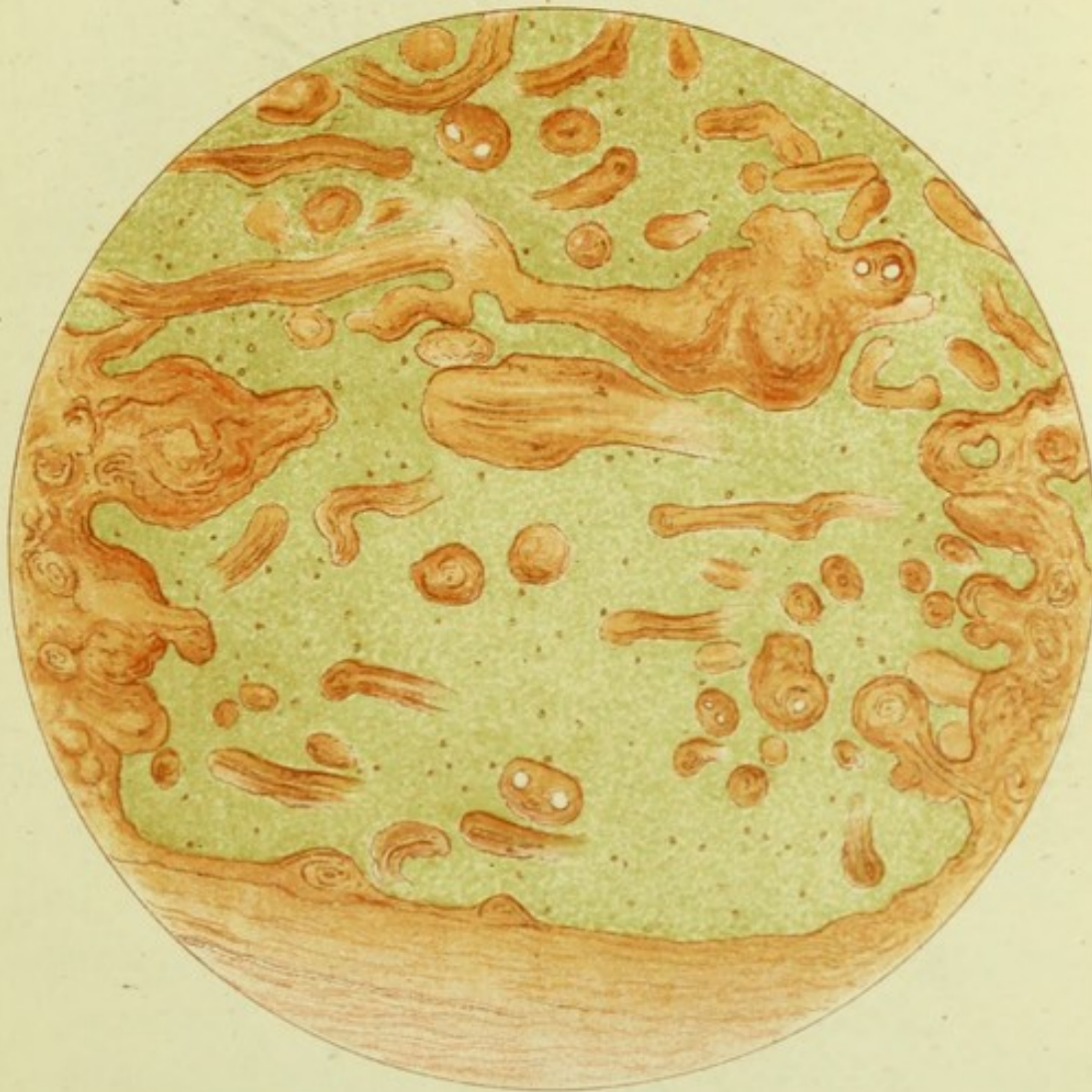


Placental  
circulation in  
the second  
stage.

not yet much information. The sections of the placenta from the second stage (*v.* Pl. IX.) show little maternal blood in the placental sinuses; for comparison with them I have reproduced in Plates X. and XI. sections that I made some years ago of the placenta from a uterus removed by Porro's operation. In this case an elastic ligature had been thrown round the uterus before amputation, and as the placenta was not cut into during the operation, and very little blood was lost from the incision in the uterus, the placental sinuses are seen distended with maternal blood.

These sections have this further interest that they demonstrate the maternal sinuses in which the villi lie. Investigations into the placental circulation have always been made by artificial injection, which disturbs the natural relation of the parts. Hence some have questioned the existence of the sinuses, and ascribed the appearances produced in injected placentæ to an artificial opening up of the tissues by the material injected. The sections given in Plates X. and XI. place the existence of the sinuses beyond a doubt, and demonstrate the relation of the two circulations—maternal and foetal. Whether there is always as much blood circulating in the maternal portion of the placenta in normal pregnancy as appears in the microscopic section in Plate X. is an open question. In no other sections of Porro uteri have I found the same amount, but this may be






Section of a PLACENTA removed by Porro's operation, showing the sinuses distended with maternal blood (stained with picrocarmine).

Trabeculae are seen on either side, forming the walls of the sinus. Foetal villi, free and attached, are divided transversely and longitudinally.







accounted for by blood lost during amputation of the uterus.

The placenta taken from the second stage uterus presents a remarkable contrast as regards the small amount of maternal blood present in it, as will be evident from the comparison of Plate IX. and X. A natural enough explanation would be that the process of uterine retraction, which goes on during the second stage, has begun to cut off the maternal blood supply. That the maternal placental circulation diminishes during the second stage is a well-known fact, of which we have evidence in the cyanosis of the foetal head as it lies at the vulva when the birth of the shoulders is delayed. This used to be ascribed to partial separation of the placenta having accompanied the partial withdrawal of the uterine contents. Of this there is no evidence. Uterine retraction, with the re-arrangement of the muscular fibres which this implies, gives a sufficient explanation. To borrow an illustration from surgery, nature applies a tourniquet before amputating the placenta.

Passing now to the puerperium, I have reproduced in Fig. 11 the frozen section from Case 34. It is the only one we have showing the relation of parts immediately after delivery in a normal pelvis, and should be compared with those given in Figs. 5 and 6, in both of which the deformity of the pelvis has modified the relations of the uterus. Unfor-

Explanation  
of small  
amount of  
blood in  
sinuses.

The puer-  
perium.



tunately, the removal of the intestines has disturbed the relations of the fundus, but the section shows very well the disposition of the lower portion of the uterus and vagina. We see the retraction ring, the collapsed lower segment, and

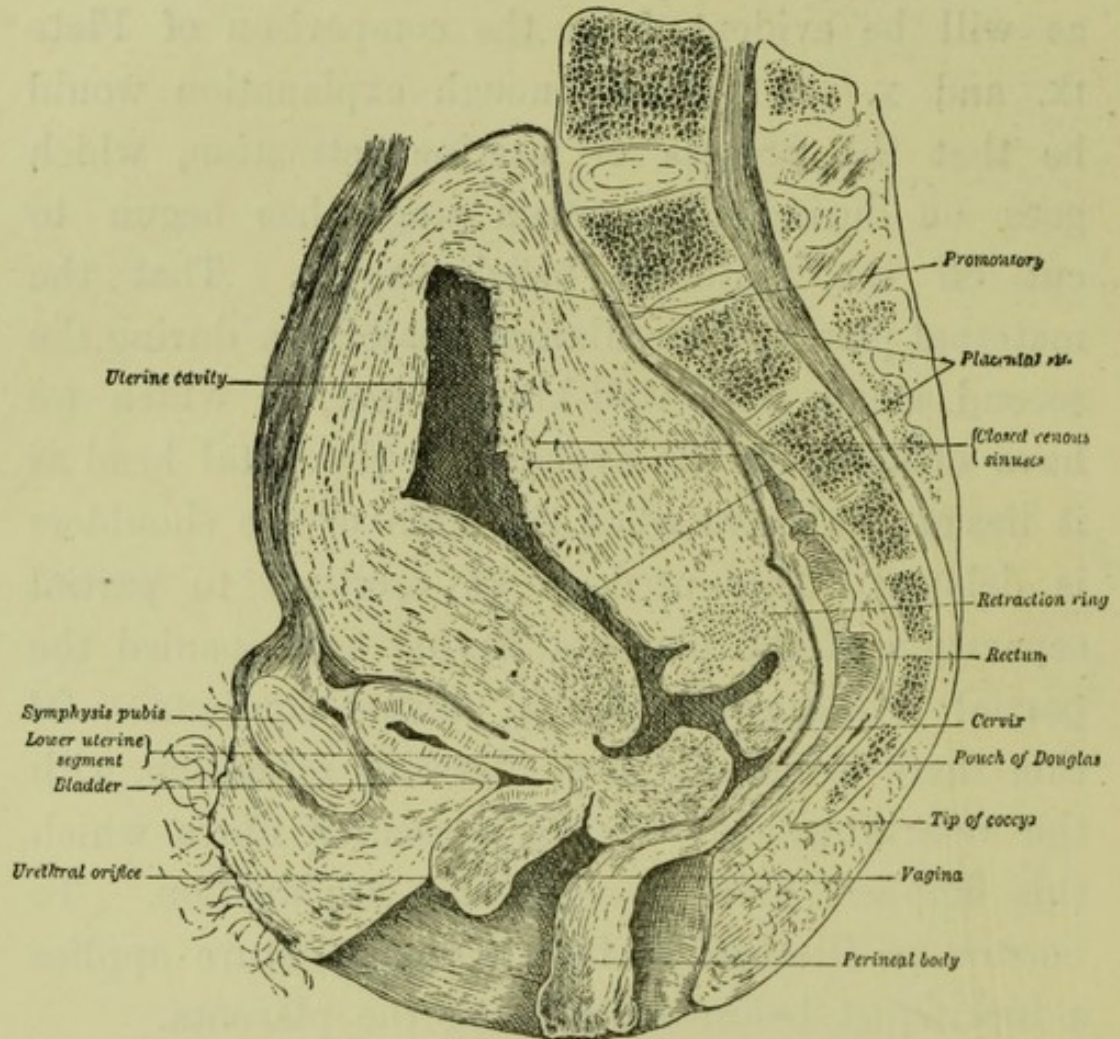
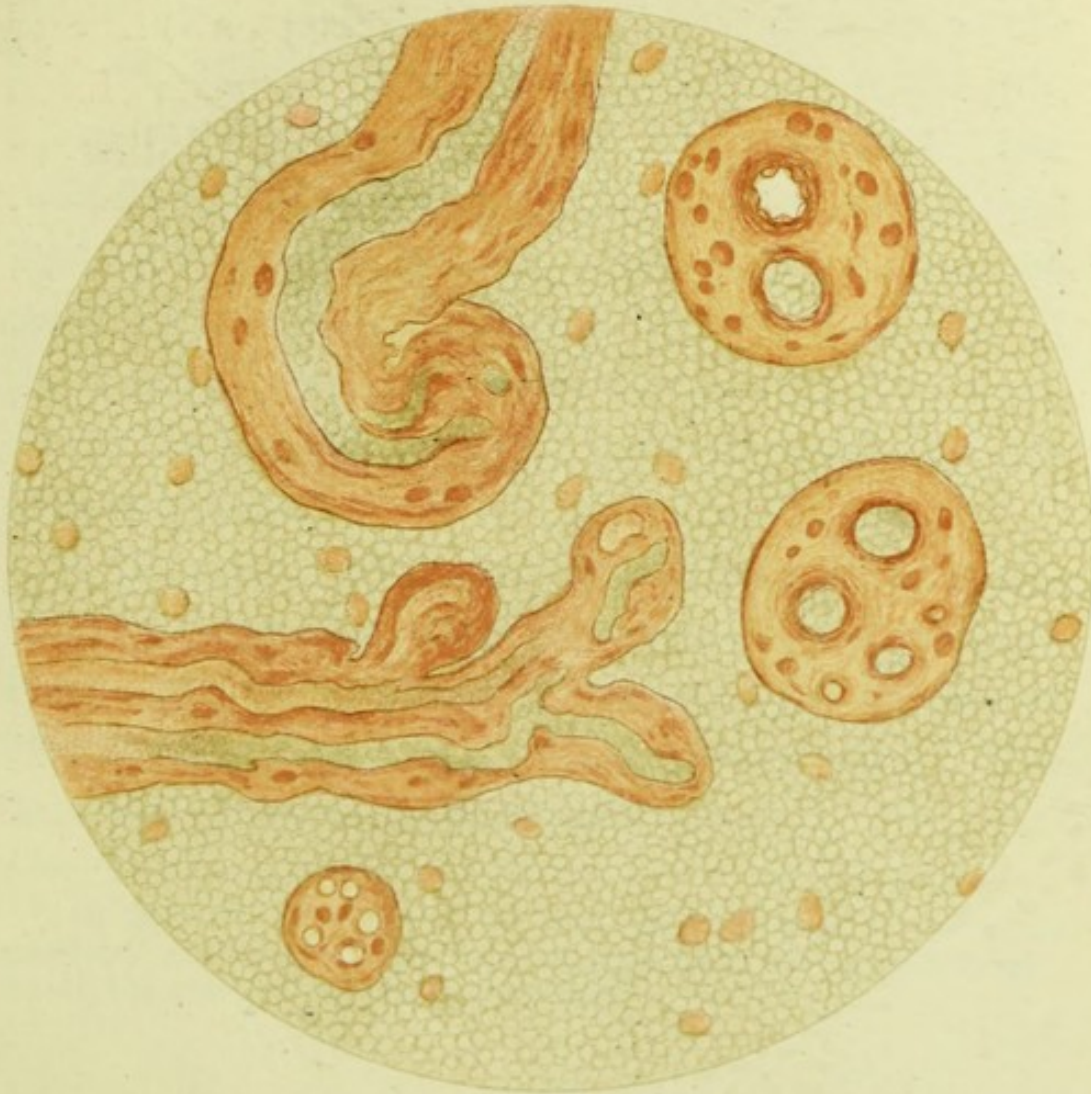

FIG. 11.

*Frozen Section made immediately after delivery.*

the cervix flattened against the posterior vaginal wall; also the position of the bladder. This section does not bring out any new points, but furnishes a valuable demonstration of the facts of the early puerperium given in chap. vi.






Section from the same placenta as given in previous plate, under a high power; to show the relation of the maternal and foetal blood streams.

As both the foetal villi and the maternal sinus are distended with blood, the relation of the blood streams is demonstrated by a natural injection.

Note that the villi lie free in the maternal blood, which forms the bulk of the section. The course of the foetal vessels in the villus, and the thickness of tissue separating the two blood streams are clearly seen, though the staining does not bring out the epithelium of the villi.







The other sections given by Webster from the puerperium have brought out two new points of interest. The first is the action of the post-partum uterus as a plug in checking bleeding. He shows how the uterus after delivery fills the pelvis and compresses the veins of the broad ligament, and thus lessens bleeding from the body of the uterus. The other point is that the uterus is not diminished much in size during the first three or four days of the puerperium. It is after that period that there occurs the marked change in bulk which we associate with involution.

In the introductory chapter we spoke of the possibility of being able, when the series of sections from every stage is complete, to construct the history of labour from a purely anatomical standpoint. The time has not come for that yet.\*

---

\* In note E, at the end of this chapter, will be found a summary of the new facts learned regarding the second stage, which the student will find of service.



## NOTES TO CHAP. VII.

NOTE A. On the position of the promontory of the sacrum as shown by frozen sections . . .	203
NOTE B. On the cervix and lower segment . . .	209
NOTE C. Braune's os internum and the retraction ring .	212
NOTE D. On the engagement of the head . . .	213
NOTE E. Summary of the new facts learned regarding the second stage . . . . .	216



## NOTE A.

ON THE POSITION OF THE PROMONTORY OF THE SACRUM  
AS SHOWN BY FROZEN SECTIONS.

Hitherto the pelvis has been studied only in the dry preparation out of the body, or clinically in the living subject. The first method has its advantages and drawbacks; while it allows us to measure the diameters with precision, it gives no data for determining the position of the pelvis during life, and it disregards altogether the effect of the soft parts. Hence the information gained must be corrected and supplemented by such investigations as have been made in the living subject by Schultze and Skutsch. In dealing with a living subject, a new set of difficulties arise, from the way in which the pelvis is buried in the soft parts, and the difficulties of getting at it so as to make exact measurements. There is a further difficulty when we endeavour to measure one pelvis after another, for it is not easy to place and to keep one patient after another in the same position while the different measurements are being made.

Frozen sections offer a third means of investigating the form and position of the pelvis, and their study brings forward a new series of facts to correct and supplement the information gained from the two methods already mentioned. This third method, like the other two, has also its advantages and drawbacks. The advantages are that it shows us the pelvis set in the body. It is now no longer a question of holding a pelvis with dried ligaments in any position, or at any angle you please, but you see it kept in the position it occupied during life. Further, and what is of the first importance for clinical work, you see the pelvic cavity in relation to the abdominal cavity. Hence the pelvis can be studied in a way which is of the greatest value both to the gynecologist and to the obstetrician. The gynecologist locates structures in their relation to the brim of the pelvis, and the position of the promontory is of interest to him when determining the position of structures, *e.g.*, uterus and ovaries, with reference to the brim. It is, however, specially to the obstetrician that this method of looking at the pelvis is of importance. The contents of the uterus are abdominal in position at the end of pregnancy, while they have to pass through the pelvis in labour; hence the relation of the long axis of the abdomen to that of the pelvis is of the first importance. A drawback to this method of study is that there will be variations



in the set of the pelvis according to the position in which the cadaver is frozen. Fortunately frozen sections are usually made with the cadaver on the back, that is to say, with the body in the same position as it occupies both in gynecological examination and during labour. But even with the cadaver in this position there is room for minor changes in the position of the pelvis relative to the abdomen. I do not, therefore, attach importance to minor differences in the measurements or the angles given in the following table; after due allowance has been made for these, there remain certain broader features which, I think, justify the conclusions given below. Of some 38 frozen sections that have been made in pregnancy, labour, and the puerperium, only 14 are available for this inquiry. The others are set on one side, either because the section was not mesial, or enough of the cadaver was not frozen or reproduced to serve our purpose.

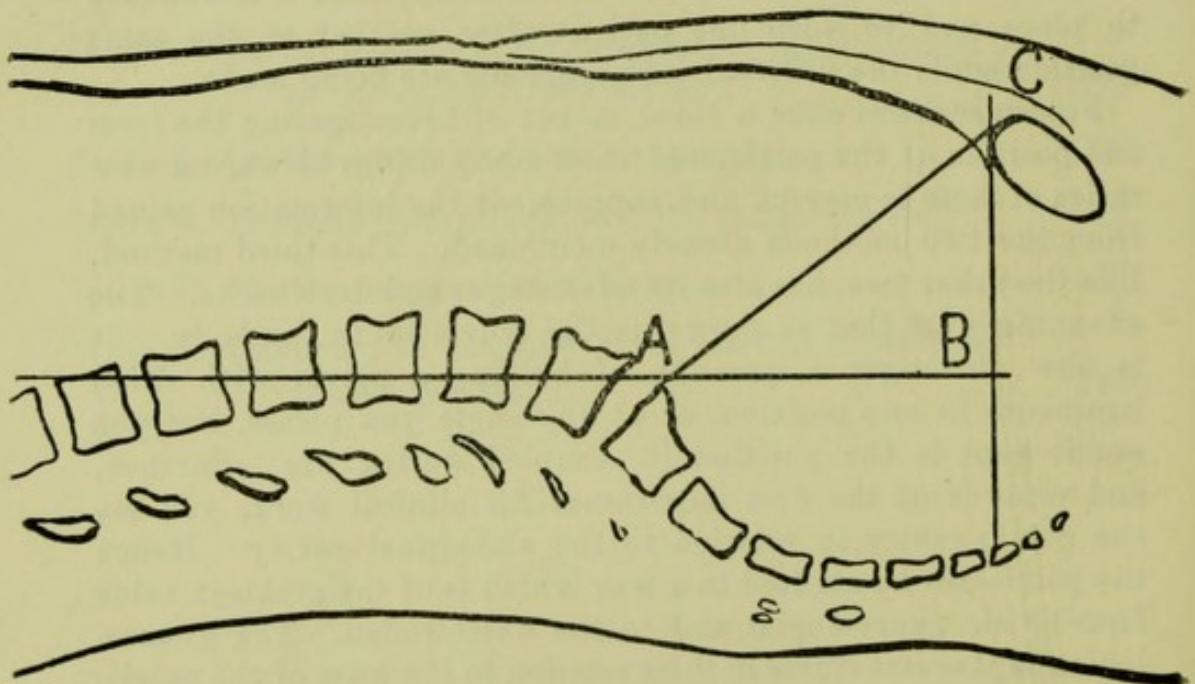


FIG. 12.

*Showing the mean height at which the promontory is found in frozen sections, the cadaver being in the dorsal posture.*

*For letters see text.*

For comparing one cadaver with another, we must have some method of studying the relation of parts to the horizontal plane. If a line be drawn passing through the upper anterior angle of



the first lumbar vertebra, and the promontory of the sacrum, it will be found, in the great majority of cases, to be parallel to the horizontal plane. In a few sections where the peculiarity in the lumbar curve has thrown this line evidently out of line with the horizontal plane, we may draw a line through the promontory, parallel to the latter. But in 10 out of the 14 sections, the line drawn through the anatomical points mentioned represents closely enough for practical purposes the direction of the horizontal plane, with the cadaver recumbent. This line also corresponds in direction to the axis of the abdomen as far as this affects the uterus. The fundus uteri at full time is usually on a level with a point between the first and second lumbar vertebra—never rising higher than the first, even when it elongates during the second stage of labour. The axis of the uterus, therefore, as it lies in the abdomen along the spine, corresponds in direction to this line.

If on this line, A B, we let fall a perpendicular C B from the centre of the upper margin of the symphysis, it will mark off on A B the height at which the promontory stands above the symphysis. By prolonging C B until it strikes the back wall of the pelvis, we learn how much of the sacrum and coccyx is above the same level, that is to say, how much of the back wall of the pelvis, and of the pelvic contents, lies opposite to the lower regions of the abdomen. Further, the length of C B shows how far the promontory stands back from the symphysis, or what proportion of the pelvic cavity is in line with that of the abdomen. This latter measurement is of great interest to the obstetrician, as the length of C B will show how much the abdominal contents will tend to rest on the pubis rather than sink down into the pelvis in pregnancy and labour. It is evident that A C, the hypotenuse of this right angle triangle, corresponds to the anatomical conjugate of the brim.

In the following table I have arranged the sections in series according to the length of A B, that is, the height at which the promontory stands above the symphysis. The second column gives the length of the line B C; the third column the intersection of A C B with the back wall of the pelvis; the fourth column the length of the anatomical conjugate. Comparing this fourth column with the first, we find that the length of the conjugate, while undoubtedly affecting the height of the promontory, cannot be the only factor; for with a conjugate of 4·8 in. (pelvis 3 and 14) we find a promontory standing 4·1 in. and 2·6 in. above the



pubis; while with a conjugate of 4.5 in. (pelvis 8 and 13) the height is 3.8 in. and 2.8 in. To find the explanation of this we must look at the fifth column, which gives the angle A C B, the size of which is found to be a factor of almost as great importance. This angle varies so considerably that we cannot explain the variation simply by changes in the position in which the cadaver was frozen. Its range is from 35° (pelvis 14) to 65° (pelvis 1) between which limits angles of all sizes are found.

	A. B. or Height of Promontory above Symphysis.	C. B. or distance of Promontory backwards from Symphysis.	Intersection of C. B. with back wall of Pelvis.	A. C. or Anatomical Conjugate.	Angle A. C. B. or set of brim.	Angle mAn or inclination of axis of Abdomen to brim.
1.	5 in.	2.4 in.	Tip of C.	5.56 in.	65°	25°
2.	4.68 in.	3.6 in.	Below S.	5.80 in.	55°	35°
3.	4.12 in.	2.56 in.	Below S.	4.8 in.	61°	29°
4.	4.12 in.	3.08 in.	1st C.	5.08 in.	55°	35°
5.	4.0 in.	2.8 in.	Below S.	4.88 in.	57°	33°
6.	3.96 in.	3.04 in.	1st and 2nd C.	4.92 in.	55°	35°
7.	3.96 in.	2.48 in.	2nd C.	4.72 in.	60°	30°
8.	3.88 in.	2.4 in.	3rd C.	4.6 in.	60°	30°
9.	3.88 in.	2.68 in.	1st and 2nd C.	4.68 in.	58°	32°
10.	3.32 in.	2.48 in.	4th and 5th S.	4.04 in.	55°	35°
11.	3.16 in.	2.8 in.	1st and 2nd C.	4.16 in.	51°	39°
12.	2.92 in.	2.96 in.	Below S.	4.08 in.	47°	43°
13.	2.88 in.	3.52 in.	1st C.	4.52 in.	41°	49°
14.	2.60 in.	4.0 in.	4th S.	4.8 in.	35°	55°

Were there a sufficient number of preparations we might take an average or mean, and thus ascertain what is the normal, or at least the most frequently recurring build of pelvis. We have however, too few specimens as yet to draw a general conclusion from, and therefore the figures given in the conclusions are provisional. I have reproduced here the sections of three cadavera. Fig. 12, which is the reproduction of section 6, has an angle of 55°, which is the mean for this series of 15 sections. It also happens to correspond with the received view of the normal inclination of the brim—viz. 55°. Alongside of it I have placed for comparison two extreme deviations from this—section 3, which has an angle of 61° (v. Fig. 13), and section 14, with an angle of 35° (v. Fig. 14). A glance at these sections side by side will show that the differences between these pelves is not simply one of inclination of the brim as a result of posture, but is due to a peculiarity in the set of the pelvis in the body.



A comparison of these three sections brings out the gynecological and obstetrical significance of this fact of the variability in the position of the promontory. To the gynecologist the length of the line A B is of chief interest ; the longer this line the more will

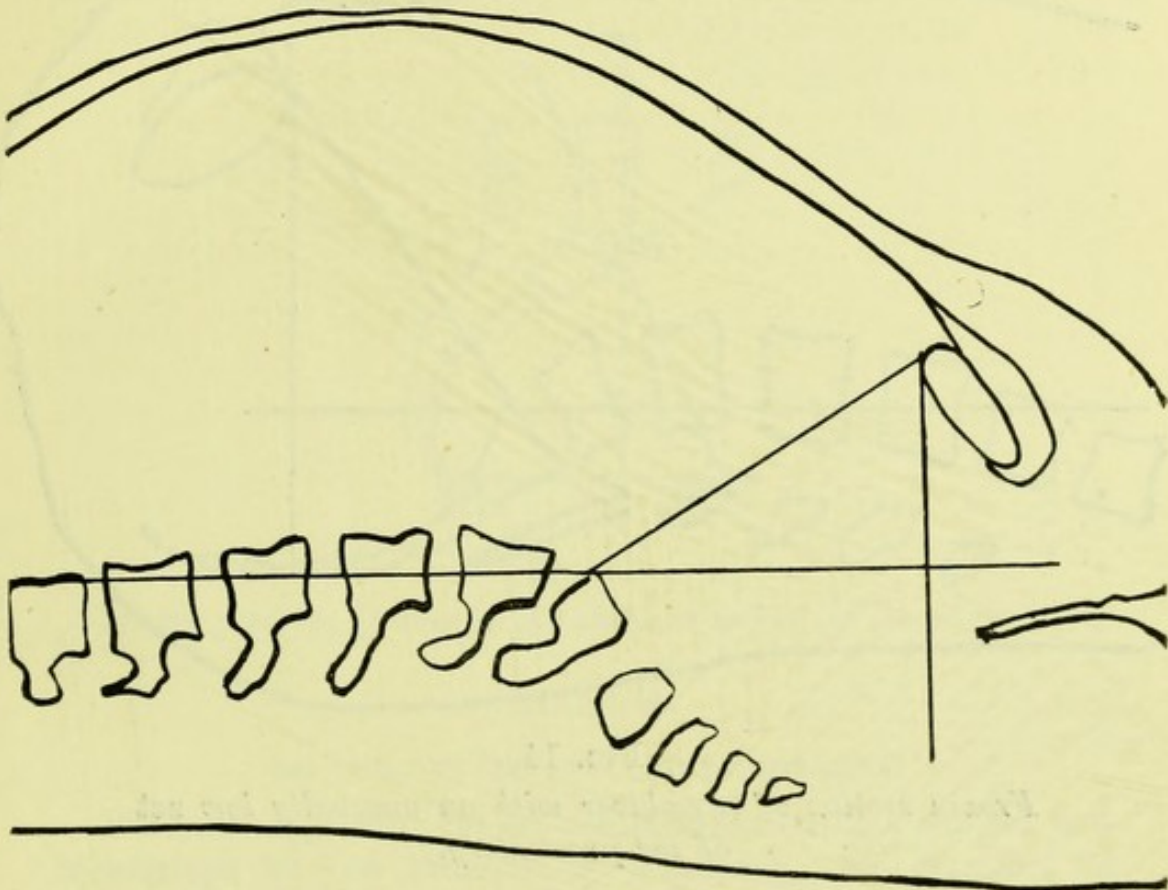


FIG. 13.

*Frozen section of a cadaver with an unusually high set of the promontory.*

the pelvic contents be brought opposite to the lower regions of the abdomen, and made accessible to abdominal palpation. On the other hand, the length of C B is of obstetric importance ; the longer this line is, the greater is the segment of the pelvis which is brought into line with the abdomen. With a uterus resting on the spinal column, and its axis parallel to A B, it is evident that the uterine contents would, in Fig. 13, be driven wholly against the pubis ; while in Fig. 14, they would partially enter the pelvis. During uterine contraction the axis of the uterus is thrown forward more or less into the axis of the pelvic inlet ; but it is evident that it would have to be thrown much less forward in such a pelvis as that of Fig. 14 than in that of Fig. 13.



The conclusions of this enquiry may be thus summed up.

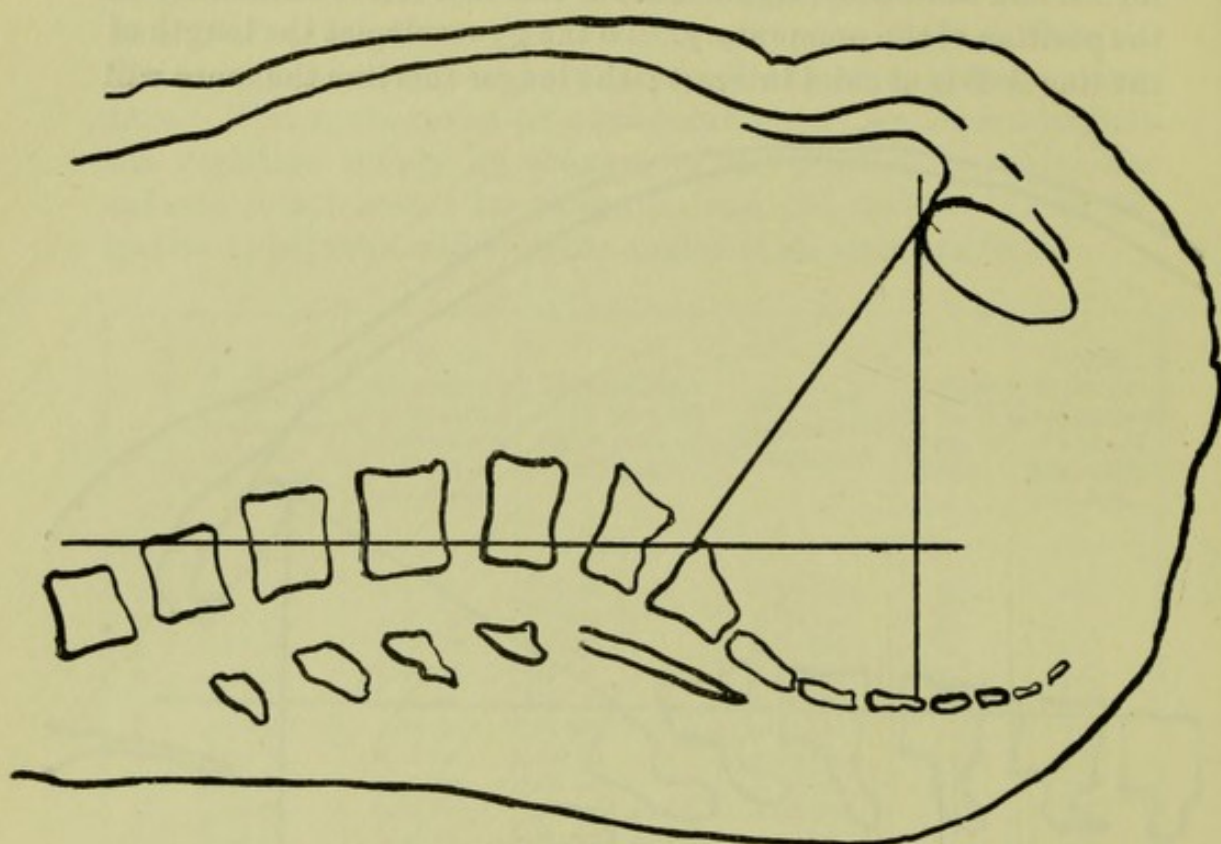


FIG. 14.

*Frozen section of a cadaver with an unusually low set of the promontory.*

1. The position of the promontory is variable, being affected, not only by a posture, but by the build of the individual pelvis, which determines the set of the brim.

2. In studying it in frozen sections we can analyse it into two measurements, one representing the height at which it stands above the symphysis, and the other the distance at which it stands back from it. The mean \* length of these lines is for the fourteen sections in which they can be measured 3·8 and 2·8 in.

3. The size of the angle A.C.B. gives not only the height of the promontory, but also the amount of divergence of the axis of the abdomen from that of the pelvic inlet. For, if a line P.A. be drawn at right angles to A.C., it will have the same direction as the axis of the brim, and the angle P.A.M. will indicate the divergence of the axis of the brim from that of the abdomen.

\* The mean, length where there are considerable divergences from it, gives a more correct idea than the average.







grows slightly in length in pregnancy. There is no evidence of its being taken up to form part of the cavity in which the ovum develops. In labour it does not become essentially elongated, the elongation from stretching being counteracted by shortening from dilatation.

The firm attachment of the peritoneum which marks the upper limit of the lower uterine segment rises higher as pregnancy advances. The segment measures from the second to the fourth month 2.3 cm., from the fifth to the sixth 4.1, and from the seventh to the tenth it is about 6 cm. During labour it varies from 3 to 10 cm. in different specimens, according to the stretching of the lower segment.

The relation of the bladder is variable. I do not attach much importance to von Franque's discussion of this question, as uteri removed from the body are of no value in settling it. He draws attention, however, to one interesting fact, that some six specimens have been described, two of them frozen sections and therefore of great value, in which the bladder is almost completely separated from the uterus, and the peritoneum descended correspondingly deep, coming into relation with the anterior fornix. Two of these specimens were from non-pregnant patients, and its occurrence in pregnancy seems simply to be the persistence in it of an anomalous disposition of the peritoneum found in some patients.

The development of a contraction ring in normal labour, and its presence in anatomical specimens, he considers established by the materials he has collected.

He has never found cervical mucosa extending over the lower uterine segment.

From this necessarily short *résumé* of von Franque's paper, it will be evident that its value consists not so much in any new facts brought forward, as in its establishing upon a broader anatomical basis what are now the generally received conclusions as to the origin and nature of the lower uterine segment. I have done but scant justice to this important contribution, extending over 120 pages, which is valuable not only on account of the description of its own specimens, but also for its criticism of the conclusions of Bayer, Küstner, and more recently Keilmann, all of whom maintain that this portion of the uterus is cervical in origin.

The nature of the Lower Uterine Segment is also discussed by Testut and Blanc, *à propos* of their frozen section of a patient.



who died of eclampsia in the sixth month of pregnancy, after rupture of the membranes.

We note in passing that the sacrum in this case was asymmetrical—the right half measuring  $1\frac{1}{2}$  in. broad, while the left measured 2 in. There was also deficiency of the anterior layer of the right broad ligament, and only a rudimentary round ligament and tube on the same side. This case resembles one of Webster's sections, in which one ovary was absent. It is also interesting to note the defective development of the uterine appendages on the same side as that of the sacrum.

The pelvic portion of the uterus in their section had its walls 3 to 4 mm. thick, as against the abdominal portion, where the walls are 7 to 11 mm. thick, except at placental site. Comparing their section with others from pregnancy and labour, they come to the conclusion that when a woman is in labour, it matters not at what month of gestation, there is present without doubt a lower segment which is distended by the presenting part. The variability in the presence of the contraction ring is accounted for by (1) the contractile energy of the uterus and the time during which it has been exerted; and (2) the relation of the wall to its contents—for there must be a depression (usually round the neck of the fœtus) into which the wall can bulge. Unless death happens during a pain no ring will be present except a *re-traction* one. They describe in detail the characters of the lower segment as ascertained clinically by passing the finger through the os internum. They believe there is no ground for describing a lower segment as present in the non-pregnant uterus; that it is present in pregnancy only after the eighth month (perhaps the seventh in a primipara), but in all cases of labour early or late.

The various anatomical data by which the lower segment has been defined are criticised. The *membranes* are not less firmly attached over it, unless contractions have been present or the segment unusually dilated; the *firm attachment of the peritoneum* is an irregular line absent entirely at the sides of the uterus, nor is its firmness specially related to the insertion of the muscular fibres into it. As to *blood-vessels*, the coronary vein is not constant; and, while fewer arteries are given off to the lower segment and their course is less tortuous, there is no big branch at the contraction ring. In the *muscular wall* they find the arrangement of the fibres in long parallel plates as described by others.

I have given Testut and Blanc's statements as to the retraction ring somewhat fully, as I think they are right in emphasizing its



clinical importance as against its anatomical. Although it was well marked in the section from the second stage made by Webster and myself, it is by no means always present in frozen sections ; and some may be sceptical of its identity when they find Braune saying, in the text of the section described by himself and Zweifel, "A contraction ring may be seen and traced round the cavity;" and Zweifel, in another part of the same text, stating that "the absence of the contraction ring points to the patient's not having been in labour."

Such discrepancy of statement is, I think, an additional reason for using the term "retraction ring" instead of "contraction ring." Contraction is a transitory phenomenon, and the chances of its being fixed by frozen sections are small ; but retraction, being a permanent thickening, will be registered in a frozen section. While there may be doubt as to the presence of a contraction ring, there never can be any question as to the presence of a retraction one ; and it will or will not be present according to the extent to which retraction has occurred in connexion with the emptying of the uterus. Further, it is to its being a retraction ring that its importance clinically is due,—that is to say, that one part of the uterus stands out thicker in contrast to a portion which has become thinner, and is therefore in danger of rupture.

#### NOTE C.

##### BRAUNE'S OS INTERNUM AND THE RETRACTION RING.

The Venezuela frontier question has not given rise to more discussion than the delimitation of the area of the body of the uterus in labour. The story of the dispute with Venezuela goes back to the map on which Schomburg drew his now famous line. The discussion which has gone on for five and twenty years round the disputed area in the lower part of the uterus goes back to Braune's classical section, and a line on it which he labelled the Os Internum. Like the old map, this section has raised a dispute which it is powerless to settle. Braune himself has said—"That he could not recall all the particulars which led him and Schatz to mark the line in question *orificium uteri internum*."\* No microscopic examination of the tissues was made, and the soft parts had to be destroyed so as to construct the bony skeleton.

\* Säger—*Ein letztes Wort sur Cervixfrage*, quoted by Döderlein in *Die Ergebnisse der Gefrierdurchschnitte durch Schwangere*: Wiesbaden, J. F. Bergmann.



In referring to the lower uterine segment, we have had occasion to take notice of the various phases through which this discussion has passed up to the solution which Schroeder gave, that the ring which Braune called the *os internum* marks the lower limit of the active contracting portion of the uterine wall, and not of the uterine cavity. That is to say, that the *os internum* lies in Braune's section, not where he indicated, but at some point in the territory below.

In Zweifel's sections a ridge is seen in the genital tract occupying much the same position as Braune's *os internum*, and which he considers to represent the *os internum* in these specimens. The evidence which he brings forward is insufficient. In his description of both sections (v. Part II. p. 117) he uses the attachment of the membranes to define the *os internum*. Now, while the membranes are attached up to that point before labour begins, it is evident that when dilatation has occurred, and still more when the fingers have been passed into the uterus to turn the foetus, the membranes must be separated to a considerable extent. The *os internum* will now lie some distance below the point up to which the membranes are attached, that is to say, at a lower level than the ridge which Zweifel marks the *os internum*. In the placenta *prævia* section alone does he make use of microscopic examination in addition to the attachment of the membranes. It is possible that the *os internum* is where he places it in this case, but the fact that the membranes are attached up to it "on the right side" makes it doubtful. Against Zweifel's section we must place Leopold's one from placenta *prævia*, as well as Chiari's section and my own. The results of the microscopic examination of the latter are given in plate xxiv. of the Atlas of the Anatomy of Labour.

#### NOTE D.

##### ON THE ENGAGEMENT OF THE HEAD.

Closely associated with the hitherto described "movement" of flexion is the engagement of the head. In French midwifery, where the mechanism of labour is analysed into six stages ("*temps*") instead of the four movements of English midwifery with which we are familiar, the engagement of the head, or "descent," is described as following flexion and preceding internal rotation. In none of the frozen sections is the head at the brim synclitic,—that is to say, its occipito frontal or suboccipito-bregmatic diameter is never parallel to the plane of the



brim, but always cuts it at an angle. I noted this (v. p. 50) as a peculiar feature in my own section made in the first stage; and considering it as abnormal, attributed it to the death of the child *in utero* having made its head unusually limp. But all the frozen sections made since, both before labour and during the first stage, show a certain amount of asynclitism, and not the asynclitism of Naegele, in which the anterior parietal bone is more prominent, but the opposite condition. By this is meant that if a line is drawn representing the plane of the brim, more of the posterior half of the head lies below that level than of the anterior.

Pinard and Varnier have noted this fact specially in their sections, and cite also Winter's and Braune and Zweifel's sections and my own in the first stage as illustrating this. They go further, and begin the part of the text of their Atlas treating of the engagement and descent of the head in normal pelvis with the thesis that the mechanism of labour in the normal pelvis is almost identical with that in the rickety. As in the rickety, the head is transverse, scarcely flexed, so that the finger touches with equal ease each of the two fontanelles; and, as the uterine axis is less oblique than that of the brim, the axis of the head does not correspond with the latter, but the sagittal suture is nearer the symphysis. The anterior parietal bone overhangs and projects beyond the symphysis, so that it is inaccessible through its greater extent; while the posterior parietal, which almost alone occupies the superior strait, can be reached and touched throughout up to the ear.

Smellie's description of the head at the brim, and his Plate XII. (in which the head is transverse, with the vertex almost resting on the pubes, and the posterior parietal bone presenting) are quoted as representing truly the position at the commencement of labour.

Then follows a sketch of the history of obstetrical teaching since then, which might be described as consisting of—first, the assertion by Naegele and his followers, that the anterior parietal bone presented; and then the recoil from that, in the generally received view that the vertex presents. Pinard and Varnier maintain that their frozen sections demonstrate that the axis of the uterus does not coincide with that of the pelvis; that the head is not synclitic, but inclined on the posterior parietal bone; that engagement is a correction of this inclination, the retarded parietal bone descending and the sagittal suture reaching the axis only when engagement is complete.



The Table given on p. 188 brings out the fact that the head is not synclitic in frozen sections ; but the figures must be taken only as indicating this generally, and not as giving the amount of it. For we cannot estimate exactly the relative amounts of the two halves of the head within the pelvis from the position of the sagittal suture in a mesial section, as this varies with the position of the head in the pelvis.

We must wait for more material before this question can be settled. It is sufficient, in the meantime, to state the following propositions :—

1. Frozen sections furnish us with the means of studying labour at a still earlier period than clinical investigation. Clinically, we cannot say with precision how the head is lying until the cervix is well dilated, and even then only when there is little fore-water. The facts that we are considering belong to a period before the mechanism of labour, as described in English midwifery, has begun.

2. The facts concern multiparæ more than primiparæ, as in the latter the head is already in the pelvis before labour begins.

3. We have been studying the position of the head in the intervals between uterine contractions. This asynclitism is probably modified during a pain.

4. Frozen sections show us generally the relations in the horizontal posture ; these will be modified when the patient is erect, as she usually is during the first stage.

One word with regard to the mode in which Pinard and Varnier state their thesis. Even if it should be proved that this change in the presentation of the head takes place as a preliminary to the mechanism of labour, it is a false analogy to compare this to what occurs in a flat pelvis. For in the latter the transverse position of the head and the presentation of one parietal bone are necessary parts of the mechanism, without which the head could not be born ; they belong essentially to the second stage, and have associated with them strong uterine contractions. There may be a resemblance between the rickety and the normal mechanisms, but it is only a superficial one ; it is, so to speak, only an accident of normal labour that we find the head transverse and asynclitic in the multipara, for neither of these conditions is found in the primipara, in whom we have the best opportunity of studying normal labour ; while they are of the essence of labour in a flat pelvis, being found there just as certainly in the primipara as in the multipara.



## NOTE E.

## SUMMARY OF NEW FACTS LEARNED REGARDING THE SECOND STAGE:

*From a study of the Section given in Pl. v. p. 160.*

1. The shortening of the antero-posterior diameters of the bony pelvis by the soft parts is for the conjugate, at the brim  $\frac{1}{2}$  inch, in the cavity  $\frac{3}{4}$  inch, at the outlet  $\frac{7}{8}$  inch; and for the oblique diameter, at the brim almost 1 inch, and in the cavity still more, due to the projection of the obturator internus.
2. The peritoneum is, during the second stage, lifted out of the pelvis anteriorly and somewhat elevated posteriorly.
3. The bladder is elevated, so that, while its neck does not change its position, a portion of the organ becomes abdominal.
4. The uterus in the interval between the pains shows a certain plasticity, like the uterus in pregnancy, but with this difference, that while the former moulds itself on the spinal column and bony pelvis, the latter moulds itself on the foetus.
5. The lower portion of the anterior uterine wall is thinner than the rest before labour begins; this thinning is increased during labour. A corresponding thin part develops posteriorly. There is, therefore, in normal labour (that is, with no pathological resistance) a separation of the uterine wall into two parts at the retraction ring.
6. The cervix appears as a canal measuring anteriorly 1.7 in.; and posteriorly 1.3 in.
7. While the anterior vaginal wall retains, during labour, its usual length and thickness (2 in.), the posterior stretches to more than twice its former length (measuring 7 in.) and becomes very thin.
8. The foetus is elongated during the second stage by the straightening of the spinal column.
9. The flexion of the head becomes, during labour, less pronounced than it was during pregnancy.
10. Rotation of the head takes place before that of the shoulders, and is therefore independent of it.
11. The process of the moulding of the head consists in a pushing of the occiput underneath the parietal bones, and a distortion of the plastic head towards its unsupported part.
12. The placenta does not become separated as a result of the diminution of its site during the second stage.
13. The membranes become separated, during the second stage, up to the retraction ring, but not above it.



## PART II


# LITERATURE

---

THE following Abstracts of Contributions to the Literature of the subjects discussed in Part I. were made in the first instance for my own use. It has occurred to me that they may be of service to others, as they bring the results of research within reach of those who may not have ready access to the original articles, and save time in reference for those who have the original articles within reach, but whose work obliges them to economise their hours for reading. Further, they place readers in direct contact with the original sources of information, and allow us to present in the First Part a systematic account of the subject unbroken by the too frequent introduction of names.

The literature up to the end of 1887 is arranged chronologically, and classified according to the order in Part I. The literature subsequent to 1887 will be found in the Appendix. To keep the latter within limits, I have confined myself to the explanatory text accompanying the various sections recently published and reproduced in the *Atlas of Sectional Anatomy*.







INDEX, IN CHRONOLOGICAL ORDER,  
OF CONTRIBUTIONS OF WHICH ABSTRACTS  
ARE HERE GIVEN.

INTRODUCTORY.

<i>Name of Writer.</i>	<i>Date.</i>	<i>Title of Contribution.</i>	<i>Page</i>
WM. HUNTER . . . .	1774.—	The Anatomy of the Human Gravid Uterus exhibited in Figures: Birmingham, Baskerville . . . .	1
„ . . . .	1794.—	An Anatomical Description of the Human Gravid Uterus and its Contents: London, J. Johnston and G. Nicol . . . .	2
E. Q. LE GENDRE . . . .	1858.—	Anatomie Chirurgicale Homologique, etc.: Paris, Baillière et Fils . . . .	5
N. PIROGOFF . . . .	1859.—	Anatome Topographica sectionibus per corpus humanum congelatum, triplici directione ductis illustrata: Petropoli, Jacobi Trey . . . .	6

BEFORE LABOUR.

W. BRAUNE . . . .	1872.—	Die Lage des Uterus und Foetus am Ende der Schwangerschaft: Leipzig, Veit und Co. . . .	8
W. WALDEYER . . . .	1886.—	Medianschnitt einer Hochschwangeren bei Steisslage des Fötus: Bonn, Max Cohen & Sohn . . . .	10

Peritoneum and Ureters.

W. M. POLK . . . .	1882.—	Landmarks in the Operation of Laparotomy: <i>New York Medical Journal</i> , Vol. xxxv., p. 449 . . . .	12
„ . . . .	„	Observations upon the Anatomy of the Female Pelvis: <i>New York Medical Journal</i> , Vol. xxxvi. p. 560 . . . .	13



BEFORE LABOUR—*continued.*

## Lower Uterine Segment.

<i>Name of Writer.</i>	<i>Date.</i>	<i>Title of Contribution.</i>	<i>Page</i>
J. MATTHEWS DUNCAN .	1859.—	On the Cervix Uteri in Pregnancy: <i>Edinburgh Medical Journal</i> , March	14
L. BANDL . . . . .	1876.—	Ueber das Verhalten des Uterus und Cervix in der Schwangerschaft und während der Geburt: Stuttgart, Enke . . . . .	14
ANGUS MACDONALD .	1877.—	On the condition of the Cervix Uteri in the later months of Utero- Gestation: <i>Trans. Edin. Obstet.</i> <i>Soc.</i> , Vol. iv. p. 331 . . . . .	17
G. LEOPOLD . . . . .	1887.—	Studien ueber die Uterusschleimhaut während Menstruation, Schwanger- schaft, und Wochenbett; ii. Theil.: <i>Archiv für Gyn.</i> , Bd. xi. S. 443 . . .	18
O. KÜSTNER . . . . .	1877.—	Beitrag zur Anatomie der Cervix Uteri während der Schwangerschaft und des Wochenbettes: <i>Archiv für</i> <i>Gyn.</i> , Bd. xii. S. 383. (See also p. vii.) . . . . .	19
P. MÜLLER . . . . .	1878.—	Anatomischer Beitrag zur Frage vom Verhalten der Cervix während der Schwangerschaft: <i>Archiv für Gyn.</i> , Bd. xiii. S. 150 . . . . .	20
TH. LANGHANS UND P. MÜLLER	1879.—	Weiterer anatomischer Beitrag zur Frage vom Verhalten der Cervix während der Schwangerschaft: <i>Archiv für Gyn.</i> , Bd. xiv. S. 184 . . .	20
M. SÄNGER . . . . .	1879.—	Zum anatomischen Beweise für die Erhaltung der Cervix während der Schwangerschaft: <i>Archiv für Gyn.</i> , Bd. xiv. S. 339 . . . . .	21
F. MARCHAND . . . . .	1880.—	Noch einmal das Verhalten der Cervix uteri in der Schwangerschaft: <i>Archiv für Gyn.</i> , Bd. xv. S. 169 . . .	21
WM. T. LUSK . . . . .	1884.—	A Note on the Ring of Bandl: <i>Amer.</i> <i>Gyn. Trans.</i> , p. 291 . . . . .	22
H. BAYER . . . . .	1885.—	Morphologie der Gebärmutter. Der Cervix und seine Stricturen: <i>Freund's Gynäkologische Klinik</i> ; Strassburg, Trübner . . . . .	22



<i>Name of Writer.</i>	<i>Date.</i>	<i>Title of Contribution.</i>	<i>Page</i>
M. HOFMEIER . . .	1886.—	Das untere Uterinsegment in anatomischer und physiologischer Beziehung: Schroeder's Der schwangere und kreissende Uterus: Bonn, Cohen und Sohn . . . . .	30
A. BENCKISER . . .	1887.—	Zur Anatomie des Cervix und unteren Uterinsegmentes: Beiträge zur Anatomie des schwangeren und kreissenden Uterus, von A. Benckiser und M. Hofmeier: Stuttgart, F. Enke . . . . .	33

### The Membranes and their Separation.\*

W. O. PRIESTLEY . . .	1860.—	Lectures on the Development of the Gravid Uterus: London, Churchill . . . . .	36
DOHRN . . . . .	1865.—	Ein Beitrag zur mikroskopischen Anatomie der reifen menschlichen Eihüllen: <i>Monats. für Geburtshunde</i> , S. 114 . . . . .	36
C. FRIEDLÄNDER . . .	1870.—	Physiologisch - anatomische Untersuchung über den Uterus: Leipzig, Simmel . . . . .	37
KUNDRAT UND ENGELMANN	1873.—	Untersuchungen über die Uterusschleimhaut: <i>Stricker's Med. Jahrbuch</i> . . . . .	37
TH. LANGHANS . . .	1875.—	Die Lösung der mütterlichen Eihäute: <i>Archiv für Gyn.</i> , Bd. viii. S. 287 . . . . .	37
K. BLACHER . . . . .	1876.—	Ein Beitrag zum Bau der menschlichen Eihüllen: <i>Archiv für Gyn.</i> , Bd. x. S. 459 . . . . .	38
G. LEOPOLD . . . . .	1877.—	Studien über die Uterusschleimhaut während Menstruation, Schwangerschaft und Wochenbett; II. Theil.: <i>Archiv für Gyn.</i> , Bd. xi. S. 443 . . . . .	38
O. KÜSTNER . . . . .	1878.—	Die Lösung der mütterlichen Eihäute vor und bei der rechtzeitigen Geburt: <i>Archiv für Gyn.</i> , Bd. xiii. S. 422 . . . . .	39

---

\* The Abstracts under this head were prepared for a paper on "The Anatomy and Relations of the Uterus during the Third Stage of Labour and the First Days of the Puerperium," and are shorter than the others.



<i>Name of Writer.</i>	<i>Date.</i>	<i>Title of Contribution.</i>	<i>Page</i>
SIR W. TURNER . . .	1878.—	On the Placentation of the Apes, with a Comparison of the Structure of their Placenta with that of the Human Female: <i>Phil. Trans. of Royal Society, London</i> . . .	39
A. KÖLLIKER . . .	1879.—	Entwickelungs-geschichte des Menschen und der höheren Thiere, IIe. Ausgabe: Leipzig . . .	39

## LABOUR.

## First Stage.

C. SCHROEDER . . .	1886.—	Der schwangere und kreissende Uterus, etc.: Bonn, Max Cohen & Sohn . . .	39
C. RUGE . . .	1886.—	Die Eihüllen des in der Geburt befindlichen Uterus: Schroeder's Der schwangere und kreissende Uterus . . .	42
A. BENCKISER . . .	1887.—	Zur Anatomie des Cervix und unteren Uterinsegmentes: Beiträge zur Anatomie des schwangeren und kreissenden Uterus, von A. Benckiser und M. Hofmeier: Stuttgart, F. Enke . . .	44

## Second Stage.

W. BRAUNE . . .	1872.—	Die Lage des Uterus und Foetus am Ende der Schwangerschaft, etc.: Leipzig, Veit & Co. . . .	45
D. CHIARA . . .	1878.—	La Evoluzione Spontanea sorpresa in atto mediante la congelazione: Milano, <i>Tipografia dei Fratelli Rechiedei</i> . . . .	47
D. B. HART . . .	1880.—	Structural Anatomy of the Female Pelvic Floor: Edinburgh, Mac-lachlan & Stewart . . . .	48
„ . . .	1884.—	Atlas of Female Pelvic Anatomy: Edinburgh, W. & A. K. Johnston . . .	49
H. CHIARI . . .	1885.—	Ueber die topographischen Verhältnisse des Genitales einer inter partum verstorbenen Primipara: Wien, Toeplitz & Deuticke . . . .	50

## Third Stage.

M. THIEDE . . .	1879.—	Ueber das Verhältniss des Cervix uteri zum "untern Uterinsegment:" <i>Zeitsch. f. Gynäk</i> , Bd. iv. S. 210 . . . .	53
-----------------	--------	--	----



Name of Writer.	Date.	Title of Contribution.	Page
C. H. STRATZ . . .	1886.—	Die Nachgeburtsperiode; in Schroeder's Der schwangere und kreissende Uterus : Bonn, Max Cohen & Sohn	54
A. BENCKISER . . .	1887.—	Zur Anatomie des Cervix und unteren Uterinsegmentes : Beiträge zur Anatomie des schwangeren und kreissenden Uterus, etc., Stuttgart F. Enke . . . . .	55

## PUERPERIUM.

J. MATTHEWS DUNCAN . . .	1853.—	The Internal Surface of the Uterus after Delivery : <i>British and Foreign Medical and Surgical Review</i> , p. 506; and <i>Researches in Obstetrics</i> , 1868 . . .	56
„ . . .	1857.—	The Internal Surface of the Uterus after Delivery : <i>Edinburgh Medical Journal</i> , December . . . . .	57
J. CHISHOLM . . .	1854.—	Two cases in Midwifery with the Description of the Internal Surface of the Uterus after Delivery : <i>Monthly Journal of Medical Science</i> , Edinburgh, September . . . . .	57
„ . . .	1858.—	Some further Remarks on the Internal Surface of the Uterus, and on its Relations with the Placenta : <i>Edin. Med. Journ.</i> , January . . . . .	57
E. Q. LEGENDRE . . .	1858.—	Anatomie Chirurgicale Homolographique, etc.: Paris, Baillière et Fils . . . . .	57
N. PIROGOFF . . .	1859.—	Anatomie Topographica sectionibus per corpus humanum congelatum triplici directione ductis illustrata: Petropolis, Jacobi Trey . . . . .	58
O. KÜSTNER . . .	1877.—	Beitrag zur Anatomie der Cervix uteri: <i>Archiv für. Gyn.</i> , Bd. xii. S. 383 . . .	58
M. THIEDE . . .	1879.—	Ueber das Verhältniss des Cervix uteri zum "unteren Uterinsegment": <i>Zeitsch f. Gynäk.</i> , Bd. iv. S. 210 . . .	60
O. KÜSTNER . . .	1882.—	Das untere Uterinsegment: Jena, G. Fischer . . . . .	63
H. BAYER . . .	1885.—	Morphologie der Gebärmutter. Der Cervix und seine Stricturen: Freund's <i>Gynäkologische Klinik</i> : Strassburg, Trübner . . . . .	66
C. H. STRATZ . . .	1886.—	Gefrorener Durchschnitt durch eine Frischentbundene; in Schroeder's Der schwangere und kreissende Uterus : Bonn, Cohen & Sohn . . .	72



<i>Name of Writer.</i>	<i>Date.</i>	<i>Title of Contribution.</i>	<i>Page</i>
A. BENCKISER . . .	1887.—	Zur Anatomie des Cervix und unteren Uterinsegmentes: Beiträge zur Anatomie des schwangeren und kreissenden Uterus, etc., Stuttgart	74

## APPENDIX.

EARLY CONTRIBUTIONS OF ANATOMY TO OBSTETRICS . . . . .	7
--	---

## Literature subsequent to 1887.

V. SAEXINGER . . . . .	1888.—	Gefrierdurchschnitte einer Kreissenden: Tübingen, H. Laupp'schen Buchhandlung . . . . .	79
G. WINTER . . . . .	1889.—	Zwei Medianschnitte durch Gebärende eine anatomische Studie: Berlin, Fischer's medicin. Buchhandlung	81
W. BRAUNE UND P. ZWEIFEL . . . . .	1890.—	Gefrierdurchschnitte in Systematischer Anordnung durch den Körper einer Hochschwangeren geführt, Veit and Co., Leipzig . . . . .	85
A. VON MARS . . . . .	1890.—	Medianschnitt durch die Leiche einer an Uterusruptur verstorbenen Kreissenden: Universitätsbuchdruckerei, Krakau . . . . .	90
E. PESTALOZZA . . . . .		Anatomia dell 'Utero Umano: Vallardi, Milano . . . . .	93
J. C. WEBSTER . . . . .	1892.—	Researches in Female Pelvic Anatomy: Young J. Pentland, Edinburgh and London . . . . .	96
L. TESTUT ET E. BLANC . . . . .	1892.—	Anatomie de l'Uterus pendant la Grossesse et l'Accouchement: Octave Doin, Paris . . . . .	102
A. PINARD ET H. VARNIER . . . . .	1892.—	Etudes d'Anatomie obstétrical: G. Steinheil, Paris . . . . .	105
P. ZWEIFEL . . . . .	1893.—	Zwei neue Gefrierschnitte Gebärender: Veit and Co., Leipzig . . . . .	115
D. TIBONE . . . . .	1894.—	Tavole Omolographiche sulla Placenta Prævia: Rosenberg e Sellier, Torino	119
G. LEOPOLD . . . . .	1897.—	Geburtshülfflich-anatomischer Atlas, 30 Tafeln enthaltend, zu Uterus und Kind, etc.: S. Hirzel, Leipzig	121
W. C. LUSK . . . . .	1898.—	Remarks on a Frozen Section, etc.: <i>Brit. Med. Jour.</i> , 1898, vol. i. p. 1506	132



# LITERATURE.

---

## INTRODUCTORY.

**WILLIAM HUNTER** made two classical contributions to the anatomy of the gravid uterus. In 1774 he brought out his "Atlas on the Anatomy of the Human Gravid Uterus exhibited in Figures." In the Preface, he said that he proposed to publish at full-length an anatomical description of the gravid uterus; and that, if by unforeseen accident he should be prevented from doing this, it could easily be done from his public lectures. He died without himself carrying out his intention, leaving behind him, however, in manuscript, his "Anatomical Description of the Human Gravid Uterus and its Contents," which was edited by Baillie (1794).

In the Preface to the Atlas, he distinguishes between two kinds of anatomical drawing—one, a simple portrait representing the object as it is actually seen; the other, a representation of it made up from a variety of studies after nature. "The former carries the mark of truth, and becomes almost as infallible as the object itself." Adopting this former method, he has reproduced his dissections life-size. While the plates are perfect as artistic productions, the minutest details are given so that nothing is left to the imagination.

Besides descriptions of ova at the third, fourth, fifth, eighth and ninth weeks, he gives dissections of thirteen uteri—two at the third month, one at the fourth, two at the fifth, one at the sixth, one at the seventh, one at the eighth, four at the ninth, and one post partum.

First we have (Plates I. to X.) a head presentation (R.O.A.) at the ninth month:—the external appearance of the uterus from the front and sides, the position of the child in the uterus, the appearance of the uterine cavity, the hypertrophy of the vessels at the placental site, and the relation of the soft parts behind the uterus. In Plates XI. and XII., he gives the relations of the placenta in Placenta Praevia. Plate XIII. shows very well the position of a child in a breech presentation.



The disposition of the muscular fibres is given in Plate XIV., while a case of death two hours post partum shows the arterial system (Plate XV.). Plates XVI. to XX., from an eighth month's uterus, gives the disposition of the injected arteries and veins, the appearance of the decidua, and the position of the child (R.O.P.); while Plates XXI. to XXII. give a uterus laid open at the seventh month with the child lying in the bag of membranes. In Plates XXIII. and XXIV., we have the contents of the uterus and the relations of the placenta at the sixth month. Plate XXV. shows a uterus laid open at the fifth month, and especially the condition of the cervix.

Plate XXVI. shows the relations of a retroverted gravid uterus at the fifth month.

The material on which he based his important discovery of the nature of the decidua vera and reflexa is given in the six following Plates (XXVII. to XXXII., showing uteri in the third and fourth months). Plates XXXIII. and XXXIV. represent abortions from the third to the ninth week.

In his "Anatomical Description of the Human Gravid Uterus and its Contents," he states the following facts. The size of the *pregnant uterus* varies greatly, depending chiefly on amount of liquor amnii. Where this is abundant, the child is small. Its figure is oviform, with broad end uppermost; but, being plastic, like a bladder of water not quite full, is moulded by pressure of neighbouring parts (*e.g.*, brim of pelvis, spine, muscles and vessels) posture of mother, and position of child (head, buttocks, or twins). Its cavity may grow unequally, or be divided above. Its situation is such that it completely fills the pelvis, compressing bladder and rectum, and displaces the intestine from the anterior abdominal wall. Its axis is oblique and less vertical in multiparae and contracted pelves.

The *Ligaments*, *Tubes* and *Ovaries* are attached lower down than before pregnancy; the uterus expands laterally at the expense of the broad ligaments, so that round ligaments come to be on its front surface. The tube becomes vertical, its fimbriated end with ovary being at level of brim. Ovary shows corpus luteum.

The thickness of the uninjected walls is from one to two-thirds of an inch (2.5 to 1.6 cm.). Thickness is greater at the placental site, from the greater number of vessels; and commonly greater also towards the fundus. There are great inequalities in the same uterus.



The *Arteries* are enlarged. The Hypogastrics, running along the sides of uterus and sending branches before and behind, supply specially the cervix; the Spermaties supply the fundus. The branches running to the placenta are most enlarged. *Veins* are proportionately larger than arteries, the main trunks corresponding to respective arteries, but the branches not accompanying the latter precisely. They have no valves, and form large plexuses, especially over the placenta. The *Lymphatics* (studied first by Cruikshank by mercurial injections) pervade its substance universally, forming crowded plexus under peritoneum, and of size of goose quill at sides of uterus. They accompany the spermatic but chiefly hypogastric vessels—to glands beside vagina, to those of iliac and sacral plexuses, and thence to those of lumbar plexus. Those of ovaries and tubes pass to lumbar glands.

The course of the hypogastric *Nerves* is described in full. The anterior branch supplies the uterus and vagina. The ovary and adjacent parts are supplied by the spermatic plexus of the same nerve.

The *Muscular* fibres in a seven days' post partum uterus show three strata—an internal one (distinctly fasciculated, with spaces between for vessels) regularly circular in the body, less so in cervix, and two concentric circular planes of fibres round each Fallopian tube; a middle stratum, less distinctly fasciculated and more irregular; an outer one, firmer and less vascular.

The *Cervix Uteri*, for the greatest part of the nine months, till it be fully distended, shows both lips projecting. In most women near full time, the os is flat and makes merely a small rugous hole.\*

The *Cord* averages two feet in length. It contains two (sometimes one) arteries and one vein. In twenty-eight out of thirty-two cases, it is twisted from right to left. It is covered by amnion and chorion, and contains the remains of the urachus and fine cellular substance loaded with a transparent ropy fluid. The winding of the vessels prevents stretching, and the interstitial substance compression.

The *Placenta*, round and flat, is, when uninjected, an inch in thickness and a span (9 in.) in breadth; when injected it becomes two inches thick. Its surfaces and the insertion of cord are fully described. Its structure is spoken of as a blending of

\* Hunter, while evidently writing under the influence of the view that the cervix is taken up into the uterine cavity during gestation, makes no statement as to the upper limit of the cervix.



two parts—a continuation of the umbilical vessels of the foetus, and the decidua or uterine portion. By injection he has satisfied himself that the circulation in these two is quite distinct. While these two parts are combined, the placenta makes a pretty firm mass; no part of it is loose or floating. But when they are carefully separated, the umbilical system is evidently nothing but loose floating ramifications of the umbilical vessels—like that vascular portion of the chorion which makes part of the placentula in a calf; and the uterine part is seen shooting out into innumerable floating processes and rugae with the most irregular and most minutely sub-divided cavities between them that can be conceived. After describing his study of the placenta by separating its parts with water and repeated injections, he thus sums up:—"From all these experiments and observations which have been often repeated and diligently attended to, with no other desire than to discover truth, it seems incontestible that the human placenta, like that of the quadruped, is composed of two distinct parts, though blended together, viz., an umbilical which may be considered as a part of the foetus, and an uterine which belongs to the mother; that each of these parts has its peculiar system of arteries and veins, and its peculiar circulation, receiving blood by its arteries, and returning it by its veins; that the circulation through these two parts of the placenta differs in the following manner: in the umbilical portion the arteries terminate in the veins by a continuity of canal, whereas in the uterine portion there are intermediate cells into which the arteries terminate, and from which the veins begin. Though the placenta be completely filled with any injection thrown into the uterine vessels, none of the wax finds its way into any of the umbilical vessels; and in the same manner fluids injected into the umbilical vessels never can be pushed into the uterine, except by rupture or transudation."

The naked eye appearances of the *Amnion* and *Chorion* are fully described. Their connecting medium is neither fibrous nor vascular. The *Decidua* is at once the outer membrane of the secundines and the internal membrane of the uterus. It is thin and sparingly vascular over the cervix, becoming thicker and more vascular towards the placenta. "It is of considerable thickness, and one stratum of it is always left upon the uterus after delivery, most of which dissolves and comes away with the lochia. Frequently a thicker stratum separates from the uterus in one part, and a thinner in another; and sometimes, especially when the discharge of the secundines is hurried in a labour, the whole



membranous part, both of the decidua and chorion, remains behind attached to the uterus. In separating the membranes from the uterus, we observe that the adhesion of the decidua to the chorion, and likewise its adhesion to the muscular fibres of the uterus, is rather stronger than the adhesion between its external and internal strata, which we may presume is the reason that in labour it so commonly leaves a stratum upon the inside of the uterus."

As to the Allantois and Urachus, he has never seen them in his dissections. The physical characters of the Liquor Amnii are given. The fœtus "is naturally contracted into an oval form adapted to the figure and circumstances of its habitation." Its long axis comes to coincide with the long axis of the uterus. Further, the back comes to be to one side of the mother, because the greatest breadth of the child is from back to front, and in that position corresponds to the greatest width of the uterus, which is lateral; the head is downwards because specifically heaviest. External appearance of the child and peculiarities of its circulation are described.

In describing the contents of the uterus in the earlier months of pregnancy, the nature of the *Decidua* is truly demonstrated. The *Decidua Vera* lines the uterus, the *Decidua Reflexa* (first discovered by Hunter) grows up round the chorion. It becomes thinner as pregnancy advances, till at the fourth month it is an extremely fine layer, and finally adheres to the *Decidua Vera*. The placenta is formed by the shaggy vessels corresponding to less than one-half of the chorion, which become severed at their floating extremities by the decidua. The cord can be traced from the sixth or seventh week. Naked-eye appearance of fœtus at seventh week is also given.

**E. Q. LE GENDRE** published in 1858 his beautiful Atlas of Homolographic Surgical Anatomy. It contains twenty-five plates showing thirty-four sections reproduced *ad naturam*.

In the Introduction, he says that a synthetic method of studying organs in any region of the body is of recent introduction. Amongst the anatomists of last century, Winslow, Sabatier and Boyer gave a general survey of all the organs in one region; Desault showed the importance of this for surgery. Different ways of doing this were adopted by different authors—some describing parts in layers, others according to their tissues. But there was wanting means of studying the organs in their relations. Velpeau in his Surgical Anatomy suggested that a transverse section would supply this want; Desault proposed this first for the limbs;



Portal for the viscera ; Chaussier and Béclard placed surgery on an anatomical basis. Thus the importance of the study of relations of organs was fully recognised by anatomists and surgeons ; and Le Gendre was led to make his investigations. The idea of representing different regions according to sections is not new. In France—Cloquet in Anatomy and Velpeau, Blandin, Bourguery in Surgical Anatomy have published such. Abroad—Loder, Rosenmüller, Bell, Froriep, Otto and Kohlrausch have figured sections of trunk ; Huschke has given transverse sections of a female subject. In all these, however, art has disturbed nature by dissection—removal of one part to show another. Some other method was necessary. Weber and Arnold used plaster of Paris in the study of joints ; Kohlrausch hardened with alcohol to study the pelvis, filling natural cavities with cotton soaked in it ; Jarjavay (1856), in studying urethra, used solution of nitric acid which softens bone and hardens soft parts. Freezing is better than these. Serres used it in 1820 in his study of the brain, Manec for other regions ; Giralès and Estevenet, in 1836, made many such preparations ; but Pirogoff carried this idea fully out by publishing in 1838 his *Plates on Articulation*, and in 1852 his *Topographical Anatomy*. Le Gendre restricts himself to Surgical Anatomy and made his sections in 1854–1855. Henle (1856), and Luschke (1857) used this method also.

Objected to the method that cold acts on tissues making them contract ; but the fluids in the tissues will expand, and he has measured and found contraction small. Where parts are surrounded by bone it does not occur at all. His sections made with body in dorsal posture, and reproduced life-size. Subjects first injected—arteries red, veins black. Sections made with a two-handled saw having a broad blade. Drawings made by placing varnished parchment on the frozen surface and transferring them to paper, details being filled in after partial thawing ; Jarjavay used diagraph, but not so exact. Sections do not photograph well. Has mounted thin sections in preservative fluid between plates of glass.

**N. PIROGOFF** was the first to use freezing systematically in studying anatomical relations. He published a series of sections of the Joints in 1846-48, and in 1859 his famous *Anatome Topographica*, Atlas and Text. This colossal \* work consists of four fasciculi of plates : the first is of the brain, neck, and vertebral column ; the second

\* For curiosity's sake we have counted the figures, and find that there are in all 996 frozen sections represented in the 212 plates.



is of the chest; the third is of the abdomen and pelvis; the last of the limbs. Each fasciculus is divided into three groups of sections—horizontal transverse, sagittal, and coronal\*—for he says in his preface that sections of any region of the body cut in one direction only do not give exact knowledge, we must have them in the three dimensions of space (*triplici directione*). It is curious that, while he has cut many sections of female cadavera, he does not figure any case of pregnancy. His work, therefore, concerns us chiefly as a landmark in the history of Sectional Anatomy.

In the preface to the Text, he states the following facts.

Mode of anatomical investigation used hitherto disturbs situation and relation (*situs et nexus et habitus*) of parts. A new method necessary. For twenty years made frozen sections of limbs, and published in 1846-48 sections of joints. Freezing does not disturb situation nor relations.

Used saw set in frame. Extent of section defined from bones—the seat and direction of the section being determined by measurement from bony landmarks. A plate of glass divided into squares was placed on the frozen section, and the drawing made accurately on a paper similarly divided into equal squares. Serous and other cavities brought out by partial thawing, and represented in the plates by triple lines. As saw removes portion, the cut faces may not be identical—in which case both are figured. In the case of joints, these cut with limbs in different positions. Parts involved in surgical operations are specially demonstrated.

In addition to making sections with saw of frozen bodies, has used another method—hammer and chisel (*sculptura anatomica*)—to expose parts beneath.

As to the history of representing things in section, we meet with the idea first in Leonardo da Vinci (1452-1519), and Jacopo Berengario da Carpi (d. 1550); then in the work of Vesalius, published in 1555, Eustachius (1564), Ambroise Paré (1607), Bartholine (1677), and other writers less well-known. First exact representation of sections is by Haller (1743), then Soemmering (1778), and many others. This method applied to surgical operations by Camperus (1762), Lizars (1822), Froriep, Scarpa, Velpeau, Cloquet, Arnold and Bonamy; Huschke (1844) published sections of female pelvis. The brothers Weber used gypsum to fix the tissues, and others have done this by needles; Pirogoff was the

\* Pirogoff calls them respectively—"Sectiones transversae; in longitudinem ductae; in longitudinem ductae quae in discum anticum et posticum diffundunt."



first to use freezing and the 'sculpture' method above-mentioned. He described his method and results to the Academy of Science, Paris, in 1853; in 1857 the same academy gave Le Gendre a grant for his frozen sections. Both these methods (by sections and sculpture) must be conjoined with dissection.

In the rest of the Preface he takes a general view of the most noteworthy facts brought out by this new mode of investigation. Of the twelve mentioned, only these two bear on our subject.—  
'(1) With the exception of the fauces, nose, bronchi, stomach, intestines and mastoid cells, sections of the frozen body show not the least vacuum nor air-filled space; and, accordingly, the walls of the separate cavities of the body and of all its canals are seen to be so apposed one to the other as to leave no vacuum anywhere; also, serous cavities, the bladder, the canals of the urethra and vagina, when cut across, appear in section as very thin lines; and the folds and inflections of the visceral serous layer are everywhere so apposed that the cut section of the cavity does not present a crumpled, but rather a smooth line, always following to the parietal layer. Canals have the same appearance, unless air or liquid be present. . . . (9) From numerous sections of the female pelvis, the following are shown: (*a*) that position of the uterus, whether in health or disease, never corresponds to the central axis of the pelvis but is always to the right or the left; (*b*) the body of the uterus is never perpendicular; (*c*) the directions of its cavities are fourfold; (*d*) variations in its direction are due to external causes (*e.g.*, pressure of intestines) rather than differences of texture. Further, the plates show true to nature the position of the peritoneal folds, form and direction of cervix, and disposition of its lips.'

#### BEFORE LABOUR.

**W. BRAUNE.**—His now classical *Atlas* gives a Vertical Mesial Section\* of a Multipara (?), age 25; committed suicide by hanging in last months of pregnancy. No further history.

Cadaver was frozen in salt and ice for six days. Drawing made in a cold cellar; stopped whenever thawing began, and section replaced in freezing mixture.

*Atlas* contains two plates—A, representing left half of body, with foetus removed from uterine cavity so that empty organ is seen; B, right half of body, with left half of foetus placed in relation to its right half so that foetus appears undivided.

\* This section reproduced in the Author's *Atlas of Sectional Anatomy of Labour, etc.*: Plate I. Fig. 1.



Child (female) \* lies R.O.A. ; measures 20·2 inches (50·5 cm.), and weighs 7·045 lbs. (3195 grammes); nails, well developed and projecting; labia closing vulva. Cord passes between head and right arm to placenta lying on right side of uterus and low down.

Uterus folded over symphysis, its walls relaxed, and showing numerous large empty veins, which in cervix and vagina appear gaping. Vaginal portion lies in left half, so that cervical canal cut into only below, the os internum lying  $\frac{1}{2}$  cm. below the surface. From length of cervix, supposed to be multipara, although no striae. Vaginal portion and contracted bladder lie low in pelvis so that os externum is at level of lower margin of symphysis, not of upper margin (Morrow) or still higher (Schultze); and urethra has a kink on it. Fundus reaches lower margin of first lumbar vertebra, agreeing with Morrow's description; while Schultze mentions the second vertebra as its height at end of pregnancy. Uterus and abdominal cavity less deep (antero-posteriorly) than usually described, perhaps due to horizontal position of body; in cadavera, abdominal cavity always shallower from higher position of diaphragm. From spinal column to posterior abdominal wall is about one-third of whole antero-posterior diameter, while in case described at second month of gestation it was more than one-half. In estimating thickness of uterine walls, must remember that the veins were not injected.

Diaphragm reaches seventh dorsal vertebra, instead of ninth or tenth as in men and non-pregnant women. Intestines pushed upwards, and lie chiefly in upper left portion of abdomen. Rectum passes into iliac flexure while still in pelvis; between it and uterus lies a coil of the ileum. Peritoneum passes only to short distance on posterior vaginal wall, and covers one-half of contracted bladder anteriorly; below it, is loose cellular tissue extending to internal orifice of urethra in front and end of rectum behind.

Thorax appears short, from high position of diaphragm, and deep; but cannot infer increase of its base during pregnancy, because we do not know its measurements for this case in the unimpregnated condition. Anatomical basis not yet got for theory that the absence of change in respiratory capacity during pregnancy is due to increased breadth compensating for diminished height—*vide* Gerhard and Dohrn.

\* In the sections made by anatomists, other points are referred to which have no bearing on labour; and we take no account of these in the following *résumés*.



Spinal column shows a slight skoliosis. Diameters of pelvis are :—

Conjugata Vera . . .	3·8 in. (9·5 cm.)
Right Sacro-Colytoid .	2·6 in. (6·5 cm.)
Left „ . . .	3·2 in. (8 cm.)
Transverse . . .	5·8 in. (14·5 cm.)
Left Oblique . . .	5·08 in. (12·7 cm.)
Right Oblique . . .	5·6 in. (14 cm.)

**W. WALDEYER** gives a vertical mesial section\* of a X-para, age 38, expecting confinement in a few days; death from hæmorrhage a few hours after both legs had been cut off by a locomotive.

Cadaver placed for ten days in salt and ice. Marked along middle line with pencil, and divided with a saw. Section washed with cool 95 per cent. alcohol, and laid in the same.

The *Atlas* contains four plates:—I. Vertical Mesial Section of right half of whole cadaver—fœtus in section also; II. Same, with left half of fœtus placed in relation to its right half so that fœtus appears undivided; III. Vertical Mesial Section of right half of abdomen and pelvis, with fœtus removed, and showing uterine cavity; IV. Vertical Mesial Section of left half of cadaver, with right half of fœtus placed in relation to its left half so as to show the whole fœtus. A Plate v., gives the Transverse Sections from a primipara dying at the end of the sixth month.

The description of Sections falls into six parts: whole figure, details, thoracic organs, abdomen, pelvis with uterus, fœtus.

Under 'Thorax' the diaphragm is described as rising to the middle of the eighth dorsal vertebra; the liver appears to be pushed upwards, as also pancreas and transverse portion of the duodenum.

Under 'Abdomen' it is noted that its antero-posterior diameter is greatest at level of umbilicus (opposite lower border of fourth lumbar vertebra), and measures 6·4 in. (16 cm.). The digestive organs all lie in the middle line and above the uterus; no intestines before or behind uterus except in pelvis.

'Pelvis with Uterus.'—Between uterus and rectum is section of coil of sigmoid flexure of colon. Symphysis somewhat upright. Fracture of body of first sacral vertebra and of its arch; body dislocated downwards, so that upper part of sacrum projects 1 cm. into pelvis. Fracture also of horizontal ramus of pubis on right side, causing bulging in uterine cavity. Uterus is an oval indented by spinal column; its upper end occupied by placenta and cord, and

\* This section reproduced in the Author's *Atlas of Sectional Anatomy of Labour*, etc.: Plate 1. Fig. 2.



rest filled with foetus, there being little liquor amnii; fundus at level of upper border of second lumbar vertebra. Uterine cavity measures in long vertical axis, from os internum slightly to the right, 9·6 in. (24 cm.); in antero-posterior axis, at level of umbilicus, 5·8 in. (14·5 cm.); transverse diameter at same height 6·4 in. (16 cm.). Fundus stands 9·6 in. (24 cm.) above symphysis, and 3·6 in. (9 cm.) above umbilicus.

Uterine wall rather thinner at fundus. No difference between veins of body and of cervix; large veins seen at os internum, and full veins seen at placental site and in middle portion of uterus. Uterine wall (muscular and cellular tissue), from os internum to hand's-breadth above it, appears almost twice as thick posteriorly as anteriorly, ·32-·4 in. to ·16-·2 in. (8-10 mm. to 4-5 mm.). In middle region anteriorly ·2 to ·24 in. (5 to 6 mm.), posteriorly ·16 to ·18 in. (4 to 4·5 mm.). At fundus ·16 to ·2 in. (4 to 5 mm.). Taking muscular tissue alone, it is almost of the same thickness throughout, except above os internum where it is slightly thinner. Cervix divided mesially, with membranes crossing at os internum, and cavity filled with mucus; difference between anterior and posterior fornices less marked than in non-pregnant condition; whole cervix thickened, vagina less so. Cervical canal measures 1·44 in. (38 mm.); its wall is ·72 in. (18 mm.) thick below, and ·4 in. (10 mm.) above; mucous membrane thickens from above downwards.

Microscopic examination of cervix and adjoining parts (with wood-cut about  $1\frac{1}{3}$  times the natural size) shows glands of cervix enlarged, and extending on to lips of os; they stop superiorly where canal ends. Canal plugged with mucus, so that membranes do not bulge into it. Membranes show amnion, chorion, and several layers of epithelial cells (combined decidua vera and reflexa). The membranes pass over os internum without change, except that the layers of cells become thinner. Cervical epithelium not preserved here, so that its relation cannot be traced. End of canal, therefore, represents os internum, and no part of cervix taken up into uterus.

Os internum below level of plane of brim; os externum is in same horizontal plane as upper border of symphysis. Bladder forms with urethra a sigmoid cleft, with its fundus at upper border of symphysis, and peritoneum covering it for ·04 to ·08 in. (1 to 2 mm.) posteriorly but not anteriorly. Tissue between cervix and bladder forms loose connection; opposite anterior fornix is firmest part, but cervix and bladder can be easily separated everywhere. Microscopic examination of this tissue shows that in the upper cervical



region a small layer of loose fatty tissue, bounded, both on uterus and bladder, by a layer of denser tissue which is scarcely fascia, because the fibres run parallel to the organ and are not compact; everywhere is the tissue lax. Opposite the anterior fornix, where connection apparently firmer, the two denser layers become replaced by lax laminated fatty tissues.

The uterus accommodates itself to the organs round, and is so plastic that the intestines cause a bulging in it.

Fœtus shows breech presentation, sacrum to the left; it measures, as it lies in uterus 9·6 in. (24 cm.) long, and weighs, after hardening in alcohol, 5·5 lbs. ( $2\frac{1}{2}$  kils.); head is bent markedly forwards and to the right, and also rotated slightly so that the face looks to the left; the extremities are pushed together, the legs being symmetrically disposed; attitude due to scanty liquor amnii. The section divides spinal column antero-posteriorly at level of shoulders, and pelvis coronally giving a beautiful section of its organs.

On removing fœtus and uterus from right half of body, the right ovary was found in its normal position surrounded by the tube; the left was not exposed.

The plasticity of the uterus is also shown in Plate v., which gives transverse sections of the uterus of a primipara towards the end of the sixth month of pregnancy. In section at level of umbilicus, the uterus is moulded by spine and ascending colon; at section through middle of sacro-iliac joint, by psoas muscles; in third section (reproduced life-size) passing just above great trochanters, we see shape of cavity of lower segment—two lateral bulgings (due to the ilio-pectineal eminences, between them a rounded border from symphysis) dividing cavity into anterior and posterior portions, of which the former lies outside the pelvis; in the posterior one lies os internum, with membranes passing across it (its position corresponds nearly to the intersection of a line joining the acetabula with vertical mesial plane of body).

#### PERITONEUM AND URETERS.

**W. M. POLK** in his first article deals especially with the course of the ureter, and this in relation to laparo-elytrotomy. After pointing out that Garrigues' description of the ureters is based on a study of it only in the non-pregnant condition, he shows that (instead of following the pelvic wall to a point near the ischial spine) they have the following course:—"Crossing the pelvic brim at the common iliac bifurcation, the left just behind, the right just in front, of that point, they descend into the canal to the brim of



the bony pelvis, the point being about the synchondrosis. In this course they accompany the internal iliac artery, the right in front of the vessel, the left crossing it obliquely. Reaching the bony brim (the ilio-pectineal line), they leave the pelvic wall, emerging from beneath the base of the broad ligaments (in pregnancy on a level with the pelvic brim, and carried back on a line with the synchondrosis), and take a course downward, forward, and somewhat inward, passing about midway between the pelvic wall and the cervico-vaginal junction, but approaching very closely the antero-lateral wall of the vagina, as they turn more decidedly inward, on a lower plane, to strike the base of the bladder three-quarters of an inch below the cervix, terminating finally in the bladder at a point (the subject being on the back) two inches below the spine of the pubes.

"A line drawn from the bifurcation of the common iliac to the spine of the pubes, I have found to correspond in the main to the line of the ureters. Along this line they have the following relations to the pelvic brim (in the recent state): At the bifurcation, half or an inch below; at the extremities of the transverse diameter of the pelvis, about an inch; and at the spine of the pubes, two inches below. As a whole, the tubes in the pelvis are situated upon a higher plane than in the non-pregnant condition, having been carried slightly upward while being separated from their close relations with the pelvic wall by the ascending uterus."

In his second paper, he describes especially the change in the peritoneum in pregnancy. It is lifted up so that (while in the non-pregnant condition a line drawn from the centre of the symphysis pubis to the junction of the third and fourth sacral bones corresponds to its lowest portion in front of the uterus and behind, except the pouch of Douglas) at the end of pregnancy and before uterus has fallen, its lowest level (excepting the pouch of Douglas) is at a line from centre of symphysis to promontory. The anterior fossa is more shallow, and posterior obliterated except the pouch of Douglas; the retro-ovarian shelf (triangular surface bounded by broad ligament, utero-sacral ligament and side wall of pelvis) being on a level with the brim. The pouch of Douglas thus becomes longer. The utero-sacral ligaments are raised to level of brim; being attached posteriorly to first (instead of junction of third and fourth) sacral vertebra, and their anterior attachment being raised with the cervix in pregnancy. The broad ligament shows in the non-pregnant condition two attachments of its outer border—either from just in front of the ischial spine directly upwards, in front of



the great sacro-sciatic notch, to a point in the brim midway between symphysis and sacro-iliac joint; or from front of ischial spine upwards and backwards, crossing sacro-sciatic notch, to sacro-iliac joint. The former is more common in parous, the latter in nulliparous women. In pregnancy, they move upwards so that their base comes to be at the brim and much widened—extending from pectineal eminence to sacro-iliac joint. The uterine artery in pregnancy has its lowest dip above the ischial spine instead of at the level of a point midway between it and the ischial tuberosity.

#### LOWER UTERINE SEGMENT.

**J. MATTHEWS DUNCAN.**—Object of paper to inculcate views of Stoltz, and especially to connect them with actual anatomical investigations. Latter days of ninth month of pregnancy excluded, because of silent and painless labour. Five propositions stated, and supported by clinical and anatomical observations. The latter comprise description of the cervix in five cases of pregnancy: two from third month, by Coste and himself; one, fifth month, by Hunter; two at seventh and eighth months respectively, by himself. The propositions, of which the first occupies the bulk of the paper, are as follows.

1st. The length of the cavity of the cervix undergoes little or no change during pregnancy.

2nd. The capacity of the cervical cavity becomes gradually greater as pregnancy advances, and this is effected by an increase of its diameters or breadth, advancing from below upwards, that is from the external to the internal os of the cervix.

3rd. The length of the vaginal portion of the cervix, or the amount of its projection into the vaginal cavity, generally diminishes as the uterus rises into the cavity of the abdomen.

4th. The softening of the cervix uteri, already commenced superficially during the menstruation preceding conception, continues and extends more deeply into the substance of the cervix as pregnancy advances; and the process is generally completed two or three months before the end of utero-gestation. This softening is accompanied by a considerable increase of bulk.

5th. In vaginal examinations during life, after the middle of pregnancy, the finger of the obstetrician feels the uterine cervix as if gradually shortened as pregnancy still further advances.

**L. BANDL.**—In a former paper on “Rupture of Uterus and its Mechanism,” he did not clearly understand the relations of cervix;



thought that cervix in Braune's section (measuring 11 cm. anteriorly and 10 cm. posteriorly) was produced by labour. Object of present paper to prove that it was produced slowly in last three months of pregnancy. After showing how Röderer's teaching was opposed by Kilian in Germany, Stoltz in France, and Duncan in England, he refers to the great number (seven) of explanations to account for the appearance of shortening the cervix, as evidence that we do not yet know the natural process. Müller makes the cervical canal from  $\frac{3}{4}$  to  $1\frac{1}{4}$  inches long, and with thin walls; with this Bandl agrees, but is not satisfied that it represented the whole 3.5 cm. virgin-cervix of Henle and Luschka. Further, the length of the vaginal portion posteriorly is, according to Müller, the same as or only slightly longer than the length of the canal. Müller's cervix does not agree with that of Braune in pregnancy, and still less with it in labour. It would become as thin as a gold leaf in embracing the head. Lott thinks that the bulging part in front of the os is formed from the wall of the lower segment, the anterior wall of the cervix, and chiefly from the neighbourhood (at sides and behind) of the os internum. With this Bandl agrees, and Müller's os internum is only the edge of the partition between cervix and head. Müller and Lott also describe the cervix after delivery as a wide lax bag, while the os internum has markedly drawn itself together. This shows that they, with Bandl, have fallen into the mistake of thinking that the cervix of pregnancy of Müller could be drawn out into the cervix of Braune. Birnbaum's two papers lay great stress on the development of the lower segment; but, as he does not define the limits of the segment, his work has not received much notice. The 'cervix' of Braune is the 'lower uterine segment' of old writers which Birnbaum has laid stress on, *plus* the small canal which Müller has described.

He found in the uterus of a patient, who died soon after delivery, that the cervix of Hecker, C. Braun, Lott, and Martin (measuring 2.8 to 4 in., *i.e.*, 7 cm. to 10 cm.), consisted chiefly of lower segment; and that the cervical mucous membrane only came on to it for .8 in. (2 cm.). He examined pregnant women, and found in almost every case that he could define its upper limit, which was indistinct in primiparae but well marked in multiparae. Müller did not push his finger high enough up, or he would have felt its upper boundary. The commencement of the cervical mucous membrane below does not always correspond with Müller's ring; in many multiparae, Bandl finds it extending .4 in. (1 cm.) above it. The ovum is not attached in this lower sac, except by mere spider



threads; the firm adhesion of the membrane described by many is very rare. A diagram is given, summing up his facts ascertained clinically.

In two uteri from Caesarean section *post mortem* in the eighth lunar month, he found the cervix 1·8 in. (4·5 cm.) long and ·6 in. (1·5 cm. thick), the lower segment present but not well marked—which feature he ascribes to the child's head not being in the pelvis and compressing it. A section of one of these is given; as also of a similar case in the ninth lunar month in which the wall of the rest of the uterus is three times as thick as that of the lower segment, and the remains of the cervix 1·2 in. (3 cm.) long. A fourth uterus, obtained in a similar way in the eighth month, is represented laid open; and the lower segment differs from the rest of the uterus in its thinner wall, the appearance of the musculature in section, softer consistence, and patchy decidua. From this uterus, it is plain that Braune's os internum does not correspond to Müller's ring but to the upper end of the lower segment.

One can satisfy oneself with finger that firm attachment of membranes corresponds to upper end of segment; where detached higher up, labour comes soon. In the first stage, the lax lower segment becomes tense and also shortened and thickened. After the rupture of the membranes it hangs lax, and the body of the uterus alone contracts on the child—the lower segment only when it is filled with part of the child.

Another uterus is given from a patient who died twelve hours after delivery, showing cervical mucous membrane ·8 to 1·2 in. (2 to 3 cm.) above os externum and lower segment for another 1·6 in. (4 cm.).

A uterus is also given from a fourth month pregnancy, laid open for the sake of comparison, in which the cervix is 1·8 in. (4·5 cm.) long and ·6 in. (1·5 cm.) thick, and appears of two layers:—an inner, dense, connective tissue one; and an outer, softer, muscular one, continuous with uterus and vagina. The formation of the lower segment takes place to the upper end of the canal. The sections of the uteri from the later months show that the upper boundary of the segment is marked by a sudden increase of thickness, as if the middle layer of the muscular wall stopped here, while the outer and inner were prolonged downwards. Here also the wall becomes more vascular, and the peritoneum is reflected on the bladder ·8 in. (2 cm.) below its firm attachment; and the softening of the tissue, due perhaps to the pressure of the head



affecting the veins more than the arteries, extends up to this point. The ovum sinks with the softened floor of the uterus into the pelvis; the mucous-membrane canal remains closed, being held together by the connective tissue while the muscular tissue is drawn out. The thinned decidua cannot follow the increase in area but opens out into patches; and the naked egg is in contact with the inner surface of the enlarged, exposed uterine segment.

The section of the wall from a *post-mortem* Caesarean operation at the 10th month shows a uterine segment of 10 cm., and cervical mucous membrane of .8 in. (2 cm.); the latter shows four overlapping folds 4 mm. long.

In a third-month's abortion, he finds the lower segment with cervix to equal in length the body; cases of ovum's being born into dilated cervix are really cases of birth into the lower segment.

Microscopic examination of two of these uteri showed that the connective tissue of the cervix forms under the mucous membrane a layer of .16 to .2 in. (4 to 5 mm.) thick, which is prolonged (becoming thinner as it passes upwards) over one-half of the lower segment; downwards, it surrounds the lower end of the vaginal portion with a layer .08 to .12 in. (2 to 3 mm.) thick. The musculature of the lower segment consists mainly of longitudinal bundles which are only loosely connected. At the upper end of the segment the arrangement becomes more complicated until it passes into a felted texture. This cannot be separated into distinct layers, but the longitudinal fibres of the lower segment seem to spring especially from the outer part. The inner half of the longitudinal bundles can be traced into the connective tissue of the lower segment and vaginal portion in which they spread out; the outer half is continued into the vagina. Opposite the upper end of the cervical mucous membrane, small vessels and transverse fibres are cut across.

**ANGUS MACDONALD.**—After mentioning that till Weitbrecht (1750) it was universally held that cervix shortened and that the shortening told the period of pregnancy, and that Stoltz, Caseaux, and Duncan resuscitated the true view, he describes preparation \* from a XIV.-para, age 40, dying at full time. Cervix not dilated, but os internum admitted two fingers. Arbor vitæ lines cervical canal, which measures  $1\frac{1}{4}$  to  $2\frac{1}{2}$  in. (3.1 to 3.7 cm.) long, and has walls  $\frac{7}{16}$  in. (1.1 cm.) thick in the spirit specimen. Membranes attached

\* Of which fine drawings *ad naturam* are given of both the surface and section in D. B. Hart's Atlas, Plate xxiii.



up to os internum. He further discusses question—At what period of pregnancy does cervix begin to be opened out? and gives Litzmann's results, who ascribes opening during last month to stretching of cavity by ovum and silent or painless contractions; he examined primiparae and multiparae as to traversableness of canal by finger, and whether membranes were adherent up to its upper end—the separation of membranes being test of opening up. Litzmann found os externum not traversable in—

I.-parae : at 36th-39th week, in  $\frac{2}{3}$ rds of cases; 38th, in  $\frac{2}{3}$ ths; at 40th, in  $\frac{1}{2}$ rd.  
M.-parae : „ „  $\frac{1}{3}$ th „ ; „ none; „ none.

The cervical canal also unfolds from below upwards through strain on its edges produced by weight of uterus, and this more frequently and earlier in multiparae than primiparae—usually present in former up to 33rd week, never in latter before 34th.

Canal traversable throughout in—

I.-parae : at 36th-39th week, rare; 39th week, in  $\frac{2}{3}$ th of cases; 40th week,  $\frac{2}{3}$ rd of cases.  
M.-parae : „  $\frac{2}{3}$ rd of cases; „  $\frac{2}{3}$ th „ ; „ always.

As to separation of membranes, observations were made in 81 cases (35 I.-parae and 46 multiparae), in the majority during the 40th, in a few during the preceding four weeks, and with this result:

Canal not traversable to finger in 14 cases (9 I.-p. and 5 m.-p.);  
Membranes not separated in 28 „ (5 I.-p. „ 23 m.-p.);  
„ separated „ 39 „ (21 I.-p. „ 18 m.-p.).

He concludes that the cavity of the cervix does not shorten except in last month, that its upper part is longer unopened in multiparae than primiparae, rarely shortening before the 39th or 40th week, and in most cases not till labour begins.

**G. LEOPOLD.**—We abstract here only the part of Leopold's paper bearing on cervix and lower segment from 4th month onwards.

Two uteri from fourth month show 1·8 in. ( $4\frac{1}{2}$  cm.) above os externum, mucous membrane of cervix passing abruptly into that of body:—"Where the upper end of this canal bends into the wide space of the uterine cavity, cervical papillae stop suddenly; the cellular ground-substance of the mucous membrane predominates, and shows the spongy layer rich in cells, with the dilated capillary net work of the surface, and with markedly twisting arteries which run tortuously in the septa between the glands."

From the fifth month he describes two uteri. The cervix is a



canal 1·6 in. (4 cm.) long, whose upper end is undilated, and has the membranes attached to it. The canal is lined with the characteristic mucous membrane, but at the os internum the appearance changes completely, because the membranes are joined to the uterine wall by the compact and spongy layers of the vera.

From the sixth and seventh months three uteri are described. The cervix is 2 in. (5 cm.) long, and forms a canal closed up to its upper end where "the mucous membrane passes at once into decidua."

From the eighth month there are two uteri, with a cervical canal of 1·8 in. (4·5 cm.). "The folds of the latter are sharply defined at its upper end from the flattened decidua."

From the full time, there is one uterus with a cervical canal 1·9 in. (4 $\frac{3}{4}$  cm.). The membranes lie flat over the os internum, "which stands prominently forwards both through its well-marked mucous-membrane boundary, and the bending of the musculature of the cervix into that of the body."

**O. KÜSTNER**, after stating that it is scarcely necessary (besides being very difficult) to study the musculature, proposes to study specially the mucous membrane; especially as Bandl has not noted the epithelium. He gives three preparations. The first is from a primipara, aged twenty-three, who died thirteen hours post partum from eclampsia. Its description will be given in its place under Post Partum Uterus.

The second preparation is a pregnant uterus at sixth month, from case of acute anæmia. Cervical canal measures 3 cm., and shows plug of mucus stretching ·8 in. (2 cm.) above it to line of attachment of membranes which is 6·8 in. (17 cm.) in circumference. Plug of mucus, folds of flat arbor vitæ seen over segment, and surface epithelium found in very many places, all show that non-attachment of membranes was structural not artificial.

The third case is of a primipara, ninth month, who died of strangulation. In canal ·8 in. (2 cm.), and membranes free for 1 in. (2 $\frac{1}{2}$  cm.) above, its end line of attachment being 4·8 in. (2 cm.) in circumference. Mucus fills lower segment, and drawn-out palmae plicatae are seen. Ciliated epithelium present in scraping from just below insertion of membranes, although not found in alcohol-hardened sections. Surface epithelium absent just below line of attachment of membranes, and corresponding chorion shows broad decidua pointing to tearing through here. Transition from large decidual cells of body to compact ones gradual.



He thus sums up.

(1.) An opening of the upper part of the cervix has already occurred in pregnancy and without pains. Over the opened portion, the cervical mucous membrane takes part in the hypertrophy of pregnancy—both as a whole and in its individual elements; it is thus changed into a skin resembling decidua, in which the crypts of the cervix play the same rôle as the uterine glands. The epithelium in the opened portion persists to the end of pregnancy as ciliated epithelium, certainly on its surface. Also after labour the same may be recognised, at least as cylindrical epithelium. At the expense of the dilatation of the upper part of the cervix, its canal becomes shorter; at the end of pregnancy, we recognise only one part of the original cervix of the non-pregnant uterus.

(2.) Separation of the ovum from its bed in the last months of pregnancy is not demonstrable.

(3.) We find the cervix after labour very long, the mucous membrane stretching upwards to 'Braune's os internum,' thus covering the whole 'lower segment' of Bandl.

**P. MÜLLER** describes two museum specimens. The first, from uterus at fourth month, examined by Langhans, who found above Müller's ring mucous membrane same as spongy layer of decidua. The second one, of which a plate\* is given, showing section of uterus with placenta and membranes; uterus has rupture of fundus stopping short at lower segment, and from size and appearance of placenta is near full time. Cervical canal scarcely admits pencil: length 1.75 in. (4.375 cm.). Bulging of uterine wall with vein in section (*b* and *c* in Plate) seen some distance above end of canal. Langhans finds the area between these points lined with spongy layer of decidua.

A third preparation is described which is figured in the following paper: death in seventh month from pleurisy; labour pains present. Cervical canal measuring 3 cm. is closed for lowest .4 in. (1 cm.), dilated in upper .8 in. (2 cm.), and contains plug of mucus. Membranes firmly attached up to line where decidua stops, which microscopically appears as os internum.

**LANGHANS and MÜLLER** figure preparation from commencing labour, described in former paper. Also beautiful naked-eye and microscopic sections from a multipara dying at 5½ months

\* Beautifully reproduced in D. B. Hart's Atlas, Plate xxxiv., fig. 3.



from renal disease. In this latter, canal measures 1·8 in. (4 cm.); is ampulla-like, but filled with swollen folds of mucous membrane rather than mucus. Müller's ring well-defined, measures ·2 in. ( $\frac{1}{2}$  cm.) across. Beyond this, membranes free for another ·2 in. ( $\frac{1}{2}$  cm.). Free surface of membranes shows cellular layer of chorion with thin layer of decidua on it (reflexa smooth on surface). The decidua vera has no surface epithelium and ends at the os internum in a ·12 in. (3 mm.) thick cushion, below which typical cervical glands begin. There are no special peculiarities in the structure of the membranes over the lower segment compared with the rest of the uterus, except that the septa between the spaces in the spongy layer are narrower.

**M. SÄNGER**, after a historical sketch and criticism of Küstner's results, describes preparation (with fine drawing of it) from a case of Caesarean section *post mortem*. Patient aetat. 25, II-para, died from hæmorrhage with eclamptic seizure. Membranes lay smooth over os internum. Finger pushed into cervix for 2·4 in. (6 cm.) before it made membranes bulge. No ring-like prominence of uterine wall at upper end of canal. Cervical canal laid open measured 3 in. (7·5 cm.) long, os internum and os externum alike 2·8 in. (7 cm.) in circumference. Microscopic examination showed the characteristic lining of cervical canal with epithelium not ciliated and low; wide-meshed network of the spongy layer of decidua abutted sharply on it at upper end of canal.

The rest of the paper discusses the relation of Müller's ring to os internum, and would divide the First Stage into two periods: the first, from commencing opening up of the cervix to its complete taking up; the second, the act of dilatation.

**F. MARCHAND** has examined uterus from primipara dying at seventh month from meningitis, and gives drawing of section of lower segment.\* Canal measures 1·2 in. (3 cm.), membranes free for ·6 in. (1·5 cm.) above it, and separated from wall by layer of mucus. On posterior wall, palmae plicatae flattened and thinned away; anteriorly, swelling of decidua ·12 to ·16 in. (3 to 4 mm.) thick.

Examined also Küstner's specimen from 9th month, finds different condition on anterior and posterior walls, and gives high-power section of the latter. This shows that separation of membranes is not artificial, gland spaces extend beyond this attachment; but

\* Reproduced in Hart's Atlas, Plate xxxiv., fig. 4.



mucous membrane loses character of decidua, becoming fibrillated and rich in cells which are smaller and less closely packed than decidual cells. Surface epithelium cylindrical, and ciliated when fresh; cells become dwarfed towards attachment of membranes. On anterior wall, a thickened decidual swelling present showing no surface epithelium; decidual formation extends lower down anteriorly: "this circumstance is not prejudicial to the fact that the upper part of the cervix in the later stages of pregnancy takes part in the formation of the uterine cavity; it proves only that this dilatation, or more correctly this flattening-out of the cervix, takes place chiefly posteriorly and to the sides."

**W. T. LUSK.**—After referring to Bandl's views, he describes three specimens. He was present at two autopsies in cases of death in the last month of pregnancy—a primipara and a multipara. No histories were obtained. The uterus in the second is figured. In both, the cervix was hypertrophied and more than 1·8 in. ( $4\frac{1}{2}$  cm.) long. Mucous plug stopped at the upper orifice. The membranes adhere closely to the lower segment and to the borders of the internal orifice. The most careful examination could not find the least trace of a second ring. The walls of the lower segment were a trifle thinner than those of body, which showed no appreciable change of mucous membrane or muscular structures. The third case was a XII.-para who died suddenly from an unknown cause a week before her expected confinement. Here also the cervix was 1·8 in. ( $4\frac{1}{2}$  cm.) long, the os internum was closed, the mucous plug stopped at end of canal. The membranes were adherent to borders of os internum and no ring of Bandl could be made out. He remarks especially on increased length and thickness of the cervix; in contrast to Bandl's cases, where the canal was shortened. "The doctrine so long taught by Dr. J. E. Taylor in this country (America) that the cervix maintains its independence till the beginning of labour is certainly true in many instances." "Meantime, it seems desirable to abandon the terms 'Ring of Bandl' and 'Ring of Müller,' as introducing into obstetrical nomenclature an unnecessary element of confusion; and to return to that of 'os internum' as expressing the true upper limit of cervical canal."

**H. BAYER** has studied the structure of the uterus from preparations made by boiling uteri in carbolic or corrosive-sublimate solution and then macerating in vinegar, glycerine, or spirit.



Some were dissected, others cut with a microtome. The distribution of the cellular tissue (the dark colour of which contrasts with the paler muscular fibre) gives, he thinks, the key to the musculature. He divides his paper as follows:—

1. The non-pregnant uterus and its musculature ;
2. The pregnant uterus and the laws of its unfolding ;
3. The uterus post partum and its changes during contraction ;
4. The uterus in the puerperium and puerperal involution.

*3 and 4 will be noticed later under "Puerperium."*

1. *The Non-pregnant Uterus and its musculature.*—He finds that the boundary between body and cervix is marked not only by difference of mucous membrane but by the peculiar arrangement of vessels, muscular fibre, and firm attachment of peritoneum. From the dissection of uteri thus prepared, he describes the internal and external layers of fibres. As to the *external*, his results agree with those of Kreitzer. It consists of longitudinal fibres, derived mostly from the round ligament, which stream over the anterior wall and fundus ; from this layer, fibres run superficially in the cervix to the anterior vaginal wall. The retractor muscles (muscular tissue of utero-sacral ligaments) come into relation with the cervix at a variable height ; but always meet at the os internum, cross here and pass up over the fundus and towards the ovarian ligament. The cervix, beneath the superficial longitudinal layer, consists of fibres so closely interlaced that they are made out with difficulty—their direction is transverse. The fibres from the os internum sink into it, and only with difficulty can the imbricated arrangement of the plates be made out.

The *internal*, submucous layer consists at the sides of the uterus of spiral fibres round the tubes and horizontal rings round the lower part of the body ; and, before and behind, of longitudinal fibres which pass chiefly into the spiral ones partly into the horizontal.

From the dissection of the infantile uterus he finds a similar arrangement of external layer—the decussating fibres forming a well-marked raphé both in front and behind, the posterior raphé bifurcating like a T at the level of the ovarian ligaments. In the internal layer, there were no horizontal circular fibres.

From sections of two uteri—from a multipara and a nullipara—he describes the course of the muscular fibre. In the former, he finds in the anterior wall of the lower portion of the uterus two musculo-fibrous knots—one at os internum, the other in lower third of the cervix. From the first, the fibres spread over the greater portion of



the cervix ; the second is the point of origin of fibres which spread into the substance of the anterior lip and fornix. By these knots, the anterior wall of the cervix is differentiated into two zones corresponding to the vaginal and supravaginal portions. The lower knot comes, he says, to occupy the place of Müller's ring in the full-time uterus. The part between this and the upper knot becomes the lower segment. He follows von Hoffman in regarding the musculature of the uterus as genetically related to the three layers of muscular fibre in the tubes, both being developed from the ducts of Müller. Further, the muscular fibres of the ligaments (ovarian, round, and especially utero-sacral) enter into its structure and thus complicate its disposition. He thus sums up.

- (1.) The musculature of the tube enters into its formation as follows :—its inner longitudinal layer, forming in the uterus the largest part of the submucous layer ; its circular layer, forming the middle felted portion ; its external longitudinal layer, forming one part of the external layer of uterus.
- (2.) From the utero-sacral ligaments arises the greater portion of the musculature of the lower pole of the body and of the cervix, so that from them come the lower portion of the posterior wall of the body, a thinner and rather higher portion of the posterior wall, the whole of the back and side walls of the cervix as well as the anterior lip.
- (3.) The rest of the muscular wall of the uterus is derived from an expansion of the round ligament.

He regards the uterus and whole cervix as containing sphincter fibres : as the uterus stretches, the sphincter action is broken—the upper limit of the cervix sphincter corresponding always with the commencement of cervical canal. In the lower section of the cervix, the sphincter action persists even after the dilatation of the uterus in pregnancy.

2. *The Pregnant Uterus and the laws of its unfolding.*—He describes a beautiful vertical mesial section of pelvis with three months' pregnant uterus ; also uterus alone from fourth, fifth, and seventh months ; also sections of lower segment from ninth and tenth months ; and uterus with pelvis at full time : in all, eight uteri. He also refers to but does not figure a uterus from the second month.

*The Third-Month Uterus* is sharply anteflexed, the cervix looking downwards and forwards. The os internum is at the sharp angle



of flexion where several veins are seen in section. The homogeneous appearance of the wall prevents our recognising the knots of muscular tissue. The sharp flexure makes it difficult to say to what point of the uterus the utero-vesical fold of the peritoneum is opposite. The condition of the uterus in this preparation is referred to the action of the utero-sacral ligaments pulling the posterior wall upwards and backwards, as also the upper part of the anterior. Opposed to this is the traction of the vaginal wall on the lower muscular knot, whence also the ampulla-like dilatation of the cervix. Further, the portion of the round ligaments which enters into the formation of the inner and middle layers of the uterus pulls against the utero-sacral ligaments; while that in connection with the outer layer pulls on the lower of the two muscular knots and causes the ante flexion of the uterus and the apparent upward movement of the utero-vesical pouch. We have here the action of the factors which produce the lower uterine segment: viz., the traction of the utero-sacral and round ligaments, and the counter-pressure of the ovum. These produce the essential features of the gravid uterus so long as it lies in the pelvis, viz., the sharp bending with the arch-shaped stretching of the posterior and inward projection of the anterior wall; the upward and backward direction of the cervix; the shortening of the vesico-uterine pouch with apparent upward displacement of the peritoneum. In the uterus from the second month was found an arrangement of the muscular fibres similar to that found in the non-pregnant uterus.

*The Fourth-Month Uterus* shows the body in a line with the cervix; the cervical canal measures 1·8 in. ( $4\frac{1}{2}$  cm.), and opposite to its upper end is a large sinus in section, and also the firm attachment of the peritoneum. Above the large vessel, the muscular fibres divide into two layers; of which, the outer passes down over the cervix to the anterior fornix, the inner passes to the os internum and upper part of the cervix. 1·2 in. (3 cm.) above the anterior lip appears a spindle-shaped figure which extends upwards so as to embrace the large vein. The cervix is still intact, the os internum not being opened out. The orifices of the Fallopian tubes in the uterus appear opened out, which is the chief feature in this preparation.

*In the Fifth-Month Uterus* the cervix measures 5 cm. The firm attachment of the peritoneum is ·6 in. ( $1\frac{1}{2}$  cm.) above the upper opening of the cervical canal, where also is seen the vein in section. The membranes are less firmly attached for some little distance above the cervical canal—anteriorly for ·8 in. (2 cm.), posteriorly



for .6 in. ( $1\frac{1}{2}$  cm.). Between end of canal and the firm attachment of the membranes, the surface of the uterus showed transverse folds and a peculiar mucosa provided with surface epithelium transitional to the decidua above, where, 1 in. ( $2\frac{1}{2}$  cm.) from the tip of the anterior lip, there is found a star-like knot of connective tissue, with blood-vessels in it, radiating into the anterior fornix and the substance of the cervix; and above this a thicker oviform bundle of fibres, above which again there is a layer of longitudinal fibres joining the section of the large vein with the upper end of the cervical canal. These two knots represent the lower ends of two layers of muscular fibre in anterior wall of the uterus; the star-like knot is the end of the outer layer which has not materially moved from its position in the non-pregnant uterus; the knot with the large vein is the lower end of the inner layer which has moved to a considerable distance up. Hence the outer layer has been fixed by its firm attachment to the anterior fornix, the inner layer has slid upwards on it. *This sliding of inner layer upon outer layer governs the whole changes of pregnancy during the early months.* This unfolding of the upper part of the cervix takes place only on the anterior wall; the fibres of the posterior wall are fixed by the interlacing of those from the utero-sacral ligaments.

*Seventh-Month Uterus.*—Cervical canal measures 4.3 cm. Firm attachment of peritoneum is 6.4 cm. above the upper end of cervical canal and the membranes are loosely attached for the same distance in front, but not quite so far behind. The veins stop in the anterior wall at the same level, but posteriorly they come lower down. The muscular fibres run longitudinally, but the action of the spirit prevents their course from being studied. The preparation shows the fully-formed lower uterine segment, the supravaginal portion of the cervix having unrolled as far as the fibres coming from the utero-sacral ligaments.

*Uterus from the Ninth Month—Labour commencing.*—Cervical canal measures .6 in. ( $1\frac{1}{2}$  cm.). Firm attachment of peritoneum was 4 in. (10.2 cm.) from its upper end. Below this, the uterine wall was very thin (1 to  $1\frac{1}{2}$  mm.). The membranes were firmly attached for a considerable distance below this point to within 2 cm. of end of cervical canal, and here was also found normal decidua. Unaltered cervical mucous membrane extended for a certain distance into the uterine cavity, and between it and normal decidua was an area of transitional decidua (covered with a continuous layer of epithelium which becomes lower and flatter as we pass upwards until, where the membranes are firmly attached, it



becomes quite flat and finally disappears). The muscular fibre of the lower uterine segment is arranged longitudinally, and consists of plates covering one another like the tiles of a house with their free ends on the inner surface. This tile-like arrangement begins high above the firm attachment of the peritoneum and extends to within 1 cm. from the cervical canal. Below this point the plates cannot be separated although the tile-like arrangement is still visible.

*Tenth-Month Uterus.*—Cervical canal measures 1·2 in. (3 cm.). Membranes separated behind for 2·8 in. (7 cm.); in front for ·8 in. (2 cm.), but can be easily detached for 2·4 in. (6 cm.) up to the firm attachment of the peritoneum. Cervical canal was lined by typical mucous membrane, which extended for ·4 in. (1 cm.) on the posterior wall of the lower segment. Anteriorly was transitional mucous membrane passing into decidua. The muscular tissue of the lower segment consisted of superimposed plates which could be separated without any difficulty. In the anterior wall the end of the plates was free on the inner surface, all except the external ones which passed into a knot lying behind the attachment of the bladder, from which fibres streamed to the anterior fornix and lip. In the posterior wall, the internal fibres run down parallel to the cervical canal, while the external plates run towards the posterior surface of uterus and fornix. From this Bayer infers that “hence there occurs in the stretching of the uterus upward a sliding of the muscular fibres—posteriorly from without inwards; anteriorly from within outwards” (*i.e.*, the inward layer posteriorly is that which has advanced least, while anteriorly the external layer is the one which has remained stationary).

*Uterus of a Primipara from the Tenth Month.*—Cervix 1·2 in. (3 cm.) long, anterior wall 3 in. (7½ cm.) from the upper end of the canal becomes suddenly thicker and shows a large vein and the firm attachment of the peritoneum. Muscular fibres run longitudinally in this segment, and it is covered with a thin membrane.

*Uterus of a Primipara at Full-Time.*—Cervix 3 cm. long. Firm attachment of peritoneum 6 cm. above it, where also vein in section. The muscular fibres of the whole uterus were prepared so as to show the arrangement; and he found three layers—an external one (with spaces in it above the firm attachment of the peritoneum, along the whole side walls from the utero-sacral ligament up to the attachment of the broad ligament, also over the fornix, and finally over the insertion of the ovarian ligament); under this, a second complete layer, with smaller corresponding spaces; also,



a third layer with somewhat smaller spaces still, beneath the second. These muscular plates are prolonged over the lower segment, forming cruciform figures through the junction of the anterior and posterior plates by trabeculae at the level of the utero-sacral ligaments.

*Conclusions with regard to the Changes of the Muscular Architecture of the Gravid Uterus.*—The uterus grows during pregnancy in every direction; the os internum becomes dilated from about the middle of pregnancy, so that the supra-vaginal portion of the cervix is gradually taken up to cover the lower pole of the ovum; the unfolding of the same progresses up to a certain distance, as far as the anterior end of the utero-sacral ligaments. The stretching of the uterus takes place essentially by separation and sliding of the muscular plates. This spreading out into plates is under the influence of differences in the arrangement of the component systems of fibres, and adjusts itself at a given point according to the character of the dominating muscular system. The systems which influence the uterus are the Round, Ovarian, and Utero-Sacral Ligaments, and spiral fibres from the Tubes, the action of each of which is described in detail. The general hypertrophy of the walls and the pressure of the ovum are also factors.

In his paper on the Stricture of the Cervix, Bayer gives a historical résumé, and then the result of the examination of the mucous membrane in the above preparations. In the uteri of the second and fourth months, he found at the upper end of the cervical canal its characteristic mucous membrane passing into typical decidua. In the fifth month, between the upper end of the canal and the firm attachment of the membranes, the mucous membrane of the anterior wall was characterised by its thinness, its papillary folds, and the smallness of the trabeculae, but consisting of decidual elements; just at the canal it becomes compacter, and has a continuous surface epithelium. The posterior wall showed, first, cervix-like epithelium on ampullary tissue without decidual elements; above this, a broken-down tissue resembling that of cervix, but without decidua; finally and suddenly, typical decidua.

In the seventh-month uterus, the tissue was unfit for microscopic examination but cervical mucous membrane could be traced for 1 cm. on the posterior wall.

In the ninth month, he found from above downwards—(1) normal decidua in the body; (2) in lower segment a decidua of looser build, with thinned trabeculae and elongated spaces; (3) immediately below attachment of membranes, a mucous membrane with



surface epithelium, numerous glands, and cells like those of decidua; (4) transitional mucous membrane with no spongy layer, small cells, no glands, and continuous surface epithelium; (5) then mucous membrane with cervical glands in deeper layers, and surface epithelium; (6) finally, normal cervical mucous membrane. On the posterior wall, below firm attachment of membrane, was a layer of thin decidua without enlargement of glands, but covered with surface epithelium.

In the tenth month, he found on the posterior wall typical unrolling of cervical mucous membrane, then sudden transition into decidua. On the anterior wall, there is not the same sharp boundary between decidua and cervical mucous membrane. The cervical surface-epithelium extends 2 in. ( $\frac{1}{2}$  cm.) into lower segment, the cells becoming rapidly dwarfed. Then, transitional mucous membrane of looser build with small decidual cells and glands more numerous.

From these preparations he concludes that, with the formation of the lower segment, a true decidua develops—but differently on the anterior and posterior walls. This decidua is characterised by its remarkable thinness and elongation of the meshes of its spongy layer. On the posterior wall normal cervical mucous membrane could always be followed up for a certain distance into the lower segment. His results agree with those of Küstner who found, in a post-partum uterus three hours after delivery, in the zone between the contraction swelling and the commencement of the *palmae plicatae*—(1) characteristic decidua; (2) a very thin mucous membrane, with few glands and without surface epithelium; (3) thick, large-celled mucosa, with numerous glands and surface-epithelium passing into cervical mucous membrane. He differs from Küstner in not believing in a special predisposition in the upper part of the cervix to form a decidua in multiparae; but regards the change in the mucous membrane as specially connected with the unfolding of the cervix, as he found that it did not affect the cervical mucous membrane of the canal. Further, the transitional mucous membrane does not line the whole of the lower segment. The cervical mucous membrane does not, therefore, produce a decidua different from that produced by the body; and the transitional mucous membrane is therefore only decidua at a younger stage. His conclusion is that the determination of the *os internum* from mucous membrane is entirely misleading, and further investigations along this line are entirely superfluous. The mucous membrane of the cervix will not produce a decidua different from the mucous mem-



brane of the body, otherwise we should find this transitional mucous membrane over the whole of the lower segment.

**M. HOFMEIER** seeks to settle three questions:—

- (1.) Does the cervix as such persist till the commencement of labour, or is it taken up into the uterine cavity during pregnancy?
- (2.) If the cervix as such remains in whole or part, is there a portion of the pregnant uterus differing in its anatomical structure from the rest and which may be called lower uterine segment?
- (3.) How can the clinical be made to agree with the anatomical facts?

As to the question of *persistence of the cervix*, after stating that Küstner's conclusions show that we can not determine the situation of the os internum from the mucous membrane, and that Schatz's proposal to distinguish the segments of the uterus according to physiological function is impracticable, he shows that during pregnancy the arrangement of the muscular fibre in the part of uterus round ovum essentially differs from that in the part forming cervical canal. In the former, both on longitudinal and transverse sections, the arrangement is in leaves or "plates" which lie beside each other, and are only loosely connected so that they can be separated without much labour; in the latter the tissue is thick and almost inseparable, felted and closely interwoven, and even in thin layers can only be separated by the tearing of the whole. Only at the periphery of the cervix is the tissue laxer, due to the coming down of muscular fibres from the outer layer of the uterus to the os externum. He has found this characteristic arrangement from the third month throughout pregnancy, in labour, and also in puerperium. The limit between these kinds of tissue corresponds to the point where the canal dilates into uterine cavity and cervical mucous membrane extends up to it; thus, he defines the os internum in terms of the muscular wall.

He has examined the cervix and lower uterine segment from a puerperal uterus at third month, one gravid at sixth, two at the seventh, one at the ninth, two at the tenth, and one in parturition—in all, eight uteri. He finds that the cervix persists as a canal to the end of pregnancy. In the two cases from the tenth month there is a funnel-shaped opening up of the upper portion similar to what Küstner describes. This dilatation may be due to a patho-



logical stretching of the uterus as in hydramnios, or to commencing uterine pains.

The condition in these preparations agrees with that found by Säger, Martin, Müller, and Langhans ; also by Waldeyer and Lusk. He has observed the wave-like arrangement of the muscular fibres which Ruge refers to (in those uteri where uterine contractions had been present). They were most marked in a case of rupture of uterus. He has never seen them in puerperal uteri. The reflexion of the peritoneum, which Küstner following Kohlrausch regards as indicating the os internum, is unreliable as Lott points out. The apparent shortening of the cervix noted clinically in the last months of pregnancy may be explained by the head's pressing down the anterior fornix, the cervix being fixed posteriorly by the utero-sacral ligaments ; also the muscular fibres which run in the outer portion of the cervix may shorten it without the canal's becoming dilated. Schatz's proposal to divide the uterus according to its physiological functions is unworkable ; for, taking a new standpoint, it shifts the question instead of settling it.

The determination of the '*Lower Uterine Segment*' in the puerperal uterus is extremely difficult: (1) because death does not occur usually for a few days after delivery, when uterine contractions have produced alterations in the musculature ; (2) further, there must be an abrupt difference between the segments, such as only occurs in cases of obstruction ; (3) hence, the best material is found only in cases of rupture with immediate death. In his gravid uteri, he finds that the firm attachment of the peritoneum begins from 1.2 to 2.4 in. (3 to 6 cm.) from upper end of cervical canal, or 2.8 in. to 4 in. (7 to 10 cm.) from os externum. Followed from below upwards, the wall becomes suddenly thinner where cervical mucous membrane ends, then passes with the same thinness sometimes slightly increasing in thickness into the body of the uterus. Has made sections of all these uteri, prepared according to Ruge's method (cutting thin slices through the whole uterus and cervix, soaking in water, and then stretching them with pins on cork plates), and found that the same plate-like arrangement of the muscular fibre obtains in the lower segment as in the rest of the uterus, only that the plates are less coherent one with another and with the peritoneum. The difference between tissue of lower segment of uterus and that of cervix is very marked ; the muscular plates spread into its thick and firm tissue but so that only on the outer part of it, do they run down to its lower end. The tissue, when stretched, breaks up only at its very periphery



into separable elements. In some cases the muscular fibres run in a straight line into the cervix; in other cases (especially in anterior lip of primiparae) at a sharp angle, which accounts for its slow thinning. A photograph is given of the anterior lip of the cervix in labour. In puerperal uteri, he has found the same arrangement. Drawings are given of sections of all his pregnant uteri prepared as above.

As to the attachment of membranes, he found them in two cases (seventh and eighth months) easily separable though still attached. In all the others, the attachment was firm except in the case where labour had begun and they were free over the whole of the lower segment up to the contraction ring. The separability of the membranes over the lower segment has an influence on labour; Lorenz has shown that in placenta praevia, where the placenta is central, pregnancy is less likely to be interrupted than where it is marginal. He describes two uteri from cases of placenta praevia.

Comparing sections of the lower segment of the uterus with those of the body, he finds that in the former the constituent parts are more loosely united; and that the elements in the individual muscle plates themselves are in all directions interwoven: in the body, the individual layers are more differentiated, the fibres are arranged in distinct bundles, and the layers correspond to the long and cross axes of the uterus. The section given of the wall from case of rupture shows that the lower segment has the structure referred to above, while the contracted part is an inextricable wattle of fibres. Although this segment rapidly undergoes evolution, we can still trace for a long time a difference in the structure; the complete restoration of this portion in fact never occurs; and he has published a case which finally ended in rupture—but death did not follow till the ninth day from peritonitis.

The conclusion of his paper is that the lower uterine segment of the pregnant and puerperal uterus, from its whole anatomical structure, belongs to uterus and not to cervix. Of why a portion of the uterus remains passive and dilates, although it has the same structure as the contracting portion, he can give no explanation. Bandl's view that it was due to the difference of structure between cervix and body falls through; and Ruge's, that the fibres here run only longitudinally and not circularly, is not supported. As to the reconciling of *clinical with anatomical facts*, he thinks that he has satisfied himself clinically that the lower portion of the uterus is passive during uterine contraction, just like the cervix; not merely that it does not contract so powerfully (as Lahs supposes), but that it does not contract at all. He admits the difficulty of



distinguishing by touch between a surface subjected to stretching and one undergoing muscular contraction.

In a case of labour in contracted pelvis, between the pains, the contraction ring was felt; and, below, the equally flabby lower uterine segment and cervix. During a pain the contraction ring became tense, but the lower segment was not stretched till the membranes bulged and brought out the difference between the tense lower segment and the flabby cervix.

He thinks also that the chief factor in dilating the cervix is the bulging bag of membranes.

His three questions are answered thus in the summary :

- (1.) The cervix, which has a characteristic mucous membrane, persists almost entirely as a canal up till labour. Slight opening of its upper part is due to uterine contractions.
- (2.) The 'lower uterine segment' forms, both in its anatomical structure and mucous membrane, a well-marked part of the body of the uterus; and is essentially different from the cervix both in pregnancy and in puerperium. It also differs macro-scopically and micro-scopically from the body of the uterus so as to be worthy of this separate name.
- (3.) Physiologically the lower segment is essentially passive in labour, contrasting with the rest of the uterus which by its contractions becomes sharply marked off from it. As the line of separation is only distinct after powerful contractions, the term 'contraction ring' is not inappropriate.

**BENCKISER.**—Omitting his description of a two months' pregnant uterus,\* we have two pregnant uteri figured and described.

*Uterus, four months pregnant; death from cerebral meningitis; IV.-para, ætat. 26.* Section given of whole uterus with vagina and bladder, *ad naturam*; and similar one of cervix showing canal throughout. *Uterus* anteflexed, with lower part of body on bladder. Contour irregular, and vagina bent back below from pressure of freezing apparatus. Body from os internum to fundus 12·5 cm. (5 in.) long, 9·3 cm. (3·7 in.) deep; and the breadth of half of it is 5·5 cm. (2·2 in.). *Peritoneum* firmly attached before to 3·5 cm. (1·4 in.), behind to 1·6 cm. (·64 in.) from os internum; descends between uterus and bladder to 2·5 cm. (1 in.) from the same; descent posteriorly not determined. Thick-

\* These Abstracts deal with the uterus during and after the fourth month of gestation. See Chapter III. of Part I.



ness of *musculature* of body averages .8 cm. to 1 cm., being greatest (1.3 cm.) above os internum both before and behind, and least (.4 cm.) at placental site; laminated texture present throughout. Attempt to separate into plates "gave a recognisable but not very marked difference in the size of the muscle-rhomboids of the lower and upper segments; and it was quite impossible to split up the cervical tissue in this manner." Bundles could be followed into the anterior wall of vagina and cervix, and into posterior lip and vaginal wall. Axis of cervical canal forms angle of about  $160^{\circ}$  with that of uterine cavity. *Cervix* is sigmoid in section, 5 cm. (2 in.) long, averages 1 cm. (.4 in.) thick—anterior wall being rather the thicker. Texture closely felted and rich in connective tissue. Vaginal portion looks downwards and backwards; anterior fornix .5 cm. (.2 in.), posterior 1 cm. (.4 in.) deep. Cervical canal gapes somewhat at os externum, then narrows into sigmoid canal, and not till 1.5 cm. (.6 in.) from os internum is dilated by mucous plug, above which narrows again and then suddenly opens out in uterus. Its mucous membrane, which begins somewhat above os externum, shows numerous recesses especially midway, and averages .3 cm. (.12 in.) thick; where mucous plug is, it is thin and scarcely recognisable to naked eye; but at os internum mucous-membrane boundary is pronounced, for decidua (.2 to .3 cm. thick) begins with distinct cushion. *Decidua* shows characteristic glandular structure, and on anterior wall thins to a fraction of a millimetre at fundus; on posterior wall passes without change into placenta about 2 cm. (.8 in.) above os externum. *Membranes* separated over area of a half-crown; placenta is on posterior wall extending to fundus, and is 2 cm. thick (.8 in.) at thickest part. Cavity of amnion shows no foldings at os internum or Fallopian-tube openings. *Vessels* vary greatly, being numerous at placental site and few in anterior wall—the first large one being in front 2.5 cm. (1 in.), behind 1.5 cm. (.6 in.), above os internum; few in cervix. *Fætus* female, 21 cm. (8.4 in.) long, lies in second transverse position with back towards os, head markedly bent on breast, arms crossed before face, legs bent on belly and crossed; cord runs between legs and over back to placenta. *Bladder* firmly attached to cervix for 1 cm. above anterior fornix; its walls 2 cm. (.8 in.) thick.

*Uterus about four months pregnant; death from eclampsia; IX.-para; ætat. 38. Uterus partially injected from aorta; frozen almost as it lay in the body. Right half of uterus represented in section. Uterus slightly anteflexed, and rests with lower part on*



fundus of bladder. Anterior wall markedly convex; posterior irregularly depressed by ice. Length (to os internum) 14.4 cm. (5.86 in.), greatest depth 10.2 cm. (4.08 in.), breadth of half 4.4 cm. (1.76 in.). *Peritoneum* intimately attached to musculature of fundus and rest of body anteriorly to 3.5 cm. (1.4 in.) from os internum; below this the muscle plates rise from the loosely attached peritoneum which is reflected on bladder at os internum. Posteriorly, peritoneum firmly attached 3 cm. (1.2 in.) above os internum; below which point it is loose, and reflected on the rectum 2 cm. (.8 in.) above posterior fornix. *Musculature* is thickest just above os internum—1.3 cm. (.5 in.) anteriorly, 1 cm. (.4 in.) posteriorly; above this, it diminishes equally; average thickness is .8 cm. (.32 in.), at fundus .5 cm. (.2 in.); thinnest part at placental site on posterior wall .4 cm. (.16 in.). Structure throughout laminated. It is only toward outer surface that we recognise a distinct difference in coherence of lamellae of wall just above os internum and that of rest of uterus; there, the individual plates at their origin from the peritoneum are distinct and easily separable, as they are not above firm attachment of peritoneum. The walls suddenly thicken to 1.5–1.7 cm. (.6–.68 in.) at the cervix, which is set on the uterus as a cylinder with equally thick walls. Its texture is entirely different from that of the body, the plate-like structure of which stops at the os internum: while the internal plates cross from anterior to posterior wall, the external of the anterior wall go to anterior lip, vaginal wall, and bladder; and those of the posterior go to the posterior lip and vaginal wall. The middle plates, interwoven with connective tissue and vessels, form the chief bulk of the cervix. *Vaginal portion* of cervix is 3 cm. (1.2 in.) thick, and has two lips closely approximated, the anterior 1.6 cm. (.64 in.), and the posterior 1.9 cm. (.76 in.) long. *Cervical Canal* is curved with concavity forwards; its mucous membrane has distinct crypts, is 3 cm. (1.2 in.) thick as far as 1 cm. (.4 in.) above os internum; here it thins, the canal being dilated and filled with mucus, and then passing with small funnel-shaped dilatation into uterine cavity. Into this funnel projects a .3-to-.4-cm.-thick decidua, the dilated glands of which give to the naked-eye appearance of cervical membrane, but the microscopic characters are those of decidua. Below this decidual cushion, is cervical mucous membrane poor in glands; above it, the decidua thins to .15 or .2 cm. (.06 or .08 in.)—its average thickness throughout. The *Placenta* is situated on the posterior wall extending from 4 cm. (1.6 in.) above os internum to



fundus, and being 1.5 cm. (.6 in.) thick. The *Membranes* are detached above cervical canal over the area of a penny piece, they appear smooth in frozen section with only slight wrinkles near the os internum, but in the thawed and gradually hardened portion are wrinkled over lower two-thirds of cavity. *Vessels* most developed at placental site, sparing in anterior wall, frequent as small arteries in cervix, with no circular sinus at firm attachment. *Fœtus* male, 24 cm. (9.6 in.) long, lies up and down with feet over os, and with back to right; arms crossed on breast, and legs drawn up on belly. Empty *Bladder* loosely attached throughout to cervix to  $\frac{1}{2}$  cm. (.2 in.) below fornix, where more firmly attached for 1 cm. (.4 in.); has walls .8 mm. (.003 in.) thick.

Comparing these two uteri, Benckiser finds greatest thickness of uterine wall just above end of cervix—measuring anteriorly (up to firm attachment) 3.5 cm. in both, posteriorly 1.6 cm. and 3 cm. respectively. In the former, the texture of the tissue here differs distinctly from that of cervix below and less distinctly from that of uterine wall higher up; in the latter, it differs from that of the cervix. We have thus, in the fourth month of pregnancy, a Lower Uterine Segment with its characteristic marks and not inconsiderably thicker than the rest of the wall of the body; upper end of canal corresponds to limit of cervical mucous membrane—the decidua bulging into it in the latter preparation. Firm attachment of membranes not at os, but a little above it; reflexa and vera have therefore not blended in the lowest part of the body—last unfolded.

#### THE MEMBRANES AND THEIR SEPARATION.\*

**W. O. PRIESTLEY** describes, amongst other preparations, a uterus from the ninth month of gestation, in which he found that the membranes when artificially detached left “a layer of nucleated particles, subtended by delicate fibrous tissue lying between the muscular fibres and the decidua.” He also speaks of “tubular follicles deeply planted in the uterine substance, which do not separate with the membranes, but remain as centres of reproduction, to assist in spreading a thick secretion of epithelium over the surface of the uterus when occasion requires.”

**DOHRN** was the first to give a clear and complete account of the minute anatomy of the membranes; but his original paper does not deal with their separation in Labour.

\* See note on p. iv. of Index to Literature.



**FRIEDLÄNDER** gives the results of the careful microscopic examination of a uterus from an early period of gestation, and also from the sixth and eighth months, also one 14 hours, and another three days after delivery. He describes the decidua in the later months of gestation as differentiated into two layers—an inner cellular and outer glandular. The inner consists superficially of cells, .02-.06 mm. thick, mostly rounded, and separated by a delicately punctate intermediate tissue; more deeply it is mainly composed of fusiform cells. The outer or glandular layer shows compressed cavities, which only exceptionally communicate with each other, and are usually empty. These are lined with a single layer of cylindrical epithelium. During the first week after delivery he found the whole of the glandular and part of the cellular layers lining the uterus, and he concludes that both the membranes and placenta are detached in the plane of the cellular layer. In the second week the cellular layer comes away in the lochia, and the glandular spaces are opened into. Subsequently the epithelium of adjoining exposed gland-spaces comes to be continuous through the melting down of the intermediate tissue.

In a second paper\* he confirms these observations.

**KUNDRAT** and **ENGELMANN**† have examined three uteri with ova, and two from which ova had been expelled, from the first month; one with ovum, from the second; two with ova, from the third; and nine with ova, from the fourth month to full time; also several post-partum uteri. They confirm Friedländer's description of the membranes, but find the spaces in the spongy layer to have lost their epithelium in the later months, except at the very bottom of the glands, and speak of the entire spongy layer as remaining in the uterus post-partum. Along with Friedländer, they describe as belonging to the decidua reflexa a layer of cells, which Kölliker, Dohrn, and others rightly refer to the chorion.

**LANGHANS**, describing a uterus from the 14th week of pregnancy, divides the decidua into three layers according to the condition of the glands: the upper containing their straight ducts,

\* "Ueber die Innenfläche des Uterus post-partum," *Archiv f. Gynäk.*, Bd. ix. s. 22.

† In *American Journal of Obstet.*, May 1875, Engelmann embodies these investigations in a very full and interesting paper on "The Mucous Membrane of the Uterus."



widely separated by decidual cells; the middle, their dilated and convoluted portions which produce the appearance of a spongy layer; the lowest, their contracted terminations. Underneath the placenta, the last layer is not distinguishable; at its margin, the spongy layer is not very well developed. This preparation suggested to him that the line of separation was in the spongy layer, and examination of uteri from the 20th and the 30th week and at full time strengthened this view. In the post-partum uterus he found a reticular appearance, which he ascribes to the divided glandular spaces. There was no fatty degeneration along the plane of separation.

**BLACHER**, from the examination of fresh placentae, two ova at the third month, some spirit preparations at various months of pregnancy, and one fresh uterus at end of pregnancy, maintains that a few of the spaces in the spongy layer are glands, but that the majority are dilated veins, and that they are more numerous in the decidua serotina than in the vera. The difference in his results may be due to his having injected his preparations, which would distend the sinuses and compress the gland spaces; otherwise, it is difficult to reconcile his statements with those of the majority of other observers.

**LEOPOLD** gives a very complete and consecutive account of the membranes at the various periods of pregnancy. His material was as follows:—From 1st month, in addition to some separated ova, one uterus with ovum; from 2nd, four ova, some still attached in part to uterus; from 3rd, septate uterus with ovum, as well as three isolated ova; from 4th, two uteri; from 5th, two uteri; from 6th and 7th, three uteri; from 8th, two fresh uteri; at full time, one fresh uterus as well as other spirit-hardened ones. A full description is given, illustrated by beautiful coloured drawings, which, though reproduced from photographs for exactness, are somewhat diagrammatic in their detail. The most important facts with regard to the membranes may be thus summarized,—the two layers of the decidua vera, compact and ampullary (cellular and glandular, as named by Friedländer), are distinguishable from the first. On separating the membranes artificially by traction, in a uterus at the eighth month, “the tear runs in the meshy layer of the decidua,” the septa between the spaces breaking across; two-thirds of the decidua vera remain attached to the uterine wall, and a number of arteries and veins are torn across. He confirms Fried-



länder's observation as to the occurrence of spontaneous thrombosis in the veins below the placental site, and finds the same change in the serotinal veins.

**KÜSTNER** has examined the membranes after delivery, and finds the layer of decidua on the chorion to be thickest near the placenta; usually it has a honey-combed appearance, which means that the separation has taken place in the spongy layer; where this is absent, and the decidual layer on the chorion is thin and smooth, separation has occurred in the compact layer. Round the rent in the bag of membranes the chorion was sometimes (in 12 out of 52 cases) bared of decidua, which began distinctly at some distance from it; in the other cases the decidua was continued up to the rent, but as a thinner layer. This implies a difference in the thickness of the presenting bag of membranes.

**TURNER** has described and figured the relation of the decidua in a uterus at the fifth month. He describes the spongy layer as composed of spaces "separated from each other by trabeculae, which were sometimes broad bands of tissue, but at other times slender bars." He did not find epithelium lining them in this preparation or in uteri at later stages of gestation.

**KÖLLIKER** has made a fresh investigation of the glands in the decidua during pregnancy, which he described in the first edition (1861) of his *Entwickelungs-geschichte*. The hypertrophy at first affects the whole course of the glands, but is afterwards limited to their upper and middle portions,—the latter forming the spongy layer; in the last months, after the blending of the vera and reflexa, they disappear not only in the cellular but also in the upper part of the spongy layer. Their epithelium becomes destroyed from above downwards, and at last may only be found at the very bottom of the glands.

#### LABOUR—FIRST STAGE.

**C. SCHROEDER** gives a Vertical Mesial Section\* of a IV.-para: aged 28, within a week of full time, died in first stage of labour from heart and lung affections and albuminuria. Os dilated to the size of palm of hand; sagittal suture transverse, with posterior fontanelle to the left; head in the pelvis; no foetal heart.

\* This section reproduced in Author's Atlas of Sectional Anatomy of Labour, Plate I., fig. 3.



Body frozen in salt and ice about six hours after death, in horizontal posture. After forty-eight hours, cut with a hand-saw. Surface washed with alcohol, and one-half put in a lead vessel full of that spirit at freezing point. Tracings made with a dioptric apparatus and transferred to paper, which took six hours. The drawing was coloured from the other half, which was kept in ice. The completion of drawing took twenty days. The section runs mesially in front, but posteriorly a little to the left of the middle line. The drawing presents the surface unchanged, except that the mucus was picked out of the mucous cavities. There are four plates: a vertical mesial section of right half of cadaver; a drawing of empty uterine cavity of same side; two plates of child, one from before and the other from behind.

The chief pathological conditions are the dilated portal veins and right side of heart, and atrophied liver. Distension of stomach by gas was *post mortem*.

*Pelvis* cut to left of middle line—in upper part of symphysis 1 cm., in lower part  $\frac{1}{2}$  cm.; in upper sacral vertebra 2.3 cm., in lowest bony point (arch of fourth sacral vertebra) 2.1 cm. Top of cervix is 4.9 cm. distant from this last, and 2 cm. beneath surface. Pelvis measures—conjugata vera, 4.9 in. (12.3 cm.); conjugate of cavity, 5.6 in. (14.2 cm.); conjugate of outlet, 3.9 in. (9.9 cm.).

A line from coccyx to lower end of symphysis cuts bladder and deepest part of membranes,\* so that soft parts of pelvis bulge 3.6 in. (9 cm.) below this line. *Urethra* divided only in lowest part. *Bladder*, mostly to right of middle line, is not cup-shaped above. *Vaginal walls* show distended veins, and mucous membrane folded (especially that of anterior wall). *Muscular fibres* run below the mucous membrane, passing into musculature of uterus. Anterior fornix 2.2 cm. deep; anterior lip pressed against posterior fornix—3.1 cm. deep, and 1 cm. below line joining coccyx and symphysis.

*Uterus* measures in circumference from anterior to posterior lip 82 cm. Anterior portion of cervix is 4.2 cm. long, ends at right angle with body of uterus and its glands abut on decidua; posterior portion drawn upwards and backwards, its tip being 3.4 cm. from tip and .8 cm. from nearest point of anterior. Os internum more difficult to recognise here because there is no distinct angle; but posterior lip loses the characteristic glands at 3.2 cm.

\* Tip of coccyx, according to Schroeder's measurements, should be  $1\frac{1}{2}$  cm. higher up than his diagram represents; this makes line cut lowest part of child's head, not membranes.



from its tip, above which is a very thin layer of mucous membrane apparently that of the thinned upper portion of cervix. The line of separation between cervix and body is seen best in Plate II. showing empty uterus, and lies 2.2 in. (5.5 cm.) from tip of posterior lip. Os internum therefore dilated to 1.92 in. (4.8 cm.). Both in front and behind there is above the os internum a portion where muscular wall is unusually thin. The thin portion (2 mm. thick) extends for 5.5 cm., beyond which the wall becomes four times as thick; posteriorly, this difference is less marked, the wall becoming only twice the thickness (from 2.8 to 5 mm.) at 3.5 cm. from the lip. This thin portion is lower segment, and the place where wall thickens is contraction ring. Contraction ring is about same height anteriorly and posteriorly (9.7 and 9 cm. above os externum). Above the ring, wall varies from 4 to 6.9 mm. in thickness, being greatest at fundus corresponding to placental site. The whole wall is traversed with large and small vessels, most numerous at placental site and in contraction ring.

Membranes are separated up to contraction ring (v. Plate II.). Peritoneum descends anteriorly to attachment of bladder and cervix, posteriorly (to right of section) to 1 cm. below posterior fornix. Between uterus and spinal column are only meso-rectum, loose connective tissue and the compressed rectum.

Plate II. shows the empty uterine cavity with the placenta. The membranes are cut away up to line of attachment along contraction ring. Uterine cavity shows irregularities corresponding to shape of child; it contained little liquor amnii—in front of the head, round the limbs, but chiefly at the fundus. The child lies in 'first position' with posterior fontanelle low down and directed backwards; weighed 22.9 oz. (50 gram.) and measured  $19\frac{1}{2}$  in. (49 cm.).

Plates III. and IV. show the lie of the child. The head is bent on the trunk at an angle of  $110^\circ$  and rotated round its long axis so that it faces to the right ilio-pubic tuberosity of the mother.

The right round ligament is inserted 4 in. (10 cm.) below the surface of the section and 5.2 in. (13 cm.) from its anterior border; the left one lies 2.4 in. (6 cm.) from the surface and the same distance from the front, so that uterus rotated with left angle coming forwards.

In studying frozen sections, two sources of error are to be avoided:—(1) those due to *post-mortem* change; (2) those from pathological conditions.

(1.) *Post-mortem* change explains the difference of opinion between anatomists and gynecologists. Thus, Claudius and latterly Henke



maintain that the uterus is retroverted ; while Kölliker, Ruedinger, and latterly, Simpson, Barbour and Hart, show that it is anteverted. Change in its position after death is due to alteration in the utero-sacral and round ligaments. The distension of the vessels must also determine the relation of body to cervix during life ; as the uterus after death is more flaccid, and His found uterus anteverted in injected bodies. In Braune's case of two-months' pregnancy, the retroversion may be a *post-mortem* change. The effect of dorsal posture is seen in Braune's section during pregnancy, where intestines are present in front of the uterus down even below the umbilicus ; so also in Schroeder's own case. The child has normal attitude but exaggerated ; the fundus uteri where not filled by it is flattened. To flaccidity of uterine wall is also due the bulging of anterior wall beyond symphysis, seen also in Braune's case. (A diagram is given to show how form of uterus in frozen section differs from that during life in pregnancy and labour.) Soft parts of pelvic floor show little *post-mortem* alteration in Schroeder's case. Noteworthy that not only vagina but whole cervix lies below the true pelvis.

(2.) As to *Pathological changes*, the difference between anterior and posterior lips, though frequent, is not normal. In five hundred cases (58 primiparae) this condition present only in ten. The condition of concentrically contracted bladder is the normal one ; but bladder may vary in form, and has been found as a tubular structure behind abdominal wall—corresponding to course of urachus ; where walls are lax, as in multiparae, it has plate form ; where uterus is retroposed and fixed, it may become separated from cervix and utero-vesical pouch contain intestine.

**CARL RUGE** has studied Schroeder's frozen section of the first stage of labour with regard to *the changes which take place in the structure of placenta, decidua, and uterine wall, during uterine contractions*. Although there is no retroplacental effusion, there are hæmorrhages in the interplacental spaces. The direction of the villi has changed. Instead of running in bundles and streaming out towards the uterine surface, they interlace—some running parallel to the surface of the decidua, while others run obliquely in opposite directions. Between the villi are also numerous circumscribed extravasations. Through contractions, the smooth surface of the decidua serotina becomes hilly, projecting as teeth and points into the villous portion of the placenta ; frequently, the villi tear off (Von Hoffman described this but referred it to the



irregular breaking down of decidua in producing uterine milk). The decidual cells take up a more definite arrangement, running towards the points of the heights. The vessels appear scantier and smaller. The decidua serotina becomes differentiated into two zones (*fœtalis* and *materna*), between which is a more or less broad space formed of a delicate alveolar network. A mechanical separation has taken place—the firmer layer united to the unyielding uterine wall is separated from the upper layer which follows the displacement and thickening of the placenta. Blood is poured into this alveolar tissue ‘but not in the sense that it is primarily effused so as to separate the layers of the decidua. This alveolar tissue is not formed of pre-existing glandular spaces but is the result of contractions.’ Where the villi have grown more intimately into the decidua serotina so as to produce a firmer tissue, the separation will take place at a lower level.

As to the changes in the membranes and decidua vera produced by contractions,—at the end of pregnancy they form a very thin membrane, the amnion almost as broad as the chorion and quite as broad as the decidua which shows clear cystic spaces without recognisable epithelium, and cells four or five deep but not specially arranged in layers. After fœtus expelled, the decidua becomes more than ten times as thick and the amnion crumpled into delicate processes; chorion is in part attached to the amnion and in part separated, and also sends folds into the decidua. The spaces in the decidua are partly glandular (though rarely showing epithelium) partly tears. The muscular tissue is thrown into peculiar folds like the teeth of a saw, and the wall loses its lamellated appearance. In the lower segment of the uterus, this zigzag appearance of the muscle is not seen; and the mucous membrane is thinned instead of thickened and crumpled, and shows no alveolar arrangement.

With regard to the structure of the decidua vera and serotina, he finds that the distinction into cellular and glandular layers cannot be made out. The decidua is much thinner than the fœtal layers above it, cells in places only five to six deep and showing clear oval spaces without epithelium. Near the os internum where decidua is free from membranes he finds here and there a surface epithelium present, and the decidual cells smaller than at an earlier period. Glands also are present running parallel to the surface, and elongated without bulgings. In the serotina also there is no trace of a spongy and a cellular layer, and glands are rarely found. The surface of the serotina shows in places a continuous epithelial border resembling that of the villi, which may be simply torn off a



villus but certainly also arises independently through an extension of the villous epithelium on to decidual tissue. Winkler and Langhans have described an epithelium derived from the mother, which may be present. As to muscular fibre in the serotina, Ruge finds none.

The other points discussed in this paper are thus summed up. The intervillous circulation considered necessary for the nutrition of the child has not been demonstrated; the vessels opening into the spaces are probably foetal; such a circulation does not explain the interchange of nutrition but only provides a plausible place for the osmosis; in the early months the osmosis takes place before such a circulation is formed; and his explanation of a decidual circulation is not less intelligible and makes the nutrition of the human embryo not so essentially different from that of other mammals.

During labour, there are great changes which must disturb the nutrition but do not affect respiration. As to separation of the placenta, this does not depend upon the layers (which are no longer recognisable) but occurs in the plane of least resistance. The distinction of the decidua also into different layers does not hold at the end of pregnancy and is not scientifically necessary.

**BENCKISER** describes a *Uterus* from a *IV.-para*, *ætat. 27*, died at sixth month from *Cerebro-spinal Meningitis*. Pains noted for the last few days of her life. Right half represented in section  $\frac{9}{10}$  of natural size. *Uterus* 22.4 cm. (8.9 in.), cervix 2.6 cm. (1.04 in.) long; uterus 8.4 cm. (3.36 in.) deep, has form of elongated oval and is tense. Firm attachment of *Peritoneum* 7 cm. (2.8 in.) anteriorly, and about the same posteriorly above os internum. In thawed half, loose attachment curves round to attachment of round ligament. *Musculature* of anterior and posterior wall about 1 cm. (.4 in.) thick, thinning towards fundus to .6 or .8 cm. (.24 or .32 in.), and below firm attachment to .4 cm. (.16 in.). Texture laminated, but not different in upper and lower portions. *Cervix* very slender, 2.5 cm. (1 in.) long, and walls 1.3 cm. (.56 in.) thick. Mucous membrane bulges into uterine cavity, beginning posteriorly at edge of canal, and extending as an irregular curve  $\frac{1}{2}$  to 1 cm. in circumference to a point 1 cm. in front of the os.

*Membranes* detached further over area of a florin. Microscopically, decidua stops a centimetre from end of canal. 'The high cylindrical epithelium becomes lower, cubical and finally flat, and covers in this form the decidual swelling.' Membranes become rather thicker (.1 to .2 cm.) posteriorly above firm attachment of



peritoneum. *Placenta*, on anterior wall from level of firm attachment of peritoneum to fundus, is 1.5 to 2 cm. (.6 to .8 in.) thick, and united by several firm white vascular bands to the muscular wall. *Vessels* small in cervix; almost absent above os; numerous and large at and above firm attachment, especially at placental site; scanty again at fundus. Slight prominence of membranes corresponding to line of firm attachment. *Fœtus* male, 30.5 cm. (12.2 in.) long; arms crossed on breast, legs drawn up, hands clenched, back to left, cord round neck, bladder enormously distended with urine; liquor amnii scanty. Slenderness of cervix ascribed to original smallness. *Membranes*, detached only over small area, although decidua is thinned over lower segment. The extension of cervical mucous membrane for 1 cm. (.4 in.) into the cavity of the uterus anteriorly is accounted for partly by variability in upper limit of cervical mucous membrane, partly by labour pains.

From this preparation and one of hydrocephalus,\* he concludes that already in the commencement of pains even before the cervix has opened itself there may be a marked stretching of the lower segment through which the membranes are loosened in their attachment and the decidua thinned.

## LABOUR—SECOND STAGE.

**W. BRAUNE** gives a Vertical Mesial Section† of a primipara (?) about 35; who drowned herself while labour pains were going on. No further history.

Before freezing, it was determined that the head of the child was in the pelvis, the bag of membranes unruptured and bulging as a tumour the size of an apple in the vagina.

The body was frozen in the horizontal posture, and kept for eight days in a freezing mixture of salt and ice (mixture 3 of ice to 1 of salt) at a temperature of  $-12^{\circ}$  Reaumur ( $27^{\circ}$  F. below freezing point).

The Plates are four in number:—I. Vertical Mesial Section of right half of body; II. Same with left half of fœtus placed in relation to its right half, so that fœtus appears undivided; III. Right half of uterine cavity, with fœtus removed; IV. Body of child seen from behind.

*Child* was a well-developed full-time boy, weighing with its cord 3319.2 grms. (7 lbs. 5.17 oz.); cord passes under left thigh, over

\* This extremely valuable preparation lies beyond these Abstracts as it is distinctly pathological—the uterus having ruptured.

† This section reproduced in Author's Atlas of Sectional Anatomy of Labour: Plate I. fig 4.



left ankle, and then along abdomen again to *placenta* situated in upper part of uterus. Child lay probably at commencement of labour R.O.P., but has partially rotated to the front and head more to the front than shoulders. The head is in the pelvis which is not roomy; and from its shape has been exposed to considerable pressure. The child appears as if packed together into the smallest possible space. The skin shows lines and corners indicating compression; the neck is reduced to a cleft in the unfolded skin, and the head has been pressed inwards over the left ear by the symphysis pubis. On the left upper-arm and right fore-arm is a furrow produced by *os internum*. Child's abdomen is divided coronally—the thorax, and still more the head, in a plane between coronal and antero-posterior.

Liquor amnii is not abundant; chiefly as fore-waters. Chorion and amnion seen to form bag of membranes.

The uterus embraces the child closely, and shows no folding indicative of relaxation of its walls. Its long axis is at right angles to plane of brim, as if it still retained after death its position in contraction.

The *os internum* lies somewhat over the brim of the pelvis, and is marked by a large vein in addition to a small one beside it—the only ones which, being filled with blood, could be seen in the wall of the uterus. In the empty cavity the *os internum* appears as a distinct ring 1·4 inch (3·5 cm.) above the symphysis and ·8 inch (2 cm.) above the promontory. The fully dilated *os externum* appears only as a small projection running from the lower margin of the symphysis to the junction of sacrum and coccyx. The uterus measures from surface of section to deepest part of cavity 2·5 in. (6·5 cm.), from *os internum* to fundus 6·5 in. (16·5 cm.), and from *os internum* to *os externum* along axis of pelvis 4·4 in. (11 cm.). The *walls* vary in thickness. The *placenta* lies in fundus uteri mostly to the left side.

While the *rectum* shows portions of its lumen here and there, the *bladder* is completely empty and compressed. Behind the symphysis, its walls are so thin that they are scarcely recognisable. Above and below, where pressure is not so great, they are more easily recognised. The pushing forward of the abdominal walls by the uterus is more marked than in the section made at the end of pregnancy. The pelvis is normal, having a conjugate of 4·4 in. (11 cm.). The spine shows a marked kyphotic curvature between cervical and upper dorsal regions.

The *intestines* and *abdominal* organs show nothing worthy of



note. The *peritoneal cavity* from symphysis to arch of diaphragm is the same as in former section, while the heights of the two thoracic cavities markedly differ;—no weight, therefore, can be laid on the agreement of both sections in the depth of the base of the chest. Conclusions as to the depth of the chest in pregnancy must be based on the study of the living subject so that we can compare the measurements of the same thorax before and after labour.

**D. CHIARA** gives a Vertical Mesial Section\* of a IV.-para, who died of syncope during spontaneous version of the foetus; former labours normal; midwife had ruptured the membranes, and pains coming on, the arm and loop of cord were driven down; a surgeon called in tried repeatedly to turn but failed, and sent patient to hospital—where she died a few minutes after admission. Twenty-four hours after death the body was frozen, remaining for twelve days in a mixture of salt and ice at a temperature of 5° F. (–12° R.). The section was made with an ordinary saw; the surface was then washed in alcohol and drawn.

Six plates are given, reduced to  $\frac{2}{3}$  of the natural size:—I. and II. right and left halves of trunk with foetus divided; III. and IV. right and left halves of body with whole foetus shown; V. and VI. right and left halves of uterine cavity.

The plates show that spontaneous evolution had reached its third stage; the shoulder is fixed under the pubic arch; the neck is elongated; and the head rotating round the pubis. When the tissues were thawed in warm water, it was seen that there was a large blood-clot round the upper limb of the foetus. The uterus and vagina show no trace of rupture; there is no effusion in the peritoneal cavity. In the periuterine connective tissue, especially in the broad ligaments, there was extensive blood extravasation. The pelvis is well-shaped and normal; child, female, weighing 7 lbs. 2 $\frac{3}{4}$  oz. (3250 grms.). These are the only anatomical facts mentioned in Chiara's commentary on the case which is chiefly taken up with discussing spontaneous evolution.

From the reports of the Milan Lying-in Hospital during three years, he gives six cases out of 29 shoulder presentations in which spontaneous version occurred with a favourable result to the mother; this seventh case being the only one which terminated fatally. Children were all females, four at full time, two at the

\* This section reproduced in Author's Atlas of Sectional Anatomy of Labour: Plate I. Fig. 6.



seventh month ; mothers multiparae, and well-developed ; in none of them was turning attempted.

Chiara concludes that where the shoulder is impacted and immobile, and the uterus retracted, no attempt should be made to turn ; and that in a multipara with a roomy pelvis and small child, we may reasonably wait for delivery by spontaneous evolution without interfering. He opposes the view that delivery by spontaneous version is a process which should never be counted on.

**D. B. HART**, in the first part of his admirable Thesis, considers the female pelvic floor in its structural aspects : describing first the closed female pelvic floor as seen in vertical mesial and coronal mesial section ; next, the pelvic floor opened up naturally in parturition and genupectoral posture, and displaced pathologically in sacro-pubic hernia (prolapsus uteri) and in hauling down the uterus. The pubic segment is described in detail. The second part (the manual exploration of the pelvic floor) describes artificial opening up by Sims' speculum, and artificial support by pessaries.

Under the 'pelvic floor opened up naturally in parturition,' he compares Braune's two sections at the end of pregnancy and during the second stage, drawing attention to the following points. At the end of pregnancy we find—

"That (1) the anterior and posterior uterine walls have about the same thickness (6 mm.). (2) The os internum is below the level of the pelvic brim. (3) The bladder is below the level of the symphysis pubis. (4) The peritoneum covers it as usual. (5) The pubic segment of the pelvic floor is in its normal position, and is in exact apposition with the sacral one. (6) The sacral segment is not driven down, and the vagina is a mere slit."

During labour we find—

"(1) The anterior uterine wall is much thicker (15 mm.) than the posterior. (2) The os internum is 5 cm. above the level of the pelvic brim in front, while posteriorly it is almost on a level with it. (3) The bladder is above the symphysis. (4) The peritoneum is stripped off the bladder. (5) The pubic segment of the pelvic floor is separated from the sacral one, is a thin flattened-out hour-glass segment with the part of it below the symphysis shortened. (6) The sacral segment is being driven down, and the vagina is no longer a slit. (7) The os externum is on a higher plane anteriorly than posteriorly."

The explanation of this change is found in the attachment of the cervix by its anterior lip to the posterior angle of the pubic seg-



ment, and by its posterior lip to the upper part of the sacral segment just below the pouch of Douglas. When the uterus contracts it pulls on both lips and pushes fœtus down; pubic segment can be pulled up while the sacral cannot. The pelvic floor during labour thus opens in a perfectly definite way—the uterus pulling up the pubic segment and driving the child down against the sacral segment. “We therefore see that in labour the pubic segment is pulled up and the sacral one driven down; a differentiation in function of the segments as marked as their difference in anatomical structure.” The cervix during labour is elongated, thinned, dilated, and drawn up; becoming from a canal of 4 cm. in length admitting one or two fingers, a tube 10 cm. long and 9 cm. broad. Its upper limit anteriorly is 5 cm. higher above the brim than it is posteriorly. In Braune’s section of normal labour, the os internum is through elevation of the pubic segment already 5 cm. above the brim. An unduly elongated cervix has, therefore, elongated from this point and not from the symphysis. Chiara’s plate is also cited as showing the same phenomena.

Under the pubic segment in detail, the change in the position of the bladder, retropubic fat and peritoneum is described. In a midwifery case where rigidity of the os called for early application of long forceps, suprapubic inspection and palpation showed a fluctuating tumour roughly triangular with apex down and having a vertical and transverse measurement of 4 in. The catheter showed that this tumour was the bladder, which contained only  $2\frac{1}{2}$  oz. of urine. “The bladder was drawn up and its relations were as follows:—In front, it touched anterior abdominal wall; behind, the child’s head—the cervix of course intervening. In this way the anterior and posterior vesical walls were in contact, and thus the film of urine as it were gave the appearance of distension.” The retropubic fat is above the pubis during labour. “The peritoneum lying over the lower part of the anterior abdominal wall and bladder can be elevated; that on the uterus and sacral segment cannot.” During labour the peritoneum is stripped from the anterior abdominal wall to an extent varying with the distension of the bladder and is also drawn off the bladder itself.

Section V. of his Atlas is devoted to the ‘Cervical Canal in pregnancy and parturition.’ The difficulty of settling the part played by the cervical canal in pregnancy is set down to the difficulty in settling what is os internum in unimpregnated uterus, to the variation in upper limit of cervical canal in nulliparae compared with multiparae, and to the difficulty of settling in any



uterus at an advanced period of pregnancy whether the upper part of the canal has not been opened up by slight labour pains. After a note on the history and nomenclature and various views now held, he describes Braune's section, drawing attention to the points mentioned in the abstract of his Thesis, and especially to the fact that in normal labour the upper limit of the cervical canal may be felt about 5 cm. above the pelvic brim, and that an unduly elongated cervix has elongated from this point and not from the symphysis pubis. Chiara's section is cited as showing the bladder above the pubis, the pubic segment drawn up, and the anterior uterine wall thicker than the posterior. Six beautiful plates show—his own preparation of a uterus in sagittal mesial section of a multipara two months pregnant; Braune's retroflexed gravid uterus from early pregnancy; Bandl's uterus from five months' pregnancy laid open in front; his own preparations of pelvis and pelvic tissues from a case of Porro's operation showing cervix uteri at the end of pregnancy; Angus Macdonald's preparation of uterus pregnant at full time; anterior cervical wall from Braune's section of Second Stage; part of anterior uterine wall, pubic bone, bladder and peritoneum relations from Braune's section at the end of pregnancy; Müller's preparation of cervical canal and lower uterine segment from the end of pregnancy; Marchand's preparation of cervical canal and lower uterine segment from seven months' pregnancy; Bandl's diagrams of pregnant uterus and pelvic floor in primiparae and of cervix and uterus in cross-birth; his own preparations of posterior part of right half of cervix and vagina from a case of ruptured uterus with vertical mesial section of same.

**H. CHIARI** gives Vertical Mesial section\* of a primipara, aetat. 29; died of tuberculosis. No further history.

Before freezing, the fundus was found three fingers'-breadths above the umbilicus; the back of the child to the left side. Vagina showed remains of the hymen; and 6 in. ( $1\frac{1}{2}$  cm.) from the vulva, the distended bag of membranes; behind this the head of the child almost filling the pelvis, slightly movable, with the posterior fontanelle to the left.

The head and extremities having been amputated, the trunk was frozen for five days—the freezing mixture being 8 in. (20 cm.) thick all round. A proportion of six of ice to one of salt was used, and in all 1200 kilograms (2395 lbs.) of ice were required. The section

\* This Section reproduced in Author's Atlas of Sectional Anatomy of Labour: Plate I. Fig. 5.



was made with a saw in a frame. The right half was photographed and drawn, and then put in 96 p.c. alcohol with as little disturbance of parts as possible. After nine days the alcohol which had sunk to 80 p.c. was replaced by a new 96 p.c. solution. By this means the tissues were hardened for microscopic examination.

Five plates are given :—I. Right half of vertical mesial section, with foetus divided ; II. Right half with foetus whole ; III. Left half with foetus whole ; IV. Right half with foetus removed, showing uterine cavity ; V. Left half, with foetus removed, showing the same. Microscopic sections of lower segment of uterus are also given.

*Plate I. showing right half.*—Section through pelvis is slightly to left of the mesial plane, so that while it passes through the anus it also goes through the left labium minus.

The *bladder* is flattened from before backwards, and divided to the left of the middle line so that the urethra is not seen.

The *uterus* stands with its highest point 8 in. (22 cm.) above the symphysis or three fingers'-breadths above the umbilicus. Antero-posteriorly its external measurement is, at level of cartilage between third and fourth lumbar vertebræ, 3·3 in. (8·4 cm.); between fourth and fifth, 3·4 in. (8·5 cm.). Its walls average in thickness above the coronal vein ·28 inch (7 mm.); below this, it thins anteriorly and posteriorly, and in front more quickly and markedly than behind. Os externum is at level anteriorly of middle of symphysis, posteriorly at that of junction of second and third sacral vertebræ. The utero-vesical fold of peritoneum lies 1·1 inch (2·8 cm.) above the symphysis and ·64 in. (1·6 cm.) below the coronary vein. The pouch of Douglas comes to level of lower end of sacrum and 2·5 in. (6·4 cm.) below the coronary vein. The uterine walls were studded with sections of veins, which were very small below the greatly dilated coronary vein.

The *vagina* was in its upper two-thirds markedly stretched. Anteriorly, being 1 mm. thick; posteriorly in the region of the fornix 2 mm. thick, and only below that excessively thin.

The *foetus* lay with the lowest part of its head ·8 in. (2 cm.) from the vulva. The *placenta*, 'nowhere loosened but everywhere firmly attached,' lay on the posterior wall stretching from fundus to near the coronary vein, and mostly to right of middle line.

*Plates II. and III.* show the position of the foetus. Especially noteworthy is the compression of the extremities and the foldings of the skin. The cord runs along abdomen and thorax to chin, then over left arm and leg to placenta on fundus. The foetus is



poorly nourished, measuring  $16\frac{1}{2}$  in. (47 cm.) in length; its head 3.28 in. (8.2 cm.) transversely, 4.1 inch (10.3 cm.) antero-posteriorly, and 12 inch (30 cm.) in circumference. From its appearance and the extent of ossification of bones, it appears about a fortnight short of full time.

*Plates IV. and V.* show the internal surface of the genital tract. Just above the coronary vein is a wavy white line, above which the membranes appear thicker and are firmly attached to the uterus, while below it they are movable and easily lifted. This line is .72 in. (1.8 cm.) above the anterior, and 2.6 in. (6.6 cm.) above the posterior reflection of the peritoneum. The peritoneum anteriorly could be stripped off easily as far as this 'line of attachment of the membranes.' It is opposite this line that the muscular wall begins to thin. The os externum is also indicated by sudden thinning in the wall so that it forms a distinct projection into the genital tract; and it lies anteriorly 1.75 in. (4.4 cm.) below, posteriorly .8 inch (2.1 cm.) above, the reflection of peritoneum; and anteriorly 2.4 in. (6.2 cm.) posteriorly 1.8 in. (4.5 cm.) below the line of attachment of membranes. Above os externum the palmae plicatae of the cervix could be followed but only for a short distance, above which the cervix was smooth.

*Pelvis* has a conjugate of 4.6 in. (11.5 cm.) and is quite symmetrical.

Chiari concludes that the coronary vein and line of attachment of membranes correspond with Braune's os internum, it having the same relations to the reflection of the peritoneum and to the point where the uterine wall becomes thinner. The portion of genital tract between this region and os externum must be considered as the so-called lower uterine segment in addition to cervix.

*Microscopic Examination.*—The microscopic section of the anterior wall shows the following structures from above downwards: line of attachment of membranes, coronary vein, utero-vesical fold of peritoneum, palmae plicatae of cervix, os externum. The white line is seen to be due to a folding of the membranes. The amnion is separated from the chorion and decidua, and runs straight over; while the chorion and decidua beneath it are detached from the uterus and thrown into numerous folds. From this line for 4 cm. downwards decidua is present but thinner than that above. This decidua shows the characteristic decidual cells and spaces, the latter mostly filled with débris and seldom showing glandular epithelium. Only in the neighbourhood of the folded part was the chorion applied to the decidua; and here also could



a reflexa be traced. Below, the chorion showed decidua on it only as individual cells or patches—the decidua on the muscular wall appearing as if torn through. Immediately below this begin abruptly the glands lined with columnar epithelium characteristic of the cervix, which extend for 2·3 cm. The palmae plicatae stop on the top of the ridge marking the os externum, the vaginal epithelium extending so far on to it. The limit therefore between cervical mucous membrane and decidua lies ·6 in. ( $1\frac{1}{2}$  cm.) below utero-vesical fold of peritoneum.

While the muscular wall becomes thinner at the coronary vein, we find in it only longitudinally running bundles until opposite the palmae plicatae where the bundles are irregular. Above the reflection of the peritoneum there extends for a small distance fatty cellular tissue between it and the muscular wall, and then they become closely united. The condition is similar on the posterior wall: folding of membranes for 1·2 in. (3 cm.); coronary vein; 1·2 in. (3 cm.) of thinner decidua; ·8 in. (2 cm.) of palmae plicatae, to top of ridge marking os externum; then, vaginal epithelium.

The *Vagina* shows almost no papillae and is very thin; its epithelium was preserved, its mucosa poor in cells.

From the microscopic examination, Chiari concludes that the portion of the uterus marked by the coronary vein and the thinning of the walls is not the os internum, but of interest in relation to the separation of the membranes and the thinning of the wall; he has no objection to identify this with Schroeder's contraction ring, and to call the portion below this 'lower uterine segment,' characterised by thinness of decidua and of muscular wall. The greater thinning of the latter anteriorly may be related to the attachment of the muscle to the peritoneum. The actual os internum is where decidua stops and cervical mucous membrane begins, and cervix measures only ·8 inch (2 cm.). The os externum is determined by the bulging of the muscular wall, the vaginal epithelium extending unusually high up as it sometimes does.

The cause of the sliding of the decidua so as to become folded is not clear.

#### LABOUR—THIRD STAGE.

**M. THIEDE** describes a uterus from death during delivery. Patient, aetat. 24; I-para; delivered with forceps; died before placenta was removed. Uterus measures 19·5 cm. (7·8 in.). From os externum to attachment of membranes, 4·5 cm. (1·8 in.). The wall is 1·4 cm. (·56 in.) thick at fundus; 2·2 cm. (·88 in.)



anteriorly, 1.7 cm. (.68 in.) posteriorly below placenta. Cervix is 1.4 cm. (.56 in.). At attachment of membranes the wall is .9 to 1 cm. (.36 to .4 in.) thick. Lower segment extends, gradually thickening, for 3 cm. The epithelium of the cervix extends as continuous border to within 1 mm. of attachment of membranes. The cells become lower and broader as we pass upwards. The connective tissue appears below as a meshwork with very broad bundles; while, above, the meshes become larger; the cells are double the size of the normal connective-tissue cells of the cervix; the blood-vessels are numerous and distended; and the glands are lined with a high epithelium. Where the membranes are attached, the typical decidual cells are present; but glands are less numerous than usual, and lined with a lower epithelium than that of the cervix. Although the child was born, the separation of membranes has not begun.

**C. H. STRATZ**, in his paper on the Third Stage (the bulk of which is taken up with clinical observations lying beyond the scope of these abstracts), describes the only two frozen sections we have as yet of the third-stage uterus.\* They are of the uterus removed from the body, not of the whole cadaver.

The first he takes as an illustration of the expulsion of the placenta in the way described by Matthews Duncan: "The preparation comes from a VI.-para, aged 36, who was brought into the Maternity [at Berlin] pulseless and with placenta praevia. Turning and the delivery of a dead child was made *in articulo mortis* and with cervix not fully dilated. The placenta was left *in situ*, as death occurred. In the preparation no part of the placenta is attached to the uterus, but the membranes are still adherent; the lower edge of the placenta projects into the vagina."

The second preparation is given as showing to "what a remarkable degree the contraction in the placental site may be prevented by the attachment of the placenta. The preparation is taken from a II.-para with eclampsia, aged 33, who was delivered with forceps *in articulo mortis*. After death, the uterus with placenta attached to it was frozen. The part of the uterine wall to which the

\* These sections are reproduced in the Author's Atlas of Sectional Anatomy of Labour: Plate ix.

Müller's preparation referred to on p. 17 of the Literature shows the uterus containing the placenta and membranes. It is, however, from a case of Rupture of the Uterus; and all that he says of the placenta is that it "in part fills the cavity of the uterus, in part bulges through the rent."



placenta is still attached is remarkably thin, .12 in. (.3 cm.), compared with the other parts, 1.2 in. (2.8 cm.) The uterus was ante-flexed. The placenta lay with its foetal surface forwards, the bending backwards of the lower segment and of the cervix is the result of the position of the preparation in the freezing apparatus."

**BENCKISER** describes a *Uterus from a IX.-para, died at tenth month from eclampsia; Caesarean Section made post mortem.* Child extracted dead; uterus, with wound in its walls sewed up, was removed from body and hardened in alcohol. *Uterus* appears as a regular ovoid, having cervix as thick cone on it; with cervix (which is 4.3 cm.), it is 22.5 cm. (9 in.) long and 10.5 cm. (4.2 in.) deep. This includes a space of 5 cm. (2 in.) between walls, produced in hardening. *Peritoneum* smooth on posterior, wrinkled on anterior surface of body, but the wrinkles are irregular; firmly attached to musculature for 4 cm. (1.6 in.) above end of canal anteriorly and same posteriorly, below which it is wrinkled. *Musculature* is 1 cm. (.4 in.) thick at fundus; increases to 2.8 cm. (1.1 in.) in middle of anterior wall, thinning to 2.2 cm. (.88 in.) at firm attachment; posterior wall, where placenta is seated, averages 1 to 1½ cm. (.4 to .6 in.) at its site, below which thickens to 3 cm. (1.2 in.). Its texture varies also: in upper part of anterior wall the bundles are matted, and only in fundus are they plate-like; below firm attachment, plates again distinct up to cervix; here the inner plates pass to os internum, outer to periphery of cervix, middle into its felted texture. Cervix is a cone 4½ cm. (1.8 in.) high—its anterior wall being 3 cm. (1.2 in.), its posterior 2.8 cm. (1.1 in.) thick. Its lumen is size of pencil and full of mucus; its folded mucous membrane begins .1 to .2 cm. (.04 to .08 in.) above os externum, reaches greatest thickness of .6 or .7 cm. (.24 or .28 in.) in lower half of canal, diminishes at os internum to .1 or .2 cm. (.04 or .08 in.) and there abruptly stops. *Membranes* attached right up to os internum posteriorly, crumpled over it and separated in front of it through the decidua for 1 cm. (.4 in.).\* Above this, on anterior wall, the membranes are thin (.1 cm.), and show few folds; on the posterior, they are .2 to .3 cm. (.08 to .12 in.) thick and much folded. *Placenta*, on posterior wall and divided mesially, is 14 cm. (5.6 in.) long and 3 to 3½ cm. (1.2 to 1.4 in.)

\* A drawing is given of the membranes over this area, magnified six times; as also a detailed description of the microscopic appearances, which confirm the view of the persistence of the cervix throughout pregnancy.



thick ; it bulges all round 1 to  $1\frac{1}{2}$  cm. (.4 to .6 in.) beyond its site. *Vessels* numerous at placental site and down to os internum, scanty on anterior wall and fundus ; more numerous in anterior than in posterior wall of cervix. Uterine cavity faceted, but that in no definite arrangement.

Thus though the operation was done *post mortem*, the uterus shows condition of a puerperal one. Two forces operate—elasticity and active contraction. Elasticity of non-contracting uterine muscle is slight, for the trivial pressure of the ovum in pregnancy produces marked stretching ; elasticity of uterus seen in delivery of patient under chloroform and also in Caesarean section. From analogy he concludes that active contractions occur also after death. Both forces operated here—the former increasing thickness of wall, the latter the interlacing of fibres. This interlacing less marked at placental site. Placenta still firmly attached throughout, thick, and with bulging border as Schroeder-Stratz found it in First Stage ; this condition speaks for the remarkable power of adaptation in the placenta to the condition of its site. Still it must be looked upon as a uterus from pregnancy, because its lower segment does not show the changes produced by uterine contractions. This segment measures 4 cm. (1.6 in.) long after uterus is emptied, has plate-like structure anteriorly but marked rearrangement of fibres posteriorly. The firm attachment of membranes posteriorly up to end of the 4.3 cm. (1.7 in.) long cervical canal speaks for persistence of cervix in pregnancy. Size of cervix indicates its hypertrophy in pregnancy.

#### PUERPERIUM.

**J. MATTHEWS DUNCAN.** Dividing the internal surface of the uterus into three parts—cervix, placental site, and rest of surface—his paper in 1853 deals with the last two only. He describes five uteri from different periods after delivery—one day, soon, fourth day, some time, some weeks ; and finds in every case a soft membrane on the surface of the uterus, covering the muscular wall. Of the placental site, he says : “ After the separation of the after-birth, the internal surface of the contracted uterus at its former site is left covered by a thicker layer of the decidua than elsewhere. The internal surface is at this part more rough and irregular, and more prominent, than elsewhere. The vascular openings are numerous and spread over a surface which is, from the contraction



of the entire organ, much smaller than the original surface occupied by the placenta."

His paper in the *Edinburgh Medical Journal*, 1857,\* deals especially with the literature of the subject—referring to the work of Heschl, Virchow, and Chisholm. He maintains that his view given in 1853 is the correct one, in opposition to that of Cruveilhier and of Heschl, who asserted that the inner surface of the uterus was laid bare down to the muscular coat.

**J. CHISHOLM** describes the internal surface of the uterus, excluding the placental site from a case that died on the seventh day *post partum*. He found on section of a dried portion a "narrow clear line" of tissue internal to the muscular wall, and in a macerated portion a membrane which could be moved separately on the muscular tissue. A scraping of the internal membrane showed nucleated cells resembling the normal epithelium of the uterus. The surface of the uterus was smooth and studded with minute oval and circular depressions—the follicles of the mucous membrane.

In his paper published in 1858, he says that he has made frequent dissections of the uteri of pregnant and parturient animals and found the same appearance as described in his former paper, and is convinced that the thin clear line internal to the muscular substance is the mucous membrane.

**E. Q. LE GENDRE** in Plate XIX. of his Atlas gives a vertical mesial section of the pelvis of a female, aged 35, who died immediately after delivery. Pelvis measures—conjugate of brim 12·5 cm. (5 in.), of outlet, 8·2 cm. (3·28 in.). Bladder, with capacity of 127 c.c., pressed by body of uterus against symphysis—its fundus reaching the middle; urethra measures 3·2 cm. (1·28 in.), and forms angle with it—neck of bladder being 2·5 cm. (1 in.) from pubis. Uterus shows pronounced ante flexion, cervix forming acute angle with body; and angle of curvature is back against rectum. Uterus measures 10·5 cm. (4·2 in.) in length—cavity 9 cm., thickness at fundus 1½ cm. Antero-posterior measurements—walls about 1½ cm. (·6 in.), dilated cavity about 3 cm. (1·2 in.). Length of cervix to angle of flexion 3½ cm. (1·4 in.), posterior fornix 2½ cm. (1 in.) deep. Vagina 9 cm. (3·6 in.) long, with

\* His paper in the same Journal for February 1858, "Notes on the History of the Mucous Membrane of the Body of the Uterus, etc.," reviews the work of the illustrious William Hunter.



marked sigmoid curve; its walls are not quite in contact; the base of bladder comes into relation with the middle of its anterior wall, from which it is separated by cellular tissue .5 cm. thick. The posterior wall is in relation to the rectum throughout (recto-vaginal septum thin above), and the peritoneum comes down on it for only a few millimetres—so that the pouch of Douglas is 9 cm. (3.6 in.) distant from the perineum. The vesico-uterine peritoneum, after covering the upper surface of the bladder, comes to within 6 mm. of the anterior vaginal wall. Rectum compressed by uterus, and empty.

**N. PIROGOFF** in his Atlas (Fasciculus III. A., Tab. 25) gives two sections of uteri from the puerperium. The first is of a woman aged 30, seven to eight months post partum, and therefore beyond the scope of this book. The second (Fig. 2) is from a patient aged 24, who died some days after delivery; no traces of peritonitis. Body of uterus divided almost mesially, lies to the right, and markedly anteflexed so that its anterior wall rests on the fundus of the bladder; walls of uterus thickened, and cavity, especially upper part, dilated with coagula. Canal of cervix and body form a curve convex backwards. Os dilated, lips swollen, retro-uterine fold of peritoneum comes for 3 cm. (1½ in.) on posterior vaginal wall. Bladder contains some urine; rectum empty.

**O. KÜSTNER** describes a post-partum uterus from a primipara, aged 23, died thirteen hours post partum from eclampsia.

Uterus measures from fundus to Bandl's ring 12 cm. (4.8 in.), from ring to os externum 6.5 cm. (2.6 in.), of which 2.5 to 3 cm. (1 to 1.2 in.) is undoubtedly cervix. Wall above ring averages 2.6 cm. (1 in.) thick, at ring 1.5 cm. (.6 in.), below it .8 cm. (.32 in.), and in cervix 1 cm. (.4 in.). Musculature is pale. Mucous membrane is covered with flat shreds, easily washed off, below which the mucosa is pale red. This colour extends far above the ring (3 to 3.5 cm.), and below it as far as a well-marked line 2.5 to 3 cm. (1 to 1.2 in.) above the os externum where it becomes deep bluish red. The upper boundary of this dark blue portion is on the level of the vaginal fornix. The reflection of peritoneum is at the ring or above it. Above the ring is a layer of decidua, which is thickest just at it, with tags of ½ to 1 cm. Below this the skin is smooth, the shreds less stringy and more like torn surfaces. Such torn surfaces are also seen over reddish-blue portion. On the



latter the long *palmae plicatae* are distinctly seen, and at first glance mark it out from the lower segment. But a closer examination of the lower segment shows here also ridges much lower and further apart. Comparing the surface of the lower segment with that of the rest of the body, we find it smoother and having very short shreds, but the sieve-like appearance of open glands is much better marked—the spaces being like pin heads, but fewest on the ridges. On microscopic examination, the mucous membrane of the lower segment is 1.5 to 3 mm. thick, ending sharply at the muscular wall. The upper compact, middle ampullary, and deep fundal layers are easily recognised although the compact is very thin, being only  $\frac{1}{8}$  to  $\frac{1}{4}$  of the thickness of the ampullary (perhaps result of microscopic mounting). The gland spaces are at the bottom very small, flat, compressed, and parallel to the section.

This decidua in the puerperal organ resembles that of the pregnant, except that the trabeculae are broader, the meshes being smaller than the interglandular tissue. It thus resembles decidua at fourth to fifth month, not that at end of pregnancy. The individual decidual cells are also smaller, being only two to three instead of six to ten times the size of an epithelial cell. The most striking and radical difference is in the epithelium: not only is it well preserved in the glands but the surfaces show over a large area a well-preserved border of epithelium. In the glands, epithelium is constant in the fundal layer—low cylindrical cells with an easily recognised nucleus; in the ampullary layer they are absent, the spaces being often filled with granular debris. On the surface, the individual cells stand very high, are cloudy, the nucleus varies in position; the cells are not simple cylinders but irregular in form, wedge-shaped with the apex up or down, and fitted-in past each other so that the layer appears in many places not single but one-and-a-half or double. No *membrana propria* could be seen. Epithelium was not ciliated (perhaps due to hardening in alcohol). “While I found here in the lower segment epithelium in almost all sections which I made through the surface, it was absent with similar constancy over the portion of the cervical canal rich in folds—in the part that is below Müller’s ring; on the other hand, we have it here well-preserved in the glands, sometimes cubical, sometimes cylindrical.” The mucous membrane of the cervical canal is 3 to 4 mm. thick, is not separated into three layers, the connective-tissue elements are enlarged, congestion striking especially on the surface, and considerable hæmorrhages.



The conclusions from these conditions are—that since where surface epithelium is present the ovum has not become attached, therefore only attached here up to Bandl's ring; where also the tearing through took place at which the decidual tags are most marked.

“If we now make the mucous membrane of the body of the uterus stop at the point where decidua stops in the usual sense of the word (*i.e.*, adhering to chorion in the first months of pregnancy), and below this limit cervical canal begin, we must in our case place the commencement of the cervical canal at Braune's os internum, because we found mucous membrane covered with cylindrical epithelium there.”

The absence of cilia may be set down to the hardening in alcohol. On the other hand, the arrangement of the epithelium in several layers, in contradistinction to the epithelium of the body which is in one layer, make it certain that the lower segment is in this preparation covered with cervical mucous membrane. He agrees with Bandl's clinical facts. The absence of epithelium in the cervical canal he ascribes to frequent vaginal examination and the pressure of the child's head.

**M. THIEDE** describes six uteri *post partum*.

The first is *seven hours after delivery*; patient I.-para, aetat. 36; twins, delivered after protracted labour by forceps and turning; died from eclampsia. The uterus (which in the body was at the level of the brim of the pelvis) being laid open, the surface shows three areas distinctly marked out. In both the upper portions the surface is, with the exception of the placental site, pale red and covered with shreds; and the muscular wall shines distinctly through at points. The lowest third is of a dark bluish colour, has a soft velvety texture, and is covered with sticky mucus. On washing this off, the *palmae plicatae* are seen extending up to the middle third. The uterus measures 22 cm. in length, of which 6 cm. is cervical canal. The anterior wall is 1.5 cm. (.6 in.) thick in the cervix, 1 cm. (.4 in.) immediately above it; and at 6 cm. (2.4 in.) above its upper end, thickens to 2 cm. (.8 in.), becoming finally in its thickest part 3.5 cm. (1.4 in.). The posterior wall at corresponding points is 1.5 cm. (.6 in.), 1.5 cm. (.6 in.), 2.7 cm. (1.08 in.), and 4.5 cm. (1.8 in.) thick.

Over fundus the thickness is 2.8 cm. (1.12 in.). The lower segment is 6 cm. (2.4 in.) long. A scraping from the upper limit of the lowest third shows besides small round cells a high cylindrical epithelium arranged in long layers, the cells in part



ciliated, in part with a dark almost double contour. The scraping from the surface of the lower segment is membranous and made up of a conglomerate of large decidua cells, with here and there glands of decidua vera but no high cylindrical epithelium. The tissue of the wall below Müller's ring is close, studded with small hæmorrhages, and has a delicate epithelial lining; but above the ring there are remains of decidua. The musculature of the lower segment is apparently formed of longitudinal bundles. It thickens in the cervix partly through transverse bundles, partly through serous infiltration. Above Bandl's ring, the musculature is an irregular meshwork of fibres pushing itself between the longitudinal bundles. The peritoneum at the level of Bandl's ring is more firmly attached to the wall; below, it is movable on it.

The second uterus is *seventeen hours after delivery*; I.-para, aetat. 34; died from lung oedema and nephritis at commencement of tenth month. The uterus measures 19 cm. (7·6 in.) in length, of which cervical canal is 5 cm. (2·4 in.) anteriorly, 5 cm. (2 in.) posteriorly; lower segment is 4 cm. (1·6 in.). Posterior wall above Müller's ring is 1·8 cm. (·72 in.), at Bandl's 2·9 cm. (1·16 in.). At thickest point 3·3 cm. (1·3 in.) thick. Anterior wall at corresponding points 1·3, 2·5, and 4 cm. (·5, 1 and 1·6 in.). Lower segment marked off from cervix by a ridge projecting 1 mm. beyond the surface. Above this, the tissue is irregularly ragged with many small spaces; while below, the texture of the wall seems equally firm and of smooth surface.

Microscopically, below the ridge we find on the surface a somewhat firm fibrous meshy tissue, with round and spindle cells in it more than twice the size of the connective-tissue cells in the non-pregnant uterus; and numerous blood-vessels. The glands are few and far between, of rounded outline and lined with epithelium, the cells being glandular and enlarged. On the surface, the epithelial border is away. In the deeper part, the tissue is not so compact. Above the ridge, we find the looser tissue of large decidua cells, the characteristic dense texture of the cervical tissue being absent. The gland spaces lie in many layers, in part pressed flat, in part drawn out irregularly into corners, and lined with cells broader than high. These same low cells are found on the surface often for some distance, 'and must be looked on as the future epithelial covering.' The muscular fibre is arranged as in the first case—in the lower segment only longitudinal bundles, which below Müller's ring seem increased with transverse layers. At Bandl's ring, begins suddenly the complex interlacing of the fibres. In the substance



of the wall is a cross section of a large vein ; while on the surface is the firm attachment of the peritoneum.

The third uterus is *eight days post partum*, patient aetat. 24, II.-para died of ileo-typhus. Uterus measures 17.5 cm. (7 in.), of which 5 cm. (2 in.) is cervical canal, and 11.5 cm. (4.6 in.) cavity. Thickness of fundus 1.3 cm. (.5 in.). The anterior wall is, above cervix, 1.3 cm., becoming at its thickest part 2.7 cm. Posterior is 1.7 becoming 3 cm. Microscopic examination of cervix shows in its lower part connective-tissue hyperplastic but dense cells, enlarged and arranged in small bundles, with between them sections of vessels and glands. The surface epithelium is like that of the non-pregnant uterus. Further up, the epithelium becomes lower ; cells being small and delicate and sometimes one and a half deep. The tissue below is still somewhat dense, but deeper down it is in meshes. The glands are fewer and larger, the epithelium lower and broader. The lower uterine segment carries somewhat thick remains of decidua ; in places, however, quite thin ; and here we find considerable area covered with the low epithelium. The arrangement of the muscular fibre is not so distinctly marked off as in the preceding cases. While longitudinal in the lower part, it shows transverse bundles also above. Firm attachment of the peritoneum appears to have come lower down. The involution of the uterus seems to have been retarded by the typhus.

The fourth uterus is *seventeen hours after abdominal section* for rupture. Patient aetat. 29, IV.-para ; after delivery with forceps tried, admitted to Maternity with rupture in posterior wall of cervix. Uterus measured 22 cm. (8.8 in.) anteriorly, posteriorly 17 cm. (6.8 in.). Cervical canal anteriorly 6 cm. (2.4 in.) ; posteriorly 2 cm. (.8 in.). Lower segment  $3\frac{1}{2}$  to 4 cm. (1.4 to 1.6 in.) ; rest of cavity 11.5 cm. (4.6 in.). The anterior wall measures 4.5 cm. (1.8 in.) at its thickest, 3.5 cm. (1.4 in.) at commencement of lower segment, and 2 cm. (.8 in.) in thinnest part ; and posterior wall is 4 cm. (1.8 in.) in thickest, 2.5 cm. (1 in.) at fundus, and 2 cm. (.8 in.) in thinnest (lower segment), in cervix 2.5 cm. A fresh scraping from surface of upper part of cervix shows it to be covered with epithelium, while the lower segment is not. The lower segment is marked off from the cervix by a projecting swelling of characteristic decidua. Below this, in the cervix, the glands are fewer ; while immediately above it are the characteristic uterine glands lined with flattened epithelium. The change in the character of the muscular fibre at Bandl's ring is very marked, the cross bundles coming in suddenly, and the peritoneum becomes firmly attached at the same level.



The fifth uterus belongs to the Third Stage of Labour and is there described.

The sixth case was from death *half-an-hour after delivery*; I.-para, aetat. 17, with hydatid mole. Length of uterus not given; of cervix  $2\frac{1}{2}$  cm. (1 in.), thickness of cervix 2 cm. (.8 in.), of wall above cervix .9 cm. (.36 in.), further up 1 to 1.1 cm. (.4 to .44 in.), at fundus 1.3 to 1.4 cm. (.5 to .56 in.). The cervical canal is lined with *palmae plicatae*, immediately above which the decidua with hydatid chorionic villi begins.

Thiede's conclusions are:—1st. That, as the lower segment is in these cases covered with remains of decidua to Müller's ring, and in one had membranes adherent to it, he regards it as essentially uterine. He says it is rightly lower *uterine* segment, in opposition to Küstner who would make it an upper *cervical* segment. 2nd. The cervical mucous membrane passes through marked changes in pregnancy; but shows generally a superficial firmer, and a deeper more meshy, connective tissue. The looser texture of the upper end admits of the bloody infiltration which marks it out after delivery from the lower uterine segment. The epithelium of the upper part of the canal is often lower, broader and more granular. 3rd. The decidua remaining on the lower segment is so well characterised by the arrangement of its connective tissue, and especially the condition of the glands, that it can always be distinguished from the cervix, although the mucous membrane of the latter has also undergone change.

**O. KÜSTNER** describes twelve non-pregnant uteri from nulliparae and multiparae, with regard to mucous membrane at the os internum; and criticises the specimens given by Bandl, Säger, and Thiede.

He then describes the uterus of a X.-para who died *three hours post partum* from bleeding. The uterus after lying some weeks in alcohol measures 19.5 cm. (7.8 in.). The wall is thickest at placental site (1.7 cm.), falling below it to .8 cm. (.32 in.), then thickening again 5 cm. (2 in.) above the os externum to 1.3 cm. (.5 in.), and immediately above the fornix to 1.7 cm. (.68 in.). Firm attachment of peritoneum is 6.1 cm. (2.4 in.) above the border of the anterior lip, 3.6 cm. (1.44 in.) above the anterior fornix. Mucous membrane surface consists of three areas. The first zone is from the fundus to place where the wall suddenly falls to half its thickness. Here we have typical inner surface of the post partum uterus covered with its shreds. Boundary



between zones 1 and 2 is 2 cm. (.8 in.) above firm attachment of peritoneum. The second zone, from this line to the commencement of the palmae plicatae, is smooth, almost shining; and the shreds are fewer and flatter. The surface also is paler and shows small heights and hollows. No gland openings are to be seen. The third area shows the characteristic palmae plicatae.

Microscopic investigation of these zones gives the following result. In the upper part of zone 2, characteristic decidua with compact and ampullary layers. The gland spaces are wide, drawn out and lying more than three deep. Beginning at the free surface the dominating cell is first round or polygonal. Underneath this, still in the compact layer, we come on an elongated, spindle cell—which also predominates in the network of the ampullary layer. The round cells are .015 mm. in diameter, the spindles .03 to .06 mm. The free border of the decidua ends sharply, and shows nowhere torn-through gland spaces and nowhere surface epithelium. In the middle and lower parts of zone 2, we have mucous membrane very thin, the glands scarcer. The mucous membrane consists of closely packed round cells like those on the surface above. The surface is wavy but ends sharply and shows no epithelium. On the limit of the lower segment towards the cervix, we have a great number of drawn-out elongated glands lined with cylindrical epithelium, the septa being thicker and glands smaller than higher up; glands show well-preserved epithelium; and on the surface, over large areas, is well-preserved cylindrical epithelium.

He describes also a uterus from an XI.-para, aet. 46, who died from eclampsia *shortly after delivery*. After lying for some weeks in strong spirit, the uterine cavity measures 12 cm. (4.8 in.). At 8½ cm. (3.4 in.) from the fundus, the body passes suddenly with a furrow ½ cm. (.2 in.) across (1 cm. drawn out) into the cervix which is 2½ cm. (1 in.) long. The 3-to-4-cm.-thick (1.2 to 1.6 in.) wall of body becomes suddenly 1 cm. (.4 in.) thick at furrow, 1½ to 2 cm. (.6 to .8 in.) thick in cervix; firm attachment of peritoneum ¾ cm. (.3 in.) above furrow. The body shows 1-to-2-cm.-long (.4 to .8 in.) tags which are more delicate and scarce in the furrow; in the cervix are palmae plicatae. The lower segment is here either imperfectly developed or rapidly retrograded. At any rate, the distance from end of cervical mucous membrane to contraction ring is scarcely a centimetre, and this short bit is covered with decidua of the same structure as we find in the body, but exclusively the fundal layer—smallest imaginable fragments of decidua.



He thus sums up his conclusions.<sup>1</sup>

(1) Os internum (isthmus uteri) lies where the canal of the uterus is narrowest, and the complicated felted musculature of the body suddenly passes into the simpler arranged musculature of the cervix. (2) This in adult nulliparae corresponds to the limit between the smooth mucous membrane of the body which lies above and the folded mucous membrane which lies below; there are, however, adult uteri in which the folds extend beyond the os internum into the body. (3) The folds of the upper part of the cervix are always flatter than those of its lower part and run longitudinally. (4) In the case of women who have borne, the folds frequently do not reach to the os internum; but become lost at a varying height in the cervix. (5) Microscopically, the mucous membrane of upper part of cervix (say  $\frac{1}{2}$  cm. of it) is very similar to that of the part of the body above it, both in the form and arrangement of the glands and the form and shape of the cells. In many uteri there is absolutely no difference between the upper 5 mm. of the cervix and the lower 5 mm. of the body.

(6) From the foregoing conditions, it is *à priori* probable that the changes which the uterine mucous membrane passes through and which have been hitherto regarded as peculiar to that of the body are also gone through by that of the upper part of the cervix. (7) It is further *à priori* probable that in the upper section of the cervical mucous membrane corresponding to its generally diminished thickness, these changes would occur to a slighter degree. (8) Thus, the upper section of the cervical mucous membrane hypertrophies before each menstrual period; whether this hypertrophy leads under normal condition to an approximately complete expulsion, as it does in the body, is yet unknown; in pathological conditions (membranous dysmenorrhœa) it does occur.

(9) Thus also, the upper section of the cervical mucous membrane hypertrophies in pregnancy, and resembles a decidua so as to be mistaken for it. (10) No rule can be laid down as to how far this cervical decidua extends downwards from the os internum. In many cases it may be very unimportant, perhaps only the fraction of a centimetre; in others to a larger extent. In his figure showing the extent of the decidua-formation semi-

<sup>1</sup> Conclusions given in full to make Küstner's position clear, although they are based on non-pregnant uteri (which we have not given) as well as pregnant and puerperal ones.



diagrammatically, the decidua (represented by a red line) reaches 14 mm. below the os internum into the cervix. (11) How far the covering of the ovum can become adherent to such a cervical decidua must be decided by further investigation. As yet it seems probable that all degrees between non-adhesion and firm adhesion may occur; so that in one case after the expulsion of the ovum, this decidua still has its compact layer with surface epithelium; in another, the compact layer is torn through by the ovum. Of both extremes there are examples (Bandl, Küstner, Thiede). In the cases where also on the lowest zone of the body the adhesion of the decidua was slighter than in the rest of the body, this lowest zone has after expulsion of the child, if we look at it from its mucous membrane surface, an appearance unusually like the upper zone of the cervix—they pass into each other. (12) Below the place which undergoes a decidua-like formation, begins the typical cervical mucous membrane. At this point has been placed generally up to this time the upper limit of the cervix, *i.e.*, the os internum during pregnancy and puerperium. On the other hand, the zone which has the decidua-like formation, and lies below the os internum was called the lower uterine segment. (13) During labour, the stretching affects chiefly the part between the os internum and the vaginal portion. The part in question experiences marked changes in its shape, a drawing out in its length;—a circumstance which has as yet materially hindered the true interpretation of this part. (14) No anatomical proof is needed of the fact that in the case of primiparae in the last weeks of pregnancy, frequently (perhaps very frequently) does the pre-existing cervical canal experience a funnel-like dilatation. That further, in the case of other primiparae, this 4-to-5-cm.-long. (1·6 to 2 in.) canal persists to the actual commencement of labour; just as, in the case of multiparae, such a funnel-like dilatation does not occur. These facts can be ascertained by careful clinical examination, the delicate touch of a practised hand can determine them.

**H. BAYER** has examined many puerperal uteri (after boiling and maceration) by dissection, and microscopically. Of these, he describes five: two immediately, one three hours, and one eight days, after delivery; and one after four months' abortion.

1. The first preparation is of a uterus *three hours after delivery*, in which the arrangement of the muscular fibre was studied. Dissecting from the outside, he finds peritoneum firmly attached



anteriorly down to line from contraction ring to round ligament; posteriorly, while coming down to fornix, loose below a curved line dipping down from the ovarian to utero-sacral ligaments. Posteriorly, the superficial fibres run in the middle line over the fundus and to the sides over the ovarian ligaments and tubes. The retractor fibres of the utero-sacral ligaments cross at the level of the thin portion, sending fibres on to posterior surface which join the middle fibres running down to the posterior vaginal wall. Anteriorly, the round ligaments send a broad bundle running horizontally along the firm attachment of the peritoneum; the superficial fibres going right across, the deep ones uniting in a longitudinal band over the anterior wall of the body. Fibres also pass to the side of the uterus which bend round again on the anterior wall to meet others from the central band. Between the lower cross band and these upper side branches, there is a space with the fibres passing upwards and then bending downwards towards the middle. This peculiar loop-like bending of the fibres (described by Hélie as the muscular drapery of the anterior wall) must be due to the contraction of the body, because in the pregnant uterus the fibres of the round ligament run either horizontally or obliquely upwards. Fibres run from the posterior wall on to the tube curving over it to its anterior wall like the spiral fibres in the pregnant uterus. From the horizontal layer anteriorly, fibres run downwards in the middle line over the lower segment as far as the nick in the anterior wall, where they run horizontally to the sides and obliquely upwards to the crossing of the utero-sacral fibres. Below this, is a still broader muscular layer. At the level of the utero-sacral ligaments, the fibres form loops round the vessels. Here, as well as in the body of the uterus, we see in the gaps between the superficial layers described, fibres running horizontally.

Dissecting *from the inside*, on scraping off the decidua, he finds anteriorly and posteriorly a triangular muscular plate with the base upwards. From both pass fibres arching round into the mouth of the Fallopian tubes, forming a spiral arrangement. There are also fibres running horizontally at the sides and arching over the fundus. On the anterior wall about 3 cm. (1·2 in.) above the os externum is a slight prominence above which is the bulging lower segment. Posteriorly, there is no such prominence but the wall becomes thinner opposite the utero-sacral ligaments. Above the prominence on the anterior wall, the muscular tissue could be split up into separate plates; but, below, this could not be done. Commenting on this Bayer says:—"We have here a general



drawing together of the posterior wall of the uterus beginning from the internal surface and extending to the utero-sacral ligaments. The fibres which were before parallel have their ends approximated so that the original fan-shaped arrangement is restored. The wall also increases in thickness, the more so that the fibres taken from the lower segment pass backwards to their former position. If we think of the whole lower portion of the uterus below the contraction ring and utero-sacral ligaments as divided into four, by a mesial frontal plane and a horizontal plane at the level of the prominence in the anterior wall, we find that the anterior upper portion (that is to say, the lower uterine segment) behaves as in pregnancy,—that is, its fibres are drawn upwards and forwards—while those of the posterior upper portion are contracted downwards and backwards; while the two lower segments simply show the effects of the great stretching in the period of dilatation."

2. Uterus *immediately after delivery*; from a IV.-para, aet. 23, delivered by forceps, died of heart disease. Examined by making sections.

Beautiful drawings are given of the naked-eye and microscopic sections from this case. The uterus measures 19 cm. (7·6 in.) in length externally, and 12 cm. (4·8 in.) in breadth. 8 cm. (3·2 in.) above os externum is firm attachment of peritoneum. Bladder is widely separated from cervix, so that vesico-uterine pouch comes down to 5 cm. (2 in.) above os externum. The Vertical Mesial Section shows that the posterior wall of the uterus is of about uniform thickness; the anterior wall is thin towards the fundus, becomes thick towards the middle, and very thin again below. Opposite firm attachment of the peritoneum is a large vessel; and at this point the wall thins from 2·5 to ·8 cm. (1 to 3·2 in.) In the posterior wall below the attachment of the utero-sacral ligaments, several vessels are seen in section. About  $2\frac{1}{2}$  cm. from the os externum and 5 cm. from the firm attachment of peritoneum the anterior wall projects inwards as a spur. The connective-tissue framework of the posterior wall shows elongated spaces, different from the curved lines of the anterior wall. This is due to the contraction of the anterior wall and the influence of the fixed round ligaments. It is to the action of the latter also that the ovarian plates and corner of the Fallopian tubes are drawn forwards and the uterus bent on itself to the front. The contraction of the utero-sacral ligaments pulls the posterior wall downwards and backwards, and makes it concave. In the anterior wall, there is no counter-traction downwards, so that it contracts concen-



trically and is thickest in the centre where the round ligaments make their traction. The changes here occur in the inner portion of the wall; the external layer, which runs down into the lower segment and is fixed to the anterior end of the utero-sacral fibres, does not enter into them. This superficial layer also runs down to the prominence on the anterior wall where it bifurcates, passing to the anterior lip and fornix. A series of sagittal and frontal sections is also given, and he sums up his conclusions from them thus. "As a fact, we can find nowhere in the puerperal uterus, a sphincter; and what I described as a moving sphincter in the unfolding of the supra-vaginal portion is a passing phenomenon which is of no importance in full-time labour or contraction in puerperium."

The microscopic examination of the Lower Segment and Cervix is thus described.

On the anterior wall there are above the contraction swelling normal remains of decidua (a superficial layer infiltrated with blood corpuscles and round cells, and showing in some places decidual elements and in the fundal layer glands with epithelium). On the posterior wall similar decidual remains extend to a lower level, below which is a mucous membrane with characteristic cervical epithelium. The lower half of this cervical mucous membrane shows the typical papillary projections and large follicles; while, above, the surface is smoother and the follicles smaller. Anteriorly, in lower part of cervix, there is cervical mucous membrane which extends beyond the spur into lower segment. Above this, up to the contraction swelling the surface is broken into artificial papillae. On the rest of the horizontal portion is a thick mucous membrane which is very like the transitional decidua seen in the pregnant uterus: there are numerous glands in several layers—the deeper ones flat, the more superficial ones angular or round, and also a great number of vessels surrounded with decidual-like cells. Only in the deepest layer were spindle-like elements: there is no surface epithelium; that lining the glands was cubical, not the high cylindrical epithelium of the cervix. This thick mucous membrane is separated from the muscular layer below by numerous small blood extravasations. In the upper part, infiltration of blood corpuscles and small cells was so great that it was impossible to say if elements of true mucous membrane were present. In many places, the muscular wall was bare. He attaches no importance to the extension of the mucous membrane beyond the projection on the anterior wall—whether the cervix had not unrolled completely, or whether the projection does not represent the termination of the



utero-sacral fibres (which according to Bayer form usually the limit of the unrolling). He thus concludes: "This preparation gave us the most important conclusion that the mucous membrane of the lower segment was in the anterior wall much fissured so that in many (indeed in most) places the muscular wall lay bare; while posteriorly the usual cervical mucous membrane (stretched and elongated in its upper part) with continuous surface epithelium covered the greater portion of the cervix, and only in the cleft and a small portion below it was there any splitting of the mucous membrane and tearing open of the glands, while here only in small places was the muscular wall visible."

3. *Uterus after four-months' abortion*; shown laid open. Three segments: above, the thick muscular wall bounded below by the contraction swelling opposite which is firm attachment of the peritoneum, with interior lined by decidua showing glands with well-preserved epithelium; below this, a segment with thinner walls lined with mucous membrane smoother than the decidua and more bloody—it had the characters of cervical mucous membrane (a continuous layer of decidual cells, but without cilia); below this, is the third segment—with characteristic cervical mucous membrane. As to muscular tissue, we find in the body an external longitudinal layer; underneath this, the muscular framework of the body; and finally, above the contraction swelling, the usual tile-like fibres streaming down into the lower segment. The appearance is ascribed to stretching of the supra-vaginal portion of the cervix before the ovum was expelled.

4. *Uterus shortly after delivery*, with defective unfolding of the cervix—degenerative stricture. VII.-para, aet. 32; delivered by turning to save child, when mother moribund with symptoms of meningitis. The Vertical Mesial Section shows firm attachment of peritoneum 5 cm. above the os externum, with two vessels in section opposite it. The whole cervix is short and there is no typical lower segment. The body is unusually stretched, its walls thin, and thickening in the anterior wall less abrupt. On front wall, decidua was found down to the contraction swelling and in the lower part of cervix usual mucous membrane; while in zone between, a mucous membrane with groups of cells (not so large as typical decidua) in a connective tissue matrix; no surface epithelium nor glands. On back wall, decidua comes down to contraction swelling, below which is cervical mucous membrane. In the whole body, the arrangement of the muscular fibres was longitudinal; just above the firm attachment of the peritoneum



began the usual tile-like arrangement, which could not be followed far downwards. To account for these appearances, he supposes that the cervix had remained till the commencement of labour entirely or in greater part intact.

In gathering up his conclusions as to the relations of the uterine muscle in labour he says, that on examining after delivery, we find the anterior lip hanging down loosely; above it a more or less distinct prominence, beyond which is the lax bulging sac of the lower segment, limited above by the contraction swelling. The posterior wall hangs as a bulging muscular mass continued into the posterior lip, which is drawn upwards and backwards, there being no thinning corresponding to the lower segment. Above the contraction swelling, the hand passes into a rigid cavity with convex bulging and concave bulged-out posterior wall. In the Fallopian-tube corners, we find a little cavity having the same form as the central body-cavity— anterior wall convex, posterior concave, and limited below by a crescentic prominence of the side wall. In the muscular wall, the following change has taken place. During pregnancy, the felted middle stratum had by a process of laminating, stretching and sliding of the different layers, come to have a longitudinal arrangement. It now returns to its original relation; further, the gaps found in the plates of fibres now become closed. A diagram is given to show how two muscular plates covering each other will, when one end of each is fixed (the anterior wall by round ligament, posterior by utero-sacral), under the expanding force of the ovum, slide upon each other until they merely overlap; and how, when the uterine contents are emptied, the muscular contraction will make them slide back again so as to lie beneath each other. Further, the muscular plates forming the inner layer of the lower segment slide up into the anterior wall of the body which thus increases in thickness to form the contraction ring; and the lower segment comes to consist only of the longitudinal layer running down to the star-like knot.

5. *Uterus from ninth day of Puerperium*, from a XVI.-para who died suddenly with thrombosis of the right saphenous and femoral vein, and embolism of the right lung. The uterus was taken out intact, boiled, and macerated in vinegar. The attachment of the bladder is unusually high—up to the firm attachment of the peritoneum  $6\frac{1}{2}$  cm. (2.6 in.) from the anterior lip. The uterus measures 13 cm. (5.2 in.) long, 2 cm. (.8 in.) thick at fundus, 2.7 cm. (1.1 in.) at thickest part of anterior, and 3 cm. (1.2 in.) at the



same of posterior wall. Its cavity runs straight, not bent forwards; and the anterior wall on which the placenta was partially situated is slightly concave. The cervix has reproduced itself for 3 cm. (1.2 in.); for several centimetres above its upper end we find a thinner portion of the wall limited by the firm attachment of the peritoneum and bladder, and a large vessel. There is no corresponding thinning in the posterior wall.

Two centimetres above the tip of the anterior lip is a vessel surrounded by connective-tissue fibres, and to this knot stream bundles from the firm attachment of the peritoneum; while from it fibres pass to the anterior lip and fornix. Above this, lie in tile-like arrangement plates which arise partly from the peritoneum, partly from the middle felted layer, and run towards the inner surface of the cervical canal. By this time, therefore, the greater number of the plates of the middle felted layer which were drawn up have come back to their former position. One part of the supra-vaginal portion has been restored, but not the whole; while the upper part of the cervical canal is still funnel-shaped. In the first week of the puerperium, therefore, the supra-vaginal portion has been about one-half restored.

From the examination of other preparations not detailed, he finds always the contraction swelling and firm attachment of the peritoneum at the same level. The lower segment always becomes shorter and thicker, the contraction swelling comes lower and lower down, while conversely the lowest portion of the cervix elongates itself upwards.

**C. H. STRATZ** has made a frozen section\* of a I.-para, aetat. 28; pelvis rachitic, with diagonal conjugate of 4 inches (10 cm.). Child turned, but the after-coming head could not be delivered without perforation. Placenta delivered by Credé's method. Great atony. Perineum torn into anus and stitched. Towards end of operation, patient collapsed and died within half an hour. Death set down to prolonged narcosis and loss of blood, with fatty degeneration of heart.

Body frozen in horizontal posture twenty-four hours after death, lying in freezing mixture four days. Uterus stood a hand's-breadth over the umbilicus, falling over to the right side, so that it could not be kept in the middle line. A Vertical Mesial Section of the pelvis and abdomen is given. Section not quite mesial (2 mm. to

\* This section is reproduced in Author's Atlas of Sectional Anatomy of Labour, Plate I., Fig. 7.



left of symphysis), and completely to left of spinal canal in lower dorsal region. Uterine cavity cut into in lower third, and exposed above by taking off another three millimetres. Pelvis measures—conjugata vera 3.12 in. (7.8 cm.), of outlet to lower end of coccyx 3.7 in. (9.2 cm.\*), from promontory to tip of coccyx 4 in. (9.9 cm.), height of symphysis 1.8 in. (4.6 cm.), from middle of symphysis to bend on lower edge of fourth sacral vertebra 3.6 in. (9.1 cm.\*). Soft parts of pelvis project 2.6 in. (6.6 cm.) below line joining lower end of symphysis and tip of coccyx. The empty rectum is drawn markedly forwards out of the hollow of the sacrum, so that the meso-rectum is greatly stretched. The empty bladder lies above the symphysis, measuring 2.48 in. (6.2 cm.). It is oval, having walls varying from .6 to .7 in. (1.5 to 1.8 cm.). The orifice of the urethra lies .08 in. (2 mm.) below the section; its canal is divided. The vagina is drawn out, and measures 2.6 in. (6.5 cm.\*). The muscular fibres of the vaginal wall pass direct into those of the uterus. The tissue between the bladder and anterior vaginal wall is behind the symphysis and filled with hæmorrhages. The peritoneum reaches anteriorly to the point of union of bladder and uterus, posteriorly to level of posterior fornix. Of the uterus, only the cervix extends into the pelvis, the fundus resting on the spinal column. Its cavity is filled with some blood-clot. The placental site is over the fundus, where it can be easily recognised. The lips of the os externum are easily recognised and closely approximated. The os internum lies about 1 in. (2.5 cm.) posteriorly, about 2.2 in. (5.5 cm.) anteriorly, above the os externum—giving an opening of 1.2 in. (3 cm.) wide.

The bend between cervical canal and uterine cavity is not well marked in front, but the os internum can be traced in the preparation as a continuous ring, with a deep tear into the parametrium on the right side. The canal of the cervix forms an angle of 120° with that of the vagina and also of the uterus. The lower uterine segment has fallen together, there being in front 1.2 in. (3 cm.), and behind .4 in. (1 cm.) from contraction-ring to os internum. The lower part of the thinnest segment is .32 in. (8 cm.) anteriorly, 1.2 in. (3 cm.) posteriorly. Contraction-ring is .88 in. (2.2 cm.) thick in front, 1.2 in. (2.8 cm.) behind. From contraction-ring to upper end of uterine cavity is 4.8 in. (12 cm.) in front, 6.8 in. (17 cm.) behind. A thread adapted to the uterine cavity measures from the anterior lip to the fundus 10 in. (25 cm.), and

\* The figures marked with an asterisk are given by Stratz in his text but do not correspond with measurements on the plate.



the same from the posterior lip; in all, 20 in. (50 cm.), or 12 in. (30 cm.) less than in the first stage. The flaccid lower segment makes, however, the measurement too short. The greatest thickness of the uterine muscle is behind 1·8 in. (4·5 cm.), in front 1·6 in. (4·1 cm.), at the fundus ·88 in. (2·2 cm.). We have a greater thickness of posterior wall from the obliqueness of section. The cavity is also divided obliquely from above downwards. The vessels in the wall are compressed and obliterated. The muscular tissue is, in the neighbourhood of the contraction-ring, stuck through with extravasations. The individual bundles are separated from each other by the hæmorrhages—strikingly in front round the neighbourhood of the contraction-ring; where also the external not-ecchymosed portion is markedly fatty.

On the right side, the position of the ligaments was noted. The tube was inserted at the level of the upper end of the cavity, with the round ligament 3·2 in. (8 cm.) below and in front, and the ovarian ligament 1·6 in. (4 cm.) below and behind, these two being 2 in. (5 cm.) apart. The broad ligament forms a pouch between the ovary and tube, at the lower end of which pouch a large bundle of vessels enters and runs between the folds to the muscular wall.

**BENCKISER** describes a *uterus from I.-para, ætat. 28, flat pelvis, contraction ring at umbilicus, and os almost fully dilated; delivered by cranioclasm and died; air found in right side of heart.* Right half of the uterus represented  $\frac{4}{5}$  of size of nature. Uterus measures with cervix 24 cm. (9·6 in.); cavity, 21 cm. (8·4 in.) long, divided by circular furrow into two equal parts—upper 8 cm. (3·2 in.) deep, having thick walls and narrow lumen, lower with thin walls and lumen dilated with bloodclot. *Peritoneum* wrinkled irregularly all over body down to contraction ring, but smooth over lower segment, which is distended with coagula. *Musculature* of anterior wall, where placenta was,  $2\frac{1}{2}$  to 3 cm. (1 to 1·2 in.) thick, of fundus 2·5 cm. (1 in.), of posterior wall maximum 5 cm. (2 in.), and average 3 cm. (1·2 in.). Texture matted, being plate-like only at fundus; the interlacing bundles having a general direction downwards and inwards; but in lower segment, which thins from 2–3 cm. above to ·4–·5 cm. below, consists of longitudinal easily separable plates. At level of peritoneal reflection on bladder, this texture replaced by firmer tissue about ·5 cm. (·2 in.) thick, which ends in the anterior lip 1 cm. (·4 in.) thick. Posteriorly, the tissue becomes firmer at 4·5 cm. (1·8 in.) from the tip of the lip, is 1 cm. (·4 in.) thick, and



ends in well-defined lip, which is 1·5 cm. (.6 in.) long. The *surface* of cervix shows folds along and across; that of lower segment shows small shreds of decidua. This preparation is a beautiful example of a puerperal uterus, the lower segment being dilated with blood.

---

## APPENDIX.

### Early Contributions of Anatomy to Obstetrics.

IN studying the history of Sectional Anatomy we were led to inquire into the sources of our knowledge of the Anatomy of the Uterus. The results of this inquiry became so bulky that it was evident that they would be out of proportion here. They were, therefore, given in a Paper on the above subject, which has appeared in the *Edinburgh Medical Journal* for 1888. Of that paper this Appendix is a brief summary.

Under 'Early Contributions' we include the period from Hippocrates with whom the history of medicine begins, to the end of the sixteenth century when our knowledge of the anatomy of the non-pregnant uterus was established. This period may for convenience be divided into three epochs, each beginning with a great name.

FIRST EPOCH—from Hippocrates (circa B.C. 400) to the beginning of the Christian Era.

During these four centuries the ideas of the human uterus were taken from the study of the lower animals. According to *Hippocrates* and *Aristotle*, it consisted of two cavities—a right and left; in the former of these male foetuses, and in the latter female foetuses grew. The dissection of the human body, begun in the Alexandrian Medical School under the Ptolemies by Herophilus and Erasistratus, did not in this epoch correct these erroneous views. The absence of anatomical data gave play to the imagination, and we have Diocles describing mammary processes inside the uterus placed there by nature that the foetus might practise the art of sucking before its birth. *Celsus*, with whom this period closes, though versed in general anatomy, had no accurate knowledge of the anatomy of the female pelvis.



SECOND EPOCH—from Soranus (circa 100 A.D.) to the end of the fifteenth century.

The first great contribution of anatomy to obstetrics is the remarkable work of *Soranus* of Ephesus (flor. circa 100 A.D.) 'Concerning Diseases of Women,' a work which, with the exception of a single chapter, has only in this century been rescued from oblivion—undeserved, and to obstetric and gynecological science most hurtful. One of the first chapters is devoted to anatomy. In reading it no one can fail to be impressed with the scientific orderliness with which the subject is treated, the exclusion of matter adventitious to anatomy, and the dogged holding to fact. It has the style rather of the scientific teacher than of the investigator, and is to be regarded as the finished product of the anatomical investigation done by many hands, probably in the dissecting-rooms of Alexandria. To sum up the contents of this chapter, we have the relations of the uterus to the bladder exactly as they would appear on dissection (*i.e.*, with the cadaver on the back); its ligaments; and (what is noteworthy) the effect of inflammation in causing cicatrization and consequent displacement; the external form of the uterus described under various names suggested by its resemblance to an ancient cupping glass; the os externum with its distance from the vulva, which differs in multiparae and nulliparae; the canal said to have the calibre of the external auditory meatus, and to become more patulous in menstruation and orgasm of coitus; the blood-vessels—in which the ovarian, but not the uterine, artery is described; the position and form of the ovaries and of what is described as their duct; this last must be either the ureter or uterine artery, for the Fallopian tube escaped Soranus unless he refers to them under the special 'suspensory ligaments' of the ovary. The structure of the uterus is described in terms of what we now call the peritoneal and mucous-membrane surfaces of the wall which are accurately contrasted. Incidentally it is said that from the body of the uterus the menstrual discharge comes, and in it the ovum grows; the folds of the mucous membrane (*arbor vitae?*) are more marked in nulliparae than in multiparae. The vagina and external genitals are described each by itself—the relations of the former with the method of a systematic teacher of anatomy in our day, its length and absence of rugae in multiparae being noted. He denies the existence of the hymen as a membrane completely closing the vaginal orifice. In the external genitals the clitoris is described as the nymphē.



One was surprised to come at this early period upon a contribution so large and solid as that of Soranus; and it is remarkable that *Galen*, who lived immediately after, in describing the human uterus simply repeats the Hippocratic teaching, and adds that he intends to write a treatise on the 'function of its horns.'

Probably three centuries after the work of Soranus, there appeared a book on "Diseases of Women" by *Moschion*. It is the teaching of Soranus thrown into the form of question and answer, and was written for the use of Latin-speaking matrons and obstetricians. While containing no new matter, it is an instructive example of how systematic and thorough the teaching of obstetrics at that time must have been. It contains what has been supposed to be the first drawing of the uterus, but there is evidence that this is a modern interpolation of the time of Vesalius.

After the lethargic sleep of the Dark Ages, in which it fared even worse than other sciences through Islam's forbidding dissection, anatomy aroused itself again in Italy. *Mondino* of the University of Bologna is regarded as the founder of modern anatomy, yet he contributed nothing to obstetrical anatomy and describes the uterus as containing seven cavities.

THIRD EPOCH—from Berengario da Carpi (1521) to the end of the sixteenth century.

In *Berengario's* Commentary on the text-book of *Mondino* we find the first drawing of the non-pregnant uterus, with a description not nearly so detailed as that of Soranus but overturning the erroneous teaching of *Mondino*. In the plates of *Vesalius* and *Eustachius* we have very good drawings of the unimpregnated uterus in the pelvis, and also removed from the body. The greatest contribution made in this epoch was from *Fallopian*, who gives a careful description of the anatomy of the clitoris, hymen and round ligaments; of the tube with which his name has always been associated; of the ovarian and uterine arteries, and of their anastomoses with each other and the vessels of the opposite side. By this last contribution our knowledge of the naked-eye anatomy of the non-pregnant uterus was established, but the Anatomy of Pregnancy was as yet untouched.

Bridging over the gap between these 'Early Contributions, etc.' and modern work, we have a cluster of brilliant names which group themselves round that of Haller in the 18th century. *Ruyssch* described the muscular fibre of the uterus as detruding the placenta;



*Douglas* gave us the peritoneal relations of the uterus, and especially of the pouch that bears his name; *Albinus* was the first to publish plates of the gravid uterus; which, along with those of *Roederer* (one of *Haller's* pupils) and the beautiful series by *Smellie*, form the first considerable contribution to the Anatomy of Pregnancy—to be crowned by the work of the illustrious *William Hunter*.



## LITERATURE SUBSEQUENT TO 1887.

---

VON SAEXINGER<sup>1</sup> gives a vertical mesial section<sup>2</sup> of a *I.-para* aged 18, expecting confinement in a month, died in first stage of labour from sepsis, due to phlegmonous inflammation of the right breast. Ten days before death, uterus was four finger-breadths above the umbilicus, child living and L.O.A. Pelvis measured—interspinous 10 in. (25 cm.); intercrystal 11·3 in. (28·3 cm.); intertrochanteric 12·1 in. (30·3 cm.); external conjugate 7·4 in. (18·5 cm.); periphery of false pelvis 34 in. (85 cm.), and of abdomen 36 in. (90 cm.).

*Per Vaginem* : Vagina, narrow; vaginal portion of cervix 4 in. (1 cm.) long, and closed; pelvis contracted in the true conjugate.

A few hours before death the head was found low down and both external and internal os admitted the finger. The unconscious and restless condition of the patient prevented saying definitely when labour began. As the child was dead for some time, Caesarean section *post mortem* was not called for.

Trunk was frozen supine for some days in salt and ice, and section made with a saw. Tracing was made on glass, and colours noted while fresh; section preserved in 96 % alcohol.

Atlas contains three plates: I. Vertical Mesial Section of left half of body—foetus in section also; II. Same of right half, with foetus removed to show uterine cavity; III. Same of left half, with whole foetus in situ.

Length of trunk 22·8 in. (57 cm.), of *Uterus* from os externum to fundus 10 in. (25 cm.). Greatest thickness at level of cartilage between 4th and 5th lumbar vertebrae 6·4 in. (16 cm.). Length of empty half of cavity from os internum to fundus along wall 12·4 in. (31 cm.).

*Pelvis* measures—conjugata vera 3·68 in. (9·2 cm.), from pro-

<sup>1</sup> Gefrierdurchschnitt einer Kreissenden: Tübingen, H. Laupp'schen Buchhandlung. 1888.

<sup>2</sup> This section reproduced in Author's *Atlas of the Anatomy of Labour etc.*—Second Edition, Pl. XII.



montory to tip of coccyx 4·6 in. (11·5 cm.), conjugate of outlet 4·6 in. (11·5 cm.), depth of symphysis 2 in. (5 cm.), breadth ·9 in. (2·3 cm.). Sacrum divided almost mesially, rectum distended with fæces. *Vagina* divided mesially, walls in apposition, length to anterior lip 2·8 in. (7 cm.); posterior fornix extends above os externum 1·1 in. (2·8 cm.) on the left, and ·9 in. (2·25 cm.) on the right. In dilated cervix and upper part of the vagina some frozen mucus. Anterior vaginal wall measures in thickness in upper part ·8 in. (2 cm.), posterior ·36 in. (.9 cm.). *Bladder* extends 1·8 in. (4·5 cm.) above symphysis; its posterior wall extends 2·4 in. (6 cm.) below the same. Urethra 1·1 in. (2·9 cm.) long.

Reflection of *Peritoneum* anteriorly ·48 in. (1·2 cm.) above symphysis, posteriorly ·4 in. (1 cm.) below the fornix.

*Uterine walls* at fundus and body of almost equal thickness ·24 in. (.6 cm.) and ·2 in. (.5 cm.); vessels scarcely visible. Below promontory and symphysis, anteriorly and posteriorly, walls thin to ·2 cm. and ·3 cm. respectively. The thinner portion extends from os externum anteriorly to reflection of peritoneum 3·7 in. (9·4 cm.), posteriorly to promontory 3·8 in. (9·6 cm.). The thin portion passes gradually into the thick; no contraction ring is seen in the section of the wall, but there is a ridge in the cavity of the uterus which may represent it. Os internum ·28 in. (.7 cm.), externum ·2 in. (.5 cm.) wide: above latter, frozen liquor amnii extends below head for ·6 in. (1·5 cm.).

*Placenta* is on anterior wall and divided almost mesially, measuring 7 in. (17·5 cm.) along its site, and 1 in. (2·5 cm.) in thickness. Cord once round neck.

*Child's* head lies with vertex at level of lower margin of the symphysis, and has its bones slightly pressed in. Length from breech to vertex 8·8 in. (22 cm.), and from breech to chin 4·4 in. (11 cm.). Chin appears pressed against breast, posterior fontanelle lies lowest, neck shows bending backwards. Liquor amnii all round foetus, at fundus and in body. Child weighs 5 lbs. 1 oz. (2300 grms.).

On Plate II., showing the uterine cavity, the positions of the tube and ovarian ligament are marked. "To this description of the mesial section I require to add nothing: the representations gained are so characteristic that they are fully evident even without text; they give a clear insight into the changes in labour at its commencement with the child in its normal attitude and position, and show in a most beautiful way how the head has



firmly and favourably engaged in the entrance of the narrow pelvis. They are thus well suited for clinical demonstration; while they do not offer anything characteristic as regards the question of the formation of the lower uterine segment and contraction ring, as labour has just begun."

**G. WINTER**<sup>1</sup> gives two frozen sections made in the I.-Stage of Labour.

The first is of a *II.-para, ætate 32, at full time, who died in the coma of eclampsia after a month's œdema.*<sup>2</sup> The uterus was three finger-breadths above the umbilicus; short pains were present every ten minutes, and the foetal heart heard at the umbilicus seventeen hours before death. The os externum admitted the point of the finger; the lower portion of the cervix was somewhat open, the upper completely closed. The child died twelve hours before the mother.

Before freezing, the bowel was punctured to let out gas and allow the uterus to be placed central. Gas also escaped into the abdominal cavity and was present in the pouch of Douglas. The cadaver was frozen on the belly to avoid post-mortem retroversion. After eighty hours, it was cut with an ordinary saw. Tracing of the section was taken on glass, transferred to paper and coloured.

The Atlas gives three plates: I. Water-colour of Mesial Section; II. Ink-tracing, and with the foetus shown undivided; III. Empty uterus. In the last the surface has been pared down so as to make the section exactly mesial, the drawing being made from the spirit preparation. In the frozen sections, the body is divided 5 cm. to left of middle line at symphysis and 2.5 cm. at promontory, the sacrum being lost at its fourth vertebra, and the lumbar vertebræ divided at the base of their transverse processes.

The *heart* shows a patent foramen ovale. The *Uterus* lies with vertical diameter at right angles to the conjugate, its highest point one-fifth of an inch (.5 cm.) above the umbilicus, its anterior wall in contact with abdominal wall (except at fundus where free gas separates them). It bulges slightly over symphysis, causing some increase of the antero-posterior diameter here. This bending over the symphysis is exaggerated by post-mortem flaccidity of tissue. Posterior wall lies along lumbar region of spine, and in

<sup>1</sup> Zwei Medianschnitte durch Gebärende—Eine anatomische Studie: Berlin, Fischer's medicinische Buchhandlung. 1889.

<sup>2</sup> This section reproduced in Author's *Atlas of the Anatomy of Labour etc.*—Second Edition, Pl. XII.



pelvis is separated from sacrum by sigmoid flexure of colon above and gas in pouch of Douglas below. *Peritoneum* extends over one-third of bladder in front, and covers one-half of the cervix posteriorly. The *walls* are about one-fifth of an inch (4 to 5 mm.) thick at fundus; thicken in upper part of anterior wall to one-third of an inch (8 mm.); and thin below that to 4 mm. between symphysis and cervix—thinning gradual, there being no contraction ring nor coronary vein. Posterior wall is 7 mm. thick above, and thins below to 4 mm. without contraction ring. The *Cervix* is seen in the spirit section to have the upper end of its canal open—the margin forming distinct ring separating the smooth decidua from cervical surface rich in thick folds. The transition from uterine cavity to cervix forms a sharp angle in front, becoming obtuse at the sides and disappearing entirely behind. Microscopic examination of portions cut out shows decidua stopping sharply at the distinct ring which is os internum. The os externum was masked posteriorly by an erosion, but was found at tip of lip and at same place anteriorly.

The *Membranes* are separated over the Lower Segment—in front .56 in. (1.4 cm.), at sides .8 in. (2 cm.), and behind 1.2 in. (3 cm.) from the above-mentioned ring—the amnion and chorion being united.

The *Placenta* is on the right side of the anterior wall, its site occupying almost the lower half of the uterus, its lower border being 2 cm. from the os internum. Above the brim it is bulky, reaching 1.2 in. (3 cm.) in thickness; below it is thinner, being only .2 in. (.5 cm.) thick. Even to the naked eye, the part below the brim appears more compressed than that above, and the vessels on the surface empty and flattened. Microscopic examination shows “in the bulky upper part of the placenta the tissue laxer; the chorionic villi lie widely separated from each other, so that between them here and there is a wide intervillous space; between the villi there is in many places a great quantity of blood, and the blood-vessels are mostly distended with blood. . . . The decidua serotina shows a distinct opening-out of its deeper layers uniting it with the uterine muscle, and gives appearance such as Ruge has described as the result of the first uterine contractions in labour. In the part of the placenta in the pelvis, the chorionic villi lie very close, are thick-set and interlocked, so that one can scarcely speak of an intervillous space. Between the villi there is nowhere blood, the vessels of this part being completely empty. The decidua serotina shows here no opening-out of its deeper layers, and its limit runs almost in a



straight line." These anatomical facts are of great importance in the pathology of *placenta prævia*, showing that the pressure of the child's head in the pelvis can almost stop the circulation. It can thus materially affect its own circulation, although scarcely enough to cause its death. The pressure of the head may also stop bleeding from the placenta if separated (which has not occurred here)—the membranes being detached not quite to its border.

*Liquor Amnii* inconsiderable in quantity and green-coloured from presence of meconium. It comes between head and cervix as fore-water.

*Child* is in normal attitude of flexion. The sagittal suture of the head runs in the transverse diameter of the pelvis, and the back is directed to the right side, so that there is as yet no torsion of the trunk either as regards the uterine wall or the direction of the child's head. The head is in the pelvis, with the sagittal suture in the cavity, the small fontanelle slightly deeper than the large.

The conjugate of the *Pelvis* measures anatomically 4·3 in. (10·8 cm.), obstetrically 4·1 in. (10·3 cm.). The sacrum is flattened. The *Bladder* lies wholly in the pelvis, the upper wall resting on the lower in plate-like form. The separation of the tissue between it and cervix into two plates, one belonging to each organ (as Waldeyer has described), was not marked; but the tissue between bladder and uterus was laxer than that between bladder and vagina.

The Second Section is from a *I.-para*, æt. 27, who died at the eighth month of gestation from eclampsia.<sup>1</sup> Had been well till two days previously, when, after twenty-four hours of premonitory symptoms, the fits began; œdema and albuminuria considerable; fundus three finger-breadths above the umbilicus; foetal heart heard to the left. *Cervix* 4 in. (1 cm.) long, its canal patent admitting one finger quite easily; membranes unruptured, pains present. Patient at first insensible, responding to no stimuli; but after ten hours' narcosis, fits stopped, consciousness regained so that she answered questions, and then slept quietly with a pulse of 70; then suddenly, thirty-six hours after the first fit, breathing stopped, while pulse remained good—then pulse became weak and she died without drawing breath spontaneously. Examination after death showed vaginal portion of *Cervix* low, os externum admitting finger, while os internum could not be felt distinctly, the cervix being apparently

<sup>1</sup> This section reproduced in the Author's *Atlas of the Anatomy of Labour* etc.—Second Edition, Pl. xii.



fully taken up ; through the unruptured membranes the breech was felt (with feet to left) above the pelvis, projecting only slightly into it, but causing the anterior fornix to bulge out ; bloody mucus abundant on examining finger.

Post-mortem examination of *brain* showed in the right hemisphere a cavity 4·4 in. (11 cm.) long lying to the outer side of the lateral ventricle and taking up almost the whole hemisphere ; it was distended with fluid and coagulated blood, causing this half of the brain to bulge beyond its own side, pushing the corpus callosum to the left, and flattening the convolutions ; its walls were of white matter, uneven but not broken down save at one point, where a deeper sulcus in the grey matter allowed the wall to break through and the blood to pass out through the membranes and spread over the surface of the brain ; no large vessel or source of bleeding visible, though there were numerous smaller ones with thrombi in the walls of the cavity.

On opening the abdomen, the *Uterus* was found mesial but rotated, so that the insertion of the left tube was seen 8·4 in. (21 mm.) above upper border of pubes, while the right tube was concealed. Left *Ovary* 4 finger-breadths above pubes. Anterior wall of uterus in contact with abdomen throughout, while behind fundus are some intestines. Pelvis and uterus removed and frozen.

One plate is given showing the uterine cavity with placenta and membranes, foetus being removed. The section is mesial at promontory, ·7 cm. to right at pubis, and to the left in lumbar region. *Spinal canal* divided in lower part of sacrum—the fifth vertebra of which appears, while the coccyx is lost through being to the right. Coils of sigmoid flexure lie behind the *Uterus*, fundus of which has sunk two-fifths of an inch (1 cm.) after removal of pelvis from body. The cavity from fundus to end of unfolded part of canal is 10 in. (25·2 cm.) long. *Peritoneum* descends anteriorly to upper border of bladder, posteriorly to the fornix.

*Wall* at fundus ·28 in. (·7 cm.) thick ; anterior thins from ·24 in. (·6 cm.) above to ·2 in. (·5 cm.) in middle, and ·08 in. (·2 cm.) in lower segment ; posterior measures at upper margin of placenta ·3 in. (·8 cm.) in middle of same, ·4 in. (1·1 cm.) at lower margin, ·28 in. (·7 cm.), and below ·12 in. (·3 cm.). No distinct contraction-ring. Firm attachment of *Peritoneum* is anteriorly 3·2 in. (8 cm.), posteriorly 2·4 in. (6 cm.), above the upper end of canal. *Cervical canal* shows anterior lip in part preserved and bent at right angles, while posterior only enters into canal for ·4 in. (1 cm.). Upper end of canal dilated and marked off by its folded surface



from the decidua, the line running in a circle, although there is no bending at an angle between cervical canal and uterine cavity. Microscopic examination shows cervical surface to be characterised by cylindrical epithelium and glands, while decidua is scarcely recognisable through the shrinking of its cells. The os internum is here therefore anteriorly  $\cdot 6$  in. (1.5 cm.), posteriorly 1.8 in. (4.5 cm.), from the end of the canal.

The *Membranes* are separated below anteriorly 1.8 in. (4.5 cm.) from os internum, and 2.6 in. (6.5 cm.) from end of canal; posteriorly,  $\cdot 4$  in. (1 cm.) from os internum, and 2.12 in. (5.3 cm.) from end of canal—the line of separation running in a gentle curve convex upwards. The amnion is unruptured, but the chorion is torn through and retracted off it, so that its edge is  $\cdot 48$  in. (1.2 cm.) from the middle line. A thin layer of blood seen underneath the membrane extending downwards from placenta and lifting membranes off the wall for 2.4 in. (6 cm.) in the middle line. *Placenta* is on posterior wall, chiefly on the right half, and bulges in humps into the cavity of the uterus, even touching anterior wall on the right side. A hæmatoma separates it from the wall, above almost to its edge, and below to within 1.6 in. (4 cm.) of it; it is central; on the right side has pierced placental tissue nearly to the foetal surface; and at right margin comes up to edge of placenta, where the blood has escaped through to beneath the membranes. About the half of the placenta is separated from its site. *Liquor Amnii* shows no meconium, though colour is greenish; mostly in upper part of uterus, though there is a thin layer of forewaters.

*Child* in second breech position. *Bladder* empty, in the pelvis, attached to lower segment or 1.8 in. (4.5 cm.). The intermediate tissue is lax, and with much fat, broken up into layers close to bladder wall. Its union to vagina is firmer.

**BRAUNE** and **ZWEIFEL** give a series of sections of a primipara who died suddenly in the ninth month of pregnancy from failure of the heart. After freezing the trunk in the dorsal posture so as to preserve the spinal curvature, the thorax was cut off. A vertical mesial section was made and drawn. The two halves of the body were then embedded in plaster, and the right half cut antero-posteriorly into slabs.

The Atlas consists of twelve Plates: I. Vertical Mesial Section, left half; II. Uterine cavity of same; III. Vertical Mesial right half; \* IV. Same, showing whole Foetus; v. to x. Lateral Sagittal

\* This section reproduced (combined with Plate iv.) in the Author's *Atlas of the Anatomy of Labour*, etc.—Third Edition, Plate xxv. Fig. 3.



Sections, to the right ; XI. Position of Sections and attitude of Fœtus, and bony pelvis—left half ; XII. Obstetric canal as bounded by bone, and diminished by soft parts—(1) at brim, (2) in cavity, (3) in a plane extending from lower edge of symphysis parallel to brim, and (4) at outlet.

The text consists of an anatomical and an obstetrical portion by Braune and Zweifel, respectively. We select from the anatomical section the facts which have an obstetrical bearing. The conjugate of the brim is 11·15 cm. ; of the cavity, 13·2 cm. ; of the outlet (measured to sacrum), 10·15 cm. ; and the height of the symphysis is 5·2 cm. The curvature of the spine in the thoracic and lumbar regions is lessened in advanced pregnancy, the spine being a straight line sloping backwards. Waldeyer's and Schroeder's Sections confirm this ; but most others are of little value as to this point, because the body was not frozen intact. The symphysis is less vertical than in Braune's former section, in which its direction was perhaps due to kyphosis. The depth of the thorax at the ensiform cartilage is 13 cm.—greater than in Saexinger's and Winter's. The umbilicus is opposite the middle third of the fourth lumbar vertebra, as against the upper third in his former section, the lower in Waldeyer's, and the lower margin of the fifth in Saexinger's. The stomach is much distended, and the diaphragm is at the level of the ninth dorsal vertebra.

In the pelvis, the *Peritoneum* descends posteriorly to 7 cm. from the anus ; anteriorly to level of symphysis, covering the posterior wall of the abdominal portion of the bladder only. The *Bladder* extends far above the symphysis, and is compressed behind it by the foetal head to a thin cleft. There is lax *cellular tissue* separating vagina from bladder and rectum, allowing of considerable movement. The *uterus*, though deflected to the right, is cut in its greatest length in the mesial section ; it reaches the lower border of the second lumbar vertebra, as against the middle of same in Waldeyer's and Saexinger's, the first lumbar in Chiara's, and above that in his own former one. The *cervical canal* measures 2·6 cm., the os externum is on a level with the lower part of the symphysis, the os internum being on a level with the upper part. The *lower segment* extends for 5·5 cm. from the os externum, the contraction ring being anteriorly 9·7 cm., posteriorly 9 cm. from os externum. The *cervix* forms with the body an angle open to the front. This is present also in Winter's and Schroeder's Sections ; it may be characteristic of labour, as in Waldeyer's Section of pregnancy the angle is open backwards.



The anterior lip is not unusually projecting, nor is there marked swelling of the vaginal mucous membrane, as in his former cases. He thinks Schroeder may be right as to the thinning of the lower segment when labour begins; but the obliquity of sections of wall prevents definite statements with regard to this special section. A *contraction ring* may be seen\* in the vertical mesial section, and traced round the cavity, running from the upper edge of the bladder to near the promontory, and corresponding to the neck of the fœtus. A big vein appears in section anteriorly, but could not be traced round with a probe; numerous sections of veins are present throughout the wall.

The *Fœtus* is 24·3 cm. long, small though at full time, and R.O.P. The head is flexed on the thorax, but not rotated. Its attitude is shown in Plate XI. (constructed from the lateral sagittal sections); its contour shrunk slightly owing to its being in spirit, hence the distance between breech and placenta is exaggerated.

Measurements are given from twelve cases in the living subject to compare the horizontal and erect postures as regards the circumference and depth of abdomen, the height of the uterus above symphysis, and the distance of the fundus from the spine, of the fifth lumbar vertebra. From these, the conclusions drawn are as follows:—The full-time uterus is soft and plastic, is increased in length by the horizontal posture, lying along the spine, but somewhat obliquely, as if it had slipped to one side; the obliquity being most marked in multiparæ, while in the erect posture the abdomen bulges anteriorly, and has its circumference increased; the position and form of the uterus, therefore, changes with the posture of the patient, and the greatest prominence is almost always at the level of the fifth lumbar vertebra.

In the *obstetrical part* of the text, Zweifel mentions that the patient had mitral incompetence. The fœtus died before the mother. The fundus uteri, during life, stood 17·5 cm. above the symphysis (along the skin 29 cm.); the distance from symphysis to sternum was 42 cm. The pelvic diameters measured on the section are, in addition to those given above: Obstetrical conjugate, 10·8 cm.; the diagonal, 12·5 cm.; that of outlet (to coccyx), 10·15 cm. A table is given comparing these measurements with those of other frozen sections. The left half of the cadaver was put in 96 p.c. of alcohol to study thickness of soft parts.

\* Zweifel questions this, and it is not evident from the Plate of the section.



The *Uterus* lies in the axis of the brim, the vertex of the foetus being 6·5 cm. below the plane of the brim and ·5 cm. above that of the outlet (to lower end of sacrum). The greatest diameter of the head is below the plane of the brim. The patient did not complain of pains, and there is no trace of a contraction ring; and the prominence of the abdomen was present before death. On the other hand, the *rigor mortis* might cause contractions, and the deep position of the uterus is set down to this.

The diameters of the pelvis, alone and with soft parts, are given in four planes (Plate XII.)—at the *brim*, not passing through the conjugate but through the *linea innominata*; in the *cavity*, from centre of symphysis to bend in middle of third sacral vertebra; in the *second parallel plane of Hodge* or the “chief plane” of Veit; and the *outlet*, at lower end of sacrum. The soft parts are shrunk in alcohol, but they would have been compressed when the patient was in labour. The brim shows in front no muscle, to the sides and behind ·5 cm. of the ileo-psoas. The soft parts in the oblique are only approximate, because only one half of the pelvis is given. The antero-posterior diameter of the cavity is drawn by some to the bending angle which may be in the third sacral vertebra (as here) or in the fourth; others draw it to cartilage between second and third. Hodge’s “second parallel” plane is a more useful one, and might well be called the “plane of the cavity,” which is a better name than “chief.” The thickness of the soft parts\* is as follows:—

	Conj.	Obl.†	Trans.
In plane of Brim	1·4 cm.	·7 cm.	1·7 cm.
„ Cavity	1·5 cm.	·5 cm.	2·4 cm.
„ parallel of Hodge	3·1 cm.	·7 cm.	·0 cm.
„ Outlet		1·7 cm.	5·3 cm.

In considering the bearing of the anatomical facts upon the “Mechanism of Labour” Zweifel considers (1) the *engaging of the head*. The bony pelvis has no influence on the mechanism, being roomy enough to let this flexed head pass in any of its diameters, the sub-occipito bregmatic diameter being 9·1 cm. while the conjugate with its soft parts is 9·4 cm. Zweifel objects to Veit’s statement that the position of the head is a question of growth,

\* Zweifel’s Table gives the respective lengths of the diameters of the hard and the soft canals, and the Table in our text is the difference between these.

† As to the shortening of the oblique diameters of the brim, the Plate does not agree with the Table: the Plate shows almost as great a thickness of soft parts as in the conjugate and transverse, while the Table gives it as only one half as much.



because the action of the uterus can never be eliminated. Face and forehead presentations show that flexion is not constant; and Barbour's Section, that it is not always as marked as here. Marked flexion with firm pressure of chin on sternum must be the result of labour; and it is not necessary to suppose a different position of the head in the fœtus from that of the child. There is first, therefore, a greater flexion and more marked approximation of the chin to the breast. Olshausen's view is quoted, that the escape of the *Liquor Amnii* causes a transverse flattening of the uterus, a return to its characteristic shape, and hence rotation; but the fœtus *in utero* has its greatest diameter antero-posterior, therefore, to cause rotation, the flattening of the uterus would need to be antero-posterior. Further, Braune's Section shows rotation of the head while the back is directed laterally, and also Chiari's. The antero-posterior flattening of the uterus is present in this Section and in Barbour's First Stage one. It is admitted that Olshausen describes this as occurring after the waters escape; but Braune's, Chiari's, and Schroeder's Sections show a rotation before that has taken place. (2) As to the *descent of the head* and the *second turning* (internal rotation), the greatest diameter of the head is here 3 cm. above Hodge's parallel plane, and 4 cm. above the ischial spines; while the "leading point" is 5 cm. deeper than the greatest circumference. If the head descended 3 cm. further, the leading point would be in the plane of the outlet—running to the coccyx. The head has descended thus far in this section without rotation, which will occur when it has descended three finger-breadths or 2 cm. further. Rotation, therefore, takes place during the time that the greatest diameter is descending from 3 cm. above the parallel plane to 2 cm. below it. The pelvis in this parallel plane, and in that of the outlet has the form of a long ovoid even without soft parts, and still more with them. In Braune's Section, the greatest circumference is in the parallel plane, and in Chiari's still lower; in Schroeder's, rotation has begun with the head in the cavity. This rotation is separated in time from the engagement. When the head has reached a point in which its greatest circumference is 4 cm. above the parallel plane, it remains there for some time—the dilatation and the retraction of the os externum taking place before rotation begins. (3) As to the *third turning* (extension), the muscular masses concerned are the obturator internus and the levator ani. The levator ani is markedly stretched; but drawing itself together again, pushes the head round the



symphysis. (4) As regards the *general-contents-pressure of the uterus and the pressure through the foetal axis*, it is not possible that the living child is an inert mass; on the contrary, it modifies the shape of the uterus, and must come into contact with its walls and be pushed onwards; but this pressure is not propagated to the head on account of the flexibility of the latter. Schatz is, therefore, so far right; but the uterus does not tend to a round form, for it elongates during contraction; nor is it globular even with a mole. This section shows how the head forms an angle with the body. While the chin is touching the anterior shoulder, it is the posterior (not the anterior) part of the head which is being pressed lowest down. There is a slight angular bending of the foetal axis with the angle open forward, and a consequent rolling of the head, so that the posterior parietal bone lies deeper—the opposite of what has happened in Saexinger's and Barbour's Sections. The uterine wall looks as if it were weaker over the placental site, *i.e.* posteriorly; and the foetal axis is bent towards the stronger anterior side. The head has been rolled in this case so as to be flexed: it might be rolled so as to be extended. The usual deviation of the uterus to the right side makes the rolling so as to produce extension, less likely to occur in left than in right positions: hence, L.M.A. is commoner than R.M.P. So, also, with right side obliquity: if the head be not engaging, the patient being on the right side, by turning her on her left, the direction of the pressure through the foetal axis is changed, and the occiput set free to rotate.

**ANTON v. MARS** gives a vertical mesial section of an VIII.-para, æt. 44, who died from rupture of the uterus during the Second Stage when the head was at the vulva.

Her former labours were normal. On washing day, after lifting a pot at 2 p.m., she was taken ill and felt the waters break. The midwife found the cervix taken up, the os externum the size of a crown piece, and the head high in the pelvis without a caput succedaneum; there was slight hæmorrhage. No further pains till 4 p.m., when they returned, but at very long intervals. At 8 p.m., the os was fully dilated, and the head began to descend; it advanced rapidly, but without the patient's complaining of pains. On reaching the pelvic floor it remained there, and there were no further pains. At 9 p.m. there was a rigor and some abdominal pain; at 10 p.m. a second rigor with pain, after which she fainted, and in half an hour died. After death, foetal



movements were noticed through the abdominal wall; but the doctor arrived too late for Cæsarean Section. The examination of the head and chest showed only anæmia; the abdomen was frozen.

The Atlas contains four Plates: a Vertical Mesial Section, right half; same, left half, with *fœtus*, *in situ*; \* right and left halves, with *fœtus* and placenta removed.

In the *bony pelvis*, the conjugate of the brim measures—*anatomical*,  $4\frac{1}{2}$  in.; *obstetrical*,  $4\frac{1}{8}$  in.; of the cavity,  $5\frac{1}{2}$  in.; of the outlet, *sacral*,  $4\frac{3}{5}$  in.; and *coccygeal*, 4 in. Depth of symphysis,  $1\frac{1}{2}$  in.

The *peritoneum* is reflected anteriorly  $\frac{1}{2}$  in. above the brim, the pouch containing some blood;  $6\frac{1}{4}$  inches above its reflection, the parietal peritoneum ceases at the transverse rent in the uterus. Posteriorly, it is reflected at the middle of the 5th sacral vertebra, the pouch of Douglas also containing some blood, and ceases at the 3rd lumbar, after turning round the left round ligament, which is here seen torn through. The *bladder* extends  $\frac{5}{8}$  in. above the pubes, its posterior wall being folded into its cavity.

The anterior wall of the *uterus*, at first  $\frac{3}{16}$  in. thick, thins till it ceases 2 in. above the pubes—the right arm of the *fœtus* for a further 2 in. above this point being separated from the anterior wall of the abdomen by peritoneum only. At this level, uterine tissue appears again, thickening into a retraction ring  $\frac{3}{8}$  in. in section, and standing 5 in. above the pubes (opposite the umbilicus). Above this it thins, ceasing altogether an inch higher up at the point where the peritoneum ceases also—the transverse rent. The posterior wall shows, at the level of the upper border of the 5th lumbar vertebra, a retraction ring 1 in. thick in cross-section, above which the wall thins rapidly, to cease and be torn through in the left round ligament at the level of the 3rd lumbar vertebra, or 4 in. above the retraction ring.

The head of the *fœtus* occupies the cervix and vagina, the *caput succedaneum* being  $\frac{3}{4}$  in. below the level of the outlet. The right leg of the *fœtus* lies between the torn-through anterior wall of the uterus and the abdominal wall. The *placenta* appears in section lying in the peritoneal cavity, folded upon itself between the legs of the child.

Upon removing the *fœtus* and placenta, the os externum appears as a wavy line running from  $\frac{3}{8}$  in. below the upper margin of the

\* This section reproduced in the Author's *Atlas of the Anatomy of Labour*, etc.—Third Edition, Plate xxvi., Fig. 2.



symphysis backwards to the junction between the second and third sacral vertebræ. The anterior *vaginal wall* is  $2\frac{3}{4}$  in. long, the posterior  $5\frac{1}{2}$  in. long. The cervix and lower segment are much stretched in front and behind, less at the sides. The retraction ring, standing 5 in. above the pubes, runs downwards parallel to the axis of the brim to within  $1\frac{3}{4}$  in. of the os externum, then turns upwards and backwards to where it is cut across posteriorly at the upper margin of the 5th lumbar vertebra. Anteriorly it is 6.6 in. (including rent) from the os externum; posteriorly,  $3\frac{3}{4}$  in. There is a longitudinal rent anteriorly in the lower segment and cervix, stopping short at the peritoneum. The *uterine wall* is here laminated, the laminae running parallel to the rent. Above the retraction ring is the contracted fundus uteri, lying almost horizontally to the right. Both muscular wall and peritoneum are torn through, the rent extending for  $3\frac{3}{4}$  in. antero-posteriorly through the cervix and lower segment on the left side. The placental site extends to near the rent anteriorly. This transverse rent has extended on the left side beyond the retraction ring.

The *fœtus* was L.O.A. with the head on the pelvic floor, partially rotated. The *caput succedaneum*, though prominent, has a narrow base.

As to the cause of rupture, there was no history of disease of the uterine tissue; former labours were normal—this one lasted only  $8\frac{1}{2}$  hours; there was no interference, and no pathological resistance. Spastic contraction (tetanus) of the uterus is the only explanation of rupture, in support of which are the long intervals between the pains, the rapid descent of the head to the pelvic floor without the patient's complaining of pain, and its remaining there for some time before death. The narrow base of the caput succedaneum, which from its position must have formed while the head was in the vagina, points to a rigidity of the vagina checking the advance of the head. The anterior incomplete rupture occurred first, and gradually; then followed the sudden rupture of the left side, which was carried above the contraction ring by the fœtus passing through the rent. The tetanus developed gradually during labour. The arrest was in the lower part of the vagina, because the upper part of the vagina was opened up along with the dilatation of the cervix. The anterior vaginal wall measures  $2\frac{3}{4}$  in.; the posterior,  $5\frac{1}{2}$  in. The anterior is less than Luschka gives for the non-pregnant vagina ( $4\frac{1}{2}$  in. to 5 in.); the posterior is elongated, but not



distended like the cervix. This is held to support the author's view that the vagina is active, not passive, in labour. The contraction of the vagina has also prevented the os from slipping up round the child's neck after the head has passed through it.

**E. PESTALOZZA** gives Sections from commencing Labour at full time, the Third Stage, the sixth month of Pregnancy, and the Third Stage with twins.

The first case (Plates I.-IV.) is a *VI.-para, æt. 37, who died a few days before full time, labour commencing*. Cadaver cut across above diaphragm, and frozen in a posture between upright and recumbent.

Plate I. is a Vertical Mesial Section, right half. The section passes slightly to the left of the middle plane behind and below, not passing through the coccyx. The *fundus uteri* reaches the upper margin of the first lumbar vertebra, and has intestines between it and the spine—probably due to semi-erect posture in freezing. The *rectum* is divided as it passes to the right of the middle line, the anus having been displaced in freezing. The *bladder* is contracted, thick-walled, triangular externally, cavity slit-like; it is behind the pubes, and has the utero-vesical peritoneum on it for 1 cm. The *uterus* is rotated to the right, the right ovary being in relation to the spine. The peritoneum, which is anteriorly 1 cm. below the pubes, rises at the sides up to 7 cm. above the same, leaving a triangular area uncovered at the sides of the uterus, extending 14 cm. above the os externum; posteriorly it descends to .5 cm. below the posterior fornix. A fold of peritoneum passes from the aorta at the level of the third lumbar vertebra to a coil of intestine which may favour the right obliquity of the uterus. The *uterine walls* are thinner at the lower segment; they measure 11 mm. at fundus, 7 mm. at placental site on anterior wall, and but 2 mm. at pubes; the upper limit of this segment is not well-defined. The os is dilated to 1.5 cm. antero-posteriorly, and 3 cm. transversely. The *membranes* are detached, anteriorly to 4.6 cm., posteriorly to 5.3 cm. from the os. The *liquor amnii* is meconium-stained, and forms a layer 1.2 cm. thick between the breech and the fundus. The *fœtus* is L.O.A. The chin is markedly flexed on the sternum, the head being inclined to the right as well as forwards, and the cord is round the neck; the vertical axis of the head is deflected backwards from the axis of the brim to 22°, the anterior ear being 2.4 cm. above the plane of the brim, and the posterior the same below.



Plate II.\* is a Vertical Mesial Section, left half, showing uterine cavity, with foetus removed. The *cavity* is 29 cm. vertically, 12.3 cm antero-posteriorly, and 15 cm. deep from the surface of the section (not mesial *quâ* the uterus) there is a slight prominence corresponding to the linea innominata; the axis of the abdominal part is parallel to the spine, that of pelvic to the axis of the brim. *Membranes* adherent except over os, as in Plate I.

Plates III. and IV. show the attitude of the foetus *in utero*. It forms an ovoid with slight depressions at the neck, and between the limbs. The head is asynclitic, while the back looks forward, and to the left; the occiput is between the right oblique and transverse diameters, being slightly rotated on the shoulders. The usual normal attitude of flexion is disturbed, in that the left arm is extended down the side, and the left leg semi-extended at the knee. The close relation of the foetus and the wall shows how much can be learned by palpation. The right shoulder, which, from the position of the foetus, should have been to the right of the symphysis, was by lateral deviation of uterus carried opposite to it. *The rotation of the head* on the trunk shows that the position of latter does not determine former. The flexibility of the cervical spine of the foetus prevents the rotation of shoulders from determining that of the head, as Olshausen has suggested. The position of the cord on the neck shows how it can be compressed by the finger on palpation, and thus a slowing of the foetal heart produced which can be recognised on auscultation. The presence of marked flexion before labour shows that this is not due to the resistance of the canals, but to the head's taking up the smallest space in the lower segment.

The second case (Plate v.) † was *a-para, æt. 38, who died of pulmonary oedema (nephritis and pleuro-pneumonia) immediately after the extraction by forceps of a still-born child*. The abdomen alone was frozen and in the upright posture; hence the abdominal walls have fallen forward, and the anteversion of the uterus has been exaggerated. The section is oblique, passing to the right of the mesial plane posteriorly. The *bladder* is behind the pubes, and elliptical from before backwards. The *uterus* is markedly ante-flexed, its posterior surface looking directly upwards, and on a level with the promontory. The *peritoneum* descends anteriorly

\* This section is reproduced (combined with Plate IV.) in the Author's *Atlas of the Anatomy of Labour*—Third Edition, Plate xxv., Fig 4.

† This section is reproduced in the Author's *Atlas of the Anatomy of Labour*, etc.—Third Edition, Plate xxvi., Fig. 4.



or 2.5 cm. upon the bladder, and within 4 cm. of vagina; posteriorly, it follows the marked inward folding of the posterior wall, and then descends to the level of the posterior fornix, within .25 cm. of the vaginal cavity. The uterus measures externally—vertically, 20 cm.; antero-posteriorly, 10 cm. The placenta is attached to the fundus, and the posterior wall to within 2 cm. of the lower segment. The wall at its site is 3 to 7 mm. thick, in contrast with the opposite wall, which is 25 mm. The lower segment has its fibres arranged in an undulating manner, is flaccid, more folded posteriorly. The *placenta* is sponge-like, rosy-red below, brownish above, and shows no signs of separation through its attachment of 21 cm. The *membranes* are separated over the lower segment, hanging in folds into the vagina, but still adhere to the rest of the uterus, though not everywhere, with equal firmness; the amnion is detached over considerable areas from the chorion. Microscopic sections of the wall show fragments of decidua over the lower uterine segment, and spaces with granular debris; above this the membranes are still adherent, with marked disturbance of the trabeculæ of the spongy layer, the amnion detached in places from the chorion, and raised in folds. Condensation of layers at placental site indicates approaching separation. The reduction in size of the uterus is here due to retraction, which has not specially affected the placental site and lower segment. A moderate retraction, such as usually accompanies the emptying of the uterus, is not sufficient to initiate separation of the placenta, if contractions do not intervene.

The fourth case (Plate IX.) is *a-para* who died from asphyxia due to swelling of the thyroid in the Third Stage of Labour, after delivery of twins by forceps and turning. The post-mortem revealed the dilated vessels of the thyroid at the sides of a cystic mass of colloid matter, and thus showed that an old-standing goitre may suddenly swell up by the congestion of labour so as to endanger life. The abdomen was frozen, and eight sections made in various directions, of which the vertical mesial is given.

Plate IX.\* shows a bulging of the pubes reducing the anatomical conjugate of 12.5 cm. to an obstetrical one of 11.5 cm. The *fundus* is at the level of the upper border of the fourth lumbar vertebra; the external measurement of the uterus is vertically 20.5 cm., and antero-posteriorly 12 cm. It rests on the spine. The *peritoneum* just touches the empty bladder anteriorly, being

\* This section is reproduced in the Author's *Atlas of the Anatomy of Labour*, etc.—Third Edition, Plate XXVI., Fig. 5.



4.5 cm. from the fornix; posteriorly it extends for 2 cm. on the vaginal wall. The *cervix* appears as if it had regained the form and disposition of its fibres present before labour, and the fornices are restored; its canal contains the two cords. The *uterine walls* are 10 to 20 mm. thick, where the placentæ are attached, increasing to 35 mm. anteriorly where there is no placenta. The thinner walls at the site is explained by the poorer development there before labour, and deficient contraction and retraction during it. The *coronary vein* is seen in section; its position corresponding to the firm attachment of the peritoneum. The *lower segment* measures 7 cm. anteriorly, and 4.5 cm. posteriorly. The two *placentæ* are attached over the fundus and lower segment, touching each other on the posterior walls; from this point rises a septum of *membranes* dividing the two sacs, and its folds fill up the space between the two placentæ, the uterine cavity being only potential; it passes to the anterior edge of the upper placenta. The two sacs are thus one above the other. The upper placenta extends also on to the left half of the uterus, while the lower is on the right half, extending on to the lower segment. The placentæ are still attached, and there was no bleeding before delivery, probably because the membranes were ruptured artificially at the commencement of labour. There is no sign at any point of the detachment of the placentæ, and no hæmorrhage, in spite of the great reduction of area through the removal of two fœtuses from the uterus. The *lower segment* is not folded, the lower placenta distending it, and by its attachment preventing its relaxation. Probably, there were some contractions of uterus after delivery, death not having been so immediate as in case 2. The differentiation between the upper and lower segments is not marked. The *rectum* passes to the right of the promontory, and the *urethra* is 4 cm. long.

J. C. WEBSTER gives Sections from the 1st, 2nd, 3rd, 4th, 6th, and 15th days of the puerperium.

The case from the 1st day has been already described in Chap. VII.

The case from the 2nd day—of which a vertical mesial (Plate IV.)\* and transverse (Plate V.) sections, and also pelvic contents seen from above (Plate VI.) are given—died of eclampsia thirty-six hours after delivery. The *pelvic diameters* are—anat. conj. 5 in., obst. conj.  $4\frac{5}{8}$  in., cavity  $5\frac{3}{8}$  in., outlet (sacral) 5 in. The length

\* This section is reproduced in the Author's *Atlas of the Anatomy of Labour*—Third Edition, Plate XXVI., Fig. 8.



of the *uterus*, externally, is 7 in.; internally it is  $6\frac{1}{8}$  in., the fundus being  $1\frac{5}{8}$  in. above the brim, the greatest thickness of the body being  $3\frac{3}{4}$  in. The greatest thickness of the anterior wall is  $1\frac{3}{4}$  in., of the posterior 2 in., of the fundus  $\frac{7}{8}$  in. No *lower uterine segment* can be distinguished. The *vagina* is 5 in. long, with walls apposed. The *bladder* is Y-shaped and behind the symphysis, and the urethra is  $1\frac{5}{8}$  in. long. The *peritoneum* descends in front of the uterus for  $2\frac{1}{4}$  in., and behind for 4 in. below the brim.

The transverse section through the first sacral vertebra and acetabula, shows that the *uterus* is rounded, and nearly fills the pelvis, its cavity being transverse. The *rectum* is a compressed slit to the right of the middle line. The *broad ligaments* have their layers separated and cellular tissue compressed between the uterus and the pelvis; the anterior layer of the left is opposite the posterior border of the acetabulum, and the posterior an inch further back; the right ligament is  $1\frac{1}{2}$  in. thick and slightly further forward. The right *ureter* is opposite the sacro-iliac joint; the left half an inch nearer the middle line. The *ovaries* lie just above the brim, the left being lower than the right. The *broad ligaments* lie in the iliac fossæ, the right beginning at the junction of the posterior part of the cœcum with the fossa, the left being continuous with the mesentery at the sigmoid flexure.

The case from the 3rd day—of which a vertical mesial (Plate VII.) and coronal section (Plate VIII.) are given—died on the 3rd day of acute yellow atrophy. The *pelvic diameters* are—anat. conj.  $5\frac{1}{8}$  in., obst. conj. 5 in., cavity  $4\frac{3}{4}$  in., outlet (sacral)  $4\frac{5}{8}$  in. The *uterus* measures externally  $6\frac{3}{8}$  in. long, internally  $5\frac{5}{8}$  in., the fundus being  $1\frac{3}{16}$  in. above the brim, and the greatest thickness  $3\frac{9}{16}$  in. The greatest thickness of the anterior wall is  $1\frac{7}{8}$  in., of the posterior  $1\frac{1}{2}$  in., and of the fundus 1 in. A *lower segment* is not distinguishable. The *vagina* measures  $2\frac{3}{4}$  in. long. The *bladder* is behind the pubes, with walls partly contracted, and is an oblong cavity at right angles with the urethra ( $1\frac{1}{2}$  in. long) entering its posterior end. The *peritoneum* descends for  $2\frac{3}{8}$  in. anteriorly, and  $4\frac{1}{8}$  in. posteriorly below the brim.

The coronal section which passes behind the acetabula and through the tip of the coccyx shows the pelvic cavity  $5\frac{1}{4}$  in. wide, of which the uterus occupies 4 in. The *ovary* is divided on the right side below the brim, the peritoneum dipping here  $1\frac{3}{4}$  in., while on the left it is reflected  $\frac{7}{8}$  in. below the brim. The left ovary (not seen in this section) was further forward and at a



higher level. The *ureter* is divided about  $1\frac{1}{2}$  in. below the brim and  $\frac{1}{2}$  in. from the pelvic wall.

The case from the 4th day—of which a vertical mesial (Plate IX.) \* and transverse (Plate IX.) sections, and also the pelvic contents, are described—died from Bright's disease about eighty hours after delivery. The *pelvic diameters* are—anat. conj.  $4\frac{1}{8}$  in., obst. conj.  $3\frac{7}{8}$  in., cavity  $4\frac{1}{8}$  in., outlet (sacral)  $4\frac{3}{4}$  in. The *uterus*, which measures externally  $7\frac{1}{8}$  in. long (of which  $5\frac{1}{8}$  in. is body and 2 in. cervix), internally  $6\frac{1}{4}$  in., and in thickness  $3\frac{1}{2}$  in., has its fundus  $1\frac{3}{8}$  in. above the brim, and is anteflexed. The greatest thickness of the anterior wall is 2 in., of the posterior  $1\frac{3}{4}$  in., and of the fundus  $\frac{7}{8}$  in. No *lower segment* can be traced. The *peritoneum* descends in front for  $2\frac{7}{8}$  in., behind for 4 in. below the brim.

The transverse section shows the *uterus*, which measures  $4\frac{1}{4}$  in. transversely, filling the pelvis, its cavity being a transverse slit of  $1\frac{3}{8}$  in., and the side walls  $1\frac{1}{8}$  in. thick. The *rectum* is to the right of the middle line. The *broad ligaments* have their anterior layer opposite the posterior margin of the acetabulum and are 1 in. and  $1\frac{5}{16}$  in. thick on the left and the right side respectively. The right *ureter* is opposite the sacro-iliac joint, the left being nearer the middle line. The *ovaries* are entirely above the brim, the left being slightly the anterior. The broad ligaments begin a little above the brim. The utero-sacral ligaments are at the level of the third sacral vertebra.

The case from the 6th day—of which a vertical mesial (Plate XII.) and four coronal (Plate XIII.–XV.) sections, and also the pelvic contents seen from above (Plate XVI., figs. 1 and 2) are given—died of acute lobar pneumonia. The diameters of the pelvis (justo-major) are—ant. conj.  $5\frac{3}{8}$  in., obst. conj.  $5\frac{1}{8}$  in., cavity  $5\frac{1}{8}$  in., outlet  $4\frac{7}{8}$  in. The *uterus* occupies the cavity of the pelvis, lying below the conjugate, and is markedly anteflexed. It measures  $2\frac{3}{16}$  in. antero-posteriorly. The greatest thickness of the anterior wall is  $1\frac{1}{2}$  in., of the posterior  $1\frac{3}{8}$  in. and of fundus  $\frac{5}{8}$  in. Neither cervix nor lower segment are defined. The bladder is Y-shaped, the limbs measuring  $2\frac{3}{8}$  in. and  $1\frac{1}{2}$  in., and the wall is very thin. The *peritoneum* descends for  $2\frac{7}{8}$  in. below the brim anteriorly, and  $3\frac{1}{2}$  in. posteriorly.

The coronal sections show that the *uterus* has rotated so that its right margin is lower than the left; it also lies nearer the right pelvic wall. The greatest transverse diameter is  $3\frac{3}{4}$  in. There is no trace to be found of a left ovary or left Fallopian tube,

\* This section is reproduced in the Author's *Atlas of the Anatomy of Labour*,—Third Edition. Plate XXVI., Fig. 9.



and the left broad ligament is less well-formed than the right, which crosses the brim about  $1\frac{1}{2}$  in. behind the middle of the ilio-pectineal eminence.

The case from the 15th day—of which vertical mesial (Plate XVII.) and transverse (Plate XVIII.) sections, and also pelvic contents seen from above (Plate XIX.), are given—died of heart disease. The *pelvic diameters* are—anat. conj.  $4\frac{7}{8}$  in. obst. conj.  $4\frac{3}{4}$  in., cavity  $4\frac{1}{8}$  in., outlet (sacral)  $4\frac{1}{2}$  in. The *uterus*, which lies well back in the pelvis and is retroflexed, measures in length  $3\frac{3}{4}$  in. externally (of which  $2\frac{1}{2}$  is body and  $1\frac{1}{4}$  in. cervix),  $3\frac{1}{8}$  in. internally, and  $2\frac{9}{16}$  in. in thickness. The *peritoneum* descends anteriorly for  $1\frac{3}{4}$  in., posteriorly for  $3\frac{3}{4}$  in.; the utero-vesical pouch contains intestines.

The transverse section shows a transverse diameter for the uterus of  $2\frac{5}{8}$  in., the uterus being separated from the pelvis by  $1\frac{1}{8}$ – $1\frac{3}{4}$  in. of soft parts over the acetabula—the anterior layer of the broad ligament not coming into the section. The ovaries are below the brim. The *broad ligaments* rise as mere ridges above the brim, the left for 2 in. and the right for  $1\frac{1}{4}$  in.

*Resumé.* At the beginning of the puerperium the uterus fills the pelvis, the fundus being  $1\frac{1}{4}$  in. above the brim or  $4\frac{3}{4}$  in. above the symphysis. The uterus is anteverted, there being no flexion between the cervix and the body. The lower segment is much shorter than during labour and best marked anteriorly; it is about half an inch long; posteriorly it is thicker, and passes more gradually into the upper segment. There is a well-marked retraction ring, not that of labour, but nearer the cervix, part of lower segment having been taken up into it. The cervix is thick, flattened vertically, and partly everted. The os internum cannot be defined even microscopically. The uterus is symmetrically placed in the pelvis: a higher level of the fundus to the right may give the impression clinically that the organ is to the right. There was no rotation in the frozen section, though Kehrer finds it in 30 p.c.

*After the first day.* The uterus is still abdominal on the fourth, and on the sixth just within the brim at the conjugate, but above it at the sides; by the fifteenth day it is entirely pelvic. The measurements are thus summarised:—

Cases.	Cervix.	Body.	Whole Uterus.	Cavity
Beginning of puerperium	—	—	$7\frac{7}{8}$ inch.	$6\frac{1}{4}$ inch.
2nd day    ,,	$2\frac{1}{8}$ inch.	$4\frac{7}{8}$ inch	$7\frac{1}{8}$ ,,	$6\frac{1}{8}$ ,,
3rd day    ,,	2    ,,	$4\frac{5}{8}$ ,,	$6\frac{3}{8}$ ,,	$5\frac{5}{8}$ ,,
4th day    ,,	2    ,,	$5\frac{1}{8}$ ,,	$7\frac{1}{8}$ ,,	$6\frac{1}{4}$ ,,
6th day    ,,	$1\frac{5}{8}$ ,,	$3\frac{1}{8}$ ,,	$5\frac{1}{8}$ ,,	$4\frac{3}{8}$ ,,
15th day   ,,	$1\frac{1}{4}$ ,,	$2\frac{1}{2}$ ,,	$3\frac{3}{4}$ ,,	$3\frac{3}{8}$ ,,



Frozen sections do not support the view that the uterus diminishes within the first twelve or twenty-four hours, but support Heschl's statement that there is little change till the fourth day. On section, there is the appearance of contracted and anæmic non-striped muscle, without any naked-eye appearances of fatty degeneration. The wrinkling of the peritoneum on the surface disappears on the sixth day, except beside the broad ligaments. The shape is pyriform, not more rounded posteriorly.

A drawing (Plate xx.) of the interior of the uterus three hours after delivery shows the appearances usually described. The placental site has an area of about  $11\frac{1}{2}$  sq. in. ; while the placenta (Plate xxi.) from the same case has an area of 28 sq. in.

The post-partum uterus acts as a plug in the pelvis. The ovarian and uterine arteries are twisted and compressed by the uterus against the pelvic wall, the uterus, with the exception of the cervix, being anæmic. The cervix is congested and will bleed easily ; the post-partum hæmorrhage from the torn cervix is most marked where the pelvis is large (because the uterus does not plug so efficiently) or contracted (because uterus cannot sink down). Barbour's and Stratz's Sections are cited in support of this.

The *bladder* returns to the same shape as before labour, but varies slightly in position. It may be lower than in pregnancy but never higher, as Croom affirms. The vagina is larger in its dimensions, and may return to its sigmoid shape in three days ; it has, in the early puerperium, its walls in apposition only above, and gaping below. The pelvic-floor projection is for the first day 2 in., for the second  $1\frac{7}{8}$  in., for the third  $1\frac{5}{8}$  in., for the fourth  $2\frac{1}{8}$  in., for the sixth  $1\frac{1}{2}$  in., and for the fifteenth 1 in. The broad ligaments are in the upper portion as in pregnancy, but below are shortened through the uterus extending between their layers almost to the pelvic wall. The ovaries from this lateral extension of the uterus come close to its wall, the ovarian ligaments being obliterated through their spreading out on the wall. Though this limits their movements, their position is variable. Haig Ferguson's statement as to the left ovary's being brought forward by a rotation of the uterus so as to be grasped in the Credé manipulation is criticised. The rotation of the uterus is insufficient to bring its transverse diameter into the right oblique of the pelvis ; and the ovaries do not take up positions corresponding to the rotation.

The *female pelvic floor* has been studied in twenty-one pelves—in the non-pregnant condition, pregnancy, labour, and the



puerperium. Hart's work on the pelvic-floor\* forms the basis of the investigation, and the views advanced by him and those of Symington are criticised. The term pelvic "floor" is not a good one, because the structures do not form a rigid partition, nor do they run transversely. The importance of dissection as against frozen sections is emphasised, and the pelvic fascia, the superficial fascia, and the pelvic floor muscles are fully described as studied by dissection. Further, the bladder and the vagina, on account of their attachments are held to be part of the floor, but the rectum is not. As to the uterus (in the foetus, child, and adult), it is in its cervical portion embedded in the pelvic floor so as to form part of it; and being suspended by its ligaments, resists intra-abdominal pressure, though not to the same degree as the fascia does. As to frozen sections, a vertical mesial gives a wrong impression: the floor is divided into pubic and sacral segments only by the width of the vagina. Hart's description omits the fascial frame-work; and the bladder is limited in its movements by its fascial attachments. The description of the pubic segment as resting on the sacral is not borne out by dissection. The bulging of the pelvic-floor in pregnancy is demonstrated by measurements (in a nullipara, and in pregnancy at the fifth, eighth, and ninth month) showing the skin distance from coccyx to symphysis, position of base of bladder, urethral orifice, cervix, and uterovesical pouch. As to the floor in labour, Hart's view as to the drawing-up of the pubic segment is confirmed, but qualified as to the amount of this. Measurements are given of the position of the same points in the First and Second Stages, and the following conclusions drawn: the pubic segment is not pushed down, but elevated, and that mainly by uterine traction, which works from the commencement of labour, but through opposing forces, does not raise the segment till the First Stage has advanced; in the Second Stage, the effects of this traction are more marked, and the advancing child compresses the pubic segment thus moved forwards, and the upward and forward resistance of the sacral segment increases this pressure; the bladder remains in great part behind the pubes (the urethra not being elongated) while its peritoneum is largely stripped off; the elevation of the pubic segment is retarded by a persistent bag of membranes; the sacral segment is driven down, and the parametric and paravaginal tissues are greatly stretched.

The relation of the floor to prolapsus uteri is also discussed.

\* See Part II., p. 48 of this book.



TESTUT and BLANC give sections of a *I.-para*, *æt.* 29, at the sixth month, who died in coma with eclampsia, the os being dilated to admit two fingers. The membranes had ruptured during a fit, and the head (L.O.A.) was felt resting on the os externum. The vessels were injected—arteries red, veins blue. The whole cadaver was then frozen in the horizontal posture, and a vertical mesial section made.

The *Atlas* contains six Plates,\* showing Sections of the whole cadaver, right and left halves; uterine cavity with foetus, right and left halves; the same, with foetus *in situ*.

In the description, instead of taking the individual plates, the authors describe the anatomical structures, maternal and foetal.

Omitting the muscles, nerves and vessels, thoracic organs and spinal column, which have no obstetrical bearing, we note that the *pelvis* is small in all its diameters, with traces of rickets, the intercrystal diameter being 27 cm., and the interspinous 22 cm. The anatomical conjugate is 10 cm., the obstetrical 9.5 cm. There is also slight oblique contraction, the right† oblique being 10.4 cm., the left 9 cm. The sacrum is asymmetrical—right half measuring 4.2 cm., the left 5.2 cm. transversely. There is a scoliosis with a lumbar curve to the right.

The *diaphragm* is at the level of the disc between the eighth and ninth dorsal vertebræ.

The *vagina* is sigmoid and almost at right angles to axis of brim. Its walls are 5 mm. thick, becoming 10 mm. at the vesico-vaginal septum. The *urethra* is 3 cm. long. The *uterus* is an ovoid, with the narrow end in the pelvis. The fundus is at the level of the lower margin of the fourth lumbar vertebra; the os internum at the level of the conjugate of the outlet. It measures vertically 24 cm., antero-posteriorly—8.3 cm. in pelvis, 10.8 cm. in abdomen.

There is no *liquor amnii*, the uterine walls being applied to the foetus.

The *placenta* is at the fundus on the posterior wall, its greatest thickness being 2.5 cm. The anterior wall bulges above the symphysis, the posterior not being moulded on the spine. The uterus is deviated to the right. The left half of the empty uterus shows the walls of the pelvic portion to be thinner (3 to 4 mm.)

\* Plate II., a Vertical Mesial Section of the whole body (combined with Plate VI., showing attitude of foetus), is reproduced in the Author's *Atlas of the Anatomy of Labour*, etc.—Plate xxv., Fig. 6.

† I.e. "right" in English nomenclature.



than the abdominal—which is thicker anteriorly (7 to 11 mm.) than at placental site (6 to 7 mm.). Its form suggests two ovoids apposed at the level of the brim, and thickening at their junction. The lower (pelvic) ovoid has 1·2 cm. soft parts in front, 2 to 3 cm. behind. The right half has a similar form; the abdominal portion is 18 cm. deep, making with 4 cm. of the left a total of 22 cm. for the breadth of the uterine cavity. The greatest cross diameter is not exactly transverse but oblique, through rotation of the uterus to the right. This rotation explains the oblique position of the foetus at the brim. The *placenta* and cord (13 cm. long) are chiefly in this part. The uterus is moulded on adjacent organs, while its axis, oblique to right in abdomen, becomes vertical in the pelvis.

The left broad ligament is normal, while the right is deficient in its anterior layer, which passes directly from the uterus to the iliac fossa. There is only a rudimentary round ligament and tube.

The relations of the uterus in the pelvis are—posteriorly, sigmoid flexure, first sacral vertebra, rectum with pouch of Douglas intervening; to the left, left broad ligament; to the right, promontory, first part of sacrum, sacro-iliac joint, posterior layer of broad ligament and cellular tissue; anteriorly, the bladder, which measures 10·2 cm. vertically (2·6 cm. being abdominal), and 1 to 1·2 cm. antero-posteriorly.

The *rectum* is, above, in its ampulla, 2·5 cm. thick, below, 1·2 cm. (the uterine wall being ·6 cm., so that soft parts here measure 1·8 cm.). The *bladder* is compressed antero-posteriorly (8 mm. behind pubes), and extends 2·6 cm. above, and 2·3 cm. below the symphysis.

The *foetus* measures 32 cm., and lies L.O.A. The head is markedly flexed on thorax. Its limbs are in flexion (except the extended fingers of the right hand) and compressed by the uterus. The head has undergone the first two movements (according to the French description of the Mechanism of Labour) owing to its smallness and the uterine contractions. It has descended to the floor, and turning towards the right, has slipped under the symphysis so as to leave a space behind as shown by the distended rectum.

Then follows in the text an anatomical comparison of this section with others from the 9th, 8th, 6th, 5th, 4th, and 2nd month. From these, the conclusion drawn is that when a woman is in labour, it matters not at what month of gestation, there is



present without doubt a *lower segment*, which is thinner and distended by the presenting part. The variability in presence of a *contraction ring* is explained by (1) the contractile energy of the uterus and the time during which it has been exerted; and (2) the relation of the wall to its contents. There must be a depression usually round the neck of the foetus, in which it may form. Unless death happens during a pain, no ring will be present except a retraction one.

The next division of the text is a comparison of the anatomical with the clinical *lower segment*. After referring to Fehling's, Bandl's, Martin's, and Bayer's results, Blanc gives his own observations. He finds the os internum 3·5 to 4·5 cm. above the os externum; if the distance is less, uterine contractions must have occurred. Above this, the finger feels an area (with membranes adherent over it, unless the cervix has been partially taken up by uterine contractions or the lower segment been unusually distended) which is regular, smooth, thin, and supple. Its upper limit is not marked by any muscular prominence but by the walls becoming thicker, resistant, and firmer. If the finger excites contraction, then Bandl's ring appears, and a pain is felt; but the lower segment is not affected by the contraction. These phenomena are noted best when there is moderate tension, the uterus contractile, and the presenting part not pushed down. A vertex presentation favours the early recognition of the lower segment. So does multiparity, unless the presenting part is kept from engaging. In labour, in primiparæ, the contraction ring rises to the upper border of the symphysis, embracing the largest diameter of the presenting part; in multiparæ it may be felt below presenting part—Bayer's "physiological stricture"—but as soon as pains are strong it rises to its normal position.

There is no ground for Acconci's view that the lower segment is present in the non-pregnant uterus, being defined by the firm attachment of the peritoneum. Clinical examination shows that it arises during pregnancy, and frozen sections show that the wall is not thinner here in early pregnancy; but Blanc has noted it clinically in cases of two and a half and four months' abortion. His conclusion is that the lower segment is present in pregnancy only from the eighth to the ninth month (perhaps the seventh in primiparæ); but in all cases of labour, early or late.

Under histological study of the lower segment, he criticises the four anatomical data of membranes, peritoneum, vessels, and muscle.



The *membranes* are not less firmly attached, unless contractions have been present, or the segment unusually dilated. The firm attachment of the *peritoneum* is an irregular line, and is absent at the sides of the uterus; nor is this firmness specially related to the insertion of muscular fibres into it, as these pass towards the mucous aspect as well. Further, the contraction ring varies in its position. As to *vessels*, the coronary vein is not constant. There are fewer arteries given off to the lower segment and their course is straight—not tortuous as in the body of the uterus; but there is no big branch at the contraction ring. In this, he agrees with Pestalozza, but differs from Hofmeier, who describes large vessels as beginning to be given off at the contraction ring. In describing the structure of the *muscular wall* he would distinguish preparations taken from cases of death before labour from those where contractions were present and the lower segment formed. In the former, the wall may be thinner, but shows no other difference. Of the latter, his own case is an example. A section of the wall teased out from below upwards shows—first, 4 cm. of dense tissue (cervix), and then, 6 cm. of parallel plates united by oblique septa into lozenge-like figures. The superficial plates spring from the peritoneum, can be isolated for 4 to 5 cm., and are then lost in the cervix; the deeper ones are not related to the peritoneum, but run from the cervix into a compact, dense, inextricable web of the muscular tissue of the body. A microscopic section shows a great predominance of longitudinal over transverse fibres and a smaller number of cellular fibres than in the body. The elastic tissue described by Acconci could not be made out on account of the prolonged freezing.

**PINARD and VARNIER** have published a beautiful Atlas of Obstetrical Anatomy, containing forty-four coloured plates, fifteen phototypes, and thirty-one explanatory diagrams. The sections are taken from the following cases—(1) Vertical Mesial of uterus and vagina of I.-para who died immediately after extraction of foetus (Plates I. and II.); (2) Vertical Mesial Section of the uterus, and one 1.5 cm. to the right, of a multipara, who died before the extraction *per vaginam* of triplets alive at full time (Plates III. and IV.); (3) two Sections of the uterus, to the right of the mesial plane (Plates V. and VI.) from a case of I.-para at full time, with eclampsia delivered by Cæsarean Section; (4) Vertical Mesial Section of the uterus, and another 1 cm. to the right, from a I.-para delivered at eight and a half months by



Cæsarean Section (Plates VII. and VIII.); (5) Vertical Mesial and Coronal Sections of uterus (Plates IX. and X.), from a multipara who died immediately after expulsion of the foetus; (6) Vertical Mesial Section of uterus and vagina (Plates XI. and XII.) from a I.-para who died thirty-nine hours after a three and a half months' abortion; (7) Coronal Section of a bicornous uterus (Plates XIII. and XIV.) from a I.-para who died of septicæmia six days after abortion at six and a half months; (8) front view and various sections (Plates XV.-XXII.) of an extra-uterine intra-ligamentous pregnancy, with rupture of the cyst at the seventh month, extraction of foetus by laparotomy, *in extremis*—the placenta being left; (9) Vertical Mesial Section of pelvis (Plates XXIII. and XXIV.) of a I.-para who died from strangulated hernia when two and a half months pregnant; (10) Vertical Mesial Section of four and a half months' ovum with pelvic presentation (Plate XXV.); (11) three and a half months' abortion with meningo-encephalocele from amniotic band (Plate XXVI.); (12) Twins—one dead, with digital malformation from amniotic band (Plate XXVII.); (13) Vertical Mesial Section of uterus and foetus (Plates XXVIII. and XXIX.) from a multipara, dying of internal and external hæmorrhage, with premature separation of placenta due to short cord; (14) Vertical Mesial Section and foetus (Plates XXX. and XXXI.) from a I.-para who died from eclampsia in the seven and a half month of pregnancy—head transverse, and to the left, and inclined on the parietal bone; (15) Vertical Sections, slightly to right and left of mesial plane, also uterine cavity and foetus (Plates XXXII.-XXXIX.) from a II.-para who died suddenly in the eighth month of pregnancy, head not engaged, lying L.O.A., and inclined on the posterior parietal bone; (16) Vertical Sections to the right and slightly to the left of the mesial plane, transverse section about the level of the brim, and foetus (Plates XL.-XLVIII.) from a I.-para who died from eclampsia about the eighth month, labour commencing, vertex presentation directly posterior.

In the descriptive text there are—first, *General Considerations on Parturition*. As regards the relation of placenta to uterine wall in pregnancy, the authors have examined thirty-seven anatomical preparations, and found the placenta on the posterior wall in twenty-two, on the anterior in twelve, on the fundus in one, on the right wall in one, on both walls one (triplets). (Plates XXXII. and XXXVIII. and frozen sections by others show that the wall at the placental site is thinner than elsewhere; and Plates XXIII. and XXIV. demonstrate that the thinness is present from early pregnancy.



During labour, before the foetus is expelled, the placenta does not separate (Plate XL.) After the expulsion of the foetus there is no cavity in the uterus (Plates I., IV., V. and VII.) The uterine walls do not thicken equally, the placental site remains thinner, the placenta being embedded in the uterine wall (*enchatonné*) further, the placenta becomes thicker, bulges, but does not yet separate. When separation begins, it is at the margin (Plate III.), and is due to elasticity, retractility, and contractility of the muscle. The term *enchatonnement* of Leveret may be retained, if we understand by it, not that the placenta is shut in by spasm, but “set” or embedded in the wall. As regards the membranes in labour, the decidua may not separate round the os internum; the chorion leaves it behind. The amnion may slide on the chorion and appear at the vulva leaving the chorion behind. Their preparations show that they do not separate, as a rule, till after the placenta. The placenta coming into the lower segment, makes the fundus rise 3 to 4 cm.; this is the average of 1000 cases studied clinically. The placenta presented (out of 1000 cases) in 789 by foetal aspect, in 166 by border, and 45 by uterine aspect. Plate IX. shows that Baudelocque’s description of the presentation of the placenta by the cord was correct.

Then follows the description of Plates I. to XXVII. Plates I. and II. show sections of the uterus removed from the body of a primipara with hæmorrhagic scarlatina, who died immediately after the extraction of the foetus by forceps.

The *uterus* consists of two parts, an upper and a lower segment—the former enclosing the placenta not separated on the anterior wall and fundus. The membranes are folded and undergoing separation. The vagina has its walls in apposition below; above, they are separated by a packet of membranes; anterior wall 9 cm. long, posterior 11·8 cm.; the vaginal portion of cervix is thicker behind than in front. The *uterus* is 19·5 cm. long, of which 5 cm. in front and 5·5 cm. behind is cervix. The firm attachment of peritoneum is 3·3 cm. above the vesico-uterine pouch, and 5 cm. above pouch of Douglas or 6·3 cm. and 6·6 cm. above os externum. Thickness of walls: anterior—at cervix 1 cm., os internum ·6 cm., just above it ·3 cm., at firm attachment of peritoneum 1·4 cm.; in the upper segment it varies from 1 cm. in lower part of anterior wall, 2·2 cm. in its middle, ·2 cm. beneath the placenta, and 1·2 cm. below it posteriorly. In spite of the reduction of its site produced by retraction, the *placenta* is not separated; it has been able without letting go its hold to



accommodate to this reduction by folding itself on its foetal aspect, by making its borders project—which from being mere lines in the gravid uterus have become thick and rounded—and by bulging towards the uterine cavity instead of towards the uterine wall, as in pregnancy. The *membranes* do not appear as a mere line as in the gravid uterus, but are folded into a layer 2 to 8 mm. thick.

Plates III. and IV.\* are sections (mesial and 1·5 cm. to the right) of the uterus with placenta from triplets. The patient was at full time, became suddenly cyanotic, and collapsed during the first stage, and died; three living children were extracted by turning. The post-mortem showed the arteries of the heart almost obliterated by endo-arteritis with increase of connective tissue, but no fatty degeneration of the muscle.

The *uterus* is 33·5 cm. long, of which 5·5 cm. is cervix, the os internum being marked by a slight bulging. Cervix *plus* lower segment (measured to where walls thickened, as peritoneum not noted) 9 cm. anteriorly, 10 cm. posteriorly. *Thickness* of walls: anterior—at cervix, ·4 cm., at os internum ·5 cm., at bulging, 1·8 cm., and above this, 1·4 cm.; posterior—at cervix, ·3 cm., at os internum ·5 cm., at bulging 3·2 cm. (vessel here); above this, 1·7 cm.; in the body of the uterus, the wall is thicker anteriorly, becoming 3·2 cm. near the fundus, thinning to ·7 cm. at placental site, where it is attached, and thickening again (1·2 cm.) where it is separated. There is a large *placental mass* (with two cords passing from it on the posterior wall) measuring 23·5 cm. vertically, and 2 to 3 cm. thick, attached throughout above, but separated below for 2 cm. The uterine wall (3·2 cm.) becomes ·7 cm. where placenta is thickest. It is folded, thickened, and has its borders projecting. The section to right of middle line shows the *third* placenta on the anterior wall, measuring 13·2 cm. vertically, and 2·7 cm. thick. It is not separated, but has its borders projecting, especially the lower.

Plates v. and vi. are two sections of the uterus, with placenta from a I.-para, who died at term of eclampsia, the os being dilated to the size of the palm and the membranes ruptured. Cæsarean Section was done *post-mortem*, but the child was dead.

The *uterus* is 31 cm. long and 8 cm. antero-posteriorly; retraction has not affected its length much. The os internum is 4·5 cm. from the point of the cervix, the *bladder* being in relation to the lower segment for 2·8 cm., and vesico-uterine pouch 5·6 cm. from

\* Reproduced in the Author's *Atlas of the Anatomy of Labour*, etc.—Third Edition, Plate xxvi. Fig. 6.



anterior fornix. The *placenta* is on the posterior wall, but extending in part on to the anterior. The *wall* is thinner (.5 cm.) where the placenta is attached, thicker (1.56–1.7 cm.) where “work of separation is in great part accomplished.” The placental mass is thick below, but very thin above at the fundus where it is bent on itself.

Plates VII. and VIII. are two sections of the uterus with placenta from a I-para who died in coma, at eight and a half months, with premonitory symptoms of eclampsia, epileptiform movements of arms only, and no albuminuria. She was delivered by Cæsarean section post-mortem; child living, but died in two hours. No description of plates is given, but they show the placenta attached to posterior wall and fundus, thickened and bulging markedly below its lower border, and the wall thinnest at its site.

Plates IX.\* and X. show vertical and transverse sections of the uterus and placenta from a V.-para, kyphotic and at full time, who died shortly after the natural expulsion of the foetus. There were convulsions, coma, and bleeding from the vagina, before death. The post-mortem showed a longitudinal tear of the lower segment with considerable sub-peritoneal extravasation into the right broad ligament, and extending upwards into the iliac fossa. Before freezing the uterus, it was noted that the cord was presenting.

The *uterus* measures 21 cm. long, and 8.7 cm. antero-posteriorly above contraction ring, falling to 8 cm. above and below it. The firm attachment of peritoneum is distant from os externum 9 cm. anteriorly, and 11 cm. posteriorly. The *placenta*, which was attached to anterior wall, lies inverted in the lower segment distending it, and presents by the cord at the os externum, which is dilated to 1 cm. There is a cup behind the placenta filled with blood, measuring 6.5 cm. deep, and from .9 to 2.4 cm. across. Thickness of walls: anterior—in lower segment .5 cm., at firm attachment of peritoneum 3 cm., in body 2.6 to 3.6 cm.; posterior—in lower segment .5 cm., at firm attachment of peritoneum 3.6 cm., in body 4.2 to 4.4 cm.

This preparation shows that the placenta pulls on the membranes so as to detach them, that the os may have to dilate a second time to let it pass, that the distended bladder will impede the passage, that pressure on the fundus will favour its expulsion, and that the descent of the placenta to the lower segment produces an elevation of the fundus.

\* Reproduced in the Author's *Atlas of the Anatomy of Labour*, etc.—Third Edition, Plate xxvi. Fig. 7.



We pass over *post-partum* uteri after three and a half months' abortion (Plates XI. and XII.), and six and a half months' abortion from one horn of a bicornous uterus (Plates XIII. and XIV.), a sub-peritoneal extra-uterine gestation at seven months (Plates XV.-XXII.), a two and a half months' pregnant primipara, dying from a strangulated hernia (Plates XXIII. and XXIV.), a four and a half months' ovum, with breech presentation (Plates XXV.), and foetal malformations with amniotic bands (Plates XXVI. and XXVII.)

Plates XXVIII. and XXIX. are frozen sections of the uterus from a patient who died from hæmorrhage when eight and a half months pregnant. The *placenta* is entirely separated by a large retro-placental clot; the cord is 35 cm. long, taut round the neck, and evidently exerting traction on the placenta; *fœtus* is *in utero*, the *liquor amnii* absent, and the *membranes* ruptured artificially. The os is only slightly dilated.

"The *engagement and descent of the head in normal pelves*" is discussed in the descriptive text in reference to the remaining sections. The authors propose to demonstrate that according to the anatomical hypothesis of Farabœuf, formulated and figured in 1886, the mechanism of the engaging of the head in normal pelves is almost identical with that in the rickety. In the latter, the head is transverse, *slightly* flexed, so that the finger touches with equal ease the two fontanelles; and, as the uterine axis is less oblique than that of the brim, the axis of the head does not correspond with the latter, but the sagittal suture is nearer the symphysis; the anterior parietal bone overhangs and projects beyond the symphysis, so that it is inaccessible through its greater extent; while the posterior parietal, which alone occupies the superior strait, can be reached and touched throughout up to the ear. Smellie's description of the position of the head at the commencement of labour in a normal pelvis is quoted—flexion, with a transverse position; inclination of the posterior parietal, at least after rupture of the membranes; the uterine axis remaining backwards; the head upon the pubes; the mechanism of engaging gradually correcting this posterior inclination. "There was little to add to this description to make it true," and the question seemed settled after Solayres and Saxtorph demonstrated the engagement in the oblique diameter. Nagele's view overturned this by stating that the anterior parietal bone presented. Baudelocque and La Chapelle contradicted this. While Dubois admitted a slight obliquity, Moreau regarded it as anomalous.



The source of error for these fifty years was the regarding of the foetus as a solid whole, the deviation of the trunk being thought of as necessarily followed by a corresponding one of the head. Smellie's representation of the long axis of the uterus as parallel to the spine was also disregarded. The more modern views of Duncan, Leishman, Tarnier, Küneke, and Schroeder are stated. Barnes' description of the double curve is accepted, but the inclination on the anterior parietal is disputed by the authors. The frozen sections of the authors demonstrate that the axis of the uterus does not coincide with that of the pelvis; that the head is not synclitic, but inclined on the posterior parietal bone; that "engagement" is a correction of the inclination, the retarded parietal bone descending, and the sagittal suture reaching the axis only when the engagement is complete. Thus, synclitism is produced in the lower part of the pelvis, and exists only temporarily in passing from the posterior asynclitism to the anterior one, which occurs at the end of descent and before rotation.

As to the *inclination of the uterus*—in the dorsal posture in which most observers have placed the cadavera, there is no parallelism of the uterine and the pelvic axis; the axis of the body of the uterus is always more or less inclined backwards. All the sections which have been made during the last three months of pregnancy, and during labour at full time or premature, show this; the axis is not straight, but a curved line moulded on the spine (*cf.* Plates XXX. and XXXII.). These sections show also that we must not consider head and trunk as being in a straight line.

As to the *inclination of the head* before engagement, it is not synclitic but inclined on the posterior parietal. The sincipito-facial axis crosses obliquely the axis of the superior straight; the chin is behind, the sagittal suture in front (*i.e.* the fronto-mental diameter is oblique to the axis of the brim, its mental end being behind and its frontal end forwards). The latter is also nearer the symphysis than the promontory. While the posterior parietal eminence is engaged, the anterior is above the brim; the posterior ear is at or below the promontory, the anterior is several cm. above the symphysis (*cf.* Plates XXX. XXXI. and XXXII.)

As to *engagement and descent*, engagement is made, and only made, by the progressive destruction of this inclination; it is complete when the anterior eminence is in the plane of the brim. During engagement and descent, until the vertex is on the perinæum, it



is the anterior eminence that leads. Compare Zweifel and Braune's section, in which the head is engaged and inclined on the posterior parietal bone, the anterior ear being above, while the posterior is below the plane of the brim. The posterior inclination of the uterus is less marked because the abdominal wall is insufficient as a support. In Winter's section of placenta prævia, the head is more engaged, but still inclined on the posterior parietal bone, the sagittal suture being in front of the axis; the head is transverse and to the right. In Barbour's First Stage Section, the inferior asynclitism is present and at its maximum, the anterior eminence being on a level with the outlet, but the posterior in the upper part of the cavity. A diagram is given of these three sections super-imposed to show the mechanism. Barbour's Second Stage Section is cited as showing the commencement of an oscillating movement which without rotation would allow the posterior eminence—moving alone and pivoting round the anterior (which is fixed under the arch)—to sweep round the sacral concavity, push back the coccyx, and pass over the distended perinæum.

Plates XXX. and XXXI.\* are vertical mesial sections and foetus from a primipara, aged 21, who died at the seven and a half month of pregnancy from eclampsia. Only the bones and the uterus are detailed in Plate XXX.

The *pelvis* has an anatomical conjugate of 12 cm., an obstetrical of 11.1 cm. The *uterus* is kidney-shaped with the hilum at the promontory; anteriorly it is in relation to the abdominal wall for 12.2 cm. above the pubes, where it leaves it, the omentum and colon coming between. The fundus is at the level of the third lumbar vertebra. The posterior wall rests on the spine, but the lower pole is nearer the symphysis than the sacrum, the space between posterior wall and the fourth sacral vertebra being 5 cm. The uterus is markedly inclined to the right. The *placenta* extends over 18 cm. of the anterior wall, its site being thicker (7 to 8 mm.) than the wall at the fundus or posteriorly; this is partly due to hæmorrhages.

The *fœtal* head is transverse and to the left, the posterior parietal bone presenting. The anterior ear is 3.5 cm. above the pubes and .8 cm. to left of middle line; the posterior is a corresponding distance to the right and below the promontory. The head is inclined on the posterior shoulder.

Plates XXXII.-XXXIX. are vertical sections of a II.-para, who

\* Reproduced in the Author's *Atlas of the Anatomy of Labour*.—Third Edition, Plate xxv. Fig. 1.



died suddenly in the eight month of pregnancy. She had no previous symptoms except a slight albuminuria, when she was seized suddenly with a convulsion and died. The whole cadaver was frozen, and the thorax and legs cut off. A vertical mesial slab, 1 cm. thick, was cut out. Plate XXXVII.\* shows the *fœtus in utero*.

The *vagina* extends upwards and backwards parallel to the brim— anterior wall 4·4 cm., posterior 9·2 cm. long. The *uterus* measures vertically 25 cm., the fundus being at the level of the middle of the first lumbar vertebra; its antero-posterior diameter diminishes from below upwards, being 10·8 cm. across the lower segment, 9·6 cm. at the promontory, 9·1 cm. opposite the fifth lumbar, and 9·5 cm. towards the fundus. In form it resembles a kidney with the anterior border applied to the abdominal wall up to 21·8 cm. above the pubes, where colon and omentum intervene, the hilum opposite space between fourth and fifth lumbar vertebræ. The posterior border is applied to the spine above, but leaves a considerable space between it and the sacrum below occupied by the rectum and fat. The uterus is retroverted, *qua* the axis of the inlet, and rests on the supporting pubes. Thickness of walls: lower segment—anterior 3 mm., posterior 6 mm.; body—anterior 5, posterior 2–4 mm. (placental site); fundus, 6 mm. (under placenta 3 mm.). The *bladder* is an ovoid pointed anteriorly, compressed between the uterus and the pubes, and measuring 6·5 cm. in vertical diameter, its wall varying from 3 to 9 mm. in thickness. It rises 1·9 cm. above the pubes (of significance for Cæsarean section). The *peritoneum* descends for 2·7 cm. between the bladder and uterus, but not below the level of the symphysis, and for 1·2 cm. on the posterior vaginal wall. Three deposits of *cellular tissue* are noted anteriorly: the space of Retzius above the symphysis; a “pre-vesical” space extending from between the bladder and the pubes upwards to the umbilicus; and a vesical space, triangular in form, extending from immediately above the bladder for 12 mm. (significant for symphysiotomy).

The *fœtus* has its head well flexed on the thorax (Plate XXXIII. and XXXIV.); and the section passes through the pavilion of the right ear, but 2 cm. in front of the left. The head is not engaged, the right parietal eminence being above the brim. It is asynclitic posteriorly; without this asyncliticism being undone, it cannot engage. The right leg is markedly flexed, the knee being separated

\* Reproduced in the Author's *Atlas of the Anatomy of Labour*, etc.—Third Edition, Plate xxv. Fig. 2.



from the cheek by the right hand alone; the left leg is flexed at the hip, but extended at the knee, the foot indenting the left cheek. The back looks forwards and to the left, while the occiput is more towards the transverse. The axis of head and trunk form an angle open backwards, but the posterior (left) ear is further from the corresponding shoulder than the anterior, the head being inclined on the anterior shoulder. Plate XXXVI. is the right face of the slab, and Plate XXXVII. shows the rest of the foetus placed on it to show position *in utero*. Plates XXXV. and XXXVIII. show the uterine cavity with placenta on the posterior wall, and Plate XXXIX., the attitude of the foetus.

Plates XL. to XLVIII. are vertical and transverse sections of a I.-para who died from eclampsia about the eight month. The foetus is a vertex presentation R.O.P. The cervix was taken up but the membranes unruptured. The body was frozen in the dorsal posture; and, in addition to two vertical sections, a transverse one is given about the level of the brim.

Plate XLII. is a section slightly to the left of the mesial plane. The *vagina* has the anterior wall short and folded, the posterior one curving round the projecting cervix. The *cervix* looks not backwards but downwards and forwards, hence the more rapid taking-up of the posterior lip; the os internum is dilated to 5.5 cm., and is distant from the os externum 3.2 cm. in front, and 5 cm. behind. The *membranes* are free over the dilated cervix, but become attached a few mm. above the os internum. The wall of the *cervix* is 4 mm. thick anteriorly at os internum, 2 mm. over anterior fornix, 7 mm. in anterior lip, and thins from that down to 2 mm. posteriorly at os internum. The wall of the lower segment is uniformly thin in front (3 mm.); behind it falls from 5 mm. to 2 mm. at the os internum. The head of the *foetus* is cut almost sagittally, being directed towards the sacrum; it is extended (Plate XLIII),\* the chin being 3 cm. off the chest, and the occiput forming an angle with the back—open posteriorly. The anterior fontanelle is lower than the posterior, but is against the pubes, while the posterior is in the concavity of the sacrum. The vertex presents. The head is engaged, but not completely; it is asynclitic posteriorly. The occipito-frontal plane, which is engaging, is posteriorly below, anteriorly above, the plane of brim. The head is remarkably moulded, the maximum diameter being 13 cm., the occipito-frontal 8.3 cm.,

\* Reproduced in the Author's *Atlas of the Anatomy of Labour*, etc.—Plate xxv. Fig. 5.



and the sub-occipito-bregmatic 9·5 cm.; the increase in the maximum is partly due to a cephal-hæmatoma which has formed before the cervix is taken up and the membranes ruptured. The soft parts of the mother reduce the canal much more than is generally believed; from the obstetrical conjugate of 11·3 cm., we must deduct 3 cm. for soft parts which had left a depression on the foetal head. The occipital and frontal bones are depressed below the parietals, and the frontal also below the temporal. (Plates XLIV. and XLVII.).

Plate XL. is a vertical section to the right of the mesial plane. The *uterus* measures vertically 26·5 cm.; its antero-posterior diameter increases from below upwards from 9·2 cm. in upper part of lower segment to 12·8 cm. near the fundus. The inferior segment is very thin—2 mm. anteriorly, and 3 to 5 mm. posteriorly. The rest of the body is 4 to 5 mm. thick, except where placenta is attached (posterior wall and fundus), where it is 2 mm. The section of the whole uterus is kidney-shaped, with the hilum on the fifth lumbar; above, it is moulded on the spine and in contact with the abdominal wall; below, it is applied to the anterior wall of the pelvis (the bladder between) while, behind, it comes away from the sacrum, leaving a considerable space occupied by the rectum and connective tissue. The *bladder* is flattened between the uterus and the pubes, extends 2·3 cm. above the level of the pubes; it measures vertically 7·5 cm. Its *bas-fond* is attached by lax cellular tissue to anterior vaginal wall; its posterior wall to the cervix and to 2·5 cm. of the lower segment and has peritoneum on it for 1·2 mm. The bladder is separated from the pubes by the pre-vesical space. These relations are described in connection with symphysiotomy.

Plate XLVIII. shows the attitude of the *fetus*. The head is slightly rotated on the trunk, so that while the back was to right and posterior, the occiput was turned more to the hollow of the sacrum. The left ear is nearer the corresponding shoulder, forming an angle open to the front.

**ZWEIFEL** gives sections from two unique cases—of rupture of the Uterus, the child's head only being born; and of placenta prævia, the child turned, but not delivered. In both cases, only the pelvis with genital organs could be removed and frozen.

In Case I. he made a vertical mesial (Plate I.) and two right lateral-



sagittal sections, (Plates II. III., and IV.,)\* transverse sections of the left half in the plane of the brim (Plate V.) in a plane parallel to it 1 cm. below the lower edge of the symphysis, and that of the outlet—sacrum (Plate VI.). Casts were also taken of the canal.†

In Case II., besides the vertical mesial (Plates VII. and VIII.),‡ cross-sections (Plate IX.) were made in the plane of the *linea innominata* (a line running from the upper edge of the symphysis to the tip of the fifth lumbar spine just hits this plane), one in the second parallel plane (Plate X.), and another (Plate X.) in the plane of the outlet (sacrum). Photographs were made of these sections to guide the drawing.

The case of rupture was in a VII.-para, æt. 38, who died of eclampsia near full time. She was semi-comatose on admission, had no albumen in the urine, but had an eclamptic fit in labour; and the *post-mortem* showed opaque, yellow-white patches of the necrosis of liver tissue present in eclampsia. There was also a purulent discharge from the left nostril. The head had begun to appear at the vulva when the patient died, and it was fully born on moving her. There was a considerable amount of blood in the abdominal cavity *post-mortem*, which made rupture to be suspected before the parts were frozen. The child had died *in utero*, probably from the eclampsia. As to the rupture, though Werth says that the human uterus is not capable of prolonged action after death, Zweifel ascribes it to *post-mortem* contractions, for, unless the rupture had occurred after death, the head would not have been born. The purulent discharge from the nose (found *post-mortem* to have come from the antrum of Highmore, while there was also pus in the left frontal sinus) is noted as of significance in connection with eclampsia, as also the liver changes.

The case of placenta prævia was in a primipara, æt. 30, who had had hæmorrhages a month and a fortnight previously, then a severe one which called for the plugging of the vagina on admission to hospital. She was profoundly anæmic, and transfusion with salt solution gave no relief. The cervix was dilated with

\* Which with the lateral section given in Plate II., with the parts of the foetus removed to show the rupture, is reproduced in the Author's *Atlas of the Anatomy of Labour*.—Third Edition, Plate xxvi. Fig. 3.

† Photographs for a stereoscope are given.

‡ Plate VIII., which is the section given in Plate VII. with the parts of the foetus removed to show the parturient canal and the placenta, is reproduced in the Author's *Atlas of the Anatomy of Labour*.—Third Edition, Plate xxvi. Fig. 1.



the hand, which came upon the placenta lying separated to a great extent. The child was turned, but not extracted, as its peeling leg showed that it had been dead for some time. No hæmorrhage occurred during turning, and death was set down to anæmia, which a post-mortem confirmed. The organs were not only blanched, but oedematous from the salt solution: hence the conclusion that if the "air-hunger" persists after transfusion with salt solution, transfusion of human blood will alone be of use.

In the anatomical description of the preparations it is noted that both cases show the parturient canal dilated even to the vulva. The *vagina* is stretched and smooth, also laminated, so that the epithelium is easily separated from the connective tissue. Under the surface are numerous clefts, formed by compressed vessels. The rarity of vaginal hæmorrhage may be due to its elasticity. The *os externum* stands remarkably high, its anterior end being in both cases opposite the upper third of the symphysis, and its posterior opposite the upper margin of the second sacral vertebra in the rupture case, and opposite the cartilage between the second and third in the placenta prævia. In the latter, the *os externum* hangs as a fold on the right side, but is fully taken up on the left. The *os internum* is, in the second case, easily recognised as a fold running at the level of the promontory, with no vein at it, but with cervical mucous membrane below and decidua above; and membranes are attached up to it on the right side. In the first case, its position can be decided only by the attachment of the membranes. This is distant from the *os externum*, on the anterior wall, 7.5 cm.; and the same distance measured on the posterior wall brings us to the seat of rupture. The measurements of the *pelvis* during life showed an external conjugate (from the upper edge or the symphysis) of 19 cm. for both cases; while the true conjugate on the Frozen Section is, in the two sections respectively—anatomical, 11.4 cm. and 11.3 cm.; obstetrical, 10.5 cm. and 10.7 cm.

In Plates I. and II., the perineum is less stretched than it would be by the passage of the head, and the bending back of the coccyx is slight. The *vagina* is continued into the cervix without the wall becoming thicker. The *os externum* is in front, 1.7 cm. below upper edge of symphysis; behind, between first and second sacral vertebræ. The posterior wall of the *uterus* is unusually thick behind, and ruptured in its lower part. The trunk of the *fœtus* is slightly curved round the pubes, and measures 8.6 cm. to 9.9 cm. posteriorly; in the bony pelvis there is room for dilated intestine



behind it, but lower down the pelvic floor compresses it firmly; the thorax is squeezed so that the ribs are pushed in, showing the pressure exerted by the vagina. In Plate II., the retracted *uterus* above the child is the great feature, the posterior wall being very thick above, and very thin at the innominate line.

Plate III. shows the *uterine cavity*, right side, with rupture and the markedly retracted fibres of the body torn away from the cervix. The rupture is due to retraction, the uterus tearing itself. It is just above the ileo-psoas, where the latter ceases to be a support to the uterine wall. There is no evidence of fatty degeneration of the muscular fibre, nor of coagulation (necrosis). The *peritoneum* was separated from the muscle for some distance like a fringe. In Plate IV., the section passes through the right horn of the uterus, with a considerable part of the placenta in it.

Plate V., in the plane of the conjugate of the brim, shows the *bladder* compressed, and the position of the spine of the *fœtus* at this level. Plate VI., fig. 7, gives the section through the parallel plane—slightly above it, anteriorly. The *fœtus* is here surrounded by the vagina, and the spine is turned further forward  $5^{\circ}$ , from the last section. Plate VI., fig. 8, in the plane of the outlet, shows the obturator fascia distinctly, and the pressure which the levator ani, obturator, and pyriformis muscles exert on the child's ribs.

Plate VII. is the right half of the vertical mesial section, from the case of placenta prævia. The *bladder* extends above the brim, and is compressed, and the *rectum* drawn out. The coccyx is unusually thick and long. Plate VIII. gives the left half without the child. The *os internum* is a hand's-breadth above the symphysis; this is the same position as in Braune's section, and he is therefore right in calling it the "*os internum*."\* The *placenta* is separated to a considerable extent, and is not compressed by the *fœtal* parts against its site, and yet the bleeding stopped as soon as the child was turned. There were only 50 ccm. of bloody *liquor amnii* in the uterus. Plates IX., X., XI. are sections, in the right half, through the planes of the innominate line, the cavity, and the outlet.†

Under the "*Mechanism in the Passage of the Shoulders*," Fehling's defence of Olshausen's view, "*ut dorsum primum motum sit*," is criticised. According to him, rotation can occur with the head in

\* "All explanations trying to smooth away the *os internum*'s standing so high must be dumb before the facts."

† Note the thickness of the soft parts in the oblique diameters; the *peritoneum* is not shown.



any part of the canal. Zweifel's cast of the foetus shows that the longest diameter of its trunk runs antero-posteriorly, not across the shoulders. Further, the mobility of the head on the trunk is against this view. In the placenta prævia section, the back is, in the fundus, almost exactly to the left; while, lower down, it is rotated so that the shoulder-blade is anterior. This twisting of the body must be the result of the form of the lower part of the canal. The "rolling" motion of the head also shows its mobility; it is more correct to speak of the advance of one part of the head beyond another as a "rolling" than as a "rotation"—as the latter suggests a fixed axis without forward motion. The Frozen Section confirms the usual description of the birth of the shoulders. The anterior shoulder is three fingers'-breadth below the pubes, and is pressed against it, while the posterior is pushed over the perineum. Schmidt's description of the mechanism in L.O.A. is accepted, as far as the rotation of posterior fontanelle in the "rolling" motion is concerned; but his theory that the abdominal muscles force the uterus against the spine, bringing the longer abdominal portion of the foetus backwards and the shorter pelvic portion against the pubes, is disputed. It is contradicted by the clinical fact that during a pain the uterus erects itself so as to be thrown forwards. Against Chiari's section, which supports Schmidt's view, we must put Braune's, Schroeder's, Winter's, and Zweifel's previous one. The pressure of the head against the pubes is due to a different cause, viz. the squeezing in of foetal parts into the back part of the pelvis.

Under the "*Lower Uterine Segment and the Cervix Uteri in Labour*," Bandl's and Schroeder's position with regard to Braune's section are stated; and in the light of these two sections, the theory of the latter as to the formation of a lower uterine segment can no longer be held. "The contraction ring is the os internum, or, more exactly, the thickened portion of the muscle of the body immediately above it; the stretched lower uterine segment is nothing more than the cervical canal, and the spontaneous rupture is in our case a tearing-off of the body *from the cervix* in the neighbourhood of the os internum."

**TIBONE** gives sections from a case of placenta prævia. The patient was a II.-para, aged 36, who died at term from hæmorrhage, after two slighter ones.

The *Atlas* contains five Plates: \* I., Vertical Mesial Section;

\* Reproduced in Author's *Atlas of the Anatomy of Labour*, Third Edition, Plate xxv., Fig. 7.



II. and III., Two left lateral, 4.5 cm. and 7.5 cm. from middle line respectively; IV., Right lateral 5 cm. from middle; V., Fœtus, showing its attitude.

Plate I., diaphragm at level of ninth dorsal vertebra, and fundus uteri at level of cartilage between first and second lumbar vertebræ. The *uterus* is forwards, and in contact with the abdominal wall in front, the vertebral column behind, and the large and small intestines above. It measures from os externum to fundus 26 cm., and antero-posteriorly at level of promontory 16.5 cm.; walls 4.12 mm. thick, being thickest anteriorly towards the fundus. The *bladder* is tri-radiate, the two upper limbs being behind the lower part of symphysis, the lower extending below it. The *vagina* is distended with blood, the posterior fornix being 2.7 cm. deep, and the anterior one obliterated. The *cervical canal* is partly taken up into the lower segment, the os externum being dilated to 18 mm. antero-posteriorly. The os internum (no minute anatomy given) is marked at level of middle of symphysis anteriorly, between third and fourth sacral vertebræ posteriorly, distant from os externum, anteriorly 47 mm., posteriorly 36 mm. The posterior lip is long and tongue-like; the anterior, short and triangular. The upper limit of the lower segment is not clear, but is considered to be anteriorly at upper margin of symphysis, posteriorly between first and second sacral vertebræ—walls thicker here and vessels seen. The traction ring is not developed, because placenta is prævia and first stage half through. The placenta is over the os 7 mm. thick, and extends further on to posterior than to anterior wall of uterus.

The *liquor amnii* is collected at upper and lower poles, the fœtus is a breech presentation.

The *Pelvis*, Conjugate—11.8 cm.—The brim forms an angle of 50° with horizon; the axis of brim, one of 24° with axis of uterus.

Plate II. shows section of uterus, with right leg of fœtus and the greater portion of the placenta. The uterus being oblique to right, shows only a relatively small portion of its cavity; the placenta running round the section of its walls with the exception of 6 cm. The greatest thickness of the *placenta* is below and behind, 4.5 cm. The thickness is due to the obliquity of the section, where also vessels from insertion of cord are cut across. Below in front, above, and behind, it is only 2 cm. thick. Its anatomical centre will correspond to the left posterior quadrant if the lower pole is divided into four quadrants. It is difficult



to recognise the extent of the separation, but it might be described as an area having a diameter of 9 cm.

Plate III. shows circular portion of uterus with placenta only.

Plate IV. shows uterus almost as in the vertical mesial. It measures vertically 23 cm., antero-posteriorly 15 cm. The head of the foetus is divided at fundus, and the right foot at lower segment.

Plate V. shows foetus in usual attitude, with cord round neck. It measures from vertex to breech 34 cm.; when extended, 49 cm. Occipito-frontal diameter is 12 cm.

Commenting on the sections, he says that the uterine wall is thin where there is most pressure on surrounding parts, and that the insertion of the placenta does not affect the thickness materially. Barnes' and Duncan's modes of estimating the area of detachment are criticised. The size of the foetal head is taken to determine the amount of dilatation required, and the amount is estimated for the sixth, seventh, eighth, and ninth months.

**LEOPOLD** in his *Atlas Uterus und Kind*, has made the most important contribution to the sectional anatomy of pregnancy. It contains 30 Plates of sections of the pregnant uterus from the first week up to full time. The cases from which the preparations were obtained are the following:—(1) Uterus with ovum from 7 to 8 days; (2) same from about 14 days; (3) uterus with foetus of  $3\frac{1}{2}$  months, commencing placenta prævia; (4) uterus with foetus of 4 months; (5) uterus with child of 5th month; (6) middle tubal gestation from beginning of 5th month, injected; (7) uterus and child, end of 5th month, injected; (8) uterus from 6th month, with *breech* presentation; (9) uterus from 7th month, with *breech* presentation; (10) uterus from 8th month, with *breech* presentation, dilatation of os internum beginning; (11) pelvis with uterus from 9th month, *breech* presentation, death from uræmia without pains; (12) uterus from end of 9th month, with *head presentation*, injected—death from eclampsia, labour commencing; (13) uterus from beginning of 10th month, with *head presentation*—eclampsia, labour beginning; (14) uterus from end of pregnancy, *head in first position*—labour commencing; (15) pelvis with uterus from end of pregnancy, child in *first vertex position*—death from eclampsia with labour beginning; (16) pelvis with uterus, child in *posterior parietal bone* presentation, full time pregnancy; (17) *placenta prævia*, child turned and *right leg drawn down*; (18) extra-uterine gestation,



tubo-ovarian at 10th month, removed seven weeks later ; breech presentation.

The first part of the text contains the description of the sections. We give here only those from the later months of pregnancy or commencing labour, and in which the pelvis was removed with the uterus. Of these there are four.

*Commencement of 9th month, pelvis with uterus and child, breech presentation*—multipara aged 32, death from eclampsia. Child was in second vertex position on clinical examination before death. Cervix undilated. Uterus with pelvis removed, frozen, and cut in coronal section. The section has divided the acetabulum on the left side, but on the right has passed behind it.

The highest point of the fundus is 8 cm. above a line joining the iliac crests. The breech and feet of the foetus extend 6 cm. below the brim, *i.e.* a line joining the lower limits of the iliac bones. The membranes are firmly attached up to the os internum. The decidua vera ends in a sharp line at the upper end of the cervical canal. Large veins are seen at the lower margin of the placenta, which is situated on the anterior wall. The foetus is in a crouching position, the chin on the breast and the face on the knees. The left foot is underneath the right, both arms being down by the sides.

The placenta shows a broad layer of canalised fibrin (2 mm. thick), containing spaces in it close to the chorion—perhaps due to a metritis. Also the ampullary layer disappears as we pass beneath the placenta, the latter being separated from the muscular wall by a narrow band of the compact layer. The parts round the os internum are shown in Plate XXIX., fig. 40. The laminated muscular tissue of the lower segment is distinguished from the felted texture of cervix. The one mucosa abuts on the other without any transition.

*Full time pregnancy, first vertex position.* Primipara, aged 25. Died from eclampsia. Foetal heart not heard. Pains not noticed. Pelvis and four lower lumbar vertebræ removed and frozen.

The bending of child's head on shoulder noteworthy, as also its rotation so that while the back is to the left and front, the occiput is to the left. Conjugata vera 10·5 cm. The vertex extends 4 cm. below it. The fore-waters make membranes 1·2 cm. lower.

The membranes are separated up to the point a.b. in Plate XVIII. "The membranes lie closely applied, up to a circle marked by the points a.b., to the mucosa of the lower uterine segment. From



the points a. and b. they hang free over the dilated opening of the cervical canal in an area fully as large as a three-mark piece—the lower pole of the ovum. At the ring a. b. there lies, as the microscopic investigation shows, the boundary between the mucous membrane of the body and cervix.”

The microscopic sections of the decidua at the os internum and of the placenta show nothing worthy of note.

As regards the position of the child, its head forms almost a right angle with the body. The long diameter of the shoulders lies in the left oblique diameter, the back looking to the front and forwards; the head has, however, not succeeded yet in rotating forwards, but having passed the brim, it finds most room in the transverse.

*Full time pregnancy, posterior parietal bone presentation.* Primipara, aged 36. Flat rickety pelvis. Conjugata vera estimated clinically at 7.5 cm. Death from eclampsia. Fœtal heart not heard for a few days before death. Slight pains. Pelvis and lumbar and lower dorsal vertebræ frozen. Section to right of mesial plane. Brim measures antero-posteriorly at this point 8 cm. Lower pole of uterus 5.5 cm. below this. Os externum about 2 cm. lower down. The sagittal suture is 2 cm. behind the symphysis, and the anterior parietal bone is pressed inwards, but not under posterior. The caput succedaneum is not yet present, but without doubt is beginning to form, as the skin over the left parietal bone is three times as thick, and shows blood extravasation. The perpendicular of the head forms with the axis of the trunk an open angle of  $170^{\circ}$ ; and the anterior parietal bone with the muscular wall of the uterus projects 2.3 cm. beyond the pubes, the anterior fold of the neck of the child showing a slight but distinct impress. The opening “o” resembles the os internum, but on lifting the membranes we find that in the immediate neighbourhood of this opening they are chiefly fastened to the tissue below by cervical mucus, and around this there is an area about 3 cm. long, which shows the plicæ palmatæ arranged in parallel rings like the seats of an amphitheatre; o.i. is therefore the os internum (compare fig. 47 on Plate XXIX.) The placenta is on the right half of the uterus. In the view of the fœtus on Plate XXIII. fig. 31, the fœtus is seen from the back and *right*. The chin is pressed on the sternum. On comparing the normal position of the head on Plate XVIII. with this on Plate XXII., we see that in the former the head keeps the direction of the pelvic axis, while in the latter its line would cut the lower border of the symphysis.



On microscopic examination the number of dilated vessels in the wall is striking. At the placental site two layers are distinguishable, an external of elongated gland spaces, and an inner more compact. In the latter we scarcely recognise a connective tissue basis; it consists rather of fibrin, with here and there larger spaces containing granular coagulated material. Between the layers of this are numerous well preserved decidual cells.

*Full time pregnancy—multipara—placenta prævia* in which the placenta was pushed through so as to turn by the right foot, when the os was the size of a three-mark piece. About a fortnight before full time the patient fell over a jar, and three days later lost a litre of blood. It stopped spontaneously on her lying down, but was profuse again three days later. When she was taken into the hospital she was profoundly anæmic. Only the placenta could be felt through the cervix, which admitted one finger. After stimulants and subcutaneous saline injection (foetal heart not now heard) the placenta was perforated and the right knee hooked down, the cervical canal being dilated to a three-mark piece. Little blood was lost during the operation, but the patient died in four hours. The uterus and anterior part of the pelvis with bladder and rectum were removed and frozen.

The external right leg of the foetus is in the vagina. The left leg, the trunk, and head are in the uterus, the os externum embracing the right thigh at its upper third. The musculature, which is 3·5 to 4 cm. thick at fundus, thins rapidly in front and behind to 1·5–1 cm., is ·5 at placental site, and ·7 in the cervix anteriorly. The placenta begins about 7·5 cm. below the centre of the fundus, and extends from this 10 cm. downwards, covering chiefly the left half of the section. The muscle of the fundus therefore appears in section as a crescent on whose extended limbs the placenta lies, united to it for 6 cm., free beyond for 3 cm. The lower segment is covered with fragments of decidua, and stops sharply at the os internum, which is behind 3·5 cm., in front 4 cm. from the os externum. On the surface of the cervical canal, plicæ palmatæ are distinctly seen. A lobe of placenta about the size of a saucer, therefore, occupies the lower pole of the uterine cavity, and has been perforated so that bits of placental tissue are found in both halves of the section.

The foetus lay with its head towards the mother's back, and the relation to uterus and placenta will be evident from Plate XXVI. The head of the foetus looks to the left, and is twisted. Before turning, the head was R.O.A., and the right leg was seized, and the



peculiar relation of head and trunk is explained in relation to the revolution in turning.

Microscopic description is given justifying the location of the os internum.

The cause of the bleeding after turning was, that from the narrowness of the cervix, the breech of the child was not allowed to descend far enough to compress the placenta. Where the cervix is unyielding it will be best to introduce a bag extending above the os internum, which will compress the placenta, or, at least, to rupture the membranes so as to excite strong pains, and let the head come down. This procedure has done better service in many very difficult cases of placenta prævia, where the cervix was incompletely dilated and the indications were pressing, than the pulling down of the foot and gradual extraction. His preparation compared with those of Runge, Veit-Kramer, and Zweifel. In Runge's and Veit's, as here, the cervical canal is similar. The placenta can thus grow over the os internum, but as to whether this occurs in the reflexa these preparations say nothing. Zweifel makes the cervix twice as long, and the os internum coincide with the retraction ring.

The Second Part deals with *explanations* and *results*.\* *Decidua Vera*. Already at the end of the first week of pregnancy, the mucosa is swollen, and shows all the known characteristics of the decidua vera—glands drawn out, in parts spiral, and with a cubical epithelium, the upper portion elongated, the lower showing bulgings and foldings; thus a compact and spongy layer. Decidual cells well marked, and spiral arteries, which run parallel to the glands in the mucosa.

There is no sub-mucosa, the mucosa abutting on the muscular wall in a wavy, sometimes toothed line. In the teeth are blind ends of glands often buried, which will remain when the decidua is shed. The change in the mucosa is well-defined at os internum, which can be recognised throughout pregnancy, and also in the parturient and puerperal uterus by macro- and microscopic characters. The decidua is like a thick carpet with spaces and meshes below, and closer compact layer above, while the cervical mucosa shows processes, branches, and twigs, the stem of which is formed of delicate muscular bundles. Their covering is a cylindrical epithelium, which never becomes cubical or desquamates

\* We give these fully here from their bearing on the abstracts of earlier papers on the decidua and placenta.



as the decidual does. This structure shows how the cervix can open out and stretch.

During the fourth month the vera and reflexa blend, the surface epithelium is lost, the glands flattened and stretched, but cubical epithelium preserved. Up to the end of pregnancy the decidua still shows same type, but altered by the expansion of ovum.

*Decidua capsularis—Reflexa.* At the end of the first week we find the ovum completely grown round by uterine mucosa. The ovum has anchored itself on a ridge of mucosa, and the growing mucous membrane folds have surrounded it on all sides. The tissue is thinnest at the inner pole, consisting in part of villi and fibrin. The capsularis has all the constituents of the vera, glands, capillaries, and decidual cells, but has no epithelial investment on its outer or inner surface.

Fourteen days later the capsule is increased in thickness, but has same structure. With its inner surface the heads of the villi are united, but differently in different places—on the arch and sides of the capsularis, more by juxtaposition, by fibrinous or syncytial adhesion; at the base by burying and heaping up of the mucosa.

As ovum grows, villi atrophy, and reflexa also, although glands have been described in the latter by Hofmeier as late as the fourth month.

The *decidua basalis (serotina)* is that part of the mucosa on which the ovum has first anchored itself—the bottom of the nest. To it the villi become first attached. With the growth of the ovum and the uterus, it enlarges and contributes essentially to the placenta. Plate II. shows a ridge of mucosa, with the ovum's bed extending beyond it, to which the latter is attached by some villi. This ridge consists of decidual tissue with the glands and blood vessels, and shows epithelium on its right border (S). Its surface is smooth, except where broken through by vessels at C., which open into the spaces between the villi and decidual capsule. The cubical epithelium (S) shows syncytial form.

In the main, the basal decidua has the same structure as the vera, showing a compact and spongy layer. On its surface towards the ovum it is thrown up into heaps of cells (text, Plate II. Fig. 7). The commencement of the trabeculæ, in which the villi bury themselves, in the serotina become larger, and push their way between the villi like interwoven fingers. With this proliferation of the compact layer, the capillaries become dilated and opened, and the cavern system seems to form in that these dilated and



burst capillaries communicate with the spaces left between the villi. Already at the end of the first week there are processes of decidual cells carrying vessels and surrounded by blood spaces.

The *placenta* is built on this plan. The basal decidua is the site of the house, the decidual processes are the first pillars from which, later, the outer and inner walls are formed, and they bring the arterial blood. Between the pillars and walls the villi are hung from above as a mesh work, of which the larger and stronger bury themselves on the site and walls. Reichert's view that the villi grow into the glands received no countenance from this section, because the villi have only a single layer of epithelium.

The uterine glands have a perfect epithelium here, but a week later (Plate III.), it is desquamating, and forming masses in the gland cavities. Giant-cells, which Leusden has described as the source of the new epithelium in the puerperium, are not seen. In Plate III. numerous trabeculæ are seen on section as islands and subchorionic deposits, and carrying vessels from the serotina. Some of these deposits may be cut off, and pathological. Their being without nourishment may cause abortion.

Two processes now go on together—the attachment of the villi, and the opening of the vessels between them. As yet the firm attachment by embedding in decidual cells, which we find later, is not present, only a syncytial and fibrinous adhesion. The surface is broken by funnel-like mouths of vessels, the epithelium of which extends into the funnel. The funnels communicate with dilated capillaries in the compact layer. “I will not dare to decide whether these funnels are arteries or veins. It seems to me more correct to consider them as corresponding to the great capillary network which covers the surface of the mucosa—that they are dilated capillaries from which, in the course of pregnancy, spiral arteries and veins will develop later.” In the capsularis also there are large blood spaces opening on its surface. “Already in the second or third week we have intervillous spaces communicating directly with blood-vessels. And thus we must reject the view hitherto retained that the intervillous spaces do not develop till the fifth month.” Hofmeier has described a placenta at the end of the first month. He finds islands of decidua immediately under the chorion, and in addition to the surface attachment of the villi, a deeper extension of the intervillous space by the decidua. In all preparations till the fifth month he finds a deep extension into the intervillous spaces. He makes no reference, however, to their carrying vessels. Bloch says they do not.



As pregnancy goes on, the glandular layer becomes compressed. No spongy layer seen, but remains of glands (although Ruge and Hofmeier deny this) are found on almost every ripe placenta; giant-cells develop from epithelium not connective tissue, and probably do not cause spontaneous thrombosis, as formerly thought. It is due rather to growth of the intima. He agrees with Bloch, Hofmeier, etc. in describing the arteries as opening at the foot of the trabeculæ (see Plate IV.). This shows that the trabeculæ themselves contain vessels.

The trabeculæ have two forms—some like tree stems, others like a wall with a broad base and toothed border.

*The development of the placenta* is discussed in a separate section by Dr Gaiser. To give the embryo a hold and food, the foetal contribution forms the chief bulk. The upper part of the decidua always comes away with the placenta on account of the firm attachment of villi to it.

The trabeculæ show three forms—low, broad, bed-like, ending in processes; long pillar-like which end in a swollen point, or reach the chorion at the placental margin; broad based ones enclosing irregular spaces, and often reaching the chorion.

The firm attachment occurs late after the second month. The serotina begins to lose epithelium before the first week, then it grows round the villi, which lose their epithelium where they are embedded.

The ovum is not equally surrounded with villi at first, which are best developed at the sides and next the uterine wall.

Langhans' layer is seen in Plate II., Fig. 6 of text, as a single layer of cubical cells. The epithelium outside this is a nucleated syncytium. From the third month Langhans' layer disappears, and a single layer is left without any maternal contribution. The branching of the villi begins at the first week. The syncytial protoplasm thickens into a knob, which becomes pediculated. Then connective tissue and vessels grow into it. In the early stages, when Langhans' layer is equally developed and syncytium still covers the villi in a broad layer, processes extend from the latter which are much longer than the later villi. At the same time Langhans' layer multiplies. How long formation of villi continues it is hard to say. By the ninth month it is limited, for we do not find new ones then. The source of the double covering of the villus is much disputed. Waldeyer says there are ten different views. G. follows Langhans in holding that the inner layer is of connective tissue, and the outer of ectodermal



syncytium. The presence of delicate connections between the cells of the connective tissue and those of Langhans' layer, and the fact that Langhans' layer only exists as long as the connective tissue is young, disappearing when it becomes fibrous and firm, supports this view. This specimen proves that the syncytium on the villus is foetal, because you find it on villi which have not yet come near the decidua. If we look at the border of the chorion itself or the youngest villi, which have not yet come into contact with the maternal tissue, or the layer which has, we find that all have the same epithelial investment.

The function of the syncytium may be to open up the decidual tissue and erode the vessels.

In addition to the diminution of the syncytial covering of the villi as is noted in the later stages of development, we find under certain circumstances another relation of the same. Occasionally, where a villus has become applied to a process of decidua, we find that the epithelium has disappeared over the surface of contact, the stroma of the villus passing into the decidua. At the sides, however, the syncytium has extended from the villus, and applied itself in a varying extent to the decidua, sometimes so delicately that it resembles a layer of epithelium. In the shrinking of the preparation this syncytial crust is easily lifted, and the appearance given which Waldeyer has described as lamellæ of epithelium. Hofmeier has correctly recognised it.

Occasionally there is found on individual villi of a ripe placenta a homogeneous mass, which in its appearance is usually compared to fibrin, and described as canalised fibrin. G. agrees with Minot, who holds it not to be fibrin, which must be derived from the blood, but a degenerated product of syncytium. On such villi we never find the slightest trace of preserved syncytium.

While Coste found vascular villi in the early weeks, and Hofmeier denies them for the first month, both our preparations show development of delicate vessels.

The architecture of the placenta based on the results of Waldeyer, Langhans, von Kolliker, Rohr, Bloch, Hofmeier, Bumm, and Merttens and his own specimens in first and second week, fifth and ninth month, is as follows:—The ovum is at first relatively loose in its capsule. The ends of the larger villi stick to the adjacent decidual cells and produce syncytial processes which burrow between them. In this process these cells are pushed aside and heaped up, and the capillaries beside them dilated and torn, so that already in the first week maternal blood flows free between the villi. In measure, as the villi push themselves forward,



processes and pillars of decidual cells rise up between them, to which also the villi become attached. In them, blood-vessels are seen (Plate v.) arterial in nature. The venous channels seem to be the funnel-like depressions which are found on the inner surface of the serotina and reflexa. The reflexa consists in the second and third week of an arch broad at the base and narrowing at the top to 1 to 2 mm. containing decidual cells, some giant-cells, glands with cubical epithelium and numerous vessels, mostly with walls like capillaries.

During the second month the "attaching villi" develop opposite the serotina, and are complete by the fourth. At the same time the decidual pillars rise up, and the reflexa and its villi shrivel.

The pillars rising from the serotina carry arteries with arterial blood. These run sometimes through the whole pillar, and must reach the spaces which remain between the pillars. In these spaces the branches of the chorion hang like fine strings, and float free in the mother's blood.

The course of the blood-stream is shown in Plate v. of the text. It enters chiefly by the decidual trabeculæ and at their base, and leaves by the floor of the intervillous space.

Plate xxx. is from a placenta at the ninth month, the final network of villi being removed. It shows a floor of injected muscular wall with the toothed serotina on it, a roof of amnion and chorion and the villi of the latter, a partition of decidua with, on either side of it, a network of villi.

*Situation of Placenta.*—It is posterior when the tubes converge on the anterior wall of the uterus; anterior when these are parallel to its long axis. In the seventh case it was posterior; in four, five, nine, eleven, and thirteen, it was anterior.

*The Cervix Uteri in Pregnancy and Labour, and the Os Internum.*—Von Franqué's conclusions are endorsed by Leopold. Even at the ninth month no part of the cervical canal is taken up to cover the ovum. When pains are present, a funnel-shaped depression forms, consisting of the upper part of the cervical canal.

*The Lower Uterine Segment.*—Von Franqué endorses Pestalozza's conclusion that the thinning of the lower uterine segment precedes dilatation of the cervix, and Leopold agrees. Acconci's\* description of the formation of the lower segment during labour accepted.

*Attitude and Position of Child.*—Six breech (one an extra-uterine) and three vertex cases.

\* See his description of a frozen section from placenta prævia at the end of pregnancy, reported by Tibone.



*Breech presentations.*—In the incomplete foot presentation of Plate VIII., the child has lifted the right leg in its free movements, and the cord keeps it temporarily in that position. From it we see how the child might come to ride on the cord.

In the other footling—the result of turning—the bending of the head on the shoulder is noteworthy, and shows the importance of choosing the proper limb. The child was in the second position, and the right leg was taken—that is, the posterior. In head presentations the anterior limb should always be seized, so that thigh and hip—that is, a smooth surface—comes under the pubes. If a posterior leg is seized, the flexed anterior hip strikes against the anterior wall of the pelvis and rotates backwards. The rule is, if the child's back is to the right in a head presentation, take the right hand and pull on the left foot.

Plate x. shows also a transitory condition in which the position is also due to the relations of the cord.

In the extra-uterine gestation the foetus, dead for several weeks, is compressed together, the extremities occupying the space below the head and the abdomen.

In Plate XII. pains were present. The walls embrace the child, and compress it into the most convenient shape.

In Plate XIII., although from the condition of the cervix it is evident that no pains are present, the breech is already 6 cm. below the brim.

*Head Presentations.*—As the thirteenth case is not available, only three have to be considered.\*

*Generally Contracted Pelvis. Head at brim, end of tenth month.*—The head fills the pelvis for more than one third, and seeks the most comfortable place; this can only be the transverse. The back of the child is, however, already to the front and left. This raises the question whether the back has not rotated here before the head, which is still transverse, has done so.

The bending of the head on the shoulder at almost a right angle is noteworthy. The cases from this period fall into two groups. In Schroeder's and Zweifel's with the angle to the front; in Barbour's, Saexinger's, and mine, with it to the back. His own and Schroeder's show the bending most markedly, only in Schroeder's, the posterior, in his the anterior parietal bone presents.

*Posterior Parietal Bone Presentation—flat ricketty pelvis.*—The right parietal bone is driven against the symphysis, and the left bulges into the pelvis. The membranes are intact. From this

\* One of these sections, being of the uterus removed from the body, is of no value for topographical anatomy. We give therefore only two.



plate one can easily see how a bag placed in the vagina will keep the membranes from bursting, and thus allow dilatation to go on.


**LUSK** has published sections of a VII.-para, æt. 37, who died suddenly during first stage. The case was not seen till 2 or 3 hours after death. The os then admitted one finger, and was dilated artificially till it admitted three; the cadaver was frozen some days later in the erect posture. A verticle mesial section was made, and casts were also taken of the foetus and the uterine cavity; reduced drawings,  $\frac{1}{4}$  natural size, are given.

Obstetrical Conjugate, 4·4 in.; transverse, 4·9 in.; obliques, about 5 in. Conjugate narrowed by soft parts, ·5 in. anteriorly, and ·48 posteriorly; transverse by ·9 on each side; obliques by 1 in. anteriorly, and ·6 posteriorly. Uterus globular—long axis of cavity, 5·4 in. Walls, ·4 in. thick above and ·2 below. Fundus, opposite cartilage, between 3rd and 4th lumbar vertebræ, or 7 in. above symphysis. Placenta measures 8 in. in section. Foetus L.O.A. with head engaged. Caput succedaneum present; head bent on trunk at angle of  $135^{\circ}$ , open posteriorly. Peritoneum descends 1·2 in. below brim in front, and behind to line joining lower angle of symphysis with 4th and 5th S.V. Laterally reflected at middle of iliac fossa. Bladder flattened between child's head and pubes, its apex reaching just above brim. Interior of left half of uterine cavity shows a ridge, terminating in thickening of posterior wall. Cavity of right half shows distinct indentations by foetal parts. The cubic contents of uterine cavity are 97·6 cub. in.; of foetus 92·1 cub. in., making the amniotic fluid 5·5 cub. in. Head of foetus slightly rotated on trunk backwards, the middle of the back being more anterior than the occiput. Bones overlap at coronal and lambdoidal sutures, but not at sagittal. At the coronal the parietals overlap the frontals; while at the lambdoidal, the left or posterior overlaps and the right or anterior is depressed beneath the occipital bone. Microscopic examination made, but from post-mortem changes unsatisfactory as regards decidua and mucosa. The difference between the muscular bundles of the body, lower segment, and cervix same as that noted by others. Small amount of liquor amnii noteworthy. Uterus considered to be in contraction from its globular shape. The thickening of the muscular wall posteriorly ascribed to retraction, because preserved in the hardened specimen. Its absence anteriorly referred to pressure between head and brim. As reduced by soft parts, diameters of brim estimated at 3·4, 3·4, 3·1 in. Hence, practically justo-minor pelvis, which explains extreme flexion of head.



I N D E X







## INDEX

---

The numbers in *italics* refer to pages of the Second Part dealing with the Literature of the subject

- Albuminuria in pregnancy, cause of, 27  
Amnion, 21  
    Hunter on, 4  
Anatomy of gravid uterus, Hunter on 1  
Anatomy of obstetrics, history of, 1, 5, 7, 75  
    Berengario's work in, 2, 4, 77  
    Le Gendre's work in, 5, 5<sub>2</sub>  
    Moschion's work in, 77  
    Pirogoff's work in, 5, 6  
    Soranus' work in, 2, 76  
Anatomy, sectional, *see* Sectional Anatomy  
Before labour, 12  
    anatomical facts, Hart on, 48  
    bladder, *see* Bladder  
    cervix, 179 (*see also* Cervix in Pregnancy)  
    dimensions of uterus, 14  
    engaging of foetal head, Braune and Zweifel on 88  
    foetus, Braune and Zweifel on, 87 (*see also* Fœtus)  
        Braune on, 9  
        Leopold on, 122  
        Waldeyer on, 12  
    form of uterus, 14, 173  
    height of diaphragm, Braune on, 9  
        Waldeyer on, 10  
    lower uterine segment, 28  
        Bandl on, 15  
        Benckiser on, 33  
        Duncan on, 14  
        Hofmeier on, 30



Before labour, lower uterine segment—*continued*.

Küstner on, 19  
Langhans and Müller on, 20  
Leopold on, 18  
Lusk on, 22  
Macdonald on, 17  
Marchand on, 21  
Müller on, 20  
Sänger on, 21

membranes, 20, 100

peritoneum, 15, 27, 170

Braune on, 9

Polk on, 13

Waldeyer on, 11

posterior parietal bone presentation, Leopold on, 123

ureters, 19, 27

Polk on, 12

uterine wall, 180

uterus, 15, 173

Bandl on, 16

Braune on, 9

Braune and Zweifel on, 86

Tibone on, 120

Waldeyer on, 10

Bladder before labour, 28, 172, 173

Braune and Zweifel on, 86

Hart on, 48

von Franqué on, 210

in first stage, 50, 172

Lusk on, 132

Pestalozza on, 93

Pinard and Varnier on, 113

Winter on, 83

second stage, 91, 172

third stage, 173

Pestalozza on, 94

puerperium, Webster on, 100

Breech presentation, 186

Leopold on, 131

Waldeyer on, 12

Cadaver, preparation of for freezing, 11

Cellular tissue, in pregnancy, 18

in puerperium, 114

Cellulitis, 128

Cervix before labour, 23, 179, 209

dilatation of, 40, 55

in first stage, 48, 57

in second stage, 183, 209



- Cervix uteri during pregnancy, 33, 134-141, 179, 209  
     Bandl on, 14  
     Bayer on, 22  
     Benckiser on, 33  
     Duncan on, 14  
     Hart on, 49  
     Hofmeier on, 30  
     Küstner on, 19  
     Leopold on, 18, 130  
     Lusk on, 22  
     Macdonald on, 17  
     Marchand on, 21  
     Müller on, 20  
     Sänger on, 21  
     relations of, 29  
     structure of, 29
- Chief plane of Veit, 88
- Chorion, 21, 56  
     Hunter on, 4
- Classification of frozen sections, 10, 165
- Clinical work assisted by frozen sections, 8  
     relation to sectional anatomy, 6, 8, 87.
- Conjugate diameter of pelvis, 71  
     soft parts in, 77, 184
- Contraction ring, 82. *See also* Retraction Ring  
     Schroeder on, 41  
     Testut and Blanc on, 104
- Decidua, 20  
     Bayer on, 28  
     Friedländer on, 37  
     Hunter on, 4  
     Köl liker on, 39  
     Kundrat and Engelmann on, 37  
     Küstner on, 39  
     Leopold on, 38  
     during uterine contractions, Ruge on, 43  
     in puerperium, 123  
         Duncan on, 56  
         Küstner on, 59, 64  
     reflexa, 21  
         Leopold on, 126  
     serotina, 21  
         Leopold on, 126  
     vera, 20  
         Leopold on, 125
- Descent of foetal head, Braune and Zweifel on, 89  
     Pinard and Varnier on, 110
- Diameters of bony pelvis, 72
- Diaphragm, height of, 16



- Dissection, relation to sectional anatomy, 5
- Engagement of foetal head, Pinard and Varnier on, 110
- Evolution, spontaneous, Chiara on, 47
- Extension of foetal head, 104  
     Braune and Zweifel on, 89  
     foetal trunk, 192
- Fallopian Tubes, described by Fallopius, 77  
     and position of placenta, 195
- First stage of labour, 39, 171, 174  
     Barbour's section from, 42, 58, 165  
     Barbour and Webster's section from, 162, 165  
     Benckiser's section from, 74  
     bladder in, 50, 172  
     cervix in, 50, 172  
     frozen sections from, 41, 165  
     duration of, 39  
     foetus during, 50  
     hæmorrhage in, 55  
     height of fundus uteri in, 174  
     Leopold's section from, 162, 165, 123  
     Lusk's section from, 162, 165, 132  
     lower uterine segment in, 46  
     membranes during, 49  
     peritoneum in, 170  
     Pestalozza's section from, 162, 165, 93  
     Pinard and Varnier's section from, 162, 165, 114  
     placenta in, 48  
     Säxinger's section from, 41, 53, 165, 79  
     Schroeder's section from, 41, 54, 165, 39  
     significance of, 39  
     Testut and Blanc's section from, 162, 165, 102  
     Tibone's section from, 162, 165, 119  
     uterus, dimensions of, 44  
         form of, 44  
         walls of, 45, 180  
     Winter's section from, 41, 52, 165, 81
- Flexion in labour. *See* Foetal Head
- Foetal head, descent of, 89, 110  
     description of, 70, 85  
     engagement of, 213, 110  
     extension of, 104, 89  
     flexion of, 73, 92, 185, 190  
     moulding of, 191  
     relation to pelvis, 86, 187  
     rotation of, 73, 192, 89, 119  
     ovoid, size of, 23, 185
- Foetus, attitude of, 23, 185, 94, 115  
     before labour, 23, 185



- Fœtus, before labour—*continued*.  
     Braune on, 9  
     Braune and Zweifel on, 87  
     Leopold on, 122  
     Pinard and Varnier on, 113  
     Waldeyer on, 12  
     extension of, 192  
     in first stage, 50  
         Barbour on, 50  
         Benckiser on, 45  
         Lusk on, 132  
         Leopold on, 123  
         Pestalozza on, 93  
         Pinard and Varnier on, 113  
         Schroeder on, 41  
         Testut and Blanc on, 103  
         Von Säxinger on, 80  
         Winter on, 83  
     in second stage 84, 189  
         Braune on, 45  
         Chiari on, 51  
     length of, 185  
 Frozen sections, casts from, 164  
     classified table of, 165  
     help to clinical work, 8  
     history of, 5, 6, 7  
     objections to, 6  
     preparation of, 10  
 Fundus uteri, height of, 25, 79, 114, 174  
 Genital tract in second stage, 80, 182  
     Braune on, 46  
     Chiari on, 52  
     Zweifel on, 117  
     puerperium, 127  
     soft parts around, 178  
 Head of fœtus, *see* Fœtal Head  
 Internal rotation, *see* Fœtal Head, rotation of  
     os, *see* Os Internum  
 Intestines, relations of, 17  
 Labour, factors of, 68  
     first stage, 39, 172, 197  
     mechanism of, 69, 88, 92, 189  
     membranes during, 101, 197  
     placental circulation in, 197  
     second stage, 68, 181-194



Labour—*continued*.

third stage, 94, 195

uterine muscle in, 78, 180

Bayer on, 71

Length of foetus, 185

Lower uterine segment, 28 30, 210

Bandl on, 15

Bayer on, 28

Bayer's view of, 143

Benckiser on, 33

Duncan on, 14

v. Franqué on, 210

Hofmeier on, 30

Küstner on, 19

Langhans and Müller on, 20

Leopold on, 18, 130

Lusk on, 22

Macdonald on, 17

Marchand on, 21

Müller on, 20

Sänger on, 21

in first stage, 46

Lusk on, 132

Testut and Blanc on, 104

puerperium, Bayer on, 69

Stratz on, 73

Thiede on, 63

second stage, Zweifel on, 119

Küstner's view of, 142

origin of, 36

structure of, 34

Mechanism of labour, 69, 73, 88, 189

Membranes, before labour, 20, 100. *See also* Separation of

Membranes

in first stage, 49

Benckiser on, 44

Winter on, 82

during labour, 101, 197

in second stage, 83, 197

in third stage, 100, 197

Pestalozza on, 95

expulsion of, 105

Dohrn on, 36

Friedländer on, 37

Köl liker on, 39

Kundrat and Engelmann on, 37

Küstner on, 39

Langhans on, 37



Membranes—*continued*.

separation of, Leopold on, 38  
Priestley on, 36

Moulding of foetal head, 191

Nægele obliquity, 50

Oblique diameters of pelvis, 71

soft parts in, 78

Os internum, in first stage, 48

position of, 212

in puerperium, Küstner on, 65

in second stage, Braune on, 46  
Zweifel on, 118

Palpation in pregnancy, 25

Passages, definition of, 88

Pelvic floor, 17

Hart on, 48

Webster on, 100

Pelvis, bony, diameters of, 72

in frozen sections, 167, 206

form of, 166

position of promontory, 168, 203

inclination of brim, 169

kyphotic, descriptions of sections of, 129

Percussion in pregnancy, 25

Peritoneum before labour, 15, 27, 170

Polk on, 13

Waldeyer on, 11

in first stage, 170

Pinard and Varnier on, 113

Schroeder on, 41

von Säxinger on, 80

in second stage, 90, 170

Hart on, 48

Webster on, 97

in puerperium, 118

in third stage, 171

Pestalozza on, 95

Placenta, circulation in, during labour, 197

development of, Gaiser on, 128

during uterine contractions, Ruge on, 42

expulsion of, 104, 197

Stratz on, 54

in first stage, 48

Winter on, 82

second stage, 83, 195

relation to uterine wall of, Pinard and Varnier on, 106



- Placenta—*continued*,  
     in third stage, 97, 195  
     separation of, 100, 106  
     situation of, 194  
         Leopold on, 130  
         Pinard and Varnier on, 106  
     structure of, 22, 196  
         Leopold on, 127
- Placenta prævia, Leopold's section of, 124  
     Tibone's     ,,     ,,     119  
     Winter's    ,,     ,,     84  
     Zweifel's   ,,     ,,     116
- Powers, definition of, 88
- Pregnancy, anatomy of, *see* Before Labour and Uterus  
     clinical examination in, 25  
     length of cervix in, 33, 134, *see also* Cervix
- Pregnant uterus, its unfolding, Bayer on, 24
- Presentation breech, 186  
     head, 75, 185  
         Leopold on, 131  
         posterior parietal bone, Leopold on, 123
- Pressure, general of uterine contents, Braune and Zweifel on, 90
- Promontory of sacrum, mean height of, 205  
     position of, 203
- Puerperium, 110, 199  
     appearance of uterus in, 122  
     Barbour's section of, 113  
     bladder in, Webster on, 100  
     cellular tissue in, 114  
     decidua in, 123, *see* Decidua  
     genital tract in, 127  
     uterus from, Bayer on, 66  
         Benckiser on, 74  
         Chisholm on, 57  
         Duncan on, 56  
         Küstner on, 58, 63  
         Le Gendre on, 57  
         Pirogoff on, 58  
         Thiede on, 60  
     uteri described from, 150  
     Stratz's section of, 112, 73  
     Webster's section from second day of, 96  
         third day of, 97  
         fourth day of, 98  
         sixth day of, 98  
         fifteenth day, 99  
     dimensions of uterus in, 115  
     form of uterus in, 115  
     frozen sections from, 111, 148



Puerperium—*continued*.

- inner surface of uterus in, 121
- lower uterine segment, Bayer on, 69
  - Stratz on, 73
  - Thiede on, 63
- pelvic floor in, Webster on, 100
- os internum in, Küstner on, 65
- peritoneum in 118
- size of uterus, Webster on, 99
- Rectum during first stage, 51
- Retraction, nature of, 82, 182
  - in first stage, 47
- Retraction ring, 82, 181, 211, 212
  - indenting foetus, 182
- Rotation, in labour, *see* Foetal Head, rotation of
- Rupture of uterus, 27, 184
  - Anton v. Mars' section of, 92
  - Zweifel's section of, 116
  - in second stage, 91
- Second stage of labour, 68, 174, 181, 185, 216
  - Barbour and Webster's section from, 161
  - bladder in, 91, 172
  - Braune's section from, 75, 45
  - cervix in, 183
    - Hart on, 49
  - contour of foetal head in, 85
  - Chiara's section from, 76, 47
  - Chiari's section from, 75, 50
  - definition of, 68
  - duration of, 68
  - foetus in, 84, 189
    - Braune on, 45
    - Chiari on, 51
  - genital tract in, 80, 180
    - Chiari on, 52
  - lower uterine segment in, *see* Lower Uterine Segment
  - membranes in, 83
  - os internum, 183,
    - Braune on, 46
    - Zweifel on, 118
  - peritoneum in, 90, 170
  - placenta in, 83, 195
  - pubic segment in, Hart on, 49
  - retraction ring in, 82, 182
  - sections of, 75, 165
  - soft parts in, 184
  - summary of anatomical facts, 216



Second stage of labour—*continued*.

uterus in, 78, 176, 181

Chiari on, 51

vessels in uterine wall in, 83

von Mars, section from, 165, 194, 90

Zweifel's, „ „ 166, 184, 194, 115

Sections, *see* Frozen Sections

## Sectional anatomy, function of, 5

history of, 1, 5, 7

Pirogoff's work in, 7

relation to clinical work, 6

relation to dissection, 5

value of, 1, 163

## Separation of Membranes, 101,

Blacher on, 38

Dohrn on, 36

Friedländer on 37

Kölliker on, 39

Kundrat and Engelmann on, 37

Küstner on, 39

Langhans on, 37

Leopold on, 38

Priestley on, 36

Turner on, 39

## Soft parts, before labour, thickness of, 16, 178

Braune and Zweifel on, 88

in second stage, 76, 184

## Spontaneous evolution, Chiara on, 47

## Synclitism, 87, 215

## Syncytium, Gaiser on, 128

## Third stage of labour, 94, 196

bladder in, 173

Pestalozza on, 94

duration of, 94

expulsion of placenta, 103

Stratz on, 54

Pinard and Varnier  
on, 107

management of, 105

membranes in, 94, 100 (*see also* Membranes)

Pestalozza on, 95

Pestalozza's sections from, 166, 196, 93

peritoneum, 171

Pestalozza on, 95

placenta in, 94, 100, 195

placenta, separation, 100, 196

Stratz's sections from, 95

uterus in, Benckiser on, 55



- Third stage of labour, uterus in—*continued*.  
     Pinard and Varnier on, 107  
     Thiede on, 53
- Twin placentæ, Pestalozza on, 96
- Ureters, course of, 19, 27  
     Polk on, 12
- Uteri from puerperium, 150
- Uterine cavity, lining of, 20  
     contents, pressure of, Braune and Zweifel on, 90  
     fundus, height of, 25, 79, 114, 174  
     muscle in labour, Bayer on, 71  
     segment, lower, *see* Lower Uterine Segment  
     wall, before labour, 19, 180  
         in first stage, 180  
         second stage, 81, 181  
     walls, vessels in, 47
- Uterus before labour, Braune and Zweifel on, 86  
     Tibone on, 120  
     Waldeyer on, 10  
     dimensions of, 14  
     form of, 14, 176  
     position of, 15, 173
- casts of, 175  
     cubic capacity of, 176  
     during a pain, condition of, 88  
     first stage, 44, 180  
         Benckiser on, 44  
         Lusk on, 132  
         Pestalozza on, 93  
         Pinard and Varnier on, 113  
         Schroeder on, 39  
         Testut and Blanc on, 102  
         von Säxinger on, 79
- puerperal, 122, 150, 199  
     Bayer on, 66  
     Benckiser on, 74  
     Chisholm on, 57  
     Duncan on, 56  
     Küstner on, 58, 63  
     Le Gendre on, 57  
     Pirogoff on, 58  
     Stratz on, 73  
     Thiede on, 60  
     Webster on, 96  
     dimensions of, 115  
     diminution of, 118  
     form of, 115  
     inner surface of, 121



- Uterus, puerperal—*continued*.  
    relations of, 114  
    walls of, 119  
    second stage, 78, 174, 181  
        Chiari on, 51  
    third stage, 96, 196  
        Benckiser on, 55  
        Pestalozza on, 94  
        Pinard and Varnier on, 107  
        Thiede on, 53  
    moulding of in pregnancy, 26  
    musculature of, Bayer on, 23  
    pregnant, contents of, 23  
    its unfolding, Bayer on, 24  
    rupture of, 91  
        von Mars on, 92  
        Zweifel on, 116  
    washing out of, 127
- Vagina before labour, 17, 26  
    in first stage, 51  
        second stage, 80, 183  
        puerperium, 128
- Vessels in placenta, 198  
    uterine walls, 47





By the same Author.

---

*Third Edition, with Twenty-six Plates.  
Price 30s.*

---

ATLAS  
OF THE  
ANATOMY OF LABOUR  
AS EXHIBITED IN FROZEN SECTIONS.

This Edition contains Reproductions of the Frozen Sections published by Braune, Chiara, Chiari, Pestalozza, Pinard and Varnier, Säxinger, Schroeder, Testut and Blanc, Tibone, v. Mars, Waldeyer, Webster, Winter, and Zweifel, as well as the Original Coloured Drawings of the Author's Sections.

---

*\* \* For the convenience of those who have the previous Edition, the additional plates (xiii.-xxvi.) can be had separately, in Portfolio form. Price 21s.*

---

W. & A. K. JOHNSTON,  
EDINBURGH AND LONDON.



THE  
JOURNAL OF  
THE  
AMERICAN  
ASSOCIATION  
OF  
GEOLOGICAL  
SOCIETIES  
FOR THE YEAR  
1891  
PUBLISHED BY THE  
AMERICAN ASSOCIATION OF  
GEOLOGICAL SOCIETIES  
WASHINGTON, D. C.  
1892













Riley Dunn & Wilson Ltd  
EXPERT CONSERVATORS & BOOKBINDERS



